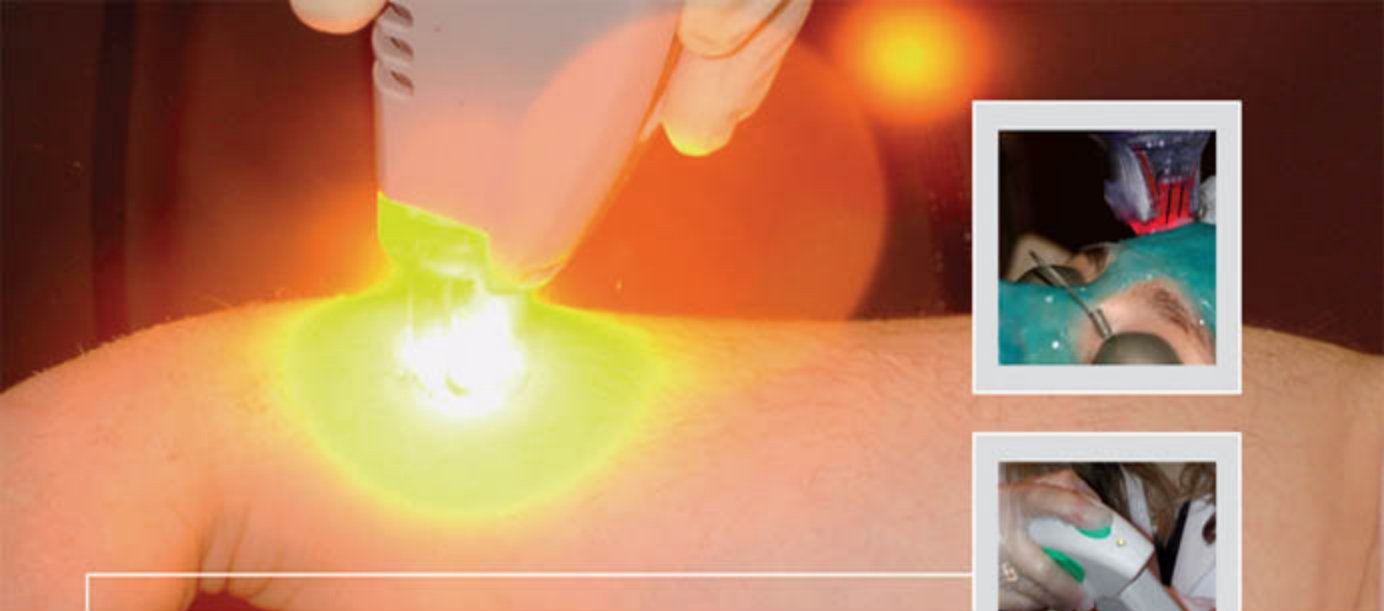



**CONCISE MANUAL OF**

# **Cosmetic Dermatologic Surgery**

**NEIL SADICK • RON MOY • NAOMI LAWRENCE • RANELLA HIRSCH**

**CONCISE MANUAL OF  
COSMETIC  
DERMATOLOGIC  
SURGERY**

## **NOTICE**

Medicine is an ever-changing science. As new research and clinical experience broaden our knowledge, changes in treatment and drug therapy are required. The authors and the publisher of this work have checked with sources believed to be reliable in their efforts to provide information that is complete and generally in accord with the standards accepted at the time of publication. However, in view of the possibility of human error or changes in medical sciences, neither the authors nor the publisher nor any other party who has been involved in the preparation or publication of this work warrants that the information contained herein is in every respect accurate or complete, and they disclaim all responsibility for any errors or omissions or for the results obtained from use of the information contained in this work. Readers are encouraged to confirm the information contained herein with other sources. For example and in particular, readers are advised to check the product information sheet included in the package of each drug they plan to administer to be certain that the information contained in this work is accurate and that changes have not been made in the recommended dose or in the contraindications for administration. This recommendation is of particular importance in connection with new or infrequently used drugs.

# CONCISE MANUAL OF COSMETIC DERMATOLOGIC SURGERY

**Neil Sadick, MD**

Weill Medical College of Cornell University  
New York, New York

**Naomi Lawrence, MD**

Marlton, New Jersey

**Ron Moy, MD**

UCLA Medical Center  
Los Angeles, California

**Ranella J. Hirsch, MD**

Skincare Doctors  
Cambridge, Massachusetts



New York Chicago San Francisco Lisbon London Madrid  
Mexico City New Delhi San Juan Seoul Singapore Sydney Toronto

Copyright © 2008 by The McGraw-Hill Companies, Inc. All rights reserved. Manufactured in the United States of America. Except as permitted under the United States Copyright Act of 1976, no part of this publication may be reproduced or distributed in any form or by any means, or stored in a database or retrieval system, without the prior written permission of the publisher.

0-07-159328-4

The material in this eBook also appears in the print version of this title: 0-07-145366-0.

All trademarks are trademarks of their respective owners. Rather than put a trademark symbol after every occurrence of a trademarked name, we use names in an editorial fashion only, and to the benefit of the trademark owner, with no intention of infringement of the trademark. Where such designations appear in this book, they have been printed with initial caps.

McGraw-Hill eBooks are available at special quantity discounts to use as premiums and sales promotions, or for use in corporate training programs. For more information, please contact George Hoare, Special Sales, at [george\\_hoare@mcgraw-hill.com](mailto:george_hoare@mcgraw-hill.com) or (212) 904-4069.

#### TERMS OF USE

This is a copyrighted work and The McGraw-Hill Companies, Inc. (“McGraw-Hill”) and its licensors reserve all rights in and to the work. Use of this work is subject to these terms. Except as permitted under the Copyright Act of 1976 and the right to store and retrieve one copy of the work, you may not decompile, disassemble, reverse engineer, reproduce, modify, create derivative works based upon, transmit, distribute, disseminate, sell, publish or sublicense the work or any part of it without McGraw-Hill’s prior consent. You may use the work for your own noncommercial and personal use; any other use of the work is strictly prohibited. Your right to use the work may be terminated if you fail to comply with these terms.

THE WORK IS PROVIDED “AS IS.” MCGRAW-HILL AND ITS LICENSORS MAKE NO GUARANTEES OR WARRANTIES AS TO THE ACCURACY, ADEQUACY OR COMPLETENESS OF OR RESULTS TO BE OBTAINED FROM USING THE WORK, INCLUDING ANY INFORMATION THAT CAN BE ACCESSED THROUGH THE WORK VIA HYPERLINK OR OTHERWISE, AND EXPRESSLY DISCLAIM ANY WARRANTY, EXPRESS OR IMPLIED, INCLUDING BUT NOT LIMITED TO IMPLIED WARRANTIES OF MERCHANTABILITY OR FITNESS FOR A PARTICULAR PURPOSE. McGraw-Hill and its licensors do not warrant or guarantee that the functions contained in the work will meet your requirements or that its operation will be uninterrupted or error free. Neither McGraw-Hill nor its licensors shall be liable to you or anyone else for any inaccuracy, error or omission, regardless of cause, in the work or for any damages resulting therefrom. McGraw-Hill has no responsibility for the content of any information accessed through the work. Under no circumstances shall McGraw-Hill and/or its licensors be liable for any indirect, incidental, special, punitive, consequential or similar damages that result from the use of or inability to use the work, even if any of them has been advised of the possibility of such damages. This limitation of liability shall apply to any claim or cause whatsoever whether such claim or cause arises in contract, tort or otherwise.

DOI: 10.1036/0071453660



# Professional



## Want to learn more?

We hope you enjoy this McGraw-Hill eBook! If you'd like more information about this book, its author, or related books and websites, please [click here](#).

## DEDICATION

We would like to acknowledge Samuel Stegman, Theodore Tromovitch, and Richard Glogau—authors of the previous volumes *Flaps and Graft in Dermatologic Surgery* and *Manual of Cosmetic Surgery*, upon which this present book is modeled. It is through their pioneering efforts as leaders in dermatologic surgery that this present volume has become a reality. All dermasurgeons have profited from their wisdom, education, instruction, and guidance.

The present publication is dedicated to Dr. Stegman, Dr. Tromovitch, and Dr. Glogau in remembrance to their contribution to the field of cosmetic and reconstructive dermatologic surgery.

*This page intentionally left blank*



# CONTENTS

<b>Preface</b> . . . . .	ix	<b>Chapter 8: Hair Transplantation</b> . . . . .	73
		<i>Neil Sadick</i>	
<b>Chapter 1: Approach to the Dermasurgery Patient</b> . . . . .	01	<b>Chapter 9: Evaluation and Treatment of Varicose and Telangiectatic Leg Veins</b> . . . . .	81
<i>Neil Sadick</i>		<i>Neil Sadick</i>	
<b>Chapter 2: Facial Flaps and Grafts</b> . . . . .	09	<b>Chapter 10: Lasers</b> . . . . .	91
<i>Naomi Lawrence</i>		<i>Neil Sadick</i>	
<b>Chapter 3: Chemical Peels</b> . . . . .	31	<b>Chapter 11: Lower Lid Blepharoplasty</b> . . . . .	101
<i>Ranella J. Hirsch</i>		<i>Ron Moy</i>	
<b>Chapter 4: Dermal Fillers</b> . . . . .	37	<b>Chapter 12: Upper Lid Blepharoplasty</b> . . . . .	107
<i>Ranella J. Hirsch</i>		<i>Ron Moy</i>	
<b>Chapter 5: Botulinum Toxin Injections</b> . . . . .	47	<b>Chapter 13: Forehead Lift</b> . . . . .	113
<i>Ranella J. Hirsch</i>		<i>Ron Moy</i>	
<b>Chapter 6: Liposuction</b> . . . . .	57	<b>Chapter 14: Minimal Incision Facelift and Facelift</b> . . . . .	119
<i>Naomi Lawrence</i>		<i>Ron Moy</i>	
<b>Chapter 7: Fat Transfer</b> . . . . .	69	<b>Index</b> . . . . .	127
<i>Naomi Lawrence</i>			

*This page intentionally left blank*

# PREFACE

*Concise Manual of Cosmetic Dermatologic Surgery* is meant to be an all-inclusive guide for physicians entering the field of cosmetic surgery, including both residents as well as physicians who wish to expand their knowledge in this arena.

The book includes information regarding reconstructive techniques, i.e., flaps and grafts, so as to enhance readers' overall surgical skills. It details in an illustrative how-to fashion all of the other cosmetic procedures commonly practiced by dermasurgeons. Topics covered include hair transplantation, lasers, fillers, liposuction, aesthetic usage of neurotoxins, and aesthetic approaches to the management of cosmetic veins. A section describing the workup, approach, and evaluation of the aesthetic patient is also included.

What makes this volume unique is its uniform consistency in each chapter's presentation. Pearls to clinical success highlight this illustrative approach. Sections that outline indications as well as contraindications and avoidance pitfalls also help this illustrative paradigm.

Illustrative diagrams demonstrating step-by-step technique of each procedure can help the dermasurgeon entering this field to begin a comprehensive mastery of each of the procedures presented.

It is the hope of the authors that physicians reading this book will enhance their knowledge and begin to expand the number of cosmetic procedures within their practice settings.

The goal of *Concise Manual of Cosmetic Dermatologic Surgery* is to expand the number of practicing cosmetic dermasurgeons and guide more individuals inclined in this regard to pursue this clinical path.

Neil Sadick  
Naomi Lawrence  
Ron Moy  
Ranella J. Hirsch

*This page intentionally left blank*

## Neil Sadick, MD

In order to assure a successful outcome in a dermatology patient, the initial patient consultation is of utmost importance. This initial encounter can be divided into 10 specific areas (Table 1.1). Careful attention to these factors will ensure a greater probability of a successful surgical outcome. A carefully prepared medical questionnaire may be helpful in this regard.

### KEY POINTS FOR SUCCESS

- Complete and detailed medical history and physical examination.
- Understanding of patient's medication history and any potential drug interactions.
- Appropriate antibiotic prophylaxis when indicated.
- Detailed informed consent (including outlining of all relevant complications).
- Photographic documentation.
- Realistic expectations.
- Fee structure consultation for a given procedure.
- Careful postoperative care and monitoring.

### MEDICAL CONSIDERATIONS (TABLE 1.2)

- Medications—A detailed history of ingestion of anticoagulants, aspirin, NSAIDs, platelet inhibitors, vitamin E,

Accutane, herbal preparations, and beta-blockers as well as history of topical agents, i.e., alpha hydroxy acids, retinoids, etc., must be elicited.

- Knowledge of pacemaker insertion is also of importance.
- An elicited history of heart murmurs or joint or heart prosthesis may necessitate the institution of appropriate antibiotic prophylaxis.
- Fainting tendencies are important to document because appropriate therapeutic measures may be ready on a stand-by basis and more importantly, it may be helpful in distinguishing this entity from true seizures.
- HIV and hepatitis status may be elicited by history at the time of initial consultation, but should also further be ruled out by appropriate serologic testing when blood-disseminating procedures are contemplated. This will help to protect both the physician and the staff as well as the patient when invasive bloodborne procedures are being contemplated.
- Smoking—Smoking may create vascular compromise when undermining a large flap, such as in rhytidectomy procedure. Smoking also increases the risk of DVT after liposuction and may impede healing after ablative resurfacing.

**TABLE 1.1 ■ Clinical Checklist for Screening the Dermatology Patient**

- Patient's medical/surgical history
- Present medications/interactions
- Decision on antibacterial/antiviral/antifungal prophylaxis
- Psychosocial history
- Informed consent
- Photography
- Patient expectation
- Complication risks
- Postoperative course/care
- Insurance reimbursement/fee structure

**TABLE 1.2 ■ Medical Considerations for the Dermatology Patient**

- Medications
  - Anticoagulants, iticlopanamide, platelet inhibitors, vitamin E, Accutane, herbal preparations, beta-blockers
- Allergens
- Pacemakers
- Heart murmurs
- Joint prosthesis
- Fainting tendencies
- HIV/hepatitis
- Smoking
- Genetics
- Keloid formation
- Coagulopathy
- Pregnancy

- Genetics—History of keloid formation in the patient or a related family member should be elicited and considered as a relative risk potential.
- Allergies—An allergy history of anesthetics, topical agents, and adhesives should be elicited.
- Finally, a detailed history of possible coagulopathies should be obtained by documented history of easy bruisability or excessive bleeding with trauma as well as by serologic evaluation of quantitative platelet function and clotting parameters.
- Pregnancy—Ascertaining of last menstrual period will allow utilization of all classes of medications and anesthetic agents.
- A sample patient questionnaire is presented in Fig. 1.1.

### **SURGICAL CONSIDERATIONS (TABLE 1.3)**

A detailed surgical history is also of importance in predicting outcomes and preventing complications. The following are important queries to consider:

- Previous surgeries
  - A detailed surgical history, i.e., previous abdominal procedures prior to considering liposuction, is of importance. This may also elicit occult coagulopathies or unusual healing tendencies (i.e., keloid formation).
- Previous artificial prostheses
  - Prosthetic joints may require appropriate antibiotic prophylaxis.
- Pacemaker/defibrillators
  - Pacemakers or defibrillators may necessitate the use of alternative modalities other than electrosurgery for hemostasis.
- Scarring tendencies
  - Examination of previous surgical sites may give clues as to the probability of hypertrophic scarring or keloidal tendencies in a given individual.

**TABLE 1.3 ■ Surgical Considerations for the Dermatology Patient**

- Previous surgeries
- Artificial prostheses
- Pacemaker/defibrillator
- Keloid tendencies

### **MEDICATIONS—DRUG INTERACTION (TABLE 1.4)**

- Direct questions toward specific drugs (Accutane, aspirin, Ecotrin, Coumadin, Estrogen, Plavix, vitamin E, herbal preparations, beta-blockers, NSAIDS, Ticlid, etc.).
- Role of discontinuance of platelet inhibiting drugs is controversial. This is especially important in more extensive procedures such as liposuction, hair transplantation, and ambulatory phlebectomy. In such cases, discontinuance is recommended 1 week prior to surgery.
- Herbal preparations are a frequent cause of impaired platelet function and should be recognized in a detailed medical history. A list of common preparations and suggested guidelines for discontinuance is presented in Table 1.5.

### **ANTIBIOTIC PROPHYLAXIS**

- Most common pathogens are *Staphylococcus epidermidis*, for incision and drainage or curettage or cutting of normal skin, and *Staphylococcus aureus*, for surgical manipulation of diseased or overtly infected skin.
- Antibiotic prophylaxis is most important in patients with prosthetic valves or artificial joints.
- A list of recommended antibiotic regimens is presented in Table 1.6.
- Antiviral prophylaxis is important when ablative resurfacing procedures are performed or a history of recent herpes infection is elicited.
- Suggested guidelines are
  - valacyclovir (Valtrex) 500 mg b.i.d. for 5 days, begin 1–2 days prior.
  - famcyclovir (Famvir) 250 mg b.i.d. for 5 days, begin 1–2 days prior.

**TABLE 1.4 ■ Common Problems: Medications Requiring Considerations in the Dermatology Patient**

Accutane  
Aspirin  
Coumadin  
NSAIDS  
Plavix  
Vitamin E  
Estrogen  
Beta-blockers

**TABLE 1.5 ■ Clinically Important Effects and Perioperative Concerns of Eight Herbal Medicines and Recommendations for Discontinuation of Use Before Surgery**

Herb: Common Name(s)	Relevant Pharmacological Effects	Perioperative Concerns	Preoperative Discontinuation
Echinacea: purple coneflower root	Activation of cell-mediated immunity	Allergic reactions; decreased effectiveness of immunosuppressants; potential for immunosuppression with long-term use	No data
Ephedra: ma huang	Increased heart rate and blood pressure through direct and indirect sympathomimetic effects	Risk of myocardial ischemia and stroke from tachycardia and hypertension; ventricular arrhythmias with halothane; long-term use depletes endogenous catecholamines and may cause intraoperative hemodynamic instability; life-threatening interaction with monoamine oxidase inhibitors	At least 24 h before surgery
Garlic: ajo	Inhibition of platelet aggregation (may be irreversible); increased fibrinolysis; equivocal antihypertensive activity	Potential to increase the risk of bleeding, especially when combined with other medications that inhibit platelet aggregation	At least 7 days before surgery
Ginkgo: duck foot tree, maidenhair tree, silver apricot	Inhibition of platelet-activating factor	Potential to increase the risk of bleeding, especially when combined with other medications that inhibit platelet aggregation	At least 36 h before surgery
Ginseng: American ginseng, Asian ginseng, Chinese ginseng, Korean ginseng	Lowering of blood glucose; inhibition of platelet aggregation (may be irreversible); increased PT-PTT in animals; many other diverse effects	Hypoglycemia; potential to increase the risk of bleeding, potential to decrease the anticoagulation effect of warfarin	At least 7 days before surgery
Kava: awa, intoxicating pepper, kawa	Sedation, anxiolysis	Potential to increase the sedative effect of anesthetics; potential for addiction, tolerance, and withdrawal after abstinence unstudied	At least 24 h before surgery
St. John's Wort: amber, goat week, hardhay, Hypericum, klamath weed	Inhibition of neurotransmitter reuptake, monoamine oxidase inhibition is unlikely	Induction of cytochrome P450 enzymes, affecting cyclosporine, warfarin, steroids, protease inhibitors, and possibly benzodiazepines, calcium channel blockers, and many other drugs; decreased serum digoxin levels	At least 5 days before surgery
Valerian: all heal, garden heliotrope, vandal root	Sedation	Potential to increase the sedative effect of anesthetics; benzodiazepine-like acute withdrawal; potential to increase anesthetic requirements with long-term use	No data

**TABLE 1.6 ■ Antibiotic Prophylaxis for High-Risk Patients During Cutaneous Surgery**

Surgical Procedure	Primary Pathogen of Concern	Preferred Regimen	Alternative Therapy in Patients Allergic to Penicillin
Incision or curettage of normal skin	<i>Staphylococcus epidermidis</i>	Dicloxacillin, 2.0 g orally 1 h before surgery; then 1.0 g, 6 h later	Erythromycin, 1.0 g orally 1 h before surgery; then 0.5 g, 6 h later
Incision or curettage of diseased or overtly infected skin	<i>Staphylococcus aureus</i>	Same as above	Same as above

## PSYCHOSOCIAL HISTORY

- Try to obtain patient motivations for a given cosmetic procedure, i.e., recent spouse or partner separation, loss of a loved one, job insecurity, etc.
- Be careful of the patient who is undergoing multiple, frequent procedures in this regard.
- Patients with unrealistic expectations at the initial patient consultation should be approached with caution.

## INFORMED CONSENT

- The cornerstone of procedural success and medicolegal safety is based upon this document (Table 1.7).
- Exact procedure delineation, indications, treatment alternatives, and full complication profiles remain the cornerstone of this binding physician–patient document.
- Key components of the informed consent include
  - exact procedure delineation
  - procedure alternatives
  - indications for procedure
  - full complication profile
  - procedural fee

**TABLE 1.7 ■ Components of Informed Consent**

Exact procedure delineation
Procedure alternatives
Indications for procedure
Full complication profile
Procedural fee
Photographic consent
Signed by patient/physician/witness
Touch-up policy

- photographic consent
- signed by patient/physician/witness
- touch-up policy
- This form should be signed by the patient, the physician, and a witness in a dated format and should be copied and given to the patient for his/her individual record.

## PHOTOGRAPHY (TABLE 1.8)

- Photography is a necessity in the pre- and postoperative evaluation.
- Photography should be standardized in terms of lighting, distance, background, markers, hairstyles, and clothing.

### ■ Keys of Importance

- High-grade camera.
- Proper light sources.
- Standard background—blue or black best.
- Standardization of views is of importance.
  - Front view should include the top of the head to the sternal notch.
  - Side profile should include the top of the head to just above the sternal notch and the nasal tip to the occiput.
- Professional photography may be preferable in selected cases.

## PATIENT EXPECTATIONS

There are several factors that will affect the odds of optimizing patient results when performing dermasurgical procedures.

- Over-promising results/mismatch of patient–physician expectations.



### Patient Medical/Surgical History Questionnaire

Name \_\_\_\_\_ Date of Birth \_\_\_\_\_ Age \_\_\_\_\_ Occupation \_\_\_\_\_

**Dermatologic History** Referred by: \_\_\_\_\_

1. Reason for visit \_\_\_\_\_  
 How long has this been going on? \_\_\_\_\_  
 What areas are affected? \_\_\_\_\_  
 How has it been treated? \_\_\_\_\_
2. Other skin conditions \_\_\_\_\_
3. Topical (skin) medications \_\_\_\_\_
4. Other products applied to your skin \_\_\_\_\_

**Medical History** (includes system review)

Do you have or have you had any of the following?

	Yes	No		Yes	No		Yes	No
High Blood Pressure	[ ]	[ ]	Anemia	[ ]	[ ]	Stomach/Bowel Problem	[ ]	[ ]
Heart Disease	[ ]	[ ]	Glaucoma	[ ]	[ ]	Recent Weight Loss	[ ]	[ ]
Cardiac Pacemaker	[ ]	[ ]	Cancer	[ ]	[ ]	Tobacco Use	[ ]	[ ]
Rheumatic Fever	[ ]	[ ]	Arthritis	[ ]	[ ]	Keloids/Excessive Scar	[ ]	[ ]
Heart Murmur	[ ]	[ ]	Liver Disease or Hepatitis	[ ]	[ ]	Cold Sore/Fever Blister	[ ]	[ ]
Mitral Valve Prolapse	[ ]	[ ]	Hay Fever/Allergies	[ ]	[ ]	Radiation Therapy	[ ]	[ ]
Artificial Joints	[ ]	[ ]	Seizures	[ ]	[ ]	Ultraviolet Light Tx	[ ]	[ ]
Stroke	[ ]	[ ]	Kidney/Bladder Problem	[ ]	[ ]	History of Skin Cancer	[ ]	[ ]
Diabetes	[ ]	[ ]	Asthma or Lung Problems	[ ]	[ ]			
HIV Infection	[ ]	[ ]						

Do you need antibiotics before surgical or dental procedures? [ ] [ ]  
 List any other medical problems or surgeries and  
 Explain any of above if needed

[ ] [ ]  
 Please list all medications you are using (including  
 non-prescription, aspirin, birth control pills, vitamins)

Family history of skin cancer/skin diseases  
 \_\_\_\_\_  
 \_\_\_\_\_  
 \_\_\_\_\_

Women Only: Are you...	Yes	No
Pregnant or think you may be?	[ ]	[ ]
Nursing (breast-feeding)?	[ ]	[ ]
Taking oral contraceptives?	[ ]	[ ]
Taking hormone replacements?	[ ]	[ ]

List any allergies (including medications)  
 \_\_\_\_\_

**Information Request** (check if you would like more information)

Wrinkle treatments	[ ]	Filler/Botox	[ ]	Hair transplantation	[ ]	Liposuction	[ ]
Chemical peels	[ ]	Leg veins	[ ]	Laser hair removal	[ ]	Pigmentation	[ ]
Laser treatment + (dark spots, blood vessels)	[ ]			Skin cancer	[ ]		

Signature of patient (or parent if minor) \_\_\_\_\_ Date \_\_\_\_\_ Physician's initials \_\_\_\_\_ Date \_\_\_\_\_

**FIGURE 1.1** Patient medical/surgical history questionnaire

**TABLE 1.8 ■ Important Features in Photography**

Background	Same color background, for better contrast; standardize background to black or blue
Lighting	Even and continuous light source, bright light with backlights to decrease shadowing, allows for accuracy
Proper equipment	Professional camera, digital, correct flash, proper computer program
Repetition	Standardized positions for patient poses

- Not explaining adequate complication profiles.
- Lack of photographic documentation.
- Poor postoperative follow-up.
- Inability to recognize inappropriate psychological motivations.

Perhaps the most important pitfall in this setting is overpromising results and mismatch of patient–physician expectations. Conservative or realistic expectations, which may be easily overachieved, are a good general approach to ensure patient satisfaction with a given procedure.

## COMPLICATION RISKS

- A major factor leading to patient dissatisfaction is an unexpected complication that has not been well explained.
- A detailed discussion of the majority of expected complications, which are signed and documented, will help to minimize this scenario.

## POSTOPERATIVE COURSE/CARE (TABLE 1.9)

- During the preoperative consultation, the patient should be told of the postoperative course including wound care, bandages, antibiotic coverage, activity restrictions, and the time duration for which the suture needs to remain in place.
- For example, in the Restylane treatment the patient may expect swelling at injection sites for 24–48 hours. Botulinum toxin may take 3–7 days to show effects.
- Postoperative bruising after liposuction may last for 2–3 weeks.

**TABLE 1.9 ■ Postoperative Care Considerations**

Wound care (dressings, ointments)
Bandages
Duration sutures remain in place
Compression garments/hosiery
Antibiotic coverage
Activity restrictions
Restarting of medications (i.e., aspirin, anticoagulants, etc.) as well as topical agents

- Patients undergoing follicular unit hair transplantation may experience some degree of crusting at recipient sites for 7–10 days.
- Patients undergoing endovascular laser procedure may experience tightness in the treated greater saphenous vein segment for 5–10 days.
- Postoperative care, i.e., wound dressings after ablative laser resurfacing procedures, compression after liposuction or ambulatory phlebectomy are also important factors for patient consideration to be discussed and planned for at the initial consultation.
- Poor postoperative follow-up may lead to inferior results and a higher complication profile.
- Patients also need to be instructed as to when they can resume medications, such as aspirin, anticoagulants, etc., following surgical intervention or topical agents, such as retinoid or alpha hydroxy acids, following chemical peels or other ablative resurfacing procedures.

## INSURANCE REIMBURSEMENT/FEE STRUCTURE

- Patient should be adequately informed about the fee of a given procedure that is being considered.
- They should also have a reasonable understanding as to whether this is a covered procedure by insurance or considered cosmetic in nature.
- Preoperative clearance by a given insurance carrier is often necessary and may be required to be accompanied by a letter of medical necessity, an appropriate instance, i.e., symptomatic varicose veins, botulinum toxin therapy for hyperhidrosis, etc.
- This document should be signed by both the patient and the physician and included in the medical record.
- A sample of an informed fee consent is presented in Fig. 1.2.

**SURGERY FEE CONSENT**

I hereby consent to and authorize Dr. Sadick and/or his assistants to perform the operative procedure stated upon me.

Procedure: \_\_\_\_\_ Fee: \_\_\_\_\_  
 \_\_\_\_\_  
 \_\_\_\_\_

I fully understand the necessity and/or elective reasoning of this procedure which has been explained to me by Dr. Sadick and/or his assistants.

I acknowledge I have been explained in detail the charges for these services and I am fully aware I am responsible for full payment at the time the services are rendered. I understand that cosmetic procedures are not covered by insurance carriers.

_____	_____
DATE	PATIENT SIGNATURE
_____	_____
DATE	DOCTOR
	_____
	WITNESS

**FIGURE 1.2** *Surgery fee consent*

## CONCLUSION

---

Careful consideration of detail in obtaining a complete medical history, matching patient expectations with physician capabilities, detailed informed consent with appropriate photographic documentation, detailed informed consent, and adequate postoperative follow-up will lead to gratifying results and fewer complications when performing many of the procedures presented in the following chapters.

## SUGGESTED READING

---

- Sadick NS. Evaluating and approaching the cosmetic patient. *Am J Cos Surg* 2003;20:143–147.
- Foster CR. A plastic surgeon's perspective. In: T Romo, III, AL Millman (eds.). *Aesthetic Facial Plastic Surgery*, Thieme, New York, 2002.
- Galitz RM. Traditional photo documentation. *Aesthetic facial plastic surgery*. In: T Romo, III, AL Millman (eds.). *Aesthetic Facial Plastic Surgery*, Thieme, New York, 2002.
- Sclafani, AP. A facial plastic surgeon's perspective. In: T Romo, III, AL Millman. *Aesthetic Facial Plastic Surgery*, Thieme, New York, 2002.
- Shiffman MA. Dangers of herbs when performing surgery. *Int J Cos Surg Aesthetic Dermatol* 2000; 2:95–97.
- Ang-Lee M, Moss J, Yuan C. Herbal medicines and perioperative care. *JAMA* 2001;286:208–216.
- Goldsmith SM, Leshin B, Owen J. Management of patients taking anticoagulants and platelet inhibitors prior to dermatologic surgery. *J Dermatol Surg Oncol* 1993;19:553–559.
- Alcalay J, Alcalay R. Controversies in perioperative management of blood thinners in dermatologic surgery: Continue or discontinue? *Dermatol Surg* 2004;30:1091–1094.
- Ah-Weng A, Natarajan S, Velangi S, Langtry JAA. Preoperative monitoring of warfarin in cutaneous surgery. *Br J Dermatol* 2003;149:386–389.
- Richards KR, Stasko T. Dermatologic surgery and the pregnant patient. *Dermatol Surg* 2002;28: 248–256.
- Kovich O, Otley C. Perioperative management of anticoagulants and platelet inhibitors for cutaneous surgery: A survey of current practice. *Dermatol Surg* 2002;28:513–517.
- Shiffman MA. Estrogen and thromboembolic disorders: Should patients stop hormones prior to cosmetic

- surgery? *Int J Cos Surg Aesthetic Dermatol* 2002;4: 213–215.
13. Alam M, Goldberg LH. Serious adverse vascular events associated with perioperative interruption of antiplatelet and anticoagulant therapy. *Dermatol Surg* 2002;28:992–998.
  14. Billingsley EM, Maloney ME. Intraoperative and postoperative bleeding, problems in patients taking warfarin, aspirin, and nonsteroidal anti-inflammatory agents. *Dermatol Surg* 1997;23:381–385.
  15. Otley CC, Fewkes JL, Frank W, Olbricht SM. Complications of cutaneous surgery in patients who are taking warfarin, aspirin, or nonsteroidal anti-inflammatory drugs. *Arch Dermatol* 1996;132: 161–166.
  16. Kovich O, Otley C. Thrombotic complications related to discontinuation of warfarin and aspirin therapy perioperatively for cutaneous operation. *J Am Acad Dermatol* 2003;48:233–237.
  17. Wagner RF, Grande DJ, Feingold DS. Antibiotic prophylaxis against bacterial endocarditis in patients undergoing dermatologic surgery. *Arch Dermatol* 1986;122:799–801.
  18. Robins P. The Ten Commandments: What every surgeon should know about performing dermatologic surgery. *J Drugs Dermatol* 2002;2:140–144.

## CHAPTER 2

## Facial Flaps

Naomi Lawrence, MD

### KEY POINTS OF SUCCESS

- Flaps are most commonly performed for defects after cancer extirpation.
- Tissue rearrangement is best performed after margin evaluation either through Mohs technique, frozen sections, or permanent section evaluation.
- There are four primary flap categories: advancement, rotation, transposition, and interpolation.

### FLAP TYPES

#### ■ Advancement Flaps (Table 2.1)

- In advancement flaps, the flap movement is primarily from one direction (lateral, superior, or inferior).
- The length-to-width ratio is typically in the range of 3:1 to 4:1.
- Advancement flaps are commonly employed in a bilateral motion by using two flaps to close one central defect. Often, these flaps may be used at a cosmetic junction to avoid crossing an important anatomic border such as the lip, nose, or brow.

#### ■ Rotation Flaps (Table 2.2)

- The rotation flap moves in two directions along an arc from the primary defect.

#### TABLE 2.1 ■ Advancement Flaps

Unilateral advancement  
Sliding H (Bilateral) advancement  
A to T advancement  
Burow's triangle advancement  
Mercedes advancement  
Island pedicle flap  
V to Y advancement  
Antia-Buch  
Lip wedge resection

#### TABLE 2.2 ■ Rotation Flaps

Simple rotation  
Bilateral rotation  
O to Z rotation  
Dorsal nasal (back-cut) rotation

- The flap is typically sized to be three to four times the area of the primary defect.
- Adding a back-cut into the pedicle is a common variation (the dorsal nasal flap, for example). This allows a greater arc of rotation and is not detrimental to flap survival as the flap has a broad pedicle by design.

#### ■ Transposition Flaps (Table 2.3)

- Movement of the transposition flap is tangential or perpendicular to the defect over normal adjacent skin.
- Flap movement uses both advancement and rotation.

#### ■ Interpolation Flaps

- These flaps move remote skin into the area of the defect attached to a pedicle of skin, subcutaneous tissue, and sometimes muscle. This pedicle is then taken down with the flap inserted into the defect after 2–3 weeks.

### GENERAL PRINCIPLES OF TISSUE MOVEMENT

- Cutting the skin ALWAYS creates a scar.
- Younger patients have skin with high elasticity leading more commonly to “stretch-back” and resultant “stretch-mark” scars compared to older patients

#### TABLE 2.3 ■ Transposition Flaps

Rhombic flap  
Bilobed flap  
Melolabial flap

whose skin has less elasticity in addition to rhytides and skin folds to camouflage scars.

- Boundaries between cosmetic units provide scar camouflage.
- Restoring contour, particularly on a convex surface, is important to minimizing deformity.
- In a concave area or some areas on the trunk and extremities, consider second intention healing. The cosmetic result may be better than that from any reconstruction.
- If possible, choose skin for the flap that matches the missing skin in color, texture and sebaceous quality.
- To choose the type of flap and best direction of tissue movement, pinch the surrounding skin to look for area of greatest laxity.
- Look for flap counter-movement, i.e., even though you may determine that most of the movement may be from one direction, all of the skin around the defect will move somewhat. Consider how this may affect the final cosmesis.
- Always consider the effect of movement on any free margin. Distortion of a free margin causes both functional and cosmetic problems.
- Undermine widely and generously bury subcutaneous suture to minimize trap-door effect (outward puckering of the flap).
- Know the anatomy of the surgical area to minimize risk of damaging important underlying structures.

- Healing on the face is, in general, superior to nonfacial healing. This is most likely due to the greater vascularity of this area.

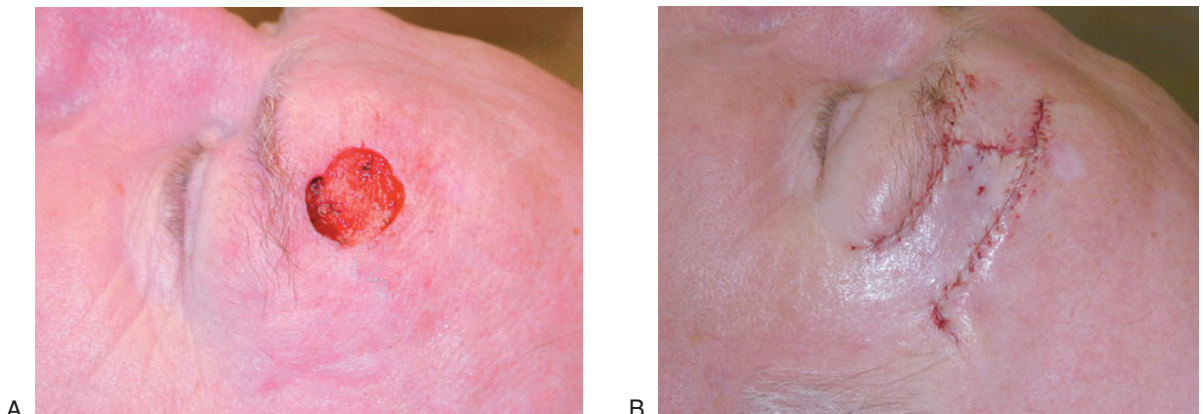
### ■ Forehead

- Midline defect
  - Vertical primary closure
    - With M-plasty at glabella to preserve inter-brow distance
- Advancement
  - Unilateral
  - Bilateral (sliding H) (Fig. 2.1)
- Lateral Defect
  - Horizontal primary closure
  - Vertical or oblique closure also acceptable
  - Rotation (Fig. 2.2 and 2.3)

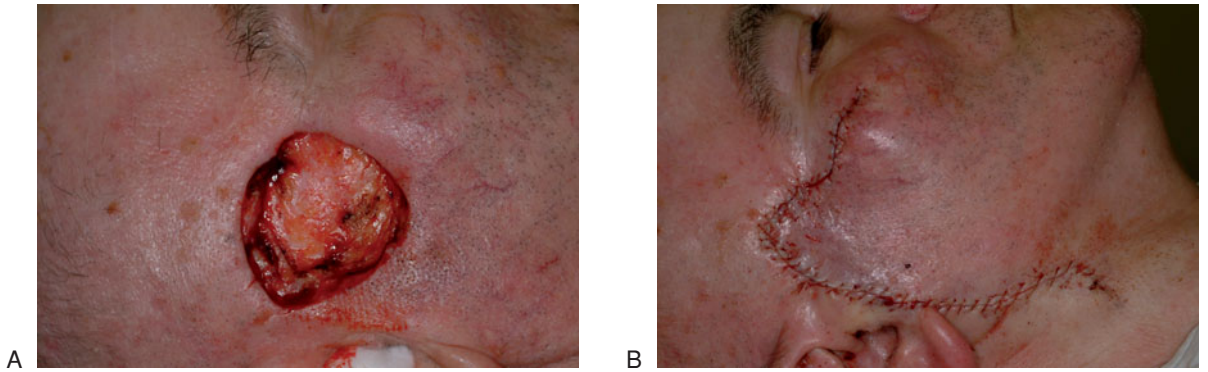
*Potential Limitations:* Lack of mobility necessitates long flaps with little movement.

### ■ Eyebrows

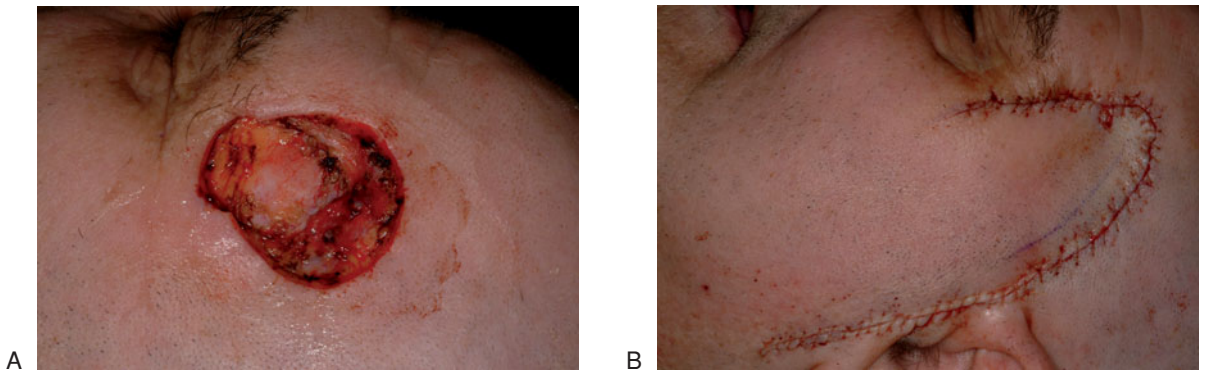
- Above the brow
  - Primary
    - Advancement
      - Unilateral or bilateral (sliding H or A to T) O to Z (Fig. 2.4 and 2.5)
      - Burow's triangle advancement
    - Rotation: O to Z



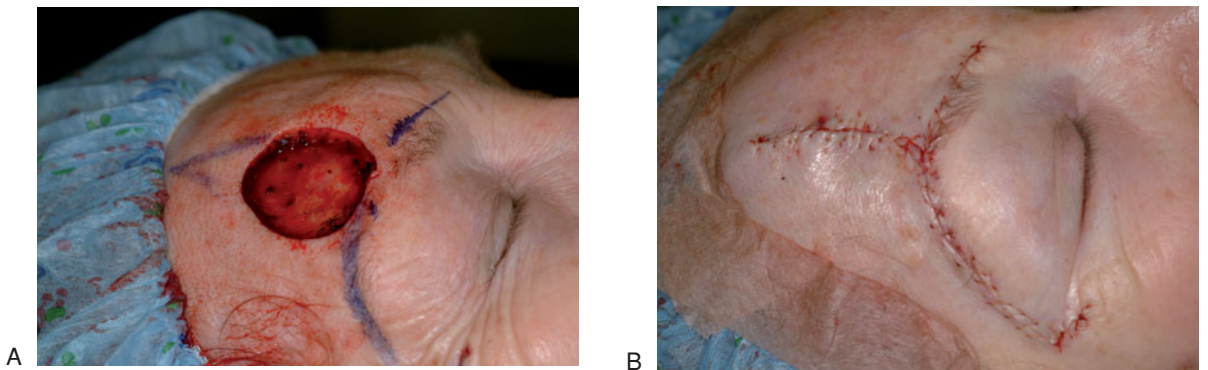
**FIGURE 2.1** **A.** Forehead defect. **B.** Sliding H—immediately postsuture



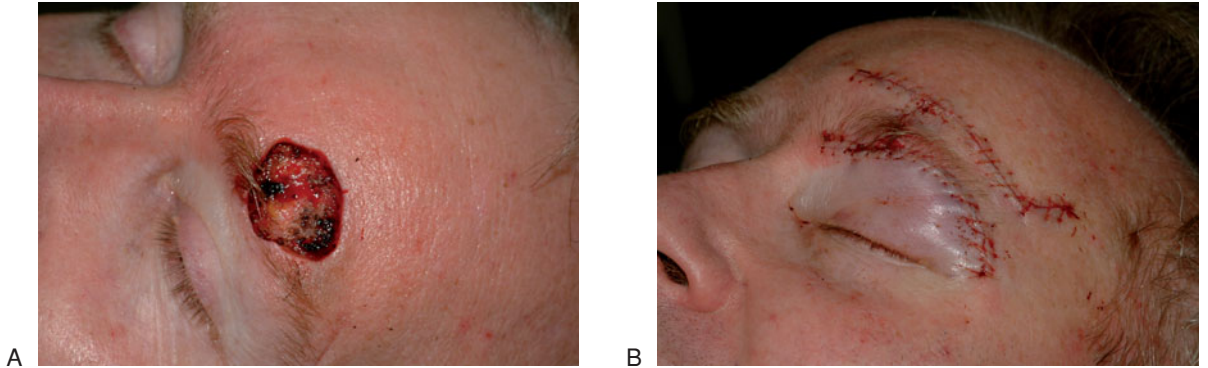
**FIGURE 2.2** **A.** Cheek defect. **B.** Rotation—immediately postsuture



**FIGURE 2.3** **A.** Cheek defect. **B.** Rotation—immediately postsuture



**FIGURE 2.4** **A.** Brow defect. **B.** A to T—immediately postsuture



**FIGURE 2.5** **A.** Brow defect. **B.** Sliding H—immediately postsuture

- Within the brow
- Advancement: Unilateral or bilateral
- Island pedicle
- Rotation: V to Y Advancement (Fig. 2.6)

*Potential Problems:* Shorter brow and brow elevation.

### ■ Eyelid

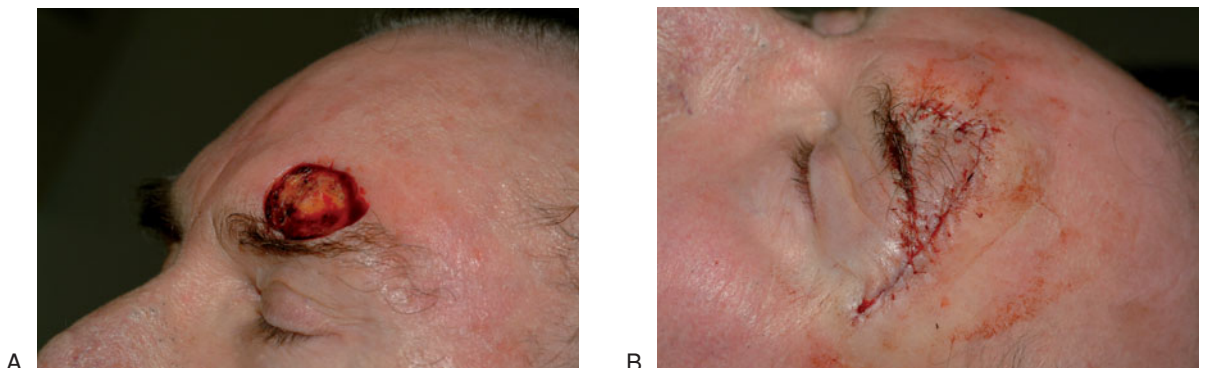
- Upper: Primary horizontal skin graft
- Lower
  - Primary (vertical oblique)
  - Horizontal with deep anchoring sutures to prevent ectropion
  - Graft (Fig. 2.7)
  - Advancement (Mustarde)

- Lid wedge advancement
- Medial canthus
  - Second intention
  - Primary closure
  - Rotation
    - To Z (Fig. 2.8 and 2.9)
    - Dorsal nasal (Fig. 2.10) (rotation with back-cut)

*Potential Problems:* Free margin distortion and webbing (anticipate contraction for second intention healing).

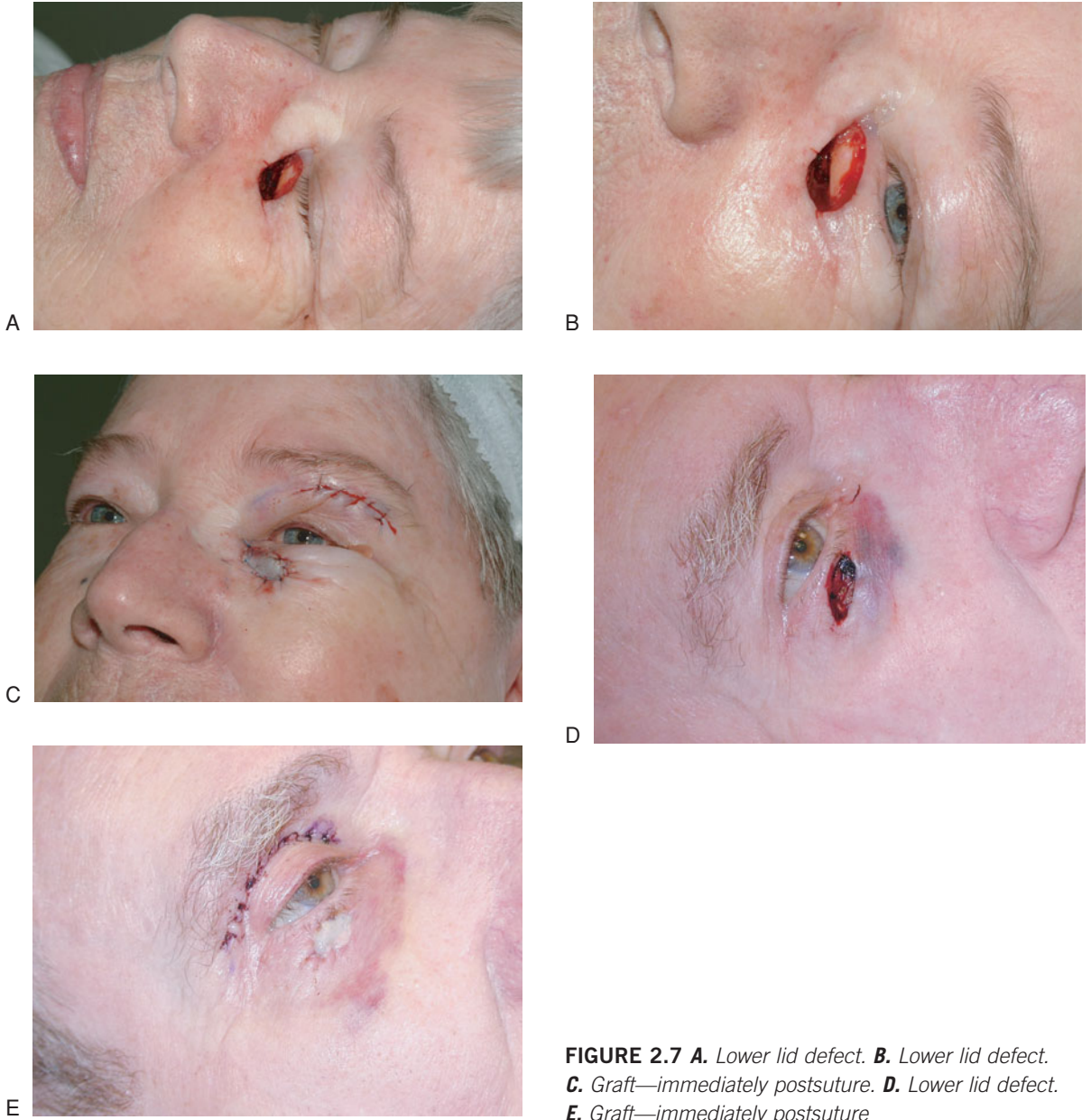
### ■ Cheek

- Medial
  - Primary
  - Rotation: O to Z

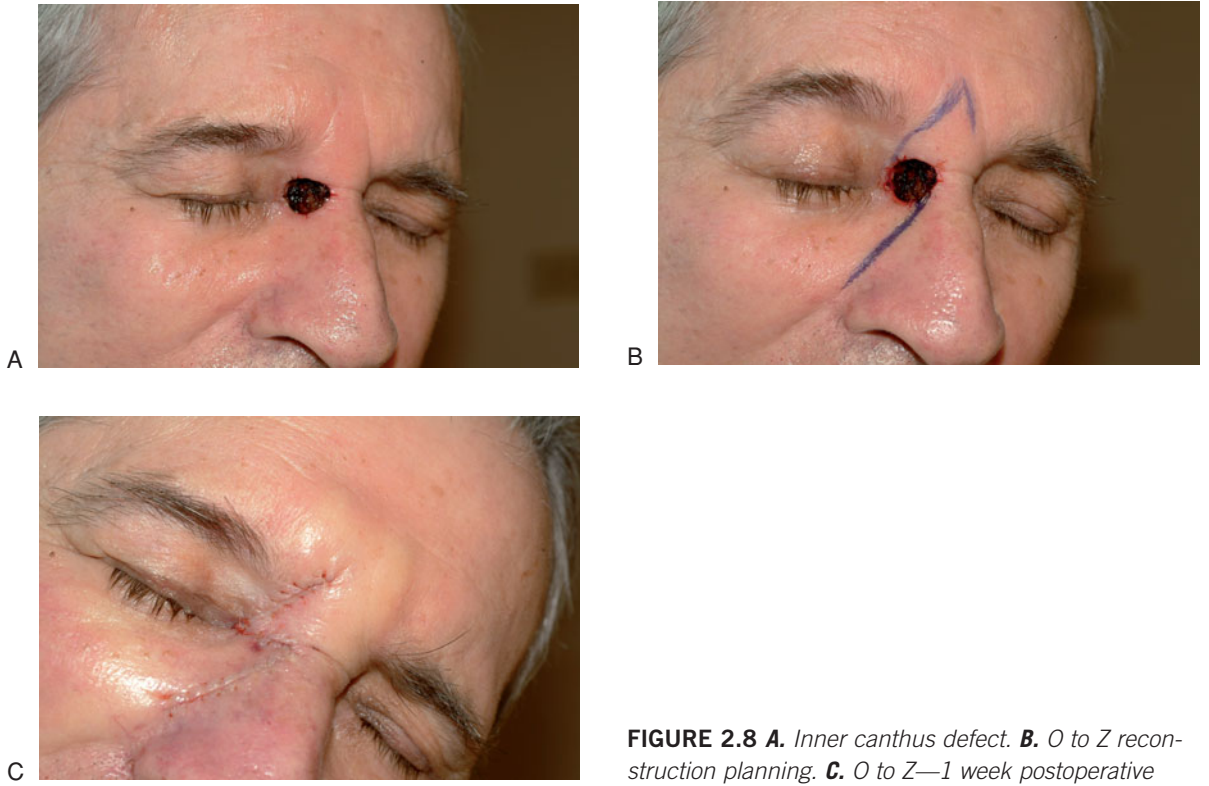


**FIGURE 2.6** **A.** Brow defect. **B.** V to Y—immediately postsuture

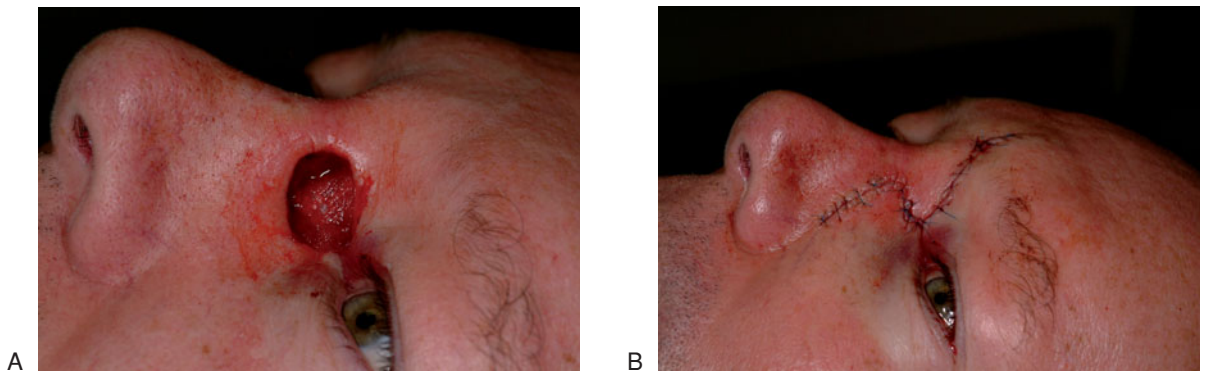




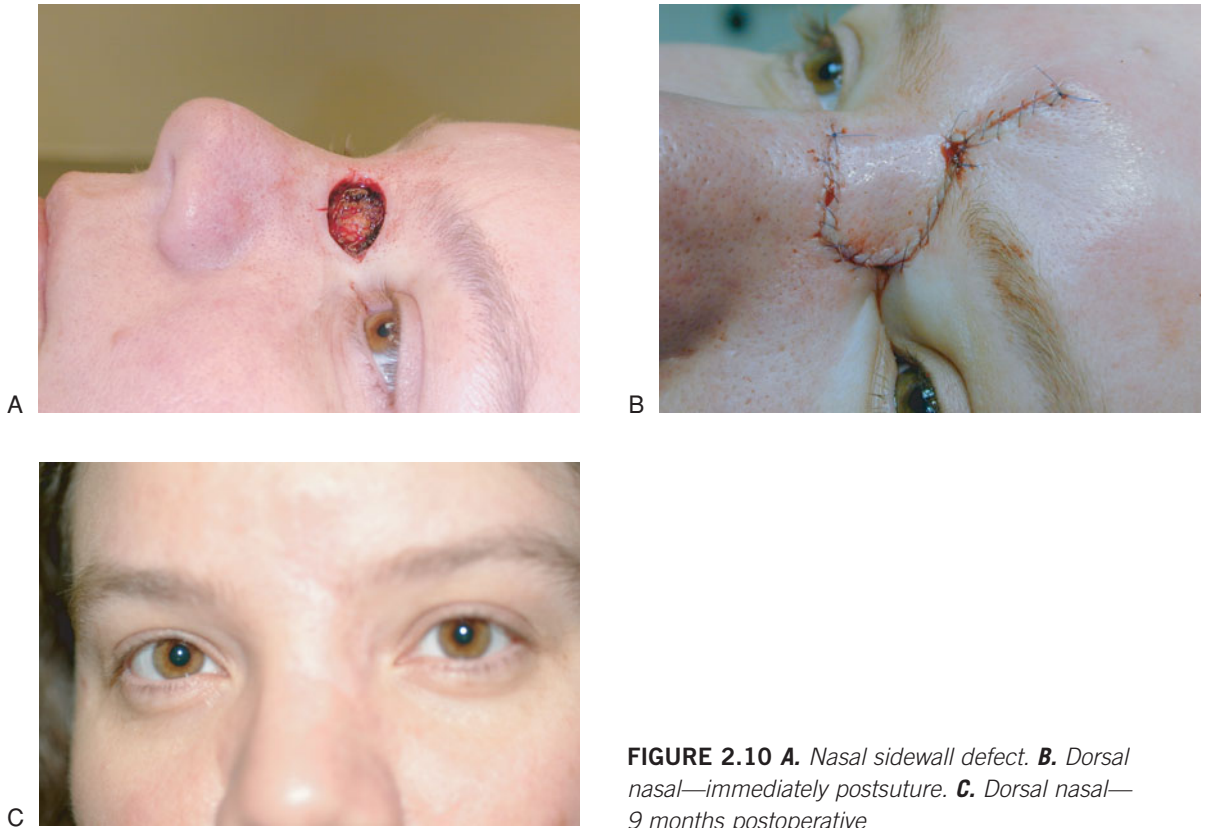
**FIGURE 2.7** **A.** Lower lid defect. **B.** Lower lid defect. **C.** Graft—immediately postsuture. **D.** Lower lid defect. **E.** Graft—immediately postsuture



**FIGURE 2.8** *A. Inner canthus defect. B. O to Z reconstruction planning. C. O to Z—1 week postoperative*



**FIGURE 2.9** *A. Inner canthus defect. B. O to Z—immediately postsuture*



**FIGURE 2.10** *A. Nasal sidewall defect. B. Dorsal nasal—immediately postsuture. C. Dorsal nasal—9 months postoperative*

- Advancement (Fig. 2.11)
  - Mustarde (Fig. 2.12)
  - Crescentic (Fig. 2.13)
- Mid
  - Primary
  - V to Y advancement (Fig. 2.14)
- Infraocular (see lower lid)
- Lateral
  - Primary
  - Rotation

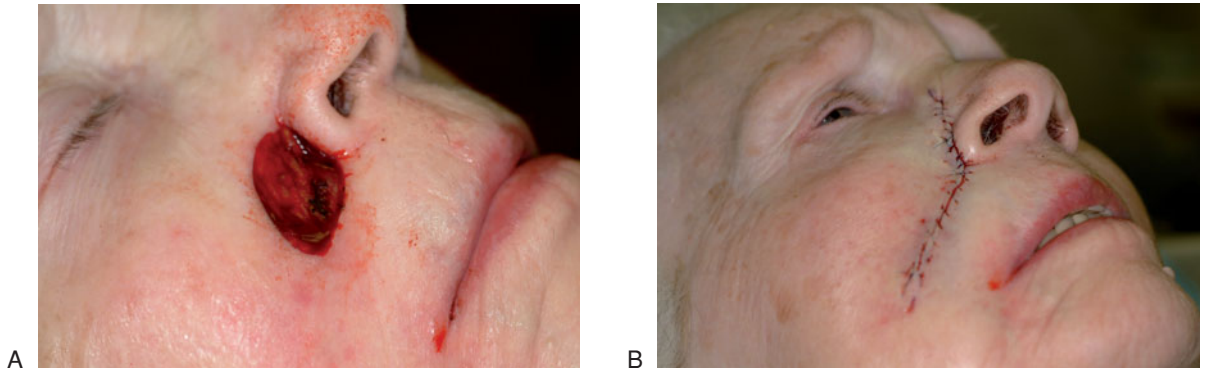
### Tips

- Avoid distortion of the lower lid, upper lip, and corner of the mouth.
- Scars on the mid-cheek (convex surface) are often most apparent.

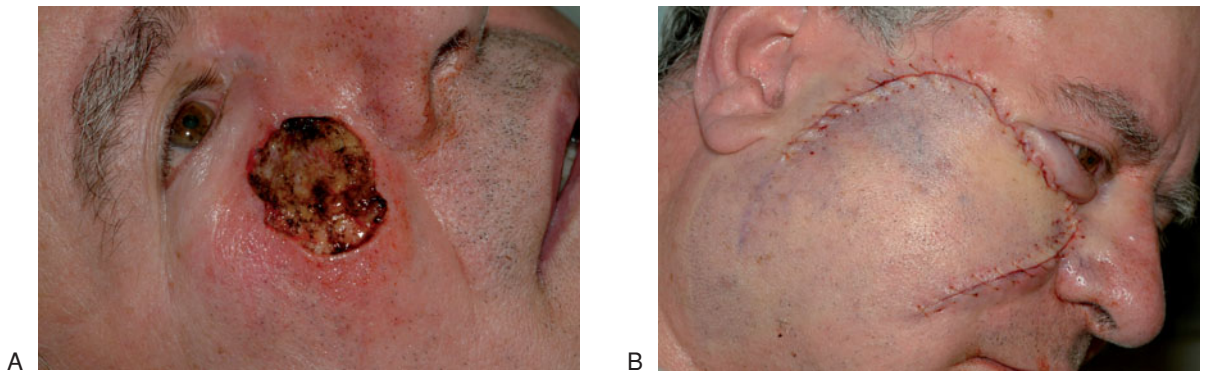
- A scar line at the lower lid/cheek junction (such as with the Mustarde) results in lower lid edema, which can persist for 6 months up to 1 year.
- For the rotation flap, use the back-cut at the glabella (dorsal nasal flap) for the upper limb.
- Anchor the upper margin of the V to Y advancement to the deep tissues to prevent ectropion.
- In a patient with lower lid laxity, always consider canthopexy.

### ■ Nose

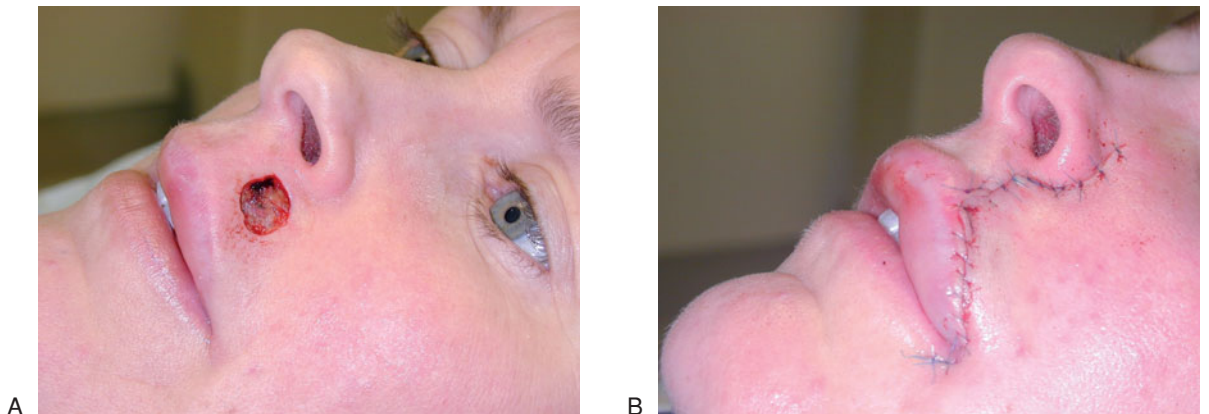
- Sidewall
  - Primary (Fig. 2.15)
  - Advancement (Fig. 2.16)
  - Dorsal nasal (Fig. 2.17 and 2.18)
  - Full-thickness graft



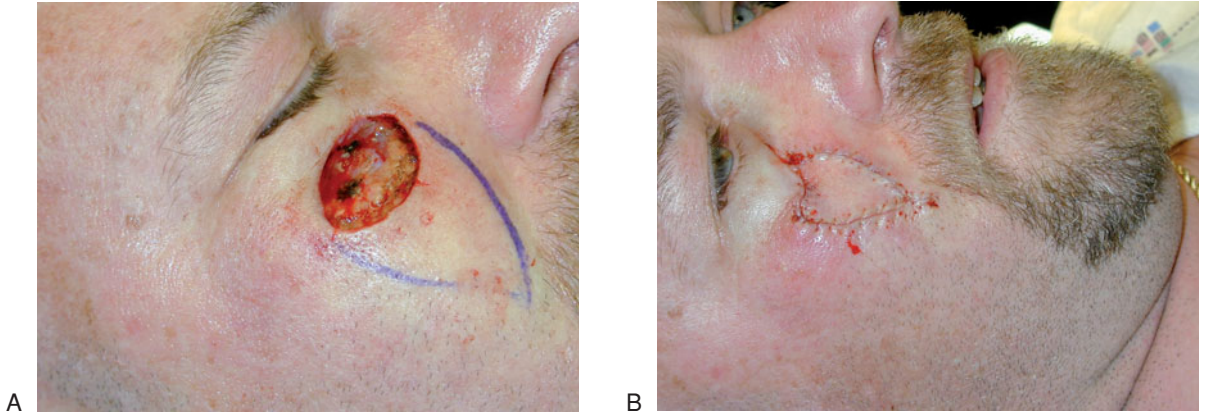
**FIGURE 2.11** *A. Cheek defect. B. Advancement—immediately postsuture*



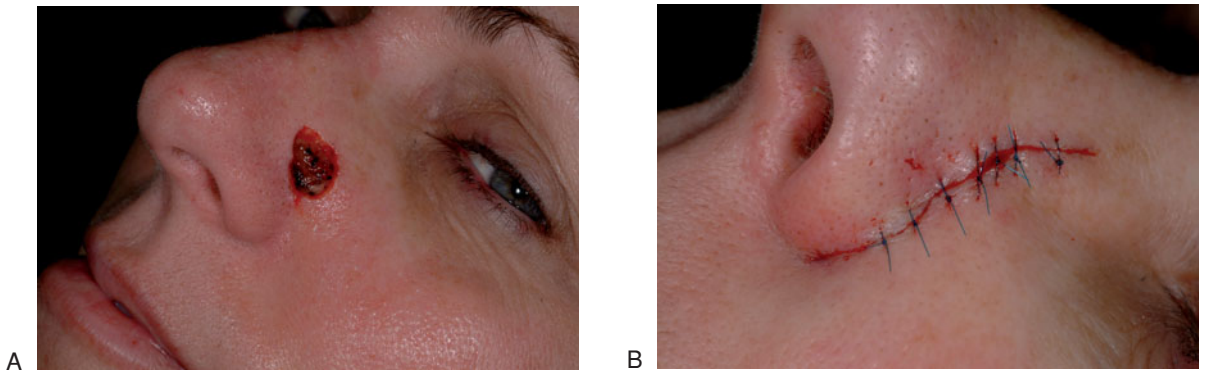
**FIGURE 2.12** *A. Cheek defect. B. Mustarde—immediately postsuture*



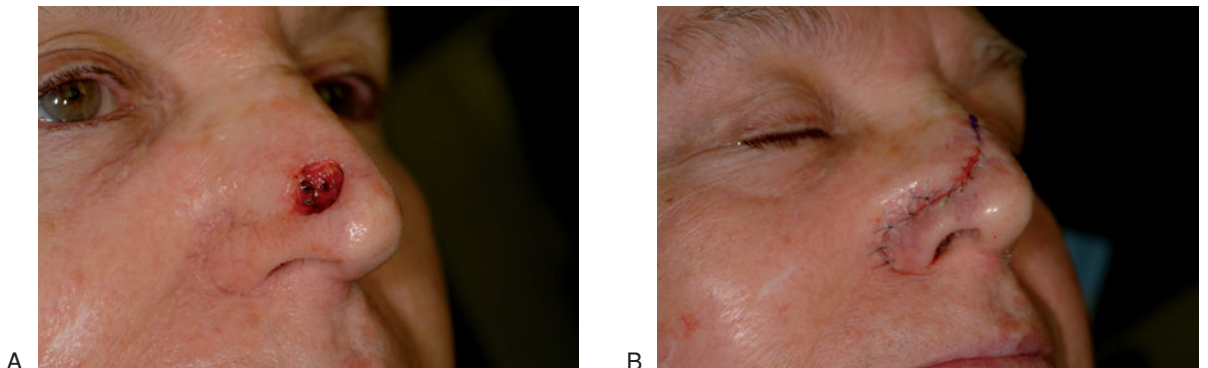
**FIGURE 2.13** *A. Cutaneous lip defect. B. Advancement—immediately postsuture*



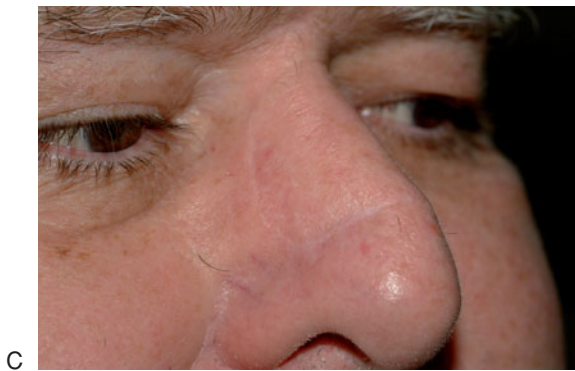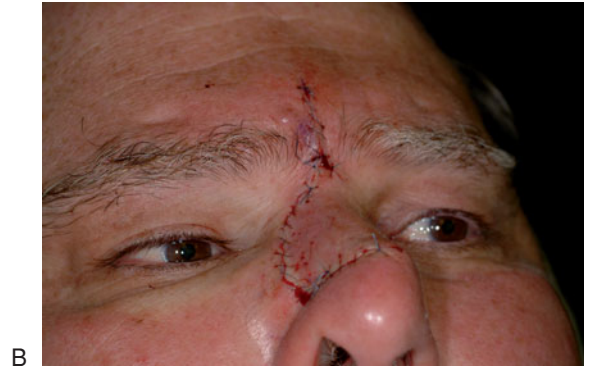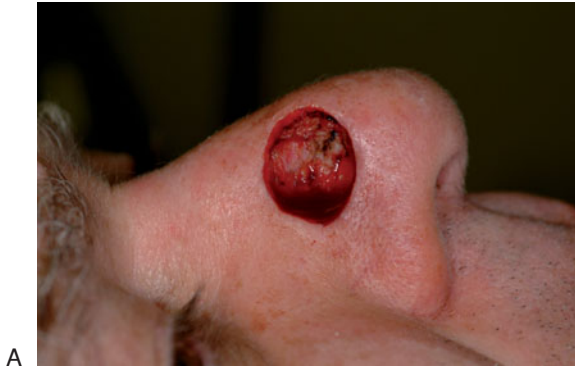**A** **B**  
**FIGURE 2.14** **A.** Cheek defect with planned reconstruction. **B.** V to Y—immediately postsuture



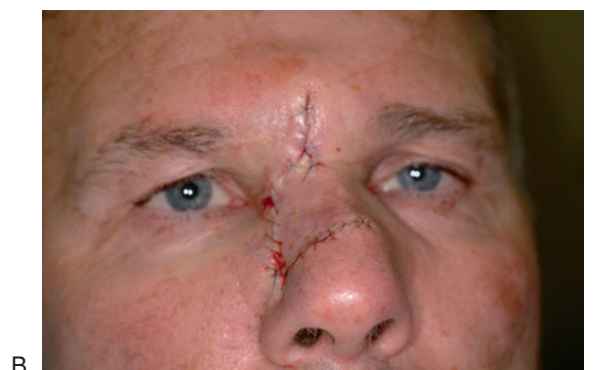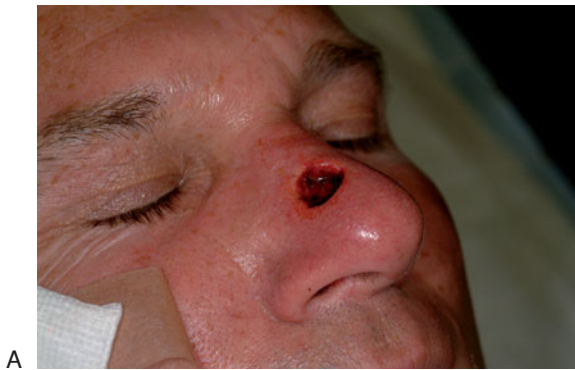**A** **B**  
**FIGURE 2.15** **A.** Nasal sidewall defect. **B.** Primary—immediately postsuture



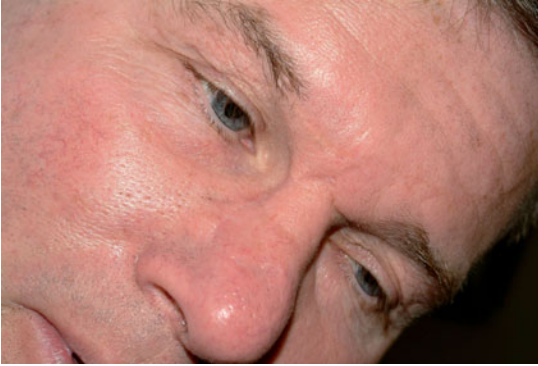**A** **B**  
**FIGURE 2.16** **A.** Nasal tip defect. **B.** Advancement—immediately postsuture



**FIGURE 2.17** **A.** Nasal sidewall defect. **B.** Dorsal nasal—immediately postsuture. **C.** Dorsal nasal—9 months postoperative



**FIGURE 2.18** **A.** Nasal defect. **B.** Dorsal nasal—immediately postsuture (Figure continues.)



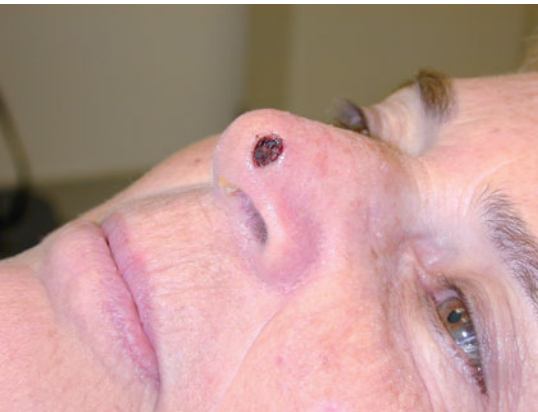C

**FIGURE 2.18 (continued) C.** Dorsal nasal—6 months postoperative

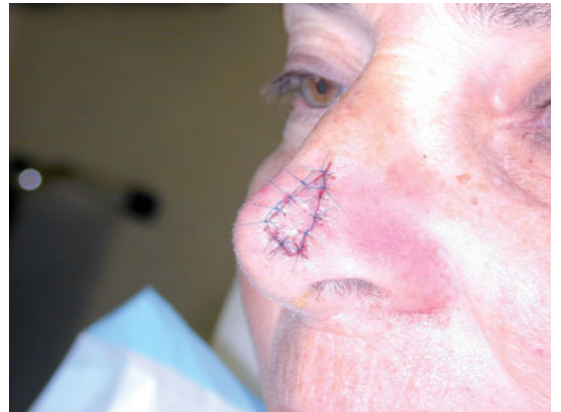- Upper dorsum
  - Primary
  - Advancement (dorsal nasal)
  - Full thickness graft

**Nasal tip**

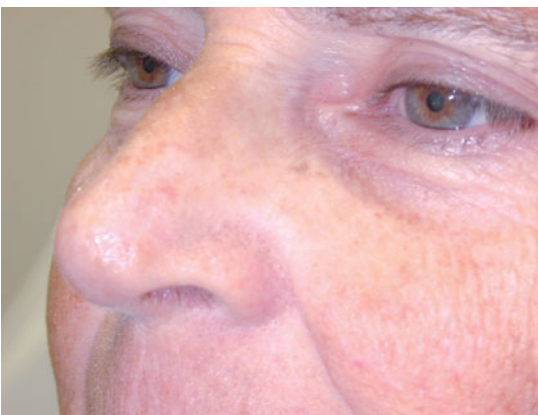- Primary
  - Island pedicle (Fig. 2.19)
  - Dorsal nasal (Fig. 2.20)
  - Peng (bilateral dorsal nasal)
  - Bilobed transposition (Fig. 2.21)
  - Paramedian forehead (Fig. 2.22)



A

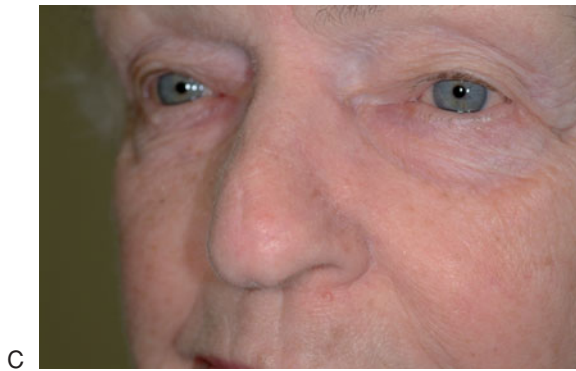
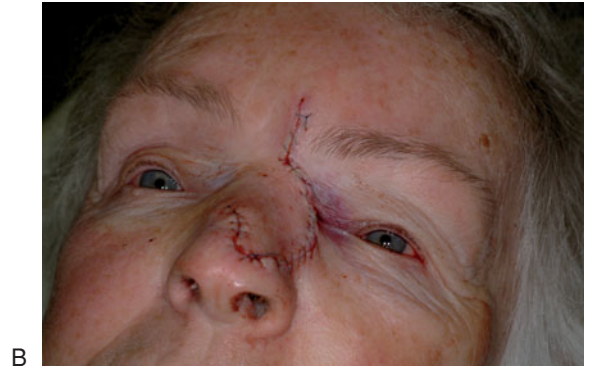
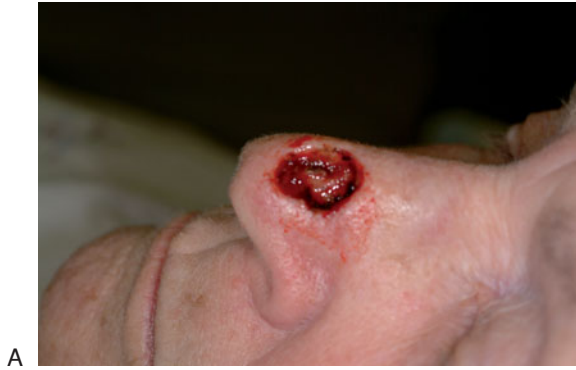B

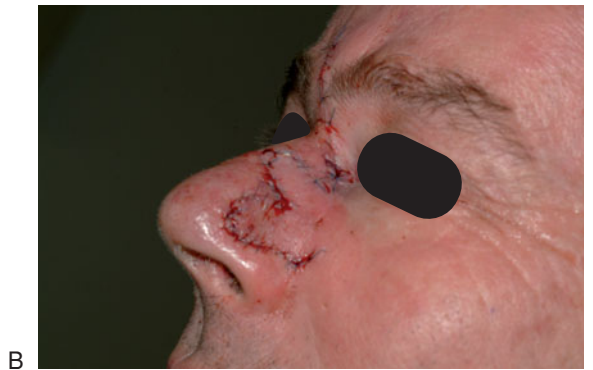
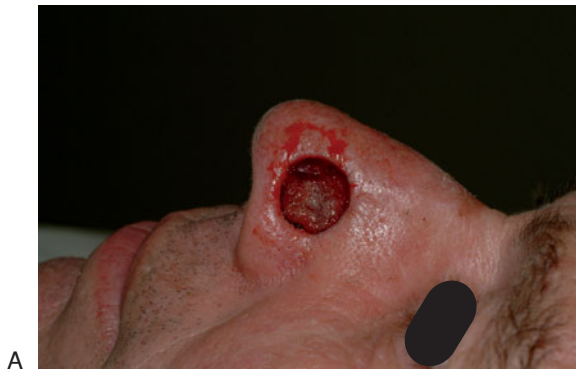
C

**FIGURE 2.19 A.** Nasal defect. **B.** Island pedicle—immediately postsuture. **C.** Island pedicle—3 months postoperative

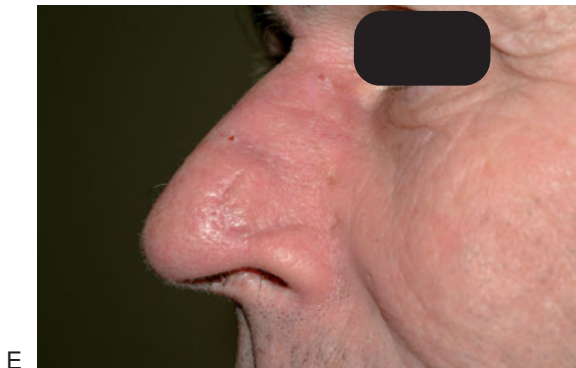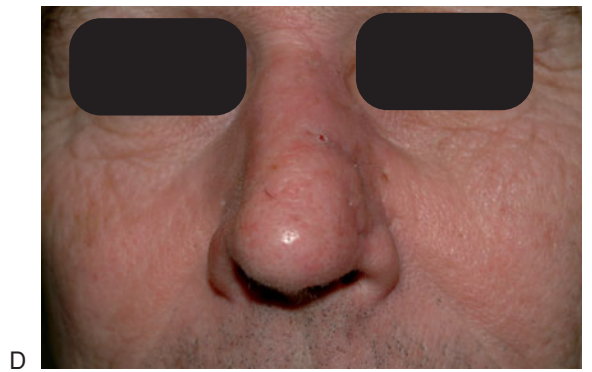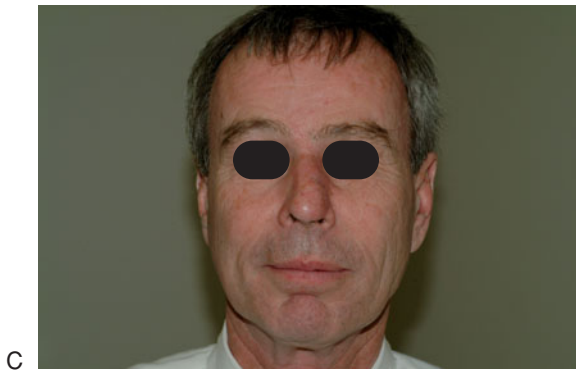


**FIGURE 2.20** **A.** Nasal defect. **B.** Dorsal nasal—immediately postsuture. **C.** Dorsal nasal—11 months postoperative

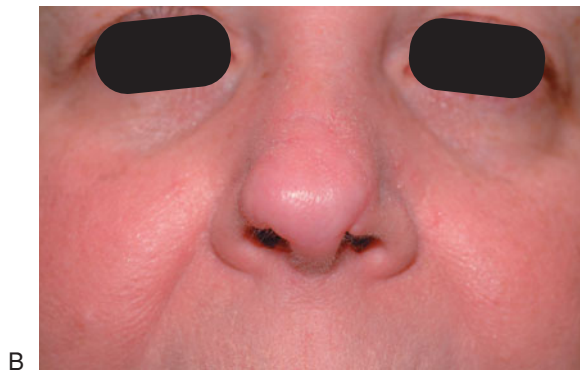
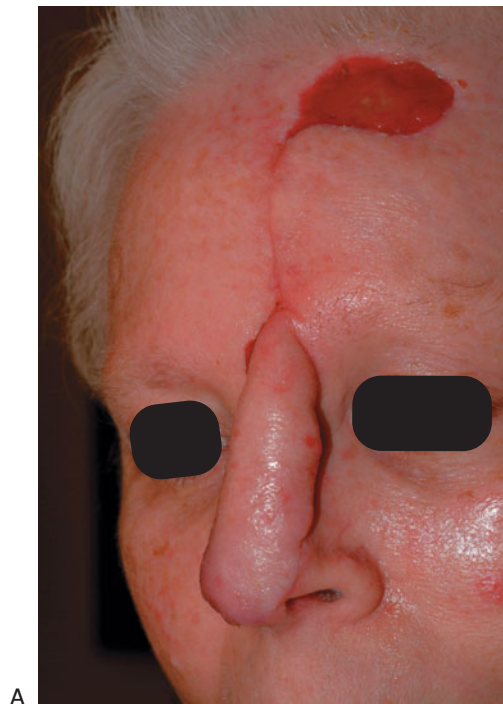
**FIGURE 2.21** **A.** Nasal defect. **B.** Bilobed—immediately postsuture (Figure continues.)

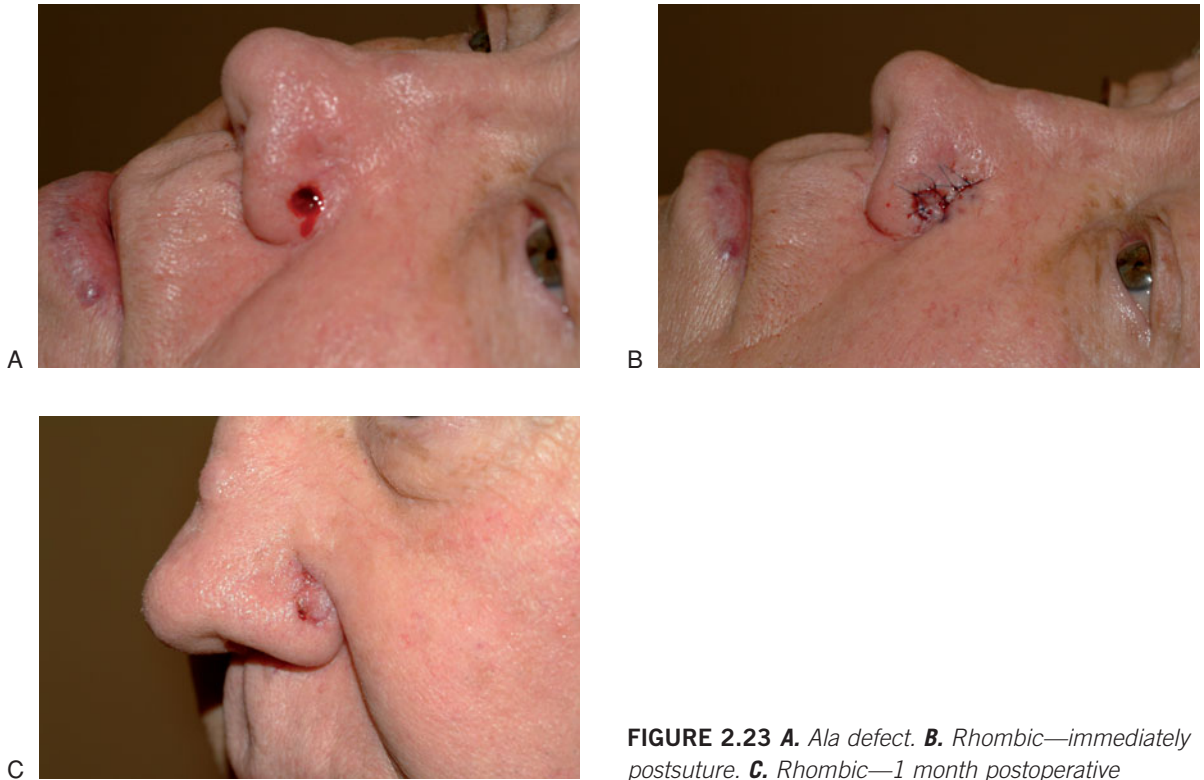




**FIGURE 2.21 (continued)** *C. Bilobed—2 months postoperative. D. Bilobed—2 months postoperative. E. Bilobed—2 months postoperative*



**FIGURE 2.22** *A. Forehead flap—immediately postsuture. B. Forehead flap—8 months postoperative*



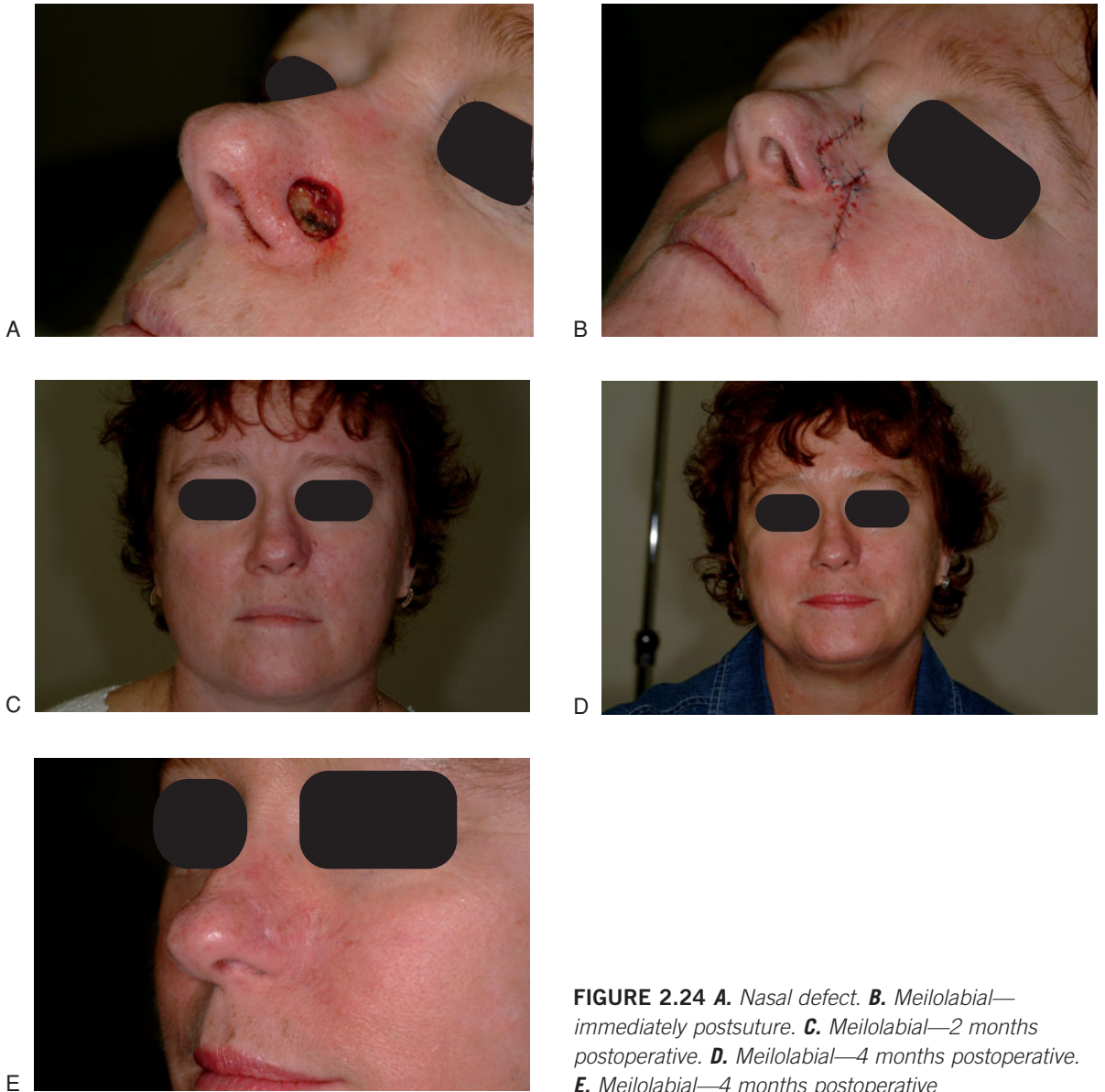**FIGURE 2.23** **A.** Ala defect. **B.** Rhombic—immediately postsuture. **C.** Rhombic—1 month postoperative

- Melolabial
- Rhombic
- Ala
  - Rhombic (Fig. 2.23)
  - V to Y advancement
  - Meilolabial (Fig. 2.24)
  - Rotation

**Tips**

- Nasal sidewall
  - Very small defect or laterally placed? Use the junction of the nose and the cheek and consider a primary closure.
  - Have the patient squint so as to best direct the ellipse of a primary closure.
  - Is the distal-medial sidewall defect at the junction with the tip anteriorly? Consider advancement using the alar crease to hide the lower incision and remove excess around the crease of the ala with the cheek.
  - Large defect? Consider the dorsal nasal flap (rotation with a back cut) or a full-thickness skin graft.

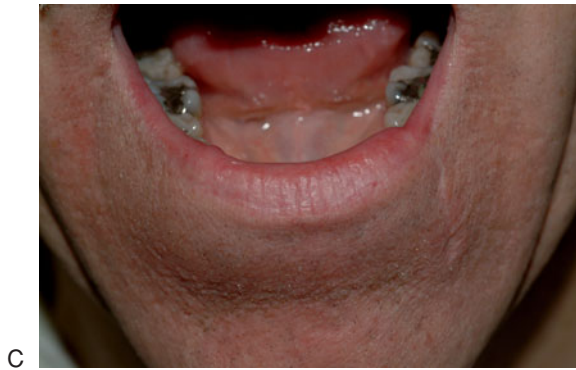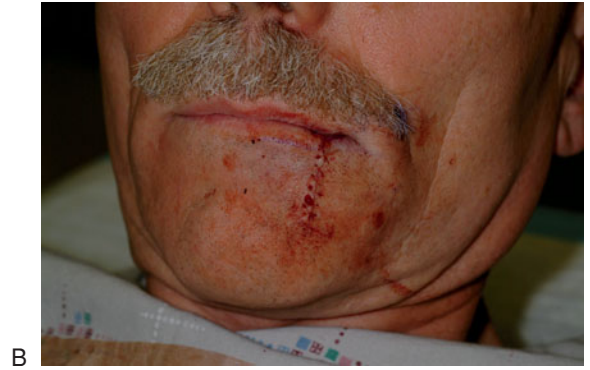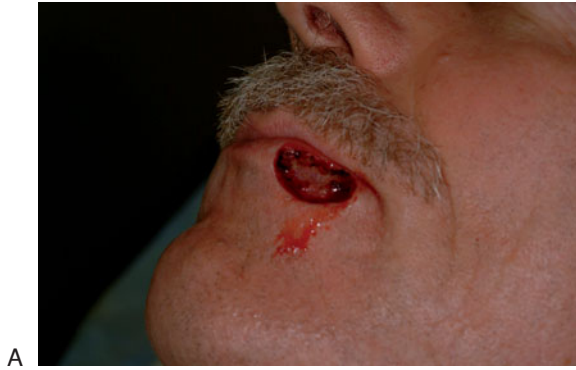- Nasal ala
  - Small and laterally placed defect? Consider a rhombic flap from the nose/cheek crease.
  - Medial defect? Consider a V to Y advancement.
  - Lateral defect? Consider a meilolabial flap.
- Nasal tip
  - Lateral defect, 1.5 cm or less? The bilobed transposition is often the best choice. You can use the bilobed transposition for defects up to 2 cm, but it cannot be used for defects placed too far superiorly on the nose or on an excessively short nose as the inner canthus does not allow for good pivotal movement of tissue.
  - Small defect, 1–1.5 cm? If centrally placed and skin laxity permits, use a primary closure (make sure to take appropriate dog-ears—often this means extending the lower triangle into the columella).
  - Small central or off-center defect? Consider the island pedicle. If superiorly based, the blood supply is more tenuous. These can also be laterally based.



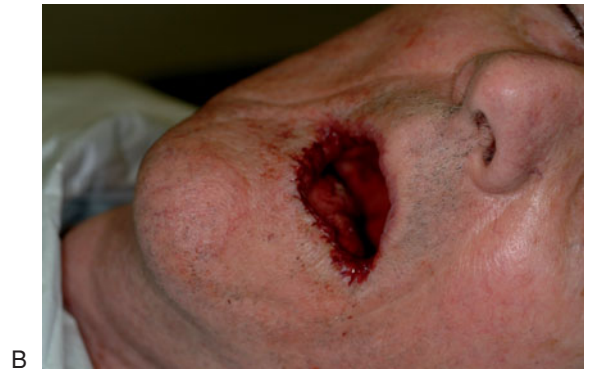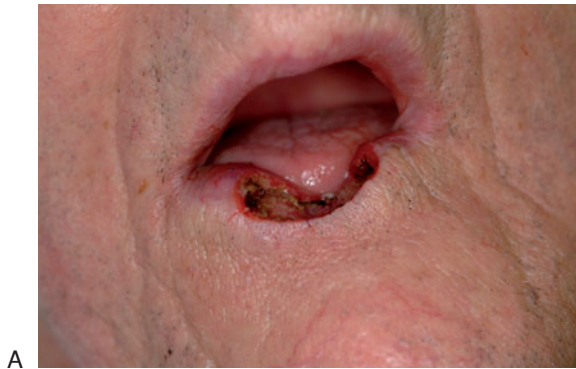- Dorsal-nasal flap: Can also be used in tip defects of 1–1.5 cm.
- Bilateral dorsal nasal (Peng flap): For large defects (2 cm) of the skin and subcutaneous tissue. A small amount of cartilage may be missing, but the structure must be intact or replaced.
- The paramedian forehead flap and meilolabial interpolation flaps are also used for large defects (>2 cm) on the nasal tip.

### ■ Lips

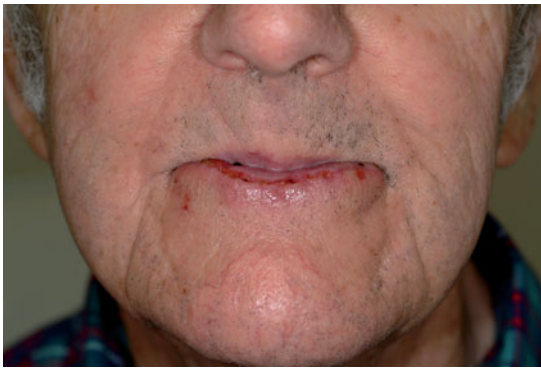- Pink portion only (usually lower lip)
  - Wedge resection (Fig. 2.25)
  - Mucosal advancement (Fig. 2.26)
- Central upper
  - Bilateral advancement (Fig. 2.27)
  - Primary



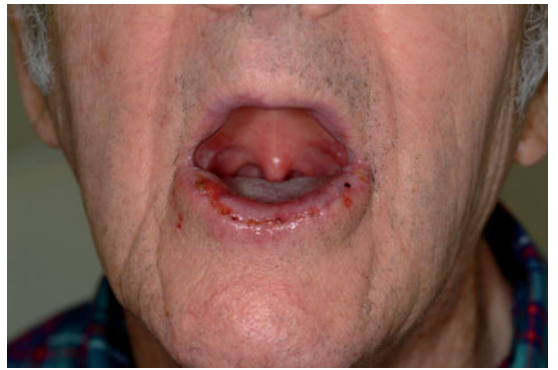**FIGURE 2.25** **A.** Lower lip defect. **B.** Wedge resection—immediately postsuture. **C.** Wedge resection—5 months postoperative



**FIGURE 2.26** **A.** Lower lip defect. **B.** Mucosal advancement—immediately postsuture (Figure continues.)

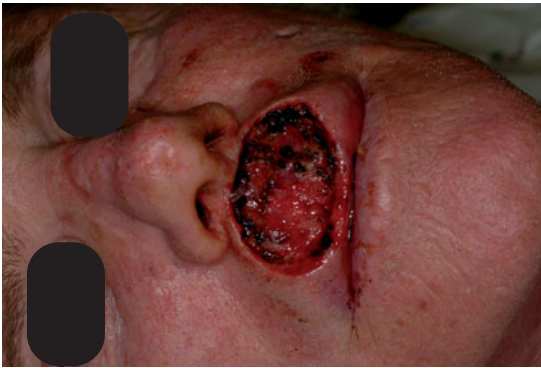

C

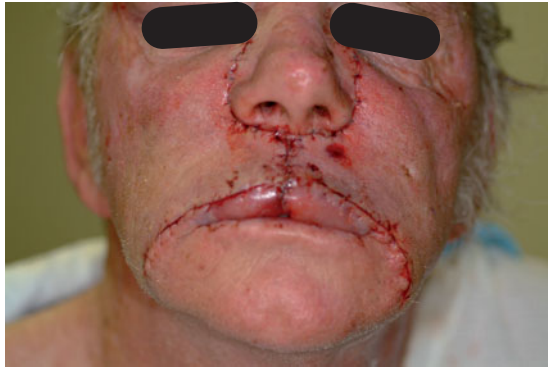

D

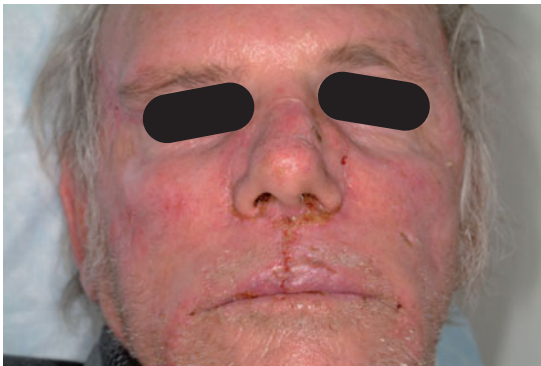**FIGURE 2.26 (continued)** C. Mucosal advancement—1 week postoperative. D. Mucosal advancement—1 week postoperative



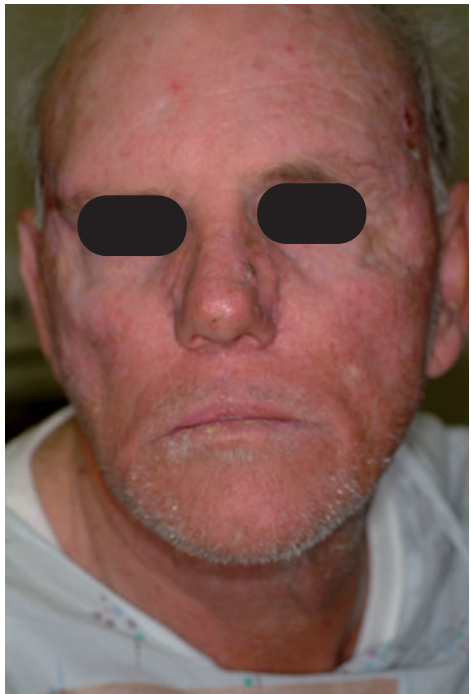A



B

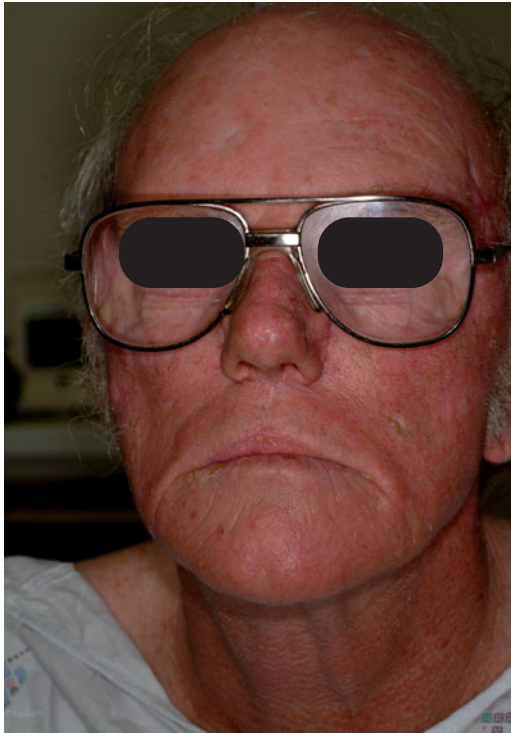

C

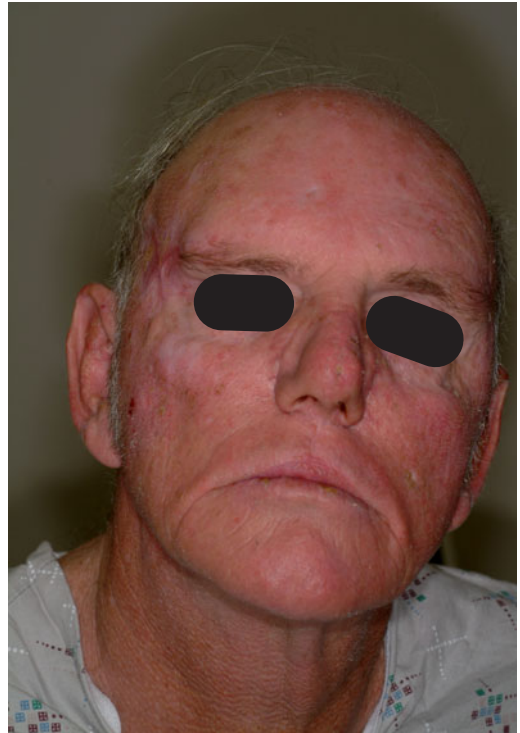

D

**FIGURE 2.27** A. Upper lip defect. B. Bilateral advancement—immediately postsuture. C. Bilateral advancement—1 week postoperative. D. Bilateral advancement—4 months postoperative (Figure continues.)



E



F

**FIGURE 2.27 (continued) E.** Bilateral advancement—8 months postoperative. **F.** Bilateral advancement—9 months postoperative

- Lateral upper
  - A to T advancement (Fig. 2.28)
  - Burow's advancement (Fig. 2.29)
  - Island pedicle (Fig. 2.30)
  - Cheek advancement

**Tips**

- The philtrum is an important three-dimensional unit that should not be distorted.
- Wedge resection of the lower lip causes shortening and cannot be done if the defect width is greater than one-third that of the lower lip length.
- Mucosal advancement: Undermining on the mucosal side should be wide and may extend close to the gingival sulcus. This flap results in a thinner lip. If it is done in a male, they may require hair removal, as the whisker hairs may irritate the lower lip.
- With a large lateral upper lip defect, the island pedicle flap has the advantage of restoring the nasolabial

crease. The cheek advancement blunts the boundary between the upper lip and the cheek.

- One can use the Burow's advancement in conjunction with a small mucosal advancement to repair a defect that encompasses a small portion of the pink upper lip.

■ **Chin**

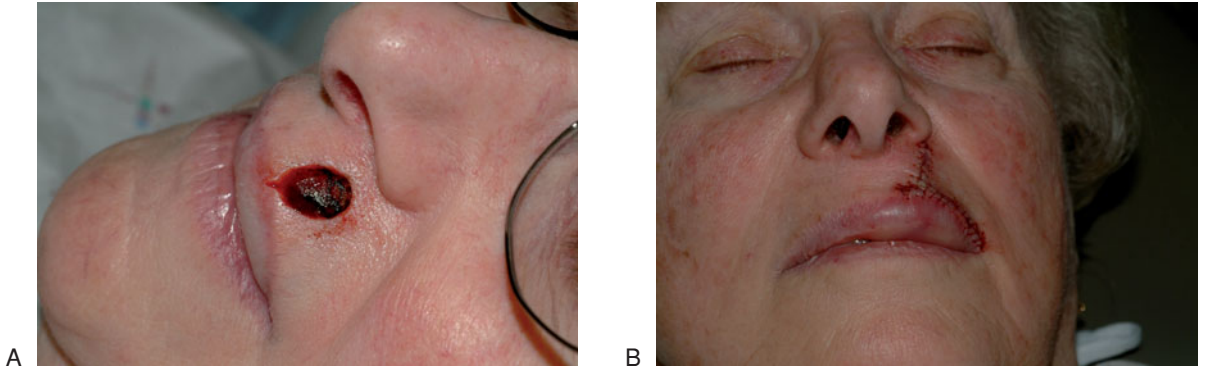
- Primary
- Rotation: A to T

**Tip**

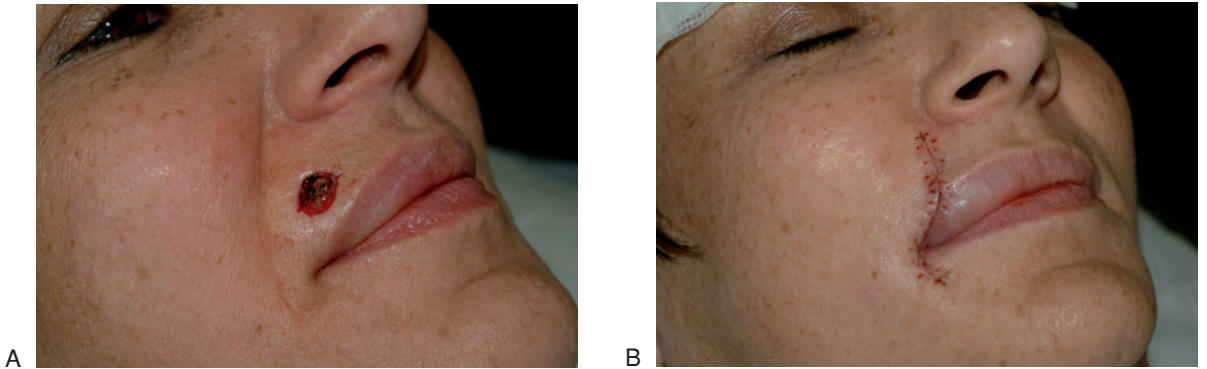
Scars often become fibrotic and require a series of steroid injections to soften. Hypertrophic scars are more common in this area.

■ **Ear**

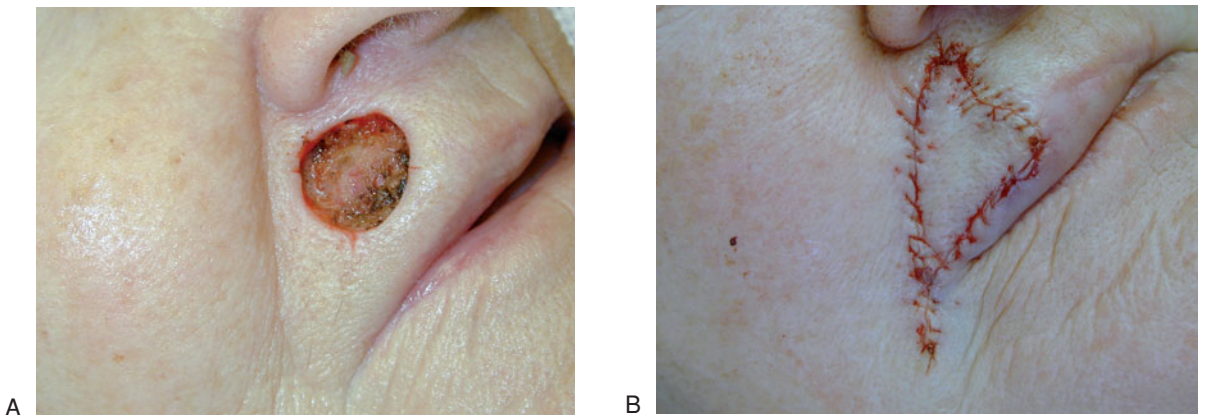
- Helical rim
  - Primary (wedge)



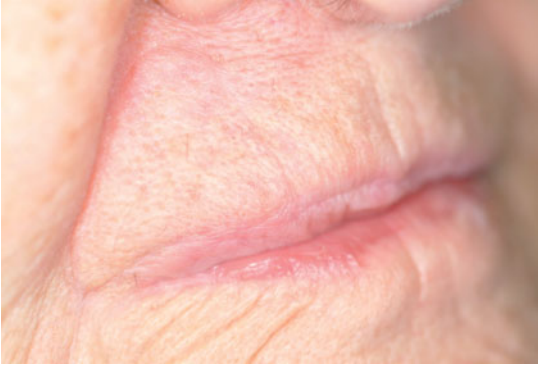**FIGURE 2.28** **A.** Upper cutaneous lip defect. **B.** A to T—immediately postsuture



**FIGURE 2.29** **A.** Upper cutaneous lip defect. **B.** Burrow's advancement—immediately postsuture



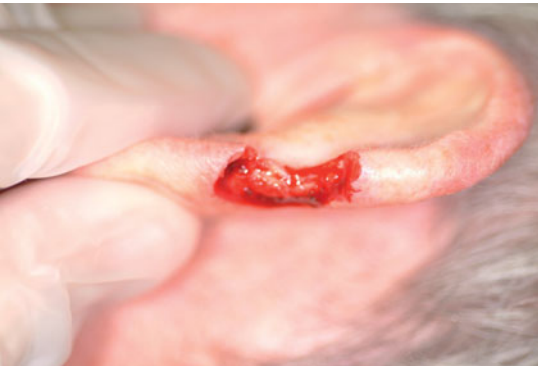**FIGURE 2.30** **A.** Upper cutaneous lip defect. **B.** Island pedicle—immediately postsuture (Figure continues.)



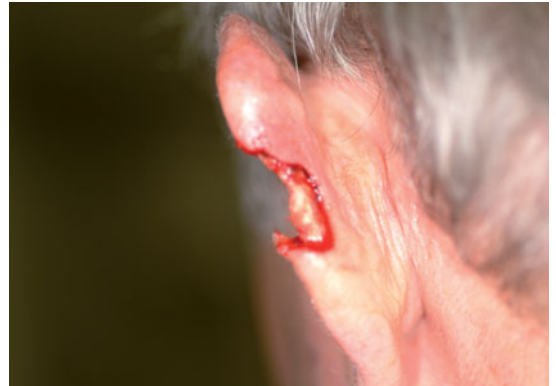C

**FIGURE 2.30 (continued) C.** Island pedicle—5 months postoperative

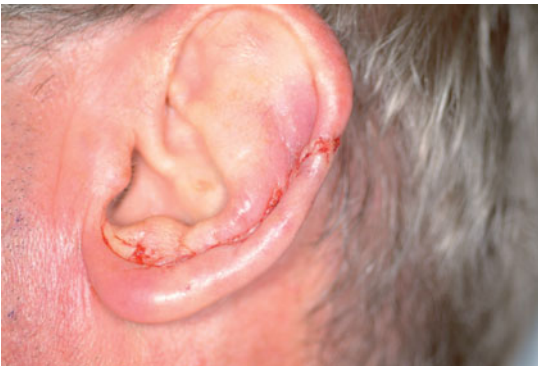- Antia-Buch advancement (Fig. 2.31 and 2.32)
- Postauricular transposition
- Primary (along edge) (Fig. 2.33 and 2.34)
- Conchal bowl: Second intention
- Earlobe
  - Primary
  - Advancement
- Postauricular
  - Primary
  - Advancement
  - Rotation



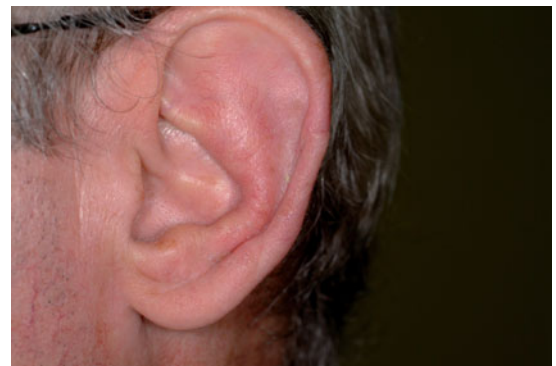A



B



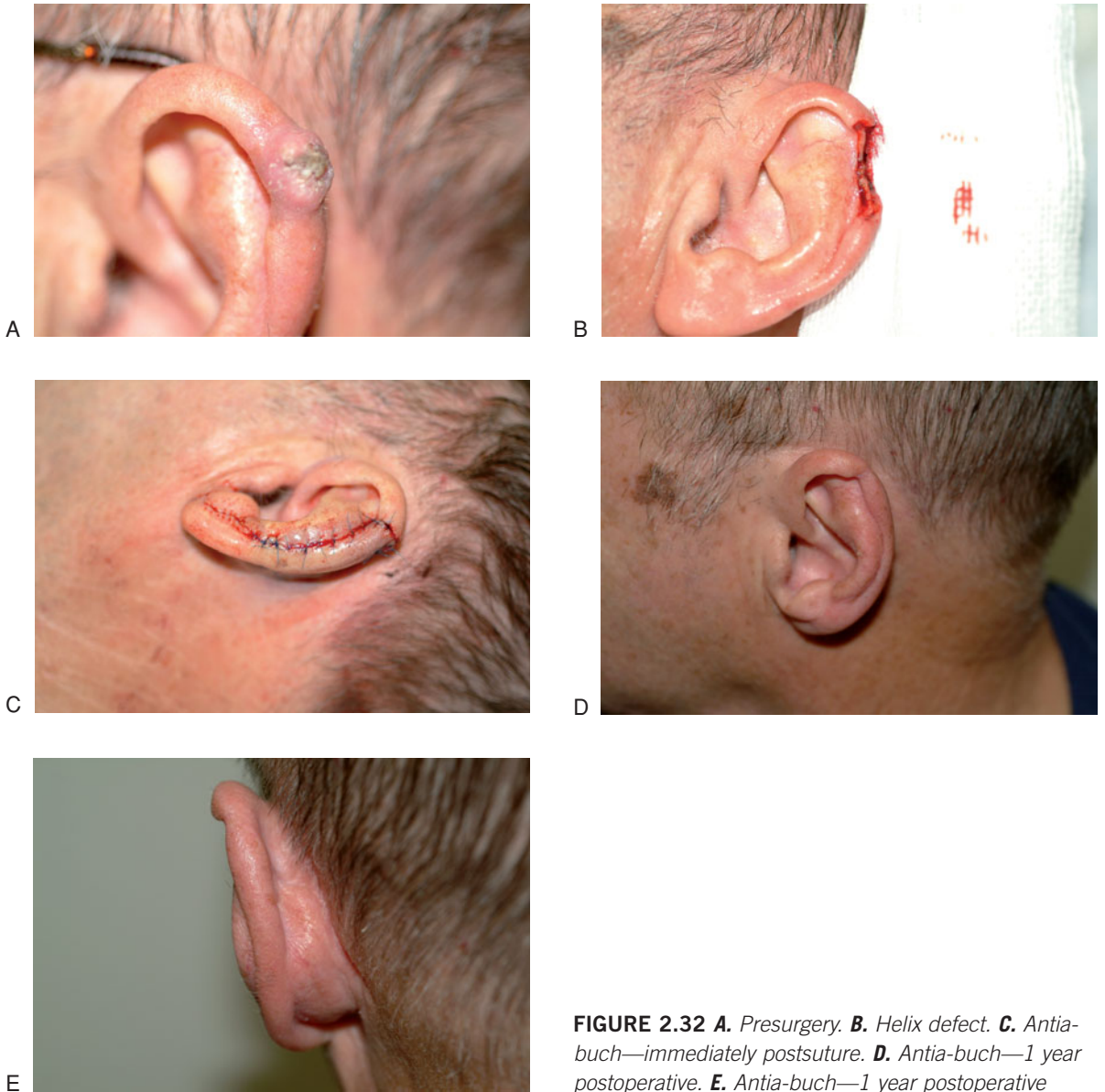
C



D

**FIGURE 2.31 A.** Helix defect. **B.** Helix defect. **C.** Antia-buch—immediately postsuture. **D.** Antia-buch—1 month postoperative





**FIGURE 2.32** *A. Presurgery. B. Helix defect. C. Antia-buch—immediately postsuture. D. Antia-buch—1 year postoperative. E. Antia-buch—1 year postoperative*

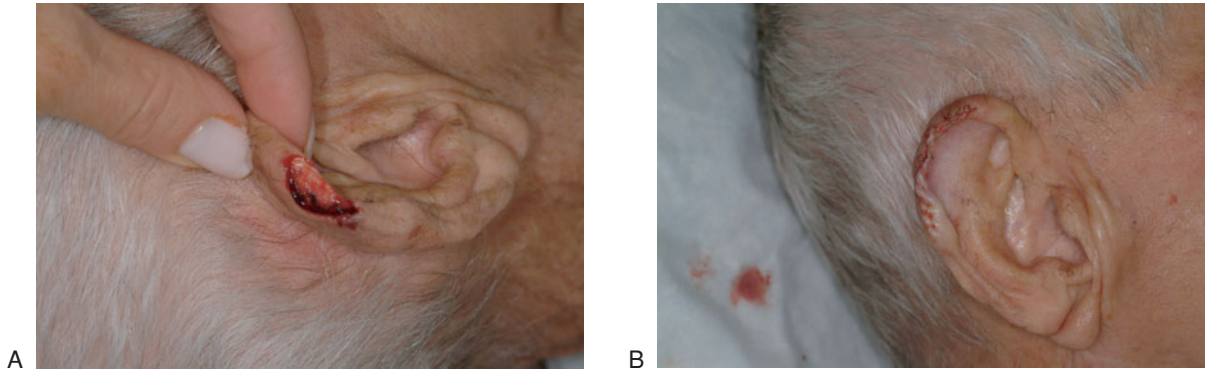
- Transposition
- Second intention
- Preauricular: Primary

### Tips

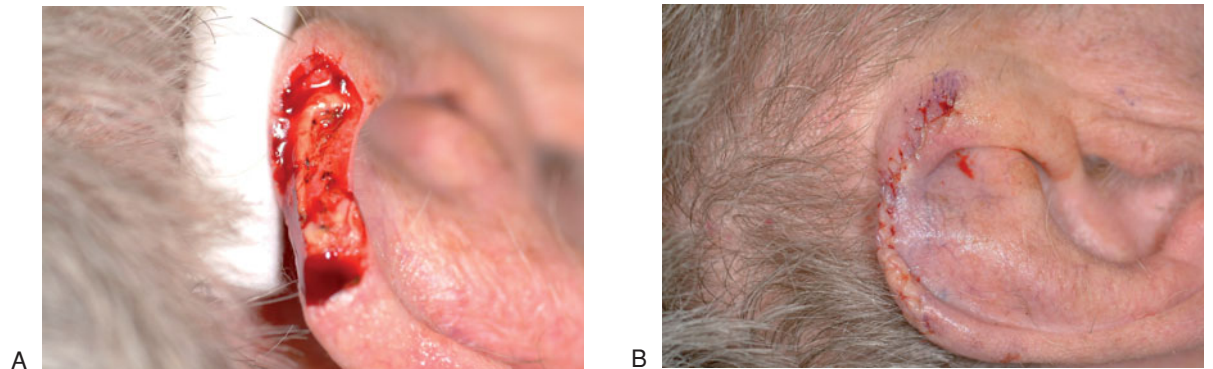
- The conchal bowl and the postauricular area heal best by second intention.
- If the defect on the helical rim is not deep, one can

thin the helical rim cartilage and close primarily without affecting contour significantly.

- Wedge resection works best for small defects.
- Antia-Buch shortens the length of the ear, but restores contour. A unilateral Antia-Buch works well for defects less than 2 cm. If the defect is greater than 2 cm, a bilateral flap is necessary.



**FIGURE 2.33** *A. Helix – defect. B. Primary—immediately postsuture*



**FIGURE 2.34** *A. Helix defect. B. Primary—immediately postsuture*

### **SUGGESTED READING**

1. Wheeland RG. Cutaneous Surgery, 1st edn. WB Saunders, Philadelphia, PA, 1994.
2. Baker SR, Swanson NA. Local Flaps in Facial Reconstruction, 1st edn. Mosby, St Louis, MO, 1995.
3. Robinson JK, Hanke WC, Sengleemann RD, Seigel DM. Surgery of the Skin. Procedural Dermatology. Elsevier Mosby, Philadelphia, PA, 2005.

# CHAPTER 3

# Chemical Peels

Ranella J. Hirsch, MD

## KEY POINTS OF SUCCESS

- Choose the appropriate candidates, i.e., realistic expectations.
- Peels can be done on face and body; the latter requires reduced acid strengths.
- Prepare patient for related down time.
- If appropriate, prophylaxis with antiviral medications.
- Prepare patient for necessary aftercare (sun avoidance, gentle cleansing).

## MECHANISM—CHEMICAL PEELING

- Chemical peeling refers to the application of exfoliating agents to produce a controlled partial thickness skin injury with the intent of improving skin color and texture. A better cosmetic appearance is realized when the most sun damaged layers are removed and replaced with newer, more normalized tissue.
- With more superficial peels, the process yields stimulation of epidermal growth through selective removal of the stratum corneum (Table 3.1)

**TABLE 3.1 ■ Classification of Peeling Agents**

Very superficial

Glycolic acid 10–40%	Jessner's solution 1–2 coats	TCA 10%
-------------------------	---------------------------------	---------

Superficial

Glycolic acid 40–70%	Jessner's solution 3–5 coats	TCA 10–30%
-------------------------	---------------------------------	------------

Medium depth

Glycolic acid 70% and greater	TCA 35–50%	Augmented TCA (Jessner's plus TCA, glycolic +TCA)
-------------------------------------	------------	--

Deep

Phenol 88%	Baker Gordon phenol formula
------------	--------------------------------

- Deeper peels create necrosis and inflammation in the epidermis, papillary, or reticular dermis depending on the depth of the peel.

## PHARMACOLOGY—CHEMICAL PEELING

- Certain variations are unavoidable such as differences in skin type and biologic response.
- While techniques such as method and pressure of application may vary from clinician to clinician, such variances can be standardized.
- Pharmacological anomalies in the preparation itself can actually be a source of significant variation.
- USP-grade material ought to be used. The initials after a drug or chemical name indicate that the material so labeled meets the standards of the United States Pharmacopoeia. The USP is a compendium that provides a legal standard for the identity, purity, strength, and quality of listed drugs.

## PREPARING THE SKIN FOR CHEMICAL PEELING

Goals in optimizing skin preparation are to:

- Reduce wound healing time
- Permit more uniform penetration of the peeling agent.
- Decrease the possibility of postinflammatory hyperpigmentation
- Determine which products a particular patient can tolerate
- Reinforce the need for ongoing maintenance and establish guidelines for patient compliance

## VARIABLES AFFECTING DEPTH OF PEEL

- Selected peeling agent
- Concentration of the peeling agent
- Number of applications of the agent applied
- Application technique
- Level of preparation prior to application of peeling agent (was skin degreased?)

**TABLE 3.2 ■ Peel Types and Depth of Penetration**

Type of Peel	Penetration Depth of Peel
Superficial	Epidermis to upper papillary dermis
Medium depth	Papillary dermis to upper reticular dermis
Deep	Mid-reticular dermis and below

- Was skin primed in preparation for the peel?
- Skin type (thick or thin)
- Anatomic location of skin to be peeled
- Duration of contact that the peeling agent has with the skin

**CLASSIFICATION OF PEEL DEPTHS (TABLE 3.2)**

- Very superficial (exfoliation)—Thins or removes the stratum corneum and does not create a wound below the stratum granulosum.
- Superficial peels—Necrosis/destruction anywhere from the epidermis to the papillary dermis as far as the basal cell layer.
- Medium depth—Necrosis of the epidermis and destruction extends to all of papillary dermis.
- Deep peels—Necrosis of epidermis and papillary dermis extending into the reticular dermis.

**INDICATIONS FOR CHEMICAL PEELING (TABLE 3.3)**

Must match appropriate chemical peeling agent to correct depth of peel as determined by the indication being treated. Since it is difficult to assess the depth of damage with naked eye, so a Woods light examination, which is easily performed in the clinic setting, is an ideal test.

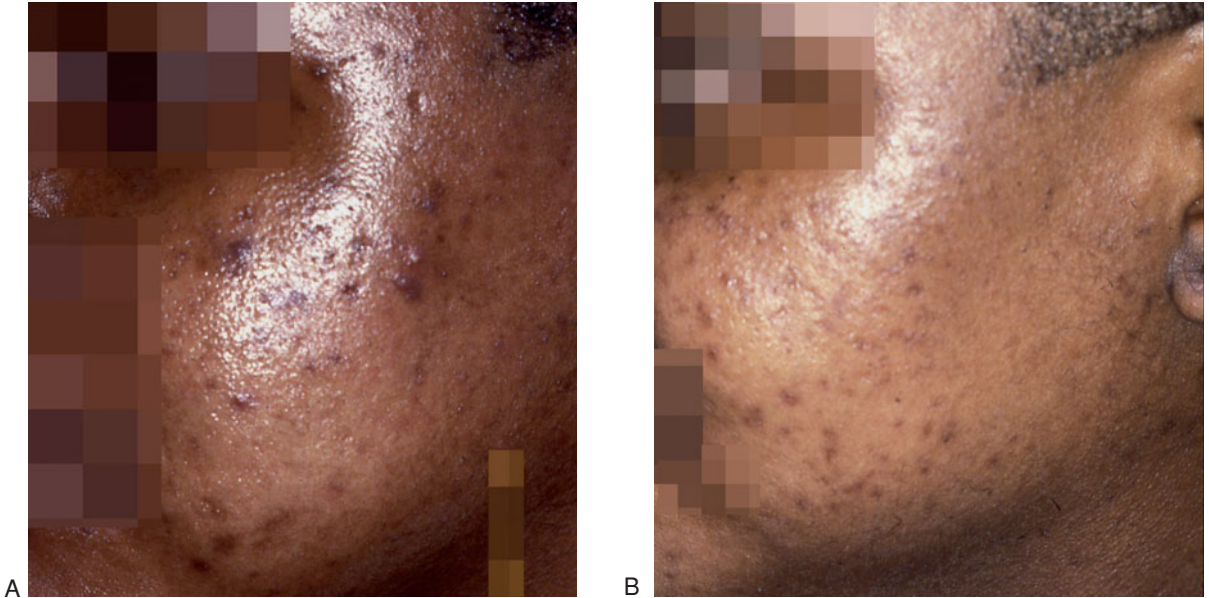
- Wood’s Lamp is a black light that emits light at a wavelength of 354 nm.
- When the skin is viewed with this apparatus, areas of epidermal pigmentation become more pronounced and areas of deeper dermal pigmentation become less pronounced.
- Simply stated, the worse a patient appears under Wood’s light examination, the easier their pigmentation is to treat.

**■ Clinical Hyperpigmentation**

- Most common types of hyperpigmentation include
  - Freckles (ephelides)
  - Lentigines
  - Flat seborrheic keratoses
  - Nevi
  - Melasma
  - Postinflammatory hyperpigmentation from a variety of primary cutaneous insults (Fig. 3.1)

**TABLE 3.3 ■ Peel Results with Lesion Subtypes and Depth (Summary of Peel Results with Lesion Subtypes and Depth)**

Excellent Results	Variable Results	Poor Results
<i>Epidermal peels</i>		
Ephelides	Lentigines	Seborrheic keratoses
Epidermal melasma and postinflammatory hyperpigmentation	Mixed (epidermal and dermal) melasma and postinflammatory hyperpigmentation	Dermal melasma and postinflammatory hyperpigmentation
<i>Dermal peels</i>		
Ephelides	Seborrheic keratoses	Nevi
Lentigines		
Epidermal melasma and postinflammatory hyperpigmentation	Mixed (epidermal and dermal) melasma and postinflammatory hyperpigmentation	



**FIGURE 3.1** **A.** Hyperpigmentation on left side of face before treatment. **B.** Improvement after a series of salicylic acid peels and topical application of 4% hydroquinone. (Photographs courtesy of Pearl E. Grimes, MD; reprinted with permission from Avram et al., *Color Atlas of Cosmetic Dermatology*, McGraw-Hill, New York, 2007)

- Mild to severe dermatoheliosis
- Epidermal melasma and assorted pigmentary disorders (Fig. 3.2)
- Inflammatory acne
- Epidermal growths including actinic keratoses

### ■ Wrinkling

- Fine wrinkles are the result of epidermal thinning and can appear as crosshatched lesions on the face. They can be described by their crêpe-y or cigarette paper type of appearance.
- Mimetic wrinkles are the result of repeated movement.
- Accordion pleating is due to loose redundant skin with epidermal and dermal atrophy in addition to a loss of elasticity.
- Folds are the result of downward skin sagging and gravity.

## PEELING AGENTS

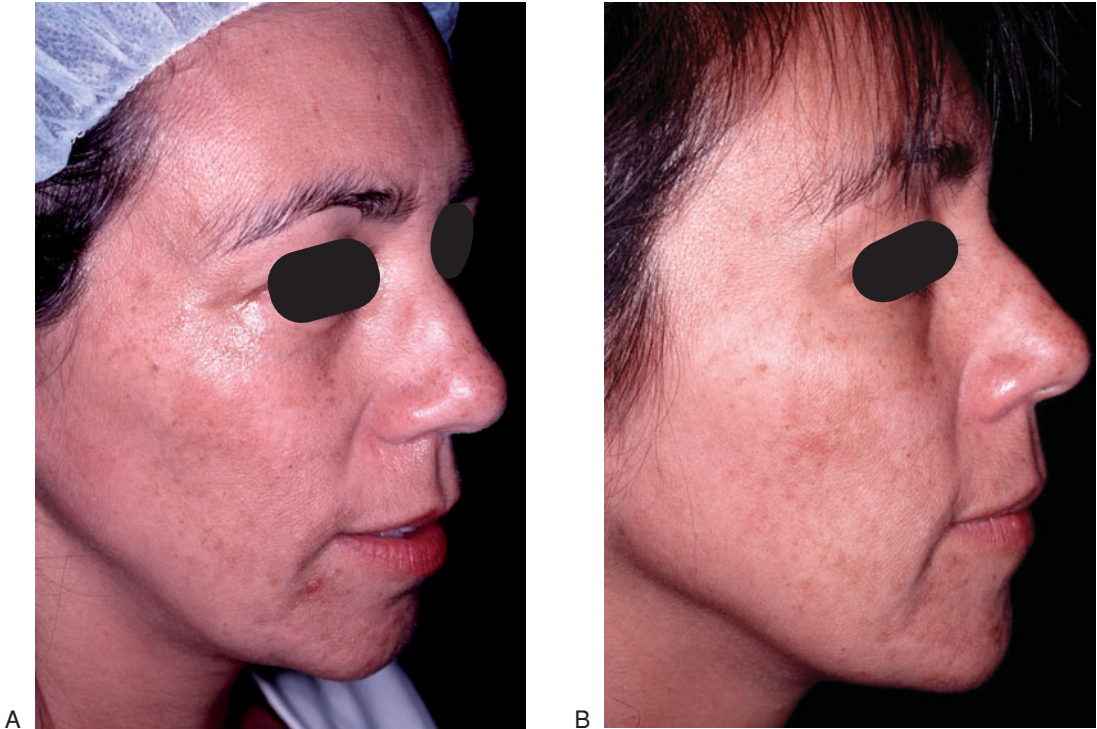
- Retinoids
- 5-FU (5-Fluorouracil)

- Jessner's solution (Fig. 3.3)
- Resorcinol
- Salicylic acid (Fig. 3.4)
- TCA (trichloroacetic acid)
- Hydroxy acids—Alpha-hydroxy acid (AHA) peels exert effects in the epidermis at the level of the stratum corneum. Studies have shown that sustained AHA use for 6 months leads to a 25% increase in epidermal thickness, which correlates histologically with a thinner stratum corneum with a more organized basket weave epidermal pattern.

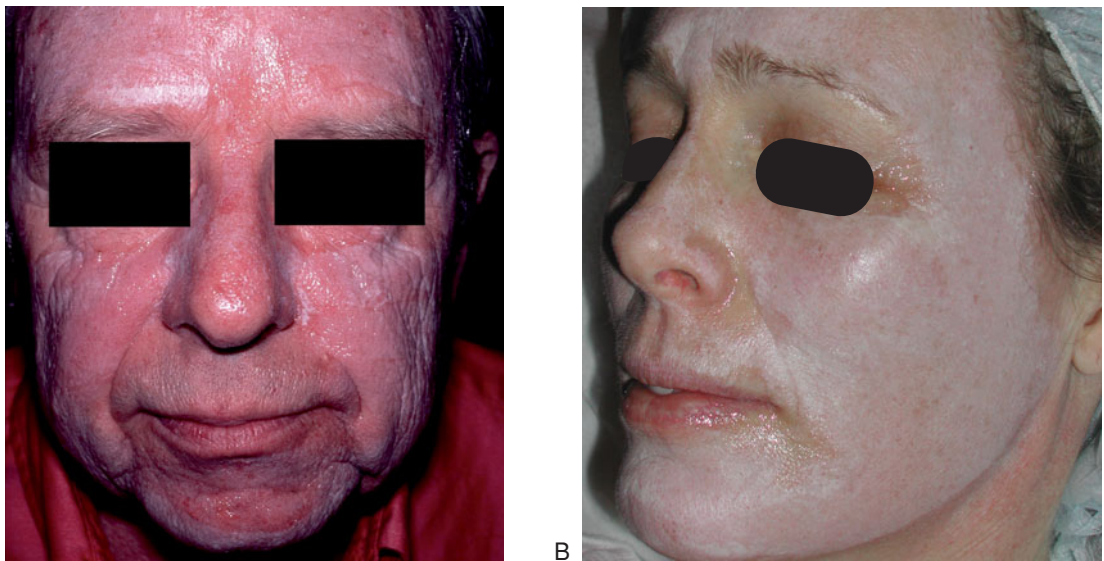
## CHEMICAL PEELING—FREQUENCY

- Very superficial chemical peels can be performed once weekly.
- Superficial (intraepidermal) peels can be repeated every 2–4 weeks.
- Medium depth (papillary dermis) peels can be repeated every 3–6 months.

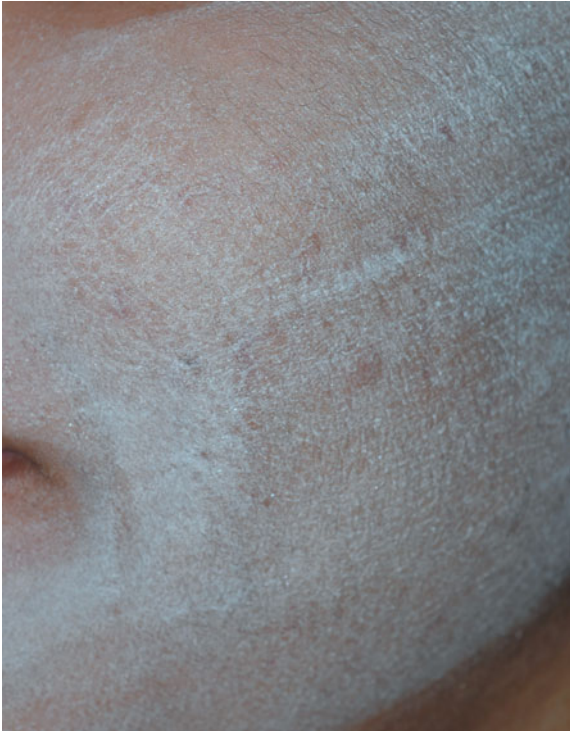These are general guidelines only and can be adapted depending on the complications and indications. Never re-peel a patient who has residual sensitivity or erythema



**FIGURE 3.2** **A.** Epidermal melasma unresponsive to topical bleaching creams. **B.** Mild improvement noted following two 50% glycolic acid peels. (Reprinted with permission from Avram et al., *Color Atlas of Cosmetic Dermatology*, McGraw-Hill, New York, 2007)



**FIGURE 3.3** **A.** Pale white color immediately following a Jessner peel. **B.** Solid white color immediately following is Jessner/35% TCA peel. (Reprinted with permission from Avram et al., *Color Atlas of Cosmetic Dermatology*, McGraw-Hill, New York, 2007)



**FIGURE 3.4** *Frosting is a sign of self-neutralization of salicylic acid peel. Here it is being applied for acne scars in a patient with type IV skin. This superficial peel is relatively safe in darker skin phototypes. (Reprinted with permission from Avram et al., Color Atlas of Cosmetic Dermatology, McGraw-Hill, New York, 2007)*

from a previous peel. Such patients have not completely healed and will experience an exaggerated response to any additional peeling.

### CHEMICAL PEELING—ANESTHESIA

- Setting realistic expectations is critical in the course of management of the pain due to chemical peeling.
  - Inform patients that there is going to be some discomfort with the process.
  - A brief but not constant burning slowly builds and typically reaches crescendo when the applied product is at maximal erythema or frost on the skin.
- With superficial peels, anesthesia is typically not necessary.
  - With medium depth peels, the sensation is more uncomfortable.
    - We encourage patients to take two acetaminophen 60 minutes prior to the procedure for analgesia, and find that this along with a cool fan is typically adequate for comfort.
    - Talkesthesia is also extensively used.
  - With deeper medium peels assorted other sedatives are advisable including the use of intramuscular meperidine, hydroxyzine, diazepam, and if appropriate IV sedation.

### CHEMICAL PEELING—NONFACIAL

Nonfacial wounds take longer to reepithelize because there are fewer pilosebaceous units present in nonfacial areas.

#### ■ Contraindications

- Absolute: Pregnancy
- Relative: Oral cold sores

#### ■ Procedure

- Level of injury/depth of skin penetration quantifies classification of peels as superficial/medium/deep strength.
- Must match patient pathology to appropriate peel depth.
- Important to realize that any classification of peeling agents is an approximation since an agent that produces a superficial peel in one patient may yield a medium strength peel in another.
  - For example, a man with thick oily skin that was not primed prepeel treated with 25% TCA on a cotton swab will likely only develop a superficial intraepidermal peel.
  - By contrast, a thin skinned woman who is properly primed and has 25% TCA applied from a soaking gauze will likely have a medium depth peel from the same 25% TCA application.
- As a consequence, we recommend in clinical practice that all dermasurgeons
  - Standardize their peels specifically
  - Prime all patients in a similar fashion
  - Apply the acid with a similar technique
- Doing so greatly reduces some of the extraneous variables that can affect final outcome.

## SUGGESTED READING

---

1. Camacho FM. Medium-depth and deep chemical peels. *J Cosm Dermatol* 2005;4(2):117–128.
2. Tse Y, Ostad A, Lee HS, et al. A clinical and histologic evaluation of two medium-depth peels. Glycolic acid versus Jessner's trichloroacetic acid. *Dermatol Surg* 1996;22(9):781–786.
3. Matarasso SL, Glogau RG. Chemical face peels. *Dermatol Clin* 1991;9(1):131–150.
4. Brody HJ. Variations and comparisons in medium-depth chemical peeling. *J Dermatol Surg Oncol* 1989; 15(9):953–963.
5. Rubin MJ. Trichloroacetic acid and other non-phenol peels. *Clin Plast Surg* 1992;19(2):525–536.
6. Monheit GD. Combination medium-depth peeling: the Jessner's + TCA peel. *Facial Plast Surg* 1996; 12(2): 117–124.
7. Monheit GD. Medium-depth chemical peels. *Dermatol Clin* 2001;19(3):413–425, vii.



## CHAPTER 4

## Dermal Fillers

Ranella J. Hirsch, MD

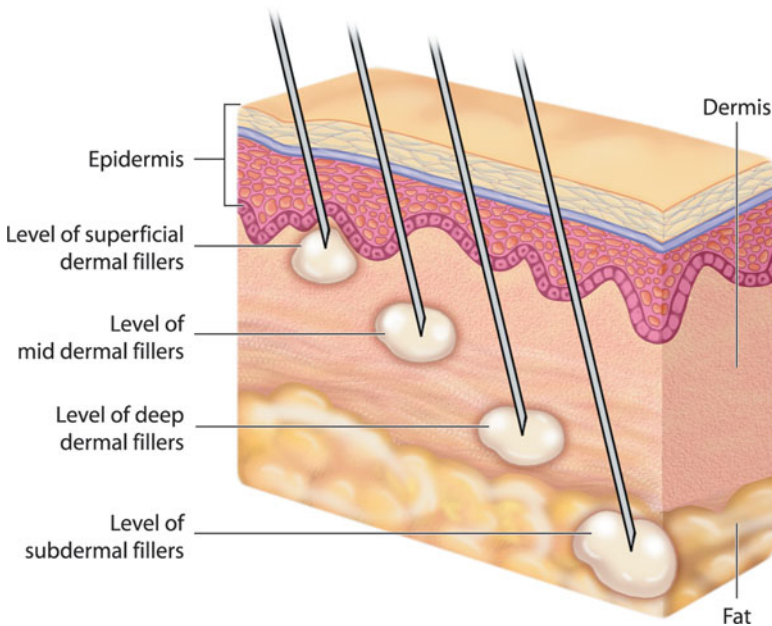
### KEY POINTS FOR SUCCESS

- Judicious patient selection.
- Detailed pretreatment medical and psychosocial history.
- Detailed informed consent covering reasonable and severe risks.
- Pre- and post-photography.
- Precise knowledge of relevant cutaneous anatomy.
- Technique dependent—correct depth of placement is critical (Fig. 4.1).

### PHARMACOLOGY—DERMAL FILLERS

- Collagen-based products include those from human and bovine sources.

- Hyaluronic acid is a naturally occurring polysaccharide sugar in the dermis.
- Unlike collagen, it has neither species nor tissue specificity; the chemical structure is uniform throughout nature.
- In the skin, it forms the elastoviscous fluid matrix in which collagen fibers, elastic fibers, and other intercellular fibers are embedded.
- The amount of hyaluronic acid in the skin decreases with age, resulting in reduced dermal hydration and increased wrinkling.
- Radiesse is a product made of injectable calcium hydroxylapatite, a matrix material of bone and tissue.
- This bioengineered product serves as a scaffold for native cells, including osteoblasts and fibroblasts, to yield long-term soft tissue correction.
- It is best reserved for patients who have had good experience with other soft tissue augmentation products.



**FIGURE 4.1.** Recommended filler injection depths. (Reprinted with permission from Avram et al., *Color Atlas of Cosmetic Dermatology*, McGraw-Hill Medical, New York, 2007)

## INDICATIONS

- Treatment for tissue contour defects resulting from loss of
  - dermal tissue due to both aging and chronic environmental damage;
  - subcutaneous fat;
  - supporting tissues.
- Can serve to fill preexisting facial defects or augment existing facial structures.
- Rhytids in the upper third of the face are largely dynamic in origin and the result of muscular movement as opposed to sun damage and physiological aging alone.
- In the upper third of the face, uses include restoring volume to augment temporal lipodystrophy.
- Under the lateral third of the brow, uses include
  - elevating a ptotic lateral brow segment;
  - correcting nasojugal fold depression.
- In the central third of the face, fillers can
  - fill preexisting asymmetry;
  - replace volume to the sinking malar eminence (Fig. 4.2);
  - improve the nasal contour.
  - augment scars secondary to acne, chickenpox and trauma.
- The lower third of the face includes the most popular anatomic area treated—the nasolabial folds.

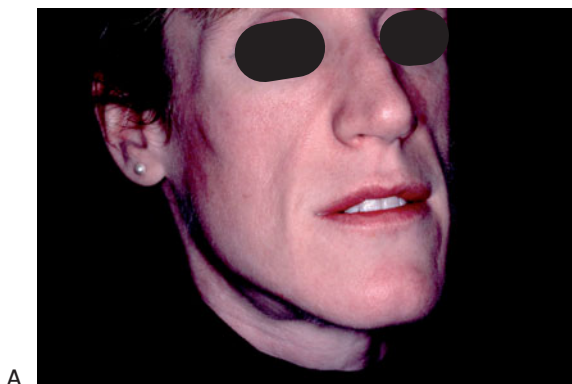- Volume restoration to the lips, melolabial folds and marionette lines is widely performed.
- Restoration of the jawline contour is another very effective use of filler materials.
- There is a recognized synergy with botulinum toxin:
  - Botulinum toxin reduces mimetic effect on wrinkles and folds.
  - Dermal fillers function by promoting support for facial structures.
  - When used in conjunction, each prolongs the effects of the other.

## CONTRAINDICATIONS—ABSOLUTE

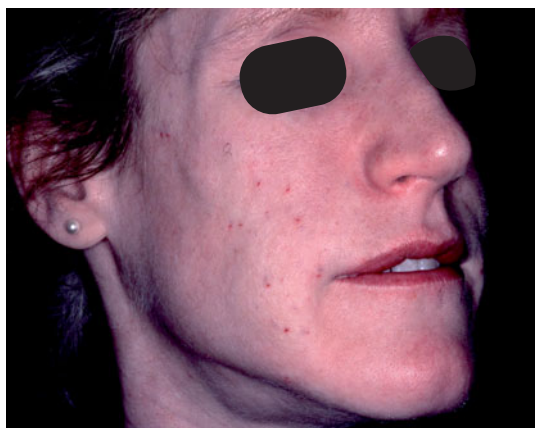- Allergy to bovine collagen, certain meat products, and assorted antibiotics.
- Any history of severe allergy manifested by documented history of anaphylaxis.

## CONTRAINDICATIONS—RELATIVE

- History of keloid formation or the development of hypertrophic scars.
- History of oral cold sores (antiviral prophylaxis required).
- Allergies to local anesthetics.
- Active infection or inflammation at the site of treatment.
- Active koebnerizing inflammatory skin disease.



A



B

**FIGURE 4.2. A.** Facial lipoatrophy with “sunken cheek appearance” prior to treatment. **B.** Improvement in cheek volume after treatment. (Reprinted with permission from Baumann, *Cosmetic Dermatology*, McGraw-Hill Medical, New York, 2002)

## PREOPERATIVE PLANNING

### ■ Patient Evaluation—Aesthetic

- Are fillers the most appropriate therapeutic modality? Or, is the patient a candidate for other therapies, i.e., botulinum injections, laser treatment, surgery, etc.?
- Age-related changes of the lower face include
  - atrophy of both the upper and lower lips;
  - actinic changes of the mucosal surface and the vermilion border;
  - atrophy at the corners of the mouth with a resultant downturned appearance.
- Even subtle changes in the lips and the surrounding tissue can produce significant improvement.
- Evaluate patient's goals for the procedure—use hand mirror to permit specific delineation of their perceived trouble spots.
- Clarify realistic versus unrealistic expectations.

### ■ Medications and Drug Interactions

- Direct questions toward specific drugs isotretinoin (Accutane), aspirin, warfarin (Coumadin), estrogen, clopidogrel bisulfate (Plavix), vitamin E, herbal preparations (St. John's Wort), beta blockers, NSAIDs, ticlopidine (Ticlid) (Table 4.1)
- Discontinuance of platelet-inhibiting drugs is controversial. This is especially important in more extensive

procedures such as liposuction, hair transplantation, and ambulatory phlebectomy than in implantation of temporary dermal fillers. In cases where it is necessary to discontinue use, discontinuance is recommended 1 week prior to surgery, with clearance obtained from the treating physician.

- History of smoking—Smoking creates an increased risk of vascular compromise and contributes to decreased longevity of the injected product.

### ■ Psychosocial History

- Evaluate patient's motivations for a given cosmetic procedure, e.g., recent spouse or partner separation, loss of a loved one, job insecurity, etc.
- Proceed with care in a patient who is undergoing multiple, frequent procedures with minimal satisfaction or is doctor shopping.
- Patients identified as having unrealistic expectations at the initial patient consultation should be approached with caution—realistic expectations are a cornerstone of successful therapy.

### ■ Informed Consent

- Document reasonable risks; best to prepare an informed consent document with an attorney familiar with local standards of care.
- Must delineate exact procedure, indications for therapy, treatment alternatives, and complication profile.

**TABLE 4.1 ■ Medications and Herbs That Can Affect Hemostasis**

Medications	Mechanism of Action	Details
Aspirin	Irreversibly inhibits cyclooxygenase	Discontinue 7 days prior to injection
Garlic	Inhibits platelet aggregation and thromboxane B2 in vitro	Taken for migraines, arthritis and cardiac health
Ginger	Enhances anticoagulant effects of Warfarin	For use in management of nausea and vomiting
NSAIDs (Non-aspirin nonsteroidal anti-inflammatory drugs)	Reversibly inhibit platelet COX-1	Discontinue 7 days prior to injection
Plavix (Clopidogrel)	Oral platelet aggregation inhibitor	Discontinue 5 days pretreatment
Vitamin E	Decreases platelet adhesion	Mild anticoagulant effect can be increased significantly when taken with aspirin and garlic
Warfarin	Oral Vitamin K antagonist	Discontinue 3–4 days pretreatment

- Consent for photography advisable.
- The form should be signed by the patient and a witness in a dated format and should be copied and made available to the patient for his/her individual record.

## ■ Photography

- Allow for objective data recording prior to procedure.
- Pre- and posttreatment photography is essential.
- Optimal to standardize for lighting, distance, background, and remove distractions such as jewelry and hairstyles.

## ■ Selecting the Right Filler

- If necessary, is skin testing an option for patient?
- Time constraints—risks of bruising and untoward effects vs. product longevity.
- Are the rhytids superficial, medium, or deep; must assess for use of appropriate product.
- Folds and wrinkles that are readily distensible respond best to therapy with dermal fillers.
- Deep, nondistensible, and “ice pick” type scars, which do not easily efface with manual stretching of adjacent skin, will not respond well.
- Does patient understand that with select modalities (i.e., poly-L-lactic acid [Sculptra]) multiple treatments would be required?
- For greater longevity or duration of effect, is patient a candidate for semipermanent or permanent filler injection?
- The patient must comprehend that permanent products have attendant permanent risks (nodules, granulomas, hardening, etc.).

## ■ Volume Selection

- An appropriate volume of the selected filler material is critical. Undercorrection in order to decrease patient costs will only yield an unsatisfied patient and is thus best avoided.
- We recommend beginning a therapeutic session by assessing an approximate sense of the facial asymmetry, predicting the total amount of filler that will be needed, and then dividing half of the allotted material for the contralateral fold.

## TECHNIQUE

- Wrinkles come in assorted depths, thus treatment must be tailored according to the individual patient.
- More superficial rhytids respond best to intradermal treatment.
- Deeper rhytids typically have a subcutaneous component, with or without a muscular element, and are best approached from the subcutaneous space.
- Duration of correction with any filling substance depends on multiple factors, such as the
  - type of material implanted;
  - procedural technique;
  - amount of product;
  - particular nature of the defect.
- Chronic mechanical stresses on the treatment site may shorten the lifespan of a given product.
- Regular maintenance is necessary with nonpermanent fillers.

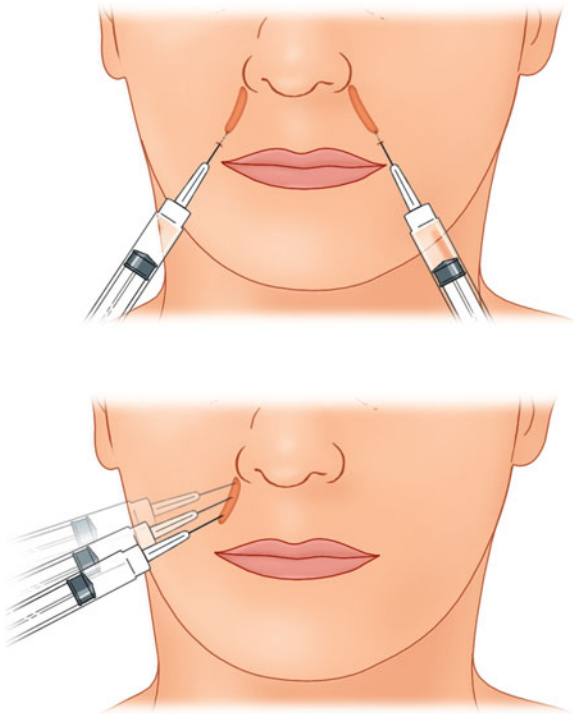
## ■ Injection Techniques

- Any of the following three injection techniques (Fig. 4.3) can be used:
  - Serial puncture—multiple injections into the mid-dermis.
    - Injections are medial to the fold being addressed.
    - Injected material is then massaged for even distribution.
  - Threading—a 30-gauge needle is used.
    - Needle advanced at a 30-degree angle below the depth of the fold.
    - Injecting the filler as the needle is withdrawn.
    - Result is an even filling of the fold depth.
  - Fanning—a technique used for diffuse volume filling.
    - Involves multiple 30-degree mid-dermal pathways formed out from the groove to elevate the superior angle evenly.

## ■ Injection Sites

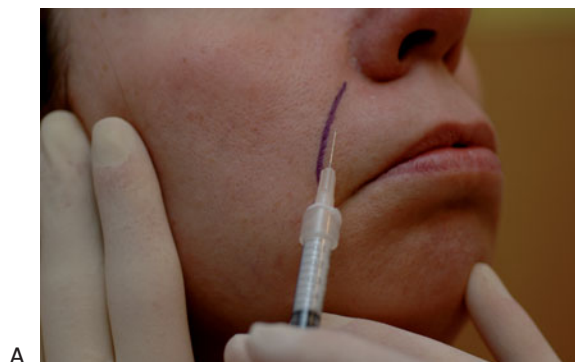### Nasolabial folds (Fig. 4.4)

- Colloquially termed “smile lines,” these are the creases from the nose to the side of the oral commissure separating the cheek from the upper lip.

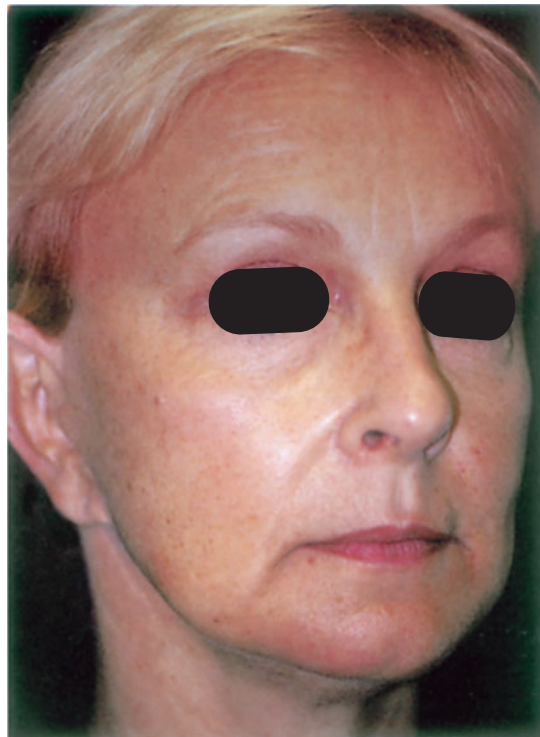

**FIGURE 4.3.** Injection techniques. **A.** Linear threading technique. **B.** Serial puncture technique. Fanning is a technique in which the needle direction is continually changed without removing the needle. (Reprinted with permission from Avram et al., *Color Atlas of Cosmetic Dermatology*, McGraw-Hill Medical, New York, 2007)

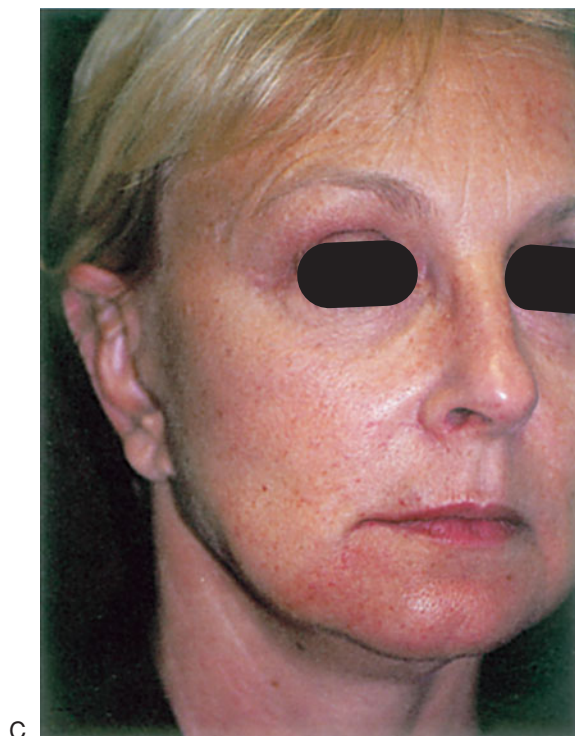- Wrinkles that extend from the angle of the nose to the corner of the upper lip are a frequent site for soft tissue replacement.
  - The goal of the treatment of the nasolabial creases is to correct volume deficits in the deep dermis.
  - Depth of the fold is the key determinant of the final volume used for replacement, and placement of an adequate filler volume is an essential tenet of therapy.
  - Effacing the nasolabial fold involves injecting with a needle at a depth of 1–2 mm depending on the depth of the rhytid.
  - Injection should involve injecting the entire expanse of the nasolabial crease to the nasal ala.
  - Include the mildly depressed triangle just immediately lateral to the ala; if this area is not treated, there is often an appearance of undercorrection throughout the treatment unit.
  - Anatomically, the facial vein and artery traverse this triangle; inadvertent intravascular placement can yield tissue necrosis and must be avoided.
- ### Lips (Fig. 4.5)
- There are two components to lip enhancement:
    - Improvement of the defined lip line with injections along the cutaneous/vermilion border; this is particularly useful for patients who complain of lipstick bleeding into the vertical lip rhytids.
    - Increasing the volume of the lip body.
  - Linear threading with implantation into the potential space between the lip mucosa and the skin along the vermilion border is best achieved with the syringe held parallel to the long axis of the lip.
  - A 0.5-inch needle will reach 20–25% of the lip line in most patients and so four to five threading injections should cover the entire lip. We use a 30- or 31-gauge needle bent at 45 degrees, with more superficially placed filler in the white roll.
  - Increased lip volume is achieved by judiciously directing the injection into the bulk of the vermilion.
    - By holding the syringe parallel to the long axis of the lip and using a threading technique, the filler is injected along the “wet line” of the red of the lip—the line at which the dry outer mucosa meets the moist inner mucosa.
    - It is important to inject uniformly as the needle is withdrawn from the track to create a smooth and symmetrical enlargement of the lip bulk.
  - For sharpening the philtrum, the injector can hold the syringe vertically, perpendicular to the upper lip to define below each philtral crest. Ideally, the natural shape of the Cupid’s bow is preserved and enhanced.
  - Semipermanent and permanent fillers are not recommended for lip augmentation due to the increased risk of product migration and the risk of granuloma formation.
  - It is ill-advised to have the patient assess symmetry at the time of lip augmentation because localized areas of swelling can develop. It is advisable to assess symmetry after a week or two has passed rather than risk overcorrection.



A



B



C

**FIGURE 4.4.** **A.** The linear threading method of injection is used to treat nasolabial folds. (Reprinted with permission from Avram et al., *Color Atlas of Cosmetic Dermatology*, McGraw-Hill Medical, New York, 2007.) **B.** Preoperative photograph. **C.** Postoperative photograph. (B and C reprinted with permission from Baumann, *Cosmetic Dermatology*, McGraw-Hill Medical, New York, 2002)

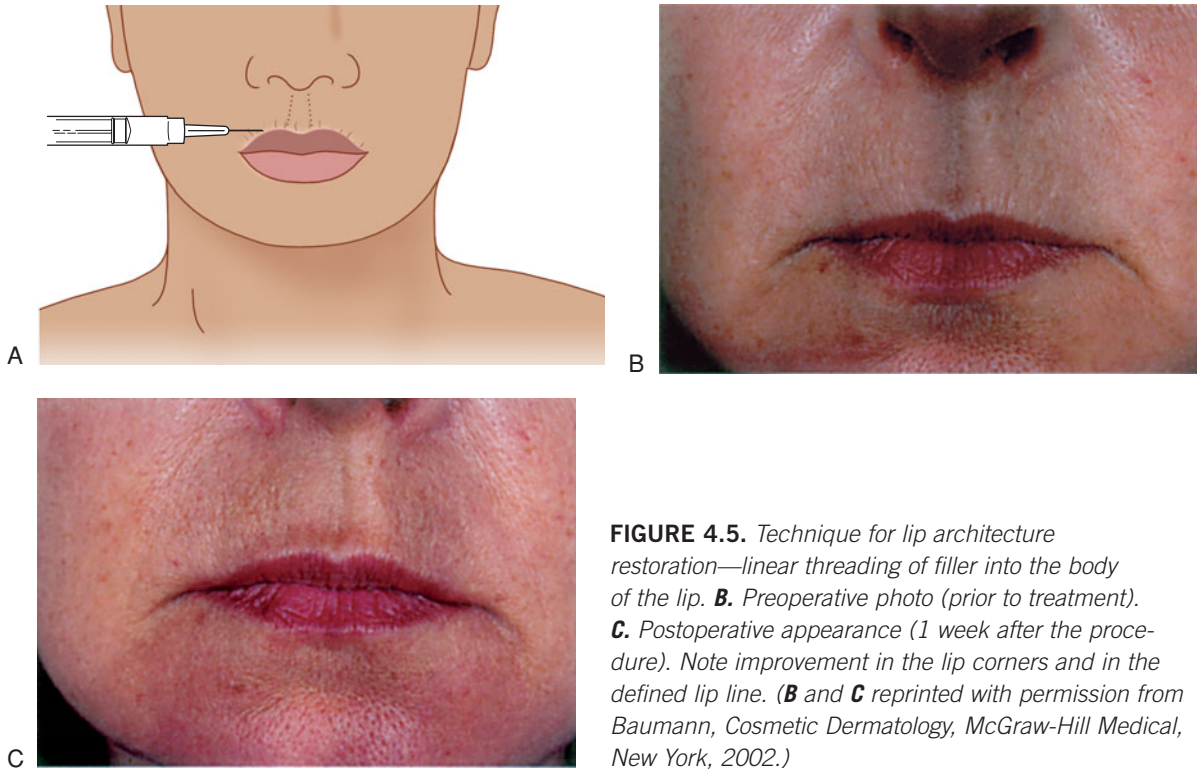
### Oral commissures

- The lower melolabial folds and a droopy chin are addressed with medium-depth fillers. Improved outcomes can be seen with BTX-A injected into the depressor anguli oris muscle in appropriate candidates.
- Our preferred technique involves fanning to the corners of the mouth, whereas a serial threading technique is ideal for placement in the lower melolabial folds.

- In both cases, we use a bent 30-gauge needle directed medially.
- Full correction of this area is advisable.

### Jawline restoration

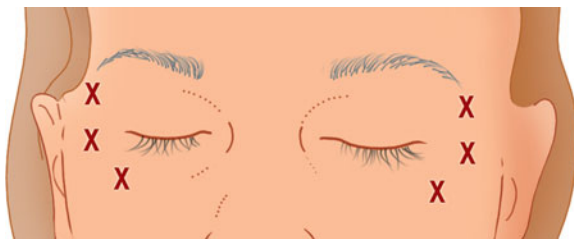
- Aim is to restore rounded angularity characteristic of a youthful jawline.
- We prefer a linear threading technique in this region.



**FIGURE 4.5.** Technique for lip architecture restoration—linear threading of filler into the body of the lip. **B.** Preoperative photo (prior to treatment). **C.** Postoperative appearance (1 week after the procedure). Note improvement in the lip corners and in the defined lip line. (**B** and **C** reprinted with permission from Baumann, *Cosmetic Dermatology*, McGraw-Hill Medical, New York, 2002.)

### Periocular rhytids (Fig. 4.6)

- “Crow’s feet” that radiate from the lateral ocular canthus; dynamic rhytids should be addressed with botulinum toxin and fillers serve best as adjunct.
- Periocular skin is exquisitely thin with a rich vascular supply that makes filler treatment very unforgiving. There can frequently be the risk of visible product and significant post-treatment purpura.



**FIGURE 4.6.** Injection sites for periocular lines are deep in the lateral orbicularis muscle as shown. (Reprinted with permission from Avram et al., *Color Atlas of Cosmetic Dermatology*, McGraw-Hill Medical, New York, 2007.)

- Ideally, the smallest bore needle possible should be used and in a very superficial plane.
- Minimal force should be applied to the plunger with serial injections to fill the rhytids.

### Nasojugal crease

- Given the tight anatomy of this space, we recommend the use of limited product volume.
- Placement is best under the orbicularis oculi muscle.
  - Too superficial placement of the material can yield a bluish tint secondary to the Tyndall effect and is best avoided by proper depth of the placement.
- Use the nondominant hand to protect the globe at all times. Have the patient lean the head on something firm for the injection.
- Instruct the patient to turn off any distractions, e.g., cellular telephones, spit out gum or hard candy.
- Semipermanent fillers are ill-advised in this anatomic location.

### Glabellar complex

- Primary treatment involves judicious use of botulinum toxin to address the hypertrophy of the bilateral corrugator supercilii and midline.
- For patients in whom there remain deeply etched parallel lines despite appropriate muscular immobility, fillers are an appropriate addition.
- The deep placement required to treat this area makes the use of deeper fillers absolutely contraindicated.

### POSTOPERATIVE CARE

- Following injection, the injector can perform gentle massage; however, this can increase posttreatment bruising and must be done with care.
- Cool packs (frozen peas are an excellent option) should be applied in a 15-minute on and 15-minute off course during the first 24 hours.
- Encourage the patient to elevate the head as much as possible so as to decrease posttreatment edema. Advise patients to sleep elevated on an extra pillow the evening after the procedure.
- If extensive swelling known to occur and there are no other contraindications, pretreatment with low-dose diuretic (OTC) or oral corticosteroids can be considered.
- Instruct the patient to avoid vitamin E, aspirin, and NSAID ingestion for the first postoperative week.
- If needed for analgesia, give acetamenophin (Tylenol) or prescription-strength analgesics.
- For procedures involving the mouth, it is best to limit the posttreatment diet to soft-to-chew foods for the first 2 days. Advise the patient to avoid any contact sports where the area treated might be injured.
- The patient must be instructed to contact the treating physician immediately if there is significant bleeding, pain, irregular swelling, dusky discoloration, eye pain, blurred vision, vision loss, or headache (Table 4.2).

**TABLE 4.2 ■ Side Effects**

Common	Rare
Erythema	Local hypersensitivity
Swelling	Formation of granulomas
Pain/Tenderness	Abscess development
Bruising	Necrosis and sloughing
	Acneiform eruption
	Reactivation of latent HSV

### COMPLICATIONS

- Bruising and swelling are both expected sequella and are best managed preoperatively with proper patient preparation.
- Swelling is typically a 24–48-hour phenomenon, but the bruising can last for as long as a week.
- Coverage makeup such as Dermablend (L'Oreal, New York) can be very helpful.
- Immediate postoperative cold therapy can also help.
- Rare complication is the reactivation of latent labial herpes simplex.
- Ideally, prophylaxis prevents such an occurrence.
- If recurrence does happen, the appropriate course of systemic antivirals will manage the situation.
- To avoid the Tyndall effect,
  - remove the material via direct removal procedure (incision with an 11 blade and expressing it out);
  - use a QS 1064-nm YAG laser device, as recently reported;
  - judicious injection of hyaluronidase if an HA filler.
- Necrosis represents the most concerning complication.
  - If localized pain or blanching develops acutely during treatment, immediately discontinue injection and manually massage the area until color returns.
  - If blanching remains, apply warm water compresses to the area; this helps in quick vasodilatation.
- Have the patient take an aspirin immediately to promote vasodilatation.
- Apply nitroglycerin paste every 2 hours for 24 hours and then every 4–6 hours; the patient must be warned about the severe headache that can ensue.
- Injection of hyaluronidase provides an important adjunct to resolution; there are several recent protocols (see Suggested Reading).

### SUGGESTED READING

1. Landau M. Combination of chemical peelings with botulinum toxin injections and dermal fillers. *J Cosmet Dermatol* 2006;5(2):121–126.
2. Fernandez-Acenero MJ, Zamora E, Borbujo J. Granulomatous foreign body reaction against hyaluronic acid: Report of a case after lip augmentation. *Dermatol Surg* 2003;29(12):1225–1226.



3. Friedman PM, Mafong EA, Kauvar AN, Geronemus RG. Safety data of injectable nonanimal stabilized hyaluronic acid gel for soft tissue augmentation. *Dermatol Surg* 2002;28(6):491–494.
4. Klein AW. Skin filling: Collagen and other injectables of the skin. *Dermatol Clin* 2001;19(3):491–508.
5. Narins RS, Brandt F, Leyden J, et al. A randomized, double blind, multicenter comparison of the efficacy and tolerability of Restylane versus Zyplast for the correction of nasolabial folds. *Dermatol Surg* 2003;29(6):588–595.
6. Goldberg RA, Fiaschetti D. Filling the periorbital hollows with hyaluronic acid gel: initial experience with 244 injections. *Ophthal Plast Reconstr Surg* 2006;22(5):335–341; Discussion 341–343.
7. Maas CS. Botulinum neurotoxins and injectable fillers: minimally invasive management of the aging upper face. *Facial Plast Surg Clin North Am* 2006;14(3):241–245.
8. Lowe NJ, Grover R. Injectable hyaluronic acid implant for malar and mental enhancement. *Dermatol Surg* 2006;32(7):881–885; Discussion 885.
9. Carruthers JDA, Carruthers A. Facial sculpting and tissue augmentation. *Dermatol Surg* 2005;31(11 Pt 2):1604–1612.
10. Klein AW. In search of the perfect lip: 2005. *Dermatol Surg* 2005;31(11 Pt 2):1599–1603.
11. Jones D. HIV facial lipoatrophy: Causes and treatment options. *Dermatol Surg* 2005;31(11 Pt 2):1519–1529; Discussion 1529.
12. Biesman B. Soft tissue augmentation using Restylane. *Facial Plast Surg* 2004;20(2):171–177; Discussion 178–179.
13. Hirsch RJ, Cohen JL, Carruthers JD. Successful management of an unusual presentation of impending necrosis following a hyaluronic acid injections embolus and a proposed algorithm for management with hyaluronidase. *Dermatol Surg* (in press).
14. Glaich AS, Cohen JL, Goldberg LH. Injection necrosis of the glabella: Protocol for prevention and treatment after use of dermal fillers. *Dermatol Surg* 2006;32(2):285–290.
15. Brody HJ. Use of hyaluronidase in the treatment of granulomatous hyaluronic acid reactions or unwanted hyaluronic acid misplacement. *Dermatol Surg* 2005;31:8;893–897.
16. Hirsch RJ, Narurkar V, Carruthers JD. Management of hyaluronic acid induced tyndall effects. *Lasers Surg Med* 2006;38(3):202–204.
17. Hirsch RJ, Carruthers JDA, Carruthers A. Infraorbital hollow treatment by dermal fillers. *Dermatol Surg* 2007;33:1–4.

*This page intentionally left blank*

## CHAPTER 5

# Botulinum Toxin

Ranella J. Hirsch, MD

### KEY POINTS FOR SUCCESS

- Careful patient selection.
- Detailed informed consent.
- Pre- and postphotography.
- Knowledge of precise anatomy for optimal placement.
- Injecting the underlying muscles, not the overlying wrinkles.
- Technique dependent—treatment must be individualized for each patient.
- Goal is to soften rhytids without total loss of expression.

### PHARMACOLOGY—BOTULINUM TOXIN

- Seven distinct serotypes A, B, C, D, E, F, and G, which vary by size and cellular mechanism of action.
- Botulinum toxins A and B are commercially available; these are composed of different strains of *Clostridium botulinum* bacteria.
- Both botulinum toxins A and B are 150-kD dichain polypeptides composed of a heavy chain and a light chain linked by a disulfide bond. The heavy chain is responsible for select binding of the toxin molecule to presynaptic cholinergic nerve terminals, whereas the light chain acts inside the cell to prevent acetylcholine vesicle release.

### MECHANISM OF ACTION—BOTULINUM TOXIN

- It smoothes dynamic rhytids by inhibiting the activity at the neuromuscular junction.
- Within the target cell, light chain of type A cleaves SNAP-25 or light chain of type B cleaves VAMP.
- It binds to the motor nerve terminals and inhibits the release of acetylcholine via cleavage of SNAP-25—a protein necessary for the docking and release of acetylcholine filled vesicles, resulting in temporary chemical denervation of affected muscle.

- After both treatments, a collateral sprouting of new nerve terminals occurs over time; however, the original functional endplate is established so that sprouts regress as the clinical effects of botulinum subside.

### AVAILABLE PRODUCTS

- Type A toxins: Botox (Allergan, Irvine, CA) and Dysport (Ipsen, Berkshire, England).
- Type B toxin: Myobloc (Elan, San Francisco, CA).
- Botox was approved by the United States Food and Drug Administration in April 2002 for the cosmetic treatment of glabella; other cosmetic uses are off-label.

### MEDICAL CONSIDERATIONS

- To minimize purpura, medications to avoid include anti-coagulants (warfarin (Coumadin), heparin), NSAIDS, aspirin, platelet inhibitors, isotretinoin, vitamin E, and assorted herbal preparations.
- Check for history of smoking. Smoking creates an increased risk of vascular compromise and contributes to decreased longevity of the injected product.
- Inquire about known allergy to medications and/or anesthetics.
- Inquire about tendency to faint so that appropriate preventative measures can be provided.
- Confirm that female patients of childbearing age are neither pregnant nor lactating.
- Check for history of keloid formation or tendency for poor scarring.

### PSYCHOSOCIAL HISTORY

- Realistic expectations are critical—What is the motivation to undergo the procedure?
- Beware of patients who have had multiple procedures done by various clinicians with minimal satisfaction.

### INFORMED CONSENT

- Document reasonable risks, which are optimally reviewed by an attorney familiar with local standards of care.

- Delineate the exact procedure, indications for therapy, treatment alternatives, and complications.
- Consent for photography advisable.
- The form should be signed by the patient and the witness in a dated format and should be offered to the patient for his/her individual record.

## PHOTOGRAPHY

---

- Pre- and posttreatment photography advisable.
- Standardize lighting, distance, and background.
- Remove distracting jewelry and clothing.

## DOSAGE

---

- Both Botox and Dysport are available in lyophilized form, which must be reconstituted with saline prior to clinical use. Preserved saline has been noted to provide a beneficial mild analgesic effect.
- Myobloc is available as a stable, nonpreserved aqueous solution that may be further diluted.
- Higher concentration injections allow for very low volume injections with precise toxin placement and little spread to nontargeted areas. Lower concentration injections deliberately spread the toxin over a wider area.
- The amount of saline to be used for the reconstitution depends upon the particular clinical use and whether the amount of neurotoxin diffusion desired is more or less. For example, in the neck bands more diffusion is desired and thus a lower concentration would be beneficial, whereas in the treatment of the glabellar furrow a discretely focal effect of botulinum is desired in order to avoid diffusion into the levator palpebrae superioris with a possible resultant ptosis.

## RELEVANT FACIAL MUSCULATURE (FIG. 5.1)

---

- Frontalis is a large, vertically oriented muscle that inserts superiorly to the galea aponeurotica and inferiorly to the procerus, the orbicularis oculi, the corrugator supercilii, and the eyebrow skin.
- Frontal belly of occipitofrontalis raises the eyebrow and is responsible for transverse forehead lines.
- Orbicularis oculi is the sphincter of the eye; orbital portion depresses the eyebrow and the palpebral portion affects the eyebrow and lid.

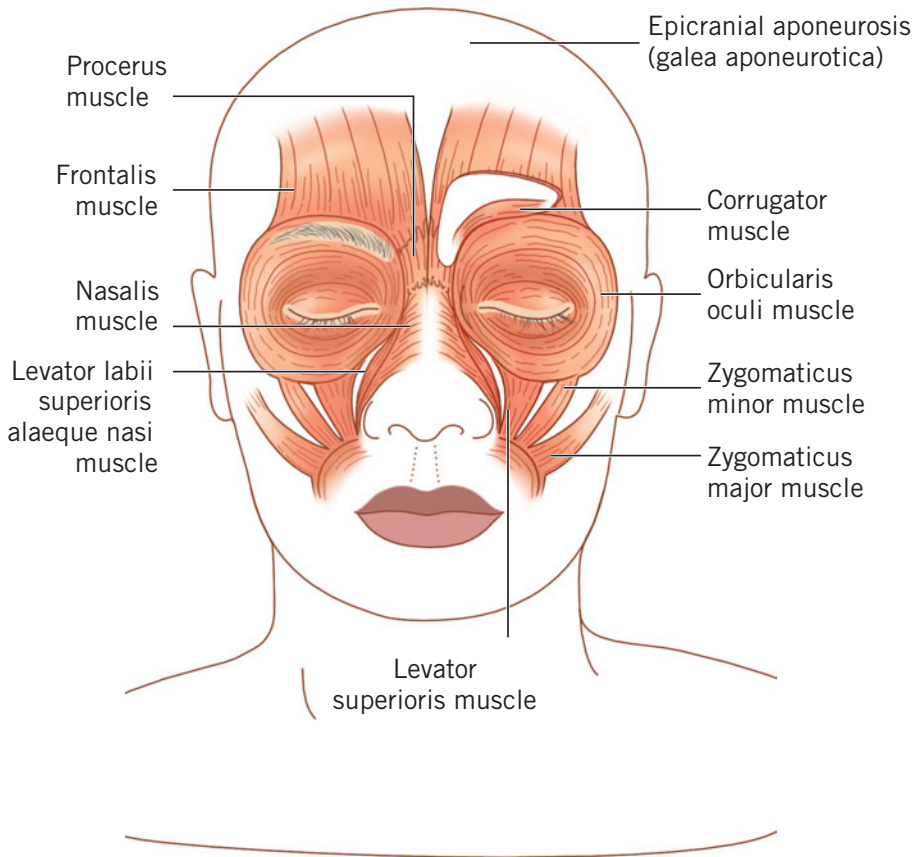
- Procerus pulls the forehead skin inferiorly and determines medial eyebrow height.
- Vertical perioral rhytids, commonly referred to as “smoker’s lines,” or “lipstick bleeders,” are the product of repeated activity of the orbicularis oris muscle. Orbicularis oris is a sphincter muscle that permits closure and puckering of the lips.
- Fibers that comprise orbicularis oris are derived from buccinators and zygomaticus major and minor, risorius, and depressor anguli oris.
- Orbicularis oris plays an important role in communication especially in mastication and phonation and hence the dermasurgeon’s primary challenge is to treat rhytids while preserving optimal functioning.

## INJECTION SITES

---

### ■ Glabellar Complex—Frown Lines

- Four muscles are entirely responsible for the downward and inward movements of the brow—corrugator supercilii, orbicularis oculi, procerus, and depressor supercilii.
- To inject glabellar frown lines, the technique involves five to seven injections with the total dosage dependent on the particular brow to be treated.
- An average female brow with normal muscular volume requires 25–30 U while male brow with greater muscle mass requires 35–45 U. More toxin may be needed to optimize results, especially in heavy brows.
- First, inject 5–10 U into the procerus at the midline point just above the point joining the medial brow and the contralateral medial canthus. Immediately postinjection, massage horizontally to encourage diffusion into the depressor supercilii. Second, insert needle at the medial canthus directly into the head of the corrugator just above the bony supraorbital ridge. Inject 4–7 U, then slightly withdraw the needle without removing from the skin. Advance with the tip pointing superiorly and inject an additional 3–7 U, approximately 1 cm above the previous injection. (Fig. 5.2)
- If lateral brow elevation is desired and is appropriate (in patients with a more horizontal baseline brow), an additional 3–5 U can be injected 1 cm above the supraorbital notch bilaterally in the midpupillary line.



**FIGURE 5.1 A.** *Upper and midfacial musculature*

### ■ Brow Lift—Lateral

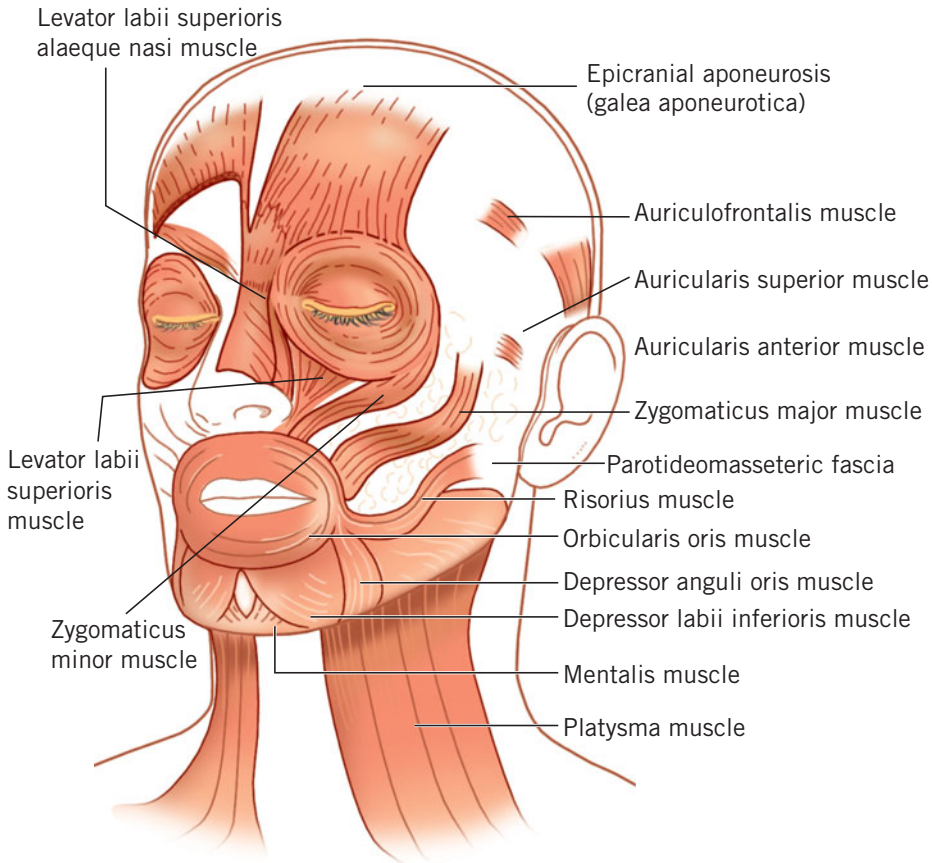
- Eyebrow ptosis is common and creates the negative impression of being tired.
- Eyebrows can be elevated by successful injection of the depressor musculature, thus permitting the brow elevators to act unopposed. Lifting is most likely the result of partial weakening of central frontalis fibers by diffusion of the toxin.
- In a study on dose range, Carruthers reported that approximately 30 U is an optimal dose for this indication.
- With lateral brow ptosis, inject at the superolateral orbital rim where the fibers of orbicularis oculi curve from horizontal to vertical. Injecting at the point just above where the temporal fusion line reaches the bony orbital rim produces a subtle lateral brow lift.
- Dose of 4–6 U in females and 7–10 U in males.

### ■ Brow Lift—Medial

- Drooping brow creates an unintentional tired and angry appearance.
- Injecting 10–20 U Botox into the procerus and 5–10 U into each medial corrugator weakens the medial brow depressors, thus permitting frontalis to elevate the medial brow.

### ■ Combination Brow Lifting

- Injecting in both the procerus and the lateral brow, at its junction with the temporal fusion line, produces a brow lift of 1–3 mm and reveals more of the prized eyelid skin in both females and male patients.
- The result is a rested and alert appearance.



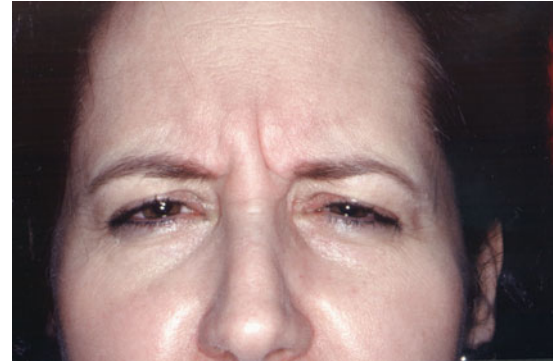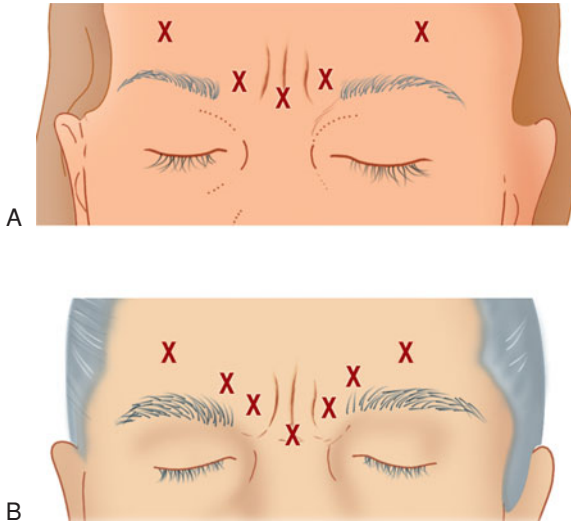
**FIGURE 5.1 (continued) B.** Lower face and neck musculature. (Reprinted with permission from Avram et al., *Color Atlas of Cosmetic Dermatology*. McGraw-Hill Medical, New York, 2007)

### **Eyebrow—special considerations**

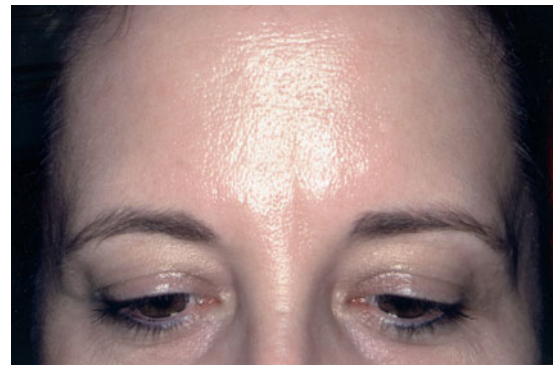- Characteristic of a well-proportioned female brow: The medial aspect should begin at a point defined by a line drawn from the lateral nose through the medial canthus of the eye.
- Lateral female brow should end at a point defined by a line starting from the lateral nose upward through lateral canthus.
- Lack of expression can be the result of too lateral injection of the frontalis (lateral to midpupillary line).
- Injection in the forehead should always be above the lowest fold produced when the patient is asked to elevate the brow.

### **Eyebrows—cautions**

- If the patient has a low-lying brow, treatment of the forehead lines should be avoided or limited to 4 cm or more above the brow.
- The lower 2.5–4 cm of the frontalis muscle moves upward to elevate the eyebrows; older patients often rely on this movement to raise the brows for vision and the loss of this ability with Botulinum therapy is undesirable.
- The glabella and the entire forehead should not be injected in a single session to minimize risk of ptosis, if it can be avoided.
- Women frequently shape the brows artificially hence it is critical to rely on the bony landmarks and not on the actual brow location.



C



D

**FIGURE 5.2 A & B.** Injection sites for glabellar frown lines. **C.** Glabellar complex before BTX-A injection and **D.** 3 weeks after BTX-A injection. (Reprinted with permission from Avram et al., *Color Atlas of Cosmetic Dermatology*. McGraw-Hill Medical, New York, 2007)

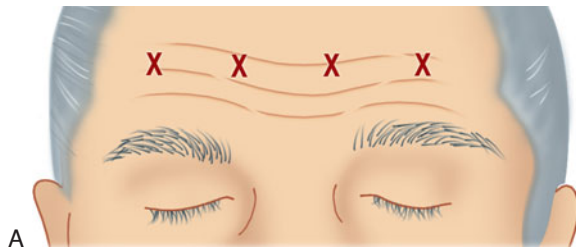
### ■ Horizontal Forehead Lines

- These lines are the product of the anterior frontalis portion of the occipitofrontalis muscle.
- The frontalis inserts superiorly into the galea and inferiorly into the procerus, corrugator supercillii, orbicularis oculi, depressor supercillii, and brow skin.
- It is crucial to recognize that this represents sole brow elevator, yielding brow ptosis as a significant concern of poor injection technique. Anyone with significant preinjection brow ptosis must either be excluded or be injected with extreme care.
- Critical goal is to weaken but not paralyze the frontalis.
- Concomitant treatment of the brow depressors with 10 U into the procerus and 5 U into each lateral orbicularis yields reduced downward force, causing brow depression for the elevating frontalis muscle to counteract. If this approach is taken, as little as 10–20 total U are needed (2–4 U in each of the four or five sites) across the forehead. It is advisable to massage the forehead upward and obliquely immediately after injecting to provide a smooth brow appearance. (Fig. 5.3)

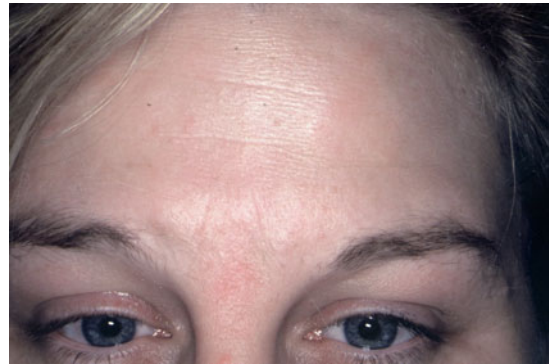- Avoid injecting lower than 2–3 cm above brow because the lower fibers of frontalis are the focus of most of its elevating action.

### ■ Crow's Feet

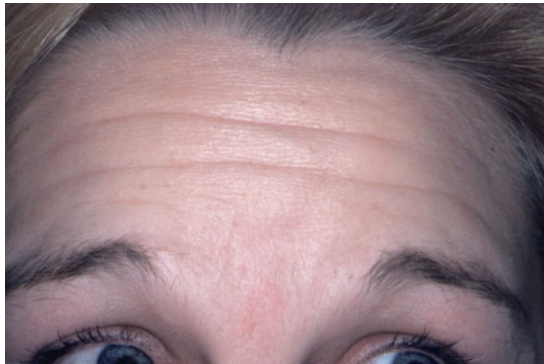- Crow's feet are the result of the vertically oriented fibers of orbicularis oculi and the elevators and retractors of the corner of the mouth, zygomaticus, and risorius.
- The goal is to weaken only the lateral part of orbicularis oculi.
- Crow's feet injections must be placed outside the bony orbital margin to avoid diffusion to the extraocular muscles in which case diplopia can result.
- They should not be placed less than 1 cm above the zygomatic notch in order to avoid the potential of midfacial and lip ptosis.
- Inject up to 12–15 U per side at three or four injection sites. (Fig. 5.4)
- Aim for as superficial injection (dermal) as possible to minimize bruising.



A

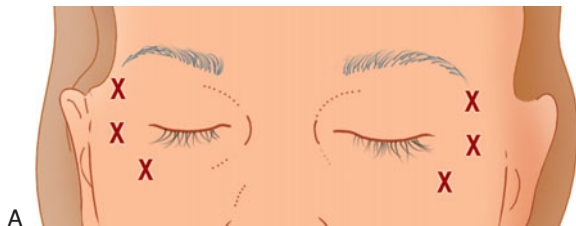


C

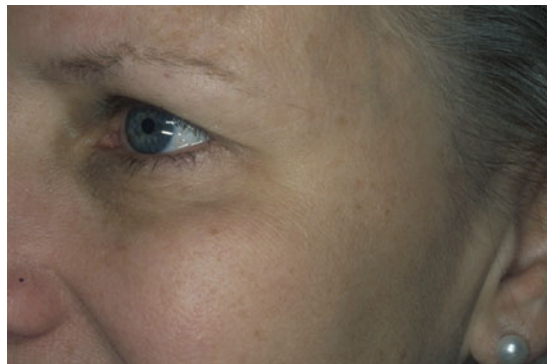


B

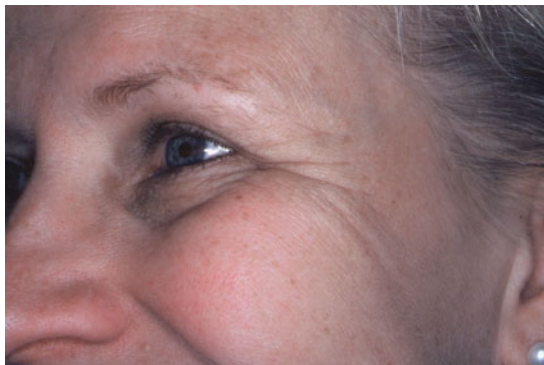
**FIGURE 5.3** **A.** Injection sites for horizontal forehead lines. **B.** Forehead lines prior to BTX-A treatment. **C.** The same patient one month after treatment. (Reprinted with permission from Avram et al., *Color Atlas of Cosmetic Dermatology*. McGraw-Hill Medical, New York, 2007)



A



C



B

**FIGURE 5.4** **A.** Injection sites for periorbital lines. **B.** Periorbital lines prior to treatment with BTX-A. **C.** The same patient 6 weeks after treatment. (Reprinted with permission from Avram et al., *Color Atlas of Cosmetic Dermatology*. McGraw-Hill Medical, New York, 2007)



- Visual avoidance of vessels with magnifiers is also advisable to minimize purpura.

### ■ Hypertrophic Orbicularis Oculi

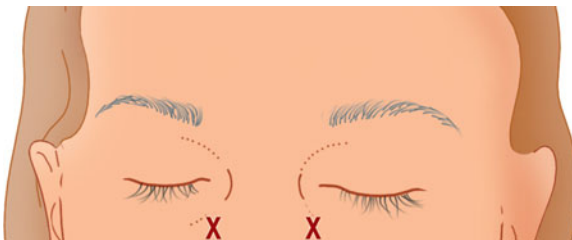
- Popular in patients of Asian ethnic origin or in patients desiring a wider eye shape.
- Injection of 2–4 U of Botox into the lower pretarsal orbicularis 3 mm below the inferior ciliary margin in the midpupillary line relaxes the palpebral aperture.
- Do not perform in patients with a negative pretreatment snap test or those who have had a previous ablative resurfacing or a lower blepharoplasty (increased risk of ectropion.)

### ■ Mid Face

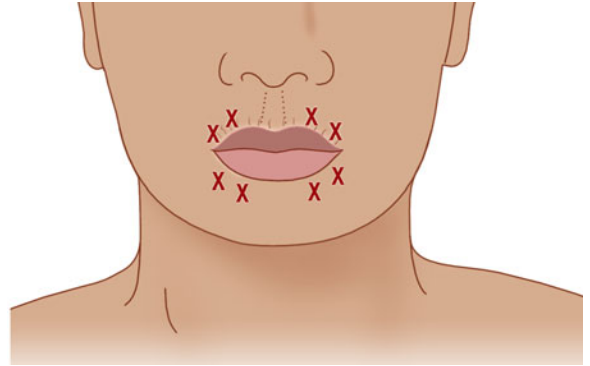
As a general rule, the mid- and lower facial musculature requires by and large much smaller unit injections than do the muscles of the upper face. Overdosing the mid and lower facial musculature can yield a facial palsy that can last for approximately 6 months. It is advisable to treat conservatively, have patients return, and slowly increase the dose.

### ■ Nasalis

- Contraction of the muscular fibers of upper nasalis yields radial rhytides at the tip of the nose, colloquially termed “bunny lines.”
- Bunny lines are treated with 3–5 U placed high on the dorsum of the nose away from the lip elevators located in nasofacial groove (Fig. 5.5).



**FIGURE 5.5** Injection sites for upper nasal root rhytides (bunny lines). (Reprinted with permission from Avram et al., *Color Atlas of Cosmetic Dermatology*. McGraw-Hill Medical, New York, 2007)



**FIGURE 5.6** Injection sites for the perioral muscles. (Reprinted with permission from Avram et al., *Color Atlas of Cosmetic Dermatology*. McGraw-Hill Medical, New York, 2007)

- “Botox sign” is what is referred to by the lay media as a sign of Botulinum injection and represents recruitment of the upper nasalis in compensation for the inability to mobilize the forehead rhytids and is best avoided.

### ■ Repetitive Nasal Flare

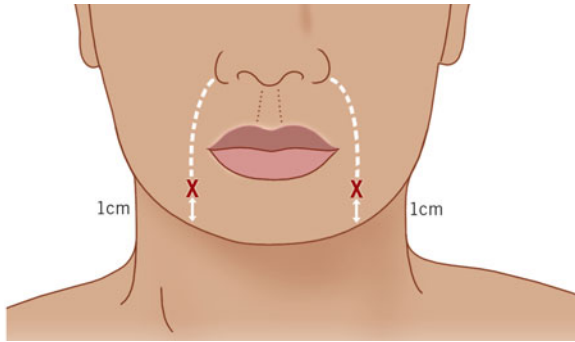
- Muscular fibers of the dilator naris bridge the dorsum of the nose closer to the tip and insert into the lateral alar cartridges. When contracted, these muscles yield dilatation of the nares.

### ■ Perioral Rhytids

- Injection of 1–2 U per lip quadrant as symmetrically as possible across the philtrum can create a pseudoover-division of the lips (Fig. 5.6).
- Great care must be taken to avoid creating a paresis of the orbicularis oculi with a resultant interference with elocution and suction, however this must be covered in the informed consent as it is rarely unavoidable.
- Unpredictably, some patients complain of lost proprioception after the treatment.

### ■ Upper Gum Show

- This affects people with a naturally short upper lip; when they smile both the incisor base and the gum line become visible.



**FIGURE 5.7** Injection sites for frown lines. (Reprinted with permission from Avram et al., *Color Atlas of Cosmetic Dermatology*. McGraw-Hill Medical, New York, 2007)

- Injecting 1 U of Botox into each lip elevator complex in each nasofacial groove relaxes the upper lip so it cannot fully retract.

### ■ Depressor Anguli Oris/Frown

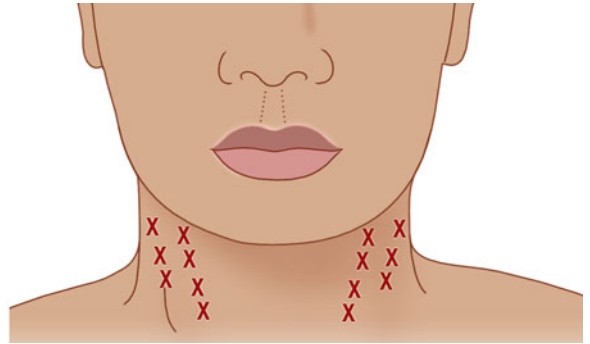
- Downward movement of the lateral corners of the mouth is caused by the action of the depressor anguli oris in association with aging and the normal course of photodamage (Fig. 5.7).
- Injecting too medially can affect the lip depressor muscles and by extension elocution and smiling.
- Zygomaticus major is the direct antagonist to the depressor anguli oris; thus, weakening DAO with 3–5 U of Botox allows zygomaticus to elevate mouth corners to a more horizontal position.

### ■ Mentalis

- Can get apple-dumpling appearance
- Injection technique is to stay low at the point of the mentum and avoid the depressor labii.

### ■ Cervical Injections/Necklace Lines

- The platysmal muscle is a larger muscle on the superficial anterior neck.
- The simplest approach is to inject 1–2 U of Botox, approximately 1 cm apart, along each necklace line followed with gentle massage postinjection (Fig. 5.8).



**FIGURE 5.8** Injection sites for the platysma muscle complex. (Reprinted with permission from Avram et al., *Color Atlas of Cosmetic Dermatology*. McGraw-Hill Medical, New York, 2007)

- Raising a wheal as in a deep dermal injection is preferable to reduce the risk of bruising.
- We limit each session to injections of 10–20 U because of the immediate proximity of the muscles of deglutination and speech.

### POSTOPERATIVE COURSE/CARE

- Botulinum toxin may take 3–8 days to show effect. Advise patients not to expect immediate results.
- We recommend that patients remain vertical for 2–3 hours after the injections and utilize the treated musculature as much as possible in the 60 minutes subsequent to injection to promote binding of the toxin.
- Patients are urged to avoid manipulation of the treated areas for several hours postinjection.

### EFFICACY

- Peaks in 3–4 weeks and declines after 3–4 months. However, there are some individuals who experience sustained efficacy for as long as 6–12 months.
- Anecdotally, patients who have undergone a series of treatment seem to require less frequent reinjections.

### COMPLICATIONS: TREATMENT AND PREVENTION

- Pain—decreases with use of topical anesthetics or application of coolants (ice, cold air).

- Edema and erythema—minimize with the application of ice immediately prior to and after the injection.
  - Ecchymosis and purpura—can be reduced by asking the patient to avoid the ingestion of NSAIDs, aspirin, and other procoagulants prior to injections.
  - In addition, minimizing the amount of injections, and postinjection manipulations is also helpful.
  - Headache—patients identified to be at risk can be pre-treated with OTC acetaminophen.
  - The major factor leading to patient dissatisfaction is an unexpected complication that has not been well explained.
  - Detailed discussion of the majority of expected complications, which are signed and documented, helps to minimize this scenario.
2. Carruthers A, Carruthers JDA. Botulinum toxin type A: history and current cosmetic use in the upper face. *Semin Cutan Med Surg* 2001;20:71–84.
  3. Carruthers JDA, Carruthers A. Botox use in the mid and lower face and neck. *Semin Cutan Med Surg* 2001;20:85–92.
  4. Klein AW. Complications and adverse reactions with the use of botulinum toxin. *Semin Cutan Med Surg* 2001;20:109–120.
  5. Said S, Meshkinpur A, Carruthers A, Carruthers JDA. Botulinum toxin A: its expanding role in dermatology and esthetics. *Am J Clin Dermatol* 2003;4(9): 609–616.
  6. Frampton JE, Easthope SE. Botulinum toxin A (Botox Cosmetic): A review of its use in the treatment of glabellar frown lines. *Am J Clin Dermatol* 2003;4(10): 709–725.
  7. Lowe NJ, Ascher B, Heckman M, Kumar C, Fraczek S, Eadie N. Botox Facial Aesthetics Study Team. Double-blind, randomized, placebo-controlled, dose-response study of the safety and efficacy of botulinum toxin type A in subjects with crow's feet. *Dermatol Surg* 2005;31(3):257–262.

## SUGGESTED READING

---

1. Semchyshyn N, Sengelmann RD. Botulinum toxin: A treatment of perioral rhytids. *Dermatol Surg* 2003;29: 490–495.

*This page intentionally left blank*

**Naomi Lawrence, MD**

## KEY POINTS FOR SUCCESS

---

- Choose an appropriate candidate who has a stable weight pattern and reasonable expectations that you can meet.
- Perform a thorough assessment of the area.
- Consider and determine the relative contribution of the following to the deformity:
  - fat compartments—deep (or below muscle) and superficial,
  - bone structure, and
  - skin thickness.
- Estimate the amount you think will be suctioned and compare to actual aspirate.
  - This exercise will train you to have a sense of what can be removed from a particular area.
  - If the amounts differ by more than 200 cc, consider whether the muscle mass or deep fat compartment was underestimated.
- Make safety the top priority in performing liposuction.
  - Use a good tumescent technique.
  - Monitor the patient when appropriate.
  - Minimize the use of sedative medication.
  - Maintain an ACLS certification.
  - Have the appropriate resuscitative equipment and medications on hand.
- The patient will see a good portion of the result in a week, but the area will continue to improve over the following months as the skin retracts.
  - Delay touch-ups, ideally for 1 year, but minimum 6 months.

## INDICATIONS

---

- The primary purpose of liposuction is to contour disproportionate areas of fat deposition in patients, close to their ideal body weight, with realistic expectations of changes in contour and not weight loss.

- It is not for the treatment of obesity. Liposuction as a treatment of obesity is an experimental procedure and should not be performed.
- It should not be performed on persons who fulfill DSM-IV criteria for body dysmorphic disorder.
- It is not for the treatment of cellulite.
- It can be used successfully to treat a number of adipose-related disease conditions and to assist in soft tissue remodeling and reconstruction.
- It can be used for cosmetic contouring:
  - Face—jowls, buccal, and lateral nasolabial area.
  - Neck—lateral neck and submental areas.
  - Trunk—anterior abdomen, iliac crest, lateral trunk, posterior waist, back, and gynecomastia (when due to fat in both males and females).
  - Extremities—lateral trochanteric area and buttocks, medial anterior and posterior thigh, suprapatellar and medial patellar areas, calves, ankles, and upper outer arms.
- Other indications
  - Lipomas, single or multiple.
  - Gynecomastia or pseudogynecomastia in males and females.
  - Lipodystrophy, especially that related to Cushing's disease or HIV disease.
  - Axillary hyperhidrosis and bromhidrosis.
  - Lymphedema.
  - Evacuation of hematomas and seromas.
- Reconstruction
  - Flap elevation and movement.
  - Subcutaneous fat debulking, following flap and full thickness grafting procedures.

## CONTRAINDICATIONS

---

- Absolute
  - Hematologic abnormalities that cannot be corrected
  - Abdominal hernia
  - Anticoagulant medication

- Pregnancy
- True allergy to lidocaine (very rare)
- Body dysmorphic disorder
- Consider additional discussion or a waiting period in case of
  - weight cycling,
  - unrealistic expectations,
  - recent large weight loss, or
  - very low calorie diet (VLCD).
- The following may necessitate medical clearance:
  - Diabetes
  - Cardiac disease
  - Hypertension
  - Chronic disease
  - Liver disease
  - Immunosuppression
  - Patient at risk for thromboembolism
- Some of these patients may be allergic to the methylparaben preservative in the anesthetic and so use preservative-free lidocaine—Xylocaine-MPF (Astra, USA Inc., Westborough)
- Epinephrine—this is an endogenous catecholamine and so true allergy is not possible.
  - Many patients are sensitive to the effects of epinephrine in the dental setting as the oral mucosa is highly vascular and absorption is rapid.
  - Majority of the patients do not have a problem with tumescent anesthesia as epinephrine is infused into the adipose, which has a low vascularity.
  - The use of 0.65-mg epinephrine (rather than 1 mg) in each tumescent liter and preoperative 0.1-mg clonidine (Boehringer, Ingelheim) in patients with BP > 100/70 minimizes the incidence of epinephrine-induced tachycardia.

## PREOPERATIVE CONSIDERATIONS

### ■ History

- Medical—see contraindications.
- Surgical—any previous surgeries in the area to be liposuctioned, hernias, or if there is some change in the underlying anatomy.
- Allergies/medicine sensitivities.
- Medications.

### ■ Allergy

- Antibiotic—patient receives IV cephalosporin (Ancef, Merck & Co) 30 minutes prior to procedure. If the patient is allergic to penicillin or cephalosporin, then to give oral clindamycin (Watson) the night before the procedure.
- Latex—Wear latex-free gloves and use latex-free dressings.
- Lidocaine—True allergy to lidocaine is extremely rare and is currently a contraindication to tumescent anesthesia as there is no alternative local anesthetic with safety testing.
  - If a patient has a questionable history of allergy to lidocaine, it is best to send him/her for allergy testing.

### ■ Medication

- Any medication or herbal supplement (Tables 6.1 and 6.2) that prolongs bleeding time.
- Warfarin, clopidogrel bisulfate (Plavix, Bristol-Myers Squibb), aspirin, nonsteroidals—*contraindicated*.
  - Discontinue 2 weeks prior to surgery *with* medical clearance.
- Drugs that interfere with lidocaine metabolism (Table 6.3). Management strategy:
  - Discontinue with medical clearance or substitution.
  - Decrease the maximum dose of lidocaine from 55 mg/kg to 35 mg/kg.
- Hormones
  - A high dose of estrogen increases the risk for thromboembolism from any surgery, particularly if the patient is a smoker, or within the first year of therapy (see Refs. 1–3).
  - Low-dose oral contraceptives—probably extremely low risk. Management strategy:
    - For high dose, or hormonal replacement in smokers, stop the hormone prior to surgery with medical clearance.
    - For low-dose oral contraceptives (OCP), counsel the patient and give the option of discontinuing OCP and using alternative contraceptive methods or accepting the minimal risk associated with continuing.

**TABLE 6-1 ■ Herbs Affecting Coagulation**

Coagulant	Anticoagulant	Antiplatelet
Agrimony	Alfalfa (Coumarin constituent)	Angelica
Alfalfa (vitamin K)	Angelica	Aspen
European mistletoe	Anise	Black cohosh
Goldenseal	Arnica	Borage seed oil
Plantain	Asafoetida	Capsicum
Stinging nettle	Bogbean	Celery
Yarrow	Boldo	Clove
	Borage seed oil	Dong quai
	Bromelain	Feverfew
	Danshen	Fish oils
	Dong quai	Garlic
	Fenugreek	Ginkgo
	Fucus	Ginseng
	Ginger	Licorice
	Ginseng	Onion
	Horse chestnut	Poplar
	Horseradish	Turmeric
	Meadowsweet	Vitamin E (alpha-tocopherol)
	Northern prickly ash	Willow bark
	Papain	
	Passionflower	
	Pau d'arco	
	Quassia	
	Red clover	
	Roman chamomile	
	Safflower	
	Southern prickly ash	
	Sweet clover	
	Sweet vernal grass	
	Tonka bean	
	Wild carrot	
	Wild lettuce	

### ■ Physical Examination (see Fig. 6.1)

- Skin features of the area—striae, cellulite, scars, skin tone, and elasticity
- Bone structure
  - Neck—forward placed hyoid bone can make the neck angle more obtuse.
  - The shape of the pelvis and the orientation of the femur socket can contribute to the shape of the outer thigh.
  - Bone structure may be responsible for asymmetry in *any* area.
- Muscle
  - Examine the abdomen. A poorly toned rectus allows abdominal contents to protrude and contribute to the bulk and rounded shape of the abdomen.
  - In the upper arm, poorly toned muscle may be as important as fat deposits to girth.

**TABLE 6.2 ■ Medicines Affecting Coagulation**

4-Way Cold Tablets	Clinoril Tablets	Ketoprofen Capsules
Adprin – B Tablets	Congesprin	Lanorinal Tablets
A.S.A. Enseals	Cope Tablets	Lodine Capsules/Tablets
A.S.A. tablets	Coricidin	Lodine XL
Aches-N-Pain Tablets	Coumadin	Lortab
Advil	Darvon Compound Pulvules	Magan Tablets
Alcohol	Darvon Compound –65	Magnaprin Arthritis Captabs
Aleve Tablets	Darvon with A.S.A Pulvules	Magsal Tablets
Alka-Seltzer Products	Darvon-N with A.S.A.	Marnal Capsules
Amigesic Capsules	Dasin Capsules	Marthritic Tablets
Anacin Tablets and Capsules	Doan's Pills	Maximum Bayer Aspirin
Anaprox, Anaprox DS Tablets	Dolobid Tablets	Measurin Tablets
Anodynos Tablets	Dristan	meclor Fenamate Capsules
Ansaid Tablets	Duoprin-S Syrup	Meclomen Capsules
APC	Duradyne Tablets	Mediipren Tablets and Caplets
Argesic Tablets	Easprin	Menadol Tablets
Artha-G Tablets	Ecotrin Tablets	Meprogesic Tablets
Arthralgen Tablets	Emagrin Tablets	Micrainin Tablets
Arthritis Bayer Timed Release Aspirin	Empirin Tablets	Midol 200 Tablets
Arthritis Pain Formula Tablets	Emprazil	Midol, All products
Arthropan Liquid	Endoran Tablets	Mobidin Tablets
Arthrotec	Epromate Tablets	Mobigesic Tablets
Ascodeen	Equagesic Tablets	Momentum Tablets
Ascriptin, all products	Equazine M Tablets	Motrin Tablets
Asperbuf Tablets	Etodolac	Nalfon Capsules/Tablets
Aspergum (chewing gum)	Excedrin Tablets and Capsules	Nalfon Pulvules
Aspirin	Feldene Capsules	Naprosyn Tablets/suspension
Asprimox Tablets	Fenoprofen Tablets	Naproxen Tablets
Axdone	Fiorgen PF Tablets	Neocylate Tablets
Axotal Tablets	Fiorinal Tablets	Norgesic/Norgesic Forte Tablets
Bayer, all products	Fluriprofen Tablets	Norwich Extra-Strength Tablets
BC Tablet and Power	Gelpirin Tablets	Nuprin Tablets and Cap[lets
Brufen	Gensan Tablets	Orphengesic
Buf-Tabs	Goody's Headache Powder	Orudis Capsules
Buff-A Comp Tablets and Capsules	Halfprin Tablets	Oruvail Capsules
Buffaprin Tablets	Haltran Tablets	Pabalate
Bufferin, all products	Ibu-Tab Tablets	Pabalate-SF Tablets
Buffets II Tablets	Ibuprin Tablets	PAC Tablets
Buffex Tablets	Ibuprobm Tablets and Caplets	Pamprin_IB Tablets
Buffinol Tablets	Indochron E-R Capsules	Pepto-Bismol Tablets and Suspension
Cama Arthritis Pain Reliever	Indocin Capsules/Suspension	Percodan/Percodan-Demi Tablets
CataFlam Tablets	Indocin Suppositories	Phenaphen
Cephalgesic	Indocin-SR Capsules	Piroxicam Capsules
Charcol	Indomethacin Capsules	Ponstel Capsules
Children's Aspirin	Indomethacin Suspension	Presalin Tablets
Children's Advil Suspension	Isollyl Improved Tablets/Capsules	Relafen Tablets
Children's Motrin Suspension	Ketrolac Tablets	



**TABLE 6.2 ■ Medicines Affecting Coagulation (continued)**

Robaxisal Tablets	Soma CMD	Tolmetin Tablets/Capsules
Rufen Tablets	St. Joseph Adult Chewable	Toradol Injection/Tables
S-A-C	Aspirin	Trendar Tablets
Saeto Tablets	St. Joseph Cold Tablets fo	Tricosal Tablets
Saeto-200,400,600,800 Tablets	Children	Tri-Pain Tablets
SalFlex Tablets	St. Joseph Aspirin for children	Trigesic
Salocol Tablets	Sulindac Tablets	Trigesic Tablets
Salsalate Tablets	Supac	Trilisate Tablets a& Liquid
Salsitabs Tablets	Synalogs Capsules	Vanquis Caplets
Sine-Aid	Synalogs-DC Capsules	Verin
Sine-Off	Talwin Compound Tablets	Voltaren tablets
SK-65 Compound Capsules	Tolectin 200,600 Tablets	Zactin
Soma	Tolectin DS Capsules	Zorprin Tablets

- Examine bulk—anterior thigh, calves, upper back and arms, and buttocks are all areas where muscle bulk may be responsible for a significant portion of the contour.

- Adipose

Neck and abdomen have superficial and deep compartments. Deep compartment fat cannot be “pinched away” from the underlying muscle.

In each area examine with muscles flexed to determine the amount of adipose that is suctionable.

*Tip:* As you perform the physical examination, explain to the patient how much of the protuberance is suctionable fat and how much is due to bone structure, muscle, or deep fat. Give the patient the percentage improvement they will gain from liposuction.

### ■ Preoperative Labs

- SMA20 (general chemistry profile)
- CBC with differential and platelets—complete blood count including platelet count and cell differential
- PT/PTT (protime/prothrombin time)
- Hepatitis screening profile
- HIV screen
- Urine pregnancy test (morning of the surgery day)

### ■ Surgical Suite Setup

- Emergency medication cart
- Defibrillator

- Oxygen

- Continuous blood pressure monitor (if IV or IM sedation is to be used)

### ■ Instrument Tray (see Fig. 6.2)

#### Cannulas

- A diameter of 3 mm or less for most procedures (12–16 gauge) (see Fig. 6.3A)
- Aggressive (Fig. 6.3B)
- Moderate cannulas (Fig. 6.3C)
- Aspiration pumps and powered pumps (Tiemann/Bernsco Co., Hauppauge, NY; HK Surgical, San Clemente, CA; Byron Medical, Tuscon, AZ) (Fig. 6.4)

### TECHNIQUE

Two weeks prior to surgery:

- Pictures are taken.
- Consent is signed.
- Patient is counseled.
- Bloodwork is ordered.
- Payment is made.

One week prior to surgery:

- Bloodwork is checked.

One day prior to surgery:

- Patient’s chart is reviewed.

**TABLE 6.3 ■ Drugs That Interfere with Lidocaine Metabolism****Antiarrhythmic drug**

amiodarone (Cordarone)

**Anti-histamines (H2 blockers)**

cimetidine (Tagamet)

**Beta blockers**

propranolol (Inderol)

**Calcium channel blockers**

amiodarone (Cordarone)

diltiazem (Cardiazam)

felodipine (Plendil)

nicardipine (Cardene)

nifedipine (Procardia)

verapamil (Calan)

**Cholesterol-lowering drugs**

cervistatin (Baycol)

atorvastatin (Lipitor)

lovastatin (Mevacor)

simvastatin (Zocar)

**Antibiotics**

ciprofloxacin (Cipro)

clarithromycin (Biaxin)

erythromycin

**Antifungal medications**

fluconazole (Diflucan)

itraconazole (Sporanox)

ketoconazole (Nizoral)

miconazole (Monistat)

**Immunosuppressants**

cyclosporine

**Benzodiazepines**

alprazolam (Xanax)

diazepam (Valium)

flurazepam (Dalmane)

midazolam (Versed)

triazolam (Halcion)

**Antiseizure medications**

carbamazepine

divalproex (Depakote)

phenytoin (Dilantin)\*

valproic acid (Depakene)

**Antidepressants**

amitriptyline (Elavil)

clomipramine (Anafranil)

flouxetine (Prozac)

fluvoxamine (Luvox)

nefazodone (Serzone)

paroxetine (Paxil)

sertraline (Zoloft)

**Anti-neoplastics**

tamoxifen (Nolvadex)

**Protease inhibitors/antivirals**

diethylthiocarbamate

indinavir

nevirapine (Viramune)

nelfinavir (Viracept)

ritonavir (Norvir)

saquinavir (Invirase)

- Determine the maximum dose of anesthesia.
- Write the anesthesia order.
- Patient takes lorazepam 0.5–1.0 mg, the night before the surgery.
- Room is set up (if this surgery is the first procedure of the morning).

**■ Surgery Day**

- Patient takes 0.5–1.0-mg lorazepam 1 hour prior to the procedure.
- Urine pregnancy test on arrival at the office.
- Vital signs—if BP > 100/70, then 0.1-mg clonidine given PO.
- IV is placed and the antibiotic given (1-g cefaxolin—give 1 slow push over 5-minutes)
- Patient puts on sterile panties with assistance.
- Surgical scrub of all areas with patient in standing position.
- Patient (in standing position) is marked with a sterile pen (Fig. 6.5).
- Patient is assisted into an appropriate position on the sterile drape and sterile towels are draped to catch drainage and to cover the patient.
- Local for incision sites are drawn up onto a sterile field.
- Sterile infusion tubing is hooked up.

Patient Name \_\_\_\_\_ Date \_\_\_\_\_

Body Habitus: Thin      Normal      Mild obese      Morbid obesity

---

Extent of suctionable adiposity: Mild      Moderate      Extensive

---

Skin Quality – Elasticity: Poor      Adequate      Good

---

Cellulite: Mild      Moderate      Severe

---

Stria: Absent      Present      Extensive

---

Muscle Tone: Poor      Average      Good

---

Abdominal adipose \_\_\_\_\_ deep compartment

Neck adipose \_\_\_\_\_ superficial compartment

Scars from previous surgery: None \_\_\_\_\_

Hernia: Absent      Present

---

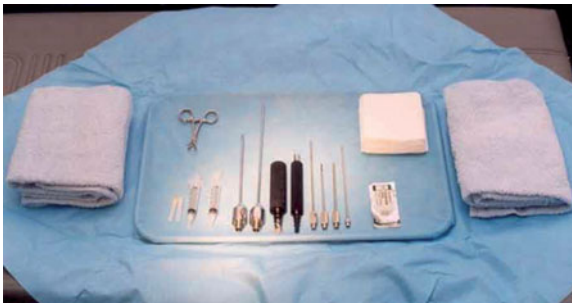Asymmetry: Absent      Present

---

Notes: \_\_\_\_\_

---

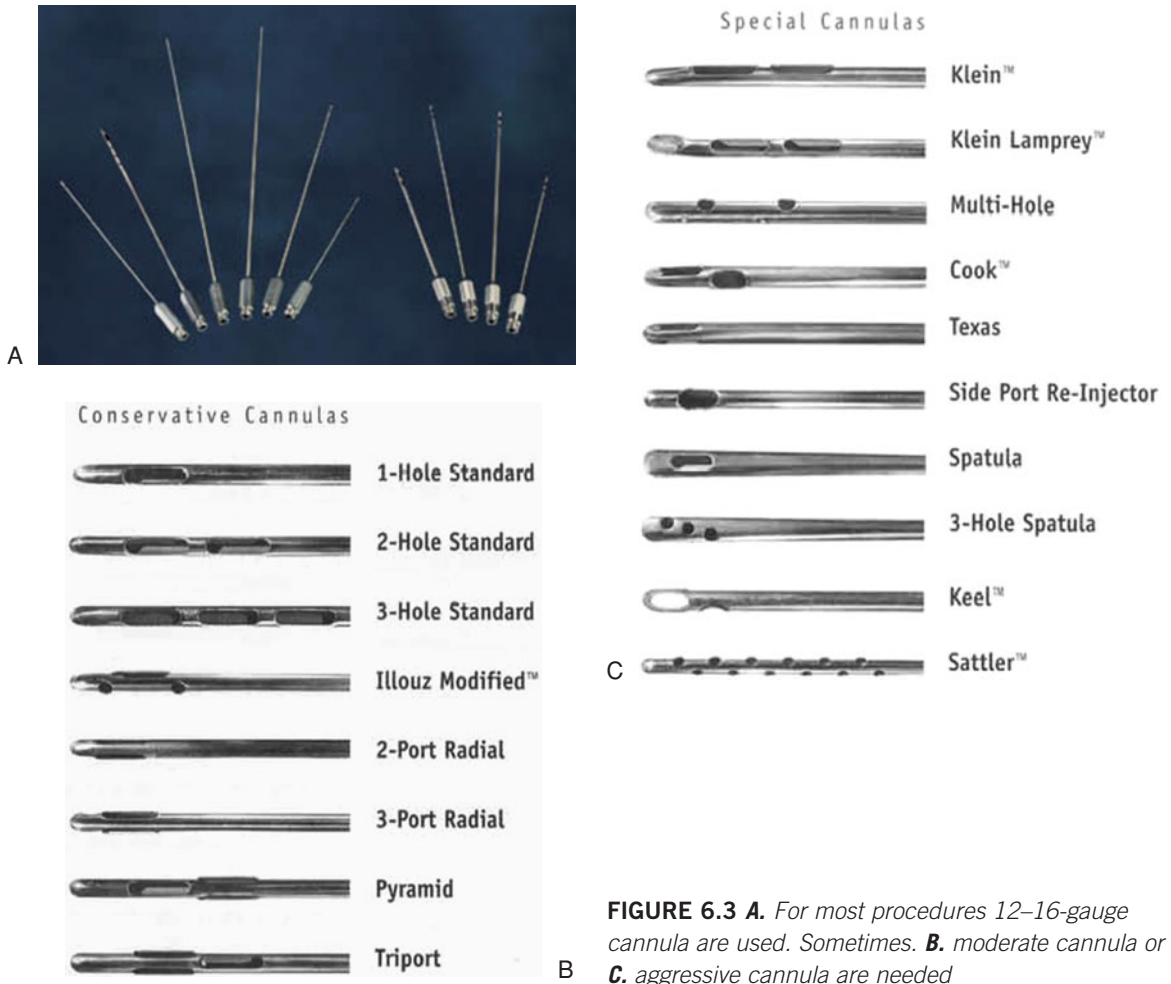
**FIGURE 6.1** Physical examination of the patient preoperatively should include this information



**FIGURE 6.2** The instrument tray for liposuction

## ■ Anesthesia

- Tumescent anesthesia is prepared by a licensed medical personnel only (see tables/tips).
  - Liter 0.9% sodium chloride solution
  - 0.65-mg epinephrine, 1:1000
  - 500-mg lidocaine (25 cc, 2% lidocaine) for a 0.05% solution
  - Bicarbonate (8.4%) in 1:10 dilution with lidocaine (i.e., if 25 cc used, add 2.5-cc bicarbonate)
- Tips on anesthesia
  - Warm liter bag before adding medicine.

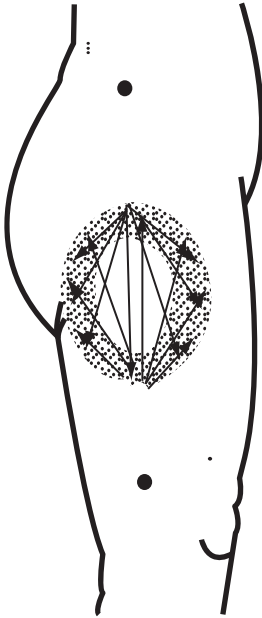


**FIGURE 6.3** *A.* For most procedures 12–16-gauge cannula are used. Sometimes *B.* moderate cannula or *C.* aggressive cannula are needed



**FIGURE 6.4** *Aspiration pump*

- Save the empty bottles used in mixture so that the physician can double check the amount used.
- Use 0.1% solution in more sensitive areas such as abdomen (particularly around the umbilicus) and upper and inner thighs.
- Be consistent in the method of mixing—always use the same percent of lidocaine.
- If during suctioning you run into a “hot spot,” i.e., an area that has incomplete anesthesia, re-infuse with a higher concentration of lidocaine (such as 0.1%). Accessing the area from a different entry site can also be helpful.
- Entrance sites are anesthetized with 1% lidocaine with epinephrine and small stab incisions made.



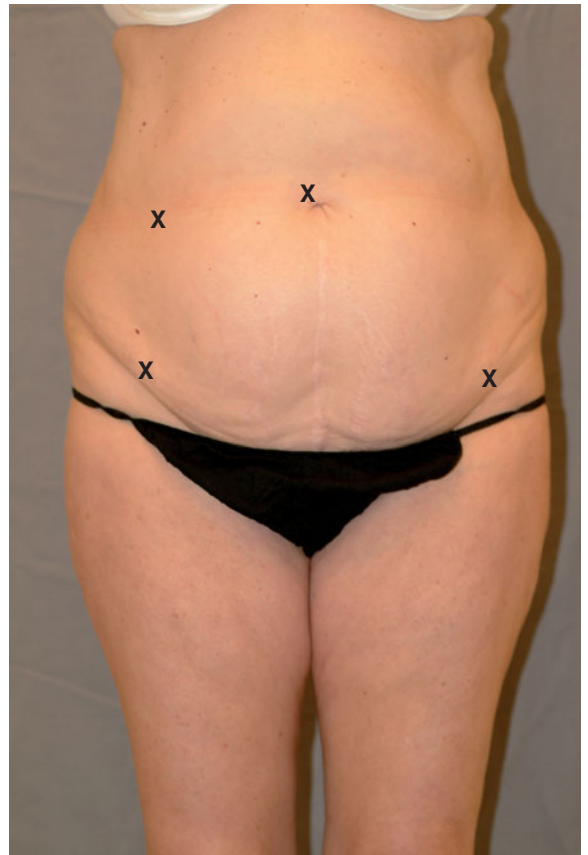
**FIGURE 6.5** The patient is marked with a sterile pen in standing position

- Infusion rate is set between 2 and 3 on the Klein pump (correlates to 25–125 cc/min).
- Infuse all areas.
  - Infusion tips:
    - Take care not to stretch entrance sites.
    - Allow infusion to dissect ahead of advancing the cannula.
    - Superficial and deep.
    - In face and neck, use a 25-gauge, 1.5-inch needle to perform infusion.
    - Infusion endpoint—Area is swollen, indurated, and begins to blanch slightly beyond the edges of the marked area.

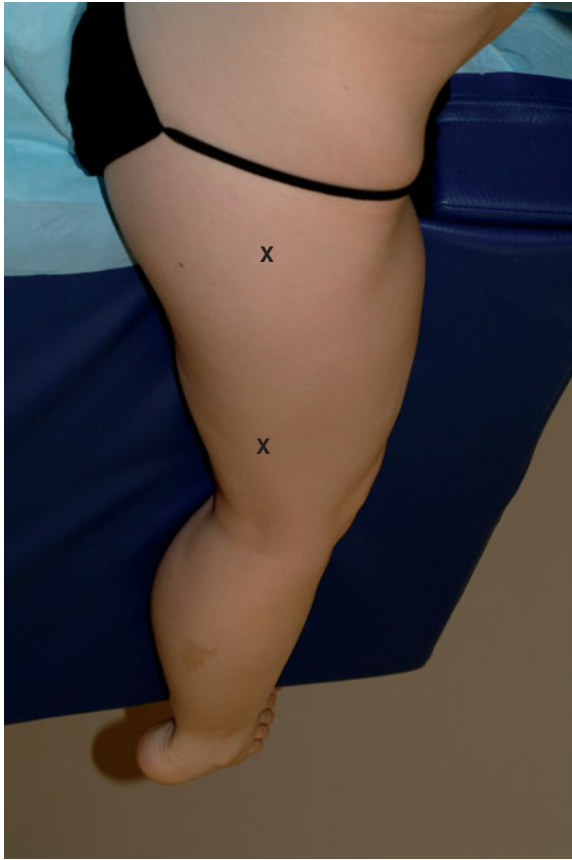### ■ Suction Procedure

- For best aspirate quality (high fat, low fluid, least blood tinged), allow the anesthesia to sit for 15 minutes after initial infusion before suctioning.
- When suctioning multiple areas, return to first infusion site to suction.

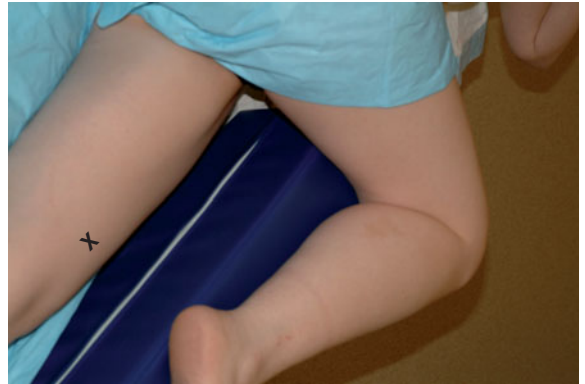- Proper positioning is very important for a good result in all areas.
- Special considerations:
  - Abdomen (see Fig. 6.6)
    - approach from traditional lower entrance sites.
    - approach from side entrance using three to four sites both to
      - cross tunnels in lower abdomen and
      - form tunnels in upper abdomen.
    - Have patients lie on their side to get to a mid-deep fat compartment.
  - Outer thigh (Fig. 6.7):
    - Use positioning pillow to avoid over-suctioning over trochanteric bulge.
    - Use upper and lateral entrance sites.



**FIGURE 6.6** Abdominal liposuction



**FIGURE 6.7** *Liposuction of the outer thigh*



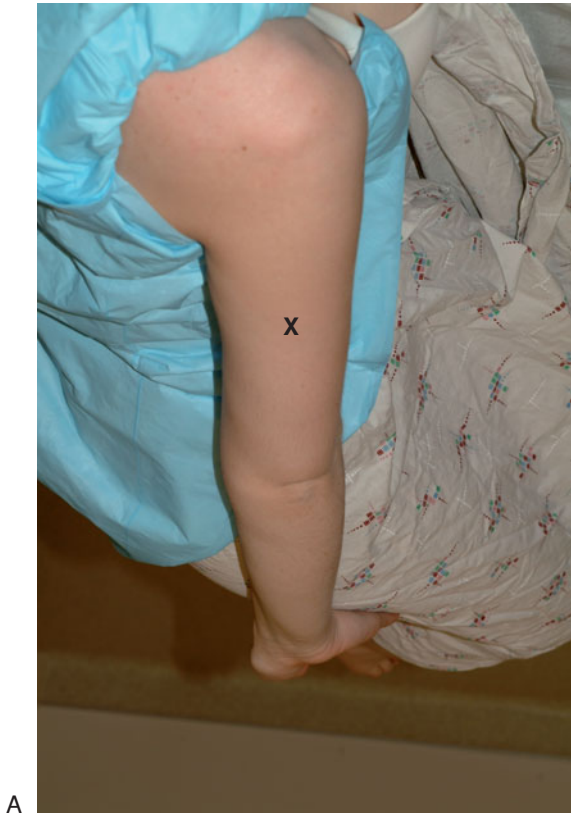**FIGURE 6.8** *Liposuction of the inner thigh*

- Inner thigh (see Fig. 6.8):
  - Use positioning pillow and high-step position.
  - Finish in frog leg position to check anterior feathering only.
- Arms (Fig. 6.9):
  - Lateral position.
  - Check Klein “bent arm position.”
- Fibrous areas:
  - Start with a thin, aggressive tip cannula (such as a 16-gauge Capistrano) to break up the area.
  - A powered liposuction machine is good for this too.
  - Follow with a larger diameter cannula having a less aggressive tip.
  - Perform deep tunneling first.
  - Criss-cross the tunnels to minimize uneven retraction.

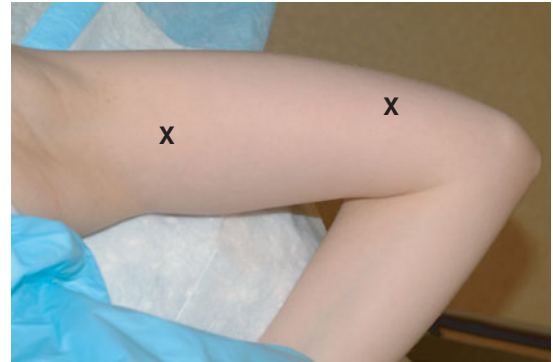
- As an area becomes flaccid, have an assistant place countertraction on the skin to improve ease of fat removal.
- Endpoint:
  - Tunnels are empty, little fat left in aspirate, mostly blood tinged fluid.
  - Pull up on cannula toward dermis (with suction off) to look for residual fat pockets.
  - Pinch suctioned areas between thumb and forefinger (Fig. 6.10) to feel a thinned adipose layer (in comparison to what was felt presuctioning).

## POSTOPERATIVE CARE

- Patient showers—hand towel is given to the patient and is shown how to compress areas to drain some of the residual fluid out of the entrance sites.
- Absorbent pads placed over incision sites that may need to be changed several times in the first 24 hours.
- Compression garment—firm but not so much that it restricts normal movement; the garment is to be used for 1 week.
- Intermittent application of ice in the first 24 hours.
- Drainage is copious at first, but stops usually by noon of the following day.
- Once drainage stops, each incision site should be covered with an ointment (such as Vaseline, Chesebrough-Pond’s, Greenwich, CT) and a spot Band-Aid.
- Patient instruction sheet (Fig. 6.11) is given to the patient.

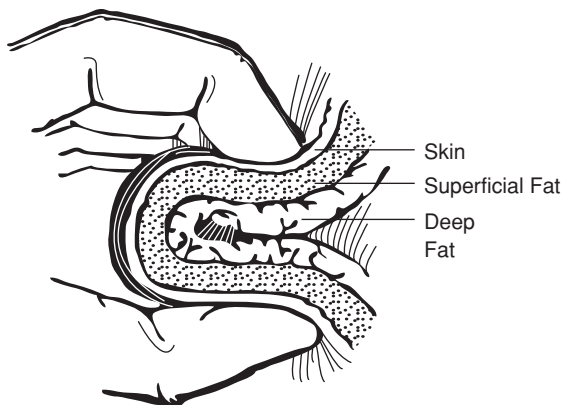


A



B

**FIGURE 6.9 A&B** Liposuction of the arm



**FIGURE 6.10** After the procedure the pinch technique should allow appreciation of a thinned adipose layer

## COMPLICATIONS AND FOLLOW UP

- Some patients gain weight after the procedure.
  - A gain of 5–10 pounds can negate improvement in a small abdomen.
  - *Always measure* the preoperative weight and the dimensions of the area.
- Vasovagal reaction is not uncommon.
  - Most patients respond to the Trendelenburg position.
  - IV access also allows the physician to use fluids.
- Poor healing of incision sites can be due to traumatization during the procedure or noncompliance with applying Band-Aid.
  - Use at least two access sites for each area and do not stretch the skin around the site excessively.
  - Remind patients both with written instructions and a phone call, on the first postoperative day, to wear Band-Aid.

**LIPOSUCTION SURGERY****POST-OP INSTRUCTIONS**

1. **Rest the day of surgery. Use ice on all areas for the first 24 hours. This will help with swelling and discomfort. Use the ice twenty minutes out of every hour that you are awake.**
2. **The day after surgery-up for meals, bathroom and light activity. Second day begin normal activity without heavy lifting. You may shower.**
3. **Kotex pads should be worn under compression garment, and on top of insertion sites while they are draining.**
4. **Spot bandage and Vaseline applied to insertion sites until seen 1 week post liposuction.**
5. **Wear compression garment and binder (if given one) immediately post-op until 24 hours AFTER noted time that drainage from insertion sites has stopped. (Drainage usually ceases 12-24 hours after surgery). When removing the compression garment you should do so in a seated position.**
6. **If wearing binder — wear for 24 hours. Compression garment 24 hours first and second day, then 12 hours a day for 1 week.**
7. **You may shower, but please do not soak in the tub while the insertion sites are open.**
8. **Be available by phone the next day.**
9. **Follow up in 1 week.**

**FIGURE 6.11** *Postsurgical patient instructions*

- Hyperpigmentation of incision sites is fairly common in all skin types.
  - Warn the patients to look for it and treat it early with hydroquinone (Solage—mequinol 2%, tretinoin .1%)
- Guidelines for touch-ups
  - Minor irregularities even out over time; do not do touch-ups before 1 year (or at least 6 months) after each procedure.
  - Do not touch up a patient-perceived irregularity that you cannot appreciate clinically.
  - Some asymmetry may be due to some bony structure that was not evident before the fat was removed (or was evident but not due to the fat).

## **SUGGESTED READING**

---

1. Brown S, Cropfield O. The case for a lower dose pill. Assessing the impact of estrogen dose. *ORGYN* 1995;(2):36–39.
2. Peverill RE. Hormone therapy and venous thromboembolism. *Best Pract Res Clin Endocrinol Metab* 2003;17(1):149–164.
3. Lidegaard O, Edstrom B, Kreiner S. Oral contraceptives and venous thromboembolism: A five-year national case-control study. *Contraception* 2002; 65(3):187–196.



Naomi Lawrence, MD

## KEY POINTS FOR SUCCESS

- Prepare the patient for a *process* of improvement. With current techniques, only 30% of the graft survives in most patients. At least three transfers are required for full augmentation.
- Follow proper technique of laying small pearls of fat in multiple tunnels.
- Have three transfer sessions.
- Fat frozen at  $-20^{\circ}\text{C}$  has been shown to be not viable. Do all transfers with fresh fat until better techniques are developed for cryopreservation.
- The future of fat transfer may be in transfer of adipose stem cells, which are small and more resilient than mature adipocytes.
  - These cells can be expended and differentiated in culture.
  - Later on these may be transferred and induced to differentiate post-transfer. These cells are also used as adipose filler in patients with inadequate donor area.

## INDICATIONS

- Facial lipoatrophy

## CONTRAINDICATIONS

- Absolute:
  - Hematologic abnormalities that cannot be corrected
  - Abdominal hernia
  - Anticoagulant medication
  - Pregnancy
  - True allergy to lidocaine (very rare)
  - Body dysmorphic disorder
- Consider additional discussion or a waiting period in case of:
  - Weight cycling
  - Unrealistic expectations

- Recent large weight loss
- Very low calorie diet (VLCD)
- The following may necessitate medical clearance:
  - Diabetes
  - Cardiac disease
  - Hypertension
  - Chronic disease
  - Liver disease
  - Immunosuppression
  - Patient at risk for thromboembolism

## PATIENT SELECTION

- Patient should be 30–60 years old with moderate (rather than severe) atrophy.
- Atrophy of the temples, lateral jawline, malar and buccal cheek, premarionette, sulcus on chin, and premaxillary upper lip.
- Focal area of fat atrophy on the body (better success if within scar tissue).

## PREOPERATIVE PLANNING

- Preoperative labs
  - SMA20 (general chemistry profile)
  - CBC with differential and platelets—complete blood count including platelet count and cell differential
  - PT/PTT (protime/prothrombin time)
  - Hepatitis screening profile
  - HIV screen
  - Urine pregnancy test (morning of the surgery day)
- Pictures—oblique view is important to show depth of atrophy.
- Stop all medications that interfere with platelet function 2 weeks prior to surgery and restart 1 week after procedure (see Tables 6-1 and 6-2).
  - These medications include nonsteroidal anti-inflammatory agents, aspirin, and vitamin E.

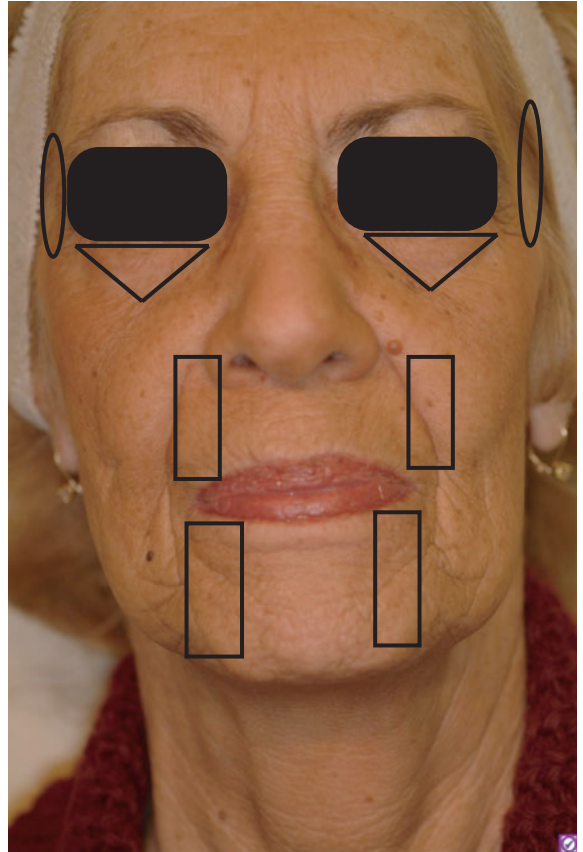
- Patient should stop smoking 2 days prior to surgery, through 1 week following the procedure.
- Duricef: 500 mg, on the evening before the procedure and continued twice daily for 1 week after procedure.
- Acyclovir: 500 mg, on the morning of the procedure then twice daily for 1 week.
- Lorazepam: 0.5–1 mg, 1 hour before the procedure.
- Take history for drugs interfering with lidocaine metabolism (see Table 6-3).
  - Liposuction is usually limited to one or two areas.
  - A single drug interfering with lidocaine metabolism would not have to be discontinued.
  - In a patient on multiple drugs interfering with lidocaine metabolism, or a very thin patient, in whom it is necessary to infuse multiple areas to obtain adipose tissue, it may be necessary to work with the patient's internist to see which drugs could be substituted or discontinued.

## INSTRUMENTS

- Infusion pump
- Infusion cannula/tubing
- 11 blade
- Coleman extraction cannula (an open aperture at tip)
- Coleman (fat) infusion cannulas I and II
- Nokor needle
- Topical mucosal anesthetic

## TECHNIQUE

- Prepare the face and mark the areas of atrophy with the patient in a sitting position (Fig. 7.1).
- Prepare and sterile drape the area to be liposuctioned.
- Infuse liposuction areas with tumescent anesthesia 0.05–0.1% (see Chapter 6).
- Suction gently with Coleman extractor on a 3-cc syringe.
- Place syringes in a beaker (plunger up) on a sterile field to allow the fat to separate from the fluid.
  - At this point some surgeons centrifuge at 3300 rpm for 30 seconds to 1 minute to concentrate the fat. The disadvantage of this technique is that in order to do this in a typical blood centrifuge, one must



**FIGURE 7.1** Areas of facial atrophy are marked while the patient is seated

expose the fat to open air, which breaks the sterile technique.

- Once the fat and fluid have separated, the fluid is discarded and the fat is transferred into 1-cc luer lock syringes through a three-way stopcock.
- Why are 1-cc syringes important?
  - They allow the surgeon to reinject the fat under less pressure than do syringes with a larger plunger, thus minimizing the risk of introducing fat into vasculature (which can have catastrophic complications such as blindness).
  - Smaller pearls are laid down, which theoretically improves vascularization and survival of the graft.
- Recipient site preparation
  - Pre ice while liposuction is being done.

- Topical mucosal anesthesia followed by infraorbital and mental (supraorbital if forehead augmentation is planned) blocks 1.5–2 cc, 2% lidocaine in each area.
- Small bleb of anesthesia below jawline of marionette fold and at the corner of the mouth allows access to the chin, the lip, and the cheek area.

## TRANSPLANTATION TECHNIQUE

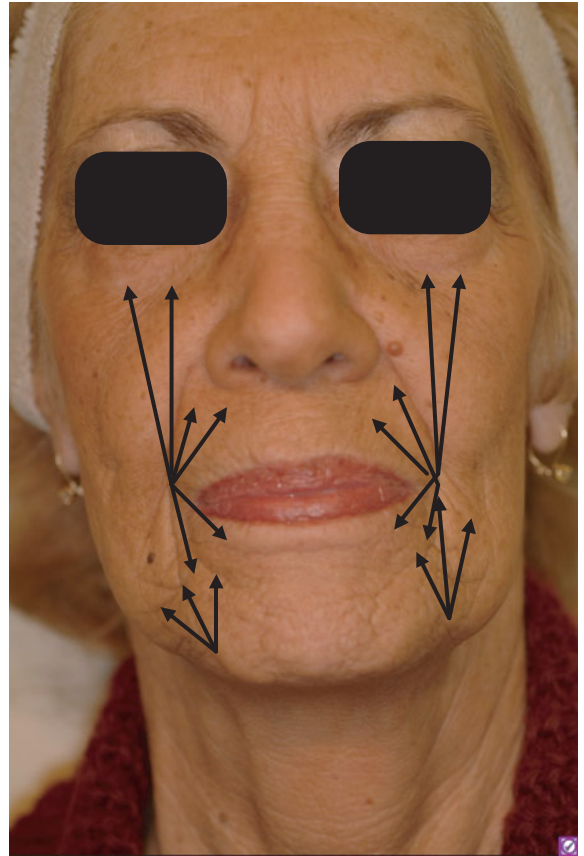
- Stab incision in predetermined entrance sites with Nokor needle.
- Introduce infusion cannula as deeply as possible to allow cannula movement.
- Currently, there is a debate in this field that whether fat should be put in the subcutis or should be placed in muscle (FAMI technique).
  - In the face, muscles insert onto the under surface of the skin so that in many areas the fat and the muscle are in the same plane.
  - Deep placement allows the fat proximity to the muscle, which is more vascular than the fat.
- Small pearls of fat (0.1-mL aliquots) are laid down.
- In the withdrawal phase of cannula movement, multiple tunnels at multiple levels are made in each area, fanning out from each entrance site (Fig. 7.2).

## POSTOPERATIVE CARE

- Ice for 10 minutes after the procedure, then the patient can ice for 15 minutes per hour for the first 4–6 hours
- Band-Aids with petroleum jelly or an antibiotic ointment on all entrance sites until healed (1 week).
- Light compression to the liposuctioned area.
- Continue antibiotic and antiviral medication for 1 week.

## COMPLICATIONS AND FOLLOW-UP

- Periorbital area is at greatest risk of developing visible clumps of adipose.
  - Get experience in other areas before attempting this area.
- Resist temptation to over-correct or correct completely in one session.



**FIGURE 7.2** During cannula withdrawal, multiple tunnels are made in each area

- Fat survival is better when amounts are small (1–3 cc) in each area and small deposits (0.1 mL) are implanted.
- Most common adverse effects are swelling and bruising.
  - With pre- and post-icing this is minimized but warn each patient.
- Fat survival is variable with augmentation, lasting for more than 5 years in some patients and only a year in others. This is most likely due to the handling of graft and preparation of the recipient bed.

## **SUGGESTED READING**

---

1. Wheeland RG. Cutaneous Surgery, 1st edn. WB Saunders, Philadelphia, PA, 1994.
2. Shan RB, Swanson NA. Local flaps in facial reconstruction, 1st edn. Mosby, St Louis, MO, 1995.
3. June KR, Hanke WC, Sengleemann RD, Seigel DM. Surgery of the Skin. Procedural Dermatology. Elsevier Mosby, Philadelphia, PA, 2005.

Neil Sadick, MD

## KEY POINTS FOR SUCCESS

---

- Choose the appropriate surgical candidate, i.e., appropriate donor site density.
- Perform the procedure utilizing “follicular unit” grafting in order to present natural hair grouping.
- Dissection of the donor strip should be performed under stereoscopic control.
- Perform hair transplantation with an integrated team including a surgeon, a cosmetic coordinator, and well-trained technicians.

## INDICATIONS FOR HAIR TRANSPLANTATION

---

- Androgenetic alopecia—male or female.
- Usually hair transplantation is not performed until the patient is at least 25 years of age.
- Senescent alopecia—women.
- Scarring alopecia (inactive disease for at least 6 months duration), i.e., discoid lupus, lichen planopilaris, burns, etc.
- Congenital defects, i.e., alopecia triangularis.

## CONTRAINDICATIONS FOR HAIR TRANSPLANTATION

---

- Severe coagulopathy
- Platelet inhibitors—blood thinners (Coumadin, NSAIDs, and aspirin), which the patient is unable to discontinue
- Herbal preparations
- Active HIV or hepatitis B (relative)
- Poor donor area
- Unrealistic expectations
- Active inflammatory scarring alopecia

## CHOOSING THE RIGHT CANDIDATE

---

- Age
- Degree of baldness
- Hair shaft diameter
- Hair color
- Contrast characteristics of skin and hair
- Donor hair density
- Patient expectations

## PHYSICAL EXAMINATION

---

- Key factors
  - Look at other family members—the patient’s own hair loss pattern may mimic in pattern as well as in chronological course, the pattern and rapidity of other family members.
  - Personal history—if hair loss began at a young age it most likely will be progressive.
  - Evaluate the degree of hair loss to measure the degrees of miniaturization on both the donor and the recipient areas. This can be performed with a hair-magnifying device called a densitometer (Fig. 8.1). Assessing the degree of miniaturization from various areas of the scalp (normally no more than 20%) will allow predictor insight as to the progression or hair loss in various anatomic areas as well as the stability of the donor area, which translates into long-term viability of the transplanted hair.

## PREOPERATIVE GOALS

---

- Creation of a natural hairline
  - The most natural hairlines are those that are not exact but have a natural feathered appearance. It should be high enough when planned to give a natural tethered appearance of a mature individual so that it can be functional for the patient’s entire lifetime. The general rule is to place the hairline 3–4 fingerbreadths above the glabellar notch. Discuss the location with the patient preoperatively.



**FIGURE 8.1** Portable hair densitometer may be used to calibrate donor hair density. Large caliber hair shafts greater than 70 microns yield most optimal results

- Area to be transplanted
  - The area to be transplanted should be discussed with the patient—front, vertex, and crown sites are specified. If a limited number of grafts are available, the transplant surgeon may choose not to treat the crown area.
- Number of sessions
  - Using follicular unit technology, most patients can achieve natural coverage in one or two treatment sessions. The standard has been to transplant 30 follicular units/cm<sup>2</sup>. The recipient area is usually about 80 cm<sup>2</sup>.
- Optimizing donor site
  - Maximal number of grafts.
  - A small linear donor site is the optimal goal in this region. In order to maximize the number of grafts as well as to improve cosmesis, it is often helpful to excise the previous donor site scar as part of the donor area if a second procedure becomes necessary.

## **INSTRUMENTATION (Fig. 8.2)**

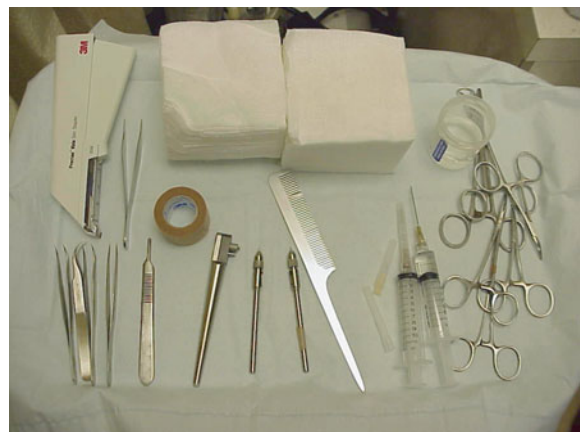Instrumentation utilized for hair transplantation is listed in Table 8.1.

- Appropriate blade device for excision of the donor area.

- Implantation device for follicular unit based micro- and minigrafts.
- Stereoscopic microscopic dissecting device.

## **MEDICATION**

- All medications that increase bleeding time should be stopped two weeks prior to the surgery.
- NSAIDS



**FIGURE 8.2** Instrumentation tray for performing hair transplantation

**TABLE 8.1 ■ Instrumentation Used in Hair Transplantation**

- 2 Addson forceps with teeth
  - 1 #3 knife handler
  - 4 Kelly clamps curved
  - 1 Needle holder
  - 1 Curved 5" sharp scissor
  - 1 Suture scissor
  - 1 Multiblade knife handle
  - 2 Addson forceps smooth
  - 2 Curved jeweler's forceps
  - 1 metal comb
  - 1 Elli's #4 multiblade knife handle
  - 2 Handle for 91 and 61 blades
  - 1 Dissecting microscope
  - Klein tumescent anesthesia inserter
  - Prone-Prop-Pillow
  - #15 Personna surgical blade
- 
- ASA
  - Warfarin
  - Clopidogrel bisulfate (Plavix)
  - Herbal preparations Bristol-Myers Squibb
  - Allergies: antibiotics, lidocaine, and epinephrine

## PREOPERATIVE BLOOD WORK-UP

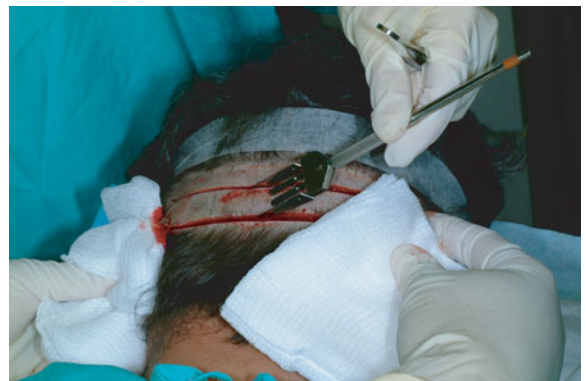- CBC, chemistry profile, PT, PTT (INR), platelet count, HIV, and hepatitis profile.

## PREOPERATIVE ANESTHESIA

- Preanesthesia
  - Ativan 1 mg p.o.
  - Percocet (7.5-mg Hydrocodone) 500-mg Acetaminophen
  - Other preanesthetic agents such as nitrous oxide have been employed in this setting.
  - Local ring blocks in the donor and recipient areas have been employed with lidocaine 1% with epinephrine 1:100,000.

## PROCEDURE TECHNIQUES

- Harvesting hair from the donor area.
  - Taken from the occipital scalp where donor terminal hair grows for an individual's lifetime.
  - Trimming of area with a PANASONIC trimmer.
  - Tumescent donor site formula, "ring block": approximately 15 cc of 0.5% lidocaine with 1:200,000 epinephrine utilizing a 3-cc syringe.
  - Followed by instillation of 20–30-cc saline solution to create a tissue turgor so as to minimize the risk of follicular dissection.
  - Excision of the donor site may be through a long single elliptical (20 cm × 7 mm) strip with average donor density (over 1.5 mm) or through a multiblade knife to create multiple thinner strips. This will yield over 1000 follicular units.
  - Factors affecting the amount of donor area excised
    - Donor tissue laxity
    - Donor tissue density
    - Previous scars
  - Donor strip is usually excised in a supine position.
  - An angle to 110–120° will minimize graft dissection (Fig. 8.3).
  - With a #10 BP blade, the depth of strip dissection is usually 1–2 mm. The ends of the strip are tapered at the ends with a #11 BP blade.
  - Hemostasis is obtained with electrocautery or more rarely with ligation of sutures.



**FIGURE 8.3** Double-bladed knife allows uniform width of donor site dissection and standardization of depth of dissection

- Donor area is closed using a buried interlocking suture of 4-0 Vicryl followed by a surface running 4-0 Monocryl suture.
- Sutures are removed in 10–14 days leaving a small linear 1- to 2-mm scar.

## PEARLS AND PITFALLS IN DONOR DISSECTION

- Appropriate planning in size of donor site.
- Prone pillow to assure the patient comfort and relative immobility.
- Tumescent anesthesia to produce adequate tissue turgor.
- Double-bladed knife to ensure uniformity of width and depth of the donor ellipse.
- Buried interlocking suturing to decrease wound-healing tension.
- Re-excision of previous donor scars to ensure a single scar after multiple hair transplantation sessions.
- Examine donor site as the strip is being dissected to be sure that a significant transection of follicles is not occurring.
- Keep the dissection angle at 110–120° in order to minimize transection.
- At repeat procedures, the donor scar can be re-excised, thus improving cosmetic appearance.

## PREPARING THE GRAFTS

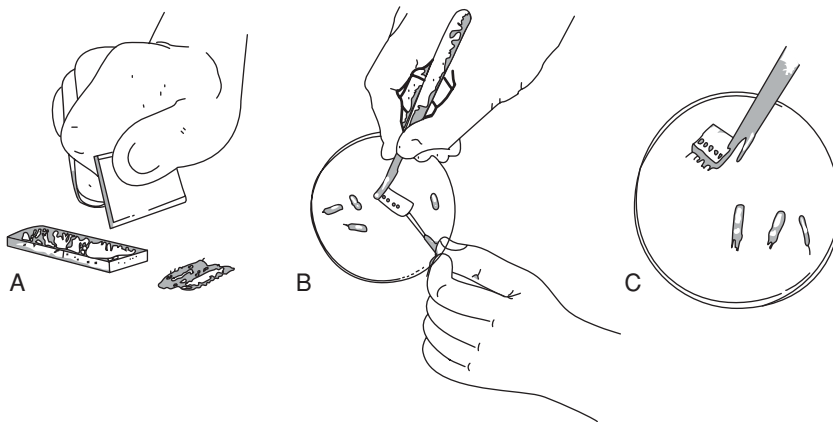
- After examination of the donor strip, it is placed in a Petri dish containing chilled isotonic saline.
- A team of trained technicians and the physician supervise dissecting the strip into slivers of tissue approximately 2 mm in width and subsequently these slivers are dissected into single, double, or triple haired follicular unit grafts (Fig. 8.4).
- A magnifying microscope is used for this purpose.
- A #10 Personna razor blade in conjunction with a fine jeweler's forceps is used.
- Use a transilluminating light source.
- Follicular units should be kept in chilled saline in order to retain moisture prior to implantation.

## PEARLS AND PITFALLS OF GRAFT PREPARATION

- Use a dissecting microscope with backlighting.
- Avoid transection of hair follicles when cutting strips.
- Keep cut grafts in a moist cool environment.
- Remove excess fat and fibrous tissue from the area surrounding the grafts.

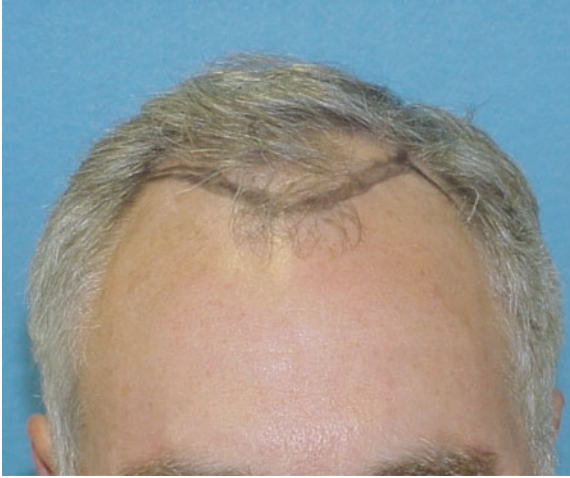## PLANTING THE RECIPIENT AREA

- Keys:
  - Try to recapitulate the prebalding hair pattern.



**FIGURE 8.4** Technique for graft dissection involves (A) slivering of tissue into 2 mm sections, (B) followed by dissecting into follicular units, and then (C) followed by separation into single, double, and triple hair grafts





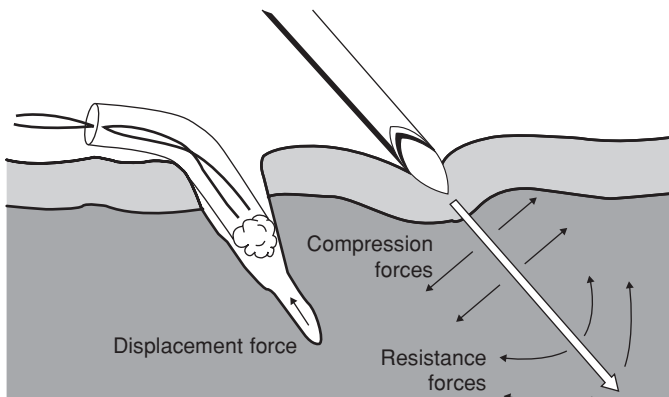
**FIGURE 8.5** Proposed recipient hairline is usually mapped 3–4 fingerbreadths above the mid glabellar notch with lateral tapering at the temporal fringes

- Keep hair placement in its naturally growing direction.
- In the frontal scalp, try to maximize natural facial framing.
- The hairline should be created 3–4 fingerbreadths above the intraglabellar notch creating curved bell-shaped hairline tapering at the lateral temporal fringes (Fig. 8.5).
- Recipient anesthesia is accomplished using a ring block with 2% lidocaine.
- A maximum of 40 grafts/cm<sup>2</sup> should be implanted in order to avoid excess packing and vasoocclusive crushing of grafts.
- Anteriorly, plant with a sharp angle of 20°.
- Posteriorly, plant with greater angle of 20–45°.
- A 19-gauge needle may be used to make all single hair insertion sites.
- Alternatively a 91-gauge Beaver blade may be used to create slits for double and triple haired follicular units (keep distance of 1–2 mm between slits in order to prevent crushing).
- Jewelry forceps are best to assure meticulous graft placement.
- Hairs in the grafts must be aligned at the appropriate angle and direction to create a snug fit into the recipient sites (Fig. 8.6).

## PEARLS AND PITFALLS OF RECIPIENT PLACEMENT

- Meticulous technique of insertion markedly improves graft survival.
- Plant with a back to front pattern to avoid displacement of grafts, compression, and popping.
- Create a mature frontal hairline with temporal blunting.
- Recreate a whorled pattern in the occipital region to recreate the natural pattern of hair growth.
- Use a feathered pattern in the anterior hairline to create a natural graded zone of hair density.

Forces displacing graft when needle is inserted behind the graft



**FIGURE 8.6** Implantation of follicular unit grafts into slits is accomplished using a jeweler's forceps

- A backward forward direction of graft insertion will help minimize graft pop out.

## TREATMENT PLANS

- Majority of patients with Norwood Class V–VI alopecia require three treatment sessions of approximately 3000 total follicular unit grafts.
- Partial alopecia may be addressed with 1 or 2 sessions.
  - Time required for this treatment: 5–6 hours.
- Alternatively, larger sessions (mega sessions) of 1000–1500 grafts may be transplanted over the entire scalp in a single session.
  - Time required: 6–10 hours.
- Author's personal approach
  - 600–900 grafts: to cover the anterior scalp.
  - 500–800 grafts: to cover the midvertex scalp.
  - 400–500 grafts: to cover the occiput.

## POSTOPERATIVE COURSE

- Pearls and Pitfalls
  - Provide adequate postoperative instructions (Table 8.2),
  - Four to seven days are average for crusts to dissipate.
  - In most cases no postoperative bandage is necessary.
  - Shampooing may be begun gently within 24 hours.
  - Facial edema and forehead swelling, particularly in the periorbital area, may begin 24–48 hours after the procedure and last for 5–7 days.
 

This may be treated with ice packs, upright positioning (45°), sleeping on two pillows, or alternatively, a short course of prednisone 20–40 mg/day for 3–5 days
  - Full exercise may be resumed in 1 week.

### TABLE 8-2 ■ Post-op Hair Transplant Instructions

- Please follow instructions carefully. If you have any questions or concerns during your recovery please call the office.
- You will receive products from us to be used during your recovery. These consist of treatment shampoo, post-Biotin spray, and postsurgical gel.
- Keep taking the Propecia as prescribed before, and also keep using the Rogaine.
- You may take a light shower the day after the procedure. Do not get the area of the hair transplant under the spray. You can PAT the shampoo we give you on the area of the transplant, and rinse by a very gentle spray or by patting water over the area. DO NOT RUB AREA. This you have to do for 5 days until the grafts attach. After 5 days, you need to start washing the area more aggressively. After 7 days you should be washing your hair normally. All the scabs should be off the graft area in 10–14 days. After the light shower, you may pat hydrogen peroxide over the area to cleanse area. Then you may apply the post-Biotin spray and postsurgical gel, very gently. Be very careful when brushing or combing to avoid the transplant area for the first 5–7 days. This is to prevent the comb from catching on the grafts/scabs.
- You will have scabs on the area of the transplant. Do not pick at them. They will fall off when you start washing your hair more aggressively. All scabs should be off your head by day 14. You may pat hydrogen peroxide on the area twice a day to help cleanse the area and to decrease the scabbing. Also, during the first month there will be particles that fall from the graft area. This is normal. It does not mean that the grafts are falling out.
- You may resume normal daily activity after the procedure. Do not do vigorous physical activity for one week after the procedure.
- You will be put on an antibiotic the day you come in to get the hair transplant. You may also need an oral steroid to help with inflammation a week after the treatment.
- After the procedure is finished you may feel tight in the area of the donor site. You may take acetaminophen for any discomfort. Refrain from aspirin and ibuprofen.
- You should not expect to see hair growth until 6–8 months after the treatment is complete. This can take up to 18 months to see full growth. You may need additional treatments after the first hair transplantation.

- The author places all males on Finasteride 1 mg/day routinely prior and 5% Minoxidil solution twice a day in order to decrease posttransplantation telogen effluvium and shorten the growth course of transplanted hair.

## PEARLS AND PITFALLS

- Provide adequate postoperative instructions (Table 8.2).
- Cooper peptide dressings such as Graftcyte may be used to promote wound healing and angiogenesis.
- Short courses of prednisone 20–40 mg/day to decrease postoperative swelling.
- Wait for 6–12 months between transplant sessions in order to assess results and to allow hair to begin to grow.

## COMPLICATIONS

Complications following hair transplantation are relatively rare and may include the following:

- Nausea and vomiting caused by medications
- Postoperative bleeding (less than 5%)
- Infection (less than 5%)
- Swelling (5%)
- Temporary headache
- Temporary numbness of the scalp
- Scarring around the grafts (less than 1%)
- Poor growth of grafts
  - X-factor—vasoconstriction, poor host growth factor, and poor operative technique have all been hypothesized but none proven.
- Syncope
- Folliculitis
- Keloid formation
  - May be secondary to genetic healing tendencies or increased wound tension secondary to taking too large of a donor strip.
- Neuroma
- Paresthesias

- Usually resolves in 6–12 months; most common in donor occiput area.
- Telogen effluvium
  - More common in females and in area where transplants are performed into existing areas of residual hair.
- Arteriovenous fistula formation
  - May last for 6–12 months
  - Should be explained during the initial consultation
  - Topical Minoxidil solution 5% applied b.i.d. may minimize this sequelae

## CONCLUSIONS

Hair transplantation surgery has evolved with increased patient satisfaction related to improved cosmetic techniques. Like all other cosmetic surgical procedures, best results are achieved with careful surgical planning, fastidious technique, and carefully outlined postoperative surgical care.

## SUGGESTED READING

1. Tan E, Shapiro J. Hair transplantation update. *Cos Dermatol* 2002;13:39–41.
2. Stough DB, Whitworth L, Seage DJ. Hair restoration, In: *Techniques in Dermatologic Surgery*, Chapter 27, 2003, Mosby, St. Louis, pp. 217–232.
3. Bernstein RM, Rossna WR, Szanlanos KI, Halpern AJ. Follicular transplantation. *Int J Aesthet Restor Surg* 1995;3:119–132.
4. Schiell RC. Modern hair restoration surgery. *Clin Dermatol* 2001;19:179–187.
5. Auram MZ. Hair transplantation for men and women. *Cos Dermatol* 2002;15:23–27.
6. Bernstein RM, Rossman WR. The aesthetics of follicular transplantation. *Dermatol Surg* 1997;23:785–789.
7. Eisenberg EL. Avoiding problems in hair transplantation. *Cos Dermatol* 2003;16:19–23.
8. Bernstein RM, Rossman WR. Follicular transplantation: Patient evaluation and surgical planning. *Dermatol Surg* 1997;23:711–784.

*This page intentionally left blank*

## CHAPTER 9

# Evaluation and Treatment of Varicose and Telangiectatic Leg Veins

Neil Sadick, MD

### KEY POINTS FOR SUCCESS

- Correct diagnosis of proximal point of reflux.
- Mastering duplex ultrasound testing.
- Decision of which modality (endovascular radiofrequency or laser technology, ambulatory phlebectomy, sclerotherapy, or external laser) is most effective for the treatment of a vessel of given diameter.
- Fastidious technique.
- Choosing the appropriate minimal sclerosant concentration (MSC) for a given diameter vessel.
- Choosing the right grade and duration of compression.

### INDICATIONS

- Functional saphenofemoral/saphenopopliteal incompetence (pain, ulcers, stasis dermatitis, lipodermatosclerosis)
- Truncal varicosities (symptomatic or cosmetic)
- Cosmetic spider veins or reticular veins (lower extremities)
- Periorbital veins
- Hand veins

### CONTRAINDICATIONS

- Absolute
  - Pregnancy
  - Hypercoagulable states (protein S or C deficiency, antiphospholipid antibody syndrome)
  - Recurrent thrombophlebitis or deep venous thrombosis
- Relative
  - On anticoagulation therapy, ASA, NSAIDS, Plavix, herbal preparations

### HISTORY

- Family history
  - History of venous disease, recurrent thrombophlebitis or pulmonary emboli.
- Medical history
  - Same as family history plus history of bruising, bleeding.
  - Ask if veins are symptomatic, i.e. pain, edema, tiredness.
- Surgery
  - Any history of bleeding after surgery.
  - Any history of previous ligation or stripping procedures.
  - Allergies/medicine sensitivity: history of allergies to a given sclerosing agent, i.e., glycerine, sodium sotradecol sulfate, or polidocanol should be elicited.
- Medications that prolong bleeding time or interfere with platelet function, e.g., Warfarin, clopidogrel bisulfate (Plavix, Bristol-Myers), aspirin, nonsteroidals, are contraindicated.
- Hormones: high-dose estrogen therapy may increase the risk of thrombotic phenomena or telangiectatic matting after any vein procedure.

### PHYSICAL EXAMINATION

- Lower extremity vessels may be classified according to size, degree of oxygenated hemoglobin, and connection to the greater or lesser saphenous vein (Table 9.1)
- Look for signs of chronic venous insufficiency, i.e., stasis dermatitis, ulcers, hyperpigmentation, lipodermatosclerosis.

### INDICATIONS FOR VASCULAR TESTING (TABLE 9.2)

- Symptomatic veins
- Bulging varicosities: usually greater than 4 mm

**TABLE 9.1 ■ Vessel Classification**

Type	Vessel Class	Diameter	Color
I	Telangiectasis “spider veins”	0.1–0.5 mm	Red
II	Venulectasia	0.5–2.0 mm	Violaceous, cyanotic
III	Reticular veins	2–4 mm	Cyanotic to blue
IV	Nonsaphenous varicose veins (usually related to incompetent perforators)	3–8 mm	Blue to blue-green
V	Saphenous varicose veins	4–8 mm	Blue to blue-green

- Duplex examination (Fig. 9. 1)
  - Duplex evaluation of varicose veins depends upon the use of a 7.5-mHz gray scale, high-resolution B-mode scanner, and a 5-mHz Doppler probe.
  - Suggested manufacturers:
    - Biosound Esoate, 8000 Castleway Drive, Indianapolis, IN 46250; model: Mylab 25.
    - Terason, 77 Terrace Hall Avenue, Burlington, MA 01803; model: Terason 2000.

## CLINICAL APPROACH TO TREATMENT OF LOWER EXTREMITY VEINS

- Procedures: Greater/lesser saphenous veins
- Options: Endovascular technologies (performed under Duplex guidance)
  - Laser (815, 830, 870, 1320 nm)
  - Radiofrequency (VNUS procedure)
  - Foam sclerotherapy
- Endovascular laser
  - EVLT (815-nm laser; Diomed, Andover, MA) (Fig. 9.2)

**TABLE 9.2 ■ Indications for Vascular Testing**

- Symptoms (pain, fatigue)
- Clinical signs of venous insufficiency, stasis dermatitis, ulcers, lipodermatosclerosis
- Bridging varicosities
- Veins >4 mm in diameter

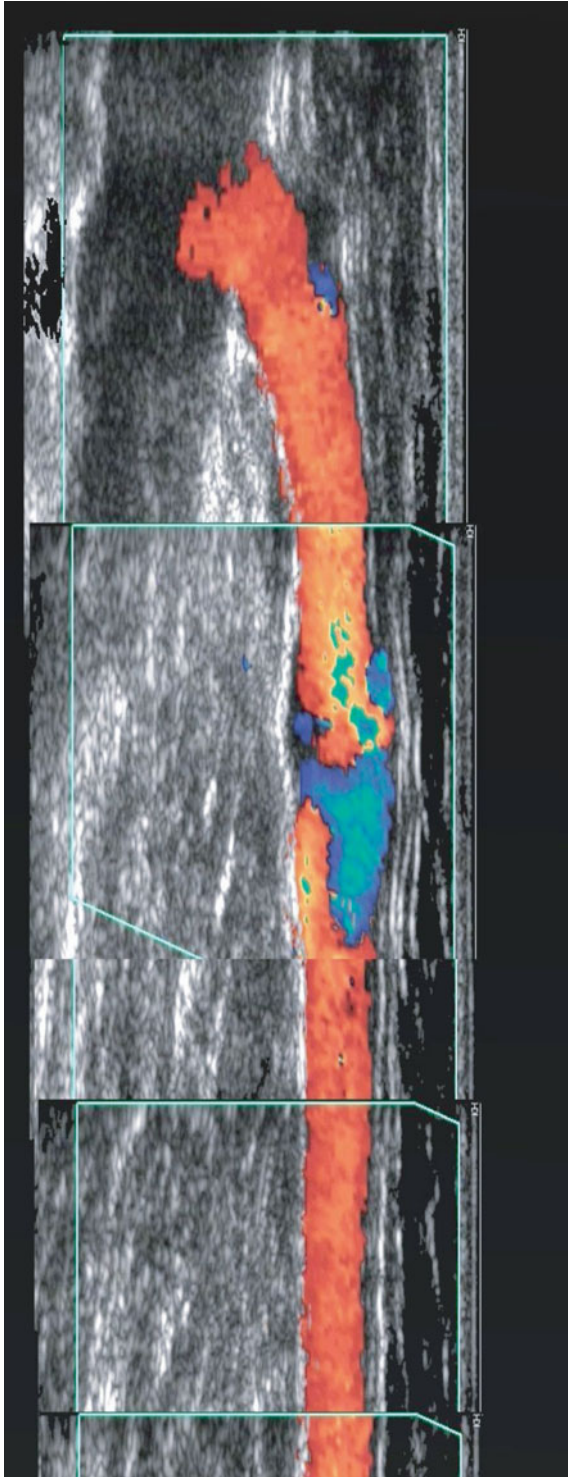
Preoperative set-up (Table 9.3)

Procedure

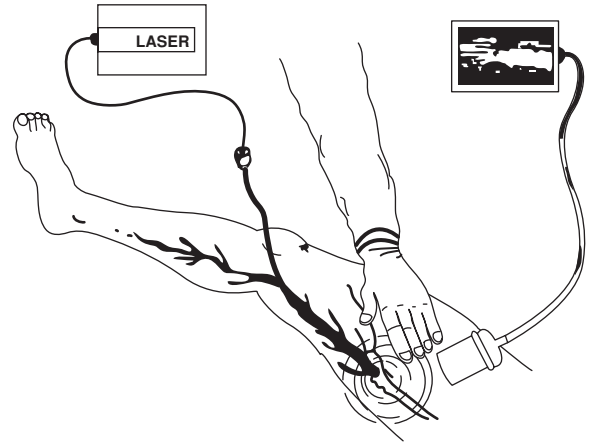
- A 5 Fr catheter is placed over a 0.035-inch diameter J guide wire with intravascular placement documented by Duplex.
- 400–750-nm bore tip filter is then introduced through the catheter.
- Vein is subsequently reduced in diameter by administration of perivenous tumescent anesthesia (lidocaine .05% with or without epinephrine).
- 12–14 W of energy is delivered in a continuous mode with a pullback rate of 10–20 cm/minute.
- Postoperative care
  - Patients are subsequently placed in a compression bandage overnight.
  - Subsequently then wear Class II 20–30 mmHg compression for 2 weeks following the procedure.

## RADIOFREQUENCY CLOSURE

- Procedure (Table 9.4)
  - The available catheter sizes 8 Fr/5 Fr allow treatment of vessels 2–12 mm in diameter
  - Catheter insertion is carried out over a guide wire followed by similar perivenous tumescent anesthesia.
  - A thermal sensor allows delivery of temperatures of 80–90°C (average 85°) heating the targeted greater GSV



**FIGURE 9.1** Color duplex evaluation of the greater saphenous vein showing reflux manifested by backward flow



**FIGURE 9.2** EVLT: endovascular laser involves insertion of a diode laser fiber 815 nm into the greater saphenous vein (14–15-W energy)

- Under Duplex guidance a pullback rate of 2–3 cm/minute is carried out (Fig. 9.3)
- Postoperative care: Same as for EVLT

### DUPLEX-GUIDED ENDOVASCULAR SCLEROSING TECHNIQUE

- Alternatively, duplex-guided sclerotherapy with sodium tetradecyl sulfate (Sotradecol) may be used in this setting

Table 9.5 presents a comparison of the three endovascular technologies.

### TRUNCAL VEINS

Treatment options: Ambulatory phlebectomy and foam sclerotherapy.

#### TABLE 9.3 ■ EVLT™ Kit Components

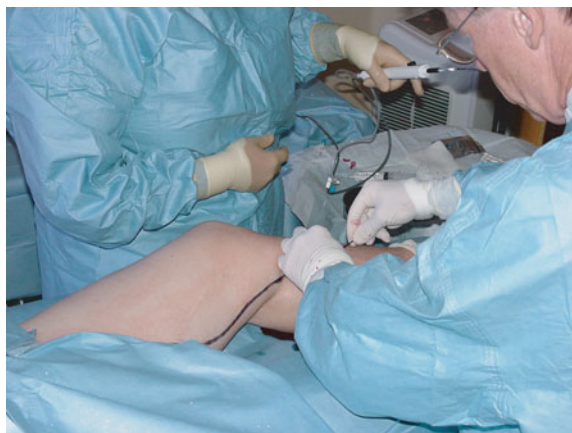- 600  $\mu\text{m}$  EVLT fiber
- 19 gauge entry needle
- 6 Fg 45 cm introducer sheath
- 0.035" J tip guide wire
- 90 cm  $\times$  90 cm plain drape

**TABLE 9.4 ■ VNUS Closure System Components**

- VNUS RF Generator
- VNUS Closure Catheter
  - CL-504 (5 F)
  - CLO-812 (8 F)
- Instrument Cable (not shown)
- Footswitch (optional not shown)

### ■ Ambulatory Phlebectomy

- Must initially rule out greater or lesser saphenous vein incompetence or may be done in conjunction with one of the endovascular techniques.
- May also be used to treat periorbital and hand veins.
- Preoperative marking (Fig. 9. 4).
  - Should be made in the standing position and confirmed in the supine position.
  - Bulging veins (area of proposed hooking) may be marked with a surgical pen or permanent marker (Acculine or vis-à-vis (Sanford Company)).
  - A transillumination device (Vein-Lite, Atlanta, GA) with the patient in a supine position may document vein shifting from the original standing marking.
- Anesthesia (Table 9.6)
  - Tumescent anesthesia is given to tumesce and produce local anesthesia. Peau d’orange firmness in the treatment limb is the endpoint of therapy. Eliminates multiple needle sticks. Allows rapid anesthesia of extensive segments of diseased vein.



**FIGURE 9.3** Radiofrequency closure of the greater saphenous vein involves insertion of a catheter to produce heat generation of approximately 85°C, causing thermal absorption of the targeted vessel

Produces temporary swelling and firmness of soft tissue aiding vein removal by pressing the vein next to the skin.

Tourniquet effect on vessels reduces blood loss and bruising.

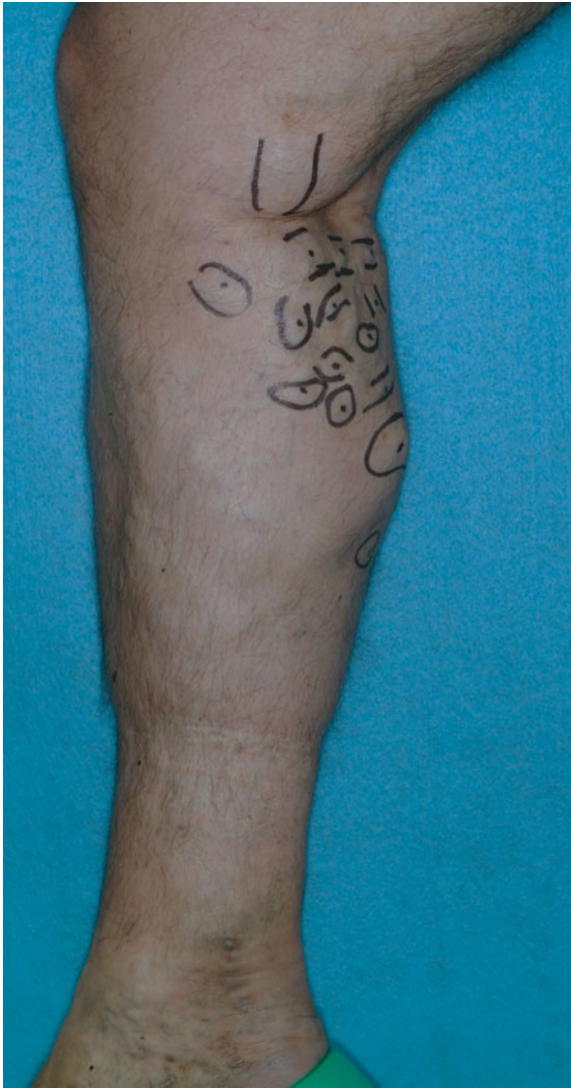Allows excellent patient comfort for a greater period of time.

- Operative set-up (Table 9.7): Multiple types of hooks are available; however, the Muller hook is an inexpensive effective tool (Fig. 9.5).
- Intraoperative procedure

**TABLE 9.5 ■ Endovascular Treatment Options for GSV Incompetence**

	Cost of Materials	Approximate Time of Procedure	Clinical Efficiency	Post-operative Discomfort	Complications
Duplex Guided Sclerotherapy	20–30	30 minutes	To be determined	Minimal	Risk of arterial injection and subsequent necrosis
Endovascular Laser	200	45 minutes	>90%	Delayed pain at 3–5 days	Bruising
Radiofrequency Closure	750	1 hour 15 minutes	>90%	Minimal	Thermal burns (minimized with tumescent anesthesia)





**FIGURE 9.4** Preoperative marking of the planned avulsed varicosities is carried out with the patient in the standing position

- Microincisions are made vertically over marked areas of bulging with an 11 BP blade or 16-gauge No-Kor needle.
- Vessel is separated from underlying fascia by means of an iris scissor or combined tissue hook dissection.
- Vein is hooked and subsequently exteriorized.
- It is then grasped with a mosquito clamp.

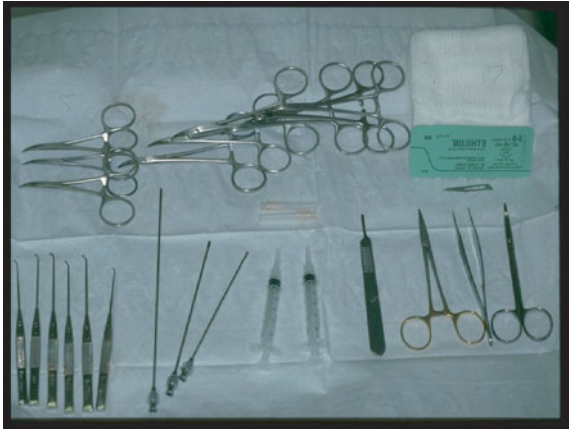
**TABLE 9.6 ■ Ambulatory Phlebectomy**

Tumescent Anesthesia Formula		
<b>Tumescent Anesthesia Solution .05%</b>		
05% = 500 mg total		
Lidocaine		
1000 cc	Normal saline	.9%
50 cc	Lidocaine	1%
1 cc	Epinephrine	1/1000
12.5 cc	Bicarbonate	8.4%
1 cc	Triamcinolone acetonide	10 mg/cc (optional)
<b>Total</b>	<b>500 mg Lidocaine = .05%</b>	

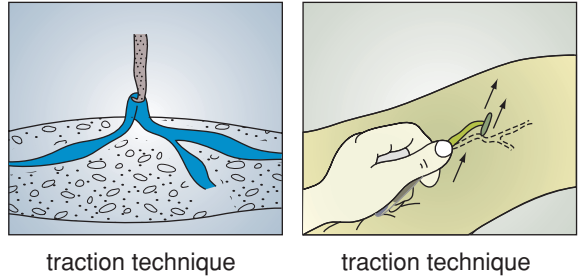
- Traction and a gentle kneading traction maneuver allows removal of the longer vein segments (Fig. 9.6).
- The diseased vein segment usually separates from underlying normal vein segment (Fig. 9.7).
- Excellent functional and cosmetic results.
- Postoperative care
  - Apply absorbent pads and an ace bandage for 24 hours immediately postoperation.
  - Then apply Class II, 30–40mm Hg graduated support hose worn daily for 3 weeks following waking hours.
  - Continue ambulating immediately postoperation.

**TABLE 9.7 ■ Setup and Instrumentation for Ambulatory Phlebectomy**

- #2, 3, 4 Muler hooks
- Knife handle
- 11 blade
- 16 gauge No-Kor needle
- Straight Iris scissor
- 4-mosquito clamps
- Towel clip – to wrap foot with towel
- Tumescent infusion tubing
- 1 or 3 mm infusion cannula
- Klein pump
- 4 × 4 opaque sterile sponges
- Maxi pads
- 4" Medi-rip



**FIGURE 9.5** Ambulatory phlebectomy operative set up includes Nokor needles, 11" blades, mosquito clamp, tumescent anesthesia instillation cannula, and set of ambulatory phlebectomy hooks

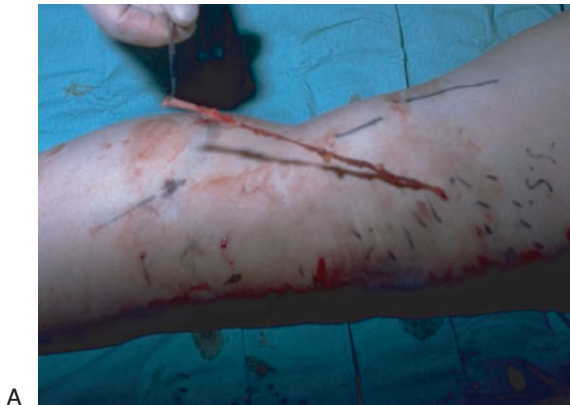

**FIGURE 9.6** Traction techniques for ambulatory phlebectomy may involve a pulling, pushing, or whirling technique

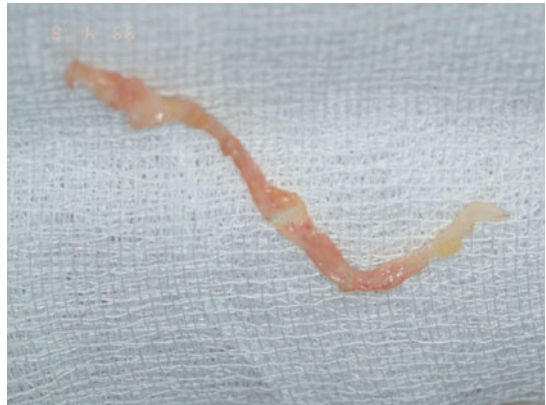- Complications: Complications of this procedure are usually minor and rare; however, these should be recognized and treated appropriately (Table 9.8).

### ■ Foam Sclerotherapy

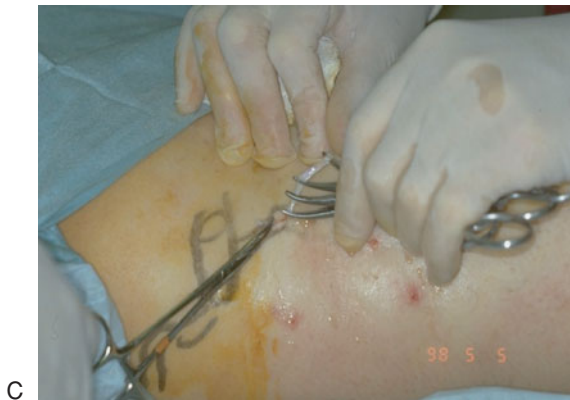- May be used as an alternative for treatment of non-saphenous truncal veins.



A



B



C

**FIGURE 9.7** Removal of an entire segment of a varicosity will lead to improved clinical results, decreased recurrence rate, and a lesser incidence of hyperpigmentation

**TABLE 9.8 ■ Complications of Ambulatory Phlebectomy**

## Vascular complications:

- Bleeding, seroma
- Superficial thrombophlebitis
- Deep venous thrombosis
- Pulmonary embolism
- Telangiectasias
- Matting

## Lymphatic complications:

- Lymphorrhea
- Persisting edema
- Lymphocele

## Neurological complications:

- Nerve damage around the ankle
- Temporary hypesthesia
- Dysesthesia (temporary/permanent)
- Traumatic neuroma

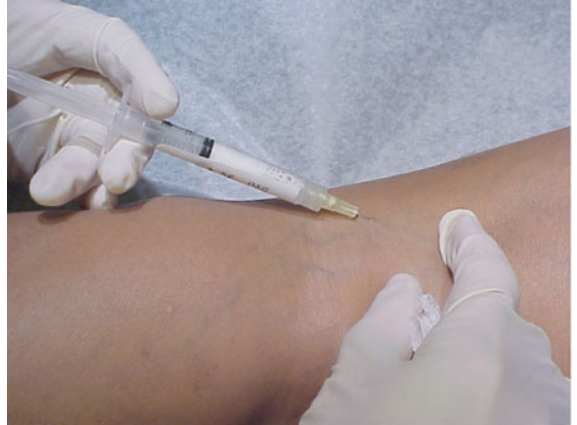## Cutaneous complications:

- Bullous detachment or blister
- Pigmentation, transitory or permanent
- Eczema
- Keloid formation
- Dimpling
- Skin necrosis
- Infection dermatitis
- Induration hypo-hyperpigmentation of microincision
- Tattooing

## Compression bandage complications:

- Swelling
- Blisters
- Skin necrosis
- Ischemia

- Sotradecol of 0.2–1.0% is most commonly used.
- Hypertonic saline (18% to 30%) also widely used.
- May at present be prepared manually utilizing a maximum of 4 parts air with 1 part sclerosant to produce a microbubble emulsion (Fig. 9-8).
- Foam agents are more potent and thus have a greater effect down stream from initial injection sites.
- Caution: Use with care when treating small telangiectasia as this potent detergent sclerosing effect may be associated with an increased incidence of postsclerotherapy hyperpigmentation.

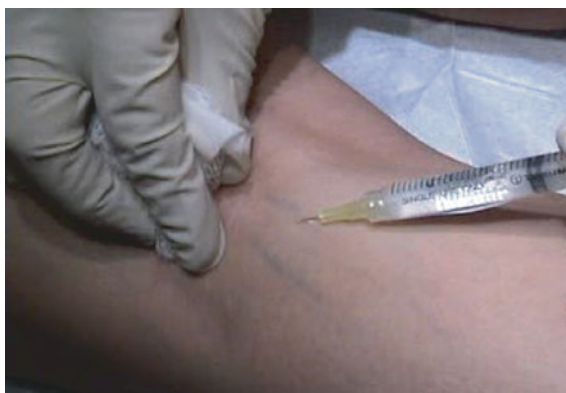**FIGURE 9.8** Foam sclerotherapy involves the production of a microfoam emulsion, which improves endothelial-sclerosant interaction yielding more effective results in treatment of large diameter varicose veins**TELANGIECTASIA/RETICULAR VEINS**

- Materials on the sclerotherapy tray include
  - cotton balls soaked with 70% isopropyl alcohol;
  - protective glasses;
  - 3-cc disposable syringes;
  - 30-gauge disposable transparent hub needles (1/2" length);
  - 32-gauge needles or 33-gauge autoclavable disposable;
  - clear light source preferably with a magnifying source.
- Basic principles of treatment
  - Always treat proximal sites of reflux first.
  - Larger and protruding vessels are treated before smaller veins.
  - An entire varicosity is treated at a given treatment session.
  - The lowest effective concentration of sclerosant should be used (MSC).
  - Adequate compression should be applied immediately after therapy.
  - Ambulation should begin immediately after treatment.
- Choice of sclerosing agent

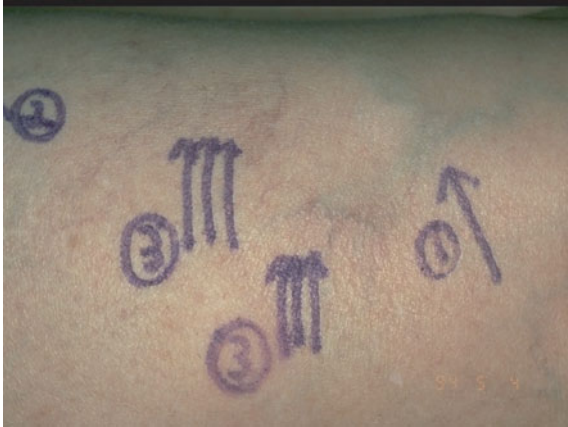**TABLE 9.9 ■ Suggested Sclerosant/Concentrations for Treatment of Telangiectasias/Reticular Veins**

VESSEL TYPE	SCLEROSANT	CONCENTRATION	
Telangiectasias <1 mm	Hypertonic saline	11.7%	
	Sodium tetradecol sulfate	0.2%	
	Polidocanol (Aethoxysklerol)	0.25%	
	Chromated glycerin	> 2%	
Venulectasia 1–2 mm	Sodium tetradecol sulfate	0.25%	
	Hypertonic saline	23.4%	
	Hypertonic glucose/saline	200 mg/mL dextrose	100 mg/mL sodium chloride
		100 mg/mL propylene glycol	8 mg/mL phenoxyalcohol 0.5%
		Polidocanol (Aethoxysklerol)	
Reticular veins > 2 mm	Hypertonic saline 1:1	23.4%	
	Hypertonic glucose/saline (Sclerodex)		
	Sodium tetradecyl sulfate (Sotradecol)	0.25–0.4%	
	Polidocanol (Aethoxysklerol)	0.5–1.0%	

- Only sodium tetradecyl sulfate and sodium morrhuate are FDA approved.
- Use the MSC agent for a given vessel diameter (Table 9.9).
- If a poor response to a given sclerosant occurs, the sclerotherapist may
  - increase the concentration of sclerosant;
  - switch to another sclerosant;
  - reexamine the patient under Duplex guidance in order to find a possible source of occult reflux.
- Injection technique
  - Two hand traction keeps the skin tight to ensure precise vessel cannulation (Fig. 9.9).
  - Large vessels are injected before small ones, i.e., injection of reticular veins feeding smaller telangiectasias or venules may eradicate larger surface areas of telangiectasias with lesser numbers of injections (Fig. 9.10).
  - Areas of vascular arborization should be treated before single vessels are cannulated (Fig. 9.11).
  - Preswiping of treatment areas with alcohol, transillumination devices such as the Venoscope or polarization devices, i.e., Syris Light (Syris Gray ME) are all aids that help in visualization of vessels and thus improved results.
- Brisk cannulation of veins causes minimal vascular trauma and thus less chance for extravasation of blood.
- Use low injection pressure.
- Use a small amount of sclerosant at each injection site (0.1–0.4 cc).

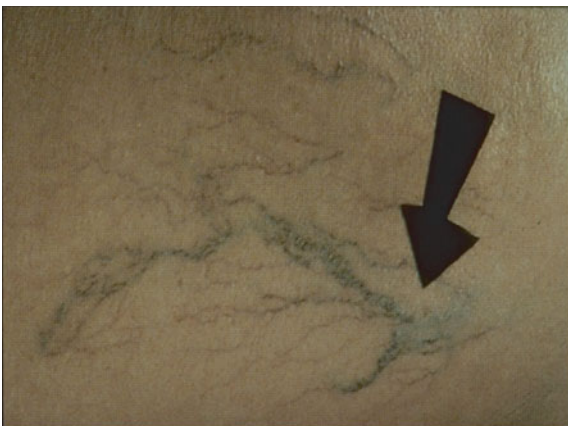

**FIGURE 9.9** Two-hand traction and brisk cannulation with injections of small amounts of sclerosant 0.1–0.3 cc at a given injection site will improve clinical results and minimize complication profiles in sclerotherapy



**FIGURE 9.10** *The sequence of sclerotherapy should always be treatment of larger vessels (areas of higher reflux) such as reticular veins prior to small telangiectasia and venulectasia*

- Injections are carried out at approximately 3-cm intervals.
- Treatment sessions are carried out at 4–6 week intervals to allow time to evaluate results of prior treatment.
- Most patients require between 2 and 5 treatment sessions.
- Compression considerations



**FIGURE 9.11** *Treatment of arborizing foci as shown with single feeding points will minimize the number of injections necessary to treat a given surface area of vessels*

- 7–14-day waking hour compression is recommended following sclerotherapy.
- Following injection of bulging varicose veins the area is wrapped with a Class 1 stocking (10–20 mmHg compression).
- For telangiectasias, fashion hose (15–18 mmHg).

## COMPLICATIONS

Fastidious technique and the choice of appropriate sclerosant for a given vessel diameter are the major cornerstones of limiting the incidence of untoward sequelae.

## CONCLUSION

A number of new technologies and therapeutic approaches allow the dermasurgeon to treat both medical and cosmetic venous problems.

## SUGGESTED READING

1. Weiss RA, Weiss MA. Controlled radiofrequency endovenous occlusion using a unique radiofrequency catheter under duplex guidance to eliminate saphenous varicose vein reflux: A 2-year follow-up. *Dermatol Surg* 2002;28:38–42.
2. Goldman MP. Closure of the greater saphenous vein with endoluminal radiofrequency thermal heating of the vein wall in combination with ambulatory phlebectomy: Preliminary 6-month follow-up. *Dermatol Surg* 2000;26:452–456.
3. Min RJ, Zimmet SE, Isaacs MN, Forrestal MD. Endovenous laser treatment of the incompetent greater saphenous vein. *J Vasc Interv Radiol* 2001;12:1167–1171.
4. Navarro L, Min RJ, Boné C. Endovenous Laser: A new minimally invasive method of treatment for varicose veins—preliminary observations using an 810-nm diode laser. *Dermatol Surg* 2001;27:117–122.
5. Sadick NS. Controlled radiofrequency mediated endovenous shrinkage and occlusion of the greater saphenous vein. *Cosmet Dermatol* 2001;18:14–16.
6. Goldman MP, Weiss RA. Transillumination mapping prior to ambulatory phlebectomy. *Dermatol Surg* 1998;24:447–450.
7. Smith SR, Goldman MP. Tumescence anesthesia in ambulatory phlebectomy. *Dermatol Surg* 1998;24:453–456.

8. Sadick NS. Multifocal pull-through endovascular cannulation technique of ambulatory phlebectomy. *Dermatol Surg* 2002;28:32–37.
9. Garde C. Ambulatory phlebectomy. *Dermatol Surg* 1995;21:628–630.
10. Olivencia JA. Pitfalls in ambulatory phlebectomy. *Dermatol Surg* 1999;25:722–724.
11. Cohn M, Seiger E, Goldman S. Ambulatory phlebectomy using the tumescent technique for local anesthesia. *Dermatol Surg* 1993;21:315–318.
12. Ricci S. Ambulatory phlebectomy: Principles and evolution of the methods. *Dermatol Surg* 1998;24:459–464.
13. Sadick NS, Li C. Small vein sclerotherapy. *Dermatol Clin* 2001;19:475–481.
14. Weiss RA, Dover JS. Leg vein management: Sclerotherapy, ambulatory phlebectomy and laser surgery. *Semin Cutan Med Surg* 2002;21:76–103.
15. Sadick NS. Foam sclerotherapy. *Cosmet Dermatol* 2002;15:81–83.
16. Sadick NS. Sclerotherapy. *Clin Prob Dermatol* 2001;31:37.
17. Leach BC, Goldman MP. Comparative trial between sodium tetradecyl sulfate and glycerin in the treatment of telangiectatic leg veins. *Dermatol Surg* 2003;29:612–615.

# CHAPTER 10

# Lasers

Neil Sadick

## KEY POINTS FOR SUCCESS

- Understanding the appropriate laser/intense pulse light source for a given clinical indication.
- Adequate cooling technology.
- Choosing appropriate pulse direction/spot size.
- Sun protection measures; do not treat patients with lasers who are tanned or sunburned.
- Postoperative wound care.
- Matching patient expectations to technology capability.
- Consider using spot tests when treating darker skin phenotypes, i.e., Fitzpatrick skin types V–VI.

## LASER CLINICAL PARAMETERS (TABLE 10.1)

- Titan 1100–1800nm 34 J
- Fraxel 1520–1580 nm 6.8 J 250 mHz.
- Wavelength will determine the major chromophore absorbed and produce a particular tissue effect, i.e., green light targets melanin, yellow light targets hemoglobin, and infrared light may target water as well as hemoglobin.
- Spot size will vary energy deliverance characteristics; smaller spot sizes allow delivery of higher fluences of energy in a concentrated fashion while larger spot sizes deliver energy over a larger surface with greater diffusion.
- Pulse duration: longer pulses allow deliverance of high fluences of energy over a longer period of time.
- Cooling technologies: allow the capability for deliverance of high energies, which protect epidermis and surrounding tissue; e.g., simple coupling gels or cooled air devices, static chilled circulating (–1 to –4°C) cooling window tips, or dynamic sprayed cooling devices.

## INDICATIONS

- Vascular lesions
- Pigmented lesions
- Hair removal

- Lipolysis/cellulite
- Stretch marks
- Photorejuvenation
- Resurfacing

## CONTRAINDICATIONS

- Infection (viral, bacterial)
- Sunburn
- Suntan
- Artificial tanners
- Pregnancy (relative)

## TREATMENT WITH ABLATIVE LASERS

### ■ Vascular Lesions

Available technologies and their wavelengths

- KTP laser 532 nm
- PDL laser 585–600 nm
- Long pulsed Nd:YAG laser 1064 nm
- Diode laser 800–900 nm
- Alexandrite laser 755 nm
- Intense pulsed light (IPL) 500–1200 nm

Indications

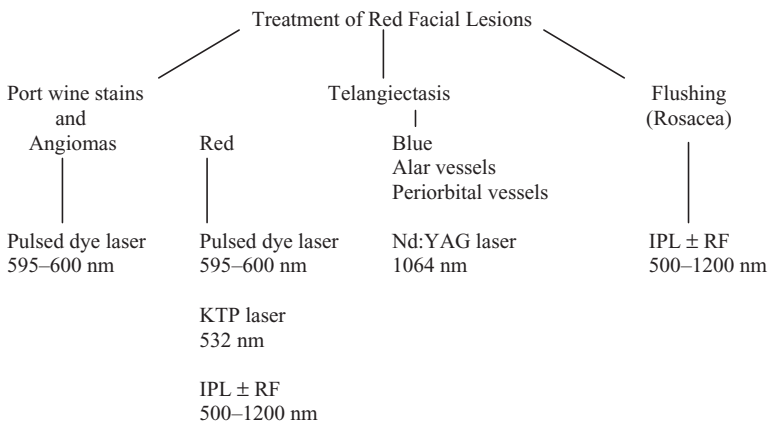
- Port wine stains
- Hemangiomas
- Actinic telangiectasias
- Rosacea/flushing
- Spider/reticular veins
- Poikiloderma
- Scars
- Striae distensae
- Warts

Treatment

- See Fig. 10.1 for an overview of choosing a course of clinical treatment for the various types of lesions.

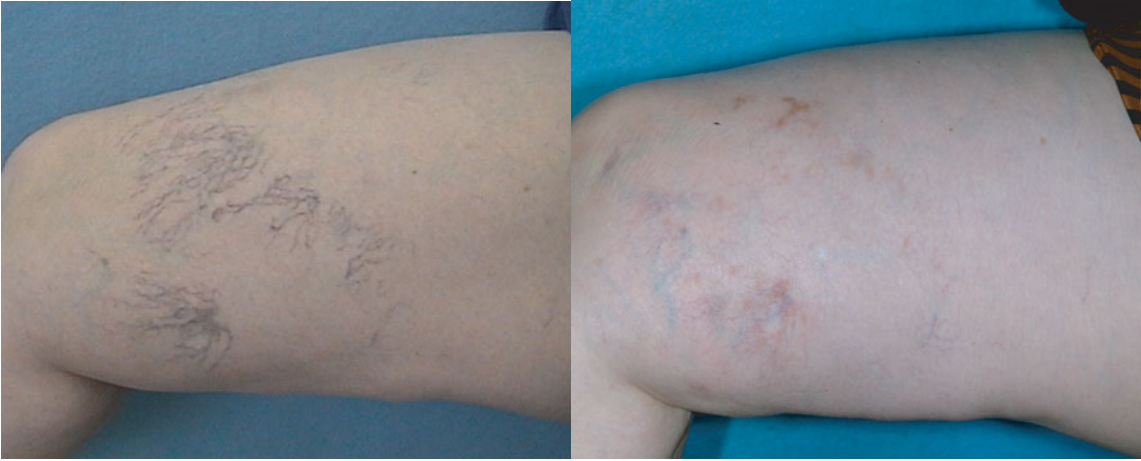
**TABLE 10.1 ■ Types of Lasers and Their Cutaneous Application**

Laser Type	Wavelength	Cutaneous Application
Argon (CW)	418/514 nm	Vascular lesions
Argon-pumped tunable dye (quasi-CW)	577/585 nm	Vascular lesions
Copper vapor/bromide (quasi-WC)	510/578 nm	Pigmented lesions, vascular lesions
Potassium-titanyl-phosphate	532 nm	Pigmented lesions, vascular lesions
Nd:YAG, frequency-doubled	532 nm	Pigmented lesions, red/orange/yellow tattoos
Pulsed dye	510 nm	Pigmented lesions
	585–595 nm	Vascular lesions, hypertrophic/keloid scars, striae, verrucae, nonablative dermal remodeling
Ruby	694 nm	
QS		Pigmented lesions, blue/black/green tattoos
Normal mode		Hair removal
Alexandrite	755 nm	
QS		Pigmented lesions, blue/black/green tattoos
Normal mode		Hair removal, leg veins
Diode	800–810 nm	Hair removal, leg veins
Nd:YAG	1064 nm	
QS		Pigmented lesions, blue/black tattoos
Normal mode		Hair removal, leg veins, nonablative dermal remodeling
Nd:YAG, long-pulsed	1320 nm	Nonablative dermal remodeling
Diode, long-pulsed	1450 nm	Nonablative dermal remodeling, acne
Erbium: glass	1540 nm	Nonablative dermal remodeling
Erbium: YAG (pulsed)	2490 nm	Ablative skin resurfacing, epidermal lesions
Carbon dioxide (CW)	10,600 nm	Actinic cheilitis, verrucae, rhinophyma
Carbon dioxide (pulsed)	10,600 nm	Ablative skin resurfacing, epidermal/dermal lesions
Intense pulsed light source	515–1200 nm	Superficial pigmented lesions, vascular lesions, hair removal, nonablative dermal remodeling



**FIGURE 10.1** Approach to choosing clinical treatment for treatment of vascular lesions





**FIGURE 10.2** Pre- and post-1064 nm Nd:YAG three treatments. Red vessels: 1.5 mm spot size, 150–400 J/cm<sup>2</sup>, 15–30 ms PD; blue vessels: 3.0 mm spot size, 100–250 J/cm<sup>2</sup>, 30–50 ms PD

## ■ Red Facial Lesions

- PDL is treatment of choice for large discrete vessels on the face as well as port wine stains.
  - Short pulse duration, i.e., 1–5 ms produce purpura, but are more effective in a single treatment.
  - Extension of the pulse duration to 8–10 ms will reduce this at 10 J/cm<sup>2</sup>, but usually requires more than one treatment session.
- 1064 Nd:YAG lasers treat deep blue vessels at the alae nasi and periorbital veins; low fluence of 90–110 J/cm<sup>2</sup> are used in this setting
  - Leg veins up to 4 mm may be treated with the 1064 nm Nd:YAG laser employing varying pulse widths (Fig. 10.2 and Table 10.2)
  - Smaller spot sizes of 1–2 mm with shorter pulse durations of 30–40 ms and high fluences of 400–500 J/cm<sup>2</sup> are used to treat small red oxygenated vessels, while larger spot sizes of 2–6 mm with larger pulse durations of 50–80 ms and lower fluences of 150–300 J/cm<sup>2</sup> are used to treat larger diameter blue vessels.
- Rosacea responds well to IPL treatments using 590 or 640 nm cut off filters with fluences of 28–32 J/cm<sup>2</sup>. Combined IPL/RF technologies are also used in this setting. Maintenance of treatments is required at 3–6-month intervals.

## ■ Pigmented Lesions and Inflammatory Hyperpigmentations

- Available technologies
  - Green light
    - 510 nm pulsed dye laser
    - 511 nm copper vapor laser
  - 532 nm Nd:YAG laser
    - Q-switched
    - 694 nm ruby
    - 755 nm alexandrite
    - 1064 nm Nd:YAG
- Indications
  - Epidermal

**TABLE 10.2 ■ Monomodal Approach to Lower Extremity Veins (1064 nm Technologies)**

	Vessel 1 mm (Red)	Vessel 1–3 mm (Blue)
Spot size	1–5 mm	3 mm
Fluence	150–400 J/cm <sup>2</sup>	100–250 J/cm <sup>2</sup>
Pulse duration	15–30 ms	30–50 ms

- Lentigos
- Labial melanotic macules
- Seborrheic keratoses, dermatosis, papulosis nigra
- Ephelides
- Café-au-lait macules
- Nevus spilus
- Epidermal and dermal
  - Becker's nevus
  - Postinflammatory hyperpigmentation
  - Melasma
  - Nevocellular nevi
    - Junctional melanocytic nevi
    - Compound melanocytic nevi
    - Congenital melanocytic nevi
  - Dermal
    - Nevus of Ota, Ito
    - Mongolia spots
    - Blue nevus
    - Tattoos (exogenous pigment)
- Anticipated results
  - Good response can be expected for
    - lentigos
    - ephilides
    - tattoos
  - Moderate response with high recurrence rate can be expected for
    - café-au-lait spot
    - veins
    - nevi
  - Poor response is seen with
    - seborrheic keratosis
    - postinflammatory hyperpigmentation
    - Becker's nevus
  - The Q-switched ruby (694 nm), alexandrite (755 nm), and Nd:YAG (532/1064 nm) lasers are most effective in this setting (fluences 5–10 J/cm<sup>2</sup>).
  - Lentigos and ephilides respond best in a single treatment session.
  - Melasma and postinflammatory hyperpigmentation

are unpredictable and often recur if the inciting event is still present.

- Fractional photothermolysis (Fraxel) is a new technology showing promise in this setting (fluence 6–8 J/cm<sup>2</sup> 250 Microthermal Zones)
- Tattoos require multiple treatments. Carbon-based particles have under absorption bands blue and green ink absorb greatest for wavelengths of 600–800 nm, whereas red ink absorbs best below 575 nm, tan below 560 nm, flesh-colored pigment below 535 nm, and yellow below 520 nm.

## ■ Hair Removal

- Indications for hair removal by wavelength
  - Short wavelength is appropriate for Fitzpatrick skin types I-III
    - Ruby (694 nm): thin hair shaft
    - Alexandrite: blonde to light brown hair
  - Intermediate wavelength is appropriate for Fitzpatrick skin type II-V
    - Diode (800–900 nm): intermediate hair shaft
    - IPL ± RF (500–1200 nm): light brown to dark brown hair
  - Long wavelength is appropriate for Fitzpatrick skin type IV-VI
    - Nd:YAG (1064): intermediate to coarse hair shaft; medium brown to black hair
- Factors involved in photoepilation
  - Body site
  - Hair depth
  - Follicle density
  - Anagen/telogen duration
  - Hair color
  - Hair coarseness
- Hair is most efficiently targeted in the anagen phase where the maximal amount of the target chromophore melanin is present
- Treatment
  - Hair removal may be long term if the entire germinative area of the follicles is destroyed or associated with varied degree and duration of regrowth of this

**TABLE 10.3** ■ Possible Effects of Photoepilation

Chromophore not targeted (i.e., light hair telogen)	No effect
Hair shaft destroyed	Exogen shedding regrowth
Partial germinative area destruction	Regrowth with dystrophic hair
Total germinative area destruction	Long-term (permanent) removal

zone is injured but not totally destroyed (Table 10.3).

- Usually three to five treatment sessions are performed at monthly intervals with touch-up treatments performed on an individual basis determined by the degree of hair regrowth.
- Short wavelength technologies, i.e., ruby, (694 nm) and alexandrite (755 nm) are most effective in targeting thin light hair and light skin phenotypes.
- Intermediate wavelength technologies, i.e., diode (800 nm) and intense pulsed light (500–1200 nm) have greatest versatility in treating the largest spectrum of skin phenotypes, varied hair hues, and shaft diameters (Fig. 10.3).
- Longer wavelengths, i.e., 1064 nm Nd:YAG lasers allow treatment of darker skin phenotypes and dark, coarse hair.

- Preoperative care

Anesthesia EMLA (lidocaine 2.5%, prilocaine 2.5%) or ELMAX (lidocaine 4%, topical application 36–60 minutes prior to treatment).

Shaving is acceptable between treatments.

Photoprotection/absence of tanning or self-tanners.

- Treatment regimens

20–100 J/cm<sup>2</sup> delivered depending upon particular technology.

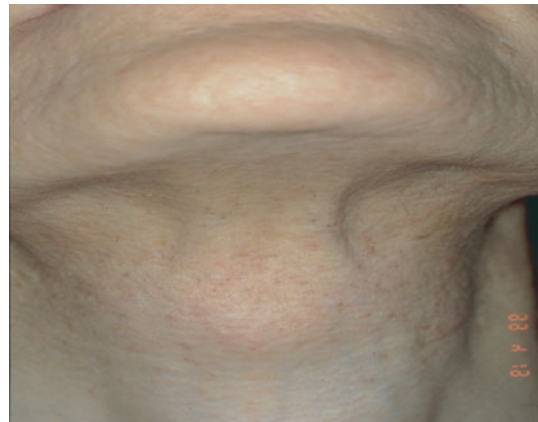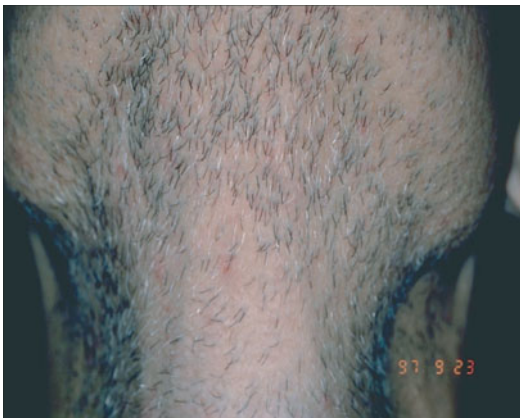
Expectations are 60–75% mean hair removal efficiency (MHRE) after three to five treatment sessions.

## TREATMENT WITH NONABLATIVE LIGHT SOURCES

Nonablative rejuvenation uses lasers and intense pulsed light sources, which improve aging parameters without disrupting cutaneous integrity, minimal downtime, and low-risk profile.

- Available Technologies: The available technologies are listed in Table 10.4.

- Indications and Contraindications: A summary of the author's approach to nonablative rejuvenation is as follows:



**FIGURE 10.3** Pre- and post-diode hair removal: 20 months/3 treatments; 22–26 J/cm<sup>2</sup>, auto

Nonablative Technology	Effective Technology
Skin toning	LED photomodulation
Vascular improvement/flushing	PDL (585–600 nm) IPL ± RF (500–1200 nm) Nd:YAG/KTP (532 nm)
Pigmentation	IPL ± RF (500–1200 nm) Nd:YAG/KTP (532 nm) Fractional photothermolysis (1520–1580 nm)
Skin smoothing	IPL ± RF (500–1200 nm) Fractional photothermolysis (1520–1580 nm)
Wrinkle reduction	CoolTouch (1320 nm) SmoothBeam (1450 nm) Erbium glass laser (1540 nm)
Skin tightening	Thermacool (RF) Titan (1100–1800 nm)

- Treatment
  - Skin toning—LEDS provide indirect biologic effect to augment skin reflectance and color.
  - Improvement in vascular lesions/flushing.

**TABLE 10.4 ■ Available Nonablative Rejuvenation Technologies (Laser/Intense Pulsed Light Sources)<sup>a</sup>**

Laser Technologies
Yellow Light
Potassium titanyl phosphate (KTP) laser (532 nm)
CuBr laser (578 nm)
Pulsed dye laser (PDL) (585–600 nm)
N-Lite laser (585 nm)
Broadband light (500–1100 nm)
Intense pulsed light (IPL) (500–1100 nm)
Infrared lasers
Nd:YAG (1064 nm)
CoolTouch (1320 nm)
SmoothBeam (1450 nm diode)
Aramis (1540- $\mu$ m erbium glass laser)
Fraxel (1570–1580 nm)
Nonlaser modalities
Radiofrequency technologies (Thermage)
Titan (1500–1800 nm)

<sup>a</sup>Intense pulsed light sources (400–1100nm) ± radiofrequency (RF).

- IPL treatments are gold standard usually performed in five monthly treatment sessions with single, i.e., maintenance treatments at 3–6-month intervals.
- Fluences of 24–32 J/cm<sup>2</sup> are normally employed.
- Combined RF/IPL technologies delivering radiofrequency energy of up to 25 J/cm<sup>2</sup> may have additive effects. This treatment is the treatment of choice for diffuse redness and idiopathic flushing syndromes.
- Discrete vessels may require touch-up with a 532 nm KTP laser.
- Larger blood vessels may require PDL 585–600 nm (Fig. 10.4).

### ■ Improvement in Pigmentation

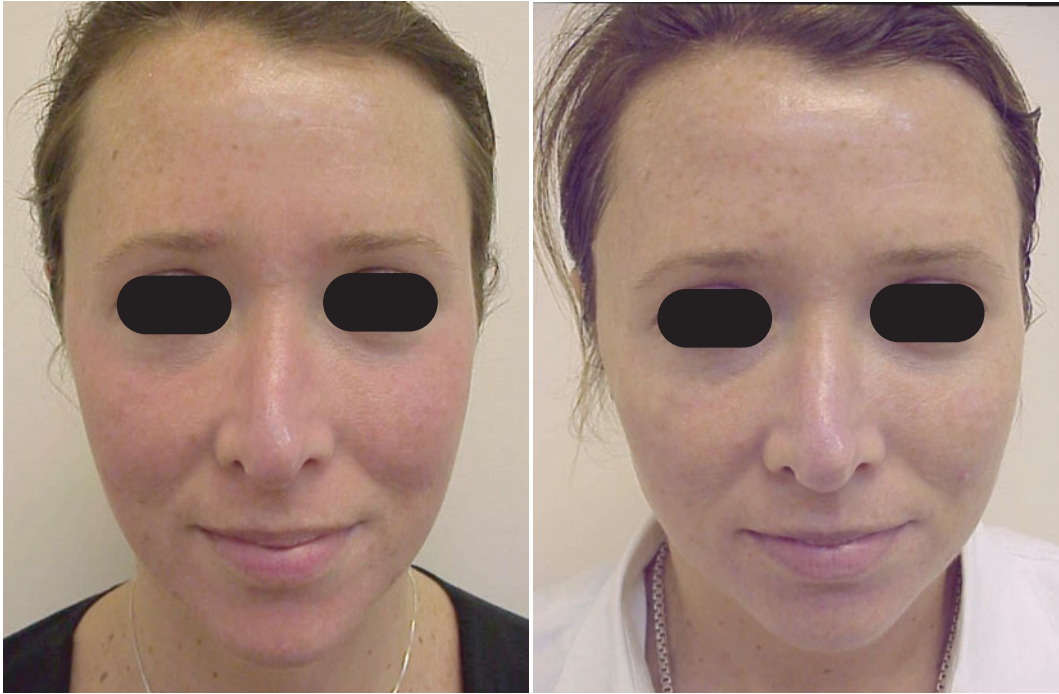A diffuse photoaging pigment as well as discrete ephelides and lentigo may be addressed by 532 nm KTP lasers, IPL or RF sources, or more recently the introduction of the concept of fractional photothermolysis (Fraxel) 1570–1580 nm at 6–8 J (250 MTZ) have been shown by causing deep microwounding focally to have a beneficial effect on diffuse inflammatory hyperpigmentation.

### ■ Skin Smoothing

- IPL or RF.
- Fractional photothermolysis.
- IPL technologies may induce skin smoothing effect by temporarily shrinking sebaceous glands and inducing a small amount of new collagen formation 560/590/640 cut-off filter, 22–34 J/cm<sup>2</sup> fluence.
- Fractional photothermolysis may induced microwound zones within the dermis leading to new collagen formation 6–8 J with 250 microthermal zone wounding parameters of MTZ one suggested initial starting parameters.

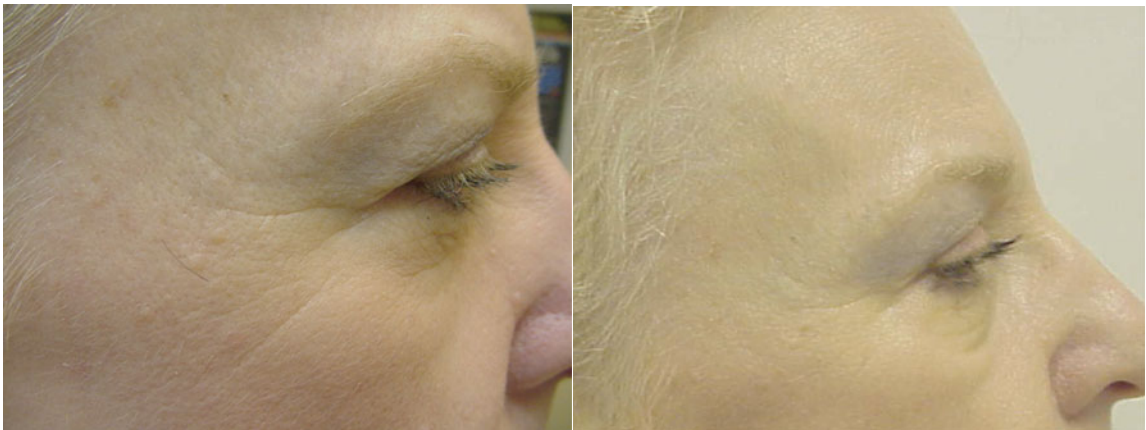### ■ Rhytid Reduction (Fig. 10.5)

- Best achieved by longer wavelength infrared lasers with water as primary chromophore
- Available technologies:
  - 1320 nm Nd:YAG (CoolTouch II) laser (New Star laser, Roseville CA) (14–18 J/cm<sup>2</sup>).
  - 1450 nm SmoothBeam diode laser (Candela, Wayland, MA); 1540 glass sphere laser (Aramis, Quantel Medical, Bozeman, MT).



**FIGURE 10.4** Pre- and post-IPL five treatments: 560 nm, 32 J/cm<sup>2</sup>, 2.4–4.2 PD; flushing/photoaged skin

- These technologies have been shown to be effective in treating mild perioral and periorbital rhytides, hand rejuvenation, and atrophic acne scars.
- These technologies are based on dermal remodeling with stimulation of new collagen.
- Treatment protocols
  - Three to four monthly treatment sessions.
  - One to two maintenance treatments in a year.
  - 40–60% improvement after initial treatment session with continued improvement up to a year after each treatment.



**FIGURE 10.5** Pre- and post-CoolTouch three treatments: 2 $\mu$ s macropulse, 30 ms pre/postcooling, 14–18 J/cm<sup>2</sup>

**TABLE 10.5 ■ Comparison of Thermacool and Titan**

Thermacool	Titan
Unipolar RF	Broadband infrared light source (1100–1800 nm)
Painful (Percocet, Valium, DMG)	Relatively painless
1 treatment session	3 treatment sessions
Multiple passes (68–71 settings)	Multiple passes 34 J/cm <sup>2</sup>
Spot size up to 3.0 cm	Spot size
Complications including atrophic panniculitis reported although relatively uncommon with multipass low energy regimens	Mild skin burns reported
Greatest efficacy in the lower face and neck	Greatest efficacy in the lower face and neck

### ■ Skin Tightening

Available technologies (see Table 10.5 for comparison):

- Thermacool (Thermage, Haywood, CA)
- Titan (Cutera, Brisbane, CA)
- Produce skin tightening by immediate skin contraction and long-term collagen remodeling

### TREATMENT WITH RESURFACING LASERS

Treatment with resurfacing lasers has lost popularity because of prolonged healing times and relatively high complication profiles; however, this treatment is still effective in severely photodamaged individuals.

- Available technologies (see Table 10.6 for comparison)
  - CO<sub>2</sub> laser 10,500 nm
  - Long pulsed erbium laser 2940 nm

- Contraindications
  - Recent tissue augmentation
  - Recent systemic isotretinoin usage (6 months)
- Preoperative care
  - Bleaching agents (hydroquinone 4%)
  - Retinoids
  - Antiviral prophylaxis (Valtrex 500 mg b.i.d. or Famvir 250 mg)
- Technique
  - Anesthesia
    - Percocet
    - Valium 10 mg ± regional blocks or tumescent anesthesia
  - 1–3 passes
  - Tissue wiping with CO<sub>2</sub> ablation
  - End point of ablation skin surface and microbleeding points with Er YAG laser

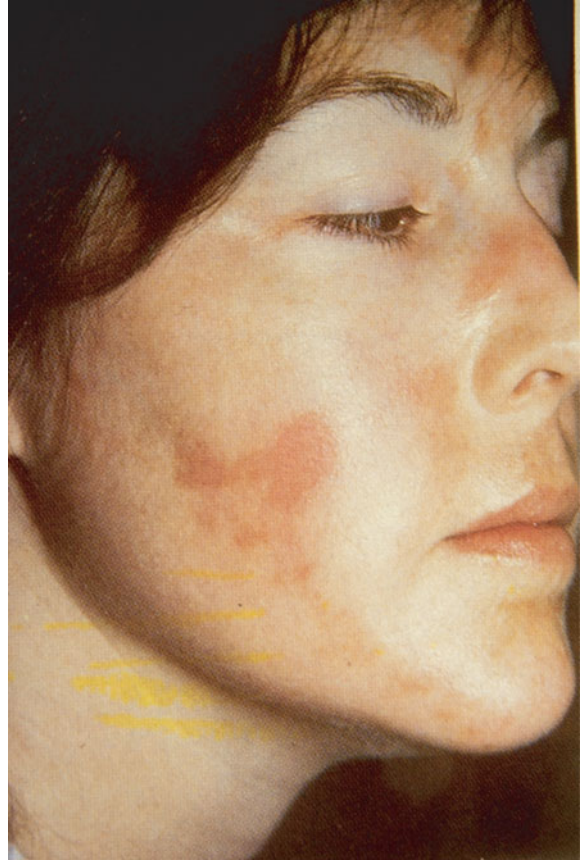**TABLE 10.6 ■ Comparison of CO<sub>2</sub> and Erbium Laser**

CO <sub>2</sub> Laser (10,500 nm)	Erbium Laser (2940 nm)
Collagen target	Water target
↑ Vaporization	↑ Ablation
Mild erythema lasting 3–6 months	Prolonged erythema lasting 1–2 months
Endpoint tissue tightening	Endpoint pinpoint bleeding
Delayed hypopigmentation	Less delayed hypopigmentation
Greater collagen remodeling	Lesser collagen remodeling

- Postoperative care
  - Open approach
  - 14% acetic acid compresses + Aquaphor (Biersdorf-Jobst, Norwalk, CT) 3–6 times per day
  - Closed technique
  - Biologically active semioclusive dressing, i.e., Silon TSR (Biosciences, Allentown, PA) (should not be left on longer than 24–48 hours to prevent secondary infection with bacteria or yeast.

## COMPLICATIONS

- Relatively rare with laser/IPL procedures
- Result from the following predominantly:
  - poor technique
  - improper setting
  - poor patient selection
  - lax sun protection measures
  - inappropriate pre- and postoperative considerations
- Scarring
  - Elicit personal or family history
  - Rare, has been most commonly reported after ablative laser resurfacing procedure
  - Overzealous fluences and stacking of pulses are the most common causes
  - Persistent erythema crust formation and ulcers are impending signs
  - Predisposing locations—bony prominences of the face, neck, hands, legs, and chest (Fig. 10.6)
- Telangiectasias
  - Commonly noted after ablative laser resurfacing procedures
  - Wait up to 6 months before instituting therapy as may correct spontaneously
- Hyper-/hypopigmentation
  - Commonly secondary to inadequate sun protection measures
  - May be secondary to inappropriate matching of wavelength with skin phenotype, i.e., utilization of a short wavelength in a Fitzpatrick Type V or VI individual
  - Footprinting is the most common sequelae of IPL procedures
  - Hypopigmentation is a long-term sequelae of CO<sub>2</sub> laser ablation. The XTRAC™ laser (PhotoMedex,



**FIGURE 10.6** *Postlaser scarring*

Montgomeryville, PA) and targeted phototherapy (UVB, UVA) with the MultiClear (Curelight LTD, Akiva, Israel) are more recently introduced technologies that may be helpful in this setting

- Demarcation irregularities are common after ablative resurfacing particularly around the neck and scalp-forehead junctions
- Feathering techniques with defocused beams, lower fluences, and combination treatments may be helpful in this setting
- Milia: Occlusion cysts are common after laser resurfacing of the face

## PEARLS/PITFALLS

- Pulse stacking should be avoided.
- Laser treatments should never be performed when one is tanned.

- All lasers and IPLs should be serviced at least one time per year.
- Conservative expectations and maintenance programs should be explained with nonablative technologies.
- Decreased hair density after laser hair removal means at least 50% of hair has been eradicated.
- Antiviral prophylaxis is essential with ablative technologies.
- The key to care after ablative resurfacing is careful follow-up and fastidious wound care.
- In dark skin phenotypes, Type V-VI, spot test sessions are recommended for all lasers and intense pulsed light sources.



Ron Moy, MD

## KEY POINTS FOR SUCCESS

- Management of patient expectations including
  - modest improvement and
  - the need for combination procedures to manage wrinkles.
- Careful anesthesia avoiding globe injury.
- Careful fat removal
  - with electrocautery for fat that surfaces above the incision and
  - transposition and not electrocautery for fat in middle compartment.
- Creation of a pedicle of fat for successful transposition.

## INDICATIONS

- Protuberant fat below the lower lid.
- A loss of fat in the tear trough deformity (loss of fat of the medial canthal side of the infraorbital area) (Fig. 11.1).
- Looser skin of the infraorbital area and a loose lower lid.
- Patient complaints of tired eyes or too much fat of the lower lids, which may be a problem of too little fat of the tear trough deformity and looser skin with wrinkles.
- Patients complain of dark circles under their eyes, which is the loss of fat of the medial side of the infraorbital area and sometimes pigmentation of the skin.
- Patients should be warned that postoperative bleeding can have terrible complications.
- Patients should be informed that avoiding aspirin products for at least 2 weeks prior to the procedure can decrease the chance of bleeding.
- Patients should be informed that avoiding a nonsteroidal anti-inflammatory 2 days prior to the procedure will also limit bleeding.

## PREOPERATIVE CONSULTATION

- Explain what can actually be accomplished by moving fat into the tear trough deformity or injecting in hyaluronic acid into the tear trough deformity (Fig. 11.1).
- Patients should understand that looser skin, wrinkled skin, and volume loss around the eye contributes to the aged eye.
  - Modest improvement can be accomplished by transposing fat from a transconjunctival blepharoplasty approach or by injection of fat or hyaluronic acid into the tear trough deformity.
  - Wrinkles can only be modestly improved by laser resurfacing or by a pinch excision of skin near the lateral ciliary margin of the lower eyelid.

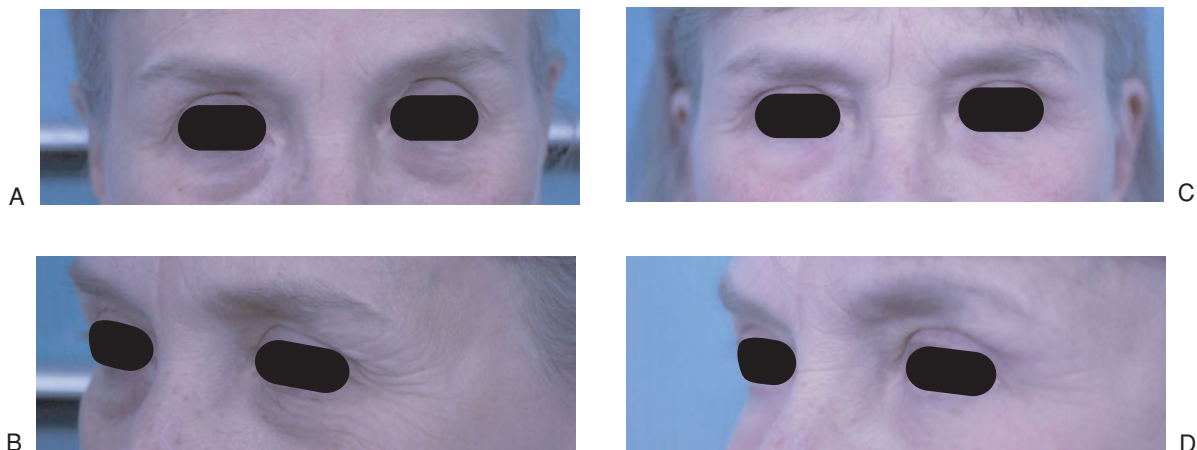
Swelling and delayed skin tightening with laser resurfacing can cause an improvement to be delayed for many months.

The swelling and bruising that can occur must be explained to the patient.

- Discussion of available techniques: Older lower blepharoplasty techniques called the skin-muscle flap blepharoplasty where the orbicularis muscle flap was incised to reach the fat weakened the muscle along with some skin excision leading to an ectropion and scleral show. Support with some type of anchoring suture and careful skin excision could prevent this problem.
- A transconjunctival blepharoplasty to remove or to transpose the fat, followed by either a pinch excision of skin (without violation of the orbicularis oculi muscle) or laser resurfacing to tighten the skin and improve the wrinkles is believed to be a safer technique than the skin muscle flap technique.
  - A canthopexy can tighten the slightly loose lower lid and at least prevent ectropion or scleral show from occurring. This can cause lumpiness or bunching of skin over the lateral canthus.

## HOW MUCH FAT TO REMOVE

- Take out less fat because volume loss contributes to the older looking eye.



**FIGURE 11.1** **A&B** Preoperative and **C&D** postoperative views of a 84-year-old woman with tear trough deformity (3 month follow-up)

- Patients with previous transconjunctival blepharoplasty may have less fat protrusion as more fat used to be removed than is currently done. However they may look older in later years from their volume loss. Some of these patients will still improve with some fat removal especially on the lateral and medial fat compartments.
- Most patients will benefit from modest fat removal and more transposition of fat into the medial tear trough deformity.
  - With the different techniques of fat transposition or of fat injection not all the fat survives.
  - Some older patients may not have enough fat that can be transposed in which case a transconjunctival blepharoplasty should not be performed.
- Lower lid tightening, volume enhancement with fat or hyaluronic acid, and skin tightening may be all that is required to make the lower eye look younger.

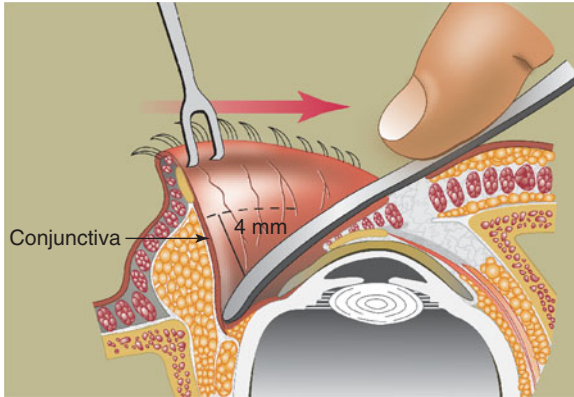
## ANESTHESIA

- Anesthesia is accomplished using 1% lidocaine with epinephrine into the
  - lower lid conjunctiva,
  - the lower lid retractors, and
  - lower lid fat compartments.

- A few days of topical tetracaine placed into the eye are necessary to use the Jaegar plate over the eye.
- The injection of local anesthesia using a 30-gauge needle maybe the most dangerous part of the procedure because care must be taken to avoid a needle stick to the globe. Pulling the lower lid away from the eye can be helpful to avoid globe injury.

## INCISION

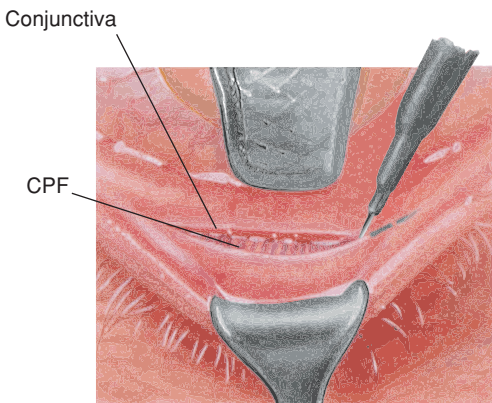
- There is usually an arcade of blood vessels on the conjunctiva that is another marker to help place the incision (Fig. 11.2). The incision is made anterior to the arcade of vessel midway between the conjunctival sulcus and the lower lid margin on the through the conjunctiva.
- The incision is made using a sharp needle type (Colorado needle) attached to the electrocautery device or using a laser so that the incision is relatively bloodless (Fig. 11.3).
- The incision is made over where fat projects with pressing on the globe with a Jaeger plate (looks like a shoe horn). A Desmarres retractor pulls the lower lid away from the globe (Fig. 11.4).
- The incision is usually made midway between the lower lid tarsus and the conjunctival sulcus.
- The incision is made through the lower lid retractors into the fat compartments (Fig. 11.5).



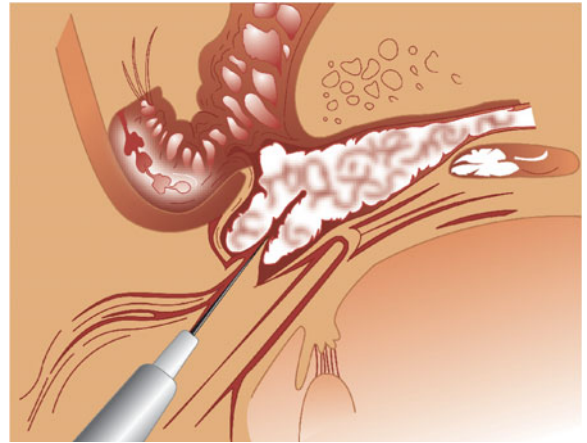
**FIGURE 11.2** The incision site for a transconjunctival blepharoplasty is usually midway between the sulcus and the lid margin where a few horizontal arcades of blood vessels exist on the conjunctival surface. Pressure on the globe helps demonstrate where the fat is bulging and where the incision should be placed

## FAT REMOVAL

- The fat is exposed by using blunt tenotomy scissors to spread through the fascia surrounding the fat compartments. The areas first exposed are those areas that bulge when pressure is applied to the globe with the Jaeger plate.

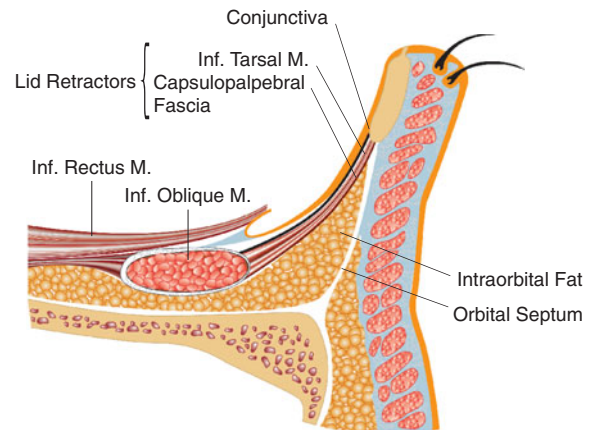


**FIGURE 11.3** The fine point needle on the electrocautery sharp needle helps make an incision without bleeding

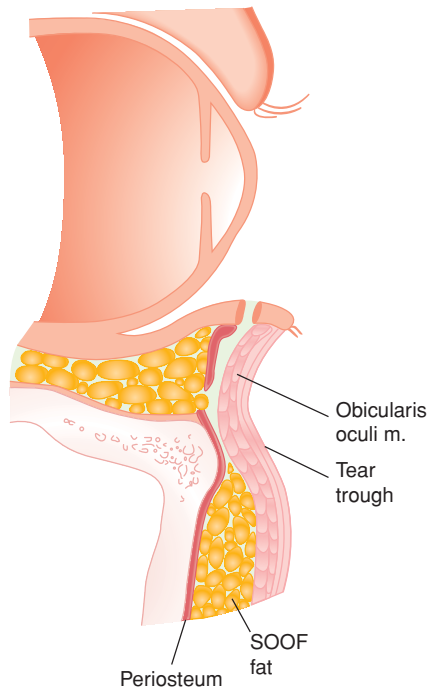


**FIGURE 11.4** Pressure on the globe pushes the fat out so that the incision is easily placed

- Fat will usually surface above the conjunctiva; this fat should be considered for removal with electrocautery.
- Most of the fat in the medial or middle fat compartments should not be vaporized and should be used to transpose into the nasojugal groove.
- The lateral fat compartment should be vaporized if the fat emerges above the surface of the conjunctival plane. Rarely will it be necessary to dissect deep below the conjunctival surface, which then requires avoiding the inferior oblique muscle.



**FIGURE 11.5** Cut through lid retractors with an electrocautery sharp needle and tenotomy scissors to remove fat



**FIGURE 11.6** The tear trough deformity or nasal jugular groove needs to be filled with fat or a filler

## FAT TRANSPOSITION

- If fat is to be transposed into the nasal jugular groove, then a pedicle of fat, which allows movement, needs to be created (Fig. 11.6).
- Tenotomy scissors can be used to dissect around the pedicle to allow the free movement (Fig. 11.7A, B).
- The area of the tear trough deformity is visualized from the skin surface.
- Tenotomy scissors are used to dissect a space above the orbicularis oculi but below the skin surface of the nasojugal tear trough deformity.

Some advocate placing the fat into a subperiosteal space. This subperiosteal space is harder to create then separating a space above the orbicularis muscle.

- Forceps are used to push the fat pedicle to the nasal jugular groove (Fig. 11.7C).
- The other hand is used to hold a needle holder with a 6-0 fast absorbing gut suture that can grab and hold the fat pedicle.
- A simple interrupted suture starts at the skin surface and grabs the fat pedicle.

- The suture holds the fat pedicle into the tear trough deformity.
- Two sutures hold the fat pedicle at the tear trough deformity.

## COMBINATION PROCEDURES WITH LASER RESURFACING, PINCH EXCISION, AND LID TIGHTENING

### ■ Laser Resurfacing

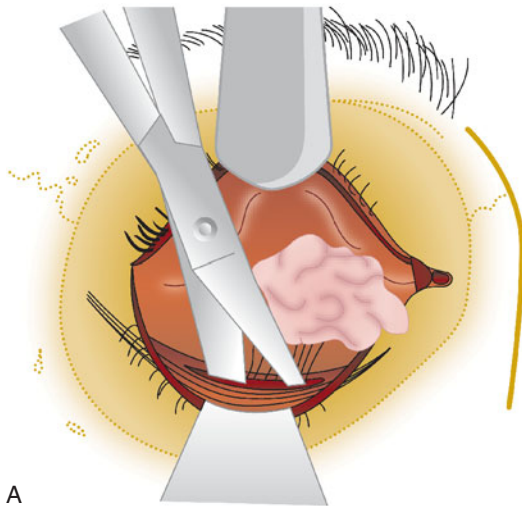
Laser resurfacing should be performed prior to the placement of fat into the tear trough deformity. Two passes of carbon dioxide lasers, erbium, or plasma resurfacing may be necessary to achieve tightening and wrinkle improvement (Fig. 11.8).

### ■ Pinch Excision

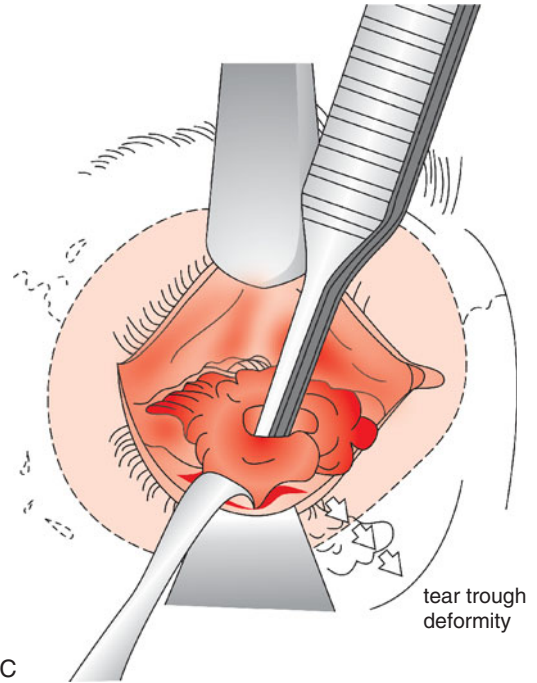
- The pinch excision is performed by pinching the skin with forceps and marking out a narrow ellipse around the lateral canthal area.
- This narrow ellipse will be
  - right below the ciliary eyelid margin;
  - start laterally;
  - extend maybe to the middle lower eyelid margin.
- This pinch excision of skin is done conservatively with minimal tension across the skin edges.
- Undermining of the entire infraorbital area will decrease the wrinkle lines and help tighten the skin.
- Closure of the skin edges is accomplished with 6-0 fast absorbing.
- More skin will need to be removed if a MACS-Lift (a vertically pulled minimal incision cranial suspension facelift) creates more skin in the infra orbital area.

### ■ Canthopexy Suture

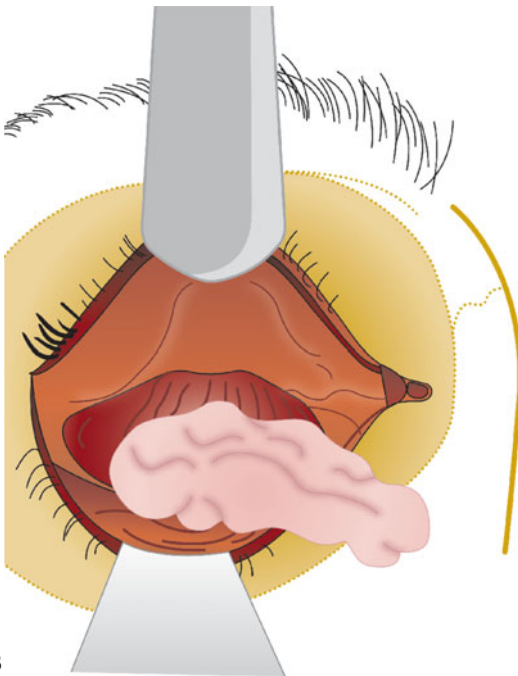
- The canthopexy suture tightening the lower lid can be placed from a small stab incision or the pinch excision opening (Fig. 11.9).
- A small stab  $\frac{1}{4}$  inch incision is created over the lateral canthal area so that a suture can be placed grabbing a portion of the lateral orbicularis oculi and tacking it to the lateral orbital rim superior to the lateral canthus.



A



C

tear trough  
deformity

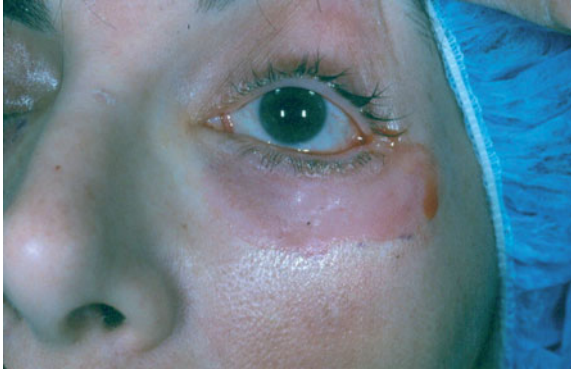
B

**FIGURE 11.7** **A.** Fat pedicles from the central and medial fat compartments remain attached and **B.** are moved into the tear trough deformity in a sub-orbicularis plane. **C.** The central fat pad is displaced into the submuscular plane of the tear trough deformity-nasojugal groove.

- A skin hook is used first to pull the skin over medially to help suture a portion of the lateral orbicularis oculi and pull the skin hook superiorly to help attach a periosteal suture to the lateral orbital rim.
- The result of this canthopexy suture is tightening of the lower lid.

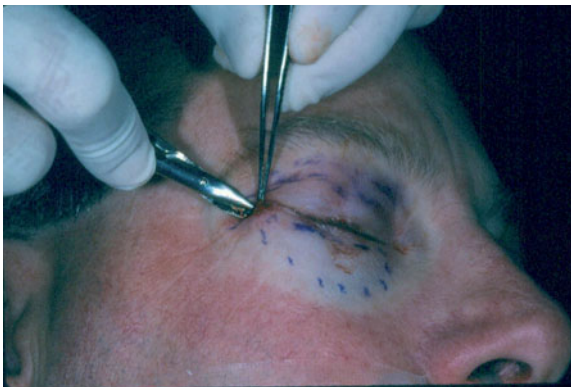## COMPLICATIONS

- Postoperatives not reported by the patient is the worst complication.
- Retrobulbar hematoma has the potential to damage the eye.



**FIGURE 11.8** Laser resurfacing is used to tighten the skin and improve wrinkles combined with a transconjunctival blepharoplasty

- Postoperative bleeding should be minimized by making sure the patient is off any aspirin products for 2 weeks prior to surgery.
- Nonsteroidal anti-inflammatories should be avoided for 1 week prior to surgery.
- Bleeding vessels should be carefully cauterized.
- Patients should report any increase in pain since it could be caused an expanding hematoma.
- Patients are called the night of surgery and usually examined the day after surgery.



**FIGURE 11.9** A canthopexy with a 5-0 absorbable suture grabs lateral canthal orbicularis muscle and tacks it to superior orbital rim so that there is lower lid tightening

- The most common complaint after a lower lid blepharoplasty is delayed improvement due to swelling and delayed skin tightening.
- A pinch excision and canthopexy can result in temporary bunching of tissue over the excision line.
  - This may require steroid injection.
  - Or, it will resolve with time.
- Bruising of the conjunctiva and skin are often seen after a lower lid blepharoplasty. The bruising will always resolve with time.
- Inadequate fat removal of the lateral fat compartment and fat not taking in the tear trough deformity are possible complications.

### SUGGESTED READING

1. Hamra ST. The role of orbital fat preservation in facial aesthetic surgery: A new concept. *Clin Plast Surg* 1996;23:17–18.
2. Mendelson BC. Fat preservation technique of lower-lid blepharoplasty. *Aesthetic Surg J* 2001;21:450–459.
3. Flowers RS. Tear through implants for correction of tear trough deformity. *Clin Plast Surg* 1003;20:403–408.
4. Loeb R. Fat pad sliding and fat grafting for leveling lid depressions. *Clin Plast Surg* 1981;8:757.
5. Codere F, Tucker N. Eyelids - Cosmetic Blepharoplasty and Browplasty. Yanoff: *Ophthalmology*, 1st edn. Mosby, 1999, Section 7.8.7.
6. Coleman SR. Facial contouring with liposculpture. *Clin Plast Surg* 1997;24:347.
7. de la Plaza R., Arroyo JM. A new technique for treatment of palpebral bags. *Plast Reconstr Surg* 1988; 81:77.
8. Goldberg RA, Edelstain C, Shorr N. Fat repositioning in lower blepharoplasty to maintain infraorbital rim contour. *Facial Plast Surg* 1999;15(3):225–229.
9. Kawamoto HK, Bradley JP. The tear ‘trough’ procedure: transconjunctival repositioning of orbital unipedicled fat. *Plast Reconstr Surg* 2003;112:1903–1907.
10. Goldberg RA, Yuen VH. Restricted ocular movements following lower eyelid fat repositioning. *Plast Reconstr Surg* 2002;110(1):302–305.
11. Goldberg RA. Transconjunctival orbital fat repositioning: transposition of orbital fat pedicles into a subperiosteal pocket *Plast Reconstr Surg* 2000;105:743–738.

## CHAPTER 12

# Upper Lid Blepharoplasty

Ron Moy, MD

### KEY POINTS FOR SUCCESS

- Management of patient expectations including
  - modest results and
  - potential complications.
- Avoidance of aspirin and NSAIDs prior to surgery.
- Careful anesthesia, including having additional lidocaine readily available for anesthetization of the fat pad after it has been dissected.
- Careful hemostasis.
- Avoiding excess tension on closure.

### INDICATIONS

- The upper lid blepharoplasty creates a more visible younger upper eyelid platform by excising excess crinkly skin and less importantly by removing fat or muscle.
- The need for a brow lift can sometime correct the lateral hooding that most patients complain about so that a brow lift with an upper lid blepharoplasty will give maximum correction of the lateral hooding.
- The main indication for an upper lid blepharoplasty is excess upper eyelid skin especially of the lateral upper eyelid with minimal brow ptosis (Fig. 12.1).
  - This skin can be crinkled and thin and so the excess removal may improve the appearance by removing the crinkled skin and by allowing more of the upper eyelid to be visualized.
  - Some patients will want a more prominent upper eyelid crease, especially Asian patients.

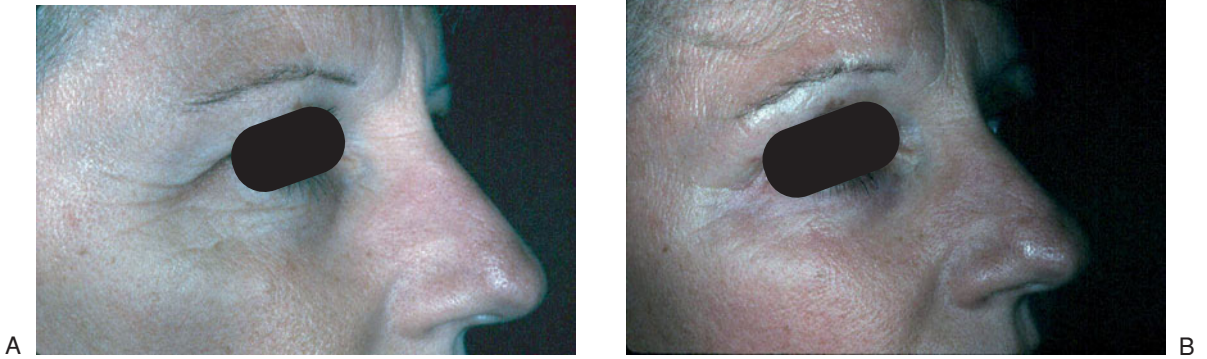
### PREOPERATIVE CONSULTATION

- Visualization of the brow ptosis component by the physician pulling up on the lateral brow shows the patient what a brow lift will do in combination with an upper eyelid.
- Blepharoplasty complications should be explained.

- Pre- and postoperative photos should show only a modest improvement in visualizing the upper eyelid.
- Patients should be warned that postoperative bleeding can have terrible complications.
- Patients should be informed that avoiding aspirin products for at least 2 weeks prior to the procedure can decrease the chance of bleeding.
- Patients should be informed that avoiding nonsteroidal anti-inflammatory 2 days prior to the procedure will also limit bleeding.
- The risks and benefits of an upper eyelid blepharoplasty include asymmetry, cyst formation and granulomas, and not being able to close the eye due to excess skin removal.
- The patient may require least 2 weeks before the eye looks presentable.

### PREOPERATIVE PLANNING AND MARKINGS

- The markings used for an upper eyelid blepharoplasty (Fig. 12.2) is determined by
  - the amount of skin to be excised,
  - the race of the patient, and
  - the natural upper lid crease of the patient.
- The excised skin is marked as an ellipse with the angle toward the medial canthus being narrow and lateral canthal side being a larger angle (Fig. 12.3).
  - The markings are usually made with small dots to maximize precision and to minimize smearing of the markings.
  - The ellipse is wider on the lateral canthal side to improve the lateral hooding that usually exists (Fig. 12.4).
- The lower incision marking is placed within the natural crease extending up to the medial canthal area out to the lateral canthus.
- Discuss with the patient that more lateral hooding can be improved if we extend the incision farther laterally into the crow's feet lines, but that this incision line could be slightly visible for months.

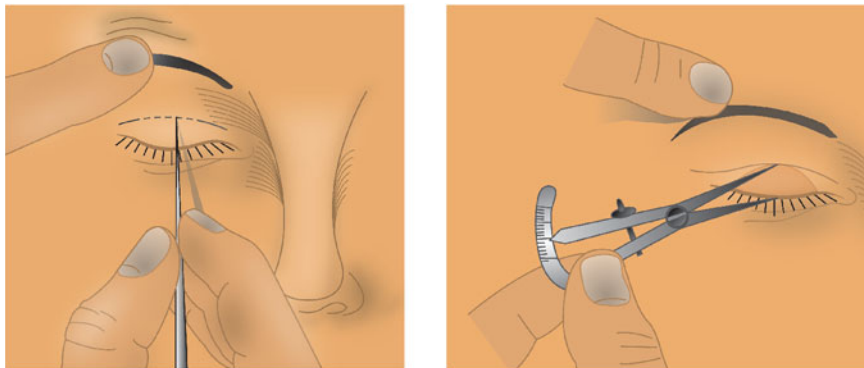


**FIGURE 12.1** Upper lid blepharoplasty removes excess upper eyelid skin. **A.** Presurgical photograph. **B.** Postsurgical result

- The lower incision marking is usually about 8–10 mm above the upper lid in Caucasian woman (slightly less in men) and 4–5 mm above the lid margin in Asians.
- The upper eyelid incision marking is decided by pinching the skin with Adson forceps and making a surgical judgment on how much skin can be safely excised and still allowing the eye to close (Fig. 12.5).
- If there is excess tension on the closure, the brow could be pulled down and the patient really needs a brow lift combined with an upper eyelid blepharoplasty.

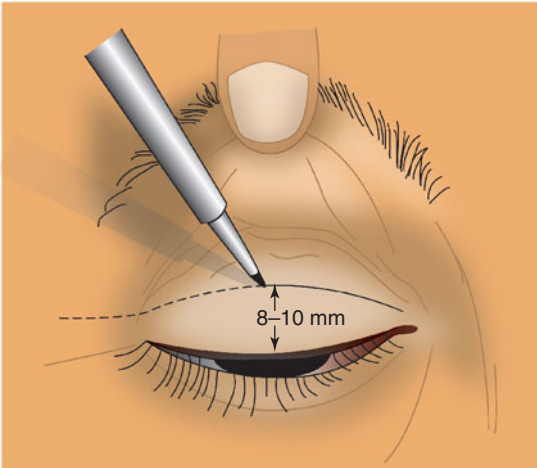
## ANESTHESIA

- Anesthesia is usually accomplished under local anesthesia with 1% lidocaine and epinephrine if this is a solitary procedure.
- This is a procedure that is easily performed under local anesthesia (although some patients may want conscious sedation).
- Anesthetize the entire upper eyelid area via one needle stick so that bruising is minimized (Fig. 12.6).



**FIGURE 12.2** The incision markings are made with small dots in the natural crease of the upper eyelid. This natural crease is usually about 8–10 mm above the lid



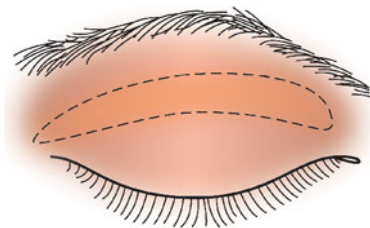


**FIGURE 12.3** The natural crease is marked. An ellipse is drawn with the natural crease as the lower part of the ellipse

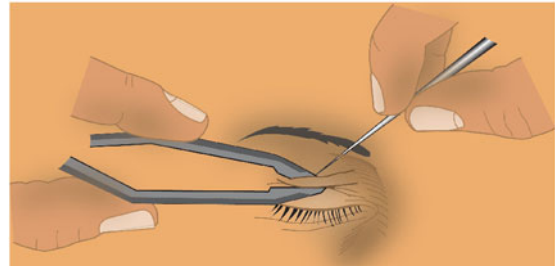
- Wait at least 10 minutes so that the lidocaine spreads and the epinephrine can decrease the amount of bleeding.
- Anesthesia may need to be added within the fat pad and so it is helpful to have some local anesthesia in a sterile syringe on the surgical tray for lidocaine administration by the surgeon in a sterile fashion after the excision of skin is accomplished.

## INCISION

- The incision is carried out with a sharp Persona #15 blade through the skin down to orbicularis muscle.



**FIGURE 12.4** Draw ellipse to include lateral hooding

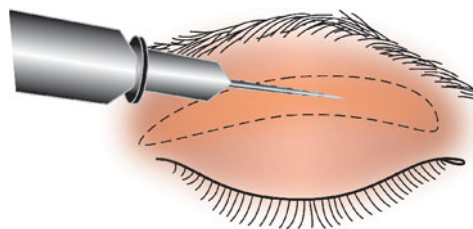


**FIGURE 12.5** The upper eyelid can be pinched with forceps to help judge how much skin can be excised

- After skin is excised, hemostasis is achieved with electrocautery.
- A carbon dioxide laser or electrocautery with a sharp needle can be used to remove skin and to minimize bleeding of the skin edges.
- The disadvantage of using these devices is that the wound healing may be delayed and a hypopigmented incision line may result.
- It would be rare to have much scarring with any technique or device since the eyelid skin is so thin and thus the results are almost always invisible scars.

## FAT AND/OR MUSCLE REMOVAL

- Sometimes fat or muscle need to be removed.
- If the patient has just crinkly excess skin without fat bulging and there is no need to define the upper eyelid crease, then the simple blepharoplasty is to remove only the skin.



**FIGURE 12.6** Anesthesia via one needle stick will minimize bruising

- If excess fat or muscle is removed the patient can have overly sculpted, hollowed look.
- There are now many patients who require no fat or muscle removal, but just skin removal.
  - This type of blepharoplasty will look more natural with more of the upper eyelid being visible but not the overly sculpted eyelid that has been called the superior sulcus syndrome.
  - The results may be more modest and natural than when muscle and fat are aggressively removed.
- Some patients can be helped by a more defined upper eyelid crease requiring modest muscle and fat removal.
  - If orbicularis ocular muscle is removed, it is important to remove a thin strip of muscle in the upper half of the wound so that any chance of damage to the levator aponeurosis is minimized (Fig. 12.7).
  - A thin conservative strip of orbicularis oculi muscle should be removed with tenotomy scissors. This removal of muscle helps create a more defined eyelid crease.
  - The amount of muscle and fat removed would be greater when operating on an Asian eyelid requiring the creation of a defined crease.
  - After the strip of muscle is removed fat may project above the surface of the orbicularis muscle or many times the surgeon will need to use Tenotomy type

scissors to poke a little hole through the underlying fascia below the muscle to expose fat (Fig. 12.8).

The preoperative analysis should determine where and how much fat should be removed.

Many patients will have more fat laterally or medially so that fat removal will be concentrated in these areas.

Laterally, the tear gland could be mistaken for fat although it does not appear as yellow globs, but less yellowy and firmer (Fig. 12.9).

The fat will need to be anesthetized prior to removal. There should be very little tugging or pulling on the fat to decrease the chance of bleeding.

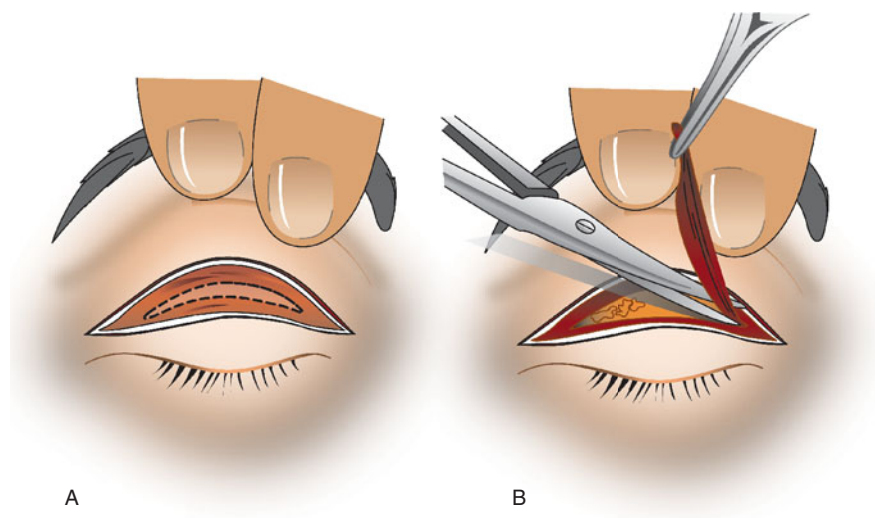
The fat is usually cauterized away with visible shrinking of fat seen.

Clamping of fat was taught as a technique of fat removal; however, this may create more pulling on the fat, which could lead to bleeding and a possible retro bulbar hematoma.

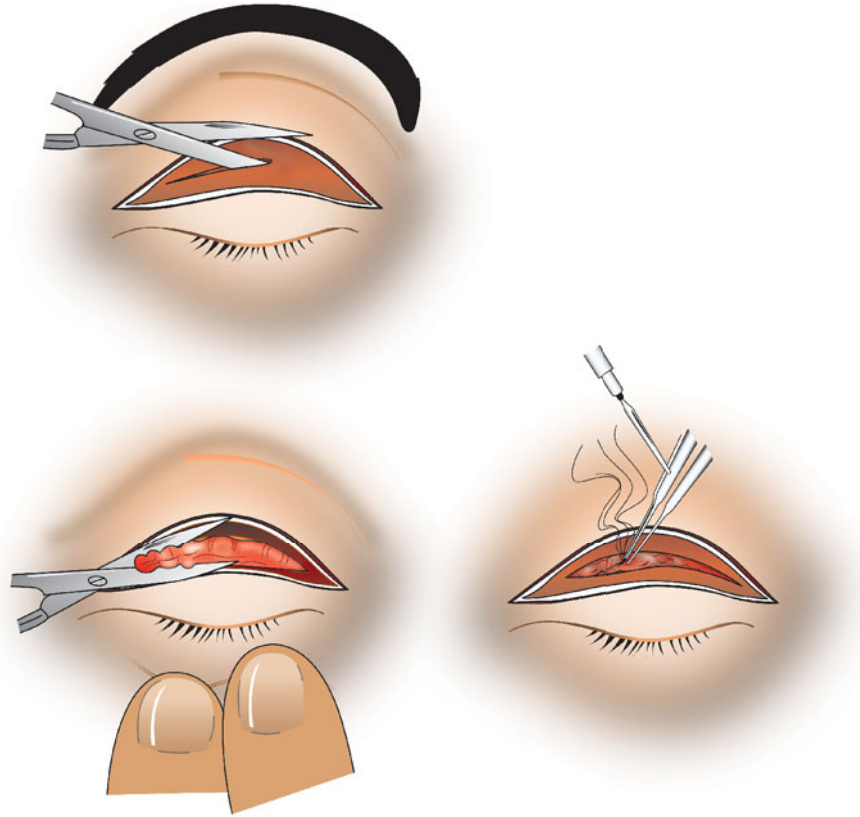
The fat should be removed very gently so that the chance of bleeding is minimized.

## CLOSURE

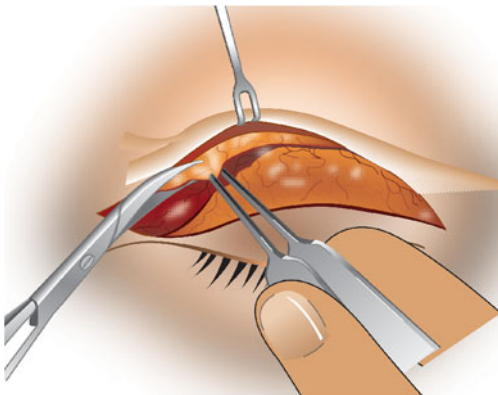
- Use a buried 5-0 or 6-0 Vicky or Dixon on the lateral canthal side since this is where most of the tension across the wound exists.



**FIGURE 12.7** Removing a strip of orbicularis muscle will help recreate the eyelid crease



**FIGURE 12.8** The orbital septum is opened with tenotomy scissors dissecting into the bulging fat areas. Exposed fat is vaporized with electrocautery



**FIGURE 12.9** Avoid lacrimal gland in the lateral upper opening by looking for prolapsed tissue that is not as yellow as fat

- Use one of these buried sutures to relieve lateral wound tension.
- Follow the one buried suture by using running 6-0 fast absorbing gut so that sutures do not have to be removed.
- Some lagophthalmos (1–2 mm) where the eye does not close is permissible postoperatively because of the swelling created by the anesthesia and surgery.

### POSTOPERATIVE CONSIDERATIONS

- The main worry for any blepharoplasty patient is to make sure that bleeding does not occur, which could lead to a retro bulbar hematoma and eye damage.
- Patient should be called the night of surgery to make sure that there is no complaint of excess pain as that could be a sign of increased pressure from a hematoma.

- A patient complaining of pain should be examined and the possibility of opening up the wound to find any bleeding vessel be entertained.
- A patient may need to be examined to make sure that any lagophthalmus has resolved.
- Swelling can peak at 48 hours after the procedure and so the patient should be warned about the possibility of the lids being swollen shut.
- Asymmetry may be noted; however, it is usually due to swelling that has occurred greater on one side or another.
- Place wound closure tape over the fast absorbing gut sutures so that the patients do not see the wound since they leave this on until one of their postoperative visits around postoperative day 3 to day 7.
- Scarring or milia type bumps of the incision line can be treated with dilute intralesional steroids.
- Upper eyelid scarring will always resolve or markedly improve with time.
- Patients complain of not enough skin being excised. This is usually due to brow ptosis requiring a forehead lift.

## COMPLICATIONS

---

- Late complications of an upper lid blepharoplasty are uncommon.

## SUGGESTED READING

---

1. Bosniak S. Reconstructive upper lid blepharoplasty. *Ophthalmol Clin North Am* 2005;18(2):279–289.
2. Collins PS. Upper lid blepharoplasty with skin, muscle and fat excision. In: Moy RL, Fincher EF, eds. *Blepharoplasty*. Elsevier Press, 2006, Ch 4, pp. 37–52.
3. Gentile R. Upper lid blepharoplasty. *Facial Plast Surg Clin North Am* 2005;13(4):511–524.
4. Eremia S, Willoughby MA. Upper lid blepharoplasty with maximal hooding correction. In: Moy RL, Fincher EF, eds. *Blepharoplasty*. Elsevier Press, 2006, Ch 4, pp. 37–52.

# CHAPTER 13 Forehead Lift

Ron Moy, MD

## KEY POINTS FOR SUCCESS

- Management of patient expectations including
  - moderate results,
  - need for a bone screw in temporal brow lifting, and
  - potential complications.
- Careful planning of the vector of lift.
- Careful and gentle undermining to prevent nerve damage.

## INDICATIONS

- Temporal brow forehead lift, pretrichial forehead lift, the endoscopic forehead lift or coronal for upper eyelid heaviness, which cannot be corrected with upper lid blepharoplasty
- Upper eyelid heaviness caused by brow ptosis.

## TYPES OF FOREHEAD LIFT

Types of forehead lift vary with

- placement of the incision,
- the plane of dissection, and
- type of fixation.

### ■ Coronal Forehead Lift

- Largest incision
  - Almost from ear to ear behind the hairline.
  - Dissection of the forehead down to the brows and corrugator muscles.
- Most dramatic lifting results, but carries risk of
  - alopecia,
  - numbness, and
  - unnatural appearance when mid forehead is pulled greater than the lateral brows where more ptosis usually occurs.

### ■ Pretrichial Forehead Lift

- Incision is at the hairline: Ideal in patients with large forehead since some of the forehead will be excised.
- Second most dramatic forehead lifting results, but carries risk of visible scar when hair pulled back. This may be minimized when the incision is beveled so that hair grow through the hairline.

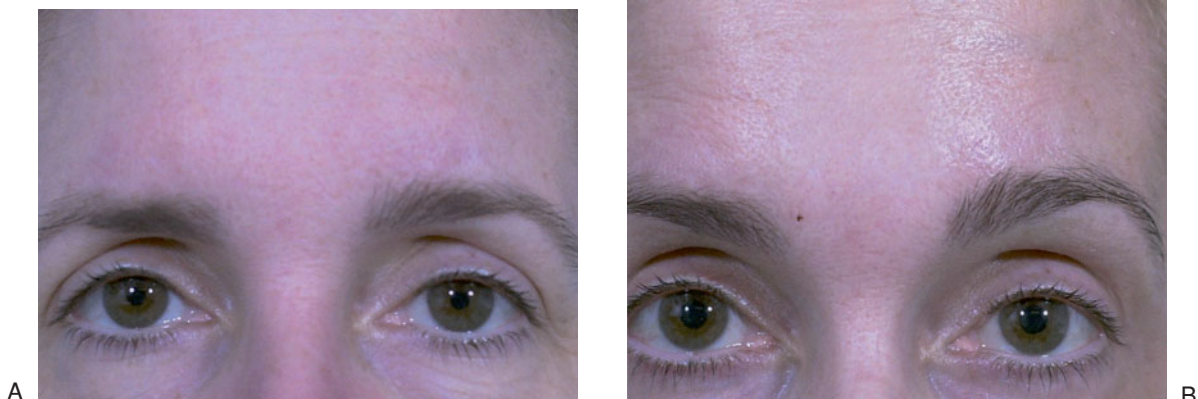
### ■ Temporal Brow Lift

- Minimal incision: Same as endoscopic brow lift, but without using endoscope.
- Corrects lateral eyelid heaviness by lifting the lateral brow (Fig. 13.1)
  - Without endoscope, bleeding is still minimal but with careful dissection and release of forehead-brow area.
  - With endoscope, blood vessels can be visualized thus minimizing bleeding.
  - Minimal complications.

## PREOPERATIVE CONSULTATION

The main issues are as follows:

- Patient expectations
  - modest correction of brow ptosis;
  - actual results and longevity of results;
  - placement of a bone screw, which remains in place for 2 weeks vs. just suture fixation.
- Potential complications
  - Damage to the temporal branch of the facial nerve, although this must be a rare event since all undermining is beneath this nerve.
  - Slight trauma to the nerve, swelling, or traction on the nerve could account for a temporary temporal nerve injury that resolves.
  - Infection
  - Scarring
  - Alopecia
  - Bleeding



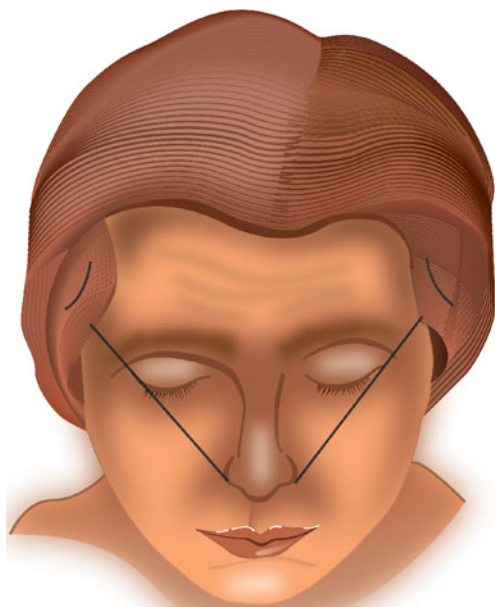
**FIGURE 13.1** Temporal browlift can improve the lateral hooding without a upper blepharoplasty and any obvious incisions on the upper eyelids

### INCISION

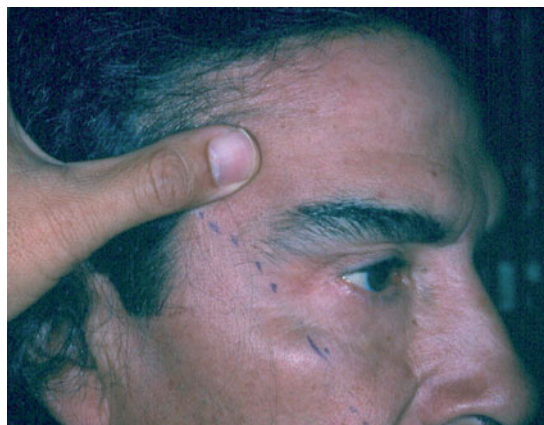- A 1-cm incision is placed at least 5 mm behind the temporal hairline to hide the incision.
- To maximize lifting, the incision is placed in the vector of pull, which is usually in a line starting from the cor-

ner of the lateral nose where the melolabial fold intersects through the lateral canthal region to the temporal hair area (Fig. 13.2).

- The incision can also be placed both perpendicular to the vector of pull and parallel to the nasal labial fold.

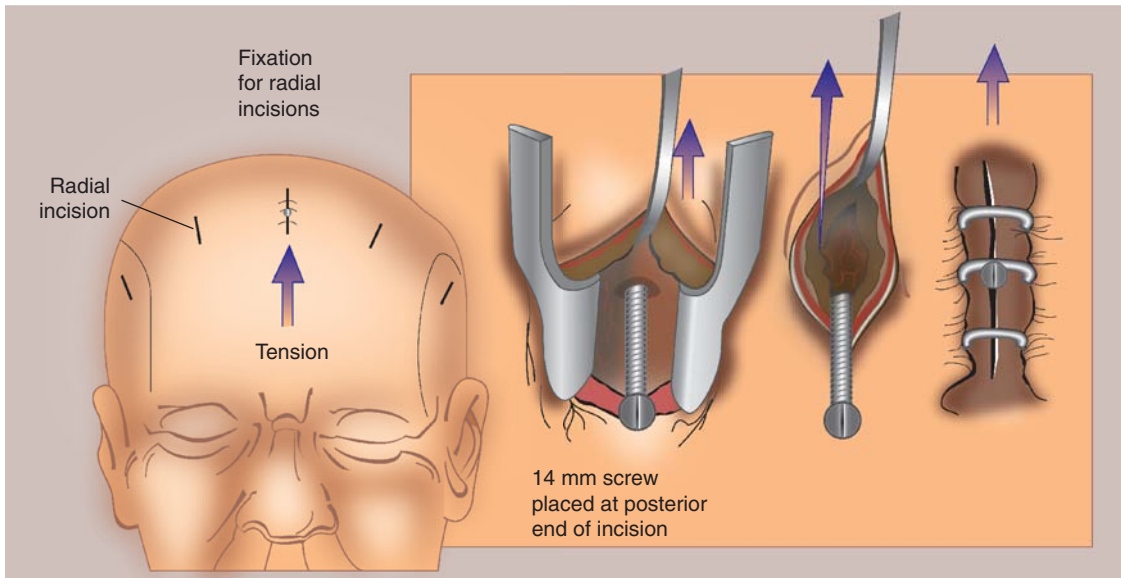


A



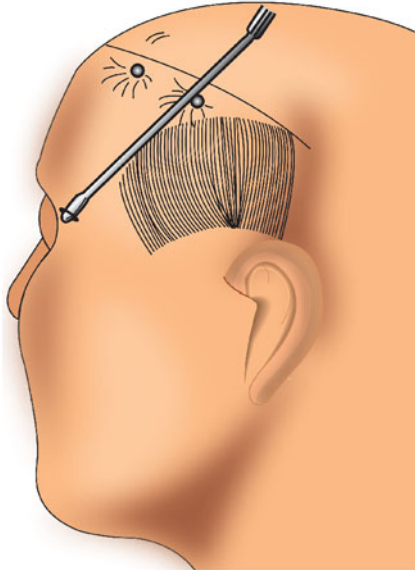
B

**FIGURE 13.2** Temporal browlift incision and vector of lift



**FIGURE 13.3** Bone screw and staple fixation places a screw behind a staple perpendicular to the temporal browlift so that the incisions are smaller but requires a screw to protrude above the skin surface for a couple of weeks

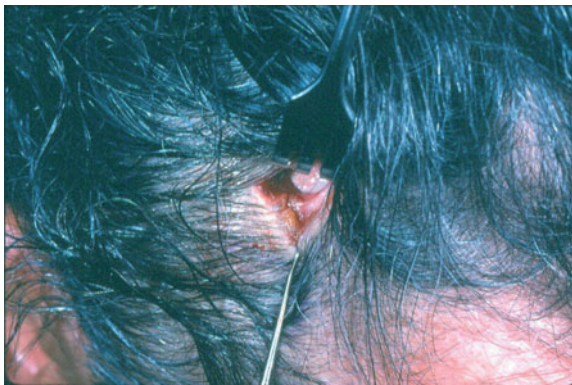- A small incision perpendicular to the nasal labial fold in the temple area is necessary when using a screw–staple for fixation (Fig. 13.3).
  - The bone screw is placed within the incision and the scalp is pulled back.
  - A staple is placed behind the screw to hold the scalp in place.
  - The other incision method is a 2-cm parallel incision with a small amount of skin excision and sutures to the temporal fascia is for fixation.
  - Suture placement can be difficult with the 1-cm minimal incision and so the incision may need to be extended.
  - The elliptical incision has the advantage of allowing more room to place the fixation sutures and allowing access for the undermining and brow release.
  - This temporal 1.5-inch incision can also be used to place the Endotine device or to place suture threads that pull up the mid-cheek fat.
  - For bone screw–staple fixation and suture fixation an “A to T” type incision is created, which allows both an elliptical excision and screw placement.
- ### UNDERMINING AND RELEASE
- Undermining occurs from the incision to the periosteal attachments below the eyebrow (Fig. 13.4).
    - The plane of undermining is over the deep temporal fascia to the periosteum of the orbit, which can be checked by making a nick over the white glistening fascia of the deep temporal fascia and seeing temporalis muscle (Fig. 13.5).
  - The undermining is carried out carefully under the temporal branch of the facial nerve to the periosteal attachments of the orbit.
  - Careful and gentle undermining will decrease any chance of damage to the nerve (Fig. 13.6).
    - A periosteal elevator is helpful especially to gently release the periosteal attachments.
    - A Metzenbaum facelift scissor can be used if the periosteal attachments are released gently.
  - Undermining across the forehead will include the fascial sheath that divides the middle forehead from the temporal forehead that needs to be released and separated.



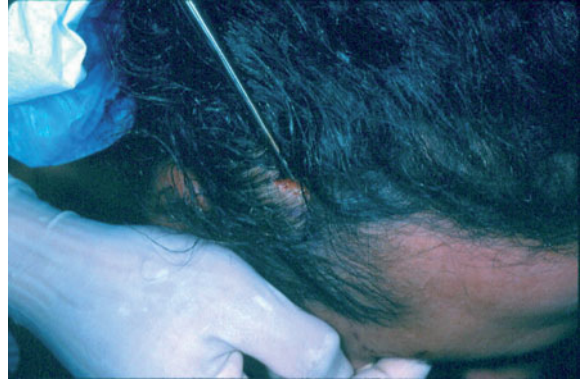**FIGURE 13.4** The most important part of a temporal browlift is the release of fibrous attachments under the eyebrow with a periosteal elevator and not the excision of skin

## FIXATION

- Fixation of the brow can be accomplished with sutures, a screw, and a dissolving needle device (Endotine) (Fig. 13.7).



**FIGURE 13.5** White glistening of deep temporal fascia above muscle



**FIGURE 13.6** A finger protects the glove and helps facilitate the release of attachments with a periosteal elevator

- The 1.5-inch incision placed behind the temporal hairline can be fixed with sutures to the deep temporalis fascia pulling in a superior direction.

A 0.25-inch small incision perpendicular to this incision can be used to use the screw–staple fixation, which will stay in place for 2 weeks (Fig. 13.3).

Botox is also used to immobilize the area and achieve better fixation.

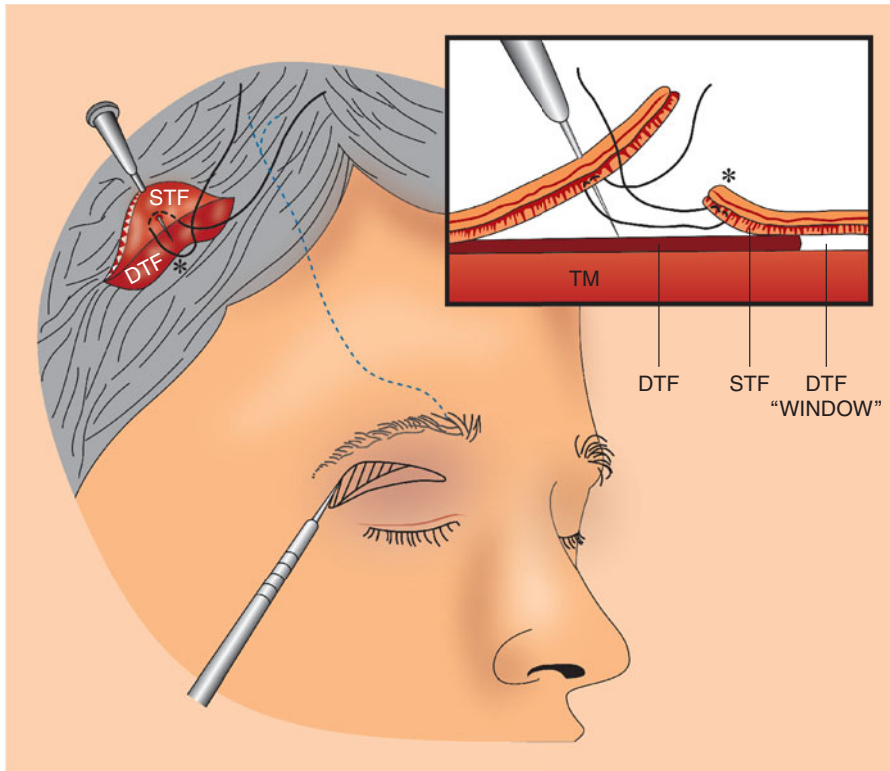
- The Endotine device placed at the forehead hairline can be an effective quick method that allows the skin to be draped superiorly over the device that has been fixated to bone.

The main disadvantage of this device is its cost and that this palpable device under the skin lasts for many months.

## COMPLICATIONS

- The chance of complications with this procedure is minimal.
- The most severe complications may be the following:
  - Permanent damage to the temporal branch of the facial nerve, which is rare.
  - Alopecia at the incision site is possible.
  - Modest results are sometime achieved compared to the coronal lift, which gives maximum results with a large incision, and sometimes does not give a natural appearance because the maximum pull can be above the middle glabella area.





**FIGURE 13.7** Fixation of the elevated brow lifted skin and superficial temporalis fascia (STF) to the deep temporalis fascia (DTF)

## SUGGESTED READING

1. Langdon RC. Endoscopic Brow Lifting. In: Moy RL, Fincher EF, eds. *Blepharoplasty*. Elsevier Press, 2006, Ch 4, pp. 37–52.
2. Knize D. Limited-incision forehead lift for eyebrow elevation to enhance upper blepharoplasty. *Plast Reconstr Surg* 1996;97(7):1334–1342; *Plast Reconstr Surg* 2001;108(2):564–567.
3. Troilius C. Subperiosteal brow lifts without fixation. *Past Reconstr Surg* 2004;114(6):1595–1603.

*This page intentionally left blank*

## CHAPTER 14

# Minimal Incision Face-Lift and Face-Lift

Ron Moy, MD

### KEY POINTS FOR SUCCESS

- Management of patient expectations including
  - complications and
  - with minimal incision face-lift the neck improvement is not quite as good as with traditional face-lift.
- Maintaining a vertical vector of pull throughout the procedure.
- Careful homeostasis and avoidance of bleeding through the use of tumescent anesthesia and electrocautery.
- Use of undermining scissors separated in a vertical, rather than horizontal, direction.
- Careful undermining in the temple region to avoid nerve damage.
- Use of multiple superficial plication sutures.
- Careful trimming of excess skin that is pulled in the vertical direction.

### INDICATIONS

- Jowls and neck sagging (Figs. 14.1 and 14.2)
- Desire to improve appearance of the lower third of the face with a minimal incision face-lift or a regular face-lift (Fig. 14.3).
- In a traditional face-lift, the incision is made behind the ear and there is a possibility of scarring, which can be noticeable for patients with short hair.
- In a minimal incision face-lift, the incision begins with a trichophytic temporal incision extending retrotragal and ends at the earlobe accomplishing excellent results for the mid-cheek area, along the jawline and even the neck if the vector of pull is more vertical instead of the sideways pull.
- This newer face-lift has the advantage of a smaller incision line, more natural result, and not causing the scar behind the ear.

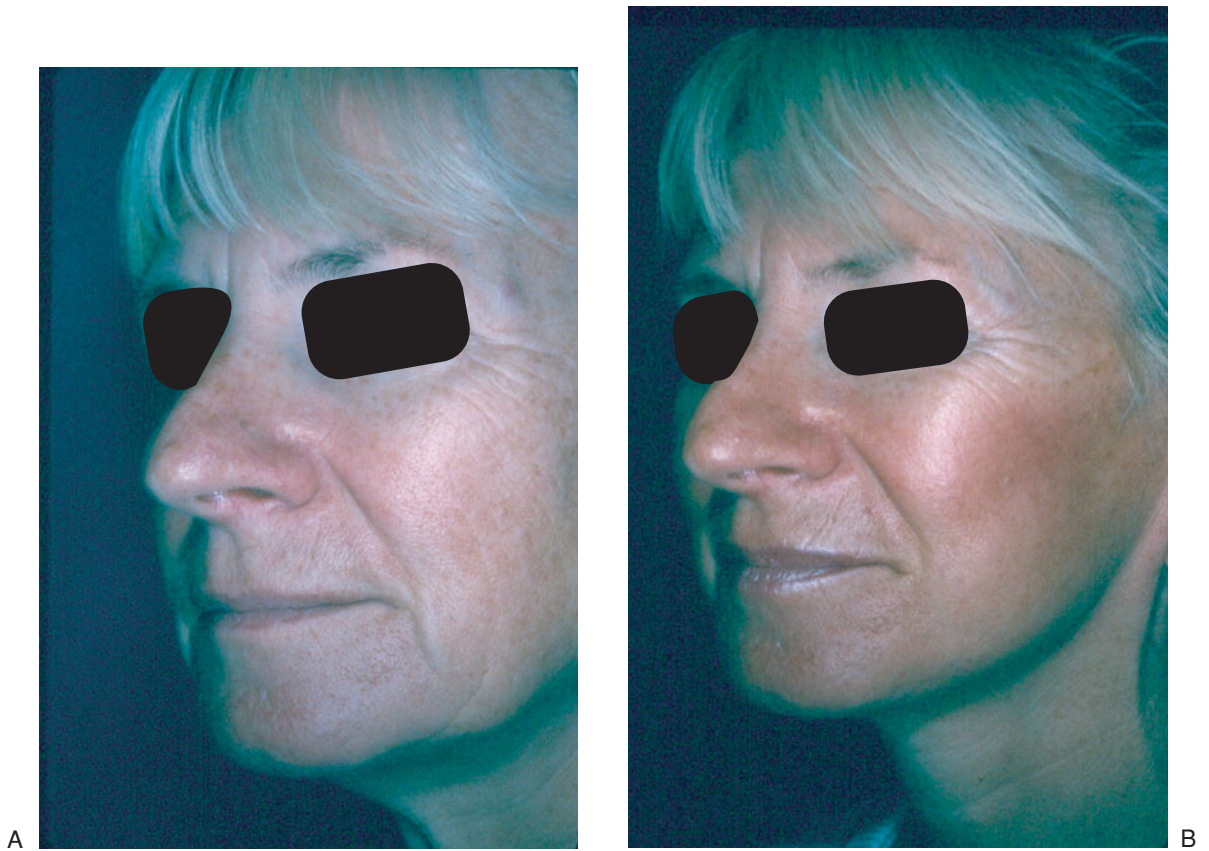
- The neck improvement is not quite as good as the conventional face-lift with the incision behind the ear, but significant improvement can be achieved.
- The results are always more significant than with any of the suture thread lifts.

### PREOPERATIVE CONSULTATION

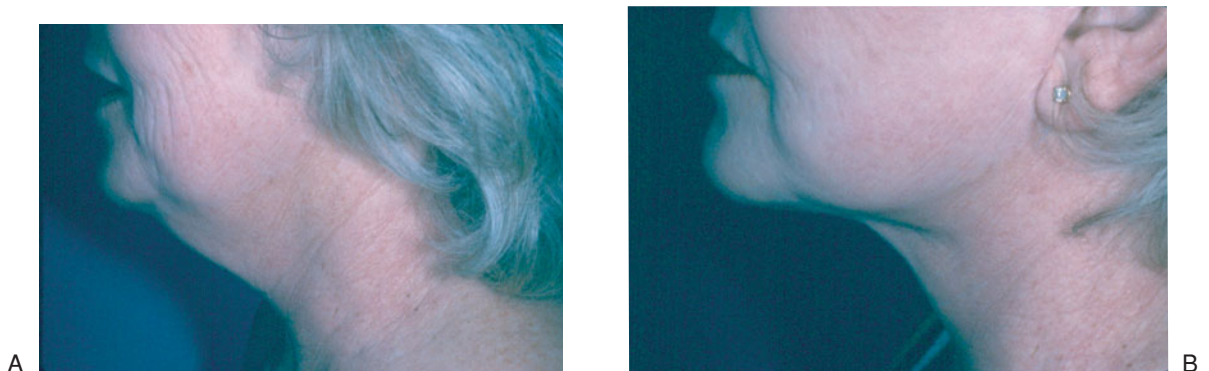
- Listen to the patient's wants and concerns and analyze what can be done for the patient.
- Establish a rapport with patients by educating them on the procedures and discussing all the pros and cons.
- Photographs of typical face-lift patients may be helpful.
- A slight pull of the skin in a vertical vector may also simulate the face-lift results.
- Risks and benefits should be described including the risks of
  - infection
  - bleeding
  - scarring
  - nerve damage
- A second consultation is suggested so that good communication can be established between the physician and the patient. A detailed description of the possible complications can be discussed during this time, including discussion of the actual consent form.
- Different types of face-lifts can be discussed, including the methods of
  - SMAS (superficial muscular aponeurotic system) tightening,
  - the incisions to be made, and
  - alternative procedures.
- The type of anesthesia, i.e., whether local anesthesia or local anesthesia with twilight sedation (Versed and Propofol), should also be discussed.

### INCISION

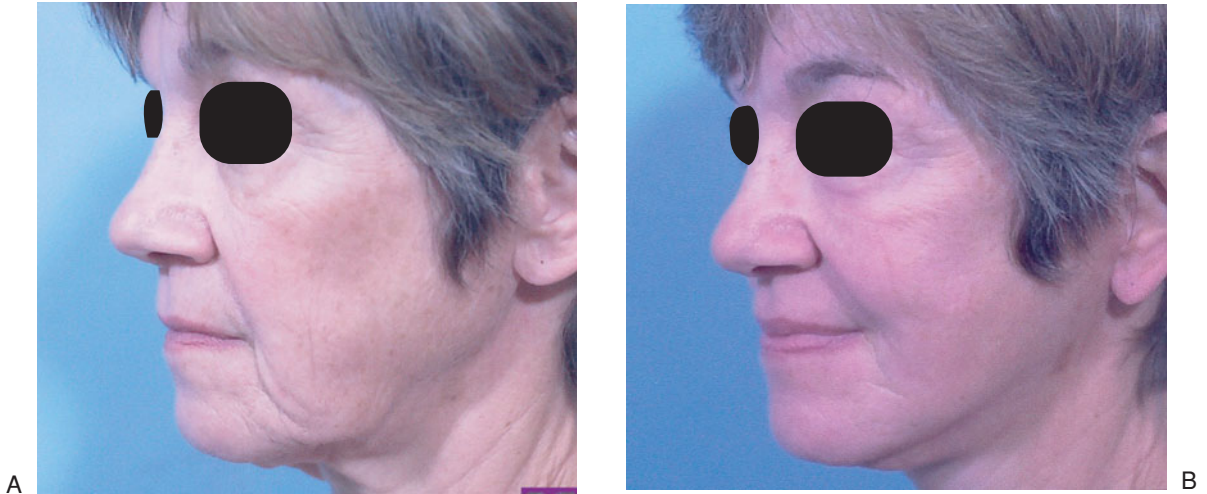- Incisions can be tailored to a patient's needs, but the most common is a temporal incision 2 mm behind the hairline so that mid-cheek and neck elevation can be achieved (Fig. 14.5).



**FIGURE 14.1** **A.** Preoperative and **B.** postoperative photos show that S-Lift gives jowl improvement and some neck improvement



**FIGURE 14.2** **A.** Preoperative and **B.** postoperative photos show improvement of a heavy neck accomplished with a postauricular incision that extends to the hairline behind the ear. A heavy neck such as in this patient makes improvement more difficult

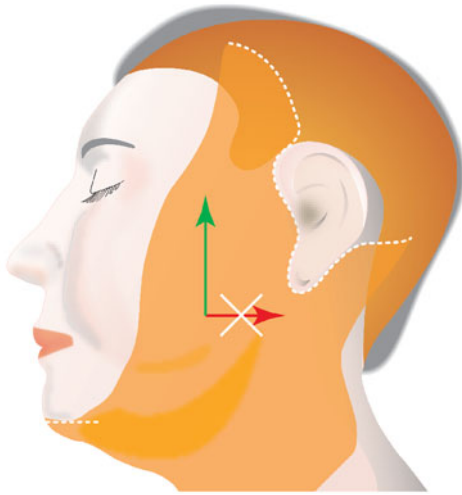


**FIGURE 14.3** **A.** Preoperative and **B.** postoperative photos show improvement of the jowls and neck with an S-Lift vertical minimal incision lift. There is less improvement of the neck than a full-face-lift with an incision behind the ear and into the hairline. Mid-face-lifting of the malar fat pad will improve the eye area, including giving the improvement of the jowls and modest improvement of the neck area

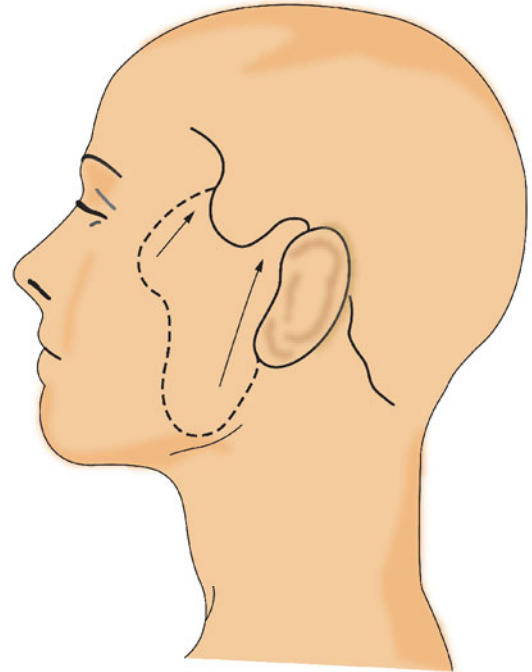
- The advantage of the temporal hairline incision is that the hairline is not altered, which can often cause the stigmata of obvious cosmetic surgery.
- The incision should be beveled in a 45° angle and in a zigzag fashion so that any dog-ear and scar is minimized.
- A temple zigzag incision will decrease any dog-ear formation in the temple area.
- The beveled incision will also allow hair to go through any scars.
- The incision then is carried down to behind the tragus and down to the earlobe without beveling.
  - A retrotragal incision hides the incision better, although care needs to be taken not to distort the tragus.
  - Sometimes the incision is carried behind the ear to remove a dog-ear; however, if the vector of pull is more vertical, the dog-ear is minimal and the neck improvement is maximized.
  - If the incision is extended to the postauricular area, it should be placed onto the back surface of the ear instead of into the postauricular sulcus.
- This extension is carried high above the level of the auditory canal so that the scar across to the hairline will not be seen.
- The incision is then carried to the hairline with a beveled incision, which can allow a vector of pull that improves the neck region.
- The other incision that can improve the neck is a small submental incision in the submental crease. With this incision, the platysma separation and banding can be tightened, subplatysmal and platysmal fat can be removed, and the neck skin can be redraped.
- An incision near the postauricular sulcus actually over the cartilage portion of the ear (so that after suturing the incision scar will fall into the postauricular sulcus) and then extending high on the postauricular sulcus and extending down into the neck hairline is used to give more of a neck-lift. This post-auricular incision will allow more of a posterior pull to the neck.

## UNDERMINING

- Undermining needs to be carried out in the best plane so that the flap created is of sufficient thickness and bleeding is minimized (Fig 14.6).
- Bleeding can be minimized with the use of tumescent anesthesia so that a natural separation occurs.
  - This natural separation can also be created by using undermining scissors separated in a vertical



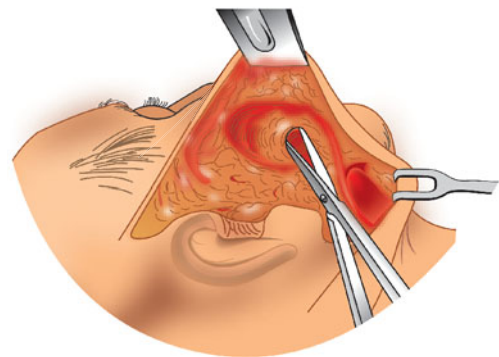
**FIGURE 14.4** Rejuvenation of the face requires elevation of the SMAS, malar fat, submental tissue, and skin. A vertical vector provides superior “lifting” compared with a posterior or horizontal vector



**FIGURE 14.5** Vertical minimal incision S-Lift. The incision extends around the temporal hairline, the retro-tragal incision down to the earlobe. Three purse string sutures are used to vertically lift the SMAS and the malar fat pad. Care must be taken so that these purse string plication sutures do not damage the facial nerve

direction instead of the more common horizontal separation.

- Another method to insure the proper flap thickness is to shine the overhead light through the flap so as to insure the flap “possesses” a uniform amount of fat.
- The incision at the retrotragal area needs to preserve the cartilage and create a flap of adequate thickness.
- The incised flap than is undermined about 6 cm away from the incision.
- The amount of undermining needs to extend a distance away from the skin edge at so that plication sutures can be placed.
- The undermining can be extended to the nasolabial fold, although this would be considered an aggressive procedure.
- Extending the undermining to the nasal labial fold does not seem to significantly improve the fold as much as using some type of mid-cheek fat plication or mid face-lift, which improves the nasal labial fold.
- Undermining in the temple area has to be done with caution because of the path of the temporal branch of the facial nerve or prominent blood vessels in this area.
- Hemostasis after undermining should be accomplished very carefully with bipolar electrocautery or



**FIGURE 14.6** Undermining should be done with the blades of the tenotomy scissors held vertically rather than horizontally

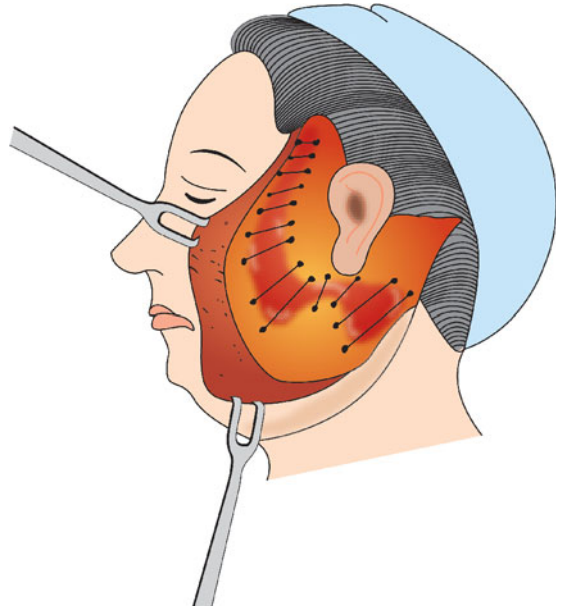
minimal light cautery (Monopolar Hyfrecator) so as not to damage any branches of the facial nerve.

- Tumescent anesthesia with a concentration of at least 1% lidocaine and epinephrine minimizes significant bleeding.

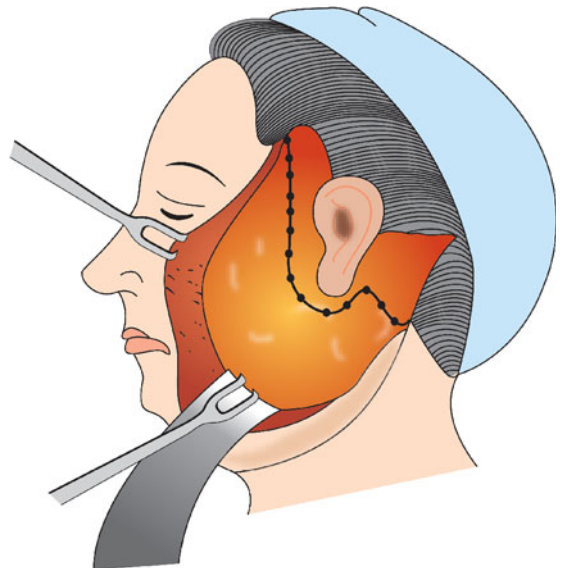
## PLICATION OF SMAS

The methods of tightening the SMAS include the following:

- Imbrications—incising into the flap and suture tightening.
- Using a technique that pulls up the mid-cheek fat with a suture or a suture thread will also give nasolabial improvement.
- Mastectomy—removing a strip of SMAS over the parotid and suturing the incised edges together.
  - A small 1-inch wide strip of the SMAS starting at the superior parotid and extending to the lateral cheek-mid face area is removed.
  - The two edges of the separated SMAS are then sutured together.
- Deep plane face-lifting—undermining deeply past the parotid area. Undermining of the SMAS into the mid-cheek and advancing it in a superior direction constitutes a deep plane face-lift.
  - This type of deep-plane face-lift was once thought to give more and longer lasting improvement of the nasolabial fold.
  - This nasolabial improvement has not been proven to be better with the deep-plane face-lift techniques compared to the plication techniques.
  - The deep-plane face-lift puts the facial nerve at more risk.
- Plication of the SMAS, which is suture tightening of the SMAS without incision into the SMAS.
  - The simplest method is to use multiple large interrupted 2-0 or 3-0 suture loops (Maxon, PDS or Ethibond) wherever there is SMAS looseness around the parotid area (Fig. 14.7).
  - The sutures encompass the loose SMAS and can be fixed to the stable tissue near the superior preauricular ear above the tragus.
  - The ideal vector of pull is in a vertical direction, which will improve the neck and the jowls (Fig. 14.8).



**FIGURE 14.7** Multiple plication sutures with 3-0 Maxon or Vicryl sutures lift and loosen SMAS. These plication sutures are best fixated on stable tissue near the ear and away from the path of the temporal branch of the facial nerve

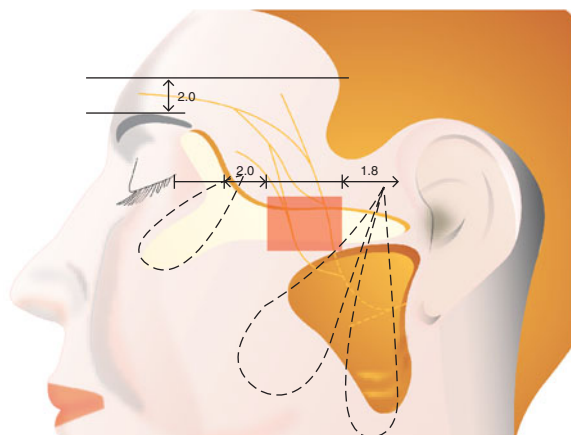


**FIGURE 14.8** Tightening of the plication sutures may tighten the SMAS as well as any deep plane face-lift according to many surgeons and paired comparison studies

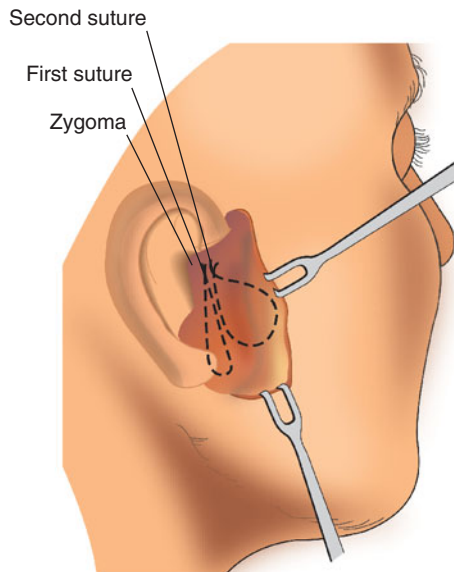
- Multiple plication sutures are the simplest and one of the safest methods of plication if the plication bites are kept superficial.
- Plication has also been described with the S-Lift and the minimal access cranial suspension lift (MACS-lift).

Once continuous purse string suture is placed, taking small bites starting from a superior pre-auricular position down to include platysma-SMAS, jowls or cheek fat or just SMAS and returning to a superior pre-auricular position and tightened. The suture is fixed to the deep temporalis fascia anterior, to the ear or below the zygomatic arch posterior to the path of temporal branch of the facial nerve. Three of the plication purse string sutures are used (Fig. 14.9).

- The first suture improves platysma ptosis.
- The second suture improves the lower jowls.
- The third suture is placed in the mid-cheek area and extends to a lateral canthal position avoiding the temporal branch of the facial nerve.
- This suture is anchored in the temporalis muscle fascia, lateral to the lateral orbital rim and anterior to the path of the temporal branch of the facial nerve.
- This suture or a suture thread provides improvement of the nasolabial fold and mid cheek areas.



**FIGURE 14.9** MACS lift: Two pursestring sutures are used to create a vertical pull on the SMAS and platysma of the neck. A third purse-string suture is used to elevate the malar fat pad to rejuvenate the midface



**FIGURE 14.10** Purse string plications sutures tighten the SMAS of the cheeks and the neck. These purse string sutures are fixated close to the ear on the zygoma so that interference of any branches of the facial nerve is minimized

Anchor sutures or suture threads can also be used to improve this mid-face area.

The use of a position on the inferior mid zygoma has also been advocated as a point of fixation since this is also a firm place with only a small chance of facial nerve injury (Fig. 14.10).

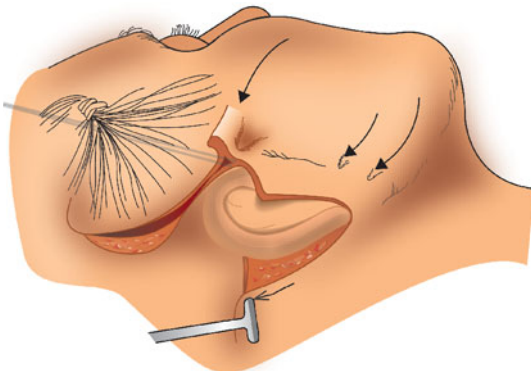
The disadvantage of using the zygoma periosteum to fixate the plication sutures is that it may more easily cross the facial nerve path and it is harder to fixate the suture to the tissue lying over the zygoma.

- With either of the plication techniques, the path of the facial should be drawn and the sutures should avoid the path and depth of the facial nerve that starts within the parotid gland and extends to the temple forehead area.
- Once the plication sutures have been placed, there is often dimpling of the skin that needs to be corrected by separating the skin from the underlying tissue with the undermining scissors.

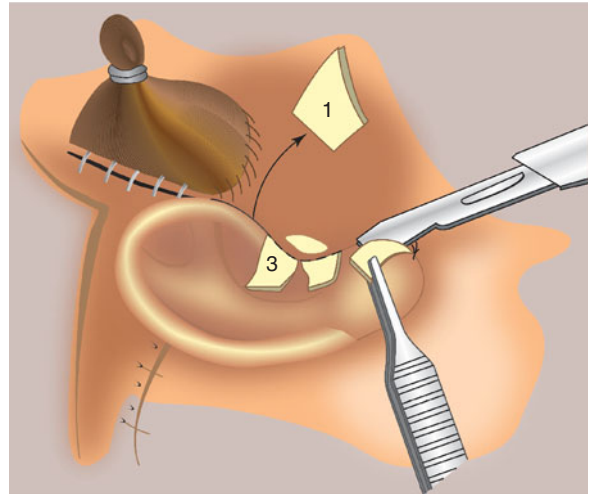


## TRIMMING OF EXCESS SKIN

- Trimming of excess skin can be the longest part of the procedure.
- The first step is to pull the skin up in a vertical direction so that the jowls and neck are improved.
  - This upward vector pull gives a more natural look than a sideways posterior vector pull and it also improves the neck.
  - The flap must be incised, trimmed, and finessed so that the tension across the wound is minimal yet improved results along the jowl-neck are achieved.
- A few staples can be used across the maximum tension points.
  - The first staple where tension occurs is above the ear (Fig. 14.11).
  - The skin flap is pulled in a superior direction and small amount of skin is excised to the point where the skin edges can be stapled with cosmetic improvement (Fig. 14.12).
  - This suture can have tension across it with the use of staples.
- Most face-lifts will relax over the first few months resulting in significant tension above the ear.
- Tension should be minimized across the tragus and earlobe.
- Buried sutures are used to take tension off the incision line and the skin edges are closed with 5-0 gut and buried with 4-0 sutures.
- It is best to start suturing at the superior end of the incision line (temple area) down to the earlobe area so that any dog-ears are minimized.



**FIGURE 14.11** First tension suture above ear



**FIGURE 14.12** Small incisions are followed by trimming of the excess skin

- If a dog-ear occurs, it can be repaired or removed behind the ear adjacent to the earlobe.
- This dog-ear removal of skin behind the ear maybe necessary in patients with excessive neck laxity.
- It is best to recreate the natural tragal contour by thinning the fat and dermis over the tragal cartilage and anterior to the tragus.
- Skin is rarely excised anterior to the tragus with the minimal incision face-lift.
- The natural earlobe without the “attached earlobe” appearance is created by not suturing the earlobe to the cheek skin. This issue should be discussed with the patient and observed prior to surgery to decide whether to suture the lobe to cheek skin or to let the earlobe heal naturally without attachment to the cheek skin.
- If the neck-lift is being added, the skin closure tension should be minimized using buried sutures.
- The skin flap tolerates less tension across the neck area than the face area. The flap is usually thinner with less subcutaneous fat in the postauricular neck area.
- It can be difficult to separate the skin from the underlying fascia and muscle in the postauricular area.

## ANCILLARY PROCEDURES

- Neck liposuction or platysmal tightening via a submental incision can create improved results. Platys-

mal plication is indicated in patients with significant platysmal banding when the face-lift has not improved banding.

- Laser resurfacing can be done at the same time as the face-lift.
  - The most common areas of laser resurfacing include the eye and lip areas.
  - The entire face can be resurfaced if resurfacing is done very conservatively, especially toward the edges of the flap.
- Pinch excision of the lower eyelid can be performed to improve infraorbital skin laxity. Pinch excision of the infraorbital skin may need to be performed when skin is pulled in a superior upward direction.
- Volume replacement is important to give natural-appearing results.
  - A tighter face does not always make a patient naturally looking younger.
  - Thin patients can benefit from fat or Sculptra injections into the mid cheeks.
  - Volume replacement will also give the mid-cheek area some lifting and rounding of the cheeks.
  - Volume replacement prevents any “wind tunnel appearance” where it appears the skin has been pulled too tight or pulled sideways.

## POSTOPERATIVE CONSIDERATIONS

- Considerable swelling and bruising can occur from any face-lift including a minimal incision face-lift.
  - It is hard to predict who will get such swelling.
  - A minimized pressure dressing around the face can prevent some of this bruising.
  - Drains are not necessary to prevent hematomas.
  - It has not been proven that the use of fibrin glues decreases the amount of bruising or hematomas.
- Patients should be seen after the procedure to look for any postoperative complications, such as hematomas.
- Facial nerve injuries are always a possibility but uncommon.

## COMPLICATIONS

- Complications from a face-lift are uncommon and rare.
- Risks of infection are very unlikely on the face because of the good blood supply.
- The chance of bleeding creating a hematoma can be decreased by making sure the patient has not been on any blood thinners and appropriate bleeding studies are performed.
 

Careful meticulous hemostasis with minimal cautery (so that the chance of nerve damage is minimized), careful dissection, and tumescent anesthesia all contribute to the least chance of a hematoma.
- Careful undermining with plication will have a low probability of any permanent nerve damage.
  - Unless the extremely deep bites of tissue are taken with the purse string plication sutures, the facial nerve will not be damaged.
  - Fixation of the periosteal suture outside of the path of the motor branches of the facial nerve will decrease the possibility of nerve damage.
  - If a patient is exhibiting unilateral motor nerve weakness, placcations sutures can be loosened or released.
- Skin necrosis is minimized with the creation of an adequate thickness flap and minimal tension. The full-face-lift is more likely to give necrosis because the postauricular flap is thinner and often is subjected to increased tension.

## SUGGESTED READING

- Brandy DA. The Quick lift: a modification of the S-Lift. *Cos Dermatol* 2004;17:351–360.
- Nobel A. *La Chirurgie Esthétique son Rolle Social*. Mason CIA, Paris, 1926, pp. 62–66.
- Nobel A. *La chirurgie Esthetique*. Claremont (Oise), Thiron et Cie, 1928.
- Tonnard PL, Verpaele AM. *The MACS-Lift. Short-Scar Rhytidectomy*. Quality Medical Publishing, St. Louis, MO, 2004.
- Moy RL, Fincher E, eds. *Advanced Facelifts*. Elsevier, 2006.

# SUBJECT INDEX

## A

Ablative lasers. *See* Aids and devices

Advancement flaps, 9

Aids and devices

ablative lasers, 91, 93–94

endovascular laser, 83f, 83t

forceps, 104

hair densitometer, 73, 74f

instrumentation, 74, 75t, 63f

tenotomy scissors, 104

Ancillary procedures, 125–26

Anesthesia, 35, 63–65, 75, 102

## B

Botox, 48

Brow lift, 49

## C

Candidate selection

for fat transfer, 69

for hair transplantation, 73

Cheek defects, 11f, 12, 15–16

Chemical peeling, 31–35

Chemical peeling, frequency of, 33, 35

Chemical peels, 31–36

Chin defects, 26

Clinical hyperpigmentation, 32–33

Closure, 110–11

Combination brow lifting, 49

Complications

ambulatory phlebectomy, 87t

botulinum injections, 54–55

dermasurgical procedures, 6

face-lifts, 126

fat transfer, 71

forehead lift, 116–17

hair transplantation, 79

liposuction, 67–68

lower lid blepharoplasty, 105–6

resurfacing lasers, 99

telangiectasia/reticular veins, 89

temporary dermal fillers, 44

upper lid blepharoplasty, 112

Considerations, postoperative. *See also* Postoperative course/care

face-lifts, 126

upper lid blepharoplasty, 111–12

Consultations, preoperative. *See also* Planning, preoperative

face-lifts, 119

forehead lift, 113–14

lower lid blepharoplasty, 101, 102f

upper lid blepharoplasty, 107

Contraindications

fat transfer, 69

hair transplantation, 73

initial patient consultation, 2, 4t

lasers, 91

liposuction, 57–58

temporary dermal fillers, 38–39

varicose and telangiectatic leg vein treatment, 81

Coronal forehead lift. *See* Forehead lift, types of Crow's feet, 51

## D

Depressor anguli oris/frown, 53–54

Dermal fillers, 37–44

Donor dissection, 76

Drug discontinuance guidelines, 3t

Dysport, 48

## E

Ear defects, 26, 28–30

Endovascular laser. *See* Aids and devices

Epidermal melasma, 32–34

Excess skin trimming, 125

Eyebrow defects, 10–12 (bis)

Eyelid defects, 12–15 (bis)

## F

Facial lipoatrophy, 38f

Facial musculature, 48–49, 50f

Fat and/or muscle removal, 103–4, 109–10  
 Fat transfer, 69–71  
 Fat transposition, 104  
 Filler selection, 40  
 Fixation, 116  
 Flap types, 9  
 Forceps. *See* Aids and devices  
 Forehead defects, 10  
 Forehead lift, types of, 113  
 Frown lines, 48

**G**

Glabellar complex, 44, 48, 51f  
 Graft preparation, 76  
 Gum show, 53

**H**

Hair densitometer. *See* Aids and devices  
 Hair removal, 94–95  
 Hair transplantation, 73–79  
 Horizontal forehead lines, 50–51, 52f  
 Hyaluronic acid, 37  
 Hyaluronidase, 44  
 Hydroxy acids, 33  
 Hypertrophic orbicularis oculi, 51, 53

**I**

Incision, 102–3, 109, 114–15, 119, 121  
 Indications
 

- chemical peeling, 32
- face-lifts, 119, 120f
- fat transfer, 69
- forehead lift, 113
- hair removal, 94
- hair transplantation, 73
- lasers, 91
- liposuction, 57
- lower lid blepharoplasty, 101
- temporary dermal fillers, 38
- upper lid blepharoplasty, 107
- varicose and telangiectatic leg vein treatment, 81
- vascular testing, 81–82

 Inflammatory hyperpigmentations, 93–94  
 Informed consent
 

- botulinum injections, 47–48
- initial patient consultation, 4, 5f
- temporary dermal fillers, 39–40

Injection sites
 

- botulinum injections, 48–54
- temporary dermal fillers, 40–44

 Instrumentation. *See* Aids and devices  
 Interpolation flaps, 9

**J**

Jawline restoration, 42–43

**K**

Key points for success
 

- botulinum injections, 47
- chemical peels, 31
- face-lifts, 119
- facial flaps, 9
- fat transfer, 69
- forehead lift, 113
- hair transplantation, 73
- initial patient consultation, 1
- lasers, 91
- liposuction, 57
- lower lid blepharoplasty, 101
- temporary dermal fillers, 37
- upper lid blepharoplasty, 107

**L**

Lasers, 91, 92t  
 Lip defects, 23–27 (bis)  
 Lip enhancement, 41, 43f  
 Liposuction, 57–68

**M**

Mastectomy, 123  
 Medical considerations
 

- botulinum injections, 47
- initial patient consultation, 1–2
- varicose and telangiectatic leg vein treatment, 81

 Medications
 

- hair transplantation, 74–75
- initial patient consultation, 2
- leg veins, 81
- temporary dermal fillers, 39

 Medicines affecting coagulation, 60t–61t  
 Mentalis, 54  
 Myobloc, 48

- N**
- Nasalis, 53
  - Nasojugal crease, 43
  - Nasolabial folds, 40–41, 42f
  - Necrosis, 44
  - Nitroglycerin paste, 44
  - Nonablative rejuvenation technologies, 96t
  - Nonfacial chemical peeling, 35
  - Nose defects, 15, 17–23 (bis)
- O**
- Oral commissures, 42
- P**
- Patient expectations, 4, 6
  - Peel depth, classification of, 32
  - Peeling agents, 33
  - Periorbital lines, 52
  - Pharmacology
    - botulinum toxin, 47
    - chemical peeling, 31
    - dermal fillers, 38
  - Photography
    - botulinum injections, 48
    - initial patient consultation, 4, 6f
    - temporary dermal fillers, 40
  - Physical examination
    - hair transplantation candidate, 73
    - leg vein patients, 81–82
    - liposuction, 59
  - Pigmented lesions, 93–94
  - Planning, preoperative. *See also* Consultations, preoperative
    - fat transfer, 75–76
    - temporary fillers, 39–40
    - upper lid blepharoplasty, 107–8
  - Postoperative course/care. *See also* Considerations, postoperative
    - botulinum injections, 54
    - fat transfer, 71
    - hair transplantation, 78–79
    - initial patient consultation, 6
    - lasers, 99
    - leg vein treatment, 83, 85
    - liposuction, 66
    - temporary dermal fillers, 44
  - Preoperative blood work-up, 25
  - Preoperative considerations, liposuction, 58–61
  - Preoperative goals, 73–74
  - Preoperative labs, 61, 69
  - Preoperative marking, 84, 85t, 107–8
  - Pretrichial forehead lift. *See* Forehead lift, types of
  - Psychosocial history
    - botulinum injections, 47
    - initial patient consultation, 4
    - temporary dermal fillers, 39
- R**
- Radiesse, 37
  - Red facial lesions, 92f, 93
  - Reimbursement/Fee structure, 6, 7f
  - Repetitive nasal flare, 53
  - Rhytids
    - face, 38
    - periocular, 43
    - perioral, 53
    - radial, 53
    - reduction of, 96–97
  - Rotation flaps, 9
- S**
- “Smoker’s lines”, 48
  - Skin smoothing, 96
  - Skin tightening, 98
  - Skin toning, 96
  - Staphylococcus aureus*, 2
  - Staphylococcus epidermidis*, 2
  - Superficial muscular aponeurotic system (SMAS)
    - plication, 123–24
  - Surgical considerations, 2, 81
  - Surgical suite setup, 61
  - Swelling, 44
- T**
- Technique
    - ambulatory phlebectomy, 84–86, 87t
    - canthopexy suture, 104–5
    - duplex guided endovascular sclerosing, 83, 84t
    - fanning, 40, 41f
    - fat transfer, 70–71
    - foam sclerotherapy, 86–87
    - graft dissection, 76f
    - hair transplantation, 75–76
    - injection, 40–41

Technique (*continued*)

- laser resurfacing, 104
- liposuction, 61–66
- nonablative rejuvenation, 95–96
- photoepilation, 94, 95t
- pinch excision, 104
- radiofrequency closure, 82–83
- recipient placement, 76–78
- serial puncture, 40, 41f
- threading, 40–42
- transplantation, 71

Temporal Brow lift. *See* Forehead lift, types of

Tenotomy scissors. *See* Aids and devices

Tissue movement principles, 9–30

Transposition flaps, 9

Treatment

- hair removal, 94–95
- lower extremity veins, 82
- resurfacing lasers, 98–100
- telangiectasia/reticular veins, 87–89
- tissue contour defects, 38
- truncal veins, 83

**U**

Undermining, 115, 116f, 121–23

**V**

Vascular lesions, 91, 92f

Volume selection, 40

**W**

Wrinkling, 33