

# Laparoscopic Surgery for Colorectal Cancer

Yoshiharu Sakai  
*Editor*

 Springer

---

# Laparoscopic Surgery for Colorectal Cancer



---

Yoshiharu Sakai  
Editor

# Laparoscopic Surgery for Colorectal Cancer

 Springer

*Editor*  
Yoshiharu Sakai  
Department of Surgery  
Kyoto University Graduate School of Medicine  
Kyoto, Japan

ISBN 978-4-431-55710-4      ISBN 978-4-431-55711-1 (eBook)  
DOI 10.1007/978-4-431-55711-1

Library of Congress Control Number: 2016930401

Springer Tokyo Heidelberg New York Dordrecht London

© Springer Japan 2016

This work is subject to copyright. All rights are reserved by the Publisher, whether the whole or part of the material is concerned, specifically the rights of translation, reprinting, reuse of illustrations, recitation, broadcasting, reproduction on microfilms or in any other physical way, and transmission or information storage and retrieval, electronic adaptation, computer software, or by similar or dissimilar methodology now known or hereafter developed.

The use of general descriptive names, registered names, trademarks, service marks, etc. in this publication does not imply, even in the absence of a specific statement, that such names are exempt from the relevant protective laws and regulations and therefore free for general use.

The publisher, the authors and the editors are safe to assume that the advice and information in this book are believed to be true and accurate at the date of publication. Neither the publisher nor the authors or the editors give a warranty, express or implied, with respect to the material contained herein or for any errors or omissions that may have been made.

Printed on acid-free paper

Springer Japan KK is part of Springer Science+Business Media ([www.springer.com](http://www.springer.com))

---

## Preface

Oncological safety as well as the minimum invasiveness of laparoscopic surgery for colorectal cancer has been acknowledged worldwide, based on long-term outcomes of several randomized controlled trials comparing laparoscopic surgery and open surgery. Single port, reduced port, and robotic surgery have also been developed following conventional laparoscopic surgery. Furthermore, the laparoscopic approach has been applied to more advanced procedures, such as intersphincteric resection, lateral pelvic node dissection, and trans-anal total mesorectal excision.

Why is laparoscopic surgery gaining popularity among surgeons even though it consists of technically demanding procedures? One of the reasons is better recognition of surgical anatomy in detail even in a deep and narrow space, thanks to the development of optics. Modern technology has been demonstrating fine structures which we have never seen in open surgery or in cadaveric dissection. In other words, we are fascinated with the beauty as well as the reality of “lap-enhanced surgical anatomy”.

We have easy access to educational or instructive textbooks and beautiful videos. Photos provide us a static process or anatomy, but it is often difficult to understand them without the help of schema. Drawings emphasize the author’s idea of surgical procedures or anatomy but are at risk of being misinterpreted or misleading, as if an invisible structure were a visible one. Videos demonstrate sequential procedures and facilitate comprehension of steric anatomy but are often inadequate to build a shared image among surgeons. My concern is whether historical technical terms such as “Denonvilliers’ fascia”, “Waldeyer’s fascia”, “Gerota’s fascia”, and others that have been used in educational materials are truly shared among surgeons or readers. The definitions of those technical terms are still in debate [1]. Without sharing definitions or clear images, we would misinterpret the procedures or surgical anatomy.

Dissection is one of the basic and important procedures in our surgery. What is dissection? Is it to recognize the pre-existing membranes and to separate them? We do not agree with that. Instead, we believe that dissection is dividing the connective fibrous tissues or entering into the “dissectable layers”, resulting in making membranes on both sides.

We have provided only the reality of each step of surgical procedures with some illustrations and excluded the historical technical terms as much as possible in order to share the reality with you. We hope you enjoy the beautiful illustrations, especially in Chap. 1 (Principles of Anatomy), and the reality expressed with many fine photos.

Finally, we would like to express our appreciation to Springer, our publisher, for giving us such a great opportunity to demonstrate our basic idea for laparoscopic colorectal surgery.

Kyoto, Japan

Yoshiharu Sakai

---

## Reference

1. Kraima AC, West NP, Treanor D, Magee DR, Rutten HJ, Quirke P, et al. Whole mount microscopic sections reveal that Denonvilliers' fascia is one entity and adherent to the mesorectal fascia; implications for the anterior plane in total mesorectal excision? *Euro J Surg Oncol.* 2015;41:738–45. doi:[10.1016/j.ejso.2015.03.224](https://doi.org/10.1016/j.ejso.2015.03.224).

---

# Contents

<b>1</b>	<b>Principles of Anatomy</b> . . . . .	<b>1</b>
	Hisashi Shinohara, Suguru Hasegawa, Shigeru Tsunoda, Hisahiro Hosogi, and Yoshiharu Sakai	
<b>2</b>	<b>Evidence of Laparoscopic Surgery for Colorectal Cancer</b> . . . . .	<b>17</b>
	Koya Hida, Ryosuke Okamura, Tatsuto Nishigori, Nobuaki Hoshino, Saori Goto, and Koichi Okumura	
<b>3</b>	<b>Laparoscopic Right-Sided Colectomy (Ileocecal Resection, Right Hemicolectomy, Extended Right Hemicolectomy)</b> . . . . .	<b>31</b>
	Junichiro Kawamura, Kazuki Ueda, Haruhiko Imamoto, and Kiyotaka Okuno	
<b>4</b>	<b>Laparoscopic Transverse Colectomy</b> . . . . .	<b>53</b>
	Kenji Kawada, Gen Nishikawa, Hisashi Shinohara, and Suguru Hasegawa	
<b>5</b>	<b>Laparoscopic Left-Sided Colectomy (Mobilization of Splenic Flexure and Sigmoidectomy)</b> . . . . .	<b>71</b>
	Akinari Nomura, Yasuo Koga, Yukie Yoda, and Hirokazu Noshiro	
<b>6</b>	<b>Laparoscopic Total Mesorectal Excision (TME) for Rectal Cancer</b> . . . . .	<b>109</b>
	Yoshiharu Sakai, Suguru Hasegawa, Hisashi Shinohara, Masahiro Yamada, and Michiaki Okada	
<b>7</b>	<b>Laparoscopic Right Lateral Pelvic Lymph Node Dissection (LPLND) with Pelvic Autonomic Nerve Preservation</b> . . . . .	<b>137</b>
	Satoshi Nagayama, Masashi Ueno, and Takeshi Sano	
<b>8</b>	<b>Restorative Proctocolectomy</b> . . . . .	<b>155</b>
	Ryo Takahashi, Gen Nishikawa, Shigeo Hisamori, Kenji Kawada, Hisashi Shinohara, and Yoshiharu Sakai	



---

<b>9</b>	<b>Transanal Minimally Invasive Surgery for Rectal Cancer . . . . .</b>	<b>169</b>
	Suguru Hasegawa, Koya Hida, Kenji Kawada, and Yoshiharu Sakai	
<b>10</b>	<b>Robotic Total Mesorectal Excision . . . . .</b>	<b>197</b>
	Akinari Nomura, Yasuo Koga, Yukie Yoda, and Hirokazu Noshiro	

Hisashi Shinohara, Suguru Hasegawa, Shigeru Tsunoda,  
Hisahiro Hosogi, and Yoshiharu Sakai

---

## Abstract

This chapter describes the development of the gastrointestinal tract and illustrates the important topographic anatomy with a focus on mesenteries. During the early weeks of the embryo, the primitive gut tube is suspended from the body wall by mesenteries that enclose the organ and connect it to the body wall, providing pathways for vessels and lymphatics to and from the abdominal viscera. With rotations of the stomach and the midgut loop, the mesenteries undergo complex deformations, positional changes, and fusions to adjacent organs. Understanding these embryological processes will be helpful in recognition of anatomical pitfalls, and the application of such knowledge is advantageous in laparoscopic colorectal surgery.

---

## Keywords

Anatomy • Embryology • Mesentery • Gastrocolic trunk of Henle • Midgut rotation

---

## 1.1 Introduction

Anatomy is not just a classical form of medicine but is instead a science that progresses with advances in surgery. In the past two decades, progress in anatomical knowledge of the digestive system has been undoubtedly achieved with the introduction of laparoscopic surgery. This is because the surgeon is now able to inspect the surgical field using extremely high-resolution images and magnification on a video screen and all surgical team members can share a common

---

H. Shinohara, M.D. (✉) • S. Hasegawa • S. Tsunoda • H. Hosogi • Y. Sakai  
Department of Surgery, Kyoto University Graduate School of Medicine, Sakyo-ku, Kyoto, Japan  
e-mail: [shinosug@kuhp.kyoto-u.ac.jp](mailto:shinosug@kuhp.kyoto-u.ac.jp)

visual perspective. Thus, after introduction of laparoscopy, surgeons' interests moved from anatomy in a formalin-fixed cadaver to that in a living body.

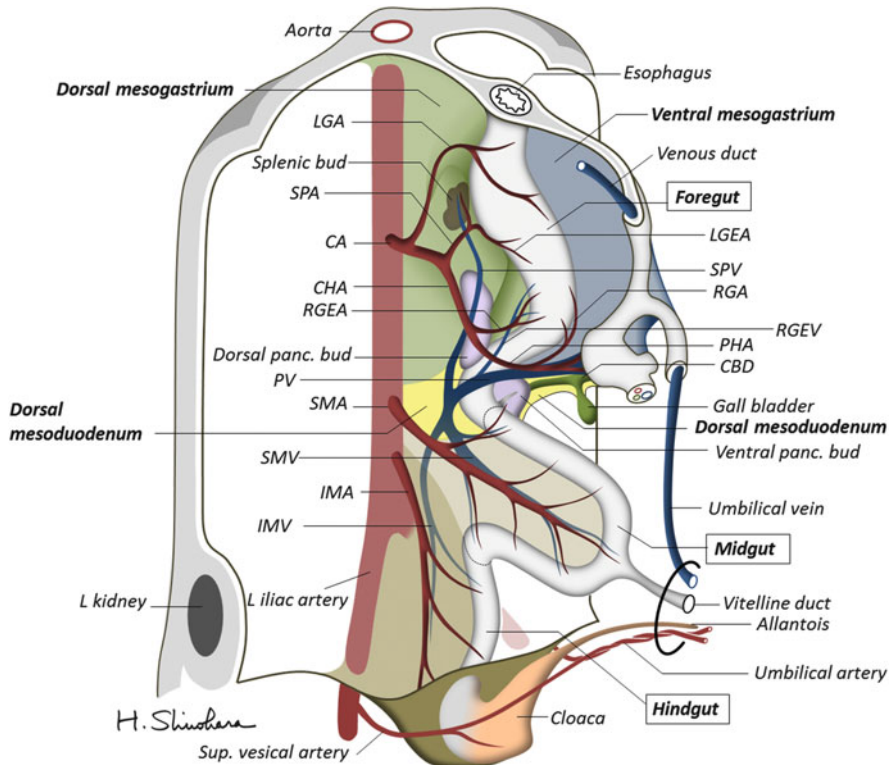
This new stage of anatomy has brought about great changes in colorectal cancer surgery. In the 1970s, E.W. Enker demonstrated that anatomic resection enhances survival of patients with colon and rectal cancer [1]. This principle developed into the concept of "mesenteric resection," which was first proposed by R.J. Heald in the 1980s as total mesorectal excision (TME) [2, 3]. In this century, a similar concept has been applied in colon cancer surgery by W. Hohenberger as complete mesocolic excision (CME) with central vascular ligation [4]. These surgical strategies have been accepted worldwide by surgeons who utilize the laparoscopic technique, since this new methodology relates to educational aspects of abdominal and, particularly, pelvic anatomy. Owing to magnification, many of the smaller structures, such as the tiny branches of vessels and nerves as well as collagenous fibers within loose connective tissue spaces, can clearly be seen during the operation. Unexpectedly, these structures have not complicated our conventional knowledge; rather, they contributed to simplifying the real anatomy for surgeons.

The best means to understand anatomy is to review embryology. This chapter will provide an outline of the development of the gastrointestinal tract and illustrate important topographic anatomy, which is helpful for laparoscopic colorectal surgery.

---

## 1.2 Development of the Primitive Gut

During the early weeks of the embryo, development of the primitive gut and its derivatives in the abdominal cavity can be discussed in three sections: (1) the foregut that forms the stomach and the proximal part of the duodenum; (2) the midgut that forms the distal part of the duodenum, small intestine, and large intestine extending to the junction of the right two-thirds of the transverse colon; and (3) the hindgut that forms the remainder of the large intestine extending from the left third of the transverse colon to the rectum (Fig. 1.1). The gut tube is suspended from the body wall by mesenteries—the double layer of peritonea that encloses the organ and connects it to the body wall, providing pathways for vessels, nerves, and lymphatics to and from the abdominal viscera. The foregut has dorsal and ventral mesenteries, namely, the dorsal and ventral mesogastrum and the dorsal and ventral mesoduodenum, while the midgut and the hindgut have only dorsal mesenteries that continue from the dorsal counterpart connecting the foregut. These organs are intraperitoneal, whereas organs that lie against the posterior body wall and are covered by peritoneum on their anterior surface only (e.g., the kidneys and the adrenal glands) are considered retroperitoneal. The liver and the gallbladder are formed in the ventral mesogastrum and connect to the duodenum via the common bile duct. The exit of the hepatobiliary tract is the major papilla, which corresponds to the junction of the foregut and the midgut tubes. Thus, the hepatoduodenal ligament is exactly the edge of the ventral mesentery of the foregut. The pancreas arises from two buds in the duodenal wall [5]. The dorsal bud grows



**Fig. 1.1** Primitive gastrointestinal tract and the various derivatives in the early weeks of embryo development. The liver is omitted in this and the following figures. *CA* celiac artery, *CBD* common bile duct, *CHA* common hepatic artery, *IMA* inferior mesenteric artery, *IMV* inferior mesenteric vein, *LGA* left gastric artery, *LGEA* left gastroepiploic artery, *PHA* proper hepatic artery, *PV* portal vein, *RGA* right gastric artery, *RGEA* right gastroepiploic artery, *RGEV* right gastroepiploic vein, *SMA* superior mesenteric artery, *SMV* superior mesenteric vein, *SPA* splenic artery, *SPV* splenic vein

in the dorsal mesoduodenum and eventually extends into the dorsal mesogastrium [6].

### 1.3 Positional Changes of the Foregut

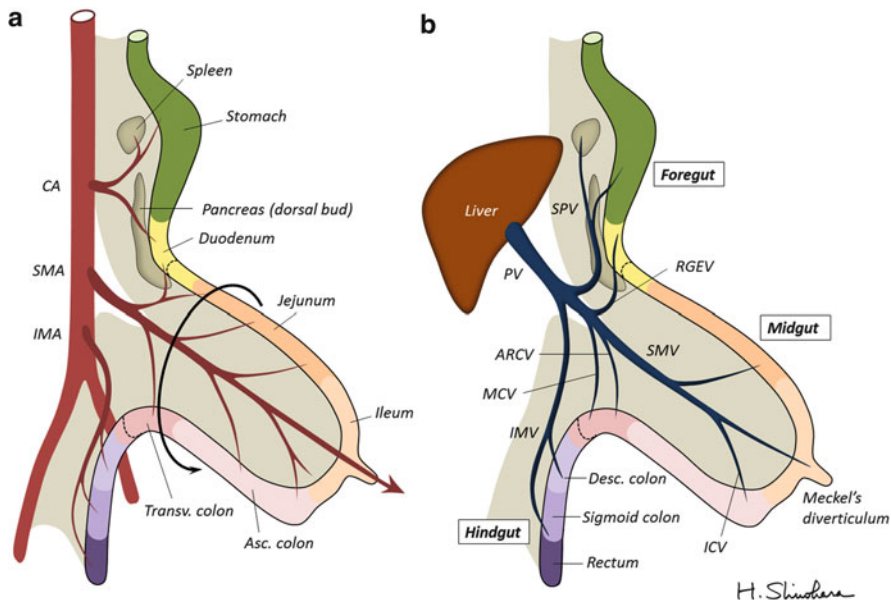
The foregut, midgut, and hindgut are supplied by the celiac artery (*CA*), superior mesenteric artery (*SMA*), and inferior mesenteric artery (*IMA*), respectively (Fig. 1.2a). These arteries independently originate from the aorta and run through the dorsal mesenteries. In contrast, the corresponding veins, that is, the splenic vein (*SPV*) from the foregut, superior mesenteric vein (*SMV*) from the midgut, and inferior mesenteric vein (*IMV*) from the hindgut, converge on the portal vein and drain into the liver (Fig. 1.2b). During the fifth week of development, the stomach

appears as a fusiform dilatation of the foregut and rotates 90° clockwise around its longitudinal axis. The mesogastrium expands into the left upper abdomen to form the omental bursa and then becomes adherent to the dorsal parietal wall (Fig. 1.3). As this process continues, the spleen primordium appears as a mesodermal proliferation within the mesogastrium. The rotation of the stomach swings the duodenum from its initial midline position to the right side of the abdominal cavity. When the duodenum rotates to the right and becomes C-shaped, the ventral pancreatic bud moves dorsally and comes to lie below and behind the dorsal bud to form the uncinuate process of the head of the pancreas. Later, the parenchyma and the duct system of both buds fuse (see Fig. 1.5). The duodenum and the head of the pancreas press against the dorsal body wall, and the posterior surface of the mesoduodenum fuses with the adjacent peritoneum via loose connective tissue. Thus, the pancreas is not a retroperitoneal organ but is a component of the mesoduodenum. This recognition is important for performing right hemicolectomy.

---

## 1.4 Rotation of the Midgut

Development of the midgut is initiated by elongation of the gut and its mesentery, resulting in formation of the primary midgut loop. It enters the extraembryonic cavity in the umbilical cord, the so-called physiological umbilical herniation, because the abdominal cavity temporarily becomes too small to contain the midgut. Occurring concurrently with elongation, the midgut loop rotates approximately 270° counterclockwise around an axis formed by the SMA. Figure 1.4 shows the intestinal loops after 90° counterclockwise rotation during herniation. The apex of the loop communicates with the yolk sac through the vitelline duct toward which the SMA runs through the proper mesentery of the midgut. After development, the cephalic limb of the midgut loop becomes the distal part of the duodenum, jejunum, and part of the ileum. The caudal limb becomes the terminal portion of the ileum, cecum, appendix, ascending colon, and proximal two-thirds of the transverse colon. Owing to the loop formation, the middle colic artery (MCA) that supplies the transverse colon branches from the SMA close to the origin of the first jejunal artery; the branching point is proximal to that of the ileocolic artery (ICA). During return of the intestinal loop into the abdominal cavity, the remaining 180° rotation occurs. Figure 1.5 shows the intestinal loops after the 180° rotation. The cephalic limb comes to lie on the caudal side, while the caudal limb lies on the cephalic side. The cecal bud appears as a small dilatation of the caudal limb of the midgut loop. The vitelline duct ordinarily ceases to exist during this process, but a small portion persists and forms Meckel's diverticulum in some individuals. The SMV moves above the SMA. The right gastroepiploic vein (RGEV), MCV, and accessory right colic vein (ARCV) empty into the close part of the SMV. The jejunum and ileum form a number of coiled loops, but the large intestine does not. The dorsal pancreatic duct (duct of Santorini) enters the proximal part of the major papilla at the site of the minor papilla. The ventral pancreatic duct (duct of Wirsung) enters



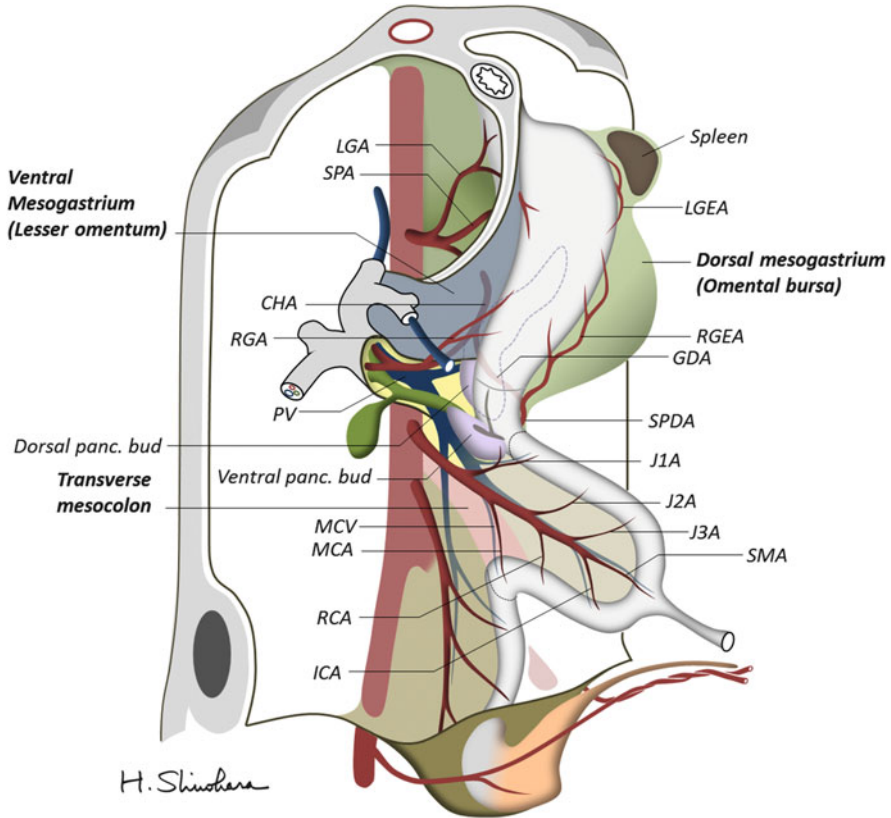
**Fig. 1.2** Primary intestinal loop before rotation. The arteries originate from the aorta and run through the dorsal mesenteries (a). In contrast, the corresponding veins converge on the portal vein and drain into the liver (b). *ARCV* accessory right colic vein, *ICV* ileocolic vein, *MCV* middle colic vein. Refer to the above figure legend for other abbreviations

the common bile duct. The duct system of both buds eventually fuses to form the main pancreatic duct.

During the tenth week, the herniated midgut loop returns to the abdominal cavity. After completion of  $270^\circ$  rotation, the proximal portion of the jejunum comes to lie on the left side, and the transverse colon lies in front of the duodenum (Fig. 1.6). The SMV moves to the right side of the SMA: this is the definitive position of the two vessels. The cecum lies in the right iliac fossa, and the ascending colon and hepatic flexure are on the right side of the abdominal cavity. The distal end of the cecum forms a narrow diverticulum, the appendix. The rotation of the midgut loop swings the cephalic portion of the hindgut, placing the descending colon on the left side of the abdominal cavity.

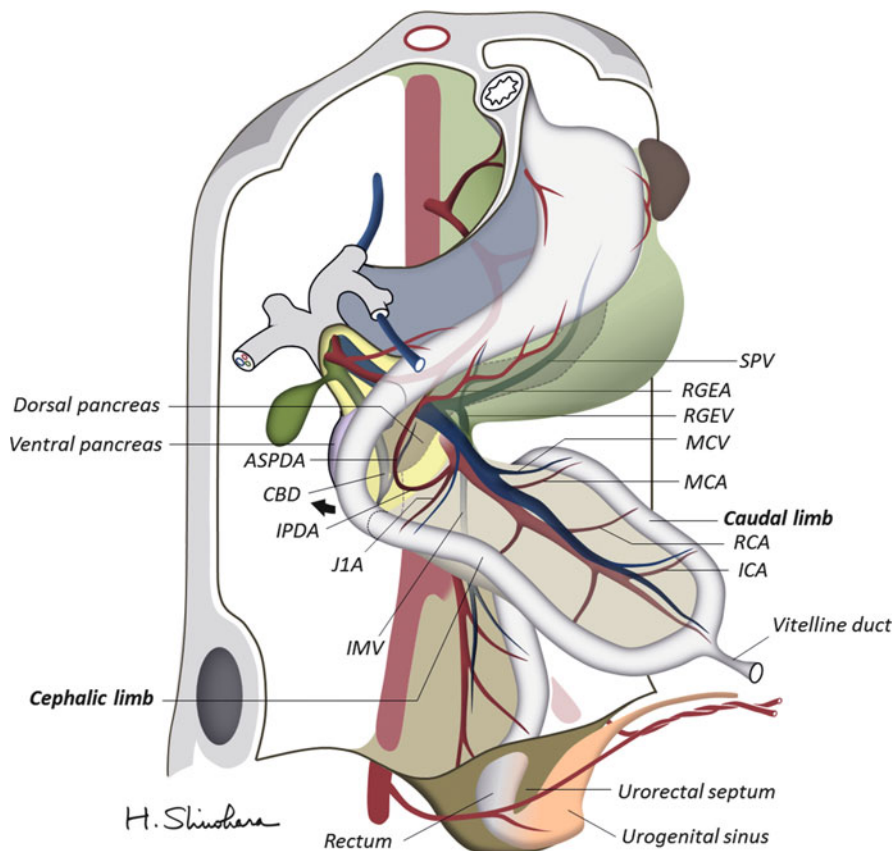
## 1.5 Transformation of the Mesenteries

With rotations of the stomach and the midgut loop, the dorsal mesenteries undergo complex deformations. They twist around the gastroduodenal trunk of Henle into which the RGEV, ARCV, and sometimes the MCV empty (Fig. 1.7). Accordingly, the confluence of the RGEV is lower (caudal side) than the origin of the right gastroepiploic artery, while the confluence of the MCV is higher (cephalic side)



**Fig. 1.3** Embryo during the fifth week of development. The stomach appears as a fusiform dilatation of the foregut and rotates 90° clockwise around its longitudinal axis. The ventral pancreatic bud moves dorsally and comes to lie below and behind the dorsal bud to form the uncinete process of the head of the pancreas. *GDA* gastroduodenal artery, *ICA* ileocolic artery, *J1A* first jejunal artery, *J2A* second jejunal artery, *J3A* third jejunal artery, *RCA* right colic artery. Refer to the above figure legend for other abbreviations

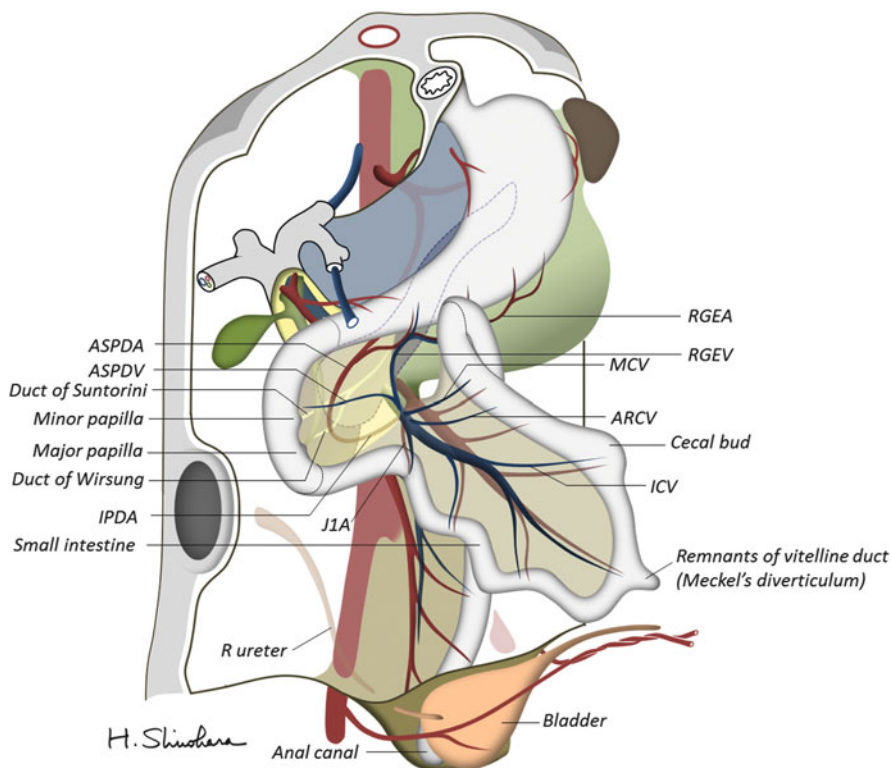
than the origin of the MCA. The anatomical term of “gastrocolic” seems to be strange, but it arose because the stomach and the transverse colon were originally adjacent across the small intestinal loop. When the ascending portion of the colon reaches its definitive position, its mesentery presses against the peritoneum of the posterior abdominal wall. After fusion of these layers, the ascending colon is anchored in a retroperitoneal position like the duodenum. On the other hand, the transverse mesocolon maintains its mobility. It comes into contact with the omental bursa: the expanded dorsal mesogastrium. Adjacent peritonea then fuse, which leads to continuity of the transverse mesocolon and mesogastrium [6]. After birth, the anterior layer of “the transverse mesocolon” is derived from the mesogastrium (see Fig. 1.11b); its attachment line finally extends from the middle colic vessels to the splenic flexure of the descending colon.



**Fig. 1.4** The intestinal loops after a 90° counterclockwise rotation. The apex of the midgut loop communicates with the yolk sac through the vitelline duct toward which the superior mesenteric artery (SMA) runs through the proper mesentery. The cephalic limb of the midgut loop becomes the distal part of the duodenum, jejunum, and part of the ileum. The caudal limb becomes the terminal portion of the ileum, cecum, appendix, ascending colon, and the proximal two-thirds of the transverse colon. *ASPDA* anterior superior pancreatoduodenal artery, *IPDA* inferior pancreatoduodenal artery. Refer to the above figure legend for other abbreviations

When the intestinal loops finish the rotation and reach their definitive position, the transverse mesocolon covers half of the bottoms of the duodenal loop (Fig. 1.8). The mesentery of the small intestine obtains a new attachment line that extends from the duodenojejunal junction (the so-called ligament of Treitz) to the ileocecal junction. This line almost goes along the ICA. The bulged dorsal mesogastrum grows down over the transverse colon to spread through the small intestine, which is named the greater omentum. Later, its layers fuse to form a single sheet like an apron hanging from the greater curvature of the stomach. The greater omentum also lengthens in the right and left direction over the hepatic and splenic flexures, respectively. During this process, the anterior surface of the mesoduodenum is

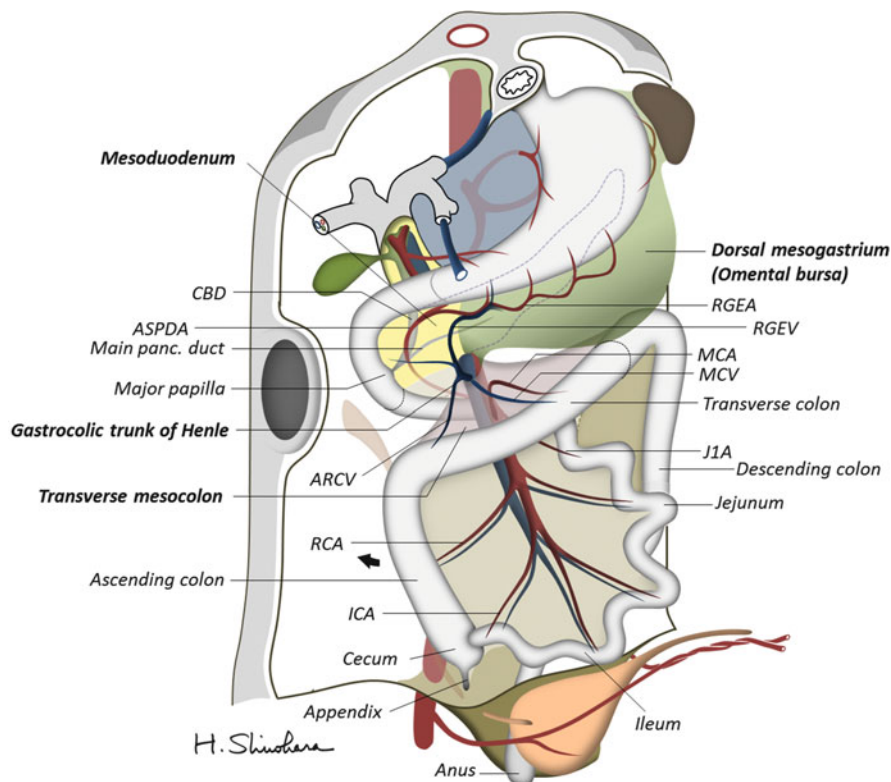




**Fig. 1.5** The intestinal loops after 180° midgut rotation. The cephalic limb comes to lie on the caudal side, while the caudal limb lies on the cephalic side. The superior mesenteric vein (SMV) moves above the superior mesenteric artery (SMA). The right gastroepiploic vein (RGEV), middle colic vein (MCV), and accessory right colic vein (ARCV) empty into the close part of the SMV. ASPDV anterior superior pancreaticoduodenal vein. Refer to the above figure legend for other abbreviations

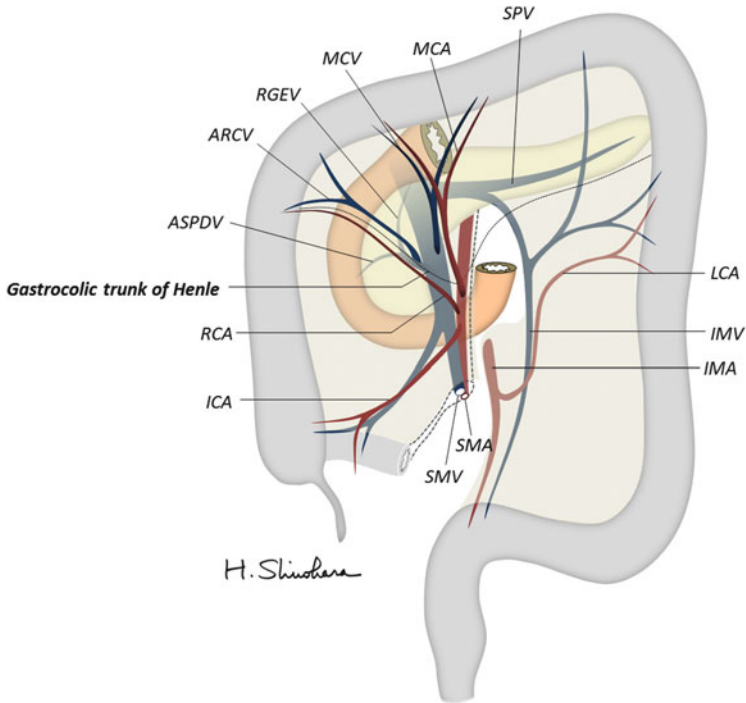
covered by the extended greater omentum. With covering by the transverse mesocolon from caudal to cephalic and by the greater omentum from medial to lateral, the duodenal loop and the head of the pancreas assume a secondary retroperitoneal position (see Fig. 1.11a). In the fully developed abdomen, the extended greater omentum forms the hepatocolic ligament in the right upper abdomen and the splenocolic ligament in the left upper abdomen, and each covers and fixes the hepatic flexure and the splenic flexure, respectively (Fig. 1.9). After birth, the lumen of the superior vesical arteries is obliterated to form the medial umbilical fold. Simultaneously, the umbilical vein is obliterated to form the round ligament of the liver, and the venous duct is also obliterated to form the venous ligament, also called the Arantius duct.

Figure 1.10 depicts a three-dimensional diagram of the mesenteries, which were transformed and folded by positional changes of the primary intestinal loop. The



**Fig. 1.6** The intestinal loops after completion of  $270^\circ$  midgut rotation. The proximal portion of the jejunum comes to lie on the left side, and the transverse colon lies in front of the duodenum. Note that the right gastroepiploic vein (RGEV) and the accessory right colic vein (ARCV) form the gastrocolic trunk of Henle and flow into the superior mesenteric vein (SMV). Refer to the above figure legend for other abbreviations

gastrocolic trunk lies in “the center of twist” where the mesogastrium, mesoduodenum, and the transverse mesocolon converge. Cross sections of the transverse mesocolon in the right side and the left side are shown in Fig. 1.11a, b, respectively. To achieve CME with central vascular ligation, surgeons have to recognize the outline of the mesocolon. In short, the mesocolon is adherent to the posterior parietal wall in its ascending portion or adjacent mesenteries (mesogastrium and mesoduodenum) in its transverse portion. Fusion of attachment sites is embryologically mediated by loose connective tissue spaces [7], which provide our desired surgically dissectable layers for mobilizing the target mesentery, equivalent to the “holy plane” in the concept of TME [8]. Sharp dissection of the dissectable layers will allow removal of the target mesentery as an “intact fascial package” while also leaving the preserved landmark organs protected by fascial coverage. This is because the separated connective tissue will spread and

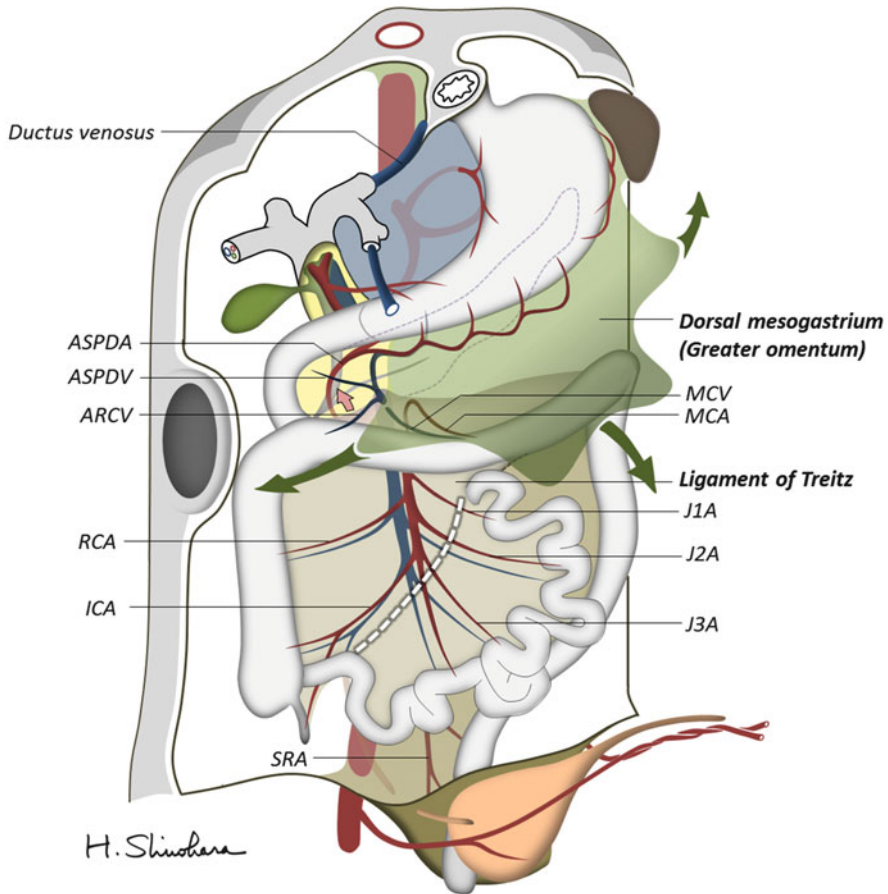


**Fig. 1.7** Representative vascular distribution of the large intestine. With rotations of the stomach and the midgut loop, the dorsal mesenteries twist around the gastrocolic trunk of Henle into which the right gastroepiploic vein (RGEV), accessory right colic vein (ARCVC), and sometimes the middle colic vein (MCV) empty. Note that the confluence of the RGEV is lower (*caudal side*) than the origin of the right gastroepiploic artery (RGEA), while the confluence of the MCV is higher (*cephalic side*) than the origin of the middle colic artery (MCA). Refer to the above figure legend for other abbreviations

eventually attach to the detachment surface of both sides to form a dense connective tissue film.

## 1.6 Derivatives from the Hindgut

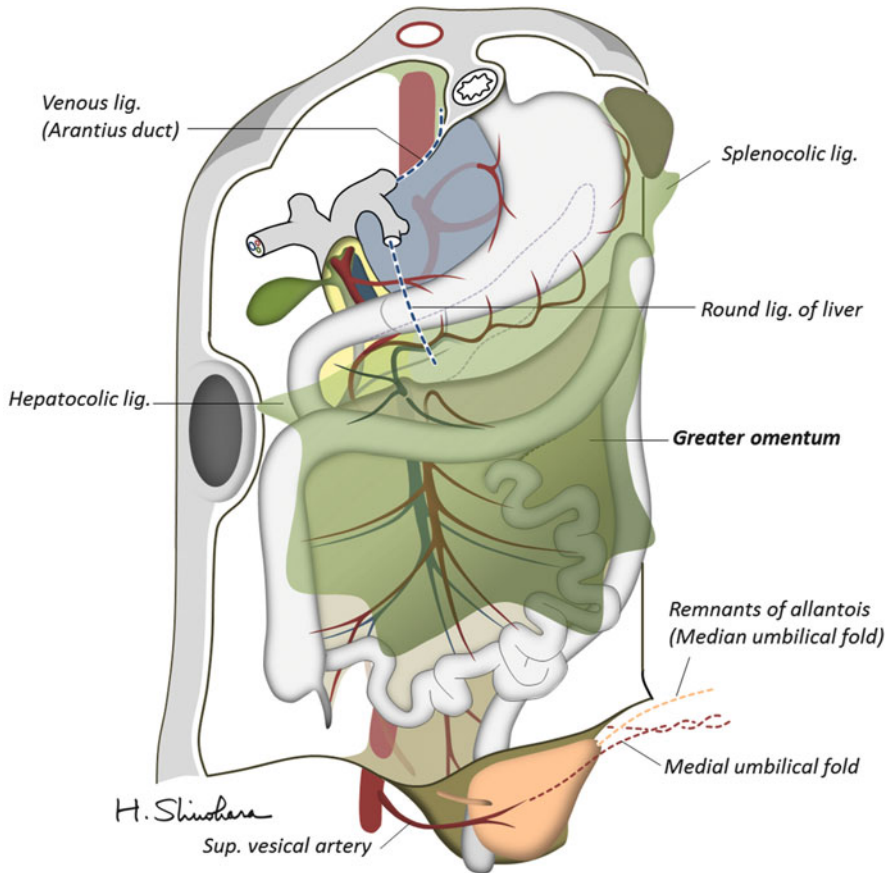
The remaining parts of the colon (the distal third of the transverse colon, descending colon, and sigmoid colon), rectum, and upper part of the anal canal are derived from the hindgut. The terminal portion of the hindgut enters into the posterior region of the cloaca (see Fig. 1.1). The allantois enters into the anterior portion of the cloaca. As the urorectal septum extends, the cloaca is separated by the anorectal canal posteriorly and urogenital sinus anteriorly (see Fig. 1.4). Between the two, the tip of the urorectal septum forms the perineal body. Subsequently, breakdown of the cloacal membrane creates an opening for the hindgut to form the anal canal and one for the urogenital sinus (see Fig. 1.5). Thus, the caudal part of the anal canal is



**Fig. 1.8** Extension of the dorsal mesogastrium to form the greater omentum. The mesentery of the small intestine obtains a new attachment line that extends from the duodenojejunal junction (ligament of Treitz) to the ileocecal junction (*white dashed line*). SRA, superior rectal artery. Refer to the above figure legend for other abbreviations

supplied by the inferior rectal arteries, branches of the internal pudendal arteries, whereas the cranial part of the anal canal is supplied by the superior rectal artery branching from the IMA, the artery of the hindgut. The upper part of the urogenital sinus differentiates in the bladder. The lumen of the allantois which initially connects the bladder with the umbilicus is later obliterated to form a thick fibrous cord, anatomically named the median umbilical fold (see Fig. 1.9).

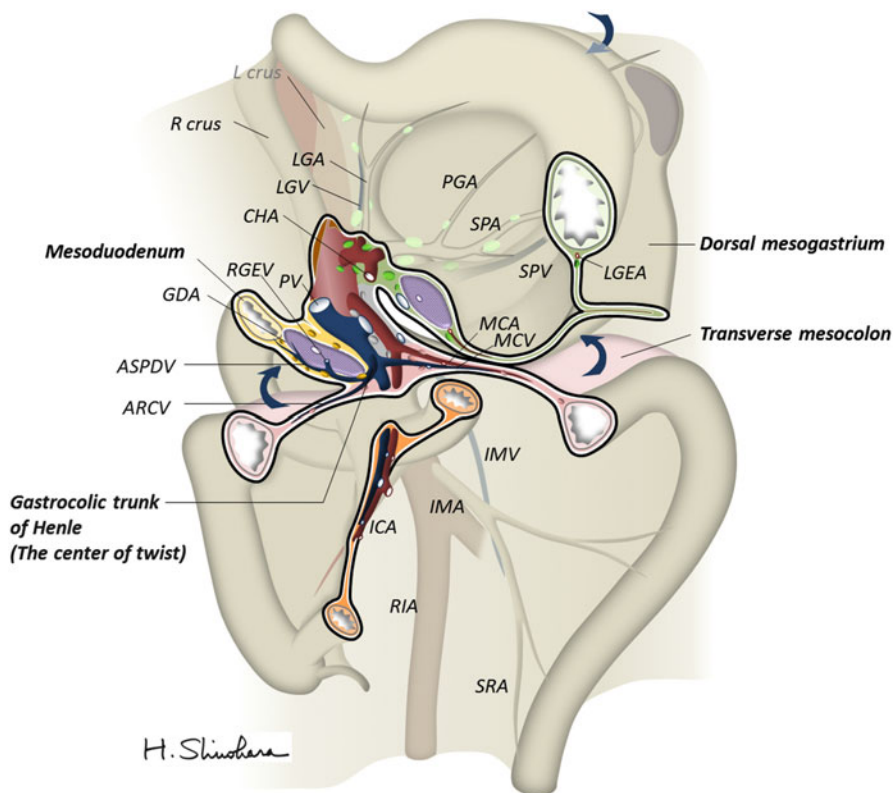
Like other primitive gut tubes, the hindgut is suspended by mesenteries from the posterior body wall into the peritoneal cavity. When the descending colon reaches its definitive position, its mesentery presses against the peritoneum of the posterior abdominal wall. After fusion, the descending colon is anchored in the retroperitoneal position. However, like the ascending mesocolon, surgeons can mobilize the



**Fig. 1.9** Fully developed abdomen after extension of the greater omentum

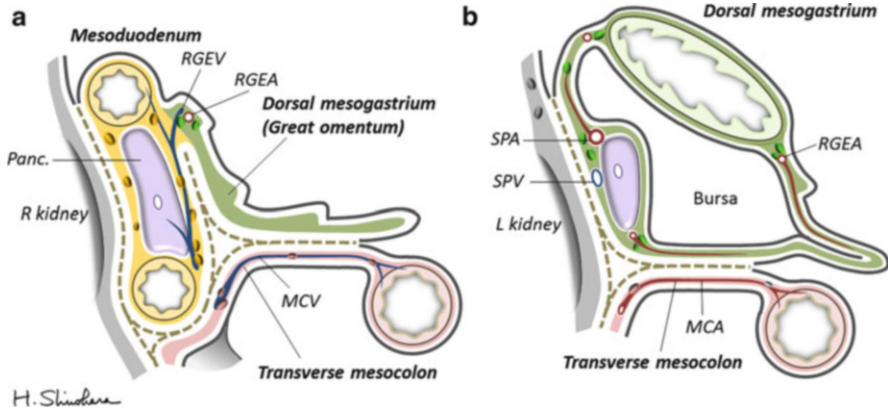
descending mesocolon by tracing the loose connective tissue space (Fig. 1.12). The sigmoid colon retains its free mesentery, but it sometimes has physiological adhesion. Mesentery does not always form in membranous structures but can be defined as a peritoneal ligament providing pathways for vessels, nerves, and lymphatics to and from the abdominal viscera [6]. Embryologically, the dorsal mesentery extends from the lower end of the esophagus to the cloacal region of the hindgut, so the rectum possesses its proper mesentery, namely, “mesorectum,” which suspends the organ from the posterior pelvic wall. This embryologic term was coined by R.J. Heald in his surgical concept of TME [2, 3].

The concept of TME is based upon sharp dissection following anatomical planes to remove the target mesentery including the tumor-bearing organ and its associated lymphatics as an “intact fascial package” from the parietal plane. This may improve both oncological safety (locoregional control) and surgical safety (avoidance of presacral venous bleeding and autonomic nerve injury). Mobilization of the

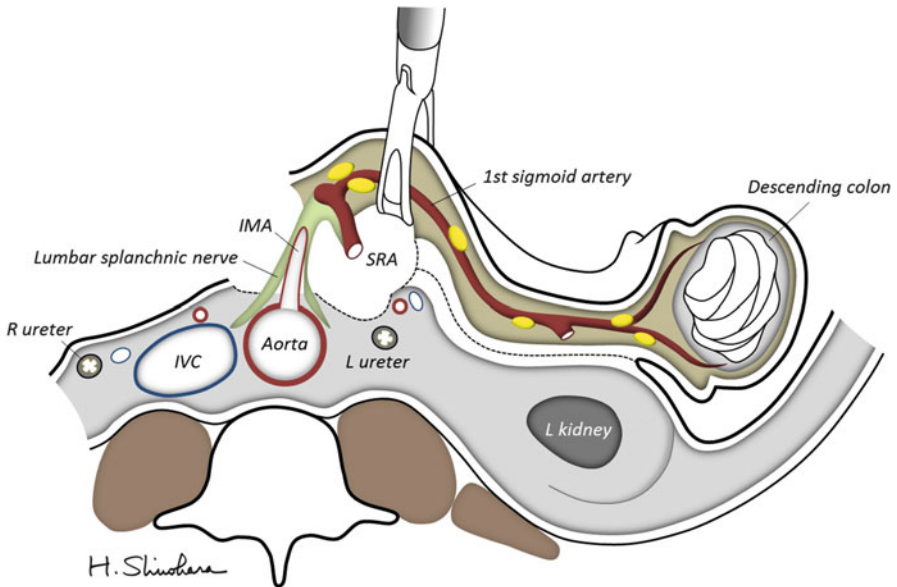


**Fig. 1.10** A three-dimensional diagram of the mesenteries. The gastrocolic trunk of Henle lies in “the center of twist” where the mesogastrum, mesoduodenum, and the transverse mesocolon converge. *PGA* posterior gastric artery, *RIA* right iliac artery. Refer to the above figure legend for other abbreviations

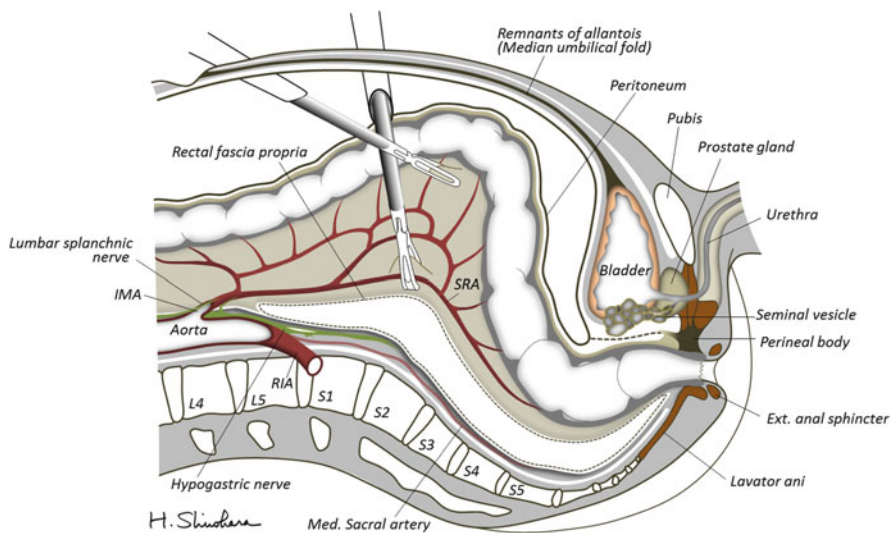
mesorectum should be performed according to the dissectable layers that consist of connective tissue. After dissection, the separated connective tissue will spread and attach to the detachment surface of both sides. Surgeons usually call such dense connective tissue film as “fascia.” The careful surgeon happens to encounter much fascia. However, descriptions about multilaminar fascial structures surrounding the mesorectum have made it difficult for surgeons to understand the anatomy in rectal surgery. Numerous fasciae have been “identified” and “named” by our predecessors, such as Waldeyer’s fascia, Denonvilliers’ fascia, rectal fascia propria, endopelvic fascia, presacral fascia, urogenital fascia, and so on. To make matters worse, different interpretations exist, that is, different names are used for the same structure and the same name is used for different structures. We think that most “fasciae” are not real membranes that originally exist in a living body but are surgical artifacts that are easily created by surgeons during dissection of the anatomically areolar plane.



**Fig. 1.11** Cross sections of the transverse mesocolon. In the right side (a), the anterior surface of the mesoduodenum is covered by the transverse mesocolon from caudal to cephalic and by the greater omentum from medial to lateral. Therefore, the duodenal loop and the head of the pancreas assume a secondary retroperitoneal position. In the left side (b), the transverse mesocolon comes into contact with the omental bursa—the expanded dorsal mesogastrium. Adjacent peritonea then fuse and account for the continuity of the transverse mesocolon and the mesogastrium; therefore, the anterior layer of “the transverse mesocolon” is derived from the mesogastrium. Refer to the above figure legend for other abbreviations



**Fig. 1.12** A cross section of the left-side colon derived from the hindgut. *IVC* inferior vena cava. Refer to the above figure legend for other abbreviations



**Fig. 1.13** Simplified sagittal section of the pelvis. Refer to the above figure legend for other abbreviations

Figure 1.13 shows a simplified sagittal section of the pelvis. After mobilization of the mesorectum, a dense connective tissue film (the so-called rectal fascia propria) covers the backside of the mesorectum, while leaving the presacral vessels and preserved hypogastric nerves protected with fascial coverage [9]. Likewise, in the frontal side of the rectum, correct dissection allows the separation of the organ within a fascial package, while leaving the gonadal organs (seminal vesicle, prostate gland, vagina, etc.) and preserved neurovascular bundle protected with fascial coverage. Our simplified concept of TME aims to consistently trace dissectable layers surrounding the mesorectum to be removed. Embryologically, these dissectable layers are not limited to the mesorectal layers but continue to the sigmoid and descending colon on the left side, ascending colon on the right side, mesoduodenum including the pancreas, and finally the mesogastrum.

## 1.7 Conclusions

This chapter described an outline of the development of the gastrointestinal tract and important topographic anatomy, the application of which would be advantageous during laparoscopic colorectal surgery. The concept behind TME or CME is expected to aid the universalization of operative strategy for other gastrointestinal cancers.



## References

1. Enker WE, Laffer UT, Block GE. Enhanced survival of patients with colon and rectal cancer is based upon wide anatomic resection. *Ann Surg.* 1979;190:350–7.
2. Heald RJ, Husband EM, Ryall RDH. The mesorectum in rectal cancer surgery: the clue to pelvic recurrence? *Br J Surg.* 1982;69:613–6.
3. Heald RJ, Ryall RD. Recurrence and survival after total mesorectal excision for rectal cancer. *Lancet.* 1986;1:1479–82.
4. Hohenberger W, Weber K, Matzel K, et al. Standardized surgery for colonic cancer: complete mesocolic excision and central ligation – technical notes and outcome. *Colorectal Dis.* 2009;11:354–64.
5. Kawaguchi Y, Cooper B, Gannon M, Ray M, MacDonald RJ, Wright CV. The role of the transcriptional regulator Ptf1a in converting intestinal to pancreatic progenitors. *Nat Genet.* 2002;32:128–34.
6. Sadler TW. *Langman’s medical embryology.* 11th ed. Lippincott, Philadelphia; 2009.
7. Shinohara H, Haruta S, Ohkura Y, Udagawa H, Sakai Y. Tracing dissectable layers of mesenteries overcomes embryological restrictions when performing infrapyloric lymphadenectomy in laparoscopic gastric cancer surgery. *J Am Coll Surg.* 2015;220:e81–7.
8. Heald RJ. The ‘Holy Plane’ of rectal surgery. *J R Soc Med.* 1988;81:503–8.
9. Kinugasa Y, Murakami G, Suzuki D, et al. Histological identification of fascial structures posterolateral to the rectum. *Br J Surg.* 2007;94:620–6.

---

# Evidence of Laparoscopic Surgery for Colorectal Cancer

# 2

Koya Hida, Ryosuke Okamura, Tatsuto Nishigori, Nobuaki Hoshino,  
Saori Goto, and Koichi Okumura

---

## Abstract

Laparoscopic surgery for colorectal cancer is widely spread all over the world. In this chapter, the history of colorectal surgery and evidences of laparoscopic colorectal surgery were described. In these 200 years, colorectal cancer surgery has dramatically changed. In the last two decade, laparoscopic surgery appeared and greatly changed the history of colorectal cancer treatment. Many evidences have reported and many inventions are being developed in the laparoscopic surgical field. A combination of great knowledge and skilled technique with novel devices will lead to an excellent outcome for colorectal cancer patients.

---

## Keywords

Laparoscopic surgery • Colorectal cancer • Evidence

---

## 2.1 The Current State of Colorectal Cancer Treatment

In the United States, colorectal cancer death is the 3rd frequent of all the malignant neoplasm death – about 56,000 deaths in a year – and there are 150,000 affected patients per year [1].

In Japan, the number of colorectal cancer patients is 220,000 at 2002, and the number of colorectal cancer death in 2013 is 47,000 at approximately 10 times

---

K. Hida (✉) • R. Okamura • T. Nishigori • N. Hoshino • S. Goto • K. Okumura  
Department of Surgery, Kyoto University Hospital, 54 Kawahara-cho, Shogoin, Sakyo-ku, Kyoto  
606-8507, Japan  
e-mail: [hidakoya@kuhp.kyoto-u.ac.jp](mailto:hidakoya@kuhp.kyoto-u.ac.jp)

more than 50 years ago. Colorectal cancer is the third cause of death in male, and it has been the first cause of death in female [2]. The stage-related 5-year survival rates in Japan are 0, 94.3 %; I, 90.6 %; II, 81.2 %; IIIa, 71.4 %; IIIb, 56.0 %; and IV, 13.2 %, respectively (National Registry of Patients with Cancer of the Colon and Rectum of the JSCCR: patients in fiscal years 1991–1994) [3].

Various chemotherapies and molecular target medicines have appeared, and the medical treatment is evolving rapidly in recent years. However, the first choice of curative treatment is still surgical approach.

---

## 2.2 Surgical Treatment for Colorectal Cancer

Surgical approach for colorectal cancer has a long history [4]. It began from the local resection of only “visible” rectal tumor without general anesthesia in early periods. It has been changed by many techniques and technologies such as staplers, laparoscopies, and surgical robots. Colorectal cancer surgery may be the most evolved surgery during these 200 years. Rectal cancer surgery had become “invisible” surgery gradually through the advance of the surgical technique. Only the surgeon’s hand knew where the dissection layer is. Particularly, the advent of laparoscopy has given a big renovation to the surgical treatment for colorectal cancer, and it re-changed lower rectal surgery from “invisible” surgery to “visible” surgery.

---

## 2.3 The Origin of the Colorectal Cancer Surgery

Surgical treatment started to be performed only for the disease which can be seen from the surface of the body, like breast tumors, inguinal hernias, and rectal tumors in early periods. In 1830, Lisfranc performed the perineal resection of the rectum, and the surgical treatment of rectal cancer was in its infancy [5].

Dieffenbach, Johann Friedrich applied Lembert suture to intestinal resections in 1836 [6, 7]. Since then, intestinal anastomosis has widely been used in colorectal surgery.

The first surgical operation under the ether anesthesia was performed in 1846 [8]; thereafter, colorectal surgeries have become performed under general anesthesia.

Kraske performed more radical resection with sacral approach [9]. Czerny performed unplanned rectal resection using both perineal and abdominal approaches before 1884 [4, 10]. After this, abdominoperineal resections have been performed in all over the world, and an abdominoperineal resection with surrounding lymph nodes dissection was reported by Quenu in 1893 [11], and the abdominoperineal resections with lymph node dissection were also reported by Ito and Torikata of Kyoto University from Japan in 1904 and 1908 [12, 13]. The famous Miles’ paper was published in 1908, and he succeeded to reduce the recurrences by resecting the surrounding tissue of the rectum widely and dissecting the lymph nodes of the inferior mesenteric area [14]. As you know, the name of the

Miles operation is still used more than 100 years around the world [4]. However, the operation risk at those periods was very high as operative death rate was more than 30 %.

After the Miles' era, the preservation of anal function was pursued, and the operations using pull-through technique that draws the colon through the anus or the operations performed only from abdominal side (anterior resection) developed. Pull-through technique was first reported by Maunsell in 1892 [15], and the technique was refined and improved by Weir in 1901 [16], Babcock and Babcock in 1939 [17], and Bacon in 1945 [18]. There was also a report of pull-through technique by Dennosuke Jinnai in 1961 [19], and the technique was widely used in that period. It might be said that the origin of the present ISR (intersphincteric resection) is this operative technique developed by the early ages.

---

## 2.4 Development of Anastomotic Instruments

The anastomotic instruments invented in 1970s contributed a great deal to the development of anterior rectal resection.

This surgical technique started by Harrison Cripps [20] in 1897 was improved by Balfour [21] and Dixon [22]. The rate of operative death was said to be decreased to 10 %. However, the hand-sewn anastomoses in the deep pelvises were extremely difficult, so the anterior resection was indicated only for higher rectal tumors. Circumferential staplers are the instruments which create connection between an intestine and another intestine [23]. Currently, the main stream of the circumferential staplers is the type which has double ring staple lines and ringed cutter inside. With linear staplers which are used for dividing the intestine, circumferential staplers are ever-progressing instruments [24]. These instruments have enabled very low anastomosis near the anus, and they have been indispensable, not only open surgery but laparoscopic and robotic surgery. The way to use the instruments is also important. We examined the stapling shapes and reported the importance of pre-compression time and slow firing for secured stapling of linear stapler [25, 26].

---

## 2.5 TME

A concept of TME (total mesorectal excision) is advocated by Heald in 1982 [27], and the rate of local recurrence of rectal cancer decreased to around 5 % [28]. Through the TME concept, removing the mesorectum neither under resection nor over resection results in less bleeding, saving of autonomic nerves, and beautiful operation. To remove the rectum and mesorectum including the tumor as a package is ideal for cancer treatment by surgical approach. In 2009, TME was translated to complete mesocolic excision (CME) for colon cancer that the concept of CME which is important was reported by Hohenverger et al. [29].

## 2.6 Laparoscopic Surgery

The laparoscopic surgery which appeared in 1980s was the one which has repainted the history of colorectal surgery.

History of a laparoscopic surgery was started with laparoscopic appendectomy (world's first gastrointestinal tract surgery) by Semm (Germany) in 1981 [30].

In 1985, Muhe (Germany) performed laparoscopic cholecystectomies [31].

In 1991, Jacobs reported the first laparoscopic colorectal resections [32].

Watanabe et al. also reported laparoscopic colorectal resection from Japan in 1993 [33].

Port site recurrences had been the problem of laparoscopic colorectal cancer surgery at the early periods, and implantation of the carcinoma at all port sites after laparoscopic removal of an unsuspected cancer was said to be a problem. However, later studies reported that wound site recurrence does not increase in laparoscopic surgery compared to open surgery [34].

Since then, laparoscopic colorectal surgery developed dramatically until now, according to the survey of Japan Society for Endoscopic Surgery in 2013, more than 32,000 cases were performed in 471 institutes, and 60 % of them were for advanced cancers. In Japan, laparoscopic surgery for early colorectal cancer became covered by health insurance from 1996, and that for advanced colorectal cancer has been covered by health insurance until 2002. The medical system was one reason that laparoscopic colorectal surgery has spread explosively. In the Japanese national registry, NCD, more than 40,000 laparoscopic colorectal surgeries are registered in a year, which became as equal level as open surgeries [35, 36].

---

## 2.7 Indication of Laparoscopic Surgery for Colorectal Cancer

In Japan, the health insurance indicated laparoscopic surgeries for early colorectal cancer in 1996, and after 6 years, laparoscopic surgeries for advanced colorectal cancer have been covered by Japanese health insurance in 2002. The indication of laparoscopic surgery for colorectal cancer differs with the institution, but the exclusion criteria which are generally acceptable are tumor invasion to other organs, huge tumors, and the histories of complicated laparotomy [3]. The number of institutions is increasing in which laparoscopic surgery is considered as the first choice for symptomatic Stage IV colorectal cancer. In our institution, usual laparoscopic colorectal surgery is performed by using two 12 mm ports and three 5 mm ports; however, in some institution, single-port methods or needlescopic surgeries are performed as optional surgeries for early cancer. As for the cancers located near to the anus, laparoscopic intersphincteric resections or laparoscopic abdominoperineal resections are chosen, and transanal approach for these cases is also tried according to the cases [37].

## 2.8 Clinical Trials and Clinical Studies of Colorectal Cancer Surgery

The short-term utility of the laparoscopic surgery for colorectal cancer beyond open surgery (less blood loss, less postoperative pain, less postoperative complications, and shorter length of stay) and non-inferiority of the long-term outcome were reported from several clinical trials, such as American COST study [38], British CLASICC trial [39], European COLOR trial [40], and Spanish Barcelona study [41] (Fig. 2.1).

About rectal cancer, there are not so many clinical trials reported [42]. In CLASICC trial for colon and rectal cancer [39], laparoscopic-assisted rectal excision might have encouraged surgeons to do total mesorectal excisions more frequently but slightly raised positive CRMs. COLOR II trial showed that laparoscopic surgery in patients with rectal cancer was associated with rates of locoregional recurrence and disease-free and overall survival similar to those for open surgery [43].

In 2004, a randomized control study of open and laparoscopic surgery JCOG0404 started also in Japan. A total of 1057 cases were enrolled until 2009, and less blood loss and less wound-related complications as short-term outcome were reported [44]. From the analysis of long-term outcome in 2014, non-inferiority of laparoscopic surgery was not proved because of the extremely good survival with

Comparison between laparoscopic and open surgery (colon)					
favorable	Open	← →	Laparoscopy		
Operative time		◆			
Blood loss			◇		
Complications			◇		
Hospitalization			◇		
Pain			◇		
QOL			◇		
Cost		◆			
Wound recurrence		◆			
Survival		◆			
( QOL: quality of life)					

**Fig. 2.1** Comparison between laparoscopic and open surgery (colon)

Comparison between laparoscopic and open surgery (rectum)					
favorable	Open	← →	Laparoscopy		
Operative time		◆			
Blood loss			◇		
Positive CRM		◆			
Bowel function			◇		
Complications		◆			
Hospitalization			◇		
QOL		◆			
Cost		◆			
Local recurrence		◆			
Survival		◆			
( CRM: circumferential radical margin, QOL: quality of life)					

**Fig. 2.2** Comparison between laparoscopic and open surgery (rectum)

too small event numbers. The 5-year survivals of both laparoscopic and open group were beyond 90 %, in spite of the advance cancers with Stage II to III.

The utility of the laparoscopic surgery for rectal cancer was also reported by Miyajima et al. as a multicenter retrospective observational study in 2009 [45], and the prospective study of laparoscopic surgery for Stage 0–I rectal cancer finished case registration, and it is in the follow-up period [46] (Figs. 2.1 and 2.2).

## 2.9 Laparoscopic Surgery for Stage IV Colorectal Cancer Patient

We have reported about the primary tumor resection for incurable Stage IV colorectal cancer as a multicenter observational study in 2012. Compared with open surgery, laparoscopic primary tumor resection has advantages in the short-term and no disadvantages in the long-term [47]. A systematic review about laparoscopic surgery for Stage IV colorectal cancer also followed this conclusion [48].

---

## 2.10 Laparoscopic Surgery for the Overweight Patients

It can be said that a laparoscopic operation for overweight patients is a very good indication. The abdominal wall destruction compared with laparotomy is much less in overweight patients, and it can be said that overweight patients receive more merit than thin patients. However, keeping a satisfactory observation field is difficult in overweight patients, and fat adherence of peritoneal cavity is often seen in overweight patients. So high-level surgical technique is often needed. Obesity is reported to be associated with increased conversion rate, operating time, and postoperative morbidity but not to affect surgical safety or oncological security [49, 50].

---

## 2.11 Laparoscopic Surgery for Transverse Colon Cancer

The patients with transverse colon cancer had been excluded from previous big trials [38–41]; therefore, it remains unclear if the results for colon cancer are similar even in transverse colon cancer. Surgical management for transverse colon cancer has several difficulties. There are various procedures according to the location or stage of tumor: right hemicolectomy, transverse colectomy, or left hemicolectomy. The running of blood vessels of transverse colon has anatomically some variations. Preservation of the pancreas and spleen is needed during the procedure. Therefore, more detailed technique by skilled surgeons is said to be needed for transverse colon cancer surgery.

A previous systematic review of five comparative observational studies reported that the laparoscopic surgery for transverse colon cancer is a safe and effective technique [51]. Although there was a significant increase in operative time in laparoscopic surgery compared with open surgery, less blood loss and faster recovery were seen with laparoscopic surgery.

---

## 2.12 Laparoscopic Surgery in Elderly Patients

In regard to the laparoscopic surgery in elderly patients, there had been a fear that the pneumoperitoneum, the surgical position, and longer anesthesia time might affect their cardiopulmonary function after surgery. However, a Japanese large cohort study evaluating the feasibility of laparoscopic procedure for colorectal cancer patients aged 80 years or older reported that the laparoscopic surgery was associated with fewer morbidities and shorter hospital stay than was the open procedure [52]. The authors have also suggested that elderly patients with colon cancer may receive greater benefits from laparoscopic surgery because there is a linear correlation between increasing age and the frequency of postoperative morbidities, such as respiratory, cardiovascular, and neurological complications. Similarly, some observational studies comparing the short-term benefit between laparoscopic surgeries for elderly and younger colorectal cancer patients have



proposed that the laparoscopic procedure for elderly patients may have the equal advantage to or greater than that for younger patients [53–57].

---

### 2.13 Postoperative Urinary and Sexual Dysfunction

It was reported that postoperative urinary and sexual dysfunction can be reduced with careful autonomic nerve preservation [58].

In 2012, we reported a paper about sexual dysfunction after laparoscopic total mesorectal excision (LTME). This indicated that the evaluation of nerve injury by using video reviews would be effective [59].

The laparoscopic surgery provided a magnified view of the pelvis which improved the visualization of constructions than the open surgery. Therefore, the surgery could preserve autonomic nerves more safely. A systematic review showed the following results [60]. The evaluation of urinary function was performed variously, but the included studies reported no significant differences in urinary function after TME between laparoscopic surgery group and open surgery group. As for sexual function, there was also no significant difference in the rate of overall sexual dysfunction between both groups.

In short, the question of whether laparoscopic surgery for rectal surgery would offer improved genitourinary outcomes over open surgery remains unanswered at present.

---

### 2.14 Transanal Surgery

TAMIS (transanal minimally invasive surgery) was started as a treatment for early rectal cancers and spread widely. Since TAMIS was applied to total mesorectal excision (TME) for advanced rectal cancers, transanal laparoscopic surgery such as TAMIS-ISR (intersphincteric resection) or TAMIS-APR (abdominoperineal resection) has just been beginning to be performed [37, 61, 62].

---

### 2.15 Single-Incision Laparoscopic Colectomy

Single-incision laparoscopic colectomy (SILC) was first reported in 2008 [63]. In this method, all surgical procedures are performed through the umbilicus, which is natural orifice located at the middle of the abdomen and could obscure the operative scar. Main advantage of SILC is considered to be cosmetic [64]. Many reports have been published and suggested the equivalence or superiority in short-term outcomes and the safety of SILC compared with multi-incision laparoscopic colectomy [65–68]. However, many of the previous reports are case reports/series or retrospective studies, and long-term outcomes of SILC are still unclear [67]. Difficulties with scissoring and interference between instruments also exist in SILC surgery, and internal and external conflicts between instruments made it difficult to achieve

ideal traction. It might be overcome with new instruments and scopes in the future. Further prospective studies and enough experience of laparoscopic surgery are needed to perform SILC as a standard treatment.

---

## 2.16 Robot-Assisted Surgery for Colorectal Cancer

In 2010, robot-assisted surgery for colorectal cancer was first reported in Japan. It has been increasing rapidly despite that it is an uninsured care.

Although robot-assisted surgery for colorectal cancer is a medical treatment not covered by insurance, it may have some advantages that we can operate finely for rectal cancer very close to the anal. However, robot-assisted surgery for colon cancer has not shown clear advantage over laparoscopic colonic surgery. We introduce the robot-assisted surgery only to the rectal cancer patients who want to receive it [69, 70].

---

## 2.17 Conclusions

Both operation and chemotherapy for colorectal cancer have made remarkable progress over the last decades. Colorectal cancer had been previously associated with a poor prognosis because of anticancer drug resistance and intensive surgical care which often needed blood transfusions and caused high incidence of dysuria. However, colorectal cancer now has a good chance of being cured with improved quality of life by research-validated effective drugs and precise surgical care with a focus on preserving function.

So far, progress in laparoscopic surgery has resulted in evolution of colorectal surgery. Many innovative surgical instruments have been developed and will be developed in the future. However, to achieve higher quality of colorectal surgery, it is essential for surgeons to master basic surgical techniques, understand surgical anatomy, and grasp new procedures and those concepts. A combination of great knowledge and skilled technique with novel devices will lead to an excellent outcome for colorectal cancer patients.

---

## References

1. Torre LA, Bray F, Siegel RL, Ferlay J, Lortet-Tieulent J, Jemal A. Global cancer statistics, 2012. *CA Cancer J Clin.* 2015;65(2):87–108. doi:10.3322/caac.21262.
2. Japanese ministry of health labour and welfare, 2013. [http://www.mhlw.go.jp/toukei/saikin/hw/jinkou/kakutei13/dl/00\\_all.pdf](http://www.mhlw.go.jp/toukei/saikin/hw/jinkou/kakutei13/dl/00_all.pdf).
3. Watanabe T, Itabashi M, Shimada Y, Tanaka S, Ito Y, Ajioka Y, et al. Japanese Society for Cancer of the Colon and Rectum (JSCCR) guidelines 2010 for the treatment of colorectal cancer. *Int J Clin Oncol.* 2012;17(1):1–29. doi:10.1007/s10147-011-0315-2.
4. Lange MM, Rutten HJ, van de Velde CJ. One hundred years of curative surgery for rectal cancer: 1908–2008. *Eur J Surg Oncol.* 2009;35(5):456–63. doi:10.1016/j.ejso.2008.09.012. S0748-7983(08)01771-X [pii].

5. Lisfranc J. Mémoire sur l'excision de la partie inférieure du rectum devenue carcinomateuse. *Mém Acad R Chir.* 1833;3:291–302.
6. Lembert A. Mémoire sur l'entéroraphie avec la description d'un procédé nouveau pour pratiquer cette opération chirurgicale. *Répertoire général d'anatomie et de physiologie pathologiques.* 1826;2:10–107.
7. Dieffenbach JF. Glückliche Heilung nach Ausscheidung eines Theiles des Darms und Netzes. *Wochenschrift für die gesammte Heilkunde.* 1836;4:401–13.
8. Bigelow HJ. Insensibility during Surgical Operations Produced by Inhalation. *Boston Med Surg J.* 1846;35:309–17.
9. Kraske P. Zur Exstirpation Hochsitzender Mast Darm Krebse. *Verh Deutsch Ges Chir.* 1885;14:464–74.
10. Czerny V. Jahresbericht der Heidelberger Chirurgischen Klinik für das Jahr. *UB Heidelberg.* 1900;1901:7401–4.
11. Quenu E. De l'extirpation sacroabdominale du rectum cancreux en deux temps. *Bull Mem Soc.* 1896;22:11–3.
12. Ito H, Kunika H. Zur kombinierten Exstirpation der hochsitzenden resp. hoch hinaufreichenden Mastdarmkarzinome bei MÄnnern. *Deutsche Zeitschrift für Chirurgie.* 1904;73:229–48.
13. Torikata R. Beitrag zur kombinierten Exstirpation der hochsitzenden respektive hoch hinaufreichenden Mastdarmcarcinome bei Männern. *Deutsche Zeitschrift für Chirurgie.* 1908;94:162–78.
14. Miles WE. A method of performing abdominoperineal excision for carcinoma of the rectum and of the terminal portion of the pelvic colon. *Lancet.* 1908;2:1812–3.
15. Maunsell HW. A new method of excising the two upper portions of the rectum and the lower segment of the sigmoid flexure of the colon. *Lancet.* 1892;2:473–6.
16. Weir RF. An improved method of treating high seated cancer of the rectum. *J Am Med Ass.* 1901;37:801.
17. Babcock WW, Babcock WW. Experience with resection of the colon and the elimination of colostomy. *Am J Surg.* 1939;4:186.
18. Bacon HE. Evolution of sphincter muscle preservation and reestablishment of continuity in the operative treatment of rectal and sigmoidal cancer. *Surg Gynecol.* 1945;81:113–7.
19. Jinnai D, Yasutomi M. Cancer of the colon and rectum. *Gann Monograph Cancer Res.* 1979;22:89–99.
20. Cripps WH. *On diseases of the rectum and anus.* 4th ed. London: Churchill; 1914.
21. Balfour DC. A method of anastomosis between sigmoid and rectum. *Ann Surg.* 1910;51:239–41.
22. Dixon CF. Anterior resection for malignant lesions of the upper part of the rectum and lower part of the sigmoid. *Ann Surg.* 1948;128(3):425–42.
23. Beart Jr RW, Kelly KA. Randomized prospective evaluation of the EEA stapler for colorectal anastomoses. *Am J Surg.* 1981;141(1):143–7.
24. Griffen FD, Knight Sr CD, Whitaker JM, Knight Jr CD. The double stapling technique for low anterior resection. Results, modifications, and observations. *Ann Surg.* 1990;211(6):745–51; discussion 751–2.
25. Nakayama S, Hasegawa S, Nagayama S, Kato S, Hida K, Tanaka E, et al. The importance of precompression time for secure stapling with a linear stapler. *Surg Endosc.* 2011;25(7):2382–6. doi:10.1007/s00464-010-1527-7.
26. Hasegawa S, Nakayama S, Hida K, Kawada K, Sakai Y. Effect of tri-staple technology and slow firing on secure stapling using an endoscopic linear stapler. *Dig Surg.* 2015;32(5):353–60. doi:10.1159/000437216. 000437216 [pii].
27. Heald RJ, Husband EM, Ryall RD. The mesorectum in rectal cancer surgery – the clue to pelvic recurrence? *Br J Surg.* 1982;69(10):613–6.
28. Heald RJ, Ryall RD. Recurrence and survival after total mesorectal excision for rectal cancer. *Lancet.* 1986;1(8496):1479–82. S0140-6736(86)91510-2 [pii].

29. Hohenberger W, Weber K, Matzel K, Papadopoulos T, Merkel S. Standardized surgery for colonic cancer: complete mesocolic excision and central ligation – technical notes and outcome. *Colorectal Dis.* 2009;11(4):354–64. doi:[10.1111/j.1463-1318.2008.01735.x](https://doi.org/10.1111/j.1463-1318.2008.01735.x); discussion 364–5. CDD1735 [pii].
30. Semm K. Endoscopic appendectomy. *Endoscopy.* 1983;15(2):59–64. doi:[10.1055/s-2007-1021466](https://doi.org/10.1055/s-2007-1021466).
31. Muhe E. Long-term follow-up after laparoscopic cholecystectomy. *Endoscopy.* 1992;24(9):754–8. doi:[10.1055/s-2007-1009119](https://doi.org/10.1055/s-2007-1009119).
32. Jacobs M, Verdeja JC, Goldstein HS. Minimally invasive colon resection (laparoscopic colectomy). *Surg Laparosc Endosc.* 1991;1(3):144–50.
33. Watanabe M, Teramoto T. Minimally invasive surgery for early colorectal cancer. *Jpn J Gastroenterol Surg.* 1993;26:2548–51.
34. Lacy AM, Delgado S, Garcia-Valdecasas JC, Castells A, Pique JM, Grande L, et al. Port site metastases and recurrence after laparoscopic colectomy. A randomized trial. *Surg Endosc.* 1998;12(8):1039–42.
35. Kobayashi H, Miyata H, Gotoh M, Baba H, Kimura W, Kitagawa Y, et al. Risk model for right hemicolectomy based on 19,070 Japanese patients in the National Clinical Database. *J Gastroenterol.* 2014;49(6):1047–55. doi:[10.1007/s00535-013-0860-8](https://doi.org/10.1007/s00535-013-0860-8).
36. Matsubara N, Miyata H, Gotoh M, Tomita N, Baba H, Kimura W, et al. Mortality after common rectal surgery in Japan: a study on low anterior resection from a newly established nationwide large-scale clinical database. *Dis Colon Rectum.* 2014;57(9):1075–81. doi:[10.1097/DCR.000000000000176](https://doi.org/10.1097/DCR.000000000000176). 00003453-201409000-00004 [pii].
37. Hasegawa S, Takahashi R, Hida K, Kawada K, Sakai Y. Transanal total mesorectal excision for rectal cancer. *Surg Today.* 2015. doi:[10.1007/s00595-015-1195-2](https://doi.org/10.1007/s00595-015-1195-2).
38. COST. A comparison of laparoscopically assisted and open colectomy for colon cancer. *N Engl J Med.* 2004;350(20):2050–9. doi:[10.1056/NEJMoa032651](https://doi.org/10.1056/NEJMoa032651). 350/20/2050 [pii].
39. Guillou PJ, Quirke P, Thorpe H, Walker J, Jayne DG, Smith AM, et al. Short-term endpoints of conventional versus laparoscopic-assisted surgery in patients with colorectal cancer (MRC CLASICC trial): multicentre, randomised controlled trial. *Lancet.* 2005;365(9472):1718–26. doi:[10.1016/S0140-6736\(05\)66545-2](https://doi.org/10.1016/S0140-6736(05)66545-2). S0140-6736(05)66545-2 [pii].
40. Bonjer HJ, Haglund E, Jeekel I, Kazemier G, Pahlman L, Hop WCJ, et al. Laparoscopic surgery versus open surgery for colon cancer: short-term outcomes of a randomised trial. *Lancet Oncol.* 2005;6(7):477–84. doi:[10.1016/S1470-2045\(05\)70221-7](https://doi.org/10.1016/S1470-2045(05)70221-7). S1470-2045(05)70221-7 [pii].
41. Lacy AM, Garcia-Valdecasas JC, Delgado S, Castells A, Taura P, Pique JM, et al. Laparoscopy-assisted colectomy versus open colectomy for treatment of non-metastatic colon cancer: a randomised trial. *Lancet.* 2002;359(9325):2224–9. S0140673602092905 [pii].
42. Toda S, Kuroyanagi H. Laparoscopic surgery for rectal cancer: current status and future perspective. *Asian J Endosc Surg.* 2014;7(1):2–10. doi:[10.1111/ases.12074](https://doi.org/10.1111/ases.12074).
43. Bonjer HJ, Deijgen CL, Abis GA, Cuesta MA, van der Pas MH, de Lange-de Klerk ES, et al. A randomized trial of laparoscopic versus open surgery for rectal cancer. *N Engl J Med.* 2015;372(14):1324–32. doi:[10.1056/NEJMoa1414882](https://doi.org/10.1056/NEJMoa1414882).
44. Yamamoto S, Inomata M, Katayama H, Mizusawa J, Etoh T, Konishi F, et al. Short-term surgical outcomes from a randomized controlled trial to evaluate laparoscopic and open D3 dissection for stage II/III colon cancer: Japan Clinical Oncology Group Study JCOG 0404. *Ann Surg.* 2014;260(1):23–30. doi:[10.1097/SLA.0000000000000499](https://doi.org/10.1097/SLA.0000000000000499).
45. Miyajima N, Fukunaga M, Hasegawa H, Tanaka J, Okuda J, Watanabe M. Results of a multicenter study of 1,057 cases of rectal cancer treated by laparoscopic surgery. *Surg Endosc.* 2009;23(1):113–8. doi:[10.1007/s00464-008-0078-7](https://doi.org/10.1007/s00464-008-0078-7).
46. Fujii S, Yamamoto S, Ito M, Yamaguchi S, Sakamoto K, Kinugasa Y, et al. Short-term outcomes of laparoscopic intersphincteric resection from a phase II trial to evaluate

- laparoscopic surgery for stage 0/I rectal cancer: Japan Society of Laparoscopic Colorectal Surgery Lap RC. *Surg Endosc.* 2012;26(11):3067–76. doi:[10.1007/s00464-012-2317-1](https://doi.org/10.1007/s00464-012-2317-1).
47. Hida K, Hasegawa S, Kinjo Y, Yoshimura K, Inomata M, Ito M, et al. Open versus laparoscopic resection of primary tumor for incurable stage IV colorectal cancer: a large multicenter consecutive patients cohort study. *Ann Surg.* 2012;255(5):929–34. doi:[10.1097/SLA.0b013e31824a99e4](https://doi.org/10.1097/SLA.0b013e31824a99e4).
  48. Yang TX, Billah B, Morris DL, Chua TC. Palliative resection of the primary tumour in patients with Stage IV colorectal cancer: systematic review and meta-analysis of the early outcome after laparoscopic and open colectomy. *Colorectal Dis.* 2013;15(8):e407–19. doi:[10.1111/codi.12256](https://doi.org/10.1111/codi.12256).
  49. Zhou Y, Wu L, Li X, Wu X, Li B. Outcome of laparoscopic colorectal surgery in obese and nonobese patients: a meta-analysis. *Surg Endosc.* 2011;26(3):783–9. doi:[10.1007/s00464-011-1952-2](https://doi.org/10.1007/s00464-011-1952-2).
  50. Makino T, Shukla PJ, Rubino F, Milsom JW. The impact of obesity on perioperative outcomes after laparoscopic colorectal resection. *Ann Surg.* 2012;255(2):228–36. doi:[10.1097/SLA.0b013e31823dcbf7](https://doi.org/10.1097/SLA.0b013e31823dcbf7).
  51. Chand M, Siddiqui MR, Rasheed S, Brown G, Tekkis P, Parvaiz A, et al. A systematic review and meta-analysis evaluating the role of laparoscopic surgical resection of transverse colon tumours. *Surg Endosc.* 2014;28(12):3263–72. doi:[10.1007/s00464-014-3634-3](https://doi.org/10.1007/s00464-014-3634-3).
  52. Hinoi T, Kawaguchi Y, Hattori M, Okajima M, Ohdan H, Yamamoto S, et al. Laparoscopic versus open surgery for colorectal cancer in elderly patients: a multicenter matched case-control study. *Ann Surg Oncol.* 2014;22(6):2040–50. doi:[10.1245/s10434-014-4172-x](https://doi.org/10.1245/s10434-014-4172-x).
  53. Delgado S, Lacy AM, Garcia Valdecasas JC, Balague C, Pera M, Salvador L, et al. Could age be an indication for laparoscopic colectomy in colorectal cancer? *Surg Endosc.* 2000;14(1):22–6.
  54. Sklow B, Read T, Birnbaum E, Fry R, Fleshman J. Age and type of procedure influence the choice of patients for laparoscopic colectomy. *Surg Endosc.* 2003;17(6):923–9. doi:[10.1007/s00464-002-8949-9](https://doi.org/10.1007/s00464-002-8949-9).
  55. Chautard J, Alves A, Zalinski S, Bretagnol F, Valleur P, Panis Y. Laparoscopic colorectal surgery in elderly patients: a matched case-control study in 178 patients. *J Am Coll Surg.* 2008;206(2):255–60. doi:[10.1016/j.jamcollsurg.2007.06.316](https://doi.org/10.1016/j.jamcollsurg.2007.06.316). S1072-7515(07)01099-X [pii].
  56. Person B, Cera SM, Sands DR, Weiss EG, Vernava AM, Noguera JJ, et al. Do elderly patients benefit from laparoscopic colorectal surgery? *Surg Endosc.* 2008;22(2):401–5. doi:[10.1007/s00464-007-9412-8](https://doi.org/10.1007/s00464-007-9412-8).
  57. Tomimaru Y, Ide Y, Murata K. Outcome of laparoscopic surgery for colon cancer in elderly patients. *Asian J Endosc Surg.* 2011;4(1):1–6. doi:[10.1111/j.1758-5910.2010.00061.x](https://doi.org/10.1111/j.1758-5910.2010.00061.x).
  58. Glenn DR, McClure N, Lewis SE. The hidden impact of diabetes on male sexual dysfunction and fertility. *Hum Fertil (Camb).* 2003;6(4):174–9. huf0060174 [pii].
  59. Hida K, Hasegawa S, Kataoka Y, Nagayama S, Yoshimura K, Nomura A, et al. Male sexual function after laparoscopic total mesorectal excision. *Colorectal Dis.* 2012;15(2):244–51. doi:[10.1111/j.1463-1318.2012.03170.x](https://doi.org/10.1111/j.1463-1318.2012.03170.x).
  60. Lim RS, Yang TX, Chua TC. Postoperative bladder and sexual function in patients undergoing surgery for rectal cancer: a systematic review and meta-analysis of laparoscopic versus open resection of rectal cancer. *Tech Coloproctol.* 2014;18(11):993–1002. doi:[10.1007/s10151-014-1189-x](https://doi.org/10.1007/s10151-014-1189-x).
  61. Sylla P, Rattner DW, Delgado S, Lacy AM. NOTES transanal rectal cancer resection using transanal endoscopic microsurgery and laparoscopic assistance. *Surg Endosc.* 2010;24(5):1205–10. doi:[10.1007/s00464-010-0965-6](https://doi.org/10.1007/s00464-010-0965-6).
  62. Tuech JJ, Bridoux V, Kianifard B, Schwarz L, Tsilivlidis B, Huet E, et al. Natural orifice total mesorectal excision using transanal port and laparoscopic assistance. *Eur J Surg Oncol.* 2011;37(4):334–5. doi:[10.1016/j.ejso.2010.12.016](https://doi.org/10.1016/j.ejso.2010.12.016). S0748-7983(10)00634-7 [pii].
  63. Bucher P, Pugin F, Morel P. Single port access laparoscopic right hemicolectomy. *Int J Colorectal Dis.* 2008;23(10):1013–6. doi:[10.1007/s00384-008-0519-8](https://doi.org/10.1007/s00384-008-0519-8).

64. Remzi FH, Kirat HT, Kaouk JH, Geisler DP. Single-port laparoscopy in colorectal surgery. *Colorectal Dis.* 2008;10(8):823–6. doi:[10.1111/j.1463-1318.2008.01660.x](https://doi.org/10.1111/j.1463-1318.2008.01660.x). CD11660 [pii].
65. Fung AK, Aly EH. Systematic review of single-incision laparoscopic colonic surgery. *Br J Surg.* 2012;99(10):1353–64. doi:[10.1002/bjs.8834](https://doi.org/10.1002/bjs.8834).
66. Maggiori L, Gaujoux S, Tribillon E, Bretagnol F, Panis Y. Single-incision laparoscopy for colorectal resection: a systematic review and meta-analysis of more than a thousand procedures. *Colorectal Dis.* 2012;14(10):e643–54. doi:[10.1111/j.1463-1318.2012.03105.x](https://doi.org/10.1111/j.1463-1318.2012.03105.x).
67. Katsuno G, Fukunaga M, Nagakari K, Yoshikawa S, Azuma D, Kohama S. Short-term and long-term outcomes of single-incision versus multi-incision laparoscopic resection for colorectal cancer: a propensity-score-matched analysis of 214 cases. *Surg Endosc.* 2015. doi:[10.1007/s00464-015-4371-y](https://doi.org/10.1007/s00464-015-4371-y).
68. Lujan JA, Soriano MT, Abrisqueta J, Perez D, Parrilla P. Single-port colectomy vs multi-port laparoscopic colectomy. Systematic review and meta-analysis of more than 2800 procedures. *Cir Esp.* 2015;93(5):307–19. doi:[10.1016/j.ciresp.2014.11.009](https://doi.org/10.1016/j.ciresp.2014.11.009). S0009-739X(14)00373-X [pii].
69. Yang Y, Wang F, Zhang P, Shi C, Zou Y, Qin H, et al. Robot-assisted versus conventional laparoscopic surgery for colorectal disease, focusing on rectal cancer: a meta-analysis. *Ann Surg Oncol.* 2012;19(12):3727–36. doi:[10.1245/s10434-012-2429-9](https://doi.org/10.1245/s10434-012-2429-9).
70. Trinh BB, Jackson NR, Hauch AT, Hu T, Kandil E. Robotic versus laparoscopic colorectal surgery. *JLS.* 2014;18(4). doi:[10.4293/JLS.2014.00187](https://doi.org/10.4293/JLS.2014.00187). JLS-D-14-00187 [pii].

---

# Laparoscopic Right-Sided Colectomy (Ileocecal Resection, Right Hemicolectomy, Extended Right Hemicolectomy)

# 3

Junichiro Kawamura, Kazuki Ueda, Haruhiko Imamoto,  
and Kiyotaka Okuno

---

## Abstract

The most common disease for right-sided colectomy is right-sided colon cancer. Although transverse colon cancer has been excluded from most of the major prospective randomized controlled trials due to technical concerns, laparoscopic surgery for right-sided colon cancer has been well established. The procedure of right-sided colectomy is divided into four parts: (1) mobilization of the right colon and its mesentery; (2) division of the vascular pedicles; (3) division of the lateral attachments, hepatic flexure, and omental attachments; and (4) specimen extraction and anastomosis. There are four commonly used approaches to a laparoscopic right-sided colectomy, namely, the medial, inferior, lateral, and superior approaches. The most important thing in all approaches is to create and maintain proper tension during the procedure by corporation between both hands of the assistant and the surgeon's one hand. We will present a safe and steady procedure for right-sided colectomy with the regional lymph node dissection along the superior mesenteric vein.

---

## Keywords

Laparoscopy • Right-sided colon cancer • Right colectomy • Lymph node dissection • Inferior approach

---

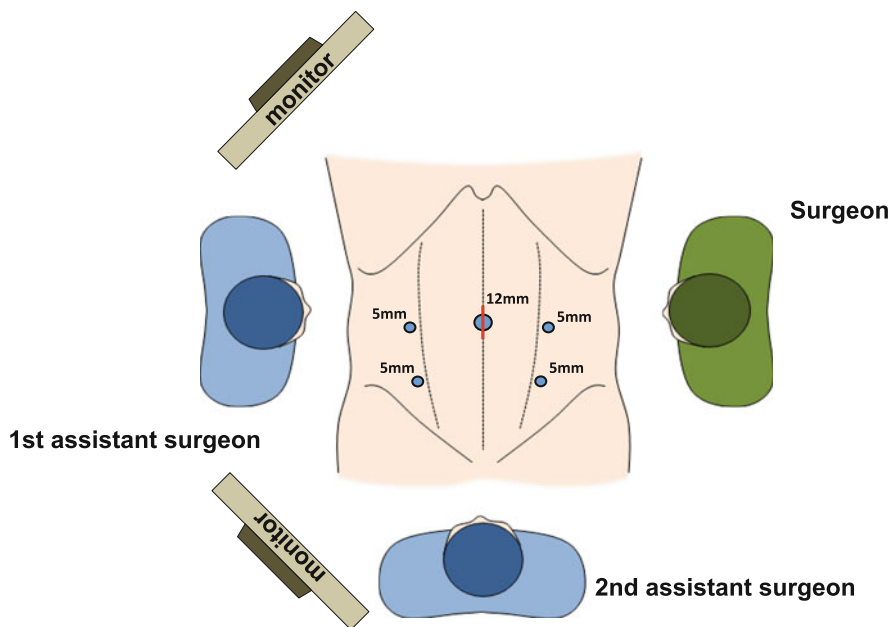
J. Kawamura, MD (✉) • K. Ueda • H. Imamoto • K. Okuno  
Department of Surgery, Faculty of Medicine, Kinki University, 377-2 Ohno Higashi, Osaka  
Sayama, Osaka 589-8511, Japan  
e-mail: [kawamura@surg.med.kindai.ac.jp](mailto:kawamura@surg.med.kindai.ac.jp)

### 3.1 Patient Positioning and Operating Room Setup

The patient is placed in a modified lithotomy position with the legs placed in padded, adjustable stirrups and subjected to intermittent pneumatic compression. Both arms are positioned routinely alongside the body, although the right arm could be placed at a 90° angle. The surgeon stands on the patient's left side, the assistant on the right side, and the second assistant (camera operator) between the patient's legs or on the left side. The main monitor is placed near the patient's right shoulder, and the second monitor is placed near the patient's right leg (Fig. 3.1). The operating team views the same monitor throughout the entire procedure.

### 3.2 Instruments

Specific instruments recommended for laparoscopic right hemicolectomy are 5 cannulas (1 × 12 mm, 4 × 5 mm), 1 dissecting device (ultrasonic shears and electrocautery), 1 laparoscopic dissector, and 4 laparoscopic bowel graspers.



**Fig. 3.1** Position of the equipment and the surgical team for the laparoscopic right-sided colectomy. The second assistant (camera operator) stands between the patient's legs or on the left side depending on situations.

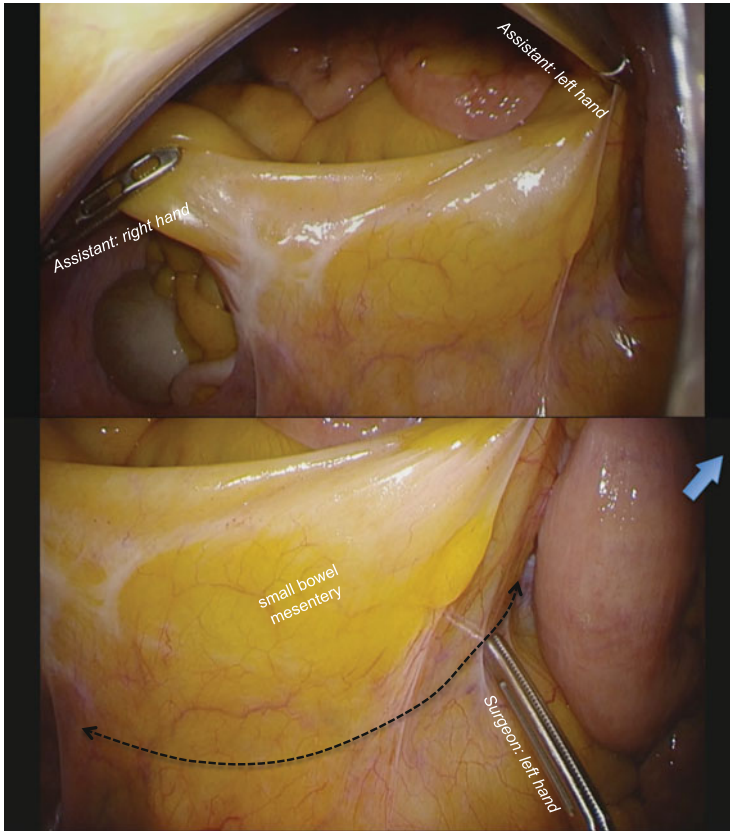


### 3.3 Cannula Positioning

We routinely use the “open Hasson” technique to safely insert the first cannula through the umbilicus. Pneumoperitoneum is established and maintained at 8 mmHg. Then, cannulas are placed in the following order (all 5 mm): left lower abdominal region, left middle, right lower, and right middle abdominal regions. The surgeon uses the left-sided cannulas and the assistant uses the right-sided cannulas [1] (Fig. 3.1).

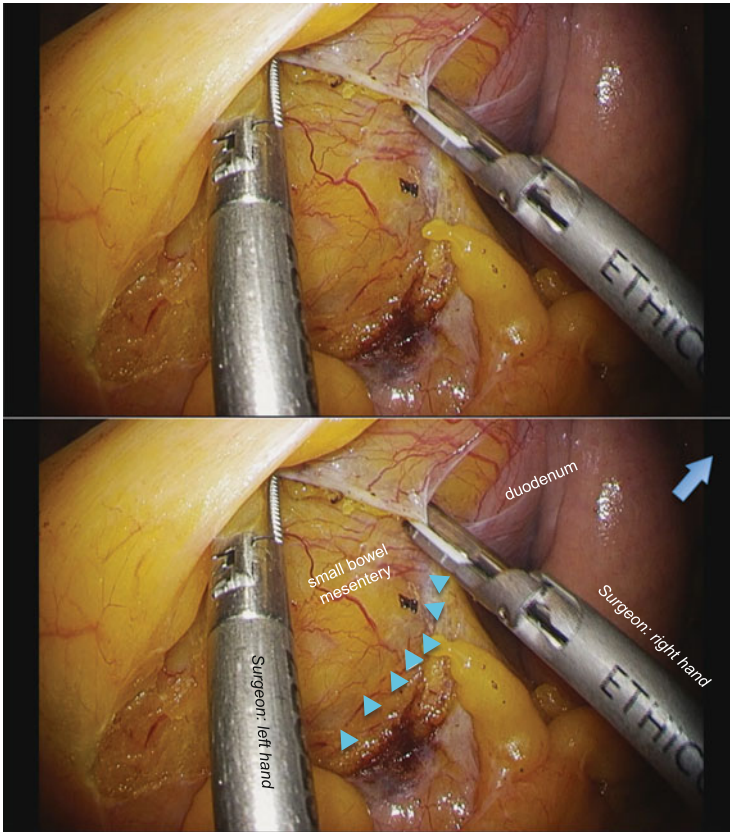
### 3.4 Technique

The procedure is divided into four parts: (1) mobilization of the right colon and its mesentery; (2) division of the vascular pedicles; (3) division of the lateral attachments, hepatic flexure, and omental attachments; and (4) specimen extraction and anastomosis. There are four commonly used approaches to a laparoscopic right-sided colectomy, namely, the medial, inferior, lateral, and superior approaches. We prefer to use the inferior approach to mobilize the right colonic mesentery because it enables faster and wider mobilization of the right colon compared with the medial approach and also makes the subsequent division of the vascular pedicles easier. The operating table is tilted into the Trendelenburg position with the right side slightly down to move the small intestine toward the right upper quadrant. After the omentum and transverse colon are moved toward the upper abdomen and the small intestine toward the upper right quadrant, the assistant grasps the small bowel mesentery near the terminal ileum and near the ligament of Treitz and retracts widely to allow the surgeon to identify the imaginary dissection plane between the small bowel mesentery and the retroperitoneum (Fig. 3.2). This is at a slight reverse angle to the scope and takes time to master, so the surgeon should help the assistant to grasp the mesentery properly. The surgeon needs to confirm the correct orientation of the field; if the imaginary dissection plane is not identified, another attempt is made in cooperation with the assistant. After creating the proper field, the surgeon incises the mesentery to identify the dissection plane, which lies between the shiny surface of the small bowel mesentery and meshwork tissue of the retroperitoneum (Fig. 3.3). The plane is developed underneath the small bowel mesentery until the duodenum is identified cranially (Fig. 3.4). The plane is developed laterally to identify the right ureter and the gonadal vessels underneath the retroperitoneum. Using the left hand, the surgeon lifts up the small bowel mesentery and, using the right hand, sweeps down the right ureter and the gonadal vessels underneath the retroperitoneum (Fig. 3.5). Dissection to the caudal portion of the pancreas is needed to facilitate the medial approach. After completing the lateral dissection to the base of the ileal mesentery, the peritoneum is incised, and the lateral attachment of the ascending colon is divided around the cecum. Surgical gauze could be placed on the dissection plane as a landmark for the medial approach.



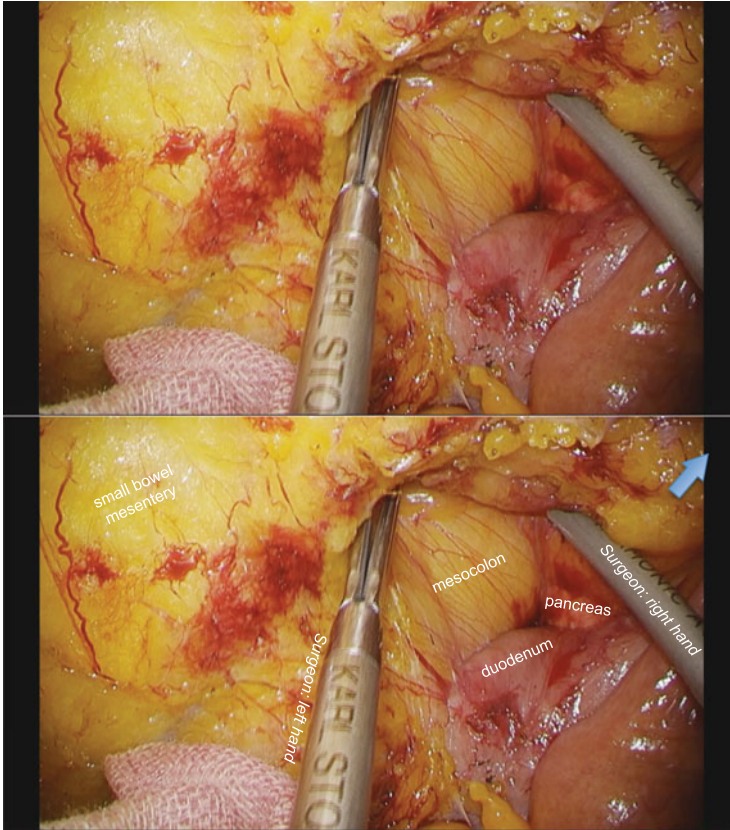
**Fig. 3.2** The assistant grasps the small bowel mesentery near the terminal ileum and near the ligament of Treitz and retracts widely to allow the surgeon to identify the imaginary dissection line (dotted line) between the small bowel mesentery and the retroperitoneum. The blue arrow indicates the caudal direction

Next, the medial approach is commenced. The operating table is reversed and tilted slightly into the Trendelenburg position with the left side down. The small intestine is moved to the left side of the abdomen, the omentum and transverse colon are moved toward the upper abdomen, and the ventral side of the right colon is visualized. The surgeon lifts up the mesocolon near the ileocecal junction to identify the “ridge” of ileocolic vessels, which is grasped by the assistant’s right hand (Fig. 3.6). The peritoneum is incised between the ridge and the periphery of the superior mesenteric vein to identify the previously dissected plane (surgical gauze) easily. The assistant retracts the ileocolic pedicle ventrally using the right hand and raises cephalad the transverse mesocolon slightly using the left hand in order to identify the ileocolic vessels and the superior mesenteric vessels. The peritoneum is incised over the superior mesenteric vessels from the previously incised peritoneum below the ileocolic pedicle. The surgeon should grasp and



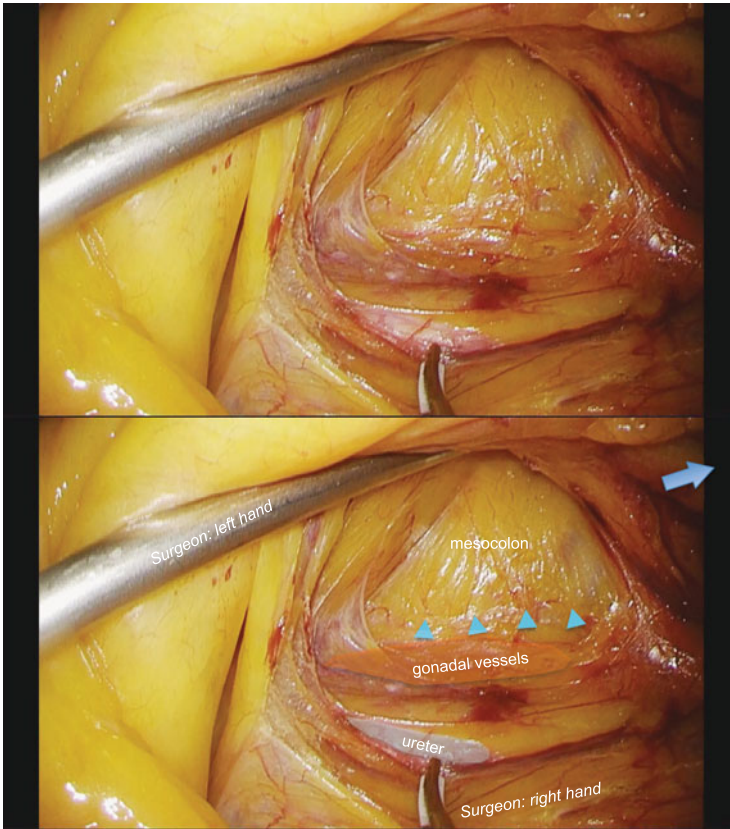
**Fig. 3.3** The dissection plane lies between the shiny surface of the small bowel mesentery and meshwork tissue of the retroperitoneum (*blue arrowheads*). The *blue arrow* indicates the caudal direction

retract the cut edge of the peritoneum with adequate traction of the ileocolic pedicles in order to confirm the root of the ileocolic vein and the surface of the superior mesenteric vein (Fig. 3.7). The mesocolon is dissected to expose the second portion of the duodenum and the pancreas head widely (Fig. 3.8). Care must be taken not to dissect between the duodenum and the pancreatic tissue. The root of the ileocolic vessels is usually located at the lower border of the duodenum. The ileocolic artery runs either in front of or behind the superior mesenteric vein, with approximately the same frequency. In the former case, the ileocolic artery is cut at the root; in the latter case, the artery is cut at the right border of the superior mesenteric vein, although the boundary for radical lymph node dissection along the surgical trunk for advanced right colon cancer is always on the left border of the superior mesenteric vein (Figs. 3.9 and 3.10). The dissection of the cellular adipose tissue at the ventral side of the superior mesenteric vessels is continued to expose the origin of the ileocolic vessels, and the ileocolic vessels are cut at their root. After



**Fig. 3.4** The plane is developed underneath the small bowel mesentery until the duodenum is identified cranially. The *blue arrow* indicates the caudal direction

dividing the ileocolic vessels, the ascending mesocolon is separated from the retroperitoneal tissues, duodenum, and pancreas head, up to the hepatocolic ligament cranially. The surgeon lifts up the ascending mesocolon, and the assistant holds it with two bowel graspers placed through the dissection window. The right mesocolon is dissected away from the duodenum and the retroperitoneal structures from medial to lateral, and the hepatocolic ligament could be ruptured with continued dissection (Fig. 3.11). The most important points are to separate the pancreas head and mesocolon widely and maintain the elevation of the ascending and transverse mesocolon. This maneuver is accomplished by the assistant grasping the pedicle of the ileocolic vessels with a grasper in the left hand and holding the ascending mesocolon with another grasper in the right hand (Fig. 3.12). This part of the procedure reveals the course of right colic artery and vein (if present) and the accessory right colic vein running on the dorsal surface of the transverse mesocolon. The dissection along the superior mesenteric vessels is continued cephalad to expose the root of the gastrocolic trunk, and then the imaginary line

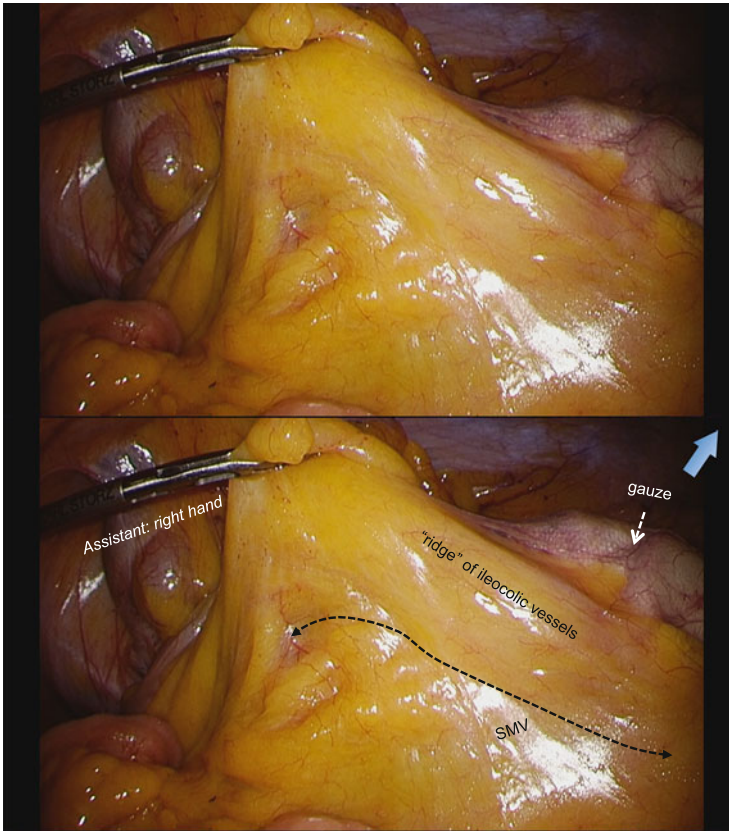


**Fig. 3.5** The right ureter and the gonadal vessels were swept down from ascending mesocolon underneath the meshwork tissue of the retroperitoneum (*blue arrowheads*). The *blue arrow* indicates the caudal direction

connecting the gastrocolic trunk and the accessory right colic vein is identified (Fig. 3.13). The right colic artery or the middle colic artery is occasionally identified to the right of the gastrocolic trunk, and in such cases, these arteries could be cut at their roots prior to the dissection around the gastrocolic trunk.

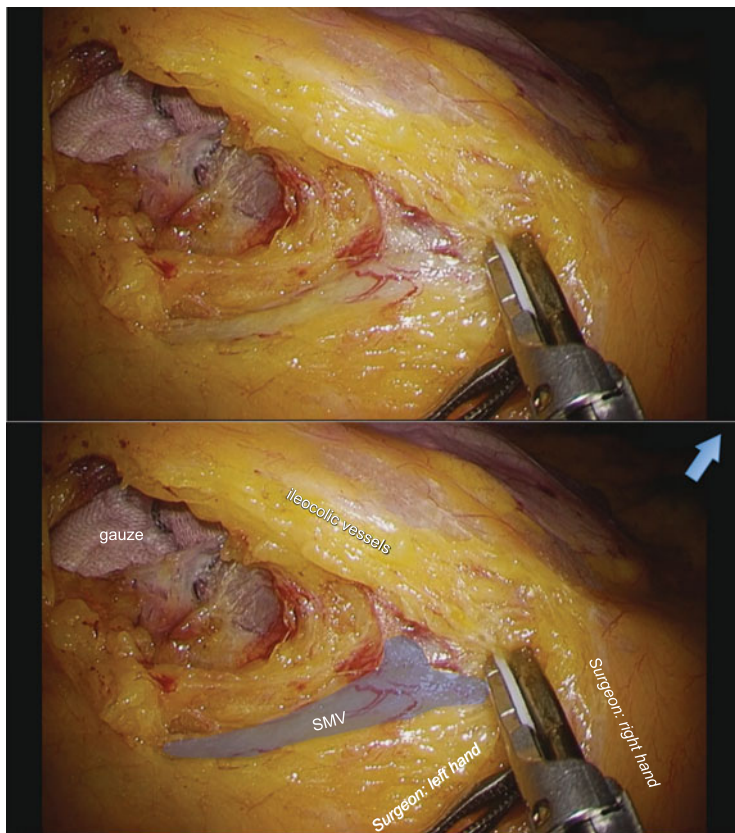
After confirming the line connecting the gastrocolic trunk and the accessory right colic vein, careful dissection is performed around the gastrocolic trunk peripherally from the root, revealing the anterior superior pancreaticoduodenal vein, which runs from the head of the pancreas, and the right gastroepiploic vein, which runs tangentially to the transverse mesocolon. The accessory right colic vein is clipped and divided. Sometimes an accessory right colic vein is difficult to confirm in this situation; the vein may be detected later at the takedown of the right flexure.

When a tumor is advanced and located in the transverse colon, lymph node dissection around the middle colic artery is usually required, and this artery is cut at



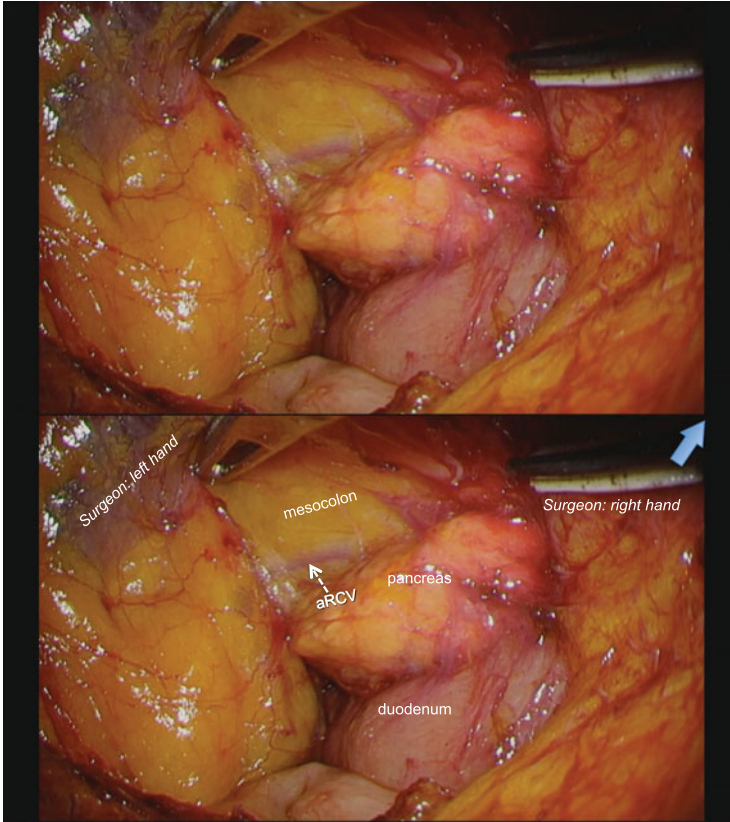
**Fig. 3.6** The “ridge” of ileocolic vessels is grasped by the assistant’s right hand. The peritoneum is incised between the ridge and the periphery of the superior mesenteric vein (*dotted line*). The *blue arrow* indicates the caudal direction

the root. Although the boundary for radical lymph node dissection along the surgical trunk for advanced right colon cancer is on the left border of the superior mesenteric vein, the incisional line should be drawn over the superior mesenteric artery, and the cellular adipose tissue around the root of the middle colic artery should be dissected (Fig. 3.14). The second assistant stands between the patient’s legs. The peritoneum is incised toward the ligament of Treitz. The middle colic artery is usually encountered to the right of the gastrocolic trunk. The middle colic artery can be identified by lifting the peripheral portion of the middle colic vessel that is visible on the transverse mesocolon. The dissection plane should be over the mesh-like nerve plexus around the superior mesenteric artery, and once the surgeon identifies this structure, the root of the middle colic artery can be identified (Fig. 3.15). The surgeon should take care to avoid injury to the pancreatic tissue during dissection around the root of the middle colic artery. The assistant elevates the transverse mesocolon in the vertical plane with both hands, accomplished by



**Fig. 3.7** The cut edge of the peritoneum is retracted in order to confirm the root of the ileocolic vein and the surface of the superior mesenteric vein. The *blue arrow* indicates the caudal direction

holding the left side of the transverse mesocolon with a grasper in the right hand and holding the right side with a grasper in the left hand (a “matador-like” maneuver). The surgeon incises transversely the planned resection line on the transverse mesocolon to the left of the middle colic vessels to maintain a 10 cm margin from the tumor edge. With this maneuver, a free space usually emerges into the lesser sac, and the lower edge of the pancreatic body is identified in order to avoid injury to the pancreatic tissue (Fig. 3.16). The pancreas head is already identified to the right of the middle colic vessels along the gastrocolic trunk, and the imaginary line connecting the lower edge of the pancreas head and body can be obtained. The dissection at the ventral side of the superior mesenteric vessels is very important to identify the root of the middle colic vein, and in doing so, the surgeon can see where the middle colic artery runs from its right side. The surgeon can dissect and cut the middle colic artery at its root. The dissection at the ventral side of the superior mesenteric vessels is further continued to reach the origin of the middle colic vein (Fig. 3.17). The middle colic vein is cut at its root.

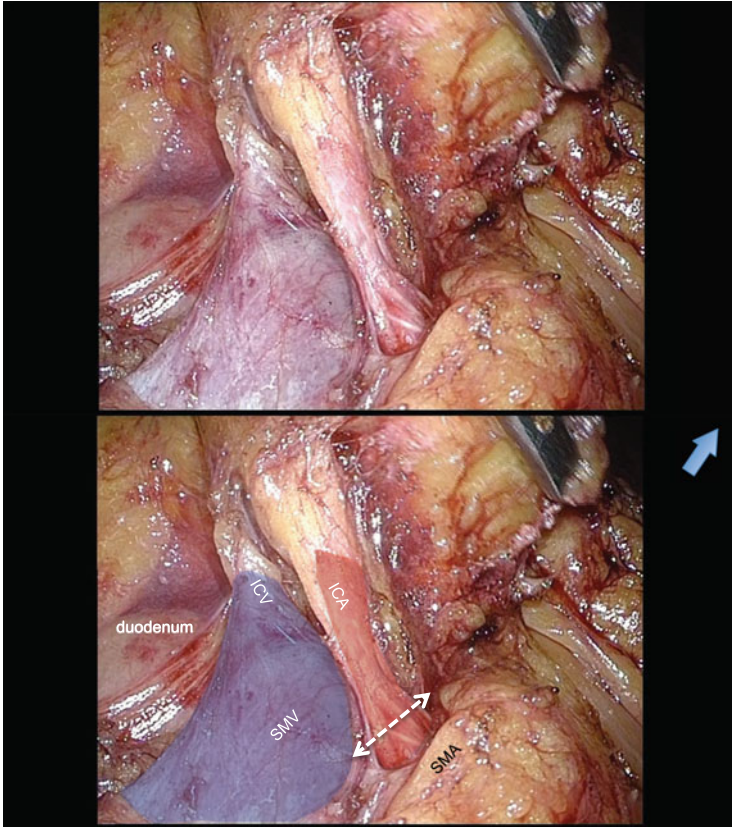


**Fig. 3.8** The mesocolon is dissected to expose the second portion of the duodenum and the pancreas head widely. The *blue arrow* indicates the caudal direction

When the tumor is located in the ascending colon, division of the right branch of the middle colic artery is adequate for radical lymph node dissection. Once the middle colic artery is identified to the right of the gastocolic trunk by lifting the peripheral portion of the middle colic vessel visible on the transverse mesocolon, the surgeon separates the adipose tissue along the middle colic artery and divides the right branch of the middle colic artery near its origin (Fig. 3.18).

The ascending mesocolon has already been almost separated from the retroperitoneal structures through the inferior and medial approaches. The lateral approach is now commenced. The assistant grasps the appendix or cecum with a grasper in the right hand and the middle of the ascending colon with a grasper in the left hand to move the ascending colon medially (Fig. 3.19). There is an open space, which has been dissected previously during the medial mobilization of the right colon mesentery. If the dissection between the ascending mesocolon and the retroperitoneal tissues is not enough, the surgeon can dissect the right mesocolon away from the retroperitoneal structures from medial to lateral again; only a fine line of attachment

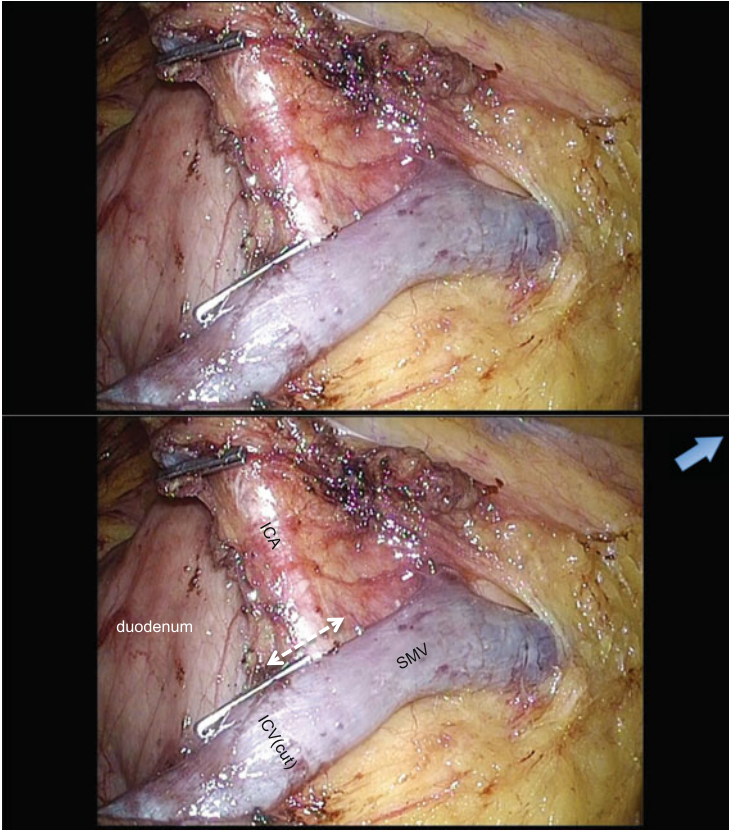




**Fig. 3.9** The ileocolic artery is cut at the root in the case the ileocolic artery runs in front of the superior mesenteric vein. The *blue arrow* indicates the caudal direction

of the colon to the lateral sidewall remains afterward. The attachment is easily divided. The dissection then continues caudally up to and over the duodenum, and then the lateral attachment is divided further. Around the hepatic flexure, the greater omentum is attached to the distal ascending colon, and the omentum can be divided from the ascending colon to the extent necessary that allows the surgeon to undertake the lateral approach when the tumor is located in the proximal ascending colon.

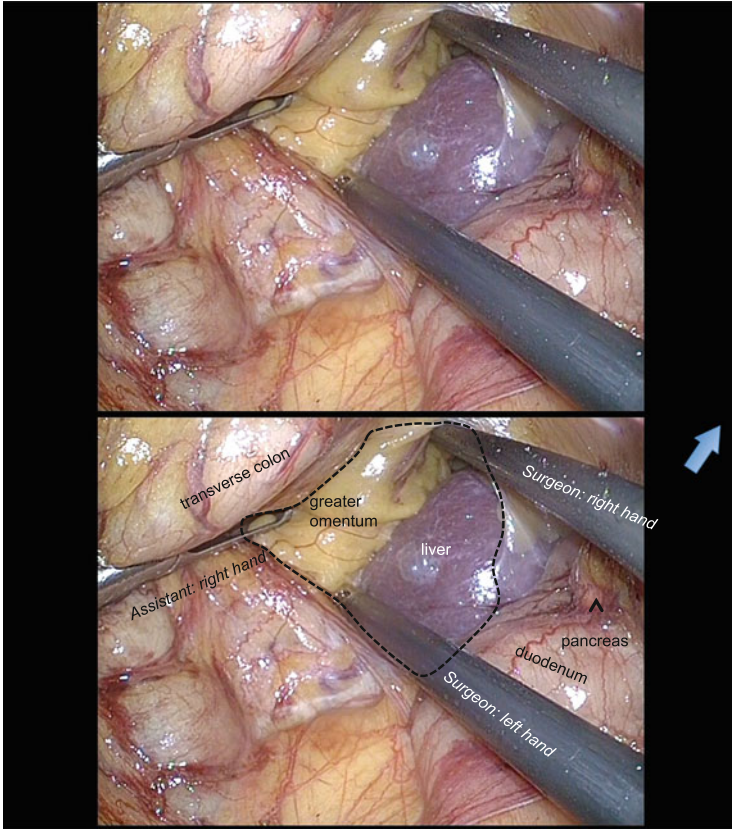
When the tumor is located in the distal ascending colon or the transverse colon, the greater omentum is dissected using a superior approach, keeping the right omentum on the specimen. The operating table is tilted into the slightly head-down position. The assistant elevates the omentum in the vertical plane with both hands and the surgeon provides countertraction to divide the greater omentum to the left midline where the lesser sac is usually well developed, although the greater omentum and the transverse mesocolon are fused to each other to varying degrees (Fig. 3.20). Once the lesser sac is entered, the dissection is continued until the



**Fig. 3.10** The ileocolic artery is cut at the right border of the superior mesenteric vein in the case the ileocolic artery runs behind the superior mesenteric vein. The *blue arrow* indicates the caudal direction

previously dissected plane in the lateral approach is encountered. Then, the right colon is fully mobilized from the surrounding tissue, and the hepatic flexure can be taken down from left to right, and the proximal transverse mesocolon can be easily divided. Up to this point, the entire right colon is mobilized.

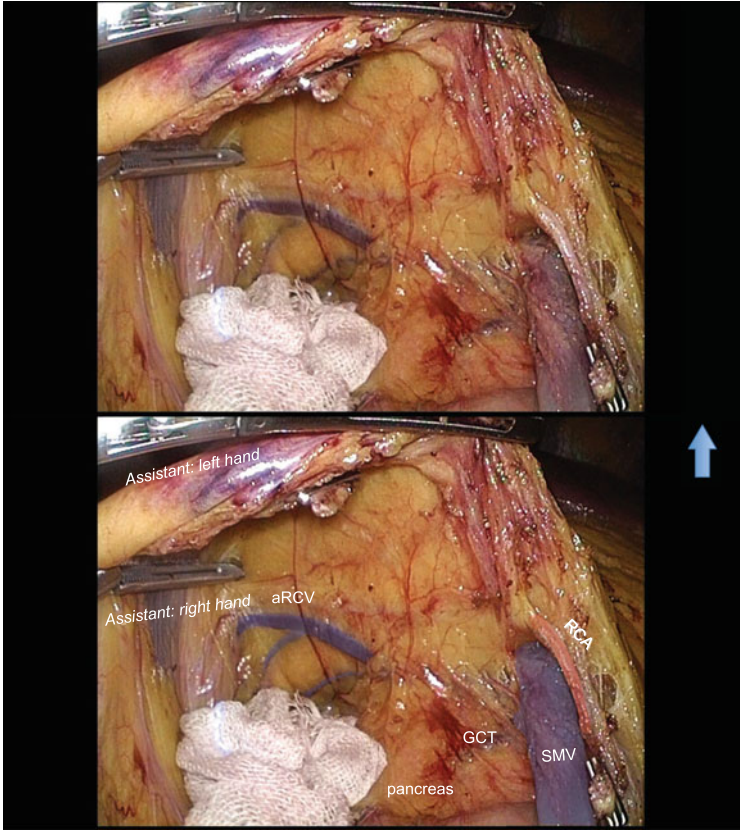
The umbilical wound is extended in a craniocaudal direction for an additional 3 cm. A wound protector is inserted and the right colon is exteriorized. The resection of the ileum and the colon and the anastomosis are accomplished extracorporeally by functional end-to-end anastomosis. We prefer the closed method of the functional end-to-end anastomosis because of the reduced surgical site infection rate compared with the open method [2]. The ileal mesentery and the colonic mesentery are divided while preserving good blood flow to the residual colon, and the ileum and colon are divided separately using a linear stapler. Small holes are made in the walls, and another stapler is then inserted into the ileum and the colon through these holes to perform the side-to-side anastomosis. Finally, another



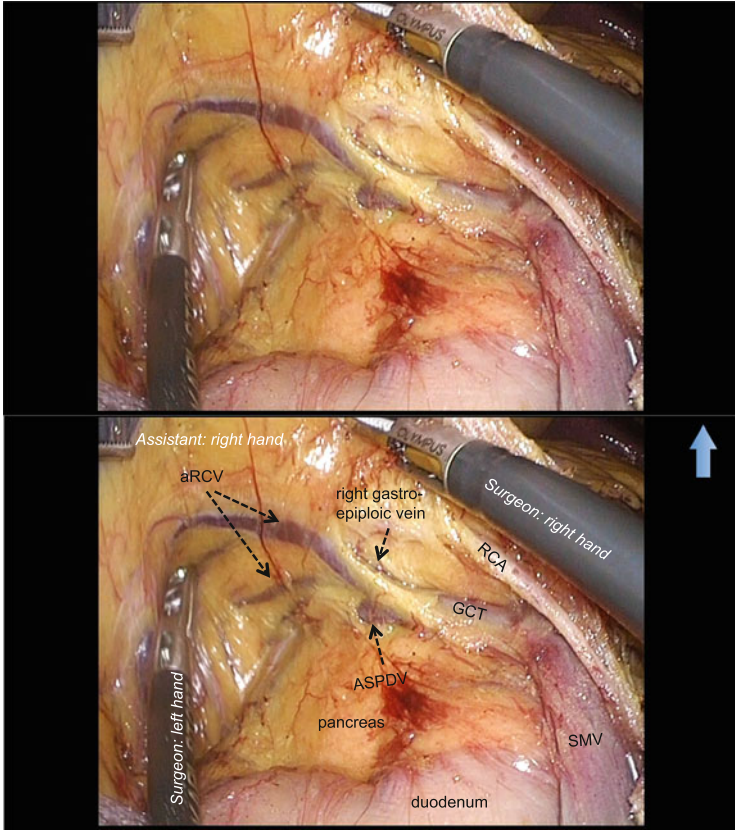
**Fig. 3.11** The hepatocolic ligament is ruptured with medial to lateral approach (*dotted line*). The *blue arrow* indicates the caudal direction

stapler closes the holes. Four cartridges are used for this method. The stapled edge and parts of the double-stapled edge are usually inverted and reinforced with interrupted sutures. The bowel is placed back in the abdomen. The orientation of the small bowel is confirmed, hemostasis is confirmed, and the mesenteric defect should not be trapping any part of the bowel.

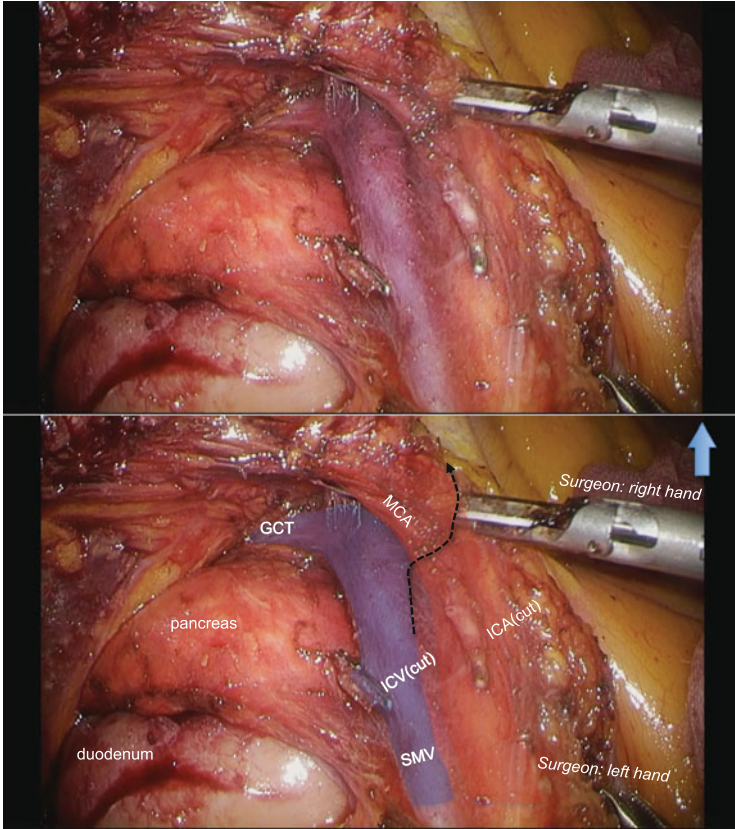
The wound retractor is removed. All ports are removed. The fascia of the minilaparotomy is closed with interrupted #0 Polysorb sutures. The wounds are irrigated and closed with 4-0 subcuticular sutures. Steri-Strips are applied and the wounds are dressed.



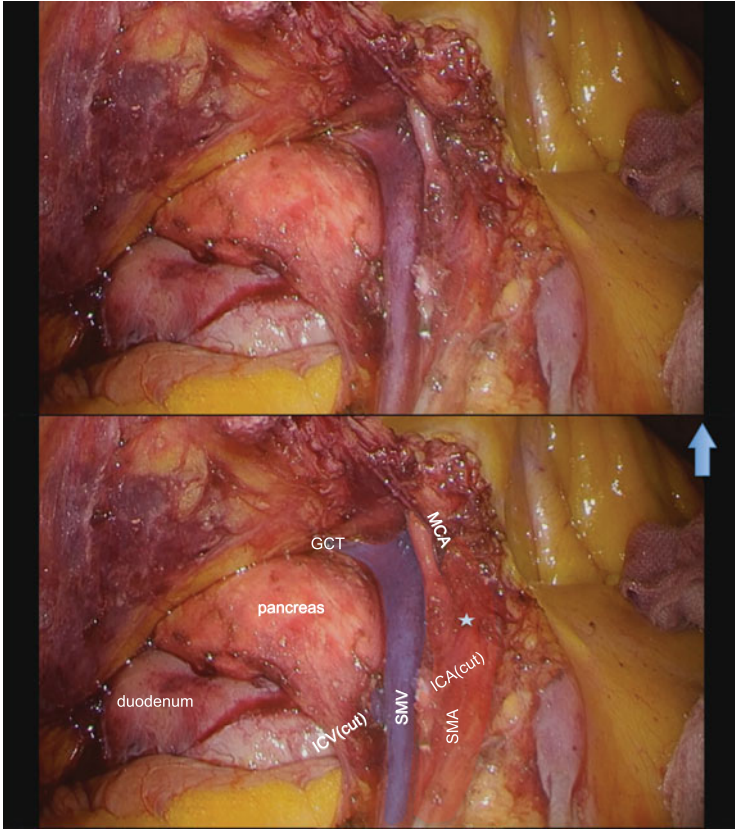
**Fig. 3.12** The assistant grasps the pedicle of the ileocolic vessels with a grasper in the left hand and holds the ascending mesocolon with another grasper in the right hand. The *blue arrow* indicates the caudal direction



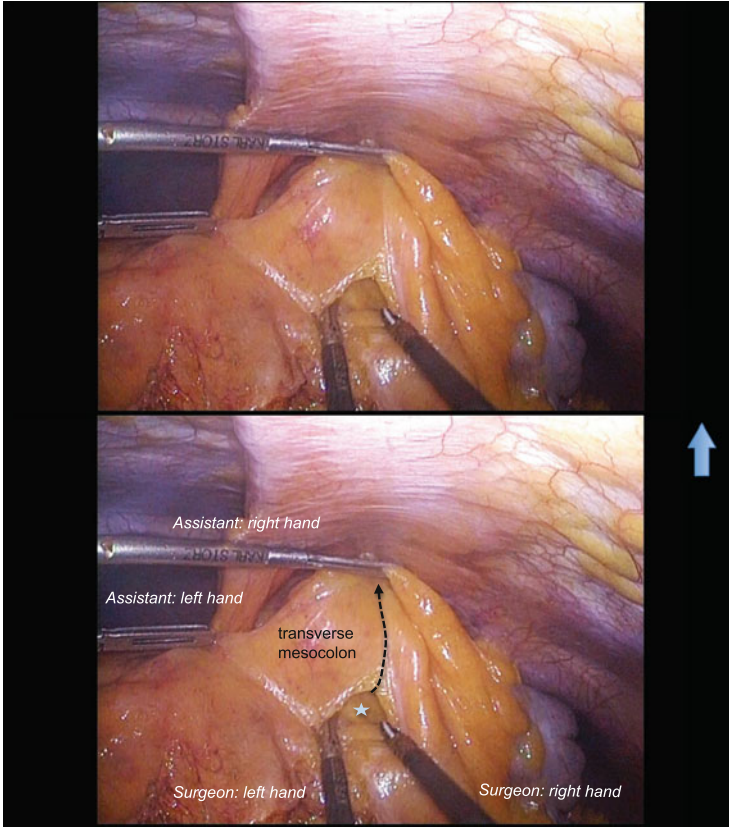
**Fig. 3.13** Careful dissection around the gastrocolic trunk reveals the anterior superior pancreaticoduodenal vein, which runs from the head of the pancreas, and the right gastroepiploic vein, which runs tangentially to the transverse mesocolon. The blue arrow indicates the caudal direction



**Fig. 3.14** The incisional line should be drawn over the superior mesenteric artery around the middle colic artery (*dotted line*), and the cellular adipose tissue around the root should be dissected. The *blue arrow* indicates the caudal direction

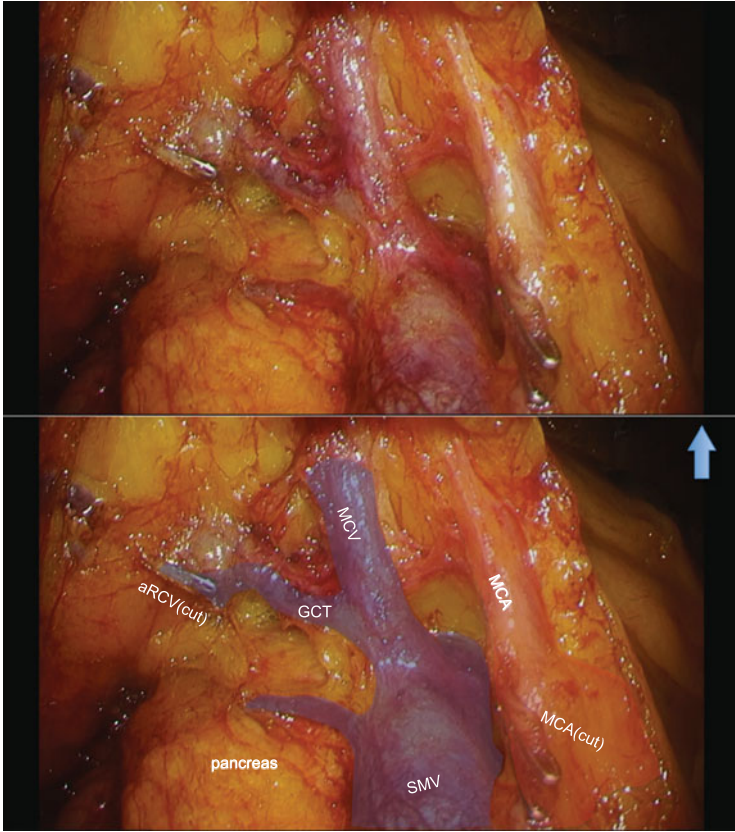


**Fig. 3.15** The dissection plane should be over the mesh-like nerve plexus (*asterisk*) around the superior mesenteric artery, and once the surgeon identifies this structure, the root of the middle colic artery can be identified. The *blue arrow* indicates the caudal direction

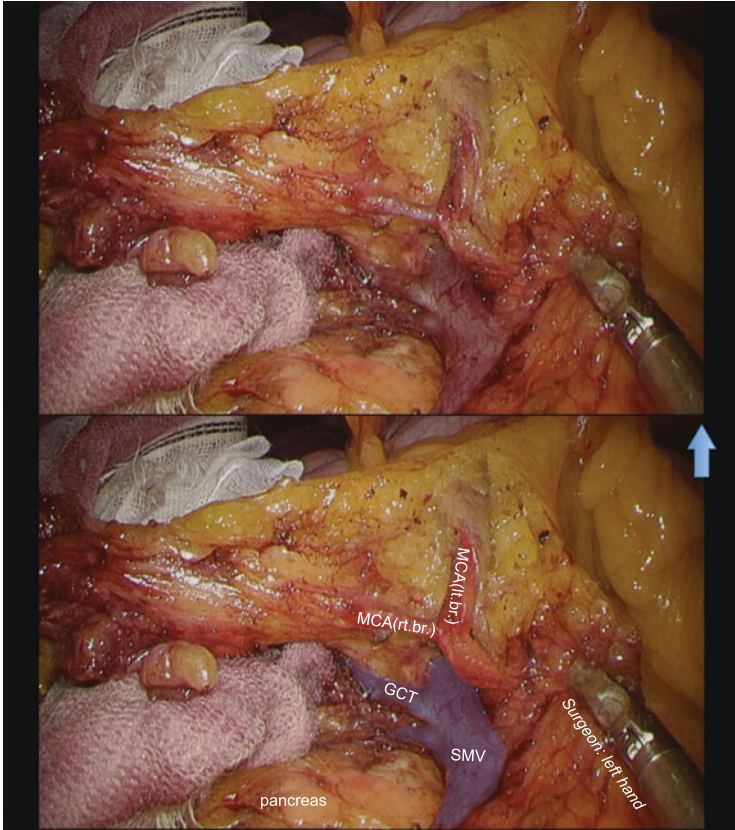


**Fig. 3.16** The planned resection line (*dotted line*) is incised on the transverse mesocolon to save a 10 cm margin from the tumor edge. By this maneuver, a free space usually emerges into the lesser sac (*asterisk*). The *blue arrow* indicates the caudal direction

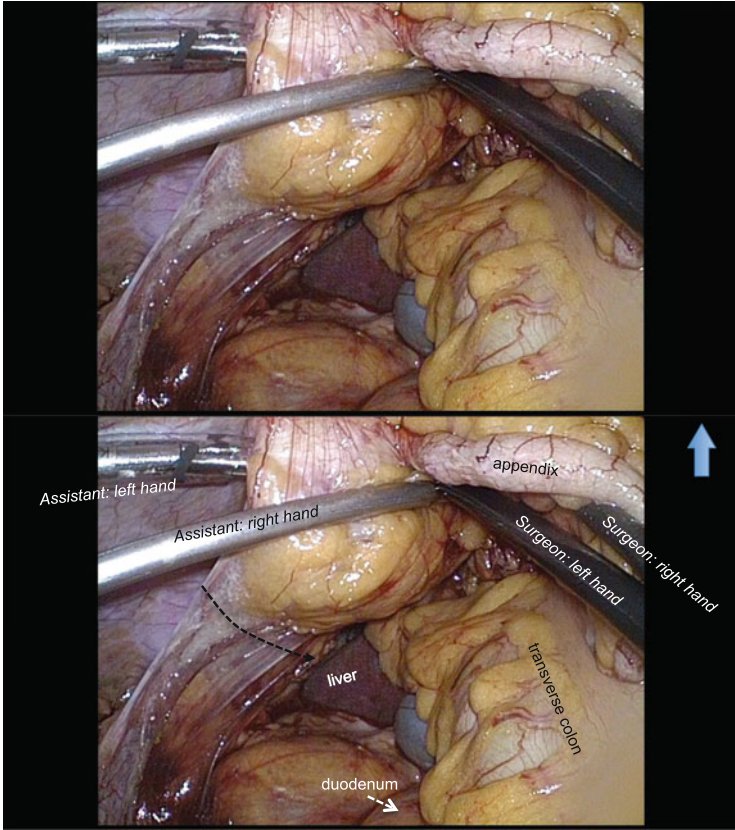




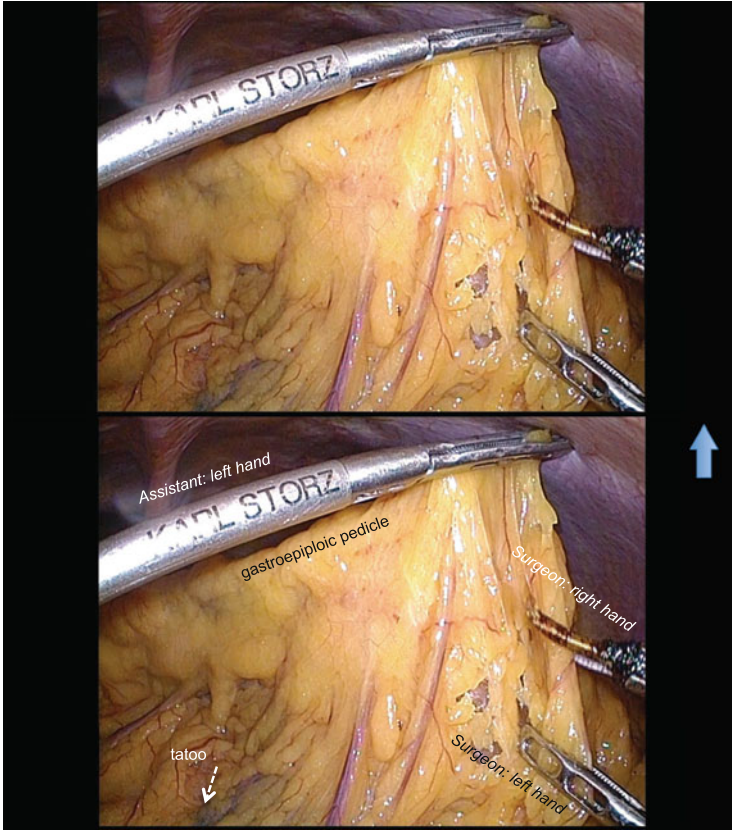
**Fig. 3.17** The dissection at the ventral side of the superior mesenteric vessels is further continued to reach the origin of the middle colic vein. The *blue arrow* indicates the caudal direction



**Fig. 3.18** The adipose tissue along the middle colic artery is separated and the right branch of the middle colic artery is divided near its origin. The *blue arrow* indicates the caudal direction



**Fig. 3.19** The lateral approach; there is an open space, which has been dissected previously during the medial mobilization of the right colon mesentery. A fine line (*dotted line*) of attachment of the colon to the lateral sidewall is easily divided. The *blue arrow* indicates the caudal direction



**Fig. 3.20** The superior approach; the omentum is elevated in the vertical plane with graspers in assistant's both hands. The *blue arrow* indicates the caudal direction

## References

1. Hasegawa S, Kawamura J, Nagayama S, Nomura A, Kondo K, Sakai Y. Medially approached radical lymph node dissection along the surgical trunk for advanced right-sided colon cancers. *Surg Endosc.* 2007;21:1657.
2. Ojima H, Sohda M, Ando H, Sano A, Fukai Y, Ogawa A, et al. Relationship between functional end-to-end anastomosis for colon cancer and surgical site infections. *Surg Today.* 2015;22:3653–8.

Kenji Kawada, Gen Nishikawa, Hisashi Shinohara,  
and Suguru Hasegawa

---

## Abstract

Although laparoscopic surgery is one of the treatment options for colorectal cancer, certain technical problems remain unresolved. In particular, laparoscopic transverse colectomy is one of the most technically challenging laparoscopic colectomy. The most difficult aspect is mobilization of the transverse colon, with division of the middle colic artery. Here we present a safe procedure for laparoscopic transverse colectomy to dissect the regional lymph nodes along the superior mesenteric vessels. The key characteristic of our procedure is that the middle colic vessels are cut along the surgical trunk using only a medial approach.

---

## Keywords

Laparoscopic surgery • Transverse colectomy • Surgical procedure • Lymph node dissection

---

## 4.1 Introduction

Transverse colon cancer is defined as a cancer between the hepatic and splenic flexure. According to the location of the tumor and the extent of lymph node dissection, extended right hemicolectomy, transverse colectomy, or extended left hemicolectomy is performed. Several multi-institutional prospective randomized trials have demonstrated not only short-term benefits but also long-term oncological safety using laparoscopy for colon cancer [1–4]. However, in all prior trials,

---

K. Kawada, M.D., Ph.D. (✉) • G. Nishikawa • H. Shinohara • S. Hasegawa  
Department of Surgery, Graduate School of Medicine, Kyoto University, Kyoto, Japan  
e-mail: [kkawada@kuhp.kyoto-u.ac.jp](mailto:kkawada@kuhp.kyoto-u.ac.jp)

transverse colon cancer was excluded, because it requires technical difficulties associated with lymph node dissection around the middle colic vessels depending on the surgeon's experience. Therefore, it has not yet been determined whether laparoscopy can be used in the setting of transverse colon cancer.

Transverse colectomy is defined as a procedure requiring the division of the middle colic vessels at their origins. The most important technical aspect of laparoscopic transverse colectomy for colon cancer is lymph node dissection around the origin of the middle colic artery (MCA). This artery arises from the superior mesenteric artery (SMA) just below the pancreas, passing between layers of the transverse mesocolon. The proximity of the transverse colon to the adjacent structures, including the pancreas, duodenum, spleen, and base of the mesenteric vessels, may cause major complications. In addition, an exact anatomical knowledge of the right and middle colic veins is important because of many variations [5]. Excessive and inadvertent traction of the transverse mesocolon during dissection around the middle colic vein (MCV) can be a cause of venous bleeding, which is not easily controlled using laparoscopic techniques. Therefore, laparoscopic transverse colectomy is one of the most technically challenging laparoscopic colectomy.

There are no absolute contraindications to laparoscopic transverse colectomy in our institution; however, patients with multiple previous abdominal surgeries, those with bowel obstruction and/or marked bowel dilation, and those with a bulky tumor invading the adjacent organs may be inappropriate candidates.

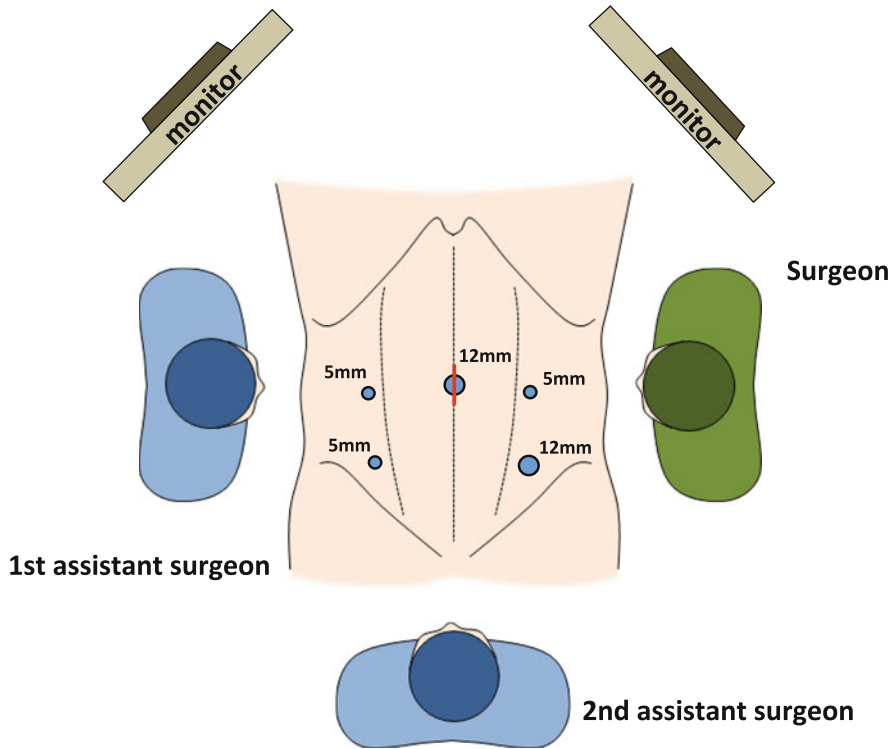
An adequate preoperative evaluation includes a thorough history and physical examination, blood tests, X-ray, computed tomography, colonoscopy, and barium enema. If the tumor is small, preoperative colonoscopy is necessary to localize the tumor by tattooing with India ink or using endoscopic clips. Properly placed colonoscopic tattoos are long lasting and easily found during the operation. Intraoperative colonoscopy is also an option for tumor localization in the case of a tattoo failure.

Taking a case with a slightly right-sided transverse colon cancer as an example, this chapter discusses the surgical procedure and provides several technical points related to laparoscopic transverse colectomy, especially focusing on the lymph node dissection around MCA.

---

## 4.2 Positioning and Setup

Under general anesthesia, the patient is placed in the modified lithotomy and Trendelenburg position. Pneumoperitoneum is established with carbon dioxide at a pressure of about 10 mmHg. In general, five ports are employed with the camera port placed on the umbilical position and the other four ports symmetrically placed on both sides ( $2 \times 2$ ) of the lower abdomen (Fig. 4.1). The surgeon uses the two left-sided ports and the assistant uses the two right-sided ports, although the surgeon

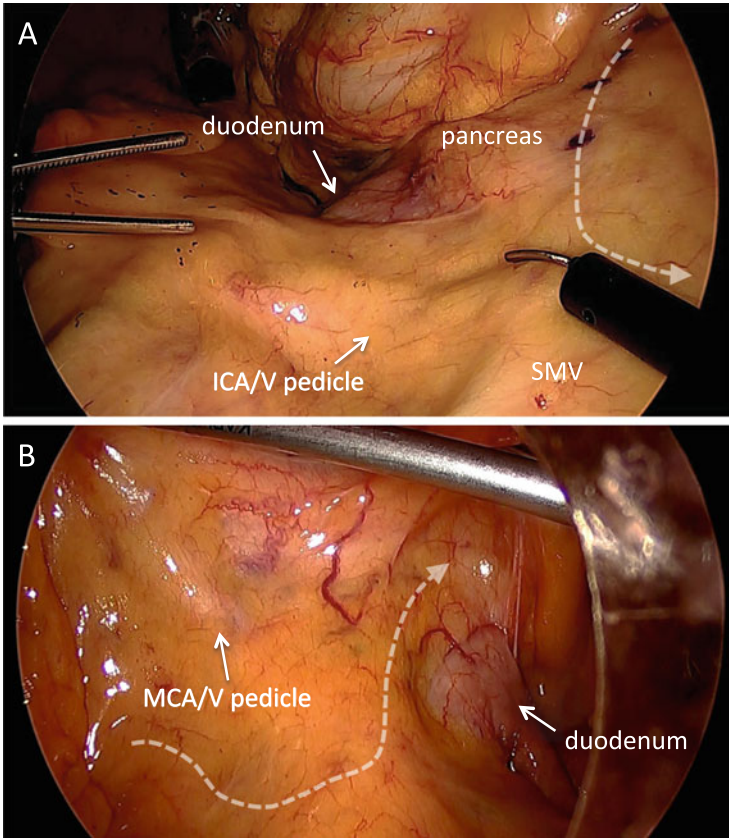


**Fig. 4.1** Port placement and operating room setup for the laparoscopic transverse colectomy

may elect to move to the right side for dissection of the splenic flexure. The television monitors are placed near the shoulder of the patient on both sides to give the surgical team optimal viewing.

### 4.3 Surgical Procedures

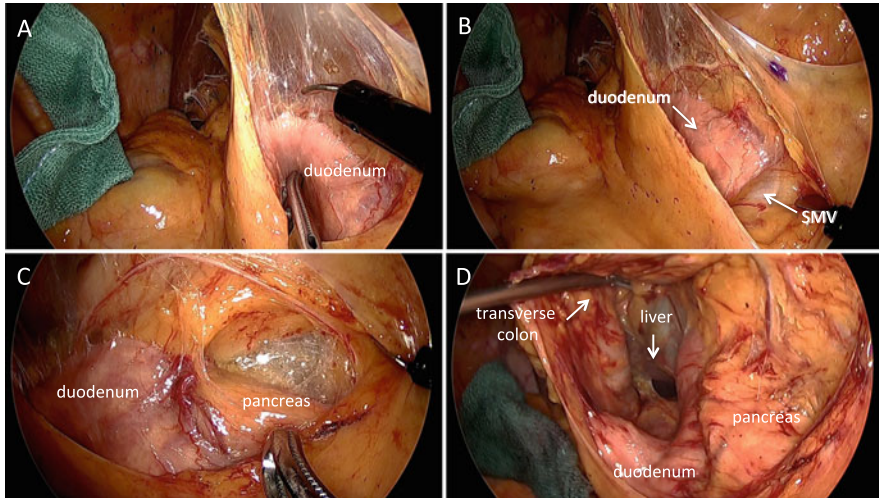
After the omentum and transverse colon are moved toward the upper abdomen, tenting the transverse mesocolon creates the optimal operative field: the middle colic pedicle, duodenum, and pancreas can be well visualized from the ventral side if severe adhesion does not occur (Fig. 4.2). In a thin patient, the middle colic pedicle is readily obvious, whereas the pedicle is subtle in an obese patient. The ileocolic pedicle needs to be identified by retracting the right mesocolon. Before starting dissection, it is useful to assume the line of the dissection range according to the location of the tumor and the extent of lymph node dissection (Fig. 4.2, white dotted arrows).



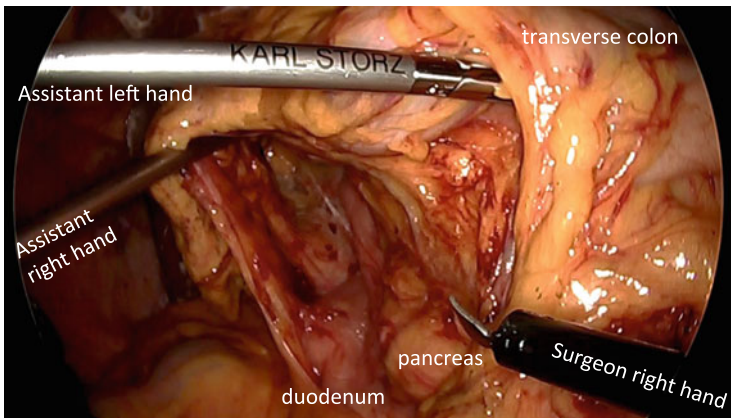
**Fig. 4.2** Tenting the transverse mesocolon makes the optimal operative field. Right-sided (a) and left-sided (b) views. *White dotted arrows* represent the planned line of the dissection range according to the location of the tumor and the extent of lymph node dissection. *ICA/V* ileocolic artery/vein, *MCA/V* middle colic artery/vein, *SMV* superior mesenteric vein

For the right-sided dissection, the ventral peritoneum of the cranial portion of the ileocolic pedicle is incised, followed by medial-to-lateral mobilization of the right mesocolon. Although various approaches such as lateral-to-medial (lateral approach), medial-to-lateral (medial approach), and retroperitoneal approaches have been reported in laparoscopic colon surgery, we believe that the medial approach is the most useful to facilitate exposure of the mesentery, with the assistance of peritoneal fixation of the right colon [6]. The second portion of the duodenum is an important landmark to identify (Fig. 4.3a). The right mesocolon is carefully separated from the retroperitoneal tissues, duodenum, and pancreatic caudal portion up to the hepatocolic ligament (Fig. 4.3b–d). The assistant medially





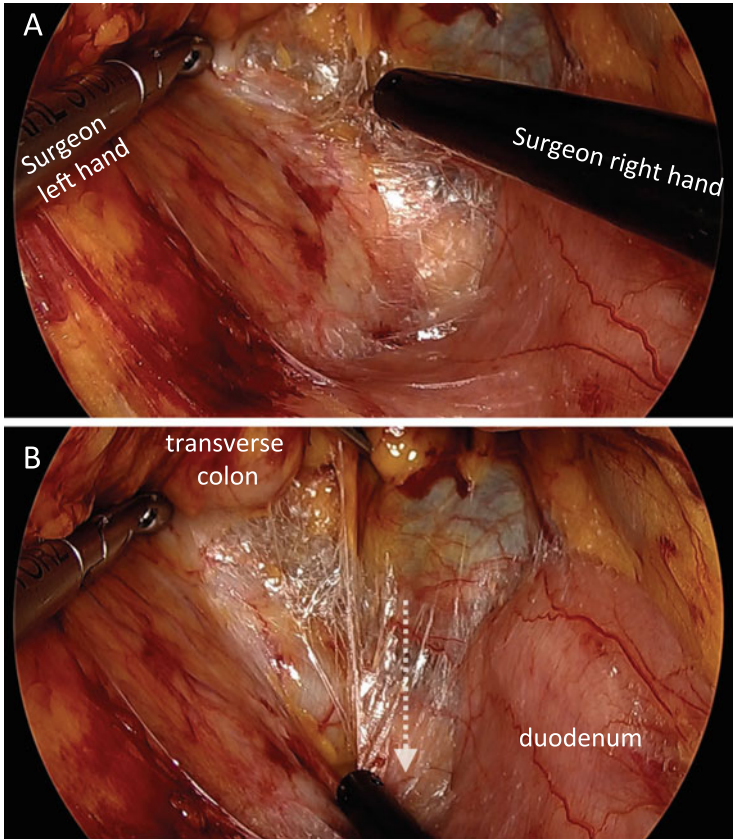
**Fig. 4.3** (a) The retroperitoneal portion of the duodenum is an important landmark for medial approach. (b–d) The right mesocolon is separated from the retroperitoneal tissues, duodenum, and pancreatic caudal portion up to the hepatocolic ligament



**Fig. 4.4** The assistant retracts the right colon medially with both atraumatic graspers to maintain the right-sided peritoneal window

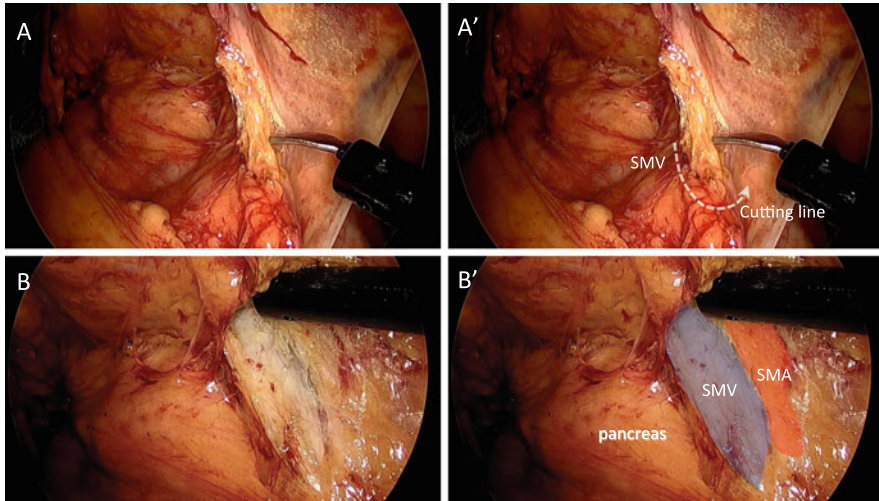
retracts the right colon with both atraumatic graspers to maintain the peritoneal window (Fig. 4.4). This enables the surgeon to provide his own countertraction with forceps of both hands (Fig. 4.5).

Next, the peritoneum over the superior mesenteric vessels is incised (Fig. 4.6a), and then ventral surfaces of superior mesenteric vessels are exposed (Fig. 4.6b).



**Fig. 4.5** In the right-sided peritoneal window maintained by the assistant, the surgeon provides his own countertraction with forceps of both hands. Operative fields are shown before dissection (a) and after dissection (b). White dotted arrow represents the motion of the surgeon's right hand

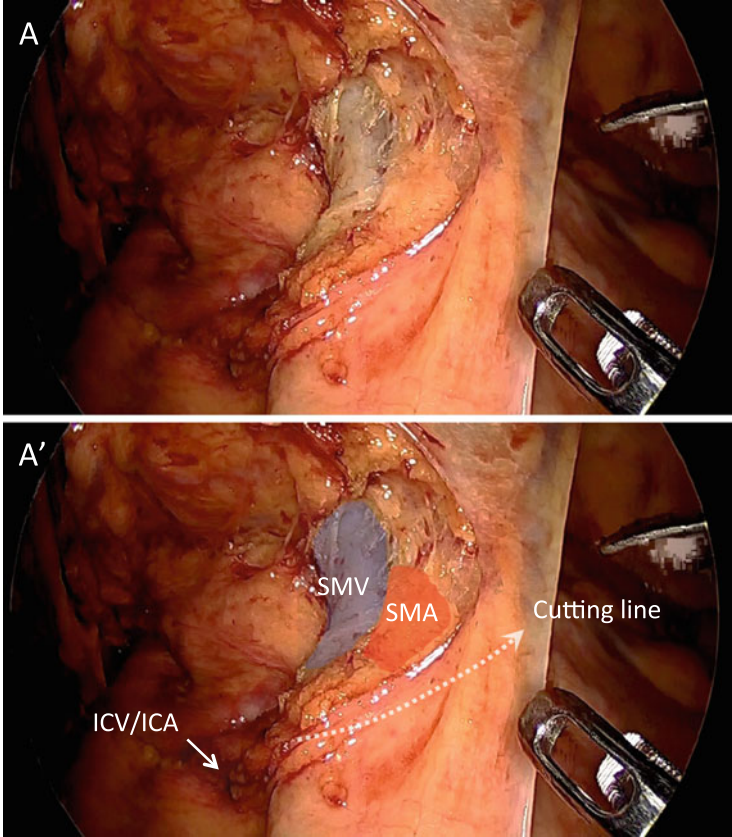
The vascular sheath of the superior mesenteric vein (SMV) can be directly exposed, whereas SMA is exposed with being covered by the nerve sheath (Fig. 4.7). When proceeding to dissect the ventral surface of SMV and SMA in a caudal to cranial direction, MCA, MCV, and Henle's trunk (gastrocolic trunk) are gradually identified (Fig. 4.8). MCA is skeletonized below the pancreas and then divided at its origin (Fig. 4.9a, b). The independent right colic artery, if present, is located around the upper border of the duodenum, although the majority of patients do not have the independent right colic artery. MCV is usually identified just below the inferior border of the pancreas, which can become an important landmark (Fig. 4.10a, b). Understanding anatomical relationship of MCA and MCV is necessary for appropriate lymph nodes dissection in laparoscopic transverse



**Fig. 4.6** (a) The peritoneum over the superior mesenteric vessels is incised. (a') Cutting line of the peritoneum is shown. (b) Ventral surfaces of superior mesenteric vessels are exposed. (b') Overlaid view with colored shadow. *SMA* superior mesenteric artery

colectomy (Fig. 4.11). Careful dissection onto the duodenum and the pancreatic caudal portion must be exercised to expose the right and middle colic vessels. When the root of the accessory right colic vein (aRCV) is clearly identified, aRCV is divided just before it drains into the Henle's trunk (Fig. 4.12a, b). However, if aRCV is difficult to confirm in this situation, this vein may be easily detected later at the takedown of the hepatic flexure. It is important to understand that the venous anatomy between the hepatic flexure and the middle colic vessels has many variations, including Henle's trunk, the fusion between the right gastroepiploic vein (RGEV), and a branch of RCV or MCV. After division of aRCV, RGEV is clearly exposed and then cranially dissected from the transverse mesocolon, which can lead to wide separation between the pancreatic head and transverse mesocolon (Fig. 4.16a).

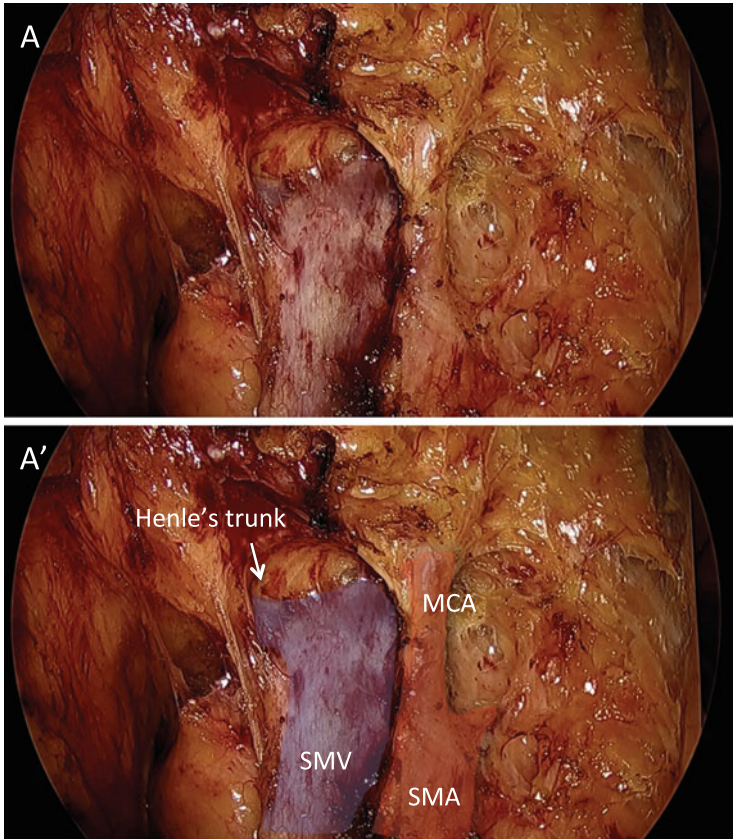
For the left-sided dissection, the correct place for the mesocolic dissection is a sulcus that is created by adequate traction of the transverse mesocolon. The incision of the peritoneum is extended along the sulcus (Fig. 4.13a, b), followed by dividing within the transverse mesocolon. This step must be performed carefully: the incision is first made on the exposed visceral peritoneum and then gradually through the mesenteric fat, followed by the other layer of visceral peritoneum to enter the lesser sac (Fig. 4.14a). When the lesser sac is opened from its left side, identification of the pancreatic body and the base of the transverse mesocolon is



**Fig. 4.7** (a) Exposed superior mesenteric vessels. Note that the vascular sheath of SMV is directly exposed, while SMA is exposed with covered by the nerve sheath. (a') Overlaid view with colored shadow of (a). Cutting line of the peritoneum is shown

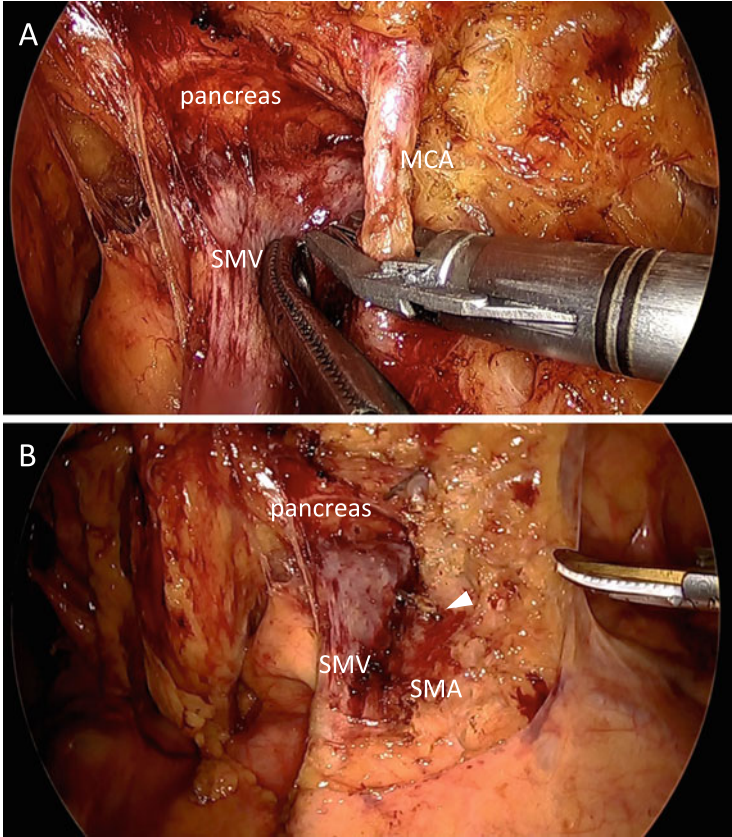
possible (Fig. 4.14b). The base of the transverse mesocolon is gradually divided along the lower edge of the pancreas toward the right-sided peritoneal window previously established (Fig. 4.15a, b), which results in connection of both the right-sided and left-sided dissection fields. Once the pancreas has been reached on either side, it is also safe to gradually narrow the base of the transverse mesocolon from both sides. When the middle colic vessels are identified in this situation, they are divided at their origin.

The greater omentum is caudally taken down and then divided from the greater curvature of the stomach. To mobilize the hepatic flexure, the greater omentum is laterally divided so that it typically reaches the lateral right lobe of the liver (Fig. 4.16). In addition, hepatocolic ligament and lateral attachment of the



**Fig. 4.8** (a) Dissection of superior mesenteric vessels in a caudal to cranial direction reveals MCA and Henle's trunk. (a') Overlaid view with colored shadow of (a)

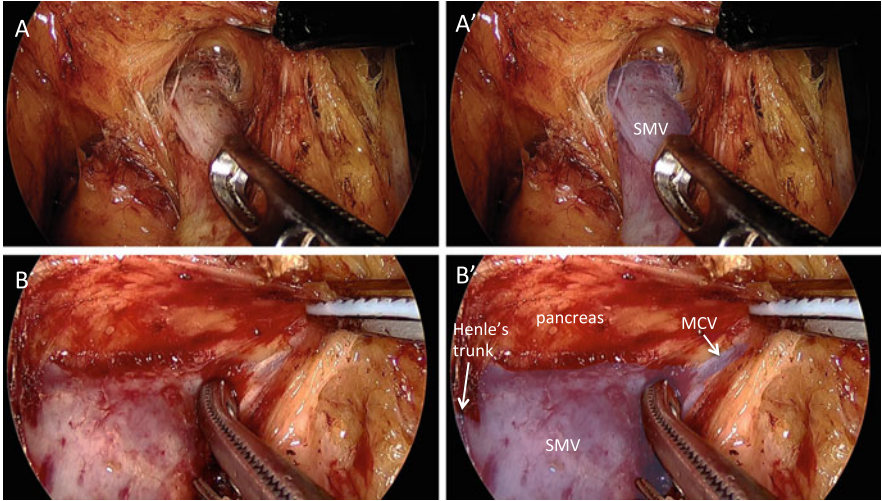
ascending colon are divided, which completes the hepatic flexure mobilization (Fig. 4.16d). For transverse colectomy, either hepatic or splenic flexure mobilization is performed according to the tumor location. If necessary, mobilization of both flexures is performed without hesitation to avoid tension on the anastomosis. When mobilization of the transverse colon is completed, the camera port is extended to about 4 cm, and the specimen is extracted under a wound protector through this site. After the marginal vessels are divided, functional end-to-end anastomosis is extracorporeally performed using linear staplers. The anastomotic site is returned to the peritoneal cavity. The mesenteric defect is not repaired, and no drain is placed. After all wounds are copiously irrigated, they are closed and the operation is completed (Fig. 4.17).



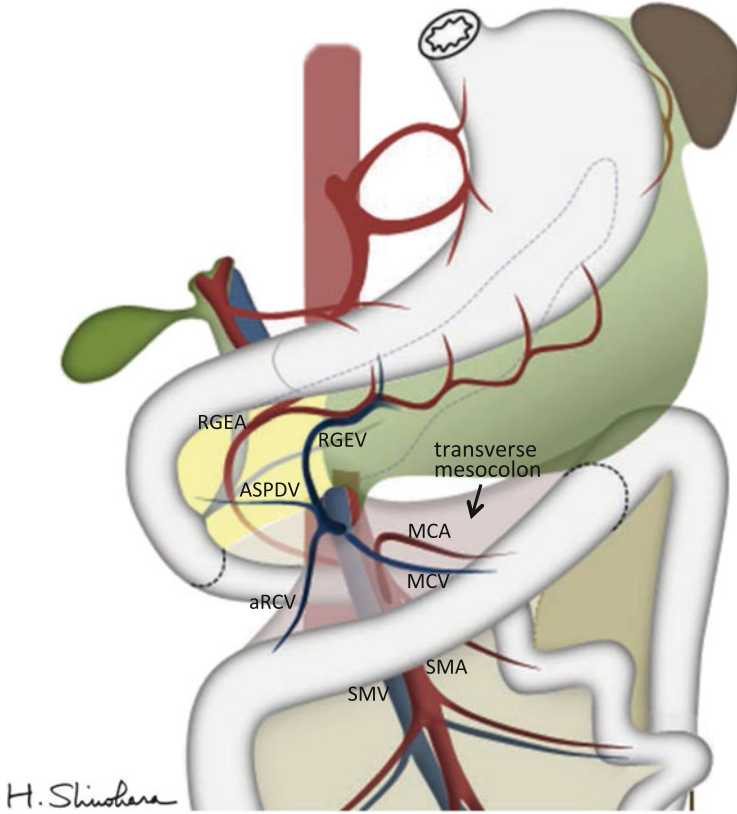
**Fig. 4.9** (a) MCA is skeletonized below the pancreas. (b) MCA is divided at its origin. *Arrow-head* represents the clipped origin of MCA

#### 4.4 Conclusion

Transverse colon cancer can be adequately treated by proper laparoscopic procedures adherent to the oncological principles. Our method of laparoscopic transverse colectomy may be beneficial for the standardization and popularization of this procedure. We believe that laparoscopic transverse colectomy for colon cancer is acceptable as a less invasive surgery without decreasing the survival benefit compared with conventional open transverse colectomy.

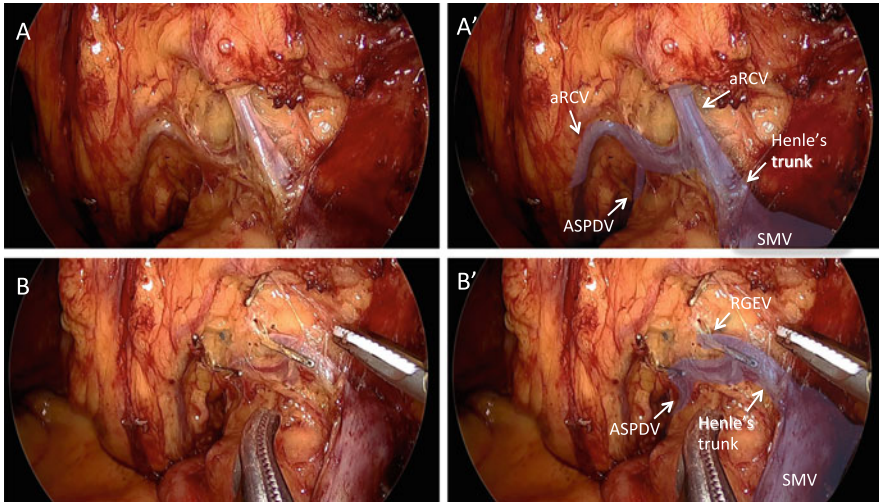


**Fig. 4.10** (a) Dissection of the ventral surface of SMV in a caudal to cranial direction. (a') Overlaid view with colored shadow of (a). (b) MCV is identified just below the inferior border of the pancreas. (b') Overlaid view with colored shadow of (b)

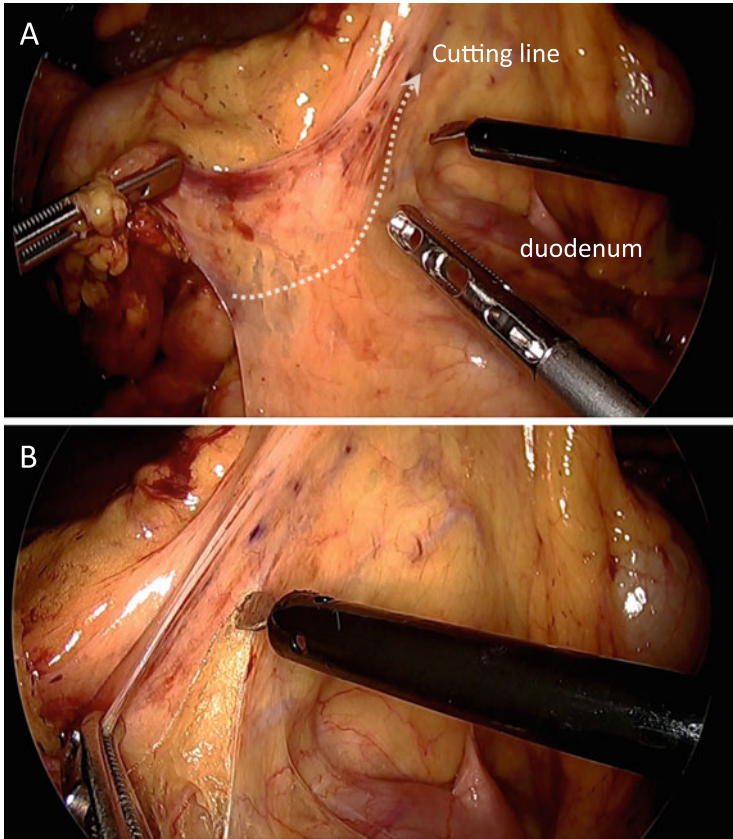


**Fig. 4.11** An illustration showing the anatomical relationship of the transverse mesocolon. Note the positional difference between MCA and MCV

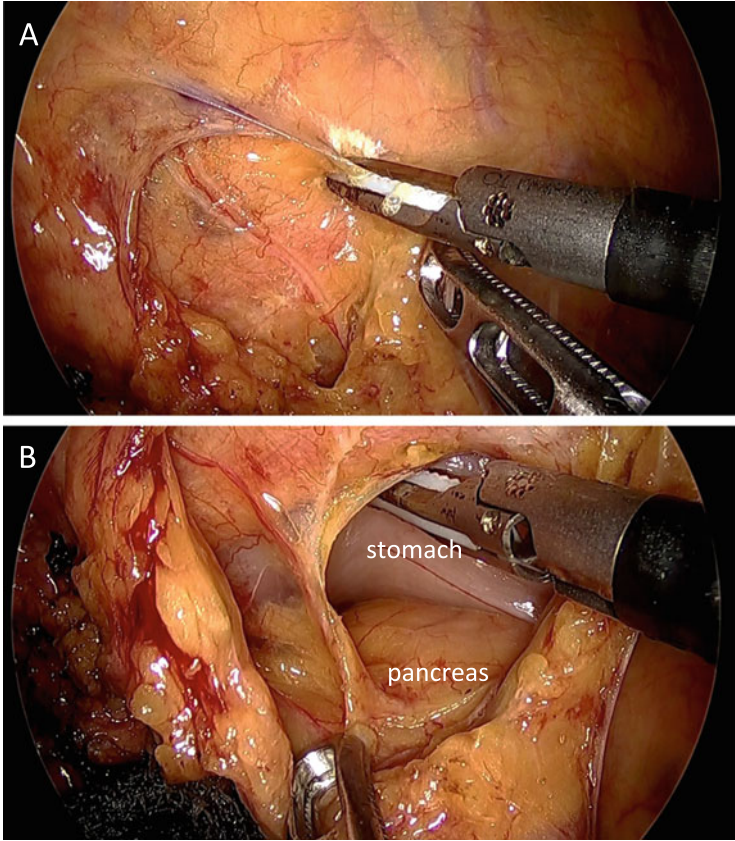




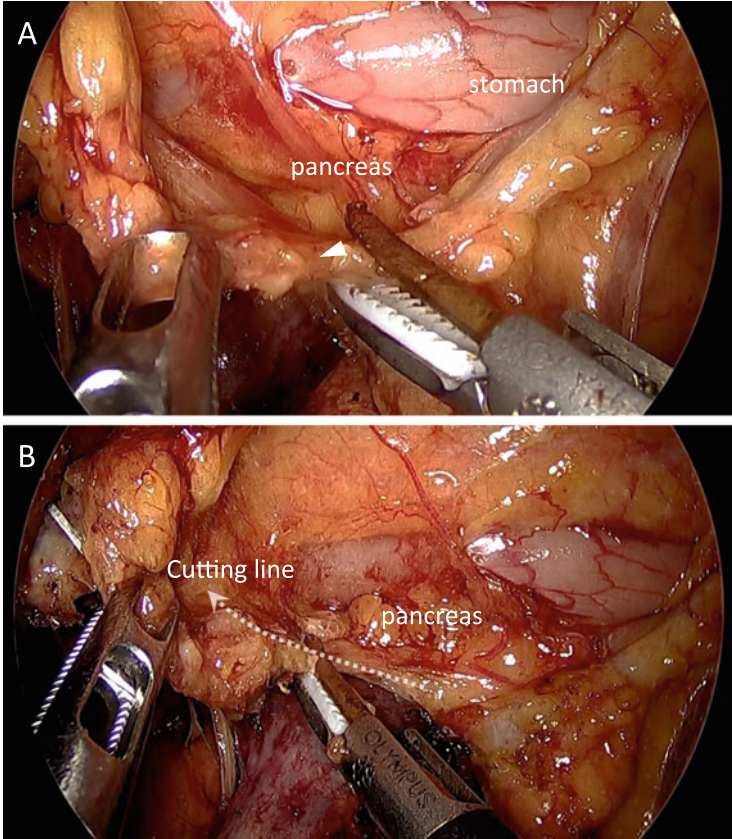
**Fig. 4.12** (a) Careful dissection onto the duodenum and the pancreatic caudal portion reveals two aRCV, ASPDV, and Henle's trunk. (a') Overlaid view with colored shadow of (a). (b) Two aRCVs are divided just before it is drained into the Henle's trunk. After aRCVs are divided, RGEV can be clearly identified. (b') Overlaid view with colored shadow of (b). *aRCV* accessory right colic vein, *ASPDV* anterior superior pancreaticoduodenal vein, *RGEV* right gastroepiploic vein



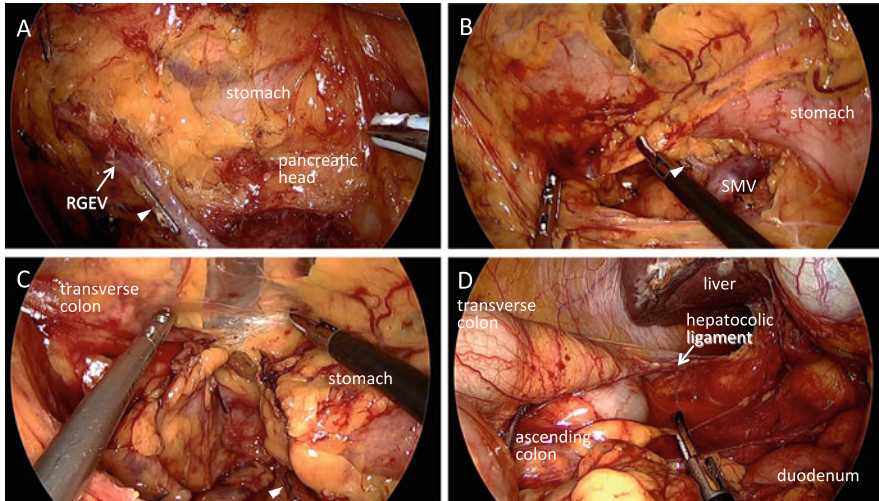
**Fig. 4.13** (a) The correct place to start the mesocolic dissection is the sulcus created by adequate traction of the transverse mesocolon. Cutting line of the peritoneum is shown. (b) The incision of the peritoneum is extended along the sulcus



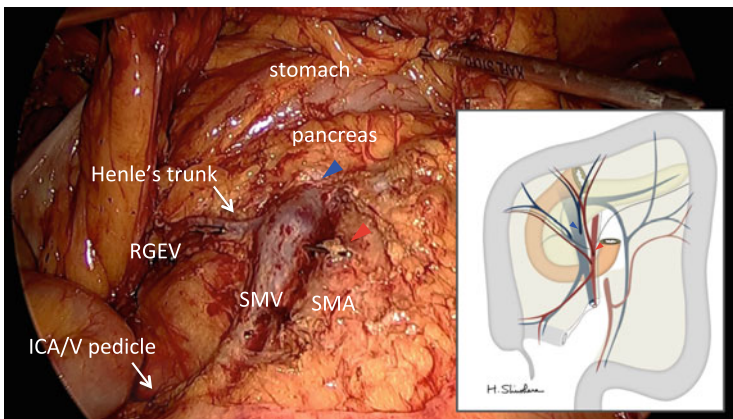
**Fig. 4.14** (a) Dividing through the mesenteric fat of the transverse mesocolon. (b) After the lesser sac is opened, the pancreatic body and the base of the transverse mesocolon are clearly identified



**Fig. 4.15** (a) The base of the transverse mesocolon is clearly identified just below the pancreas. *Arrowhead* represents the base of the transverse mesocolon. (b) The base of the transverse mesocolon is gradually divided laterally along the lower edge of the pancreas. Cutting line of the base of the transverse mesocolon is shown



**Fig. 4.16** (a) RGEV is cranially dissected from the transverse mesocolon. *Arrowhead* represents the clipped origin of aRCV. (b, c) To mobilize the hepatic flexure, the greater omentum is divided laterally, typically almost reaching to the lateral right lobe of the liver. *Arrowhead* represents the clipped origin of aRCV. (d) Hepatic flexure mobilization is completed by division of lateral attachment of the ascending colon



**Fig. 4.17** Operative field after finishing lymph node dissection along the superior mesenteric vessels. *Red arrowhead* represents the clipped origin of MCA. *Blue arrowhead* represents the origin of MCV divided by the ultrasonic dissection device

## References

1. Clinical Outcomes of Surgical Therapy Study Group. A comparison of laparoscopically assisted and open colectomy for colon cancer. *N Engl J Med.* 2004;350:2050–9.
2. Hazebroek EJ, Color Study Group. COLOR: a randomized clinical trial comparing laparoscopic and open resection for colon cancer. *Surg Endosc.* 2002;16:949–53.
3. Guillaou PJ, Quirke P, Thorpe H, Walker J, Jayne DG, Smith AM, Heath RM, Brown JM, MRC CLASICC Trial Group. Short-term endpoints of conventional versus laparoscopic-assisted surgery in patients with colorectal cancer (MRC CLASICC trial): multicentre, randomised controlled trial. *Lancet.* 2005;365:1718–26.
4. Kitano S, Inomata M, Sato A, Yoshimura K, Moriya Y, Japan Clinical Oncology Group Study. Randomized controlled trial to evaluate laparoscopic surgery for colorectal cancer: Japan Clinical Oncology Group Study JCOG 0404. *Jpn J Clin Oncol.* 2005;35:475–7.
5. Yamaguchi S, Kuroyanagi H, Milsom JW, Sim R, Shimada H. Venous anatomy of the right colon: precise structure of the major veins and gastrocolic trunk in 58 cadavers. *Dis Colon Rectum.* 2002;45:1337–40.
6. Hasegawa S, Kawamura J, Nagayama S, Nomura A, Kondo K, Sakai Y. Medially approached radical lymph node dissection along the surgical trunk for advanced right-sided colon cancers. *Surg Endosc.* 2007;21:1657.

---

# Laparoscopic Left-Sided Colectomy (Mobilization of Splenic Flexure and Sigmoidectomy)

# 5

Akinari Nomura, Yasuo Koga, Yukie Yoda, and Hirokazu Noshiro

---

## Abstract

Laparoscopy is characterized by its ability to provide direct, magnified views of deep structures in narrow spaces and by the fact that laparoscopic observation and manipulation are carried out from foreground to background. It is logical, therefore, to perform laparoscopic surgery via a medial approach.

Because laparoscopy requires coordination between the surgeon, first assistant surgeon (assistant), and second assistant surgeon (videoscopist), the procedure for creating an adequate operative field should be standardized. Under sufficient countertraction, the loose connective tissue between the mesocolon and retroperitoneal organs, such as the autonomic nerves, left ureter, left gonadal vessels, and pancreas, expands like a spider's web and is recognizable as the dissectable layer.

Through the medial approach and with cooperation between the three surgeons, the interior surface of the peritoneum on the left side of the upper mesorectum, the anterior lobe of the transverse mesocolon, and the splenicocolic ligament can be fenestrated to communicate through to the left side of the rectum and colon, the omental bursa, and the lateral side of the splenic flexure, respectively. The deep dissection is performed to communicate with the lateral space from the medial side, which expedites the subsequent lateral approach.

---

## Keywords

Laparoscopic colectomy • Left-sided colon cancer • Splenic flexure mobilization • Sigmoidectomy • Medial approach • Dissectable layer

---

A. Nomura (✉) • Y. Koga • Y. Yoda • H. Noshiro  
Department of Surgery, Faculty of Medicine, Saga University, Saga City, Saga, Japan  
e-mail: [cpa1nixa@kuhp.kyoto-u.ac.jp](mailto:cpa1nixa@kuhp.kyoto-u.ac.jp)

---

## 5.1 Introduction

The first laparoscopic colectomy was reported by Jacobs et al. [1] in 1991. The procedure is now widely performed and is currently indicated in the treatment of patients with early to advanced colorectal cancers.

Cancer of the sigmoid colon is a common disease that accounts for approximately one third of all colorectal cancers. Laparoscopic sigmoidectomy includes many of the basic procedures required to master laparoscopic colectomy. Mobilization of the splenic flexure is a fundamental procedure that is required not only in surgery for rectal cancer but also in transverse colectomy and left hemicolectomy.

This chapter describes laparoscopic sigmoidectomy and laparoscopic mobilization of the splenic flexure.

---

## 5.2 Indication for Laparoscopic Surgery

Laparoscopic surgery is indicated for patients regardless of previous laparotomy and tumor location, except those with marked tumor invasion into adjacent organs, severe intestinal obstruction, or cardiopulmonary dysfunction. However, the decision to perform laparoscopic surgery depends on the skill level of the surgical team.

---

## 5.3 Positioning

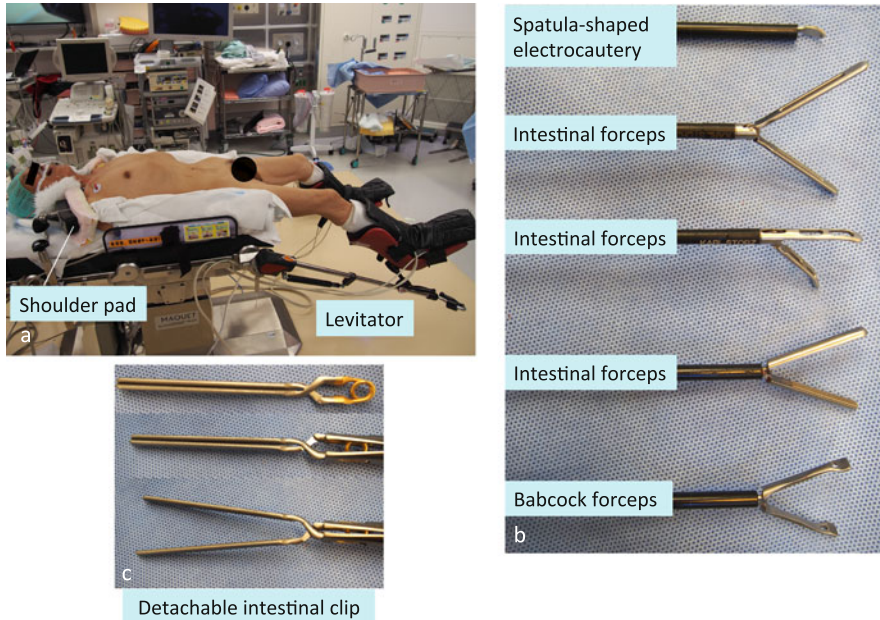
The patient is placed in a modified lithotomy position using a levitator, with both arms fixed to the trunk of the body. Shoulder pads are used to prevent the patient from slipping downward (Fig. 5.1a).

---

## 5.4 Instruments

A 12-mm flexible endoscope or a 30° rigid scope, a spatula-shaped electric scalpel, three 5-mm double-action intestinal forceps, a 5-mm single-action intestinal forceps, and a 5-mm Babcock forceps are used (Fig. 5.1b). Transection of the rectum is performed using a detachable intestinal clip (Fig. 5.1c), a 60-mm linear stapler, and a 29-mm circular stapler; anastomosis is performed using the double-stapling technique (DST). In cases of anal stenosis and long DST, the use of a smaller 25-mm circular stapler allows it to be more easily inserted into the rectum.

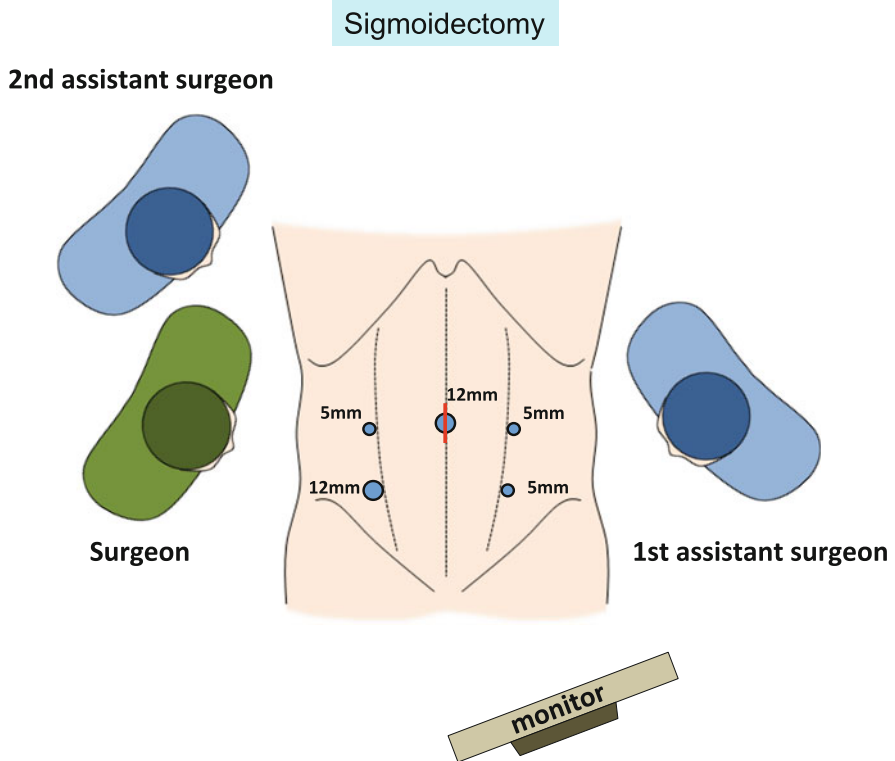




**Fig. 5.1** Positioning and instruments. The patient is placed in a modified lithotomy position using a levigator, with both arms fixed to the body trunk. Shoulder pads are used to prevent the patient from slipping downward (a). The set of instruments used for laparoscopic colectomy (b). A detachable intestinal clip is used to occlude the rectal lumen before irrigating and transecting the rectum (c)

## 5.5 Port Placement

A vertical intraumbilical incision is made and a 12-mm camera port is installed via the open method (Figs. 5.2, 5.3, and 5.4). A 12-mm port for the surgeon's right hand is placed in the right lower abdomen at the lateral border of the right rectus abdominis muscle and approximately 2 cm cranial to the right inferior epigastric vessels. A 5-mm port for the surgeon's left hand is placed approximately 4 fingerbreadths cranial to the 12-mm port placed in the right lower abdomen. Two 5-mm ports for the assistant are placed symmetrically opposite the two ports for the surgeon in the left lower abdomen. The surgery is performed via these five ports.

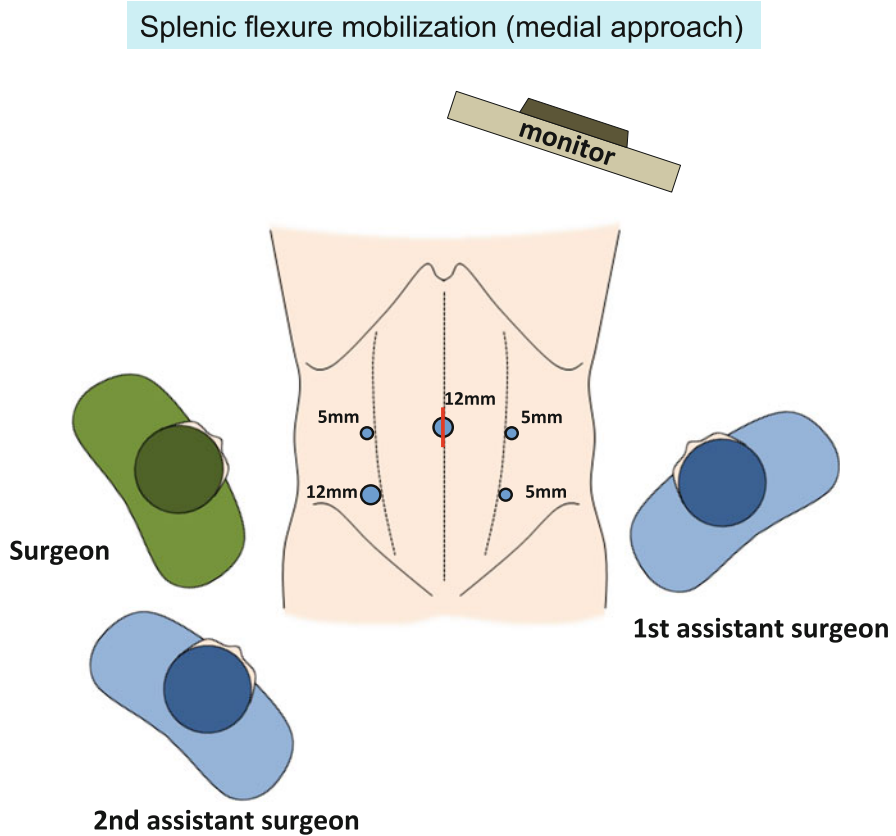


**Fig. 5.2** Port placement and the arrangement of surgeons in laparoscopic sigmoidectomy

## 5.6 Surgical Anatomy

Loose connective tissue lies between the mesorectum/mesocolon and pelvic wall/retroperitoneal organs. By applying and maintaining adequate tension between tissues, the loose connective tissue extends into a layer of foamy appearance and thus can be identified as the dissectable layer [2] (Figs. 5.5 and 5.6).

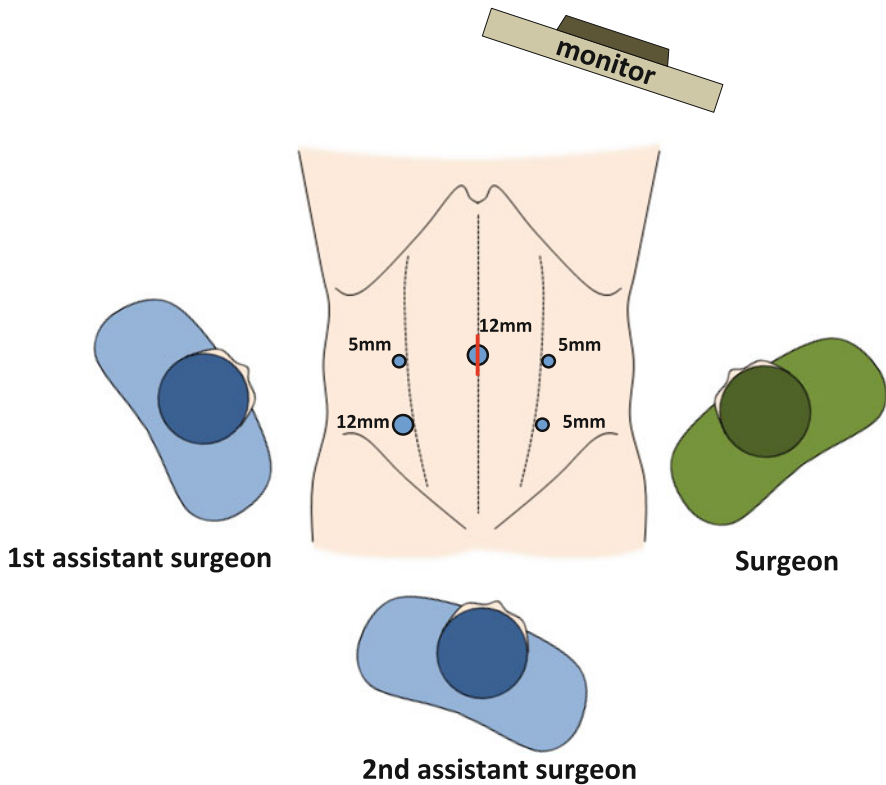
The autonomic nervous system—consisting of the lumbar splanchnic nerve, superior hypogastric nerve plexus, hypogastric nerve, pelvic splanchnic nerve, pelvic nerve plexus, and neurovascular bundle—and the left ureter and left gonadal vessels lie within the dissectable layer (Figs. 5.7 and 5.8). In particular, note that the dissectable layer exists on both the ventral and dorsal sides of the autonomic nerves, ureter, and gonadal vessels. Care must be taken to avoid straying into the dorsal side of the structures (Figs. 5.5, 5.6, 5.7, and 5.8).



**Fig. 5.3** Port placement and the arrangement of surgeons in laparoscopic splenic flexure mobilization via a medial approach

The autonomic nerve runs longitudinally through the dissectable layer accompanied by adipose tissue and thin vessels (Fig. 5.7a). This autonomic nerve is pulled toward the rectum and inferior mesenteric artery (IMA) by the nerve branch that penetrates the dissectable layer and runs toward the mesorectum and IMA (Fig. 5.7a). The peak that is caused by this pulling action—that is, the nerve branch—is cut and the autonomic nerve is preserved (Fig. 5.7b, c). Once the dissectable layer is resected, the “foamy” loose connective tissue, which has now lost the tension maintained by its connection to the structures on both sides, now contracts and resembles a membrane, and the structures on both sides—the mesorectum and mesocolon on one side and the pelvic wall and retroperitoneal organs on the other side—are now covered in this membranous tissue (Fig. 5.7c). This membranous tissue, derived from the contracted foamy loose connective tissue, is variously referred to as the proper rectal fascia, retroperitoneum, Gerota’s

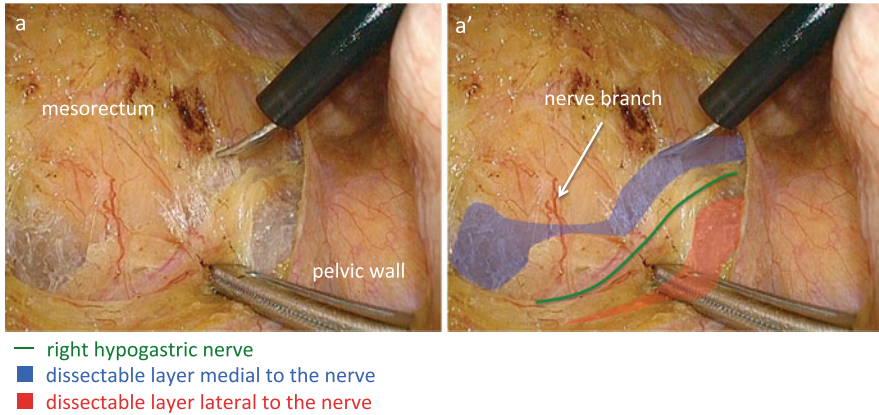
## Splenic flexure mobilization (lateral approach)



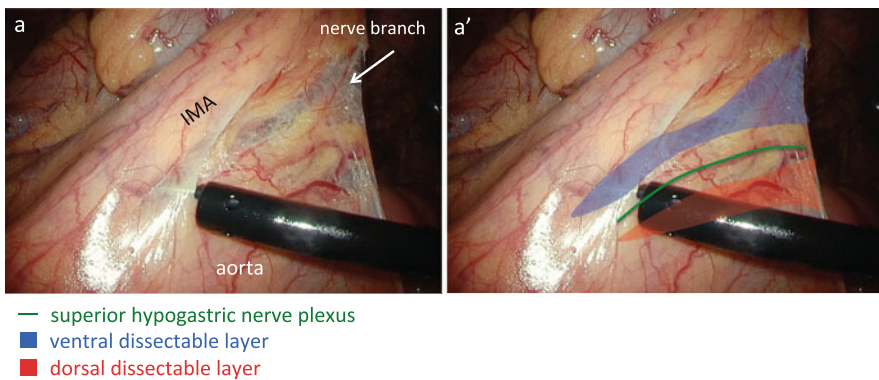
**Fig. 5.4** Port placement and the arrangement of surgeons in laparoscopic splenic flexure mobilization via a lateral approach

fascia, pre-hypogastric nerve fascia, Denonvilliers' fascia, and so forth, depending on the location. These membrane-like structures can be created artificially by dissecting the foamy loose connective tissue (i.e., the dissectable layer).

By dissecting the space between the descending mesocolon and retroperitoneal area in the cranial direction, the dissection proceeds behind the pancreas, because the inferior mesenteric vein (IMV) is contained within the descending mesocolon and runs behind the pancreas (Figs. 5.9 and 5.37b, c). At the inferior margin of the pancreas, the dissection plane is intentionally shifted so that it is between the root of the transverse mesocolon and pancreas, and then fenestration of the anterior lobe of the transverse mesocolon will allow access to the omental bursa (Figs. 5.9 and 5.38).



**Fig. 5.5** The dissectable layer around the right hypogastric nerve. The right hypogastric nerve lies within the foamy loose connective tissue (i.e., the dissectable layer). The dissectable layer lies both medial and lateral to the nerve



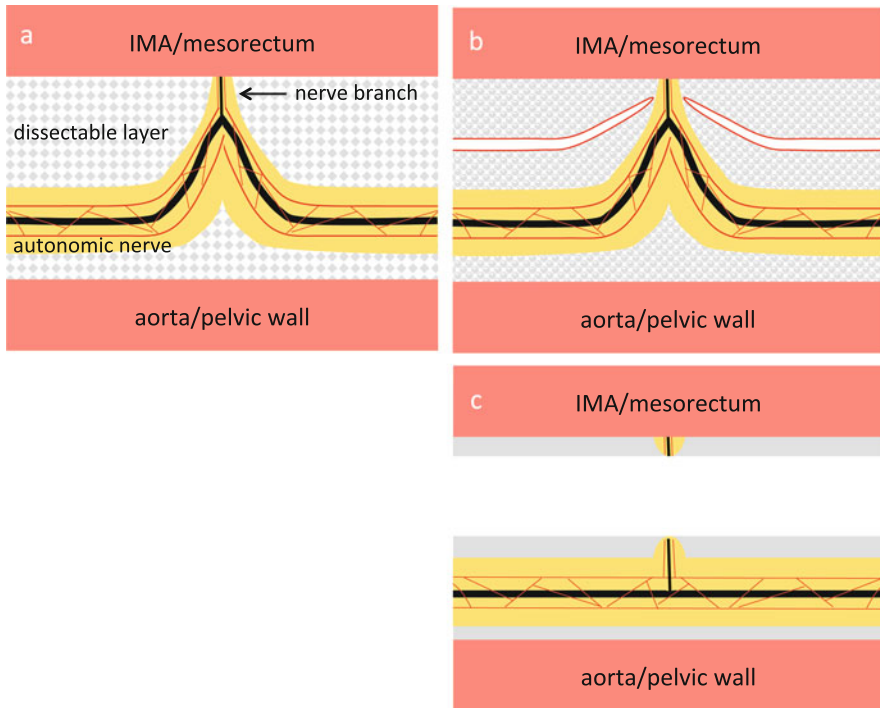
**Fig. 5.6** The dissectable layer around the superior hypogastric nerve plexus. The superior hypogastric nerve plexus runs within the foamy loose connective tissue identified as the dissectable layer. The dissectable layer lies both ventral and dorsal to the nerve

## 5.7 Procedure

### 5.7.1 Sigmoidectomy

#### 5.7.1.1 Creation of the Operative Field

The patient's head is tilted downward by approximately 15° until the small intestines move out of the pelvis, with the right side slanted approximately 5° lower. After moving the omentum and transverse colon to the epigastric region, the

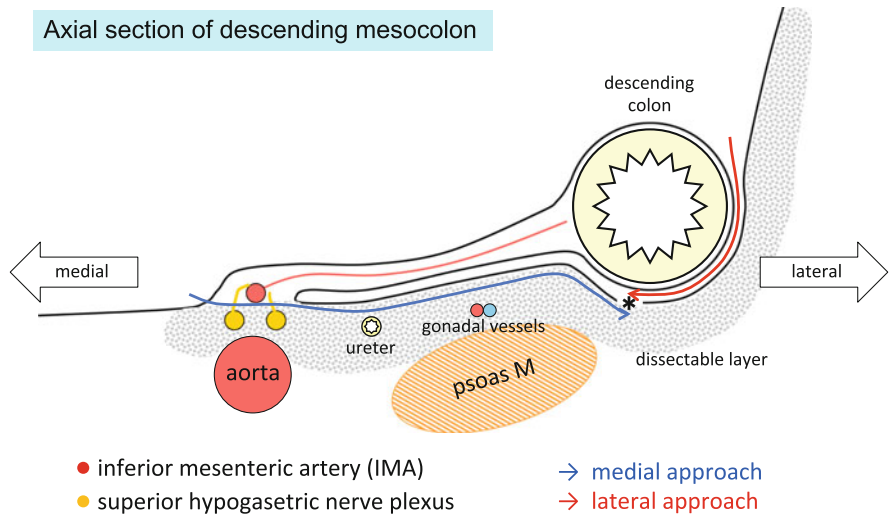


**Fig. 5.7** The relationship between the autonomic nerve and the dissectable layer. The autonomic nerve runs within the dissectable layer accompanied by adipose tissue (yellow paint) and thin vessels (red line) and is pulled toward the IMA and mesorectum by the nerve branch (a). After cutting the nerve branch at the peak of pulled autonomic nerve, the dissectable layer contracts and the autonomic nerve is preserved (b, c). *IMA* inferior mesenteric artery

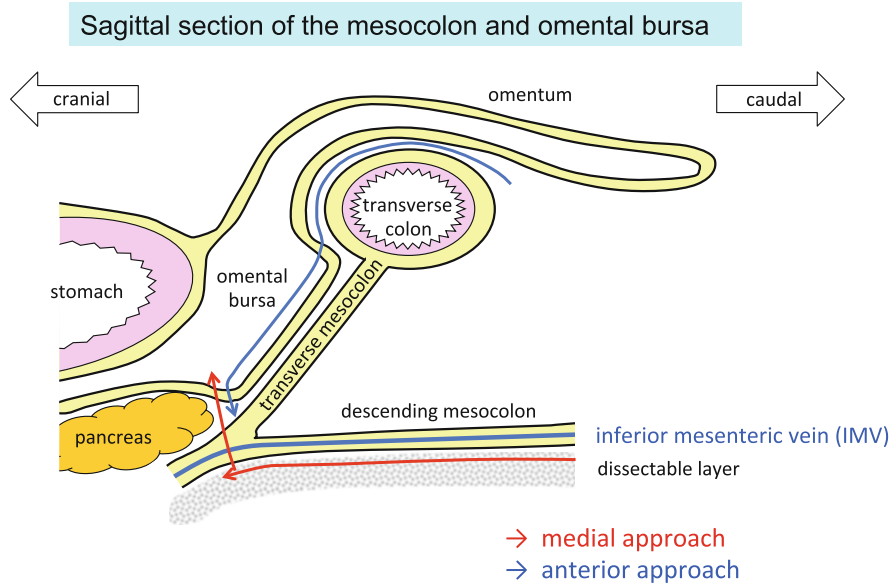
mesentery and small intestines are moved to the right abdominal area as if turning a page of a book, enabling visualization of the duodenum, root of the IMA, left abdominal area, and pelvic cavity (Fig. 5.10).

### 5.7.1.2 Mobilization of the Upper Rectum

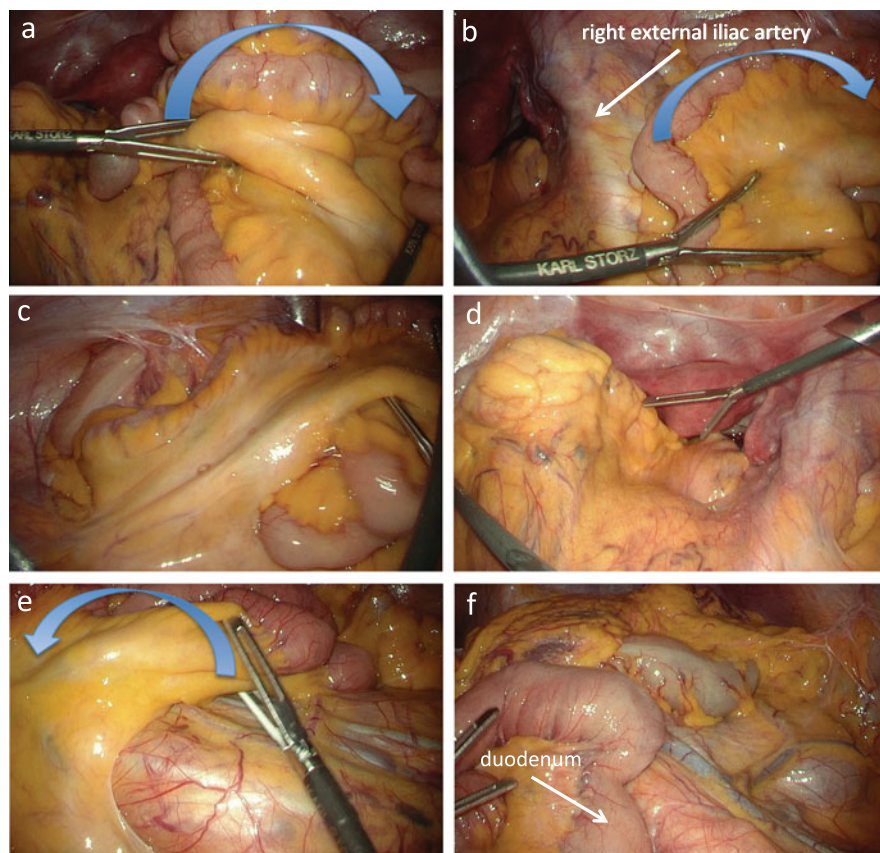
Before further preparations, the sigmoid colon is drawn out of the pelvis using intestinal forceps, with the surgeon using both hands to straighten the rectum. Using the intestinal forceps, the surgeon grasps the fatty appendage on the right side of the sigmoid colon and lifts it in the left ventrocranial direction. The assistant then uses the intestinal forceps in the right hand to press the right side of the sigmoid mesocolon in the lateral direction, allowing identification of the vascular pedicle of the sigmoidal vessels (Fig. 5.11a). Using the Babcock forceps in the left hand, the assistant grasps the vascular pedicle of the sigmoidal vessels and draws it in the left ventrocranial direction and then uses the intestinal forceps in the right hand to grasp



**Fig. 5.8** Axial section of the descending mesocolon. The autonomic nerve, the left ureter, and the left gonadal vessels lie within the dissectable layer. The descending mesocolon is mobilized by a medial approach. The Toldt's white line (\*) can be incised also by a lateral approach



**Fig. 5.9** Sagittal section of the mesocolon and omental bursa. The descending mesocolon is mobilized and the omental bursa is opened by a medial approach. The omental bursa can be opened also by an anterior approach

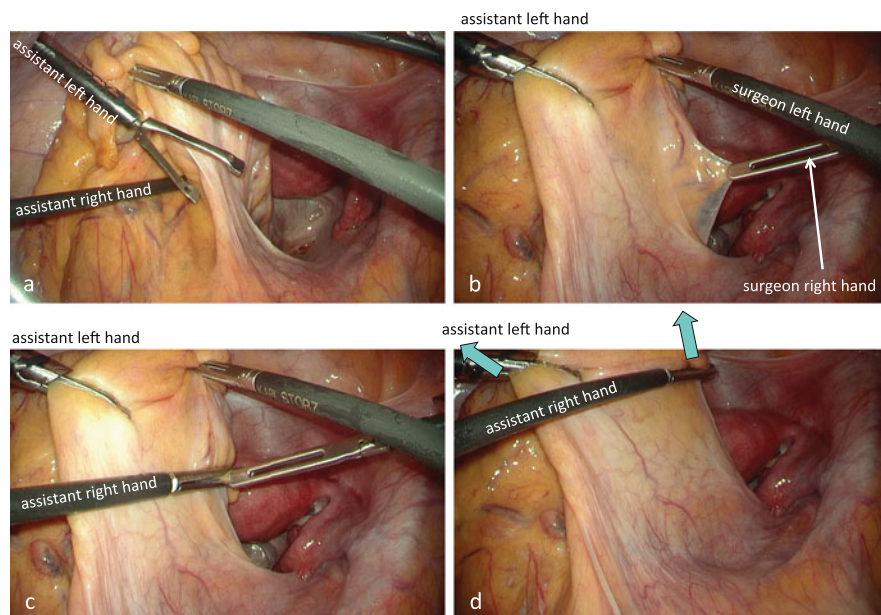


**Fig. 5.10** Creation of the wide operative field. The distal small intestines are moved to the right abdominal area to empty the pelvic cavity (a–d). The proximal small intestines are moved to the right upper abdomen to observe the duodenum, IMA, and descending mesocolon in the same field of view (e, f)

the fatty appendage on the right side of the upper rectum and elevate it in the left ventrocaudal direction (Fig. 5.11b, c). Then, by drawing the tips of the forceps in both hands away from each other, the assistant can stretch out the right side of the mesorectum (Fig. 5.11d).

The traction applied by the assistant is slightly relaxed to confirm the curvature of the right pelvic peritoneum and the right surface of the mesorectum, that is, the imaginary incisional line of the peritoneum (Fig. 5.12a). Then the right surface of the upper mesorectum is once again stretched and the imaginary incisional line is verified again (Fig. 5.12b). With the intestinal forceps in the left hand, the surgeon pulls the right pelvic peritoneum in the right direction using friction force (Fig. 5.12b). Once the peritoneum on the right side of the upper rectum is incised



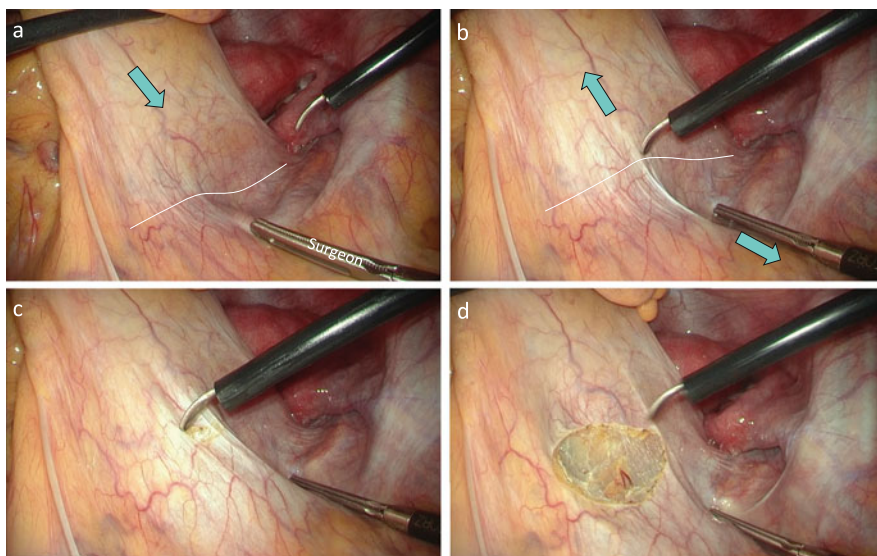


**Fig. 5.11** Stretching out the right side of mesorectum. With the Babcock forceps in the assistant's left hand, the vascular pedicle of the sigmoid vessels is pulled in the left ventrocranial direction (a, b). With the intestinal forceps in the assistant's right hand, the fatty appendage on the right side of the rectum is elevated in the left ventrocaudal direction (c, d). By drawing the tips of the forceps in both hands away from each other, the assistant can stretch out the right side of the mesorectum (d)

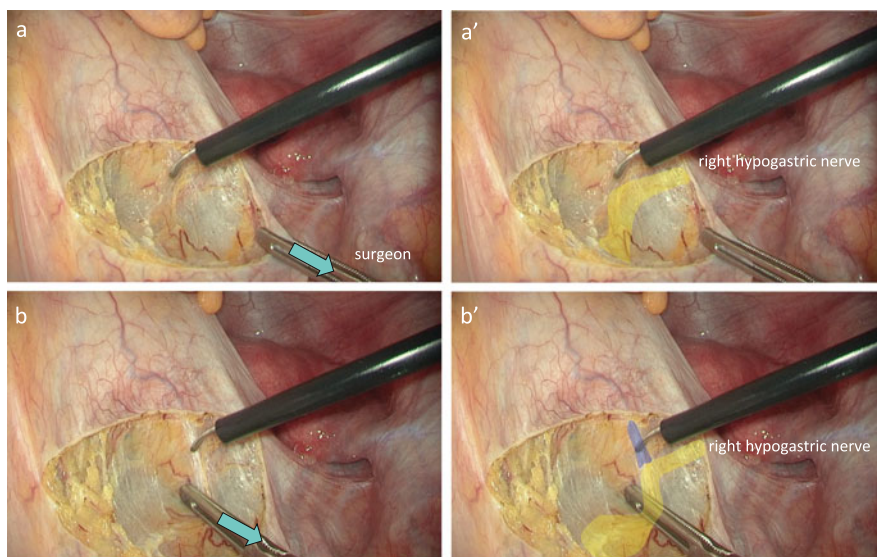
slightly caudal to the promontory, carbon dioxide gas permeates beneath the peritoneum and the dissectable layer is clearly revealed (Fig. 5.12c, d).

The right hypogastric nerve, which is surrounded by adipose tissue through which thin vessels run longitudinally, is identified first (Figs. 5.5, 5.7, and 5.13). The nerve branch extending toward the mesorectum is dissected to preserve the right hypogastric nerve. By elevating the mesorectum ventrally using the opened intestinal forceps in the left hand or by pushing down the right hypogastric nerve in the lateral–dorsal direction, the foamy loose connective tissue posterior to the rectum (i.e., the dissectable layer) is clearly revealed and is dissected caudally from the posterior to posterolateral direction in the manner of a swinging pendulum. Then the left hypogastric nerve covered in adipose tissue is identified and preserved (Figs. 5.13, 5.14, and 5.15). After resecting this loose connective tissue, it contracts toward the mesorectum and pelvic wall, where it appears like a membrane. The loose connective tissue contracted against the pelvic wall is identified as the so-called pre-hypogastric nerve fascia (Fig. 5.15b, b').

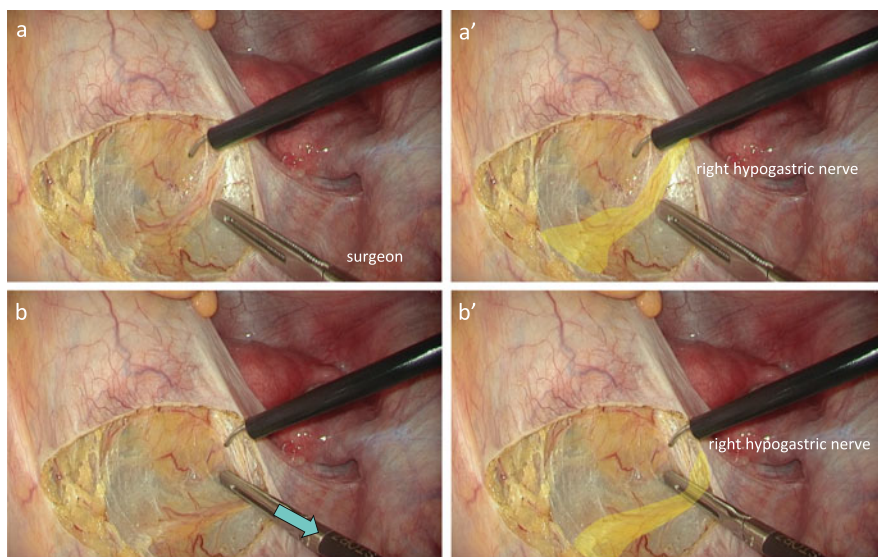
When performing sigmoidectomy, it is enough to dissect posterior to the rectum up to the level of the midpoint of the promontory and peritoneal reflection.



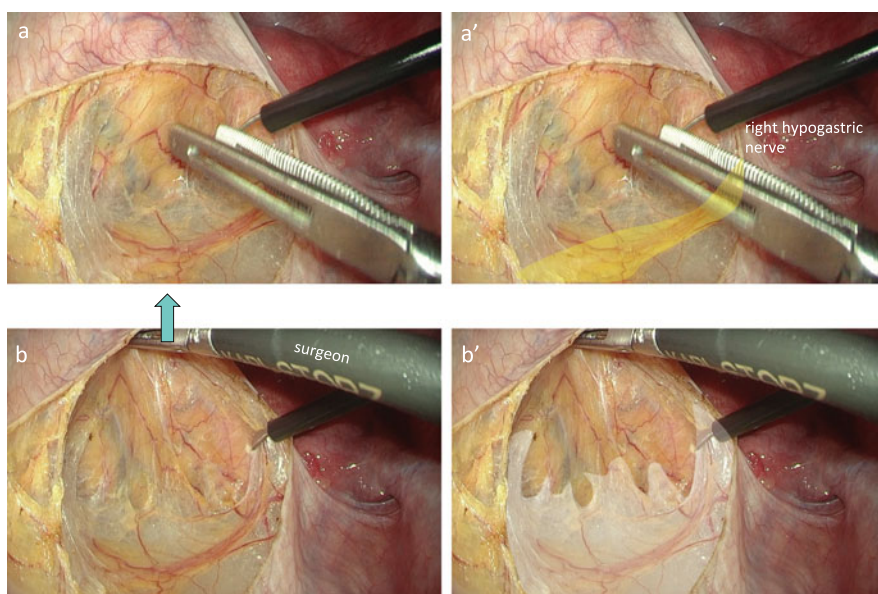
**Fig. 5.12** The imaginary incisional line on the right side of the mesorectum. The retraction of the mesorectum is slightly relaxed (a) and the right surface of the mesorectum is stretched out once again (b) to verify the imaginary incisional line (*white dotted line*). After cutting the imaginary incisional line, the dissectable layer is clearly revealed (c, d)



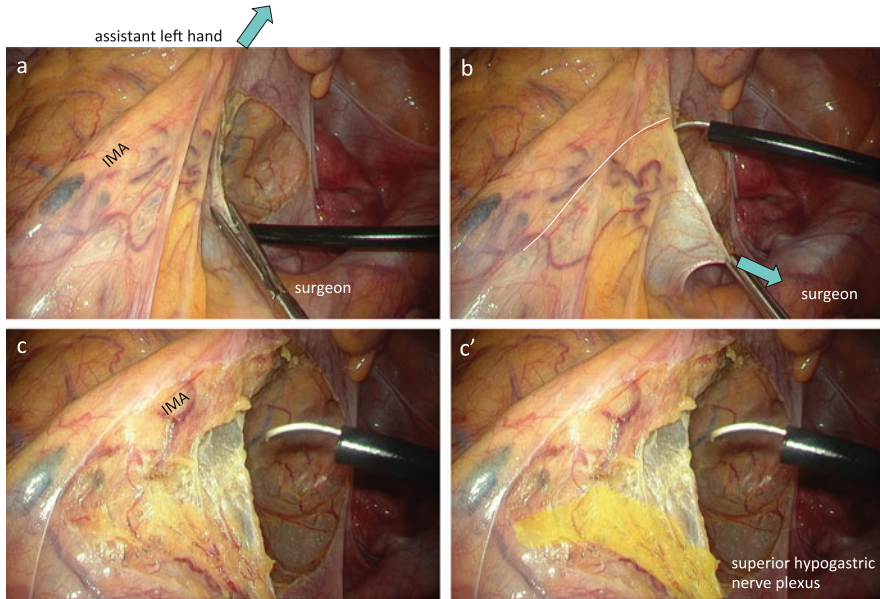
**Fig. 5.13** Identification of the right hypogastric nerve. The right hypogastric nerve is surrounded by adipose tissue through which thin vessels run longitudinally (a, a'). The nerve branch extending toward the mesorectum (*blue paint*) is dissected to preserve the nerve (b, b'). Care must be taken not to stray into the dissectable layer behind the nerve



**Fig. 5.14** The dissectable layer between the mesorectum and right hypogastric nerve. By pushing down the right hypogastric nerve in the lateral–dorsal direction, the foamy loose connective tissue between the mesorectum and the right hypogastric nerve is clearly revealed



**Fig. 5.15** The dissectable layer behind the mesorectum. By elevating the mesorectum ventrally with the opened intestinal forceps, the foamy loose connective tissue behind the mesorectum is clearly revealed (a, b). The loose connective tissue contracted against the pelvic wall is identified as the so-called pre-hypogastric nerve fascia (*white paint*) (b, b')

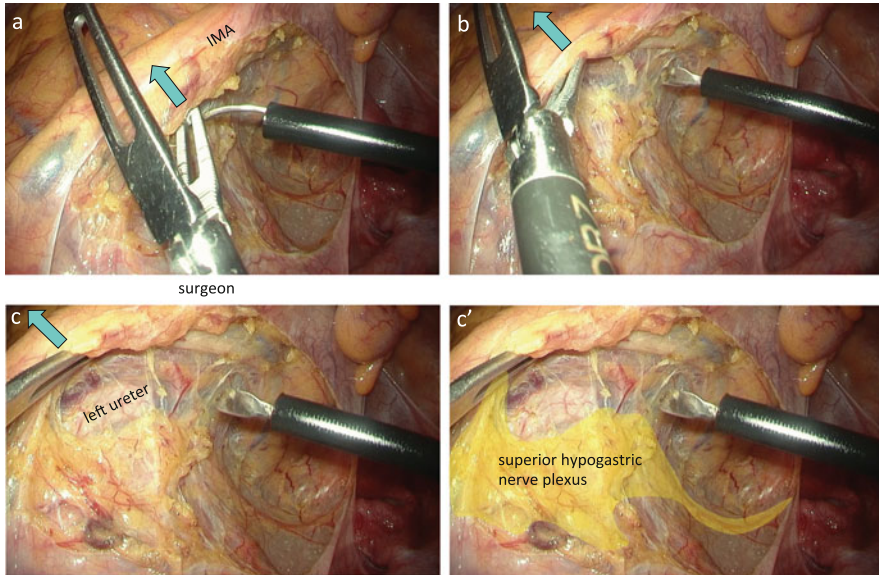


**Fig. 5.16** The dissectable layer between the IMA and superior hypogastric nerve plexus. With the Babcock forceps in the assistant's left hand, the vascular pedicle of the sigmoidal vessels is elevated in the lateral–ventral direction (a), and the surgeon grasps the cut edge of the parietal peritoneum and pulls it in the medial–ventral direction (b) to apply tension to the root of mesocolon. The dissectable layer between the IMA and superior hypogastric nerve plexus is revealed (c, c')

### 5.7.1.3 Mobilization of the Mesocolon

The assistant elevates the vascular pedicle of the sigmoidal vessels, grasped with the Babcock forceps in the left hand, in the lateral–ventral direction, and the surgeon grasps the cut edge of the parietal peritoneum and pulls it in the medial–ventral direction to apply tension to the root of mesocolon (Fig. 5.16a, b). After verifying the location of the duodenum, the peritoneum is incised in the cranial direction approximately 5 mm right to the IMA (Fig. 5.16).

After incising the peritoneum, the loose connective tissue between the IMA and aorta takes on a foamy appearance (Fig. 5.16c, c'). Using the intestinal forceps in the left hand, the surgeon grasps the peritoneal cut edge near the IMA and rotates it in the ventral–lateral direction. Alternatively, using the dorsal blade of the opened intestinal forceps in the left hand (Fig. 5.17), the surgeon elevates the IMA in the ventral–lateral direction, which allows the superior hypogastric nerve plexus to be drawn toward the IMA. The loose connective tissue ventral to the nerve and the nerve branch extending toward the dorsal side of the IMA are resected, and the

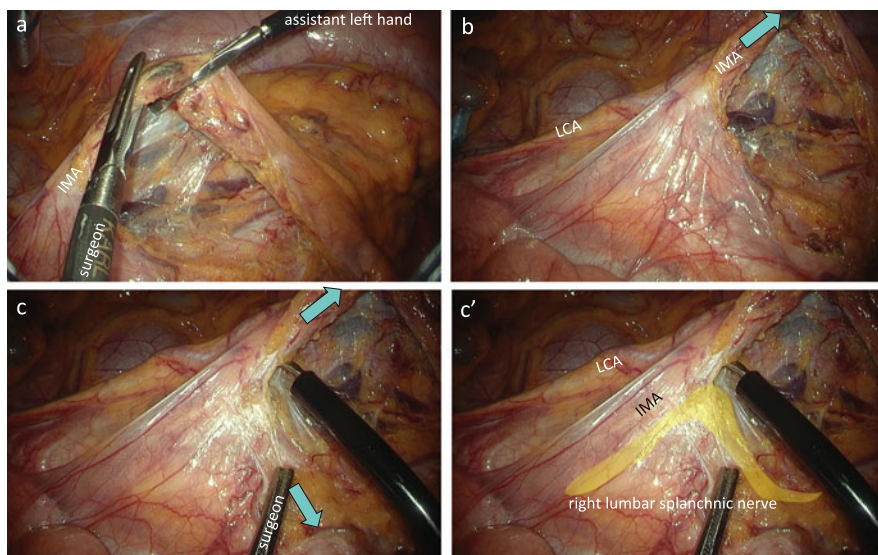


**Fig. 5.17** The superior hypogastric nerve plexus drawn toward the IMA. Using the dorsal blade of the opened intestinal forceps, the surgeon elevates the IMA in a ventral–lateral direction (**a**, **b**). The nerve branch extending toward the dorsal side of the IMA is resected, and the superior hypogastric nerve plexus is preserved dorsally (**c**, **c'**)

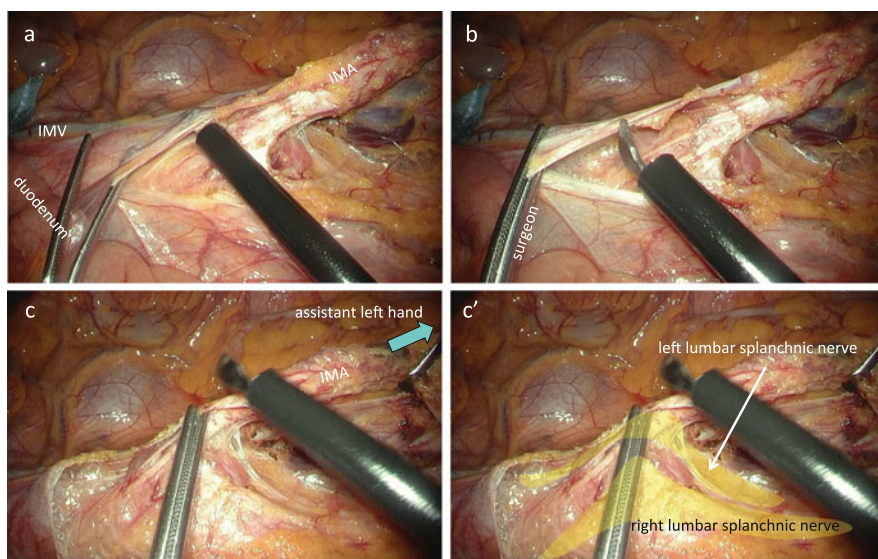
superior hypogastric nerve plexus is then separated from the IMA and is preserved dorsally (Figs. 5.16 and 5.17).

After separating the IMA and superior hypogastric nerve plexus, with the Babcock forceps in the left hand, the assistant grasps and draws the IMA in the ventral–lateral direction (Fig. 5.18). This allows better tension to be maintained between the mesocolon and retroperitoneal tissue. By elevating the descending mesocolon ventrally with the opened intestinal forceps in the surgeon’s left hand, the dissectable layer is clearly visualized. Dissection proceeds along the dorsal surface of the descending mesocolon, and the left ureter is identified and preserved. When the left psoas muscle is exposed, the dissection plane strays into the dorsal side; therefore, it should be carefully corrected to return near the descending mesocolon. The left gonadal vessels are identified and preserved prior to resecting the left colic artery (LCA) and IMV.

As the mobilization of the mesocolon proceeds, the assistant moves the Babcock forceps in the left hand, grasping the IMA ventrally so as to position the IMA in an obtuse angle to the aorta (Fig. 5.18c). This applies satisfactory tension to the space between the IMA and lumbar splanchnic nerve, allowing the surgeon to confirm that the right lumbar splanchnic nerve is being pulled toward the nerve sheath around the IMA (Fig. 5.18c, c’). The nerve branch extending toward the IMA from the right lumbar splanchnic nerve is resected, and the right lumbar splanchnic nerve is preserved (Figs. 5.18c, c’ and 5.19c, c’). At the site immediately cranial to the root



**Fig. 5.18** Identification of the right lumbar splanchnic nerve. With the Babcock forceps in the assistant's left hand, the IMA is drawn in the ventral–lateral direction (a, b). The right lumbar splanchnic nerve is pulled toward the nerve sheath around the IMA (c, c')



**Fig. 5.19** Proximal lymph node dissection. The adipose tissue surrounding the lymph nodes is transected at the level of the root of the IMA (a, b). After dissecting the nerve branch extending toward the IMA from the right lumbar splanchnic nerve, the left lumbar splanchnic nerve drawn toward the lateral–dorsal side of the IMA is identified (c, c')

of the IMA, the direction of the peritoneal incision is changed toward the patient's left side (Fig. 5.19a, b). The dissection between the descending mesocolon and retroperitoneum proceeds cranially, and then the left lumbar splanchnic nerve drawn toward the lateral–dorsal side of the IMA is identified (Fig. 5.19c, c').

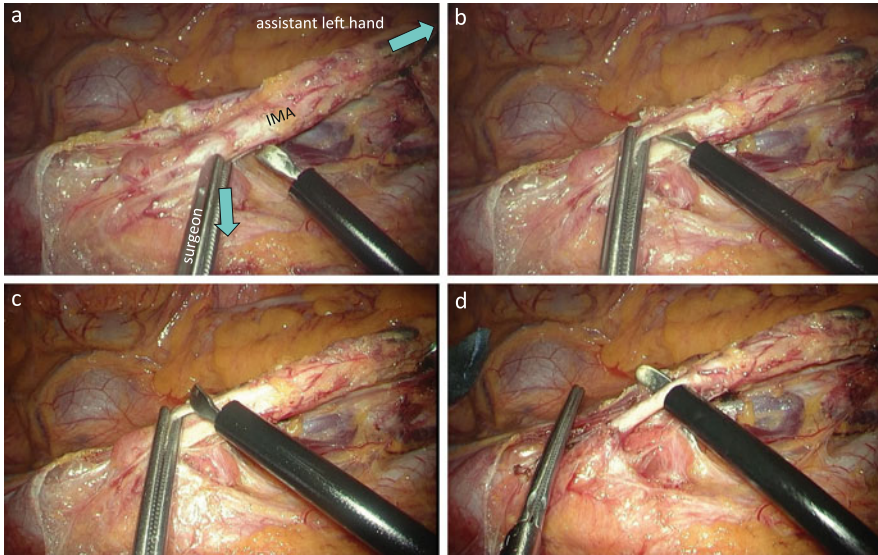
#### 5.7.1.4 Proximal Lymph Node Dissection and Transection of the IMA

The assistant moves the tip of the Babcock forceps in the left hand, grasping the IMA dorsally and caudally, and lays the IMA down (Fig. 5.19c). This provides a good view of the ventral side of the IMA. When possible, the assistant grasps the descending mesocolon near the LCA with the forceps in the right hand and draws it in the ventral–lateral direction. This stretches the descending mesocolon, and the site where the LCA branches off the IMA is thus identified.

Using the intestinal forceps in the left hand, the surgeon grasps the cut edge of the peritoneum at a point slightly peripheral to the root of the IMA and rotates it to the ventral–lateral side and then proceeds to dissect the dissectable layer between the adipose tissue that surrounds the lymph nodes and nerve sheath covering the IMA toward the proximal side. The adipose tissue surrounding the lymph nodes is transected at the level of the root of the IMA, and proximal lymph node dissection is completed (Fig. 5.19a–c).

The surgeon grasps the nerve sheath covering the IMA, approximately 5 mm peripheral to the root of the IMA with the intestinal forceps in the left hand, pulls medially, and resects for approximately 1 mm using the electric scalpel (Fig. 5.20a). This allows access to the space between the nerve sheath and outer membrane of the IMA. The spatula-shaped electric scalpel is slid into the space between the nerve sheath ventral to the IMA and the outer membrane of the IMA; this space is widened by blunt dissection (Fig. 5.20b). Then, the surgeon grasps the nerve sheath ventral to the IMA with the intestinal forceps in the left hand, rotates it counterclockwise to widen the space between the nerve sheath and outer membrane of the IMA, and resects the ventral nerve sheath using the electric scalpel (Fig. 5.20c). Next, the surgeon grasps the nerve sheath dorsal to the IMA with the intestinal forceps in the left hand and inserts the spatula-shaped electric scalpel in the space between the nerve sheath dorsal to the IMA and the outer membrane of the IMA. By turning the tip of the spatula-shaped electric scalpel, this tip is easily guided to the left margin of the IMA, which allows encirculation of the outer membrane of the IMA without using the Maryland forceps (Fig. 5.20d). After resecting the nerve sheath dorsal to the IMA, the IMA is double-clipped approximately 5 mm peripheral to the root of the IMA and cut with an ultrasonic scalpel.

It is then confirmed that the left lumbar splanchnic nerve is pulled toward the nerve plexus between the LCA and the root of the IMA. Then the nerve plexus caudal to the pulled left lumbar splanchnic nerve is dissected and the LCA, IMV, and mesocolon are separated from the root of the IMA and the left lumbar splanchnic nerve (Fig. 5.21).

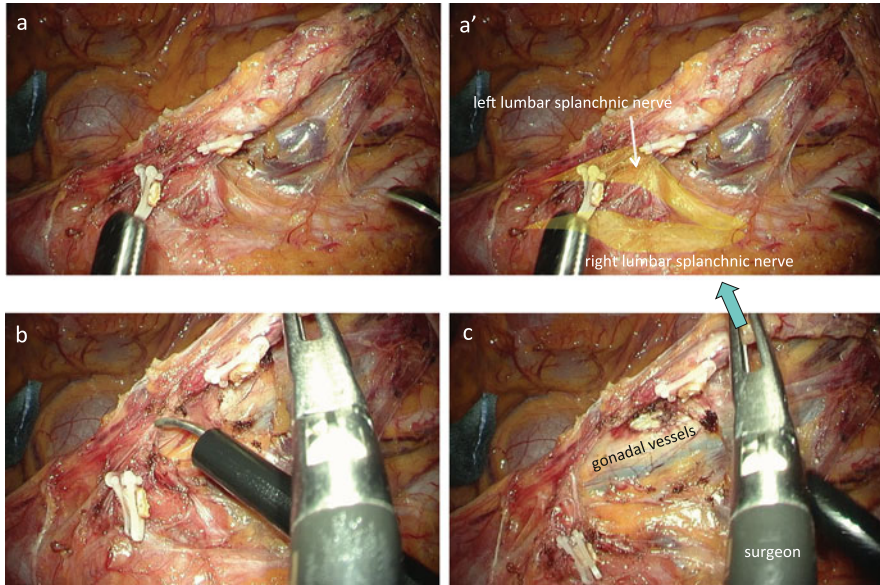


**Fig. 5.20** Transection of the IMA. With the intestinal forceps in the surgeon's left hand, the nerve sheath covering the IMA is pulled medially and resected for approximately 1 mm (a). The spatula-shaped electric scalpel is slid into the space between the nerve sheath and the outer membrane of the IMA; this space is widened by blunt dissection (b). The ventral nerve sheath is resected using the electric scalpel (c). The spatula-shaped electric scalpel is inserted in the space between the nerve sheath dorsal to the IMA and the outer membrane of the IMA, and by turning the tip of the spatula-shaped electric scalpel, this tip is easily guided to the left margin of the IMA (d)

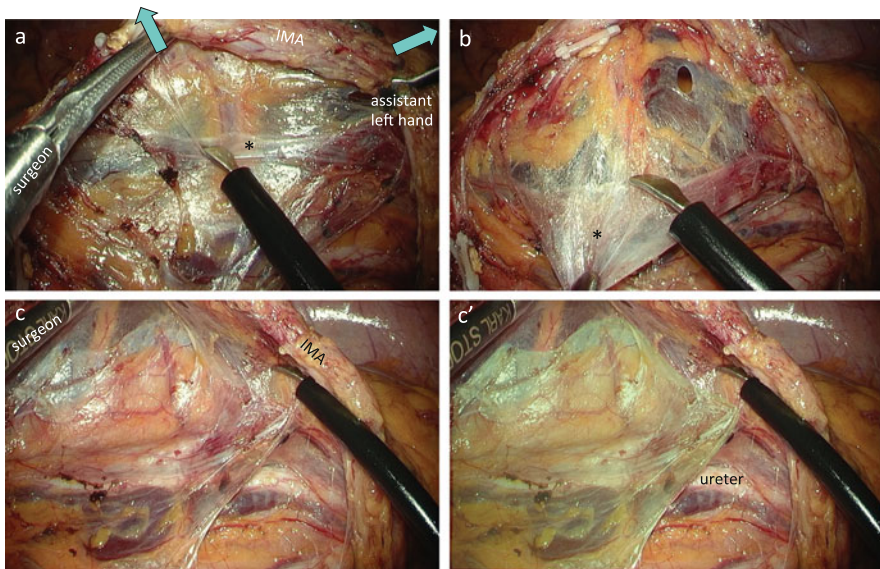
#### 5.7.1.5 Transection of the LCA and IMV, with Mobilization of the Mesocolon

Using the Babcock forceps in the left hand, the assistant grasps the IMA and draws it ventrally and caudally. This allows the straightening of the LCA and IMV, and satisfactory tension can be maintained between the descending mesocolon and retroperitoneum (Figs. 5.22 and 5.23). When possible, using the opened intestinal forceps in the right hand, the assistant elevates the descending mesocolon ventrally to apply tension between the descending mesocolon and retroperitoneum over a wider area. With the opened intestinal forceps in the left hand, the surgeon elevates the mesocolon ventrally, allowing the loose connective tissue to be expanded out with a foamy appearance. The dissectable layer exists on the ventral side as well as on the dorsal side of the retroperitoneal tissue, so it is important to confirm that the left gonadal vessels covered in adipose tissue are not pulled toward the descending mesocolon; they should be preserved before transecting the LCA and IMV (Fig. 5.23a). The shrunken connective tissue surrounding the left ureter and left gonadal vessels is recognized as the so-called Gerota's fascia (Figs. 5.22 and 5.23). Then, the surgeon clips the LCA and IMA and resects them. If the lymph node metastasis is not apparent, the LCA is divided at the common trunk to preserve a blood flow from the ascending branch to the descending branch of the IMA

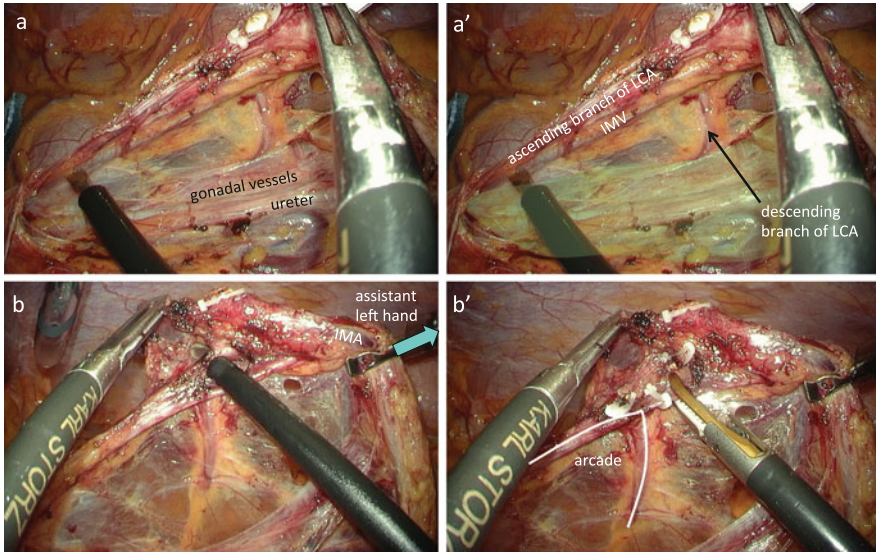




**Fig. 5.21** Preservation of the left lumbar splanchnic nerve. The left lumbar splanchnic nerve is drawn toward the lateral–dorsal side of the IMA (a, a’). The nerve plexus caudal to the pulled left lumbar splanchnic nerve is dissected (b) and the LCA, IMV, and mesocolon are separated from the root of the IMA and the left lumbar splanchnic nerve (c)



**Fig. 5.22** Dissection behind the mesocolon. Using the Babcock forceps in the assistant’s left hand, the IMA is drawn ventrally and caudally to straighten the LCA and IMV and to satisfactory maintain tension between the descending mesocolon and retroperitoneum (a). The shrunken connective tissue surrounding the left ureter and left gonadal vessels is recognized as the so-called Gerota’s fascia (\*, green paint) (b, c, c’)



**Fig. 5.23** Transection of the LCA and IMV. The gonadal vessels are preserved before transecting the LCA and IMV. The left ureter and left gonadal vessels are covered with the so-called Gerota's fascia (*green paint*) (a, a'). The LCA and IMV are clipped and divided (b, b')

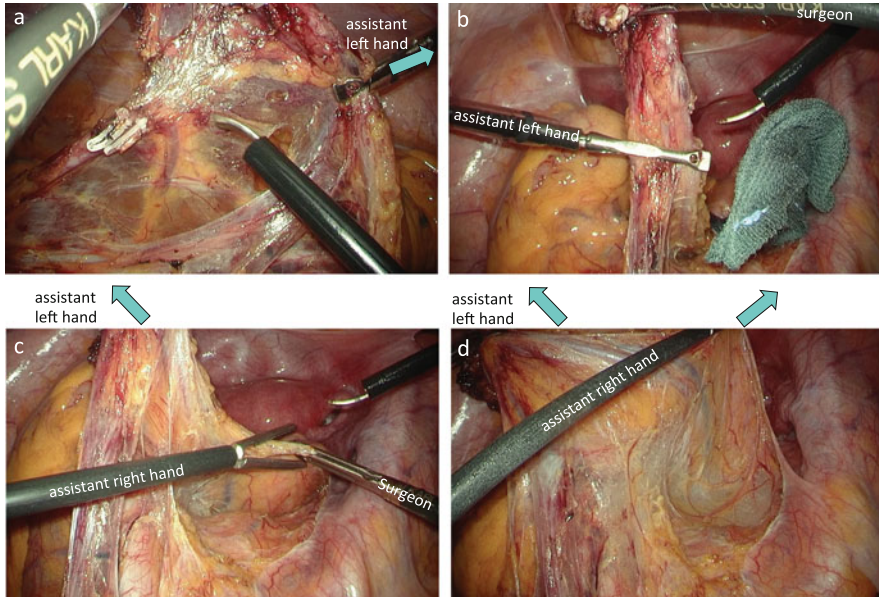
(Fig. 5.23b, b'). Next, the surgeon dissects the space between the mesocolon and retroperitoneum laterally up to the inner side of the Toldt's white line.

Then, the surgeon resects the avascular area of the descending mesocolon in the caudal–lateral direction, because resecting in the lateral direction may cause injury to the marginal artery of the descending colon (Fig. 5.24a).

#### 5.7.1.6 Completion of the Medial Approach and Fenestration of the Peritoneum on the Left Side of the Upper Mesorectum from the Medial Side

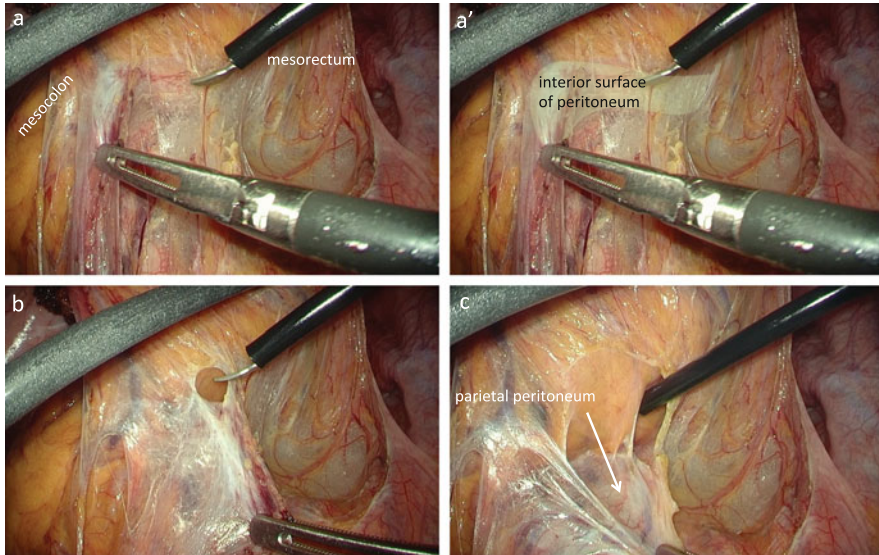
The assistant releases the Babcock forceps, in the left hand, grasping the IMA, and the surgeon then positions the IMA perpendicular to the ventral side such that the posterior side of the IMA faces in the cranial direction (Fig. 5.24b). With the Babcock forceps in the left hand, the assistant then grasps the IMA and draws it in the left ventral direction (Fig. 5.24c). With the intestinal forceps in the right hand, the assistant grasps the peritoneal cut edge on the right side of the mesorectum and elevates it in the right ventral direction (Fig. 5.24c, d). This allows complete visualization of the dissected space posterior to the rectum as well as the dissected space dorsal to the mesocolon (Figs. 5.24d and 5.25a).

The surgeon uses the opened intestinal forceps in the left hand to elevate either the mesocolon or the mesorectum ventrally and then proceeds to dissect in the



**Fig. 5.24** Visualization of the dissected spaces posterior to the rectum and mesocolon. The avascular area of the descending mesocolon is incised (a) to position the IMA perpendicular to the ventral side, and with the Babcock forceps in the assistant's left hand, the IMA is drawn in the left ventral direction (b, c). With the intestinal forceps in the assistant's right hand, the peritoneal cut edge on the right side of the mesorectum is elevated in the right ventral direction (c, d). This allows complete visualization of the dissected space posterior to the rectum as well as the dissected space dorsal to the mesocolon (d)

lateral direction to connect the dissected plane of the mesorectum and mesocolon. This line of dissection eventually reaches a white, opaque membrane where blunt dissection is difficult to perform; this is the interior surface of the peritoneum on the left side of the upper mesorectum (Fig. 5.25a, a'). Forcing blunt dissection in this area will result in straying into the mesorectum/mesocolon or the extraperitoneal space. Thus, this white opaque membrane is incised intentionally from the medial side and fenestrated in order to communicate with the lateral side of the rectum (Fig. 5.25b, c). The surgeon passes the intestinal forceps in the left hand through the fenestration in the peritoneum on the left side of the rectum and elevates it in the left ventral direction to expose the resection line on the peritoneum on the left side of the mesorectum. The peritoneum on the left side of the mesorectum is incised caudally from the medial side, prior to the lateral approach (Fig. 5.25c).

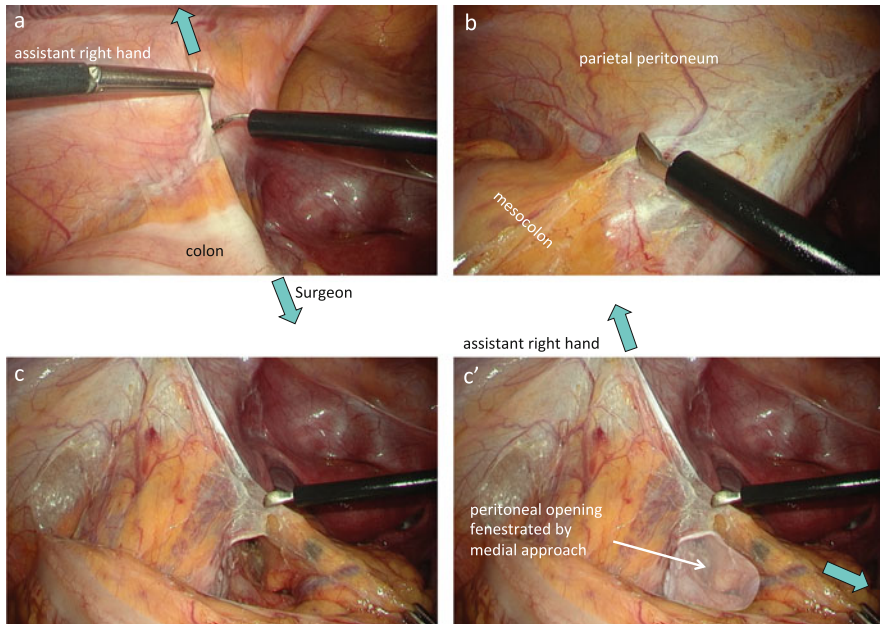


**Fig. 5.25** Fenestration of the peritoneum on the left side of the upper mesorectum from the medial side. By connecting the dissected plane of the mesorectum and mesocolon, the line of dissection eventually reaches the interior surface of the peritoneum on the left side of the upper mesorectum (**a, a'**). This white opaque membrane is incised intentionally from the medial side and fenestrated in order to communicate with the lateral side of the rectum (**b, c**)

### 5.7.1.7 Lateral Approach

Using the intestinal forceps in the right hand, the assistant grasps the parietal peritoneum that covers the left psoas muscle and draws it laterally and ventrally (Fig. 5.26a). Using the intestinal forceps in the left hand, the surgeon grasps the fatty appendage of the sigmoid colon and draws it medially (Fig. 5.26a). After dissecting the physiological adhesions between the fatty appendage of the sigmoid colon and left parietal peritoneum, the peritoneal opening on the left edge of the upper mesorectum that was medially penetrated in the previous step is confirmed from the lateral side (Fig. 5.26b, c, c').

The assistant grasps the fatty appendage in the center of the descending colon with the intestinal forceps in the right hand and pushes it medially and cranially. The surgeon pulls the descending colon medially using the intestinal forceps in the left hand (Fig. 5.27a, d). This allows satisfactory tension to be maintained on the left paracolic gutter and between the descending mesocolon and retroperitoneum (Fig. 5.27). When performing sigmoidectomy, it is enough to mobilize the descending mesocolon up to the upper pole of the left kidney. Since the peritoneum on the left side of the upper mesorectum has already been incised from the medial side (Figs. 5.25c and 5.26c), the mobilization of the distal descending colon, sigmoid colon, and upper rectum is now completed.

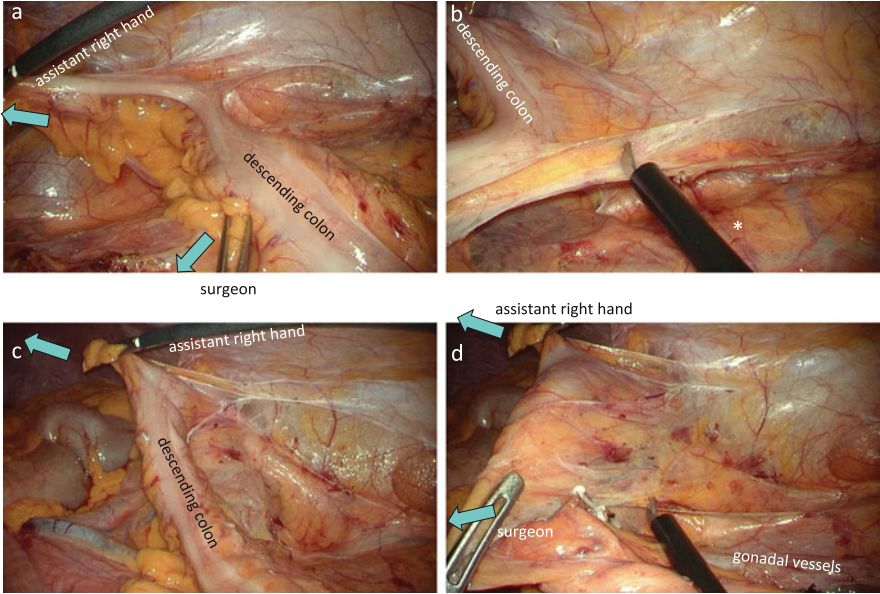


**Fig. 5.26** Adhesiolysis of the lateral attachment. The assistant draws the parietal peritoneum laterally and ventrally, and the surgeon draws the fatty appendage of the sigmoid colon medially (a). After dissecting the physiological adhesions between the fatty appendage of the sigmoid colon and left parietal peritoneum (b), the peritoneal opening on the left edge of the upper mesorectum that was medially penetrated is confirmed from the lateral side (c, c')

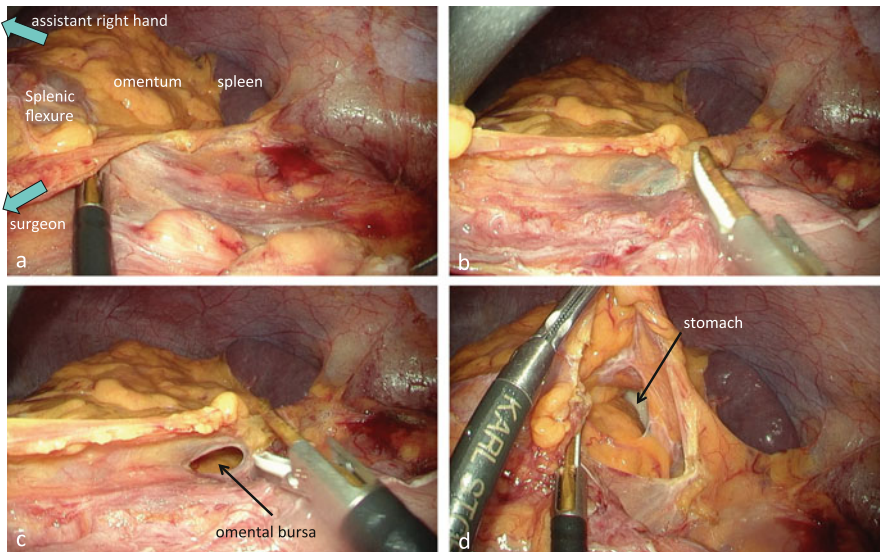
In patients with a short sigmoid colon, mobilization of the splenic flexure is inevitable [3]. The assistant grasps the fatty appendage of the splenic flexure and pushes it in the medial–cranial direction, and the surgeon grasps the fatty appendage of the proximal descending colon and pulls it medially, to straighten the splenic flexure and to maintain adequate tension between the splenic flexure and spleen (Fig. 5.28a). As the omentum in the vicinity of the splenic flexure is adherent to the spleen and paracolic gutter, the dissection along the left paracolic gutter should proceed not between the omentum and spleen but between the splenic flexure and omentum (Fig. 5.28a, b). Separating the adhesions between the splenic flexure and omentum allows access to the omental bursa from the lateral side (Fig. 5.28b–d).

### 5.7.1.8 Resection of the Mesorectum

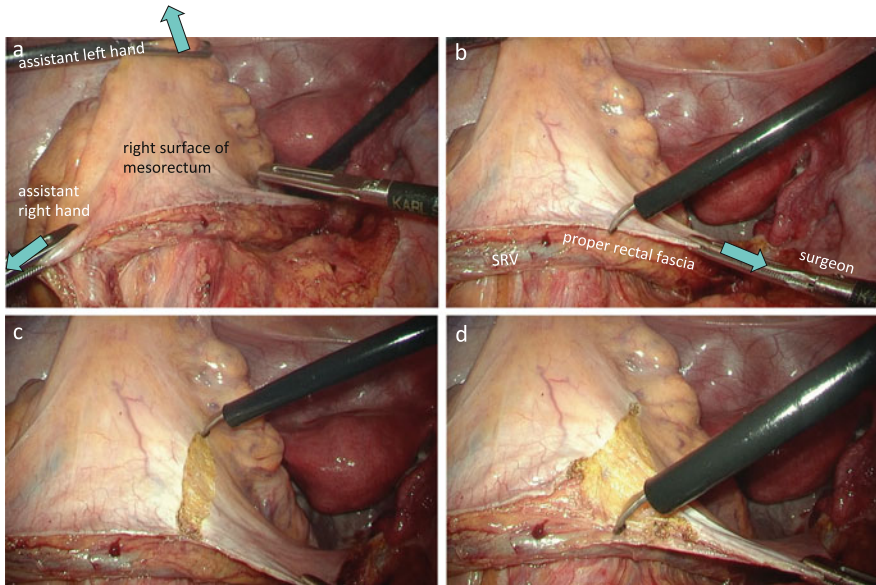
The sigmoid colon is drawn out of the pelvis to straighten the rectum. Then the surgeon marks the anterolateral surface of the mesorectum approximately 10 cm distal from the tumor, that is, where the rectum is to be transected.



**Fig. 5.27** Mobilization of the descending colon by a lateral approach. The assistant pushes the fatty appendage in the center of the descending colon medially and cranially, and the surgeon pulls the descending colon medially (a, d). This allows satisfactory tension to be maintained on the left paracolic gutter and between the descending mesocolon and retroperitoneum (b–d). \*The so-called Gerota’s fascia



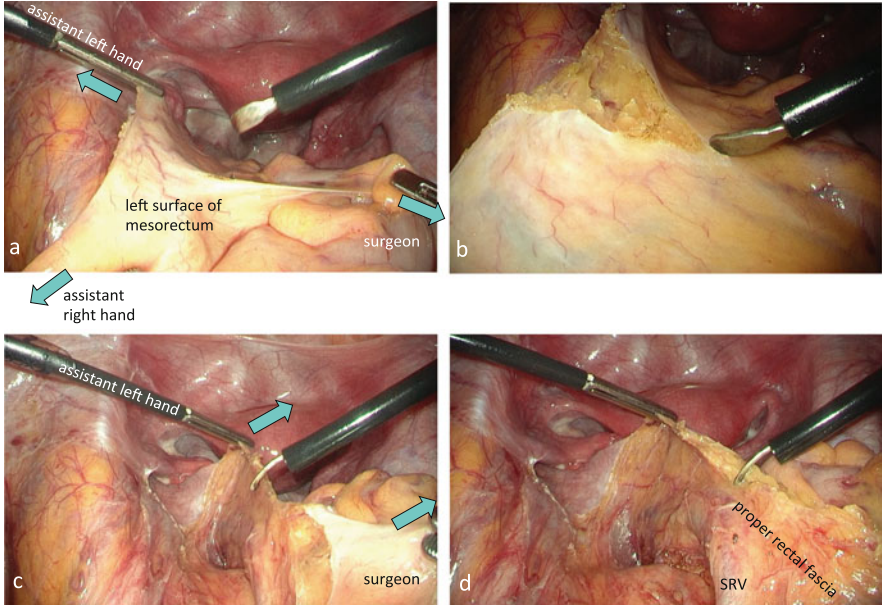
**Fig. 5.28** Mobilization of the splenic flexure by a lateral approach. The assistant pushes the fatty appendage of the splenic flexure in the medial–cranial direction, and the surgeon pulls the fatty appendage of the proximal descending colon medially, to straighten the splenic flexure and to maintain adequate tension between the splenic flexure and spleen (a). Separating the adhesions between the splenic flexure and omentum allows access to the omental bursa from the lateral side (b–d)



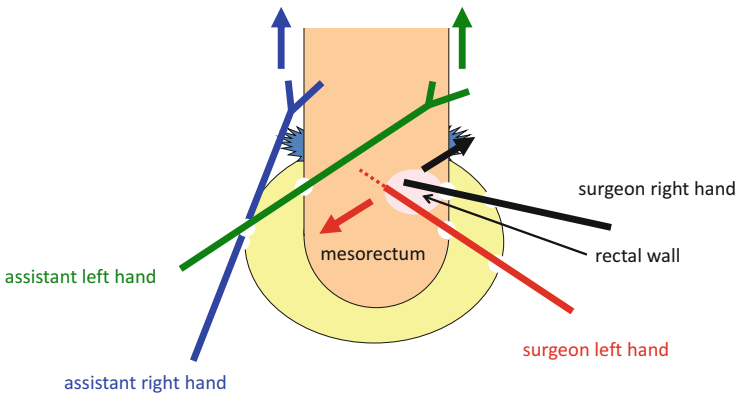
**Fig. 5.29** Resection of the mesorectum on the right side of the rectum. With intestinal forceps in the assistant's hands and in the surgeon's left hand, the peritoneum of the mesorectum is well stretched (**a**, **b**), and then the peritoneum and the proper rectal fascia covering the mesorectum are incised, and the mesorectal fat is resected (**c**, **d**)

With intestinal forceps in both of the assistant's hands and in the surgeon's left hand, the peritoneum of the mesorectum is well stretched, and then the peritoneum and the proper rectal fascia covering the mesorectum are incised, the mesorectal fat is resected, and the lateral wall of the rectum is exposed (Figs. 5.29 and 5.30).

Then the surgeon draws the sigmoid colon out of the pelvis to straighten the rectum. Using the intestinal forceps, the assistant's left hand grasps the peritoneal cut edge on the right side of the mesorectum and elevates it in the right ventral direction, and the assistant's right hand grasps the peritoneal cut edge on the left side of the mesorectum and elevates it in the left ventral direction (Figs. 5.31 and 5.32). Simultaneously, the assistant uses the shaft of the intestinal forceps in the right hand to move the sigmoid colon out of the visual field (Fig. 5.32c, d). The assistant stretches out the posterior surface of the mesorectum by spreading the tips of the intestinal forceps wide, which prevents damage to the rectal wall during resection of the mesorectum (Fig. 5.32d).

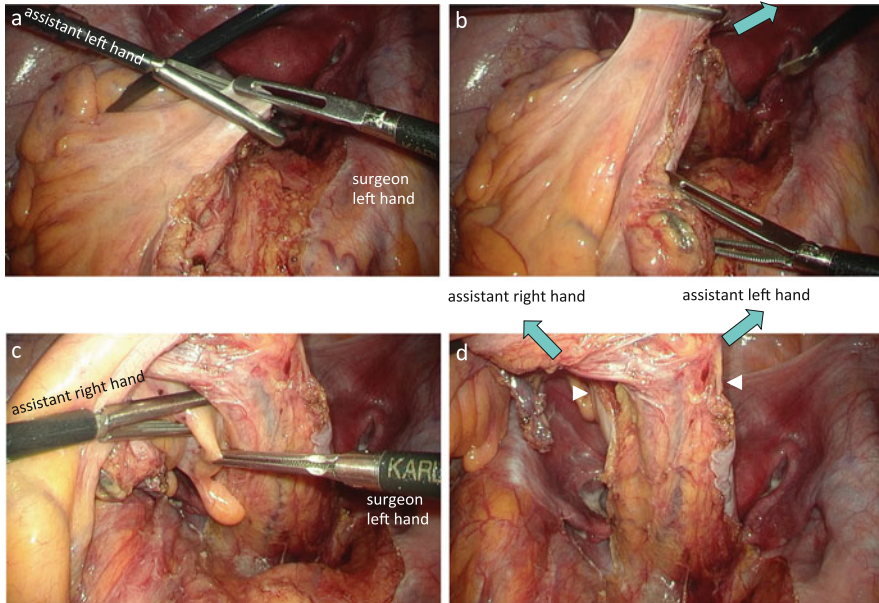


**Fig. 5.30** Resection of the mesorectum on the left side of the rectum. With intestinal forceps in the assistant’s hands and in the surgeon’s left hand, the peritoneum of the mesorectum is well stretched (**a, c**), and then the peritoneum and the proper rectal fascia covering the mesorectum are incised, and the mesorectal fat is resected (**b, d**)



**Fig. 5.31** Resection of the mesorectum on the posterior side of the rectum. With intestinal forceps in both hands, the assistant stretches out the posterior surface of the mesorectum by spreading the tips of the intestinal forceps wide. The surgeon dissects the space between the mesorectum and the rectal wall, akin to plowing the way through a crowd



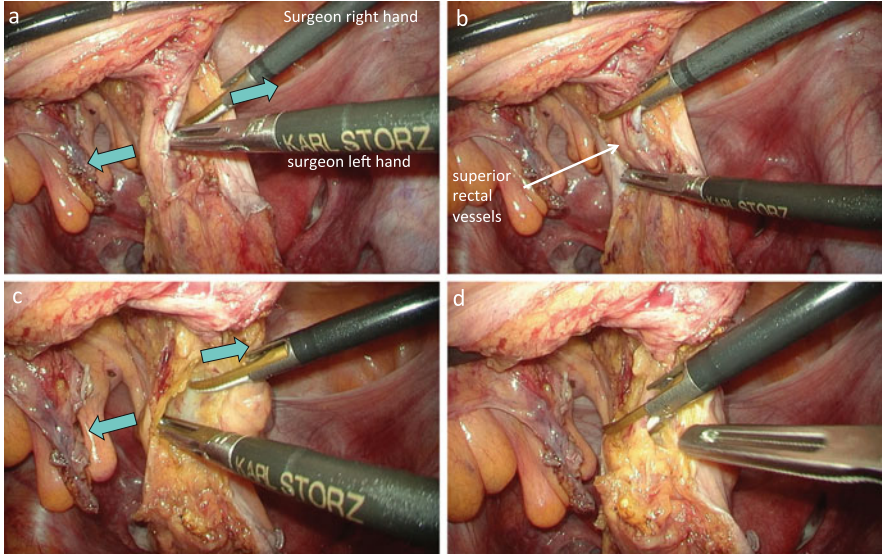


**Fig. 5.32** Stretching out the posterior surface of the mesorectum. Using the intestinal forceps, the assistant's left hand elevates the peritoneal cut edge on the right side of the mesorectum in the right ventral direction (**a**, **b**), and the assistant's right hand elevates the peritoneal cut edge on the left side of the mesorectum in the left ventral direction (**c**, **d**). The bilateral posterolateral sides of the mesorectum have already been resected (*white arrow head*), so the direction to resect the mesorectum is apparent (**d**)

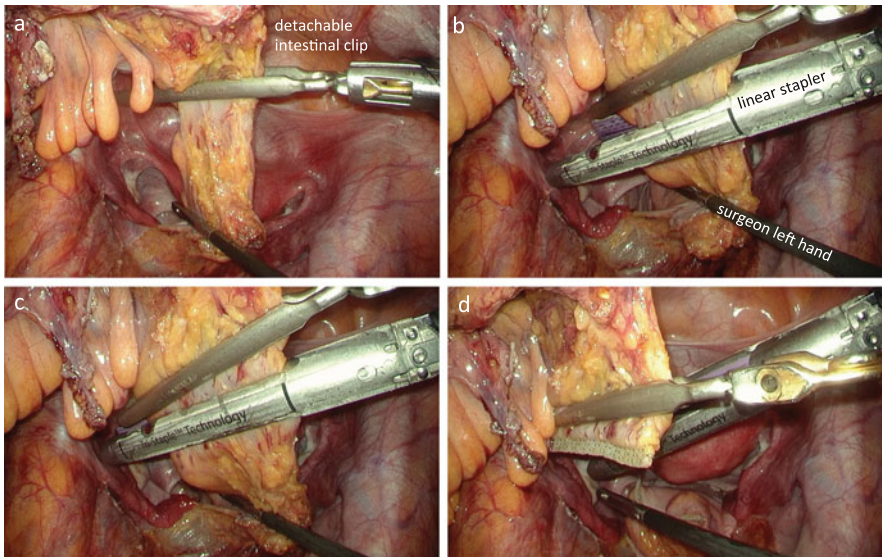
The bilateral posterolateral sides of the mesorectum have already been dissected, so the direction to resect the mesorectum is apparent (Figs. 5.32d and 5.33). The surgeon uses the tip of the intestinal forceps in the left hand and the tip of the ultrasonic scalpel in the right hand to dissect the space between the mesorectum and the rectal wall, akin to plowing the way through a crowd. Then the mesorectum is dissected from right to left using the ultrasonic scalpel to expose the posterior wall of the rectum (Fig. 5.33).

### 5.7.1.9 Transection of the Rectum

The assistant moves the intestinal forceps in the left hand cranially and the intestinal forceps in the right hand caudally to rotate the rectum clockwise, allowing the surgeon to guide the detachable intestinal clip from a three o'clock position to a nine o'clock position in relation to the rectal wall (Fig. 5.34a). Then, the detachable intestinal clip is attached to the proximal end of the exposed rectal wall, and the



**Fig. 5.33** Resection of the mesorectum on the posterior side of the rectum. The surgeon uses the tip of the intestinal forceps in the left hand and the tip of the ultrasonic scalpel in the right hand to dissect the space between the mesorectum and the rectal wall, akin to plowing the way through a crowd (a, c). Then the mesorectum is dissected from right to left using the ultrasonic scalpel to expose the posterior wall of the rectum (b, d)



**Fig. 5.34** Transection of the rectum. The detachable intestinal clip is attached to the proximal end of the exposed rectal wall (a). The rectum is transected using the linear stapler, taking care not to catch the intact mesorectum in the jaws of the cartridge (b-d)

distal rectum is irrigated with 500 mL of 5 % povidone-iodine saline to remove any suspended cancer cells. The cartridge of the linear stapler is selected based on the thickness of the rectal wall, and the rectum is transected using the linear stapler, taking care not to catch the intact mesorectum in the jaws of the cartridge (Fig. 5.34b, c). When performing sigmoidectomy and high anterior resection, it is possible to transect the rectum using a single 60-mm cartridge.

It is important to confirm whether the planned transection edge of the colon (i.e., approximately 10 cm proximal to the tumor) reaches the stump of the rectum without any tension; if any tension is noted, mobilization of the splenic flexure is additionally performed to allow tension-free anastomosis.

#### **5.7.1.10 Extracorporeal Procedures**

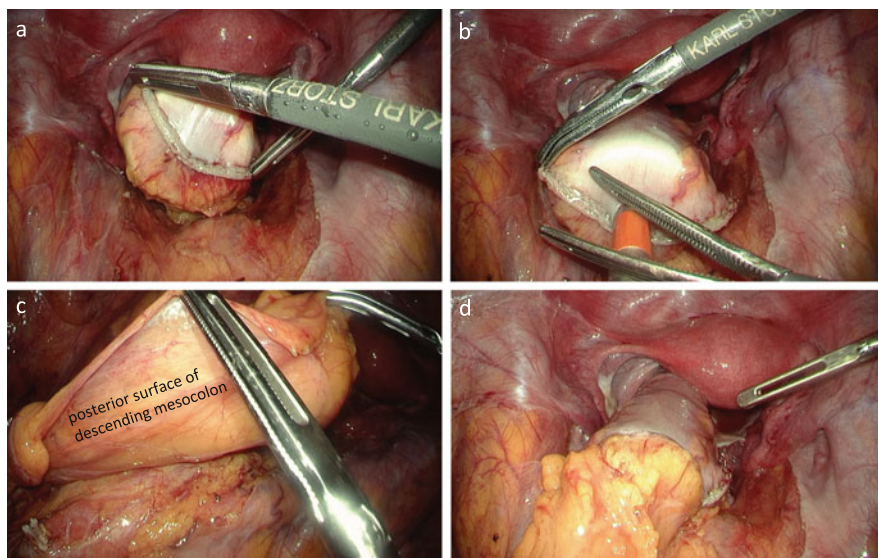
The wound in the umbilicus is extended approximately 30 mm in length in the craniocaudal direction, and the transection of the colon and fixation of the anvil in the colon are performed extracorporeally. After verifying pulsation of the marginal artery, the colon is transected at approximately 10 cm proximal to the tumor. The anvil of the circular stapler is inserted into the colon and fixed to the colon, and the colon is placed back into the abdominal cavity. Using a surgical glove, the camera port is fixed to the abdominal wall and pneumoperitoneum is resumed.

#### **5.7.1.11 Reconstruction**

After verifying that the stump of the colon reaches the rectal stump without any tension, a circular stapler is inserted into the anal canal. With intestinal forceps in both hands of the surgeon, the bilateral edges of the stapled line are grasped and the tip of the circular stapler is guided up to the rectal stump (Fig. 5.35a). In the case of low anterior resection, in order to prevent the urethra or the vagina being caught in the anastomosis, the rectal stump immediately dorsal to the stapled line is penetrated by the center rod of the circular stapler; however, in the case of sigmoidectomy or high anterior resection, the rectal stump immediately ventral to the midpoint of the stapled line is penetrated by the center rod of the circular stapler so that the anterior wall of the rectum accompanied by the serosa is included dominantly within the anastomosis (Fig. 5.35b).

After confirming that the mesocolon is not twisted [4] and that the small bowel is not invaginated behind the mesocolon, the anvil is connected to the center rod. The cut edge of the mesocolon is oriented ventrally; that is, the colon is positioned onto the sacrum in order to reduce the tension of anastomosis (Fig. 5.35c, d).

The circular stapler is tightened entirely, allowing two minutes of standby time to compress the colon and rectal walls evenly, and then the circular stapler is fired [5, 6]. After another minute of standby time for hemostasis, the circular stapler is removed (Fig. 5.35d). The “doughnut” created after anastomosis is inspected for completeness.



**Fig. 5.35** Reconstruction by double-stapling technique. With intestinal forceps in the surgeon's hands, the bilateral edges of the stapled line are grasped and the tip of the circular stapler is guided up to the rectal stump (a). The rectal stump immediately ventral to the midpoint of the stapled line is penetrated by the center rod of the circular stapler (b). The cut edge of the mesocolon is oriented ventrally; that is, the colon is positioned onto the sacrum in order to reduce the tension of anastomosis (c, d)

The pelvic cavity is filled with warm saline and, using intestinal forceps in the left hand, the surgeon pushes the colon toward the promontory to block the colonic lumen. Then, 50 mL of air is vigorously injected into the rectum transanally to confirm an airtight anastomosis. An identified air leak site can be repaired intracorporeally by suturing all the layers of the colon and rectum with 4-0 PDS. In the event that an air leak site cannot be identified or repaired, the anastomosis is removed completely and colorectal anastomosis is performed once again.

### 5.7.2 Medially Approached Mobilization of the Splenic Flexure

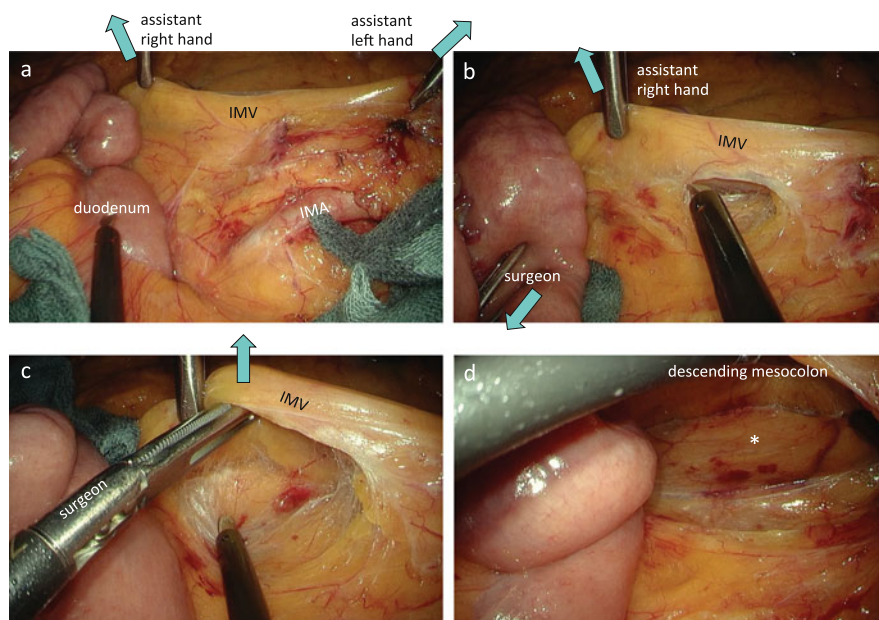
Several methods are used for laparoscopic mobilization of the splenic flexure [7]. Laparoscopy is characterized by the fact that laparoscopic observation and manipulation is carried out from foreground to background. It is logical, therefore, to perform laparoscopic mobilization of the splenic flexure via a medial approach.

### 5.7.2.1 Mobilization of the Proximal Descending Mesocolon

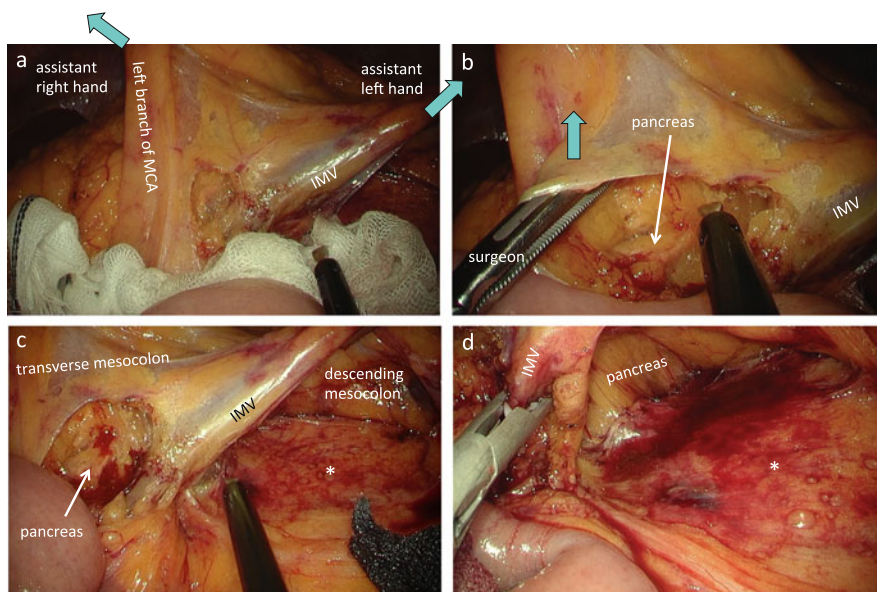
The surgeon stands to the right of the patient, the first assistant surgeon to the left of the patient, and the second assistant surgeon to the left of the surgeon (Fig. 5.3).

With the intestinal forceps, the assistant's right hand grasps the IMV cranial to the root of the IMA and draws it ventrocranially, and the assistant's left hand grasps the IMV around the root of the IMA and draws it ventrocaudally, so the root of the proximal descending mesocolon is well stretched (Fig. 5.36a). The adhesion between the jejunum and mesocolon is dissected prior to mobilizing the splenic flexure.

Using the intestinal forceps in the left hand, the surgeon draws the jejunum or peritoneum medially and incises the peritoneum cranially, approximately 5 mm medial to the IMV (Fig. 5.36b). With the intestinal forceps in the left hand, the surgeon grasps and lifts the peritoneal cut edge ventrally or elevates the IMV ventrally and dissects dorsal to the IMV to reach the dissectable layer between the descending mesocolon and retroperitoneum (Fig. 5.36b, c). Using the opened intestinal forceps in the left hand, the surgeon elevates the descending mesocolon



**Fig. 5.36** Mobilization of the proximal descending mesocolon. With the intestinal forceps in the assistant's hands, the IMV is drawn ventrally, so the root of the proximal descending mesocolon is well stretched (a). The peritoneum medial to the IMV is incised cranially (b). With the intestinal forceps, the surgeon elevates the IMV ventrally and dissects dorsal to the IMV to reach the dissectable layer between the descending mesocolon and retroperitoneum (c). Using the opened intestinal forceps, the surgeon elevates the descending mesocolon ventrally and extends the dissection between the mesocolon and retroperitoneum cranially and laterally (d). \*The so-called Gerota's fascia



**Fig. 5.37** Relationship between the pancreas and the IMV. Using the intestinal forceps in the assistant's right hand, the left branch of the middle colic artery is drawn ventrocranially, and with the intestinal forceps in the assistant's left hand, the IMV is drawn ventrocaudally, in order to elevate and stretch out the transverse and descending mesocolon (a). On the medial side of the IMV, the peritoneal incision is extended to the inferior margin of the pancreas (b), and the positional relation between the inferior margin of the pancreas body and the IMV is confirmed (c). The IMV is resected at the inferior margin of the pancreas (d). \*The so-called Gerota's fascia

ventrally and extends the dissection between the mesocolon and retroperitoneum cranially and laterally (Fig. 5.36d).

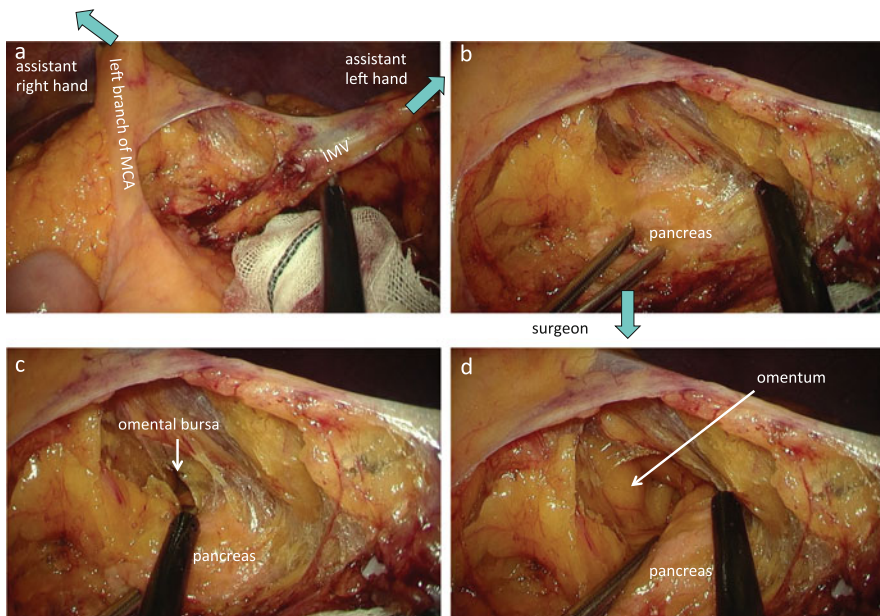
As the IMV runs behind the pancreas, continuing dissection in this plane in the cranial direction will reach the dorsal side of the pancreas (Figs. 5.9 and 5.37b, c). Therefore, cranial dissection behind the descending mesocolon is stopped at this point.

### 5.7.2.2 Opening the Omental Bursa from the Medial Side

Using the intestinal forceps in the right hand, the assistant grasps the left branch of the middle colic artery (MCA) and draws it ventrocranially and then grasps the IMV with the intestinal forceps in the left hand and draws it ventrocaudally, in order to elevate and stretch out the transverse and descending mesocolon (Fig. 5.37a). On the medial side of the IMV, the peritoneal incision at the root of the descending mesocolon is extended to the inferior margin of the pancreas, and the positional

relation between the inferior margin of the pancreas body and the IMV is confirmed (Fig. 5.37). If only the splenic flexure is being mobilized, the IMV can be preserved. However, to perform left hemicolectomy, the IMV must be resected at the inferior margin of the pancreas (Fig. 5.37d).

With the intestinal forceps in the surgeon's left hand, the root of the transverse mesocolon is elevated ventrally or the pancreas body is pushed dorsally, allowing the loose connective tissue between the mesocolon and pancreas to be extended with a foamy appearance (Fig. 5.38b). Dissection between the mesocolon and pancreas body proceeds cranially up to the anterior lobe of the transverse mesocolon. The anterior lobe of the transverse mesocolon is then incised and fenestrated to reach the omental bursa (Fig. 5.38b, c). The surgeon inserts the intestinal forceps in the left hand into the omental bursa, elevates the root of the transverse mesocolon ventrally, incises the anterior lobe of the transverse mesocolon and widens it toward both the left and right sides, and finally makes a large opening in the omental bursa (Fig. 5.38d).

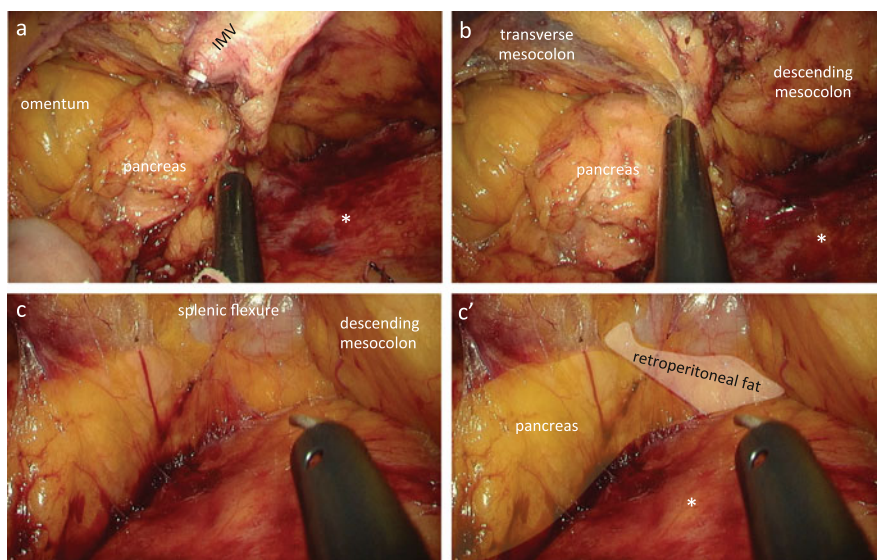


**Fig. 5.38** Opening the omental bursa from the medial side. Dissection between the mesocolon and pancreas body proceeds cranially up to the anterior lobe of the transverse mesocolon (a, b). The anterior lobe of the transverse mesocolon is incised and fenestrated to reach the omental bursa (c, d)

### 5.7.2.3 Dissection Between the Pancreas and Mesocolon

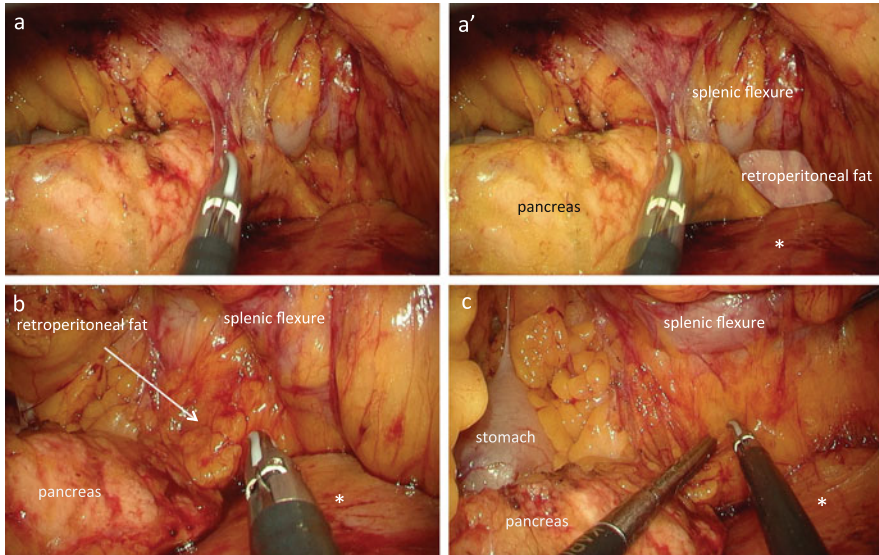
As the dissection proceeds, it becomes impossible to maintain adequate countertraction, so the assistant uses the opened intestinal forceps in the right hand to elevate the transverse mesocolon ventrally and the opened intestinal forceps in the left hand to elevate the descending mesocolon ventrally to maintain optimal countertraction and a wide operative field (Fig. 5.39a). Using the opened intestinal forceps in the left hand, the surgeon elevates the transverse mesocolon and descending mesocolon ventrally in order to observe the omental bursa, pancreas body, and dorsal side of the descending mesocolon in the same field of view. A sharp dissection is performed in the space between the transverse mesocolon/descending mesocolon and pancreas body toward the pancreas tail (Fig. 5.39a, b).

After completing the dissection between the root of the transverse mesocolon and pancreas, dissection reaches the splenic flexure. The adipose tissue between the pancreas tail and colon wall is not the mesocolon but retroperitoneal fat; therefore, there is no need to further expose the pancreas tail (Figs. 5.39c, c' and 5.40). Dissection is continued between the colon wall and retroperitoneal adipose tissue to reach the interior surface of the so-called splenocolic ligament (Figs. 5.40b, c and 5.41).

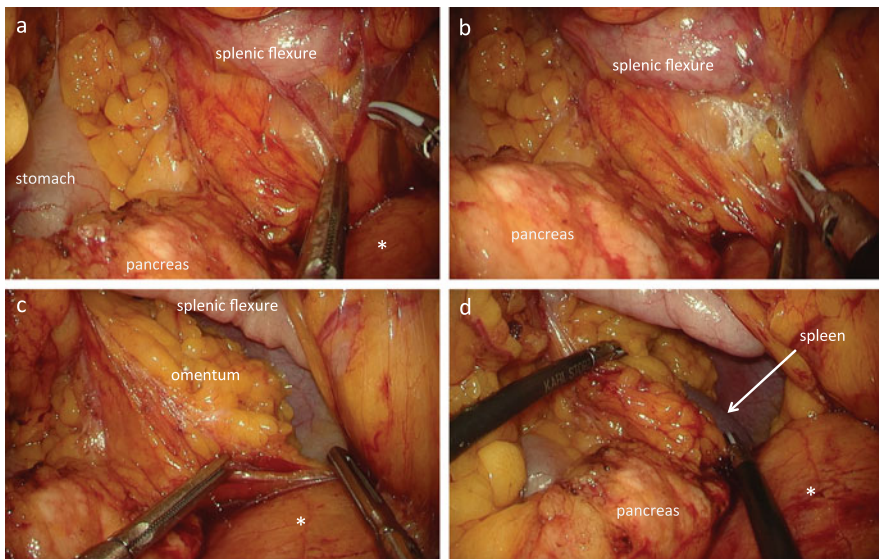


**Fig. 5.39** Dissection between the pancreas and mesocolon. Using the opened intestinal forceps, the surgeon elevates the transverse mesocolon and descending mesocolon ventrally in order to observe the omental bursa, pancreas body, and dorsal side of the descending mesocolon in the same field of view (a). A sharp dissection is performed in the space between the mesocolon and pancreas body toward the pancreas tail (b). The adipose tissue (white paint) between the pancreas tail and colon wall is not the mesocolon but retroperitoneal fat; therefore, there is no need to further expose the pancreas tail (c, c'). \*The so-called Gerota's fascia





**Fig. 5.40** Dissection to reach the interior surface of the so-called splenocolic ligament. Dissection is continued between the colon wall and retroperitoneal adipose tissue (*white paint*) to reach the interior surface of the so-called splenocolic ligament. \*The so-called Gerota's fascia



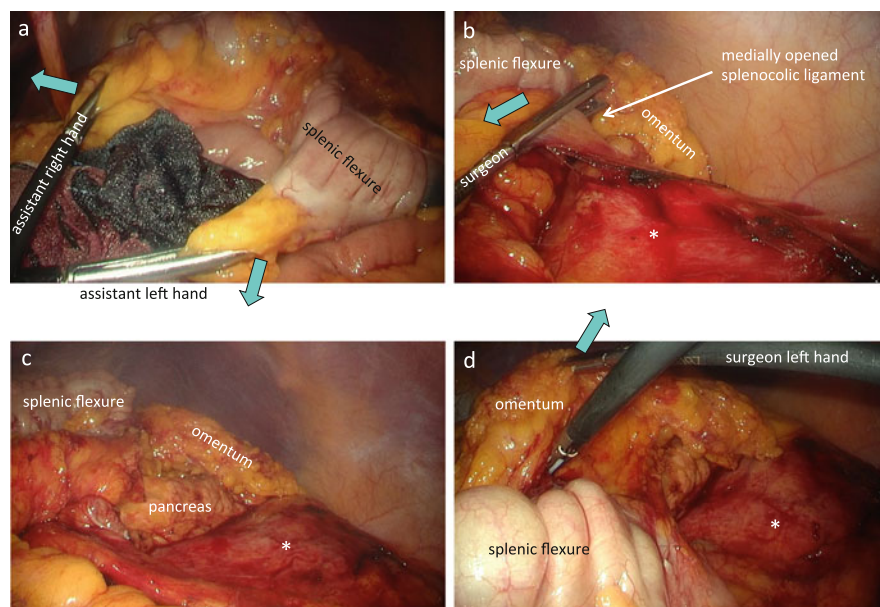
**Fig. 5.41** Fenestration of the splenicocolic ligament from the medial side. The so-called splenicocolic ligament can be incised and fenestrated from the medial side (**a**, **b**) to communicate with the space lateral to the splenic flexure (**c**, **d**). \*The so-called Gerota's fascia

### 5.7.2.4 Fenestration of the Splenocolic Ligament and Mobilization Around the Splenic Flexure from the Medial Side

The so-called splenocolic ligament can be incised and fenestrated from the medial side to communicate with the space lateral to the splenic flexure (Fig. 5.41). The interior surface of Toldt's white line is incised caudally, and the omentum is dissected at the site of adhesion to the transverse colon in the medial direction. Dissecting around the splenic flexure by a medial approach facilitates the following lateral approach.

### 5.7.2.5 Mobilization of the Splenic Flexure by the Lateral Approach

The assistant moves to the patient's right side, and the surgeon moves to stand between the patient's legs or to the patient's left side (Fig. 5.4). With the intestinal forceps, the assistant's right hand grasps the fatty appendage of the distal transverse colon and draws it medially and cranially, while the assistant's left hand grasps the fatty appendage of the proximal descending colon and draws it medially and caudally. The assistant spreads the tips of the intestinal forceps in both the hands to straighten the splenic flexure and draw it medially, allowing good tension between the splenic flexure and abdominal side wall (Fig. 5.42a, b). Using the



**Fig. 5.42** Mobilization of the splenic flexure by the lateral approach. The assistant's right hand draws the fatty appendage of the distal transverse colon medially and cranially, while the assistant's left hand draws the fatty appendage of the proximal descending colon medially and caudally (a). The assistant spreads the tips of the intestinal forceps in both hands to straighten the splenic flexure and draw it medially, allowing good tension between the splenic flexure and abdominal side wall (a). The splenocolic ligament has already been fenestrated from the medial side (b), so the dissection line of the left paracolic gutter is easily connected to the fenestrated site of the splenocolic ligament as well as the omental bursa (b–d). \*The so-called Gerota's fascia

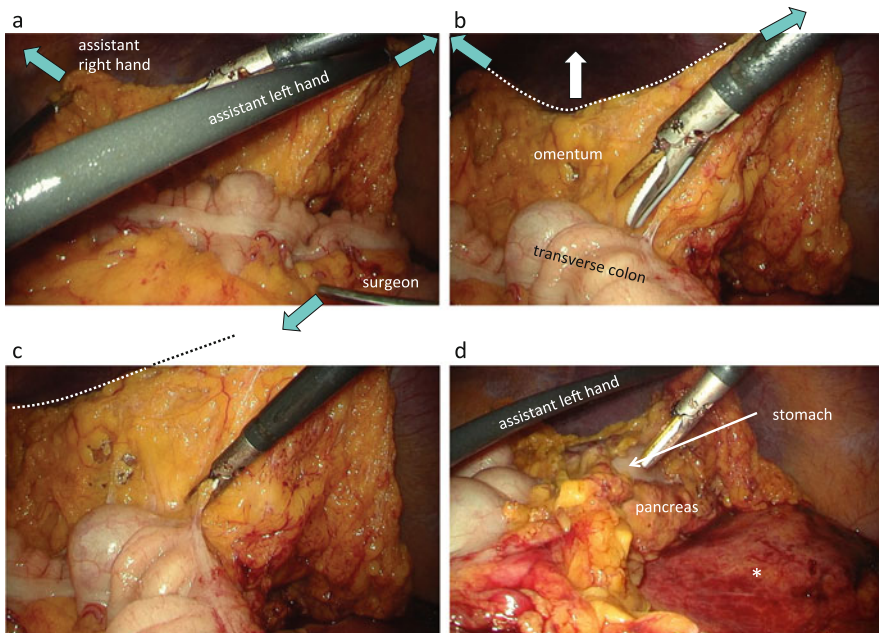
intestinal forceps in the left hand, the surgeon pulls the descending colon medially and resects Toldt's white line of the descending colon cranially toward the splenic flexure.

The splenocolic ligament has already been fenestrated from the medial side, so the dissection line of the left paracolic gutter is easily connected to the fenestrated site of the splenocolic ligament as well as the omental bursa (Fig. 5.42b–d).

### 5.7.2.6 Mobilization of the Transverse Colon by the Lateral Approach

The assistant remains on the right side of the patient, and the surgeon moves to the left side of the patient (Fig. 5.4). Using the intestinal forceps in the left hand, the assistant grasps the omentum near the splenic flexure and draws it laterally and ventrally. Using the intestinal forceps in the right hand, the assistant grasps the omentum near the center of the transverse colon and draws it medially and ventrally (Fig. 5.43a).

Then the assistant spreads the tips of the intestinal forceps in both hands to stretch out the omentum ventrally like a partition, and the surgeon grasps and pulls



**Fig. 5.43** Mobilization of the transverse colon by the lateral approach. The assistant's left hand draws the omentum near the splenic flexure laterally and ventrally, while the assistant's right hand draws the omentum near the center of the transverse colon medially and ventrally (a). The assistant spreads the tips of the intestinal forceps in both hands to stretch out the omentum ventrally like a partition, and the surgeon pulls the fatty appendage of the distal transverse colon in the medial–caudal direction, allowing good tension between the transverse colon and omentum (a–c). The omentum is dissected at the site of attachment to the transverse colon in the lateral to medial direction to mobilize the distal transverse colon (d). \*The so-called Gerota's fascia

the fatty appendage of the distal transverse colon in the medial–caudal direction, allowing good tension between the transverse colon and omentum (Fig. 5.43a–c).

The omentum is dissected at the site of attachment to the transverse colon in the lateral to medial direction to mobilize the distal transverse colon and complete the mobilization of the splenic flexure (Fig. 5.43c, d).

---

## 5.8 Conclusions

Standardizing the procedures for creating an optimal operative field with clear presentation of the dissectable layer enables the surgeon to perform laparoscopic sigmoidectomy and mobilization of the splenic flexure in a safe and reliable manner. Mastery of the basic surgical procedures can then be applied to transverse colectomy and total mesorectal excision (TME), both of which are regarded as procedures with a high degree of difficulty.

---

## References

1. Jacobs M, Verdeja JC, Goldstein HS. Minimally invasive colon resection (laparoscopic colectomy). *Surg Laparosc Endosc.* 1991;1(3):144–50.
2. Shinohara H, Haruta S, Ohkura Y, Udagawa H, Sakai Y. Tracing dissectable layers of mesenteries overcomes embryologic restrictions when performing infrapyloric lymphadenectomy in laparoscopic gastric cancer surgery. *J Am Coll Surg.* 2015;220:e81–7.
3. Kye BH, Kim HJ, Kim HS, Kim JG, Cho HM. How much colonic redundancy could be obtained by splenic flexure mobilization in laparoscopic anterior or low anterior resection? *Int J Med Sci.* 2014;11:857–62.
4. Lacy AM, García-Valdecasas JC, Delgado S, Sabater L, Grande L, Fuster J, Visa J. Unusual intraoperative complication in laparoscopic sigmoidectomy. *Surg Endosc.* 1998;12:448–9.
5. Kawada K, Hasegawa S, Hida K, Hirai K, Okoshi K, Nomura A, Kawamura J, Nagayama S, Sakai Y. Risk factors for anastomotic leakage after laparoscopic low anterior resection with DST anastomosis. *Surg Endosc.* 2014;28:2988–95.
6. Nakayama S, Hasegawa S, Hida K, Kawada K, Sakai Y. Obtaining secure stapling of a double stapling anastomosis. *J Surg Res.* 2015;193:652–7.
7. Benseler V, Hornung M, Iesalnieks I, von Breitenbuch P, Glockzin G, Schlitt HJ, Agha A. Different approaches for complete mobilization of the splenic flexure during laparoscopic rectal cancer resection. *Int J Colorectal Dis.* 2012;27:1521–9.

---

# Laparoscopic Total Mesorectal Excision (TME) for Rectal Cancer

# 6

Yoshiharu Sakai, Suguru Hasegawa, Hisashi Shinohara,  
Masahiro Yamada, and Michiaki Okada

---

## Abstract

Details of laparoscopic total mesorectal excision (TME) are described. Except for the divisions of the main vessels, such as the inferior mesenteric artery (IMA), the inferior mesenteric vein (IMV), and the left colic artery (LCA), the procedures consist of continuous dissection between the mesorectum and the surrounding tissues or organs. Essential prerequisites for the dissection are only two: making a good coordinated counter-traction by both the surgeon and the assistant and then recognizing the fibrous tissues between the mesorectum and the surrounding tissues or organs. The positions of assistant's hands as well as the surgeon's left hand to make coordinated tractions are described in the figures. As the definitions or images of historically famous terminologies, such as Waldeyer's fascia, Denonvilliers' fascia, etc. seem to be different among surgeons, I avoided using them. Instead, to share the images of "fibrous tissues," the planes created with dividing those fibrous tissues are pasted with half-tone colors. Some histological figures will help you to understand the surgical anatomy of the pelvic floor.

---

## Keywords

Rectal cancer • Total mesorectal excision • Intersphincteric excision • Low anterior resection

---

Y. Sakai, M.D., Ph.D. (✉) • S. Hasegawa, M.D., Ph.D. • H. Shinohara, M.D., Ph.D. • M. Okada, M.D.

Department of Surgery, Kyoto University, 54 Shogoin Kawara-cho, Sakyo-ku, Kyoto 606-8507, Japan

e-mail: [ysakai@kuhp.kyoto-u.ac.jp](mailto:ysakai@kuhp.kyoto-u.ac.jp)

M. Yamada, M.D., Ph.D.

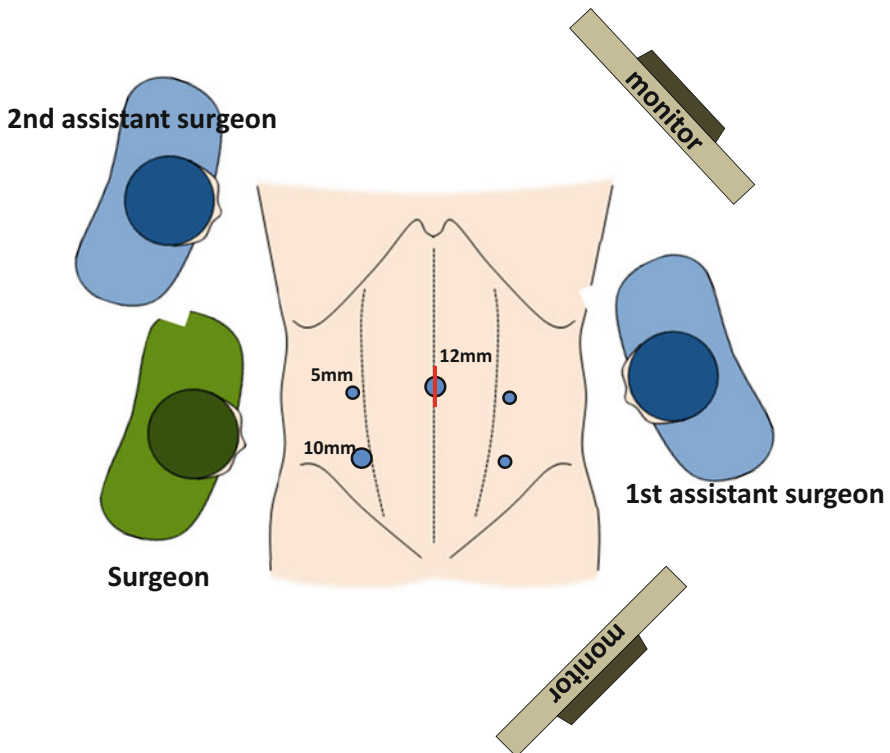
Department of Surgery, Shiga Medical Center for Adults, Moriyama, Shiga 524-8524, Japan

## 6.1 Patient Position

The patient should be in steep Trendelenburg position and tilted right side down so that the small intestine moves out from the pelvis and falls into the right upper quadrant due to its gravity.

## 6.2 Port Placement

The surgeon stands on the right side of the patient, the first assistant on the left side of a patient, and the second assistant on the left side of the surgeon. The cannulae are placed as shown in Fig. 6.1.



**Fig. 6.1** Positions of the cannulae and the surgical team. The camera port is at the umbilicus. Two ports on the right side are for a surgeon, and two ports on the left are for the first assistant. The specimen is extracted through an extended wound at the umbilicus

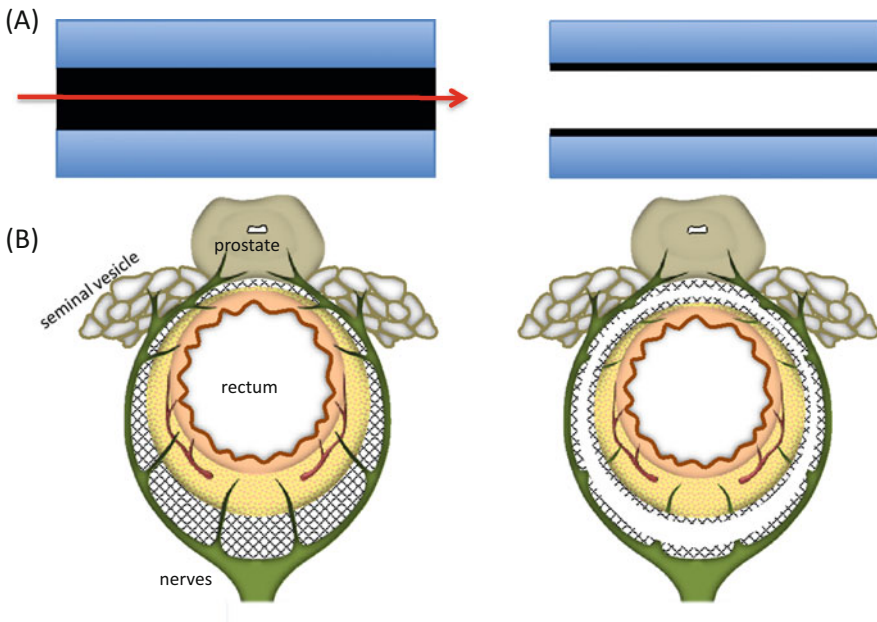
## 6.3 Procedures

### 6.3.1 Basic Principles for Dissection

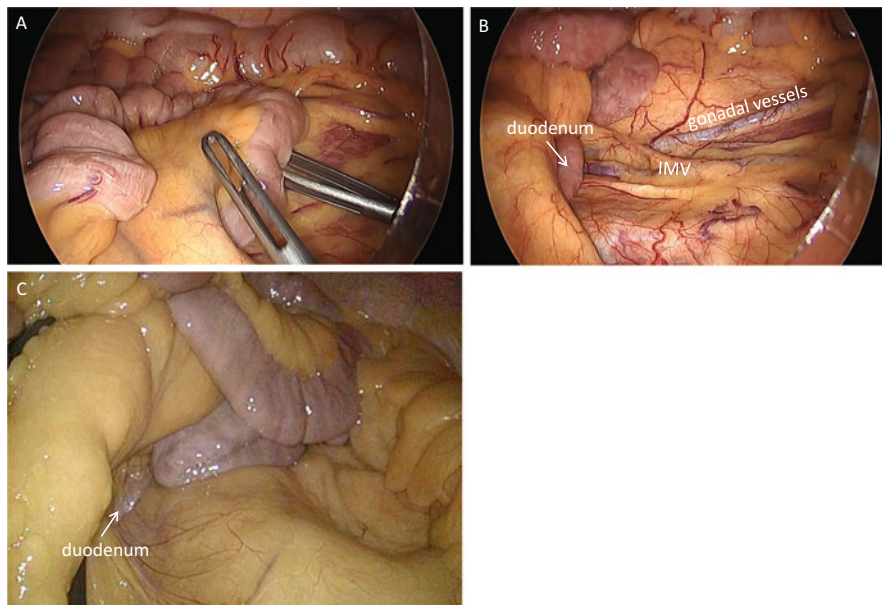
All tissues and organs are covered with connective fibers, the so-called “fascia.” Dissection means the dividing of these fibrous tissues between the other tissues or organs, creating new fasciae on both sides (Fig. 6.2a). Your dissection between the rectum and the neural system, such as the hypogastric nerves, the pelvic nerve plexus, and the neurovascular bundles, creates the so-called “prehypogastric nerve fascia” (fibrous tissues covering the nerves) and the “rectal fascia propria” (fibrous tissues covering the rectum and its proper adipose tissue). A good counter-traction is a prerequisite to identify the fibrous tissues. You may divide the adipose tissue intentionally only at the time when you divide vascular or neural branches to the rectum, because these branches are accompanied with the adipose tissues.

### 6.3.2 Medial to Lateral Dissection

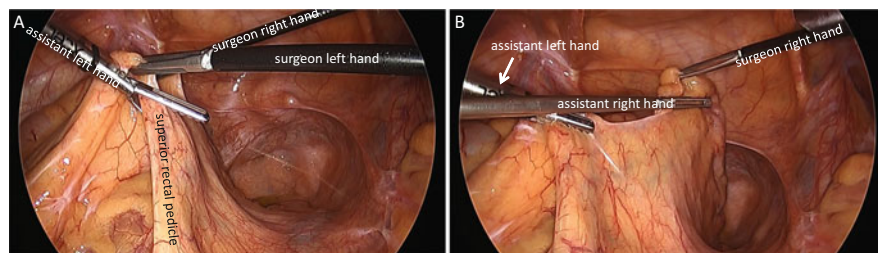
The greater omentum and the transverse colon are placed in the left upper quadrant, and the small bowel loops are placed in the upper right quadrant to expose the terminal portion of duodenum and the inferior mesenteric vein (IMV) (Fig. 6.3).



**Fig. 6.2** Basic principles of dissection. (A) Dissection means cutting the connective fibers (fascia) between the tissues or organs, creating the new fasciae on both sides. (B) The connective fibers (fascia) between the rectum and the nerves are dissected, creating two new fasciae: the prehypogastric nerve fascia and rectal fascia propria



**Fig. 6.3** The small intestinal loops are placed in the right upper quadrant to expose the duodenum and IMV (A, B). In an obese patient, the IMV is not clearly seen (C)

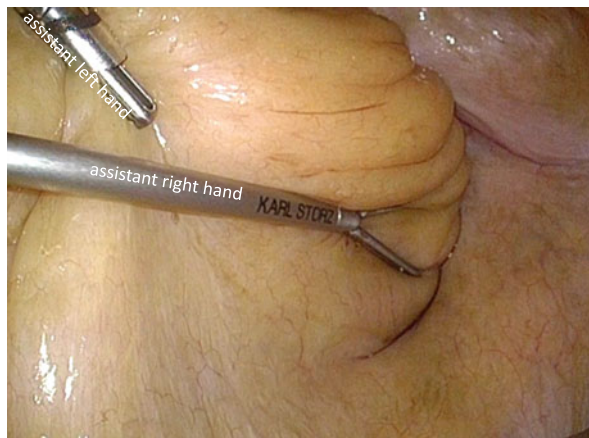

**Fig. 6.4** The assistant grasps the superior rectal pedicle by the left hand (A) and the anterior wall of the rectum by the right hand, in order to extend the right surface of mesorectum (B)

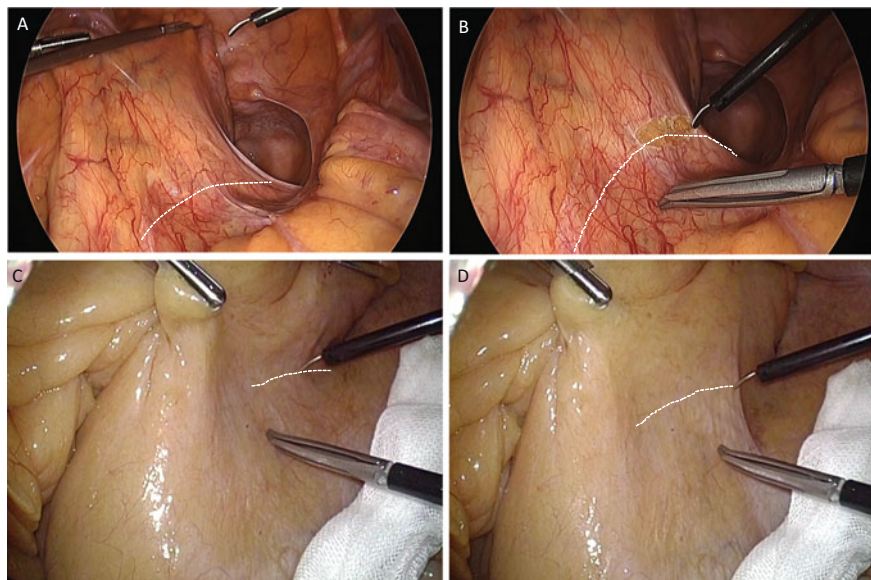
Sigmoid colon and rectum are retracted out from the pelvis to identify the tumor location. If the tumor location is unclear, proctoscopy or colonoscopy is recommended to exactly determine the distal cutting line of the rectum. Preoperative tattooing is not recommended because the ink often exudates extramurally to make dissection layer obscure.

The anterior wall of the rectum and the pedicle of superior rectal vessels are grasped gently and retracted ventrally by the assistant to extend the right-side peritoneum of rectum widely (Fig. 6.4). If the grasping of the anterior wall of the rectum is difficult, the assistant can push the rectum ventrally and laterally with an opened intestinal grasper (Fig. 6.5). An incision is made on the peritoneum at the



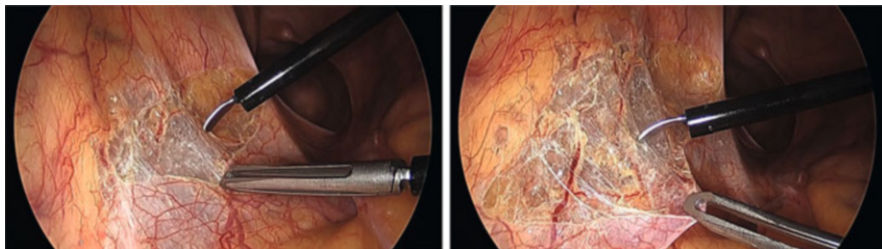


**Fig. 6.5** The assistant can push the rectum ventrally and laterally with an opened grasper

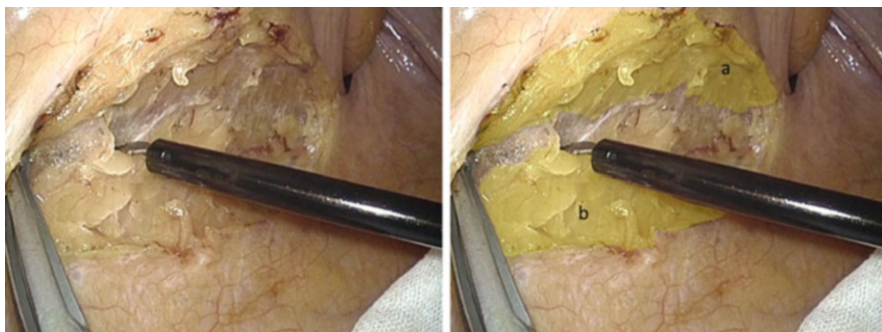


**Fig. 6.6** When the assistant relaxes his retraction, the incisional lines are imagined as the dotted lines along the concave of peritoneum (A, C). Those lines are moved ventrally with full retraction by the assistant (B, D)

level of promontory, going toward the peritoneal reflection (Fig. 6.6). Picking up the cutting edge of peritoneum facilitates the recognition of the subperitoneal connective fibers (Fig. 6.7). Cutting these fibers, not the adipose tissues, prevents the injury on the hypogastric nerves. Even if you are dissecting a wrong plane with



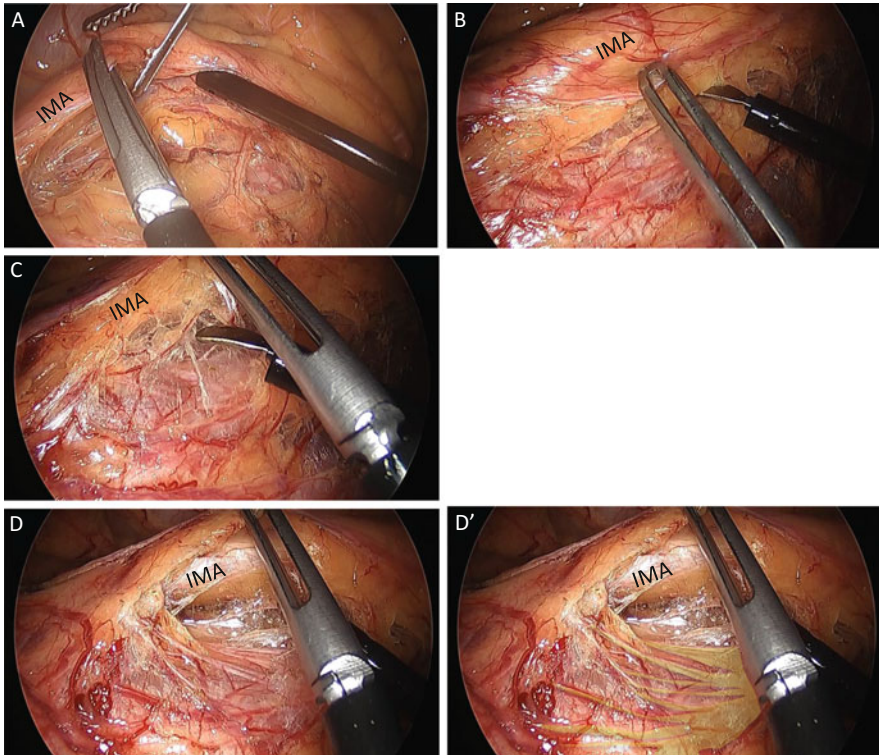
**Fig. 6.7** Picking up the edge of peritoneum extends the subperitoneal fibrous tissues widely and facilitates easy dissection



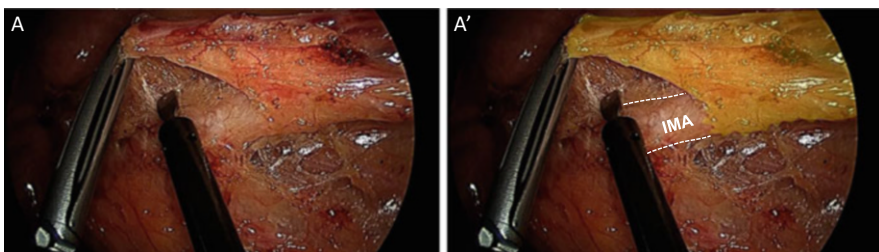
**Fig. 6.8** The rectal fascia propria (a) and the prehypogastric nerve fascia (b) are separated

dividing the fibers, it is able to easily return to a correct plane without any oncological as well as physiological complications.

Cutting of these fibrous tissues creates fibrous membranes on both sides: the so-called rectal fascia propria (proper rectal fascia) and prehypogastric nerve fascia (Fig. 6.8). You can advance the dissection as deep as possible toward the pelvic floor. If it is difficult, you should move to cephalad dissection. Incision of peritoneum is continued up to the origin of IMA. The assistant should now grasp the IMA pedicle proximally to extend subperitoneal connective tissues. This maneuver facilitates the recognition of fine structure of connective fibers and prevents the injuries to the lumbar splanchnic nerves, the ureter, and the gonadal vessels (Fig. 6.9). The borderline between the lymph nodes along the IMA and the lymph nodes along the aorta is unclear so that you should make the border yourself dividing the adipose tissues between them. I recommend an ultrasonic or a bipolar energy device to divide the adipose tissues. It is safe and easy to dissect between adipose tissues containing lymph nodes and neural tissues surrounding the IMA (Fig. 6.10). You should divide the sigmoidal branches of the lumbar splanchnic nerves, especially the branches from the right lumbar splanchnic nerves, to skeletonize the IMA. Following the skeletonization and division of the IMA, the sigmoidal branches from the left lumbar splanchnic nerves are identified and



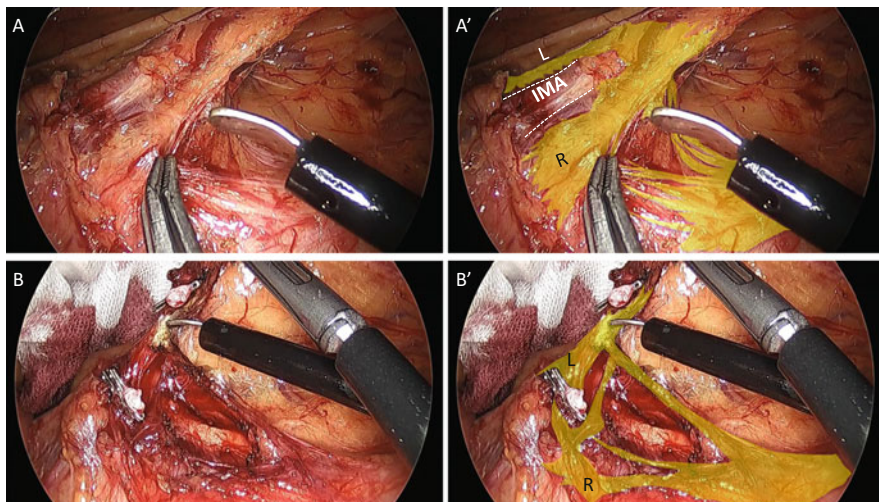
**Fig. 6.9** Following the initial peritoneal incision and dissection, the assistant now grasps the IMA pedicle proximally (A). The additional ventral traction of the IMA pedicle by the surgeon extends the fibrous tissues behind the pedicle (B, C) and facilitates the following dissection between the sigmoidal mesentery and retroperitoneum (D). Yellow lines are left lumbar splanchnic nerves (D')



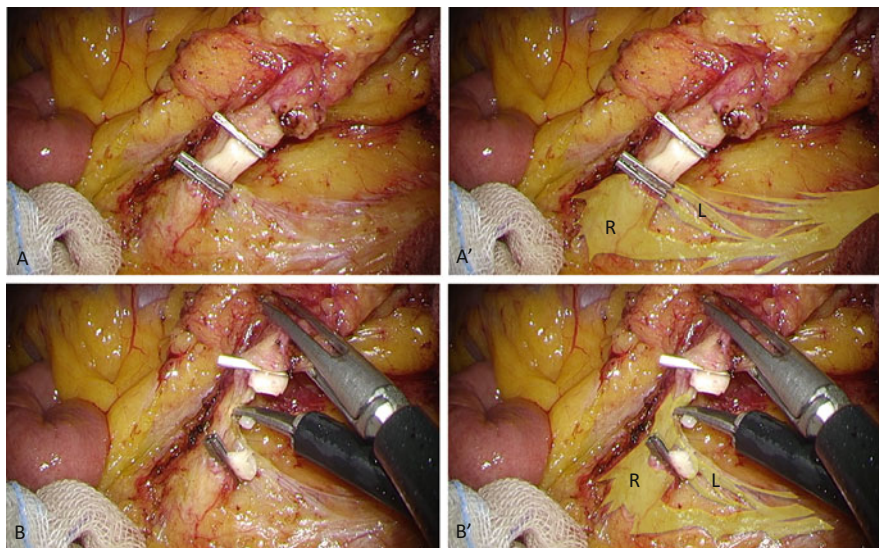
**Fig. 6.10** The adipose tissues (yellow area) containing the lymph nodes around the IMA (dotted white line) are dissected from the IMA, which is covered with the sigmoidal branches of splanchnic nerves

divided (Fig. 6.11). Or you can divide the IMA distally to avoid the injury to the left splanchnic nerves (Fig. 6.12).

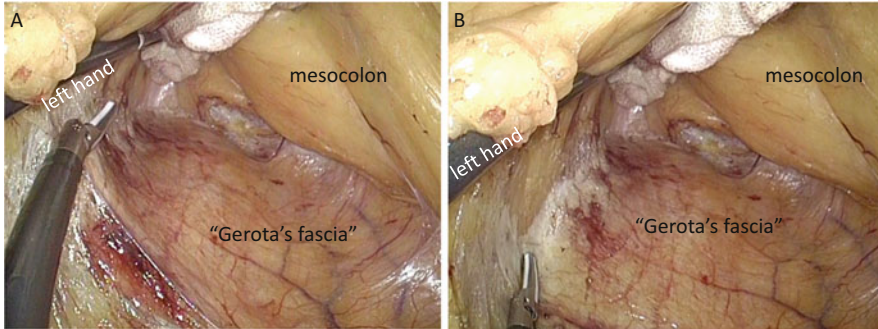
The assistant now grasps the distal edge of IMA and retracts it ventrally to extend the dissection plane between the sigmoidal mesentery and retroperitoneum.



**Fig. 6.11** (A) The sigmoidal branches from the right splanchnic nerves are divided prior to the division of the IMA. The skeletonization of the IMA is necessary to preserve the left splanchnic nerves. (B) Following the division of the IMA, the sigmoidal branches from the left splanchnic nerves are divided. *Yellow area* lumbar splanchnic nerves, *L* left branch, *R* right branch



**Fig. 6.12** Comparing the case in Fig. 6.11, the IMA is divided more distally so that the left lumbar splanchnic nerves are easily preserved. (A) The IMA is completely skeletonized. (B) The sigmoidal branches from the left lumbar splanchnic nerves are divided. *Yellow area* lumbar splanchnic nerves, *L* left branch, *R* right branch



**Fig. 6.13** The ventral retraction by the surgeon's left hand extends the fibrous tissues between the dissected planes: mesocolon and Gerota's fascia (A). Continuous division of the fibrous tissues creates membranes clearly on both sides (B)

The inferior mesenteric vein (IMV) and the left colic artery (LCA) are divided at the same level of the IMA division. In some case the LCA is running far away from the IMV [1]. The dissection between the mesocolon and the retroperitoneum is advanced laterally and cephalad. Again the dissection means cutting of the connective fibers. In order to recognize these connective fibers, counter-traction is very important. Your own ventral retraction often extends the fibrous tissues between the sigmoidal mesocolon and the retroperitoneum (Fig. 6.13). Dividing the connective fibers creates a fibrous membrane covering the left kidney, the so-called the Gerota's fascia. You can recognize the lower border of pancreas.

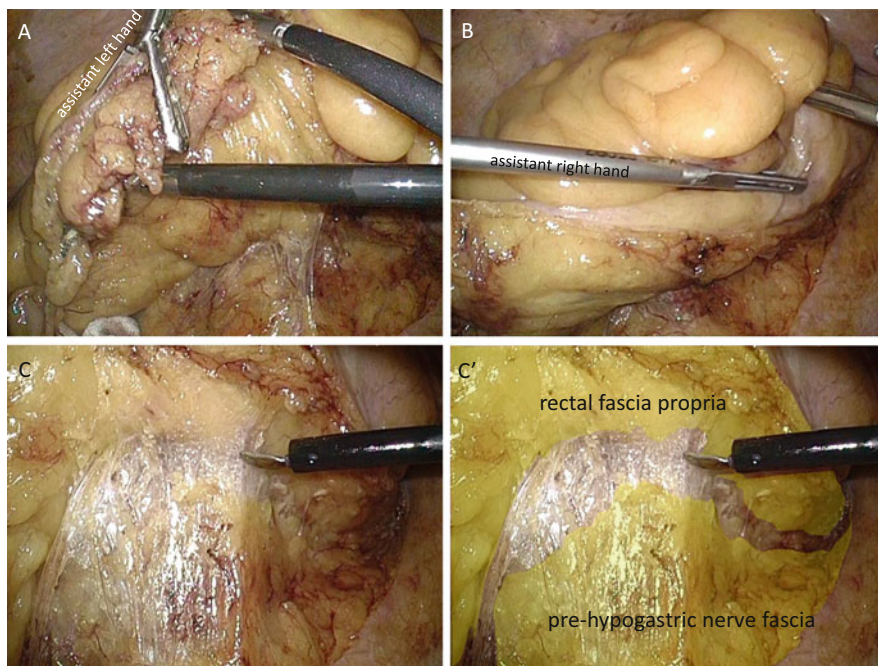
Following the cephalad dissection, you come back to the posterior dissection of the rectum. The assistant grasps the distal edge of the IMA by the left hand and the right edge of the incised peritoneum of the mesorectum by the right hand (Fig. 6.14A, B). The following ventral and cephalad traction by the assistant extends the fibrous tissues between the mesorectum and the retroperitoneum (Fig. 6.14C, C'). The dividing these fibers creates the rectal fascia propria and the prehypogastric nerve fascia on both sides.

### 6.3.3 Lateral Mobilization and Takedown of Splenic Flexure (Refer to Another Chapter)

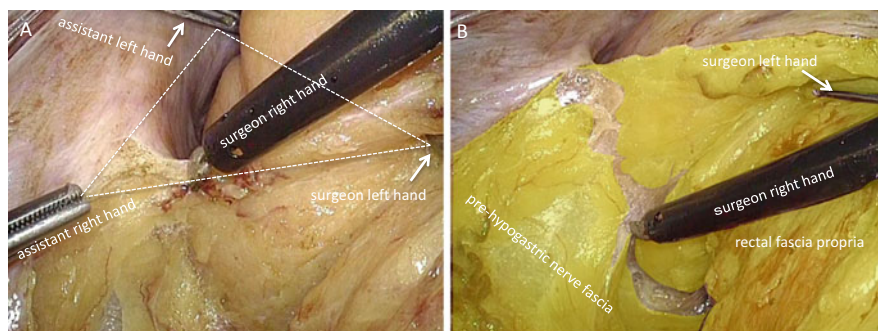
Chapter 5 Laparoscopic left sided colectomy (mobilization of splenic flexure and sigmoidectomy)

### 6.3.4 Posterior and Lateral Dissection of the Rectum

The patient is restored in the Trendelenburg position following the mobilization of the splenic flexure. For the continuous incision of the peritoneum on the left side of the mesorectum, the surgeon retracts the rectum medially and cephalad, and the assistant picks the edge of incised peritoneum by the right hand and retracts the



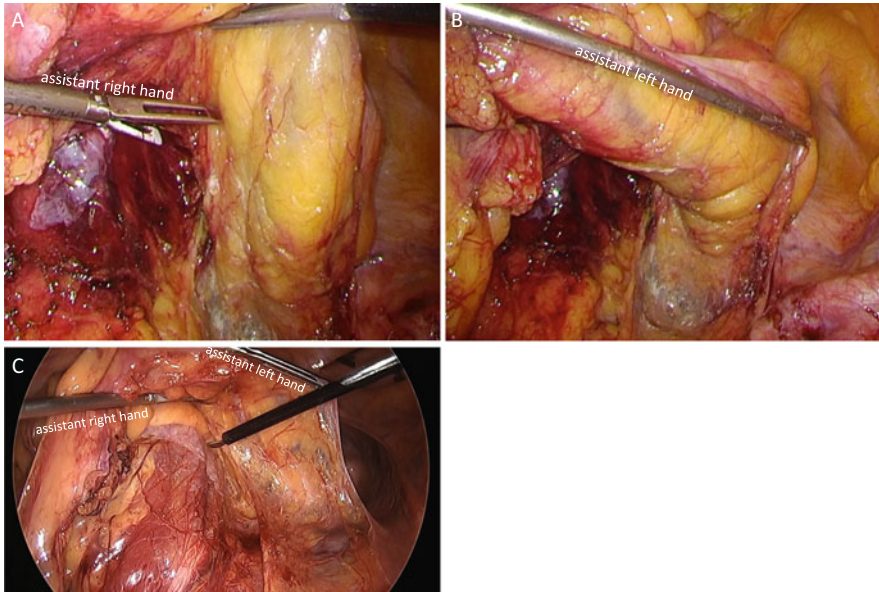
**Fig. 6.14** The assistant grasps the distal edge of the IMA pedicle (A) and the right edge of incised peritoneum of the mesorectum (B). The sufficient ventral traction extends the fibrous tissues for the following dissection (C, C')



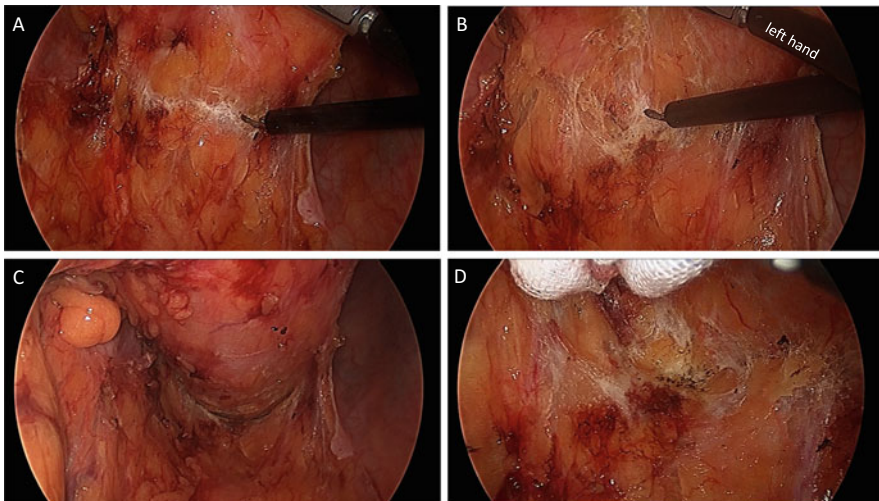
**Fig. 6.15** Triangulation made by both hands of the assistant and the surgeon's left hand facilitates the continuous incision of the peritoneum on the left side (A) and extends the fibrous tissues between the rectal fascia propria and the prehypogastric nerve fascia (B)

rectum by the left hand ventrally if necessary (Fig. 6.15A). The fibrous tissues are extended and the following dissection plane is easily recognized (Fig. 6.15B).

Next you move to the posterior dissection of the rectum in the midline. The assistant grasps the left edge of mesorectum by the right hand and the right edge by the left hand like a “matador” (Fig. 6.16). The sufficient traction by the assistant



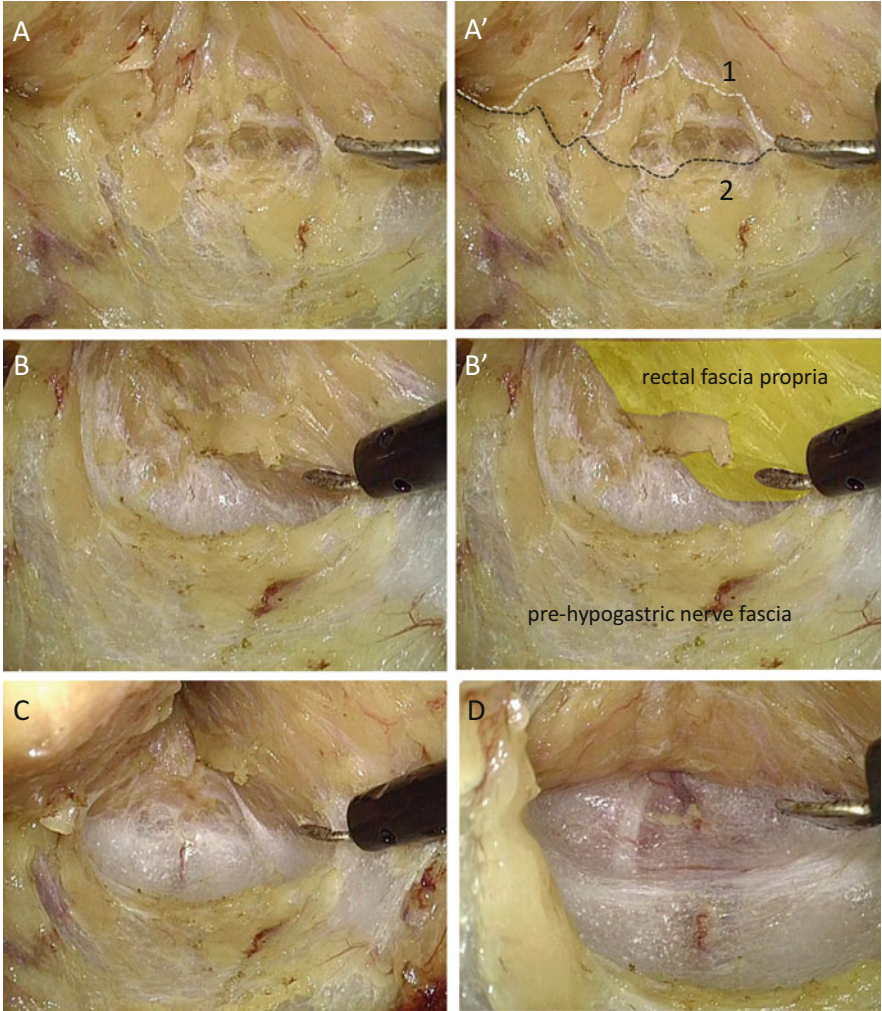
**Fig. 6.16** The assistant grasps the left edge of the mesorectum by the right hand (A) and the right edge by the left hand (B) and retracts the rectum ventrally like a “matador.” (C) is in another case



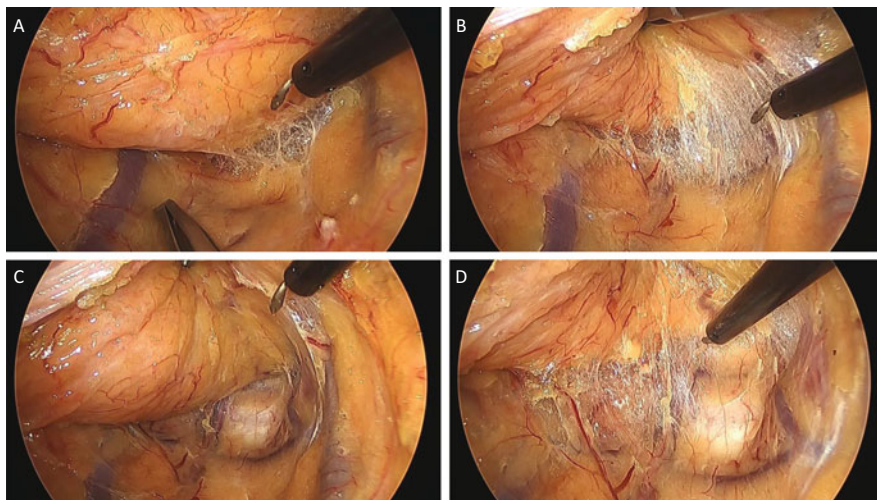
**Fig. 6.17** The push-up of the posterior wall of the rectum by the left hand (A, B) or with a piece of gauze (C, D) extends the fibrous tissues to recognize them

shows you the fibrous tissue posteriorly to the rectum. The dissection of this fibrous tissue starts in the midline adjacent to the rectum. Your push-up of the posterior wall of the rectum by the left hand or with a piece of gauze extends the fibrous tissue more widely and facilitates the following dissection (Fig. 6.17). It is sometimes

difficult to recognize the fibrous tissues or the dissection plane, especially in an obese patient (Fig. 6.18). In such a case we recommend to readjust the counter-traction to somehow find the fibrous tissues. Once recognizing even a small amount of fibers, dividing them and readjusting counter-traction facilitate the following recognition of the fibrous tissues. Another importance is to divide the fibrous tissues adjacent to the rectum in order to avoid the injury to the median or lateral sacral





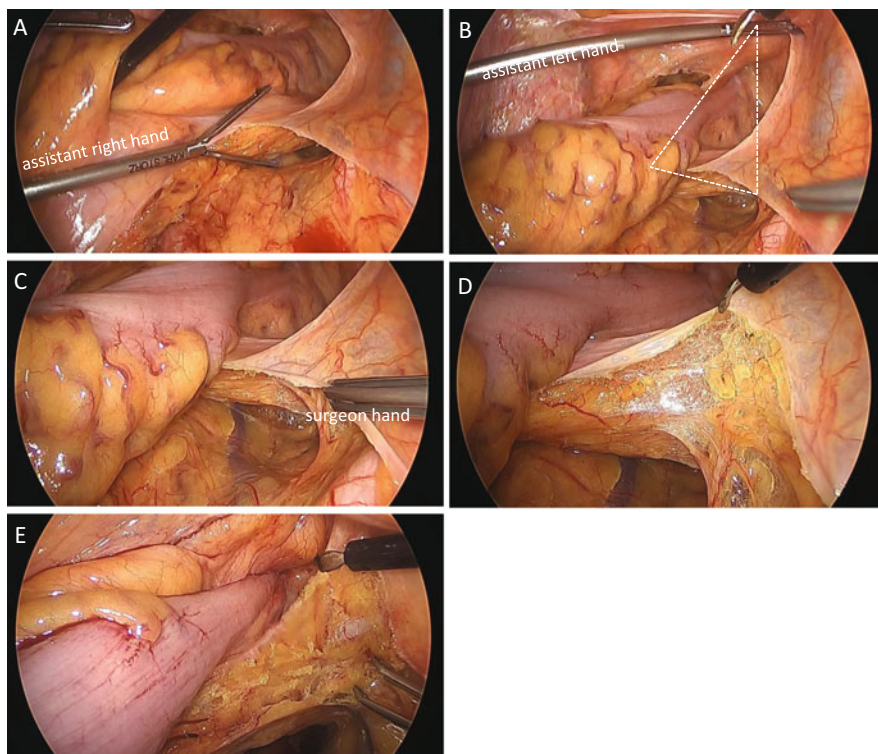


**Fig. 6.19** The sufficient traction or pushing up the rectal wall extends the fibrous tissues over the pelvic floor (A, B) and the dissection adjacent to the rectum prevents the injury to the median or lateral sacral vessels. No fibrous tissues seem to remain on the sacrum (C), but they are confirmed with an additional traction (D)

vessels (Fig. 6.19). You should advance the posterior dissection as caudal as possible.

The assistant now retracts the rectum cephalad and laterally with an opened grasper by the right hand. The surgeon picks the edge of the incised peritoneum to form the so-called tissue triangulation (Fig. 6.20A–C). The continuous incision of the peritoneum discloses the subperitoneal fibrous tissues, which cover the right hypogastric nerve, the pelvic nerve plexus, and the neurovascular bundle (Fig. 6.20D). The seminal vesicle is identified with continuously dividing the fibrous tissues (Fig. 6.20E). When you are unable to follow the fibrous tissues, you and the assistant should change the points of grasping or adjust the direction of traction. The dissection should not be advanced without the recognition of the fibrous tissues.

The left lateral dissection is done in a similar fashion as on the right side. The surgeon retracts the rectal left wall cephalad and medially with an opened grasper, and the assistant picks up the edge of the incised peritoneum by the left hand and

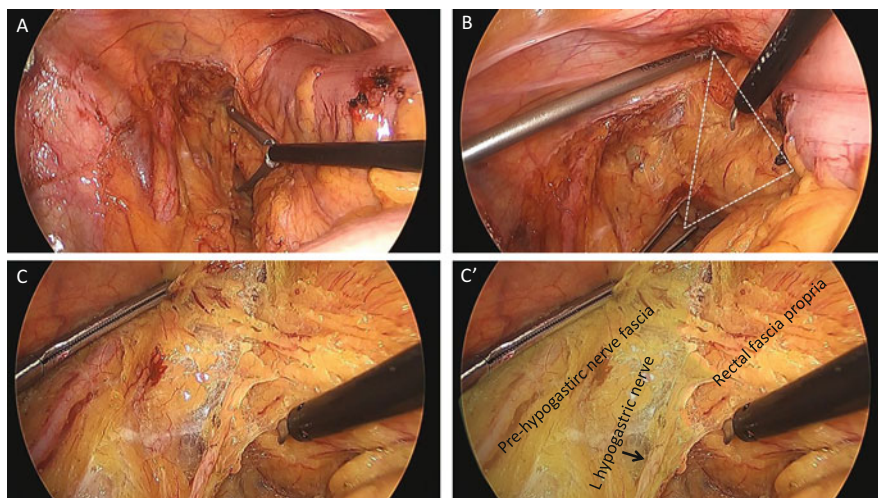


**Fig. 6.20** The assistant retracts the rectum cephalad and laterally with an opened grasper by the right hand (A) and the peritoneum by the left hand (B). The surgeon picks up the edge of the incised peritoneum (tissue triangulation) (C). Incision on the peritoneum discloses the subperitoneal fibrous tissues, which covers the hypogastric nerves (D). The right seminal vesicle is identified with continuous dissection (E)

pushes the dissected plane by the right hand (Fig. 6.21A, B). A well-coordinated “tissue triangulation” reveals clearly the border between the rectal fascia propria and the prehypogastric nerve fascia (Fig. 6.21C, C’).

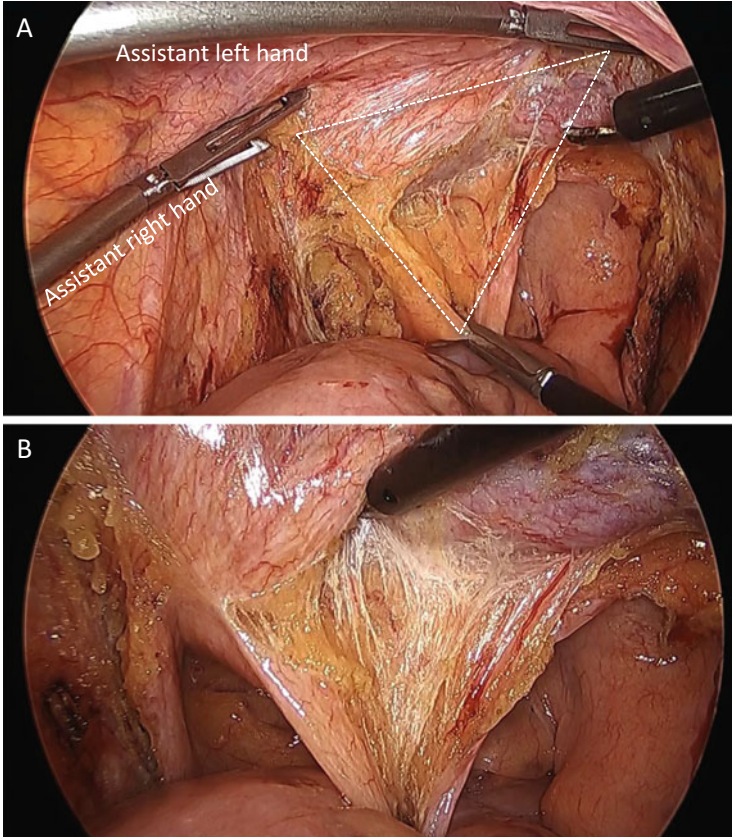
### 6.3.5 Anterior Dissection of the Rectum

The peritoneal reflection is opened with communicating peritoneal incision. The assistant pushes up the urinary bladder by his both hands. The surgeon picks the edge of peritoneum and pulls it up to extend the fibrous tissues between the seminal



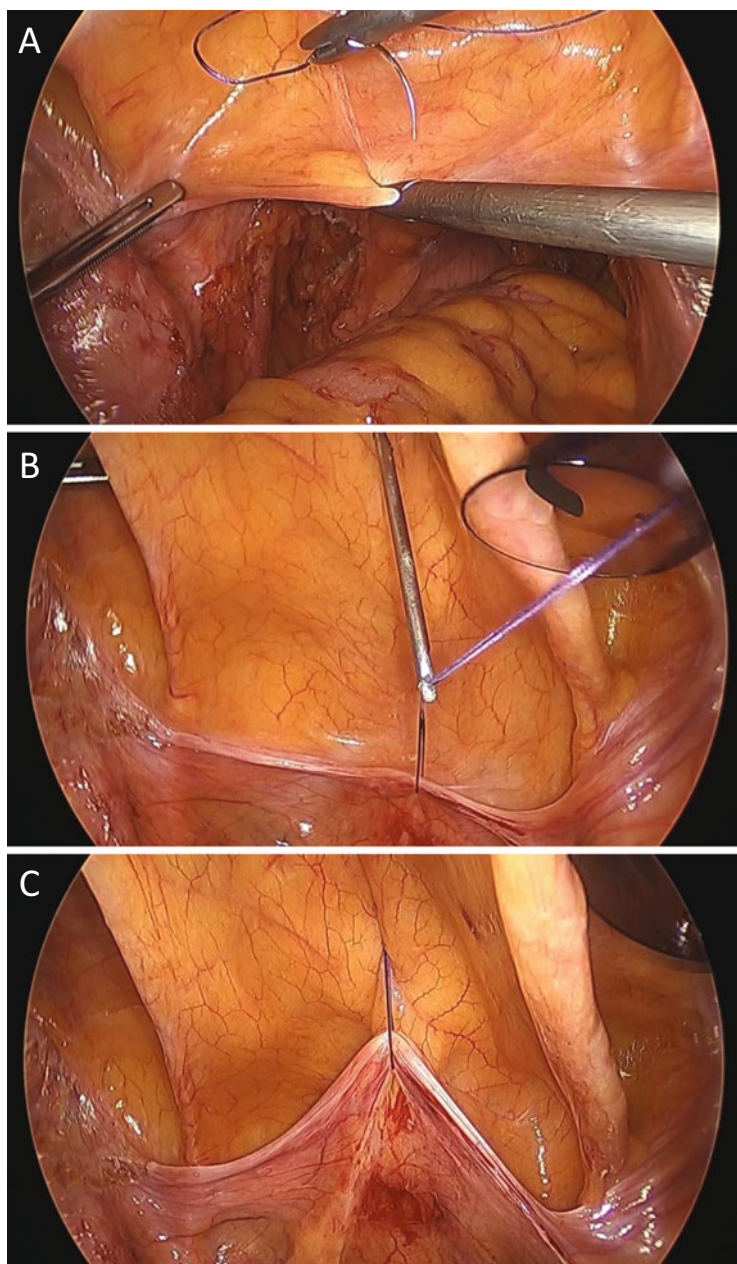
**Fig. 6.21** The surgeon retracts the rectum cephalad and medially with an opened grasper (A). The assistant picks up the edge of the incised peritoneum by the left hand and pushes the dissected plane by the right hand, resulting in a well-coordinated tissue triangulation (B). It is clearly seen that the prehypogastric nerve fascia consists of fibrous tissues (C, C')

vesicle and the rectum (Fig. 6.22). Hanging up of the urinary bladder with a suture may help the counter-traction (Fig. 6.23). The so-called Denonvilliers' fascia is also considered to consist of the fibrous tissues between the rectum and the seminal vesicles, the prostate, and the neurovascular bundles. The dissection in the middle of the fibrous tissues ("Denonvilliers' fascia") may be ideal, leaving the same amount of fibrous tissues on both sides: the seminal vesicle, the prostate, and the neurovascular bundles are one side, and the other is the rectum (Fig. 6.24). When you divide the fibrous tissues in close proximity to the rectum, much amount of fibrous tissues which looks like a white shining membrane is left on the seminal vesicles and the prostate (Fig. 6.25). The continuous dissection reaches easily the pelvic floor (levator ani muscle) at the anterolateral corner, creating the so-called lateral ligament (Fig. 6.26). The ligament is divided sharply. On the contrary, the dissection in close proximity to the prostate or the neurovascular bundle causes small bleedings easily (Fig. 6.27). The elaborate counter-traction is important to keep a fine dissection close to but slightly away from the prostate or the neurovascular bundle.

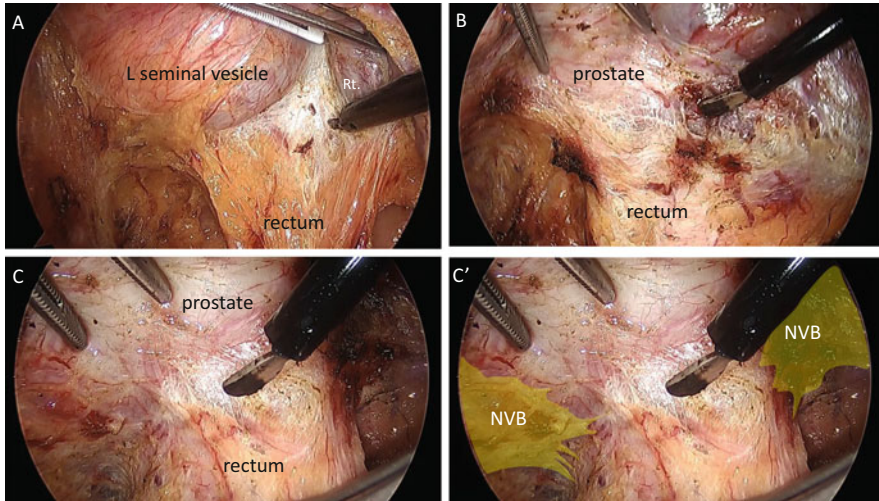


**Fig. 6.22** The peritoneal reflection is opened. The assistant pushes the urinary bladder cephalad and ventrally by both hands, and the surgeon pulls up the incised edge of peritoneum (A). The coordinated tissue triangulation discloses the fibrous tissues between the rectum and the seminal vesicles (B)

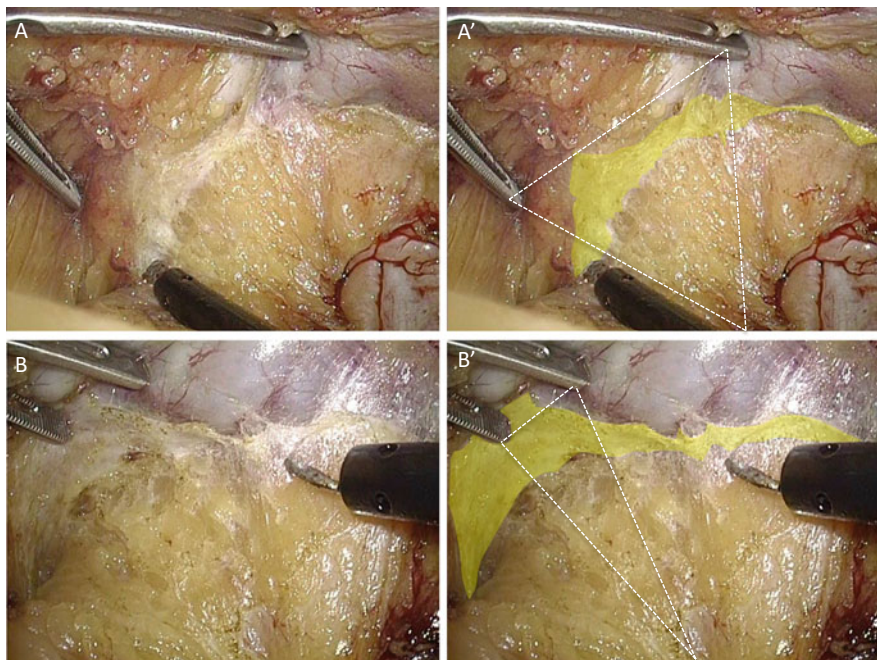
The neurovascular bundle sometimes adheres tightly to the rectum (Fig. 6.28). In such a case you must evert the neurovascular bundle from the rectum. In another case the neurovascular bundle is pulled toward the rectum under a counter-traction (Fig. 6.29), in which you should pay attention not to enter into the bundle. The right neurovascular bundle is also dissected from the rectum in the same manner (Fig. 6.30).



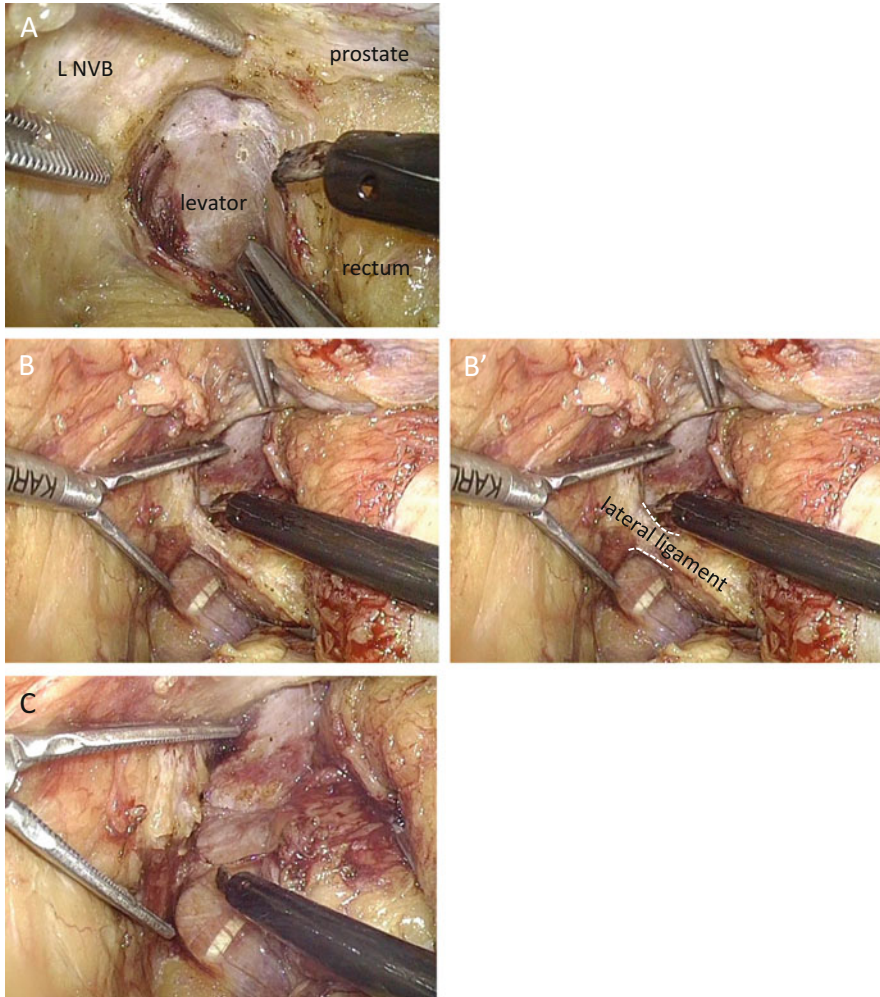
**Fig. 6.23** Hanging up of the urinary bladder with a suture may help the counter-traction



**Fig. 6.24** The anterior dissection means the dividing of the fibrous tissues between the rectum and the seminal vesicles (A), the prostate (B), and the neurovascular bundles (NVB) (C, C')



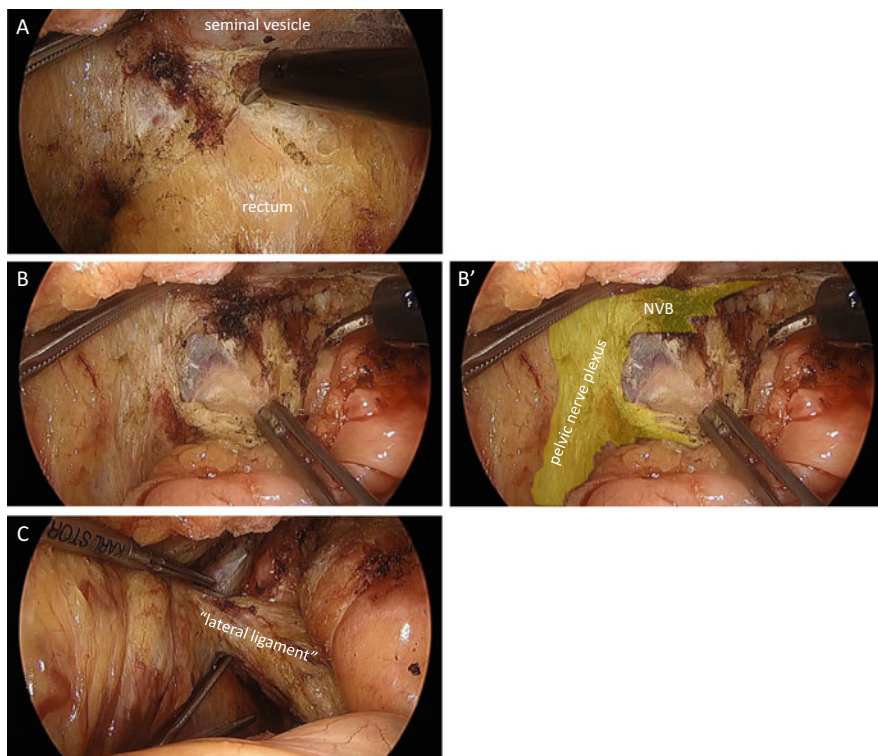
**Fig. 6.25** The dissection in close proximity to the rectum leaves much amount of fibrous tissues over the seminal vesicles and the prostate (A, B), which look like a white shining membrane (yellow area in A' and B'). Dotted white lines indicate tissue triangulation (A', B')



**Fig. 6.26** Following Fig. 6.25, the dissection reaches the pelvic floor at the left anterolateral corner (A). The so-called lateral ligament is created (B, B'), and it is divided sharply (C). NVB: neurovascular bundle

### 6.3.6 Clamping, Lavage, and Division of the Rectum

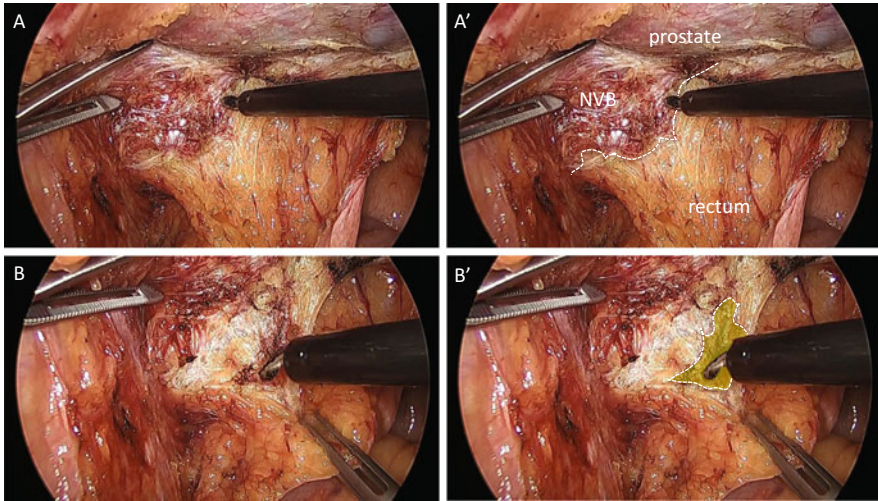
A Gut Clamper® (Kobe Biomedix Inc., Kobe, Japan) is our preference to clamp the rectum (Fig. 6.31). The clamper is applied perpendicularly and horizontally to the rectum and distally to the tumor. Your accurate rectal exam prior to its application is absolutely mandatory. The advantages of its use are to secure a stable and tight



**Fig. 6.27** The dissection in close proximity to the prostate (A) or the neurovascular bundle (B, B') causes small bleedings. The elaborate counter-traction is needed to keep a fine dissection (C)

clamping, to facilitate the following application of a linear stapler, and sometimes to facilitate the additional dissection of the rectum prior to the application of a stapler by controlling the clamper. Following the rectal irrigation through the anus, a linear stapler is applied in parallel to the clamper. The selection of cartilage depends on the thickness of the rectal wall [2–4]. If it takes time to apply a clamper due to the thickness of the rectal wall, a green cartilage is recommended. Otherwise a purple cartilage is preferred. You can advance a linear stapler distally to obtain a sufficient distal margin. Pulling a suture on the other side of the clamper may be helpful for the adjustment of a stapler (Fig. 6.32).





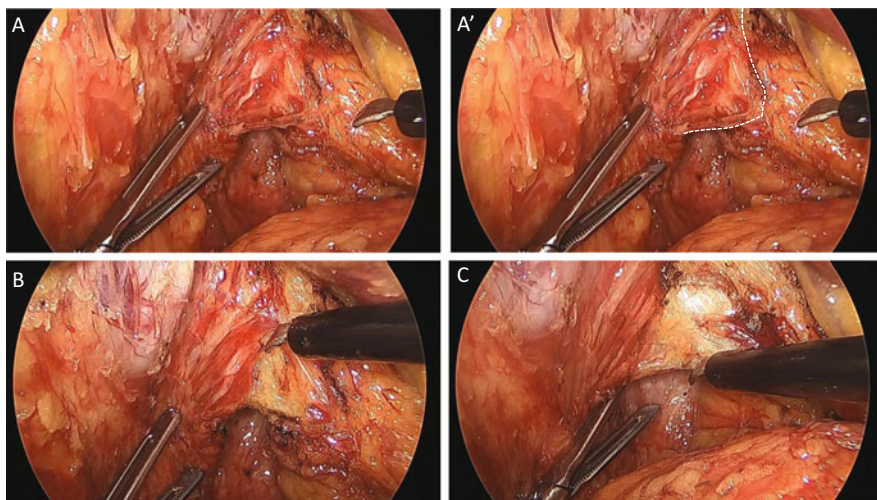
**Fig. 6.28** The inferior mesenteric neurovascular bundle (NVB) adheres tightly to the rectum (A). The correct dissection line is the *white dotted line* in (A'). But a tiny amount of the bundle is excised and left on the rectum (B, *yellow area* in B')

Anastomosis is performed with either a double-stapling technique or a trans-anal hand-sewn technique, depending on the tumor location.

### 6.3.7 Additional Distal Dissection of the Rectum

For a lower anastomosis or an intersphincteric resection (ISR), it is necessary to advance the dissection more caudally between the rectum and the levator ani muscle posteriorly and between the prostate and the rectum ventrally.

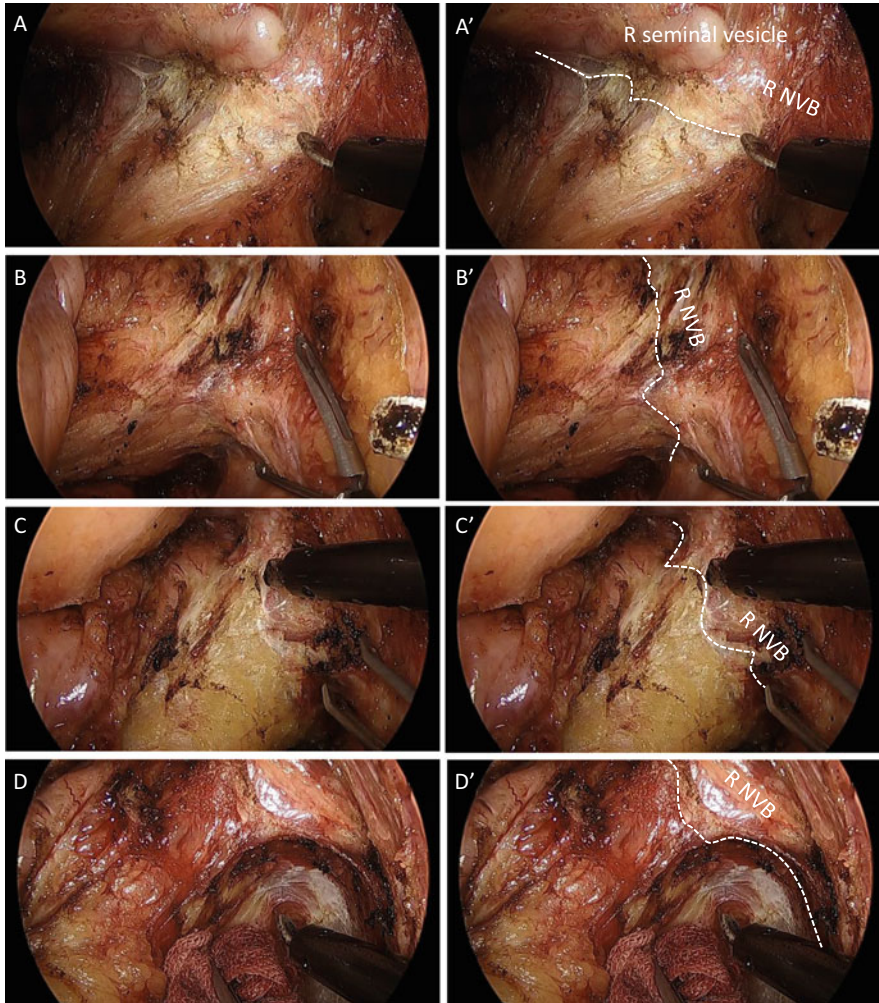
You can recognize a band-like structure extended from the tips of the sacrum to the posterior wall of the rectum (Fig. 6.33). It is called the “hiatal ligament” [5]. The



**Fig. 6.29** The neurovascular bundle is pulled toward the rectum (A, *white line* in A'). We should pay attention not to enter into the bundle (B, C)

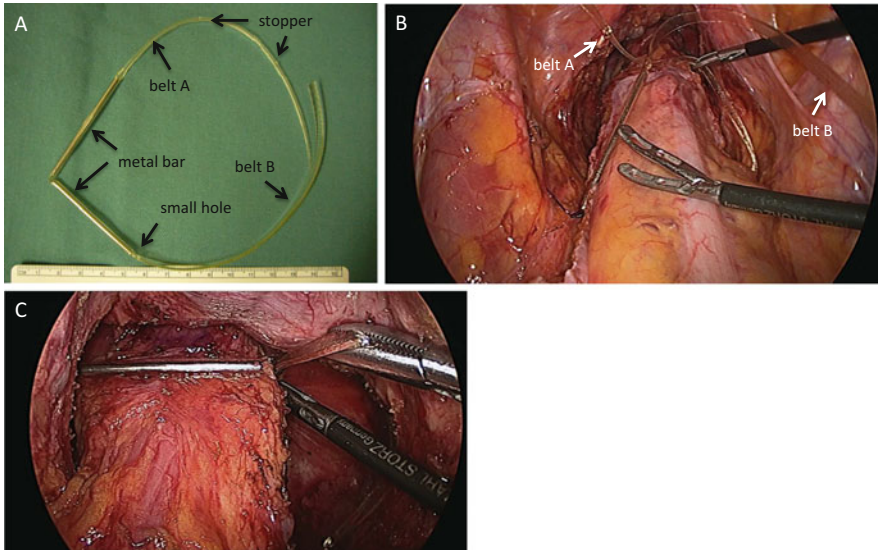
hiatal ligament consists of the smooth muscle fibers and they communicate with the longitudinal muscles of the rectum (Fig. 6.34). Dissecting the posterior wall of the rectum, you should divide the hiatal ligament adjacent to the levator ani muscle to avoid the injury to the rectal wall.

Figure 6.35A shows the final view following the ventral dissection between the rectum and the prostate. The longitudinal muscles of the rectum seem to communicate with the muscles around the apex of the prostate. The dissection between the internal and external sphincter muscle from the perineum displays the safe cutting line of the muscles between the rectum and the base of the prostate (Fig. 6.35B). The histology of the anterior wall of rectum demonstrates a certain amount of smooth muscle fibers outside the longitudinal muscles of the rectum (Fig. 6.36). One of my cadaveric resections indicates that the dissection lines along the

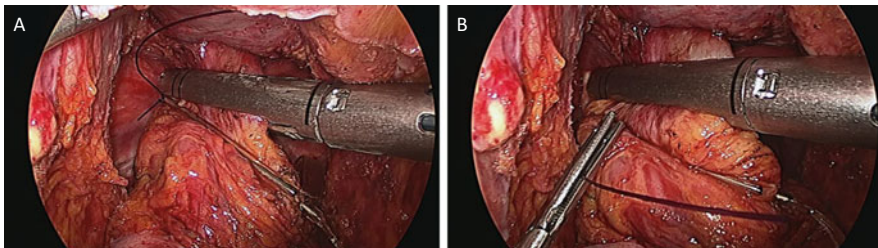


**Fig. 6.30** The right neurovascular bundle (NVB) is dissected from the rectum (A, B, C, D). The *white lines* are the dissection lines (A', B', C', D')

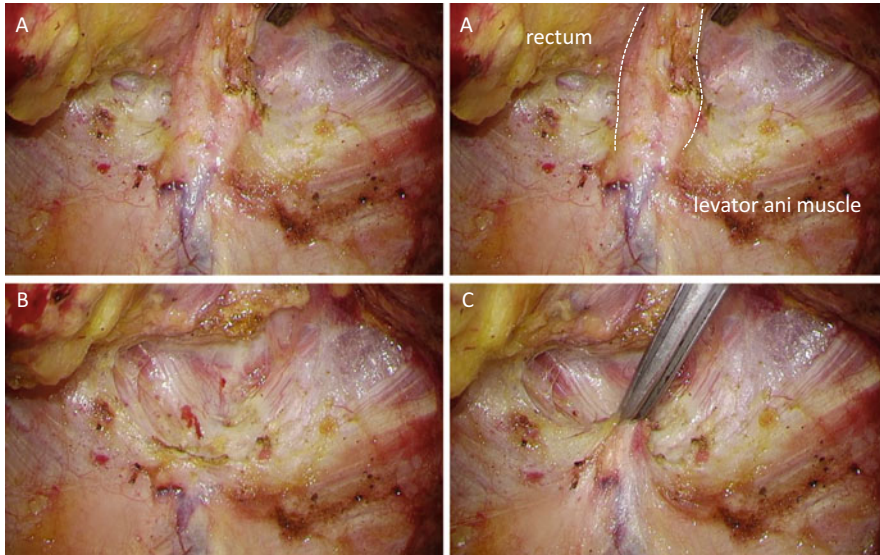
longitudinal muscles of the rectum become obscure around the apex of the prostate (Fig. 6.37). Thus it is clearly demonstrated histologically as well as anatomically that we lose our dissection line around the apex of the prostate. The smooth muscle fibers between the anterior wall of the rectum and the apex of the prostate might be the “perineal body.”



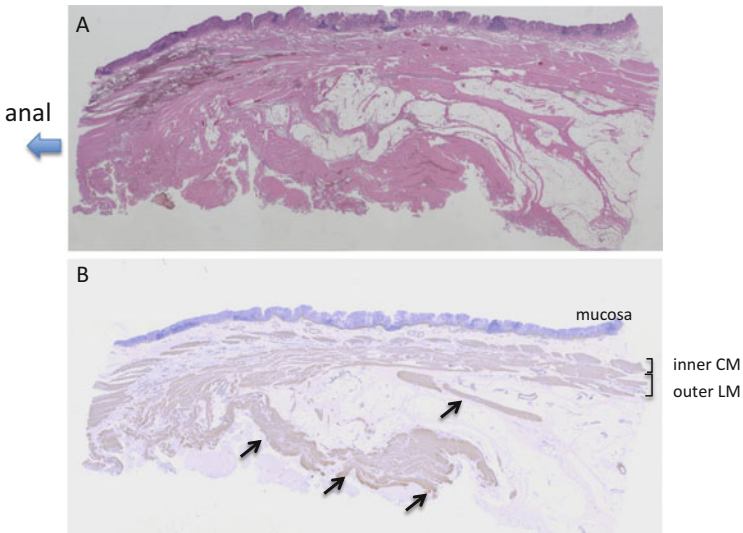
**Fig. 6.31** (A) Gut-clamper®; (B) the tip of belt A is inserted in the small hole of belt B to tie the rectum loosely; (C) the rectum is fully tied horizontally



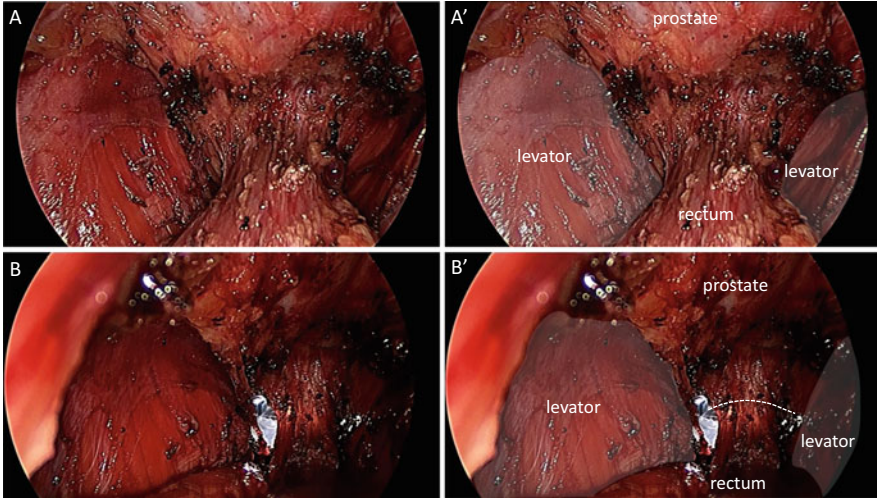
**Fig. 6.32** A nylon suture at the hinge between the two pieces of metal bar is convenient to adjust a stapler perpendicularly to the rectum and to advance it to obtain a sufficient distal margin



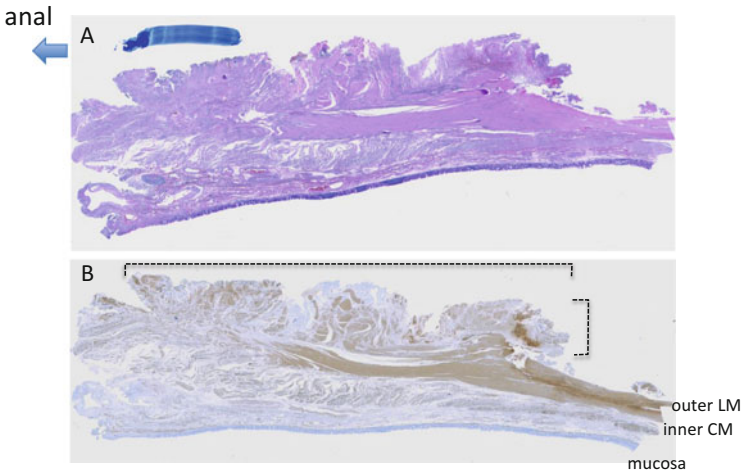
**Fig. 6.33** (A) “Hiatal ligament” is a band-like structure between the posterior wall of the rectum and the tips of the sacrum. (B) Completion of dividing “hiatal ligament.” (C) Pulling up of the edge of the divided ligament



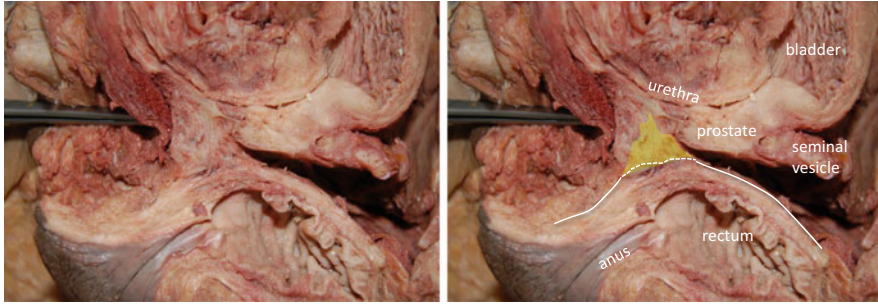**Fig. 6.34** Histological specimens of the posterior wall of the rectum. (A) Stained with hematoxylin-eosin. (B) Stained with anti-smooth antibody. The *black arrows* indicate the hiatal ligament. The smooth muscle fibers of the ligament communicate with the longitudinal muscles of the rectum. *CM* circular muscle, *LM* longitudinal muscle



**Fig. 6.35** (A, A') The final view of the ventral dissection between the rectum and the prostate. The longitudinal muscles of the rectum seem to communicate the muscles around the apex of the prostate. (B, B') Dissection from the perineum displays the incisional line (a dotted white) of the muscles



**Fig. 6.36** The histological specimens of the anterior wall of rectum. (A) Stained with hematoxylin-eosin. (B) Stained with anti-smooth muscle antibody. A certain amount of smooth muscle fibers is confirmed outside the longitudinal muscles of the rectum. They seem to communicate each other



**Fig. 6.37** The sagittal view of a cadaver. The *white line* is a dissection line along the longitudinal muscles of the rectum. It is unclear around the apex of the prostate. *Yellow area* might be the “perineal body”

## References

1. Muro K, Kawai K, Kazama S, Ishihara S, Yamaguchi H, Sunami E, Kitayama J, Watanabe T. Anatomy of the inferior mesenteric artery evaluated using 3-dimensional CT angiography. *Dis Colon Rectum*. 2015;58(2):214–9. doi:[10.1097/DCR.0000000000000285](https://doi.org/10.1097/DCR.0000000000000285).
2. Nakayama S, Hasegawa S, Nagayama S, Kato S, Hida K, Tanaka E, Itami A, Kubo H, Sakai Y. The importance of precompression time for secure stapling with a linear stapler. *Surg Endosc*. 2011;25(7):2382–6. doi:[10.1007/s00464-010-1527-7](https://doi.org/10.1007/s00464-010-1527-7).
3. Nakayama S, Hasegawa S, Hida K, Kawada K, Sakai Y. Obtaining secure stapling of a double stapling anastomosis. *J Surg Res*. 2015;193(2):652–7. doi:[10.1016/j.jss.2014.08.044](https://doi.org/10.1016/j.jss.2014.08.044).
4. Hasegawa S, Nakayama S, Hida K, Kawada K, Sakai Y. Effect of Tri-Staple™ technology and slow firing on secure stapling using an endoscopic linear stapler. *Dig Surg*. 2015;32:353–60. doi:[10.1159/000437216](https://doi.org/10.1159/000437216).
5. Muro S, Yamaguchi K, Nakajima Y, Watanabe K, Harada M, Nimura A, Akita K. Dynamic intersection of the longitudinal muscle and external anal sphincter in the layered structure of the anal canal posterior wall. *Surg Radiol Anat*. 2014;36(6):551–9. doi:[10.1007/s00276-013-1228-8](https://doi.org/10.1007/s00276-013-1228-8).

---

# Laparoscopic Right Lateral Pelvic Lymph Node Dissection (LPLND) with Pelvic Autonomic Nerve Preservation

# 7

Satoshi Nagayama, Masashi Ueno, and Takeshi Sano

---

## Abstract

During lateral pelvic lymph node dissection (LPLND), it is important to visualize the lateral pelvic space to be removed and to identify the proper dissection boundaries. Dissection proceeds along (1) the pelvic wall side of the plexus (internal LPLND margin), (2) the external iliac vessels (superior margin), (3) the pelvic sidewall (lateral margin), (4) the internal iliac vessels (dorsal margin), and (5) the bladder (ventral margin). In addition, beyond the bifurcation of the inferior vesical artery, the most caudal part of the lymph node tissues should be dissected, which is surrounded by the lateral sidewall, the pelvic nerve plexus, and the levator ani muscles. It is recommended that the lymph node tissues caudal to the root of the inferior vesical artery and around Alcock's canal be completely removed. Arterioles and venules penetrating the pelvic sidewall should be cut meticulously with an appropriate vessel-sealing system to prevent unnecessary bleeding. In some cases of metastatic lateral lymph nodes, an en bloc resection along with the surrounding plexus and/or internal iliac vessels is necessary to ensure a satisfactory clearance to the circumferential resection margin.

---

## Keywords

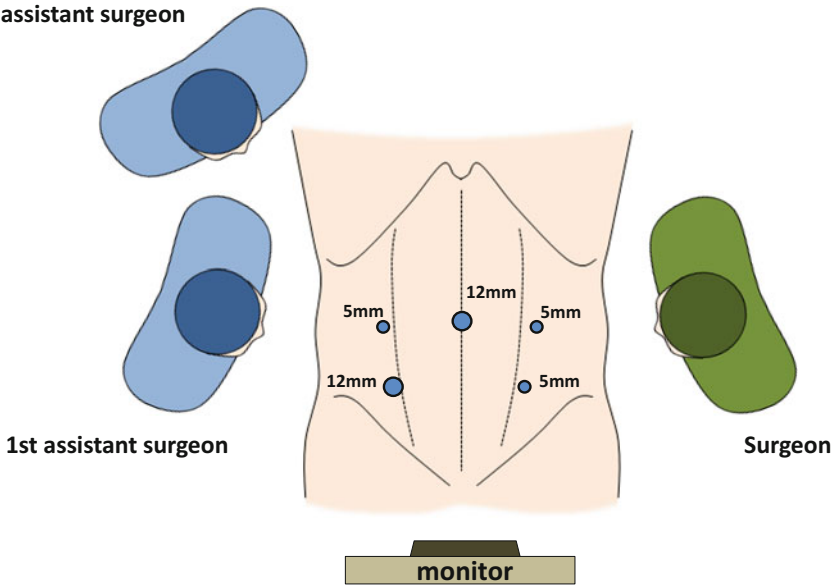
Lateral lymph node dissection • Autonomic nerve preservation • Obturator lymph node • Alcock's canal

In this case, the rectum has already been dissected in the usual manner for total mesorectal excision (TEM), followed by subtotal intersphincteric resection (ISR).

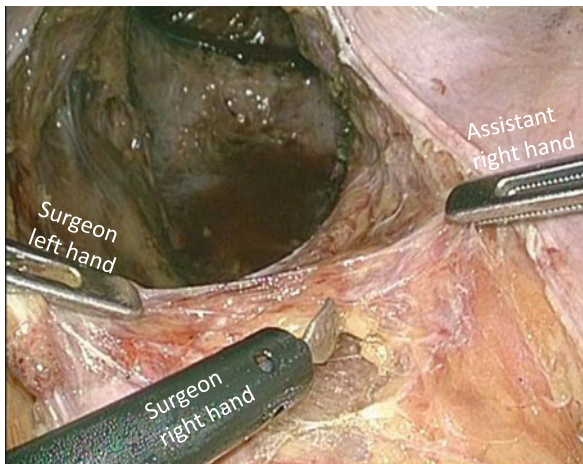
---

S. Nagayama (✉) • M. Ueno • T. Sano  
Department Gastroenterological Surgery, Cancer Institute Hospital, Tokyo, Japan  
e-mail: [satoshi.nagayama@jfc.or.jp](mailto:satoshi.nagayama@jfc.or.jp)



**2nd assistant surgeon**

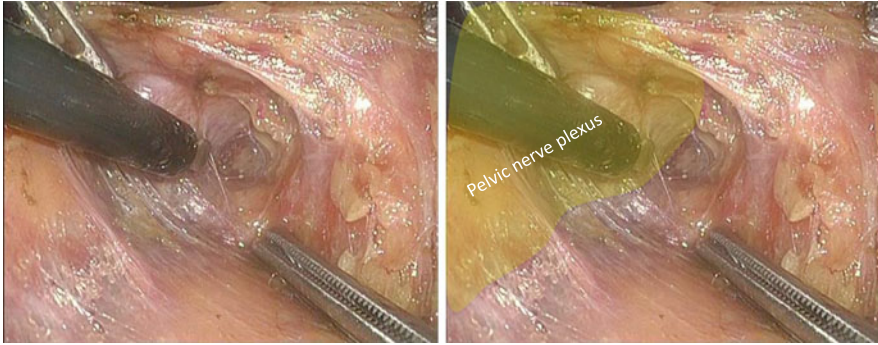
**Fig. 7.1** Port placement and surgeon's standing position



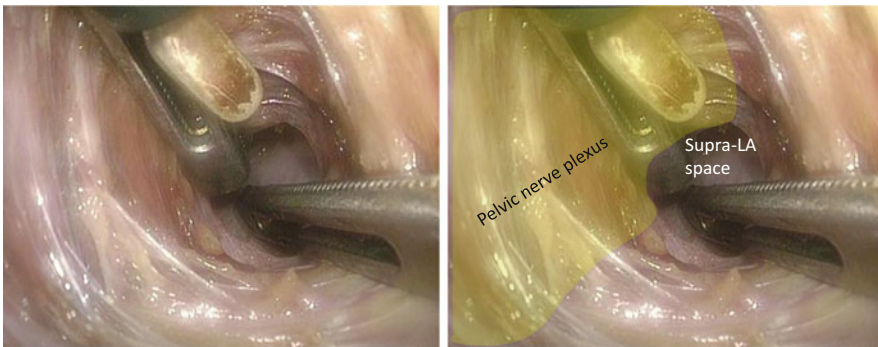
**Fig. 7.2** Dissection along the pelvic wall side of the right pelvic nerve plexus – 1

When performing the right LPLND, the operator stands on the left side of the patient and the first assistant stands on the right side of the patient (Fig. 7.1).

The right pelvic nerve plexus is dissected caudally along the pelvic wall side of the plexus, and thus, the internal margin of LPLND is determined (Figs. 7.2 and 7.3). If possible, on the most caudal aspect of the plexus, the dissection can be continued to the supra-levator ani (LA) space (Fig. 7.4).



**Fig. 7.3** Dissection along the pelvic wall side of the right pelvic nerve plexus – 2



**Fig. 7.4** Dissection along the pelvic wall side of the right pelvic nerve plexus – 3

The right ureter is separated from the surrounding tissues as caudally as possible and is pulled to the left side with a vessel tape inserted from the left inferior abdominal port.

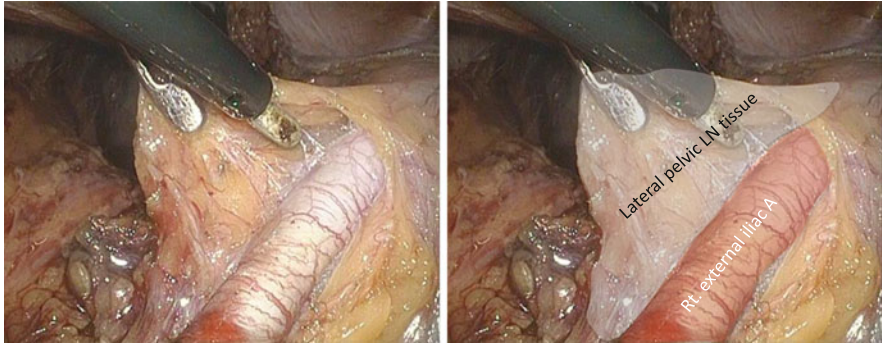
The right external iliac artery is exposed, thereby determining the superior margin of LPLND (Fig. 7.5).

The pelvic sidewall muscles are exposed by deeper dissection along the right external iliac vein, thereby determining the lateral margin of LPLND (Figs. 7.6 and 7.7). Small vessels penetrating the pelvic sidewall should be cut meticulously with an appropriate vessel-sealing system.

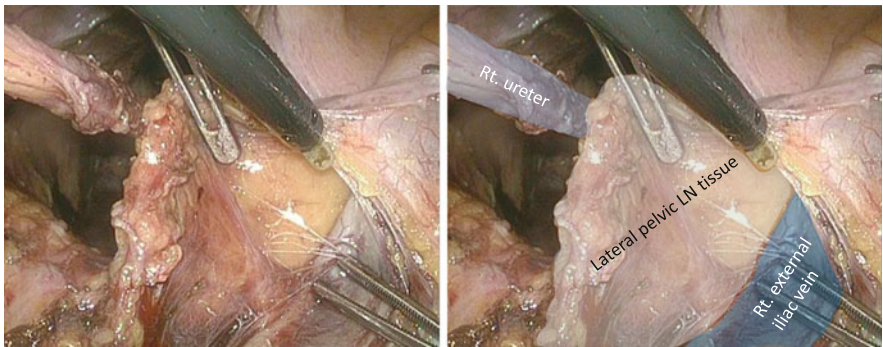
The proximal portion of the lateral lymph node (LN) tissues is dissected caudally along the right internal iliac artery with the artery trunk intact (Figs. 7.8, 7.9, 7.10, 7.11, and 7.12).

The right pelvic nerve plexus is preserved as a thin screen between the TME and LPLND (Fig. 7.13).

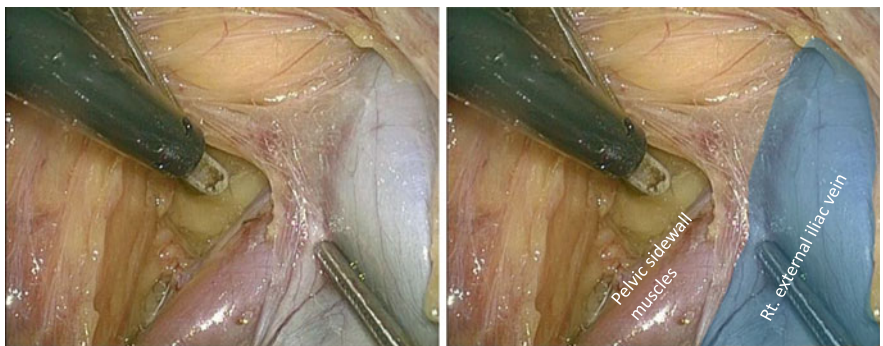
The LN tissues are dissected meticulously to expose the bifurcation of the right internal and external veins (Fig. 7.14). By deeper dissection toward the pelvic sidewall, the right obturator nerve is identified and preserved (Fig. 7.15).



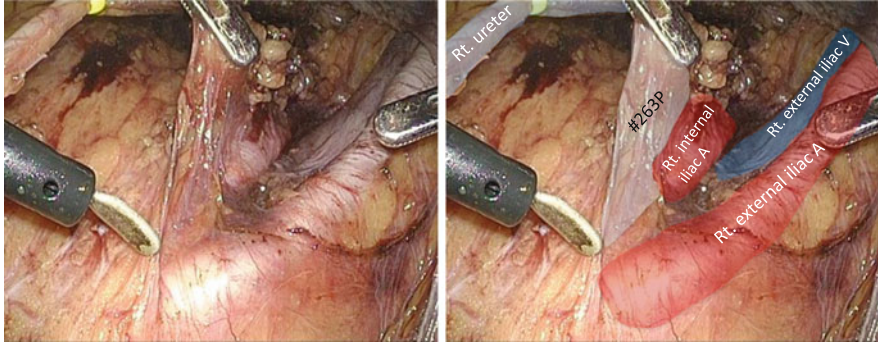
**Fig. 7.5** Exposure of the right external iliac artery



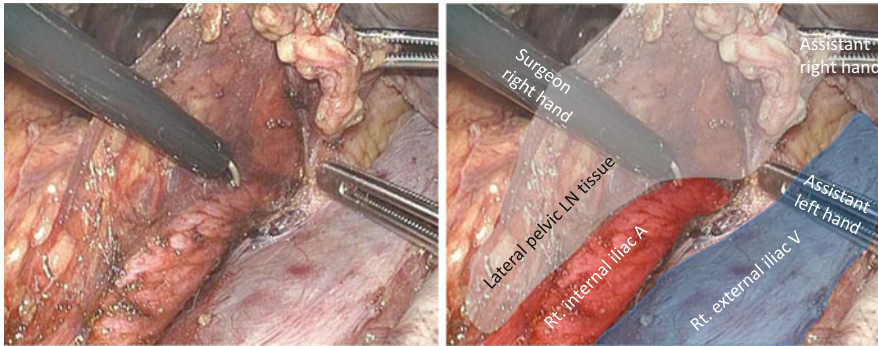
**Fig. 7.6** Dissection along the right external iliac vein



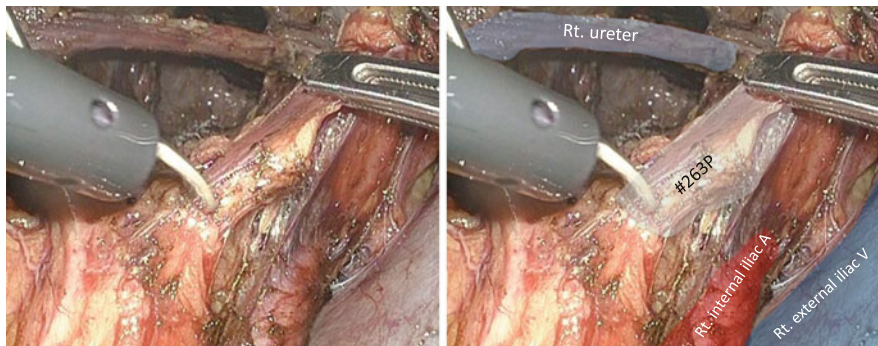
**Fig. 7.7** Exposure of the right pelvic sidewall muscles



**Fig. 7.8** Dissection of the proximal portion of the lateral lymph node tissues along the right internal iliac artery – 1



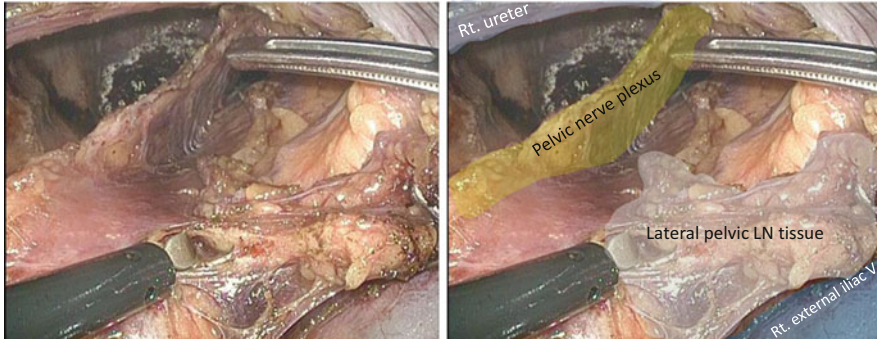
**Fig. 7.9** Dissection of the proximal portion of the lateral lymph node tissues along the right internal iliac artery – 2



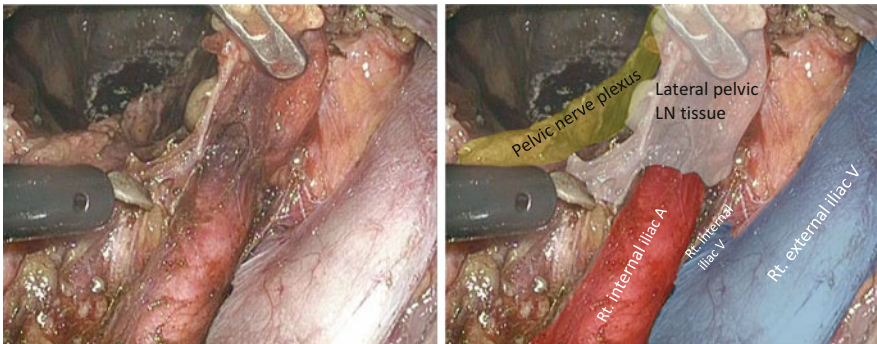
**Fig. 7.10** Dissection of the proximal portion of the lateral lymph node tissues along the right internal iliac artery – 3

The right obturator LN tissues are divided along the right obturator nerve (Fig. 7.16).

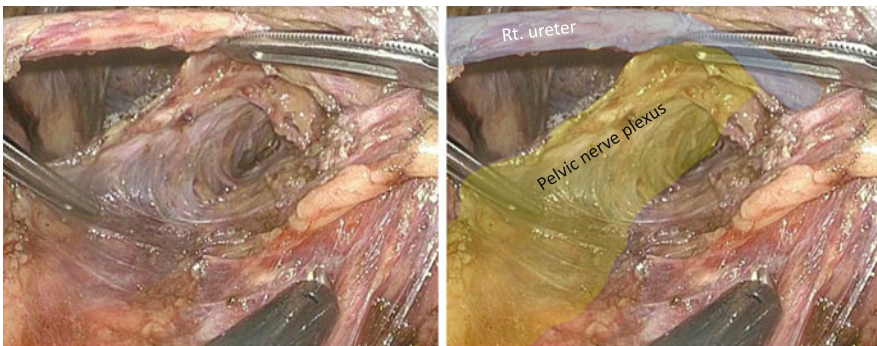
The right obturator LN tissues are dissected along the right pelvic sidewall, thereby determining the lateral margin of LPLND. Arterioles and venules



**Fig. 7.11** Dissection of the proximal portion of the lateral lymph node tissues along the right internal iliac artery – 4



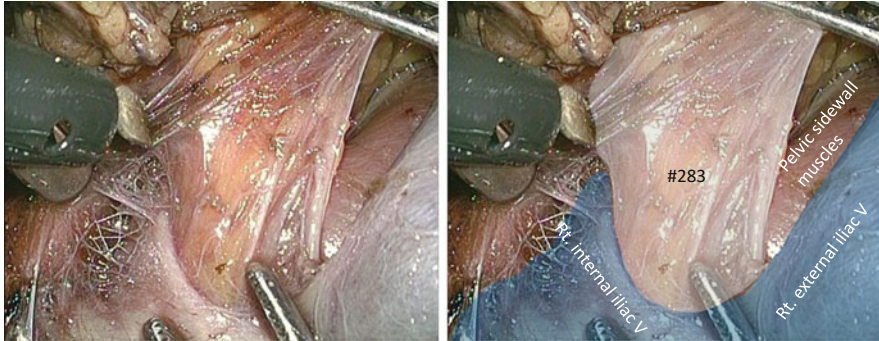
**Fig. 7.12** Dissection of the proximal portion of the lateral lymph node tissues along the right internal iliac artery – 5



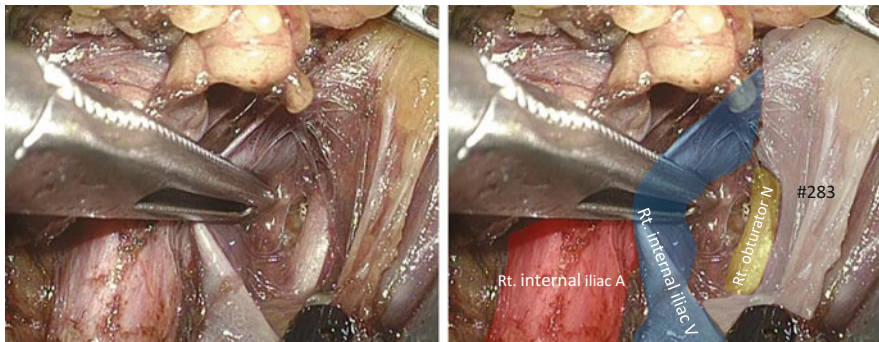
**Fig. 7.13** Preservation of the right pelvic nerve plexus

penetrating the pelvic sidewall should be cut meticulously with an appropriate vessel-sealing system.

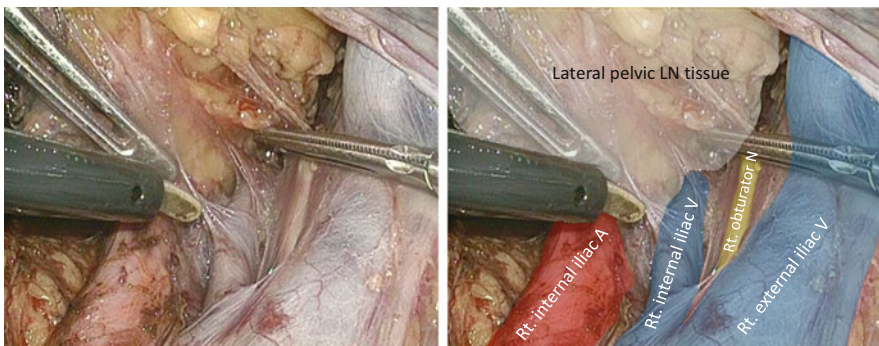
The right obturator vessels are cut at their roots (Fig. 7.17). In this case, the obturator vessels do not bifurcate directly from the internal iliac trunk as a normal



**Fig. 7.14** Exposure of the bifurcation of the right internal and external vein



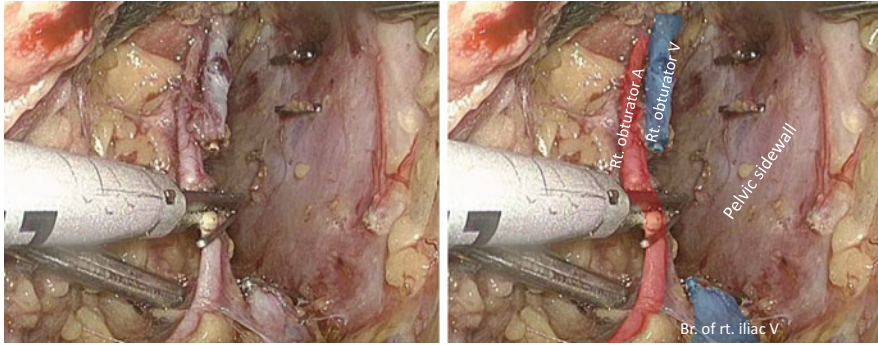
**Fig. 7.15** Identification of the right obturator nerve



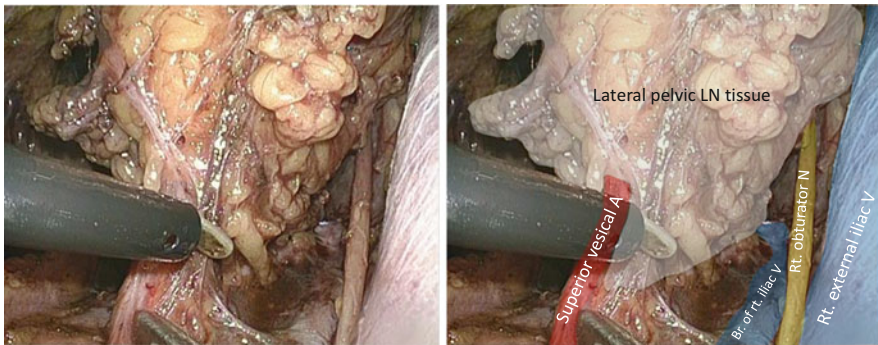
**Fig. 7.16** Dissection of the right obturator lymph node tissues along the right obturator nerve

anatomical variant. With the meticulous removal of the obturator LN tissues, the obturator nerve is preserved toward the obturator foramen (Fig. 7.18).

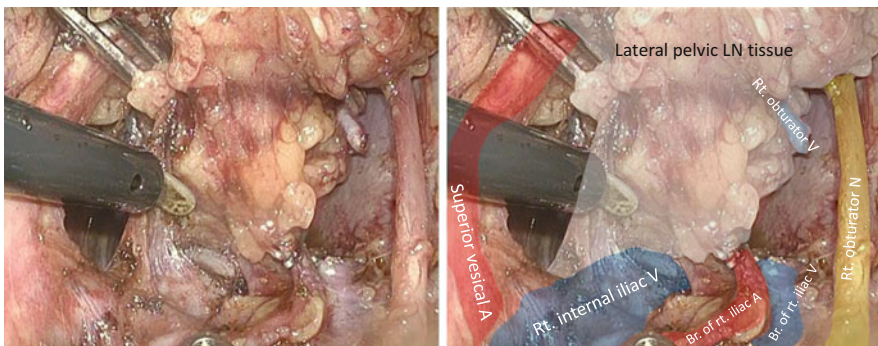
The right iliac LN tissues are dissected caudally along the right internal iliac artery and vein with these vessel trunks intact (Figs. 7.19 and 7.20).



**Fig. 7.17** Cut of the right obturator artery and vein at their roots

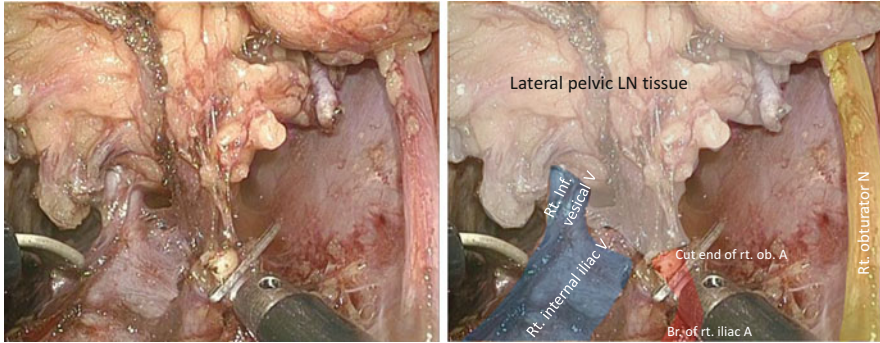


**Fig. 7.18** Preservation of the right obturator nerve

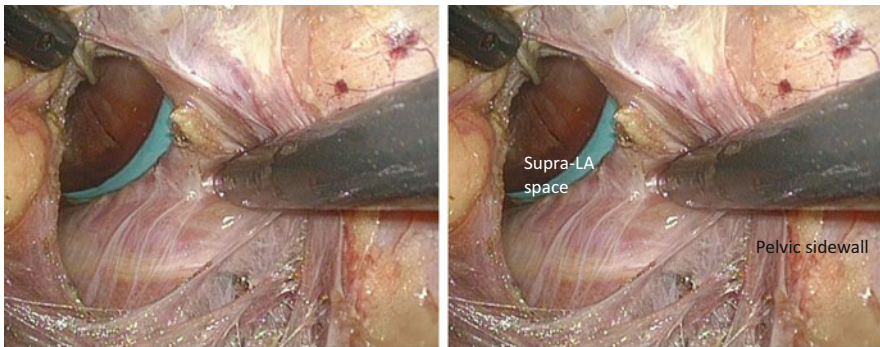


**Fig. 7.19** Dissection of the right iliac lymph node tissues – 1

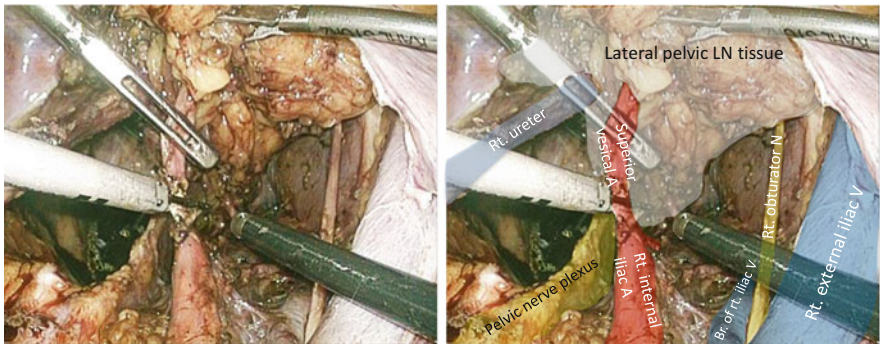
The dissection along the pelvic sidewall is continued to the supra-LA space at the most caudal aspect so that the three-dimensional location can be easily identified (Fig. 7.21).



**Fig. 7.20** Dissection of the right iliac lymph node tissues – 2



**Fig. 7.21** Continuation of the pelvic sidewall cavity to the supra-levator ani space

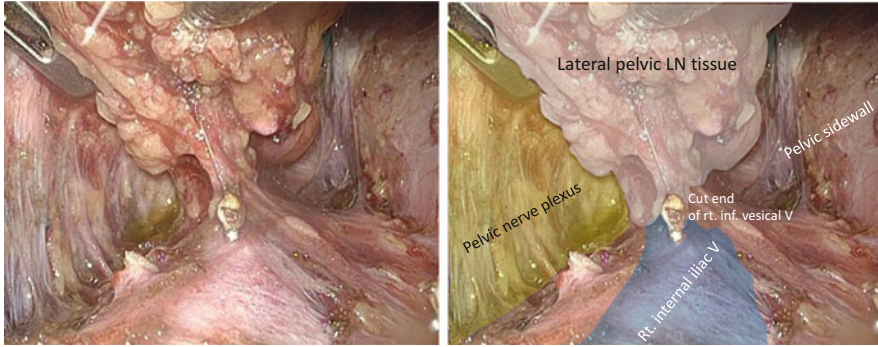


**Fig. 7.22** Cut of the right superior and inferior vesical vessels – 1

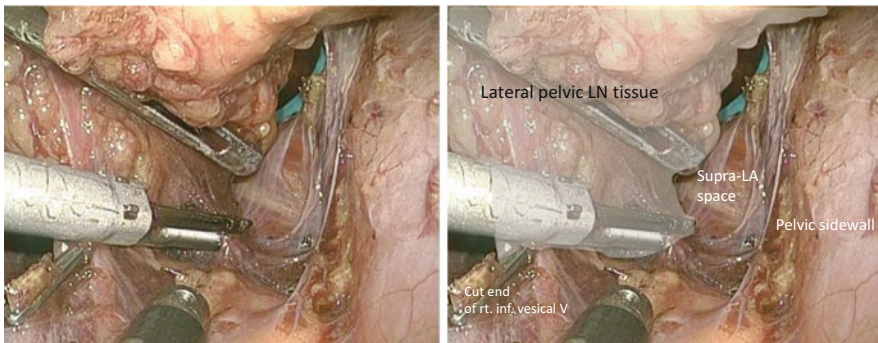
The right superior and inferior vesical vessels are cut at their roots along the internal iliac artery (Figs. 7.22 and 7.23).

Beyond the bifurcation of the right inferior vesical artery, the most caudal part of the LN tissues including #263D is dissected, which is surrounded by the right

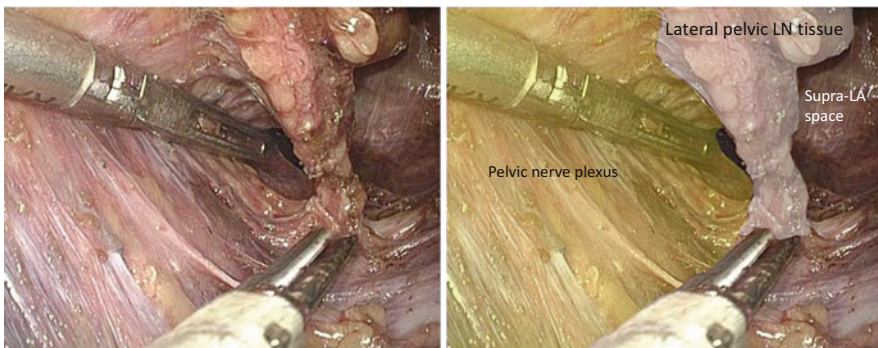




**Fig. 7.23** Cut of the right superior and inferior vesical vessels – 2



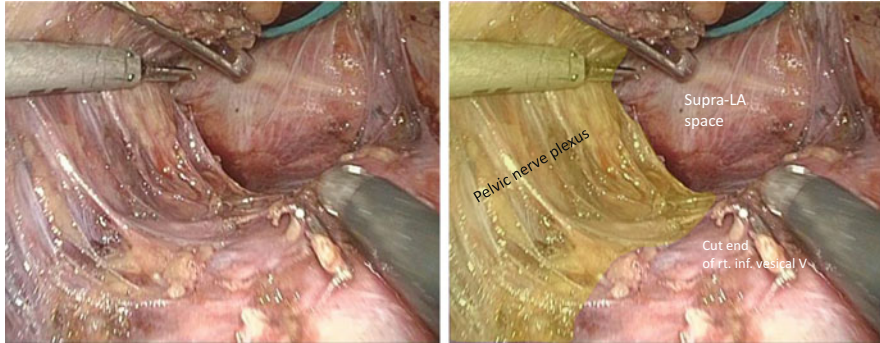
**Fig. 7.24** Dissection of the most caudal part of the lateral lymph node tissues – 1



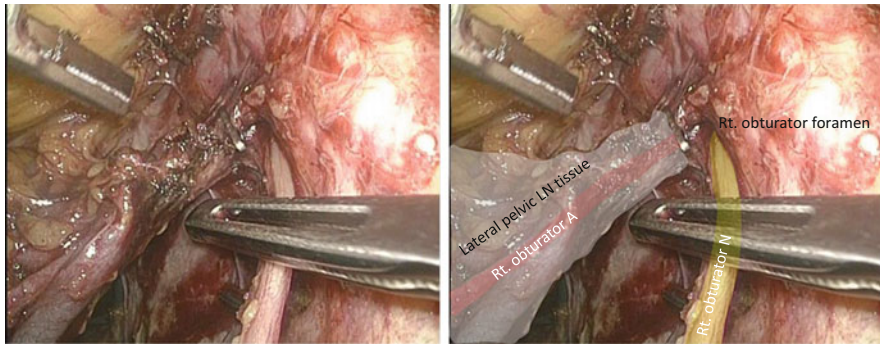
**Fig. 7.25** Dissection of the most caudal part of the lateral lymph node tissues – 2

lateral sidewall, the right pelvic nerve plexus, and LA muscles (Figs. 7.24, 7.25, and 7.26).

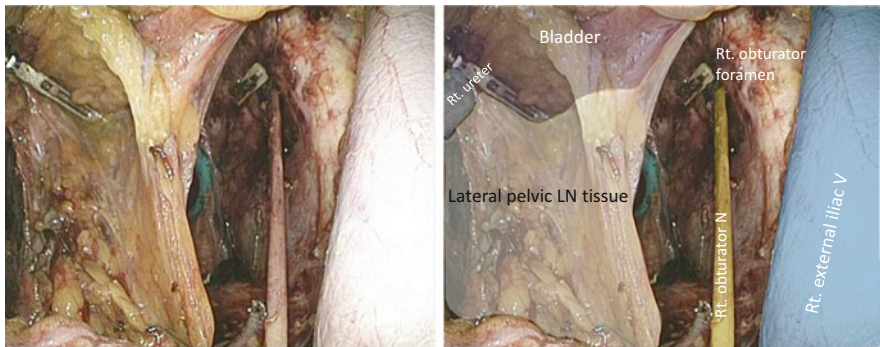
The right obturator artery and vein are cut at the obturator foramen (Fig. 7.27).



**Fig. 7.26** Dissection of the most caudal part of the lateral lymph node tissues – 3



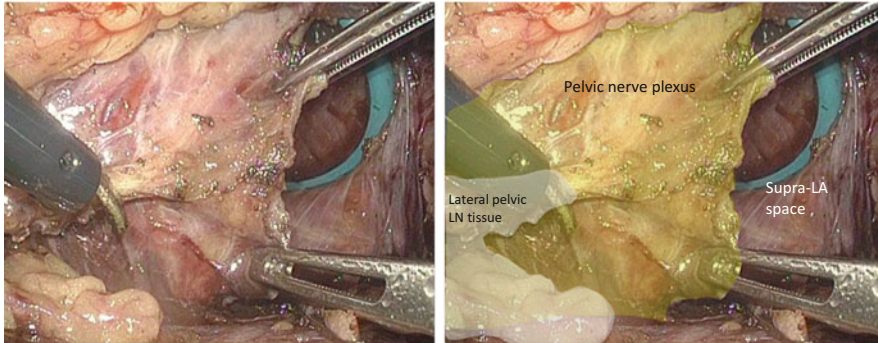
**Fig. 7.27** Cut of the right obturator artery and vein at the obturator foramen



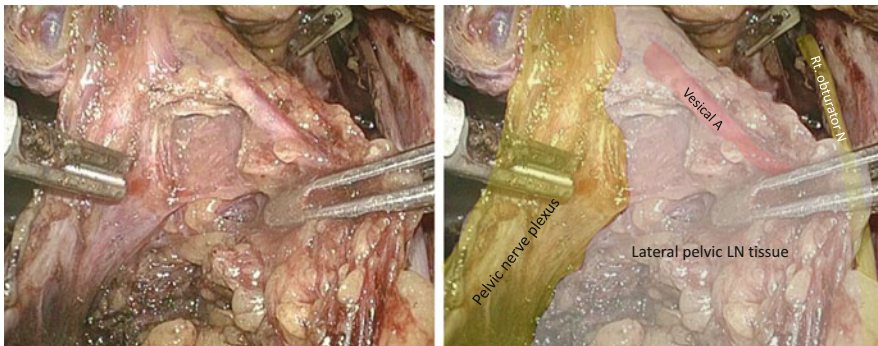
**Fig. 7.28** Dissection between the bladder and lymph node tissues

Dissection is performed between the bladder and LN tissues, thereby determining the ventral side of LPLND (Fig. 7.28), and the vesical arteries and veins are cut at the vesical side.

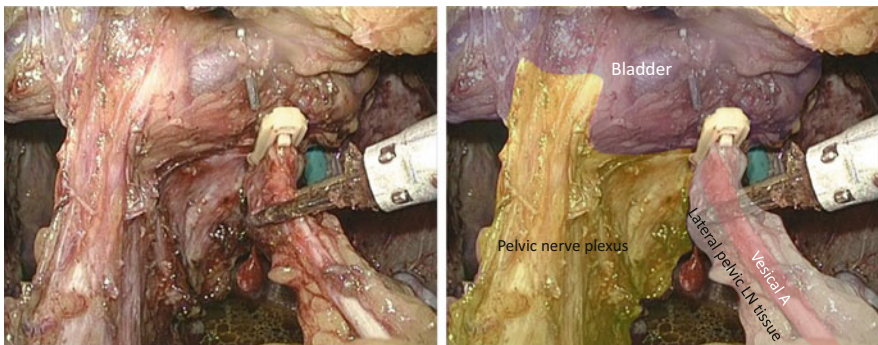
The LN tissues are dissected along the pelvic sidewall side of the right pelvic nerve plexus and neurovascular band (NVB), thereby completing LPLND (Figs. 7.29, 7.30, and 7.31).



**Fig. 7.29** Dissection along the pelvic sidewall side of the right pelvic nerve plexus and neurovascular band – 1

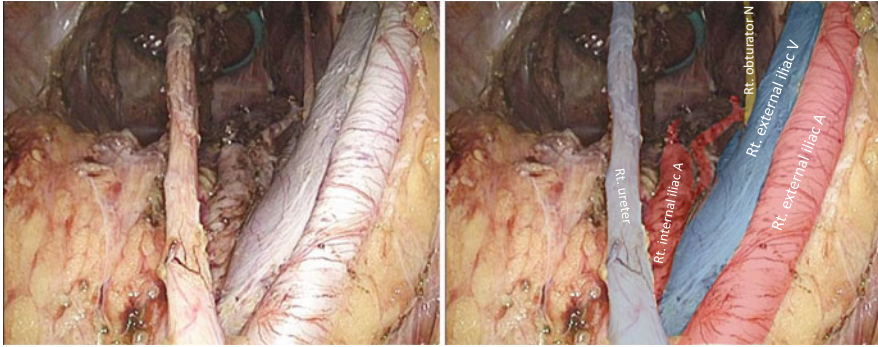


**Fig. 7.30** Dissection along the pelvic sidewall side of the right pelvic nerve plexus and neurovascular band – 2

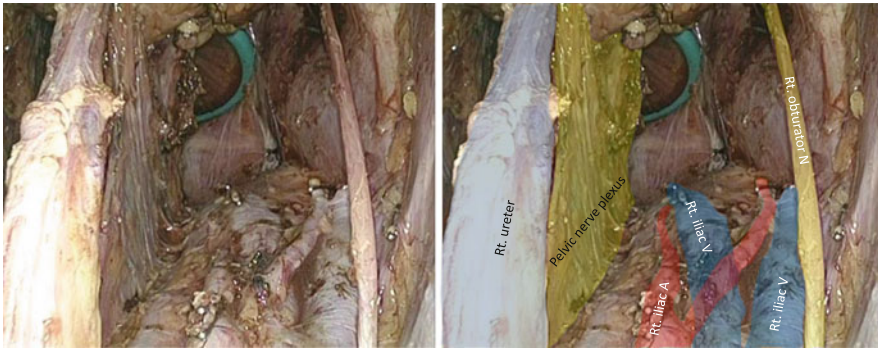

**Fig. 7.31** Dissection along the pelvic sidewall side of the right pelvic nerve plexus and neurovascular band – 3

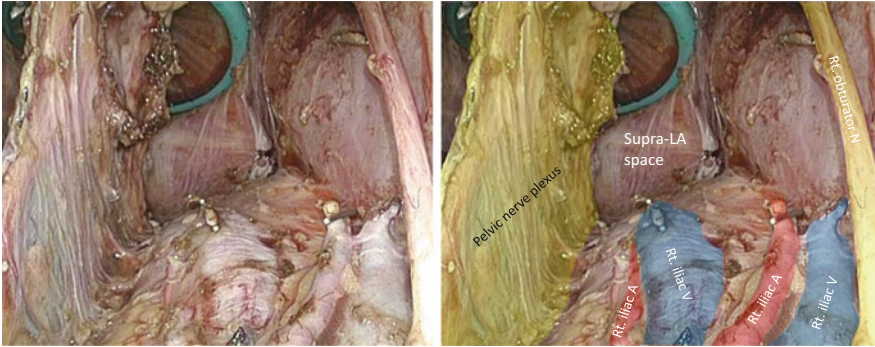
After the right LPLND, the superior and inferior vesical vessels and obturator vessels are cut at the roots and peripheral sides. The LN tissues caudal to the root of the inferior vesical artery and around Alcock's canal are completely removed (Figs. 7.32, 7.33, 7.34, and 7.35).



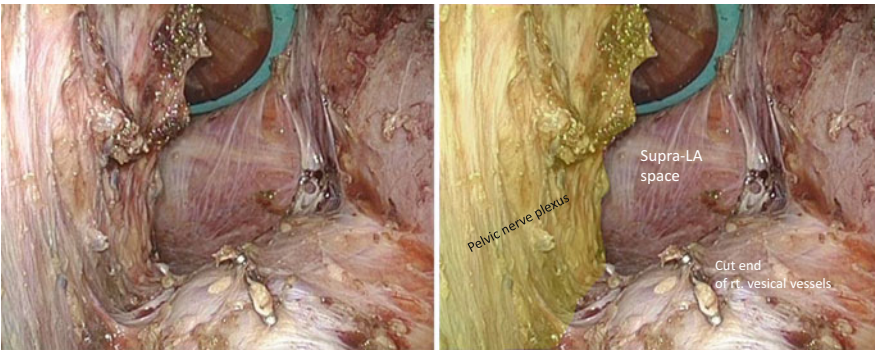
**Fig. 7.32** Completion of the right lateral pelvic lymph node dissection – 1



**Fig. 7.33** Completion of the right lateral pelvic lymph node dissection – 2

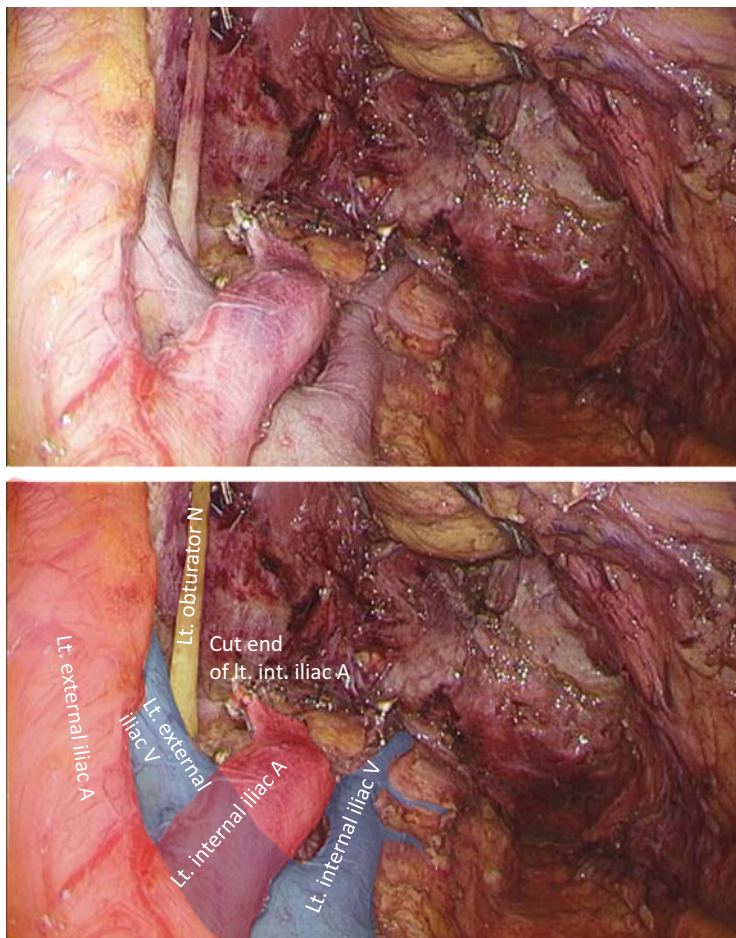


**Fig. 7.34** Completion of the right lateral pelvic lymph node dissection – 3

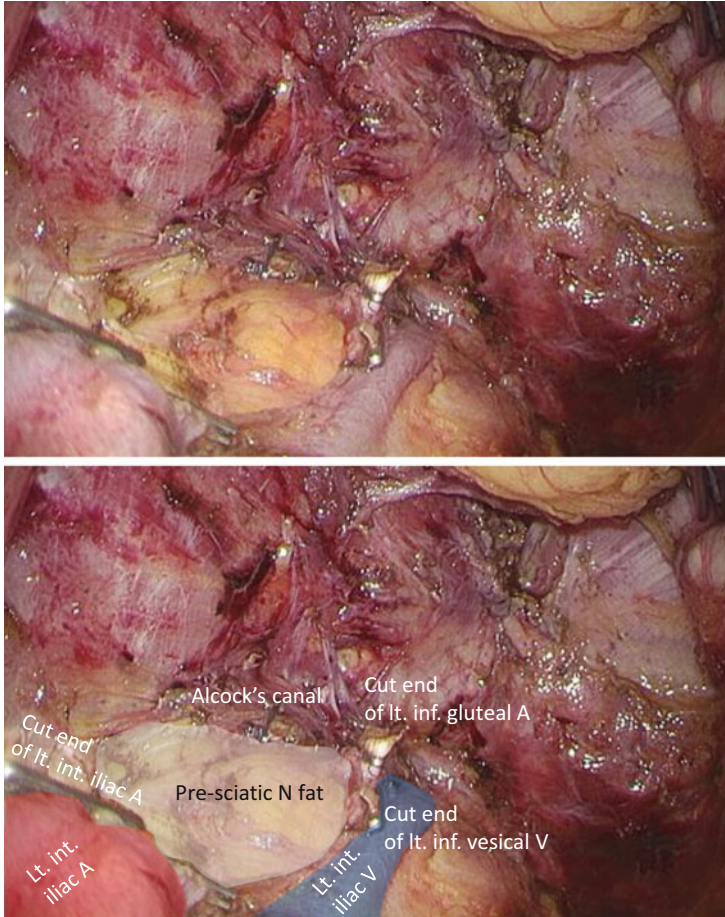


**Fig. 7.35** Completion of the right lateral pelvic lymph node dissection – 4

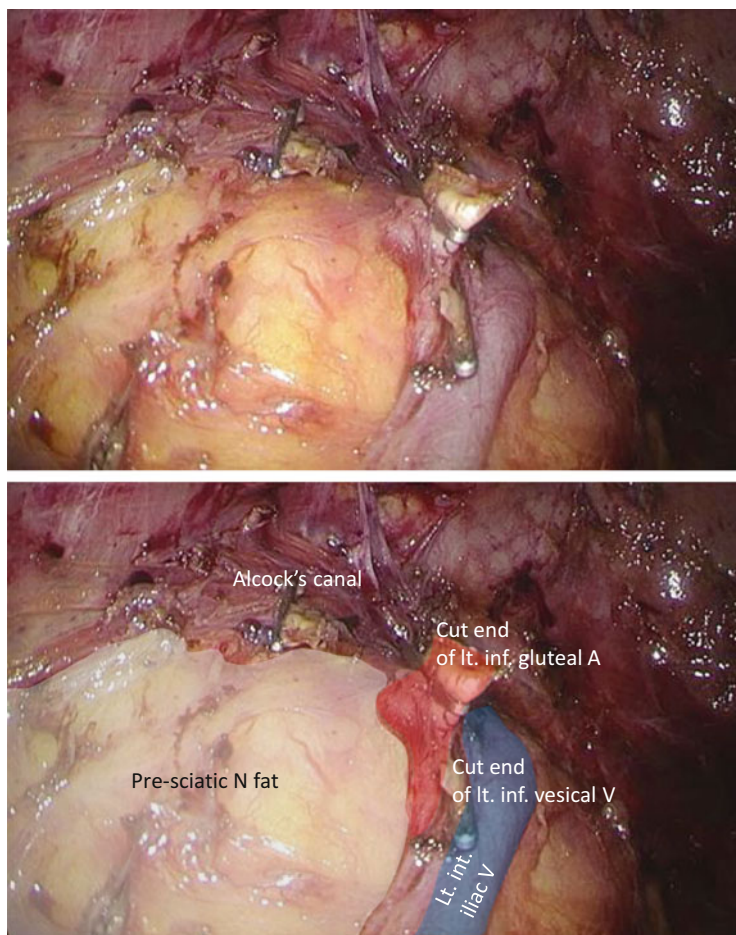
In another case of left LPLND, the LN tissues are dissected together with the left internal iliac artery trunk and the pelvic plexus. The fat tissues anterior to the left sciatic nerve are exposed (Figs. 7.36, 7.37, and 7.38).



**Fig. 7.36** Lymph node dissection together with the left internal iliac artery trunk and the pelvic plexus in another case – 1



**Fig. 7.37** Lymph node dissection together with the left internal iliac artery trunk and the pelvic plexus in another case – 2



**Fig. 7.38** Lymph node dissection together with the left internal iliac artery trunk and the pelvic plexus in another case – 3



Ryo Takahashi, Gen Nishikawa, Shigeo Hisamori, Kenji Kawada, Hisashi Shinohara, and Yoshiharu Sakai

---

## Abstract

The safety and feasibility of the laparoscopic restorative proctocolectomy (RPC) with ileal pouch-anal anastomosis (IPAA) has been established as a standard option of surgical approach for ulcerative colitis (UC) patients. We perform this technique for most patients irrespective of severity of UC with satisfactory results. RPC consists of the combination of three operative procedures, namely, right hemicolectomy, left hemicolectomy, and low anterior rectal resection. The procedures start with the right-side colon mobilization by “inferior approach.” It is essential not to injure the ileocecal vessels for adequate blood supply to the ileal pouch. Subsequently, the left-side mesocolon is mobilized from the medial side, and the rectum is mobilized down to the pelvis. The pelvic autonomic nervous system must be preserved because of the benign and juvenile property of UC. Thereafter, the splenic flexure, the transverse colon, and the hepatic flexure are mobilized in this order. Finally, rectal mucosectomy is performed transanally, and the constructed 15-cm-long ileal J-pouch is delivered to the anus. IPAA is achieved by hand sewing. Here, we describe the surgical procedures of laparoscopic RPC with IPAA.

---

## Keywords

Restorative proctocolectomy • Total colectomy • Ileal pouch-anal anastomosis • IPAA • Ulcerative colitis

---

R. Takahashi, M.D., Ph.D. (✉)

Department of Surgery, Graduate School of Medicine, Kyoto University, 54 Shogoin Kawara-cho, Sakyo-ku, Kyoto 606-8507, Japan

e-mail: [ryotak@kuhp.kyoto-u.ac.jp](mailto:ryotak@kuhp.kyoto-u.ac.jp)

## 8.1 Introduction

A total proctocolectomy is the surgical treatment option for familial adenomatous polyposis (FAP), Lynch syndrome, and inflammatory bowel disease (IBD) such as Crohn's disease and ulcerative colitis (UC) [1]. With emerging experiences of laparoscopic surgery, laparoscopic restorative proctocolectomy (Lap-RPC) with mucosal resection for UC patients has been first reported in the 1990s [2]. Whereafter, several reports have described the safety and feasibility of Lap-RPC with ileal pouch-anal anastomosis (IPAA) [3–7], and this technique has currently been accepted as a standard option of surgical approach. To date, the indication of laparoscopic approach has been extended to severe UC cases among highly experienced surgeons [8–10]. We perform IPAA for most patients irrespective of severity of UC with satisfactory results, although the cases with fulminant UC, perforated colitis, massive bleeding, and toxic megacolon are excluded from the indication of laparoscopic approach [11, 12].

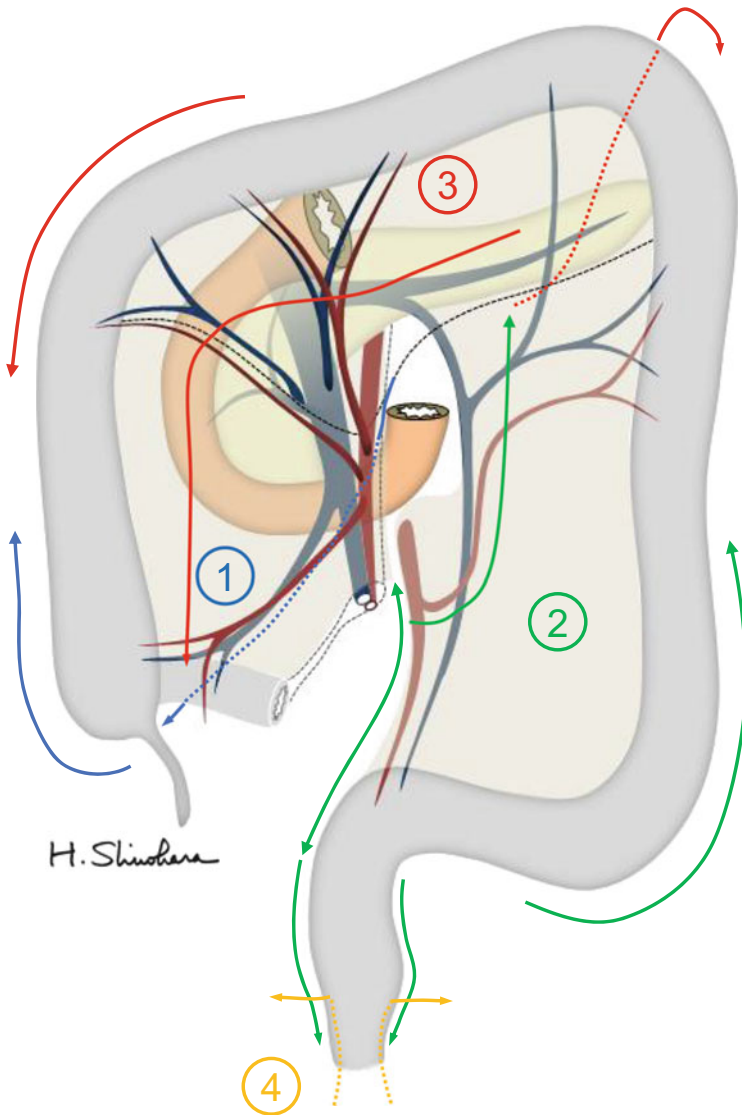
RPC consists of the combination of three operative procedures, namely, right hemicolectomy, left hemicolectomy, and low anterior rectal resection. Because of the benign and juvenile property of UC, it is essential that surgeons must avoid injury to the pelvic autonomic nervous system and subsequent urinary and sexual dysfunction [12]. Also, providing excessive traction would damage the fragile tissues of UC patients; thus, the first assistant should carefully and gently manipulate the bowel or the adjacent tissues in each procedure. Here, we describe the surgical procedures of Lap-RPC with IPAA.

---

## 8.2 Surgical Procedures

### 8.2.1 Operation Settings

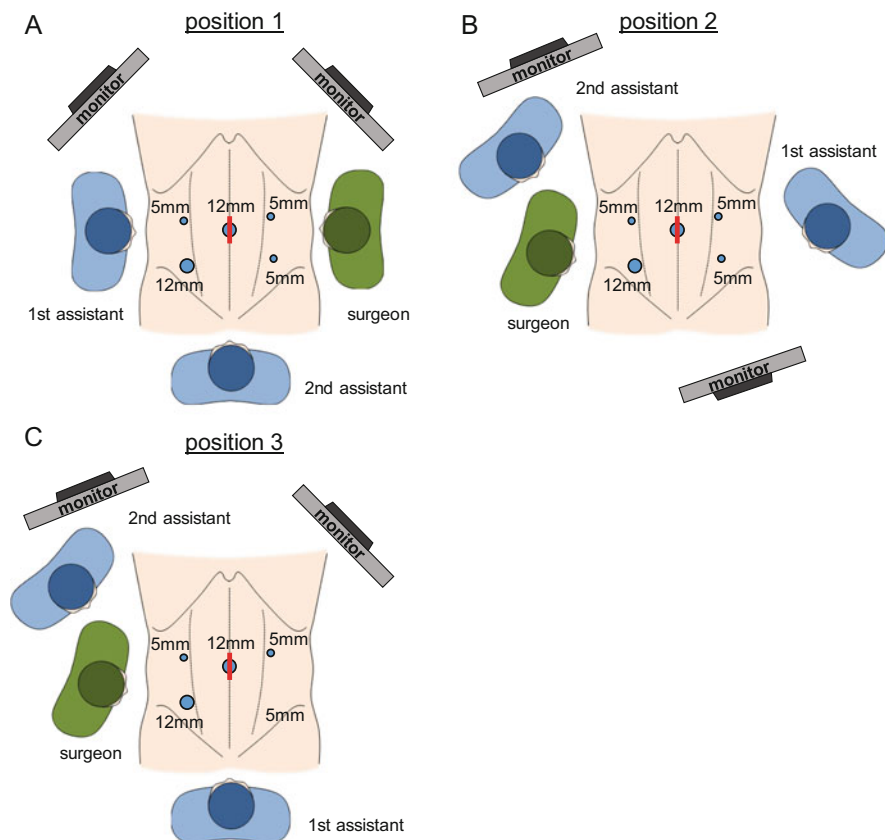
The patient is placed in the modified lithotomy position with legs abducted and both arms tucked to the sides. We employ five ports method as previously described by Kim and Milsom [13]. The initial trocar for the laparoscope is placed at the umbilicus under direct vision. After pneumoperitoneum is established and maintained at 8 mmHg, four additional trocars are then placed lateral to the rectus abdominis muscles at both sides of lower abdomen. Vessels or mesenteries are efficiently divided when performed closer to its origin, because the length of dissection would be shorter. All vessels can be divided using vessel-sealing system (i.e., clipless). The general scheme of surgical procedures is shown in Fig. 8.1. The scheme of surgeon's position, port placement, and monitor location is indicated in Fig. 8.2.



**Fig. 8.1** The general scheme of surgical procedures for laparoscopic restorative proctocolectomy with mucosal resection. Maneuvers of mobilization and division are performed in order of indicated numbers

### 8.2.2 Mobilization of the Right-Side Colon and the Small Bowel

At first, the surgeon stands on the right side of the patient (Fig. 8.2a). In the Trendelenburg position, the small bowel is completely moved to the upper right quadrant of the abdomen. The small bowel mesentery is elevated and spread by the



**Fig. 8.2** The scheme of surgeon's position, port placement, and monitor location. Each figure shows the setting for mobilization of (a) the right-side colon and the hepatic flexure, (b) the left-side colon and rectum, and (c) the splenic flexure

first assistant (Fig. 8.3a). This maneuver is a critical step in the “inferior approach,” because it enables the operator to thoroughly recognize the dissection line, that is, boundary between the root of the small bowel mesentery and the retroperitoneum. Subsequently, the small bowel mesentery is dissected all the way from the ligament of Treitz to the cecum. The ascending mesocolon is mobilized through the same dissection layer as far as possible toward the hepatic flexure (Fig. 8.3b, c). This dissection layer runs beneath the superior mesenteric artery and vein (SMA&V) and over the duodenum and the retroperitoneum, preserving the right ureter and the gonadal vessels (Fig. 8.3c, d). These maneuvers elongate the mesentery of the ileal pouch and reduce the tension on the IPAA. By retracting the cecum to the left, “the white line” at lateral side of the ascending colon is divided (Fig. 8.3e). During the mobilization of the right-side colon, it is essential not to injure the ileocecal vessels, because these will be the feeder of the ileal pouch.

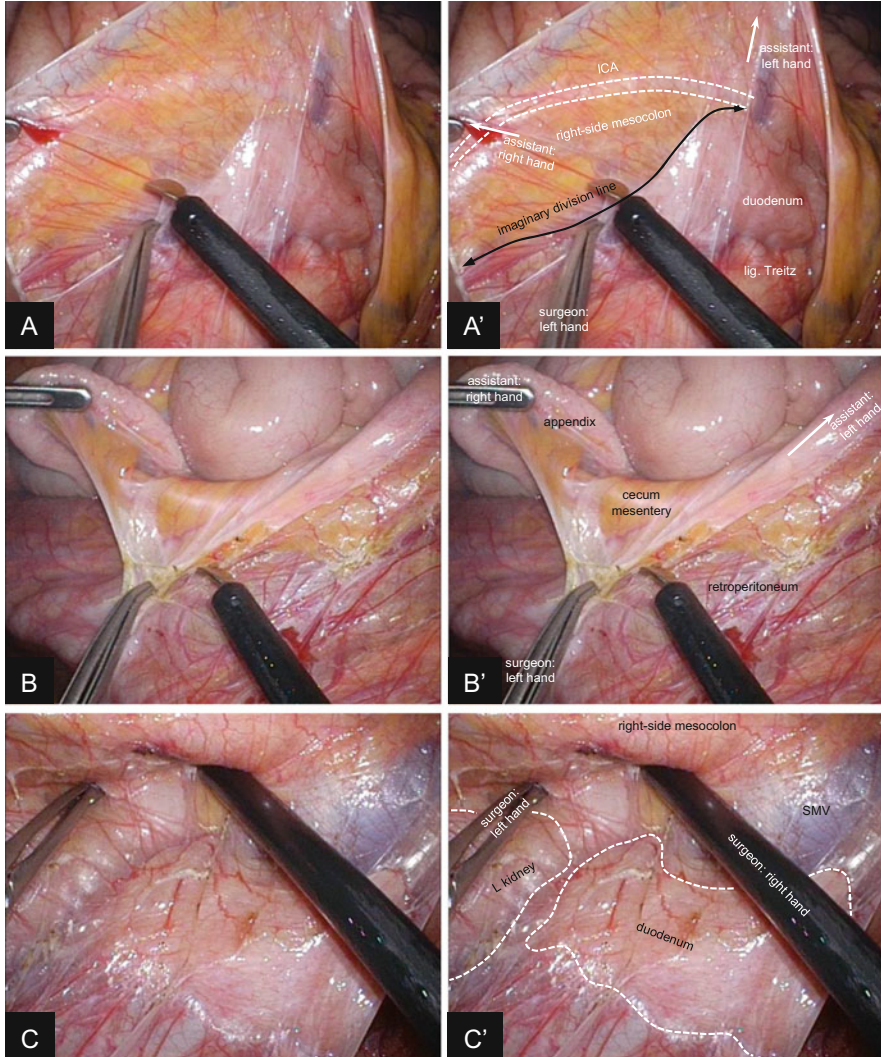
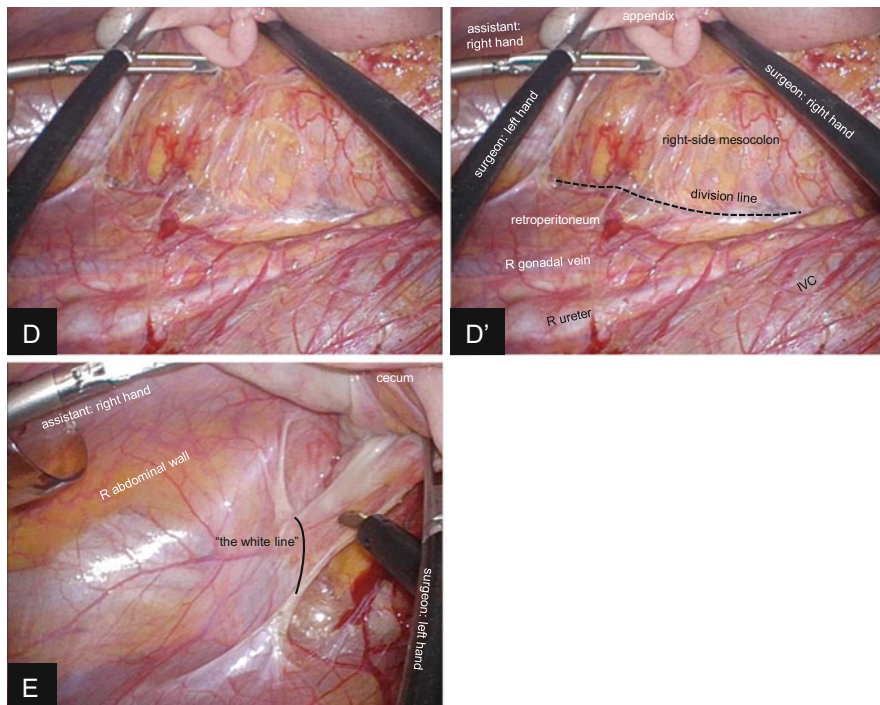


Fig. 8.3 (continued)

### 8.2.3 Mobilization of the Sigmoid Colon and the Rectum

Surgeons move as indicated in Fig. 8.2b. In the same patient's position as previous step, the rectosigmoid mesocolon is dissected from its right side (Fig. 8.4a), and the hypogastric nerves are carefully preserved (Fig. 8.4b, c). The inferior mesenteric artery (IMA) is divided at distal side of the left colic artery (LCA) branching (Fig. 8.4d), and the inferior mesenteric vein (IMV) is divided at the same level.

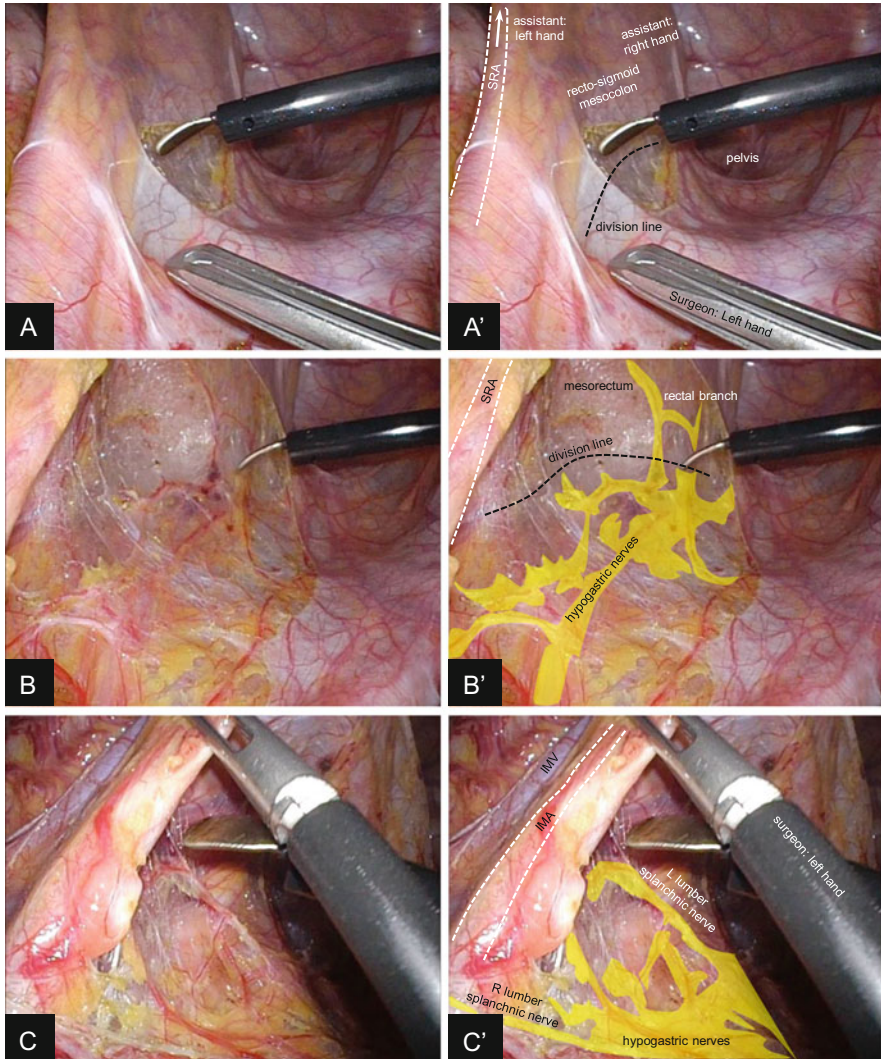


**Fig. 8.3** Mobilization of the right-side colon by “inferior approach.” (a,a’) The small bowel mesentery is elevated and completely spread by the first assistant. The *black arrow* indicates the boundary between the small bowel mesentery and the retroperitoneum (i.e., imaginary division line). (b,b’) The cecum is mobilized from the retroperitoneum. (c,c’) The right-side mesocolon is further mobilized toward the hepatic flexure. The duodenum is swept dorsally. (d,d’) The right ureter and the gonadal vessels are carefully preserved. (e) Lateral attachment of the ascending colon is divided at “the white line.” ICA ileocolic artery. SMV superior mesenteric vein, IVC inferior vena cava

The descending mesocolon is mobilized first from medial side and then from lateral. The left ureter and the gonadal vessels are swept dorsally and preserved (Fig. 8.4e, f).

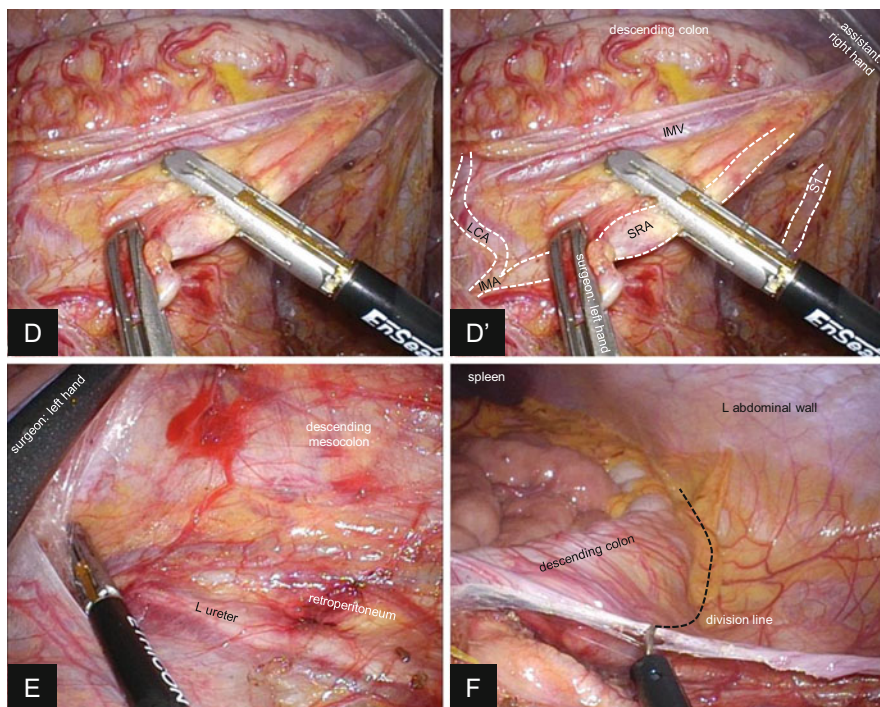
The posterior side of the rectum is dissected on the mesorectal plane, identifying and preserving the hypogastric nerves and pelvic plexus (Fig. 8.5a, b) [14, 15]. In UC patients, we often experience difficulty in identifying the appropriate layer of dissection due to chronic inflammation. It is acceptable that dissection line penetrates into mesorectum except the case that rectal cancer is diagnosed. However, such dissection plane is time consuming by substantial bleeding. Thus, the layer of total mesorectal excision (TME) is more reasonable in this maneuver [16].

At the anterior aspect of the mesorectum, we encounter the area of glistening connective tissue by providing proper traction. We consider that it is recognized as “the Denonvilliers’ fascia” in cadavers by collapsing and condensing with formalin



**Fig. 8.4** (continued)

fixation [17]. The appropriate dissection line generally divides the connective tissue, and parts of the connective tissues remain at both sides to form the so-called fascia. In RPC for UC, the connective tissue is divided on the line which preserves as much thickness as possible on the anterior pelvic wall. By keeping this line, the seminal vesicles and the prostate gland are left covered by the connective tissue (Fig. 8.5c). This situation differs from that used for cancer resection, which proceeds more anterior in the connective tissue.



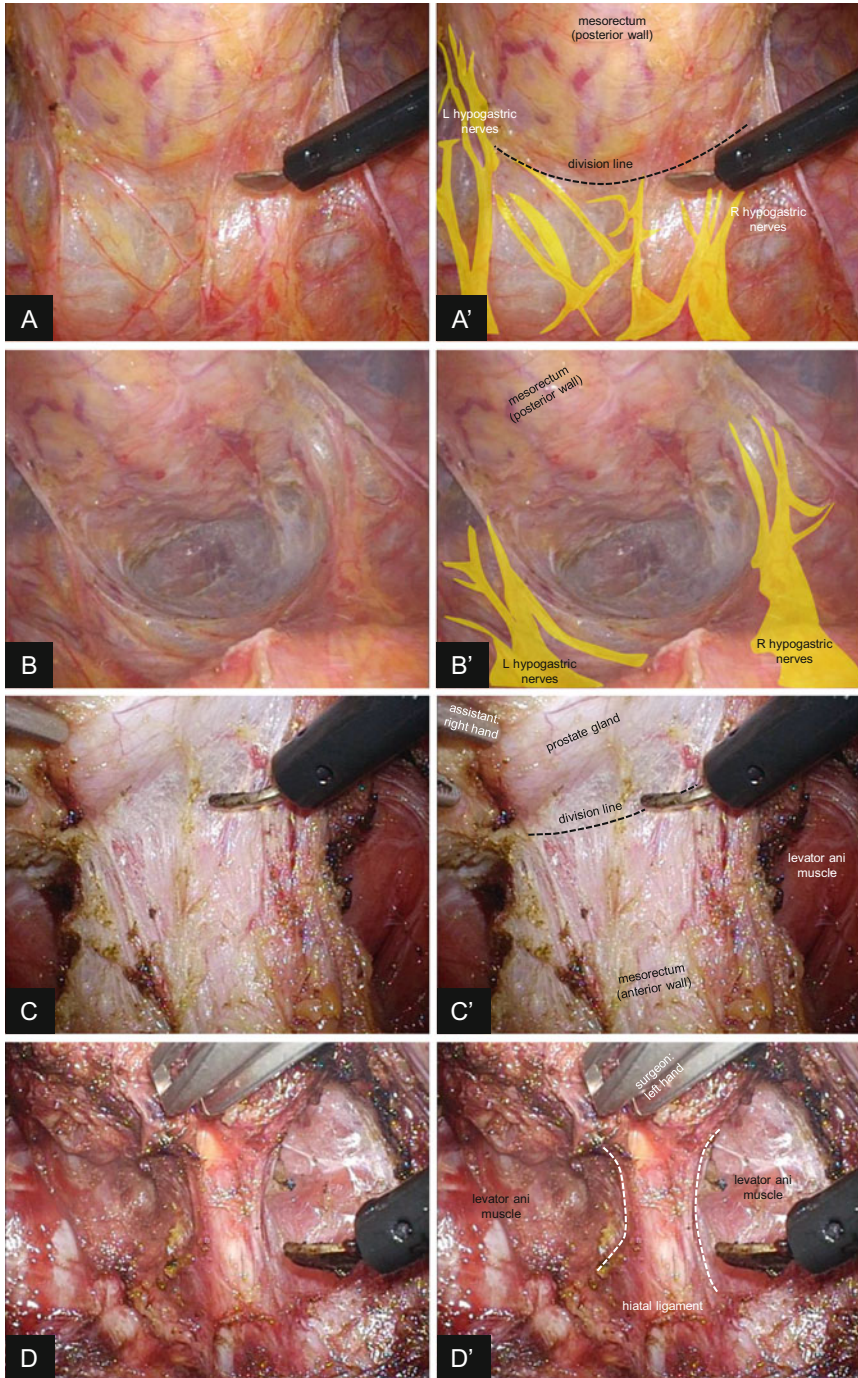
**Fig. 8.4** Mobilization of the left-side colon. (a,a') The rectosigmoid mesocolon is spread by the first assistant and is dissected from its right side. The loose connective tissue is divided. (b,b') The hyogastric nerves are carefully preserved except the rectal branches. (c,c') Bilateral splanchnic nerves are identified at the origin of IMA and preserved. (d,d') The SRA is divided at the distal side of the branching of the LCA using vessel-sealing system. (e) The descending mesocolon is mobilized from the medial side. The left ureter and the gonadal vessels are preserved dorsally. (f) Lateral attachment of the descending colon is divided. SRA superior rectal artery, IMA inferior mesenteric artery, IMV inferior mesenteric vein, LCA left colic artery, SI 1st sigmoid colon branch of the superior rectal artery

Subsequently, the rectum is circumferentially dissected down to the pelvic floor, and the hiatal ligament is divided under laparoscopic view (Fig. 8.5d).

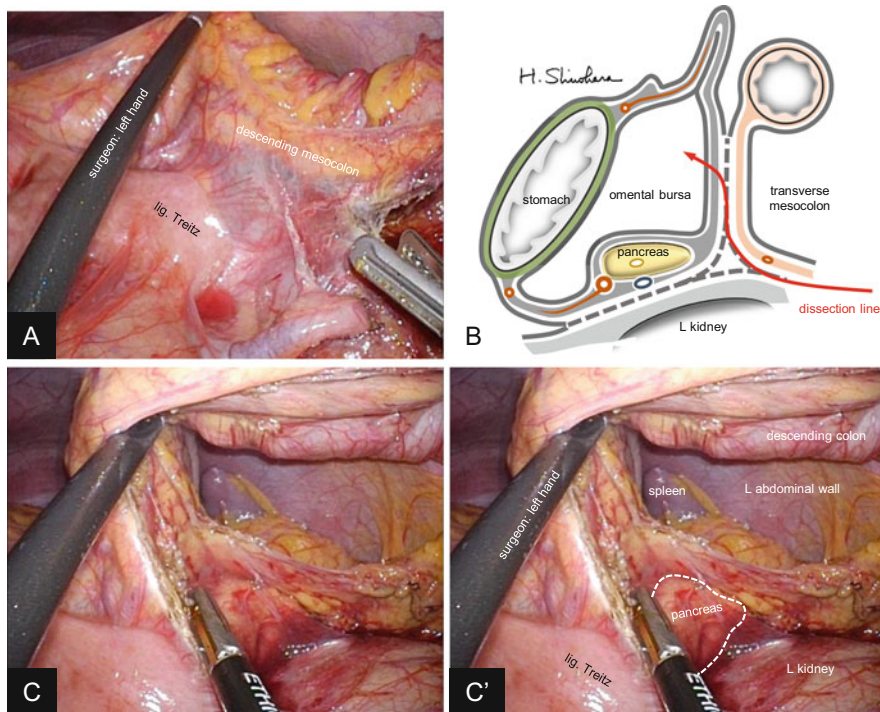
### 8.2.4 Mobilization of the Splenic Flexure

Surgeons stand at the same position as previous maneuver, using the monitor located on the left side of the patient's head (position 3, Fig. 8.2c). The first assistant may stand between the patient's legs depending on the situation. In the same table position, the descending mesocolon is further divided toward the upper left, by continuing the layer of the sigmoid mesocolon mobilization (Fig. 8.6a). The scheme of the subsequent dissection line is shown in Fig. 8.6b. The lower edge of the





**Fig. 8.5** Mobilization of the rectum. (a,a') At the posterior side of the rectum, the loose connective tissue is divided close to the mesorectum preserving the hypogastric nerves. (b,b') The posterior side of the mesorectum is dissected down to the pelvic floor. (c,c') At the anterior



**Fig. 8.6** Mobilization of the splenic flexure. (a) The descending mesocolon is mobilized and divided toward the splenic flexure. (b) The scheme of the dissection line. The omental bursa is opened by dividing the anterior layer of the transverse mesocolon, after identifying and preserving the pancreas. (c,c') The pancreas is identified on the dorsal side of the dissection line. The descending mesocolon has already been divided and the left abdominal wall is observed through the window. The transverse mesocolon is retracted to the right by the surgeon's left hand

pancreas is identified, and the omental bursa is opened from this view by dividing the anterior layer of the transverse mesocolon (Fig. 8.6c). The transverse mesocolon is further divided toward the left carefully preserving the pancreas dorsally, and the remaining attachment of the descending colon ("the white line" at lateral side) is divided. In the case this approach is difficult to achieve, another option is to divide the omentum to enter the omental bursa from the ventral side and to mobilize the splenic flexure from the superior side after identifying the pancreas.

**Fig. 8.5** (continued) aspect of the mesorectum, the area of glistening connective tissue is identified. In restorative proctocolectomy for ulcerative colitis patient, the connective tissue is divided on the line which preserves as much thickness as possible on the anterior pelvic wall. (d,d') The hiatal ligament at the pelvic floor is divided under laparoscopic view

### 8.2.5 Dividing the Transverse Mesocolon and Mobilization of the Hepatic Flexure

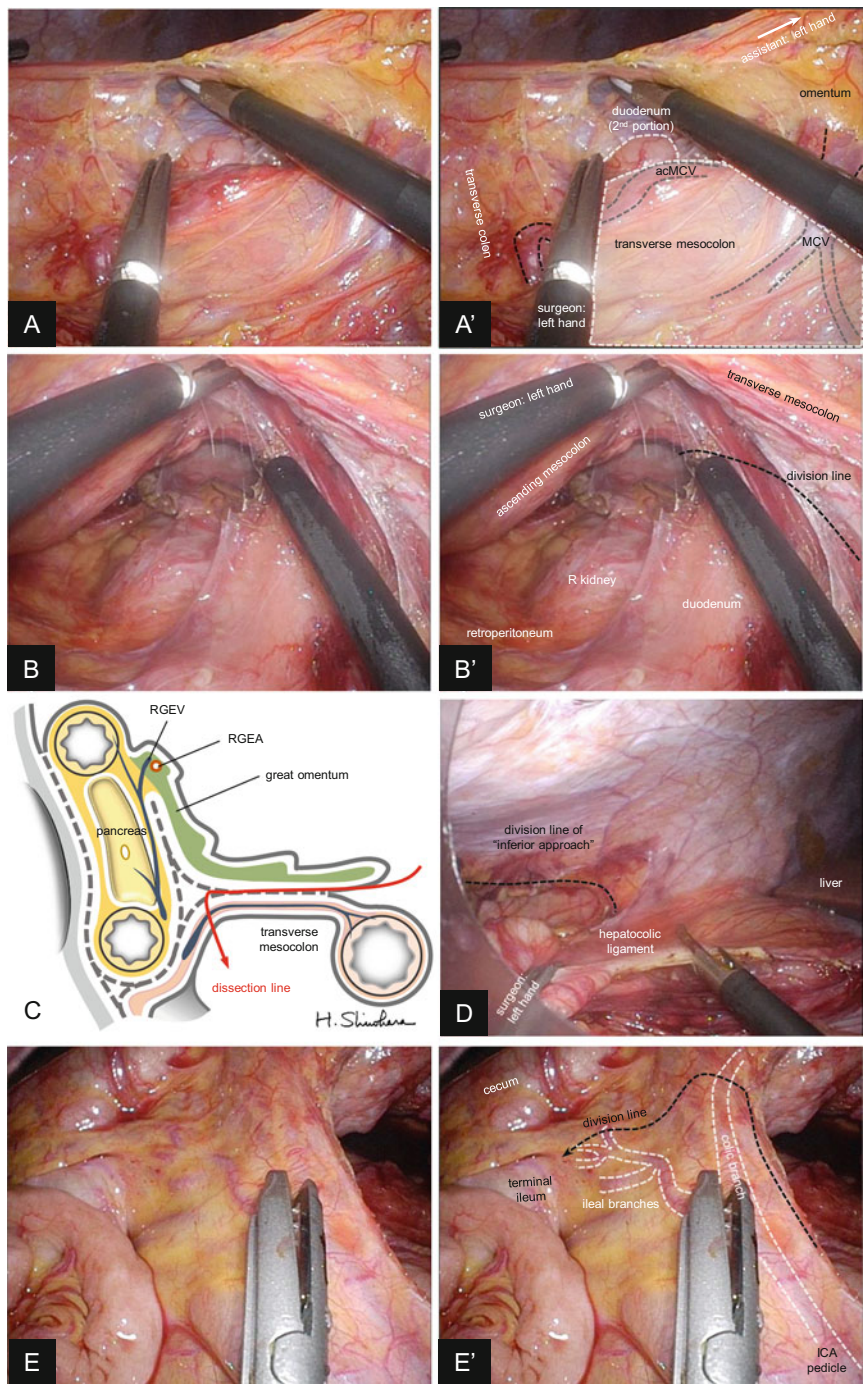
The table position is changed to the reverse Trendelenburg. The surgeons move back to position 1 (Fig. 8.2a). The omentum is divided from the ventral side, and the transverse mesocolon is isolated (Fig. 8.7a). The transverse mesocolon is further divided toward the hepatic flexure, and this dissection line communicates with the layer of “inferior approach” (Fig. 8.7b). The middle colic vessels (MCA&V) are divided during this step. The scheme of the dissection line is indicated in Fig. 8.7c. Finally, the remaining attachment of the colon and its mesentery is divided to complete mobilization (Fig. 8.7d). The ileocecal vessels are preserved to maintain an adequate blood supply to the ileal pouch (Fig. 8.7e).

### 8.2.6 Transanal Rectal Mucosectomy and IPAA

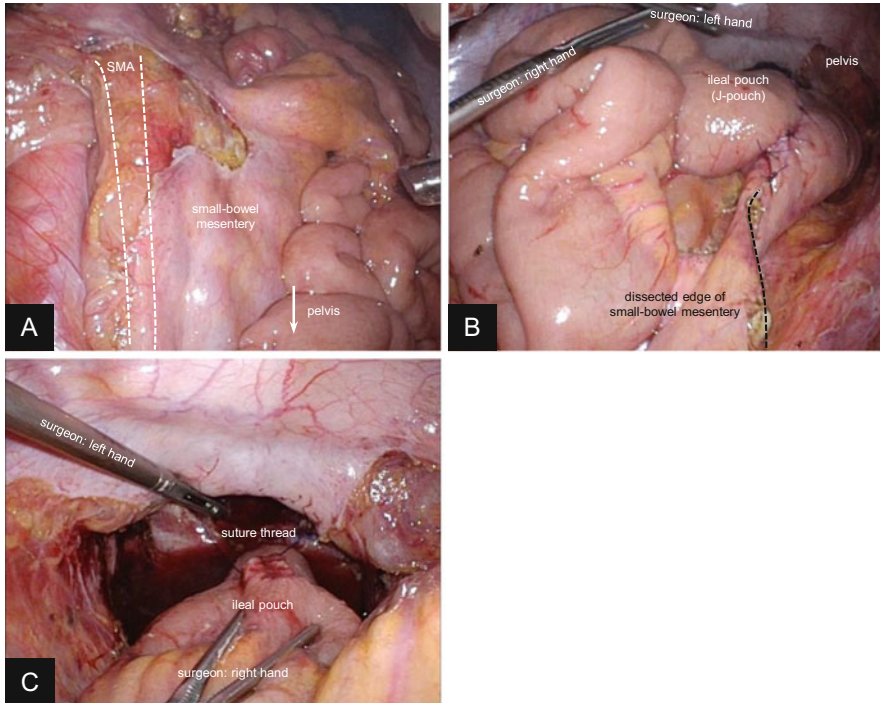
Transanal rectal mucosectomy is performed by using a modification of the Kusunoki method [18]. With the patient in the Lloyd-Davies position, the circumferential mucosectomy is started at the lower margin of the dentate line. The mucosa is stripped to approximately 3–4 cm from the dentate line above the levator ani muscle, and the circumferential muscular layer of the rectum is transected to communicate with the laparoscopic dissection plane. The transection of the muscular layer is usually initiated at the posterior side of the rectum. After rectal mobilization and transection, the umbilical wound is minimally enlarged to exteriorize the bowel. Mobilized bowel should be placed anterior to the small bowel in advance, to avoid the strangulation of the small bowel during this maneuver.

The terminal ileum is then transected (preserving ileocolic vessels), and a 15-cm ileal J-pouch is constructed. As a simulation, the J-pouch is taken down toward the pelvis extracorporeally to assess the extensibility. In the case the tip of the J-pouch does not delivered as far as 2 fingerbreadth inferior to lower end of the pubic bone, it is generally difficult to achieve anal anastomosis. Further mobilization of the small bowel mesentery at its root, if possible, would improve the extensibility. Sacrificing a part of the small bowel mesentery or its vessels is usually necessary for elongation, although this option has the risk of insufficient blood perfusion at the J-pouch. The intestinal wall is opened at the tip of the J-pouch, and the forks of linear stapler are inserted. Three to four cartridges are required to achieve the construction. Ringed suture thread or Nelaton catheter is placed at the tip of the J-pouch for the following maneuver.

The anal canal is packed with several wet gauzes, and the pneumoperitoneum is established again. The J-pouch is delivered to the anus under laparoscopic view, placing the mesentery upside. At this point, surgeons must confirm the alignment of the small bowel and its mesentery to avoid the torsion or the internal hernia




**Fig. 8.7** Mobilization of the hepatic flexure. (a,a') The omentum is divided from the ventral side, and the transverse mesocolon is isolated. The duodenum must be identified in this maneuver. (b,b') The dissection layer of the “inferior approach” is further extended toward the upper right and



**Fig. 8.8** Ileal pouch-anal anastomosis. (a) The alignment of the small bowel mesentery is confirmed to avoid torsion or the internal hernia. (b) The ileal pouch is adjusted dorsal to its mesentery (c) and is delivered to the anus. *SMA* superior mesenteric artery

(Fig. 8.8a-c). After removal of gauzes, the first assistant grasps the suture thread transanally before the pneumoperitoneum is completely lost. The second assistant should manage to capture the procedure on the monitor as long as possible for safe and secure maneuver. IPAA is performed by hand sewing. Using the suture holder, the J-pouch is fixed by 4 sutures on the internal sphincter. Subsequently, 24 sutures are performed on the J-pouch all layers and the dentate line. Closed drainage tube is placed in the pelvis. The temporary loop ileostomy is performed if required.



**Fig. 8.7** (continued) finally communicates with the dissection line of the ventral approach which is shown in (a). The duodenum is thoroughly swept dorsally under this view, and the transverse mesocolon is divided along the indicated dotted line (usually from ventral side). (c) The scheme of the dissection line shown in (a) and (b). (d) The remaining attachment is divided to complete mobilization. (e,e') The ICA pedicle, its colic branch, and ileal branches are carefully identified. The ileal branches are preserved as much as possible to maintain an adequate blood supply to the ileal pouch. The division line (*dotted line*) runs closely along the cecum toward the terminal ileum, dividing the colic branch. *MCV* middle colic vein, *acMCV* accessory middle colic vein, *RGEV* right gastroepiploic vein, *RGEA* right gastroepiploic artery, *ICA* ileocolic artery

## References

1. Cotte E, Mohamed F, Nancey S, François Y, Glehen O, Flourié B, et al. Laparoscopic total colectomy: does the indication influence the outcome? *World J Gastrointest Surg.* 2011;3(11):177–82.
2. Peters WR. Laparoscopic total proctocolectomy with creation of ileostomy for ulcerative colitis: report of two cases. *J Laparoendosc Surg.* 1992;2(3):175–8.
3. Wexner SD, Johansen OB, Noguerras JJ, Jagelman DG. Laparoscopic total abdominal colectomy. A prospective trial. *Dis Colon Rectum.* 1992;35(7):651–5.
4. Thibault C, Poulin EC. Total laparoscopic proctocolectomy and laparoscopy-assisted proctocolectomy for inflammatory bowel disease: operative technique and preliminary report. *Surg Laparosc Endosc.* 1995;5(6):472–6.
5. Marcello PW, Milsom JW, Wong SK, Hammerhofer KA, Goormastic M, Church JM, et al. Laparoscopic restorative proctocolectomy: case-matched comparative study with open restorative proctocolectomy. *Dis Colon Rectum.* 2000;43(5):604–8.
6. Tan JY, Tjandra JJ. Laparoscopic surgery for ulcerative colitis – a meta-analysis. *Colorectal Dis.* 2006;8(8):626–36.
7. Larson DW, Davies MM, Dozois EJ, Cima RR, Piotrowicz K, Anderson K, et al. Sexual function, body image, and quality of life after laparoscopic and open ileal pouch-anal anastomosis. *Dis Colon Rectum.* 2008;51(4):392–6.
8. Holubar SD, Long KH, Loftus EV, Wolff BG, Pemberton JH, Cima RR. Long-term direct costs before and after proctocolectomy for ulcerative colitis: a population-based study in Olmsted county, Minnesota. *Dis Colon Rectum.* 2009;52(11):1815–23.
9. Telem DA, Vine AJ, Swain G, Divino CM, Salky B, Greenstein AJ, et al. Laparoscopic subtotal colectomy for medically refractory ulcerative colitis: the time has come. *Surg Endosc.* 2010;24(7):1616–20.
10. Pandey S, Luther G, Umanskiy K, Malhotra G, Rubin MA, Hurst RD, et al. Minimally invasive pouch surgery for ulcerative colitis: Is there a benefit in staging? *Dis Colon Rectum.* 2011;54(3):306–10.
11. Kawamura J, Hasegawa S, Kawada K, Yamaguchi T, Nagayama S, Matsusue R, et al. Feasibility and safety of laparoscopic total proctocolectomy with ileal pouch-anal anastomosis for severe ulcerative colitis. *Asian J Endosc Surg.* 2013;6(4):271–8.
12. Hasegawa S, Nomura A, Kawamura J, Nagayama S, Hata H, Yamaguchi T, et al. Laparoscopic restorative total proctocolectomy with mucosal resection. *Dis Colon Rectum.* 2007;50(8):1152–6.
13. Michelassi F, Milsom J. Operative strategies in inflammatory bowel disease. New York: Springer; 1999. p. 326–37.
14. Hasegawa S, Nagayama S, Nomura A, Kawamura J, Sakai Y. Autonomic nerve-preserving total mesorectal excision in the laparoscopic era. *Dis Colon Rectum.* 2008;51(8):1279–82.
15. Hida K, Hasegawa S, Kataoka Y, Nagayama S, Yoshimura K, Nomura A, et al. Male sexual function after laparoscopic total mesorectal excision. *Colorectal Dis.* 2013;15(2):244–51.
16. Lindsey I, George BD, Kettlewell MG, Mortensen NJ. Impotence after mesorectal and close rectal dissection for inflammatory bowel disease. *Dis Colon Rectum.* 2001;44(6):831–5.
17. Sakai Y, Nomura A, Masumori K, Kawamura J, Nagayama S. Recent interpretations of Denonvilliers' fascia and the lateral ligament of the rectum. *Asian J Endosc Surg.* 2009;2(1):8–12.
18. Kusunoki M, Shoji Y, Yanagi H, Ikeuchi H, Noda M, Yamamura T. Current trends in restorative proctocolectomy: introduction of an ultrasonically activated scalpel. *Dis Colon Rectum.* 1999;42(10):1349–52.

Suguru Hasegawa, Koya Hida, Kenji Kawada, and Yoshiharu Sakai

---

## 9.1 Introduction

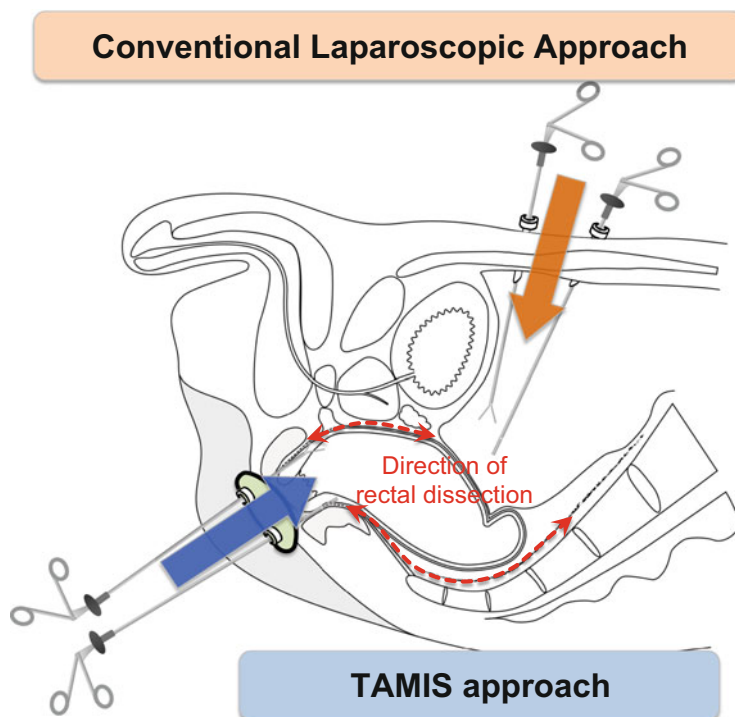
Laparoscopic dissection of the lower rectum is a technically demanding procedure in patients with a narrow pelvis and a bulky tumor or in those who are obese [1]. Moreover, transection of the rectum using a stapling device deep in the narrow pelvis is the most difficult part of this operation. Transanal mesorectal dissection using transanal endoscopic microsurgery aims to overcome these limitations and was first reported in 2010 [2]. Moreover, following the report by Tuech et al. in 2011 [3], a single-port device with laparoscopic instruments is now widely used as a platform for transanal total mesorectal excision (TME). This convenient approach, referred to as transanal minimally invasive surgery (TAMIS), has been welcomed by surgeons who are used to laparoscopic surgery.

The TAMIS approach has several advantages over the conventional laparoscopic approach for rectal cancer. First, it facilitates perianal dissection especially in patients with a narrow pelvis or a bulky tumor, because transanal access offers an in-line vantage point to the distal rectum (Fig. 9.1) [4–6]. Second, accurate determination of a safe distal margin is assured because the distal rectal incision is made under direct vision. Third, the number of abdominal ports necessary for the laparoscopic part can be reduced, because the most difficult part of the dissection is performed through TAMIS. Furthermore, when the specimen is extracted through the anus, there is no need for elongation of the abdominal wound to facilitate specimen extraction.

---

S. Hasegawa, M.D., Ph.D., F.A.C.S. (✉) • K. Hida, M.D., Ph.D. • K. Kawada, M.D., Ph.D. • Y. Sakai, M.D., Ph.D., F.A.C.S.

Department of Surgery, Kyoto University Graduate School of Medicine, Sakyo-ku Kyoto, Japan  
e-mail: [shase@kuhp.kyoto-u.ac.jp](mailto:shase@kuhp.kyoto-u.ac.jp)

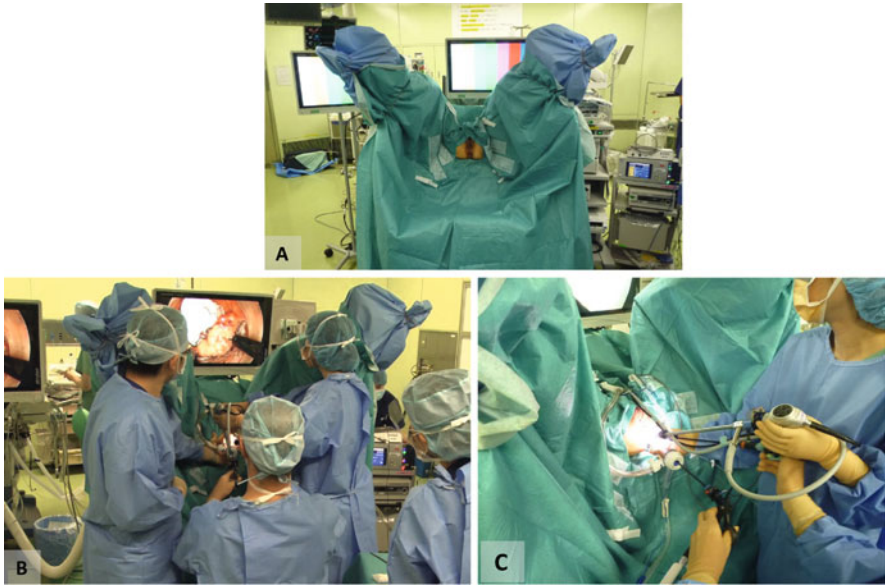


**Fig. 9.1** Advantage of transanal minimally invasive surgery (TAMIS) for rectal cancer. Compared with the conventional laparoscopic approach, the TAMIS approach offers an in-line vantage point to the distal rectum, and this facilitates perianal dissection, especially in patients with a narrow pelvis or a bulky tumor

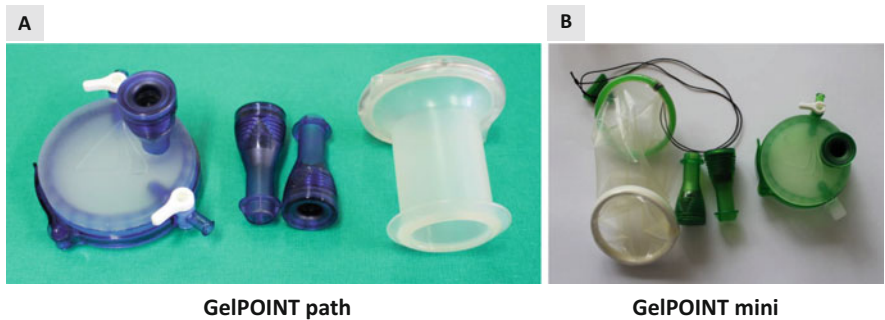
## 9.2 Patient Position and Operative Setup

The patient is placed in a lithotomy position with slight head-down tilting. The perineal region is prepped and draped. The location of the monitor and surgical devices is shown in Fig. 9.2. As an operative platform, we usually use GelPOINT mini or GelPOINT path device (Fig. 9.3); the latter is the only device that was designed specifically for transanal use. Three trocars are placed in the Gelseal cap: one for the camera and the other two for the surgeon to use. A rigid endoscope ( $0^\circ$  or  $30^\circ$ ) with a high-definition camera is used for the operation. Electrocautery or ultrasonic scissors can be used as the energy device, though we prefer electrocautery. Appropriate selection of a  $\text{CO}_2$  insufflator is very important for this procedure because the operative space in this approach is small, and smoke evacuation and instability of the operative field due to loss of pneumoperirectum are major problems. A real-time pressure sensor (AirSeal, SurgiQuest, or PneumoSure, Stryker) is helpful in maintaining a constant  $\text{CO}_2$  pressure and stable operative field (Fig. 9.4). In particular, the AirSeal device constantly evacuates the smoke through automatic circulation of  $\text{CO}_2$ .





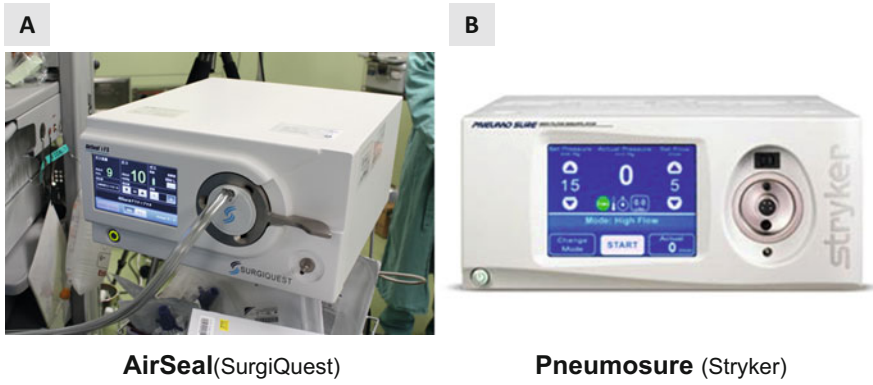
**Fig. 9.2** Operative setup. (a) Patient position. (b) Location of the surgeons and operative monitor. (c) Closer view of the setup



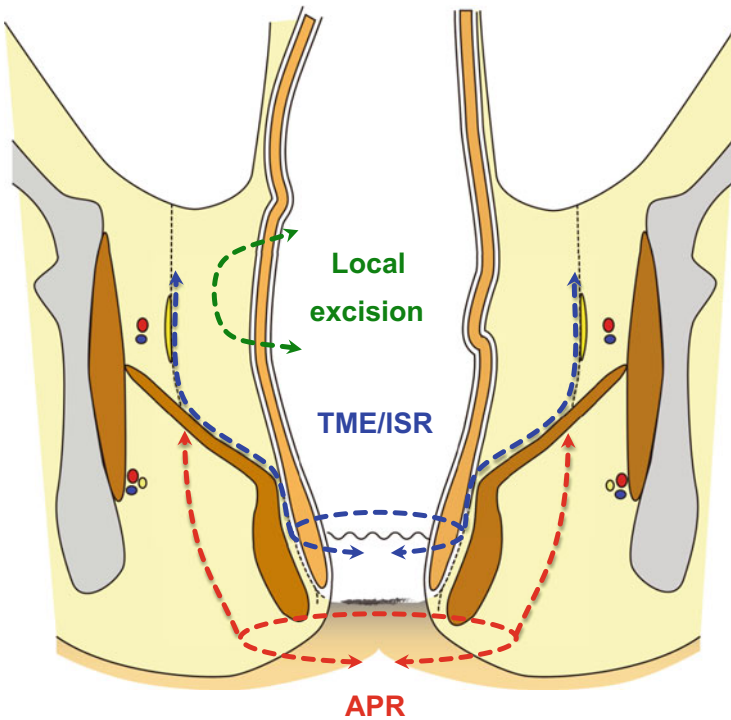
**Fig. 9.3** Platform for transanal access. (a) GelPOINT path. (b) GelPOINT mini (Applied Medical)

### 9.3 Operative Procedure

Using the TAMIS approach, several types of rectal surgery can be performed, including local excision, TME, intersphincteric resection (ISR), and abdomino-perineal resection (APR) (Fig. 9.5). In the following section, the technical details of TAMIS-TME/ISR and APR will be discussed.



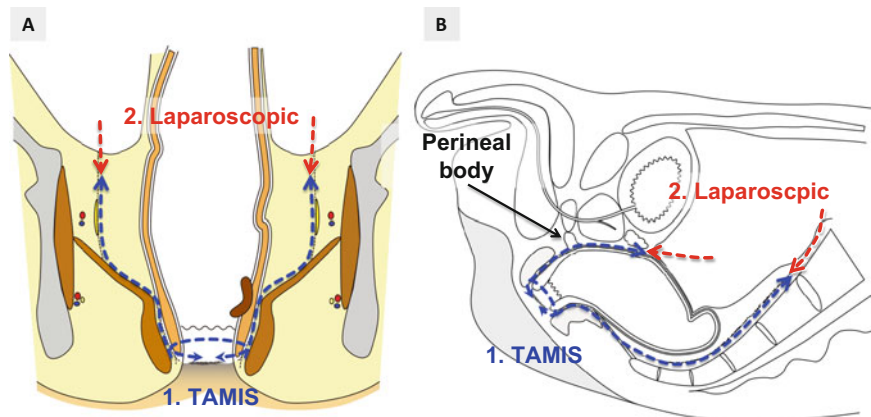
**Fig. 9.4** CO<sub>2</sub> insufflator. (a) AirSeal (SurgiQuest). (b) PnuemoSure (Stryker)



**Fig. 9.5** Schema of operative procedures using the TAMIS approach

**TAMIS-TME/ISR**

The operative schema of TAMIS-TME/ISR is shown in Fig. 9.6.



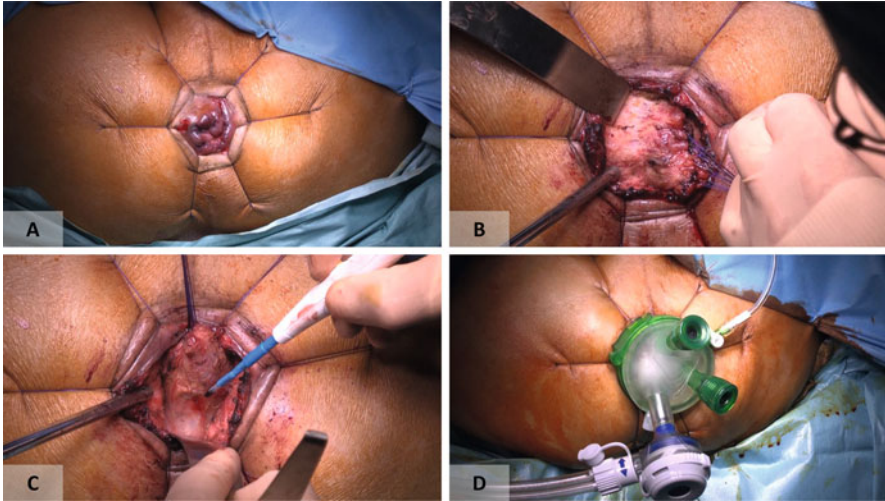
**Fig. 9.6** Operative schema of TAMIS-intersphincteric resection (ISR)/total mesorectal excision (TME). (a) Coronal view. (b) Sagittal view

### 9.3.1 Distal Transection of the Rectum

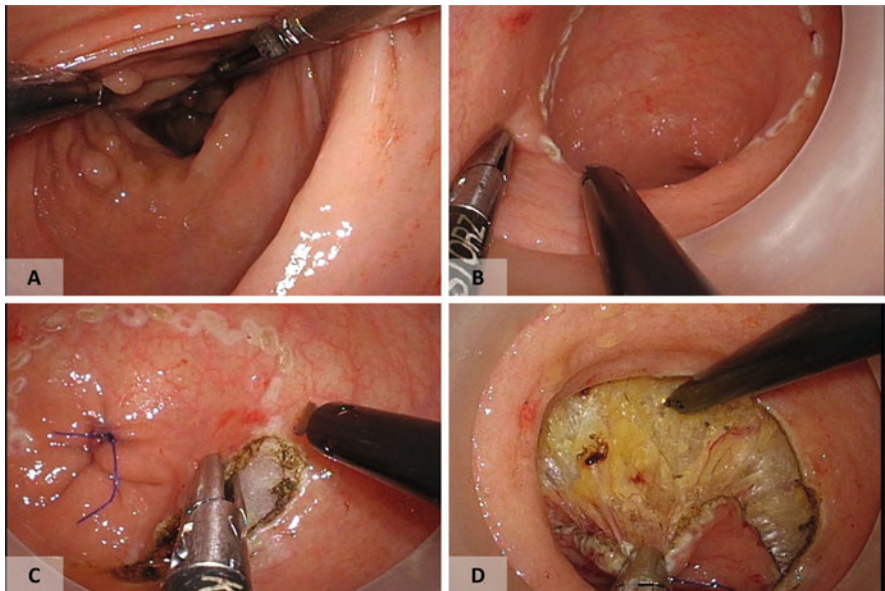
The anus is gently dilated and the location of the tumor is confirmed. The intersphincteric groove is identified by palpation and the external anal sphincter is dilated with six threads. Use of a Lone Star Retractor is also beneficial. Determination of the distal margin is an important part of this procedure, and it depends on the location of the tumor and how the distal rectum (or anal canal) is transected. When the tumor is very low lying near the anal verge, full-thickness circumferential incision of the anal canal under direct vision is usually made with a sufficient distal margin. Subsequently, intersphincteric dissection is performed under direct vision to some extent (2–3 cm) to fix the sleeve portion of the GelPOINT device to the anal canal (Fig. 9.7). When the tumor is located more proximally, the GelPOINT path is inserted into the anal canal, and rectal occlusion and distal incision of the rectal wall are performed under endoscopic vision (Fig. 9.8). Secure closure of the distal stump and sufficient irrigation of the surgical field are important to prevent spillage of tumor cells and bacterial contamination.

### 9.3.2 TAMIS Mesorectal Dissection

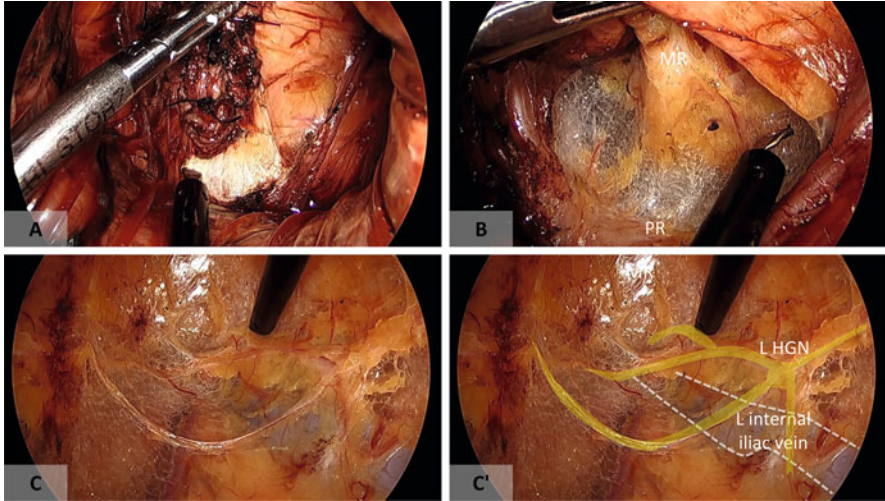
Pneumoperirectum is maintained at 8–12 mmHg. Posterior presacral dissection is usually performed first because the anatomical dissection plane is easier to identify posteriorly (Fig. 9.9). It should be noted that posterior dissection tends to migrate into the mesorectum because of the sharp angle of the dissection line due to the pull of the puborectal sling at the anorectal flexure (Fig. 9.10) [7]. Once the appropriate dissection plane is found, posterior dissection is performed along the curve of the sacrum until the sacral promontory is reached. Because the dissection goes easily



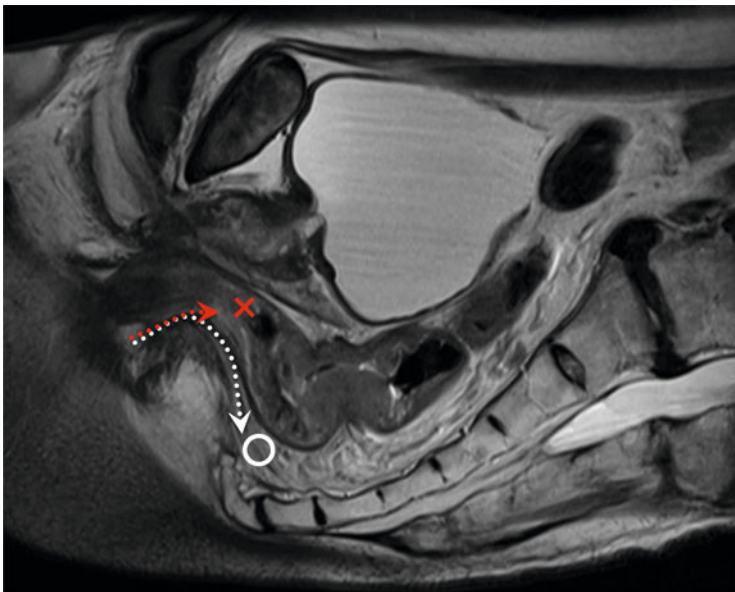
**Fig. 9.7** (a) Full-thickness incision of the anal canal is made following the assessment of tumor location. (b) Intersphincteric dissection. (c) Posterior dissection. (d) Placement of GelPOINT mini



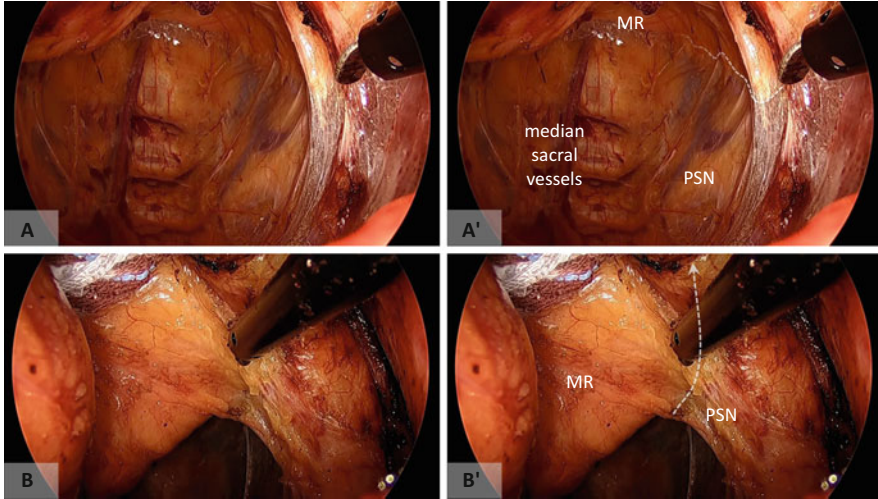
**Fig. 9.8** Distal incision of the rectum through the TAMIS approach (optional). (a, b) The location of the tumor is examined and circumferential marking is made with an appropriate distal margin. (c, d) The rectum is tightly closed and a full-thickness rectal incision is made



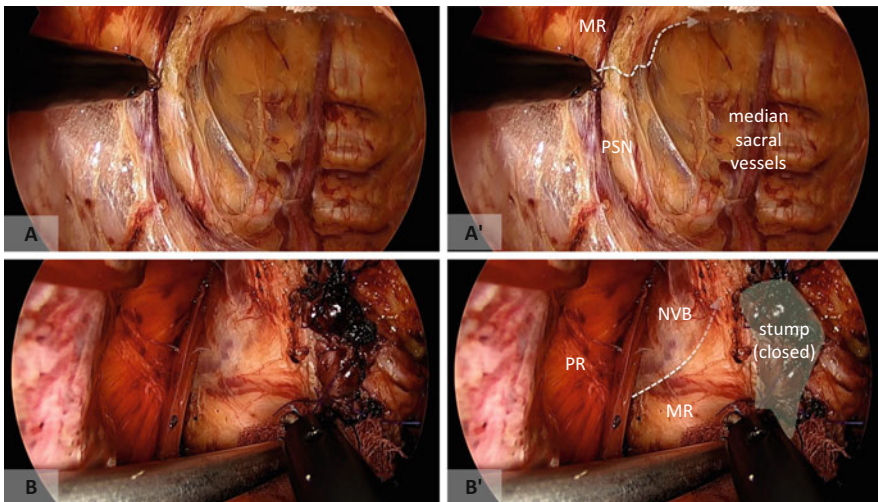
**Fig. 9.9** Posterior dissection (TAMIS-ISR). (a) The rectal dissection is usually initiated at the posterior side. (b) The mesorectal plane is easy to identify at the posterior side. (c) Dissection tends to go behind the hypogastric nerves (HGN). MR mesorectum, PR puborectal muscle



**Fig. 9.10** Median sagittal view of the anorectal region on magnetic resonance imaging. As indicated by the red dotted line, posterior dissection tends to migrate into the mesorectum (or posterior rectal wall) because of the sharp angle of the dissection line made by the puborectal sling. The white dotted line should be followed

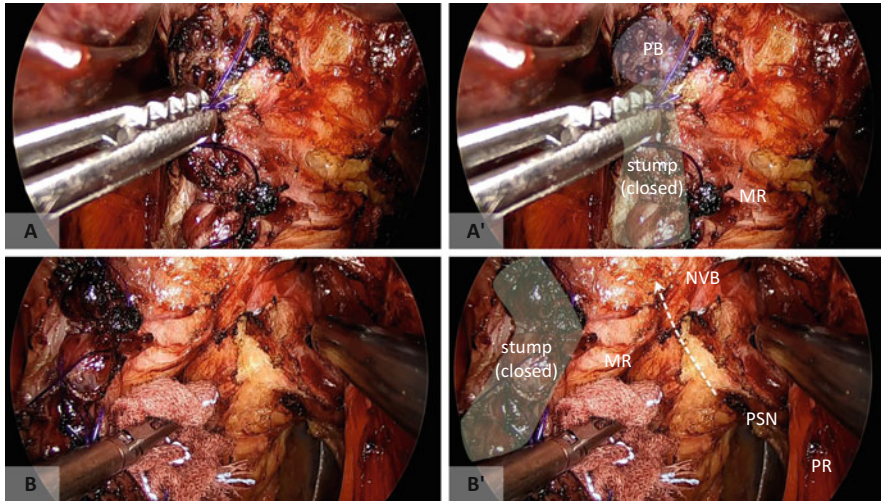


**Fig. 9.11** (a, b) Identification and preservation of the left pelvic autonomic nerves. The pelvic splanchnic nerves (*PSN*) can be identified at the posterolateral side and dissected from the mesorectum (*MR*). *White broken lines* indicate mesorectal dissection line



**Fig. 9.12** (a, b) Identification and preservation of the right pelvic autonomic nerves. The pelvic splanchnic nerves (*PSN*) are identified as was done on the left side. When dissection is preceded anteriorly, the lateral aspect of the neurovascular bundle (*NVB*) is identified. Imaginary dissection line is indicated in *white broken lines*

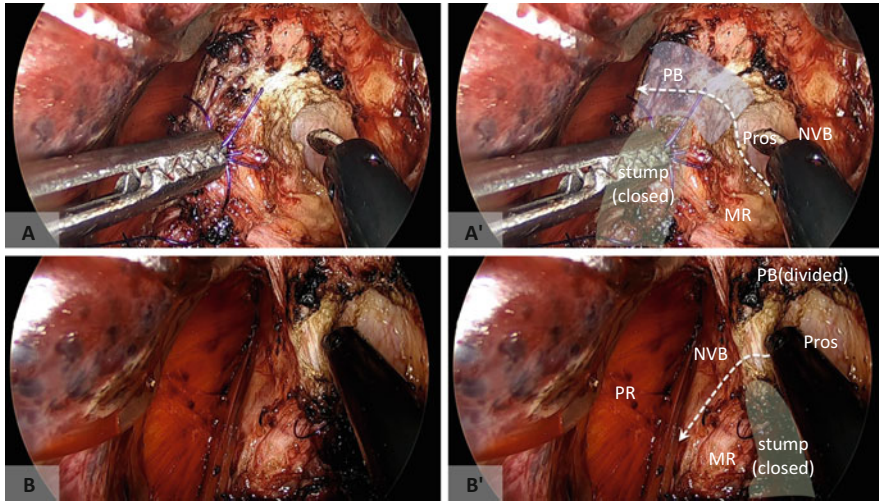
behind the layer of hypogastric nerves, care should be taken not to injure them. After sufficient mobilization of the posterior side, identification and preservation of pelvic autonomic nerves are crucial at the posterior-lateral side (Figs. 9.11a and 9.12a). The dissection between the mesorectum and pelvic autonomic nerves



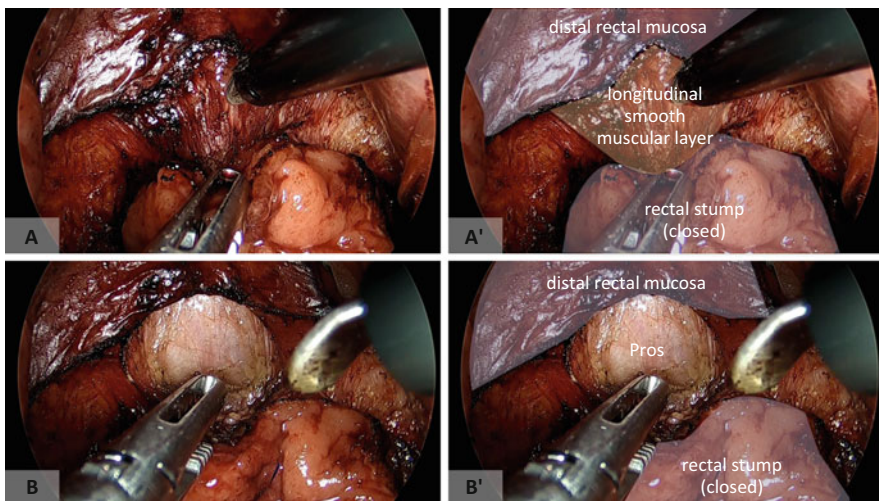
**Fig. 9.13** Anterior dissection in TAMIS-ISR. (a) The anterior dissection plane is usually obscure because of the perineal body (*PB*). (b) Dissection from the lateral to anterior aspects while identifying the pelvic autonomic nervous system (*white broken line*) might be useful for identifying the appropriate anterior dissection plane. *MR* mesorectum, *PSN* pelvic splanchnic nerve, *NVB* neurovascular bundle, *PR* puborectal muscle

progresses laterally, and it will help in the identification of the neurovascular bundle running alongside the prostate and vagina as well as facilitate the dissection of the anterior side (Figs. 9.11b and 9.12b).

When the tumor is low lying, rectal dissection starts from the intersphincteric plane, and the dissection layer of the anterior side is usually obscure because of the perineal body (rectourethral) muscle (Figs. 9.13 and 9.14). On the other hand, when the level of the distal rectal incision is above the perineal body, it is relatively easy to identify the proper anterior dissection plane (Fig. 9.15). Once the proper dissection plane is established between the anterior side of the rectum and the prostate or vagina, maintaining this plane is relatively easy under good exposure and close endoscopic view (Fig. 9.16). Finally, lateral mesorectal dissection is performed by connecting the dissection layer of the anterior and posterior sides. It should be kept in mind that there is an easily dissectible layer outside of the autonomic nervous system (Fig. 9.17). The appearance of the operative field after TAMIS dissection is shown in Figs. 9.18 and 9.19. Anteriorly, the peritoneum at the cul-de-sac may be opened to enter into the peritoneal cavity (Fig. 9.20). However, premature entry into the peritoneal cavity might disturb exposure of the operative field.

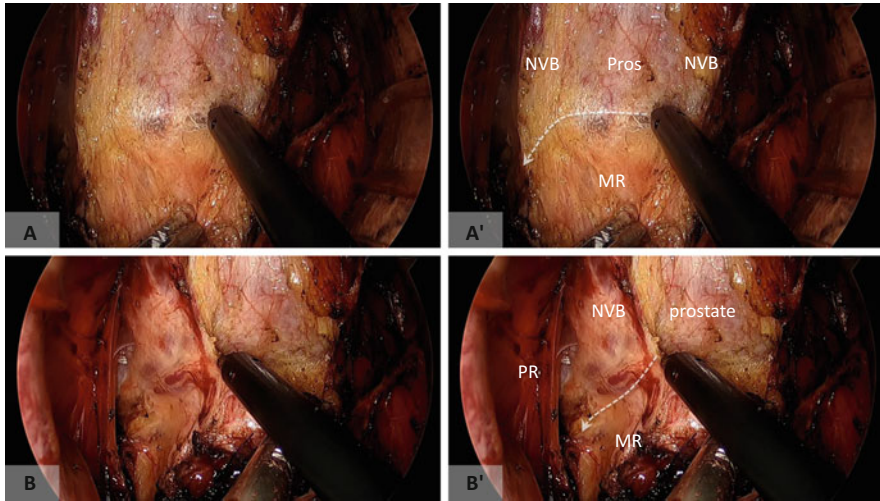


**Fig. 9.14** Anterior dissection in TAMIS-ISR. (a) Identification of the prostate (*Pros*) from the left side facilitates division of the perineal body (*PB*; white broken line) (b). Division of the perineal body is followed by dissection between the mesorectum (*MR*) and right *NVB* (white broken line)

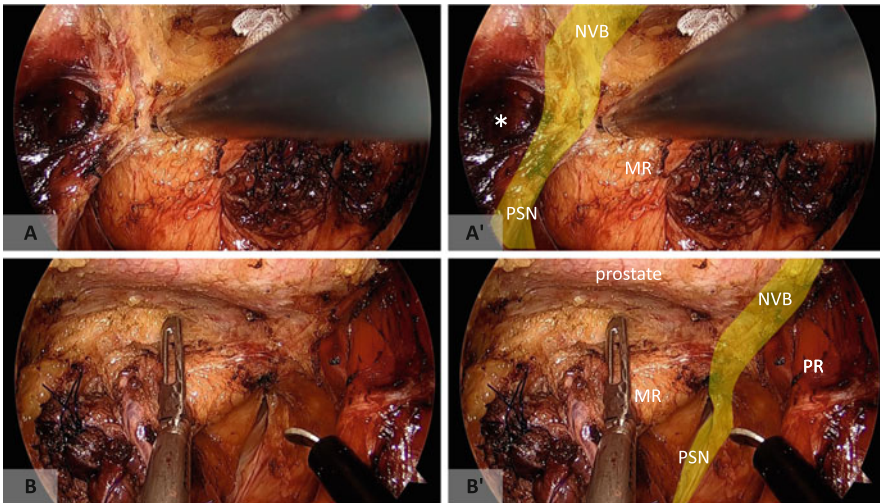


**Fig. 9.15** Anterior dissection (optional). (a, b) When the distal incision is made above the level of the perineal body, an appropriate anterior dissection plane behind the prostate (*Pros*) is easy to identify

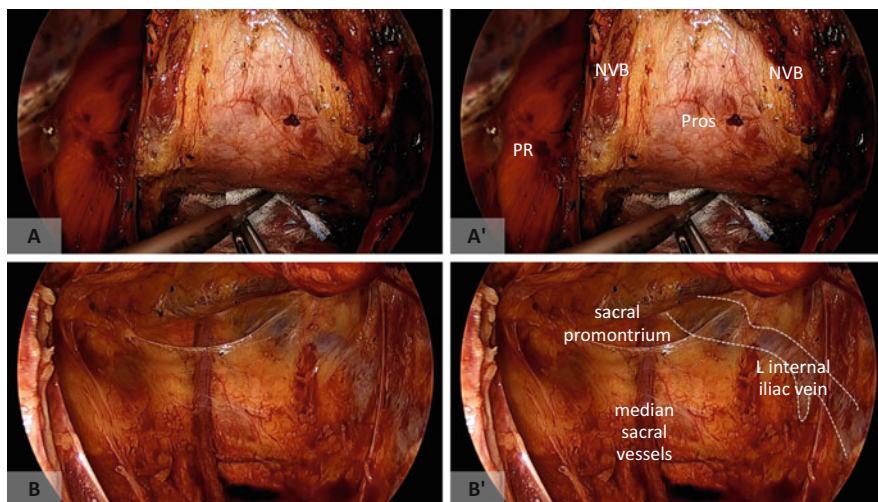




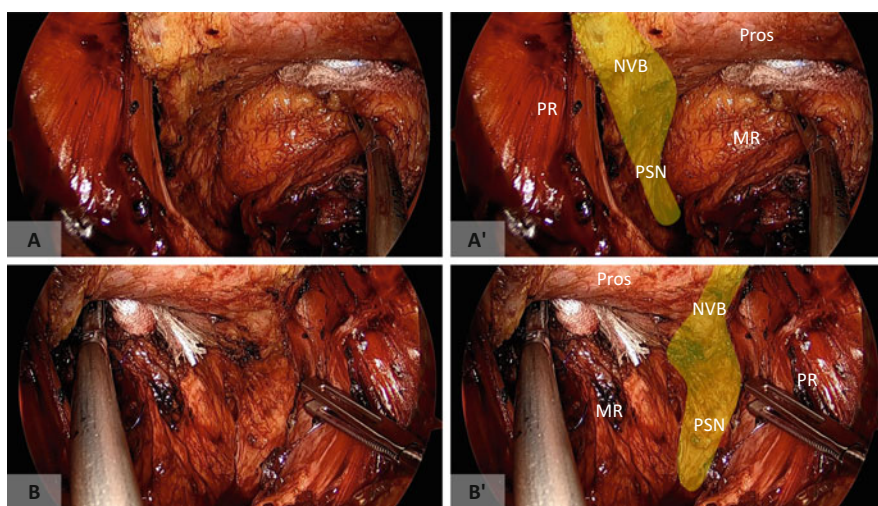
**Fig. 9.16** Anterior dissection. (a) Once the appropriate dissection plane is identified, it is easy to dissect the mesorectum (*MR*) from the prostate (*Pros*) and neurovascular bundle (*NVB*) bilaterally (b). The small vessels branching from the right *NVB* are divided. Imaginary dissection lines are indicated in *white broken lines*



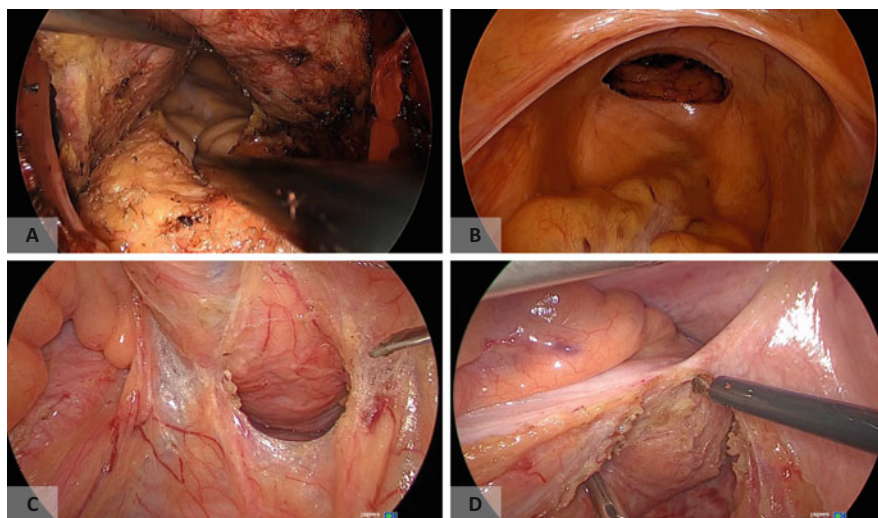
**Fig. 9.17** The anterior dissection plane is connected with that from the posterior side on the right (a) and left sides (b). Note that the dissection line easily goes outside of the pelvic autonomic nerves (*white asterisk in a'*)



**Fig. 9.18** The operative field after completion of TAMIS dissection. (a) Anterior side. (b) Posterior side. *NVB* neurovascular bundle, *PR* puborectal muscle, *Pros* prostate



**Fig. 9.19** The operative field after completion of TAMIS dissection. (a) Right side. (b) Left side. The pelvic splanchnic nerves (*PSN*) bilaterally and neurovascular bundles (*NVB*) are preserved. *Pros* prostate, *MR* mesorectum, *PR* puborectal muscle



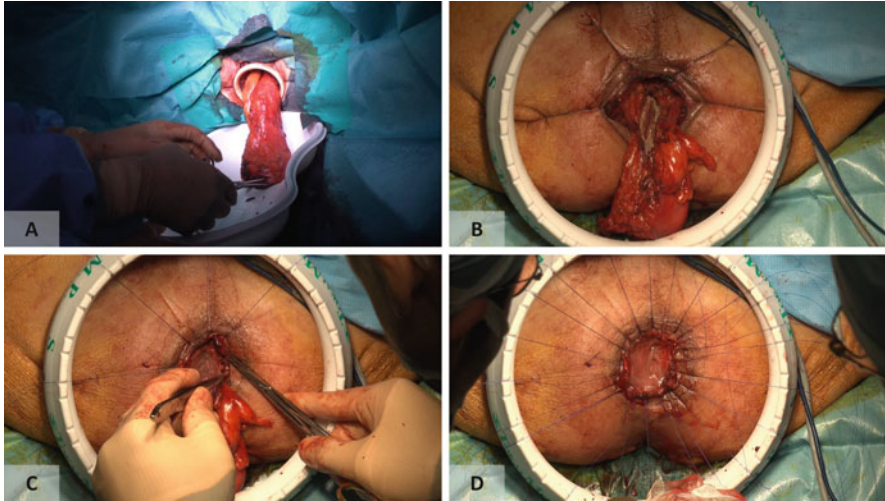
**Fig. 9.20** (a) The abdominal cavity can be entered by opening the peritoneum of the cul-de-sac. (b–d) Laparoscopic view of the anterior side (b), posterior side (c), and right side (d)

### 9.3.3 Laparoscopic Approach

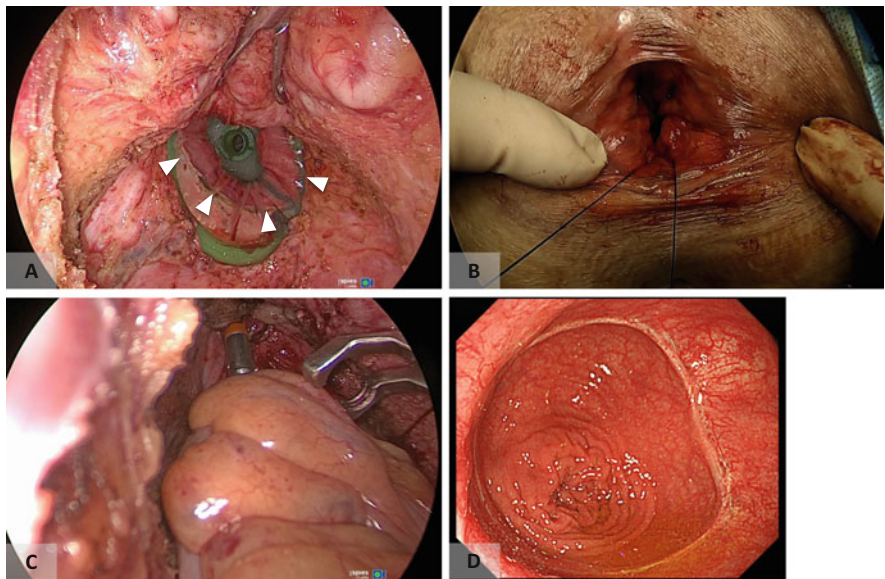
At present, an appropriate instrument with the optimal length and angle is not available for division of the inferior mesenteric vessels and mobilization of the left colon (and splenic flexure, if necessary) through the TAMIS approach. Therefore, these steps are usually performed laparoscopically. Because these steps are technically easy, the number of laparoscopic ports may be reduced, which contributes to better cosmesis. The resected specimen is usually extracted transanally (Fig. 9.21a) if possible, which can spare patients from the creation of an abdominal specimen extraction site. In patients with bulky rectal mesentery or a bulky tumor, transabdominal specimen extraction might be required [8].

### 9.3.4 Anastomosis

Anastomotic mode depends on the level of distal rectal incision. When possible, hand-sewn colo-anal anastomosis (Fig. 9.21b–d) is performed under direct vision. When the distal end is located more proximally, a purse-string suture is made in both proximal and distal ends of the bowel, and single-stapled anastomosis using a circular stapler is done (Fig. 9.22) [7]. Stapled anastomosis is a technically demanding procedure in the TAMIS approach. At present, there is no circular stapler commercially available that is specifically designed for this type of anastomosis.



**Fig. 9.21** (a, b) The resected specimen is extracted transanally. (c, d) The colo-anal anastomosis is fashioned using interrupted hand-sewn sutures

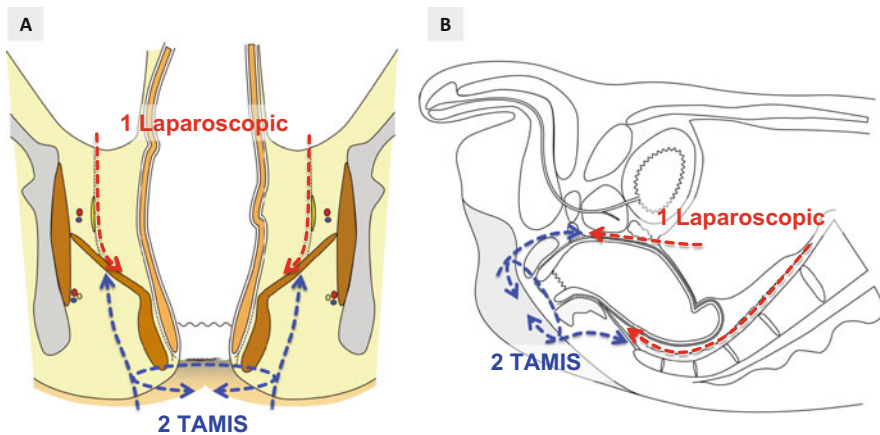


**Fig. 9.22** Stapled anastomosis (optional). (a) The distal rectal stump is indicated by white arrowheads. (b) A full-thickness purse-string suture is made around the distal rectal stump. (c) The anastomosis is made using the single-stapling technique. (d) Endoscopic view of the anastomosis 3 months after the operation

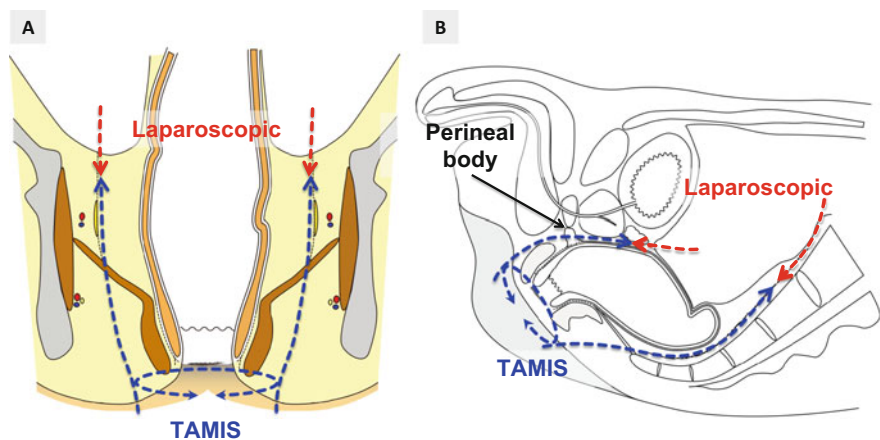
### 9.3.5 Abdominoperineal Resection

The conventional perineal phase of APR is usually performed under direct vision, which is associated with poor exposure of the surgical field, especially on the anterior side. This area is often dissected blindly, which might threaten the oncological margin or damage the autonomic nervous system [9, 10]. Therefore, APR is a good option for the transanal (transperineal) endoscopic approach, because it offers excellent exposure of the surgical field.

This procedure can be done with the assistance of laparoscopy following the laparoscopic approach (Fig. 9.23) or without it (Fig. 9.24). We feel that the



**Fig. 9.23** Operative schema of TAMIS-abdominoperineal resection (APR). (a) Coronal view. (b) Sagittal view



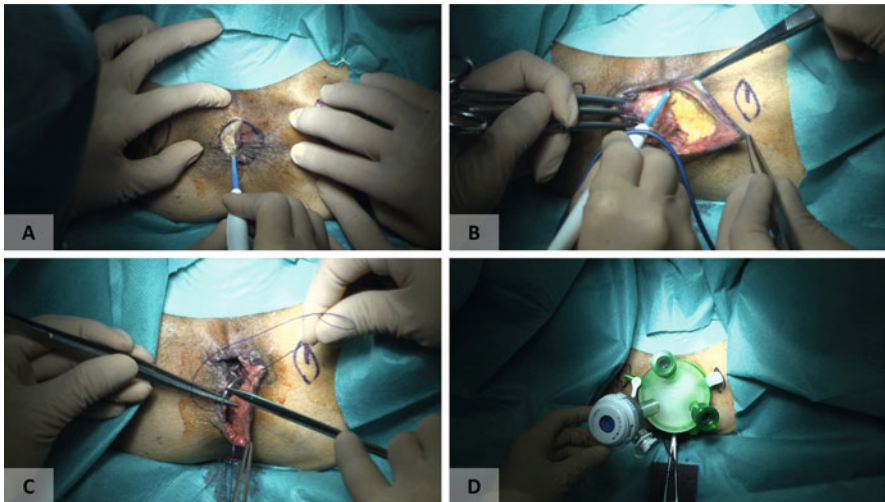
**Fig. 9.24** Operative schema of TAMIS-APR (perineal first approach). (a) Coronal view. (b) Sagittal view

upfront laparoscopic approach is more feasible in the early stages of the learning curve.

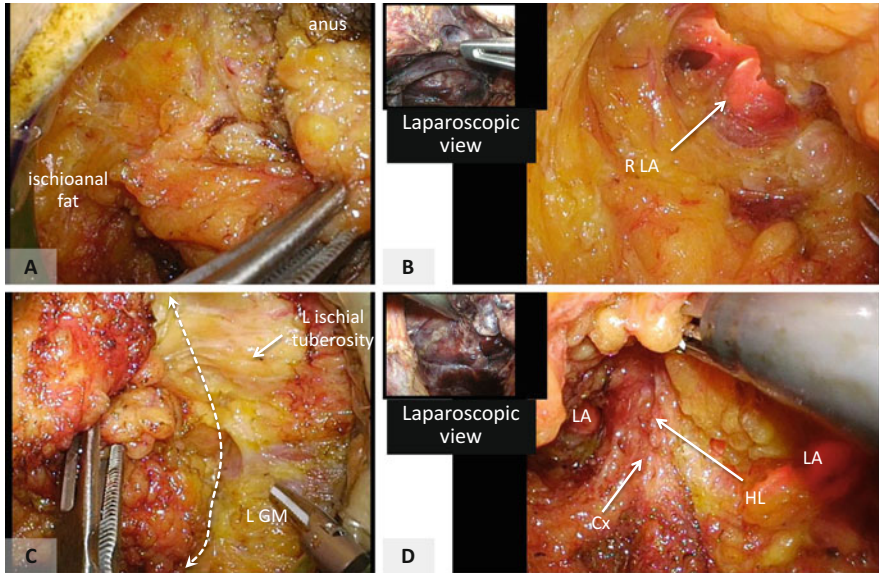
### 9.3.6 Upfront Laparoscopic Approach

Division of the inferior mesenteric vessels and mobilization of the left colon and upper rectum are performed laparoscopically. Laparoscopic rectal mobilization is continued as deep as possible; however, too much dissection between the mesorectum and levator ani muscle should be avoided because it may threaten the circumferential resection margin [11], especially when tumor invasion of the levator ani muscle is suspected.

The anus is closed securely and a perianal skin incision is made. Subcutaneous dissection is performed to make space for GelPOINT mini device placement. Tightening of the purse-string suture around the anus helps to fix the inner portion of GelPOINT (Fig. 9.25). Pneumoperirectum is established and ischioanal



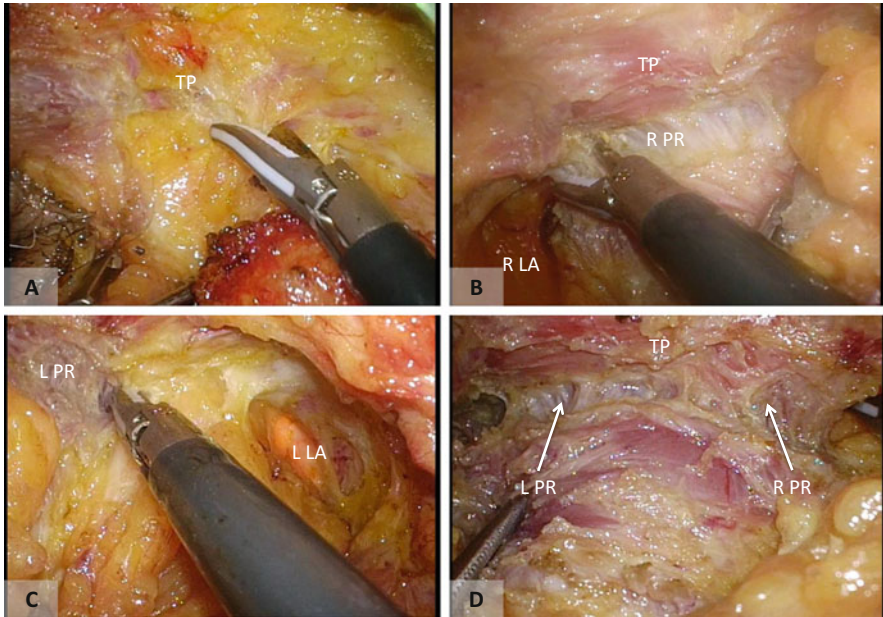
**Fig. 9.25** (a) The perianal skin incision is made around the tightly closed anus. (b) The subcutaneous fat is divided to make space for GelPOINT placement. (c, d) A purse-string suture around the wound facilitates fixation of GelPOINT



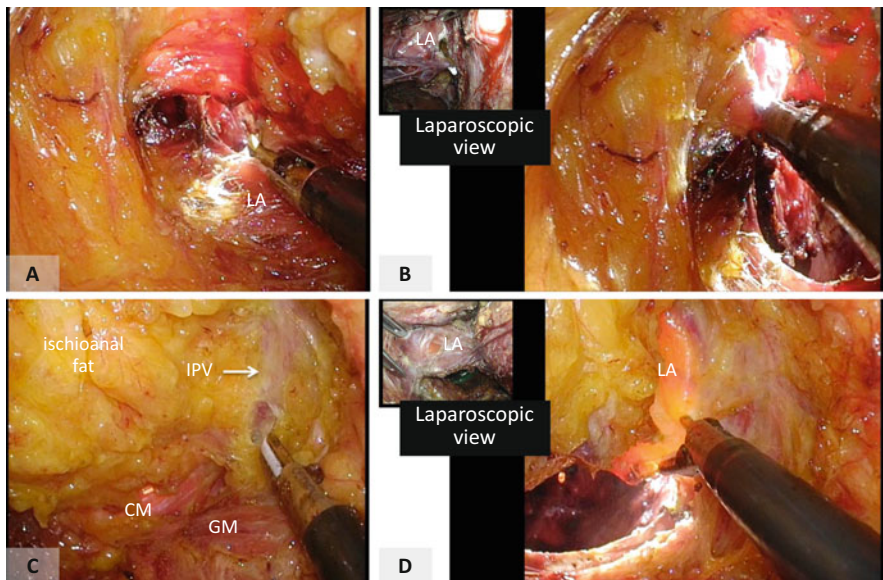
**Fig. 9.26** (a) The anus is retracted to the left side and the right ischioanal fossa is dissected. (b) The right levator ani muscle (LA) is exposed. The laparoscopic light can be transilluminated through the LA. Left upper box: concurrent laparoscopic view. (c) Extended dissection of the left ischioanal fossa. Dissection is done along the left gluteus maximus muscle (GM) and ischial tuberosity (white dotted line). (d) The hiatal ligament (HL) is identified at the posterior side. Cx coccyx

dissection is initiated. Fat tissue of the ischioanal fossa is divided using electrocautery or ultrasonic shears. Dissection of the ischioanal fossa at the posterior-lateral side is done first until the levator ani muscle is widely exposed. When laparoscopic rectal dissection is adequate, the light of the laparoscope can transilluminate the levator ani muscle. The tip of the coccyx is identified and care should be taken not to dissect behind it. Several different types of dissection plane including extralevator or ischioanal [11] can be followed depending on the tumor status (Fig. 9.26). Anteriorly, the dissection is performed just behind the transverse perineal muscle, and both sides of the puborectal sling are identified (Fig. 9.27).

Next, the levator ani muscle is divided circumferentially, and the space that has already been dissected laparoscopically is entered (Fig. 9.28). Anteriorly, both sides

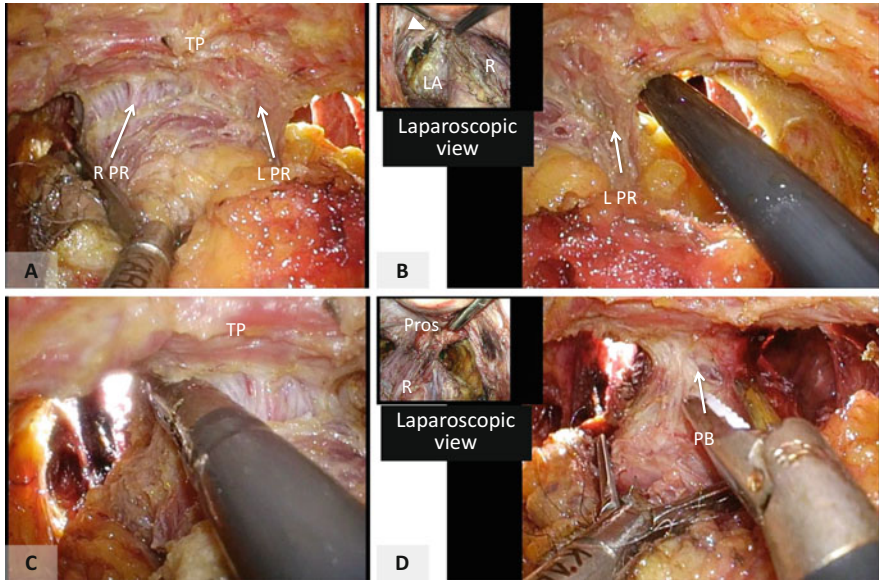


**Fig. 9.27** (a) Anterior dissection is performed just behind TP. (b–d) The puborectal muscle (PR) is exposed at the right (b), left (c), and anterior side (d). LA levator ani muscle



**Fig. 9.28** (a) The levator ani muscle (LA) is divided at the right side and dissection is connected with that from the laparoscopic procedure. (b) Laparoscopic assistance (left upper box) is helpful for identifying the appropriate dissection line. (c) The ischioanal fat has been completely dissected on the left side. (d) Division of the levator muscle on the left side. IPV internal pudendal vessels, CM coccygeal muscle, GM gluteus maximus muscle



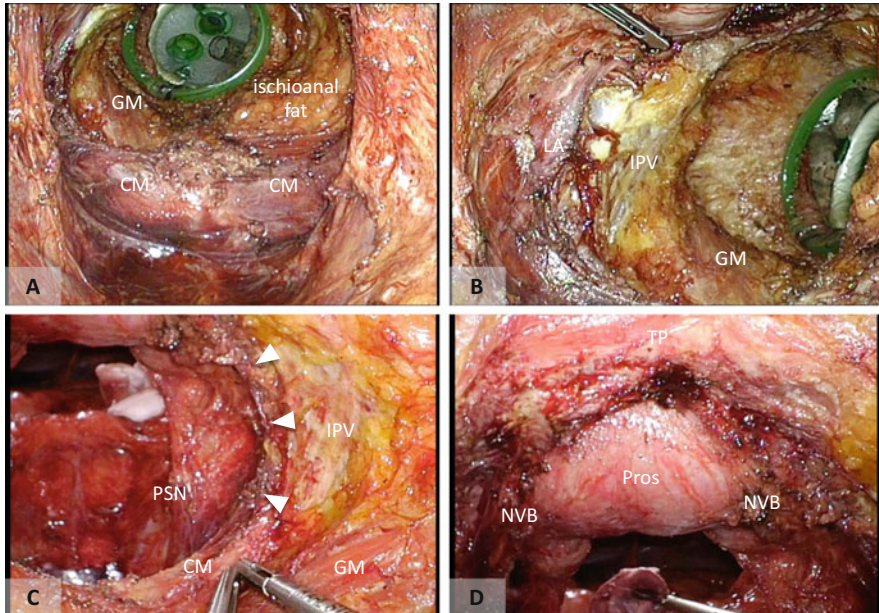


**Fig. 9.29** (a) Dissection of the anterior side. (b) The left side of the puborectal sling is divided at the appropriate level with laparoscopic assistance (*left upper box*). (c) Division of the right side of the puborectal sling. (d) Finally, the perineal body (*PB*) is divided. *TP* transverse perineal muscle, *LA* levator ani muscle, *R* rectum, *Pros* prostate

of the puborectal sling are divided at an appropriate level (Fig. 9.29). Laparoscopic assistance is helpful for better recognition of surgical anatomy. Care should be taken not to injure the neurovascular bundle or migrate into the anterior rectal wall. Lastly, the perineal body is divided and the specimen is extracted transanally. The transanal view of the surgical field is shown in Fig. 9.30.

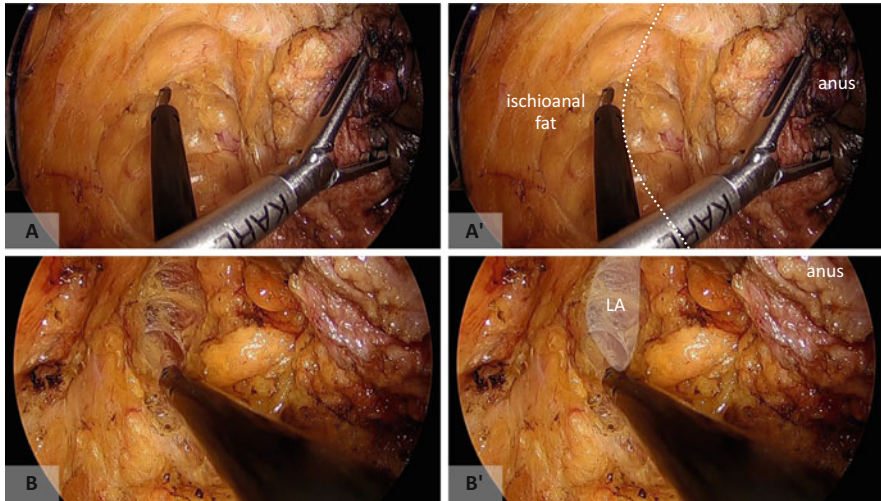
### 9.3.7 Upfront Perineal Approach

The procedure in the upfront perineal approach is the same from the skin incision to dissection of the ischioanal fossa as described above (Figs. 9.31, 9.32, and 9.33). Division of the levator ani muscle is initiated at the level of the coccygeal tip, and the posterior mesorectal plane is entered just like in the TAMIS-TME/ISR procedure (Fig. 9.34). Posterior dissection is continued until the sacral promontory is reached and then dissection is extended bilaterally. The pelvic autonomic nerves

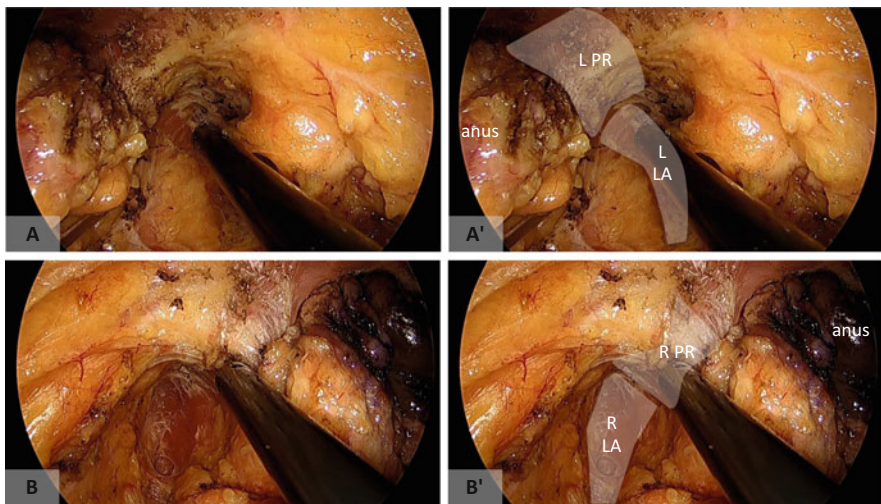


**Fig. 9.30** Operative field after specimen extraction. (a, b) Laparoscopic view. (c, d) TAMIS view. Note that the fat tissue of the left ischioanal fossa had been completely dissected. *MGM* major gluteal muscle, *CM* coccygeal muscle, *LA* levator ani muscle, *IPV* inferior pudendal muscle, *PSN* pelvic splanchnic nerve, *Pros* prostate, *NVB* neurovascular bundle, *TP* transverse perineal muscle

are identified bilaterally, and dissection between the mesorectum and the pelvic autonomic nervous system is extended anteriorly (Figs. 9.35 and 9.36). It is important to recognize the continuity of the pelvic autonomic nervous system from the pelvic splanchnic nerves to the neurovascular bundle. Anteriorly, both sides of the sling of puborectal muscle are divided at the level just behind the transverse perineal muscle, and the division line is joined with that from the posterior-lateral side to expose the lateral aspect of the neurovascular bundle (Figs. 9.37 and 9.38). The perineal body is divided, with special care taken not to injure the urethra or migrate into the rectal wall (Fig. 9.39a, b). Once the inferior aspect of the prostate is identified, it is relatively easy to find the appropriate

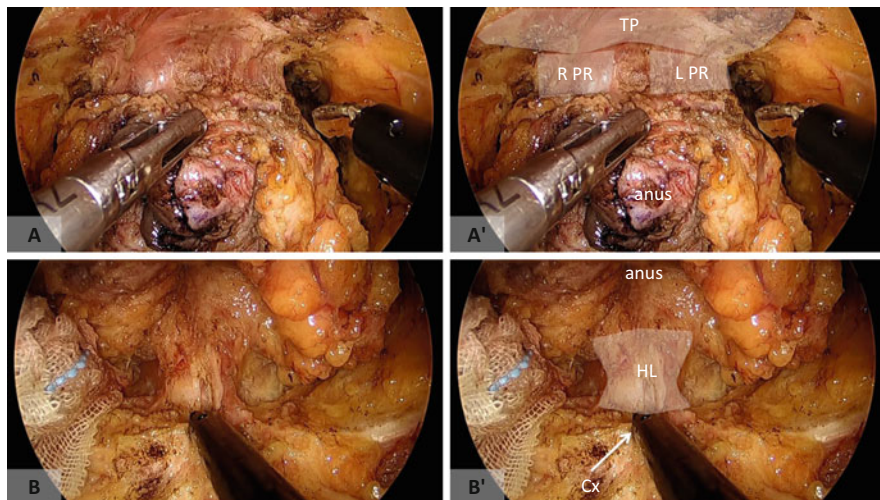


**Fig. 9.31** (a) The anus is retracted to the left and ischioanal fat is dissected. (b) The right levator ani muscle (*LA*) is exposed

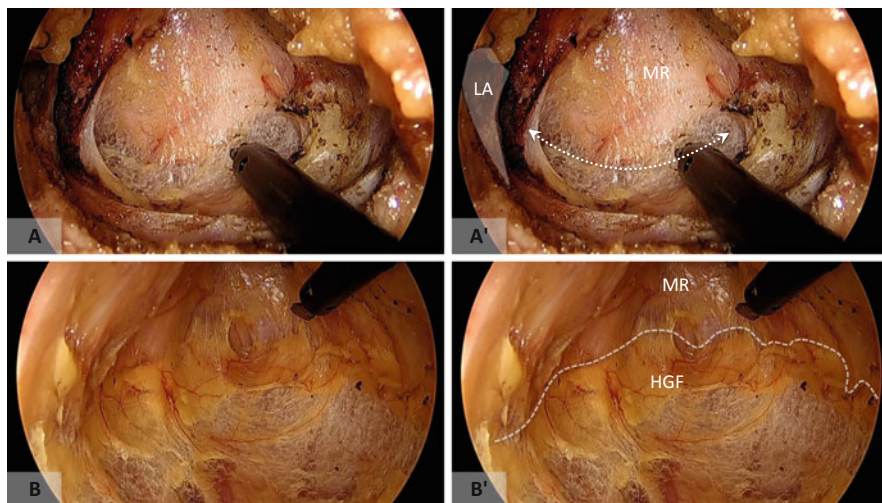


**Fig. 9.32** Dissection of the anterolateral side. Both sides of the levator ani muscle (*LA*) and puborectal sling (*PR*) were exposed. (a) Left side. (b) Right side

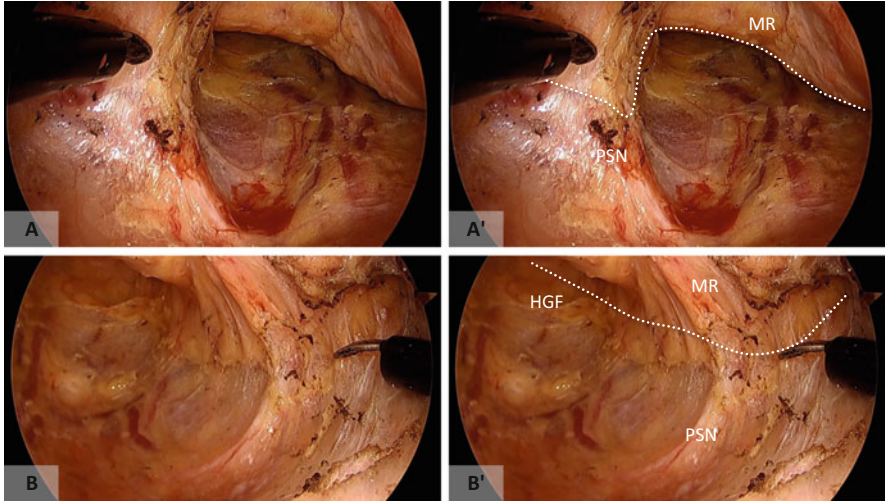
dissection plane (Figs. 9.39c, 9.40, and 9.41). The following procedure is the same as that described in the TAMIS-TME/ISR section. The specimen is extracted transanally and a sigmoid colostomy is made. Figure 9.42 is the transanal view of the operative field.



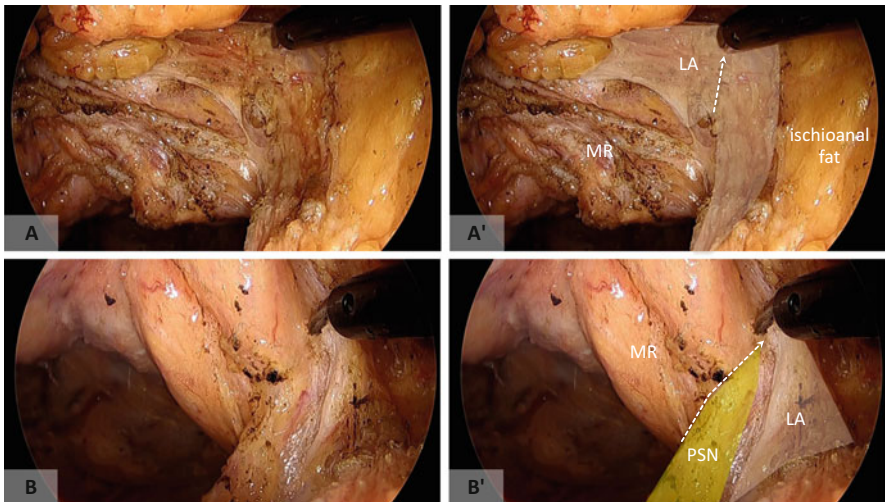
**Fig. 9.33** (a) Anterior dissection is performed behind the transverse perineal muscle (*TP*). Both sides of the puborectal sling are exposed (*PR*). (b) Posteriorly, the hiatal ligament (*HL*) is divided at the level of the tip of the coccyx (*Cx*)



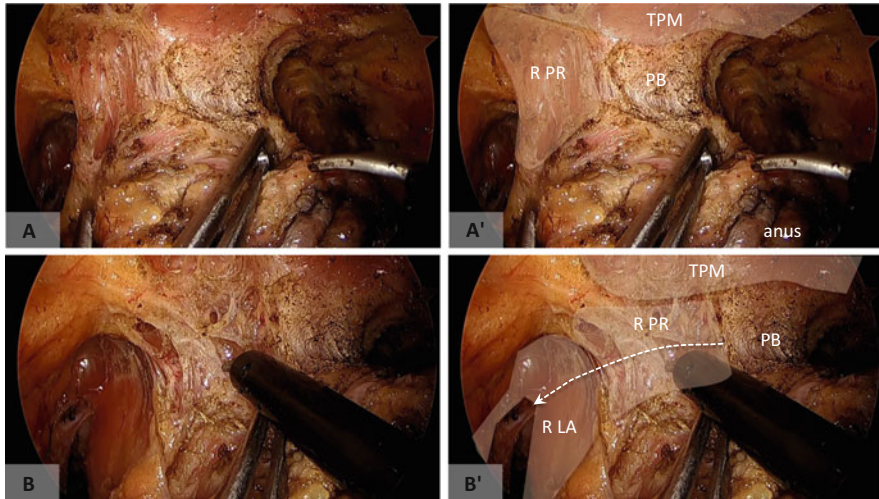
**Fig. 9.34** (a) The levator ani muscle (*LA*) is divided and the mesorectal plane is entered. (b) Dissection tends to go deep behind the layer that contains the hypogastric nerve (*HGF*). Imaginary dissection lines are indicated with *white broken line*. *MR* mesorectum



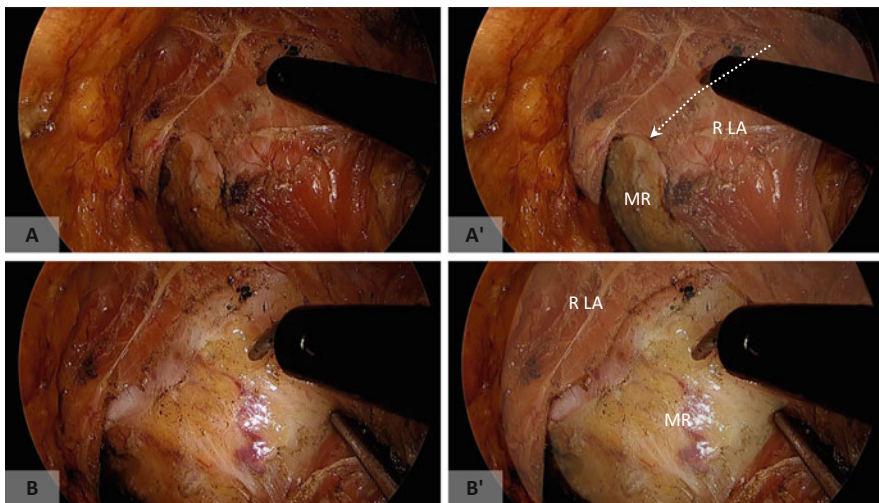
**Fig. 9.35** At the posterolateral side, the pelvic splanchnic nerves are identified bilaterally and carefully preserved. (a) *Right side.* (b) *Left side.* MR mesorectum, HGF hypogastric fascia



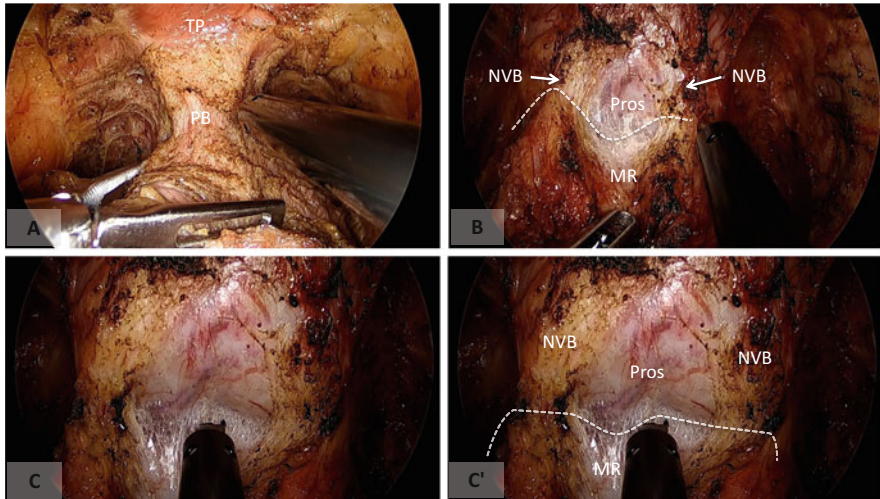
**Fig. 9.36** (a) Division of the left levator ani muscle (LA) is continued to the anterior side (white dotted line). (b) At the lateral side, the pelvic splanchnic nerve (PSN) was carefully dissected from the mesorectum (MR). Note that PSN is just behind the LA at the lateral side



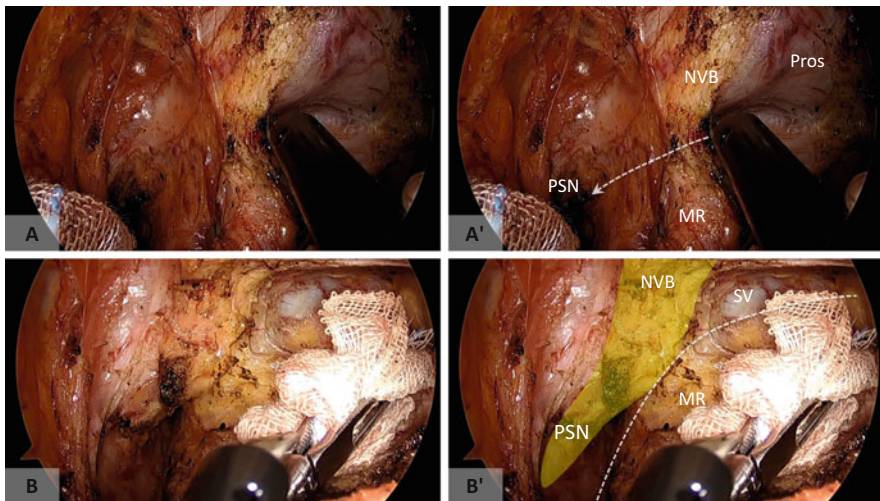
**Fig. 9.37** At the anterolateral side, the division of the puborectal muscle (*PR*) and levator ani muscle (*LA*) is initiated from the level of the perineal body (*PB*) (a) and joined with the division line from the posterolateral side (b)



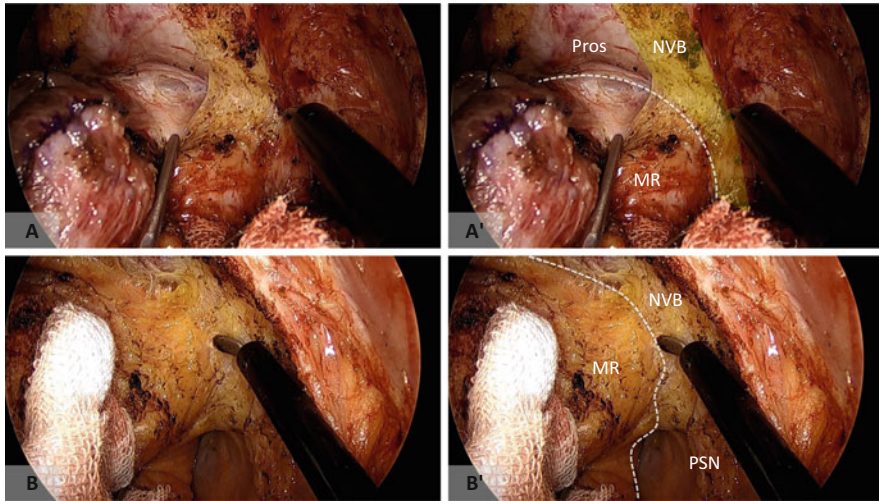
**Fig. 9.38** When the levator ani muscle (*LA*) has been divided (a), the mesorectal fascia (*MR*) is exposed (b)



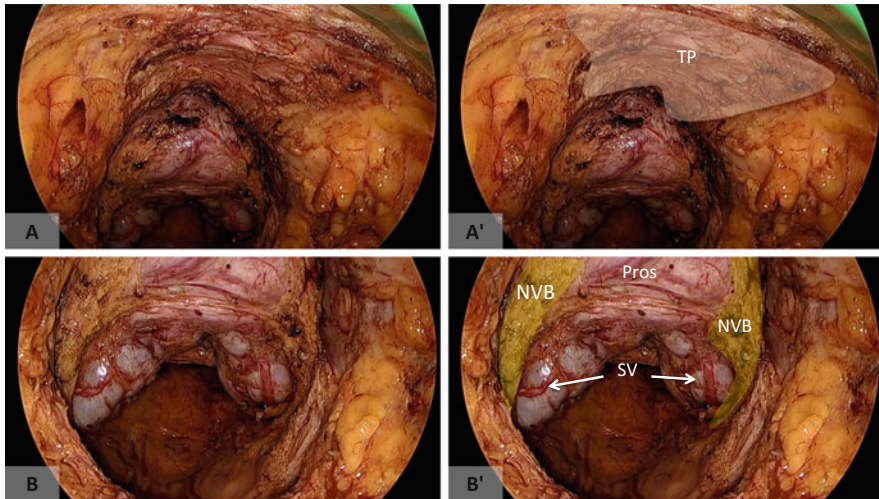
**Fig. 9.39** (a) Following complete division of the levator and puborectal muscles, the perineal body is divided. (b) When division of the perineal body is completed at the appropriate level, the apex of the prostate (*Pros*) can be identified. (c) Once the proper dissection plane between the prostate and mesorectum (*MR*) has been identified, it is easy to maintain the anterior dissection plane. *NVB* neurovascular bundle, *TP* transverse perineal muscle



**Fig. 9.40** Anterior dissection is continued to the right side (a) and it is connected with that from the posterolateral side (b). Note the continuity of pelvic autonomic nerves (*PSN* and *NVB*). The white broken line indicates the boundary of the mesorectum (*MR*). *SV* seminal vesicle



**Fig. 9.41** Anterior dissection is continued to the left side (a), and it is connected with that from the posterolateral side (b). Note the continuity of pelvic autonomic nerves (*PSN* and *NVB*). The white broken line indicates the boundary of the mesorectum (*MR*). *Pros* prostate



**Fig. 9.42** (a, b) Transperineal view of the operative field after specimen extraction. *TP* transverse perineal muscle, *NVB* neurovascular bundle, *Pros* prostate, *SV* seminal vesicle



## References

1. Targarona EM, Balague C, Pernas JC, et al. Can we predict immediate outcome after laparoscopic rectal surgery? Multivariate analysis of clinical, anatomic, and pathologic features after 3-dimensional reconstruction of the pelvic anatomy. *Ann Surg.* 2008;247:642–9.
2. Sylla P, Rattner DW, Delgado S, Lacy AM. NOTES transanal rectal cancer resection using transanal endoscopic microsurgery and laparoscopic assistance. *Surg Endosc.* 2010;24:1205–10.
3. Tuech JJ, Bridoux V, Kianifard B, et al. Natural orifice total mesorectal excision using transanal port and laparoscopic assistance. *Eur J Surg Oncol.* 2011;37:334–5.
4. Atallah S, Martin-Perez B, Albert M, et al. Transanal minimally invasive surgery for total mesorectal excision (TAMIS-TME): results and experience with the first 20 patients undergoing curative-intent rectal cancer surgery at a single institution. *Tech Coloproctol.* 2014;18:473–80.
5. Cahill RA. Single port surgery for rectal cancer-going up or down? *Dis Colon Rectum.* 2013;56:1199–200.
6. Heald RJ. A new solution to some old problems: transanal TME. *Tech Coloproctol.* 2013;17:257–8.
7. Knol JJ, D'Hondt M, Souverijns G, Heald B, Vangertruyden G. Transanal endoscopic total mesorectal excision: technical aspects of approaching the mesorectal plane from below—a preliminary report. *Tech Coloproctol.* 2015;19(4):221–9.
8. Atallah S, Martin-Perez B, Pinan J, et al. Robotic transanal total mesorectal excision: a pilot study. *Tech Coloproctol.* 2014;18:1047–53.
9. Stelzner S, Holm T, Moran BJ, et al. Deep pelvic anatomy revisited for a description of crucial steps in extralevator abdominoperineal excision for rectal cancer. *Dis Colon Rectum.* 2011;54:947–57.
10. Holm T. Controversies in abdominoperineal excision. *Surg Oncol Clin N Am.* 2014;23:93–111.
11. Holm T, Ljung A, Haggmark T, Jurell G, Lagergren J. Extended abdominoperineal resection with gluteus maximus flap reconstruction of the pelvic floor for rectal cancer. *Br J Surg.* 2007;94:232–8.

Akinari Nomura, Yasuo Koga, Yukie Yoda, and Hirokazu Noshiro

---

## Abstract

Surgical robotics is particularly beneficial in surgery for lower rectal cancer, which is mainly performed deep within the narrow pelvic cavity. Since optimal tension can be maintained between tissues to clearly expose the dissectable layer using this modality, destruction of the mesorectum surrounding rectal cancer and lymph nodes can be avoided. Furthermore, robot-assisted surgery allows total mesorectal excision to be performed, ensuring preservation of the autonomic nervous system responsible for urinary and sexual functions. Another advantage of robot-assisted surgery is that suture and ligation can be performed easily deep in the narrow space. With the single-stapling technique, transection of the rectum and anastomosis can be performed in the deep narrow pelvis where the double-stapling technique would normally be technically challenging, thereby possibly avoiding unnecessary intersphincteric resection.

---

## Keywords

Robotic surgery • Rectal cancer • Dissectable layer • Total mesorectal excision • Low anterior resection • Intersphincteric resection • Single-stapling technique

---

## 10.1 Introduction

Total mesorectal excision (TME) is the standard surgical procedure for lower rectal cancer [1–3], and the introduction of laparoscopy, which enables the anatomical dissection of deep narrow spaces using a magnified frontal view, has revolutionized such surgery [4–6]. Moreover, the advent of robot-assisted surgery—with its advantageous features including stable three-dimensional high-definition vision,

---

A. Nomura (✉) • Y. Koga • Y. Yoda • H. Noshiro  
Department of Surgery, Faculty of Medicine, Saga University, Saga City, Saga, Japan  
e-mail: [cpa1nixa@kuhp.kyoto-u.ac.jp](mailto:cpa1nixa@kuhp.kyoto-u.ac.jp)

manipulation at will through use of the master-slave system, hand-like movements using surgical instruments with seven articulations, and minute manipulation through motion scaling and tremor filtering—has allowed for delicate manipulations of minute structures within the narrow spaces of the abdominal and pelvic cavities and is expected to improve the quality of surgery for lower rectal cancer.

This chapter describes robot-assisted autonomic nerve-preserving TME for lower rectal cancer.

---

## 10.2 Indications for Robot-Assisted Surgery

Endoscopic surgery is indicated for patients regardless of previous laparotomy and tumor location, except those with marked tumor invasion into adjacent organs, severe intestinal obstruction, or cardiopulmonary dysfunction. Robot-assisted surgery, however, is contraindicated in those patients with aortic or iliac aneurysm, due to concerns over possible aneurysmal rupture through contact with the robotic device. As the major advantages of robot-assisted surgery are the ability to observe and manipulate tissues minutely in deep narrow spaces, we therefore apply robot-assisted surgery for colorectal surgery only in patients with lower rectal cancer requiring TME.

---

## 10.3 Positioning

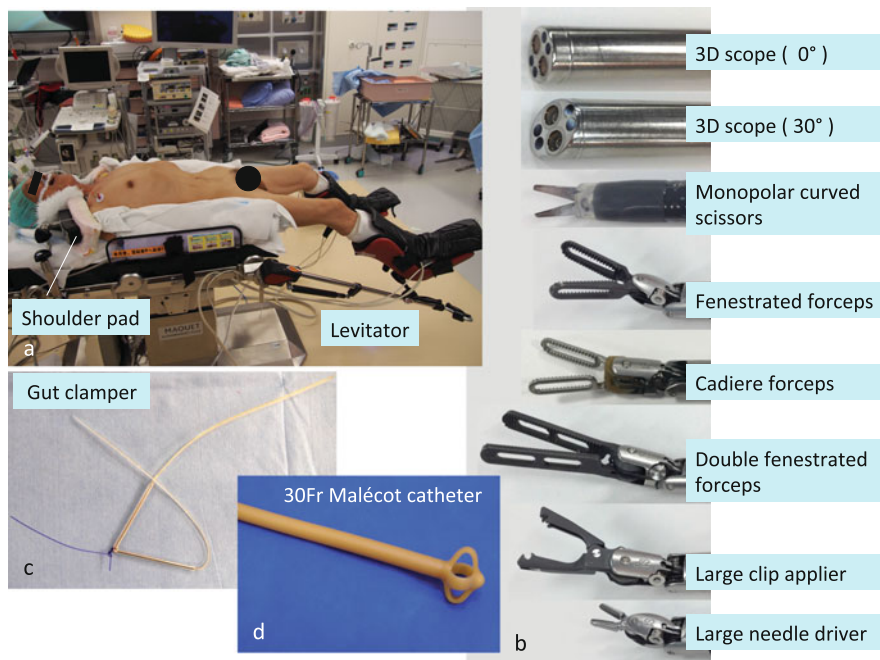
The patient is placed in a modified lithotomy position using a levitator with both arms fixed to the body trunk. Shoulder pads are used to prevent the patient from slipping downward (Fig. 10.1a).

---

## 10.4 Instruments

The da Vinci® Si surgical system (Intuitive Surgical Inc., Sunnyvale, CA, USA) is used for elaborate operations. A 12-mm camera port, 12-mm port, and four 8-mm da Vinci ports are used. The robotic instruments used include a 30-degree rigid endoscope, a straight rigid endoscope, a monopolar curved scissors, a fenestrated forceps, a Cadere forceps, a double fenestrated forceps, a large clip applier, and a large needle driver (Fig. 10.1b). Additionally, an intestinal forceps with a ratchet and needle driver are used by the assistant surgeon.

A VIO®300D electrosurgical generator (ERBE Inc., Tübingen, Germany) is used. For monopolar applications, dry cut (50 W, effect 4) and forced coagulation (50 W, effect 3) are used; for bipolar applications, soft coagulation (60 W, effect 6) is used. A monopolar curved scissors and fenestrated forceps are connected to the monopolar and bipolar power sources, respectively.



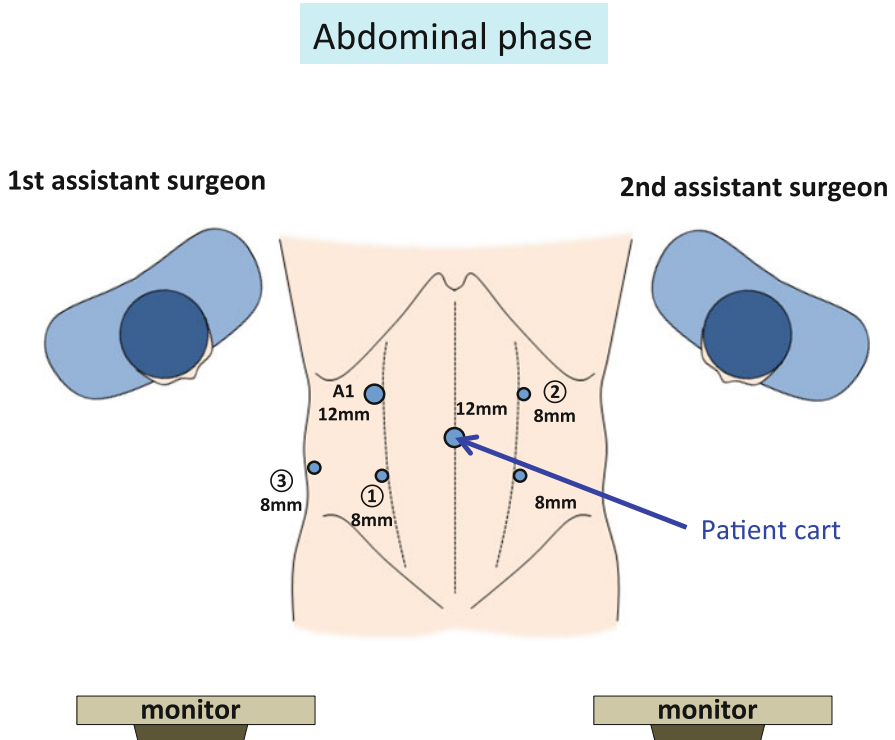
**Fig. 10.1** Positioning and instruments used in robot-assisted total mesorectal excision. The patient is placed in a modified lithotomy position using a levitator with both arms fixed to the body trunk. Shoulder pads are used to prevent the patient from slipping downward (a). The instruments used for robot-assisted total mesorectal excision (b). A gut clammer is used to occlude the rectal lumen before irrigating and transecting the rectum (c). A 30-Fr Malécot catheter is inserted transanally to decompress the intraluminal pressure around the anastomosis (d)

Transection of the rectum and anastomosis are performed using a gut clammer (Kobe Biomedix Co., Ltd., Kobe, Japan), 45-mm linear stapler, and 29-mm circular stapler (Fig. 10.1c). For patients with anal stenosis or those undergoing super-low anastomosis in the anal canal, a 25-mm circular stapler is used. A 30-Fr Malécot catheter (C. R. Bard Inc., Covington, GA, USA) is inserted transanally to decompress intraluminal pressure around the anastomosis (Fig. 10.1d).

### 10.5 Port Placement

The patient cart is set up so that robot arm ③ is placed to the lateral side of robot arm ①. Manipulations in the abdominal cavity and pelvic cavity are performed using the dual docking technique (Figs. 10.2 and 10.3).

A 12-mm camera port is installed through the umbilicus, and pneumoperitoneal pressure is maintained at 10 mmHg. Manipulation ports are placed to ensure a distance of four or more fingerbreadths between each point and a distance of 15 cm or more from the superior border of the pubic bone.



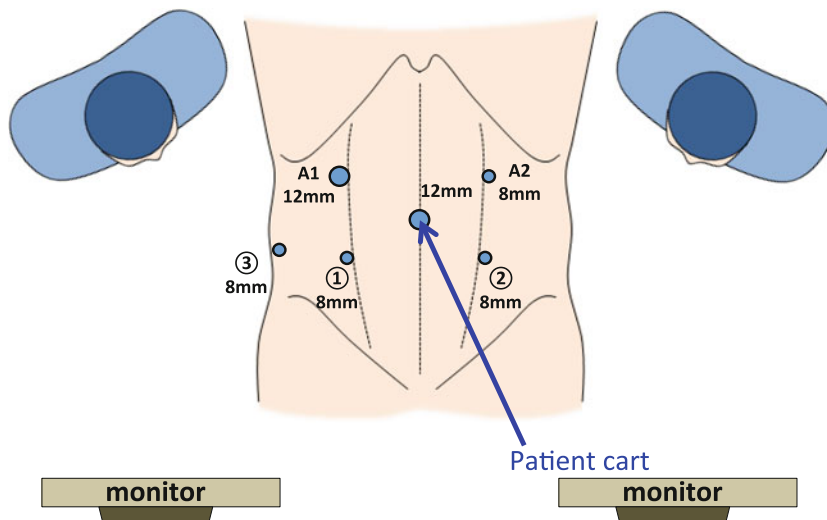
**Fig. 10.2** Port placement and arrangement of the surgeons in the abdominal phase of robot-assisted total mesorectal excision. The patient cart is rolled in and positioned such that the center column, camera arm, the point approximately 3 cm cranial to the left anterior superior iliac spine, and camera port are aligned in a straight line. A1 the port used by the first assistant surgeon

- 8-mm da Vinci port ③ in the right flank: This is placed approximately 3 cm cranial to the right anterior superior iliac spine and immediately medial to the right paracolic gutter.
- 8-mm da Vinci port ① in the right lower abdomen: This is placed approximately 2 cm caudal to the midpoint between the camera port and the 8-mm da Vinci port ③. At the time of transection of the rectum, the port is changed to a 12-mm port, and the first assistant surgeon sitting to the right of the patient transects the rectum using a couple of linear staplers.
- 12-mm port in the right upper abdomen: This is placed approximately five fingerbreadths cranial to the 8-mm da Vinci port ①. In both abdominal and pelvic manipulations, the first assistant surgeon assists by inserting and removing gauze using intestinal forceps.
- 8-mm da Vinci port ② in the left lower abdomen: This is placed symmetrically to the 8-mm da Vinci port ①. This port is used only for pelvic manipulations, not for abdominal manipulations.

## Pelvic phase

1st assistant surgeon

2nd assistant surgeon



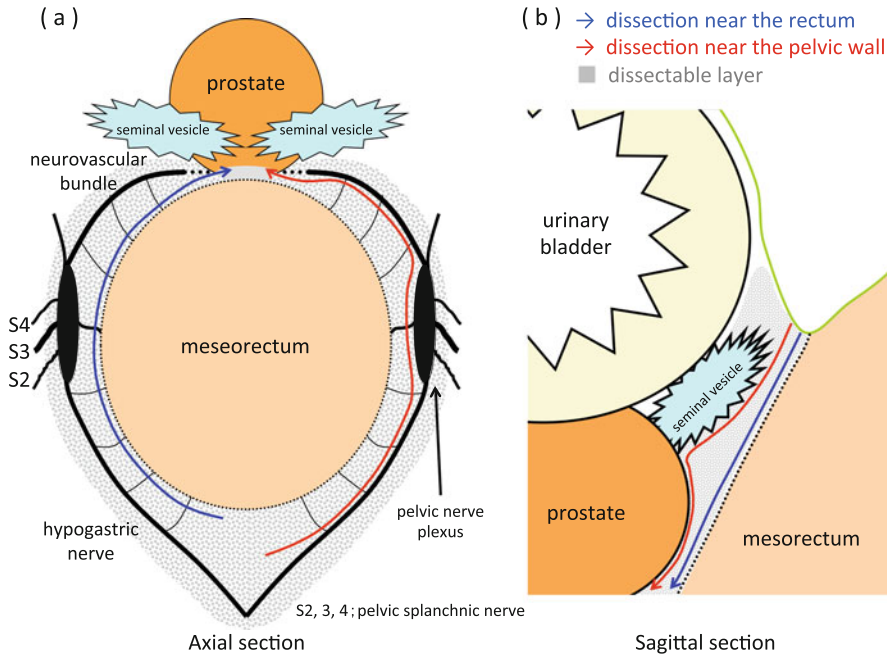
**Fig. 10.3** Port placement and arrangement of the surgeons in the pelvic phase of robot-assisted total mesorectal excision. The patient cart is rolled in and positioned so that the center column, camera arm, the midpoint between the pubis and the left anterior superior iliac spine, and camera port are aligned in a straight line. A1 the port used by the first assistant surgeon, A2 the port used by the second assistant surgeon

- 8-mm da Vinci port ② in the left upper abdomen: This is placed symmetrically to the 12-mm port. For manipulations in the abdominal cavity, the robotic forceps on arm ② is used. For pelvic manipulations, the second assistant surgeon positioned to the left of the patient holds the string wrapped around the rectum with the needle driver to linearize the rectum.

## 10.6 Surgical Anatomy

Loose connective tissue lies between the mesorectum and pelvic wall. By maintaining adequate tension between tissues, the loose connective tissue, which extends into a layer of foamy appearance, can be identified as the dissectable layer [7] (Fig. 10.4a, b).

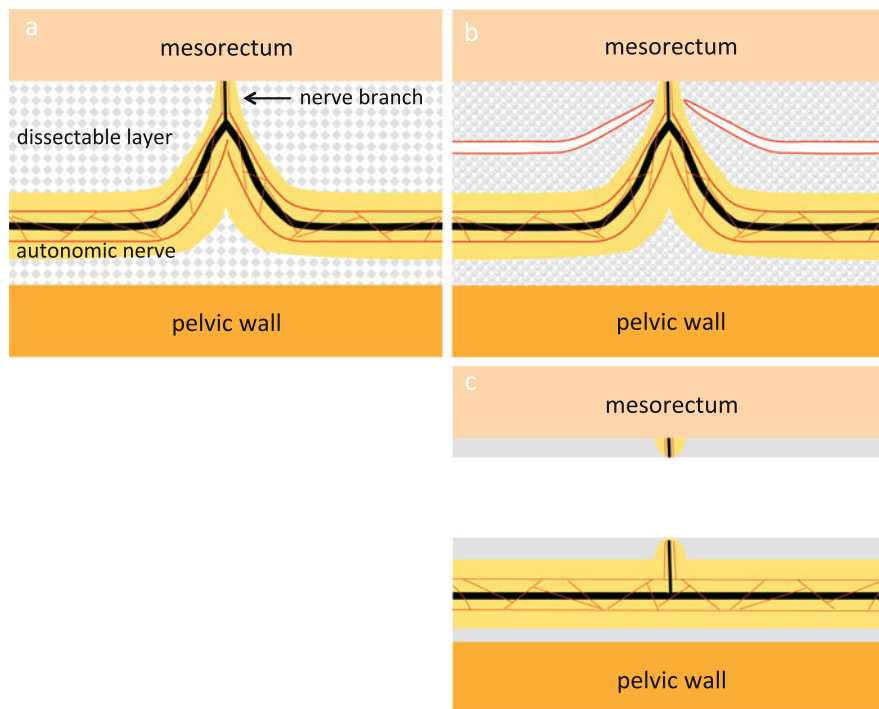
The autonomic nervous system, consisting of the lumbar splanchnic nerve, superior hypogastric nerve plexus, hypogastric nerve, pelvic splanchnic nerve,



**Fig. 10.4** The dissectable layer around the rectum. Axial section (a) and sagittal section (b) of the mesorectum and surrounding tissues are schematically illustrated. Loose connective tissue lies between the mesorectum and pelvic wall. By maintaining adequate tension between tissues, the loose connective tissue extending into a foamy appearance can be identified as the dissectable layer. In the dissectable layer, the decision whether to dissect near the mesorectum or near the pelvic wall should be based on the location and depth of the tumor

pelvic nerve plexus, and neurovascular bundle, runs longitudinally through the dissectable layer accompanied by adipose tissue and thin vessels (Fig. 10.5a). The autonomic nerve branch extending to the rectum passes through the dissectable layer toward the mesorectum. On dissecting the dissectable layer or the rectal branch of the autonomic nerve passing through the dissectable layer, the foamy loose connective tissue loses tension between the two planes, contracts, and appears membrane-like (Fig. 10.5b, c). Both the mesorectum and pelvic wall appear to be covered by this membrane-like tissue. This membrane-like tissue may be recognized as Denonvilliers' fascia, the pre-hypogastric nerve fascia, or the proper rectal fascia, depending on the location. These membrane-like structures can be created artificially by dissecting the foamy loose connective tissue (i.e., the dissectable layer) (Fig. 10.5c).

In the dissectable layer, the decision whether to dissect near the mesorectum or near the pelvic wall should be based on the location and depth of the tumor (Fig. 10.4a, b).



**Fig. 10.5** The relationship between the autonomic nerve and the dissectable layer. The autonomic nerve runs within the dissectable layer accompanied by adipose tissue (yellow paint) and thin vessels (red line) and is pulled toward the mesorectum by the nerve branch (a). After cutting the nerve branch at the peak of pulled autonomic nerve, the dissectable layer contracts and the autonomic nerve is preserved (b, c)

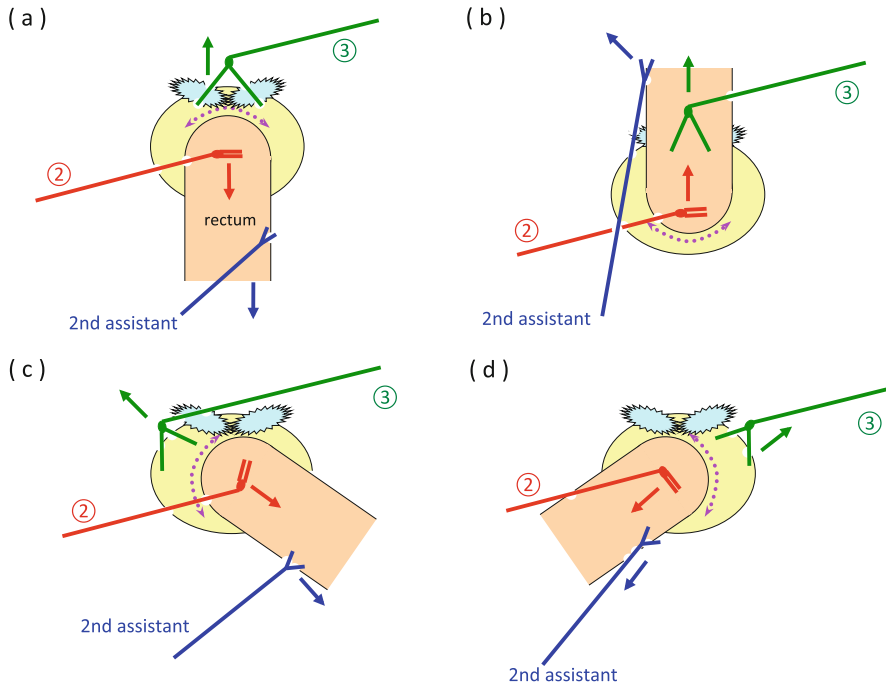
## 10.7 Creation of the Operative Field

**Abdominal phase:** During mobilization of the upper rectum and colon, the first assistant surgeon grasps and elevates the fatty appendage of the colon or vascular pedicle of the sigmoidal vessels using the intestinal forceps. Then the Cadieere forceps on arm ③ is used to grasp and elevate the fatty appendage of the rectum or the inferior mesenteric artery (IMA) to create a surgical plane (Figs. 10.8a and 10.17a). With the fenestrated forceps on arm ②, the tissue is manipulated to maintain adequate countertraction.

**Pelvic phase:** The second assistant surgeon grasps and pulls the string around the upper rectum with the needle driver to straighten the rectum (Fig. 10.18).

- Dissection posterior to the rectum (Fig. 10.6b): The fenestrated forceps on arm ② is guided into the pelvic cavity via the space behind the sigmoid colon. The second assistant surgeon pulls the rectum ventrally to straighten it, and the double fenestrated forceps on arm ③ is used to push the posterior wall of the





**Fig. 10.6** Creation of the operative field around the rectum. The second assistant surgeon grasps and pulls a string wrapped around the upper rectum with the needle driver to straighten the rectum. The standardized procedures to create the operative field anterior to the rectum (a), posterior to the rectum (b), left to the rectum (c), and right to the rectum (d) are schematically illustrated. ② the fenestrated forceps on arm ②, ③ the double fenestrated forceps on arm ③

mesorectum in the ventral direction to stretch the posterior wall of the rectum. The posterior wall of the rectum is then lifted ventrally or the loose connective tissue on the pelvic side is grasped and pulled dorsally using the fenestrated forceps on arm ② to visualize the dissectable layer.

- Dissection of the right side of the rectum (Fig. 10.6d): The second assistant surgeon pulls the rectum in the left cranial direction to straighten the rectum, and the opened double fenestrated forceps on arm ③ is used to push up the right anterior pelvic wall using friction force. With the fenestrated forceps on arm ②, the right side of the mesorectum is manipulated in the left cranial direction to visualize the dissectable layer.
- Dissection of the left side of the rectum (Fig. 10.6c): The second assistant surgeon pulls the rectum in the right cranial direction to straighten the rectum. Then the opened double fenestrated forceps on arm ③ is used to push up the left anterior pelvic wall using friction force. With the fenestrated forceps on arm ②, the left side of the mesorectum is manipulated in the right cranial direction to visualize the dissectable layer.
- Dissection anterior to the rectum (Fig. 10.6a): The second assistant surgeon pulls the rectum in the cranial direction to straighten the rectum. The opened double

fenestrated forceps on arm ③ is then used to push up the seminal vesicles and prostate gland in male patients or the uterus and posterior wall of the vagina in female patients. With the fenestrated forceps on arm ②, the anterior surface of the mesorectum is manipulated in the dorsocranial direction to visualize the dissectable layer.

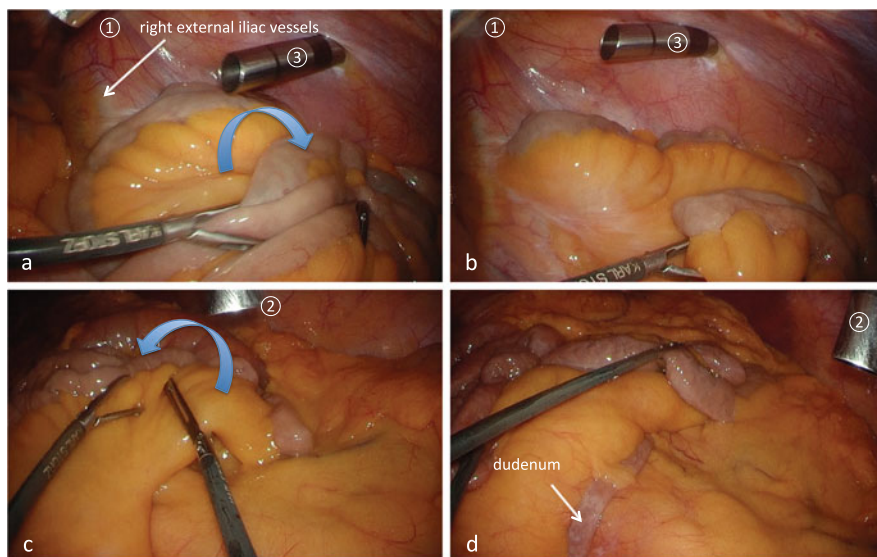
## 10.8 Procedure

### 10.8.1 Robotic Total Mesorectal Excision (TME)

#### 10.8.1.1 Creation of a Wide Operative Field

In female patients, initially, the uterus is sutured to the abdominal wall using 2-0 Prolene. In male patients, if necessary, the vesical peritoneum is fixed to the abdominal wall after incising the peritoneal reflection.

The patient's head is tilted downward by approximately 15° until the small intestines move out of the pelvis, with the right side slanted approximately 5° lower. After moving the omentum and transverse colon to the epigastric region, the mesentery and small intestines are moved to the right abdominal area as if turning a page of a book, enabling visualization of the duodenum, root of the IMA, left abdominal area, and pelvic cavity (Fig. 10.7). As there is a risk that the axis of the forceps on arm ③ can push the small intestine in the dorsal direction and crush it,



**Fig. 10.7** Creation of a wide operative field. The mesentery and small intestines are moved to the right abdominal area as if turning a page of a book, enabling visualization of the duodenum, root of the IMA, left abdominal area, and pelvic cavity (a, c, d). There is a risk that the axis of the forceps on arm ③ can push the small intestine in the dorsal direction and crush it; therefore, the small intestine moved to the right side of the abdomen is placed cranial to the da Vinci port ③ (b)

the small intestine moved to the right side of the abdomen is placed cranial to da Vinci port ③ (Fig. 10.7b).

### 10.8.1.2 Docking of the Patient Cart (Dual Docking-1; Abdominal Phase)

The patient cart is rolled in and positioned such that the center column, the camera arm, the point approximately 3 cm cranial to the left anterior superior iliac spine, and the camera port are aligned in a straight line (Fig. 10.2).

The camera arm is fixed to the camera port, arm ③ is fixed to da Vinci port ③ in the right flank, arm ① is fixed to da Vinci port ① in the right lower abdomen, and arm ② is fixed to da Vinci port ② in the left upper abdomen.

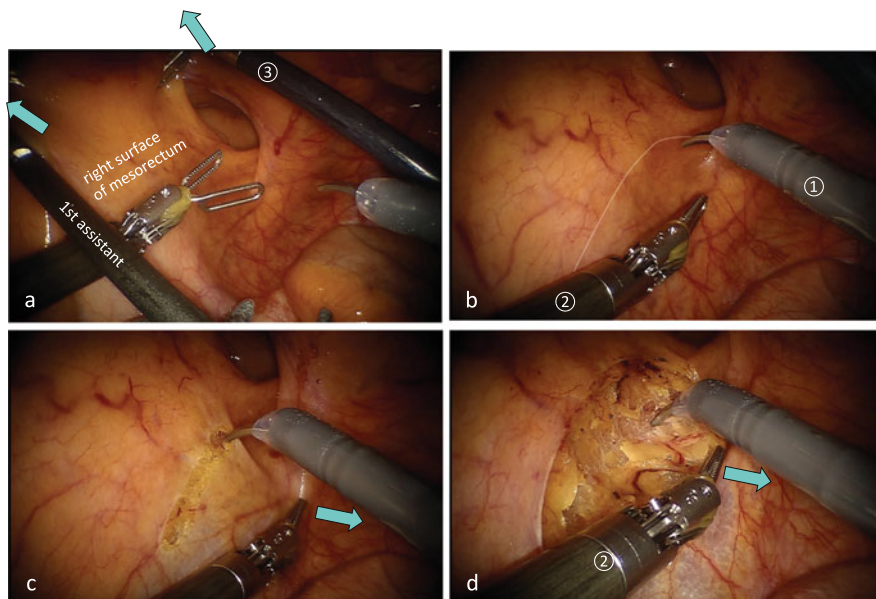
The interval between the elbows of the robot arms is left wider than the width of a fist. Robot arm ③ is positioned so as not to touch the right thigh of the patient.

The operation is performed with a 30-degree rigid scope angled downward. The Cadiere forceps on arm ③ is used to create key traction, the fenestrated forceps on arm ② is then used to apply countertraction, and sharp dissection is performed using the monopolar curved scissors on arm ①.

### 10.8.1.3 Mobilization of the Upper Rectum

The fatty appendages on the right side of the sigmoid colon are grasped using the fenestrated forceps on arm ② and the Cadiere forceps on arm ③ and are pulled out from the pelvis to straighten the rectum. The vascular pedicle of the sigmoidal vessels is then grasped by the first assistant surgeon using the intestinal forceps and pulled in the left ventrocranial direction (Fig. 10.8a). The fatty appendage on the right side of the upper rectum is grasped using the Cadiere forceps on arm ③ and elevated in the left ventrocaudal direction; thus, the right surface of the upper mesorectum is well stretched (Fig. 10.8a). The left ventral traction applied by the first assistant surgeon using forceps and by the Cadiere forceps on arm ③ is slightly relaxed to confirm the curvature of the right pelvic peritoneum and the right surface of the mesorectum (i.e., the imaginary incisional line of the peritoneum). Then the right surface of the upper mesorectum is once again stretched and the imaginary incisional line is verified again (Fig. 10.8b). With the fenestrated forceps on arm ②, the right pelvic peritoneum is pulled in the right direction using friction force (Fig. 10.8c).

Once the peritoneum on the right side of the upper rectum is incised slightly caudal to the promontory, carbon dioxide gas permeates beneath the peritoneum and the dissectable layer is clearly revealed (Fig. 10.8c). With the fenestrated forceps on arm ②, the cut edge of the right pelvic peritoneum is grasped and pulled to the right to widen the peritoneal incision. This stretches the foamy loose connective tissue between the mesorectum and pelvic wall and enables the right hypogastric nerve to be identified and verified (Fig. 10.8d). With the fenestrated forceps on arm ②, the right hypogastric nerve is manipulated slightly to the right, or the mesorectum is pushed ventrally, to reveal the dissectable layer between the mesorectum and right hypogastric nerve. The nerve branch toward the mesorectum is then dissected to preserve the right hypogastric nerve (Fig. 10.9). With the

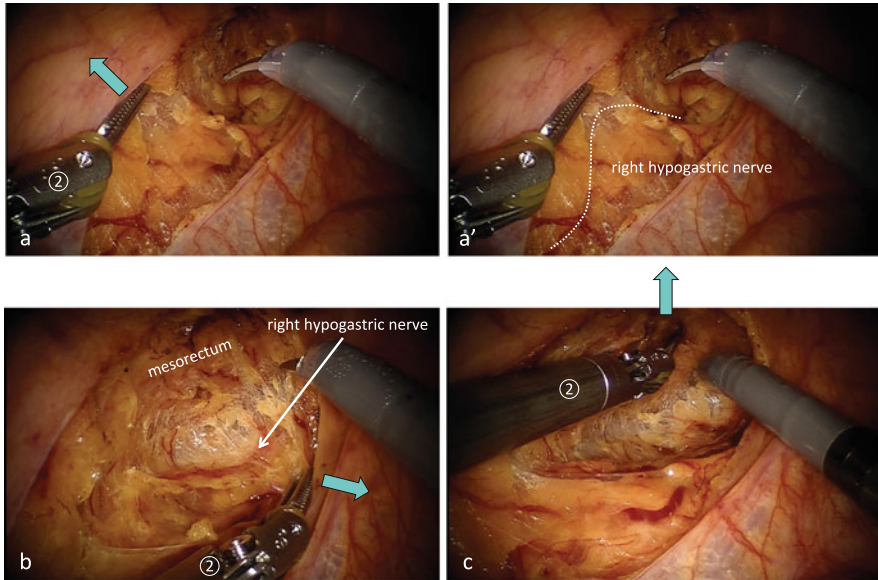


**Fig. 10.8** The imaginary incisional line of the peritoneum on the right surface of the mesorectum. With the intestinal forceps in the first assistant's hand and with the Cadiere forceps on arm ③, the right surface of the mesorectum is stretched out (a). The retraction of the mesorectum is slightly relaxed and the right surface of mesorectum is stretched out once again to verify the imaginary incisional line (*white dotted line*) (b). With the fenestrated forceps on arm ②, the right pelvic peritoneum is pulled in the right direction using friction force (c). After cutting the imaginary incisional line, the dissectable layer is clearly revealed (d)

opened fenestrated forceps on arm ②, the posterior surface of the mesorectum is lifted in the ventral direction to stretch the loose connective tissue posterior to the rectum, the dissectable layer is dissected caudally from the posterior to posterolateral direction in the manner of a swinging pendulum (Fig. 10.9c), and the left hypogastric nerve is identified and preserved. When feasible, the posterior dissection of the mesorectum proceeds up to the interior surface of the peritoneum on the left side of the upper mesorectum in this step.

#### 10.8.1.4 Proximal Lymph Node Dissection, Transection of the IMA, and Mobilization of the Mesocolon

The vascular pedicle of the sigmoidal vessels is grasped with the Cadiere forceps on arm ③ and pulled in the lateroventral direction to straighten the IMA, and the peritoneum around the IMA is grasped with the fenestrated forceps on arm ② and pulled in the lateral-ventrocranial direction to apply countertraction to the peritoneum at the root of the mesocolon (Fig. 10.10a, b). The peritoneum is incised approximately 5 mm medial to the IMA in the cranial direction, and then the loose connective tissue between the IMA and aorta is stretched out, appearing as foamy layer, allowing the superior hypogastric nerve plexus to be identified (Fig. 10.10c,

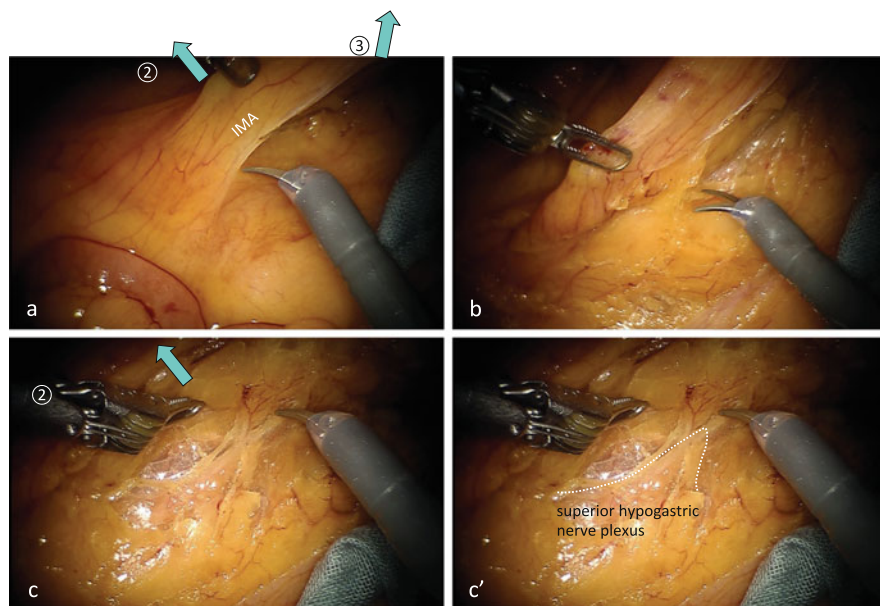


**Fig. 10.9** Dissection behind the mesorectum. The right hypogastric nerve is surrounded by adipose tissue through which thin vessels run longitudinally and is pulled toward the mesorectum by the nerve branch (a, a'). With the fenestrated forceps on arm ②, the right hypogastric nerve is manipulated slightly to the right (b) or the mesorectum is pushed ventrally (c) to reveal the dissectable layer between the mesorectum and right hypogastric nerve

c'). The nerve branch toward the IMA is dissected between the IMA and superior hypogastric nerve plexus.

The peritoneal incision is extended cranially, and the proximal margin for lymph node dissection is set cranial to the root of the IMA. With the Cadieere forceps on arm ③, the IMA is grasped and pulled in the ventrolateral direction. With the fenestrated forceps on arm ②, the descending mesocolon is lifted in the ventral direction, or the loose connective tissue is grasped and pulled in the dorsal direction, to visualize the dissectable layer (Figs. 10.10c and 10.11). The dorsal side of the mesocolon is dissected laterally and cranially to preserve the left ureter. The nerve branch from the right lumbar splanchnic nerve toward the IMA is dissected and the right lumbar splanchnic nerve is spared. The left lumbar splanchnic nerve can be identified being pulled toward the lateral margin of the IMA (Fig. 10.12).

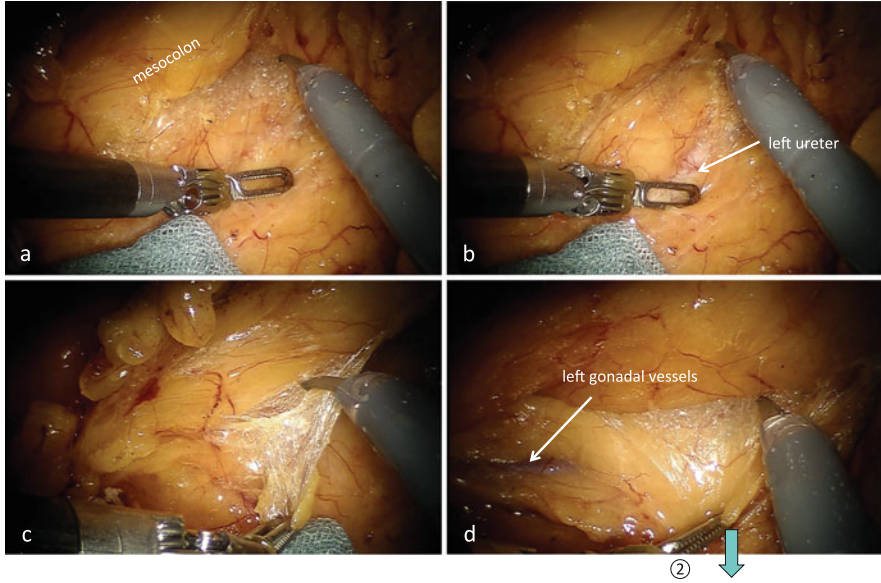
The IMA held by the Cadieere forceps on arm ③ is then manipulated in the dorsocaudal direction to allow visualization of the ventral side of the IMA. With the fenestrated forceps on arm ②, the fatty tissue surrounding the lymph nodes slightly peripheral to the root of the IMA is grasped and lifted together with the peritoneum, followed by lymph node dissection up to the root of the IMA along the nerve sheath covering the IMA and the left colic artery (LCA) (Fig. 10.12b, b').



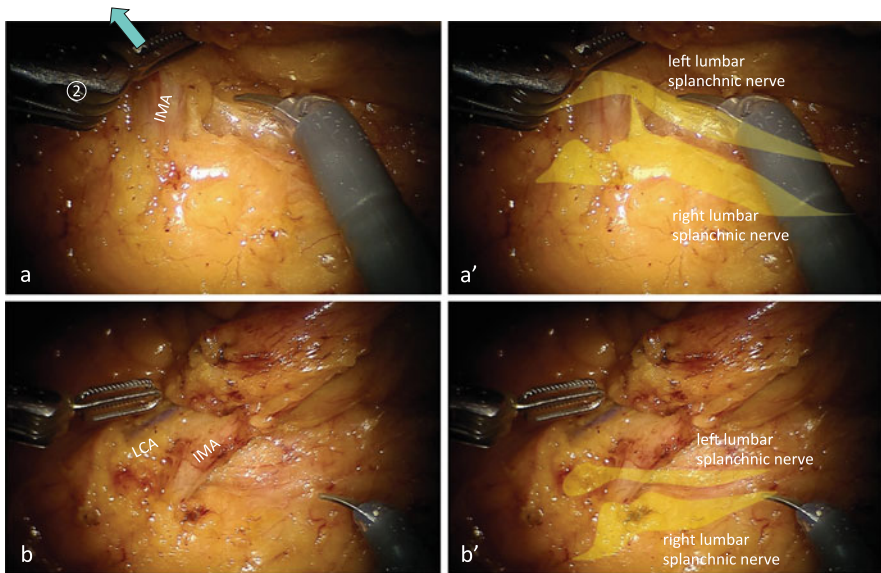
**Fig. 10.10** Dissection behind the IMA. The vascular pedicle of the sigmoidal vessels is grasped with the Cadiere forceps on arm ③ and pulled in the lateroventral direction to straighten the IMA, and the peritoneum around the IMA is grasped with the fenestrated forceps on arm ② and pulled in the lateral and ventrocranial direction to apply countertraction to the peritoneum at the root of the mesocolon (a, b). The loose connective tissue between the IMA and aorta is stretched into a layer of foamy appearance, allowing the superior hypogastric nerve plexus to be identified (c, c')

With the fenestrated forceps on arm ②, the nerve sheath around the IMA is grasped approximately 5 mm peripheral to the root of the IMA, pulled medially, and then cut with the monopolar curved scissors on arm ① to reach between the nerve sheath and the outer membrane of the IMA (Figs. 10.13b, c and 10.14b). The nerve sheath is dissected before the IMA is double clipped and transected. The left lumbar splanchnic nerve is then verified as being pulled toward the nerve plexus between the LCA and root of the IMA. Then the nerve plexus caudal to the pulled left lumbar splanchnic nerve is dissected and the LCA, inferior mesenteric vein (IMV), and mesocolon are separated from the root of the IMA and the left lumbar splanchnic nerve (Fig. 10.14a, a' and c, c').

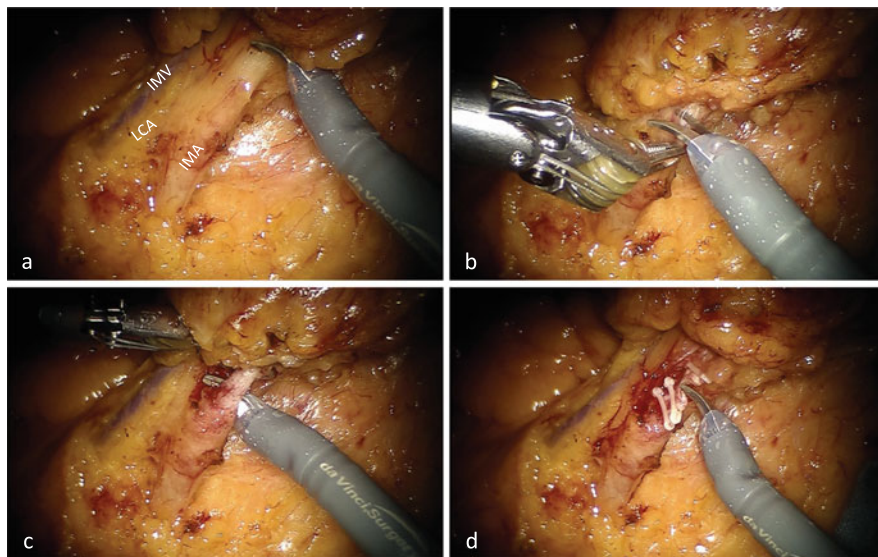
The removal side of the IMA stump is grasped with the Cadiere forceps on arm ③ and pulled in the ventral direction. The fenestrated forceps on arm ② is then used to elevate the descending mesocolon in the ventral direction, or to grasp and pull the retroperitoneum in the dorsal direction, to clearly expose the dissectable layer between the descending mesocolon and retroperitoneum and to separate it in the lateral direction. After confirming that the left gonadal vessels are set aside dorsally, the LCA and IMV are clipped and cut.



**Fig. 10.11** Dissection behind the mesocolon. With the fenestrated forceps on arm ②, the descending mesocolon is lifted in the ventral direction, or the loose connective tissue is grasped and pulled in the dorsal direction to visualize the dissectable layer



**Fig. 10.12** Relationship between the IMA and bilateral lumbar splanchnic nerves. The nerve branch from the right lumbar splanchnic nerve toward the IMA is dissected and the right lumbar splanchnic nerve is spared (a, a'), and then the left lumbar splanchnic nerve can be identified being pulled toward the lateral margin of the IMA (b, b')



**Fig. 10.13** Transection of the IMA peripheral to the branch off site of the LCA. With the fenestrated forceps on arm ②, the nerve sheath around the IMA is grasped, pulled medially, and then cut with the monopolar curved scissors on arm ① to reach between the nerve sheath and the outer membrane of the IMA (a–c). The nerve sheath is dissected before the IMA is double clipped and transected (d)

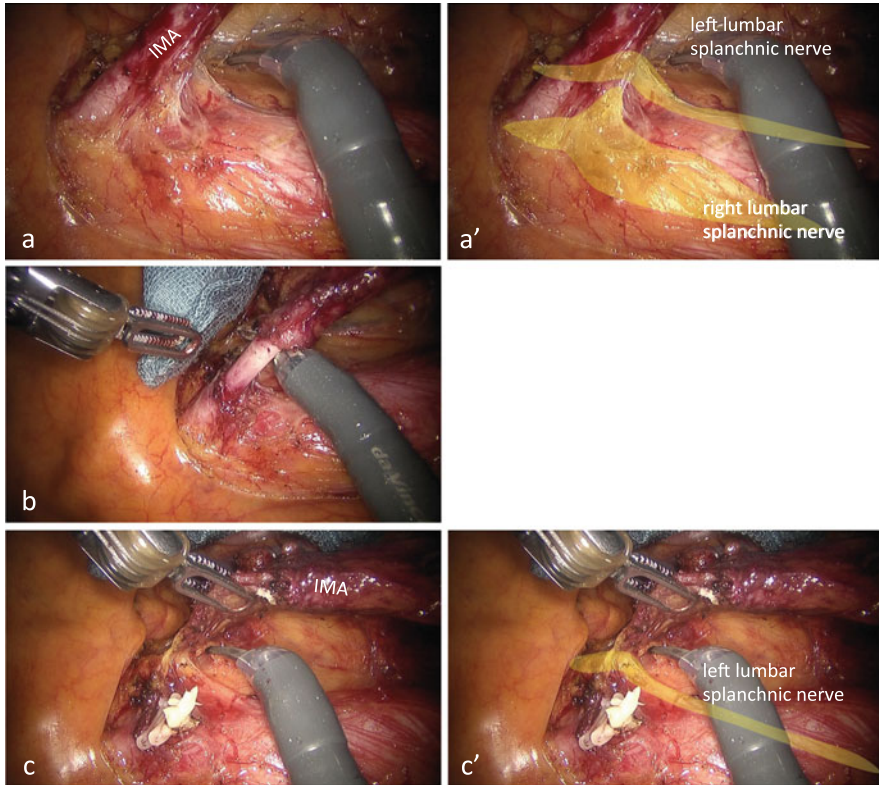
Separation of the mesocolon and retroperitoneum is performed up to the upper pole of the left kidney on the cranial side and up to the interior surface of the white line of Toldt on the lateral side.

In almost all cases, the peritoneum on the left side of the upper mesorectum can be incised from the medial side and fenestrated to enable communication through to the lateral side (Fig. 10.15). This fenestration facilitates the following lateral approach.

#### 10.8.1.5 Lateral Approach

With the Cadieere forceps on arm ③, the left parietal peritoneum covering the left psoas muscle is grasped and pulled in the lateral–ventrocaudal direction (Fig. 10.16a). Using the intestinal forceps, the first assistant surgeon then pulls the fatty appendage of the distal descending colon in the medial–cranial direction. With the fenestrated forceps on arm ②, the fatty appendage of the sigmoid colon is pulled in the medial direction to create countertraction, and the physiological adhesion with the left parietal peritoneum is dissected, and the peritoneal opening fenestrated from the medial side can then be identified (Fig. 10.16b, c, and c'). With the fenestrated forceps on arm ②, the fatty appendage of the distal descending colon is grasped and pulled in the medial direction, applying tension to the left paracolic gutter. The peritoneal incision line is then extended cranially along the white line of Toldt, thus completing mobilization of the distal descending colon.

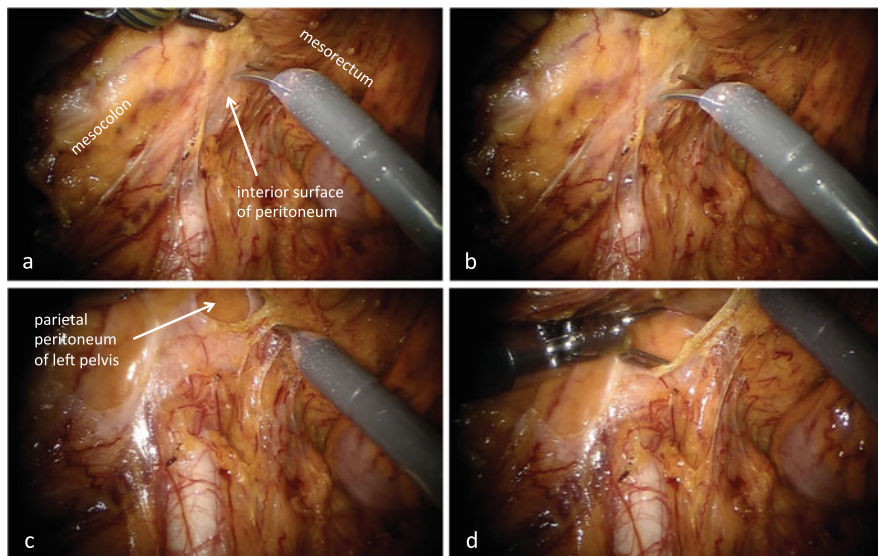




**Fig. 10.14** Transection of the root of the IMA. Relationship between the IMA and bilateral lumbar splanchnic nerves (a, a'). The nerve sheath is dissected before the IMA is double clipped and transected (b). The left lumbar splanchnic nerve is pulled toward the nerve plexus between the LCA and root of the IMA (c, c')

Using the intestinal forceps, the first assistant surgeon grasps and pulls the fatty appendage on the left side of the upper rectum in the right ventrocranial direction. Then with the Cadieere forceps on arm ③, the fatty appendage on the left side of the middle rectum is grasped and pulled in the right ventral direction (Fig. 10.17a). The fenestrated forceps on arm ② pulls the peritoneal cut edge on the left pelvic wall in the left ventrocranial direction to apply countertraction to the left side of the upper rectum (Fig. 10.17b). After the space posterior to the mesorectum which has already been dissected from the medial side is verified, the peritoneum on the left side of the upper mesorectum is dissected caudally and the left hypogastric nerve is preserved, completing mobilization of the colon and upper rectum (Fig. 10.17c, c').

The patient cart is then rolled out.



**Fig. 10.15** Fenestration of the peritoneum on the left side of the upper mesorectum from the medial side. By connecting the dissected plane of the mesorectum and mesocolon, the line of dissection eventually reaches the interior surface of the peritoneum on the left side of the upper mesorectum (a). This white opaque membrane is incised intentionally from the medial side and fenestrated in order to communicate with the lateral side of the rectum (b–d)

#### 10.8.1.6 Redocking of the Patient Cart (Dual Docking-2; Pelvic Phase)

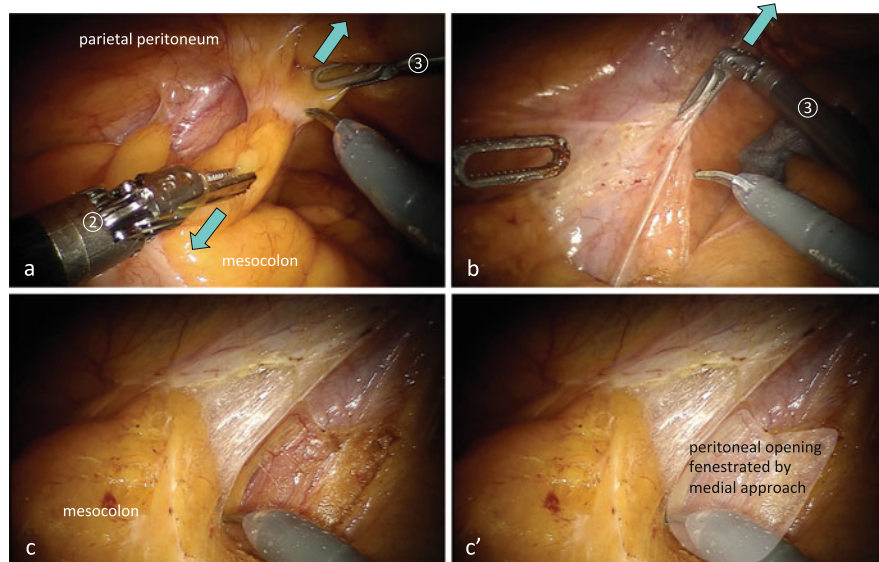
The patient cart is rolled in and positioned so that the center column, the camera arm, the midpoint between the pubis and left anterior superior iliac spine, and the camera port are aligned in a straight line (Fig. 10.3).

The camera arm is fixed to the camera port, arm ③ is fixed to da Vinci port ③ in the right flank, arm ① is fixed to da Vinci port ① in the right lower abdomen, and arm ② is fixed to da Vinci port ② in the left lower abdomen.

The interval between the elbows of the robot arms is left wider than the width of a fist. Robot arm ③ is positioned so as not to touch the right thigh of the patient.

The pelvic operation is performed with a 30-degree rigid scope angled downward. When operating in the deepest part of the pelvis, a straight rigid scope and a 30-degree rigid scope angled upward are used if necessary.

The second assistant surgeon, positioned to the left of the patient, grasps and pulls the string wrapped around the rectum with the needle driver to straighten the rectum (Fig. 10.18). The double fenestrated forceps on arm ③ is used to create key traction, the fenestrated forceps on arm ② is used to apply countertraction, and sharp dissection is performed using the monopolar curved scissors on arm ① (Fig. 10.6).



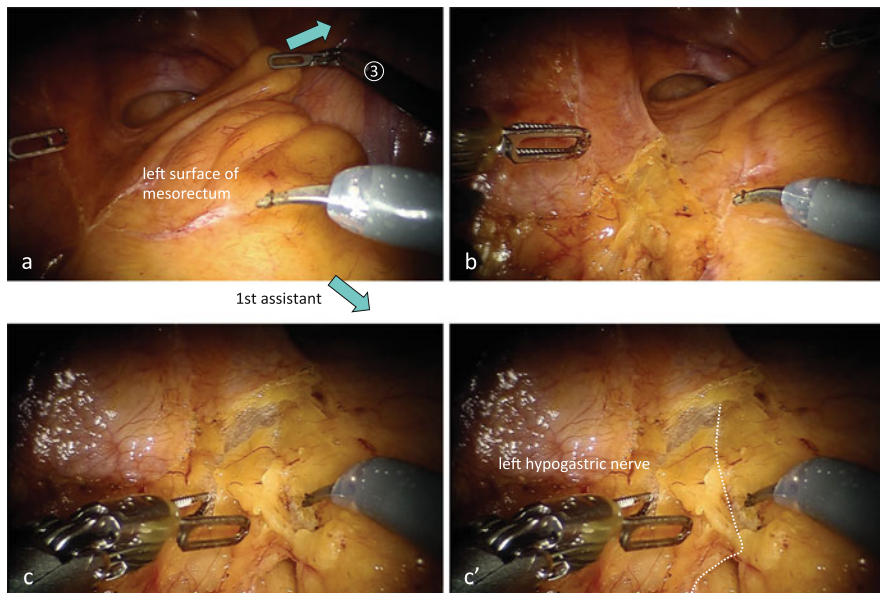
**Fig. 10.16** Lateral approach. With the Cadiere forceps on arm ③, the left parietal peritoneum is pulled in the lateral–ventrocaudal direction, and with the fenestrated forceps on arm ②, the fatty appendage of the sigmoid colon is pulled in the medial direction to create countertraction (a, b). The physiological adhesion is dissected (b), and then the peritoneal opening fenestrated from the medial side is identified (c, c')

### 10.8.1.7 Dissection Posterior and Posterolateral to the Mid-lower Rectum

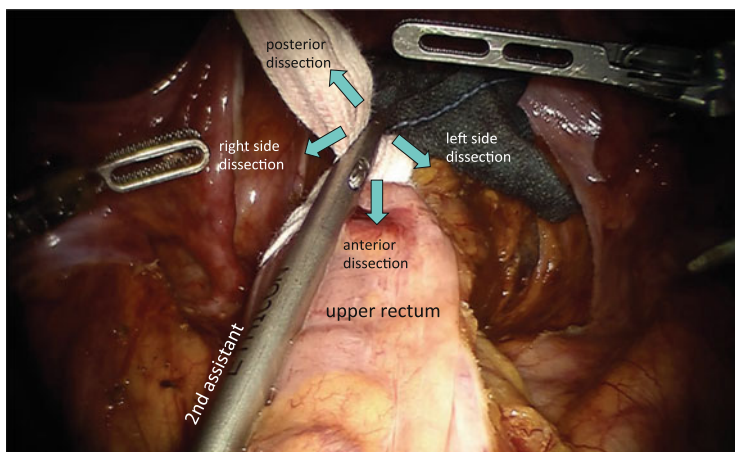
The second assistant surgeon pulls the rectum in the left ventral direction to straighten the rectum (Fig. 10.19a). The double fenestrated forceps on arm ③ is guided posterior to the rectum, and the peritoneal cut edge on the left side of the upper mesorectum is grasped with the double fenestrated forceps on arm ③, the posterior wall of the upper mesorectum is elevated ventrally, and the posterior surface of the mesorectum is stretched and flattened, forming a kind of partition (Fig. 10.19a, b). With the fenestrated forceps on arm ②, the mesorectum is lifted in the ventral direction and the dissectable layer between the mesorectum and pelvic wall is expanded, akin to a spider's web (Fig. 10.20).

At a level more caudal than the bifurcation of the hypogastric nerves, the dissectable layer posterior to the rectum is cut close to the pelvic wall to ensure an adequate circumferential resection margin (CRM) (Figs. 10.20c, d and 10.21). The dissection posterior to the rectum is then extended caudally from the posterior to posterolateral and lateral directions in the manner of a swinging pendulum.

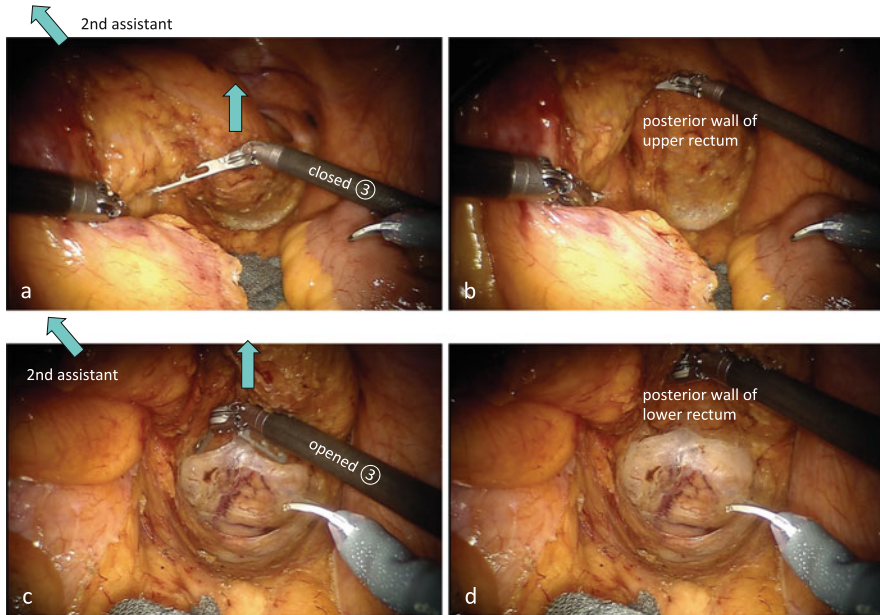
Coming down to the pelvic floor, the partition-like stretching of the mesorectum is loosened by the preceding posterior dissection, so the mesorectum is re-tied with the string at the more distal side and the second assistant surgeon grasps the string with the needle driver and again pulls it in the ventrocranial direction. With the



**Fig. 10.17** Dissection on the left side of the upper mesorectum. With the intestinal forceps in the first assistant’s hand and with the Cadieere forceps on arm ③, the left surface of the mesorectum is stretched out (a). The fenestrated forceps on arm ② pulls the peritoneum on the left pelvic wall in the left ventrocranial direction to apply countertraction to the left side of the upper mesorectum (b). After the space posterior to the mesorectum which has already been dissected from the medial side is verified, the peritoneum on the left side of the upper mesorectum is dissected caudally and the left hypogastric nerve is preserved (c, c’)



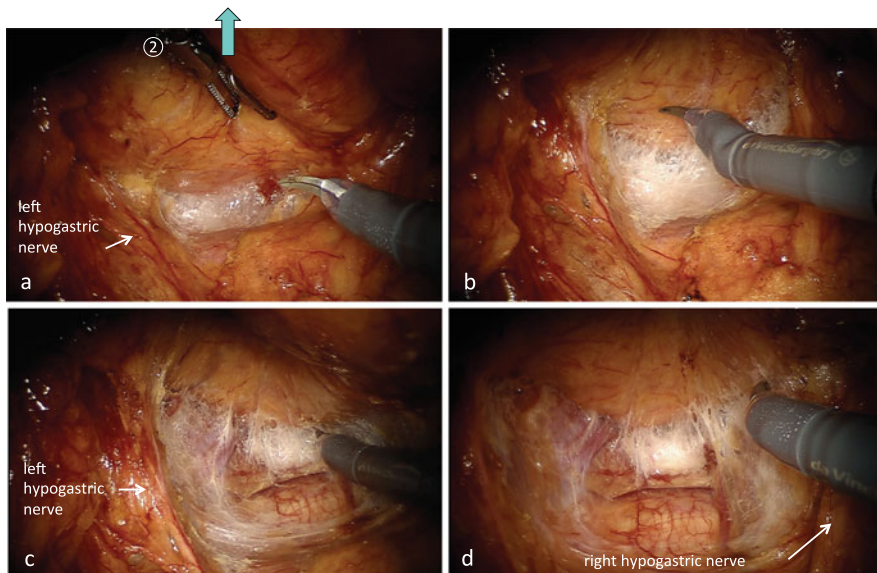
**Fig. 10.18** The role of the second assistant surgeon during manipulations in the pelvic cavity. The second assistant positioned to the left of the patient grasps and pulls a string wrapped around the rectum with the needle driver to straighten the rectum



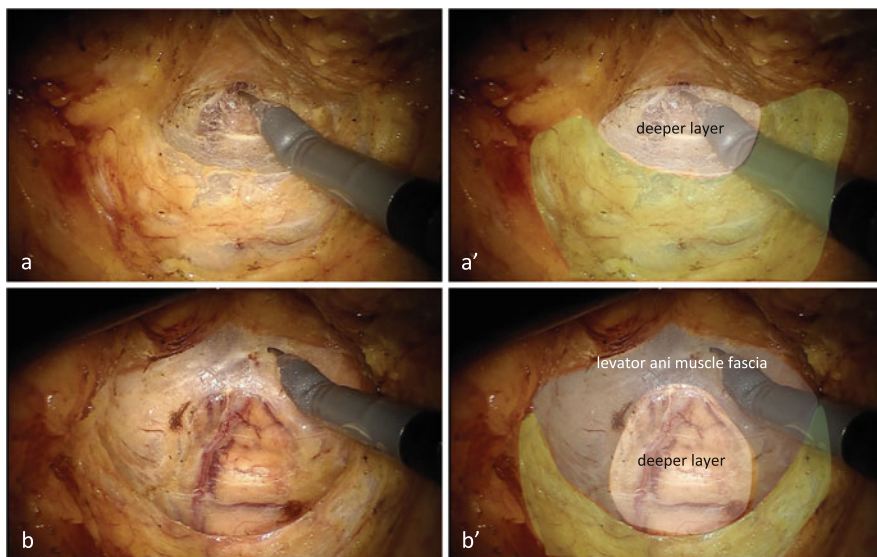
**Fig. 10.19** Creation of the operative field posterior to the rectum. The peritoneal cut edge on the left side of the upper mesorectum is grasped with the double fenestrated forceps on arm ③, the posterior wall of the upper mesorectum is then elevated ventrally, and the posterior surface of the upper mesorectum is flattened out like a partition (a, b). Coming down to the pelvic floor, the partition-like stretching of the mesorectum is loosened by the preceding posterior dissection; therefore with the opened double fenestrated forceps on arm ③, the mesorectum is lifted ventrally and the posterior surface of the lower mesorectum is flattened out again (c, d)

opened double fenestrated forceps on arm ③, the mesorectum is then lifted ventrally and the posterior surface of the lower mesorectum is flattened out again (Fig. 10.19c, d). The posterior dissection of the mesorectum proceeds caudally, and then the dissectable layer between the mesorectum and levator ani muscle fascia is dissected sufficiently up to the level of the tip of the coccyx (Figs. 10.20c, d and 10.21). The dissection is extended along the levator ani muscle fascia from the posterior to posterolateral direction, exposing the interior surfaces of the pelvic splanchnic nerves (Fig. 10.22). The mesorectum expands as though it is swelling in the direction caudolateral to the pelvic splanchnic nerve. Then the dissection proceeds caudolaterally along the levator ani muscle fascia below the pelvic splanchnic nerve to completely open the space above the levator ani muscle (Figs. 10.21b, b' and 10.22).

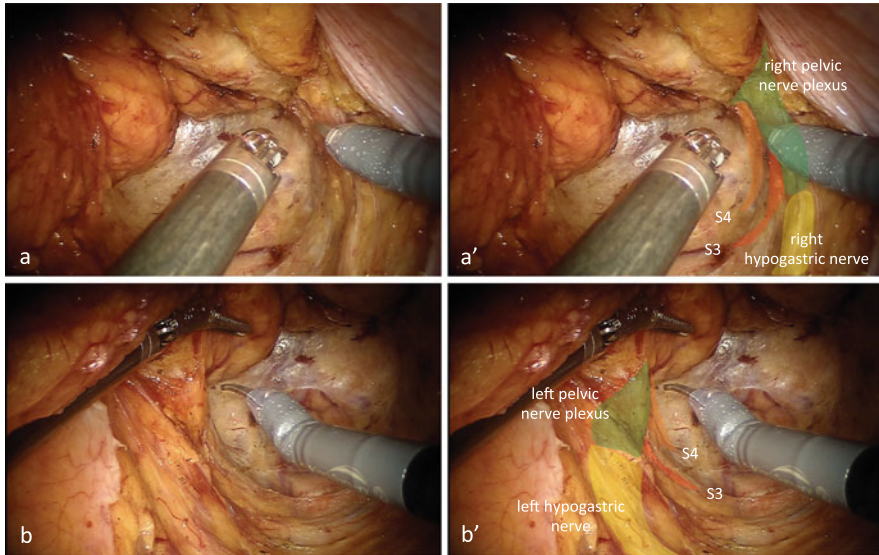
The wide dissection to expose the levator ani muscle fascia expedites the following lateral, anterolateral, and anterior dissections.



**Fig. 10.20** Dissectable layer posterior to the rectum. With the fenestrated forceps on arm ②, the mesorectum is lifted in the ventral direction and the dissectable layer between the mesorectum and pelvic wall is expanded like a spider’s web (a, b). The dissection posterior to the rectum is then extended caudally from the posterior to posterolateral and lateral directions in the manner of a swinging pendulum (c, d)



**Fig. 10.21** Dissection plane posterior to the rectum. At a level more caudal than the bifurcation of the hypogastric nerves, the dissectable layer posterior to the rectum is cut close to the pelvic wall in order to ensure an adequate circumferential resection margin (CRM). The translucent membrane-like connective tissue covering the pelvic wall is the shrunken dissectable layer, which is the so-called pre-hypogastric nerve fascia (green paint)



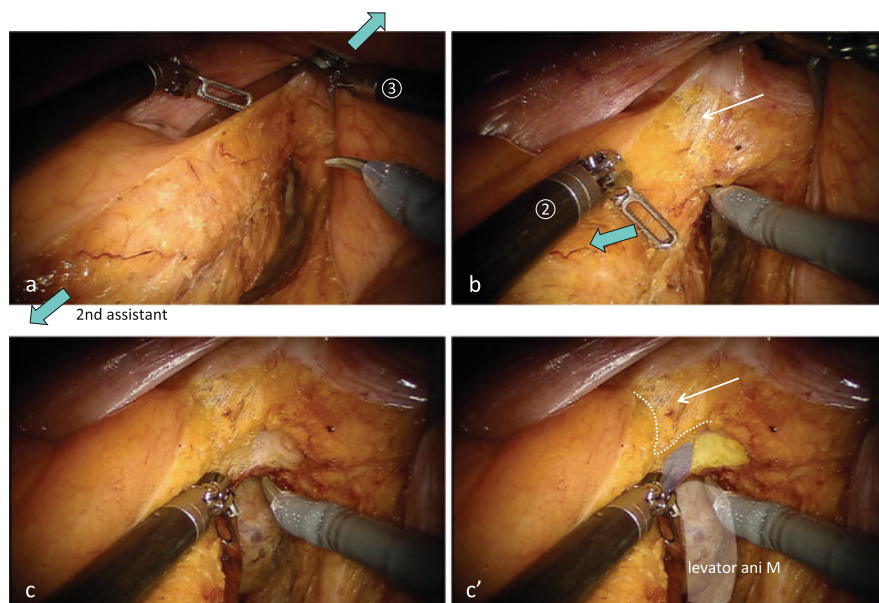
**Fig. 10.22** Dissection along the levator ani muscle fascia up to the pelvic floor. The dissection is extended along the levator ani muscle fascia from the posterior to posterolateral direction, exposing the interior surfaces of the pelvic splanchnic nerves. The mesorectum expands as though it is swelling in the direction caudolateral to the pelvic splanchnic nerve. Then the dissection proceeds caudolaterally along the levator ani muscle fascia below the pelvic splanchnic nerve to completely open the space above the levator ani muscle. *S3* the third pelvic splanchnic nerve, *S4* the fourth pelvic splanchnic nerve

### 10.8.1.8 Dissection Lateral to the Mid-lower Rectum and Anterolateral and Anterior to the Lower Rectum

The string wrapped around the rectum is grasped by the second assistant surgeon with a needle driver and pulled to straighten the rectum (Fig. 10.18).

The opened double fenestrated forceps on arm ③ pushes up the pelvic wall using friction force. By using the closed and bent fenestrated forceps on arm ②, the rectum is pushed aside in order to maintain optimal tension between the mesorectum and pelvic wall (Figs. 10.6, 10.23a, b, 10.24a, b, and 10.25a, b).

The peritoneum of the left and right edges of the mesorectum is dissected toward the peritoneal reflection. The dissectable layer between the mesorectum and pelvic wall is dissected from the posterolateral to lateral direction along the interior surface of the pelvic splanchnic nerve, and then the pelvic nerve plexus can be identified (Fig. 10.22). Under adequate countertraction between the two planes, the pelvic nerve plexus is pulled toward the mesorectum and therefore the nerve branch extending toward the rectum is dissected at the top of the medially pulled pelvic nerve plexus to preserve the pelvic nerve plexus (Fig. 10.22).



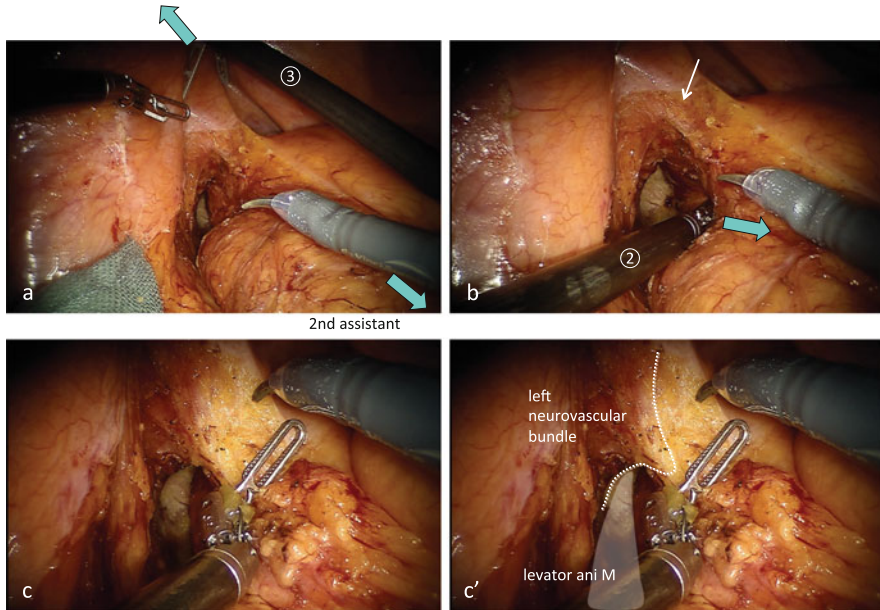
**Fig. 10.23** Dissection anterolateral to the middle rectum (*right side*). The opened double fenestrated forceps on arm ③ pushes up the pelvic wall using the friction force. Using the closed and bent fenestrated forceps on arm ②, the rectum is pushed aside in order to maintain optimal tension between the mesorectum and pelvic wall (a, b). The translucent membrane-like connective tissue covering the seminal vesicle is the shrunken dissectable layer, which is the so-called Denonvilliers' fascia (*white arrow*). The adipose tissue (*blue paint*) surrounding the right neurovascular bundle (*yellow paint*) is peeled to ensure an adequate circumferential resection margin (CRM) (c, c')

After dissecting the foamy connective tissue around the mesorectum caudally along the interior surface of the pelvic nerve plexus, the dissection proceeds anterolaterally between the mesorectum and seminal vesicles or vagina, and then the space above the levator ani muscle comes into view even from the anterolateral side (Figs. 10.23 and 10.24). The translucent membrane-like connective tissue covering the seminal vesicles or vagina is the shrunken dissectable layer, the so-called Denonvilliers' fascia (Figs. 10.23b, c, c' and 10.24a, b).

The peritoneal reflection is incised so that the incision line comes into contact with the bilateral peritoneal dissection line of the middle rectum (Fig. 10.25). If necessary, the vesical peritoneum is ligated to the abdominal wall.

Anterior to the rectum, the dissectable layer between the mesorectum and seminal vesicles, prostate gland, or vagina is usually sharply dissected near the mesorectum in order to preserve the neurovascular bundle (Figs. 10.26 and 10.29). When the tumor lies on the anterior wall of the lower rectum and a risk of

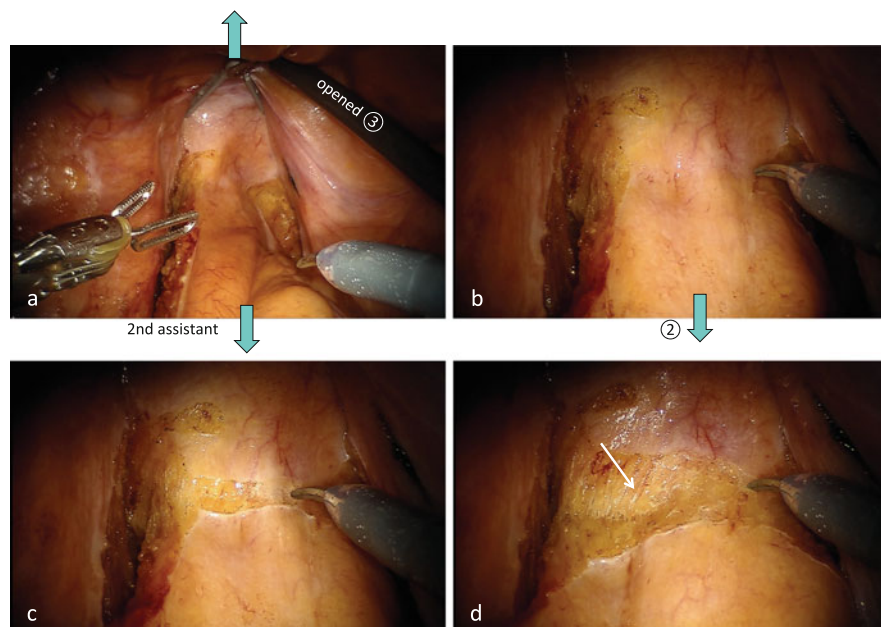




**Fig. 10.24** Dissection anterolateral to the middle rectum (*left side*). The opened double fenestrated forceps on arm ③ pushes up the pelvic wall using the friction force. Using the closed and bent fenestrated forceps on arm ②, the rectum is pushed aside in order to maintain optimal tension between the mesorectum and pelvic wall (a, b). The translucent membrane-like connective tissue covering the seminal vesicle is the shrunken dissectable layer, which is the so-called Denonvilliers' fascia (*white arrow*). The left neurovascular bundle is pulled toward the mesorectum by the nerve branch (c, c')

insufficient CRM is a matter of concern, the dissection plane is selected near the seminal vesicles or vagina for substantial exposure (Figs. 10.27 and 10.28). However, Denonvilliers' fascia adheres closely to the prostate gland, so is difficult to detach in the majority of cases [8]; it covers the neurovascular bundle running along both sides of the prostate. Therefore, at the level of the base of the prostate, the dissection plane between the mesorectum and prostate may have to be shifted to near the mesorectum in order to preserve the neurovascular bundle (Figs. 10.27, 10.28, and 10.30).

On visualizing both the bilateral spaces above the levator ani muscle in the field of view, dissection is performed anterior and anterolateral to the rectum, proceeding caudally (Figs. 10.25, 10.26, 10.27, 10.28, 10.29, and 10.30). The medial top of the neurovascular bundle pulled toward the rectum is sharply dissected to preserve the neurovascular bundle (Figs. 10.31, 10.32, 10.33, and 10.34). The anterior dissection of the mesorectum proceeds sufficiently up to the apex of the prostate or lower end of the vagina, and the venous plexus can then be seen at the distal end of the rectum.



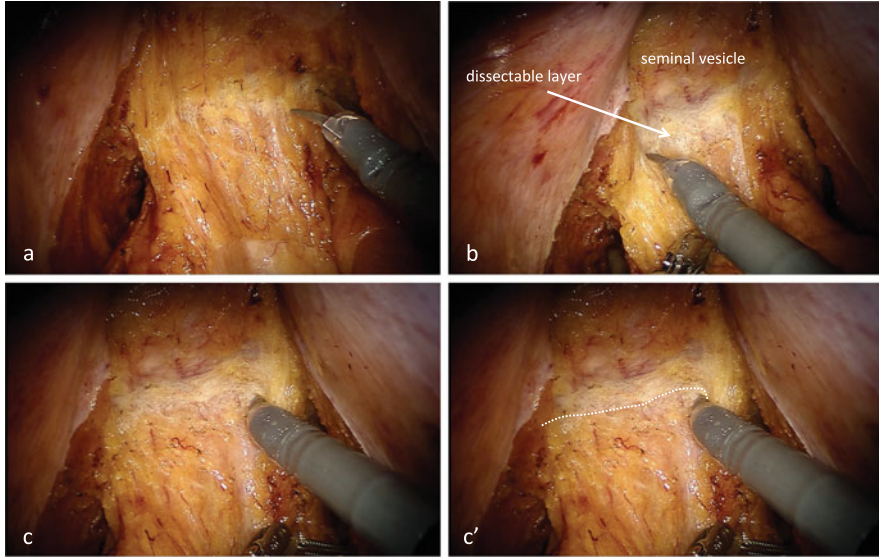
**Fig. 10.25** Incision of the peritoneal reflection. The opened double fenestrated forceps on arm ③ pushes up the pelvic wall using the friction force. Using the closed and bent fenestrated forceps on arm ②, the rectum is pushed dorsocranially (a, b). The peritoneal reflection is incised so that the incision line comes into contact with the bilateral peritoneal dissection line of the middle rectum (c). The translucent membrane-like connective tissue covering the seminal vesicle is the shrunken dissectable layer, which is the so-called Denonvilliers' fascia (*white arrow*) (d)

Once the thick middle rectal artery passing through the neurovascular bundle toward the rectum is identified, it is coagulated with the bipolar fenestrated forceps on arm ② and cut with the monopolar curved scissors on arm ① (Fig. 10.35).

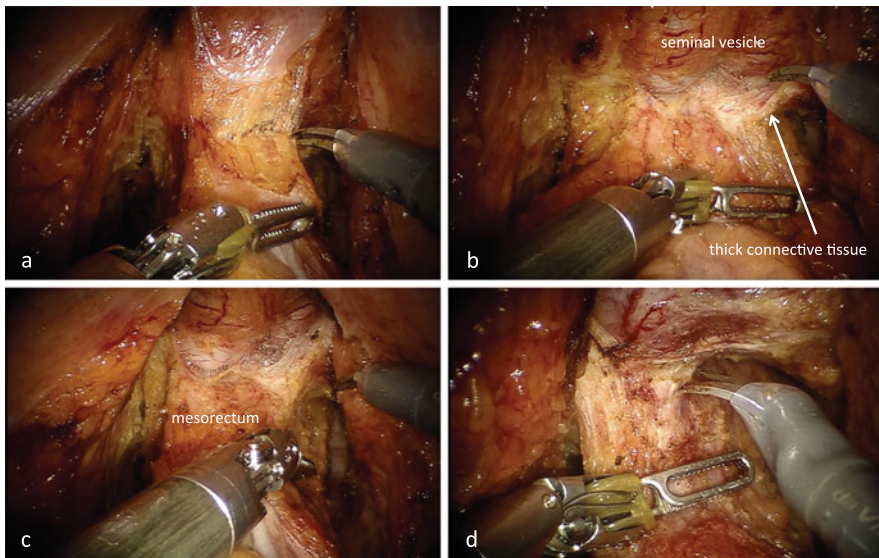
### 10.8.1.9 Dissection into the Anal Canal

When transecting the rectum at the pelvic floor or inside the anal canal and performing reconstruction with the double-stapling technique (DST), it is necessary to dissect into the anal canal sufficiently. When performing intersphincteric resection, it is important to dissect the space between the rectal wall and puborectal muscle from the abdominal side in order to make the transanal dissection easier and faster (Figs. 10.36 and 10.37).

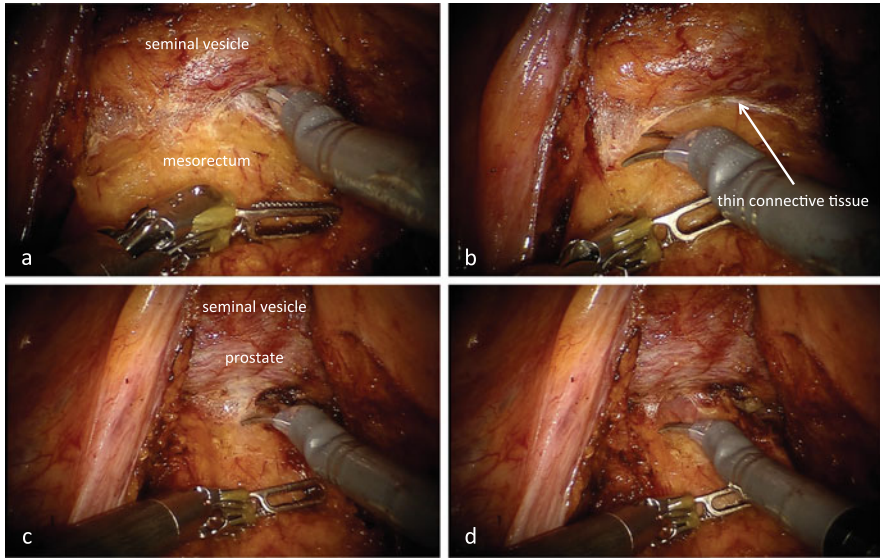
After dissecting the entire nerve branch extending from the neurovascular bundle toward the rectum, the space between the pubococcygeal muscle and rectal wall is reached from a direction anterolateral to the rectum (Fig. 10.37a, b). The conjoined longitudinal muscle, consisting of intermingling muscle fibers between the pubococcygeal muscle and rectal wall, is dissected and the space between the pubococcygeal muscle and rectal wall is dissected caudally. Then the dissection



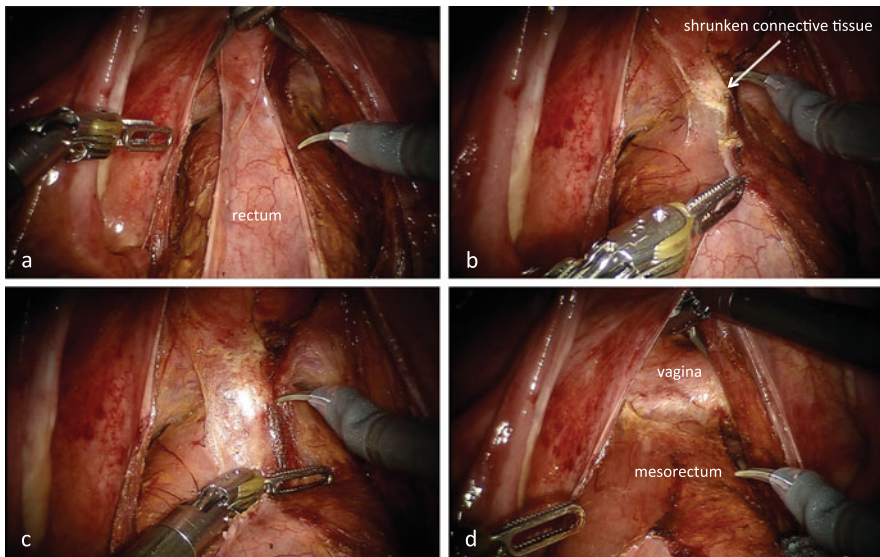
**Fig. 10.26** Dissection anterior to the rectum. To preserve the neurovascular bundle, the dissectable layer between the mesorectum and the seminal vesicle (**a, b**) is sharply dissected near the mesorectum (**c, c'**)



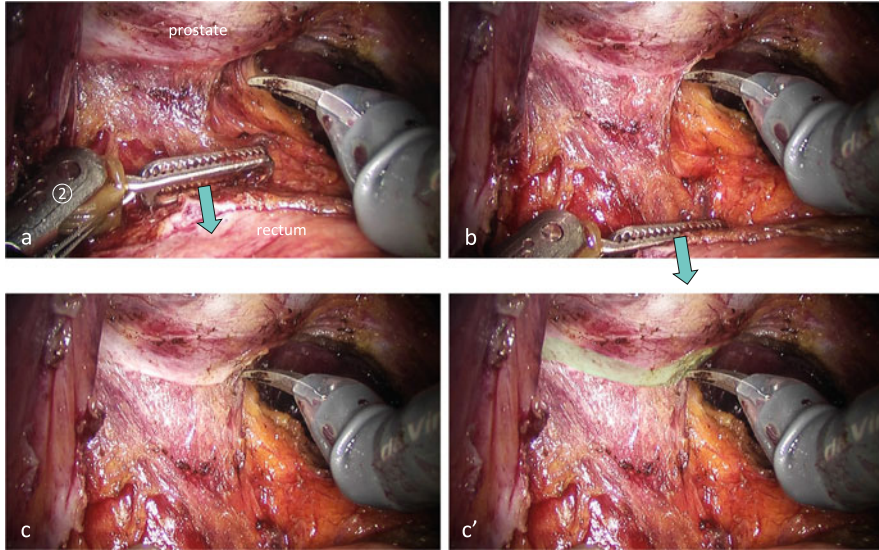
**Fig. 10.27** The thick so-called Denonvilliers' fascia. The dissection plane is selected near the seminal vesicle for substantial exposure (**a, b**). At the level of the base of the prostate, the dissection plane between the mesorectum and the prostate is shifted to near the mesorectum to preserve the neurovascular bundle (**c, d**)



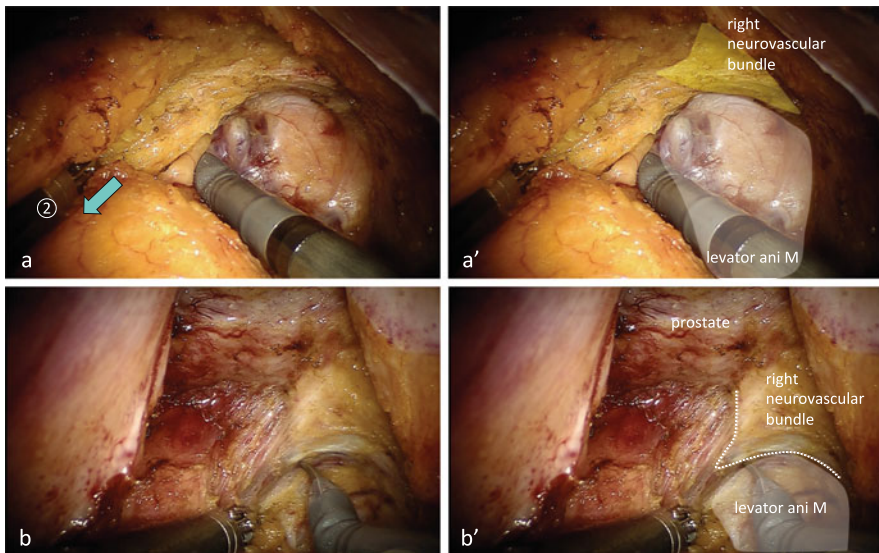
**Fig. 10.28** The thin so-called Denonvilliers’ fascia. The dissection plane is selected near the seminal vesicle for substantial exposure (a, b). At the level of the base of the prostate, the dissection plane between the mesorectum and the prostate is shifted to near the mesorectum to preserve the neurovascular bundle (c, d)



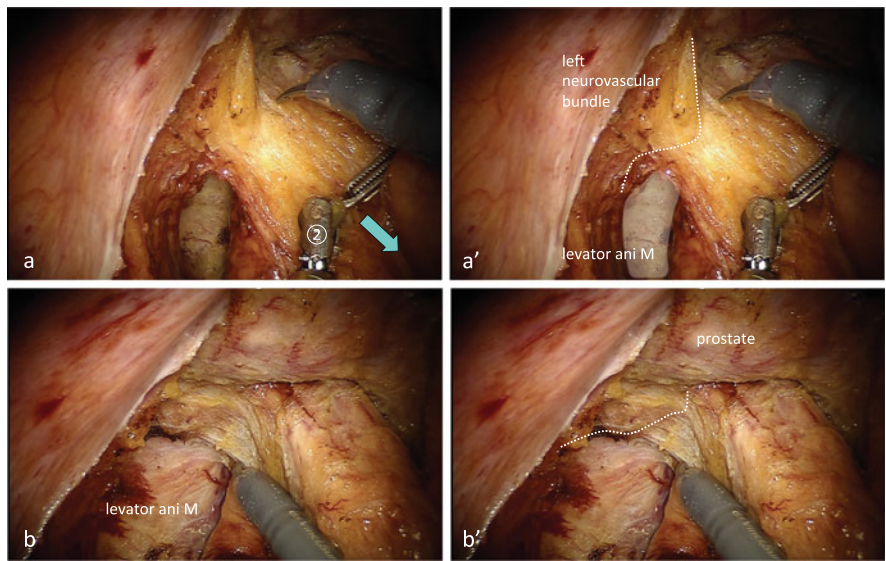
**Fig. 10.29** The so-called Denonvilliers’ fascia in female. After dissecting the peritoneal reflection (a, b), the shrunken loose connective tissue is recognized as the so-called Denonvilliers’ fascia (b–d)



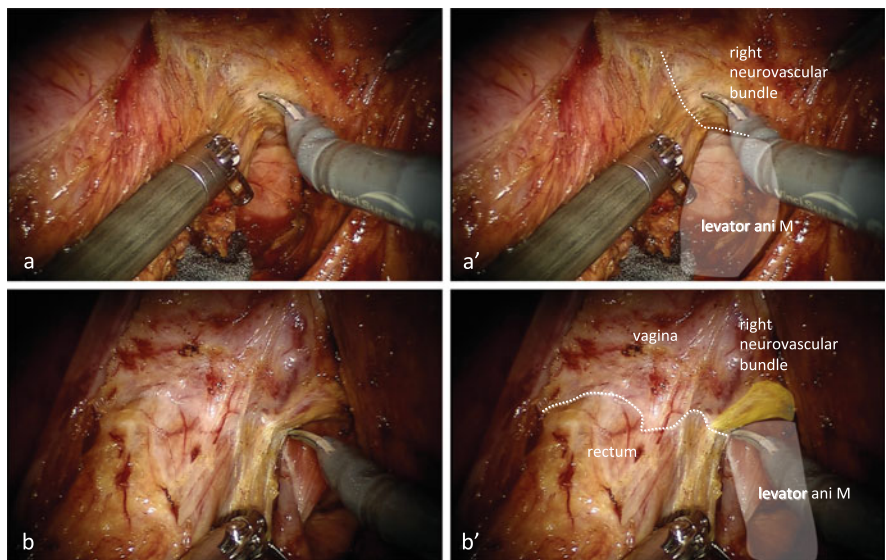
**Fig. 10.30** The so-called Denonvilliers' fascia detachable from the prostate. Using the closed and bent fenestrated forceps on arm ②, the rectum is pushed dorsocranially (a, b). The membrane-like connective tissue (i.e., the so-called Denonvilliers' fascia) is separated from the prostate (*green paint*) (c, c')



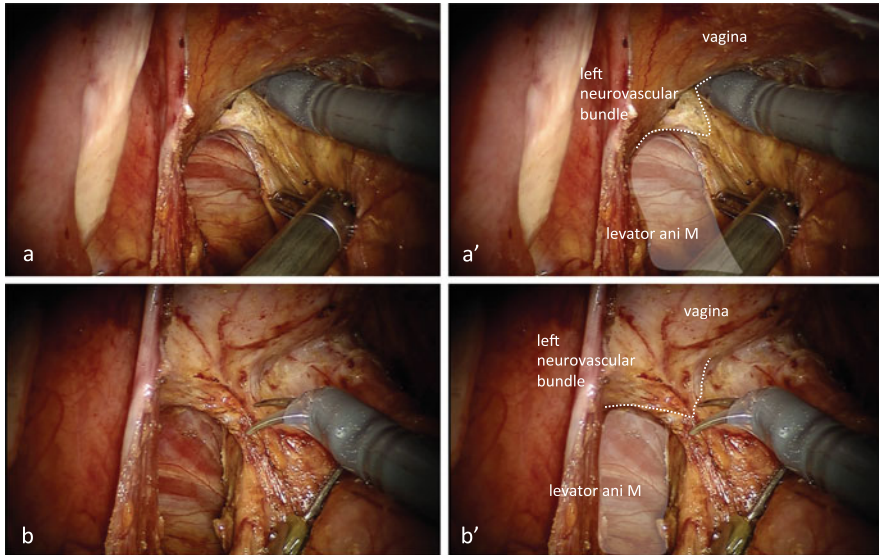
**Fig. 10.31** The right neurovascular bundle (male patient). The medial top of the neurovascular bundle pulled toward the rectum is sharply dissected to preserve the neurovascular bundle



**Fig. 10.32** The left neurovascular bundle (male patient). The medial top of the neurovascular bundle pulled toward the rectum is sharply dissected to preserve the neurovascular bundle



**Fig. 10.33** The right neurovascular bundle (female patient). The medial top of the neurovascular bundle pulled toward the rectum is sharply dissected to preserve the neurovascular bundle



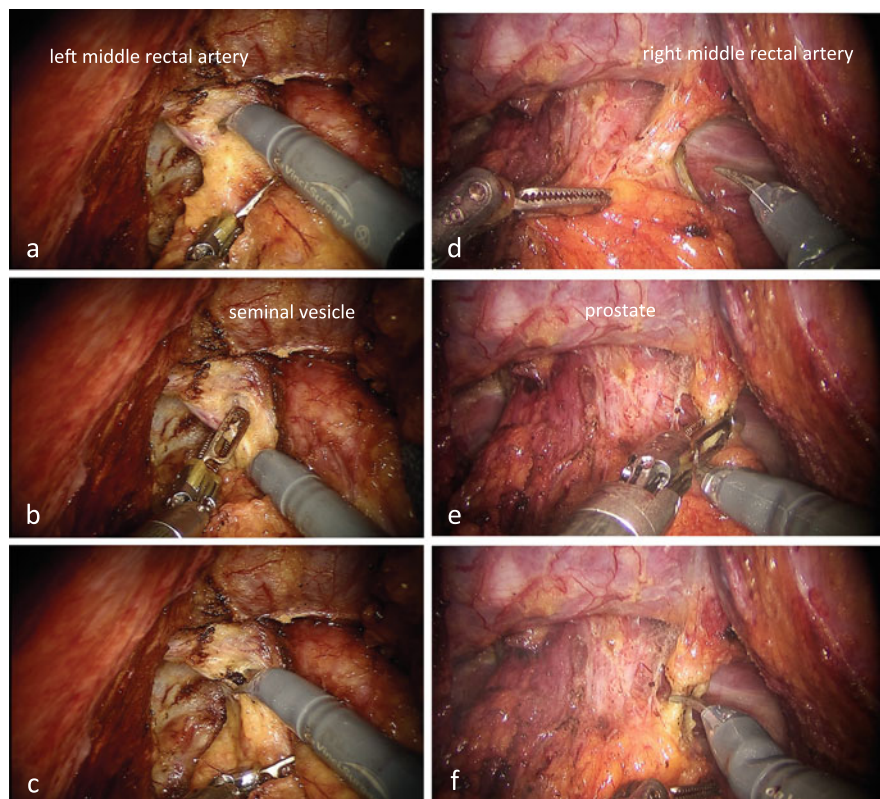
**Fig. 10.34** The left neurovascular bundle (female patient). The medial top of the neurovascular bundle pulled toward the rectum is sharply dissected to preserve the neurovascular bundle

layer is changed between the puborectal muscle and rectal wall. With the fenestrated forceps on arm ②, the pubococcygeal muscle is grasped and pulled laterally, or the rectum is pushed medially, to reveal the dissectable layer inside the anal canal (Fig. 10.37a, b). Thereafter, the space between the puborectal muscle and rectal wall is dissected from the anterolateral to lateral direction.

The second assistant surgeon pulls the rectum in the left ventral direction to straighten it, and the mesorectum is lifted with the opened double fenestrated forceps on arm ③ ventrally to stretch out the distal end of the rectum (Fig. 10.36a). With the fenestrated forceps on arm ②, the pubococcygeal muscle is grasped and pulled in the dorsocranial direction, or the rectum is pushed ventrally, to clearly show the dissectable layer between the rectal wall, pubococcygeal muscle, and puborectal muscle (Fig. 10.36). The dissection plane between the rectum and puborectal muscle is extended from the posterolateral to posterior direction, and then the anal canal is dissected sufficiently (Fig. 10.37c, d).

#### 10.8.1.10 Transection of the Rectum Using a Couple of Linear Staplers

With the opened double fenestrated forceps on arm ③, the bladder, seminal vesicles, and prostate, or the posterior wall of the vagina, are elevated ventrally to create the operative field anterior to the rectum (Fig. 10.38a). The instrument on arm ① is changed to a large needle driver. Extracorporeally, no. 1 PDS (Ethicon

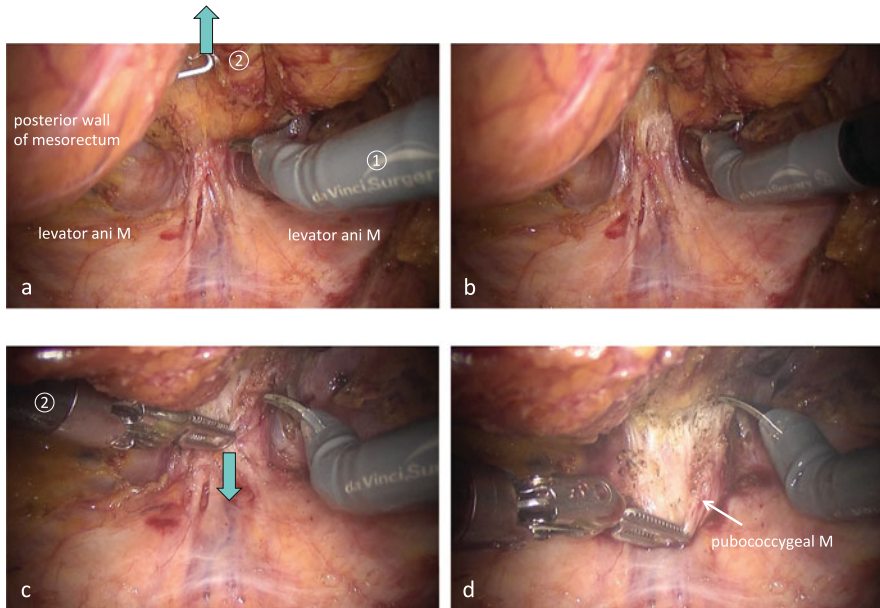


**Fig. 10.35** The thick middle rectal artery passing through the neurovascular bundle toward the rectum. Once the thick middle rectal artery passing through the neurovascular bundle toward the rectum is identified (**a, d**), it is coagulated with the bipolar fenestrated forceps on arm ② (**b, e**) and cut with the monopolar curved scissors on arm ① (**c, f**)

Inc., Somerville, NJ, USA) is ligated at the intersection of the metal bar of the gut clumper and is cut to approximately 5 cm in length. The first assistant surgeon inserts the gut clumper into the pelvic cavity. The intersection of gut clumper is oriented to the left, and the longer metal bar of the gut clumper is located behind the rectum. The gut clumper is then guided distal to the tumor. The orientation and position of the gut clumper are adjusted from the 3 o'clock direction to the 9 o'clock direction to the rectum before fastening the gut clumper (Fig. 10.38a, b).

Using a catheter tip passed through the anus, the rectum and anal canal are washed with 500 mL of 5 % povidone-iodine solution. To enable the first assistant surgeon to use a linear stapler, arm ① is taken out and da Vinci port ① in the right lower abdomen is removed and changed to a 12-mm port (Fig. 10.3).



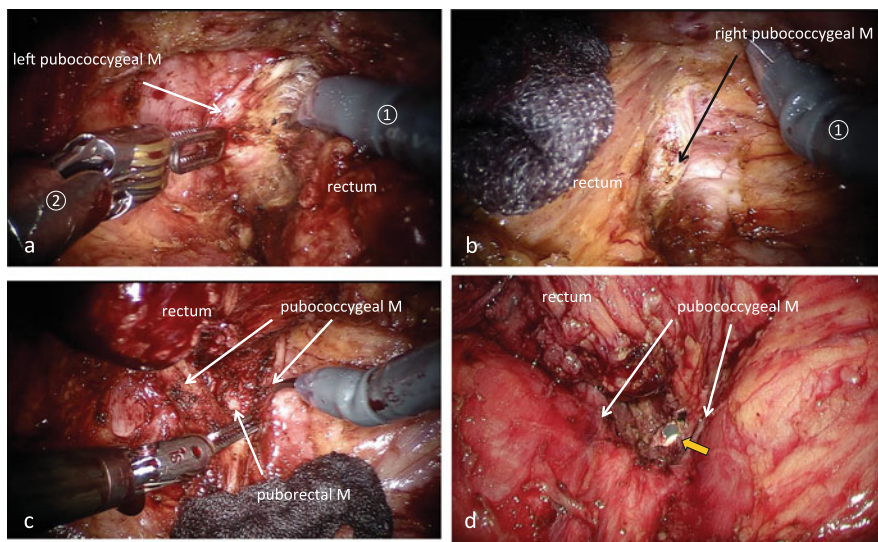


**Fig. 10.36** Dissection between the rectum and the pubococcygeal muscle. The mesorectum is lifted with the opened double fenestrated forceps on arm ③ ventrally to stretch out the distal end of the rectum (a, b). With the fenestrated forceps on arm ②, the pubococcygeal muscle is grasped and pulled in the dorsocranial direction to clearly show the dissectable layer between the rectal wall and pubococcygeal muscle (c, d)

The second assistant surgeon grasps the no. 1 PDS tied to the gut clasper with the needle driver and pulls it in the left cranial direction. With the fenestrated forceps on arm ②, the polyethylene belt of the gut clasper is then grasped and pulled in the left ventrocranial direction and adjusted so that the metal bar of the gut clasper is parallel to the linear stapler inserted through the right lower abdominal port (Fig. 10.38c).

The thickness of the rectal wall is estimated according to the resistance felt when the gut clasper is fastened. The linear stapler cartridge is selected according to the thickness of the rectal wall. The first assistant surgeon inserts the 45-mm linear stapler into the pelvis through the 12-mm port in the right lower abdomen and the rectum is transected using a couple of linear staplers (Fig. 10.38c, d). At the time of the second transection, the left wall of the rectum is pushed to the right with the fenestrated forceps on arm ② so that the entire rectum is contained within the linear stapler [9] (Fig. 10.38d).

The patient cart out is then rolled out.



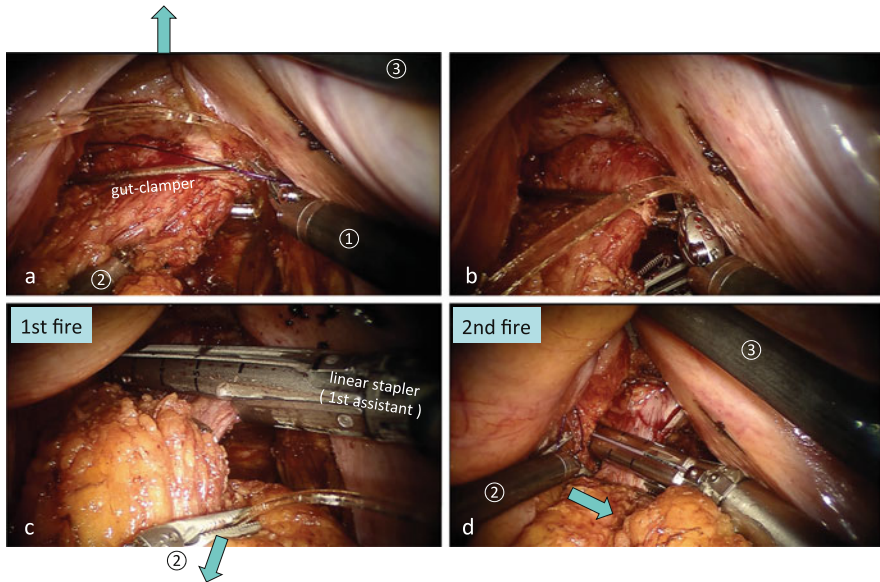
**Fig. 10.37** Dissection into the anal canal. After dissecting the entire nerve branch extending from the neurovascular bundle toward the rectum, the space between the pubococcygeal muscle and rectal wall is reached from a direction anterolateral to the rectum. With the fenestrated forceps on arm ②, the pubococcygeal muscle is grasped and pulled laterally, or the rectum is pushed medially to reveal the dissectable layer within the anal canal (a, b). The dissection plane between the rectum and puborectal muscle is extended from posterolaterally to posteriorly, and then the anal canal is dissected sufficiently (c). The sufficient dissection into the anal canal expedites the intersphincteric dissection from the anal side (orange arrow) (d)

#### 10.8.1.11 Extracorporeal Procedures: Transection of the Colon and Fixation of the Anvil

The wound in the umbilicus is extended to approximately 30 mm in length in the craniocaudal direction, and transection of the colon and fixation of the anvil in the colon are performed extracorporeally. The colon more than 10 cm proximal to the tumor is confirmed to reach the inferior border of the pubis without any tension. After verifying pulsatile blood flow of the marginal artery, the colon is transected approximately 10 cm proximal to the tumor. The anvil of the circular stapler is inserted into the colon and fixed to the colon, and the colon is placed back in the abdominal cavity. Using a surgical glove, the camera port is fixed to the abdominal wall and the pneumoperitoneum is resumed.

#### 10.8.1.12 Reconstruction with the Double-Stapling Technique (DST)

The surgeon stands to the right of the patient, the first assistant surgeon to the left of the patient, and the second assistant surgeon to the left of the surgeon. Using the opened intestinal forceps in the left hand, the first assistant surgeon elevates the right anterior wall of the pelvis in the right ventral direction. With the opened intestinal forceps in the right hand, the first assistant surgeon elevates the left



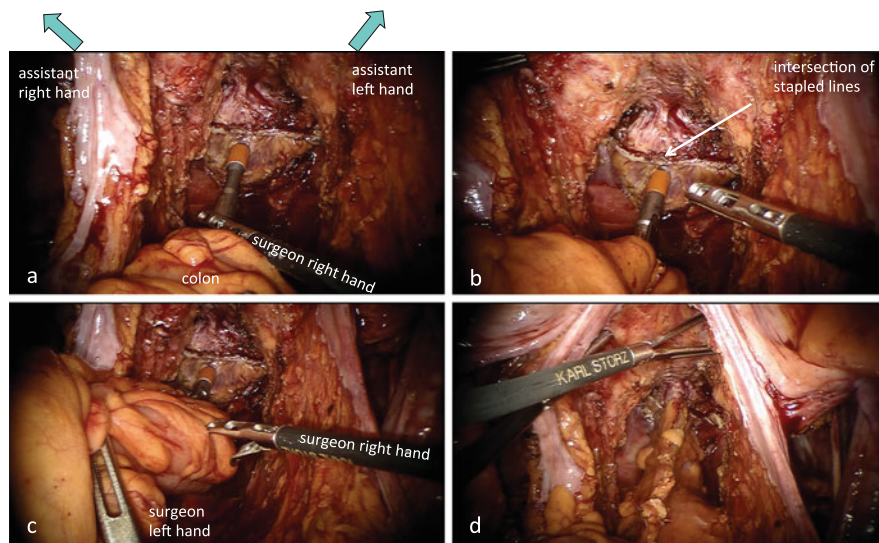
**Fig. 10.38** Transection of the rectum. The orientation and position of the gut clamper are adjusted from the 3 o'clock direction to the 9 o'clock direction to the rectum before fastening the gut clamper (a, b). With the fenestrated forceps on arm ②, the polyethylene belt of the gut clamper is pulled in the left ventrocranial direction and adjusted so that the metal bar of the gut clamper is parallel to the linear stapler inserted through the right lower abdominal port (c). At the time of the second firing, the left wall of the rectum is pushed to the right with the fenestrated forceps on arm ② so that the entire rectum is contained within the linear stapler (d)

anterior pelvic wall in the left ventral direction to expose an overview of the prostate or the posterior wall of the vagina, along with the rectal stump (Fig. 10.39a).

After verifying that the stump of the colon reaches the pelvic floor without any tension, a circular stapler is inserted into the anal canal. With intestinal forceps in the right hand, the surgeon grasps the intersection of the stapled lines and guides the tip of the circular stapler up to the rectal stump. To prevent the urethra or vagina being caught into the anastomosis, the rectal stump immediately dorsal to the intersection of the stapled lines is penetrated by the center rod of the circular stapler (Fig. 10.39a, b).

After confirming that the mesocolon is not twisted and that the small bowel is not invaginated behind the mesocolon, the anvil is connected to the center rod. The cut edge of the mesocolon is oriented ventrally; that is, the colon is positioned onto the sacrum in order to reduce the tension of anastomosis (Fig. 10.39c, d).

The circular stapler is tightened entirely, allowing 2 min of standby time to compress the colon and rectal walls evenly, and then the circular stapler is fired.



**Fig. 10.39** Reconstruction with the double-stapling technique. The pelvic wall is elevated by the opened intestinal forceps in the both hands of the first assistant to expose an overview of the prostate, or posterior wall of the vagina, and the rectal stump (a). To prevent the urethra or the vagina being caught into the anastomosis, the rectal stump immediately dorsal to the intersection of the stapled lines is penetrated by the center rod of the circular stapler (a, b). The cut edge of the mesocolon is oriented ventrally; that is, the colon is positioned onto the sacrum in order to reduce the tension of anastomosis (c, d)

After another minute of standby time for hemostasis, the circular stapler is removed [10, 11] (Fig. 10.39d). The “doughnut” created after anastomosis is inspected for completeness.

Rectal examination is performed, and the height of the anastomosis and the orientation of the colon are verified. Then, in order to decompress the intraluminal pressure around the anastomosis, a 30-Fr Malécot catheter is inserted transanally into the colon approximately 5 cm above the anastomosis and is anchored to the perianal skin with a suture.

The pelvic cavity is filled with warm saline and the colon is pushed toward the promontory with the intestinal forceps in the surgeon’s left hand to block the colonic lumen. Then, 50 mL of air is vigorously injected into the colon via the Malécot catheter to confirm an airtight anastomosis. An air leak site can be repaired intracorporeally or transanally by suturing all the layers of the colon and rectum with 4-0 PDS. In the event that an air leak site cannot be identified or repaired, a covering ileostomy may be created.

A closed circuit drain is placed in the presacral space from the 8-mm da Vinci port ② in the left lower abdomen.

## 10.8.2 Single-Stapling Technique (SST)

The major limitations of the double-stapling technique (DST) are as follows.

- The first assistant surgeon is required to insert the linear stapler in a constrained posture between the robot arm ③ and camera arm (Fig. 10.3).
- The 12-mm port in the right lower abdomen used for insertion of the linear stapler is placed cranially to the right lower abdominal port for laparoscopy. Therefore, in the event that the tumor is located much lower, the tumor is huge, the pelvic cavity is narrow, or the prostate gland is large, it is likely that the transection of the rectum will be difficult (Fig. 10.3; see also Chap. 5, Fig. 5.2).
- The surgeon on the console can manipulate only the fenestrated forceps on arm ②, meaning that the first assistant surgeon's right hand that is manipulating the linear stapler must coordinate with the surgeon's left hand in order to transect the rectum securely.

The following are advantages of the single-stapling technique (SST) [12, 13]:

- The surgeon alone can accurately dissect the rectum, regardless of the first assistant surgeon's skills.
- End-to-end anastomosis is possible as a linear stapler is not used. Also, because there is no point of intersection, the risk of anastomotic failure might be reduced.

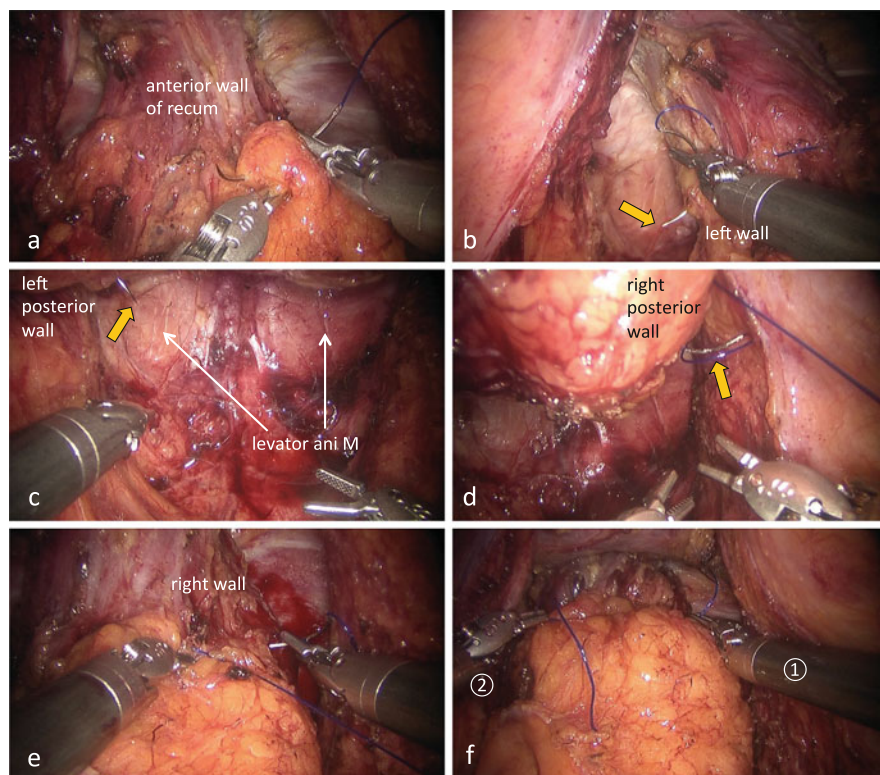
### 10.8.2.1 Transection of the Rectum

The tool on arm ① is changed to a large needle driver. When suturing the rectal wall, the fenestrated forceps on arm ② holds the needle or manipulates the rectal wall.

The first assistant surgeon inserts and removes the 2-0 Prolene suture via the 12-mm port in the right upper abdomen.

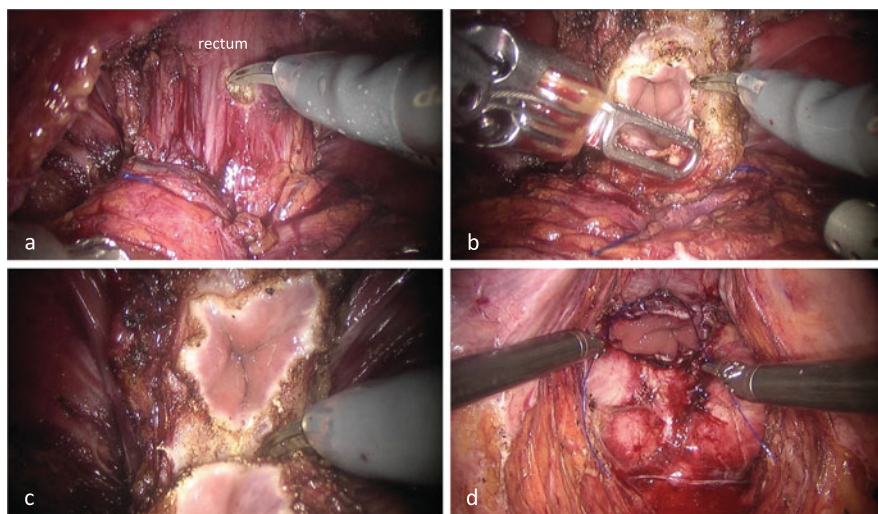
When suturing the seromuscular layer of the anterior wall of the rectum, the seminal vesicles and prostate, or the uterus and vagina, are elevated ventrally with the opened double fenestrated forceps on arm ③. The second assistant surgeon then pulls the string wrapped around the rectum, which straightens the rectum in the dorsocranial direction and creates a field of view anterior to the lower rectum (Fig. 10.6a).

When suturing the seromuscular layer of the posterior wall of the rectum, the second assistant surgeon pulls the rectum in the left ventral direction to straighten it. With the opened double fenestrated forceps on arm ③, the posterior wall of the mesorectum is lifted ventrally to create a field of view posterior to the lower rectum (Fig. 10.6b).



**Fig. 10.40** Occluding the rectal lumen by a purse-string suture. A purse-string suture is applied with 2-0 Prolene to the seromuscular layer of the rectum immediately anal to the lower margin of the tumor in the counterclockwise direction (a–e). The 2-0 Prolene string is tied to occlude the rectal lumen (f). *orange arrow* the needle stuck in the lateral wall of the rectum

The site of the lower margin of the tumor is verified by rectal examination. After creating a field of view anterior to the rectum, a purse-string suture is applied using 2-0 Prolene to the seromuscular layer of the rectum immediately anal to the lower margin of the tumor in the counterclockwise direction from the anterior wall of the rectum (Fig. 10.40a). Once the needle reaches the left wall of the rectum, the rectum is elevated ventrally to create the operative field posterior to the lower rectum with the needle stuck in the left wall of the rectum (Fig. 10.40b, c). This needle in the left wall of the rectum is then drawn and a purse-string suture is applied, proceeding in the right direction, in the seromuscular layer of the posterior wall of the rectum. Once the needle reaches the right wall of the rectum, the rectum is placed back dorsally once again to create the operative field anterior to the rectum with the needle stuck in the right wall of the rectum (Fig. 10.40d, e). This needle in the right



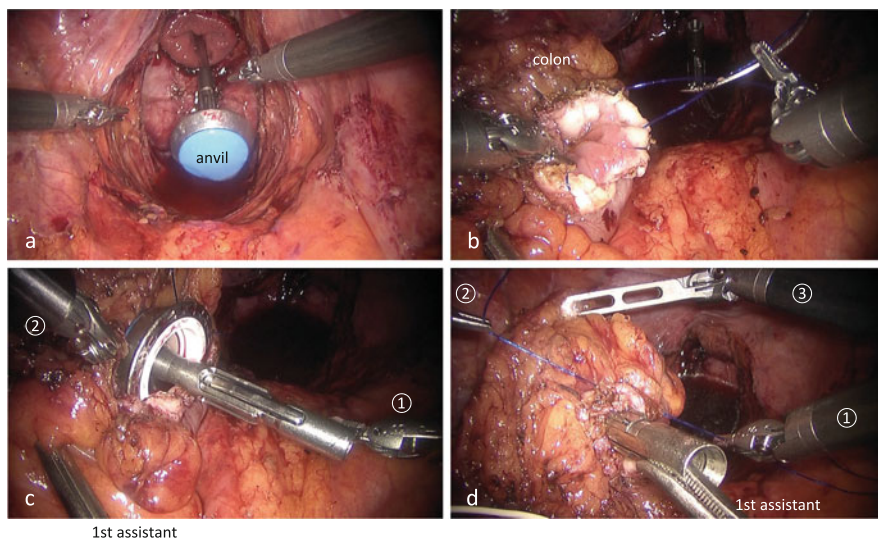
**Fig. 10.41** Transection of the rectum. The rectum is dissected approximately 2 cm anal to the lower margin of the tumor (a–c). A running whipstitch suture is applied with 2-0 Prolene through all the layers of the rectal stump (d)

wall of the rectum is then drawn and a purse-string suture is applied in the seromuscular layer of the anterior wall of the rectum to complete the procedure (Fig. 10.40e). The tool on arm ② is changed to a large needle driver, and the 2-0 Prolene string is tied to occlude the rectal lumen (Fig. 10.40f). Using a catheter tip passed through the anus, the rectum and anal canal are washed with 500 mL of 5 % povidone-iodine solution.

The tools on arms ① and ② are changed to the monopolar curved scissors and the fenestrated forceps, respectively, and the rectum is dissected by the monopolar curved scissors on arm ① approximately 2 cm anal to the lower margin of the tumor (Fig. 10.41a–c). Once again, the tool on arm ① is changed to a large needle driver, and a running whipstitch suture is applied with 2-0 Prolene through all the layers of the rectal stump (Fig. 10.41d). At this point in time, the Prolene thread is left without ligation.

### 10.8.2.2 Transection of the Colon, Specimen Extraction, and Anvil Fixation (Robot-Assisted Intracorporeal Procedure)

This procedure is indicated only when specimen can be extracted through the anus. In patients with anal stenosis, huge tumor, or a bulky mesorectum, transection of the colon and fixation of the anvil in the colon are performed as an extracorporeal procedure from the umbilicus.



**Fig. 10.42** Transection of the colon and fixation of the anvil of the circular stapler in the colon (robot-assisted intracorporeal procedure). The anvil of the circular stapler is inserted into the pelvic cavity via the anus (a). A running whipstitch suture is applied with 2-0 Prolene through all the layers of the colonic stump (b). The anvil is inserted into the colonic lumen and then fixed by ligation (c, d)

A purse-string suture with 2-0 Prolene is applied through the seromuscular layer of the colon approximately 10 cm proximal to the tumor and ligated to occlude the colonic lumen. The colon is dissected by the monopolar curved scissors on arm ① immediately proximal to the site of ligation. A specimen collection bag is inserted via the anus into the pelvic cavity, and the resected specimen is collected in the bag and extracted via the anus. The anvil of the circular stapler is inserted into the pelvic cavity via the anus (Fig. 10.42a). A running whipstitch suture is applied with 2-0 Prolene through all the layers of the colonic stump (Fig. 10.42b). The anvil is inserted into the colonic lumen and then fixed by ligation (Fig. 10.42c, d).

### 10.8.2.3 Transection of the Colon and Anvil Fixation (Extracorporeal Procedure)

Once the patient cart is rolled out, the wound in the umbilicus is extended to approximately 30 mm in length in the craniocaudal direction in order to switch to an extracorporeal procedure. Thereafter, the procedure follows the method described in Sect. 10.8.1.11.

As outlined in Sect. 10.8.1.6, the patient cart is rolled in again, and the robot arms and ports are docked.



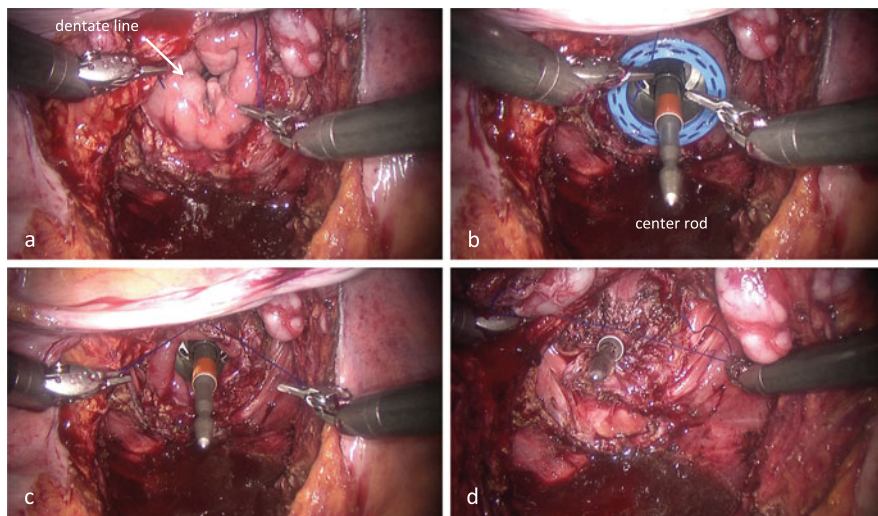
#### 10.8.2.4 Reconstruction with the Single-Stapling Technique (SST)

With the opened double fenestrated forceps on arm ③, the seminal vesicles and prostate, or the vagina, are elevated in the ventrocaudal direction to expose an overview of the prostate, or posterior wall of the vagina, and the rectal stump. The large needle drivers on arms ① and ② are installed (Fig. 10.43a).

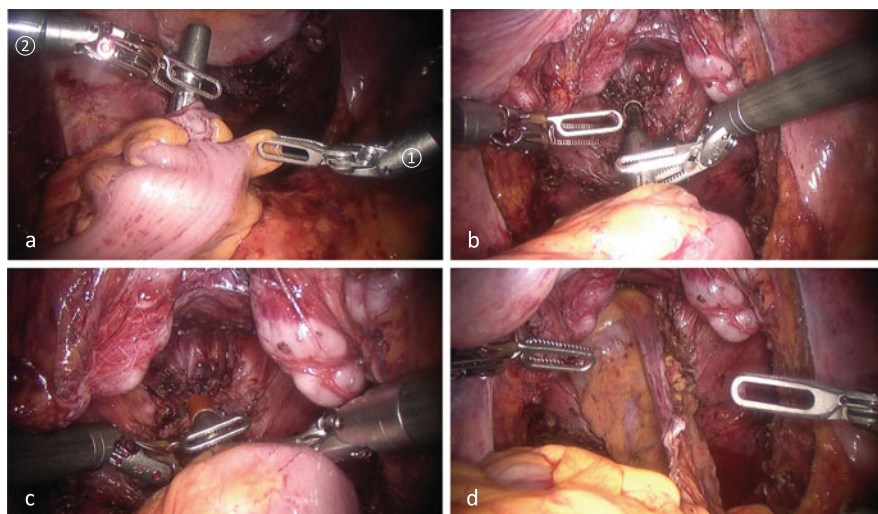
The tip of the circular stapler is inserted via the anus past the rectal stump into the pelvic cavity, and once the center rod is positioned appropriately, the tip of the circular stapler is pulled just anal to the rectal stump within the anal canal (Fig. 10.43b, c).

The 2-0 Prolene running whipstitch suture already applied through all the layers of the rectal stump is ligated to fasten the rectal stump to the center rod (Fig. 10.43d). An additional purse-string suture is then applied to the seromuscular layer of the rectal stump with 2-0 Prolene and ligated to securely fasten the rectal stump to the center rod.

The tools on arms ① and ② are changed to the fenestrated forceps and the Cadieere forceps, respectively. After confirming that the mesocolon is not twisted and that the small bowel is not invaginated behind the mesocolon, the colon is guided into the pelvic floor and the anvil is connected to the center rod (Fig. 10.44a–c). The cut edge of the mesocolon is oriented ventrally; that is, the colon is positioned onto the sacrum in order to reduce the tension of anastomosis (Fig. 10.44d).



**Fig. 10.43** Fixation of the rectal stump to the center rod of the circular stapler. The dentate line is visible from the pelvic side (a). The tip of the circular stapler is inserted via the anus past the rectal stump into the pelvic cavity, and once the center rod is positioned appropriately, the tip of the circular stapler is pulled just anal to the rectal stump within the anal canal (b, c). The 2-0 Prolene running whipstitch suture already applied through all the layers of the rectal stump is ligated to fasten the rectal stump to the center rod (d)



**Fig. 10.44** Reconstruction with the single-stapling technique. The colon is guided into the pelvic floor and the anvil is connected to the center rod (a–c). The cut edge of the mesocolon is oriented ventrally; that is, the colon is positioned onto the sacrum in order to reduce the tension of anastomosis (d)

The circular stapler is tightened entirely, allowing two minutes of standby time to compress the colon and rectal walls evenly, and then the circular stapler is fired. After another minute of standby time for hemostasis, the circular stapler is removed.

Thereafter, the procedure follows the technique described in Sect. 10.8.1.12.

## 10.9 Conclusions

The use of surgical robotics in TME for lower rectal cancer allows the preservation of urogenital function without the loss of curative potential. In the future, the short- and long-term outcomes of robot-assisted TME, in addition to its utility in maintaining urinary and sexual functions, should be examined in detail and the cost-effectiveness of this procedure should also be discussed.

## References

1. Heald RJ, Husband EM, Ryall RD. The mesorectum in rectal cancer surgery – the clue to pelvic recurrence? *Br J Surg.* 1982;69:613–6.
2. Heald RJ. The ‘Holy Plane’ of rectal surgery. *J R Soc Med.* 1988;81:503–8.
3. Enker WE. Total mesorectal excision – the new golden standard of surgery for rectal cancer. *Ann Med.* 1997;29:127–33.

4. Hasegawa S, Nagayama S, Nomura A, Kawamura J, Sakai Y. Autonomic nerve-preserving total mesorectal excision in the laparoscopic era. *Dis Colon Rectum*. 2008;51:1279–82.
5. Sakai Y, Nomura A, Masumori K, Kawamura J, Nagayama S. Recent interpretations of Denonvilliers' fascia and the lateral ligament of the rectum. *Asian J Endosc Surg*. 2009;2:8–12.
6. Hida K, Hasegawa S, Kataoka Y, Nagayama S, Yoshimura K, Nomura A, Kawada K, Kawamura J, Kinjo Y, Sakai Y. Male sexual function after laparoscopic total mesorectal excision. *Colorectal Dis*. 2013;15:244–51.
7. Shinohara H, Haruta S, Ohkura Y, Udagawa H, Sakai Y. Tracing dissectable layers of mesenteries overcomes embryologic restrictions when performing infrapyloric lymphadenectomy in laparoscopic gastric cancer surgery. *J Am Coll Surg*. 2015;220:e81–7.
8. Kiyoshima K, Yokomizo A, Yoshida T, Tomita K, Yonemasu H, Nakamura M, Oda Y, Naito S, Hasegawa Y. Anatomical features of periprostatic tissue and its surroundings: a histological analysis of 79 radical retropubic prostatectomy specimens. *Jpn J Clin Oncol*. 2004;34:463–8.
9. Kuroyanagi H, Oya M, Ueno M, Fujimoto Y, Yamaguchi T, Muto T. Standardized technique of laparoscopic intracorporeal rectal transection and anastomosis for low anterior resection. *Surg Endosc*. 2008;22:557–61.
10. Kawada K, Hasegawa S, Hida K, Hirai K, Okoshi K, Nomura A, Kawamura J, Nagayama S, Sakai Y. Risk factors for anastomotic leakage after laparoscopic low anterior resection with DST anastomosis. *Surg Endosc*. 2014;28:2988–95.
11. Nakayama S, Hasegawa S, Hida K, Kawada K, Sakai Y. Obtaining secure stapling of a double stapling anastomosis. *J Surg Res*. 2015;193:652–7.
12. Choi GS, Park IJ, Kang BM, Lim KH, Jun SH. A novel approach of robotic-assisted anterior resection with transanal or transvaginal retrieval of the specimen for colorectal cancer. *Surg Endosc*. 2009;23:2831–5.
13. Kim HJ, Choi GS, Park JS, Park SY. Comparison of intracorporeal single-stapled and double-stapled anastomosis in laparoscopic low anterior resection for rectal cancer: a case-control study. *Int J Colorectal Dis*. 2013;28:149–56.