

Clubfoot: Ponseti Management

Foreword

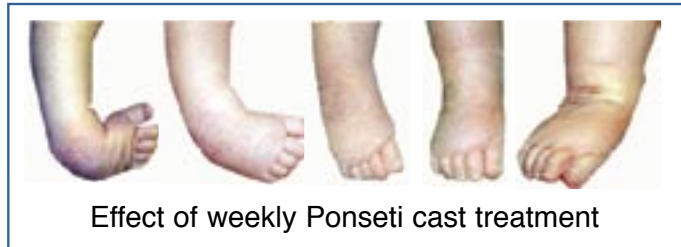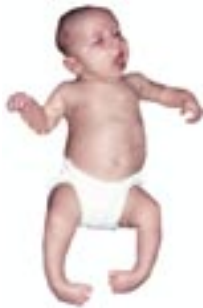Ignacio Ponseti

Contributors

Shafique Pirani
 Fred Dietz
 Jose Morcuende
 Vincent Mosca
 John Herzenberg
 Stuart Weinstein
 Norgrove Penny
 Michiel Steenbeek

Editor

Lynn Staheli



Contents

Contents 1
 Preface 2
 Global-HELP 2
 Contributors 3
 Foreword 4

Management

Scientific basis of management 6
 Overview of Ponseti management 8
 Cavus correction 10
 Correction of varus and adduction 12
 Correction of equinus 14
 Night bracing 15
 Managing relapses 17

Reference

Public health approach to clubfoot 18
 Management worldwide 20
 Severity scoring 22
 Errors in management 23
 Useful contacts and links 23
 Steenbeek brace 24
 Transfer of tibialis anterior tendon 26

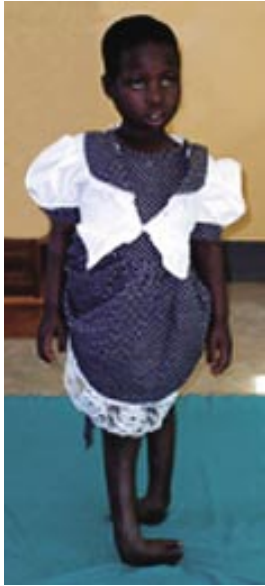For parents

General information 28
 Instructions for brace use 30
 Common questions 31



Preface

Most infants with clubfoot are born in countries where they receive no treatment, leaving them to face a life of disability.



In developed countries, clubfoot is usually treated by extensive surgery. The long-term, follow-up studies of clubfoot that is treated by extensive surgery show poor results, including weakness, stiffness, and early arthritis.

Dr. Ignacio Ponseti developed a method of clubfoot management that is inexpensive and effective. Long-term follow-up studies show that feet treated by Ponseti management are strong, flexible, and pain free. These studies prove that Ponseti management of clubfoot is best for all countries and cultures.

We produced this book to provide an affordable, authoritative, easy-to-follow guide for health care professionals to learn the Ponseti method

of clubfoot management. This book is designed to be engaging and colorful, with sufficient detail to help newcomers master the method.

In the foreword, Dr. Ponseti tells us how he developed the method. He reviews the scientific basis of management and he summarizes the expanding literature.

Dr. Shafique Pirani provides magnetic resonance imaging showing how Ponseti casts remodel the deformed tarsals and normalize the intertarsal relationships. He provides a way of classifying clubfoot at initial presentation, a flowchart for management, and a reliable and valid method of assessing the amount of deformity. Dr. Pirani, Dr. Penny, and Mr. Steenbeek detail the public health approach to clubfoot treatment using Ponseti management and demonstrate its successful application in Uganda.

Dr. Ponseti’s colleagues, Drs. Dietz, Morcuende, and Weinstein, guide us through the steps in correction. They stress the importance of learning and applying these steps exactly as described by Dr. Ponseti. The principles of Ponseti management are simple, but application requires careful attention to detail. Many illustrations are included to clarify each step.

We recommend that Ponseti management be learned from those with extensive experience using this method. The learning experience can be simplified by attending specialty courses, such as those taught in Iowa City and at other centers throughout the world.

As early users of Ponseti management outside of Iowa, Drs. Herzenberg and Mosca contribute their experience with bracing, and managing recurrent deformity. They detail the technique of anterior tibialis tendon transfers, and offer suggestions for managing late and complex clubfoot.

We include affirmation of the effectiveness of Ponseti management from a sampling of centers throughout the world, showing that the management is effective and applicable in varied social and economic settings.

Night bracing is necessary after correction to prevent recurrence, so we include an overview of the use of the Steenbeek brace. This brace is made using simple tools and materials that are readily available and inexpensive throughout the world.

Family compliance using night bracing is a critical part of management, so information for parents is provided. This information may be copied and distributed to the families.

This book is created by a team who donated their time and experience. We encourage duplication when it is done without financial gain. Translations of this book into multiple languages are planned.

We anticipate that with time, this book will be improved and enhanced. We appreciate your feedback and suggestions for improving subsequent editions.

This book is produced by the Global-HELP organization (GHO), a not-for-profit organization that produces and distributes free or affordable health care education materials worldwide.

Printing of this book was made possible by the financial contributions of our GHO Board members: Ms. Susan Elliott, Mr. Lars Jonsson, Mr. Paul Merriman, and Drs. Lana and Lynn Staheli.



We appreciate the donated professional text editing by Ms. Dori Kelly and the high quality printing by the McCallum Print Group of Seattle.

Lynn Staheli, MD
Editor and Producer, 2003

This is a Global-HELP publication

Visit our web site at global-help.org

Global-HELP
Health Education Low-cost Publications

Global-HELP is a not-for-profit, humanitarian organization that creates low-cost publications to improve the quality of health care in transitional and developing countries.

Sponsors

Susan Elliott

Susan is an organization consultant who has worked in both the public and nonprofit sectors. She served on the executive committee for HIV/AIDS education for Group Health Cooperative in Seattle, Washington.

Lars Jonsson

Lars is the Chairman, CEO, and President of Stellar International Holdings and is responsible for the overall strategic direction of his company. Lars is actively involved in commercial real estate in Spain, Sweden, and the United States.

Paul Merriman

Paul is the president of Merriman Capital Management and co-portfolio manager of a family of mutual funds. He is a publisher and editor of FundAdvice.com, host of a weekly radio and webcast show, author of investing books, and weekly columnist for CBSMarketWatch.com.

Lana Staheli, PhD

Lana is a counselor and author. She serves on the Harvard University's Kennedy School of Government Women's Leadership Board and on the University of Washington's Women and Democracy board.

Dori Kelly, MA

Dori is a senior editor and publications manager in Baltimore, Maryland. She donated her skill as a professional text editor for this book.



Publisher's Information

Published by

Global-HELP Organization

Copyright

Copyright, Global-HELP.Org, 2003

Every effort has been made to confirm the accuracy of the presented information. The authors and publisher are not responsible for errors of omission or for any consequences from the application of the information in this book and make no warranty, expressed or implied, with respect to the currency, completeness, or accuracy of the contents of this publication. Application of this information in a particular situation remains the professional responsibility of the practitioner.

Authors

Ignacio Ponseti, MD

Dr. Ponseti developed his method of management more than 50 years ago and has treated hundreds of infants using this method. Currently Professor Emeritus at the University of Iowa, he provided guidance throughout the production of the book and wrote the Foreword and Scientific Basis of Management.

Shafique Pirani, MD

A major contributor skilled in Ponseti management, Dr. Pirani is an advocate and early user of the method in Canada. He has created a successful model for using Ponseti management in undeveloped countries.

Fred Dietz, MD

A colleague of Dr. Ponseti, Dr. Dietz contributed the images and text for the management section.

Jose A. Morcuende, MD, PhD

A colleague of Dr. Ponseti, Dr. Morcuende provided the text for the sections on questions and answers and information for parents.

Vincent Mosca, MD

Dr. Mosca is an advocate and early user of Ponseti management in western America. He provided the text for complex clubfoot management, and demonstrated the anterior tibialis transfer procedure. He provided detailed editing.

John Herzenberg, MD

One of the first physicians to adopt the Ponseti method of clubfoot management outside of Iowa. Dr. Herzenberg contributed the text and illustrations for the sections on bracing and management of relapses.

Stuart Weinstein, MD

A long-term colleague of Dr. Ponseti and early advocate of his management, Dr. Weinstein contributed suggestions and support.

Norgrove Penny, MD

Dr. Penny is a major contributor to the Uganda project. He has made many contributions for health care delivery in developing countries.

Michiel Steenbeek

Mr. Steenbeek is an orthotist and physiotherapist who designed a brace that is constructed by using widely available tools and materials, making it useful in developing countries.



Foreword

It is estimated that more than 100,000 babies are born worldwide each year with congenital clubfoot. Eighty percent of the cases occur in developing nations. Most are untreated or poorly



Dr. Ponseti

treated. Neglected clubfoot causes crushing physical, social, psychological, and financial burdens on the patients, their families, and the society. Globally, neglected clubfoot is the most serious cause of physical disability among congenital musculoskeletal defects.

In developed countries, many children with clubfoot undergo extensive corrective surgery, often with disturbing failures and complications. The need for one or more revision surgeries is common. Although the foot

looks better after surgery, it is stiff, weak, and often painful. After adolescence, pain increases and often becomes crippling.

Clubfoot in an otherwise normal child can be corrected in 2 months or less with our method of manipulations and plaster cast applications, with minimal or no surgery. This was proven by the results of our 35-year follow-up study and confirmed in many clinics around the world.

This method is particularly suited for developing countries where there are few orthopaedic surgeons. The technique is easy to learn by allied health professionals, such as therapists and orthopaedic assistants. A well-organized health system is needed to ensure that parents follow the instructions for use of the foot abduction brace to prevent relapses.

The treatment is economical and easy on the babies. If well implemented, it will greatly decrease the number of clubfoot cripples.

Development of the technique

In the mid 1940s, I examined 22 patients with clubfoot that had been surgically treated in the 1920s by Arthur Steindler, a good surgeon. The feet had become rigid, weak, and painful.

Effect of operative correction

In the 1940s, we were doing many posteromedial releases and I saw that most of the important ligaments of the tarsus had to be severed to loosen the subtalar and midtalar joints so that the foot could be abducted under the talus. When operating on relapses, I noticed severe scarring in the foot and stiffness in the misshapen joints. The posterior tibial and toe flexor tendons that had been lengthened in the first operation, were matted and immobilized in a mass of scar tissue. After a few years of this experience, I was convinced that surgery was the wrong approach for treatment of clubfoot.

Anatomical studies

A study of histological sections of ligaments from virgin clubfeet, obtained in the operating room and from fetuses and stillborns, revealed that the abundant young collagen in the ligaments was wavy, was very cellular, and could be easily stretched. I conceived, therefore, that the displaced navicular, cuboid, and calcaneus could be gradually abducted under the talus without cutting any of the tarsal ligaments. I discovered that this was so based on cineradiography of clubfeet I had partially or fully reduced without surgery.

From dissections of normal feet of children and adults in the anatomy department and of clubfeet of stillborns, I fully understood the mechanism of the interdependent movements of the tarsal bones and realized that clubfoot deformity was simple to correct. The Huson thesis, *An Anatomical and Functional Study of the Tarsal Joints*, published in 1961 in Leiden, Holland, corroborated my understanding of the functional anatomy of the foot.

Casting technique

My casting technique was learned from Böhler and applied during the Spanish Civil War in 1936–1939 when treating more than 2,000 war-wound fractures with unpadded plaster casts. Precise, gentle molding of the plaster over the reduced subluxations of the tarsal bones of a clubfoot is just as basic as the molding of a plaster cast on a well-reduced fracture.

Cavus correction

The cavus, or high arch, is a characteristic deformity of the forefoot that is associated with inversion, or supination, of the hindfoot. It results from a greater flexion of the first metatarsal bone, causing pronation of the forefoot in relation to the hindfoot. Hicks described it in the 1950s as a “pronation twist.” The surgeon’s misconception that pronation is necessary to correct clubfoot causes a further increase of the cavus: an iatrogenic deformity. When the functional anatomy of the foot is well understood, it becomes clear that one must correct the cavus first by supinating the forefoot to place it in proper alignment with the hindfoot.

Varus, inversion, and adduction correction

Next, one must correct simultaneously the varus, inversion, and adduction of the hindfoot, because the tarsal joints are in a strict mechanical interdependence and cannot be corrected sequentially.

Maintaining correction

The genes responsible for clubfoot deformity are active starting from the 12th to the 20th weeks of fetal life and lasting until 3 to 5 years of age. The deformity occurs during the very fast period of growth of the foot. (Such transient gene activity occurs in many other biological events; it is observed in developmental dysplasia of the hip, idiopathic scoliosis, Dupuytren’s contracture, and osteoarthritis). With our technique of clubfoot correction, the joint surfaces of the bones reshape congruently in their normal position. It is important to apply the last plaster cast with the foot in an overcorrected position: 75 degrees of abduction and 20 degrees of ankle dorsiflexion.

While kicking in the foot abduction brace full time for 3 months, the baby strengthens the peroneal muscles and foot extensor muscles that counteract the pull of the tibialis and gastrosoleus muscles. Relapses are rare with the continued use of the foot abduction brace for 14 to 16 hours a day (when the baby sleeps) until 3 to 4 years of age. In a few cases, anterior tibialis tendon transfer to the third cuneiform is necessary to permanently balance the foot.

Delayed acceptance of the technique

It was disappointing that my first article on congenital clubfoot, published in the *The Journal of Bone & Joint Surgery* in March 1963, was disregarded. It was not carefully read and, therefore, not understood. My article on congenital metatarsus adductus, published in the same journal in June 1966, was easily understood, perhaps because the deformity occurs in one plane. The approach was immediately accepted, and the illustrations were copied in most textbooks.

A few orthopaedic surgeons studied my technique and began to apply it only after the publication of our long-term follow-up article in 1995, the publication of my book a year later, and the posting of Internet support group web sites by parents of babies whose clubfoot I had treated. I have been reprimanded for not pushing the method more forcefully from the beginning.

The reason that congenital clubfoot deformity was not understood for so many years and was so poorly treated is related, I believe, to the misguided notion that the tarsal joints move on a fixed axis of motion. Orthopaedists try to correct the severe supination that is associated with clubfoot by forcefully pronating the forefoot. This causes an increase of the cavus and a breach in the midfoot. The breach in the midfoot is caused by jamming the anterior tuberosity of the adducted calcaneus against the undersurface of the head of the talus. Clubfoot is easily corrected when the functional anatomy of the foot is well understood. The completely supinated foot is abducted under the talus that is secured against rotation in the ankle mortise by applying counterpressure with the thumb against the lateral aspect of the head of the talus. The varus, inversion, and adduction of the hindfoot are corrected simultaneously, because the tarsal joints are in strict mechanical interdependence and cannot be corrected sequentially.

I. Ponseti, 2003

Bibliography

- 1963** Ponseti IV, Smoley EN. "Congenital Clubfoot: The Results of Treatment." *Journal of Bone & Joint Surgery* 45A(2): 2261–2275.
- 1966** Ponseti IV, Becker JR. "Congenital Metatarsus Adductus: The Results of Treatment." *Journal of Bone & Joint Surgery* 43A(4):702–711.
- 1972** Campos J, Ponseti IV. "Observations on Pathogenesis and Treatment of Congenital Clubfoot." *Clinical Orthopaedics and Related Research* 84:50–60.
- 1974** Ionasescu V, Maynard JA, Ponseti IV, Zellweger H. "The Role of Collagen in the Pathogenesis of Idiopathic Clubfoot: Biochemical and Electron Microscopic Correlations." *Helvetica Paediatrica Acta* 29(4):305–314.

1980 Ippolito E, Ponseti IV. "Congenital Clubfoot in the Human Fetus: A Histological Study." *Journal of Bone & Joint Surgery* 62A(1):8–22.

1980 Laaveg SJ, Ponseti IV. "Long-term Results of Treatment of Congenital Clubfoot." *Journal of Bone & Joint Surgery* 62A(1):23–31.

1981 Brand RA, Laaveg SJ, Crowninshield RD, Ponseti IV. "The Center of Pressure Path in Treated Clubfoot." *Clinical Orthopaedics and Related Research* 160:43–47.

1981 Ponseti IV, El-Khoury GY, Ippolito E, Weinstein SL. "A Radiographic Study of Skeletal Deformities in Treated Clubfoot." *Clinical Orthopaedics and Related Research* 160:30–42.

1992 Ponseti IV. "Treatment of Congenital Clubfoot." [Review, 72 refs] *Journal of Bone & Joint Surgery* 74A(3):448–454.

1994 Ponseti IV. "The Treatment of Congenital Clubfoot." [Editorial] *Journal of Orthopaedic & Sports Physical Therapy* 20(1):1.

1994 Farsetti P, Weinstein SL, Ponseti IV. "The Long-term Functional and Radiographic Outcomes of Untreated and Non-Operatively Treated Metatarsus Adductus." *Journal of Bone & Joint Surgery* 76(2):257–265.

1995 Cooper DM, Dietz FR. "Treatment of Idiopathic Clubfoot: A Thirty-Year Follow-up Note." *Journal of Bone & Joint Surgery* 77(10):1477–1489.

1996 Ponseti IV. *Congenital Clubfoot: Fundamentals of Treatment*. Oxford University Press.

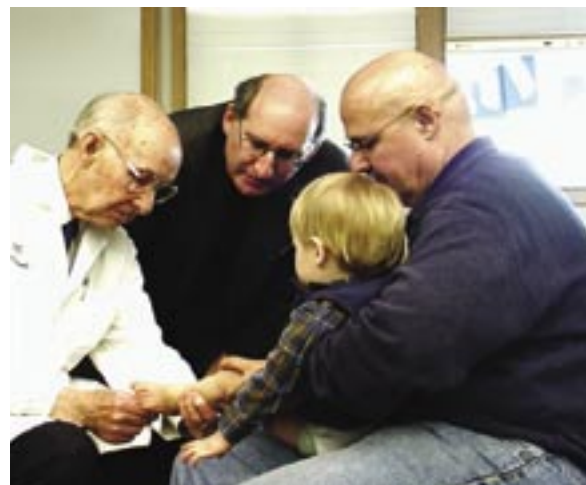1997 Ponseti IV. "Common Errors in the Treatment of Congenital Clubfoot." *International Orthopaedics* 21(2):137–141.

1998 Ponseti IV. "Correction of the Talar Neck Angle in Congenital Clubfoot with Sequential Manipulation and Casting." *Iowa Orthopaedic Journal* 18:74–75.

2000 Ponseti IV. "Clubfoot Management." [Editorial] *Journal of Pediatric Orthopedics* 20(6):699–700.

2001 Pirani S, Zeznik L, Hodges D. "Magnetic Resonance Imaging Study of the Congenital Clubfoot Treated with the Ponseti Method." *Journal of Pediatric Orthopedics* 21(6):719–726.

2003 Ippolito E, Farsetti P, Caterini R, Tudisco C. "Long-term Comparative Results in Patients with Congenital Clubfoot Treated with Two Different Protocols." *Journal of Bone & Joint Surgery* 85A(7):1286–1294.



Scientific Basis of Management

Our treatment of clubfoot is based on the biology of the deformity and of the functional anatomy the foot.

Biology

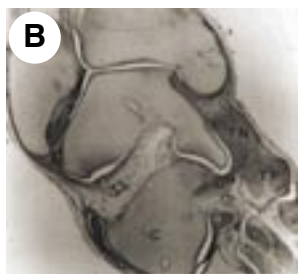
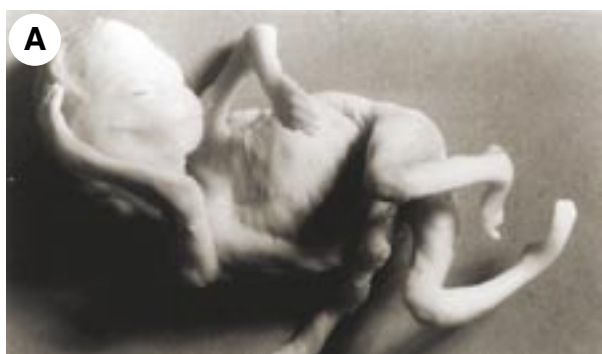Clubfoot is not an embryonic malformation. A normally developing foot turns into a clubfoot during the second trimester of pregnancy. Clubfoot is rarely detected with ultrasonography before the 16th week of gestation. Therefore, like developmental hip dysplasia and idiopathic scoliosis, clubfoot is a developmental deformation.

A 17-week-old male fetus with bilateral clubfoot, more severe on the left, is shown [A]. A section in the frontal plane through the malleoli of the right clubfoot [B] shows the deltoid, tibionavicular ligament, and the tibialis posterior tendon to be very thick and to merge with the short plantar calcaneonavicular ligament. The interosseous talocalcaneal ligament is normal.

A photomicrograph of the tibionavicular ligament [C] shows the collagen fibers to be wavy and densely packed. The cells are very abundant, and many have spherical nuclei (original magnification, x475).

The shape of the tarsal joints is altered relative to the altered positions of the tarsal bones. The forefoot is in some pronation, causing the plantar arch to be more concave (cavus). Increasing flexion of the metatarsal bones is present in a lateromedial direction.

In the clubfoot, there appears to be excessive pull of the tibialis posterior abetted by the gastrosoleus, the tibialis anterior, and the long toe flexors. These muscles are smaller in size and shorter than in the normal foot. In the distal end of the gastrosoleus, there is an increase of connective tissue rich in collagen, which tends to spread into the tendo Achillis and the deep fasciae.



In the clubfoot, the ligaments of the posterior and medial aspect of the ankle and tarsal joints are very thick and taut, thereby severely restraining the foot in equinus and the navicular and calcaneus in adduction and inversion. The size of the leg muscles correlates inversely with the severity of the deformity. In the most severe clubfeet, the gastrosoleus is seen as a muscle of small size in the upper third of the calf. Excessive collagen synthesis in the ligaments, tendons, and muscles may persist until the child is 3 or 4 years of age and might be a cause of relapses.

Under the microscope, we see an increase of collagen fibers and cells in the ligaments of neonates. The bundles of collagen fibers display a wavy appearance known as *crimp*. This crimp allows the ligaments to be stretched. Gentle stretching of the ligaments in the infant causes no harm. The crimp reappears a few days later, allowing for further stretching. That is why manual correction of the deformity is feasible.

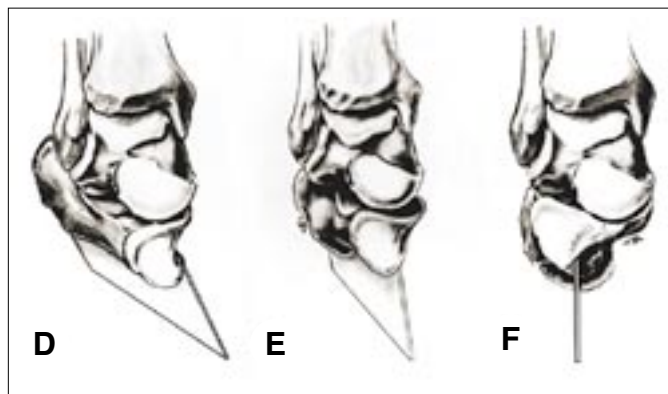
Kinematics

The correction of the severe displacements of the tarsal bones in clubfoot requires a clear understanding of the functional anatomy of the tarsus. Unfortunately, most orthopaedists treating clubfoot act on the wrong assumption that the subtalar and Chopart joints have a fixed axis of rotation that runs obliquely from anteromedial superior to posterolateral inferior, passing through the sinus tarsi. They believe that by pronating the foot on this axis, the heel varus and foot supination can be corrected. This is not so.

Pronating the clubfoot on this imaginary fixed axis tilts the forefoot into further pronation, thereby increasing the cavus and pressing the adducted calcaneus against the talus. The result is a breach in the hindfoot, leaving the heel varus uncorrected.

In the clubfoot [D], the anterior portion of the calcaneus lies beneath the head of the talus. This position causes varus and equinus deformity of the heel. Attempts to push the calcaneus into eversion without abducting it [E] will press the calcaneus against the talus and will not correct the heel varus. Lateral displacement (abduction) of the calcaneus to its normal relationship with the talus [F] will correct the heel varus deformity of the clubfoot.

The clubfoot deformity occurs mostly in the tarsus. The tarsal bones, which are mostly made of cartilage, are in the most extreme positions of flexion, adduction, and inversion at birth. The talus is in severe plantar flexion, its neck is medially and plantarly deflected, and its head is wedge shaped. The navicular



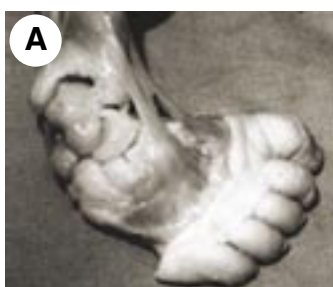is severely medially displaced, close to the medial malleolus, and articulates with the medial surface of the head of the talus. The calcaneus is adducted and inverted under the talus.

As shown in [A], in a 3-day-old infant, the navicular is medially displaced and articulates only with the medial aspect of the head of the talus. The cuneiforms are seen to the right of the navicular, and the cuboid is underneath it. The calcaneocuboid joint is directed posteromedially. The anterior two-thirds of the calcaneus is seen underneath the talus. The tendons of the tibialis anterior, extensor hallucis longus, and extensor digitorum longus are medially displaced.

No single axis of motion (like a mitered hinge) exists on which to rotate the tarsus, whether in a normal or a clubfoot. The tarsal joints are functionally interdependent. The movement of each tarsal bone involves simultaneous shifts in the adjacent bones. Joint motions are determined by the curvature of the joint surfaces and by the orientation and structure of the binding ligaments. Each joint has its own specific motion pattern. Therefore, correction of the extreme medial displacement and inversion of the tarsal bones in the clubfoot necessitates a simultaneous gradual lateral shift of the navicular, cuboid, and calcaneus before they can be everted into a neutral position. These displacements are feasible because the taut tarsal ligaments can be gradually stretched.

Correction of clubfoot is accomplished by abducting the foot in supination while counterpressure is applied over the lateral aspect of the head of the talus to prevent rotation of the talus in the ankle. A well-molded plaster cast maintains the foot in an improved position. The ligaments should never be stretched beyond their natural amount of give. After 5 days, the ligaments can be stretched again to further improve the degree of correction of the deformity.

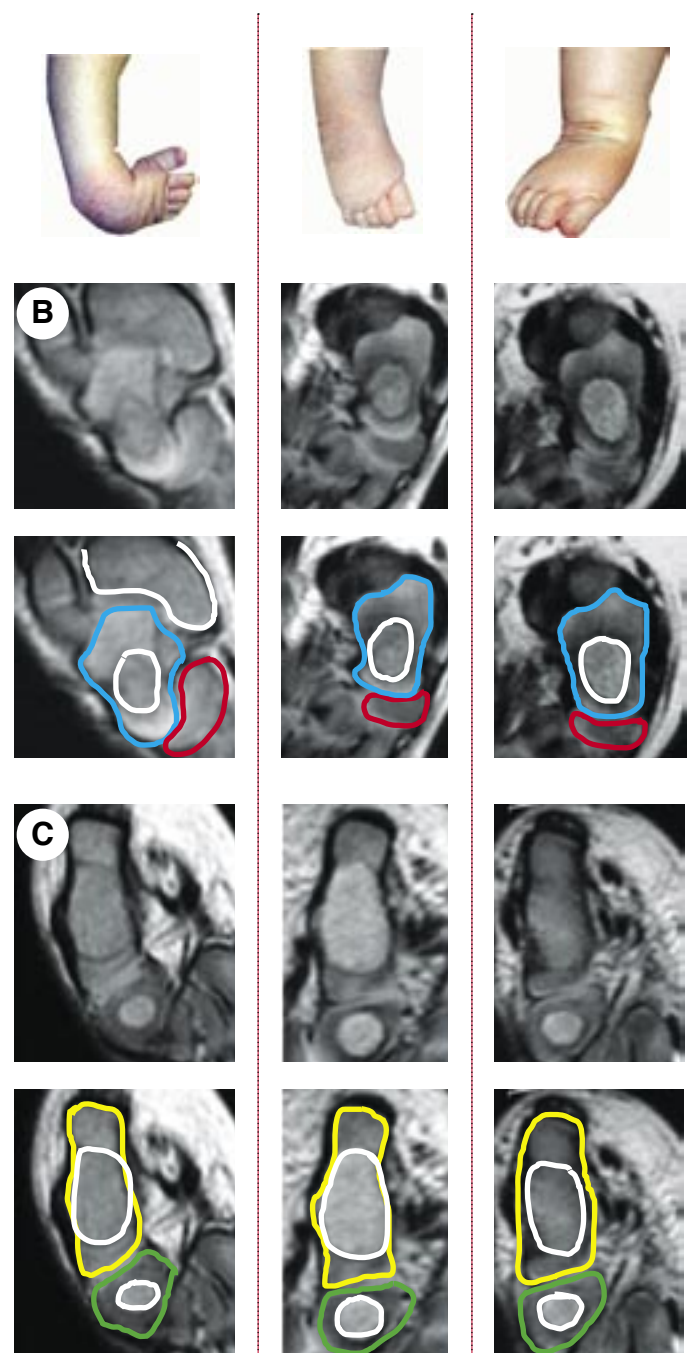
The bones and joints remodel with each cast change because of the inherent properties of young connective tissue, cartilage, and bone, which respond to the changes in the direction of mechanical stimuli. This has been beautifully demonstrated by Pirani, comparing the clinical and magnetic resonance imaging appearance before, during, and at the end of cast treatment. Note the changes in the talonavicular joint [B] and calcaneocuboid joint [C]. Before treatment, the navicular (red outline) is displaced to the medial side of the head of the talus (blue). Note how this relationship normalizes during cast treatment. Similarly, the cuboid (green) becomes aligned with the calcaneus (yellow) during the same cast treatment.



Before applying the last plaster cast, the tendo Achillis may have to be percutaneously sectioned to achieve complete correction of the equinus. The tendo Achillis, unlike the tarsal ligaments that are stretchable, is made of non-stretchable, thick, tight collagen bundles with few cells. The last cast is left in place for 3 weeks while the severed Achilles tendon regenerates in the proper length with minimal scarring. At that point, the tarsal joints have remodeled in the corrected positions.

In summary, most cases of clubfoot are corrected after five to six cast changes and, in many cases, a tendo Achillis tenotomy. This technique results in feet that are strong, flexible, and plantigrade. Maintenance of function without pain has been demonstrated in a 35-year follow-up study.

I. Ponseti, 2003



Overview of Ponseti Management

Can clubfoot be classified?

Yes, classifying clubfoot into categories improves understanding for communication and management [A].

Untreated clubfoot: under 2 years of age

Neglected clubfoot: untreated after 2 years

Corrected clubfoot: corrected by Ponseti management

Recurrent clubfoot: supination and equinus develop after initial good correction

Resistant clubfoot: Stiff clubfoot seen in association with syndromes such as arthrogyposis

Complex clubfoot: initially treated by a method other than Ponseti management

How does Ponseti management correct the deformity?

Keep in mind the basic clubfoot deformity with the deformed talus and the medially displaced navicular [B].

Ponseti's model shows the mechanism of correction. In the sequence [A opposite page], observe that all elements are corrected when the foot is rotated around the head of the talus. This occurs during cast correction.

As viewed from behind [B opposite page], note that correction of the heel varus occurs during this manipulation.

When should treatment with Ponseti management be undertaken?

When possible, start soon after birth (7 to 10 days). When started before 9 months of age, most clubfoot deformities can be corrected by using this management.

When treatment is started early, how many cast changes are usually required?

Most clubfoot deformities can be corrected in approximately 6 weeks by weekly manipulations followed by plaster cast applications. If the deformity is not corrected after six or seven plaster cast changes, the treatment is most likely faulty.

How late can treatment be started and still be helpful?

Treatment is most effective if started before 9 months of age. Treatment between 9 and 28 months is still helpful in correcting all or much of the deformity.

Is Ponseti management useful for neglected clubfoot?

Management that is delayed until early childhood may be started with Ponseti casts. In most cases, operative correction will be required but the magnitude of the procedure may be less than would have been necessary without Ponseti management.

What is the expected outcome in adult life for the infant with clubfoot treated by Ponseti management?

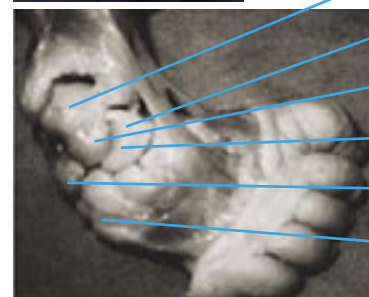
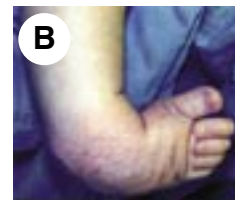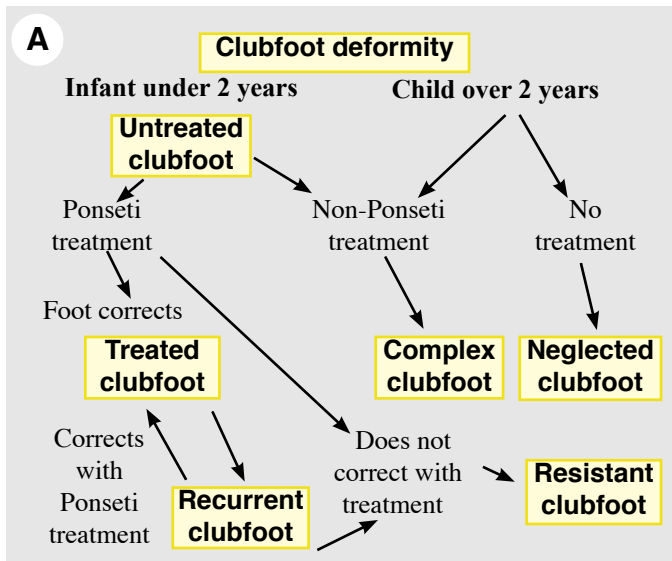
In all patients with unilateral clubfoot, the affected foot is slightly shorter (mean, 1.3 cm) and narrower (mean, 0.4 cm) than the normal foot. The limb lengths, on the other hand, are the same, but the circumference of the leg on the affected side is smaller (mean, 2.3 cm). The foot should be strong, flexible, and pain free.

What is the incidence of clubfoot in children with one or two parents who also are affected?

When one parent is affected with clubfoot, there is a 3% to 4% chance that the offspring will also be affected. However, when both parents are affected, the offspring have a 15% chance of developing clubfoot.

How do the outcomes of surgery and Ponseti management compare?

Surgery improves the initial appearance of the foot but does not prevent recurrence. Importantly, no long-term follow-up studies of operated patients have been published to date. Adult foot and ankle surgeons report that these surgically treated feet become weak, stiff, and often painful in adult life.



- Tibiotalar plantar flexion
- Medial displacement of navicular
- Wedge-shaped head of talus
- Wedge-shaped navicular
- Adducted and inverted calcaneus
- Medially displaced cuboid

How often does Ponseti management fail and operative correction become necessary?

The success rate depends on the degree of stiffness of the foot, the experience of the surgeon, and the reliability of the family. In most situations, the success rate can be expected to exceed 90%. Failure is most likely if the foot is stiff with a deep crease on the sole of the foot.

Is Ponseti management useful for resistant clubfoot?

Ponseti management is appropriate for use in children with arthrogryposis, myelomeningocele, and Larsen syndrome. The results may not be as gratifying as they are in the child with idiopathic clubfoot treated from birth, but there are advantages to this approach. The first is that the clubfoot could respond completely to Ponseti management, with or without the need for an Achilles tenotomy. Additionally, even partial preoperative correction of these severe deformities can decrease the extent of surgery and improve the ability to approximate the edges of the contracted skin.

Arthrogryptic clubfoot is perhaps the most challenging. Often, initial percutaneous heel cord tenotomy is required to enable any manipulative deformity correction. Creating a calcaneocavus deformity is not a concern because of the severe contracture of the posterior joint capsules. Anticipate the need for surgery.

Is Ponseti management useful in myelodysplasia?

Concern has been raised regarding manipulation and casting of the insensate clubfoot in children with myelomeningocele. The physician must apply pressure based on his/her experience with idiopathic clubfoot, in which the child's comfort dictates appropriateness. One must be patient during manipulation and expect that more than the usual number of casts will be needed. The maneuvers are gentle. Concentrated forceful molding over bony prominences is avoided, as it is in all children.

Is Ponseti management useful for complex clubfoot?

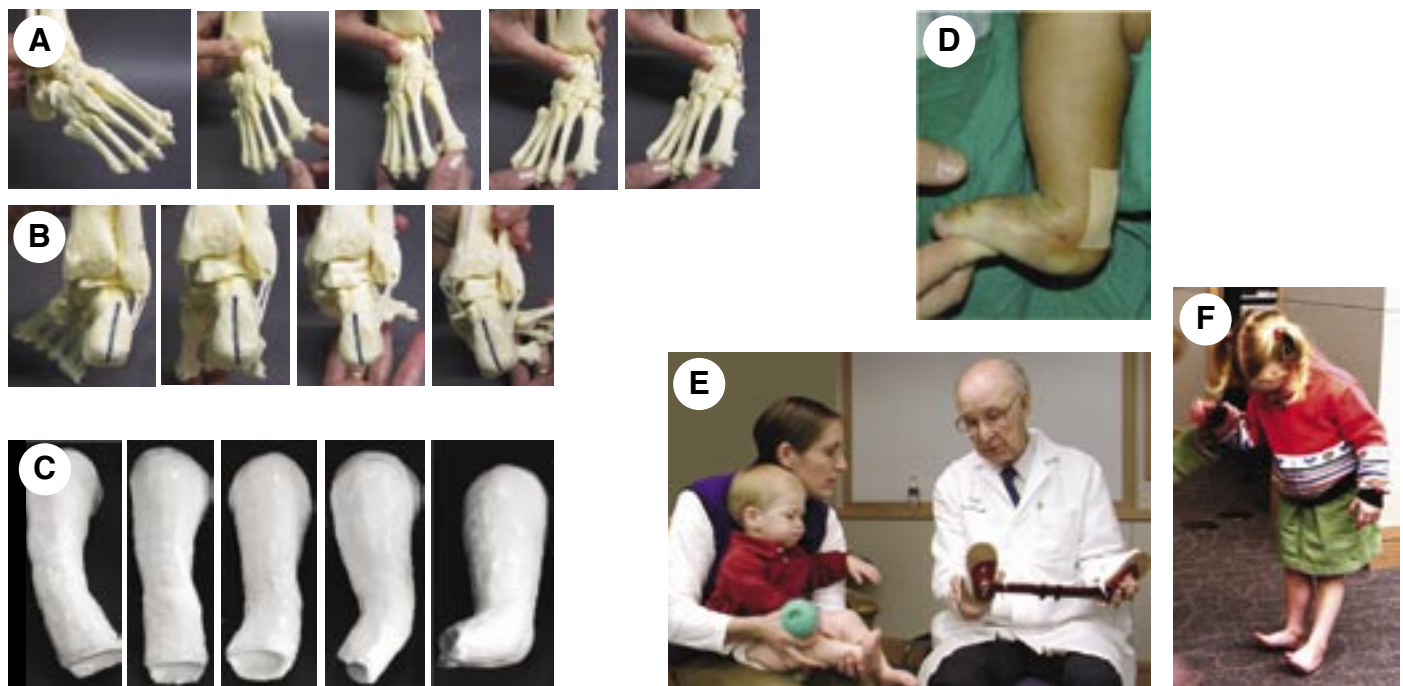Personal experience, and that of others, has shown that Ponseti management can often be successful when applied to feet that have been manipulated and casted by other practitioners who are not yet skilled in this very exacting management.

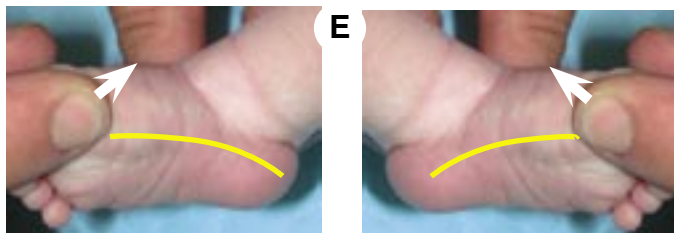
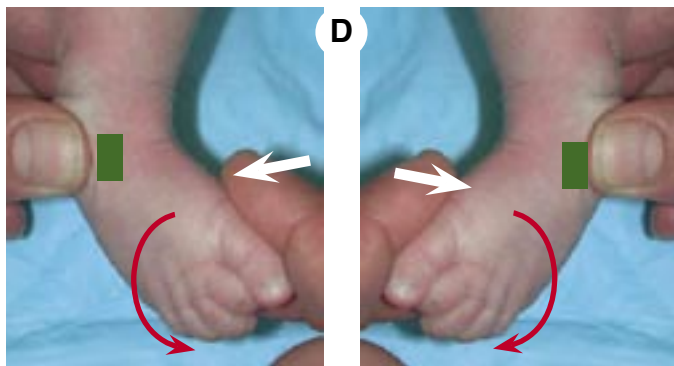
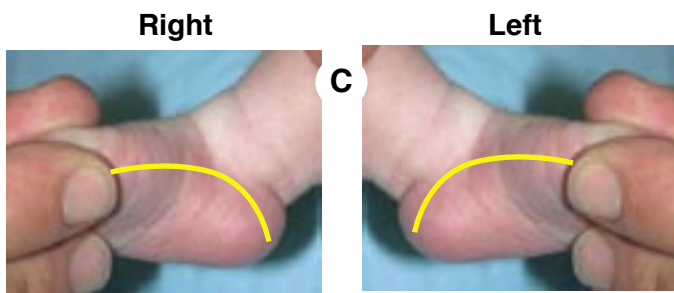
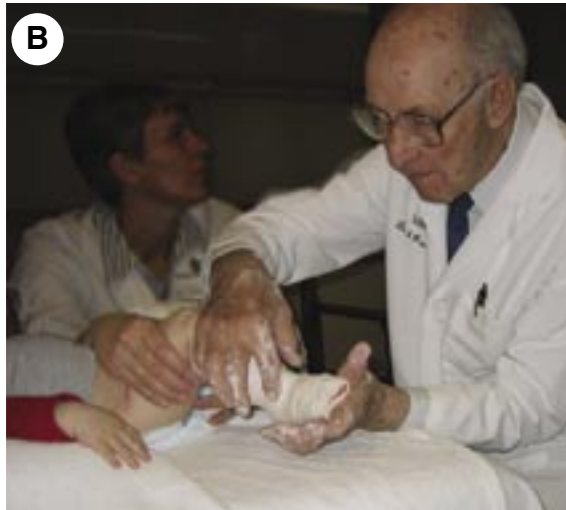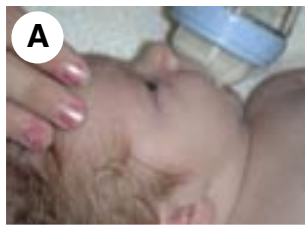What are the features of recurrent clubfoot?

The foot usually develops supination and equinus.

What are the usual steps of clubfoot management?

Most clubfeet can be corrected by brief manipulation and then casting in maximum correction. After approximately five casting periods [C], the adductus and varus are corrected. A percutaneous heel cord tenotomy [D] is performed in nearly all feet to complete the correction of the equinus, and the foot is placed in the last cast for 3 weeks. This correction is maintained by night splinting using a foot abduction brace [E], which is continued until approximately 2 to 4 years of age. Feet treated by this management have been shown to be strong, flexible, and pain free [F], allowing a normal life.





Details of the Ponseti Technique

First four or five casts (more if necessary)

Start as soon after birth as possible. Make the infant and family comfortable. Allow the infant to feed during the manipulation and casting processes [A]. Casting should be performed by the surgeon when possible [B]. Each step in management is shown for both the right and left feet.

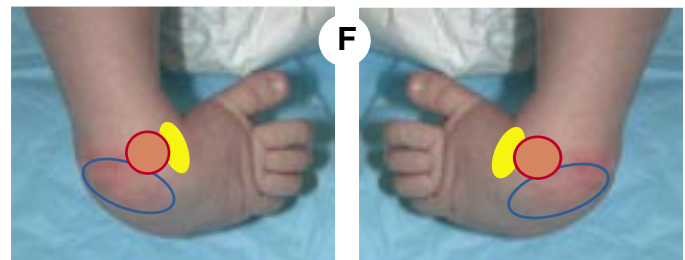
Reduce the cavus

The first element of management is correction of the cavus deformity by positioning the forefoot in proper alignment with the hindfoot. The cavus, which is the high medial arch [C, yellow arc] is due to the pronation of the forefoot in relation to the hindfoot. The cavus is always supple in newborns and requires only supinating the forefoot to achieve a normal longitudinal arch of the foot [D and E]. In other words, the forefoot is supinated to the extent that visual inspection of the plantar surface of the foot reveals a normal appearing arch—neither too high nor too flat. Alignment of the forefoot with the hindfoot to produce a normal arch is necessary for effective abduction of the foot to correct the adductus and varus.

Manipulation

The manipulation consists of abduction of the foot beneath the stabilized talar head. Locate the head of the talus. All components of clubfoot deformity, except for the ankle equinus, are corrected simultaneously. To gain this correction, you must locate the head of the talus, which is the fulcrum for correction.

Exactly locate the head of the talus This step is essential [F]. First, palpate the malleoli with the thumb and index finger of hand A while the toes and metatarsals are held with hand B. Next, slide your thumb and index finger of hand A forward to palpate the head of the talus (red) in front of the ankle mortis. Because the navicular (yellow) is medially displaced and its tuberosity is almost in contact with the medial malleolus, you can feel the prominent lateral part of the talar head (red) barely covered by the skin in front of the lateral malleolus. The anterior part of the calcaneus (blue) will be felt beneath the talar head.



While moving the forefoot laterally in supination with hand B, you will be able to feel the navicular move ever so slightly in front of the head of the talus as the calcaneus moves laterally under the talar head.

Stabilize the talus Place the thumb over the head of the talus, as shown by the yellow arrows in the skeletal model [A]. Stabilizing the talus provides a pivot point around which the foot is abducted. The index finger of the same hand that is stabilizing the talar head should be placed behind that lateral malleolus. This further stabilizes the ankle joint while the foot is abducted beneath it and avoids any tendency for the posterior calcaneal-fibular ligament to pull the fibula posteriorly during manipulation.

Manipulate the foot Next, by abducting the foot in supination [A], with the foot stabilized by the thumb over the head of the talus, as shown by the yellow arrow, abduct the foot as far as can be done without causing discomfort to the infant. Hold the correction with gentle pressure for about 60 seconds, then release. The lateral motion of the navicular and of the anterior part of the calcaneus increases as the clubfoot deformity corrects [B]. Full correction should be possible after the fourth or fifth cast. For very stiff feet, more casts may be required. The foot is never pronated.

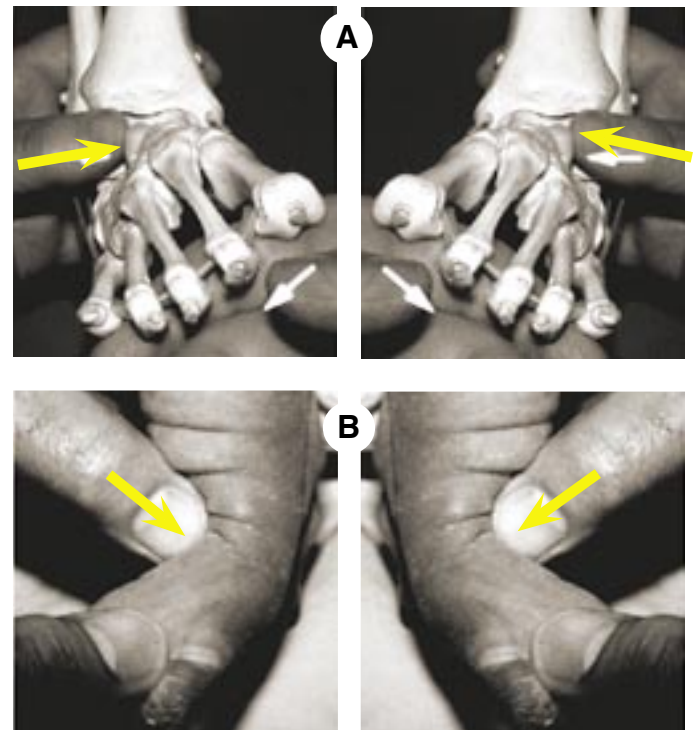
Second, third, and fourth casts During this phase of treatment, the adductus and varus are fully corrected. The distance between the medial malleolus and the tuberosity of the navicular when palpated with the fingers tells the degree of correction of the navicular. When the clubfoot is corrected, that distance measures approximately 1.5 to 2 cm and the navicular covers the anterior surface of the head of the talus.

Each cast shows improvement Note the changes in the cast sequence [C].

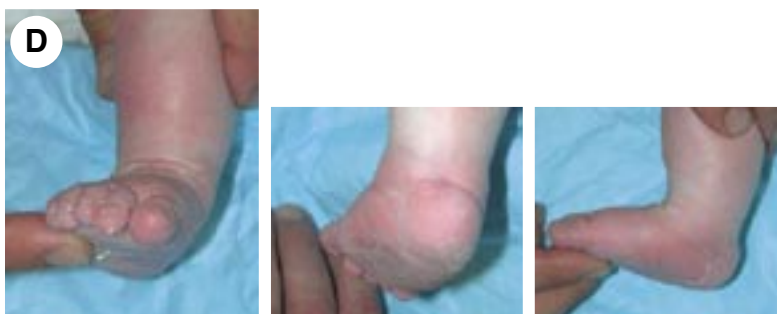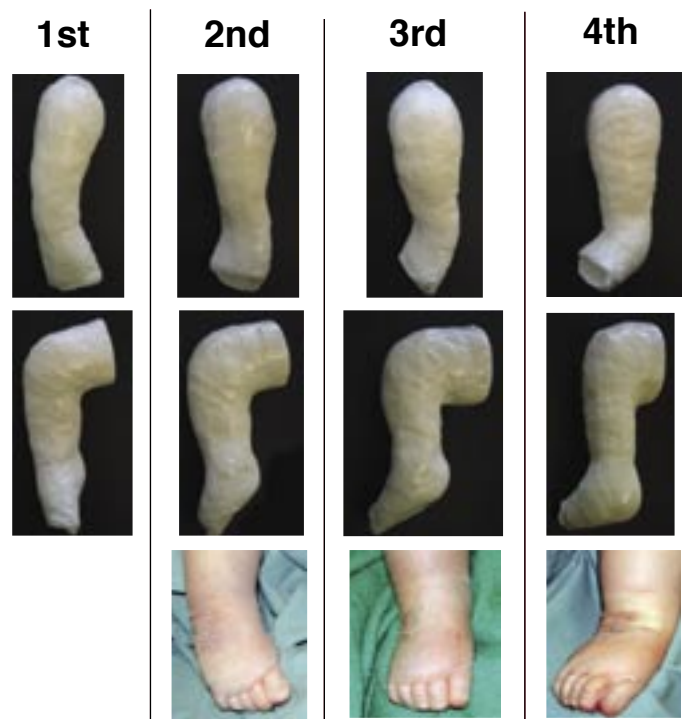
Adductus and varus Note that the first cast shows the correction of the cavus and adductus. The foot remains in marked equinus. Casts 2 through 4 show correction of adductus and varus.

Equinus The equinus deformity gradually improves with correction of adductus and varus. This is part of the correction because the calcaneus dorsiflexes as it abducts under the talus. No direct attempt at equinus correction is made until the heel varus is corrected.

Foot appearance after the fourth cast Full correction of the cavus, adductus, and varus are noted [D]. Equinus is improved, but this correction is not adequate, necessitating a heel cord tenotomy. In very flexible feet, equinus may be corrected by additional casting without tenotomy. When in doubt, perform the tenotomy.



C Appearance of casts and foot



Cast Application, Molding, and Removal

Success in Ponseti management requires good casting technique. Those with previous clubfoot casting experience may find it more difficult than those learning clubfoot casting for the first time.

We recommend that plaster material be used because the material is less expensive and plaster can be more precisely molded than fiberglass.

Steps in cast application

Preliminary manipulation Before each cast is applied, the foot is manipulated [A].

Applying the padding Apply only a thin layer of cast padding [B] to make possible effective molding of the foot. Maintain the foot in the maximum corrected position by holding the toes while the cast is being applied.

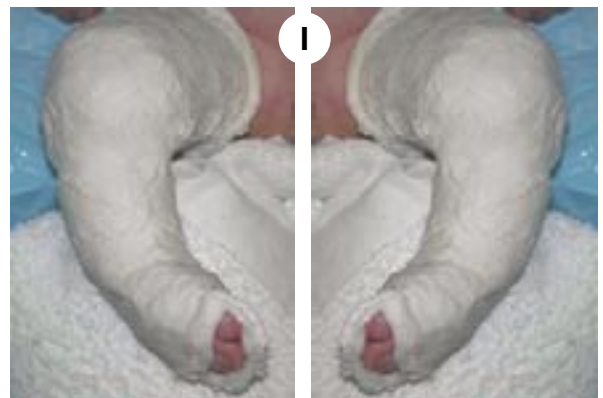
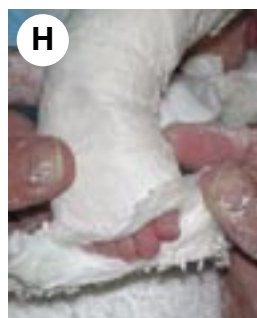
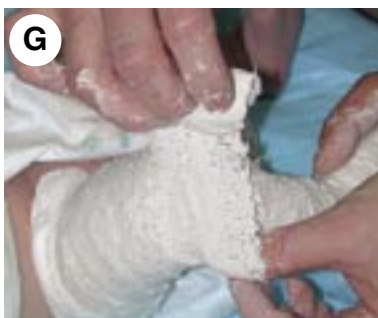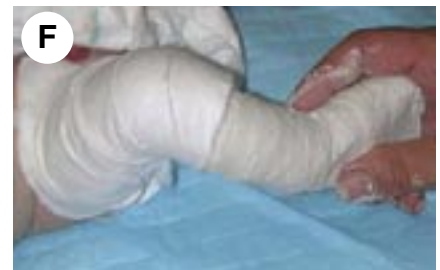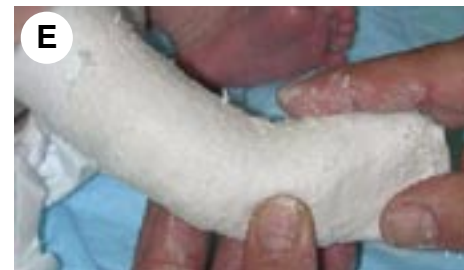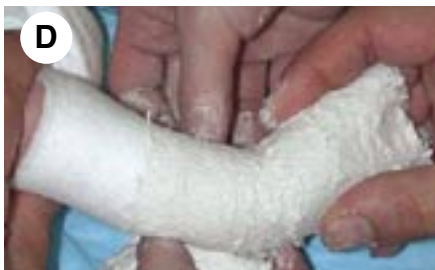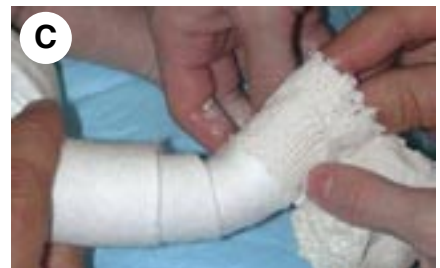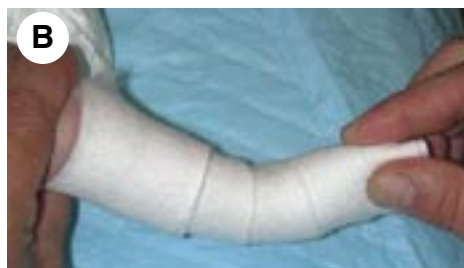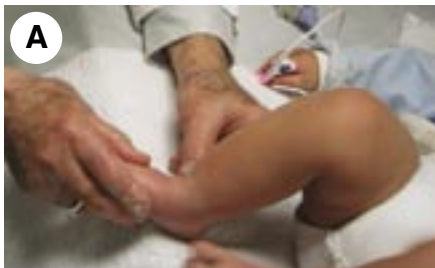Applying the cast First apply the cast below the knee and then extend the cast to the upper thigh. Begin with three to four turns around the toes [C], and then work proximally up the leg. Apply the plaster smoothly. Add a little tension [D] to the turns of plaster above the heel. The foot should be held by the toes and plaster wrapped over the “holder’s” fingers to provide ample space for the toes.

Molding the cast Do not try to force correction with the plaster. Use light pressure.

Do not apply constant pressure with the thumb over the head of the talus; rather, press and release repetitively to avoid pressure sores of the skin. Mold the plaster over the head of the talus while holding the foot in the corrected position [E]. Note that the thumb of the left hand is molding over the talar head while the index finger of the left hand is molding above the calcaneus. The arch is well molded to avoid flatfoot or rocker-bottom deformity. The index finger of the right hand is maintaining the correction. There is no pressure over the calcaneus. The calcaneus is never touched during the manipulation or casting. Molding should be a dynamic process; constantly move the fingers to avoid excessive pressure over any single site. Continue molding while the plaster hardens.

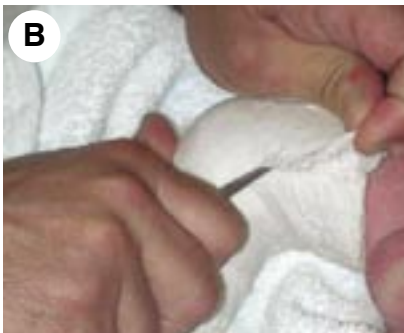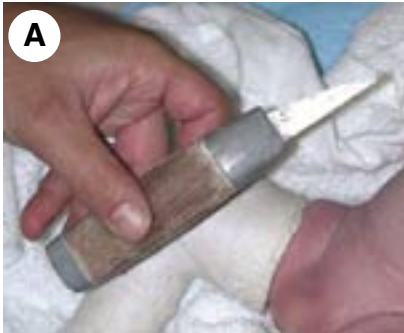Extend cast to thigh Use much padding at the proximal thigh to avoid skin irritation [F]. The plaster may be layered back and forth over the anterior knee for strength [G] and for avoiding a large amount of plaster in the popliteal fossa area, which makes cast removal more difficult.

Trim the cast Leave the plantar plaster to support the toes [H], and trim the cast dorsally to the metatarsal phalangeal joints, as marked on the cast. Use a plaster knife to remove the dorsal plaster by cutting the center of the plaster first and then the medial and lateral plaster. Leave the dorsum free. Note the appearance of the first cast when completed [I]. The foot is in equinus, and the forefoot is fully supinated.



Cast removal

Remove each cast in clinic just before a new cast is applied. Avoid cast removal before clinic because considerable correction can be lost from the time the cast is removed until the new one is placed. Although a cast saw can be used, use of a plaster cast knife is recommended because it is less frightening to the infant and family and also less likely to cause any accidental injury to the skin. Soak the cast in water for about 20 minutes, and then wrap the cast in wet cloths before removal. Use the plaster knife [A], and cut obliquely [B] to avoid cutting the skin. Remove the above-knee portion of the cast first [C]. Finally, remove the below-knee portion of the cast [D].



Decision to perform tenotomy

A major decision point in management is determining when sufficient correction has been obtained to perform a percutaneous tenotomy to gain dorsiflexion and to complete the treatment. This point is reached when the anterior calcaneus can be abducted from underneath the talus. This abduction allows the foot to be safely dorsiflexed without crushing the talus between the calcaneus and tibia [E]. If the adequacy of abduction is uncertain, apply another cast or two to be certain.

Characteristics of adequate abduction Confirm that the foot is sufficiently abducted to safely bring the foot into 15 to 20 degrees of dorsiflexion before performing tenotomy.

The best sign of sufficient abduction is the ability to palpate the anterior process of the calcaneus as it abducts out from beneath the talus.

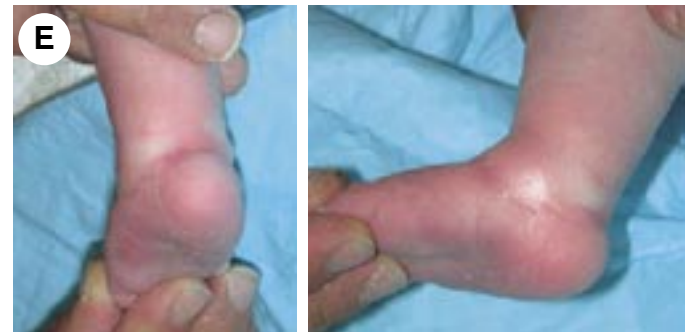Abduction of approximately 60 degrees in relationship to the frontal plane of the tibia is possible.

Neutral or slight valgus of os calcis is present. This is determined by palpating the posterior os calcis.

Remember that this is a three-dimensional deformity and that these deformities are corrected together. The correction is accomplished by abducting the foot under the head of the talus.

The final outcome

At the completion of casting, the foot appears to be overcorrected into abduction with respect to normal foot appearance during walking. This is not in fact an overcorrection. It is actually a full correction of the foot into maximum normal abduction. This correction to complete, normal, and full abduction helps prevent recurrence and does not create an over-corrected or pronated foot.



Equinus Correction and Fifth Cast

Indications

Make certain the indications for equinus correction have been met.

Percutaneous heel cord tenotomy

Plan to perform the tenotomy in clinic.

Preparing the family

Prepare the family by explaining the procedure. Sometimes a mild sedative may be given to the infant [A].

Equipment

Select a tenotomy blade such as a #11 or #15 or any other small blade such as an ophthalmic knife.

Skin preparation

Prep the foot medially, posteriorly, and laterally [B].

Anesthesia

A small amount of local anesthetic may be infiltrated near the tendon [C]. Be aware that too much local anesthetic makes palpation of the tendon difficult and makes the procedure more dangerous.

Heel cord tenotomy

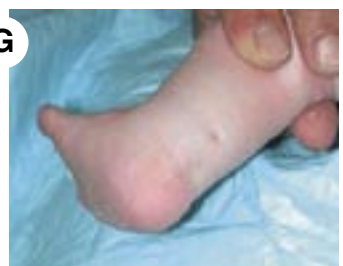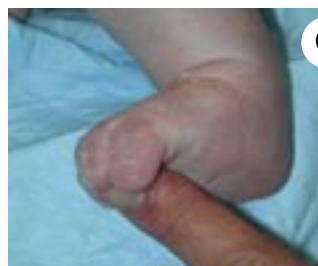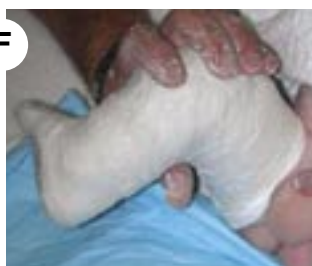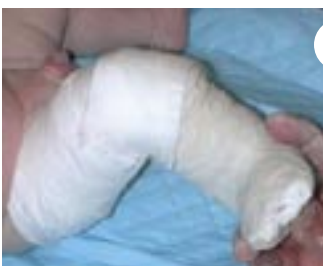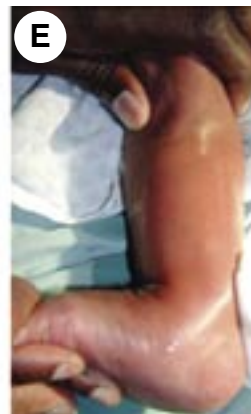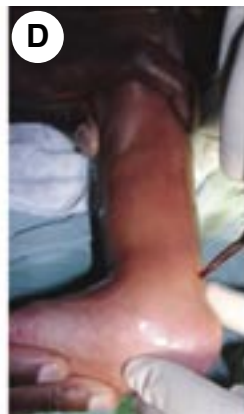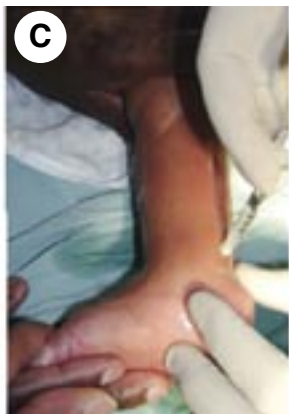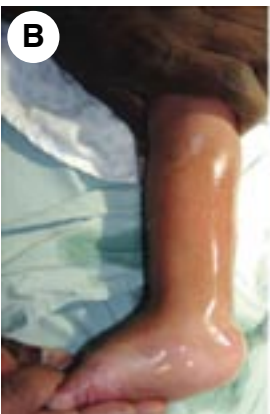Perform the tenotomy [D] approximately 1 cm above the calcaneus. Avoid cutting into the cartilage of the calcaneus. A “pop” is felt as the tendon is released. An additional 10 to 15 degrees of dorsiflexion is typically gained after the tenotomy [E].

Post-tenotomy cast

Apply the fifth cast [F] with the foot abducted 60 to 70 degrees with respect to the frontal plane of the tibia. Note the extreme abduction of the foot with respect to the leg and the overcorrected position of foot. The foot is never pronated. This cast is left in place for 3 weeks after complete correction.

Cast removal

After 3 weeks, the cast is removed. Note the correction [G]. Thirty degrees of dorsiflexion is now possible, the foot is well corrected, and the operative scar is minimal. The foot is ready for bracing.



Bracing

Bracing protocol

The brace is applied immediately after the last cast is removed, 3 weeks after tenotomy. The brace consists of open toe high-top straight last shoes attached to a bar [A]. For unilateral cases, the brace is set at 75 degrees of external rotation on the clubfoot side and 45 degrees of external rotation on the normal side [B]. In bilateral cases, it is set at 70 degrees of external rotation on each side. The bar should be of sufficient length so that the heels of the shoes are at shoulder width. A common error is to prescribe too short a bar, which the child finds uncomfortable [C]. A narrow brace is a common reason for a lack of compliance. The bar should be bent 5 to 10 degrees with the convexity away from the child, to hold the feet in dorsiflexion [D].

The brace should be worn full time (day and night) for the first 3 months after the tenotomy cast is removed. After that, the child should wear the brace for 12 hours at night and 2 to 4 hours in the middle of the day for a total of 14 to 16 hours during each 24-hour period. This protocol continues until the child is 3 to 4 years of age.

Types of braces

Several types of commercially made braces are available. With some designs, the bar is permanently attached to the bottoms of the shoes. With other designs, it is removable. With some designs, the bar length is adjustable, and with others, it is fixed. Most braces cost approximately US \$100. In Uganda, Steenbeek designed a brace, which is made at a cost of approximately US \$12 (see p. 24). Parents should be given a prescription for a brace at the time of the tenotomy. This gives them 3 weeks to organize themselves. In the United States, the Markell shoe and brace is most commonly used, but other countries have different options [E].

Rationale for bracing

At the end of casting, the foot is abducted [A] to an exaggerated amount, which should measure 75 degrees (thigh-foot axis). After the tenotomy, the final cast is left in place for 3 weeks. Ponseti's protocol then calls for a brace to maintain the

abduction. This is a bar attached to straight last open toe shoes. This degree of foot abduction is required to maintain the abduction of the calcaneus and forefoot and prevent recurrence. The foot will gradually turn back inward, to a point typically of 10 degrees of external rotation. The medial soft tissues stay stretched out only if the brace is used after the casting. In the brace, the knees are left free, so the child can kick them "straight" to stretch the gastrosoleus tendon. The abduction of the feet in the brace, combined with the slight bend (convexity away from the child), causes the feet to dorsiflex. This helps maintain the stretch on the gastrocnemius muscle and Achilles tendon [D].

Importance of bracing


The Ponseti manipulations combined with the percutaneous tenotomy regularly achieve an excellent result. However, without a diligent follow-up bracing program, recurrence and relapse occur in more than 80% of cases. This is in contrast to a relapse rate of only 6% in compliant families (Morcuende et al.).

Alternatives to foot abduction brace

Some surgeons have tried to "improve" Ponseti management by modifying the brace protocol or by using different braces. They think that the child will be more comfortable without the bar and so advise use of straight last shoes alone. This strategy always fails. The straight last shoes by themselves do nothing. They function only as an attachment point for the bar.

Some braces are no better than the shoes by themselves and, therefore, have no place in the bracing protocol. If well fitted, the knee-ankle-foot braces, such as the Wheaton brace, maintain the foot abducted and externally rotated. However, the knee-ankle-foot braces keep the knee bent in 90 degrees of flexion. This position causes the gastrocnemius muscle and Achilles tendon to atrophy and shorten, leading to recurrence of the equinus deformity. This is particularly a problem if a knee-ankle-foot brace is used during the initial 3 months of bracing, when the braces are worn full time.

In summary, only the brace as described by Ponseti is an acceptable brace for Ponseti management and should be worn at night until the child is 3 to 4 years of age.



Strategies to increase compliance to bracing protocol

The families who are the most compliant to the bracing protocol are those who have read about the Ponseti method of clubfoot management on the Internet and have chosen that method. They come to the office educated and motivated. The least compliant parents are often from families who did no background research on the Ponseti method and need to be “sold” on it. The best strategy to ensure compliance is to educate the parents and indoctrinate them into the Ponseti culture. It helps to see the Ponseti method of management as a lifestyle that demands certain behavior.

Take advantage of the face-to-face time that occurs during the weekly casting to talk to the parents and emphasize the importance of bracing. Tell them that the Ponseti management method has two phases: the initial casting phase, during which the doctor does all the work, and the bracing phase, during which the parents do all the work. On the day that the last cast comes off after the tenotomy, “pass the baton” of responsibility to the parents.

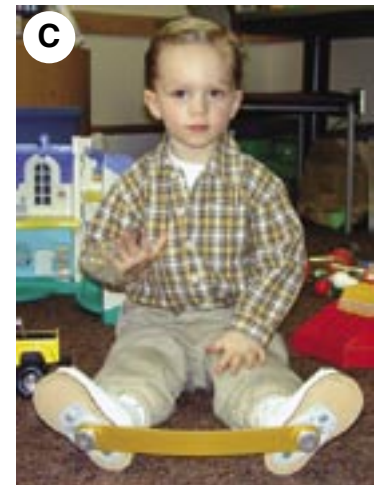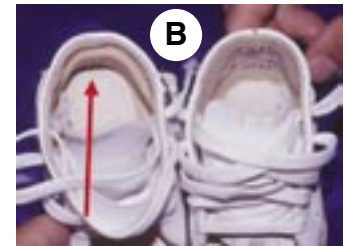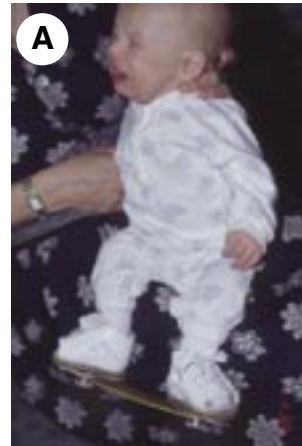During the initial instructions, teach the parents how to apply the brace. Suggest they practice putting it on and taking it off several times during the first few days and have them leave the brace off for brief periods of time during these few days to allow the child’s feet to get accustomed to the shoes. Teach the parents to exercise the child’s knees together as a unit (flex and extend) in the brace, so that the children get accustomed to moving two legs simultaneously. (If the child tries to kick one leg at a time, the brace bar interferes, and the child may get frustrated). Warn the parents that there may be a few rough nights until the child gets accustomed to the brace [A]. Suggest the analogy of “saddle training” a horse: it requires a firm but patient hand. There should be no “negotiations” with the child. Schedule the first return visit in 10 to 14 days. The main purpose of that visit is to monitor compliance. If all is well, then the next scheduled visit is in 3 months, when the child advances to the nighttime only protocol (or “nights and naps”).

It is useful to approach brace compliance as a public health issue, similar to tuberculosis treatment. It is not sufficient to prescribe anti-tuberculosis medications; you must also monitor compliance through a public health nurse. We monitor compliance by frequently calling the families of our patients, who are in the brace phase, between office visits. All families are encouraged to call us if they hit a period of difficulty with bracing, so that we can work through the issues. In the beginning, for example, children may kick off the shoes if they aren’t tightened correctly. Gluing a small pad at the upper rim of the heel counter can help keep the feet captured in the shoes [B].

When to stop bracing

Occasionally, a child will develop excessive heel valgus and external tibial torsion while using the brace. In such instances, the physician should dial the external rotation of the shoes on the bar from approximately 70 degrees to 40 degrees.

How long should the nighttime bracing protocol continue? There is no scientific answer to this question. Severe feet should be braced until age 4 years, and mild feet can be braced until age 2 years [C]. It is not always easy to distinguish which foot is mild and which is severe, especially when observing them at age 2 years. Therefore, it is recommended that even the mild feet should be braced for up to 3 to 4 years, provided the child still tolerates the nighttime bracing. Most children get used to the bracing, and it becomes part of their life style. However, if compliance becomes very problematic after age 2 years, it may become necessary to discontinue the bracing to ensure that the child and parents get a good night’s sleep. This leniency is not tolerable in the younger age groups. Below age 2 years, the children and their families must be encouraged to comply with the bracing protocol at all costs.



Managing Relapses

Recognizing relapses

After applying the brace for the first time after the tenotomy cast is removed, the child returns according to the following suggested schedule.

- 2 weeks (to troubleshoot compliance issues)
- 3 months (to graduate to the nights-and-naps protocol)
- every 4 months until age 3 years (to monitor compliance and check for relapses)
- every 6 months until age 4 years
- every 1 to 2 years until skeletal maturity

Early relapses in the infant show loss of foot abduction and/or loss of dorsiflexion correction and/or recurrence of metatarsus adductus.

Relapses in toddlers can be diagnosed by examining the child walking. As the child walks toward the examiner, look for supination of the forefoot, indicating an overpowering tibialis anterior muscle and weak peroneals [A]. As the child walks away from the examiner, look for heel varus [B]. The seated child should be examined for ankle range of motion and loss of passive dorsiflexion.

Reasons for relapses

The most common cause of relapse is noncompliance to the post-tenotomy bracing program. Morcuende found that relapses occur in only 6% of compliant families and more than 80% of noncompliant families. In brace-compliant patients, the basic underlying muscle imbalance of the foot is what causes relapses.

Casting for relapses

Do not ignore relapses! At the first sign of relapse, consider reapplying one to three casts to stretch the foot out and regain correction. This may appear at first to be a daunting task in a wriggly 14-month-old toddler, but it is important. The casting

management is identical to the original Ponseti casting used in infancy. Once the foot is re-corrected with the casts, the bracing program is again begun.

Equinus relapse

Recurrent equinus is a structural deformity that can complicate management. Equinus can be assessed clinically, but to illustrate the problem, a radiograph is included to show the deformity [C].

Several plaster casts may be needed to correct the equinus to at least a neutral position of the calcaneus. Sometimes, it may be necessary to repeat the percutaneous tenotomy in children up to 1 or even 2 years of age. They should undergo casting for 4 weeks postoperatively, with the foot abducted in a long leg bent knee cast, and then go back into the brace at night. In rare situations, open Achilles lengthening may be necessary in the older child.

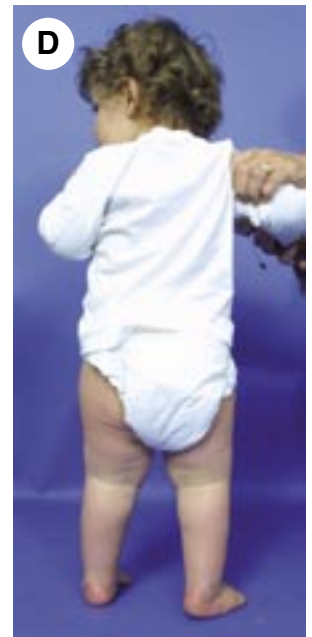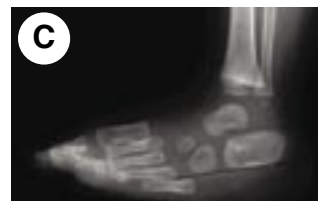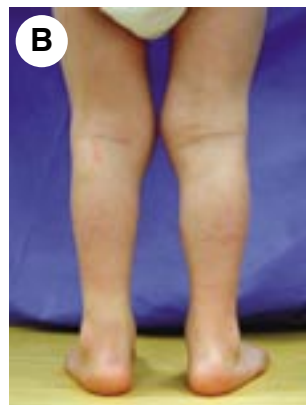Varus relapse

Varus heel relapses are more common than equinus relapses. They can be seen with the child standing [D] and should be treated by re-casting in the child between age 12 and 24 months, followed by reinstitution of a strict bracing protocol.

Dynamic supination

Some children will require anterior tibialis tendon transfer (see page 26) for dynamic supination deformity, typically between ages 2 and 4 years. Anterior tibialis tendon transfer should be considered only when the deformity is dynamic and no structural deformity exists. Transfers should be delayed until radiographs show ossification of the lateral cuneiform that typically occurs at approximately 30 months of age. Normally, bracing is not required after this procedure.

One thing is certain: relapses that occur after Ponseti management are easier to deal with than relapses that occur after traditional posteromedial release surgery.



Public Health Approach to Clubfoot

Approximately 100,000 infants are born annually with clubfoot, 80% in developing nations. Developing nations have inadequate medical and surgical resources.

The real wealth of nations varies dramatically, as detailed by the world bank in 1996. For example, in the United States, health care expenditure exceeds US \$3,000 per person each year and there are about 245 MDs and 878 RNs for each 100,000 persons. In contrast, in the poorest of developing nations, health care expenditures are less than US \$10 for each person each year and health care is provided by only 14 MDs and 26 RNs for each 100,000 persons.

Approximately 75% of all doctors reside in five countries (Australia, Canada, Germany, United Kingdom, United States). Eighty percent of all orthopaedic surgeons in the world practice in 26 “developed” nations (of 191 nations). The orthopaedic surgeon-to-population ratio in Malawi is 1 per 4 million.

Many, if not most, children born with congenital clubfoot in developing nations do not receive any treatment of their deformity and therefore grow up with neglected clubfoot deformity. In Uganda alone, there are an estimated 10,000 children with neglected clubfoot [A].

Neglected clubfoot

The human cost of neglected clubfoot is enormous, particularly for women and children. Afflicted females are less likely to marry and more likely to suffer abuse. Worldwide, neglected clubfoot is considered to be the most serious cause of physical disability from musculoskeletal birth defects.

The child with neglected clubfoot is condemned to the downward spiral of deformity, disability, dependency, demoralization, depression, and despair. Digging, plowing, harvesting, and carrying firewood and water are unmanageable tasks for children whose limbs are maimed by heredity, accident, or disease. These children are intellectually capable of integrating into the normal school system but never have the opportunity because their needs are not a high priority. Fewer than 2% of children with disabilities attend school in developing countries. The more difficulty the children experience in locomotion, the less likely they are to attend school.

In agrarian societies, physical disability is a major cause of poverty and ill health. Afflicted individuals are socially and economically disadvantaged, with reduced educational and employment opportunities. The burden of care of the disabled child falls on the mother, who has less time for other children and for domestic, agricultural, and economic activities. Ill health is the most frequent cause and consequence of poverty.

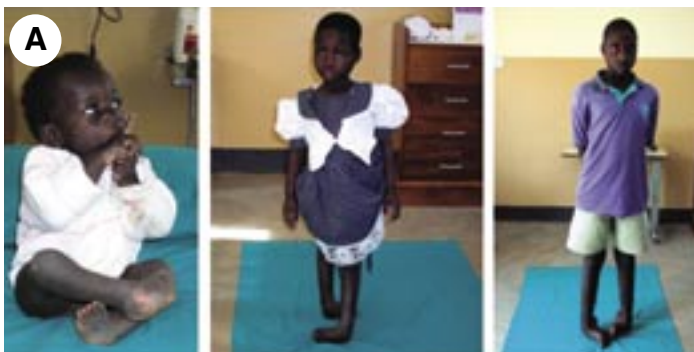The neglected clubfoot deformity results in disability for the individual, a reduced standard of living for the entire family, and a burden to the community.

The Uganda Clubfoot Project

With an estimated 1,000 infants born each year with clubfoot and only 12 orthopaedic surgeons in the entire country, Uganda simply does not have enough surgical resources to manage all clubfeet surgically. Dr. Ponseti’s essentially nonsurgical method presents an opportunity to approach the problem of congenital clubfoot with public health principles.

In his editorial on orthopaedic health problems in developing nations “Can We Make a Difference?” (September 2001), Alan Levine, Editor in Chief of *The Journal of the American Academy of Orthopaedic Surgeons*, writes “...It is our responsibility to seek out *workable solutions*. It has become apparent that one of the most useful approaches is to become involved in the *education of local health-care workers* in techniques that are *economically and socially feasible for their society*...”

In 1999, Drs. Pirani and Penny, Michiel Steenbeek, and the tutors of the School of Orthopaedic Officers in Uganda [B], set up the Uganda Clubfoot Project. This is a “train the trainer” based program to *educate local health care workers* (orthopaedic officers) in the Ponseti management. The Uganda Clubfoot Project seeks to determine whether the Ponseti management is a *workable solution* for the problem of clubfoot in the developing world, whether it is *economically and socially feasible*, and whether it should be promoted as the standard of care where resources are scarce. Funded by The Rotary Foundation, Uganda Clubfoot Project’s 3-year experience has been most encouraging. There are four steps.



1. Build consensus

Uganda Clubfoot Project provided evidence to build consensus among all stakeholders (Department of Orthopaedics, Makerere University; Government of Uganda Ministry of Health; and relevant non-governmental organizations) that the Ponseti management is a workable solution for the problem of congenital clubfoot. They examined the results of Ponseti treatment at pilot clinics in Uganda [A shows an Ugandan infant’s clubfoot corrected by Ponseti management as implemented by Ugandan orthopaedic officers]. It was then endorsed as the appropriate method for their medical system and was incorporated within the undergraduate and postgraduate curricula of their medical and paramedical teaching schools. The Ministry of Health and non-governmental organizations agreed to facilitate care by providing resources (plaster and braces).

2. Build capacity to detect clubfoot

Uganda Clubfoot Project developed a poster-based awareness campaign for the public and frontline health care workers. It states that the clubfoot deformity needs to be diagnosed at birth, that treatment must begin shortly thereafter at designated district level clubfoot clinics (manned by trained personnel), and that treatment is generally quite successful [B].

3. Build capacity to treat clubfoot

Uganda Clubfoot Project provided training in fabrication of night splints made from locally available materials [C]. Using models, Uganda Clubfoot Project trained existing district level medical and paramedical health care professionals (orthopaedic clinical officers in Uganda) in the implementation of Ponseti management. This provided adequate staffing for these clubfoot clinics [D].

4. Results of Uganda Clubfoot Project

Training

- 110 health care professionals from 32 of 53 districts
- 6 local teaching faculty
- pilot data show efficacy of method in Uganda in the hands of orthopaedic officers

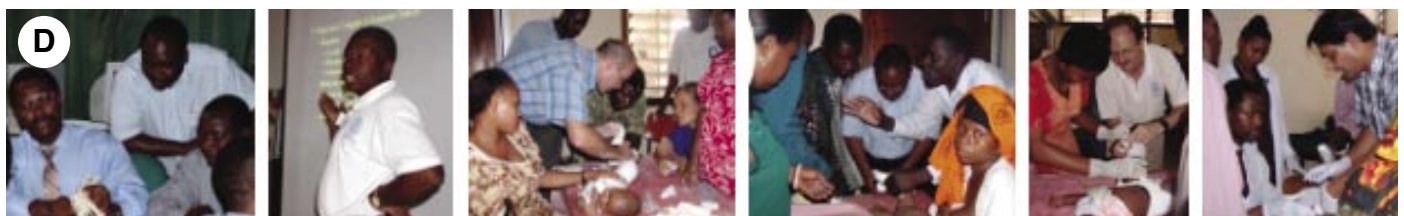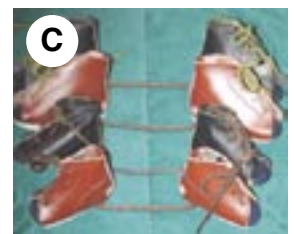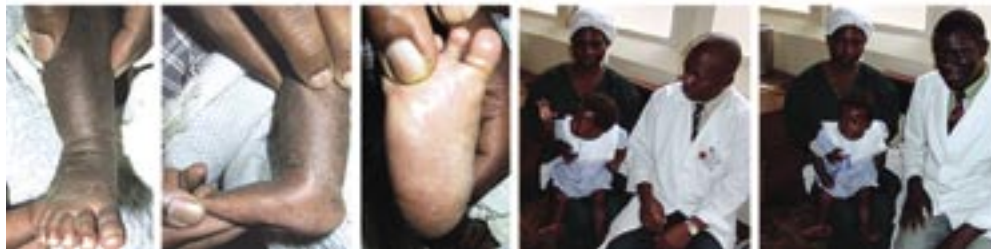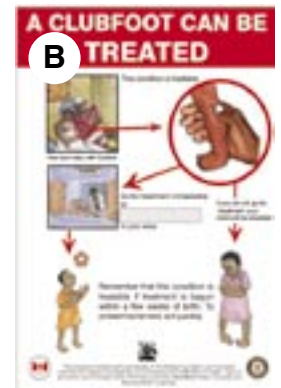
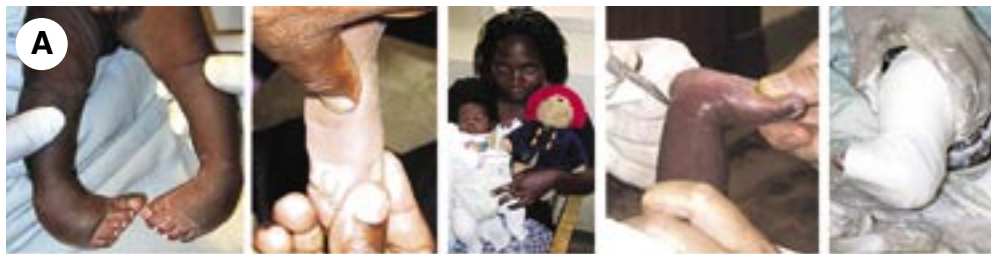Ponseti management results

- Mulago Hospital clubfoot clinics (run mostly by orthopaedic clinical officers): 236 clubfeet in 155 consecutive patients, seen between November 1999 and October 2002
- 118 infants with 182 clubfeet completed corrective phase of treatment
 - 176 of 182 clubfeet (96.7%) corrected
 - 6 of 182 clubfeet did not correct
 - 37 infants (23.4%) did not complete corrective phase of treatment, possibly because parents are unable to attend because of financial constraints, the need to harvest crops, etc.

Lesson Advise parents that, if necessary, it is preferable to postpone treatment until the family has enough time to complete the course of treatment without interruption. This delay should not exceed several weeks.

Beyond Uganda

Using programs similar to Uganda Clubfoot Project, Ponseti management is now being introduced in three other African countries (Ghana, Kenya, Malawi, and Tanzania) and three states in India (Gujarat, Maharashtra, and Tamil Nadu). A program blueprint has been developed that can be “boiler plated” for appropriate developing countries.



Application in Brazil

Monica Nogueira (Sao Paulo)

Between 2000 and 2003, we treated 68 clubfeet in 40 patients using the Ponseti method of clubfoot management. Fifty-three feet were severe, with Pirani scores of 6. Mean age at the first clinic visit was 70 days (range, 2–300 days). Mean number of casts before tenotomy was six (range, four to 10). Fifty-eight tenotomies (85.3%) were performed. Posteromedial release was performed in two feet (3%).



Follow-up averaged 17 months (range, 1–32 months). Brace compliance was poor in seven patients (10.3%). Four underwent recasting and achieved good results. Ninety-seven percent were managed without posteromedial release, with final Pirani scores of 0 to 0.5. We consider our results to be excellent, and we are pleased that the Ponseti method of clubfoot management is gaining widespread acceptance in Brazil.

Hospital Beneficência Portuguesa
monipn@uol.com.br

Application in Germany

Marc Sinclair (Hamburg)

Since July 2002, 32 clubfeet were treated by the Ponseti technique. The average total score following the Pirani classification was 4.6. Nineteen feet had been exposed to conventional casting before initiating Ponseti management at our institution. Twenty-five feet (78%) were treated by percutaneous Achilles tenotomy after an average of 6.5 casts. Brace was applied after an average of 6.9 casts (range, four to 10). All patients were compliant throughout the treatment. Serial casting failed to correct one foot that required a posteromedial release.



Early results confirm the success rates reported in the current literature. Applying Ponseti management has improved functional outcome and successfully avoided open surgery in almost all cases. Conventional casting has been abandoned at our institution.

Altonaer Children's Hospital
sinclair@akkev.net

Application in Canada

Shafique Pirani (Vancouver, BC)

We treated 51 consecutive clubfeet in 35 patients (mean total score = 5.1, mean midfoot score = 2.3, mean hindfoot score = 2.8). Forty-eight feet (94%) corrected. Total scores after correction were 1.5 or less, midfoot scores were 0.5 or less, and hindfoot scores were 1.0 or less, with an average of 6.3 casts per foot.



Two-thirds underwent Achilles tenotomy. The Ponseti method of clubfoot management failed in three feet (6%) that then underwent open surgery and achieved correction.

The Ponseti method of clubfoot management, using an average of 6.3 casts for each clubfoot, successfully corrected the deformities in 94% of 51 consecutive congenital clubfeet.

Royal Columbian Hospital
piras@aol.com

Application in India

Dhiren Gangwala (Ahmedabad)

I became acquainted with the Ponseti method of clubfoot management by surfing the Internet. I learned the method by observing Dr. Ponseti's video and reading his monograph in 2001. Since then, I have treated 34 feet in 22 infants with congenital clubfoot by using the Ponseti method of clubfoot management. Infants ranged from 1 day to 5 months in age; three feet in three children had been treated elsewhere without success. Average number of plaster casts was 4.3 per foot. All except four feet in three patients underwent percutaneous tenotomy, with the patients under short-term general anesthesia. One required a second tenotomy. Bracing was initially done with a fiberglass splint, but later, the Steenbeek brace was used. Four cases of recurrence were corrected by serial casts. It has been difficult to continue with bracing in children older than 18 months.



We have been delighted with the Ponseti method of clubfoot management and consider it to be an ideal method for our patients in India. The physician's learning curve is short, and the treatment is well accepted by the families, who appreciate the excellent correction that is achieved without the need for major surgery.

Ganjwala Orthopedic Hospital
ganjwala@icenet.net

Application in United Kingdom

Naomi Davis (Manchester)

Since February 2002, we have treated 60 children up to 18 months of age. Early results show a 6.7% recurrence rate, related to poor brace compliance; recurrence was treated by recasting. One child required posterior release, and three will need anterior tibialis tendon transfer. A survey revealed that families feel supported by the team approach.



After the First Manchester International Clubfoot Conference, the Ponseti User's Group was founded to discuss problems and protocols. The British Society for Children's Orthopaedic Surgery is involved in the construction of a National Database to collate results from the United Kingdom. A second conference was held in 2003.

Booth Hall Children's Hospital
Naomi.Davis@CMMC.nhs.uk

Application in the United States

Vince Mosca (Seattle)

Deformities of the child's foot constitute the majority of my clinical practice. I have always personally performed the manipulations and cast applications for clubfoot. Historically, approximately 85% to 90% of my patients needed clubfoot surgery. Since I adopted Ponseti management in 1997 and gradually mastered it, fewer than 5% have needed surgery. With approximately 35 to 40 new clubfeet per year in my clinic, the opportunity to practice the management is plentiful. It comes down to the following: be gentle, supinate first, slightly overcorrect all deformities, perform Achilles tenotomy as the default option, externally rotate, and note that the heels should be no closer together on the bar than the lateral aspect of the shoulders (to ensure compliance and comfort).



Children's Hospital and Regional Medical Center
vincent.mosca@seattlechildrens.org

Application in the United States

John Herzenberg (Baltimore)

Primary treatment In a combined series from Baltimore, Maryland, and Afula, Israel, together with Dr. Noam Bor, we compared our first 34 feet in 27 infants using Ponseti management with the same number of matched control patients using traditional treatment. In the Ponseti group, percutaneous Achilles tenotomy was performed in 31 feet between 2 and 3 months of age. The average duration of casting was 2 months, and one of 34 feet required posteromedial release surgery. In the control group, 32 of 34 feet required posteromedial release within the first year of life, despite a longer casting period. Based on our initial success with the Ponseti management, we no longer think that posteromedial release is required for most cases of idiopathic clubfoot. Foot abduction braces are crucial to avoid recurrence.

Delayed treatment In a combined series from Baltimore, Maryland, and Charlotte, North Carolina, with Drs. Frick and Bor, we treated 29 feet in 18 children with idiopathic clubfoot who presented to us at age 3 to 6 months after having been unsuccessfully treated by serial casting by other physicians. We applied an average of six Ponseti casts and performed percutaneous Achilles tenotomy in 28 (96%) feet. Three needed repeat casting for relapse. Two required anterior tibialis transfer. Only one (3%) required open surgical release (posterior only). Our data suggest that even late presentation, up to age 6 months, and previously treated clubfoot can be successfully treated by Ponseti management.



Sinai Hospital
frcsc@aol.com

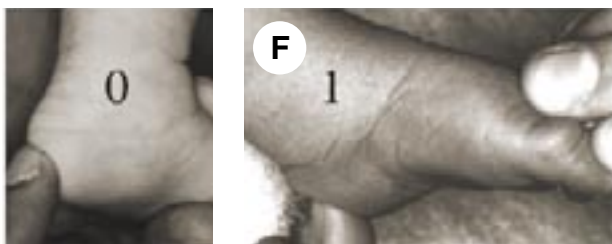
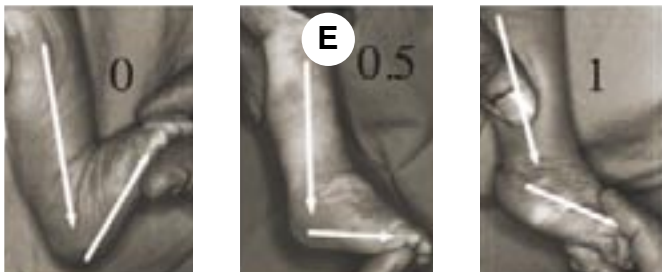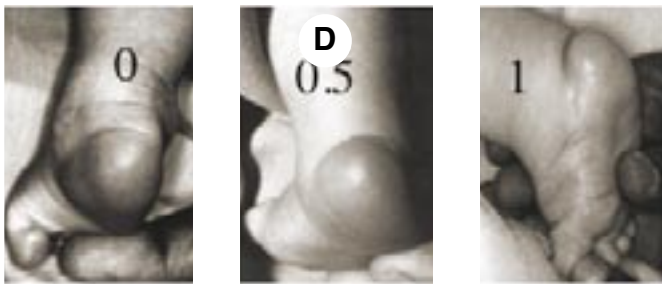
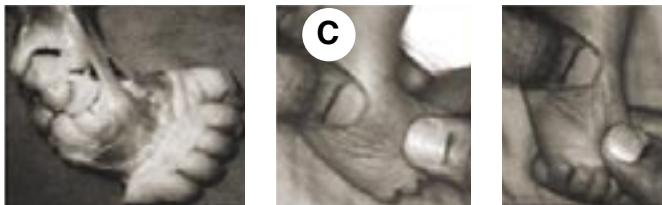
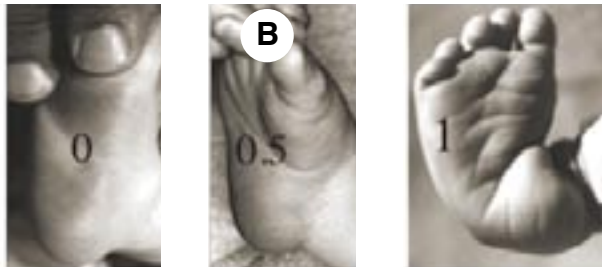
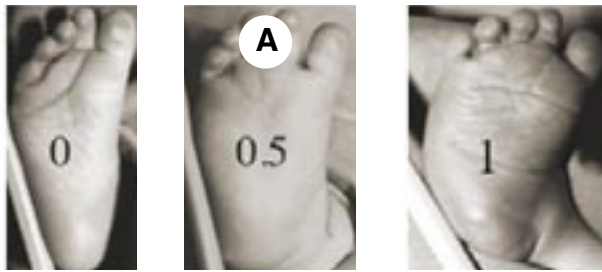
Application in Other Centers

J. Berard in Lyon, France

E. Ippolito in Rome, Italy

Anna Ey in Barcelona, Spain

Bertil Romanus in Goteborg, Sweden



Pirani Severity Scoring

Rationale

Dr. Pirani has developed a reliable and valid method of clinically assessing the amount of deformity present in an unoperated congenital clubfoot under 2 years of age. It is useful because there is no science without reliable and valid measurement. Documenting the amount of deformity allows the treating practitioner (especially if inexperienced) to know where he or she is with respect to the roadmap of treatment, to know when tenotomy is indicated, and to reassure parents regarding progress. It allows meaningful comparison of results, extraction of subgroups, etc. The Pirani scheme scores six clinical signs either 0 (normal), 0.5 (moderately abnormal), or 1 (severely abnormal).

Midfoot score

Three signs comprise the Midfoot Score (MS), grading the amount of midfoot deformity between 0 and 3.

- Curved lateral border [A]
- Medial crease [B]
- Talar head coverage [C]

Hindfoot score

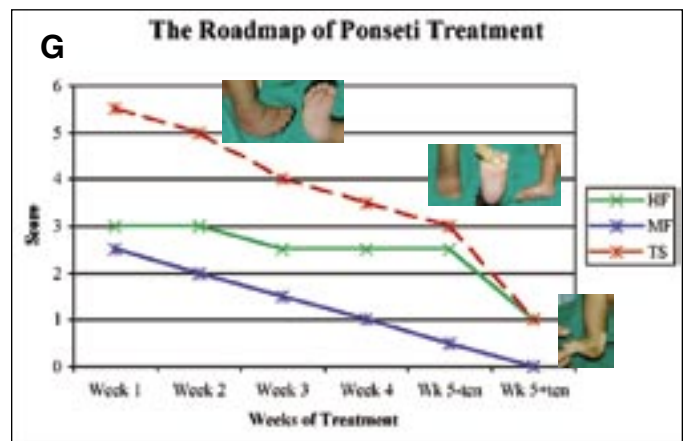
Three signs comprise the Hindfoot Score (HS), grading the amount of hindfoot deformity between 0 and 3.

- Posterior crease [D]
- Rigid equinus [E]
- Empty heel [F]

For details, contact:
Shafique Pirani
Piras@aol.com

Use of Pirani score

1. Every clubfoot under Ponseti management is “scored” each week for HS, MS, and total score, [G].
2. Plotting scores on a graph shows where the foot is on the roadmap of treatment, visually and easily reassuring parents of satisfactory progress.
3. Tenotomy is indicated when HS > 1, MS < 1, and the head of the talus is covered.



Common Management Errors

Pronation or eversion of the foot

This condition worsens the deformity by increasing the cavus. Pronation does nothing to abduct the adducted and inverted calcaneus, which remains locked under the talus. It also creates a new deformity of eversion through the mid and forefoot, leading to a bean-shaped foot. *Thou shall not pronate!*"

External rotation of foot to correct adduction while calcaneus remains in varus

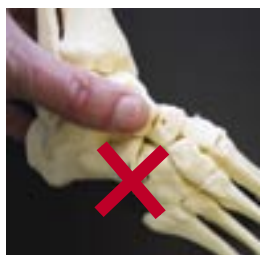This causes a posterior displacement of the lateral malleolus by externally rotating the talus in the ankle mortise. This displacement is an iatrogenic deformity.

Avoid this problem by abducting the foot in flexion and slight supination to stretch the medial tarsal ligaments, with counter-pressure applied on the lateral aspect of the head of the talus. This allows the calcaneus to abduct under the talus with correction of the heel varus.

Kite's method of manipulation

Kite believed that the heel varus would correct simply by evert-ing the calcaneus. He did not realize that the calcaneus can evert only when it is abducted (i.e., laterally rotated), under the talus.

Abducting the foot at the midtarsal joints with the thumb pressing on the lateral side of the foot near the calcaneocuboid joint (red "X") blocks abduction of the calcaneus and interferes with correction of the heel varus.



Casting errors

1. The foot should be immobilized with the contracted ligaments at maximum stretch obtained after each manipulation. In the cast, the ligaments loosen, allowing more stretching at the next session.

2. The cast must extend to the groin. Short leg casts do not hold the calcaneus abducted.

3. Attempts to correct the equinus before the heel varus and foot supination are corrected will result in a rocker-bottom deformity. Equinus through the subtalar joint can be corrected by calcaneal abduction.

Failure to use night brace

Failure to use shoes attached to a bar in external rotation full time for 3 months and at night for 2 to 4 years is the most common cause of recurrence.

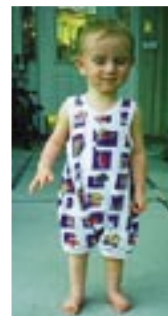Attempts to obtain perfect anatomical correction

It is wrong to assume that early alignment of the displaced skeletal elements will result in normal anatomy. Long-term follow-up radiographs show abnormalities. However, good long-term function of the clubfoot can be expected. There is no correlation between the radiographic appearance of the foot and long-term function.

Family Resources

Parent support groups

Parents of children with clubfoot are grateful for information and support relating to their children's condition and treatment. Since 1997, the Internet has provided ways for parents to share their experiences, suggestions, and encouragement with each other. At least 20 clubfoot Internet support groups have been established by sponsoring groups or individuals around the world, with more being created each year. Many of these groups are international, regional, or language specific. Ponseti management-specific or regional support groups with members who have used the Ponseti management can be found at the listed web sites.



Martin Egbert,
father of Joshua, born 1999 with bilateral
clubfoot corrected by Ponseti management

martinegbert@earthlink.net

Parent groups

International The main Ponseti management parents' support group has 384 members: <http://groups.yahoo.com/group/nosurgery4clubfoot>

United Kingdom STEPS charity group: <http://www.steps-charity.org.uk/forum/home.html>

France Hospital Debrosse, Lyon; Ponseti-specific site: <http://ifrance.com/piedbot/>

Germany Iris and Stephan's Klumpfuß Info: <http://www.klumpfuss-info.de/>

Finland Kampurat: <http://groups.yahoo.com/group/kampurat/>

Portugal Pe Boto; Ponseti-specific: <http://www.peboto.grupos.com.pt/>

Brazil Pe Torto; Ponseti-specific: <http://www.petorto.com.br/>

Additional links

University of Iowa site: <http://www.uihealthcare.com/news/pacemaker/2002/fall/ponsetti.html>

Dr. Ponseti's web site: <http://www.vh.org/pediatric/patient/orthopaedics/clubfoot/index.html>

Parent support group: <http://groups.yahoo.com/group/clubfoot>

Support bulletin board: <http://messageboards.ivillage.com/iv-ppclubfoot>

Sites showing treatment

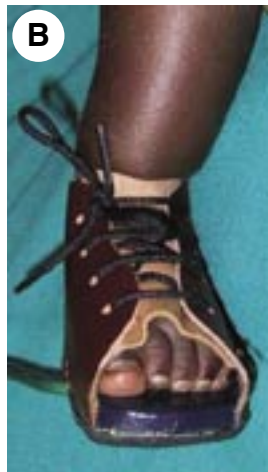Graham's treatment: <http://www.datahaus.net/family/Graham/CF/>

Rose's treatment: <http://community-2.webtv.net/joybelle15/ROSESCLUBFOOTPAGE/>

Cotton Family: <http://members.aol.com/vc11/>

Other links

John Mitchell makes clubfoot models for teaching: www.mdanatomical.com



Steenbeek Foot Abduction Brace

Bracing is an essential part of Ponseti management. Unless effective braces can be provided, the treatment will fail. H.M. Steenbeek, working for the Christoffel Blinden Mission in Katalamwa Cheshire Home in Kampala, Uganda, developed a brace that can be made from simple, easily available materials. The brace is effective in maintaining correction, easy to use, easy to fabricate, inexpensive, and ideally suited for wide-spread use.

What is the Steenbeek Brace?

This brace [A] maintains correction in children with treated clubfoot [B]. The brace forms an integral part of Ponseti management.

This brace has open toe leather shoes with lace closures. A round metal bar holds the shoes in 70 degrees of abduction and 10 to 15 degrees of dorsiflexion. The positions of both shoes can be changed toward more or less abduction and dorsiflexion by bending the round bar close to the shoe.

The shoe has an inspection hole on the medial side of a well-molded heel counter to confirm that the heel is properly placed in the shoe. The heel counter has a low posterior cut (in contrast to high-top shoes) which prevents the heel from slipping out from the brace.

There are eight sizes with standardized patterns for all parts, which allows prefabrication and bulk production. This enables the clinician to fit braces off the shelf. These braces are, in most cases, reusable for other children with treated clubfoot.

Tools required

All that a skilled shoemaker or technician needs to fabricate the brace are ordinary shoe-making tools, a leather-sewing machine, and tools for metalworking and welding. These include mechanic's vice, wood hand saw or electric jigsaw, wood rasp or router machine, sand paper, scissors, hammer, and pop rivets/blind rivets with lazy tong riveter.

Materials required

The required materials are widely available [C]. These include leather, glue, 6-mm plywood, cardboard, stocking liner, flat metal sheet material of 1.5- to 2-mm thickness, mild steel rod of 6 mm in diameter, and rubber from a discarded tire or other flexible (scrap) sheet material.



How to measure for correct size

The therapist or orthopaedic officer measures the real length, in centimeters, of the foot sole of the baby. Do not add a centimeter as allowance for growth (this allowance is already incorporated in the patterns). If this measurement is, for example, 8 cm, then the therapist or orthopaedic officer orders a size 8 brace and the technician will issue a size 8.

For unilateral clubfoot

Prefabricated braces are designed for bilateral clubfoot with 70 degrees of abduction. For unilateral deformity, for the normal foot, bend the bar to approximately 30 to 40 degrees abduction/external rotation

Overview of brace construction

Make leather uppers

Start by cutting out the leather uppers from the pattern [D] and sewing them together. Flatten out the seam by hammering [E].

Make heel strap

Next, cut out the heel strap [F] and sew it to the leather upper over the seam on the posterior side of the upper.

Make heel counter

Make the heel counter [G] by cutting out the leather from the pattern. Skive the upper borders. Next, glue heel counters to the inside of the uppers, creating one continuous piece.

Make tongue

Cut out the tongue, and stitch it on the inside of the medial leather upper [H].

Punch inspection hole

Punch the lacing holes to be as big as possible. Create a larger inspection hole on the medial side [H].

Fix leather upper to outsole

Glue the 6-mm plywood outsole to the leather upper and heel counter [I]. Smooth the seam with a hammer.

Attach abduction bar

With a pop rivet, attach the shoe plates made of 1.5- to 2-mm sheet metal to the bar made of 6-mm mild steel rod [J].

Glue insole

Glue the cardboard insole to the outsole inside the shoe [K]. Glue the sock lining inside the shoe to provide a smooth lining.

Cover sole

Finally, the bottoms of the shoes and rod are covered with a durable rubber cover made from a tire casing or other sheet material [L].

The brace is complete [A opposite page].

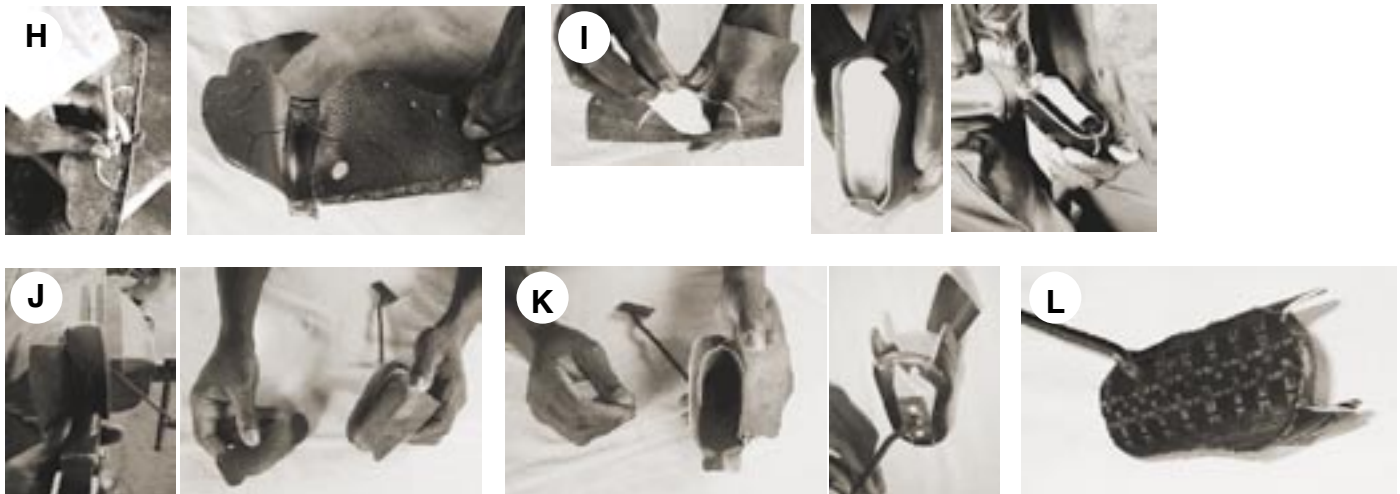Time required for fabrication

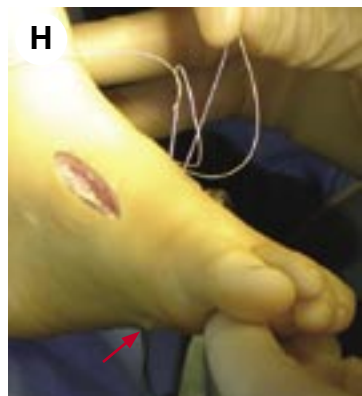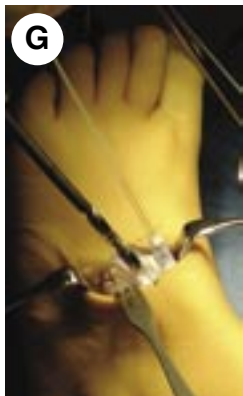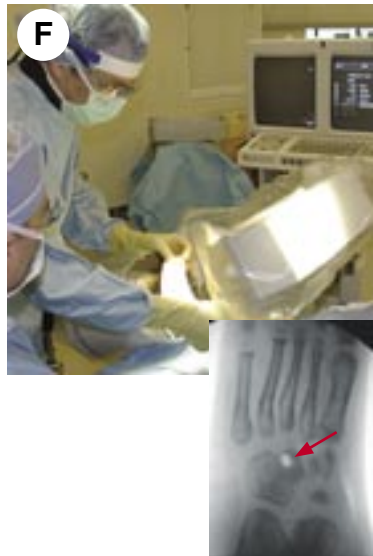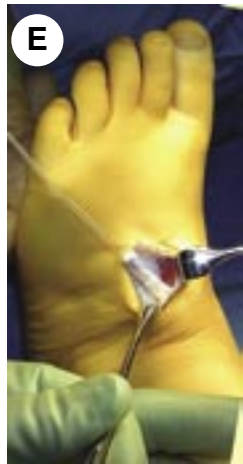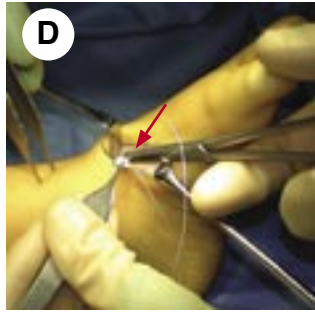
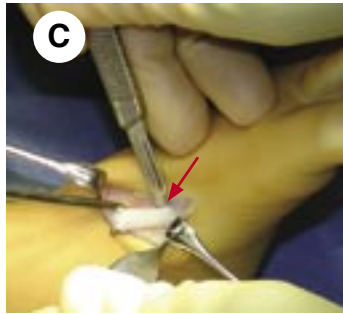
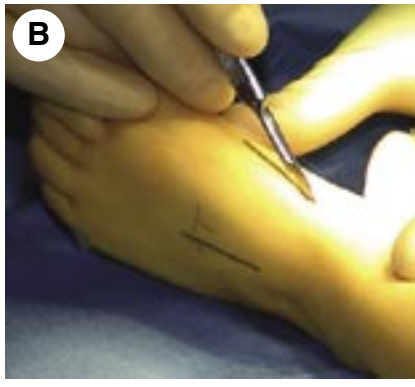
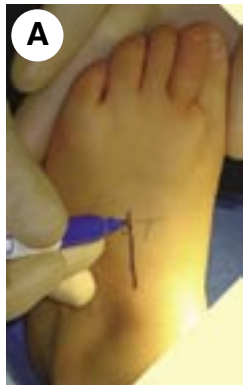Mr. Steenbeek estimates that an average brace requires about 3 hours to make and approximately 45 minutes to fit. In case of mass production, one technician can produce about five braces per day.

How to use the brace

On the day the last cast is removed, when correction is completed, the brace will be fitted. The brace is worn full time, day and night, except for bathing, for 3 months. After 3 months, the brace is worn only at night until the child is 3 to 4 years of age. It is very important to fit the brace the same day the last cast is removed to prevent recurrence of the deformity.

For details contact:
 Michiel Steenbeek
 steenb@africaonline.co.ug





Anterior Tibialis Transfer

Indication

Transfer is indicated if the child has persistent varus and supination during walking. The sole shows thickening of the lateral plantar skin. Make certain that any fixed deformity is corrected by two or three casts before performing the transfer. Transfers are best performed when the child is between 3 and 5 years of age.

Often, the need for transfer is an indication of poor compliance to brace management.

Mark the sites for incisions

The dorsolateral incision is marked on the mid-dorsum of the foot [A].

Make medial incision

The dorsomedial incision is made over the insertion of the anterior tibialis tendon [B].

Expose anterior tibialis tendon

The tendon is exposed and detached at its insertion [C]. Avoid extending the dissection too far distally to avoid injury to the growth plate of the first metatarsal.

Place anchoring sutures

Place a #0 dissolving anchoring suture [D]. Make multiple passes through the tendon to obtain secure fixation.

Transfer the tendon

Transfer the tendon to the dorsolateral incision [E]. The tendon remains under the extensor retinaculum and the extensor tendons. Free the subcutaneous tissue to allow the tendon a direct course laterally.

Option: localize site for insertion

Using a needle as a marker, radiography may be useful in exactly localizing the site of transfer in the third cuneiform [F]. Note the position of the hole in the radiograph (arrow).

Identify site for transfer

This should be in the mid-dorsum of the foot and ideally into the body of the third cuneiform. Make a drill hole large enough to accommodate the tendon [G].

Thread sutures

Thread a straight needle on each of the securing sutures. Leave the first needle in the hole while passing the second needle to avoid piercing the first suture [H]. Note that the needle penetrates the sole of the foot (arrow).

Pass two needles

Place the needles through a felt pad and then through different holes in the button to secure the tendon [A].

Secure tendon

With the foot held in dorsiflexion, pull the tendon into the drill hole by traction on the fixation sutures and tie the fixation sutures with multiple knots [B].

Supplemental fixation

Supplement the button fixation by suturing the tendon to the periosteum at the site where the tendon enters the cuneiform [C], using a heavy absorbable suture.

Neutral position without support

Without support, the foot should rest in approximately 10 degrees of plantar flexion [D] and neutral valgus-varus.

Local anesthetic

A long-acting local anesthetic is injected into the wound [E] to reduce immediate postoperative pain.

Skin closure

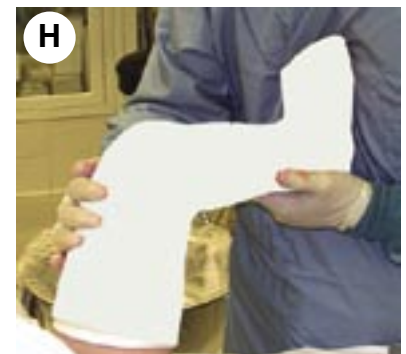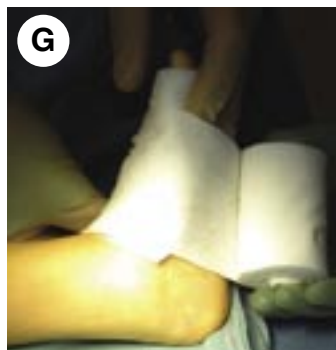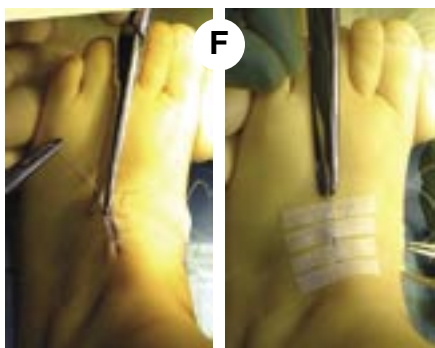
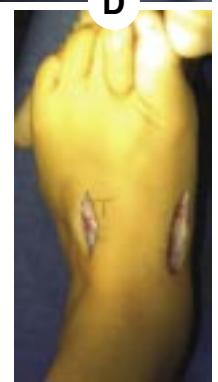
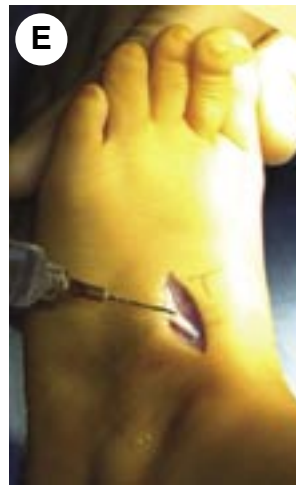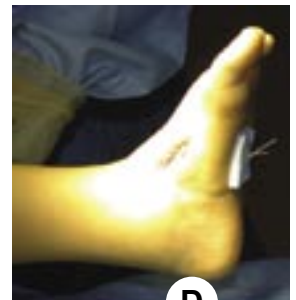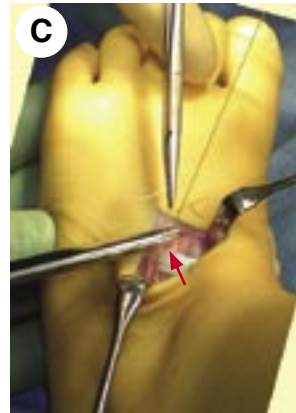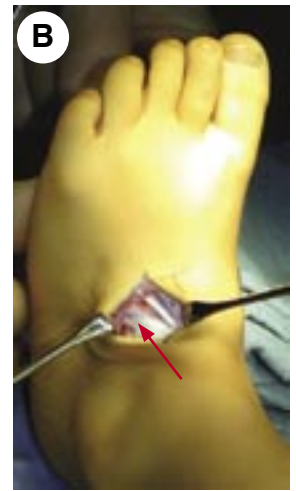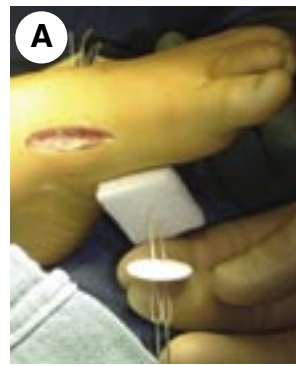Close the incisions with absorbable subcutaneous sutures [F]. Tape strips reinforce the closure.

Cast immobilization

A sterile dressing is placed [G], and a long leg cast is applied [H].

Postoperative care

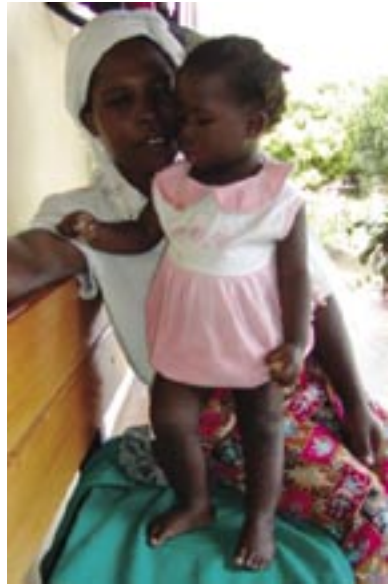This patient was discharged on the same day of the procedure. Usually, the patients remain hospitalized overnight. The sutures absorb. Remove the cast at 6 weeks. No bracing is necessary after the procedure. See the child again in 6 months to assess the effect of the transfer.



General Information for Parents

Before treatment

Parents of an infant born with clubfoot can be reassured that their babies, if otherwise normal, when treated by expert hands, will have normal looking feet with normal function for all practical purposes. The well-treated clubfoot, like those of the 2-year-old girl shown here, has no handicap and is fully able to live a normal active life.



Overview of management

The majority of clubfeet can be corrected in infancy in approximately 6 weeks with the proper gentle manipulations and plaster casts (below). The treatment is based on sound understanding of the functional anatomy of the foot and of the biological response of muscles, ligaments, tendons, and cartilage to the corrective positional changes obtained by manipulation and casting.

Severe clubfoot

Fewer than 5% of infants born with clubfoot may have very severe, short, plump feet with stiff ligaments that are unyielding to stretching. These babies may need surgical correction. However, the results are better if bone and joint surgery can be avoided altogether. Clubfoot surgery invariably leads to scarring, stiffness, and muscle weakness, which becomes more severe and disabling after adolescence.

Starting treatment

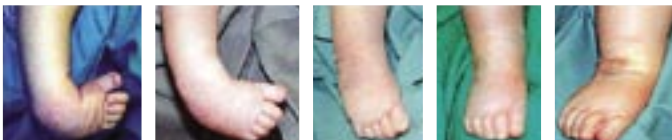The treatment should begin during the first week or two of life to take advantage of the favorable elasticity of the tissues forming the ligaments, joint capsules, and tendons. These structures are stretched with weekly gentle manipulations. An above-knee plaster cast is applied after each weekly session to retain the degree of correction obtained and to soften the ligaments. Thereby, the displaced bones are gradually brought into correct alignment.

Duration of active treatment

Five to seven plaster casts extending from the toes to the upper thigh with the knees at a right angle should be sufficient to correct the clubfoot deformity. Even very stiff feet require no more than eight or nine plaster casts to obtain maximum correction. Before applying the last plaster cast, the Achilles tendon is often cut in an office procedure to complete the correction of the foot. By the time the cast is removed 3 to 4 weeks after the heel cord lengthening, the tendon has regenerated to a proper length. After the end of the treatment, the foot should appear overcorrected. However, it will return to normal in a few weeks. Because the surgeon can feel with his/her fingers the position of the bones and the degree of correction, radiographs of the feet are not necessary except in complex cases.

Abduction brace

After correction, clubfoot deformity tends to relapse. To prevent relapses, after the last plaster cast is removed, a foot abduction brace must be worn full-time for 2 to 3 months and thereafter at night for 2 to 4 years. The brace consists of high-top open toed shoes attached to the ends of a bar, with the shoes rotated out approximately 70 degrees. The length of the bar equals the width of the baby's shoulders. A strip of plastizote must be glued inside the counter of the shoe, above the baby's heel to prevent the shoe from slipping off. The baby may feel uncomfortable at first when trying to alternately kick the legs. However, the baby soon learns to kick both legs simultaneously and feels comfortable. In children with only one clubfoot, the shoe for the normal foot is fixed on the bar in 40 degrees of external rotation. During the daytime, the child wears regular shoes.



Relapse

When the deformity relapses, further weekly manipulations are performed and plaster casts are applied. Occasionally, another percutaneous Achilles tenotomy may need to be performed. In some cases, despite proper bracing, a simple operation may be needed when the child is older than 2 years to prevent further relapses. The operation consists of transferring the anterior tibialis tendon to the third cuneiform.

Find experienced doctors

Surgeons with limited experience in the treatment of clubfoot should not attempt to correct the deformity. They may succeed in correcting mild clubfoot, but severe cases require experienced hands. Referral to a center with expertise in the nonsurgical correction of clubfoot should be sought before considering surgery. Poorly conducted manipulations and casting will further compound the clubfoot deformity rather than correct it, making treatment difficult or impossible.

After cast application

Your child's foot has been placed in a cast to begin to correct the turning in of his/her foot and to prevent future deformity. Your baby may be restless, but he/she should be comfortable after a time. Please consider the following.

1. Check the circulation in the foot every hour for the first 12 hours after application and then four-times a day. This is done by pinching the toes and watching the return flow of blood. The toes will turn white and then quickly return to pink if the blood flow to the foot is good. This is called blanching. If the toes are dark and cold and do not blanch (white to pink) the cast may be too tight. If this occurs, call your local doctor, emergency department, or orthopaedic clinic staff and ask them to check the cast.

2. The top of the toes should be exposed. If you cannot see the toes, it may mean the cast has slipped and correct reduction is not being maintained. Call the orthopaedic clinic immediately, and tell the doctor that you cannot see your baby's toes.

3. Keep the cast clean and dry. The cast may be wiped with a slightly dampened cloth if it becomes soiled.

4. The wet cast should be placed on a pillow or soft pad (hard surfaces may dent wet plaster). Whenever your child is on his/her back, place a pillow under the cast to elevate the leg so that the heel extends just beyond the pillow. This prevents pressure on the heel, that could cause a sore.

5. Use disposable diapers and change the baby often to prevent cast soiling. Apply the diaper above the top of the cast to prevent urine/stool from getting inside the cast. Diapers with elasticized legs work well.

Notify your doctor or the clinic nurse if you notice any of the following.

- any drainage on the cast
- any foul smelling odors coming from inside the cast
- skin at the edges of the cast becoming very red, sore, or irritated
- child running a fever of 38.5°C/101.3°F or higher without an explainable reason, such as a cold or virus

A new cast will be applied every 5 to 7 days. The nurse will remove the cast with a special plaster knife; therefore, the cast must be softened the day you are coming to the clinic. To do this, put your child in a tub or sink, making sure that warm water is getting inside the cast (about 15–20 minutes). After the bath, wrap a soaking wet hand towel around the cast and cover with a plastic bag. A bread sack works well for this.

After removal of the last cast and to prevent relapse, the baby will be fitted with a night brace (foot abduction brace consisting of shoes attached to a metal bar). The brace will be worn 23 hours a day for 3 months and thereafter at night and during naps for an additional 2 to 4 years. The first and second nights of wearing the brace, the baby may be uncomfortable, but it is important that the brace not be removed. After the second night, the baby will adapt to the splint. Relapses will almost invariably occur if the splint is not worn as prescribed. Once the brace is removed, ordinary shoes can be worn. Yearly visits will be scheduled for 8 to 10 years to check for possible relapses.

Instructions for Brace Use

The foot abduction brace is used only after the clubfoot has been completely corrected by manipulation and serial casting. Even when well corrected, the clubfoot has a tendency to relapse until the age of approximately 4 years. The foot abduction brace, which is the only successful method of preventing a relapse when used consistently as described herein, is effective in 90% of the patients. Use of the brace will not delay your child's sitting, crawling, or walking.

Foot abduction brace

The brace consists of an adjustable aluminum bar with adjustable footplates to which straight last shoes attach. The orientation of the footplates to the bar is set by the orthotist. The shoes are straight last, meaning they can go on either foot, but the shoes are set up with the buckles on the inside, so that you do not have to turn the baby over to tighten the straps and laces. The foot strap is the key to this device; it does not matter if the strap goes through the top or bottom holes on the sides of the shoe. On the inside of the shoe, above the heel, there is a pink pad that creates an area for a normal heel to develop and grow into; it also helps to prevent the heel from coming out of the shoe.

Wearing schedule

Use the brace once the last set of casts is removed. The infant wears the brace for 23 hours a day for the first 3 months after cast removal. The brace is removed only for baths. For the next 3 to 4 years, the brace is used at night and nap time only. Your physician will decide on the duration of bracing depending upon the clubfoot severity. However, do not end treatment early. If you are unsure, ask your doctor.

Wearing instructions

1. Always use cotton socks that cover the foot everywhere the shoe touches the baby's foot and leg. Your baby's skin may be sensitive after the last casting, so you may want to use two pairs of socks for the first 2 days only. After the second day, use only one pair of socks.
2. If your child does not fuss when you put the brace on, you may want to focus on getting the worst foot in first and the better one in second. However, if your baby tends to kick a lot when

putting on the brace, focus on the better foot first, because the baby will tend to kick into the second shoe.

3. Hold the foot into the shoe and tighten the strap first. The strap helps keep the heel firmly down into the shoe. Do not mark the hole on the strap that you use, because with use, the leather strap will stretch and your mark will become meaningless.
4. Check that the child's heel is down in the shoe by pulling up and down on the lower leg. If the toes move backward and forward, the heel is not down, so you must retighten the strap. A line should be on the insole of the shoe, indicating the location of the child's toes; the toes will be at or beyond this line if the heel is down.
5. Lace the shoes tightly, but do not cut off circulation. Remember: the strap is the most important part. The laces are used to help hold the foot in the shoe.
6. Be sure all the baby's toes are out straight and that none of them are bent under. Until you are certain of this, you may want to cut the toe portion out of a pair of socks so you can clearly see all the toes.

Set up brace

The brace will be set up for you by your orthotist, but you may be responsible for changing the shoes and widening the bar as your child grows. Change the shoes only when the baby's toes completely curl over the edge of the shoe. The forefoot adduction (inward curving) usually does not recur, so waiting will not affect the correction but will save you money. If you do not know what size shoes were used on the bar, measure the length of the shoe and contact your orthotist. New shoes will be two sizes larger than the current shoes. You may contact your local orthotist to order new straight last shoes for the foot abduction brace. Screws are used on the bottoms of the shoes to attach the shoes to the footplate on the bar. Mark the joints on the bar before changing the shoes to ensure a return to the proper alignment. Attach the shoes with the buckles toward the inside. You should adjust the width of the bar at this time. Measure the distance between the outside of the shoulders, this will be equal to the distance between the center heel screws in the shoe; lengthen the bar to match your measurements. Mark a line for the location of the toes the first time the shoes are worn to indicate that the heel is down.

Helpful tips

1. Expect your child to fuss in the brace for the first 2 days. This is not because the brace is painful but because it is something new and different.

2. Play with your child in the brace. This is key to getting over the irritability quickly. The child is unable to move his/her legs independently of each other. You must teach your child that he/she can kick and swing the legs simultaneously with the brace on. You can do this by gently flexing and extending the knees by pushing and pulling on the bar of the brace.

3. Make it routine. Children do better if you make this treatment a routine in your life. During the 3 to 4 years of night and nap time wear, put the brace on any time your child goes to the “sleeping spot.” The child will know that when it is that time of day, the brace needs to be worn. Your child is less likely to fuss if you make the use of this brace a part of the daily routine.

4. Pad the bar. A bicycle handlebar pad works well for this. By padding the bar, you will protect your child, yourself, and your furniture from being hit by the bar when the child is wearing it.

5. Never use lotion on any red spots on the skin. Lotion makes the problem worse. Some redness is normal with use. Bright red spots or blisters, especially on the back of the heel, usually indicate that the shoe was not worn tightly enough. Make sure that the heel stays down in the shoe. If you notice any bright red spots or blistering, contact your physician.

6. If your child continues to escape from the brace, and the heel is not down in the shoe, try the following.

- a. Tighten the strap by one more hole.
- b. Tighten the laces.
- c. Remove the tongue of the shoe (use of the brace without the tongue will not harm your child).
- d. Try lacing the shoes from top to bottom, so that the bow is by the toes.

7. Periodically tighten the screws on the bar.

Tools have been provided.

Common Questions

What causes clubfoot?

Parents may be concerned that they have done something wrong and caused their child’s clubfoot. Doctors agree that clubfoot is not caused by anything the family did or did not do.

The cause of clubfoot is not exactly known. Doctors know that clubfoot is more common in certain families. The usual incidence of clubfoot is about 1 in 1,000 births. The chances of having a second child with clubfoot is approximately 1 in 30. In summary, there is no reason for parents to feel guilty about having a child with clubfoot.

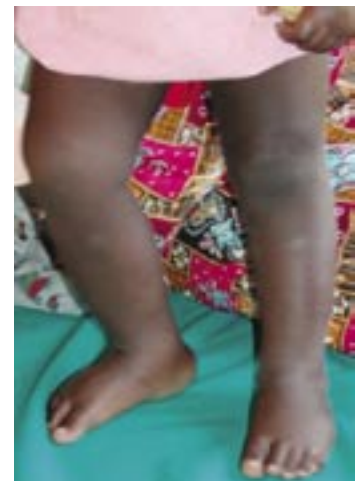What is the future of children with clubfoot?

The child with a clubfoot corrected by Ponseti management can be expected to have a nearly normal foot. Some minor effects may be noticed.

Size difference The treated clubfoot is often very slightly smaller than the normal foot. There may be a slight reduction in the size of the calf. How much reduction depends on the original severity of the clubfoot. No significant shortening of the leg occurs.

Subtle differences do not cause any problem and often go unnoticed by the child. During adolescence, when people become very concerned about body image, this slight difference may be noticed, but is usually forgotten in a year or two.

Sports Outcome studies of patients treated by Ponseti management show that children and adults with corrected clubfoot may participate in athletics like anyone else. We know many excellent athletes who have corrected clubfoot.



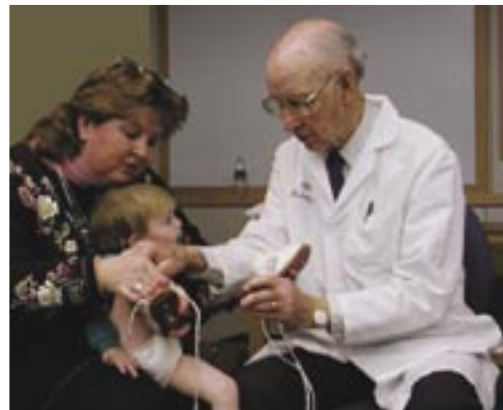

Global-HELP Publication

Clubfoot is one of the most common congenital deformities, affecting about 1 infant in every 1,000 births. Worldwide, approximately 100,000 new cases of clubfoot occur each year. Most occur in countries without adequate health care, leaving the infant to face a life of disability.

Dr. Ponseti has developed a method of treatment that is effective, simple, minimally invasive, inexpensive, and ideally suited for all countries and cultures. Long-term studies at 35 years show that the feet treated by Ponseti management are flexible and pain free. These outcomes are better than those of reported series treated by other methods.

The Ponseti method of clubfoot management is detailed in the book.



Global-HELP (GHO) is a not-for-profit, non-political, humanitarian organization that creates low-cost publications to improve the quality of health care in transitional and developing countries.

Global-HELP's objective is to create and distribute publications using desktop computer technology, digital imaging, and electronic media. This new technology makes possible the production of low-cost books, brochures, pamphlets, and CDs that are affordable to health care providers in countries with limited resources.

Other Global-HELP Publications

English:

*What Parents Should Know
Bibliography of Orthopaedic Problems
in Developing Countries*

Turkish:

*Cerebral Palsy
Spina Bifida
Parent's Guide to Cerebral Palsy
Parent's Guide to Spina Bifida*

Publications in Development:

*Management of Poliomyelitis
Management of Tuberculosis*

For more information about Global-HELP and other publications,
visit our web site at global-help.org