

A close-up photograph of a human eye, heavily tinted with a teal or cyan color. The eye is looking slightly to the right. The eyelashes are dark and prominent. The background is dark, making the eye the central focus.

# Atlas of Oculoplastic and Orbital Surgery

**informa**  
healthcare

Thomas C Spoor

# ATLAS OF OCULOPLASTIC AND ORBITAL SURGERY

**Thomas C Spoor MD, FACS**

Professor Emeritus

Departments of Ophthalmology and Neurosurgery

Wayne State University School of Medicine

and

Oculoplastic and Orbital Surgery

St John Hospital System, Detroit, Michigan and

Sarasota Retina Institute, Sarasota, Florida

USA

**informa**  
healthcare

© 2010 Informa UK

First published in 2010 by Informa Healthcare, Telephone House, 69-77 Paul Street, London EC2A 4LQ. Informa Healthcare is a trading division of Informa UK Ltd. Registered Office: 37/41 Mortimer Street, London W1T 3JH. Registered in England and Wales number 1072954.

All rights reserved. No part of this publication may be reproduced, stored in a retrieval system, or transmitted, in any form or by any means, electronic, mechanical, photocopying, recording, or otherwise, without the prior permission of the publisher or in accordance with the provisions of the Copyright, Designs and Patents Act 1988 or under the terms of any licence permitting limited copying issued by the Copyright Licensing Agency, 90 Tottenham Court Road, London W1P 0LP.

Although every effort has been made to ensure that all owners of copyright material have been acknowledged in this publication, we would be glad to acknowledge in subsequent reprints or editions any omissions brought to our attention.

A CIP record for this book is available from the British Library.  
Library of Congress Cataloging-in-Publication Data

Data available on application

ISBN-13: 978 1 841 84586 9

Orders from

Informa Healthcare  
Sheepen Place  
Colchester  
Essex CO3 3LP  
UK

Telephone: +44 (0)20 7017 5540  
Email: [CSDhealthcarebooks@informa.com](mailto:CSDhealthcarebooks@informa.com)

Typeset by Exeter Premedia Services Private Ltd., Chennai, India  
Printed and bound in Great Britain by MPG Books Ltd, Bodmin, Cornwall, UK

# Contents

<i>Dedication</i>	<i>iv</i>
<i>Foreword</i>	<i>v</i>
<i>Preface</i>	<i>vi</i>
<b>1 Lower Eyelid Surgery</b>	<b>1</b>
<b>2 Ectropion Repair</b>	<b>16</b>
<b>3 Entropion Repair</b>	<b>26</b>
<b>4 Lower Eyelid Retraction</b>	<b>32</b>
<b>5 Complications of Lower Eyelid Surgery</b>	<b>38</b>
<b>6 Upper Eyelid Surgery</b>	<b>48</b>
<b>7 Complications of Upper Eyelid Surgery</b>	<b>73</b>
<b>8 Tearing and Dry Eye—Evaluation and Treatment</b>	<b>84</b>
<b>9 Orbital Surgery, Optic Nerve Sheath Decompression, and Temporal Artery Biopsy</b>	<b>95</b>
<i>Index</i>	<i>118</i>

## Dedication

I would like to dedicate this book to those who made me what I am (for better or worse). My parents Herbert and Edna Spoor, my wife Deanne and daughter Kristen.

I also thank the members of the oculoplastic service at the New York Eye and Ear Infirmary where I was an OR technician and a resident. Many are long dead but are still quoted and remembered. Thanks also to my preceptor in Orbital surgery Dr John S Kennerdell for giving me an opportunity to do a unique fellowship in orbital disease. Thanks also to my many fellows and residents. Their input, ideas and mistakes were always stimulating.

## Foreword

One might appropriately ask whether there is a need for yet another atlas of oculoplastic surgery. Dr. Thomas Spoor has nicely compiled and detailed his personal experience with common oculoplastic conditions over his nearly 30 years of practice. This book, while not claiming to be comprehensive, emphasizes more of the common oculoplastic conditions likely to present to a busy comprehensive ophthalmologist with an interest in oculoplastic conditions. There are nine chapters in the book and the first seven deal with the eyelids. Separate chapters on complications of upper eyelid and lower eyelid surgery are timely and helpful. Another chapter devoted to the evaluation and treatment of tearing and a dry eye contains many practical pearls. The final chapter is much more specialized and deals with temporal artery biopsy, orbital surgery, and optic

nerve sheath fenestration. The last two procedures are more fitting for an oculoplastic or neuro-ophthalmic surgeon. The chapters are short and practical with helpful hints and suggestions to avoid or manage complications. Surgical points are emphasized with many patient photographs. For the conditions listed and the procedures described, Dr. Spoor's techniques have stood the test of time. Dr. Spoor's new surgical atlas is a useful addition to anyone's library.

James A Garrity MD  
Whitney and Betty MacMillan  
Professor of Ophthalmology  
Mayo Clinic  
Rochester, MN

## Preface

Over 50 years ago, three surgeons in New York—Byron Smith, Wendell Hughes, and Sidney Fox—working quite independently, realized that plastic surgery around the eye was different. The eye has special needs and should be treated in a special manner to protect its function. Since its inception two generations ago, oculoplastic surgery has constantly evolved. What was once dogma may now be passé. Procedures that were once passé may be resurrected and utilized again. The only constant in oculoplastic surgery is change and evolution. Although I learned this specialty from some of the best in the business, little I do today is the way it was taught to me. Thirty years of teaching residents and fellows modifies conventional wisdom and we all learn from one another.

There is a need to describe practical, simple surgical techniques allowing the comprehensive ophthalmologist to manage basic eyelid and orbital disorders in a safe and effective manner. There is also a need for younger or inexperienced oculoplastic surgeons, neuro-ophthalmologists, and plastic surgeons to benefit from the mistakes and successes of an experienced practitioner. The practice environment 30 years ago was much less competitive and more forgiving, providing a large volume of surgery and allowing for a great deal of innovation.

This book presents a practical, problem-oriented guide to the management of common oculoplastic and orbital disorders. These are mostly simple solutions to often-complicated problems that I have learned over a lifetime of academic and private practice. The procedures are described with surgical photos and illustrations in a casual, didactic fashion, as I would use instructing a resident or fellow. This is not an all-encompassing, encyclopedic text but a practical, somewhat dogmatic approach to the management of common eyelid and orbital disorders. I describe these procedures in a step-by-step manner, which should be very user friendly and has successfully educated a generation of ophthalmology residents and fellows.

This book will teach you to avoid and manage surgical complications and provide guidance for performing a variety of oculoplastic and neuro-ophthalmic surgical procedures effectively and quickly, as developed over a busy 30-year surgical career with extensive input from a plethora of residents and fellows. There may be better ways to perform these procedures but not many.

Thomas C Spoor MD, FACS

# 1 Lower Eyelid Surgery

## BASIC LOWER EYELID BLEPHAROPLASTY—TRANSCONJUNCTIVAL Basic Anatomy

There are three fat pads in the lower eyelid: medial, central, and lateral (Fig. 1.1). The inferior oblique muscle separates the medial from the central fat pad (Fig. 1.2). When approaching the lower eyelid via a transconjunctival incision, this is really all you need to know. As the conjunctival flap is dissected and the eyelid is retracted, the fat pads become readily apparent (Fig. 1.3). The orbital septum and capsulopalpebral fascia are retracted with the rest of the eyelid (Fig. 1.3A).

Most transconjunctival dissections of the lower eyelid are done behind the orbital septum, directly exposing the orbital fat pads. Deep to the orbital fat is the capsulopalpebral fascia, which is analogous to the levator aponeurosis in the upper eyelid (Fig. 1.1). The capsulopalpebral fascia needs to be identified and reattached to the tarsus to properly repair an involutional entropion (see chapter “Entropion Repair”).

Transconjunctival blepharoplasty with or without a tarsal strip procedure is the mainstay of lower eyelid surgery. The vast majority of lower eyelid blepharoplasties should be performed via a transconjunctival approach. Excessive skin rarely needs to be removed in younger patients since it takes more skin to fill the concavity remaining after removal of orbital fat than it did to cover the antecedent convexity formed by the herniated fat (Fig. 1.3B). Transcutaneous lower eyelid blepharoplasty should be reserved for elderly patients with excessive festoons (bags on bags) or patients with an entropion that needs repair by reattaching the capsulopalpebral fascia (see chap. 3, “Entropion Repair”).

## Technique

Inject a local anesthetic containing epinephrine into the eyelid 10 to 15 minutes prior to surgery (Fig. 1.4). Pass two 4-0 silk traction sutures through the eyelid margin and invert the lower eyelid. Inject  $\frac{1}{2}$  to 1 cm<sup>3</sup> of anesthetic solution beneath the palpebral conjunctiva (Fig. 1.5). A lateral canthotomy (Fig. 1.6) may or may not be performed. A canthotomy often facilitates removal of the lateral fat pad avoiding an unsightly inferior orbital mass after surgery. Make an incision through the conjunctiva just posterior to the tarsus and extend it along the entire horizontal length of the eyelid (Fig. 1.7A–C). Pass two 6-0 Vicryl™ traction sutures through the conjunctiva applying upward traction with hemostats (Fig. 1.8). Dissect a conjunctival flap and obtain hemostasis with a hot Ocutemp™ cautery (Fig. 1.9A and B). This exposes the lower eyelid fat pads. Enhance exposure by retracting the lower eyelid with a Desmarres or similar retractor (Fig. 1.3). Use bipolar cauterization to coagulate any large overlying blood vessels (Fig. 1.10). Expose the inferior orbital fat pads by dissecting with the Ocutemp cautery. Enhance exposure of the fat pads by applying gentle pressure on the globe (Fig. 1.11A and B). Clamp the prolapsed fat with a hemostat, excise it with scissors, and cauterize the clamped fat

with a bipolar cautery (Fig. 1.12A–D). Before releasing the fat, grasp it with forceps and inspect it for bleeding. If there is none, release the fat back into the orbit (Fig. 1.13). It is much easier to cauterize visible vessels before they have retracted into the orbit. If you do release a bleeding fat pad into the orbit, expose it by applying gentle pressure to the globe, grasp the fat with forceps, and cauterize the bleeding vessel again.

Approach the medial fat pad in a similar fashion. Apply pressure to the globe, prolapse the fat pad (Fig. 1.14A), dissect it with the Ocutemp cautery (Fig. 1.14B), cauterize the overlying vessels (Fig. 1.14C), clamp and excise the fat pad (Fig. 1.14C–E), cauterize the stump of fat, and maintain control and observe for bleeding before releasing the hemostat (Fig. 1.14C and D). Use bipolar cauterization for hemostasis. The middle fat pad may be removed in a similar fashion (Fig. 1.15). The inferior oblique muscle lies between the medial and middle fat pad and is easily identified and avoided (Figs. 1.2 and 1.16). It is very difficult to cause clinical diplopia by inadvertent injury to the inferior oblique muscle, as any experienced eye muscle surgeon can relate that the inferior oblique muscle continues to function quite well when partially removed. After obtaining hemostasis, inspect the eyelid for contour and symmetry (Fig. 1.17A and B). Reattach the conjunctiva and recess it about 5 mm posterior to its original attachment to the tarsus (Fig. 1.18A and B). Reattaching the conjunctiva avoids potential pyogenic granuloma formation. Now tighten the lower eyelid, if necessary, with a tarsal strip procedure.

## TARSAL STRIP PROCEDURES

Variations on the theme of tightening the lateral canthal tendon are the mainstays of lower eyelid surgery. Do this by splitting the canthus for lesser degrees of laxity, splitting the eyelid into an anterior and posterior lamella for greater degrees of laxity, or tightening the common canthal tendon to treat rounding of the canthus and mild canthal dystopia. These procedures are so important that they are worth describing in the context of lower eyelid blepharoplasty and later when discussing ectropion repair.

Clamp the lateral canthus and incise it with scissors (Fig. 1.19). Extend the lateral canthotomy incision with a sharp blade (Fig. 1.20). Dissect the lower eyelid into an anterior (skin and orbicularis muscle) and posterior lamella (tarsus and conjunctiva) (Fig. 1.21). A horizontal cut posterior and parallel to the tarsus forms a tarsal strip (Fig. 1.22). Pass a double-armed 5-0 Dexon™ or polypropylene suture with a large curved needle through the tarsal strip from posterior to anterior and tie it to prevent it from pulling through the tissue (Fig. 1.23). Pass both arms of the suture through the lateral orbital wall at the level of the lateral orbital tubercle. This suture placement has classically been described as through the periosteum at the lateral orbital rim, but you will get much better fixation of the eyelid to the lateral orbital rim if you pass the



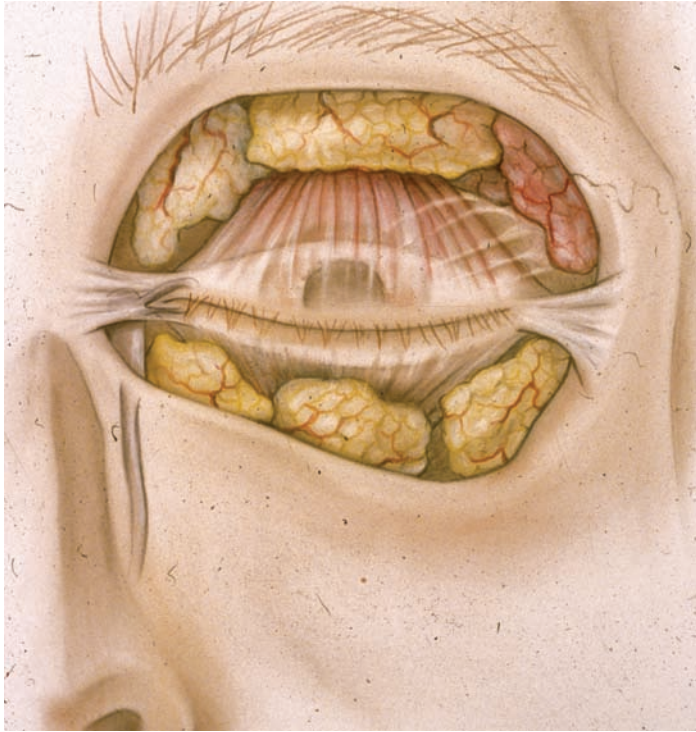
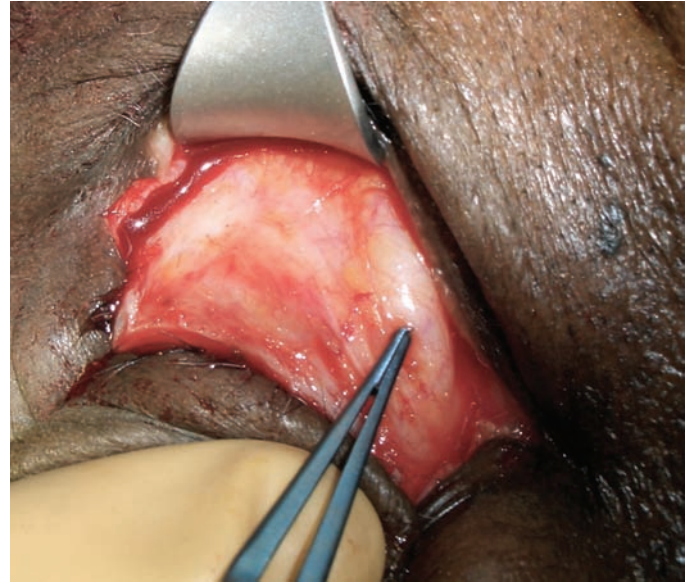


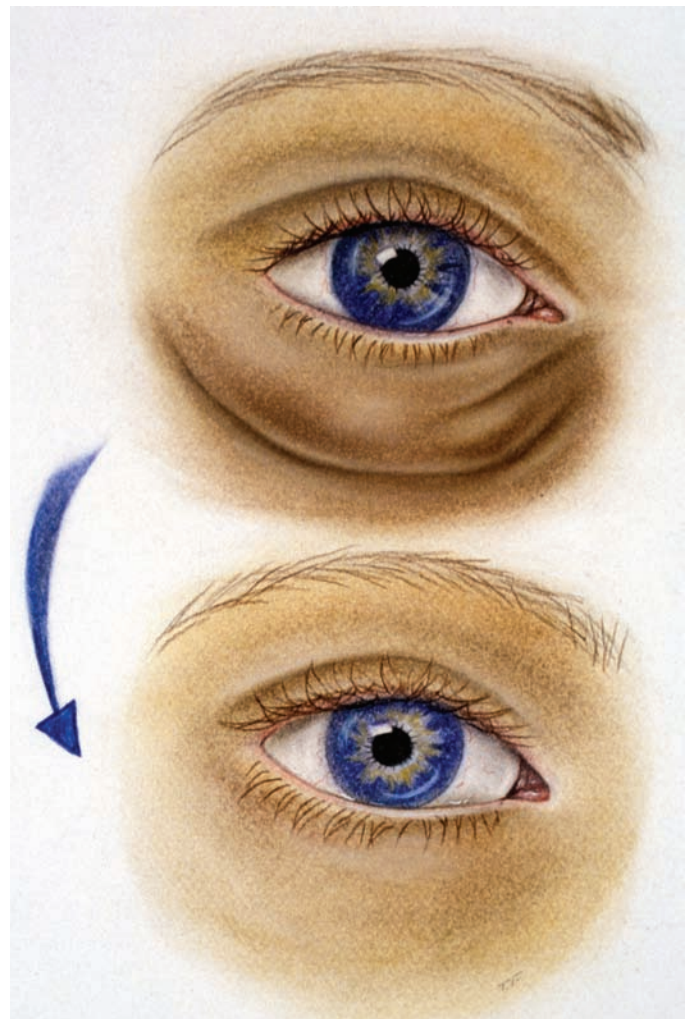
Figure 1.1 Preaponeurotic fat pads of the upper and lower eyelids.



(A)

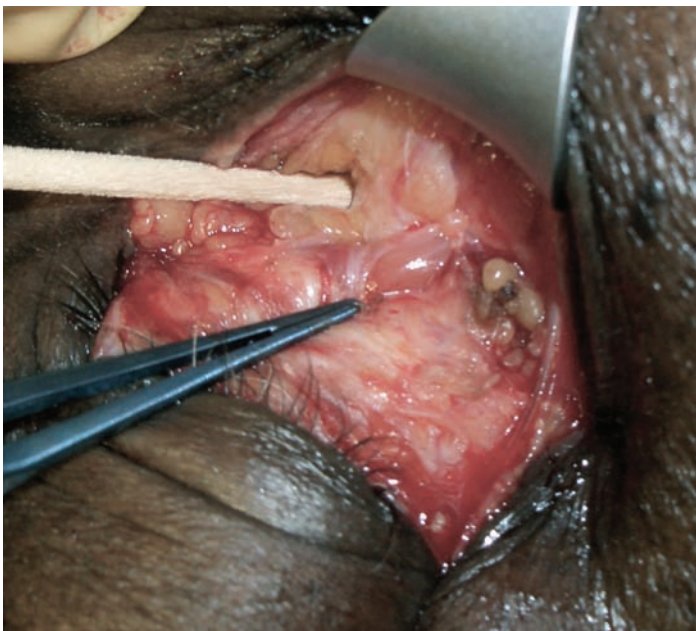

Figure 1.2 The inferior oblique muscle lies between the medial and central fat pads.



(B)

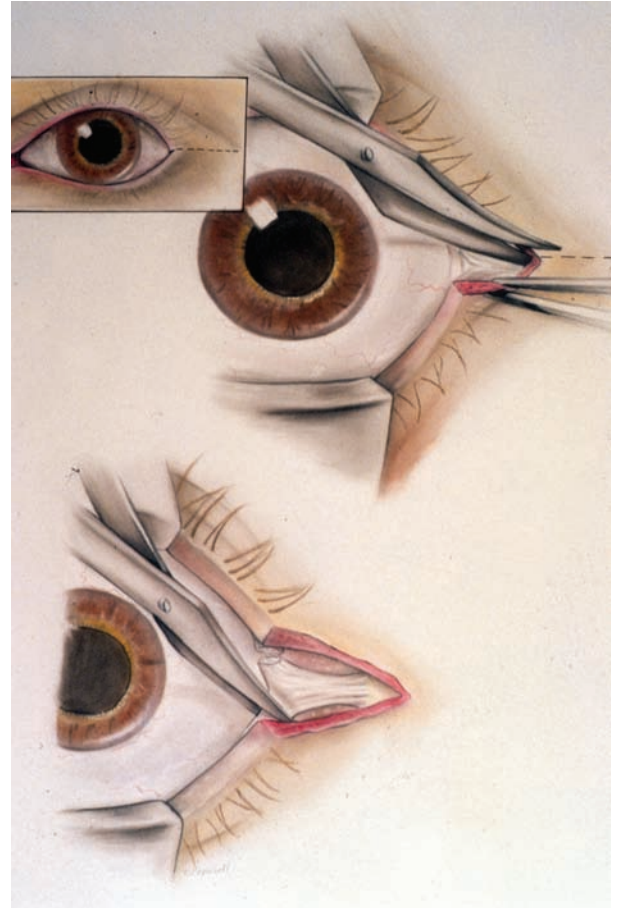
Figure 1.3 Apply gentle pressure to the globe. This facilitates exposure of the lower eyelid fat pads (A). It takes more skin to fill a concavity than a convexity hence most patients can undergo a transconjunctival blepharoplasty without an external incision and removal of skin (B).

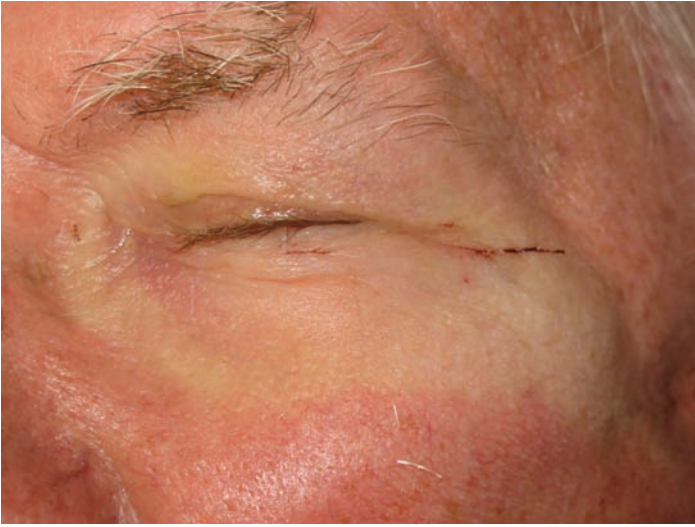
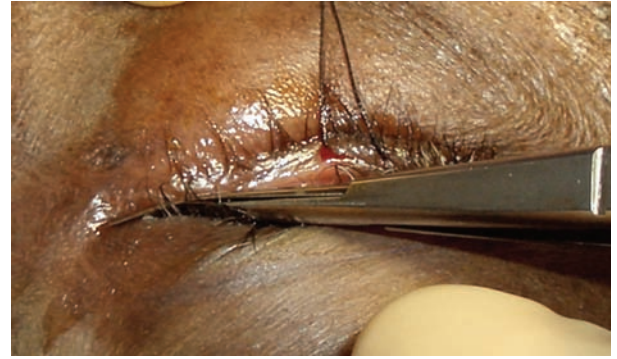
Figure 1.4 Blanching of the skin at the operative site indicates sufficient vasoconstriction to enhance hemostasis and greatly facilitates the operation. It is very helpful to inject the anesthetic in the preoperative holding area and let the epinephrine constrict the vessels while the patient is prepared for surgery.



(A)



(B)

Figure 1.6 A lateral canthotomy (A) with or without a cantholysis facilitates exposure of the lateral fat pads (A, B). Cantholysis entails cutting the inferior crus of the lateral canthal tendon (B).

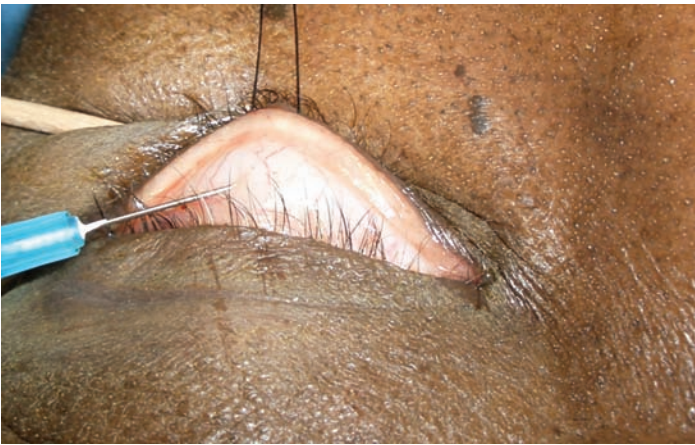
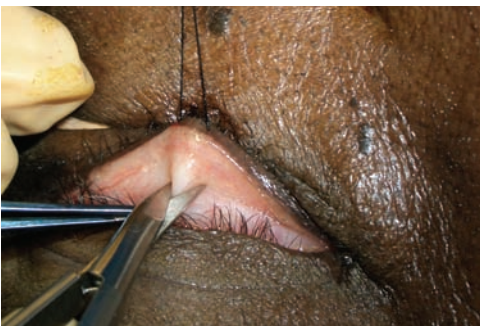
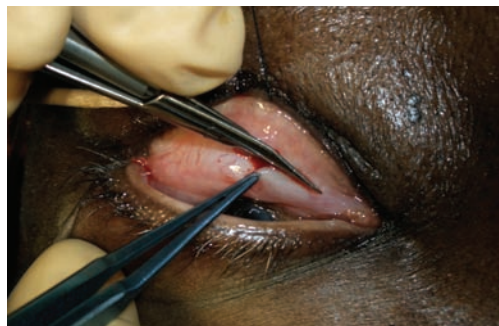
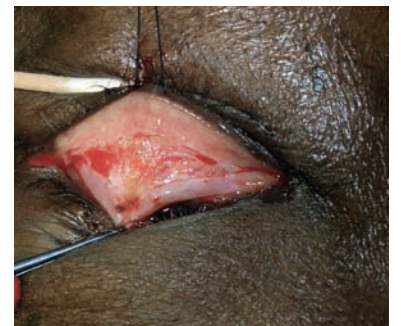Figure 1.5 Invert the lower eyelid with a 4-0 silk suture and inject additional anesthetic beneath the conjunctiva.



(A)

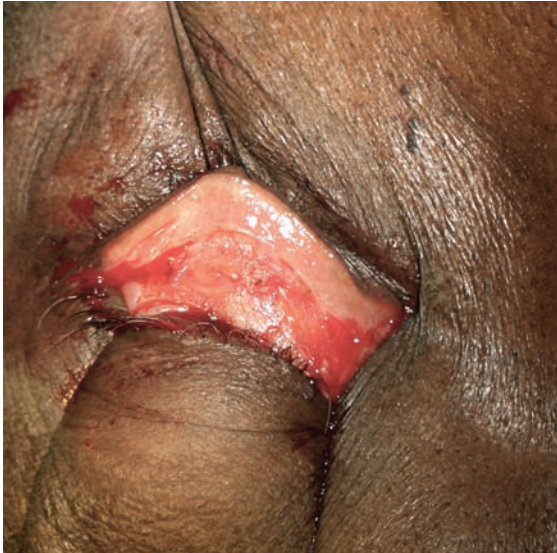

(B)

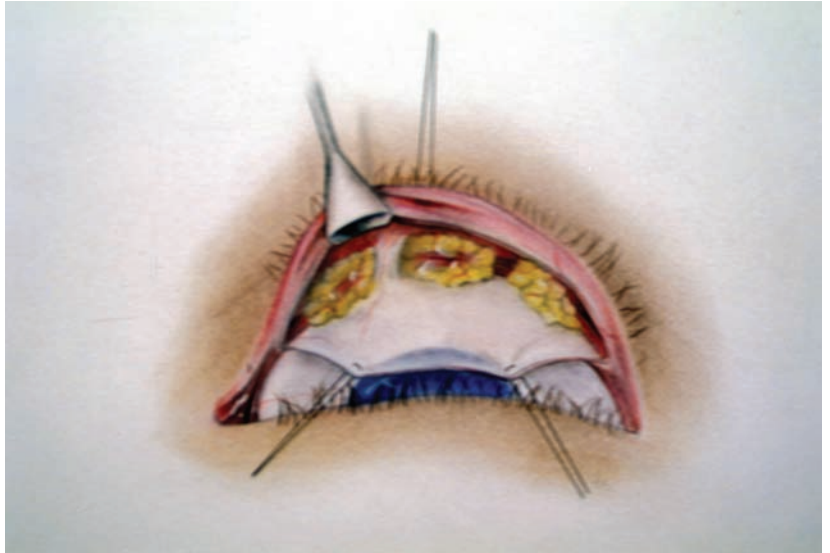


(C)

Figure 1.7 Make an incision just below the tarsus (A) and extended it along the entire horizontal length of the eyelid (B, C).

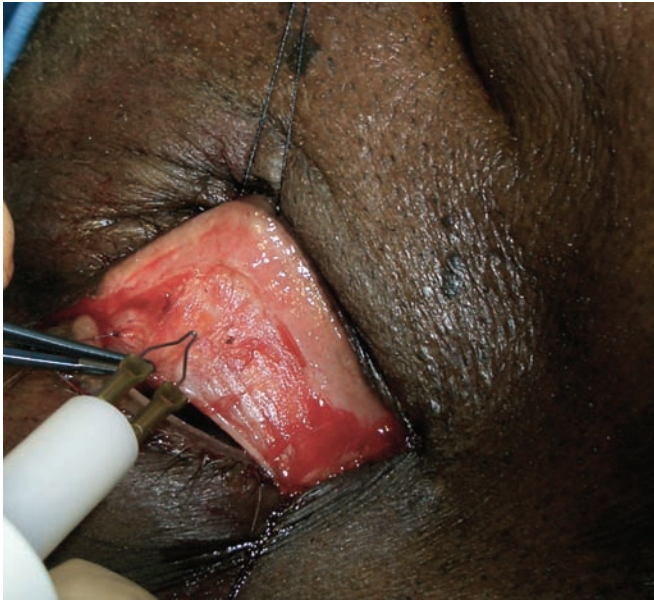

(A)

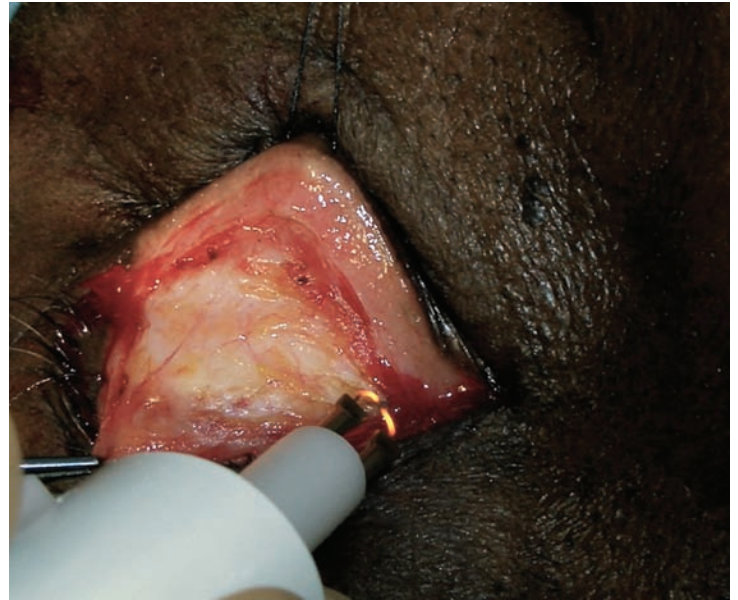

(B)

Figure 1.8 Nasal and temporal sutures retract the conjunctival flap superiorly, facilitating dissection (A, B).



(A)



(B)

Figure 1.9 The conjunctival flap can be dissected in a bloodless fashion using hot cauterization (A, B). Make sure the supplemental nasal oxygen is discontinued before using this form of cauterization.

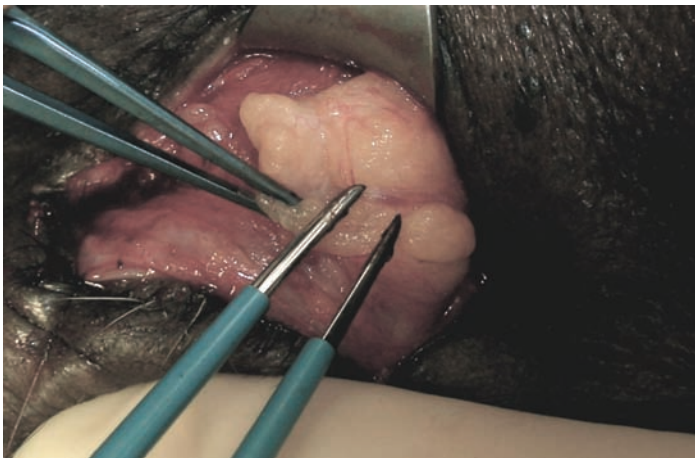
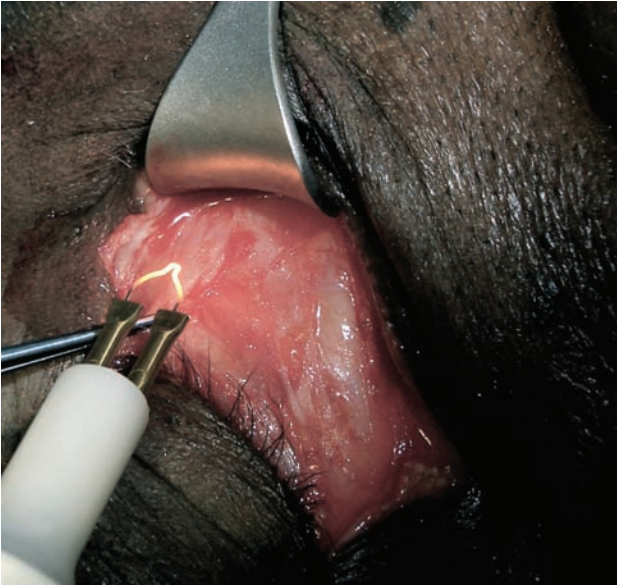
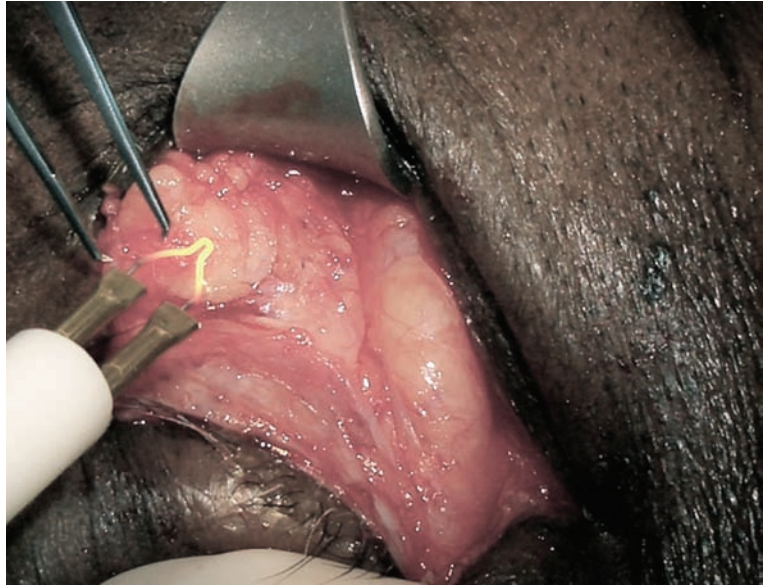


Figure 1.10 Large vessels should be cauterized with a bipolar cautery.

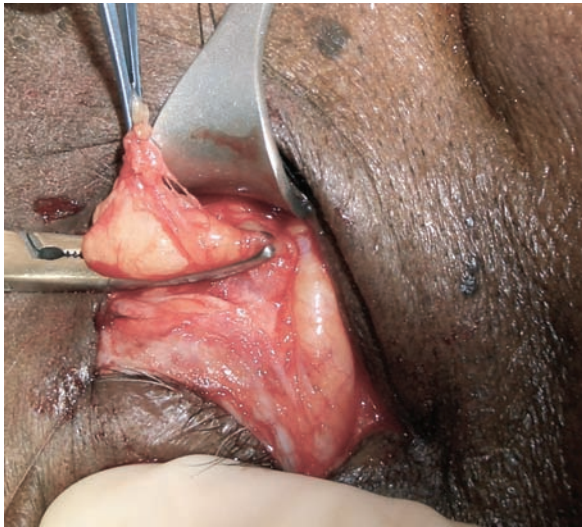


(A)

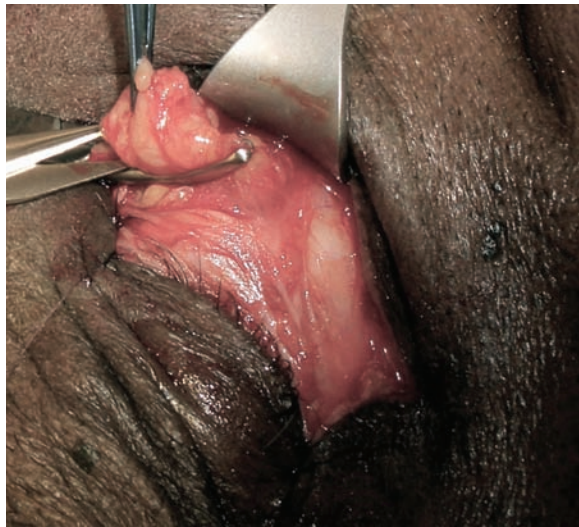

(B)

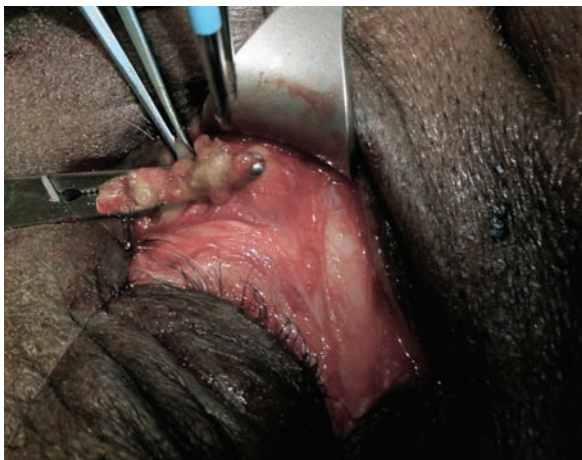Figure 1.11 Ocutemp hot cauterization facilitates dissection of the orbital fat capsule (A), exposing the individual orbital fat pads (B).



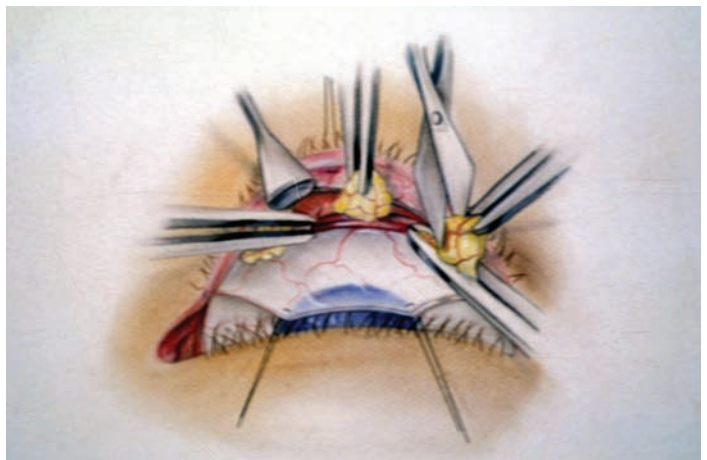
(A)



(B)



(C)



(D)

Figure 1.12 Technique for removal of orbital fat requires exposure, enhanced by digital pressure on the globe (A), clamping the protruding fat (B), excising the clamped fat (C), and cauterizing the clamped fat (C). This busy illustration (D) demonstrates the techniques of clamping, cutting, and cauterizing the fat pads.

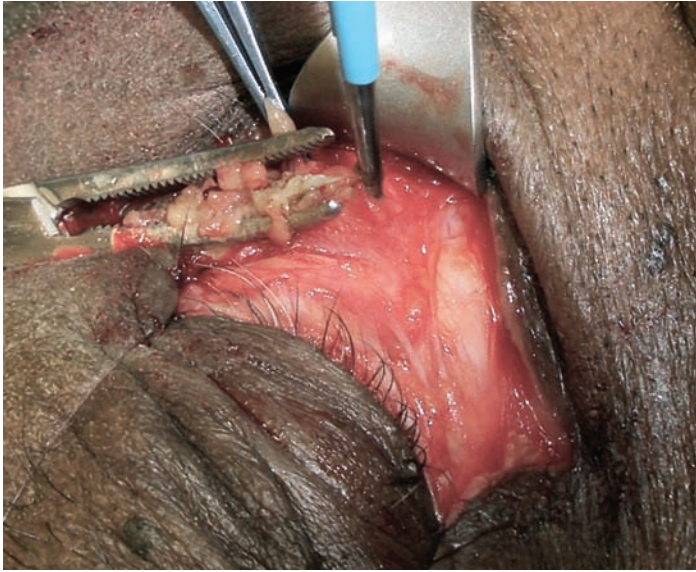
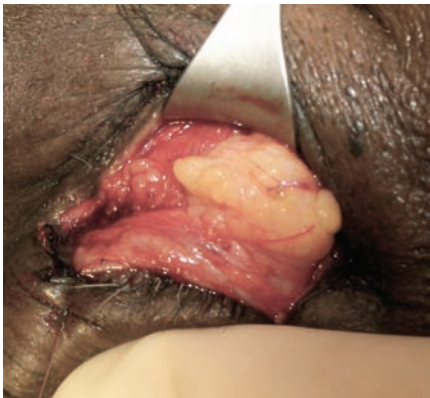
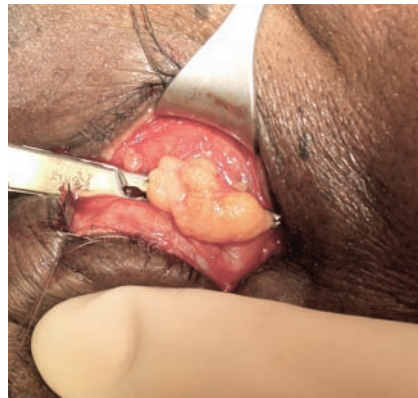
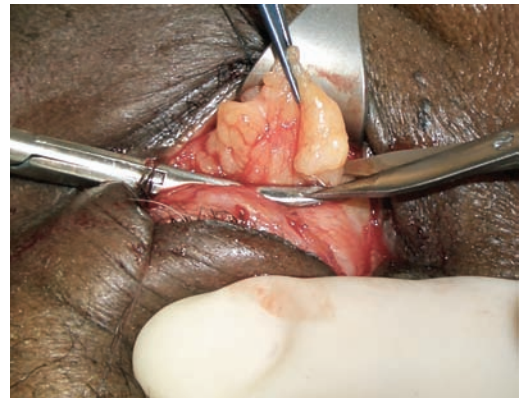Figure 1.13 Hold the fat stump with forceps, inspect it for bleeding, and cauterize as necessary before releasing it into the orbit.



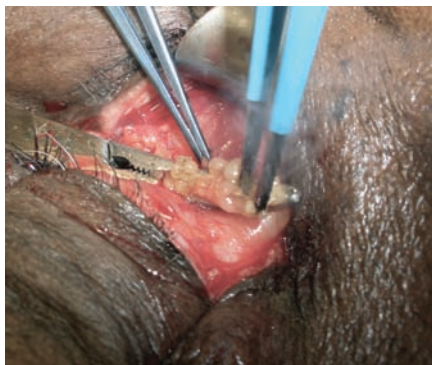(A)



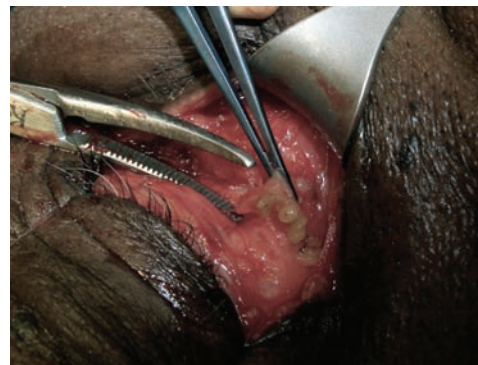(B)



(C)



(D)



(E)

Figure 1.14 Expose the medial fat pad by applying gentle pressure upon the globe (A). The capsule is dissected with hot cauterization (Fig. 1.11A). Exposed vessels are cauterized with a bipolar cautery. The exposed fat pad is clamped (B), cut (C), cauterized (D), and inspected before being released back into the orbit (E).

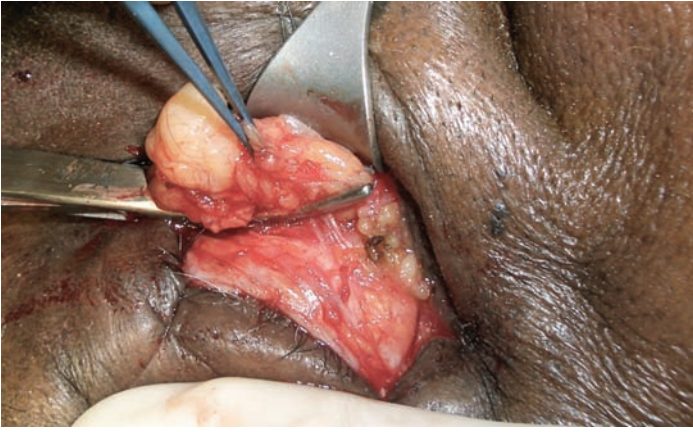


Figure 1.15 The middle fat pad is clamped, cut, and cauterized in a similar fashion.

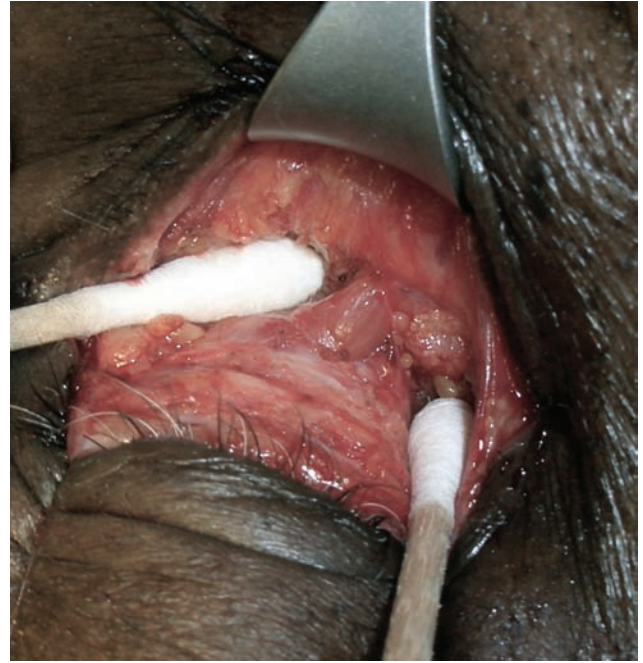
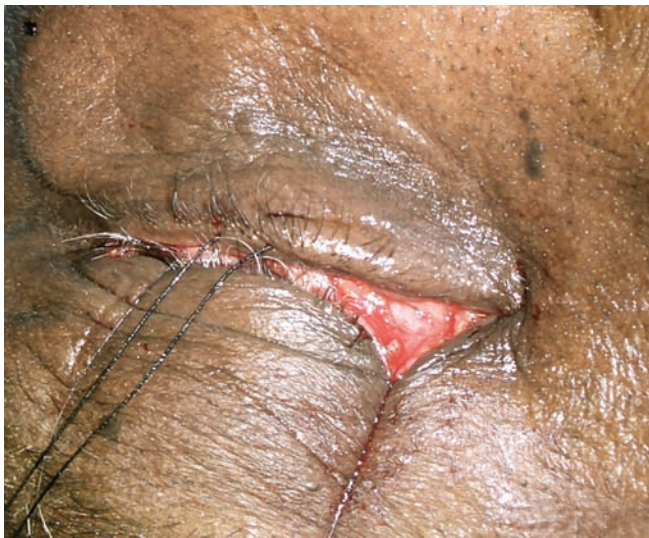
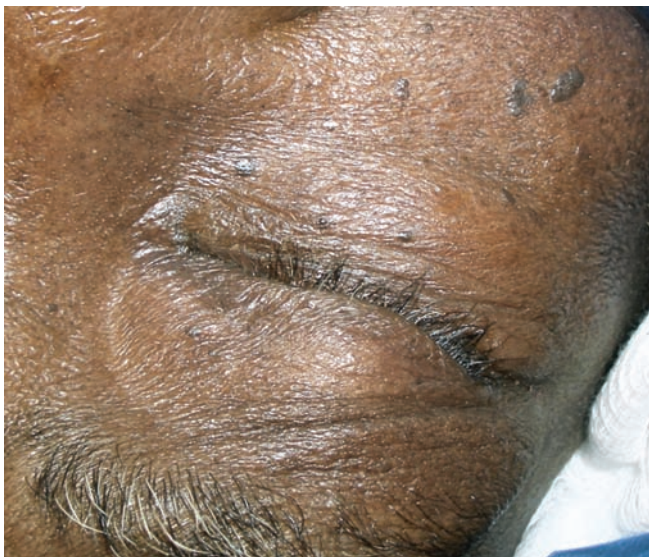Figure 1.16 The inferior oblique muscle separates the middle from the medial fat pad.

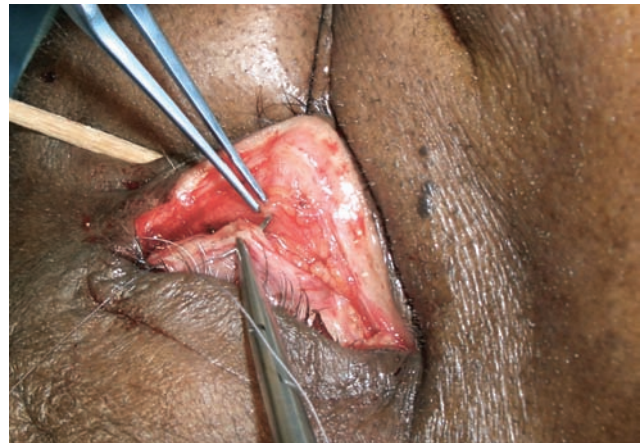

(A)

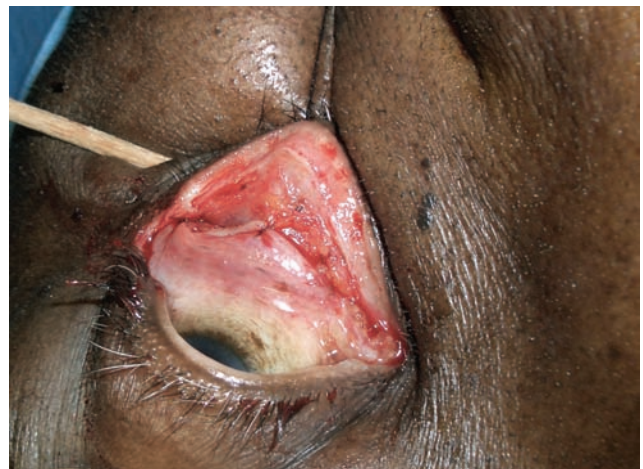

(B)

Figure 1.17 The contour and symmetry of the concave, just operated upon lower eyelid (A) compared to the contralateral, convex, unoperated lower eyelid (B).

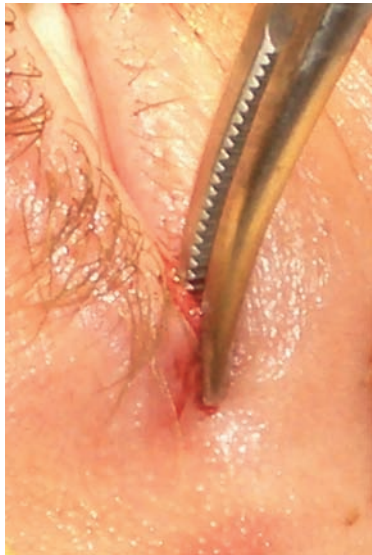

(A)

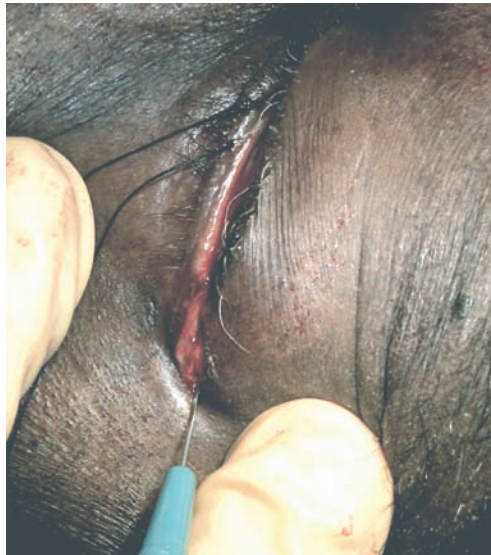

(B)

Figure 1.18 Reposition the conjunctiva to the eyelid and recess it about 5 mm (A, B). This can be done with sutures or with Evicel™ fibrin/thrombin sealant.



(A)



(B)

Figure 1.19 Clamp the lateral canthus (A) and incise it with scissors (B).

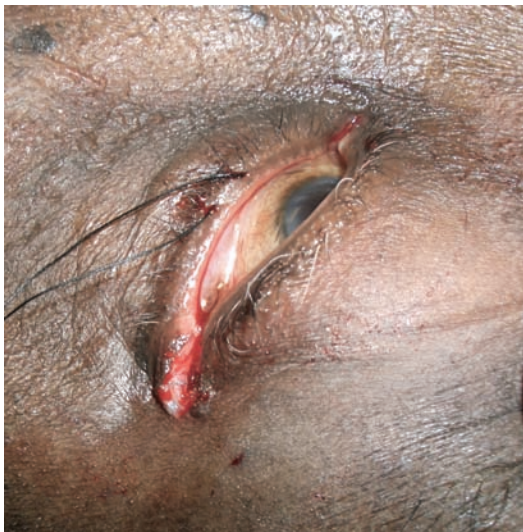

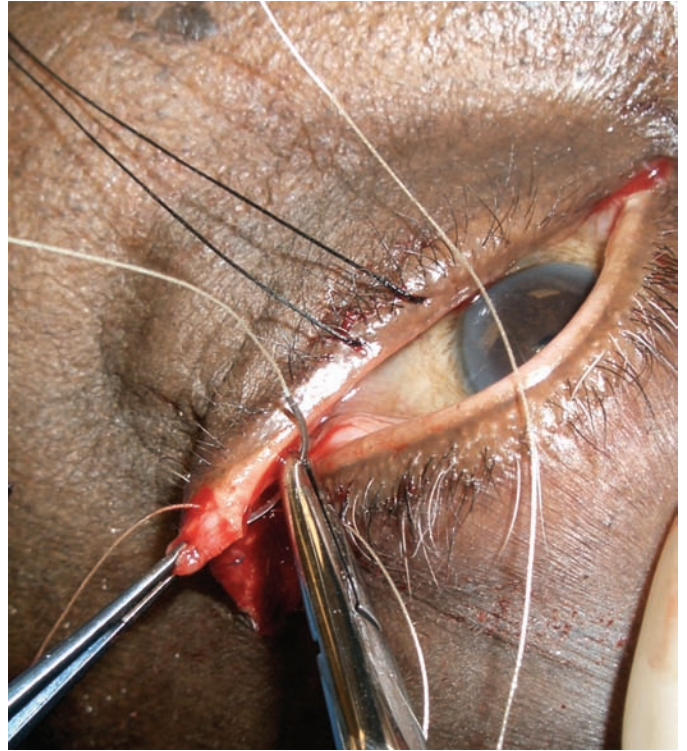
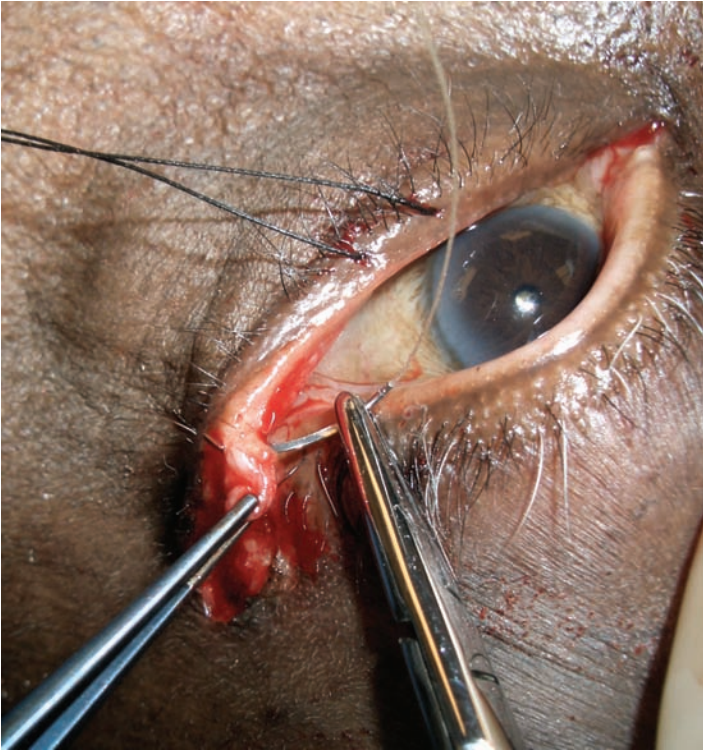
Figure 1.20 Extend the incision over the lateral canthus with a sharp blade.

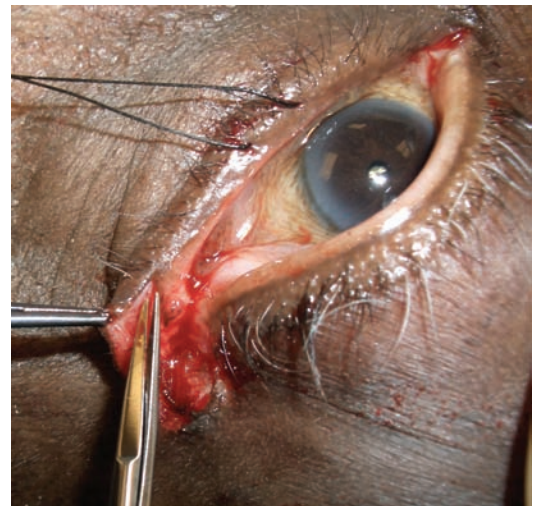

Figure 1.21 Divide the eyelid into an anterior lamella of skin and orbicularis muscle and a posterior lamella containing conjunctiva and tarsus. Do this with a sharp blade and straight scissors.

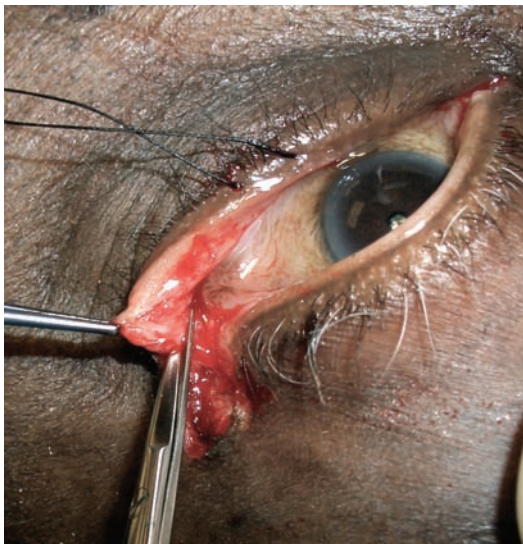

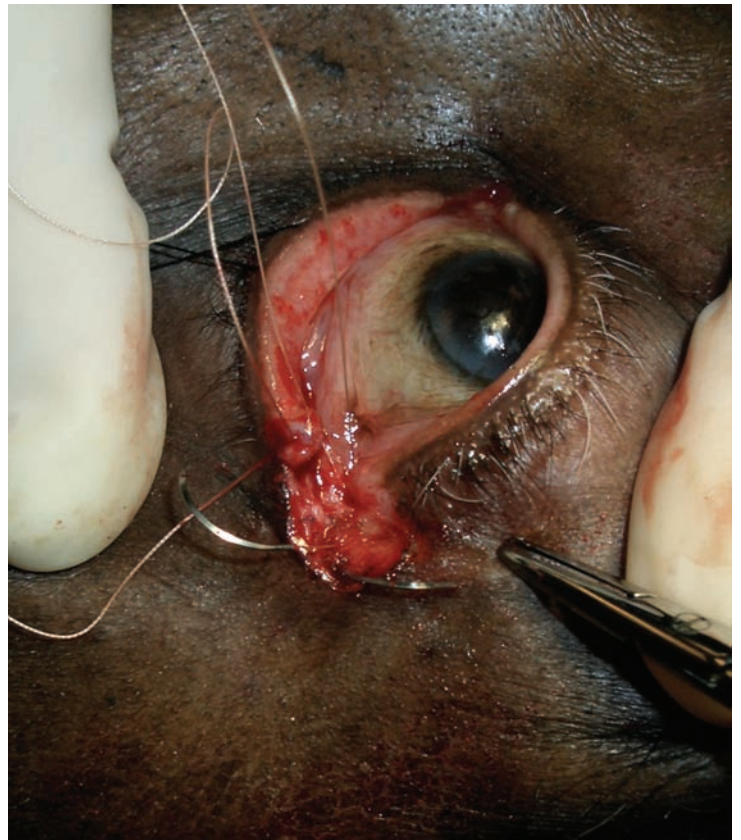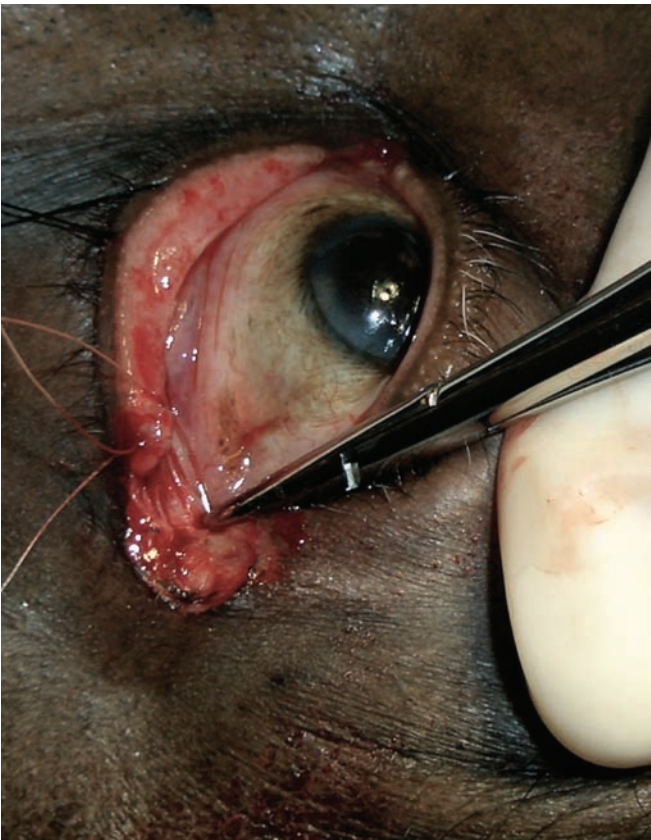Figure 1.22 A cut parallel to the eyelid margin forms a tarsal/conjunctiva strip.



(A)

(B)

Figure 1.23 Pass both arms of a double-armed suture with a sharp, curved needle through the tarsal strip (A) and tied in a double knot (B).



(A)

(B)

Figure 1.24 If possible, pass both needles through the bone (not periosteum as described for years) of the lateral orbital rim at the level of the lateral orbital tubercle (A, B).



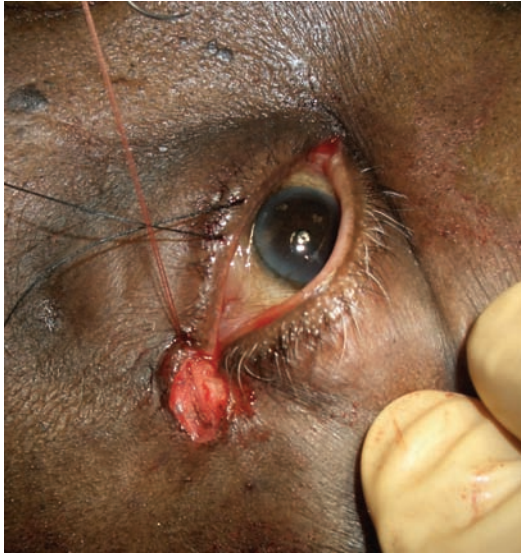

Figure 1.25 Passing the needles through the bone ensures excellent apposition of the eyelid to the globe when the suture is tied.

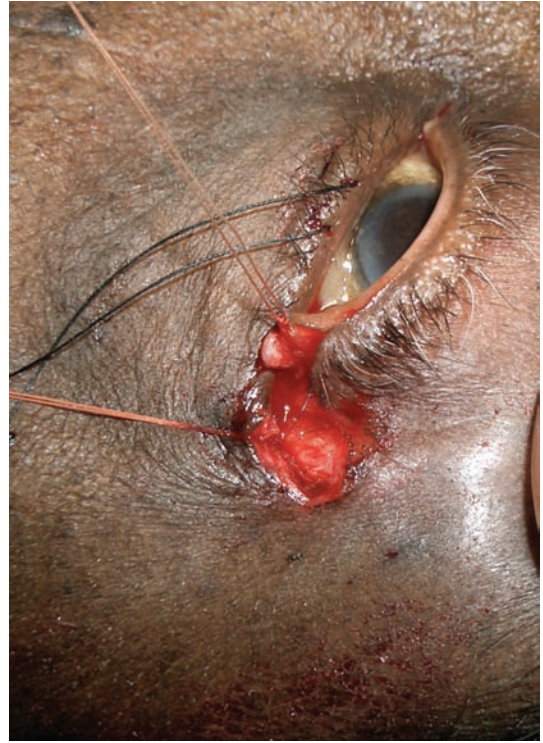
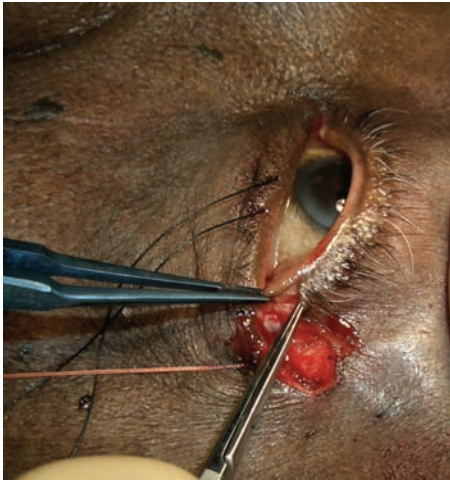
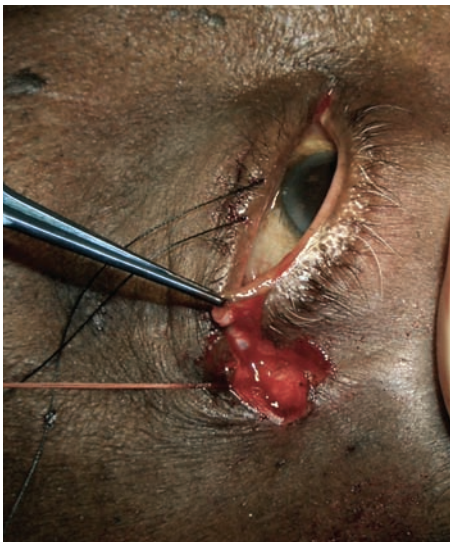Figure 1.27 Passing both arms of the suture through the strip and tying a double knot.



(A)



(B)

Figure 1.26 The upper eyelid may be shortened in a similar fashion by forming a tarsal strip (A, B).

suture directly into the bone (Fig. 1.24). This is actually easily accomplished if you use the proper needles (needle types) and results in excellent eyelid tightening (Fig. 1.25). If the eyelid is in the appropriate position—not too slanting and not too retracted—tie the suture and close the skin incision (Fig. 1.25).

If the upper eyelid needs to be tightened due to floppy eyelid syndrome or windshield wiper epitheliopathy, do this at the same time. Divide the upper eyelid into an anterior and posterior tarsal strip. Pass a double-armed suture placed through the posterior strip as described for the lower eyelid (Figs. 1.26 and 1.27). Then pass both arms of the suture through the bone at the level of the lateral orbital tubercle (Figs. 1.28 and 1.29). Tighten and tie the suture, reapproximating the eyelid to the globe.

If there is a minimal degree of eyelid laxity, it is not necessary to perform an eyelid splitting tarsal strip. The edges of the eyelids outlined by the canthotomy can be reattached to the lateral orbital wall (Fig. 1.30). This will correct a mild degree of eyelid laxity and is especially useful in cosmetic blepharoplasty when you wish to tighten the eyelid but not distort the canthus.

It is imperative to place the sutures inside the orbital rim to obtain the appropriate tightening and contour (Fig. 1.31). A superficial suture placement will result in an upper eyelid that is not flush against the globe and the eyelid will remain dysfunctional.

#### TRANSCUTANEOUS LOWER EYELID BLEPHAROPLASTY

Reserve this procedure for patients with excessive, redundant lower eyelid skin or extensive festoons (Fig. 1.32A).

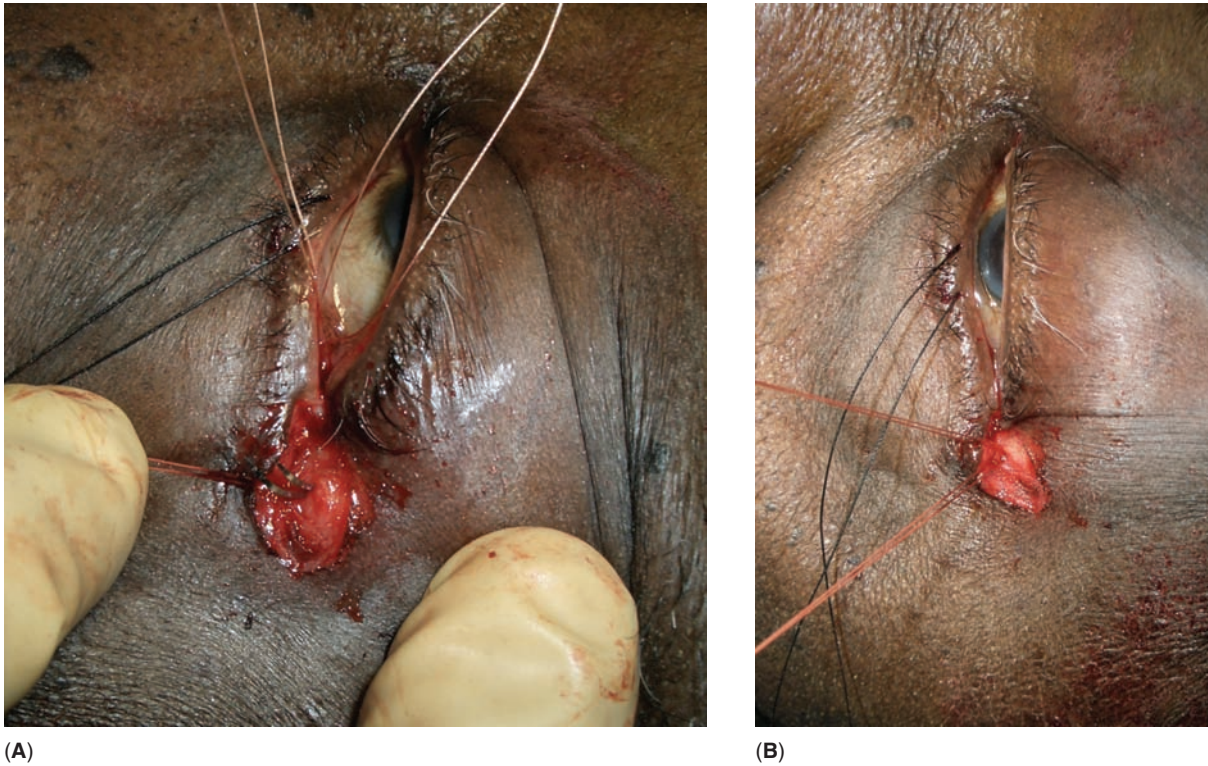


Figure 1.28 Try to pass both needles through the lateral orbital bone (A). This effectively tightens both upper and lower eyelids (B).

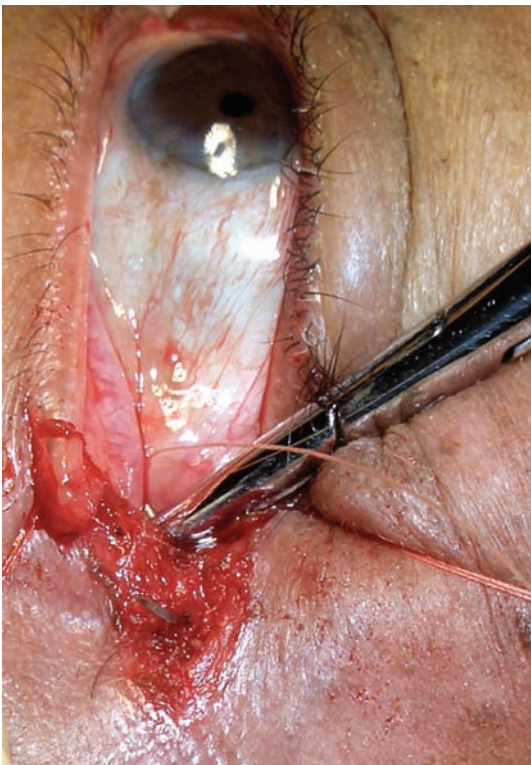


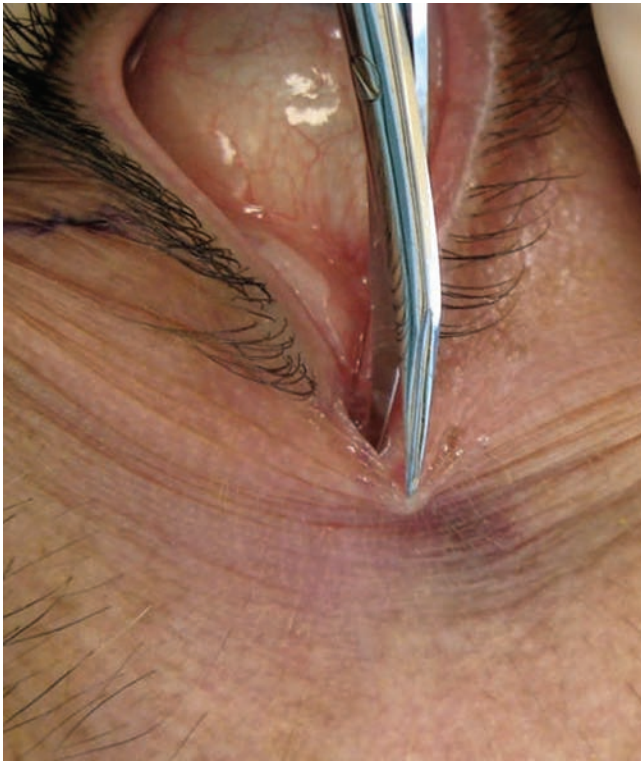Figure 1.29 A more graphic photo to emphasize the importance of passing the sutures through the bone of the lateral orbital wall, not the periosteum.

Avoid this procedure in younger patients who really need inferior orbital fat removal, best accomplished through the conjunctiva. It takes more skin to fill a concavity than a convexity. Removal of orbital fat converts the bulging, convex preoperative lower eyelid outline to a concave postoperative appearance (Fig. 1.32B). This change in topography usually accommodates the excessive skin.

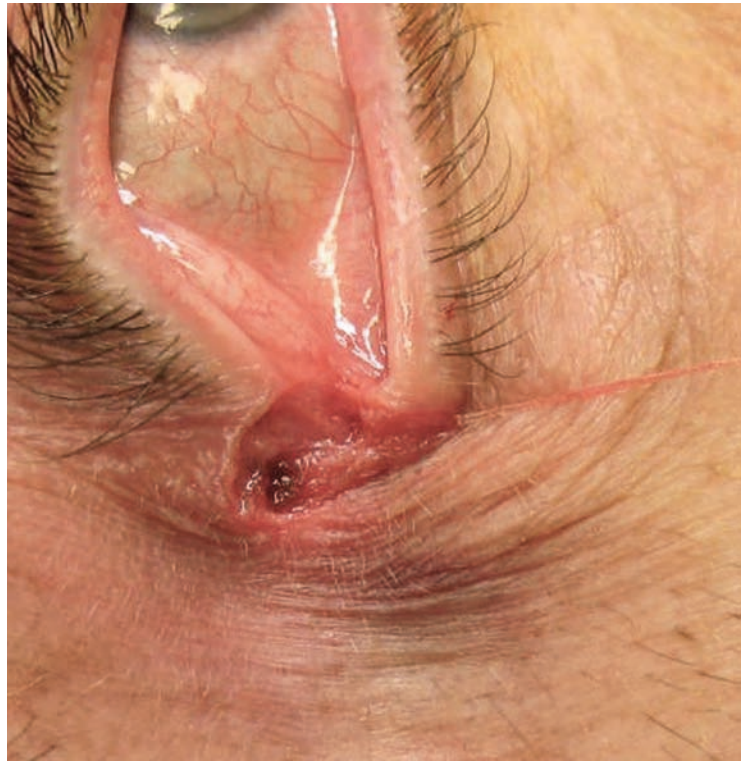**Technique**

Outline a subciliary incision just below the lash line and extend it about 1 to 2 cm lateral to the lateral canthus—more or less depending on the amount of skin that needs to be removed (Fig. 1.33). Make an incision with a superblade™ along the entire horizontal length of the eyelid and extend it over the lateral canthus. Place a double-armed 4-0 silk suture through the eyelid at the incision line. This allows you to apply upward traction on the eyelid. Make a button hole incision through the orbicularis at the lateral portion of the incision.

Place a hemostat into the incision, extend it along the entire horizontal length of the eyelid, and spread it open. This will rapidly develop a skin muscle flap and exposes the inferior orbital fat pads (Fig. 1.34). Control bleeding with bipolar cauterization augmented with cotton pledgets soaked in xylocaine with epinephrine and added phenylephrine (one drop of 10% topical phenylephrine per cubic centimeter of anesthetic solution). Obtain superficial hemostasis before removing the orbital fat.

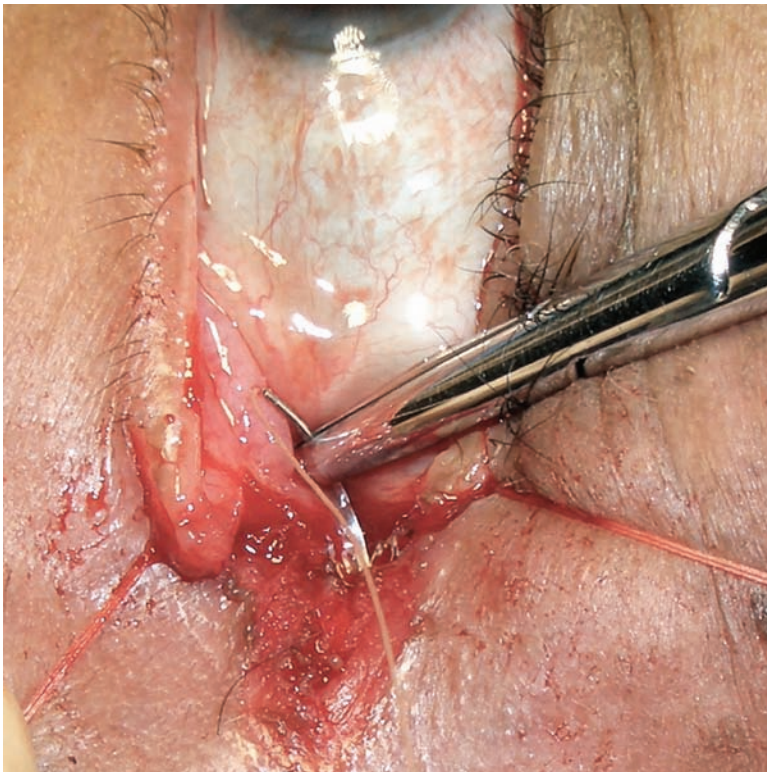


(A)

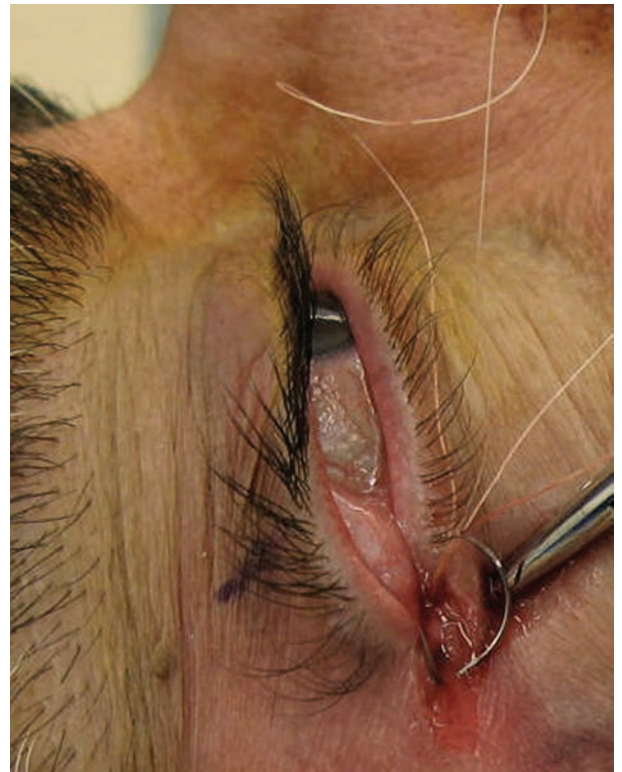


(B)

Figure 1.30 If less tightening is necessary, a lateral canthotomy may be performed (A) and the lids tightened with a double-armed suture passed through the lateral lid margin (B). A formal tarsal strip may not be necessary if the eyelid laxity is not too great. This technique is excellent for tightening the lower eyelid during a cosmetic blepharoplasty.

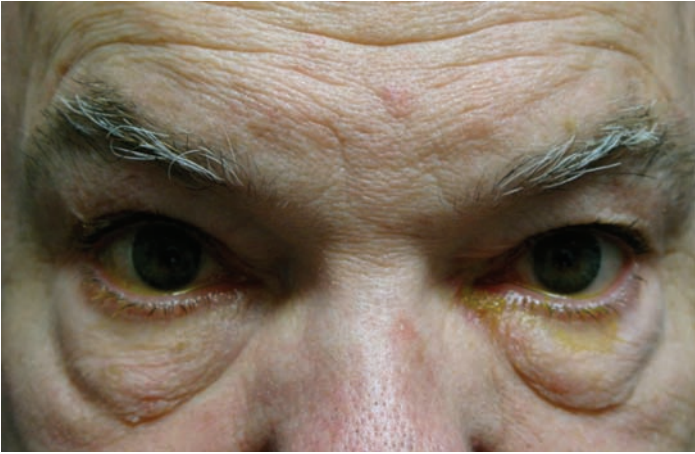

(A)



(B)

Figure 1.31 Again, it is essential to pass both needles through the bony lateral orbital wall (A, B).



(A)

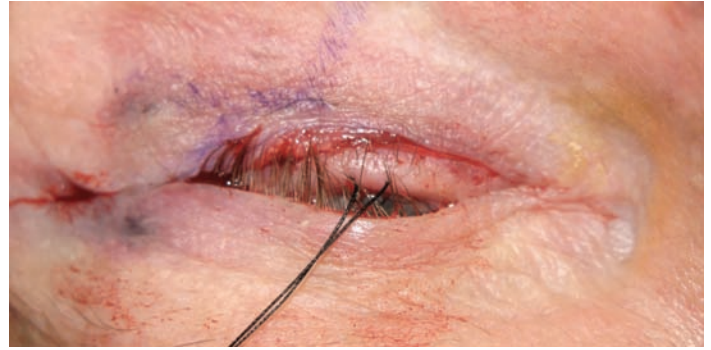
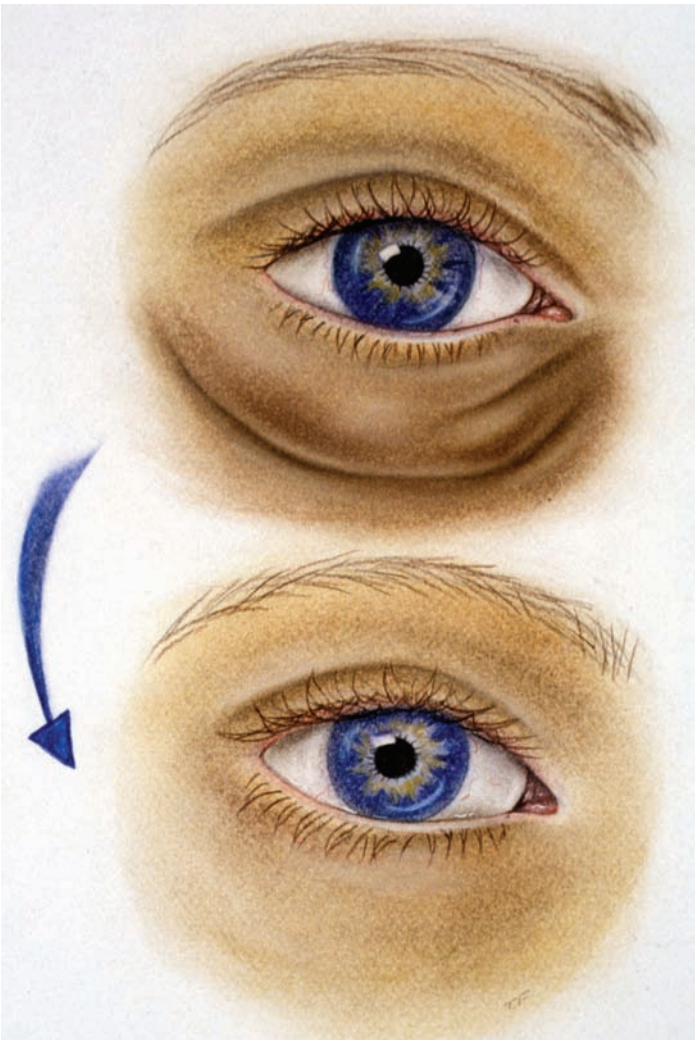
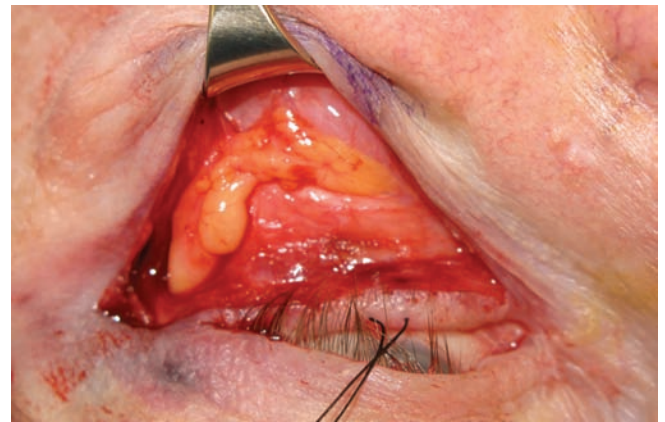

Figure 1.33 Make a subciliary incision and extend it over the lateral canthus.

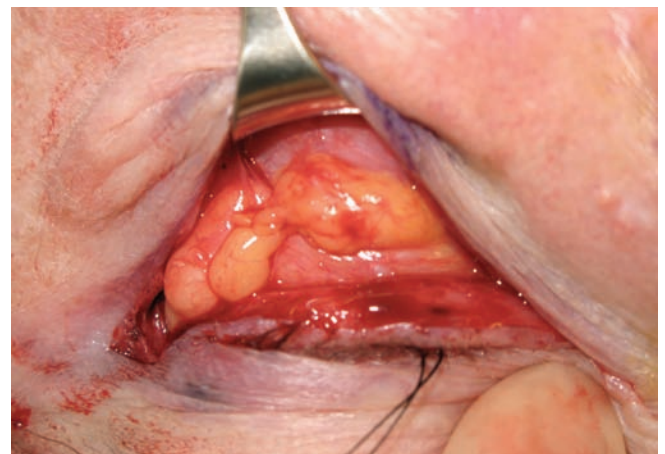


(B)

Figure 1.32 Patients with excessive lower eyelid skin and/or festoons are excellent candidates for transcutaneous lower eyelid blepharoplasty (A). Removing excessive orbital fat converts a convex lower eyelid into a concave lower eyelid (B). It requires more skin to fill a concavity than a convexity.



(A)



(B)

Figure 1.34 Develop a skin muscle flap exposing the inferior orbital fat pads (A). Gentle digital pressure accentuates the appearance of the fat pads (B).

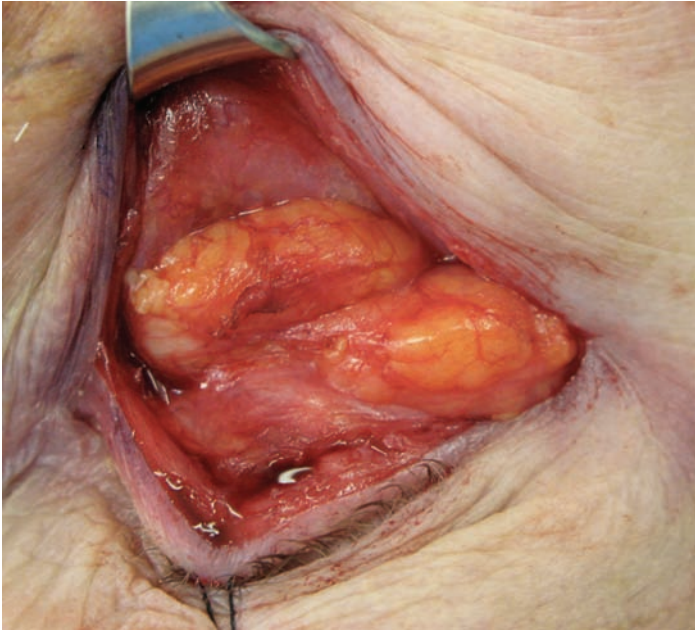


Figure 1.35 Exposure of the medial and lateral fat pads.

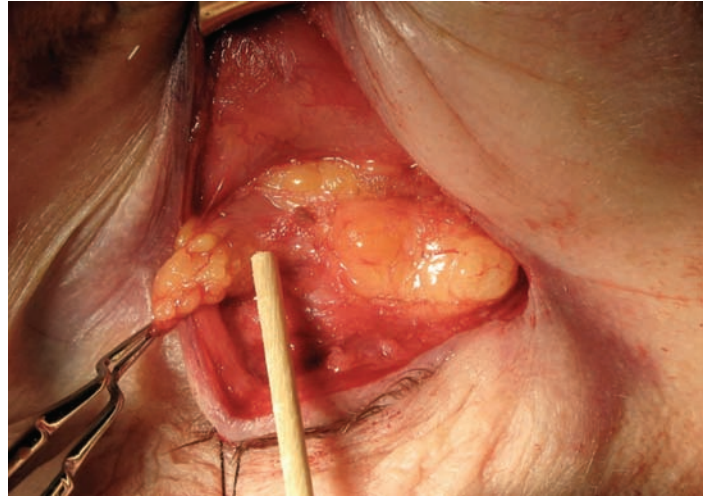


Figure 1.36 The applicator stick points to the inferior oblique muscle located between the middle and nasal fat pads.

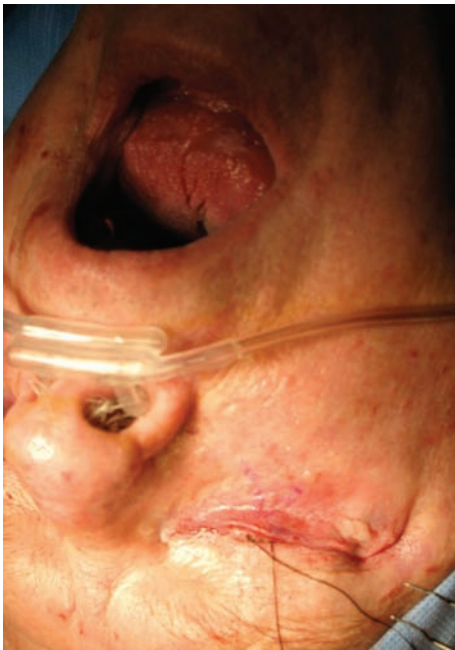

Figure 1.37 Opening the mouth mimics the effect of gravity and will help prevent excising an excessive amount of skin.

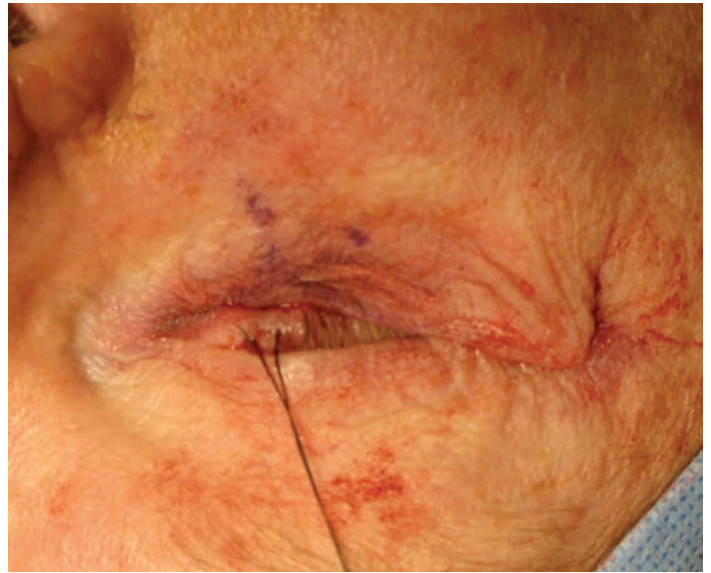


Figure 1.38 With the patient's mouth open, overlap the skin edges to determine the amount of skin that needs to be removed.

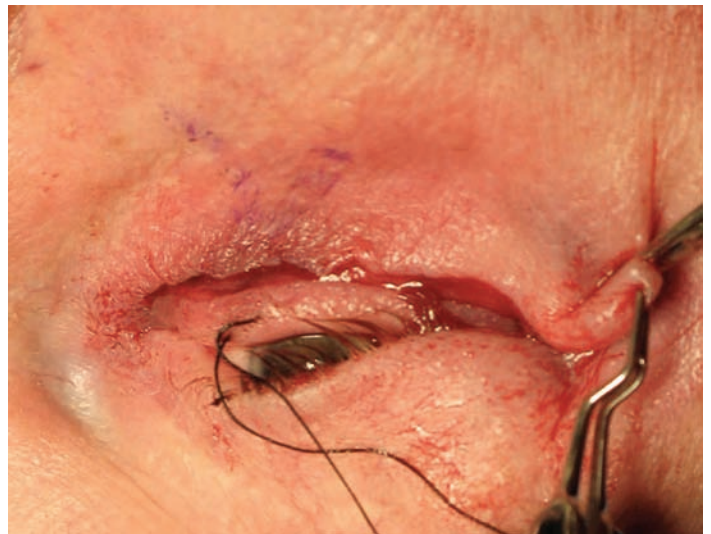

Figure 1.39 A thin strip of skin is excised beneath the lower eyelid. A larger amount of skin is excised in the lateral canthal area.

This ensures that you will not confuse superficial bleeding with deep orbital fat bleeding. Superficial bleeding is benign, untreated deep bleeding may be blinding. It is important to distinguish between them.

Dissect the inferior orbital fat pads with a hot cauterization exactly as described above. Enhance exposure by applying gentle pressure upon the globe (Fig. 1.34B). Clamp the exposed fat pad with a hemostat, excise it with scissors, and cauterize with a bipolar cautery. Release the clamp while holding the fat with forceps, inspect it for bleeding, and release it into the orbit as described above. Start with the lateral fat pad and work toward the medial fat pad (Fig. 1.35). Remember that the inferior oblique muscle lies between the middle and nasal fat pads (Fig. 1.36). Remove fat from both sides before tightening the eyelids and removing the skin. Compare the contour of both lower eyelids. If equal, tighten both with the tarsal strip variant appropriate for the degree of eyelid laxity (see above). Tightening the lower eyelid often makes the residual lateral fat pad more obvious. If that occurs, remove more lateral fat pad. Obtain meticulous hemostasis. Apply gentle pressure to the globe. This exposes the remnants of

the fat pads allowing you to inspect them for residual bleeding. Cauterize any residual bleeding vessels with bipolar cautery, irrigate the wound, and take another look to ensure that there is no bleeding.

After hemostasis is obtained and the eyelid is tightened, conservatively remove excessive skin. Ask the patient to open their mouth. This puts the lower eyelid skin on inferior stretch mimicking the effect of gravity (Fig. 1.37). Grasp the eyelid skin with forceps and overlap the eyelid margin (Fig. 1.38). Make sure that the patient's mouth is still open. Make a vertical incision through the excessive skin to the level where it overlaps the eyelid margin (Fig. 1.39). Err on the conservative side. Incise a triangle of excessive skin from the vertical incision to the punctum. Narrow the amount of skin removed asymptotically as you approach the punctum. Remove less skin medially than laterally. Now excise the excessive lateral skin, extending the incision lateral to the lateral canthus as necessary to obtain a smooth contour of skin removal (Fig. 1.39). Excise a thin strip of orbicularis muscle with the hot cautery. This enhances the appearance of the incision after healing. Close the incision with interrupted sutures.

## 2 Ectropion Repair

Ectropion may be punctal, involutional, or cicatricial (Figs. 2.1–2.3). It is often a combination of several or all of the above. Many surgical techniques have been described for ectropion repair, some are good and some are not so good. I will describe three techniques that work most of the time and can be used in combination to treat any type of ectropion.

### PUNCTAL ECTROPION

Simple punctal ectropion of the lower eyelid (Fig. 2.1) is a common cause of tearing. Punctal ectropion may be subtle but still symptomatic. Careful slit lamp examination usually leads to the correct diagnosis. This can be facilitated with lissamine green staining. The devitalized conjunctival tissue of the ectropic punctum will stain with lissamine green. This staining will be obvious even when obfuscated by an increased tear film (Fig. 2.4).

A simple punctal ectropion, with minimal eyelid laxity, can be inverted with a transcutaneous figure of eight suture placed posterior to the ectropic punctum (Fig. 2.5). This is a simple technique that can easily be performed in the office.

### Technique

The conjunctiva posterior to the ectropic punctum is anesthetized with a piece of cotton soaked in 4% topical lidocaine. Local anesthetic containing epinephrine and hyaluronidase is then painlessly injected through the conjunctiva into the medial eyelid. The lower eyelid is exposed with either a traction suture or finger pressure. An oval wedge of conjunctiva and subconjunctival tissue posterior to the punctum is excised with scissors (Fig. 2.6). The incision may be deepened, and hemostasis is obtained with hot cauterization (Fig. 2.7). A 5-0 Dexon™ suture is passed through the eyelid from the skin surface into the wound (Fig. 2.8). It is then passed through the conjunctival edges anterior to posterior, posterior to anterior in a figure of eight pattern (Figs. 2.5 and 2.9). The needle is then passed back through the eyelid exiting the skin surface adjacent to its entry site (Fig. 2.10). It is then tied. This very effectively inverts the punctum obviating the ectropion (Fig. 2.11).

### ECTROPION WITH LOWER EYELID LAXITY

If there is significant laxity of the lower eyelid, it needs to be tightened (horizontally shortened) with a variation on the theme of the lateral tarsal strip procedure. Clamp the lateral canthus and perform a canthotomy. Extend the incision exposing the lateral orbital rim (Fig. 2.12). Pass each arm of a double-armed 5-0 Dexon suture through the lateral portion of the lower eyelid and tie a double knot (Fig. 2.13). Pass both arms of the suture through the bone of the lateral orbital rim at the level of the lateral orbital tubercle (Fig. 2.14). The type of suture is not that important. I prefer an absorbable suture but a multifilament nonabsorbable suture (i.e., polypropylene is certainly acceptable).

The important issues are the stout, curved, double-armed suture needles. They need to be sufficiently curved and stout to pass through the lateral orbital wall or periosteum without breaking. Conventional teaching suggests passing the suture through the periosteum of the lateral orbital rim but passage through the bone itself provides more stable fixation. This is easily accomplished in over 90% of patients. One or two skin sutures will close the lateral canthal wound.

More severe eyelid laxity and ectropion may require a formal tarsal strip procedure as described by Anderson. The lower eyelid is split into anterior and posterior lamellae with a blade and scissors (Fig. 2.15). The posterior lamella contains tarsus and conjunctiva, the anterior lamella contains skin and orbicularis muscle. A cut is made in the posterior lamella, parallel to the eyelid margin with scissors (Fig. 2.16). This forms the tarsal strip. Both arms of a double-armed suture are passed through the tarsal strip and tied in a double knot (Fig. 2.17A and B). This is sutured to the lateral orbital rim as described above and effectively tightens even the most lax eyelids (Fig. 2.18A and B). It is best to use two sutures when performing a formal tarsal strip. This avoids total dehiscence of the lower eyelid if a lone suture breaks immediately after surgery.

A tarsal strip may also be performed to tighten the upper eyelid in patients with floppy eyelids and windshield wiper epitheliopathy (see section “Wedge Resection of Upper Eyelid” in chap. 8).

### CICATRICAL ECTROPION

If there are significant cicatrizing forces exacerbating the ectropion (Figs. 2.19 and 2.20), they need to be released and a skin graft is placed in the defect. These areas may be small, just below the punctum (Fig. 2.19) or extend the entire horizontal length of the eyelid (Fig. 2.20).

Make a subciliary incision along the horizontal length of the cicatricial ectropion (Figs. 2.21 and 2.22). Pass a 4-0 silk suture through the eyelid margin and stretch it superiorly (Fig. 2.22). Dissect a flap of skin and orbicularis muscle with scissors until the cicatrizing forces are released (Fig. 2.22). This is the bed for the skin graft. Invert the punctum and then tighten the eyelid with a tarsal strip procedure (see “Tarsal Strip Procedures” in chap. 1). The eyelid must be tightened before sizing and placing the skin graft. Tightening the eyelid decreases the size of skin graft needed to fill the defect.

If the area needing a skin graft is small, a pinch graft from the lateral portion of either upper eyelid is ideal. Obtain the graft by pinching the excessive skin with a forceps and excising it with straight scissors (Fig. 2.23A and B). The donor site is closed with sutures or Indermil® surgical glue. The graft is placed on and sutured into the recipient site (Figs. 2.24 and 2.25).

If a larger skin graft is needed, the next best place to obtain it is the retroauricular area of the ipsilateral ear, followed by the supraclavicular region (Fig. 2.26). The graft site is often determined

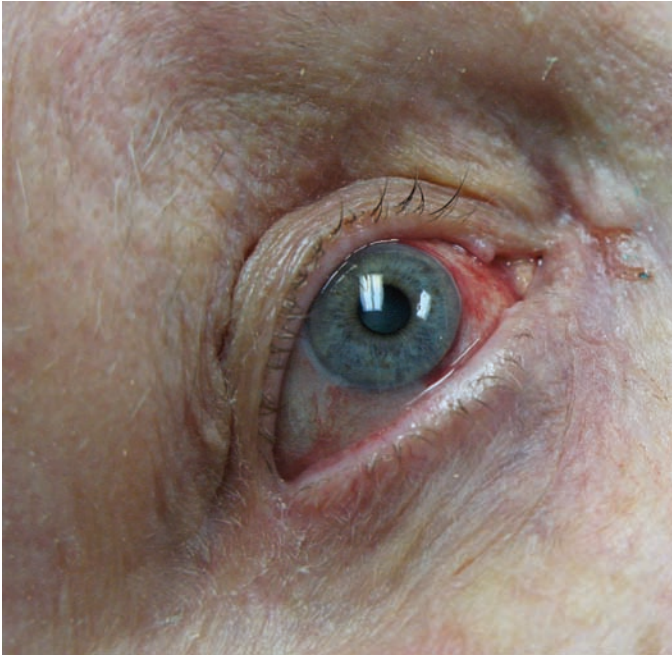


Figure 2.1 Punctal ectropion: The punctum is ectopic. Lower eyelid laxity and scarring is not an issue and does not need correction.

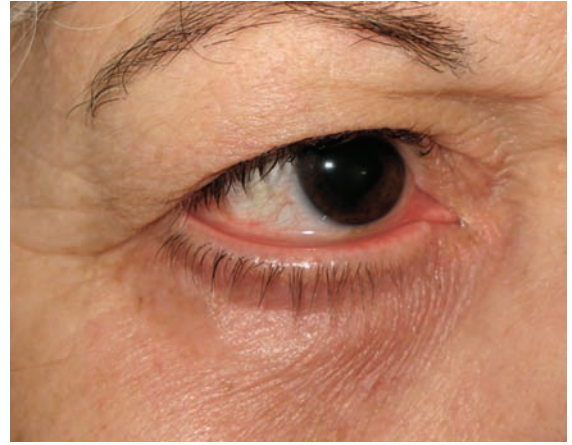


Figure 2.2 Punctal ectropion combined with eyelid laxity is an involutional ectropion. Repair requires tightening the lower eyelid in addition to inverting the punctum.

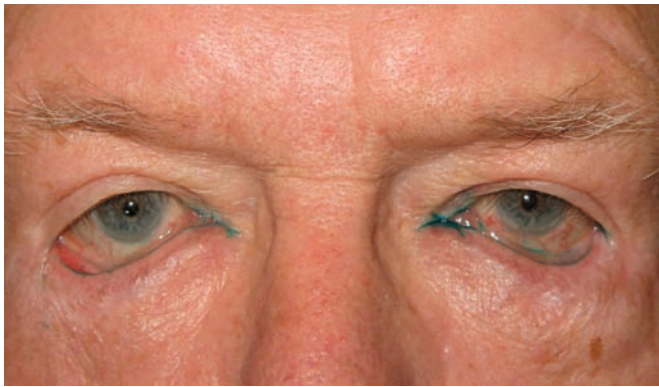

Figure 2.3 Cicatricial ectropion resulting from previous eyelid and facial surgery. Repair most always requires a skin graft in addition to eyelid tightening and punctal inversion.

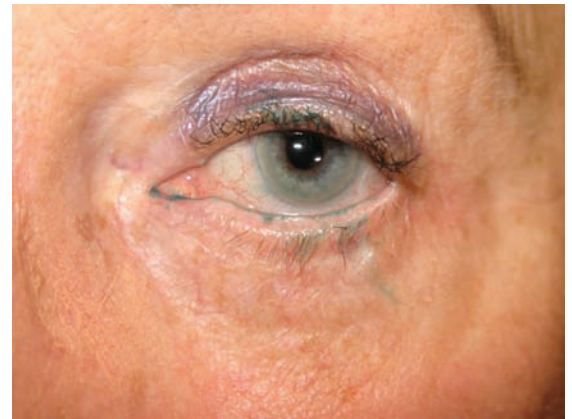


Figure 2.4 Lissamine green staining of a subtle punctal ectropion makes it easier to recognize.



Figure 2.5 Diagrammatic representation of the transcutaneous figure of eight suture used to invert the punctum.

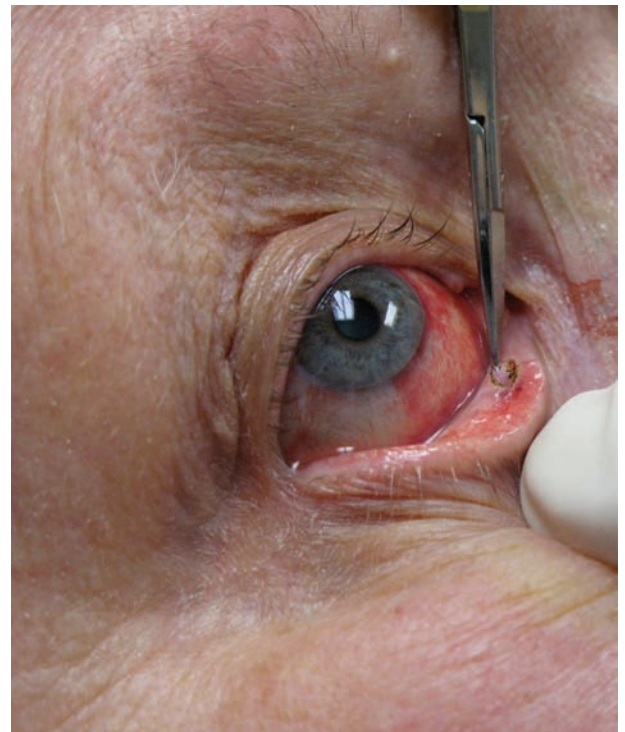
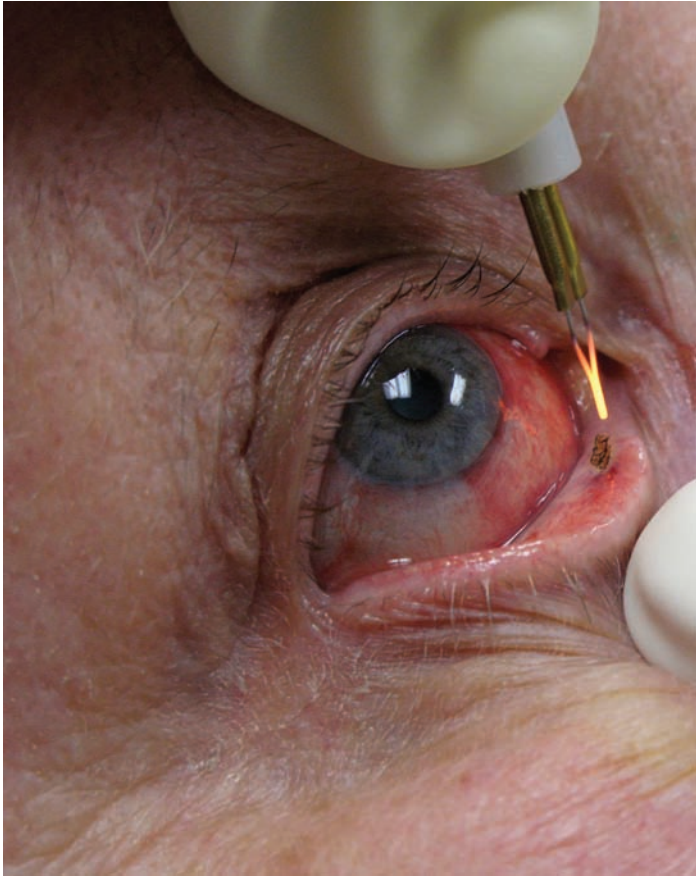
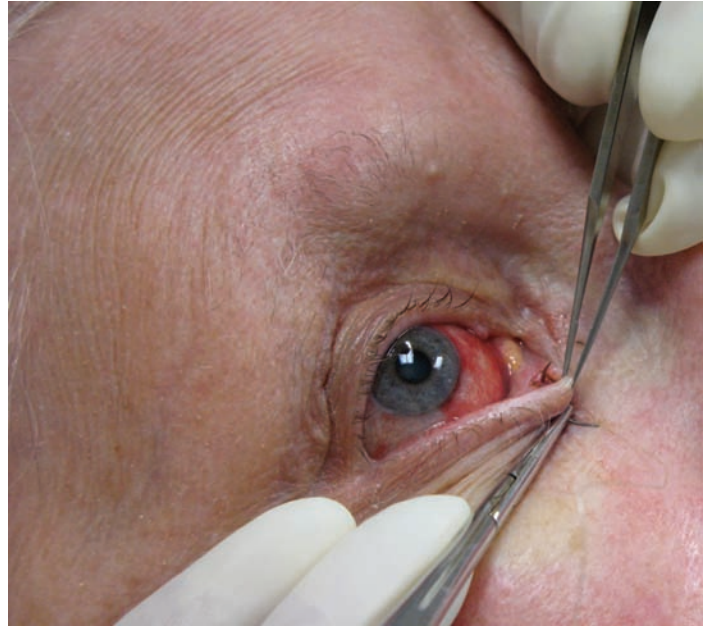


Figure 2.6 Invert the medial eyelid with digital pressure or a suture and excise an oval of conjunctiva and deeper tissue.

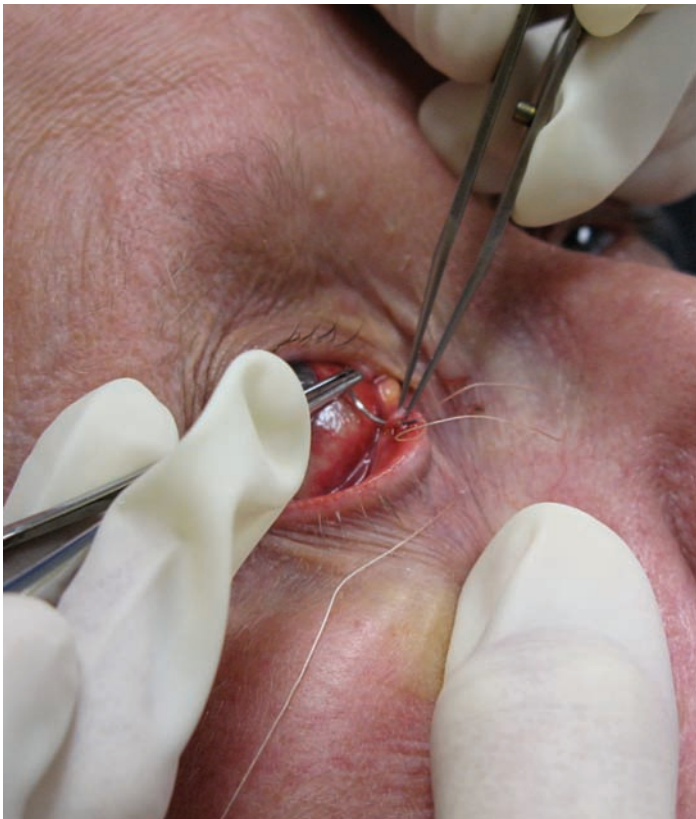



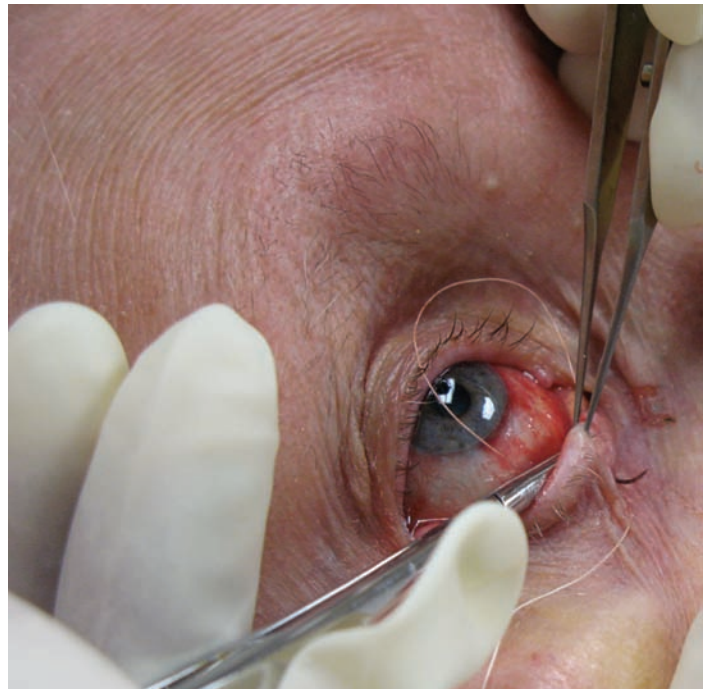
*Figure 2.7* The oval is deepened with a hot cauterization.



*Figure 2.8* Pass a 5-0 Dexon suture through the eyelid into the oval defect.



*Figure 2.9* Pass the suture through the edges of the oval in a figure of eight pattern.



*Figure 2.10* Pass the needle back through the eyelid.

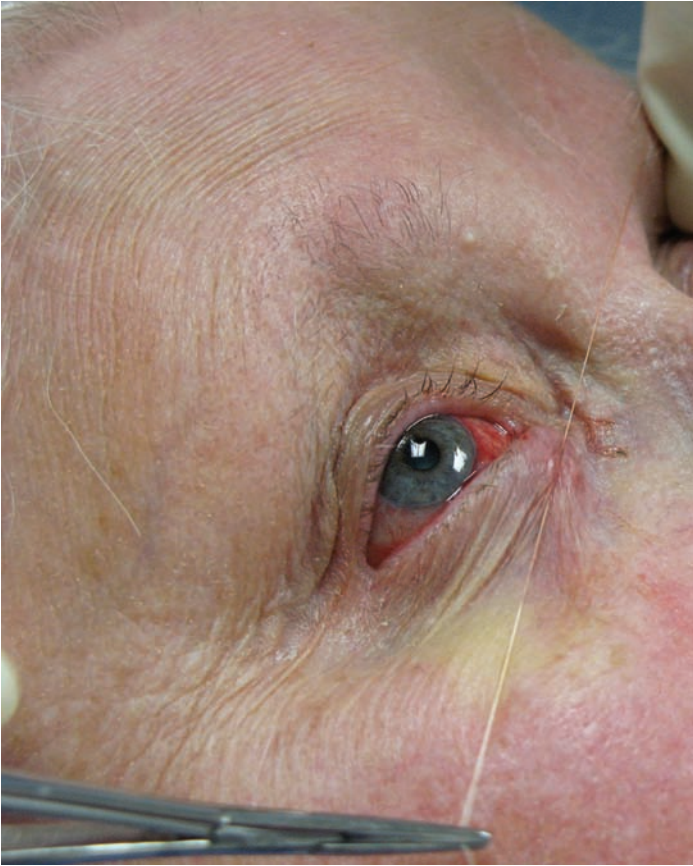

Figure 2.11 Tying the suture inverts the punctum and corrects the ectropion.

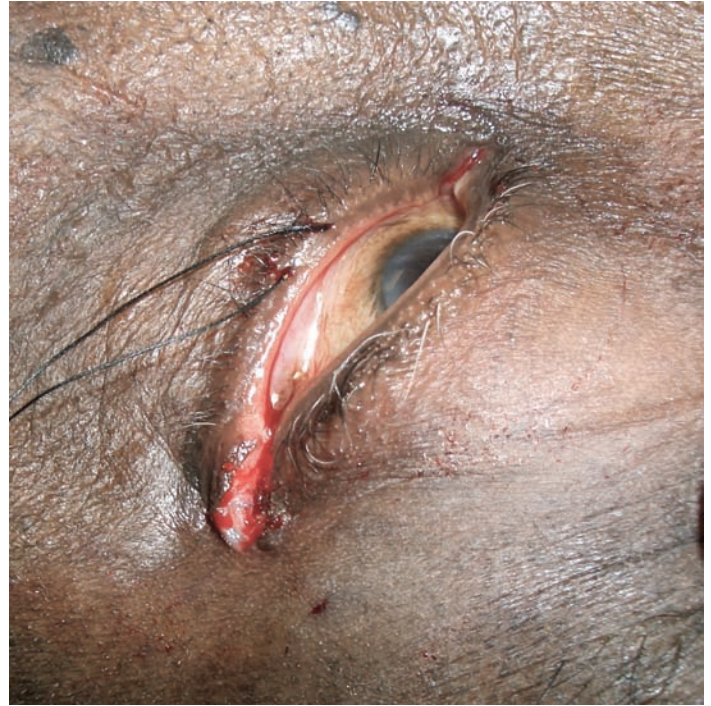

Figure 2.12 Extend the lateral canthotomy incision to expose the lateral orbital rim.

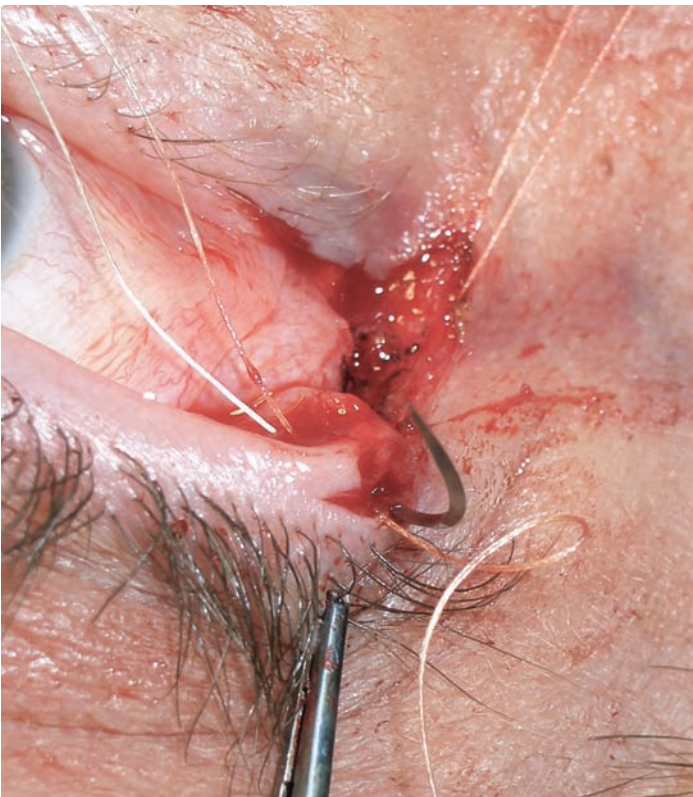

Figure 2.13 Pass each arm of a double-armed suture through the lateral portion of the eyelid and tie it in a double knot to prevent "cheese wiring" through the tissue.

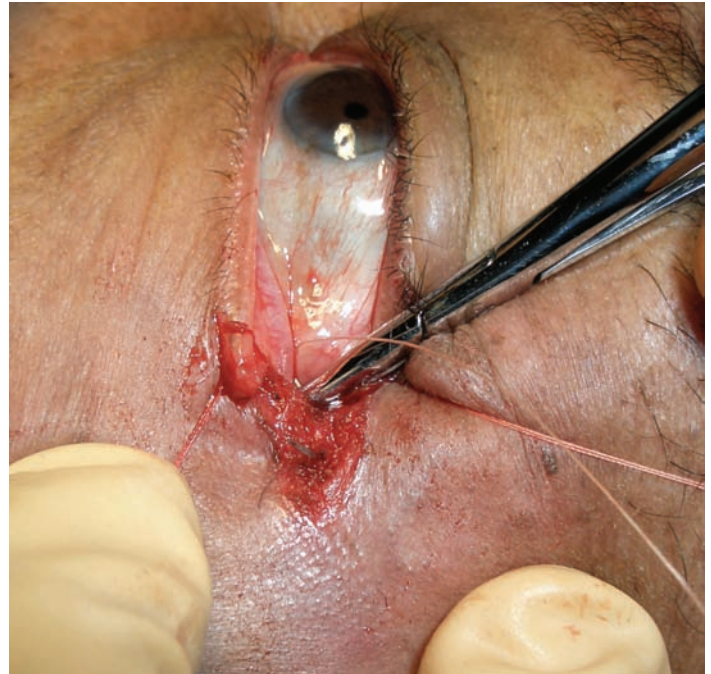


Figure 2.14 Pass the suture needles through the bone of the lateral orbital rim.

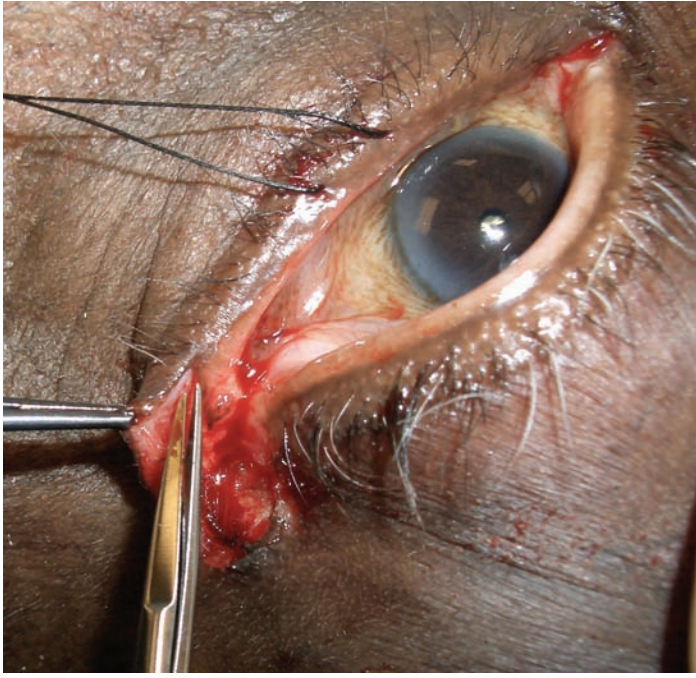
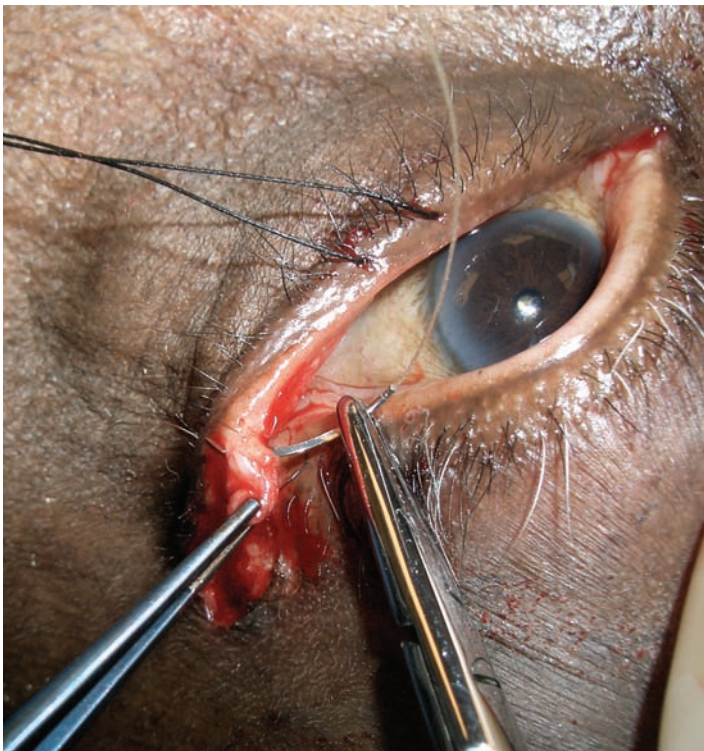


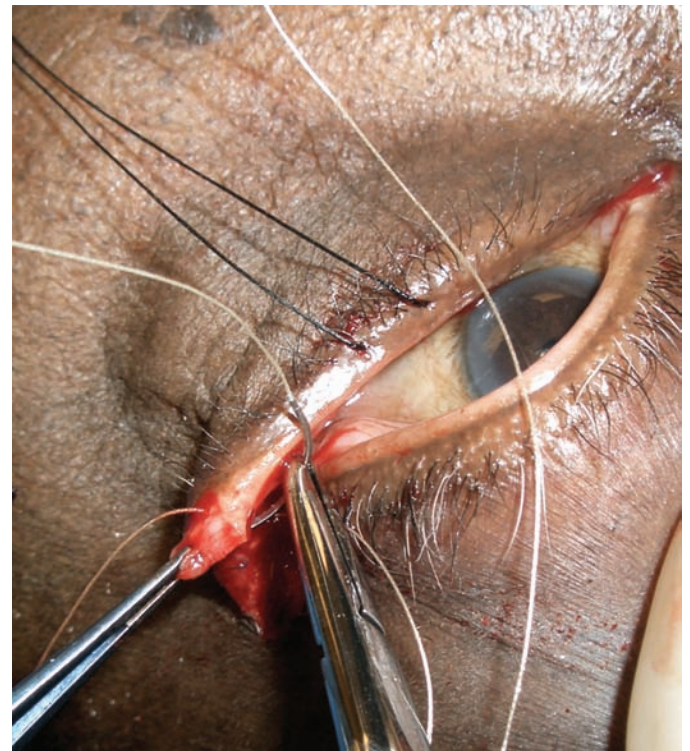
Figure 2.15 Divide the eyelid into an anterior lamella of skin and orbicularis muscle and a posterior lamella of tarsus and conjunctiva by splitting it at the grey line.

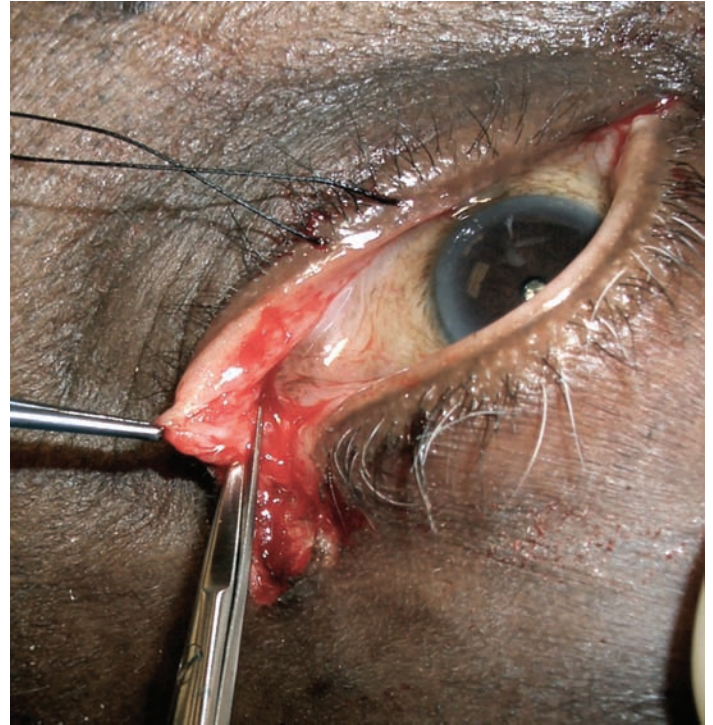

Figure 2.16 Make an incision parallel to the eyelid margin to form the tarsal strip.

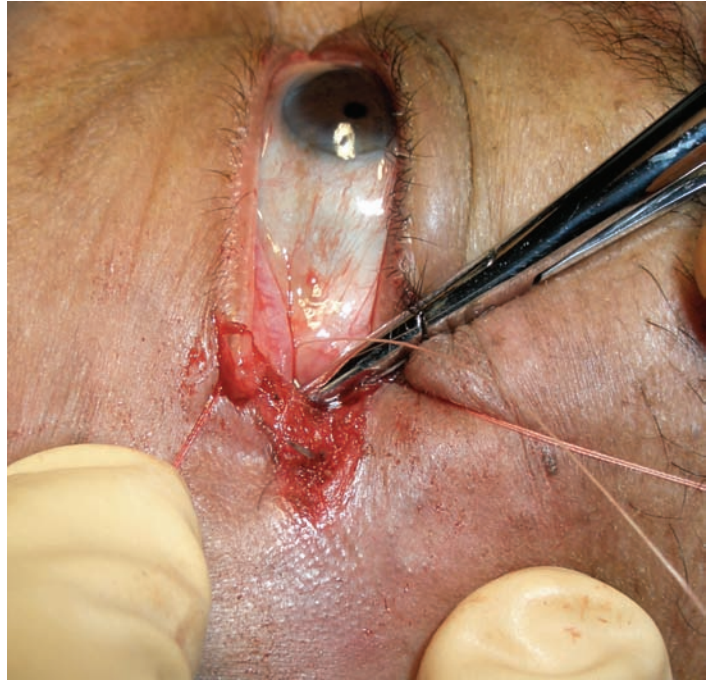
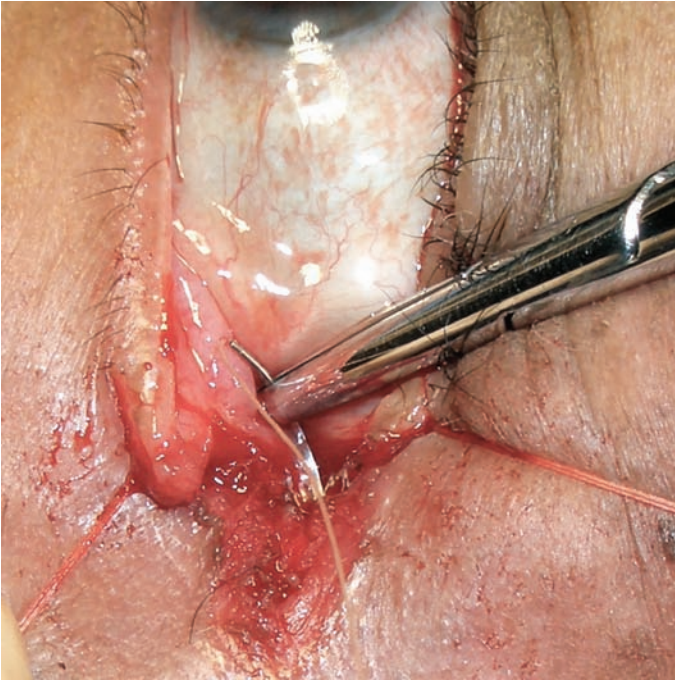


(A)



(B)

Figure 2.17 Pass both arms of the suture through the tarsal strip (A) and tie in a double knot (B).



(A)

(B)

Figure 2.18 Pass both needles through the lateral orbital rim starting inside the rim (A) and force through the bony orbital wall with gentle pressure (B).

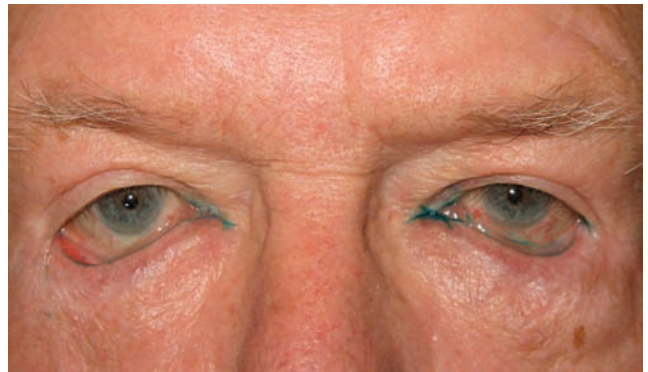
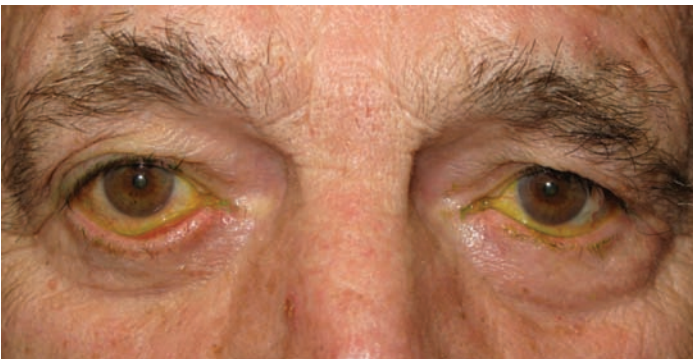
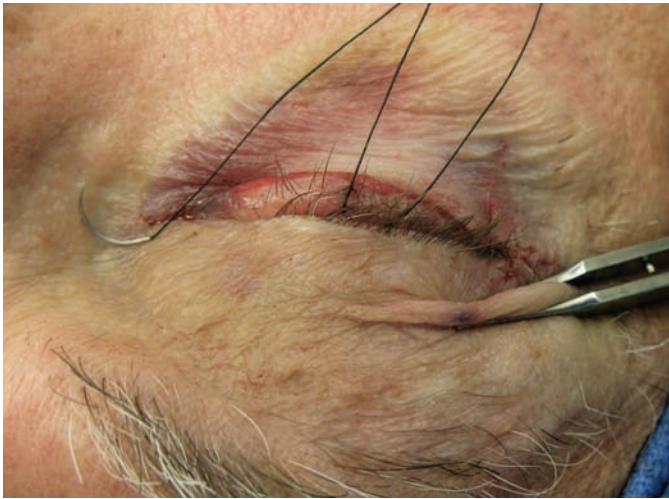
Figure 2.19 Cicatrizing ectropion of the right lower lid compared to a punctal ectropion of the left lower eyelid. The right lower eyelid will require a small skin graft to allow punctal inversion, the left eyelid will not.

Figure 2.20 A cicatricial ectropion after face lift and lower eyelid blepharoplasty. Repair requires a large supraclavicular skin graft.

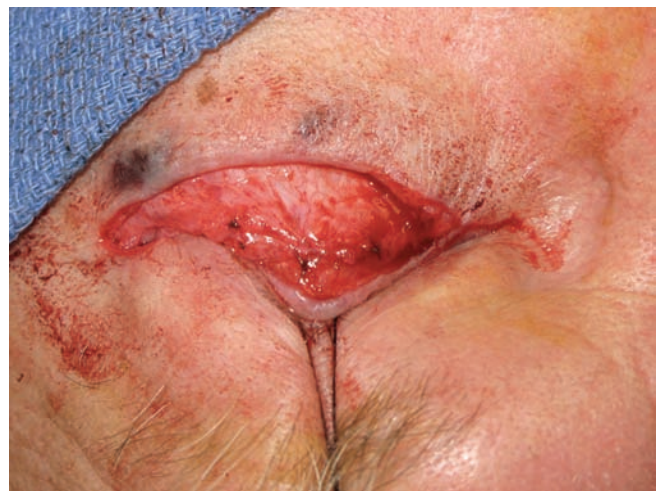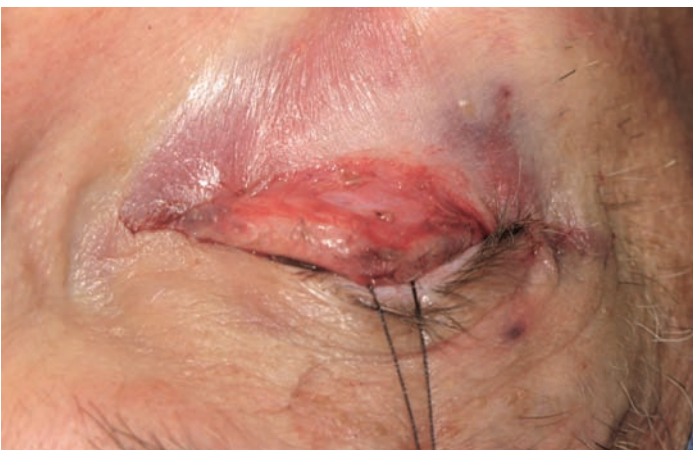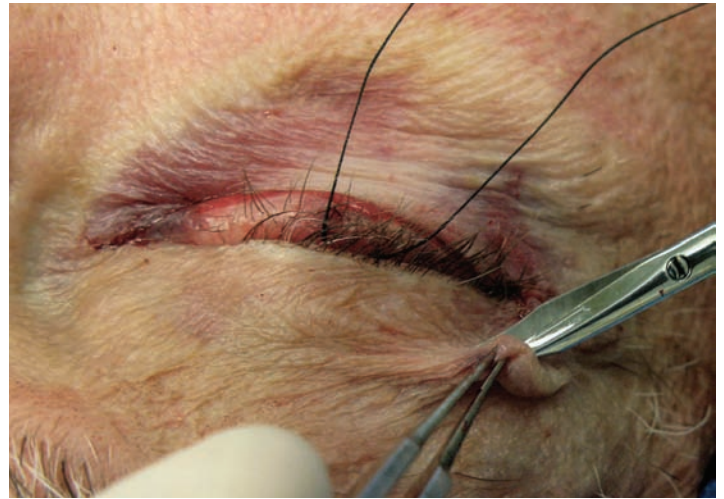


Figure 2.21 A subciliary incision along the horizontal length of the lower eyelid releases cicatrizing forces and will require a small skin graft from the upper eyelid.

Figure 2.22 A large defect remains after releasing the cicatrizing forces from the lower eyelid (Fig. 2.20). Retract the eyelid margin superiorly with a 4-0 silk traction suture. A much larger skin graft is required.



(A)



(B)

Figure 2.23 Obtain a pinch skin graft from the upper eyelid by tenting the required length of skin with forceps (A) and excising it with scissors (B).

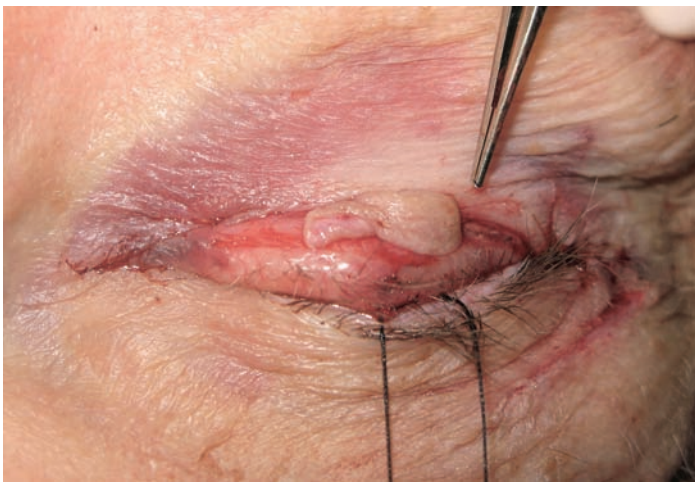

Figure 2.24 Place the skin graft into the recipient bed of the lower eyelid. Thinning skin grafts from the upper to lower eyelid is rarely necessary.

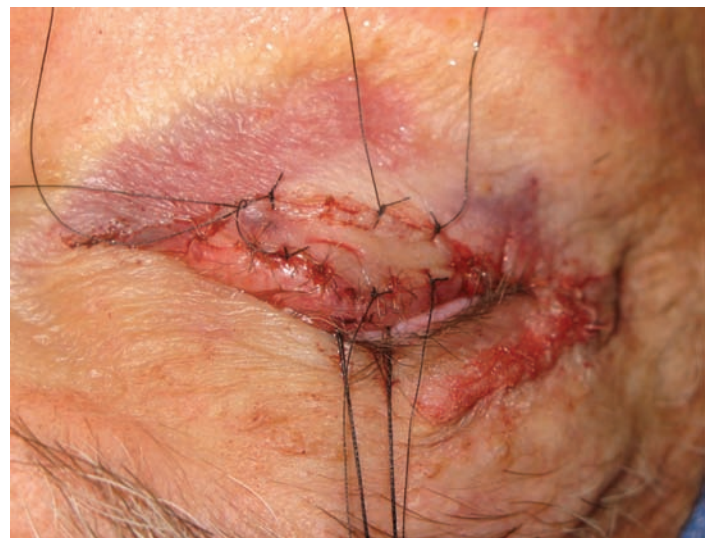

Figure 2.25 With the eyelid stretched superiorly with the traction suture, sew the skin graft into position with interrupted 6-0 sutures.

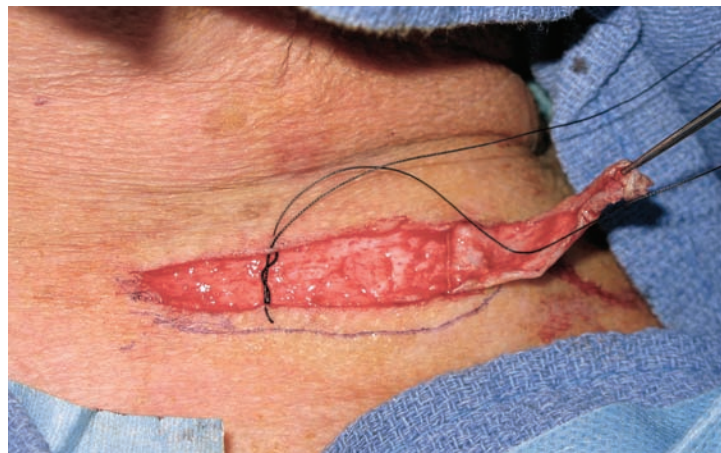
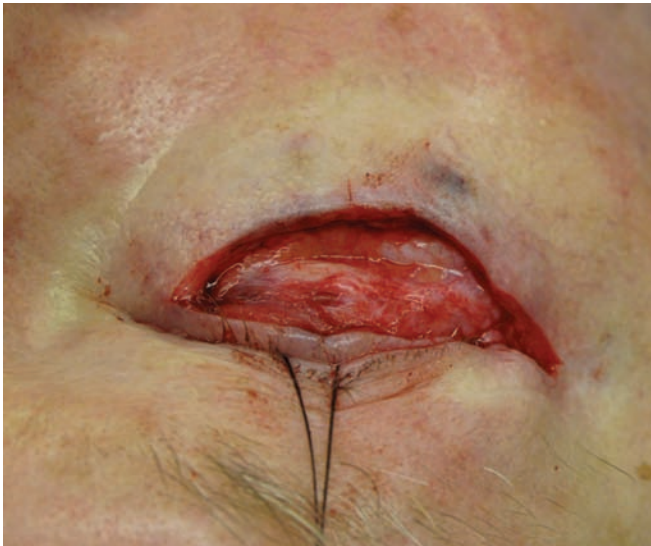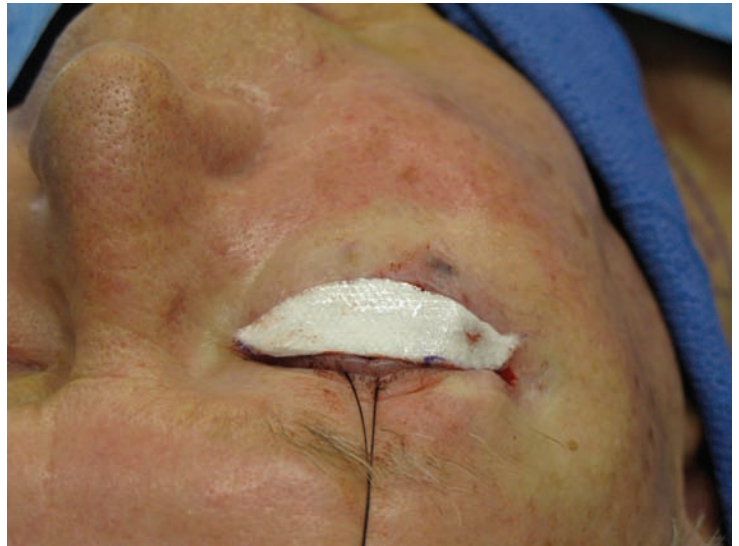


Figure 2.26 If a larger skin graft is necessary, obtain it from the retroauricular or supraclavicular region.

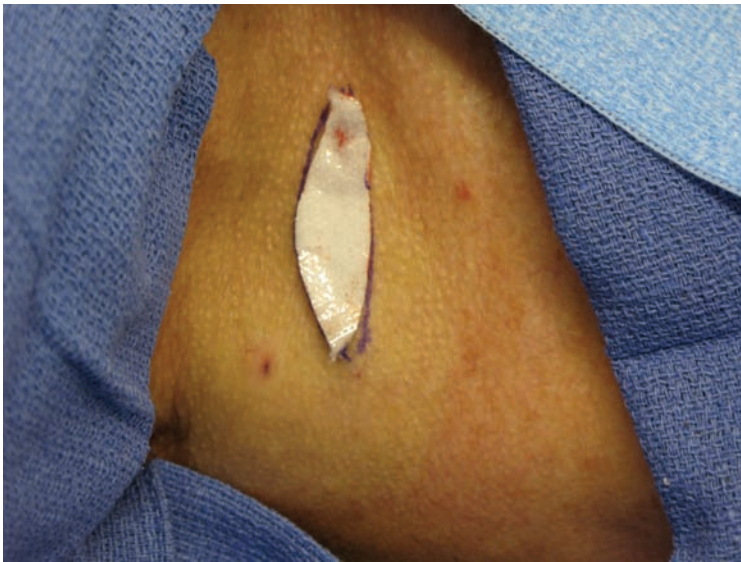
## ECTROPION REPAIR



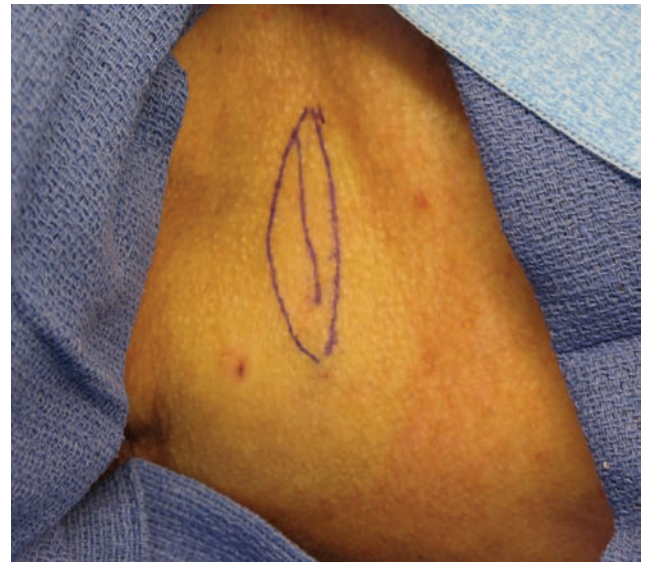(A)



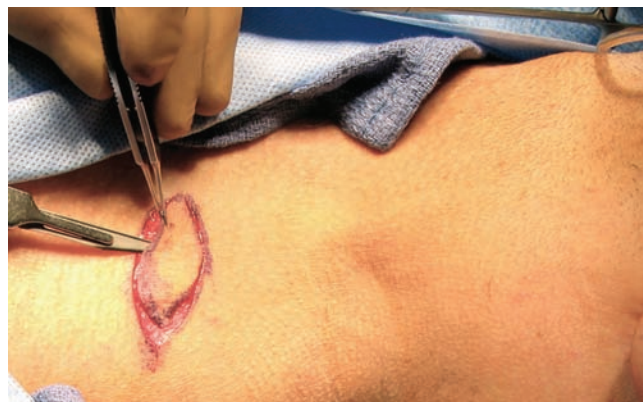(B)



(C)



(D)



(E)

*Figure 2.27* The skin graft size is determined with a Telfa template. The eyelid defect is retracted with the traction suture (A), a piece of Telfa is placed on the defect, size is marked by blood, and the template is cut to size (B). The template is outlined on the donor site (C, D). The donor graft is incised with a sharp blade and filleted with a #11 blade (E) or excised with scissors (Fig. 2.26).

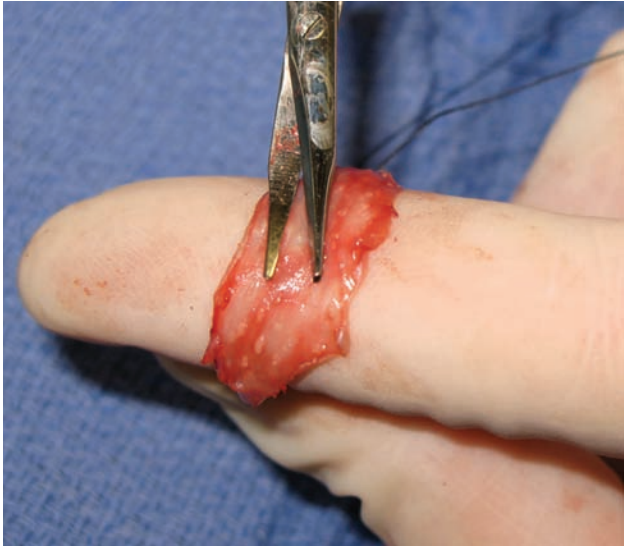

Figure 2.28 These skin grafts must be meticulously thinned. Thinning the skin graft is best done by stretching the graft over your finger with a traction suture and removing the subcutaneous tissue with rounded, sharp scissors. Thin the graft until you think it is too thin, and then thin it some more.

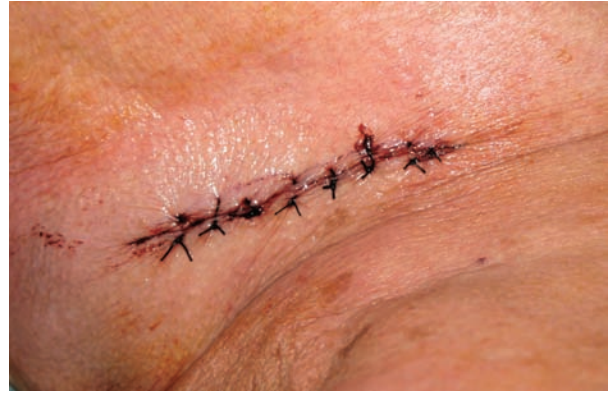

Figure 2.29 Close the donor site (Fig. 2.26) with interrupted 4-0 silk sutures in a far-far/near-near fashion.

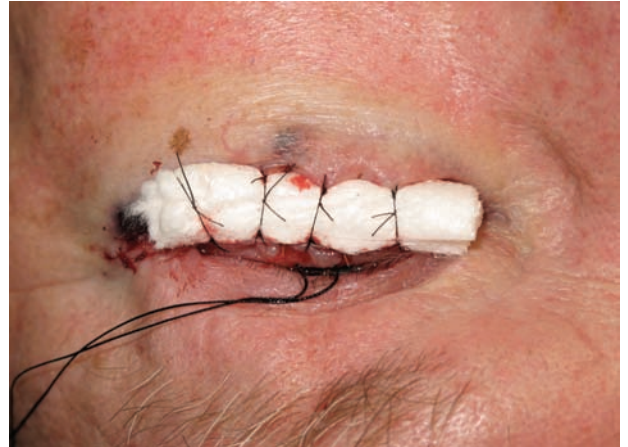

Figure 2.31 The skin graft is compressed to the recipient site for 24 to 48 hours with a Telfa bolster.

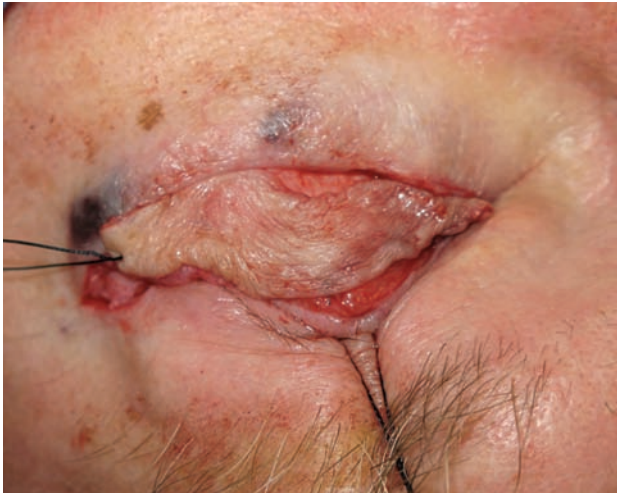

Figure 2.30 A large skin graft is placed into the recipient site and sutured into position just like a smaller skin graft (Fig. 2.25).

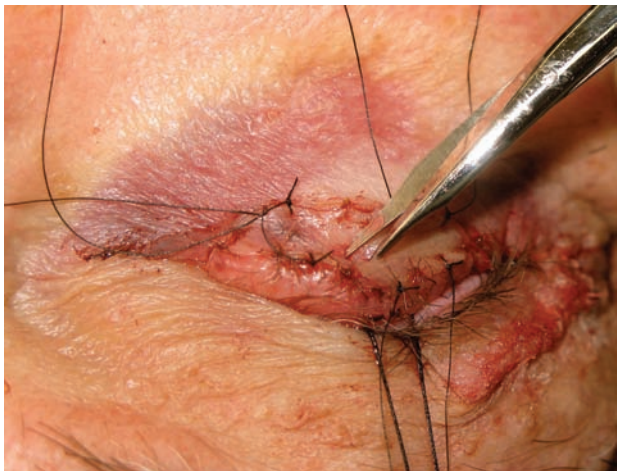
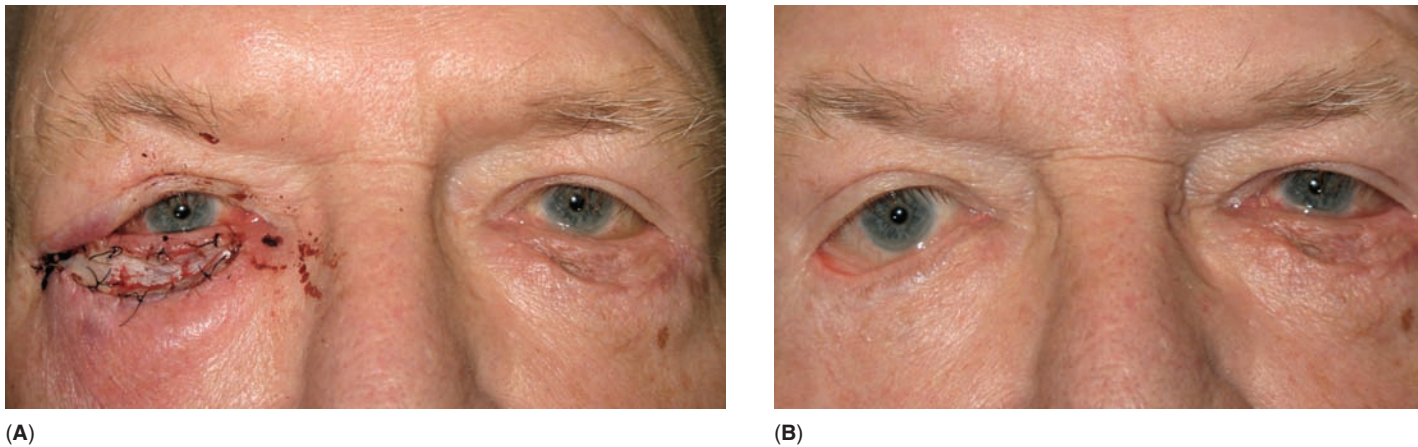


Figure 2.32 Make an incision into larger skin grafts to prevent blood from accumulating between the graft and the recipient site.

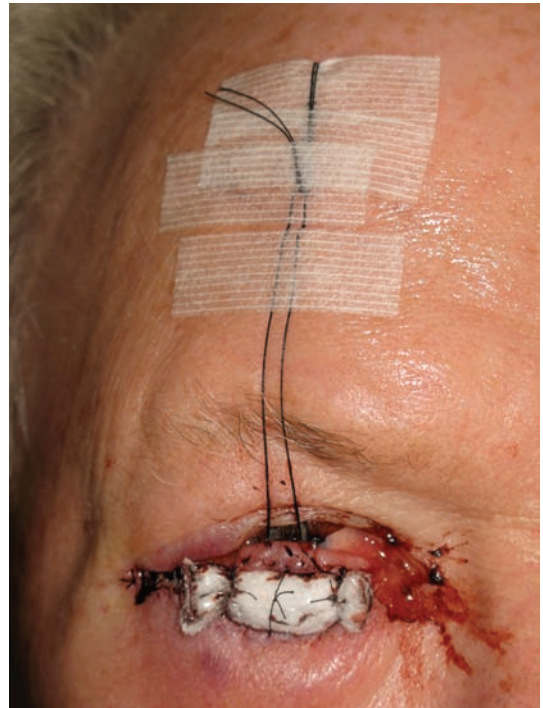

Figure 2.33 Fixate the skin graft to the eyelid with a bolster and sutures. Apply upward traction to the eyelid with a Frost suture.



(A)

(B)

Figure 2.34 Appearance of skin grafts 24 hours (right eye) and one month (left eye) after ectropion repair (A). Appearance of right lower eyelid ectropion immediately before surgery (B).

by previous surgery. If the retroauricular region has been disturbed by a previous facelift, the supraclavicular region would be a more desirable donor site. Graft size is determined with a Telfa® template placed into the recipient site (Fig. 2.27A–D). Blood outlines the size of graft needed to fill the recipient site and the Telfa is cut to the appropriate size (Fig. 2.27B). Since the eyelid is on upward stretch, this is about 25% larger than the size of the defect.

Place a 4-0 silk suture through the superior pinna of the ear or stretch the supraclavicular area by turning the head in the opposite direction. This stretches the region and facilitates excising the skin graft. Use the Telfa template to mark the donor site (Fig. 2.27C and D), outlining it with a marking pen and incising it with a sharp blade. Pass a #11 blade just beneath the skin and with a sawing motion in both directions excise the graft (Fig. 2.27E). With a little practice, this quickly and easily delivers a reasonably thin skin graft. When the sawing motion is no longer effective or becoming destructive, excise the remaining graft with scissors.

A supraclavicular graft may be obtained in a similar fashion and excised with sharp scissor (Fig. 2.26). The #11 blade sawing technique is not always feasible in the supraclavicular region. Rotating the head and stretching the supraclavicular region facilitates the sawing technique. It is worth the effort since the resultant graft will be thinner and less skin graft thinning will be necessary.

The most important step is thinning the skin graft. If the graft is too thick, it will not look good or function well regardless where it was obtained. Pass a 4-0 silk suture through the graft and stretch it over your thumb. Excise the subcutaneous tissue

with scissors by snipping it with the belly of the scissors (Fig. 2.28). Thin the skin graft until it is as thin as it can be. The thinner the graft the more it will resemble eyelid skin. Close the donor site with 4-0 silk sutures in a far-far, near-near fashion (Fig. 2.29).

Place the graft onto the recipient site (Fig. 2.30) and suture it into position with interrupted 6-0 mild chromic and silk sutures (Fig. 2.25). A small graft may be adhered to the recipient site by passing a double-armed 5-0 Dexon suture through the base of the defect and passing both arms through the graft. You can tie this suture over a Telfa bolster at the conclusion of the procedure to better adhere the graft to the recipient site. You may secure larger grafts by leaving a few sutures long on either side of the graft. This is best done with 6-0 silk sutures. These sutures are tied over a Telfa bolster at the end of the procedure (Fig. 2.31). Make a buttonhole incision (Fig. 2.32) into larger grafts to prevent blood from accumulating under the graft, preventing it from adhering to the recipient site. The bolster is left in position for 24 to 48 hours. Place the bolstered eyelid on upward stretch with a traction suture (Fig. 2.33). The suture and the bolster are removed in 24 to 48 hours. The bolster is best removed after cutting the sutures, after soaking it with saline for 10 to 15 minutes. Telfa should not adhere to the wound. The wet bolster may be easily and gently removed from the eyelid after it has been soaked with saline (Fig. 2.34). Recently, we have been adhering smaller grafts to the recipient site with Evicel™ (fibrin/thrombin sealant) and sutures. This may eliminate the need for a bolster, but we still put pressure on the graft with Telfa, a dental roll, and eye pad.



## 3 Entropion Repair

There are two ways to repair an involutional entropion (Fig. 3.1). One is a quick, easy office procedure popularized with a huge Chinese experience by Liu et al. many years ago (*American Journal of Ophthalmology* article). The second is a more elegant surgical procedure allowing you to reconstruct the anatomy, tighten the eyelid, and remove excessive orbital fat to obtain a more elegant cosmetic and functional result. There is a place for both in your surgical repertoire. There is really no need for the plethora of other procedures that do not correct the anatomic defects and often do not work very well.

### SUTURE ENTROPION REPAIR

Anesthetize the lower eyelid by placing a cotton pledget soaked in 4% topical xylocaine into the inferior fornix. Let it sit for five minutes. This anesthetizes the conjunctiva and allows for the almost painless injection of xylocaine with epinephrine (Fig. 3.2). For optimal hemostasis wait 10 to 15 minutes for optimal epinephrine induced vasoconstriction (Fig. 3.3). Do not operate on the eyelids without using an epinephrine-containing anesthetic. The cardiovascular risk is minimal as compared to the hemostatic advantage. Pass two or three double-armed absorbable or silk sutures through the center, nasal, and temporal portions of the lower eyelid from deep in the conjunctival fornix to the more anterior portion of the eyelid, exiting the skin surface just below tarsus (Figs. 3.4A–C). Each suture is tied over a cotton bolster (Figs. 3.4D–F). This effectively turns out the lower eyelid, obviating the entropion (Fig. 3.4G). Leave the sutures in place for 7 to 10 days.

### Complications

#### Overcorrection

If the sutures are tied too tightly, frank ectropion may occur (Fig. 3.4E). This may be prevented by raising the patient to the sitting position after tying the first knot of each suture. If ectropion is present, loosen the knot. If the ectropion is still present, remove and replace the suture.

#### Suture Abscess

If the sutures are not tied over a bolster, the knots have a tendency to “cheese wire” into the skin and cause irritation and an occasional abscess. This can be prevented by tying the knots over a small cotton bolster or treated by removing the offending suture.

### SURGICAL ENTROPION REPAIR—TECHNIQUE

Make a subciliary incision as close to the lash line as possible extending it lateral to the lateral canthus (Fig. 3.5). Develop a skin-muscle flap in the following fashion. Make a button hole incision through the orbicularis muscle at the lateral end of the incision. Place a hemostat into the incision and extend it along the horizontal length of the eyelid beneath the orbicularis muscle. Spreading the hemostat develops the skin-muscle flap, which can then be totally mobilized by incising the incision line with scissors (Fig. 3.5). Hemostasis is obtained with wet field or hot cauterization. Hemostasis may be augmented by placing pledgets soaked in a solution of xylocaine with epinephrine fortified with topical 10% phenylephrine eye drops onto the wound (one drop of phenylephrine per cubic centimeter of local anesthetic has been safe in our experience).

The inferior orbital fat pads are now exposed (Fig. 3.6B). The dehisced capsulopalpebral fascia lies just deep to the fat pads (Fig. 3.6A and B). Grasp the fascia with forceps, advanced and reattached it to tarsus with multiple interrupted sutures (Fig. 3.7A–C). Pass both arms of a double-armed suture through the capsulopalpebral fascia and advance it superiorly. Pass both arms through tarsus (Fig. 3.7B and C) and tie the suture. The temporal and nasal portions of the dehisced fascia may then be sutured to tarsus with interrupted sutures (Fig. 3.8). This turns the eyelid out and corrects the entropion.

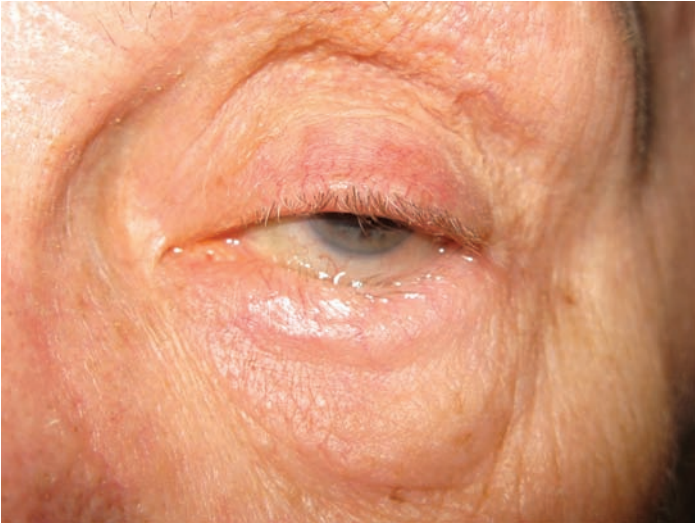To improve the cosmetic result, remove the inferior orbital fat pads and excise a conservative amount of lower eyelid skin after repairing the entropion and tightening the eyelid (see chapter “Lower Eyelid Surgery”).

### Complications

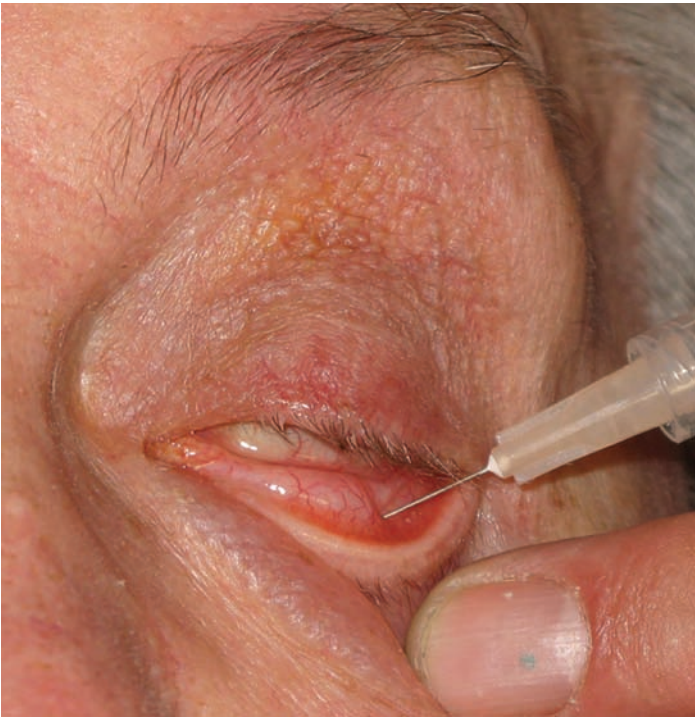If tied too tightly, the eyelid will be overcorrected and an ectropion will result (Fig. 3.9). This can be prevented by tightening the eyelid with a tarsal strip type procedure (see chapter “Ectropion Repair”). If ectropion persists despite tightening the lower eyelid, remove and replace the aponeurotic sutures and tie them less tightly.

Ectropion may occur weeks to months after entropion repair especially if the inferior orbital fat pads had been violated (removed for cosmesis—no good deed will go unpunished) (Fig. 3.10A). Repair requires tightening the eyelid, reopening the incision, incising the cicatricial component, and placing a skin graft into the resultant defect (Fig. 3.10A and B).

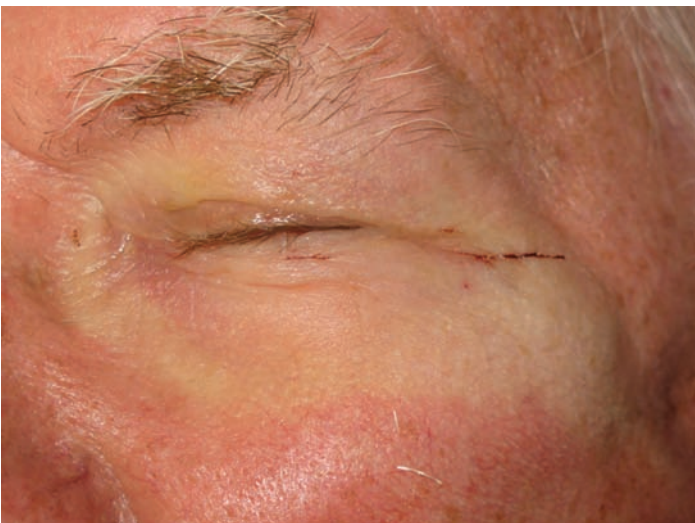## ENTROPION REPAIR



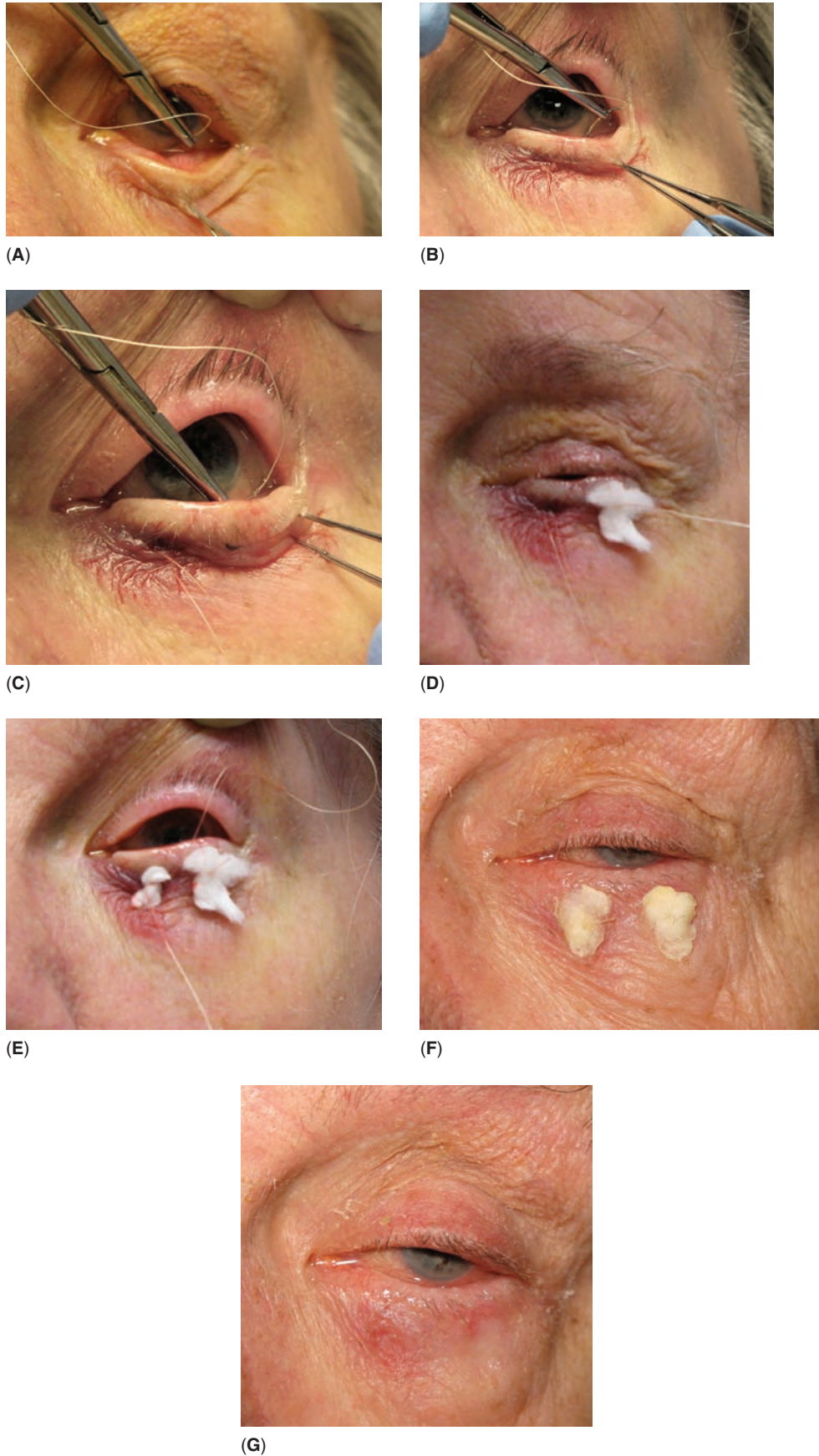
*Figure 3.1* Entropion of lower eyelid. The lashes are inverted and scratching the cornea.



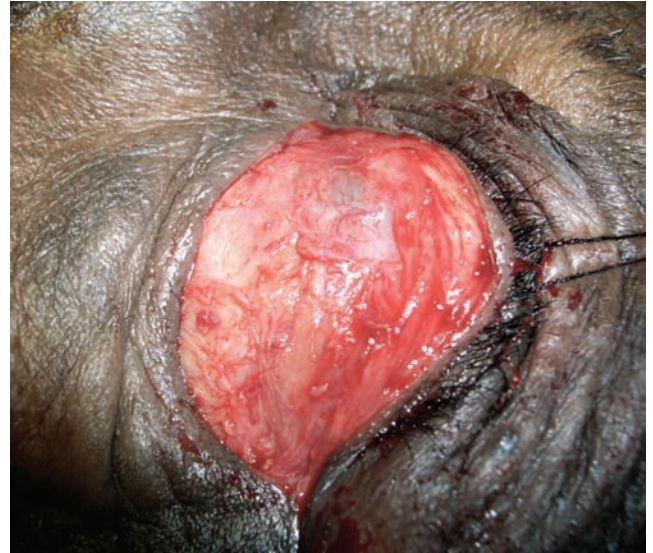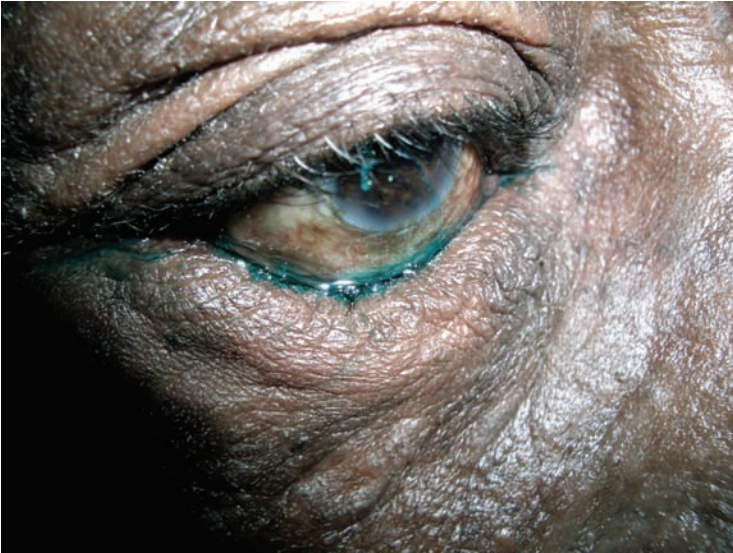*Figure 3.2* Anesthetizing the inferior fornix with a cotton pledget soaked in 4% topical lidocaine allows for the almost painless injection of anesthetic.



*Figure 3.3* Optimal vasoconstriction occurs 15 minutes after injection of an epinephrine-containing anesthetic.



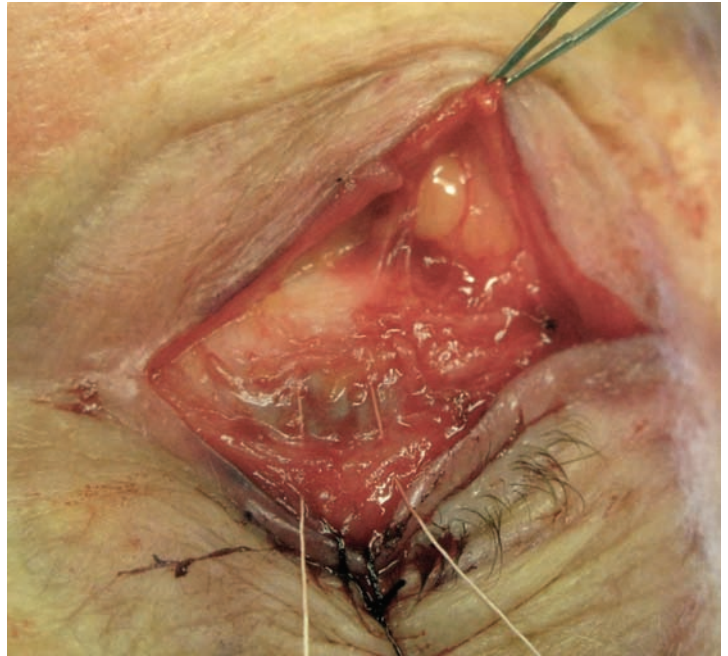
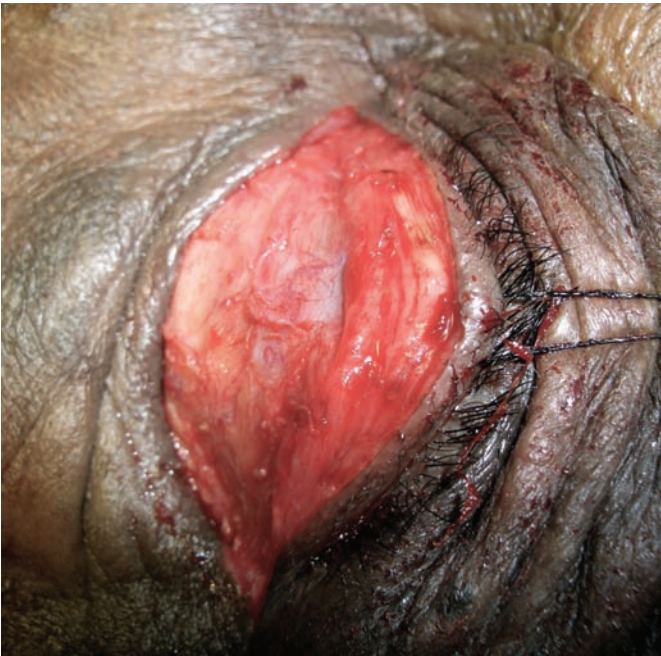*Figure 3.4* Suture entropion repair. A double-armed suture is passed from the conjunctival fornix (A) through the lower eyelid, exiting the skin surface just below the eyelid margin (B, C). Sutures are tied over a cotton bolster to avoid cutting through the eyelid (D). If tied too tightly, a frank ectropion will occur (E) requiring loosening or replacing the sutures. Ten days later bolsters are removed (F) and entropion resolved (G).



(A)

(B)

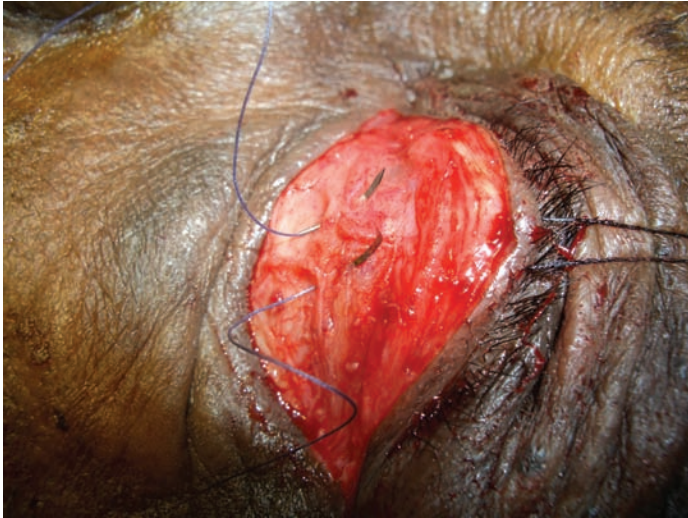Figure 3.5 Entropion right lower eyelid (A). Elevating a skin-muscle flap exposes the capsulopalpebral fascia dehiscent from the inferior tarsal border. Note the clear conjunctiva and blood vessels visible between the fascia and the tarsus (B).



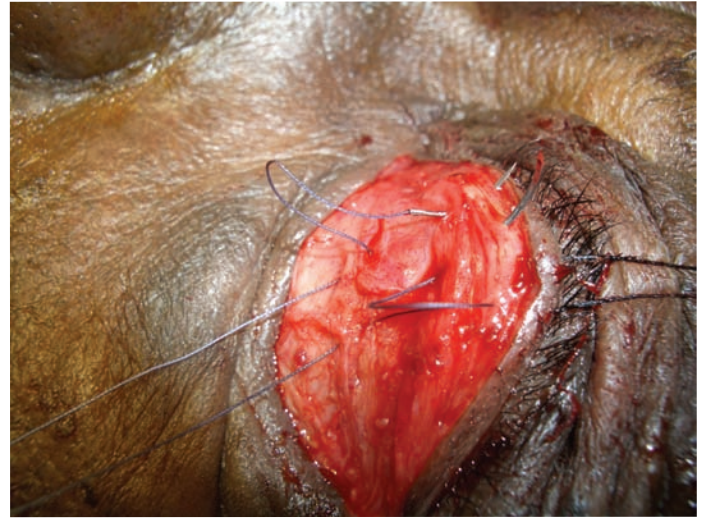(A)

(B)

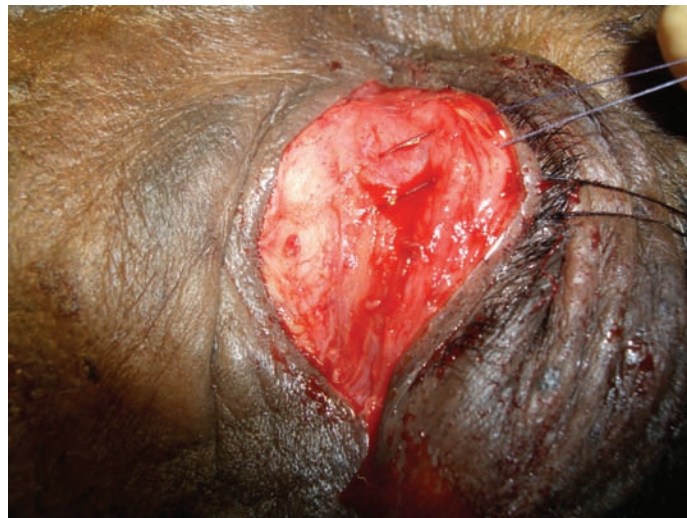Figure 3.6 The inferior orbital fat pads lie above the capsulopalpebral fascia (A). This relationship is better appreciated on the surgeon's eye view (B). Note that the suture is passed through the capsulopalpebral fascia and tarsus with the conjunctiva between the two. The inferior orbital fat pads lie superior to the fascia (beneath the forceps).



(A)



(B)



(C)

Figure 3.7 Sutures are passed through the capsulopalpebral fascia (A) and then through the inferior tarsus (B, C).

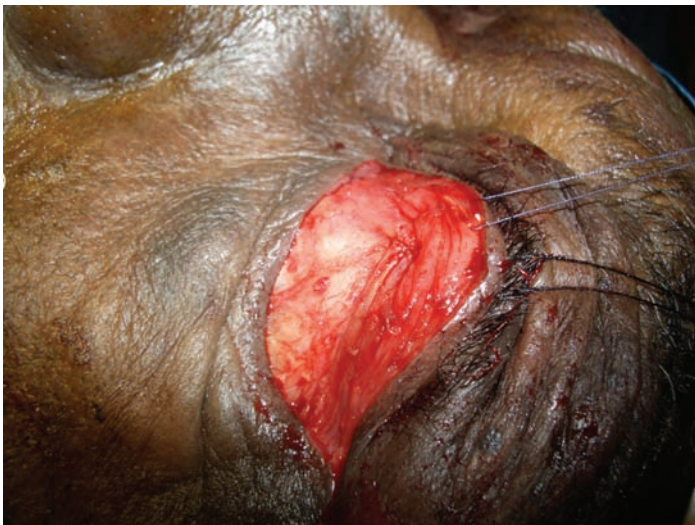

Figure 3.8 Tightening and tying the suture reattaches the capsulopalpebral fascia to the tarsus and corrects the lower eyelid margin.

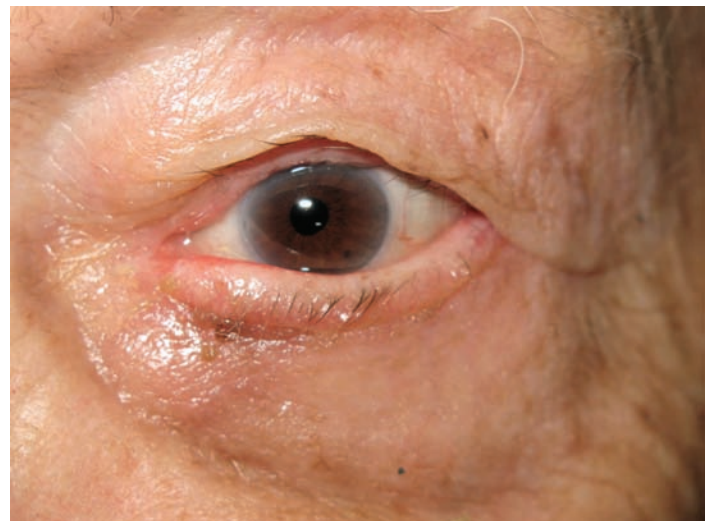
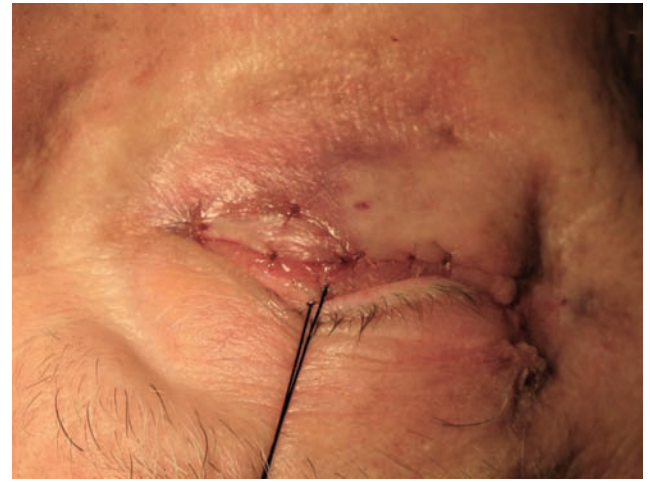
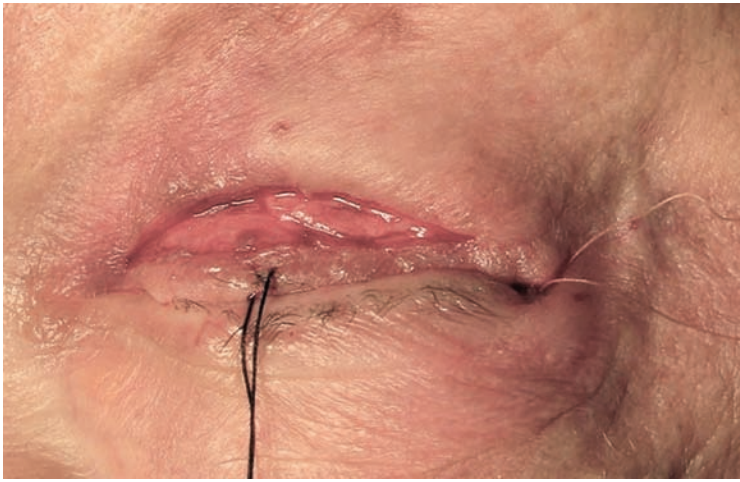


Figure 3.9 Cicatricial ectropion after entropion repair. Note the punctal and medial eyelid ectropion.



(A)

(B)

Figure 3.10 The incision is opened, the eyelid is tightened by a tarsal strip technique (A), and a skin graft from the upper eyelid is sutured into the defect (B).

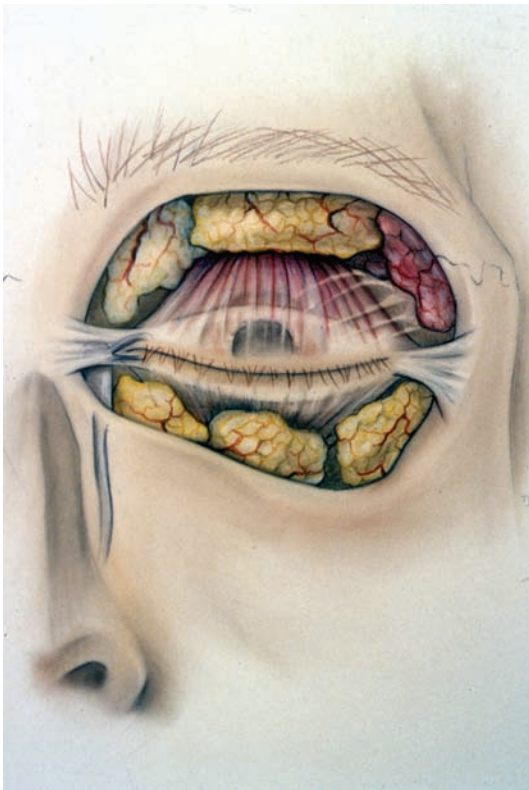


Figure 3.11 Diagram demonstrating the relationship between the upper and lower eyelid fat pads and the underlying levator aponeurosis and capsulopalpebral fascia.

### Recurrent Entropion

In spite of an initial excellent surgical result, entropion may recur.

#### Solution

Fix it again in the same fashion, making sure that you are really reattaching the capsulopalpebral fascia and not the orbital septum to the tarsus. The real capsulopalpebral fascia is analogous to the

levator aponeurosis in the upper eyelid (Fig. 3.11). It is always located just deep to the fat pads, whereas the orbital septum lies superficial to the fat pads. This is basic but often forgotten anatomy. Also, the capsulopalpebral fascia will retract when the eye is depressed. Having the patient look up and down will help you identify this structure in the lower eyelid as it will help you identify the levator aponeurosis during upper eyelid surgery.

## 4 Lower Eyelid Retraction

Over the years, many materials have been utilized as surgical spacers to prevent recurrent lower eyelid retraction after surgical repair.

These materials include eyebank sclera, Medpor®, Alloderm®, ear cartilage, hard palate, ENDURAGEN™, and tarsoconjunctival grafts from the upper eyelid. All have had vocal advocates. Always certain often wrong, they have had equal number of detractors and most are now out of favor.

Our present favorite is ENDURAGEN (acellular porcine dermis) (Fig. 4.1) which produces a functional and cosmetically acceptable long-term result in most patients (Fig. 4.2A–C). It is easy to obtain and use, albeit expensive. The major downside has been inferior corneal erosions caused by the suture material and the unsightly bolsters used to hold the graft in position. These complications can be avoided by minimizing the use of suture material and fixating the graft in position with fibrin/thrombin sealant (Evicel™). This technique hastens recovery time by eliminating postoperative keratopathy but greatly reduces surgical time.

### TECHNIQUE

The initial portion of the procedure is analogous to the lower eyelid blepharoplasty as described and illustrated above. The usual epinephrine-containing anesthetic is injected into the eyelid 10 to 15 minutes prior to incision. A 4-0 silk traction suture is passed through the eyelid margin and the eyelid is inverted over a cotton-tipped applicator. A lateral canthotomy is performed to enhance exposure and allow the lower eyelid to be tightened at the conclusion of the procedure.

Anesthetic solution is injected beneath the conjunctiva to facilitate dissection as in the lower eyelid blepharoplasty. The conjunctiva is incised with scissors several millimeters posterior to the tarsus and the incision is extended along the entire horizontal length of the eyelid. The 6-0 Vicryl™ sutures are placed through the nasal and temporal conjunctiva and used for retraction. The conjunctiva is grasped with forceps and counter traction is applied to the eyelid. A conjunctival flap is dissected from the eyelid utilizing a hot cauterization. The flap is secured to the drapes with hemostats covering the globe (Fig. 1.8 in chap. 1).

A groove is dissected beneath the posterior tarsus with scissors. The graft will be placed in the groove to help fixate it to the eyelid. An appropriately sized piece of ENDURAGEN is outlined and excised (Fig. 4.3). Since reabsorption is usually not an issue, the graft can just be several millimeters wider than the degree of eyelid retraction you intend to correct. The superior portion of the graft is placed into the groove posterior to the tarsus (Figs. 4.4 and 4.5). The posterior portion of the graft may be fixated to the eyelid bed with several 6-0 Vicryl sutures in a hem type fashion if necessary. Tying these sutures will help flatten the graft and fixate it to the eyelid. Prior to final placement and suture tying, fibrin/thrombin sealant (tissue glue) (Evicel) is applied to the eyelid bed (Figs. 4.5

and 4.6). The graft is positioned and the sutures tied. A bit more fibrin glue is placed on the anterior surface of the graft; the conjunctival flap is placed over the posterior portion of the graft (Fig. 4.7). A moist neurosurgical cottonoid is placed between the globe and the graft (Fig. 4.8).

This may be narrowed if necessary. The eyelid is placed in its anatomic position against the globe and gentle pressure is applied to it with a dental roll (Fig. 4.9) for two to three minutes. During this time, the eyelid may be tightened by a modified tarsal strip procedure (see Figs. 1.19–1.24 in chap. 1 and Figs. 2.12–2.18 in chap. 2). You may preplace these sutures in the tarsal strip and lateral orbital wall, leaving the eyelid lax until the graft is in position and then tightening the suture to help flatten the graft. This flattens the eyelid against the globe, smoothing both the graft and the lower eyelid. The final result should be a smooth eyelid with no retraction, maybe a little overcorrected since the patient is in the supine position (Fig. 4.2B). There should be no sutures touching the cornea either in primary or down gaze and no external bolsters. With experience, suturing may be eliminated with small to medium sized grafts. These may be fixated only with fibrin/thrombin sealant (Evicel). Larger grafts may require fixation with a few sutures or 24 to 48 hours of upward traction utilizing a Frost suture. This stretches the lower eyelid, allowing the graft to flatten and fill the entire surgical defect without buckling upon itself (Fig. 4.10).

Figure 4.11 demonstrates the amount of correction or lower eyelid retraction that you can obtain with ENDURAGEN grafts.

As with any surgical procedure, there is a learning curve and complications can and do occur.

### COMPLICATIONS

#### *Problem*

Bulky, thick lower eyelid and recurrent lower eyelid retraction (Fig. 4.12).

#### *Reason*

Graft not held in position long enough to let the fibrin glue secure it and graft too large to secure only with fibrin/thrombin sealant.

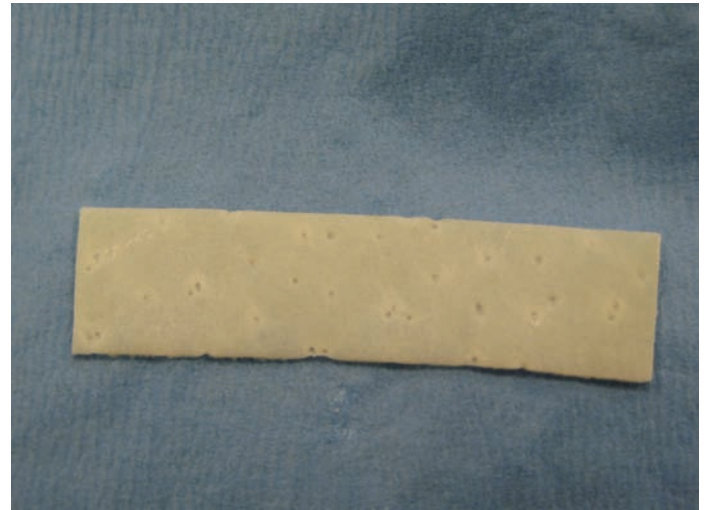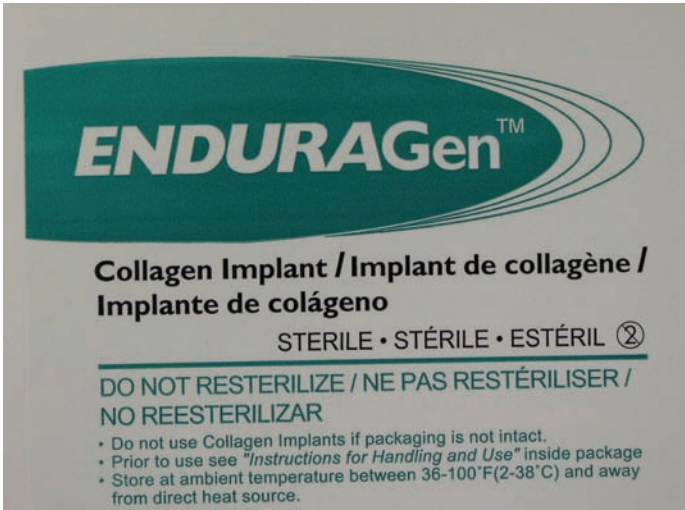#### *Solution*

Figure 4.12 demonstrates a bulky lower eyelid secondary to a large ENDURAGEN graft folding upon itself. The best treatment is prevention by securing a large graft with sutures, bolsters, and a Frost suture as necessary.

#### *Treatment*

Expose the graft through a subciliary incision. Then, thin the graft by excising the excessive material with scissors or shaving it with a #11 blade. The entire graft may be removed and replaced. If the graft material is scarred into position, it is easier to thin it with scissors, then make an incision beneath it along its entire horizontal length. This recesses and elevates the lower eyelid. Place another graft in the defect suturing it to the surrounding tissue and adjacent graft. Tighten the eyelid with a tarsal strip variant as necessary and close the incision. Apply upward traction to the

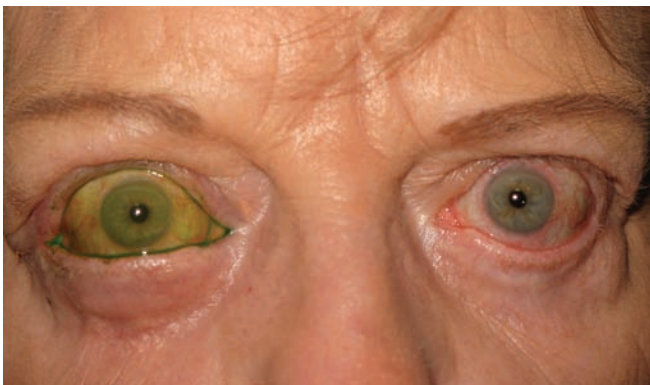LOWER EYELID RETRACTION



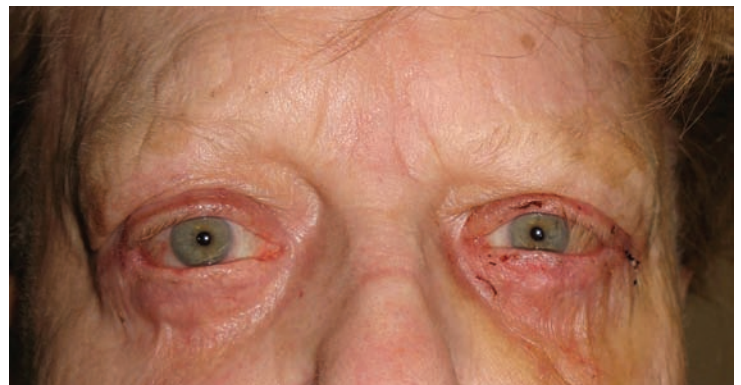(A)

(B)

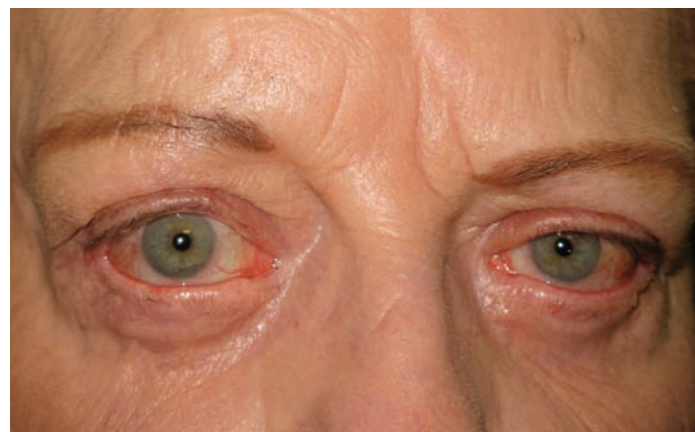Figure 4.1 ENDURAGen (A) is an acellular porcine collagen that is pliable and easily cut into any pattern (B).



(A)



(B)



(C)

Figure 4.2 Patient one week after ENDURAGEN implant to right lower eyelid. Note retraction of the other three eyelids (A). One week after ENDURAGEN implant to left lower eyelid (B). Note mild overcorrection. One month later, gravity and contraction resolve the overcorrection (C).



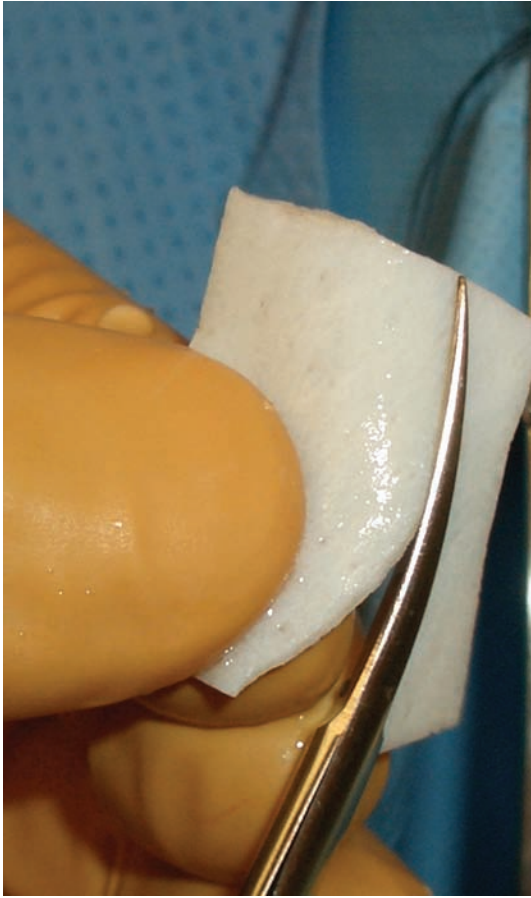


Figure 4.3 ENDURAGEN graft is cut to the appropriate size and shape.

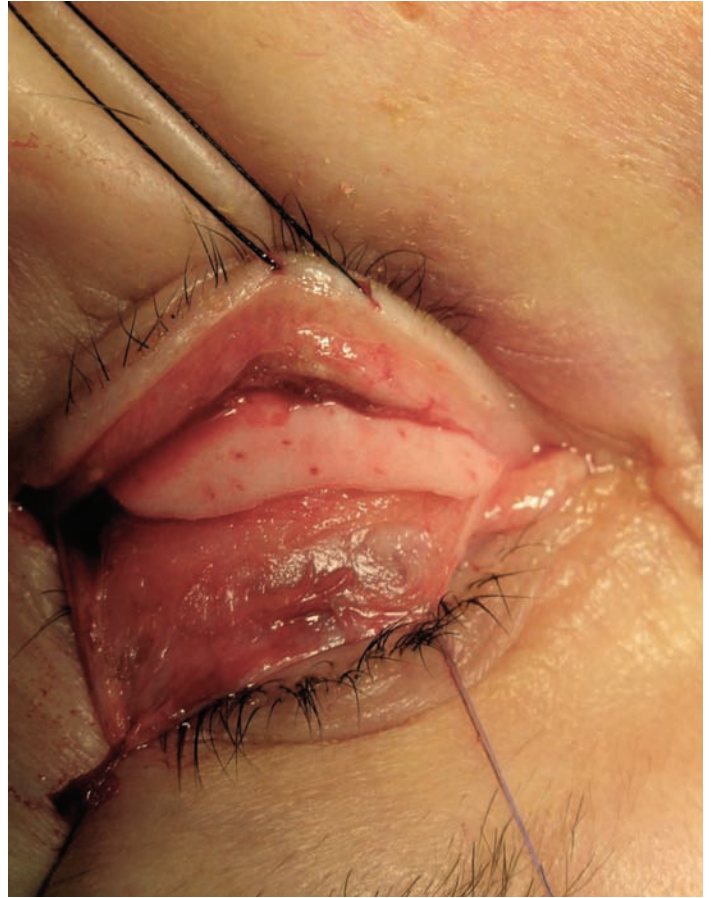


Figure 4.4 ENDURAGEN graft is placed into the lower eyelid recipient site. The eyelid is retracted with the black silk suture, the conjunctival flap with the purple Vicryl sutures.

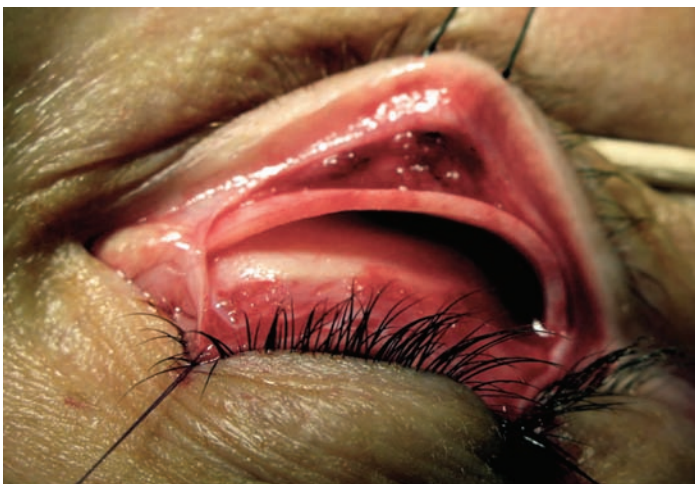

Figure 4.5 The graft is in position between the tarsus and the conjunctival flap. The sealant will be applied both anterior and posterior to the graft.

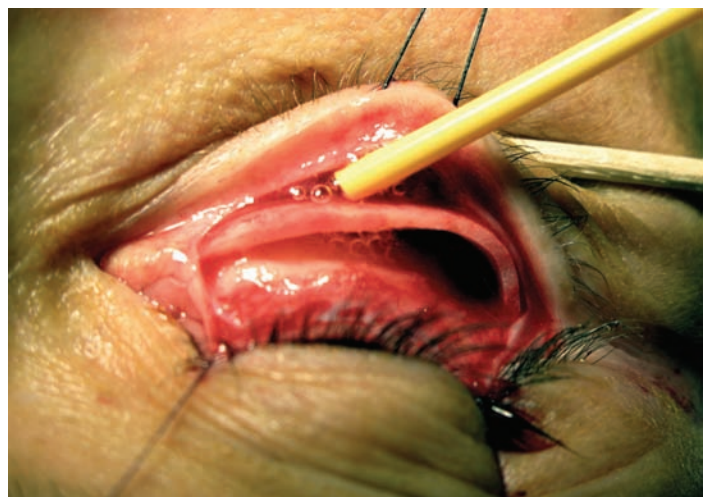
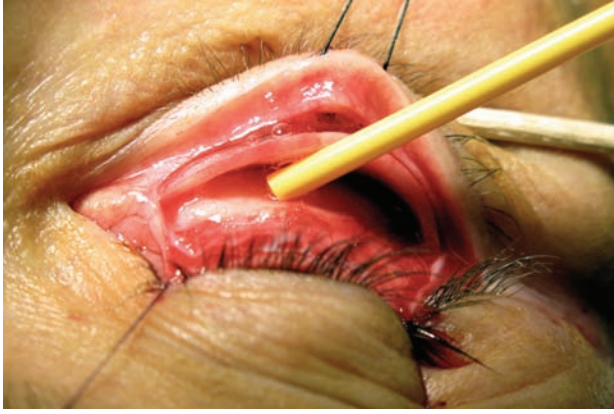
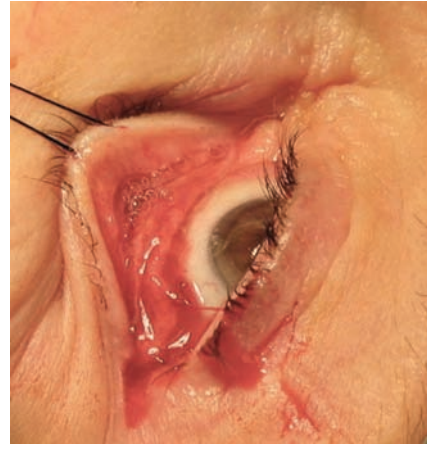


Figure 4.6 Fibrin/thrombin sealant is applied to both sides of the graft.

LOWER EYELID RETRACTION



(A)



(B)

Figure 4.7 Sealant is applied to the posterior portion of the graft (A). Graft is sealed into position with the fibrin/thrombin sealant (B).

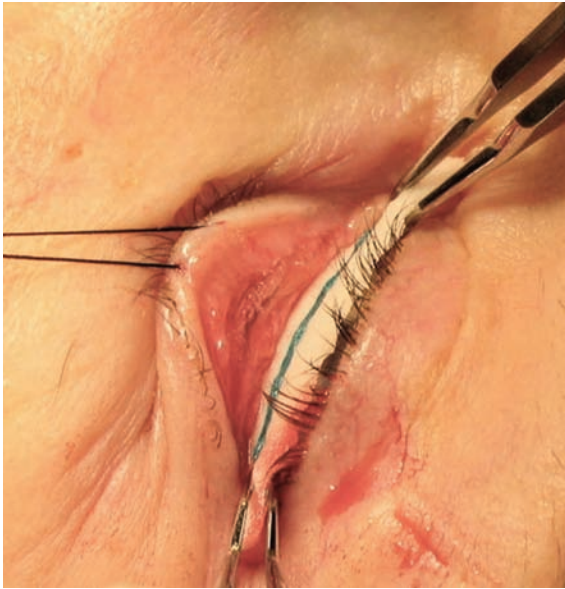
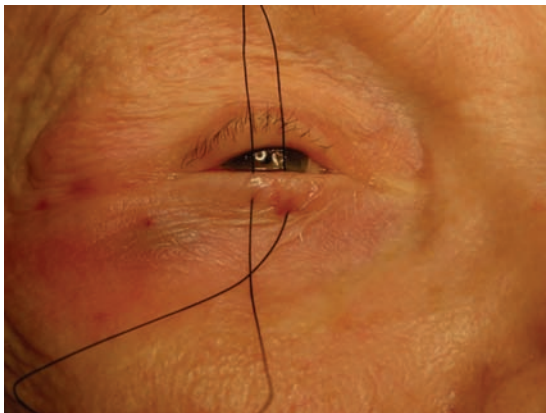


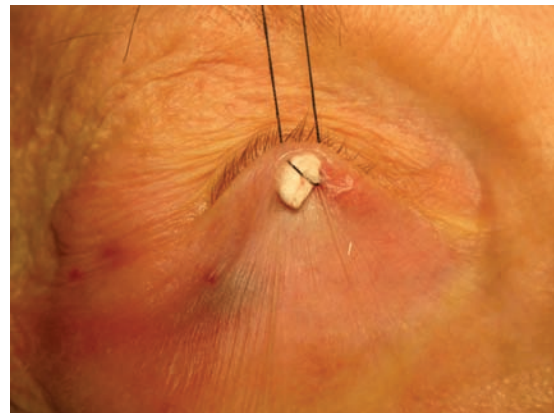
Figure 4.8 A cottonoid is trimmed and placed in the fornix posterior to the graft.

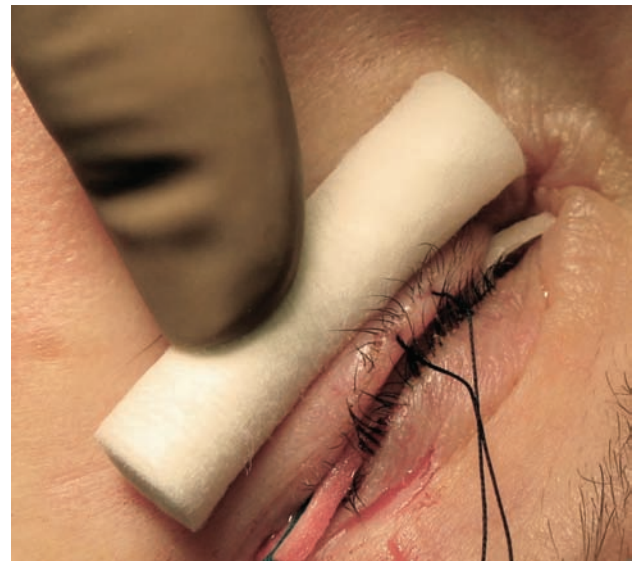

Figure 4.9 Gentle pressure is applied to the eyelid with a dental roll to fixate the graft in the appropriate position.

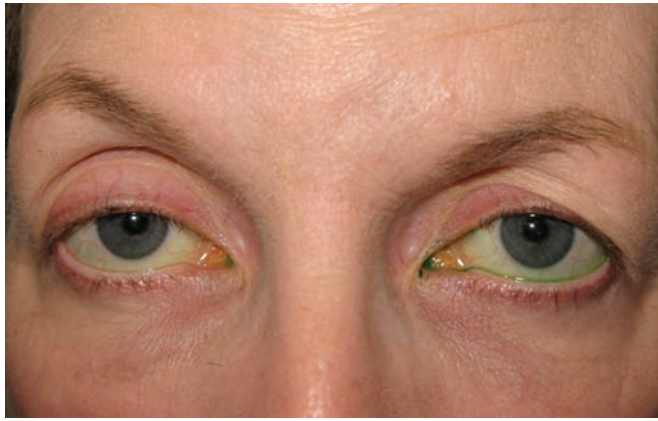

(A)

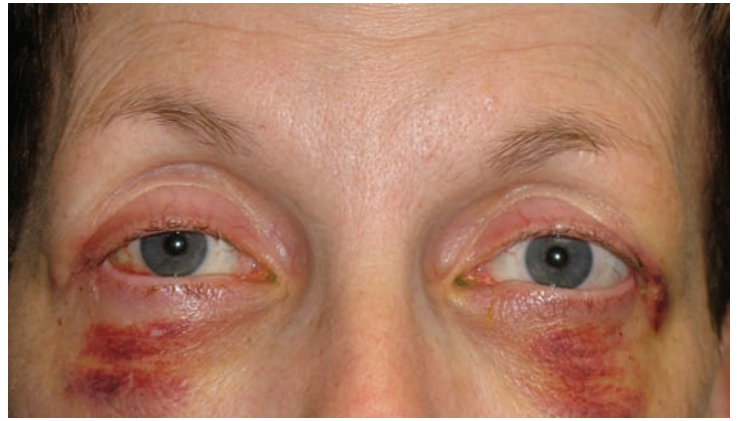


(B)

Figure 4.10 Do not forget the Frost suture, a double-armed 4-0 silk suture is passed through the eyelid margin and is used to put upward traction on the lower eyelid (A). A bolster must be placed beneath the suture loop to avoid erosion of the eyelid margin over a cotton bolster (B).



(A)



(B)

Figure 4.11 Patient with bilateral lower eyelid retraction (A) before and (B) one week after bilateral ENDURAGEN implants and tarsal strip.

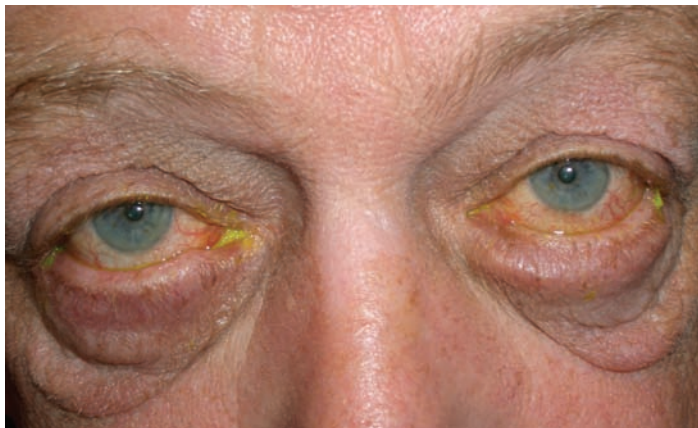

Figure 4.12 Patient with recurrent eyelid retraction and buckling of ENDURAGEN graft after eyelid reconstruction.

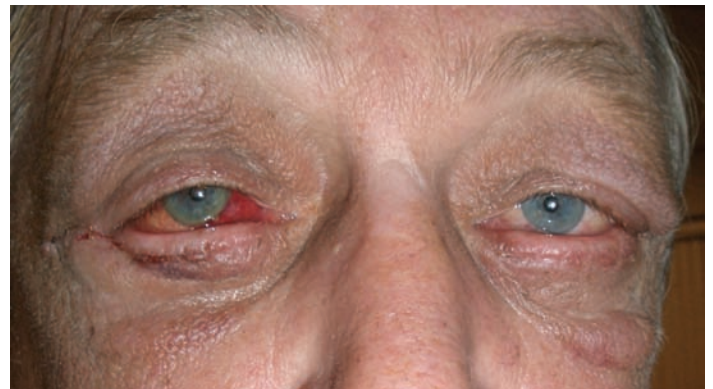

Figure 4.13 After revision of the graft via a skin-muscle advancement flap, lid retraction and festoons are improved.

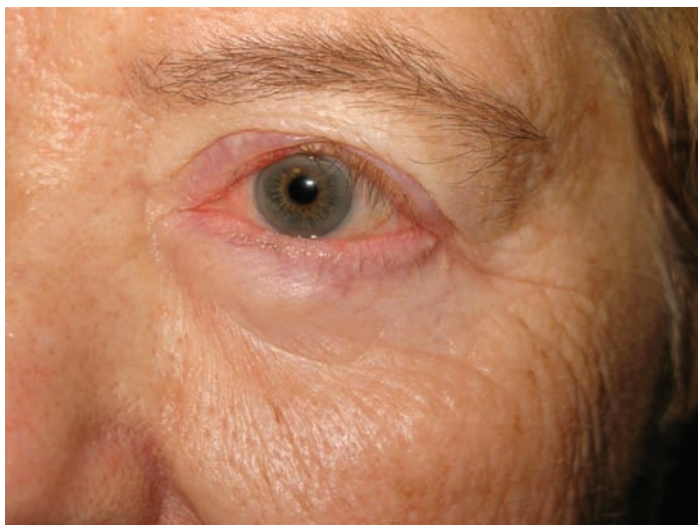


Figure 4.14 Mild eyelid thickening can be thinned or observed for resolution by reabsorbing the porcine collagen.

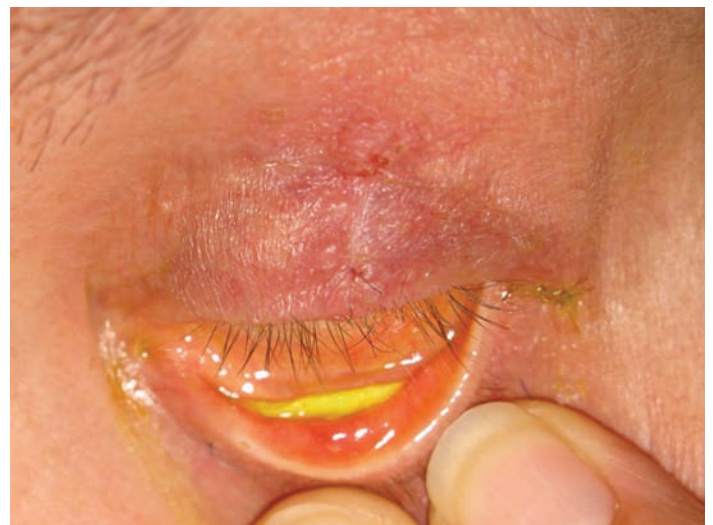

Figure 4.15 An exposed implant may cause corneal erosions and should be suspected in patients with persistent complaints and corneal erosions. This is much more common when the implants are sutured into position.

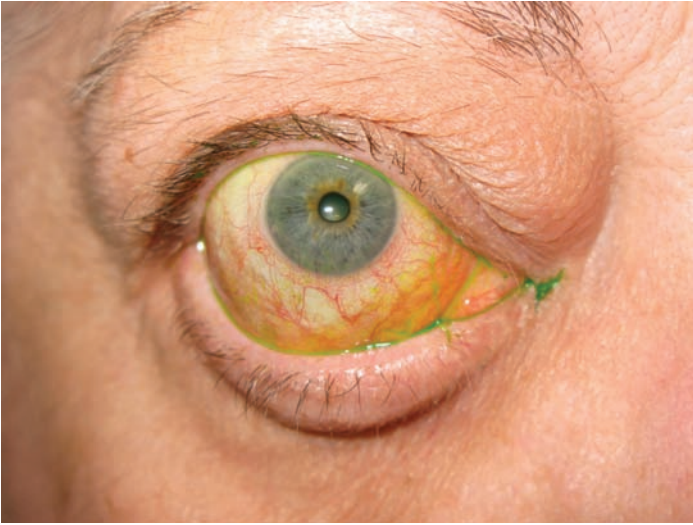

Figure 4.16 Recurrent lower eyelid retraction after several ENDURAGen grafts caused by reabsorbing the implant is more common in patients with thyroid eye disease. Might it have an immune etiology?

lower eyelid with a Frost suture for three to four days. This procedure will thin, elevate, and tighten the eyelid (Fig. 4.13).

*Problem*

The graft is too large and not secured well (Fig. 4.12).

*Treatment–Prevention*

If the eyelid is too thick and bulky at the conclusion of the procedure, do not quit! Take out the graft, make it narrower, replace it, and use a few more hem sutures to ensure that it is fixated to the eyelid bed. If necessary, a suture can be passed in full thickness through the graft and the eyelid and tied on the skin surface in

several areas. This effectively flattens the graft. This is not often necessary.

If using a very large graft, putting the lower eyelid on upward stretch with a Frost suture (double-armed 4-0 silk suture through the eyelid margin and tied over a bolster) (Fig. 4.10) for one to two days may be a helpful adjunct. If prevention is not possible—someone else’s complication—the graft may be thinned via a subciliary incision. The bulky, folded graft is exposed and the thickened portion is excised with scissors. This results in significant thinning of the eyelid with improved appearance (Fig. 4.13).

Milder degrees of eyelid thickening (Fig. 4.14) can be dealt with in a similar fashion, thinning the graft with scissors after exposing it with a subciliary incision. This complication can also be treated with benign neglect allowing for some reabsorbing to occur or prevented by using the new, thinner (0.5 mm thick) ENDURAGen grafts.

*Problem*

*Suture keratopathy:* obvious or subtle (cornea rubbing on suture ends in down gaze). This was quite common prior to the using fibrin/thrombin sealant but is rarely seen now; it can occur when the graft is exposed in the fornix (Fig. 4.15).

*Problem*

Recurrent inferior scleral show (Fig. 4.16).

*Reason*

Graft reabsorbs. This is not common but it occurs on occasion, most often in patients with thyroid eye disease.

*Solution*

Reoperate and place another graft in the new surgical defect, effectively recessing the remnants of the previous graft. If this is unsuccessful, try a different spacer material like Alloderm, ear cartilage, or hard palate.

## 5 Complications of Lower Eyelid Surgery

### EDEMA AND CHEMOSIS

After transconjunctival (Fig. 5.1A) or transcutaneous (Fig. 5.1B) lower eyelid surgery, there may be extensive swelling and chemosis caused by the trauma of surgery, removal of orbital fat, allergic reaction, or hemorrhage (discussed separately below). Chemosis is often asymmetric—one eye very chemotic, the other appearing normal (Fig. 5.2). This is best managed by reassurance and observation, which may be augmented with a short course of corticosteroids (Medrol® dose pack) and incision and drainage of the chemotic conjunctiva (Fig. 5.3A and B). This is usually not necessary but may be very helpful if the swollen conjunctiva is pushing the lower eyelid away from the globe with the potential for breaking the sutures and developing an ectropion (Fig. 5.4A and B). The resultant lateral ectropion (Fig. 5.5) needs to be repaired by replacing the broken suture and retightening the eyelid.

You may avoid this complication by incising the offending, chemotic conjunctiva and draining the subconjunctival fluid in the following manner (Fig. 5.3).

Anesthetize the chemotic conjunctiva with topical 4% lidocaine and incise it with scissors. Massage the excessive fluid from the wound and apply a pressure patch for 24 hours. This makes the patient look better immediately and may obviate the potential ectropion. If the chemosis reoccurs, you may repeat the procedure.

### FAILURE TO REMOVE ORBITAL FAT

Some surgeons neglect to remove orbital fat when performing lower eyelid blepharoplasty (Figs. 5.6 and 5.7). The effective treatment is surgical removal of the offending orbital fat, as described for lower eyelid blepharoplasty. You may also do this by making a small subciliary incision over the offending fat pad, then dissecting and removing it or debulking it with bipolar cauterization.

### LOWER EYELID RETRACTION

The vast majority of lower eyelid surgery should be transconjunctival. It takes more skin to fill a concavity than a convexity, so when the orbital fat is removed, the lower eyelid contour changes from convex to concave (Fig. 5.8). Hence little, if any, skin needs removal to affect a pleasing cosmetic result in most patients except those with excessive lower eyelid skin or extensive lower eyelid festooning (bags on bags) (Fig. 5.9).

Skin removal from the lower eyelids has a tendency to cause ectropion or eyelid retraction (Fig. 5.10). You may avoid ectropion by asking the patient to open their mouth widely as you measure the amount of skin to remove. This mimics gravity and allows removal of an appropriate amount of skin. Less is better! Lower eyelid retraction may be quite subtle and still cause inferior superficial punctate keratopathy. This may be very symptomatic (Fig. 5.11). Treatments entail elevating the lower eyelid by either replacing the skin (anterior lamella) or implanting a spacer graft into the posterior lamella. Merely tightening the lower eyelid with

a tarsal strip type procedure without fixing the lamellar shortening usually worsens the condition by exacerbating the lower eyelid retraction [“belt and belly” phenomenon (Fig. 5.7)].

Less severe cicatricial ectropion (Fig. 5.12A) may be treated by lengthening the anterior lamella of the eyelid with a skin graft after releasing the cicatrizing forces with sharp dissection and shortening the eyelid with a tarsal strip procedure (Fig. 5.12B). The upper eyelid is the donor site of choice followed by the retroauricular region. Obtaining a graft from the upper eyelid is quite simple. After injecting xylocaine with hyaluronidase, wait for 10 to 15 minutes. This allows you to tent the skin with a pair of forceps (Fig. 5.13A) and use scissors to excise the amount of skin needed (Fig. 5.13B). The result is a very thin skin graft that can be placed in the lower eyelid defect (Fig. 5.14). The donor site may be sutured or closed with Indermil® glue.

Larger defects require a retroauricular or supraclavicular skin graft. These must be compulsively thinned to be cosmetically acceptable but the result is worth the effort (see section “Cicatricial Ectropion” in chap. 2).

### PYOGENIC GRANULOMA

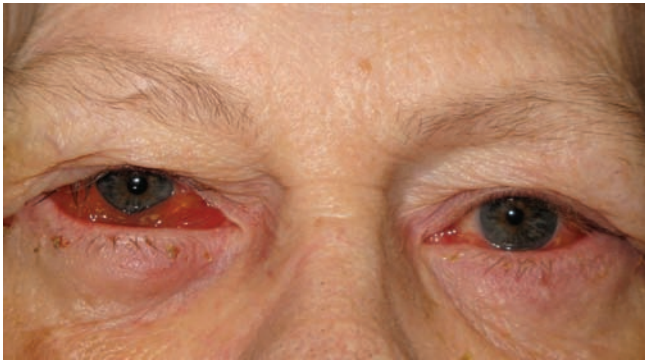
Pyogenic granulomas may occur at the lateral canthal or conjunctival incisions (Fig. 5.15). They often scare the patients who think that they have developed a tumor. These are easily removed with a scissor, forceps, and topical anesthetic.

### DIPLOPIA

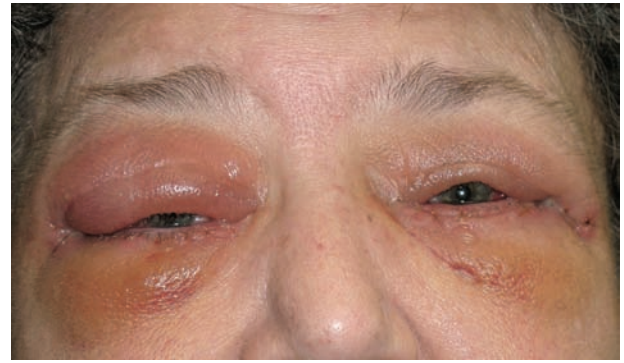It is difficult to cause diplopia after lower eyelid surgery, but it can be done. Diplopia may result from postoperative hemorrhage. This should be obvious and treated as described below if it is interfering with visual function. Injury to the inferior oblique muscle is possible, but it should be directly visualized and easily avoided when removing the fat pockets (see chapter “Lower Eyelid Surgery”). Remember from strabismus surgery that failure to completely extirpate the inferior oblique is the leading cause of surgical failure. It is hard to imagine that inadvertent cauterization or partial clamping should have any lasting adverse effect. Injury to the inferior rectus muscle is also possible but difficult to envision although it does occur. If the surgeon makes a very posterior conjunctival incision and becomes somewhat disoriented with the altered anatomy, he/she can injure the inferior rectus muscle. Avoid this by keeping the conjunctival incision immediately posterior or a few millimeters posterior to tarsus and carefully differentiating fat from muscle. Recess the conjunctiva to a more posterior position at the conclusion of the procedure.

### HEMORRHAGE AND VISUAL LOSS

There are two types of hemorrhage occurring after lower eyelid surgery. Deep, blinding, bleeding may occur immediately after surgery (Figs. 5.16 and 5.17). This results from incomplete cauterization of an orbital blood vessel and usually occurs in the



(A)

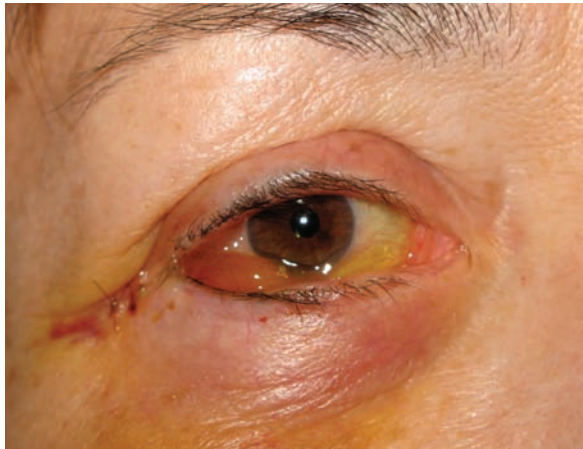


(B)

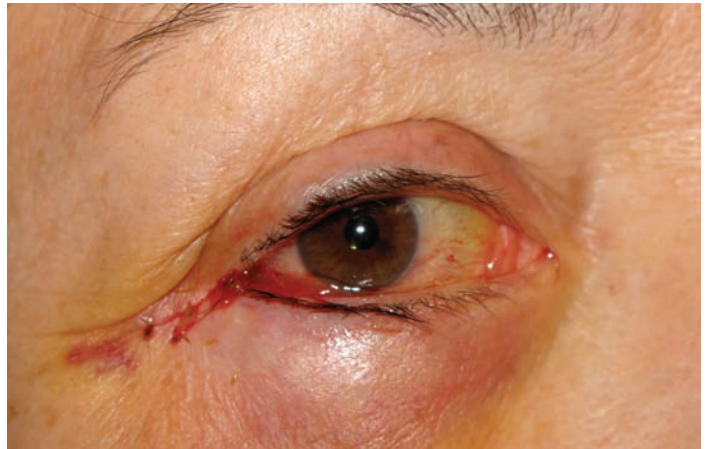
Figure 5.1 Severe conjunctival chemosis after transconjunctival lower eyelid surgery (A). Note how the right lower eyelid is displaced from the globe. Severe chemosis and eyelid edema after transcutaneous eyelid surgery (B). With this much upper eyelid swelling suspect a contact allergy.

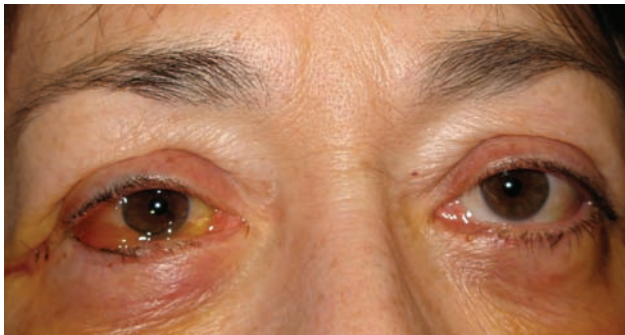

Figure 5.2 Markedly asymmetric conjunctival chemosis a few days after lower eyelid surgery.

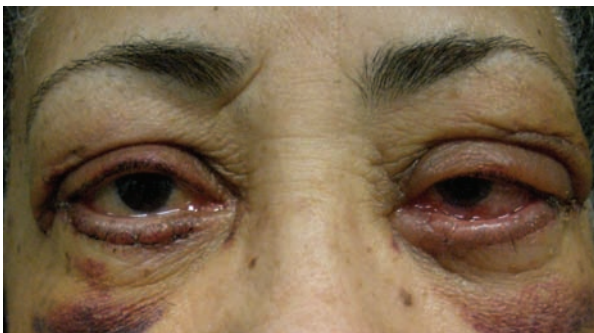


(A)

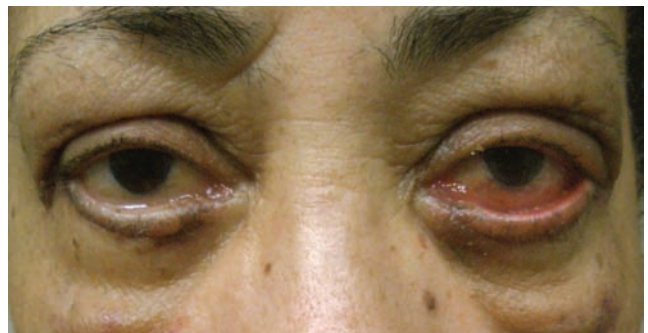

(B)

Figure 5.3 Conjunctival chemosis before (A) and immediately after (B) incision and drainage of chemotic conjunctiva.



(A)



(B)

Figure 5.4 Conjunctival chemosis shortly after lower eyelid surgery (A) causing bilateral ectropion several days later (B).

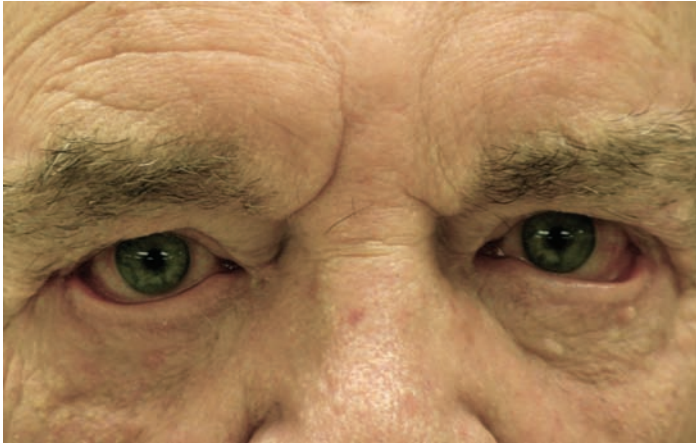

Figure 5.5 Bilateral ectropion due to disruption of tarsal strip sutures. Repair requires retightening the eyelid by repeating the tarsal strip procedure.

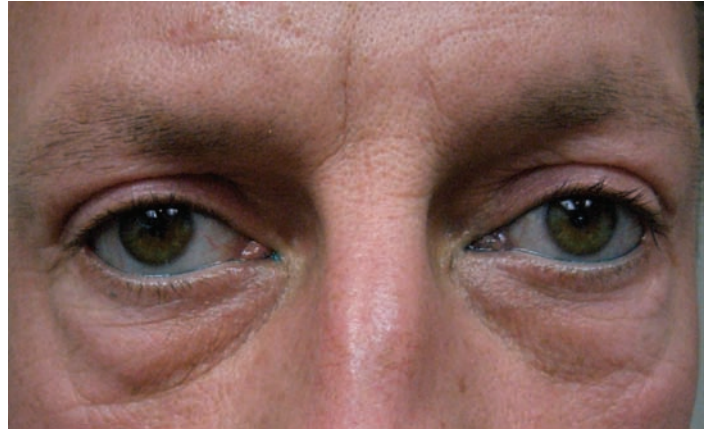

Figure 5.6 Failure to remove orbital fat during lower eyelid blepharoplasty.

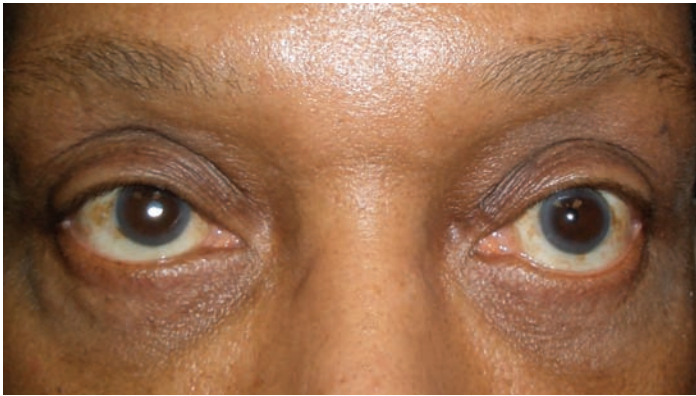


Figure 5.7 Residual lateral orbital fat pads after lower eyelid blepharoplasty. Fat pad may be removed via a small external incision. Note the lower eyelid retraction necessitating more extensive repair with an Enduragen™ graft.

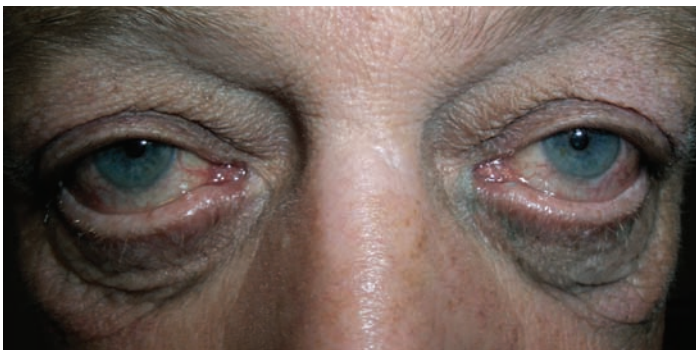

Figure 5.9 A patient with "bags on bags" of excessive skin and fat will require an external blepharoplasty.

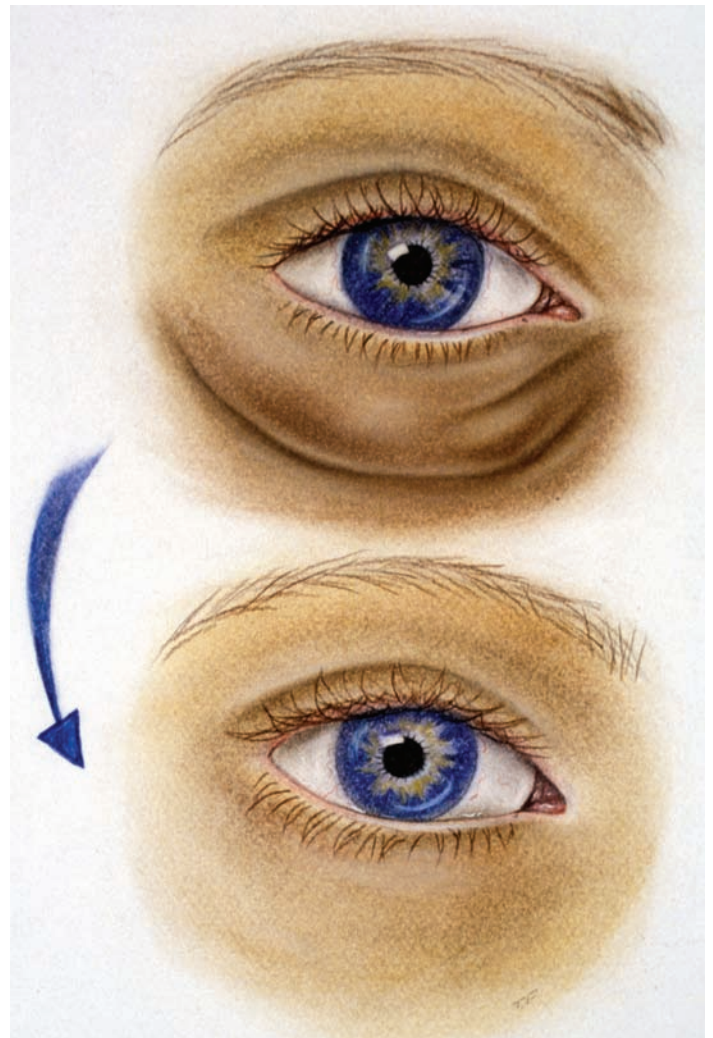


Figure 5.8 Diagram describing how it takes more eyelid skin to fill a concavity than a convexity. This is the rationale for performing most lower eyelid surgery through the conjunctiva.

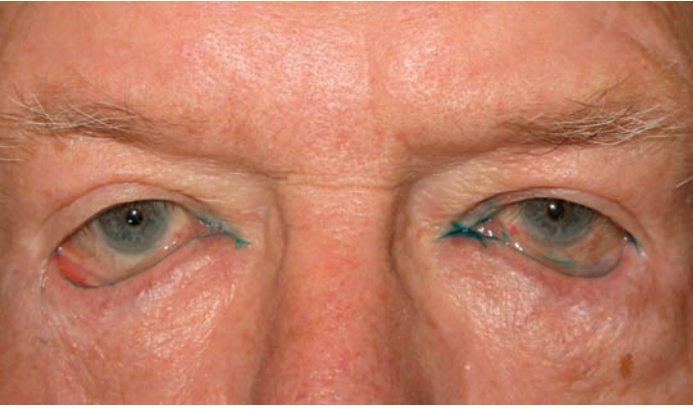

Figure 5.10 Severe cicatricial ectropion due to excessive skin removal.

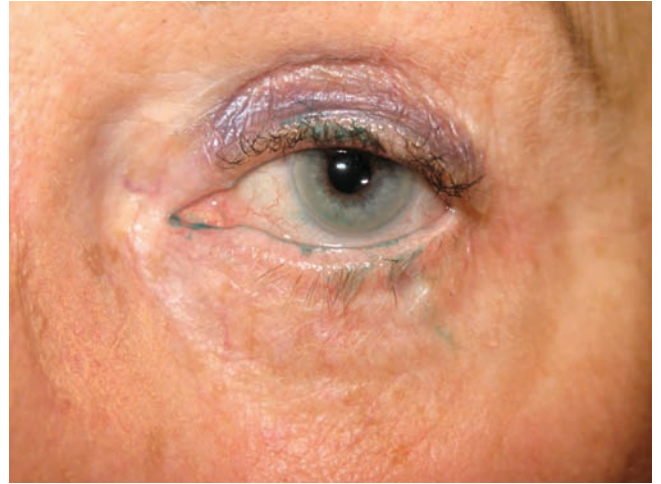
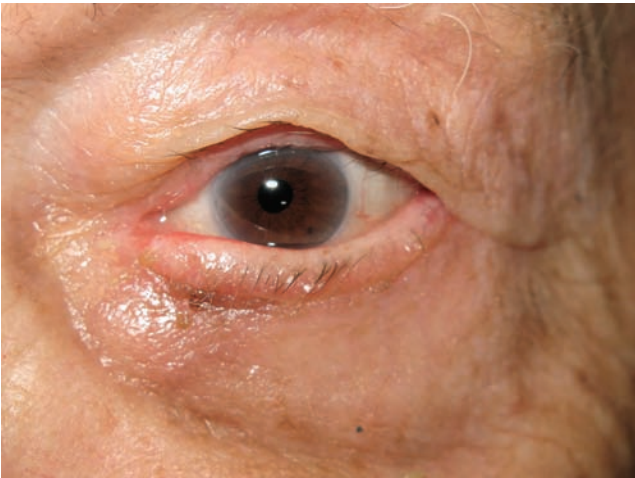
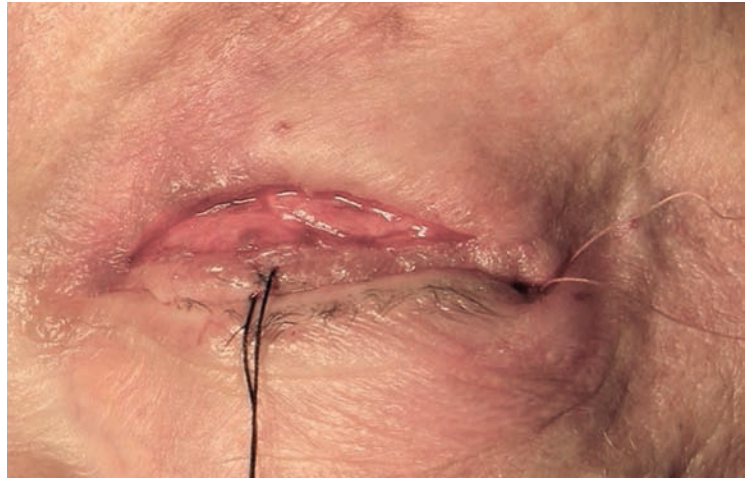

Figure 5.11 Subtle lower eyelid retraction may cause chronic ocular irritation due to inferior punctate keratopathy. Lissamine green staining facilitates making this diagnosis.

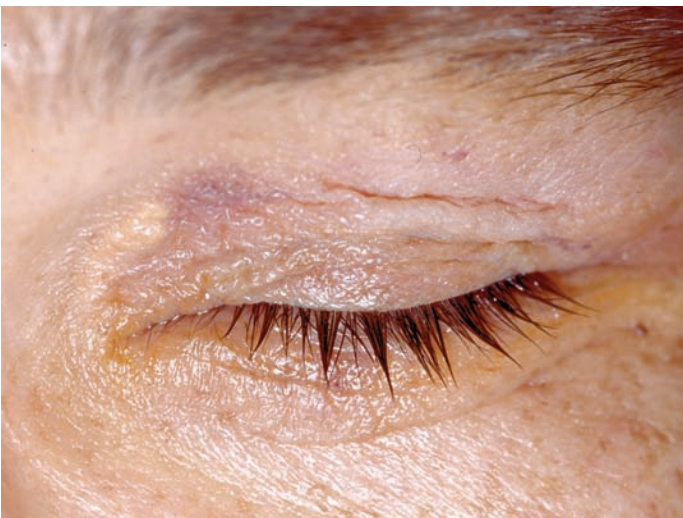


(A)

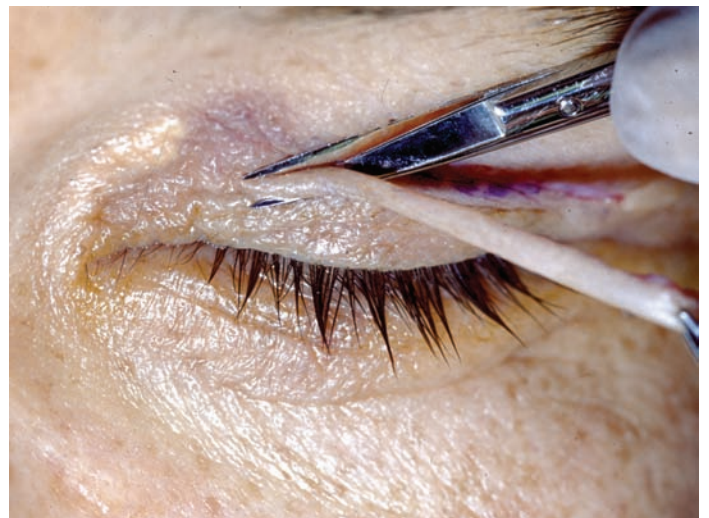

(B)

Figure 5.12 A cicatricial ectropion after lower eyelid surgery (A). The cicatrizing forces have been neutralized with a subciliary incision and sharp dissection. The eyelid is horizontally shortened with a tarsal strip (B).



(A)



(B)

Figure 5.13 A thin skin graft is best obtained from the upper eyelid. Ten to fifteen minutes after injection of xylocaine with hyaluronidase, the upper eyelid skin can be tented with forceps (A) and excised with scissors (B).

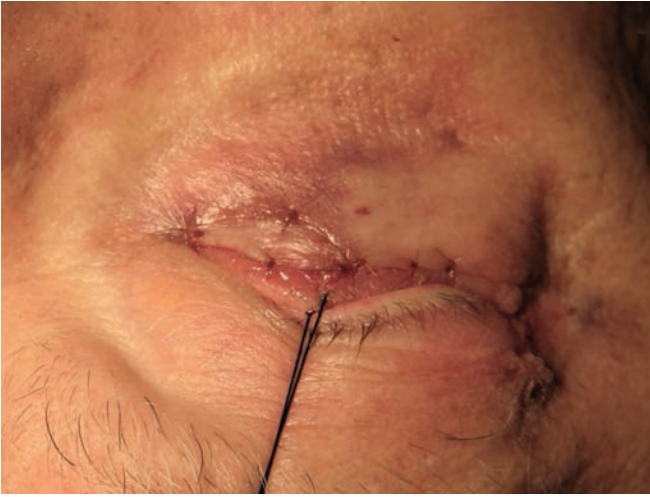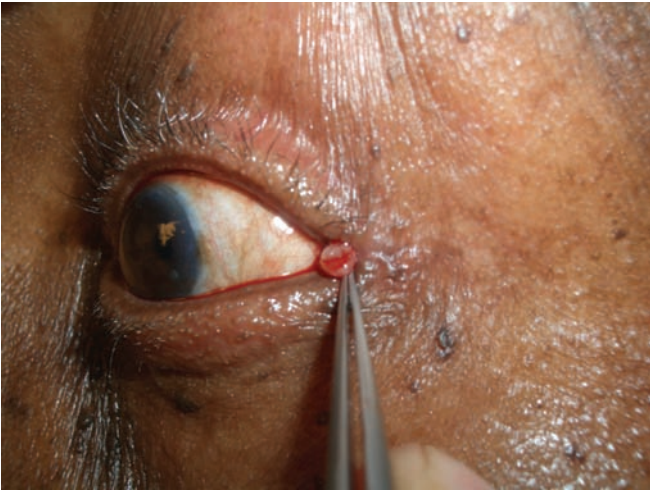




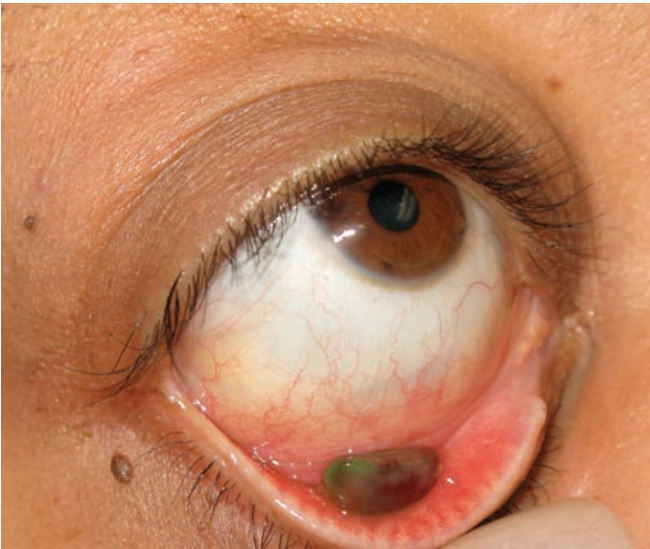
Figure 5.14 The skin graft is then sutured to the recipient site. The donor site may be closed with Indermil skin glue or sutures.

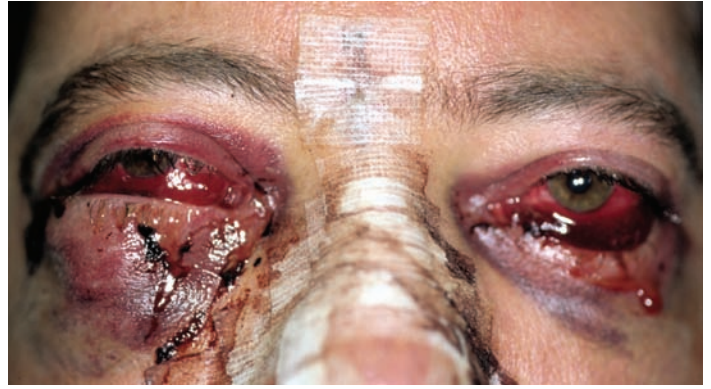

Figure 5.16 Severe bilateral orbital hemorrhage after rhinoplasty and lower eyelid blepharoplasty. Vision is decreased in the right eye due to a compressive optic neuropathy.

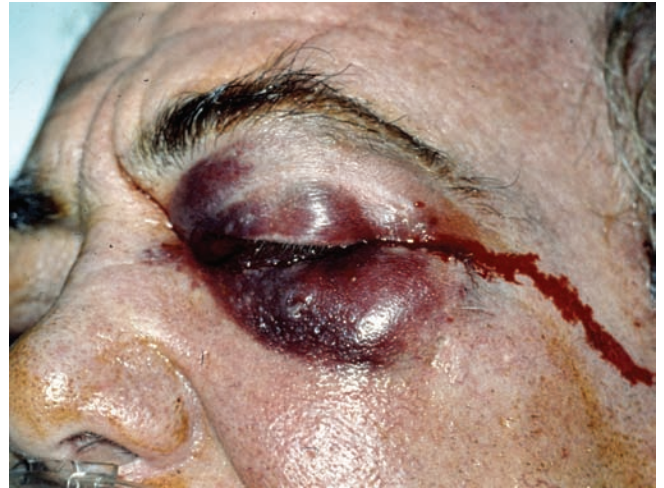

(A)

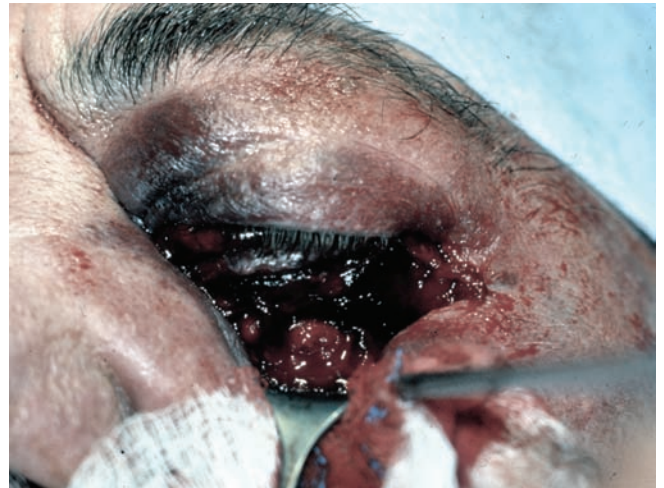

(B)

Figure 5.15 Pyogenic granulomas may occur at the lateral canthus (A) or lower eyelid incision site (B). These are easily removed with topical anesthetic (4% xylocaine) and excision with scissors.



(A)



(B)

Figure 5.17 Patient referred several hours after postoperative hemorrhage (A). Patient was taken directly to the operating room and the clot was evacuated (B).

immediate perioperative period. If treated promptly (Fig. 5.17B), optic nerve compression is relieved and vision recovers without a deficit. If ignored by either physician or patient, vision may be irreparably lost due to a compressive optic neuropathy. Hemorrhage can occur in any patient operated upon by any surgeon. It can be minimized by careful attention to hemostasis, utilizing bipolar cauterization, and assuring deep wound hemostasis before closure. Follow the procedures for fat removal in chap. 1 and you will minimize the chances of perioperative hemorrhage. This is so important that it bears repeating.

Severe orbital hemorrhage usually results from inadequate or incomplete cauterization of blood vessels in the orbital fat that had been clamped, cauterized, and released back into the orbit. As with other complications, this is best treated by prevention. Treat the orbital fat in the following fashion and this complication will be very rare.

Expose all three orbital fat pads. Incise the lateral fat pad first using a hot cautery (Fig. 5.18A). Gentle pressure on the globe prolapses the orbital fat. Clamp the fat with a hemostat, excise the clamped fat with a scissor (Fig. 5.18B), and cauterize the clamped fat with bipolar cauterization. Release the hemostat while holding onto the fat with a pair of forceps (Fig. 5.18C).

Examine the fat for residual bleeding—if present, cauterize the offending vessel(s) (Fig. 5.18D). If not, release the stump of fat into the orbit. If bleeding later seems to occur, do not deny it, but gently press on the globe to expose the fat and cauterize the bleeding vessel with bipolar cautery. Do not conclude the procedure until you are certain that there is no bleeding from the orbital fat.

Check the patient in the recovery area prior to discharge. These hemorrhages almost invariably occur in the immediate postoperative period and are easily treated by opening the incision and draining the hemorrhage (Fig. 5.17A and B). Patients will complain of increased pain and decreased vision. The bleeding is usually obvious, an afferent pupillary defect is present, and increased orbital pressure is obvious (Figs. 5.16 and 5.17). Forget appearance, it can be addressed later. Open the wound and drain the hemorrhage (Fig. 5.17B) or perform a lateral canthotomy/cantholysis to relieve the orbital pressure and optic nerve compression. This prevents the visual loss. The eyelid can be repaired and revised at a later date. Delayed diagnosis and treatment causes blindness in these patients. This is actually an oculoplastic emergency and should be treated very expeditiously. These patients do not need immediate clotting studies, neuroimaging,

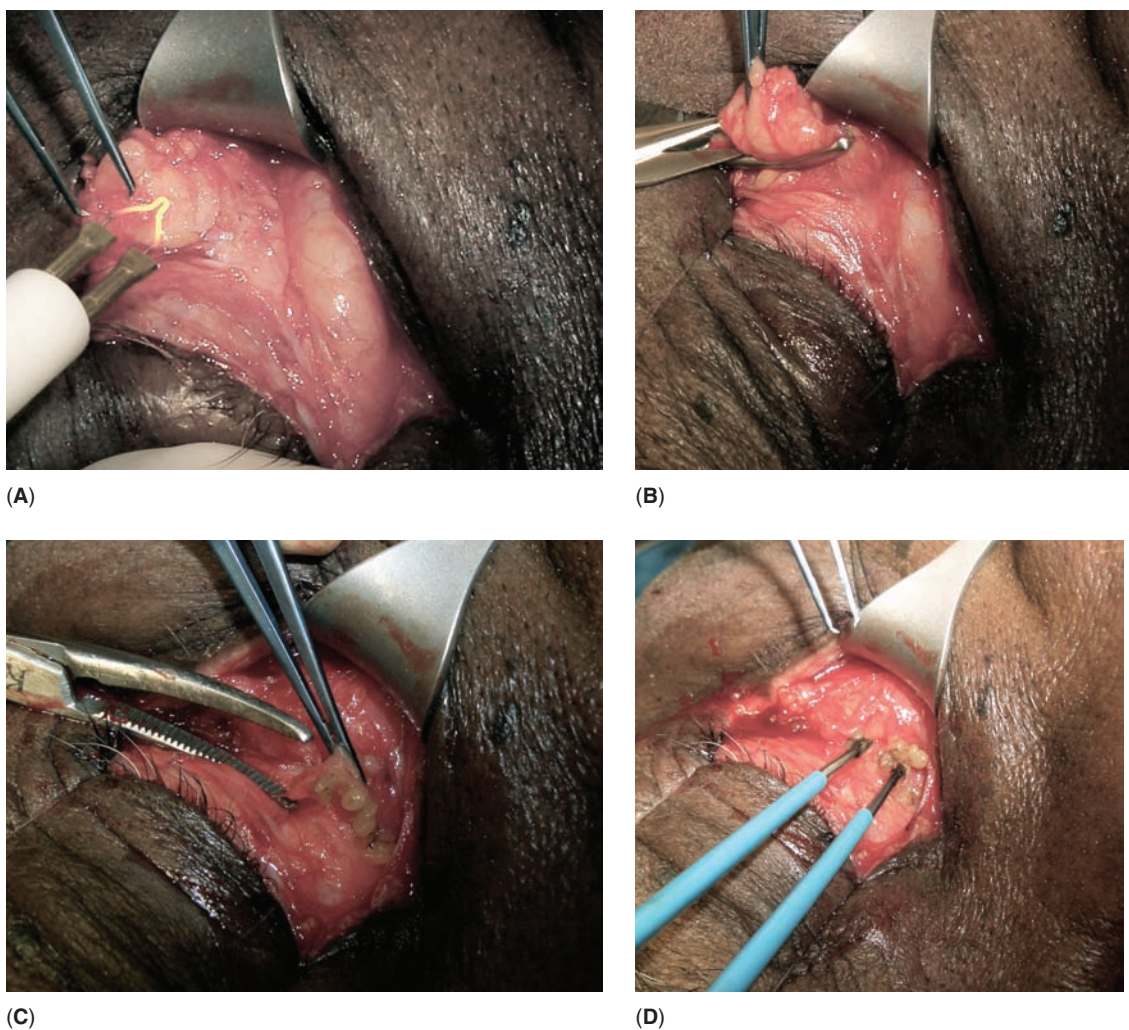
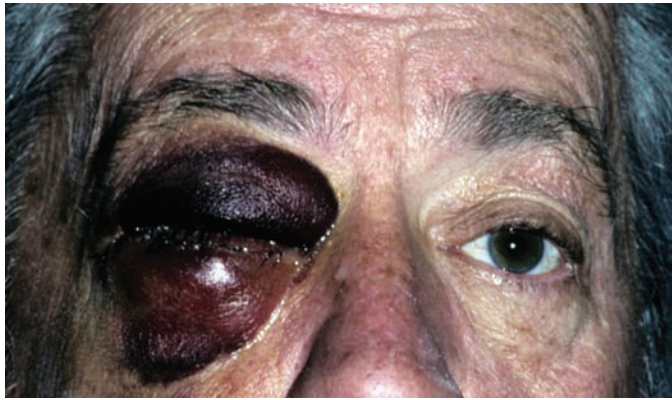
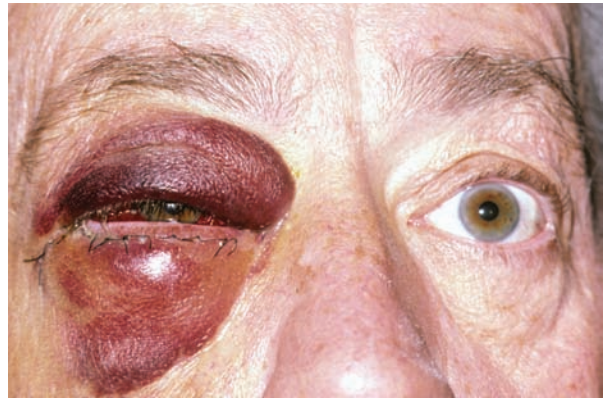
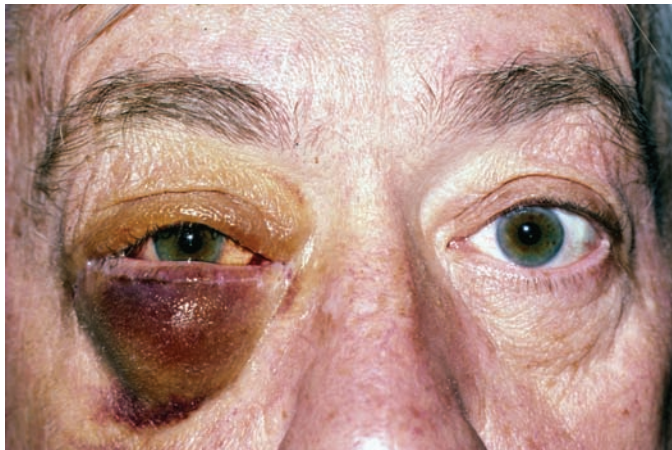Figure 5.18 Technique for fat pad hemostasis. Expose the fat pads by dissecting with hot cauterization (A). Clamp the protruding fat with a hemostat and excise it with scissors (B). Hold the fat with forceps while releasing the hemostat (C) and inspect it for residual bleeding. Cauterize with bipolar forceps (D).



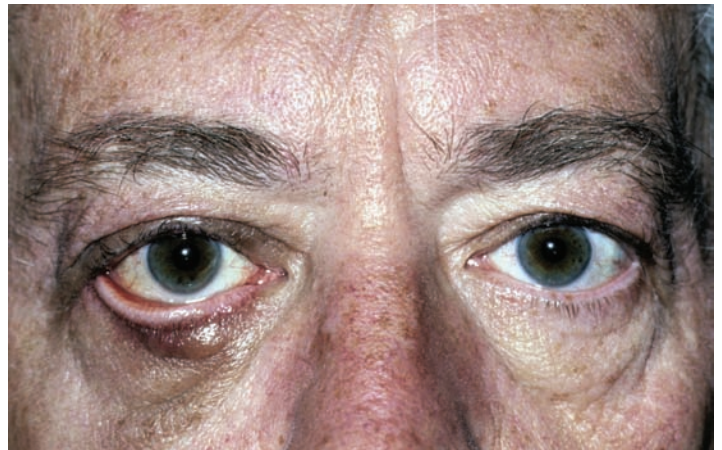(A)



(B)

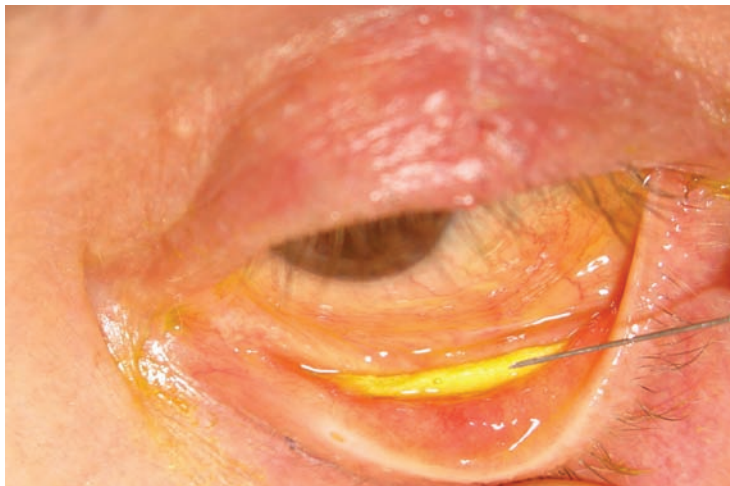

(C)

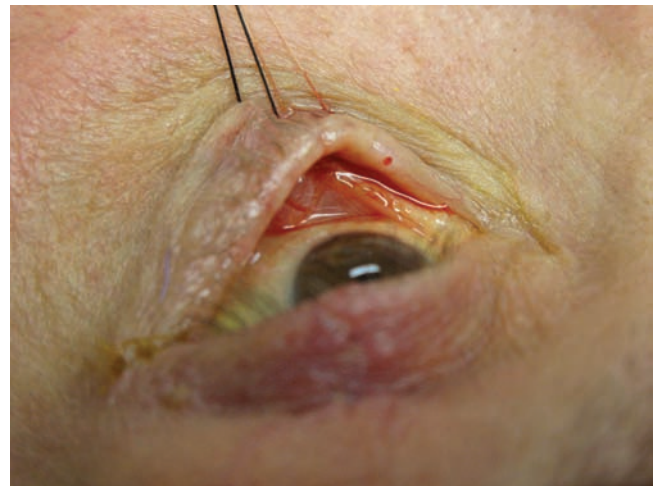

(D)

Figure 5.19 Severe hemorrhage occurring several days after lower eyelid surgery (A). There was no evidence for optic nerve compression (visual acuity normal and no relative afferent pupillary defect). Hemorrhage slowly resolved after several weeks (B, C) leaving a residual ectropion (D) that was later repaired with a tarsal strip procedure.

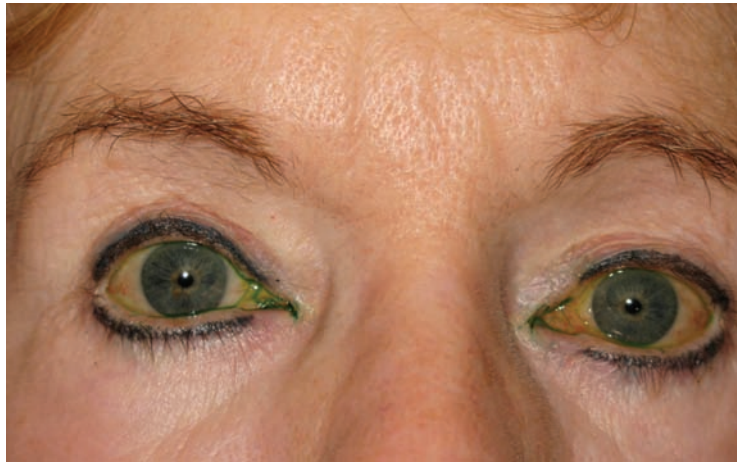

(A)

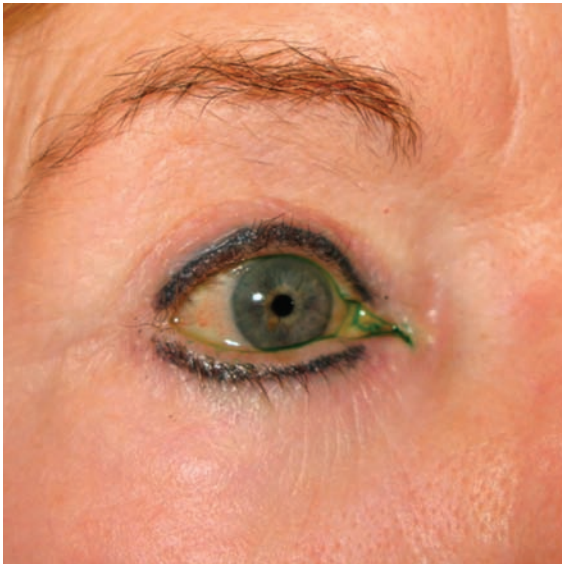


(B)

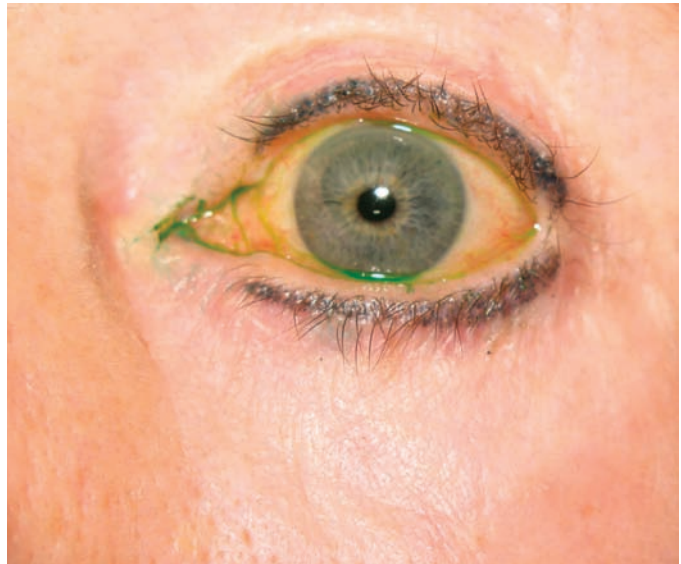
Figure 5.20 Extruding Enduragen implant one week after lower eyelid reconstruction (A). Patient complained of chronic foreign body sensation. The implant was covered by mobilizing a conjunctival flap and fixating it over the implant with a double-armed suture passed through conjunctiva and the eyelid (B).



(A)



(B)



(C)

Figure 5.21 Rounding of the lateral canthus is a common complication of external lower eyelid blepharoplasty (A–C).

or neuro-ophthalmology consultations. They need their wound opened, the hemorrhage drained, and optic nerve compression relieved.

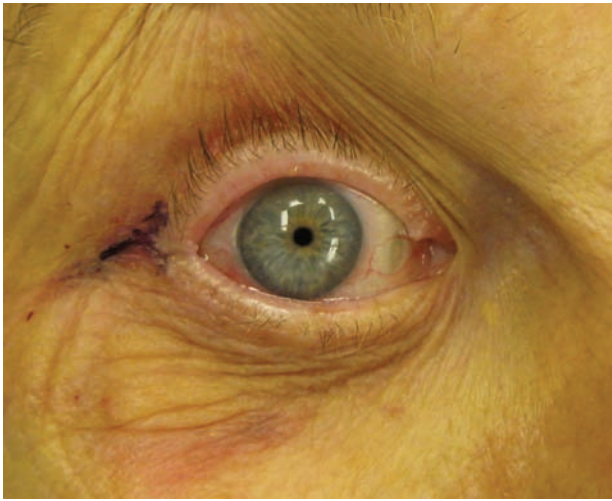
Hemorrhages may be severe (Fig. 5.19A) and occur several days after surgery. What do you do with severe hemorrhages that are not causing a compressive optic neuropathy? You may evaluate these patients for a clotting disorder. You will rarely find one, but when you do, it may be lifesaving, that is, severe thrombocytopenia. You may carefully watch the hemorrhage resolve, periodically checking the patient's visual function. Repair the resultant ectropion after the hemorrhage has completely resolved (Fig. 5.19B–D).

Hemorrhages may occur two to three weeks after surgery. The cause is often a bleeding vessel at the conjunctiva–eyelid suture interface. They may look terrible but it rarely causes visual dysfunction. Several patients have returned after surgery, complaining of intermittent bleeding from the operated eyelid. There was no obvious etiology or evidence for bleeding. The patient may return on several occasions with the same complaint. Just as you

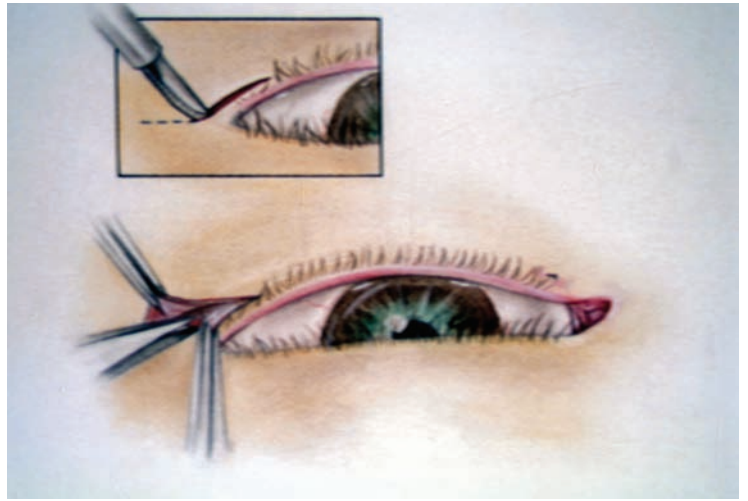
are convinced that they are crazy, they present you with a tissue full of blood convincing you that something is actually wrong. This bleeding is superficial and the offending vessel can often be cauterized in the office.

#### CORNEAL EROSIONS AND FOREIGN BODY SENSATION

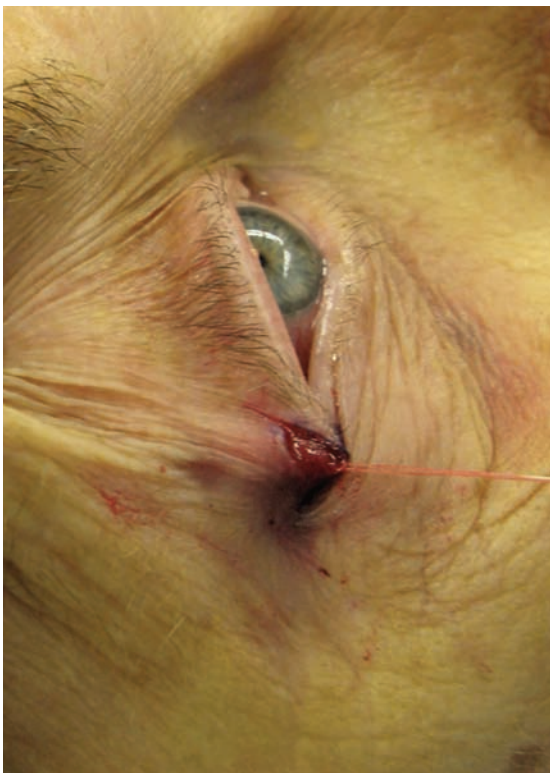
Some patients will complain of persistent ocular irritation after lower eyelid surgery especially in down gaze. Fluorescein staining will be evident on the inferior cornea, appearing much like the stain resulting from a foreign body under the upper eyelid. This results from the cornea rubbing against the suture ends or knots reattaching the conjunctiva to the eyelid. Removal of the offending sutures is curative. The cornea may also rub against an exposed implant on down gaze (Fig. 5.20A). Removing or covering the implant will resolve the erosions (Fig. 5.20B). They will not resolve with patching, bandage contact lenses, or wishful thinking. The offending agent must be removed or covered before significant, permanent, corneal damage occurs.



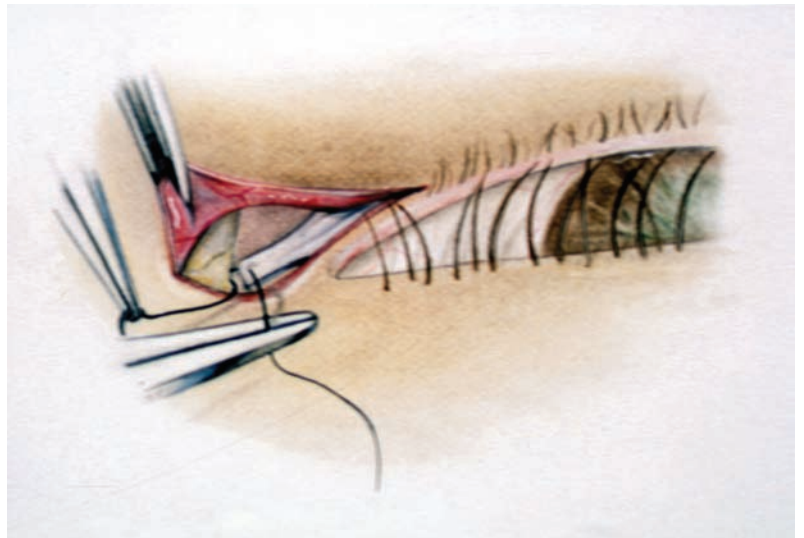
(A)



(B)

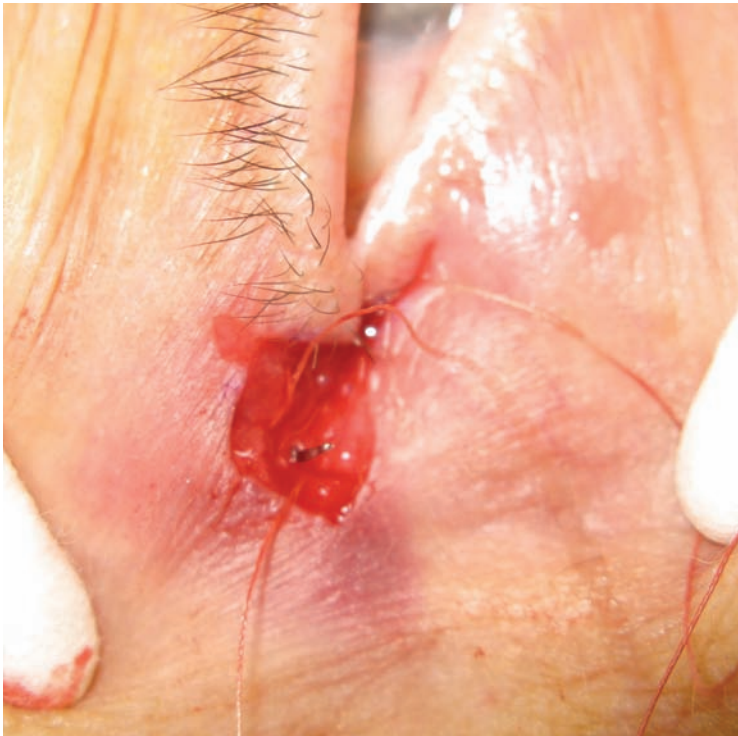

(C)

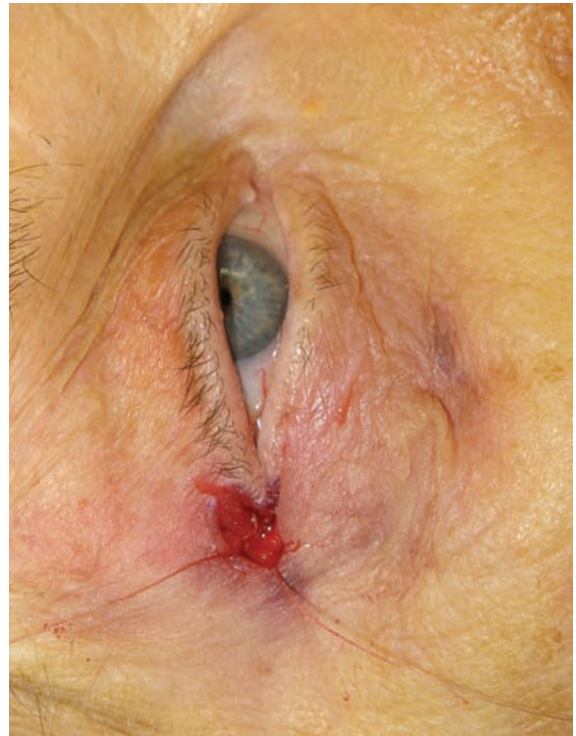

(D)

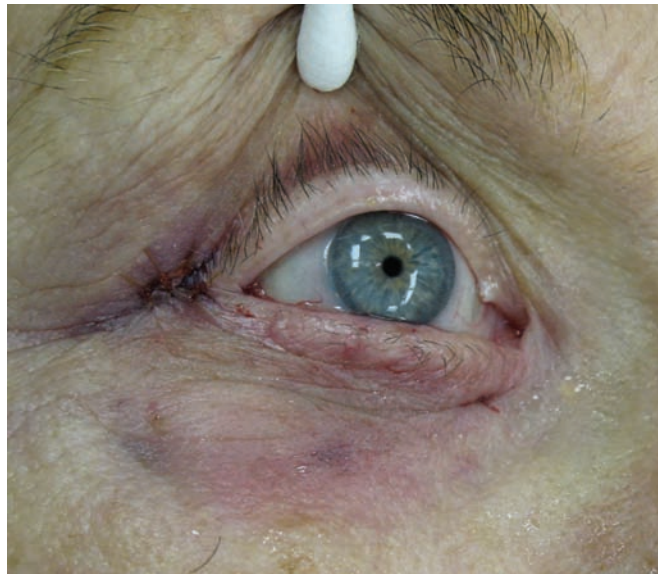
Figure 5.22 Technique of lateral canthal tendon plication: loss of the lateral canthal angle due to previous surgery (A). An incision is marked over the lateral canthal tendon (B). A skin flap is elevated and the lateral canthal tendon is isolated from the surrounding tissue. This usually requires a few snips with the scissors. A 5-0 Dexon suture is placed through the tendon with multiple, locking bites (C, D). (Continued)



(E)



(F)



(G)

Figure 5.22 (Continued) Both needles are passed through the lateral orbital wall at the level of the orbital tubercle (E). Tightening and tying the suture elongates the canthal angle (F), effectively treating the canthal rounding (G).

#### ROUNDING OF THE LATERAL CANTHUS (FIG. 5.21)

This is rarely if ever a problem after transconjunctival blepharoplasty. It is a common problem after an external blepharoplasty due to cicatrizing forces of the healing skin-muscle flap. There may be an obvious lateral ectropion (Fig. 5.10) or subtle loss of the lateral canthal angle (Fig. 5.22A). Avoid this complication by tightening the canthus with a lateral canthal tendon plication. Repair this complication by performing a common canthal tendon plication.

Make an incision just lateral to the lateral canthus, as marked on Figure 5.22B. Dissect the skin overlying the lateral canthal

tendon from it with sharp scissors. Identify the common canthal tendon and dissect it free from the surrounding tissue. Place a 5-0 Dexon™ or polypropylene suture through the tendon with several locking bites (Figs. 5.22C and D).

Pass both arms of the suture through the lateral orbital wall at the level of the lateral orbital tubercle (Fig. 5.22E) (see section “Tarsal Strip Procedures” in chap. 1). Tightening the suture elongates the lateral canthus and obviates the rounding (Fig. 5.22F and G). This is a quick and simple to perform procedure that may be done in the office if necessary.

## 6 Upper Eyelid Surgery

### ANATOMY

There are seven distinct layers in the upper eyelid: skin, orbicularis oculi muscle, orbital septum, preaponeurotic fat pads, levator aponeurosis or levator muscle, Mueller's muscle, and conjunctiva (Fig. 6.1). There are also several key facts that simplify and facilitate upper eyelid surgery. Knowledge of these allows you to avoid most complications and potential problems in upper eyelid surgery.

The orbital septum separates the preseptal orbit from the post-septal orbit and is firmly attached to the superior orbital rim at the arcus marginalis (Fig. 6.2). Tugging on this structure while palpating it at the arcus marginalis clearly differentiates orbital septum from levator aponeurosis. The septum is clearly attached to the orbital rim (arcus marginalis). The levator muscle is clearly not. If the eyelid is inadvertently suspended from the orbital septum, the eye will not close. Pulling and palpating the suspect tissue easily detect this.

Preaponeurotic fat pads are *always* anterior to the levator aponeurosis and deep to the orbital septum (Fig. 6.3). This allows differentiation between levator aponeurosis and orbital septum even in eyelids having undergone multiple surgical procedures or extensive trauma. If you forget to pull and palpate, this stable relationship gives you another chance to correctly differentiate the two structures.

Occasionally, a levator muscle may be so infiltrated with fat that this distinction is obfuscated (Fig. 6.4), but with a bit of diligence you can differentiate the true preaponeurotic fat from a fatty infiltrated levator muscle (Fig. 6.4). Also, remember that a patient with significant fatty infiltration of the levator muscle will probably have decreased levator function detected *prior* to surgery.

The lacrimal gland lies posterior to the lateral preaponeurotic fat pad (Fig. 6.5) and is easily distinguished from it. The preaponeurotic fat is yellow and relatively avascular (Fig. 6.6). The lacrimal gland is pink to white and bleeds profusely when incised (Fig. 6.6). This distinction should be evident prior to excision.

The medial fat pad causes the bulging mass in the medial upper eyelid when it is not removed during upper eyelid surgery (Fig. 6.7); I refer to it as the equal opportunity fat pad for if it is not removed, patients will complain about the bump in their eyelid regardless of their station in life. It is often not removed for a number of reasons. First, it may be surrounded by relatively large blood vessels that bleed and retract into the orbit when incised. Second, although easy to distinguish, if you remember that the medial fat pad contains more fibrous tissue than the other fat pads and hence has a much whiter color, many surgeons fail to do this for the fear of bleeding. The medial fat pad may be treated with relative impunity if you remember the following suggestions. Identify the medial fat pad by pressing on the globe and expressing it from the deeper orbit (Fig. 6.8).

The white color should distinguish it from the yellow preaponeurotic fat (Fig. 6.8). If there are blood vessels overlying the fat pad capsule, coagulate them with bipolar cauterization. As the

assistant applies gentle pressure to the globe, incise the medial fat pad capsule with the hot Ocutemp™ cauterizer. The white orbital fat will egress from the capsule and may be clamped, cauterized, inspected, and released (Fig. 6.9) without causing excessive bleeding. Only clamp, cauterize, and remove the medial fat pad that egresses from the capsule. Do not aggressively pull on the fat or reach into the orbit in an effort to remove excessive fat. The superior oblique tendon and trochlea lie deep in the fat pad, and although difficult to damage, when damage occurs it results in a very unhappy patient with diplopia that may be very difficult to treat. You should not see the tendon, the muscle, or the trochlea when removing the medial fat pad. If you do, you are too deep in the orbit for eyelid surgery.

One final comment: once you incise and penetrate the orbital septum in either the upper eyelid or the lower eyelid, you are now performing orbital surgery with all of its potential complications (blindness, hemorrhage, diplopia, etc.). Treat the orbital fat and deeper orbital structures with respect, avoid and manage bleeding utilizing bipolar cauterization and moist cottonoids. Make sure that the bleeding is controlled before closure. Utilize hemostatic agents like thrombin/fibrin sealant (Evicel™) to ensure complete hemostasis.

### PATIENT SELECTION

Many flow sheets, algorithms, and other words of alleged wisdom have been used to describe the preoperative evaluation of the ptosis patient. Much of this is redundant and a make-work exercise.

Preoperative evaluation prior to upper eyelid surgery should include assessment of levator function—is it present or absent and to what degree? Detection of clinically significant dry eye or ocular surface abnormalities including a history of refractive or intraocular surgery, presence or absence of Bell's phenomenon, and an informed patient with realistic expectations are important bits of preoperative information.

Evaluate the position of the lower eyelids. Are they retracted (Fig. 6.10A)? and need to be elevated (Fig. 6.10B). Will elevating the upper eyelids increase tear evaporation to such an extent that the dry eye will decompensate or the inferior cornea will erode? Any lissamine green staining on the cornea (Fig. 6.11) is diagnostic of exposure keratopathy or severe dry eye and is a harbinger of potential danger after elevating the upper eyelids. Schirmer testing is subjective, variable, time consuming, and often inaccurate. You can obtain all the necessary information about the condition of the ocular surface in 10 seconds of observation after lissamine green staining. Lissamine green staining will detect and differentiate mild (scattered stippling), moderate (conjunctival staining), or severe dry eye (corneal and conjunctival staining) (Fig. 6.11). It will also reveal subtle punctal ectropion, floppy eyelids, and conjunctivochalasia. After reviewing the record for medicolegal issues, the only preoperative clue that the patient in Figure 6.12 would have devastating visual loss due to a refractory keratopathy was the evidence for inferior punctate keratopathy.

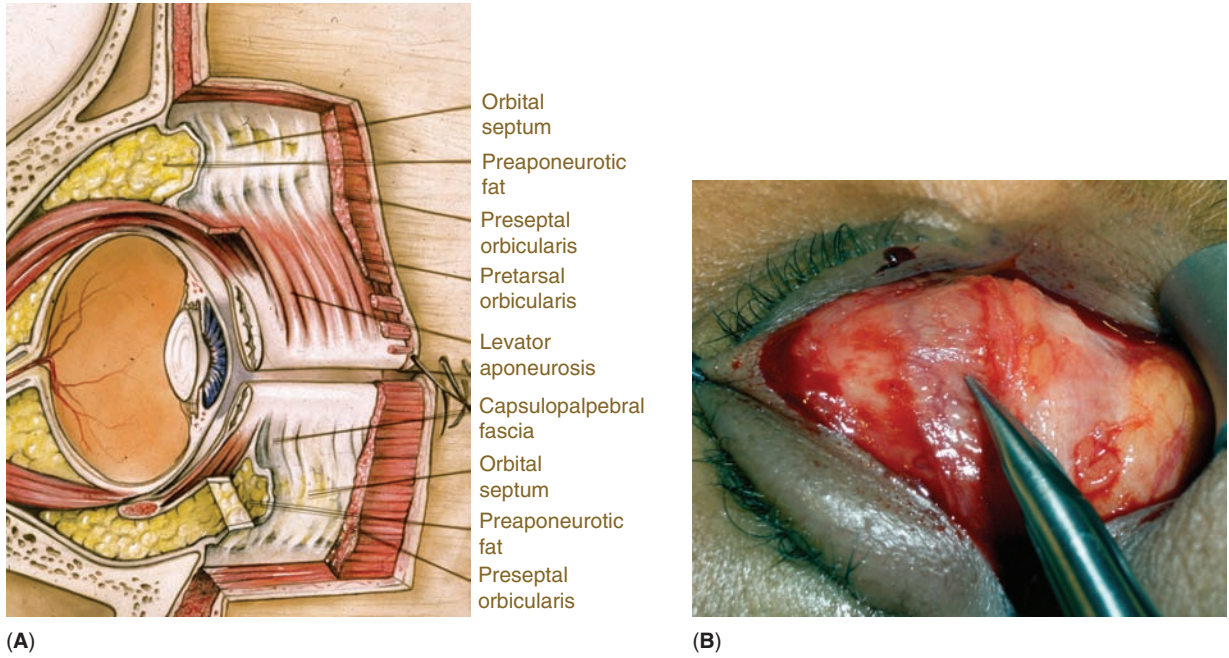


Figure 6.1 The multiple layers of the upper eyelid (A). Surgical view of upper eyelid anatomy (B). Scissor blades demonstrate the area of levator aponeurosis dehiscence, conjunctiva, and Mueller’s muscle. The preaponeurotic fat pad lies superficial to the dehisced levator aponeurosis.

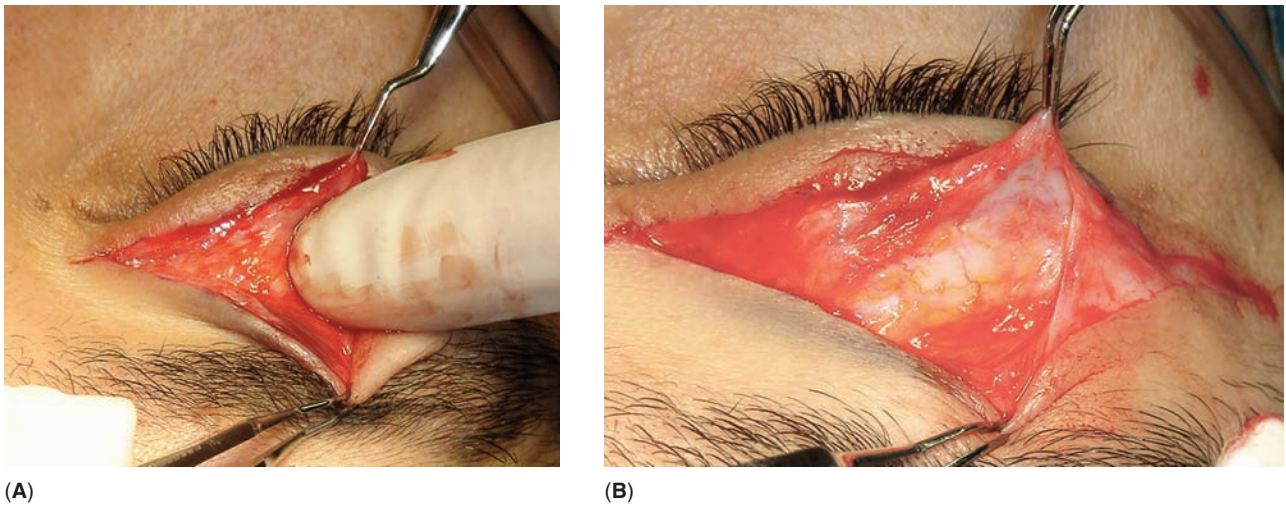


Figure 6.2 The orbital septum is firmly attached to the superior orbital rim (arcus marginalis). You can appreciate this by pulling on the orbital septum and feeling the attachment with your finger (A). This maneuver is especially useful in differentiating levator aponeurosis from orbital septum in previously operated, scarred eyelids. The orbital septum has been incised, preaponeurotic fat is visible between the levator aponeurosis and the more superficial orbital septum (B).

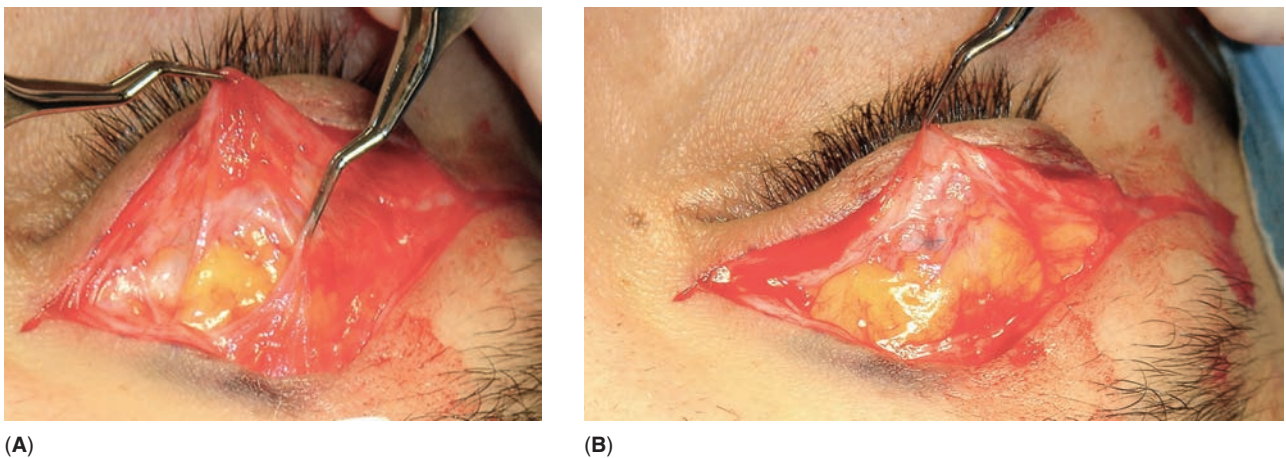


Figure 6.3 Preaponeurotic fat lies superficial to the levator aponeurosis (A, B). Note the suture in the previously operated levator aponeurosis (B).



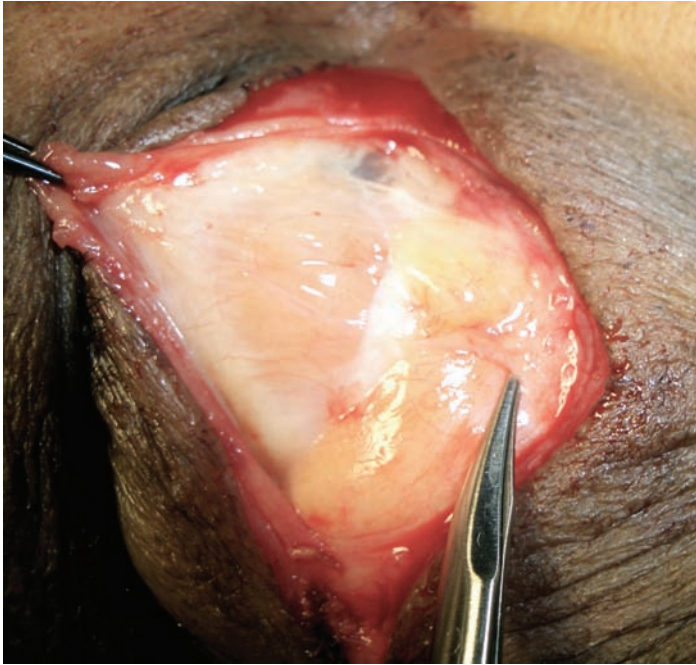


Figure 6.4 A fatty infiltrated levator muscle must be differentiated from the preaponeurotic fat pad (scissor tips).

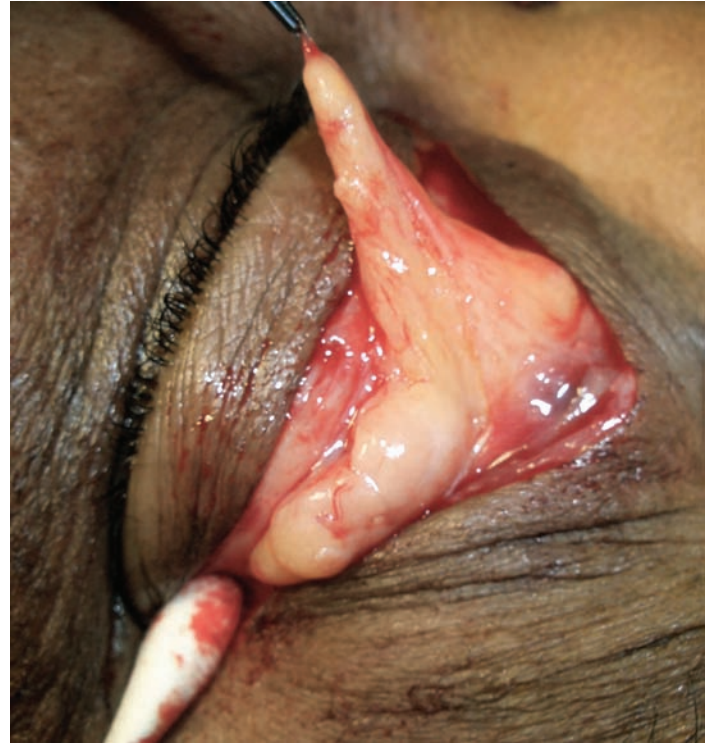

Figure 6.5 A prolapsed lacrimal gland lies posterior and lateral to the preaponeurotic fat pad (forceps elevate fat, applicator tip points to the lacrimal gland).

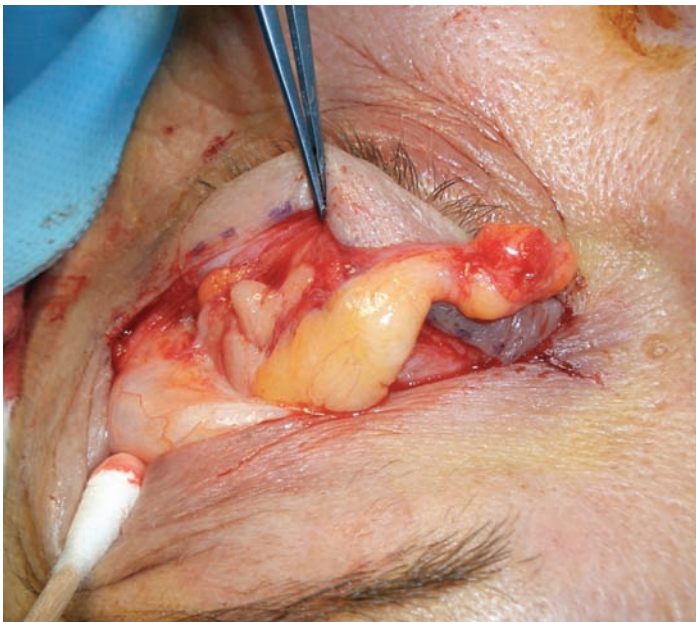


Figure 6.6 Relationship between the preaponeurotic fat pad (yellow), the prolapsed lacrimal gland (white), and the superior orbital rim (beneath applicator).

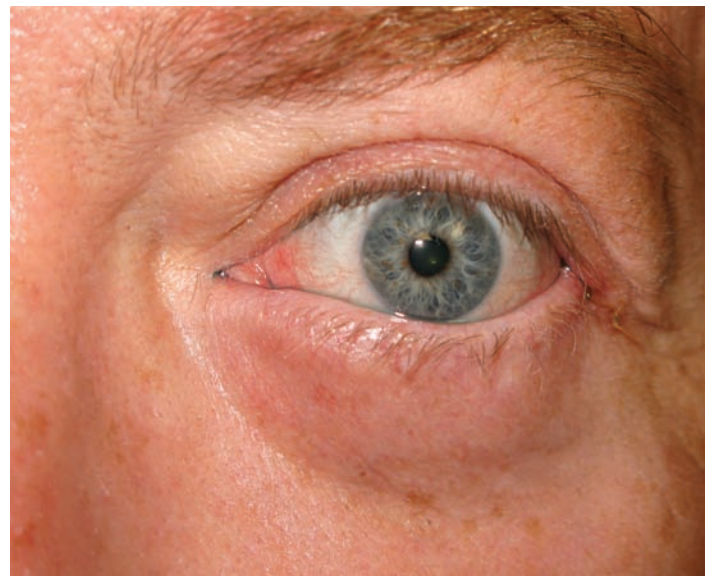


Figure 6.7 Medial orbital fat pad appears as a mass in the nasal portion of the upper eyelid.

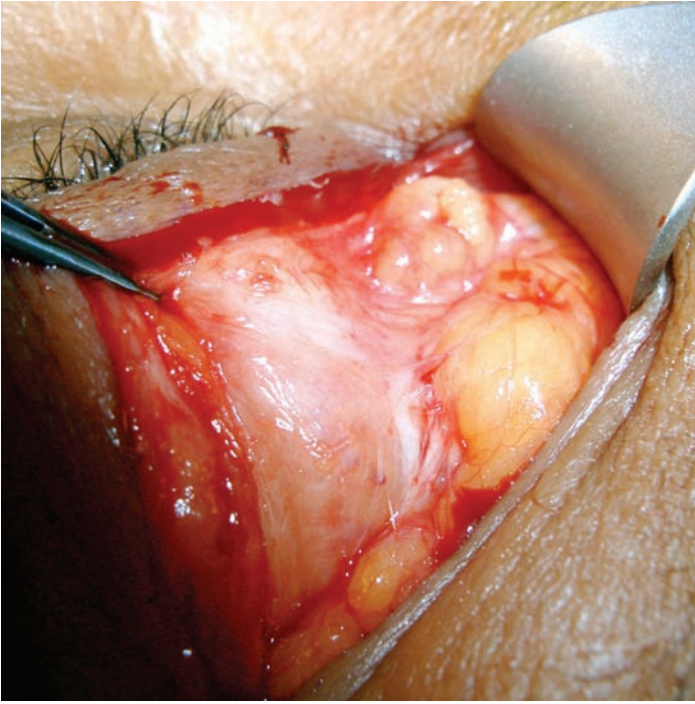


Figure 6.8 Gentle pressure on the globe prolapses the medial fat pad.

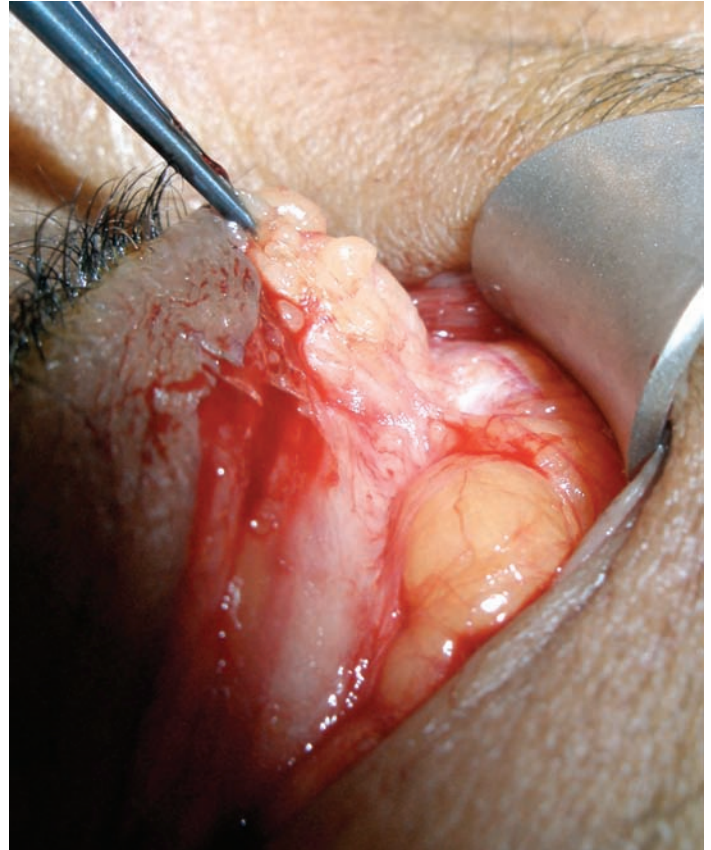
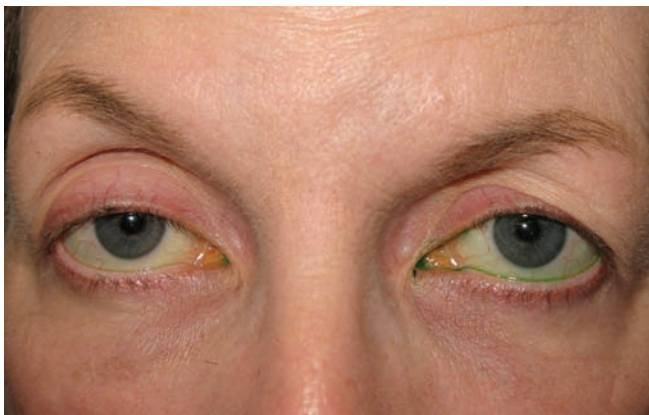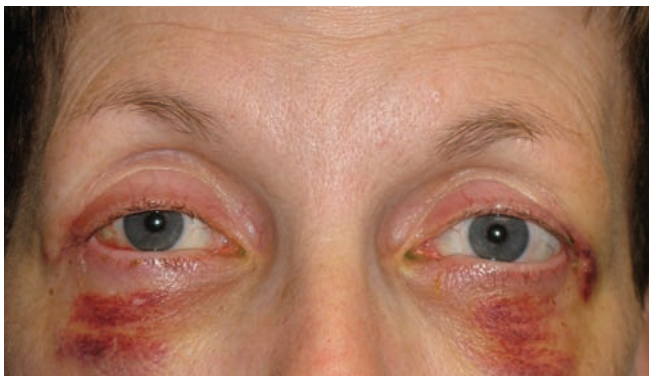


Figure 6.9 The medial fat pad is whiter and is readily distinguished from the yellow preaponeurotic fat pad.



(A)



(B)

Figure 6.10 Retraction of the lower eyelids should be recognized and repaired before elevating the upper eyelids (A). Failure to do so may result in exposure keratopathy after surgery. Appearance of lower eyelids immediately after reconstruction with Enduragen™ grafts (B).

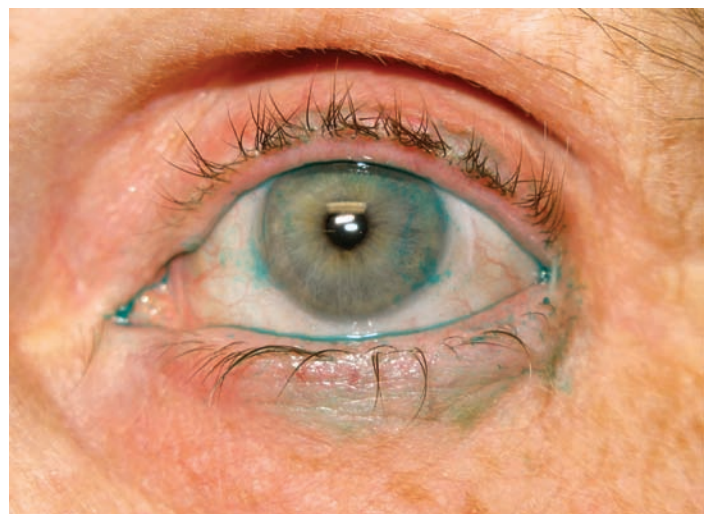


Figure 6.11 Lissamine green stains devitalized (dry) tissue. This stippled staining of the conjunctiva and cornea is diagnostic of severe dry eye.

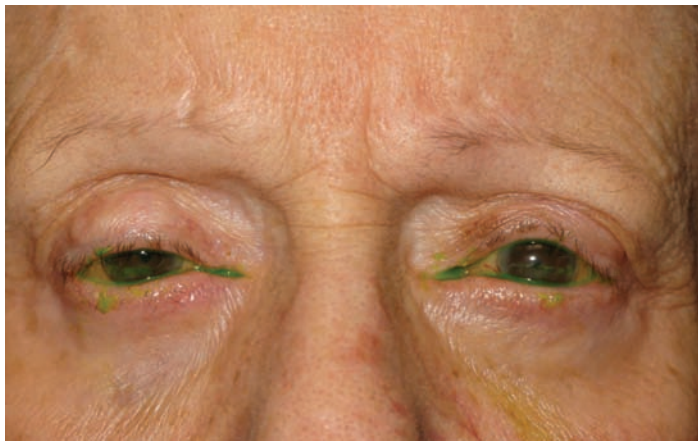

Figure 6.12 Inferior punctate keratopathy noted before surgery was the only indication that this patient would suffer severe keratopathy after ptosis surgery in spite of multiple reconstructive procedures.

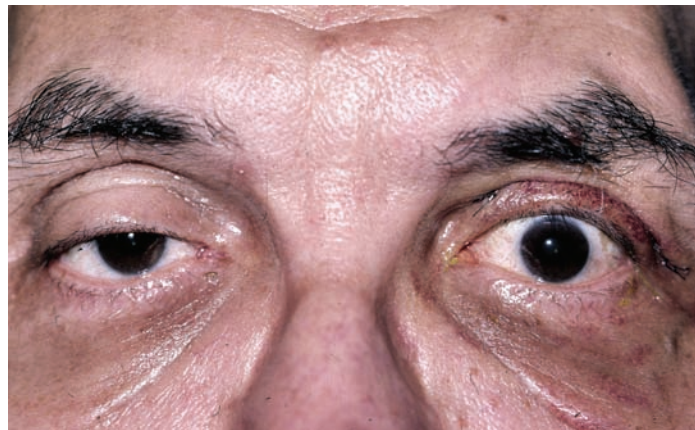

Figure 6.13 Herring's law of equal innervation. One central caudate nucleus innervates both levator muscles. The degree of ptosis or upper eyelid retraction will vary depending upon with which eye the patient is fixating.

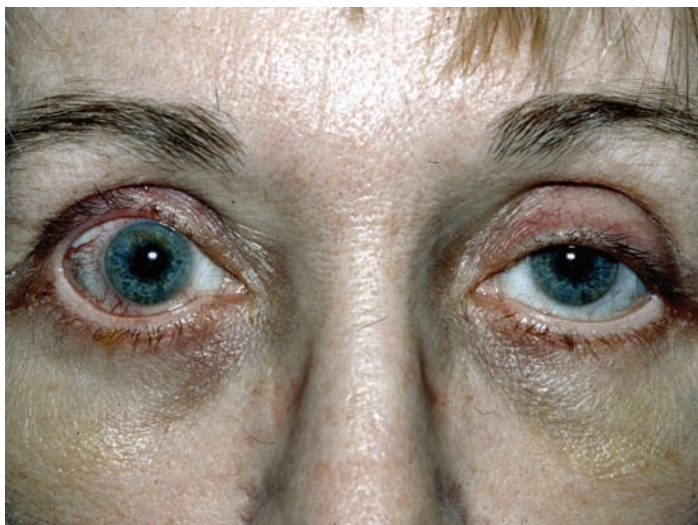

Figure 6.14 Ptosis of the left upper eyelid due to inadvertent levator dehiscence during blepharoplasty. There is variable retraction of the right upper eyelid due to Herring's law.

It is also necessary to consider the diagnosis of ocular myasthenia gravis, do a complete eye examination including dilated fundus exam. Undiagnosed retinal detachment or ischemic optic neuropathy is an unpleasant reminder that all superior visual field defects are not caused by ptosis and dermatochalasia.

#### HERRING'S LAW

No discussion of upper eyelid surgery is complete without mentioning Herring's law of reciprocal innervations. The control of both levator muscles by the central caudate nucleus is what differentiates the oculoplastic surgeon skilled in levator surgery from all the other occasional upper eyelid surgeons. This is what makes matching eyelid height and contour a challenge and more of an art than a science.

Both levator muscles receive equal innervations from the central caudate nucleus. The patient in Figure 6.13 has ptosis of the right upper eyelid. If the patient fixates with the right (ptotic)

eye, the central caudate nucleus will over react, minimizing the right upper lid ptosis and producing or exacerbating retraction of the left upper eyelid. Fixation with the left eye produces the opposite effect. It takes less neural energy to elevate the normal left upper eyelid, therefore the levator muscle in the right upper eyelid receives less neural input and the ptosis worsens. This is especially perplexing when a patient has an unexpected result after upper eyelid surgery (Fig. 6.14). The patient in Figure 6.14 was referred after an upper eyelid blepharoplasty. The patient had an inadvertent dehiscence of the levator aponeurosis and subsequent ptosis of the left upper eyelid. Note that the right upper eyelid appears retracted. It will lower (by Herring's law) when the left eyelid is elevated and really does not need intervention.

#### PTOSIS SURGERY

Our preferred procedure for repairing acquired ptosis with any levator muscle function is a variation on the theme of levator aponeurosis advancement. This is based on the concept of aponeurotic ptosis repair as popularized by Anderson. The levator aponeurosis may be advanced or the muscle resected and advanced depending on the degree of levator muscle function. We always use an external (transcutaneous) approach to upper eyelid surgery. This allows positive identification of the levator aponeurosis and muscle, visualization, and a graded removal of the preaponeurotic fat pads—especially the sometimes-elusive medial fat pad and skin removal at the conclusion of the procedure that entirely obviates removal of excessive eyelid skin with resultant difficulties with eyelid closure and lagophthalmos. This technique allows you to perform a functional and elegant ptosis repair and blepharoplasty. There are few patients whose cosmetic upper eyelid surgery would not be enhanced by advancing or recessing the levator aponeurosis. Levator aponeurosis advancement is usually necessary to optimize functional and cosmetic results in the senior population.

#### Technique

In adults, all upper eyelid surgery is performed under local, infiltrative anesthetic with or without intravenous sedation. I will not

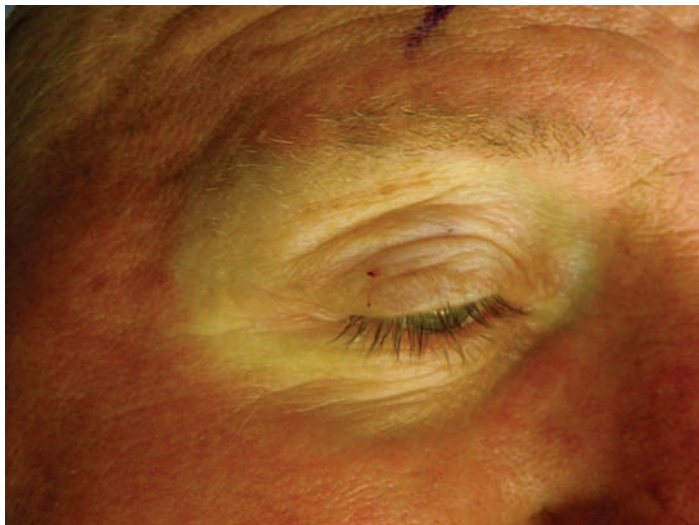


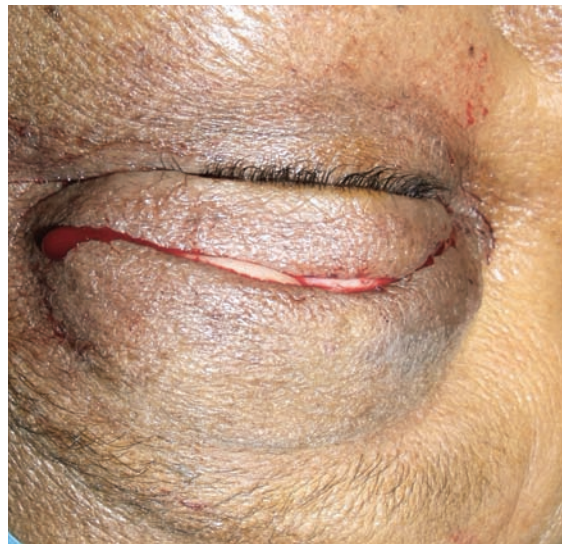Figure 6.15 Exceptional vasoconstriction occurs 15 to 20 minutes after injecting an epinephrine-containing anesthetic into the operative site. The resulting hemostasis facilitates the procedure.

perform ptosis surgery on a sane adult under general anesthetic. This surgery is humbling enough with full patient cooperation and in most hands quite unpredictable in the totally anesthetized patient. I ask those who insist upon general anesthetic, after this has been explained to them, to seek their care elsewhere.

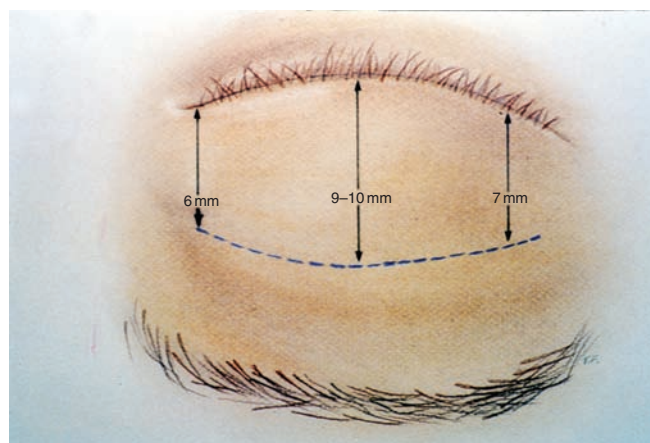
Local anesthetic with epinephrine is used in all eyelid surgery. The eyelids are too vascular to operate upon without the hemostatic effect of vasoconstriction caused by the epinephrine. The resultant bleeding may result in a less than pleasing surgical result. Infiltrative anesthetic is injected into the eyelid, usually in the preoperative holding area, 10 to 15 minutes before incision. It takes time for the epinephrine to cause vasoconstriction (Fig. 6.15). The vasoconstrictive effect lasts only 20 to 30 minutes, so the surgical procedure should be timed accordingly and more anesthetic with vasoconstrictor is administered if and when necessary, but not until the levator aponeurosis has been advanced and the final eyelid height and contour is determined. Injection of additional anesthetic during surgery may result in partial or total paralysis of the levator muscle and makes subsequent adjustment of the eyelid height and contour guesswork at best.

Outline an eyelid crease incision with a marking pen. If the natural eyelid crease is present, it is incised. If there is no discernable eyelid crease, make one measuring 10 mm from the lash line centrally, 6 mm medially, and 7 mm laterally (Fig. 6.16B). Make a skin incision with a sharp blade (Fig. 6.16A). Use scissors to dissect to the tarsus. Enlarge the incision along the entire horizontal length of the eyelid in the relatively avascular tarsal plane. A thin strip of preseptal orbicularis muscle is excised (Fig. 6.17), exposing the dehisced levator aponeurosis and the overlying preaponeurotic fat pads (Fig. 6.18A).

The levator aponeurosis/muscle is separated from the orbital septum and preaponeurotic fat pads (Fig. 6.18B) and advanced over tarsus with a double-armed 5-0 suture. This may be absorbable or permanent at your discretion. After spending years removing permanent sutures from upper eyelids, I now prefer to use an



(A)



(B)

Figure 6.16 An incision is made in the eyelid crease with a sharp blade (A). If there is no crease, one can be outlined as described in (B).

absorbable suture to advance the levator aponeurosis. Take your pick. The suture is placed in the tarsus, taking care to avoid passing it full thickness (Fig. 6.19A and B). Invert the eyelid to ensure that you have not passed the suture through it. This will avoid a potential suture keratopathy (Fig. 6.20). Both arms of the suture are passed through the levator muscle advancing it over tarsus (Fig. 6.21). The suture is tied (Fig. 6.22) with a single knot and the patient is raised to the sitting position. The eyelid height and contour is observed and the suture is adjusted accordingly (Fig. 6.23A–C). The central suture controls the height of the eyelid. You may alter the contour of the eyelid by placing a suture nasal or temporal to the central suture. In most patients, this is not necessary if the central suture is placed about 14 mm from the upper punctum (Fig. 6.23D) or at the nasal end of a dehisced tarsus. If it does not look right at the time of surgery, it is not going to improve with time. What you see is what you get. Adjust the eyelid height and contour until you are pleased with the appearance, then tie the suture with three or four knots.

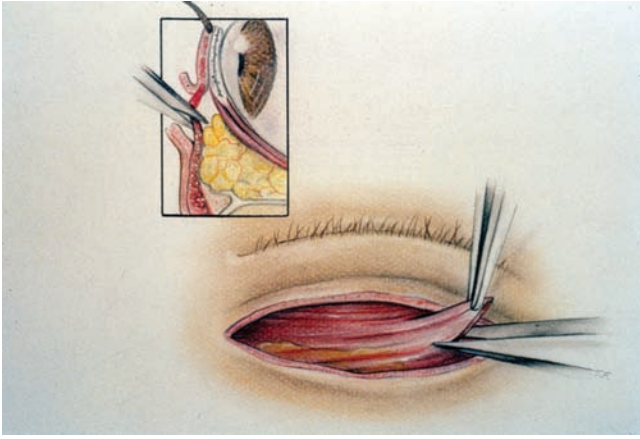
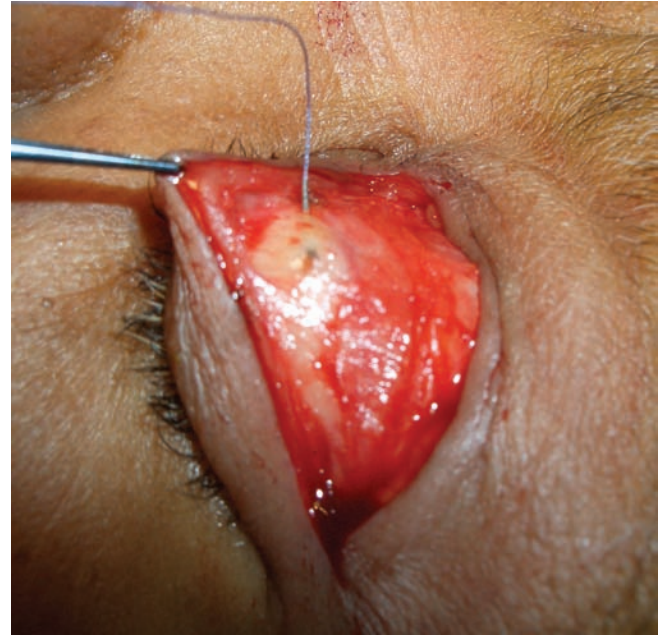
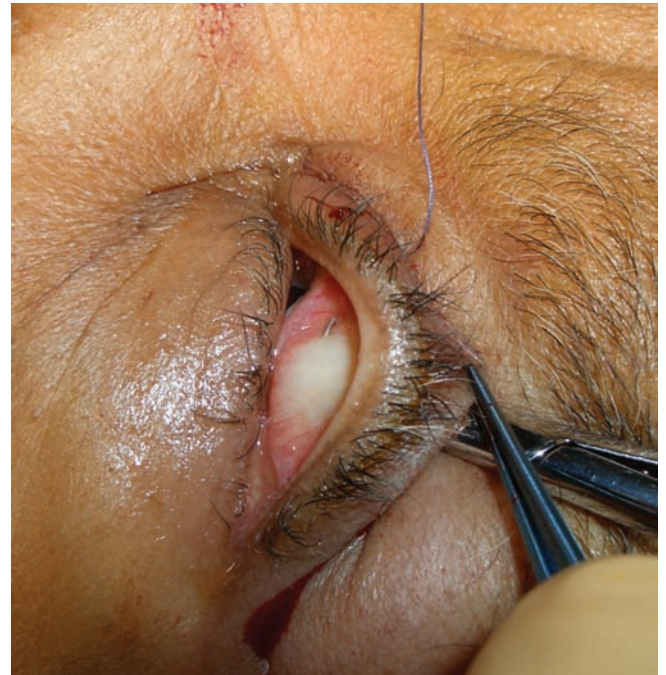

Figure 6.17 Excision of a thin strip of pretarsal and preseptal orbicularis muscle exposes the dehisced levator aponeurosis.

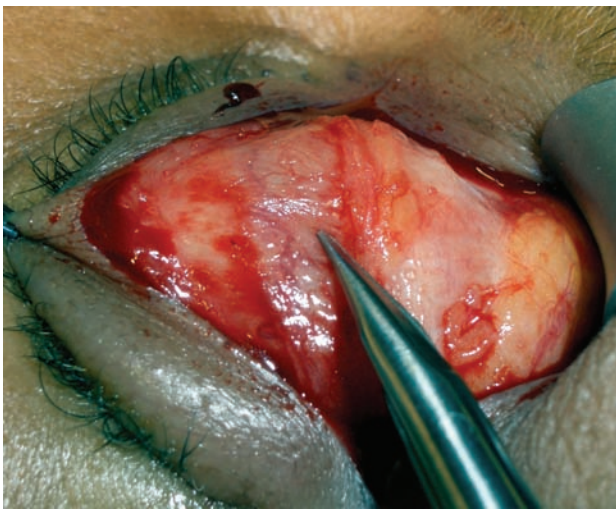


(A)

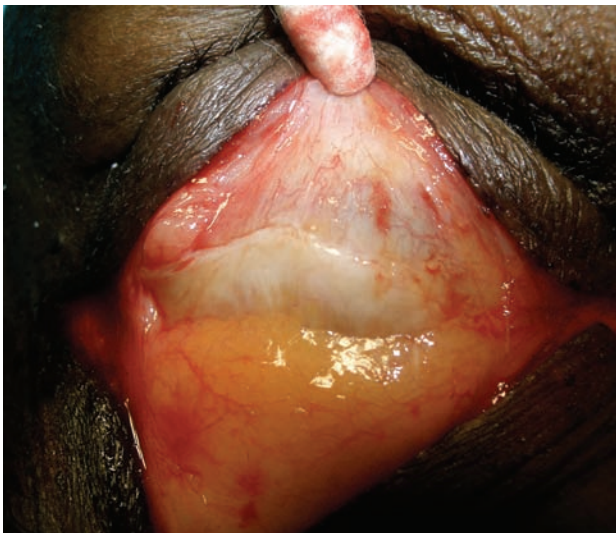

(B)

Figure 6.19 A suture passed through the tarsus (A) inverting the eyelid demonstrates full thickness passage (B) that would result in a severe suture keratopathy. When passing the needle in tarsus, elevate the eyelid from the globe. This will eliminate the possibility of injury to the eye. Inverting the eyelid will allow you to detect penetration and avoid suture keratopathies (B).



(A)



(B)

Figure 6.18 Scissors point to the conjunctiva and Mueller's muscle at the site of dehiscence. To the right of the scissors the levator aponeurosis and the overlying preaponeurotic fat pad are visible. To the left is the exposed tarsus (A). Surgeon's view showing the relationship between the site of dehiscence, levator aponeurosis, and the preaponeurotic fat pad (B).

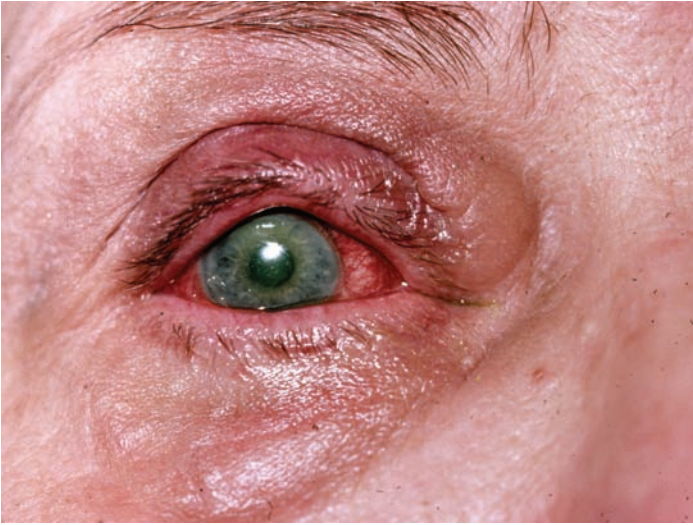

Figure 6.20 Suture keratopathy as a result of erosion of a suture through tarsus.

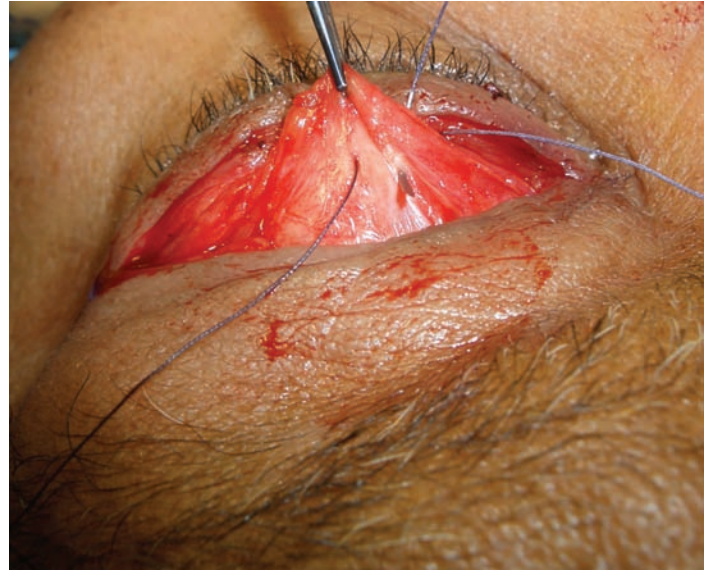

Figure 6.21 Both needles of a double-armed suture are passed through the levator aponeurosis.

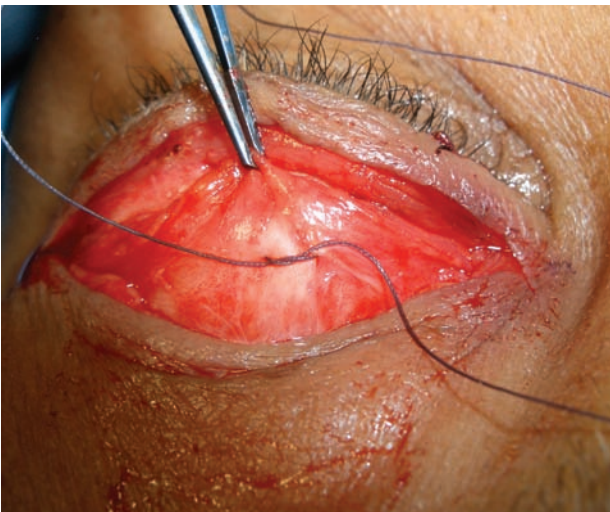
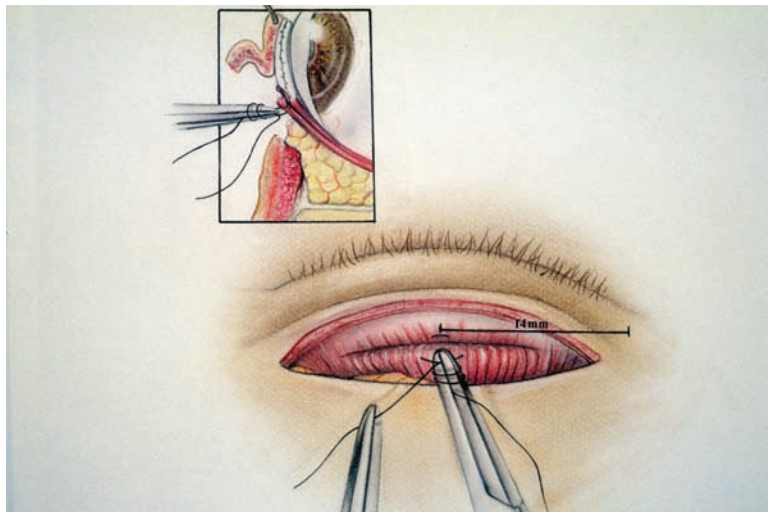


Figure 6.22 Suture is tied with a slip knot.



### Removal of Fat Pads

The preaponeurotic fat pads (Fig. 6.24A and B) may be removed or sculpted by cauterization (Fig. 6.24C). If you use a hot Ocutemp cauterization, discontinue the supplemental nasal oxygen to avoid a potentially devastating flash fire over the patient's face.

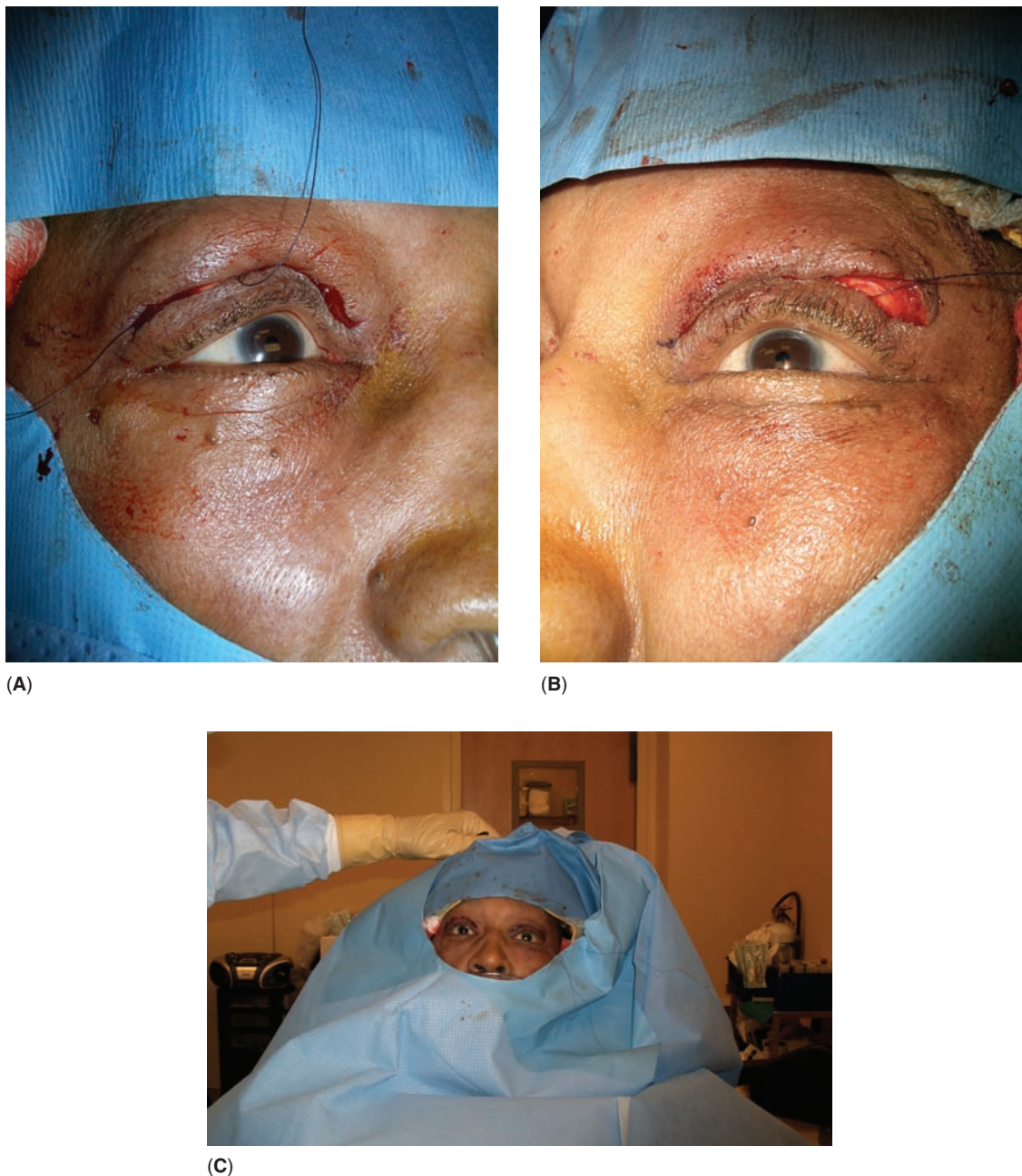The medial fat pad appears whiter than the preaponeurotic fat pads (Fig. 6.25), and if you partially remove it, you will avoid an unsightly appearing mass in the nasal eyelid that patients invariably notice. This fat pad is often surrounded by blood vessels. These should be cauterized with a bipolar cautery during dissection. The fat pad capsule is incised with hot cauterization and the protruding fat is clamped and cauterized. The stump of the fat pad is held with forceps as the hemostat is released. This allows you to detect bleeding prior to releasing the fat pad stump into the orbit.

The most lateral "fat pad" in the upper eyelid is the lacrimal gland. If the lacrimal gland is not prolapsed, preaponeurotic fat often obscures it. If it is prolapsed (Fig. 6.26), it is easily differentiated from the fat pads (Fig. 6.27). It is paler in color, lobulated, and bleeds profusely when incised.

### Lacrimal Gland Biopsy and Prolapse Repair

You may encounter a prolapsed lacrimal gland during ptosis surgery and must distinguish it from the adjacent fat pad (Figs. 6.5, 6.6, and 6.27). It may be evident preoperatively as a palpable mass in the superior temporal orbit (Fig. 6.26). A simple method of repair was described many years ago and has withstood the test of time.

Separate the adjacent preaponeurotic fat from the lacrimal gland with an Ocutemp cautery or sharp dissection. The lacrimal



*Figure 6.23* Patient is raised to the sitting position and the eyelid height and contour is inspected, and the sutures are adjusted until the eyelids are symmetrical. Note the peaking of the right upper eyelid (A) as opposed to the smooth contour of the left upper eyelid (B). Loosening the offending knot smooths the peak and equalizes the height of the eyelids (C).

gland is secured with three to four passes of a 5-0 Dexon™ suture with a stout, curved needle (Fig. 6.28). Expose the periosteum of the superior temporal orbital rim by retracting the overlying brow with a Desmarres or similar retractor (Fig. 6.29). Pass each needle of the double-armed suture through the periorbita inside the orbital rim (Fig. 6.30). Tension on the suture repositions the lacrimal gland in the superior temporal fossa where it belongs (Fig. 6.31). If the repositioning is adequate, the sutures are tied. If a biopsy is necessary, this can be done prior to repositioning by excising a small piece of gland. The lacrimal gland is quite vascular. Profuse bleeding is the norm and can be easily controlled with bipolar or hot cauterization. Except for an encapsulated, primary,

lacrimal gland tumor, there is rarely, if ever, an indication to remove a large portion of the lacrimal gland.

The lacrimal gland is easily biopsied with local anesthetic through an upper eyelid crease incision. This incision is identical to the incision made for ptosis surgery, but only involves the lateral portion of upper eyelid. The incision extends one-third to one-half the horizontal length of the upper eyelid through skin and orbicularis oculi muscle. The orbital septum is firmly attached to the orbital rim and is incised. The lacrimal gland lies deep to the orbital septum and superficial to the levator aponeurosis. It is often hidden by preaponeurotic fat from which it is easily differentiated (Fig. 6.27). Excise a small piece of gland for pathologic

UPPER EYELID SURGERY

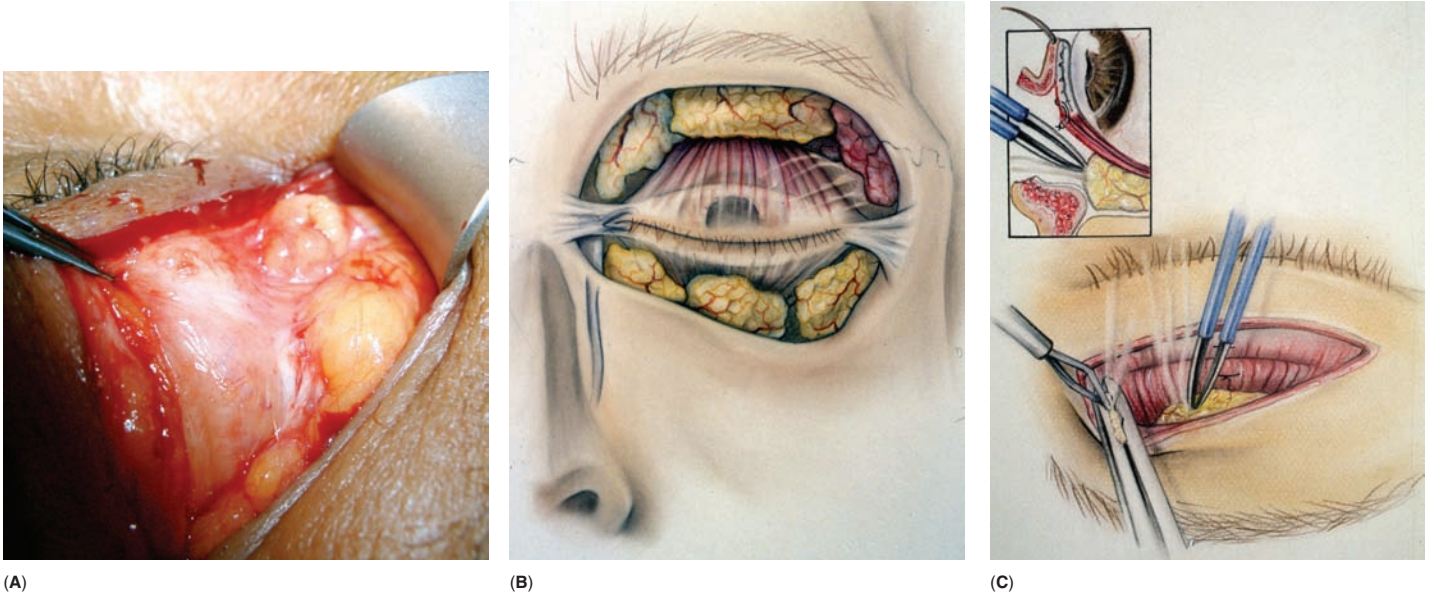


Figure 6.24 The preaponeurotic fat pads in the upper eyelid. (A) Note that the medial fat pad is significantly paler (whiter) than the central and lateral fat pads. (B) Diagram demonstrating the relationship between the upper eyelid fat pads and the lacrimal gland. (C) Removal of the fat pads by clamping and cauterizing.

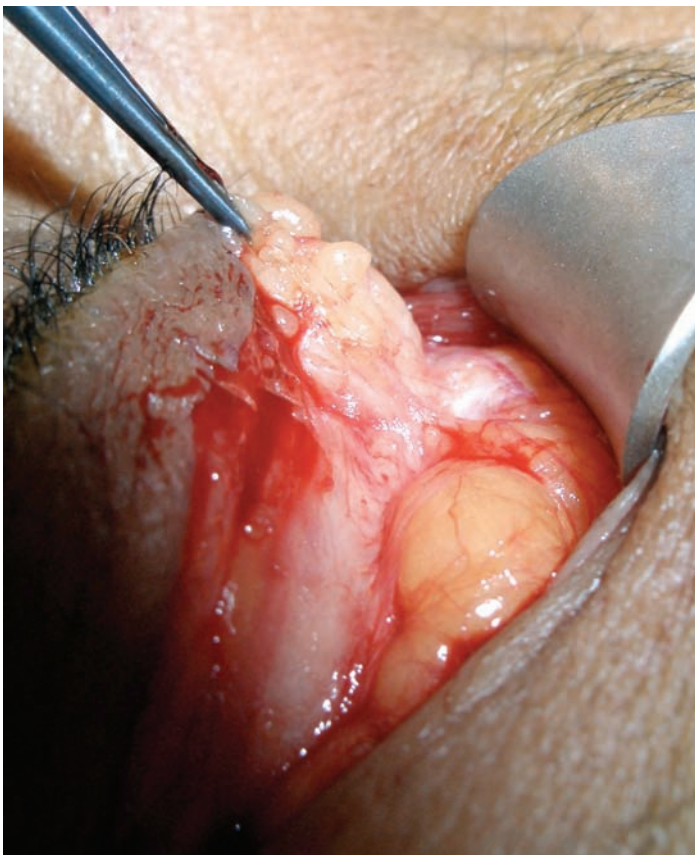
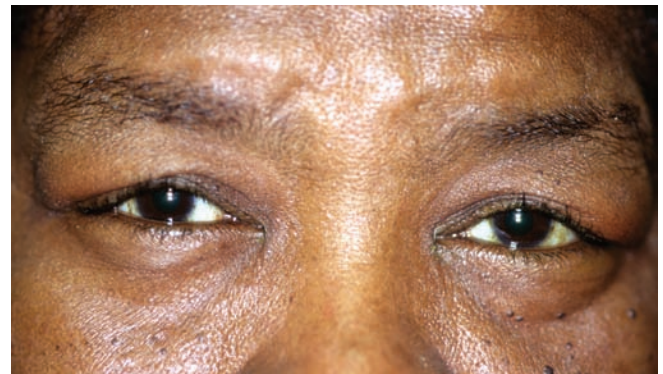
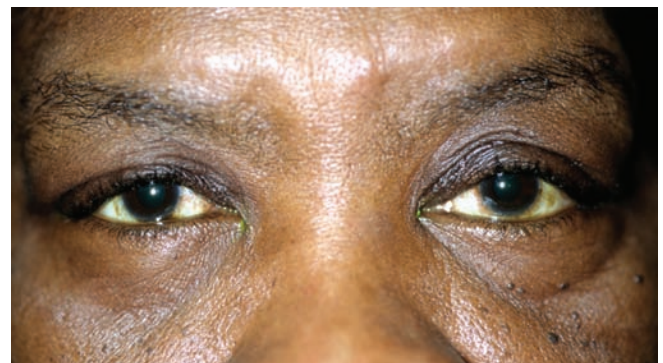
Figure 6.25 Removal of the medial fat pad.



(A)



(B)

Figure 6.26 Lacrimal gland prolapse appears as a palpable mass in the superior temporal orbit before (A) and after (B) repair.



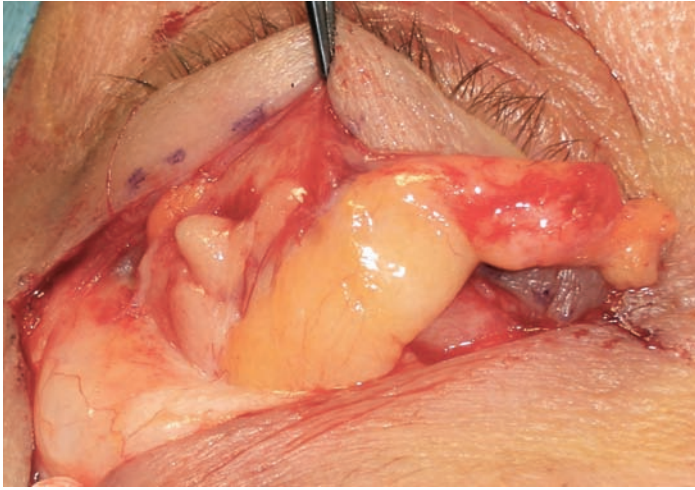


Figure 6.27 Compare the prolapsed lacrimal gland with the lateral preaponeurotic fat pad. The lacrimal gland is pinkish white in color while the lateral preaponeurotic fat pad is in obvious yellow color. Texture is also quite different. It should not be difficult to distinguish between them.

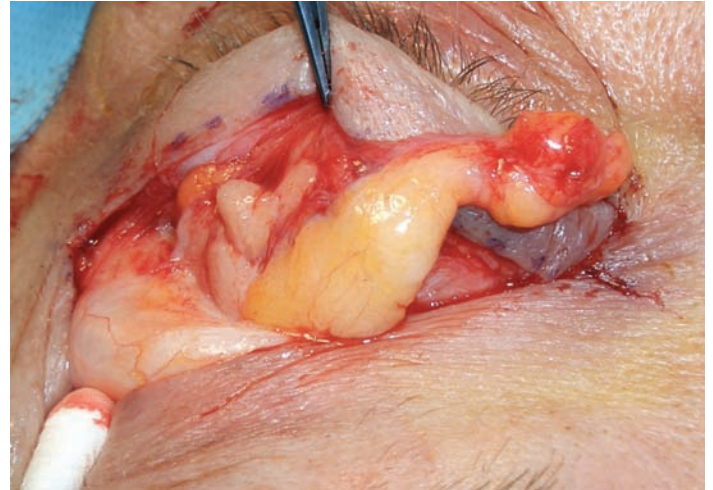


Figure 6.28 The periosteum of the superior lateral orbital rim is exposed.

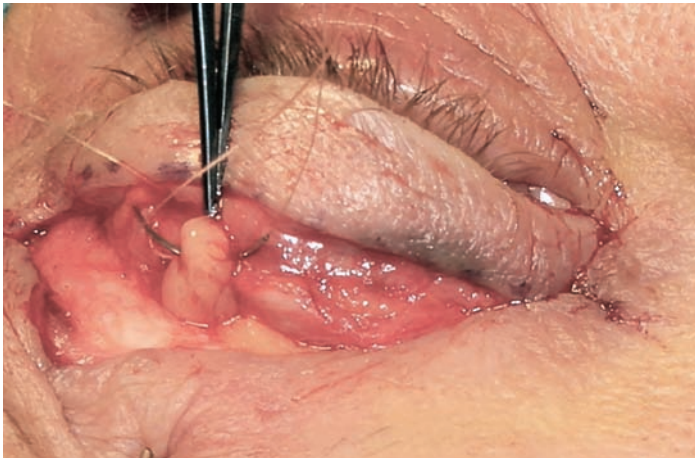


Figure 6.29 Multiple passes through the lacrimal gland are accomplished with a 5-0 Dexon suture.

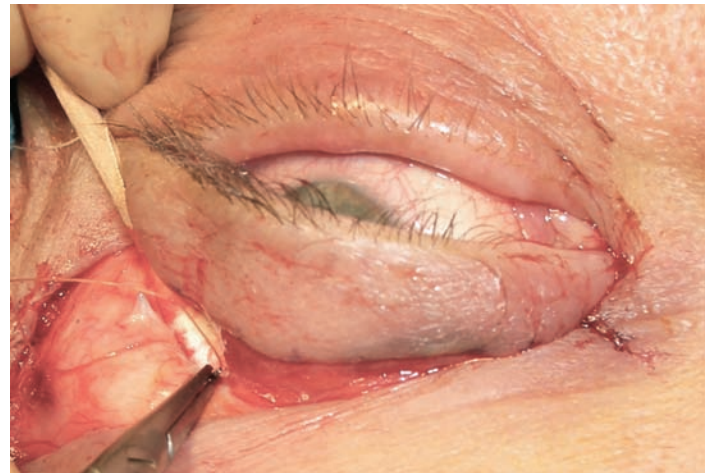

Figure 6.30 The lacrimal gland is retracted with a cotton-tipped applicator and both arms of the suture are passed through the periosteum *inside* the orbital rim.

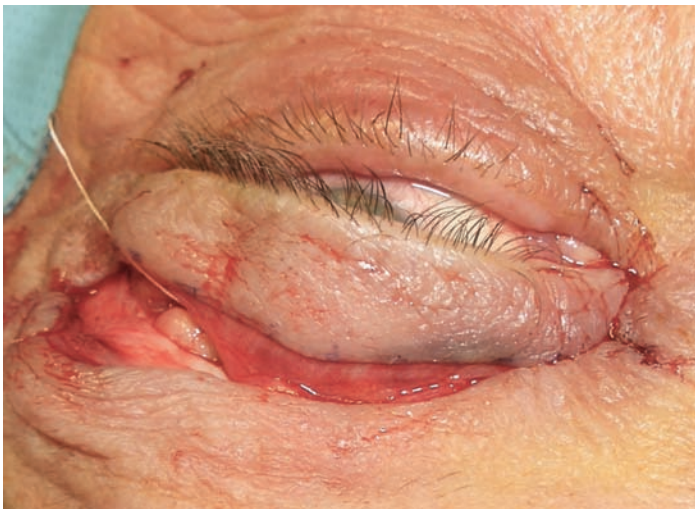

Figure 6.31 Tying the suture repositions the gland in the lacrimal fossa.

diagnosis, obtain hemostasis by cauterization and close the skin incision with sutures or surgical glue.

### Intraoperative Complications

#### *Loss of Levator Muscle Function*

On occasion, especially in patients who have had previous upper eyelid surgery, the injection of local anesthetic will totally or partially paralyze the levator muscle. If you detect this prior to incision, cancel the case if a long acting anesthetic has been used. If a short acting anesthetic has been used, juggle the schedule, wait for the anesthetic to dissipate, and try again. If the paresis is detected intraoperatively, take your best guess as to how much to advance the levator, err on the side of overcorrection and hope for the best. See the patient the next day and adjust the eyelid height as necessary. It is easier to lower an eyelid in the office than to elevate it.

#### *Levator Functions and Eyelid Still Does Not Elevate*

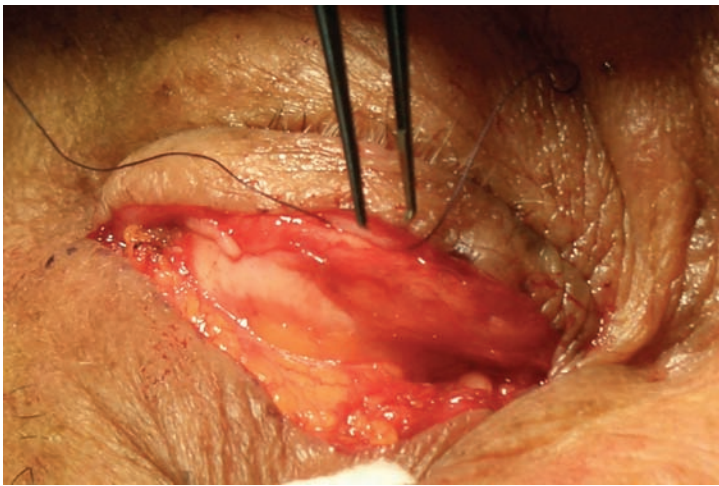
This is caused by injury to the levator muscle or by advancing a prominent Mueller's muscle instead of the dehiscenced levator aponeurosis (Fig. 6.32A). Take another look, find the defect or the

aponeurosis. Look for the glistening white tissue and advance it (Fig. 6.32B). This usually works. The eyelid elevates, you adjust the height, tie the sutures, and finish the operation.

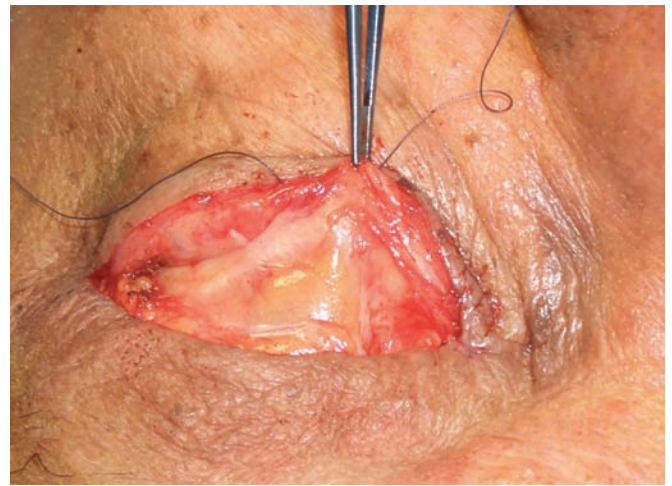
#### BLEPHAROPLASTY

After the levator aponeurosis has been advanced, the preaponeurotic fat and medial fat pad have been reduced or removed, the prolapsed lacrimal gland has been repositioned, and the brow has been internally fixated, you may remove excessive skin. This is almost always necessary after ptosis surgery to prevent an unsightly skin fold in the upper eyelid. Gently close the patient's eye and overlap the excessive skin from the upper incision over the lower incision (Fig. 6.33). Excise a strip of skin with straight scissors (Fig. 6.34). Excise more skin laterally than medially. The wound

edges should be touching with the eye gently closed (Fig. 6.35). Excising skin at the conclusion of the procedure, rather than at the onset, ensures that an excessive amount of skin will not be removed with resultant difficulties with eye closure or decrease in spontaneous blinking (Fig. 6.36). Waiting until the conclusion of the procedure to excise excess skin allows you to remove the medial fat pad and elevate the brow without fear of excising too much skin. It almost ensures that you cannot excise too much skin. It also allows you to adjust the symmetry of the eyelid creases by removing a thin strip of skin from the inferior portion of the incision. The incision may be closed with an interrupted or running suture, taking care to approximate the skin edges. Careful closure will result in an almost invisible scar (Fig. 6.37). Sloppy closure results in a thickened, hypertrophic, and unsightly scar (Fig. 6.38). If you

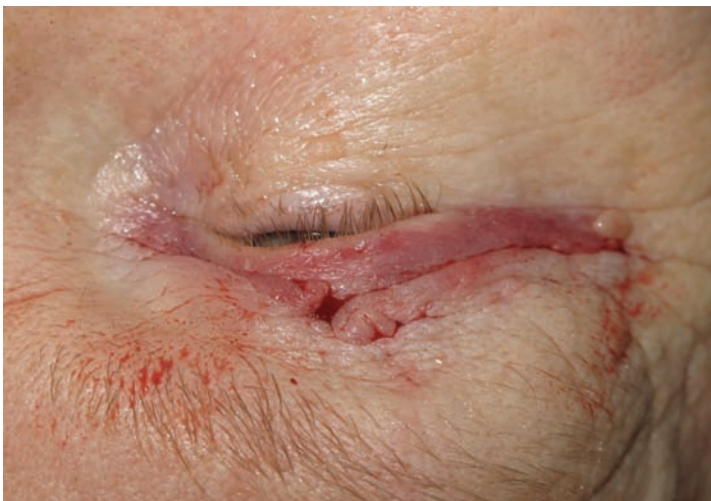

(A)

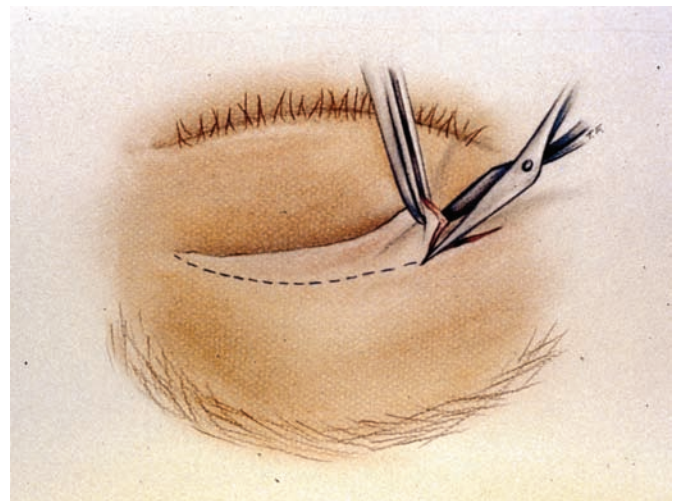


(B)

*Figure 6.32* Injury to the levator aponeurosis during ptosis surgery may result in difficulty elevating the eyelid. (A) Here the aponeurosis has been severed and retracted. The eyelid will not elevate well until the aponeurosis is reattached. (B) The eyelid did not elevate since a hypertrophic Mueller's muscle (held by forceps) was advanced instead of the levator aponeurosis (glistening white structure) above forceps and beneath the preaponeurotic fat. Pass the needle through the aponeurosis and the lid will elevate nicely.



(A)



(B)

*Figure 6.33* The patient's eye is gently closed (A). The redundant upper eyelid skin is gently stretched over the inferior edge of the incision and excised (B).

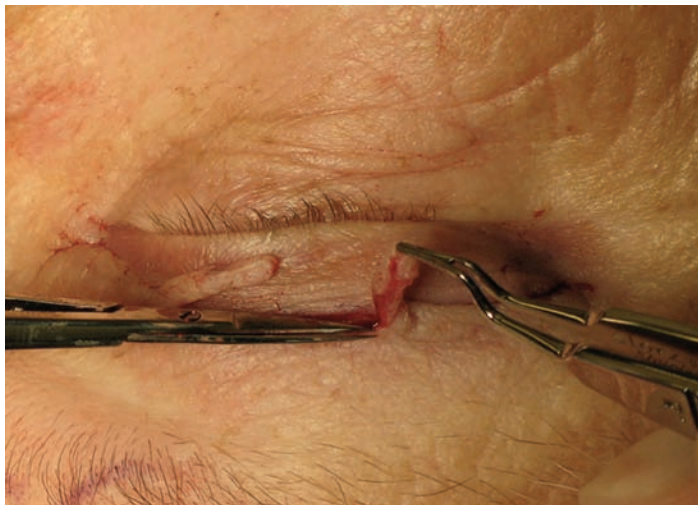


Figure 6.34 Only excessive skin overlapping the inferior edge of the wound is excised. More skin may be excised from the lateral eyelid than from the medial eyelid.

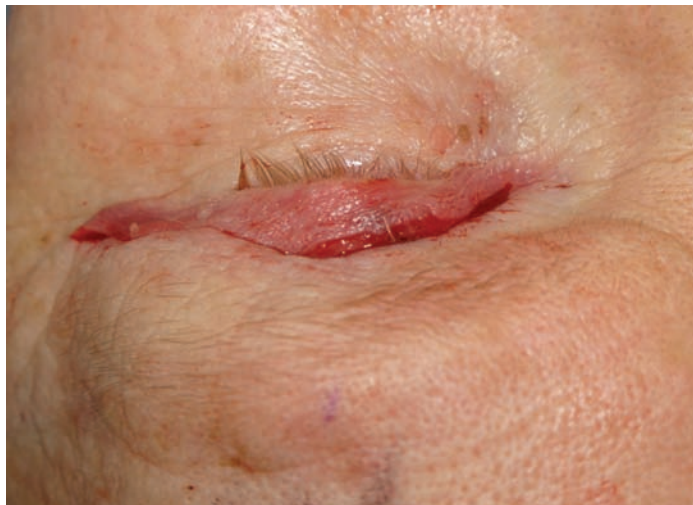

Figure 6.35 The wound edges should be touching with the eye gently closed.

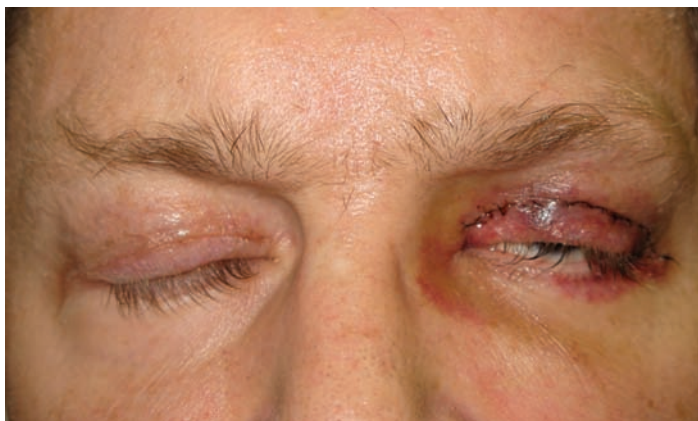

Figure 6.36 Excessive removal of upper eyelid skin may result in incomplete closure, lagophthalmos, and keratopathy.

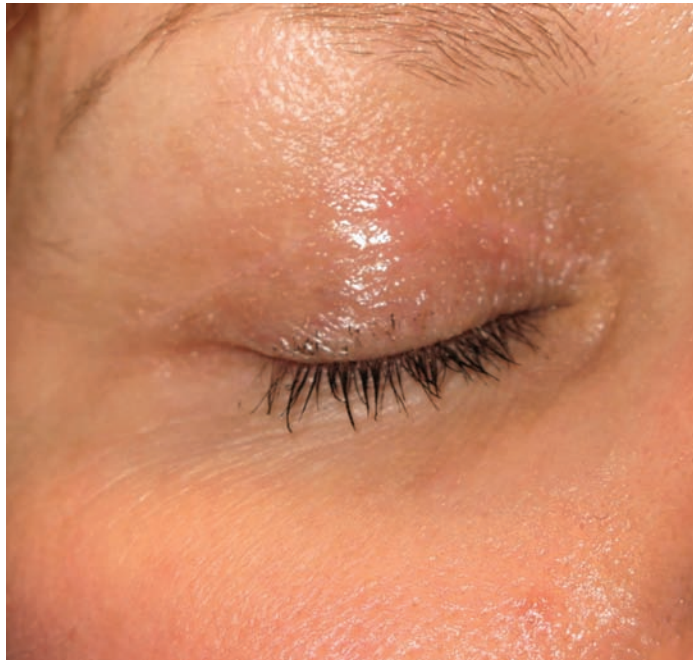

Figure 6.37 No scarring of the upper eyelid occurs after careful closure.

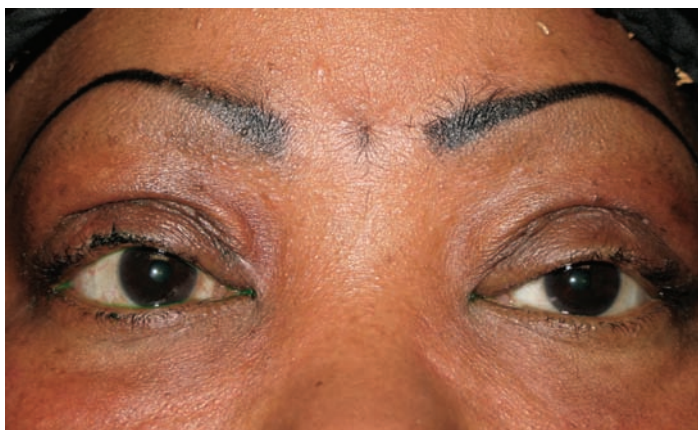

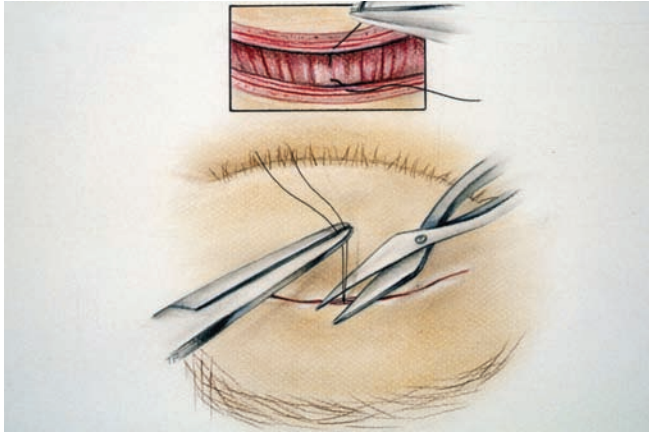
Figure 6.38 Unsightly hypertrophic scarring may occur after sloppy closure sutures or improper use of skin glue.

wish to accentuate the upper eyelid crease, the incision may be attached to the tarsus in two to three areas (Fig. 6.39A). We reserve this for younger patients undergoing cosmetic blepharoplasty and ptosis repair (Fig. 6.39B and C). If you are going to accentuate the eyelid crease, be certain that the incisions are symmetrical. If there

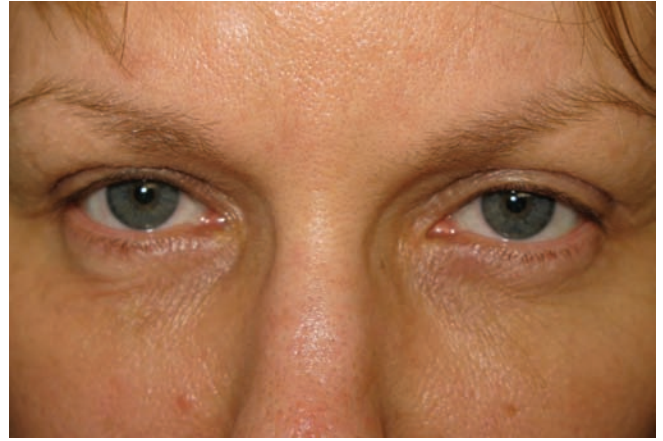is some asymmetry, the higher pretarsal portion of the incision may be lowered by excising a thin strip of it prior to removing skin from the superior portion of the incision. When the incision heights match, then proceed with excision of the excess skin and close with three-point supratarsal fixation (Fig. 6.39A).

### Pinch Blepharoplasty

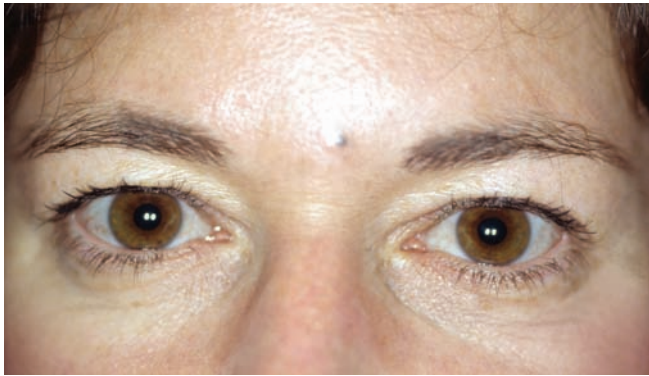Younger patients with excessive upper eyelid skin, no fat herniation, and without ptosis (Fig. 6.40) may benefit from a “pinch” blepharoplasty. This technique may also be used to obtain skin grafts or to remove residual skin after previous upper eyelid surgery (Fig. 6.41A–C). The key to success is the addition of hyaluronidase to the local anesthetic (Fig. 6.42). Infiltrate the upper eyelid with anesthetic 10 to 15 minutes before surgery. With a pair of



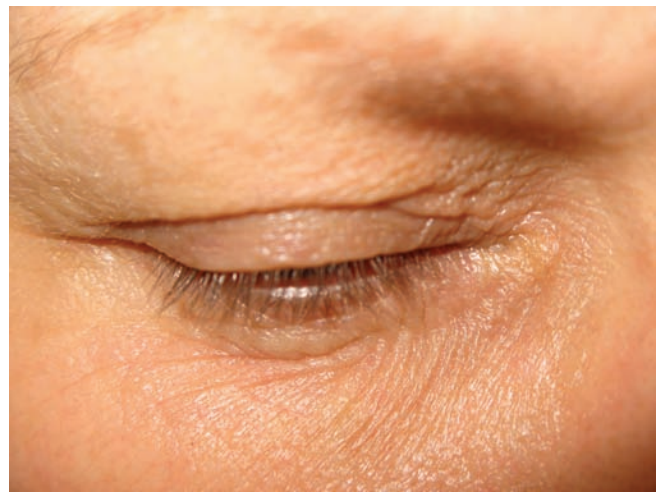(A)



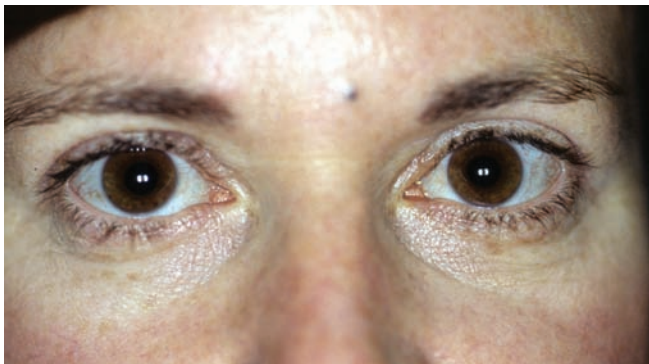(A)



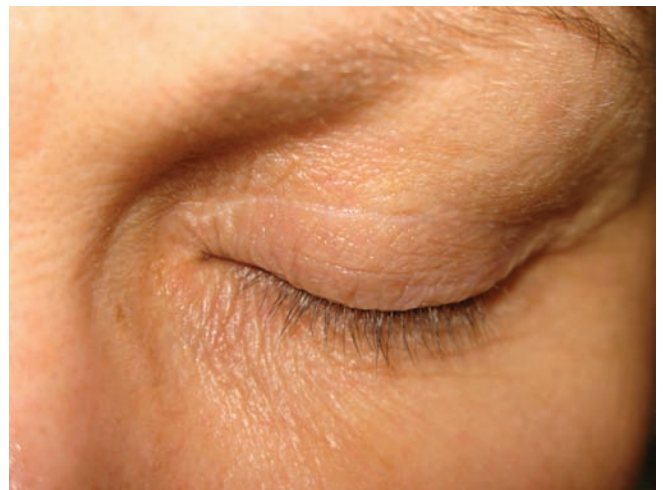(B)



(B)



(C)



(C)

Figure 6.39 The upper eyelid crease may be accentuated by fixing the skin edges to the levator aponeurosis in three areas (A). Formation of an upper eyelid crease augments the cosmetic effect of surgery, especially in younger patients (B, C).

Figure 6.41 Patient with a small amount of unsightly redundant skin on the right upper eyelid (A–C) three months after a ptosis repair and blepharoplasty. Compare the excess skin present on the right upper eyelid (B) to the left upper eyelid (C). The patient is also an excellent candidate for a pinch blepharoplasty.

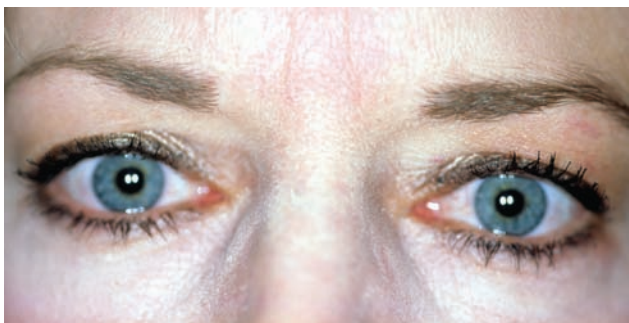

Figure 6.40 Young patient with redundant upper eyelid skin, no fat herniation, or ptosis is an ideal candidate for the pinch blepharoplasty.

toothed forceps, pinch the redundant skin along the horizontal length of the eyelid (Fig. 6.42). It will tent up and remain in the tented position. Excise the tented skin with scissors (Fig. 6.43A and B). Obtain hemostasis and accentuate the eyelid crease by applying hot cautery (Fig. 6.43C). Approximate the skin edges with your skin suture of choice, reforming the eyelid crease by supratarsal fixation (Figs. 6.39A and 6.43D). The results are effective and subtle (Figs. 6.44A, B and 6.45A, B).

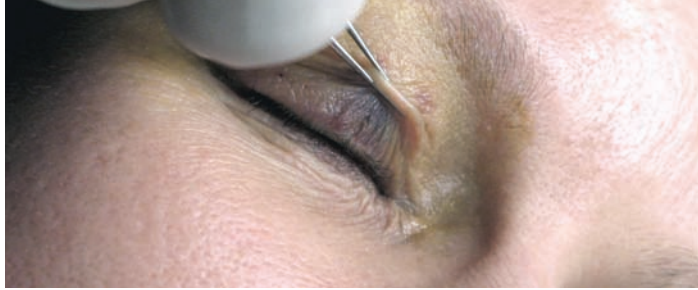
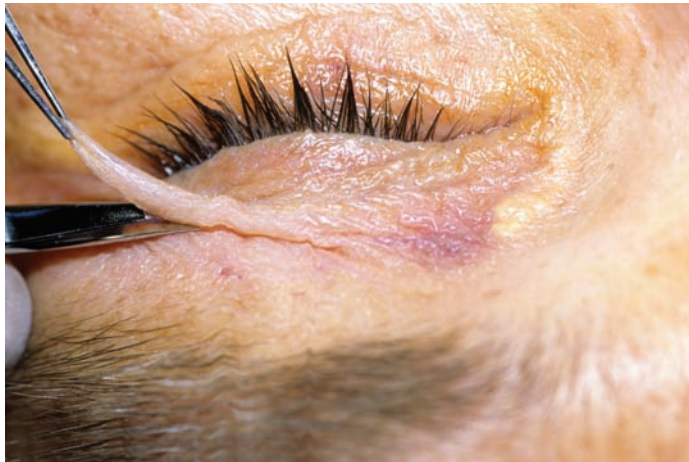
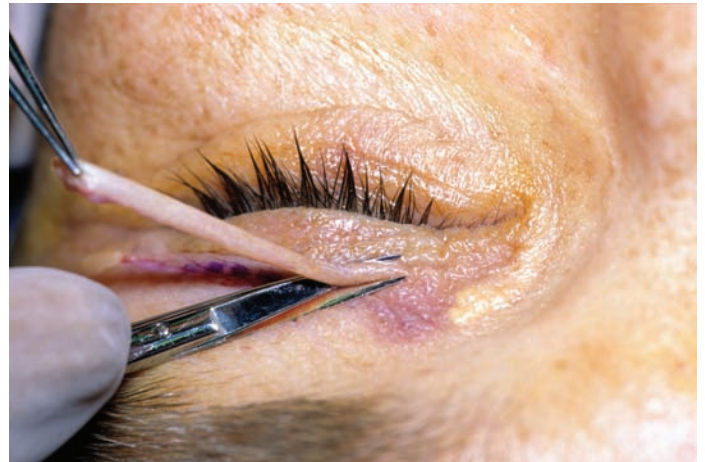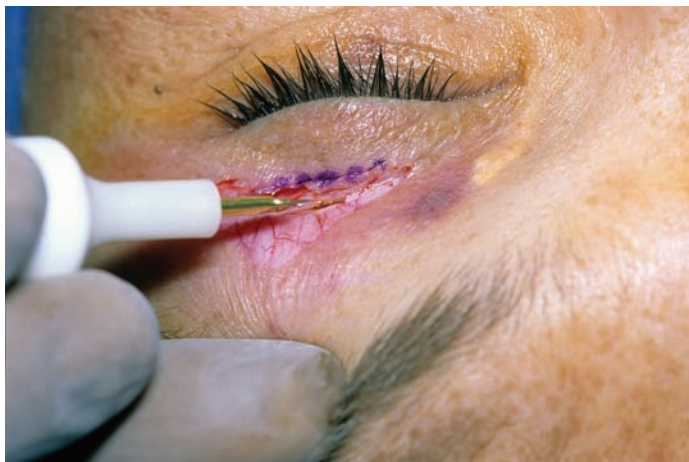Figure 6.42 The key to a successful pinch blepharoplasty is tenting the redundant skin with a forceps 15 minutes after injection of a hyaluronidase-containing anesthetic.



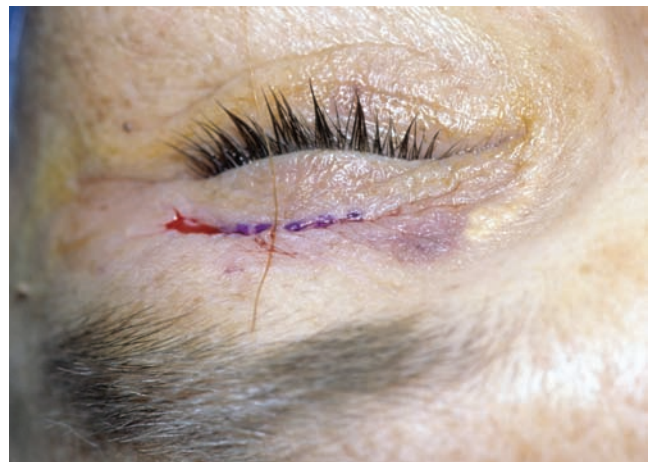(A)



(B)



(C)



(D)

Figure 6.43 The tented skin is excised with straight, sharp scissors (A, B). Hot cautery may be used for hemostasis and to accentuate the eyelid crease (C). The eyelid crease may be further accentuated by supratarsal fixation (D).

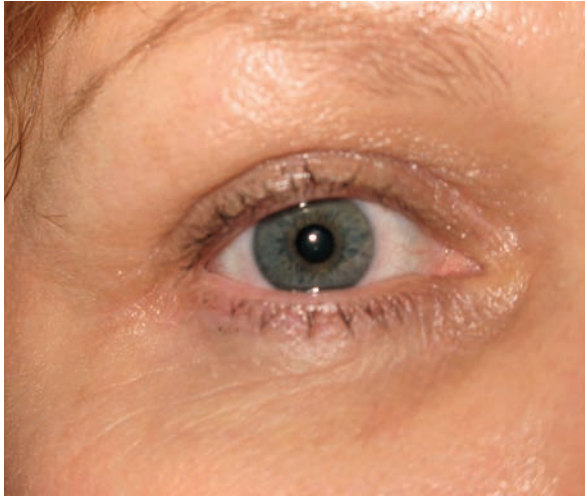
#### PTOSIS WITH ABSENT LEVATOR FUNCTION

If there is any levator function, first opt for a levator advancement procedure ranging from aponeurotic repair to a maximum levator resection to the level of Whitnall's ligament.

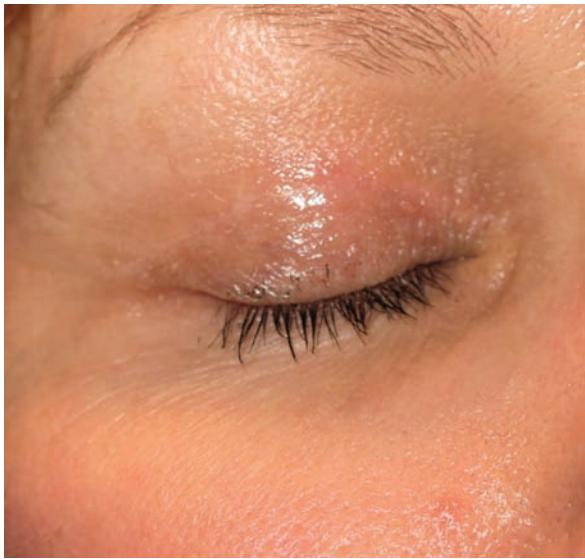Advancing a nonfunctioning levator is rarely beneficial. Sling procedures using fascia and Crawford needles border on cruel and unusual punishment. Supramid slings are quick and easy to perform but have a tendency to cause significant granuloma formation (Fig. 6.46). I prefer an open sky fascia lata or Gortex sling procedure that we described in 1993. This allows a relatively controlled elevation of the eyelid as well as cosmetic enhancements from skin and fat removal. Placement of the suspensory material deep to the orbital septum allows for a more natural lid height and contour (Figs. 6.47A, B and 6.48A, B).

Mark the eyelid crease and incise it with a sharp blade (Fig. 6.49). Dissect a skin-muscle flap and extend the incision along the entire horizontal length of the eyelid. Excise a strip of pretarsal and preseptal orbicularis muscle exposing the orbital septum, preaponeurotic fat, and levator aponeurosis exactly as done in a levator advancement procedure (see subsection "Technique" under "Ptosis Surgery").

Remove some of the preaponeurotic fat. Excise some pretarsal orbicularis muscle exposing bare tarsus. Mark incisions on the



(A)



(B)

Figure 6.44 Patient in Figure 6.41 one month after a pinch blepharoplasty of the right upper eyelid with the eye open (A) and closed (B).

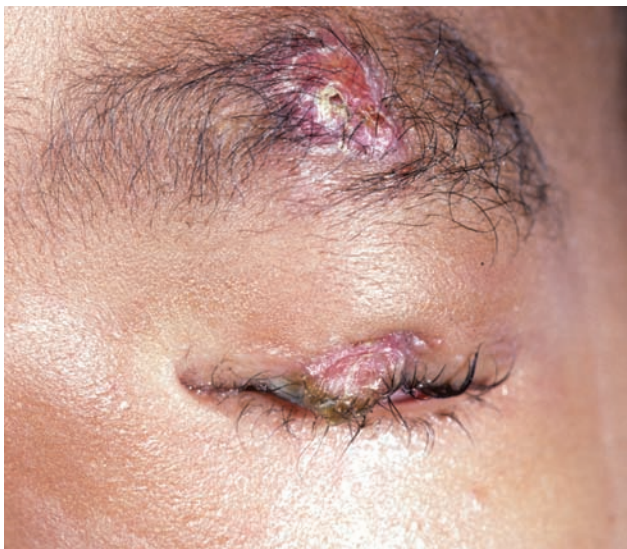
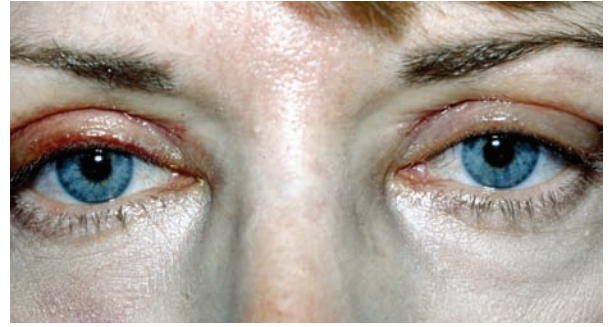
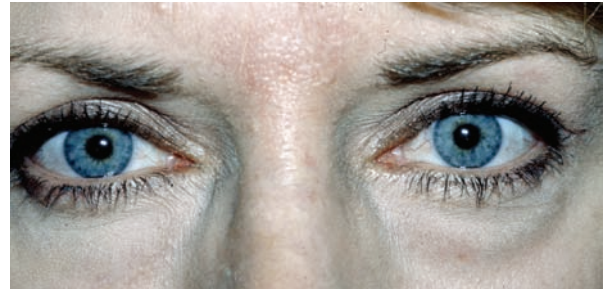
Figure 6.46 Supramid slings are quick and easy but may cause severe granuloma formation.

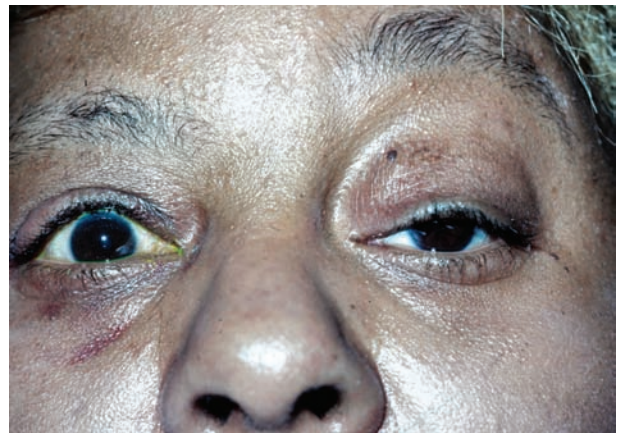


(A)

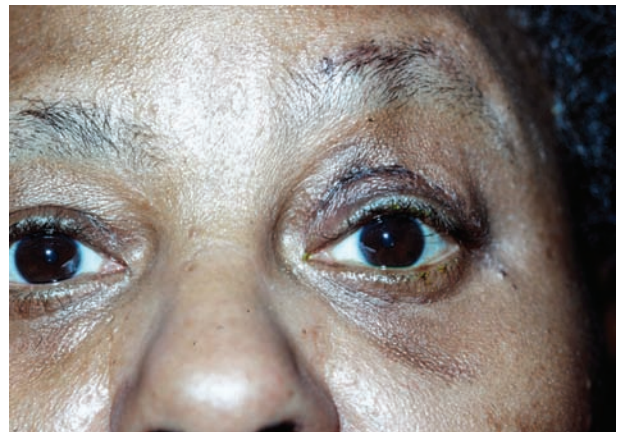


(B)

Figure 6.45 Patient in Figure 6.40 one week (A) and one month (B) after pinch blepharoplasty of the upper eyelids.

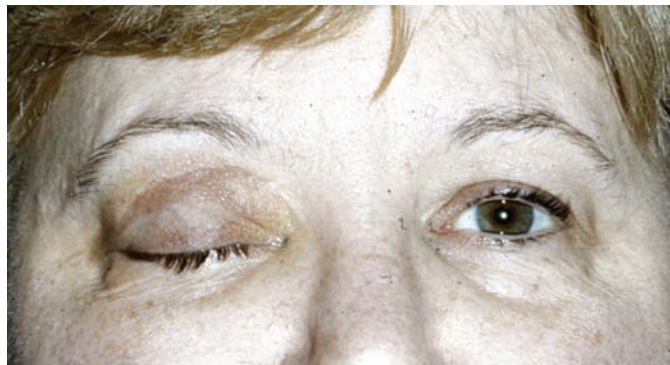

(A)

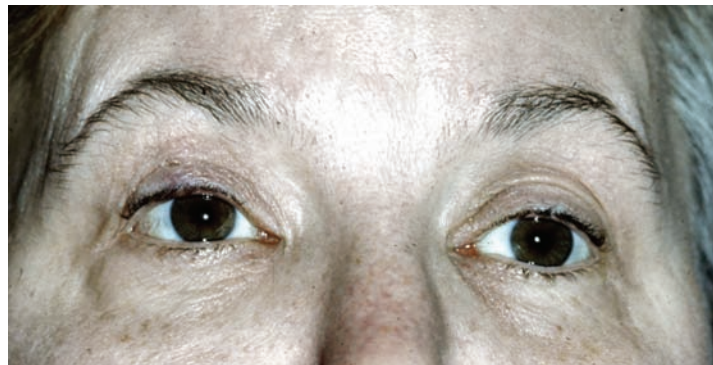


(B)

Figure 6.47 Patient with congenital ptosis and no levator function before (A) and after (B) an open sky fascia lata sling.



(A)



(B)

Figure 6.48 Patient whose levator muscle was extirpated during an orbital surgical misadventure before (A) and after (B) an open sky fascia lata sling.

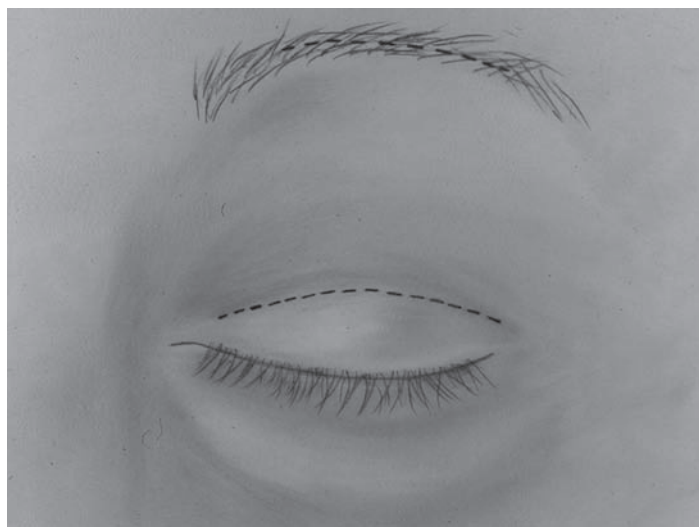


Figure 6.49 Incisions are marked and incised in the upper eyelid crease and brow.

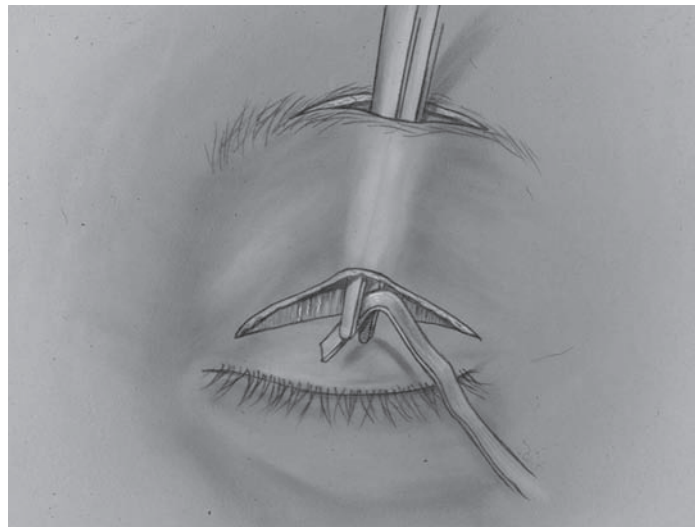


Figure 6.50 A curved hemostat is passed from the eyelid to the brow deep to the orbital septum and a piece of fascia or gortex is passed from the eyelid to the brow in this plane.

superior aspect of the brow, nasal and temporal to the mid-brow (Fig. 6.49). Incise each incision deep to the periosteum. Pass a curved hemostat from the eyelid incision *deep* to the remnants of orbital septum and exit the brow incision under direct visualization. Fold a strip of fascia lata or gortex and grasp the folded end with the hemostat, pulling it into the eyelid incision (Fig. 6.50).

Suture the folded end of the sling to tarsus with a 5-0 suture (Fig. 6.51).

Fixate each loop in two to three areas (Fig. 6.52). Pull the free ends of the loops through the brow incisions. These are used to elevate and adjust the contour of the upper eyelid (Fig. 6.53A and B). When you are satisfied with the height and contour of the upper eyelid, suture the strips to the deep brow tissue with a 5-0 Dexon suture with a curved needle (Fig. 6.54). Close the brow incisions with a subcutaneous suture and the skin with surgical glue or your skin suture of choice (Fig. 6.55). Remember that the scar you see prior to the skin closure is the scar you will see after the incision heals, so close the subcutaneous tissue carefully.

The eyelid incision is sutured in the usual, careful fashion.

### Problems and Solutions

Overcorrection, lagophthalmos, incomplete closure, and a resultant keratopathy are potential complications. Lagophthalmos is guaranteed with any procedure that slings the eyelid or shortens the levator muscle. It has to happen, so minimize the chances of damage to the cornea. Before surgery, check for Bell's phenomenon, dry eye, and any evidence for keratopathy.

### BROW PTOSIS REPAIR

There are many ways to repair brow ptosis—none of them excellent or only one technique would be utilized. All of them have advantages and disadvantages. The direct brow lift—excising a portion of scalp above the brow and directly closing it—is no longer a popular option. Disadvantages include numbness and scarring. It might be an acceptable procedure on a patient with severe brow ptosis and bushy eyebrows, but its use is quite limited.

Utilizing a coronal approach, burying the scar in the hairline or hair, was popular for a while and effectively elevates the brow. Complications included significant hemorrhage (Fig. 6.56A–C) and loss of forehead sensation. This has been largely replaced by

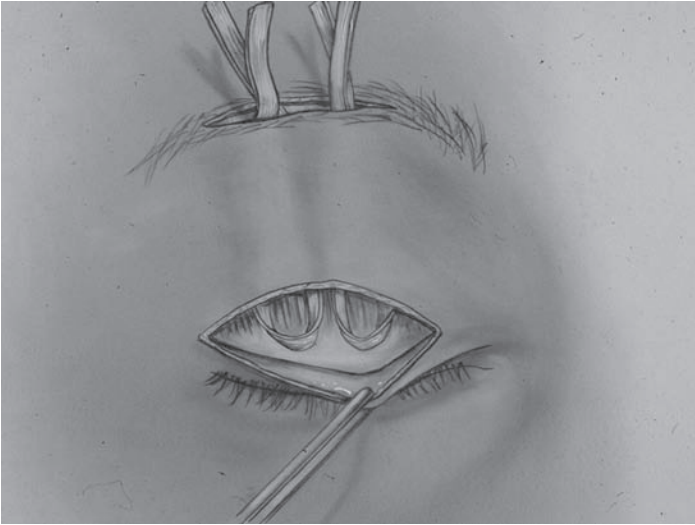


Figure 6.51 The folded ends of the strips lie upon tarsus, the free ends are in the brow incision.

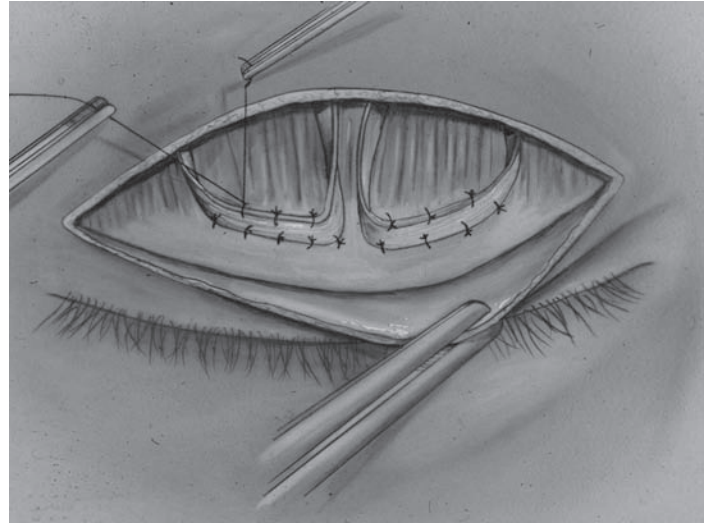
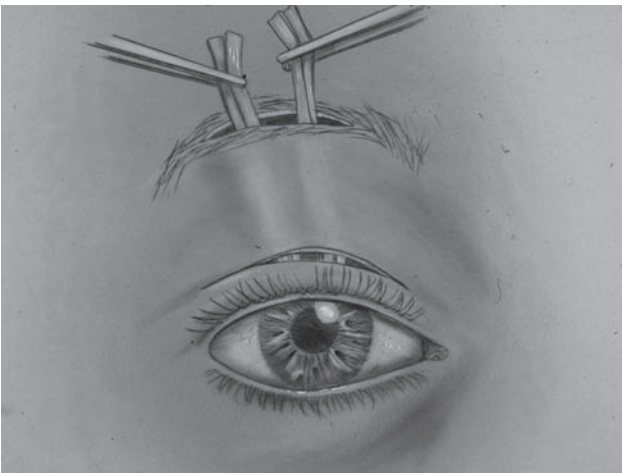
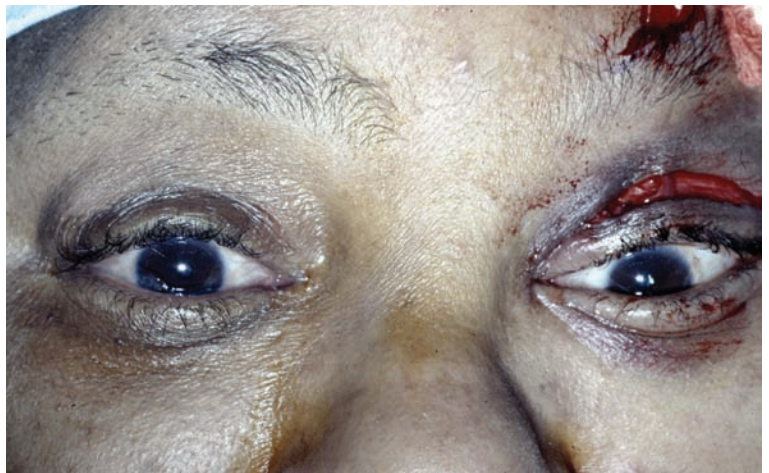

Figure 6.52 The folded ends of the strips are sutured to the tarsus with multiple interrupted sutures.



(A)



(B)

Figure 6.53 The patient is raised to a sitting position and the eyelid height and contour is adjusted (A, B).

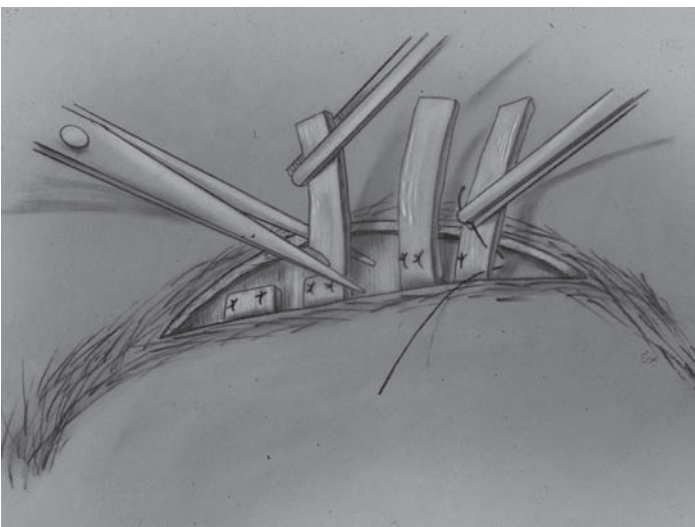


Figure 6.54 After the eyelid height and contour is adjusted, the ends of the suspensory material are sutured to the periosteum with a 5-0 Dexon suture. The excessive material is excised.

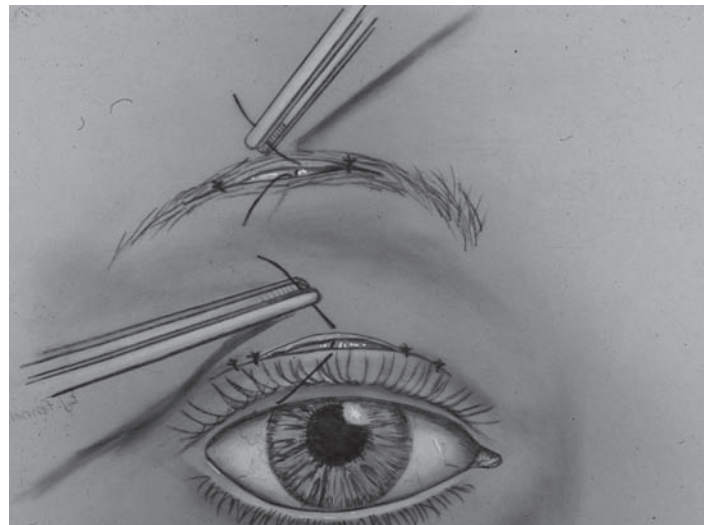
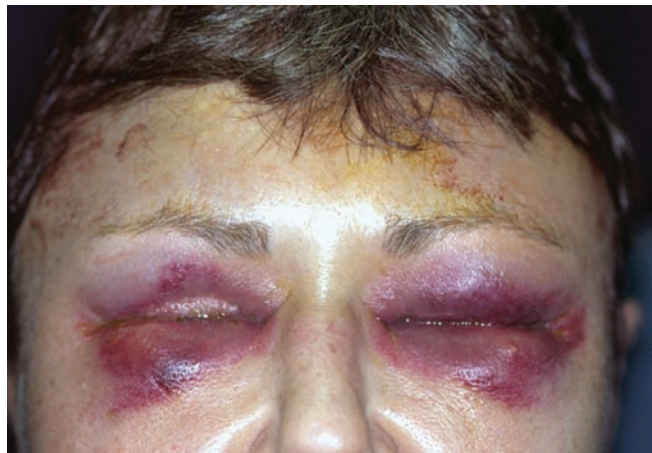
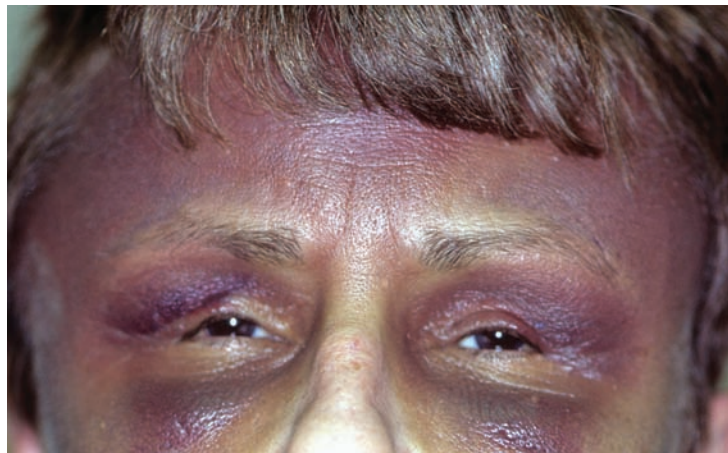
Figure 6.55 The eyelid incision is closed in the usual fashion. The brow incision is closed in layers to minimize scarring.

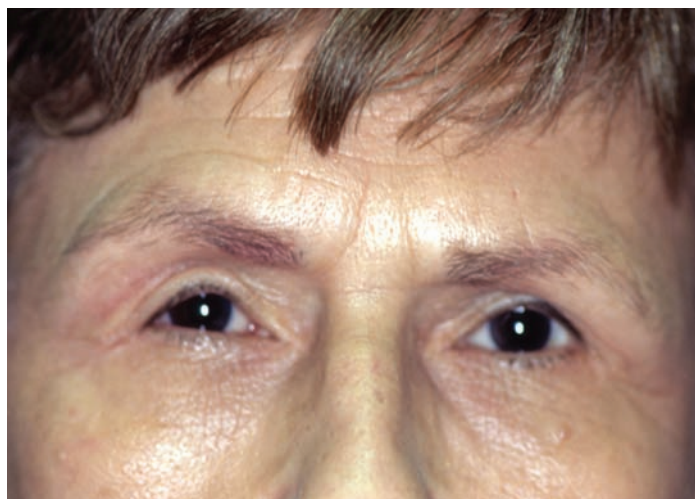



(A)



(B)



(C)

Figure 6.56 Hemorrhage after coronal brow lift (A), partially resolved two weeks later (B), and total resolution after one month (C).

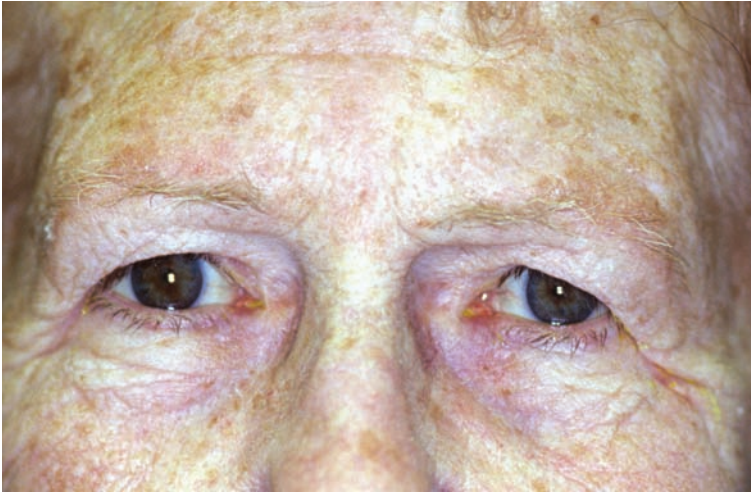endoscopic procedures, which continue to evolve. These approaches have a tendency to overcorrect the brow, and when combined with excessive botulinum injections, give the patient that frozen stare appearance that you see so often on television news persons.

Significant temporal brow ptosis may be treated via a hairline incision in the temporal brow. Elevate and mobilize a skin-muscle flap to elevate the brow. Excise the excessive skin and subcutaneous tissue. Fixate the flap to the underlying temporalis muscle or periosteum with a 4-0 Vicryl™ suture. Close the subcutaneous tissue with the same suture. The incision can be hidden in the hairline (Fig. 6.57A–C).

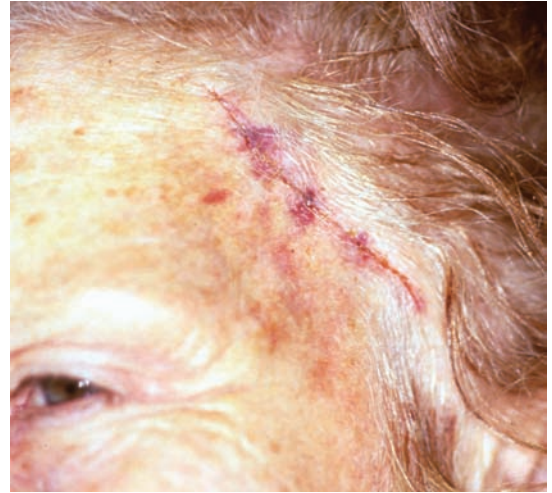A more subtle approach is to elevate the lateral brow through an eyelid crease incision at the time of ptosis repair and blepharoplasty. In cases of isolated brow ptosis, you can perform a mini-incision direct brow lift that is the poor man's equivalent of expensive fixation devices and endoscopic surgical instrumentation. Both of these procedures are easy to perform, improve mild to moderate brow ptosis, and are cosmetically quite acceptable. Extensive brow ptosis requires one of the more extensive procedures such as a coronal brow lift or extensive endoscopic surgery.

#### Brow Lift Through an Eyelid Crease Incision

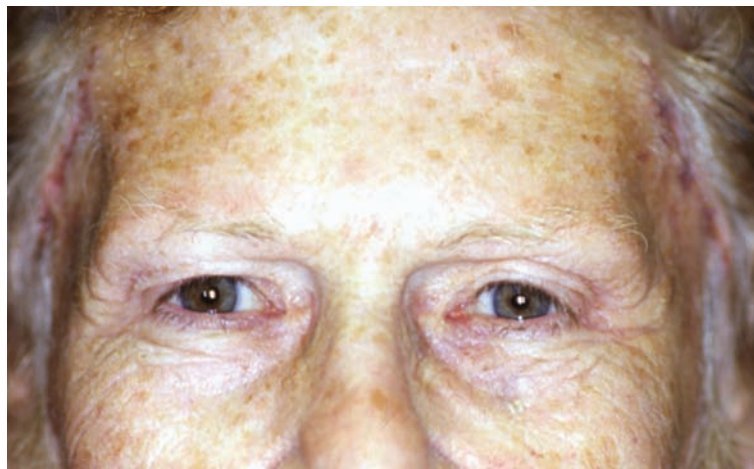
During ptosis repair and blepharoplasty, extend the eyelid crease incision laterally to facilitate mobilization of a skin-muscle flap to expose the mid-brow and lateral brow (Fig. 6.58). Expose and isolate the preaponeurotic fat pads and levator aponeurosis in the usual fashion. Dissect a skin-muscle flap superiorly, exposing the superior temporal orbital rim (Fig. 6.58). The mid-brow and lateral brow can be elevated with this approach. Dissection lateral to the supraorbital notch avoids injury to the supraorbital neurovascular bundle with subsequent bleeding and a numb forehead after surgery. After dissecting the flap (stouter Adson forceps and Metzenbaum scissors facilitate this dissection), pass one or two 4-0 silk marking sutures through the brow, identifying the areas that need elevation (Fig. 6.59). Elevate a flap of skin, orbicularis muscle, and sub-brow tissue from the orbital rim. Fixate the brow to the orbital rim at a higher level with several 4-0 Vicryl sutures (Fig. 6.59). Tie these sutures and inspect the brow for symmetry and to ensure that the sutures have not puckered the superficial tissue in an unsightly fashion. Now advance the levator aponeurosis and perform a blepharoplasty as described in the section “Ptosis Surgery”.



(A)



(B)



(C)

Figure 6.57 Treat significant temporal brow ptosis (A) with a direct temporal brow lift hiding the incision in the hairline (B) and elevating the brow (C) without removing eyelid skin.

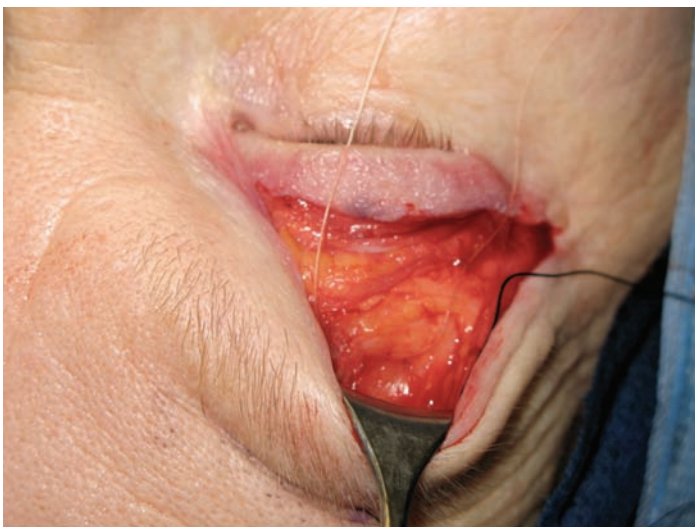


Figure 6.58 Extend the eyelid crease incision laterally and elevate a skin-muscle flap exposing the superior orbital rim. A black silk marking suture was placed through the brow, exiting at the sites selected for fixation. A 4-0 Vicryl suture is passed through the periosteum of the superior orbital rim at the site selected for brow fixation.

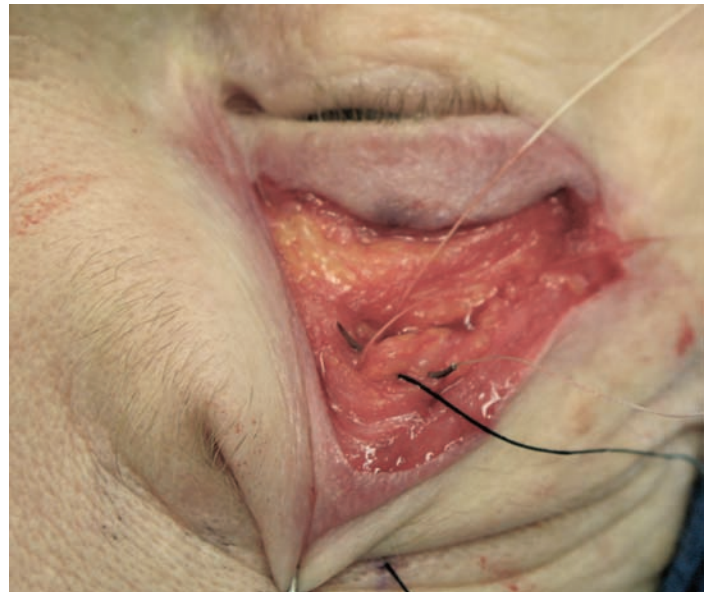


Figure 6.59 Invert the skin-muscle flap. The black silk suture marks the fixation site on the inner surface of the brow. A needle is passed through the brow in the area marked by the black suture.

One caveat bears emphasis. This is an excellent reason to defer excising the excessive upper eyelid skin until the conclusion of the procedure. After the brow is elevated, much less skin needs to be removed than you would have expected prior to brow elevation. If skin was excised initially as conventional teaching dictates, you would be wasting time, effort, and money suturing the excised skin back to the eyelid to ensure adequate closure, assuming that you recognized the problem before you finished the procedure.

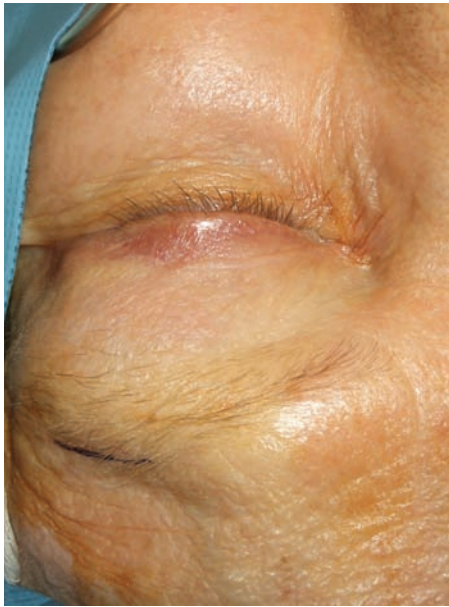
**Mini-incision Direct Brow Lift**

Small incisions in the superior brow may be used to repair mild to moderate brow ptosis medial and lateral to the superior orbital

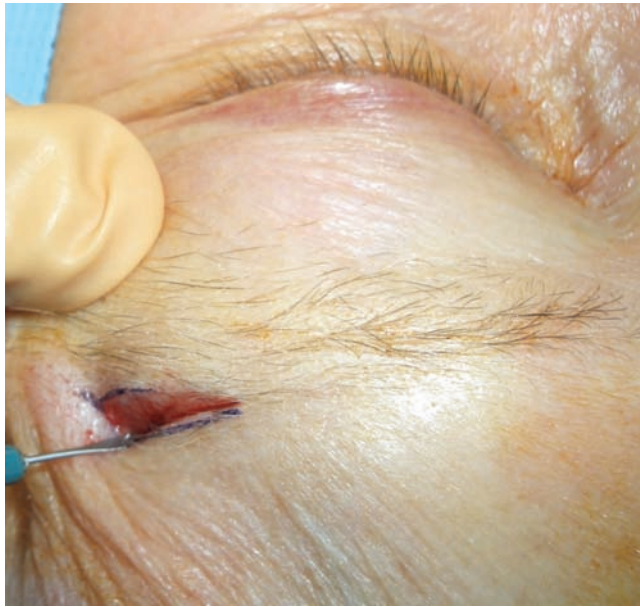
notch. Ideal patients have prominent, bushy eyebrows that easily hide incisions.

Mark the brow in the areas that need to be elevated. Make the incisions at the superior border of the eyebrow. Extend them deep to the periosteum (Fig. 6.60A and B). Undermine the incision and mobilize it superiorly to provide a space to fixate the brow tissue (Fig. 6.61).

Dissect a subcutaneous flap of brow tissue with scissors (Fig. 6.62A and B), leaving enough subcutaneous tissue to effectively close the wound at the conclusion of the procedure. This is the key step in this operation. If the flap is not dissected, the wound will not close evenly, resulting in an unsightly scar. Retract the superior portion

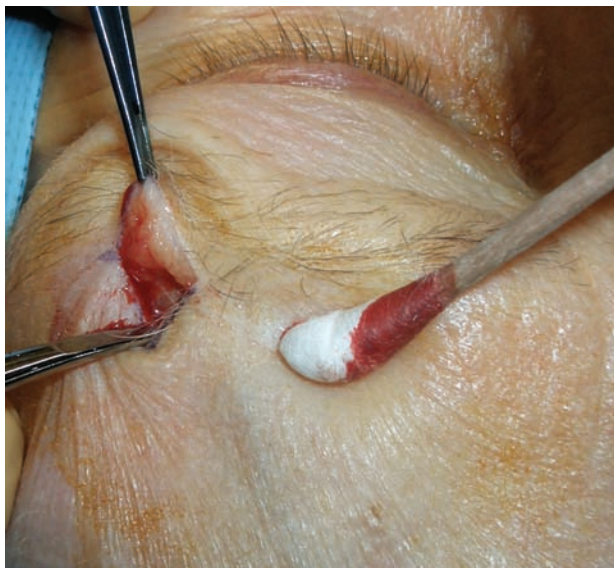


(A)

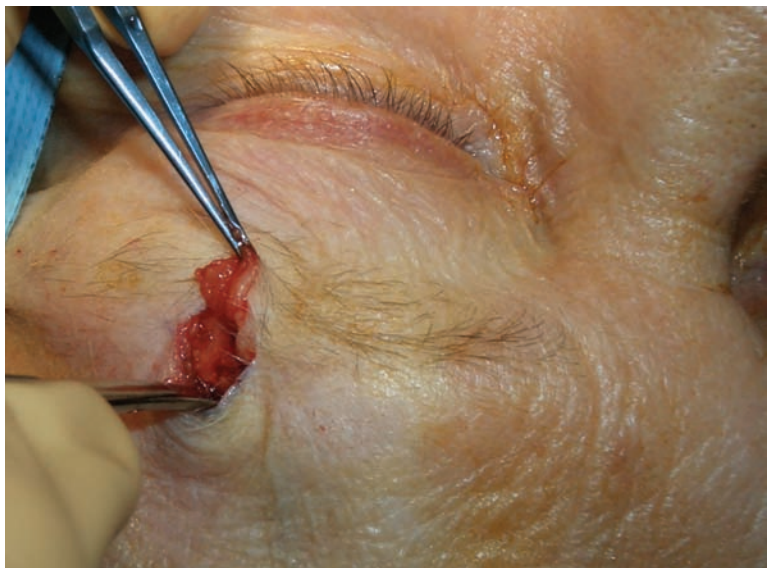

(B)

Figure 6.60 Outline an incision just superior to the portion of the eyebrow that you wish to elevate (A). Make the incision with a sharp blade extending to the periosteum (B).



(A)



(B)

Figure 6.61 Undermine the incision above (A) and below (B) at the level of the periosteum.

of the incision with a small Desmarres or vein retractor and place a 4-0 Vicryl suture in the underlying periosteum at the desired level (Fig. 6.63A and B). Pass the suture through the flap with two to three passes locking it upon itself (Fig. 6.64A and B).

Tie the suture (Fig. 6.65), and if the brow height and contour is acceptable, the subcutaneous tissue is closed with the residual suture (Fig. 6.66). The skin is then approximated with sutures or glue. Repeat this procedure wherever the brow needs elevation. The incision is effectively hidden in the eyebrow or obscured by it.

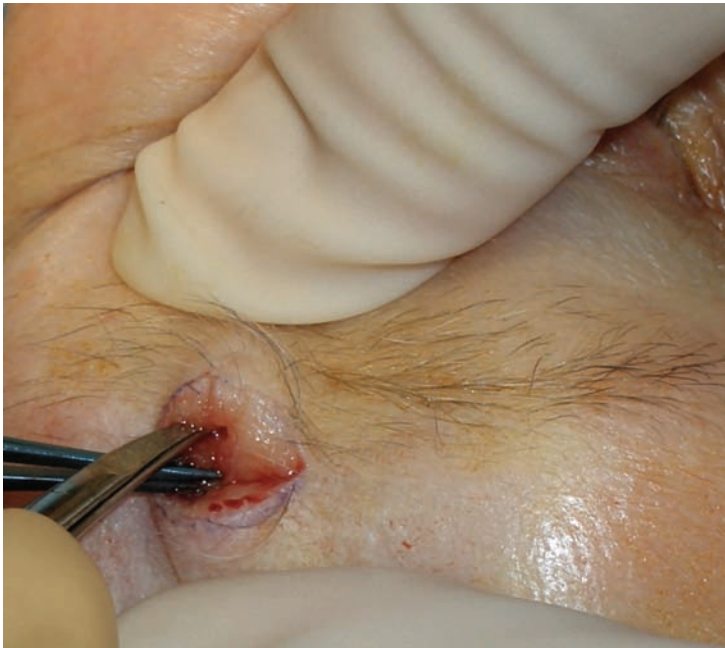**Problems and Solutions**

*Asymmetry*

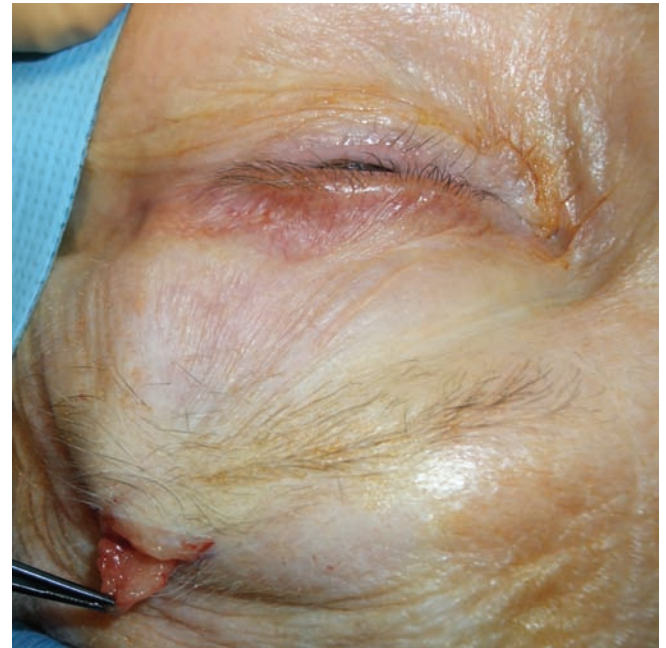
Have the patient sit up on the operating table and inspect the brow elevation for height and symmetry prior to closure. If a small overcorrection is detected after surgery, massaging the higher brow in an inferior direction may lower it a few millimeters.

*Unsightly Scar*

Dissect the flap of brow tissue and leave enough subcutaneous tissue to effectively close the wound.

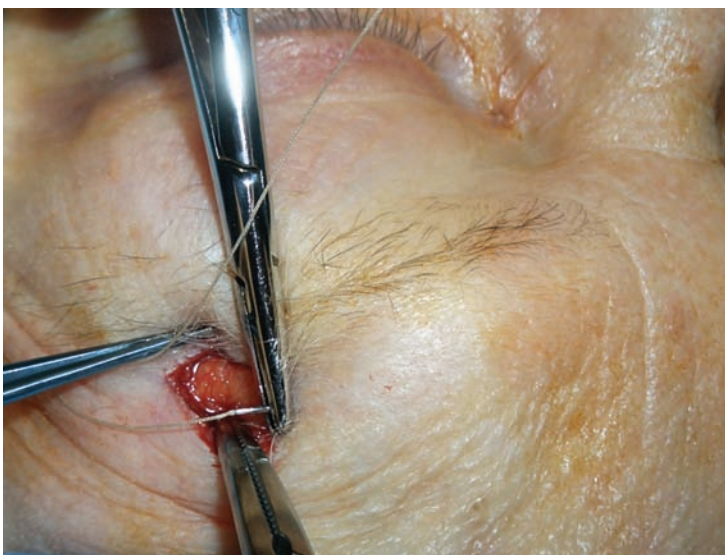


(A)

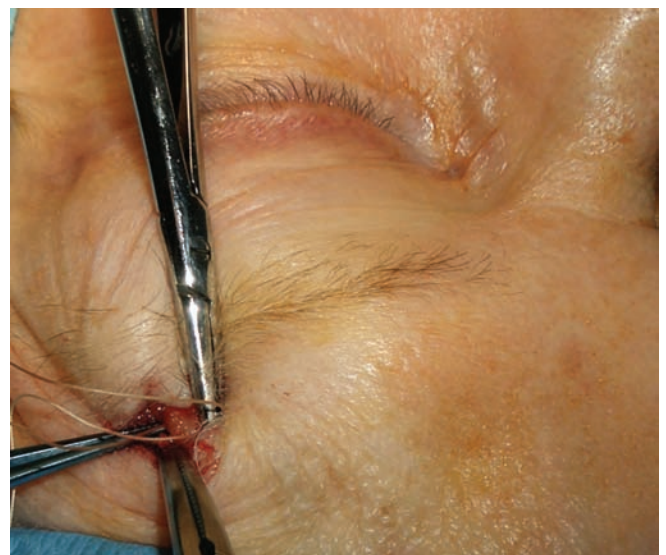


(B)

Figure 6.62 Divide the sub-brow tissue into two layers—a superficial layer of dermis and epidermis and a deeper layer that will be mobilized to fixate the brow to the underlying periosteum (A). Advancing this layer elevates the brow. Mobilize the superior portion of the incision, enhancing exposure of the underlying periosteum (B).

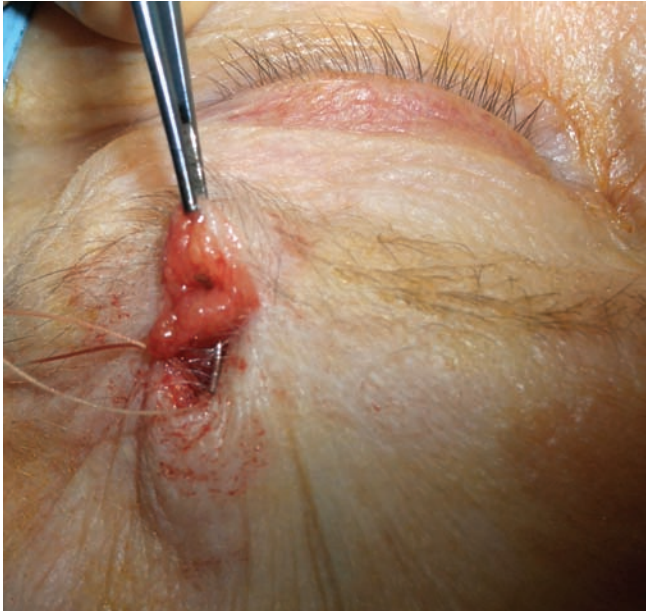


(A)

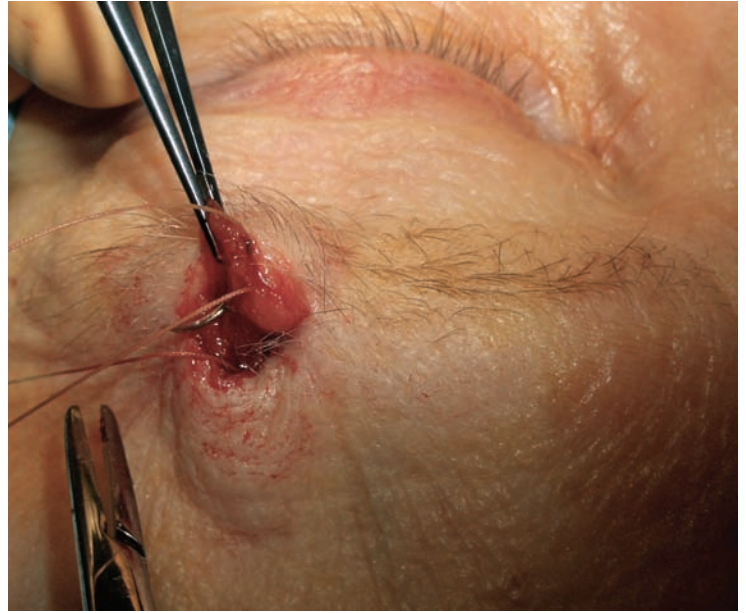


(B)

Figure 6.63 Retract the superior portion of the incision with a muscle hook or hemostat tip and pass a suture with a small curved cutting needle through the periosteum (A, B).



(A)



(B)

Figure 6.64 The suture is then passed through the posterior brow flap in a figure of eight type pattern (A, B).

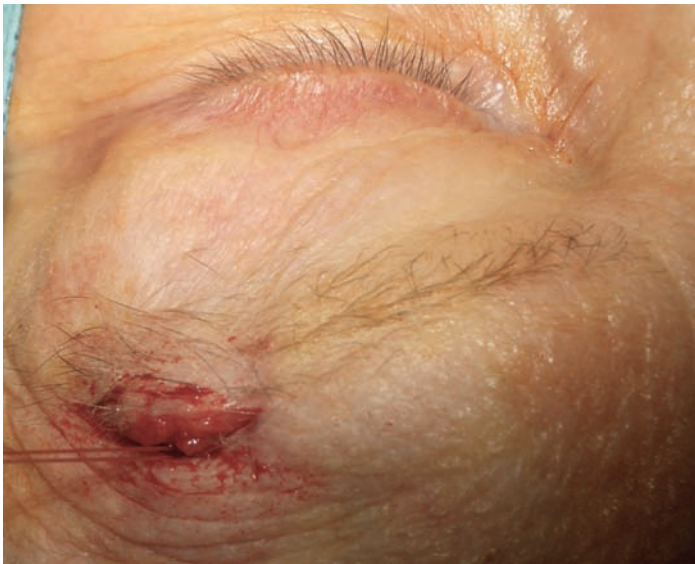

Figure 6.65 Tying the suture advances the posterior flap and fixates that portion of the brow.

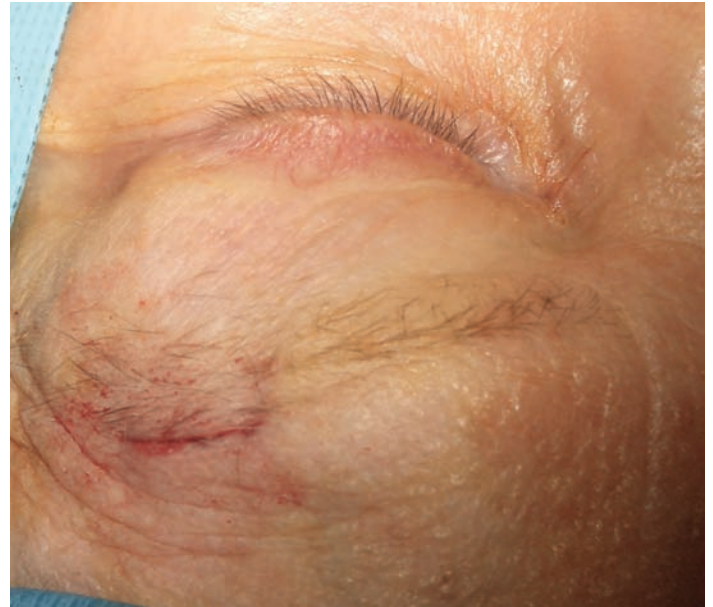


Figure 6.66 Close the anterior flap with a buried 5-0 Dexon suture approximating the skin and minimizing scarring. Close the skin with glue or suture.

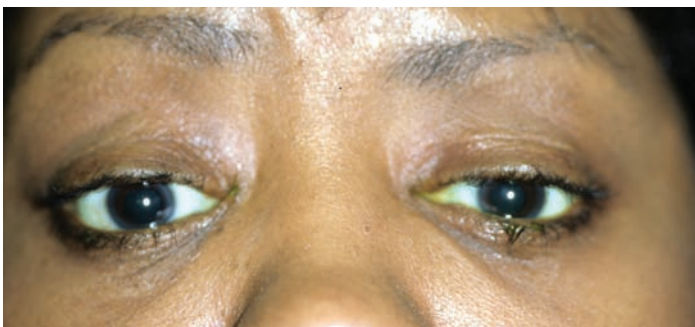

Figure 6.67 The Garfield look: Flattening of the upper eyelid after levator recession causes patient's eyelids to resemble Garfield the cat.

#### *Numb Forehead*

Operate lateral to the supraorbital neurovascular bundle. Palpate the supraorbital notch and stay lateral to it.

#### EYELID RETRACTION

The basic complication of treating upper eyelid retraction is overcorrection—making the patient ptotic with flattening of the upper eyelid (the Garfield look) (Fig. 6.67). To avoid complications, treat all upper eyelid surgery like a levator aponeurotic ptosis repair (Fig. 6.68). First identify and isolate the levator aponeurosis as described in section “Ptosis Surgery.” Then lower the eyelid. This can be graded depending on the degree of upper

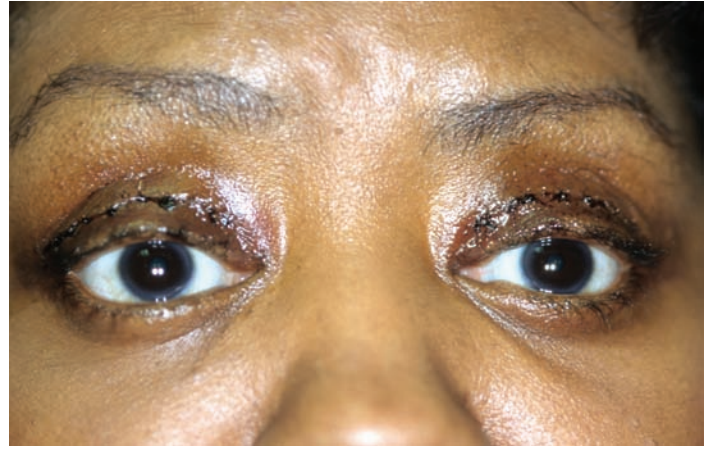
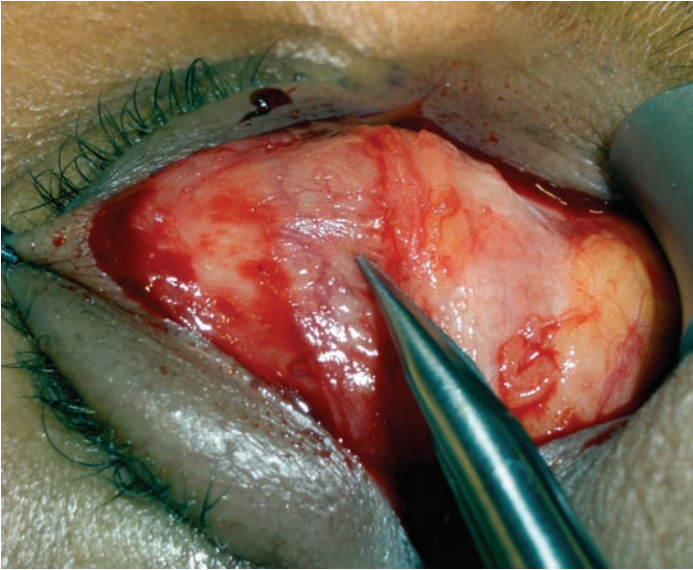
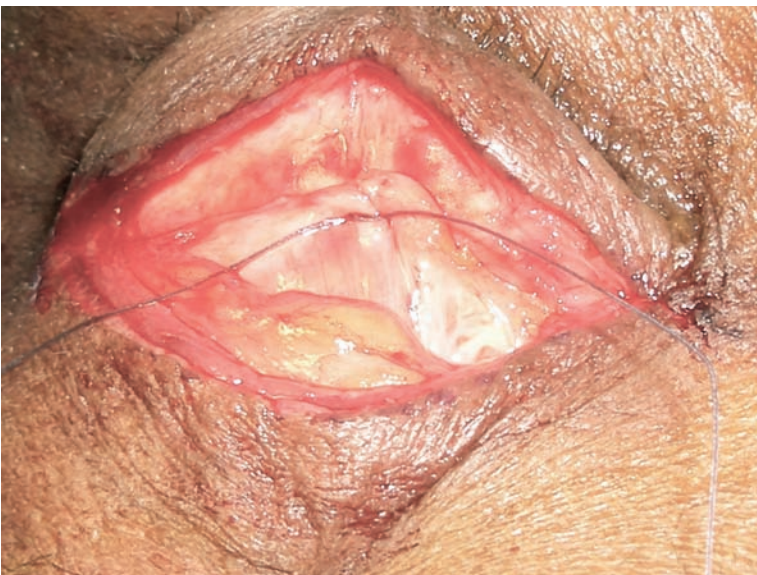
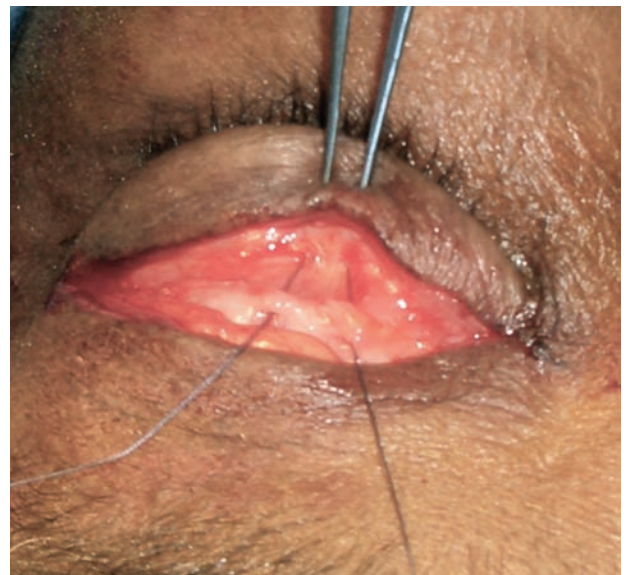
Figure 6.69 Resolution of the “Garfield look” after advancement of the levator aponeurosis.

Figure 6.68 Surgical anatomy of the levator aponeurosis and the underlying Mueller’s muscle (pointer). Successful treatment of upper eyelid retraction. Depending on the severity, requires a combination of levator aponeurosis recession, excision of the underlying Mueller’s muscle, conjunctival incision, and levator aponeurosis advancement with a “hang-back” technique.



(A)



(B)

Figure 6.70 The levator aponeurosis may be advanced and tightened (A). If it causes recurrent upper eyelid retraction (which it will), loosen the suture (B) and adjust the upper eyelid to an appropriate height and contour.

eyelid retraction. Minimal upper eyelid retraction requires a minimal amount of levator recession. Excessive retraction requires more levator recession and excision of Mueller’s muscle. There is a critical point in lowering the eyelid where you flatten the normal contour and achieve the Garfield the cat look. This is unacceptable to most patients and can be repaired by advancing the levator aponeurosis to achieve a more appropriate eyelid contour (Fig. 6.69). Here the levator needs to be suspended with a hang-back suture (Fig. 6.70), for if it is tightened, upper eyelid retraction will again occur.

Korneef and later Freuh have advocated a simplified approach to upper eyelid retraction. They describe a horizontal blepharotomy incising the conjunctiva at the top of the tarsus. This effectively lowers the eyelid but in an uncontrolled fashion. This technique helps to selectively lower portions of the upper eyelid, especially the temporal portion where extensive dissection might damage the lacrimal ductules. This technique augments recession of the levator aponeurosis and excision of Mueller’s muscle. If excessive ptosis and contour flattening occur, you can repair it by advancing the levator aponeurosis. Some experienced oculoplastic surgeons

advocate total excision of Mueller's muscle and then treating the subsequent ptosis by advancing the levator aponeurosis. This is a reasonable approach to severe upper eyelid retraction, but I prefer a more graded, individualized approach.

In 30 years, I have never used a spacer material in the upper eyelid and I doubt if I will start now.

#### EYELID RETRACTION AND BLEPHAROPLASTY

Excise fat and skin after you have adjusted the eyelid height and contour. Unlike ptosis repair, treating a retracted eyelid actually

lengthens it. It will require less skin removal than if the eyelid were elevated and shortened.

After you are satisfied with the eyelid height and contour, remove excessive preaponeurotic fat, especially the medial fat pad, in patients with thyroid eye disease. Remember that it takes more skin to fill a concavity than a convexity, so less skin removal will be necessary after the medial fat pad has been reduced. This is especially critical in the medial upper eyelid where excessive skin removal is more likely to cause problems with eyelid closure.

## 7 Complications of Upper Eyelid Surgery

### HEMORRHAGE

Hemorrhage after upper eyelid surgery may occur immediately or may be delayed. Interestingly, unlike lower eyelid hemorrhages, these hemorrhages rarely seem to cause a compressive optic neuropathy even when severe (Fig. 7.1A and B).

The patient in Figure 7.1 returned to the surgical center several hours after surgery with a severe hemorrhage. There was no evidence for visual dysfunction. Since the hemorrhage was very severe, the wound was opened, the hemorrhage was drained, and hemostasis was obtained by coagulating a small arterial bleeding vessel. Over the ensuing weeks, the hemorrhage slowly resolved leaving the patient quite ptotic due to a recurrent dehiscence of the levator aponeurosis but otherwise unimpaired (Fig. 7.2A–D).

Most upper eyelid hemorrhages may be observed for spontaneous resolution. They may be unsightly for a time, but eventually resolve often with an acceptable cosmetic and functional result (Fig. 7.3).

### EDEMA

Postoperative upper eyelid swelling can ruin an otherwise successful operation. Excessive swelling is often caused by excessive intraoperative manipulation or an allergic reaction to topical medications (Figs. 7.4 and 7.5). Minimize intraoperative manipulation. Edema is best avoided by minimizing tissue manipulation. Inexperienced surgeons like to touch everything several times. A dab here, cauterize there, another touch with the dental roll. The more you touch, the more swelling will occur. I have used the cataract surgery analogy for years, telling the residents to think of the eyelid as the corneal endothelium. The more manipulation in the eye, the more postoperative corneal edema. The eyelids are no different. Less manipulation is better.

Eyelid swelling may cause the levator aponeurosis suture to break causing recurrent ptosis. Some patient's eyelids—dysthyroid, rosacea—have a tendency to swell more than others and may benefit from intraoperative, intravenous steroids. Postoperative edema may be treated with a short course of corticosteroids (Medrol® dose pack) and identification and elimination of the offending medication.

### LAGOPHTHALMOS AND INCOMPLETE BLINKING

#### Upper Eyelid Retraction

##### *Eyelid Closure*

##### Avoid

Make sure that the levator aponeurosis is separated from the orbital septum. Advancing the orbital septum onto tarsus may elevate the upper eyelid but it will not close. If you cannot differentiate orbital septum from levator aponeurosis, you should not be performing upper eyelid surgery (see subsection “Technique” under “Ptosis Surgery” in chap. 6).

Since the orbicularis muscle is paretic due to the infiltration of local anesthetic, it is nearly impossible to detect defective eyelid closure during surgery. It is best prevented by not excising an excessive amount of skin.

Do not perform the blepharoplasty at the beginning of the procedure. Save it for the conclusion of the procedure. After the levator has been advanced and the eyelid height and contour deemed satisfactory, passively close the eyelid and overlap the superior portion of the incision over the inferior (Fig. 7.6A). Now excise excessive skin (Fig. 7.6B).

Always remove less skin medially than laterally and remember that if you remove the medial orbital fat pad, it will take more skin to fill a concavity than a convexity, so remove fat before removing skin. If you follow these rules, it is almost impossible to excise an excessive amount of skin.

If you do manage to excise too much skin and notice it at the time of surgery, replace it. If you neglected to replace it but, in your heart, you know that you have taken too much, refrigerate the excess skin in saline. It will still be viable 24 hours later and can be used to correct the lagophthalmos. If you think you excised too much skin, the chances are that you did, bite the bullet and replace it. You will be glad that you did.

Patients with excessive skin removal may be obvious (Fig. 7.7) or much more subtle (Fig. 7.8). These patients may complain bitterly of ocular irritation and photophobia. The only positive finding may be subtle lissamine green staining of the inferior cornea and an incomplete spontaneous blink visible only at the slit lamp. These complaints should not be taken lightly for they may result in a severe keratopathy, especially in patients having had previous intraocular surgery (Fig. 7.9).

#### Treatment

Replace the excised skin. The best skin for grafting the upper eyelid is skin from the upper eyelid. Sometimes you are lucky and there is enough excessive lateral upper eyelid skin to transpose to the medial portion of the upper eyelid and obviate the incomplete closure (Fig. 7.8). Usually, more skin is needed and the best source is the retroauricular region. This must be painstakingly thinned as described in section “Cicatrical Ectropion” in chap. 2. A thinner graft is a better graft. After compulsive thinning, it is adequate for grafting onto the upper eyelid.

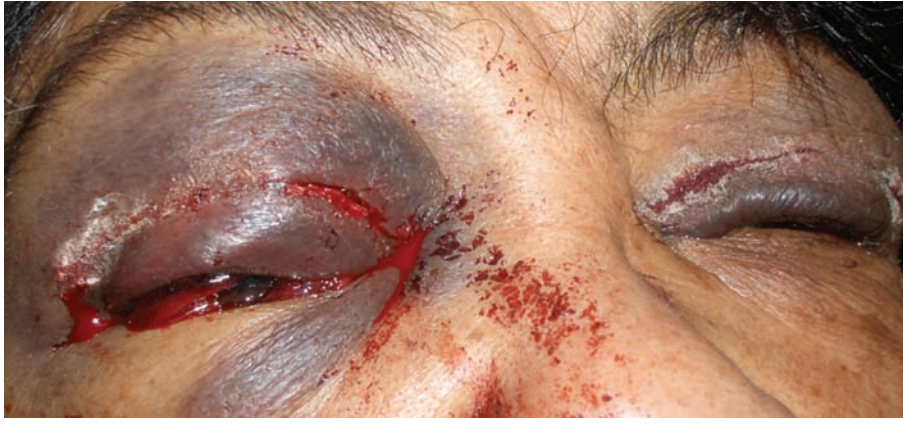#### Lower Eyelid Retraction

Another cause of keratopathy after ptosis surgery is failure to detect significant lower eyelid retraction prior to ptosis repair (Fig. 7.10). If significant lower eyelid retraction is present, even conservative upper eyelid elevation may result in a painful inferior keratopathy.

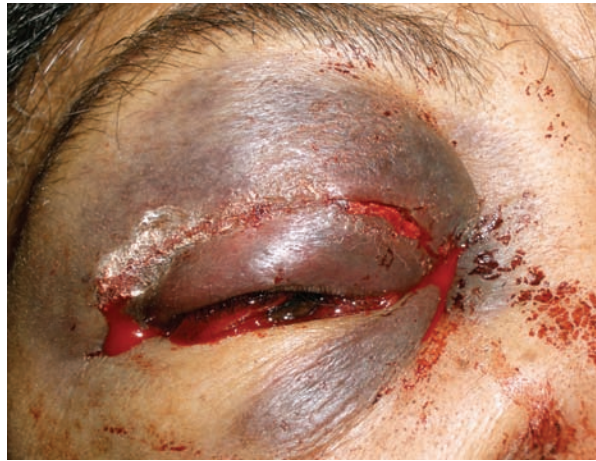Treatment entails elevation of the lower eyelid with an Enduragen™ graft (see chap. 4 “Lower Eyelid Retraction”).

If a patient develops a keratopathy after ptosis surgery, treat it aggressively. If it is not healing after lubrication and punctal occlusion, lower the upper eyelid by recessing the levator aponeurosis. If this does not resolve the problem, a small lateral tarsorrhaphy may be helpful. Do not depend on the corneal specialist alone to solve your surgical complication. Take a proactive role and treat



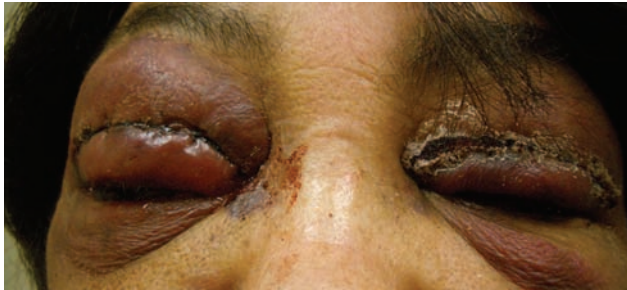

(A)

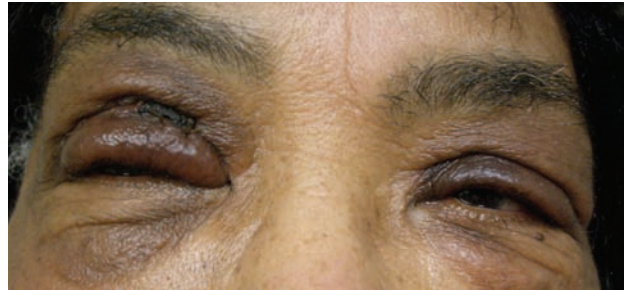

(B)

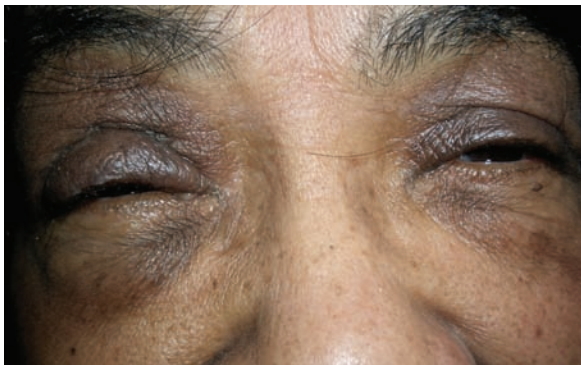Figure 7.1 Severe hemorrhage several hours after uneventful ptosis surgery (A, B). The wound was explored and an active arteriole vessel was cauterized.



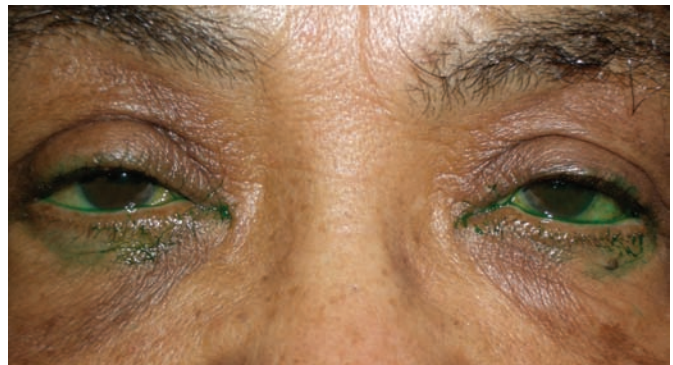(A)



(B)

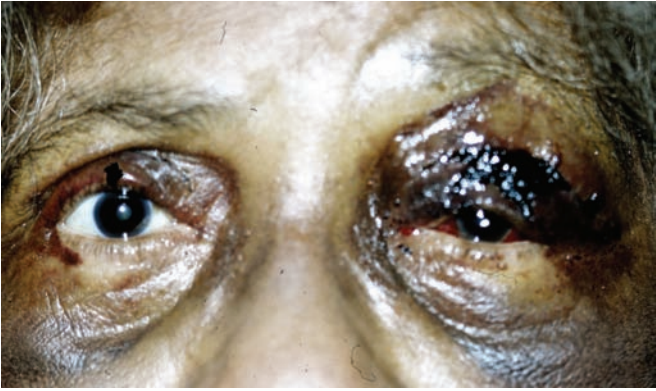


(C)

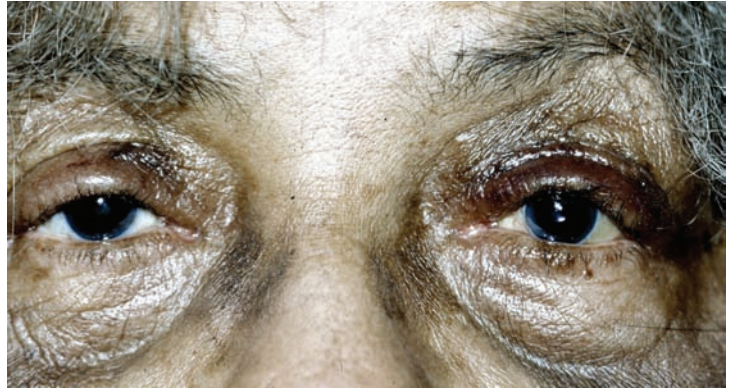

(D)

Figure 7.2 The hemorrhage slowly resolved without further intervention: one week later (A), two weeks (B), six weeks (C), and three months (D).



(A)



(B)

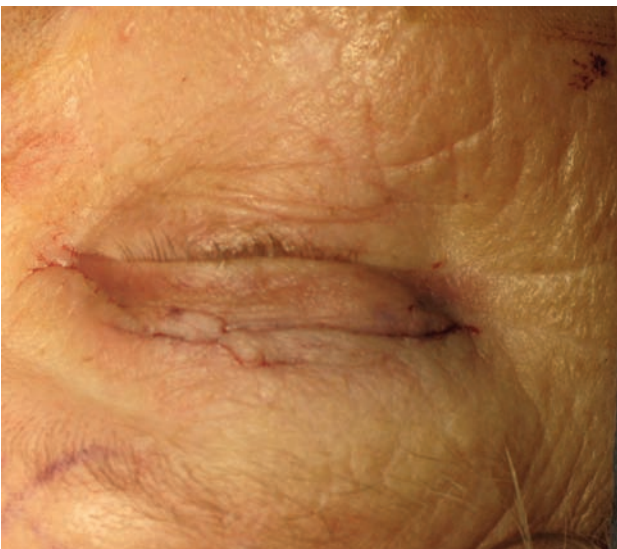
Figure 7.3 Upper eyelid hemorrhage shortly after ptosis surgery (A). Complete resolution of hemorrhage six weeks later without intervention (B).

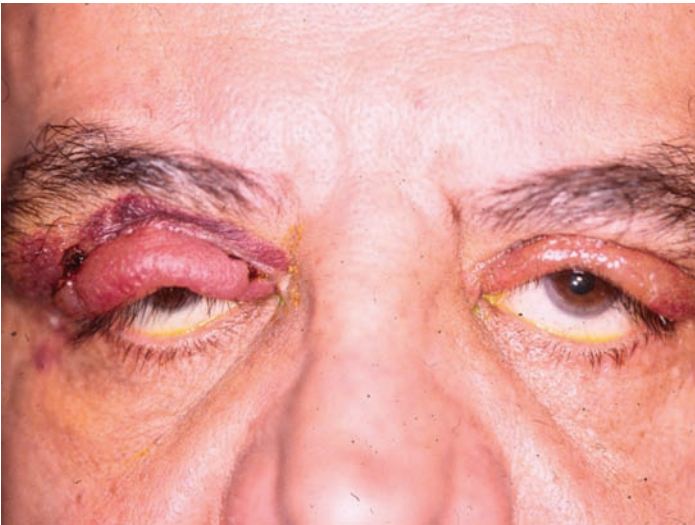

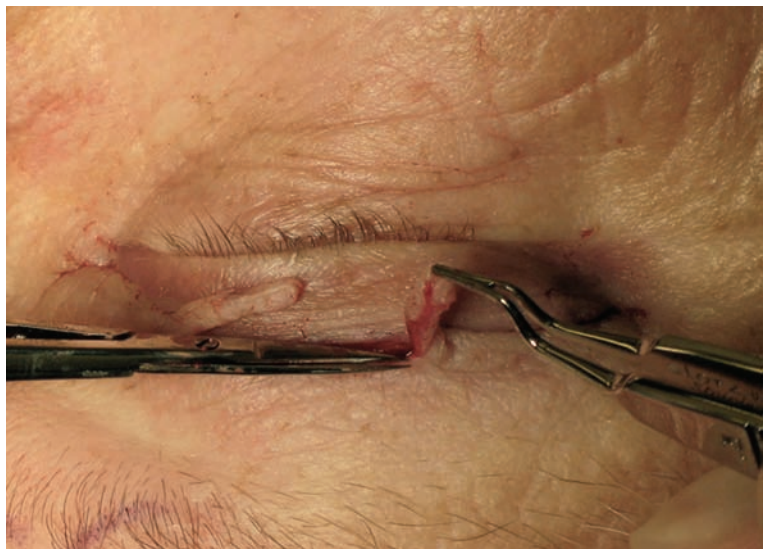
Figure 7.4 Severe upper eyelid edema due to excessive manipulation during ptosis surgery.

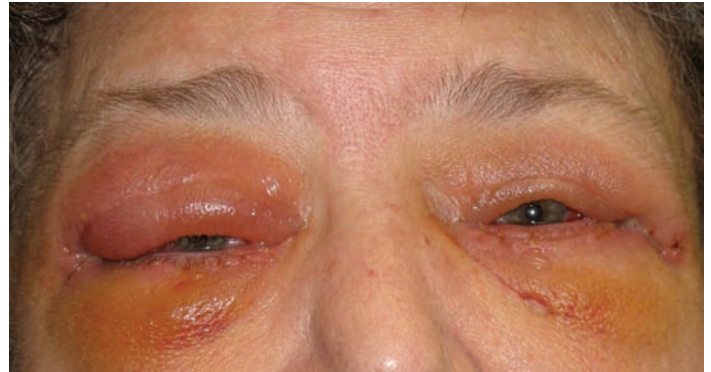

Figure 7.5 Severe upper eyelid edema due to an atopic reaction.

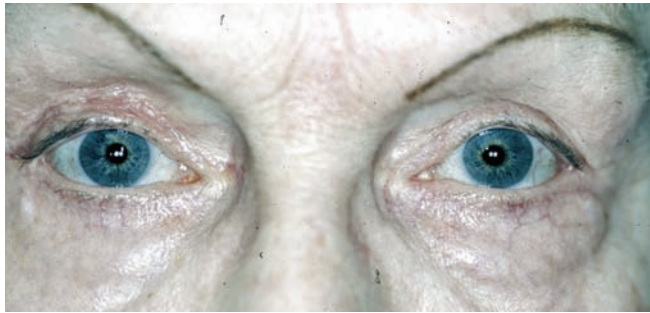


(A)

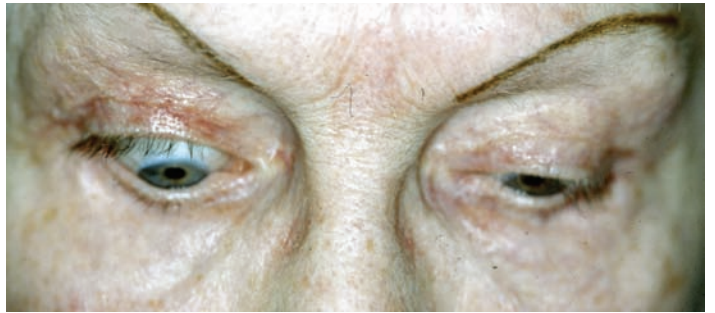


(B)

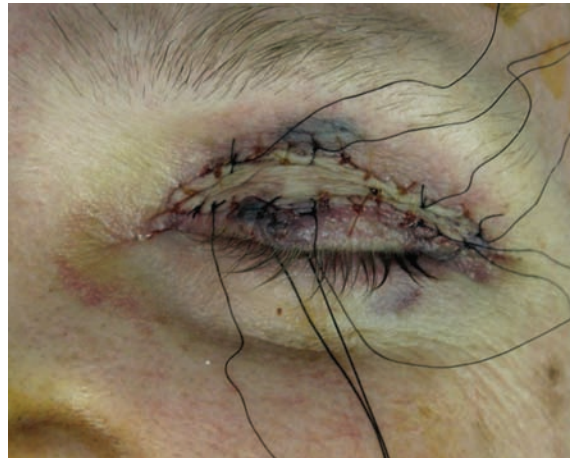Figure 7.6 Excising excessive skin at end of the procedure prevents excessive skin removal. Passively close the eye, overlap the upper edge of the incision over the lower (A), and excise two triangles of skin (B).



(A)

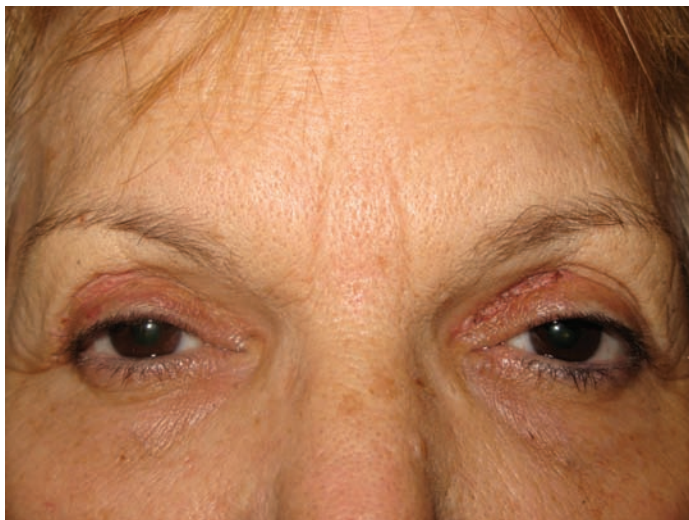

(B)

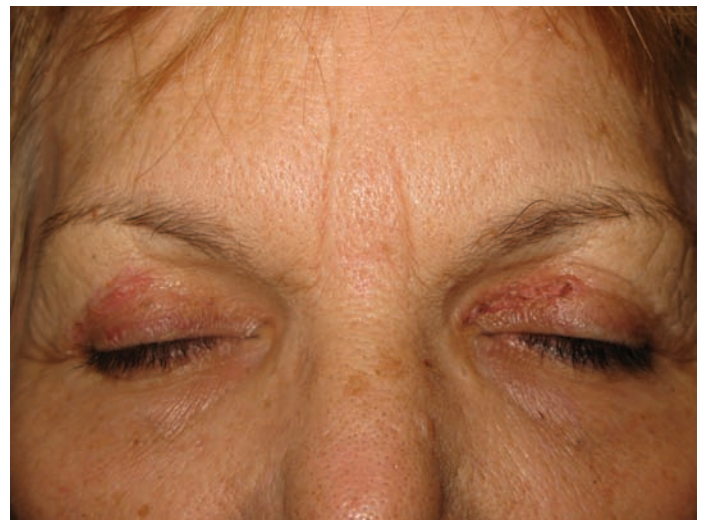

(C)

*Figure 7.7* Severe lagophthalmos is very evident in down gaze (B) in spite of the normal appearance in primary gaze (A). Severe shortening of the anterior lamella is obvious in down gaze. Correction requires replacement of the anterior lamella—a skin graft (C).



(A)



(B)

*Figure 7.8* Patient complained of chronic irritation in the left eye after ptosis surgery and blepharoplasty (A). Subtle lissamine green staining of the inferior cornea was evident on slit lamp examination confirming the reality of the patient's complaints. Small skin graft to the left medial upper eyelid from the right lateral upper eyelid resolved the symptoms and improved the patient's appearance (B).

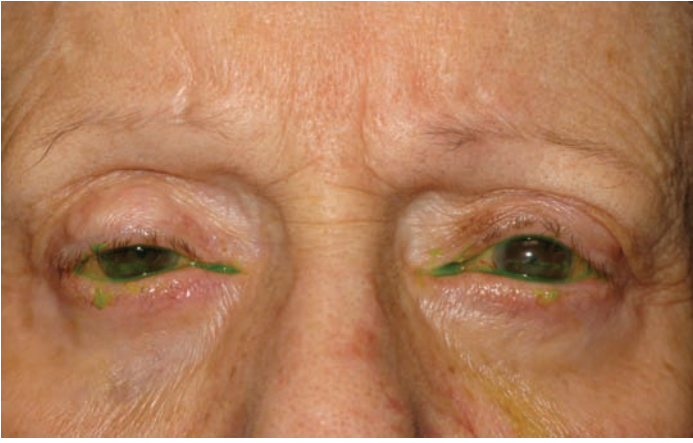

Figure 7.9 Severe keratopathy caused by decreased spontaneous blink persisted in spite of multiple attempts to lower the upper eyelids, raise the lower eyelids and partially close the eyes.

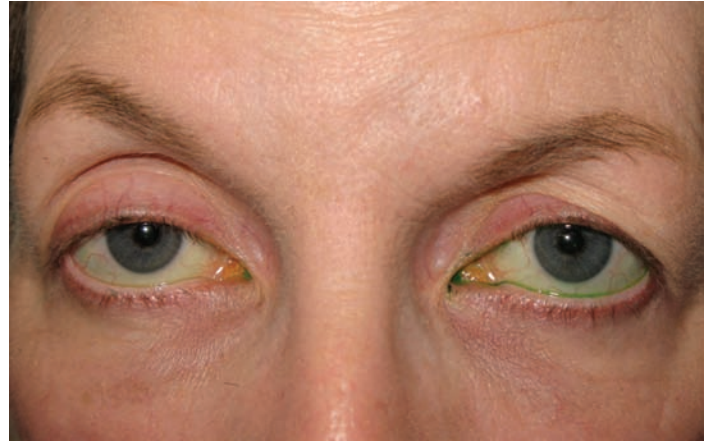
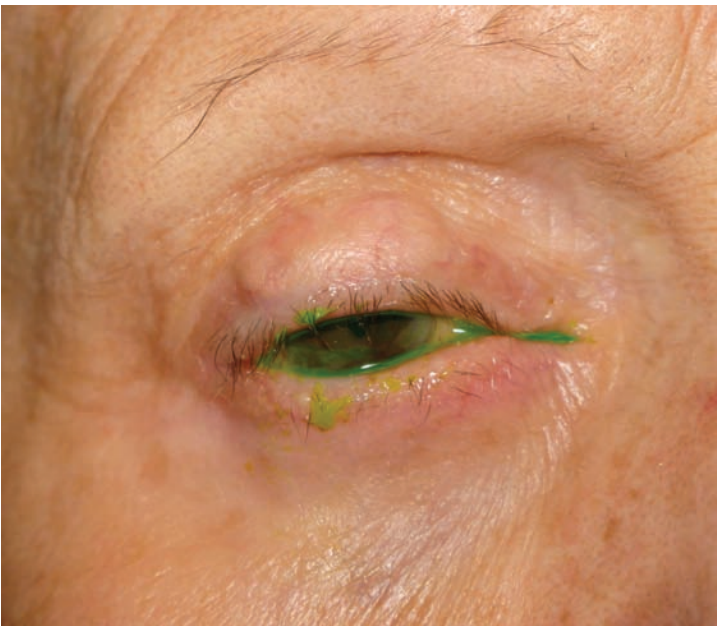
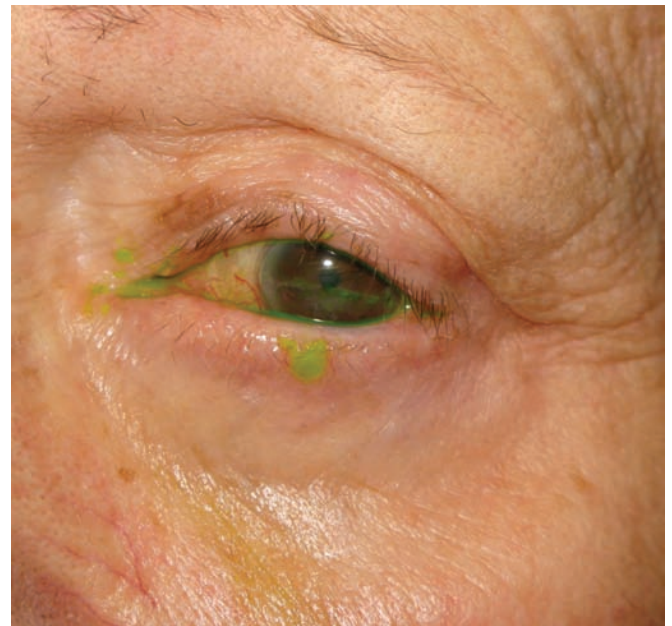


Figure 7.10 Significant lower eyelid retraction should be repaired prior to elevating even very ptotic upper eyelids. Note the subtle lissamine green staining of the inferior corneas (left eye). A sure sign of impending problems if the upper eyelid is elevated.



(A)



(B)

Figure 7.11 Severe bilateral keratopathy persisted in spite of multiple attempts to adjust the upper and lower eyelids (A, B).

the problem. Closing the eye for a few days with a patch or Frost suture may be very helpful in restoring corneal integrity. Prompt restoration of corneal integrity may prevent profound visual loss (Fig. 7.11).

#### Problem

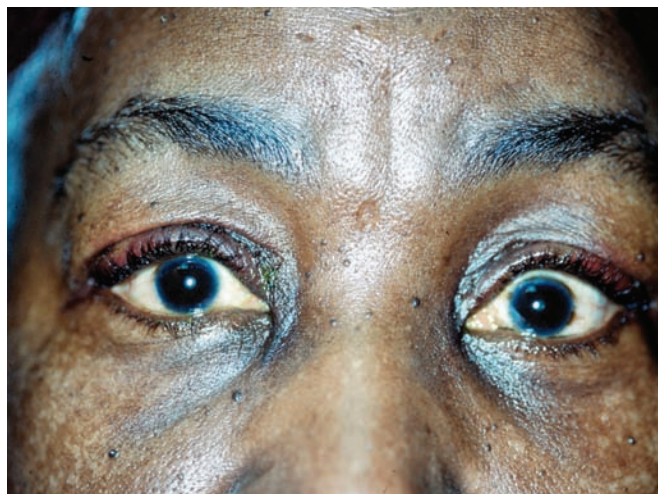
Asymmetric upper eyelid height and/or contour.

We really do not like to see our ptosis patients until six to seven days after surgery unless something unusual occurred during surgery, that is, loss of levator function during the procedure, fear of excessive skin removal, or excessive bleeding. Evaluating the routine ptosis patient too soon after surgery is bad for your self-esteem. There is too much swelling and you really cannot evaluate upper eyelid height and contour in the presence of

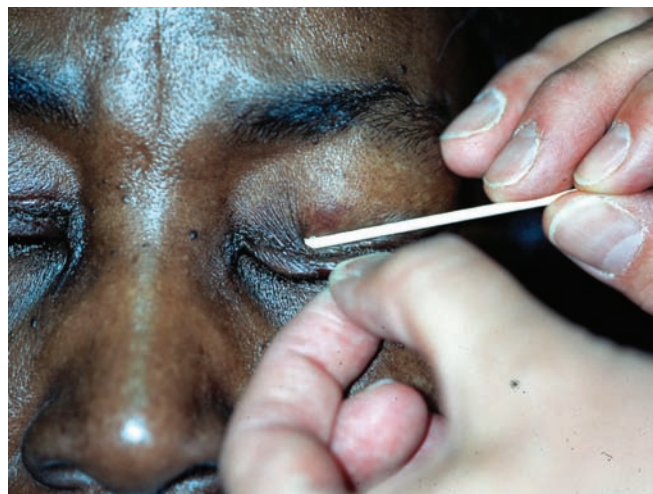excessive swelling. A week after surgery is adequate time for the edema to subside and allow you to still be able to salvage an excellent surgical result. Overcorrections are much easier to treat than undercorrections.

A small overcorrection may be treated by downward, digital massage or stretching the eyelid over an applicator stick (Fig. 7.12A–C). This will often resolve the overcorrection immediately.

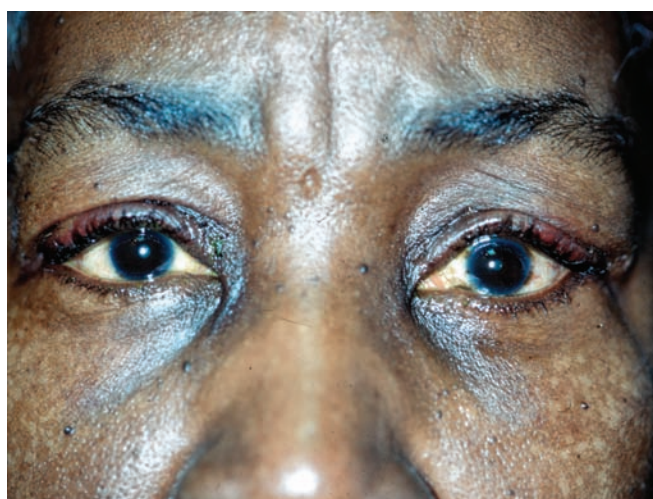
Large overcorrections may be treated by spreading the wound apart with cotton-tipped applicators, applying some 4% topical xylocaine to the wound and cutting the offending suture that is too tight. Gentle downward pressure lowers the eyelid. It is amazing how effective this is. The wound can then be anesthetized and closed with suture or approximated and closed with surgical glue (Indermil®). Treat long standing overcorrections, especially when



(A)



(B)



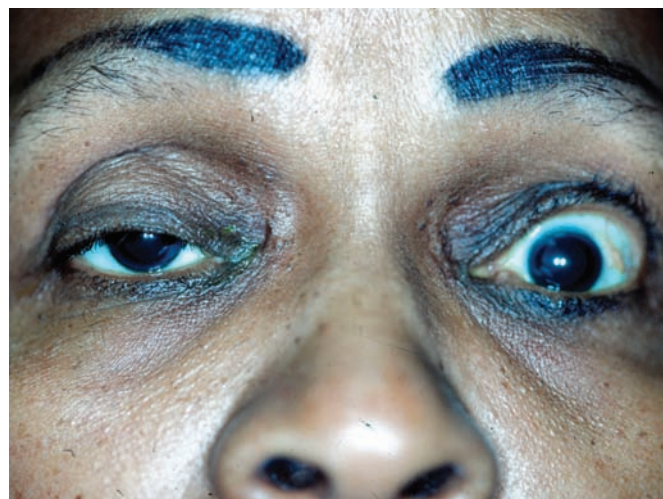(C)

*Figure 7.12* Treat mild peaking and retraction of the upper eyelid (A) by stretching the eyelid over an applicator stick (B). This loosens the attachment of levator aponeurosis to tarsus, lowering the eyelid and obviating the peak (C).

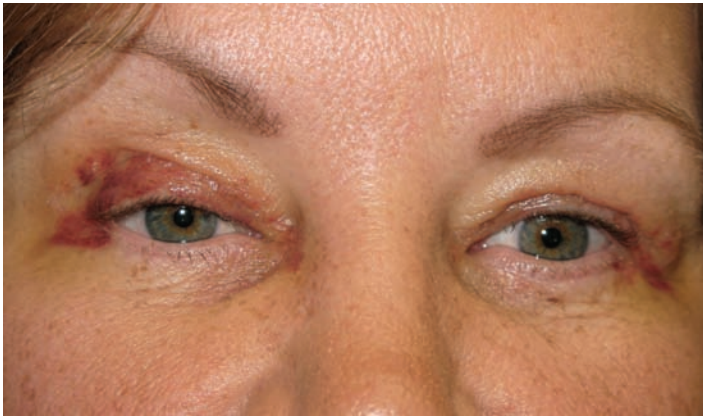accompanied by contralateral undercorrections, by repeating the operation (Fig. 7.13). Advance the levator aponeurosis of the undercorrected eyelid and recess the levator aponeurosis of the overcorrected eyelid.

Undercorrections cannot be evaluated in the presence of eyelid edema. A little bit of upper eyelid swelling may cause significant ptosis even if the levator advancement was perfect. All you can do is wait for the edema to subside and then reevaluate the eyelid height and contour. If you balance the eyelids adequately at the initial surgery, it is very likely that they will be fine after the edema subsides. If the edema has caused the supporting suture to break and the levator aponeurosis to dehisce, all you can do is advance the levator again. Do it sooner rather than later. Once the swelling has subsided, there is little to be gained by waiting and procrastinating (Fig. 7.14A and B).

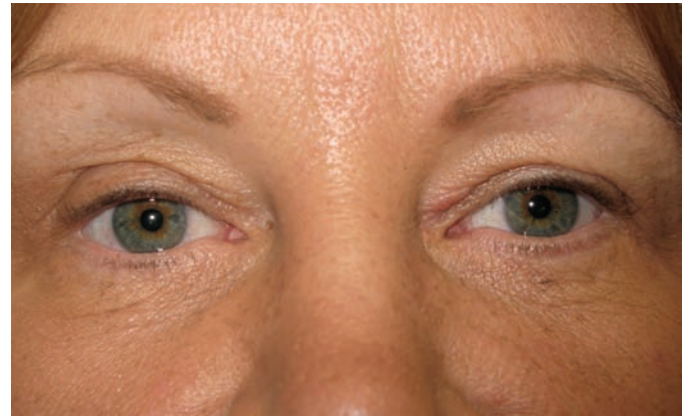A vintage glaucoma medication, Iopidine 0.5% or 1% drops, has a helpful side effect of elevating ptotic eyelids (Fig. 7.15). This lasts about 12 hours and is very helpful after overenthusiastic Botox® administration or undercorrected ptosis surgery.



*Figure 7.13* Long-standing asymmetric result after ptosis surgery. These are best treated by redoing the surgery, advancing the levator aponeurosis in the ptotic eyelid, and either recessing or advancing the contralateral levator after Herring's law has been neutralized by elevating the ptotic upper eyelid.

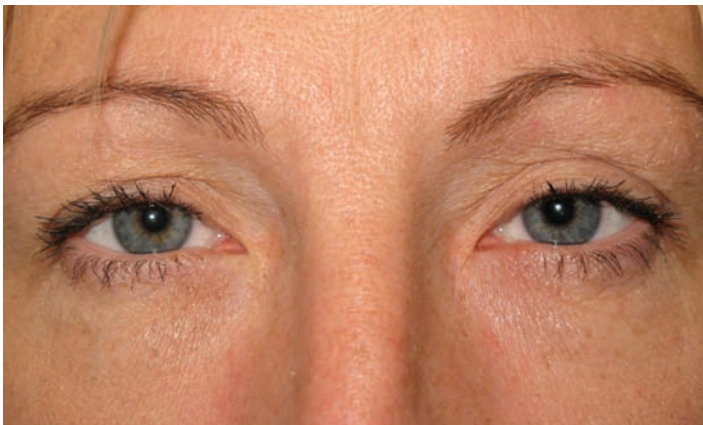

(A)

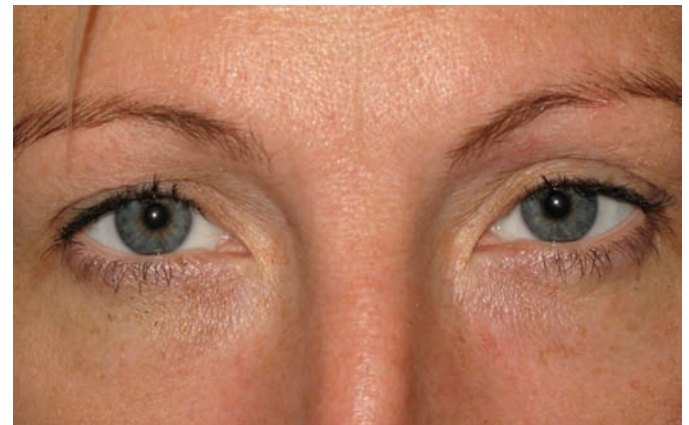

(B)

Figure 7.14 Upper eyelid edema after ptosis surgery makes eyelid height and contour difficult to evaluate: one week after surgery (A). The best course is waiting for the edema to resolve—six weeks after surgery (B), often with a very acceptable result.



(A)



(B)

Figure 7.15 Beneficial effect of Iopodine on mild to moderate ptosis: before (A) and 10 minutes after (B) instillation of a drop of 1% Iopodine in each eye.

#### MEDIAL CANTHAL WEBBING

Medial canthal webbing (Fig. 7.16) occurs when the upper eyelid incision extends medially beyond the punctum. It also seems to occur when the surgeon is certain that the incision did not extend too far medially. It usually occurs in patients with excessive dermatochalasia. Treatment by massage and steroid injection may be helpful. Significant webbing often requires repair with a small skin graft and/or a V-Y plasty. Webbing is best avoided by limiting the medial extension of the incision and conservative skin removal. You can always excise more skin in the office with a pinch incision (see subsection “Intraoperative Complications” under “Ptosis Surgery” in chap. 6), or shrink excessive skin with a resurfacing laser. It is more difficult and time consuming to replace it.

#### SUTURE KERATOPATHY

Prevention is the key to managing this complication. Invert the eyelid after placing the tarsal suture (Fig. 7.17). If the needle is visible or if the suture is “maybe visible” replace it. Always elevate

the eyelid from the globe when placing the tarsal suture. Routine elevation of the eyelid will eliminate the small risk of globe perforation in ptosis surgery.

An exposed suture in the tarsus results in a chronic keratopathy and a very unhappy patient (Fig. 7.18A). The key to diagnosis is suspicion. The classic corneal ice-skating sign (Fig. 7.18B) is the evidence that something is scratching the cornea. Inverting or double inverting the eyelid will identify the offending suture (Fig. 7.18C), which must be identified and removed.

Suture erosion higher in the eyelid may cause a chronic conjunctival granuloma and persistent upper eyelid swelling (Fig. 7.19A and B). Double inverting the eyelid is diagnostic; removal of the offending suture is curative.

#### DIPLOPIA

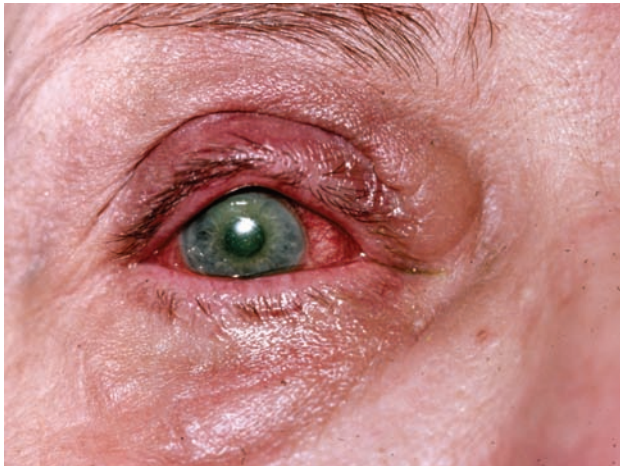
Diplopia after upper eyelid surgery results from injury to the superior oblique muscle, tendon, or the trochlea (Fig. 7.20A). Patients with damage to their superior oblique muscle present with vertical

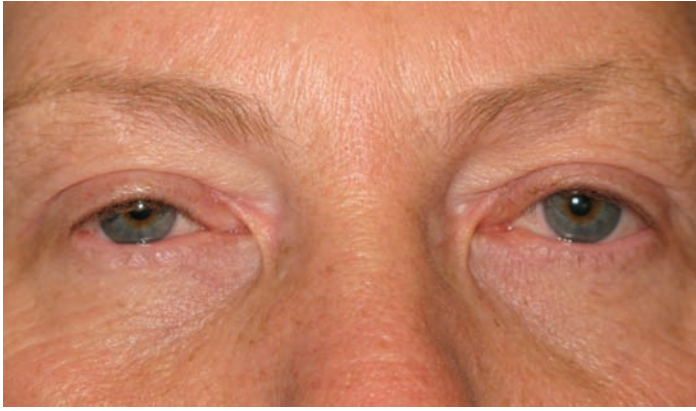

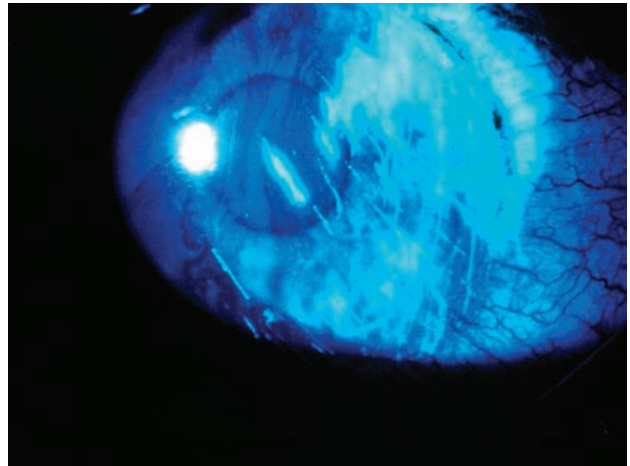
Figure 7.16 To prevent medial canthal webbing, do not extend the upper eyelid incision medial to the punctum. Treatment involves excising the scar with a V-Y plasty and inserting a small skin graft from the lateral upper eyelid if necessary.

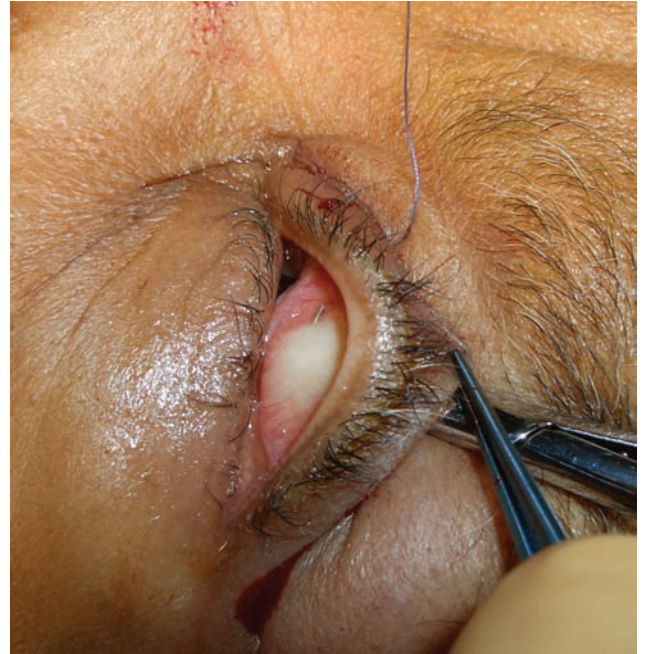

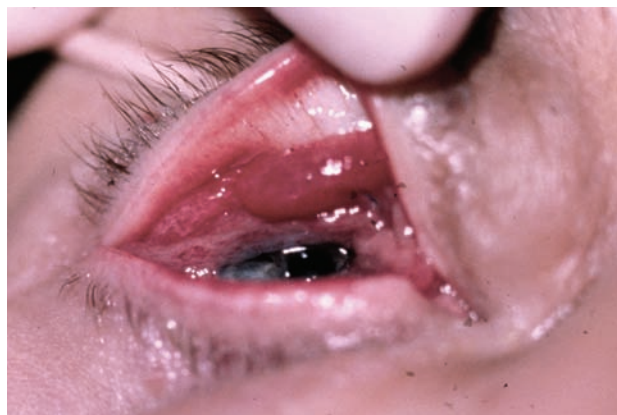Figure 7.17 Inverting the upper eyelid after passing the suture through the tarsus will detect penetration of the tarsus and prevent postoperative suture keratopathy.



(A)

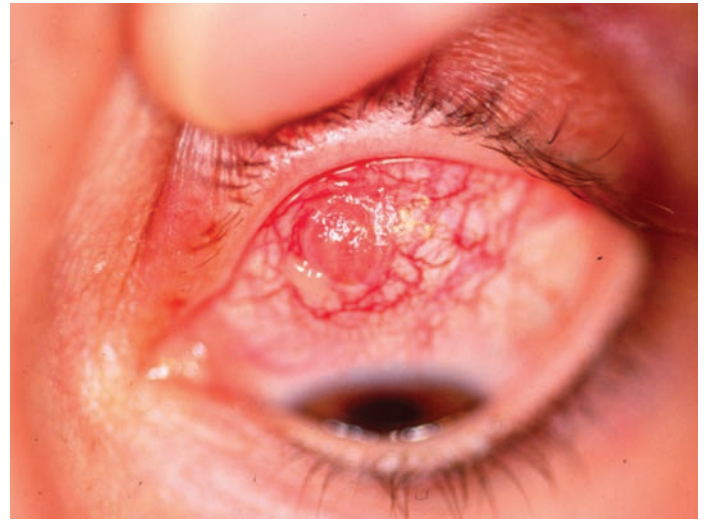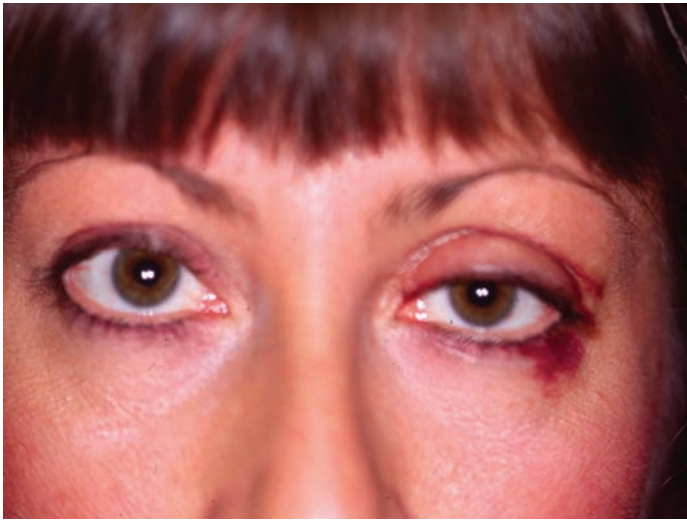


(B)



(C)

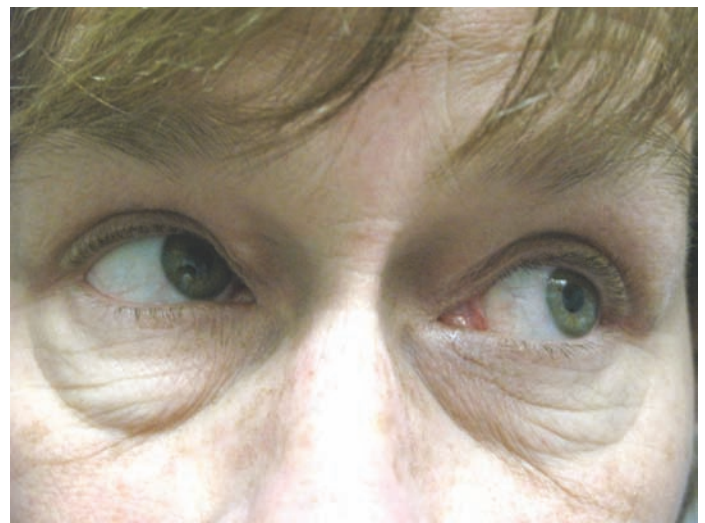
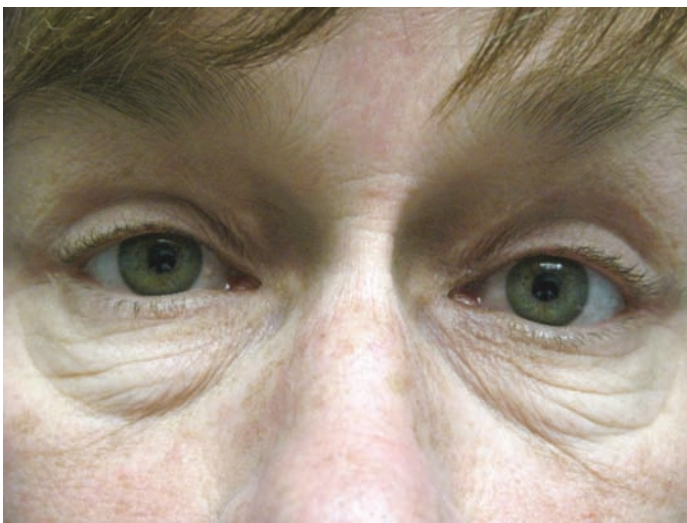Figure 7.18 Patient complained of red painful eye (A) for a week after upper eyelid surgery. Multiple emergency room visits failed to detect the now significant corneal staining (B) and the offending suture eroding through the tarsus (C).



(A)

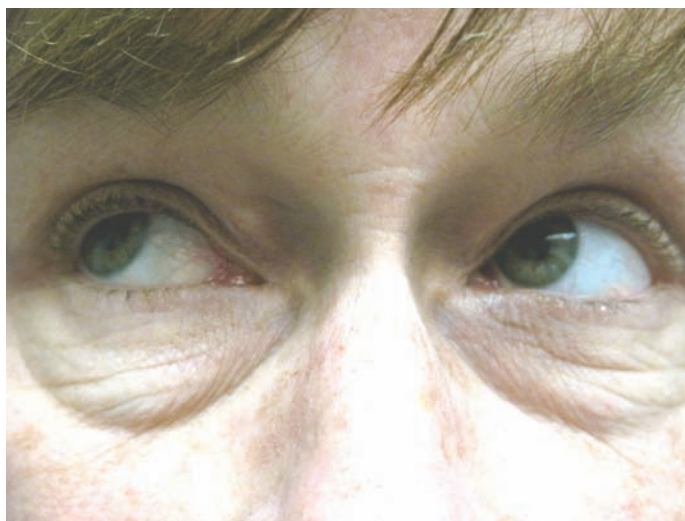
(B)

Figure 7.19 Recurrent ptosis several weeks after surgery (A) resulting from chronic irritation and granuloma formation (B) by an eroding suture in the superior fornix.



(A)

(B)



(C)

Figure 7.20 Patient complained of vertical diplopia immediately after cosmetic upper eyelid surgery. The patient had a right hypertropia (A) and an overacting right inferior oblique muscle (B) compared to the left inferior oblique (C). Right inferior oblique recession resolved the patient's diplopia.



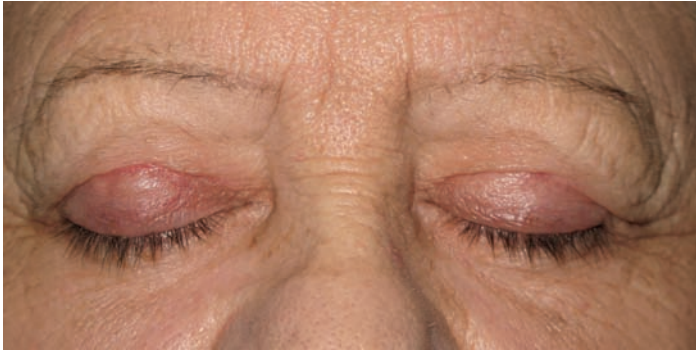

Figure 7.21 Persistent erythema and nodules after upper eyelid surgery suggests an atypical mycobacterium infection.

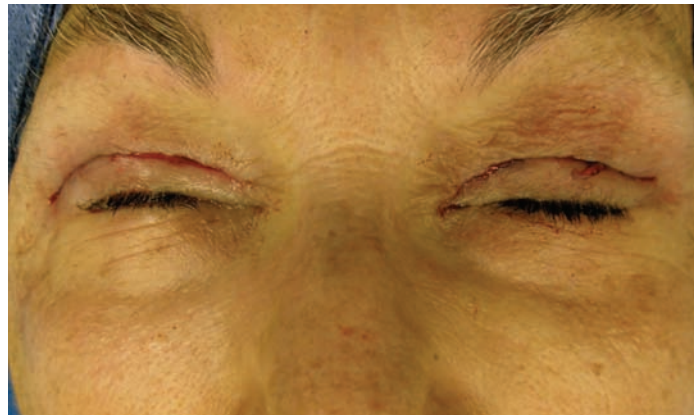
How are they prevented? Do not dig for the medial fat pad. Apply gentle pressure to the globe and let the fat pad surface into the wound where you can incise the capsule and clamp and cauterize only the presenting portion of the fat pad. Avoid reaching into the medial orbit with forceps and deep cauterization attempting to remove the fat pad. This will only cause damage to the superior oblique muscle, tendon, trochlea, or superior ophthalmic vein.

**ATYPICAL MYCOBACTERIUM INFECTION**

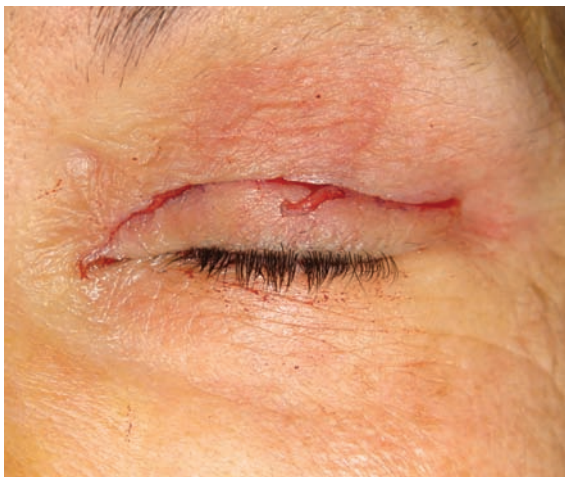The appearance of erythema and skin nodules in the upper eyelid weeks to months after surgery suggests an atypical mycobacterium infection (Fig. 7.21). Excision and culture of the offending tissue will reveal atypical mycobacterium, but culture may take up to six weeks and the laboratory must be informed of your suspicions if they are to culture the specimen appropriately. Routine culture techniques will not be effective.

Treatment with oral clarithromycin 500 mg twice daily for many months is usually curative. Start treatment while awaiting the culture results. Let the infectious disease experts guide the antibiotic therapy.

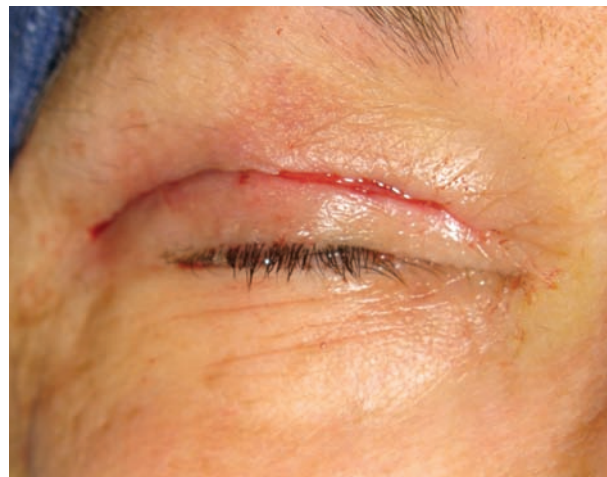diplopia, a hypertropia and an overacting inferior oblique muscle (Fig. 7.20B and C). Patients with damage to the trochlea present with vertical diplopia, a hypotropia, an apparent underaction of the inferior oblique and positive forced ductions indicating obstruction at the trochlea (pseudo-Brown's syndrome). These are rare complications and occur after removal of the medial fat pad.



(A)



(B)



(C)

Figure 7.22 Mild asymmetry of upper eyelid incisions will result in asymmetric eyelid creases (A). This may be avoided by excising a thin strip of skin from the inferior incision so that the higher side (B) will now equal the lower side (C) and the resultant creases will be symmetrical.

ASYMMETRIC EYELID CREASES

Some of us are incapable of drawing and cutting symmetrical upper eyelid creases. If you are reforming the upper eyelid crease with supratarsal fixation attempting to make it prominent, it is important for the tarsal platforms and creases to match. If the incisions are asymmetric (Fig. 7.22A), the eyelid folds will be asymmetric and the patient will be unhappy. Correct this by excising a

thin strip of the inferior portion of the incision (Fig. 7.22B and C) to equalize the creases before closure. Excision of this millimeter of skin can make a significant difference in patient satisfaction. This is especially important in young women undergoing cosmetic upper eyelid surgery. If the incision is closed skin to skin as in most patients with functional ptosis repair and blepharoplasty, this is not usually an issue unless the creases are very asymmetric.

## 8 Tearing and Dry Eye—Evaluation and Treatment

Patients complaining of tearing and dry eye symptoms are ubiquitous in any ophthalmology practice, especially if you ask the patient. Too often these patients are given a sample of whatever artificial tears are available and sent on their way. This chapter presents a rational and practical plan for evaluating and effectively treating these patients. Detection and treatment of ocular surface dysfunction prior to eyelid surgery is important. Proactive treatment of dry eye and potential corneal exposure can prevent complications ranging from discomfort to pain and visual loss.

At the initial slit lamp examination, before the usual drops, stain each eye with a lissamine green strip. This will rapidly differentiate aqueous tear deficiency (Fig. 8.1) from conjunctivochalasia (Fig. 8.2) and allow easy detection of subtle punctal ectropion and an excessive tear film (Fig. 8.3A and B). If there is a normal to decreased tear film and stippled staining of the conjunctiva with lissamine green (Fig. 8.1), the patient's symptoms are due to dry eye (aqueous tear deficiency). If both the cornea and conjunctiva stain with lissamine green (Fig. 8.4), the dry eye by definition is severe and treatment should be aggressive and include temporary punctal occlusion, Restasis® drops twice daily, and ocular lubrication. Staining only the exposed bulbar conjunctiva (Fig. 8.1) indicates moderate dry eye, which may be treated as severe dry eye though you may omit punctal occlusion or long-term Restasis therapy. Ocular lubrication and temporary punctal occlusion are effective first-line treatments supplemented by long-term treatment with Restasis and “permanent” punctal occlusion as necessary.

If the tear film appears excessive (Fig. 8.3B), look carefully for a subtle punctal ectropion (Fig. 8.3A). Since the conjunctiva surrounding the punctum is desiccated from exposure (it is not in the tear film), these puncta will often stain with lissamine green. Obvious ectropic puncta (Fig. 8.5) will always stain with lissamine green. Determine the patency of the nasolacrimal excretory system by dilatation and irrigation (Fig. 8.6A–D). Repairing the ectropion will not cure the epiphora if the nasolacrimal system is obstructed. An obstructed nasolacrimal system usually requires a dacryocystorhinostomy (DCR) to restore function and relieve epiphora. Less invasive treatments have been advocated but may not be as effective.

The purpose of a DCR is to bypass the obstructed nasolacrimal system by anastomosing the lacrimal sac to the nasal mucosa. There are many variations in technique with their usual vocal advocates. I will describe a technique for external DCR that is reasonably successful and has withstood the test of time. It involves routine canalicular intubation with sialastic tubing and routine use of topical mitomycin-C in the anastomosis site.

If properly incised and closed, the external incision should be barely detectable after surgery. An external incision also allows for improved visibility and exposure.

Make a linear incision between the medial canthus and the bridge of the nose and extend it deep to the periosteum. Bleeding

from the angular vessels invariably occurs and is controlled with bipolar cauterization. Reflect the periosteum over the lacrimal crest with a periosteal elevator. This exposes the lacrimal sac behind a layer of periosteum (Fig. 8.7). Enhance exposure by cutting the anterior portion of the medial canthal tendon with scissors. Use a small, cottonoid pledget soaked in Afrin™ to reflect the lacrimal sac and enhance hemostasis. Remove the cocaine soaked packing from the nose and fracture the nasoethmoid bone with a hemostat. Enlarge the osteotomy with Kerrison rongeurs (Fig. 8.8). As the bone is removed, the nasal mucosa is exposed. Inject it with an epinephrine-containing local anesthetic. It will immediately blanch. This enhances hemostasis when you incise the mucosa. Bleeding is controlled by gentle pressure with afrinized cottonoids and judicious use of bipolar cauterization and bone wax.

Now pass a lacrimal probe through the inferior canaliculus into the lacrimal sac. This will indent the sac and periosteum. With a #12 or similar sickle blade make a superior to inferior incision over the indenting probe. You will feel the probe beneath the blade. When the probe is visible in the lacrimal sac, you are assured that you have opened the sac and the periosteum. You can see the probe exiting the common canaliculus (Fig. 8.9). Using the same blade make an incision perpendicular to the initial incision at both the superior and inferior border. This forms the anterior lacrimal sac flap. Now excise the posterior lacrimal sac flap as well as the posterior mucosa flap. A similar incision is made in the nasal mucosa after tenting the mucosa with a hemostat passed through the ipsilateral nostril (Fig. 8.9). As the mucosa is opened, the hemostat is visible in the nose. A large anterior flap is cut with the #12 blade. The posterior mucosa flap is excised. Now you can see the probe in the lacrimal sac covered by the anterior sac flap and the hemostat in the nose covered by the nasal mucosal flap (Fig. 8.10). A purist would suggest anastomosing the posterior flaps rather than excising them. This is technically difficult and, in my mind, not worth the time and effort. Others might disagree. It probably makes little difference.

Pass Crawford sialastic tubing sequentially through the inferior and superior canaliculi replacing the Bowman probe. The thin metal probe is grasped with an Adson forceps and extracted through the incision. Excise both probes from the sialastic tubing and tie the tubes together with a single knot (Fig. 8.11). Pass the knotted tubing into the nose and grasp it with the hemostat, extracting it through the nostril. This tubing lies in the anastomosis site. A 1½-inch cottonoid, dampened with mitomycin-C is placed into the anastomosis site. This is best done by passing a hemostat up the nostril into the incision, grasping the string attached to the cottonoid and pulling the cottonoid into the anastomosis. Folding the cottonoid vertically facilitates passage. The cottonoid now lies on top of the sialastic tubing and fills the anastomotic site from the common canaliculus to the nose. The anterior nasal mucosal flap is sutured to the anterior lacrimal sac flap with a 4-0 chromic or 5-0 Vicryl™ suture in a figure of eight fashion (Fig. 8.11).

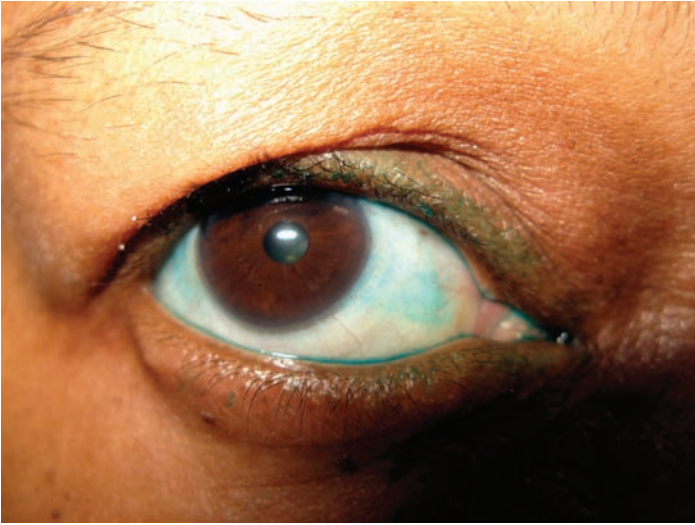
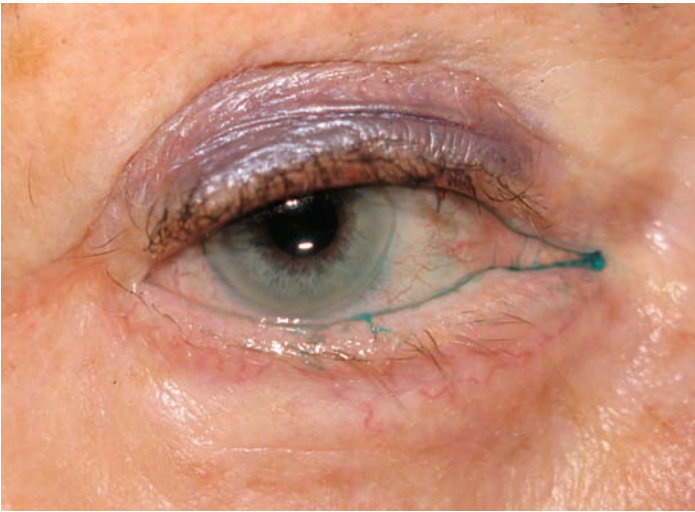


Figure 8.1 Lissamine green stains exposed bulbar conjunctiva in the palpebral fissure in patients with dry eye.

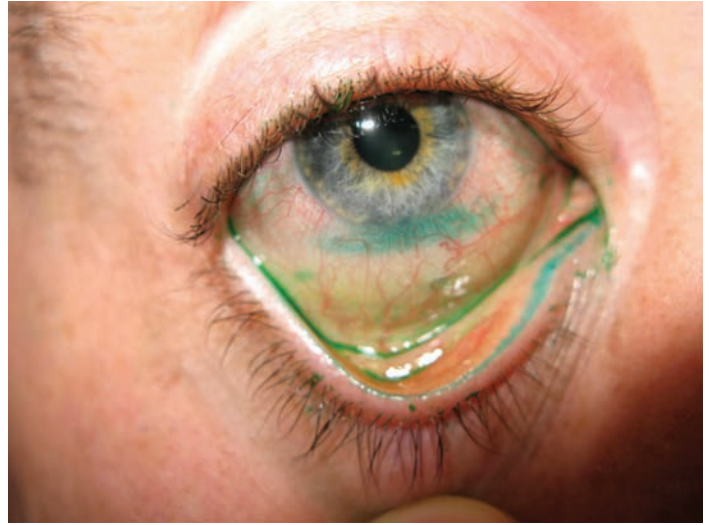

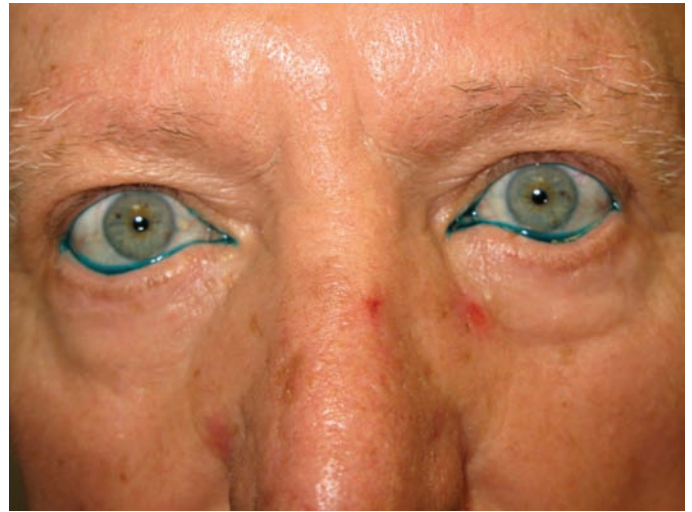Figure 8.2 Lissamine green stains the unexposed conjunctiva in patients with conjunctivochalasia.



(A)



(B)

Figure 8.3 Subtle punctal ectropion (A) stain with lissamine green. Excessive tear film is also more obvious (B).

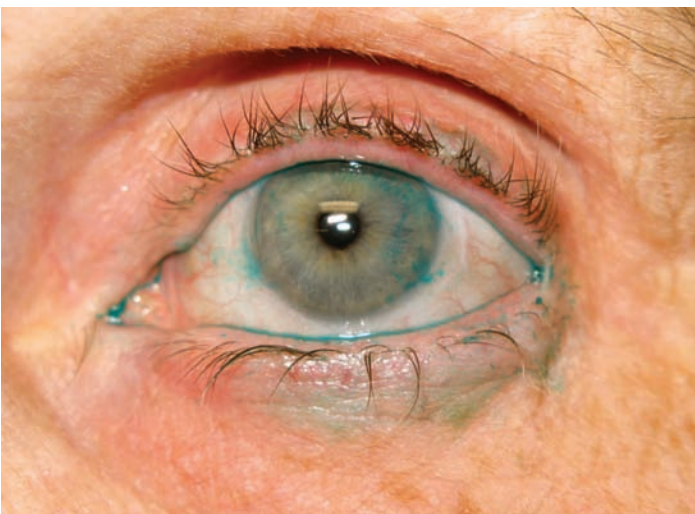


Figure 8.4 Lissamine green staining of both conjunctiva and cornea is diagnostic of severe dry eye.

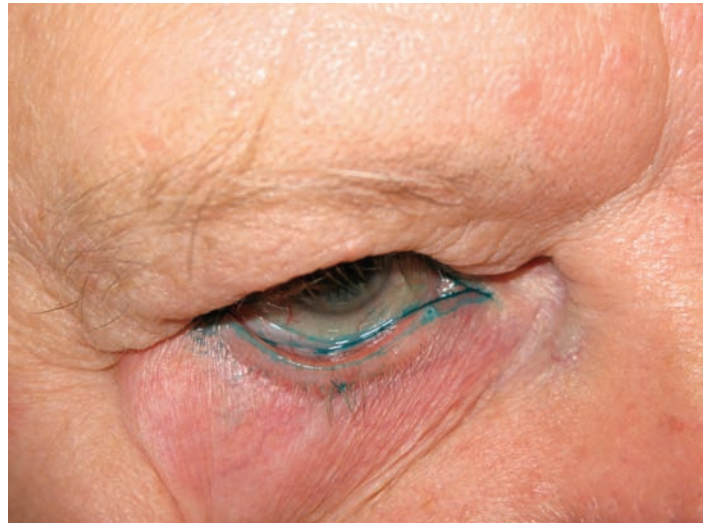
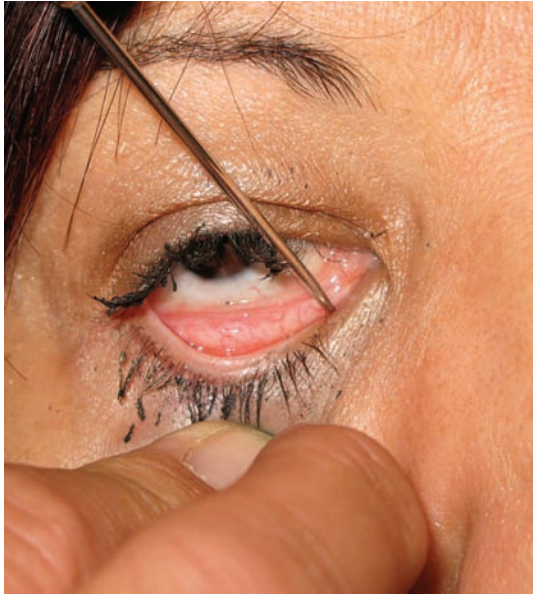
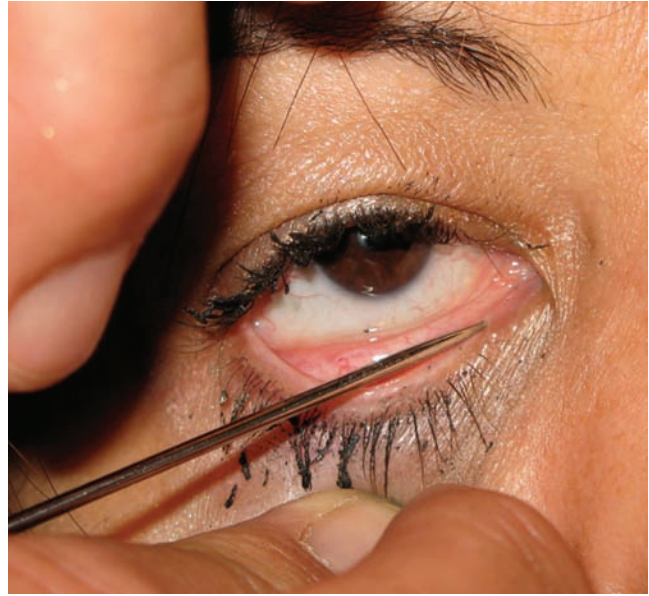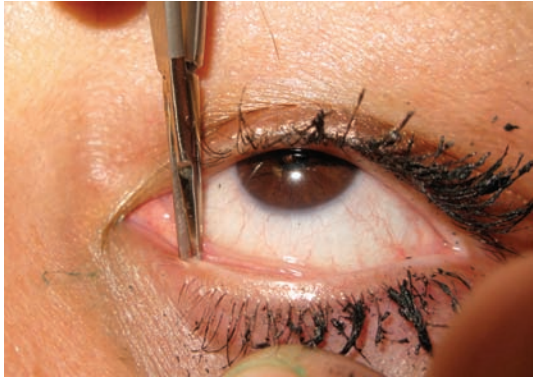Figure 8.5 Ectopic puncta staining with lissamine green. Also note the conjunctivochalasia.



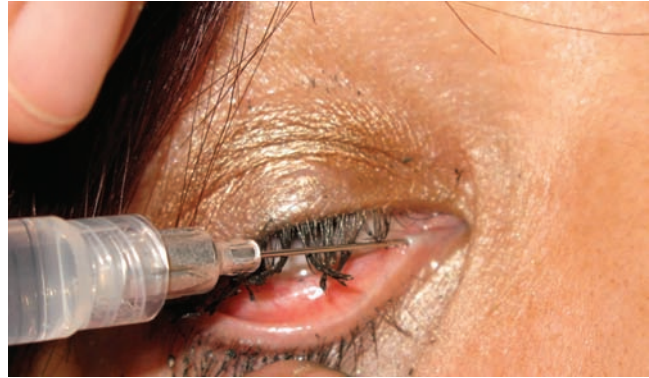(A)



(B)

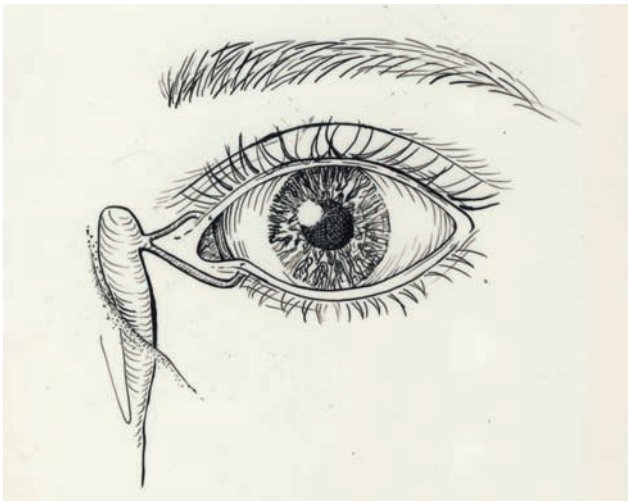


(C)

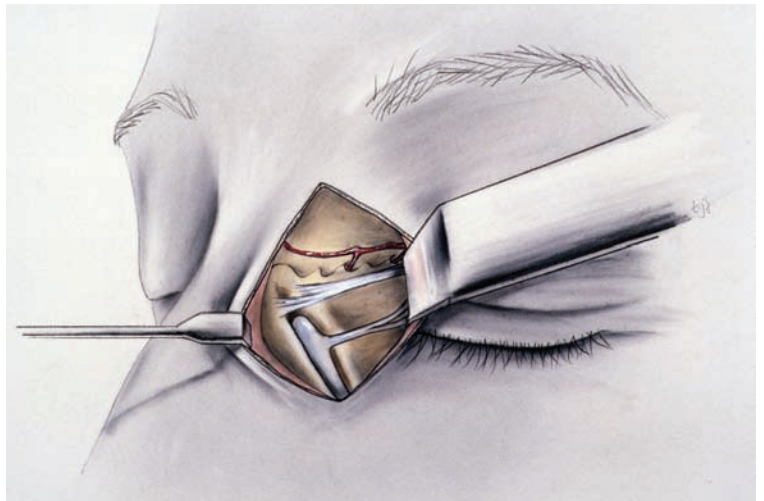


(D)

Figure 8.6 Dilating the punctum (A, B) and irrigating (D) the nasolacrimal excretory system is an integral part of the epiphora evaluation. If the punctum is stenotic, a one-snip punctoplasty may be performed by inserting a scissor blade into the punctum and making one vertical snip (C).



(A)



(B)

Figure 8.7 Relationship between the eye, canaliculi, and the lacrimal sac (A). Diagram (B) demonstrates the relationship between the lacrimal sac, the medial canthal tendon, and the anterior ethmoidal vessels. The anterior portion of the medial canthal tendon may be incised to enhance exposure of the lacrimal sac. All bone removal should be well inferior to the anterior ethmoidal vessels, which demarcate the boundary between the orbit below and the brain above.

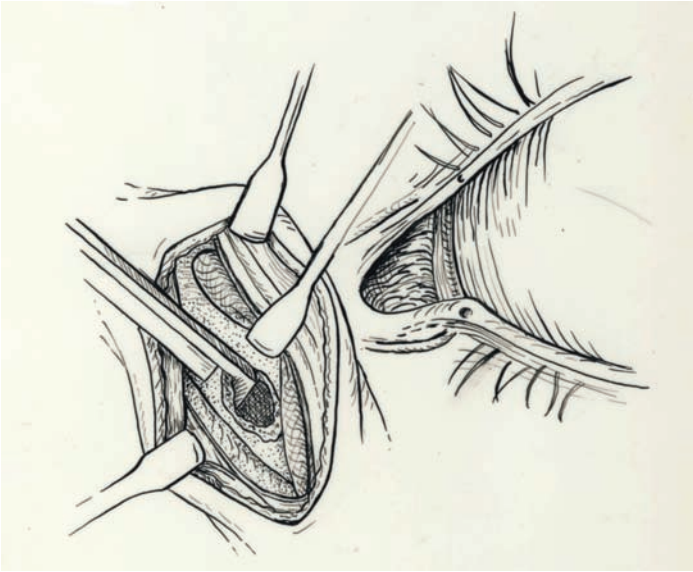


Figure 8.8 The periosteum and the underlying lacrimal sac is reflected towards the eye, exposing the bony lacrimal crest. After fracturing the bone at the nasolacrimal junction with a hemostat, the bony defect is enlarged with Kerrison rongeurs exposing the underlying nasal mucosa.

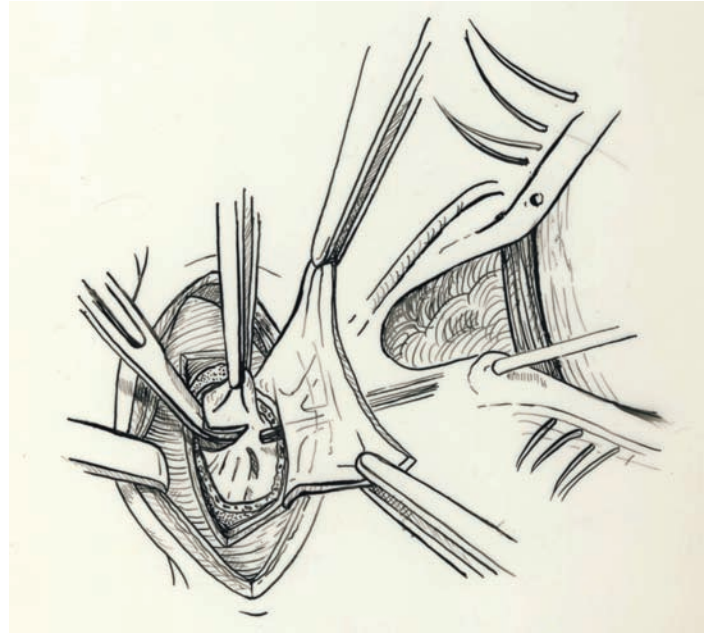


Figure 8.9 The bone has been removed, exposing the nasal mucosa which is tented from below with a transnasal hemostat and incised with a curved blade. A lacrimal probe has been passed from the punctum to the common canaliculus.

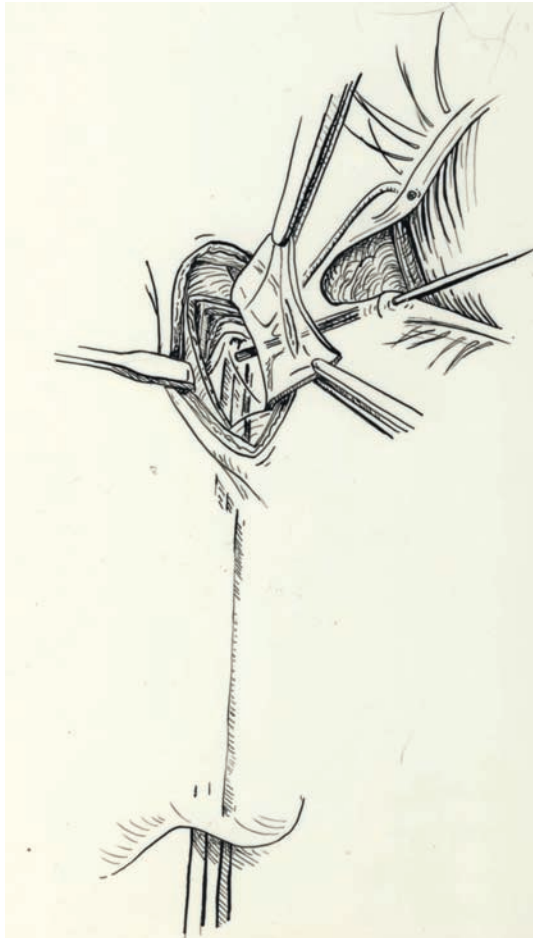


Figure 8.10 Sialastic tubing is passed through the lacrimal system and the anastomotic site exiting the nose.

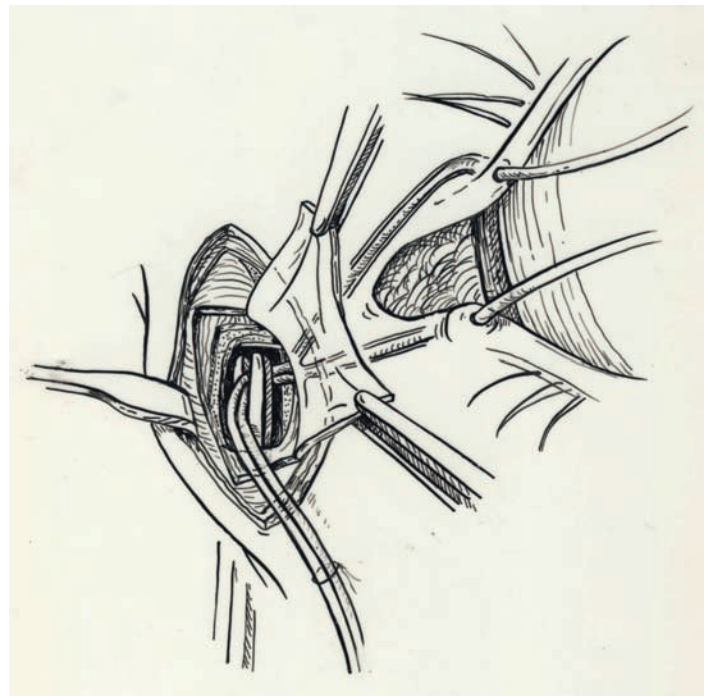


Figure 8.11 Sialastic tubing is passed through both upper and lower canaliculi, extracted from the nose and tied in a square knot. After the sialastic tubing has been positioned and the cottonoid damp with mitomycin-C has been placed in the anastomosis, the anterior lacrimal sac flap is sutured to the anterior nasal mucosal flap. The posterior flaps may be sutured or excised.

The suture type is of minimal importance. However, a small, sharply curved needle makes this maneuver much easier, especially if you are masochistic enough to suture posterior flaps.

After the flaps are sutured together, the mitomycin-soaked cottonoid is removed through the nose by pulling on the attached string. The sialastic tubes are tied together with a single square knot. If a single square knot is used, the tubes can be easily removed in the office by cutting the loop in the medial canthus and extracting them from either canaliculus. Now fill the anastomosis and surgical site with fibrin/thrombin sealant (Evicel™) to ensure hemostasis, but this is optional. The skin incision is carefully closed with interrupted 6-0 mild chromic sutures in a far-far, near-near fashion. A Telfa® pad and dental roll is placed over the incision. An eye pad is tapped over the eye and incision putting gentle pressure on the wound. A Meroceol® cellulose sponge is placed in the nostril and then wet with Afrin.

If the nasolacrimal system is patent and functional, restoring the punctum to its normal position in the tear film should relieve the tearing.

The punctum does not have to be ectopic for the lacrimal pump to dysfunction. Patients with lower eyelid laxity may be unable to pump tears from the tear lake into the lacrimal sac. These patients may have symptomatic tearing without a frankly ectopic punctum. This is diagnosed by the “snap-back” test. If a lower eyelid can be distended greater than 7 to 8 mm from the globe, it is dysfunctional (Fig. 8.12). These eyelids will not promptly return to the globe when released (they will not snap back), but slowly return to their normal position. They are too lax to perform their normal tear pumping function with resultant

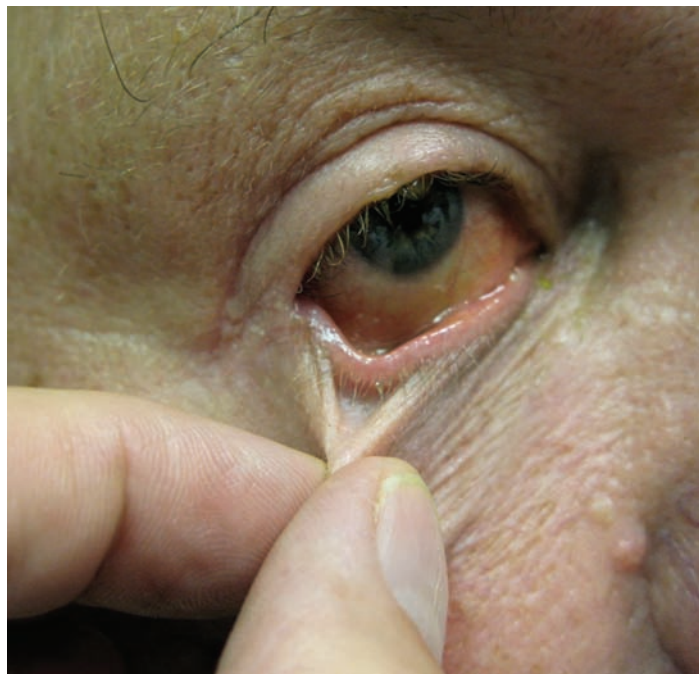

Figure 8.12 Snap-back test: if you can distend the lower eyelid greater than 7 to 8 mm from the globe and it does not promptly snap back to the globe, eyelid laxity is contributing to the patient’s epiphora.

epiphora. Treatment entails tightening the lower eyelid either by wedge resection or by tarsal strip.

CONJUNCTIVOCHALASIA

There are many degrees of conjunctivochalasia, ranging from obvious folds of redundant conjunctiva to mild—only visible if elicited by rubbing the eyelid against the globe. The diagnosis, if you are aware of it, is usually obvious at slit lamp examination (Fig. 8.13). There is also a different staining pattern with lissamine green—the unexposed conjunctiva stains (Fig. 8.2). Depending on the severity of the excessive conjunctiva, these patients may have symptoms of dry eye or epiphora. These are differentiated in Table 8.1.

When necessary, treatment entails excision of the redundant conjunctiva and replacement with an amniotic membrane graft (Fig. 8.14).

Lissamine green stain is invaluable for diagnosing a floppy upper eyelid causing windshield wiper epitheliopathy (WWE) (Fig. 8.15A and B). These patients complain of chronic ocular irritation. They have usually been unsuccessfully treated by a number of physicians with a variety of drops and punctal occlusion. The key to making the diagnosis is lissamine green staining of

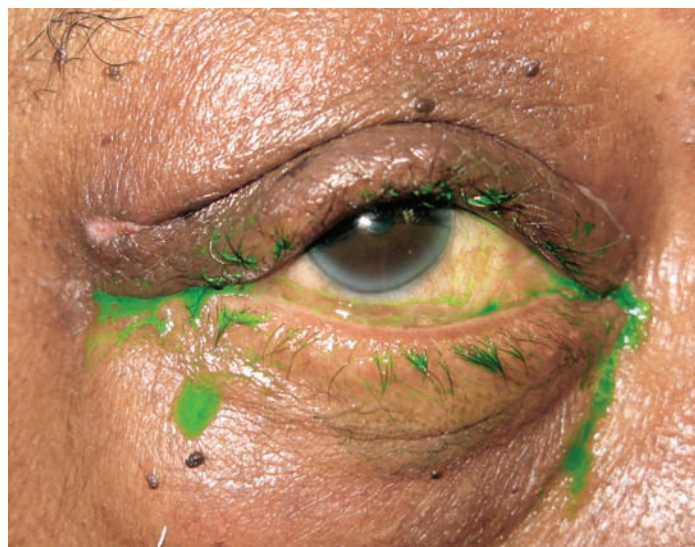

Figure 8.13 Obvious, inferior redundant conjunctiva diagnostic of conjunctivochalasia.

Table 8.1 Dry Eye Vs. Conjunctivochalasia

Dry eye	Conjunctivochalasia
Symptoms worse in PM	No difference
Symptoms worse upgaze	Symptoms worse downgaze
Better with blink	Symptoms worsen with blink
LG stains exposed area	LG stains nonexposed area
Better with punctal plugs	Worse with punctal plugs

Abbreviations: PM, post meridiem; LG, lissamine green.

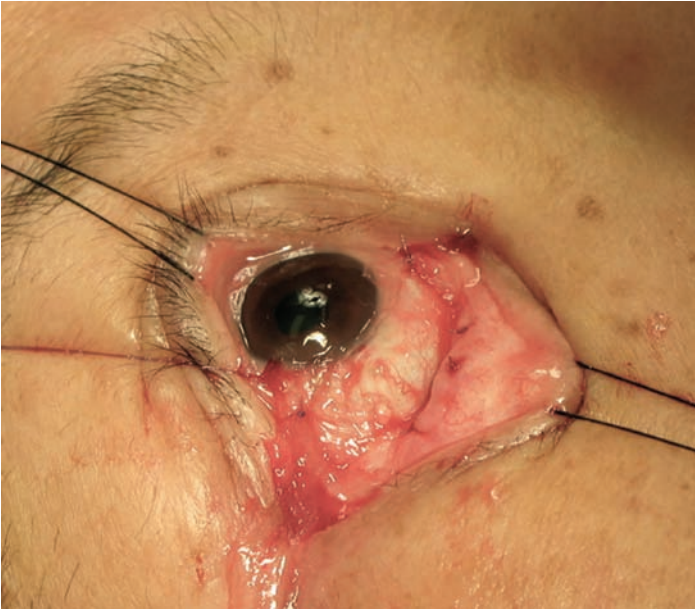
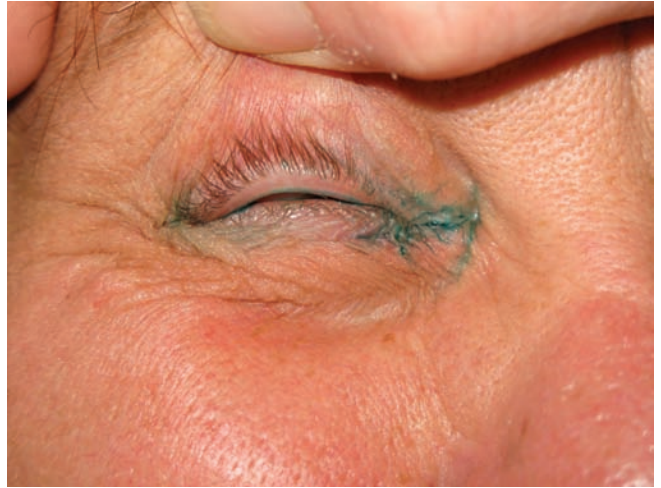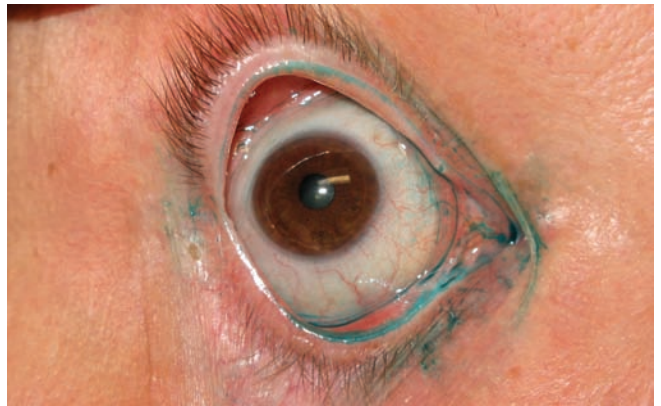


Figure 8.14 An amniotic membrane graft sutured and “glued” into position with fibrin/thrombin sealant (Evicel).

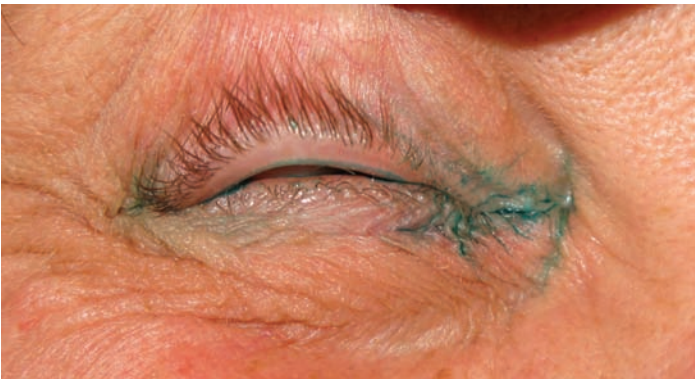

(A)

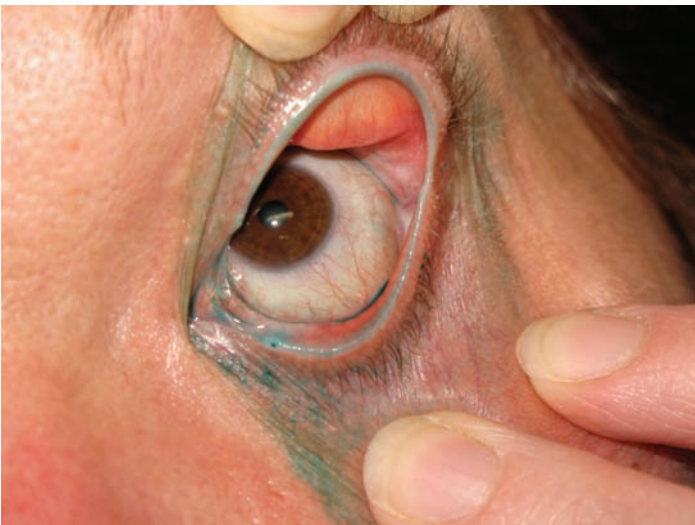

(B)

Figure 8.16 Floppy eyelids caused by excessive upper eyelid laxity. The conjunctival surface of the upper eyelid overlaps the skin and lashes of the lower eyelid when blinking (A), causing chronic ocular irritation. Lissamine green staining of the conjunctival surface of the upper eyelid is diagnostic (B).



(A)



(B)

Figure 8.15 Floppy upper eyelids: note that the conjunctival surface of the upper eyelid overlaps the skin and lashes of the lower eyelid (A). This scratches the conjunctival surface of the upper eyelid, resulting in positive lissamine green staining (B) and chronic irritation.

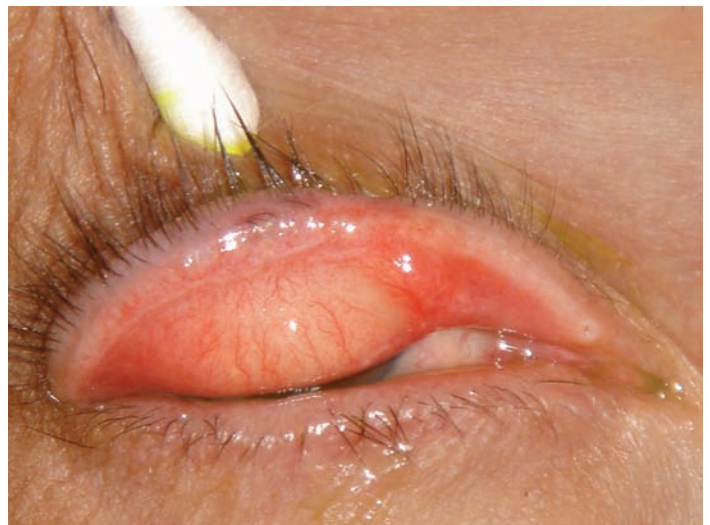

Figure 8.17 Distichitic eyelashes represent normal lashes growing from an atypical area—the meibomian gland of the upper eyelid, causing chronic and constant ocular irritation.



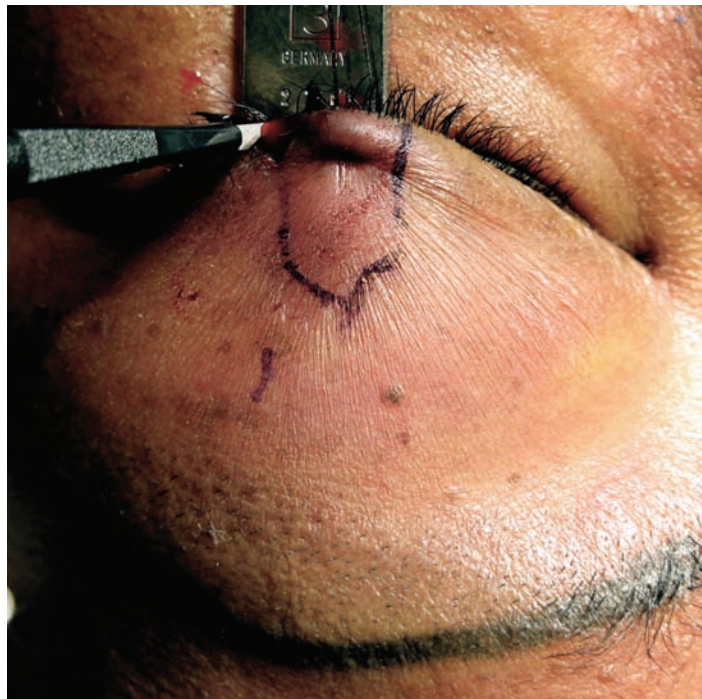

Figure 8.18 A pentagonal area for resection is outlined. A double-armed 4-0 silk suture is placed through the eyelid margin, and it is stretched over a flat surface to incise the margin with a sharp blade while protecting the cornea.

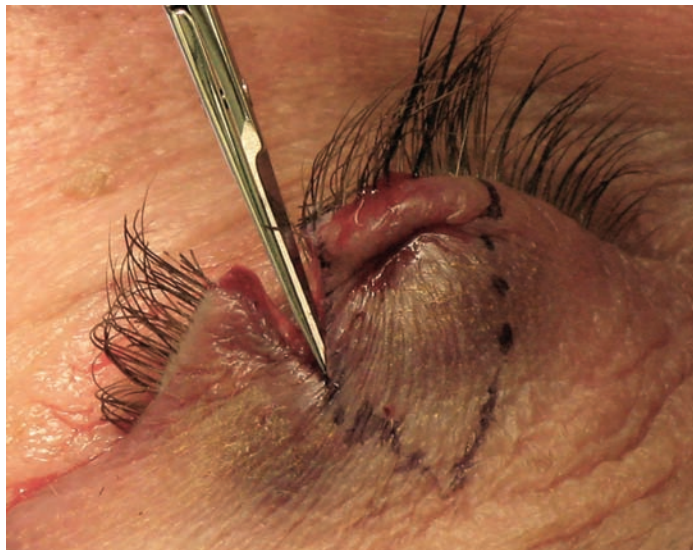


Figure 8.19 The eyelid margin incision is extended along the entire vertical length of the tarsus.

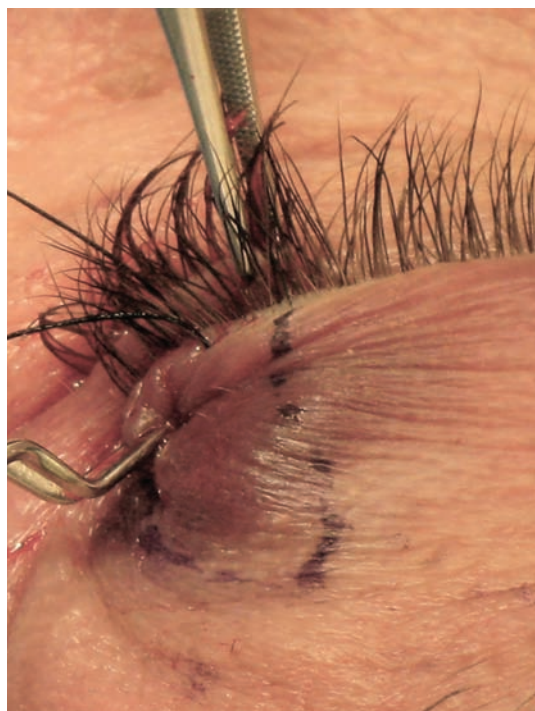

Figure 8.20 The incision is overlapped to determine the proper amount of eyelid to resect.

the conjunctival surface of the upper eyelid. This may involve the entire upper eyelid (Fig. 8.15B) or just a portion of it. Regardless, it is diagnostic of a roughened surface of the upper eyelid rubbing on the cornea with each blink causing chronic irritation. Horizontal shortening of the upper eyelid by removing a pentagonal wedge is usually curative. If further tightening is

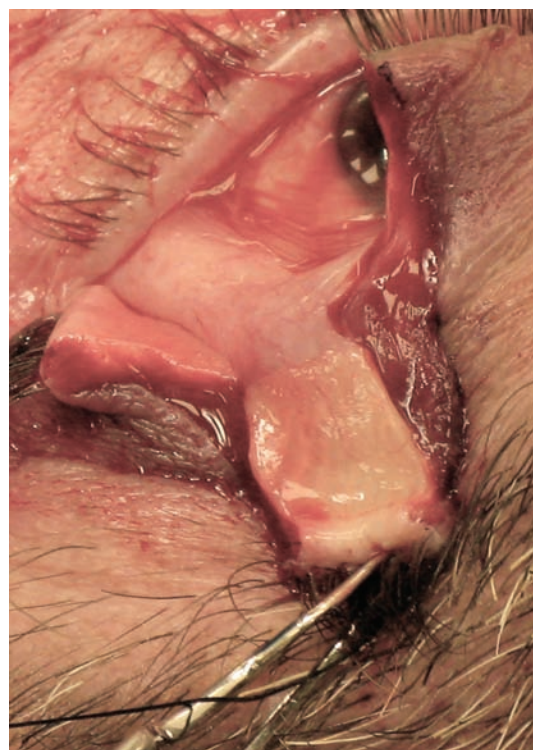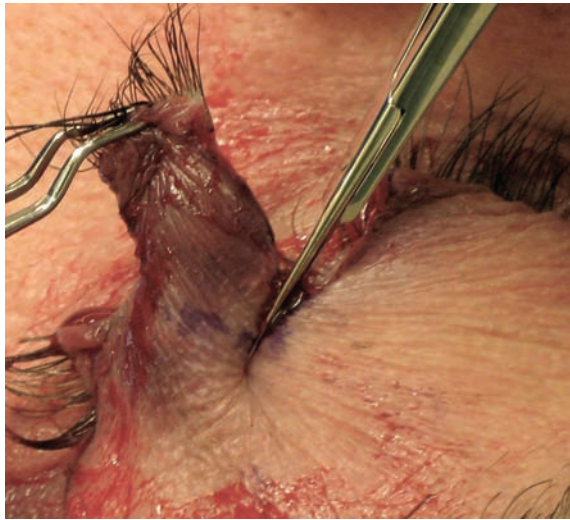


Figure 8.21 A parallel incision is made and both are extended to the top of the tarsus.

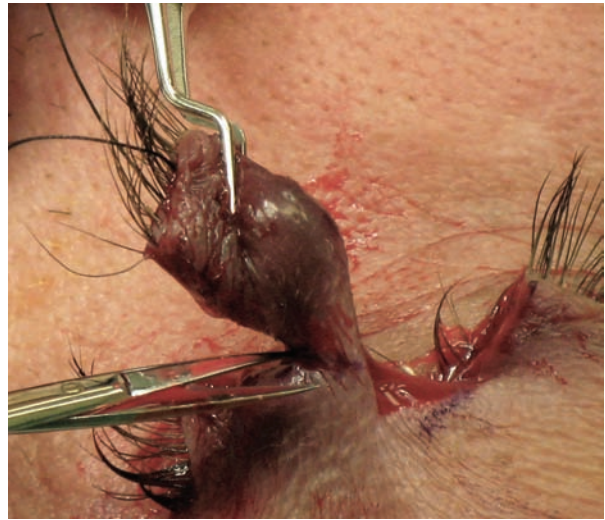
necessary, a modified tarsal strip procedure may be used to augment the wedge resection.

#### WEDGE RESECTION UPPER EYELID

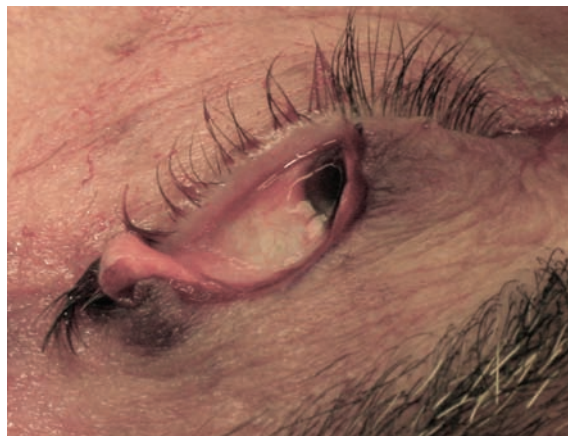Prime indications for resecting a portion of the upper eyelid are tumor, distichiasis, and floppy eyelids causing WWE and chronic ocular irritation (Figs. 8.16 and 8.17). WWE is more common than recognized and is a common cause of ocular discomfort. These patients do not have to be morbidly obese. Lissamine green staining of the upper eyelid conjunctival margin is diagnostic (Fig. 8.16B). Treatment is horizontal shortening of the upper



(A)



(B)



(C)

Figure 8.22 The incisions meet at the apex or the pentagon well above tarsus (A, B). Excision of the pentagon leaves a large defect in the eyelid that needs to be closed (C).

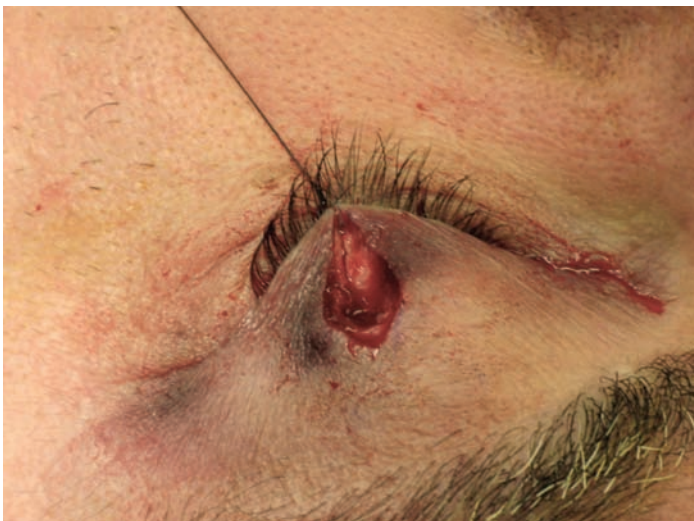

Figure 8.23 The eyelid margins have been approximated with two 6-0 silk sutures.

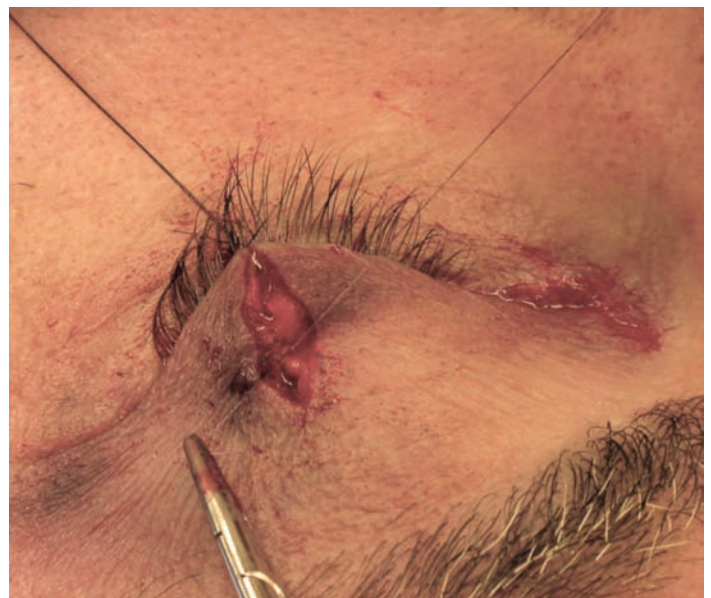

Figure 8.24 As the eyelid is placed on downward stretch, the exposed tarsus is sutured with interrupted 6-0 vicryl sutures.

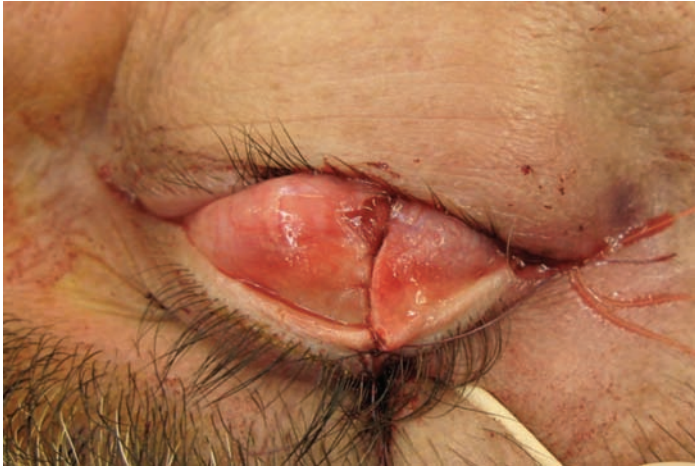
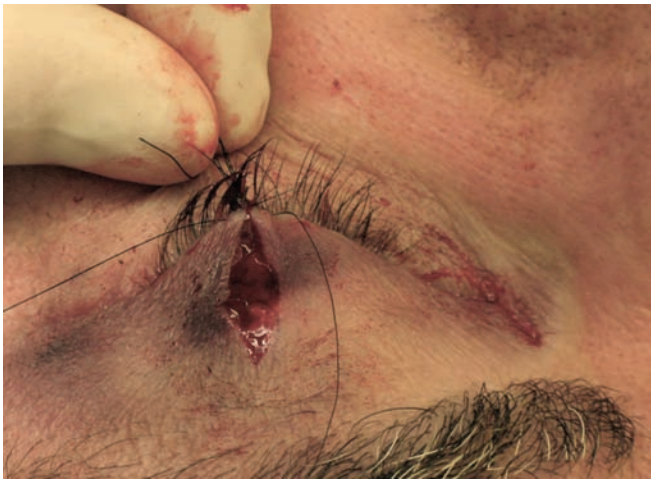
Figure 8.25 The eyelid is inverted to ensure that no sutures have been passed full thickness through the eyelid.

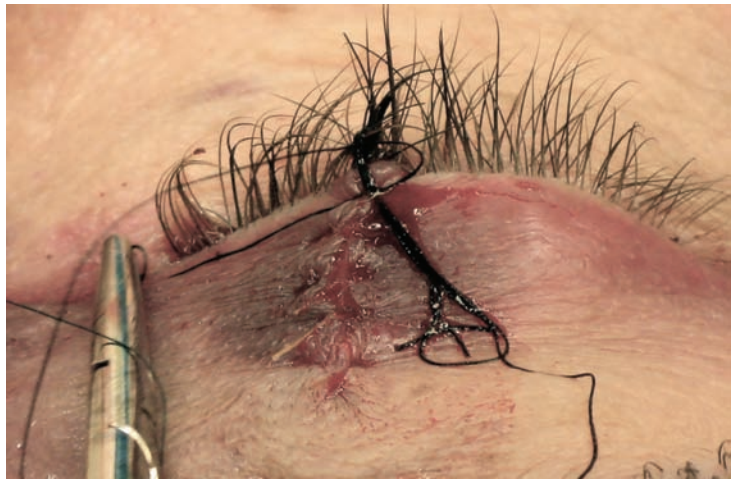eyelid. Mild cases may respond to tightening the upper eyelid with a tarsal strip procedure. More severe cases require resection of greater than one-fourth of the eyelid. This not only resolves the ocular irritation, but actually elevates the upper eyelid as well. This is rather radical but successful ptosis repair when indicated.

**Technique**

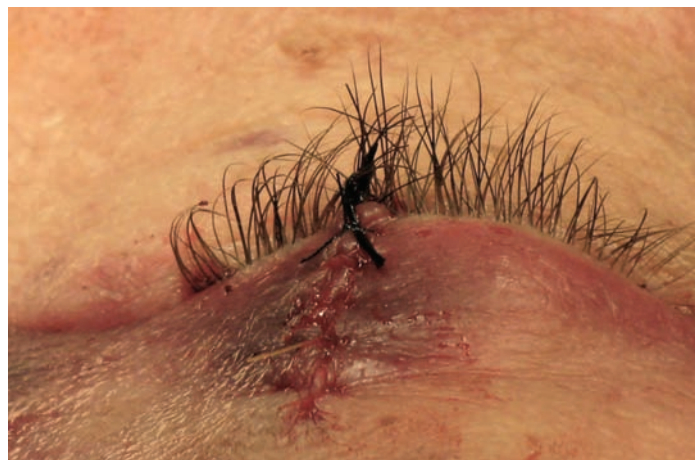Outline the pentagon of upper eyelid you wish to excise (Fig. 8.18). Pass a double-armed 4-0 silk suture through the eyelid margin and extend it over an eyelid plate or blade handle (Fig. 8.18). Incise the eyelid margin with a sharp blade (Fig. 8.18). With straight scissors extend the incision along the entire vertical length of upper eyelid tarsus (Fig. 8.19). Now check the amount of eyelid that actually needs to be excised by overlapping the eyelid margins (Fig. 8.20). Change your outline if necessary. Do not remove too much eyelid; you can always tighten the lid a bit more with a modified tarsal strip if necessary. Incise the other wound margin with a sharp blade and extend the incision parallel to the first one with straight scissors (Fig. 8.21). Extend both incisions to the top of the tarsus. Now connect the two incisions at the apex of the



(A)



(B)



(C)

Figure 8.26 A final 6-0 silk marginal suture is placed at the upper eyelid skin margin (A). The other marginal sutures are folded back on the eyelid and secured with the silk suture (B, C). The skin incision has been closed with interrupted 6-0 mild chromic sutures.

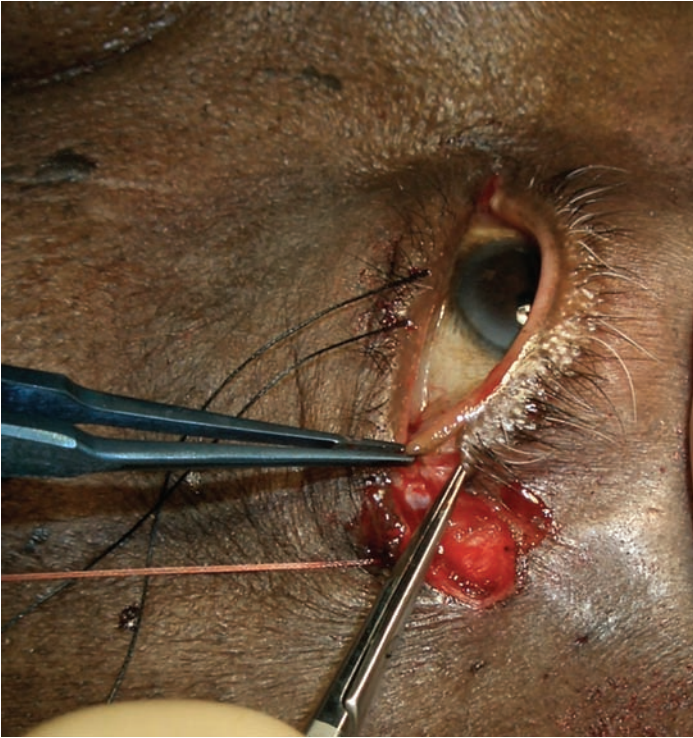


Figure 8.27 The upper eyelid is divided into an anterior (skin and orbicularis) and posterior (conjunctiva and tarsus) lamella with a blade and scissors. A cut parallel to the eyelid margin forms the tarsal strip.

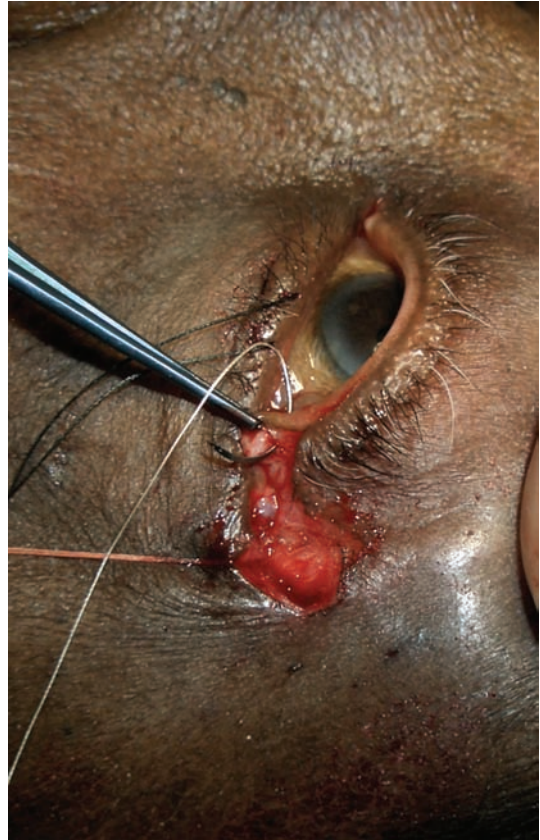


Figure 8.28 A double-armed suture is passed through the tarsal strip and tied in a square knot.

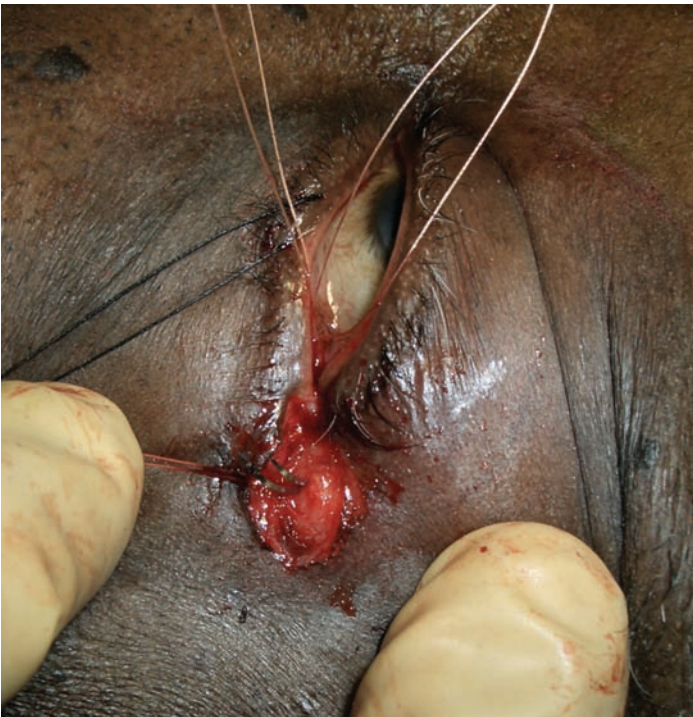

Figure 8.29 Both suture needles are passed through the lateral orbital wall at the lateral orbital tubercle.

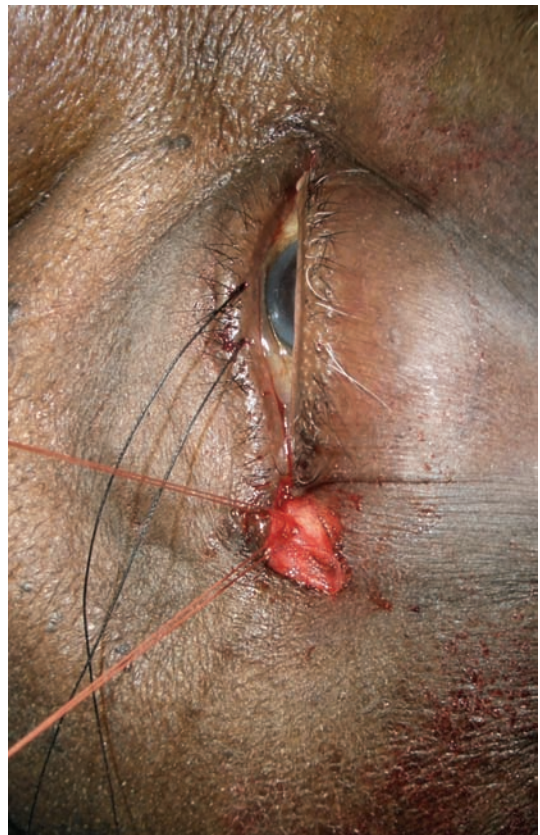
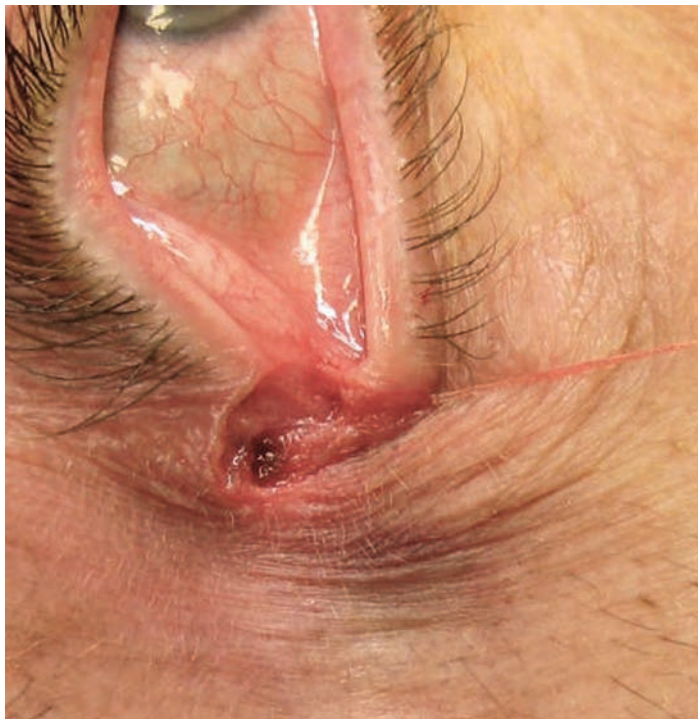
Figure 8.30 Tying the suture tightens the upper eyelid.



*Figure 8.31* You may resolve lesser degrees of upper eyelid laxity by performing a lateral canthotomy and reattaching the upper eyelid to the lateral orbital wall with a double-armed suture.

pentagon (Fig. 8.22A–C). Stop the bleeding with light bipolar cauterization. Pass a 6-0 silk suture through the grey line at the eyelid margin. Tie it and inspect the eyelid margin. It should be in perfect apposition (Fig. 8.23). Place another 6-0 silk suture anterior and posterior to the initial suture, making sure that the anterior suture does not extend over the conjunctival border. If it does, replace it and avoid the subsequent keratopathy. Leave the suture ends long and with a hemostat apply inferior traction to the incision (Fig. 8.23). This exposes the tarsus. Suture the tarsus together with two or three 5-0 or 6-0 Vicryl sutures making

sure that they are not passed full thickness through the eyelid (Fig. 8.24). This will cause a refractory keratopathy. Invert the eyelid and inspect the conjunctival surface of the wound (Fig. 8.25). No sutures should be visible. If they are visible, remove and replace them.

Suture the orbicularis muscle at the apex of the pentagon with several superficial Vicryl sutures. Keeping the eyelid on downward stretch, approximate the skin with 6-0 mild chromic or silk suture. A small triangle of excess skin may be excised at the apex of the pentagon. Take the long, marginal silk sutures and reflect them over the wound and tie them into position with a silk suture (Fig. 8.26A–C). This ensures that the ends will not rub against the cornea.

A similar procedure may be used to remove a portion of the lower eyelid. The tarsal suturing is not as critical because exposed sutures in the lower eyelid should not constantly irritate the cornea. The repair of the lower eyelid margin is similar to the upper eyelid, ensuring that the apposition is perfect and the sutures do not irritate the cornea.

Although I believe that the wedge resection is the definitive treatment for patients with severe floppy eyelids, a modified or formal tarsal strip may be used as an adjunct or instead of a wedge resection in patients with lesser degrees of eyelid laxity. Perform a canthotomy/cantholysis, freeing the upper eyelid from its attachments to the lateral orbital wall. Split the upper eyelid into an anterior and posterior lamella and make a cut parallel to the eyelid margin (Fig. 8.27), exactly as described for the lower eyelid. This forms the tarsal strip. Pass double-armed sutures through the tarsal strip (Fig. 8.28), tie a double knot, and pass both needles through the lateral orbital wall at the level of the lateral orbital tubercle (Fig. 8.29). Tying the sutures tightens the eyelid (Fig. 8.30). As with the lower eyelid, lesser degrees of eyelid laxity may be treated with a lesser degree of surgery. A lateral canthotomy and reattaching the eyelid to the lateral orbital wall is quick and easy (Fig. 8.31) but not as effective as a formal tarsal strip, which is not as effective as a wedge resection. The degree of eyelid laxity determines the procedure(s) of choice.

## 9 Orbital Surgery, Optic Nerve Sheath Decompression, and Temporal Artery Biopsy

### ORBITAL SURGERY

#### Techniques and Caveats

There is a marked difference between eyelid and orbital surgery. Surgical misadventures during eyelid surgery are usually correctable by an experienced surgeon. Errors made during orbital surgery can result in death or blindness. The learning curve for orbital surgery is steep and may be unforgiving. Orbital cases are not that common, and experienced orbital surgeons are becoming equally uncommon.

Anytime you penetrate the orbital septum, you are an orbital surgeon whether or not you wish to be. Post-septal hemorrhage and infection are potentially blinding complications and need to be avoided.

Avoid injuring the optic nerve. Know where the mass is in relation to the optic nerve. Choose a surgical approach that keeps the mass that you wish to excise or biopsy between your surgical instruments and the optic nerve.

Know, prior to surgery, what lesions to excise completely and those to biopsy. Choose the surgical approach that will facilitate this.

Remember medical treatment for medical disease and surgical treatment for surgical disease. Encapsulated tumors (Fig. 9.1) should be excised completely. Nonencapsulated tumors (Fig. 9.2) should be biopsied and the appropriate treatment decided after the pathology has been reviewed.

Have imaging studies available in the operating room. This is easy to forget now that most are on CD and an envelope full of imaging studies is difficult to obtain in many institutions. Intraoperative review of magnetic resonance imaging (MRI) or computed tomography (CT) scans may be very helpful in avoiding a potentially devastating complication. Loss of orientation may lead to potentially devastating complications in orbital surgery. Have a quality skull in the operating room with you for the first 10 to 15 years that you are doing orbital surgery. You do not need it often, but when you do, it is very helpful for orientation (Fig. 9.3). Disorientation is a major cause of devastating complications (brain injury) in orbital surgery. Scans and skulls will help keep you oriented.

Know what you are cutting or excising. There are too many stories of surgeons getting confused and inadvertently biopsying the optic nerve or converting an orbito-sinus procedure into an intracranial procedure and not recognizing it until the odd appearing sinus mucosa is diagnosed as normal brain or the patient does not wake up after surgery due to an intracranial hemorrhage.

Prior to incision, infiltrate the operative site with an epinephrine containing anesthetic. This will help control superficial bleeding. For the same reason, if you are working in the nose or the ethmoid sinus, treat the nose and sinus mucosa with Afrin prior to incision and continue to do so intraoperatively. This will greatly decrease bleeding from the sinus mucosa.

You are much more likely to use excessive amounts of perioperative antibiotics and corticosteroids early in your career rather than later. It is reasonable to administer antibiotics if you are contaminating a clean orbit with a dirty sinus, otherwise you are likely treating yourself. Corticosteroids do decrease edema and chemosis after orbital surgery, and it is reasonable to treat patients with 40 to 80 mg methylprednisolone perioperatively, especially if there is potential for active orbital inflammation as in patients with dysthyroid orbitopathy. Most patients do very well without antibiotics or steroids and the risks and benefits of both should be considered before knee-jerk administration of either medication.

Surgical approaches to orbital masses should be predicated on their location and relationship to the optic nerve.

The inferior orbit is best approached via the conjunctiva after performing a lateral canthotomy and cantholysis. This is also an excellent approach to the orbital floor for decompression or fracture repair. The lateral canthal incision can be extended if it is necessary to remove the lateral orbital wall for adequate exposure of inferior-lateral tumors (Fig. 9.4B).

Tumors located in the superior orbit can be approached via an upper eyelid crease incision (Fig. 9.4A) or an incision beneath the brow extending over the lateral orbital wall (Fig. 9.4C). This incision is especially useful for lacrimal gland tumors. Lateral orbital tumors may be removed by a pure lateral orbitotomy incision (Fig. 9.4D). We rarely use the Lynch incision (Fig. 9.4F) but combine it with an inferior incision to form the gull wing incision (Fig. 9.4E).

Superior lesions posterior to the mid-orbit (Fig. 9.5) and superior to the optic nerve need to be approached via craniotomy and subsequent removal of the orbital roof. Approach the apical, lateral orbital lesions in a similar fashion (Fig. 9.6). This needs to be done in conjunction with a neurosurgeon. Kennerdell and Maroon have described an approach that greatly facilitated exposure of the orbit in these cases.

Approach the medial orbital tumors, in the intraconal space (Fig. 9.7), via a transconjunctival orbitotomy. Facilitate exposure, if necessary, by combining this approach with removal of the lateral orbital wall via a separate incision.

Remove the medial apical orbital lesions (Fig. 9.8) via an external ethmoidectomy and removal of the medial orbital wall. This will spare the patient a craniotomy (Fig. 9.4E). This procedure may also decompress the optic nerve even if the tumor cannot be easily and safely removed.

Approach the medial orbital wall and ethmoid sinus with a gull wing incision centered on the medial canthal tendon (Fig. 9.4E). A transcaruncular/transconjunctival approach has its advocates, but better exposure is obtained with the larger incision. Enhancing exposure leads to better visualization and this minimizes the complications. A cosmetically acceptable scar in the medial canthal region is a small price to pay for a safe, successful, and complication-free operation.

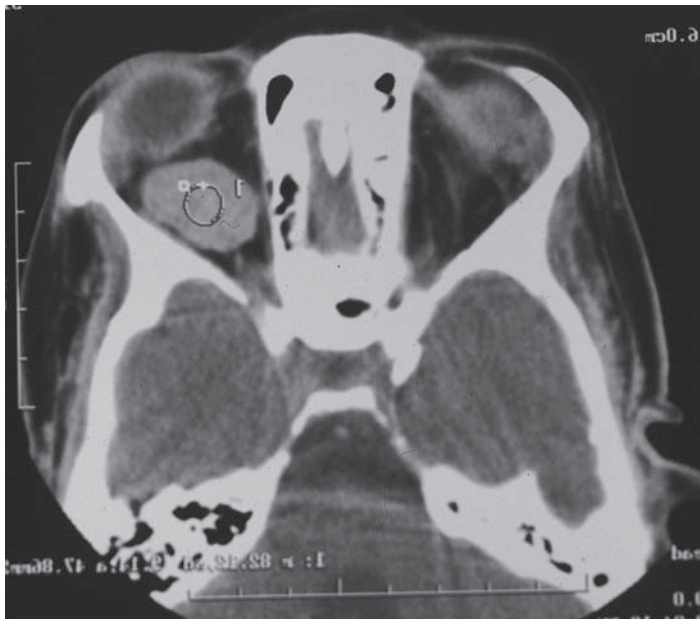

Figure 9.1 CT scan demonstrating an encapsulated orbital tumor requiring total excision.

#### Lateral Orbitotomy with Bone Removal

Lesions in the lateral orbit (Fig. 9.9) may be approached through a straight incision extending from the lateral canthus (Berke) (Fig. 9.4D) or a sub-brow incision extending over the lateral orbital wall (Stallard–Wright) (Fig. 9.4C). The former is best for inferior lateral lesions, the latter for superolateral lesions (Fig. 9.1).

The patient in Figure 9.10 has an encapsulated tumor of the lacrimal gland as depicted in the CT scan in Figure 9.1. Make a superior temporal incision and elevate skin muscle flaps to expose the periosteum of the lateral orbital wall (Fig. 9.11). Use a cutting Bovie cautery to separate the temporalis muscle from the back of the lateral orbital rim and place a large cottonoid into the defect (Figs. 9.12 and 9.13). Incise the periosteum with a #15 blade in a T fashion centered on the lateral orbital wall. Elevate the periosteum from the underlying bone with a periosteal elevator. It is firmly attached to the underlying bone. After the periosteum is reflected over the orbital rim, it is less adherent and when it becomes periorbital, it is easily separated from the bone. Completely expose the lateral orbital wall by elevating periosteum beyond the superior and inferior orbital rims (Fig. 9.13). These are the landmarks for the osteotomy incisions. Make parallel incisions along the orbital wall, just inside the respective orbital rims (Fig. 9.14A and B). If the inferior incision is too low, you are incising the thick malar bone and will not be able to remove the orbital wall. If your superior incision is too high, you may enter the brain and play neurosurgeon for a day, not a comfortable experience. This may result in a cerebrospinal fluid leak or an intracranial hemorrhage. Careful attention to the bony landmarks of the orbital rims prevents both of these potential problems. Reference to an available skull (Fig. 9.3) helps you maintain proper orientation. Protect the orbital contents with a malleable retractor large enough to cover the periorbital (Fig. 9.13). Use an oscillating Stryker saw to incise the orbital rim with parallel incisions (Fig. 9.14A). The operator controls the saw with two hands. Oscillating saws held with one

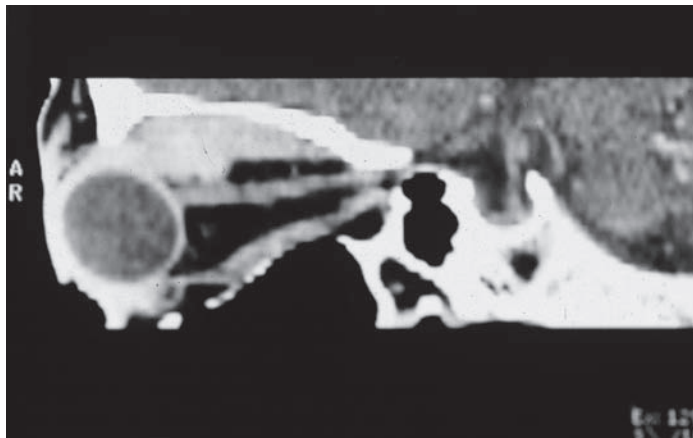


Figure 9.2 CT scan demonstrating a diffuse orbital mass requiring an adequate biopsy for accurate diagnosis.

hand have a tendency to bounce. Bouncing saw blades are nothing but potential trouble. The assistant protects the orbital contents with the malleable retractor and irrigates the osteotomy sites with saline solution (Fig. 9.14B). Hold the malleable retractor firmly against the periorbital but do not compress the apical orbital structures with the tip of the retractor. When the osteotomies are complete, grasp the lateral orbital rim with a rongeur and break it away from its posterior attachment (Fig. 9.15). Save the lateral orbital wall in saline and replace it at the end of the procedure (Fig. 9.16). Bleeding usually occurs from the temporalis muscle. This may be cauterized with the Bovie cautery. This is the last time you should use Bovie cauterization during this procedure. Bipolar cauterization should be used for all intraorbital cauterization to avoid inadvertent damage to orbital structures. The periorbital should be intact. Any bleeding should be controlled with bipolar cauterization. The remains of the posterior lateral orbital wall may be removed with straight rongeurs. Bone bleeding may be controlled by application of bone wax to the bleeding sites. An air drill may also be used to extend the orbitotomy posteriorly. To avoid entering the brain, stop drilling when the bone thickens. The temporal dura is posterior to the thickened bone.

If greater exposure is needed inferiorly, expose the inferior orbit by extending the canthotomy/cantholysis, incising the conjunctiva of the lower eyelid and approaching the orbit as described for inferior orbitotomy. If more superior exposure is needed, portions of the orbital roof may be partially and carefully removed with a Kerrison rongeur.

After exposure is complete, you are ready to biopsy or excise the tumor. Before opening the periorbital, control all bleeding in the operative field. Expose the globe with a speculum and place a 4-0 silk traction suture through the conjunctiva and beneath the bellies of the lateral rectus and the superior or inferior rectus muscles, depending upon the location of the tumor. This allows you to remain oriented throughout the procedure. Do not sew the eye shut with a suture. This will prevent you from examining the pupil during the procedure. If you are concerned about exposure keratopathy, put some viscoelastic or fibrin/thrombin sealant on the cornea and replace it as necessary during the operation. You are now ready to incise the periorbital and enter the orbit.

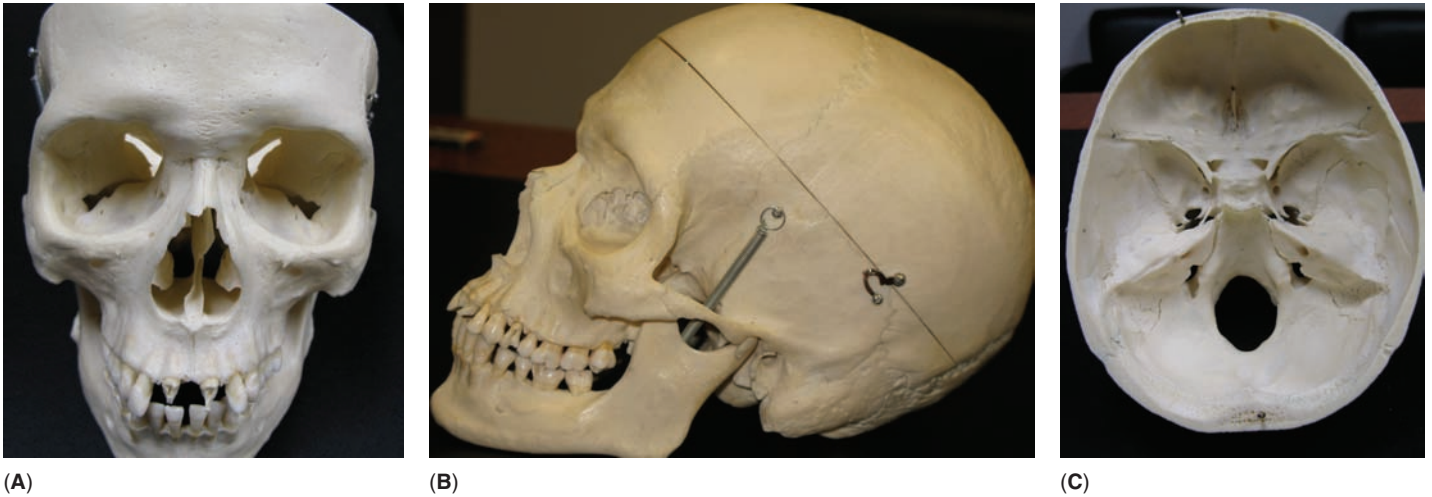


Figure 9.3 A real human skull is a very helpful and often comforting tool to have available in the operating room during orbital floor (A), lateral orbital (B), and cranio-orbital surgery (C). An available skull will help you stay oriented in sometimes unfamiliar territory.

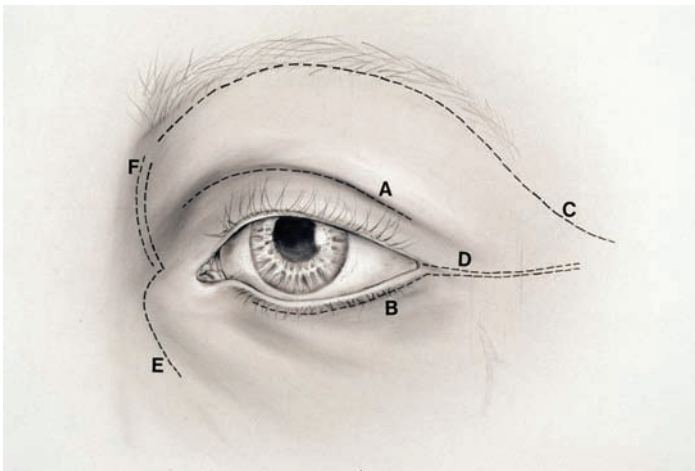


Figure 9.4 Diagram demonstrating various surgical approaches to orbital surgery: upper eyelid crease (A), subciliary with lateral extension (B), superior lateral (Stallard–Wright) (C), lateral orbitotomy (Berke) (D), gull wing (E), and Lynch incision (F).

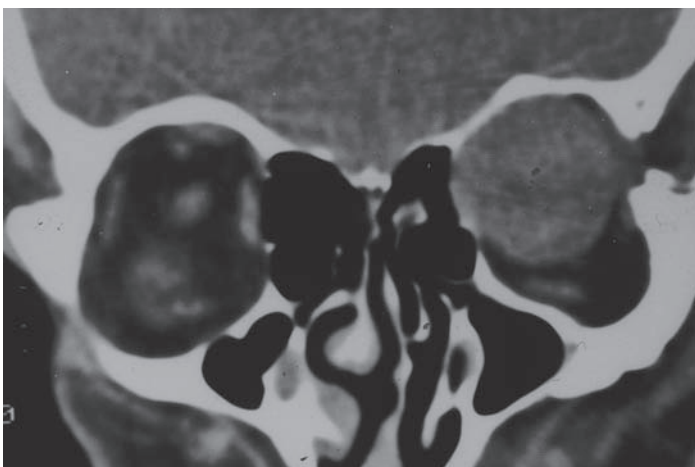


Figure 9.5 CT scan demonstrates a large posterior encapsulated orbital mass located superior to the optic nerve. A craniotomy and superior orbitotomy was required for removal. Note the lateral orbital wall defect resulting from a previous attempt at removal via lateral orbitotomy.

A Kennerdell–Maroon retractor (Fig. 9.11) is very helpful for separating the incision and retracting the temporalis muscle. If this is not available, the incision may be retracted with 4-0 silk sutures or rubber bands and fishhooks borrowed from the neurosurgical service.

Locate the lateral rectus muscle by pulling on the traction suture. Incise above or below the muscle as necessary. If the muscle is inadvertently incised, the resultant bleeding is distracting. As the periorbita is incised, the field becomes obscured by prolapsing orbital fat. How to find the tumor? It is somewhat amazing how such an obvious, large tumor on the CT or MRI scan becomes difficult to find when surrounded by fat. Gentle pressure on the globe may help push the tumor into view. There is really little place in deep orbital surgery for sharp dissection. Use cotton-tipped applicators and cottonoids to manipulate the orbital fat and expose the tumor (Fig. 9.17). Use the traction sutures to maintain orientation. The intraorbital lateral rectus muscle may be encircled with a vessel loupe and retracted one way or the other to enhance exposure. Maintain meticulous hemostasis with bipolar cauterization.

#### Tumor Biopsy and Removal

When the tumor is exposed, it may be biopsied or excised. A portion of the tumor is grasped with toothed or biopsy forceps and excised. Hemostasis is obtained with bipolar cauterization. It is still a good idea for the surgeon to communicate with the pathologists and give them some insight as to your clinical impression. Make sure that the pathologist has enough tissue to make a definitive diagnosis before you finish the operation.

Reserve medical treatment for medical disease and surgical treatment for surgical disease.

Encapsulated orbital tumors are surgical disease and should be completely excised—intact. Diffuse, infiltrative orbital lesions should be biopsied and treated medically. There is little if any benefit from “debulking” a metastatic orbital tumor or lymphoma. Obtain enough tissue to make the diagnosis and refer the patient for appropriate treatment.



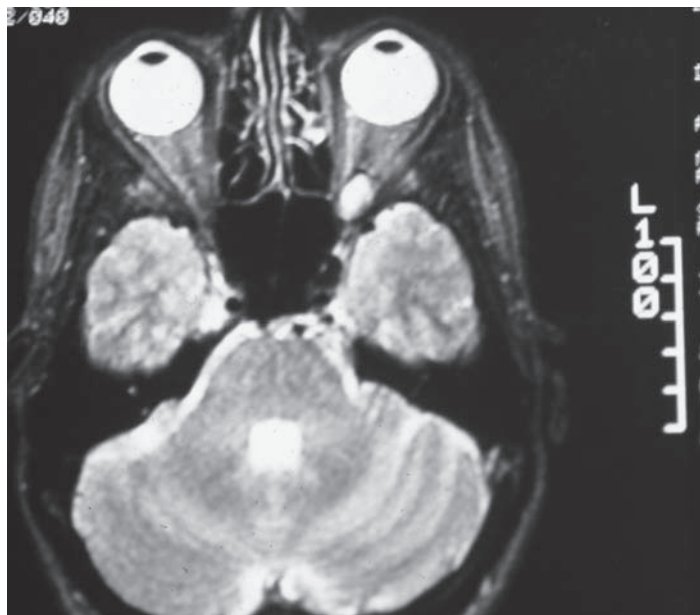


Figure 9.6 MRI demonstrates an apical orbital mass requiring craniotomy for removal.

#### Encapsulated Tumors

After a portion of an encapsulated tumor is exposed, secure it with a cryoprobe. Use the cryoprobe to manipulate the tumor and free it from the surrounding tissue (Fig. 9.18). This is best done bluntly using small cottonoids to retract the orbital fat and progressively expose more and more of the tumor. The assistant may manipulate the tumor with the cryoprobe while the surgeon bluntly dissects the tumor from the surrounding tissue with cottonoids. Blood vessels feeding the tumor may be coagulated with bipolar cauterization and then cut with scissors to help free the tumor. As dissection continues, the tumor is delivered intact. Large tumors are actually shrunk by the cryoprobe making them easier to remove. After the tumor is removed, hemostasis is obtained with bipolar cauterization.

The periorbita does not need to be closed. The lateral orbital wall is replaced in the osteotomy site (Fig. 9.19A). It is usually too small, but as the opening had been enlarged to enhance exposure. The bone may be sutured, wired, plated, or glued into position. The periosteum may be closed over it with 5-0 Dexon™ suture (Fig. 9.19B), which may also be used for the subcutaneous closure (Fig. 9.19C). The skin is closed with suture or Indermil® surgical glue.

#### Inferior Orbitotomy

This approach can be used for orbital floor fracture repair, orbital floor decompression, and biopsy or excision of inferior orbital masses. The initial approach is similar to the lower eyelid blepharoplasty. Start by passing a 4-0 silk suture beneath the belly of the inferior rectus muscle. This facilitates intraoperative forceductions during orbital fracture surgery and keeps you oriented during orbital tumor surgery. Perform a lateral canthotomy and lyse the inferior crus of the lateral canthal tendon (Fig. 9.20). Place a 4-0 silk suture through the lateral and medial lower eyelid. Use the sutures to invert the eyelid over a cotton-tipped applicator (Fig. 9.21). Inject an epinephrine containing anesthetic into the conjunctiva of the lower eyelid. Use scissors to incise the conjunctiva

just posterior to tarsus and extend the incision along the entire horizontal length of the eyelid (Figs. 9.22 and 9.23).

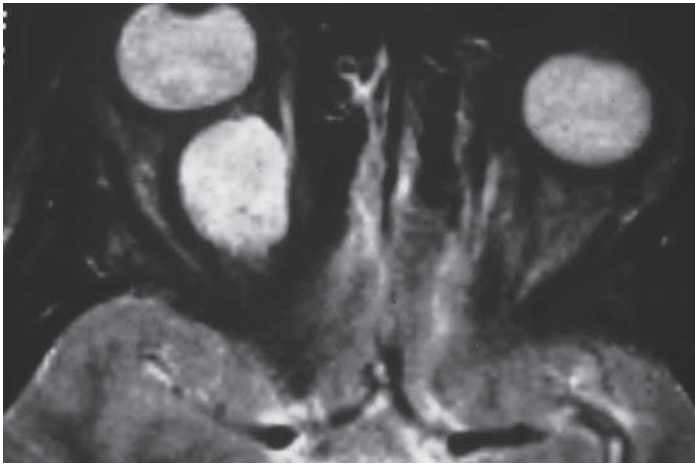
Pass a 6-0 Vicryl™ suture through the nasal and temporal ends of the conjunctiva flap (Fig. 9.24). Free the conjunctiva flap from the overlying tissue with sharp or hot dissection (Fig. 9.25). Retract the conjunctiva flap superiorly by clipping the Vicryl sutures to the surgical drapes (Fig. 9.26). Finish dissecting the conjunctiva flap. The end point should be easy access to the inferior orbit or the inferior orbital rim with gentle traction on the lower eyelid with a Desmarres retractor (Fig. 9.27). This exposes the inferior orbital fat pads. This approach is very similar to lower eyelid blepharoplasty. If decompressing the orbital floor for dysthyroid orbitopathy, the orbital fat may be debulked now in exactly the same manner as you would during lower eyelid surgery. If removing or biopsying an orbital mass, the fat may be retracted or displaced with cottonoids or partially removed. The orbital tumor may now be biopsied or dissected and removed with the aid of a cryoprobe.

When approaching the floor of the orbit for fracture repair, it is best not to disturb or remove the orbital fat. Retract it behind a malleable retractor and cottonoid. Clean the orbital rim with a piece of gauze exposing the periosteum. Incise the periosteum with a #15 blade (Fig. 9.28). Grasp the periosteum with a forceps and dissect it over the inferior rim of the orbit with a periosteal elevator (Fig. 9.29). As the periosteum is dissected over the orbital rim, it loses its adherence and is easily separated from the orbital floor (Fig. 9.30). A 5-0 Dexon traction suture augments retraction of the periosteum. A malleable retractor further aids retraction of the orbital contents and exposure of the orbital floor. Before exposing the orbital floor, obtain superficial hemostasis so as not to confuse intraorbital bleeding with eyelid and soft tissue bleeding at the conclusion of the procedure. After the orbital floor is exposed, identify the inferior orbital neurovascular bundle. It almost always appears as a mildly elevated, bluish line along the floor of the orbit—more lateral than medial (Fig. 9.31). Orbital floor fractures will almost always be located medial to and are often contiguous with the neurovascular bundle.

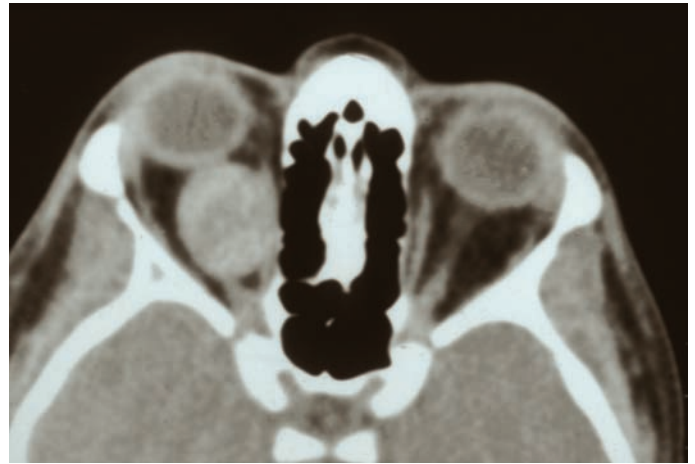#### Orbital Decompression

Identify the infraorbital neurovascular bundle and penetrate the orbital floor medial to it. How you penetrate the orbital floor depends on your patient's bone structure. In some patients, gentle pressure with a hemostat suffices. In others, a mallet and osteotome are necessary. After fracturing the orbital floor, the opening may be enlarged with Kerrison rongeurs and Takahashi forceps. Try to keep the underlying maxillary sinus mucosa intact until the conclusion of the procedure. Sinus mucosa hemostasis may be enhanced with topical Afrin or injection of epinephrine containing local anesthetic. Pick away the orbital floor bone under direct visualization. Gently retract the orbital contents with a malleable retractor in one hand and your rongeur of choice in the other. This is greatly facilitated by Takahashi forceps attached to a suction apparatus. These are available on most ENT sinus surgery trays.

The end points for bone removal are the back wall of the maxillary sinus, the infraorbital neurovascular bundle laterally, and the orbital strut medially (Fig. 9.32). If a greater degree of decompression is needed the strut may be removed along with a portion of



(A)



(B)

Figure 9.7 MRI demonstrating an encapsulated orbital tumor, distinct from the adjacent optic nerve (A). This should be approached via a transconjunctival medial orbitotomy. Compare the CT scan (B) that nicely demonstrates the encapsulated tumor but does not distinguish it from the optic nerve.

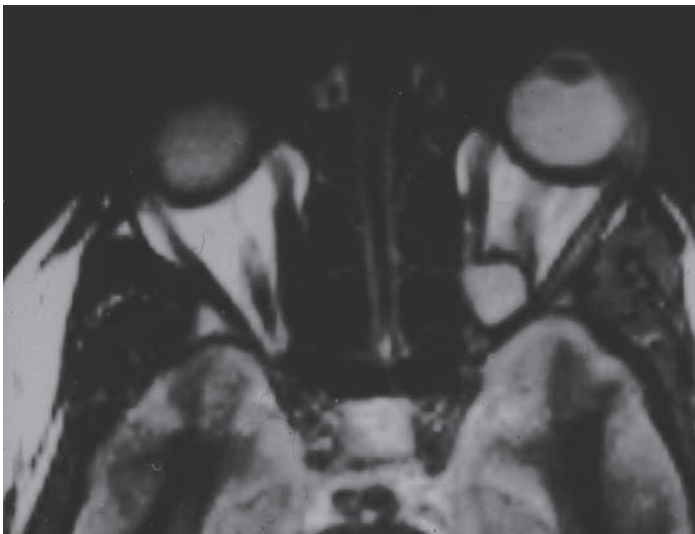


Figure 9.8 Medial apical orbital lesions may be removed via an external ethmoidectomy and medial orbitotomy, sparing the patient a craniotomy.

the medial orbital wall. This often results in an unacceptable degree of hypo-ophthalmos. If the medial orbit needs decompression due to a compressive optic neuropathy, I prefer to do that under direct visualization via a separate incision (see external ethmoidectomy Figs. 9.47–9.49) You really cannot decompress the optic nerve at the orbital apex by removing the orbital floor. The floor of the orbit ends at the back wall of the maxillary sinus. This is about 10 mm anterior to the orbital apex. This anatomy tells us two things. First, it is difficult to injure the optic nerve by removing the floor of the orbit, not only does it end before the apex but the inferior rectus muscle lies between the periosteum and the optic nerve. Second, you really cannot decompress an optic nerve compressed by an enlarged medial rectus muscle by removing the orbital floor. You must remove the medial orbital wall and open the medial periorbital, allowing the enlarged muscle to prolapse into the ethmoid sinus.

After the orbital floor has been removed, a few incisions may be made in the maxillary sinus mucosa or it may be left intact or removed completely. By this time, it often has a large rent in it due to overzealous use of the rongeurs while removing the orbital floor. Now the inferior orbital periorbital must be incised to effect an adequate decompression. This is best accomplished with a #12 or similar sickle blade under direct visualization (Fig. 9.33). Retract the intact periorbital with a medium-sized malleable retractor exposing the orbital floor defect. Slide the #12 blade into the defect and rotate it so that the sharp point is facing the intact periorbital. Engage the periorbital with the blade and drag it forward. This incises the periorbital and allows the orbital fat to prolapse into the orbital floor defect (Fig. 9.34). This procedure may be repeated medial or lateral to the original incision but with practice, this is not often necessary.

#### *Orbital Floor Fracture Repair*

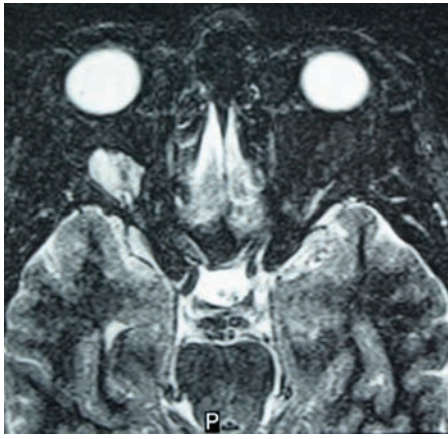
A similar technique allows exposure of the orbital floor for repairing fractures. One variation is to leave a bit more periosteum on the orbital rim so that you can suture the periosteum closed to secure the implant.

This is conventional wisdom and a bit archaic.

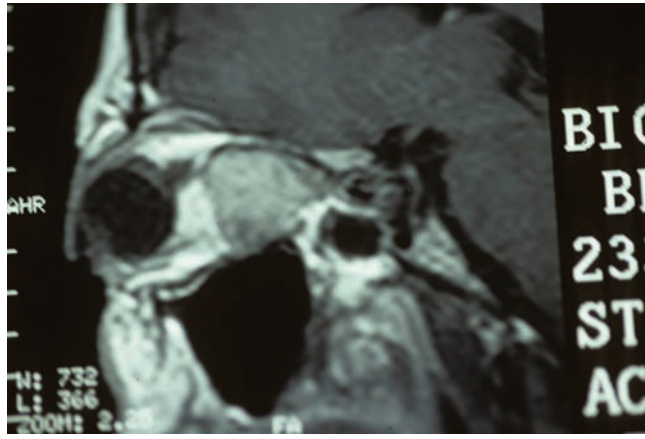
Modern implants, either hydroxyapatite or titanium, with internal screw fixation do not often extrude, and if properly placed, do not need to be covered with a layered closure of periosteum to periorbital. However, the eyelids have a tendency to adhere to exposed hardware or bone and cause significant lower eyelid retraction (Figs. 9.35 and 9.36). The periosteum is incised with the #15 blade and dissected over the orbital floor to which it is loosely attached. A 5-0 Dexon suture may be used for traction and the orbital floor is exposed with a malleable retractor.

Unlike orbital decompression surgery, the orbital anatomy is usually disrupted in patients with orbital floor fractures. The periorbital is often violated and orbital fat fills the wound.

The traction suture placed beneath the inferior rectus facilitates identification. Pulling the suture allows you to see the entrapped muscle move and often verify the fracture site, almost always



(A)



(B)

Figure 9.9 Lateral orbital lesions may be removed by removing the lateral orbital wall (A). This may be combined with an inferior or superior approach depending upon the location of the tumor. Large encapsulated tumor inferior to the optic nerve can be approached by combining an inferior and lateral orbitotomy (B).

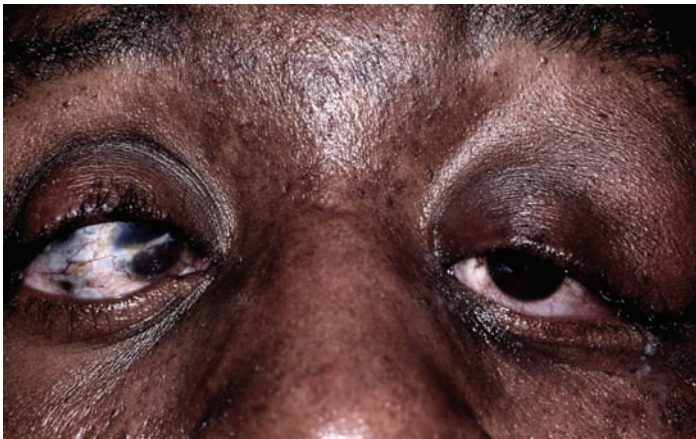

Figure 9.10 Patient with superior lateral orbital tumor compressing the only sighted eye.

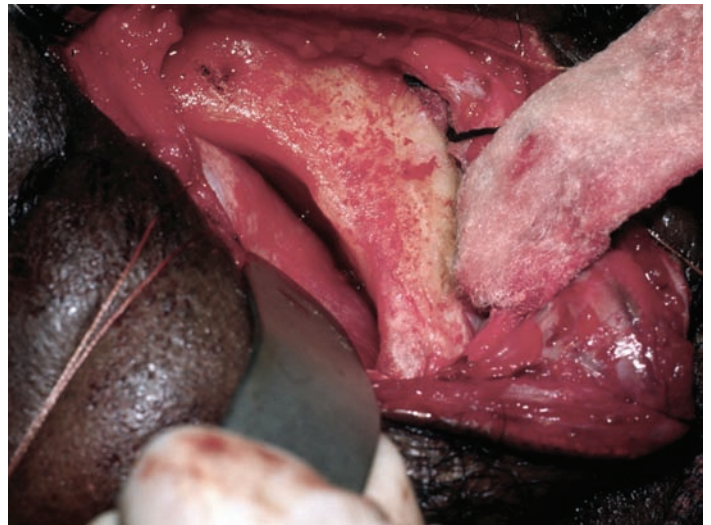

Figure 9.12 The periosteum of the lateral orbital wall has been incised and elevated with a periosteal elevator. A malleable retractor protects the orbital contents. A cottonoid separates the lateral orbital bone from the adjacent temporalis muscle.

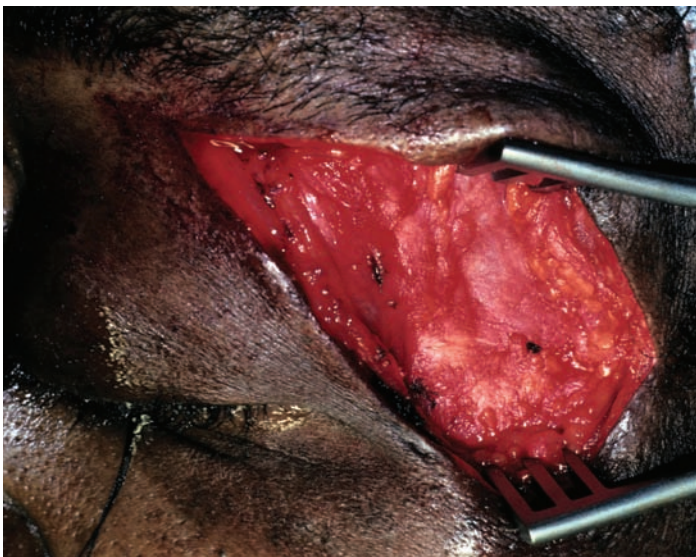

Figure 9.11 Superior lateral incision and elevation of skin muscle flaps exposed the periosteum of the lateral orbital wall. Flaps are retracted with a Kennerdell-Maroon retractor.

located medial to the infraorbital neurovascular bundle. There are several types of fractures with different presentations and levels of surgical difficulty. Patients with large saucer fractures usually present with enophthalmos (Fig. 9.37A and B). A large segment of orbital floor is depressed into the maxillary sinus, and there is no extraocular muscle entrapment or motility defect. These fractures are easily treated by elevating the orbital contents with a malleable retractor and bridging the defect with a sheet of Medpor™ or titanium mesh (Fig. 9.37C). This restores orbital volume and obviates the enophthalmos. These fractures may be repaired with minimal morbidity.

Old fractures, greenstick fractures, and others entrapping the inferior rectus muscle may present a challenge in judgment as well as surgical skill (Figs. 9.38 and 9.39). Greenstick fractures with inferior rectus entrapment in children may be challenging (Fig. 9.38A and B). These really need to be repaired and the muscle released. Repair may be challenging and ischemic injury to the

inferior rectus may not permit significant improvement in extraocular motility in spite of normalized forced ductions. The following technique has been useful.

Locate the fracture and convert a small or old fracture into a larger one by carefully removing the adjacent orbital floor with Kerrison rongeurs. Use the traction suture to locate the entrapped

medial rectus. Removing orbital floor anterior and medial to the entrapped muscle with the Kerrison rongeur allows you to free it with a small malleable retractor and a suction tip in a hand over hand fashion. Large neurosurgical cottonoids are helpful to separate the muscle and fat from the fracture site. After sufficient orbital floor has been removed, the muscle freed, and forced ductions normalized, cut a 1 mm thick Medpor sheet to the appropriate size, retract the orbital contents with a malleable retractor and cottonoids, and slide the implant into the orbit with a pair of Adson forceps. It should bridge the defect at least medially and laterally. Beware of the posterior orbit and do not forget that it narrows (look at skull in Fig. 9.3) and too vigorous retraction or insertion and manipulation of the implant can damage the optic nerve.

Very posterior fractures with entrapment (Fig. 9.39A and B) may require a combined approach via inferior orbitotomy and a Caldwell–Luc approach to the inferior orbit via the maxillary sinus. This allows reduction of the fracture and freeing the entrapped muscle without excessive posterior orbital manipulation.

Remember that not all fractures can be fixed and not all entrapped muscles can be released. Even if they are, the muscles may not function properly! Avoid excessive pressure on the orbital contents with the malleable retractor. Every few minutes release the pressure, check the pupil, and let the eye rest. It does no good to cure the diplopia by blinding the eye! Anatomic cures only count in retinal surgery. Residual diplopia can always be improved by eye muscle surgery at a later date.

Avoid too much manipulation and applying prolonged pressure on the orbital contents.

Avoid too large an implant (Figs. 9.40 and 9.41) and insufficient postoperative monitoring. Decreased vision and pain does not

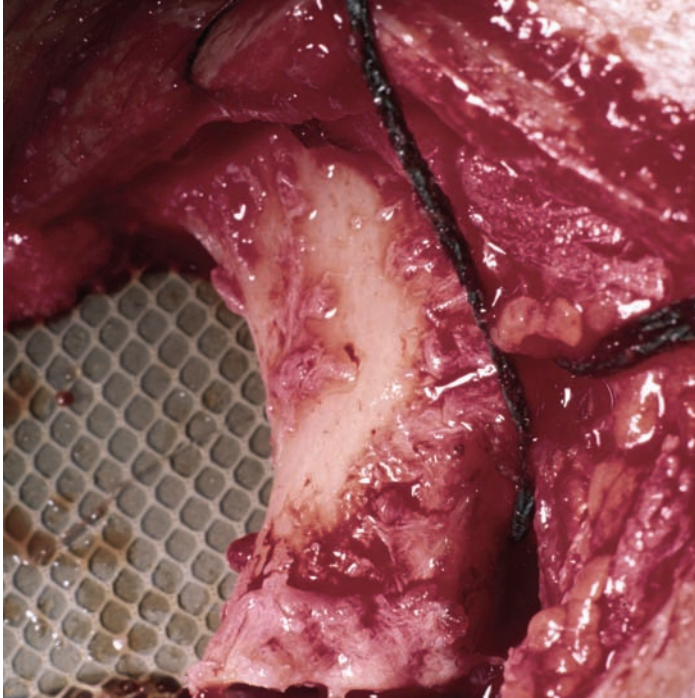
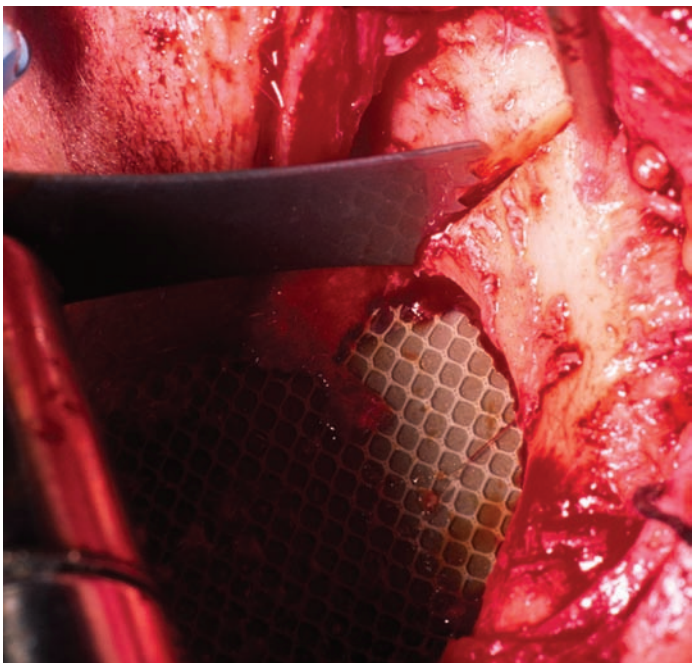
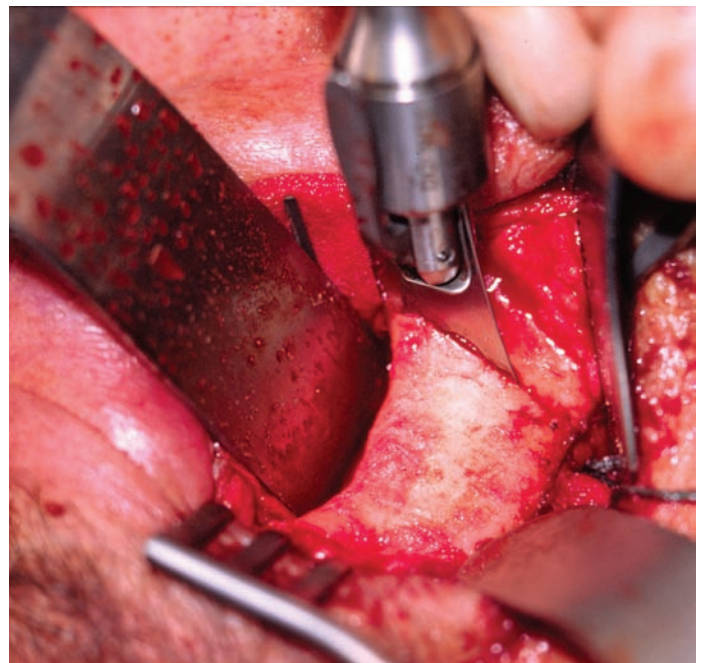


Figure 9.13 The lateral orbital wall is exposed and the orbital contents protected with a malleable retractor.

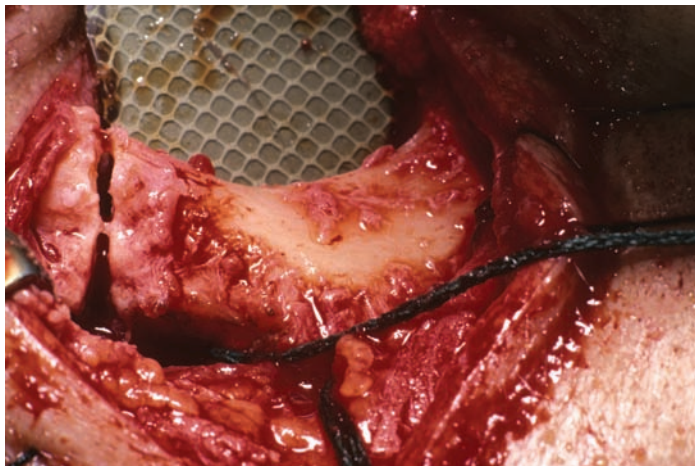


(A)

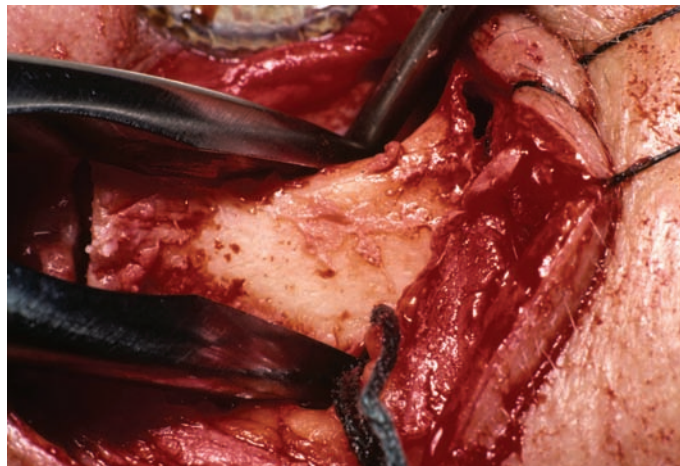


(B)

Figure 9.14 Superior and inferior osteotomy incisions are made with an oscillating saw (A). The orbital contents are retracted and protected with a malleable retractor (B).



(A)



(B)

Figure 9.15 The osteotomies are completed (A). The retractor and cottonoids are removed. The lateral orbital wall is removed with a rongeur (B). If it does not fracture easily, recheck the osteotomies to ensure that they are appropriately positioned and complete.

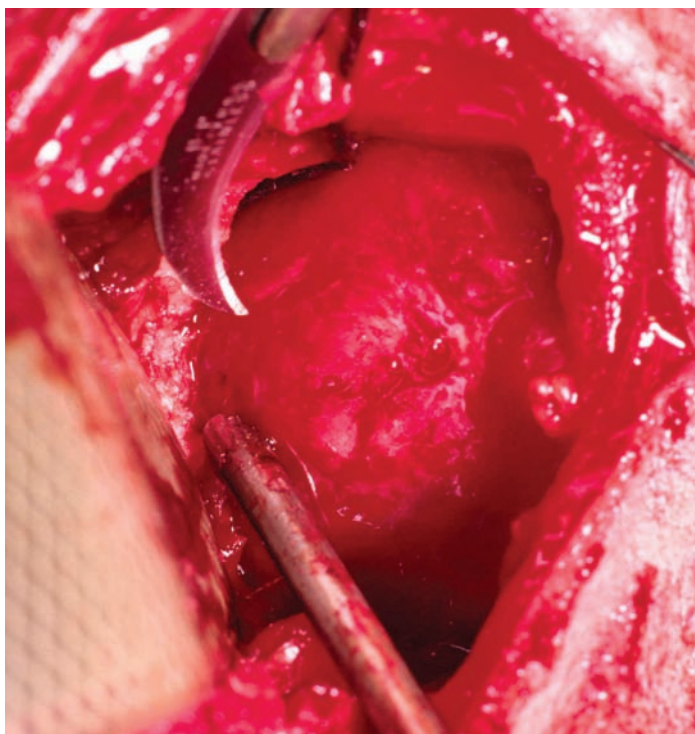


Figure 9.16 The lateral orbital wall has been removed and the periorbital is being incised with a #12 blade.

require a neuro-ophthalmology consult and an MRI scan. It requires expeditiously opening the incision and removing the implant.

#### Medial Orbital Wall Fractures

Patients with medial orbital wall fractures may present with orbital emphysema (Fig. 9.42A and B), medial rectus muscle entrapment with an abduction deficit (Fig. 9.43), or be asymptomatic. Surgery is only necessary if the patient has medial rectus entrapment and diplopia. Patients may also have disruption of their medial canthal tendon with resultant traumatic telecanthus (Fig. 9.44).

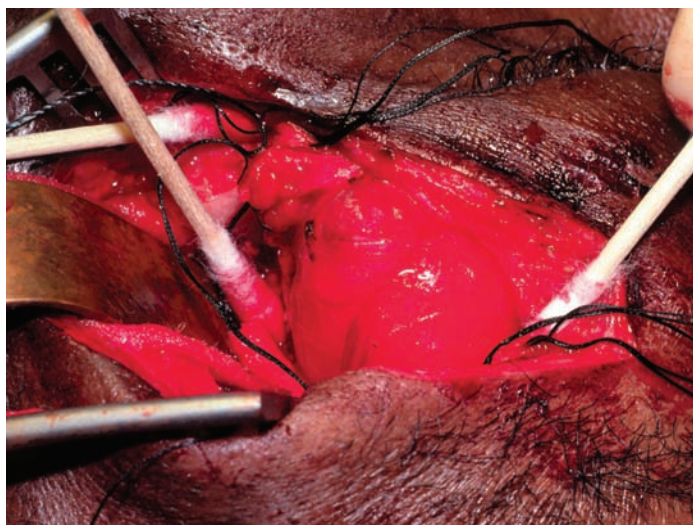


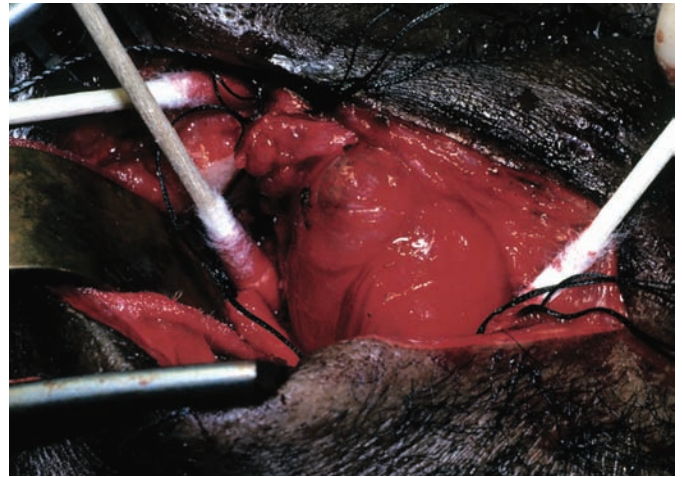
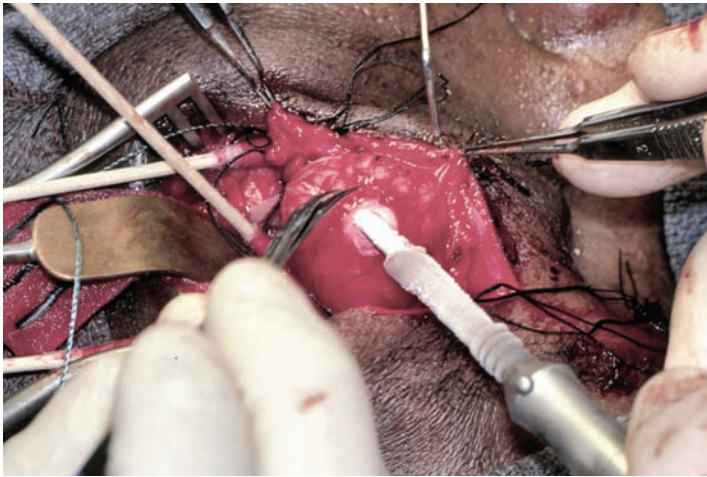
Figure 9.17 The tumor is isolated with blunt dissection utilizing cottonoids and cotton-tipped applicators. Use bipolar cauterization to cauterize any vessels prior to cutting them.

Both of these may be approached as described below for medial orbital wall decompression. The fracture may be reduced and the entrapped muscle freed as described for orbital floor fractures. Take extra care when placing the implant. Do not point the implant towards the orbital apex. Rotate the implant so that the narrow ends are in the superior/inferior plane. An implant placed in this manner cannot migrate posteriorly and injure the optic nerve.

Traumatic telecanthus requires approaching the medial orbital wall in a similar fashion. Repair the fracture if necessary and reattach the medial canthal tendon to the medial orbital wall with a pinion or screw. Variations on this theme have pretty much replaced transnasal wiring for treating traumatic telecanthus.

#### Medial Orbital Decompression

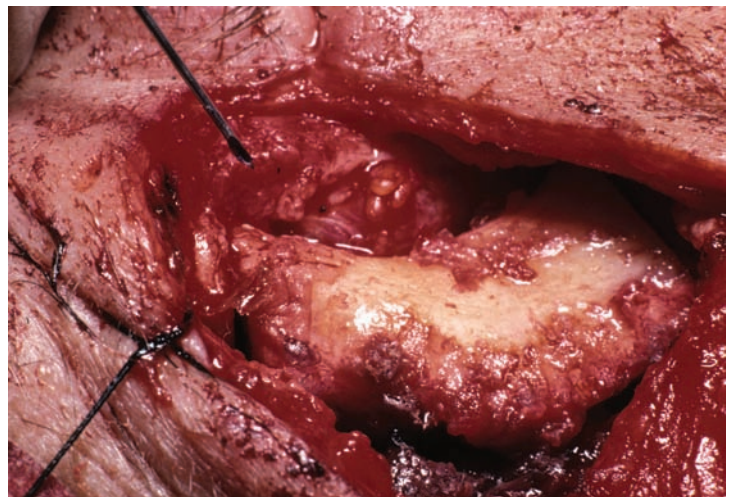
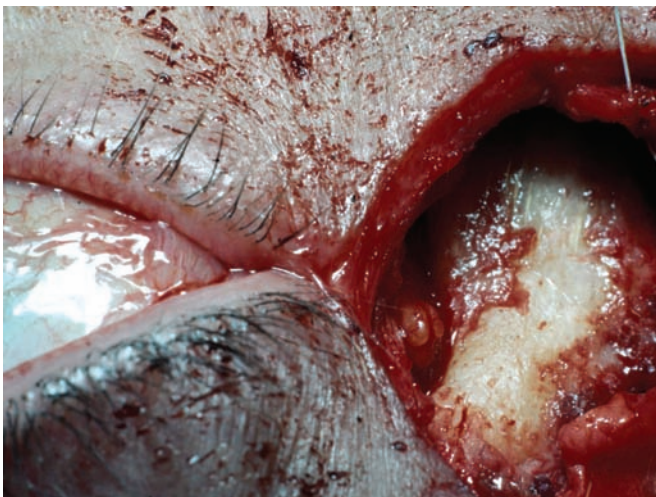The most common indication for external ethmoidectomy and medial orbital decompression is compressive optic neuropathy



(A)

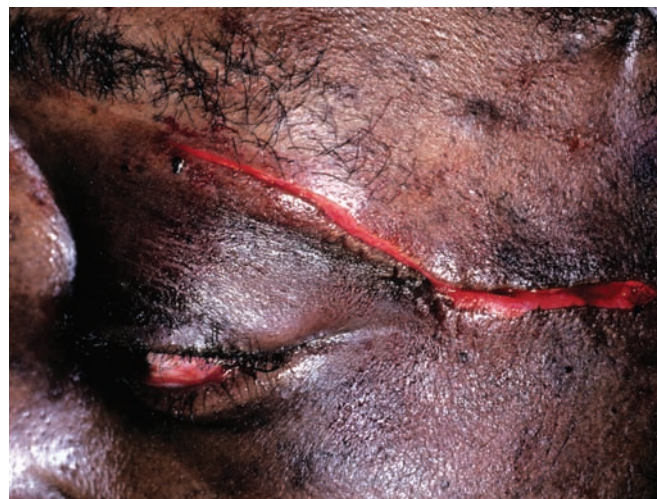(B)

Figure 9.18 A cryoprobe facilitates manipulation, dissection (A), and removal (B) of the tumor. The assistant manipulates the tumor as the surgeon frees it from surrounding structures with a combination of sharp and blunt dissection.



(A)

(B)



(C)

Figure 9.19 The lateral orbital wall has been replaced (A), the lateral canthus reformed and sutures have been placed in the periosteum to secure the lateral orbital wall (B). The subcutaneous tissue is closed with absorbable sutures and the skin incision is sutured (C).

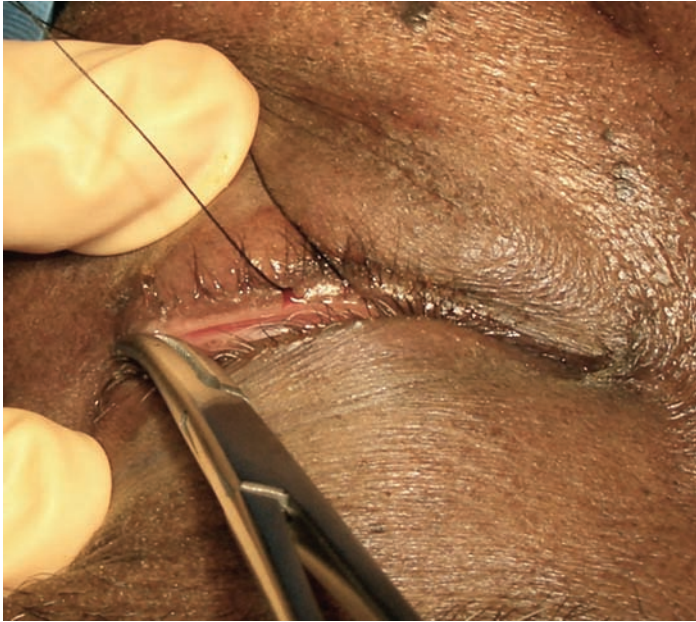

Figure 9.20 Clamp the lateral canthus and then perform canthotomy and cantholysis with scissors.

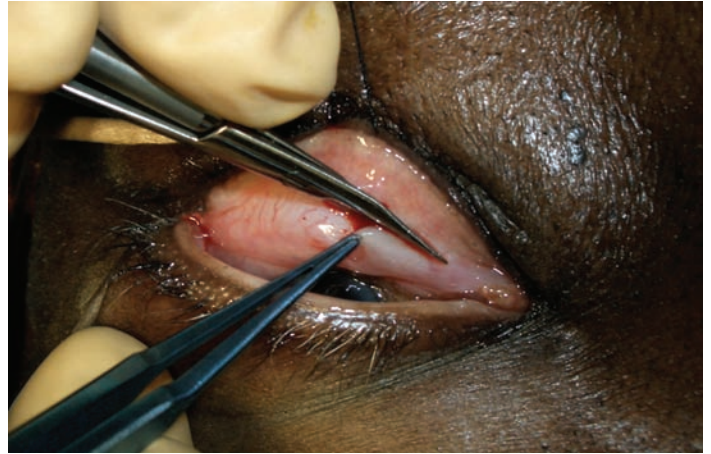


Figure 9.23 Extend the incision along the entire horizontal length of the eyelid.

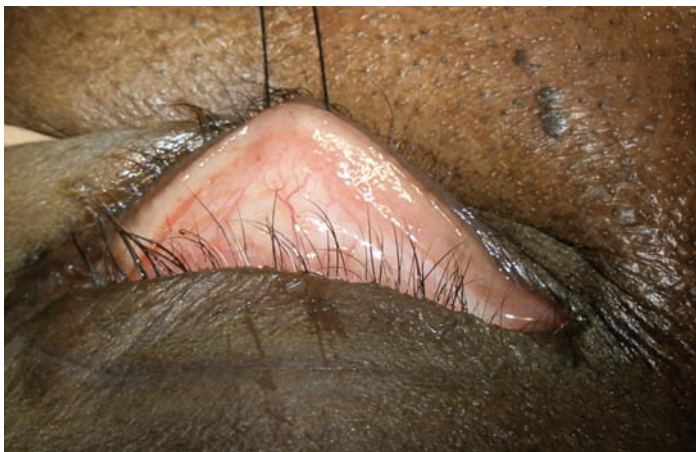

Figure 9.21 Use traction sutures to invert the eyelid and expose the conjunctival surface. Inject local anesthetic beneath the conjunctiva.

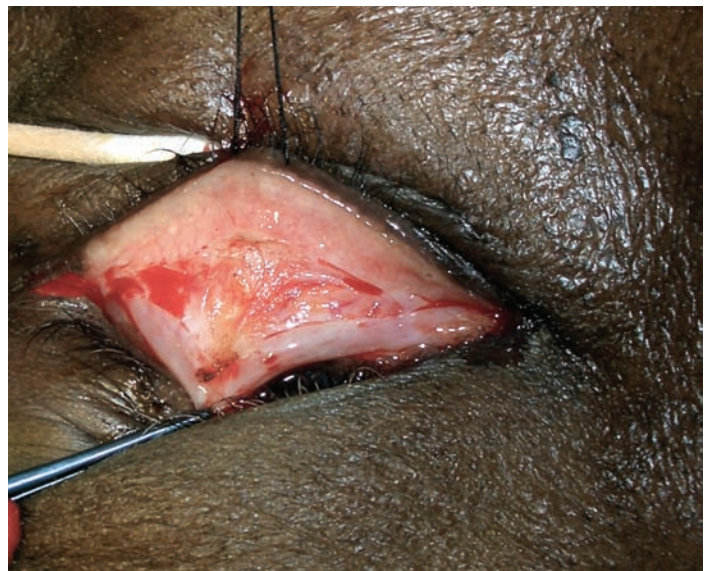

Figure 9.24 Place traction sutures (6-0 Vicryl) in the nasal and temporal aspect of the conjunctival flap.

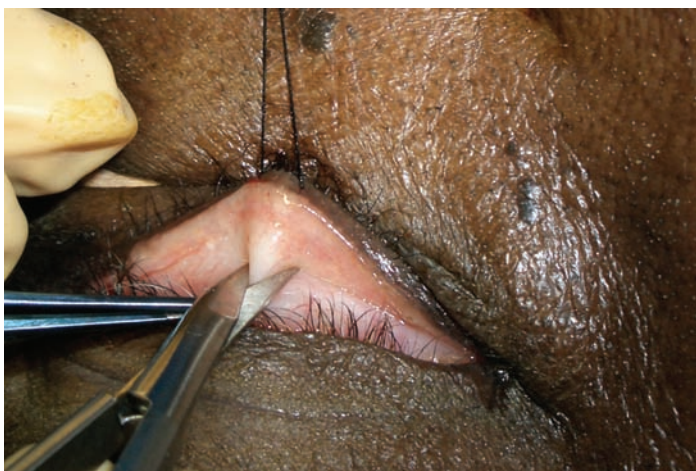

Figure 9.22 Incise the conjunctiva posterior to the tarsus.

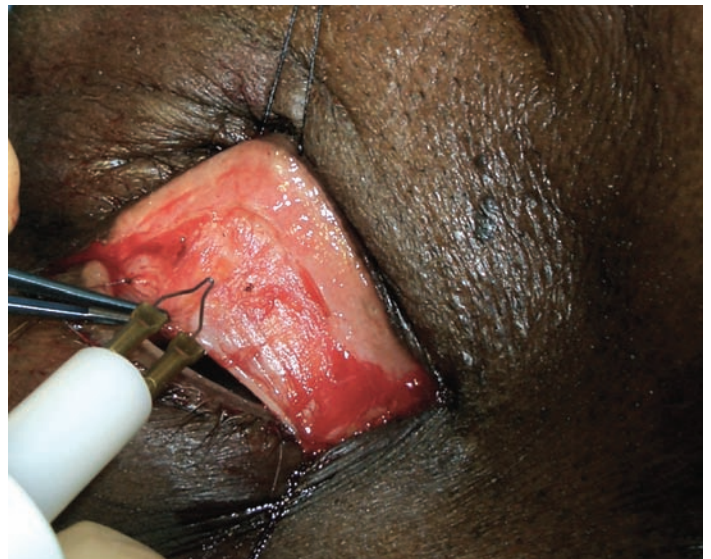


Figure 9.25 Dissect the conjunctival flap with scissors or hot cauterization.

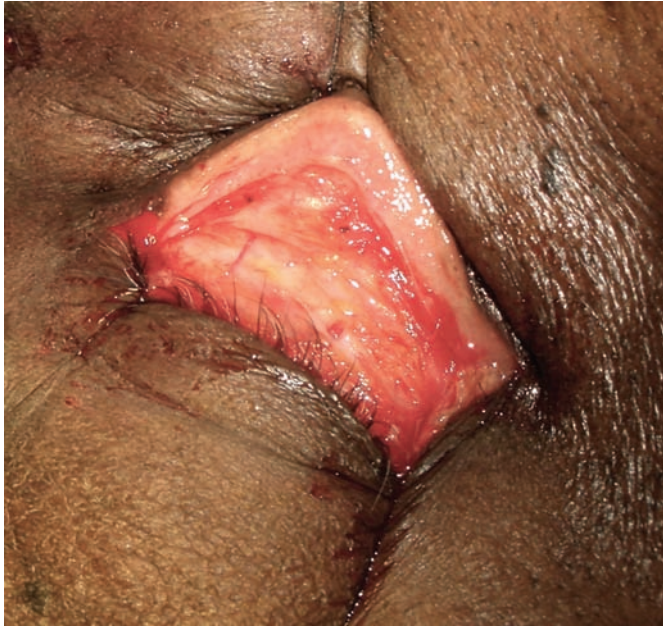

Figure 9.26 Dissection is completed when the inferior orbital rim is palpable.

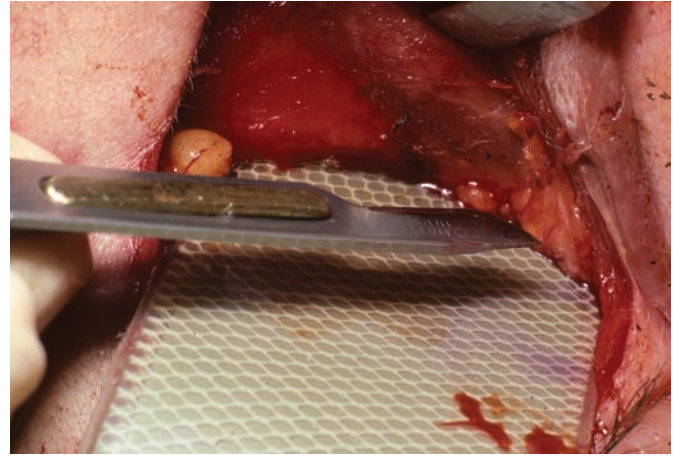


Figure 9.28 The orbital contents are protected with a large malleable retractor. A #15 blade is used to incise the periosteum on the inferior orbital rim.

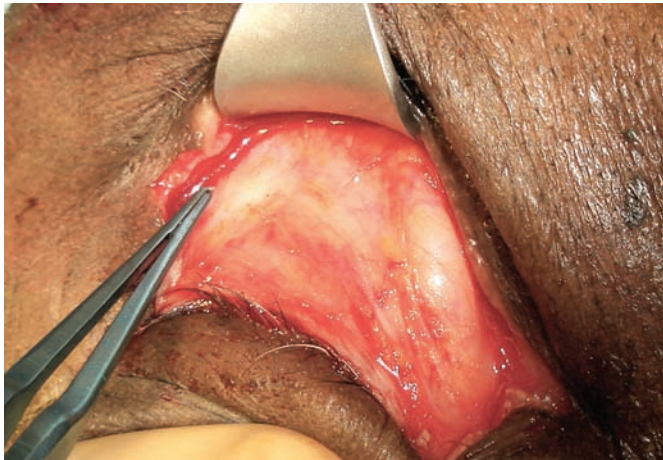


Figure 9.27 The inferior orbital fat pads are exposed. A retractor exposes the inferior orbital rim. The periosteum on the orbital rim may be cleaned of overlying tissue with a piece of gauze.

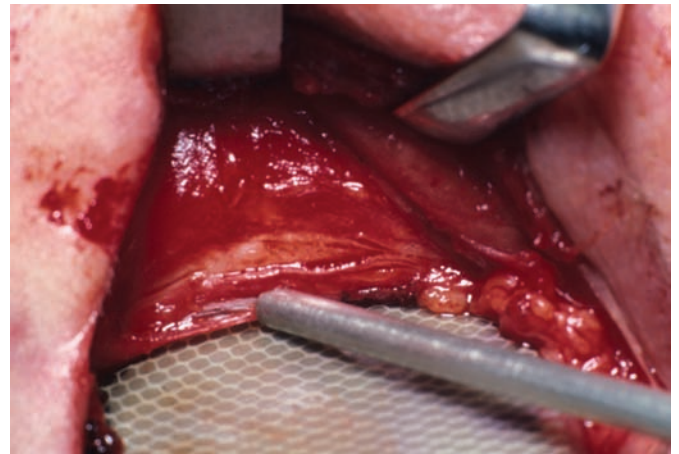
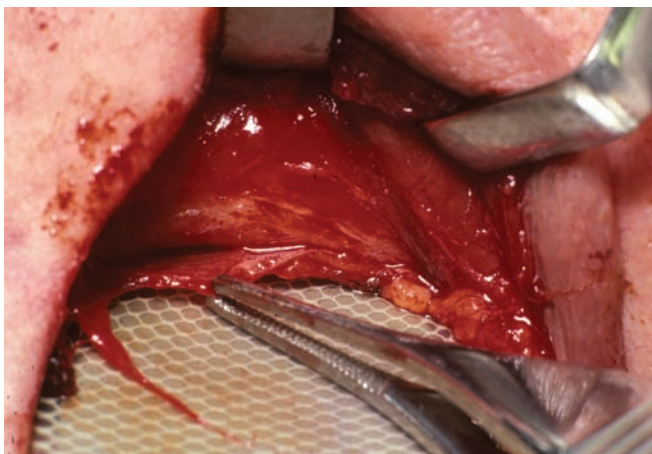
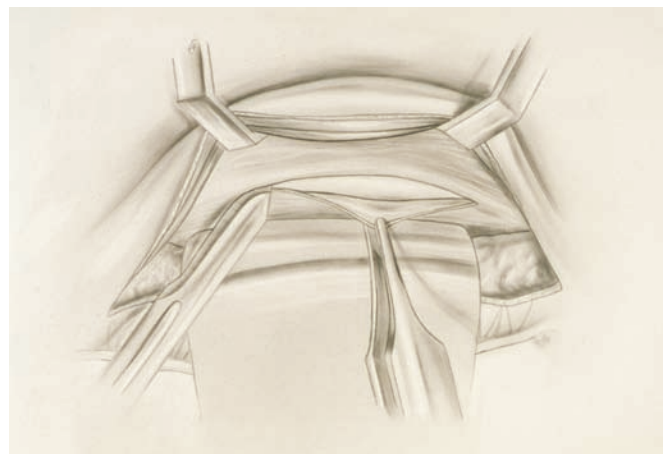


Figure 9.29 The periosteum has been incised and partially elevated with a Freer elevator.



(A)



(B)

Figure 9.30 The periosteum is firmly adhered to the orbital rim and loosely adhered to the orbital floor (A, B).



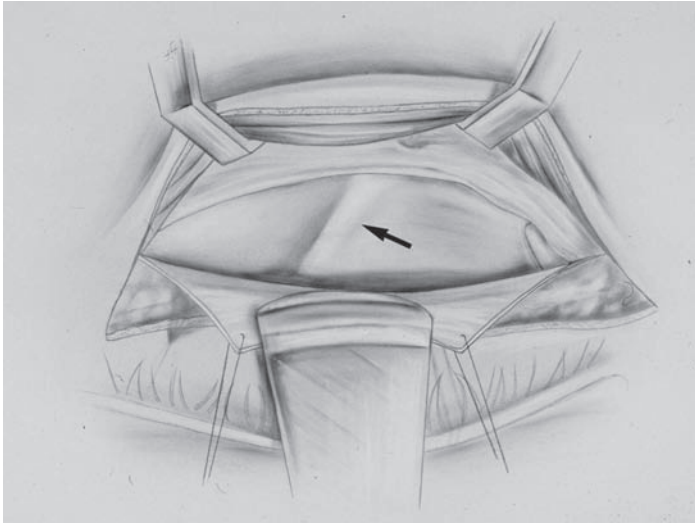


Figure 9.31 Diagram demonstrating the surgeon's view of the bony orbital floor. The periosteum is retracted with traction sutures. The bulge in the orbital floor is the infraorbital neurovascular bundle. Enter the orbital floor medial to this landmark.

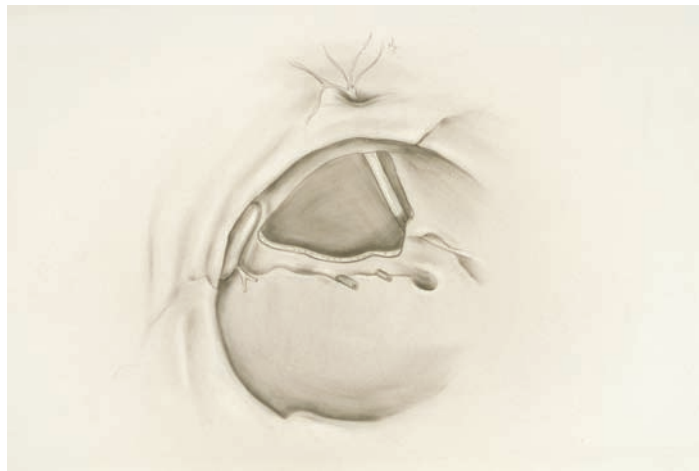
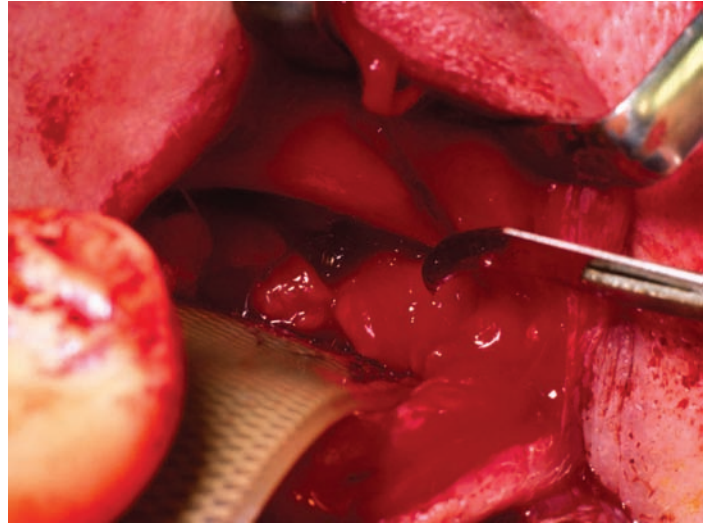


Figure 9.32 The orbital floor medial to the neurovascular bundle has been removed, exposing the posterior wall of the maxillary sinus, the infraorbital neurovascular bundle, and the medial orbital wall.

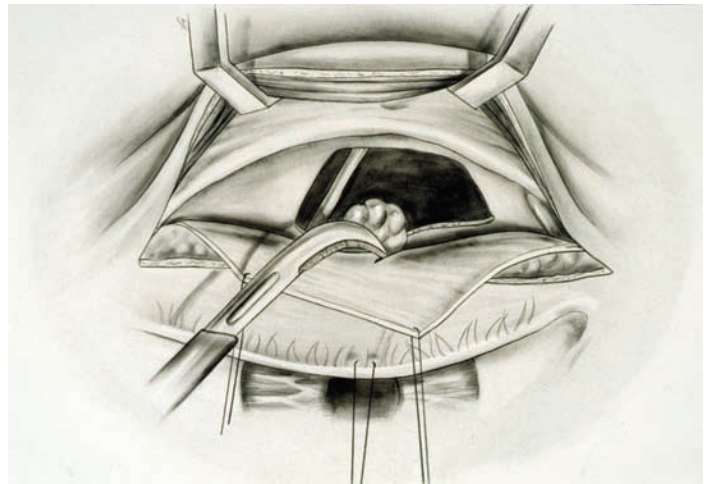
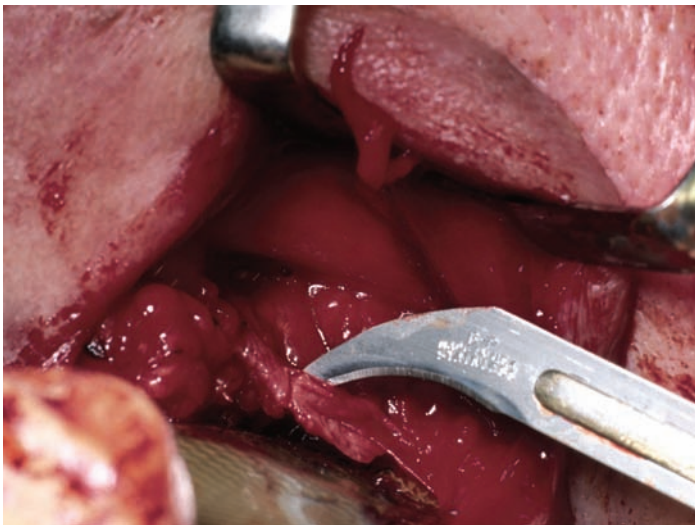

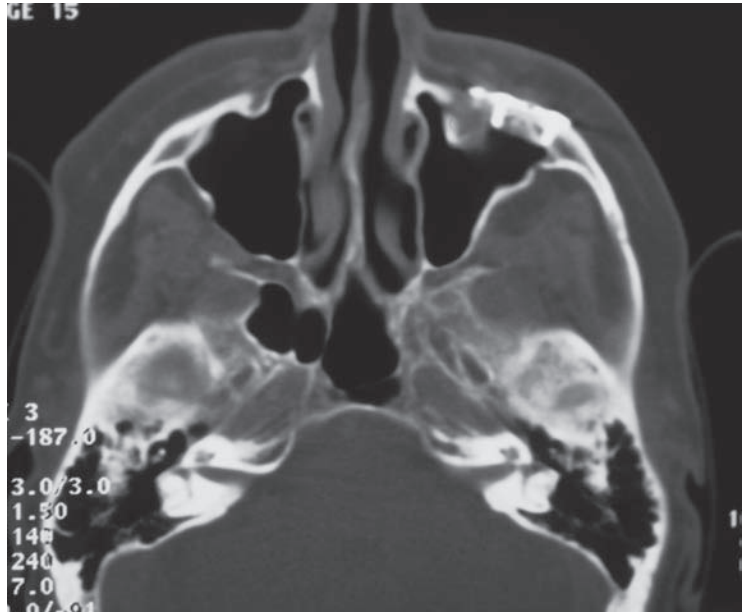
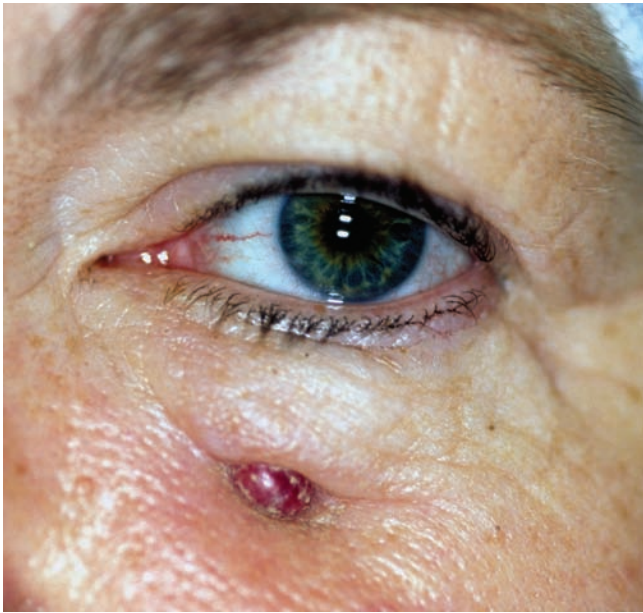
Figure 9.34 Orbital fat prolapses from the incised periorbita, completing the orbital decompression.

caused by an enlarged medial rectus muscle in patients with dysthyroid orbitopathy (Fig. 9.45). After this technique has been mastered, it can be extended to perform optic canal decompression if this ever returns to favor in the neuro-ophthalmologic community.

This is the operation where the ophthalmologist can really cause significant harm to a patient by getting disoriented and entering the brain—often without being aware of it (Fig. 9.46). Following a few simple guidelines will make this procedure much simpler and safer.

Inject the operative sites with epinephrine containing anesthetic. Pack gauze around the endotracheal tube and instill 30 to 60 cm<sup>3</sup> of Afrin into the ipsilateral nostril. This will slowly flow through the nose and ethmoid sinus and greatly enhance hemostasis. Outline a gull wing incision centered on the medial canthus with a marking pen (Fig. 9.47). Incise to the periosteum. You will invariably encounter bleeding from an angular vessel, cauterize it and go on. Incise the periosteum and reflect it into the medial orbit. This will disinsert the medial canthal tendon. You will reinsert when you close the periosteum at the conclusion of

Figure 9.33 Retracting and protecting the orbital contents with a malleable retractor, a sharp, curved blade is used to incise the periorbita.



(A) (B)  
 Figure 9.35 Lower eyelid retraction and fistula (A) due to adherence to an orbital floor implant evident on CT scan (B).

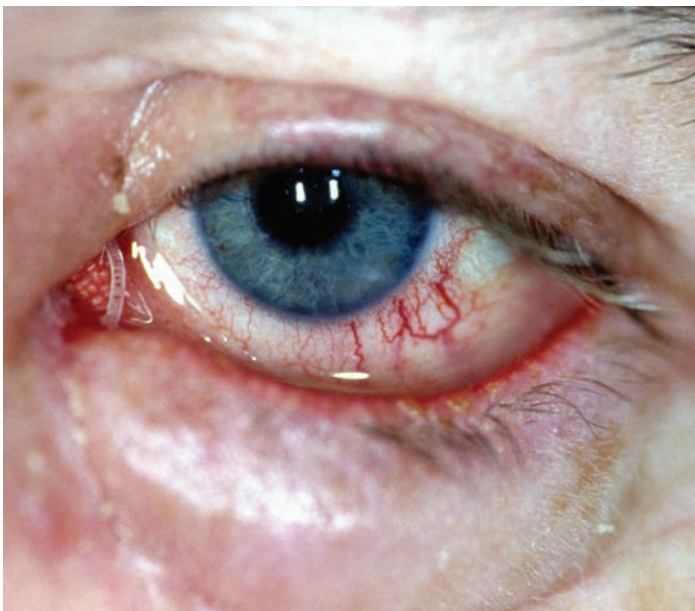

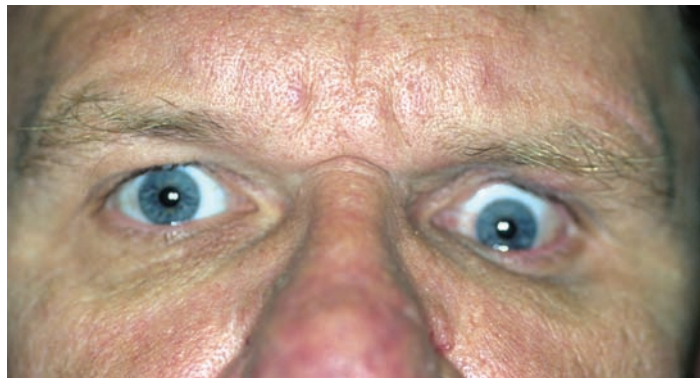Figure 9.36 Severe lower eyelid retraction secondary to adherence to a bone graft.

the procedure. Use a periosteal elevator to reflect the lacrimal sac and nasolacrimal duct behind intact periosteum (Fig. 9.48). Enter the ethmoid sinus with a hemostat at the juncture of the ethmoid and lacrimal bone. The bone is thin and easily penetrated. This is a good time to decongest the ethmoid sinus. Directly pour Afrin into the hole you made in the ethmoid bone. This is facilitated by using an angiocatheter and a syringe.

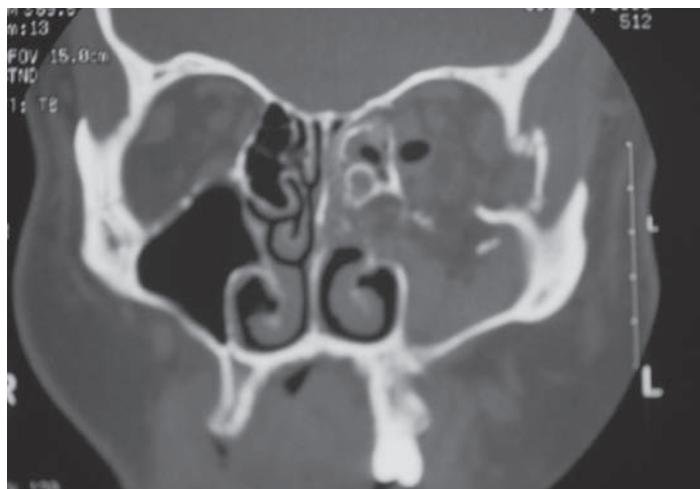
Use a malleable retractor to gently retract the periorbital while you remove the medial orbital wall and ethmoid sinus mucosa

with Kerrison rongeurs and a Takahashi rongeur (Fig. 9.49). The medial orbital wall is thin and easily fractured and removed. Locate the anterior ethmoidal vessels and keep the bone removal inferior to them. This will avoid penetration of the cribriform plate with resultant cerebrospinal fluid leak (Fig. 9.48). The apex of the orbit is recognized by a confluence of periosteal fibers forming a white band. This is the end point. Obtain hemostasis with afrinized cottonoids. Locate the medial rectus with the 4-0 silk suture that you placed under its insertion at the beginning of the procedure. Use a #12 blade (or any small, curved sickle blade), insert it into the incision and engage the posterior periorbital above and below the medial rectus muscle. Draw the blade anteriorly, incising the periorbital and allowing the orbital fat to prolapse. This avoids incising the medial rectus with resultant bleeding. If orbital bleeding does occur, control it with bipolar cauterization. Do not use Bovie cauterization in the orbit. It may injure to the optic nerve. Be careful to avoid the lacrimal sac and duct while extending the incision anteriorly. If you suspect that you have injured either one, instill hyaluronic acid (Healon®) into the lacrimal system via the punctum. If the lacrimal system is damaged, it can be repaired at that time. Often, a simple suture repair is all that is necessary.

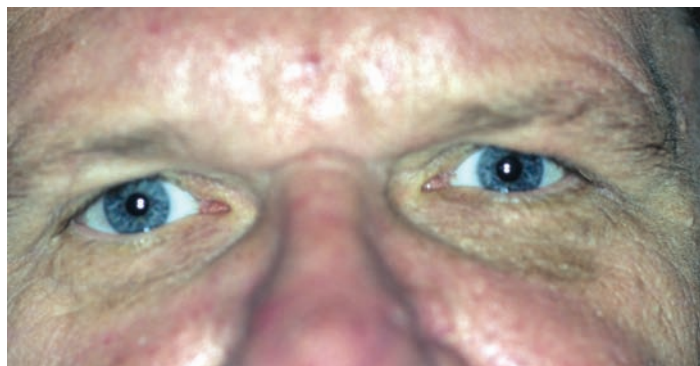Pass a hemostat into the nose and enter the wound through the nasal mucosa. Grasp the afrinized Vaseline gauze with the hemostat and pull some out of the nostril. Use this to pack the nose. The remaining gauze is used to pack the ethmoid sinus. The packing may be removed the following morning or the evening of surgery by pulling it out of the nose. Removing the packing is also an excellent way to rapidly decompress the orbit if a postoperative hemorrhage occurs. The blood in the sinus will drain from the nose, relieving the optic nerve compression and allows you time to regroup, return to the operating room, and stop the bleeding if necessary.



(A)



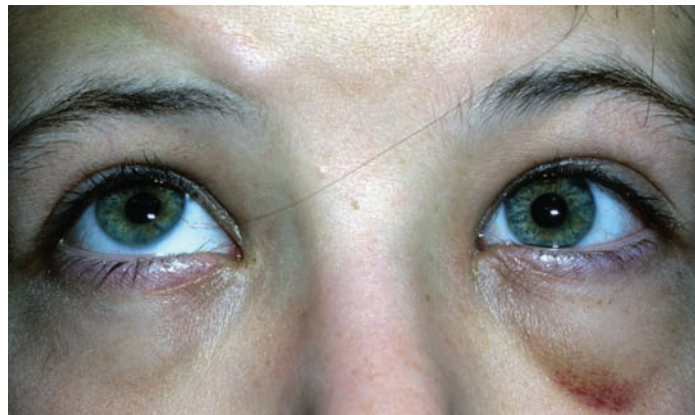(B)



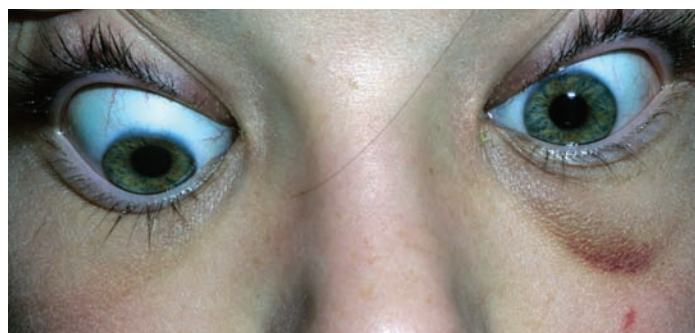(C)

Figure 9.37 Patient referred with severe hypo-ophthalmos (A) secondary to a large orbital floor fracture evidenced on CT scan (B). Same patient after surgical repair of orbital floor (C).

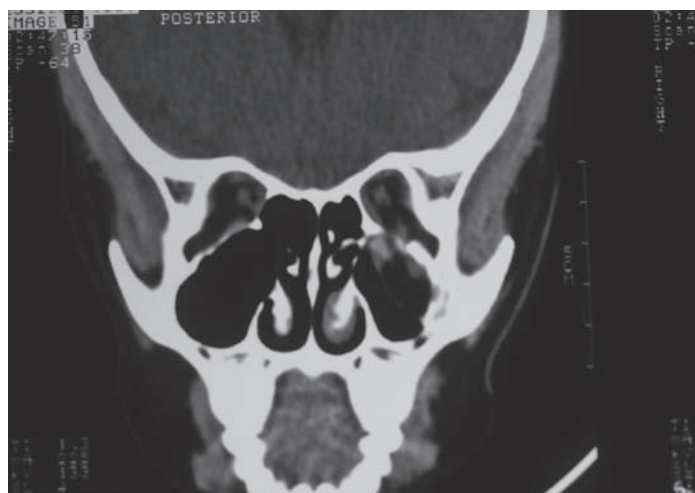
Have scan and skull available in the operating room and consult them before and during surgery as needed. Look at the coronal CT scan and determine how thick the roof of the ethmoid sinus is. If it is thick, it is less likely to be injured with a resultant cerebrospinal fluid leak. The roof of the ethmoid is the cribriform plate (the base of the brain) and it is located just superior to the ethmoidal neurovascular bundles (Fig. 9.50). Locate the anterior ethmoidal vessels and stay inferior to them. Also, avoid torquing motions with



(A)



(B)

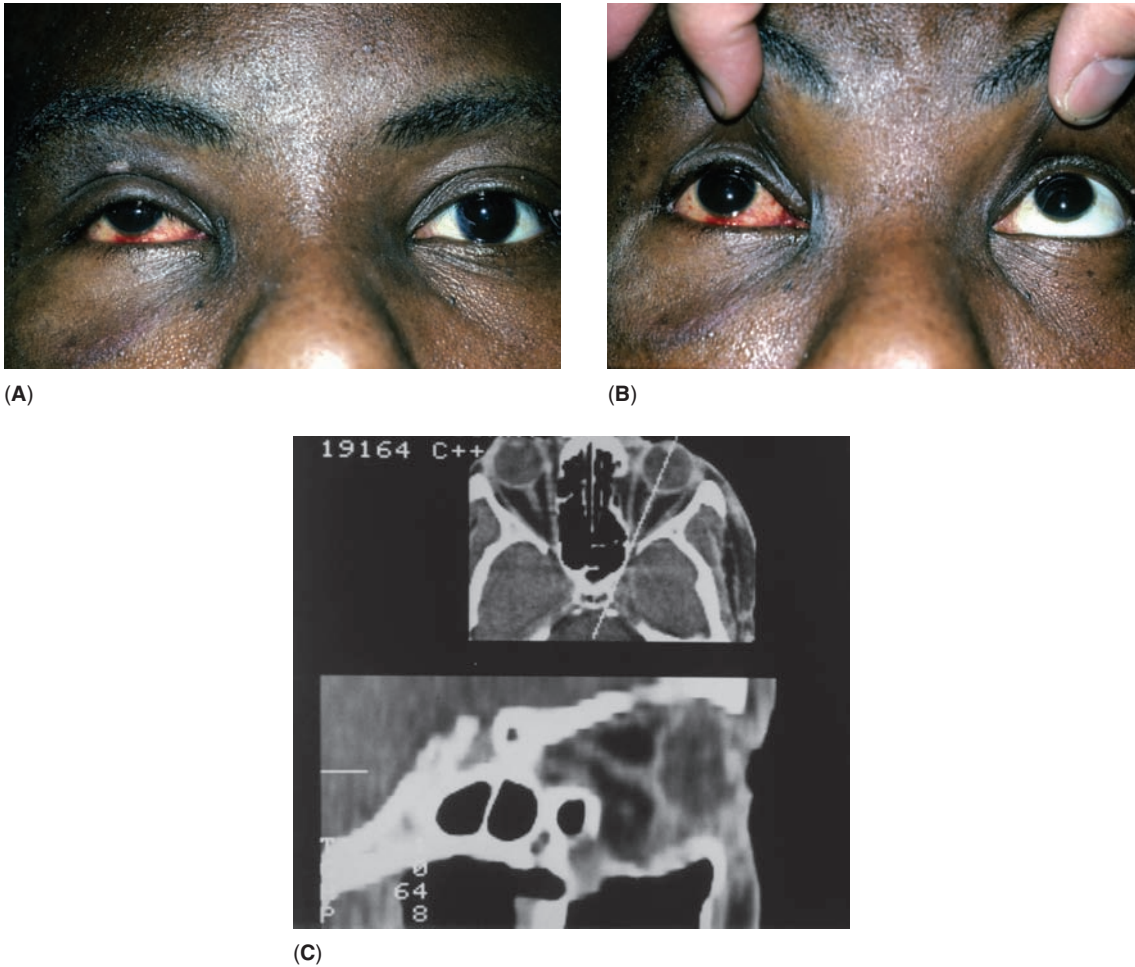


(C)

Figure 9.38 Greenstick fracture of the orbital floor causing diplopia and restriction of both up and down gaze (A, B). CT scan demonstrates a posterior orbital floor fracture with inferior rectus muscle entrapment (C). These should be repaired expeditiously and are often challenging.

the Takahashi rongeurs when working near the cribriform plate. Clean bites of bone with a Kerrison rongeur are much safer.

If a cerebrospinal fluid leak occurs, recognize it. First, differentiate it from the Afrin you have placed in the sinus. Suction it out. If the clear fluid is Afrin, it will disappear completely. If it is cerebrospinal fluid, it will continue to leak and flow. What do you do now? Attempt to repair the fracture causing the leak. This once required packing the bony defect with fat or muscle and applying a layer



*Figure 9.39* This patient had several previous surgeries attempting to free the entrapped inferior rectus. The patient was referred with diplopia and restricted upgaze (A, B). CT scan demonstrates a posterior “greenstick” fracture entrapping the inferior rectus muscle (C). Repair required a combined approach from the orbit and maxillary sinus. Note the relationship between the fracture, the back wall of the maxillary sinus, and the optic nerve. Appreciate how you can approach a posterior orbital floor fracture with relative safety through the sinus, whereas intraorbital manipulation alone may well cause optic nerve damage.

of Surgicil and superglue or mobilizing a nasal mucosal flap to plug the leak. This is more easily accomplished by instilling fibrin thrombin sealant (Evicel™) into the bony defect. This should successfully resolve the cerebrospinal fluid leak. Treat the patient with perioperative antibiotics for infection prophylaxis.

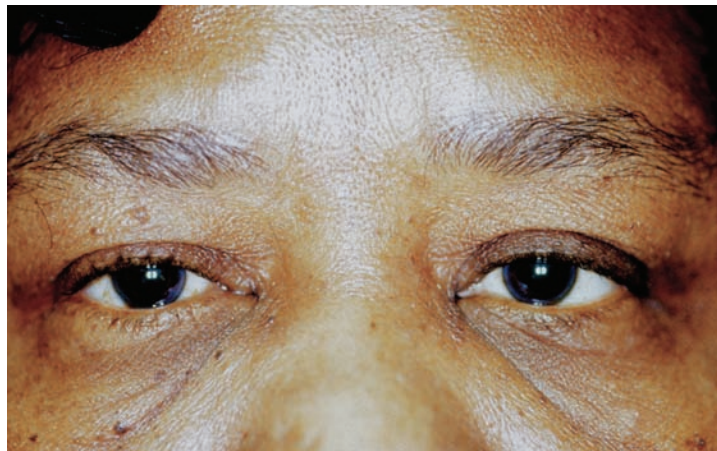Always operate from the same position when performing this surgery. This sounds both anal and banal but it is good advice. Stand on the lateral side of the orbit you are operating on. This allows you to retract the orbital contents with a malleable retractor and stay oriented. You know exactly where the orbital contents are (behind your retractor) and you cannot inadvertently injure them. This also allows direct visualization of the ethmoid sinus mucosa and the medial orbital wall that you are removing and the cribriform plate that you do not wish to remove. Every important structure is in view minimizing chances of accidental damage.

Do not rongeur what you cannot see. If excessive bleeding impairs visibility, stop operating. Afrinize and pack the sinus mucosa and wait a few minutes. The bleeding will slow and stop. It almost always does.

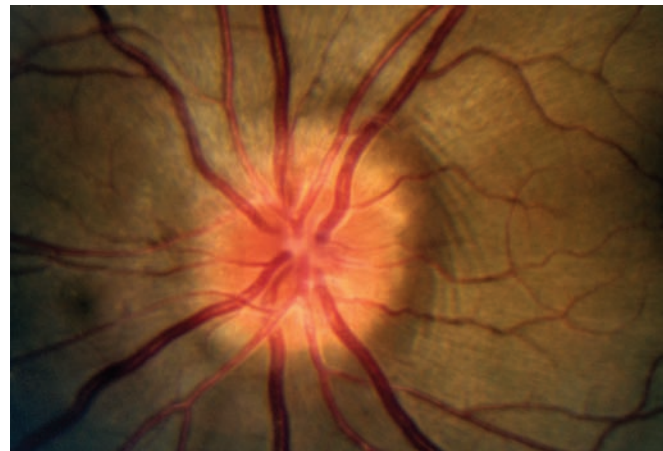
Be cautious in removing the posterior portion of the medial orbital wall. This is an excellent time to stop and consult the axial CT scan and see just what is adjacent to the posterior orbital wall—posterior ethmoid sinus or sphenoid sinus. Penetrating the posterior wall or the ethmoid sinus or the anterior wall of the sphenoid sinus enhances the bony orbital decompression. Penetration of the posterior sphenoid enters the brain and is inviting disaster.

#### OPTIC NERVE SHEATH DECOMPRESSION

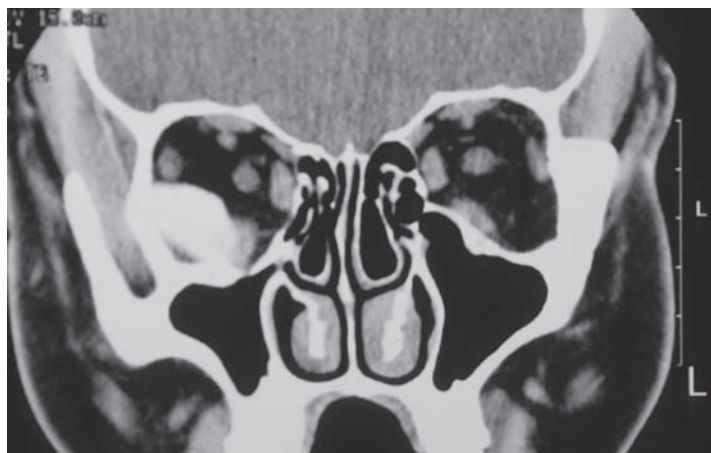Several techniques have been described for decompressing the optic nerve. My tried and true method is via a transconjunctival medial orbitotomy and has been successful and essentially free of major operative complications in over one thousand cases. It can be safely performed as an outpatient procedure under local anesthesia with sedation. I instill peribulbar anesthetic with an angiocatheter in almost all extraocular muscle surgery and optic nerve sheath fenestrations. This allows excellent anesthesia and analgesia with essentially no risk of damage to the globe or optic nerve.



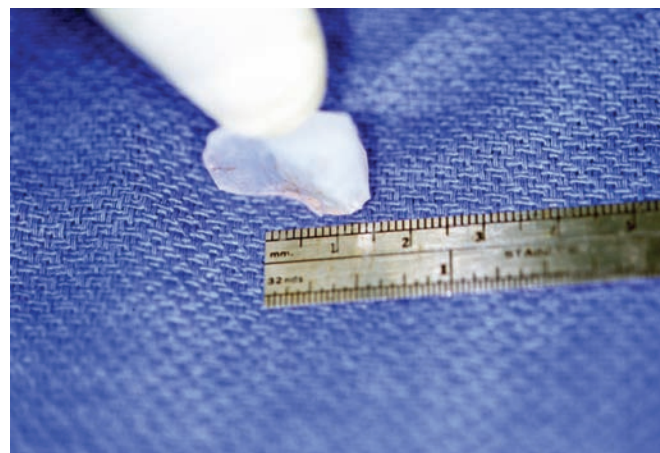(A)



(B)



(C)



(D)

Figure 9.40 Large orbital floor implants may exert excessive pressure on the optic nerve causing visual loss (A–C). Remove the implant (D).

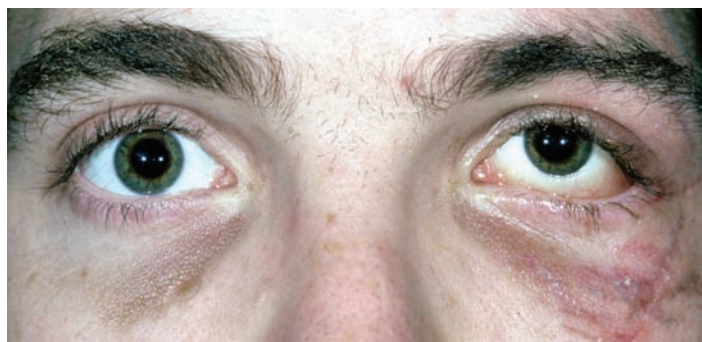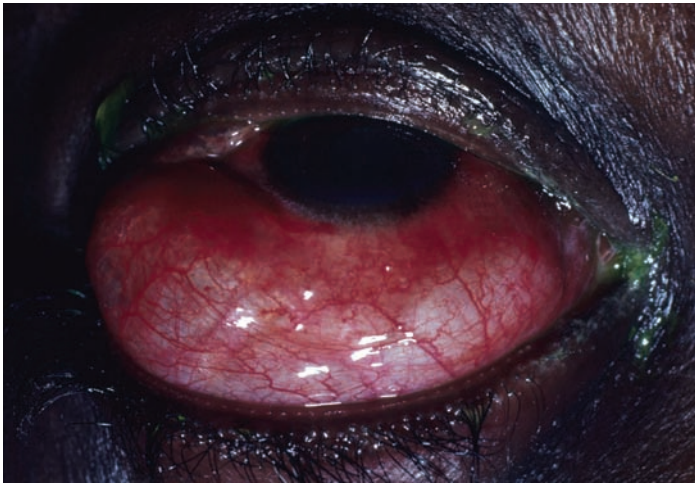


Figure 9.41 Hyperophthalmos secondary to a large implant on the orbital floor. Treatment requires removing the implant and replacing it with a more appropriately sized implant.

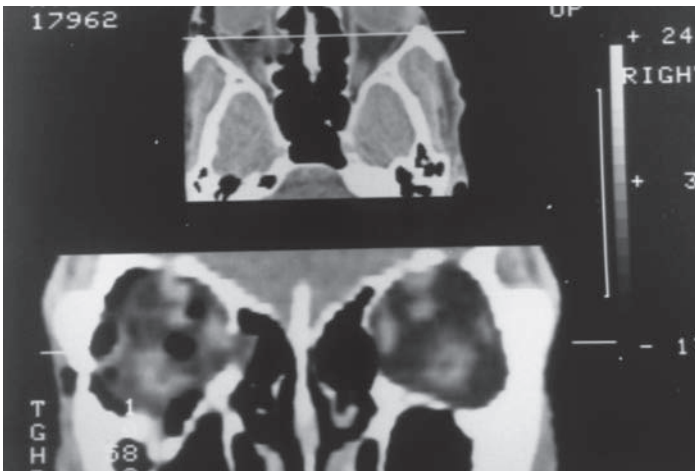
One percent plain xylocaine with hyaluronidase is injected into the lateral canthal area to minimize eyelid motion and test the level of intravenous sedation. No harm is done if the patient makes an abrupt move with a needle under the lateral canthus skin, but with the needle under the conjunctiva, a sudden motion may convert an extraocular case to an intraocular procedure. Using a 30-gauge needle, approximately 1 cm<sup>3</sup> of anesthetic is

injected beneath the conjunctiva (Fig. 9.51), ballooning it up quite nicely to facilitate the conjunctival peritomy. Perform a 360-degree peritomy with scissors (Fig. 9.52). Make a relaxing incision superior and inferior to the medial rectus. Use blunt scissors to create a tunnel between the medial and inferior rectus. Place an 18 or 20 gauge shortened angiocatheter in the tunnel and instill 2 to 3 cm<sup>3</sup> of anesthetic into the peribulbar space (Fig. 9.53). The eye bulges forward and the pupil promptly dilates as the anesthetic rapidly spreads through the anterior orbit. Pass a 6-0 Vicryl suture through the medial rectus muscle posterior to its insertion and fixated it in three places. Disinsert the muscle leaving a 1 to 2 mm stump of muscle at the insertion. Two 6-0 Vicryl sutures are passed through the superior and inferior stump at the insertion. These will be used to abduct the eye, retracting it laterally to expose the optic nerve sheath (Fig. 9.54). By leaving a 1 to 2 mm muscle stump to suture, you minimize the possibility of penetrating the globe when passing sutures through the insertion site.

Retract the medial rectus muscle behind a Sewall ethmoidectomy retractor. Any flat blade retractor of appropriate size will do, but there is a handle on the Sewall retractor, which greatly facilitates retraction, avoiding a tight grip and subsequent tremulous

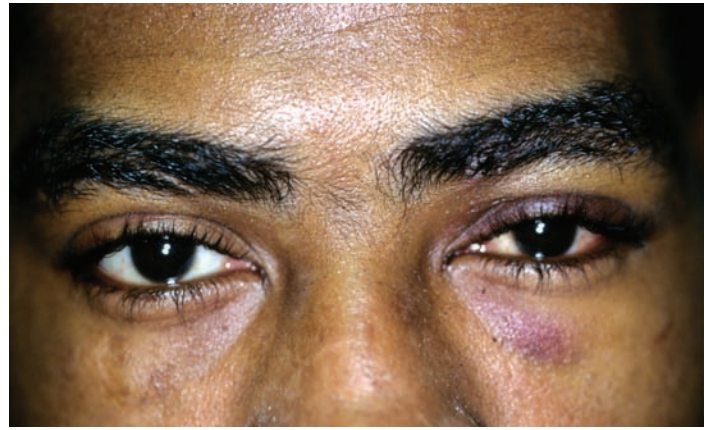

(A)

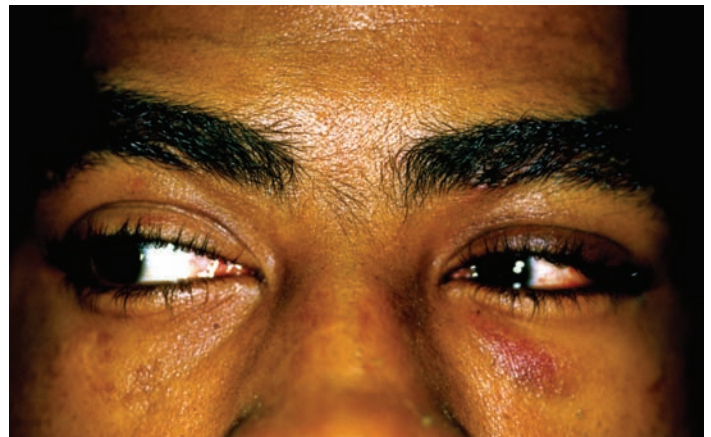

(B)

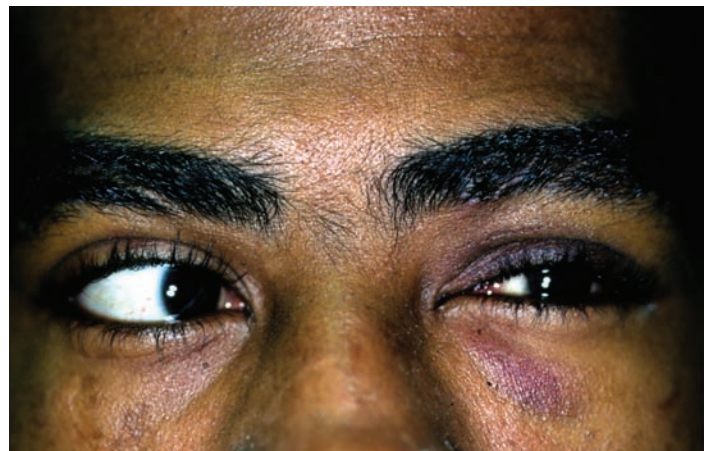Figure 9.42 Severe orbital emphysema (A) after medial orbital wall fracture evident on CT scan (B). Note the relationship of the medial rectus muscle to the fracture site in the medial orbital wall. This muscle is not entrapped and extraocular mobility was normal after the swelling subsided.



(A)



(B)



(C)

Figure 9.43 Patient has a medial orbital wall fracture with medial rectus entrapment. Eyes are straight in primary gaze (A). Right gaze is unimpaired (B). Abduction is significantly impaired in left gaze (C) and forced ductions are positive. The patient needs surgery.

fingers. With the eye retracted in abduction and the medial rectus retracted medially, the muscle cone is exposed (Fig. 9.54). Proceed posteriorly towards the optic nerve. This is facilitated by bluntly displacing the orbital fat with small neurosurgical cottonoids and cotton-tipped applicators (Fig. 9.55). Sharp dissection and nerve hooks are not necessary at this stage of the operation. Several attempts at retracting the orbital fat are usually necessary and exposure of the optic nerve sheath becomes easier as the manipulation softens the globe. It is often helpful to place the Sewall retractor over a few cottonoids. This also protects the medial rectus from excessive bruising.

The optic nerve sheath, covered by short ciliary vessels and nerves, is identified at its juncture with the globe. These are manipulated with a dull nerve hook exposing an area of nerve sheath devoid of overlying structures (Fig. 9.56).

This is the ideal area to incise with a small, sharp pointed blade (Fig. 9.56). Incise the sheath and if the surgery was indicated, you will be rewarded with an egress of cerebrospinal fluid.

Enlarge your incision by bluntly spreading it with two nerve hooks before releasing traction and letting the globe rest (Fig. 9.57). This maneuver facilitates finding your incision when you re-expose the operative site.

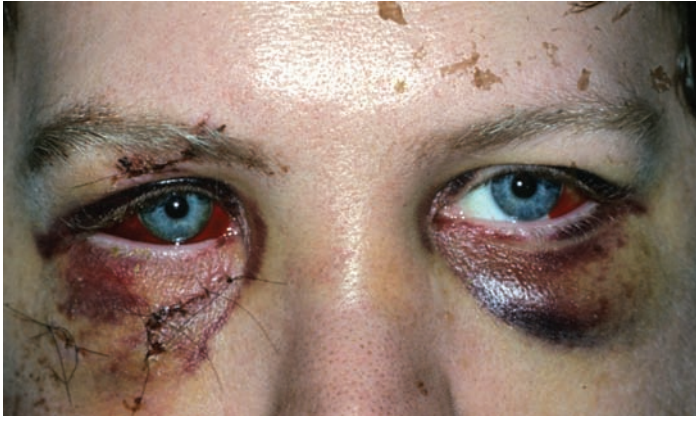

Figure 9.44 Rounding of the medial canthus and widening of the intracanthal distance are the hallmarks of medial canthal tendon disruption in traumatic telecanthus.



Figure 9.47 Gull wing incision outlined in the medial canthus. This incision gives excellent access to the medial orbital wall and very acceptable cosmesis.

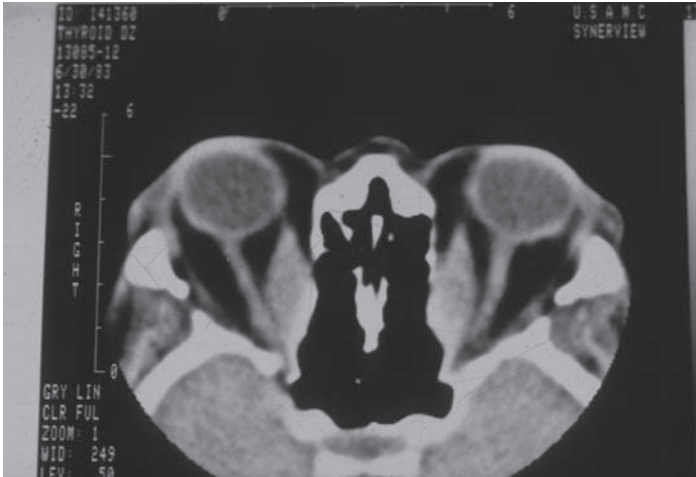


Figure 9.45 CT scan demonstrates enlarged medial recti muscles causing a compressive optic neuropathy in a patient with dysthyroid orbitopathy.

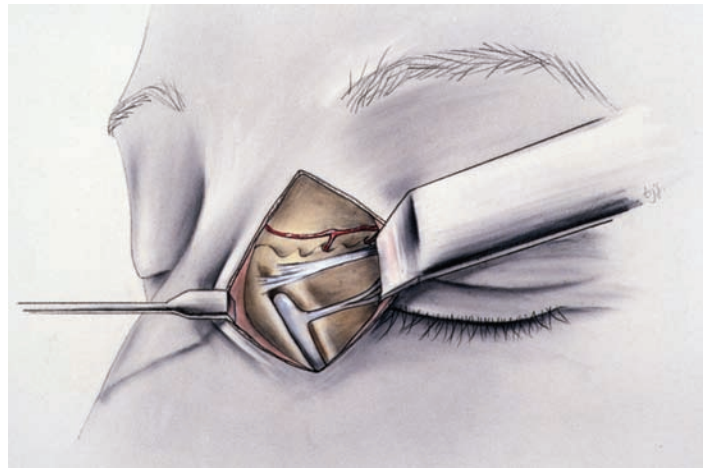


Figure 9.48 Relationship between the anterior ethmoidal artery, the medial canthal tendon, and the lacrimal sac.



Figure 9.46 Axial fresh cadaver section demonstrating the relationship between the medial orbital wall and the intracranial structures at the orbital apex.

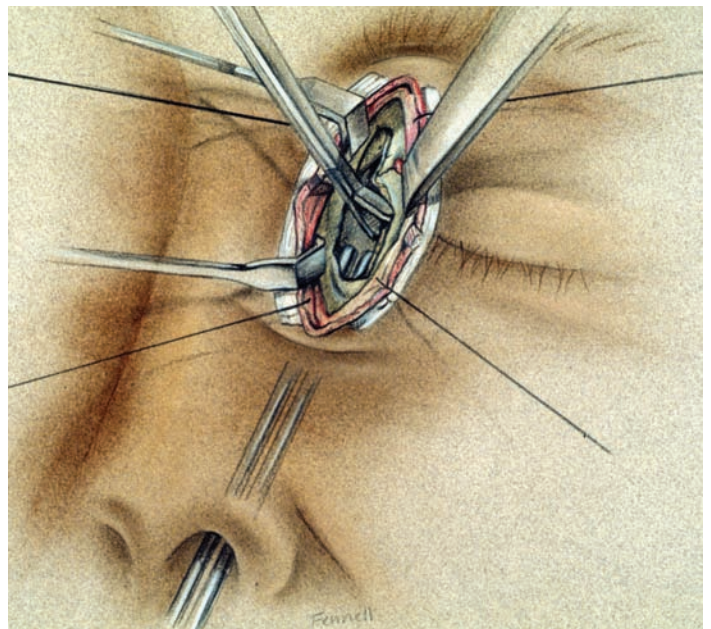


Figure 9.49 Removal of the medial orbital wall inferior to the anterior ethmoidal artery.

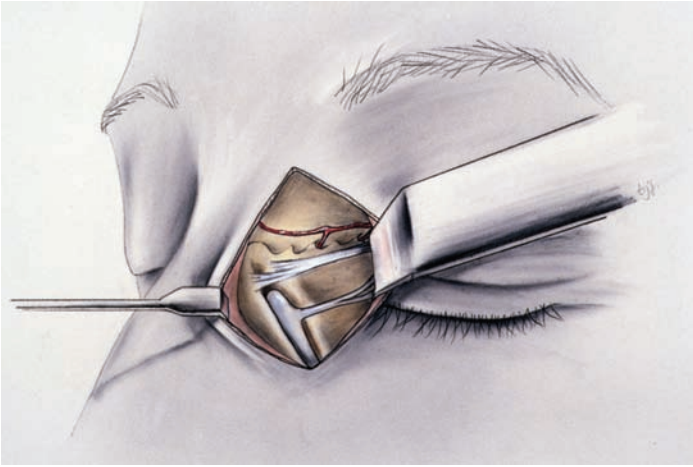


Figure 9.50 Diagram demonstrating the relationship between the anterior ethmoidal vessels, medial canthal tendon, and lacrimal sac. The ethmoidal vessels are the key landmark to avoid damage to the cribriform plate.

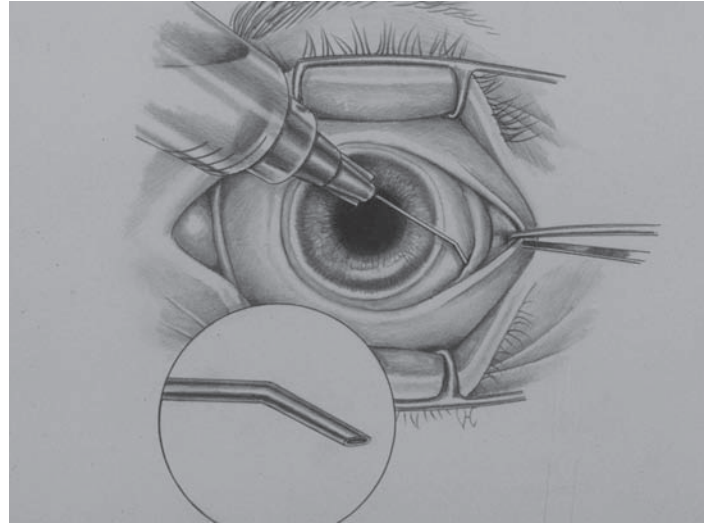


Figure 9.53 A blunt cannula or shortened angiocatheter is inserted in the peribulbar space between the medial and inferior rectus muscles.

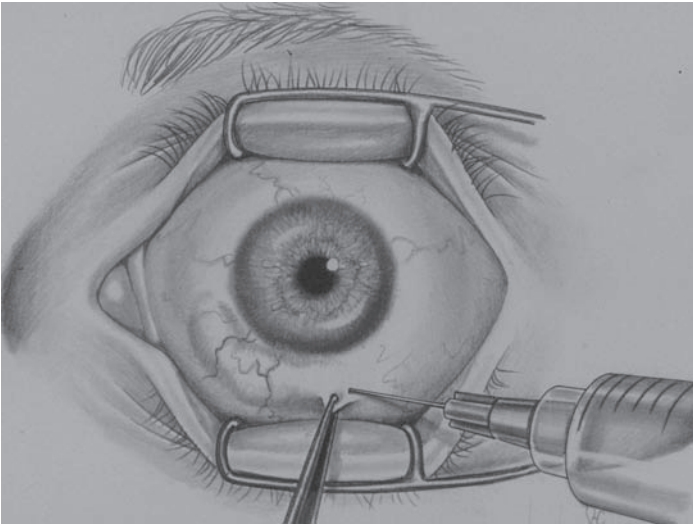


Figure 9.51 Subconjunctival injection of anesthetic solution.

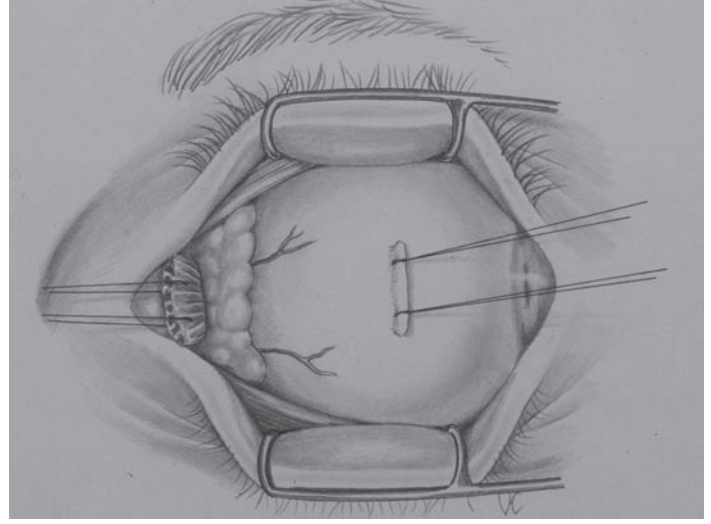


Figure 9.54 A 6-0 Vicryl suture passed through the medial rectus insertion abducts the eye. The medial rectus muscle is retracted exposing intraconal fat and the posterior ciliary vessels.

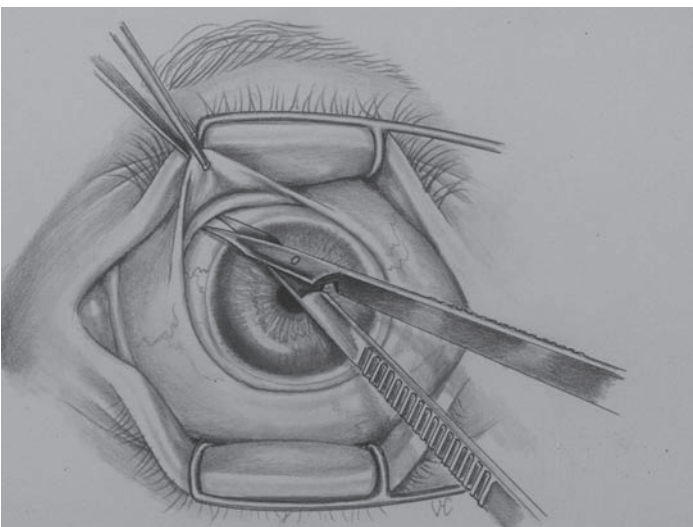


Figure 9.52 A 360-degree peritomy is made with curved scissors.

Failure to do so may result in a “lost incision” and necessitates making another incision into a now decompressed optic nerve sheath.

This invites violation of the optic nerve although this is rarely clinically significant. Why? Because you are dealing with peripheral nasal fibers subtending far peripheral temporal visual field, which will rarely be missed. This is also a good reason to avoid the lateral approach to the optic nerve where you are incising over the papillomacular bundle. An overzealous incision into the optic nerve fibers here will injure the papillomacular bundle and will surely be noticed after surgery.

Re-expose the now incised optic nerve sheath, find your enlarged incision, and put the tip of a blunt, bent nerve hook into it. Retract the incision with the nerve hook and incise and excise



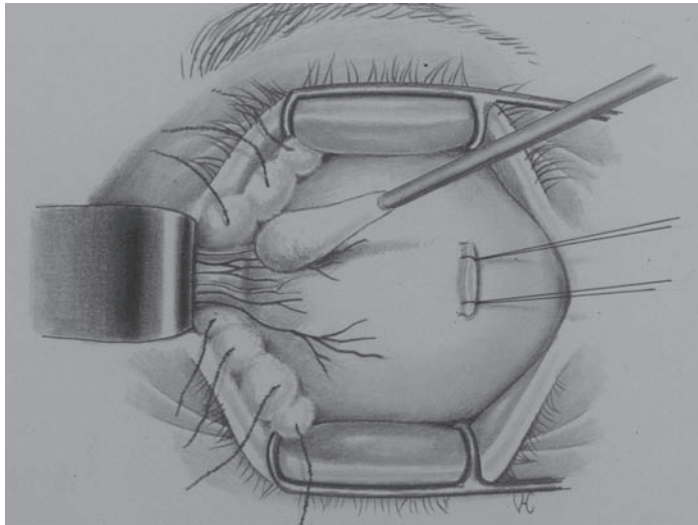


Figure 9.55 Cottonoids and cotton-tipped applicators are used to reposition the orbital fat and expose the optic nerve sheath and its overlying vessels. The medial rectus muscle is retracted with a blade retractor.

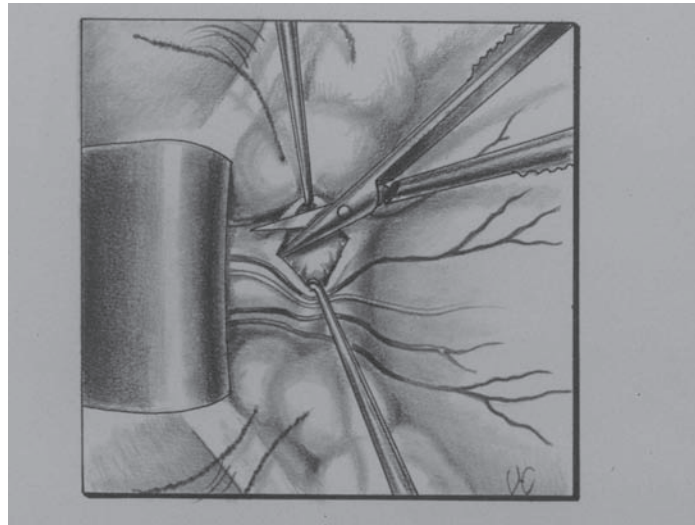


Figure 9.57 The incision is spread apart and elevated from the optic nerve with two nerve hooks while it is incised with microscissors.

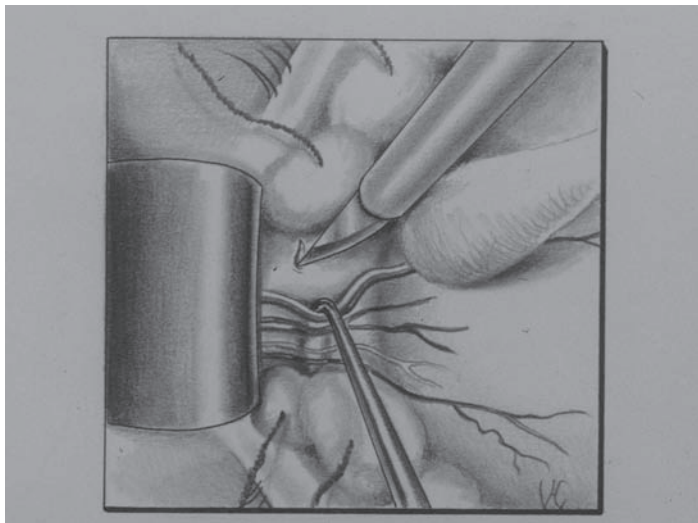


Figure 9.56 The short ciliary vessels are manipulated and retracted with a blunt nerve hook and the optic nerve sheath is incised with a sharp, pointed blade.

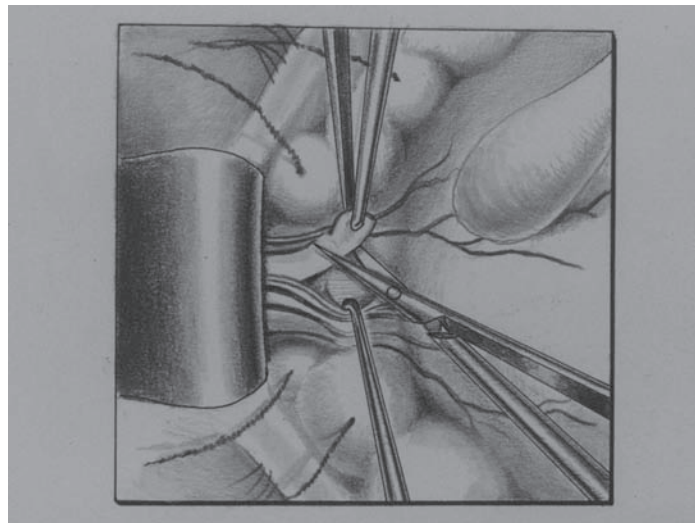


Figure 9.58 A portion of the optic nerve sheath is excised. Note sparing of the short ciliary vessels.

as much of the sheath with microscissors (I prefer vitreoretinal scissors) as you are comfortable doing (Figs. 9.57 and 9.58). Trabeculations in the subarachnoid space between the optic nerve and its sheath may be lysed with blunt nerve hooks (Fig. 9.59). This maneuver is actually overrated and in my experience rarely necessary.

Your comfort level will vary with the quality of exposure, preoperative visual function, location of overlying short ciliary vessels, and your surgical experience. This is the end of the procedure. Inspect the operative site for bleeding. When present, this can almost always be controlled by gentle pressure applied with a moist cottonoid. Bipolar cauterization is rarely needed and if used should be very low power in a wet field. Most all bleeding will stop and with a little patience and pressure this will also.

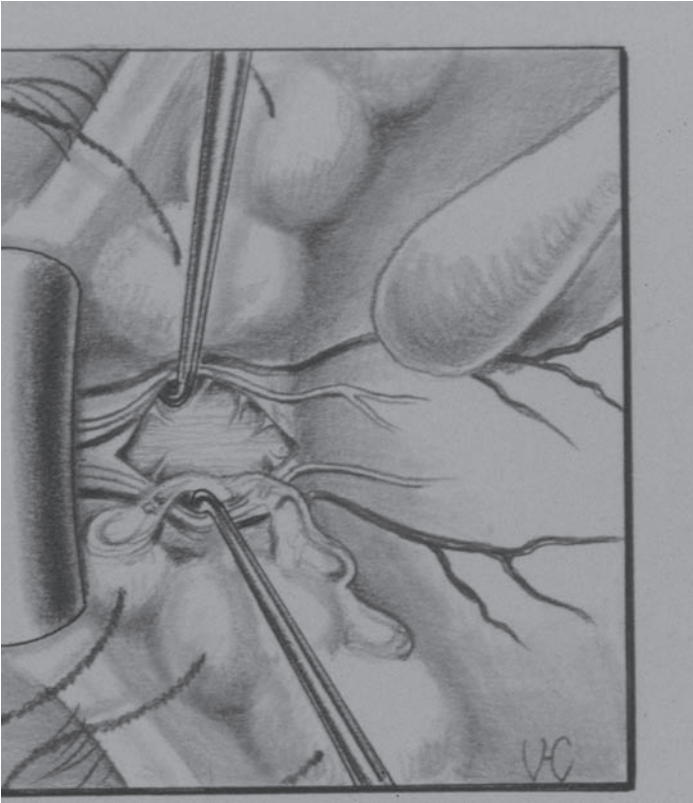
Remove the sutures from the stump of the medial rectus insertion and reattach the medial rectus to its insertion with the previously

placed double-armed suture. Recess it 1 to 2 mm depending on how much muscle you excised at the insertion. A hang-back recession is fine (Fig. 9.60). Close the conjunctival peritomy with a few 6-0 Vicryl sutures with buried knots and patch the eye with your antibiotic/steroid ointment of choice.

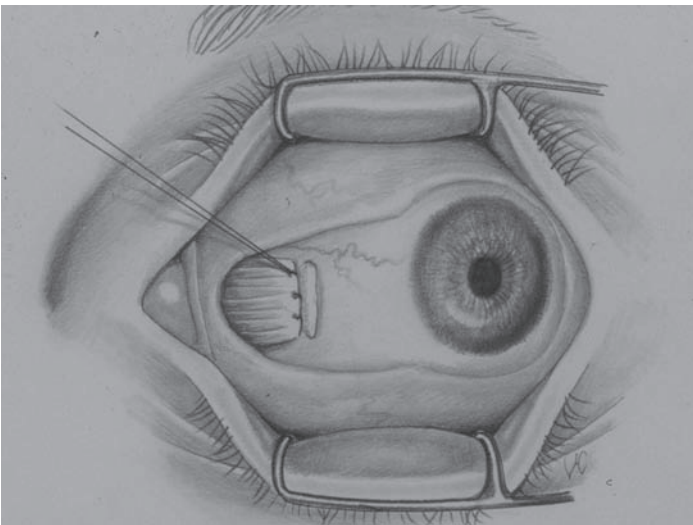
### Complications

Significant complications are relatively uncommon after well-performed optic nerve sheath decompression. In reality, this is little more than an extended medial rectus recession. If the operation is indicated, the nerve sheath is distended with cerebrospinal fluid, it is readily visualized and can be incised with minimal manipulation and trauma.

Problems arise when exposure is limited and manipulation is excessive and prolonged. Release pressure on the globe every one to two minutes to avoid ischemic injury to the optic nerve or



*Figure 9.59* The fenestration is completed by lysing the trabeculations in the subarachnoid space with blunt nerve hooks allowing more cerebrospinal fluid to egress. An assistant using a cotton-tipped applicator can enhance exposure during the operation by applying gentle pressure to the globe or retracting orbital fat.



*Figure 9.60* The medial rectus is reattached to the globe at its insertion or it may be recessed a few millimeters. The conjunctiva is closed with several sutures. Bury the knots. Close the conjunctiva carefully to avoid corneal dellen formation.

retina. Do not aggressively cauterize bleeding vessels. The bleeding will stop with gentle pressure and time.

#### Caveats

Use plain lidocaine with hyaluronidase to avoid epinephrine induced vasoconstriction. It is also short acting enough to allow you

to check the patient's vision prior to discharge from the recovery area.

Do not keep the eye retracted and clamped in abduction for more than a minute at a time without releasing it and restoring circulation to the optic nerve. I think that this is a key step in avoiding intraoperative complications. A minute or so is more than ample time to perform the various sequential steps described here.

Exposing the optic nerve sheath is easiest in those patients really needing the operation. The nerve sheath is distended and contains a significant amount of fluid under pressure. When operating on patients who have been treated medically for a time, discontinue their medications for a few days before surgery to allow their cerebrospinal fluid pressure to increase and distend the optic nerve sheath, making the operation much easier. A corollary to this is that when performing bilateral optic nerve sheath decompression in a patient with one good eye and one bad eye operate on the good eye first and enjoy the advantage of a distended optic nerve sheath. It really does make the surgery much easier and safer both by facilitating exposure and by protecting the optic nerve from the surgeon's blade with a layer of cerebrospinal fluid.

#### TEMPORAL ARTERY BIOPSY

Over the past 30 years, I have watched a variety of surgeons including, on occasion, myself make fools of themselves performing this simple procedure. Blunders observed have included failure to find the artery after two hours exploration, biopsy of the vein, and excessive bleeding due to uncontrolled, accidental early incision into the artery. The technique presented here is simple and relatively foolproof.

#### Technique

If you can palpate the superficial temporal artery, you can biopsy it in the office or in the surgical center. Patients with true temporal arteritis often have very obvious, chord-like superficial temporal arteries bulging in their temporal fossa (Fig. 9.61). These patients will often have positive biopsies (Fig. 9.62). When less obvious, the artery can be palpated and outlined with a marking pen. In patients with a barely palpable superficial temporal artery, a Doppler unit can be used to identify the artery in the preauricular region and trace it to the temporal region. This is not often necessary but very helpful in some cases. If a Doppler is not available, the artery may very often be located 2 cm in front and superior to the ear (Fig. 9.63).

After the incision site over the artery has been identified (Fig. 9.64), inject the operative site with plain lidocaine. Do not use lidocaine with added epinephrine for it will constrict the artery and make the procedure much more difficult. Make an incision through the skin and superficial dermis. Grasp both sides of the incision and elevate it from the underlying tissue. Incise it with scissors, insert a hemostat, and spread it apart (Fig. 9.65A and B). Open the incision with scissors. This technique should allow you to expose the artery without injuring it and causing excessive, premature bleeding (Fig. 9.66A and B).

The artery lies on the superficial temporal fascia (Fig. 9.67). Grasp the artery with blunt forceps and dissect it from the surrounding tissue with scissors. Pass a hemostat beneath the artery and replace it with a 4-0 silk suture. Use the suture to retract the

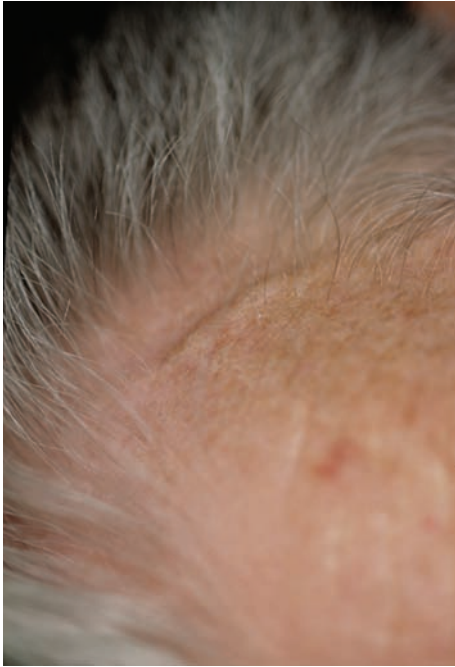

Figure 9.61 Patient with a large, chord-like superficial temporal artery.

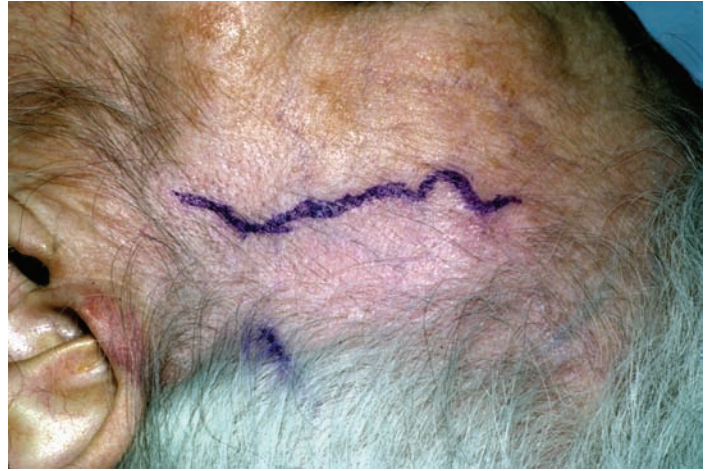

Figure 9.64 Mark the course of the artery or an incision adjacent to it. Note that the patient's artery is located exactly where described in Figure 9.63.

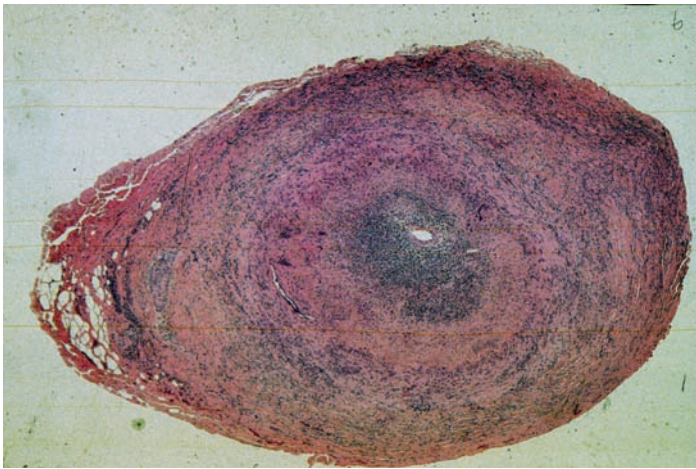
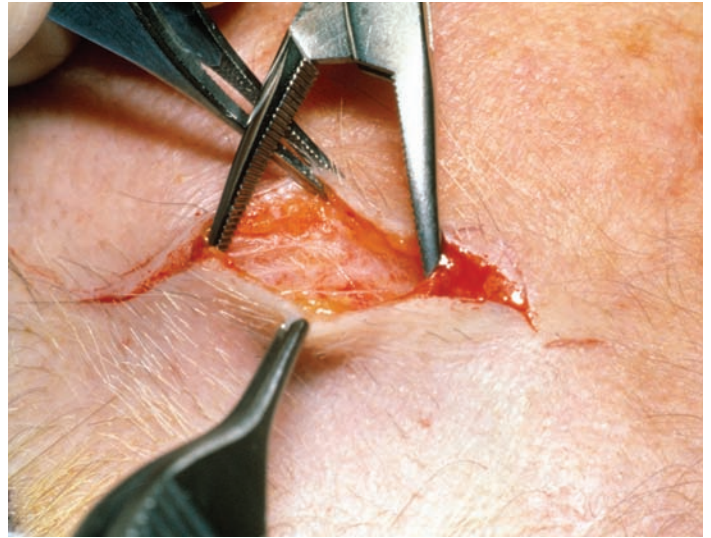


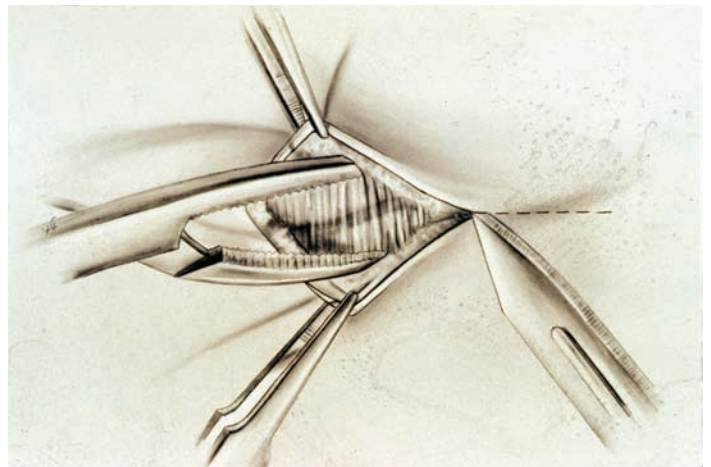
Figure 9.62 Floridly positive temporal artery biopsy with a plethora of giant cell granulomas.



(A)

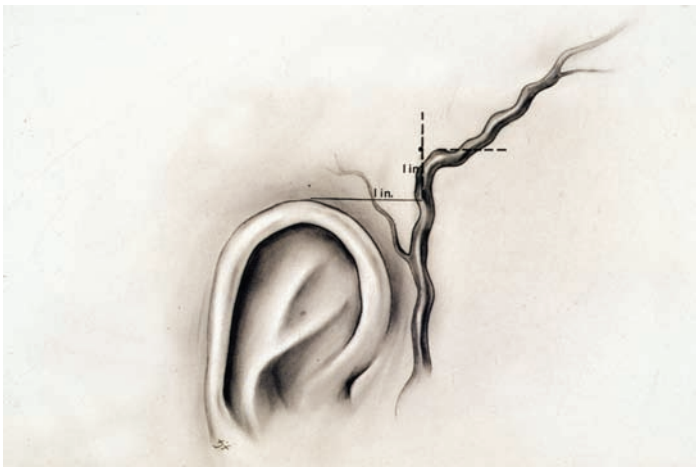

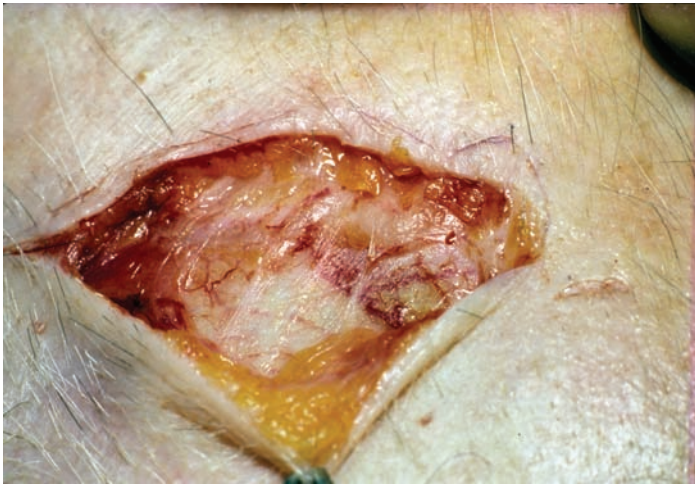Figure 9.63 The superficial temporal artery can often be located 2 cm above and in front of the earlobe.

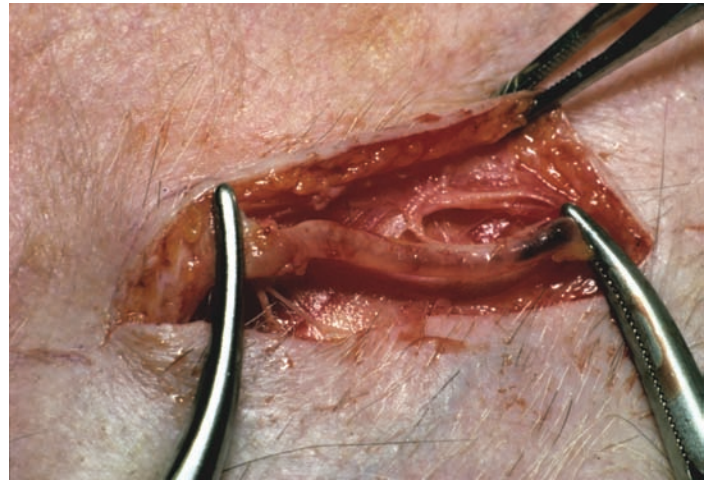

(B)

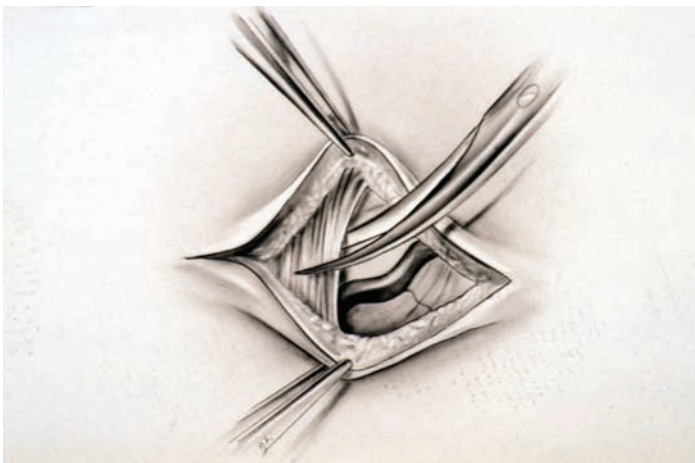
Figure 9.65 Elevate both sides of the incision from the underlying tissue and spread the incision with a hemostat (A, B).



(A)

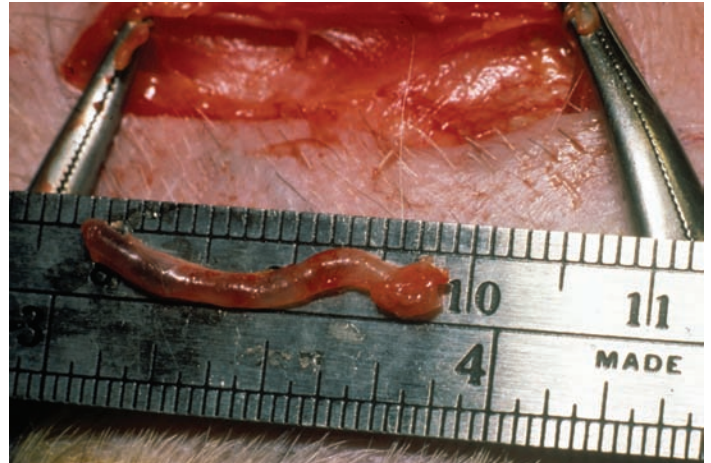


(A)



(B)

Figure 9.66 The superficial temporal artery enveloped in surrounding tissue (A) which is dissected from it with scissors (B).



(B)

Figure 9.68 The distal and proximal ends of the artery are clamped with hemostats (A) and the specimen excised (B).

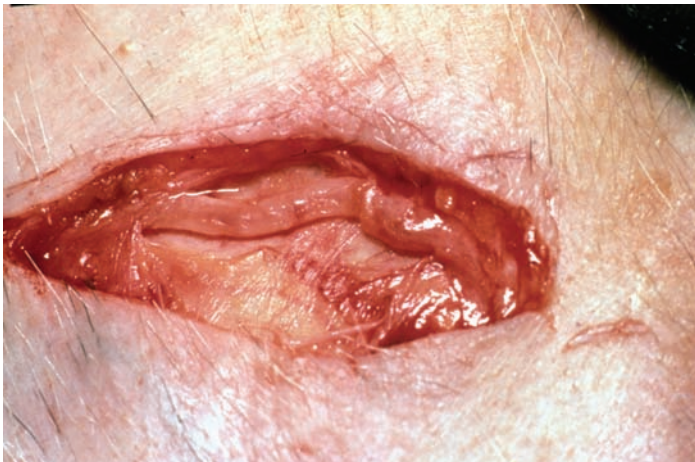

Figure 9.67 The surrounding tissue has been removed and the artery exposed on the superficial temporal fascia.

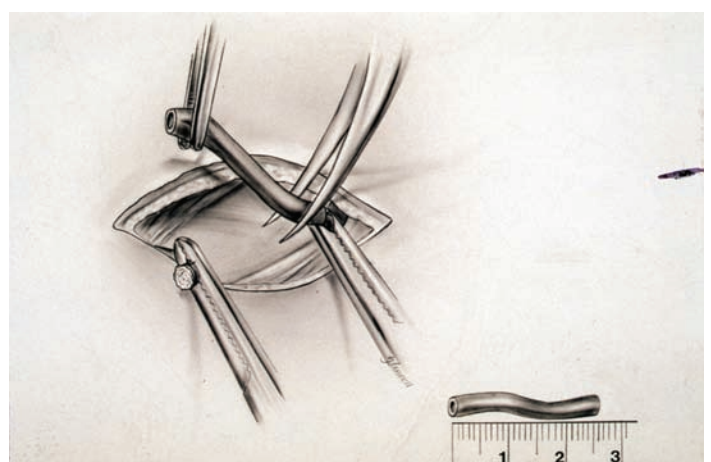


Figure 9.69 The proximal and distal ends of the artery are cauterized and sutured if necessary.

vessel and facilitate further dissection. After an ample specimen has been isolated (Fig. 9.68A), clamp both ends of the vessel with hemostats and excise the specimen (Fig. 9.68B). Cauterize the stumps of the vessel. If the artery is large and functional, apply a

silk suture tie to the proximal end in addition to cauterizing it (Fig. 9.69). After hemostasis is completed, close the subcutaneous tissue with 5-0 Dexon sutures and apply Indermil to the skin edges or suture them with your skin suture of choice.

# Index

- American Journal of Ophthalmology* 26
- Aqueous tear deficiency 84
- Asymmetric eyelid creases 82, 83
- Atypical mycobacterium infection 82
  
- “Belt and belly” phenomenon 40
- Bilateral ectropion 38, 40
- Bilateral keratopathy 77
- Bilateral lower eyelid retraction 36
- Bipolar cauterization 1, 4
- Blepharoplasty 59–60
  - chronic irritation after 76
  - eyelid retraction and 72
- Blinking (incomplete), after upper eyelid surgery 73
  - upper eyelid retraction 73
- Bony orbital floor
  - surgeon’s view of 106
- Brow lift through eyelid crease incision 66, 68
- Brow ptosis repair 64, 66
  
- Canaliculi
  - relationship between eye/lacrimal sac and 86
- Canthotomy 1
- Capsulopalpebral fascia 1
  - inferior orbital fat pads above 29
  - levator aponeurosis and 31
  - sutures through 30
  - tightening and tying 30
- Cauterization
  - inspection for bleeding and 6
  - medial fat pad 6
- “Cheese wire,” 26
- Chemosis 38, 39
- Chemotic conjunctiva 38, 39
  - after lower eyelid surgery 39
- Chronic irritation
  - after ptosis surgery/blepharoplasty 76
- Cicatricial ectropion 16, 17, 25
  - after face lift and lower eyelid blepharoplasty 21
  - cicatrizing forces 21
  - less severe 41
  - skin graft 21
    - closing donor site 24
    - determining size of 23
    - larger 22
    - pinch skin graft from upper eyelid 22
    - thinning 24
- Congenital ptosis 63
- Conjunctiva
  - anesthetizing 26, 27
  - incision through 1, 3
  - in palpebral fissure 85
  - repositioning 7
- Conjunctival flap, dissecting 4
- Conjunctivochalasia 84, 85, 88, 89
  - dry eye vs. 88
  - technique 92–94
  
- Corneal erosions
  - exposed implant causing 36
  - and foreign body sensation 45
- Coronal brow lift
  - hemorrhage after 66
- Cryoprobe 103
  
- Dacryocystorhinostomy (DCR) 84
- Dehisced capsulopalpebral fascia 26
- Diplopia 38, 80, 82
- Distichitic eyelashes 89
- Dry eye 84
  - ocular lubrication and temporary punctal occlusion 84
  - severe 85
  - vs. conjunctivochalasia 88
  
- Ectropic puncta 85
- Ectropion
  - with lower eyelid laxity 16, 17
    - cutting posterior lamella 20
    - split into anterior and posterior lamellae 20
  - repair 16–25
    - tying suture inverts punctum and corrects 19
  - skin removal causing 38, 41
- Edema
  - after upper eyelid surgery
    - due to atopic reaction 75
    - during ptosis surgery 73
  - and chemosis 38
- Encapsulated tumors 98
- ENDURAGen graft 32, 33, 34
  - applying sealant 35
  - fixing in appropriate position 35
  - outlining and excising 34
  - placing cottonoid 35
- ENDURAGen implant 33
- Entropion repair 26–31
  - cicatricial ectropion after 30
  - complications 26
  - obviating 26, 28
  - right lower eyelid 29
  - suture 26, 28
    - complications 26
- Evicel™ 25, 32
- Extruding Enduragen implant 44
- Eyelid retraction 70–72
  - and blepharoplasty 72
  - buckling of ENDURAGen graft, recurrent 36
  - skin removal causing 38, 41
- Eyelid thickening 36
  
- Fat pads
  - exposure of medial and lateral 13
  - hemostasis, technique for 43
  - removal of 55
- Fibrin/thrombin sealant 34
- Floppy upper eyelids 89

- Frank ectropion 26, 28  
 Frost suture 24, 35
- The Garfield look 70  
 resolution of 71
- Gull wing incision 112
- Hemorrhage 38, 42, 45  
 after uneventful ptosis surgery 74  
 after upper eyelid surgery 73  
 and orbital fat pads 43  
 postoperative 42  
 slowly resolved 74  
 upper eyelid, shortly after ptosis surgery 75
- Herring's law 52  
 of equal innervation 52
- Human skull 97
- Hyperophthalmos 110
- Hypertrophic scarring 60
- Hypo-ophthalmos 108
- Involitional entropion 26, 27
- Kennerdell–Maroon retractor 97, 100
- Keratopathy  
 caused by decreased spontaneous blink 77  
 inferior punctate 52  
 suture 55, 79  
 avoiding potential 53
- Kerrison rongeurs 84
- Lacrimal fossa, suture repositions gland in 58
- Lacrimal gland  
 biopsy 55–56, 58  
 multiple passes through 58  
 prolapse 57  
 retracted 58  
 tumor 56
- Lagophthalmos 64  
 after upper eyelid surgery 73  
 in down gaze 76
- Lateral canthal  
 skin excised beneath in 14  
 tendon plication, technique of 46–47
- Lateral canthotomy 1, 3  
 incision, extending 8, 19
- Lateral canthus  
 clamping 8  
 extending incision 8  
 rounding of 47  
 subciliary incision and extending over 13
- Lateral canthus, rounding of 45
- Lateral orbital rim  
 extending lateral canthotomy incision to expose 19  
 passing suture needles through bone of 19  
 periosteum of superior 58
- Lateral orbital tubercle 11
- Lateral orbital wall 12  
 replaced 103
- Lateral orbitotomy with bone removal 96–98
- Levator aponeurosis 31  
 advancing and tightening 71  
 dehisced 59, 60  
 double-armed suture are passed through 55  
 surgical anatomy of 71
- Levator muscle  
 extirpated 64  
 fatty infiltrated 49
- Lissamine green staining  
 devitalized tissue 51  
 for dry eye diagnosis 85
- Lower eyelid  
 approaching via transconjunctival incision 1  
 fat pads in 1, 2  
 inferior oblique muscle 1, 2  
 retraction 32–37  
 complications 32, 37  
 technique 32  
 surgery 1–15  
 complications of 38–47
- Lower eyelid blepharoplasty 38, 40  
 rounding of lateral canthus 45  
 transconjunctival  
 tarsal strip procedures 1  
 technique 1
- Lower eyelid retraction 38, 73, 77  
 causing inferior superficial punctate keratopathy 38, 41  
 fistula 107  
 problem 77–78  
 recognizing and repairing 51  
 severe 107
- Lower eyelid surgery  
 hemorrhage after 44
- Medial canthal webbing 79, 80
- Medial fat pad  
 distinguished from yellow preaponeurotic fat pad 51  
 exposing and cauterization 6–7  
 inferior oblique muscle separating middle from 7  
 removal of 57
- Medial orbital decompression 102, 106–109
- Medial orbital fat pad 50  
 prolapsing 51
- Medial orbital wall fractures 102
- Medrol® 38
- Mini-incision direct brow lift 68–69  
 dividing sub-brow tissue 69  
 outlining incision 68  
 passing through posterior brow flap 70  
 problems and solutions 69–70  
 retracting superior portion of incision 69  
 tying suture 70  
 undermining incision 68
- Nasal and temporal sutures 4
- Nasal mucosa, exposed 87
- Oblique muscle, inferior  
 applicator stick points to 14  
 and medial fat pad 7
- Ocular surface dysfunction, detection and treatment of 84
- Ocutemp cauterization 55
- Ocutemp® cautery 1, 4
- Ocutemp hot cauterization 5
- Optic nerve sheath decompression 109–114  
 complications 114–115
- Orbital decompression 98
- Orbital emphysema 111
- Orbital fat pads  
 failure to remove 38  
 inferior 26  
 skin muscle flap exposing 13  
 removal of 5, 13

- Orbital floor fracture repair 99
- Orbital lesions
  - lateral 100
  - medial apical 99
- Orbital septum 49, 56
  - levator aponeurosis/muscle separated from 53, 54
- Orbital surgery 95
  - optic nerve sheath decompression/temporal artery biopsy 95–117
  - surgical approaches to 97
- Orbital tumor
  - apical 98
  - diffuse 96
  - encapsulated 96
    - distinct from adjacent optic nerve 99
  - human skull and 97
  - isolated 102
  - large posterior encapsulated requiring craniotomy and superior orbitotomy 97
  - superior lateral 100
- Orbital wall
  - fracture with medial rectus entrapment 111
  - periosteum of lateral 100
- Orbitotomy
  - completed 102
  - inferior 98–99
- Osteotomy
  - superior/inferior 101
- Oval wedge of conjunctiva and subconjunctival tissue 16, 17, 18
  
- Palpebral conjunctiva 1, 3
- Periosteum and lacrimal sac 87
- Pinch blepharoplasty 60–62
  - successful 62
- Postoperative suture keratopathy, preventing 80
- Preaponeurotic fat pads
  - upper/lower eyelids 2
- Preaponeurotic fat pads
  - levator aponeurosis/muscle separated from 49, 53, 54
  - medial fat pad appears whiter 55, 57
  - and prolapsed lacrimal gland/ superior orbital rim 50
- Preseptal orbicularis muscle 53, 54
- Prolapsed lacrimal gland 49
  - vs. lateral preaponeurotic fat pad 58
- Prolapse repair 55–56, 58
- Ptosis surgery 52
  - chronic irritation after 76
  - iopodine on mild to moderate, beneficial effect of 79
  - of left upper eyelid 52
  - long-standing asymmetric result after 78
  - prolapsed lacrimal gland during 55
  - recurrent 81
  - technique 52–53
  - upper eyelid edema after 79
  - upper eyelid hemorrhage shortly after 75
- Ptosis with absent levator function 62–64
  - contour adjustment 65
  - fixating loops 64
  - folding end of sling to tarsus 65
  - problems and solutions 64
- Punctal ectropion 16, 17
  - lissamine green staining of 17
- Punctum, dilating and irrigating 86
- Pyogenic granuloma 38, 42
  
- Recurrent entropion 31
- Recurrent lower eyelid retraction 37
- Restasis® 84
  
- Sialastic tubing 87
- Snap-back test 88
- Subtle punctal ectropion 85
- Supraclavicular graft 25
- Supramid slings 62, 63
- Surgical entropion repair, technique 26
- Suture placement
  - superficial 10
  
- Tarsal strip procedure 1, 8, 16
  - double-armed suture and 20
  - lateral orbital rim 20
  - passing sharp, curved needle 9
  - shortening eyelid with 41
  - stitching 9–10
  - tightening eyelid 31
- Tarsus 54
- Tearing and dry eye—evaluation and treatment 84–94
- Telfa bolster 25
- Telfa template 23
- Temporal artery biopsy 115
  - technique 115, 117
- Temporal brow ptosis 67
- Transconjunctival blepharoplasty 1, 2
- Transconjunctival dissections 1
- Transconjunctival lower eyelid surgery 38, 39
- Transcutaneous figure of eight suture, diagrammatic representation of 17
- Transcutaneous lower eyelid blepharoplasty 1, 10–15
  - preventing excising excessive amount of skin 14
- Transcutaneous lower eyelid surgery 38, 39
- Tumor biopsy and removal 97
  
- Upper eyelid
  - crease 61
  - edema, after ptosis surgery 79
  - excessive removal of skin resulting in incomplete closure/ lagophthalmos/ keratopathy 60
  - mild peaking and retraction of 78
  - multiple layers of 48, 49
  - preaponeurotic fat pads in 57
  - ptosis of 52
  - redundant skin 61
- Upper eyelid laxity 89
- Upper eyelid surgery 48–72
  - anatomy 48
  - complications of 73–83
  - cosmetic, vertical diplopia immediately after 81
  - intraoperative complications 58–59
  - patient selection 48, 52
  - persistent erythema and nodules after 82
  - red painful eye after 80
  
- Vasoconstriction 53
  - hemostatic effect of 53
- Vasoconstriction, optimal epinephrine induced 26
- 6-0 Vicryl™ sutures 1, 32
- Visual loss 38, 43, 45
  
- Wedge resection upper eyelid 90, 92, 94
- Windshield wiper epitheliopathy (WWE) 88

# Atlas of Oculoplastic and Orbital Surgery

## About the book

This book is a practical, problem-orientated guide to the management of common oculoplastic and orbital disorders, and provides simplified solutions to complex problems. This text covers upper and lower eyelid surgery and repair as well as orbital surgery, and the prevention and treatment of potential complications. With superb colour surgical photographs and illustrations, *Atlas of Oculoplastic and Orbital Surgery* is essential reading for ophthalmologists, oculoplastic surgeons, neuro-ophthalmologists and plastic surgeons.

## About the author

**Thomas C Spoor** MD FACS, joined the Sarasota Retina Institute, Florida, USA in 2006, while also maintaining a private practice in Detroit, Michigan, USA. Dr Spoor is renowned the world over for his pioneering work in oculoplastic, orbital and neuro-ophthalmic surgery. In his extensive academic and medical career, spanning 30 years, special recognition has been celebrated for his dedication in the field of optic nerve surgery, as well as his ground-breaking treatments of patients with optic nerve and orbital dysfunction.

## Also available

### **Atlas of Neuro-Ophthalmology**

By Thomas C Spoor  
(ISBN: 9781853177736)

### **Controversies in Neuro-Ophthalmology**

Edited by Andrew G Lee, Jacinthe Rouleau and Reid Longmuir  
(ISBN: 9781420070927)

### **Garner and Klintworth's Pathobiology of Ocular Disease, Third Edition**

Edited by Gordon K Klintworth and Alec Garner  
(ISBN: 9780849398162)

### **Practical Manual of Ocular Inflammation**

Edited by Andrew D Dick, Annabelle A Okada and John V Forrester  
(ISBN: 9780849391835)

### **Facial Rejuvenation**

By Thomas C Spoor and Ronald L Moy  
(ISBN: 9781853177743)

**informa**  
healthcare

Telephone House, 69-77 Paul Street,  
London EC2A 4LQ, UK

52 Vanderbilt Avenue, New York, NY 10017, USA

[www.informahealthcare.com](http://www.informahealthcare.com)

ISBN 978-184184586-9



9 781841 845869