

# PRE TEST

Prepare Early... Score Higher

## Clinical Vignettes for the USMLE Step 2

**second edition**

- 1000 vignettes covering all 27 medical specialties
- 1000 questions covering all 27 specialties
- 1000 answers
- Content reviewed by USMLE's chief writing officer for USMLE Step 2



**Clinical Vignettes  
for the USMLE Step 2**

PreTest® Self-Assessment and Review

# NOTICE

Medicine is an ever-changing science. As new research and clinical experience broaden our knowledge, changes in treatment and drug therapy are required. The authors and the publisher of this work have checked with sources believed to be reliable in their efforts to provide information that is complete and generally in accord with the standards accepted at the time of publication. However, in view of the possibility of human error or changes in medical sciences, neither the authors nor the publisher nor any other party who has been involved in the preparation or publication of this work warrants that the information contained herein is in every respect accurate or complete, and they disclaim all responsibility for any errors or omissions or for the results obtained from use of the information contained in this work. Readers are encouraged to confirm the information contained herein with other sources. For example and in particular, readers are advised to check the product information sheet included in the package of each drug they plan to administer to be certain that the information contained in this work is accurate and that changes have not been made in the recommended dose or in the contraindications for administration. This recommendation is of particular importance in connection with new or infrequently used drugs.



**Clinical Vignettes**  
**for the USMLE Step 2**  
PreTest® Self-Assessment and Review  
Second Edition

 **McGraw-Hill**  
**Medical Publishing Division**  
**PreTest® Series**

NEW YORK ST. LOUIS SAN FRANCISCO AUCKLAND  
BOGOTÁ CARACAS LISBON LONDON MADRID  
MEXICO CITY MILAN MONTREAL NEW DELHI  
SAN JUAN SINGAPORE SYDNEY TOKYO TORONTO

# McGraw-Hill



A Division of The McGraw-Hill Companies

Copyright © 2001, 1999 by The McGraw-Hill Companies, Inc. All rights reserved. Manufactured in the United States of America. Except as permitted under the United States Copyright Act of 1976, no part of this publication may be reproduced or distributed in any form or by any means, or stored in a database or retrieval system, without the prior written permission of the publisher.

0-07-137640-2

The material in this eBook also appears in the print version of this title: 0-07-136453-6.

All trademarks are trademarks of their respective owners. Rather than put a trademark symbol after every occurrence of a trademarked name, we use names in an editorial fashion only, and to the benefit of the trademark owner, with no intention of infringement of the trademark. Where such designations appear in this book, they have been printed with initial caps.

McGraw-Hill eBooks are available at special quantity discounts to use as premiums and sales promotions, or for use in corporate training programs. For more information, please contact George Hoare, Special Sales, at [george\\_hoare@mcgraw-hill.com](mailto:george_hoare@mcgraw-hill.com) or (212) 904-4069.

## TERMS OF USE

This is a copyrighted work and The McGraw-Hill Companies, Inc. (“McGraw-Hill”) and its licensors reserve all rights in and to the work. Use of this work is subject to these terms. Except as permitted under the Copyright Act of 1976 and the right to store and retrieve one copy of the work, you may not decompile, disassemble, reverse engineer, reproduce, modify, create derivative works based upon, transmit, distribute, disseminate, sell, publish or sublicense the work or any part of it without McGraw-Hill’s prior consent. You may use the work for your own noncommercial and personal use; any other use of the work is strictly prohibited. Your right to use the work may be terminated if you fail to comply with these terms.

THE WORK IS PROVIDED “AS IS”. McGRAW-HILL AND ITS LICENSORS MAKE NO GUARANTEES OR WARRANTIES AS TO THE ACCURACY, ADEQUACY OR COMPLETENESS OF OR RESULTS TO BE OBTAINED FROM USING THE WORK, INCLUDING ANY INFORMATION THAT CAN BE ACCESSED THROUGH THE WORK VIA HYPERLINK OR OTHERWISE, AND EXPRESSLY DISCLAIM ANY WARRANTY, EXPRESS OR IMPLIED, INCLUDING BUT NOT LIMITED TO IMPLIED WARRANTIES OF MERCHANTABILITY OR FITNESS FOR A PARTICULAR PURPOSE. McGraw-Hill and its licensors do not warrant or guarantee that the functions contained in the work will meet your requirements or that its operation will be uninterrupted or error free. Neither McGraw-Hill nor its licensors shall be liable to you or anyone else for any inaccuracy, error or omission, regardless of cause, in the work or for any damages resulting therefrom. McGraw-Hill has no responsibility for the content of any information accessed through the work. Under no circumstances shall McGraw-Hill and/or its licensors be liable for any indirect, incidental, special, punitive, consequential or similar damages that result from the use of or inability to use the work, even if any of them has been advised of the possibility of such damages. This limitation of liability shall apply to any claim or cause whatsoever whether such claim or cause arises in contract, tort or otherwise.

DOI: 10.1036/0071376402

# CONTENTS

---

<i>Preface</i> .....	vii
<b>BLOCK 1 50 QUESTIONS</b> .....	<b>1</b>
<b>BLOCK 2 50 QUESTIONS</b> .....	<b>19</b>
<b>BLOCK 3 50 QUESTIONS</b> .....	<b>39</b>
<b>BLOCK 4 50 QUESTIONS</b> .....	<b>59</b>
<b>BLOCK 5 50 QUESTIONS</b> .....	<b>79</b>
<b>BLOCK 6 50 QUESTIONS</b> .....	<b>99</b>
<b>BLOCK 7 50 QUESTIONS</b> .....	<b>121</b>
<b>BLOCK 8 50 QUESTIONS</b> .....	<b>141</b>
<b>BLOCK 1 ANSWERS, EXPLANATIONS, AND REFERENCES</b>	<b>161</b>
<b>BLOCK 2 ANSWERS, EXPLANATIONS, AND REFERENCES</b>	<b>179</b>
<b>BLOCK 3 ANSWERS, EXPLANATIONS, AND REFERENCES</b>	<b>197</b>
<b>BLOCK 4 ANSWERS, EXPLANATIONS, AND REFERENCES</b>	<b>215</b>
<b>BLOCK 5 ANSWERS, EXPLANATIONS, AND REFERENCES</b>	<b>233</b>

**BLOCK 6 ANSWERS, EXPLANATIONS, AND REFERENCES 253**

**BLOCK 7 ANSWERS, EXPLANATIONS, AND REFERENCES 269**

**BLOCK 8 ANSWERS, EXPLANATIONS, AND REFERENCES 287**

*Bibliography* . . . . . **305**

# PREFACE

The current format of the United States Medical Licensing Examination Step 2 emphasizes clinical vignettes as the primary test questions. The exam is 400 questions, broken into eight blocks of 50 questions each. Students have one hour to complete each block.

*Clinical Vignettes for the USMLE Step 2: Second Edition*, parallels this format. The book is 400 clinical-vignette-style questions covering the clinical sciences and assembled based on the published content outline for the USMLE Step 2. The questions are divided into eight blocks of 50 questions. As on the Step 2 exam, each block tests the student in all clinical areas. Halfway through each block, a stopwatch set at 30 minutes is included to remind the student of the one-hour limit. Answers are in the second half of the book. Each answer is accompanied by a concise but comprehensive explanation and is referenced to a key textbook or journal article, a trademark of the PreTest® series.

The questions in this book were culled from the eight PreTest® Clinical Science books and were edited as needed to reflect the current USMLE format. The publisher acknowledges and thanks the following authors for their contributions to the book:

Pediatrics: Robert J. Yetman, MD

Psychiatry: Giulia Mancini-Mezzacappa, MD

Medicine: Steven L. Berk, MD and William R. Davis, MD

Surgery: Peter L. Geller, MD

Preventive Medicine and Public Health: Sylvie Ratelle, MD, MPH

Neurology: Mitchell Elkind, MD

Physical Diagnosis: Jo-Ann Reteguiz, MD and Beverly Cornel-Avendaño, MD

Obstetrics and Gynecology: Mark I. Evans, MD and Kenneth A. Ginsburg, MD

McGraw-Hill

November 2000




*This page intentionally left blank.*



**Clinical Vignettes  
for the USMLE Step 2**

PreTest® Self-Assessment and Review

# ***BLOCK I***



***YOU HAVE 60 MINUTES  
TO COMPLETE 50 QUESTIONS.***

---

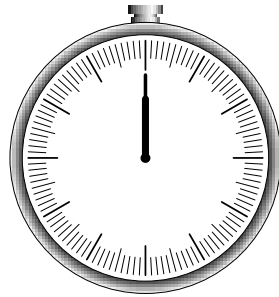
Terms of Use

*This page intentionally left blank.*

---

# Block I

---



**YOU HAVE 60 MINUTES  
TO COMPLETE 50 QUESTIONS.**

---

## Questions

**1-1.** An infant can move his head from side to side while following a moving object, can lift his head from a prone position 45 degrees off the examining table, smiles when encouraged, and makes cooing sounds. He cannot maintain a seated position. The most likely age of the infant is

- a. 1 months
- b. 3 months
- c. 6 months
- d. 9 months
- e. 12 months

**1-2.** After witnessing a violent argument between her parents, a young woman develops sudden blindness, but she does not appear as distraught as would be expected. Her pupils react normally to light and she does not get hurt when she trips over obstacles. Her parents, who are in the middle of a bitter divorce, put aside their differences to focus on their daughter's illness. What is the most appropriate diagnosis?

- a. Factitious disorder
- b. Malingering
- c. Somatization disorder
- d. Conversion disorder
- e. Histrionic personality disorder

#### 4 Clinical Vignettes for the USMLE Step 2, 2/e

---

**I-3.** A 70-year-old patient with long-standing Type 2 diabetes mellitus presents with complaints of pain in the left ear with purulent drainage. On physical exam, the patient is afebrile. The pinna of the left ear is tender, and the external auditory canal is swollen and edematous. The peripheral white blood cell count is normal. The organism most likely to grow from the purulent drainage is

- a. *Pseudomonas aeruginosa*
- b. *Staphylococcus aureus*
- c. *Candida albicans*
- d. *Haemophilus influenzae*
- e. *Moraxella catarrhalis*

**I-4.** A 45-year-old woman with Crohn's disease and a small intestinal fistula develops tetany during the second week of parenteral nutrition. The laboratory findings include Ca 8.2 meq/L; Na 135 meq/L; K 3.2 meq/L; Cl 103 meq/L;  $P_{O_2}$  2.4 meq/L; albumin 2.4; pH 7.48; 38 kPa; P 84 kPa; bicarbonate 25 meq/L. The most likely cause of the tetany is

- a. Hyperventilation
- b. Hypocalcemia
- c. Hypomagnesemia
- d. Essential fatty acid deficiency
- e. Focal seizure

**I-5.** A 6-year-old comes to the clinic with the rapid onset of fever, muscle pain, and rash. The rash that developed is maculopapular, beginning on the flexor surfaces of the wrist and evolving to a hemorrhagic-type appearance. The history is positive for his going camping with the Boy Scouts 9 days prior to presentation. Ticks were found on several of the campers. Which of the following is likely?

- a. Lyme disease
- b. Tularemia
- c. Measles
- d. Toxic shock syndrome
- e. Rocky Mountain spotted fever

**I-6.** A 60-year-old asymptomatic man is found to have a leukocytosis when a routine complete blood count (CBC) is obtained. Physical exam shows no abnormalities. The spleen is normal size. Lab data includes:

Hemoglobin: 9 g/dL (normal: 14 to 18 g/dL)

Leukocyte count: 40,000/ $\mu$ L (normal: 4,300 to 10,800/ $\mu$ L)

Peripheral blood smear shows a differential that includes 97% small lymphocytes. The most likely diagnosis is

- a. Acute monocytic leukemia
- b. Chronic myelogenous leukemia
- c. Chronic lymphocyte leukemia
- d. Tuberculosis

**1-7.** During endoscopic biopsy of a distal esophageal cancer, perforation of the esophagus is suspected when the patient complains of significant new substernal pain. An immediate chest film reveals air in the mediastinum. You would recommend

- Placement of a nasogastric tube to the level of perforation, antibiotics, close observation
- Spit fistula (cervical pharyngostomy), gastrostomy
- Left thoracotomy, pleural patch oversewing of perforation, drainage of mediastinum
- Esophagogastrectomy via celiotomy and right thoracotomy
- Transhiatal esophagogastrectomy with cervical esophagogastrostomy

**1-8.** A 47-year-old secretary has lost her job because, due to her perfectionism and excessive attention to trivial details, she could never finish an assignment on time. She writes innumerable lists of things to be done and follows rules scrupulously. She consistently annoys friends and family members with her lack of flexibility and her pedantic remarks. Her diagnosis is likely to be

- Obsessive-compulsive disorder
- Paranoid personality disorder
- Obsessive-compulsive personality disorder
- Narcissistic personality disorder
- Passive-aggressive personality disorder

**1-9.** An investigator wishes to perform a randomized clinical trial to evaluate a new beta blocker as a treatment for hypertension. To be eligible for the study, subjects must have a resting diastolic blood pressure of at least 90 mm Hg. One hundred patients seen at the screening clinic with this level of hypertension are recruited for the study and make appointments with the study nurse. When the nurse obtains the patients' blood pressure 2 wk later, only 65 of them have diastolic blood pressures of 90 mm Hg or more. The most likely explanation for this is

- Spontaneous resolution
- Regression toward the mean
- Baseline drift
- Measurement error
- Hawthorne effect

**1-10.** A mother brings her 1-year-old child because she is concerned about potential exposure to lead. Renovations are being made in their older home, and the mother is now considering moving to another house until the work is completed. You want to check the child's blood lead level. Which of the following is the most accurate method of screening for lead poisoning?

- Erythrocyte protoporphyrin
- Capillary blood lead
- CBC
- Venous blood lead
- Ferritin

## 6 Clinical Vignettes for the USMLE Step 2, 2/e

---

**I-11.** A 35-year-old woman complains of aching all over. She sleeps poorly and all her joints hurt. Symptoms have progressed over several years. Physical exam shows multiple points of tenderness over the neck, shoulders, elbows, and wrists. There is no joint swelling or deformity. Complete blood count and erythrocyte sedimentation rate are normal. Rheumatoid factor is negative. There is no tenderness over the median third of the clavicle, the medial malleolus, or the forehead. The best therapeutic option in this patient is

- Amytriptyline at night
- Prednisone
- Aspirin and methotrexate
- Plaquenil

**I-12.** A 6-mo-old infant has eaten a diet with the following content and intake for the past 5 mo: protein, 4% of calories; fat, 50% of calories; carbohydrates, 46% of calories; 105 calories per kilogram of body weight per day. The patient's disturbance is

- Rickets
- Marasmus
- Obesity
- Tetany
- Kwashiorkor

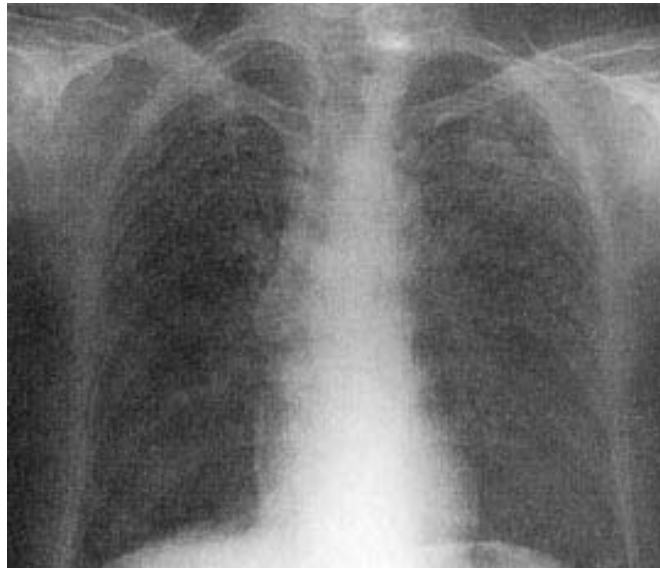
**I-13.** A 65-year-old man undergoes a technically difficult abdominoperineal resection for a rectal cancer, during which he receives 3 units of packed red blood cells. Four hours later, in the intensive care unit, he is bleeding heavily from his perineal wound. Emergency coagulation studies reveal normal prothrombin, partial thromboplastin, and bleeding times. The fibrin degradation products are not elevated, but the serum fibrinogen content is depressed and the platelet count is 70,000/ $\mu$ L. The most likely cause of the bleeding is

- Delayed blood transfusion reaction
- Autoimmune fibrinolysis
- A bleeding blood vessel in the surgical field
- Factor VIII deficiency
- Hypothermic coagulopathy



**Items I-14 through I-15**

A 45-year-old quarry worker presents with a history of progressive nonproductive cough and dyspnea. He has no fever or weight loss. Complete blood count is normal. Chest x-ray is as follows.



Reprinted, with permission, from Ratelle S: *Preventive Medicine and Public Health: PreTest Self-Assessment and Review*, 9th ed. New York, McGraw-Hill, 2001.

**I-14.** The most likely diagnosis is

- a. Caplan syndrome
- b. Silicosis
- c. Asbestosis
- d. Byssinosis
- e. Sarcoidosis

**I-15.** The patient is at highest risk of developing

- a. Lung cancer
- b. Tuberculosis
- c. Cryptococcosis
- d. Chronic bronchitis
- e. Emphysema

## 8 Clinical Vignettes for the USMLE Step 2, 2/e

---

**I-16.** A 25-year-old woman with a history of epilepsy presents to the emergency room with impaired attention and unsteadiness of gait. Her phenytoin level is 37. Examination of the eyes is most likely to show which of the following?

- Weakness of abduction of the left eye
- Lateral beating movements of the eyes
- Impaired convergence
- Papilledema
- Impaired upgaze

### Items I-17 through I-18

While you are on duty in the emergency room, a 12-year-old boy arrives with pain and inflammation over the ball of his left foot and red streaks extending up the inner aspect of his leg. He remembers removing a wood splinter from the sole of his foot on the previous day.

**I-17.** The most likely infecting organism is

- Clostridium perfringens*
- C. tetanus*
- Staphylococcus
- Escherichia coli*
- Streptococcus

**I-18.** The appropriate antibiotic to prescribe while awaiting specific culture verification is

- Penicillin
- Erythromycin
- Tetracycline
- Azathioprine
- Cloxacillin

### Items I-19 through I-20

A 26-year-old graduate student presents to the emergency room with a severe left-sided throbbing headache associated with nausea, vomiting, and photophobia. She has tried taking ibuprofen without relief. On further questioning, the patient relates that she has been having similar headaches three to four times per month for the past year. Her mother had a similar problem. Her exam is normal.

**I-19.** Appropriate therapy for the patient's present headache might include which of the following drugs?

- Ergotamine tartrate
- Nitroglycerine
- Verapamil
- Amitriptyline
- Phenobarbital

**I-20.** Appropriate long-term management might include a prescription for daily use of which of the following medications?

- a. Metoclopramide
- b. Sumatriptan
- c. Oral contraceptives
- d. Amitriptyline
- e. Ergotamine tartrate

**I-21.** A 65-year-old man with mild congestive heart failure is to receive total hip replacement. He has no other underlying diseases and no history of hypertension, recent surgery, or bleeding disorder. The best approach to prevention of pulmonary embolus in this patient is

- a. Aspirin, 75 mg per day
- b. Aspirin, 325 mg per day
- c. Warfarin with INR of 2 to 3
- d. Early ambulation

### Items I-22 through I-23

A 13-year-old asymptomatic girl is found to have an enlarged thyroid. She states that the front of her neck has been growing slowly for more than a year.

- I-22.** The most likely diagnosis is
- a. Iodine deficiency
  - b. Congenital hypothyroidism
  - c. Graves' disease
  - d. Exogenous ingestion of synthroid
  - e. Lymphocytic (Hashimoto's) thyroiditis

**I-23.** Treatment for this patient includes

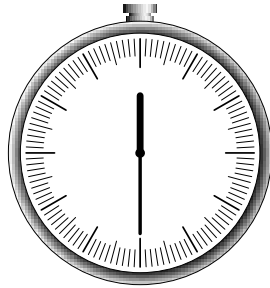
- a. Iodine
- b. Synthroid if she becomes symptomatic
- c. Propylthiouracil (PTU)
- d. Psychiatry consult
- c. Surgical removal of thyroid

**I-24.** A 61-year-old woman with a 10-year history of rheumatoid arthritis presents with painful swelling at the back of the knee that is visible on physical examination only when the knee is extended. Which of the following is the most likely diagnosis?

- a. Anserine bursitis
- b. Baker's cyst
- c. Deep venous thrombosis
- d. Prepatellar bursitis
- e. Infrapatellar bursitis

**I-25.** A 19-year-old woman presents for voluntary termination of pregnancy 6 wk from her expected menses. She previously had regular menses every 28 days. Pregnancy is confirmed by  $\beta$ -hCG and ultrasound confirms expected gestational age. Which technique for termination of pregnancy is indicated in this patient at this time?

- a. Intraamniotic prostaglandin  $F_{2\alpha}$
- b. Hypertonic saline
- c. RU-486 pills
- d. 15-methyl  $\alpha$ -prostaglandin
- e. Prostaglandin  $E_2$  suppositories



***YOU SHOULD HAVE COMPLETED APPROXIMATELY  
25 QUESTIONS AND HAVE 30 MINUTES REMAINING.***

---

**I-26.** A 68-year-old man with controlled hypertension complains of gradual impairment of vision. His history further reveals that he was recently diagnosed with mild adult-onset diabetes that is also well controlled. He is a retired fisherman. The most likely cause of his visual impairment is

- a. Glaucoma
- b. Cataract
- c. Diabetic retinopathy
- d. Macular degeneration
- e. Xerophthalmia

**I-27.** A 21-year-old man presents to your office for a preemployment physical examination. He is 6 ft, 3 in. tall and weighs 70 kg. Heart examination is remarkable for a midsystolic click and a grade 2 systolic murmur that increases with Valsalva maneuver. The patient has an arm span that exceeds his height and has long, slender fingers. The thumb sign (Steinberg sign) is positive. Which of the following is the most likely diagnosis?

- a. Lesch-Nyhan syndrome
- b. Turner syndrome
- c. Ehlers-Danlos syndrome
- d. Marfan syndrome
- e. Noonan syndrome

**I-28.** A 2-year-old boy with undescended testes is referred to a urologist. Surgical correction will probably eliminate the risk of

- a. Testicular malignancy
- b. Decreased sperm count
- c. Torsion of testes
- d. Urinary tract infection
- e. Epididymitis

**I-29.** A wildlife worker presents to the emergency room because he was bitten on the hand by a raccoon while trying to capture the animal, which appeared ill. He states he received a primary course of rabies vaccination 1½ years ago when he first started his job. The wound is immediately thoroughly cleaned by the emergency room staff. It is small because the patient was wearing gloves. Which is the most appropriate intervention for rabies prevention?

- a. No further prophylaxis is necessary because of the recent vaccination
- b. Administer rabies immune globulin (RIG) only
- c. Administer RIG and one dose of vaccine
- d. Administer one dose of vaccine only
- e. Administer two doses of vaccine

**I-30.** A 36-year-old woman, 20 wk pregnant, presents with a 1.5-cm right thyroid mass. Fine-needle aspiration is consistent with a papillary neoplasm. The mass is “cold” by scan and solid by ultrasound. Which method of treatment is contraindicated?

- a. Right thyroid lobectomy
- b. Subtotal thyroidectomy
- c. Total thyroidectomy
- d. Total thyroidectomy with lymph node dissection
- e. <sup>131</sup>I radioactive ablation of the thyroid gland

**I-31.** A 30-year-old man presents complaining of facial pain and nasal congestion with a yellow nasal discharge after an upper respiratory tract infection 10 days ago. Physical examination reveals a temperature of 100.8°F. The patient has maxillary sinus tenderness with palpation and the nasal mucosa is pale with some yellowish drainage. Clouding of the maxillary sinus is seen with transillumination. Which of the following is the most likely diagnosis?

- a. Acute sinusitis
- b. Chronic sinusitis
- c. Vincent's angina
- d. Ludwig's angina
- e. Orbital cellulitis

**I-32.** A 70-year-old man complains of 2 mo of low back pain and fatigue. He has developed a fever with production of purulent sputum. On physical exam, he has pain over several vertebrae and rales at the left base. Laboratory results are as follows:

Hemoglobin: 7 g/dL

Mean corpuscular volume (MCV):  
86 fl (normal: 86 to 98 fl)

White blood cells (WBCs):  
12,000/ $\mu$ L

Blood urea nitrogen (BUN):  
44 mg/dL

Creatinine: 3.2 mg/dL

Ca<sup>++</sup>: 11.5 mg/dL

Chest x-ray: LLL infiltrate

Reticulocyte count: 1%

The definitive diagnosis is best made by

- 24-h urine protein
- Greater than 10% plasma cells in bone marrow
- Renal biopsy
- Rouleaux formation on blood smear

**I-33.** A 19-year-old woman develops auditory hallucinations and persecutory delusions over the course of 3 days. She is hospitalized and started on 2 mg haloperidol (Haldol) three times daily. Within 1 wk of treatment she develops stooped posture and a shuffling gait. Her head is slightly tremulous and her movements are generally slowed. Her medication is changed to thioridazine (Mellaril), and trihexyphenidyl (Artane) is added. Over the next 2 wk, she becomes much more animated and reports no recurrence of her hallucinations. What is the most likely diagnosis?

- Akinetic mutism
- MPTP poisoning
- Locked-in syndrome
- Postencephalitic parkinsonism
- Neuroleptic effect

**I-34.** A woman is found to have a unilateral, invasive vulvar carcinoma that is 2 cm in diameter but not associated with evidence of lymph node spread. Initial management should consist of

- Chemotherapy
- Radiation therapy
- Simple vulvectomy
- Radical vulvectomy
- Radical vulvectomy and bilateral inguinal lymphadenectomy

**I-35.** An 18-year-old woman, previously in good health, seeks help at an emergency room for lightheadedness, headaches, and nausea. She appears anxious and is tremulous, sweating, and breathing heavily. These symptoms appeared suddenly 20 min before the patient's arrival to the ER. While waiting to see a physician, the patient begins to complain of tingling around her mouth and in her fingertips. The physician should first

- Ask the patient to breathe into a paper bag
- Order immediate intravenous infusion of 50 ml of 50% glucose solution
- Arrange for a brain scan
- Conduct an amobarbital interview
- Draw a blood sample to evaluate blood alcohol concentration

**I-36.** A 16-year-old boy is referred to your practice for leg claudication. Blood pressure in his right arm is 150/110 mm Hg, while blood pressure in his left leg is 80/60 mm Hg. On auscultation, a systolic murmur best heard over the middle of the upper back is detected. You also find that the patient's femoral pulses are diminished when compared to his brachial pulses. Which of the following is the most likely diagnosis?

- Patent ductus arteriosus
- Ventricular septal defect
- Coarctation of the aorta
- Atrial septal defect
- Tetralogy of Fallot

**I-37.** A 20-year-old college student presents with a 3-mo history of left-sided pleuritic chest pain, shortness of breath with exertion, and night sweats. He admits to a 10-lb weight loss over the last several months. He is a nonsmoker and does not use illicit drugs. He is heterosexual. He recalls a negative PPD when he started college 2 years ago. On physical examination, his temperature is 100.9°F and his respiratory rate is 24 breaths/min. Lung examination reveals decreased fremitus, dullness to percussion, and diminished breath sounds over the left posterior lung. A pleural friction rub is audible at the left lung base. Which of the following is the most likely diagnosis?

- Pneumonia
- Pneumothorax
- Pleural effusion
- Lung abscess
- Pulmonary nodule

**I-38.** A 25-year-old man with major depression discusses the potential benefits and side effects of various antidepressants with his psychiatrist. He clearly indicates that he does not want a medication that could decrease his libido or interfere with his ability to obtain and maintain an erection. Which of the listed antidepressants is appropriate for this patient?

- a. Bupropion
- b. Clomipramine
- c. Amitriptyline
- d. Sertraline
- e. Paroxetine

**I-39.** A 35-year-old woman presents to your office complaining of hair loss, bone pain, and dryness and fissures of the lips. She tells you that she has been taking large amounts of vitamins in hopes of preventing cancer and infections. Her symptoms are most likely caused by an excess of

- a. Vitamin A
- b. Vitamin E
- c. Vitamin C
- d. Vitamin D
- e. Vitamin K

**I-40.** In evaluating an adolescent, the examiner looks for evidence of healthy mental development. Which of the following manifestations of midadolescence should raise concern?

- a. Close, enduring friendships with peers of the same gender
- b. Rejection of parental standards and beliefs, such as those regarding religion or sexual conduct
- c. Disregard for physical well-being
- d. Concern for weight and body configuration
- e. Frequent bickering and quarreling with siblings

**Items I-41 through I-42**

A 35-year-old man complains of substernal chest pain that is aggravated by inspiration and relieved by sitting up. The patient has had a history of tuberculosis. Chest x-ray shows an enlarged cardiac silhouette. Lung fields are clear.

**I-41.** The next step in evaluation is

- a. Right lateral decubitus film
- b. Cardiac catheterization
- c. Echocardiogram
- d. Serial electrocardiograms (ECGs)
- e. Thallium stress test



**I-42.** The patient develops jugular venous distention. There is an inward movement of the jugular pulse synchronous with the pulse of the carotid artery. The ECG shows electrical alternans. The most likely additional finding is

- a. Basilar rales halfway up both posterior lung fields
- b.  $S_3$  gallop
- c. Pulsus paradoxus
- d. Strong apical beat

**I-43.** A 37-year-old woman in her 32nd wk of gestation (G2P1) presents with a seizure. She has been healthy and does not smoke cigarettes, drink alcohol, or use illicit drugs. She has been poorly compliant in receiving her prenatal care. Physical examination reveals a blood pressure of 150/95 mm Hg. The patient's face and hands appear edematous. Other than the patient being postictal (confused and disoriented after the seizure), the neurologic examination is normal. Urinalysis reveals proteinuria. The rest of the laboratory data is normal. Which of the following is the most likely diagnosis?

- a. HELLP syndrome
- b. Preeclampsia
- c. Eclampsia
- d. Essential hypertension
- e. Primary seizure disorder

**I-44.** An elderly pedestrian collides with a bicycle-riding pizza delivery man and suffers a unilateral fracture of his pelvis through the obturator foramen. You would manage this injury by

- a. External pelvic fixation
- b. Angiographic visualization of the obturator artery with surgical exploration if the artery is injured or constricted
- c. Direct surgical approach with internal fixation of the ischial ramus
- d. Short-term bed rest with gradual ambulation as pain allows after 3 days
- e. Hip spica

### Items I-45 through I-46

A 19-year-old woman with complaints of headaches and visual blurring has prominent bulging of both optic nerve heads with obscuration of all margins of both optic discs. Her physician is reluctant to pursue neurologic studies because the patient is 8 mo pregnant and had similar complaints during the last month of another pregnancy. The physical and neurologic examination is otherwise unrevealing.

**I-45.** If neuroimaging studies are performed on this patient, they will probably reveal

- a. A subfrontal meningioma
- b. Intraventricular blood
- c. Slitlike ventricles
- d. Transtentorial herniation
- e. Metastatic breast carcinoma

**I-46.** The treatment of choice for this patient is

- a. Lumbar puncture
- b. Cesarean section
- c. Induction of labor
- d. Vitamin A supplements
- e. Acetazolamide

### Items I-47 through I-48

An 18-year-old sexually active college student presents with complaints of lower abdominal pain and irregular bleeding for 5 days. She has no fever. She uses oral contraceptives as her method of birth control. Upon examination, the cervix is friable and there is cervical motion tenderness and adnexal tenderness. Pregnancy test is negative.

**I-47.** Which etiologic agent is most likely responsible for these findings?

- a. *Neisseria gonorrhoeae*
- b. *Chlamydia trachomatis*
- c. *Treponema pallidum*
- d. Herpes simplex virus type 2
- e. *Mycoplasma hominis*

**I-48.** The patient tells you that she had a similar episode 2 years ago. What is her risk of infertility following this second clinical episode of pelvic inflammatory disease?

- a. <1%
- b. 5%
- c. 10%
- d. 20%
- e. 40%

**I-49.** A 50-year-old woman has developed pink macules and papules on the hands and forearms in association with a sore throat. The lesions are targetlike, with the centers a dusty violet. A diagnosis of erythema multiforme is made. The most important information obtained from this patient's history is that


- a. The patient has been using tampons
- b. The patient is taking Dilantin
- c. The patient has never had measles
- d. No other family members have a sore throat

**I-50.** A 19-year-old with insulin-dependent diabetes mellitus is taking 30 U of NPH insulin each morning and 15 U at night. Because of persistent morning glycosuria with some ketonuria, the evening dose is increased to 20 U. This worsens the morning glycosuria and now moderate ketones are noted in urine. The patient complains of sweats and headaches at night. The next step in management is

- a. Increasing the evening dose of insulin
- b. Increasing the morning dose of insulin
- c. Switching from human NPH to pork insulin
- d. Obtaining blood sugar levels between 2 and 5 A.M.

*This page intentionally left blank.*

## ***BLOCK 2***



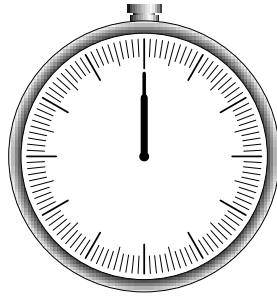
***YOU HAVE 60 MINUTES  
TO COMPLETE 50 QUESTIONS.***

---

*This page intentionally left blank.*

# BLOCK 2

---



**YOU HAVE 60 MINUTES  
TO COMPLETE 50 QUESTIONS.**

---

## Questions

### Items 2-1 through 2-2

A previously well 1-year-old infant has had a runny nose and has been sneezing and coughing for 2 days. Two other members of the family had similar symptoms. Four hours ago, the patient's cough became much worse. On physical examination, he is in moderate respiratory distress with nasal flaring, hyperexpansion of the chest, and easily audible wheezing without rales.

**2-1.** The most likely diagnosis is

- a. Bronchiolitis
- b. Viral croup
- c. Asthma
- d. Epiglottitis
- e. Diphtheria

**2-2.** The most likely agent responsible for the infant's condition in the previous question is

- a. *Staphylococcus aureus*
- b. *Haemophilus influenzae*
- c. *Corynebacterium diphtheriae*
- d. Respiratory syncytial virus
- e. Echovirus

**2-3.** A 4-year-old boy is seen 1 h after ingestion of a lye drain cleaner. No oropharyngeal burns are noted, but the patient's voice is hoarse. Chest x-ray is normal. Of the following, which is the most appropriate therapy?

- a. Immediate esophagoscopy
- b. Parenteral steroids and antibiotics
- c. Administration of an oral neutralizing agent
- d. Induction of vomiting
- e. Rapid administration of 1 qt of water to clear the remaining lye from the esophagus and dilute material in the stomach

**2-4.** A 30-year-old Canadian immigrant farmer consults with symptoms of night sweats, low-grade fever, cough, and fatigue. He does not smoke. He has a history of asthma. The chest x-ray required for immigration was normal 5 mo ago. He received the BCG vaccine as a child. The skin test for tuberculosis is positive at 15 mm. The most likely diagnosis is

- a. Influenza
- b. Brucellosis
- c. Aspergillosis
- d. *Mycobacterium bovis*
- e. *M. tuberculosis*

**2-5.** A 75-year-old man with a history of recent memory impairment is admitted with a headache, confusion, and a left homonymous hemianopsia. He has recently experienced two episodes of brief unresponsiveness. There is no history of hypertension. CT scan shows a right occipital lobe hemorrhage with some subarachnoid extension of the blood. MRI scan with gradient echo sequences reveals foci of hemosiderin in the right temporal and left frontal cortex. The likely cause of the patient's symptoms and signs is

- a. Gliomatosis cerebri
- b. Multi-infarct dementia
- c. Mycotic aneurysm
- d. Amyloid angiopathy
- e. Undiagnosed hypertension



**2-6.** A 28-year-old man is brought to the emergency room of a local hospital by the police, who found him wandering without a coat in subzero weather, muttering about being persecuted by a secret organization. During the evaluation he is disorganized and distractible and from time to time dozes off in the middle of a sentence. Family members deny previous psychiatric or substance abuse history, but they add that lately the patient has complained of fatigue and increased thirst. Toxic screen is negative and glucose level is 450 mg/dL. Choose the most likely diagnosis.

- a. Delirium
- b. Psychotic depression
- c. Brief psychotic episode
- d. Paranoid schizophrenia
- e. Dementia

**2-7.** A 68-year-old man is admitted to the coronary care unit with an acute myocardial infarction. His postinfarction course is marked by congestive heart failure and intermittent hypotension. On the fourth hospital day, he develops severe midabdominal pain. On physical examination, blood pressure is 90/60 mm Hg and pulse is 110 beats/min and regular; the abdomen is soft with mild generalized tenderness and distension. Bowel sounds are hypoactive; stool hematest is positive. The next step in this patient's management should be which of the following?

- a. Barium enema
- b. Upper gastrointestinal series
- c. Angiography
- d. Ultrasonography
- e. Celiotomy

**Items 2-8 through 2-9**

A 25-year-old male student presents with the chief complaint of rash. There is no headache, fever, or myalgia. A slightly pruritic maculopapular rash is noted over the abdomen, trunk, palms of hands, and soles of feet. Inguinal, occipital, and cervical lymphadenopathy is also noted. Hypertrophic, flat wartlike lesions are noted around the anal area. Laboratory studies show the following:

HCT: 40%

Hgb: 14 g/dL

WBC: 13,000/ $\mu$ L

Diff:

Segmented neutrophils: 50%

Lymphocytes: 50%

**2-8.** The most useful laboratory test in this patient is

- a. Weil-Felix titer
- b. Venereal Disease Research Laboratory (VDRL) test
- c. *Chlamydia* titer
- d. Blood cultures

**2-9.** The treatment of choice for this patient is

- a. Penicillin
- b. Ceftriaxone
- c. Tetracycline
- d. Interferon  $\alpha$
- e. Erythromycin

**2-10.** A 2950-g black baby boy is born at home at term. On arrival at the hospital, he appears pale, but the physical examination is otherwise normal. Laboratory studies reveal the following: mother's blood type A, Rh-positive; baby's blood type O, Rh-positive; hematocrit 38; reticulocyte count 5%. Which of the following is the most likely cause of the anemia?

- a. Fetomaternal transfusion
- b. ABO incompatibility
- c. Physiologic anemia of the newborn
- d. Sick-cell anemia
- e. Iron-deficiency anemia

**2-11.** A 24-year-old woman is chronically sleepy and fatigued. Her sleep is constantly interrupted because, as soon as she begins to fall asleep, an uncomfortable, “crawling” feeling in her calves forces her to walk or move her legs. A condition often associated with this disorder is

- a. Niacin deficiency
- b. Panic disorder
- c. Arteriosclerosis
- d. Pregnancy
- e. Obstructive apnea

**2-12.** A 70-year-old woman with mild dementia complains of hip pain. There is some limitation of motion in her right hip. The first step in evaluation is

- a. CBC and erythrocyte sedimentation rate
- b. Rheumatoid factor
- c. X-ray of right hip
- d. Bone scan

**2-13.** A 75-year-old widowed woman is brought to the emergency room because she fell while trying to go to the bathroom. Her daughter states that the patient has become more confused over the last few weeks. The patient has been disabled by arthritis for many years and lives with her daughter, who is single and works full time. Examination reveals multiple ecchymoses on different areas of the patient’s body. She is very underweight, but her daughter states that she refuses to eat. Which of the following factors is most likely to cause the clinical findings?

- a. Cancer
- b. Abuse
- c. Alzheimer’s disease
- d. Diabetes
- e. Depression

**2-14.** Glycosylated hemoglobin (hemoglobin A<sub>1c</sub>) is often used as an indicator of control in patients with diabetes mellitus. Its level usually reflects the blood concentration of glucose over the preceding

- a. 8 h
- b. 1 wk
- c. 1 mo
- d. 2 mo
- e. 6 mo

**2-15.** A 35-year-old man complains of severe, throbbing pain that wakes him from sleep at night and persists into the day. This pain is usually centered about his left eye and appears on a nearly daily basis for several weeks or months each year. It occurs most prominently at night within a few hours of the patient falling asleep and is associated with a striking personality change. The patient becomes combative and agitated. He never vomits or develops focal weakness. What is the most likely diagnosis?

- a. Classic migraine
- b. Cluster headache
- c. Common migraine
- d. Trigeminal neuralgia
- e. Sinusitis
- f. Temporal arteritis
- g. Vertebrobasilar migraine
- h. Hemiplegic migraine
- i. Atypical facial pain
- j. Postherpetic neuralgia

**2-16.** A 20-mo-old girl is admitted to a pediatric ward because she weighs only 15 lb, but an extensive medical workup does not reveal any organic cause for the child's failure. The child is listless and apathetic and does not smile. The parents rarely come to visit, and, when they do, they do not pick the child up and do not play or interact with her. This scenario proves the established notion that

- a. Lack of adequate emotional nurturance causes depression and failure to thrive in infants
- b. Neglected infants fail to thrive but do not have the intrapsychic structures necessary for experiencing depression
- c. Infants reared in institution are likely to become autistic
- d. Neglected infants are at higher risk for developing schizophrenia
- e. Environmental variables have little impact on the health of infants as long as enough food is provided

**2-17.** A 60-year-old man has had a chronic cough for over 5 years with clear sputum production. He has smoked 1 pack of cigarettes per day for 20 years and continues to do so. X-ray of the chest shows hyperinflation without infiltrates. Arterial blood gases show pH, 7.38;  $P_{CO_2}$ , 40 mm Hg;  $P_{O_2}$ , 65 mm Hg. Spirometry shows a forced expiratory volume FEV1/FVC of 65%. The most important treatment modality for this patient is

- Oral corticosteroids
- Home oxygen
- Broad-spectrum antibiotics
- Smoking cessation program

**2-18.** A 23-year-old woman arrives to an emergency room complaining that “out of the blue,” she was seized by an overwhelming fear associated with shortness of breath and a pounding heart. These symptoms lasted for approximately 20 min and, while the patient was experiencing them, she feared that she was dying or going crazy. The patient has had four similar episodes during the past month and she has been worrying that they will continue recurring. The most likely diagnosis is

- Acute psychotic episode
- Hypochondriasis
- Panic disorder
- Generalized anxiety disorder
- Posttraumatic stress disorder

**2-19.** A 58-year-old man with a basilar tip aneurysm is referred by a neurosurgeon. He has a 4-year history of progressive spastic paraparesis and has recently been experiencing incontinence of urine. He also has numbness in the right more than left toes, and pain in the thighs and back. There have been some gradual fluctuations, but no clear, discrete episodes of deterioration. The patient has had no disturbances of vision, eye movement, or motor control of the upper extremities. He was referred when surgical clipping of the aneurysm 3 mo ago failed to help his symptoms.

Which of the following is the most appropriate next diagnostic test?

- Cerebral angiography
- Spinal angiography
- MRI of the spinal cord
- Spinal cord biopsy
- Visual evoked responses

**2-20.** A 16-year-old boy with ADHD has been increasingly irritable, sad, and withdrawn for several weeks. Which medication has been proven to be effective for depression and ADHD in children and adults?

- Clonidine
- Pemoline
- Imipramine
- Fluvoxamine
- Bupropion

**2-21.** A 59-year-old man presents with fever and agitation. On physical examination, his temperature is 103.2°F. Respirations are 26 breaths/min, pulse is 126 beats/min, and blood pressure is 100/70 mm Hg. The patient appears to be warm and flushed. A Swan-Ganz catheter is inserted and demonstrates increased cardiac output, decreased peripheral vascular resistance (vasodilation), and normal pulmonary capillary wedge pressure (PCWP). Urine gram stain reveals pyuria and gram-negative rods. Which of the following is the most likely diagnosis?

- a. Late septic shock
- b. Early septic shock
- c. Cardiogenic shock
- d. Hypovolemic shock
- e. Neurogenic shock

### Items 2-22 through 2-24

The results of a study of the incidence of pulmonary tuberculosis in a village in India are given in the table below. All persons in the village are examined during two surveys made 2 years apart, and the number of new cases is used to determine the incidence rate.

Category of Household at First Survey	Number of Persons	Number of New Cases
With culture-positive case	500	10
Without culture-positive case	10,000	10

**2-22.** What is the incidence of new cases per 1000 person-years in households that had a culture-positive case during the first survey?

- a. 0.02
- b. 0.01
- c. 1.0
- d. 10
- e. 20

**2-23.** What is the incidence of new cases per 1000 person-years in households that did not have a culture-positive case during the first survey?

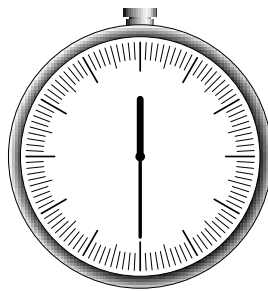
- a. 0.001
- b. 0.1
- c. 0.5
- d. 1.0
- e. 5.0

**2-24.** What is the relative risk of acquiring tuberculosis in households with a culture-positive case compared with households without tuberculosis?

- a. 0.05
- b. 0.5
- c. 2.0
- d. 10
- e. 20

**2-25.** A 69-year-old man is suspected of having an acute onset of multiple small cerebral infarcts. The finding on mental status examination that would be most supportive of this diagnosis is

- a. A decline in cognitive functioning
- b. Bizarre and idiosyncratic proverb interpretation
- c. An elated affect
- d. Loose associations
- e. Catatonic posturing



***YOU SHOULD HAVE COMPLETED APPROXIMATELY 25  
QUESTIONS AND HAVE 30 MINUTES REMAINING.***

---

**2-26.** A 36-year-old man sustains a gunshot wound to the left buttock. He is hemodynamically stable. There is no exit wound, and an x-ray of the abdomen shows the bullet to be located in the right lower quadrant. Correct management of a suspected rectal injury includes

- a. Barium studies of the colon and rectum
- b. Barium studies of the bullet track
- c. Endoscopy of the bullet track
- d. Angiography
- e. Sigmoidoscopy in the emergency room

**2-27.** A 19-year-old woman comes to the emergency room and reports that she fainted at work earlier in the day. She has mild vaginal bleeding. Her abdomen is diffusely tender and distended. In addition, she complains of shoulder and abdominal pain. Her temperature is 36.4°C (97.6°F), pulse rate is 120 beats/min, and blood pressure is 96/50 mm Hg. To confirm the diagnosis suggested by the available clinical data, the best diagnostic procedure is

- a. Pregnancy test
- b. Posterior colpotomy
- c. Dilation and curettage
- d. Culdocentesis
- e. Laparoscopy

**2-28.** A 22-year-old man is brought to the emergency room after being found unconscious in a swimming pool. The patient is mildly cyanotic. Blood pressure is 80/50 mm Hg, heart rate is 60 beats/min, and respiratory rate is 26 breaths/min. The patient's core body temperature is 89°F. Pupils are 4 mm bilaterally and reactive. The patient is moving all extremities and responds appropriately to questions. Crackles are heard bilaterally on lung auscultation. Pulse oximetry reveals a saturation of 94% on 50% oxygen. Chest radiograph reveals bilateral perihilar infiltrates with a normal sized heart. Which of the following is the most likely diagnosis?

- a. Fracture of the C<sub>5</sub> vertebral body
- b. Fracture of the C<sub>7</sub> vertebral body
- c. Congestive heart failure
- d. Noncardiogenic pulmonary edema
- e. Drowning

**2-29.** A 20-year-old man finds a mass in his scrotum. The first step in evaluating this mass is

- a. Palpation and transillumination
- b. hCG and  $\alpha$  fetoprotein tests
- c. Scrotal ultrasonography
- d. Evaluation for inguinal adenopathy



**2-30.** A 22-year-old nulliparous woman has recently become sexually active. She consults you because of painful coitus, with the pain primarily located at the vaginal outlet. It is accompanied by painful involuntary contraction of the pelvic muscles. Of the following, what is the most common cause of this condition?

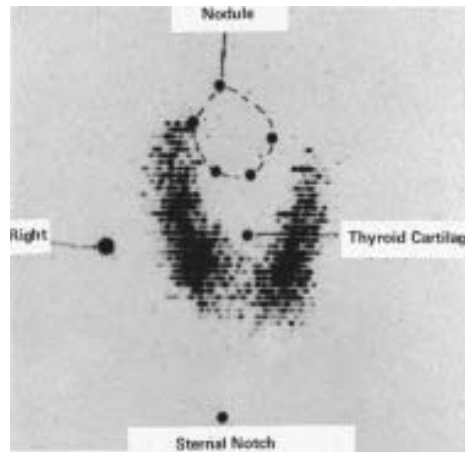
- Endometriosis
- Psychogenic
- Bartholin's gland abscess
- Vulvar atrophy
- Ovarian cyst

**2-31.** A 16-year-old boy is referred to your office for a blood pressure of 140/55 mm Hg. He has a well-healed surgical scar about 12 cm long over the medial aspect of his left thigh. On questioning he states that he acquired the scar 4 years ago by impaling his thigh on a large nail after falling. Auscultation of the scar reveals a bruit and there is a palpable thrill. Which of the following is the most likely diagnosis?

- Premature atherosclerosis
- An arteriovenous fistula
- Scar tissue compressing the femoral artery
- Congenital femoral artery bruit
- Patent ductus arteriosus

**2-32.** A 17-year-old girl presents with an anterior neck mass. Her thyroid scan, shown below, is most consistent with which of the following disorders?

- Hypersecreting adenoma
- Parathyroid adenoma
- Thyroglossal duct cyst
- Graves' disease
- Carcinoma



Reprinted, with permission, from Geller PL: *Surgery: PreTest Self Assessment and Review*, 9th ed. New York, McGraw-Hill, 2001.

**2-33.** A 71-year-old man complains of difficulty in seeing street signs when driving and some difficulty with vision when reading. The patient's vision is 20/100 in his right eye and 20/80 in his left eye. The vision in either eye does not improve with the pinhole test. There is a dullness in the red reflex bilaterally and details of the fundi are difficult to see during funduscopic examination. Intraocular pressure is measured to be 15 mm Hg in both eyes. Which of the following is the most likely diagnosis?

- a. Glaucoma
- b. Macular degeneration
- c. Presbyopia
- d. Cataract
- e. Arcus senilis

**2-34.** A patient with a history of familial polyposis undergoes a diagnostic polypectomy. Which of the following types of polyps is most likely to be found?

- a. Villous adenoma
- b. Hyperplastic polyp
- c. Adenomatous polyp
- d. Retention polyp
- e. Pseudopolyp

**2-35.** One of your patients returns to your office for the results of his HIV test. You inform him that his test is positive for antibodies to HIV. He is married and sexually active with his wife. In the course of subsequent counseling, you tell the patient it is important that his wife be advised of the exposure. He refuses to tell his wife or have anyone else inform her of the exposure. At this time, what is the most appropriate management of the situation?

- a. Tell the patient you refuse to continue seeing him unless his wife is informed
- b. Send an anonymous letter to his wife informing her of the exposure
- c. Try to convince the patient of the importance of informing his wife and offer assistance
- d. Contact public health authorities so they can inform the patient's wife
- e. Call the patient's wife and set up an appointment at your office to inform her of the exposure

**2-36.** A 50-year-old woman is 5 ft, 7 in. tall and weighs 165 lb. There is a family history of diabetes mellitus. Fasting blood glucose is 150 mg/dL on two occasions. The patient is asymptomatic and physical exam shows no abnormalities. The treatment of choice is

- a. Observation
- b. Diet and weight reduction
- c. Insulin
- d. Oral hypoglycemic agent

**2-37.** An 18-mo-old infant is found with the contents of a bottle of drain cleaner in his mouth. A true statement concerning treatment for this caustic ingestion is

- a. Emesis is the immediate emergency treatment
- b. Endoscopic examination is indicated within the first 12 to 24 h
- c. Decontamination by activated charcoal is effective
- d. Neutralization by drinking a solution of the opposite pH is effective
- e. Having the patient drink copious amounts of milk or water to dilute the caustic is essential

**2-38.** A 55-year-old woman with cancer of the cervix undergoes hysterectomy and is found to have pelvic lymph nodes involved with cancer. The patient then receives a course of external beam radiation (4500 rads). When the physician counsels her prior to her radiation treatment, she should be told of all the possible complications of radiation enteritis. These include all the following EXCEPT

- a. Malabsorption
- b. Intussusception
- c. Ulceration
- d. Fistulization
- e. Perforation

**Items 2-39 through 2-40**

A 47-year-old woman begins to have difficulty swallowing food at dinner. Over the following 3 h, she develops diplopia, dysarthria, and ultimately anarthria. She has a history of hypothyroidism and is on thyroid hormone replacement. There is no history of exposure to ticks or recent travel. On exam, the patient nods her head appropriately to questions, and she can write. Forced vital capacity is 500 ml, and the patient is intubated. She is afebrile, tachycardic, and normotensive. Bilateral ptosis and ophthalmoparesis are present; pupils are 6 mm in diameter and minimally reactive. Facial sensation is intact. Bifacial paresis is present and the tongue is weak. Extremity muscle bulk and tone are normal, and proximal strength is 4/5 in the arms and legs. Finger and toe movements are rapid and symmetrical. Plantar responses are flexor. Blood tests are normal. Motor nerve conduction studies show low-amplitude compound muscle action potentials with normal velocities. Sensory nerve action potentials are normal.

**2-39.** Which of the following organisms could be responsible for the patient's syndrome?

- a. Cytomegalovirus
- b. *Treponema pallidum*
- c. *Chlamydia pneumoniae*
- d. *Clostridium botulinum*
- e. *Campylobacter jejuni*

**2-40.** On further questioning it turns out that the patient made her own jam several months before, and tasted a sample of it the previous evening prior to discarding it because it smelled rancid. On further electrophysiologic testing, which of the following abnormalities would be most characteristic of this patient's illness?

- a. Abnormal visual evoked responses
- b. Abnormal brainstem auditory evoked potentials
- c. Posttetanic potentiation of the compound muscle action potential
- d. Conduction block
- e. Fibrillation potentials

**2-41.** An infant who sits with only minimal support, attempts to attain a toy beyond reach, and rolls over from the supine to the prone position, but does not have a pincer grasp, is at a developmental level of

- a. 2 mo
- b. 4 mo
- c. 6 mo
- d. 9 mo
- e. 1 year

**2-42.** A couple presents to the infertility clinic because of inability to conceive for over 1 year. A semen analysis on the man reveals oligospermia. He works for a company that manufactures storage batteries. A blood level should be obtained for which of the following agents?

- a. Chromium
- b. Nickel
- c. Lead
- d. Antimony
- e. Boron

**2-43.** A 49-year-old man presents with painful, recurring episodes of swelling in his left great toe. He takes 25 mg of hydrochlorothiazide daily for blood pressure control but otherwise is in good health. On physical examination, the patient is afebrile but his great toe is warm, swollen, erythematous, and exquisitely tender to palpation. He has several subcutaneous nodules in his pinna. Which of the following is the most likely diagnosis?

- a. Calcium pyrophosphate dihydrate deposition disease
- b. Calcium oxalate deposition disease
- c. Monosodium urate deposition disease
- d. Calcium phosphate deposition disease
- e. Osteoarthritis of the great toe

**2-44.** A 29-year-old, gravida 3, para 2 black woman in the 33rd wk of gestation is admitted to the emergency room because of acute abdominal pain that developed and is increasing during the past 24 h. The pain is severe and is radiating from the epigastrium to the back. The patient has vomited a few times and has not eaten or had a bowel movement since the pain started.

On examination you observe an acutely ill patient lying on the bed with her knees drawn up. Her blood pressure is 150/100 mm Hg, her pulse is 110 beats/minute, and her temperature is 38.18°C (100.68°F). On palpation the abdomen is somewhat distended and tender, mainly in the epigastric area, and the uterine fundus reaches 31 cm above the symphysis. Hypotonic bowel sounds are noted. Fetal monitoring reveals a normal pattern of fetal heart rate (FHR) without uterine contractions. On ultrasonography the fetus is in vertex presentation and appropriate in size for gestational age; fetal breathing and trunk movements are noted and the volume of amniotic fluid is normal. The placenta is located on the anterior uterine wall and of grade 2 to 3.

Laboratory values show mild leukocytosis (12,000 cells/ $\mu$ L); hematocrit of 43; mildly elevated SGOT, SGPT, and bilirubin; and serum amylase of 180 U/dL. Urinalysis is normal.

The most probable diagnosis in this patient is

- a. Acute degeneration of uterine leiomyoma
- b. Acute cholecystitis
- c. Acute pancreatitis
- d. Acute appendicitis
- e. Severe preeclamptic toxemia

**2-45.** A 45-year-old man with Parkinson's disease has macular areas of erythema and scaling behind the ears and on the scalp, eyebrows, glabella, nasal labial folds, and central chest. The diagnosis is

- a. Tinea versicolor
- b. Psoriasis
- c. Seborrheic dermatitis
- d. Atopic dermatitis
- e. Dermatophyte infection

**Items 2-46 through 2-47**

A 56-year-old man is brought into the emergency room having collapsed at work 30 min ago. He has no medical history and takes no medications. He is alert and speaking but has no awareness of any deficit. He has a right gaze preference, dense left face and arm plegia, and mild left leg weakness. When asked to raise his legs, he lifts only the right leg. He has reduced blink to threat from the left side.

**2-46.** The most appropriate initial diagnostic step is

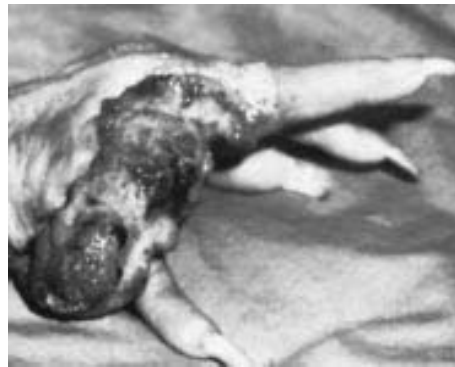
- Head CT
- Cerebral angiogram
- C-spine MRI
- T<sub>2</sub>-weighted brain MRI
- Skull x-rays

**2-47.** A head CT scan shows no evidence of intracranial hemorrhage. The most appropriate therapy at this point is

- Intravenous recombinant tissue plasminogen activator
- Intravenous streptokinase
- Oral aspirin
- Intravenous heparin
- Intravenous mannitol

**2-48.** A 60-year-old woman presents with the skin lesion shown below, which has been present for 10 years. She reports a history of radiation treatments to that hand for “eczema.” Correct statements concerning this lesion include

- It is more malignant than basal cell carcinoma
- It occurs more frequently in brunettes
- It rarely metastasizes to regional lymph nodes
- It should be treated by radiation therapy
- It is rarely associated with chronic sun exposure



Reprinted, with permission, from Geller PL: *Surgery: PreTest Self-Assessment and Review*, 9th ed. New York, McGraw-Hill, 2001.

**2-49.** In the course of investigating a 24-year-old HIV-infected man, the hepatitis B surface antigen (HBsAg) is found to be positive. The patient is currently symptomatic, his physical examination is essentially normal, and his CD4 cell count is 800. Which of the following tests is most helpful in determining whether the patient is in the acute phase of viral hepatitis?


- a. ALT levels
- b. HBeAg
- c. HBsAg
- d. IgG anti-HBcAg
- e. IgM anti-HBcAg

**2-50.** A 30-year-old man is evaluated for a thyroid nodule. The patient reports that his father died from “thyroid cancer” and that a brother had a history of recurrent renal stones. Blood calcitonin concentration is 2000 pg/mL (normal is less than 100 pg/mL); serum calcium and phosphate levels are normal. Before referring the patient to a surgeon, the physician should

- a. Obtain a liver scan
- b. Perform a calcium infusion test
- c. Measure urinary catecholamines
- d. Administer suppressive doses of thyroxine and measure levels of thyroid-stimulating hormone
- e. Treat the patient with radioactive iodine



# ***BLOCK 3***



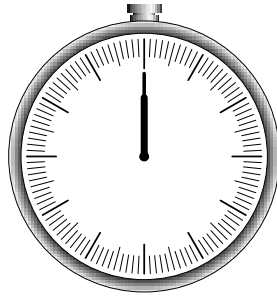
***YOU HAVE 60 MINUTES  
TO COMPLETE 50 QUESTIONS.***

---

*This page intentionally left blank.*

# BLOCK 3

---



**YOU HAVE 60 MINUTES  
TO COMPLETE 50 QUESTIONS.**

---

## Questions

**3-1.** A 5-year-old boy comes to the emergency department at midnight with a complaint of severe scrotal pain since 7 P.M. There is no history of trauma. Your first step is to

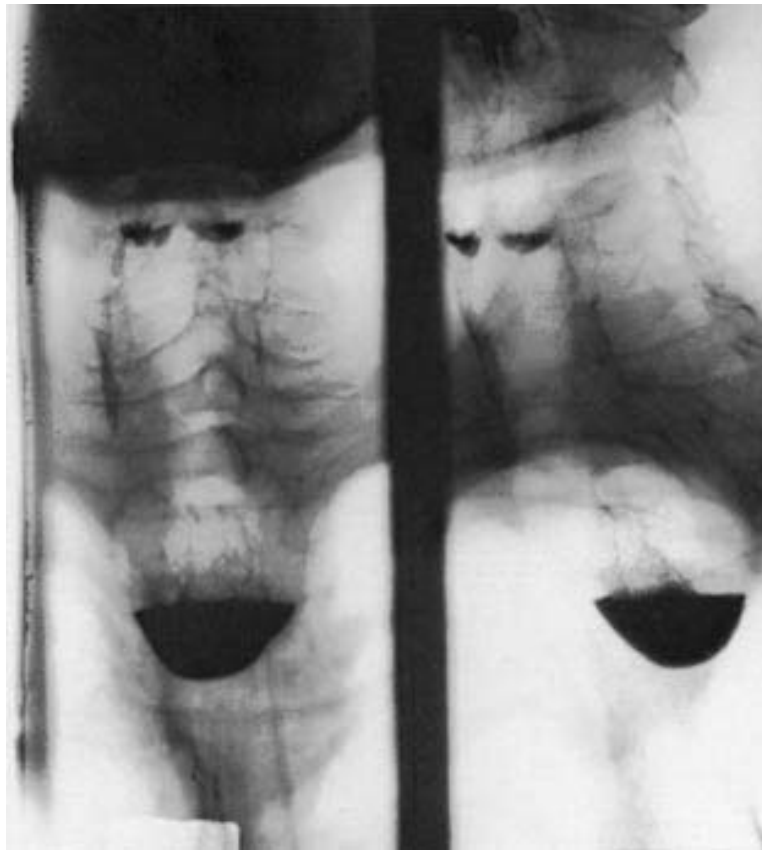
- a. Order a surgical consult immediately
- b. Order a radioisotope scan on an emergency basis
- c. Order a urinalysis and gram stain for bacteria
- d. Arrange for an ultrasound examination
- e. Order a Doppler examination

**3-2.** A 30-year-old woman in the last trimester of pregnancy suddenly develops massive swelling of the left lower extremity from the inguinal ligament to the ankle. The correct sequence of workup and treatment should be

- a. Venogram, bed rest, heparin
- b. Impedance plethysmography, bed rest, heparin
- c. Impedance plethysmography, bed rest, vena caval filter
- d. Impedance plethysmography, bed rest, heparin, warfarin (Coumadin)
- e. Clinical evaluation, bed rest, warfarin

**3-3.** A 56-year-old woman has been treated for 3 years for wheezing on exertion, which was diagnosed as asthma. The chest radiograph shown below is obtained and reveals a midline mass compressing the trachea. The most likely diagnosis is

- a. Lymphoma
- b. Neurogenic tumor
- c. Lung carcinoma
- d. Goiter
- e. Pericardial cyst



Reproduced, with permission, from Geller PL: *Surgery: PreTest Self-Assessment and Review*, 9th ed. New York, McGraw-Hill, 2001.

**3-4.** You are a physician in charge of the patients who reside in a nursing home. Several of the patients have developed influenza-like symptoms, and the community is in the midst of an influenza A outbreak. None of the nursing home residents have received the influenza vaccine. What course of action is most appropriate?

- Give the influenza vaccine to all residents of the nursing home who do not have a contraindication to the vaccine (allergy to eggs)
- Give the influenza vaccine to all residents of the nursing home who do not have a contraindication to the vaccine; also give amantadine for a 2-wk period
- Give amantadine alone to all nursing home residents
- Do not give any prophylactic regimen

**3-5.** A preterm black male infant is found to be jaundiced 12 h after birth. At 36 h of age, his serum bilirubin is 18 mg/dL, hemoglobin concentration is 12.5 g/dL, and reticulocyte count is 9%. Many nucleated red cells and some spherocytes are seen in the peripheral blood smear. The differential diagnosis should include which of the following?

- Pyruvate kinase deficiency
- Hereditary spherocytosis
- Sickle-cell anemia
- Rh incompatibility
- Polycythemia

**3-6.** A 35-year-old woman undergoes her first screening mammogram. Which of the following mammographic findings would require a breast biopsy?

- Breast calcifications larger than 2 mm in diameter
- Five or more clustered breast microcalcifications per square centimeter
- A density that effaces with compression
- Saucer-shaped microcalcifications
- Multiple round well-circumscribed breast densities

**3-7.** A 65-year-old woman who has a 12-year history of symmetrical polyarthritis is admitted to the hospital. Physical examination reveals splenomegaly, ulcerations over the lateral malleoli, and synovitis of the wrists, shoulders, and knees. There is no hepatomegaly. Laboratory values demonstrate a white blood cell count of 2500/ $\mu$ L and a rheumatoid factor titer of 1:4096. This patient's white blood cell differential count is likely to reveal

- Pancytopenia
- Lymphopenia
- Granulocytopenia
- Lymphocytosis
- Basophilia

**3-8.** A middle-aged man is chronically preoccupied with his health. For many years he feared that his irregular bowel functions meant he had cancer. Now he is very preoccupied about having a serious heart disease, despite his physician's assurance that the occasional "extra beats" he detects when he checks his pulse are completely benign. What is the most likely diagnosis?

- a. Somatization disorder
- b. Hypochondriasis
- c. Delusional disorder
- d. Pain disorder
- e. Conversion disorder

**Items 3-9 through 3-10**

An 18-year-old high school football player is kicked in the left flank. Three hours later he develops hematuria. His vital signs are stable.

**3-9.** Initial diagnostic tests in the emergency room should include which of the following?

- a. Retrograde urethrography
- b. Retrograde cystography
- c. Arteriography
- d. Intravenous pyelogram
- e. Diagnostic peritoneal lavage

**3-10.** The diagnostic tests performed reveal extravasation of contrast into the renal parenchyma. Treatment should consist of

- a. Resumption of normal daily activities, excluding sports
- b. Exploration and suture of laceration
- c. Exploration and wedge resection of left kidney
- d. Nephrostomy
- e. Antibiotics and serial monitoring of blood count and vital signs

**3-11.** A 7-year-old girl is brought to your office by her mother because of a rash that appeared 3 days ago. Her temperature is 37.2°C (99°F) and her face has an intense rash with a "slapped-cheek" appearance. The most likely etiologic agent is

- a. Adenovirus
- b. Rotavirus
- c. Parvovirus
- d. Coxsackievirus
- e. Echovirus

**3-12.** A 16-year-old girl with complex partial seizures and mild mental retardation has an area of deep red discoloration (port wine nevus) extending over her forehead and left upper eyelid. A computed tomography (CT) scan of her brain would be likely to reveal

- a. A hemangioblastoma
- b. A Charcot-Bouchard aneurysm
- c. An arteriovenous malformation
- d. A leptomenigeal angioma
- e. A fusiform aneurysm

**3-13.** A 27-year-old man presents with hoarseness for 6 mo. He has no other symptoms or complaints. He has no past medical history, takes no medications, and does not smoke cigarettes or drink alcohol. He uses no illicit drugs. He has been employed as a telephone operator for the last 8 mo. Which of the following is the most likely diagnosis?

- a. Postnasal drip syndrome
- b. Cancer of the larynx
- c. Reflux esophagitis
- d. Voice strain
- e. Kallman syndrome

**3-14.** After an uneventful labor and delivery, an infant is born at 32 wk gestation weighing 1500 g (3 lb, 5 oz). Respiratory difficulty develops immediately after birth and increases in intensity thereafter. The child's mother (gravida 3, para 2, no abortions) previously lost an infant because of hyaline membrane disease. At 6 h of age, the patient's respiratory rate is 60 breaths/min. Examination reveals grunting, intercostal retraction, nasal flaring, and marked cyanosis in room air. Physiological abnormalities compatible with this data include

- a. Decreased lung compliance, reduced lung volume, left-to-right shunt of blood
- b. Decreased lung compliance, reduced lung volume, right-to-left shunt of blood
- c. Decreased lung compliance, increased lung volume, left-to-right shunt of blood
- d. Normal lung compliance, reduced lung volume, left-to-right shunt of blood
- e. Normal lung compliance, increased lung volume, right-to-left shunt of blood

**3-15.** A 6-year-old boy who had a mild respiratory tract infection for 2 days awakens in the middle of the night with shortness of breath and difficulty breathing, and his parents bring him to the emergency room. His respiratory rate is 36 breaths/min and his heart rate is 150 beats/min. He has a prolonged expiratory phase when breathing. He is afebrile. Lung auscultation reveals high-pitched, squeaky, musical breath sounds in all lung fields during inspiration and expiration. Which of the following is the most likely diagnosis?

- a. Epiglottitis
- b. Asthma
- c. Croup
- d. Tonsillitis
- e. Pneumonia

**3-16.** A 28-year-old, otherwise healthy white woman on no medications presents to the emergency room with chest pressure, dizziness, numbness in both hands, and a feeling of impending doom that began while the patient was walking in the mall. The most likely diagnosis on the differential is

- a. Angina
- b. Congenital heart disease
- c. Gastroesophageal reflux
- d. Panic disorder
- e. Pulmonary embolus

**3-17.** Two brothers, 4 and 7 years of age, exhibit limb ataxia, nystagmus, and mental retardation. MRI of their brains reveals areas of abnormal signal in the white matter. Cerebellar involvement is substantial. Both boys also have abnormally low serum cortisol levels. Select the most likely diagnosis.

- a. Neuromyelitis optica (Devic's disease)
- b. Central pontine myelinolysis
- c. Marchiafava-Bignami disease
- d. Acute disseminated encephalomyelitis
- e. Pelizaeus-Merzbacher disease
- f. Leber's optic atrophy
- g. Alexander's disease
- h. Adrenoleukodystrophy
- i. Canavan's disease

### Items 3-18 through 3-19

A patient has been standing immobile for several hours. One of his arms is stretched upward, the other is wrapped around his neck. The patient does not appear aware of his surroundings and actively resists any attempt to make him change position.

**3-18.** This is an example of

- a. Apraxia
- b. Dystonia
- c. Sinesthesia
- d. Catatonia
- e. Trance



**3-19.** This symptom is usually seen in patients with

- a. Schizophrenia
- b. Parkinson's disease
- c. Delirium
- d. Neuroleptic malignant syndrome
- e. Huntington's disease

**3-20.** A 71-year-old man complains of occasional lower back pain. His blood pressure is 150/85 mm Hg and his pulse is 80 beats/min. Cardiac examination reveals an S<sub>4</sub> gallop. Abdominal examination reveals a pulsatile mass approximately 5.0 cm in diameter palpable in the epigastric area. Peripheral pulses are normal. Which of the following is the most likely diagnosis?

- a. Abdominal aortic aneurysm
- b. Cancer of the proximal colon
- c. Peptic ulcer disease
- d. Chronic pancreatitis
- e. Lipoma of the abdominal wall

**3-21.** A 9-year-old girl presents with precocious puberty and episodes of uncontrollable laughter. Which of the following mass lesions might explain her symptoms?

- a. Craniopharyngioma
- b. Choroid plexus papilloma
- c. Giant aneurysm
- d. Metastatic carcinoma
- e. Hypothalamic hamartoma

**3-22.** A 27-year-old patient previously treated with external beam radiation for stage IB cervix cancer has a central recurrence 2 years later. A curative surgical procedure is contemplated in which the uterus, both adnexa, the rectum, and the bladder will be removed, diverting the fecal stream with a colostomy and the urinary stream with an ileal conduit. Such a procedure is called a

- a. Radical hysterectomy
- b. Supraradical hysterectomy
- c. Hemiexenteration
- d. Total pelvic exenteration
- e. Radical exenteration

**3-23.** A healthy 2-mo-old infant is brought to the office for routine child care. The child has a normal growth curve. She received the first dose of hepatitis B vaccine at birth as well as a dose of hepatitis B immunoglobulin (HBIG) because the mother was hepatitis B surface antigen (HBsAg) positive. Which of the following vaccine series should be administered at this time?

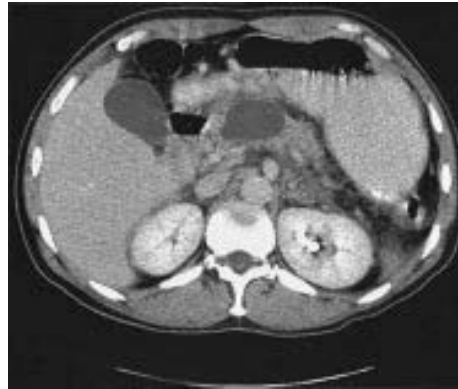
- a. MMR, OPV, DTP, Hepatitis B
- b. IPV, Hib, DTP, Hepatitis B
- c. Hepatitis B, DTaP, Hib, IPV
- d. DTaP, Hib, IPV
- e. IPV, DTaP, Hepatitis B

**3-24.** An attractive and well-dressed 22-year-old woman is arrested for prostitution, but on being booked at the jail, she is found to actually be a male. The patient tells the consulting physician that he is a female trapped in a male body and he has felt this way since he was a child. He has been taking female hormones and is attempting to find a surgeon who will remove his male genitals and create a vagina. The most likely diagnosis is

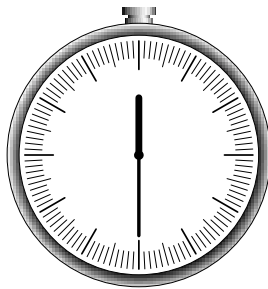
- a. Homosexuality
- b. Gender identity disorder
- c. Transvestite fetishism
- d. Delusional disorder
- e. Schizophrenia

**3-25.** A previously healthy 80-year-old woman presents with early satiety and abdominal fullness. The CT scan shown below is obtained. The lesion is most likely a

- a. Pancreatic pseudocyst
- b. Pancreatic adenocarcinoma
- c. Pancreatic cystadenocarcinoma
- d. Retroperitoneal lymphoma
- e. Pancreatic serous cystadenoma



Reprinted, with permission, from Geller PL: *Surgery: PreTest Self-Assessment and Review*, 9th ed. New York, McGraw-Hill, 2001.



---

***YOU SHOULD HAVE COMPLETED APPROXIMATELY  
25 QUESTIONS AND HAVE 30 MINUTES REMAINING.***

---

**3-26.** A 30-year-old woman complains of palpitations, fatigue, and insomnia. On physical exam, her extremities are warm and she is tachycardic. There is diffuse thyroid gland enlargement and proptosis. There is an orange thickening of the skin in the pretibial area. Which of the following lab values would you expect in this patient?

- a. Increased TSH, total thyroxine, and total  $T_3$
- b. Decreased TSH, increased total thyroxine
- c. Increased  $T_3$  uptake, decreased  $T_3$
- d. Normal  $T_4$ , decreased TSH

**3-27.** A 20-year-old patient presents to the office for contraception counseling. Her history reveals no past medical problems. Her physical and pelvic examinations are normal. She has been sexually active with the same partner for 9 mo. Which of the following contraceptive methods is most appropriate?

- a. Barrier method
- b. Combined oral contraceptives
- c. Progestin-only contraceptives
- d. Intrauterine device (IUD)
- e. Barrier method and combined oral contraceptives

**3-28.** A 23-year-old Japanese man attends a party where he drinks three glasses of wine. In a short period of time, he develops facial erythema and experiences severe facial flushing. Which of the following is the most likely diagnosis?

- a. Alcohol dehydrogenase deficiency
- b. Glucuronyl transferase deficiency
- c. Aldehyde dehydrogenase deficiency
- d. Angioedema
- e. Photosensitivity reaction

**3-29.** A young man with multiple sclerosis exhibits paradoxical dilation of the right pupil when a flashlight is redirected from the left eye into the right eye. Swinging the flashlight back to the left eye produces constriction of the right pupil. This patient apparently has

- a. Early cataract formation in the right eye
- b. Occipital lobe damage on the left
- c. Oscillopsia
- d. Hippus
- e. Optic atrophy

**3-30.** A 56-year-old woman with bipolar disorder, who has been managed with lithium for years, is brought to the emergency room by her relatives with clear signs of lithium toxicity. She is tremulous, ataxic, and somnolent, and her lithium level is 1.8. There were no recent changes in dosage and the patient is not dehydrated. During the previous week she has been taking several daily doses of an over-the-counter medication. What medication has she used?

- a. Acetylsalicylate
- b. Acetaminophen
- c. Ibuprofen
- d. Diphenhydramine
- e. Pseudoephedrine

**Items 3-31 through 3-32**

About 1% of boys are born with undescended testes. To determine whether prenatal exposure to tobacco smoke is a cause of undescended testes in newborns, the mothers of 100 newborns with undescended testes and the mothers of 100 newborns whose testes had descended were questioned about smoking habits during pregnancy. The study revealed an odds ratio of 2.6 associated with exposure to smoke, with 95% confidence intervals from 1.1 to 5.3.

**3-31.** Some reviewers are concerned that the study may overestimate the association between maternal smoking and undescended testes in the offspring because of potential

- a. Confounding
- b. Nondifferential misclassification
- c. Differential misclassification
- d. Selection bias
- e. Loss to follow-up

**3-32.** What is the most appropriate conclusion to be drawn from the study?

- a. There is no association between maternal smoking and undescended testes in the offspring
- b. The study results, if accurate, suggest that an offspring whose mother smoked is about 2.6 times more likely to be born with undescended testes than an offspring whose mother did not smoke
- c. The *P* value is  $>0.05$
- d. The 90% confidence interval for these results would probably include 1.0
- e. A larger sample size would increase the confidence interval

**Items 3-33 through 3-34**

A patient has been complaining of fatigue and night sweats associated with itching for 2 mo. On physical exam there is diffuse, non-tender lymphadenopathy, including small supraclavicular, epitrochlear, and scalene nodes. A chest x-ray shows hilar lymphadenopathy.

**3-33.** The next step in evaluation is

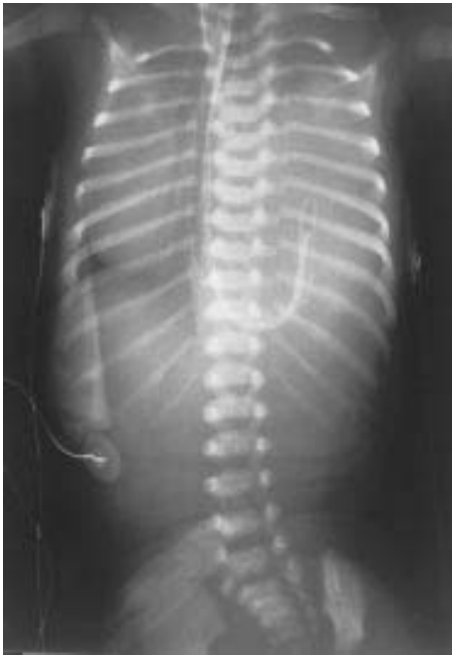- a. Excisional lymph node biopsy
- b. Monospot test
- c. Toxoplasmosis IgG
- d. Angiotension converting enzyme

**3-34.** The patient described is found on biopsy to have mixed-cellularity Hodgkin's lymphoma. Liver function tests are normal and the spleen is nonpalpable. The next step in evaluation is

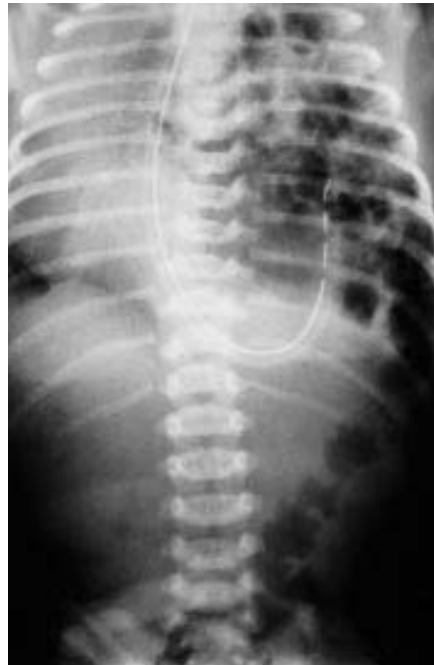- a. CT scan or MRI
- b. Liver biopsy
- c. Repeat node biopsy
- d. Erythrocyte sedimentation rate

**3-35.** A newborn infant develops respiratory distress immediately after birth. His abdomen is scaphoid. No breath sounds are heard on the left side of his chest, but they are audible on the right. Immediate intubation is successful with little or no improvement in clinical status. Emergency chest x-ray is shown (A) along with an x-ray 2 hours later (B). The most likely explanation for this infant's condition is

**A**



**B**



Reprinted, with permission, from Yetman RJ: *Pediatrics: PreTest Self-Assessment and Review*, 9th ed. New York, McGraw-Hill, 2001: 62–63.

- a. Pneumonia
- b. Cyanotic heart disease
- c. Diaphragmatic hernia
- d. Choanal atresia
- e. Pneumothorax

**3-36.** A 62-year-old man presents for his annual health maintenance visit. The review of systems is positive for occasional fatigue and headache. The patient admits to generalized pruritus following a warm bath or shower. He has plethora and engorgement of the retinal veins. A spleen is palpated on abdominal examination. Hematocrit is 63%. The patient has a leukocytosis and thrombocytosis. Peripheral blood smear is normal. The patient does not smoke. Which of the following is the most likely diagnosis?

- a. Spurious polycythemia
- b. Essential thrombocytosis
- c. Myelofibrosis
- d. Polycythemia vera
- e. Secondary polycythemia
- f. Chronic myeloid leukemia
- g. Erythropoietin-secreting renal tumor

**3-37.** A 39-year-old woman, gravida 3, para 3, complains of severe, progressive secondary dysmenorrhea and menorrhagia. Pelvic examination demonstrates a tender, diffusely enlarged uterus with no adnexal tenderness. Results of endometrial biopsy are normal. This patient most likely has

- a. Endometriosis
- b. Endometritis
- c. Adenomyosis
- d. Uterine sarcoma
- e. Leiomyoma

**3-38.** One month after her mother's death from heart failure, a 25-year-old woman with no prior psychiatric history is still very sad and tearful. She has difficulty concentrating and falling asleep at night and she has lost 3 lb. The most likely diagnosis is

- a. Major depression
- b. Dysthymia
- c. Posttraumatic stress disorder
- d. Adjustment disorder
- e. Uncomplicated bereavement

**3-39.** During a diving expedition to explore sunken ships, one of the divers starts to experience lightheadedness, dizziness, ataxia, and nausea after reaching 110 ft of depth. Which of the following is the most likely diagnosis?

- a. Nitrogen narcosis
- b. Barotrauma
- c. Vertigo
- d. Barosinusitis
- e. Bends

**3-40.** A little girl who was underweight and hypotonic in infancy is obsessed with food, eats compulsively, and at age 4 is already grossly overweight. She is argumentative, oppositional, and rigid. She has a narrow face, almond-shaped eyes, and a small mouth. What is her diagnosis?

- a. Down syndrome
- b. Fragile X syndrome
- c. Fetal alcohol syndrome
- d. Hypothyroidism
- e. Prader-Willi syndrome

**3-41.** A 50-year-old man complaining of dizziness is found to have a cyst occupying 50% of his posterior fossa and incomplete fusion of the cerebellar elements inferiorly. There is no evidence of an obstructive hydrocephalus. His longevity can be estimated to be

- a. Less than 3 mo
- b. Less than 1 year
- c. Less than 5 years
- d. Less than 10 years
- e. Unaffected by this finding

**3-42.** A 19-year-old woman attending school in Massachusetts presents with the chief complaint of bloody diarrhea for 2 mo. She has abdominal discomfort and feels she has lost some weight. She also complains of tenesmus. Abdominal examination is normal. The rectal exam reveals stool containing blood and pus. Which of the following is the most likely diagnosis?

- a. Irritable bowel syndrome
- b. Ulcerative colitis
- c. Giardiasis
- d. Hemorrhoids
- e. Diverticulosis

**3-43.** A 55-year-old woman complains of seborrhea, acne, and mild facial hirsutism since menopause 2 years ago. Her serum androstenedione and estrone levels are moderately elevated. Which of the following is the most likely cause of her condition?

- a. Amount of body fat
- b. Increased ovarian steroid secretion
- c. Increased adrenal steroid secretion
- d. Diminished renal steroid elimination
- e. Diminished hepatic steroid clearance



**3-44.** A 44-year-old woman presents with diffuse myalgias and excessive fatigue. She has morning stiffness and pain of all her joints, especially her wrists, elbows, shoulders, hips, knees, and neck. She does not sleep well at night. Her symptoms have been progressing for over 4 years. On physical examination, the patient has 13 tender points at the elbows, knees, shoulders, and hips. Which of the following is the most likely diagnosis?

- a. Polymyalgia rheumatica
- b. Fibromyalgia syndrome
- c. Rheumatoid arthritis
- d. Scleroderma
- e. Polymyositis

**3-45.** A 23-year-old woman presents for evaluation of a 7-mo history of amenorrhea. Examination discloses bilateral galactorrhea and normal breast and pelvic examinations. Pregnancy test is negative. Which of the following classes of medication is a possible cause of the patient's condition?

- a. Antiestrogens
- b. Gonadotropins
- c. Phenothiazines
- d. Progestogens
- e. GnRH analogs

**3-46.** A term, 4200-g female infant is delivered via cesarean section because of cephalopelvic disproportion. The amniotic fluid is clear and the infant cries almost immediately after birth. Within the first 15 min of life, however, the infant's respiratory rate increases to 80 breaths/min and she begins to display intermittent grunting respirations. The infant is transferred to the level 2 nursery and is noted to have an oxygen saturation of 94%. The chest radiograph shows fluid in the fissure, overaeration, and prominent pulmonary vascular markings. The most likely diagnosis in this infant is

- a. Diaphragmatic hernia
- b. Meconium aspiration
- c. Pneumonia
- d. Idiopathic respiratory distress syndrome
- e. Transient tachypnea of the newborn

**3-47.** A 42-year-old woman presents to the emergency room complaining of the sudden onset of right upper abdominal pain. Her pain started after eating a hamburger for lunch. She is nauseated and vomited twice at home. She denies diarrhea. Her temperature is 102.2°F, blood pressure is 140/90 mm Hg, and pulse is 110 beats/min. The patient appears anxious and distressed. She is not jaundiced. Abdominal examination reveals normal bowel sounds. While you are palpating under her right costal margin, the patient abruptly arrests her inspiration and pulls away because of sharp pain. Which of the following is the most appropriate next step in management?

- a. Abdominal radiograph
- b. Ultrasound of the abdomen
- c. HIDA scan
- d. MRI of the abdomen
- e. Upper endoscopy

**3-48.** A 64-year-old woman presents with vaginal bleeding similar to spotting, which has occurred daily for 1 mo. Her last menses was at age 50 and she has been healthy her entire life. She denies fever, weight loss, or abdominal pain. Physical examination is normal. Which of the following is the most likely diagnosis?

- a. Atrophic vaginitis
- b. Endometriosis
- c. Uterine leiomyoma
- d. Endometrial carcinoma
- e. Polycystic ovarian syndrome

**3-49.** A 55-year-old woman who has a history of severe depression and who had radical mastectomy for carcinoma of the breast 1 year ago develops polyuria, nocturia, and excessive thirst. Laboratory values are as follows:

Serum electrolytes: Na<sup>+</sup>, 149 meq/L; K<sup>+</sup>, 3.6 meq/L

Serum calcium: 9.5 mg/dL

Blood glucose: 110 mg/dL

Blood urea nitrogen: 30 mg/dL

Urine osmolality: 150 mOsm/kg

The most likely diagnosis is


- a. Psychogenic polydipsia
- b. Renal glycosuria
- c. Hypercalciuria
- d. Diabetes insipidus
- e. Inappropriate antidiuretic hormone syndrome

**3-50.** Your 60-year-old male patient, followed for chronic stable angina on aspirin, nitrates, and a beta blocker, presents to the ER with history of two to three episodes of more severe and long-lasting anginal chest pain each day over the past 3 days. His ECG and cardiac enzymes are normal. The best course of action of the following is to

- a. Admit the patient and begin intravenous digoxin
- b. Admit the patient and begin intravenous heparin
- c. Admit the patient and give prophylactic thrombolytic therapy
- d. Admit the patient for observation with no change in medication
- e. Discharge the patient with increases in nitrates and beta blockers

*This page intentionally left blank.*

# ***BLOCK 4***



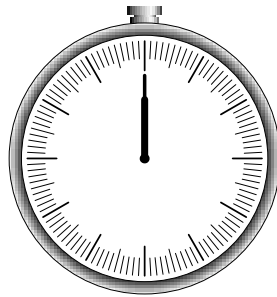
***YOU HAVE 60 MINUTES  
TO COMPLETE 50 QUESTIONS.***

---

*This page intentionally left blank.*

# BLOCK 4

---



**YOU HAVE 60 MINUTES  
TO COMPLETE 50 QUESTIONS.**

---

## Questions

**4-1.** The Coronary Drug Project was a randomized trial to evaluate the efficacy of several lipid-lowering drugs. The 5-year mortality of the men who adhered to the regimen of clofibrate (i.e., took 80% of their medicine or more) was 15%; among those assigned to the clofibrate group who were less compliant, it was 24.6%. The result was highly statistically significant ( $P < 0.0001$ ). From this, one can conclude that

- a. Clofibrate was very beneficial to the patients who took it reliably
- b. Clofibrate is not effective unless patients take at least 80% of the recommended doses
- c. Either clofibrate or something associated with taking it reliably is strongly associated with reduced total mortality
- d. There was a problem with blinding in this study
- e. Only those who were compliant should be included in the data

**4-2.** A 16-year-old boy complains of several months of swelling but no pain just above his left testicle. He is sexually active but states that he uses condoms. On physical examination, he has a mass along the spermatic cord that feels like a “bag of worms.” Which of the following is appropriate for this condition?

- a. Doppler flow study of the testes
- b. Radionuclide scan of the testes
- c. Urinalysis and culture
- d. Ceftriaxone intramuscularly and doxycycline orally
- e. Reassurance and education only at this time

**4-3.** An 18-year-old man has been seen in clinic for urethral discharge. He was treated with ceftriaxone, but the discharge has not resolved and the culture has returned as no growth. The most likely etiologic agent to cause this infection is

- a. Ceftriaxone-resistant gonococci
- b. *Chlamydia psittaci*
- c. *C. trachomatis*
- d. Herpes simplex

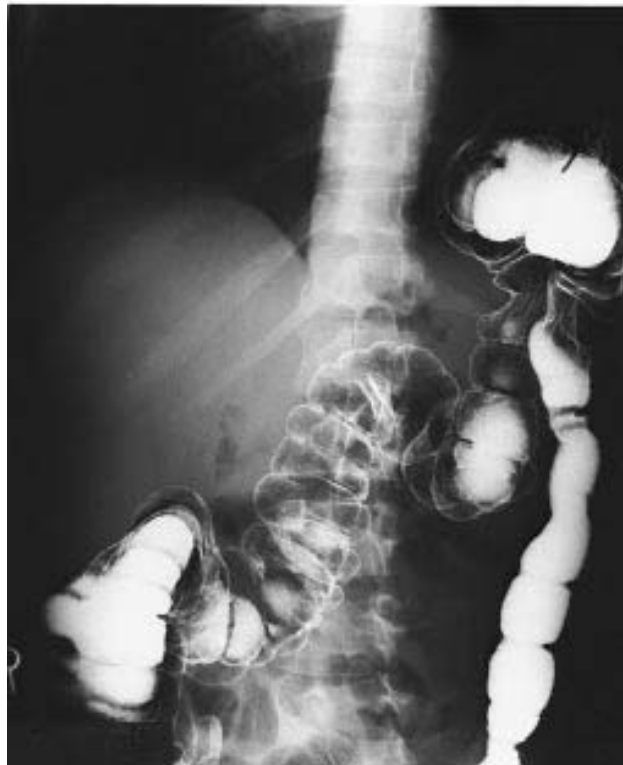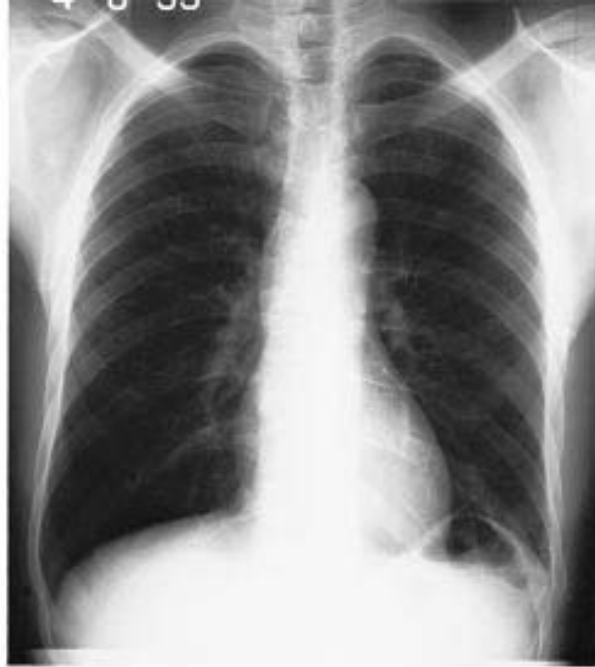**4-4.** A cirrhotic patient with abnormal coagulation studies due to hepatic synthetic dysfunction requires an urgent cholecystectomy. A transfusion of fresh frozen plasma is planned to minimize the risk of bleeding due to surgery. The optimal timing of this transfusion is

- a. The day before surgery
- b. The night before surgery
- c. On call to surgery
- d. Intraoperatively
- e. In the recovery room

**4-5.** The patient illustrated on the chest x-ray film and contrast study on the following page was hospitalized after a car collision in which he suffered blunt trauma to the abdomen. He sustained several left rib fractures, but was hemodynamically stable. True statements about the injury demonstrated in the films include

- a. The injury depicted is the most frequent organ injury in the setting of blunt trauma to the abdomen
- b. Delayed operative repair is indicated after allowing the patient's rib fractures to stabilize
- c. Surgical treatment of this injury is indicated during this hospitalization
- d. Early repair of this injury is preferably accomplished through a left posterolateral thoracotomy
- e. If this injury is incidentally discovered during a surgical exploration, it should not be repaired





Reprinted, with permission, from Geller PL: *Surgery: PreTest Self-Assessment and Review*, 9th ed. New York, McGraw-Hill, 2001.

**4-6.** A patient with low-grade fever and weight loss has poor excursion on the right side of the chest with decreased fremitus, flatness to percussion, and decreased breath sounds, all on the right. The trachea is deviated to the left. Likely diagnosis is

- a. Pneumothorax
- b. Pleural effusion secondary to histoplasmosis
- c. Consolidated pneumonia
- d. Atelectasis

**4-7.** A large explosion occurs at a construction site during excavation. None of the workers appear injured. Some were exposed to sound pressure levels of 190 dB. Which of the following is the most likely outcome for these workers?

- a. Temporary tinnitus
- b. Temporary conductive hearing loss
- c. Permanent conductive hearing loss
- d. Temporary sensorineural hearing loss
- e. Permanent sensorineural hearing loss

**4-8.** A 39-year-old woman experiences diplopia several times a day for 6 wk. She consults a physician when the double vision becomes unremitting and also complains of dull pain behind her right eye. When a red glass is placed over the patient's right eye and she is asked to look at a flashlight off to her left, she reports seeing a white light and a red light. The red light appears to her to be more to the left than the white light. The patient's right pupil is more dilated than her left pupil and responds less briskly to a bright light directed at it than does the left pupil.

Before any further investigations can be performed, the patient develops the worst headache of her life and becomes stuporous. Her physician discovers that she has marked neck stiffness and photophobia. The physician performs a transfemoral angiogram. This radiologic study is expected to reveal that the patient has

- a. An arteriovenous malformation
- b. An occipital astrocytoma
- c. A sphenoidal meningioma
- d. A pituitary adenoma
- e. A saccular aneurysm

**4-9.** A 20-year-old woman presents with the sudden onset of severe lower abdominal pain that radiates to her left shoulder. She has some vaginal bleeding now, but her last menstrual period was 6 wk ago. She has no history of sexually transmitted diseases and has never been pregnant. She uses condoms inconsistently about 50% of the time with her partner of 18 mo. She denies dysuria or frequency. On physical examination, blood pressure is 100/70 mm Hg, heart rate is 100 beats/min, and temperature is normal. Abdominal exam reveals tenderness and rebound in the left lower quadrant. Adler sign is positive. Pelvic examination reveals a boggy and poorly delineated mass in the left adnexa. The patient's abdominal pain worsens upon slight movement of the cervix. Which of the following is the most likely diagnosis?

- a. Pelvic inflammatory disease
- b. Pyelonephritis
- c. Appendicitis
- d. Ectopic pregnancy
- e. Ruptured corpus luteum cyst

**4-10.** A 21-year-old man presents with a sore throat. He also complains of dysphagia, odynophagia, and otalgia. His temperature is 102.5°F. The patient speaks with a "hot potato" voice and is drooling. Examination of the throat reveals a hypertrophied right tonsil that appears to be displaced inferiorly and medially. There is contralateral deflection of the uvula. The patient has trismus and cervical lymphadenopathy. Which of the following is the most likely diagnosis?

- a. Retropharyngeal abscess
- b. Peritonsillar abscess
- c. Exudative pharyngitis
- d. Cancer of the right tonsil
- e. Mononucleosis

**4-11.** A 62-year-old black man presents with hypertension, a decreased urine stream, and low back pain. Physical examination shows a hard, nodular left prostatic lobe and percussion tenderness in the lumbar vertebral bodies and left seventh rib. The next step in evaluation is

- a. Bone scan
- b. Biopsy of prostate
- c. CT scan
- d. Bone marrow biopsy

**4-12.** A 40-year-old woman is found to have a 1- to 2-cm, slightly tender cystic mass in her breast; she has no perceptible axillary adenopathy. What course would you follow?

- a. Reassurance and reexamination in the immediate postmenstrual period
- b. Immediate excisional biopsy
- c. Aspiration of the mass with cytologic analysis
- d. Fluoroscopically guided needle localization biopsy
- e. Mammography and reevaluation of options with new information

**4-13.** A 16-year-old student with a history of herpetic gingivostomatitis develops a generalized and symmetric rash. The lesions are 1–2 cm in diameter and look like round patches. They consist of two concentric rings surrounding a central disk. The rash is burning and pruritic. A few erosive lesions are visible in the oral mucosa. Which of the following is the most likely diagnosis?

- a. Erythema multiforme
- b. Secondary syphilis
- c. Systemic lupus erythematosus
- d. Pemphigus vulgaris
- e. Urticaria

**4-14.** A 5-year-old girl cuts her face on broken glass. Initially the injury appears superficial except for a small area of deeper penetration just above the right eyebrow. Within 4 days, the child complains of periorbital pain and double vision. The tissues about the eye are erythematous and the eye appears to bulge slightly. The optic disc is sharp and no afferent pupillary defect is apparent. Visual acuity in the affected eye is preserved. This child probably has

- a. Orbital cellulitis
- b. Cavernous sinus thrombosis
- c. Transverse sinus thrombosis
- d. Optic neuritis
- e. Diphtheritic polyneuropathy

#### Items 4-15 through 4-16

**4-15.** A 1-day-old infant who was born by a difficult forceps delivery is alert and active. She does not move her left arm, however, but keeps it internally rotated by her side with the forearm extended and pronated; she also does not move it during a Moro reflex. The rest of her physical examination is normal. This clinical picture most likely indicates

- a. Fracture of the left clavicle
- b. Fracture of the left humerus
- c. Left-sided Erb-Duchenne paralysis
- d. Left-sided Klumpke paralysis
- e. Spinal injury with left hemiparesis

**4-16.** The infant in the previous question immediately develops tachypnea with cyanosis. She improves somewhat on oxygen but has predominantly thoracic breathing movements, and the chest x-ray, which appears to have been taken inadvertently at expiration, seems normal. The procedure most likely to provide a specific etiologic diagnosis is

- a. Venous blood gas
- b. CT scan of the head
- c. Ultrasound or fluoroscopy of the chest
- d. Bronchoalveolar lavage
- e. Blood culture

**4-17.** A 30-year-old woman complains of fatigue, constipation, and weight gain. There is no prior history of neck surgery or radiation. The patient's voice is hoarse and her skin is dry. Serum TSH is elevated and  $T_4$  is low. The most likely cause of these findings is

- a. Autoimmune disease
- b. Postablative hypothyroidism
- c. Pituitary hypofunction
- d. Thyroid carcinoma

**4-18.** A 42-year-old man with no history of use of nonsteroidal anti-inflammatory drugs (NSAIDs) presents with recurrent gastritis. Infection with *Helicobacter pylori* is suspected. Which of the following statements is true?

- a. Morphologically, the bacteria is a gram-positive, tennis-racket-shaped organism
- b. Diagnosis can be made by serologic testing or urea breath tests
- c. Diagnosis is most routinely achieved via culturing endoscopic scrapings
- d. The most effective way to treat and prevent recurrence of this patient's gastritis is through the use of single-drug therapy aimed at eradicating *H. pylori*
- e. The organism is easily eradicated

**4-19.** A 23-year-old woman presents to your office for a prenatal visit. She has not received any previous prenatal care and does not know the date of her last menstrual period. On physical examination, the fundal height is palpated to be at the level of the umbilicus. Which of the following is the estimated number of weeks of gestation?

- a. 10 wk
- b. 15 wk
- c. 20 wk
- d. 25 wk
- e. 30 wk

**4-20.** A 19-year-old college student presents to the university student health center complaining of severe coughing spells for the last 4 days, following initial symptoms of coryza and malaise. She is afebrile. Her medical history is uneventful, and immunizations are up to date. She is a member of the basketball team. During weekends, she babysits a 10-month-old and a 2-year-old. In terms of management of contacts, which etiological agent is the most important to include in the differential diagnosis?

- a. *Streptococcus pneumoniae*
- b. *Mycoplasma pneumoniae*
- c. *Bordetella pertussis*
- d. Influenza virus
- e. *Legionella pneumophila*

**4-21.** A 61-year-old man develops progressive cramping of his legs and pins and needles sensations in his feet over the course of a year. He consulted a physician when he noticed the paresthesias in his hands and unsteadiness of his gait. The patient's family reports that he has had some urinary incontinence, but was too embarrassed to report it. On examination, the patient has a spastic paraparesis with severe disturbance of position and vibration sense in his legs. Despite obvious spasticity in the legs, the deep tendon reflexes are absent at the knees and ankles. Peripheral blood smear reveals hypersegmented polymorphonuclear leukocytes. Select the nutritional deficiency that is most likely responsible.

- a. Deficiency amblyopia
- b. Vitamin B<sub>12</sub> deficiency
- c. Pyridoxine (vitamin B<sub>6</sub>) deficiency
- d. Vitamin E ( $\alpha$  tocopherol) deficiency
- e. Vitamin D deficiency
- f. Thiamine (vitamin B<sub>1</sub>) deficiency
- g. Nicotinic acid deficiency
- h. Kwashiorkor
- i. Vitamin C deficiency

**4-22.** Two weeks after hospital discharge for documented myocardial infarction, 65-year-old Mr. Chang returns to your office very concerned about low-grade fever and pleuritic chest pain. There is no associated shortness of breath. Lungs are clear to auscultation and heart exam is free of significant murmurs, gallops, or rubs. ECG is unchanged from the last ECG in the hospital. The most effective therapy is likely

- a. Antibiotics
- b. Anticoagulation with warfarin (Coumadin)
- c. An anti-inflammatory agent
- d. An increase in antianginal medication
- e. An antianxiety agent

**4-23.** An adolescent presents to the emergency room with his distraught parents. His neck is bent to one side, his eyes are rolled upward, and his tongue is hanging out of his mouth. These symptoms disappear after he is given 50 mg of Benadryl intravenously. When he is able to talk, the boy admits that, earlier that evening, he had taken “a few pills” at a party. Which of the following is most likely to cause these symptoms?

- a. Methamphetamine
- b. Demerol
- c. Alprazolam
- d. Methylphenidate
- e. Haloperidol

**4-24.** A 28-year-old patient, GoPoAo, comes for her first prenatal visit at 6 wk of pregnancy. Her examination is normal for gestational age. Her history reveals that she does not smoke. She drinks one glass of wine about 2 days a week. She has been married for 3 years and her husband is her only sexual partner. She is employed as a paralegal. Her family history is negative. She is very concerned about preserving the mental and physical health of her baby. Which of the following interventions is most likely to reduce the risk of neurological defect in the infant?

- a. Eliminating alcohol use
- b. Folic acid supplements
- c. Ultrasound
- d. Amniocentesis
- e.  $\alpha$  fetoprotein testing

**4-25.** On a routine well-child examination, a 1-year-old boy is noted to be pale. He is in the 75th percentile for weight and the 25th percentile for length. Results of physical examination are otherwise normal. Having performed a complete history and physical examination on the patient, you proceed with a diagnostic workup. Initial laboratory results are as follows:

Hemoglobin: 8 g/dL

Hematocrit: 24%

Leukocyte count: 11,000/ $\mu$ L with 38% neutrophils, 7% bands, 55% lymphocytes

Hypochromia on smear

Free erythrocyte protoporphyrin (FEP): 110  $\mu$ g/dL

Lead level: 7  $\mu$ g/dL, whole blood

Platelet count: adequate

Reticulocyte count: 0.5%

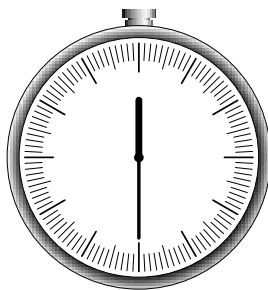
Sickle cell preparation: negative

Stool guaiac: negative

Mean corpuscular volume (MCV): 65 fL

You would most appropriately recommend

- a. Blood transfusion
- b. Oral ferrous sulfate
- c. Intramuscular iron dextran
- d. An iron-fortified cereal
- e. Calcium EDTA



***YOU SHOULD HAVE COMPLETED APPROXIMATELY  
25 QUESTIONS AND HAVE 30 MINUTES REMAINING.***

---



**4-26.** A 60-year-old man with a history of appendectomy 30 years ago presents to the emergency room complaining of abdominal pain. He describes the pain as colicky and crampy and feels it builds up and then improves on its own. He has vomited at least 10 times since the pain started this morning. He states that he has not had a bowel movement for 2 days and cannot recall the last time he passed flatus. The abdomen is slightly distended. Abdominal auscultation reveals high-pitched bowel sounds and peristaltic rushes. Percussion reveals a tympanic abdomen. The patient is diffusely tender on palpation but has no rebound tenderness. Rectal examination reveals the absence of stool. Which of the following is the most likely diagnosis?

- a. Cholecystitis
- b. Diverticulitis
- c. Pancreatitis
- d. Gastroenteritis
- e. Intestinal obstruction

**Items 4-27 through 4-28**

A 35-year-old G3,P3 patient with a Pap smear showing high-grade squamous intraepithelial lesion of the cervix (CIN III) has an inadequate colposcopy. Cone biopsy shows squamous cell cancer that has invaded only 1 mm beyond the basement membrane. There are no confluent tongues of tumor, and there is no evidence of lymphatic or vascular invasion. The margins of the cone biopsy specimen are free of disease.

**4-27.** The disease is staged as

- a. Carcinoma of low malignant potential
- b. Microinvasive cancer
- c. Atypical squamous cells of undetermined significance
- d. Carcinoma in situ
- e. Invasive cancer, stage IA

**4-28.** Of the following, appropriate therapy of this lesion is

- a. External beam radiation therapy
- b. Radioactive cesium implantation
- c. Simple hysterectomy
- d. Simple hysterectomy with pelvic lymphadenectomy
- e. Radical hysterectomy

**4-29.** You are called to evaluate a 57-year-old man with pressurelike chest pain that occurred while he was shoveling snow. The pain radiates to the jaw and the medial aspect of the left arm. The patient denies dizziness, nausea, vomiting, or palpitations. He has a past medical history of hypertension and he smokes 2 packs of cigarettes per day. The patient's brother had a myocardial infarction that required balloon angioplasty when he was in his forties. The patient has recently been told to modify his diet because of recently discovered high glucose and cholesterol levels. On physical examination the patient appears pale and diaphoretic. Blood pressure is 160/100 mm Hg and pulse is 108 beats/min. His extremities are cool. Heart examination reveals an S<sub>4</sub> gallop. Lungs are normal. Peripheral pulses are palpable and bilaterally equal. There is no peripheral edema. Which of the following is the most likely diagnosis?

- a. Right ventricular infarction
- b. Cardiogenic shock
- c. Acute myocardial infarction
- d. Congestive heart failure (CHF)
- e. Prinzmetal's angina

**4-30.** A 47-year-old woman presents to your office complaining of bone pain. She has a past medical history significant for peptic ulcer disease and pancreatitis. Routine laboratory studies reveal a serum calcium of 12.0 mg/dL (normal is <10.5 mg/dL) and hypophosphatemia. Which of the following is the most likely diagnosis?

- a. Underlying malignancy
- b. Vitamin D intoxication
- c. Familial hypocalciuric hypercalcemia
- d. Osteitis fibrosa cystica
- e. Primary hyperparathyroidism

**4-31.** A 40-year-old woman undergoes wide excision of a pigmented lesion of her thigh. Pathologic examination reveals malignant melanoma that is Clark's level IV. Findings on examination of the groin are normal. The patient should be advised that

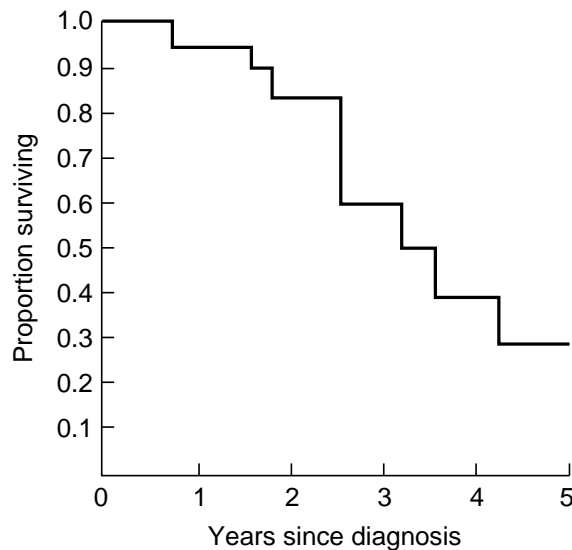
- a. Radiotherapy will be an important part of subsequent therapy
- b. The likelihood of groin node metastases is remote
- c. Immunotherapy is an effective form of adjunctive treatment for metastatic malignant melanoma
- d. Groin dissection is not indicated unless and until groin nodes become palpable
- e. Intralesional bacille Calmette-Guérin (BCG) administration has been found to aid in local control in the majority of patients

**4-32.** During a regular checkup on an 8-year-old child, you note a loud first heart sound with a fixed and widely split second heart sound at the upper left sternal border that does not change with respirations. The patient is otherwise active and healthy. The mostly likely heart lesion to explain these findings is

- a. Atrial septal defect
- b. Ventricular septal defect
- c. Isolated tricuspid regurgitation
- d. Tetralogy of Fallot
- e. Mitral valve prolapse

**4-33.** Consider the following survival curve for women diagnosed with disease XYZ. This curve suggests that the 5-year survival rate is

- a. 10%
- b. 20%
- c. 30%
- d. 40%
- e. 50%



Reprinted, with permission, from Ratelle S: *Preventive Medicine and Public Health: PreTest Self-Assessment and Review*, 9th ed. New York, McGraw-Hill, 2001.

**Items 4-34 through 4-37**

A 35-year-old man complains of stumbling and slurred speech. His problem started several months earlier and has progressed slowly but consistently. On neurologic examination he is found to have scanning speech, nystagmus, limb dysmetria, and kinetic tremor. His intellectual function is normal.

**4-34.** The most appropriate investigation to request initially is

- a. Lumbar puncture
- b. Serum drug screen
- c. Routine urinalysis
- d. Posterior fossa myelogram
- e. Precontrast CT scan

**4-35.** Admission studies include a hematocrit of 55% and a routine urinalysis, which reveals excess protein and some red blood cells in the urine. Urine culture is negative. The initial physical examination reveals an enlarged liver and spleen. Additional physical findings will most likely include

- a. A Kayser-Fleischer ring around the cornea
- b. Hypopigmented (ash leaf) spots on the patient's trunk
- c. Telangiectasias in the fundi on retinal examination
- d. Bilateral hearing loss
- e. Generalized hyporeflexia

**4-36.** A postcontrast CT scan reveals a cyst and two smaller masses in the left cerebellar hemisphere. Your recommendation is that the patient

- a. Submit to surgical resection of the cerebellar lesions as soon as possible
- b. Submit to radiation therapy of the cerebellar lesions immediately
- c. Have follow-up magnetic resonance imaging (MRI) to look for involution of the lesions
- d. Have a diagnostic lumbar puncture to look for evidence of parasitic infestation of the brain
- e. Have a needle biopsy of the cerebellum to establish the histology of the cystic lesion

**4-37.** Within 6 years of the patient's initial visit, he returns with a pathologic fracture of his spine. Biopsy reveals metastatic cancer. The source of the tumor is most likely the

- a. Cerebral hemisphere
- b. Cerebellar hemisphere
- c. Liver
- d. Kidney
- e. Spleen

**4-38.** A 48-year-old man presents with peripheral edema. He has been healthy and physically active all of his life. His family history is unremarkable. His blood pressure is normal. On physical examination, the patient is noted to have anasarca. Kidneys are not palpable. Urinalysis reveals a moderate amount of proteinuria and “grape clusters” are seen under light microscopy. Which of the following is the most likely diagnosis?

- a. Glomerulonephritis
- b. Rhabdomyolysis
- c. Nephrotic syndrome
- d. Acute interstitial nephritis
- e. Acute tubular necrosis

**4-39.** Your 39-year-old patient is contemplating discontinuing birth control pills in order to conceive. She is concerned about her fertility at this age, and inquires about when she should anticipate resumption of normal menses. You counsel her that by 3 mo after discontinuation of birth control pills, the following proportion of patients will resume normal menses

- a. 99%
- b. 95%
- c. 80%
- d. 50%
- e. 5%

**4-40.** A 55-year-old woman without a previous psychiatric history becomes depressed, withdrawn, and despondent. One month later the patient is diagnosed with cancer. Which type of carcinoma is most likely manifest with depressive symptoms?

- a. Prostatic
- b. Renal
- c. Gastric
- d. Pancreatic
- e. Ovarian

#### Items 4-41 through 4-43

A 34-year-old woman is brought in from a sporting event complaining of headache, nausea, and weakness. She was jogging outside in sunny weather where the temperature was 90°F with a relative humidity of 70%. She started a training program 2 wk ago. She is hyperventilating, her skin is moist, and her core body temperature is 38.8°C.

**4-41.** The patient most likely suffers from

- a. Sunstroke
- b. Heat cramps
- c. Heat exhaustion
- d. Heat stroke
- e. Heat syncope

**4-42.** The most appropriate cooling measure for this patient is

- a. Immersion in an ice water bath
- b. Iced gastric lavage
- c. Ice packs to the groin, axilla, and neck
- d. Evaporative cooling
- e. A cool and shaded environment

**4-43.** In addition to proper hydration, rest, and attention to heat index guidelines, the patient should be advised to avoid reexposure to heat for at least

- a. 1 day
- b. 1 wk
- c. 2 wk
- d. 3 wk
- e. 4 wk

**4-44.** A 28-year-old nulligravid patient complains of bleeding between her periods and increasingly heavy menses. Over the past 9 mo she has had two dilation and curettages (D&Cs), which have failed to resolve her symptoms, and oral contraceptives and antiprostaglandins have not decreased the abnormal bleeding. Of the following options, which is most appropriate at his time?

- a. Performing a hysterectomy
- b. Performing a hysteroscopy
- c. Performing an endometrial ablation
- d. Treating with a GnRH agonist
- e. Starting the patient on a high-dose progestational agent

**4-45.** A 46-year-old woman complains of headache, sweating, and diaphoresis that occurs on a daily basis or sometimes twice a day while she is at work. She has gone to the company nurse during these episodes and was told that her blood pressure was elevated. Aside from that, the nurse could not find any other problem. Physical examination is normal, including blood pressure, which is 130/80 mm Hg. Which of the following is the most likely diagnosis?

- a. Carcinoid syndrome
- b. Thyroid storm
- c. Pheochromocytoma
- d. Syndrome X
- e. CHAOS

**4-46.** A 25-year-old man presents with morning back pain and stiffness and tenderness over the sacroiliac joints. The patient denies any previous history of eye or genitourinary problems. On physical examination, there is diminished chest expansion with breathing. Which of the following is the most likely diagnosis?

- a. Rheumatoid arthritis
- b. Ankylosing spondylitis
- c. Sjögren syndrome
- d. Systemic lupus erythematosus
- e. Reiter syndrome

**4-47.** A 65-year-old woman with a history of prolonged alcohol abuse cheerfully greets the resident doctor of her nursing home, whom she has met many times before, and calls him “My dear friend Jack.” The physician explains who he is and tells the patient his name. Two minutes later, when he asks the patient if she knows who he is, she answers with a smile: “Of course, you are my cousin Anthony from New Jersey.” Deficiency of which vitamin can cause this particular form of alcohol-induced amnesic disorder?

- a. Panthotenic acid
- b. Folate
- c. Thiamin
- d. Riboflavin
- e. Niacin

**4-48.** A 34-year-old investment banker complains of intermittent episodes of vertigo associated with a feeling of fullness in his right ear. These last for several hours. He has had progressive hearing loss in the right ear. There are no other symptoms. He takes no medications and has no history of head trauma. This man probably has

- a. Ménière’s disease
- b. Cholesteatoma
- c. Vestibular schwannoma
- d. Benign positional vertigo
- e. Aminoglycoside toxicity

**4-49.** At 43 wk of gestation, a long, thin infant is delivered who is apneic, limp, pale, and covered with “pea soup” amniotic fluid. The first step in the resuscitation of this infant at delivery should be

- a. Suction of the trachea under direct vision
- b. Artificial ventilation with bag and mask
- c. Artificial ventilation with endotracheal tube
- d. Administration of 100% oxygen by mask
- e. Catheterization of the umbilical vein


**4-50.** A 50-year-old black man with a history of alcohol and tobacco abuse has complained of difficulty swallowing solid food for the past 2 mo. More recently, swallowing fluids has also become a problem. The patient has noted black, tarry stools on occasion and has lost 10 lb. Which of the following statements is correct?

- a. The patient’s prognosis is good
- b. Barium contrast study is indicated
- c. The most likely tumor is an adenocarcinoma
- d. The patient has achalasia

*This page intentionally left blank.*



# ***BLOCK 5***



***YOU HAVE 60 MINUTES  
TO COMPLETE 50 QUESTIONS.***

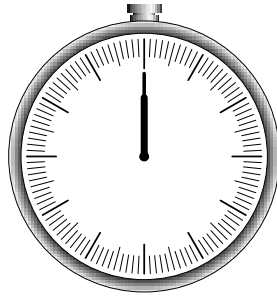
---

Terms of Use

*This page intentionally left blank.*

# BLOCK 5

---



**YOU HAVE 60 MINUTES  
TO COMPLETE 50 QUESTIONS.**

---

## Questions

**5-1.** A 64-year-old man afflicted with severe emphysema, who receives oxygen therapy at home, is admitted to the hospital because of upper gastrointestinal bleeding. The bleeding ceases soon after admission, and the patient becomes agitated and then disoriented; he is given 5 mg intramuscular diazepam (Valium). Twenty minutes later he is unresponsive. Physical examination reveals a stuporous but arousable man who has papilledema and asterixis. Arterial blood gases are pH, 7.17;  $P_{O_2}$ , 42 kPa;  $P_{CO_2}$ , 95 kPa. The best immediate therapy is to

- a. Correct hypoxemia with high-flow nasal oxygen
- b. Correct acidosis with sodium bicarbonate
- c. Administer 10 mg intravenous dexamethasone
- d. Intubate the patient
- e. Call for neurosurgical consultation

**5-2.** A 75-year-old man with angina has been increasingly moody and irritable for 5 wk. He has lost interest in sex and his favorite leisure activities and nothing seems to cheer him up. He has difficulty falling asleep at night and his appetite is decreased, although he has not lost any weight. His heart medications have not been changed for the past year. There have been no changes or stressful events in his life during the past 6 mo. What is the most likely diagnosis?

- a. Depression secondary to medication side effects
- b. Adjustment disorder
- c. Atypical depression
- d. Major depression
- e. Double depression

**5-3.** A teenage boy falls from his bicycle and is run over by a truck. On arrival in the emergency room, he is awake and alert and appears frightened but in no distress. The chest radiograph suggests an air-fluid level in the left lower lung field and the nasogastric tube seems to coil upward into the left chest. The best next step in management is

- a. Placement of a left chest tube
- b. Immediate thoracotomy
- c. Immediate celiotomy
- d. Esophagogastroscopy
- e. Removal and replacement of the nasogastric tube; diagnostic peritoneal lavage

**5-4.** A 62-year-old woman complains of limb discomfort and trouble getting off the toilet. She is unable to climb stairs and has noticed a rash on her face about her eyes. On examination she is found to have weakness about the hip and shoulder girdle. Not only does she have a purplish-red discoloration of the skin about the eyes, but she also has erythematous discoloration over the finger joints and purplish nodules over the elbows and knees. Which of the following is the most probable diagnosis?

- a. Systemic lupus erythematosus
- b. Psoriasis
- c. Myasthenia gravis
- d. Dermatomyositis
- e. Rheumatoid arthritis

**5-5.** One of your patients, a 30-year-old developer, tells you he is planning a trip to the Dominican Republic the following month. He will need to travel in rural areas. Which is the most appropriate intervention for malaria prophylaxis for this patient?

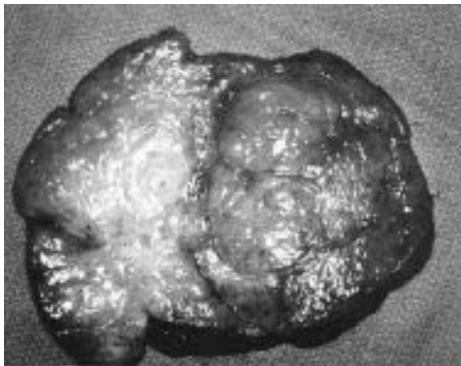
- a. No prophylaxis
- b. Chloroquine
- c. Mefloquine
- d. Doxycycline
- e. Primaquine

**5-6.** A 60-year-old woman with a history of urinary tract infection, steroid-dependent chronic obstructive lung disease, and asthma presents with bilateral infiltrates and an eosinophil count of 15%. The least likely diagnosis is

- Bronchopulmonary aspergillosis
- Hypersensitivity pneumonitis
- Strongyloides hyperinfection syndrome
- Drug effect of nitrofurantoin

**5-7.** A 14-year-old black girl has her right breast removed because of a large mass. The tumor weighs 1400 g and is found to have a bulging, very firm, lobulated surface with a whorl-like pattern, as illustrated below. This neoplasm is most likely

- Cystosarcoma phylloides
- Intraductal carcinoma
- Malignant lymphoma
- Fibroadenoma
- Juvenile hypertrophy



Reprinted, with permission, from Geller PL: *Surgery: PreTest Self-Assessment and Review*, 9th ed. New York, McGraw-Hill, 2001.

**5-8.** A 60-year-old woman complains of dry mouth and a gritty sensation in her eyes. She sometimes finds it difficult to speak for more than a few minutes. There is no history of diabetes mellitus and no history of neurologic disease. The patient is on no medications. On exam the buccal mucosa appears dry and the salivary glands are enlarged bilaterally. The next step in evaluation is

- Lip biopsy
- Schirmer test and measurement of autoantibodies
- IgG antibody to mumps virus
- Use of corticosteroids

**5-9.** You are advised by the obstetrician that the mother of a baby he has delivered is a carrier of hepatitis B surface antigen (HBsAg). The most appropriate action in managing this infant is to

- Screen the infant for HBsAg
- Isolate the infant for enteric transmission
- Screen the mother for hepatitis B e antigen (HBeAg)
- Administer hepatitis B immune globulin and hepatitis B vaccine
- Do nothing, because transplacentally acquired antibodies will prevent infection

**5-10.** A 15-year-old girl presents to your office because she has been having vaginal discharge. In the course of the history, she informs you that she is sexually active with her boyfriend, who is also 15 years of age. The examination reveals mucopurulent cervicitis, but no lower abdominal, cervical motion, or adnexal tenderness. The most appropriate intervention is to

- a. Notify the department of social services
- b. Obtain parental consent for treatment
- c. Provide counseling, testing, and treatment for STDs
- d. Refer the patient to a family planning clinic
- e. Notify the department of public health

**5-11.** A spry octogenarian who has never before been hospitalized is admitted with signs and symptoms typical of a small bowel obstruction. Which of the following clinical findings would most help in ascertaining the diagnosis?

- a. Coffee-grounds aspirate from the stomach
- b. Aerobilia
- c. Leukocyte count of 40,000/ $\mu$ L
- d. pH 7.5,  $P_{CO_2}$  50 kPa, and paradoxically acid urine
- e. Palpable mass in the pelvis

**5-12.** A 49-year-old man with multiple myeloma presents with glucosuria, hypophosphatemia, hypokalemia, hypouricemia, aminoaciduria, and proteinuria. Further analysis of the electrolytes reveals that the patient has a metabolic acidosis. The urine pH is <5.5. Which of the following is the most likely diagnosis?

- a. Fanconi syndrome
- b. Type 1 renal tubular acidosis
- c. Distal renal tubular acidosis
- d. Type 4 renal tubular acidosis
- e. Kimmelstiel-Wilson disease

**5-13.** A 45-year-old morbidly obese patient undergoes abdominal hysterectomy for leiomyomas and menorrhagia. On the third postoperative day, you become concerned that the incision is not healing. Copious serosanguineous drainage is noted from the incision. The most likely diagnosis is

- a. Hematoma
- b. Dehiscence
- c. Evisceration
- d. Seroma
- e. Wound infection

**5-14.** A mother delivers a neonate with meconium staining and Apgar scores of 3 at 1 and 5 min of life. The mother has had no prenatal care and the delivery is by emergency cesarean section for severe fetal bradycardia. Which of the following sequelae could be expected to develop in this intubated neonate with respiratory distress?

- a. Sustained rise in systemic blood pressure
- b. Hyperactive bowel sounds
- c. Microcephaly
- d. Cataracts
- e. Thrombocytosis

**5-15.** A 10-year-old boy is admitted to the hospital because of bleeding. Pertinent laboratory findings include:

Platelet count: 50,000/ $\mu$ L

Prothrombin time (PT): 15 s (control: 11.5 s)

Activated partial thromboplastin time (APTT): 51 s (control: 36 s)

Thrombin time (TT): 13.7 s (control: 10.5 s)

Factor VIII level: 14% (normal: 38% to 178%)

The most likely cause of the bleeding is

- a. Immune thrombocytopenic purpura (ITP)
- b. Vitamin K deficiency
- c. Disseminated intravascular coagulation (DIC)
- d. Hemophilia A
- e. Hemophilia B

**5-16.** An 18-year-old patient consults you for evaluation of disabling pain with her menstrual periods, which has been present since menarche. The pain is accompanied by nausea and headache. History is otherwise unremarkable, and pelvic examination is normal. You diagnose primary dysmenorrhea and recommend initial treatment with which of the following?

- a. Ergot derivatives
- b. Antiprostaglandins
- c. GnRH analogs
- d. Danazol
- e. Codeine

**5-17.** A 92-year-old woman with Type II diabetes mellitus has developed cellulitis and gangrene of her left foot. She requires a life-saving amputation but refuses to give consent for the surgery. She has been ambulatory in her nursing home but states that she would be so dependent after surgery that life would not be worth living for her. She has no living relatives; she enjoys walks and gardening. She is competent and of clear mind. You would

- a. Perform emergency surgery
- b. Consult a psychiatrist
- c. Request permission for surgery from a friend of the patient
- d. Follow the patient's wishes

**5-18.** A 32-year-old woman presents with the recent onset of petechiae of her lower extremities. She denies menorrhagia and gastrointestinal bleeding. She has no family history of a bleeding disorder and has been in excellent health her entire life. Physical examination is remarkable for petechiae of both legs. There is no hepatosplenomegaly. The rest of the physical examination is normal. Her platelet count is 8000/ $\mu$ L. Hemoglobin and white blood cell count are normal. Peripheral smear reveals reduced platelets and an occasional megathrombocyte. Which of the following is the most likely diagnosis?

- a. Thrombocytopenic thrombotic purpura (TTP)
- b. Hemolytic-uremic syndrome (HUS)
- c. Evans syndrome
- d. Disseminated intravascular coagulation (DIC)
- e. Idiopathic thrombocytopenic purpura (ITP)
- f. Henoch-Schönlein purpura (HSP)



**Items 5-19 through 5-20**

A 24-year-old woman presents with lethargy, anorexia, tachypnea, and weakness. Laboratory studies reveal a BUN of 150 mg/dL, serum creatinine of 16 mg/dL, and potassium of 6.2 meq/L. Chest x-ray shows increased pulmonary vascularity and a dilated heart.

**5-19.** Management of this patient includes

- a. Emergency kidney transplantation
- b. Creation and immediate use of a forearm arteriovenous fistula
- c. Sodium polystyrene sulfonate (Kayexalate) enemas
- d. A 100-g protein diet
- e. Cardiac biopsy via femoral vein catheterization

**5-20.** In the course of 3 mo of treatment, the patient's congestive heart failure resolves, her lethargy and weakness diminish markedly, and she is able to return to work part time. Family immune profile studies reveal that her mother and father are haplotype identical with regard to HLAs and that her sister is a six-antigen match. At this time, the patient should be urged to

- a. Continue hemodialysis three times a week
- b. Undergo cadaveric renal transplantation
- c. Accept a kidney transplant from her sister
- d. Accept a kidney transplant from her father
- e. Accept a kidney transplant from her mother

**5-21.** A 31-year-old man presents to the emergency room 3 days after undergoing a hernia repair operation. He is febrile and hypotensive. The symptoms began with the sudden onset of a diffuse maculopapular rash that was pruritic and erythematous. On cutaneous examination, the erythroderma involves the palms and soles and is beginning to desquamate. The patient has no other illnesses and takes no medications. Which of the following is the most likely diagnosis?

- a. Toxic epidermal necrolysis
- b. Toxic shock syndrome
- c. Necrotizing fasciitis
- d. Scarlet fever
- e. Cellulitis

**5-22.** A 74-year-old man presents with the abrupt onset of pain in the left lower abdomen. The pain has been progressively worsening over the last 2 days. The patient states that the pain is unremitting. He has some diarrhea but no nausea or vomiting. He has no dysuria or hematuria. His temperature is 102°F. Bowel sounds are decreased. The patient exhibits involuntary guarding. There is tenderness and rebound tenderness when the left lower quadrant is palpated. The referred rebound test is positive. A fixed sausage-like mass is palpable in the area of tenderness. There is no CVA tenderness. Rectal examination reveals brown stool, which is FOBT positive. Bloodwork demonstrates a leukocytosis. Which of the following is the most likely diagnosis?

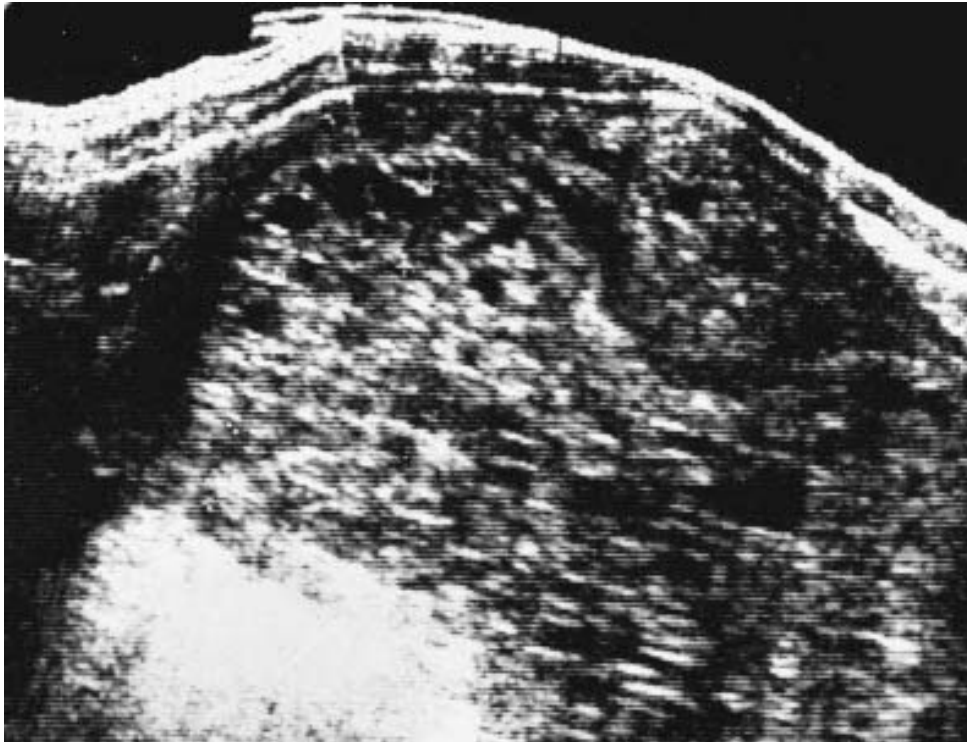
- a. Colon cancer
- b. Diverticulitis
- c. Pancreatitis
- d. Pyelonephritis
- e. Appendicitis

**Items 5-23 through 5-24.**

A 19-year-old primigravid woman is expecting her first child; she is 12 wk pregnant by dates. She has vaginal bleeding and an enlarged-for-dates uterus. In addition, no fetal heart sounds are heard. The ultrasound below is obtained.

**5-23.** The most likely diagnosis of this woman's condition is

- a. Sarcoma botryoides
- b. Tuberculous endometritis
- c. Adenocarcinoma of the uterus
- d. Hydatidiform mole
- e. Normal pregnancy



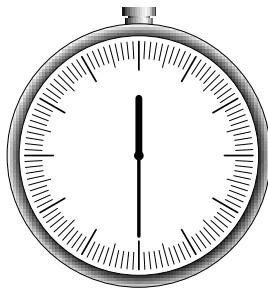
Reprinted, with permission, from Evans MD, Ginsburg KA: *Obstetrics and Gynecology: PreTest Self-Assessment and Review*, 9th ed. New York, McGraw-Hill, 2001.

**5-24.** After uterine evacuation, management of the woman described above, who has no clinical or radiographic evidence of metastatic disease, should include

- a. Weekly hCG titers
- b. Hysterectomy
- c. Single-agent chemotherapy
- d. Combination chemotherapy
- e. Radiation therapy

**5-25.** The medical evaluation of a 25-year-old intravenous drug user reveals elevated liver enzymes and a positive anti-HBsAg. The most likely cause of the abnormal liver profile is hepatitis

- a. A
- b. B
- c. C
- d. D
- e. E



***YOU SHOULD HAVE COMPLETED APPROXIMATELY  
25 QUESTIONS AND HAVE 30 MINUTES REMAINING.***

---

**5-26.** A young mother is involved in a car accident that claims the life of her two sons. When she is told that her two children have died from the injuries they suffered in the crash, she becomes agitated and combative. Her speech is disorganized and incoherent, but observers understand that she hears the voices of her children screaming to her to help them and that she believes that the hospital nurses are prison guards. These symptoms remit spontaneously in 1 wk. What is the most likely diagnosis?

- a. Delirium secondary to brain injury
- b. Schizophreniform disorder
- c. Major depression with psychotic features
- d. Brief psychotic disorder
- e. Posttraumatic stress disorder

**5-27.** On routine physical exam, a young woman is found to have a thyroid nodule. There is no pain, hoarseness, hemoptysis, or local symptoms. TSH is normal. The next step in evaluation is

- a. Ultrasonography
- b. Thyroid scan
- c. Surgical resection
- d. Fine-needle aspiration of the thyroid

**5-28.** A 7-year-old girl suddenly develops acute separation anxiety, oppositional behavior, nighttime fears, and a variety of compulsive behaviors (lining up her toys, ritualistic counting, excessive washing). Two weeks earlier the girl

- a. Was diagnosed with Group A  $\beta$ -hemolytic streptococcal pharyngitis
- b. Was scratched by the family cat
- c. Went camping in a tick-infested area
- d. Ate a poorly cooked pork sausage
- e. Suffered several mosquito bites

**5-29.** A 30-year-old woman with a history of diabetes mellitus presents with a 3-wk history of hand numbness that often awakens her from sleep. The symptoms resolve after she shakes her hands for a few minutes. On physical examination, there is no sensory or motor deficit of her hands, but the patient has a positive Tinel sign. Which of the following is the most likely diagnosis?

- a. Thoracic outlet syndrome
- b. Carpal tunnel syndrome
- c. Dupuytren's contracture
- d. Mallet finger
- e. Ganglion
- f. Trigger finger

**5-30.** A 7-year-old girl is seen by her pediatrician for left lower quadrant pain. You are consulted because an ovarian neoplasm is identified by ultrasound. Of the following, the most likely ovarian tumor in this patient is

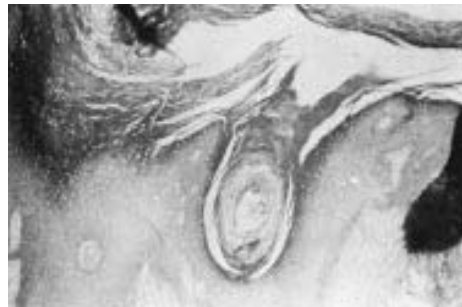- a. Germ cell
- b. Papillary serous epithelial
- c. Fibrosarcoma
- d. Brenner
- e. Sarcoma botryoides

**5-31.** A 19-year-old woman presents with severe right-sided flank pain accompanied by fever, shaking chills, dysuria, and frequency. She is sexually active with one partner and always uses condoms. Her last menstrual period was 5 days ago. On physical examination, her temperature is 103.8°F and her heart rate is 120 beats/min. Blood pressure and respirations are normal. Abdominal examination reveals suprapubic tenderness with palpation. The patient complains of pain when percussion is performed with the ulnar surface of the fist over the right costovertebral angle (CVA). Pelvic examination is normal. Which of the following is the most likely diagnosis?

- a. Diverticulitis
- b. Acute cystitis
- c. Renal calculi
- d. Pyelonephritis
- e. Appendicitis

**5-32.** Which of the following primary treatments is most appropriate for this patient with extensive vulvar lesions shown below?

- a. Application of podophyllum
- b. 5-Fluorouracil
- c. Morcellation
- d. Simple vulvectomy
- e. Local excision



Reprinted, with permission, from Evans MI, Ginsburg KA: *Obstetrics and Gynecology: PreTest Self-Assessment and Review*, 9th ed. New York, McGraw-Hill, 2001.

**5-33.** A 70-year-old intensive care unit patient complains of fever and shaking chills. The patient develops hypotension, and blood cultures are positive for gram-negative bacilli. The patient begins bleeding from venipuncture sites and around his Foley catheter.

HCT: 38%

WBC:  $1500 \times 10^3/\mu\text{L}$

Platelets:  $40,000/\mu\text{L}$  (normal: 130,000 to 400,000/ $\mu\text{L}$ )

Peripheral blood smear: fragmented RBCs

PT: elevated

PTT: elevated

Plasma fibrinogen: 70 mg/dL (normal: 200 to 400 mg/dL)

The best course of therapy in this patient is to

- a. Begin heparin
- b. Treat underlying disease
- c. Begin plasmapheresis
- d. Give vitamin K
- e. Begin red blood cell transfusion

**5-34.** A 59-year-old woman presents complaining of a cough productive of sputum for nearly 10 years. Her cough occurs during the day and she produces sputum daily. The woman states that as a child she had several episodes of pneumonia requiring hospital admissions and antibiotics. Several times a year, her sputum becomes purulent and she requires antibiotic therapy. She denies smoking cigarettes and has worked as a seamstress all of her life. On physical examination, the lungs are clear without wheezes, rhonchi, or crackles. A chest radiograph reveals “tram-track” markings at the bases. Which of the following is the most likely diagnosis?

- a. Asthma
- b. Cystic fibrosis
- c. Chronic bronchitis
- d. Emphysema
- e. Bronchiectasis

**5-35.** A 75-year-old man presents to the emergency room after a sudden syncopal episode. He is alert and in retrospect describes occasional substernal chest pressure and shortness of breath on exertion. His lungs have a few bibasilar rales and his blood pressure is 110/80. On cardiac auscultation, the classic finding you expect to hear is

- a. A harsh systolic crescendo-decrescendo murmur heard best at the upper right sternal border
- b. A diastolic decrescendo murmur heard at the mid-left sternal border
- c. A holosystolic murmur heard best at the apex
- d. A midsystolic click

**5-36.** A 23-year-old woman (gravida 2, para 2) calls her physician 7 days postpartum because she is concerned that she is still bleeding from the vagina. It would be appropriate to tell this woman that it is normal for bloody lochia to last up to

- a. 2 days
- b. 5 days
- c. 8 days
- d. 11 days
- e. 14 days

**5-37.** A 19-year-old woman with a lifelong history of easy bruisability presents with menorrhagia. She also admits to occasional nosebleeds. She has no family history of bleeding disorders and takes no medications. Physical examination is normal. Laboratory investigation reveals a normal platelet count but a prolonged bleeding time. Which of the following is the most likely diagnosis?

- a. Hemophilia A
- b. Hemophilia B
- c. Type III von Willebrand disease
- d. Type I von Willebrand disease
- e. Christmas disease
- f. Bernard-Soulier syndrome

**5-38.** A 10-mo-old infant has poor weight gain, a persistent cough, and a history of several bouts of pneumonitis. The mother describes the child as having had very large, foul-smelling stools for months. Which of the following diagnostic maneuvers is likely to result in the diagnosis of this child?

- a. CT of the chest
- b. Serum immunoglobulin test
- c. TB skin test
- d. Inspiratory and expiratory chest x-ray
- e. Sweat chloride test



**5-39.** A 42-year-old welder presents to his employee health service complaining of tearing eye pain and photophobia. A photokeratoconjunctivitis is diagnosed. The most likely cause of this condition is

- a. Infrared radiation
- b. Visible radiation
- c. Ultraviolet radiation A
- d. Magnetic radiation
- e. Ultraviolet radiation B

**Items 5-40 through 5-42**

A 73-year-old man with a history of hypertension complains of a 10-min episode of left-sided weakness and slurred speech. On further questioning, he relates three brief episodes in the last month of sudden impairment of vision affecting the right eye. His examination now is normal.

**5-40.** Which of the following is the most appropriate next diagnostic test?

- a. Creatine kinase (CK)
- b. Holter monitor
- c. Visual evoked responses
- d. Carotid artery Doppler ultrasound
- e. Conventional cerebral angiography

**5-41.** The episodes of visual loss are most likely related to

- a. Retinal vein thrombosis
- b. Central retinal artery ischemia
- c. Posterior cerebral artery ischemia
- d. Middle cerebral artery ischemia
- e. Posterior ciliary artery ischemia

**5-42.** A thorough evaluation reveals that there is a 90% stenosis of the right internal carotid artery at the bifurcation. The management option most likely to prevent a future stroke is which of the following?

- a. Warfarin
- b. Carotid artery angioplasty
- c. Carotid endarterectomy
- d. Extracranial-intracranial bypass
- e. Aspirin

**5-43.** A 56-year-old woman in the last stages of amyotrophic lateral sclerosis asks that her life support be stopped and that she be allowed to die. Her family members disagree with her decision and go to court to keep the patient alive. A psychiatric evaluation finds the patient mentally sound and fully able to understand the consequences of her decision. Referring to the Supreme Court's decision on the Cruzan v. Director case, the court decides that

- a. The family's desires overrule the patient's wishes
- b. Terminating one's life is illegal
- c. A legal guardian must be appointed to make decisions on behalf of the patient
- d. Since the patient's life expectancy is more than 2 wk, she cannot be allowed to die
- e. The patient is competent and as such she has the right to refuse unwanted medical treatment

**5-44.** A 37-year-old man presents to the emergency room after 3 days of feeling weak. He drinks alcohol daily but denies illicit drug use. He called the paramedics when he began to experience palpitations and lightheadedness with exertion. On physical examination, his blood pressure is 120/80 mm Hg and his pulse is irregularly irregular at a rate of 126 beats/min. Electrocardiogram in this patient would most likely demonstrate which of the following?

- a. Sinus tachycardia
- b. Premature ventricular contractions (PVCs)
- c. Atrial fibrillation (AF)
- d. Premature atrial contractions (PACs)
- e. Sinus arrhythmia

**5-45.** A 24-year-old woman, gravida 3, para 2, presents with the chief complaint of some lower abdominal pain accompanied by a small amount of vaginal bleeding. She is 16 wk pregnant and has been healthy throughout the pregnancy. She does not smoke cigarettes, drink alcohol, or use illicit drugs. Abdominal examination is normal. Pelvic examination reveals that the internal cervical os is closed. Which of the following is the most likely diagnosis?

- a. Complete abortion
- b. Incomplete abortion
- c. Threatened abortion
- d. Inevitable abortion
- e. Missed abortion

**5-46.** A 60-year-old man is involved in a head-on motor vehicle accident and sustains significant head trauma. He is awake and oriented to person, place, and time but complains of dizziness. Physical examination reveals normal vital signs, no orthostasis, and no neurologic findings. Heart and lung exams are normal. Overnight in the surgical intensive care unit, the patient develops excessive thirst, polydipsia, and polyuria. He displays orthostatic changes on physical examination. His serum sodium rises to 160 meq/L (normal  $\leq 145$  meq/L); his serum glucose is normal. Which of the following is the most likely diagnosis?

- a. Impaired glucose intolerance
- b. Nephrogenic diabetes insipidus
- c. Central diabetes insipidus
- d. SIADH
- e. Iatrogenic saline infusion

**5-47.** You are evaluating a 13-year-old girl with delayed puberty and short stature. hGH assay done on a fasting blood sample suggests hGH deficiency. You wish to schedule a provocative test of hGH release. Which of the following will stimulate hGH release?

- a. Lysine
- b. L-dopa
- c. Glucose
- d. Bed rest
- e. Gonadotropin-releasing hormone

#### Items 5-48 through 5-49

A 50-year-old man presents to a health center for routine care. His last visit was 5 years ago and he has no complaints. He has been smoking 1 pack of cigarettes a day since he was 15 years old. When counseled about his smoking, he says he has no intention to quit and feels fine. He drinks two alcoholic beverages per week. Records show that his blood cholesterol is 235 mg/dL, with a HDL level of 40 mg/dL and a LDL level of 140 mg/dL. The patient has no family history of coronary artery disease (CAD). His height is 5 ft, 10 in and he weighs 170 lbs. His blood pressure is 110/75 mm Hg.

**5-48.** What is the most appropriate approach to promote smoking cessation for this patient?

- a. Refer him to classes for smoking cessation and reassess progress in 2 wk
- b. Provide self-help materials and reassess in 3 mo
- c. Prescribe nicotine replacement therapy and reassess progress in 2 wk
- d. Set a quit date with the patient and reassess his situation 2 days after this date
- e. Give clear, personalized advice to quit and readdress the issue at the next visit


**5-49.** The patient's blood cholesterol test is repeated, and the results are the same. Which of the following is the most appropriate intervention for his lipid profile?

- a. Repeat blood cholesterol in 1 year; no therapy is indicated
- b. Recommend one alcoholic drink per day
- c. Recommend dietary therapy
- d. Recommend dietary and drug therapy
- e. Recommend dietary therapy; if ineffective, add drug therapy

**5-50.** A 50-year-old man presents with jaundice, right upper quadrant tenderness, spider angiomas, and ascites. He takes no medication but has been drinking alcohol heavily. Which of the following is most likely in this patient?

- a. Jugular venous distention on physical examination
- b. SGPT much higher than SGOT (AST)
- c. Mallory bodies on liver biopsy
- d. Rapid clinical recovery after abstinence

# ***BLOCK 6***



***YOU HAVE 60 MINUTES  
TO COMPLETE 50 QUESTIONS.***

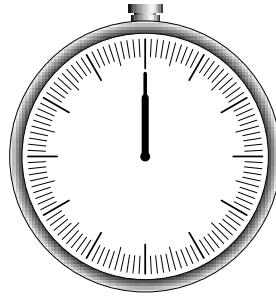
---

Terms of Use

*This page intentionally left blank.*

# BLOCK 6

---



**YOU HAVE 60 MINUTES  
TO COMPLETE 50 QUESTIONS.**

---

## Questions

**6-1.** A 2-wk-old female infant is noted to have a thin membrane adhering together the upper portion of labia minora. The most appropriate course of action for these labial adhesions is to

- a. Apply estrogen cream daily
- b. Refer for surgical repair
- c. Apply traction to the opposing labia until the adhesion breaks
- d. Evaluate the patient for congenital adrenal hyperplasia
- e. Do nothing as the lesions are of no consequence

**6-2.** A 6-year-old child presents with flesh-colored papules on the hand that are not pruritic. Examination reveals lesions that are approximately 4 mm in diameter with central umbilication. A halo is seen around those lesions undergoing regression. Which of the following is the most likely diagnosis?

- a. Verruca vulgaris
- b. Molluscum contagiosum
- c. Keratoacanthoma
- d. Herpetic whitlow
- e. Hemangioma

**6-3.** A 48-year-old woman develops pain in her right lower quadrant while playing tennis. The pain progresses and she presents to the emergency room (ER) later that day with a low-grade fever, a white blood count of 13,000, and complaints of anorexia and nausea as well as persistent, sharp pain of the right lower quadrant. On examination she is tender in the right lower quadrant with muscular spasm and there is a suggestion of a mass effect. An ultrasound is ordered and shows an apparent mass in the abdominal wall. Which of the following is the most likely diagnosis?

- a. Acute appendicitis
- b. Cecal carcinoma
- c. Hematoma of the rectus sheath
- d. Torsion of an ovarian cyst
- e. Cholecystitis

**6-4.** A 75-year-old man has complained of malaise and slowly progressive weight loss for the better part of 3 mo. Laboratory tests reveal a hematocrit of 32%, an erythrocyte sedimentation rate (ESR) of 97 mm/h, and a white blood cell count of 10,700/ $\mu$ L. Serum creatine kinase (CK) and thyroxine ( $T_4$ ) levels are normal. Which of the following is most likely the explanation for the patient's complaints?

- a. Polymyositis
- b. Dermatomyositis
- c. Polymyalgia rheumatica
- d. Rheumatoid arthritis
- e. Hyperthyroid myopathy

**6-5.** A 50-year-old man complains of low back pain and stiffness that becomes worse on bending and is relieved by lying down. There are no symptoms of fever, chills, weight loss, or urinary problems. The patient had similar pain several years ago. On exam there is paraspinal tenderness and spasm of the lower lumbar back. There are no sensory deficits, and reflexes are normal. The next step in management is

- a. Lumbosacral spine films
- b. Stretching exercises
- c. Weight training
- d. Bed rest with pain control
- e. MRI



**6-6.** A 62-year-old man who was diagnosed with schizophrenia in his early twenties is found wandering around his halfway house confused and disoriented. He is rushed to a local emergency room, where his serum sodium concentration is found to be 123 meq/L. His urine sodium concentration is 5 meq/L. The patient has been treated with risperidone 4 mg a day for the past 3 years with good symptoms control. His roommate reports that the patient makes many trips to the water cooler and often complains of being thirsty. What is the most likely cause of this patient's metabolic imbalance?

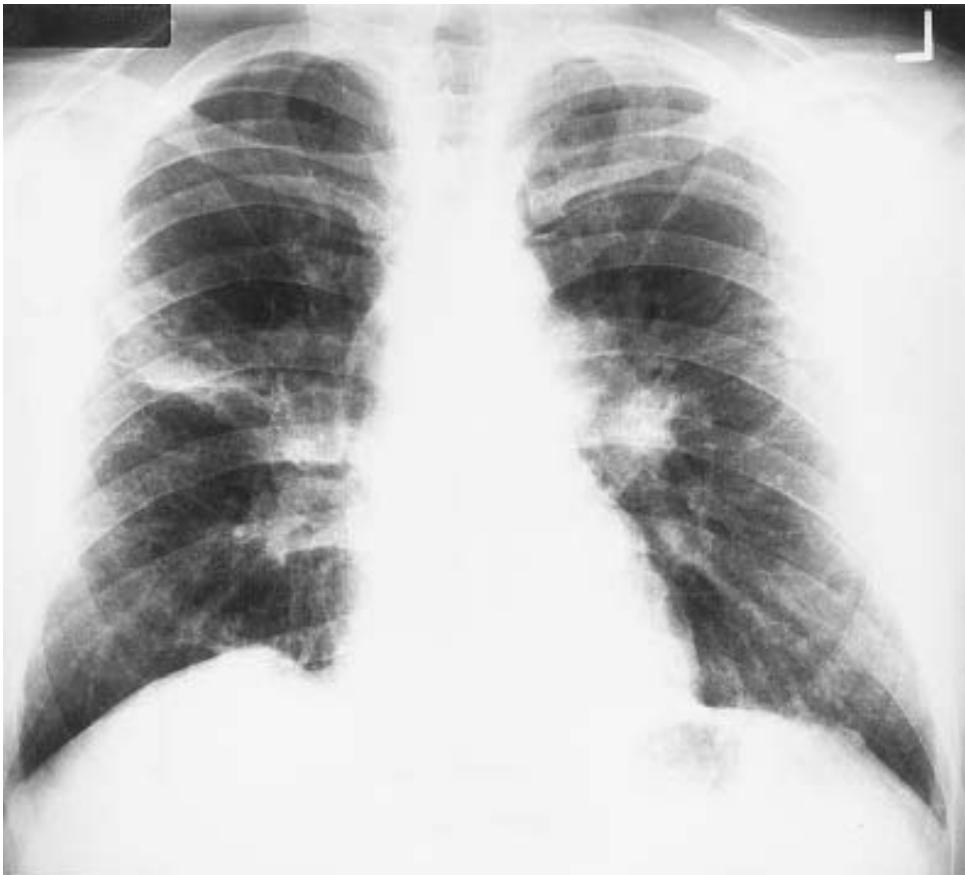- a. Renal failure
- b. Inappropriate ADH secretion
- c. Addison's disease
- d. Psychogenic polydipsia
- e. Nephrotic syndrome

**6-7.** A full-term infant is born after a normal pregnancy; delivery, however, is complicated by marginal placental separation. At 12 h of age the child, although appearing to be in good health, passes a bloody meconium stool. Which of the following diagnostic procedures should be performed first to determine the cause of the bleeding?

- a. A barium enema
- b. An Apt test
- c. Gastric lavage with normal saline
- d. An upper gastrointestinal (GI) series
- e. A platelet count, prothrombin time, and partial thromboplastin time

**6-8.** A 34-year-old black woman presents to your office with symptoms of cough, dyspnea, and lymphadenopathy. Physical exam shows cervical adenopathy and hepatomegaly. The patient's chest radiograph is shown in the illustration above. How would you pursue diagnosis?

- a. Open lung biopsy
- b. Liver biopsy
- c. Bronchoscopy and transbronchial lung biopsy
- d. Scalene-node biopsy
- e. Serum angiotensin converting enzyme (ACE) level



Reproduced, with permission, from Berk SL, Davis WR: *Medicine: PreTest Self-Assessment and Review*, 9th ed. New York, McGraw-Hill, 2001.

**Items 6-9 through 6-10**

A 53-year-old woman presents with complaints of weakness, anorexia, malaise, constipation, and back pain. While being evaluated, she becomes somewhat lethargic. Laboratory studies include a normal chest x-ray; serum albumin, 3.2 mg/dL; serum calcium, 14 mg/dL; serum phosphorus, 2.6 mg/dL; serum chloride, 108 mg/dL; BUN of 32 mg/dL; creatinine of 2.0 mg/dL.

**6-9.** Appropriate initial management includes

- Intravenous normal saline infusion
- Administration of thiazide diuretics
- Administration of intravenous phosphorus
- Use of mithramycin
- Neck exploration and parathyroidectomy

**6-10.** After appropriate immediate management, the patient's symptoms resolve. Diagnostic tests to perform at this point include which of the following?

- Abdominal angiogram
- Measurement of serum gastrin hormone levels
- Kveim test
- Serum and urine protein electrophoresis
- Neck exploration

**6-11.** The parents of an 8-year-old boy with a normal IQ are concerned because he is a very slow reader and does not appear to understand what he reads. When the boy reads aloud, he misses words and changes the sequence of the letters. Choose the correct statement about this disorder.

- It is diagnosed on the basis of a defect in visual or hearing acuity
- It is often associated with spelling and verbal language difficulties
- It occurs in less than 1% of the population
- It occurs more often in girls than boys
- It is often associated with brainstem neurologic defects

**6-12.** A 22-year-old man presents with a 6-mo history of a red, non-pruritic rash over his trunk, scalp, elbows, and knees. These eruptions are more likely to occur during stressful periods and have occurred at sites of skin injury. On exam, sharply demarcated plaques with a thick scale are seen. Which of the following statements is correct?

- Lesions are contagious, and contact should be carefully avoided
- The patient is allergic to metals
- The clinical description is most consistent with psoriasis
- The rash is unrelated to stress

**6-13.** The crude death rate in the United States is 150 per 100,000. The crude death rate in a smaller, developing country is 75 per 100,000. Based on these data, which one of the following statements best explains this data?

- a. The health care system of the developing country is far better than that of the United States
- b. More people die in the United States because it has a larger population
- c. Infant mortality in the first week is higher in developing countries, but it is not included in the crude death rate
- d. Death rates in the developing country are lower due to the emigration effect
- e. Crude death rates are usually higher in developed countries because of a higher proportion of older persons in the population

**Items 6-14 through 6-15**

A 68-year-old hypertensive man undergoes successful repair of a ruptured abdominal aortic aneurysm. He receives 9 L of Ringer's lactate solution and 4 units of whole blood during the operation. Two hours after the patient is transferred to the surgical intensive care unit, the following hemodynamic parameters are obtained:

Systemic blood pressure (BP): 90/60 mm Hg

Pulse rate: 110 beats/min

Central venous pressure (CVP): 7 mm Hg

Pulmonary artery pressure: 28/10 mm Hg

Pulmonary capillary wedge pressure (PCWP): 8 mm Hg

Cardiac output: 1.9 L/min

Systemic vascular resistance: 35 Woods units (normal: 24 to 30 Woods units)

Pa<sub>O<sub>2</sub></sub>: 140 kPa (FI<sub>O<sub>2</sub></sub>: 0.45 kPa)

Urine output: 15 mL/h (specific gravity: 1.029)

Hematocrit: 35%

**6-14.** Proper management now calls for

- Administration of a diuretic to increase urine output
- Administration of a vasopressor agent to increase systemic blood pressure
- Administration of a fluid challenge to increase urine output
- Administration of a vasodilating agent to decrease the elevated systemic vascular resistance
- A period of observation to obtain more data

**6-15.** The patient then has an improvement in all hemodynamic parameters. However, 6 h later he develops ST segment depression, and a 12-lead electrocardiogram shows anterolateral ischemia. New hemodynamic parameters are obtained:

Systemic BP: 70/40 mm Hg  
 Pulse rate: 100 beats/min  
 CVP: 18 cm H<sub>2</sub>O  
 PCWP: 25 mm Hg  
 Cardiac output: 1.5 L/min  
 Systemic vascular resistance: 25 Woods units

The single best pharmacologic intervention is

- Sublingual nitroglycerin
- Intravenous nitroglycerin
- A short-acting beta blocker
- Sodium nitroprusside
- Dobutamine

**6-16.** A 38-year-old HIV-infected woman presents for follow-up evaluation. She is on antiretroviral therapy. She has no complaints. Her physical examination is normal. Her PPD is reactive at 2 mm. Chest x-ray is normal. The patient has no history of past TB or recent known contact with infectious TB. She lives at home alone. Her CD4 + T cell count is 180/ $\mu$ L. Her previous count was 175/ $\mu$ L. Prophylaxis is most appropriate for which of the following infections?

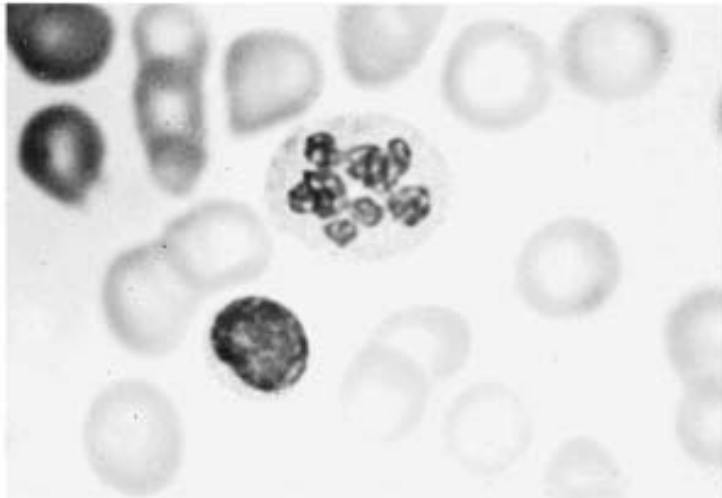
- Mycobacterium avium* complex (MAC)
- Cryptococcus neoformans*
- M. tuberculosis*
- Toxoplasma gondii*
- Pneumocystis carinii*

**6-17.** A 4-year-old boy exhibits the onset of episodes of loss of body tone with associated falls as well as generalized tonic-clonic seizures. His cognitive function has been deteriorating. EEG shows 1.5- to 2-Hz spike and wave discharges. The most likely diagnosis is

- Landau-Kleffner syndrome
- Lennox-Gastaut syndrome
- Juvenile myoclonic epilepsy
- Mitochondrial encephalomyopathy
- Febrile seizures

**6-18.** In a seemingly healthy child, the polymorphonuclear neutrophil shown in the following illustration is most likely to be associated with

- a. Malignancy
- b. Iron deficiency
- c. Folic acid deficiency
- d. Döhle inclusion bodies
- e. Pelger-Huët nuclear anomaly



Reproduced, with permission, from Yetman RJ: *Pediatrics: PreTest Self-Assessment and Review*, 9th ed. New York, McGraw-Hill, 2001.

**6-19.** An emaciated and lethargic 16-year-old girl arrives in the ER. Her BP is 75/50, her HR is 52, her potassium is 2.8, and her bicarbonate is 40 meq/L. The girl's parents report that she has lost 35 lb in 3 mo but is still convinced that she is overweight. She eats only very small amounts of low-calorie food and she runs 2 to 3 h every day. What other activity is the patient likely to have engaged in?

- a. Sexual promiscuity
- b. Ethanol abuse
- c. Purging
- d. Wearing tight clothes
- e. Shoplifting

**6-20.** A 20-mo-old child presents to your office with a mild viral infection. The results of examination are normal except for a temperature of 37.2°C (99°F) and clear nasal discharge. Review of the patient's vaccination records reveals that she received only two doses of polio vaccine and diphtheria-tetanus-pertussis (DTaP) vaccine, and that she did not receive the measles-mumps-rubella (MMR) vaccine. The mother is 20 wk pregnant. Her brother is undergoing chemotherapy for leukemia. Which of the following is the most appropriate intervention?

- Schedule a visit in 2 wk for DTaP
- Administer inactivated polio vaccine (IPV) and DTaP
- Administer DTaP, oral polio vaccine (OPV), and MMR
- Administer DTaP, IPV, and MMR
- Administer DTaP and OPV and schedule a visit in 3 mo for MMR

**6-21.** You are awakened in the night by your 2-year-old son, who has developed noisy breathing on inspiration, marked retractions of the chest wall, flaring of the nostrils, and a barking cough. He has had a mild upper respiratory infection (URI) for 2 days. The most likely diagnosis is

- Asthma
- Epiglottitis
- Bronchiolitis
- Viral croup
- Foreign body in the right main stem bronchus

**6-22.** A 55-year-old man, as part of a review of systems, describes an inability to achieve erection. The patient has mild diabetes and is on a beta blocker for hypertension. The first step in evaluation is

- Serum testosterone testing
- Serum gonadotropin testing
- Information about libido and morning erections
- Papaverine injection

**6-23.** A 23-year-old man presents complaining of hematuria for 1 day. He has no other symptoms but states the hematuria started after he played in a fast-paced basketball game. He takes no medications and does not drink alcohol or use illicit drugs. He recalls having a sore throat yesterday but denies cough or fever. He takes no medications and has no family history of renal disease. Physical examination is normal. Rapid streptococcal antigen test is negative. Urinalysis reveals erythrocytes and erythrocyte casts. Which of the following is the most likely diagnosis?

- a. Bladder carcinoma
- b. IgA nephropathy
- c. Poststreptococcal glomerulonephritis
- d. Alport syndrome
- e. Minimal change disease

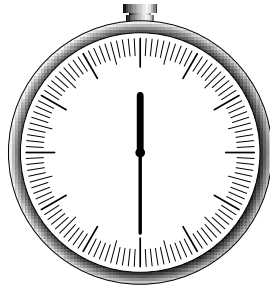
**6-24.** You are discussing surgical options with a patient with symptomatic pelvic relaxation. Partial colpocleisis (Le Fort procedure) may be more appropriate than vaginal hysterectomy and AV repair for patients who

- a. Do not desire retained sexual function
- b. Need periodic endometrial sampling
- c. Have had endometrial dysplasia
- d. Have cervical dysplasia that requires colposcopic evaluation
- e. Have a history of urinary incontinence

**6-25.** A 65-year-old retired steelworker, who has never had any sexual dysfunction, experiences difficulties in obtaining and maintaining an erection shortly after he starts taking a medication prescribed by his primary care physician. What medication is most likely to cause such a side effect?

- a. Propranolol
- b. Amoxicillin
- c. Lorazepam
- d. Bupropion
- e. Thyroid hormone



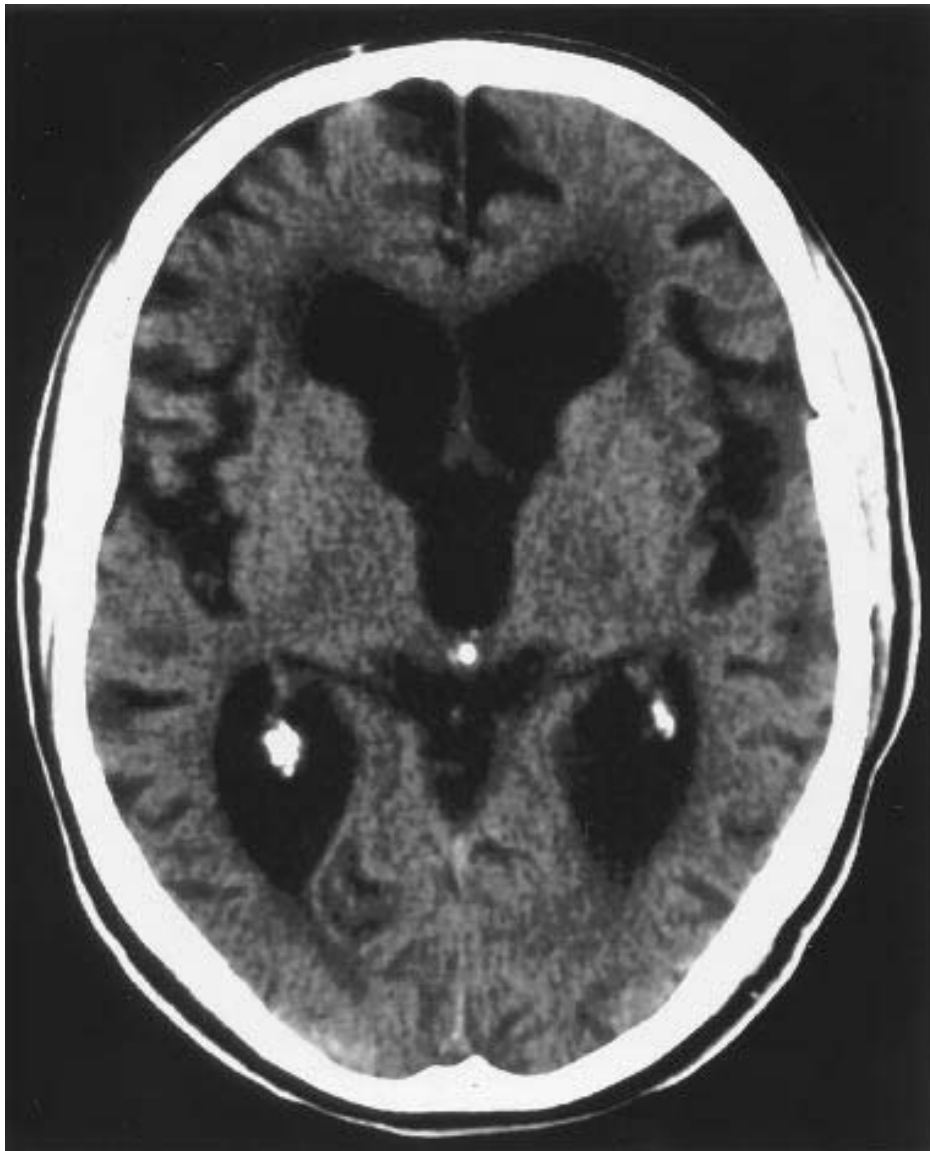

***YOU SHOULD HAVE COMPLETED APPROXIMATELY  
25 QUESTIONS AND HAVE 30 MINUTES REMAINING.***

---

**Items 6-26 through 6-28**

An 80-year-old man has a history of 2 years of progressive gait disturbance and incontinence that has been attributed to old age and prostatism. Within the past 3 mo, the patient has been forgetful, confused, and withdrawn. His gait is short-stepped, and he turns very slowly, almost toppling over. He has a history of head trauma 30 years ago. His CT scan is shown on the following page.



Reproduced, with permission, from Elkind MSV: *Neurology: PreTest Self-Assessment and Review*, 4th ed. New York, McGraw-Hill, 2001.

- 6-26.** The most likely diagnosis is
- a. Alzheimer's disease
  - b. Creutzfeldt-Jakob disease
  - c. Progressive multifocal leukoencephalopathy (PML)
  - d. Normal pressure hydrocephalus
  - e. Chiari malformation

**6-27.** The patient undergoes lumbar puncture. Forty cc of fluid are removed. Three hours later the patient is able to walk unassisted, and turns well. Spinal fluid would be expected to show

- a. No abnormalities
- b. Elevated protein
- c. Low protein
- d. Atypical lymphocytes
- e. Low glucose

**6-28.** The patient undergoes ventriculoperitoneal shunt placement. He is discharged 2 days later, his gait and cognition much improved. The following morning his wife finds him lying in bed, very confused, and complaining of a headache. He is unable to walk. The surgeon who performed the procedure is concerned that his new symptoms are due to

- a. Chemical meningitis
- b. Subdural hematoma
- c. Epidural hematoma
- d. Seizures
- e. Bacterial ventriculitis

**6-29.** A 28-year-old woman presents with nausea, vomiting, and diarrhea. She has no fever. Her history reveals that she attended a reception about 6 h ago. She ate roast beef with gravy, salad, and cream-filled pastries. Prevention of this foodborne illness could have been achieved by

- a. Freezing the food
- b. Heating the food to 140°F
- c. Proper hand washing by food handlers
- d. Proper cleaning of contaminated surfaces
- e. Control of flies

**6-30.** Following blunt abdominal trauma, a 12-year-old girl develops upper abdominal pain, nausea, and vomiting. An upper gastrointestinal series reveals a total obstruction of the duodenum with a “coiled spring” appearance in the second and third portions. Appropriate management is

- a. Gastrojejunostomy
- b. Nasogastric suction and observation
- c. Duodenal resection
- d. TPN to increase size of retroperitoneal fat pad
- e. Duodenojejunostomy

**6-31.** A 50-year-old woman complains of leakage of urine when she laughs, coughs, or sneezes. After stress incontinence, the most common cause of this urinary leakage is

- a. Detrusor dyssynergia
- b. Unstable bladder
- c. Unstable urethra
- d. Urethral diverticulum
- e. Overflow incontinence

**6-32.** A 30-year-old woman presents with the chief complaint of shortness of breath with minimal activity. In retrospect, she feels she has been dyspneic for at least 1 year but has now progressed to the point where she has difficulty climbing stairs or walking short distances. She denies fever, cough, or chest pain. On physical examination, the patient has JVD and a palpable right ventricular lift. On heart auscultation, there is a loud S2 and a systolic murmur that increases with inspiration. Lungs are clear. There is no clubbing. Which of the following is the most likely diagnosis?

- a. Sarcoidosis
- b. Coronary heart disease
- c. Idiopathic pulmonary fibrosis
- d. Primary pulmonary hypertension
- e. Systemic lupus erythematosus

**6-33.** An active 78-year-old woman has been followed for hypertension but presents with new onset of mild left hemiparesis and the finding of atrial fibrillation on ECG. She was in sinus rhythm 6 mo earlier. Optimal treatment by hospital discharge includes antihypertensives plus

- a. Close observation
- b. Permanent pacemaker
- c. Aspirin
- d. Warfarin (Coumadin)
- e. Subcutaneous heparin

**6-34.** A 73-year-old man presents complaining of right lateral hip pain that worsens when he lies on his right side or when he is standing. He has no other complaints. Physical examination is normal. He has a negative Faber test. Which of the following is the most likely diagnosis?

- a. Ischial bursitis
- b. Osteoarthritis of the hip
- c. Avascular necrosis of the hip
- d. Trochanteric bursitis
- e. Fracture of the proximal femur

**6-35.** A 62-year-old woman presents for her annual examination. Her last spontaneous menstrual period was 9 years ago, and she has been reluctant to use postmenopausal hormone replacement because of a strong family history of breast cancer. She complains of diminished interest in sexual activity. Which of the following is the most likely cause of her complaint?

- a. Decreased vaginal length
- b. Decreased ovarian function
- c. Increased alienation from partner
- d. Untreatable sexual dysfunction
- e. Physiologic anorgasmia

**6-36.** A 57-year-old woman presents to your office because of vaginal bleeding. She had her menopause at age 50. She does not use hormonal replacement therapy. Her last periodic health examination was 1 year ago. Physical and pelvic examinations are normal. Which of the following is the most likely diagnosis?

- a. Atrophic vaginitis
- b. Blood coagulation disorder
- c. Endometrial carcinoma
- d. Cervical carcinoma
- e. Ovarian cancer

**6-37.** A 27-year-old man who is in excellent health presents for a routine physical examination. Family history reveals that the patient's mother died of colon cancer at the age of 40 years and that a brother, who is 36 years old, was recently diagnosed with colon cancer. The patient also has two maternal aunts with ovarian cancer. Physical examination is normal and fecal occult blood test (FOBT) is negative. Laboratory data is normal. Which of the following statements is true in this patient?

- a. He most likely has the *BRCA2* mutation
- b. He needs an annual colonoscopy beginning at age 36
- c. He should have a prophylactic colectomy
- d. If he develops colon cancer, it will most likely be in the proximal colon
- e. If he develops colon cancer, it will most likely be in the distal colon

**6-38.** A 70-year-old man with unresectable carcinoma of the lung metastatic to liver and bone has developed progressive weight loss, anorexia, and shortness of breath. The patient has executed a valid living will that prohibits the use of a feeding tube in the setting of terminal illness. The patient becomes lethargic and stops eating altogether. The patient's wife of 30 years insists on enteral feeding for her husband. Since he has become unable to take in adequate nutrition, you would

- Respect the wife's wishes as a reliable surrogate decision maker
- Resist the placement of a feeding tube in accordance with the living will
- Call a family conference to get broad input from others
- Place a feeding tube until such time as the matter can be discussed with the patient

**6-39.** An infant weighing 1400 g (3 lb) is born at 32 wk gestation in a delivery room that has an ambient temperature of 24°C (75°F). If left in an open crib for a few minutes, this child is likely to demonstrate

- Ruddy complexion
- Shivering
- Hypertension
- Increased respiratory rate
- Metabolic alkalosis

### Items 6-40 through 6-41

A 57-year-old woman with a history of diabetes mellitus and hyperthyroidism presents to the emergency room with a history of 2 days of vertical and horizontal diplopia. There is moderate orbital pain. On examination the patient's left eye is deviated downward and outward. It can be passively moved medially and upward. The pupils both react normally.

**6-40.** The patient most likely has a(n)

- Third nerve palsy
- Fourth nerve palsy
- Sixth nerve palsy
- Orbital fracture
- Graves' disease

**6-41.** The etiology of the patient's diplopia is most likely

- Hyperthyroidism
- Diabetes mellitus
- Cerebral aneurysm
- Orbital pseudotumor
- Orbital infection

**6-42.** A 42-year-old woman, G2,P2, presents with the chief complaint of severe bilateral breast pain that seems worse around the time of menses. Physical examination reveals bilateral breast tenderness with palpation. Multiple lumps are palpated in both breasts. Mammogram reveals dense bilateral breast tissue. Which of the following is the most likely diagnosis in this patient?

- a. Fibroadenoma
- b. Fibrocystic disease
- c. Paget's disease
- d. Mastitis
- e. Mammary duct ectasia

**6-43.** A 32-year-old man presents with severe abdominal pain. He describes the pain as sharp and diffuse. He does not drink alcohol or take any medications. He has a past medical history significant for peptic ulcer disease over 5 years ago. The patient has stable vital signs and has no orthostatic changes. You observe the patient to be lying very still on the emergency room stretcher. On physical examination, he has a rigid abdomen and decreased bowel sounds. He has localized left upper quadrant guarding and rebound tenderness. There is referred rebound tenderness on palpation of the right upper quadrant. Rectal examination is FOBT negative. Which of the following is the best method of confirming the diagnosis in this patient?

- a. Barium swallow
- b. Leukocytosis
- c. Upper endoscopy
- d. Abdominal radiograph
- e. Colonoscopy

**6-44.** A 27-year-old pregnant woman is brought to the emergency room with multiple ecchymoses to the chest and abdomen. Her breath smells of alcohol. The most likely cause of these findings is

- a. Hepatic failure
- b. Domestic violence
- c. An accidental fall
- d. An automobile accident
- e. Disseminated intravascular coagulation

**6-45.** An edentulous 72-year-old man with a 50-year history of cigarette smoking presents with a nontender, hard mass in his lateral neck. The simplest way to establish an accurate histological diagnosis of a neck mass suspected to be cancerous is

- a. Fine needle aspiration cytology
- b. Bone marrow biopsy
- c. Nasopharyngoscopy
- d. CT scan of the head and neck
- e. Sinus x-ray

**6-46.** A 55-year-old man is being evaluated for constipation and change in bowel habits. He has no history of gastrectomy or upper GI symptoms. Laboratory values are as follows:

Hemoglobin: 10 g/dL

Mean corpuscular volume (MCV): 72 fL

Serum iron: 8  $\mu\text{mol/L}$  (normal: 9 to 27  $\mu\text{mol/L}$ )

Iron binding capacity: 75  $\mu\text{mol/L}$  (normal: 45 to 66  $\mu\text{mol/L}$ )

Saturation: 10% (normal: 20% to 40%)

Ferritin: 10  $\mu\text{g/L}$  (normal: 15 to 400  $\mu\text{g/L}$ )

The next step in the evaluation of this patient's anemia is

- a. Red blood cell folate studies
- b. Iron absorption studies
- c. Sigmoidoscopy
- d. Lead level study

**6-47.** You see five postmenopausal patients in the clinic. Each patient has one of the conditions listed below, and each patient wishes to begin hormone replacement therapy today. Which patient would you start on therapy at the time of this visit?

- a. Mild essential hypertension
- b. Liver disease with abnormal liver function tests
- c. Malignant melanoma
- d. Undiagnosed genital tract bleeding
- e. Treated Stage III endometrial cancer



**Items 6-48 through 6-49**

A 72-year-old man complained of pain about the waist at the level of the umbilicus. The pain was often burning and occasionally shooting. It did not extend down his legs, but he did notice some weakness in his legs at the time of the pain. With exertion, such as walking, he developed pain in his legs and a tingling sensation in his feet. He took aspirin for the discomfort, but noticed no substantial change in the sensation. Roentgenograms of his spine revealed no abnormalities. Pain and weakness became increasingly frequent over the course of several months. Because he complained of urinary hesitancy and frequency in association with an enlarged prostate, he was advised to have a transurethral prostatectomy. A general anesthetic was given for the surgery. On recovering consciousness postoperatively, the patient cannot move his legs and has persistent pain at the level of the umbilicus. His plantar responses are bilaterally extensor.

**6-48.** The most appropriate emergency evaluation for this patient is

- A voiding cystometrogram
- An electroencephalogram (EEG)
- Somatosensory evoked potentials (SSEPs)
- An aortogram
- A penile-brachial index (PBI)

**6-49.** The patient has a greatly dilated abdominal aorta with a normal thoracic aorta. The most likely cause of this damage is


- Syphilis
- Trauma
- Chronic hypertension
- Diabetes mellitus
- Atherosclerosis

**6-50.** About 12 days after a mild upper respiratory infection, a 12-year-old boy complains of weakness in his lower extremities. Over several days, the weakness progresses to include his trunk. On physical examination, he has the weakness described and no lower extremity deep tendon reflexes, muscle atrophy, or pain. Spinal fluid studies are notable for elevated protein only. The most likely diagnosis in this patient is

- Bell's palsy
- Muscular dystrophy
- Guillain-Barré syndrome
- Charcot-Marie-Tooth disease
- Werdnig-Hoffmann disease

*This page intentionally left blank.*

# ***BLOCK 7***



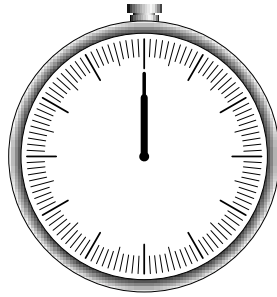
***YOU HAVE 60 MINUTES  
TO COMPLETE 50 QUESTIONS.***

---

*This page intentionally left blank.*

# BLOCK 7

---



**YOU HAVE 60 MINUTES  
TO COMPLETE 50 QUESTIONS.**

---

## Questions

**7-1.** A 55-year-old man who is extremely obese reports weakness, sweating, tachycardia, confusion, and headache whenever he fasts for more than a few hours. He has prompt relief of symptoms when he eats. These symptoms are most suggestive of which of the following disorders?

- a. Diabetes mellitus
- b. Insulinoma
- c. Zollinger-Ellison syndrome
- d. Carcinoid syndrome
- e. Multiple endocrine neoplasia, type 2

**7-2.** An 18-year-old woman develops urticaria and wheezing after an injection of penicillin. Her blood pressure is 120/60 mm Hg, her heart rate is 155 beats/min, and her respiratory rate is 30 breaths/min. Immediate therapy should include

- a. Intubation
- b. Epinephrine
- c. Beta blockers
- d. Iodine
- e. Fluid challenge

**7-3.** A 64-year-old woman is found to have a left-sided pleural effusion on chest x-ray. Analysis of the pleural fluid reveals a ratio of concentration of total protein in pleural fluid to serum of 0.38, a lactate dehydrogenase (LDH) level of 125 IU, and a ratio of LDH concentration in pleural fluid to serum of 0.46. Which of the following disorders is most likely in this patient?

- a. Uremia
- b. Congestive heart failure
- c. Pulmonary embolism
- d. Sarcoidosis
- e. Systemic lupus erythematosus

**7-4.** A 60-year-old man complains of pain in both knees gradually worsening over the past 2 years. The pain is relieved by rest and worsened by movement. There is bony enlargement of the knees with mild inflammation. Crepitation is noted on motion of the knee joint. The only other finding is bony enlargement at the distal interphalangeal joint. The patient is 5 ft, 9 in. tall and weighs 190 lbs. The best way to prevent disease progression is

- a. Weight reduction
- b. Calcium supplementation
- c. Total knee replacement
- d. Aspirin
- e. Prednisone orally

**7-5.** A 13-year-old girl grunts and clears her throat several times an hour, and her conversation is often interrupted by random shouting. She also performs idiosyncratic, complex motor activities such as turning her head to the right while she shuts her eyes and opens her mouth. She can prevent these movements for brief periods of time, with effort. The most appropriate treatment for this disorder is

- a. Individual psychodynamic-oriented psychotherapy
- b. Lorazepam
- c. Methylphenidate
- d. Haloperidol
- e. Imipramine

**Items 7-6 through 7-7**

You are a public health physician working at a city health department. You receive a report of a case of hepatitis A virus (HAV) infection in a 32-year-old man who lives with his wife and 1-year-old twins. He is a self-employed contractor who often eats on the run. His wife works part-time at a book store and his children attend day care. He has no history of travel, eating raw fish, or known contact with other cases of HAV infection.

**7-6.** The first step in investigating this case is to confirm the diagnosis of HAV with

- a. A report of the history and examination from the treating physician
- b. Stool cultures
- c. Total anti-HAV antibodies
- d. IgM anti-HAV
- e. HAV RNA

**7-7.** The most likely source of infection is

- a. A coworker
- b. Food
- c. The patient's wife
- d. Water
- e. The patient's children

**7-8.** A previously healthy 18-month-old has been in a separate room from his family. The family notices the sudden onset of coughing, which resolves over a few minutes. Subsequently, the patient appears to be normal except for increased amounts of drooling and refusal to take foods orally. The most likely explanation for this toddler's condition is

- a. Severe gastroesophageal reflux
- b. Foreign body in the airway
- c. Croup
- d. Epiglottitis
- e. Foreign body in the esophagus

**7-9.** A 37-year-old man developed involuntary twitching movements in his left thumb. Within 30 s he noticed that the twitching had spread to his entire left hand and involuntary movements had developed in his left forearm and the left side of his face. He cannot recall what happened subsequently, but his wife reports that he fell down and the entire left side of his body appeared to be twitching. The patient appeared to be unresponsive for about 3 min and confused for another 15 min. During the episode he bit his tongue and wet his pants. Which of the following seizure types did this person experience?

- a. Generalized tonic-clonic
- b. Generalized absence
- c. Complex partial
- d. Epilepsia partialis continua
- e. Simple partial sensory
- f. Jacksonian march
- g. Psychomotor status
- h. Tonic-clonic status epilepticus
- i. Pseudoseizures
- j. Myoclonic

### Items 7-10 through 7-12

A 28-year-old man is brought to the ER for a severe head injury after a fall. Initially lethargic, he becomes comatose and does not move his right side. His left pupil is dilated and responds only sluggishly.

**7-10.** The most common initial manifestation of increasing intracranial pressure in the victim of head trauma is

- a. Change in level of consciousness
- b. Ipsilateral (side of hemorrhage) pupillary dilation
- c. Contralateral pupillary dilation
- d. Hemiparesis
- e. Hypertension

**7-11.** Initial emergency reduction of intracranial pressure is most rapidly accomplished by

- a. Saline-furosemide (Lasix) infusion
- b. Urea infusion
- c. Mannitol infusion
- d. Intravenous dexamethasone (Decadron)
- e. Hyperventilation



**7-12.** In the patient described, compression of the affected nerve is produced by

- a. Infection within the cavernous sinus
- b. Herniation of the uncus process of the temporal lobe
- c. Laceration of the corpus callosum by the falx cerebri
- d. Occult damage to the superior cervical ganglion
- e. Cerebellar hypoxia

**7-13.** A 32-year-old woman experiences a severe anaphylactic reaction following a sting from a hornet. Which of the following statements is correct?

- a. She would not have a similar reaction to a sting from a yellow jacket
- b. She would have a prior history of an adverse reaction to an insect sting
- c. Adults are unlikely to die as a result of an insect sting as compared to children with the same history
- d. She should be skin-tested with venom antigens and, if positive, immunotherapy should be started

**7-14.** A 54-year-old obese woman presents with the chief complaint of hemoptysis. She states that over the last day she has coughed up approximately 10 cc of blood-streaked sputum. She denies any fever, chills, chest pain, or shortness of breath. She does admit to a recent upper respiratory tract infection with cough and a copious amount of sputum production. She remembers similar episodes of cough with bloody sputum occurring after colds for the last several years. She has smoked 1 pack of cigarettes per day since high school. Examinations of the pharynx and lungs are normal. Which of the following is the most likely diagnosis?

- a. Chronic bronchitis
- b. Tuberculosis
- c. Adenocarcinoma of the lung
- d. Congestive heart failure
- e. Pulmonary infarction

**7-15.** A 41-year-old woman with no previous medical problems presents with the chief complaint of generalized weakness. The patient states that she has been irritable lately and finds it difficult to concentrate at work. She has been amenorrheic for 12 mo and feels her symptoms might be related to early menopause. On physical examination, blood pressure is 160/90 mm Hg. The patient has a “moon face” and a “buffalo hump.” She is hirsute. Abdominal examination reveals purple striae. Her extremities appear to be atrophied. Her fingerstick glucose is 210 mg/dL. Which of the following is the most likely diagnosis?

- a. Cushing syndrome
- b. Cushing’s disease
- c. Pseudo-Cushing state
- d. Polycystic ovary disease
- e. Normal menopause

**7-16.** A 2-year-old boy presents with progressive clumsiness and difficulty walking. On physical examination, the child has large calves. He has difficulty walking on his toes and has a waddling gait. Gower maneuver is positive. Which of the following is the most likely diagnosis?

- a. Becker muscular dystrophy
- b. Myotonic dystrophy
- c. Facioscapulohumeral dystrophy
- d. Duchenne muscular dystrophy

**7-17.** After several years of successful antiparkinsonian treatment, a patient abruptly develops acute episodes of profound bradykinesia and rigidity. Remission of these signs occurs as abruptly as the onset. This patient probably suffers from

- a. Acute dystonia
- b. Absence attacks
- c. On-off phenomenon
- d. Complex partial seizures
- e. Drug toxicity

**7-18.** The parents of a 14-year-old boy are concerned about his short stature and lack of sexual development. By history, you learn that the patient’s birth weight and length were 3 kg and 50 cm, respectively, and that he had a normal growth pattern, although he was always shorter than children his age. The physical examination is normal. The patient’s upper-to-lower segment ratio is 0.98. A small amount of fine axillary and pubic hair is present. There is no scrotal pigmentation; the patient’s testes measure 4.0 cm<sup>3</sup> and his penis is 6 cm in length. In this situation, you should

- a. Measure pituitary gonadotropin
- b. Obtain a CT scan of pituitary area
- c. Biopsy the patient’s testes
- d. Measure serum testosterone levels
- e. Reassure the parents that the boy is normal

**7-19.** A 50-year-old alcoholic man presents to the emergency room with upper gastrointestinal (GI) bleeding. Examination reveals ataxia, confusion, and ophthalmoplegia. In addition to treatment of the GI bleeding, the patient would benefit from receiving which of the following?

- a. Niacin
- b. Pyridoxine
- c. Folic acid
- d. Thiamin
- e. Cobalamin

**7-20.** A 90-year-old man complains of hip and back pain. He has also developed headaches, hearing loss, and tinnitus. On physical exam the skull appears enlarged with prominent superficial veins. There is marked kyphosis and the bones of the legs appear deformed. Plasma alkaline phosphatase is elevated. A skull x-ray shows sharply demarcated lucencies in the frontal, parietal, and occipital bones. X-rays of the hip show thickening of the pelvic brim. The most likely diagnosis is

- a. Multiple myeloma
- b. Paget's disease
- c. Hypercalcemia
- d. Metastatic bone disease

**7-21.** A 14-year-old boy presents to your office after being hit in the face by a soccer ball. He complains of left eye pain, and on physical examination, you see blood in the anterior chamber. Pupils are equal and reactive to light and extraocular muscles are intact. Which of the following is the most likely diagnosis?

- a. Hyphema
- b. Esotropia
- c. Amblyopia
- d. Subconjunctival hemorrhage
- e. Strabismus

**7-22.** A 32-year-old woman in her third trimester presents with painless and profuse bright red vaginal bleeding. Pelvic examination is deferred. Transvaginal ultrasonography reveals an abnormally positioned placenta. Which of the following is the most likely diagnosis?

- a. Placenta accreta
- b. Placenta previa
- c. Abruptio placentae
- d. Bloody show
- e. Vasa previa

**7-23.** A 30-year-old man takes a can of beer out of his refrigerator at the end of the day and rapidly swallows a mouthful of its contents before he realizes that it is not beer. Within a few minutes he develops severe abdominal cramps, blurred vision, twitching, and loss of consciousness. His wife notifies emergency medical personnel that she placed some roach spray in the beer can for storage and left it in the refrigerator to deal with roaches that were nesting there. She claims she forgot to advise her husband. Emergency personnel check the insecticide brand and determine that it is an organophosphate. To counteract the cholinesterase-inhibiting activity of the organophosphate poison, the patient should receive

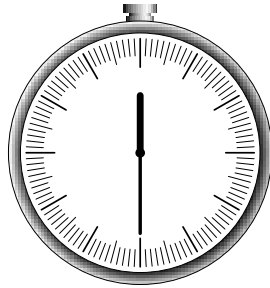
- a. Methacholine
- b. Pyridostigmine
- c. Physostigmine
- d. Edrophonium
- e. Atropine

**7-24.** A 35-year-old woman is recovering from *mycoplasma pneumoniae* pneumonia and feels weak. Her hemoglobin is 9.0 g/dL with a normal MCV. The best test to determine whether or not the patient has a hemolytic anemia is

- a. Serum bilirubin
- b. Reticulocyte count and blood smear
- c. Mycoplasma antigen
- d. Serum LDH

**7-25.** For the past 10 years, the memory of a 74-year-old woman has progressively declined. Lately she has caused several small kitchen fires by forgetting to turn off the stove, she cannot remember how to cook her favorite recipes, and she becomes disoriented and confused at night. She identifies an increasing number of objects as “that thing” because she cannot recall the correct name. Her muscle strength and balance are intact. Choose the most likely diagnosis.

- a. Huntington’s disease
- b. Multi-infarct dementia
- c. Creutzfeldt-Jakob disease
- d. Alzheimer’s disease
- e. Wilson’s disease



***YOU SHOULD HAVE COMPLETED APPROXIMATELY  
25 QUESTIONS AND HAVE 30 MINUTES REMAINING.***

---

**7-26.** A 23-year-old student presents to your office for health clearance to play collegiate sports. He is asymptomatic and exercises daily. On physical examination his blood pressure is 160/50 mm Hg and his pulse rate is 60 beats/min. There is pulsus bisferiens. Heart examination reveals an early diastolic rumble at the apex and a blowing diastolic murmur at the left sternal border. Nailbeds reveal a Quincke pulse. Which of the following is the most likely diagnosis?

- a. Cardiac tamponade
- b. Aortic insufficiency (AI)
- c. Mitral stenosis (MS)
- d. Atrial septal defect (ASD)
- e. Tetralogy of Fallot

**7-27.** A 24-year-old white woman has a maternal serum  $\alpha$  fetoprotein (MSAFP) at 17 wk gestation of 6.0 multiples of the median. The next step should be

- a. A second MSAFP test
- b. Ultrasound examination
- c. Amniocentesis
- d. Amniography
- e. Recommendation of termination

**7-28.** A 40-year-old man without a significant past medical history comes to the emergency room with a 3-day history of fever, shaking chills with a 15-min episode of rigor, non-productive cough, and anorexia, as well as the development of right-sided pleuritic chest pain and shortness of breath over the last 12 h. A chest roentgenogram reveals a consolidated right middle lobe infiltrate and a CBC shows an elevated neutrophil count with many band forms present. Which of the following statements regarding pneumonia in this patient is correct?

- Sputum culture is more helpful than sputum gram stain in choosing empiric antibiotic therapy
- If the gram stain reveals numerous gram-positive diplococci, numerous white blood cells, and few epithelial cells, *Streptococcus pneumoniae* is the most likely diagnosis
- Although *S. pneumoniae* is the agent most likely to be the cause of this patient's pneumonia, this diagnosis is very unlikely if blood cultures are negative
- The absence of rigors would rule out a diagnosis of pneumococcal pneumonia
- Penicillin is the drug of choice in all cases of pneumococcal pneumonia

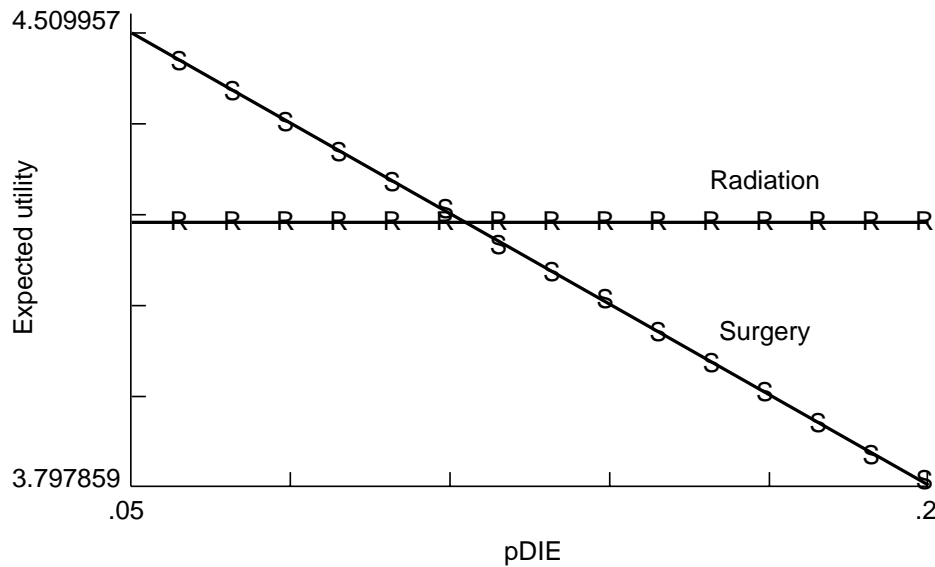
**7-29.** A 52-year-old patient with chronic cough and shortness of breath is diagnosed with chronic obstructive lung disease. Which of the following factors is the most important contributor to this finding?

- Tobacco use
- Deficiency of  $\alpha$  antitrypsin
- Asthma
- Repeated childhood respiratory tract infections
- Occupation

**7-30.** A 17-year-old girl presents with a pruritic rash localized to the wrist. Papules and vesicles are noted in a bandlike pattern, with slight oozing from some lesions. The most likely cause of the rash is

- Herpes simplex
- Shingles
- Contact dermatitis
- Seborrheic dermatitis

**7-31.** A decision analysis is undertaken in an attempt to determine which approach—radiation therapy or surgery—is best for the management of prostate cancer. A sensitivity analysis is plotted on the graph shown below. The x axis represents the probability of death from surgery, and the y axis represents the life expectancy (“expected utility”) expressed in quality-adjusted life years (QALYs).



Reproduced, with permission, from Ratelle S: *Preventive Medicine and Public Health: PreTest Self-Assessment and Review*, 9th ed. New York, McGraw-Hill, 2001.

Based on this information, you conclude that

- Radiation therapy is always the best approach
- Surgery is always the best approach
- Radiation therapy is the best approach when mortality from surgery exceeds 11%
- Mortality from surgery does not affect the choice of approach
- Surgery is the preferred approach when mortality from the procedure exceeds 20%

**7-32.** An 11-year-old girl presents to your office because of a family history of medullary carcinoma of the thyroid. Physical examination is normal. Which of the following tests would you perform?

- a. Urine vanillylmandelic acid (VMA) level
- b. Serum insulin level
- c. Serum gastrin level
- d. Serum glucagon level
- e. Serum somatostatin level

**7-33.** A 32-year-old farmer presents to the emergency room with a crushing injury of the index finger and thumb that occurred while he was working with machinery in his barn. Records show that he received three doses of Td in the past, and that his last dose was given when he was 25 years old. In addition to proper wound cleaning and management, which of the following is the most appropriate preventive intervention?

- a. No additional prophylaxis
- b. Administration of tetanus toxoid
- c. Administration of tetanus immunoglobulin only
- d. Administration of tetanus toxoid and immunoglobulin
- e. Administration of tetanus and diphtheria toxoid

**7-34.** You are helping with school sports physicals and see a 13-year-old boy who has had some trouble keeping up with his peers. He has a cardiac murmur that you correctly diagnose as a ventricular septal defect based on the following auscultatory finding

- a. A systolic crescendo-decrescendo murmur heard best at the upper right sternal border with radiation to the carotids and augmented with transient exercise
- b. A systolic murmur at the pulmonic area and a diastolic rumble along the left sternal border
- c. A holosystolic murmur at the mid-left sternal border
- d. A diastolic decrescendo murmur at the mid-left sternal border
- e. A continuous murmur through systole and diastole at the upper left sternal border

**7-35.** A 1-wk-old previously healthy infant presents to the emergency room with the acute onset of bilious vomiting. The abdominal plain film shows dilated proximal loops of bowel and stomach. Barium enema reveals the cecum to be in the left lower quadrant. The most likely diagnosis for this patient is

- a. Jejunal atresia
- b. Hypertrophic pyloric stenosis
- c. Malrotation of the intestines with volvulus
- d. Appendicitis
- e. Intussusception



**Items 7-36 through 7-37**

An 18-year-old man complains of fever and transient pain in both knees and elbows. The right knee was red and swollen for 1 day the week prior to presentation. On physical exam, the patient has a low-grade fever but appears generally well. There is an aortic diastolic murmur heard at the base of the heart. A nodule is palpated over the extensor tendon of the hand. There are pink erythematous lesions over the abdomen, some with central clearing. The following laboratory values are obtained:

Hematocrit: 42

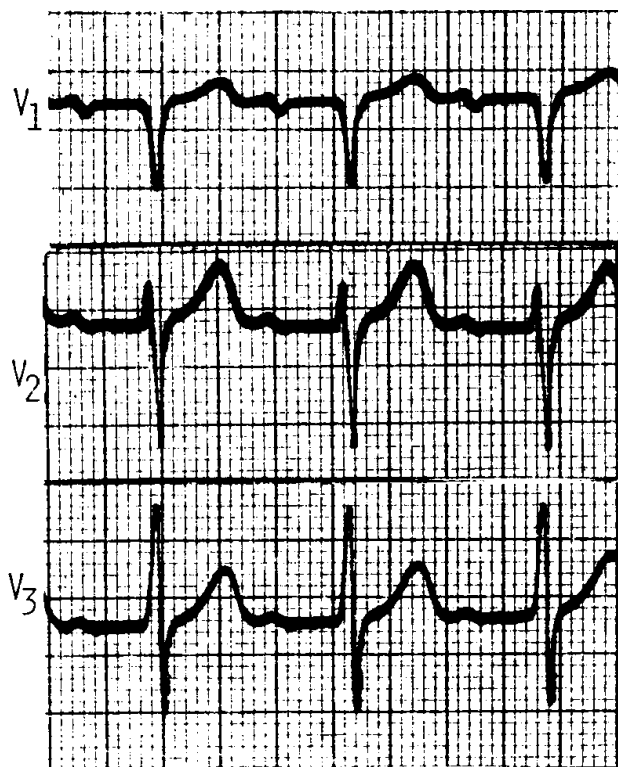
WBC: 12,000/ $\mu$ L

Polymorphonuclear leukocytes: 20%

Lymphocytes: 80%

ESR: 60 mm/h

The patient's ECG is shown below.



Reproduced, with permission, from Berk SL, Davis WR: *Medicine: PreTest Self-Assessment and Review*, 9th ed. New York, McGraw-Hill, 2001.

**7-36.** Which of the following tests is most critical to diagnosis?

- a. Blood cultures
- b. Antistreptolysin O antibody
- c. Echocardiogram
- d. Antinuclear antibodies
- e. Creatinine phosphokinase

**7-37.** Based on the data available, the best approach to therapy is

- a. Ceftriaxone
- b. Corticosteroids plus penicillin
- c. Acetaminophen
- d. Penicillin plus streptomycin
- e. Ketoconazole

**Items 7-38 through 7-41**

A 22-year-old woman presents to the emergency room with an episode of acute painful loss of vision in the right eye. On examination there is right afferent pupillary defect, and papillitis is seen on fundoscopic examination. The patient has no history of neurologic symptoms. MRI shows a few foci of T2 signal increase in a periventricular distribution.

**7-38.** Appropriate treatment for presumed optic neuritis in this patient is

- a. Oral prednisone
- b. Intravenous methylprednisolone
- c. Cyclophosphamide
- d. Plasma exchange
- e. Intravenous gammaglobulin

**7-39.** Six months later the patient again presents to the ER. Her vision has recovered. She now complains of brief, sharp pain radiating into the left side of her face. The vision in her right eye has largely recovered, and there is no evidence of sensory loss on the right side of her face. She describes the pain as “ice-pick-like” and grimaces with each attack. She is most likely to have symptomatic relief from her facial pain if she is managed with

- a. Aspirin
- b. Acetaminophen
- c. Ibuprofen
- d. Carbamazepine
- e. Codeine

**7-40.** On further questioning, the patient reveals that she has had recurrent episodes of bed-wetting (enuresis) over the preceding month. This would decrease with the administration of

- a. Imipramine
- b. Phenytoin
- c. Carbamazepine
- d. Baclofen
- e. Methacholine

**7-41.** Over the course of the next few months, the patient develops painful spasticity in her left leg that interferes with flexion of the leg. The spasticity progresses to the point of interfering with her sleep. She should now be treated with

- a. Imipramine
- b. Phenytoin
- c. Carbamazepine
- d. Baclofen
- e. Methacholine

**7-42.** A 26-year-old gravida 3 woman has a history of gestational diabetes and a delivery of two previous infants at term that were greater than 4000 g, each of whom had severe hypoglycemia. Which of the following maneuvers is least likely to reduce the chance of the next child's having hyperglycemia?

- a. Careful control of maternal blood glucose levels during pregnancy
- b. Maternal intravenous loading with 10% glucose beginning 2 to 4 h prior to the expected time of delivery
- c. Careful glucose monitoring of the infant
- d. Early feedings of the infant
- e. Maintenance of the infant in a neutral thermal environment

**7-43.** A 52-year-old woman presents to your office for her annual gynecological examination. She stopped menstruating about 6 mo ago and is getting some hot flashes. Her history reveals that she drinks one glass of wine per day and smokes about 10 cigarettes per day. She does not exercise much and is overweight. Her most important risk factor for developing osteoporosis is

- a. Smoking
- b. Alcohol use
- c. Lack of physical activity
- d. Age
- e. Obesity

#### Items 7-44 through 7-45

**7-44.** A 10-year-old obese boy has central fat distribution, arrested growth, hypertension, plethora, purple striae, and osteoporosis. Which of the following disorders is most likely to be responsible for the clinical picture that this boy presents?

- a. Bilateral adrenal hyperplasia
- b. Adrenal adenoma
- c. Adrenal carcinoma
- d. Craniopharyngioma
- e. Ectopic adrenocorticotropin-producing tumor

**7-45.** Appropriate initial management of this patient is

- Measurement of evening cortisol levels
- MRI of the adrenals
- Bilateral inferior petrosal blood sampling
- MRI of the brain and pituitary
- Adrenal scintigraphy with radiocholesterol

**Items 7-46 through 7-47**

A 24-year-old primigravid woman, who is intent on breast feeding, decides upon a home delivery. Immediately after the birth of a 4.1-kg (9-lb) infant, the patient bleeds massively from extensive vaginal and cervical lacerations. She is brought to the nearest hospital in shock. Over 2 h, 9 units of blood are transfused, and the patient's blood pressure returns to a reasonable level. A hemoglobin value the next day is 7.5 g/dL, and 3 units of packed red blood cells are given.

**7-46.** The most likely late sequela to consider in this patient is

- Hemochromatosis
- Stein-Leventhal syndrome
- Sheehan syndrome
- Simmonds syndrome
- Cushing syndrome

**7-47.** Development of the sequela could be evident as early as

- 6 h postpartum
- 1 wk postpartum
- 1 mo postpartum
- 6 mo postpartum
- 1 year postpartum

**7-48.** A 24-year-old HIV-positive patient who has had AIDS for 3 years presents with painful swallowing and dysphagia to solids and liquids. He has no previous history of heartburn or reflux disease. His CD4 count is 41/ $\mu$ L and he recently required 3 wk of antibiotics for *Pneumocystis carinii* pneumonia. Examination of the pharynx reveals no oral thrush. Barium swallow demonstrates multiple nodular filling defects of various sizes that resemble a "cluster of grapes." Which of the following is the most likely diagnosis?

- Candida* esophagitis
- Reflux disease
- Barrett's esophagus
- Pneumocystis* esophagitis
- Achalasia
- Plummer-Vinson syndrome
- Schatzki ring

**7-49.** On a hot summer day in a large urban center located in the southwestern United States, an emergency room department reports an increase in admissions for asthma in children and young adults, but not among patients suffering from chronic bronchitis or ischemic heart disease. The most likely air pollutant responsible for the exacerbation of asthma is


- a. Carbon monoxide
- b. Ozone
- c. Nitrogen dioxide
- d. Particulate matter
- e. Lead

**7-50.** A 30-year-old female patient who presents with bleeding per rectum is found at colonoscopy to have colitis confined to the transverse and descending colon. A biopsy is performed. Which of the following statements is true about this patient?

- a. The inflammatory process is likely to be confined to the mucosa and submucosa
- b. The inflammatory reaction is likely to be continuous
- c. Superficial as opposed to linear ulcerations can be expected
- d. Noncaseating granuloma can be expected in up to 50% of patients with similar disease
- e. Microabscesses within crypts are common

*This page intentionally left blank.*

# ***BLOCK 8***



***YOU HAVE 60 MINUTES  
TO COMPLETE 50 QUESTIONS.***

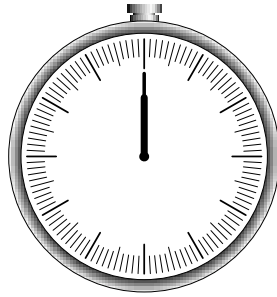
---

*This page intentionally left blank.*



# BLOCK 8

---



**YOU HAVE 60 MINUTES  
TO COMPLETE 50 QUESTIONS.**

---

## Questions

### Items 8-1 through 8-2

A 35-year-old man stumbles into the ER. His pulse is 100 beats/min, his blood pressure is 170/95 mm Hg, and he is diaphoretic. He is tremulous and has difficulty relating a history. He does admit to insomnia the past two nights and states that he sees spiders walking on the walls. He has been a drinker since age 19, but has not had a drink in 3 days.

**8-1.** The most likely diagnosis is

- a. Alcohol-induced psychotic disorder
- b. Wernicke's psychosis
- c. Alcohol withdrawal delirium
- d. Alcohol intoxication
- e. Alcohol idiosyncratic intoxication

**8-2.** Initial treatment usually includes

- a. Haloperidol 10 mg IM
- b. Chlorpromazine 50 mg IM
- c. Lithium 300 mg PO
- d. Chlordiazepoxide 50 mg PO
- e. Naloxone 1 mg IV

**8-3.** A 31-year-old man is brought to the emergency room following an automobile accident in which his chest struck the steering wheel. Examination reveals stable vital signs, but the patient exhibits multiple palpable rib fractures and paradoxical movement of the right side of the chest. Chest x-ray shows no evidence of pneumothorax or hemothorax, but a large pulmonary contusion is developing. Proper treatment consists of which of the following?

- Tracheostomy, mechanical ventilation, and positive end-expiratory pressure
- Stabilization of the chest wall with sandbags
- Stabilization with towel clips
- Immediate operative stabilization
- No treatment unless signs of respiratory distress develop

**8-4.** A 25-year-old woman with blonde hair and a fair complexion complains of a “mole.” The lesion is on the upper back. The lesion is 6 mm, darkly pigmented, and asymmetric with a very irregular border. The next step in management is to

- Tell the patient to avoid sunlight
- Follow the lesion for any evidence of growth
- Obtain a metastatic workup
- Obtain a full-thickness excisional biopsy
- Obtain a shave biopsy

**8-5.** A 14-year-old boy is seen in the emergency room because of a 3-wk history of fever between 38.3°C and 38.9°C (101°F and 102°F), lethargy, and a 6-lb weight loss. Physical examination reveals marked cervical and inguinal adenopathy, enlarged tonsils with exudate, small hemorrhages on the soft palate, a WBC differential that has 50% lymphocytes (10% atypical), and a palpable spleen 2 cm below the left costal margin. Which of the following conditions is the likely diagnosis?

- HIV disease
- Varicella
- Kawasaki’s disease
- Streptococcal throat infection
- Infectious mononucleosis

**8-6.** A 25-year-old woman presents to the delivery room in labor. She has had no prenatal care. The female newborn weighs 4.5 lb and has episodes of seizures shortly after birth. Irritability and hypertonicity are also noted. The most likely cause for these findings in the newborn is

- Cocaine
- Alcohol
- HIV
- Syphilis
- Heroin

**8-7.** A 16-year-old high school student presents with the sudden onset of sharp right-sided chest pain associated with shortness of breath. He denies any history of trauma. On physical examination, the patient is afebrile with a respiratory rate of 28 breaths/min. His blood pressure is 100/70 mm Hg and his heart rate is 120 beats/min. Neck examination reveals no tracheal deviation. On lung auscultation, the patient has decreased fremitus, hyperresonance, and diminished breath sounds over the right posterior hemithorax. Which of the following is the most likely diagnosis?

- a. Tension pneumothorax
- b. Secondary pneumothorax
- c. Pulmonary embolus
- d. Spontaneous pneumothorax
- e. Pneumonia

**8-8.** A 9-year-old girl presents for evaluation of regular vaginal bleeding. History reveals thelarche at age 7 and adrenarche at age 8. The most common cause of this condition in girls is

- a. Idiopathic
- b. Gonadal tumors
- c. McCune-Albright syndrome
- d. Hypothyroidism
- e. Tumors of the central nervous system

**8-9.** A 42-year-old man presents to your office for a checkup. He has been in excellent health except for a recent diagnosis of mild hypertension and bilateral carpal tunnel syndrome. On physical examination, the patient is tall with large and doughy hands. His facial features are coarse and he has a prominent mandible with wide-spaced teeth. His voice is deep and he has macroglossia. Heart examination reveals the point of maximum impulse (PMI) to be displaced 2 cm laterally. Which of the following is the most likely diagnosis?

- a. Acromegaly
- b. Gigantism
- c. Hypothyroidism
- d. Familial prognathism
- e. Amyloidosis

**8-10.** Incisional biopsy of a breast mass in a 35-year-old woman demonstrates a hypercellular fibroadenoma (cystosarcoma phylloides) at the time of frozen section. Appropriate management of this lesion could include

- a. Wide local excision with a rim of normal tissue
- b. Lumpectomy and axillary lymphadenectomy
- c. Modified radical mastectomy
- d. Excision and postoperative radiotherapy
- e. Excision, postoperative radiotherapy, and systemic chemotherapy

**8-11.** Professional organizations recommend that all pregnant women be routinely counseled about HIV infection and be encouraged to be tested. What is the most important reason for early identification of HIV infection in pregnant women?

- a. A cesarean section can be planned to reduce HIV transmission to the newborn
- b. Breast feeding can be discouraged to reduce transmission to the newborn
- c. Early identification of a newborn at risk of HIV infection will improve survival
- d. Counseling on pregnancy options, such as termination, can be offered
- e. Antiretroviral therapy can be offered to reduce the chance of transmission of HIV to the newborn

**8-12.** A 45-year-old woman has pain in her fingers on exposure to cold, arthralgias, and difficulty swallowing solid food. The most useful test to make a definitive diagnosis would be

- a. Rheumatoid factor
- b. Antinucleolar antibody
- c. ECG
- d. BUN and creatinine

**8-13.** A 42-year-old woman of Italian descent presents for a pre-employment physical examination. She has no past medical problems and takes no medications. Her physical examination is normal except for pale conjunctiva. FOBT is negative. CBC is remarkable for a hemoglobin of 11.4 g/dL, a MCV of 60 fL, and a reticulocyte count of 0.6%. White blood cell count and platelets are normal. Peripheral smear reveals microcytosis, hypochromia, acanthocytes (cells with irregularly spaced projections), and occasional target cells. Which of the following is the most likely diagnosis?

- a. Iron-deficiency anemia
- b. Sideroblastic anemia
- c. Anemia of chronic disease
- d. Thalassemia trait
- e. Hemolytic anemia

**8-14.** A 68-year-old woman with a history of hypertension and diabetes mellitus presents with shortness of breath. She denies chest pain and palpitations. Physical examination reveals a blood pressure of 130/60 mm Hg and a heart rate of 72 beats/min. The patient's lungs are normal. Heart auscultation reveals an S4 gallop. There is no JVD and no peripheral edema. Chest radiograph shows a normal-sized heart and ECG shows left ventricular hypertrophy. Echocardiogram reveals concentric left ventricular hypertrophy with a hyperdynamic left ventricle. Which of the following is the most likely diagnosis?

- a. Systolic dysfunction
- b. Diastolic dysfunction
- c. Left heart failure
- d. Right heart failure
- e. Normal heart

**8-15.** A pregnancy of approximately 10 wk gestation is confirmed in a 30-year-old gravida 5, para 4 woman with an IUD in place. The patient expresses a strong desire for the pregnancy to be continued. On examination, the strings of the IUD are protruding from the cervical os. The most appropriate course of action is to

- a. Leave the IUD in place without any other treatment
- b. Leave the IUD in place and continue prophylactic antibiotics throughout pregnancy
- c. Remove the IUD immediately
- d. Terminate the pregnancy because of the near certain risk of infection, abortion, or both
- e. Perform laparoscopy to rule out an ectopic pregnancy

**8-16.** A 6-year-old boy has just been diagnosed with ADHD and started on methylphenidate 5 mg tid. The parents report that the child is able to focus better, is less hyperactive, and seems to have more tolerance for frustration. They are concerned, however, because he is never hungry. The child psychiatrist explains that decreased appetite is a common side effect of methylphenidate. Another, more serious side effect of this medication is

- a. Night terrors
- b. Choreiform movements
- c. Tics
- d. Cardiac arrhythmias
- e. Leukopenia

**8-17.** A 43-year-old woman complains of lancinating pains radiating into the right side of her jaw. This discomfort has been present for more than 3 years and has started occurring more than once a week. The pain is paroxysmal and is routinely triggered by cold stimuli, such as ice cream and cold drinks. The patient has sought relief with multiple dental procedures and has already had two teeth extracted. Multiple neuroimaging studies reveal no structural lesions in her head. Assuming there are no contraindications to the treatment, a reasonable next step would be to prescribe

- a. Clonazepam (Klonopin) 1 mg orally three times daily
- b. Diazepam (Valium) 5 mg orally two times daily
- c. Divalproex sodium (Depakote) 250 mg orally three times daily
- d. Indomethacin (Indocin) 10 mg orally three times daily
- e. Carbamazepine (Tegretol) 100 mg orally three times daily

**Items 8-18 through 8-19**

A 57-year-old man develops acute shortness of breath shortly after a 12-h automobile ride. The patient consults his internist, and findings on physical examination are normal except for tachypnea and tachycardia. An electrocardiogram reveals sinus tachycardia but is otherwise normal.

**8-18.** Which of the following is correct?

- a. A definitive diagnosis can be made by history alone
- b. The patient should be admitted to the hospital, and if there is no contraindication to anticoagulation, intravenous heparin should be started pending further testing
- c. Normal findings upon examination of the lower extremities are extremely unusual in this clinical setting
- d. Early treatment has little effect on overall mortality

**8-19.** The most important next step in the diagnosis of the patient above would be

- a. Pulmonary angiogram
- b. Ventilation-perfusion scan
- c. D-dimer assay
- d. Venous ultrasound

**8-20.** A newborn infant has mild cyanosis, diaphoresis, poor peripheral pulses, hepatomegaly, and cardiomegaly. Respiratory rate is 60 breaths/min, and heart rate is 250 beats/min. The child most likely has congestive heart failure caused by

- a. A large atrial septal defect and valvular pulmonic stenosis
- b. A ventricular septal defect and transposition of the great vessels
- c. Total anomalous pulmonary venous return
- d. Hypoplastic left heart syndrome
- e. Paroxysmal atrial tachycardia

**8-21.** A 70-year-old man complains of the sudden onset of visual loss in his right eye accompanied by a headache. He has a history of hypertension and diabetes mellitus. On physical examination, visual acuity in the left eye is 20/20 while visual acuity in the right eye is 20/90. Fundoscopic exam shows the right disc to be pale and swollen with some hemorrhages. Which of the following is the most likely diagnosis?

- a. Diabetic retinopathy
- b. Retinal vein occlusion
- c. Retinal artery occlusion
- d. Ischemic optic neuropathy
- e. Hypertensive retinopathy
- f. Retinal detachment

**8-22.** A 53-year-old postmenopausal woman, gravida 3, para 3, presents for evaluation of troublesome urinary leakage of 6 wk duration. Of the following choices, which is the most appropriate first step in this patient's evaluation?

- a. Urinalysis and culture
- b. Urethral pressure profiles
- c. Intravenous pyelogram
- d. Cystourethrogram
- e. Urethrocytostcopy

**8-23.** A 50-year-old woman is evaluated for hypertension. Her blood pressure is 130/98 mm Hg. She complains of polyuria and mild muscle weakness. She is on no diuretics or other blood pressure medication. On physical exam the PMI is displaced to the 6th intercostal space. There is no sign of congestive heart failure and no edema. Laboratory values are as follows:

Na<sup>+</sup>: 147 meq/dL  
K<sup>+</sup>: 2.3 meq/dL  
Cl<sup>-</sup>: 112 meq/dL  
HCO<sub>3</sub><sup>-</sup>: 27 meq/dL

The patient is on no other medication. She does not eat licorice. The first step in diagnosis is

- a. 24-h urine for cortisol
- b. Urinary metanephrine
- c. Plasma resin and aldosterone
- d. Renal angiogram

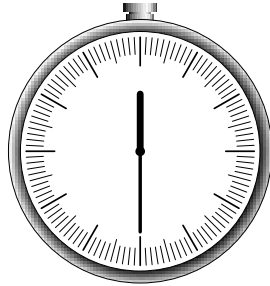
**8-24.** A 10-year-old boy with sickle cell disease presents with headache, anorexia, and fever. He complains of pain in the right tibia and local inflammation is noted. Osteomyelitis is diagnosed. The most likely etiologic agent is

- a. Listeria
- b. Salmonella
- c. Shigella
- d. Cryptosporidium
- e. Campylobacter

**8-25.** An 8-year-old is accidentally hit in the abdomen by a baseball bat. After several minutes of discomfort, he seems to be fine. Over the ensuing 24 h, however, he develops a fever, abdominal pain radiating to the back, and persistent vomiting. On examination, the child appears quite uncomfortable. The abdomen is tender with decreased bowel sounds throughout, but especially painful with guarding in the mid-epigastric region. The test likely to confirm your suspicions is

- a. Serum amylase
- b. Complete blood count with differential and platelets
- c. Serum total and direct bilirubin levels
- d. Abdominal radiograph
- e. Electrolyte panel





***YOU SHOULD HAVE COMPLETED APPROXIMATELY  
25 QUESTIONS AND HAVE 30 MINUTES REMAINING.***

---

**8-26.** An obese 50-year-old woman undergoes a laparoscopic cholecystectomy. In the recovery room she is found to be hypotensive and tachycardic. Her arterial blood gases reveal a pH of 7.29, partial pressure of oxygen of 60 kPa, and partial pressure of CO<sub>2</sub> of 54 kPa. The most likely cause of this woman's problem is

- a. Acute pulmonary embolism
- b. CO<sub>2</sub> absorption from induced pneumoperitoneum
- c. Alveolar hypoventilation
- d. Pulmonary edema
- e. Atelectasis from high diaphragm

**8-27.** A 52-year-old woman complains of recurrent episodes during which she becomes extremely hot and diaphoretic. During these episodes, she becomes anxious and feels like her heart is racing. Each episode lasts approximately 5 min. The episodes are so intense that she must put on the air conditioner or open a window until the discomfort resolves. Hot weather and stress often precipitate the symptoms. The episodes seem to be worse at night. The patient further states that she has been amenorrheic for 12 mo and has recently begun experiencing vaginal dryness and dyspareunia. Physical examination is normal. Which of the following is the most likely diagnosis?

- a. Depression
- b. Menopause
- c. Hypothyroidism
- d. Somatization
- e. Personality disorder

**8-28.** A 50-year-old man has a 10-year history of chronic active hepatitis from hepatitis C virus. He is brought to the emergency room because of cachexia and disturbed mental status. On physical examination, the patient has palmar erythema and clubbing. He is jaundiced with massive ascites. He has asterixis. Laboratory data reveals severe hypoalbuminemia and hyperbilirubinemia. Which of the following is the most likely diagnosis?

- a. Child class A cirrhosis
- b. Child class B cirrhosis
- c. Child class C cirrhosis
- d. Child class D cirrhosis
- e. Child class E cirrhosis

**8-29.** A 22-year-old woman, gravida 3, para 2 (one abortion), is brought to the hospital because she says she has been raped by a 35-year-old man whom she knows to have had a vasectomy 2 years ago. Both persons have an A positive blood type. Which of the following would be most useful to the victim in the prosecution of this case?

- a. Accurate description of the introitus
- b. Smear for sperm from the cervix
- c. Vaginal washings for acid phosphatase
- d. Specific typing of vaginal washings
- e. Examination of pubic hair

**8-30.** An 8-year-old girl becomes tearful and distressed and claims she feels sick every morning on school days. Once in school, she often goes to the nurse, complaining of headaches and stomach pains. At least once a week she misses school, or she is picked up early by her mother, due to her complaints. Her pediatrician has ruled out organic causes for the physical symptoms. The child is usually symptom-free on week-ends, unless her parents go out and leave her with a babysitter. The most likely diagnosis is

- a. Separation anxiety
- b. Juvenile depression
- c. Somatization disorder
- d. Generalized anxiety disorder
- e. Attachment disorder

**8-31.** A 52-year-old woman presents to her private physician with the chief complaint of hoarseness. She is a singer in her church choir and her friends have noticed a voice change. Her past medical history is significant for heart arrhythmias, which are well controlled for 3 years with amiodarone. Physical examination reveals a woman with coarse hair and skin. Her fingernails are thick and her eyes appear puffy. The thyroid gland is normal and nontender. Muscle strength is excellent but the relaxation phase of the ankle reflex is prolonged. Which of the following is the most likely diagnosis?

- a. Cushing's disease
- b. Acromegaly
- c. de Quervain's disease
- d. Amiodarone-induced hypothyroidism
- e. Cretinism

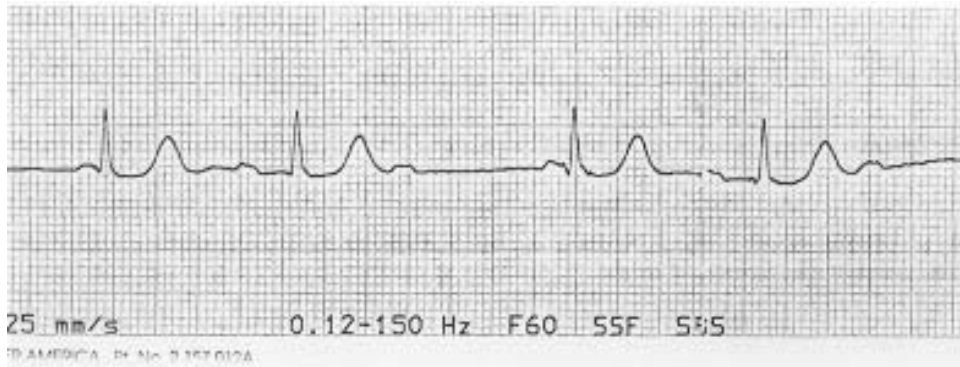
**8-32.** A 19-year-old patient has extensive vaginal flat condylomas that have recurred after laser treatment 3 mo ago. At this point, the best therapy is to

- a. Repeat laser treatment
- b. Apply podophyllum
- c. Apply trichloroacetic acid
- d. Apply 5% 5-fluorouracil cream
- e. Perform cryotherapy

**8-33.** A 27-year-old man undergoes general anesthesia for a hernia repair. As the anesthesia begins, his jaw muscles tense and he becomes generally rigid. He becomes febrile, tachycardic, and tachypneic. Intravenous administration of which agent may be lifesaving?

- a. Suxamethonium
- b. Nitrous oxide
- c. Succinylcholine
- d. Dantrolene
- e. Phenobarbital

**8-34.** A 36-year-old white female nurse comes to the ER due to a sensation of fast heart rate, slight dizziness, and vague chest fullness. The following rhythm strip is obtained, which shows



Reproduced, with permission, from Berk SL, Davis WR: *Medicine: PreTest Self-Assessment and Review*, 9th ed. New York, McGraw-Hill, 2001.

- a. Atrial fibrillation
- b. Atrial flutter
- c. Supraventricular tachycardia
- d. Ventricular tachycardia

**8-35.** A 10-year-old boy from the Connecticut coast is seen because of discomfort in his right knee. He had a large, annular, erythematous lesion on his back that disappeared 4 wk prior to the present visit. His mother recalls pulling a small tick off his back. The correct statement about this child's likely illness includes which of the following?

- a. The tick was probably a *Dermacentur andersoni*
- b. The disease is caused by a rickettsial agent that is transmitted by the bite of a tick
- c. In addition to skin and joint involvement, CNS and cardiac abnormalities may be present
- d. Therapy with antibiotics has little effect on the resolution of symptoms
- e. The pathognomonic skin lesion is required for diagnosis

**8-36.** A 45-year-old woman reported to the police her discovery that her husband had added a suspicious material to her food. She had experienced matrimonial problems for several years and had developed progressive fatigue with frequent headache over the prior 3 mo. She had consulted a physician when she developed recurrent bouts of severe stomach pain and was told by neighbors that she had been talking to herself and attacking invisible assailants. The physician noted that she had an unexplained anemia and white lines running transversely across her fingernails. She also had problems with her memory, excessive drowsiness, and a sensorimotor neuropathy with absent tendon reflexes. The physician sent a sample of her hair for analysis and found a neurotoxin present. Which of the following toxins most likely produced the woman's condition?

- a. Lead
- b. Arsenic
- c. Manganese
- d. Mercury
- e. Carbon monoxide
- f. Ergot
- g. Nitrous oxide

**8-37.** A 54-year-old man presents with a 2-wk history of headache, fever, chills, and night sweats. He complains of myalgias and easy fatigability. He has just returned from a business trip to Africa and the Middle East. Before the trip, the patient received immunizations against poliomyelitis, hepatitis A, hepatitis B, and dengue fever. Throughout the trip, he took chloroquine prophylaxis against malaria. On physical examination, the patient has a temperature of 103.2°F and is diaphoretic. There is no neck stiffness, photophobia, or lymphadenopathy. Heart and lung examinations are normal. There is mild splenomegaly. Which of the following is the most likely diagnosis in this patient?

- a. Malaria
- b. Tuberculosis
- c. Mononucleosis
- d. Trypanosomiasis
- e. Toxoplasmosis

**8-38.** A 47-year-old homeless woman attempts suicide by jumping off an overpass and is admitted for the treatment of several fractures. Tearfully, she reports to the physicians that devil worshippers have tormented her for many years. She is convinced that her persecutors have managed to infiltrate the ward, masquerading as nurses and maintenance workers. She is treated with risperidone and sertraline. After 3 wk her mood has greatly improved and she is not suicidal, but her beliefs about being persecuted have not changed. This patient has had three similar episodes in the past 10 years. Choose the most appropriate diagnosis

- a. Major depression, recurrent with psychotic features
- b. Schizoaffective disorder
- c. Chronic schizophrenia, paranoid type
- d. Delusional disorder, paranoid type
- e. Schizophreniform disorder

**Items 8-39 through 8-40**

A 30-year-old primigravida complains of headaches, restlessness, sweating, and tachycardia. She is 18 wk pregnant and her blood pressure is 200/120 mm Hg.

**8-39.** Appropriate workup might include

- Exploratory laparotomy
- Mesenteric angiography
- Head CT scan
- Abdominal CT scan
- Abdominal ultrasonogram

**8-40.** Appropriate treatment might consist of

- Therapeutic abortion
- Urgent excision of the tumor and a therapeutic abortion
- Phenoxybenzamine and propranolol followed by a combined cesarean section and excision of the tumor
- Metyrosine (Demser) blockade followed by a combined cesarean section and excision of the tumor
- Phenoxybenzamine and propranolol followed by a combined vaginal delivery at term and excision of the tumor

**8-41.** A 40-year-old literary agent has had worsening tremor of the hands. This has been present for 2 years, but has increasingly impaired her ability to work because she is frequently required to take her clients to lunch, and she is embarrassed by her inability to eat and drink normally. A glass of wine with the meal typically helps somewhat. On exam, there is a mild head tremor, but no rest tremor of the hands. When the patient holds a pen by the tip at arm's length, however, a coarse tremor is readily apparent. Exam is otherwise normal. What is the most likely diagnosis?

- Meigs syndrome
- Dopa-responsive dystonia
- Parkinson's disease
- Whipple's disease
- Essential tremor

**8-42.** A 9-year-old girl has breast and pubic hair development. Evaluation demonstrates a pubertal response to a gonadotropin-releasing hormone (GnRH) stimulation test and a prominent increase in luteinizing hormone (LH) pulses during sleep. These findings are characteristic of patients with

- Theca cell tumors
- Iatrogenic sexual precocity
- Premature thelarche
- Granulosa cell tumors
- Idiopathic/constitutional precocious puberty

**8-43.** A mother brings her 14-year-old daughter to your office because she is concerned about her child's eating patterns. The daughter's nutritional history reveals that she generally eats very little because she says she is not hungry. She occasionally engages in junk food binges with friends. She is often constipated. She exercises regularly. She is 5 ft, 6 in. tall and weighs 108 lb. Her menarche was at age 13, but she stopped having periods 4 mo ago. She says she has no concerns about her body image, and thinks her mother is exaggerating because everyone in the family is tall and thin. The history and findings are most likely associated with

- a. Typical adolescent behavior
- b. Depression
- c. Hyperthyroidism
- d. Bulimia
- e. Anorexia

**8-44.** A 32-year-old woman presents to the hospital with a 24-h history of abdominal pain in the right lower quadrant. She undergoes an uncomplicated appendectomy for acute appendicitis and is discharged on the fourth postoperative day. The pathologist notes the presence of a carcinoid tumor (1.2 cm) in the tip of the appendix. Which of the following statements is true?

- a. The patient should be advised to undergo ileocelectomy
- b. The most common location of carcinoids is in the appendix
- c. The carcinoid syndrome occurs in more than half of patients with carcinoid tumors
- d. The tumor is an apudoma
- e. Carcinoid syndrome is seen only when the tumor is drained by the portal venous system



**Items 8-45 through 8-46**

A 70-year-old man complains of 2 mo of low back pain and fatigue. He has developed a fever with purulent sputum production. On physical exam, he has pain over several vertebrae and rales at the left base. Laboratory results are as follows:

Hemoglobin: 7 g/dL  
 MCV: 86 fL (normal: 86 to 98 fL)  
 WBCs: 12,000/ $\mu$ L  
 BUN: 44 mg/dL  
 Creatinine: 3.2 mg/dL  
 Ca<sup>++</sup>: 11.5 mg/dL  
 Chest x-ray: LLL infiltrate  
 Reticulocyte count: 1%

**8-45.** The most likely diagnosis is

- Multiple myeloma
- Lymphoma
- Metastatic bronchogenic carcinoma
- Primary hyperparathyroidism

**8-46.** The definitive diagnosis is best made by

- 24-h urine protein
- Greater than 10% plasma cells in bone marrow
- Renal biopsy
- Rouleaux formation on blood smear

**8-47.** A 3-year-old child presents with a petechial rash but is otherwise well and without physical findings. Platelet count is 20,000/mm<sup>3</sup>; hemoglobin and WBC count are normal. The most likely diagnosis is

- Immune thrombocytopenic purpura (ITP)
- Henoch-Schönlein purpura
- Disseminated intravascular coagulopathy (DIC)
- Acute lymphoblastic leukemia
- Systemic lupus erythematosus (SLE)

**8-48.** The mother of a 7-day-old infant has developed chickenpox. Which of the following is the most appropriate measure?

- Isolate the infant from the mother
- Hospitalize the infant in the isolation ward
- Administer acyclovir to the infant
- Administer varicella-zoster immunoglobulin to the infant
- Advise the mother to continue regular well-baby care for the infant

**8-49.** A hypothetical study examining the association between serum cholesterol ( $>280$ ) and cardiovascular disease (CVD) demonstrates a crude relative risk of 3.0. When the data is stratified by gender, the relative risk for men is 4.0 and the relative risk for women is 1.0. The adjusted risk is 3.0. The most appropriate interpretation of the results of this study is that

- a. Gender is both a confounder and an effect modifier
- b. Gender is a confounder only
- c. Gender is an effect modifier only
- d. Gender is neither a confounder nor an effect modifier
- e. Gender is causal pathway

**8-50.** A 34-year-old successful lawyer presents to the ER with chest pain. His pupils are dilated and his blood pressure is 160/95 mm Hg. The toxic screen is likely to be positive for

- a. Cannabinoids
- b. Opiates
- c. Cocaine
- d. LSD
- e. PCP

# BLOCK I

---

## Answers

**1-1. The answer is b.** (*Behrman, 16/e, p 35. McMillan, 3/e, pp 756–761. Rudolph, 21/e, pp 121–128.*) Infants who are developing normally should be able to smile and coo when smiled at or talked to by 8 wk of age. By 3 mo of age, infants should be able to follow a moving toy not only from side to side but also in the vertical plane. When placed on his or her abdomen, a normal 3-mo-old infant can raise his or her face 45 degrees to 90 degrees from the horizontal. Not until 6 to 8 mo of age should an infant be able to maintain a seated position.

**1-2. The answer is d.** (*Sadock, 7/e, pp 1505–1511.*) Conversion disorder is characterized by the sudden appearance of one or more symptoms simulating an acute neurological illness in the context of severe psychological stress. The symptoms with which conversion disorder manifests conform to the patient's own understanding of the medical condition and are not associated with the usual diagnostic signs. Contrary to malingering and factitious disorder, conversion disorder is nonvolitional. Conversion disorder is more frequent in women, with a female-to-male ratio of 2–5 to 1. In childhood, both sexes are equally represented. Prevalence is highest in rural areas and among the underprivileged, the undereducated, and the cognitively delayed. The sudden onset and the temporal relation to a severe stress help differentiate conversion disorder from more chronic conditions such as somatization disorder and personality disorders.

**1-3. The answer is a.** (*Fauci, 13/e, p 518.*) Ear pain and drainage in an elderly diabetic patient must raise concern about malignant external otitis. The swelling and inflammation of the external auditory meatus strongly suggests this diagnosis. This infection usually occurs in older diabetics and is almost always caused by *Pseudomonas aeruginosa*. *Haemophilus influenzae* and *Moraxella catarrhalis* frequently cause otitis media but not external otitis.

**1-4. The answer is c.** (*Schwartz, 7/e, pp 64–66.*) Magnesium deficiency is common in malnourished patients and patients with large gastrointestinal fluid losses. The neuromuscular effects resemble those of calcium deficiency—namely, paresthesia, hyperreflexia, muscle spasm, and ultimately tetany. The cardiac effects are more like those of hypercalcemia. An electrocardiogram therefore provides a rapid means of differentiating between hypocalcemia and hypomagnesemia. Hypomagnesemia also causes potassium wasting by the kidney. Many hospital patients with refractory hypocalcemia will be found to be magnesium deficient. Often this deficiency becomes manifest during the response to parenteral nutrition when normal cellular ionic gradients are restored. A normal blood pH and arterial  $P_{CO_2}$  rule out hyperventilation. The serum calcium in this patient is normal when adjusted for the low albumin. Hypomagnesemia causes functional hypoparathyroidism, which can lower serum calcium and thus result in a combined defect.

**1-5. The answer is e.** (*Behrman, 16/e, pp 797–798, 865–867, 910–914, 922–925. McMillan, 3/e, pp 717–718, 898–902, 951–953, 1012, 1017–1021, 1137–1140, 2160–2162. Rudolph, 20/e, pp 582–583, 626–628, 689–692, 2010–2011.*) The incubation period for Rocky Mountain spotted fever (RMSF) has a range of 1 to 14 days. A brief prodromal period consisting of headache and malaise is typically followed by the abrupt onset of fever and chills. A maculopapular rash starts on the second to fourth day of illness on the flexor surfaces of the wrists and ankles before moving in a central direction. Typically, the palms and soles are involved. The rash can become hemorrhagic within 1 or 2 days. Hyponatremia and thrombocytopenia may be seen.

Tularemia has a variable presentation, including abrupt onset of fever, chills, malaise, weakness, and headache, and also a variety of skin rashes. Children often have fever, pharyngitis, hepatosplenomegaly, and nonspecific constitutional symptoms.

In the differential diagnosis of RMSF are a number of other diseases. A morbilliform eruption can precede a petechial rash caused by *Neisseria meningitidis*. Viral infections, particularly by the enteroviruses, can cause a severe illness that resembles RMSF. Atypical measles is seen primarily in persons who received the killed measles vaccine before 1968. After exposure to wild-type measles, such a person can develop a prodrome consisting of fever, cough, headache, and myalgia. This is usually followed by the

development of pneumonia and an urticarial rash beginning on the extremities. Toxic shock syndrome (TSS) is a disease characterized by sudden onset of fever, diarrhea, shock, inflammation of mucous membranes, and a diffuse macular rash resulting in desquamation of the hands and feet. Lyme disease is seen with an early period of localized disease including erythema migrans, possibly with flulike symptoms, followed by a distinctive period of erythema migrans, arthralgia, arthritis, meningitis, neuritis, and carditis.

**1-6. The answer is c.** (*Stobo, 23/e, p 744.*) Chronic lymphocytic leukemia is the most common of all leukemias with an increasing incidence with age. Patients are usually asymptomatic, but may complain of weakness, fatigue, or enlarged lymph nodes. The diagnosis is made by peripheral blood smear, as mature small lymphocytes constitute almost all the white blood cells seen. No other process produces a lymphocytosis of this morphology and magnitude.

**1-7. The answer is d.** (*Schwartz, 7/e, pp 1156–1158.*) Perforation of the esophagus in the chest is a surgical catastrophe that requires aggressive intervention in virtually all circumstances. While that intervention can usually consist of efforts to patch the perforation and drain the mediastinum, concomitant obstructive esophageal disease, whether inflammatory stenosis or cancer, mandates removal or bypass of the obstruction if control of the leak and its consequent persisting mediastinal and pleural contamination is to be accomplished. For distal esophageal cancers, many thoracic surgeons would use the classic Ivor-Lewis operation, which consists of mobilizing the stomach in the abdomen and then performing a right thoracotomy with mediastinal cleanout, esophagectomy, and esophagogastrostomy. In some circumstances, and by some surgeons' preference, a left thoracotomy approach might be used. The transhiatal approach would probably be avoided in this situation where an unknown amount of mediastinal contamination has taken place.

**1-8. The answer is c.** (*DSM-IV, pp 669–673.*) The essential feature of obsessive-compulsive personality disorder is a preoccupation with perfection, orderliness, and control. Individuals with this disorder lose the main point of an activity and miss deadlines because they pay too much attention to rules and details and are not satisfied by anything less than “perfec-

tion.” As in other personality disorders, symptoms are ego-syntonic and create considerable interpersonal, social, and occupational difficulties. Obsessive-compulsive disorder is differentiated from obsessive-compulsive personality disorder by the presence of obsessions and compulsions. Paranoid personality disorder is characterized by suspiciousness and distrust of others. Individuals with narcissistic personality disorder are preoccupied with perfection, but usually they are convinced of having already reached it. Individuals with obsessive-compulsive personality disorder, instead, are rarely satisfied with themselves. Passive-aggressive personality disorder is characterized by a passive resistance to perform in occupational and social settings, manifested by forgetfulness, procrastination, and intentional lack of efficiency.

**1-9. The answer is b.** (*Ingelfinger, 3/e, ch 9, pp 198–202.*) Although hypertension can resolve spontaneously, this is an unlikely explanation for resolution over a 2-wk period in 35% of the subjects. A much more likely explanation is regression toward the mean. Because of random fluctuations, any one measurement of blood pressure may be far from a person’s normal blood pressure. If patients are referred for the study based on a single measurement, those in whom the measurement was high (which proved later not to reflect the actual blood pressure) are much more likely to be referred than those in whom the measurement was too low. Thus, in any group selected based on a characteristic with substantial day-to-day variation, many will have values closer to the population mean when the measurement is repeated, and the “worst patients” will improve. Neither baseline drift (which occurs with measurements on certain machines that require frequent calibration) nor measurement error is as likely an explanation. The Hawthorne effect refers to a tendency among study subjects to change simply because they are being studied. It is much more likely to affect studies of behavior or attitudes than a study of blood pressure.

**1-10. The answer is d.** (*USPSTF, 2/e, pp 251–252.*) Venipuncture is the best way to accurately measure blood lead levels. Capillary blood is often contaminated, which results in falsely elevated levels. It is more cost effective to collect venous blood initially than to do so only if the capillary blood level is high. Although many infants with lead poisoning also have iron deficiency anemia, the complete blood count will not identify all cases of lead poisoning. The erythrocyte protoporphyrin is no longer recommended for

screening as it will not identify lead levels below 25 µg/dL. It may be used for the detection of iron deficiency. Testing for ferritin is used to estimate body iron stores.

**1-11. The answer is a.** (*Fauci, 14/e, pp 1955–1956.*) The patient's multiple trigger points, associated sleep disturbance, and lack of joint or muscle findings make fibromyalgia a possible diagnosis. The diagnosis hinges on the multiple tender points. Complete blood count (CBC) and erythrocyte sedimentation rate (ESR) are characteristically normal. Tricyclic antidepressants restore sleep; aspirin and anti-inflammatory drugs are not helpful. Biofeedback and exercise programs have been partially successful. The clavicle, medial malleolus, and forehead are never trigger points for the process.

**1-12. The answer is e.** (*Behrman, 16/e, pp 169–171. McMillan, 3/e, p 1472. Rudolph, 20/e, pp 1005–1006, 1015–1016.*) The syndrome of kwashiorkor is caused by a diet that is deficient in protein, leading to low serum albumin, which causes decreased plasma volume and increased interstitial fluid or edema. The term marasmus refers to a combined inadequacy of protein and energy in which the deficiency is dominated by the lack of food in general. The minimum requirement for protein is 8% of the total daily calories when the protein provided is from high-quality animal sources. These patients have a high death rate from intercurrent infections.

**1-13. The answer is c.** (*Sabiston, 15/e, pp 131–133.*) Whenever significant bleeding is noted in the early postoperative period, the presumption should always be that it is due to an error in surgical control of blood vessels in the operative field. Hematologic disorders that are not apparent during the long operation are most unlikely to surface as problems postoperatively. Blood transfusion reactions can cause diffuse loss of clot integrity; the sudden appearance of diffuse bleeding during an operation may be the only evidence of an intraoperative transfusion reaction. In the postoperative period, transfusion reactions usually present as unexplained fever, apprehension, and headache—all symptoms difficult to interpret in the early postoperative period. Factor VIII deficiency (hemophilia) would almost certainly be known by history in a 65-year-old man, but if not, intraoperative bleeding would have been a problem earlier in this long

operation. Severely hypothermic patients are not able to form clots effectively, but clot dissolution does not occur. Care should be taken to prevent the development of hypothermia during long operations through the use of warmed intravenous fluid, gas humidifiers, and insulated skin barriers.

**1-14 through 1-15. The answers are 1-14 b, 1-15 b.** (*LaDou, 2/e, pp 320–321.*) Silicosis, a pneumoconiosis, is caused by respiratory exposure to silica, a major component of rock and sand. Patients with silicosis are at risk of mycobacterium infection, both atypical and typical. A positive purified protein derivative (PPD) in a patient with chronic silicosis warrants preventive tuberculosis therapy. Such a patient is also at higher risk for fungal infections such as cryptococcosis. Asbestos increases the risk of lung cancer and mesothelioma. Byssinosis is an occupational form of asthma due to inhalation of cotton dust. Caplan syndrome may occur in coal miners who have rheumatoid arthritis and is characterized by rapidly evolving rounded densities on chest x-rays.

**1-16. The answer is b.** (*Wyllie, 1993, p 895.*) Most rhythmic to-and-fro movements of the eyes are called *nystagmus*. Nystagmus has a fast component in one direction and a slow component in the opposite direction. Nystagmus with a fast component to the right is called *right-beating nystagmus*. Phenytoin (Dilantin) may evoke nystagmus at levels of 20 to 30 mg/dL. The eye movements typically appear as a laterally beating nystagmus on gaze to either side; this type of nystagmus is called *gaze-evoked*. If the patient has nystagmus on looking directly forward, he or she is said to have nystagmus in the position of primary gaze. Therapeutic levels for phenytoin are usually 10 to 20 mg/dL, and some patients develop asymptomatic nystagmus even within that range. Ataxia, dysarthria, impaired judgment, and lethargy may also occur at toxic levels of phenytoin. Many other drugs also evoke nystagmus. Weakness of abduction of the left eye, or abducens palsy, is due either to injury to the sixth cranial nerve or to increased intracranial pressure. Impaired convergence can occur normally with age or may be a sign of injury to the midbrain. Papilledema is a sign of increased intracranial pressure. Impaired upgaze may occur in many conditions, and would not be expected to occur with a toxic phenytoin level.

**1-17 through 1-18. The answers are 1-17 e, 1-18 a.** (*Greenfield, 2/e, p 1970.*) The significant observation in this question is the description of



lymphangitic inflammatory streaking up the inner aspect of the patient's leg. This is highly suggestive of a streptococcal infection, and the presumptive therapy should be high doses of a bactericidal antibiotic. Penicillin remains the mainstay of therapy against presumed streptococcal infections. Most streptococcal cellulitis is adequately treated by penicillin, elevation of the infected extremity, and attention to the local wound to ascertain adequate local drainage and absence of any persisting foreign body. However, the clinician must be alert to the possibility of a more fulminant and life- or limb-threatening infection by clostridia, microaerophilic streptococci, or other potentially synergistic organisms that can produce rapidly progressive deep infections in fascia or muscle. Smears and cultures of drainage fluid or aspirates should be taken. Close observation of the wound is essential, and aggressive debridement in the operating room is mandatory at the slightest suggestion that fasciitis or myonecrosis may be ensuing.

**1-19. The answer is a.** (*Silberstein, p 78.*) This patient has common migraine. Of the agents listed, only ergotamine tartrate is generally considered of use in treatment to abort a headache. Verapamil and amitriptyline may be used as prophylactic, or preventative, therapy. Phenobarbital is an anticonvulsant and is not typically used to treat migraine. Nitroglycerine can actually precipitate headaches in susceptible individuals. Nausea is a frequent accompaniment of migraine, and metoclopramide (Reglan) may be effective in relieving the nausea. It also reduces gastric stasis, which can retard absorption of oral medications. Certain antiemetics, such as prochlorperazine, may relieve nausea and also provide relief from the headache itself. Additional agents that might be of benefit in abortive therapy include ibuprofen (which this patient has already tried without relief), aspirin, acetaminophen, isometheptene (Midrin), ergotamine, or a triptan. The triptans are a group of medications that act as agonists at serotonergic receptors (specifically, 5HT-1 receptors), and they have been found to be very effective at stopping migraine headaches.

**1-20. The answer is d.** (*Silberstein, p 78–80.*) Several medications are effective as prophylactic agents in the treatment of migraine. These include amitriptyline, propranolol, verapamil, and valproate. Most experts recommend initiating prophylactic therapy only when headaches occur at least one to two times per month. Metoclopramide, sumatriptan, and ergota-

mine tartrate are appropriately used to treat an acute attack of migraine, and should not be prescribed on a daily basis. Daily use of these medications can establish a rebound syndrome that results in a daily headache. Oral contraceptives (OCPs) may be associated with either an increase or decrease in the frequency of migraines, but are not generally used as a treatment for migraine. Some experts recommend not prescribing OCPs for patients with migraine for fear of increasing the risk of a stroke, although OCPs are probably safe to use in most patients with common migraine.

**1-21. The answer is c.** (*Stein, 5/e, p 504.*) Warfarin is the principal agent recommended for the prophylaxis of acute pulmonary embolus in patients who receive total hip replacement. Warfarin is started preoperatively, and the daily dose is adjusted to maintain an international normalized ratio (INR) of 2 to 3. The value of aspirin in this setting is unclear. Early ambulation and elastic stockings are also important in preventing thromboembolism, but are not adequate in themselves in this high-risk situation.

**1-22 through 1-23. The answers are 1-22 e, 1-23 b.** (*Behrman, 16/e, pp 1704–1705. McMillan, 3/e, pp 1808–1809. Rudolph, 20/e, pp 1762–1763.*) Lymphocytic (Hashimoto's) thyroiditis is a typical organ-specific autoimmune disease characterized by lymphocytic infiltration of the thyroid gland with or without goiter. It is the most common cause of juvenile hypothyroidism, peaking in adolescence and affecting as many as 1% of school children. The condition is four to seven times more prevalent in girls than in boys and may persist for many years without symptoms. Patients are initially euthyroid, but with the eventual atrophy of the gland, they become hypothyroid. Spontaneous remission can occur in one-third of the affected adolescents. Hashimoto's thyroiditis is not related to endemic goiter caused by iodine deficiency.

Autoimmune thyroiditis is associated with many other autoimmune disorders; its association with Addison's disease and insulin-dependent diabetes mellitus is called type II polyglandular autoimmune disease (Schmidt syndrome). Family clusters of autoimmune thyroiditis are common; nearly 50% of the patients have siblings with antithyroid antibodies.

In Hashimoto's thyroiditis, thyroid function tests are often normal, although an elevated thyroid-stimulating hormone (TSH) level may be seen in a euthyroid child. With progressive thyroid failure, T<sub>3</sub> and T<sub>4</sub> levels drop and TSH level rises. Most patients have titers of thyroid antimicrosomal

antibodies; elevated antithyroglobulin titers occur infrequently. Blocking TSH antibodies are thought to be related to development of hypothyroidism. Congenital rubella infection can cause late-onset thyroiditis and hypothyroidism on an autoimmune basis. Antirubella antibodies cannot be used for diagnostic purposes in this 13-year-old child because she has probably been immunized with the attenuated vaccine or may have had rubella in childhood.

**1-24. The answer is b.** (*Mehta, pp 296–297.*) A Baker's cyst occurs in the midline of the popliteal fossa and is often a complication of rheumatoid arthritis. The cyst represents a diverticulum of the synovial sac that protrudes through the joint capsule of the knee. The knee is composed of 12 different bursae. Anserine bursitis occurs with inflammation of the bursa on the medial side of the proximal tibia. There is localized tenderness and swelling over the knee. Prepatellar bursitis is called *housemaid's knee* (i.e., from scrubbing floors) and is characterized by inflammation of the bursa anterior to the patella. Usually, the history supports the diagnosis. Inflammation of the infrapatellar bursa is called *clergyman's* or *carpet-layer's knee*. Deep venous thrombosis (DVT) is due to partial or complete occlusion of a vein by a thrombus and may be characterized by a painful, swollen calf or thigh. Occasionally, there will be a positive Homan sign (pain with dorsiflexion of the foot), but often a DVT will be asymptomatic.

**1-25. The answer is c.** (*Rock, 8/e, pp 485–497.*) Surgical abortion is among the safest procedures in medicine, with a serious complication rate in the first trimester of less than 1% and a mortality of only one-twentieth that of term delivery. In the first trimester, suction dilatation and curettage is the method of choice. The oral agent RU-486 followed by injection of prostaglandin has been shown to be highly effective and safe in European trials, but as of 2000 this medication was not yet available for clinical use in the United States. It is effective up to about 9 wk of gestation. 15-methyl  $\alpha$ -prostaglandin can be used as an intramuscular abortifacient, as can prostaglandin E<sub>2</sub> suppositories or intraamniotic prostaglandin F<sub>2a</sub> for second-trimester induction of preterm labor. Intraamniotic injection of hypertonic saline is no longer considered appropriate because it has a much higher incidence of serious complications including death, hyperosmolar crisis, cardiac failure, peritonitis, hemorrhage, and coagulation abnormalities. There are far better medicines available, and saline should no longer be used.

**1-26. The answer is b.** (Wallace, 14/e, pp 1031–1035.) Cataract is the main cause of visual loss globally and is the most common eye problem associated with age in the United States. It can be treated surgically. Risk factors include hypertension, diabetes, exposure to ultraviolet radiation, and corticosteroid therapy. Diabetic retinopathy is less likely to occur in recent-onset diabetes, particularly if the diabetes is well controlled. Xerophthalmia refers to blindness due to vitamin A deficiency. Age-related macular degeneration is the leading cause of blindness for persons over the age of 65 in the United States. Prevalence is estimated to be from 6% to 16%. Its pathophysiology is not well understood.

**1-27. The answer is d.** (Fauci, 14/e, pp 2120, 2192–2193. Goldman, 21/e, p 1102.) Persons with Marfan syndrome have arm spans that are greater than their height and an above-average crown-to-heel height. Joints are hyperextensible and patients have long, spiderlike, slender fingers (arachnodactyly). The Steinberg sign or thumb sign is positive when the fingers are clenched over the thumb and the thumb protrudes beyond the ulnar margin of the hand. These patients often have a high-arched palate, kyphoscoliosis, subluxation of the lens, and a murmur of mitral valve prolapse. Aortic regurgitation and dissection of the aorta may complicate Marfan syndrome. Patients with Lesch-Nyhan syndrome (X-linked disorder) present with self-mutilation, choreoathetosis, spasticity, gout, and mental retardation. Patients with gonadal dysgenesis or Turner syndrome are 45,X; the syndrome is characterized by primary amenorrhea, short stature, webbed neck with low posterior hairline, and multiple congenital abnormalities. Patients with Ehlers-Danlos syndrome (EDS) present with hyperelasticity of the skin (“rubber man” syndrome) and hypermobile joints. Noonan syndrome is an autosomal dominant disorder characterized by webbed neck, short stature, and congenital heart disease. Patients have normal karyotypes and normal gonads.

**1-28. The answer is c.** (Behrman, 16/e, pp 1650–1651. McMillan, 3/e, pp 1555–1556. Rudolph, 20/e, pp 1404–1405.) At 1 year of age, 0.7% of boys born at term still have cryptorchidism. In adults with cryptorchidism, the risk of testicular malignancy is much higher than in unaffected men. Orchiopexy does not eliminate this risk, but repositioning the testes makes them accessible for periodic examinations. Whether the testes are brought into the scrotum or not, the sperm count can be reduced. The failure of the

testes to develop, and their subsequent atrophy, can be detected by 6 mo of age. Torsion of the testis is a potential risk because of the excessive mobility of the undescended testis. Orchiopexy helps to eliminate this problem.

**1-29. The answer is e.** (CDC, *MMWR* 1999;48, pp 5–7.) Two doses of vaccine intramuscularly, one immediately and one 3 days later, are recommended for those who were previously immunized. A primary course of vaccination consists of three doses of one of the three approved vaccines at 0, 7, and 21 or 28 days. It is recommended for persons in high-risk groups, such as veterinarians, animal handlers, and certain laboratory personnel.

**1-30. The answer is e.** (Schwartz, 7/e, pp 1681–1684.) This patient has cytologic evidence of a papillary lesion, possibly papillary carcinoma. Papillary carcinoma is a relatively nonaggressive lesion with long-term survival (>20 years) of more than 90%. The lesion is frequently multicentric, which argues for more complete resection. Metastases, when they occur, are usually responsive to surgical resection or radioablation therapy. Removal of the involved lobe, and possibly the entire thyroid gland, is appropriate. Central and lateral lymph node dissection is performed for clinically suspect lymph nodes. Papillary carcinoma is frequently multifocal. Bilateral disease mandates total thyroidectomy. The use of radioactive  $^{131}\text{I}$ , however, is contraindicated in pregnancy and should be used with caution in women of childbearing age.

**1-31. The answer is a.** (Ludman, pp 33, 42–45.) Acute sinusitis is predominantly due to *Streptococcus pneumoniae*, *Haemophilus influenzae*, or *Moraxella catarrhalis* infection that occurs when the cleaning mechanism—namely, the ciliary activity through the sinuses into the nasal passages—fails. Patients often complain of headache, facial pain, nasal congestion, and purulent discharge. Facial pain is worsened with percussion of the affected sinus and cloudiness of the sinus may be seen with transillumination. Computed tomography (CT) films of the sinuses (air-fluid levels) are the best method of making a definitive diagnosis but should only be done if the patient fails to respond to a 2-wk course of antibiotic therapy aimed at the common bacteria. Chronic sinusitis occurs after adequate treatment of acute sinusitis has failed to eradicate the symptoms. Common organisms for chronic sinusitis include anaerobes and *Staphylococcus aureus*. Ludwig's angina is a rare accumulation of pus in the floor of the mouth (cellulitis) and

causes induration of the neck. Orbital cellulitis may follow ethmoid or maxillary sinusitis and causes the upper eyelid to become swollen, red, and tender. Vincent's angina is a necrotizing ulcerative gingivitis (trench mouth).

**1-32. The answer is b.** (*Fauci, 14/e, pp 713–717.*) Definitive diagnosis is made by demonstrating greater than 10% plasma cells in bone marrow. None of the other findings are specific enough for definitive diagnosis. Renal biopsy would not be helpful.

**1-33. The answer is e.** (*Bradley, 3/e, p 1905.*) Butyrophenones, the most commonly prescribed of which is haloperidol, routinely produce some signs of parkinsonism if they are used at high doses for more than a few days. This psychotic young woman proved to be less sensitive to the parkinsonian effects of the phenothiazine thioridazine than she was to those of haloperidol. Adding the anticholinergic trihexyphenidyl may also have helped to reduce the patient's parkinsonism. Another commonly used medication that can cause parkinsonism, in addition to tardive dyskinesia, is metoclopramide (Reglan).

**1-34. The answer is e.** (*DiSaia, 5/e, pp 153–160.*) Women who have invasive vulvar carcinoma are usually treated surgically. If the lesion is unilateral, is not associated with fixed or ulcerated inguinal lymph nodes, and does not involve the urethra, vagina, anus, or rectum, then treatment usually consists of radical vulvectomy and bilateral inguinal lymphadenectomy. If inguinal lymph nodes show evidence of metastatic disease, bilateral pelvic lymphadenectomy is usually performed. Radiation therapy, though not a routine part of the management of women who have early vulvar carcinoma, is employed (as an alternative to pelvic exenteration with radical vulvectomy) in the treatment of women who have local, advanced carcinoma.

**1-35. The answer is a.** (*Hales, 3/e, p 573.*) The symptoms experienced by this patient are classical symptoms of hyperventilation, which commonly is associated with panic disorder and other anxiety states. Hyperventilation causes a drop in blood CO<sub>2</sub> and alkalosis, which in turn causes a decrease in the ionized fraction of the serum calcium and constriction of the cerebral vessels. Dizziness, lightheadedness, and feelings of derealization follow the cerebral hypoxia. The lower ionized calcium level causes

signs of tetany, such as painful muscle spasms in the hands, perioral tingling, and paresthesias. Breathing into a paper bag reverses the symptoms because the recycled air has a higher concentration of carbon dioxide than does normal air.

**1-36. The answer is c.** (*Seidel, 4/e, pp 476–478.*) Coarctation of the aorta is narrowing of the aorta usually just distal to the origin of the ductus arteriosus and subclavian artery. Patients may complain of epistaxis, headache, cold peripheral extremities, and claudication. Absent, delayed, or markedly diminished femoral pulses may also be found. The low arterial pressure in the legs in the face of hypertension in the arm is also a clue to the diagnosis. Chest radiograph in coarctation shows rib notching secondary to the dilated collateral arteries. Patent ductus arteriosus (PDA) is associated with a loud continuous murmur. Tetralogy of Fallot consists of ventricular septal defect (VSD), pulmonic stenosis (PS), dextroposition of the aorta, and right ventricular hypertrophy (RVH).

**1-37. The answer is c.** (*Seidel, 4/e, pp 382, 392–393.*) This patient has a pleural effusion most likely due to tuberculosis. Chest examination of a pleural effusion will reveal distant or absent breath sounds, a pleural friction rub, decreased fremitus, and flatness to percussion. A pleural friction rub is a raspy, grating sound heard on both inspiration and expiration due to inflamed surfaces rubbing against each other. Occasionally, exaggerated bronchial breath sounds are audible at the area of the effusion.

**1-38. The answer is a.** (*Schatzberg, 2/e, p 710.*) Tricyclic antidepressants such as clomipramine and amitriptyline and selective serotonin reuptake inhibitors (SSRIs) such as paroxetine and sertraline, as well as monoamine oxidase inhibitors (MAOIs), can cause erectile dysfunction, delayed ejaculation, anorgasmia, and decreased libido. Bupropion, mirtazapine, trazodone, and nefazodone, in contrast, do not affect sexual functions in a negative way.

**1-39. The answer is a.** (*Fauci, 14/e, p 487.*) Symptoms of chronic toxicity of vitamin A (25,000 U or more for a protracted period) include bone pain, hyperostosis, hair loss, dryness and fissures of the lips, and weight loss. High doses of vitamin C for long periods can cause an increase in the

risk of oxalate kidney stones and uricosuria. Vitamin E excess is present in persons receiving anticoagulants and in premature infants, and can prolong prothrombin time. Vitamin D excess results in hypercalcemia. Excess of vitamin B<sub>1</sub> or thiamin has not been described. Vitamin K excess results in blockage of the effect of anticoagulants. Excess most frequently occurs in the fat-soluble vitamins (A, D, E, K).

**1-40. The answer is c.** (*Behrman, 16/e, pp 52–57. McMillan, 3/e, pp 531–536. Rudolph, 20/e, pp 39–45.*) Adolescence is a time of major physical, cognitive, and emotional changes. The tasks of the adolescent are directed toward determining his or her ultimate adult self. He or she must become independent of his or her parents, and in so doing, take responsibility for his or her own welfare and start preparing for his or her future work or career. He or she must define himself or herself sexually and move toward lasting attachments. The range of normality is broad and the variations numerous. Evaluation of the adolescent requires weighing the normal and abnormal tendencies to determine where the balance lies. To neglect schoolwork and have no vision or plan for the future suggests either immaturity or depression. A certain degree of concern for appearance is a healthy adolescent phenomenon. On the other hand, excessive concern for physical well-being and physical symptoms suggests an abnormal level of anxiety or depression. Constant quarreling with friends indicates a lack of flexibility and accommodation. Close friends help in the separation from parents and the achievement of independence by providing mutual support and self-justification. Bickering with siblings, on the other hand, is a holdover from childhood and, if not excessive, may be considered normal. Brief superficial romantic attractions fueled more by fantasy than reality start in early to middle adolescence. These are rehearsals for the more serious attachments to come.

**1-41. The answer is c.** (*Fauci, 14/e, pp 1334–1335.*) The patient's chest pain is most likely due to pericarditis. An enlarged cardiac silhouette without other chest x-ray findings of heart failure suggests pericardial effusion. Echocardiography is the most sensitive, specific way of determining whether or not pericardial fluid is present. The effusion appears as an echo-free space between the moving epicardium and stationary pericardium. It is unnecessary to perform cardiac catheterization for the purpose of evalu-



ating pericardial effusion. Radionuclide scanning is not a preferred method for demonstrating pericardial fluid.

**1-42. The answer is c.** (*Fauci, 14/e, pp 1336–1337.*) The patient has developed cardiac tamponade, a condition in which pericardial fluid under increased pressure impedes diastolic filling, resulting in reduced cardiac output and hypotension. On exam there is elevation of jugular venous pressure. The jugular venous pulse shows a sharp x descent, the inward impulse seen at the time of the carotid pulsation. In contrast to pulmonary edema, the lungs are usually clear. Neither a strong apical beat nor an S<sub>3</sub> gallop is expected in tamponade.

**1-43. The answer is c.** (*Cunningham, 20/e, pp 718–725. DeCherney, 8/e, pp 380–386.*) Preeclampsia is defined as hypertension, proteinuria (>300 mg/24 h), and/or nondependent edema of the face and hands. Risk factors for preeclampsia include black race, nulliparity, multiple gestations, extremes of age (<15 or >35 years), chronic hypertension, and a family history positive for preeclampsia. Eclampsia is defined as seizures in a patient with preeclampsia. The cure for preeclampsia/eclampsia is delivery. Magnesium sulfate is often used for seizure prophylaxis and management.

The **HELLP syndrome** (Hemolysis, Elevated Liver enzymes, Low Platelets) is a variant of preeclampsia.

**1-44. The answer is d.** (*Schwartz, 7/e, pp 169, 204.*) Most pelvic fractures are the result of automobile-pedestrian accidents, and these fractures are a frequent cause of death. The pelvis is extremely vascular with a diffuse blood supply that makes hemorrhage common and surgical control of bleeding difficult. This patient has a type II fracture (single break in pelvic ring) through a non-weight-bearing portion of the pelvis. These fractures are best treated by bed rest until hemodynamic stability is assured and thereafter by gentle ambulation as pain permits. The clinician must watch carefully for associated injuries to the bladder, urethra, and colon and must be alert to the many other possible concurrent injuries to an elderly patient who has suffered a collision, even a low-velocity attack from a pizza man.

**1-45. The answer is c.** (*Bradley, 3/e, pp 1552–1554.*) Although papilledema must be considered evidence of a potentially life-threatening

intracranial process, optic nerve bulging in this young woman is most likely from pseudotumor cerebri. This is a relatively benign condition that occasionally develops in obese or pregnant women. Cerebrospinal fluid (CSF) pressure is markedly elevated in these patients, but they are not at risk of herniation. The condition is presumed to arise from hormonal problems. Without treatment, the increased intracranial pressure will produce optic nerve damage with loss of visual acuity.

**1-46. The answer is a.** (*Bradley, 3/e, pp 1552–1554.*) With pseudotumor cerebri, removal of some of the CSF produces a protracted lowering of the intracranial pressure. This pressure reduction is desirable because persistent pressure elevations will damage the optic nerve. Pseudotumor cerebri in the pregnant woman usually abates soon after the fetus leaves its mother, but this condition is not serious enough to justify termination or acceleration of a pregnancy. Vitamin excess may cause pseudotumor in some persons. Diuretics are sometimes used to manage patients who are not pregnant, but they are usually less effective than repeated lumbar puncture when that is practical.

**1-47 through 1-48. The answers are 1-47 b, 1-48 d.** (*Holmes, 3/e, ch 79, p 1081.*) *Chlamydia trachomatis* is the most frequently reported bacterial sexually transmitted disease (STD) in the United States. Infections of the cervix may present as a friable cervix, but are most often without signs or symptoms. Pelvic inflammatory disease (PID) caused by chlamydia often presents with milder symptoms than when gonorrhea is the cause. Prompt treatment reduces the occurrence of long-term sequelae such as infertility, ectopic pregnancy, and chronic pelvic pain. The risk of infertility appears to be higher for chlamydial infections compared to any other STD. Screening women is important to reduce the risk of PID and its sequelae.

**1-49. The answer is b.** (*Freedberg, 5/e, pp 636–643.*) Erythema multiforme is often caused by drugs. It is most important to identify the offending agent. Phenytoin can induce erythema multiforme, so this information is critical. Sulfa drugs, barbiturates, and penicillin can also cause the rash. The rash with its target lesions should not be confused with toxic shock or measles. The sore throat is likely to be a symptom from the process itself, suggesting involvement of the oral mucosa.

**1-50. The answer is d.** (*Stein, 5/e, p 1861.*) Episodic hypoglycemia at night is followed by rebound hyperglycemia. This response, called the Somogyi phenomenon, develops in response to excessive insulin administration. An adenergetic response to hypoglycemia results in increased glycogenolysis, gluconeogenesis, and diminished glucose uptake by peripheral tissues. After hypoglycemia is documented, the insulin dosages are slowly reduced.

*This page intentionally left blank.*

# BLOCK 2

---

## Answers

**2-1 through 2-2. The answers are 2-1 a, 2-2 d.** (*Behrman, 16/e, pp 1285–1287. McMillan, 3/e, pp 1214–1216. Rudolph, 20/e, pp 672–677.*) Of the choices given, bronchiolitis is the most likely, although asthma, pertussis, and bronchopneumonia can present similarly. The family history of upper respiratory infections, the previous upper respiratory illness in the patient, and the signs of intrathoracic airway obstruction make the diagnosis of bronchiolitis more likely. Viral croup, epiglottitis, and diphtheria are not reasonable choices because there are no signs of extrathoracic airway obstruction.

The most likely cause of the illness is infection by respiratory syncytial virus, which causes outbreaks of bronchiolitis of varying severity, usually in the winter and spring. Other viruses, such as parainfluenza and the adenoviruses, have also been implicated in producing bronchiolitis. Treatment is usually supportive in this generally self-limited condition. Ribavirin, an expensive antiviral agent, is reserved for the most severe cases, those who have congenital heart disease, BPD, immune deficiency, and chest wall abnormalities.

**2-3. The answer is b.** (*Schwartz, 7/e, pp 1158–1161.*) Corrosive injuries of the esophagus most frequently occur in young children due to accidental ingestion of strong alkaline cleaning agents. Significant esophageal injury occurs in 15% of patients with no oropharyngeal injury, while 70% of patients with oropharyngeal injury have no esophageal damage. Signs of airway injury or imminent obstruction warrant close observation and possibly tracheostomy. The risk of adding injury, particularly in a child, makes esophagoscopy contraindicated in the opinion of most surgeons. Administration of oral “antidotes” is ineffective unless given within moments of ingestion; even then, the additional damage potentially caused by the chemical reactions of neutralization often makes use of them unwise. A barium esophagogram is usually done within 24 h unless evidence of perforation is present. In most reports, steroids in conjunction with antibiotics

reduce the incidence of formation of strictures from about 70% to about 15%. Vomiting should be avoided, if possible, to prevent further corrosive injury and possible aspiration. It is probably wise to avoid all oral intake until the full extent of injury is ascertained.

**2-4. The answer is d.** (*Chin, 17/e, pp 75–77, 521–525.*) Clinical symptoms caused by *Mycobacterium bovis* are indistinguishable from those of *M. tuberculosis*. This patient is unlikely to have been in contact with someone with active tuberculosis (TB), given that he lives in a rural area. His occupation, however, may lead to contact to *M. bovis*. Brucellosis may also cause fever, sweats, fatigue, but is not associated with cough. The incubation period generally does not exceed 2 mo.

**2-5. The answer is d.** (*Barnett, 3/e, pp 945–948. Osborn, pp 192–194.*) Cerebral amyloid angiopathy (CAA), or congophilic angiopathy, is the most common cause of lobar hemorrhage in elderly patients without hypertension. The deposition of amyloid beta protein, the same as that found in Alzheimer's disease, in brain blood vessels leads to disruption of the vessel walls that predisposes these patients to hemorrhage. Patients are usually over age 70, and may present with multiple cortical hemorrhages with or without a history of dementia. At times, additional hemorrhages may be seen only with the use of special imaging techniques such as gradient echo magnetic resonance imaging (MRI), which magnifies the effects of hemosiderin in regions of prior hemorrhage.

**2-6. The answer is a.** (*Yudofsky, 3/e, pp 455–459.*) The patient's persecutory delusions and disorganized thinking could suggest a psychotic disorder such as schizophrenia or brief reactive psychosis, but fluctuations in consciousness and disorientation are typically found in delirium. Disturbances in memory, language, and sleep-wake cycles are also typical of delirium. Delusions, hallucinations, illusions, and misperceptions are also common. The causes of delirium are many and include metabolic encephalopathies, such as the hyperglycemic encephalopathy experienced by the patient in the vignette; intoxication with drugs and poisons; withdrawal syndromes; head trauma; epilepsy; neoplasms; vascular disorders; allergic reactions; and injuries caused by physical agents (heat, cold, radiations).

**2-7. The answer is c.** (*Schwartz, 7/e, pp 966–967.*) Acute mesenteric ischemia may be difficult to diagnose. The condition should be suspected in patients with either systemic manifestations of arteriosclerotic vascular disease or low cardiac output states associated with a sudden development of abdominal pain that is out of proportion to the physical findings. Lactic acidosis and an elevated hematocrit reflecting hemoconcentration are common laboratory findings. Abdominal films show a nonspecific ileus pattern. The cause may be embolic occlusion or thrombosis of the superior mesenteric artery, primary mesenteric venous occlusion, or nonocclusive mesenteric ischemia secondary to low cardiac output states. A mortality of 65% to 100% is reported. The majority of affected patients are at high operative risk, but since early diagnosis followed by revascularization or resectional surgery or both is the only hope for survival, celiotomy must be performed once the diagnosis of arterial occlusion or bowel infarction has been made. Initial treatment of nonocclusive mesenteric ischemia includes measures to increase cardiac output and blood pressure and the direct intraarterial infusion of vasodilators such as papaverine into the superior mesenteric system. The patient presented in the question is at risk for both occlusive and nonocclusive mesenteric ischemic disease. If his clinical status permits, angiographic studies should be performed before the operation to establish the diagnosis and to determine whether embolectomy, revascularization, or nonsurgical management is indicated as initial treatment.

**2-8 through 2-9. The answers are 2-8 b, 2-9 a.** (*Fauci, 14/e, pp 1026–1027.*) The diffuse rash involving palms and soles would in itself suggest the possibility of secondary syphilis. The hypertrophic, wartlike lesions around the anal area are called condyloma lata and are specific for secondary syphilis. The Venereal Disease Research Laboratory (VDRL) slide test will be positive in all patients with secondary syphilis. The Weil-Felix titer has been used as a screening test for rickettsial infection. In this patient who has condyloma and no systemic symptoms, Rocky Mountain spotted fever would be unlikely. No chlamydial infection would present in this way. Blood cultures might be drawn to rule out bacterial infection such as chronic meningococemia; however, the clinical picture is not consistent with a systemic bacterial infection. Penicillin is the drug of choice for secondary syphilis. Ceftriaxone and tetracycline are usually considered to be alternate therapies. Interferon  $\alpha$  has been used in the

treatment of condyloma acuminata, a lesion that can be mistaken for syphilitic condyloma.

**2-10. The answer is a.** (*Behrman, 16/e, pp 519–521. McMillan, 3/e, pp 359–362. Rudolph, 20/e, pp 1168–1170, 1176–1180, 1203–1207.*) The absence of a major blood group incompatibility and the finding of a normal reticulocyte count argue strongly in favor of a recent fetomaternal transfusion, probably at the time of delivery. A Betke-Kleihauer stain for fetal hemoglobin-containing red cells in the mother's blood would confirm the diagnosis. After birth, erythropoiesis ceases, and the progressive decline in hemoglobin values, reaching a nadir at 6 to 8 wk of age, has been termed physiologic anemia of infancy. Iron-deficiency anemia is common in the term infant between 9 and 24 mo of age, when the iron stores derived from circulating hemoglobin have been exhausted and an exogenous dietary source of iron has not been provided. The manifestations of sickle cell disease do not appear until 4 to 6 mo of life, coincident with the replacement of fetal hemoglobin with sickle hemoglobin.

**2-11. The answer is d.** (*Sadock, 7/e, p 1691.*) This patient suffers from restless legs syndrome, a disorder characterized by the irresistible urge to move one's legs while trying to fall asleep. Patients describe the unpleasant feelings in their calves as worms or ants crawling. Only moving the legs or walking alleviates the discomfort. Restless legs syndrome can be caused by pregnancy, anemia, renal failure, and other metabolic disorders.

**2-12. The answer is c.** (*Stein, 5/e, p 2290.*) A film of the right hip is mandatory in this patient. Fracture of the hip must be ruled out, particularly in a woman with mental status abnormalities who may be prone to falls.

**2-13. The answer is b.** (*Wallace, 14/e, pp 1247–1249.*) Elders who are disabled are more likely to suffer from physical abuse or neglect. Most abuse occurs at the hands of a relative, and most abused elders are likely to live with the abuser, who is often stressed both emotionally and financially as the elder requires more care. Many abused elders become depressed as a result of abuse.

**2-14. The answer is d.** (*Behrman, 16/e, p 1782. McMillan, 3/e, p 1797. Rudolph, 20/e, p 1817.*) Glucose is nonenzymatically attached to hemoglo-



bin to form glycosylated hemoglobin. The major component of this reaction proceeds very slowly and is irreversible until the hemoglobin is destroyed. The concentration of glycosylated hemoglobin thus reflects glucose concentration over the half-life of the red cell, or about 2 to 3 mo.

**2-15. The answer is b.** (*Adams, 6/e, pp 180–182.*) The term *cluster headache* refers to the tendency of these headaches to cluster in time. They may be distinctly seasonal, but the triggering event is unknown. The pain of cluster headache is usually described as originating in the eye and spreading over the temporal area as the headache evolves. In contrast to migraine, men are more often affected than women, and extreme irritability may accompany the headache. The pain usually abates in less than an hour. Affected persons routinely have autonomic phenomena associated with the headache that include unilateral nasal congestion, tearing from one eye, conjunctival injection, and pupillary constriction. The autonomic phenomena are on the same side of the face as the pain. These phenomena are similar to those elicited by the local action of histamine and gave rise to the now largely abandoned term of *Horton histamine headaches*.

**2-16. The answer is a.** (*Lewis, 2/e, pp 579–580. Sadock, 7/e, p 2741.*) Although the relationships between emotional deprivation and failure to thrive are complex, the fact that children who are emotionally deprived do not grow well even when an adequate amount of food is available is well proved. Renee Spitz studied institutionalized children and demonstrated that, due to lack of adequate nurturing, they become apathetic, withdrawn, and less interested in feeding, which in turn causes failure to thrive and, in extreme cases, death. Spitz called this syndrome “analytic depression.” Schizophrenia and autism have not been associated with emotional deprivation in infancy.

**2-17. The answer is d.** (*Stobo, 23/e, pp 138–139.*) This patient’s chronic cough, hyperinflated lung fields, abnormal pulmonary function tests, and smoking history are all consistent with chronic bronchitis. A smoking cessation program can decrease the rate of lung deterioration and is successful in as many as 40% of patients, particularly when the physician gives a strong antismoking message and uses both counseling and nicotine replacement. Continuous low-flow oxygen becomes beneficial when arterial oxygen concentration falls below 55 mm Hg. Antibiotics are only indi-

cated for acute exacerbations of chronic lung disease, which might present with fever, change in color of sputum, and increasing shortness of breath. Oral corticosteroids are helpful in some patients, but are reserved for those who have failed inhaled bronchodilator treatments.

**2-18. The answer is c.** (*Hales, 3/e, pp 570–573.*) This patient displays typical symptoms of recurrent panic attacks. Panic attacks can occur in a wide variety of psychiatric and medical conditions. The patient is diagnosed with panic disorder when there are recurrent episodes of panic and there is at least 1 mo of persistent concern, worry, or behavioral change associated with the attacks. The attacks are not due to the direct effect of medical illness, medication, or substance abuse and are not better accounted for by another psychiatric disorder. While anxiety can be intense in generalized anxiety disorder, major depression, acute psychosis, and hypochondriasis, it does not have the typical acute presentation described here.

**2-19. The answer is c.** (*Bradley, 3/e, p 1446.*) This patient has a gradually progressive myelopathy. The differential diagnosis is broad, but multiple sclerosis (MS) is high on the list. A subset of patients with MS consists of middle-aged men with a progressive form of the disease. MRI of the spinal cord could show MS plaques in the cord or other abnormalities intrinsic to the spinal cord parenchyma, and could also exclude compressive lesions. Vascular malformations of the spinal cord can also be seen in this way, although sometimes spinal angiography is required for definitive diagnosis. Cerebral angiography would not be helpful except to evaluate for residual aneurysm, which is unlikely to be related to this patient's problem. Spinal cord biopsy is unwarranted in this case unless a specific indication is provided on neuroimaging. Visual evoked responses may be abnormal in MS, even without clinical evidence of disease, but would not account for this patient's spastic paraparesis.

**2-20. The answer is e.** (*Schatzberg, 2/e, pp 259–260.*) Bupropion is an effective antidepressant, and it has been found to be as effective as stimulants in treating attention deficit hyperactive disorder (ADHD) in children and adults. It may exacerbate tics in children with comorbid Tourette disorder.

**2-21. The answer is b.** (*Tintinalli, 5/e, pp 229–250.*) The early phase of septic shock is characterized by vasodilation, resulting in a warm, flushed patient with a normal or elevated cardiac output. Fever, agitation, or confusion is often present. In late septic shock, patients become obtunded with decreased cardiac output and hypotension that is not reversible by volume replacement. Patients with cardiogenic shock have signs of pulmonary vascular congestion (jugular venous distension, S<sub>3</sub> gallop, bilateral lung crackles), increased pulmonary capillary wedge pressure (PCWP), and decreased cardiac output. Neurogenic shock follows a spinal cord injury (warm skin, bradycardia, neurologic deficits), and hypovolemic shock is characterized by a physical examination consistent with volume depletion (tachycardia; hypotension; cool, clammy skin; poor capillary refill) and decreased PCWP. A mnemonic to remember the causes of shock is **SHOCK**: Sepsis, Hypovolemia, Other (i.e., Addison's disease), CNS (neurogenic), and Kardiatic causes.

**2-22. The answer is d.** (*Greenberg, 2/e, ch 2, p 18.*) According to the table, 10 new cases of tuberculosis developed among the 500 persons belonging to households with a case of tuberculosis at the time of the first survey. Because these 500 persons were followed for 2 years, the number of person-years of exposure is 1000. Therefore, the incidence rate is calculated as follows:

$$\frac{10 \text{ new cases}}{500 \text{ persons} \times 2 \text{ years}} = 10 \text{ cases per 1000 person-years}$$

**2-23. The answer is c.** (*Greenberg, 2/e, ch 2, p 18.*) Ten new cases of tuberculosis developed among 10,000 persons belonging to households that had no culture-positive cases at the time of the first survey. Since these 10,000 persons were followed for 2 years, the number of person-years of exposure is 20,000. Therefore, the incidence rate is calculated as follows:

$$\frac{10 \text{ new cases}}{10,000 \text{ persons} \times 2 \text{ years}} = 0.5 \text{ cases per 1000 person-years}$$

**2-24. The answer is e.** (*Greenberg, 2/e, ch 2, pp 98–99.*) The relative risk is the ratio of the incidence of a disease in a group exposed to a factor (in this case, household contact with tuberculosis) to the incidence in a group

not exposed to the factor (persons without household contact). Therefore, the relative risk is

$$\frac{\text{Incidence in households with exposure}}{\text{incidence in households without exposure}} = \frac{10}{0.5} = 20$$

Identification of groups with a high level of relative risk can be useful in planning disease control programs.

**2-25. The answer is a.** (*Yudofsky, 3/e, pp 842–843.*) Multiple cerebral infarcts cause a progressive dementia, focal neurological signs and, often, neuropsychiatric symptoms, such as depression, mood lability (but not usually elated mood), and delusions. Loose associations, catatonic posturing, and bizarre proverb interpretations are typical symptoms of schizophrenia.

**2-26. The answer is e.** (*Sabiston, 15/e, pp 324–325. Schwartz, 7/e, pp 199–200.*) Penetrating injury to the intraperitoneal or extraperitoneal rectum should be diagnosed by immediate sigmoidoscopy. Contrast studies of the rectum, when sigmoidoscopy is inconclusive, should use a water-soluble radiopaque medium such as Gastrografin. The use of barium is contraindicated since spillage of barium mixed with feces into the peritoneal cavity would increase the likelihood of subsequent intraabdominal abscesses. Instrumentation of the bullet track is also contraindicated because of the risk of injury to adjacent structures (e.g., bladder, ureters, iliac vessels). Angiography is not a sensitive method for demonstrating injury to the intestinal wall.

**2-27. The answer is d.** (*Rock, 8/e, pp 121–122.*) The clinical history presented in this question is a classic one for a ruptured tubal pregnancy accompanied by hemoperitoneum. Because pregnancy tests are negative in almost 50% of cases, they are of little practical value in an emergency. Dilation and curettage would not permit rapid enough diagnosis, and the results obtained by this procedure are variable. Posterior colpotomy requires an operating room, surgical anesthesia, and an experienced operator with a scrubbed and gowned associate. Refined optic and electronic systems have improved the accuracy of laparoscopy, but this new equipment is not always available, and the procedure requires an operating room and, usually, surgi-

cal anesthesia. Culdocentesis is a rapid, nonsurgical method of confirming the presence of unclotted intraabdominal blood from a ruptured tubal pregnancy. Culdocentesis, however, is also not perfect, and a negative culdocentesis should not be used as the sole criteria for whether or not to operate on a patient.

**2-28. The answer is d.** (*Tintinalli, 5/e, pp 1278–1280.*) The definition of drowning is death from suffocation after submersion. Fresh water drowning in swimming pools is actually more common than saltwater drowning. The patient described has noncardiogenic pulmonary edema, which is a complication of near-drowning (survival after suffocation from submersion). This is a result of direct pulmonary injury, loss of surfactant, and contaminants in the water. Respiratory failure, severe hypothermia, and neurologic injury are the three most common threats to life after submersion.

**2-29. The answer is a.** (*Stobo, 23/e, pp 794–796.*) The first step in evaluating a scrotal mass is to determine whether or not the mass is in the testis or outside the testis. Most solid masses arising from within the testis are malignant. Palpation of the scrotal mass and transillumination (holding a flashlight directly against the posterior wall of the scrotum) will distinguish testicular lesions from other masses within the scrotum, such as hydrocele. Ultrasonography will confirm a solid testicular mass. Human chorionic gonadotropin (hCG) and  $\alpha$  fetoprotein are important in assessment of seminoma versus nonseminomatous testicular cancer once testicular mass lesion is confirmed.

**2-30. The answer is b.** (*Mishell, 3/e, pp 179–182.*) Vaginismus is painful spasm of the pelvic muscles and vaginal outlet. It is usually psychogenic. It should be differentiated from frigidity, which implies lack of sexual desire. Treatment is primarily psychotherapeutic, as organic vulvar (such as atrophy, Bartholin's gland cyst, or abscess) or pelvic causes are very rare. Vaginismus should be differentiated from dyspareunia, which is deep pelvic pain with coitus. Dyspareunia is frequently associated with pelvic pathology such as endometriosis, pelvic adhesions, or ovarian neoplasms.

**2-31. The answer is b.** (*Seidel, 4/e, p 481.*) An acquired arteriovenous fistula may be diagnosed by the presence of a continuous murmur and a pal-

pable thrill over an area of previous trauma. The large pulse pressure is an indication that a large portion of the cardiac output is bypassing the systemic vascular resistance through the fistula.

**2-32. The answer is c.** (*Schwartz, 7/e, pp 601–602, 1717.*) The thyroid gland originates embryologically from the foramen cecum at the base of the tongue. Normally, the thyroglossal duct becomes obliterated and resorbed, but portions may remain patent and become filled with serous fluid, which produces a midline cervical mass. Observe that in the scan of the patient described in the question, the mass is central and appears not to be part of the gland itself.

**2-33. The answer is d.** (*Berson, pp 40–49.*) A cataract is opacity of the lens; patients often present complaining of a disturbance in vision. When the lens has a cataract, the red reflex is diminished and it becomes difficult to see the fundus through the opacity. Patients with macular degeneration present with central vision loss, and drusen bodies (yellow-white lesions), retinal atrophy, and neovascularization are often found on funduscopic examination. Presbyopia is a decreased ability to focus on near objects (because of loss of accommodation) that occurs with aging. Glaucoma is an insidious disease, and symptoms occur late in the disease. Patients complain of peripheral vision loss (central vision is spared until late in the disease) and scotomas. Intraocular pressure is usually elevated.

**2-34. The answer is c.** (*Greenfield, 2/e, pp 1109–1127.*) Various types of colonic polyps can be distinguished on pathologic examination. Adenomatous polyps are distributed throughout the entire large bowel, more commonly in the right and left colon than the rectum. They are often pedunculated and show an increased number of glands compared with normal mucosa. Although polyps that appear in familial polyposis are indistinguishable from single adenomatous polyps, they manifest much earlier in life. Carcinomatous changes in patients who have familial polyposis occur approximately 20 years before carcinomatous changes of the bowel occur among patients in the general population.

**2-35. The answer is c.** (*Pozgar, 7/e, pp 476–477.*) The major issues are confidentiality and duty to warn a third party. When a person initially learns that he or she is human immunodeficiency virus (HIV) positive, this information

in itself is often overwhelming. The patient may not feel able or willing to inform exposed partners. The best approach is to try to convince the patient of the necessity of this, perhaps at a later visit. Some states have enacted laws that allow the physician to inform third parties of HIV exposure, but only after efforts by the physician have failed to convince the person to disclose. These laws protect the physician against legal liability for breach of confidentiality, but they do not obligate the physician to disclose to third parties. Some few state laws allow only state disease intervention specialists (DISs) to inform third parties of HIV exposure after the physician has contacted DIS. Many states do not have any of these laws, and the only option is to try to convince an infected patient to disclose. As a rule, for all other sexually transmitted diseases (STDs), partner notification is confidential and voluntary, and the DISs cannot inform third parties without the consent of the infected person, even if requested by the physician. They can assist consenting infected persons in informing contacts either by doing it for them (contacts are never informed of the source) or coaching them to do it themselves.

**2-36. The answer is b.** (*Stobo, 23/e, pp 324–330.*) The primary treatment for Type 2 diabetes is dietary. About half of all patients can maintain normal blood sugar with weight reduction. If weight reduction fails, a number of oral hypoglycemics are available as the next step.

**2-37. The answer is b.** (*Behrman, 16/e, pp 1126–1127. McMillan, 3/e, pp 618–619. Rudolph, 20/e, pp 1062–1063.*) Endoscopic examination of the esophagus and stomach is a diagnostic method of determining the extent of the mucosal injury. Vomiting is to be avoided since it would expose the mucosal surfaces to the caustic agent a second time. The child can be given small amounts of milk or water, but large amounts, which might cause vomiting, are unwise. Neutralization of the caustic can result in an exothermic reaction and produce a thermal burn. The use of steroids after endoscopy in second-degree chemical burns of the esophagus has been effective in diminishing the inflammatory response in some patients. Optimal treatment is still controversial and requires expert consultation or review of the most current literature. Charcoal, however, does not absorb the alkaline agent in drain cleaner.

**2-38. The answer is b.** (*Schwartz, 7/e, pp 1253–1255.*) The effects of radiation on the intestine depend on a variety of factors, which include the age

of the patient, temperature, degree of oxygenation, and metabolic activity. Acute intestinal radiation injury is manifested in the bowel by the cessation of viable cell production and is seen clinically as diarrhea or gastrointestinal bleeding. Progressive vasculitis and fibrosis are seen in the latter stages.

**2-39. The answer is d.** (*Adams, 6/e, p 1208.*) The rapid onset of bulbar paresis is consistent with acute inflammatory demyelinating polyneuropathy (AIDP, or Guillain-Barré syndrome), botulism, tick paralysis, and several other conditions. The normal conduction velocities argue against demyelinating neuropathy, which may be associated with *Campylobacter jejuni*. Cytomegalovirus (CMV), and *Treponema pallidum* may cause several different neurologic syndromes, but acute bulbar paresis is not among them. *Chlamydia pneumoniae* is under investigation as a cause of atherosclerosis, strokes, and multiple sclerosis, but does not cause acute motor weakness.

**2-40. The answer is c.** (*Adams, 6/e, p 1208.*) Botulism is a disorder of the neuromuscular junction (NMJ). The characteristic findings are decremental response of the muscles to repetitive stimulation of the nerve at a low frequency (2 to 5 Hz) and incremental response to repetitive stimulation at high frequency (20 to 50 Hz). Other disorders of the NMJ, such as myasthenia gravis and Lambert-Eaton myasthenic syndrome (LEMS), also manifest with decremental response to repetitive stimulation at low frequencies due to depletion of acetylcholine in the synaptic cleft. Higher rates of stimulation lead to increased calcium in the presynaptic terminal, which allows more acetylcholine to be released in presynaptic disorders such as botulism and LEMS, thereby increasing the response of muscle. In myasthenia gravis, which is characterized by loss of acetylcholine receptors postsynaptically, there is no increase in response at higher rates of stimulation, since there is already a maximal amount of acetylcholine present in the synaptic cleft. Abnormal visual evoked and brainstem auditory evoked potentials are seen in disorders affecting central pathways, as in multiple sclerosis. Conduction block occurs in demyelinating disorders affecting the nerves. Fibrillation potentials are present in denervation and certain myopathic conditions; they may occur in botulism, as well as in patients treated with botulinum toxin for therapeutic purposes, but this is not diagnostic of clinical botulism.



**2-41. The answer is c.** (*Behrman, 16/e, pp 35–37. McMillan, 3/e, pp 756–761. Rudolph, 20/e, pp 121–128.*) At 6 to 6½ mo of age, infants are able to sit alone, leaning forward to support themselves with arms extended—the so-called tripod position. They can reach for an object by changing the orientation of the torso. They can purposefully roll from a prone to supine as well as from a supine to prone position. By 12 mo, they can grasp a pellet between the thumb and forefinger without ulnar support. Motor development occurs in a cephalocaudal and central-to-peripheral direction. Therefore, truncal control precedes arm control, which precedes finger dexterity.

**2-42. The answer is c.** (*LaDou, 2/e, p 398.*) Carbon disulfide, chloroprene, estrogens, excessive heat, lead, and ionizing radiation have all been strongly linked to oligospermia. Exposure to lead can occur during the manufacturing of storage batteries. Chromium, nickel, and antimony levels are measured in urine and are not associated with oligospermia.

**2-43. The answer is c.** (*Fauci, 14/e, pp 1941–1944.*) Tophaceous gout is characterized by the finding in synovial fluid of monosodium urate crystals that are needle-shaped and strongly negative birefringent (bright yellow when parallel to the axis). Gouty attacks may be precipitated by trauma, medications that inhibit tubular secretion of uric acid (aspirin, hydrochlorothiazide), surgery, stress, alcohol, and a high-protein diet. Patients may have an accumulation of tophi in and around the joints and earlobes. Radiographs may show “rat bite” erosions. Pseudogout is due to deposition of calcium pyrophosphate dihydrate (CPPD); these crystals are rhomboid-shaped and weakly positive birefringent (blue when parallel to the axis). Calcium oxalate deposition disease is usually seen in patients with end-stage renal disease, and calcium phosphate deposition disease causes calcific tendinitis or Milwaukee shoulder.

**2-44. The answer is c.** (*Reece, 2/e, pp 1142–1145.*) The most probable diagnosis in this case is acute pancreatitis. The pain caused by a myoma in degeneration is more localized to the uterine wall. Low-grade fever and mild leukocytosis may appear with a degenerating myoma, but liver function tests are usually normal. The other “obstetric” cause of epigastric pain, severe preeclamptic toxemia (PET), may exhibit disturbed liver function

[sometimes associated with the HELLP syndrome (hemolysis, elevated liver enzymes, low platelets)], but this patient has only mild elevation of blood pressure and no proteinuria. Acute appendicitis in pregnancy is one of the more common nonobstetric causes of abdominal pain. In pregnancy, symptoms of acute appendicitis are similar to those of nonpregnant patients, but the pain is more vague and poorly localized and the point of maximal tenderness moves with advancing gestation to the right upper quadrant. Liver function tests are normal with acute appendicitis. Acute cholecystitis may cause fever, leukocytosis, and pain of the right upper quadrant with abnormal liver function tests, but amylase levels would be only mildly elevated, if at all, and the pain would be less severe than described in this patient. The diagnosis that fits the clinical description and the laboratory findings is acute pancreatitis. This disorder may be more common during pregnancy, with an incidence of 1:100 to 1:10,000 pregnancies. Cholelithiasis, chronic alcoholism, infection, abdominal trauma, some medications, and pregnancy-induced hypertension are known predisposing factors. Patients with pancreatitis are usually in acute distress—the classic finding is a person who is rocking with knees drawn up and trunk flexed in agony. Fever, tachypnea, hypotension, ascites, and pleural effusion may be observed. Hypotonic bowel sounds, epigastric tenderness, and signs of peritonitis may be demonstrated on examination.

Leukocytosis, hemoconcentration, and abnormal liver function tests are common laboratory findings in acute pancreatitis. The most important laboratory finding is, however, an elevation of serum amylase levels, which appears 12 to 24 h after onset of clinical disease. Values may exceed 200 U/dL (normal values are 50 to 160 U/dL). A useful diagnostic tool in the pregnant patient with only modest elevation of amylase values is the amylase/creatinine ratio. In patients with acute pancreatitis, the ratio of amylase clearance to creatinine clearance is always greater than 5% to 6%.

Treatment considerations for the pregnant patient with acute pancreatitis are similar to those in nonpregnant patients. Intravenous hydration, nasogastric suction, enteric rest, and correction of electrolyte imbalance and of hyperglycemia are the mainstays of therapy. Careful attention to tissue perfusion, volume expansion, and transfusions to maintain a stable cardiovascular performance are critical. Gradual recovery occurs over 5 to 6 days.

**2-45. The answer is c.** (*Freedberg, 5/e, pp 1482–1487.*) The patient has the typical areas of involvement of seborrheic dermatitis. This common dermatitis appears to be worse in many neurological diseases. It is also very common and severe in patients with acquired immune deficiency syndrome (AIDS). In general, symptoms are worse in the winter. *Pityrosporum ovale* appears to play a role in seborrheic dermatitis and dandruff, and the symptoms improve with the use of certain antifungal preparations (e.g., ketoconazole) that decrease this yeast. Mild topical steroids also produce an excellent clinical response.

**2-46. The answer is a.** (*Shuaib, p 33.*) The head computed tomography (CT) scan is the mainstay of emergency department management of acute stroke. It is crucial to exclude intracranial hemorrhage prior to the potential administration of intravenous thrombolytic agents. A cerebral angiogram may play a role in the management of the acute stroke patient, particularly if there is evidence of cerebral or subarachnoid hemorrhage or if there exists a possibility of performing intraarterial thrombolysis, but CT scan is required first. T<sub>2</sub>-weighted MRI may also show ischemic and hemorrhagic injury, but infarction may not appear this quickly on MRI and hemorrhage may also be missed. MRI is also not as widely available as CT. In the absence of evidence of trauma at the time of this patient's fall, C-spine MRI and skull x-rays play no role in the management of this patient.

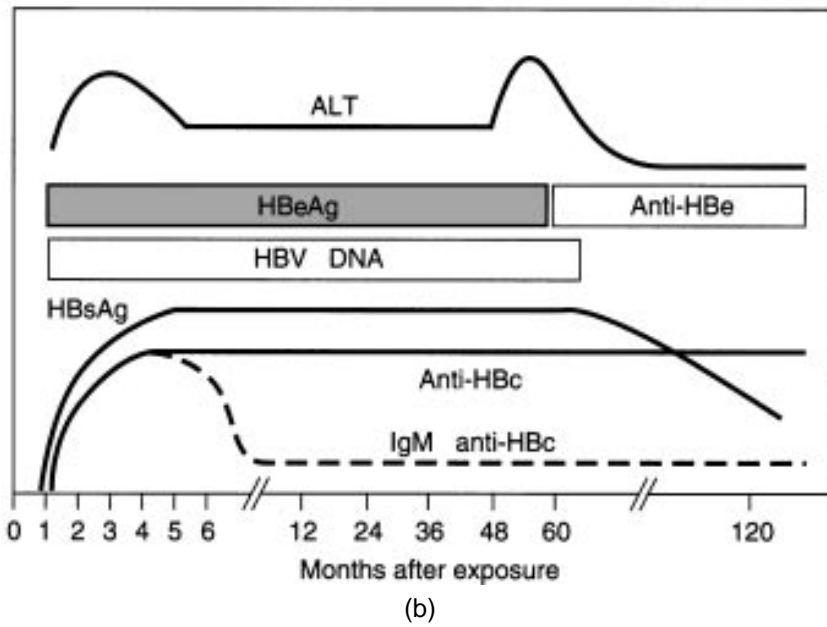
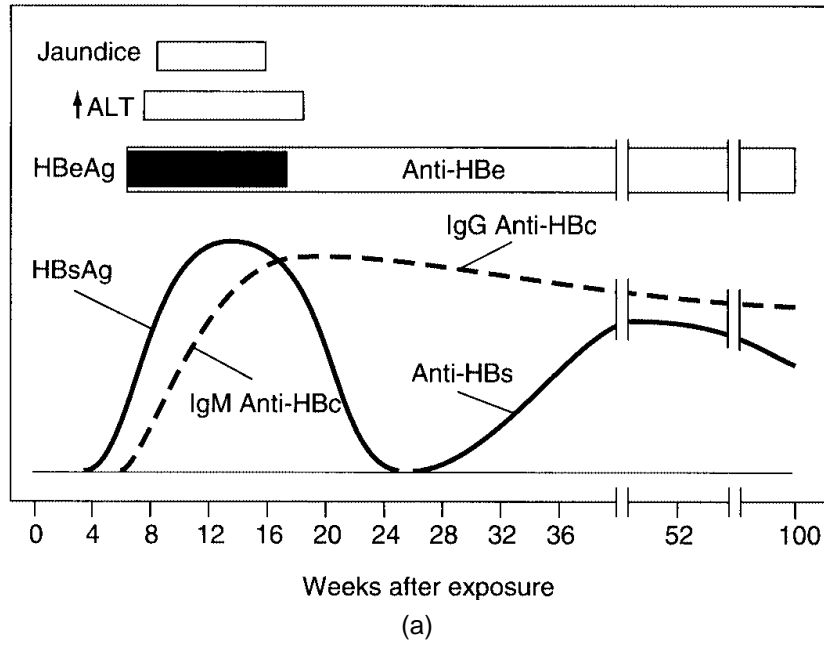
**2-47. The answer is a.** (*Shuaib, pp 328–329.*) Thrombolytic therapy with intravenous recombinant tissue plasminogen activator (rt-PA) has been shown in a large, multicenter randomized trial sponsored by the National Institutes of Health (NIH) to be of benefit to patients with acute ischemic stroke who can be treated early enough. The study demonstrated a statistically significant benefit from the use of rt-PA in the treatment of ischemic stroke patients who can be treated within 3 h of symptom onset. A total of 624 patients arriving at the hospital within 3 h of symptom onset underwent CT scan to exclude hemorrhagic stroke. Patients were randomized to receive either 0.9 mg/kg of rt-PA or placebo. At 3 mo, treated patients were at least 30% more likely to have minimal or no disability on several disability scales. Even with a symptomatic hemorrhage rate of 6.4% within 36 h among the active treatment patients, the mortality and disability among treated patients was less than that among placebo patients at 3 mo.

The overall acute neurologic deterioration even after accounting for early hemorrhages was the same in treated and placebo patients, indicating that the increased risk of hemorrhage with rt-PA therapy is offset by an increased risk of neurologic deterioration from progressing stroke, cerebral edema, and other causes in non-treated patients. The benefit of rt-PA was not limited to patients with cardioembolic or large vessel strokes, but also extended to patients with small-vessel strokes, who had a better prognosis.

**2-48. The answer is a.** (*Schwartz, 7/e, pp 257, 522, 527, 617–621.*) Squamous cell carcinoma occurs in people who have had chronic sun exposure, chronic ulcers or sinus tracts (draining osteomyelitis), and a history of radiation or thermal injury (Margolin's ulcer). It is more malignant than basal cell carcinoma, grows more rapidly, and metastasizes. It occurs more frequently in blondes and fair-skinned people. A radiation-induced carcinoma, or one arising in a burn scar, should not be treated with radiation therapy for fear of further damage.

**2-49. The answer is e.** (*Holmes, 3/e, p 368. Fauci, 14/e, pp 1679–1681.*) Currently available laboratory tests for hepatitis B include hepatitis B surface antigen (HBsAg), anti-HBs (antibody to hepatitis B surface antigen), immunoglobulin M (IgM) anti-HBc, immunoglobulin G (IgG) anti-HBc (antibodies to the core antigen), hepatitis B e antigen (HBeAg), and anti-HBe. Because HBcAg is sequestered within an HBsAg coat, HBcAg is not routinely detected in patients with hepatitis B. IgM Anti-HBc appears soon after the onset of infection and the detection of HBsAg, and precedes by many weeks detectable levels of anti-HBsAg. It generally disappears after 6 to 8 months. The presence of IgM is a marker for acute (less than 6 months) hepatitis B. IgG anti-HBc appears somewhat later than the IgM and may persist for years. Elevated alanine aminotransferase (ALT) may be present both in the early and chronic phases of the disease. HBeAg may persist for years in patients with chronic disease, and is associated with high infectivity. HBsAg remains detectable beyond 6 months in chronic hepatitis B.

**2-50. The answer is c.** (*Fauci, 14/e, pp 2030–2031, 2057, 2228–2229.*) For the patient described in the question, the markedly increased calcitonin levels indicate the diagnosis of medullary carcinoma of the thyroid. In view of the family history, the patient most likely has multiple endocrine neoplasia (MEN) type II, which includes medullary carcinoma of the thy-



Reprinted, with permission, from Fauci AS, Braunwald E, Isselbacher KJ, Wilson JD et al (eds): *Harrison's Principles of Internal Medicine*, 14th ed. New York, McGraw-Hill, 1998.

roid gland, pheochromocytoma, and parathyroid hyperplasia. Pheochromocytoma may exist without sustained hypertension as indicated by excessive urinary catecholamines. Before thyroid surgery is performed on this patient, pheochromocytoma must be ruled out through urinary catecholamine determinations; the presence of such a tumor might expose the patient to a hypertensive crisis during surgery. The entire thyroid gland must be removed, because foci of parafollicular cell hyperplasia, a premalignant lesion, may be scattered throughout the gland. Successful removal of the medullary carcinoma can be monitored with serum calcitonin levels. Hyperparathyroidism, while unlikely in this patient, is probably present in his brother.

# BLOCK 3

---

## Answers

**3-1. The answer is a.** (*McMillan, 3/e, pp 1556–1557. Rudolph, 20/e, p 1404.*)

The majority of all cases of acute scrotal pain and swelling in boys under 6 years of age are caused by testicular torsion. If surgical exploration occurs within 4 to 6 h, the testes can be saved 90% of the time. Too often, delay caused by scheduling of various imaging modalities and laboratory tests results in an unsalvageable gonad.

**3-2. The answer is b.** (*Schwartz, 7/e, pp 1007–1014.*) This patient has a left iliofemoral vein thrombosis, as evidenced by sudden massive swelling of her entire left lower extremity. Noninvasive venous testing should be quite helpful as the venous obstruction extends above the knee and therefore venography and x-ray exposure are unnecessary. Heparin is the preferred agent because it does not cross the placenta, while warfarin does. The vena caval filter is not indicated because there is no contraindication against heparin therapy and there has not been any evidence of pulmonary embolus.

**3-3. The answer is d.** (*Schwartz, 7/e, pp 771–780.*) The boundaries of the mediastinum are the thoracic inlet, the diaphragm, the sternum, the vertebral column, and the pleura bilaterally. The mediastinum itself is divided into three portions delineated by the pericardial sac: the anterosuperior and posterosuperior regions are in front of and behind the sac, respectively, while the middle region designates the contents of the pericardium. Mediastinal masses occur most frequently in the anterosuperior region (54%) and less often in the posterosuperior (26%) and middle (20%) regions. Cysts (pericardial, bronchogenic, or enteric) are the most common tumors of the middle region; neurogenic tumors are the most common (40%) of the primary tumors of the posterior mediastinum. The primary neoplasms of the mediastinum in the anteroposterior region are thymomas (31%), lymphomas (23%), and germ-cell tumors (17%). More commonly, though, a mass in this area represents the substernal extension of a benign subster-

nal goiter. Diagnosis may be made by visualization of an enhancing structure on computed tomography (CT); radioactive iodine scanning is useful in management as it may make the diagnosis if the mediastinal tissue is functional and will also document the presence of functioning cervical thyroid tissue to prevent removal of all functional thyroid tissue during mediastinal excision.

**3-4. The answer is b.** (*Fauci, 14/e, pp 1115–1116.*) Influenza A is a potentially lethal disease in the elderly and chronically debilitated patient. In institutional settings such as nursing homes, outbreaks are likely to be particularly severe. Hence, prophylaxis is extremely important in this setting. All residents should receive the vaccine unless they have known egg allergy (patients can choose to decline the vaccine). Since protective antibodies to the vaccine will not develop for 2 wk, amantadine can be used for protection against influenza A during the interim 2-wk period. A reduced dose is given to elderly patients.

**3-5. The answer is b.** (*Behrman, 16/e, pp 513–517, 1475–1477, 1479–1483, 1488. McMillan, 3/e, pp 1450–1451, 1453–1455. Rudolph, 20/e, pp 1203–1207, 1213–1214, 1219.*) Spherocytosis can be seen in hyperthermia, hereditary spherocytosis, glucose-6-phosphate dehydrogenase (G6PD) deficiency, or ABO incompatibility. Hyperbilirubinemia has been associated with black preterm infants with G6PD deficiency. The blood smear of the affected infant usually reveals nucleated red cells, spherocytes, poikilocytes, “blister” cells, and fragmented cells. Neonatal hyperbilirubinemia occurs in about 50% of patients with hereditary spherocytosis. Spherocytosis occurs in ABO incompatibility but not in Rh incompatibility. The hemolytic manifestations of ABO incompatibility and hereditary spherocytosis are very similar. The blood types of the mother and the infant should be determined, along with the results of a direct Coombs test on the infant and the presence or absence of a family history of hemolytic disease (spherocytosis). Sickle cell disease would not be expected to cause problems in newborns due to protection by fetal hemoglobin.

**3-6. The answer is b.** (*Schwartz, 7/e, pp 543–546.*) Breast biopsies have traditionally been performed to obtain histology for clinically suspicious palpable masses. In more recent years, the advent of screening mammography has led to the discovery of nonpalpable but radiographically suspi-



cious breast lesions that have a strong correlation with breast cancer. These nonpalpable, mammographically detected lesions are (1) breast calcifications that are (a) smaller than 2 mm, (b) punctate, microlinear, or branching, and (c) clustered along ducts or concentrated in clusters greater than five calcifications per square centimeter; (2) stellate-shaped lesions; (3) masses with ill-defined borders or nodular contours; (4) solitary dominant masses that are significantly larger than any other mass in either breast; and (5) areas of increased noneffacing tissue density or distorted breast architecture. A parenchymal density that effaces with compression represents normal glandular tissue. Saucer-shaped microcalcifications are seen in patients with microscopic cystic disease, a benign condition. Multiple round well-circumscribed densities are usually cysts, whose nature may be confirmed with breast sonography.

**3-7. The answer is c.** (*Fauci, 14/e, p 1884.*) Felty syndrome consists of a triad of rheumatoid arthritis, splenomegaly, and leukopenia. In contrast to the lymphopenia observed in patients who have systemic lupus erythematosus, the leukopenia of Felty syndrome is related to a reduction in the number of circulating polymorphonuclear leukocytes. The mechanism of the granulocytopenia is poorly understood. Felty syndrome tends to occur in people who have had active rheumatoid arthritis for a prolonged period. These patients commonly have other systemic features of rheumatoid disease such as nodules, skin ulcerations, the sicca complex, peripheral sensory and motor neuropathy, and arteritic lesions.

**3-8. The answer is b.** (*Sadock, 7/e, pp 1520–1522.*) Hypochondriasis is characterized by fear of developing or having a serious disease. This fear is based on the patient's distorted interpretation of normal physical sensations or signs. The patient continues worrying even though physical exams and diagnostic tests fail to reveal any pathological process. The fears do not have the absolute certainty of delusions. Hypochondriasis can develop in every age group, but onset is most common between 20 and 30 years of age. Both genders are equally represented, and there are no differences in prevalence based on social, educational, or marital status. The disorder tends to have a chronic, relapsing course.

**3-9 through 3-10. The answers are 3-9 d, 3-10 e.** (*Cass, Urol Clin North Am 16:213–220, 1989.*) In stable patients with suspected genitouri-

nary tract injury, the first urologic study other than a urinalysis should be the intravenous urogram. The technique of high-dose drip infusion is desirable because the high concentration of contrast achieved greatly facilitates interpretation in an unprepared patient. Intravenous pyelography should be performed before retrograde cystography to avoid obscuring visualization of the lower ureteral tract. The study may also preclude the need for retrograde urethrography in cases where (unlike the case presented) there is a suspicion of urethral injury. Renal arteriography is not indicated routinely but should be performed to rule out renal pedicle injury when no kidney function is demonstrated by drip infusion urography. Peritoneal lavage is not useful in the diagnosis of genitourinary injuries, as the structures involved are retroperitoneal. Seventy to eighty percent of patients with blunt renal trauma are successfully treated nonsurgically. Bed rest may reduce the likelihood of secondary hemorrhage; antibiotics may reduce the chance of development of infection in a perirenal hematoma. Failure of conservative treatment is indicated by rising fever, increasing leukocytosis, evidence of secondary hemorrhage, and persistent or increasing pain and tenderness in the region of the kidney.

**3-11. The answer is c.** (*Fauci, 14/e, companion Hbk., p 566.*) Erythema infectiosum (EI), caused by parvovirus type B19, is a mild, limited viral infection characterized by a distinctive rash on the face often called *slapped cheek* because of its intensity. The infection may cause chronic anemia in immunodeficient persons and aplastic crisis in those with chronic hemolytic anemia. Adenoviruses cause upper respiratory tract infections and occasionally severe pneumonia. Adenovirus types 31, 40, and 41 have been associated with gastroenteritis. Coxsackieviruses cause multiple clinical manifestations. Type A16 causes the hand, foot, and mouth syndrome, and type A24 has been associated with hemorrhagic conjunctivitis. Rotaviruses are implicated in diarrheal syndromes, and echovirus type 9 in petechial exanthem and meningitis. Coxsackieviruses and echoviruses are nonpolio enteroviruses.

**3-12. The answer is d.** (*Berg, pp 924–925.*) This patient has encephalofacial angiomas (Sturge-Weber syndrome), a congenital disturbance that produces facial cutaneous angiomas with a distinctive and easily recognized appearance, along with intracranial abnormalities such as leptomeningeal angiomas. Persons with the syndrome may be mentally retarded and often

exhibit hemiparesis or hemiatrophy on the side of the body opposite the port wine nevus. Both men and women may be affected, and seizures may develop in affected persons. The nevus associated with Sturge-Weber syndrome usually extends over the sensory distribution of V1, the first division of the trigeminal nerve. The lesion usually stays to one side of the face. Affected persons usually also have angiomas of the choroid of the eye. Intracranial angioma is unlikely if the nevus does not involve the upper face. Deficits develop as the person matures and may be a consequence of focal ischemia in the cerebral cortex that underlies the leptomeningeal angioma.

Hemangioblastomas are vascular tumors seen in association with polycystic disease of the kidney and telangiectasias of the retina (von Hippel-Lindau syndrome). Charcot-Bouchard aneurysms are very small and may be microscopic. They develop in patients with chronic hypertension and most commonly appear in perforating arteries of the brain. The lenticulostriate arteries are most commonly affected. Hemorrhage from these aneurysms is likely, and the putamen is the most common site for hematoma formation. Hemorrhage may extend into the ventricles and lead to subarachnoid blood. Other locations commonly affected include the caudate nucleus, thalamus, pons, and cerebellum. The dentate nucleus of the cerebellum is especially susceptible to the formation of Charcot-Bouchard aneurysms. Fusiform aneurysms are diffusely widened arteries with evaginations along the walls, but without stalks as occur with the typical berry-shaped structures of the saccular aneurysm. This type of aneurysm may be a late consequence of arteriosclerotic damage to the artery wall.

**3-13. The answer is d.** (*Ludman, p 34. Sapira, p 218.*) Hoarseness may be due to edema or swelling of the larynx or vocal cords, or to external compression of the larynx or the recurrent laryngeal nerve. Certain occupations, such as being a singer or telephone operator, place people at risk for voice strain (chronic laryngitis) due to overuse. Medications, such as inhaled corticosteroids, may contribute to the problem. Viral laryngitis is a common cause of hoarseness, but the patient would have other signs of a viral syndrome. Laryngeal carcinoma must be considered in patients with a history of heavy tobacco use. Reflux disease may cause hoarseness, but the patient would complain of heartburn, nocturnal cough, chronic sore throat, and excess phlegm production. Postnasal drip syndrome leads to chronic throat clearing, and physical examination reveals “cobblestoning” of the posterior pharynx. Kallman syndrome is bilateral loss of smell

and may be seen with asthma, sarcoidosis, diabetes, chronic renal failure, cirrhosis, multiple sclerosis, and Parkinson's disease. A mnemonic for hoarseness is **VINDICATE**: **V**ascular (thoracic aneurysm), **I**nflammation, **N**eoplasm, **D**egenerative (i.e., amyotrophic lateral sclerosis), **I**ntoxication (smoking, alcohol), **C**ongenital (laryngeal web), **A**llergies, **T**rauma, and **E**ndocrine (thyroiditis).

**3-14. The answer is b.** (*Behrman, 16/e, pp 498–505. McMillan, 3/e, pp 254–258. Rudolph, 20/e, pp 1598–1605.*) For the child described, prematurity and the clinical picture presented make the diagnosis of hyaline membrane disease likely. In this disease, lung compliance is reduced; lung volume also is reduced and a significant right-to-left shunt of blood can occur. Some of the shunt can result from a patent ductus arteriosus or foramen ovale, and some can be due to shunting in the lung. Minute ventilation is higher than normal and affected infants must work harder in order to sustain adequate breathing.

**3-15. The answer is b.** (*Fauci, 14/e, pp 1422–1423.*) Asthma is an airway disease characterized by a hyperreactive tracheobronchial tree that manifests physiologically as narrowing of the airway passages. The classic triad of symptoms is dyspnea, cough, and wheezing. Attacks are usually episodic and nocturnal and often follow exposure to specific allergens, exertion, viral infection, or emotional excitement. Wheezing is described as whistling and is typically heard on both inspiration and expiration. The expiratory phase becomes prolonged and the patient develops tachypnea, tachycardia, and mild systolic hypertension. Accessory muscles of respiration (sternocleidomastoid and intercostals) may be used to improve breathing. If the asthma attack is severe, the patient will develop pulsus paradoxus (an inspiratory drop in systolic blood pressure of more than 10 mm Hg). Patients with epiglottitis present with fever, drooling, and dysphagia; lung examination is normal. Children with croup or laryngotracheobronchitis present with labored breathing and stridor and use accessory muscles to assist breathing.

**3-16. The answer is d.** (*Fauci, 14/e, p 2486.*) Although other possibilities need to be considered and possibly evaluated, the patient's age and symptoms are consistent with panic disorder. The diagnostic criteria for panic attack are a discrete period of intense fear or discomfort, in which four or

more of the following symptoms develop abruptly and reach a peak within 10 min: palpitations, pounding heart, or accelerated heart rate; sweating; trembling or shaking; sensations of shortness of breath or smothering; feeling of choking; chest pain or discomfort; nausea or abdominal distress; feeling dizzy, unsteady, lightheaded, or faint; derealization or depersonalization; fear of losing control or going crazy; fear of dying; paresthesias; chills or hot flushes.

**3-17. The answer is h.** (*Berg, pp 957–960.*) Adrenal dysfunction in association with a progressive degenerative disease of the white matter suggests adrenoleukodystrophy. Some types are X-linked defects, and the fact that two brothers were affected in similar ways suggests that they had the X-linked form of adrenoleukodystrophy. X-linked adrenoleukodystrophy produces rapidly evolving brain damage in male infants or boys, with survival from onset of symptoms usually limited to 3 years. The underlying defect in this X-linked disorder is an adenosine 5'-triphosphate (ATP)-binding transporter in the peroxisomal system responsible for long-chain fatty acid metabolism. Long-chain fatty acids accumulate in adrenal cortical and other cells. Pathophysiologically similar to but otherwise distinct from adrenoleukodystrophy is adrenomyeloneuropathy. It may develop in heterozygous women and usually involves less pronounced damage to the brain and more obvious damage to the spinal cord and peripheral nerves. Persons with adrenomyeloneuropathy routinely develop spastic paraparesis, problems with bladder and bowel control, and sensory disturbances in the legs.

**3-18 through 3-19. The answers are 3-18 d, 3-19 a.** (*Sadock, 7/e, pp 680, 819.*) The voluntary assumption of an inappropriate or bizarre posture for long periods of time is called catatonic posturing, and it is usually seen in schizophrenia, especially of the catatonic type. In catatonic posturing, patients actively resist attempts to make them change position. A similar symptom, waxy flexibility, refers to patients who maintain the body position into which they are placed. Apraxia refers to the inability to perform voluntary motor activity in the absence of motor or sensory deficits. Dys-tonia refers to the protracted contraction of a group of muscles. In synesthesia the stimulation of one sensory modality produces a sensation belonging to another sensory modality (a color is perceived as a smell). Trance is a sleeplike condition characterized by a reduced state of con-

sciousness. Parkinson's disease, neuroleptic malignant syndrome, and Huntington's disease are characterized by different motor disturbances.

**3-20. The answer is a.** (*Goldman, 21/e, p 354.*) Abdominal aortic aneurysms (AAAs) are usually due to atherosclerosis, and >90% originate below the renal arteries. The aneurysms are typically asymptomatic until they rupture, but patients may complain of lower back or hypogastric pain. These aneurysms may be associated with emboli to the feet and kidneys. Normal diameter of the aorta is <2 cm. When the diameter of the AAA is >4.5 cm, repair is generally suggested. Risk of rupture is 1% to 2% over 5 years when the AAA is <5 cm but 20% to 40% when the AAA reaches 6 cm in diameter. The best method of evaluating the AAA is ultrasound or CT scan.

**3-21. The answer is e.** (*Berg, p 453. Adams, 6/e, p 514.*) Hypothalamic hamartomas are nonneoplastic malformations involving neurons and glia in the region of the hypothalamus. They may be discovered incidentally, either on imaging performed for other reasons or at autopsy, or they may cause symptoms referable to the hypothalamus. Most often, the latter involves neuroendocrine functions, causing precocious puberty or acromegaly due to overproduction of growth hormone–releasing hormone. Patients may also experience paroxysms of laughter, known as gelastic seizures. Hypothalamic hamartomas may be cured surgically. Craniopharyngiomas are epithelial neoplasms arising in the sellar and third ventricular regions. They may cause hypopituitarism and visual field disturbances. Choroid plexus papillomas usually develop intraventricularly and do not extend down into the sella turcica. These tumors affect both children and adults, but they are rare. They are benign if they are surgically accessible and are extirpated early in their evolution. Giant aneurysms occur in many locations, but typically do not cause gelastic seizures or precocious puberty. Metastatic carcinoma generally occurs in older patients and would not be expected to cause these symptoms.

**3-22. The answer is d.** (*DiSaia, 5/e, pp 93–99.*) Pelvic exenteration has significantly increased the survival rate in recurrent cervical cancer and allowed a quality of life not previously possible. A total pelvic exenteration includes removal of the structures described, with diversion of fecal and urinary streams. Attempts to preserve organs such as the bladder (termed a

*posterior exenteration*, preserving the anterior bladder) or rectum (called an *anterior exenteration*, preserving the posterior rectum) usually have higher complication rates than total exenterations and are generally no longer performed. Major improvement in quality of life and electrolyte balance has resulted from the use of an ileal conduit for urinary diversion rather than the earlier technique of tunneling the ureters directly into the transverse colon. Pelvic wall nodes are a contraindication to the surgery, as there is a survival rate of less than 5% in such patients.

**3-23. The answer is c.** (*Chin, 17/e, pp 248, 346, 377, 402.*) Immunization schedules recommended by the Centers for Disease Control (CDC) have evolved rapidly in the last 2 years and are becoming increasingly complicated. The state health department should keep providers up to date. As of early 2000, the schedule described in answer c is recommended for children born to hepatitis B surface antigen (HBsAg)-positive mothers. These children should receive hepatitis B immunoglobulin (HBIG) and the first dose of vaccine within 12 h of birth, the second dose of vaccine at 1 to 2 mo of age, and the third dose at 6 mo of age. Schedules may differ for mothers who are HBsAg negative. Oral polio vaccine (OPV) is no longer recommended. Acellular preparations (DTaP) that contain two or more protective antigens of *Bordetella pertussis* are used in the United States for primary series and boosters.

**3-24. The answer is b.** (*DSM-IV, pp 532–538.*) In adolescents and young adults, gender identity disorder is characterized by a strong cross-gender identification, a persistent discomfort with one's sex, and clinically significant distress or impairment. Such patients usually trace their conviction to early childhood, often live as the opposite sex, and seek sex reassignment surgery and endocrine treatment. These patients feel a sense of relief and appropriateness when they are wearing opposite-sex clothing. In contrast, patients with transvestite fetishism are sexually aroused by this behavior. Homosexuality is not a diagnosis in DSM-IV. While some homosexuals cross-dress to seek a same-sex partner, they do not feel that they belong to the opposite sex, nor do they seek sex reassignment surgery.

**3-25. The answer is c.** (*Greenfield, 2/e, p 916.*) This woman has a cystadenocarcinoma arising from the pancreatic body and tail, which was successfully resected. About 90% of primary malignant neoplasms of the

exocrine pancreas are adenocarcinomas of duct cell origin. The remaining neoplasms include adenosquamous carcinoma, mucinous carcinomas, microadenocarcinoma, giant cell carcinoma, and cystadenocarcinoma of uncertain histogenesis. The clinical presentation is usually quite subtle, with symptoms related primarily to the enlarging mass. There are no diagnostic laboratory findings, and definitive preoperative diagnosis is rare. An elderly patient with no history of pancreatitis is unlikely to have a pseudocyst, and a benign neoplasm is also less likely in this age group. These less common carcinomas are often several times the size of typical ductal cancers and often arise in the body or tail of the pancreas. They may become very large without invading adjacent viscera and do not generally cause significant pain or weight loss. Therefore, even large tumors may be cured by resection, and aggressive surgical management is indicated.

**3-26. The answer is b.** (*Stobo, 23/e, pp 293–298.*) This patient has clinical symptoms of thyrotoxicosis. Most patients with thyrotoxicosis have increases in total and free concentrations of  $T_3$  and  $T_4$ . (Some may have isolated  $T_3$  or  $T_4$  increases.) Most thyrotoxicosis results in suppression of pituitary thyroid-stimulating hormone (TSH) secretion, so low TSH levels can also confirm the diagnosis.

**3-27. The answer is e.** (*Fauci, 14/e, p 2111. Wallace, 14/e, pp 1189–1192.*) Only barrier methods, particularly condom use, can reduce the risk of acquiring sexually transmitted diseases (STDs). However, their ability to reduce the rate of pregnancy is less than that of combined oral contraceptives (COC). Progestin-only pills are slightly less effective than COC. The intrauterine device (IUD) is not recommended for young women: they may be at higher risk of STDs, which may increase the risk of pelvic inflammatory disease (PID) and infertility.

**3-28. The answer is c.** (*Fauci, 14/e, p 2503.*) Fifty percent of Chinese and Japanese lack aldehyde dehydrogenase (ALDH), and, after ingestion of alcohol, develop facial flushing and erythema. The lack of this enzyme results in accumulation of acetaldehyde after ingestion of alcohol.

**3-29. The answer is e.** (*Bradley, 3/e, p 1439.*) The test performed is usually called the swinging flashlight test, and the pupillary finding is a Marcus



Gunn or afferent pupillary defect. It commonly develops in persons with multiple sclerosis as a sequela of optic neuritis. Damage to the optic nerve reduces the light perceived with the affected eye. If the other eye has less or no optic atrophy, the consensual response of the pupil to light perceived by the better eye will constrict the pupil in the atrophic eye, even though direct light to the injured eye does not elicit a strong pupillary constriction.

**3-30. The answer is c.** (*Schatzberg, 2/e, p 408.*) Several nonsteroidal anti-inflammatory drugs, including ibuprofen, naproxen, diclofenac, and indomethacin, can increase plasma lithium levels and have been associated with toxicity. The mechanism of action is thought to be an inhibition of renal tubular prostaglandin synthesis.

**3-31. The answer is c.** (*Greenberg, 2/e, pp 123–126, 136–140.*) Recall bias, a form of information bias and differential misclassification, occurs when cases are more likely to recall past events than controls. Indeed, persons experiencing a bad outcome may be more likely to search their past (and prod their memory) about potential causes for the occurrence. This is a particular problem with case control studies. Recall bias could cause a falsely high odds ratio; it is potentially a problem when using maternal recall to investigate exposures associated with birth defects. In this case, mothers with children with undescended testes may be more accurate in quantifying smoking habits. Because this misclassification of exposure is not random in both the case and controls, it is termed differential misclassification.

Nondifferential misclassification occurs when the memory of an exposure is unrelated to the fact that a person has a disease or not. It is often the consequence of an imprecise measurement of exposure (remembering specific nutrition information that occurred many months ago). The important point to remember is that differential misclassification may result in an overestimate of an association, while non-differential misclassification nearly always causes the results to move toward the null (no association). Selection bias refers to systematic errors in the way subjects are included in a study. Confounding occurs when the apparent effect of an exposure is partly or entirely due to a third factor associated with both exposure and outcome. Although a third factor could potentially be present, it has not been identified here, and the major concern in this case should be the recall bias.

**3-32. The answer is b.** (*Rosner, 5/e, ch 6.5, pp 181–183; ch 7.3, p 219.*) Since undescended testes are uncommon, the odds ratio in this study approximates the relative risk (risk ratio). The fact that the 95% confidence interval excludes 1.0 means that  $P$  is less than 0.05. Confidence intervals describe the range of values not significantly different from the observed value, with a type 1 error rate ( $\alpha$ ) of 1.0 minus the level of confidence. Thus, a 95% confidence interval shows the numbers that are not significantly different statistically from what was observed at the 5% level. The lower the level of confidence, the narrower the confidence interval, so a 90% confidence interval would be narrower than a 95% confidence interval, in this case excluding 1.0 for certain. Thus, if the study is accurate, it suggests that baby boys whose mothers smoke are 2.6 times as likely to have undescended testes. A larger sample size decreases variability, thus decreasing the confidence interval.

**3-33. The answer is a.** (*Stobo, 23/e, pp 797–801.*) The long-term nature of these symptoms, the fact that the nodes are nontender, and their location, including scalene and supraclavicular loci, all suggest the likelihood of malignancy. Hence toxoplasmosis and Epstein-Barr virus (EBV) are unlikely causes of this clinical picture. An angiotensin converting enzyme test would give nonspecific evidence for sarcoidosis, a possible diagnosis. Excisional biopsy is necessary to rule out malignancy, particularly lymphoma.

**3-34. The answer is a.** (*Stobo, 23/e, pp 797–801.*) The staging of Hodgkin's disease is important so that proper treatment can be determined. To determine whether the patient has stage 3 or 4 disease, the presence or absence of disease in the abdomen must be known. A CT scan or magnetic resonance imaging (MRI) scan of the abdomen would be the test of choice. Staging laparotomy is not as necessary as in the past because CT and MRI can usually identify or exclude disease of the abdomen.

**3-35. The answer is c.** (*Behrman, 16/e, pp 1231–1233. McMillan, 3/e, pp 177, 217–218, 222. Rudolph, 20/e, pp 215, 1588–1590.*) Diaphragmatic hernia occurs with the transmittal of abdominal contents across a congenital or traumatic defect in the diaphragm. In the newborn, this condition results in profound respiratory distress with significant mortality. Prenatal diagnosis is common and necessitates that the birth take place at

a tertiary-level center. In the neonate, respiratory failure in the first hours of life, a scaphoid abdomen, and the presence of bowel sounds in the chest are common findings. Intensive respiratory support, including mechanical ventilation and extracorporeal membrane oxygenation (ECMO), has increased survival. Mortality can be as high as 50% despite aggressive treatment.

**3-36. The answer is d.** (*Tierney, 39/e, pp 518–525.*) The patient most likely has polycythemia vera. This is an acquired myeloproliferative disorder characterized by a primary erythrocytosis, but there is overproduction of all three cell lines. Hematocrit is >54% in males and >51% in females. Patients present with symptoms related to an increase in blood volume and viscosity. Pruritus after a warm bath or shower is due to histamine release by basophils. Splenomegaly exists in virtually every patient with polycythemia vera. The treatment of choice for polycythemia vera is phlebotomy. Spurious polycythemia or Gaisböck syndrome is due to a contracted plasma volume (diuretic use); secondary polycythemia may be due to smoking, high altitudes, cardiac or pulmonary disease, and erythropoietin-secreting cysts or tumors. Patients with chronic myeloid leukemia (CML) typically have a leukocytosis and the Philadelphia chromosome. Patients with essential thrombocythemia have platelet counts >2 million/ $\mu\text{L}$ . Patients with myelofibrosis have splenomegaly, dry bone marrow taps, and peripheral blood smears showing abnormal and bizarre morphologies and immature forms.

**3-37. The answer is c.** (*Mishell, 3/e, pp 537–540.*) Adenomyosis is a condition in which normal endometrial glands grow into the myometrium. Symptomatic disease primarily occurs in multiparous women over the age of 35 years, compared to endometriosis, in which onset is considerably younger. Patients with adenomyosis complain of dysmenorrhea and menorrhagia, and the classical examination findings include a tender, symmetrically enlarged uterus without adnexal tenderness. Although patients with endometriosis can have similar complaints, the physical examination of these patients more commonly reveals a fixed, retroverted uterus, with scarring and tenderness along the uterosacral ligaments. Leiomyoma is the most common pelvic tumor, but the majority are asymptomatic and the uterus is irregular in shape. Patients with endometritis can present with abnormal bleeding, but endometrial biopsies show an inflammatory pat-

tern. Uterine sarcoma is rare, and presentation in an older woman is of postmenopausal bleeding with uterine enlargement without tenderness.

**3-38. The answer is e.** (*Sadock, 7/e, pp 1976–1977. DSM-IV, pp 684–685.*)

The loss of a loved one is often accompanied by symptoms reminiscent of major depression, such as sadness, weepiness, insomnia, reduced appetite, and weight loss. When these symptoms do not persist beyond 2 mo after the loss, they are considered a normal manifestation of bereavement. A diagnosis of major depression in these circumstances requires the presence of marked functional impairment, morbid preoccupations with unrealistic guilt or worthlessness, suicidal ideation, marked psychomotor retardation, or psychotic symptoms.

**3-39. The answer is a.** (*LaDou, 2/e, pp 163–166.*)

Nitrogen narcosis is due to increased partial pressure of nitrogen in the nervous system; symptoms are analogous to those of alcohol intoxication. Barotrauma (barosinusitis, middle ear or barotitis media) is due to the mechanical effects of expansion and contraction of gases when pressure differences exist between the body cavities and the environment. These two syndromes are manifestations of *compression* sickness occurring during descent. “The bends” (so called because the person can be stooped due to severe joint pain) are a form of *decompression* sickness (also called caisson disease) due to inadequate elimination of dissolved gas after a dive affecting the skin and joints. Decompression sickness can occur either after a too-rapid ascent from a dive below 9 m or a sudden pressure loss at altitudes above 7000 ft.

**3-40. The answer is e.** (*Coffey, pp 669–674.*)

Prader-Willi syndrome is a genetic disorder due to a defect of the long arm of chromosome 15. Characteristically, children with Prader-Willi syndrome are underweight in infancy. In early childhood, due to a hypothalamic dysfunction, they start eating voraciously and quickly become grossly overweight. Individuals with this syndrome have characteristic facial features and present with a variety of neurologic and neuropsychiatric symptoms including autonomic dysregulation, weakness, hypotonia, mild to moderate mental retardation, temper tantrums, violent outbursts, perseveration, skin picking, and a tendency to be argumentative, oppositional, and rigid.

**3-41. The answer is e.** (*Greenberg, 2/e, pp 587–588.*) That the cerebellar elements are not fused in the midline suggests an asymptomatic Dandy-Walker malformation. This congenital disorder of brain formation may become symptomatic soon after birth if an obstructive hydrocephalus develops as one facet of the anomaly. In the absence of an obstructive hydrocephalus, the patient may remain asymptomatic throughout life.

**3-42. The answer is b.** (*Fauci, 14/e, pp 1636–1640.*) It is often difficult to clinically distinguish between ulcerative colitis (UC) and Crohn's disease (CD). Patients with CD usually have less rectal bleeding and rarely have tenesmus. The barium enema showing involvement of the colon supports UC. Typically, patients with CD have skip lesions and rectal sparing. Patients with irritable bowel syndrome complain of abdominal pain with altered frequency or consistency of stool but have no weight loss or bleeding. More than half of patients with irritable bowel syndrome have psychiatric disorders. Patients with diverticulosis (saclike protrusions of the mucosa through the muscularis) are usually older and asymptomatic; hemorrhage occurs in a small percentage of patients. Giardiasis may be found in immunocompromised patients, day care workers, male homosexuals, individuals who drink untreated water (hikers and campers), and international travelers (especially to Russia).

**3-43. The answer is b.** (*Speroff, 6/e, pp 658–662.*) Peripheral conversion of androstenedione to estrone in the fat tissue is the major source of estrogens in the menopausal woman. The conversion rate and the resulting estrogen levels are dependent on the percentage of body fat and increase as women age. In obese women, higher estrone levels will be found and the menopausal symptoms will be less frequent. These women are also less likely to develop osteoporosis. Especially in obese postmenopausal women, this prolonged and unopposed estrogen stimulation may cause uterine bleeding, endometrial hyperplasia, and adenocarcinoma.

**3-44. The answer is b.** (*Fauci, 14/e, pp 1955–1956.*) The history and physical examination revealing tender points makes fibromyalgia syndrome the most likely diagnosis. This is a disorder predominantly of females; patients complain of insomnia, easy fatigability, and widespread musculoskeletal pain and stiffness. There are up to 18 symmetrical bilateral

tender points that occur in the same locations on all patients. Laboratory data are normal in primary fibromyalgia syndrome.

**3-45. The answer is c.** (*Speroff, 6/e, pp 605–607.*) Amenorrhea and galactorrhea may be seen when something causes an increase in prolactin secretion or action. The differential diagnosis involves several possible causes. Excessive estrogens, such as in birth control pills, can reduce prolactin-inhibiting factor, thus raising serum prolactin level. Similarly, intensive suckling (during lactation and associated with sexual foreplay) can activate the reflex arc that results in hyperprolactinemia. Phenothiazine-derivative drugs are also known to have mammatropic properties. Hypothyroidism appears to cause galactorrhea secondary to thyrotropin-releasing hormone (TRH) stimulation of prolactin. In cases of persistent elevated prolactin levels without obvious cause (e.g., breast feeding), an evaluation for pituitary adenoma becomes necessary.

**3-46. The answer is e.** (*Behrman, 16/e, p 505. McMillan, 3/e, p 259. Rudolph, 20/e, pp 1597–1598.*) Transient tachypnea of the newborn is usually seen after a normal vaginal or especially after a cesarean delivery. These patients have tachypnea, retractions, grunting, and sometimes cyanosis. The chest examination is usually normal; the chest radiograph demonstrates prominent pulmonary vascular markings with fluid in the fissures and hyperexpansion (flat diaphragms). Therapy is supportive with maintenance of normal oxygen saturation. Resolution usually occurs in the first 3 days of life.

**3-47. The answer is c.** (*Tintinalli, 5/e, pp 576–578.*) The finding of abruptly arresting inspiration with palpation of the right upper quadrant (RUQ) is called Murphy's sign and is consistent with a diagnosis of cholecystitis. The liver and gall bladder move inferiorly as the diaphragm contracts on deep inspiration. The inferior movement of the diaphragm causes the inflamed gall bladder to become compressed against the inverted wall; the patient experiences sharp pain and abruptly halts inspiration. Cholecystitis risk factors are the **4 Fs** (**F**at, **F**orty, **F**emale, and **F**ertile). Other risk factors include diabetes, a positive family history, and medications such as oral contraceptives. The most sensitive test for detecting gallstones is the HIDA scan (98% sensitive and 81% specific for chole-

cystitis). It will show obstruction of the cystic duct (the primary cause of cholecystitis). Plain films detect gallstones in 15% of cases. Abdominal ultrasound has a sensitivity of 67% and a specificity of 82% for detection of gallstones.

**3-48. The answer is a.** (*DeCherney, 8/e, pp 668–669.*) The most common cause of postmenopausal vaginal bleeding is atrophic vaginitis (with or without trauma). Endometriosis is the most common cause of infertility; patients present with dyspareunia (painful intercourse), abnormal vaginal bleeding, and pelvic pain. Uterine leiomyomas (uterine fibroids) change in size with the menstrual cycle but regress in size during menopause. Often the fibroids are palpable on pelvic examination. Polycystic ovary syndrome (Stein-Leventhal syndrome) affects younger women (15 to 30 years of age). The etiology of polycystic ovary syndrome is unknown; patients present with amenorrhea, obesity, hirsutism, and infertility. All postmenopausal women with vaginal bleeding require a biopsy to rule out endometrial carcinoma.

**3-49. The answer is d.** (*Fauci, 14/e, p 2004.*) Metastatic tumors rarely cause diabetes insipidus, but of the tumors that may cause it, carcinoma of the breast is by far the most common. In this patient, the diagnosis of diabetes insipidus is suggested by hyponatremia and low urine osmolality. Psychogenic polydipsia is an unlikely diagnosis since serum sodium is usually mildly reduced in that condition. Renal glycosuria would be expected to induce a higher urine osmolality than that seen in this patient because of the osmotic effect of glucose. While nephrocalcinosis secondary to hypercalcemia may produce polyuria, hypercalciuria does not. Finally, the findings of inappropriate antidiuretic hormone syndrome are the opposite of those observed in diabetes insipidus and thus incompatible with the clinical picture in this patient.

**3-50. The answer is b.** (*Alexander, 9/e, pp 1324–1327.*) This patient presents with unstable angina, a change from the previous chronic stable state in that chest pain has become more frequent and more severe. Intravenous heparin is indicated. There is no role for digoxin. Thrombolytic therapy is reserved for the treatment of electrocardiogram (ECG)-documented myocardial infarction.

*This page intentionally left blank.*



# BLOCK 4

---

## Answers

**4-1. The answer is c.** (Greenberg, 2/e, pp 94–97. Hennekens, pp 206–208.)

Intent-to-treat analysis, that is, including in the final results all the subjects who were initially randomized to receive either the drug or the placebo, is the preferred method of analysis for intervention studies. Although it may be tempting to include only those who complied with the medication, the results can be misleading. This study is a classic example of this pitfall. Indeed, the study showed that the difference in mortality between those who did and did not adhere to the *placebo* was even greater: 15% versus 28%. The difference persisted even after controlling for 40 different confounders. Thus, something related to compliance (with either the medication or the placebo) appeared to decrease mortality. Therefore, as a rule, remember that once randomization has been performed, all participants, regardless of their compliance, should be included in the results.

**4-2. The answer is e.** (Behrman, 16/e, p 1653. McMillan, 3/e, p 1558.

Rudolph, 20/e, p 59.) Varicocele, a common condition seen after 10 years of age, occurs in about 15% of adult males. It results from the dilation of the pampiniform venous plexus (usually on the left side) due to valvular incompetence of the spermatic vein. Reduced sperm counts are possible with this condition; surgery may ultimately be indicated for infertility problems. Typically, these lesions are not painful but can become tender with strenuous exercise. Their typical “bag of worms” appearance on palpation makes diagnosis apparent in most cases. For a 16-year-old boy, reassurance and education seem appropriate.

**4-3. The answer is c.** (Fauci, 14/e, pp 803–804.)

About half of all cases of nongonococcal urethritis are caused by *Chlamydia trachomatis*. *Ureaplasma urealyticum* and *Trichomonas vaginalis* are rarer causes of urethritis. Herpes simplex would present with vesicular lesions and pain. *C. psittaci* is the etiologic agent in psittacosis.

**4-4. The answer is c.** (*Schwartz, 7/e, pp 95–96.*) Transfusions with fresh frozen plasma (FFP) are given to replenish clotting factors. The effectiveness of the transfusion in maintaining hemostasis is dependent on the quantity of each factor delivered and its half-life. The half-life of the most stable clotting factor, factor VII, is 4 to 6 h. A reasonable transfusion scheme would be to give FFP on call to the operating room. This way the transfusion is complete prior to the incision with circulating factors to cover the operative and immediate postoperative period.

**4-5. The answer is c.** (*Cameron, 4/e, pp 820–824.*) Traumatic injuries to the diaphragm are associated with both blunt and penetrating trauma. The spleen, kidneys, intestines, and liver are the most frequently injured abdominal organs in blunt trauma; the diaphragm is the least. Missed injuries lead to problems with herniation and bowel strangulation with sufficient frequency that repair should not be delayed. All such injuries require repair once the diagnosis is made and the patient has been stabilized. Most acute defects in the diaphragm can be repaired via an abdominal approach, which allows exploration for coexisting injuries.

**4-6. The answer is b.** (*Stobo, 23/e, pp 121–125.*) The diagnosis in this patient is suggested by the physical exam findings. The findings of poor excursion, flatness of percussion, and decreased fremitus on the right side are all consistent with a right-sided pleural effusion. A large right-sided effusion may shift the trachea to the left. A pneumothorax should result in hyperresonance of the affected side. Atelectasis on the right side would shift the trachea to the right. A consolidated pneumonia would characteristically result in increased fremitus and would not cause tracheal deviation.

**4-7. The answer is b.** (*LaDou, 2/e, pp 135–136.*) Acute exposures to sound pressure levels above 180 dB result in traumatic rupture of the tympanic membrane and conductive hearing loss. The rupture should repair spontaneously unless infection occurs. If the loss persists for more than 3 mo, surgical repair is possible. Sensorineural loss is generally due to fractures or trauma to the inner ear. Mixed hearing loss can occur secondary to fractures of the temporal bone when both the middle and the inner ear are traumatized.

**4-8. The answer is e.** (*Weir, pp 144–147.*) The clinical picture suggests a saccular aneurysm that has become symptomatic by compressing structures about the base of the brain and subsequently leaking. Aneurysms enlarge with age and usually do not bleed until they are several millimeters across. Persons with intracerebral or subarachnoid hemorrhages before the age of 40 are more likely to have their hemorrhages because of arteriovenous malformations rather than aneurysms. Aneurysms occur with equal frequency in men and women below the age of 40, but in their 40s and 50s, women are more susceptible to symptomatic aneurysms. This is especially true of aneurysms that develop on the internal carotid on that segment of the artery that lies within the cavernous sinus. An angiogram is useful in establishing the site and character of the aneurysm. A computed tomography (CT) scan would be more likely to reveal subarachnoid, intraventricular, or intraparenchymal blood, but it would reveal the structure of an aneurysm only if it were several (more than 5) millimeters across. Magnetic resonance imaging (MRI) will reveal relatively large aneurysms if the system is calibrated and programmed to look at blood vessels. This patient had a transfemoral angiogram, a technique that involves the introduction of a catheter into the femoral artery; the catheter is threaded retrograde into the aorta and up into the carotid or other arteries of interest.

**4-9. The answer is d.** (*Cunningham, 20/e, pp 607–615. DeCherney, 8/e, pp 316–319.*) The incidence of ectopic pregnancy (outside the uterine cavity) is 1 in 100 pregnancies. Risk factors include previous history of pelvic inflammatory disease (PID) or ectopic pregnancy, use of an intrauterine device (IUD), diethylstilbestrol (DES) exposure, and prior pelvic surgery. Patients present with abdominal pain that may radiate to the shoulder (indicating irritation of the diaphragm from hemoperitoneum), vaginal bleeding, cervical motion tenderness (CMT), and the presence of a boggy and poorly delineated pelvic mass 1 to 8 wk after a missed period. The patient may have other symptoms of pregnancy, such as nausea, vomiting, and breast tenderness. If the ectopic pregnancy ruptures, the patient may present with signs of shock. The Adler sign is the presence of “fixed” abdominal tenderness on turning the patient and may be seen in ectopic pregnancy. A ruptured corpus luteum cyst causes a tender ovary but no palpable mass. PID causes fever and bilateral lower quadrant pain and tenderness. Appendicitis is right-sided pain. Pelvic examination is typically normal in appendicitis and pyelonephritis.

**4-10. The answer is b.** (*Tintinalli, 5/e, pp 1556–1559.*) The patient has a peritonsillar abscess, which is an accumulation of pus between the tonsillar capsule and the superior constrictor muscle of the pharynx. Patients present with a “hot potato” voice, fever, cervical lymphadenopathy, trismus, and a displaced uvula due to a unilaterally enlarged tonsil. Patients complain of dysphagia, odynophagia, and otalgia. A retropharyngeal abscess is an infection of the deep spaces of the neck (from the base of the skull to the tracheal bifurcation); patients are often young children who present with fever, cervical lymphadenopathy, neck pain, neck swelling, torticollis (rotation to the affected side), difficulty breathing, and stridor. Patients with an exudative pharyngitis will have fever, cervical lymphadenopathy, bilateral tonsillar enlargement, erythema, edema of the midline uvula, and discrete tonsillar exudate.

**4-11. The answer is b.** (*Stobo, 23/e, pp 790–791.*) A prostatic biopsy is necessary to confirm the diagnosis of prostatic carcinoma. A metastatic workup including bone scan would then follow. Bone scan is routinely used to evaluate for metastatic disease. Imaging of pelvic nodes by CT is unreliable because of lack of sensitivity. CT is also unable to reliably detect spread of prostatic cancer beyond the capsule.

**4-12. The answer is c.** (*Greenfield, 2/e, p 1373.*) Most clinicians would recommend aspiration and cytologic examination of the cyst fluid in this situation. Cysts are common lesions in the breasts of women in their thirties and forties; malignancies are relatively rare. All such lesions justify attention, however, and physicians must not underestimate the fear associated with the discovery of a mass in the breast, even in low-risk situations. If the lesion does not completely disappear after aspiration, excision is advised. In young women the breast parenchyma is dense, which limits the diagnostic value of mammography. The American Cancer Society (ACS) does not suggest a baseline mammographic examination until age 35 unless a suspicious lesion exists.

**4-13. The answer is a.** (*Fitzpatrick, 3/e, pp 314–318, 332–335, 401–405, 877–882.*) Erythema multiforme (EM) minor due to the herpes infection is the most likely diagnosis in this patient. The lesions of EM are classically target lesions; they are burning and pruritic. They are generalized and often involve the oral mucosa. Etiologies of EM major include drugs such as

phenytoin, sulfonamides, barbiturates, and allopurinol. Finger pressure in the vicinity of a lesion in EM major leads to a sheetlike removal of the epidermis (Nikolsky sign). Pemphigus vulgaris is a chronic, bullous, autoimmune disease usually seen in middle-aged adults. The Nikolsky sign is positive in pemphigus vulgaris. Secondary syphilis appears 2 to 6 mo after primary infection and consists of round to oval maculopapular lesions 0.5 to 1.0 cm in diameter. The eruptions typically involve the palms and soles. Secondary syphilis lesions that are flat and soft with a predilection for the mouth, perineum, and perianal areas are called condylomata lata. The skin lesions of systemic lupus erythematosus (SLE) range from the classic butterfly malar rash to the discoid plaques of chronic cutaneous lupus erythematosus (CCLE). Urticaria is characterized by pruritic wheals typically lasting several hours.

**4-14. The answer is a.** (*Adams, 6/e, pp 270–271.*) The fact that vision is preserved excludes optic neuritis and cavernous sinus thrombosis. Optic neuritis produces pain in the affected eye and may be associated with a normal optic disc, but visual acuity should be deficient and an afferent pupillary defect should be apparent. Cavernous sinus thrombosis usually produces proptosis and pain, but impaired venous drainage from the eye should interfere with acuity, and the retina should appear profoundly disturbed. With a diphtheritic polyneuropathy, an ophthalmoplegia may develop, but this would not be limited to one eye and is not usually associated with facial trauma. Transverse sinus thrombosis may produce cerebrocortical dysfunction or stroke, but ophthalmoplegia would not be a manifestation of this problem.

**4-15 through 4-16. The answers are 4-15 c, 4-16 c.** (*Behrman, 16/e, p 491. McMillan, 3/e, pp 164, 2122. Rudolph, 20/e, pp 214–215, 224, 1939.*) In a difficult delivery in which traction is applied to the head and neck, several injuries, including all those listed in the question, may occur. Erb-Duchenne paralysis affects the fifth and sixth cervical nerves; the affected arm cannot be abducted or externally rotated at the shoulder, and the forearm cannot be supinated. Injury to the seventh and eighth cervical and first thoracic nerves (Klumpke paralysis) results in palsy of the hand and also can produce Horner syndrome. Fractures in the upper limb are not associated with a characteristic posture, and passive movement usually elicits pain. Spinal injury causes complete paralysis below the level of injury.

When paralysis of an upper extremity from injury to the brachial plexus is found in a neonate, injury to the phrenic nerve should also be suspected because the nerve roots are close together and can be injured concurrently. The paralyzed diaphragm can be noted to remain elevated on a chest x-ray taken during deep inspiration, when it will contrast with the opposite normal diaphragm in its lower normal position, but on expiration this asymmetry cannot be seen. On inspiration, not only is breathing impaired since the paralyzed diaphragm does not contract, but the negative pressure generated by the intact diaphragm pulls the mediastinum toward the normal side, impairing ventilation further. The diagnosis can easily be made by fluoroscopy, where these characteristic movements on inspiration and expiration can be seen. Rarely, both diaphragms can be paralyzed, producing much more severe ventilatory impairment. Fortunately, these injuries frequently improve spontaneously.

**4-17. The answer is a.** (Stobo, 23/e, pp 298–302.) In primary hypothyroidism, autoimmune thyroiditis is the most common insult. Primary hypothyroidism can result from surgery or radiation therapy, but there is no such history in this patient. Thyroid cancer does not cause hypothyroidism.

**4-18. The answer is b.** (Schwesinger, *Am J Surg* 172:411–417, 1996.) *Helicobacter pylori* infections have become extremely common. Nearly one-third of all American adults are now infected. Morphologically, the organism is a gram-negative, corkscrew-shaped, motile bacillus with three to seven flagella. Noninvasive approaches with simple, relatively inexpensive serologic and urea breath tests can establish the diagnosis of *H. pylori* infection. Culturing endoscopic scrapings or biopsy specimens has proved to be impractical because of the need for special media and elaborate growth conditions. A rapid urease test is used when endoscopy provides a specimen for analysis. Therapy is problematic because the organism is not easily eradicated. Monotherapy is largely ineffective. However, dual- and triple-drug therapy can achieve eradication in 80% to 90% of patients. Unfortunately, compliance rates with multidrug therapy are low.

**4-19. The answer is c.** (Seidel, 4/e, p 614.) At 20 wk of pregnancy, fundal height is at the level of the umbilicus. Part of the obstetrics and gynecology

history should include **GPAL (Georgia Power and Light):** Gravida, Para, Abortions, and Living children.

**4-20. The answer is c.** (*Chin, 17/e, pp 375–378.*) Pertussis has been recognized with increased frequency in the United States among young adults and adolescents who were previously immunized. The immunity provided by the vaccine is limited and fades over time. The infection can be particularly severe in children under the age of 1. Antibiotic prophylaxis with erythromycin is recommended for all household and close contacts to prevent disease and outbreaks. The symptoms are not typical of influenza, legionellosis, or pneumonia due to streptococci. Prophylaxis of contacts is not recommended for mycoplasma infections; these are much less contagious than pertussis.

**4-21. The answer is b.** (*Adams, 6/e, pp 1151–1154.*) The slow evolution of gait difficulty, bladder dysfunction, paresthesias, hyporeflexia, impaired position and vibration sense, and anemia suggests combined systems disease, the neurologic equivalent of pernicious anemia. Persons with this disease may have a diet rich in vitamin B<sub>12</sub>, but if they lack intrinsic factor in the stomach, they will develop the deficiency. Patients usually acquire a megaloblastic anemia associated with the spastic paraparesis. Finding hypersegmented polymorphonuclear cells on the peripheral blood smear helps establish the diagnosis.

**4-22. The answer is c.** (*Fauci, 14/e, p 1363–1364.*) The history and physical are consistent with post–myocardial infarction syndrome (Dressler syndrome) rather than infection, pulmonary embolus, angina, or anxiety. This syndrome represents an autoimmune pleuritis, pneumonitis, or pericarditis, characterized by fever and pleuritic chest pain, with onset days to 6 wk post myocardial infarction. Therefore the most effective therapy is a nonsteroidal anti-inflammatory drug.

**4-23. The answer is e.** (*Sadock, 7/e, p 2368.*) This patient experienced an acute dystonic reaction, an adverse effect of neuroleptic medications secondary to blockage of dopamine receptors in the nigro-striatum system. Dystonic reactions are sustained spasmodic contractions of the muscles of the neck, trunk, tongue, face, and extraocular muscles. These can be quite

painful and frightening. They usually occur within hours to 3 days after the beginning of the treatment and are more frequent in males and young people. They are also usually associated with high-potency neuroleptics. Occasionally dystonic reactions are seen in young people who ingest a neuroleptic medication, mistaking it for a drug of abuse.

**4-24. The answer is b.** (*Wallace, 14/e, p 1054. USPSTF, 2/e, pp 568–569.*)

Folic acid use during the first trimester of pregnancy has been shown to decrease the incidence of neural tube defect, which is often associated with hydrocephalia, which in turn may be associated with intellectual disability that can be severe. In fact, folic acid supplements are recommended beginning 1 mo prior to conception for all women capable of becoming pregnant. It is advisable to counsel women to avoid alcohol during pregnancy, although the risk of fetal alcohol syndrome is increased with 14 drinks per week or more. The effect of lower levels of drinking has been inconsistent.

**4-25. The answer is b.** (*Behrman, 16/e, pp 1469–1471. McMillan, 3/e, pp 1447–1448. Rudolph, 20/e, pp 1176–1180.*)

Iron-deficiency anemia is the most common nutritional deficiency in children between 9 and 15 mo of age. Low availability of dietary iron, impaired absorption of iron related to frequent infections, high requirements for iron for growth, and, occasionally, blood loss, all favor the development of iron deficiency in infants. A history regarding anemia in the family, blood loss, and gestational age and weight can help to establish the cause of an anemia. The strong likelihood is that anemia in a 1-year-old child is nutritional in origin, and its cause will be suggested by a detailed nutritional history.

Response to a therapeutic trial of iron is an appropriate and cost-effective method of diagnosing iron-deficiency anemia. A prompt reticulocytosis and rise in hemoglobin and hematocrit follow the administration of an oral preparation of ferrous sulfate. Intramuscular iron dextran should be reserved for situations in which compliance cannot be achieved. This is because this treatment is expensive, painful, and no more effective than oral iron. Dietary modifications, such as limiting the intake of cow's milk and including iron-fortified cereals along with a mixed diet, are appropriate long-term measures, but they will not make enough iron available to replenish iron stores. The gradual onset of iron-deficiency anemia enables a child to adapt to surprisingly low hemoglobin concentrations. Transfusion is rarely indicated unless a child becomes symptomatic or is further compromised by a superimposed infection. When the iron available for



production of hemoglobin is limited, free protoporphyrins accumulate in the blood. Levels of erythrocyte protoporphyrin (EP) are also elevated in lead poisoning. Iron-deficiency anemia can be differentiated from lead intoxication by measuring blood lead, which should be less than 10  $\mu\text{g/dL}$ .

**4-26. The answer is e.** (*Tintinalli, 5/e, pp 539–541.*) The patient has a past medical history of appendectomy, which predisposes him to adhesions and small bowel obstruction (SBO). Other etiologies for SBO include incarcerated hernia, stricture, and malignancy. The high-pitched bowel sounds, the peristaltic rushes, and the tympany with percussion are physical findings when air is under pressure in viscera and intestinal fluid is present (i.e., obstruction). The hallmarks of intestinal obstruction are abdominal pain, distension, vomiting, and obstipation. Abdominal radiographs may reveal dilated loops of bowel in a ladderlike pattern and air-fluid levels. Large bowel obstruction (LBO) is due to malignancy, diverticulitis, and volvulus. A mnemonic for abdominal distension is the **6 Fs**: Fat, Fluid, Food, Fetus, Feces, and Flatus.

**4-27 through 4-28. The answers are 4-27 b, 4-28 c.** (*Hoskins, 2/e, pp 793–794, 802–803.*) Microinvasive carcinoma of the cervix includes lesions within 3 mm of the base of the epithelium, with no confluent tongues or lymphatic or vascular invasion. The overall incidence of metastases from 751 reported cases is 1.2%. Simple hysterectomy is accepted therapy.

**4-29. The answer is c.** (*Fauci, 14/e, pp 1352–1353, 1361, 1374.*) Myocardial infarction occurs when an atherosclerotic plaque ruptures or ulcerates. Patients having myocardial infarctions are typically anxious, restless, and uncomfortable secondary to the extreme pain. They may demonstrate the Levine sign (clenching of the fist to demonstrate the severity of the pain). Risk factors for this patient include male gender, positive family history, hypertension, diabetes mellitus, tobacco use, and hyperlipidemia. Electrocardiogram (ECG) will show ST elevations, and cardiac isoenzymes [troponin, creatine phosphokinase (CPK)-MB fraction, and lactate dehydrogenase (LDH)] will be elevated. Patients with Prinzmetal's angina have recurrent attacks of chest pain at rest or while asleep (unstable angina) due to a focal spasm of an epicardial coronary artery. The diagnosis is confirmed by detecting the spasm after provocation during coronary arteriography. Cardiogenic shock is a form of severe left ventricular heart failure; patients are typically hypotensive. Right ventricular infarction is a compli-

cation of inferoposterior myocardial infarction. Patients present with jugular venous distension (JVD), the Kussmaul sign, and hypotension. Diagnosis is made by a right-sided electrocardiogram in which the leads are placed to the right of the sternum instead of the left.

**4-30. The answer is e.** (*Fauci, 14/e, pp 2227–2230.*) Primary hyperparathyroidism is the most common cause of hypercalcemia in the outpatient setting. It is seen more frequently in women than men and is usually due to one parathyroid adenoma (usually in the inferior lobe). Patients often have a history of hypophosphatemia, fatigue, hypertension, depression, peptic ulcer disease, pancreatitis, bone pain, hypercalciuria, and nephrolithiasis from calcium oxalate stones. The most common cause of hypercalcemia in hospitalized patients is malignancy (i.e., breast, lung, multiple myeloma, head and neck, and renal cell) due to the secretion of parathyroid hormone–related peptide (PTHrp). Patients with familial hypocalciuric hypercalcemia (FHH) have hypocalciuria, a positive family history, and no end organ damage. Other causes of hypercalcemia include sarcoidosis, mycobacteria, milk-alkali syndrome, and medications (i.e., thiazide diuretics). Osteitis fibrosa cystica (replacement by fibrous tissue) is the bone abnormality seen with hyperparathyroidism.

**4-31. The answer is d.** (*Greenfield, 2/e, pp 2231–2242.*) The survival of patients with malignant melanoma correlates with the depth of invasion (Clark) and the thickness of the lesion (Breslow). It is widely held that patients with thin lesions (<0.76 mm) and Clark's level I and II lesions are adequately managed by wide local excision. The incidence of nodal metastases rises with increasing Clark's level of invasion such that a level IV lesion has a 30% to 50% incidence of nodal metastases. The assumption that removal of microscopic foci of disease is beneficial, in conjunction with retrospective data indicating improved survival in patients who have undergone removal of clinically negative but pathologically positive nodes, has led to the widely held belief that prophylactic node dissections are indicated for melanoma. Prospective data has challenged this concept. Veronesi and Sim have found that patients who underwent prophylactic node dissections survived no longer than those who were followed closely and underwent node dissections only after nodes became palpable. The subject remains controversial and further study and follow-up are necessary. Immunotherapy has not been successful in controlling widespread

metastatic melanoma even when added to chemotherapy. Intralesional administration of bacille Calmette-Guérin (BCG) has been demonstrated to control local skin lesions in only 20% of patients. Dinitrochlorobenzene (DNCB) can also be used.

**4-32. The answer is a.** (*Behrman, 16/e, pp 1365–1366, 1369–1371, 1383–1390. McMillan, 3/e, pp 287, 1329–1332, 1346–1350, 1354–1357, 1378–1380. Rudolph, 20/e, pp 1466–1469, 1474–1475, 1497–1502.*) Most commonly, children with atrial septal defect (ASD) are asymptomatic, with the lesion found during a routine examination. In older children, exercise intolerance can be noted if the lesion is of significant size. On examination, the pulses are normal, a right ventricular systolic lift at the left sternal border is palpable, and a fixed splitting of the second heart sound is audible. For lesser degrees of ASD, surgical treatment is more controversial. Ventricular septal defect commonly presents as a harsh or blowing holosystolic murmur best heard along the left lower sternum, often with radiation throughout the precordium. Tricuspid regurgitation is a mid-diastolic rumble at the lower left sternal border. Often, a history of birth asphyxia or findings of other cardiac lesions are present. Tetralogy of Fallot is a very common form of congenital heart disease. The four abnormalities include right ventricular outflow obstruction, ventricular septal defect, dextroposition of the aorta, and right ventricular hypertrophy. The cyanosis presents in infants and young children. Mitral valve prolapse occurs with the billowing into the atria of one or both mitral valve leaflets at the end of systole. It is a congenital abnormality that frequently only manifests during adolescence or later, is more common in girls than in boys, and seems to be inherited in an autosomal dominant fashion. On clinical examination, an apical murmur is noted late in systole, which can be preceded by a midsystolic click. The diagnosis is confirmed with an echocardiogram that shows prolapse of the mitral leaflets during mid to late systole. Antibiotic prophylaxis is recommended for dental work (especially if a murmur is present) as the incidence of endocarditis can be higher in these patients.

**4-33. The answer is c.** (*Greenberg, 2/e, pp 2–22. Rosner, 5/e, pp 713–716.*) This is an example of the Kaplan-Meier method, also called the product-limit method, of estimating survival. This technique takes into consideration that not all individuals may be followed until they experience the end-point or “failure” (in this example, death). Some may be lost to follow-

up prior to failure (they may move away, refuse to continue to participate any longer, etc.), and others who have not experienced an end-point may not have been followed for the whole observation period because they entered late in the course of the study. These are called *censored observations* (incomplete observations of a time to failure). Kaplan-Meier curves appear like uneven steps. Other methods can be used (actuarial method), but the Kaplan-Meier method is the most frequently employed.

**4-34. The answer is e.** (*Berg, pp 681–682.*) This man has signs of cerebellar dysfunction. That the deficit has been slowly progressive and is not associated with cognitive dysfunction makes it especially likely that a structural lesion in the posterior fossa is responsible for the deficit. Because the lesion need not disturb the external shape of the cerebellum, a posterior fossa myelogram will not necessarily yield an answer. The CT scan will show if there is an intraparenchymal or extraparenchymal lesion. Drug abuse is not likely to be a factor in this cerebellar syndrome because all the phenomena observed on examination are coordination problems, rather than combined cognitive and motor functions.

**4-35. The answer is c.** (*Berg, pp 681–682.*) The association of erythrocytosis with cerebellar signs, microscopic hematuria, and hepatosplenomegaly suggests von Hippel–Lindau syndrome. This hereditary disorder is characterized by polycystic liver disease, polycystic kidney disease, retinal angiomas (telangiectasias), and cerebellar tumors. This is an autosomal dominant inherited disorder with variable penetrance. Men are more commonly affected than women. Although neoplastic cysts may develop in the cerebellum in persons with von Hippel–Lindau syndrome, these usually do not become sufficiently large to cause an obstructive hydrocephalus. Other abnormalities that occur with this syndrome include adenomas in many organs. Hemangiomas may be evident in the bones, adrenals, and ovaries. Hemangioblastomas may develop in the spinal cord or brainstem as well as in the cerebellum. This syndrome is not associated with acoustic schwannomas that could cause bilateral hearing loss and is not accompanied by peripheral neuropathy, which could cause diffuse hyporeflexia.

**4-36. The answer is a.** (*Berg, pp 681–682.*) The cystic lesion and the other cerebellar lesions are most likely hemangioblastomas. These hemangioblastomas often bleed and produce potentially lethal intracranial

hematomas. Radiation therapy and needle biopsies would increase the risk of bleeding. Rather than spontaneously involuting, these lesions generally enlarge and become more unstable as time passes. Intracerebellar hemorrhage is increasingly likely as time passes.

**4-37. The answer is d.** (*Berg, pp 681–682.*) von Hippel–Lindau syndrome is associated with a high incidence of renal carcinomas. These malignant renal tumors usually develop years after the cerebellar hemangioblastomas, liver disease, or polycystic renal disease become symptomatic. People surviving intracranial hemorrhages caused by the intracerebellar hemangioblastomas often succumb to metastatic renal carcinoma. Treating the intracranial lesions does nothing to reduce the risk of metastatic renal cancer.

**4-38. The answer is c.** (*Tierney, 39/e, pp 892–913.*) Anasarca is generalized body edema that is often seen in the nephrotic syndrome. The grape clusters (lipid deposits or oval fat bodies in sloughed tubular epithelial cells) that appear under light microscopy appear as Maltese crosses under the polarized light. One-third of patients with nephrotic syndrome have a systemic disease (i.e., diabetes mellitus, SLE) and two-thirds have either (1) membranous nephropathy due to hepatitis C, SLE, syphilis, or medications; (2) minimal change disease; (3) focal glomerular sclerosis [human immunodeficiency virus (HIV) or heroin use]; or (4) membranoproliferative glomerulonephritis. Patients with glomerulonephritis present with a nephritic syndrome (hypertension, hematuria, and edema). Patients with acute interstitial nephritis from drugs or infection usually present with rash, arthralgias, eosinophiluria, and eosinophilia. Acute tubular necrosis (ATN) typically occurs after an insult, such as ischemia or exposure to a nephrotoxin (i.e., contrast media, paraproteins in multiple myeloma, antibiotics). Myoglobinuria is a consequence of rhabdomyolysis that leads to ATN.

**4-39. The answer is c.** (*Mishell, 3/e, pp 1054–1055.*) Though the estimated incidence of postpill amenorrhea is given as 0.7% to 0.8%, there is no evidence to support the idea that oral contraception causes amenorrhea. Eighty percent of women resume normal periods within 3 mo of ceasing use of the pill, and 95% to 98% resume normal ovulation within a year. If there were a true relationship between the pill and amenorrhea, one would expect an increase in infertility in the pill-using population. This has not been found. Infertility rates are the same for those who have used the pill

and those who have not. Patients who have not resumed normal periods 12 mo after stopping use of the pill should be evaluated as any other patients with secondary amenorrhea. Women who have irregular menstrual periods are more likely to develop secondary amenorrhea whether they take the pill or not.

**4-40. The answer is d.** (*Sadock, 7/e, pp 868.*) Major depression can be the first manifestation of an occult carcinoma of the pancreas. The mechanism for this phenomenon is not known, although it may be due to humoral factors secreted by the tumor that act directly on the brain.

**4-41 through 4-43. The answers are 4-41 c, 4-42 e, 4-43 a.** (*LaDou, 2/e, pp 142–148.*) Heat stroke is characterized by the presence of mental status changes and a core body temperature of more than 39° C. Cardiovascular collapse will occur if the patient is not treated immediately, as the body temperature may reach 41.1° C. This is a medical emergency requiring intravenous hydration and rapid cooling: cool water or isopropyl alcohol 70% on the body with fanning, sponge baths, ice packs on the groin/axilla/neck and/or iced gastric lavage until the core body temperature drops to 39° C. Patients should be advised to avoid heat exposure for at least 4 wk because hypersensitivity to heat may persist for a long period of time after an episode of heat stroke. Heat cramps are characterized by painful muscle cramps along with some nausea and vomiting. The core body temperature is normal. This is caused by sodium depletion due to sweating: the patient should be placed in a cool environment and hydrated with a balanced salt solution. Rest for at least 1 to 3 days is recommended. Heat syncope is a sudden loss of consciousness due to vasodilatation secondary to heat. Heat exhaustion is what this patient is experiencing. She should be placed in a cool and shaded environment. This patient should also receive hydration and salt replenishment with intravenous fluids. Milder cases can be treated with oral hydration. At least 1 day of rest is recommended after heat exhaustion. Heat index guidelines are developed by the National Weather Service and predict risk of heat-related disorders based on ambient heat and humidity.

**4-44. The answer is b.** (*Mishell, 3/e, pp 229–232.*) In patients with abnormal bleeding who are not responding to standard therapy, a hysteroscopy should be performed. The hysteroscopy can rule out endometrial polyps or small fibroids, which, if present, can be resected. In patients

with heavy abnormal bleeding who no longer desire fertility, an endometrial ablation can be performed. If a patient has completed childbearing and is having significant abnormal bleeding, a hysteroscopy rather than a hysterectomy would still be the procedure of choice to rule out easily treated disease. Treatment with a gonadotropin-releasing hormone (GnRH) agonist would only temporarily relieve symptoms.

**4-45. The answer is c.** (*Fauci, 14/e, pp 2057–2059.*) Pheochromocytoma is a life-threatening disease if left undiagnosed. Patients present with episodic symptoms of headache, sweating, and palpitations. Pheochromocytoma may be associated with von Recklinghausen syndrome, neurofibromatosis, or von Hippel–Lindau syndrome. The diagnosis is made by 24-h urine for catecholamines and metanephrines. Ten percent of pheochromocytomas are bilateral and 10% are extra-adrenal. Increased levels of 5-HIAA are associated with carcinoid syndrome (facial flushing and diarrhea) from a tumor usually located in the lung or ileum. Patients with thyroid storm present with nausea, diarrhea, jaundice, fever, dyspnea, shortness of breath, diaphoresis, delirium, and tachycardia. The combination of diabetes mellitus, hypertension, obesity, insulin resistance, and dyslipidemia [increased very-low-density lipoproteins (VLDLs), increased triglycerides, and decreased high-density lipoproteins (HDLs)] is called syndrome X or **CHAOS** (Coronary artery disease, Hypertension, Atherosclerosis, Obesity, and Stroke).

**4-46. The answer is b.** (*Fauci, 14/e, pp 1904–1906.*) Ankylosing spondylitis (Marie-Strümpell arthritis) is a chronic and progressive inflammatory disease that most commonly affects spinal, sacroiliac, and hip joints. All patients have symptomatic sacroiliitis. Other symptoms may include uveitis and aortitis. Men in the third decade of life are most frequently affected, and there is a strong association with human leukocyte antigen (HLA)-B27 (90%) in white patients. Patients with advanced disease present with a bent-over posture. A positive Schober test indicates diminished anterior flexion of the lumbar spine. Involvement of the costovertebral joints limits chest expansion and eye involvement may cause an iritis. Patients with Reiter syndrome may present with a history of conjunctivitis, urethritis, arthritis, and enthesopathy (Achilles tendinitis).

**4-47. The answer is c.** (*Hales, 3/e, p 351.*) Severe anterograde memory deficits with an inability to form new memories are the main feature of Korsakoff syndrome or Alcohol Persisting Amnestic Disorder. Retrograde

amnesia is also present, with the most severe loss of memory occurring for events that are closer to the beginning of the disorder. Remote memories are relatively preserved. The disorder is due to dietary thiamin deficiency and subsequent damage of the thiamin-dependent structures of the brain (mammillary bodies and the regions surrounding the third and fourth ventricle). Korsakoff syndrome can rarely be due to other causes of thiamin deficiency, such as diseases that cause severe malabsorption.

**4-48. The answer is a.** (*Bradley, 3/e, pp 245, 741.*) Ménière's disease is characterized by repeated brief episodes of fullness in the ear, tinnitus, hearing loss, and severe vertigo. The episodes may last hours to days. Attacks may be so severe as to cause the patient to fall to the ground due to severe dysequilibrium. The cause is generally idiopathic, but is thought to relate to distension of the semicircular canal and an increase in the volume of the endolymphatic fluid. For this reason, the condition has been called endolymphatic hydrops. Treatment is generally salt restriction and diuretics. Surgery with endolymphatic shunts is of unproven value.

**4-49. The answer is a.** (*Behrman, 16/e, pp 505–506. McMillan, 3/e, pp 173–178. Rudolph, 20/e, pp 238–243.*) Infants who are postmature (more than 42 wk of gestation) and show evidence of chronic placental insufficiency (low birth weight for gestational age and wasted appearance) have a higher-than-average chance of being asphyxiated, and passage of meconium into the amniotic fluid thus places these infants at risk for meconium aspiration. To prevent or minimize this risk, these infants should undergo immediate nasopharyngeal suction as their heads are delivered. Immediately after delivery and before initiation of respiration, their tracheas should be carefully and thoroughly suctioned through an endotracheal tube under direct vision with a laryngoscope. Afterward, appropriate resuscitative measures should be undertaken to establish adequate ventilation and circulation. Artificial ventilation performed before tracheal suction could force meconium into smaller airways.

**4-50. The answer is b.** (*Stobo, 23/e, pp 430–438.*) The most likely diagnosis in this patient is esophageal carcinoma. Dysphagia is progressive first for solids and then liquids. There is blood in the stool and a history of weight loss. The patient has alcohol use and cigarette smoking as risk factors. Prognosis is not good, because once there is trouble swallowing, there



is significant esophageal narrowing and the disease is usually incurable. A barium contrast study should demonstrate an esophageal carcinoma with marked narrowing and an irregular, ragged mucosal pattern. Ninety percent of esophageal carcinoma is squamous cell; 10% is adenocarcinoma. Achalasia should not cause guaiac-positive stools or progressive symptoms.

*This page intentionally left blank.*

# BLOCK 5

---

## Answers

**5-1. The answer is d.** (*Schwartz, 7/e, pp 59–61.*) The patient presented in the question is suffering from acute, life-threatening respiratory acidosis that has been compounded, if not produced, by the injudicious administration of a central nervous system depressant. While hypoxemia must also be corrected, the immediate task is to correct the acidosis caused by carbon dioxide accumulation. Both disturbances can be resolved by skillful endotracheal intubation and ventilatory support. Sodium bicarbonate and high-flow nasal oxygen would both be inappropriate. Bicarbonate should not be administered because buffer reserves are already adequate (serum bicarbonate is still 34 meq/L based on the Henderson-Hasselbalch equation). Nasal oxygen administration is not warranted because both acidemia and hypoxemia are themselves potent stimulants to spontaneous ventilation. Headache, confusion, and papilledema are all signs of acute carbon dioxide retention and do not imply the presence of a structural intracranial lesion.

**5-2. The answer is d.** (*DSM-IV, pp 339–344.*) Irritable or sad mood, anhedonia, decreased motivation, insomnia, and decreased appetite are consistent with a diagnosis of major depression. Although heart medications often cause psychiatric symptoms, and in particular depression, in this case the patient's depression is unlikely to be a medication side effect, since there have been no recent changes in the pharmacological treatment. Atypical depression is characterized by hypersomnia, increased appetite, and increased reactivity to criticisms. Double depression is diagnosed when a patient with dysthymia develops a major depressive episode.

**5-3. The answer is c.** (*Greenfield, 2/e, pp 284, 337.*) The finding of an air-fluid level in the left lower chest with a nasogastric tube entering it after blunt trauma to the abdomen is diagnostic of diaphragmatic rupture with gastric herniation into the chest. This lesion needs to be fixed immediately. With continuing negative pressure in the chest, each breath sucks more of the abdominal contents into the chest and increases the likelihood of vascu-

lar compromise of the herniated viscera. While the diaphragm is easily fixed from the left chest, this injury should be approached from the abdomen. The possibility of injury below the diaphragm after sufficient blunt injury to rupture the diaphragm mandates examination of the intraabdominal solid and hollow viscera; adequate exposure of the diaphragm to allow secure repair is possible from this approach.

**5-4. The answer is d.** (*Adams, 6/e, pp 1405–1406.*) This patient presents with proximal muscle weakness and pain and a heliotrope rash about her eyes. The term *heliotrope* refers to the lilac color of the periorbital rash characteristic of dermatomyositis. The rash surrounds both eyes and may extend onto the malar eminences, the eyelids, the bridge of the nose, and the forehead. It is usually associated with an erythematous rash across the knuckles and at the base of the nails and may be associated with flat-topped purplish nodules over the elbows and knees. Men with dermatomyositis are at higher than normal risk of having underlying malignancies. Psoriatic arthritis may be associated with reddish discoloration of the knuckles and muscle weakness, but the heliotrope rash would not be expected with this disorder. The age of onset for a psoriatic myopathy is also atypical. Similarly, the patient's rashes are not suggestive of systemic lupus erythematosus (SLE), although a myopathy may occur with this connective tissue disease as well.

**5-5. The answer is b.** (*Chin, 17/e, p 318.*) The Dominican Republic is one area of high risk for malaria where no chloroquine-resistant strains of *Plasmodium falciparum* have been identified. Other areas include Central America west of the Panama Canal Zone, Haiti, Egypt, and most of the Middle East. Almost all other countries with a high risk for malaria have resistant strains. The drug of choice for prophylaxis in these areas is mefloquine or doxycycline. Primaquine is given to prevent relapses due to *P. vivax* or *P. ovale*. Current information on the foci of drug-resistant *P. falciparum* is available through the Centers for Disease Control (CDC) travel Web site or the annual publication of the World Health Organization (WHO).

**5-6. The answer is b.** (*Fauci, 14/e, p 1428.*) This patient has peripheral eosinophilia in association with pulmonary infiltrates. The differential diagnosis for eosinophilic pneumonia includes allergic bronchopulmonary aspergillosis, parasitic infections, drug reactions, and a category of idio-

pathic disease. Nitrofundantoin and sulfonamides are among the drugs most likely to cause eosinophilic pneumonia. Hypersensitivity pneumonitis may cause bilateral infiltrates but does not, of itself, cause eosinophilia.

**5-7. The answer is d.** (*Schwartz, 7/e, pp 552–553.*) Fibroadenomas occur infrequently before puberty but are the most common breast tumors between puberty and the early thirties. They are usually well demarcated and firm. Although most fibroadenomas are no larger than 3 cm in diameter, giant or juvenile fibroadenomas are frequently very large. The bigger fibroadenomas (greater than 5 cm) occur predominantly in adolescent black girls. The average age at onset of juvenile mammary hypertrophy is 16 years. This disorder involves a diffuse change in the entire breast and does not usually manifest clinically as a discrete mass; it may be unilateral or bilateral and can cause an enormous and incapacitating increase in breast size. Regression may be spontaneous and sometimes coincides with puberty or pregnancy. Cystosarcoma phylloides may also cause a large lesion. Together with intraductal carcinoma, it characteristically occurs in older women. Lymphomas are less firm than fibroadenomas and do not have a whorl-like pattern. They display a characteristic fish-flesh texture.

**5-8. The answer is b.** (*Stobo, 23/e, pp 211–214.*) The complaints described are characteristic of Sjögren syndrome, an autoimmune disease with presenting symptoms of dry eyes and dry mouth. The disease is caused by lymphocytic infiltration and destruction of lacrimal and salivary glands. Dry eyes can be measured objectively by the Schirmer test, which measures the amount of wetness of a piece of filter paper exposed to the lower lid for 5 min. Most patients with Sjögren syndrome produce autoantibodies, particularly anti-RO (SSA). Lip biopsy is needed only to evaluate uncertain cases, such as when dry mouth occurs without dry eye symptoms. Mumps can cause bilateral parotitis, but would not explain the patient's dry eye syndrome. Corticosteroids are reserved for life-threatening vasculitis, which may cause a secondary Sjögren syndrome.

**5-9. The answer is d.** (*Behrman, 16/e, pp 771–773, 775–776. McMillan, 3/e, pp 447–449, 1724–1725. Rudolph, 20/e, pp 227, 648–650.*) The infant of a mother who is a carrier of hepatitis B surface antigen (HBsAg) has a significant risk of acquiring infection. This usually occurs at the time of delivery, but infection can also be acquired during pregnancy and postnatally. A

small percentage of infected neonates develop acute icteric hepatitis, but the majority remain asymptomatic. Of these infected asymptomatic infants, 80% or more will develop chronic antigenemia, the long-term consequences of which are chronic liver disease and possibly hepatocellular carcinoma. Combined passive-active immunoprophylaxis in the form of immune globulin and hepatitis B vaccine affords protection not only from immediate perinatal infection but also from infection that may be acquired as a result of continued exposure in the household of a chronic carrier.

Immunization is indicated regardless of the presence of hepatitis B e antigen (HBeAg) in the mother. Although the presence of HBeAg, especially in the absence of antibodies to HBeAg, is associated with high rates of transmission to neonates, any woman positive for Hepatitis B surface antigen (HBsAg) is potentially infectious. It is not necessary to isolate infants born to carriers of HBsAg, and screening of neonates for HBsAg is not indicated. Testing for HBsAg and anti-HBsAg at least 1 mo after the third dose of hepatitis B vaccine will determine the efficacy of these measures.

**5-10. The answer is c.** (*Pozgar, 6/e, p 406.*) Most states have laws that allow physicians to provide medical services to minors for sexually transmitted disease without parental consent. Although referring to a family planning clinic (where teens can always be seen without parental consent) can be an option, there is a probability that the patient will delay (or forgo) the visit, resulting in a complicated infection, such as pelvic inflammatory disease (PID). Notifying the department of public health is not necessary, but the department could assist in partner notification if the patient consents. At the very least, the patient must be informed that it is crucial that her partner be evaluated and treated. Consensual sexual activity between minors does not need to be reported to social services as statutory rape. Sexual activity with an adult should raise concern about abusive relationships.

**5-11. The answer is b.** (*Maingot, 10/e, pp 581–591.*) The finding of air in the biliary tract of a nonseptic patient is diagnostic of a biliary enteric fistula. When the clinical findings also include small bowel obstruction in an elderly patient without a history of prior abdominal surgery (a “virgin” abdomen), the diagnosis of gallstone ileus can be made with a high degree of certainty. In this condition, a large chronic gallstone mechanically erodes through the wall of the gallbladder into the adjacent stomach or duode-

num. As the stone moves down the small intestine, mild cramping symptoms are common. When the gallstone arrives in the distal ileum, the caliber of the bowel no longer allows passage and obstruction develops. Surgical removal of the gallstone is necessary. The diseases suggested by each of the other response items (bleeding ulcer, peritoneal infection, pyloric outlet obstruction, pelvic neoplasm) are common in elderly patients, but each would probably present with symptoms other than those of small bowel obstruction.

**5-12. The answer is a.** (*Fauci, 14/e, pp 1566–1569.*) Fanconi syndrome is a generalized defect in proximal tubule transport involving amino acids, glucose, uric acid, potassium, phosphate, sodium, and bicarbonate. It may be secondary to multiple myeloma, amyloidosis, and heavy metal toxicity. Fanconi syndrome is a type 2 (proximal) renal tubular acidosis (RTA). Type 1 (distal) RTA causes a metabolic acidosis with an alkaline (>5.5) urine pH. Type 4 RTA causes hyperkalemia and is due to inadequate aldosterone production from diabetes mellitus, sickle cell disease, obstructive uropathy, or use of medication [heparin, nonsteroidal anti-inflammatory drugs, and angiotensin converting enzyme (ACE) inhibitors]. Diabetic patients may develop a specific kind of nephropathy (glomerulosclerosis) in which Kimmelstiel-Wilson lesions (nodules that stain periodic acid–Schiff positive and are deposited in the periphery of the glomerulus) are found histologically.

**5-13. The answer is c.** (*Rock, pp 310–311.*) Serosanguineous drainage occurs very frequently before evisceration from the incision. Drainage can be accompanied by pain or by the feeling that something is “giving way.” Serous or sanguineous drainage is often noted postoperatively and usually suggests involvement of the superficial wound.

**5-14. The answer is a.** (*Behrman, 16/e, pp 493–495. McMillan, 3/e, pp 179–180, 235–237. Rudolph, 20/e, pp 1882–1884.*) During a period of asphyxia, the resulting hypoxemia, acidosis, and poor perfusion can damage a neonate’s brain, heart, kidney, liver, and lungs. The resulting clinical abnormalities include cerebral edema, irritability, seizures, cardiomegaly, heart failure, renal failure, poor liver function, disseminated intravascular coagulopathy, and respiratory distress syndrome. There can be excessively high pulmonary arterial pressure at the same time systemic blood pressure

begins to fall, resulting in a persistent right-to-left shunt across a patent ductus arteriosus or foramen ovale.

**5-15. The answer is c.** (*Behrman, 16/e, pp 1519–1520. McMillan, 3/e, p 1448. Rudolph, 20/e, pp 1241–1242, 1245–1249, 1251.*) The prolongation of prothrombin time (PT), activated partial thromboplastin time (aPTT), and thrombin time (TT) excludes the diagnosis of immune thrombocytopenic purpura (ITP). PT tests principally for factors I, II, V, VII, and X and is not prolonged in hemophilia A (factor VIII deficiency) or hemophilia B (factor IX deficiency). In vitamin K deficiency, there is a decrease in the production of factors II, VII, IX, and X, and PT and aPTT are prolonged. The thrombin time, which tests for conversion of fibrinogen to fibrin, however, should be normal and the platelet count should also be normal. In disseminated intravascular coagulation (DIC), there is consumption of fibrinogen; factors II, V, and VIII; and platelets. Therefore, there is prolongation of PT, aPTT, and TT and a decrease in factor VIII level and platelet count. In addition, the titer of fibrin split production is usually increased.

**5-16. The answer is b.** (*Scott, 8/e, p 613.*) Dysmenorrhea is considered secondary if associated with pelvic disease such as endometriosis, uterine myomas, or pelvic inflammatory disease. Primary dysmenorrhea is associated with a normal pelvic examination and with ovulatory cycles. The pain is usually accompanied by other symptoms—nausea, fatigue, diarrhea, and headache—which may be related to excess of prostaglandin  $F_{2\alpha}$ . The two major drug therapies effective in dysmenorrhea are oral contraceptives and antiprostaglandins. Gonadotropin-releasing hormone (GnRH) analogs are used in several gynecological conditions, but would not be first-line therapy for primary dysmenorrhea. Similarly, danazol is used for the treatment of endometriosis, and ergot derivatives for hyperprolactinemia. Analgesics such as codeine or narcotics are generally employed only in very severe cases when no other treatment provides adequate relief. Treatment will reduce the number of women incapacitated by menstrual symptoms to about 10% of those treated. Contrary to past beliefs, psychological factors play only a minor role in dysmenorrhea.

**5-17. The answer is d.** (*Fauci, 14/e, pp 6–7.*) The principle of autonomy is an overriding issue in this patient who is competent to make her own decisions about surgery. Consulting a psychiatrist is inappropriate unless there



is some reason to believe the patient is not competent. No such concern is present in this description of the patient. Since the patient is competent, no friend or relative can give permission for the procedure.

**5-18. The answer is e.** (*Tierney, 39/e, pp 535–538.*) Idiopathic thrombocytopenic purpura (ITP) is an autoimmune disorder in which an immunoglobulin G (IgG) autoantibody binds to platelets. Destruction of the platelets takes place in the spleen, where macrophages bind to the antibody-coated platelets. Fifty percent of patients with ITP have no associated disease, but human immunodeficiency virus (HIV) infection, SLE, or a lymphoproliferative disorder should be considered. ITP is a disease of persons between the ages of 20 and 50 years and occurs in women more than men. There is no splenomegaly in ITP. The diagnosis is one of exclusion, but often megathrombocytes are seen on peripheral smear. Evans syndrome is ITP with coexistent autoimmune hemolytic anemia. DIC is a systemic coagulation disorder that can be accompanied by thrombocytopenia. It may be secondary to transfusion, infection, malignancy, trauma, or obstetric complications. Thrombocytopenic thrombotic purpura (TTP) is unlikely since the patient does not have the pentad of symptoms seen in 40% of patients (**FAT R.N.** = Fever, Autoimmune hemolytic anemia, Thrombocytopenia, Renal disease, Neurologic disease). Hemolytic-uremic syndrome (HUS) presents with three of the five symptoms seen in TTP (**RAT** = Renal, Autoimmune hemolytic anemia, and Thrombocytopenia). Fever and neurologic disease are lacking. Henoch-Schönlein purpura occurs in children and patients present with **AGAR** (Abdominal pain, Glomerulonephritis, Arthralgia, and Rash that is purpuric).

**5-19 through 5-20. The answers are 5-19 c, 5-20 c.** (*Greenfield, 2/e, pp 571–581.*) Hemodialysis, rather than management by dietary manipulation alone, should be instituted in patients with end-stage renal failure whose serum creatinine is over 15 mg/dL or whose creatinine clearance is less than 3 mL/min. It is important that hemodialysis be initiated prior to the onset of uremic complications. These complications include hyperkalemia, congestive heart failure, peripheral neuropathy, severe hypertension, pericarditis, bleeding, and severe anemia. The uremic hyperkalemic patient in congestive heart failure may require emergency dialysis in addition to the standard conservative measures, which include (1) limitation of protein intake to less than 60 g/day and restriction of fluid intake and (2) reduction

of elevated serum potassium levels by treatment with insulin-glucose or sodium polystyrene sulfonate (Kayexalate) enemas. Arteriovenous fistulas require about 2 wk to develop adequate size and flow. While awaiting maturation, temporary dialysis can be satisfactorily performed using either an external arteriovenous shunt or the peritoneal cavity. Renal biopsy would be performed in an attempt to obtain a diagnosis of the underlying renal disease. Patients who are acceptable candidates for kidney transplantation should usually undergo this form of treatment, after they are stabilized, rather than chronic hemodialysis, the mortality for which is now higher than for transplantation. Despite adequate dialysis, problems of neuropathy, bone disease, anemia, and hypertension remain difficult to manage. Compared with chronic dialysis, transplantation restores more patients to happier and more productive lives. It had been conjectured that, all other issues being equal, sex matching was important in the graft survival and that a mother-daughter graft was preferred to a father-daughter. Review of the current data does not support such a conclusion. The best graft survival rates for living related transplants—over 90% at 5 years—are obtained when all six histocompatibility loci are identical. All family members of potential transplant recipients should be tissue typed and the donor selected on the basis of closest match, if psychological and medical evaluation makes this feasible. With the development of cyclosporine-based immunosuppression, cadaveric kidney graft survival has approached that of living-related transplantation. There are some transplanters who believe that the slight improvement with living-related kidneys does not justify the risk to the donor and that these transplantations should no longer be performed.

**5-21. The answer is b.** (*Fitzpatrick, 3/e, pp 590–595, 630–647.*) Toxic shock syndrome (TSS) is the most likely diagnosis in this patient. This disease is a toxin-mediated multisystem infection caused by *Staphylococcus aureus*. Risk factors for TSS include surgical wounds, nasal packs, burns, skin ulcers, postpartum infections, eye injuries, and use of vaginal tampons. The rash is typically generalized and macular and involves the mucous membranes. Desquamation of the epithelium of the palms and soles and subsequent multisystem failure occur in TSS. Cellulitis is an acute infection of the dermal and subcutaneous tissues characterized by erythema, warmth, and tenderness of the skin at the site of the entry of the bacteria. Necrotizing fasciitis begins as a painful induration of the underly-

ing soft tissues with rapid development of an eschar and necrotic mass. Scarlet fever is seen in children and is due to an exotoxin-producing strain of group A *Streptococcus*. It has a characteristic confluent (scarlatiniform) erythema, which begins centrally, spreads to the extremities, and then desquamates. Toxic epidermal necrolysis (TEN) is a mucocutaneous, primarily drug-induced eruption characterized by a generalized erythema and exfoliation that may lead to multisystem failure. Drugs that have been implicated include sulfa derivatives, allopurinol, and hydantoins. TEN is a more severe variant of Stevens-Johnson syndrome (SJS) and begins 1 to 3 wk after drug exposure.

**5-22. The answer is b.** (*Sapira, p 374, Tintinalli, 5/e, pp 554–555.*) Complications of diverticular disease include diverticulitis and gastrointestinal bleeding. Diverticulitis is an acute inflammatory process caused by bacteria in a diverticulum (outpouching of the mucosa or submucosa). It may occur in up to 50% of patients with diverticulosis. The patient most likely has diverticulitis, which is usually left-sided since the diameter of the sigmoid colon is the smallest of the colon (higher wall tension and intraluminal pressure in this area are probably responsible for the diverticular formation). The palpable mass reflects adherent loops of bowel. Peritonitis often results in involuntary guarding (abdominal rigidity due to reflex muscle spasm from the peritoneal irritation). Decreased bowel sounds may be heard in peritonitis or in any condition that causes an ileus (absence of peristalsis). Tenderness when the hand is withdrawn abruptly (rebound tenderness or Blumberg sign) occurs because when the abdominal wall passively springs back into place, it carries with it the inflamed peritoneum. The referred rebound test is conducted in the same way but in a location away from the area of tenderness. The patient will experience pain in the area of stated tenderness rather than the site where the test is performed.

**5-23. The answer is d.** (*Fleisher, 5/e, pp 732–735. Ransom, pp 511–515.*) The history, clinical picture, and ultrasound of the woman described are characteristic of hydatidiform mole. The most common initial symptoms include an enlarged-for-dates uterus and continuous or intermittent bleeding in the first two trimesters. Other symptoms include hypertension, proteinuria, and hyperthyroidism. Hydatidiform mole is 10 times as common in the Far East as in North America, and it occurs more frequently in women

over 45 years of age. A tissue sample would show a villus with hydropic changes and no vessels. Grossly, these lesions appear as small, clear clusters of grapelike vesicles, the passage of which confirms the diagnosis.

**5-24. The answer is a.** (*Rock, 8/e, pp 1631–1632.*) The condition of women who have hydatidiform moles but no evidence of metastatic disease should be followed routinely by human chorionic gonadotropin (hCG) titers after uterine evacuation. Most authorities agree that prophylactic chemotherapy should not be employed in the routine management of women having hydatidiform moles because 85% to 90% of affected patients will require no further treatment. For a young woman in whom preservation of reproductive function is important, surgery is not routinely indicated.

**5-25. The answer is c.** (*Chin, 17/e, pp 238–257.*) Hepatitis C is primarily parenterally transmitted, and a high percentage of intravenous drug users are found to be infected. Hepatitis A and E are transmitted via the fecal/oral route, and result in similar self-limited acute symptomatic episodes. Hepatitis E is rare in the United States, occurring among travelers returning from endemic areas such as Asia, India, Africa, and Central America. Living conditions of intravenous drug users may also increase the risk of acquiring such infections, but hepatitis C is much more prevalent. Hepatitis D only occurs with coinfection with hepatitis B. The presence of antibodies against hepatitis B signals a past infection and clearance of the virus.

**5-26. The answer is d.** (*DSM-IV, p 302–304.*) Brief psychotic disorder is characterized by the sudden appearance of delusions, hallucinations, and disorganized speech or behavior usually following a severe stressor. The episode lasts at least 1 day and less than 1 mo and is followed by full spontaneous remission. This patient's psychotic episode was clearly precipitated by the tragic death of her sons. Schizophreniform disorder is differentiated from brief psychotic disorder by the temporal factor (in schizophreniform disorder, symptoms are required to last more than 1 mo) and lack of association with a stressor. Posttraumatic stress disorder has a more chronic course and is characterized by affective, dissociative, and behavioral symptoms.

**5-27. The answer is d.** (*Stobo, 23/e, pp 300–301.*) Thyroid fine-needle biopsy now plays a central role in the differential diagnosis of thyroid nodules. Thyroid scan can show a hot nodule, which would be reassuring that

the nodule is benign; a biopsy would be necessary for the cold nodules. Thyroid sonography can seldom rule out malignancy in palpable nodules. Surgery is indicated if the aspiration biopsy shows malignancy or, in most cases, if it is indeterminate.

**5-28. The answer is a.** (*Sadock, 7/e, p 790–1456.*) An acute onset of obsessions and compulsions in a prepubertal child is characteristic of a pediatric autoimmune neuropsychiatric disorder associated with streptococcal (group A,  $\beta$  hemolytic) infection (PANDAS). Behavioral problems, new-onset separation anxiety, emotional lability, and motor hyperactivity are accompanying symptoms. Lyme disease (transmitted by tick bites), encephalitis (transmitted by mosquitoes bites), trichinosis (from poorly cooked pork), and cat-scratch disease have different clinical presentations.

**5-29. The answer is b.** (*Mehta, pp 231–235, 245–247.*) Carpal tunnel syndrome (CTS) is the most likely diagnosis. It is due to median nerve compression by the transverse carpal ligament. Risk factors for this disorder include diabetes mellitus, pregnancy, hypothyroidism, rheumatoid arthritis, repetitive activity, and acromegaly. The Tinel sign (paresthesias or pain are reproduced with percussion of the volar surface of the wrist) and Phalen sign (symptoms are reproduced by holding the wrist in passive flexion for 1 min) may be positive. Patients may complain of pain in the forearm, the thenar eminence, and the first three digits. Thoracic outlet syndrome usually causes medial arm pain and paresthesia when using the arms. The presence of a cervical rib is a risk factor for this disorder. Dupuytren's contracture is a fibrotic process of the palmar fascia that causes fixed flexion of the ring finger. Mallet finger is a flexion deformity of the distal interphalangeal joint and is generally the result of traumatic rupture of the extensor tendon of the distal phalanx. A ganglion is a painless, firm cystic mass arising from any joint or tendon sheath. A trigger finger may be seen in patients with rheumatoid arthritis. It occurs when an enlarged flexor tendon sheath passes through the pulleys of the digits, causing locking or catching.

**5-30. The answer is b.** (*DiSaia, 5/e, p 285.*) The most common ovarian neoplasms in children are of germ cell origin, and about half of these tumors are malignant. Functioning ovarian tumors have been reported to produce precocious puberty in about 2% of affected patients. Epithelial

tumors of the ovary, which are quite rare in prepubertal girls, are benign in approximately 90% of all cases; papillary serous cystadenocarcinoma is an example of such a malignant epithelial tumor. Stromal tumors (such as fibrosarcoma) and Brenner tumors are not seen in this age group. Sarcoma botryoides, a tumor seen in children, is a malignancy associated with mulle-rian structures such as the vagina and uterus, including the uterine cervix.

**5-31. The answer is d.** (*Fauci, 14/e, pp 818–822.*) The patient presents with pyelonephritis, which is an infection of the kidney and renal pelvis. It is characterized by flank pain, fever, dysuria, and frequency. Patients often experience suprapubic and costovertebral angle (CVA) tenderness. Patients with acute cystitis may present with dysuria, frequency, urgency, and suprapubic tenderness, but typically the patient is afebrile and the physical examination is normal. The organisms responsible for urinary tract infections are **SEEK PP** = *Serratia marcescens*, *Escherichia coli*, *Enterobacter cloacae*, *Klebsiella pneumoniae*, *Proteus mirabilis*, and *Pseudomonas aeruginosa*.

**5-32. The answer is e.** (*Ransom, p 53.*) The lesions shown in the figure accompanying the question are condyloma acuminatum, also known as venereal warts. This is a squamous lesion caused by a human papillomavirus (HPV). The lesion reveals a treelike growth microscopically with a mantle that shows marked acanthosis and parakeratosis. The treatment is local excision, cryosurgery, application of podophyllum or trichloroacetic acid, or laser therapy, although podophyllin is not recommended for extensive disease because of toxicity (peripheral neuropathy). For intractable condyloma of the vagina, 5-fluorouracil can be employed. Vulvectomy is rarely indicated. A strong relationship between condyloma and intraepithelial neoplasia and carcinoma of the cervix has recently been demonstrated.

**5-33. The answer is b.** (*Fauci, 14/e, pp 739–740.*) This patient with gram-negative bacteremia has developed disseminated intravascular coagulation as evidenced by multiple-site bleeding, thrombocytopenia, fragmented red blood cells on peripheral smear, prolonged PT and partial thromboplastin time (PTT), and reduced fibrinogen levels from depletion of coagulation proteins. Initial treatment is directed at correcting the underlying disorder (in this case infection). The use of heparin is somewhat controversial, but

it is generally recommended only in association with acute promyelocytic leukemia.

**5-34. The answer is e.** (*Fauci, 14/e, pp 1445–1447, Goldman, 21/e, pp 405–406.*) Bronchiectasis is an acquired disease that causes abnormal dilation of the bronchi leading to pooling of secretions in the airways and recurrent infections. Patients typically present with cough and with the production of purulent sputum. Lung auscultation may be normal or remarkable for wheezes, rhonchi, or crackles. Chest radiograph may be normal, but occasionally the damaged, dilated airways appear as “tram-tracks” or “ring shadows.” Bronchiectasis may be a sequela of foreign body aspiration, cystic fibrosis, rheumatic diseases (rheumatoid arthritis, Sjögren syndrome), pulmonary infections (tuberculosis, pertussis, mycoplasma), acquired immune deficiency syndrome (AIDS), or allergic bronchopulmonary aspergillosis (ABPA).

**5-35. The answer is a.** (*Fauci, 14/e, pp 1318–1319.*) The classic symptoms of aortic stenosis are exertional dyspnea, angina pectoris, and syncope. Physical findings include a narrow pulse pressure and the systolic murmur as described in answer a (rather than the aortic insufficiency murmur of answer b, the mitral regurgitation murmur of answer c, or the mitral valve prolapse click of answer d).

**5-36. The answer is e.** (*Cunningham, 20/e, pp 540, 551.*) Bloody lochia can persist for up to 2 wk without indicating an underlying pathology; however, if bleeding continues beyond 2 wk, it may indicate placental site subinvolution, retention of small placental fragments, or both. At this point, appropriate diagnostic and therapeutic measures should be initiated. The physician should first estimate the blood loss and then perform a pelvic examination in search of uterine subinvolution or tenderness. Excessive bleeding or tenderness should lead the physician to suspect retained placental fragments or endometritis. A larger-than-expected but otherwise asymptomatic uterus supports the diagnosis of subinvolution.

**5-37. The answer is d.** (*Tierney, 39/e, pp 539–541.*) von Willebrand disease (vWD) is the most common inherited bleeding disorder (autosomal dominant). It is due to an abnormality in the quantity or quality of von Willebrand factor (vWF). The most common type, type I (80% of cases), is

caused by a quantitative decrease in vWF. Type IIA and IIB vWD are qualitative disorders, and type III vWD is a rare autosomal recessive disorder in which vWF is nearly absent. Most bleeding from vWD is mucosal (epistaxis, gingival, menorrhagia) or gastrointestinal, and bleeding is exacerbated by aspirin use. Hemarthrosis does not occur in vWD. The treatment for vWD types I and IIA is desmopressin, which stimulates the release of vWF from endothelial cells. Spontaneous hemarthroses are characteristic of hemophilia A or factor VIII deficiency (classic hemophilia); the diagnosis is made by finding a decrease level of factor VIII:C. Specific assays can distinguish between factor VIII and factor IX hemophilia (hemophilia B or Christmas disease). Hemophilia has an X-linked pattern of inheritance and the symptoms and prognosis are similar for hemophilia A and B. Bernard-Soulier syndrome is a rare platelet disorder in which platelets cannot adhere to the endothelium because they lack receptors for vWF. Patients present with severe bleeding, especially postoperatively. Platelets appear abnormally large on peripheral smear. Measurements of vWF in Bernard-Soulier syndrome are normal.

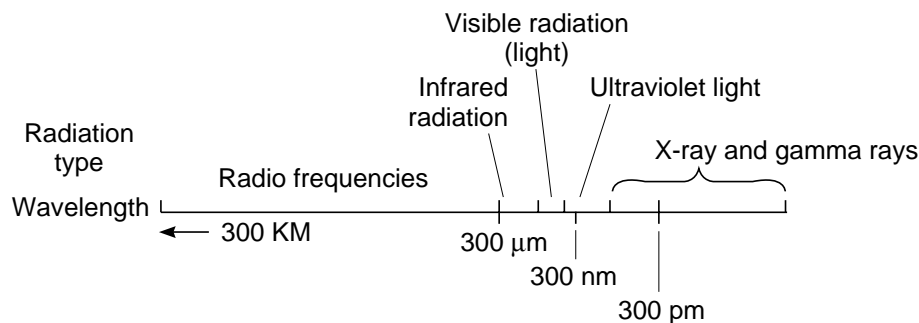
**5-38. The answer is e.** (*Behrman, 16/e, pp 1315–1327. McMillan, 3/e, pp 1242–1254. Rudolph, 20/e, pp 1640–1650.*) Cystic fibrosis (CF) is a multi-system disease caused by an abnormally functioning cystic fibrosis transmembrane regulator protein. Abnormal secretions are produced as a result of decreased permeability of ionized chloride in the secretory epithelium of a number of organs. Progressive lung failure is caused by accumulation of viscid secretions that obstruct the airway and lead to infection, bronchiectasis, and inflammatory changes. Survival has improved during the past few decades as a result of prompt recognition of CF and aggressive treatment; the median age at death has increased from less than 10 years to more than 30 years. Therapeutic approaches have included inhalation therapy, chest physical therapy, aggressive antibiotic administration, bronchodilators, oxygen, and nutritional support. Heart-lung transplants have prolonged life and improved quality of life for some terminal patients. Several new approaches to the treatment of CF have been proposed, namely the use of amiloride, purified human plasma  $\alpha_1$ -antitrypsin, recombinant DNAase, and gene therapy. The rationale for these therapeutic modalities is that they focus directly on ameliorating or correcting the basic deficit: amiloride by inhibiting sodium, and with it water reabsorption, and thereby improving airway hydration;  $\alpha_1$ -antitrypsin by counteracting the effects on the lungs of neutrophil elas-



tase, a proteolytic enzyme released by neutrophils; DNAase by reacting with DNA released by dead leukocytes to reduce sputum viscosity; and gene therapy by altering genetic material. Lung cancer does not appear to be associated with cystic fibrosis.

Unlike many other tests, there is almost no overlap in chloride values in sweat between patients with cystic fibrosis and normal control participants. A chloride concentration of greater than 60 mEq/L is diagnostic, values less than 40 are normal, and values between 40 and 60 are intermediate. Conditions other than cystic fibrosis, including adrenal insufficiency, ectodermal dysplasia, nephrogenic diabetes insipidus, hypothyroidism, and malnutrition, can manifest an elevated sweat chloride.

**5-39. The answer is e.** (*LaDou, 2/e, pp 152–157.*) Ultraviolet (UV) radiation covers the spectrum between visible radiation (light) and ionizing radiation (100 to 400 nm). Ultraviolet radiation B ranges from 280 to 315 nm, the range where the eye is particularly sensitive and where most injuries occur. Acute exposure to UV of less than 315 nm results in photokeratoconjunctivitis, with symptoms appearing 6 to 12 h after exposure. Prolonged exposures to UV between 295 and 320 nm can result in cataract formation. UV A ranges from 315 to 400 nm. Injuries caused by visible radiation (light), which covers the spectrum between infrared and ultraviolet radiation (400 to 750 nm) affect primarily the retina, which is most sensitive to blue light (eclipse blindness). Infrared light covers the spectrum between visible light and radiofrequency (750 to 3 million nm). It is given off by any material of a temperature greater than absolute zero. Thermal injury can occur with intense exposure to infrared light of less than 2000 nm and has been associated with cataract formation.



Reprinted, with permission, from Ratelle S: *Preventive Medicine and Public Health: PreTest Self-Assessment and Review*, 9th ed. New York, McGraw-Hill, 2001.

**5-40. The answer is d.** (*Barnett, 3/e, pp 377–381. Osborn, pp 332–334.*)

This patient is experiencing the classical symptoms of extracranial internal carotid artery disease, which include episodes of ipsilateral transient monocular blindness (amaurosis fugax) and contralateral transient ischemic attacks (TIAs) consisting of motor weakness. Patients with symptomatic extracranial carotid artery disease have a high likelihood of going on to develop strokes (approximately 26% over 2 years on medical therapy). The appropriate test to confirm the suspicion of carotid stenosis is a Doppler ultrasound test of the carotid arteries. This test utilizes the fact that sound waves will bounce back from particles moving in the bloodstream, primarily red blood cells, at a different frequency depending on the velocity and direction of the blood flow. A great deal of important information about the structure of the blood vessel can be obtained in this way. Although angiography can also provide this information, it is invasive, carries a risk of causing a stroke, and is more expensive.

**5-41. The answer is b.** (*Barnett, 3/e, pp 377–381. Adams, 6/e, p 250.*)

The presumed mechanism of transient monocular blindness in carotid artery disease is embolism to the central retinal artery or one of its branches. Although classic teaching has emphasized the role that cholesterol emboli play in causing this blindness, it has been noted that cholesterol emboli (Hollenhorst plaques) may be seen on fundoscopic examination even of asymptomatic individuals. Retinal vein thrombosis may produce a rapidly progressive loss of vision with hemorrhages in the retina, but would not be associated with the TIAs described here. Although both posterior and middle cerebral artery ischemia can cause visual loss, they would not be expected to cause the monocular blindness described here. Posterior ciliary artery ischemia can cause ischemic optic neuropathy, but this is usually acute, painless, and not associated with preceding transient monocular blindness or TIAs.

**5-42. The answer is c.** (*Shuaib, pp 503–506.*)

Based on the results of the North American Symptomatic Carotid Endarterectomy Trial (NASCET), it is known that carotid endarterectomy can reduce the risk of stroke in patients with symptomatic stenoses by 70% or more. The risk of ipsilateral stroke was reduced from 26% in the medically treated group to 9% in the surgically treated group. Carotid endarterectomy should be offered to all eligible patients with symptomatic disease of the internal carotid artery.

There is currently no randomized, controlled trial data to support the use of warfarin, carotid angioplasty, or stenting in the management of these patients, although studies of angioplasty are under way. Extracranial-intracranial bypass has been tried unsuccessfully, although it may still play a role for certain patients with inaccessible lesions or hypoperfusion in the setting of complete occlusions. Aspirin would be appropriate after endarterectomy.

**5-43. The answer is e.** (*Hales, 3/e, pp 1514–1515.*) Nancy Cruzan had been in a vegetative state and kept alive by feeding tubes over 4 years. Because her prognosis was hopeless, her parents went to court to have the feeding stopped so that she could die. The case ultimately found its way to the Supreme Court, which ruled that competent persons have a constitutional right to refuse unwanted medical treatment. The court left it to the states to decide how to handle the situation of the incompetent patient; in many states, that has limited the rights of families to make decisions unless there is an advance directive such as a living will or a durable power of attorney.

**5-44. The answer is c.** (*Fauci, 14/e, p 1264.*) Atrial fibrillation (AF) is a common dysrhythmia that can occur in normal people, especially during emotional stress, after surgery or exercise, in hyperthyroidism, in underlying heart disease, or following an alcoholic binge (“holiday heart syndrome”). It may also be seen in patients with hypoxemia, hypercapnea, or some metabolic or hemodynamic disturbance. Chronic AF occurs in patients with cardiovascular disease, rheumatic heart disease, mitral valve disease, cardiomyopathy, atrial septal defect (ASD), thyroid disease, pulmonary embolus, or chronic lung disease. Whenever the pulse is found to be irregularly irregular, AF is almost always the diagnosis. A major complication of AF is formation of mural thrombi, which may embolize to cerebral vessels, causing stroke or TIAs.

**5-45. The answer is c.** (*Cunningham, 20/e, pp 591–594, DeCherney, 8/e, pp 306–310.*) Threatened abortion, incomplete abortion, complete abortion, and inevitable abortion all present with vaginal bleeding and occur at <20 wk gestation. Patients with threatened abortion complain of abdominal pain and vaginal bleeding. The membranes remain intact and no products of conception are expelled. The internal cervical os is closed and the fetus

is viable. The internal cervical os is open and some products of conception are expelled in incomplete abortion. In complete abortion, all products of conception are expelled and the internal cervical os is closed. Inevitable abortion is when the membranes rupture, the internal cervical os is open, and no products of conception are expelled. Patients complain of abdominal cramps in inevitable abortion. Missed abortion is retained fetal tissue with no cardiac activity in a uterus that is not growing. There is no vaginal bleeding, no products of conception are expelled, and the internal cervical os is closed.

**5-46. The answer is c.** (*Fauci, 14/e, pp 2004–2008.*) This patient had trauma to his posterior pituitary stalk from the car accident, resulting in central diabetes insipidus (DI) due to lack of vasopressin. The diagnosis may be made by raising the patient's serum osmolality through water restriction, then observing the urine osmolality response to injected vasopressin. Nephrogenic DI will not respond to stimulation by vasopressin. Patients with the syndrome of inappropriate antidiuretic hormone secretion (SIADH) present with hyponatremia.

**5-47. The answer is b.** (*Mishell, 3/e, p 95.*) A single fasting blood sample is not sufficient for screening for growth hormone (GH) deficiency. Many believe that inadequate GH secretion is not established until the absence of significant release is documented following the use of several provocative stimuli. Strenuous exercise has been recognized as a potent physiologic stimulus to GH secretion. The L-dopa, insulin tolerance, and arginine tolerance tests all assess GH secretion.

**5-48 through 5-49. The answers are 5-48 e, 5-49 c.** (*Fauci, 14/e, pp 1350–1352, 2145–2146. Paron, J Resp Di 19:S6–12, 1998. USPS Task Force, 2/e, ch 15.*) For patients in a precontemplative stage of change, advising them to quit and personalizing the message to their risk factor is the best approach. It is important to continuously assess smoking status and advise to quit at every encounter to help motivate patients until they are ready for action. Those who are not ready to quit are unlikely to follow through on a quit date, go to smoking cessation classes, or use nicotine replacement therapy or self-help materials. According to the National Cholesterol Education Program (NCEP) guidelines, persons with borderline-high cholesterol 200 to 239 mg/dL with two or more risk factors for

coronary heart disease (CHD), in this case, smoking and male 45 years of age should have a lipoprotein analysis performed, even if the HDL is 35 mg/dL. Dietary therapy would be the recommendation (no CHD, two or more risk factors) if the low-density lipoprotein (LDL) value is  $\geq 130$  mg/dL. Drug therapy is recommended by the NCEP if, despite dietary therapy, the following conditions are present: (1) LDL remains  $\geq 190$  mg/dL in the absence of CHD and fewer than two risk factors; (2) LDL  $\geq 160$  mg/dL in the absence of CHD and two or more risk factors for CHD; (3) LDL  $\geq 130$  mg/dL in the presence of CHD. Dietary changes can reduce the cholesterol levels by as much as 15%, particularly if associated with weight loss and exercise.

**5-50. The answer is c.** (*Fauci, 14/e, pp 1704–1710.*) The patient's signs and symptoms suggest alcoholic hepatitis. Mallory bodies are alcoholic hyaline seen in damaged hepatocytes. Mallory bodies are likely to be seen in alcoholic hepatitis (but are not specific for the disease). Jugular venous distension should not be part of the process of chronic liver disease. (Ascites and pedal edema are secondary to hypoalbuminemia and portal hypertension, not increased right-sided pressure.) In alcoholic hepatitis, ratios of aspartate aminotransferase (AST) to alanine aminotransferase (ALT) are usually greater than 2, due to the proportionately greater inhibition of ALT synthesis by ethanol. Even after abstinence, clinical recovery is often prolonged.

*This page intentionally left blank.*

# BLOCK 6

---

## Answers

**6-1. The answer is a.** (*Behrman, 16/e, pp 1660–1661.*) This common condition is diagnosed when a central line of adherence is noted extending from the area inferior to the clitoris to the fourchette. It is a common, asymptomatic condition seen in girls less than 6 years of age. Labial adhesions can be responsible for vulvovaginitis and increased urinary tract infections in girls because of pooling of urine in the vagina. Treatment with topical estrogen cream daily results in resolution of this problem. Mechanical separation is not advisable under normal circumstances.

**6-2. The answer is b.** (*Fitzpatrick, 3/e, pp 149, 170, 766–767, 772–775, 797.*) The description of the skin lesions is most consistent with molluscum contagiosum. This is a self-limited viral infection due to a pox virus (molluscum contagiosum virus) seen in children, sexually active adults, and human immunodeficiency virus (HIV)-infected patients. These lesions characteristically have a central keratotic plug that gives them the appearance of being dimpled (umbilication). The lesions resolve spontaneously. Common warts or verrucae vulgaris are due to human papillomavirus (HPV). Warts are firm, hyperkeratotic, round papules that are 1 to 10 mm in diameter. They have no umbilication but have a predilection for sites of trauma, including hands, fingers, and knees. A keratoacanthoma is a skin-colored, isolated, dome-shaped nodule with a central hyperkeratotic core, usually found on the face. A herpetic whitlow, due to herpes simplex virus, consists of a painful group of vesicles on the volar finger. Capillary hemangiomas are bright red or purple nodules or plaques that develop at birth and spontaneously disappear by the fifth year.

**6-3. The answer is c.** (*Greenfield, 2/e, p 1236.*) Hematomas of the rectus sheath are more common in women and present most often in the fifth decade of life. A history of trauma, sudden muscular exertion, or anticoagulation can usually be elicited. The pain is of sudden onset and is sharp in nature. The hematoma is most common in the right lower quadrant; irrita-

tion of the peritoneum leads to fever, leukocytosis, anorexia, and nausea. The diagnosis can be established preoperatively with an ultrasound or computed tomography (CT) scan showing a mass within the rectus sheath. Management is conservative unless symptoms are severe and bleeding persists, in which case surgical evacuation of the hematoma and ligation of bleeding vessels is required.

**6-4. The answer is c.** (*Adams, 6/e, p 1495.*) The markedly elevated sedimentation rate, anemia, weight loss, and malaise in a person this age suggest polymyalgia rheumatica, although the same complaints in someone 20 years younger could not be explained on the basis of this disorder. Fever may also be evident in the affected person. This constellation of symptoms also suggests an occult neoplasm or infection, and investigations should be conducted to reduce the likelihood of overlooking one of these diseases. Polymyalgia rheumatica is an arteritis of the elderly and is improbable in someone less than 60 years of age. The normal creatine kinase activity markedly reduces the likelihood that this myalgia is the result of polymyositis or dermatomyositis. The new onset of rheumatoid arthritis at this age is also improbable. A hyperthyroid myopathy in the face of a normal thyroxine level is possible on the basis of an elevated  $T_3$  level but is also much less likely than polymyalgia rheumatica in this age group.

**6-5. The answer is d.** (*Stobo, 23/e, pp 261–265.*) The patient presents with symptoms consistent with acute mechanical low back pain. Even patients with lumbar disk herniation and sciatica improve with nonoperative care, and imaging studies do not affect initial management. Three to 7 days of bed rest is recommended, with adequate pain control and reassurance. Active therapy to restore range of motion and function is appropriate after pain and spasm are relieved.

**6-6. The answer is d.** (*Sadock, 7/e, p 1190.*) Self-induced water intoxication should always be considered in the differential diagnosis of confusional states and seizures in schizophrenic patients. As many as 20% of patients with a diagnosis of schizophrenia drink excessive amounts of water. At least 4% of these patients suffer from chronic hyponatremia and recurrent acute water intoxication. Medications that cause excessive water retention, such as lithium and carbamazepine, can aggravate the symptomatology.



**6-7. The answer is b.** (*Behrman, 16/e, pp 526–527, 1101. McMillan, 3/e, p 360. Rudolph, 20/e, p 1042.*) Hematemesis and melena are not uncommon in the neonatal period, especially if gross placental bleeding has occurred at the time of delivery. The diagnostic procedure that should be done first is the Apt test, which differentiates fetal from adult hemoglobin in a bloody specimen. If the blood in an affected infant's gastric contents or stool is maternal in origin, further workup of the infant is obviated.

**6-8. The answer is c.** (*Fauci, 14/e, pp 1924–1925.*) Sarcoidosis is a systemic illness of unknown etiology. Many patients have respiratory symptoms including cough and dyspnea. Hilar and peripheral lymphadenopathy is common. Twenty to thirty percent of patients exhibit hepatomegaly. The chest x-ray shown shows symmetrical hilar lymphadenopathy. The diagnostic method of choice is transbronchial biopsy, which will show a mononuclear cell granulomatous inflammatory process. While liver and scalene node biopsies are often positive, noncaseating granulomas are so frequent in these sites that they are not considered acceptable for primary diagnosis. Angiotensin converting enzyme (ACE) levels are elevated in two-thirds of patients, but false positive values are common in other granulomatous disease processes.

**6-9. The answer is a.** (*Schwartz, 7/e, pp 1679–1707.*) The patient exhibits classic signs and symptoms of hyperparathyroidism. In addition, if a history is obtainable, frequently such a patient will relate a history of renal calculi and bone pain—the syndrome characterized as “groans, stones, and bones.” The acute management of the hypercalcemic state includes vigorous hydration to restore intravascular volume, which is invariably diminished. This will establish renal perfusion and thus promote urinary calcium excretion. Thiazide diuretics are contraindicated, as they frequently cause patients to become hypercalcemic. Instead, diuresis should be promoted with the use of “loop” diuretics such as furosemide (Lasix). The use of intravenous phosphorus infusion is no longer recommended, as precipitation in the lungs, heart, or kidney can lead to serious morbidity. Mithramycin is an antineoplastic agent that in low doses inhibits bone resorption and thus diminishes serum calcium levels; it is used only when other maneuvers fail to decrease the calcium level. Calcitonin is useful at times. Bisphosphonates are newer agents that are particularly useful for lowering calcium levels in resistant cases, such as those associated with

humoral malignancy. Finally, emergency neck exploration is seldom warranted. In unprepared patients, the morbidity is unacceptably high.

**6-10. The answer is d.** (*Schwartz, 7/e, pp 64, 1698.*) The mechanism of hypercalcemia of malignancy is thought to be due either to elaboration of a parathyroid hormone (PTH)-like humoral factor or, many times, to direct bone destruction by metastatic disease. Breast, prostatic, pulmonary, and hematologic malignancy all may give rise to hypercalcemia. Serum and urine electrophoresis may identify a malignancy that causes bone destruction, such as multiple myeloma. Sarcoidosis may produce hypercalcemia, but the presence of the normal chest x-ray essentially rules out this possibility. Thus, a Kveim test is not indicated. An abdominal angiogram would not be expected to identify a likely cause of hypercalcemia. Serum gastrin is not implicated in the differential diagnosis of hypercalcemia. A neck exploration would not be indicated unless a parathyroid adenoma or carcinoma was suspected.

**6-11. The answer is b.** (*Coffey, pp 691–717. Lewis, 2/e, pp 520–526.*) Dyslexia occurs in 3% to 10% of the population and is more often found in boys than in girls. When a reading disorder is caused by a defect in visual or hearing acuity, it is excluded by diagnostic criteria from the diagnosis of developmental reading disorder. Almost all patients with this problem have spelling difficulties, and nearly all have verbal language defects. It is believed that the most common etiology relates to cortical brain pathology.

**6-12. The answer is c.** (*Fauci, 14/e, p 301.*) The rash described is classic for psoriasis. Stress and skin injury commonly exacerbate the disease. The distribution of the described rash would make contact dermatitis unlikely. Psoriasis is not contagious and is not spread by contact.

**6-13. The answer is e.** (*Greenberg, 2/e, ch 4, pp 49–53.*) Comparison of crude death rates of countries with different population compositions is fruitless. Adjusting both crude death rates to a standard population gives age-adjusted rates, which can be compared. Developed nations have higher crude death rates because a larger proportion of their population is elderly and thus has a higher probability of dying. Since rates account for population size, a larger population can be compared with a smaller one. Death rates are just one factor in evaluating health care systems.

**6-14. The answer is c.** (*Sabiston, 15/e, pp 81–84.*) A ruptured abdominal aneurysm is a surgical emergency often accompanied by serious hypotension and vascular collapse before surgery and massive fluid shifts with renal failure after surgery. In this case, all the hemodynamic parameters indicate inadequate intravascular volume, and the patient is therefore suffering from hypovolemic hypotension. The low urine output indicates poor renal perfusion, while the high urine specific gravity indicates adequate renal function with compensatory free water conservation. The administration of a vasopressor agent would certainly raise the blood pressure, but it would do so by increasing peripheral vascular resistance and thereby further decreasing tissue perfusion. The deleterious effects of shock would be increased. A vasodilating agent to lower the systemic vascular resistance would lead to profound hypotension and possibly complete vascular collapse because of pooling of an already depleted vascular volume. This patient's blood pressure is critically dependent on an elevated systemic vascular resistance. To properly treat this patient, rapid fluid infusion and expansion of the intravascular volume must be undertaken. This can be easily done with lactated Ringer's solution or blood (or both) until improvements in such parameters as the pulmonary capillary wedge pressure, urine output, and blood pressure are noted.

**6-15. The answer is e.** (*Sabiston, 15/e, pp 84–86.*) This patient has developed pump failure due to a combination of preexisting coronary artery occlusive disease and high preload following a fluid challenge; afterload remains moderately high as well because of systemic vasoconstriction in the presence of cardiogenic shock. Poor myocardial performance is reflected in the low cardiac output and high pulmonary capillary wedge pressure. Therapy must be directed at increasing cardiac output without creating too high a myocardial oxygen demand on the already failing heart. Administration of nitroglycerin could be expected to reduce both preload and afterload, but if it is given without an inotrope it would create unacceptable hypotension. Nitroprusside similarly would achieve afterload reduction but would result in hypotension if not accompanied by an inotropic agent. A beta blocker would act deleteriously by reducing cardiac contractility and slowing the heart rate in a setting in which cardiac output is likely to be rate dependent. Dobutamine is a synthetic catecholamine that is becoming the inotropic agent of choice in cardiogenic shock. As a  $\beta_1$ -adrenergic agonist, it improves cardiac performance in pump failure by both positive inotropy and periph-

eral vasodilation. With minimal chronotropic effect, dobutamine only marginally increases myocardial oxygen demand.

**6-16. The answer is e.** (*Fauci, 14/e, pp 1826–1827. MMWR 1998; 47, RR-20.*) The management of HIV infection is a rapidly evolving field as new scientific information emerges and new drugs are developed. As of 1999, prophylaxis for *Pneumocystis carinii* remains the recommendation for patients with a CD4 + T cell count of under 200/ $\mu$ L or CD4 % of less than 15%. Prophylaxis for *Mycobacterium avium* complex (MAC) should begin when the CD4 cell count is less than 100/ $\mu$ L or 50/ $\mu$ L. Prophylaxis for cryptococcus is optional depending on the risk and should be given when CD4 counts are less than 50/ $\mu$ L. Because the medications used for toxoplasmosis have severe side effects, they do not make good choices for primary prophylaxis. Fortunately, patients receiving trimethoprim/sulfamethoxazole, dapsone, or pyrimethamine for prophylaxis of *P. carinii* pneumonia (PCP) have a decreased incidence of toxoplasmosis. Candidates for tuberculosis (TB) preventive therapy in HIV-infected persons include persons with a purified protein derivative (PPD)  $\geq 5$  mm who have not previously received treatment for TB, persons with a contact with an infectious case, persons with prior untreated/inadequately treated/healed without treatment TB, and persons at high risk of acquiring TB because of living in jails or homeless shelters.

**6-17. The answer is e.** (*Bradley, 3/e, p 1758.*) Lennox-Gastaut syndrome is a disturbance seen in children. It is often difficult to control the seizures that develop in children with this combination of retardation and slow spike-and-wave discharges on electroencephalography (EEG). Many of the affected children have a history of infantile spasms (West syndrome). Infants and children with infantile spasms exhibit paroxysmal flexions of the body, waist, or neck and usually have a profoundly disorganized EEG pattern called hypsarrhythmia.

**6-18. The answer is c.** (*Behrman, 16/e, pp 1467–1468. McMillan, 3/e, pp 1448–1449. Rudolph, 20/e, pp 1181–1182.*) The finding of hypersegmented neutrophils in the peripheral blood is one of the most useful laboratory aids in making an early diagnosis of folate deficiency. Serum folate levels become low within weeks if dietary sources are inadequate. The Pelger-Huët anomaly is an inherited disorder in which neutrophils have no more

than two lobes. Neutrophils in severe bacterial infections have toxic granulation, Döhle inclusion bodies, and cytoplasmic vacuoles. Methotrexate, phenytoin, trimethoprim, and birth control pills can be associated with megaloblastic anemia, but these patients are usually not healthy and an appropriate history will give diagnostic clues.

**6-19. The answer is c.** (*Sadock, 7/e, pp 1669–1673.*) Anorexia nervosa is characterized by the refusal to maintain a minimal normal weight for height and age, intense fear of gaining weight, distorted body image, and amenorrhea. Body weight is controlled by drastic reduction of caloric intake, but most anorectic patients also use diuretics and laxatives. Purging, which causes hypokalemic alkalosis, can also be present, but not as frequently as in bulimia. The other listed behaviors are not characteristic of patients with anorexia.

**6-20. The answer is d.** (*Chin, 17/e, p 402.*) Children who are late in their immunization schedule should be vaccinated when the opportunity arises. Mild acute illness or antibiotic use is not a contraindication to immunization. Measles-mumps-rubella (MMR) is not contraindicated in children of pregnant women. Oral polio vaccine (OPV), but not MMR, is contraindicated in any household contact of a severely immunocompromised person. In fact, in an effort to reduce vaccine-associated paralytic polio (VAPP), OPV is no longer recommended for the first two doses of polio immunizations in infants since 1997, and effective January 2000, the Centers for Disease Control (CDC) recommendations are to give four doses of inactivated polio vaccine (IPV) at 2 mo, 4 mo, 6 to 18 mo, and then at 6 to 8 years. OPV can be considered only under a few specific circumstances. If the parents refuse the schedule, OPV could only be given for the third or fourth dose and the parents should be counseled about the possible occurrence of VAPP. In this case scenario, however, OPV would not be acceptable given the sibling situation. Live and inactivated vaccines can be given at the same time.

**6-21. The answer is d.** (*Behrman, 16/e, pp 1275–1278. McMillan, 3/e, pp 1307–1311. Rudolph, 20/e, pp 672–677.*) The signs of illness described are those involving the airway above the point at which the trachea enters the neck and leaves the thorax, as in croup syndrome. Intrathoracic airway diseases, such as asthma or bronchiolitis, produce breathing difficulty on expiration with expiratory wheezing, prolonged expiration, and signs of air

trapping due to the increased narrowing during expiration as the airways are exposed to the same intrathoracic pressure changes as the alveoli. The extrathoracic airway, to the contrary, tends to collapse on inspiration, producing the characteristic findings this patient demonstrates.

Agents causing croup include parainfluenza types I and III, influenza A and B, respiratory syncytial virus (RSV), and occasionally other viruses. Treatment is usually supportive, but racemic epinephrine and corticosteroids reduce the length of time in the emergency room and hospitalizations.

**6-22. The answer is c.** (*Stobo, 23/e, pp 309–310.*) The first step in the evaluation of impotence is a complete and detailed history—including libido and ability to attain erection unrelated to sexual intercourse. Loss of all erectile function suggests an organic cause for the disease. In this patient impotence may be the result of depression from the antihypertensive agent or a direct effect of the beta blocker on sexual performance. Diabetes may cause impotence as an effect on the penile blood supply or the parasympathetic nervous system function. A decrease in libido suggests testosterone deficiency. Serum testosterone should then be measured and, if that value is low, serum gonadotropins should be measured. In a diabetic with claudication or abnormal femoral pulses, injection of papaverine into the corpora cavernosa can test vascular insufficiency as the cause of impotence. A normal response is an erection within 10 min.

**6-23. The answer is b.** (*Fauci, 14/e, p 1544.*) Immune globulin A (IgA) (Berger's) nephropathy is the most commonly encountered form of focal glomerulonephritis worldwide. Patients often exhibit microhematuria. The disease may follow an upper respiratory tract infection or physical exertion. Bladder cancer is a common cause of asymptomatic microhematuria, but is usually found in patients over the age of 50. Risk factors for bladder neoplasia include exposure to aniline dyes, rubber, organic solvents, or industrial dyes, or tobacco use. Minimal change disease almost always presents with severe proteinuria, and erythrocyte casts are not seen in rhabdomyolysis. Patients with Alport syndrome have the nephritic syndrome and hearing loss.

**6-24. The answer is a.** (*Rock, 8/e, pp 375–378.*) Partial colpocleisis via the Le Fort procedure is reasonable for elderly patients who are not good

candidates for vaginal hysterectomy and AV repair for prolapse. The technique involves partial denudation of opposing surfaces of the vaginal mucosa followed by surgical apposition, thereby resulting in scarification and partial obliteration of the vagina. Patients who are candidates for this procedure must have no evidence of cervical or endometrial dysplasia, have atrophic endometrium, and no longer desire sexual function. Urinary incontinence can be a side effect, so care must be exercised in the denudation of vaginal mucosa near the bladder.

**6-25. The answer is a.** (*Crenshaw, pp 225–226.*) Among beta blockers, propranolol is the most likely to cause impotence (23% according to Hogan et al. 1980). Furthermore, through its effect on the serotonin system, propranolol can also inhibit orgasm and reduce sex drive. Fatigue and depressed mood, frequent side effects of propranolol, can also have a negative effect on sexual function.

**6-26. The answer is d.** (*Bradley, 3/e, pp 1556–1557.*) Normal pressure hydrocephalus (NPH) is a chronic, communicating form of hydrocephalus affecting elderly adults. The cause is unknown, but it may relate to prior episodes of trauma, infection, or subarachnoid hemorrhage. The clinical picture typically includes a triad of gait disturbance, dementia, and incontinence. The gait disorder may be difficult to distinguish from that of Parkinson's disease, and has been labeled an apraxic gait because patients often have difficulty even lifting their feet off the floor, though they have no weakness and may perform motor tasks well with the legs when seated. CT or magnetic resonance imaging (MRI) in these patients usually shows enlargement of the temporal and frontal horns of the lateral ventricles out of proportion to the degree of cortical atrophy. There may also be a squaring off or blunted appearance of the frontal horns, and increased signal on T<sub>2</sub>-weighted images may be seen in the periventricular regions, consistent with the presence of fluid related to transependymal flow of cerebrospinal fluid (CSF).

**6-27. The answer is a.** (*Bradley, 3/e, pp 1556–1557.*) The CSF in patients with NPH is typically normal. Abnormalities in protein or cellularity should suggest an alternate diagnosis. The pressure of the CSF is also usually normal, although studies using long-term pressure monitoring in these patients have shown that they have periods of pressure elevation, often at night.

**6-28. The answer is b.** (*Bradley, 3/e, pp 1556–1557.*) Up to 28% of patients who undergo ventriculoperitoneal shunting for NPH may suffer major complications, including subdural hematoma. Subdural hematoma occurs because the reduction in intracranial pressure brought on by the reduction in CSF volume may cause the brain to pull away from the covering meninges, stretching and potentially rupturing the bridging veins.

**6-29. The answer is c.** (*Chin, 17/e, pp 203–206.*) The short incubation period and symptoms are characteristic of food poisoning due to the toxin produced by *Staphylococcus aureus*. Organisms and toxin are not destroyed by freezing. Although the organisms can be killed by heating food to 66° C (150° F), the preformed toxin generally survives. Optimum growth of the bacteria occurs at 59 to 99° F (growth is inhibited below 39° F), with toxin production optimal after 4 to 6 h. The source is human skin, mouth, and nose. Proper hand washing by food handlers and excluding those with skin infections is the best way to prevent contamination.

**6-30. The answer is b.** (*Schwartz, 7/e, pp 194–195.*) Duodenal hematomas result from blunt abdominal trauma. They present as a high bowel obstruction with abdominal pain and occasionally a palpable right upper quadrant mass. An upper gastrointestinal series is almost always diagnostic, with the classic coiled spring appearance of the second and third portions of the duodenum secondary to the crowding of the valvulae conniventes (circular folds) by the hematoma. Nonsurgical management is the mainstay of therapy, as the vast majority of duodenal hematomas resolve spontaneously. Simple evacuation of the hematoma is the operative procedure of choice. However, bypass procedures and duodenal resection have been performed for this problem. In patients with duodenal obstruction from the superior mesenteric artery syndrome, the obstruction is usually the result of a marked weight loss and, in conjunction with this, loss of the retroperitoneal fat pad that elevates the superior mesenteric artery from the third and fourth portions of the duodenum. Nutritional repletion and replenishment of this fat pad will elevate the artery off the duodenum and relieve the obstruction.

**6-31. The answer is b.** (*Scott, pp 768–770.*) Stress incontinence is the involuntary loss of urine when intravesical pressure exceeds the maximum urethral pressure in the absence of detrusor activity. The most common cause of urinary incontinence is incompetence of the urethral sphincter,



termed *genuine stress incontinence*. The other major cause of incontinence is unstable bladder. An unstable bladder is the occurrence of involuntary, uninhibited detrusor contractions of greater than 15 cm H<sub>2</sub>O with simultaneous urethral relaxation. The incidence of patients with incontinence due to unstable bladder can vary from 8.7% to 63% of patients presenting with incontinence. Other causes of urinary incontinence are less common, and include overflow secondary to urinary retention, congenital abnormalities, infections, and fistulas. Detrusor dyssynergia implies that when the patient has an uninhibited detrusor contraction, there is simultaneous contraction of the urethral or periurethral striated muscle (normally there is urethral relaxation with a detrusor contraction). This is generally seen in patients with neurologic lesions. Urethral diverticula classically present with dribbling incontinence after voiding.

**6-32. The answer is d.** (*Fauci, 14/e, pp 1466–1468.*) Primary pulmonary hypertension (PPH) is of unknown etiology and primarily affects women in their thirties or forties. The underlying problem in the disorder is a fixed increased resistance to pulmonary blood flow. Pulmonary function in PPH is usually normal, but the elevation in pulmonary artery pressure causes a decrease in cardiac output and, eventually, right ventricular failure. Patients become dyspneic and hypoxemic due to the mismatch of pulmonary ventilation and perfusion and the reduced cardiac output. Physical examination reveals signs of right ventricular hypertrophy, right- and left-sided heart failure, and tricuspid and pulmonic regurgitation. The mean survival for this disease is 2 to 3 years from the time of diagnosis.

**6-33. The answer is d.** (*Fauci, 14/e, pp 1264–1265.*) In general, in patients with atrial fibrillation, therapeutic anticoagulation with warfarin (Coumadin) reduces the incidence of future stroke to a greater extent than the use of aspirin. This particular patient may be a candidate for medical or electrical cardioversion, which requires pretreatment with Coumadin for 2 to 3 wk (if the atrial fibrillation has been present for over 48 to 72 h or is of unknown time onset).

**6-34. The answer is d.** (*Mehta, pp 253–288.*) Trochanteric bursitis is a common cause of hip pain in the elderly, but may also be seen in bicyclists and runners. Pain is exacerbated by standing and by external rotation. Lying on the affected side compresses the inflamed bursa. Ischial bursitis (“weaver’s bottom,” so named because weavers had to sit for long periods

of time, which led to ischial bursitis) causes pain in the buttock made worse with sitting and with hip flexion. Today, it is usually an injury to workers who operate heavy equipment on rough roads. Avascular necrosis (AVN) of the hip may be due to trauma or to medications, such as corticosteroids. Patients are usually between the ages of 30 and 60 years and often complain of groin pain made worse with weight bearing. Fracture of the proximal femur usually follows trauma. On inspection, the affected lower extremity lies in external rotation and is shorter than the normal side. Hip osteoarthritis presents with groin pain exacerbated by the Faber maneuver (also called the Patrick test), which is a mnemonic for **F**lexion, **AB**duction, and **E**xternal **R**otation.

**6-35. The answer is b.** (*Lobo, pp 438–443.*) Sexuality continues despite aging. However, there are physiological changes that must be recognized. Diminished ovarian function may lower libido, but estrogen replacement therapy may help. Sexual dysfunction can be physiological—for example, from lowered libido. As with younger patients, however, lowered libido is in most cases treatable. Psychological evaluation is critical because aging does not alter orgasm, vaginismus, or impotence.

**6-36. The answer is c.** (*Fauci, 14/e, pp 608–609.*) Endometrial cancer most often presents with vaginal bleeding (80%) and is the most common postmenopausal gynecological cancer. Atrophic vaginitis does not present as spontaneous vaginal bleeding. A blood coagulation disorder would most likely present with other signs (petechiae, bleeding gums) and symptoms. An endometrial biopsy should be performed in this situation.

**6-37. The answer is d.** (*Fauci, 14/e, pp 512–514.*) The pedigree of the patient (multiple primary cancers) is most consistent with hereditary non-polyposis colon cancer (HNPCC). The median age for adenocarcinoma of the colon is 50 years and the most common site is the proximal colon. Inheritance is autosomal dominant, and members of the family should undergo biennial colonoscopy starting at age 25. Prophylactic colectomy is recommended for patients with familial adenomatous polyposis, an autosomal dominant disorder characterized by small polyps that develop during the second decade of life and undergo malignant transformation before the age of 40. Breast cancer is not associated with HNPCC (the genetic defect is in DNA mismatch repair genes).

**6-38. The answer is b.** (*Fauci, 14/e, p 7.*) The patient's autonomy as directed by the living will must be respected. This autonomy is not transferred to a surrogate decision maker, even one who is very credible. A family conference in this case would not change the overriding issue—that a valid living will is in effect.

**6-39. The answer is d.** (*McMillan, 3/e, p 218. Rudolph, 20/e, pp 225, 230–231.*) A room temperature of 24°C (approximately 75°F) provides a cold environment for newborn infants. Aside from the fact that these infants emerge from a warm 37.6°C (99.5°F) intrauterine environment, at birth infants (and especially preterm infants) are wet, have a relatively large surface area for their weight, and have little subcutaneous fat. Within minutes of delivery, the infants are likely to become pale or blue and their body temperature will drop. In order to bring body temperature back to normal, they must increase their metabolic rate; ventilation, in turn, must increase proportionally to ensure an adequate oxygen supply. Because a preterm infant is likely to have respiratory problems and to be unable to oxygenate adequately, lactate can accumulate and lead to a metabolic acidosis. Infants rarely shiver in response to a need to increase heat production.

**6-40. The answer is a.** (*Adams, 6/e, pp 270–271, 1440.*) The third cranial nerve (the oculomotor nerve) controls several movements of the globe, including upward and medial movements, through its control of the medial rectus, superior rectus, and inferior oblique muscles. Its inactivity leads to displacement of the eye down and out. Fourth nerve palsy leads to weakness of the superior oblique muscle, with resultant difficulty looking down and medially; patients often complain of trouble walking down stairs. Sixth nerve palsy produces weakness of the lateral rectus muscle, causing horizontal diplopia. Fractures of the orbit can entrap individual muscles, but there is no history of this here. Thyroid ophthalmopathy, or Graves' disease, can produce diplopia, but there is usually proptosis or lid retraction. The inferior and medial recti are most frequently affected. Because this is caused by infiltration of the muscles, there is usually limitation of passive movement of the eyes (i.e., forced ductions).

**6-41. The answer is b.** (*Seidel, 4/e, pp 508–512.*) Women between the ages of 30 and 55 years may develop benign cyst formation of the breasts or fibrocystic breast disease. Patients typically state that the symptoms

worsen premenstrually or as they approach menopause (decreased progesterone). Physical examination often reveals bilateral lumpy and tender breasts. Mammography shows dense breast tissue. Mastitis is most common in lactating breasts and is usually secondary to *Staphylococcus aureus* infection. In these cases the breast is warm, tender, swollen, and erythematous. Mammary duct ectasia is a nonmalignant condition that affects menopausal women. The subareolar ducts become blocked with debris, causing pain, inflammation, nipple discharge, and retraction of the nipple.

**6-42. The answer is b.** (*Adams, 6/e, p 270.*) Diabetes is a common cause of third nerve palsy, being implicated in approximately 10% of cases of third nerve palsy. Usually, when diabetes is the cause, there is sparing of the pupillomotor parasympathetic fibers that travel on the outside of the nerve. The mechanism by which diabetes causes third nerve palsy is due to nerve infarction, which affects the interior of the nerve but spares the external fibers. Compressive lesions, however, can injure the surface fibers, thereby causing pupillary dilation from unopposed sympathetic activity.

**6-43. The answer is d.** (*Seidel, 4/e, p 545. Tierney, 39/e, p 607.*) Guarding, rigidity, absent or diminished bowel sounds, rebound and referred rebound tenderness, and lying perfectly still are all signs of peritonitis. A plain film of the abdomen in this patient with a probable perforated ulcer might show free intraperitoneal air under the diaphragm (in up to 75% of patients). The free air would establish the diagnosis and no further studies would be needed. Barium studies are contraindicated in perforation.

**6-44. The answer is b.** (*Wallace, 14/e, pp 854–855. Fauci, 14/e, p 2503.*) It is estimated that between 20% and 25% of pregnant women suffer from domestic violence, and pregnancy is a particularly high-risk period for abuse. Battered women are much more likely to be injured on the chest, breasts, and abdomen than nonabused women. Over half of women who are battered eventually abuse alcohol.

**6-45. The answer is a.** (*Schwartz, 7/e, pp 329–331.*) Isolated enlarged cervical lymph nodes in the adult are malignant nearly 80% of the time (excluding benign tumors of the thyroid gland). They are usually metastatic squamous cell carcinomas arising from primary sources above the clavicles in the aerodigestive tract. Fine needle aspiration cytology is commonly used to obtain histological confirmation of suspected cancer. Aspiration cytology

can usually diagnose carcinoma accurately, but lymphoma may be difficult to identify by this method, and open biopsy is often necessary. Bone marrow biopsy is not indicated prior to lymph node biopsy. It is done as part of the staging process after a diagnosis of lymphoma has been made. Endoscopy and scanning of the oropharynx and nasopharynx are part of the diagnostic workup of a suspected malignant cervical lymph node, but do not provide histological proof of cancer.

**6-46. The answer is c.** (*Stobo, 23/e, pp 707–711.*) The patient has a microcytic anemia. Low serum iron, low ferritin, and high iron binding capacity all are consistent with iron-deficiency anemia. Most iron-deficiency anemia is explained by blood loss. This patient's symptoms of constipation point to blood loss from the lower gastrointestinal (GI) tract. Sigmoidoscopy would be the highest-yield procedure. Lead poisoning can cause a microcytic, hypochromic anemia, but this would be uncommon in a 55-year-old man with no clues to suggest the diagnosis. Folate deficiency presents as a megaloblastic anemia.

**6-47. The answer is a.** (*Speroff, 6/e, pp 761–766.*) Absolute contraindications to postmenopausal hormone replacement therapy include estrogen-dependent tumors (breast or uterus), active thromboembolic disease, undiagnosed genital tract bleeding, active severe liver disease, and malignant melanoma. Past or current history of hypertension, diabetes, or biliary stones does not automatically disqualify a patient for hormone replacement therapy.

**6-48. The answer is d.** (*Rowland, 9/e, pp 291–292.*) This patient's complaints are suggestive of ischemic spinal cord disease. The principal source of blood for the spinal cord is the aorta. Vessels that supply the cord are somewhat variable in their origins, but they most commonly arise as branches of the vertebral and hypogastric arteries, as well as of the aorta at the level of the upper and lower thoracic vertebrae. The artery most implicated in a patient with this constellation of complaints is the great anterior medullary artery (of Adamkiewicz), which arises from the aorta at the level of T10–L1 and supplies the anterior median spinal artery.

**6-49. The answer is e.** (*Rowland, 9/e, pp 291–292.*) Syphilis may produce an aortic aneurysm, but this is characteristically at the level of the thoracic aorta (the arch of the aorta). With aneurysmal dilation of the aorta, defects

in the wall of the vessel may be exacerbated and dissection of the aortic wall may develop. As this dissection extends into branches of the aorta, it usually narrows and may occlude the lumina of the vessels. Diabetes mellitus may contribute to the formation of atherosclerotic damage in the wall of the aorta, but it is the atherosclerosis itself that is most implicated in the eventual deterioration of the vascular wall. Chronic hypertension may develop with damage that involves the renal arteries, but hypertension would not be expected to be the cause of the aortic pathology.

**6-50. The answer is c.** (*Behrman, 16/e, pp 1892–1893. McMillan, 3/e, pp 1962–1963. Rudolph, 20/e, pp 1668, 1970–1972.*) The paralysis of Guillain-Barré syndrome occurs about 10 days after a nonspecific viral illness. Weakness is gradual over days or weeks, beginning in the lower extremities and progressing toward the trunk. Later, the upper limbs and the bulbar muscles can become involved. Involvement of the respiratory muscles is life threatening. The syndrome seems to be caused by a demyelination in the motor, and occasionally the sensory, nerves. Spinal fluid protein is helpful in the diagnosis; protein levels are increased to more than twice normal, while glucose and cell counts are normal. Hospitalization for observation is indicated. Treatment can consist of intravenous immunoglobulin, steroids, or plasmapheresis. Recovery is not always complete.

# BLOCK 7

---

## Answers

**7-1. The answer is b.** (*Greenfield, 2/e, pp 919–923.*) Tumors arising from the pancreatic beta cells give rise to hyperinsulinism. Seventy-five percent of these tumors are benign adenomas; in 15% of affected patients the adenomas are multiple. Symptoms relate to a rapidly falling blood glucose level and are due to epinephrine release triggered by hypoglycemia (sweating, weakness, tachycardia). Cerebral symptoms of headache, confusion, visual disturbances, convulsions, and coma are due to glucose deprivation of the brain. Whipple's triad summarizes the clinical findings in patients with insulinomas: (1) attacks precipitated by fasting or exertion; (2) fasting blood glucose concentrations below 50 mg/dL; (3) symptoms relieved by oral or intravenous glucose administration. These tumors are treated surgically; simple excision of an adenoma is curative in the majority of cases.

**7-2. The answer is b.** (*Schwartz, 7/e, pp 211–212.*) This patient is having an anaphylactoid reaction with destabilization of the cardiovascular and respiratory systems. Anaphylactoid reactions are most commonly caused by iodinated contrast media,  $\beta$ -lactam antibiotics (e.g., penicillin), and Hymenoptera stings. Manifestations of anaphylactoid reactions include both the lethal (bronchospasm, laryngospasm, hypotension, dysrhythmia) and the nonlethal (pruritus, urticaria, syncope, weakness, and seizure). Epinephrine is the initial treatment for laryngeal obstruction and bronchospasm, followed by histamine antagonists (H1 and H2 blockers), aminophylline, and hydrocortisone. Vasopressors and fluid challenges may be given for shock. Conscious patients are usually stabilized with injected or inhaled epinephrine, while unconscious patients and those with refractory hypotension or hypoxia should be intubated.

**7-3. The answer is b.** (*Fauci, 14/e, pp 1472–1474.*) Classifying a pleural effusion as either a transudate or an exudate is useful in identifying the underlying disorder. Pleural fluid is exudative if it has any one of the following three properties: a ratio of concentration of total protein in pleural

fluid to serum greater than 0.5, an absolute value of lactate dehydrogenase (LDH) greater than 200 IU, or a ratio of LDH concentration in pleural fluid to serum greater than 0.6. Causes of exudative effusions include malignancy, pulmonary embolism, pneumonia, tuberculosis, abdominal disease, collagen vascular diseases, uremia, Dressler syndrome, and chylothorax. Exudative effusions may also be drug induced. If none of the aforementioned properties are met, the effusion is a transudate. Differential diagnosis includes congestive heart failure, nephrotic syndrome, cirrhosis, Meigs syndrome, and hydronephrosis.

**7-4. The answer is a.** (*Stobo, 23/e, pp 240–244.*) The clinical picture of a noninflammatory arthritis of weight-bearing joints is suggestive of degenerative joint disease, also called osteoarthritis. Crepitation over the involved joints is characteristic, as are the bony enlargements of the distal interphalangeal (DIP) joints. In this overweight patient, weight reduction is the best method to decrease the risk of further degenerative changes. Aspirin can be used as symptomatic treatment, but does not affect the course of the disease. Calcium supplementation may be relevant to associated osteoporosis, but not to the osteoarthritis. Oral prednisone would be contraindicated; intraarticular corticosteroid injections may be given once or twice per year for symptom reduction, but will accelerate damage to cartilage. Knee replacement is the treatment of last resort, usually when pain occurs around the clock and symptoms are not controlled by medical regimens.

**7-5. The answer is d.** (*Lewis, 2/e, pp 623–627.*) Vocal tics (grunting, barking, throat clearing, coprolalia, shouting) and simple and complex motor tics are characteristic findings of Tourette syndrome. Pharmacological treatment of this disorder includes neuroleptics and  $\alpha_2$  agonists (clonidine, guanfacine).

**7-6 through 7-7. The answers are 7-6 d, 7-7 e.** (*CDC, MMWR 1999; 48 I-37.*) RNA quantification is not generally used for diagnostic purposes, but rather for typing strains and epidemiologic research. Immune globulin M (IgM) antibodies can be detected 5 to 10 days before the onset of symptoms and must be present to confirm a diagnosis of hepatitis A. They persist for 6 mo. Commercial tests are also available for the detection of total antibodies [immune globulin G (IgG) and IgM]. IgG antibodies are detectable early



in disease, persist for life, and provide lifelong immunity. Children, because they are often asymptomatic, play an important role in the transmission of the infection. In one study of adults where no source of infection was identified, 52% had children under the age of 6 years, and the presence of a young child in the household was associated with hepatitis A virus (HAV) transmission. In this situation, children should be tested as well as other household contacts. Most cases of hepatitis A in the United States result from person-to-person transmission: 11% to 26% from either household or sexual contact and 11% to 16% from day care settings. An additional 4% to 6% are reported from international travelers, and 2% to 3% from recognized water or foodborne disease outbreaks. Outbreaks have also occurred among injecting drug users and men who have sex with men.

**7-8. The answer is e.** (*Behrman, 16/e, pp 1127–1128. Rudolph, 20/e, p 1064.*) Many types of objects produce esophageal obstruction in young children, including small toys, coins, and food. Most are usually lodged below the cricopharyngeal muscle at the level of the aortic arch. Initially, the foreign body may cause a cough, drooling, and choking. Later, pain, avoidance of food (liquids are tolerated better), and shortness of breath can develop. Diagnosis is by history (as outlined in the question) and by radiographs (especially if the object is radiopaque). The usual treatment is removal of the object via esophagoscopy.

**7-9. The answer is f.** (*Adams, 6/e, p 317.*) With a jacksonian march, or sequential seizure, the patient develops focal seizure activity that is primarily motor and spreads. This type of seizure often secondarily generalizes, at which point the patient loses consciousness and may have a generalized tonic-clonic seizure. The hand is a common site for the start of a jacksonian march. The face may be involved early because the thumb and the mouth are situated near each other on the motor strip of the cerebral cortex.

**7-10 through 7-12. The answers are 7-10 a, 7-11 e, 7-12 b.** (*Schwartz, 7/e, pp 179–180.*) Closed head injuries may result in cerebral concussion from depression of the reticular formation of the brainstem. This type of injury is usually reversible.

Local bleeding and swelling (intracranial or extracranial) produce an increase in the intracranial pressure. A characteristic symptom pattern occurs, initiated by progressive depression of mental status. Increasing

intracranial pressure tends to displace brain tissue away from the source of the pressure; if the pressure is sufficient, herniation of the uncus process through the tentorium cerebri occurs.

Pupillary dilation is caused by compression of the ipsilateral oculomotor nerve and its parasympathetic fibers. If the pressure is not relieved, the contralateral oculomotor nerve will become involved and, ultimately, the brainstem will herniate through the foramen magnum and cause death. Hypertension and bradycardia are preterminal events.

Emergency measures to reduce intracranial pressure while preparing for localization of the clot or for a craniotomy or both include hyperventilation, dexamethasone (Decadron), and mannitol infusion. Of these, hyperventilation produces the most rapid decrease in brain swelling.

**7-13. The answer is d.** (*Hurst, 4/e, pp 185–187.*) The incidence of insect sting allergy is difficult to determine. Approximately 40 deaths per year occur as a result of Hymenoptera stings. Additional fatalities undoubtedly occur and are unknowingly attributed to other causes. Both atopic and nonatopic persons experience reactions to insect stings that range from large local reactions with erythema and swelling at the sting site to acute anaphylaxis. The majority of fatal reactions occur in adults, with most persons having had no previous reaction to a stinging insect. Reactions can occur with the first sting and usually begin within 15 min. Enzymes, biogenic amines, and peptides are the allergens present in the insects' venom that provoke allergic reactions. Venoms are commercially available for testing and treatment. Within the Vespidae family, which consists of hornets, yellow jackets, and wasps, cross-sensitivity to the various insect venoms occurs. The honeybee, which belongs to the Apidae family, does not show cross-reactivity with the vespids. Venom immunotherapy is indicated for patients with a history of sting anaphylaxis and positive skin tests.

**7-14. The answer is a.** (*Fauci, 14/e, pp 1451–1455.*) Massive life-threatening hemoptysis is >100 cc of blood in 24 h. The most common cause for nonmassive hemoptysis (<30 cc/day) in smokers and non-smoking patients with a normal chest radiograph is bronchitis. Chronic bronchitis is characterized by excessive secretions manifested by a productive cough, often purulent or bloody, for 3 mo or more for 2 consecutive years in the absence of any other disease to explain the symptoms.

Patients are often obese and cyanotic (“blue bloaters”). The mnemonic is **BBB = Bronchitis/Blue Bloater**.

**7-15. The answer is b.** (*Tierney, 39/e, pp 1130–1133.*) Cushing syndrome occurs secondary to corticosteroid use, nonpituitary neoplasms (i.e., small cell carcinoma of the lung), adrenal adenomas, adrenal carcinomas, and bilateral adrenal nodular hyperplasia. Cushing’s disease is hypercortisolism due to adrenocorticotrophic hormone (ACTH) hypersecretion by the pituitary gland usually because of a small, benign pituitary microadenoma (<1 cm). Symptoms include central obesity, striae, hirsutism, easy bruisability, proximal myopathy, osteoporosis, amenorrhea, hypertension, glucose intolerance, and hypokalemia. Measurement of urinary cortisol is a good screening test for Cushing syndrome. Alcoholic patients and depressed patients may have hypercortisolism (pseudo-Cushing state). Polycystic ovary disease (Stein-Leventhal syndrome) is a disorder that causes increased levels of testosterone, hirsutism, infertility, and menstrual irregularity.

**7-16. The answer is d.** (*Behrman, 16/e, pp 1797, 1873–1882.*) Children with Duchenne muscular dystrophy (DMD) present between the ages of 2 and 6 years with fatigability, clumsiness, difficulty standing, difficulty walking on their toes, pseudohypertrophy of the calf muscles, and a waddling gait. DMD results from a deficiency of dystrophin while Becker muscular dystrophy is abnormal dystrophin. Becker muscular dystrophy is less severe than DMD and occurs after the age of 5 years. Both Becker and Duchenne muscular dystrophy are X-linked myopathies. The autosomal dominant myopathies are myotonic dystrophy and facioscapulohumeral dystrophy. Myotonic dystrophy occurs in adolescence and is characterized by diminished facial movements, cataracts, testicular atrophy, and muscle weakness. Facioscapulohumeral dystrophy occurs between the ages of 10 and 20 years and is characterized by facial and shoulder girdle weakness. The Gower maneuver (pushing off with the hands when rising from the floor because of proximal muscle weakness) is positive in muscular dystrophy.

**7-17. The answer is c.** (*Watts, p 191.*) The on-off effect is commonly seen in persons who have had Parkinson’s disease for several years. Maintaining more stable levels of antiparkinsonian medication in the blood does

not eliminate this phenomenon of abruptly worsening and remitting symptoms. Variability in the responsiveness of the central nervous system (CNS) to the medication, rather than variability in the medication levels, underlies the phenomenon.

**7-18. The answer is e.** (*Behrman, 16/e, p 1679. McMillan, 3/e, pp 1775–1780. Rudolph, 20/e, pp 1800–1802.*) A record of the sequential pattern of growth in height is very helpful in the differential diagnosis of a child with short stature. A child with constitutionally short stature and delayed puberty will have a consistent rate of growth below but parallel to the average for his or her age, whereas patients with organic disease do not follow a given percentile but progressively deviate from their prior growth percentile. A knowledge of the patterns of growth and sexual maturation of family members is helpful, because such patterns are often familial. Puberty is said to be delayed in males if physical changes are not apparent by 14 years of age. Identification of the earliest signs of sexual maturation by means of careful physical examination avoids unnecessary workup. In this case, measurement of pituitary gonadotropins is unnecessary because the child already shows evidence of pubertal development (a testicular length of more than 2.5 cm, volume 3.0 cm<sup>3</sup>). The single most useful laboratory test is the determination of bone age. In constitutionally short stature with delayed pubertal maturation, the bone age is equal to the height age, both of which are behind chronological age. In familial short stature, bone age is greater than height age and equal to chronological age. In a child at any age, the administration of human chorionic gonadotropin (hCG) will stimulate interstitial cells of testes to produce testosterone, thereby serving as a method of assessing testicular function. The finding of testicular enlargement is evidence of pituitary secretion of gonadotropins and of testicular responsiveness and obviates the need for administration of hCG. Elevated serum gonadotropins are found in children 12 years of age or older who have primary hypogonadism (Klinefelter syndrome, bilateral gonadal failure from trauma or infection). Because the secretion of gonadotropins is not constant but occurs in spurts, children with constitutional delay of puberty may have normal or low levels of gonadotropins.

**7-19. The answer is d.** (*Fauci, 14/e, ch 26, p 145; ch 79, pp 483–484; ch 108, pp 656–657.*) This patient has the Charcot triad of ataxia, confusion, and ophthalmoplegia, which occurs in malnourished individuals. Par-

enteral thiamin may reverse the disease if given within a few days of the occurrence of symptoms. Prolonged, untreated deficiencies can result in permanent damage. Vitamin B<sub>12</sub> (cobalamin) deficiency, which can occur in pernicious anemia, causes a spinal cord syndrome resulting in sensory loss with depressed tendon reflexes. Niacin deficiency results in pellagra and is associated with a high uptake of maize in the American South. Deficiency of pyridoxine or vitamin B<sub>6</sub> is associated with the intake of certain drugs, such as isoniazid, and results in abnormal tryptophan metabolism and convulsions. Folate deficiency can result in glossitis, cheilosis, and diarrhea, but does not cause neurological problems (except for neural tube defect during pregnancy).

**7-20. The answer is b.** (*Stobo, 23/e, pp 319–320.*) This patient has widespread Paget's disease of bone. Excessive resorption of bone is followed by replacement of normal marrow with dense, trabecular disorganized bone. Hearing loss and tinnitus are due to direct involvement of the ossicles of the inner ear. Plasma alkaline phosphatase levels represent increased bone turnover. Neither myeloma or metastatic bone disease would result in bony deformity such as skull enlargement.

**7-21. The answer is a.** (*Berson, pp 77, 85, 90–95.*) A common sequela of blunt trauma to the eye is a hyphema (blood in the anterior chamber). This is caused by rupture of the small blood vessels lying close to the cornea. Strabismus is a misalignment of the eyes. Esotropia is a kind of strabismus in which one eye is deviated inward. Amblyopia ("lazy eye") is loss of visual acuity in an otherwise healthy eye. This happens because the healthy eye closes to compensate for the deviating eye to avoid the discomfort of diplopia. This is treatable if discovered early. A subconjunctival hemorrhage (between the conjunctiva and sclera) causes the sudden appearance of a bright red spot.

**7-22. The answer is b.** (*Cunningham, 20/e, pp 746–751, 755–757, 765–767.*) Placenta previa and abruptio placentae are the two most common causes of third-trimester bleeding. Placenta previa is abnormal implantation of placenta near or at the cervical os; it may be total, partial, marginal, or low-lying. Risk factors for placenta previa include advanced maternal age, multiparity, smoking history, and prior cesarean section. Patients present at 30 wk gestation with painless vaginal bleeding. There is

no fetal distress. Vaginal examination is contraindicated and sonogram is required to make the diagnosis. Abruption placentae is premature separation of normally implanted placenta. Patients present with painful (unremitting abdominal and back pain) vaginal bleeding, and there is fetal distress. Risk factors for abruption placentae include advanced maternal age, multiparity, diabetes, hypertension, tobacco use, alcohol use, and cocaine use. Placenta accreta is a placenta that adheres to the myometrium without an intervening decidual layer; it is associated with postpartum hemorrhage. In vasa previa, the fetal vessels associated with the cord traverse the lower uterine segment and present in advance of the fetal presenting part, causing rapid bleeding when disrupted during labor. Bloody show is a blood-tinged vaginal discharge that occurs when the cervix is dilated and the onset of labor is imminent.

**7-23. The answer is e.** (*Adams, 6/e, pp 1205–1217.*) Methacholine is a cholinergic agent and would be expected to worsen the symptoms exhibited by this patient. Pyridostigmine, physostigmine, and edrophonium are all cholinesterase inhibitors used in the evaluation or treatment of myasthenia gravis, and they too would only hasten the patient's deterioration. Atropine is usually given in combination with pralidoxime. This patient is at most immediate risk of severe bronchospasm and diaphragmatic paralysis with subsequent respiratory arrest. Even if the patient does survive the acute poisoning, he is at risk for a delayed deterioration of the motor system, which may itself prove fatal and which does not respond to atropine treatment.

**7-24. The answer is b.** (*Fauci, 14/e, pp 669–671.*) An elevated reticulocyte count in a patient with normocytic, normochromic anemia strongly suggests hemolysis. The reticulocyte count must be corrected for degree of anemia. Peripheral blood smear may show abnormalities of shape that can suggest hemolysis. Indirect bilirubin and serum LDH are usually mildly elevated in hemolytic anemia, but are less specific.

**7-25. The answer is d.** (*Sadock, 7/e, pp 884–885.*) Alzheimer's disease is the most common dementing disorder in North America, Europe, and Scandinavia. Typical symptoms are progressive memory loss, aphasia, anomia (inability to recall the name of objects), apraxia (inability to perform voluntary motor activity in the absence of motor and sensory

deficits), and agnosia (inability to process and understand sensory stimuli in the absence of sensory deficit). Motor functions are spared until the very end. Personality is preserved in the early stages of the disorder, but considerable deterioration follows in later stages.

**7-26. The answer is b.** (*Fauci, 14/e, pp 1320–1322.*) The patient has physical findings consistent with aortic insufficiency (AI). Etiologies may include dissecting aorta, Marfan syndrome, bicuspid aortic valve, rheumatic heart disease, ankylosing spondylitis, endocarditis, or syphilis. Associated signs of AI include pulsus bisferiens (double wave pulse), the de Musset sign (head-bobbing with the heartbeat), waterhammer pulse (rapidly rising pulse), Corrigan pulse (collapsing pulse that follows rising pulse), the Hill sign (an increase of >40 mm Hg in femoral artery systolic blood pressure compared to brachial artery blood pressure), Quincke pulse (blanching of the root of the nail when pressure is applied to the tip), capillary pulsations, “pistol shots” (booming sound heard over the femoral arteries), and the Duroziez sign (bruit auscultated over the femoral artery when compressed). Patients with AI have a wide pulse pressure and a rumbling murmur of mitral stenosis (MS) (Austin Flint murmur) heard at the apex.

**7-27. The answer is b.** (*Gleisher, 3/e, pp 199–205.*) The recommended sequence for maternal serum  $\alpha$  fetoprotein (MSAFP) screening program for 1000 hypothetical patients would normally produce about 30 with an elevated level [2.5 multiples of the median (MOM)] on the first MSAFP. If the patient does not have an extremely elevated value (i.e., the value is <4.0 MOM) and is relatively early (<19 wk gestation), a second MSAFP value is usually drawn. About two-thirds of these patients will have an elevated test or will be very high the first time. Those that are normal a second time drop back into the normal population. However, if the value is extremely high (4.0 MOM) or if the gestational age is approaching the limit of options for termination of pregnancy (19+ wk), most programs then skip a second test and go directly on to ultrasound and possibly amniocentesis. A thorough ultrasound on patients with two elevations or one very high elevation will reveal an obvious reason for the elevation in about 10 of 30 patients. These reasons may include anencephaly, twins, wrong gestational age of the fetus, or fetal demise. The approximately 20 patients with no obvious cause for elevation should then be offered counseling and amniocentesis. There is debate in the literature about whether amniocentesis is unnecessary if the

ultrasound is normal. We believe that it is appropriate to adjust odds, but that ultrasound can never be perfect. Of patients without a benign explanation, about 5% have an elevated amniotic fluid  $\alpha$  fetoprotein and positive acetylcholinesterase. Such patients will have a greater than 99% chance of having a baby with an open neural tube defect or other serious malformations, such as a ventral wall defect. Amniography is an outmoded procedure in which radiopaque dye is injected into the amniotic cavity for the purpose of taking x-rays. Under no circumstances whatsoever should termination of pregnancy be recommended on the basis of MSAFP testing alone. MSAFP is only a screening test used to define who is at risk and requires further testing; it is never diagnostic per se.

**7-28. The answer is b.** (Fauci, 14/e, pp 1437–1445.) Pneumonia is a common disorder and is a major cause of death, particularly in hospitalized, elderly patients. Before choosing empiric therapy for presumed pneumonia, it is necessary to know the age of the patient, whether the infection is community acquired or nosocomial, and whether there are any underlying debilitating illnesses. Community-acquired pneumonias in patients over the age of 35 are most likely due to *Streptococcus pneumoniae*, *Legionella* species (e.g., *pneumophila*), and *Haemophilus influenzae*. In the case outlined, the history is strongly consistent with pneumococcal pneumonia, which is manifested by a short prodrome, shaking chills with rigor, fever, chest pain, sparse sputum production associated with cough, and a consolidated lobar infiltrate on chest roentgenogram. The most reliable method of diagnosing pneumococcal pneumonia is seeing gram-positive diplococci on an adequate sputum (many white cells, few epithelial cells). Sputum culture is also important in the era of penicillin-resistant pneumococci, but is not helpful in initial diagnosis. Blood cultures are positive in only about 20% of patients, and, when positive, are indicative of a more severe case. Although rigors may suggest pneumococcal bacteremia, the absence of rigors does not rule out the diagnosis. About 25% of pneumococci in the United States are partially or completely resistant to penicillin due to chromosomal mutations resulting in penicillin-binding protein changes. Penicillin is no longer the regimen of choice for pneumococcal pneumonia pending the results of sensitivity testing. The flouroquinolones or ceftriaxone are widely used as initial therapy for pneumococcal pneumonia.



**7-29. The answer is a.** (Fauci, 14/e, p 1452; Wallace, 14/e, p 986.) From 80% to 90% of all cases of chronic obstructive pulmonary disease (COPD) in the United States are attributable to cigarette smoking. Some occupations that involve particle or dust exposure may also be associated with COPD. Deficiency of  $\alpha$  antitrypsin is uncommon, and is generally associated with emphysema. There is some data to suggest that severe viral pneumonia early in life may lead to obstructive disease.

**7-30. The answer is c.** (Stobo, 23/e, pp 979–980.) Contact dermatitis causes pruritic plaques or vesicles localized to an area of contact. In this case, a bracelet or wrist band would be the inciting agent. The dermatitis may have vesicles with weeping lesions. Zoster would be painful and occur in a dermatomal distribution. Herpes simplex produces grouped vesicles, but they are painful and also unlikely to occur around the wrist. Seborrheic dermatitis presents as red, scaly lesions over a circular area and appear to resolve after several hours, with new lesions developing in the nasolabial folds, scalp, and retroauricular areas.

**7-31. The answer is c.** (Greenberg, 2/e, ch 12, pp 161–163.) Sensitivity analysis is used in decision analysis to determine how much impact different probabilities of a particular event will have on the choice of one intervention over another. Computer programs can calculate and plot this data. The maximum quality-adjusted life years (or QALYs) is 4.5 for surgery and 4.2 for radiation. QALYs are plotted for radiation therapy and surgery for different probabilities of mortality from surgery. As expected, mortality from surgery does not impact the QALYs obtained from radiation therapy. However, as mortality from surgery increases, the QALYs for that intervention decrease. If mortality did not impact QALYs for surgery, you would obtain a straight line with the y coordinate at 4.5. The threshold is the point at which both interventions intersect: decisions will be made above or below that point. In this case, surgery is superior to radiation if the mortality is below 11%. However, if the mortality from surgery is higher than 11%, then you gain more QALYs from radiation therapy. The sensitivity analysis from this example demonstrates that mortality from surgery is an important variable for determining the best strategy.

**7-32. The answer is c.** (Schwartz, 7/e, pp 1686–1688.) Medullary carcinomas occur in families as part of syndromes called multiple endocrine neo-

plasia (MEN) type 2A and 2B. MEN 2A consists of multicentric medullary thyroid cancer, pheochromocytomas or adrenal medullary hyperplasia, and hyperparathyroidism. MEN 2B consists of medullary cancer, pheochromocytoma and mucosal neuromas, gangliomas, and a Marfan-like habitus. These patients may develop medullary carcinoma at a very young age, and any patient with MEN 2B should be assumed to have medullary cancer until proved otherwise. Patients are followed carefully for pheochromocytoma with urine vanillylmandelic acid (VMA), for hyperparathyroidism with serum calcium, and for medullary carcinoma with serum calcitonin. However, as some patients have a normal basal calcitonin, a pentagastrin or provocative calcium infusion test should be performed in these high-risk patients. Patients thought to have MEN 1 syndrome (pituitary, parathyroid, and pancreatic tumors) or Zollinger-Ellison syndrome should be assayed for serum gastrin, insulin, glucagon, and somatostatin. These assays may prove to be inappropriately high in MEN 1 syndrome due to pancreatic islet cell tumors.

**7-33. The answer is e.** (*CDC, MMWR 1991; 40, RR-12.*) If a person has received three doses or more of the combined diphtheria and tetanus booster (Td), and the last dose was given more than 5 years before an injury, a tetanus and diphtheria booster should be given if the wound is contaminated, such as the one described. It is preferable to administer Td. You are then also using the opportunity to provide primary prevention for diphtheria. If the last dose of Td was given in the preceding 5 years, then no further action is necessary. Td and tetanus immunoglobulin (TIG) is recommended for prophylaxis of contaminated wounds when the history of tetanus toxoid is unknown or the person received less than three doses. TIG is never recommended as sole prophylaxis as prolonged immunity is desired.

**7-34. The answer is c.** (*Fauci, 14/e, pp 200–201, 1303–1305.*) A holosystolic murmur at the mid-left sternal border is the murmur most characteristic of a ventricular septal defect. Both the murmur of ventricular septal defect and the murmur of mitral regurgitation are enhanced by exercise and diminished by amyl nitrate. Answers a, b, d, and e describe the usual findings in aortic stenosis, atrial septal defect, aortic insufficiency, and patent ductus arteriosus, respectively.

**7-35. The answer is c.** (*Behrman, 16/e, pp 1135–1136. McMillan, 3/e, pp 311–312. Rudolph, 20/e, pp 1067–1068.*) Malrotation results when incom-

plete rotation of the intestines occurs during embryologic development. The most common type of malrotation is failure of the cecum to move to its correct location in the right lower quadrant. Most patients present in the first weeks of life with bilious vomiting indicative of bowel obstruction and/or intermittent abdominal pain. Acute presentation, similar to that in the question, is caused by a volvulus of the intestines. The diagnosis is confirmed by radiographs; barium contrast studies (upper GI and/or enema) demonstrate malposition of the cecum in the vast majority of cases. Treatment is surgical.

**7-36 through 7-37. The answers are 7-36 b, 7-37 b.** (*Fauci, 14/e, pp 1310–1311.*) This 18-year-old presents with classic features of rheumatic fever. His clinical manifestations include arthritis, fever, and murmur. A subcutaneous nodule is noted and a rash of erythema marginatum is described. These subcutaneous nodules are pea-sized and usually seen over extensor tendons. The rash is usually pink with clear centers and serpiginous margins. Laboratory data shows an elevated erythrocyte sedimentation rate, as usually occurs in rheumatic fever. The electrocardiogram (ECG) shows evidence of first-degree atrioventricular (AV) block. An anti-streptolysin O antibody is necessary to diagnose the disease by documenting prior streptococcal infection. Most experts recommend the use of glucocorticoids when carditis is part of the picture of rheumatic fever. Hence, in this patient with first-degree AV block, corticosteroids would be indicated. Penicillin should also be given to eradicate Group A  $\beta$  hemolytic streptococci.

**7-38. The answer is b.** (*Bradley, 3/e, p 1455.*) Clinical trials have shown that intravenous methylprednisolone for an attack of optic neuritis reduces the likelihood of development of multiple sclerosis (MS) over 2 years from 16.7% to 7.5%. It also is associated with a better outcome than oral prednisone. Intravenous methylprednisolone is thus recommended by most experts as appropriate therapy for acute exacerbations of multiple sclerosis involving more than sensory manifestations alone.

**7-39. The answer is d.** (*Adams, 6/e, p 187.*) This patient exhibits two different complaints separated in time and space, a clinical pattern that must raise the possibility of multiple sclerosis in a woman this age. The pattern of pain is suggestive of trigeminal neuralgia (tic douloureux), an idiopathic facial pain syndrome that often develops in persons with multiple sclerosis.

Alternatives to carbamazepine in the palliation of trigeminal neuralgia include phenytoin and baclofen.

**7-40. The answer is a.** (*Bradley, 3/e, pp 1453–1454.*) Bladder dysfunction with multiple sclerosis is usually a consequence of corticospinal tract disease. This lesion of the upper motor neuron produces a spastic bladder. Tricyclic antidepressants such as imipramine exert an anticholinergic effect and thereby inhibit premature emptying of the bladder. Cholinergic drugs, such as methacholine, are useful if the patient has a flaccid bladder, but that is much less frequently the problem with multiple sclerosis.

**7-41. The answer is d.** (*Bradley, 3/e, p 1453.*) Baclofen affects spasticity through an unknown mechanism and may cause considerable sedation. Sedation is less a concern if spasticity is interfering with the patient's ability to sleep. The drug is usually given orally at a dose of 10 mg three or four times daily, but most patients must start at a much lower dose and gradually build up tolerance. Baclofen has been given intrathecally with an implanted pump injector, but this highly invasive therapy is only appropriate in patients with extreme spasticity. Candidates for intrathecal treatment are functionally paraplegic and may recover considerable mobility with elimination of the spasticity. Tizanidine is a centrally active  $\alpha_2$ -adrenergic agonist that appears to relieve spasticity without affecting strength.

**7-42. The answer is b.** (*Behrman, 16/e, pp 441, 532–533. McMillan, 3/e, pp 346–347, 356–358. Rudolph, 20/e, pp 248–251.*) Glucose loading of the mother will result in fetal hyperglycemia, which causes insulin release and reactive hypoglycemia. Careful medical support of the antepartum woman diminishes the hypertrophy of the fetal islet cells. Careful monitoring of the infant with early feeding or intravenous infusion of glucose can prevent hypoglycemia. A neutral thermal environment diminishes glucose consumption and therefore helps with glucose homeostasis.

**7-43. The answer is d.** (*Fauci, 14/e, p 2248.*) Bone loss increases with age, particularly in women after menopause, when lack of estrogen accelerates the process. To a lesser extent, smoking, lack of physical activity, and alcohol abuse can also increase the risk of osteoporosis. Obesity, presumably because it is accompanied by an increase in estrogen production, does not increase the risk of osteoporosis.

**7-44 through 7-45. The answers are 7-44 a, 7-45 a.** (*Behrman, 16/e, pp 1737–1739. McMillan, 3/e, pp 1819–1820. Rudolph, 20/e, pp 1731–1734.*) Although the administration of exogenous adrenocorticotrophic hormone or of glucocorticoids is the most common cause of Cushing syndrome, bilateral adrenal hyperplasia can also be a cause. In the latter case, the concentration of adrenocorticotrophic hormone can be normal or high. The basic abnormality, however, is thought to be in the hypothalamic-pituitary axis, not the adrenal gland, because a distinct pituitary adenoma is found in some patients. Furthermore, many patients who have undergone bilateral adrenalectomy develop Nelson syndrome (invasive pituitary adenoma) despite receiving adequate cortisol replacement. If the patient were an infant, however, the most likely answer would be an adrenal carcinoma.

The initial management of this child would consist of measuring evening cortisol levels, which, in a normal child, are expected to be less than 50% of the 8:00 A.M. value. Additionally, 24-h excretion of 17-hydroxycorticosteroids is almost always increased. In difficult-to-diagnose cases, a dexamethasone suppression test can be required. After the diagnosis has been established, further testing is indicated to determine if the condition is ACTH-dependent or ACTH-independent. At that point, corticotropin-releasing hormone testing and imaging will be required.

**7-46 through 7-47. The answers are 7-46 c, 7-47 b.** (*Cunningham, 20/e, pp 4, 538, 763, 1235.*) A disadvantage of home delivery is the lack of facilities to control postpartum hemorrhage. The woman described in the question delivered a large baby, suffered multiple soft tissue injuries, and went into shock, needing 9 units of blood by the time she reached the hospital. Sheehan syndrome seems a likely possibility in this woman. This syndrome of anterior pituitary necrosis related to obstetric hemorrhage can be diagnosed by 1 wk postpartum, as lactation fails to commence normally. Although many modern women choose hormonal therapy to prevent lactation, the woman described in the question was intent on breast feeding and so would not have received suppressants. She therefore could have been expected to begin lactation at the usual time. Other symptoms of Sheehan syndrome include amenorrhea, atrophy of the breasts, and loss of thyroid and adrenal function.

The other presented choices for late sequelae are rather far-fetched. Hemochromatosis would not be expected to occur in this healthy young woman, especially since she did not receive prolonged transfusions. Cush-

ing, Simmonds, and Stein-Leventhal syndromes are not known to be related to postpartum hemorrhage.

It is important to note that home delivery is not a predisposing factor to postpartum hemorrhage.

**7-48. The answer is a.** (*Fauci, 14/e, pp 1590–1595.*) Odynophagia (painful swallowing) is the most common presenting symptom of infectious esophagitis. In an HIV-positive patient, *Candida albicans* (even without oral thrush) is the most common organism. Other organisms include cytomegalovirus and herpes simplex virus. Reflux disease may cause a non-infectious esophagitis, but it is less likely in this patient. Barrett's esophagus (pre-malignant lesion for adenocarcinoma of the esophagus) is replacement of the squamous epithelium by columnar epithelium and may also result in esophagitis. Achalasia is failure of the lower esophageal sphincter to relax (motor disorder of smooth muscle); patients complain of dysphagia (difficulty swallowing) to liquids and solids. Patients with cancer typically present with dysphagia to solids that progresses to include liquids and is accompanied by weight loss. Middle-aged women develop Plummer-Vinson syndrome (hypopharyngeal web); they present with dysphagia to solids and iron-deficiency anemia. A Schatzki ring is a weblike constriction near the lower esophageal sphincter (LES) that produces dysphagia to solids. The first step in the workup of dysphagia is a barium swallow.

**7-49. The answer is b.** (*LaDou, 2/e, pp 707–712.*) The major air pollutants are particulates, sulfur oxides, carbon monoxide, oxides of nitrogen, hydrocarbons, lead, and ozone. The latter is formed by sunlight irradiating an atmosphere containing hydrocarbons and oxides of nitrogens, and has been associated with Southern California smog. It has primarily been linked to an exacerbation of asthma. Hydrocarbons are precursors of smog. Carcinogenicity is debated. Oxides of nitrogen are also precursors of smog; important sources are automobiles and airplanes. They are primarily mucosal irritants; studies on respiratory effects are conflicting. Carbon monoxide, although a plentiful pollutant, is quickly transformed into carbon dioxide. Increases aggravate coronary artery disease, precipitate myocardial infarction, and reduce exercise tolerance. Particulate matter most severely affects persons with chronic obstructive pulmonary disease. Sulfur oxide is the most important air pollutant.

**7-50. The answer is d.** (*Podolosky, N Engl J Med 325:928–937, 1991.*) The patient depicted in this question has Crohn's disease of the colon (Crohn's colitis). Crohn's colitis is characterized by linear mucosal ulcerations, discontinuous ("skip") lesions, a transmural inflammatory process, and non-caseating granulomata in up to 50% of patients. Because their clinical features and management differ, Crohn's colitis must be distinguished from ulcerative colitis. Ulcerative colitis is usually found in the rectum, although in rare cases the rectum is spared involvement. The entire colon, from cecum to rectum, may be involved (pancolitis). Ulcerative colitis typically presents as a grossly continuous inflammatory process (without skip lesions) that microscopically is confined to the mucosa and submucosa of the colon. In addition, crypt abscesses and superficial ulcerations are common in ulcerative colitis.

*This page intentionally left blank.*



# BLOCK 8

---

## Answers

**8-1 through 8-2. The answers are 8-1 c, 8-2 d.** (*Sadock, 7/e, p 962.*)

Alcohol withdrawal delirium (delirium tremens) is the most severe form of alcohol withdrawal. In this syndrome, coarse tremor of the hands, insomnia, anxiety, agitation, and autonomic hyperactivity are accompanied by severe agitation, confusion, and tactile or visual hallucinations. When alcohol use has been heavy and prolonged, withdrawal phenomena start within 8 h of cessation of drinking. Symptoms reach peak intensity between the second and the third day of abstinence and are usually markedly diminished by the fifth day. In a milder form, withdrawal symptoms may persist for weeks as part of a protracted syndrome. Wernicke's psychosis is an encephalopathy caused by severe thiamin deficiency and usually associated with prolonged and severe alcohol abuse. It is characterized by confusion, ataxia, and ophthalmoplegia. In alcohol hallucinosis, vivid auditory hallucinations start shortly after cessation or reduction of heavy alcohol use. Hallucinations may present with a clear sensorium and are accompanied by signs of autonomic instability that are less prominent than in alcohol withdrawal delirium.

Benzodiazepines are the preferred treatment for alcohol withdrawal delirium. Diazepam and chlordiazepoxide are the most commonly used. Elderly patients, or patients with severe liver damage, may better tolerate intermediate-acting benzodiazepines, such as lorazepam and oxazepam. Thiamin (100 mg) and folic acid (1 mg) are routinely administered to prevent central nervous system (CNS) damage secondary to vitamin deficiency. Thiamin should be always administered prior to glucose infusion, because glucose metabolism may rapidly deplete the patient's thiamin reserves in cases of long-term poor nutrition. When the patient has a history of alcohol withdrawal seizures, magnesium sulfate should be administered.

**8-3. The answer is a.** (*Schwartz, 7/e, pp 688–689.*) Flail chest is diagnosed in the presence of paradoxical respiratory movement in a portion of the chest wall. At least two fractures in each of three adjacent ribs or costal car-

tilages are required to produce this condition. Complications of flail chest include segmental pulmonary hypoventilation with subsequent infection and ultimately respiratory failure. Management of flail chest should be individualized. If adequate pain control and pulmonary toilet can be provided, patients may be managed without stabilization of the flail. Often intercostal nerve blocks and tracheostomy aid in this form of management. If stabilization is required, external methods such as sandbags or towel clips are no longer used. Surgical stabilization with wires is used if thoracotomy is to be performed for another indication. If this is not the case, “internal” stabilization is performed by placing the patient on mechanical ventilation with positive end-expiratory pressure. Tracheostomy is recommended because these patients usually require 10 to 14 days to stabilize their flail segment and postventilation pulmonary toilet is simplified by tracheostomy. Indications for mechanical ventilation include significant impedance to ventilation by the flail segment, large pulmonary contusion, an uncooperative patient (e.g., owing to head injury), general anesthesia for another indication, fractures of more than five ribs, and the development of respiratory failure.

**8-4. The answer is d.** (*Fauci, 14/e, pp 543–546.*) The lesion has characteristics of melanoma (pigmentation, asymmetry, irregular border), and a full-thickness excisional biopsy is required. Shave biopsy of a suspected melanoma is always contraindicated. Diagnosis is urgent; the lesion cannot be observed over time. Once the diagnosis of melanoma is made, the tumor must then be staged to determine prognosis and treatment.

**8-5. The answer is e.** (*Behrman, 16/e, pp 977–981. McMillan, 3/e, pp 1107–1110. Rudolph, 20/e, pp 639–642.*) To prove a diagnosis of infectious mononucleosis, a triad of findings should be present. First, physical findings can include diffuse adenopathy, tonsillar enlargement, an enlarged spleen, small hemorrhages on the soft palate, and periorbital swelling. Second, the hematologic changes should reveal a predominance of lymphocytes, with at least 10% of these cells being atypical. Third, the characteristic antibody response should be present. Traditionally, heterophil antibodies can be detected when confirming a diagnosis of infectious mononucleosis. These antibodies may not be present, however, particularly in young children. Alternatively, specific antibodies against viral antigens on the Epstein-Barr virus can be measured. Antibodies to viral capsid antigen (VCA) and to anti-D early antigen are elevated prior to the appearance of Epstein-Barr

nuclear antigen (EBNA) and are, therefore, markers for acute infection. Immunoglobulin G (IgG) VCA and EBNA persist for life, whereas anti-D disappears after 6 mo.

**8-6. The answer is a.** (*Wallace, 14/e, p 1055. USPSTE, 2/e, p 585.*) The findings are typical of cocaine use during pregnancy, which has also been associated with impaired fetal growth and increased risk of placenta abruptio. Infants exposed to opiates during pregnancy may exhibit symptoms of withdrawal. Fetal alcohol syndrome is characterized by microcephaly, stunting, flattened nasolabial facies, and narrow palpebral tissues. Human immunodeficiency virus (HIV) infection is asymptomatic at birth.

**8-7. The answer is d.** (*Fauci, 14/e, pp 1474–1475.*) The patient most likely has a spontaneous pneumothorax. This disorder affects tall, thin men and may be recurrent. It is thought to be due to the rupture of subpleural blebs in response to high negative intrapleural pressures. Physical examination often reveals unilateral chest expansion, decreased fremitus, hyperresonance, and diminished breath sounds. Patients with chronic obstructive pulmonary disease (COPD), cystic fibrosis, *Pneumocystis carinii* pneumonia (PCP), and tuberculosis may have blebs and are at risk for secondary pneumothorax.

**8-8. The answer is a.** (*Speroff, 6/e, pp 392–403. Adashi, pp 990–1006.*) In North America, any pubertal changes before the age of 8 years in girls and 9 years in boys are regarded as precocious. Although the most common type of precocious puberty in girls is idiopathic, it is essential to ensure close long-term follow-up of these patients to ascertain that there is not serious underlying pathology, such as tumors of the central nervous system or ovary. In only 1% to 2% of patients with precocious puberty is an estrogen-producing ovarian tumor the causative factor. McCune-Albright syndrome (polyostotic fibrous dysplasia), also relatively rare, consists of fibrous dysplasia and cystic degeneration of the long bones, sexual precocity, and café au lait spots on the skin. Hypothyroidism is a cause of precocious puberty in some children, making thyroid function tests mandatory in these cases. Tumors of the central nervous system as a cause of precocious puberty occur more commonly in boys than in girls; they are seen in about 11% of girls with precocious puberty.

**8-9. The answer is a.** (*Tierney, 39/e, pp 1088–1090.*) Acromegaly (hypersecretion of growth hormone after closure of the epiphyses) is almost always caused by a pituitary adenoma (benign 99% of the time). Patients present with tall stature, large hands and feet, prominent mandible, prognathism, coarse facial features, wide tooth spacing, deep voice, macroglossia, and carpal tunnel syndrome. Patients may have headache, visual field defects, hypertrophy of the laryngeal tissue causing obstructive sleep apnea, hypertension, cardiomegaly, multiple skin tags, premalignant colonic polyps, and diabetes mellitus. Gigantism occurs before the closure of the epiphyses. Amyloidosis is a group of disorders characterized by infiltration of various organs (kidney, heart, intestine, endocrine) by protein fibrils. Patients with amyloidosis may have macroglossia and carpal tunnel syndrome. Macroglossia is also seen in hypothyroidism. Coarse features may run in families (familial prognathism).

**8-10. The answer is a.** (*Schwartz, 7/e, pp 552–553.*) Cystosarcoma phylloides is a tumor most often seen in younger women. It can grow to enormous size and at times ulcerate through the skin. Still, it is a lesion with low propensity toward metastasis. Local recurrence is common, especially if the initial resection is inadequate. Simple reexcision with adequate margins is curative. Very large lesions may necessitate simple mastectomy to achieve clear margins. Axillary lymphadenectomy, however, is seldom indicated without biopsy-positive demonstration of tumor in the nodes. The low incidence of metastatic disease suggests that adjunctive therapy is indicated only for known metastatic disease, even when the tumors are quite large and ulcerated.

**8-11. The answer is e.** (*Holmes, 3/e, ch 80, pp 1117–1120, Eur. Mod. Deliv. Collab., Lancet, 1999.*) The landmark randomized placebo controlled trial ACTG 076 demonstrated that zidovudine (ZDV) given at the beginning of the second trimester, during labor and delivery, and to the newborn for 6 wk significantly reduced the transmission of HIV to the newborn from 25.5% in the control group to 8.3% in the treatment group. Thus, ZDV can be highly effective for primary prevention in the newborn. Other promising treatment schedules with ZDV and other antiretrovirals are under study. Recent data demonstrates that a cesarean section can reduce vertical transmission, but it should not supersede antiretroviral therapy. Currently, it appears that it is not a routinely recommended procedure for HIV-infected

pregnant women, but this may change in the future. HIV can be transmitted by breast feeding, and in some studies the risk is increased by 14%. However, breast feeding has no impact on the highest risk of transmission, which occurs during gestation, labor, and delivery. Early identification of newborns at risk of HIV infection will guide the medical management and improve outcomes. It has no impact on the primary prevention of the infection to the newborn. Finally, all HIV-infected women should be made aware of the benefit of ZDV so they can make informed choices.

**8-12. The answer is b.** (*Stobo, 23/e, pp 245–251.*) The symptoms of Raynaud's phenomenon, arthralgia, and dysphagia point toward the diagnosis of sclerodema. Antinucleolar antibody occurs in only 20% of patients with the disease, but a positive test is highly specific. Cardiac involvement may occur, and an electrocardiogram (ECG) could show heart block or pericardial involvement. Renal failure can develop insidiously. Rheumatoid factor is nonspecific and present in about 20% of patients with sclerodema.

**8-13. The answer is d.** (*Tierney, 39/e, pp 501–505.*) The differential diagnosis for microcytic hypochromic anemia is **TICS** (Thalassemia, Iron deficiency, Chronic disease, and Sideroblastic). This patient of Mediterranean descent most likely has thalassemia trait. Thalassemia generally produces a greater degree of microcytosis for any given level of anemia than does iron deficiency. Target cells are seen in this disorder, but are also seen in lead poisoning, liver disease, hyposplenism, and hemoglobin C disease. The most common cause of a microcytic anemia is iron deficiency but it is unlikely in this asymptomatic patient with a negative fecal occult blood test (FOBT). The mean corpuscular volume (MCV) in anemia of chronic disease is usually normal or slightly reduced; patients typically have a history of chronic infection or inflammation, cancer, or liver disease. Alcoholics, patients taking antituberculosis medication or chloramphenicol, or those with lead poisoning may develop sideroblastic anemia (a failure to incorporate heme into protoporphyrin). Bone marrow staining will demonstrate iron deposits (ringed sideroblasts) encircling the nucleus in siderocytes. Coarse basophilic stippling of the red blood cells on peripheral smear is characteristic of lead poisoning.

**8-14. The answer is b.** (*Goldman, 21/e, pp 211–213.*) Systolic dysfunction is an inability of the ventricle to contract normally (hypodynamic).

Patients (especially older patients) with hypertension and diabetes mellitus are predisposed to diastolic dysfunction (inability of the ventricle to relax for filling); typically, these patients have an S<sub>4</sub> gallop, elevated filling pressures, and a hyperdynamic (ejection fraction >50%) ventricle. Patients with left heart failure present with pulmonary congestion (i.e., crackles). Patients with right heart failure present with jugular venous distension (JVD), S<sub>3</sub> gallop, hepatomegaly, ascites, and peripheral edema.

**8-15. The answer is c.** (*Mishell, 3/e, pp 330–339.*) Although there is an increased risk of spontaneous abortion, and a small risk of infection, an intrauterine pregnancy can occur and continue successfully to term with an intrauterine device (IUD) in place. However, if the patient wishes to keep the pregnancy and if the strings are visible, the IUD should be removed in an attempt to reduce the risk of infection, abortion, or both. Although the percentage of ectopic pregnancies may be increased, the majority of pregnancies occurring with an IUD are intrauterine. Therefore, in the absence of signs and symptoms suggestive of an ectopic pregnancy, especially after ultrasound documentation of an intrauterine pregnancy, laparoscopy is not indicated.

**8-16. The answer is c.** (*Schatzberg, 2/e, p 812.*) Common side effects of methylphenidate include loss of appetite and weight, irritability, oversensitivity and crying spells, headaches, and abdominal pain. Insomnia may occur, particularly when this agent is dispensed late in the day. Tics, while a less frequent complication of stimulant treatment, can cause significant impairment. Choreiform movements and night terrors are side effects of another stimulant, pemoline. Leukopenia and cardiac arrhythmias are not associated with stimulant treatment.

**8-17. The answer is e.** (*Patten, 2/e, p 375.*) This woman probably has trigeminal neuralgia (tic douloureux). The treatment options for this facial pain disorder include carbamazepine (Tegretol). Although carbamazepine is a potent antiepileptic medication, other antiepileptic medications such as phenobarbital and divalproex sodium (Depakote) are usually ineffective in blunting the pain. Phenytoin (Dilantin) is another antiepileptic useful in the management of trigeminal neuralgia, and recently gabapentin (Neurontin) has had some success as well. Analgesics and antiinflammatory drugs such as indomethacin (Indocin) are notably ineffective in managing this disorder.

**8-18. The answer is b.** (*Fauci, 14/e, pp 1469–1472.*) The clinical situation described is characteristic of pulmonary embolic disease. In greater than 80% of cases, pulmonary emboli arise from deep venous thromboses (DVTs) of the lower extremities. DVTs often begin in the calf, where they rarely if ever cause clinically significant pulmonary embolic disease. However, thromboses that begin below the knee frequently grow, or propagate, above the knee; clots that dislodge from above the knee cause clinically significant pulmonary emboli, which, if untreated, cause mortality exceeding 80%. Interestingly, only about 50% of patients with DVT of the lower extremities have clinical findings of swelling, warmth, erythema, pain, or “cords.” As long as the superficial venous system, which has connections with the deep venous system, remains patent, none of the classic clinical findings of DVT will occur because blood will drain from the unobstructed superficial system. When a clot does dislodge from the deep venous system and travels into the pulmonary vasculature, the most common clinical findings are tachypnea and tachycardia; chest pain is less likely and is more indicative of concomitant pulmonary infarction. Arterial blood gas (ABG) is usually abnormal, and a high percentage of patients exhibit hypoxia, hypocapnia, alkalosis, and a widening of the alveolar-arterial gradient (P). ECG is frequently abnormal in pulmonary embolic disease. The most common finding is sinus tachycardia, but atrial fibrillation, pseudoinfarction in the inferior leads, and right and left axis deviation are also occasionally seen. Initial treatment for suspected pulmonary embolic disease includes prompt hospitalization and institution of intravenous heparin provided there are no contraindications to anticoagulation.

**8-19. The answer is b.** (*Fauci, 14/e, pp 1470–1471.*) Lung scanning is the principal imaging test for the diagnosis of pulmonary embolus. The diagnosis is very unlikely in patients with normal or near normal scans. The diagnosis is highly likely in patient with high probability scans. In patients with a high clinical index of suspicion for pulmonary embolus but low probability scan, the diagnosis becomes more difficult, and pulmonary angiography may be indicated. About two-thirds of patients with pulmonary embolus have evidence of deep venous disease on venous ultrasound. Therefore, pulmonary embolus cannot be excluded by a normal study. The quantitative D-dimer enzyme-linked immunoabsorbent assay is positive in 90% of patients with pulmonary embolus in some studies. It has been used to rule out pulmonary embolus in a patient with a low or intermediate probability scan.

**8-20. The answer is e.** (*Behrman, 16/e, pp 1418–1421. McMillan, 3/e, pp 290–291, 1431–1432. Rudolph, 20/e, pp 1452–1453.*) Congestive heart failure from any cause can result in mild cyanosis, even in the absence of a right-to-left shunt, and in poor peripheral pulses when cardiac output is low. Congestive heart failure from many causes can be associated with a rapid pulse rate (up to 200 beats/min). A pulse rate greater than 250 beats/min, however, should suggest the presence of a tachyarrhythmia. Common causes for supraventricular tachycardia include Wolff-Parkinson-White syndrome (WPW), congenital heart disease, and sympathomimetic drugs. In this patient, evaluation for WPW and cardiac abnormalities must be accomplished after the congestive heart failure from the increased heart rate is under control.

**8-21. The answer is d.** (*Berson, pp 30–35, 121–122.*) Ischemic optic neuropathy usually occurs in patients with a history of diabetes or hypertension (underlying vascular disease). The disc is pale and swollen with splinter hemorrhages. This disorder is due to occlusion of the posterior ciliary arteries with subsequent production of edema. Central artery occlusion is sudden and painless. It is usually due to infarction from a thrombus or embolus and causes the retina to become pale. The thin tissue of the macula area appears as a cherry red spot. Occlusion of the retinal vein occurs due to slow venous blood flow and thrombosis. Patients complain of a slowly progressing loss of vision. The funduscopic image of retinal vein occlusion is so dramatic that it is often described as “blood and thunder.” In retinal detachment, the fundus appears elevated and often has folds. Patients complain of acute vision loss after noticing flashing lights, floaters, and then a shade over the eye. Diabetic retinopathy may be proliferative or nonproliferative. In nonproliferative (background) disease, retinal findings include microaneurysms, dot-and-blot hemorrhages, hard exudates, and macular edema. Proliferative diabetic retinopathy (neovascularization with the formation of fragile vessels) is a response to continuous retinal ischemia and is responsible for most blindness in diabetes mellitus. Hypertensive retinopathy is classified by the Keith-Wagener-Barker classification:

Grade 1: arteriolar narrowing and copper wiring

Grade 2: grade 1 changes plus arteriovenous nicking

Grade 3: grade 2 changes plus hemorrhages and exudates

Grade 4: grade 3 changes with the addition of papilledema



**8-22. The answer is a.** (*Scott, p 753. Rock, 8/e, pp 1088–1089.*) When patients present with urinary incontinence, a urinalysis and culture should be performed. In patients diagnosed with a urinary tract infection, treatment should be initiated and the patient should then be reevaluated. It is not uncommon for symptoms of urinary leakage to resolve after appropriate therapy. Initial evaluation of the incontinent patient includes a history and physical examination, UA/CS, simple cystometrogram, check for residual urine, stress test, and urinary diary.

**8-23. The answer is c.** (*Stobo, 23/e, pp 288–290.*) The patient has diastolic hypertension with associated hypokalemia. She is not taking diuretics. There is no edema on physical exam. Excessive inappropriate aldosterone production will produce a hypertension with hypokalemia syndrome. Hypersecretion of aldosterone increases distal tubular exchange of sodium for potassium with progressive depletion of body potassium. The hypertension is due to increased sodium absorption. Very low plasma renin that fails to increase with appropriate stimulus (such as volume depletion) with hypersecretion of aldosterone suggests the diagnosis of primary hyperaldosteronism. Suppressed resin activity occurs in about 25% of hypertensive patients with essential hypertension. Lack of suppression of aldosterone is also necessary to diagnose primary aldosteronism. High aldosterone levels that are not suppressed by saline loading prove that there is a primary inappropriate secretion of aldosterone.

**8-24. The answer is b.** (*Chin, 17/e, p 442. Fauci, 14/e companion hbk., pp 402–403.*) Persons with sickle-cell disease have functional asplenicism due to infarction. This results in impaired immune response to polysaccharide antigens, such as *Streptococcus pneumoniae*, *Haemophilus influenzae*, and *Neisseria meningitidis*. They are more susceptible to invasive *Salmonella* infection, which is often not preceded by enteric symptoms. Localization of a systemic infection often results in osteomyelitis. Persons with sickle cell disease are also more susceptible to malaria.

**8-25. The answer is a.** (*Behrman, 16/e, pp 1191–1193. McMillan, 3/e, pp 1711–1712. Rudolph, 20/e, pp 1120–1121.*) The causes of pancreatitis in children are varied, with about one-fourth of cases without predisposing etiology and about one-third as a feature of another systemic disease. Traumatic cases are usually due to blunt trauma to the abdomen. Acute pancre-

atitis is difficult to diagnose; a high index of suspicion is necessary. Common clinical features include severe pain with nausea and vomiting. Tenderness, guarding, rebound pain, abdominal distension, or paralytic ileus are signs and symptoms often seen. No diagnostic test is completely accurate. An elevated total serum amylase with the correct clinical history and signs and symptoms is the best diagnostic tool. Plain films of the abdomen exclude other diagnoses; ultrasonography of the pancreas can reveal enlargement of the pancreas, gallstones, cysts, and pseudocysts. Supportive care is indicated until the condition resolves.

**8-26. The answer is c.** (*Schwartz, 7/e, pp 494–496.*) Because of the ease with which carbon dioxide diffuses across the alveolar membranes,  $\text{Pa}_{\text{CO}_2}$  is a highly reliable indicator of alveolar ventilation. In this postoperative patient with respiratory acidosis and hypoxemia, the hypercarbia is diagnostic of alveolar hypoventilation. Acute hypoxemia can occur with pulmonary embolism, pulmonary edema, and significant atelectasis, but in all those situations the  $\text{CO}_2$  partial pressures should be normal or reduced as the patient hyperventilates to improve oxygenation. The absorption of gas from the peritoneal cavity may transiently affect the  $\text{Pa}_{\text{CO}_2}$ , but should have no effect on oxygenation.

**8-27. The answer is b.** (*Fauci, 14/e, p 2102.*) The patient is presenting with symptoms of normal menopause, which may include hot flashes, urinary frequency, dysuria, urinary incontinence, vaginal dryness, vaginal itchiness, and dyspareunia. Patients also have amenorrhea. Patients may become anxious or depressed during this time, but there is no evidence that personality or mood changes are due to menopause.

**8-28. The answer is c.** (*Fauci, 14/e, p 1705. Tierney 39/e, p 675.*) Patients with cirrhosis may have erythema of the palms, spider angiomas, decreased body hair, gynecomastia, testicular atrophy or menstrual irregularities, and parotid and lacrimal gland enlargement. Many of these changes are due to hormonal disturbances (the production of estrogen). Patients with cirrhosis may also have clubbing of the fingers. Portal hypertension may cause caput Medusae (prominent abdominal vasculature), splenomegaly, and ascites. Patients may have jaundice and signs of hepatic encephalopathy (asterixis). The Child classification is a factor that determines survival in patients with end-stage liver disease; the patient described most likely has Child class C cirrhosis (6-mo survival of 50%).

	<b>Child Class A</b>	<b>Child Class B</b>	<b>Child Class C</b>
Bilirubin	<2.0	2.0–3.0	>3.0
Albumin	>3.5	3.0–3.5	<3.0
Ascites	None	Easily controlled	Not controlled
Neurologic	None	Minimal	Advanced (coma)
Nutrition	Excellent	Good	Wasting

**8-29. The answer is c.** (*Mishell, 3/e, pp 198–202.*) Although all the procedures mentioned in the question can be helpful in establishing a case of rape in most situations, the expected lack of sperm and the matching blood types in the situation presented would limit their value in this case. Only the finding of 50 U/mL or more of acid phosphatase in this woman's vagina could be taken as evidence of ejaculation. Her introitus probably would not be injured because of her parity. Foreign pubic hair might only indicate close contact.

**8-30. The answer is a.** (*Lewis, 2/e, pp 676–678.*) Separation anxiety disorder is characterized by manifestations of distress when the child has to be separated from loved ones. The distress often leads to school refusal, refusal to sleep alone, multiple somatic symptoms, and complaints when the child is separated from loved ones, and at times may be associated with full-blown panic attacks. The child is typically afraid that harm will come either to loved ones or to him- or herself during the time of separation.

**8-31. The answer is d.** (*Tierney, 39/e, pp 1104–1106.*) Symptoms of hypothyroidism include constipation, depression, edema, tongue thickening, cold intolerance, Queen Anne sign (missing lateral one-third of eyebrows), muscle cramps, weight gain, goiter, amenorrhea, galactorrhea, pleural effusion, pericardial effusion, cardiomegaly, bradycardia, hypothermia, hyponatremia, anemia, and hypertension. Patients are said to have hung-up reflexes (a prolonged relaxation phase). Amiodarone has a high iodine content and causes hypothyroidism in 8% of patients. Myxedema is a rare complication of hypothyroidism; patients present with coma, severe hypotension, hypothermia, hypoventilation, and hypoxemia. Cretinism is congenital (infantile) hypothyroidism.

**8-32. The answer is d.** (*Ransom, pp 53–54.*) Condyloma acuminatum is a sexually transmitted disease caused by the human papillomavirus (HPV). For many years, application of podophyllum was the treatment of choice

for vulvar warts. Because podophyllum can produce peripheral neuropathy, bone marrow depression, and occasionally death, most physicians recommend the application of trichloroacetic acid to the vulva; however, because of systemic absorption, neither medication should be applied to extensive vaginal lesions. Laser surgery and cryotherapy result in high recurrence rates because of the difficulty of reaching all areas of the vagina. Since the vaginal condylomas are generally flat, optimal medical management includes the topical application of 5% 5-fluorouracil cream.

**8-33. The answer is d.** (*Adams, 6/e, p 1486.*) Malignant hyperthermia is characterized by acute severe fever, tachypnea, tachycardia, and rigidity, and high mortality rate if left untreated. It is typically precipitated by volatile anesthetics, especially halothane, or muscle relaxants such as succinylcholine. Patients may become severely acidotic and develop rhabdomyolysis. Pathology shows diffuse segmental muscle necrosis. It appears to be a metabolic myopathy, in which there is abnormal release of calcium from the sarcoplasmic reticulum and ineffectual uptake afterward. Genetic defects in the ryanodine receptor, involved in calcium flux in the sarcoplasmic reticulum, are responsible for about 10% of cases, although as yet unidentified abnormalities of this or related proteins probably play a role in most cases. It is inherited in an autosomal dominant fashion. Certain other myopathies, including Duchenne muscular dystrophy and central core myopathy, are associated with this condition as well. Treatment consists of discontinuation of anesthesia, administration of dantrolene, which prevents release of calcium from the sarcoplasmic reticulum, and supportive measures.

**8-34. The answer is c.** (*Alexander, 9/e, pp 885–886.*) Paroxysmal supraventricular tachycardia typically displays a narrow QRS complex without clearly discernable P waves, with rate in the range of 160 to 190 beats/min. The rate is faster in atrial flutter. Atrial fibrillation would show an irregularly irregular rate. Wide QRS complexes would be expected in ventricular tachycardia.

**8-35. The answer is c.** (*Behrman, 16/e, pp 910–914. McMillan, 3/e, pp 951–953, 2160–2162. Rudolph, 20/e, pp 582–583.*) Lyme disease, caused by the spirochete *Borrelia burgdorferi* and transmitted mostly by ticks of the ioxodes family, is characterized by a unique skin lesion, recurrent attacks of

arthritis, and occasional involvement of the heart and central nervous system. Illness usually appears in late summer or early fall, 2 to 30 days after a bite by an infecting tick. Erythema chronicum migrans begins as a red macule, usually on the trunk at the site of tick attachment, that enlarges in a circular fashion with central clearing. Nonspecific systemic signs include headache, fever, and malaise. Joint involvement generally occurs days to years after onset of the rash. Cardiac disease consists primarily of disturbances of rhythm. Involvement of the central nervous system is evidenced by headache and stiff neck. The diagnosis should be suspected when any of the signs and symptoms occur, because the disease can present in an atypical manner. The characteristic lesion of erythema chronicum migrans as well as the history of tick bite are frequently not noted by the patient. It is not until late joint, heart, or neurologic manifestations occur, and Lyme disease is suspected, that serologic evidence confirms the etiology. Serologic evidence is sought when the patient has spent time in summer months in endemic areas or there is a risk of tick bite. Treatment with penicillin or tetracycline results in a faster resolution of symptoms and prevention of later complications, especially if given early in the course of the disease.

**8-36. The answer is b.** (*Adams, 6/e, p 1212.*) Acute poisoning with arsenic may cause tonic-clonic seizures or a less dramatic encephalopathy. Hemolysis may be substantial and mucosal irritation evident. Death may develop with circulatory collapse if the dose of arsenic is substantial enough. The polyneuropathy that develops with chronic poisoning is resistant to treatment with chelating agents, such as BAL. If the patient survives the poisoning, peripheral nerve damage resolves over the course of months or years.

**8-37. The answer is a.** (*Fauci, 14/e, pp 1182–1185.*) Chloroquine-resistant malaria is an increasing problem, and *Plasmodium vivax* and falciparum malaria may be multidrug resistant. Because of the increasing spread and intensity of plasmodium resistance, the Centers for Disease Control and Prevention recommends a weekly dose of mefloquine for all travelers. Chemoprophylaxis is never entirely reliable, and malaria must always be considered in the differential diagnosis of fever in patients who have traveled to endemic areas. Trypanosomiasis, caused by the protozoan *Trypanosoma cruzi*, is a parasitic illness found only in the Americas. Patients

present with the Romaña sign (unilateral and painless edema of the periocular tissues) and cardiomyopathy (Chagas disease). Patients with toxoplasmosis who are immunocompetent are generally asymptomatic and have self-limiting disease.

**8-38. The answer is b.** (*DSM-IV, 4/e, pp 292–296.*) Schizoaffective disorder is characterized by depressive or manic episodes superimposed on symptoms of chronic schizophrenia. This patient experienced a persistence of psychotic symptoms in the absence of prominent affective symptoms and consequently fits the criteria for a diagnosis of schizoaffective disorder. Although affective symptoms may be present in schizophrenia, they are not prominent. In psychotic depression, psychotic symptoms are always associated with prominent affective symptoms. Delusional disorder is characterized by one or two nonbizarre, well-organized delusions and is not accompanied by significant mood disturbances.

**8-39 through 8-40. The answers are 8-39 e, 8-40 e.** (*Schwartz, 7/e, pp 1646–1649.*) This patient presents with the symptoms of a pheochromocytoma. These tumors can initially become symptomatic during pregnancy. A noninvasive workup should be performed. Ultrasonography of the abdomen is frequently sufficient to localize the tumor to the right or left adrenal; an abdominal computed tomography (CT) scan with its large dose of radiation should be avoided in pregnancy. The treatment can be early excision of the pheochromocytoma, and in three cases in pregnant women this was done with survival of two of the three infants. A therapeutic abortion, especially at 18 wk, is not indicated, and cesarean section would not produce a viable fetus. The current approach is  $\alpha$ - and  $\beta$ -adrenergic blockade followed by vaginal delivery or cesarean section with excision of the tumor at the same time as delivery or electively after delivery. Metyrosine (Demser) inhibits tyrosine hydroxylase and results in a decrease in endogenous levels of catecholamines. This form of treatment, coupled with term delivery, is also acceptable.

**8-41. The answer is e.** (*Adams, 6/e, p 1070.*) Essential tremor comes on during action and remits when the limb is relaxed, unlike the tremor of Parkinson's disease. It often affects the head as well as the arms, also unlike Parkinson's disease. Patients are often very disturbed by the tremor, particularly as it leads to a great deal of social embarrassment. There is no asso-

ciated slowness of activity (bradykinesia), rigidity, or cognitive disturbance. Patients frequently report improvement with ingestion of alcohol, to the extent that some patients may resort to use of alcohol on a chronic basis to reduce their symptoms. Although it is often referred to as familial tremor, there is some disagreement on this point since it may simply be the case that patients with the condition are more likely to refer relatives for evaluation. Beta blockers and primidone may be used to treat this condition.

**8-42. The answer is e.** (*Speroff, 6/e, pp 392–403.*) These gonadotropin-releasing hormone (GnRH) results and luteinizing hormone (LH) pulses are seen in normal puberty. Normal signs of puberty involve breast budding (thelarche, 9.8 years), pubic hair (pubarche, 10.5 years), and menarche (12.8 years). Besides an increase in androgens and a moderate rise in follicle-stimulating hormone (FSH) and LH levels, one of the first indications of puberty is an increase in the amplitude and frequency of nocturnal LH pulses. In patients with idiopathic true precocious puberty, the pituitary response to luteinizing hormone–releasing hormone (LHRH) is identical to that in girls undergoing normal puberty. Iatrogenic sexual precocity (i.e., the accidental ingestion of estrogens), premature thelarche, and ovarian tumors are examples of sexual precocity independent of LH function.

**8-43. The answer is e.** (*Fauci, 14/e, p 463.*) Anorexia occurs predominantly in females, and begins either before or shortly after puberty. Binge eating may occur, although it is uncommon and more closely associated with bulimia. Weight is decreased in anorexia, whereas it is near normal in bulimia. Ritualized exercise is usual in anorexia, but not in bulimia. Amenorrhea is always present in anorexia because of weight loss. Antisocial behavior is more frequently associated with bulimia than with anorexia, and the depression in bulimia tends to be more severe than in anorexia, making suicide a definite risk.

**8-44. The answer is d.** (*Schwartz, 7/e, pp 1244–1246.*) Carcinoid tumors arise from the neuroectoderm and are a type of apudoma. The most common site of carcinoid tumors is the small bowel, although appendiceal carcinoids are also common. Carcinoid syndrome, which is characterized by flushing, diarrhea, and cardiac valvular disease, occurs in a small percentage of patients with carcinoid tumors; it is rarely seen with appendiceal carcinoids. It occurs when serotonin is released into the systemic circulation

and thus avoids breakdown by the liver. The appropriate therapy for a small carcinoid (less than 2 cm) of the appendix is simple appendectomy.

**8-45. The answer is a.** (*Fauci, 14/e, pp 713–717.*) The onset of multiple myeloma is usually insidious with weakness and fatigue. Pain caused by bone involvement, anemia, renal insufficiency, and bacterial pneumonia often follow. This patient presented with fatigue and bone pain and then developed bacterial pneumonia probably secondary to *Streptococcus pneumoniae*, an encapsulated organism for which antibodies to the polysaccharide capsule are not adequately produced by the myeloma patient. There is also evidence for renal insufficiency. Hypercalcemia is frequently seen in patients with multiple myeloma and may be life threatening.

**8-46. The answer is b.** (*Fauci, 14/e, pp 713–717.*) Definitive diagnosis is made by demonstrating >10% plasma cells in bone marrow. None of the other findings are specific enough for definitive diagnosis. Renal biopsy would not be helpful.

**8-47. The answer is a.** (*Behrman, 16/e, pp 1520–1522. McMillan, 3/e, pp 1477–1479, 1488, 1490–1491, 1493–1507, 2162–2165, 2176–2177. Rudolph, 20/e, pp 486–489, 497, 1241–1242, 1271–1275.*) The mean age of presentation of immune thrombocytopenic purpura (ITP) is 6 years. Patients look well except for petechial rash. Patients with acute lymphoblastic leukemia frequently have symptoms of pallor and fever in addition to bleeding. Nearly 50% have hepatomegaly and splenomegaly. CBC reveals anemia, leukocytosis or leukopenia, and thrombocytopenia. DIC is secondary to a severe underlying disease, such as fulminant bacterial sepsis with hypotension or profound hypoxia. Patients invariably appear ill and have leukocytosis, thrombocytopenia, and abnormal coagulation studies [e.g., prolonged prothrombin time (PT) and partial thromboplastin time (PTT)], decreased fibrinogen concentration, and elevated fibrin split products). Patients with Henoch-Schönlein purpura have symptoms of skin rash and abdominal or joint pain. The rash is usually urticarial and purpuric and is present over the buttocks or lower extremities. The platelet count is normal or elevated. Systemic lupus erythematosus (SLE) is very rare in 3-year-old children. Findings include fever, joint pain, and skin rash. CBC can reveal anemia, leukopenia, and thrombocytopenia.



**8-48. The answer is e.** (*Behrman, 16/e, pp 974, 977, 1088. McMillan, 3/e, pp 436–437. Rudolph, 20/e, pp 684–686.*) Varicella-zoster immunoglobulin (VZIG) should be administered to the infant immediately after delivery if the mother experienced the onset of varicella within 5 days prior to delivery, and immediately upon diagnosis if her chickenpox started within 2 days after delivery. If untreated, about half of these infants will develop serious varicella as early as 1 day of age. If a normal full-term newborn is exposed to chickenpox 2 or more days postnatally, VZIG and isolation are not necessary because these babies appear to be at no greater risk for complications than older children. Acyclovir is not approved for use in early infancy.

**8-49. The answer is c.** (*Rosner, 5/e, ch 13.5, pp 603–605; ch 13.4, pp 592–594.*) Since the crude and the gender-adjusted relative risks are the same, we can conclude that gender is not a confounder (using the change-in-estimate definition of confounding). However, the relative risk for men is different than for women. We conclude that gender is an effect modifier. Effect modification is a different concept than confounding. Confounding is a nuisance factor that needs to be eliminated because it causes a distortion of the results, simply because the factor in question is distributed unevenly in exposed and unexposed individuals. Effect modification provides important information: the magnitude of the effect of a particular exposure on the outcome will vary according to the presence of a third factor—in this case, gender. It is not related to the fact that there may be more men than women in one group or another. A third factor can be both a confounder and an effect modifier if the adjusted risk differs from the crude risk, in addition to having different risks in women and in men. It may be neither a confounder nor an effect modifier if the adjusted and crude risks are the same and if the rates in men and women are the same. Finally, it could be only a confounder if the crude and adjusted risks differ, but the rates between men and women are the same. Stratification can be used to evaluate both confounding and effect modification: it will eliminate confounding and describe effect modification.

**8-50. The answer is c.** (*Sadock, 7/e, p 1007.*) Cocaine inhibits the normal reuptake of norepinephrine and dopamine, causing an increase of the concentration of these neurotransmitters in the synaptic cleft. This mechanism is responsible for the euphoria and sense of well-being that follow cocaine

use, but it also causes excessive sympathetic activation and diffuse vasoconstriction. High blood pressure, mydriasis, cardiac arrhythmias, coronary artery spasms, and myocardial infarcts are all seen with cocaine intoxication. Other toxic effects of cocaine include headaches, ischemic cerebral and spinal infarcts, subarachnoid hemorrhages, and seizures. Intoxications with PCP, cannabinoids, opiates, and LSD present with different symptoms and signs.

# BIBLIOGRAPHY

---

- ADAMS RA, VICTOR M, ROPPER AH (eds): *Principles of Neurology*, 6th ed. New York, McGraw-Hill, 1997.
- ADASHI EY, ROCK JA, ROSENWAKS Z (eds): *Reproductive Endocrinology, Surgery, and Technology*, vols. 1 & 2. Philadelphia, Lippincott-Raven, 1996.
- ALEXANDER RW, SCHLANT RC, FUSTER V, et al (eds): *Hurst's The Heart*, 9th ed. New York, McGraw-Hill, 1998.
- AMERICAN PSYCHIATRIC ASSOCIATION: *Diagnostic and Statistical Manual of Mental Disorders (DSM-IV)*, 4th ed. Washington, DC, American Psychiatric Press, 1994.
- BARNETT HJM, MOHR JP, STEIN BM, YATSU F (eds): *Stroke: Pathophysiology, Diagnosis, and Management*, 4th ed. New York, Churchill-Livingstone, 1998.
- BEHRMAN RE, KLEGMAN RM, JENSON HB: *Nelson's Textbook of Pediatrics*, 16th ed. Philadelphia, Saunders, 2000.
- BERG BO: *Principles of Child Neurology*. New York, McGraw-Hill, 1996.
- BRADLEY W, DAROFF RB, FENICHEL GM, MARSDEN CD (eds): *Neurology in Clinical Practice*, 3d ed. Boston, Butterworth-Heinemann, 2000.
- CAMERON JL: *Current Surgical Therapy*, 5th ed. St. Louis, Mosby, 1995.
- CARR BR, BLACKWELL RE (eds): *Textbook of Reproductive Medicine*. East Norwalk, CT, Appleton & Lange, 1993.
- CASS, AS: Renovascular injuries from external trauma: Diagnosis, treatment, and outcome. *Urol Clin North Am* 16:213–220, 1989.
- CENTERS FOR DISEASE CONTROL: MMWR 1991; 40 (No. RR-12).
- CENTERS FOR DISEASE CONTROL: Prevention and treatment of tuberculosis among patients infected with HIV: Principles of therapy and revised recommendations. MMWR 1998; 47 (No. RR-20).
- CENTERS FOR DISEASE CONTROL: Human rabies prevention—United States, 1999: Recommendations of the Advisory Committee on Immunization Practices (ACIP). MMWR 1999; 48 (No. RR-1).
- CHIN J: *Control of Communicable Diseases Manual*, 17th ed. Washington, DC, American Public Health Association, 2000.
- COFFEY CE, BRUMBACK RA (eds): *American Psychiatric Press Textbook of Pediatric Neuropsychiatry*. Washington, DC, American Psychiatric Press, 1998.

- CRENSHAW TL, GOLDBERG JP: *Sexual Pharmacology: Drugs that Affect Sexual Function*. New York, Norton, 1996.
- CUNNINGHAM FG, MACDONALS PC, GANT NF, et al: *Williams Obstetrics*, 20th ed. Stamford, CT, Appleton & Lange, 1997.
- DECHERNEY AH, PERNOLL ML: *Current Obstetric and Gynecologic Diagnosis and Treatment*, 8th ed. East Norwalk, CT, Appleton & Lange, 1994.
- DISAIA PJ, CREASMAN WT (eds): *Clinical Gynecologic Oncology*, 5th ed. St. Louis, Mosby, 1997.
- THE EUROPEAN MODE OF DELIVERY COLLABORATION: Elective caesarian-section versus vaginal delivery in prevention of vertical HIV-1 transmission: A randomized clinical trial. *Lancet* 353:1035–1039, 1999.
- EXPERT PANEL ON DETECTION, EVALUATION, AND TREATMENT OF HIGH BLOOD CHOLESTEROL IN ADULTS: Summary of the second report of the national Cholesterol Education Program (NCEP) expert panel on detection, evaluation, and treatment of high blood cholesterol in adults (adult treatment panel II). *JAMA* 269:3018–3023, 1993.
- FAUCI AS, BRAUNWALD E, ISSELBACHER KJ, WILSON JD, et al (eds): *Harrison's Principles of Internal Medicine*, 14th ed. New York, McGraw-Hill, 1998.
- FAUCI AS, BRAUNWALD E, ISSELBACHER KJ, et al (eds): *Harrison's Principles of Internal Medicine*, 14th ed. Companion Handbook. New York, McGraw-Hill, 1998.
- FITZPATRICK TB, JOHNSON RA, WOLFF K, POLANO MK, SUURMOND D: *Color Atlas and Synopsis of Clinical Dermatology*, 3d ed. New York, McGraw-Hill, 1997.
- FREEDBERG IM, EISEN AZ, WOLF K (eds): *Fitzpatrick's Dermatology in General Medicine*, 5th ed. New York, McGraw-Hill, 1999.
- GLEICHER N, et al (eds): *Principles and Practice of Medical Therapy in Pregnancy*, 3d ed. Stamford, CT, Appleton & Lange, 1998.
- GOLDMAN L, BENNETT JC. *Cecil Textbook of Medicine*, 21st ed. Philadelphia, Saunders, 2000.
- GREENBERG RS, DANIELS SR, FLANDERS WD, et al: *Medical Epidemiology*, 2d ed. Stamford, CT, Appleton & Lange, 1996.
- GREENFIELD L, et al (eds): *Surgery: Scientific Principles and Practice*, 2d ed. Philadelphia, Lippincott-Raven, 1997.
- HAJJ SN, EVANS WJ (eds): *Clinical Postreproductive Gynecology*. East Norwalk, CT, Appleton & Lange, 1993.
- HALES RE, YUDOFKY SC, TALBOTT JA (eds): *American Psychiatric Press Textbook of Psychiatry*, 3d ed. Washington, DC, American Psychiatric Press, 1999.

- HENNEKENS CH, BURING JE: *Epidemiology in Medicine*. Boston, Little, Brown, 1987.
- HOGAN MJ, WALLIN JD, BAER RM, et al: Antihypertensive therapy and male sexual dysfunction. *Psychosomatics* 21:234–237, 1980.
- HOLMES KK, SPARLING PF, MARDH PE, et al (eds): *Sexually Transmitted Diseases*, 3d ed. New York, McGraw-Hill, 1999.
- HOSKINS WJ, PEREZ CA, YOUNG RC (eds): *Principles and Practice of Gynecologic Oncology*, 2d ed. Philadelphia, Lippincott, 1997.
- HURST JW: *Medicine for the Practicing Physician*, 4th ed. Stamford, CT, Appleton & Lange, 1996.
- INGELFINGER J, MOSTELLER F, THIBODEAU LA, WARE JH: *Biostatistics in Clinical Medicine*, 3d ed. New York, McGraw-Hill, 1994.
- KURMAN RJ (ed): *Blaustein's Pathology of the Female Genital Tract*, 4th ed. New York, Springer-Verlag, 1994.
- LADOU J: *Occupational and Environmental Medicine*, 2d ed. Stamford, CT, Appleton & Lange, 1997.
- LEWIS M (ed): *Child and Adolescent Psychiatry: A Comprehensive Textbook*, 2d ed. Baltimore, Williams & Wilkins, 1996.
- LOBO RA (ed): *Treatment of the Postmenopausal Woman*, 2d ed. Philadelphia, Lippincott, Williams & Wilkins, 1999.
- LUDMAN H: *ABC of Otolaryngology*, 4th ed. London, UK: BMJ Publishing Group, BMA House, 1997.
- MCMILLAN JA, DEANGELIS CD, FEIGIN RD, WARSHAW JB: *Principles and Practice of Pediatrics*, 3d ed. Philadelphia, Lippincott, 1999.
- MEHTA AJ: *Common Musculoskeletal Problems*. Philadelphia, Hanley & Belfus, 1997.
- MISHELL DR, STENCHEVER MA, DROEGMEULLER W, HERBST AL (eds): *Comprehensive Gynecology*, 3d ed. St. Louis, Mosby, 1997.
- MOORE KL: *Clinically Oriented Anatomy*, 3d ed. Baltimore, Williams & Wilkins, 1992.
- NICHOLS DH (ed): *Gynecologic and Obstetric Surgery*. St. Louis, Mosby, 1993.
- OSBORN AG: *Diagnostic Neuroradiology*. St. Louis, Mosby, 1994.
- PARAN TV. The physician's role in smoking cessation. *J Respiratory Diseases* 19(5): S6–12, 1998.
- PATTEN J: *Neurological Differential Diagnosis*, 2d ed. London, Springer-Verlag, 1996.
- PODOLOSKY DK: Inflammatory Bowel Disease. *N Engl J Med* 325:928–937, 1991.

- POZGAR GD: *Legal Aspects of Health Care Administration*, 7th ed. Rockville, MD, Aspen, 1998.
- RANSOM SB, MCNEELEY SG (eds): *Gynecology for the Primary Care Provider*. Philadelphia, Saunders, 1997.
- REECE EA, et al (eds): *Medicine of the Fetus and Mother*, 2d ed. Philadelphia, Lippincott, 1999.
- ROCK JA, THOMPSON JD (eds): *TeLinde's Operative Gynecology*, 8th ed. Philadelphia, Lippincott-Raven, 1997.
- ROSNER B: *Fundamentals of Biostatistics*, 5th ed. Pacific Grove, CA, Duxbury, 2000.
- ROWLAND LP (ed): *Merritt's Textbook of Neurology*, 9th ed. Baltimore, Williams & Wilkins, 1995.
- RUDOLPH AM, HOFFMAN JIE, RUDOLPH CD: *Rudolph's Pediatrics*, 20th ed. Stamford, CT, Appleton & Lange, 1996.
- SABISTON DC JR, et al (eds): *Surgery: The Biological Basis of Modern Surgical Practice*, 15th ed. Philadelphia, Saunders, 1997.
- SADOCK BJ, SADOCK VA (eds): *Kaplan and Sadock's Comprehensive Textbook of Psychiatry*, 7th ed. Philadelphia, Lippincott Williams & Wilkins, 2000.
- SAPIRA JD: *The Art and Science of Bedside Diagnosis*. Baltimore, Williams & Wilkins, 1990.
- SCHATZBERG AF, NEMIROFF CB (eds): *American Psychiatric Press Textbook of Psychopharmacology*, 2d ed. Washington, DC, American Psychiatric Press, 1998.
- SCHWARTZ SI, et al (eds): *Principles of Surgery*, 7th ed. New York, McGraw-Hill, 1993.
- SCHWESINGER WH: Is *Helicobacter pylori* a myth or the missing link? *Am J Surg* 172:4110417, 1996.
- SCOTT JR, et al (eds): *Danforth's Obstetrics and Gynecology*, 8th ed. Philadelphia, Lippincott-Raven, 1999.
- SEIDEL HM, BALL JW, DAINS JE, BENEDICT GW: *Mosby's Guide to Physical Examination*, 4th ed. St. Louis, Mosby, 1999.
- SHUAIB A, GOLDSTEIN LB (eds): *Management of Acute Stroke*. New York, Dekker, 1999.
- SILBERSTEIN SD, LIPTON RB, GOADSBY PJ: *Headache in Clinical Practice*. Oxford, Isis, 1998.
- SPEROFF L, GLASS RH, KASE NG (eds): *Clinical Gynecologic Endocrinology, and Infertility*, 6th ed. Baltimore, Lippincott, Williams & Wilkins, 1999.
- STEIN JH: *Internal Medicine*, 5th ed. Boston, Little, Brown, 1998.

- STOBO JD, HELLMAN DB, LADENSON PW, et al (eds): *The Principles and Practice of Medicine*, 23d ed. Stamford, CT, Appleton & Lange, 1996.
- TALLEY N, O'CONNOR S: *Clinical Examination*, 2d ed. Philadelphia, MacLennan & Petty, 1992.
- TIERNEY LM JR, MCPHEE SJ, PAPADAKIS MA: *Current Medical Diagnosis and Treatment*, 39th ed. New York, McGraw-Hill, 2000.
- TINTINALLI JE, KELEN GD, STAPCZNYSKI JS: *Emergency Medicine: A Comprehensive Study Guide*, 5th ed. New York, McGraw-Hill, 2000.
- US PREVENTIVE SERVICES TASK FORCE (USPSTF): *Guide to Clinical Preventive Services*, 2d ed. Baltimore, Williams & Wilkins, 1996.
- WALLACE RB, DOEBBELING BN, LAST JM, et al: *Maxcy-Rosenau-Last Public Health and Preventive Medicine*, 14th ed. Stamford, CT, Appleton & Lange, 1998.
- WALTERS HL, et al: Peritoneal lavage and the surgical resident. *Surg Gynecol Obstet* 165:496–502, 1988.
- WATTS RL, KOLLER WC (eds): *Movement Disorders: Neurologic Principles and Practice*. New York, McGraw-Hill, 1997.
- WEIR B: *Subarachnoid Hemorrhage: Causes and Cures*. New York, Oxford University Press, 1998.
- WYLLIE E: *The Treatment of Epilepsy: Principles and Practice*, 1st ed. Philadelphia, Lippincott, Williams & Wilkins, 1993.
- YUDOFKY SC, HALES RE (eds): *American Psychiatric Press Textbook of Neuropsychiatry*, 3d ed. Washington, DC, American Psychiatric Press, 1997.
- ZINNER MJ, et al (ed): *Maingot's Abdominal Operations*, 10th ed. Stamford, CT, Appleton & Lange, 1997.