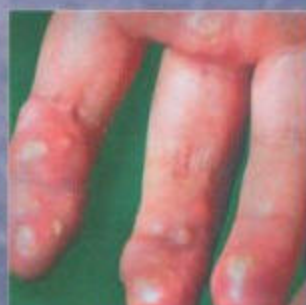
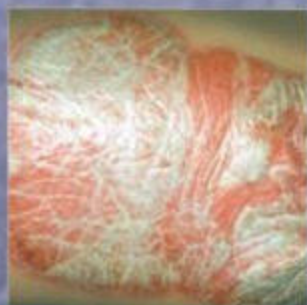
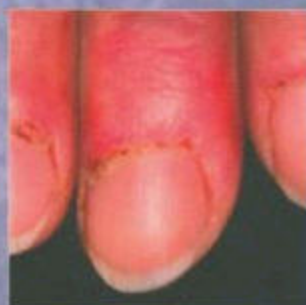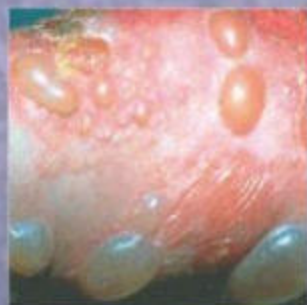# autoimmune diseases of the skin

pathogenesis, diagnosis, management  
second edition



 SpringerWienNewYork

Michael Hertl (ed.)

Autoimmune Diseases of the Skin

Pathogenesis, Diagnosis,  
Management

Second, revised  
and enlarged edition

SpringerWienNewYork

Prof. Michael Hertl, MD  
Department of Dermatology and Allergology, Philipps University,  
Marburg, Germany

This book was supported by *Gesellschaft für Autoimmun-Krankheiten e.V.*,  
Schönkirchen bei Kiel

This work is subject to copyright.  
All rights are reserved, whether the whole or part of the material is concerned, specifically  
those of translation, reprinting, re-use of illustrations, broadcasting, reproduction by photo-  
copying machines or similar means, and storage in data banks.

© 2001 and 2005 Springer-Verlag Wien · Printed in Austria  
SpringerWienNewYork is a part of Springer Science + Business Media  
springeronline.com

Product Liability: The publisher can give no guarantee for all the information contained  
in this book. This also refers to that on drug dosage and application thereof. In each indi-  
vidual case the respective user must check the accuracy of the information given by con-  
sulting other pharmaceutical literature. The use of registered names, trademarks, etc.  
in this publication does not imply, even in the absence of a specific statement, that such  
names are exempt from the relevant protective laws and regulations and therefore free for  
general use.

Cover illustration: M. Hertl  
Typesetting: Composition & Design Services, Minsk 220027, Belarus  
Printing: Druckerei Theiss GmbH, A-9431 St. Stefan im Lavanttal  
Printed on acid-free and chlorine-free bleached paper  
SPIN: 10975923

With 77 partly coloured Figures

Library of Congress Control Number: 2005920465

ISBN 3-211-20686-8 SpringerWienNewYork  
ISBN 3-211-83598-9 1<sup>st</sup> edition SpringerWienNewYork

## Foreword

Based on recent advances in the understanding of the immunological pathogenesis of many chronic inflammatory disorders there is increasing evidence that several of them are characterized and potentially mediated by autoimmune phenomena. Classical examples are rheumatoid arthritis, myasthenia gravis, pemphigus vulgaris, lupus erythematosus and multiple sclerosis. Others, such as psoriasis vulgaris, some less well-characterized collagen vascular disorders, vasculitides and a subtype of chronic urticaria have a more or less pronounced autoimmune background that has to be considered in the overall management of these disorders. A significant portion of autoimmune diseases precipitate primarily or secondarily at the skin. Understanding the cutaneous symptoms may be therefore crucial for the diagnosis, classification and therapeutic management of organ-specific and systemic disorders that require special attention by the physician.

This book is set out to present the most recent scientific and clinically relevant state-of-the-art-knowledge on the broad spectrum of autoimmune disorders affecting the skin. It is meant to provide the most recent information on these disorders for clinicians as well as practitioners in dermatology, medicine, rheumatology, ENT, pediatrics, ophthalmology, orthopedics etc and for basic scientists interested in human autoimmunity. Each book chapter dealing with a distinct cutaneous autoimmune disorder consists of an introduction focusing on the state of knowledge regarding pathogenesis and epidemiology followed by a practical guide how to identify and handle the particular disorder(s). Special attention is paid to genuine cutaneous autoimmune disorders such as autoimmune bullous skin disorders including pemphigus, pemphigoid and epidermolysis bullosa acquisita. These disorders can be considered as paradigms of organ-specific autoimmune disorders because autoantigens and autoantibody-mediated pathogenesis are well-characterized.

Major progress has been made in the diagnosis and classification of collagen vascular disorders such as systemic sclerosis, lupus erythematosus, dermatomyositis and overlap syndromes. These advances have provided the basis for more specific therapeutic interventions. Recent pathogenetic findings in psoriasis, lichen planus and chronic urticaria have led to novel therapeutic concepts that will replace the "classical" symptomatic treatments that have been established for decades. One striking example is the therapeutic effect of biologics in severe psoriasis vulgaris and psoriatic arthritis and the

modulatory effect of high dose immunoglobulins in dermatomyositis and severe vasculitides. In addition to the book chapters on distinct clinical cutaneous disorders, the introductory chapter explains basic immunological principles leading to autoimmunity and the final chapter gives an overview of the mode of action of novel immunomodulatory drugs. The present book which is edited by my co-worker Dr. Michael Hertl is set out to combine major scientific advances in the understanding of autoimmunity with the clinical presentation and management of these disorders. I am convinced that the book constitutes a very successful effort to provide a handbook for those who are scientifically or clinically interested in autoimmune disorders of the skin. I wish the editor and the authors success with this endeavor.

Erlangen, July 2001

*Gerold Schuler*

## Preface to the First Edition

Hundred years ago, Paul Ehrlich speculated whether an individual is able to produce toxic autoantibodies and about the implications of such antibodies for disease. The contention that an alteration of the body fluids causes disease followed the traditional teachings of Hippocrates and Galen that disease results from dysfunction of the four humors. However, Ehrlich introduced the novel concept of antigen specificity that was based on his side chain theory of antibody formation: (1) antibodies are naturally occurring substances that serve as receptors on the cell surface; (2) the specificity of antibody for antigen is determined by a unique stereochemical configuration of atoms that permits the antibody to bind tightly and chemically to its appropriate antigen; (3) the number of different combining sites structures available is so great that each one differs from the others, with little or no cross reactivity among them; (4) and in order to induce active antibody formation, it is only necessary that appropriate receptors be present on the cells for antigen to interact with them and so stimulate their overproduction and liberation into the blood. According to this description by Paul Ehrlich, the antibody appeared to be a polymorphous cytoplasmic agent with a unique feature – a highly organized combining site (the haptophore group) that determined its unique antigen specificity.

It was Bordet who showed that anti-erythrocyte antibodies were capable of mediating immune hemolysis giving rise to the idea that self-produced hemolytic antibodies might assist in destroying autologous erythrocytes.

This and similar findings including the description of cytotoxic antibodies against a variety of other cell types prompted Ehrlich to say: "... the organism possesses certain contrivances by means of which the immunity reaction, so easily produced by all kinds of cells, is prevented from acting against the organism's own elements and so giving rise to autotoxins ... so that we might be justified in speaking of a 'horror autotoxicus' of the organism. These contrivances are naturally of the highest importance for the individual" (P. Ehrlich and J. Morgenroth, Berlin. Klin. Wochenschr., 1901).

When Metalnikov was the first to demonstrate the generation of autoantibodies that were cytotoxic against spermatozoa *in vitro*, Ehrlich questioned that they were able to induce pathology *in vivo*.

It took, however, more than forty years that some distinct organ-specific immune disorders were categorized as true autoimmune diseases. Among the first identified were autoimmune orchitis, allergic encephalomyelitis, autoimmune

thyroiditis, pemphigus vulgaris and bullous pemphigoid. Noteworthy, some of these disorders are exclusively mediated by circulating autoantibodies such as the hemolytic anemias, thrombocytopenia, pemphigus, and pemphigoid while others, such as allergic autoimmune encephalomyelitis and autoimmune thyroiditis require the transfer of immunocompetent cells in addition to autoantibodies.

The existence of immunological tolerance was the logical consequence of Paul Ehrlich's postulate that there was a "horror autotoxicus" a mechanism that inhibited formation of potentially harmful autoantibodies to self *in vivo*. It was Owen to show that dizygotic calves whose circulation was connected *in utero* were unable to respond to each other's antigens after birth. Out of this and similar observations, the clonal deletion theory was invented by Burnet meaning that antigen present during embryonic life would somehow cause destruction of self-reactive clones. The observation that adult animals could be rendered unresponsive to foreign antigens by the administration of large doses of the antigen led to the notion that immunological tolerance could be also acquired.

The recognition of different central and peripheral immune mechanisms leading to immunological tolerance are all based on Ehrlich's concept of "horror autotoxicus", *i.e.* acquired or active immune regulation of unwanted immune responses against self. The finding that B lymphocytes generally require the help of T lymphocytes in their antibody response to a defined antigenic stimulus led to the discovery of distinct immune cell subsets including helper cells, cytotoxic cells and regulatory cells. The identification of the idiotype-anti idiotype network was born out of the discovery that the antigen binding site of the antibody itself can act as an antigen for anti-idiotypic antibodies. Anti-idiotypic immune responses are part of the physiological immune surveillance aimed at limiting the extent of an immune response.

The identification of different lineages of antigen presenting cells has taken away much attention from T lymphocytes as the exclusive regulators of immune and autoimmune responses. Major interest has recently focused on dendritic cells, bone marrow-derived antigen presenting cells with potent capacity to induce primary T-cell-mediated immune responses. However, accumulating evidence has demonstrated that the dendritic cell system bears much more plasticity than originally thought. Dendritic cells can arise from several different types of progenitor cells and different functional types of dendritic cells can be generated from the same precursor. It thus appears that dendritic cells have the potential to modulate immune responses within the wide spectrum of immunity on the one hand and immunological tolerance on the other hand.

The rapid development of immunological research has also provided major insights in the pathogenesis of autoimmune disorders which has implications for classification, diagnosis and therapy of these disorders. Classical examples for well-characterized autoimmune disorders are myasthenia gravis, pemphigus vulgaris, and hemolytic anemia. Furthermore, the availability of recombinant forms of the major autoantigens of these disorders has



provided critical tools to investigate autoimmunity versus immunological tolerance to these self proteins in affected patients and healthy individuals.

The increasing understanding of the mechanisms that lead to immunological tolerance to self and the role that HLA and non-HLA alleles play in antigen recognition by autoaggressive T cells may also lead to novel therapeutic strategies. Several clinical studies have sought to restore immunological tolerance to self by the administration of modified self peptides, such as the administration of altered peptide ligands of myelin proteins in multiple sclerosis. Immature dendritic cells hold great promise as highly efficient tools to induce immunological tolerance to defined self proteins or peptides as demonstrated in murine allograft rejection models. They may induce tolerance by inducing antigen-specific anergy of autoreactive T cells and/ or by the induction of regulatory T lymphocytes that inhibit the activation of autoaggressive T cells.

I am very grateful that internationally leading experts in the field of cutaneous autoimmune disorders spontaneously agreed to provide comprehensive and well-illustrated overviews of the major autoimmune disorders of the skin. It was truly fun to interact with all of them! In addition, I would like to acknowledge the support and efforts of Springer Verlag in making this kind of book possible. We hope that the concept of this book will indeed help to broaden the understanding of cutaneous autoimmune disorders for those working in the many clinical disciplines which are involved in the care of these patients. Finally, I thank my wife for her continuous support and her help and criticism during the development of this book.

Erlangen, July 2001

*Michael Hertl*

## **Preface to the Second Edition**

Thanks to the positive reception of the first edition of the book by the medical community both in Europe and in the USA, the present book has come to its second edition. All the chapters have been thoroughly revised and two new chapters on Vitiligo and Alopecia areata were included.

We hope that the present book will continue to provide state-of-the-art knowledge for those who are interested and clinically involved with autoimmune disorders of the skin.

The present edition of the book is dedicated to my clinical teacher, Professor Gerd-Klaus Steigleder, on the occasion of his 80th birthday.

Marburg, January 2005

*Michael Hertl*

# Contents

<i>List of Contributors</i> .....	XIII
1 Pathogenesis of Autoimmune Disease ( <i>Martin Röcken and Tilo Biedermann</i> ) .....	1
2 Epidemiology of Autoimmune Skin Disorders ( <i>Berthold Rzany and Niels Weller</i> ) .....	25
3 Autoimmune Bullous Skin Disorders	
3.1 Pemphigus ( <i>Michael Hertl</i> ) .....	45
3.2 Bullous Pemphigoid: Clinical Features, Diagnostic Markers, and Immunopathogenic Mechanisms ( <i>Emmanuel Laffitte and Luca Borradori</i> ).....	71
3.3 Dermatitis Herpetiformis Duhring ( <i>Christian Rose and Detlef Zillikens</i> ) .....	95
3.4 Epidermolysis Bullosa Acquisita ( <i>Mei Chen, Daina Hallel-Halevy, Celina Nadelman and David T. Woodley</i> ) .....	109
4 Scleroderma	
4.1 Localized Scleroderma ( <i>Catherine H. Orteu and Jan P. Dutz</i> ) .....	133
4.2 Progressive Systemic Scleroderma ( <i>Nicolas Hunzelmann and Thomas Krieg</i> ) .....	165
5 Lupus Erythematosus	
5.1 Chronic Cutaneous Lupus Erythematosus ( <i>Michael Sticherling</i> ) .....	183
5.2 Subacute Cutaneous and Systemic Lupus Erythematosus ( <i>Donna M. Pellowski, Jane E. Kihlslinger and Richard D. Sontheimer</i> ).....	203
6 Dermatomyositis ( <i>Jeffrey P. Callen</i> ) .....	229
7 Mixed Connective Tissue Disease ( <i>Reiji Kasukawa</i> ) .....	245
8 Sjogren's Syndrome ( <i>Robert I. Fox and Ichiro Saito</i> ).....	261
9 Psoriasis Vulgaris and Arthropathica ( <i>Jörg Christoph Prinz</i> ) .....	291
10 Chronic Urticaria as an Autoimmune Disease ( <i>Michihiro Hide and Malcolm W. Greaves</i> ) .....	309
11 Lichen Planus, Lichenoid Eruptions and Cutaneous Graft-Versus-Host-Reaction ( <i>Miklós Simon Jr.</i> ) .....	333
12 Small Vessel Vasculitides ( <i>Peter Lamprecht and Wolfgang L. Gross</i> ).....	349

13 Vitiligo ( <i>Karin U. Schallreuter</i> ) .....	367
14 Alopecia areata ( <i>Pia Freyschmidt-Paul, Kevin McElwee and Rolf Hoffmann</i> ).....	385
15 Novel Therapeutic Approaches in Autoimmune Skin Disorders ( <i>Sybille Thoma-Uszynski and Rüdiger Eming</i> ) .....	421
<i>Subject Index</i> .....	457

## List of Contributors

- Tilo Biedermann, MD  
Department of Dermatology and Allergology  
University of Tübingen  
Liebermeisterstraße 25  
72076 Tübingen  
Germany  
Tel.: 0049-70 71/ 29-8 45 74  
Fax: 0049-70 71/ 29-54 50  
e-mail: Tilo.Biedermann@med.uni-tuebingen.de
- Luca Borradori, MD  
Department of Dermatology  
Hôpital Cantonal Universitaire  
CH-1211 Geneve 14  
Switzerland  
Tel.: 0041-22 3789477  
Fax: 0041-22 3729450  
e-mail: luca.borradori@hcuge.ch
- Jeffrey P. Callen, MD  
Division of Dermatology  
University of Louisville  
310 East Broadway  
Louisville, KY 40202  
USA  
Tel.: 001-502 583 1749  
Fax: 001-502 583 3028  
e-mail: jefca@aol.com
- Mei Chen, PhD  
Division of Dermatology  
University of Southern California  
CRL-204, 1303 Mission Road  
Los Angeles, CA 90033  
USA  
Tel.: 323-224-7056  
Fax: 323-224-7679  
e-mail: chenm@hsc.usc.edu
- Jan Dutz, MD  
Division of Dermatology  
Faculty of Medicine  
University of British Columbia  
835 West 10th Ave.  
Vancouver BC, V5Z 4E8  
Canada  
Tel.: 001-604 875 4747  
Fax: 001-604 8736 9919  
e-mail: dutz@interchange.ubc.ca

- Rüdiger Eming, MD  
Department of Dermatology and Allergology  
Philipps University  
Deutschhausstraße 9  
35037 Marburg  
Germany  
Tel: 06421-28-62900  
Fax: 06421-28-62898  
e-mail: ruediger.eming@med.uni-marburg.de
- Robert I. Fox, MD, PhD  
Allergy and Rheumatology Clinic  
Scripps Memorial Hospital and Research Foundation  
9850 Genesee Ave, #860  
La Jolla, CA 92037  
USA  
Tel.: 001-858 457 2023  
Fax: 001-858 457 2721  
e-mail: bobfox@adnc.com
- Pia Freyschmidt-Paul, MD  
Department of Dermatology  
Philipp University  
Deutschhausstraße 9  
35033 Marburg  
Germany  
Tel.: 0049-64 21-286 29 44  
Fax: 0049-64 21-286 57 28  
e-mail: freyschm@mail.uni-marburg.de
- Malcolm Greaves, MD, PhD, FCRP  
Department of Medicine  
Faculty of Medicine UKM, HUKM  
Jalan Yaakob Latiff  
Bandar Tun Razak  
Cheras, 56000  
Kuala Lumpur, Malaysia  
Tel.: 603 970 2474  
Fax: 603 973 7829  
e-mail: mwatsong@hotmail.com
- Wolfgang L. Gross, MD  
Department of Rheumatology  
University of Lübeck  
Ratzeburger Allee 160  
23538 Lübeck  
Germany  
Tel.: 0049-451 5002368  
Fax: 0049-451 5003650  
e-mail: gross@medinf.mu-luebeck.de
- Dafna Hallel-Halevy, MD  
Department of Dermatology  
Soroka Medical Center  
Ben Gurion University of the Negev  
Bee-Sheva  
Israel  
Tel.: 00972-8-6400308  
Fax: 00972-8-6108606  
e-mail: dafnah@bgumail.bgu.ac.il

- Michael Hertl, MD  
Department of Dermatology and Allergology  
Philipps University  
Deutschhausstraße 9  
35037 Marburg  
Germany  
Tel: 06421-28-62900  
Fax: 06421-28-62898  
e-mail: hertl@med.uni-marburg.de
- Rolf Hoffmann, MD  
Dermaticum  
Kaiser-Joseph-Str. 262  
79098 Freiburg  
Germany  
Tel: 0761-383 7400  
Fax: 0761-383  
e-mail: rolf.hoffmann@dermaticum.de
- Nicolas Hunzelmann, MD  
Department of Dermatology  
University of Cologne  
J.-Stelzmann-Str. 9  
50924 Köln  
Germany  
Tel.: 0049-221 478-4517  
Fax: 0049-221 478-4538  
e-mail: nico.hunzelmann@uni-koeln.de
- Reiji Kasukawa, MD  
Institute of Rheumatic Diseases  
Ohta General Hospital Foundation  
5-25, Nakamachi  
Koriyama 963-8004  
Japan  
Tel.: 0081-24 925 0088  
Fax: 0081-24 931 1155  
e-mail: ohta-found@ohta-hp.or.jp
- Jane E. Kihlslinger, MD  
Medical College of Wisconsin  
8701 Watertown Plank Rd.  
Wauwatosa, WI 53213  
USA  
Tel.: 414-456-8296  
e-mail: jkihslin@mcw.edu
- Thomas Krieg, MD  
Department of Dermatology  
University of Cologne  
J.-Stelzmann-Str. 9  
50924 Köln  
Germany  
Tel.: 0049-221 478 4500  
Fax: 0049-221 478 4538  
e-mail: thomas.krieg@uni-koeln.de
- Emmanuel Laffitte, MD  
Service de Dermatologie et Vénérologie  
Centre Hospitalier Universitaire Vaudois (CHUV)  
CH-1011 Lausanne, Switzerland  
Tel: 0041-21-314 04 06  
Fax: 0041-21-314 03 92  
e-mail: Emmanuel.Laffitte@hospvd.ch

- Peter Lamprecht, MD  
Department of Rheumatology  
University of Lübeck  
Ratzeburger Allee 160  
D-23538 Lübeck  
Germany  
Tel.: 0049-451 5002368  
Fax: 0049-451 5003650  
e-mail: lamprecht@rheuma-zentrum.de
- Kevin J. McElwee Ph.D.  
Division of Dermatology  
University of British Columbia,  
835 West 10th Avenue, Vancouver, B. C., Canada  
Tel: 001-604-875-4747  
Fax: 001-604-875-4376  
e-mail: kevin@keratin.com
- Celina Nadelman, MD  
Division of Dermatology  
Keck School of Medicine  
University of Southern California  
Los Angeles, CA  
USA  
Tel.: 001-310 276 7624  
Fax: 001-310 276 7624  
e-mail: celina@nadelman.com
- Catherine H. Orteu, MD  
Department of Dermatology  
Royal Free Hospital  
Pond Street  
London NW3 2QG  
United Kingdom  
Tel.: 0044-20 7830 2351  
Fax: 0044-20 7830 2247  
e-mail: kateorteu@hotmail.com
- Donna M. Pellowski, MD,  
Department of Dermatology  
University of Arkansas for Medical Sciences (UAMS)  
4301 West Markham, Slot #576  
Little Rock, AR 72212  
USA  
Tel: 501-686-5110  
Fax: 501-686-7264  
e-mail: pellowskidonnam@uams.edu
- Jörg C. Prinz, MD  
Department of Dermatology and Allergology  
University of Munich (LMU)  
Frauenlobstr. 9–11  
80337 München  
Germany  
Tel.: 0049-89 5466481  
Fax: 0049-89 51606002  
e-mail: joerg.prinz@lrz.uni-muenchen.de
- Martin Röcken, MD  
Department of Dermatology and Allergology  
University of Tübingen  
Liebermeisterstr. 25  
72076 Tübingen  
Germany

Tel.: 0049-7071 298-4556  
Fax: 0049-7071 295-450  
e-mail: mrocken@med.uni-tuebingen.de

Christian Rose, MD

Department of Dermatology  
University of Lübeck  
Ratzeburger Allee 160  
23538 Lübeck  
Germany  
Tel.: 0049-451 500-2512  
Fax: 0049-451 500-2981  
e-mail: Christian.rose@derma.uni-luebeck.de

Berthold Rzany, MD, ScM

Division of Evidence Based Medicine (dEBM)  
Department of Dermatology  
Charité University Hospitals  
Schuhmannstr. 20/21  
10117 Berlin  
Germany  
Tel.: 0049-30 45518-263  
Fax: 0049-30 450518-927  
e-mail: berthold.rzany@charite.de

Ichiro Saito, MD

Department of Pathology  
Tsurumi University School of Dental Medicine  
2-1-3 Tsurumi, Tsurumi-ku  
Yokohama 230-8501  
Japan  
e-mail: saito-i@tsurumi-u.ac.jp

Karin Schallreuther, MD

Clinical and Experimental Dermatology  
Department of Biomedical Sciences  
University of Bradford  
Richmond Road  
Bradford/ West Yorkshire BD7 1DP  
United Kingdom  
Tel: 0044-1274-235527  
Fax: 0044-1274-235290  
e-mail: k.schallreuther@bradford.ac.uk

Miklòs Simon Jr, MD

Department of Dermatology  
University of Erlangen  
Hartmannstr. 14  
91052 Erlangen  
Germany  
Tel.: 0049-9131 853 2707  
Fax: 0049-9131 853 3854  
e-mail: simon@derma.med.uni-erlangen.de

Richard D. Sontheimer, MD

John S. Strauss Endowed Chair in Dermatology  
Department of Dermatology  
University of Iowa College of Medicine/Health Care  
200 Hawkins-Dr BT 2045-1  
Iowa City, IA 52242-1090  
USA  
Tel.: 001-319 356 3609



- Fax: 001-319 356 8317  
e-mail: richard-sontheimer@uiowa.edu
- Michael Sticherling, MD  
Department of Dermatology  
University of Leipzig  
Stephanstr. 11  
04103 Leipzig  
Germany  
Tel.: 0049-341 97 18720/721  
Fax: 0049-341 97 18609  
e-mail: sticm@medizin.uni-leipzig.de
- Sybille Thoma-Uszynski, MD  
Department of Dermatology  
University of Erlangen  
Hartmannstr. 14  
91052 Erlangen  
Germany  
Tel.: 0049-9131 8533164  
Fax: 0049-9131 8536175  
e-mail: Sybille.Thoma@derma.med.uni-erlangen.de
- Niels Weller, MD  
Department of Dermatology  
University of Heidelberg-Mannheim  
Theodor-Kutzer-Ufer 1-3  
68135 Mannheim  
Germany  
Tel.: 0049-621 383 2344  
Fax: 0049-621 383 732344  
e-mail: nielsweller@hotmail.com
- David Woodley, MD  
Division of Dermatology  
LAC and USC Medical Center  
8 th Floor General Hospital  
1200 North State Street  
Los Angeles, CA 90033  
USA  
Tel.: 001-213 717 2289 or 001-323 224 7056  
Fax: 001-323 336 2654  
e-mail: dwoodley@hsc.usc.edu
- Detlef Zillikens, MD  
Department of Dermatology  
University of Lübeck  
Ratzeburger Allee 160  
23538 Lübeck  
Germany  
Tel.: 0049-451 500-2510  
Fax: 0049-451 500-2981  
e-mail: Detlef.zillikens@derma.uni-luebeck.de

# 1 Pathogenesis of Autoimmune Disease

*Martin Röcken and Tilo Biedermann*

## **Autoimmunity and Autoimmune Disease**

The term autoimmunity signifies the presence of specific memory-type immune reactions that are directed against one or more self-epitopes. Under most conditions, autoimmunity is determined in terms of immunoglobulins that react with either unknown or well-defined human antigens. Today it is supposed that the production of these autoantibodies requires prior activation of potentially autoreactive B cells by memory T cells. These T cells must not only recognize a closely related peptide structure. Importantly, these T cells can stimulate B cells only when primed by activated antigen presenting cells.

Autoimmunity is a relatively frequent event. Most likely, any individual raises immune reactions against numerous self antigens. This autoimmunity leads only very rarely to overt autoimmune disease. Therefore, the development of autoimmune disease requires trespassing of a large number of additional security levels, beyond autoimmune reactivity (Schwartz 1998). This is illustrated by two frequent clinical phenomena: One of the best examples are antinuclear antibodies (ANA), which are found in even more than 50% of the female population older than 50 years. Compared to this frequency, ANA-associated autoimmune diseases are relatively rare and affect less than 2% (Rubin 1997). The other is that only very few autoimmune diseases progress continuously. Most of them progress during short waves of disease activity and in between these waves have long periods of quiescence. Since autoreactive T and B cells do normally not disappear during these periods of quiescence, a series of control mechanisms protect from manifest autoimmune disease.

## **T and B Cells**

T cells are small lymphocytes that are characterized by their antigen recognition structure, the T cell receptor (TCR). According to the current state of

knowledge, the TCR is only functional as a cell bound structure. Due to the low affinity for free peptide (Weber et al. 1992), the TCR recognizes only antigens that are presented by major histocompatibility complex (MHC) molecules. The TCR acts in concert with an array of additional surface structures. The most important are the co-receptors, the CD4 and CD8 molecules. The CD8 molecule determines the interaction of the TCR with MHC class I and the CD4 molecule with MHC class II. Appropriate activation of T cells requires a series of additional events, such as adhesion molecules and costimulatory molecules (reviewed in Biedermann et al. 2003).

B cells are characterized by the production of antigen recognition structures, the B cell receptor and immunoglobulins. They produce immunoglobulins mainly when stimulated appropriately through T-B-cell interactions (Lanzavecchia 1985). However, besides antigen specific signals, induction of immunoglobulin production by B cells requires CD40-CD40L interactions and cytokines (Banchereau et al. 1994). In contrast to the TCR, immunoglobulins may have a very high affinity for their specific antigen. They recognize free antigen and their major function seems to be the binding to either cell-bound or free antigens.

T cells develop in the thymus and B cells in the bone marrow. Importantly, the structure of the TCR is definitely determined in the thymus. Thus, the thymus constitutes an important site of education which ultimately determines the specificity of the ensuing T cells (Kisielow and von Boehmer 1995). In contrast, the structure of the immunoglobulin recognition site is not terminally fixed when B cells leave the bone marrow and mature B cells undergo somatic mutation and the affinity of the antigen recognition site of secreted immunoglobulins can mature during the course of immune responses.

## **Thymic Maturation and Selection of T Cells**

Precursor T cells develop within the bone marrow and reach the thymus through the blood. These immature precursor cells undergo a series of activation and maturation events that ultimately result in a precursor population that expresses a TCR and both, CD4 and CD8 molecules. The TCR expresses two independent immunoglobulin-like chains, the  $\alpha$ - and the  $\beta$ -chain. The  $\beta$ -chain is expressed together with a pre- $\alpha$ -chain; the definite TCR  $\alpha$ -chain replaces the pre- $\alpha$ -chain prior to the development of the CD4+CD8+, double positive status. Normally, T cells express only one pair of TCR  $\alpha/\beta$ -chains. This subsequent replacement of the pre- $\alpha$ -chain by a definite TCR- $\alpha$ -chain however, may lead to the occurrence of T cells which express two receptors, one single  $\beta$ -chain assorted with two different and independent  $\alpha$ -chains. Thus, one T cell may have two, entirely independent specificities (Kretz-Rommel and Rubin 2000; Stockinger 1999).

Once the double positive status is achieved, T cells interact with thymic MHC molecules. This interaction of the double positive cells, which are highly sensitive to death signals, will decide their further outcome as most of the double positive cells die during this selection process. T cells with relatively high affinity for peptide loaded and possible also empty MHC molecules die through induction of apoptosis. T cells that express a TCR with an affinity that is too low for recognizing peptide loaded MHC molecules die from neglect. Only a small proportion of T cells, smaller than 10%, survives this selection and leaves the thymus as a single positive T cell, expressing either CD4 or CD8 and a TCR (Bouneaud et al. 2000; Kisielow et al. 1988; Rocha and von Boehmer, 1991). During thymic selection, TCR structures with high affinity for self may not only lead to deletion; another mode is temporary suppression of the TCR. If a T cell with two distinct TCR  $\alpha$ -chains then receives at the same time a survival signal by the second receptor, this cell may become positively selected and result in a peripheral T cell population with two distinct TCR; one corresponding to an autoreactive receptor (*Fig. 1*).

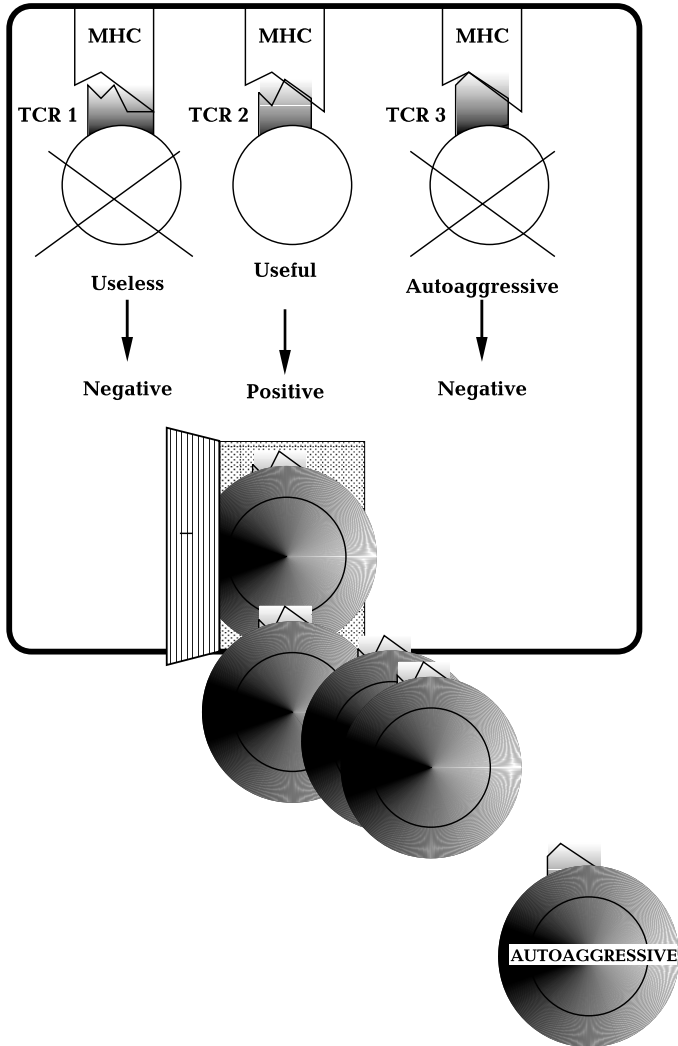
## **Tolerance of Self-Reactive T and B Cells**

### **Central Tolerance and Peripheral Tolerance**

The thymus and the apoptosis and paralysis occurring during the development of B cells recognizing abundant antigens in the periphery delete about 90% of self-reactive T and B cells. This phenomenon is termed as central tolerance. However, roughly 10% of these cells survive (Blackman et al. 1990; Kisielow et al. 1988). Moreover, not all antigens are presented in thymus, bone marrow or peripheral blood. In one individual, all cells express the same MHC class I and a large spectrum of common minor antigens. However, each cell also expresses its own set of antigens that is related to its function and localization. Thus, the mature immune system encounters a larger spectrum of antigens in the periphery than in the thymus. Tolerance against these antigens requires a multitude of mechanisms which are summarized under the term *peripheral tolerance*. While *central tolerance* is mainly based on deletion of potentially autoreactive T cells, a larger spectrum of mechanisms constitutes *peripheral tolerance* (Arnold et al. 1993; Rocken and Shevach 1996).

### **Mechanisms of Peripheral Tolerance**

One mechanism of peripheral tolerance may be deletion, too. Deletion is mainly associated with the sudden appearance of a large number of antigens. This mechanism has been demonstrated for antigens that were presented in large numbers, thus during infection or following injection of superantigens



**Fig. 1.** Modes of intrathymic selection of T cells. T cells with a very high affinity T cell receptor (TCR) for self major histocompatibility complexes (MHC) die from active deletion, those with an intermediate affinity are positively selected and those with low affinity will die from neglect

(Moskophidis et al. 1993; Webb et al. 1990). Whether this mechanism applies also under physiological conditions is not clear. But it may become relevant during tissue destruction, when large quantities of self-antigens are presented, thus in the case of skin burning, viral infections of skin, muscle or other organs or following a stroke. However, this phenomenon has not yet been analyzed in more detail.

Another mechanism is suppression of TCR expression. This has been shown with pregnant mice expressing a transgenic TCR that recognizes the foreign MHC class I molecule expressed by the father and the fetus. The level of this transgenic TCR is high before and after pregnancy, but low during pregnancy. These T cells are also functionally silenced. During pregnancy, female mice become even tolerant to otherwise highly immunogenic tumor cells expressing this same antigen (Alferink et al. 1998). Thus, suppression of a TCR expression is closely associated with the occurrence of peripheral tolerance and may contribute to it. These data, even though very elegant, do not exclude that other mechanisms significantly contribute to peripheral tolerance (Alferink et al. 1998; Schonrich et al. 1991).

One important example demonstrating the requirement for additional mechanisms was given by mice that simultaneously express a peptide antigen of the lymphocytic choriomeningitis virus (LCMV) by the endocrine pancreas and T cells with a TCR transgenic for the LCMV peptide (Ohashi et al. 1991; Oldstone et al. 1991). These animals have autoreactive CD8+ T cells that are functionally normal, express normal levels of the TCR and kill peptide loaded targets *in vitro* to the same extent as transgenic T cells from control animals. Nevertheless, these animals do not develop overt autoimmune disease, showing that, besides the target organ, the expression of an endogenous potentially immunogenic peptide and normal levels of TCR, other signals are required for the induction of autoimmune disease. Such a situation may be the consequence of 'ignorance' of the target structure by the autoreactive T cells (Ohashi et al. 1991). Ignorance may be the consequence of missing adhesion molecules or the absence of co-stimulatory signals (von Herrath et al. 1995). However, it may also be due to expression of autoantigens at immunologically privileged sites, the expression of apoptosis inducing molecules capable of killing activated T cells or secondary to local silencing of activated T cells that recognize target tissues in the absence of co-stimulatory molecules.

Reactivity and mode of action are not only given by the TCR and the spectrum of co-stimulatory T cells expressed by T cells. Most importantly, T cell functions are determined by the cytokines they produce. Naive T cells produce only interleukin (IL-) 2 when stimulated by peptides and professional antigen presenting cells (APC; Weinberg et al. 1990). Subsequently, T cells develop towards memory cells that are theoretically capable of producing a large spectrum of cytokines. Today it is established that T cells normally do not secrete a random pattern of cytokines, but differentiate into phenotypes that produce distinct sets of cytokines associated with well defined functional phenotypes (Mosmann and Sad 1996; Rocken et al. 1992; Rocken et al. 1996).

T cells that produce predominantly IL-2 and interferon- $\gamma$  (IFN $\gamma$ ) are associated with inflammatory, cell mediated immune responses. When expressing the CD4 molecule they are named Th1, when expressing the CD8 molecule, they are named Tc1 cells and induce 'type 1' immune responses (Arnold et al. 1993; Racke et al. 1994; Katz et al. 1995; Kolb et al. 1995; Powrie 1995; Rocken et al. 1996; Adorini and Sinigaglia 1997). These types of immune responses are

required for the control of infections with viruses, fungi or parasites. However, when directed against autoantigens, they may cause inflammatory autoimmune diseases. These inflammatory autoimmune diseases are normally well localized to one single organ or a group of organs that share a common antigen. These T cells do not only induce direct tissue destruction, they also induce B cells to produce complement binding antibodies, which may enhance local inflammation and tissue destruction, as it is the case in patients with bullous pemphigoid (Budinger et al. 1998).

The most important counterpart of 'type 1' immune responses are 'type 2' responses. They are induced by CD4<sup>+</sup> T cells capable of producing IL-4 and IL-13. These two cytokines seem to suppress multiple pro-inflammatory effector functions by macrophages, such as production of tumor necrosis factor (TNF). Th2 cells are primarily known by their capacity to switch the immunoglobulin isotype of human B cells towards IgE and probably also IgG4 (Mosmann and Coffman 1989). Thus, Th2 cells do not generally extinct immune responses. They may even induce autoimmune responses and probably also autoimmune disease, such as pemphigus vulgaris, which is associated with autoantibodies of the IgG4 isotype and little local inflammation (Goldman et al. 1991; Hertl et al. 1998). However, when directed against epitopes that are associated with type 1-mediated inflammatory autoimmune disease, type 2 immune responses may exert anti-inflammatory, protective effects. Treating Th1 mediated diseases with Th2 cells or the cytokine IL-4 that most potently induces Th2 and suppresses Th1 has been demonstrated in animal models of organ specific autoimmune disease and skin inflammation. Most importantly, however, this therapeutic strategy was also effective in humans suffering from psoriasis, a Th1 mediated autoimmune disease of the skin (Ghoreschi et al. 2003).

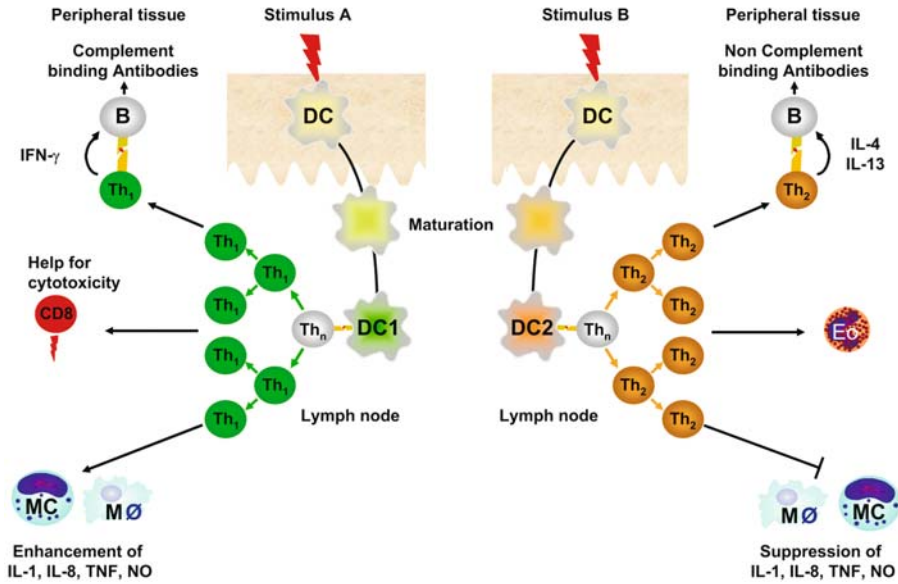
A third, probably increasingly important population are IL-10 producing regulatory or Tr cells. In contrast to all other phenotypes, these Tr cells seem to have the exquisite capacity of turning immune responses off. This regulatory effect may be of great importance in the treatment of autoimmune diseases, since Tr are obviously capable of silencing both, type 1 and type 2 immune responses (Groux et al. 1997; Akdis et al. 2000). Referring to the historical attribution given to CD8<sup>+</sup> T cells, suppressor T cells experience a time of renaissance. These CD4<sup>+</sup> T cells are capable to suppress autoaggressive immune reactions and were found to express CD25, GITR, CTLA-4, and most importantly a specific transcription factor, forkhead box p3 (Foxp3) (Bluestone and Tang 2004). Foxp3 is not only a marker for these Tr, it is of functional importance for the suppressive mode of action of Tr (Walker et al. 2003; Fontenot et al. 2003). As a consequence, patients deficient in the Foxp3 transcription factor develop a multiorgan autoimmune disease (Kriegel et al. 2004). Tr cells are very difficult to induce and grow to expand in vitro and probably also in vivo, but finding Foxp3 and increasingly elucidating the underlying mechanisms of Tr development will help to answer the questions in regard to the significance these cells may play in the therapy of autoimmune disease.

## Activation and Differentiation of T Cells

All organs are drained by dendritic APC (DC). These DC are normally considered as potent stimulators of T cells that prime primarily for interferon- $\gamma$  (IFN $\gamma$ ) producing CD4+ and CD8+ T cells (Schuler and Steinman 1997; Schuler et al. 1997; Banchereau and Steinman 1998). DC acquire this capacity following antigen uptake while they migrate to the draining lymph nodes. This capacity in activating and stimulating T cells to become efficient effector cells, capable of mediating inflammatory immune responses and of inducing immunoglobulin production by B cells, requires a certain activation status by these APC. Thus APC co-express adhesion molecules that permit adherence of naive and activated T cells. They express a panel of co-stimulatory molecules that are required for the activation of specifically binding T cells and, in addition, they produce cytokines. Both, the sum of cell bound signals and of APC derived cytokines results not only in the stimulation and maturation of the specific T cells but also determines their differentiation. Thus, the maturation process that APC and DC undergo during their migration from the periphery to the draining lymph node will ultimately determine, whether the primary activation of T cells may lead to type 1, type 2 or Tr T cells. Depending on the functional T cell phenotype they induce, APC and DC are operationally termed DC1, DC2 or DCr (Kalinski et al. 1999; Moser and Murphy 2000) (*Fig. 2*).

When residing in peripheral organs, DC are continuously processing numerous antigens delivered by the local milieu. At this stage, DC have little migratory and antigen presenting capacity. Recent data suggest that the few immature and quiescent DC that migrate from peripheral organs to the draining lymph node are not capable of activating T cells to become autoaggressive. They seem either to contribute to the phenomenon of 'ignorance' or to promote the differentiation of naive but potentially autoreactive T cells towards an immunosuppressive Tr phenotype (Jonuleit et al. 2000). In sharp contrast, DC start to mature and to leave their residing site after an appropriate stimulus. Among those innate signals highly conserved so called 'pathogen associated molecular pattern' (PAMP) derived from infectious agents, such as bacterial DNA, bind to Toll-like receptors (TLR) and are increasingly recognized as most relevant activators of DC. These innate signals transform APC not only from an antigen processing towards an antigen presenting cell, capable of attracting naive and memory T cells into lymph nodes. These innate signals also determine the differentiation of APC towards either a DC1, DC2 or DCr phenotype and, in consequence, their capacity to direct the functional phenotype of the future immune response, directed against either self or foreign antigens (Banchereau and Steinman 1998; Kalinski et al. 1999; Moser and Murphy 2000). This concept was expanded by disclosing regulatory mechanisms underlying DC induced immune responses. Thus, PAMPs present during the initial activation of DC generally instruct DC to produce



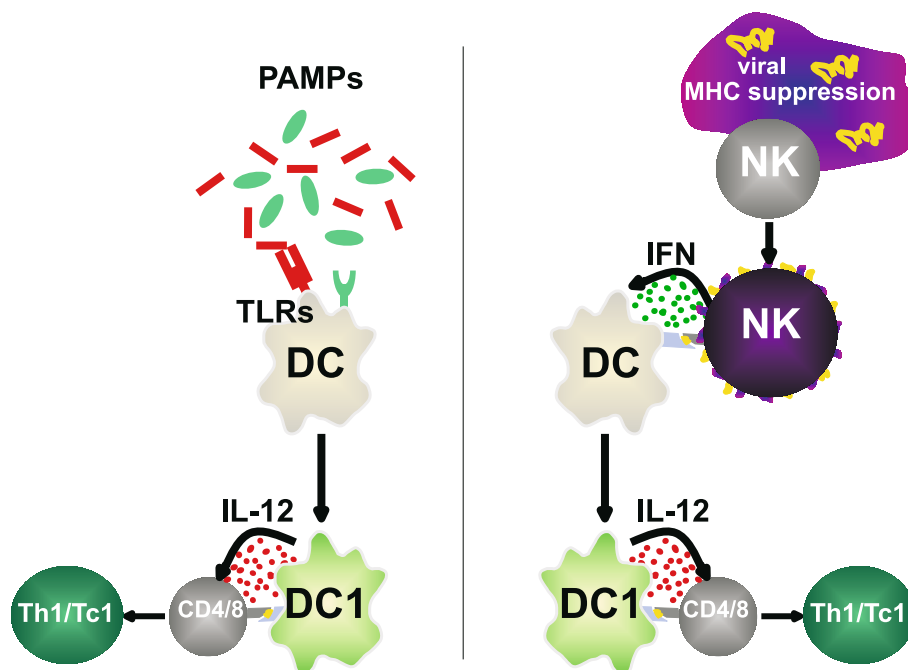


**Fig. 2.** Differentiation of T helper (Th) cells into either IFN $\gamma$  producing Th1 or IL-4 producing Th2 cells. The differentiation of Th into either Th1 or Th2 phenotypes is driven by the functional phenotype of the stimulating dendritic cells (DC), draining the site of inflammation. The 'innate' stimuli initiating both, activation and migration of the DC, also influences the differentiation of these migrating DC into either a DC1 or DC2 phenotype

IL-12 and PAMPs tend to promote Th1 development leading to a proper anti-infectious immunity (*Fig. 2, 3*). However, some PAMPs and other signals lead to an inappropriate Th2 immunity in response to microbes (*Fig. 2*). Interestingly, these Th2 reactions can be switched to effective Th1 reactions, a mechanism that may also regulate autoimmunity. Paradoxically, IL-4 is a potent factor driving this switch, because IL-4 instructs activated DC to produce IL-12 and promotes Th1 cell development (Biedermann et al. 2001). These paradox functional consequences achieved by IL-4 were investigated by the sequential analysis of immune responses. Immune responses in general develop via the consecutive activation of DC and then T cells. Thus, the contrasting effects of IL-4 on immune responses with opposing functional phenotypes are a result from IL-4 signaling in early DC activation leading to a Th1 phenotype and from IL-4 induced T cell differentiation inducing Th2 cells during a later stage.

In addition to TLR signaling, there are also PAMP and TLR independent pathways that drive T cell immunity through DC modulation. Thus, apoptotic cell material and activated NK cells can also prime DC to produce IL-12 and to induce CD8 T cell memory responses, a mechanism that may be also underlying an activation of autoreactive lymphocytes (Mocikat et al. 2003) (*Fig. 3*).

## Alternative activation pathways of specific immunity



**Fig. 3.** PAMPs tend to induce IL-12 producing DC1 that control the development of IFN $\gamma$  producing Th1 or Tc1 cells. These type 1 immune responses are effective against microbes but may also be involved in tissue destruction during autoimmune diseases. Alternatively, DC1 may also be generated under the influence of activated natural killer (NK) cells and lead to Th1 or Tc1 cells

### Activation of Self-Reactive T and B Cells

Autoimmune diseases require the presence of autoreactive T cells and, in the case of immunoglobulin mediated diseases, of autoreactive B cells. In view of the potent and large number of regulatory mechanisms that protect against autoimmune disease, activation of autoreactive T and B cells is thought to require a series of destabilizing events. One important aspect is the activation and reactivation of potentially autoreactive T cells (Rocken et al. 1992). However, induction of autoreactive T cells or B cells alone does not induce or predispose for autoimmune diseases. For example, in individuals, which are genetically predisposed of developing autoimmune diabetes, the relative risk of becoming diabetes increases significantly if their T cells respond vigorously against endogenous antigens from pancreatic islet cells. In sharp contrast, individuals from the same population are largely protected against autoimmune diabetes, when they exert high immunoglobulin titers but weak T cell responses

against the same antigens (Harrison et al. 1993). This further underlines that 'reactivity' does not equal autoimmune disease.

One of the fundamental questions that are still unanswered yields with the primary event leading to the induction of autoreactivity. Some data suggest that, in the presence of an appropriate genetic background, minimal events such as normal tissue necrosis may be sufficient for the induction of, perhaps even potentially harmful, autoreactivity (Albert et al. 1998; Matzinger and Anderson 2001).

Most data suggest that a series of tolerance inducing mechanisms normally inhibits T and B cells to react against many autoantigens (Naucler et al. 1996). Therefore, stimuli that induce reactivity against these autoantigens have to overcome the diverse tolerance inducing barriers. Epidemiologic data suggest that the realization of autoimmune diseases is often preceded by infectious diseases and attention was given to the events by which infections may abolish the status of tolerance (Sinha et al. 1990; Matzinger 1994). At least three mechanisms are thought to contribute to this phenomenon: reactivation of tolerant T and B cells, induction of autoreactive T cells by molecular mimicry and modification of the cytokine pattern during the course of infectious diseases.

### **Breaking T and B Cell Tolerance**

Experiments with transgenic or non- transgenic mice have shown that, in principle, tolerant T and B cells can be reactivated by infectious agents. Infections are capable of restoring in silenced T cells the capacity to produce cytokines (Rocken et al. 1992; Racke et al. 1994). This phenomenon was extended to the situation of transplantation induced tolerance (Ehl et al. 1998). Similarly, reactivity and immunoglobulin production by B cells that were silenced either by exogenous or transgenic endogenous antigens can be restored with mitogens, including bacteria derived lipopolisacchrides (Louis et al. 1973; Goodnow et al. 1991). Even though these experiments have shown that infectious agents can abolish solid T and B cell tolerance there are little data showing that this reactivation of tolerant T and B cells can also lead to autoimmune disease. One first example suggesting such a situation is given by double transgenic mice that bear a TCR recognizing a transgenic self-antigen expressed by hepatocytes. Injection of bacterial DNA motifs that activate DC and promote DC1-development by these activated DC did also induce transient liver damage, as evidenced by an increase of transaminases. However, this phenomenon was short lived and no data are available proving that autoimmune disease can be the direct consequence of polyclonal T cell activation (Limmer et al. 1998). In small animal models, induction of autoimmune disease by bacterial DNA motifs or more complex bacterial lysates such as complete Freund's adjuvans required, in addition, always immunization

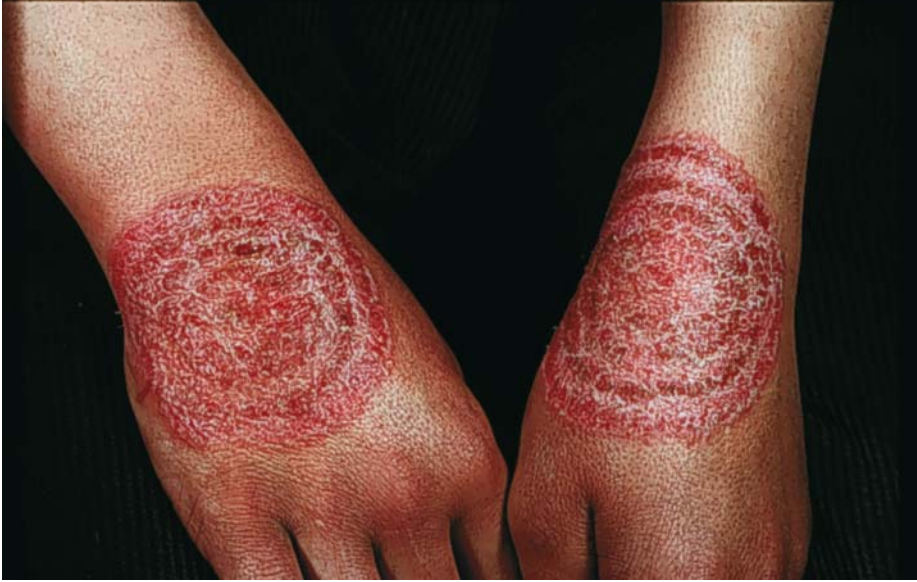with an antigen that mimics peptide motifs of the targeted self antigen (Bachmaier et al. 1999). Thus, in normal mice bacterial DNA motifs triggered the myocarditis only when co-administered with an altered self-peptide, derived from chlamydia.

These data suggest that immunization against antigens that are structurally related to self-antigens are essential for the induction of autoimmunity. This concept is further supported by functional and structural analysis of T cell epitopes of infectious agents and potential self-antigens. Chlamydia peptides can share functional similarities with peptides expressed by mammalian heart muscle, while other infectious agents share important peptide sequences with potential self-antigens such as myelin basic protein. This aspect is especially significant since molecular mimicry does not require molecular identity. Studies with altered peptide ligands have shown that induction of cytokine production or T cell proliferation requires only poor structural relation as long as important anchor positions are conserved (Gautam et al. 1994; Wucherpfennig and Strominger 1995). Various examples suggest that this may be of relevance for autoimmune diseases of the skin. Thus, the first eruption of the juvenile type of psoriasis is preceded by streptococcal infections in most patients (Prinz 1999) and lichen planus is associated in a large number of patients with an acute or chronic liver disease (Chuang et al. 1999). In some patients lichen planus may even be provoked by active or even passive vaccination against hepatitis (Tessari et al. 1996; Degitz and Röcken 1997).

Despite the experimental prove for both, re-activation of tolerant T cells and for molecular mimicry, the exact role of infections in the pathogenesis of autoimmune diseases remains open. One important alternative would be the direct infection and molecular alteration through infectious disease. One important example is chronic active hepatitis, where relatively weak immune responses follow the slowly progressing wave of infected hepatocytes and thus slowly destroy the liver. In this situation, activation of the T cell mediated immune responses, associated with a short aggravation of the hepatitis may lead to reduction and control of the viral load and cure from chronic progressive hepatitis (Berg et al. 1997; Gerlach et al. 1999; Moradpour and Blum 1999). In the skin a very similar phenomenon is visible during fungal infections. The border, the clinically manifest eczema, reflects the immune reaction against a large burden of fungi. Inside the inflammatory margin, the eczema and the fungal load are significantly milder. In the case of fast growing fungi, the eczema may present as a polycyclic disease (*Fig. 4*).

A third level where infections could directly interfere with autoreactive T cells is the pattern of cytokines that T cells produce. Thus, infection with the nematode *nippostrongylus brasiliensis* can not only restore reactivity in silenced CD4<sup>+</sup> T cells but also induce IL-4 production by these silenced T cells (Rocken et al. 1992; Rocken et al. 1994; Rocken et al. 1996).

In conclusion, increasing understanding of the TLR-mediated activation of innate immune cells and their link to adaptive immunity has helped to create a concept that also applies to the activation of autoreactive T and B cells.



**Fig. 4.** Waves of inflammation as reflected by the migrating margins of eczema found during tinea infection

Thus in a series of models, activating innate immunity via TLR has turned on or increased the adaptive immune response. These data emphasize the power of infectious diseases in mounting immune responses and in modulating the cytokine phenotype of established immune responses. PAMPs binding to TLR and regulating the transcription of pro-inflammatory genes through NF $\kappa$ B are the basis for this new understanding. Thus, PAMPs like immunostimulatory DNA binding TLR9, like lipopolysaccharides binding TLR4 and others are capable of activating DC, B cells, and probably also T cells. Instructing IL-12 producing DC via TLR9 can be achieved by injection of TLR9 ligands into mice. Using the model of progressive, Th2-mediated leishmaniasis infection in susceptible BALB/c mice, Zimmermann et al. showed that immunostimulatory DNA motifs are capable of reverting even fully established type 2 immune responses into IFN $\gamma$  dominated type 1 immune responses and DTHR (Zimmermann et al. 1998). Thus, injection of immunostimulatory DNA motifs and triggering TLR9 overcame the tolerance towards the parasite and restored control over *Leishmania major* in animals with a large parasite burden. In view of such a powerful Th1-inducing capacity, it was likely that similar immunostimulatory motifs are also capable of breaking self-tolerance and induce autoreactive Th1/Tc1 cells that cause inflammatory tissue destruction. Indeed, it was shown very recently that viruses provide TLR signals required for bypassing regulatory T cell-mediated tolerance (Yang et al. 2004). PAMPs may therefore be considered as the leading group of danger signals

that nature provides and that may also lead to activation of autoreactive T and B cells.

In addition to PAMPs derived from microbes, there is increasing evidence suggesting that endogenous ligands can also trigger TLR and activate autoreactive lymphocytes (Ulevitch 2004). Systemic lupus erythematosus is characterized by the production of autoantibodies against nucleic-acid-containing macromolecules such as chromatin or ribonucleoprotein particles. DC and B cells are effectively activated by immune complexes containing chromatin, a process that involves TLR9. This activation leads to proliferation of autoreactive T and B cells providing direct evidence for TLR promoted autoimmunity mediated by endogeneous ligands (Leadbetter et al. 2002; Boulé et al. 2004).

## Autoimmune Disease

Autoimmunity is a prerequisite for autoimmune disease. However, the events that lead from autoimmunity to an overt inflammatory disease are still unclear. Production and release of TNF seems to be important for this step, but the exact role of this cytokine is far from being elucidated (Green and Flavell 2000). Without any doubt, autoreactive T cells are not only associated with autoimmune diseases but can directly cause the disease. Analysis from mice with non obese diabetes (NOD) revealed that both, CD4<sup>+</sup> and CD8<sup>+</sup> T cells are required for the induction of both, autoimmune inflammation and autoimmune disease (Bendelac et al. 1987). Similarly, transfer of MBP-reactive T cells (Mokhtarian et al. 1984) and even more precisely, MBP-reactive CD4<sup>+</sup> T cells of the Th1 phenotype alone are capable of inducing severe autoimmune encephalitis, when transferred into naive mice (Racke et al. 1994).

## T Cells

A comparison of various models for organ-specific, inflammatory autoimmune disease unveiled that organ specific inflammatory autoimmune diseases are primarily induced by T cells of the proinflammatory Th1 phenotype. It is assumed that both, CD4<sup>+</sup> and CD8<sup>+</sup> T cells are involved under most conditions, but the exact role of CD8<sup>+</sup> T cells remains unclear. Adoptive transfer of polarized Th1 cells alone is normally enough for inducing the disease. In this context it is of interest that *ex vivo* analysis of the cytokine phenotype of T cells associated with inflammatory autoimmune diseases normally reflects a type 1 phenotype. This is valid for models of autoimmune diseases in small animals and for the analysis of autoimmune responses in humans with organ-specific autoimmune disease such as autoimmune diabetes (Kolb et al. 1995), multiple sclerosis (Martin et al. 1992; Zhang et al. 1998) or psoriasis (Austin et al. 1999; Vollmer et al. 1994).

## B Cells and Immunoglobulins

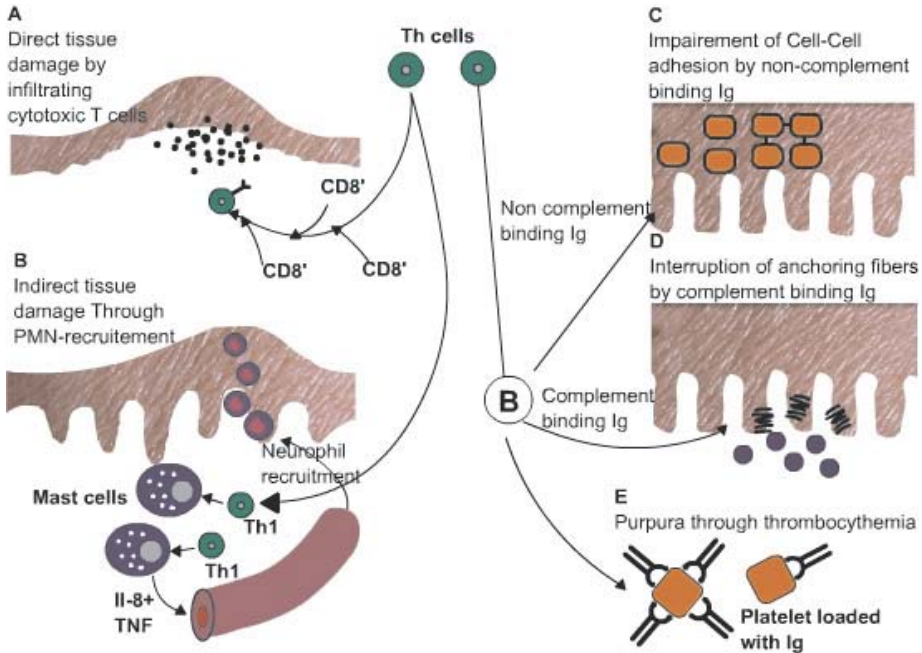
Probably the best example for an immunoglobulin-mediated disease is pemphigus vulgaris. In patients, this disease is associated with little inflammation and seems to be directly mediated by the binding of autoreactive immunoglobulins to the desmogleins that guarantee the adherence between keratinocytes (Amagai et al. 1991). Indeed, transfer of patient sera and monoclonal antibodies directed against desmoglein 3 into the skin of new-born mice can directly induce acanthosis (Rock et al. 1989). This critical role for a direct binding of immunoglobulins to desmoglein structures is further supported by the observation that in patients with pemphigus vulgaris the disease activity correlates closely with the serum levels of the autoantibodies (Hertl 2000). Such a close association is unusual for other autoimmune diseases, including lupus erythematosus or bullous pemphigoid. For comparisons, bullous pemphigoid is of special interest. It is also an immunoglobulin mediated bullous skin disease. In sharp contrast to pemphigus vulgaris, the clinical manifestation of bullous pemphigoid does not only require deposition of autoantigens but also an inflammatory milieu that causes detachment of the basement membrane (Liu et al. 1998; Liu et al. 2000). Consequently, transfer of specific sera or immunoglobulins under the skin of new born nude mice alone is not sufficient for the induction of blisters. It requires, in addition, activation of the complement cascade and inflammation, involving the recruitment of granulocytes (Liu et al. 1995).

## Tissue Damage and Type 1 T Cells

Type 1 T cells are associated with two distinct types of tissue damage. One type of tissue damage is characterized by a sterile inflammation, the other with the strong accumulation of polymorphonuclear granulocytes.

Sterile type 1 responses are found in lichen planus, multiple sclerosis or autoimmune diabetes. They are associated with activated macrophages, which seem to be the effector cells of these immune responses. Like macrophages that are stimulated *in vitro* in the presence of IFN $\gamma$ , they produce large amounts of TNF, oxygen radicals, NO and other mediators of inflammation (Stenger and Modlin 1999). Activated CD8<sup>+</sup> T cells with potent killer functions seem also to be involved (Zinkernagel 1996). In concert, these mediators can cause severe tissue destruction that ultimately results in compensatory scar formation. Due to the capacity of the skin to regenerate even severe tissue damage, lichen planus heals under most conditions without scarring. However, persistent alopecia, onychodystrophy or even scars of the normal skin are potential complications (*Fig. 5A*).

Under other conditions, type 1 mediated autoimmune diseases are associated with a strong infiltrate by PMN. Such a constellation characterizes psoriasis,



**Fig. 5.** Different types of inflammation induced by either IFN $\gamma$ -producing Th1 and by IL-4-producing Th2 cells

rheumatoid arthritis (RA) and most types of inflammatory bowel disease, especially Crohn's disease (Mican and Metcalfe 1990; Rothe et al. 1990; Strober and Ehrhardt 1993; Christophers 1996; Feldmann et al. 1996; Ackermann and Harvima 1998; Bischoff et al. 1999; Gelbmann et al. 1999; Biedermann et al. 2000). Numerous reports describe that PMN recruitment is closely associated with accumulation of IL-8, TNF and the presence of activated mast cells. Studies in an animal model of skin inflammation unraveled important mechanisms leading to strong PMN recruitment during type 1 immune responses. In a mouse model of type 1-induced tissue damage, mast cells respond to type 1 T cells and produce the two mediators required for the recruitment of PMN into inflamed tissue: the TNF, which induces the expression of intravascular adhesion molecules, and the IL-8, which is the most important chemokine attracting PMN (Biedermann et al. 2000) (Fig. 5B).

Interestingly, mast cells seem not only to recruit PMN during type 1 immune responses. Activated mast cells are also abundant during immunoglobulin mediated destruction of the basement membrane in bullous pemphigoid. Adoptive transfer of bullous pemphigoid autoantibodies into the skin of newborn mice underlined that mast cells are required also for PMN recruitment in the pathogenesis of bullous pemphigoid (Chen et al. 2000).



## **Type 2 T Cells and T-B Cell Interactions**

A large number of autoimmune diseases is immunoglobulin mediated. These 'humoral' diseases can roughly be divided into two major categories. Immunoglobulins can induce damage through direct binding of their target-antigen. This is the situation in most other bullous autoimmune diseases of the skin, especially pemphigus vulgaris. Alternatively immunoglobulins bind to circulating antigens and cause damage through deposition along basement membranes or in vessels. The former situation is given in the case of lupus (Rubin 1997) the latter at sites of vasculitis.

Thus, immunoglobulins are responsible for all types of diseases caused by immunoreaction type I, II and III according to the classification of Coombs & Gell. As the pattern of immune responses initiated by immunoglobulins strictly depends on the immunoglobuline isotype, the diseases caused by immunoglobulins depend not only on the antigen they recognize. The clinical spectrum of diseases initiated by autoantibodies ranges from urticaria, through cytopathic tissue damage leading to cytopenia, inflammatory tissue destruction following the deposition of immunoglobulins and complexes at membranes till to severe necrosis, as a consequence of acute vascular infarction.

Here again, T cells play a central regulatory role. Under most conditions, B cells start only to produce autoantibodies, when stimulated by antigen-specific T cells. During this stimulation, T cells release a distinct pattern of cytokines controlling the immunoglobulin switch in the responding B cells. Cytokines of the Th2-family, IL-4 and IL-13 induce the isotype switch towards IgE and isotypes that don't bind complement, IgG1 in the mouse and in humans probably IgG4. Th1 cells that are thought to organize the defense against intracellular pathogens and viruses induce preferentially complement-binding isotypes (*Figs. 3, 5*).

A well analyzed example is pemphigus vulgaris, where patients have frequently IgG4 antibodies against desmoglein 3 and predominant Th2 responses against this same autoantigen.

## **Therapeutic Induction of Functional Tolerance**

The therapeutic strategies available reflect a combination of corticosteroids and immunosuppressive agents, most of them acting on both T and B cells. Corticosteroids are used with the primary goal to reduce the acute inflammation and to limit tissue damage. They are also efficient in suppressing T and B cell responses, but long-term side effects are very important. Therefore, therapies normally combine corticosteroids with immunosuppressive agents in order to reduce immune responses to a level that optimally inhibits harmful immune reactions but still allows normal defense against infectious agents.

Such therapies establish a fragile balance that is helpful in some but not all autoimmune diseases. Especially the late outcome is still poorly controlled and acute relapses and chronic infections may lead to new complications such as an increased frequency of atherosclerosis, at least in some groups of immunosuppressed individuals.

This led to the development of novel strategies. They are based on either of the three principles: efficient blockade of the effector functions of immune responses, absorbing harmful immunoglobulin fractions or correction of aberrant T cell responses.

The greatest progress is currently obtained by blocking immune functions with anti-TNF-antibodies. This seems to be more efficient and better tolerated than any of the previously described immunosuppressive agents (Feldmann et al. 1996). However, therapies based on anti-TNF-antibodies inhibit any type of immune response and therefore harbor a series of risks for patients with acute or chronic infections. Among autoimmune skin diseases psoriasis has been shown to improve under anti-TNF-therapies (Mease et al. 2000). This is an important prove of principle and we know today that this therapeutic approach can be very beneficial for our patients suffering from psoriasis, psoriasis arthritis, and acrodermatitis continua suppurativa of Hallopeau. In addition, neutralizing TNF may be a promising approach for acute diseases associated with inflammatory tissue destruction such as aphthous ulcers or pyoderma gangraenosum. However, we have to keep in mind that other highly effective, less invasive, and less expensive therapies are available for psoriasis.

Absorbency of harmful immunoglobulins is a logical approach that was developed from plasmapheresis. One problem is that it acts relatively late in the immune response and B cells continue to produce pathogenic immunoglobulins.

Large efforts were undertaken to develop T cell based immunotherapies. They may affect either antigen presenting cells, co-stimulation or the T cells directly. Today, strategies modulating the co-stimulation of T cells mediated through CD28/CTLA4 or LFA-2/LFA-3 seem to be one promising approach to alter autoreactive T cell responses (Abrams et al. 2000; Krueger and Ellis 2003). One other possibility would be to correct harmful cytokine production by specific T cells. Three mechanisms are under study: induction of regulatory Tr cells capable of inhibiting immune responses in an antigen-specific fashion. The second would be the deviation of harmful Th1 responses into a protective Th2 response. Such an approach may be of special interest as Th2-responses have a tendency to perpetuate and to establish an antiinflammatory Th2-memory, once they are initiated (Biedermann et al. 2001). Indeed, a first study performed with psoriasis patients demonstrated that IL-4 therapy is a highly effective treatment strategy for autoimmune diseases (Ghoreschi et al. 2003). The third reflects the opposite, the redirection of harmful Th2 responses into a Th1-phenotype, an approach that may be of interest in IgE-mediated diseases.

These antigen-specific T cell based approaches are still at an early clinical experimental stage and even though not appropriate for acute interventions, the first studies demonstrated that it is a very promising approach (Ghoreschi et al. 2003). For future development, these vaccination approaches are of special interest as they circumvent a series of major problems associated with all other therapies. Two important aspects are: These therapies are highly specific for the targeted antigen structure and should therefore not interfere with the other physiologically required immune responses (Rocken et al. 1996). The other is that they target the site where T cell responses are translated from the innate to the adaptive immune response and they therefore should provide protection of long duration.

## References

- Abrams, J. R., Kelley, S. L., Hayes, E., Kikuchi, T., Brown, M. J., Kang, S., Lebowitz, M. G., Guzzo, C. A., Jegasothy, B. V., Linsley, P. S., and Krueger, J. G. (2000). Blockade of T lymphocyte costimulation with cytotoxic T lymphocyte-associated antigen 4-immunoglobulin (CTLA4Ig) reverses the cellular pathology of psoriatic plaques, including the activation of keratinocytes, dendritic cells, and endothelial cells. *J. Exp. Med.* 192, 681–694
- Ackermann, L., and Harvima, I. T. (1998). Mast cells of psoriatic and atopic dermatitis skin are positive for TNF-alpha and their degranulation is associated with expression of ICAM-1 in the epidermis. *Arch. Dermatol. Res.* 290, 353–359
- Adorini, L., and Sinigaglia, F. (1997). Pathogenesis and immunotherapy of autoimmune diseases. *Immunol. Today* 18, 209–211
- Akdis, C. A., Joss, A., Akdis, M., Faith, A., and Blaser, K. (2000). A molecular basis for T cell suppression by IL-10: CD28-associated IL-10 receptor inhibits CD28 tyrosine phosphorylation and phosphatidylinositol 3-kinase binding. *Faseb J.* 14, 1666–1668
- Albert, M. L., Sauter, B., and Bhardwaj, N. (1998). Dendritic cells acquire antigen from apoptotic cells and induce class I-restricted CTLs. *Nature* 392, 86–89
- Alferink, J., Tafuri, A., Vestweber, D., Hallmann, R., Hammerling, G. J., and Arnold, B. (1998). Control of neonatal tolerance to tissue antigens by peripheral T cell trafficking. *Science* 282, 1338–1341
- Amagai, M., Klaus-Kovtun, V., and Stanley, J. R. (1991). Autoantibodies against a novel epithelial cadherin in pemphigus vulgaris, a disease of cell adhesion. *Cell* 67, 869–877
- Arnold, B., Schonrich, G., and Hammerling, G. J. (1993). Multiple levels of peripheral tolerance. *Immunol. Today* 14, 12–14
- Austin, L. M., Ozawa, M., Kikuchi, T., Walters, I. B., and Krueger, J. G. (1999). The majority of epidermal T cells in Psoriasis vulgaris lesions can produce type 1 cytokines, interferon-gamma, interleukin-2, and tumor necrosis factor-alpha, defining TC1 (cytotoxic T lymphocyte) and TH1 effector populations: a type 1 differentiation bias is also measured in circulating blood T cells in psoriatic patients. *J. Invest. Dermatol.* 113, 752–759
- Bachmaier, K., Neu, N., de la Maza, L. M., Pal, S., Hessel, A., and Penninger, J. M. (1999). Chlamydia infections and heart disease linked through antigenic mimicry. *Science* 283, 1335–1339
- Banchereau, J., Bazan, F., Blanchard, D., Briere, F., Galizzi, J. P., van Kooten, C., Liu, Y. J., Rousset, F., and Saeland, S. (1994). The CD40 antigen and its ligand. *Annu. Rev. Immunol.* 12, 881–922
- Banchereau, J., and Steinman, R. M. (1998). Dendritic cells and the control of immunity. *Nature* 392, 245–252
- Bendelac, A., Carnaud, C., Boitard, C., and Bach, J. F. (1987). Syngeneic transfer of autoimmune diabetes from diabetic NOD mice to healthy neonates. Requirement for both L3T4+ and Lyt-2+ T cells. *J. Exp. Med.* 166, 823–832

- Berg, P. A., Klein, R., and Rocken, M. (1997). Cytokines in primary biliary cirrhosis. *Semin. Liver Dis.* 17, 115–123
- Biedermann, T., Kneilling, M., Mailhammer, R., Maier, K., Sander, C. A., Kollias, G., Kunkel, S. L., Hultner, L., and Rocken, M. (2000). Mast Cells Control Neutrophil Recruitment during T Cell-mediated Delayed-type Hypersensitivity Reactions through Tumor Necrosis Factor and Macrophage Inflammatory Protein 2. *J. Exp. Med.* 192, 1441–1452
- Biedermann, T., Mailhammer, R., Mai, A., Sander, C., Ogilvie, A., Brombacher, F., Maier, K., Levine, A. D., and Röcken M. (2001a). Reversal of established delayed type hypersensitivity reactions following therapy with IL-4 or antigen-specific Th2 cells. *Eur. J. Immunol.* 31, 1582–1591
- Biedermann, T., Zimmermann, S., Himmelrich, H., Gumy, A., Egeter, O., Sakrauski, A. K., Seegmuller, I., Voigt, H., Launois, P., Levine, A. D., Wagner, H., Heeg, K., Louis, J. A., and Röcken, M. (2001b) IL-4 instructs TH1 responses and resistance to Leishmania major in susceptible BALB/c mice. *Nat. Immunol.* 2, 1054–1060
- Biedermann, T., Röcken, M., and Carballido, J. M. (2004). TH1 and TH2 lymphocyte development and regulation of TH cell-mediated immune responses of the skin. *J. Invest. Dermatol. Symp. Proc.* 9, 5–14
- Bischoff, S. C., Lorentz, A., Schwengberg, S., Weier, G., Raab, R., and Manns, M. P. (1999). Mast cells are an important cellular source of tumour necrosis factor alpha in human intestinal tissue. *Gut* 44, 643–652
- Blackman, M., Kappler, J., and Marrack, P. (1990). The role of the T cell receptor in positive and negative selection of developing T cells. *Science* 248, 1335–1341
- Bluestone, J. A., and Tang, Q. (2004). Therapeutic vaccination using CD4+CD25+ antigen-specific regulatory T cells. *Proc Natl Acad Sci U S A.* [www.pnas.org/cgi/doi/10.1073/pnas.0405234101](http://www.pnas.org/cgi/doi/10.1073/pnas.0405234101)
- Bonomo, A., and Matzinger, P. (1993). Thymus epithelium induces tissue-specific tolerance. *J. Exp. Med.* 177, 1153–1164
- Boulé, M. W., Broughton, C., Mackay, F., Akira, S., Marshak-Rothstein, A., and Rifkin, I.R. (2004). Toll-like receptor 9-dependent and -independent dendritic cell activation by chromatin-immunoglobulin G complexes. *J. Exp. Med.* 199; 1631–1640
- Bouneaud, C., Kourilsky, P., and Bousso, P. (2000). Impact of Negative Selection on the T Cell Repertoire Reactive to a Self-Peptide. A Large Fraction of T Cell Clones Escapes Clonal Deletion. *Immunity* 13, 829–840
- Budinger, L., Borradori, L., Yee, C., Eming, R., Ferencik, S., Grosse-Wilde, H., Merk, H. F., Yancey, K., and Hertl, M. (1998). Identification and characterization of autoreactive T cell responses to bullous pemphigoid antigen 2 in patients and healthy controls. *J. Clin. Invest.* 102, 2082–2089
- Chen, R., Diaz, L., Giudice, G., and Liu, Z. (2000). The role of C5a in mast cell activation during subepidermal blistering in experimental bullous pemphigoid. *J. Invest. Dermatol.* 114 (A), 762
- Christophers, E. (1996). The immunopathology of psoriasis. *Int. Arch. Allergy Immunol.* 110, 199–206
- Chuang, T. Y., Stille, L., Brashear, R., and Lewis, C. (1999). Hepatitis C virus and lichen planus: A case-control study of 340 patients. *J. Am. Acad. Dermatol.* 41, 787–789
- Degitz, K., and Röcken, M. (1997). Lichen ruber planus nach Hepatitis-B-Impfung. In *Fort-schritte der praktischen Dermatologie und Venerologie 1996*, G. Plewig and B. Przybilla, eds. (Berlin Heidelberg New York: Springer), 426–427
- Ehl, S., Hombach, J., Aichele, P., Rulicke, T., Odermatt, B., Hengartner, H., Zinkernagel, R., and Pircher, H. (1998). Viral and bacterial infections interfere with peripheral tolerance induction and activate CD8+ T cells to cause immunopathology. *J. Exp. Med.* 187, 763–774
- Feldmann, M., Brennan, F. M., and Maini, R. N. (1996). Role of cytokines in rheumatoid arthritis. *Annu. Rev. Immunol.* 14, 397–440
- Fontenot, J. D., Gavin, M. A., and Rudensky, A. Y. (2003). Foxp3 programs the development and function of CD4+CD25+ regulatory T cells. *Nat. Immunol.* 4, 330–336
- Gautam, A. M., Lock, C. B., Smilek, D. E., Pearson, C. I., Steinman, L., and McDevitt, H. O. (1994). Minimum structural requirements for peptide presentation by major histocompati-

- bility complex class II molecules: implications in induction of autoimmunity. *Proc. Natl. Acad. Sci. U.S.A.* *91*, 767–771
- Gelbmann, C. M., Mestermann, S., Gross, V., Kollinger, M., Scholmerich, J., and Falk, W. (1999). Strictures in Crohn's disease are characterised by an accumulation of mast cells colocalised with laminin but not with fibronectin or vitronectin. *Gut* *45*, 210–217
- Gerlach, J. T., Diepolder, H. M., Jung, M. C., Gruener, N. H., Schraut, W. W., Zachoval, R., Hoffmann, R., Schirren, C. A., Santantonio, T., and Pape, G. R. (1999). Recurrence of hepatitis C virus after loss of virus-specific CD4(+) T-cell response in acute hepatitis C. *Gastroenterology* *117*, 933–941
- Ghoreschi, K., Thomas, P., Breit, S., Dugas, M., Mailhammer, R., Van Eden, W., Van Der Zee, R., Biedermann, T., Prinz, J., Mack, M., Mrowietz, U., Christophers, E., Schlondorff, D., Plewig, G., Sander, C. A., and Röcken, M. (2003). Interleukin-4 therapy of psoriasis induces Th2 responses and improves human autoimmune disease. *Nat. Med.* *9*, 40–46
- Goldman, M., Druet, P., and Gleichmann, E. (1991). TH2 cells in systemic autoimmunity: insights from allogeneic diseases and chemically-induced autoimmunity. *Immunol. Today* *12*, 223–227
- Goodnow, C. C., Brink, R., and Adams, E. (1991). Breakdown of self-tolerance in anergic B lymphocytes. *Nature* *352*, 532–536
- Green, E. A., and Flavell, R. A. (2000). The temporal importance of TNFalpha expression in the development of diabetes. *Immunity* *12*, 459–469
- Groux, H., O'Garra, A., Bigler, M., Rouleau, M., Antonenko, S., de Vries, J. E., and Roncarolo, M. G. (1997). A CD4+ T-cell subset inhibits antigen-specific T-cell responses and prevents colitis. *Nature* *389*, 737–742
- Harrison, L. C., Honeyman, M. C., DeAizpurua, H. J., Schmidli, R. S., Colman, P. G., Tait, B. D., and Cram, D. S. (1993). Inverse relation between humoral and cellular immunity to glutamic acid decarboxylase in subjects at risk of insulin-dependent diabetes. *Lancet* *341*, 1365–1369
- Hertl, M., Karr, R. W., Amagai, M., and Katz, S. I. (1998). Heterogeneous MHC II restriction pattern of autoreactive desmoglein 3 specific T cell responses in pemphigus vulgaris patients and normals. *J. Invest. Dermatol.* *110*, 388–392
- Hertl, M. (2000). Humoral and cellular autoimmunity in autoimmune bullous skin disorders. *Int. Arch. Allergy Immunol.* *122*, 91–100
- Jonuleit, H., Schmitt, E., Schuler, G., Knop, J., and Enk, A. H. (2000). Induction of interleukin 10-producing, nonproliferating CD4(+) T cells with regulatory properties by repetitive stimulation with allogeneic immature human dendritic cells. *J. Exp. Med.* *192*, 1213–1222
- Kalinski, P., Hilkens, C. M., Wierenga, E. A., and Kapsenberg, M. L. (1999). T-cell priming by type-1 and type-2 polarized dendritic cells: the concept of a third signal. *Immunol. Today* *20*, 561–567
- Katz, J. D., Benoist, C., and Mathis, D. (1995). T helper cell subsets in insulin-dependent diabetes. *Science* *268*, 1185–1188
- Kisielow, P., Teh, H. S., Bluthmann, H., and von Boehmer, H. (1988). Positive selection of antigen-specific T cells in thymus by restricting MHC molecules. *Nature* *335*, 730–733
- Kisielow, P., and von Boehmer, H. (1995). Development and selection of T cells: facts and puzzles. *Adv. Immunol.* *58*, 87–209
- Kolb, H., Kolb-Bachofen, V., and Roep, B. O. (1995). Autoimmune versus inflammatory type I diabetes: a controversy? *Immunol. Today* *16*, 170–172
- Kretz-Rommel, A., and Rubin, R. L. (2000). Disruption of positive selection of thymocytes causes autoimmunity. *Nat. Med.* *6*, 298–305
- Kriegel, M. A., Lohmann, T., Gabler, C., Blank, N., Kalden, J. R., and Lorenz, H. M. (2004). Defective suppressor function of human CD4+ CD25+ regulatory T cells in autoimmune polyglandular syndrome type II. *J. Exp. Med.* *199*, 1285–1291
- Krueger, G. G., Ellis, C. N. (2003). Alefacept therapy produces remission for patients with chronic plaque psoriasis. *Br. J. Dermatol.* *148*, 784–788
- Lanzavecchia, A. (1985). Antigen-specific interaction between T and B cells. *Nature* *314*, 537–539
- Leadbetter, E. A., Rifkin, I. R., Hohlbaum, A. M., Beaudette, B. C., Shlomchik, M. J., and Marshak-Rothstein, A. (2002). Chromatin-IgG complexes activate B cells by dual engagement of IgM and Toll-like receptors. *Nature* *416*, 603–607

- Limmer, A., Sacher, T., Alferink, J., Kretschmar, M., Schonrich, G., Nichterlein, T., Arnold, B., and Hammerling, G. J. (1998). Failure to induce organ-specific autoimmunity by breaking of tolerance: importance of the microenvironment. *Eur. J. Immunol.* *28*, 2395–2406
- Liu, Z., Giudice, G. J., Swartz, S. J., Fairley, J. A., Till, G. O., Troy, J. L., and Diaz, L. A. (1995). The role of complement in experimental bullous pemphigoid. *J. Clin. Invest.* *95*, 1539–1544
- Liu, Z., Shipley, J. M., Vu, T. H., Zhou, X., Diaz, L. A., Werb, Z., and Senior, R. M. (1998). Gelatinase B-deficient mice are resistant to experimental bullous pemphigoid. *J. Exp. Med.* *188*, 475–482
- Liu, Z., Shapiro, S. D., Zhou, X., Twining, S. S., Senior, R. M., Giudice, G. J., Fairley, J. A., and Diaz, L. A. (2000). A critical role for neutrophil elastase in experimental bullous pemphigoid. *J. Clin. Invest.* *105*, 113–123
- Louis, J. A., Chiller, J. M., and Weigle, W. O. (1973). The ability of bacterial lipopolysaccharide to modulate the induction of unresponsiveness to a state of immunity. Cellular parameters. *J. Exp. Med.* *138*, 1481–1495
- Martin, R., McFarland, H. F., and McFarlin, D. E. (1992). Immunological aspects of demyelinating diseases. *Annu. Rev. Immunol.* *10*, 153–187
- Matzinger, P. (1994). Tolerance, danger, and the extended family. *Annu. Rev. Immunol.* *12*, 991–1045
- Matzinger, P., and Anderson, C. C. (2001). Immunity or tolerance: Opposite outcomes of microchimerism from skin grafts. *Nat. Med.* *7*, 80–87
- Mease, P. J., Goffe, B. S., Metz, J., VanderStoep, A., Finck, B., and Burge, D. J. (2000). Etanercept in the treatment of psoriatic arthritis and psoriasis: a randomised trial. *Lancet* *356*, 385–390
- Mican, J. M., and Metcalfe, D. D. (1990). Arthritis and mast cell activation. *J. Allergy Clin. Immunol.* *86*, 677–683
- Mocikat, R., Braumüller, H., Gumy, A., Egeter, O., Ziegler, H., Reusch, U., Bubeck, A., Louis, J., Mailhammer, R., Riethmüller, G., Koszinowski, U., Röcken, M. (2003). Natural killer cells activated by MHC class I(low) targets prime dendritic cells to induce protective CD8 T cell responses. *Immunity* *19*, 561–569
- Mokhtarian, F., McFarlin, D. E., and Raine, C. S. (1984). Adoptive transfer of myelin basic protein-sensitized T cells produces chronic relapsing demyelinating disease in mice. *Nature* *309*, 356–358
- Moradpour, D., and Blum, H. E. (1999). Current and evolving therapies for hepatitis C. *Eur. J. Gastroenterol. Hepatol* *11*, 1199–1202
- Moser, M., and Murphy, K. M. (2000). Dendritic cell regulation of TH1-TH2 development. *Nat. Immunol.* *1*, 199–205
- Moskophidis, D., Lechner, F., Pircher, H., and Zinkernagel, R. M. (1993). Virus persistence in acutely infected immunocompetent mice by exhaustion of antiviral cytotoxic effector T cells. *Nature* *362*, 758–761
- Mosmann, T. R., and Coffman, R. L. (1989). TH1 and TH2 cells: different patterns of lymphokine secretion lead to different functional properties. *Annu. Rev. Immunol.* *7*, 145–173
- Mosmann, T. R., and Sad, S. (1996). The expanding universe of T-cell subsets: Th1, Th2 and more. *Immunol. Today* *17*, 138–146
- Naucler, C. S., Larsson, S., and Moller, E. (1996). A novel mechanism for virus-induced autoimmunity in humans. *Immunol. Rev.* *152*, 175–192
- Ohashi, P. S., Oehen, S., Buerki, K., Pircher, H., Ohashi, C. T., Odermatt, B., Malissen, B., Zinkernagel, R. M., and Hengartner, H. (1991). Ablation of "tolerance" and induction of diabetes by virus infection in viral antigen transgenic mice. *Cell* *65*, 305–317
- Oldstone, M. B., Nerenberg, M., Southern, P., Price, J., and Lewicki, H. (1991). Virus infection triggers insulin-dependent diabetes mellitus in a transgenic model: role of anti-self (virus) immune response. *Cell* *65*, 319–331
- Powrie, F. (1995). T cells in inflammatory bowel disease: protective and pathogenic roles. *Immunity* *3*, 171–174
- Prinz, J. C. (1999). Which T cells cause psoriasis? *Clin. Exp. Dermatol.* *24*, 291–295
- Racke, M. K., Bonomo, A., Scott, D. E., Cannella, B., Levine, A., Raine, C. S., Shevach, E. M., and Rocken, M. (1994). Cytokine-induced immune deviation as a therapy for inflammatory autoimmune disease. *J. Exp. Med.* *180*, 1961–1966

- Rocha, B., and von Boehmer, H. (1991). Peripheral selection of the T cell repertoire. *Science* 251, 1225–1228
- Rock, B., Martins, C. R., Theofilopoulos, A. N., Balderas, R. S., Anhalt, G. J., Labib, R. S., Futamura, S., Rivitti, E. A., and Diaz, L. A. (1989). The pathogenic effect of IgG4 autoantibodies in endemic pemphigus foliaceus (fogo selvagem). *N. Engl. J. Med.* 320, 1463–1469
- Rocken, M., Urban, J. F., and Shevach, E. M. (1992a). Infection breaks T-cell tolerance. *Nature* 359, 79–82
- Rocken, M., Saurat, J. H., and Hauser, C. (1992b). A common precursor for CD4+ T cells producing IL-2 or IL-4. *J. Immunol.* 148, 1031–1036
- Rocken, M., Urban, J., and Shevach, E. M. (1994). Antigen-specific activation, tolerization, and reactivation of the interleukin 4 pathway in vivo. *J. Exp. Med.* 179, 1885–1893
- Rocken, M., and Shevach, E. M. (1996). Immune deviation – the third dimension of nondeletional T cell tolerance. *Immunol. Rev.* 149, 175–194
- Rocken, M., Racke, M., and Shevach, E. M. (1996). IL-4-induced immune deviation as antigen-specific therapy for inflammatory autoimmune disease. *Immunol. Today* 17, 225–231
- Rothe, M. J., Nowak, M., and Kerdel, F. A. (1990). The mast cell in health and disease. *J. Am. Acad. Dermatol.* 23, 615–624
- Rubin, R. L. (1997). *Dubois Lupus Erythematosus*, 5th Edition, D. J. Wallace and B. H. Hahn, eds. (Baltimore: Williams & Wilkens), 871–901
- Schonrich, G., Kalinke, U., Momburg, F., Malissen, M., Schmitt-Verhulst, A. M., Malissen, B., Hammerling, G. J., and Arnold, B. (1991). Down-regulation of T cell receptors on self-reactive T cells as a novel mechanism for extrathymic tolerance induction. *Cell* 65, 293–304
- Schuler, G., and Steinman, R. M. (1997). Dendritic cells as adjuvants for immune-mediated resistance to tumors. *J. Exp. Med.* 186, 1183–1187
- Schuler, G., Thurner, B., and Romani, N. (1997). Dendritic cells: from ignored cells to major players in T-cell-mediated immunity. *Int. Arch. Allergy Immunol.* 112, 317–322
- Schwartz, R. H. (1998). Immunological tolerance. In *Fundamental Immunology*, 4th Edition, W. E. Paul, ed. (Philadelphia, New York: Lippincott-Raven), 701–740
- Sinha, A. A., Lopez, M. T., and McDevitt, H. O. (1990). Autoimmune diseases: the failure of self tolerance. *Science* 248, 1380–1388
- Stenger, S., and Modlin, R. L. (1999). T cell mediated immunity to *Mycobacterium tuberculosis*. *Curr. Opin. Microbiol.* 2, 89–93
- Stockinger, B. (1999). T lymphocyte tolerance: from thymic deletion to peripheral control mechanisms. *Adv. Immunol.* 71, 229–265
- Strober, W., and Ehrhardt, R. O. (1993). Chronic intestinal inflammation: an unexpected outcome in cytokine or T cell receptor mutant mice. *Cell* 75, 203–205
- Tessari, G., Barba, A., and Schena, D. (1996). Lichen ruber planus following the administration of human anti-hepatitis B virus immunoglobulins [letter]. *Acta Derm. Venereol.* 76, 154
- Ulevitch, R. J. (2004). Therapeutics targeting the innate immune system. *Nat. Rev. Immunol.* 4, 512–520
- Vollmer, S., Menssen, A., Trommler, P., Schendel, D., and Prinz, J. C. (1994). T lymphocytes derived from skin lesions of patients with psoriasis vulgaris express a novel cytokine pattern that is distinct from that of T helper type 1 and T helper type 2 cells. *Eur. J. Immunol.* 24, 2377–2382
- von Herrath, M. G., Guerder, S., Lewicki, H., Flavell, R. A., and Oldstone, M. B. (1995). Coexpression of B7–1 and viral (“self”) transgenes in pancreatic beta cells can break peripheral ignorance and lead to spontaneous autoimmune diabetes. *Immunity* 3, 727–738
- Walker, M. R., Kasprovicz, D. J., Gersuk, V. H., Benard, A., Van Landeghen, M., Buckner, J. H., and Ziegler, S. F. (2003). Induction of FoxP3 and acquisition of T regulatory activity by stimulated human CD4+CD25- T cells. *J. Clin. Invest.* 112, 1437–1443
- Webb, S., Morris, C., and Sprent, J. (1990). Extrathymic tolerance of mature T cells: clonal elimination as a consequence of immunity. *Cell* 63, 1249–1256
- Weber, S., Traunecker, A., Oliveri, F., Gerhard, W., and Karjalainen, K. (1992). Specific low-affinity recognition of major histocompatibility complex plus peptide by soluble T-cell receptor. *Nature* 356, 793–796
- Weinberg, A. D., English, M., and Swain, S. L. (1990). Distinct regulation of lymphokine production is found in fresh versus in vitro primed murine helper T cells. *J. Immunol.* 144, 1800–1807

- Wucherpfennig, K. W., and Strominger, J. L. (1995). Molecular mimicry in T cell-mediated autoimmunity: viral peptides activate human T cell clones specific for myelin basic protein. *Cell* 80, 695–705
- Yang, Y., Huang, C. T., Huang, X., and Pardoll, D. M. (2004). Persistent Toll-like receptor signals are required for reversal of regulatory T cell-mediated CD8 tolerance. *Nat. Immunol.* 5, 508–515
- Zhang, J., Hafler, D., Hohlfeld, R., and Miller, A., eds. (1998). *Immunotherapy in neuroimmunologic diseases* (London: Martin Dunitz Ltd)
- Zimmermann, S., Egeter, O., Hausmann, S., Lipford, G. B., Rocken, M., Wagner, H., and Heeg, K. (1998). CpG oligodeoxynucleotides trigger protective and curative Th1 responses in lethal murine leishmaniasis. *J. Immunol.* 160, 3627–3630
- Zinkernagel, R. M. (1996). Immunology taught by viruses. *Science* 271, 173–178



## 2 Epidemiology of Autoimmune Skin Disorders

*Berthold Rzany and Niels Weller*

### Introduction

Epidemiology is for most medical doctors a diffuse subject. It is often associated with biostatistics which most doctors believe to be something impossible to understand and besides that assumed to be of little use. Nevertheless every medical textbook has a section on the epidemiology of a specific disease. This section is unfortunately often a trash can of clinical features, risk factors based on case reports and case series. If data of descriptive and analytical epidemiological studies are presented it is often done unenthusiastically. In the book "Dermatologie und Venerologie" by Braun-Falco et al. (1996) for example the section about the epidemiology of a specific disease is hardly longer than two or three sentences and an independent chapter on epidemiological data is completely missing.

The purpose of this section is to (1) explain what epidemiology really is and (2) to describe, based on the available epidemiological data, a few selected autoimmune diseases of the skin; systemic lupus erythematosus, systemic scleroderma and bullous pemphigoid.

### What is Epidemiology?

Lilienfeld defined epidemiology as the "study of the distribution of a disease or a physiological condition in human populations and of the factors that influence this distribution." (Lilienfeld and Stolley 1994). Epidemiology is an integrative discipline using concepts and methods from other disciplines, such as statistics, sociology and biology, for the study of diseases in a defined population. The general purpose of epidemiology is to explain the etiology of a disease, to evaluate the consistency of these data with etiological hypotheses developed either clinically or experimentally and to provide the basis for developing and evaluating preventive strategies and public health practices. Epidemiology may follow either a descriptive or analytic path.

## Descriptive Epidemiology

The description and frequency of a disease is important to assess the burden of a disease in a defined population. Based on cross-sectional studies, information about prevalence, incidence, and mortality can be obtained. Furthermore ecological studies might lead to hypotheses concerning the etiology of a disease by correlating incidence or mortality with potential risk factors, for example nutritional habits or drug use.

### Incidence/Prevalence

To describe the *morbidity* of a disease, two general types of rates are available: *incidence* and *prevalence*. *Incidence* is defined as the number of new cases of a disease occurring in the exposed population during a specified period of time. It allows a direct estimation of the probability of developing a disease during a specified period of time. Therefore epidemiologists prefer to use incidence to compare the development of disease in different population groups or to determine whether there is a relationship between an estimated etiological factor and a disease (e.g. ecological studies).

*Prevalence* means the number of cases of disease present in a defined population at a specified period in time. This is also called period prevalence in contrast with point prevalence which refers to a specified point in time e.g. a certain day. Prevalence data is useful to the health service administrator in planning medical care services. The prevalence is equal to the incidence multiplied with the average duration of a disease.

### Analytic Epidemiology

Analytic epidemiology deals with the concept of risk. The aim is to assess the strength of a possible association with a potential risk factor. A number of specific analytical study design options can be employed. As only some risk factors can be assessed by an interventional study (e.g. a controlled clinical trial) most analytical studies are based on an observational design: a cohort or case-control studies. In a cohort study, subjects are classified by the presence or absence of exposure to a potential risk factor (e.g. silicon breast implants) and then followed for the development of the disease (e.g. systemic sclerosis). In a case-control study, a group of patients with the disease of interest (e.g. bullous pemphigoid) and a control group (e.g. without bullous pemphigoid) are compared for the proportions of the exposure of interest (e.g. number of malignancies). Risk in cohort studies is measured as relative risk and in case-control studies as Odds-ratio which is an approximation of the relative risk. A relative risk or an Odds-ratio of  $> 1$  points to an increased risk, of  $< 1$  to a decreased risk, i.e. a protective factor (Schlesselmann 1982) (*Table 1*).

**Table 1.** Interpreting Relative Risk (RR) and Odds-Ratio (OR)

RR or OR	Interpretation
< 1	Protective factor
1	No effect
> 1	Risk factor

Case-control studies are the appropriate design if a disease is rare. They are relatively easy and fast to perform, require, however, good skills in designing the study taking into account all possible sources of bias. In particular, potential risk factors associated with different surveillance, diagnosis, referral, or selection of individuals can lead to biased estimates of the relative risk and therefore to wrongful assumptions.

### Evidence Based Medicine and Epidemiology

How comes *evidence based medicine* (EBM) into epidemiology? EBM tries to gather the best available incidence to answer specific questions. EBM starts with a single patient, e.g. a patient with an autoimmune disease. Based on this unique patient, several questions can be raised:

- Is this evidence about harm important?
- Is this evidence about a treatment valid?

Based on a patient with bullous pemphigoid, the questions could be:

- Is there an increased risk for malignancies in this BP-patient? Do I have to consider to screen her/him?
- What is the best treatment for this individual patient?

The tool of EBM is a systematic review. In contrast to an ordinary review, a systematic review is precisely structured to avoid bias. Studies are grouped according to the level of evidence. The highest level of evidence is reserved for randomized controlled trials, the lowest level is the expert opinion. If enough comparable studies are available a systematic review may comprise a meta-analysis. Structured systematic reviews such as the Cochrane review (a Cochrane review is a systematic review inside the Cochrane collaboration) require a lot of time and energy. Furthermore they inherit a commitment to update them continuously. For autoimmune diseases of the skin so far three complete systematic reviews focusing on treatment questions exist (*Table 2*).

If no systematic review is available, tools exist that allow the critical appraisal of papers to answer the above questions. This might be elaborate but worthwhile. However, in the end the responsible physician has to answer

**Table 2.** Systematic Reviews on Autoimmune Diseases by the Cochrane Skin Group (www.cochrane.org 2004)

Author	Title of Review	Status of Review
Jessop S, Whitelaw D, Jordaan F	Drug treatments for discoid lupus erythematosus (Cochrane Review)	Complete Review
Khumalo N, Kirtschig G, Middleton P, Hollis S, Woinarowska F, Murrell DF	Interventions for bullous pemphigoid (Cochrane Review)	Complete Review
Kirtschig G, Murrell D, Wojnarowska F, Khumalo N	Interventions for mucous membrane pemphigoid and epidermolysis bullosa, acquisita	Complete Review

the final question if the gathered valid evidence can be applied to the individual patient.

## Descriptive and Analytic Epidemiology of Specific Autoimmune Skin Disorders

### Systemic Lupus Erythematosus (SLE) and Chronic Discoid Lupus Erythematosus (CDLE): Incidence/Prevalence

SLE and CDLE are quite frequently compared to other cutaneous autoimmune diseases. Incidence rates for SLE increased from 2/100,000 in the early 1960s to 4.6–7.6/100,000 in the 1970s. Prevalence rates of 17–48/100,000 population have been determined for the sixties worldwide (Siegel and Lee 1973; Fessel 1974; Hochberg 1985; Michet et al. 1985). Recent publications even point to an incidence rate of 5.56/100,000 and a prevalence rate of 130/100,000 (Uramato et al. 1999). The difference may not show a real increase for SLE but be explained by the use of different diagnostic criteria (i.e. different revisions of the ARA/ACR criteria) and different surveillance methods. Nevertheless incidence rates differ for gender and race (*Table 3*).

The highest incidence with rates for females of 10.5 and 18.4/100,000/year was seen in age groups 40–49 and 50–59 year, respectively. Hopkinson et al. (1994) found also race specific differences in prevalence. The overall one year period prevalence was 207 (age adjusted 95% CI: 111–302)/100,000 for Afro-Caribbeans, 48.8 (10.5–87.1)/100,000 for Asians, and 20.3 (16.6–24.0)/100,000 for Caucasians (Hopkinson et al. 1993; Hopkinson et al. 1994). In children, SLE is a rather rare disease (*Table 4*).

Although exact population-based epidemiological data are lacking, it is presumed that CDLE occurs 2–3 times more often than SLE. In selected groups of LE patients, the percentage of CDLE patients varies from 42–72% (Kind

**Table 3.** Gender Specific Incidence and Prevalence Rates for SLE in the UK (Hopkinson et al. 1993) and in the US (Jakobson et al. 1997)

Author	Incidence per 100,000/year in females	Incidence per 100,000/year in males	Prevalence per 100,000/year in females	Prevalence per 100,000/year in males
Hopkinson et al. (1993)	6.5	1.5	45.5	3.7
Jacobson et al. (1997)	6.4	0.9	20.9	2.9

**Table 4.** Annual Incidence Rates of SLE in the Childhood Population of Different Countries

Authors	Country and year of study	Incidence per 100,000 childhood population
Fujikawa and Okuni (1997)	Japan 1984–1994	0.47
Pelkonen et al. (1994)	Finland 1986	0.37
Kaipainen-Seppänen and Savolainen (1996)	Finland 1990	0.80

and Goerz 1987), whereas SCLE is found in 7–32% of the patients (Sontheimer et al. 1979; Molad 1987; Weinstein 1987; Mooney and Wade 1989).

#### *Risk Factors that Induce SLE*

Risk factors might be divided into factors that induce the disease and risk factors that effect the prognosis of the disease. Several risk factors have been evaluated and identified for SLE (*Table 5*). One risk factor is the presence of CDLE and/or SLE in the family. Lawrence et al. reported (1987) that 3.9% of first degree relatives of SLE patients and 2.6% of first degree relatives of CDLE patients developed SLE, compared with only 0.3% of the controls. Similar results were obtained by Cooper et al. who found a history of lupus in a parent or sibling in 15 (6%) cases and 7 (2%) controls (2002b). In contrast, there was no elevated risk for first degree relatives of SLE patients to develop CDLE whereas 3.5% of CDLE family members compared with 0.5% of the controls developed CDLE (Lawrence et al. 1987).

Smoking is also discussed to be a risk factor for both SLE and CDLE. Nagata et al. (1995) were able to show an increased risk of SLE for smoking (OR: 2.31; 95% confidence interval (CI) 1.34–3.97). However, in a recent study Cooper et al (2001) were not able reproduce these results for either current and previous smokers. Smoking is also discussed to be a risk factor for CDLE. Gallego et al. (1999) showed in a case-control-study based on 28 CDLE patients and 112 matched controls, and in addition by comparing a second set of 20 CDLE patients to statewide smoking prevalence data that smoking

**Table 5.** Risk Factors that May Induce Systemic Lupus Erythematosus

Risk factor studied (author, year)	Study design Size of study	Odds Ratio (95% CI)
Positive family history (Nagata et al. 1995)	Case-control study 282 cases/292 controls	5.20 (1.08–24.95)
History of lupus in parents or siblings (Cooper et al 2002b)	Case-control study 265 cases/355 controls	3.3 (1.2-8.6) *
Smoking (Nagata et al. 1995)	Case-control study Case-control study	2.31 (1.34–3.97)
Current smoking (Cooper et al. 2001)	Case-control study 265 cases/355 controls	1.1 (0.7-1.7) *
Crystalline silica dust (Parks et al. 2002)	Case-control study 265 cases/355 controls	2.2 (1.1-4.0) medium exposure* 4.6 (1.4-15.4) high exposure*
Postmenopausal Estrogen Therapy (Sánchez-Guerrero et al. 1995a) (Meier et al. 1998)	Prospective cohort study 69,435 Case-control study 75 cases/295 controls	2.1 (1.1–4.0) 2.8 (0.9–9.0)
Use of oral contraceptives (Cooper et al. 2002a)	Case-control study 240 cases/321 controls	1.3 (0.9, 2.1)
Breast feeding (Cooper et al. 2002a)	Case-control study 240 cases/321 controls	0.6 (0.4, 0.9)
Allergy to medications Particularly to antibiotics (Cooper et al. 2002b)	Case-control study 265 cases/355 controls	3.1 (2.1-4.5) *
History of shingles (Cooper et al. 2002b)	Case-control study 265 cases/355 controls	2.5 (1.1-5.9) *
Cold sores (Cooper et al. 2002b)	Case-control study 265 cases/355 controls	2.8 (1.4-5.4) *

is a risk factor for CDLE, too. In the CDLE patients, the prevalence of smoking was 83% (23 of 28) compared to 22% (25 of 112) in the control group (OR = 12.2, with  $p = 0.001$ ). They also found, that the 23 CDLE smokers smoked significantly more than the 25 control smokers (mean, standard deviation and range: CDLE 1.43 (0.56) 0.5 to 2.5 packs/day; control 0.71 (0.44) 0.05 to 1.5 packs/day;  $p = 0.0001$ , Wilcoxon's rank sum test). The second set of patients showed 15 of 20 to be smokers, resulting in a smoking rate of 75% which exceeded three times the 1992 to 1993 smoking rate for the general population of Minnesota (25,1%) (Shopland et al. 1996; Gallego et al. 1999). These results suggest that CDLE is largely a disease of chronic, particularly heavy smokers. Nevertheless other potential confounding factors as alcohol were not considered in this study.

Besides smoking, female hormones seem to be an important risk factor. Sánchez-Guerrero et al. (1995a) reported an increased relative risk of developing SLE for longer term (5–10 years) postmenopausal estrogen users compared with nonusers of 2.7 (95% CI 1.2–6.4). In a population-based, case-control study, using the UK-based General Practice Research Database (GPRD) (Jick et al. 1991; Walley and Mantgani 1997), Meier et al. (1998) analyzed 34 cases with CDLE, 41 cases with SLE and 295 age, gender and practice matched controls. After adjusting for body mass index, hysterectomy, oophorectomy, and smoking status, the RR estimate for current use versus nonuse was 1.5 (95%, CI 0.7–3.7) for SLE, 2.3 (0.8–6.7) for CDLE, and 1.7 (0.9–3.2) for CDLE and SLE combined. Never and former users were combined into a single group of nonusers, because former users did not show an increased risk. The adjusted OR for current estrogen use of a duration of less than 25 months and of 25 months or more, as compared to nonuse, were 0.7 (0.3–2.1) and 2.8 (1.3–5.8;  $p = 0.008$ ), respectively. Exposure to 1200 or more cumulative defined daily doses (DDD) resulted in elevated RR estimates (adjusted OR 2.8, 95% CI 1.1–7.2), whereas low cumulative estrogen doses of 500 or less DDD did not increase the relative risk estimates compared to nonuse. These results have been confirmed by other authors. In the Nurses Health Study, the long-term use of opposed estrogens was associated with a 2- to 3- fold increased age adjusted RR estimate (Sánchez-Guerrero et al. 1995). In addition Meier et al. (1998) found an increased risk of developing SLE and CDLE for current estrogen users compared to nonusers. This effect showed a distinct dose and duration dependency, which has been documented independently for SLE and for DLE. In contrast Cooper et al (2002a) found only little evidence that estrogen- or prolactin-related exposures were associated with an increased risk of lupus. In this study an inverse association of breast feeding and lupus was found (OR 0.6, CI 0.4–0.9). Cooper et al. (2002a) also states that natural menopause occurred earlier in women with SLE and that this finding was not considered in the Nurses Health Study.

A role for infectious agents as a risk factor for SLE has been postulated for many years (Strom et al. 1994). SLE may be the cause of an aberrant response or lack of immune control of a response to a pathogen. Cooper et al. (2002b) focused in one of her recent case-control studies on infections. She was able to show an increased risk for SLE with a past history of shingles 2.5 (95%, CI 1.1–5.9) as well as cold sores 2.8 (95%, CI 1.4–5.4).

Several studies dealt with the question whether breast implants increase the risk of acquiring any of the connective tissue diseases or not. The results will be reported in more detail in the part about systemic sclerosis. However, in studies of good grades of recommendation (Ball et al. 1999), no evidence has been found that silicone gel-filled breast implants increase the risk of developing SLE.

### **Risk Factors that Effect the Prognosis of SLE**

Renal insufficiency is a threatened outcome of SLE. Several studies tried to identify risk factors that effect the prognosis of SLE. Race is one of the speculated factors. Hopkinson et al. (2000) calculated a hazard rate ratio of 4.4 (95% CI 1.9–10.2) for Afro-Caribbeans to develop renal SLE compared with Caucasians. Johnson et al. (1994) showed in a cross-sectional analysis of SLE patients from Brazil, Sweden and England, that non-Caucasians had more active disease than Caucasians, indicating ethnic and environmental influences. Brazilian patients were most likely to develop renal disorders, English patients experienced most often photosensitivity, oral ulcers and hematological disorders and Swedish patients discoid rashes. Another risk factor might be the socio-economic status of the patient. According to Karlson et al. (1995, 1997) private insurance and higher education are associated with less disease activity at diagnosis and therefore with fewer side effects caused by the disease.

Rzany et al. (1996) showed in a study of 282 SLE patients, that younger (0–19 years) or older ( $\geq 40$  years) age at baseline (entry into the study group) is associated with a higher risk of developing hypercreatinemia (RR 5.13; 95% CI 1.4–18.8 and 4.09; 2.1–8.2, respectively). Other factors that increase the risk of renal damage are involvement of other organ systems, namely serositis (RR 2.17; 1.1–4.3) and as a trend neurologic lupus (RR 1.96; 1.0–4.0), immunosuppressive treatment (excluding prednisone) at baseline (RR 2.39; 1.0–5.6) and the presence of anti-dsDNA antibodies (RR 1.17; 1.0–1.4). Longer duration of the disease at baseline led to a 25% (10%–50%) increase in risk for every five years.

### **Morphea and Systemic Sclerosis (SSc): Incidence and Prevalence**

Incidence and prevalence rates of SSc have been investigated in different large population based studies all over the world. Incidence data is rare which might be due to the fact that the definite time of onset of this disease is more difficult to determine. Incidence rates are lower than for SLE with a range of 3.7 to 19/106 inhabitants per year (Kaipiainen-Seppänen and Aho 1996; Mayes et al. 1996) and even more rare in children (Pelkonen et al. 1994; Fujikawa and Okuni 1997). Prevalence rates for SSc are higher ranging from 31 to 350 patients/106 inhabitants per year – pointing to an overall more benign disease (Asboe-Hansen 1985; Michet et al. 1985; Silman et al. 1988; Maricq et al. 1989; Tamaki et al. 1991; Geirsson et al. 1994; Mayes et al. 1996; Valter et al. 1997; Englert et al. 1999; Mayes et al. 2003).

Morphea seems to be more common. Peterson et al. (1997) investigated incidence and prevalence of morphea patients in Olmsted County, Minnesota from 1960–1993. They reported an annual age and sex adjusted incidence rate of 2.7/100,000 population (95% CI 2.1–3.3). The incidence rate



**Table 6.** Annual Incidence Rates of Systemic Sclerosis in Different Populations

Authors	Country and year	Incidence per 1 Mio.
Pelkonen et al.(1994)	Finland 1986	0.5 *
Kaipainen-Seppänen and Aho (1996)	Finland 1990	3.7
Mayes et al. (1996)	United States 1991	19
Fujikawa and Okuni (1997)	Japan 1984–94	0.1 *

**Table 7.** Prevalence Rates of Systemic Sclerosis in Different Countries

Authors	Country and year	Prevalence per 1 Mio.	Prevalence per 1 Mio. females
Asboe-Hansen et al. <sup>2</sup> (1985)	Denmark <sup>3</sup>	126	n. e.
Michet et al. <sup>1</sup> (1985)	United States 1950–79	138	255
Silman et al. <sup>1</sup> (1988)	Great Britain <sup>3</sup>	31	48
Maricq et al. <sup>1</sup> (1989)	United States <sup>3</sup>	112	n. e.
Tamaki et al. <sup>1</sup> (1991)	Japan 1988	38	n. e.
Geirsson et al. <sup>1</sup> (1994)	Iceland 1975–90	71	119
Mayes et al. <sup>1</sup> (1996)	United States 1991	240	n. e.
Valter et al. <sup>1</sup> (1997)	Estonia <sup>3</sup>	350	540
Englert et al. <sup>1 4</sup> (1999)	Australia 1974–1988	40.7 (1974) 86.2 (1988)	65.8 (1974) 137.6 (1988)
Mayes et al. <sup>1</sup> (2003)	United States 1989-1991	242 [213-274]	398 (95% CI 353-430).

increased on an average of 3.6% per year over the whole period. The prevalence of morphea was 220/100,000 population.

#### *Risk Factors for SSc*

As for SLE a family history of SSc increases the risk of SSc. An estimated prevalence of approx. 1% of SSc in relatives was calculated in a recent study of Englert et al. (1999) based on 715 sclerosis patients and 371 controls. Possible risk factors for SSc were for a long time only in the focus of a few selected scientists. Everything changed when silicon implants were suspected as possible risk factors in a few case series. Miyoshi et al. (1964) were the first to report the development of connective tissue diseases (CTD) in cosmetic surgery patients who had received injections of foreign substances. Van Numen et

al. (1982) reported three different cases of CTD in women with silicone breast implants (SLE, MCTD, and rheumatoid arthritis (RA) with Sjogren's syndrome). In 1984, Kumagai et al. summarized the Japanese experience, reporting 24 cases of defined CTD in breast augmentation patients who had received injections of either paraffin or silicone. They suspected that a possible excess of scleroderma was primarily in patients injected with paraffin. Subsequently, case reports have included RA (Van Numen et al. 1982; Hammer and Krippner 1991), SLE (Van Numen et al. 1982; Guillaume et al. 1984), SSc (Spiera 1988; Gutierrez and Espinoza 1990; Marik et al. 1990), Sjogren's Syndrome (Van Numen et al. 1982; Haga et al. 1992), dermatomyositis/polymyositis (Haga et al. 1992) and MCTD (Van Numen et al. 1982). These cases from many different countries demonstrated world-wide concern and several epidemiological studies were initiated. Some studies focused on scleroderma alone (Weisman et al. 1988; Burns 1994; Englert and Brooks 1994; Hochberg et al. 1996), others on CTD, comprising a variety of diagnoses (Schusterman et al. 1993; Gabriel et al. 1994; Giltay et al. 1994; Goldman et al. 1995; Perkins et al. 1995; Sánchez-Guerrero et al. 1995b; Park et al. 1997; Edworthy et al. 1998; Nyrén et al. 1998). The relative risks in Tables 8–11 are for CTD if not indicated otherwise. Results for the different specified CTD (mostly SSc) are given in the text as far as available.

The first report, whose results could be compared with other studies came from Spiera (1988) of New York City, who reported that five of his 113 new female SSc patients had breast implants as had one of his 286 RA patients, and none of his patients with SLE or polymyositis. The next comparative report of SSc and breast implants from Wigley et al. (1992) stated that 1% of female SSc patients in Baltimore and Pittsburgh had breast implants and that 50% of them had received their implant only after the disease had begun or had been diagnosed. The pre-diagnosis implant prevalence was not different from the prevalence estimated for U.S. adult females. The cohort study

**Table 8.** Different Cross-Sectional Studies about Breast Implants (BI) as a Risk Factor for CTDs

Authors	Design	Size BI/No BI	Average follow-up time in years	No. of CTDs in women with BI/No BI	Relative Risk of developing a CTD (95% CI)
Goldman et al. (1995) (US)	Cross-sectional clinical-based	150/4079	10	12/709	0.52 (0.29–0.92)‡
Park et al. (1997) (UK)	Cross-sectional prevalence study	317/216	5.8	0/0	0*

‡ = Adjusted RR

\* = 95% CI not calculated

**Table 9.** Different Cohort Studies about Breast Implants as a Risk Factor for CTD

Authors	Design	Size BI/No BI	Average follow-up time in years	No. of CTDs in women with BI/No BI	Relative Risk of developing a CTD (95% CI)
Weisman et al. (1988) (US)	Clinical practice-based cohort study	125/0	7	0	0
Schusterman et al. (1993) (US)	Hospital-based cohort study	250/353	2.5	1/1	1.08 (0.1–17.2)
Wells et al. (1994) (US)§	Clinical practice-based cohort study	222/80	4	11/2	1.16 (0.15–9.04)‡
Giltay et al. (1994) (Netherlands)	Hospital-based cohort study	235/210	6.5	2/4	0.44 <sup>1</sup>
Gabriel et al. (1994) (US)	Population-based cohort study	749/1498	8	5/10	1.06 (0.34–2.97)
Sanchez-Guerrero et al. (1995b) (US)	Retrospective Cohort-study	1183/86318	9.9	3/513	0.6 (0.2–2.0)‡ 0.3 (0–1.9)‡#
Hennekens et al. (1996) (US & Puerto Rico)	Retrospective cohort-study	10830/38471 n. i. 3		231/11574	1.24 (1.08–1.41)

<sup>1</sup> According to Perkins et al. (1995)

\* BI = Number of women with breast implants

‡ Adjusted RR

§ Results for Rheumatoid Arthritis (RA) only, no cases of other CTD were identified

# RR for silicone.gel-filled implants only

from Gabriel et al. (1994) reported on 749 women who received breast implants between 1964 and 1991 in Olmsted County, Minnesota and on 1498 matched controls. This study is a population based cohort-study. Breast implant patients were followed through community-based medical records for an average of about eight years after the procedure. Five of the breast implant patients and 10 control patients suffered from one of the specified CTD (Relative Risk = 1.06, 95% CI 0.34–2.97) (Gabriel 1994).

The cohort study from Goldman et al. (1995) reported on 150 cases and 4079 controls. 17% (721) of the 4229 women participating in the study had been diagnosed as having RA and/or CTD. 3.5% (150) of the study women had breast implants. These patients as a group differed significantly from those without breast implants by age at first visit, income, and period of first visit, but not by marital status or by duration of observation. 85% of the breast implant recipients (128/150) had silicone gel breast implants. Of 150 breast

**Table 10.** Different Case-Control Studies about Breast Implants as a Risk Factor for CTD

Authors	Design	Size Cases/ controls	Average follow-up time in years	No. of CTDs in cases/ control	Relative Risk of developing a CTD (95% CI)
Nyrén et al. (1998) (Sweden)	Retrospective case-control cohort study	7442/3353	8	16/11	0.8 (0.5–1.4)‡
Edworthy et al. (1998) (Canada)	Blinded case-control cohort study	1576/727	n. i.	17/16	1.0001 (0.45–2.22)‡

‡ Adjusted RR

**Table 11.** Results of the Meta-Analyses by Perkins et al. (1995) Based on 13 Studies (one Cross-Sectional, 6 Cohort and 6 Case-Control Studies)

Authors	No. of participating Studies	Relative Risk of developing a CTD	95% CI for RR	Homogeneity p-value
Perkins et al. (1995)	13	0.73	0.53–0.99	0.22

implant recipients nine had RA, one had SLE, two had Sjogren's syndrome and nobody had SSc. Among the 4079 nonrecipients, 383 had RA and 341 (8.4%) had diffuse CTD. SLE was diagnosed in 179 (4.4%) of the non-recipients. Dermatomyositis/polymyositis, SSc, and MCTD ranged between 0.9 and 1.6%. Of the three women with breast implantation and a CTD, only one developed disease after surgery (SSc, 8 year later).

Nyrén et al. (1998) conducted a large population-based prospective study in Sweden, where little publicity has occurred, thus lessening the risk of bias in ascertainment and reporting, that covered 7442 women who had received breast implants divided into a subcohort with breast reconstruction after surgery ( $n = 3942$ ) and a subcohort with breast implants for other, mainly cosmetic reasons ( $n = 3353$ ). One control, matched for hospital, age, and calendar year at operation, for each of the women with cosmetic surgery was drawn from 33,668 women who had undergone breast reduction surgery. They compared the observed numbers of hospitalizations for connective tissue disease with the expected numbers of these events. They calculated the expected values, by counting the national rates of first hospitalizations by age, sex, and calendar year, for each of the single specified diagnoses and for all the definite connective tissue diseases combined, and then multiplied the observed number of person years by these national rates. They used the standardized

hospitalization ratio (the ratio of observed to expected numbers of fist hospitalizations) as a measure of relative risk and calculated 95% CI. The women in the breast implant cohort were followed for an average of eight years, corresponding to 59,592 person years at risk. Those with breast reduction were followed an average of 9.9 years, thus accumulating 33,288 person years. Twenty-nine patients developed one or more of the diseases compared with 25.5 expected cases (standardized hospitalization ratio 1.1 (95% CI 0.8–1.6). No significant excess risk for SLE was detected and none of them developed SSc. Among the women with breast reduction surgery there were 14 cases of definite CTD compared with 10.5 expected (standardized hospitalization ratio 1.3 (95% CI 0.7–2.2).

A report by Hennekens et al. (1996) indicated a slight overall increase in the relative risk for CTD of 1.24 (95% CI 1.08–1.41;  $p = 0.0015$ ). Borderline statistically significant increases in the incidence of dermatomyositis and SSc RR = 1.52 (95% CI 0.97–2.37;  $p = 0.068$ ), and 1.84 (95% CI 0.98–3.46;  $p = 0.060$ ), respectively occurred. The findings for SLE were not statistically significant, RR = 1.15 (95% CI 0.81–1.63;  $p = 0.44$ ). This study was based on the self-report of responders to a survey which had not been validated by chart review, nor had the type of implant been identified. Therefore no comment can be made regarding the risks of silicone gel breast implants.

A case control study by Englert and Brooks (1994) studied 251 SSc cases and compared them with age-matched controls who were chosen at random from 28 general practitioners. The direct standardized rate of augmentation mammoplasty in the Australian population adjusted for socioeconomic status was found to be 1.68% (1.65–1.71%). The adjusted RR (adjusted for socioeconomic status) for augmentation mammoplasty patients to develop SSc was 0.89 (0.23–3.41). A second population-based case/control study of SSc and augmentation mammoplasty was reported from the State of Michigan by Burns (1994). The OR for silicone breast implants was 0.72 (0.16–3.21) and for all breast implants was 0.61 (0.14–2.68). No case of SSc had been observed in women with breast implants. Based on the SSc frequency among the study women without implants, more than two cases of SSc would have been expected. Hochberg and Perlmutter (1996) identified an OR of 1.11 (0.55–2.24) for developing SSc after augmentation mammoplasty in their study of 837 cases with 2507 controls.

A recent meta-analysis, that included 13 studies (6 case-control, 6 cohort and one cross-sectional study) estimated an overall RR of 0.73 (0.53–0.99; homogeneity  $p = 0.22$ ) for women with silicone implants of developing CTD (*Table 10*) and 0.91 (0.52–1.52; homogeneity  $p = 0.11$ ) for SSc alone (Perkins et al. 1995).

Even without scientific evidence for an increased risk of the CTDs after breast implant surgery the American legal system awarded high sums of money to questionable victims. The controversies surrounding these alleged relationships have been judged to be among the most contentious, costly, and dangerous event ever to occur in women's health (Connell et al. 1998).

Fortunately now the focus of research is shifting to other possible risk factors. In a recent study from Pisa et al. (2002) reproductive factors were investigated. Among 46 female patients with SSc and 153 female control subjects a reduced risk of SSc was found for parous women compared to nulliparous women (OR of 0.3 (95% CI 0.1–0.8). This finding should encourage further research into this area.

### **Bullous Pemphigoid**

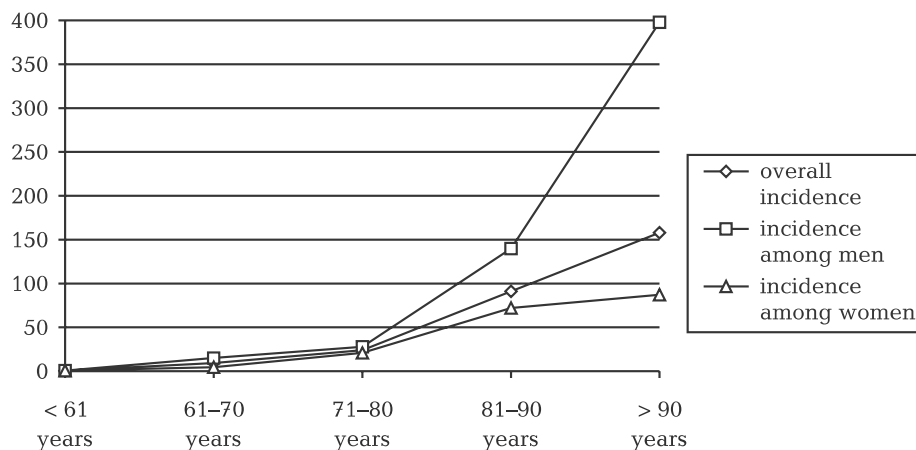
Among the autoimmune bullous diseases, most epidemiological data is restricted to bullous pemphigoid (BP).

#### *Incidence/Prevalence*

BP is the most frequent autoimmune bullous disease in Europe. In several studies, the incidence has been estimated to range from 6.6 newly diagnosed cases per one million per year for northwest Bavaria (Zillikens et al. 1995) to seven newly diagnosed cases per one million per year for three regions in France (Bernard et al. 1995). Other estimations for the incidence of BP range from 10 for Bristol, U.K. (Grattan 1985) and 30 newly diagnosed cases per one million per year for Geneva, Switzerland (Masouyé et al. 1998). However, for the U.K. and Switzerland, these numbers are only quoted as rough estimates. In a German study from participants of the German Bullous-Diseases-Group (BSD) (Jung et al. 1999), age and gender specific incidences of BP based on two regions in Germany (Mannheim and Lower Franconia) comprising a total population of 1.7 million inhabitants were reported. This study reported a crude incidence rate of 6.1 (2.2, 13) new cases per one million inhabitants per year and an overall age-adjusted incidence of BP of 8.7 (3.9, 17) for men, and 4.9 (1.6, 12) for women per one million inhabitants per year. Incidences increased with age. The incidence for patients over 60 years was 20.3 per one million inhabitants per year. The highest risk was found for patients > 90 years (*Fig. 1*). This data point to BP as one of the emerging diseases of the elderly which should be addressed with an increased public health concern as the structure of the European population is shifting towards the aged.

#### *Risk Factors*

Several risk factors have been associated with BP. Besides drugs (Bastuji-Garin et al. 1996) the rate of malignancies has been reported to be increased in BP patients. In two previous case-control studies, a trend towards an increased risk with an OR of 1.36 (0.54, 3.57) (Stone and Schroeter 1975) or a slightly increased risk for malignancies with an OR of 3.84 (1.49, 10.05) (Venning and Wojnarowska 1990; Venning et al. 1991) has been found (*Table 12*). In



**Fig. 1.** Incidence for bullous pemphigoid per one million inhabitants per year in Germany (Jung et al. 1999)

our own study from Mannheim, malignancies were reported with an increased proportion in 20% (12/61) of the BP patients and 10% (20/204) of the control patients. The overall risk found (95% CI) was 1.6 (0.8, 3.4). However, when stratifying for gender, the univariate risk for female BP patients increased to 10 (2.5, 66) (Rzany et al. 2000). Although these results are based on a small sample, the increased risk of malignancies in BP patients and that point in time we do not know of the prognosis can be significantly changed when a tumor is found. These findings warrant a thorough tumor screening of these patients.

### Summary

Epidemiology is an important science that might lead to relevant information on the frequency of a disease and the risk factors associated with a disease thus allowing the distribution of health care resources and the planning of preventive measures. An epidemiological study is only as good as the design it is based on. A stringent design tries to minimize bias and therefore errors in the interpretation of the results of a study. Study design is determined by the frequency of a disease. For rare diseases – such as cutaneous autoimmune diseases – the cross-sectional or case-control design will lead to the fastest results. If several studies with inconclusive or controversial results are available, different studies can be polled together in a meta-analysis which was shown for breast implants and CTD where cross-sectional studies, cohort studies and case control studies were analyzed together (Perkins et al. 1995).

**Table 12.** Case-Control Studies on the Risk of Malignancies in BP Patients

Author Year Country	No. of cases Age (A) Gender (G)	No. and diagnosis of controls	Risk factor investigated	Odds-Ratio or p-value
Stone and Schroeter 1975 USA	N = 73 A: 63 years G: 52% (38/73) female	two, matched for age, gender and year of diagnosis N = 146 (73 patients with contact dermatitis and 73 with psoriasis)	Malignancies (five years before and after the diagnosis of disease)	8 versus 10 (psoriasis), 11 (contact dermatitis) respectively (n.s.) OR 1.36 (0.54, 3.57) the skin
Venning and Wojnarowska 1990 UK	N = 84 A: 74 years G: 54% (45/84) female	two, matched for age, gender and year of diagnosis N = 168 (patients with leg ulcers and minor dermatological operations)	Malignancies	15 (17.9%) versus 9(5.4%) (p < 0.01) OR 3.84 (1.49, 10.05)
Rzany et al. 2000 Germany	61  28 (only females)	204 matched for gender, age, year of diagnosis  97 (only females) matched for age, year of diagnosis	Malignancies (five years before and after the diagnosis of the skin disease)  Malignancies (five years before and after the diagnosis of the skin disease)	10 (16%) versus 20 (10%) OR 1.8 (0.8, 4.1)  7 (25%) versus 3 (3%) OR 10 (2.5, 66)

## References

- Asboe-Hansen G (1985) Epidemiology of progressive systemic sclerosis in Denmark. In: Black CM, Myers AR (eds) *Systemic Sclerosis (Scleroderma)*. Gower, New York, p 78
- Ball C, Sackett D, Phillips B, Haynes B, Straus S (1999) Levels of evidence and grades of recommendations
- Bastuji-Garin S, Joly P, Picard-Dahan C, Bernard P, Vaillant L, Pauwels C, Salagnac V, Lok C, Roujeau JC (1996) Drugs associated with bullous pemphigoid. A case-control study. *Arch Dermatol* 132: 272–276
- Bernard P, Vaillant J, Labeille B, Bedane C, Arbeille B, Denoeux JP et al. (1995) Incidence and distribution of subepidermal bullous skin diseases in three french regions. *Arch Dermatol* 131: 48–52
- Braun-Falco O, Plewig G, Wolff HH (1996) *Dermatologie und Venerologie*, 4th edn Springer, Berlin Heidelberg New York
- Burns CG (1994) The epidemiology of systemic sclerosis: a population-based case-control study, PhD dissertation (Epidemiological Sciences), University of Michigan



- Connell EB (1998) The exploitation of autoimmune disease: breast implant litigation and its dire implications for women's health. *J Womens Health* 7: 329–338
- Cooper GS, Dooley MA, Treadwell EL, St. Clair WE, Gilkeson GS (2001) Smoking and use of hair treatments in relation to risk of developing systemic lupus erythematosus. *J Rheumatol* 28(12): 2653–2656
- Cooper GS, Dooley MA, Treadwell EL, St. Clair EW, Gilkeson GS (2002a) Hormonal and Reproductive Risk Factors for Development of Systemic Lupus Erythematosus. *Arthritis Rheum* 46: 1830–1839
- Cooper GS, Dooley MA, Treadwell EL, St. Clair EW, Gilkeson GS (2002b) Risk factors for development of systemic lupus erythematosus: Allergies, infections, and family history. *J Clin Epidemiol* 55: 982–989
- Cooper GS, Stroehla BC (2003) The epidemiology of autoimmune diseases. *Autoimmun Rev* 2: 119–125
- Edworthy SM, Martin L, Barr SG, Birdsell DC, Brant RF, Fritzler MJ (1998) A clinical study of the relationship between silicone breast implants and connective tissue disease. *J Rheumatol* 25: 254–260
- Englert HJ, Brooks P (1994) Scleroderma and augmentation mammoplasty – a causal relationship? *Austr NZ J Med* 24: 74–80
- Englert H, Small-McMahon J, Chambers P, O'Connor H, Davis K, Manolios N, White R, Dracos G, Brooks P (1999a) Familial risk estimation in systemic sclerosis. *Aust N Z J Med* 29: 36–41
- Englert H, Small-McMahon J, Davis K, O'Connor H, Chambers P, Brooks P (1999b) Systemic Sclerosis prevalence and mortality in Sydney 1974–88. *Aust NZ J Med* 29: 42–50
- Fessel WJ (1974) Systemic lupus erythematosus in the community. Incidence, prevalence, outcome, and first symptoms; the high prevalence in black women. *Arch Intern Med* 134: 1027–1035
- Fujikawa S, Okuni M (1997) A nationwide surveillance study of rheumatic diseases among Japanese children. *Acta Paediatr Jpn* 39: 242–244
- Gabriel SE, O'Fallon WM, Kurland LT, Beard CM, Woods JE, Melton LJ (1994) Risk of connective-tissue diseases and other disorders after breast implantation. *N Engl J Med* 330: 1697–1702
- Gallego H, Crutchfield CE, Lewis EJ, Gallego HJ (1999) Report of an association between discoid lupus erythematosus and smoking. *Cutis* 63: 231–234
- Geirsson AJ, Steinsson K, Guthmundsson S, Sigurthsson (1994) Systemic sclerosis in Iceland: A nationwide epidemiological study. *Ann Rheum Dis* 53: 502–505
- Giltay EJ, Moens HJB, Riley AH, Tan RG (1994) Silicone breast prostheses and rheumatic symptoms: a retrospective follow-up study. *Ann Rheum Dis* 53: 194–196
- Goldman JA, Greenblatt J, Joines R, White L, Aylward B, Lamm SH (1995) Breast implants, rheumatoid arthritis, and connective tissue diseases in a clinical practice. *J Clin Epidemiol* 48: 571–582
- Grattan CEH (1985) Evidence of an association between bullous pemphigoid and psoriasis. *Br J Dermatology* 113: 281–283
- Guillaume JC, Roujeau JC, Touraine R (1984) Systemic lupus after breast prosthesis. *Ann Dermatol Venerol* 111: 703–704
- Gutierrez FJ, Espinoza LR (1990) Progressive systemic sclerosis complicated by severe hypertension: reversal after silicone implant removal. *Am J Med* 89: 390–392
- Haga HJ, Haaland P, Haga T (1992) Silicone breast implants and collagen diseases. *Tidsskr Nor Laegeforen* 112: 763–764
- Hammer M, Krippner H (1991) Three cases of chronic polyarthritis after silicon implantation (breast augmentation): causal relationship? *Immun Infekt* 19: 62–63
- Hennekens CH, Lee IM, Cook NR, Hebert PR, Karlson EW, LaMotte F, Manson JAE, Buring JE (1996) Self-reported breast implants and connective-tissue diseases in female health professionals – A retrospective cohort study. *JAMA* 275: 616–621
- Hochberg MC (1985) The incidence of lupus erythematosus in Baltimore, Maryland 1970–1977. *Arthritis Rheum* 28: 80–86
- Hochberg MC, Perlmutter DL, Medsger TA Jr, Nguyen K, Steen V, Weisman MH, White B, Wigley FM (1996) Lack of association between augmentation mammoplasty and systemic sclerosis (scleroderma). *Arthritis Rheum* 39: 1125–1131

- Hopkinson ND, Doherty M, Powell RJ (1993) The prevalence and incidence of systemic lupus erythematosus in Nottingham, UK, 1989–1990. *Br J Rheumatol* 32: 110–115
- Hopkinson ND, Doherty M, Powell RJ (1994) Clinical features and race-specific incidence/prevalence rates of systemic lupus erythematosus in a geographically complete cohort of patients. *Ann Rheum Dis* 53: 675–680
- Hopkinson ND, Jenkinson C, Muir KR, Doherty M, Powell RJ (2000) Racial group, socioeconomic status, and the development of persistent proteinuria in systemic lupus erythematosus. *Ann Rheum Dis* 59: 116–119
- Jacobson DL, Gange SJ, Rose NR, Graham NMH (1997) Epidemiology and estimated population burden of selected autoimmune diseases in the United States. *Clin Immunol Immunopath* 84: 223–243
- Jick H, Jick SS, Derby LE (1991) Validation of information recorded on general practitioner based computerised data resource in the United Kingdom. *BMJ* 302: 766–768
- Johnson AE, Cavalcanti FS, Gordon C, Nived O, Palmer RG, Sturfelt G, Viner NJ, Bacon PA (1994) Cross-sectional analysis of the differences between patients with systemic lupus erythematosus in England, Brazil and Sweden. *Lupus* 3: 501–506
- Jung M, Kippes W, Messer G, Zillikens D, Rzany B (1999) Increased risk of bullous pemphigoid in male and very old patients. A population-based study on incidence. *J Am Acad Dermatol* 41: 266–268
- Kaipainen-Seppänen O, Aho K (1996) Incidence of rare systemic rheumatic and connective tissue diseases in Finland. *J Intern Med*
- Kaipainen-Seppänen O, Savolainen A (1996) Incidence of chronic juvenile rheumatic diseases in Finland during 1980–1990. *Clin Exp Rheumatol* 14: 441–444
- Karlson EW, Daltroy LH, Lew RA, Wright EA, Partridge AJ, Roberts WN, Stern SH, Straaton KV, Wacholtz MC, Grosflam JM et al. (1995) The independence and stability of socioeconomic predictors of morbidity in systemic lupus erythematosus. *Arthritis Rheum* 38: 267–273
- Karlson EW, Daltroy LH, Lew RA, Wright EA, Partridge AJ, Fessel AH, Roberts WN, Stern SH, Straaton KV, Wacholtz MC, Kavanaugh AF, Grosflam JM, Liang MH (1997) The relationship of socioeconomic status, race, and modifiable risk factors to outcomes in patients with systemic lupus erythematosus. *Arthritis Rheum* 40: 47–56
- Kind P, Goerz G (1987) Klinik und Differentialdiagnose des kutanen Lupus erythematosus. *Z Hautkr* 62: 1337–1347
- Kumagai Y, Shiokawa Y, Medsger TJ, Rodnan GP (1984) Clinical spectrum of CTD after cosmetic surgery. Observations on eighteen patients and review of the Japanese literature. *Arthritis Rheum* 27: 1–12
- Lawrence JS, Martins CL, Drake GL (1987) A family survey of lupus erythematosus. I. Heritability. *J Rheumatol* 14: 913–921
- Lilienfeld DE, Stolley PD (1994) *Foundations of Epidemiology* 3<sup>rd</sup> edn Oxford University Press, New York Oxford
- Maricq HR, Weinrich MC, Keil JE, Smith EA, Harper FE, Nussbaum AI, LeRoy EC, McGregor AR, Diat F, Rosal EJ (1989) Prevalence of scleroderma spectrum disorders in the general population of South Carolina. *Arthritis Rheum* 32: 998–1002
- Marik PE, Kark AL, Zambakides A (1990) Scleroderma after silicone augmentation mammoplasty. A report of 2 cases. *S Afr Med J* 77: 212–213
- Masouyé I, Schmied E, Didierjean I (1998) Bullous pemphigoid and multiple sclerosis: more than a coincidence? *J Am Acad Dermatol* 21: 63–68
- Mayes MD, Lacey JV, Beebe-Dimmer J, Gillespie BW, Cooper B, Laing TJ, Schottenfeld D (2003) Prevalence, Incidence, Survival, and Disease Characteristics of Systemic Sclerosis in a Large US Population. *Arthritis Rheum* 48: 2246–2255
- Mayes MD, Laing TJ, Gillespie BW et al. (1996) Prevalence, incidence and survival rates of systemic sclerosis in the Detroit metropolitan area. *Arthritis Rheum* 39: 5150
- Meier CR, Sturkenboom MCJM, Cohen AS, Jick H (1998) Postmenopausal Estrogen Replacement Therapy and the Risk of Developin Systemic Lupus Erythematosus or Discoid Lupus. *J Rheumatol* 25: 1515–1519
- Michet CJ Jr, McKenna CH, Elveback LR, Kaslow RA, Kurland LT (1985) Epidemiology of systemic lupus erythematosus and other connective tissue diseases in Rochester, Minnesota, 1950 through 1979. *Mayo Clin Proc* 60: 105–113

- Miyoshi K, Miyaoka T, Kobayashi Y, Itakura T, Nishijo K, Higashibara M, Shiragami H, Ohno F (1964) Hypergammaglobulinemia by prolonged adjuvant activity in man: disorders developed after augmentation mammoplasty. *Ijishimpo* 2122: 9
- Molad Y (1987) Clinical manifestations and laboratory data of subacute cutaneous lupus erythematosus. *Israel J Med Sci* 23: 278–280
- Mooney E, Wade TR (1989) Subacute cutaneous lupus erythematosus in Iceland. *Int J Dermatol* 28: 104–106
- Nagata C, Fujita S, Iwata H, Kurosawa Y, Kobayashi K, Kobayashi M, Motegi K, Omura T, Yamamoto M, Nose T, Nakamura K-I, Hashimoto T, Nakamura Y, Yanagawa H (1995) Systemic lupus erythematosus: a case-control epidemiologic study in Japan. *Int J Dermatol* 34: 333–337
- Nyrén O, Yin L, Josefsson S, McLaughlin JK, Blot WJ, Engqvist M, Hakelius L, Boice Jr JD, Adami H-O (1998) Risk of connective tissue disease and related disorders among women with breast implants: a nation-wide retrospective cohort study in Sweden. *BMJ* 316: 417–422
- Park AJ, Black RJ, Sarhadi NS, Chetty U, Watson ACH (1997). Silicone gel-filled breast implants and connective tissue disease. *Plast Reconstr Surg* 101: 261–268
- Parks CG, Cooper GS, Nylander-French LA, Sanderson WT, Dement JM, Cohen PL, Dooley MA, Treadwell EL, St. Clair EW, Gilkeson GS, Hoppin JA, Savitz DA (2002) Occupational Exposure to Crystalline Silica and Risk of Systemic Lupus Erythematosus. *Arthritis Rheum* 46: 1840–1850
- Pelkonen P, Jalanko H, Lantto RK, Makela AC, Pietikainen MA, Savolainen HA, Verronen PM (1994) Incidence of systemic connective tissue diseases in children: A nationwide prospective study in Finland. *J Rheumatol* 21: 2143–6
- Perkins LL, Clark BD, Klein PJ, Cook RR (1995) A meta-analysis of breast implants and connective tissue disease. *Ann Plast Surg* 35: 561–570
- Peterson LS, Nelson AM, Su WPD, Mason T, O'Fallon M, Gabriel SE (1997) The epidemiology of morphea (localized scleroderma) in Olmsted County 1960–1993. *J Rheum* 24: 73–80
- Pisa FE, Bovenzi M, Romeo L, Tonello A, Biasi D, Bambara LM, Betta A, Barbone F (2002) Reproductive factors and the risk of sclerodermia. An Italian case-control study. *Arthritis Rheum* 46: 451–456
- Rzany B, Coresh J, Whelton PK, Petri M (1999) Risk factors for hypercreatinemia in patients with systemic lupus erythematosus (SLE). *Lupus* 8: 532–540
- Rzany B, Danckwardt C, Jung M, Schuhmann M, Messer G, Bayerl C (2000) Erhöhtes Risiko von Malignomkrankungen mit bullösem Pemphigoid. *Akt Dermatol* 26: 53–59
- Sánchez-Guerrero J, Liang MH, Karlson EW, Hunter DJ, Colditz GA (1995a) Postmenopausal Estrogen Therapy and the Risk for Developing Systemic Lupus Erythematosus. *Ann Intern Med* 122: 430–433
- Sánchez-Guerrero J, Colditz GA, Karlson EW, Hunter DJ, Speizer FE, Liang MH (1995b) Silicone breast implants and the risk of connective-tissue diseases and symptoms. *N Engl J Med* 332: 1666–1670
- Schlesselman JJ (1982) *Case-Control Studies: Design, Conduct, Analysis*. New York Oxford, Oxford University Press
- Schusterman MA, Kroll SS, Reece GP, Miller MJ, Ainslie N, Halabi S, Balch CM (1993) Incidence of autoimmune disease in patients after breast reconstruction with silicone gel implants versus autogenous tissue: a preliminary report. *Ann Plast Surg* 31: 1–6
- Shopland DR, Hartman AM, Gibson JT et al. (1996) Cigarette smoking among U.S. adults by state and region: estimates from the current population survey. *J Natl Cancer Inst* 88: 1748–1758
- Siegel M, Lee SL (1973) The epidemiology of systemic lupus erythematosus. *Arthritis Rheum* 3: 1–54
- Silman A, Jannini S, Symmons D, Bacon P (1988) An epidemiological study of scleroderma in the West Midlands. *Br J Rheumatol* 27: 286–290
- Sontheimer RD, Thomas JR, Gilliam JN (1979) Subacute cutaneous lupus erythematosus – A cutaneous marker for a distinct lupus erythematosus subset. *Arch Dermatol* 115: 1409–1415
- Spiers H (1988) Scleroderma after silicone augmentation mammoplasty. *JAMA* 260: 236–238

- Strom BL, Reichenberger MM, West S, Snyder ES, Freundlich B, Stolley PD (1994) Shingles, allergies, family medical history, oral contraceptives, and other potential risk factors for systemic lupus erythematosus. *Am J Epidemiol* 140: 632-42
- Stone SP, Schroeter AL (1975) Bullous Pemphigoid and Malignant Neoplasms. *Arch Dermatol* 111: 991-994
- Tamaki T, Mori S, Takehara K (1991) Epidemiological study of patients with systemic sclerosis in Tokyo. *Arch Dermatol Res* 283: 366-370
- Uramoto KM, Michet CJ Jr, Thumboo J, Sunku J, O'Fallon WM, Gabriel SE (1999) Trends in the incidence and mortality of systemic lupus erythematosus, 1950 - 1992. *Arthritis Rheum* 42: 46-50
- Valter I, Saretok S, Maricq HR (1997) Prevalence of Scleroderma Spectrum Disorders in the General Population of Estonia. *Scand J Rheumatol* 26: 419-425
- Van Numen SA, Gatenby PA, Basten A (1982) Postmammoplasty connective tissue disease. *Arthritis Rheum* 25: 694-697
- Venning VA, Wojnarowska F (1990) The association of bullous pemphigoid and malignant disease: a case-control study. *Br J Dermatol* 123: 439-445
- Venning VA, Whitehead PH, Leigh IM, Allen J, Wojnarowska F (1991) The clinical expression of bullous pemphigoid is not determined by the specificity of the target antigen. *Br J Dermatol* 125: 561-565
- Walley T, Mantgani A (1997) The UK General Practice Research Database. *Lancet* 350: 1097-1099
- Weinstein C (1987) Lupus and non-lupus cutaneous manifestations in systemic lupus erythematosus. *Aust NZ J Med* 17: 501-506
- Weisman MH, Vecchione TR, Albert D, Moore LT, Mueller MR (1988) CTD following breast augmentation: a preliminary report. *Ann Plast Surg* 82: 626-630
- Wells KE, Cruse CW, Baker JL, Daniels SM, Stern RA, Newman C, Seleznick MJ, Vasey FB, Brozena S, Albers SE, Frenske N (1994) The health status of women following cosmetic surgery. *Plast Reconstr Surg* 93: 907-912
- Wigley FM, Miller R, Hochberg MC, Steen V (1992) Augmentation mammoplasty in patients with systemic sclerosis: data from the Baltimore Scleroderma Research Center and Pittsburgh Scleroderma Data Bank. *Arthritis Rheum* 35: 65
- [www.cochrane.org](http://www.cochrane.org) (2000)
- Zillikens D, Wever S, Roth A, Weidenthaler-Barth B, Hashimoto T, Bröcker EB (1995) Incidence on autoimmune subepidermal blistering dermatoses in a region of central Germany. *Arch Dermatol* 131: 957-958

## **3 Autoimmune Bullous Skin Disorders**

### **3.1 Pemphigus**

*Michael Hertl*

#### **Introduction**

Pemphigus (from the Greek pemphix, meaning bubble or blister) encompasses a group of life-threatening autoimmune blistering diseases characterized by intraepithelial blister formation (Lever 1953; Huilgol et al. 1995; Hertl 2000). The molecular basis for blister formation is the loss of adhesion between keratinocytes caused by circulating autoantibodies (auto-Ab) directed against intercellular adhesion structures (Amagai et al. 1991; Bedane et al. 1996). Several forms of pemphigus have been classified depending on the level of the intraepidermal split formation. In the pemphigus vulgaris (PV) group, the blisters are located just above the basal layer whereas in the pemphigus foliaceus (PF) group, the blisters occur within the upper layers of the epidermis (Bedane et al. 1996). Other members of the pemphigus group are paraneoplastic pemphigus (PNP), which generally occurs in patients with lymphoma, and drug-induced pemphigus, which usually develops after the administration of penicillamine. Based on recent immunological studies, a molecular distinction can be made by the characterization of the specificity of the auto-Ab that recognize different molecular target structures.

#### **Epidemiology of Pemphigus and Association with HLA Class II Alleles**

PV is the most common form of pemphigus but still a rare disease, the incidence varying from 0.1–0.5 per 100,000 population and being higher among Jewish patients (Ahmed et al. 1990). In areas where PV and PF are endemic, however, the ratio of cases of PF to cases of PV is nearly 20 to 1. In Brazil,

some 15,000 patients are known to have PF, and the prevalence of the disorder is 3.4 percent in regions such as the Amerindian reservation of Limao Verde (Warren et al. 2000).

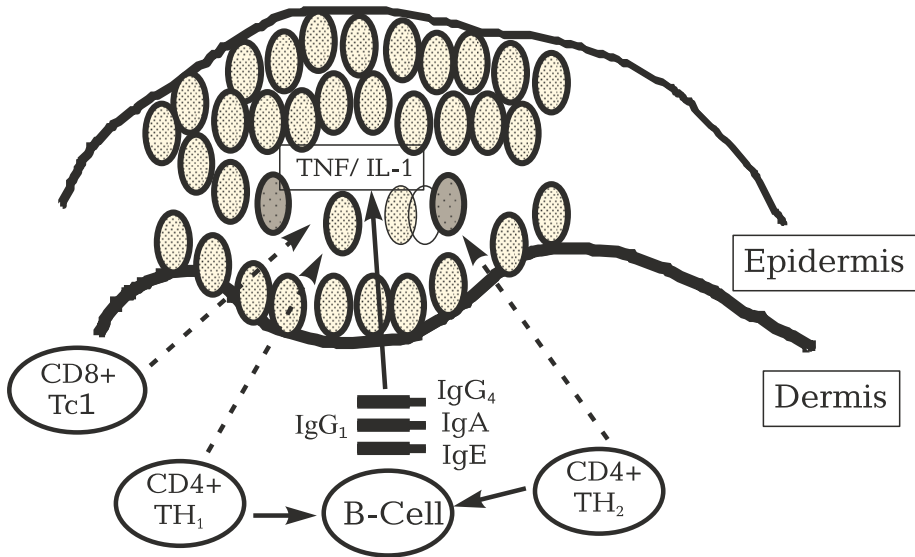
Several epidemiological studies in Jewish (Ahmed et al. 1990), in non-Jewish (Ahmed et al. 1991) and in Japanese PV patients demonstrated that the HLA-DR $\beta$ 1\*0402 and HLA-DR $\beta$ 1\*1401 alleles are highly prevalent in PV. Sinha et al. (1988) demonstrated that the DR14 susceptibility was strongly associated with a rare DQ $\beta$  allele (DQ $\beta$ 1\*0503) identifying this DQ allele as a major susceptibility factor for PV. Moreover, the auto-Ab response in Pakistani PV patients was also linked to DQ $\beta$ 1\*0503 (Delgado et al. 1997) and healthy relatives of PV patients who carried the PV susceptibility haplotypes HLA-DR4/DQ8 and DR14/DQ5 appeared to produce low titers of Dsg3-specific auto-Ab (Ahmed et al. 1993; Brandsen et al. 1997; Kricheli et al. 2000). The HLA class II alleles HLA-DR $\beta$ 1\*0402 and  $\beta$ 1\*1401 (in linkage disequilibrium with DQ $\beta$ 1\*0503) are also prevalent in drug-induced pemphigus (Matzner et al. 1995). The endemic variant of PF, fogo selvagem, is characterized by a prevalence of two HLA class II alleles, DR $\beta$ 1\*04\*\* and DR $\beta$ 1\*0101.

## **Etiopathogenesis of Pemphigus**

The molecular basis for intraepithelial blister formation is the loss of adhesion between keratinocytes, called acantholysis, which is caused by auto-Ab directed against intercellular adhesion structures of epidermal keratinocytes. Auto-Ab production in PV and PF is polyclonal and most auto-Ab are of the IgG4 subclass in PV patients with active disease (Bhol et al. 1995; Tremeau-Martinage et al. 1995; Spaeth et al. 2001). Patients in remission have mainly auto-Ab of the IgG1 subtype while healthy relatives of PV patients and healthy carriers of PV-prevalent HLA class II alleles have low levels of IgG1 auto-Ab (Brandsen et al. 1997; Kricheli et al. 2000; Spaeth et al. 2001). Evidence for the pathogenicity of these circulating auto-ab is provided by the observation that 1) the activity of PV correlates with auto-Ab titers, 2) newborns of mothers with active PV temporarily exhibit blisters due to the diaplacental transfer of maternal auto-Ab, and 3) pemphigus-like lesions are induced in neonatal mice by transfer of IgG from PV patients (reviewed in Hertl 2000) (*Fig. 1*).

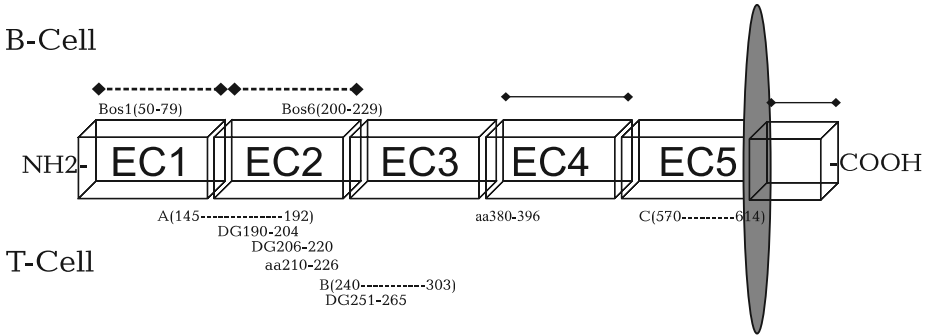
## **Autoantibody Reactivity against Desmogleins**

PV is caused by auto-Ab against the extracellular portion (ECD) of desmoglein 3 (Dsg3), a desmosomal adhesion molecule present on epidermal keratinocytes. Accordingly, PF is caused by auto-Ab against desmoglein 1 (Dsg1), a distinct desmosomal adhesion protein homologous but not identical with



**Fig. 1.** Current concepts of the immune pathogenesis of pemphigus. Auto-Ab against Dsg1 and Dsg3 have been shown to induce loss of keratinocyte adhesion in pemphigus foliaceus (PF) and in pemphigus vulgaris (PV), respectively. Ab production by B cells depends on the help of TH1 cells for IgG, and of TH2 cells for IgG<sub>4</sub>, IgA, and IgE auto-Ab (solid lines). Upon binding of the auto-Ab to desmosomal target antigens, tumor necrosis factor (TNF) and interleukin-1 (IL-1) are released from epidermal keratinocytes which presumably enhance the process of blister formation. CD8+ Tc1 cells have been identified in patients with PV that may directly exert cytotoxicity against keratinocytes (dotted line). TH<sub>1</sub> and TH<sub>2</sub> cells may also mediate direct effector functions (dotted lines)

Dsg3. Although Dsg3 is the major antigen targeted by auto-Ab in PV, recent studies showed that PV patients have frequently also auto-Ab reacting against Dsg1, the autoantigen of PF, as well as against desmocollins, other transmembranous components of desmosomes (Emery et al. 1995). The transfer of IgG from PV patients with active PV into newborn mice causes acantholysis, while circulating IgG from PV patients in remission and HLA-matched normals does not (Anhalt 1982; Amagai et al. 1991). Amagai et al. (1994) showed that the preabsorption of PV-IgG by recombinant Dsg3 protein removed all of the pathogenic auto-Ab indicating that Dsg3 auto-Ab are relevant for blister formation in PV. The specificity of the IgG response to Dsg3 has been extensively studied using peptides encompassing the entire ECD of Dsg3 (Amagai et al. 1992; Bhol et al. 1995). IgG from PV sera affinity-purified on the EC1-2 of Dsg3 causes suprabasilar acantholysis, the typical histologic finding of PV. In contrast, IgG affinity-purified on a recombinant protein representing the EC3-5 of Dsg3 did not induce acantholysis upon injection into neonatal mice (Amagai et al. 1992). IgG1 and IgG4 from patients with active PV recognize epitopes in the EC1 and EC2. Additional *in vitro* data indicate that IgG4



**Fig. 2.** T and B cell epitopes of Dsg3, the autoantigen of PV. Shown is a schematic of the extracellular portion of Dsg3 which consists of five domains (EC1-EC5). B cell epitopes (top) have been identified in the EC1 and EC2 domains (Bos 1, Bos 6) and in the EC4 domain. Recent evidence suggest that B cell epitopes are also located on the intracellular portion of Dsg3. T cell epitopes of Dsg3 (bottom) have been identified all over the extracellular domain. According to the current knowledge, T cell epitopes are clustered around the distal portion of EC1, and EC2 through EC3 (box)

directed against the EC2, and to a lesser extent, against the EC1 causes acantholysis (Bhol et al. 1995) (*Fig. 2*). In summary, the observations strongly suggest that IgG4 against the EC2 of Dsg3 is presumably the main acantholytic Ab while IgG4 against the EC1 may act as a facilitator or enhancer of this process. A recent study demonstrated that PV sera also recognize intracellular epitopes of Dsg3 (Ohata et al. 2001). The significance of this finding is yet unclear. Recently, a novel human desmosomal cadherin, Dsg4, was identified which shares 41% identity with Dsg1 and 50% with Dsg3 (Whittock & Bower, 2003). Moreover, serum Ab from a subset of patients with PV were shown to be also reactive with Dsg4 (Kljuic et al, 2003). Although the pathogenic relevance of anti-Dsg4 Ab is not fully elucidated their occurrence seems to be associated with Ab against Dsg1 in mucocutaneous PV and PF (Nishifuji et al, 2004).

Several studies suggest that binding of PV-IgG to epidermal keratinocytes induces a rapid and transient  $[Ca^{++}]$  elevation which may result in an altered Ab-transmitted signaling leading to loss of cell adhesion (Seishima et al. 1995). Acantholysis may be induced by proteases such as plasminogen activator upon binding of auto-Ab to keratinocytes (Hashimoto et al. 1983). Recent studies suggest that phospholipase C plays an important role in transmembrane signaling leading to cell-cell detachment exerted by pemphigus IgG binding to the cell surface (Esaki et al. 1995).

Classical PV presents primarily with mucosal lesions and is associated with IgG against Dsg3 (Amagai et al. 1991). In contrast, sera of PV patients with mucocutaneous lesions contain IgG4 > IgG1 against Dsg3 and Dsg1, the autoantigen of PF. The epitope(s) of Dsg1 recognized by PV sera are located in



the NH<sub>2</sub>-terminal region and are conformationally sensitive (Emery et al. 1995; Kowalczyk et al. 1995). The explanation for the association of characteristic auto-Ab profiles with distinct clinical variants of PV is given by the differential expression pattern of Dsg1 and Dsg3 in cornified and non-cornified stratified epithelia (Shimizu et al. 1995). In the skin, Dsg1 is expressed in the upper epidermal layer, i.e. the granular layer, while Dsg3 is expressed predominantly in the suprabasilar epidermal layer (Amagai et al. 1996). In non-cornified stratified epithelia, such as the oral mucosa, Dsg3 is expressed throughout the epidermal layer while Dsg1 is poorly expressed. Dsg3 is thus a crucial target antigen for the development of oral and to a lesser extent of cutaneous lesions in PV. In contrast, auto-Ab against Dsg1 in PF do not cause mucosal blisters. The concert of anti-Dsg1 and Dsg3- auto-Ab leads to the formation of both mucosal and cutaneous blisters.

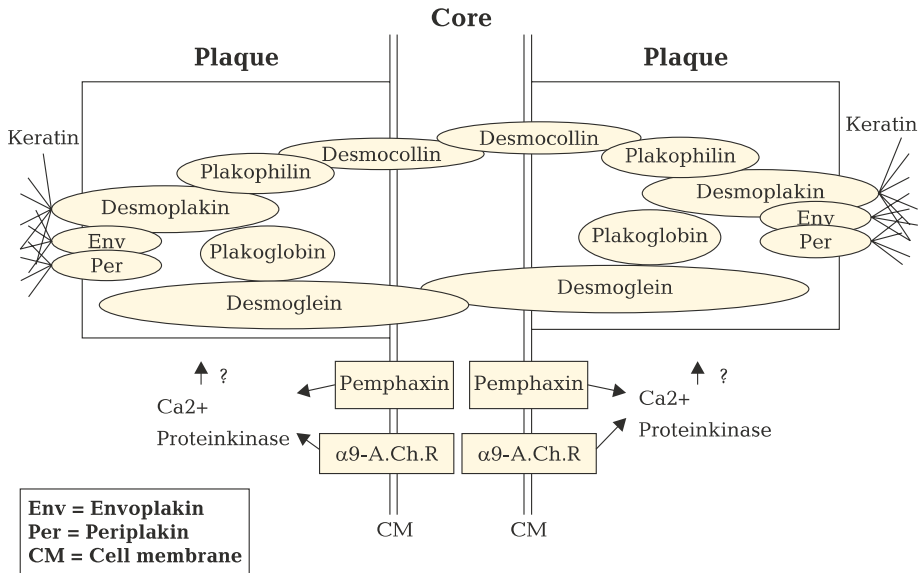
A recent study by Amagai et al. (2000b) has shed additional light on the association of anti-Dsg1/Dsg3 auto-Ab with the clinical phenotype. They showed that the toxin of bullous impetigo is a protease that selectively degrades Dsg1 leading to subcorneal split formaton which is also characteristic for PF. This finding supports the idea that anti-Dsg1 are exclusively responsible for the pathology of PF lesions.

### **Auto-Ab against Other Desmosomal Antigens**

Recent evidence strongly suggests that the target antigens of PV are more heterogeneous than anticipated (Hashimoto et al. 1995a) (*Table 1*). Antigen spreading may occur during the course of disease since extra- as well as intracellular epidermal antigens such as plakoglobin (Korman et al. 1991a) are recognized by circulating auto-Ab of different IgG subclasses in several autoimmune bullous diseases (Joly et al. 1997) (*Fig. 3*). Immunoelectron studies demonstrated that PV auto-Ab bind not only to the ECD of desmosomes but also along large portions of keratinocytes outside desmosomal structures (Bedane et al. 1996; Joly et al. 1997). Hashimoto et al. (1995a) reported that several PV patients had circulating IgG reacting with human desmocollins and bovine desmocollin 2 in addition to IgG reactive with Dsg3 and Dsg1. A recent study by Nguyen et al. (2000a) demonstrated that PV sera display an intercellular staining in the epidermis of Dsg3<sup>-/-</sup> mice suggesting that keratinocyte proteins other than Dsg1 or Dsg3, possibly other desmosomal cadherins or signaling receptors, are targets antigens for PV IgG. Two potential new target antigens were recently identified which belong to the group of cholinergic receptors. Pemphaxin is an annexin homolog that binds acetylcholine (Nguyen et al. 2000b). The second acetylcholine receptor targetted by serum IgG from PV patients is  $\alpha 9$  acetylcholine receptor which is also present on keratinocytes (Nguyen et al. 2000c). The precise role that auto-Ab against acetylcholine receptors play in the pathogenesis of PV needs to be elucidated.

**Table 1.** Autoantigens of Pemphigus Variants

Pemphigus variant	Target antigen	Reference
Pemphigus vulgaris	<b>desmoglein 3</b> desmoglein 1	Amagai et al. 1991 Emery et al. 1995 Kowalczyk et al. 1995 Ding et al. 1998
	desmoglein 4	Kljuic et al., 2003 Nishifuji et al., 2004
– Pemphigus vegetans	desmocollins other cadherin (?) cholinergic receptor pempfaxin $\alpha$ 9 acetylcholine receptor	Hashimoto et al. 1995a Bedane et al. 1996 Joly et al. 1997 Nguyen et al. 1998 Nguyen et al. 2000
Pemphigus foliaceus	<b>desmoglein 1</b>  other cadherin (?) periplakin/envoplakin	Amagai et al. 1995 Ghohestani et al. 1997 Joly et al. 1997 Kazerounian et al. 2000
Paraneoplastic pemphigus	desmoplakins I, II BP230 desmoglein 1	Anhalt et al. 1990 Oursler et al. 1992 Joly et al. 1993 Hashimoto et al. 1997
	<b>desmoglein 3</b>  periplakin/envoplakin	Hashimoto et al. 1997 Amagai et al. 1998 Kim et al. 1997 Mahoney et al. 1998
	HD1/plektin	Proby et al. 1999
IgA pemphigus		
– SPD type	<b>desmocollins</b> desmocollin 1	Hashimoto et al. 1997 Yasuda et al. 2000
– IEN type	<b>desmoglein 1</b> desmoglein 3	Karpati et al. 2000 Prost et al. 1995 Wang et al. 1997
Drug-induced pemphigus	<b>desmoglein 3</b> <b>desmoglein 1</b>	Korman et al. 1991 Brenner et al. 1997
– interferon- $\gamma$ -induced	desmoglein 1	Parodi et al. 1993 Niizeki et al. 1994 Kirsner et al. 1995 Fleischmann 1996 Ramseur et al. 1989
– interleukin-2-induced		
Pemphigus herpetiformis	<b>desmoglein 1</b> <b>desmoglein 3</b>	Ishii et al. 1998 Kubo et al. 1997 Ishii et al. 1998
Pemphigus erythematosus (Senear Usher)	<b>desmoglein 1</b> nuclear antigens	Gomi et al. 1999 Ochsendorf et al. 1987



**Fig. 3.** Schematic representation of a desmosome with the major autoantigens of pemphigus

### Autoreactive T Lymphocytes in Pemphigus

Current concepts strongly suggest that autoreactive T cells play a crucial role in the initiation and perpetuation of both Ab- and cell-mediated autoimmune diseases. Autoreactive T cells may provide critical help for B cells to continuously produce pathogenic auto-Ab in PV. Involvement of CD4<sup>+</sup> T lymphocytes in the pathogenesis of PV has been further suggested by the aforementioned strong association of PV with HLA-DRβ1\*0402 and HLA-DRb1\*0503 (Sinha et al. 1989; Ahmed et al. 1990; Hertl and Riechers 1999). The majority of peripheral T cell lines and clones generated from several patients with PV expressed a CD4<sup>+</sup> memory phenotype and a minority the CD8 receptor (Hertl et al. 1998). Both TH1- and TH2-like Dsg3-specific T cells were identified in PV patients (Wucherpfennig et al. 1995; Lin et al. 1997; Hertl et al. 1998). While the TH2 cytokines IL-4 and IL-13 have been shown to regulate the secretion of IgG4 and IgE by activated B cells, the TH1 cytokine IFN $\gamma$  induces the secretion of IgG1. Both, autoreactive TH1 and TH2 cells may be involved in the regulation of the production of pathogenic auto-Ab by B cells in PV since sera of patients with PV contain TH1-regulated IgG1 and TH2-regulated IgG4, IgA (and IgE) auto-Ab directed against Dsg3 (Bhol et al. 1995; Spaeth et al. 2001; Veldman et al, 2003) (Fig. 2). By ELISPOT assay, auto-Ab-secreting B cells were detected upon in vitro-stimulation of peripheral lymphocytes (PBMC) from PV patients with Dsg3 (Nishifuji et al. 2000). Autoreactive B cells were no more detectable upon depletion of PBMC

from CD4<sup>+</sup> T cells. Dsg3-specific, autoreactive T cells may thus provide targets to specifically modulate the T cell-dependent production of pathogenic auto-Ab in PV and PF (Riecher et al. 1999). Noteworthy, autoreactive T cells from PV patients and healthy individuals recognize identical epitopes of Dsg3 strongly suggesting that PV is the consequence of a loss of tolerance on the B cell level (Veldman et al, 2004a). This is supported by the recent finding that Dsg3-reactive healthy individuals have higher numbers of Dsg3-specific T regulatory cells than PV patients which may be critical for the maintenance of peripheral tolerance against Dsg3 (Veldman et al, 2004b).

Autoreactive T cells were also identified in a clinical variant of PF, fogo selvagem, which is endemic in limited areas of South America (Lin et al. 2000). Peripheral CD4<sup>+</sup> T cells from patients with endemic PF reacted to the ECD of Dsg1, the autoantigen of PF, and secreted TH2 cytokines.

## **Animal Models of Pemphigus Vulgaris**

### *Passive Transfer Model of Pemphigus*

Anhalt et al. (1982) demonstrated that the passive transfer of IgG from PV sera into newborn BALB/c mice induced a clinical picture resembling PV. PV-IgG caused suprabasilar acantholysis in these mice and displayed the typical intercellular staining pattern which is also seen in humans. Amagai et al. (1994) utilized this passive transfer model to demonstrate that preabsorption of PV-IgG with recombinant Dsg3 abolished the ability of the sera to induce acantholysis in mice demonstrating that anti-Dsg3 IgG are indeed critical for blister formation. Using this animal model, it has been demonstrated that anti-Dsg1 auto-Ab in PF (Amagai et al. 1995) in PV sera (Amagai et al. 1994) as well as anti-Dsg3 IgG in PNP sera (Amagai et al. 1998) is critical for blister formation.

Distinct cytokines such as tumor necrosis factor- $\alpha$  and interleukin-1 seem to be important mediators of inflammation upon binding of pemphigus auto-Ab to their desmosomal target antigens. To confirm the role of interleukin-1 and tumor necrosis factor- $\alpha$  in pemphigus, Feliciani et al. (2000) performed passive transfer studies using interleukin-1 deficient mice (ICE<sup>-/-</sup>, interleukin-1 beta<sup>-/-</sup>) and tumor necrosis factor- $\alpha$  receptor deficient mice (TNFR1R2<sup>-/-</sup>). The tumor necrosis factor- $\alpha$ -deficient mice showed a decreased susceptibility to the passive transfer of pemphigus auto-Ab suggesting that tumor necrosis factor- $\alpha$  plays a critical role in the pathogenesis of PV.

### *Desmoglein 3-Deficient Mouse*

The most impressive evidence for the central role of Dsg3 in intraepidermal adhesion was provided by Koch et al. (1997). They genetically engineered mice with a targeted disruption of the Dsg3 gene. These mice were normal at birth but developed a runting phenotype later on. These mice presented with

oral erosions/blisters leading to the observed weight loss due to the inhibited food uptake. These mice developed cutaneous blisters only when the skin was traumatized. Noteworthy, the Dsg3<sup>-/-</sup> mice developed telogen hair loss. This finding provided strong support to the idea that anti-Dsg3 auto-Ab induce mucosal but not cutaneous lesions in PV.

#### *Relationship between Anti-Desmosomal Ab Profile and Clinical Phenotype of Pemphigus*

Utilizing the Dsg3<sup>-/-</sup> mouse model, Mahoney et al. (1999) dissected the relationship between the epidermal distribution of Dsg3 and Dsg1 and the pathogenic role of circulating auto-Ab targeting these structures. The role of Dsg3 in limiting blister formation in PF was demonstrated by injection of Dsg1-reactive IgG into Dsg3<sup>+/+</sup> and Dsg3<sup>-/-</sup> mice. Upon transfer of PF IgG, the Dsg3<sup>+/+</sup> mice developed small cutaneous blisters while the Dsg3<sup>-/-</sup> mice developed gross blisters on the skin and mucous membranes (which strongly express Dsg3 but little Dsg1 (Shirakata et al. 1998)). These data also explain the observation that PV patients with anti-Dsg3 auto-Ab only have exclusively oral lesions. Once anti-Dsg1 Ab are present, skin lesions occur since blocking of both Dsg1 and Dsg3 is necessary to inhibit desmosomal adhesion in the skin (Ding et al. 1997).

#### *Active Animal Model of Pemphigus Vulgaris*

Amagai et al. (2000a) have taken advantage of the availability of Dsg3<sup>-/-</sup> mice to establish an active *in vivo* model of PV. Dsg3<sup>-/-</sup> mice were immunized with recombinant mouse Dsg3 leading to the production of anti-Dsg3 Ab. Splenocytes from the Dsg3-immunized mice were then transferred into immunodeficient Rag <sup>-/-</sup> mice that expressed Dsg3. The recipient mice produced anti-Dsg3 auto-Ab and developed erosions of the mucous membranes with the typical histological findings of PV. In addition, the mice showed telogen hair loss as found in the Dsg3<sup>-/-</sup> mice. This first active *in vivo* model of pemphigus will be very useful for the understanding of how autoimmunity develops in PV and for evaluating therapeutic strategies aimed at specifically interfering with the T cell-dependent auto-Ab production by autoreactive B cells.

#### *Humanized PBL-SCID Mouse to Study Autoimmunity against Desmoglein 3*

Immunodeficient SCID mice reconstituted with human peripheral blood lymphocytes (PBL-SCID) have shown promise in investigating cell-mediated immune disorders including autoimmune diseases *in vivo*. The PBL-SCID mouse model has been successfully utilized to study T cellular immune responses to

various infectious, nominal, and tumor antigens. Juhasz et al. (1993) and recently our group (Rädisch et al, in press) have made efforts to establish an *in vivo* model of PV by transfer of PBL from PV patients into SCID mice. In the previous study of Juhasz et al. (1993), i.p. injection of PBL from PV patients into SCID mice resulted in the detection of human pemphigus-specific Ab in the sera of 41 % of the reconstituted mice; 44% of these mice had also tissue-bound intercellular IgG deposits characteristic for PV. In our study (Rädisch et al, 2002), transfer of Dsg3-responsive PBL from a DR $\beta$ 1\*0402+ PV patient and from a Dsg3-responsive healthy DR $\beta$ 1\*0402+ donor into SCID mice did not lead to the *in vivo* induction of human auto-Ab against human Dsg3. Only 1/30 mice that received PBL from the PV patient developed anti-Dsg3 reactive IgM, but no IgG auto-Ab. Reconstituting SCID mice with PBL from PV patients may thus be more difficult than anticipated and shows little promise for establishing a highly reproducible *in vivo* model of autoimmunity against Dsg3.

## Clinical Variants of Pemphigus

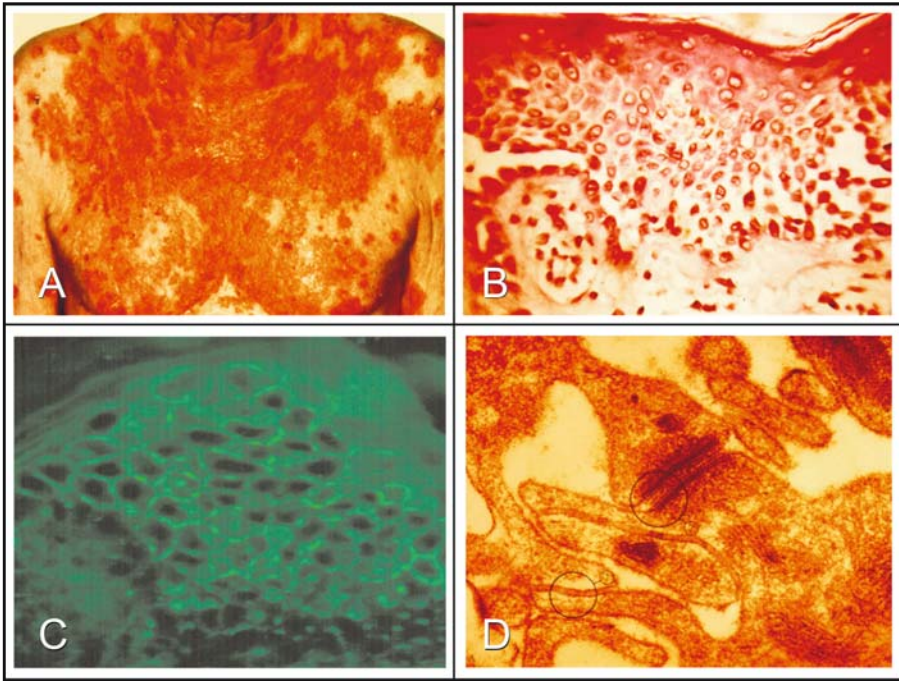
### Pemphigus Vulgaris

PV is a relatively rare disorder that primarily affects individuals in the 3<sup>rd</sup> to 5<sup>th</sup> decade without sex preference (Huilgol et al. 1995; Nousari and Anhalt 1999). PV is characterized by flaccid blisters/erosions of the mucous membranes and the skin. In the majority of patients, the oral mucosa is primarily affected but other mucous membranes may be involved as well. Initial blisters rapidly rupture leading to painful chronic lesions that may affect larynx and pharynx in addition to the oral mucosa. Once the disease progresses, skin lesions may occur at any site of the integument but there is a preferential involvement of the trunk. Due to extensive blistering of skin and mucosa, the prognosis of PV used to be fatal prior to introduction of glucocorticoids as the major therapeutic strategy. The natural course of the disease is progressive with death occurring within a few years of onset due to sepsis (*Fig. 4; 5A–B*).

Since IgG4 has the potential to pass the placenta, neonatal pemphigus may occur by the diaplacental transfer of anti-Dsg3 IgG4 from mothers with PV to their unborn children. After birth, the newborn exhibit crusty erosions of the skin with the histopathological findings of PV. These skin lesions disappear after a few months once circulating auto-Ab are degraded.

### Pemphigus Foliaceus

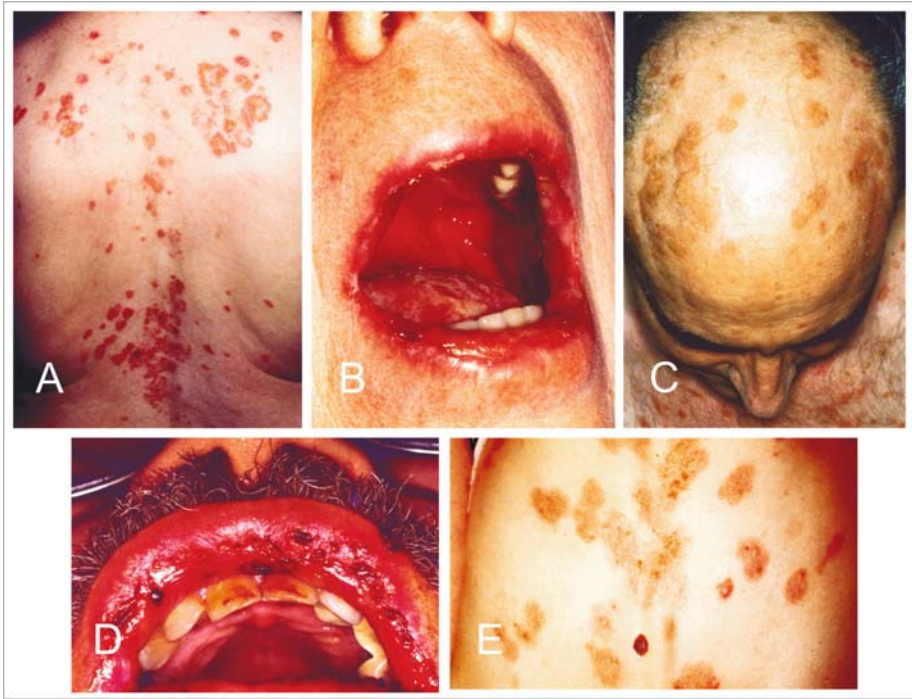In PF, the areas of central face, scalp, chest and upper back are affected by painful crusted erosions with erythema. Mucosal lesions are virtually absent



**Fig. 4.** Key features of pemphigus. **A.** Clinical appearance with extensive erosions of the trunk (provided by Dr. John R. Stanley, Philadelphia, USA). **B.** histopathology with acantholysis. **C.** direct immunofluorescence with intercellular IgG deposits in the epidermis. **D.** electron-microscopic picture of a desmosome at the contact site of two epidermal keratinocytes

in contrast to PV (Huilgol et al. 1995) (*Fig. 5*). Fogo selvagem is a variant of PF which occurs endemically in distinct regions of Brazil. In contrast to PV, the acantholytic split occurs in the granular or subcorneal layers of the epidermis. PF has attracted considerable attention, despite its low incidence, because the associated auto-Ab are directly pathogenic, their target protein is known, and the presence of foci of endemic disease suggests an infectious cause in at least one variant of the disorder. Since the clinical hallmark of PF is the disruption of the superficial part of the epidermis, intact cutaneous blisters are rarely detectable. The endemic variant, known as fogo selvagem, is clinically indistinguishable from non-endemic PF, and the increase in its incidence in distinct location of South America is striking.

Ab against Dsg1 cause PF in adults, but transplacental passage of the Ab from affected mothers does not cause skin disease in their infants. The desmosomes of subcorneal keratinocytes in newborn infants contain both Dsg1 and Dsg3, with each contributing to the strength of the intercellular desmosomal bridge (Iwatsushi et al. 1995; Wu et al. 2000). In contrast, subcorneal keratinocytes in adults express only Dsg1. The absence of mucosal lesions in PF is



**Fig. 5.** Clinical variability of pemphigus. **A.** Pemphigus vulgaris with flaccid cutaneous blisters. **B.** erosions of the oral cavity. **C.** Pemphigus foliaceus with crusty erosions of the scalp. **D.** Paraneoplastic pemphigus with extensive mucosal involvement. **E.** Pemphigus seborrhoicus with superficial crusty erosions

explained by the compensatory presence of Dsg3 at these sites. Recently, auto-Ab against constituents of the desmosomal plaque have been identified in PF sera; their significance is yet unclear (Kazerounian et al. 2000).

### Paraneoplastic Pemphigus (PNP)

Paraneoplastic pemphigus (PNP) is usually characterized by painful lesions of the mucosal surfaces and erythema multiforme-like lesions of palms and soles (Anhalt et al. 1990) (*Fig. 5D*). This relatively rare disease is mainly associated with B cell lymphoma and other hematological disorders and may precede the clinical manifestation of these disorders (Huilgol et al. 1995; Anhalt et al. 1990). PNP may be also associated with benign tumors, i.e. thymoma and Castleman's tumor. In contrast to the other pemphigus variants, PNP may involve lung epithelium. Progressive respiratory failure due to pulmonary involvement constitutes the terminal complication in up to 30% of the patients (Nousari and Anhalt 1999). Endobronchial biopsy reveals the typical pattern



of intraepithelial acantholysis of the bronchial epithelium. Direct immunofluorescence of lesional skin shows that IgG is deposited both in the intercellular space and along the basal membrane zone, and circulating auto-Ab against the intercellular space and the dermoepidermal basement membrane are present in almost all cases (Anhalt et al. 1990). PNP is primarily associated with anti-Dsg3 and anti-Dsg1 auto-Ab (Hashimoto et al. 1995b; Nousari and Anhalt 1999). A number of additional target antigens has been identified, including desmoplakins I and II (Oursler et al. 1992), bullous pemphigoid antigen 1 (BP230) (Anhalt et al. 1990) and as yet unidentified antigens of lower molecular weight (Joly et al. 1993). The reactivity of PNP sera seems to be heterogeneous, and the antigen(s) that ultimately play(s) a pathogenic role have not yet been identified. The Ab directed against these epidermal proteins represent useful markers for the diagnosis of PNP but may not play a critical role in the pathogenesis of PNP (Hashimoto et al. 1995b). Intracellular constituents of the desmosomal plaque such as envoplakin, periplakin (Kim et al. 1997; Mahoney et al. 1998; Kazerounian et al. 2000) and HD1/plekstin (Proby et al. 1999) have been recently identified as additional target antigens of PNP sera (*Table 1*).

### **Drug-Induced Pemphigus**

The drugs that cause pemphigus most commonly contain thiol or sulfur groups that may be converted to thiols, such as D-penicillamine, captopril, propranolol, indomethacin, phenylbutazone, pyritinol, piroxicam, and tuberculostatic agents (Huilgol et al. 1995; Brenner et al. 1997). The clinical picture most commonly mimics PF but may also resemble PV, pemphigus erythematosus, or herpetiform pemphigus. Oral lesions are uncommon. Direct and indirect immunofluorescence are usually positive with a pemphigus pattern. Auto-Ab against the basal membrane zone may be also present (Huilgol et al. 1995). Several target antigens have been identified in drug-induced pemphigus. Korman et al. (1991b) reported about three patients who had circulating auto-Ab to both Dsg3 and Dsg1, a pattern which is generally found in patients with PV. Brenner et al. (1997) detected serum reactivity to Dsg3 and/or Dsg1 in the sera of ten patients with drug-induced pemphigus supporting the observation of Korman et al. that the auto-Ab response was similar in both spontaneous and drug-induced pemphigus. In addition, longterm interferon- $\alpha$  therapy has been shown to induce auto-Ab against epidermal antigens (Fleischmann et al. 1996). Recently, several reports have described the induction of PV or PF upon treatment with interferon- $\gamma$  or interleukin-2 of hepatitis C (Niizeki et al. 1994), Kaposi sarcoma (Parodi et al. 1993) or lymphoma (Ramseur et al. 1989; Kirsner et al. 1995).

## IgA Pemphigus

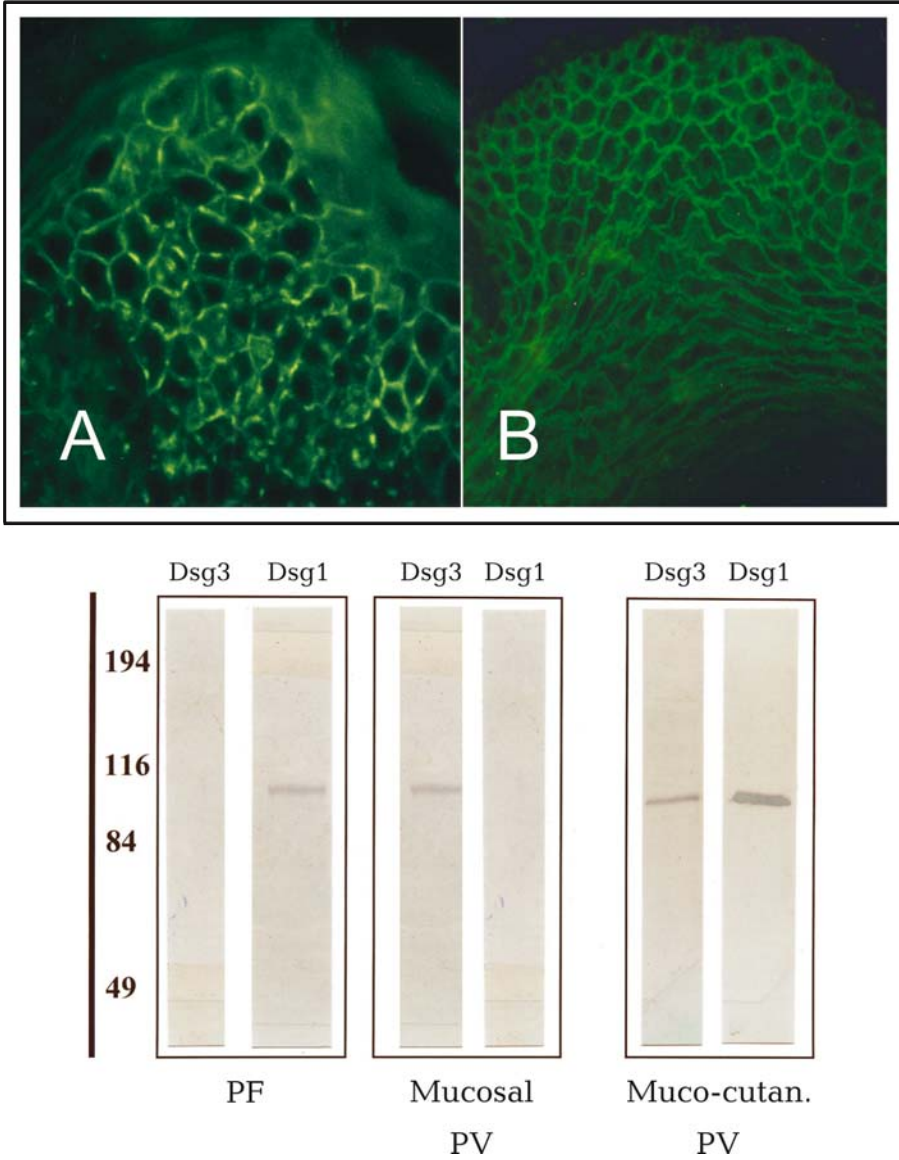
Typically, this pemphigus variant is characterized clinically by pustules with a tendency to confluence forming annular and circinate patterns (Huigol et al. 1995). Mucosal involvement is rare. There is an association with benign and malignant monoclonal IgA gammopathies and gastrointestinal disease. IgA is deposited in the epidermal intercellular space in all patients and usually represents the only tissue-bound Ig class. Circulating IgA auto-Ab are present in about 50% of cases. Several desmosomal target antigens have been identified including desmocollins I and II (Huigol et al. 1995). Hashimoto et al. (1997) identified human desmocollin I as an autoantigen for the subcorneal pustular dermatosis type of IgA pemphigus (*Table 1*). The intraepidermal neutrophilic dermatosis subtype is associated with IgA against Dsg1 and Dsg3 (Wallach 1992). While in the majority of cases IgA targets Dsg1 (Karpati et al. 2000), two independent recent studies have also identified Dsg3 as a target antigen of circulating IgA (Prost et al. 1995; Wang et al. 1997). IgA seems to possess acantholytic properties at least in vitro (Supapannachart and Mutasim 1993). It thus remains to be clarified whether anti-Dsg IgA also induces acantholysis in vivo.

## Rare Pemphigus Variants

*Pemphigus herpetiformis* is characterized by skin lesions resembling those of dermatitis herpetiformis, eosinophilic spongiosis without apparent acantholysis as well as by the presence of circulating and tissue-bound Ab against the keratinocyte surface (Jablonska et al. 1975; Santi et al. 1996). Pemphigus herpetiformis sera have been shown to contain IgG reactive with the Dsg3 antigen of PV (Kubo et al. 1997). Using two recently established ELISA with baculovirus-derived Dsg3 and Dsg1 proteins (ECD), Ishii et al. (1998) demonstrated that sera of patients with herpetiform pemphigus contain Ab against Dsg1 and Dsg3 suggesting that herpetiform pemphigus is a clinical variant of PF and PV.

*Pemphigus erythematous* (Senear Usher) can be considered as a variant of PF which is characterized by sharply demarcated erythematous plaques with scaling. The lesions are primarily localized on the face and the upper trunk (Senear and Usher 1926). A characteristic immunoserological feature is the presence of IgG and C3 deposits along the dermoepidermal membrane similar to lupus erythematosus. About 80% of these patients have serum anti-nuclear Ab. The precise nature of this disorder and the role that anti-Dsg1 auto-Ab play remains to be elucidated.

*Pemphigus vegetans* is a clinical variant of PV characterized by cutaneous blisters and pustules that tend to transform into verruciform and papillomatous vegetations. These lesions typically present in the intertriginous areas, such as the axillae and groins. In addition, oral lesions identical to those of PV are fairly common. The *type Neumann* is characterized by a more



**Fig. 6.** Immunological diagnosis of pemphigus. **A.** Direct immunofluorescence: intercellular IgG deposits of the patients' epidermis. **B.** Indirect immunofluorescence: intercellular serum IgG reactivity with epithelial cells of monkey esophagus. Ab reactivity by immunoblot analysis with recombinant Dsg1 and Dsg3. PF sera contain Ab against Dsg1. Mucosal PV is characterized by auto-Ab against Dsg3; mucocutaneous PV is associated with anti-Dsg3 and anti-Dsg1 auto-Ab

aggressive course than the *Hallopeau type* (Ahmed and Blose 1984). With regard to auto-Ab specificity and direct immunofluorescence, pemphigus vegetans is indistinguishable from PV (Hashimoto et al. 1995a).

## **Diagnosis of Pemphigus**

Diagnosis of pemphigus is made using four major criteria consisting of i) clinical, ii) light microscopic, iii) direct and iiiii) indirect immunofluorescence findings (Huilgol et al. 1995; Mutasim 1999; Hertl 2000)(Fig. 6).

### **Histopathology**

Histopathological exam of mucocutaneous lesions shows the hallmark of pemphigus, i.e. the distinctive intraepidermal split formation due to loss of adhesion between epidermal keratinocytes, called acantholysis. Loss of cell-cell attachment leads to rounding of single epidermal cells (positive Tzank's phenomenon). Inflammatory cell infiltrates of the involved skin are generally absent. PV and PNP are usually characterized by a suprabasilar loss of adhesion leaving a single layer of basal keratinocytes attached to the dermoepidermal basement membrane ("tombstone pattern"). In contrast, PF is associated with a very superficial split formation in the subcorneal layer.

### **Direct Immunofluorescence Microscopy**

Direct immunofluorescence microscopy of perilesional skin and mucosa (and frequently also of uninvolved skin/mucosa) typically reveals tissue-bound IgG or IgA (in IgA pemphigus) in a typical netlike intercellular distribution pattern in the epidermis. The immunoglobulin deposits are commonly accompanied by additional precipitation of C3. Except for PNP, these Ig and C3 deposits are not found along the dermoepidermal basement membrane.

### **Indirect Immunofluorescence Microscopy**

A hallmark of pemphigus is the presence of serum auto-Ab against desmosomal antigens. Indirect immunofluorescence analysis of pemphigus sera is thus a mainstay of diagnostic procedure for establishing the definite diagnosis of pemphigus. Typically, pemphigus sera show a characteristic netlike intercellular staining of IgG with human skin as a substrate. In most instances, monkey esophagus is the substrate of choice and pemphigus sera show a characteristic intercellular netlike staining with epithelial cells of monkey esophagus. PNP sera react in the typical intercellular staining pattern also

with other desmosome-rich substrates such as guinea pig esophagus or rat bladder epithelium which may be of diagnostic value for confirming the diagnosis of PNP (Jiao and Bystryn 1997).

### **Novel Immunoserological Test Systems**

The availability of recombinant forms of the autoantigens of distinct pemphigus variants has provided the basis for the development of novel diagnostic serological tests that very specifically confirm the diagnosis of pemphigus. Immunoblot and ELISA analysis of pemphigus sera provide the unique possibility to establish the diagnosis of pemphigus even without histology and direct immunofluorescence of a skin biopsy. ELISA analysis of anti-Dsg1 and anti-Dsg3 IgG has already found its way into clinical routine by the availability of a commercially available kit. Ishii et al. (1998) have provided the basis for the commercial ELISA by demonstrating that titers of anti-Dsg1 and anti-Dsg3 IgG correlate with disease activity of PV and PF. Immunoblot analysis with recombinant Dsg3 demonstrated that anti-Dsg3 of the IgG4, IgA, and IgE subtypes predominate in active PV while chronic remittent PV is characterized by IgG1 and IgG4 auto-Ab (Bhol et al. 1995; Kricheli et al. 2000; Spaeth et al. 2001). These novel immunoserological tests will allow to correlate titer and isotypes of anti-Dsg auto-Ab with the clinical course of disease and may thus serve as therapeutic/prognostic markers.

### **Therapy of Pemphigus**

As mentioned above, the pemphigus disorders have severe morbidity and high mortality if untreated. Major complications of extensive blistering of skin and mucous membranes result from loss of body proteins and fluids, secondary bacterial infections and decreased food uptake due to painful oral erosions.

#### **Glucocorticoids**

The introduction of systemic glucocorticosteroids has dramatically improved the prognosis of pemphigus. The strategy in PV is to induce complete remissions – no matter whether only oral lesions or a combination of mucocutaneous lesions are present – by administration of high doses (1–2 mg/kg/d) of systemic prednisolone which are gradually tapered over weeks to months (Mutasim 1999; Nousari and Anhalt 1999). The side effects of chronic glucocorticoid therapy, i.e. high blood pressure, diabetes, osteoporosis, increased susceptibility to infections and aseptic osteonecrosis contribute to the mortality of pemphigus which is still as high as 5–10%.

The therapeutic strategy in PF is somewhat similar but less stringent since the overall prognosis of (superficial) PF is more favorable. As in PV, the major concept is to induce remission by systemic administration of glucocorticoids in combination with adjuvants which allow to gradually taper the doses of glucocorticoids. Despite the availability of systemic glucocorticoids, the prognosis of PNP has remained fatal when associated with internal malignancies. PNP usually persists as long as the associated benign or malignant neoplasm and may regress as late as several months after successful removal/treatment of the tumor (Nousari and Anhalt 1999).

### **Immunosuppressive Agents (Adjuvants)**

Immunosuppressive adjuvants have been introduced as "steroid-sparing" drugs to guarantee long-lasting immunosuppression without the need of chronic administration of high doses of systemic glucocorticoids. These drugs are administered together with oral glucocorticoids and allow for a faster reduction of the glucocorticoid doses that are initially administered. The most commonly used systemic agents are azathioprin, cyclophosphamide, mycophenolate mofetil, methotrexate, and recently leflunomide. In contrast, cyclosporin A which has shown great promise in the treatment of T cell-mediated immune disorders has been shown to be ineffective as an adjuvant in pemphigus. In mild to moderate pemphigus, azathioprin or mycophenolic acid should be sufficient to induce on concert with oral prednisone remission. In refractory pemphigus, cyclophosphamide (2–3 mg/kg/d) in combination with prednisone is most efficient in controlling the disease.

Other strategies aim at directly interfering with the pathogenic auto-Ab in pemphigus. Plasmapheresis has been employed for more than 15 years to remove pathogenic auto-Ab from patients' sera. More recently, immunoadsorption over protein A or comparable columns has been introduced to more specifically remove pathogenic auto-Ab. Rapid removal of circulating Ab by immunoadsorption in combination with immediate immunosuppressive therapy (cyclophosphamide etc.) is highly efficient in controlling the disease. Administration of high dose intravenous immunoglobins has been successfully employed in cases of pemphigus that were recalcitrant to standard immunosuppressive therapy. In our own experience, two to three treatment cycles with high dose immunoglobulin (2 g/kg/month) were highly efficient in restoring responsiveness of refractory pemphigus to a standard immunosuppressive combination therapy.

### **Removal of Pathogenic Antibodies**

Immunoadsorption therapy has become an established adjuvant therapeutic strategy in many autoimmune disorders which is reflected by a number of

clinically available immunoabsorbent columns (Nakaji et al, 2001). In the past, four major affinity-type adsorbents have been introduced to clinical use, namely protein A, tryptophan, phenylalanine, and dextran sulfate as ligands. These adsorbents remove their targets through hydrophobic bonding. In an uncontrolled trial with nine patients with pemphigus, two cycles of IA with a tryptophan-linked-polyvinylalcohol adsorber led to a marked reduction of pathogenic serum auto-Ab (Lüftl et al, 2003). The most important advantages of immunoabsorption over unselected plasmapheresis are 1) the higher selectivity in the removal of pathogens, 2) reduced loss of essential plasma components, and 3) no requirement for protein replacement with all its risks. The results of the present study suggest that the combination therapy of immunoabsorption and immunosuppressants results in significant clinical improvement in the treatment of these patients with severe pemphigus. At present, however, the costs of immunoabsorption still exceed those of plasmapheresis. Among the different immunoabsorption techniques, the present tryptophan-linked column is still the least expensive procedure. Protein A columns, although being even more efficient in removing IgG antibodies than tryptophan columns are dramatically more expensive and no controlled clinical trials testing the efficacy of protein A columns in the treatment of pemphigus have been published (Schmidt et al, 2003). Recently, a novel peptide column (Globaffin, Affina) has proven highly effective in removing IgG Ab from PV and PF sera. Utilizing peptide column immunoabsorption, serum auto-Ab titers of PV and PF patients were reduced by 80% leading prolonged clinical remissions under standard immunosuppressive treatment (Eming R, et al, in preparation).

## Summary

Pemphigus encompasses a group of life-threatening autoimmune blistering disorders characterized by intraepithelial blister formation. The molecular basis for intraepithelial blister formation is the loss of adhesion between keratinocytes, called acantholysis, which is caused by auto-Ab against intercellular adhesion structures of epidermal keratinocytes. Clinically, PV is characterized by extensive bullae and erosions of the mucous membranes and also of the skin (in case that anti-Dsg1 auto-Ab are also present). Patients with untreated PV are prone to infections, loss of body fluids and proteins and to weight loss due to painful oral and esophageal erosions. The prognosis of PV was fatal prior to introduction of systemic glucocorticoids and adjuvant immunosuppressive agents as the standard treatment. Several forms of pemphigus have been identified depending of the level of the intraepidermal split formation. In PV, the blisters are located in the suprabasal layer whereas in PF, a clinically less severe disease, the blisters occur within the upper layers of the epidermis. In PV and PF, the auto-Ab target the extracellular portions of

Dsg3 and Dsg1, respectively. Auto-Ab production in PV and PF is polyclonal and most auto-Ab are of the IgG4 subclass in acute onset or active disease. Patients in remission have mainly auto-Ab of the IgG1 subtype. Evidence for the pathogenicity of these circulating auto-Ab is provided by the observation that 1) the activity of PV correlates with auto-Ab titers, 2) newborns of mothers with active PV temporarily exhibit blisters due to the diaplacental transfer of maternal auto-Ab, and 3) pemphigus-like lesions are induced in neonatal mice by transfer of IgG from PV patients. The major therapeutic strategy in pemphigus is chronic immunosuppressive therapy with glucocorticosteroids in combination with immunosuppressive adjuvants.

## References

- Ahmed AR, Blose DA (1984) Pemphigus vegetans. Neumann type and Hallopeau type. *Int J Dermatol* 23: 135–141
- Ahmed AR, Yunis EJ, Khatri K (1990) Major histocompatibility complex haplotype studies in Ashkenazi Jewish patients with pemphigus vulgaris. *Proc Natl Acad Sci USA* 87: 7658–7662
- Ahmed AR, Wagner R, Khatri K (1991) Major histocompatibility complex haplotypes and class II genes in non-Jewish patients with pemphigus vulgaris. *Proc Natl Acad Sci USA* 88: 5056–5061
- Ahmed AR, Mohimen A, Yunis AJ (1993) Linkage of pemphigus vulgaris antibody to the major histocompatibility complex in healthy relatives of patients. *J Exp Med* 177: 419–424
- Amagai M, Klaus-Kovtun V, Stanley JR (1991) Auto-Ab against a novel epithelial cadherin in pemphigus vulgaris, a disease of cell adhesion. *Cell* 67: 869–877
- Amagai M, Karpati S, Prussick R, Klaus-Kovtun V, Stanley JR (1992) Autoantibodies against the amino-terminal cadherin-like binding domain of pemphigus vulgaris antigen are pathogenic. *J Clin Invest* 90: 919–926
- Amagai M, Hashimoto T, Shimizu N, Nishikawa T (1994) Absorption of pathogenic autoantibodies by the extracellular domain of pemphigus vulgaris antigen (Dsg 3) produced by baculovirus. *J Clin Invest* 94: 59–67
- Amagai M, Nishikawa T, Shimizu N, Green KJ, Hashimoto T (1995) Antigen-specific immunoadsorption of pathogenic autoantibodies in pemphigus foliaceus. *J Invest Dermatol* 104: 895–901
- Amagai M, Koch PJ, Nishikawa T, Stanley JR (1996) Pemphigus vulgaris antigen (desmoglein 3) is localized in the lower epidermis, the site of blister formation in patients. *J Invest Dermatol* 106: 351–355
- Amagai M, Nishikawa T, Noursari HC, Anhalt GJ, Hashimoto T (1998) Antibodies against desmoglein 3 (pemphigus vulgaris antigen) are present in sera from patients with paraneoplastic pemphigus and cause acantholysis in vivo in neonatal mice. *J Clin Invest* 102: 775–782
- Amagai M, Tsunoda K, Suzuki H, Nishifuji K, Koyasu S, Nishikawa T (2000a) Use of autoantigen-knockout mice in developing an active autoimmune disease model for pemphigus. *J Clin Invest*. 105: 625–31
- Amagai M, Matsuyoshi N, Wang ZH, Andl C, Stanley JR (2000b) Toxin in bullous impetigo and staphylococcal scalded skin syndrome targets desmoglein 1. *Nature Med* 6: 1275–1277
- Anhalt GJ, Labib KS, Vorhees JS, Beals TF, Diaz LA (1982) Induction of pemphigus in neonatal mice by passive transfer of IgG from patients with the disease. *N Engl J Med* 306: 1189–1192
- Anhalt GJ, Kim S, Stanley JR (1990) Paraneoplastic pemphigus: an autoimmune mucocutaneous disease associated with neoplasia. *N Engl J Med* 323: 1729–1735



- Bedane C, Prost C, Thomine E, Intrator L, Joly P, Caux F, Blecker M, Bernard P, Leboutet MJ, Tron F, Lauret P, Bonnetblanc JM, Dubertret L (1996) Binding of autoantibodies is not restricted to desmosomes in pemphigus vulgaris: comparison of 14 cases of pemphigus vulgaris and 10 cases of pemphigus foliaceus studied by western immunoblot and immunoelectron microscopy. *Arch Dermatol Res* 288: 343–352
- Bhol K, Ahmed AR, Aoki V, Mohimen A, Nagarwalla N, Natarajan K (1995) Correlation of peptide specificity and IgG subclass with pathogenic and nonpathogenic autoantibodies in pemphigus vulgaris: a model for autoimmunity. *Proc Natl Acad Sci U S A* 92: 5239–5243
- Brandsen R, Frusic-Zlotkin M, Lyubimov H, Yunes F, Michel B, Tamir A, Milner Y, Brenner S (1997) Circulating pemphigus IgG in families of patients with pemphigus: comparison of indirect immunofluorescence, direct immunofluorescence, and immunoblotting. *J Am Acad Dermatol* 36: 44–52
- Brenner S, Bialy-Golan A, Anhalt GJ (1997) Recognition of pemphigus antigens in drug-induced pemphigus vulgaris and pemphigus foliaceus. *J Am Acad Dermatol* 36: 919–923
- Delgado JC, Yunis EJ, Ahmed AR, Alper CA, Ahmad M Khan AA, Rehman SB, Rojas AI, Bhol K, Yunis JJ, Hameed A (1997) Pemphigus vulgaris autoantibody response is linked to HLA-DQ $\beta$ 1\*0503 in Pakistani patients. *Hum Immunol* 57: 110–119
- Ding X, Fairley JA, Diaz LA, Lopez-Swidorski A, Mascaro JM Jr, Aoki V (1997). Mucosal and mucocutaneous (generalized) pemphigus vulgaris show distinct autoantibody profiles. *J Invest Dermatol* 109: 592–596
- Emery DJ, Diaz LA, Fairly JA, Lopez A, Taylor AF, Giudice GJ (1995) Pemphigus foliaceus and pemphigus vulgaris autoantibodies react with the extracellular domain of desmoglein 1. *J Invest Dermatol* 104: 323–328
- Eming R, Rech J, Kalden JR, Schuler G, Harrer T, Hertl M. Removal of pathogenic autoantibodies in patients with severe pemphigus by immunoadsorption. (in preparation)
- Esaki C, Kitajima Y, Osada K, Yamada T, Seishima M (1995) Pharmacologic evidence for involvement of phospholipase C in pemphigus IgG-induced inositol 1,4,5-trisphosphate generation, intracellular calcium increase, and plasminogen activator secretion in DJM-1 cells, a squamous cell carcinoma line. *J Invest Dermatol* 105: 329–333
- Feliciani C, Toto P, Amerio P, Pour SM, Coscione G, Shivji G, Wang B, Sauder D (2000) In vitro and in vivo expression of interleukin-1 $\alpha$  and tumor necrosis factor- $\alpha$  mRNA in pemphigus vulgaris: interleukin-1 $\alpha$  and tumor necrosis factor- $\alpha$  are involved in acantholysis. *J Invest Dermatol* 114: 71–77
- Fleischmann M, Dreno B, Litoux P, Bernard P, Celerier P (1996) Long-term interferon-alpha therapy induces autoantibodies against epidermis. *Dermatology* 192:50–55
- Gomi H, Kawada A, Amagai M, Matsuo I (1999) Pemphigus erythematosus: detection of anti-desmoglein-1 antibodies by ELISA. *Dermatology* 199: 188–189
- Hashimoto T, Shafran M, Webber PA, Lazarus GS, Singer KH (1983) Anti-cell surface pemphigus autoantibody stimulates plasminogen activator activity of human epidermal cells. A mechanism for the loss of epidermal cohesion and blister formation. *J Exp Med* 157: 259–272
- Hashimoto K, Hashimoto T, Hiashiyama M, Nishikawa T, Garrod DR, Yoshikawa K (1994) Detection of anti-desmoglein I and II autoantibodies in two cases of of Hallopeau type pemphigus vegetans by immunoblot analysis. *J Dermatol Sci* 7: 100–106
- Hashimoto T, Amagai M, Watanabe K, Dmochowski M, Chidgey MAJ, Yue KKM, Garrod DR, Nishikawa T (1995a) A case of pemphigus vulgaris showing reactivity with pemphigus antigens (Dsg1 and Dsg3) and desmogleins. *J Invest Dermatol* 104: 541–544
- Hashimoto T, Gamou S, Korman NJ, Boorsma DM, Stevens HP, Black MM, Bhogal BS, Chorzelski TP, Watanabe K, Amagai M (1995b) Characterization of paraneoplastic pemphigus autoantigens by immunoblot analysis. *J Invest Dermatol* 104: 829–834
- Hashimoto T, Nishikawa T, Amagai M, Ishii K, Komori K, Kobayashi Y, Garrod DR, Chidgey MA, Miyasato M, Mori O, Kiyokawa C (1997) Human desmoglein 1 (Dsc1) is an autoantigen for the subcorneal pustular dermatosis type of IgA pemphigus. *J Invest Dermatol* 109: 127–131
- Hertl M, Amagai M, Ishii K, Stanley J, Sundaram H, Katz SI (1998a) Recognition of desmoglein 3 by autoreactive T cells in pemphigus vulgaris patients and normals. *J Invest Dermatol* 110: 62–66

- Hertl M (1998b) Molecular characterization of autoantibodies in pemphigus: In Conrad K, Humbel RL, Meurer M, Shoenfeld Y and Tan EM (eds.): Pathogenic and diagnostic relevance of autoantibodies. Pabst Science Publishers, Berlin
- Hertl M, Riechers R (1999) Analysis of the T cells that are potentially involved in autoantibody production in pemphigus vulgaris. *J Dermatol* 26: 748–752
- Hertl M (2000) Humoral and cellular autoimmunity in autoimmune bullous skin disorders. *Int Arch Allergy Immunol* 122: 91–100
- Huilgol SC, Black MM (1995) Management of the immunobullous disorders. II. Pemphigus. *Clin Exp Dermatol* 20: 283–293
- Ishii K, Amagai M, Komai A, Ebharas T, Chorzelski P, Nishikawa T, Hashimoto T (1998) Desmoglein 1 and desmoglein 3 as autoimmune target of herpetiform pemphigus. *J Invest Dermatol* 110: 510A
- Iwatsuki KI, Harada H, Yokote R, Kaneko F (1995). Differences in the expression of pemphigus antigens during epidermal differentiation. *Br J Dermatol* 133: 209–216
- Jablonska S, Chorzelski TP, Beutner EH, Chorzelska J (1975) Herpetiform pemphigus, a variable pattern of pemphigus. *Int J Dermatol* 14: 353–359
- Jiao D, Bystryń JC (1997) Sensitivity of indirect immunofluorescence, substrate specificity, and immunoblotting in the diagnosis of pemphigus. *J Am Acad Dermatol* 37: 211–216
- Joly P, Gilbert D, Thomine E, Delpech A, Verdier S, Lauret P, Tron F (1993) Immunofluorescence and immunoelectron microscopy analyses of a human monoclonal anti-epithelial cell surface antibody that recognizes a 185-kD polypeptide: a component of the paraneoplastic pemphigus antigen complex. *J Invest Dermatol* 101: 339–345
- Joly P, Tron F, Lauret P, Delpech A, Ghohestani R, Zitouni M, Thomine E, Gilbert D (1997) Identification of a new antibody population directed against a desmosomal plaque antigen in pemphigus vulgaris and pemphigus foliaceus. *J Invest Dermatol* 108: 469–475
- Juhász I, Lazarus GS, Murphy GF, Shih IM, Herlyn M (1993) Development of pemphigus vulgaris-like lesions in severe combined immunodeficiency disease mice with lymphocytes from patients. *J Clin Invest* 92: 2401–2407
- Karpáti S, Amagai M, Liu WL, Dmochowski M, Hashimoto T, Horváth A (2000) Identification of desmoglein 1 as autoantigen in a patient with intraepidermal neutrophilic IgA dermatosis type of IgA pemphigus. *Exp Dermatol* 9: 224–228
- Kazerounian S, Mahoney MG, Uitto J, Aho S (2000) Envoplakin and periplakin, the paraneoplastic pemphigus antigens, are also recognized by pemphigus foliaceus autoantibodies. *J Invest Dermatol* 11: 505–507
- Kim SC, Kwon YD, Lee IJ, Chang SN, Lee TG (1997) cDNA cloning of the 210-kD paraneoplastic pemphigus antigen reveals that envoplakin is a component of the antigen complex. *J Invest Dermatol* 109: 365–369
- Kirsner RS, Anhalt GJ, Kerdel FA (1995) Treatment with alpha interferon associated with the development of drug-induced pemphigus. *Br J Dermatol* 132: 474–478
- Kljić A, Bazzi H, Sundberg JP, Martínez-Mir A, O’Shaughnessy R, Mahoney MG, Levy M, Montagutelli X, Ahmad W, Aita VM, Gordon D, Uitto J, Whiting D, Ott J, Fischer S, Gilliam TC, Jahoda CA, Morris RJ, Panteleyev AA, Nguyen VT, Christiano AM (2003) Desmoglein 4 in hair follicle differentiation and epidermal adhesion: evidence from inherited hypotrichosis and acquired pemphigus vulgaris. *Cell* 113:249–260
- Koch PJ, Mahoney MG, Ishikawa H, Pulkkinen L, Uitto J, Shultz L, Murphy GF, Whitacker-Menezes D, Stanley JR (1997) Targeted disruption of the pemphigus vulgaris antigen (desmoglein 3) gene in mice causes loss of keratinocyte cell adhesion with a phenotype similar to pemphigus vulgaris. *J Cell Biol* 137: 1091–1102
- Korman NJ, Eyre RW, Zone J, Stanley JR (1991a) Demonstration of an adhering-junction molecule (plakoglobin) in the autoantigens of pemphigus foliaceus and pemphigus vulgaris. *N Engl J Med* 321: 631–635
- Korman NJ, Eyre RW, Zone J, Stanley JR (1991b) Drug-induced pemphigus: autoantibodies directed against the pemphigus antigen complexes are present in penicillamine- and captopril-induced pemphigus. *J Invest Dermatol* 96: 273–276
- Kowalczyk AP, Green KJ, Stanley JR, Hashimoto T, Borgwardt JE, Anderson JE (1995) Pemphigus sera recognize conformationally sensitive epitopes in the amino-terminal region of desmoglein-1. *J Invest Dermatol* 105: 147–152

- Kricheli D, David M, Frusic-Zlotkin M (2000) The distribution of pemphigus vulgaris IgG subclasses and reactivity with desmoglein 3 and 1 in pemphigus patients and first-degree relatives. *B J Dermatol* 143: 337–342
- Kubo A, Yoshikawa K, Hashimoto K, Higashiyama M, Doi T, Hashimoto T, Amagai M (1997) Herpetiform pemphigus showing reactivity with pemphigus vulgaris antigen (desmoglein 3). *Br J Dermatol* 137: 109–113
- Lever WF (1953) Pemphigus. *Medicine* 32: 1–123
- Lin MS, Swartz SL, Lopez A, Ding X, Fernandez-Vina MA, Stastny P, Fairley JA, Diaz L (1997) Development and characterization of desmoglein 3-specific T cells from patients with pemphigus vulgaris. *J Clin Invest* 99: 31–40
- Lin MS, Fu CF, Aoki V, Hans-Filho G, Riviti EA, Moraes JR, Lazaro AM, Giuglice GJ, Stastny P, Diaz LA (2000) Desmoglein 1-specific T lymphocytes from patients with endemic pemphigus foliaceus (fogo selvagem). *J Clin Invest* 105: 207–213
- Mefl M, Stauber A, Mainka A, Klingel R, Schuler G, Hertl M (2003) Successful removal of pathogenic autoantibodies in pemphigus by immunoadsorption with a tryptophan-linked polyvinylalcohol adsorber. *Br J Dermatol* 149:598–605
- Mahoney MG, Aho S, Uitto J, Stanley JR (1998) The members of the plakin family of proteins recognized by paraneoplastic pemphigus antibodies include periplakin. *J Invest Dermatol* 111: 308–313
- Mahoney MG, Wang Z, Rothenberger KL, Koch PJ, Amagai M, Stanley JR (1999) Explanation for localization of blisters in pemphigus patients. *J Clin Invest* 103: 461–468
- Matzner Y, Erlich HA, Brautbar C, Sanilevitch A, Landau M, Brenner S, Friedmann A (1995) Identical HLA class II alleles predispose to drug-triggered and idiopathic pemphigus vulgaris. *Acta Derm Venereol* 75: 12–14
- Mutasim DF (1999) Autoimmune bullous diseases: diagnosis and management. *Dermatol Nurs* 11: 15–21
- Nakaji S (2001) Current topics on immunoadsorption therapy. *Ther Apher* 5:301–305
- Nguyen VT, Ndoye A, Shultz LD, Pittelkow MR, Grando SA (2000a) Antibodies against keratinocyte antigens other than desmogleins 1 and 3 can induce pemphigus vulgaris-like lesions. *J Clin Invest* 106: 1467–1479
- Nguyen VT, Ndoye A, Grando SA (2000b) Pemphigus vulgaris antibody identifies pemphaxin. A novel keratinocyte annexin-like molecule binding acetylcholine. *J Biol Chem* 275: 29466–29476
- Nguyen VT, Ndoye A, Grando SA (2000c) Novel human alpha9 acetylcholine receptor regulating keratinocyte adhesion is targeted by pemphigus vulgaris autoimmunity. *Am J Pathol* 157: 1377–1391
- Niizeki H, Inamoto N, Nakamura K, Tsuchimoto K, Hashimoto T, Nishikawa T (1994) A case of pemphigus foliaceus after interferon-alpha-2a therapy. *Dermatology* 189: 129–130
- Nishifuji K, Amagai M, Kuwana M, Iwasaki T, Nishikawa T (2000) Detection of antigen-specific B cells in patients with pemphigus vulgaris by enzyme-linked immunospot assay: requirement of T cell collaboration for autoantibody production. *J Invest Dermatol* 114: 88–94
- Nishifuji K, Nagasaka T, Ota T, Whittock NV, Amagai M (2004) Is desmoglein 4 involved in blister formation in pemphigus or impetigo? *J Invest Dermatol* 122: A33
- Nousari HC, Anhalt GJ (1999) Pemphigus and bullous pemphigoid. *Lancet* 354: 667–672
- Ochsendorf FR, Schofer H, Milbradt R (1987) Pemphigus erythematosus – detection of anti-DNA antibodies. *Hautarzt* 1987 38: 400–403
- Ohata Y, Amagai M, Ishii K, Hashimoto T (2001) Immunoreactivity against intracellular domains of desmogleins in pemphigus. *J Dermatol Sci* 25: 64–71
- Ongenaes KC, Temmerman LJ, Vermander F (1999) Intercellular Ig A dermatosis. *Eur J Dermatol* 9: 85–94
- Oursler JR, Labib RS, Ariss-Abdo L, Burke T, O'Keefe EJ, Anhalt GJ (1992) Human autoantibodies against desmoplakins in paraneoplastic pemphigus. *J Clin Invest* 89: 1775–1782
- Parodi A, Semino M, Gallo R, Rebora A (1993) Bullous eruption with circulating pemphigus-like antibodies following interferon-alpha therapy. *Dermatology* 186: 155–157
- Proby C, Fujii Y, Owaribe K, Nishikawa T, Amagai M (1999) Human antibodies against HD1/plectin in paraneoplastic pemphigus. *J Invest Dermatol* 112: 153–156

- Prost C, Intrator L, Wechsler J (1991) IgA autoantibodies bind to pemphigus vulgaris antigen in a case of intraepidermal neutrophilic IgA dermatosis. *J Am Acad Dermatol* 25: 846–848
- Rädisch T, Riechers R, Hertl M (2002) The humanized SCID mouse model to study HLA class II-linked autoimmunity to desmoglein 3 in pemphigus. *Br. J. Dermatol.* 146: 189–193
- Ramseur WL, Richards F, Duggan DB (1989) A case of fatal pemphigus vulgaris in association with beta interferon and interleukin 2 therapy. *Cancer* 63: 2005–2007
- Riechers R, Grötzinger A, Hertl M (1999) HLA class II restriction of autoreactive T cell responses in pemphigus vulgaris and potential application for a specific immunotherapy. *Autoimmunity* 30: 183–196
- Santi CG, Maruta CW, Aoki V, Sotto MN, Rivitti EA, Diaz LA (1996) Pemphigus herpetiformis is a rare clinical expression of nonendemic pemphigus foliaceus, fogo selvagem, and pemphigus vulgaris. *J Am Acad Dermatol* 34: 40–46
- Schmidt E, Klinker E, Opitz A, Herzog S, Sitaru C, Goebeler M, Mansouri, Taleghoni B, Brocker EB, Zillikens D (2003) Protein A immunoabsorption: a novel and effective adjuvant treatment of severe pemphigus. *Br J Dermatol* 148:1222–1229.
- Seishima M, Kitajima Y, Hashimoto T, Mori S, Osada K, Esaki C (1995) Pemphigus IgG, but not bullous pemphigoid IgG, causes a transient increase in intracellular calcium and inositol 1,4,5-triphosphate in DJM-1 cells, a squamous cell carcinoma line. *J Invest Dermatol* 104: 33–37
- Senear FE, Usher B (1926) An unusual type of pemphigus combining features of lupus erythematosus. *Arch Dermatol* 13: 761–781
- Shimizu H, Nishikawa T, Hashimoto T, Kikuchi A, Ishiko A, Masunaga T (1995) Pemphigus vulgaris and pemphigus foliaceus sera show an inversely graded binding pattern to extracellular regions of desmosomes in different layers of human epidermis. *J Invest Dermatol* 105: 153–159
- Shirakata Y, Hashimoto K, Nishikawa T, Hanakawa Y, Amagai M (1998) Lack of mucosal involvement in pemphigus foliaceus may be due to low expression of desmoglein 1. *J Invest Dermatol* 110: 76–78
- Sinha AA, Brautbar C, Szafer F, Friedmann A, Tzfon E, Todd JA, Steinman L, McDevitt HO (1988) A newly characterized HLA-DQ $\beta$  allele associated with pemphigus vulgaris. *Science* 239: 1026–1029
- Späth S, Riechers R, Borradori L, Zillikens D, Bdingler L, Hertl M (2001) Detection of autoantibodies of various subclasses (IgG1, IgG4, IgA, IgE) against desmoglein 3 in patients with acute onset and chronic pemphigus vulgaris. *Br J Dermatol* 144:1183–1188
- Supapannachart N, Mutasim DF (1993) The distribution of IgA pemphigus antigen in human skin and the role of IgA anti-cell surface antibodies in the induction of intraepidermal acantholysis. *Arch Dermatol* 129: 605–608
- Tremeau-Martinauge C, Bazex J, Oksman F (1995) Immunoglobulin G subclass distribution of anti-intercellular substance antibodies in pemphigus. *Ann Dermatol Venereol* 122: 409–411
- Veldman C, Stauber A, Wassmuth R, Uter W, Schuler G, Hertl M (2003) Dichotomy of autoreactive Th1 and Th2 cell responses to desmoglein 3 in patients with pemphigus vulgaris (PV) and healthy carriers of PV-associated HLA class II alleles. *J Immunol.* 170: 635–42.
- Veldman C, Gebhard KL, Uter W, Wassmuth R, Grotzinger J, Schultz E, Hertl M (2004a) T cell recognition of desmoglein 3 peptides in patients with pemphigus vulgaris and healthy individuals. *J Immunol* 172:3883–3892.
- Veldman C, Hohne A, Dieckmann D, Schuler G, Hertl M (2004b) Type I regulatory T cells specific for desmoglein 3 are more frequently detected in healthy individuals than in patients with pemphigus vulgaris. *J Immunol* 172:6468–6475.
- Wallach J (1992) Intraepidermal IgA pustulosis. *J Am Acad Dermatol* 27: 993–1000
- Wang J, Kwon J, Ding X, Fairley JA, Woodley DT, Chan LS (1997) Nonsecretory IgA1 autoantibodies targeting desmosomal component desmoglein 3 in intraepidermal neutrophilic IgA dermatosis. *Am J Pathol* 150: 1901–1906
- Warren SJP, Lin MS, Giudice G, Hoffmann RG, Hans-Filho G, Aoki V, Rivitti EA, Dos Santos V, Diaz LA for the cooperative group of fogo selvagem research (2000) The prevalence of antibodies against desmoglein 1 in endemic pemphigus foliaceus in Brazil. *N Engl J Med* 343: 23–30

- Whittock NV, Bower C (2003) Genetic evidence for a novel human desmosomal cadherin, desmoglein 4. *J Invest Dermatol* 120: 523–530
- Wu H, Wang ZH, Yan A, Lyle S, Fakharzadeh S, Wahl JK, Wheelock MJ, Ishikawa H, Uitto J, Amagai M, Stanley JR (2000) Protection against pemphigus foliaceus by desmoglein 3 in neonates. *N Engl J Med* 343: 31–35
- Wucherpfennig KW, Yu WB, Bhol K, Monos DS, Argyris E, Karr RW, Ahmed AR, Strominger JL (1995) Structural basis for major histocompatibility complex (MHC)-linked susceptibility to autoimmunity: charged residues of a single MHC binding pocket confer selective presentation of self-peptides in pemphigus vulgaris. *Proc Natl Acad Sci USA* 92: 11935–11939
- Yasuda H, Kobayashi H, Hashimoto T, Itoh K, Yamane M, Nakamura J (2000) Subcorneal pustular dermatosis type of IgA pemphigus: demonstration of autoantibodies to desmocollin-1 and clinical review. *Br J Dermatol* 143: 144–148

## **3.2 Bullous Pemphigoid: Clinical Features, Diagnostic Markers, and Immunopathogenic Mechanisms**

*Emmanuel Laffitte and Luca Borradori*

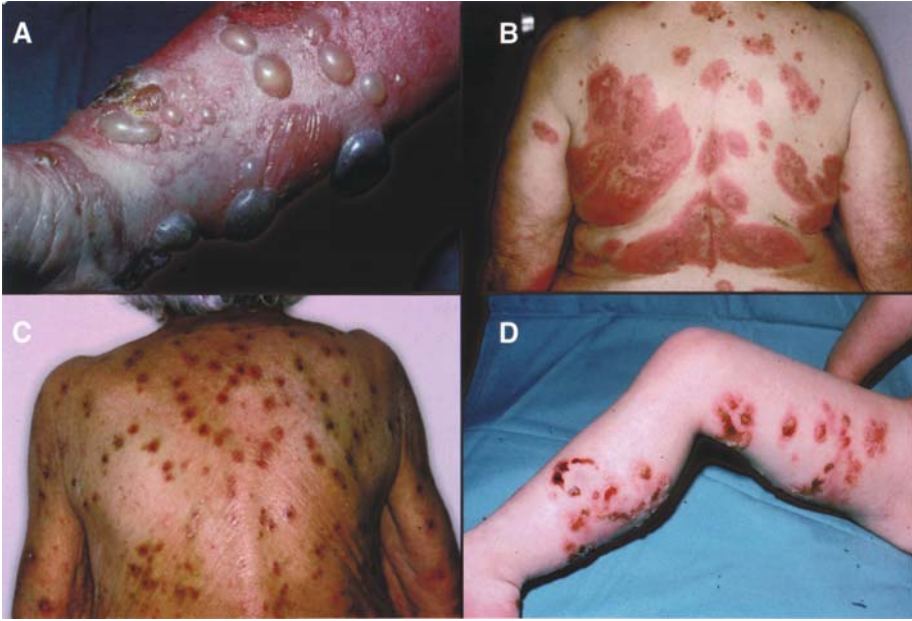### **Introduction**

Over the centuries blistering skin disorders have been described under a variety of terms, such as pemphigus, ptyctainia, phlyzaktion. However, it is only about 40 years since Lever (1956), on the basis of distinctive clinical and histological features, recognized bullous pemphigoid as a distinct disorder within the large group of blistering disorders, including the pemphigus group. One milestone in the evolution of our understanding of bullous pemphigoid was the demonstration by Jordon et al. (Jordon et al. 1967) that the disease was associated with *in vivo* bound and circulating autoantibodies directed against the basement membrane zone of stratified epithelia. Today, BP has emerged as an example of organ-specific autoimmune disease and it represents the most frequent autoimmune blistering disorder.

In this review, we will discuss the clinical and immunopathological features of BP, its differential diagnoses and therapeutic options. We will also focus on recent progress in our understanding of the pathophysiology of this disorder and on the role of targeted autoantigens in the maintenance of epithelial-stromal adhesion.

### **Clinical Features**

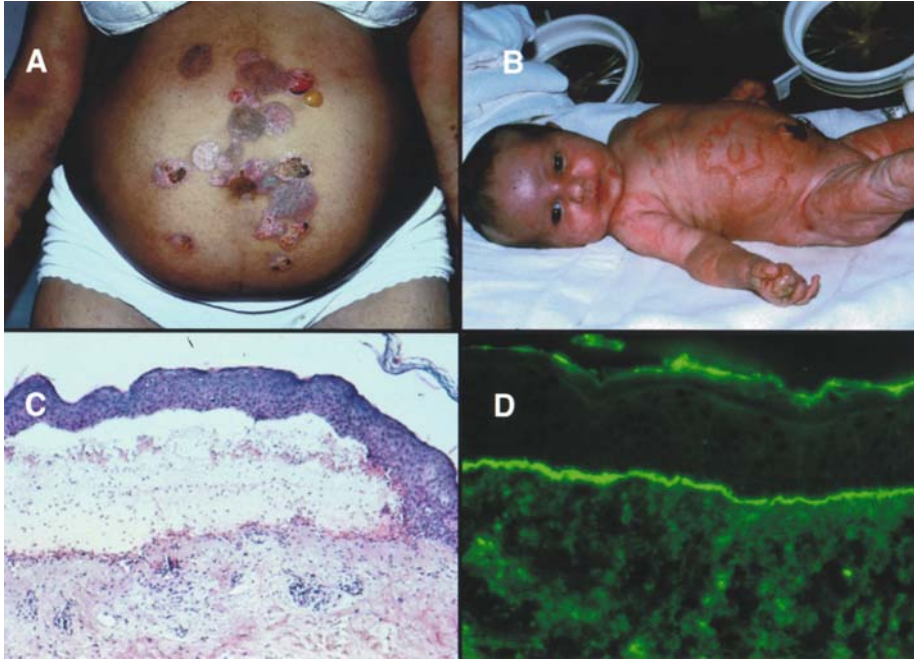
In the *prodromal, non-bullous phase* manifestations of BP are frequently non-specific and, thus, misleading. Patients complain of severe itch accompanied or not by excoriated, eczematiform, papular and or urticarial lesions that may persist for several weeks or months, or even remain the only signs of the disease.



**Fig. 1.** Bullous pemphigoid. **Panel A:** bullous lesions on the forearms; **Panel B:** urticarial erythema and elevated inflammatory plaques on the trunk distributed in a figurate pattern; **Panel C:** prurigo nodularis-like presentation with generalized papular and excoriated lesions; **Panel D:** childhood form of bullous pemphigoid with vesicular and bullous lesions arranged in jewel-like clusters. The patient had IgA autoantibodies targeting BP180

In the *bullous stage* vesicles and bullae develop on apparently normal or erythematous skin together with urticated and infiltrated plaques that have occasionally an annular or figurate pattern. The blisters are tense, with a clear exudate, and may persist for several days, leaving eroded and crusted areas (*Figure 1*). The lesions are frequently distributed symmetrically and predominate on the flexural aspects of the limbs, and abdomen. In the intertriginous spaces, vegetating plaques can be observed. Involvement of the oral cavity is observed in 10–30% of cases. The mucosae of eyes, nose, pharynx, esophagus and ano-genital areas are more rarely affected (reviewed in Lever 1953; Liu et al. 1986; Korman 1987).

Several *clinical variants* of BP have been described (reviewed in Liu et al. 1986; Korman 1987). Lesions remain occasionally localized, such as on the pretibial area ("pretibial pemphigoid"), around stomas, on the vulvar region ("vulvar pemphigoid"), on irradiated areas or confined to a paralyzed limb. Palmo-plantar involvement mimicking dyshidrosiform eczema ("dyshidrosiform pemphigoid") might be observed. Several other variants, such as a prurigo nodularis – ("pemphigoid nodularis"), and an erythroderma-like form have been described. These variants have all been described with various



**Fig. 2. Panel A:** pemphigoid gestationis: urticarial erythema, vesicles and bullae in the periumbelical area and abdomen; **Panel B:** transplacental passage of autoantibodies from a mother with gestational pemphigoid: neonate with a generalized eruption consisting of erythematous plaques with a figurate configuration and blisters; **Panel C:** bullous pemphigoid: light microscopy study shows a subepidermal blister with an inflammatory infiltrate in the blister cavity and in the upper dermis consisting predominantly of eosinophils and neutrophils; **Panel D:** bullous pemphigoid: direct immunofluorescence microscopy depicting linear IgG deposits in the epidermal basement membrane

terms: only dermatologists can afford to have so different names for the same condition!

A peculiar form of BP typically associated with pregnancy, for which a separate term appears justified, is *gestational pemphigoid* (also called "pemphigoid gestationis" or "herpes gestationis") (reviewed in Shornick 1993; Jenkins et al. 1993). This disease is also rarely found with either a choriocarcinoma or an hydatiforme mole. Gestational pemphigoid, the estimated frequency of which is of one case for 10'000 to 40'000 pregnancies, starts during the second or third trimester of pregnancy or, more rarely, after delivery. In the early phase, itchy papular and urticated lesions are observed, with later on development of vesicles and bullae (*Figure 2*). The eruption begins on the periumbelical and abdominal area and can generalize. Relapses are frequently observed during subsequent pregnancies and they might be triggered by either menstruation or intake of oral contraceptives.



## Presentation and Clinical Setting

BP typically affects the elderly, with onset after 60 years of age. Its incidence has been estimated to be 6.1 and 7 new cases per million per year in a German and a French study, respectively, and it rapidly increases with aging (Bernard et al. 1995; Jung et al. 1999). The relative risk for patients older than 90 years has been estimated to be approximately 300 fold higher than for those of 60 years of age or younger. In contrast to most autoimmune diseases, men have a higher risk of suffering from BP than women (Jung et al. 1999). Although BP is usually a disease of the elderly, it may rarely occur in children (Nemeth et al. 1991, Trueb et al. 1998).

Increasing evidence indicates that certain HLA class II alleles, that are prevalent in BP, play an important role in restricting autoreactive T cell responses to the BP target antigens (see below) and may thus be critical in the pathogenesis of the disease (Büdingner et al. 1998). A predominance of the class II HLA allele DQb1\*0301 has been found in Caucasian patients with BP and other variants, such as gestational pemphigoid and cicatricial pemphigoid (Delgado et al. 1996). However, the association of HLA class II alleles is most likely more polymorphic. In one report, the restriction with the allele DQb1\*0301 has been found to apply to men only (Banfield et al. 1998), while in a Japanese study BP was associated with the alleles DRb1\*04, DRb1\*1101 and DQb1\*0302 (Okazaki et al. 2000).

The potential occurrence of malignant diseases in patients with BP is most likely related to the old age of the patients. Some reports have suggested an increased frequency of certain cancers (such as of digestive tract, urinary bladder, and lung) and lymphoproliferative disorders. However, in two case-control studies, this excess of malignancy in BP was not significant (Venning et al. 1990; Lindelöf et al. 1990).

BP has been also described in patients with other autoimmune disorders, such as rheumatoid arthritis, Hashimoto's thyroiditis, dermatomyositis, lupus erythematosus, and autoimmune thrombocytopenia. Although a case-control study did not find any increased risk for autoimmune disorders in BP (Taylor et al. 1993), it is likely that these associations are not fortuitous, but reflect a genetically determined susceptibility to develop autoimmune diseases.

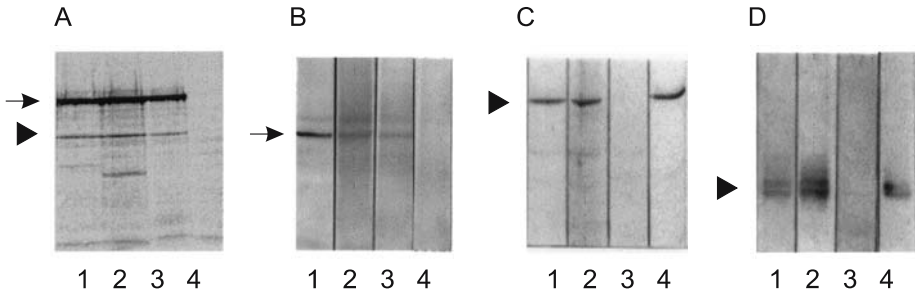
In some cases BP has been thought to be induced by trauma, burns, radiotherapy, UV radiation and, more significantly, drug intake (reviewed in Vassileva 1998). With regard to the latter, diuretics (such as furosemide), non-steroidal anti-inflammatories, D-penicillamine, antibiotics (ampicilline and ciprofloxacin), iodine, and captopril are the most frequently implicated drugs. In a case-control study, an association was found with aldosterone antagonists and neuroleptics (Bastuji-Garin et al. 1996). It is not clear yet by which mechanisms drugs affect the development of BP, but it is likely that these patients have an underlying susceptibility for the development of BP and the drugs act as triggers. BP has also been found in association with certain dermatoses,

such as psoriasis and lichen planus. In these conditions, it has been speculated that the inflammatory process at the dermo-epidermal junction is responsible for the exposure of antigens to autoreactive T lymphocytes leading to a secondary immune response (reviewed in Chan et al. 1998). Finally, BP has been described in patients presenting with neurological disorders, such as multiple sclerosis, Shy-Drager syndrome, or amyotrophic lateral sclerosis (Masouyé et al. 1989; Chosidow et al. 2000). While the significance of these associations is unclear, it is intriguing to note that one of the two autoantigens of BP, the BP antigen 230 (BP230) (see below), has several isoforms (such as BPAG1-a) that are expressed in the central and peripheral nervous system and in muscles (Leung et al., 2001). The possibility that in certain cases autoantibodies to BP230 might cross react with these isoforms and contribute to the neurological manifestations remains to be evaluated (Laffitte et al. 2004).

## Diagnosis

Because of the clinical and immunopathological overlap with other autoimmune subepidermal blistering disorders, diagnosis of BP relies on the characterization of the targeted antigens. However, immunofluorescence microscopy studies are very useful for an initial classification. Although the validity of the approach needs confirmation, we frequently perform a work-up including IF microscopy studies in elderly patients with itch with or without skin manifestations to exclude a prodromal, non-bullous phase of BP.

1. *Light microscopy studies* of an early bulla show a subepidermal blister with a dermal inflammatory infiltrate composed predominantly of eosinophils and neutrophils (*Figure 2*). In early non-bullous phases, subepidermal clefts and eosinophilic spongiosis are found. Nevertheless, in the early phase of the disease or in atypical cases of BP histological features are not diagnostic.
2. *Direct immunofluorescence microscopy studies* characteristically shows linear deposits of IgG and or C3, and more rarely, of other Ig classes along the epidermal basement membrane (*Figure 2*). Testing of autologous patient's skin after treatment with 1 M NaCl can allow the distinction of patients with BP (deposits on the epidermal side of the split or on both side of the split) from those with epidermolysis bullosa acquisita or anti-epiligrin cicatricial pemphigoid (deposits on the dermal side) (Gammon et al. 1990).
3. *Indirect immunofluorescence studies* demonstrates the presence of circulating IgG autoantibodies in 60 to 80% of patients, that typically bind to the epidermal side of saline separated normal human skin (Gammon et al. 1994a). The latter substrate has been found to be superior than intact skin and other substrates such as monkey esophagus. In gestational pemphigoid,



**Fig. 3.** Reactivity with BP180 and BP230 of serum samples from BP patients. **Panel A:** Immunoprecipitation studies of biosynthetically radiolabeled human keratinocyte extracts. *Lane 1 to 3:* serum samples from BP patients immunoprecipitate proteins of 230 kDa (arrow) and of 180 kDa protein (arrowhead), corresponding to BP230 and BP180, respectively, *lane 4:* normal human serum. **Panel B.** Reactivity with a 704-amino acid fragment encompassing the COOH-terminus of BP230 (arrow) expressed by an *in vitro* translation system. *Lanes 1 and 2:* serum samples from BP patients, *lane 3:* normal human serum, *lane 4:* mAb 9E10 directed against the c-myc tagged recombinant form of BP230. **Panel C.** Reactivity with the entire extracellular domain of BP180 that was expressed by transfection of COS-7 cells. *Lanes 1 and 2:* serum samples from BP patients, *lane 3:* normal human serum, *lane 4:* mAb 9E10 directed against the c-myc tagged recombinant form of BP180. **Panel D.** Reactivity with the intracellular domain of BP180 that was expressed by transfection of COS-7 cells. *Lanes 1 and 2:* sera from BP patients. *lane 3:* normal human serum, *lane 4:* mAb anti-FLAG™ directed against the FLAG-tagged recombinant form of BP180 (arrowhead)

patients have IgG1 and IgG3 complement-fixing antibodies which are best detectable by a complement-binding indirect method.

4. *Immunoblot and immunoprecipitation studies* of keratinocyte extracts show in 60% to 100% of patients' sera the presence of autoantibodies binding to a 180 kDa and 230 kDa protein, corresponding to the BP antigen 180 (BP180, also termed BP antigen 2, or type XVII collagen) and BP230 (also termed BP antigen 1), respectively (Stanley et al. 1981; Labib et al. 1986; Mueller et al. 1989; Bernard et al. 1989). Recombinant forms of BP180 and BP230 expressed in prokaryotic or eukaryotic systems (such as baculoviruses, epithelial cell lines, and yeast) have been increasingly used for the detection of auto-antibodies (Tanaka et al. 1991, Giudice 1993, Haase et al. 1998) (*Figure 3*). In gestational pemphigoid, patients' autoantibodies predominantly recognize BP180 (Morrison et al. 1988).
5. *Enzyme linked immunosorbent assays (ELISA)* utilizing recombinant proteins encompassing various portions of either BP180 (such as the NC16A domain, the COOH-terminal portion or its entire ectodomain) or of BP230 have been found to be highly specific and sensitive (Giudice et al. 1994, Ide et al. 1995; Zillikens et al. 1997a and 1997b; Haase et al. 1998; Hofmann et al. 2002; Kromminga et al., 2004; Thoma-Uszynski et al. 2004). Antigens are tested under native conditions and, by this means, reactivities against conformational antigens are not missed.

## Differential diagnosis

Manifestations of BP may resemble those of a variety of dermatoses, including drug reactions, contact dermatitis, prurigo, fixed urticaria, vasculitis, arthropod reaction and scabies. Clinical history, pathologic features and negative immunofluorescence microscopy findings are essential to distinguish these disorders from BP. Diseases within the pemphigus group can be easily differentiated on the basis of distinctive immunopathological features. In dermatitis herpetiformis IF microscopy findings, the clinical setting with associated (clinical or subclinical) coeliac disease and the serological profile (see *Dermatitis herpetiformis chapter*) are peculiar. In contrast, the distinction of BP from certain autoimmune blistering disorders is difficult. However, a recent study has found that in patients with a blistering disorder associated with linear deposits of IgG or C3 in the epidermal basement membrane the presence of certain clinical criteria (that is, absence of skin atrophy, absence of mucosal involvement, absence of head and neck involvement and age greater than 70 years) indicates to a diagnosis of BP with high sensitivity and specificity (Vaillant et al. 1998, Joly et al. 2004). Paraneoplastic pemphigus, a recently described autoimmune blistering disorder associated with neoplasia, might present with clinical features reminiscent of BP. However, its immunopathological features are peculiar enough to allow its differentiation from BP. The distinction of the following subepidermal blistering disorders may be challenging:

- 1) *Epidermolysis bullosa acquisita (EBA)* shows a wide spectrum of presentations (Briggaman et al. 1985; Gammon 1988; Gammon and Briggaman 1993)(see *EBA chapter*). The classical "non-inflammatory" form includes skin fragility, blistering, erosions, with milia formation, skin atrophy and scarring that typically develop over trauma-exposed sites, such as arms, elbows, hands and feet. Occasionally, nail dystrophy and scarring alopecia are observed. While the features of this classical form are suggestive, a substantial number of patients have an "inflammatory" form of EBA mimicking BP, characterized by a widespread eruption with blisters involving intertriginous and flexural areas that heal without milia or atrophic scar. In addition, in the course of the disease, a mixture of inflammatory and non-inflammatory features may be observed. Mucosal involvement can occur and potentially results in significant morbidity. Diagnosis of EBA relies on the detection of autoantibodies that bind to the dermal side of 1 M NaCl separated skin and specifically react with type VII collagen, the major component of anchoring fibrils (Briggaman et al. 1985; Woodley et al. 1984). Correct diagnosis of EBA is important for at least two reasons: the disease might be associated with other conditions, such as Crohn's disease, rheumatoid arthritis, and systemic lupus erythematosus, and second, EBA is thought to be more resistant to treatment than BP.
- 2) *Linear IgA bullous dermatosis (LABD)* was originally considered a distinct entity defined on the basis of the immunopathological finding of linear

IgA deposits in the cutaneous BMZ (Chorzelski et al. 1979; Wojnarowska et al. 1988). The condition, thought to represent the most common autoimmune blistering disorder of childhood, is associated with urticated, annular and or polycyclic lesions, with development of vesicles and bullae. The latter might be distributed in "jewel-like" clusters or "string of pearls" patterns. Involvement of mucosae is not unusual. Childhood features of LABD are often peculiar, with involvement of the genital area or around the mouth, whereas adulthood LABD is more polymorphic. The autoantigens of LABD are heterogeneous. The two most characteristic target antigens are a protein of 97kDa and a 120 kDa protein, termed the LABD antigen 1 (LABD97) and LAD-1 respectively. These two molecules correspond to the cleaved, shedded ectodomain of BP180 (Zone et al. 1998; Pas et al. 1997; Hirako et al. 1998 and 2003; Schäcke et al. 1998). It is thought that extracellular processing of BP180, which is catalyzed by members of the ADAMs family (a disintegrin and metalloprotease) (Franzke et al. 2004), results in the formation of neoepitopes which are specifically targeted by patients' IgA and, occasionally IgG, autoantibodies. Nevertheless, some patients with *bona fide* LABD have been found to possess IgA (and IgG) autoantibodies that recognize BP180 and BP230 (Ghohestani et al. 1997), type VII collagen (Hashimoto et al. 1996) or other, as yet uncharacterized antigens (Wojnarowska et al. 1991). Some of these LABD patients therefore fulfill the diagnostic criteria for BP or EBA. In summary, LABD most likely comprises a group of subepidermal blistering disorders rather than a single nosologic entity.

- 3) *Cicatricial pemphigoid* (CP) includes a heterogeneous group of blistering diseases, which have in common the involvement of the mucosae, a chronic course and a scarring tendency (Mutasim et al. 1993; Chan et al. 1993). In contrast to BP, CP skin lesions generally involve the scalp, head, and the upper trunk, and they are found in up to 25% of patients. The oral mucosa and the conjunctiva, and, less frequently, nose, esophagus, larynx and genitals are affected. Subsets of patients with either pure ocular involvement, predominant oral mucosal involvement without cutaneous lesions, or with both oral and cutaneous lesions have been identified (Chan et al. 1993). Erosions and scarring of the mucosae might result in significant morbidity. Ocular disease can lead to symblepharon formation, entropion, and trichiasis. In addition, stenoses of the nasopharynx, larynx, esophagus and urethra are observed. Patients with a CP phenotype might exhibit IgG and/or IgA autoantibodies of different specificity, that recognize BP180 and BP230 (Bernard et al. 1990a), the 97/120 kDa LABD antigen, laminin-5 and laminin-6 (Domloge-Hultsch et al. 1992; Chan et al. 1997), type VII collagen (Luke et al. 2000) or the  $\beta 4$  integrin subunit (Tyagi et al. 1996). Importantly, in the context of the so called anti-epiligrin cicatricial pemphigoid characterized by the presence of autoantibodies directed against laminin 5, there is apparently an increased relative risk for solid cancer (adenocarcinomas), especially in the first year

after blister onset (Egan et al. 2003). The latter observation probably accounts for the high incidence of mortality observed among these patients.

## Therapy and Prognosis

BP is a chronic disease showing spontaneous exacerbations and remissions, that might be associated with significant morbidity and have serious impact on the quality of life (severe itch, bullous and eroded lesions, impetiginization...). Although the majority of patients go into remission under treatment, the mortality rate, estimated between 12 to 40% in the first year, is considerable (Roujeau et al. 1998, Colbert et al. 2004). It is likely that practice patterns (e.g., use of either systemic corticotherapy or immunosuppressive drugs) critically affect overall morbidity (Roujeau et al. 1998).

Although it is based more on clinical experience than on controlled studies, the treatment of BP is relatively well codified (reviewed in Korman 2000 and Laffitte and Borradori, 2001). Systemic corticosteroids have been widely utilized in clinical practice and their efficacy has been confirmed in uncontrolled and controlled studies (Morel et al. 1983; Dreno et al. 1993, Joly et al. 2002). However, their use is associated with significant side effects (Roujeau et al. 1998, Joly et al. 2002). For patients with extensive disease, oral prednisone at the dosage of 0.5 to 1 mg per kg per day usually controls the disease within one or two weeks. This dose is then progressively tapered over a period of 6 to 9 months. The concomitant use of immunosuppressive drugs, such as azathioprine (Burton et al. 1978 ; Guillaume et al. 1993), chlorambucil, cyclophosphamide, ciclosporine, mycophenolate mofetil, and methotrexate, is a matter of debate. Some clinicians prefer to introduce them only when corticosteroids alone fail to control the disease, or if the latter are contraindicated. In addition, in certain treatment-resistant cases, pulse corticosteroid therapy, intravenous immunoglobulins, plasmapheresis and photophoresis have been utilized. The choice of the immunosuppressive drugs depends on the profile of their side effects, patients' overall condition and on the experience of the physician. Alternatively, dapsone (Venning et al. 1989), the association of nicotinamide and minocycline or tetracycline (Fivenson et al. 1994) have been tried with some success.

Potent topical corticosteroids (such as clobetasol propionate), which are useful in localized or mild forms of BP, have recently been shown to be also effective in generalized pemphigoid in a large controlled study. The latter are even better than oral prednisone in terms of both control of the disease and survival (Joly et al. 2002).

Finally, in all BP patients, it is important to undertake all measures aimed at preventing the complications of both the cutaneous lesions and of the treatment.

### Prognostic Markers

In contrast to prior findings obtained by indirect IF microscopy, studies utilizing ELISA have disclosed that serum levels of autoantibodies to BP180 are parallel to disease activity (Haase et al. 1998; Schmidt et al. 2000). The phenotype of the disease appears to relate to the autoantibody profile. For example, reactivity with both the NH<sub>2</sub>- and COOH-terminal region of the ectodomain of BP180 was found to be more frequently detected by ELISA in patients with mucosal lesions (Hofmann et al. 2002). Furthermore, in a recent study, the presence of anti-BP230 IgG autoantibody was particularly associated with a less severe clinical manifestation of BP (Thoma-Uszynski et al. 2004). Nevertheless, no data are yet available as to whether assessment of antibodies to BP180 are really useful for guiding treatment. Another question for future investigations is whether direct immunofluorescence microscopy studies might assist in the follow up of patients, based on the idea that the persistence of deposits of immunoreactants in skin would predict patients at risk for relapse. Patients with autoantibodies to BP180 as detected by immunoblotting have been found to exhibit a more severe disease with poorer prognosis and a higher mortality rate (Tanaka et al. 1996, Bernard et al. 1997). However, these findings deserve confirmation in prospective studies using more sensitive and specific assays.

### Challenging Situations

An unresolved issue is how to deal with elderly patients with an itchy skin eruption who have circulating antibodies to the BM and show reactivity with BP180 and BP230, but without evidence for deposits of immunoreactants in the skin as assessed by IF microscopy (Rieckhoff-Cantoni et al. 1992; Hashisuka et al. 1996). It is likely that in these cases the use of a more sensitive technique such as immunoelectron microscopy would disclose immune deposits in the skin at an earlier stage. As a matter of fact, some of these patients with initially negative direct immunofluorescence findings, but with circulating anti-basement membrane antibodies, develop BP later on and would probably benefit from an early treatment.

### Pathogenesis

The autoimmune etiology of BP now appears clearly established: 1) patients have autoantibodies and autoreactive T cells to well characterized self-antigens; 2) tissue injury occurs where antibody-antigen complexes are found; 3) *in vitro* models with human skin and *in vivo* animal models of the disease have provided strong evidence for the pathogenic role of autoantibodies;

4) in gestational pemphigoid, the transplacental transfer of autoantibodies from the mother into the neonate can cause a transient bullous eruption; 5) the disease occurs in association with distinct HLA genotypes and responds to immunosuppressive therapy.

### **Humoral and Cellular Immune Response and Tissue Damage**

Almost all BP patients have autoantibodies binding to an immunodominant region of BP180, the NC16A domain, which is located extracellularly close to its transmembrane domain. Recent studies have identified the presence of memory B cells specific for the NC16A domain, that can be induced *in vitro* to synthesize autoantibodies (Leyendeckers et al. 2003). Nevertheless, additional antigenic sites exist on both the extracellular and intracellular domain of BP180, which is recognized by up to 40% of the BP sera (Giudice et al. 1993; Giudice et al. 1994; Zillikens et al. 1997; Perriard et al. 1999). These findings have recently been confirmed by screening a random BP180 epitope library displayed on lambda bacteriophage using BP serum samples (Di Zenzo et al. 2004). BP patients also exhibit significant reactivity with BP230. In an initial study, more than 80% of BP sera had IgG autoantibodies immunoblotting a distal 704-residues stretch of the BP230 tail (Tanaka et al. 1991, Rico et al. 1990; Ide et al. 1995). Antigenic sites appear to be clustered within a region encompassing the B and C subdomain of the BP230 tail. However, IgG autoantibodies binding to the NH<sub>2</sub>-terminal half of BP230 are found in at least 30% of the cases (Skaria et al. 2000).

The presence of several antigenic sites throughout BP230 and BP180 most likely results from an "epitope spreading" phenomenon. This term describes the observation that in the course of an autoimmune disease, both B and T cell responses (see below) are not restricted to an unique "immunodominant" epitope, but they spread involving additional "secondary" epitopes within the same protein or distinct molecules, that may play a key role for the progression of the disease (Vanderlugt and Miller 1996; Chan et al. 1998). This phenomenon may explain the occasional finding that pemphigoid sera contain autoantibodies targeting other components of the hemidesmosomal adhesion complex, such as plectin and laminin 5 (Kawahara et al. 1998, Laffitte et al. 2001), besides BP180 and BP230. A preliminary analysis of the epitope pattern in the disease course indicated that BP patients exhibit a specific reactivity pattern and that binding to intracellular epitopes may be detectable at an early clinical stage (Di Zenzo et al. 2004).

Since autoreactive T cells are critical for driving autoantibody production, recent studies have assessed the cellular response to BP180 in both BP and gestational pemphigoid. Autoreactive T cell responses to the ectodomain of BP180 have been found in patients with BP, gestational pemphigoid and in healthy individuals (Büdingner et al. 1998, Lin et al. 1999). Strikingly, epitope recognition appeared to be restricted by certain HLA class II alleles, such as



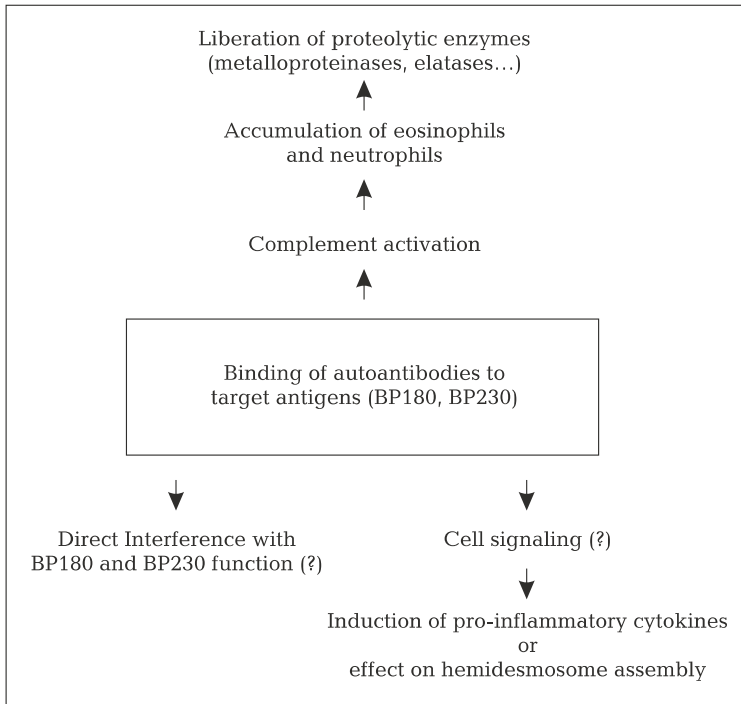
the HLA-DQ $\beta$ 1\*0301 allele, that are prevalent in BP. CD4 T cell lines and clones derived from BP patients were shown to produce both Th1 and Th2 cytokines (Büdingner et al. 1998). Since Th1 cytokines (such as IFN $\gamma$ ) are able to induce the secretion of IgG1 and IgG2, while Th2 cytokines (such as IL-4, IL-5, and IL-13) have been shown to regulate the secretion of IgG4 and IgE (reviewed in Romagnani 1992), the detection of anti-BP180 and anti-BP230 antibodies of the IgG1, IgG4 and IgE isotype (Bernard et al. 1990b) in BP patients suggest that both autoreactive Th1 and Th2 cells are involved in the regulation of the response to the BP target antigens. This idea is further supported by the analysis of the cytokine expression profile in lesional tissue and patient's serum, that shows an increase in most cytokines with significant correlations between their level and skin lesions number (reviewed in D'Auria et al. 1999). Nevertheless, the relative low concentrations of IFN $\gamma$  and IL-2 compared to those of IL-4, IL-5 and IL-10 suggest a predominance of a Th2 response (D'Auria et al. 1999).

The mechanisms by which autoantibodies are thought to be pathogenic include complement activation, recruitment of inflammatory cells and liberation of proteases, such as matrix metalloproteinase (MMP)-9 and neutrophil elastase, which are detected in lesional skin and blister fluid (Gammon et al. 1984b; Stahle-Bäckdahl et al. 1994; Verraes et al. 2000) (*Figure 4*). Specifically, these proteinases, which are strongly expressed by neutrophils and eosinophils, are thought to proteolytically degrade various extracellular matrix proteins as well as the extracellular domain of BP180 (Stahle-Bäckdahl et al. 1994; Verraes et al. 2000). Recent studies have provided evidence indicating that IgE anti-BP180 autoantibodies may contribute to lesion development by stimulating degranulation of basophils and/or mast cells (Dimson et al. 2003).

Eosinophils appear to play an important role in mediating tissue injury. It is noteworthy that high levels of IL-5 and eotaxin have been recently detected in blister fluid of BP patients. While IL-5 promotes growth and activation of eosinophils, eotaxin is an eosinophil specific chemokine regulating eosinophil migration produced by fibroblasts and probably keratinocytes (Wakugawa et al. 2000). In this regard, the latter appears to contribute to the local inflammation by releasing both pro-inflammatory cytokines as well as proteases. Recently, autoantibodies to BP180 have been shown to directly modulate the expression of IL-6 and IL-8 as well as tissue-type plasminogen activator by cultured keratinocytes (Schmidt et al. 2000 and 2004).

### **Animal Models of BP**

Early passive transfer studies in monkey, rabbit and mouse, utilizing plasma or IgG fractions have been unsuccessful in reproducing the key features of BP (Anhalt and Diaz 1987). This failure is most likely due to the fact that pathogenic BP autoantibodies did not cross-react with the homologue target



**Fig. 4.** Mechanisms potentially involved in tissue injury and subepidermal blister formation in bullous pemphigoid. Binding of autoantibodies to the target antigens result in an inflammatory response with complement activation, accumulation of neutrophils and eosinophils and liberation of proteolytic enzymes. Autoantibodies might also interfere directly with the function of BP180 and BP230 or, by means of the activation of signaling pathways, regulate the function of hemidesmosomes or further enhance the induction of pro-inflammatory cytokines

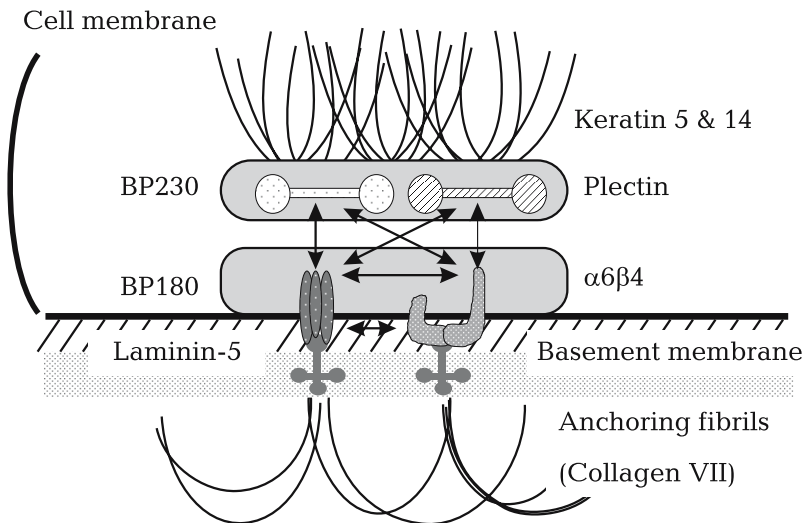
antigens in experimental animals. In an elegant study rabbit antibodies have been raised against an extracellular region of murine BP180, homologous with the human immunodominant NC16A domain and passively transferred to neonatal mice. These antibodies are capable to induce a blistering disorder mimicking BP (Liu et al. 1993). Tissue injury has been found to depend on a functional complement system, macrophages, mast cells, neutrophils, gelatinase B and neutrophil elastase as well as on the plasminogen-plasmin system (Liu et al. 2000a and 2000b, Chen et al. 2001 and 2002). In contrast, autoantibodies against the cytoplasmic protein BP230 cause an inflammatory reaction in rabbits only after additional injury to their epidermis (Hall et al. 1993). Together, these studies have lead to an as yet unsubstantiated speculation that antibodies against the extracellular domain of BP180 are pathogenetically critical, whereas the appearance of antibodies against intracellular antigenic determinants on BP230 (and on the intracellular domain of BP180)

represents a secondary event. Recently, it has been recognized that dogs, mini-pigs, horses and cats can develop BP with clinical and immunopathological features identical to those observed in humans (Olivry T et al. 2000). The availability of such spontaneous animal models of BP will provide an important tool to further gain insight into the pathophysiology of the disease.

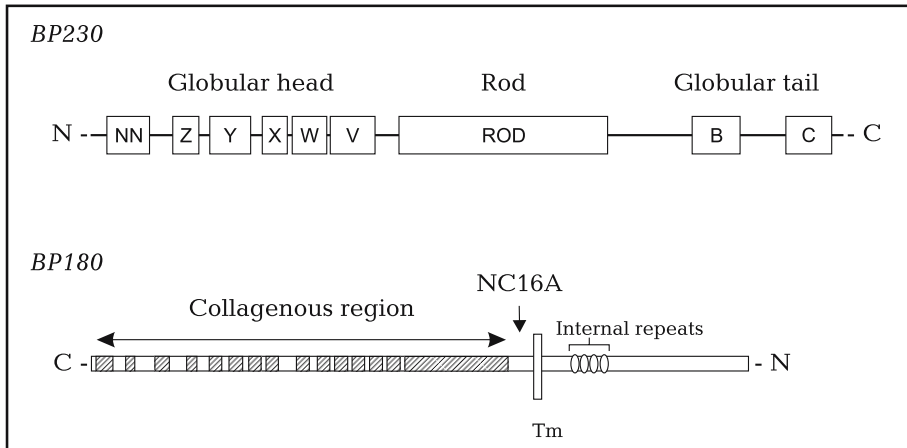
### BP180 and BP230 are Components of Hemidesmosomes, Junctional Adhesion Complexes

Recent cell biological studies have specified the role of BP180 and BP230 in maintenance of dermo-epidermal adhesion. These two proteins are components of hemidesmosomes (HD), junctional complexes promoting adhesion of epithelial cells to the underlying BM in stratified and other complex epithelia, such as skin and mucous membranes (reviewed in Borradori and Sonnenberg 1999) (Figure 5).

BP180 is a transmembrane molecule with a large collagenous extracellular domain (ECD) serving as cell adhesion molecule (Giudice et al. 1991; Hopkinson et al. 1992) (Figure 6). The idea that this protein is important for cell



**Fig. 5.** Schematic representation of a hemidesmosome at the ventral side of a basal keratinocyte. The molecular interactions involved in the assembly and stabilization of hemidesmosomes are depicted. The two intracellular components BP230 and plectin, are implicated in the attachment of the keratin filaments network and interact with the cytoplasmic domain of the transmembrane components BP180 and integrin  $\alpha6\beta4$ . The latter, by means of their extracellular domain, are able to interact with extracellular matrix proteins within the basement membrane, such as laminin-5, that is in turn connected with type VII collagen, the major component of anchoring fibrils in the upper dermis



**Fig. 6.** Structural and domain organization of the bullous pemphigoid antigen 230 (BP230) and the bullous pemphigoid antigen 180 (BP180). BP230 is predicted to contain a central coil-coiled domain flanked by two globular domains, while BP180 is a type II transmembrane protein with a collagenous COOH-terminal domain residing extracellularly. Tm, transmembrane domain

attachment is further supported by the observation that mutations in the gene encoding BP180 underly a distinct form of non-lethal junctional epidermolysis bullosa characterized by skin blistering and fragility, alopecia, dental and nail abnormalities (Jonkmann et al. 1995, McGrath et al. 1995). In contrast, BP230 is a cytoplasmic component belonging to the plakin family of proteins (Stanley et al. 1988; Sawamura et al. 1991; Li et al. 19992; Green et al. 1992) that consist of a central coiled-coil region flanked by two globular end domains (*Figure 6*).

These two antigens by means of interactions with each other and with the other components of HD, including the  $\alpha 6\beta 4$  integrin and plectin, contribute to the assembly and stabilization of HD, and, therefore, to the maintenance of cell-substrate adhesion (Hopkinson et al. 1995, Borradori et al. 1997, Koster et al. 2003). Specifically, BP230 and plectin (Guo et al. 1995, Andrä et al. 1997; Fontao et al. 2003) connect the keratin filaments to the basal plasma membrane, while the transmembrane hemidesmosomal proteins BP180 and the  $\alpha 6\beta 4$  integrin act as cell surface receptors for extracellular matrix proteins, including laminin-5. The latter interacts with type VII collagen, the major component of anchoring fibrils in the dermis. Because of their close structural organization and functional synergy, it is not unexpected that abnormalities of different structural components of HD (e.g. due to either autotibodies or a gene mutation) might result in a similar clinical phenotype.

## Unresolved Issues and Perspectives

The etiologic factors underlying the initiation of the BP remain unclear. One of the major challenges will be the elucidation of the predisposing factors, including genetic polymorphism, leading to a break of autotolerance. It is important to better characterize the humoral and cellular immune response in the various phases of the disease and to elucidate whether findings obtained from the mouse model of BP about the pathophysiology of subepidermal blister formation can be directly applied to the situation in humans. This insight will not only further our understanding of autoimmune diseases in general, but, hopefully, also facilitate the development of diagnostic tools for the identification of patients at risk for BP. Better knowledge of the autoimmune response in BP is a crucial step towards the design of novel immunomodulatory approaches devoid of the severe side effects of current immunosuppressive treatments. For example, preliminary observations indicate that the new biological therapies using monoclonal antibodies able to modulate immune response (by targeting for example B and/or T cells) may be useful in controlling BP (Szalbocs et al. 2002). Finally, it would not be surprising that better knowledge of the pathophysiology of BP and other blistering disorders will lead to a revision of their classification based on the targeted antigens. It is likely that additional factors, such as genes regulating the inflammatory and tissue repair response, critically affect clinical features and final outcome.

### Summary

Our understanding of BP, a blistering disorder of the skin and mucosae, has greatly improved. BP has emerged as a paradigm of organ-specific autoimmune disease. Patients' autoantibodies are directed against the BP antigen 230 and BP antigen 180. These two autoantigens are components of hemidesmosomes, adhesion complexes in human skin that promote dermo-epidermal cohesion. Animal models have provided convincing evidence for the pathogenic significance of these autoantibodies as well as novel insights into the cascade of events leading to subepidermal separation. Improved knowledge of the pathophysiology of BP will hopefully allow the development of new immunomodulatory treatments for this potentially devastating disease.

**Acknowledgements.** The work has been supported by grants of the Swiss National Foundation for Scientific Research (32-56727.99), the Office fédéral de l'éducation et de la science (OFES 01.0113), and Telethon Action Suisse (Aubonne, Switzerland).

### References

Andrä K, Lassmann H, Bittner R, Shorny S, Fässler R, Propst F, Wiche G (1997) Targeted inactivation of plectin reveals essential function in maintaining the integrity of skin, muscle, and heart cytoarchitecture. *Gen Develop* 11: 3143-3156

- Anhalt GJ, Diaz LA (1987) Animal models for bullous pemphigoid. *Clin Dermatol* 5: 117–125
- Balding SD, Prost C, Diaz LA, Bernard P, Bedane C, Aberdam D, Giudice GJ (1996) Cicatricial pemphigoid autoantibodies react with multiple sites on the BP180 extracellular domain. *J Invest Dermatol* 106: 141–146
- Banfield CC, Wojnarowska F, Allen J, George S, Venning VA, Welsh KI (1998) The association of HLA-DQ7 with bullous pemphigoid is restricted to men. *Br J Dermatol* 138: 1085–1090
- Bastuji-Garin S, Joly P, Picard-Dahan C, Bernard P, Vaillant L, Pauwels C, Salagnac V, Lok C, Roujeau JC (1996) Drugs associated with bullous pemphigoid. A case-control study. *Arch Dermatol* 132: 272–276
- Bernard P, Didierjean L, Denis F, Saurat JH, Bonnetblanc JM (1989) Heterogeneous bullous pemphigoid antibodies: detection and characterization by immunoblotting when absent by indirect immunofluorescence. *J Invest Dermatol* 92: 171–174
- Bernard P, Prost C, Lecerf V, Intrator L, Combemale P, Bedane C, Roujeau JC, Revuz J, Bonnetblanc JM, Dubertret L (1990a) Studies of cicatricial pemphigoid autoantibodies using direct immunoelectron microscopy and immunoblot analysis. *J Invest Dermatol* 94: 630–635
- Bernard P, Aucouturier P, Denis F, Bonnetblanc JM (1990b) Immunoblot analysis of IgG subclass of circulating antibodies in bullous pemphigoid. *Clin Immunol Immunopath* 54: 484–494
- Bernard P, Vaillant L, Labeille B, Bedane C, Arbeille B, Denoex JP, Lorette G, Bonnetblanc JM, Prost C (1995) Incidence and distribution of subepidermal autoimmune bullous skin diseases in three French regions. Bullous diseases French study group. *Arch Dermatol* 131: 48–52
- Bernard P, Bedane C, Bonnetblanc JM (1997) Anti-BP180 autoantibodies as a marker of poor prognosis in bullous pemphigoid: a cohort analysis of 94 elderly patients. *Br J Dermatol* 136: 694–698
- Borradori L, Koch PJ, Niessen CM, Erkeland S, van Leusden M, Sonnenberg A (1997) The localization of bullous pemphigoid antigen 180 (BP180) in hemidesmosomes is mediated by its cytoplasmic domain and seems to be regulated by the b4 integrin subunit. *J Cell Biol* 136: 1333–1347
- Borradori L, Sonnenberg A (1999) Structure and function of hemidesmosomes: more than simple adhesion complexes. *J Invest Dermatol* 112: 411–418
- Büdinger L, Borradori L, Yee C, Eming R, Ferencik S, Grosse-Wilde H, Merk HF, Yancey K, Hertl M (1998) Identification and characterization of autoreactive T cell responses to bullous pemphigoid antigen 2 in patients and healthy controls. *J Clin Invest* 102: 2082–2089
- Burton JL, Harman RM, Peachey RD, Warin RP (1978) A controlled trial of azathioprine in the treatment of pemphigoid. *Br J Dermatol* 99 (Suppl 16):14
- Briggaman RA, Gammon WR, Woodley DT (1985) Epidermolysis bullosa acquisita of the immunopathological type (dermolytic pemphigoid). *J Invest Dermatol*. 85:79s-84s
- Chan LS, Yancey KB, Hammerberger C, Soong HK, Regezi JA, Johnson K, Cooper KD (1993). Immune-mediated subepithelial blistering diseases of mucous membranes. *Arch Dermatol* 129: 448–455
- Chan LS, Majmudar AA, Tran HH, Meier F, Schaumburg -Lever G, Chen M, Woodley DT, Marinkovich PM (1997) Laminin-6 and laminin-5 are recognized by autoantibodies in a subset of cicatricial pemphigoid. *J Invest Dermatol* 108: 848–853
- Chen R, Ning G, Zhao ML, Fleming MG, Diaz LA, Werb Z, Liu Z (2001) Mast cells play a key role in neutrophil recruitment in experimental bullous pemphigoid. *J Clin Invest*; 108(8):1151–8
- Chen R, Fairley JA, Zhao ML, Giudice GJ, Zillikens D, Diaz LA, Liu Z (2002) Macrophages, but not T and B lymphocytes, are critical for subepidermal blister formation in experimental bullous pemphigoid: macrophage-mediated neutrophil infiltration depends on mast cell activation. *J Immunol*. 2002 Oct 1;169(7):3987–92.
- Chosidow O, Doppler V, Bensimon G, Joly P, Salachas F, Lacomblez L, Prost C, Camu W, Frances C, Herson S, Meininger V (2000) Bullous pemphigoid and myotrophic lateral sclerosis: a new clue for understanding the bullous disease? *Arch Dermatol* 136: 521–524.

- Chorzelski TP, Jablonska S, Beutner EH, et al. Linear IgA bullous dermatosis. In: Immunopathology and the Skin (Beutner EH, Chorzelski TP, Bean SF, eds). New York, NY: John Wiley & Sons Inc, 1979: 315–323
- Colbert RL, Allen DM, Eastwood D, Fairley JA (2004) Mortality rate of bullous pemphigoid in a US medical center. *J Invest Dermatol*;122:1091–5
- D'Auria L, Cordiali Fei P, Ameglio F (1999) Cytokines and bullous pemphigoid. *Eur Cytokine Netw* 10: 123–134
- Delgado JC, Turbay D, Yunis EJ, Yunis JJ, Morton ED, Bhol K, Norman R, Alper CA, Good RA, Ahmed R (1996) A common major histocompatibility complex class II allele HLA-DQB1\*0301 is present in clinical variants of pemphigoid. *Proc Natl Acad Sci* 93: 8569–8571
- Diaz LA, Ratrie H, Saunders WS, Futamura S, Squiquera HL, Anhalt GJ, Giudice GK (1990) Isolation of a human epidermal cDNA corresponding to the 180-kDa autoantigen recognized by bullous pemphigoid and herpes gestationis sera. *J Clin Invest* 86: 1088–1094
- Dimson OG, Giudice GJ, Fu CL, Van den Bergh F, Warren SJ, Janson MM, Fairley JA (2003) Identification of a potential effector function for IgE autoantibodies in the organ-specific autoimmune disease bullous pemphigoid. *J Invest Dermatol*;120:784–8.
- Di Zenzo G, Grosso F, Terracina M, Mariotti F, De Pita O, Owaribe K, Mastrogiacomo A, Sera F, Borradori L, Zambruno G (2004) Characterization of the anti-BP180 autoantibody reactivity profile and epitope mapping in bullous pemphigoid patients. *J Invest Dermatol*; 122:103–10
- Domolge-Hultsch N, Gammon WR, Briggaman RA, Gil SG, Carter WG, Yancey KB (1992) Epiligrin, the major human keratinocyte ligand, is a target in both an acquired autoimmune and in inherited subepidermal blistering skin disease. *J Clin Invest* 90: 1628–1633
- Dreno B, Sassolas B, Lacour P, Montpoint S, Lota I, Giordano F, Royer P (1993) Methylprednisolone versus prednisolone methylsulfobenzoate in pemphigoid: a comparative multicenter study. *Ann Dermatol Venereol* 120:518–21
- Egan CA, Lazarova Z, Darling TN, Yee C, Yancey KB (2003) Anti-epiligrin cicatricial pemphigoid: clinical findings, immunopathogenesis, and significant associations. *Medicine*;82:177–86
- Fivenson DP; Breneman DL; Rosen GB; Hersh CS; Cardone S; Mutasim (1994) Nicotinamide and tetracycline therapy of bullous pemphigoid. *Arch Dermatol* 6: 753–758
- Fleming TE, Korman NJ (2000) Cicatricial pemphigoid. *J Am Acad Dermatol* 43: 571–591
- Franzke CW, Tasanen K, Borradori L, Huotari V, Bruckner-Tuderman L (2004) Shedding of collagen XVII/BP180: Structural motifs influence cleavage from cell surface. *J Biol Chem*. 279:24521–24529.
- Gammon WR, Inman AO III, Wheeler CE, Jr. (1984a) Differences in complement-dependent chemotactic activity generated by bullous pemphigoid and epidermolysis bullosa acquisita immune complexes: demonstration by leukocytic attachment and organ culture methods. *J Invest Dermatol* 83:57–61
- Gammon WR, Briggaman RA, Inman AO III, Queen LL, Wheeler CE (1984b) Differentiating anti-lamina lucida and anti-sublamina densa anti-BMZ antibodies by indirect immunofluorescence on 1.0 M sodium chloride-separated skin. *J Invest Dermatol* 82:139–144
- Gammon WR, Kowalewski C, Chorzelski TP, Kumar V, Briggaman RA, Beutner EH (1990) Direct immunofluorescence studies of sodium chloride-separated skin in the differential diagnosis of bullous pemphigoid and epidermolysis bullosa acquisita. *J Am Acad Dermatol* 22: 664–670
- Gammon WR, Briggaman RA (1993) Epidermolysis bullosa acquisita and bullous systemic lupus erythematosus. *Diseases of autoimmunity to type VII collagen*. *Dermatol Clin* 11: 535–547
- Ghohestani RF, Nicolas JF, Kanitakis J, Claudy A (1997) Linear IgA bullous dermatosis with IgA antibodies exclusively directed against the 180- and 230-kDa epidermal antigens *J Invest Dermatol* 108: 854–858
- Giudice GJ, Squiquera HL, Elias PM, Diaz LA (1991) Identification of two collagen domains within the bullous pemphigoid autoantigen, BP180. *J Clin Invest* 87: 734–738
- Giudice GJ, Emery DJ, Diaz LA (1992) Cloning and primary structural analysis of the bullous pemphigoid autoantigen BP180. *J Invest Dermatol* 99: 243–250

- Giudice GJ, Emery DJ, Zelickson BD, Anhalt GJ, Liu Z, Diaz LA (1993) Bullous pemphigoid and herpes gestationis autoantibodies recognize a common non-collagenous site on the BP180 ectodomain. *J Immunol* 151: 5742–5750
- Giudice GJ, Wilske KC, Anhalt GJ, Fairley JA, Taylor AF, Emery DJ, Hofman RG, Diaz LA (1994) Development of an ELISA to detect anti-BP180 autoantibodies in bullous pemphigoid and herpes gestationis. *J Invest Dermatol* 102: 878–881
- Green KJ, Virata MLA, Elgart GW, Stanley JR, Parry DAD (1992) Comparative structural analysis of desmoplakin, bullous pemphigoid antigen and plectin: members of a new gene family involved in organization of intermediate filaments. *Int J Biol Macromol* 14: 145–153
- Guillaume JC, Vaillant L, Bernard P, Picard C, Prost C, Labeille B, Guillot B, Foldes-Pauwels C, Prigent F, Joly P (1993) Controlled trial of azathioprine and plasma exchange in addition to prednisolone in the treatment of bullous pemphigoid. *Arch Dermatol* 129: 49–53
- Guo L, Degenstein L, Dowling J-C, Yu QC, Wollmann R, Perman B, Fuchs E (1995) Gene targeting of BPAG1: abnormalities in mechanical strength and cell migration in stratified epithelia and neurologic degeneration. *Cell* 81: 233–243
- Haase C, Büdinger L, Borradori L, Yee C, Merk HF, Yancey KB, Hertl M (1998) Detection of IgG autoantibodies in the sera of patients with bullous and gestational pemphigoid: ELISA studies utilizing a baculovirus-encoded form of bullous pemphigoid antigen 2. *J Invest Dermatol* 110: 282–286
- Hachisuka H, Kurose K, Karashima T, Mori O, Maeyama Y (1996) Serum from elderly individuals contains anti-basement membrane zone antibodies. *Arch Dermatol* 132: 1201–1205
- Hall RPI, Murray JC, McCord MM, Rico JM, Streilein RD (1993) Rabbits immunized with a peptide encoded for by the 230-kD bullous pemphigoid antigen cDNA develop an enhanced inflammatory response to UVB irradiation: a potential animal model for bullous pemphigoid. *J Invest Dermatol* 101: 9–14
- Hashimoto T, Ishiko, A, Shimizu H, Tanaka T, Dodd HJ, Bhogal BS, Black MM, Nishikawa T (1996) A case of linear IgA bullous dermatosis with IgA anti-type VII collagen autoantibodies. *Br J Dermatol* 134: 336–339
- Hirako Y, Usukura J, Uematsu J, Hashimoto T, Kitajima Y, Owaribe K (1998) Cleavage of BP180, a 180-kDa bullous pemphigoid antigen, yields a 120-kDa collagenous extracellular polypeptide. *J Biol Chem* 273: 9711–9717
- Hirako Y, Nishizawa Y, Sitaru C, Opitz A, Marcus K, Meyer HE, Butt E, Owaribe K, Zillikens D (2003) The 97-kDa (LABD97) and 120-kDa (LAD-1) fragments of bullous pemphigoid antigen 180/type XVII collagen have different N-termini. *J Invest Dermatol*;121(6):1554–6
- Hofmann S, Thoma-Uszynski S, Hunziker T, Bernard P, Koebnick C, Stauber A, Schuler G, Borradori L, Hertl M (2002) Severity and phenotype of bullous pemphigoid relate to autoantibody profile against the NH2- and COOH-terminal regions of the BP180 ectodomain. *J Invest Dermatol*;119:1065–73
- Hopkinson SB, Riddelle KS, Jones JCR (1992) Cytoplasmic domain of the 180-kD bullous pemphigoid antigen, a hemidesmosomal component: molecular and cell biologic characterization. *J Invest Dermatol* 99: 264–270
- Hopkinson SB, Baker SE, Jones JCR (1995) Molecular genetic studies of a human epidermal autoantigen (the 180-kD bullous pemphigoid antigen/BP180): identification of functionally important sequences within the BP180 molecule and evidence for an interaction between BP180 and  $\alpha 6$  integrin. *J Cell Biol* 130:117–125
- Ide A, Hashimoto T, Amagai M, Tanaka M, Nishikawa T (1995) Detection of autoantibodies against the bullous pemphigoid and pemphigus antigens by an enzyme-linked immunosorbent assay using the bacterial recombinant proteins. *Exp Dermatol* 5: 112–116
- Joly P, Picard C, Roujeau JC, Delaporte E, Dreno B, Bedane C, Tancrede-Bohin E, Plantin P, D'Incan M, Sassolas B, Saiag P, Lok C, Labeille B, Pauwels C, Chosidow O, Loche F, Guillaume JC, Vaillant L, Bernard P (2000) Comparaison de deux stratégies thérapeutiques: corticothérapie locale versus corticothérapie générale dans le traitement de la pemphigoVde bulleuse (Abstract). *Ann Dermatol Venereol suppl*.4: 4S4
- Joly P, Roujeau JC, Benichou J, Picard C, Dreno B, Delaporte E, Vaillant L, D'Incan M, Plantin P, Bedane C, Young P, Bernard P; Bullous Diseases French Study Group (2002) A comparison of oral and topical corticosteroids in patients with bullous pemphigoid. *N Engl J Med*; 346:321–7



- Joly P, Courville P, Lok C, Bernard P, Saiag P, Dreno B, Delaporte E, Bedane C, Picard C, Sassolas B, Plantin P, D'Incan M, Chosidow O, Pauwels C, Lambert D, Loche F, Prost C, Tancrede-Bohin E, Guillaume JC, Roujeau JC, Gilbert D, Tron F, Vaillant L; French Bullous Study Group (2004) Clinical criteria for the diagnosis of bullous pemphigoid: a re-evaluation according to immunoblot analysis of patient sera. *Dermatology*; 208:16–20.
- Jonkman MF, de Jong MC, Heeres K, Pas HH, van der Meer JB, Owaribe K, Martinez de Velasco AM, Niessen CM, Sonnenberg A (1995) 180-kD bullous pemphigoid antigen (BP180) is deficient in generalized atrophic benign epidermolysis bullosa. *J Clin Invest* 95: 1345–1352
- Jenkins RE, Shornick JK, Black MM (1993) Pemphigoid gestationis. *J Eur Acad Dermatol* 2: 163–173
- Jordon RE, Beutner EH, Witebsky E, Blumental G, Hale WC, Lever WC (1967) Basement zone antibodies in bullous pemphigoid. *J Am Med Assoc* 200: 751–756
- Jung M, Kippes W, Messer G, Zillikens D, Rzany B (1999) Increased risk of bullous pemphigoid in male and very old patients: a population based study on incidence. *J Am Acad Dermatol* 41: 266–268
- Kawahara Y, Amagai M, Ohata Y, Ishii K, Hasegawa Y, Hsu R, Yee C, Yancey KB, Nishikawa T (1998) A case of cicatricial pemphigoid with simultaneous IgG autoantibodies against the 180 kd bullous pemphigoid antigen and laminin 5. *J Am Acad Dermatol* 38: 624–627
- Koster J, Geerts D, Favre B, Borradori L, Sonnenberg A (2003) Analysis of the interactions between BP180, BP230, plectin and the integrin alpha6beta4 important for hemidesmosome assembly. *J Cell Sci*; 116:387–99
- Korman NJ (1987) Bullous pemphigoid. *J Am Acad Dermatol* 16: 907–24
- Korman NJ (2000) New and emerging therapies in the treatment of blistering diseases. *Dermatol Clin* 18: 127–137
- Kromminga A, Sitaru C, Hagel C, Herzog S, Zillikens D (2004). Development of an ELISA for the detection of autoantibodies to BP230. *Clin Immunol* 111:146–52
- Labib RS, Anhalt GJ, Patel HP, Mutasim DF, Diaz LA (1986)Molecular heterogeneity of the bullous pemphigoid antigens as detected by immunoblotting. *J Immunol* 136: 1231–1235
- Laffitte E, Borradori L (2001) Fiche thérapeutique: prise en charge de la pemphigoïde bulleuse. *Ann Dermatol Venerol.* 128: 677–80.
- Laffitte E, Favre B, Fontao L, Riou S, Jaunin F, Tamm K, Saurat J-H, Borradori L (2001) Plectin, an unusual target in bullous pemphigoid. *Br J Dermatol*144: 136–8.
- Laffitte E, Burkhard PR, Fontao L, Jaunin F, Saurat JH, Chofflon M, Borradori L (2004).Bullous pemphigoid antigen 1 isoforms: potential new target auto-antigens in multiple sclerosis?. *Br J Dermatol, In press.*
- Leyendeckers H, Tasanen K, Bruckner-Tuderman L, Zillikens D, Sitaru C, Schmitz J, Hunzelmann N (2003) Memory B cells specific for the NC16A domain of the 180 kDa bullous pemphigoid autoantigen can be detected in peripheral blood of bullous pemphigoid patients and induced in vitro to synthesize autoantibodies. *J Invest Dermatol*;120(3):372–8
- Leung CL, Zheng M, Prater SM, Liem RK (2001) The BPAG1 locus: Alternative splicing produces multiple isoforms with distinct cytoskeletal linker domains, including predominant isoforms in neurons and muscles. *J Cell Biol* 20;154:691–7
- Lever WF (1953) Pemphigus. *Medicine* 32: 1–123
- Li K, Guidice GJ, Tamai K, Do HC, Sawamura D, Diaz LA, Uitto J (1992) Cloning of partial cDNA for mouse 180-kDa bullous pemphigoid antigen (BPAG2), a highly conserved collagenous protein of the cutaneous basement membrane zone. *J Invest Dermatol* 99: 258–63
- Lin MS, Gharra MA, Swartz SJ, Diaz LA, Giudice GJ (1999) Identification and characterization of epitopes recognized by T lymphocytes and autoantibodies from patients with herpes gestationis *J Immunol* 162: 4999–4997
- Lindelöf B, Islam N, Eklund G, Arfors L (1990) Pemphigoid and cancer. *Arch Dermatol* 126: 66–68
- Liu HH, Su DWP, Rogers RS III (1986) Clinical variants of pemphigoid. *Int J Dermatol* 25: 17–27
- Liu Z, Diaz LA, Troy JL, Taylor AF, Emery DJ, Fairley JA, Giudice GJ (1993) A passive transfer model of the organ-specific autoimmune disease, bullous pemphigoid, using antibodies generated against the hemidesmosomal antigen, BP180. *J Clin Invest* 92: 2480–2488

- Liu Z, Shapiro SD, Zhou X, Twining SS, Senior RM, Giudice GJ, Fairley JA, Diaz LA (2000a) A critical role for neutrophil elastase in experimental bullous pemphigoid. *J Clin Invest* 105: 113–123
- Liu Z, Chen R, Diaz L, Senior R, Werb Z (2000b) Plasminogen/plasmin in experimental bullous pemphigoid (Abstract). *J Invest Dermatol* 114: 778
- Luke MC, Darling TN, Hsu R, Summers RM, Smith JA, Solomon BI, Thomas GR, Yancey KB (1999) Mucosal morbidity in patients with epidermolysis bullosa acquisita. *Arch Dermatol* 135: 954–959
- Masouyé I, Schmid E, Didierjean L, Abba Z, Saurat JH (1989) Bullous pemphigoid and multiple sclerosis: more than a coincidence? Report of three cases. *J Am Acad Dermatol* 21: 63–68
- McGrath JA, Gatalica B, Christiano AM, Li K, Owaribe K, McMillan JR, Eady RA, Uitto J (1995) Mutations in the 180-kD bullous pemphigoid antigen (BPAG2), a hemidesmosomal transmembrane collagen (COL17A1), in generalized atrophic benign epidermolysis bullosa. *Nature Genet* 11: 83–86
- Miller JE, Rico JM, Hall RP (1993) IgG antibodies from patients with bullous pemphigoid bind to fusion proteins encoded by BPAG1 cDNA. *J Invest Dermatol* 101: 779–782
- Morel P, Guillaume JC (1984) Treatment of bullous pemphigoid with prednisolone only: 0.75 mg/kg/day versus 1.25 mg/kg/day. A multicenter randomized study *Ann Dermatol Venereol* 111:925–928
- Morrison LH, Labib RS, Zone JJ, Diaz LA, Anhalt GJ (1988) Herpes gestationis autoantibodies recognize a 180-kD human epidermal antigen. *J Clin Invest* 8: 2023–2026
- Mueller S, Klaus-Kovtun V, Stanley JR (1989) A 230 kD basic protein is the major bullous pemphigoid antigen. *J Invest Dermatol* 92: 32–38
- Nemeth AJ, Klein AD, Gould EW, Schachner LA (1991) Childhood bullous pemphigoid. Clinical and immunologic features, treatment, and prognosis. *Arch Dermatol* 127: 378–386
- Olivry T, Mirsky ML, Singleton W, Dunston SM, Borillo AK, Xu L, Traczyk T, Rosolia DL, Chan LS (2000) A spontaneously rising porcine model of bullous pemphigoid. *Arch Dermatol Res* 292: 37–45
- Okazaki A, Miyagawa S, Yamashina Y, Kitamura W, Shirai T (2000) Polymorphisms of HLA-DR and -DQ genes in Japanese patients with bullous pemphigoid. *J Dermatol* 27: 149–156
- Pas HH, Kloosterhuis GJ, Heeres K, van der Meer JB, Jonkman MF (1997) Bullous pemphigoid and linear IgA dermatosis sera recognize a similar 120-kDa keratinocyte collagenous glycoprotein with antigenic cross-reactivity to BP180. *J Invest Dermatol* 108: 423–429
- Perriard J, Jaunin F, Favre B, Büdinger L, Hertl M, Saurat J-H, Borradori L (1999) IgG autoantibodies from bullous pemphigoid (BP) patients bind antigenic sites on both the extracellular and the intracellular domain of the BP antigen 180. *J Invest Dermatol* 112: 141–147
- Rico MJ, Korman NJ, Stanley JR, Tanaka T, Hall RP (1990) IgG antibodies from patients with bullous pemphigoid bind to localized epitopes on synthetic peptides encoded bullous pemphigoid antigen cDNA. *J Immunol* 145: 3728–3733
- Rieckhoff-Cantoni L, Bernard P, Didierjean L, Imhof K, Kinloch-de-Loes S, Saurat JH (1992) Frequency of bullous pemphigoid-like antibodies as detected by Western immunoblot analysis in pruritic dermatoses. *Arch Dermatol* 128: 791–794
- Romagnani S (1992) Human Th1 and Th2 subsets: regulation of differentiation and role in protection and immunopathology. *Int Arch Allergy Appl Immunol* 98: 279–285
- Roujeau JC, Lok C, Bastuji-Garin S, Mhalla S, Enginger V, Bernard P (1998) High risk of death in elderly patients with extensive bullous pemphigoid. *Arch Dermatol* 134:465–469
- Sawamura D, Li K, Chu ML, Uitto J (1991) Human bullous pemphigoid antigen (BPAG1). Amino acid sequences deduced from cloned cDNAs predict biologically important peptide segments and protein domains. *J Biol Chem* 266: 17784–17790
- Schäcke H, Schumann H, Hammami-Hausli N, Raghunath M, Bruckner-Tuderman L (1998) Two forms of collagen XVII in keratinocytes. A full-length transmembrane protein and a soluble ectodomain. *J Biol Chem* 273: 25937–25943
- Schmidt E, Obe K, Brocker EB, Zillikens D (2000a) Serum levels of autoantibodies to BP180 correlate with disease activity in patients with bullous pemphigoid. *Arch Dermatol* 136: 174–178

- Schmidt E, Reimer S, Kruse N, Jainta S, Brocker EB, Marinkovich MP, Giudice GJ, Zillikens D (2000b) Autoantibodies to BP180 associated with bullous pemphigoid release interleukin-6 and interleukin-8 from cultured human keratinocytes. *J Invest Dermatol* 115:842–848
- Schmidt E, Wehr B, Tabengwa EM, Reimer S, Brocker EB, Zillikens D (2004) Elevated expression and release of tissue-type, but not urokinase-type, plasminogen activator after binding of autoantibodies to bullous pemphigoid antigen 180 incultured human keratinocytes. *Clin Exp Immunol*;135:497–504.
- Skaria M, Jaunin F, Hunziker T, Riou S, Schumann H, Bruckner-Tuderman L, Hertl M, Bernard P, Saurat JH, Favre B, Borradori L (2000) IgG autoantibodies from bullous pemphigoid patients recognize multiple antigenic reactive sites located predominantly within the B and C subdomain of the COOH-terminus of BP230. *J Invest Dermatol* 114: 998–1004
- Shornick JK (1993) Herpes gestationis. *Dermatol Clin* 11: 527–533
- Stahle-Bäckdahl M, Inoue M, Giudice GJ, Parks WC (1994) 92-kD gelatinase is produced by eosinophils at the site of blister formation in bullous pemphigoid and cleaves the extracellular domain of recombinant 180 kD in bullous pemphigoid autoantigen. *J Clin Invest* 93:P 2022–2230.
- Stanley JR, Hawley-Nelson P, Yuspa SH, Shevach EM, Katz SI (1981) Characterization of bullous pemphigoid antigen: a unique basement membrane protein of stratified squamous epithelia. *Cell* 24: 897–903
- Stanley JR, Tanaka T, Mueller S, Klaus-Kovtun V, Roop D (1988) Isolation of complementary DNA for bullous pemphigoid antigen by use of patients' autoantibodies. *J Clin Invest* 82: 1864–1870
- Szabolcs P, Reese M, Yancey KB, Hall RP, Kurtzberg J (2002) Combination treatment of bullous pemphigoid with anti-CD20 and anti-CD25 antibodies in a patient with chronic graft-versus-host disease. *Bone Marrow Transplant*; 30: 327–9
- Tanaka M, Hashimoto T, Amagai M, Shimizu N, Ikeguchi N, Tsubata T, Hasegawa A, Miki K, Nishikawa T (1991) Characterization of bullous pemphigoid antibodies by use of recombinant bullous pemphigoid antigen proteins. *J Invest Dermatol* 97: 725–728
- Tanaka M, Hashimoto T, Dykes PJ, Nishikawa T (1996) Clinical manifestations in 100 Japanese bullous pemphigoid cases in relation to autoantigen profiles. *Clin Exp Dermatol* 21: 23–27
- Taylor G, Venning V, Wojnarowska F, Welch K (1993) Bullous pemphigoid and autoimmunity. *J Am Acad Dermatol* 29: 181–184
- Thoma-Uszynski S, Uter W, Schwietzke S, Hofmann SC, Hunziker T, Bernard P, Treudler R, Zouboulis CC, Schuler G, Borradori L, Hertl M (2004) BP230- and BP180 specific autoantibodies in bullous pemphigoid. *J Invest Dermatol* 122: 1413–1422
- Trüeb RM, Didierjean L, Fellas A, Avraam E, Borradori L (1999) Childhood bullous pemphigoid. Report of a case with characterization of the targeted antigens. *J Am Acad Dermatol* 40: 338–344
- Tyagi S, Bhol K, Natarajan K, Livir-Rallatos C, Foster CS, Ahmed AR (1996) Ocular cicatricial pemphigoid antigen: partial sequence and biochemical characterization. *Proc Natl Acad Sci USA* 93: 14714–14719
- Vaillant L, Bernard P, Joly P, Labeille B, Bedane C, Arbeille B, Thomine B, Bertrand B, Lok C, Roujeau JC (1998) Evaluation of clinical criteria for diagnosis of bullous pemphigoid. French bullous study group. *Arch Dermatol* 134: 1075–1080
- Vanderlugt CJ, Miller SD (1996) Epitope spreading. *Curr Opin Immunol* 8: 831–836
- Vassileva S (1998) *Clin Dermatol* 16: 379–387
- Verraes S, Polette M, Borradori L, Hornbeck W, Bernard P (2000) Action des protéases sur l'antigène cible BP180 au cours de la pemphigoïde bulleuse (abstract). *Ann Dermatol Venereol* 127: 4S2
- Venning VA, Millard PR, Wojnarowska F (1989) Dapsone as first line therapy for bullous pemphigoid. *Br J Dermatol* 120: 83–92
- Venning VA, Wojnarowska F (1990) The association of bullous pemphigoid and malignant disease: a case control study. *Br J Dermatol* 123:439–445
- Wakugawa M, Nakamura K, Hino H, Toyama K, Hattori N, Okochi H, Yamada H, Hirai K, Tamaki K, Furue M (2000) Elevated levels of eotaxin and interleukin-5 in blister fluid of bullous pemphigoid: correlation with tissue eosinophilia. *Br J Dermatol* 143: 112–116

- Wojnarowska F, Marsden RA, Bhogal B, Black MM (1988) Chronic bullous disease of childhood, childhood cicatricial pemphigoid, and linear IgA disease of adults. A comparative study demonstrating clinical and immunological overlap. *J Am Acad Dermatol* 19: 792–805
- Wojnarowska F, Whitehead P, Leigh IM, Bhogal BS, Black MM (1991) Identification of the target antigen in chronic bullous disease of childhood and linear IgA disease of adults. *Br J Dermatol* 124: 157–162
- Woodley DT, Briggaman RA, O'Keefe EJ, Inman AO, Queen LL, Gammon WR (1984) Identification of the skin basement-membrane autoantigen in epidermolysis bullosa acquisita. *N Engl J Med* 310:1007–1013
- Zillikens D, Mascaro JM, Rose PA, et al (1997a) A highly sensitive enzyme-linked immunosorbent assay for the detection of circulating autoantibodies in patients with bullous pemphigoid. *J Invest Dermatol* 109: 679–683
- Zillikens D, Rose PA, Balding SD, Liu Z, Olague-Marchan M, Diaz LA, Giudice GJ (1997b) Tight clustering of extracellular BP180 epitopes recognized by bullous pemphigoid autoantibodies. *J Invest Dermatol* 109: 573–579
- Zone JJ, Taylor TB, Meyer LJ, Petersen MJ (1998) The 97-kDa linear IgA bullous disease antigen is identical to a portion of the extracellular domain of the 180-kDa bullous pemphigoid antigen, BPAG2. *J Invest Dermatol* 110: 207–210

## 3.3 Dermatitis Herpetiformis Duhring

*Christian Rose and Detlef Zillikens*

### Introduction

Dermatitis herpetiformis is an intensely pruritic, chronic autoimmune blistering skin disease characterized by granular IgA deposits along the dermal-epidermal junction and by an association with celiac disease. The term dermatitis herpetiformis (DH) was first proposed by Louis Duhring (1884). He described a chronic disorder characterized by intense pruritus and pleomorphic skin lesions. *Table 1* summarizes a selection of historical milestones in our understanding of DH. Marks et al. (1966) first described small-bowel changes in 9 of 12 patients with DH. Subsequently, both diseases were found to be associated with certain HLA haplotypes, especially with DR3 and DQw2 (Sachs et al. 1996). Another major advance was the finding of Cormane (1967), who described immunoglobulins which were deposited at the dermal-epidermal junction in patients with DH. Two years later, van der Meer (1969) identified this immunoglobulin as IgA. Subsequently, Chorzelski and coworkers (1979) separated linear IgA disease from DH on the basis of different findings by immunofluorescence microscopy. Whereas in DH, granular IgA deposits are found, linear IgA disease is characterized by linear IgA deposits at the dermal-epidermal junction. Later, it became evident that the two diseases have a different immunogenetic background and that linear IgA disease is not associated with gastrointestinal changes.

### Clinical Appearance/Classification

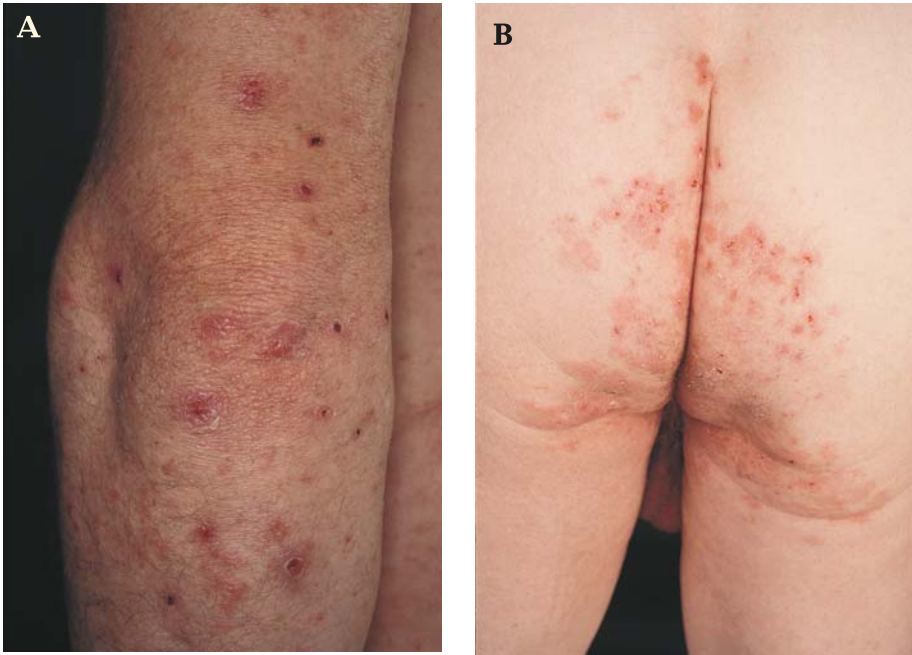DH most commonly manifests itself in early adult life, but is also found in childhood or in elderly patients. A slight male predominance has been noted (Fry 2002). Typically, patients with DH display an intense pruritic eruption of erythematous papules or vesicles. The lesions are distributed symmetrically on the extensor surfaces. Areas of predilection include elbows, knees, sacrum,

**Table 1.** Milestones in Studies on Dermatitis Herpetiformis (DH)

Clinical description and introduction of the designation DH	Duhring 1884
First use of sulphonamides for the treatment	Costello 1940
Association of DH and small bowel disease	Marks et al. 1966
In-situ deposits of immunoglobulin at the DEJ*	Cormane 1967
Granular in-situ deposits of IgA at the DEJ	van der Meer 1969
Differentiation of linear IgA disease from DH	Chorzelski et al. 1979
Detection of IgA anti-endomysium antibodies	Chorzelski et al. 1983
Identification of tissue transglutaminase as the autoantigen of anti-endomysium antibodies	Dieterich et al. 1997

\*DEJ; Dermal-epidermal junction

buttocks and scalp (*Fig. 1*). The primary lesion of DH is a small tense blister. Tiny blisters are seldom grouped. This rare manifestation led to the designation dermatitis herpetiformis. Sometimes larger blisters are found. Severe pruritus, which is often described as burning or stinging, is a hallmark of DH

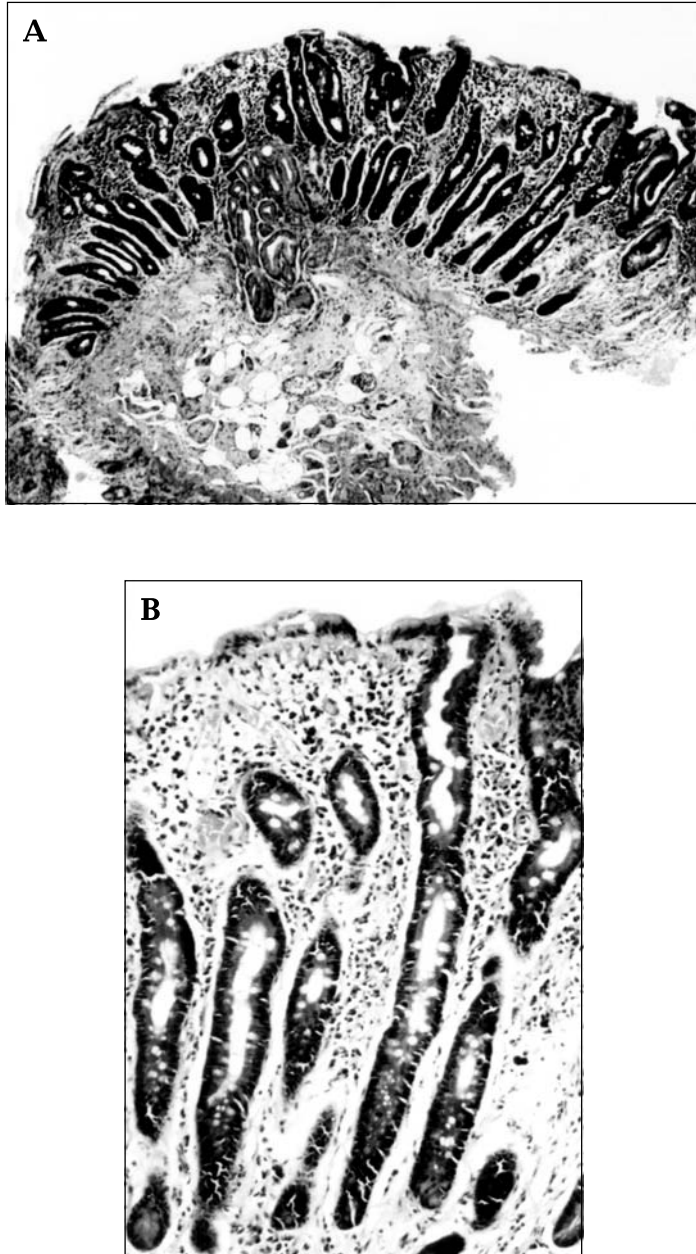


**Fig. 1.** Dermatitis herpetiformis (Duhring) **A.** Erythematous, excoriated papules on the elbow. **B.** Excoriated papules and plaques in a nearly symmetrical distribution on the buttocks

and may precede the cutaneous eruption. Frequently, only crusted or eroded lesions are present. Occasionally, DH is manifested with urticarial plaques or haemorrhagic maculae on the palms and soles (Kárpáti et al. 1986; Rütten and Goos 1989). Oral involvement is very rare (Fraser et al. 1973). Earlier reports of a more frequent oral involvement in DH may have included patients with linear IgA bullous dermatosis, in which oral lesions are more common. The differential diagnosis of DH includes scabies, eczema and subacute or chronic prurigo. If blisters are encountered, other autoimmune blistering diseases have to be considered.

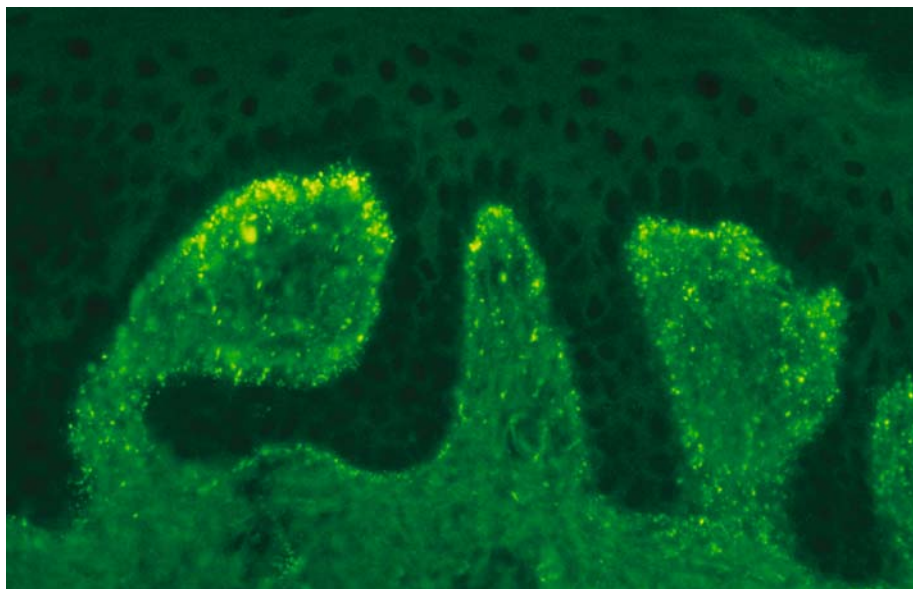
It is now well-accepted that all DH patients have celiac disease (CD), although most patients have no overt gastrointestinal symptoms. Marks et al. (1966) first reported abnormalities of the jejunal mucosa in patients with DH. Subsequently, it was recognized that the gastrointestinal abnormalities in DH are the same as in CD (Fry et al. 1967). Confusion concerning the incidence of the enteropathy in patients with DH is derived mainly from two aspects: firstly, from the inadequate criteria for the diagnosis of CD, and secondly from confusing DH and linear IgA disease. Before being able to differentiate between the two diseases, one may have thought that some patients with linear IgA-disease were suffering from DH with the absence of bowel disease. Essentially all DH patients have histologic changes of CD that vary from mononuclear infiltrates in the lamina propria and minimal villous atrophy to complete flattening of the small intestinal mucosa (*Fig. 2*). The typical histological changes are not always found when a single jejunal biopsy specimen is taken and multiple biopsies from the jejunal mucosa increase the frequency to detect the abnormalities by light microscopy (Brow et al. 1971). Today, CD is considered as the result of a complex interplay of intrinsic and extrinsic factors. The spectrum of clinical manifestations ranges from oligosymptomatic and silent diseases to severe malabsorption. Gluten peptides are thought to be presented by antigen-presenting cells and to drive the immune response leading to an inflammatory reaction in the connective tissue of the lamina propria of the small bowel (Schuppan 2000).

Chorzelski et al. (1983) first reported that sera from patients with DH and CD have IgA autoantibodies to endomysium, a specialized structure of connective tissue (*Fig. 3*). These IgA anti-endomysium autoantibodies allow a screening for CD with an almost 100% sensitivity and specificity (Corrao et al. 1994). Recently, tissue transglutaminase (tTG), an enzyme involved in cross-linking certain intracellular and extracellular molecules, has been identified as the autoantigen of anti-endomysium antibodies in CD (Dieterich et al. 1997). TTG is normally localized in the cytoplasm, but can be released to the extracellular space due to injury. The role of tTG in the pathogenesis of CD is not fully understood to date. However, by modifying gliadin it may contribute to the formation of neoantigens which, in genetically predisposed individuals, eventually lead to the initiation of an autoimmune response. Enzyme-linked immunosorbent assays using tTG derived from guinea pig and, more recently, human recombinant tTG were developed for the detection of tTG



**Fig. 2. A.** Histopathologic examination of a small bowel biopsy from a patient with dermatitis herpetiformis demonstrating a virtually complete loss of villi (low magnification). **B.** The crypts are elongated and hyperplastic and an inflammatory infiltrate is present in the lamina propria (high magnification)





**Fig. 3.** IgA anti-endomysium antibodies on monkey esophagus by indirect immunofluorescence microscopy. These antibodies are found in the serum of patients with dermatitis herpetiformis and celiac disease and are directed to tissue transglutaminase

autoantibodies in patients' sera (Dieterich et al. 1997; Sárdy et al. 1999; Seissler et al. 1999). Recent studies have demonstrated that measurement of IgA antibodies to tTG is a helpful tool to detect small bowel disease in both treated and untreated patients with CD and DH (Dieterich et al. 1998; Sulkanen et al. 1998; Dieterich et al. 1999). Furthermore, our own studies have shown that levels of IgA anti-tTG antibodies reflect the extent of histological changes in the intestine of patients with DH. These antibodies were not detected in patients with linear IgA disease or other subepidermal autoimmune bullous diseases. Therefore, the determination of serum levels of antibodies to tTG should be routinely used for the diagnosis of DH (Rose et al. 1999).

DH and CD are mainly found in Europe, but can be seen in other populations with European ancestry. In Scandinavia, Ireland and Great Britain, DH is found more frequently than in other parts of Europe. Children appear to be more commonly affected in Italy and Hungary (Ermacora et al. 1986; Kárpáti et al. 1996). In the Anglo-Saxon and Scandinavian population, the prevalence of DH ranges from 10 to 39 per 100,000 inhabitants (Mobacken et al. 1984; Smith et al. 1992). The disease is rare in Afro-Caribbeans, Asians and Orientals. The varying frequency among different ethnic populations is most probably related to a different genetic background. HLA studies in patients with DH and CD led to identical findings. Both diseases are strongly associated with DR3 (95%) and DQw2 (95 to 100%). HLA class I antigens A1 and B8 were

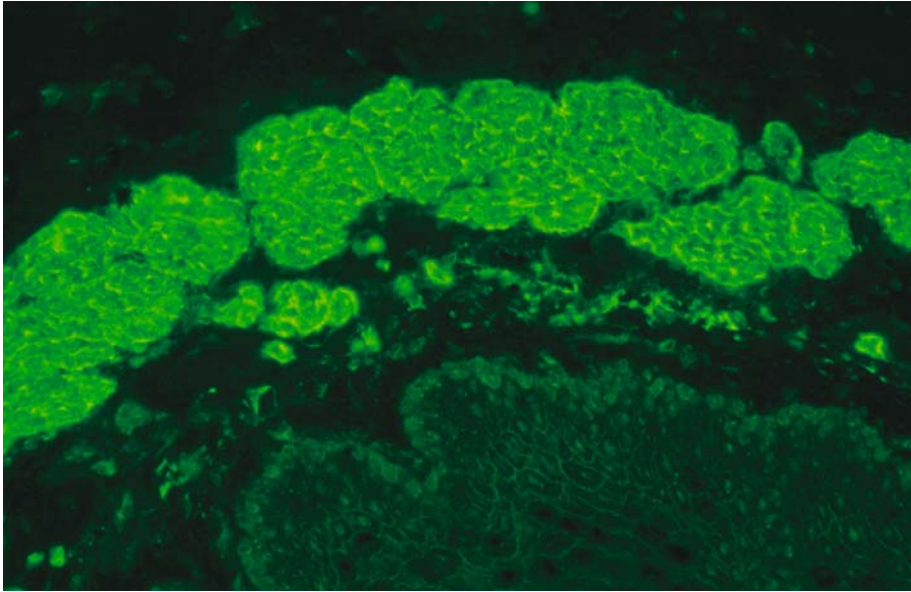
initially shown to be associated with DH, but this association may be due to linkage disequilibrium (Hall et al. 1991).

DH and CD may be associated with various autoimmune disorders, including autoimmune thyroiditis, type I diabetes, lupus erythematosus, Sjogren's disease, vitiligo, and others. DH is associated with an additional autoimmune disorder in approximately 10% of the patients (Reunala and Collin 1997). These associations have been thought to be a consequence of a common genetic background. In CD, it was recently demonstrated that the likelihood of an associated autoimmune disease is related to the duration of exposure to gluten and is higher in patients with CD diagnosed at a later stage (Ventura et al. 1999). In the majority of cases, the associated autoimmune disorder had appeared before a gluten-free diet was initiated, suggesting that long-standing untreated CD predisposes to the occurrence of other autoimmune disorders in the same patient. In addition, long-standing CD is associated with increased frequency of lymphomas of the intestine (Collin et al. 1994).

## Diagnosis

### Immunofluorescence

The diagnosis of DH is based on the finding of granular IgA deposits at the epidermal-dermal junction by direct immunofluorescence microscopy. Without this finding, the diagnosis of DH should be questioned (Fry 2002). Direct immunofluorescence microscopy is performed on a biopsy taken from clinically uninvolved perilesional skin. Lesional skin may be devoid of IgA, most likely due to degradation of the cutaneous IgA by enzymes released by neutrophils. If no IgA is found on the first section, serial sections of the biopsy should be studied. In skin areas that have never been affected by the disease, IgA has been found to be scant or absent (Zone et al. 1996). This may explain occasional reports in which direct immunofluorescence microscopy findings were negative (Beutner et al. 2000). IgA deposition is found in two patterns. More common are discontinuous granular deposits localized to the tips of the papillary dermis (*Fig. 4*). The other pattern involves a continuous granular deposition of IgA in the upper dermis beneath the basement membrane. There is no correlation between the direct immunofluorescence microscopy pattern and the clinical presentation of the disease (Fry 2002). Occasionally, granular IgM, IgG, and C3 deposits may also be seen in the upper dermis. It is essential to distinguish the continuous granular pattern of IgA deposits from the homogeneous linear IgA deposition, which is characteristic for linear IgA disease. The granular IgA staining in the skin ultrastructurally corresponds to IgA-positive amorphous grains. They are of different size and are scattered throughout the papillary dermis and represent IgA or immune complexes (Kárpáti et al. 1990). The mechanism by which IgA antibodies are deposited



**Fig. 4.** Direct immunofluorescence microscopy of a perilesional skin biopsy showing continuous granular deposits of IgA at the dermal-epidermal junction

in the skin of some patients with mild CD is not known. Indirect immunofluorescence microscopy has failed to identify an antibody in DH sera which is reactive with normal human skin (Kadunce et al. 1989). Interestingly, tTG appears to play an important role in cross-linking the papillary dermis and the dermalepidermal junction (Raghunath et al. 1996). Recently, Sárdy et al. (2002) have proposed that epidermal transglutaminase (eTG) is the autoantigen in DH. Apart from autoantibodies to tTG, those to eTG can also be found in the serum of DH and CD patients. The two transglutaminases are highly homologous, and therefore cross reactivity of the antibodies is likely. In DH, but not in CD patients, the antibodies are of high affinity and avidity to eTG. In addition, these patients have an antibody population specific to this enzyme. It was demonstrated that eTG is colocalized with IgA deposits in the papillary dermis in DH patients. These results lead to the hypothesis that in DH patients, circulating immune complexes containing IgA and epidermal transglutaminase may be trapped in the skin.

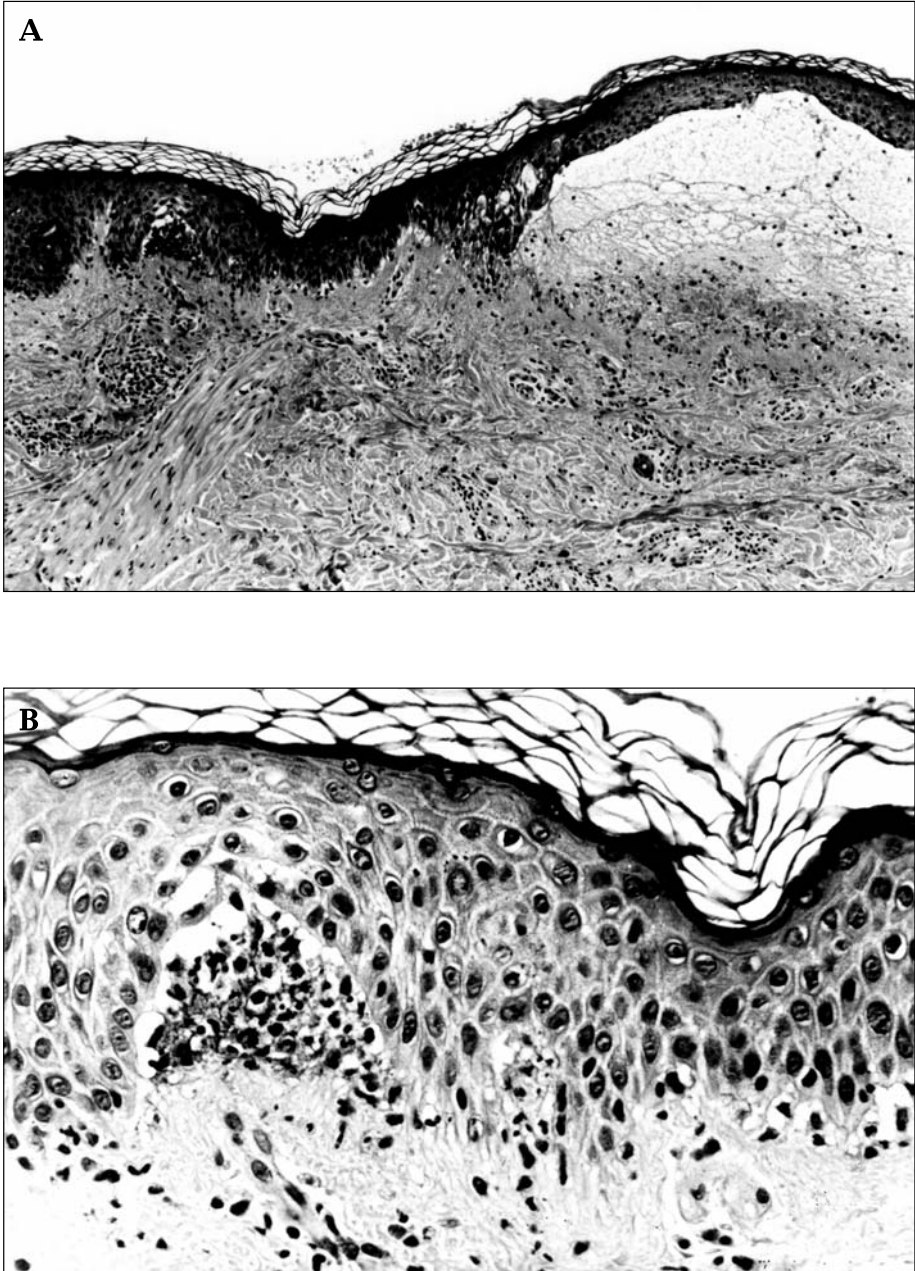
### Histopathology

As skin lesions are severely pruritic, they often become excoriated and the histological findings in these lesions may be nonspecific. A recent histopathological study of patients with DH has shown that in nearly 40% of the biopsies,

only a lymphocytic infiltrate with fibrosis and ectatic capillaries were seen (Warren and Cockerell 2002). Therefore, biopsies for histopathologic examination should be taken from an early papule, papulovesicle, or a small blister with healthy appearing skin immediately adjacent to it. Typical histological changes are best seen in the vicinity of early blisters (*Fig. 5*). The initial inflammatory event is variable edema in the papillary dermis with discrete subepidermal vacuolar alteration and neutrophils along the dermal-epidermal junction. As the lesion develops, neutrophils, to a lesser extent eosinophils, and fibrin accumulate within the dermal papillae and form microabscesses. These become confluent, resulting in a subepidermal blister. It has been demonstrated that split formation occurs within the lamina lucida of the basement membrane zone (Smith et al. 1992). The IgA deposits have been shown to act as a chemoattractant for neutrophils (Hendrix et al. 1990). In addition, interleukin 8, which is another chemoattractant for neutrophils, is strongly expressed by basal keratinocytes in the lesional skin of DH patients (Graeber et al. 1993). In early stages of the disease, the inflammatory infiltrate contains mostly neutrophils, but in later stages, variable numbers of eosinophils can be present. In rare cases eosinophils can dominate and flame figures can be found (Rose et al. 2003). Histological changes in DH are indistinguishable from those in linear IgA disease. Other autoimmune subepidermal blistering diseases may also show an inflammatory infiltrate mainly composed of neutrophils and eosinophils and may mimic DH histopathologically, including epidermolysis bullosa acquisita, cicatricial pemphigoid, bullous pemphigoid, and a recently described subepidermal bullous disease associated with autoantibodies to a dermal 200 kDa protein (anti-p200 pemphigoid) (Zillikens et al. 1996). Since histopathologic studies may not reliably differentiate between DH and these diseases, immunofluorescence microscopy is mandatory to establish the correct diagnosis. Analyses by immunoblotting and enzyme-linked immunosorbent assay aid in further characterizing the specificity of the autoantibodies. In addition, in bullous systemic lupus erythematosus, neutrophils and nuclear dust are found in the upper dermis and along the dermal-epidermal junction but in contrast to DH, mucin is commonly found in the reticular dermis. A bullous drug eruption or an arthropod bite can seldom mimic DH histopathologically (Ackerman et al. 1997, Rose et al. 2003). Since DH patients invariably also suffer from CD, one can question the necessity of a small intestinal biopsy to document the bowel disease, if the diagnosis of DH is already established.

## Therapy

Treatment of DH should consider changes in both the skin and the intestine. Dapsone usually controls the skin eruption within days and this rapid response helped to support the clinical diagnosis of DH in the past. Dapsone is most commonly used in the treatment of skin lesions of DH. Although there are no



**Fig. 5. A.** Histological examination of a skin biopsy from a newly developed lesion showing a subepidermal blister and a sparse superficial inflammatory infiltrate (low magnification). **B.** Next to the blister, neutrophils are found along the dermal-epidermal junction and clustered in a dermal papilla (high magnification)

controlled clinical trials, dapsone is considered to be more effective than sulfonamides such as sulphapyridine and sulphamethoxyipyridazine. The initial dose of dapsone is approximately 1.5 mg/kg daily and if no control of symptoms is achieved, the dose is usually increased by 50 mg daily every 2 weeks leading to a maximum dose of 400 mg daily (Fry 1988). If the skin rash has cleared, the dose should be tapered to the minimal dose required to suppress the symptoms. After a daily dose of 50 mg is achieved, the time interval between each dose should be increased before the drug is discontinued completely. When treating children, the recommended dose of dapsone is 2 mg/kg per day (Prendiville and Esterly 1991). Side effects of dapsone include hemolytic anemia, methemoglobinemia and rarely agranulocytosis. Hemolysis occurs early in the treatment and a complete blood count is therefore checked two and four weeks after starting dapsone. Patients of Mediterranean ancestry should be screened for glucose-6-phosphate dehydrogenase deficiency prior to treatment. In these patients, use of dapsone can lead to severe hemolysis. Methemoglobinemia reaches a steady state about two weeks after initiation of dapsone and may cause cyanosis, shortness of breath and angina. Other side effects of dapsone include hepatitis, hypoalbuminemia, headache, lethargy, peripheral neuropathy, and the dapsone syndrome (lymphadenopathy and hepatitis). Most side effects related to the use of dapsone occur within the first three months of use.

Sulphapyridine and sulphamethoxyipyridazine are alternatives in patients who do not tolerate dapsone (Fry 1988; McFadden et al. 1989). The initial dose of sulphapyridine is 2.0 g daily and the maximum dose should not exceed 4.0 g per day. Most patients require 0.5 to 2.0 g sulphapyridine daily to control the rash. The initial dose of the long-acting sulphonamide sulphamethoxyipyridazine is 1 g daily. This may be increased to a daily maximum of 1.5 g, but in many patients symptoms are controlled with 0.5 g daily. Side effects of both sulphonamides include nausea, lethargy and drug rash. Rarely, agranulocytosis may occur. In addition, side-effects of sulphapyridine are bone marrow depression, hemolytic anemia, and nephrolithiasis. There is a considerable variation between patients regarding the dose of the three drugs (dapsone, sulphapyridine and sulphamethoxyipyridazine) that is required to control the rash. A combination of two of the drugs can be used to reduce side-effects. None of the three sulphonamides affects the deposition of IgA in the skin, serum levels of IgA anti-endomysium antibodies, or the associated intestinal disease.

Alternative therapies for DH patients who do not tolerate sulphonamides include cholestyramine, sodium cromoglycate, cyclosporin, heparin, colchicine and a combination of tetracycline and nicotinamide (Silvers et al. 1980; Zemstov and Neldner 1993; Shah and Ormerod 2000). Intensive heparinization resulted in rapid improvement of DH in a few days. After withdrawal of heparin, skin lesion recurred within one week (Alexander 1963; Tan et al. 1996). The mode of action of heparin in DH is unclear. Interestingly, both dapsone and heparin are able to inhibit proteolytic enzymes which are released in skin lesions of DH (Olkariinen et al. 1986).

The treatment of CD and DH should always include a gluten-free diet. Since most patients with DH do not suffer from gastrointestinal symptoms and skin lesions can be controlled by dapsone, it is important to carefully inform the patient of the necessity to maintain a gluten-free diet for a lifetime. Since such a diet is difficult to maintain, patients need to be motivated and carefully educated, and the support of a dietitian is essential. In addition, in many countries, self-support groups have been established to aid the patient in dealing with the diet. Gluten is present in most common grains (wheat, rye, barley) but not in rice and corn. It was believed that oats also contain gluten and play a role in inducing DH, but recently oats have been shown to be devoid of toxicity in DH patients (Hardman et al. 1997; Reunala et al. 1998). Patients benefit from a gluten-free diet in different respects. Though only 5–10% of DH patients have gastrointestinal symptoms such as diarrhea, bloating and abdominal pain, these improve under a gluten-free diet. In addition, iron or folate deficiency, which is also found in some DH patients, will ameliorate. Under a strict diet, most patients are able to reduce the dose of dapsone required to control their skin disease and in some patients, dapsone can be discontinued completely after two to three years. However, it may take months and even years until an effect of the diet can be appreciated by the patient (Garioch et al. 1994).

IgA deposits are slowly cleared from the skin once gluten is removed from the diet (Fry et al. 1973). After an average of 12 years of avoiding gluten, no IgA was found in the skin of three of 12 patients studied. When these three patients were re-challenged with gluten, it induced new IgA deposits in their skin and two patients also developed cutaneous lesions (Fry et al. 1982; Leonard et al. 1983). After 5–10 years of a strict gluten-free diet, the risk of developing lymphoma decreases (Collin et al. 1996; Lewis et al. 1996). Furthermore, a gluten-free diet may be helpful in preventing the occurrence of additional autoimmune diseases in DH and CD patients. Interestingly, two studies have shown that patients with DH have an increased life expectancy. This finding resulted from a reduction in ischemic heart disease and was independent of a gluten-free diet (Swerdlow et al. 1993; Lear et al. 1997).

## Summary

Dermatitis herpetiformis (DH) is a pruritic autoimmune subepidermal bullous disease and is considered to be a specific cutaneous manifestation of celiac disease (CD). The diagnosis of DH is based on the detection of granular IgA deposits in biopsies of normal-appearing perilesional skin. CD and DH patients have the same genetic predisposition and demonstrate IgA anti-endomysium antibodies in their sera. These antibodies are directed against tissue transglutaminase. Serum levels of IgA antibodies to tissue transglutaminase reflect the extent of histopathologic changes of the small bowel and

are now routinely assessed in patients with DH and CD. Skin lesions can be controlled by dapsone, but the drug does not affect the small bowel disease. For CD, the treatment of choice is a gluten-free diet that should be maintained for a lifetime. The diet eventually results in remission of the skin lesions, a clearance of IgA deposits from the skin, an improvement of the bowel disease and a reduction in the risk of developing lymphoma of the intestine. It has been recently proposed that eTG is the autoantigen in DH. The question why some but not all patients with CD develop DH still remains to be elucidated.

## References

- Ackerman AB, Chongchitnant N, Sanchez J, Guo Y, Bennin B, Reichel M, Randall MB (1997) Histologic diagnosis of inflammatory skin diseases, 2nd ed. Williams & Wilkins, Baltimore, pp 271–278
- Alexander O D (1963) The treatment of dermatitis herpetiformis with heparin. *Br J Dermatol* 75: 289–293
- Beutner EH, Baughman RD, Austin BM, Plunkett RW, Binder WL (2000) A case of dermatitis herpetiformis with IgA endomysial antibodies but negative direct immunofluorescent findings. *J Am Acad Dermatol* 43: 329–332
- Brow J, Parker F, Weinstein W, Rubin CE (1971) The small intestinal mucosa in dermatitis herpetiformis: severity and distribution of the small intestinal lesion and associated malabsorption. *Gastroenterology* 60: 355–361
- Collin P, Pukkala E, Reunala T (1996) Malignancy and survival in dermatitis herpetiformis: a comparison with coeliac disease. *Gut* 38: 528–530
- Cormane RH (1967) Immunofluorescent studies of the skin in lupus erythematosus and other diseases. *Pathologica Eur* 2: 170–180
- Corrao G, Corazza GR, Andreani ML, Torchio P, Valentini RA, Galatola G, Quaglino D, Gasbarrini G, di Orio F (1994) Serological screening of coeliac disease: choosing the optimal procedure according to various prevalence values. *Gut* 35: 771–775
- Costello M (1940) Dermatitis herpetiformis treated with sulfapyridine. *Arch Dermatol Syphilol* 41: 134
- Chorzelski TP, Jablonska S, Beutner EH, Bear SF, Furey NL (1979) Linear IgA bullous dermatosis. In: Beutner EH, Chorzelski TP, Bear SF (eds) *Immunopathology of the skin*. 2nd ed. John Wiley & Sons, New York, pp 315–323
- Chorzelski TP, Sulej J, Tchorzewska H, Jablonska S, Beutner EH, Kumar V (1983) IgA class endomysium antibodies in dermatitis herpetiformis and coeliac disease. *Ann N Y Acad Sci* 4: 325–334
- Dieterich W, Ehnis T, Bauer M, Donner P, Volta U, Riecken EO, Schuppan D (1997) Identification of tissue transglutaminase as the autoantigen of celiac disease. *Nature Med* 3: 797–801
- Dieterich W, Laag E, Schöpfer H, Volta U, Ferguson A, Gillett H, Riecken EO, Schuppan D (1998) Autoantibodies to tissue transglutaminase as predictors of celiac disease. *Gastroenterology* 115: 1317–1321
- Dieterich W, Laag E, Bruckner-Tuderman L, Reunala T, Kárpáti S, Zágoni T, Riecken EO, Schuppan D (1999) Antibodies to tissue transglutaminase as serologic markers in patients with dermatitis herpetiformis. *J Invest Dermatol* 113: 133–136
- Duhring LA (1884) Dermatitis herpetiformis. *JAMA* 3: 225–229
- Ermacora E, Prampolini L, Tribbia G, Pezzoli G, Gelmetti C, Cucchi G, Tettamanti A, Giunta A, Gianotti F (1986) Long-term follow-up of dermatitis herpetiformis in children. *J Am Acad Dermatol* 15: 23–30
- Fraser NG, Kerr NW, Donald D (1973) Oral lesions in dermatitis herpetiformis. *Br J Dermatol* 89: 439–450



- Fry L, Keir P, McMinn RMH, Cowan JD, Hoffbrand AV (1967) Small-intestinal structure and function and haematological changes in dermatitis herpetiformis. *Lancet* II: 729–734
- Fry L, Seah PP, Riches DJ, Hoffbrand AV (1973) Clearance of skin lesions in dermatitis herpetiformis after gluten withdrawal. *Lancet* I: 288–291
- Fry L, Leonard JN, Swain F, Tucker WFG, Haffenden G, Ring N, McMinn RMH (1982) Long-term follow-up of dermatitis herpetiformis with and without dietary gluten withdrawal. *Br J Dermatol* 107: 631–640
- Fry L (1988) Fine points in the management of dermatitis herpetiformis. *Semin Dermatol* 7: 206–211
- Fry L (2002) Dermatitis herpetiformis: problems, progress and prospect. *Eur J Dermatol* 12: 523–531
- Garioch JJ, Lewis HM, Sargent SA, Leonard JN, Fry L (1994) 25 years' experience of gluten-free diet in the treatment of dermatitis herpetiformis. *Br J Dermatol* 131: 541–545
- Graeber M, Baker BS, Garioch JJ (1993) The role of cytokines in the generation of skin lesions in dermatitis herpetiformis. *Br J Dermatol* 129: 530–532
- Hall MA, Lanchbury JSS, Bolsover WJ, Ciclitira JP (1991) HLA association with dermatitis herpetiformis is accounted for by a cis or transassociated DQ heterodimer. *Gut* 32: 487–490
- Hardman CM, Garioch JJ, Leonard JN, Thomas HJ, Walker MM, Lortan JE, Lister A, Fry L (1997) Absence of toxicity of oats in patients with dermatitis herpetiformis. *N Engl J Med* 337: 1884–1887
- Hendrix JD, Karen L, Mangum MT, Zone JJ, Gammon WR (1990) Cutaneous IgA deposits in bullous diseases function as ligands to mediate adherence of activated neutrophils. *J Invest Dermatol* 94: 667–672
- Kadunce DP, Meyer LJ, Zone JJ (1989) IgA class antibodies in dermatitis herpetiformis: reaction with tissue antigens. *J Invest Dermatol* 93: 253–258
- Kárpáti S, Torok E, Kosnai I (1986) Discrete palmar and plantar symptoms in children with dermatitis herpetiformis Duhring. *Cutis* 3: 184–187
- Kárpáti S, Meurer M, Stolz W, Schrollhammer K, Krieg T, Braun-Falco O (1990) Dermatitis herpetiformis bodies. *Arch Dermatol* 126: 1469–1474
- Lear JT, Neary RH, Jones P, Fitzgerald DA, English JS (1997) Risk factors for ischaemic heart disease in patients with dermatitis herpetiformis. *J R Soc Med* 90: 247–249
- Leonard J, Haffenden G, Tucker W, Unsworth J, Swain F, McMinn R, Holborow J, Fry L (1983) Gluten challenge in dermatitis herpetiformis. *N Engl J Med* 308: 816–819
- Lewis HM, Reunala TL, Garioch JJ, Leonard JN, Fry JS, Collin P, Evans D, Fry L (1996) Protective effect of gluten-free diet against development of lymphoma in dermatitis herpetiformis. *Br J Dermatol* 135: 363–367
- Olkarinen AL, Reunala T, Zone JJ, Kilstala U, Uitto J (1986) Proteolytic enzymes in blister fluids from patients with dermatitis herpetiformis. *Br J Dermatol* 114: 295–302
- Marks J, Shuster S, Watson AJ (1966) Small bowel changes in dermatitis herpetiformis. *Lancet* II: 1280–1282
- McFadden JP, Leonard JN, Powles AV, Rutman AJ, Fry L (1989) Sulphamethoxypyridazine for dermatitis herpetiformis, linear IgA disease and cicatricial pemphigoid. *Br J Dermatol* 121: 759–762
- Mobacken H, Kastrup W, Nilsson L. (1984) Incidence and prevalence of dermatitis herpetiformis in Western Sweden. *Acta Derm Venereol* 64: 400–404
- Prendiville JS, Esterly NB (1991) Childhood dermatitis herpetiformis. *Clin Dermatol* 9: 375–381
- Raghunath M, Höpfner B, Aeschlimann D, Lüthi U, Meuli M, Altermatt S, Gobet R, Bruckner-Tuderman L, Steinmann B (1996) Cross-linking of the dermo-epidermal junction of skin regenerating from keratinocyte autografts. *J Clin Invest* 98: 1174–1184
- Reunala T, Collin P (1997) Diseases associated with dermatitis herpetiformis. *Br J Dermatol* 136: 315–318
- Reunala T, Collin P, Holm K, Pikkarainen P, Miettinen A, Vuolteenaho N, Maki M (1998) Tolerance to oats in dermatitis herpetiformis. *Gut* 43: 490–493
- Rose C, Dieterich W, Bröcker EB, Schuppan D, Zillikens D (1999) Circulating autoantibodies to tissue transglutaminase differentiate patients with dermatitis herpetiformis from those with linear IgA disease. *J Am Acad Dermatol* 41: 957–961

- Rose C, Bröcker EB, Krahl D (2003) Dermatitis herpetiformis with flame figures mimicking an arthropod bite. *Am J Dermatopathol* 25: 277–278
- Rütten A, Goos M (1989) Palmoplantar purpura in Dühring's herpetiform dermatitis. *Hautarzt* 40: 640–643
- Sachs JA, Awad J, McCloskey D, Navarrete C, Festenstein H, Elliot E, Walker-Smith JA, Griffiths CE, Leonard JN, Fry L (1986) Different HLA associated gene combinations contribute to susceptibility for coeliac disease and dermatitis herpetiformis. *Gut* 27: 515–520
- Sárdy M, Odenthal U, Kárpáti S, Paulsson M, Smyth N (1999) Recombinant human tissue transglutaminase ELISA for the diagnosis of gluten-sensitive enteropathy. *Clin Chem* 45: 2142–2149
- Sárdy M, Kárpáti S, Merkl B, Paulsson M, Smyth N (2002) Epidermal transglutaminase (TGase 3) is the autoantigen of dermatitis herpetiformis. *J Exp Med* 195: 747–757
- Schuppan D (2000) Current concepts of celiac disease pathogenesis. *Gastroenterology* 119: 234–242
- Seissler J, Borns S, Wohlrab U, Morgenthaler NG, Mothes T, Boehm BO, Scherbaum WA (1999) Antibodies to human tissue transglutaminase measured by radioligand assay: evidence for high diagnostic sensitivity for celiac disease. *Horm Metab Res* 31: 375–379
- Silvers DN, Juhlin EA, Berczeller PH, McSorley J (1980) Treatment of dermatitis herpetiformis with colchicine. *Arch Dermatol* 116: 1373–1374
- Shah SAA, Ormerod AD (2000) Dermatitis herpetiformis effectively treated with heparin, tetracycline and nicotinamide. *Clin Exp Dermatol* 25: 204–205
- Smith JB, Taylor TB, Zone JJ (1992a) The site of blister formation in dermatitis herpetiformis is within the lamina lucida. *J Am Acad Dermatol* 27: 209–213
- Smith JB, Tulloch JE, Meyer LJ, Zone JJ (1992b) The incidence and prevalence of dermatitis herpetiformis in Utah. *Arch Dermatol* 128: 1608–1610
- Sulkanen S, Halttunen T, Laurila K, Kolho KL, Korponay-Szabo IR, Sarnesto A, Savilahti E, Collin P, Mäki M (1998) Tissue transglutaminase autoantibody enzyme-linked immunosorbent assay in detecting celiac disease. *Gastroenterology* 115: 1322–1328
- Swerdlow AJ, Whittaker S, Carpenter LM, English JSC (1993) Mortality and cancer incidence in patients with dermatitis herpetiformis: a cohort study. *Br J Dermatol* 129: 140–144
- Tan CC, Sale JE, Brammer C, Irons RP, Freeman JG (1996) A rare case of dermatitis herpetiformis requiring parenteral heparin for long-term control. *Dermatology* 192: 185–186
- Van der Meer JB (1969) Granular deposits of immunoglobulins in the skin of patients with dermatitis herpetiformis. *Br J Dermatol* 81: 493–503
- Ventura A, Magazzu G, Greco L for the SIGEP study group for autoimmune disorders in celiac disease (1999) Duration of exposure to gluten and risk for autoimmune disorders in patients with celiac disease. *Gastroenterology* 117: 297–303
- Warren SJP, Cockerell CJ (2002) Characterization of a subgroup of patients with dermatitis herpetiformis with nonclassical histologic features. *Am J Dermatopathol* 24: 305–308
- Zillikens D, Kawahara Y, Ishiko A, Shimizu H, Mayer J, Rank CV, Liu Z, Giudice GJ, Tran HH, Marinkovich MP, Bröcker EB, Hashimoto T (1996) A novel subepidermal blistering disease with autoantibodies to a 200-kDa antigen of the basement membrane zone. *J Invest Dermatol* 106: 1333–1336
- Zemtsov A, Neldner K (1993) Successful treatment of dermatitis herpetiformis with tetracycline and nicotinamide in a patient unable to tolerate dapsone. *J Am Acad Dermatol* 28: 505–506
- Zone JJ, Laurence JM, Peterson MJ (1996) Deposition of granular IgA relative to clinical lesions in dermatitis herpetiformis. *Arch Dermatol* 132: 912–918

## 3.4 Epidermolysis Bullosa Acquisita

*Mei Chen, Dafna Hallel-Halevy, Celina Nadelman,  
and David T. Woodley*

### Introduction

*Epidermolysis bullosa acquisita* (EBA) was first described before the turn of the century and was designated as an acquired form of epidermolysis bullosa (EB) because the clinical features were so reminiscent of children who were born with genetic forms of dystrophic EB (Elliott 1985). EBA is an acquired, subepidermal bullous disease and is classified as one of the “primary” bullous diseases of the skin. In its classical form, it is a mechanobullous disease with skin fragility and trauma-induced blisters that have minimal inflammation and heal with scarring and milia – features that are highly reminiscent of hereditary dystrophic forms of epidermolysis bullosa (DEB). In DEB, there is a hereditary defect in the gene that encodes for type VII (anchoring fibril) collagen leading to a paucity of anchoring fibrils. Anchoring fibrils are structures that anchor the epidermis and its underlying basement membrane zone (BMZ) onto the dermis (Briggaman and Wheeler 1975; Uitto and Christiano 1994). In EBA, there is also a paucity of anchoring fibrils, but this is because EBA patients have IgG autoantibodies targeted against the type VII collagen within anchoring fibrils. EBA represents an acquired autoimmune mechanism by which anchoring fibrils can be compromised rather than by a gene defect. Since EBA has become defined as autoimmunity to type VII collagen, it has become evident that EBA may also present with clinical manifestations reminiscent of bullous pemphigoid (BP), cicatricial pemphigoid (CP), and Brunsting-Perry pemphigoid.

In the early 1970s, Roenigk et al. (1971) reviewed the EBA world literature, reported three new cases and established the first diagnostic criteria for EBA: (1) spontaneous or trauma-induced blisters resembling hereditary DEB, (2) adult onset, (3) a negative family history for EB, and (4) the exclusion of all other bullous diseases. In the 1980's Yaoita et al. (1981) and Nieboer et al. (1980) found that EBA, like BP, exhibited IgG deposits at the dermal-epidermal junction (DEJ). In EBA, however, the IgG deposits are found within and

below the lamina densa compartment of the BMZ, whereas in BP they are located higher, within hemidesmosomes and the lamina lucida. The sublamina densa location of the IgG deposits in EBA was understandable when it was recognized that the skin protein targeted by the IgG autoantibodies was type VII collagen within anchoring fibrils which emanate perpendicularly from the lamina densa into the high papillary dermis (Woodley et al. 1984, 1988). The primary unit of type VII collagen is a 290 kDa alpha chain which is the "EBA auto-antigen".

## **Etiology and Pathogenesis**

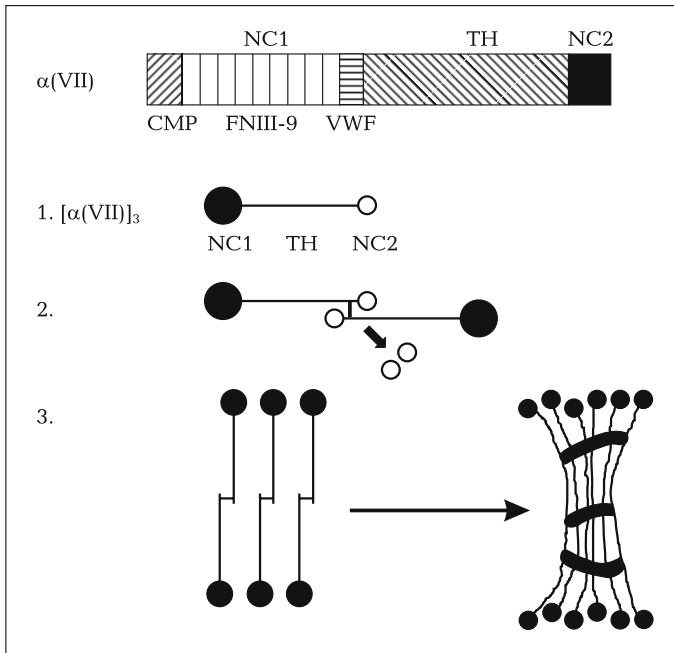
### **Etiology and Epidemiology**

The etiology of EBA is unknown, but because the disease features IgG autoantibodies directed against type VII collagen, it is thought that EBA has an autoimmune pathogenesis (Woodley et al. 1984, 1988). Another autoimmune bullous skin disease which may exhibit auto-antibodies against type VII collagen is bullous systemic lupus erythematosus (SLE) (Gammon et al. 1985). Both EBA and bullous SLE patients often have a common human leukocyte antigen (HLA) major histocompatibility (MHC) class II cell surface protein, HLA-DR2 (Gammon et al. 1988b). This HLA phenotype has been associated with hyperimmunity which again suggests an autoimmune etiology for EBA.

EBA is a rare disease with an incidence of 0.17–0.26 per million people in Western Europe (Bernard et al. 1995; Zillikens et al. 1995). EBA appears to be less common than BP, but it may be at least as common as CP, pemphigoid gestationis and linear IgA bullous dermatosis. Although there is no racial or gender predilection (Gammon and Briggaman 1993), it has recently been suggested to have higher predilection in the Korean population (Lee 1998). The age of onset varies widely from early childhood to late adult life, but most cases begin between the fourth and fifth decades (Gammon 1988a; Arpey et al. 1991).

Type VII collagen is composed of three identical alpha chains wound into a triple helical structure. Each alpha chain is 290 kDa. However, half of the size of each alpha chain is consumed by a large, globular, non-collagenous domain at the amino end of the molecule. This globular domain is 145 kDa and is called the non-collagenous 1 domain (NC1). At the other end of the alpha chain, the carboxyl terminus, there is a much smaller non-collagenous globular domain called NC2 which is only 34 kDa. In between these two globular domains, there is a long rod-shaped, helical, collagenous domain characterized by repeating Gly-X-Y amino acid sequences (*Fig. 1*) (Sakai et al. 1986; Burgeson 1993).

Within the extracellular space, type VII collagen molecules form antiparallel, tail-to-tail dimers stabilized by disulfide bonding through the small carboxyl-terminal NC2 overlap between two type VII collagen molecules. A portion of



**Fig. 1.** A schematic representation of the type VII collagen alpha chain and assembly into anchoring fibril structures. The NC1 non-collagenous domain at the amino terminus has several segments with homologies to adhesive proteins including cartilage matrix protein (CMP), nine fibronectin type III like repeats (FNIII-9), and von Willibrand factor A (VWF). Then, there is a long triple helical collagenous segment (TH) and a smaller second non-collagenous globular domain called NC2. 1. Three type VII collagen alpha chains form a homotrimer  $[\alpha(C-VII)]_3$ . 2. In the extracellular space, two procollagen molecules align to form antiparallel dimers which are stabilized by the formation of disulfide bonds. The NC2 domain is then proteolytically cleaved. 3. Several of these dimer molecules laterally aggregate to assemble into anchoring fibrils

the NC2 domain is then proteolytically removed (Bruckner-Tuderman et al. 1995). The antiparallel dimers then aggregate laterally to form anchoring fibrils with large globular NC1 domains at both ends of the structure (*Fig. 1*).

### Pathogenesis

The NC1 domain contains the major antigenic epitopes for EBA and bullous SLE autoantibodies (Gammon et al. 1993; Jones et al. 1995; Lapiere et al. 1996). The NC1 domain contains a series of domains within it that have homology with adhesive proteins such as cartilage matrix protein, fibronectin and the A domain of von Willebrand factor (VWF-A) (Christiano et al. 1994). Therefore, the NC1 domain may facilitate binding of type VII collagen to other

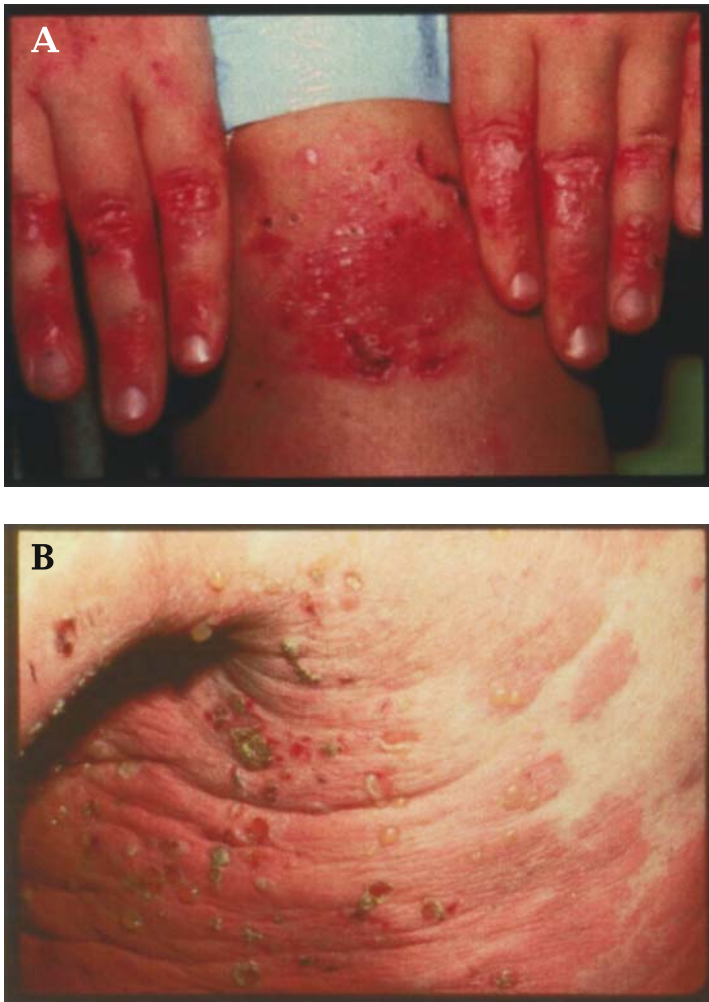
BMZ and matrix components. It is possible that autoantibodies directed against NC1 compromise the function of these adhesive proteins so that anchoring fibril collagen cannot interact well and bind to other connective tissue components of the BMZ and papillary dermis. This compromised function would lead to epidermal – dermal disadherence because of loss of anchoring fibril function. The recent observation that some EBA autoantibodies from children with EBA target other domains within the alpha chain besides NC1 suggests that the helical collagenous domain and perhaps the NC2 domain may also play important roles in maintaining fully functional type VII collagen and anchoring fibrils (Tanaka et al. 1997). For example, some EBA patients' autoantibodies recognize antigenic epitopes within both the NC1 and NC2 domains, and the latter domain appears to be important in the formation of antiparallel dimers and anchoring fibril assembly (Chen et al. 2000).

We now understand that EBA does not always present as a non-inflammatory mechanobullous disease reminiscent of DEB. Although less common, EBA may present as an inflammatory, widespread, vesiculobullous disease reminiscent of BP. Therefore, it is possible that autoantibody recognition of one or several domains of type VII collagen may invoke an inflammatory cascade which could result in proteolytic degradation of matrix components within the DEJ that are essential for epidermal-dermal adherence. Therefore, within the spectrum of EBA and autoimmunity to type VII collagen, there are several possible mechanisms for autoantibody-induced blister formation. First, because EBA often occurs with minimal clinical or histologic inflammation, it has been hypothesized that defective epidermal-dermal adherence in EBA involves autoantibodies that target and compromise functional epitopes on the NC1 domain. This then interferes with the normal interactions between NC1 and its extracellular matrix ligands such as laminin 5 and fibronectin (Chen et al. 1997a, 1999). Also, there may be an interruption in the type VII collagen-fibronectin interaction in the collagenous domain which may be important for the adherence of basement membrane and the overlying epidermis onto the papillary dermis (Lapiere et al. 1994). Alternatively, the autoantibodies might interfere directly with antiparallel dimer formation and anchoring fibril assembly (Chen et al. 2000). These mechanisms are attractive possibilities for explaining skin fragility and trauma-induced blisters in patients with classical EBA who lack significant inflammation but have markedly defective epidermal-dermal adherence.

Another possible mechanism in some EBA patients is that the EBA autoantibodies generate blisters by inducing localized inflammation with or without the amplification of complement fixation. The induced inflammatory response then causes tissue damage at DEJ, which results in blister formation (Gammone et al. 1984). This mechanism may explain those EBA and bullous SLE patients with acute inflammation at the BMZ, particularly when neutrophils are predominant in the inflammatory response because that type of inflammation is characteristic of experimental forms of immune complex and complement-mediated inflammation.

## Clinical Manifestations

There is great diversity in the clinical presentation of EBA. The common denominator for patients with EBA is autoimmunity to type VII (anchoring fibrils) collagen and diminished anchoring fibrils (Woodley 1988; Woodley et al. 1988). Although the clinical spectrum of EBA is still being defined, it appears that there are at least five clinical presentations of EBA (*Fig. 2*):



**Fig. 2.** Clinical presentations of Epidermolysis Bullosa Acquisita. **A.** Classical presentation in a white woman. **B.** Presentation of EBA that is highly inflammatory and appears like BP

- (1) "Classical" presentation that was initially described in EBA and closely resembles the features seen in patients with inherited forms of DEB
- (2) BP-like presentation
- (3) CP-like presentation
- (4) Brunsting-Perry Pemphigoid-like presentation
- (5) Linear IgA bullous dermatosis (LABD)-like disease. Its childhood presentation can be reminiscent of Chronic Bullous Disease of Childhood.

### **Classical EBA**

This form of EBA presents as a mechanobullous noninflammatory disease with an acral distribution. The blisters and erosions heal with scarring and milia formation. This presentation in its mild form is reminiscent of porphyria cutanea tarda, and in its more severe forms is reminiscent of hereditary recessive DEB (Yaoita et al. 1981). Despite the similarities between EBA and porphyria cutanea tarda, patients with EBA do not present with hirsutism, photodistribution, scleroderma like changes and high levels of urinary porphyrins (Woodley 1988; Woodley et al. 1998).

Classical EBA is a mechanobullous disease marked by skin fragility over trauma prone surfaces. Blisters, erosions and scars occur over the back of the hands, knuckles, elbows, knees, sacral area, and feet (*Fig. 2A*). There is often significant involvement of the oral mucosa with erosions and frank blisters. On the glabrous skin, the vesicles and bullae appear tense on non-inflamed or scarred skin. They can be hemorrhagic and can result in erosions, crusts, scales, scars, scarring alopecia, milia cysts and nail dystrophy. The lesions heal with scarring and frequently with the formation of pearl-like milia cysts within the scarred areas. In severe cases, there may be fibrosis of the hands and fingers and esophageal stenosis (Stewart et al. 1991; Harman et al. 1998). The histology shows dermal-epidermal separation at the BMZ and minimal inflammation.

### **BP-like Presentation**

These patients present with features characteristic of the autoimmune bullous disease, BP, or a mixture of features characteristic of both BP and classic EBA presentation (Gammon et al. 1982, 1984b). This form of EBA manifests as a widespread inflammatory vesiculobullous eruption involving the trunk, extremities and skin folds usually accompanied by pruritus (*Fig. 2B*). Tense bullae are situated on inflamed and/or urticarial skin. In contrast to classical EBA, skin fragility is not prominent and scarring and milia formation may be minimal or absent. The distribution of the lesions is not confined to trauma-prone sites. The histology shows a moderate to dense polymorphic infiltrate



of mononuclear cells and granulocytes. Neutrophils are often the predominant granulocyte, but occasionally eosinophils are seen.

### **CP-like Presentation**

The clinical features in these patients closely resemble those considered characteristic of CP. This form of EBA presents as a bullous disease with a predominance of mucosal involvement. The patient may present with erosions and scars of the mouth, upper esophagus, conjunctiva, anus, and vagina (Dahl 1979; Stewart et al. 1991; Harman et al. 1998) with or without similar lesions on the glabrous skin. Recently, tracheal involvement has been reported in the CP-like presentation of EBA (Wieme et al. 1999). There is also one report of predominantly mucosal involvement with no scarring (Tokuda et al. 1998). Unlike classical EBA, patients with the CP-like presentation often do not show significant skin fragility, evidence of trauma-induced lesions, or a predilection for blistering on extensor skin surfaces. The histology shows subepidermal blisters and usually a mixed inflammatory infiltrate in the upper dermis and at the BMZ and microscopic scarring.

### **Brunsting-Perry Pemphigoid**

Brunsting-Perry Pemphigoid is a chronic recurrent subepidermal scarring vesiculobullous eruption localized to the head and neck. In contrast to CP, it has minimal or no mucosal involvement (Kurzahls et al. 1991; Yancey 1998). IgG autoantibodies are deposited at the BMZ, but the autoantigenic target for these autoantibodies has not been defined. Recently, several patients have been reported to have the clinical, histological and immunological features of Brunsting-Perry Pemphigoid but their IgG autoantibodies are targeted against type VII (anchoring fibril) collagen (Kurzahls et al. 1991; Joly et al. 1993; Choi et al. 1998; Woodley et al. 1998). Therefore, we believe that Brunsting Perry Pemphigoid may actually be a clinical presentation of EBA.

### **LABD-like Presentation**

This form of EBA is manifested by a subepidermal bullous eruption, a neutrophilic infiltrate and linear IgA deposits at the BMZ when viewed by direct immunofluorescence microscopy. It may resemble Chronic Bullous Disease of Childhood and feature tense vesicles arranged in an annular fashion and involvement of mucous membranes (Callot-Mellot et al. 1997, Park et al. 1997). The autoantibodies are usually IgA, IgG or both.

The diagnostic category of these patients with IgA antibodies against type VII collagen deposited in a linear fashion along the BMZ is not clear. Some

clinicians regard these patients as purely LABD (Hashimoto et al. 1996), while others regard these patients as a subset of EBA (Rusenko et al. 1989; Bauer et al. 1999). It is interesting to note that in a recent study (Lee 2000), 20 EBA patients' sera were evaluated for serum IgA anti-type VII collagen antibodies by immunoblotting. The investigators detected low titers of IgA anti-type VII collagen antibodies in 80% of the patients in addition to IgG.

Childhood EBA is a rare disease with variable presentations. In a recent study of 14 children with EBA, five of the patients presented as a LABD-like disease and five patients presented with the BP-like form of EBA. The remaining four children presented with the classical mechanobullous form of EBA (Callot-Mellot et al. 1997). Eleven out of 14 had mucosal involvement and all had IgG deposits at the BMZ by direct immunofluorescence, in addition to other immunoreactants. Indirect immunofluorescence was positive in 10 out of 14 patient sera, and the predominant serum antibody was of the IgG class. Although mucosal involvement is frequent and severe in childhood EBA, the overall prognosis and treatment is more favorable than in adult EBA (Callot-Mellot et al. 1997; Edwards et al. 1998).

The clinical presentation of the EBA patient may change during the course of the disease or can show two different presentations simultaneously. About 25% of patients with EBA may appear with the BP-like clinical appearance (unpublished observation). With time, the disease of some patients will eventually smolder into a more noninflammatory classic form of EBA. Both the classical and the BP-like forms (Stewart et al. 1991), and the CP-like and BP-like forms of the disease may coexist in the same patient (Wieme et al. 1999). The clinical phenotype of EBA that is reminiscent of pure CP is probably more rare and occurs in fewer than 10% of all EBA cases.

### **The Relationship between EBA and Bullous SLE**

There have been reports of patients having both EBA and bullous SLE (Gammon and Briggaman 1993). In contrast to the classical presentation of EBA, bullous SLE patients by definition must fulfill the American Rheumatism Association criteria for SLE. The patients tend to be young women with a widespread nonscarring vesiculobullous eruption with a predilection for sun-exposed areas. EBA often presents in the fourth to fifth decades whereas bullous SLE usually presents earlier, in the second and third decades. EBA often lasts many years whereas bullous SLE is remitting and may resolve in less than a year. EBA does not respond as much as bullous SLE to treatment with dapsone or prednisone. Histologically there can also be differences. Bullous SLE may exhibit neutrophilic papillary microabscesses and vasculitis, which are seldom seen in EBA (Gammon and Briggaman 1993). Mucin is not increased in the reticular dermis in EBA unlike bullous SLE (Ackerman et al. 1997).

A reduction in the number of anchoring fibrils is seen in lesional and perilesional skin of EBA patients, but the pathway leading to this reduction is unknown (Nieboer et al. 1980; Yaoita et al. 1981). Evidence for the pathogenic role of EBA antibodies comes from the observation that when patients with SLE develop autoantibodies to the EBA antigen, they develop skin blisters and fall into a subset called "bullous SLE" (Gammon et al. 1985). Patients with SLE have an augmented immune system and frequently make autoantibodies to a variety of tissues. Normally, SLE patients do not have skin fragility or blisters. However, when SLE patients serendipitously make autoantibodies to type VII collagen, a widespread blistering eruption of the skin ensues. This "experiment of nature" suggests that EBA autoantibodies are pathogenic and capable of inducing disadherence between the epidermis and dermis. Nevertheless, consistent induction of blisters in an animal by the passive transfer of EBA IgG autoantibodies into the animal has not been achieved, despite numerous attempts (Chen et al. 1992; Borradori et al. 1995). When IgG autoantibodies are injected into a neonatal mouse, they bind to the animal's anchoring fibrils, fix complement, and generate an inflammatory infiltrate at the DEJ, but no dermal-epidermal separation occurs. This might be due to the fact that turnover of anchoring fibrils is slow, and existing resident anchoring fibrils in the animal continue to function despite the EBA autoantibodies.

### **The Relationship between EBA and Other Systemic Diseases**

In Roenigk's review of the EBA world literature (Roenigk et al. 1971), it was noted that there were many anecdotal reports of EBA associated with systemic diseases such as SLE, diabetes, inflammatory bowel disease, amyloidosis, autoimmune thyroiditis, multiple endocrinopathy syndrome, rheumatoid arthritis, pulmonary fibrosis, chronic lymphocytic leukemia, thymoma, diabetes, and others (Woodley et al. 1998). However, EBA is a relatively rare disease, and most of these are anecdotal reports. It appears that the most frequently associated disease with EBA is inflammatory bowel disease, with an estimate of 25% of 50 EBA patients reviewed by Chan and Woodley (1996). It has also been shown that patients with inflammatory bowel disease, especially Crohn's disease, have a high prevalence of circulating antibodies against type VII collagen (Chen et al. 1997). In addition, type VII collagen was recently shown to be present in the intestinal epithelium (Lohi et al. 1996). Because type VII collagen is the antigenic target for autoantibodies in patients with EBA, we speculate that autoimmunity to type VII collagen which exists in both gut and skin, may explain why these patients frequently have inflammatory bowel disease. The presence of type VII collagen antibodies in Crohn's disease patients may be an epitope spreading phenomenon whereby inflammation originally invoked by Crohn's disease could perturb the intestinal epithelial

BMZ such that BMZ components could be altered, resulting in an ongoing autoimmunity to type VII collagen (Chan et al. 1998).

## **Pathology**

Lesional skin histology initially shows papillary edema and vacuolar alteration along the DEJ and at a later stage, a subepidermal blister. Various degrees of dermal inflammatory infiltrate are seen in concordance with the clinical presentation. The classical presentation shows little inflammatory infiltrate within the dermis as opposed to the BP-like presentation (Lever and Schaumburg-Lever 1990). The infiltrate can be found around vessels, around follicles and in the interstitium. In the inflammatory subtypes, the dermal infiltrate may be rich in neutrophils. The infiltrate may be mixed with variable numbers of eosinophils and mononuclear cells. Fibrosis may be seen in older lesions (Ackerman et al. 1997). Because of the variable clinical and histological presentations, it is difficult to diagnose EBA by clinical and histological parameters alone.

Ultrastructural studies of EBA skin have demonstrated a paucity of anchoring fibrils and an amorphous, electron-dense band just beneath the lamina densa (Richer and McNutt 1979; Ray et al. 1982). Although the autoantibodies are directed against the anchoring fibrils in the sublamina densa region of the BMZ, it should be noted that the cleavage plane of the blister may be either in the lamina lucida or the sublamina densa region where anchoring fibrils are located (Fine et al. 1989). Immunomapping studies have shown that EBA blisters frequently separate above the immune deposits within the lamina lucida (Fine et al. 1989). This is because the lamina lucida is the Achilles' heel of the cutaneous BMZ and is more susceptible to disadherence than the sublamina densa zone (Briggaman and Wheeler 1975; Briggaman et al. 1980). Briggaman et al. (1980) have shown that a variety of soluble inflammatory mediators and cytokines can readily induce epidermal disadhesion through the lamina lucida space. It is likely that when there is some level of inflammation in EBA, the lamina lucida is much more vulnerable than the sublamina densa area to proteolytic degradation. Therefore, the cleavage plane of the blister is not a good way to discriminate EBA from other subepidermal bullous diseases.

## **Diagnosis**

### **Direct Immunofluorescence (DIF)**

By definition, patients with EBA have IgG deposits within the DEJ of their skin (Yaoita et al. 1981). This is best detected by DIF of a biopsy specimen obtained

from a perilesional site. The deposits are predominantly IgG, but, complement, IgA, IgM, Factor B and properidin may be detected as well (Kushniruk 1973; Yaoita et al. 1981). The DIF staining demonstrates an intense, linear fluorescent band at the DEJ. Yaoita et al (1981) have suggested that a positive DIF and IgG deposits within the sublamina densa zone are necessary criteria for the diagnosis of EBA. However, in some LABD – like patients, the deposited antibody is IgA without IgG (Hashimoto et al. 1996; Bauer et al. 1999).

Patients with porphyria cutanea tarda (a syndrome that clinically may mimic EBA) frequently have IgG and complement deposits at the DEJ similar to EBA patients (Epstein et al. 1973). However, DIF of porphyria patients as opposed to EBA patients, also demonstrates immune deposits around blood vessels in addition to the DEJ.

### **Indirect Immunofluorescence (IIF)**

Patients with EBA may have autoantibodies in their blood directed against the DEJ (Woodley et al. 1984). These antibodies can be detected by IIF of the patient's serum on a substrate of monkey or rabbit esophagus or human skin. A positive test gives a linear fluorescent band along the DEJ that may be indistinguishable from BP sera. The autoantibodies in EBA patients will label basement membranes beneath stratified squamous epithelium (skin, upper esophagus, and mucosa of the mouth and vagina) and will not bind to basement membranes within most mesenchymal organs such as blood vessels, liver, or kidney. Therefore, there is no difference in labeling pattern and distribution between EBA and BP autoantibodies in this test (Paller et al. 1986).

Distinguishing between EBA and other autoimmune subepidermal bullous diseases may be a problem if patients are evaluated only on the basis of clinical presentation, routine lesional histology and routine DIF and IIF. EBA may share clinical, pathologic, and immunohistologic features with BP, CP or LABD. In addition to the usual laboratory tests for primary blistering disorders (such as routine DIF and IIF), other special tests are necessary to confirm the diagnosis of EBA. These may include direct and indirect salt-split skin immunofluorescence (SSSI), transmission electron microscopy, immunoelectron microscopy, Western blot analysis, and enzyme-linked immunosorbent assay (ELISA).

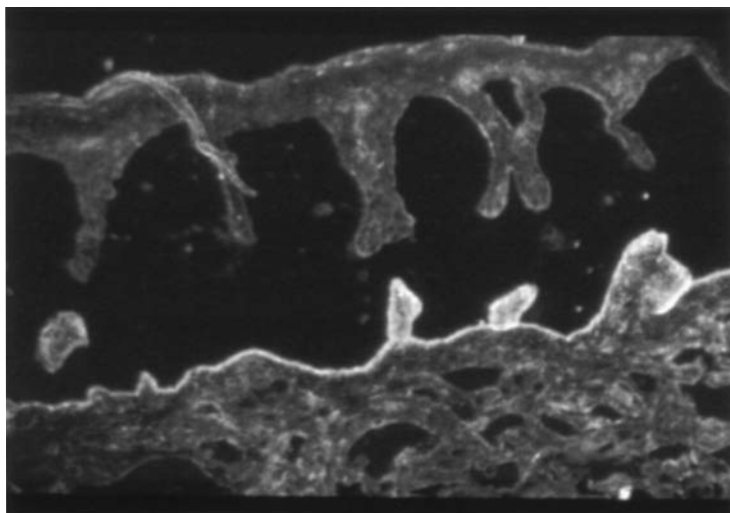
### **Transmission Electron Microscopy**

Standard transmission electron microscopy (EM) of the DEJ of human skin can suggest the diagnosis of EBA. As mentioned above, EM would reveal a decrease in the number of anchoring fibrils emanating downward into the papillary dermis from the lamina densa compartment of the DEJ. Further, electron microscopists have noted in EBA skin that there is amorphous, electron – dense, ill-defined material lying just beneath the lamina densa.

Although never definitively proven, it is likely that this material corresponds to the IgG deposits in the area attached to anchoring fibrils. This would be suggestive of the diagnosis of EBA.

### Immunoelectron Microscopy (IEM)

The "gold standard" for the diagnosis of EBA is IEM. The purpose of IEM is to localize precisely the immune deposits in the patient's skin (direct IEM) or to localize precisely the structure within normal skin to which autoantibodies in the patient's serum bind (indirect IEM). If the deposits are in the sublamina densa region where anchoring fibrils normally exist, this is strong evidence for EBA. If the deposits are higher up over the basal keratinocyte's hemidesmosomes or high within the lamina lucida zone, this is strong evidence for BP. The skin IgG deposited within the DEJ is demonstrated by a second antibody against human IgG. The second antibody is conjugated with an enzyme such as peroxidase. By incubating the preparation with a substrate such as diaminobenzadine, an electron dense reaction product is formed, thereby indicating the location of the immunoglobulin deposits by electron microscopy (*Fig. 3*). The second antibody may also be conjugated with electron dense gold particles instead of an enzyme. In EBA patients' tissue, immune



**Fig. 3.** Immunoelectron microscopy of a perilesional skin biopsy of a patient with EBA. The solid black arrow points to the IgG immune deposits which appear as a heavy, electron-dense band. Ig = immunoglobulin. LD = lamina densa. HK = human keratinocyte. TF = tonofilaments. Note that the IgG deposits are below the lamina densa leaving the lamina lucida unstained (hollow arrow)

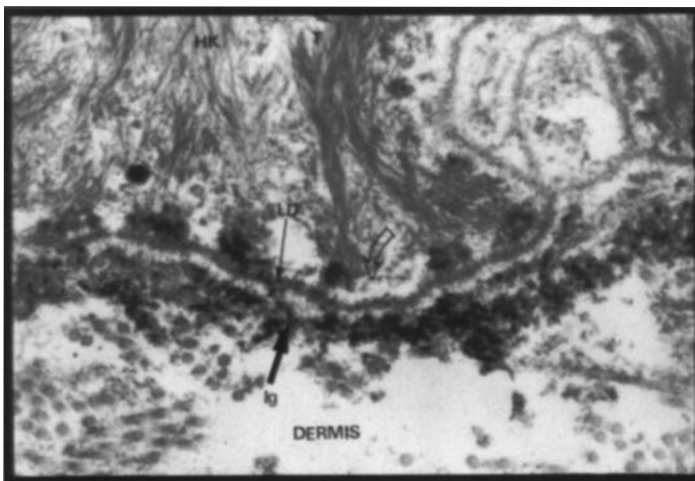
deposits are demonstrated within the sublamina densa zone of the BMZ (Nieboer et al. 1980; Yaoita et al. 1981). This localization is distinct from deposits in BP, which are higher up in the hemidesmosome area (Schaumburg et al. 1975) or lamina lucida and from CP where the antigen is confined to the lamina lucida (Domloge-Hultsch et al. 1994).

### Direct Salt Split Skin Immunofluorescence (SSSI)

This test is routine DIF performed on perilesional skin from patients that is fractured at the DEJ, through the lamina lucida zone by incubating the skin biopsy specimen with 1 M NaCl at 4°C for approximately 3 days (Woodley et al. 1983). The direct SSSI test uses fluorescein-conjugated anti-human IgG to label the IgG deposits in the salt-split skin. If the labeling antibody detects the IgG deposits on the dermal floor of the salt-split skin, the diagnosis of EBA is suggested (*Fig. 4*). In contrast, if the dermal floor is unlabeled and the fluorescent label is observed along the epidermal roof of the salt split skin, EBA is effectively ruled out and the diagnosis of BP is suggested (Gammon et al. 1990).

### Indirect SSSI

This test is designed to detect anti-BMZ autoantibodies in the serum of a patient. It is routine IIF performed on human skin substrate previously fractured



**Fig. 4.** Direct salt-split immunofluorescence microscopy of a perilesional skin biopsy showing IgG immune deposits remaining with the dermal floor and leaving the epidermis unstained

through the lamina lucida by incubation of the skin slices with 1 M NaCl. This fracture places the BP antigen on the epidermal side of the split and all other BMZ components on the dermal side. When normal human skin is fractured through the DEJ by this method and used as a substrate for IIF to test the sera of patients with primary autoimmune bullous diseases (such as BP and EBA), the EBA autoantibodies bind to the dermal floor of the salt-split skin substrate, while BP autoantibodies bind to the epidermal roof (Gammon et al. 1984a). This test may be helpful in distinguishing rapidly EBA patients from BP patients. This is particularly important because EBA and BP may have clinical, histological and immunological parameters that are identical.

While the SSSI can be helpful in distinguishing autoantibodies in patients' sera and making the diagnosis of either BP or EBA, it should be noted that the dermal pattern of staining is no longer considered specific for EBA. In one study, a combined dermal-epidermal staining seen in 5% of 98 BP sera and 45% of 23 CP sera (Ghohestani et al. 1997). All of the EBA sera (10 patients), however, only showed dermal staining. Nevertheless, an exclusive dermal staining pattern using SSSI assay may be seen in several other subepidermal bullous diseases besides EBA. It may be seen in (1) bullous SLE (Gammon and Briggaman 1993), (2) a BP-like disease in which the patients have autoantibodies to a 105 kDa lamina lucida glycoprotein that is unrelated to laminin-5 (Chan et al. 1993), (3) a subset of CP patients who have autoantibodies against laminin-5, a noncollagenous component of anchoring filaments within lamina lucida compartment (Domloge-Hultsch et al. 1994) and (4) in a newly described subepidermal bullous disease associated with a 200 kDa lower lamina lucida antigen designed "anti-p200 pemphigoid" (Mascaro et al. 2000). In contrast to EBA, the bullous diseases with autoantibodies to the novel p105 protein or the p 200 kDa protein respond promptly to topical or systemic corticosteroid treatment, and the lesions heal without scarring or milia formation.

About 50% to 80% of the EBA patients have both tissue-bound and circulating anti-BMZ antibodies (Gammon and Briggaman 1993). Indirect SSSI test seems to be more sensitive than IIF performed on intact human skin showing higher antibody titers (Gammon et al. 1982; Woodley et al. 1984). At times, no circulating autoantibodies can be demonstrated by either routine IIF or indirect SSSI. In these cases, direct immunoelectron microscopy is needed to make a diagnosis of EBA (Hoang-Xuan et al. 1997).

### **Western Immunoblotting**

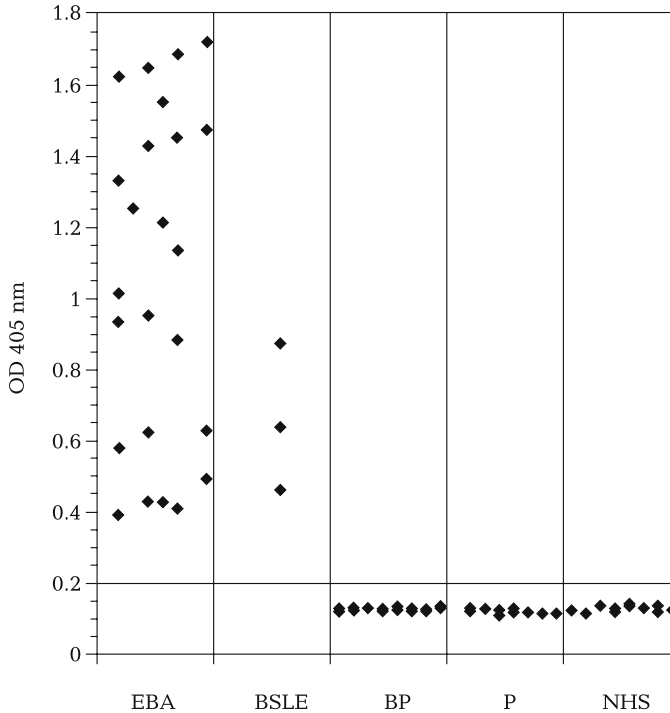
Western blot analysis can be useful in making the diagnosis of EBA. In a Western blot, extracts of crude protein from skin basement membrane, amnion or cell culture may be used and subjected to SDS-PAGE and electrophoretically transferred to a membrane. Alternatively, recombinant type VII collagen or type VII collagen purified by biochemical methods can be used as substrate



on Western blots. The membrane with immobilized proteins are incubated with EBA and control sera. EBA autoantibodies bind to either a 290 kDa band and/or a 145 kDa in Western blots of human skin basement membrane proteins, whereas sera from all other primary blistering diseases will not (Woodley et al. 1984). These proteins represent the full-length alpha chain of type VII collagen or its amino-terminal globular NC1 domain, the most frequent site of its antigenic epitopes of EBA and bullous SLE autoantibodies, respectively (Woodley et al, 1984; Gammon et al. 1993; Lapiere et al. 1993; Jones et al. 1995). Western immunoblot analysis using type VII collagen extracted from skin cells or from conditioned medium of skin cells may be difficult because of the background non-specific labeling of unrelated proteins when dealing with low titer sera. Alternatively, our recent success in producing unlimited supply of both purified recombinant full-length type VII collagen and the NC1 domain in the stably transfected human cells allows us to use purified recombinant proteins as substrate for Western analysis with virtually no non-specific background labeling (Chen et al. 1997a, 2000a).

### **Enzyme-Linked Immunosorbent Assay (ELISA)**

Recently, Chen et al (1997b) have produced milligram quantities of recombinant purified posttranslationally modified NC1 in stably transfected human 293 cells and have used this NC1 to develop an ELISA for autoantibody detection in sera from EBA and bullous SLE patients (*Fig. 5*). In contrast to other techniques such as IEM, IIF and immunoblot analysis, the NC1-based ELISA has several advantages as a screening assay: 1) It is faster and more efficient than IEM, IIF and Western immunoblot analysis, and the ELISA requires only 10–20  $\mu$ l of serum. By storing batches of NC1-coated plates at  $-70^{\circ}\text{C}$  and using them as needed, the ELISA has an assay time of under 4 hrs. 2) It is easy to perform with a standardized technique. The complete reaction can be carried out in microtiter wells and a spectrophotometer reader allows quantitative measurement. 3) It is more sensitive than conventional IEM or IIF methods, which make it very useful for detecting low titer EBA sera. 4) By using a standard amount of NC1 to coat the wells, one can easily quantitate the anti-NC1 autoantibodies. 5) While other methods (IIF, IEM, immunoblot) are qualitative, the ELISA provides an OD number for direct comparisons of sera, and 6) the ELISA detects autoantibodies which recognize the tertiary and quaternary structure of antigen (conformational epitope), because the assay is performed under native conditions. In contrast, Western immunoblot analysis would not detect autoantibodies requiring a tertiary or quaternary structure of the antigen, because the procedure requires denaturation of proteins with SDS. Thus, the newly developed ELISA using recombinant NC1 is a sensitive, specific assay and a useful tool for rapidly screening EBA and BSLE sera.



**Fig. 5.** Scatter plot representation of ELISA results using recombinant NC1. Patient and control sera (as indicated along the horizontal axis) (1:200 dilution) were incubated with immobilized purified recombinant NC1 domain of type VII collagen and the bound antibodies were detected with an alkaline-phosphatase-conjugated antibody against human IgG whole molecule. Each sample was run in triplicate and the points plotted on this graph is the average of the OD 405 obtained from study sera. Similar results were obtained in three other independent studies

### IIF Microscopy Using Substrate Deficient in Basement Membrane Molecules

IIF using a panel of skin samples which lack specific BMZ molecules, taken from subjects with inherited EB, is a relatively simple and useful tool to identify target antigens in immunobullous disorders. This IIF test is performed on a skin substrate from the most severe Hallopeau-Siemens type of recessive DEB patients, which is deficient in type VII collagen. In this test there was a lack of antibody labeling of the type VII collagen-deficient skin as compared to positive labeling on normal skin or BP180- and laminin-5 deficient skin when EBA sera were used (Vodegel et al. 1998; Jonkman et al. 2000). However, the major limitation of this technique is the availability of suitable skin samples from subjects with EB.

### **Suction Split Immunofluorescence**

This test is similar to the SSSI staining assays, but instead of making the separation between the BMZ layers *in vitro* using 1 molar salt, it is made *in vivo* by suction. This method would be faster than salt-split skin substrate methods because the DEJ fracture can be accomplished in a matter of hours instead of days (Feliciani et al. 1998).

### **Fluorescent Overlay Antigen Mapping (FOAM)**

This technique is not widely available. However, it may be less expensive and more rapid than ultrastructural studies using IEM. FOAM distinguishes between IgG deposits above the lamina densa as in BP, from those below, as in EBA (De Jong et al. 1996; Kazama et al. 1998). This technique demonstrates different antigens of the BMZ component by staining the perilesional skin of autoimmune skin disease patients with monoclonal antibodies to known BMZ components such as type VII collagen and staining the immune deposits with different markers. Using computer analysis, the stained BMZ antigens and the stained immune deposits are overlaid one on the other, with or without using confocal laser scanning microscopy, thereby giving the relation of the immune deposits to the BMZ structures.

As we reviewed the various complex diagnostic options, we were motivated to suggest slight modifications in the diagnostic criteria of Yaoita et al. (1981) to the following:

1. A bullous disorder within the clinical spectrum described.
2. Histology showing a subepidermal blister.
3. Deposition of IgG deposits at the DEJ in perilesional skin, i.e., a positive DIF of patient's skin
4. The IgG deposits are localized to the lower lamina densa and/or sublamina densa zone of the DEJ as demonstrated by direct IEM on perilesional skin.
5. Alternatives for item 4 are: indirect or direct salt-split or vacuum split skin immunofluorescence\*, IIF using substrate deficient in basement membrane molecules, Western blotting, FOAM, and ELISA.

## **Therapy**

EBA is a chronic disease which is often refractory to treatment. EBA persists for at least several years in most patients and remission is unpredictable

---

\* When the EBA presentation is CP-like, the SSSI assay may not be sufficient to differentiate from true CP as it may show dermal deposition of antibodies in both diseases. In this instance, IEM is needed to distinguish the two diseases.

(Gammon and Briggaman 1993). Because it is an incurable disease without a consistent therapeutic modality, supportive therapy is most important, including detailed and early wound care and antibiotic treatment for local skin infections. Exacerbating factors such as trauma, the use of harsh soaps, and sun exposure should be avoided (Jappe et al. 2000). The patient should be educated to recognize localized skin infections and to seek medical care and antibiotic therapy promptly when this occurs.

### **Colchicine**

Because the responses to therapy are not consistent, the clinician often needs to take an empirical approach to therapy. It is reasonable for the clinician to try therapies in the order of using those therapies with the best side effect profile first. For example, there are several reports of patients with the classic and inflammatory phenotypes of EBA who responded to high doses of colchicine (Megahed and Scharfetter-Kochanek 1994; Cunningham et al. 1996). Colchicine is a good first-line drug because its side effects are relatively benign compared with other therapeutic choices. One problem with colchicine is that many patients with EBA have inflammatory bowel disease, and the predictable, dose-dependent, gastrointestinal side effects of colchicine makes it unusable in these patients. Even patients without clinically defined inflammatory bowel disease may not be able to tolerate even the lowest doses of colchicine without suffering abdominal cramping and diarrhea. It is unclear how colchicine works in EBA, but there is evidence the colchicine can decrease the production of antibodies by plasma cells and may also inhibit antigen presenting cells from presenting antigen to T cells. Therefore, the drug may work at two levels – the inhibition of the initiation of autoimmunity and the inhibition of autoantibody production. Our experience has been that the patients who do the best on colchicine are those who are able to get up to 1.5–2.5 mg per day. We go up slowly starting at 0.4–0.6 mg per day and then double the dose every two weeks until the patient experiences gastrointestinal side-effects. We then back-off by one tablet with the hope of achieving the highest tolerable dose for the patient.

### **Immunosuppressive Agents**

EBA patients, especially with the classical mechanobullous form, are often refractory to high doses of systemic glucocorticoids, azathioprine, methotrexate, and cyclophosphamide (Woodley et al. 1998). These agents may be somewhat helpful in controlling EBA when it appears as an inflammatory BP-like disease. Childhood EBA, a rare subset which is usually the inflammatory BP-like form of the disease, appears to respond more favorably to dapsone and prednisone than adult patients with EBA (Callot-Mellot et al. 1997).

### **Cyclosporin A**

Cyclosporin, an immunosuppressive agent that is mainly used in organ transplantation, has been shown to be helpful in a number of EBA patients (Connolly and Sander 1987; Crow et al. 1988). High doses of cyclosporin (> 6mg/kg) are needed. Cyclosporin has a number of significant side-effects with its predictable nephrotoxicity being the most significant. The nephrotoxicity is time and dose dependent. Because EBA patients tend to be elderly with preexisting renal compromise due to age and because high doses of cyclosporine are needed to control the disease, the usage of cyclosporin in EBA is often problematic and limited. In most situations, the long-term toxicity of the drug makes its use warranted only as a last-resort measure.

### **High Dose Immunoglobulins**

EBA has also been reported to response to high and low dose intravenous immunoglobulins (Kofler et al. 1997), plasmapheresis in conjunction with immunoglobulins (Furue et al. 1986) and extracorporeal photochemotherapy (Gordon et al. 1997; Camara et al. 1999). Gammon and Briggaman (1993) reported having little or no success with phenytoin, gold, plasmapheresis, vitamin E or dapsone. Unfortunately, recent treatment trials with mycophenolate mofetil combined with autologous keratinocyte grafting were reported to be unsuccessful (Schattenkirchner et al. 1999).

### **Photopheresis**

Photopheresis has been used in Sezary syndrome, mycosis fungoides, and a variety of autoimmune bullous diseases (Rook et al. 1990). One EBA patient in a life-threatening situation responded dramatically to photopheresis (Miller et al. 1995). In three other EBA patients, photopheresis improved some clinical parameters and significantly lengthened the suction blistering times of the patients, suggesting an improvement in their dermal-epidermal adherence (Gordon et al. 1997). All three patients also had reductions of anti-type VII collagen antibodies in their blood.

### **Immune Adsorption**

An unexplored and potentially productive approach to treatment that is now feasible is the utilization of fragments of recombinant type VII collagen to absorb autoantibodies from patients' sera or plasma. Previous studies have identified autoreactive epitopes within NC-1 domain. Peptides synthesized from these epitopes have been coupled to affinity matrices and shown to absorb

autoantibodies to type VII collagen from patients' sera (Gammon et al. 1993). The recent method of Chen et al (1997a) for producing milligram quantities of recombinant NC1 domain in human 293 cells makes affinity plasmapheresis of patients a feasible treatment approach. The rationale for this approach, particularly in patients with the inflammatory phenotype, is supported by the relationship between autoantibody levels and the development of inflammation at the DEJ in EBA and bullous SLE.

## References

- Ackerman AB, Chongchitnant N, Sanchez J, Guo Y, Benin B, Reichel M, Randall MB (1997) Histologic diagnosis of inflammatory skin diseases: an algorithmic method based on pattern analysis. 2nd ed. Williams & Wilkins, Baltimore
- Arpey CJ, Elewski BE, Moritz DK, Gammon WR (1991) Childhood epidermolysis bullosa acquisita: report of three cases and review of literature. *J Am Acad Dermatol* 24: 706-714
- Bauer JW, Schaeppli H, Metze D, Muss W, Pohla-Gubo G, Hametner R, Ruckhofer J, Grabner G, Hintner H (1999) Ocular involvement in IgA-epidermolysis bullosa acquisita. *Br J Dermatol* 141: 887-892
- Bernard P, Vaillant L, Labeille B, Bedane C, Arbeille B, Denoeux JP, Lorette G, Bonnetblanc JM, Prost C (1995) Incidence and distribution of subepidermal autoimmune bullous skin diseases in three French regions. *Arch Dermatol* 131: 48-52
- Borradori L, Caldwell JB, Briggaman RA, Burr CE, Gammon WR, James WD, Yancey KB (1995) Passive transfer of autoantibodies from a patient with mutilating epidermolysis bullosa acquisita induces specific alterations in the skin of neonatal mice. *Arch Dermatol* 131: 590-595
- Briggaman RA, Wheeler CE Jr (1975) The epidermal-dermal junction. *J Invest Dermatol* 65: 71-84
- Briggaman RA, Schechter NM, Fraki J, Lazarus GS (1980) Degradation of the epidermal-dermal junction by proteolytic enzymes from human skin and human polymorphonuclear leukocytes. *J Exp Med* 160: 1027-1042
- Bruckner-Tuderman L, Nilssen O, Zimmermann DR, Dours-Zimmermann MT, Kalinke DU, Gedde-Dahl T Jr, Winberg JO (1995) Immunohistochemical and mutation analyses demonstrate that procollagen VII is processed to collagen VII through removal of the NC-2 domain. *J Cell Biol* 131: 551-559
- Burgeson RE (1993) Type VII collagen, anchoring fibrils, and epidermolysis bullosa. *J Invest Dermatol* 101: 252-255
- Callot-Mellot C, Bodemer C, Caux F, Bourgault-Villada I, Fraitag S, Goudie G, Heller M, de Prost Y, Prost C (1997) Epidermolysis bullosa aquisita in childhood. *Arch of Dermatol* 133: 1122-1126
- Camara A, Becherel PA, Bussel A, Lagrange S, Chosidow O, Joly P, Piette JC, Frances C (1999) Resistant acquired bullous epidermolysis with severe ocular involvement: the success of extracorporeal photochemotherapy. *Annal Dermatol Venereol* 126: 612-615
- Chan LS, Fine JD, Briggaman RA, Woodley DT, Hammerberg C, Drugge RJ, Cooper KD (1993) Identification and partial characterization of a novel 105-kDalton lower lamina lucida autoantigen associated with a novel immune-mediated subepidermal blistering disease. *J Invest Dermatol* 101: 262-267
- Chan LS, Woodley DT (1996) Pemphigoid: Bullous and cicatricial. In *Current Therapy in Allergy, Immunology and Rheumatology*, 5th ed, edited by LM Lichtenstein, AS Fauci Mosby, St Louis, p 93
- Chan LS, Vanderlugt CJ, Hashimoto T, Nishikawa T, Zones JJ, Black MM, Wojnarowask F, Stevens SR, Chen M, Failley JA, Miller SD, Gordon KB (1998) Epitope spreading: Lessons from autoimmune skin diseases. *J Invest Dermatol* 110: 103-109

- Chen D, Welsh EA, Woodley DT, Wynn KC, Briggaman RA, Kim YH (1992): Passive transfer of autoantibodies of epidermolysis bullosa acquisita antibody into xenotransduced SCID mice with human graft. *J Invest Dermatol* 98: 589
- Chen M, Marinkovich MP, Veis A, O'Toole EA, Rao CN, Cai XY, Woodley DT (1997a) Interactions of the amino-terminal noncollagenous (NC1) domain of type VII collagen with extracellular matrix components: a potential role in epidermal-dermal adherence in human skin. *J Biol Chem* 272: 14516–14522
- Chen M, Chan LS, Cai X, O'Toole EA, Sample JC, Woodley DT (1997b) Development of an ELISA for rapid detection of anti-type VII collagen autoantibodies in epidermolysis bullosa acquisita. *J Invest Dermatol* 108: 68–72
- Chen M, O'Toole EA, Sanghavi J, Mahmud N, Kelleher D, and Woodley DT (1997c) Type VII collagen exists in human intestine and serves as an antigenic target in patients with inflammatory bowel disease. *J Invest Dermatol* 108: 542
- Chen M, Marinkovich MP, Jones JC, O'Toole E, Li YY, Woodley DT (1999) NC1 domain of type VII collagen binds to the beta3 chain of laminin 5 via a unique subdomain within the fibronectin-like repeats. *J Invest Dermatol* 112: 177–183
- Chen M, Tahk SH, Costa FK, Kasahara N, Woodley DT (2000a) Recombinant expression of full-length type VII collagen alpha chain: structural and functional characterization and implication for gene therapy. *J Invest Dermatol* 114: 756
- Chen M, Wang J, Tahk SH and Woodley DT (2000b) Noncollagenous (NC2) domain of type VII collagen mediates the antiparallel-dimer formation of type VII collagen and constitutes a new antigenic epitope for EBA and BSLE autoantibodies. *J Invest Dermatol* 114: 766
- Choi GS, Lee ES, Kim SC, Lee S (1998) Epidermolysis bullosa aquisita localized to the face. *J Dermatol* 25: 19–22
- Cho HJ, Lee IJ, Kim SC (1998) Complement fixing abilities and IgG subclasses of autoantibodies in epidermolysis bullosa acquisita. *Yonsei Medical Journal* 39: 339–344
- Christiano AM, Greenspan DS, Lee S, and Uitto, J (1994) Cloning of human type VII collagen: complete primary sequence of the alpha 1(VII) chain and identification of intragenic polymorphisms. *J Biol Chem* 269: 20256–20262
- Connolly SM, Sander HM (1987) Treatment of epidermolysis bullosa acquisita with cyclosporin. *J Am Acad Dermatol* 16: 890
- Crow LL, Finkle JP, Gammon WR, Woodley DT (1988) Cleaning of epidermolysis bullosa acquisita on cyclosporin A. *J Am Acad Dermatol* 19: 937–942
- Cunningham BB, Kirchmann TT, Woodley DT (1996) Colchicine for epidermolysis bullosa (EBA). *J Am Acad Dermatol* 34: 781–784
- Dahl MG (1979) Epidermolysis bullosa acquisita – a sign of cicatricial pemphigoid? *Br J Dermatol* 101: 475–483
- De Jong MCJM, Bruins S, Heeres K, Jonkman MF, Nieboer C, Boorsma DM, Pas HH, van der Meer JB (1996) Bullous pemphigoid and epidermolysis bullosa acquisita: Differentiation by fluorescence overlay antigen mapping. *Arch Dermatol* 132: 151–157
- Domloge-Hultsch N, Anhalt GJ, Gammon WR, Lazarova Z, Briggaman R, Welch M, Jabs DA, Huff C, Yancey KB (1994) Antiepiligrin cicatricial pemphigoid: A subepithelial bullous disorder. *Arch Dermatol* 130: 1521–1529
- Edwards S, Wakelin SH, Wojnarowska F, Marsden RA, Kirtschig G, Bhogal B, Black MM (1998) Bullous pemphigoid and epidermolysis bullosa acquisita: presentation, prognosis, and immunopathology in 11 children. *Pediatr Dermatol* 15: 184–190
- Elliott GT (1895) Two cases of epidermolysis bullosa. *J Cutan Genitourin Dis* 13: 10
- Epstein JH, Tuffanelli DL, Epstein WL (1973) Cutaneous changes in the porphyrias. A microscopic study. *Arch Dermatol* 107: 689–698
- Feliciani C, Di Muzio M, Mohammad Pour S, Allegretti T, Amerio P, Toto P, Coscione G, Proietto G, Amerio P (1998) 'Suction split' as a routine method to differentiate epidermolysis bullosa acquisita from bullous pemphigoid. *J Eur Acad Dermatol Venereol* 10: 243–247
- Fine JD, Tyring S, Gammon WR (1989) The presence of intra-lamina lucida blister formation in epidermolysis bullosa acquisita: Possible role of leukocytes. *J Invest Dermatol* 92: 27
- Furue M, Iwata M, Yoon H-I, Kubota Y, Ohto H, Kawashima M, Tsuchida T, Oohara K, Tamaki K, Kukita A (1986) Epidermolysis bullosa acquisita: clinical response to plasma

- exchange therapy and circulating anti-BMZ antibody titer. *J Am Acad Dermatol* 14: 873–878
- Gammon WR, Briggaman RA, Wheeler CE Jr (1982) Epidermolysis bullosa acquisita presenting as an inflammatory bullous disease. *J Am Acad Dermatol* 7: 382–387
- Gammon WR, Briggaman RA, Inman AO, Queen LL, Wheeler CE (1984a) Differentiating antilamina lucida and antisublamina densa anti-BMZ antibodies by indirect immunofluorescence on 1.0 M sodium chloride-separated skin. *J Invest Dermatol* 82: 139–144
- Gammon WR, Briggaman RA, Woodley DT, Heald PW, Wheeler CE Jr (1984b) Epidermolysis bullosa acquisita – a pemphigoid like disease. *J Am Acad Dermatol* 11: 820–832
- Gammon WR, Woodley DT, Dole KC, Briggaman RA (1985) Evidence that basement membrane zone antibodies in bullous eruption of systemic lupus erythematosus recognize epidermolysis bullosa acquisita autoantigens. *J Invest Dermatol* 84: 472–476
- Gammon WR (1988a) Epidermolysis bullosa acquisita. *Semin Dermatol* 7: 218–224
- Gammon WR, Heise ER, Burke WA, Fine JD, Woodley DT, Briggaman RA (1988b) Increased frequency of HLA-DR2 in patients with autoantibodies to epidermolysis bullosa acquisita antigen: Evidence that the expression of autoimmunity to type VII collagen is HLA class II allele associated. *J Invest Dermatol* 91: 228–232
- Gammon WR, Kowalewski C, Chorzelski TP, Kumar V, Briggaman RA, Beutner EH (1990) Direct immunofluorescence studies of sodium chloride-separated skin in the differential diagnosis of bullous pemphigoid and epidermolysis bullosa acquisita. *J Am Acad Dermatol* 22: 664–670
- Gammon WR, Briggaman RA (1993) Epidermolysis bullosa acquisita and bullous systemic lupus erythematosus: disease of autoimmunity to type VII collagen. *Dermatol Clin* 11: 535–547
- Gammon WR, Murrell DF, Jenison MW, Padilla KM, Prisyanyh PS, Jones DA, Briggaman RA, and Hunt SW III (1993) Autoantibodies to type VII collagen recognize epitopes in a fibronectin-like region of the noncollagenous (NC1) domain. *J Invest Dermatol* 100: 618–622
- Ghohestani RF, Nicolas JF, Roussele P, Claudy AL (1997) Diagnostic value of indirect immunofluorescence on sodium chloride-split skin in differential diagnosis of subepidermal autoimmune bullous dermatoses. *Arch Dermatol* 133: 1102–1107
- Gordon KB, Chan LS, Woodley DT (1997) Treatment of refractory epidermolysis bullosa acquisita with extracorporeal photochemotherapy. *Br J Dermatol* 136: 415–420
- Harman KE, Whittam LR, Wakelin SH, Black MM (1998) Severe, refractory epidermolysis bullosa acquisita complicated by an oesophageal stricture responding to intravenous immune globulin. *Br J Dermatol* 139: 1126–1127
- Hashimoto T, Ishiko A, Shimizu H, Tanaka T, Dodd HJ, Bhogal BS, Black MM, Nishikawa T (1996) A case of linear IgA bullous dermatosis with IgA anti-type VII collagen autoantibodies. *Br J Dermatol* 134: 336–339
- Hoang-Xuan T, Robin H, Heller M, Caux F, Prost C (1997) Epidermolysis bullosa acquisita diagnosed by direct immunoelectron microscopy of the conjunctiva. *Ophthalmology* 104: 1414–1420
- Jappe U, Zillikens D, Bonnekok B, Gollnick H (2000) Epidermolysis bullosa acquisita with ultraviolet radiation sensitivity. *Br J Dermatol* 142: 517–520
- Joly P, Ruto F, Thomine E, Delpech A, Balguerie X, Tron F, Lauret P (1993) Brunsting-Perry Cicatricial Bullous Pemphigoid: a clinical variant of localized acquired epidermolysis bullosa? *J Am Acad Dermatol* 28: 89–92
- Jones DA, Hunt SW III, Prisyanyh PS, Briggaman RA, Gammon WR (1995) Immunodominant autoepitopes of type VII collagen are short, paired peptide sequences within the fibronectin type III homology region of the noncollagenous (NC1) domain. *J Invest Dermatol* 104: 231–235
- Jonkman MF, Schuur J, Dijk F, Heeres K, de Jong MC, van der Meer JB, Yancey KB, Pas HH (2000) Inflammatory variant of epidermolysis bullosa acquisita with IgG autoantibodies against type VII collagen and laminin  $\alpha_3$ . *Arch Dermatol* 136: 227–231
- Kazama T, Yamamoto Y, Hashimoto T, Komai A, Ito M (1998) Application of confocal laser scanning microscopy to differential diagnosis of bullous pemphigoid and epidermolysis bullosa acquisita. *Br J Dermatol* 138: 593–601



- Kofler H, Wambacher-Gasser B, Topar G, Weinlich G, Schuler G, Hintner H, Romani N, Fritsch P (1997) Intravenous immunoglobulin treatment in therapy – resistant epidermolysis bullosa acquisita. *J Am Acad Dermatol* 36: 331–335
- Kurzhals G, Stolz W, Meurer M, Kunze J, Braun-Falco O, Krieg T (1991) Acquired epidermolysis bullosa with the clinical feature of Brunsting-Perry cicatricial bullous pemphigoid. *Arch Dermatol* 127: 391–395
- Kushniruk W (1973) The immunopathology of epidermolysis bullosa acquisita. *Can Med Assoc J* 108: 1143–1146
- Lapiere JC, Woodley DT, Parente MG, Iwasaki T, Wynn KC, Christiano AM, Uitto J (1993) Epitope mapping of type VII collagen: identification of discrete peptide sequences recognized by sera from patients with acquired epidermolysis bullosa. *J Clin Invest* 92: 1831–1839
- Lapiere JC, Chen JD, Iwasaki T, Hu L, Uitto J, Woodley DT (1994) Type VII collagen specifically binds fibronectin via a unique subdomain within the collagenous triple helix. *J Invest Dermatol* 103: 637–641
- Lee CW (1998) Prevalences of subacute cutaneous lupus erythematosus and epidermolysis bullosa acquisita among Korean/oriental populations. *Dermatology* 197: 187
- Lee CW (2000) Serum IgA autoantibodies in patients with epidermolysis bullosa acquisita: A high frequency of detection. *Dermatology* 200: 83–84
- Lever WF, Schaumburg-Lever G (1990) Congenital disease (genodermatoses). In *Histopathology of the skin*, edited by WF Lever, G Schaumburg-Lever. Philadelphia, Lippincott, p 78
- Lohi J, Leivo I, Tani T, Kiviluoto T, Kivilaakso E, Burgeson RE, Virtanen I (1996) Laminins, tenascin and type VII collagen in colorectal mucosa. *Histochem J* 28: 431–440
- Mascaro JM Jr, Zillikens D, Giudice GJ, Caux F, Fleming MG, Katz HM, Diaz LA (2000) A subepidermal bullous eruption associated with IgG autoantibodies to a 200 kd dermal antigen: The first case report from the United States. *J Am Acad Dermatol* 42: 309–315
- Megahed M, Scharfetter-Kochanek K (1994) Epidermolysis bullosa acquisita-successful treatment with colchicine. *Arch Dermatol Res* 286: 35–46
- Miller JK, Stricklin GP, Fine JD, King LE, Arzubaiaga MC, Ellis DL (1995) Remission of severe epidermolysis bullosa acquisita induced by extracorporeal photochemotherapy. *Br J Dermatol* 133: 467–471
- Nieboer C, Boorsma DM, Woerdeman MJ, Kalsbeek GL (1980) Epidermolysis bullosa acquisita: immunofluorescence, electron microscopic and immunoelectron microscopic studies in four patients. *Br J Dermatol* 102: 383–392
- Paller AS, Queen LL, Woodley DT, Lane AT, Gammon WR, Briggaman RA (1986) Organ specific, phylogenetic and ontogenetic distribution of the epidermolysis bullosa acquisita antigen. *J Invest Dermatol* 86: 376–379
- Park SB, Cho KH, Youn JL, Hwang DH, Kim SC, Chung JH (1997) Epidermolysis bullosa acquisita in childhood – a case mimicking chronic bullous dermatosis of childhood. *Clin Exp Dermatol* 22: 220–222
- Ray TL, Levine JB, Weiss W, Ward PA (1982) Epidermolysis bullosa acquisita and inflammatory bowel disease. *J Am Acad Dermatol* 6: 242–252
- Richter BJ, McNutt NS (1979) The spectrum of epidermolysis bullosa acquisita. *Arch Dermatol* 115: 1325–1328
- Roenigk HH, Ryan JG, Bergfeld WF (1971) Epidermolysis bullosa acquisita: Report of three cases and review of all published cases. *Arch Dermatol* 103: 1–10
- Rook AH, Jegasothy BV, Heald P, Nahass GT, Ditre C, Witmer WK, Lazarus GS, Edelson RL (1990) Extracorporeal photochemotherapy for drug-resistant pemphigus vulgaris. *Ann Intern Med* 112: 303–305
- Rusenko KW, Gammon WR, and Briggaman RA (1989) Type VII collagen is the antigen recognized by IgA anti-sub lamina densa autoantibodies. *J Invest Dermatol* 92: 510 Abstract
- Sakai LY, Keene DR, Morris NP, Burgeson RE (1986) Type VII collagen is a major structural component of anchoring fibrils. *J Cell Biol* 103: 1577–1586
- Schattenkirchner S, Eming S, Hunzelmann N, Krieg T, Smola H (1999) Treatment of epidermolysis bullosa acquisita with mycophenolate mofetil and autologous keratinocyte grafting. *Br J Dermatol* 141: 932–933

- Schaumburg-Lever G, Rule A, Schmidt-Ullrich B, Lever WF (1975) Ultrastructural localization of in vivo bound immunoglobulins in bullous pemphigoid – A preliminary report. *J Invest Dermatol* 64: 47–49
- Stewart MI, Woodley DT, Briggaman RA (1991) Acquired epidermolysis bullosa and associated symptomatic esophageal webs. *Arch Dermatol* 127: 373–377
- Tanaka H, Ishida-Yamamoto A, Hashimoto T (1997) A novel variant of acquired epidermolysis bullosa with autoantibodies against the central triple-helical domain of type VII collagen. *Lab Invest* 77: 623–632
- Taniuchi K, Inaoki M, Nishimura Y, Mori T, Takehara K (1997) Nonscarring inflammatory epidermolysis bullosa acquisita with esophageal involvement and linear IgG deposits. *J Am Acad Dermatol* 36: 320–322
- Tokuda Y, Amagai M, Yaoita H, Kawachi S, Ito T, Matsuyama I, Tsuchiya S, Saida T (1998) A case of inflammatory variant of epidermolysis bullosa acquisita: Chronic bullous dermatosis associated with non scarring mucosal blisters and circulating IgG anti-type-VII-collagen antibody. *Dermatology* 197: 58–61
- Uitto J, Christiano AM (1994) Molecular basis for the dystrophic forms of epidermolysis bullosa: mutations in the type VII collagen gene. *Arch Dermatol Res* 287: 16–22
- Vodegel RM, Kiss M, De Jong MCJM, Pas HH, Altmayer A, Molnar K, Husz S, Van Der Meer JB, Jonkman MF (1998) The use of skin substrate deficient in basement membrane molecules for the diagnosis of subepidermal autoimmune bullous disease. *Eur J Dermatol* 8: 83–85
- Wieme N, Lambert J, Moerman M, Geerts ML, Temmerman L, Naeyaert JM (1999) Epidermolysis bullosa acquisita with combined features of bullous pemphigoid and cicatricial pemphigoid. *Dermatology* 198: 310–313
- Woodley DT, Sauder D, Talley MJ, Silver M, Grotendorst G, Qwarnstrom E (1983) Localization of basement membrane components after DEJ separation. *J Invest Dermatol* 81: 149–153
- Woodley DT, Briggaman RA, O'Keefe EJ, Inman AO, Queen LL, Gammon WR (1984) Identification of the skin basement-membrane autoantigen in epidermolysis bullosa acquisita. *N Engl J Med* 310: 1007–1015
- Woodley DT, O'Keefe EJ, Reese MJ, Mechanic GL, Briggaman RA, Gammon WR (1986) Epidermolysis bullosa acquisita antigen, a new major component of cutaneous basement membrane, is a glycoprotein with collagenous domains. *J Invest Dermatol* 86: 668–672
- Woodley DT (1988) Epidermolysis bullosa acquisita. *Prog Dermatol* 22: 1
- Woodley DT, Burgeson RE, Lunstrum G, Bruckner-Tuderman L, Reese MJ, Briggaman RA (1988) The epidermolysis bullosa acquisita antigen is the globular carboxyl terminus of type VII procollagen. *J Clin Invest* 81: 683–687
- Woodley DT, Gammon WR, Briggaman RA (1998) Epidermolysis bullosa acquisita. In: Fitzpatrick TB, Eisen AZ, Wolff K, Freedberg IM, Austen KF, editors. *Dermatology in general medicine*. 4th ed. Vols. I–II. McGraw-Hill, New York, 702–709
- Yancey KB. Cicatricial pemphigoid. In: Fitzpatrick TB, Eisen AZ, Wolff K, Freedberg IM, Austen KF (1998) *Dermatology in general medicine*. 4th ed. Vols. I–II. McGraw-Hill, New York, Inc., pp 674–679
- Yaoita H, Briggaman A, Lawley TJ, Provost TT, Katz SI (1981) Epidermolysis bullosa acquisita: Ultrastructural and immunological studies. *J Invest Dermatol* 76: 288–292
- Zillikens D, Wever S, Roth A, Hashimoto T, Brocker EB (1995) Incidence of autoimmune subepidermal blistering dermatoses in a region of central Germany. *Arch Dermatol* 131: 957–958

# 4 Scleroderma

## 4.1 Localized Scleroderma

*Catherine H. Orteu and Jan P. Dutz*

### Introduction

Localized scleroderma (LS) or morphea encompasses a group of disorders characterized by delimited and localized inflammatory sclerosis (thickening) and fibrosis of the skin, subcutaneous tissue, fascia and/or adjacent muscle. In contrast to systemic sclerosis, Raynaud's phenomenon, acrosclerosis and internal organ involvement do not usually occur. Morphea may be divided into 5 subtypes: plaque, generalized, bullous, linear and deep, based on the extent, form and depth of cutaneous sclerosis (Peterson et al. 1995). These subtypes frequently occur together in the same patient. Although morphea is rarely life threatening, significant morbidity and disability occur, particularly in the linear and deep forms.

### Epidemiology

Most studies suggest that morphea is commoner in women, with female to male ratios of between 6 and 2.6:1 (Christianson et al. 1956; Jablonska 1975b; Peterson et al. 1997; Silman et al. 1988). This female preponderance may be less marked in the linear group, in which ratios of 1:1 (Peterson et al. 1997) to 4:1 (Falanga et al. 1986) have been documented. The prevalence of morphea is not absolutely clear. A UK population based study in 1986, suggested prevalence rates of 13 and 48 per million in adult males and females respectively, with annual incidence rates of 1 and 6 per million (Silman et al. 1988). A second study, conducted over a 30 year period (1960–1993) by Peterson et al (1997) in Olmsted County, USA, revealed 82 cases, an overall incidence of 2.7/100 000/year. Prevalence was estimated at 0.05% at age 18 years and at

0.22% at age 80 years. Interestingly, a progressive increase in the incidence of plaque morphea was noted over the 30-year period. In this study, plaque morphea was the commonest subtype (56% of cases), followed in order of frequency by linear (20%), generalized (13%), and deep (11%). Of the 11 patients with generalized morphea, 5 initially presented with morphea en plaque and progressed over 5 months to 3 years. Coexisting morphea subtypes occurred in 11% of patients.

In a large European referral-based series, Jablonska (1975b) found that plaque morphea was commoner in adults (28.5% of adult cases versus 15% for the linear group), and that linear forms were commoner in children (31.5% and 21.3% of childhood cases respectively). These data are corroborated by those of Peterson et al (1997): the mean age at onset of disease was 12.2 years in the linear group, 31.5 years in the plaque group, 39.9 years in the generalized group, and 45.1 years in the deep group. A recent retrospective analysis of 239 cases seen at an Italian referral center further confirmed these results: Children more commonly had linear or "mixed" linear and plaque-type forms of morphea (54/126 cases) than adults (16/113 cases) (Marzano et al. 2003).

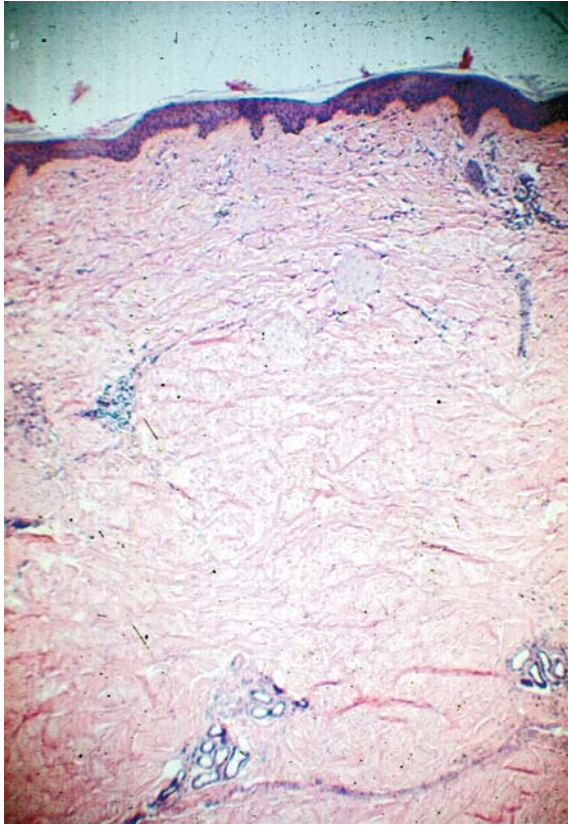
The duration of disease activity can vary from a few months up to 20–30 years, but is usually 3–5 years (Christianson et al. 1956). Plaque lesions generally resolve earlier than other subtypes. In the Olmsted county series, 50% of the patients had 50% softening (or more), or resolution by 3.8 years after diagnosis. There was 50% resolution at 2.7 years in the plaque group, at 5 years in generalized and linear groups and at 5.5 years in the deep group (Peterson et al. 1997). Relapse can occur and may be more frequent with generalized, deep and "mixed" forms (Marzano et al. 2003).

The exact relationship between LS and systemic sclerosis (SSc) remains unclear, however, it has been compared to that between discoid and systemic lupus erythematosus (Jablonska and Rodnan 1979). LS in the absence of Raynaud's phenomenon and acral sclerosis rarely if ever evolves into SSc. In larger series, transition from morphea to SSc, was reported in 2/235 (Christianson et al. 1956) and 4/253 (Jablonska 1975b) patients. Plaques of morphea can be seen in association with true SSc, and occurred in 9/135 patients in a Japanese study (Soma et al. 1993).

### Histopathology

Scleroderma derives from the Greek terms *skleros*, hard, and *derma*, skin and means hard skin. The different types of morphea do not differ in the elements of the histopathologic findings but rather with regards to severity and depth of involvement. Both early inflammatory and late sclerotic changes have been described. Most biopsies will show an intermediate picture (Figure 1).

In the early inflammatory phase, a moderately dense infiltrate of lymphocytes, plasma cells and histiocytes, and occasionally, mast cells has been described (O'Leary et al. 1957; Fleischmajer and Nedwich 1972). This infiltrate



**Fig. 1.** Biopsy specimen showing normal epidermis, sclerosis of the papillary dermis, thickened sclerotic collagen bundles and periadnexal inflammation (Original magnification x40)

may be found in the lower dermis, the subcutaneous fat and around eccrine glands. The reticular dermis shows thickened collagen bundles. Large areas of subcutaneous fat may be replaced by wavy fibers of newly formed collagen. Elastic fibers are preserved. The epidermis may be normal or slightly acanthotic (Morley et al. 1985). Electron microscopy shows the deposition of collagen fibrils with decreased diameter when compared to mature collagen (Fleischmajer and Perlish 1972). This is due, in part, to an increase in type III collagen (Perlish et al. 1988). Vascular changes are mild in the dermis and subdermis and consist of endothelial swelling and edema of vessel walls (O'Leary et al. 1957).

In the sclerotic stage, there is little inflammation. Collagen bundles in the reticular dermis are thickened, eosinophilic and oriented horizontally. Eccrine glands are entrapped by collagen, and thus appear higher in the dermis. Fewer blood vessels are seen within the thickened collagen. The fascia and striated

muscles underlying the lesions may likewise show fibrosis and sclerosis (Jaworsky 1997).

Although the histology of involved skin is almost identical in LS and SSc (Young and Barr 1985), a recent report has suggested that inflammatory changes are more prominent in morphea (Torres and Sanchez 1998). Sclerosis of the papillary dermis was noted in 10/32 morphea cases, but not in any of the 19 patients with SSc. Thus, simultaneous involvement of the superficial dermis with deep dermal changes may help differentiate localized from systemic scleroderma. Cases of morphea in which the sclerosis is limited to the superficial reticular dermis have also been described (McNiff et al. 1999). These changes were noted without any of the epidermal features of lichen sclerosus: epidermal thinning with vacuolar degeneration, lichenoid infiltrate or follicular plugging.

### Etiopathogenesis

The cause of morphea is unknown. Proposed triggers for the development of morphea have included infectious and other environmental factors. Localised scleroderma has been reported after trauma (Falanga et al. 1986; Yamanaka and Gibbs 1999), vaccination (Mork 1981; Drago et al. 1998), ischemic injury (McColl and Buchanan 1994) and radiation (Bleasel et al. 1999, Schaffer et al. 2000). Such triggers may have in common the generation of inflammatory and molecular "danger" signals that can activate the immune system and initiate fibrosis. There are rare cases of familial clustering suggesting a genetic component (Wuthrich et al. 1975). A possible association with Lyme borreliosis was proposed in 1985 (Aberer et al. 1985) but was not borne out by polymerase chain reaction analysis of affected tissues in North American patients (Dillon et al. 1995). Two possible explanations for the contradictory findings obtained in patients from Europe and Asia, and the USA have been offered (Weide et al. 2000): Either that *Borrelia burgdorferi* is not a causative agent for morphea, or that a subspecies present only in Europe and Asia, could cause morphea in a subset of patients.

Most studies on the pathophysiology of scleroderma focus on changes in patients with SSc. Here, we will focus on abnormalities detected in patients with LS. In both diseases three main themes have been pursued: vascular alterations, immune system activation and dysregulation, and changes in collagen metabolism and fibroblast biology. Abnormalities in these three areas are likely interrelated and contribute to the generation of the clinical phenotype.

#### *Vascular Activation in Morphea*

Endothelial swelling in early morphea lesions was first described by O'Leary et al (1957). Comparing biopsies from sclerotic centers, inflamed borders (lilac

rings) and adjacent, clinically normal skin, Kobayasi and Serup (1985) described three patterns of vascular changes. Uninvolved skin as well as thickened skin showed vascular wall thickening and basal lamina duplication with associated mast cell and histiocyte infiltration. In clinically inflamed lesions, the outer surfaces of pericytes were thickened, and lymphocytes and plasma cells were present. Pericyte hypertrophy was noted in clinically inflamed as well as in sclerotic lesions. There is evidence for generalized vascular activation: Jones et al (1996) noted low but increased levels of expression of the vascular adhesion molecules vascular cell adhesion molecule-1 (VCAM-1) and E-selectin on endothelium of uninvolved skin of morphea patients. More recently, increased serum levels of soluble VCAM-1 and E-selectin were found in a third of patients with generalized morphea and in approximately 10% of patients with linear and plaque type morphea (Yamane et al. 2000).

In addition to activation, the endothelium may be a primary site of damage in morphea: Endothelial cell apoptosis was noted in deep dermal vessels of 9/9 patients examined (Sgonc et al. 1996). Anti-endothelial cell antibody mediated antibody-dependent cytotoxicity has been suggested as a mechanism for the induction of endothelial cell death (Sgonc et al. 1996). Vascular damage by autologous complement activation has also been proposed as a mechanism of injury (Venneker et al. 1994). Lesional skin but not uninvolved skin showed decreased levels of endothelial membrane cofactor protein (MCP) and decay-accelerating factor (DAF) expression by immunohistochemistry. Both MCP and DAF inhibit the formation of the C3/C5 convertases of the classical and alternative pathways and it was argued that this local deficiency could increase the susceptibility of the endothelium to damage by autologous complement. Potential consequences of enhanced endothelial cell apoptosis include pro-coagulant activity, and localized release of pro-inflammatory cytokines such as IL-1 with subsequent enhanced adhesion molecule display (Stefanec 2000).

### *Immune System Activation in Morphea*

Dermal inflammatory cell infiltrates are common and both B and T cells have been identified (Whittaker et al. 1989). Elevated levels of various cytokines, including IL-2, IL-4 and IL-6 have been detected, suggesting ongoing T cell activation (Ihn et al. 1995). The levels of these cytokines, as well as soluble IL-2 receptor, released following T cell activation, correlated with the extent of skin involvement (Ihn et al. 1996). Levels of soluble CD4 receptor but not soluble CD8 receptor are elevated in LS, in contradistinction to SSc, where elevated levels of sCD8 are noted (Sato et al. 1996b). TNF- $\alpha$  and IL-13 are cytokines that can be fibrogenic and that are elevated in roughly 25% of patients (Hasegawa et al. 2003). IL-8 is a chemotactic protein that is also detectable in increased amounts in sera from patients with morphea (Ihn et al. 1994). Lastly, soluble CD30 levels are increased and this may indicate possible

involvement of T helper 2 (Th2) lymphocytes in the immunopathogenesis of disease (Ihn et al. 2000). Th2 cells promote humoral immunity and can secrete both IL-4 and IL-6. Consistent with this, elevated levels of IL-4 have been demonstrated in affected skin by immunohistochemistry (Salmon-Ehr et al. 1996). IL-4 and IL-6 have been shown to promote collagen synthesis by fibroblasts. B cell abnormalities have also been noted. Increased soluble CD23 indicates B cell activation (Sato et al. 1996a). The frequent detection of auto-antibodies provides evidence of B cell dysregulation. Anti-histone and anti-single stranded DNA (ssDNA) antibodies are found most frequently (Falanga et al. 1985 & 1987; Sato et al. 1994; Takehara et al. 1983) and suggest abnormal immune system handling of these antigens.

CD34+ dermal dendritic cells are markedly decreased in lesional skin (Aiba et al. 1994; Skobieranda and Helm 1995; McNiff et al. 1999). This feature may be of diagnostic help in difficult cases, but its significance remains unknown. These CD34+ cells may be the target of autoimmune attack (Aiba et al. 1994) or they may function to regulate collagen synthesis (Skobieranda and Helm 1995). CD34 expression correlates with progenitor cell characteristics and thus these cells have been characterized either as uncommitted mesenchymal cells (Narvaez et al. 1996) or as antigen presenting cells (Monteiro et al. 2000). Clarification of their function and the reason for their disappearance in sclerotic skin may shed light on the relationship between the immune alterations detailed here and fibrosis.

### *Altered Collagen Metabolism*

Increased collagen deposition is an essential feature of scleroderma. Enhanced type I and type III collagen mRNA levels have been detected in lesional skin *in vivo* (Scharffetter et al. 1988). Fibroblasts cultured from lesional and inflamed morphea skin contain higher levels of type I collagen mRNA and synthesize more collagen relative to total protein than fibroblasts from uninvolved skin (Hatamochi et al. 1992). Synthesis of glycosaminoglycans (Moller et al. 1985) and fibronectin (Fleischmajer et al. 1981) is also increased. Alterations in the proportions of glycosaminoglycan-derived disaccharides have been described (Fleischmajer and Perlish 1972; Akimoto et al. 1992; Passos et al. 2003). Enhanced expression of class II antigens on lesional fibroblasts has been interpreted as a sign of activation, likely secondary to cytokine stimulation (Branchet et al. 1992). Indeed, a subpopulation of fibroblasts shows increased type I and type III collagen mRNA expression (Kahari et al. 1988b) and these fibroblasts are often in proximity to mononuclear cells expressing transforming growth factor- $\beta$  (Higley et al. 1994). Elevated circulating levels of TGF- $\beta$  have also been documented (Higley et al. 1994) and TGF- $\beta$  receptors are upregulated in dermal fibroblasts in the affected skin of patients with localized scleroderma (Kubo et al. 2001). TGF- $\beta$  is known to induce collagen production by fibroblasts. Other cytokines that may directly mediate fibroblast activation



include IL-1, PDGF (Zheng et al. 1998) and connective tissue growth factor (CTGF) (Igarashi et al. 1996). In addition to increased synthesis of collagen, there is evidence of decreased turnover of fibrotic dermal extracellular matrix. Inhibitors of matrix turnover such as tissue inhibitor of matrix metalloproteinases-3 (TIMP-3) are upregulated at the mRNA level in lesional skin (Mattila et al. 1998). Thus the fibrosis may be a net result of increased collagen deposition as well as decreased matrix turnover.

## Clinical Appearance/Classification

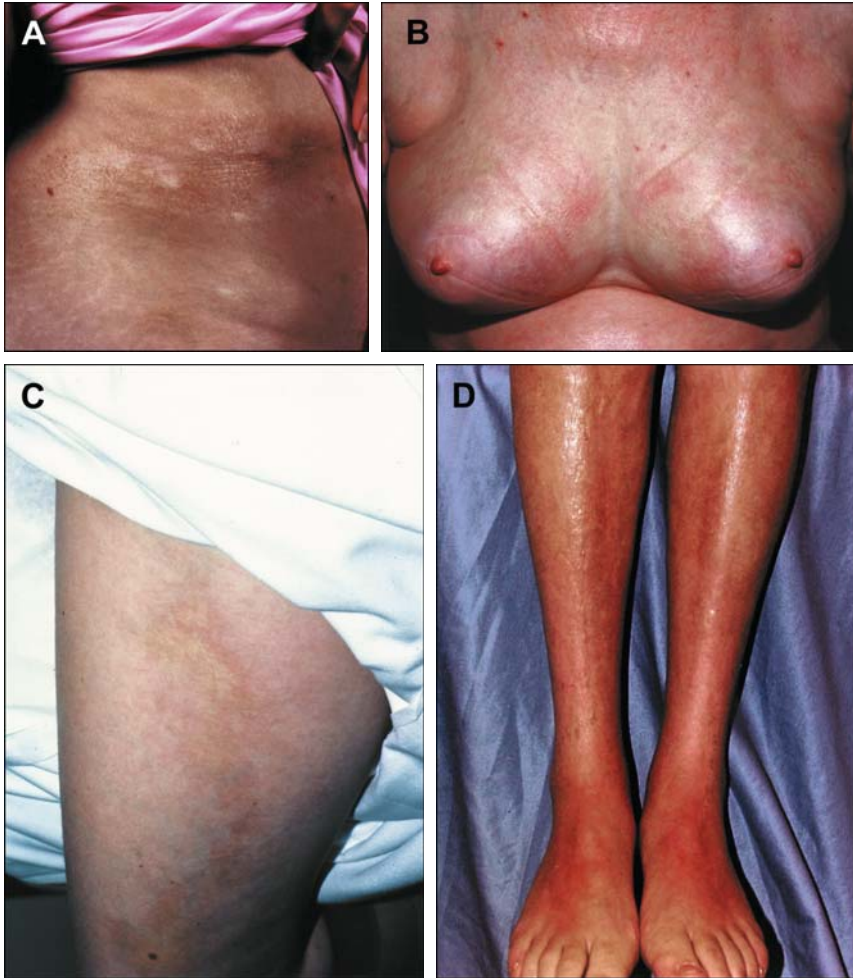
### Plaque Morphea

#### *Morphea en Plaque*

This commonest form of LS is defined by the presence of lesions >1cm in diameter, occurring in 1 or 2 anatomical sites (Peterson et al. 1995 & 1997). The trunk is the most commonly involved site (41–74% patients), but plaques can occur anywhere, including the face and neck (12–13% of patients) (Christianson et al. 1956; Peterson et al. 1997). Onset is usually slow and insidious. Circumscribed oval patches may be erythematous and oedematous in the earliest stages, becoming indurated, yellowish-white or ivory coloured (*Figure 2a*). A surrounding violaceous halo, the "lilac ring", suggests active inflammation, but was documented in only 43% of patients in one study (Peterson et al. 1997). The patches subsequently become waxy, shiny and sclerotic. Over months to years they soften, become atrophic and hypo- or hyperpigmented. Atrophy may involve the epidermis, dermis and/or subcutaneous tissue, producing wrinkling or depression of the skin surface. Lesions may be pruritic and/or paraesthetic. Loss of appendigeal structures results in reduced hair growth and decreased sweating.

#### *Guttate Morphea*

These lesions resemble morphea en plaque, but are smaller (<1 cm in diameter), and occur on the upper trunk as multiple, faintly erythematous oval lesions, which become yellowish, mildly indurated and which resolve leaving pigmentary changes. Winkelmann (1985) and Tuffanelli (1998) consider this to be a type of lichen sclerosis associated with morphea. The histologic features of lichen sclerosis and its frequent occurrence with other morphea subtypes (both in the same patients and the same biopsy specimen) suggest that these conditions share a common pathogenesis (Uitto et al. 1980). Interestingly, patients with lichen sclerosis specifically demonstrate antibodies to extracellular matrix protein 1 (Oyama et al. 2003; Oyama et al. 2004). Lesions of lichen sclerosis, but not of morphea, demonstrate discontinuities of the basement



**Fig. 2.** a) Morphea en plaque with induration and pigmentary changes. b) Generalized morphea of the chest, with erythema, edema and induration. Note sparing of the areolae. c) Linear lesion on the thigh. d) Eosinophilic fasciitis showing erythema, swelling and induration (Peau d'orange)

membrane zone (Kowalewski et al. 2004) possibly in relation to the presence of these auto-antibodies. Whether patients with morphea or clinical overlap with lichen sclerosus develop auto-antibodies with this specificity is unknown.

#### *Atrophoderma of Pasini and Pierini*

Atrophoderma is uncommon and thought to represent a superficial abortive form of morphea with a benign course (Jablonska 1975b; Kencka et al. 1995).

It usually occurs in childhood, with lesions distributed symmetrically on the trunk (Canizares et al. 1958), but it may occur in a zosteriform distribution (Wakelin and James 1995). Superficial morphea is a term coined by McNiff and colleagues in 1999 to describe patients with pigmentary changes, minimal cutaneous induration and superficial reticular dermal change (McNiff et al. 1999) and that likely describes a condition that overlaps with atrophoderma (Jablonska and Blaszczyk 2004). Atrophoderma of Moulin is a term used to describe clinically and histologically identical, but linear lesions, which follow the lines of Blaschko (Wollenberg et al. 1995). They consist of depressed areas of skin, typically with a sharply demarcated "cliff-drop" border, and grey or blue-brown pigmentation. The histology resembles the late atrophic stages of morphea. In a study of 139 patients followed for a mean of 10 years, areas of induration appeared within the lesions in 17% and plaques of morphea elsewhere on the body were found in 22% of cases (Kencka et al. 1995).

### *Keloid/Nodular Morphea*

This rare subtype is characterized by the presence of keloid-like nodules in patients with previous or co-existent morphea elsewhere. Lesions are commonest on the upper trunk and may coalesce or occur in a linear pattern (Krell et al. 1995; Hsu et al. 1999). Histology shows homogenization and thickening of collagen bundles with an increase in mucin (Micalizzi et al. 1994). Such keloidal and nodular reactions have also been described in the setting of progressive systemic sclerosis (Cannick et al. 2003; Labandeira et al. 2003; Rencic et al. 2003) and likely arise in patients with scleroderma (either localized or progressive) predisposed to keloid formation.

### **Generalized morphea**

Morphea is referred to as "generalized" when plaque type lesions occur in 3 or more anatomical sites (Peterson et al. 1995). Commonest sites are the trunk, upper thighs and lumbosacral region. Plaques are often distributed symmetrically and may become confluent (*Figure 2b*). Plaques at varying stages of evolution usually coexist.

### **Bullous morphea**

This rare subtype is characterized by the presence of tense subepidermal bullae, which appear to develop as a result of subepidermal oedema, and which may occur in the presence of any of the subtypes of morphea (Su and Greene 1986; Kobayasi et al. 1990; Daoud et al. 1994). In a study of 13 cases, bullae were most frequent on the legs, and lymphatic dilatation, attributed to obstruction from sclerosis, was observed in 77% of the patients (Daoud et al. 1994).

## Linear Morphea

Linear forms include linear morphea, en coup de sabre lesions and progressive hemifacial atrophy. Sclerotic lesions are distributed in a linear, band-like pattern (*Figure 2c*). Clinical evidence of inflammation, the "lilac ring" is seen less often in this type (19%)(Peterson et al. 1997). Their distribution may be dermatomal, however, it has been argued that they follow Blaschko's lines and may thus occur partly as a result of postzygotic mosaicism (Hauser et al. 1996; Itin and Schiller 1999). Frontoparietal lesions in particular, appear "Blaschkoid" rather than dermatomal (Soma and Fujimoto 1998; Itin and Schiller 1999). Trauma is more often sited as a possible precipitating factor in this type of morphea (Falanga et al. 1986; Yamanaka and Gibbs 1999). Facial and limb asymmetry caused by impaired growth of the bones and soft tissues in the affected area, as well as multiple joint contractures, can cause severe cosmetic, orthopedic, and psychologic problems.

### *Linear Morphea*

Unilateral lesions predominate, although bilateral lesions are described in 5.5% (Christianson et al. 1956) – 46%(Falanga et al. 1986) of patients. They most often occur on the lower limbs. Multiple sites are involved in up to 60% of cases, and plaque forms often coexist on the trunk (Falanga et al. 1986). Generalised arthralgias and edema of the involved extremity can precede the onset of disease (Christianson et al. 1956). Induration can involve the dermis, subcutis, underlying muscle and bone. Multiple joint contractures, are common, occurring in 56% of cases in one study (Falanga et al. 1986). Myopathic changes, atrophy and weakness of involved and adjacent muscles may occur (Uziel et al. 1994). Discrepancies of limb length are a frequent complication in children with limb involvement (Liu et al. 1994).

### *En Coup de Sabre*

This type affects the face and scalp. Lesions generally follow one of two lines. The first descends vertically from the frontal scalp to the side of the nose, adjacent to the midline. The second starts close to the vertex and progresses forwards to the lateral forehead, and then medially towards the inner canthus (Soma and Fujimoto 1998; Blaszczyk and Jablonska 1999). Bilateral lesions occur rarely (Rai et al. 2000). Concomitant linear and plaque lesions at other sites are commoner (Falanga et al. 1986; Peterson et al. 1997). The sclerosis is thought to involve the skin and subcutis first, and later extend to underlying fascia and bone (Jablonska 1975a). Epilepsy is the most frequent neurological complication occurring in up to 10% (Jablonska 1975a). Ocular and auditory complications may also be present (Luer et al. 1990; David et al. 1991). Intracranial calcification and white matter abnormalities have been

noted on CT and MR scans (Liu et al. 1994). One case study suggests sclerodermatous involvement of underlying brain tissue (Chung et al. 1995): dense sclerosis with increased collagen deposition, gliosis, scattered calcifications, and thickened sclerotic blood vessel walls were present in the involved dura and brain. The presence of oligoclonal banding on CSF examination, of lymphocytic inflammation on brain biopsy and of improvement in MRI white matter abnormalities following corticosteroid treatment all attest to the primary inflammatory nature of the underlying CNS lesions (Stone et al. 2001; Unterberger et al. 2003).

### *Progressive Hemifacial Atrophy (Parry–Romberg Syndrome)*

This is thought to be a primary atrophic disorder of the subcutaneous tissue, muscle and bone. The absence of skin induration distinguishes it from "en coup de sabre" lesions (Sakuraoka et al. 1992). Progressive hemifacial atrophy (PHA) often begins at the sites described above, and then extends to involve the cheek, tongue and mandible. Hypoplasia of the maxilla and mandible may cause marked facial asymmetry, particularly if lesions first develop in early childhood. There is overlap between the two conditions (Menni et al. 1997; Blaszczyk and Jablonska 1999). In one series 20/58 cases of linear scleroderma of the face (en coup de sabre) showed transition to PHA (Jablonska 1975a). Similar radiographic and clinical neurologic abnormalities and ocular complications are encountered, but may be commoner in PHA (Fry et al. 1992; Liu et al. 1994). Morphea lesions elsewhere have been noted in patients with PHA and both groups with PHA (without skin induration) and those with "en coup de sabre" lesions have abnormalities in cerebral blood flow as detected by SPECT analysis (Blaszczyk et al. 2003).

## **Deep Morphea**

In deep morphea the sclerotic process occurs in the subcutaneous tissue, in other words, in the fat, fascia or superficial muscle. The various subtypes are classified according to the level of maximal involvement on a deep tissue biopsy. Lesions are frequently bilateral and symmetrical and involve the upper and lower limbs (Peterson et al. 1997).

### *Subcutaneous Morphea*

The primary site of involvement is the subcutaneous fat, although the fascia may also be involved, making it difficult to distinguish this form from "morphea profunda". In Person and Su's description of 16 cases, plaques were usually extensive, ill-defined and bound-down, and showed rapid centrifugal

progression (Person and Su 1979). Disease activity ranged from 6 months to 7 years. Five patients had coexistent plaques of morphea or lichen sclerosus, and five had a peripheral eosinophilia.

### *Morphea Profunda*

Su and Peterson (1981) originally suggested a number of diagnostic criteria: the presence of diffuse, taut, bound-down deep cutaneous sclerosis; of significant hyalinization and thickening of collagen bundles in both the subcutaneous fat and fascia; and a response to treatment with antimalarials or corticosteroid. Some authors do not distinguish between this subtype and subcutaneous morphea (Weedon 1997). Solitary lesions have been described both in children (Kobayashi et al. 1991) and adults (Whittaker et al. 1989). Recently 3 unusual cases of deep linear, primarily atrophic lesions, without preceding inflammation or sclerosis, involving the subcutis and deeper tissues were described. They may have a more benign outcome. Their relationship to morphea is underscored by the coexistence of hemifacial atrophy in one case (Blaszczyk et al. 2000).

### *Eosinophilic Fasciitis (Shulman Syndrome)*

This condition is characterized by a diffuse sclerosis, predominantly involving the fibrous septa of the subcutis and deep fascia, a high ESR, hypergammaglobulinaemia and peripheral eosinophilia (Mitchet et al. 1981; Shulman 1974). Inflammatory changes may extend into the underlying muscle (Weedon 1997). It usually occurs on the extremities, but spares the hands and feet (*Figure 2d*). It can result in severe joint contractures and associated morbidity. Associated haematologic abnormalities including aplastic anemia, thrombocytopenia and leukaemia have been noted (Doyle and Ginsburg 1989). Other subtypes of morphea may be present (Miller 1992).

### *Disabling Pansclerotic Morphea of Childhood*

This extremely rare variant is at the most severe end of the clinical spectrum. Rapid progression of deep cutaneous fibrosis occurs, extending to involve muscle, fascia and bone (Diaz-Perez et al. 1980). It usually results in severe joint contractures and cutaneous ulceration. Unlike other forms of LS, this disease does not undergo spontaneous remission. Increased serum IgG, a positive ANA and peripheral eosinophilia are documented (Scharffetter-Kochanek et al. 1995; Todd et al. 1998).

### **Associated Symptoms**

Arthralgias are relatively common (40% of patients) (Christianson et al. 1956; Uziel et al. 1994b). Synovitis has been documented mainly in deep forms (Peterson et al. 1997). Associated pulmonary and esophageal involvement can occur. Routine testing revealed that 7/41 (17%) patients had esophageal dysmotility and 9/53 (17%) had abnormal gas transfer on lung function testing. These abnormalities were asymptomatic over 4yrs follow up in all but 2 of the patients (Dehen et al. 1994). In a series of 16 cases of subcutaneous morphea, 4/10 and 3/10 patients investigated had asymptomatic abnormal lung function and esophageal dysmotility respectively (Person and Su 1979). This suggests that the frequency of internal involvement may be underestimated. Other associated findings include carpal tunnel syndrome (Winkelmann et al. 1982) and vertebral anomalies (in particular spina bifida) present in 47% of 68 patients examined radiographically (Christianson et al. 1956). Associated cutaneous diseases include lichen sclerosus (see above), vitiligo, alopecia areata, and lichen planus (Uitto et al. 1980; Winkelmann 1985). Morphea may also occur with other connective tissue diseases, including lupus erythematosus (Dubois et al. 1971; Umbert and Winkelmann 1978), dermatomyositis and rheumatoid arthritis (Jablonska 1975b). Morphea has also been associated with Hashimoto's thyroiditis (Lee et al. 2002), another auto-immune condition.

### **Laboratory Abnormalities**

Eosinophilia occurs in all types of morphea, but is more pronounced in patients with generalized and deep forms. Levels of eosinophilia may parallel disease activity (Falanga et al. 1986). A mean of 5.4% (percentage of total leukocytes) at diagnosis and 2.8% at last follow up was observed in Peterson et al's series (Peterson et al. 1997). Polyclonal hypergammaglobulinemia and a positive rheumatoid factor were present in 50% and 26% respectively of 53 patients with linear or generalized morphea. Both were correlated with more extensive, active disease (Falanga et al. 1986). In recent studies on Hep2 cells, anti-nuclear antibody (ANA)-positivity occurred in 46–76% of cases, in decreasing order of frequency in generalized, linear and plaque forms (Falanga et al. 1986; Rosenberg et al. 1995; Uziel et al. 1994b). Antibodies to ssDNA are usually of the IgM subtype (Ruffatti et al. 1991), and are seen mainly in patients with longstanding, extensive linear or generalized disease (Falanga et al. 1985; Rosenberg et al. 1995). Antihistone antibodies may also be present but anti-Scl 70 (polymerase III) and anticentromere antibodies are rare. Anti-phospholipid antibodies of both the IgM and IgG subtypes are detected with increased frequency in patients with generalized and linear morphea, in the absence of increased thrombotic events (Sato et al. 2003). The similarity in auto-antibody specificities between drug-induced lupus and morphea has prompted the suggestion that morphea, like drug-induced lupus, is an

environmentally driven disease. Recent studies have identified serum autoantibodies to fibrillin 1 (Arnett et al. 1999), the major component of microfibrils in the extracellular matrix, and to Hsp73 (Fujimoto et al. 1995). It is likely that these autoantibodies are by-products of the underlying pathologic process, rather than being primarily pathogenic. Unique disease-associated autoantibody profiles may nevertheless give a clue to pathogenesis. In this regard, 76% of patients with localized disease and 85% of patients with generalized disease are found to have antibodies to anti DNA topoisomerase IIa in contrast to only 14% of patients with progressive systemic sclerosis (Hayakawa et al. 2004). This is a ubiquitous enzyme that modulates the topologic state of DNA and it was hypothesized that, as this protein is selectively cleaved during Fas-mediated apoptotic cell death, it may be presented to the immune system during the endothelial cell apoptosis detected in early morphea lesions. Most patients (41/46) with morphea and 13/13 patients with generalized morphea were recently shown to have antibodies to a cytosolic form of superoxide dismutase (Cu/Zn SOD or SOD1) (Nagai et al. 2004). In patients with generalized disease, the presence of IgM antibodies to Cu/Zn SOD correlated with severity of disease. These observations suggest that reactive oxygen species may participate in disease pathogenesis.

### **Diagnosis and Measurement of Disease Activity**

The diagnosis is based on characteristic clinical findings and histology. Characteristic cutaneous ultrasound images may aid in diagnosis (Cosnes et al. 2003). No reliable laboratory markers of disease activity are available. Clinical features suggestive of active disease include extension of lesions, appearance of new lesions and the presence of a violaceous or erythematous halo. More objective assessments can be made using modified Rodnan skin scores (Rodnan et al. 1979). Ideally this should be combined with the use of a durometer (Seyger et al. 1997) or 20MHz ultrasound (Levy et al. 1993) to assess skin thickness and elasticity. Recently, thermography has been used to aid in the assessment of disease activity (Birdi et al. 1992; Martini et al. 2002). These apparatus are unfortunately not widely available. It has been suggested that serum IL-2 receptor levels may distinguish between active and inactive disease (Uziel et al. 1994) but the utility of this test in clinically following disease activity has not been independently confirmed. Serial determinations of eosinophilia, hypergammaglobulinaemia and ANA titers may be of value in patients with extensive disease as these values may fluctuate with disease activity.

### **Therapy**

There is no uniformly accepted or effective therapy for LS. Because immune cell activation is believed to underlie the development of skin sclerosis, both



topical and systemic immunosuppressants have been used. Unfortunately, few controlled studies are available with which to objectively assess the benefits obtained. In a majority of older studies the improvements described are based on poorly documented clinical observations. Recently more objective outcome measures have been employed. Given the propensity for skin thickening to improve in morphea, larger controlled studies are needed to confirm the efficacy of both traditional and newer treatments.

### **Topical Corticosteroids**

Although high potency topical corticosteroids have been the "first-line" treatment for patient with plaque morphea for many years, no prospective or controlled studies of their effectiveness in LS have been published. They have, however, retrospectively been shown to be useful in children with active plaque morphea (Bodemer et al. 1999), and to be highly effective in the treatment of lichen sclerosis (Garzon and Paller 1999), a clinically associated and possibly related condition.

### **Ultraviolet A**

Ultraviolet light A is increasingly being used to treat morphea. Published reports detailed in *Table 1* suggest that high dose UVA<sub>1</sub> (130 J/cm<sup>2</sup>/treatment) may be the most efficacious form of ultraviolet light, followed in order, by low-dose UVA<sub>1</sub> (20 J/cm<sup>2</sup>/treatment), UVA in conjunction with topical and systemic psoralens (PUVA).

Effective therapy with UVA<sub>1</sub>(340–400nm) has been reported in 52/54 treated patients, with disease durations of up to 25 years (Gruss et al. 1997a & b; Kerschler et al. 1995 & 1998; Stege et al. 1997). Deep forms appear least responsive. Outcome measures have included assessment of lesion size and induration, and ultrasonographic and biopsy assessments of dermal thickness and elasticity. In one study, a direct comparison of high-dose UVA<sub>1</sub> versus low-dose therapy showed that high-dose was superior for all the parameters assessed (Stege et al. 1997). The effects may be seen as early as after 4–10 treatments. Maximal responses may require 25 or more treatments. The use of medium dose UVA<sub>1</sub> (48J/cm<sup>2</sup>/treatment) in 8 patients was associated with improved skin scores and increased skin elasticity as measured by a cutometer in all patients after 20 treatments. In an effort to limit UVA<sub>1</sub> dosing, low-dose UVA<sub>1</sub> therapy has been combined with topical calcipotriol ointment therapy for childhood morphea. A 19-patient uncontrolled trial of this therapy showed a 67% improvement in skin scores. (Kreuter et al. 2001). Follow-up has not been reported much beyond 3 months after cessation of therapy.

**Table 1.** UVA Treatment for Localized Morphea

Treatment	Morphea type	Number published	Dose and duration	Improved	Comment	Reference
High dose UVA1	P/G	9	130J/cm <sup>2</sup> /Rx x4/wk for 5 wks and	9	Effective and superior to low dose, 38% vs 15% decrease in skin thickness, but high total irradiation (3900J/cm <sup>2</sup> ).	Stege et al. 1997
	L	1	x2/wk for 5wks	1		
Low dose UVA1	P/G	24	20J/cm <sup>2</sup> /Rx x4/wk for 5-6 wks +/-	24	Effective, 50-80% clearance, 15-37% decrease in skin thickness, lower total exposure (600J/cm <sup>2</sup> )	Grucs et al. 1997a, 1997b Kerscher et al. 1995, 1998 Stege et al. 1997
	L	16	x1-2/wk for 5-6wks	16		
	D	4		2		
Low dose UVA1 + calcipotriol	P	8	20J/cm <sup>2</sup> /Rx x4/wk for 10 wks and	8	67% improvement in clinical score, improvement in skin thickness in 4/4, no comparison to either Rx alone	Kreuter et al. 2001
	L	9	calcipotriol 0.005% ung	9		
	D	2	BID	2		
Low dose broadband UVA	P	3	20 J/cm <sup>2</sup> x3/wk,	3	? as effective as low dose UVA <sub>1</sub> , but no objective clinical scores, lower total exposures effective (400J/cm <sup>2</sup> )	ElMoffy et al. 2000 Steger and Matthews 1997
	G	7	20 Rx or x4/wk for 6 wks	7		
	L (ECS)	3 (1)	and x1/wk for 6wks	3		
Bath PUVA	G	10	1.2-3.5J/cm <sup>2</sup>	8	Slightly less effective, but up to 40% decrease in skin thickness and up to 80% clearance in some patients (10-60J/cm <sup>2</sup> )	Kerscher et al. 1994, 1996 Schiener et al. 2000
	P	3	25-35 Rx	3		
	L	5		4		
	D	2		1		
	P	4		4		
PUVA Cream	P	4	0.001%-0.0025% 8MOP + 30% H <sub>2</sub> O in oil emulsion x4/week, 30 Rx	4	84% reduction in skin thickness, useful if small number of plaques/area involved. Lower total irradiance (121J/cm <sup>2</sup> )	Grundmann-Kollman 2000
	L	2		2		
Systemic PUVA	P/G	5	0.4-0.6 mg/kg	4	Less effective and prolonged Rx often required (total doses up to 840J/cm <sup>2</sup> ), few objective outcome measures reported	Garcia-Bustinchy et al. 1998 Kauskura et al. 1997 Todd et al. 1998 Yamaguchi et al. 1998
	L	2	8MOP, 3-4 x/wk	2		
	D	2	1-9 months	1		

P = plaque, G = generalized, L = linear, D = deep morphea, Rx = treatment, ECS = bullous morphea

Limited access to UVA<sub>1</sub> light sources remains a major obstacle. This has prompted trials of broadband UVA therapy. In 13 patients with disease durations of 1 month to 3 years (Steger and Matthews 1999; El-Mofty et al. 2000), clinical improvement (without objective skin scoring) was observed in all cases. Those with early disease were said to respond best. A significant reduction in upper dermal collagen concentration was seen on biopsy in 9/12 cases. At follow up 1 year later two patients had relapsed. Improved skin thickness as assessed by ultrasound was detected in 3 out of 4 patients with morphea after 30–60 treatments of broadband UVA (Oikarinen and Knuutinen 2001). When treatments with 20 J/cm<sup>2</sup>/session, 10 J/cm<sup>2</sup>/session and 5 J/cm<sup>2</sup>/session of broadband UVA were compared, a significant clinical dose-response association was not demonstrated (El-Mofty et al. 2004) despite UV dose-related decreases in collagen and TGF- $\beta$  mRNA levels (El-Mofty et al. 2004). 6/16 (38%) patients receiving 20 sessions of 5 J/cm<sup>2</sup> were perceived to have a good to very-good response compared to 15/26 (58%) receiving 20 sessions of 20 J/cm<sup>2</sup> prompting the authors to conclude that lower doses of broadband UVA may also be beneficial.

Psoralens increase the overall cytotoxicity of UVA, but reduce the total number of joules required for effective therapy in other cutaneous inflammatory diseases. The effects of bath PUVA have been documented in 20 patients. 80% or more of the sclerotic plaques regressed in 15/19 patients within 3 months, based on clinical skin scores, ultrasound and histologic evaluations (Kerscher et al. 1994 and 1996). The effect lasted 1 year in 15/17 patients. Most recently, cream PUVA was used in 4 patients. All improved significantly as judged by 20MHz ultrasound and lesional biopsy (Grundmann-Kollmann et al. 2000). Systemic PUVA therapy may be somewhat less effective. Of 9 patients reported (Scharffetter-Kochanek et al. 1995; Kanekura et al. 1996; Morison 1997; Garcia-Bustinduy et al. 1998; Todd et al. 1998; Yamaguchi et al. 1998), all but one (Todd et al. 1998) showed some clinical improvement. However, prolonged or maintenance treatment was often required, increasing the risks of long-term toxicity. Again, combination therapy with calcipotriol ointment has been suggested as a strategy to limit irradiation dosage (Gambichler et al. 2003).

All forms of UVA therapy appear to act via a direct effect on the irradiated skin area, since plaques covered during treatment fail to show any improvement. The mechanism of action of UVA is suggested by studies which show that it induces apoptosis in skin-infiltrating T cells (Morita et al. 1997) and upregulates collagenase I (MMP1) mRNA expression both in vitro and in vivo (Wlaschek et al 1995; Gruss et al. 1997a; Stege et al. 1997). Treatment has also resulted in partial normalization in the number of CD34<sup>+</sup> dermal dendritic cells (Camacho et al. 2001). While the long-term oncogenic potential of PUVA is well documented, the potential long-term toxicity of long wave UVA is still unknown. Controlled studies are required to establish the safest and most efficacious form of UVA therapy, both in terms of dosage and duration of therapy.

### Vitamin D Derivatives

Both oral calcitriol (Caca-Biljanovska et al. 1999; Elst et al. 1999; Hulshof et al. 1994; Humbert et al. 1990 & 1995) and topical calcipotriol (Cunningham et al. 1998; Koeger et al. 1999) have been used effectively in small, uncontrolled series of patients with all forms of LS (see *Table 2*). Systemic treatment with 0.25 µg/day is increased by 0.25µg weekly up to a maximum of 2.5 µg/day (Humbert et al. 1995). Documented effects include improved well-being and joint mobility, a reduction in the appearance of new lesions, and of induration in existing lesions. Improvement occurred within 2–6 months, suggesting a therapeutic effect. An open randomized controlled trial of immunosuppressive therapy (corticosteroids plus methotrexate) versus oral calcitriol, is currently ongoing in the UK. With oral supplementation, regular monitoring for hypercalcemia, hypercalciuria and potential nephrocalcinosis is required. Increases in urinary calcium have been reported, but the absolute values remained within the normal range. Concurrent dietary calcium restriction to 600 mg/day is suggested.

The mechanism of action of vitamin D derivatives in morphea remains uncertain. Receptors for 1,25 dihydroxyvitamin D<sub>3</sub> have been detected on human dermal fibroblasts, keratinocytes and lymphocytes (Clemens et al. 1983; Holick et al. 1987). It may inhibit antigen induced T cell activation and proliferation, both by inhibiting T cell-monocyte interactions, and reducing IL-2 and IFN $\gamma$  synthesis (Rigby et al. 1987; Rigby and Waugh 1992). In addition, it causes a dose dependant inhibition of fibroblast growth and collagen synthesis (Boelsma et al. 1995; Bottomley et al. 1995). Vitamin D analogues may thus have immunomodulatory, antisynthetic and antiproliferative effects.

### Methotrexate

Anecdotal evidence of benefit was initially reported in a child with linear disease and in an adult with eosinophilic fasciitis (Janzen et al. 1995; Foeldvari 1998). Two observational studies have since been published. In the first, 9 adults were treated (Seyger et al. 1998). Improvement in skin thickness scores was noted in 6/9 patients. Durometer readings, skin itch scores, and levels of type III procollagen propeptide showed no significant improvement. In a second study, 9 children were treated with methotrexate and pulsed intravenous methylprednisolone (Uziel et al. 2000). A good response, defined as skin softening, and lack of progression or appearance of new lesions, occurred in all 9 patients. The median time to response was 3 months, was fastest in those with early disease, and persisted over the treatment period. The authors suggested treating patients for at least 1 year of inactive disease before tapering the dose of methotrexate. It is of note that a total of 4/18 patients were withdrawn from the two studies because of significant side effects (raised liver enzymes, stomatitis, weight loss and leukopenia).

**Table 2.** Systemic and Topical Therapies for Localized Scleroderma

Treatment	Morphea type	Number published	Dose and duration	Improved	Comment	Reference
Oral Calcitriol	G	5	0.25–1.25 µg OD	5	Significant objective improvement in skin extensibility documented in 12 patients, relatively non toxic	Caca-Biljanovska 1999 Elst et al. 1999 Hulshof et al. 1994 Humbert et al. 1990, 1995
	D	2	3–10.5 months	2		
	L	7	0.25–2.5 µg/day 2–36 months	6		
	unspecified	7		7		
Topical calcipotriol	P/G and L	13	0.005% ointment or cream BID +/- occlusion nocte 3–6 months	13	44% improvement in skin scores, safe and non toxic	Cunnigham et al. 1998 Koeger et al. 1999
	Corticosteroids	G 5 L 28 D 9	Prednisone 0.5–1 mg/kg/day for up to 70 months	5 9 8	Benefits appear greatest in deep group, few objective outcome measures	Balat et al. 1999 Bodemer et al. 1999 Castanet et al. 1994 Gordon 1981 Joly et al. 1994 Miller 1992
Methotrexate	G P	7 2	15–25mg/wk 24 weeks	5/6 who completed	Moderate effect, 20% reduced scores in responders	van den Hoogen et al. 1996
Methotrexate + Methylprednisolone	G	5	0.3–0.6 mg/kg/wk 22.3 months + 30mg/kg/day x3days, monthly for the 1 <sup>st</sup> 3 months	9/9	Combination promising, needs larger studies and more objective outcome measures	Uziel et al. 2000
	L	4				
Aminoquinoline antimalarials	P/G	4	Hydroxychloroquine 200–400 mg OD	2/4	No objective outcome measures but may be of benefit in deep group.	Person and Su 1979 Winkelmann et al. 1982 Wuthrich et al. 1975
	D	7	Chloroquine 250 mg OD Duration not specified	4/7		
D-penicillamine	G	3	2–7.5 mg/kg/day 13–53 months	14	Effects unproven, few objective outcome measures, mean 24% decrease in skin scores where documented	Curley et al. 1987 Falanga and Medsger 1990 Moynahan 1973 van Bergen et al. 1997
	L	14				
Sulphasalazine	P/G	6	1–5g/day 7–13 months	4/6 1	Effects unproven, based on subjective assessments reported	Czarnecki and Taft 1982 Micalizzi et al. 1996 Stava and Kobikova 1997 Taveira et al. 1999
	B	1				

P = plaque, G = generalized, L = linear, D = deep morphea, Rx = treatment, B = bullous morphea

Methotrexate, possibly by enhancing monocyte differentiation (Seitz et al. 1998), has been shown to reduce serum levels of soluble IL-2 receptors (Rose et al. 1994), and of IL-1 $\beta$ , IL-6, IL-8 and TNF- $\alpha$  (Barrera et al. 1995; Seitz et al. 1995). It may thus modulate cytokine production and T cell-monocyte interactions, in addition to its well-documented anti-metabolite action. Elevated levels of tenascin in the center and margins of lesional skin and numbers of mast cells at the margins of lesions were found to be decreased by methotrexate treatment (Seyger et al. 2001).

### **Systemic Corticosteroids**

Systemic therapy has rarely been described in patients with rapidly progressive generalized disease and linear forms. It has variably been reported to be of benefit (Joly et al. 1994) or not (Balat et al. 1999; Bodemer et al. 1999). The need for prolonged treatment, associated with well documented side effects, and the significant risk of relapse on withdrawal (Joly et al. 1994), are all factors which should be taken into account when considering using this treatment modality, particularly as monotherapy. It may be of greater benefit when used in combination with other therapies such as methotrexate or plasmapheresis (Wach et al. 1995; Uziel et al. 2000). A possible exception may be eosinophilic fasciitis for which anecdotal evidence suggests greater steroid responsiveness (Gordon 1981; Miller 1992; Castanet et al. 1994).

### **D Penicillamine**

Isolated case reports and small series have suggested benefit, predominantly in patients with severe, progressive, linear disease (Moynahan 1973; Curley et al. 1987; van Bergen et al. 1997). In the largest published study of 11 patients, improvement was noted in 7 and began within 3–6 months (Falanga and Medsger 1990). There were no new or active lesions, skin softening occurred in 5/7 and normalization of growth of the affected limb in 2/3 children. Significant, but reversible side effects (nephrotic syndrome, milder proteinuria, leukopenia, thrombocytopenia) occurred in 4 patients. In a further study of six children with eosinophilic fasciitis and morphea en plaque elsewhere on the body, addition of long term penicillamine, following initial treatment with prednisone, produced little additional benefit (Miller 1992).

### **Antimalarials**

Aminoquinolone antimalarials are relatively safe and well tolerated. They were of benefit in 6/11 reported patients (Wuthrich et al. 1975; Person and Su 1979; Winkelmann et al. 1982). Although not studied in morphea, the use of

combination antimalarial therapy, i.e., either hydroxychloroquine or chloroquine with quinacrine, can be of benefit in patients with cutaneous lupus refractory to single agent therapy alone (Chung and Hann 1997). This may be a safe and worthwhile strategy in generalized morphea, but requires clinical studies.

### Interferon- $\gamma$

Interferon- $\gamma$  (IFN $\gamma$ ) has a strong inhibitory effect on collagen synthesis by normal and scleroderma fibroblasts in vitro (Kahari et al. 1988a), which provides a rationale for its use in morphea. Unfortunately, in one of the rare double-blind controlled studies conducted in 24 patients, no significant differences were found between IFN $\gamma$  and placebo when considering fibrosis, lesion size or collagen mRNA expression (Hunzelmann et al. 1997).

### Other Therapies

The description of a large number of anecdotal therapies for morphea attests, in part, to their lack of efficacy. Phenytoin (200mg/day) resulted in skin softening within 2–3 months in 5/5 patients with linear disease (Neldner 1978). Interestingly these patients all received concomitant vitamin D supplements, which may have contributed to the observed effects. 5/7 patients with progressive plaque or generalized disease responded to sulphasalazine (Stava and Kobikova 1977; Czarnecki and Taft 1982; Micalizzi et al. 1996; Taveira et al. 1999). Benefit was seen within 4 weeks of starting cyclosporine therapy (5mg/kg/day tapered to 1.5mg/kg/day after 8 months) in 2 patients (Peter et al. 1991); and after 3 months of intravenous immunoglobulin therapy (5g alphasglobulin/day x5 days, then monthly for 1 year) in a child with pansclerotic morphea (Wollina et al. 1998). Poor or incomplete responses have been noted after extracorporeal photochemotherapy (2 patients) (Cribier et al. 1995), acitretin (8 patients) (Neuhofer and Fritsch 1984), and topical tocotrienate (4 patients) (Mizutani et al. 1999). In contrast, topical photodynamic therapy, was recently objectively shown to be effective in 5/5 patients with progressive disease (Karrer et al. 2000). A single report suggests the efficacy of repeated treatment with a 585 nm pulsed dye laser (Eisen and Alster 2002). Penicillin, used because of the possible association with *borrelia* infection, and a suggested effect on collagen fibrillogenesis (Hunzelmann et al. 1998), was also recently shown to reduce skin thickness in a child with linear disease (Mohrenschlager et al. 1999). Tacrolimus ointment 0.1% applied topically twice daily with plastic wrap occlusion was of benefit in 2 patients over 12 weeks (Mancuso and Berdondini 2003) and imiquimod cream 5% may have been of benefit in one case (Man and Dytoc 2004).

## Summary

Morphea is an uncommon but potentially disabling condition. Abnormalities in immune system parameters, endothelial activation and fibroblast metabolism have been described, but a unifying pathophysiologic model remains to be tested. The clinician is faced with considerable uncertainty when choosing a treatment modality for LS. Given the benign natural progression of plaque type morphea, treatment with topical modalities such as super-potent corticosteroids or calcipotriol is prudent. For more generalized forms of morphea, as well as the linear forms, UVA is currently the best-documented therapeutic modality. In the absence of access to UVA treatment, oral calciferol or systemic immunosuppression may be contemplated. Recent studies support the use of methotrexate with systemic corticosteroids for the management of aggressive disease. The authors have had variable success with PUVA, broadband UVA, and methotrexate in severe disease. Resolution of therapeutic uncertainty must await the organization and completion of controlled trials.

## References

- Aberer E, Neumann R, and Stanek G (1985) Is localised scleroderma a *Borrelia* infection? *Lancet*, 2: 278
- Aiba S, Tabata N, Ohtani H, Tagami H (1994) CD34+ spindle-shaped cells selectively disappear from the skin lesion of scleroderma. *Arch Dermatol*, 130: 593–597
- Akimoto S, Hayashi H, Ishikawa H (1992). Disaccharide analysis of the skin glycosaminoglycans in systemic sclerosis. *Br J Dermatol*, 126: 29–34
- Arnett FC, Tan FK, Uziel Y, Laxer RM, Krafchik BR, Antohi S, and Bona C (1999) Autoantibodies to the extracellular matrix microfibrillar protein, fibrillin 1, in patients with localized scleroderma. *Arthritis Rheum*, 42: 2656–2659
- Balat A, Akinci A, Turgut M, Mizrak B, Aydin A (1999) Eosinophilic fasciitis – progression to linear scleroderma: a case report. *Turk J Pediatr*, 41: 381–385
- Barrera P, Haagsma CJ, Boerbooms AM, Van Riel PL, Borm GF, Van de Putte LB, Van der Meer JW (1995) Effect of methotrexate alone or in combination with sulphasalazine on the production and circulating concentrations of cytokines and their antagonists. Longitudinal evaluation in patients with rheumatoid arthritis. *Br J Rheumatol*, 34: 747–755
- Birdi N, Shore A, Rush P, Laxer RM, Silverman ED, Krafchik B (1992). Childhood linear scleroderma: a possible role of thermography for evaluation. *J Rheumatol*, 19: 968–973
- Blaszczyk M, Jablonska S (1999) Linear scleroderma en coup de sabre. Relationship with progressive facial hemiatrophy (PFH). *RheumaDerm*, M. a. Uitto, ed., Kluwer Academic/Plenum Publishers, New York, 101–104
- Blaszczyk M, Krysicka-Janiger K, Jablonska S (2000) Primary atrophic profound linear scleroderma. Report of three cases. *Dermatology*, 200: 63–66
- Blaszczyk M, Krollicki L, Krasu M, Glinska O, Jablonska S (2003). Progressive facial hemiatrophy: central nervous system involvement and relationship with scleroderma en coup de sabre. *J Rheumatol*, 30: 1997–2004
- Bleasel NR, Stapleton KM, Commens C, Ahern VA (1999) Radiation-induced localized scleroderma in breast cancer patients. *Australas J Dermatol*, 40: 99–102
- Bodemer C, Belon M, Hamel-Teillac D, Amoric JC, Fraitag S, Prieur AM, De Prost Y (1999) Scleroderma in children: a retrospective study of 70 cases. *Ann Dermatol Venereol*, 126: 691–694



- Boelsma E, Pavel S, Ponec M (1995) Effects of calcitriol on fibroblasts derived from skin of scleroderma patients. *Dermatology*, 191: 226–33
- Bottomley WW, Jutley J, Wood EJ, Goodfield MD (1995) The effect of calcipotriol on lesional fibroblasts from patients with active morphea. *Acta Derm Venereol*, 75: 364–366
- Branchet MC, Boisnic S, Bletry O, Robert L, Charron D, Frances C (1992) Expression of HLA class II antigens on skin fibroblasts in scleroderma. *Br J Dermatol*, 126: 431–435
- Caca-Biljanovska NG, Vlckova-Laskoska MT, Dervendi DV, Pesic NP, Laskoski DS (1999) Treatment of generalized morphea with oral 1,25-dihydroxyvitamin D3. *Adv Exp Med Biol*, 455: 299–304
- Camacho NR, Sanchez JE, Martin RF, Gonzalez JR, Sanchez JL (2001). Medium-dose UVA1 phototherapy in localized scleroderma and its effect in CD34-positive dendritic cells. *J Am Acad Dermatol*, 45: 697–699
- Canizares O, Sachs P, Jaimovich L, Torres V (1958) Idiopathic atrophoderma of Pasini and Pierini. *Arch Dermatol*, 77: 42–59
- Cannick L, 3rd, Douglas G, Crater S, Silver R (2003). Nodular scleroderma: case report and literature review. *J Rheumatol*, 30: 2500–2502
- Castanet J, Lacour JP, Perrin C, Taillan B, Dubois D, Ortonne JP (1994) Association of eosinophilic fasciitis, multiple morphea and antiphospholipid antibody. *Dermatology*, 189: 304–307
- Christianson H, Dorsey C, O'Leary P, Kierland R (1956) Localized scleroderma: a clinical study of twohundred thirty-five cases. *Arch Dermatol*, 74: 629–639
- Chung MH, Sum J, Morrell MJ, Horoupian DS (1995) Intracerebral involvement in scleroderma en coup de sabre: report of a case with neuropathologic findings. *Ann Neurol*, 37: 679–681
- Chung H, Hann S (1997) Lupus panniculitis treated by a combination therapy of hydroxychloroquine and quinacrine. *J Dermatol*, 24: 569–572
- Clemens TL, Adams JS, Horiuchi N, Gilchrest BA, Cho H, Tsuchiya Y, Matsuo N, Suda T, Holick MF (1983) Interaction of 1,25-dihydroxyvitamin-D3 with keratinocytes and fibroblasts from skin of normal subjects and a subject with vitamin-D-dependent rickets, type II: a model for study of the mode of action of 1,25-dihydroxyvitamin D3. *J Clin Endocrinol Metab*, 56: 824–830
- Cosnes A, Anglade MC, Revuz J, Radier C (2003). Thirteen-megahertz ultrasound probe: its role in diagnosing localized scleroderma. *Br J Dermatol*, 148: 724–729
- Cribrier B, Faradji T, Le Coz C, Oberling F, Grosshans E (1995) Extracorporeal photochemotherapy in systemic sclerosis and severe morphea. *Dermatology*, 191: 25–31
- Cunningham BB, Landells ID, Langman C, Sailer DE, Paller AS (1998) Topical calcipotriene for morphea/linear scleroderma. *J Am Acad Dermatol*, 39: 211–215
- Curley RK, Macfarlane AW, Evans S, Woodrow JC (1987) The treatment of linear morphea with D-penicillamine. *Clin Exp Dermatol*, 12: 56–57
- Czarnecki DB, Taft EH (1982) Generalized morphea successfully treated with salazopyrine. *Acta Derm Venereol*, 62: 81–82
- Daoud MS, Su WP, Leiferman KM, Perniciaro C (1994) Bullous morphea: clinical, pathologic, and immunopathologic evaluation of thirteen cases. *J Am Acad Dermatol*, 30: 937–943
- David J, Wilson J, Woo P (1991) Scleroderma "en coup de sabre". *Ann Rheum Dis*, 50: 260–262
- Dehen L, Roujeau JC, Cosnes A, Revuz J (1994) Internal involvement in localized scleroderma. *Medicine (Baltimore)*, 73: 241–245
- Diaz-Perez J, Connolly S, Winkelmann R (1980) Disabling pansclerotic morphea of children. *Arch Dermatol*, 116: 169–173
- Dillon WI, Saed GM, Fivenson DP (1995) *Borrelia burgdorferi* DNA is undetectable by polymerase chain reaction in skin lesions of morphea, scleroderma, or lichen sclerosus et atrophicus of patients from North America. *J Am Acad Dermatol*, 33: 617–620
- Doyle JA, Ginsburg WW (1989) Eosinophilic fasciitis. *Med Clin North Am*, 73: 1157–1166
- Drago F, Rampini P, Lugani C, Rebora A (1998) Generalized morphea after antitetanus vaccination. *Clin Exp Dermatol*, 23: 142
- Dubois EL, Chandor S, Friou GJ, Bischel M (1971) Progressive systemic sclerosis (PSS) and localized scleroderma (morphea) with positive LE cell test and unusual systemic manifestations compatible with systemic lupus erythematosus (SLE): presentation of 14 cases including one

- set of identical twins, one with scleroderma and the other with SLE. Review of the literature. *Medicine (Baltimore)*, 50: 199–222
- Eisen D, Alster TS (2002). Use of a 585 nm pulsed dye laser for the treatment of morphea. *Dermatol Surg*, 28: 615–616
- El-Mofty M, Zaher H, Bosseila M, Yousef R, Saad B (2000) Low-dose broad-band UVA in morphea using a new method for evaluation. *Photodermatol Photoimmunol Photomed*, 16: 43–49
- El-Mofty M, Mostafa W, El-Darouty M, Bosseila M, Nada H, Yousef R, Esmat S, El-Lawindy M, Assaf M, El-Enani G (2004). Different low doses of broad-band UVA in the treatment of morphea and systemic sclerosis. *Photodermatol Photoimmunol Photomed*, 20: 148–156
- El-Mofty M, Mostafa W, Esmat S, Youssef R, Bousseila M, Nagi N, Shaker O, Abouzeid A (2004). Suggested mechanisms of action of UVA phototherapy in morphea: a molecular study. *Photodermatol Photoimmunol Photomed*, 20: 93–100
- Elst EF, Van Suijlekom-Smit LW, Oranje AP (1999) Treatment of linear scleroderma with oral 1,25-dihydroxyvitamin D3 (calcitriol) in seven children. *Pediatr Dermatol*, 16: 53–58
- Falanga V, Medsger TA, Reichlin M (1985) High titers of antibodies to single-stranded DNA in linear scleroderma. *Arch Dermatol*, 121: 345–347
- Falanga V, Medsger TA, Jr, Reichlin M, Rodnan GP (1986) Linear scleroderma. Clinical spectrum, prognosis, and laboratory abnormalities. *Ann Intern Med*, 104: 849–857
- Falanga V, Medsger TA, Jr, Reichlin M (1987) Antinuclear and anti-single-stranded DNA antibodies in morphea and generalized morphea. *Arch Dermatol*, 123: 350–353
- Falanga V, Medsger TA, Jr (1990) D-penicillamine in the treatment of localized scleroderma. *Arch Dermatol*, 126: 609–612
- Fleischmajer R, Nedwich A (1972) Generalized morphea. I. Histology of the dermis and subcutaneous tissue. *Arch Dermatol*, 106: 509–514
- Fleischmajer R, Perlish JS (1972). Glycosaminoglycans in scleroderma and scleredema. *J Invest Dermatol*, 58: 129–132
- Fleischmajer R, Prunieras M (1972) Generalized morphea. II. Electron microscopy of collagen, cells, and the subcutaneous tissue. *Arch Dermatol*, 106: 515–524
- Fleischmajer R, Perlish JS, Krieg T, Timpl R (1981) Variability in collagen and fibronectin synthesis by scleroderma fibroblasts in primary culture. *J Invest Dermatol*, 76: 400–403
- Foeldvari I (1998) Progressive linear scleroderma and morphea in a child. *J Pediatr*, 133: 308
- Fry A, Alvarellos A, Fink C, Blaw M, Roach E (1992) Intracranial findings in progressive facial hemiatrophy. *J Rheumatol*, 19: 956–958
- Fujimoto M, Sato S, Ihn H, Takehara K (1995) Autoantibodies to the heat-shock protein hsp73 in localized scleroderma. *Arch Dermatol Res*, 287: 581–585
- Gambichler T, Kreuter A, Rotterdam S, Altmeyer P, Hoffmann K (2003). Linear scleroderma 'en coup de sabre' treated with topical calcipotriol and cream psoralen plus ultraviolet A. *J Eur Acad Dermatol Venereol*, 17: 601–602
- Garcia-Bustinduy M, Noda A, Sanchez R, Gonzalez de Mesa MJ, Guimera F, Garcia-Montelongo R (1998) PUVA therapy in localized scleroderma. *J Eur Acad Dermatol Venereol*, 10: 283–284
- Garzon M, Paller A (1999) Ultrapotent topical corticosteroids treatment of childhood genital lichen sclerosus. *Arch Dermatol*, 135: 525–528
- Gordon GV (1981) Eosinophilic fasciitis. A case report and review of the literature. *Cutis*, 28: 268, 271–273
- Grundmann-Kollmann M, Ochsendorf F, Zollner TM, Spieth K, Sachsenberg-Studer E, Kaufmann R, Podda M (2000) PUVA-cream photochemotherapy for the treatment of localized scleroderma. *J Am Acad Dermatol*, 43: 675–678
- Gruss C, Reed JA, Altmeyer P, McNutt NS, Kersch M (1997a) Induction of interstitial collagenase (MMP-1) by UVA-1 phototherapy in morphea fibroblasts. *Lancet*, 350: 1295–1296
- Gruss C, Stucker M, Kobyletzki G, Schreiber D, Altmeyer P, Kersch M (1997b) Low dose UVA1 phototherapy in disabling pansclerotic morphea of childhood. *Br J Dermatol*, 136: 293–294
- Hasegawa M, Sato S, Nagaoka T, Fujimoto M, Takehara K (2003). Serum levels of tumor necrosis factor and interleukin-13 are elevated in patients with localized scleroderma. *Dermatology*, 207: 141–147

- Hatamochi A, Ono M, Arakawa M, Takeda K, Ueki H (1992) Analysis of collagen gene expression by cultured fibroblasts in morphoea. *Br J Dermatol*, 126: 216–221
- Hauser C, Skaria A, Harms M, Saurat JH (1996) Morphoea following Blaschko's lines. *Br J Dermatol*, 134: 594–595
- Hayakawa I, Hasegawa M, Takehara K, Sato S (2004). Anti-DNA topoisomerase IIalpha autoantibodies in localized scleroderma. *Arthritis Rheum*, 50: 227–232
- Higley H, Persichitte K, Chu S, Waegell W, Vancheswaran R, Black C (1994). Immunocytochemical localization and serologic detection of transforming growth factor beta 1. Association with type I procollagen and inflammatory cell markers in diffuse and limited systemic sclerosis, morphea, and Raynaud's phenomenon. *Arthritis Rheum*, 37: 278–288
- Holick MF, Smith E, Pincus S (1987) Skin as the site of vitamin D synthesis and target tissue for 1,25-dihydroxyvitamin D3. Use of calcitriol (1,25-dihydroxyvitamin D3) for treatment of psoriasis. *Arch Dermatol*, 123: 1677–1683a
- Hsu S, Lee MW, Carlton S, Kramer EM (1999) Nodular morphea in a linear pattern. *Int J Dermatol*, 38: 529–530
- Hulshof MM, Pavel S, Breedveld FC, Dijkmans BA, Vermeer BJ (1994) Oral calcitriol as a new therapeutic modality for generalized morphea. *Arch Dermatol*, 130: 1290–1293
- Humbert PG, Dupond JL, Rochefort A, Vasselet R, Lucas A, Laurent R, Agache P (1990) Localized scleroderma – response to 1,25-dihydroxyvitamin D3. *Clin Exp Dermatol*, 15: 396–398
- Humbert P, Aubin F, Dupond JL, Delaporte E (1995) Oral calcitriol as a new therapeutic agent in localized and systemic scleroderma. *Arch Dermatol*, 131: 850–851
- Hunzelmann N, Anders S, Fierlbeck G, Hein R, Herrmann K, Albrecht M, Bell S, Muehle R, Wehner-Caroli J, Gaus W, Krieg T (1997) Double-blind, placebo-controlled study of intralesional interferon gamma for the treatment of localized scleroderma. *J Am Acad Dermatol*, 36: 433–435
- Hunzelmann N, Scharffetter Kochanek K, Hager C, Krieg T (1998) Management of localized scleroderma. *Semin Cutan Med Surg*, 17: 34–40
- Igarashi A, Nashiro K, Kikuchi K, Sato S, Ihn H, Fujimoto M, Grotendorst GR, Takehara K (1996) Connective tissue growth factor gene expression in tissue sections from localized scleroderma, keloid, and other fibrotic skin disorders. *J Invest Dermatol*, 106: 729–733
- Ihn H, Sato S, Fujimoto M, Kikuchi K, Takehara K (1994) Demonstration of interleukin 8 in serum samples of patients with localized scleroderma. *Arch Dermatol*, 130: 1327–1328
- Ihn H, Sato S, Fujimoto M, Kikuchi K, Takehara K (1995) Demonstration of interleukin-2, interleukin-4 and interleukin-6 in sera from patients with localized scleroderma. *Arch Dermatol Res*, 287: 193–197
- Ihn H, Sato S, Fujimoto M, Kikuchi K, Takehara K (1996) Clinical significance of serum levels of soluble interleukin-2 receptor in patients with localized scleroderma. *Br J Dermatol*, 134: 843–7
- Ihn H, Yazawa N, Kubo M, Yamane K, Sato S, Fujimoto M, Kikuchi K, Soma Y, Tamaki K (2000) Circulating levels of soluble CD30 are increased in patients with localized scleroderma and correlated with serological and clinical features of the disease. *J Rheumatol*, 27: 698–702
- Itin PH, Schiller P (1999) Double-lined frontoparietal scleroderma en coup de sabre. *Dermatology*, 199: 185–186
- Jablonska S (1975a) Facial hemiatrophy and its relation to localized scleroderma. In: Jablonska S (ed) *Scleroderma and pseudoscleroderma*. PZWL, Warsaw, pp 537–548
- Jablonska S (1975b) Localized Scleroderma. In: Jablonska S (ed) *Scleroderma and pseudoscleroderma*. PZWL, Warsaw, pp 277–303
- Jablonska S, Rodnan G (1979) Localized forms of scleroderma. *Clin Rheumatol Dis*, 5: 215–241
- Jablonska S, Blaszczyk M (2004). Is superficial morphea synonymous with atrophoderma Pasini-Pierini? *J Am Acad Dermatol*, 50: 979–980
- Janzen L, Jeffery JR, Gough J, Chalmers IM (1995) Response to methotrexate in a patient with idiopathic eosinophilic fasciitis, morphea, IgM hypergammaglobulinemia, and renal involvement. *J Rheumatol*, 22: 1967–1970
- Jaworsky C (1997) Connective tissue diseases. In: Elder D (ed) *Lever's Histopathology of the Skin*. Lippincott-Raven, Philadelphia, pp 253–285

- Joly P, Bamberger N, Crickx B, Belaich S (1994) Treatment of severe forms of localized scleroderma with oral corticosteroids: follow-up study on 17 patients. *Arch Dermatol*, 130: 663–664
- Jones SM, Mathew CM, Dixey J, Lovell CR, McHugh NJ (1996) VCAM-1 expression on endothelium in lesions from cutaneous lupus erythematosus is increased compared with systemic and localized scleroderma. *Br J Dermatol*, 135: 678–686
- Kahari VM, Heino J, Vuorio T, Vuorio E (1988a) Interferon-alpha and interferon-gamma reduce excessive collagen synthesis and procollagen mRNA levels of scleroderma fibroblasts in culture. *Biochim Biophys Acta*, 968: 45–50
- Kahari VM, Sandberg M, Kalimo H, Vuorio T, Vuorio E (1988b) Identification of fibroblasts responsible for increased collagen production in localized scleroderma by in situ hybridization. *J Invest Dermatol*, 90: 664–670
- Kanekura T, Fukumaru S, Matsushita S, Terasaki K, Mizoguchi S, Kanzaki T (1996) Successful treatment of scleroderma with PUVA therapy. *J Dermatol*, 23: 455–459
- Karrer S, Abels C, Landthaler M, Szeimies RM (2000) Topical photodynamic therapy for localized scleroderma. *Acta Derm Venereol*, 80: 26–27
- Kencka D, Blaszczyk M, Jablonska S (1995) Atrophoderma Pasini-Pierini is a primary atrophic abortive morphea. *Dermatology*, 190: 203–6
- Kerscher M, Volkenandt M, Meurer M, Lehmann P, Plewig G, Rocken M (1994) Treatment of localised scleroderma with PUVA bath photochemotherapy. *Lancet*, 343: 1233
- Kerscher M, Dirschka T, Volkenandt M (1995) Treatment of localised scleroderma by UVA1 phototherapy. *Lancet*, 346: 1166
- Kerscher M, Meurer M, Sander C, Volkenandt M, Lehmann P, Plewig G, Rocken M (1996) PUVA bath photochemotherapy for localized scleroderma. Evaluation of 17 consecutive patients. *Arch Dermatol*, 132: 1280–1282
- Kerscher M, Volkenandt M, Gruss C, Reuther T, von Kobyletzki G, Freitag M, Dirschka T, Altmeyer P (1998) Low-dose UVA phototherapy for treatment of localized scleroderma. *J Am Acad Dermatol*, 38: 21–26
- Kobayashi KA, Lui H, Prendiville JS (1991) Solitary morphea profunda in a 5-year-old girl: case report and review of the literature. *Pediatr Dermatol*, 8: 292–295
- Kobayashi T, Serup J (1985) Vascular changes in morphea. *Acta Derm Venereol*, 65: 116–120
- Kobayashi T, Willeberg A, Serup J, Ullman S (1990) Generalized morphea with blisters. A case report. *Acta Derm Venereol*, 70: 454–456
- Koeger AC, Rozenberg S, Fautrel B (1999) Effectiveness of topical calcitriol for localized scleroderma. *J Rheumatol*, 26: 239–240
- Kowalewski C, Kozłowska A, Zawadzka M, Wozniak K, Blaszczyk M, Jablonska S (2004). Alterations of basement membrane zone in bullous and non-bullous variants of extragenital lichen sclerosus. *Am J Dermatopathol*, 26: 96–101
- Krell JM, Solomon AR, Glavey CM, Lawley TJ (1995) Nodular scleroderma. *J Am Acad Dermatol*, 32: 343–345
- Kreuter A, Gambichler T, Avermaete A, Jansen T, Hoffmann M, Hoffmann K, Altmeyer P, von Kobyletzki G, Bacharach-Buhles M (2001). Combined treatment with calcipotriol ointment and low-dose ultraviolet A1 phototherapy in childhood morphea. *Pediatr Dermatol*, 18: 241–245
- Kubo M, Ihn H, Yamane K, Tamaki K (2001). Up-regulated expression of transforming growth factor beta receptors in dermal fibroblasts in skin sections from patients with localized scleroderma. *Arthritis Rheum*, 44: 731–734
- Labandeira J, Leon-Mateos A, Suarez-Penaranda JM, Garea MT, Toribio J (2003). What is nodular-keeloidal scleroderma? *Dermatology*, 207: 130–132
- Lee HJ, Kim MY, Ha SJ, Kim JW (2002). Two cases of morphea associated with Hashimoto's thyroiditis. *Acta Derm Venereol*, 82: 58–59
- Levy JJ, Gassmuller J, Audring H, Brenke A, Albrecht-Nebe H (1993) Imaging subcutaneous atrophy in circumscribed scleroderma with 20 MHz B-scan ultrasound. *Hautarzt*, 44: 446–451
- Liu P, Uziel Y, Chuang S, Silverman E, Krafchik B, Laxer R (1994) Localized scleroderma: Imaging features. *Pediatr Radiol*, 24: 207–209
- Luer W, Jockel D, Henze T, Schipper HI (1990) Progressive inflammatory lesions of the brain parenchyma in localized scleroderma of the head. *J Neurol*, 237: 379–381

- Man J, Dytoc MT (2004). Use of Imiquimod Cream 5% in the Treatment of Localized Morphea. *J Cutan Med Surg*, 8: 166-9
- Mancuso G, Berdondini RM (2003). Topical tacrolimus in the treatment of localized scleroderma. *Eur J Dermatol*, 13: 590-592
- Martini G, Murray KJ, Howell KJ, Harper J, Atherton D, Woo P, Zulian F, Black CM (2002). Juvenile-onset localized scleroderma activity detection by infrared thermography. *Rheumatology (Oxford)*, 41: 1178-1182
- Marzano AV, Menni S, Parodi A, Borghi A, Fuligni A, Fabbri P, Caputo R (2003). Localized scleroderma in adults and children. Clinical and laboratory investigations on 239 cases. *Eur J Dermatol*, 13: 171-176
- Mattila L, Airola K, Ahonen M, Hietarinta M, Black C, Saarialho-Kere U, Kahari VM (1998). Activation of tissue inhibitor of metalloproteinases-3 (TIMP-3) mRNA expression in scleroderma skin fibroblasts. *J Invest Dermatol*, 110: 416-421
- McColl G, Buchanan RR (1994). Unilateral scleroderma following ischemic hand injury. *J Rheumatol*, 21: 380-381
- McNiff JM, Glusac EJ, Lazova RZ, Carroll CB (1999). Morphea limited to the superficial reticular dermis: an underrecognized histologic phenomenon. *Am J Dermatopathol*, 21: 315-319
- Menni S, Marzano AV, Passoni E (1997). Neurologic abnormalities in two patients with facial hemiatrophy and sclerosis coexisting with morphea. *Pediatr Dermatol*, 14: 113-116
- Micalizzi C, Parodi A, Rebora A (1994). Morphea with nodular lesions. *Br J Dermatol*, 131: 298-300
- Micalizzi C, Parodi A, Rebora A (1996). Generalized bullous morphoea. Efficacy of salazopyrin. *Clin Exp Dermatol*, 21: 246-247
- Miller J (1992). The fasciitis-morphea complex in children. *Am J Dis Child*, 146: 733-736
- Mitchet C, Doyle J, Ginsburg W (1981). Eosinophilic fasciitis: report of 15 cases. *Mayo Clin Proc*, 56: 27-34
- Mizutani H, Yoshida T, Nouchi N, Hamanaka H, Shimizu M (1999). Topical tocoretinate improved hypertrophic scar, skin sclerosis in systemic sclerosis and morphea. *J Dermatol*, 26: 11-7
- Mohrenschlager M, Jung C, Ring J, Abeck D (1999). Effect of penicillin G on corium thickness in linear morphea of childhood: An analysis using ultrasound technique. *Pediatr Dermatol*, 16: 314-316
- Moller R, Serup J, Ammitzball T (1985). Glycosaminoglycans in localized scleroderma (morphoea). *Connect Tissue Res*, 13: 227-236
- Monteiro MR, Murphy EE, Galaria NA, Whitaker-Menezes D, Murphy GF (2000). Cytological alterations in dermal dendrocytes in vitro: evidence for transformation to a non-dendritic phenotype. *Br J Dermatol*, 143: 84-90
- Morison WL (1997). Psoralen UVA therapy for linear and generalized morphea. *J Am Acad Dermatol*, 37: 657-659
- Morita A, Werfel T, Stege H, Ahrens C, Karmann K, Grewe M, Grether-Beck S, Ruzicka T, Kapp A, Klotz LO, Sies H, Krutmann J (1997). Evidence that singlet oxygen-induced human T helper cell apoptosis is the basic mechanism of ultraviolet-A radiation phototherapy. *J Exp Med*, 186: 1763-1768
- Mork NJ (1981). Clinical and histopathologic morphea with immunological evidence of lupus erythematosus: a case report. *Acta Derm Venereol*, 61: 367-368
- Morley SM, Gaylarde PM, Sarkany I (1985). Epidermal thickness in systemic sclerosis and morphoea. *Clin Exp Dermatol*, 10: 51-57
- Moynahan EJ (1973). Morphoea (localized cutaneous scleroderma) treated with low-dosage penicillamine (4 cases, including coup de sabre). *Proc R Soc Med*, 66: 1083-1085
- Nagai M, Hasegawa M, Takehara K, Sato S (2004). Novel autoantibody to Cu/Zn superoxide dismutase in patients with localized scleroderma. *J Invest Dermatol*, 122: 594-601
- Narvaez D, Kanitakis J, Faure M, Claudy A (1996). Immunohistochemical study of CD34-positive dendritic cells of human dermis. *Am J Dermatopathol*, 18: 283-288
- Neldner KH (1978). Treatment of localized linear scleroderma with phenytoin. *Cutis*, 22: 569-572
- Neuhofer J, Fritsch P (1984). Treatment of localized scleroderma and lichen sclerosus with etretinate. *Acta Derm Venereol*, 64: 171-174

- Oikarinen A, Knuutinen A (2001). Ultraviolet A sunbed used for the treatment of scleroderma. *Acta Derm Venereol*, 81: 432-433
- O'Leary P, Montgomery H, Ragsdale W (1957) Dermatohistopathology of various types of scleroderma. *Arch Dermatol*, 75: 78-87
- Oyama N, Chan I, Neill SM, Hamada T, South AP, Wessagowit V, Wojnarowska F, D'Cruz D, Hughes GJ, Black MM, McGrath JA (2003). Autoantibodies to extracellular matrix protein 1 in lichen sclerosus. *Lancet*, 362: 118-123
- Oyama N, Chan I, Neill SM, South AP, Wojnarowska F, Kawakami Y, D'Cruz D, Mepani K, Hughes GJ, Bhogal BS, Kaneko F, Black MM, McGrath JA (2004). Development of antigen-specific ELISA for circulating autoantibodies to extracellular matrix protein 1 in lichen sclerosus. *J Clin Invest*, 113: 1550-1559
- Passos CO, Werneck CC, Onofre GR, Pagani EA, Filgueira AL, Silva LC (2003). Comparative biochemistry of human skin: glycosaminoglycans from different body sites in normal subjects and in patients with localized scleroderma. *J Eur Acad Dermatol Venereol*, 17: 14-19
- Perlish JS, Lemlich G, Fleischmajer R (1988) Identification of collagen fibrils in scleroderma skin. *J Invest Dermatol*, 90: 48-54
- Person JR, Su WP (1979) Subcutaneous morphea: a clinical study of sixteen cases. *Br J Dermatol*, 100: 371-380
- Peter RU, Ruzicka T, Eckert F (1991) Low-dose cyclosporine A in the treatment of disabling morphea. *Arch Dermatol*, 127: 1420-1421
- Peterson LS, Nelson AM, Su WP (1995) Classification of morphea (localized scleroderma). *Mayo Clin Proc*, 70: 1068-1076
- Peterson LS, Nelson AM, Su WP, Mason T, O'Fallon WM, Gabriel SE (1997) The epidemiology of morphea (localized scleroderma) in Olmsted County 1960-1993. *J Rheumatol*, 24: 73-80
- Rai R, Handa S, Gupta S, Kumar B (2000) Bilateral en coup de sabre-a rare entity. *Pediatr Dermatol*, 17: 222-224
- Rencic A, Brinster N, Nousari CH (2003). Keloid morphea and nodular scleroderma: two distinct clinical variants of scleroderma? *J Cutan Med Surg*, 7: 20-24
- Rigby WF, Denome S, Fanger MW (1987) Regulation of lymphokine production and human T lymphocyte activation by 1,25-dihydroxyvitamin D3. Specific inhibition at the level of messenger RNA. *J Clin Invest*, 79: 1659-1664
- Rigby WF, Waugh MG (1992) Decreased accessory cell function and costimulatory activity by 1,25-dihydroxyvitamin D3-treated monocytes. *Arthritis Rheum*, 35: 110-119
- Rodnan GP, Lipinski E, Luksick J (1979) Skin thickness and collagen content in progressive systemic sclerosis and localized scleroderma. *Arthritis Rheum*, 22: 130-140
- Rose CD, Fawcett PT, Gibney K, Doughty RA, Singsen BH (1994) Serial measurements of soluble interleukin 2 receptor levels (sIL2-R) in children with juvenile rheumatoid arthritis treated with oral methotrexate. *Ann Rheum Dis*, 53: 471-474
- Rosenberg AM, Uziel Y, Krafchik BR, Hauta SA, Prokopchuk PA, Silverman ED, Laxer RM (1995) Antinuclear antibodies in children with localized scleroderma. *J Rheumatol*, 22: 2337-2343
- Ruffatti A, Peserico A, Rondinone R, Calligaro A, Del Ross T, Ghirardello A, Germino M, Todesco S (1991) Prevalence and characteristics of anti-single-stranded DNA antibodies in localized scleroderma. Comparison with systemic lupus erythematosus. *Arch Dermatol*, 127: 1180-1183
- Sakuraoka K, Tajima S, Nishikawa T (1992) Progressive facial hemiatrophy: report of five cases and biochemical analysis of connective tissue. *Dermatology*, 185: 196-201
- Salmon-Ehr V, Serpier H, Nawrocki B, Gillery P, Clavel C, Kalis B, Birembaut P, Maquart FX (1996) Expression of interleukin-4 in scleroderma skin specimens and scleroderma fibroblast cultures. Potential role in fibrosis. *Arch Dermatol*, 132: 802-806
- Sato S, Fujimoto M, Ihn H, Kikuchi K, Takehara K (1994) Antigen specificity of antihistone antibodies in localized scleroderma. *Arch Dermatol*, 130: 1273-1277
- Sato S, Fujimoto M, Kikuchi K, Ihn H, Tamaki K, Takehara K (1996a) Elevated soluble CD23 levels in the sera from patients with localized scleroderma. *Arch Dermatol Res*, 288: 74-88
- Sato S, Fujimoto M, Kikuchi K, Ihn H, Tamaki K, Takehara K (1996b) Soluble CD4 and CD8 in serum from patients with localized scleroderma. *Arch Dermatol Res*, 288: 358-362

- Sato S, Fujimoto M, Hasegawa M, Takehara K (2003). Antiphospholipid antibody in localised scleroderma. *Ann Rheum Dis*, 62: 771-774
- Schaffer JV, Carroll C, Dvoretzky I, Huether MJ, Girardi M (2000) Postirradiation morphea of the breast presentation of two cases and review of the literature. *Dermatology*, 200: 67-71
- Scharffetter-Kochanek K, Goldermann R, Lehmann P, Holzle E, Goerz G (1995) PUVA therapy in disabling pansclerotic morphoea of children. *Br J Dermatol*, 132: 830-831
- Scharffetter K, Lankat-Buttgereit B, Krieg T (1988) Localization of collagen mRNA in normal and scleroderma skin by in-situ hybridization. *Eur J Clin Invest*, 18: 9-17
- Schiener R, Behrens-Williams SC, Gottlob P, Pillekamp H, Peter RU, Kerscher M (2000) Eosinophilic fasciitis treated with psoralen-ultraviolet A bath photochemotherapy. *Br J Dermatol*, 142: 804-807
- Seitz M, Loetscher P, Dewald B, Towbin H, Rordorf C, Gallati H, Baggiolini M, Gerber NJ (1995) Methotrexate action in rheumatoid arthritis: stimulation of cytokine inhibitor and inhibition of chemokine production by peripheral blood mononuclear cells. *Br J Rheumatol*, 34: 602-9
- Seitz M, Zwicker M, Loetscher P (1998) Effects of methotrexate on differentiation of monocytes and production of cytokine inhibitors by monocytes. *Arthritis Rheum*, 41: 2032-2038
- Seyger MM, van den Hoogen FH, de Boo T, de Jong EM (1997) Reliability of two methods to assess morphea: skin scoring and the use of a durometer. *J Am Acad Dermatol*, 37: 793-796
- Seyger MM, van den Hoogen FH, de Boo T, de Jong EM (1998) Low-dose methotrexate in the treatment of widespread morphea. *J Am Acad Dermatol*, 39: 220-225
- Seyger MM, van den Hoogen FH, van Vlijmen-Willems IM, van de Kerkhof PC, de Jong EM (2001). Localized and systemic scleroderma show different histological responses to methotrexate therapy. *J Pathol*, 193: 511-516
- Sgonc R, Gruschwitz MS, Dietrich H, Recheis H, Gershwin ME, Wick G (1996) Endothelial cell apoptosis is a primary pathogenetic event underlying skin lesions in avian and human scleroderma. *J Clin Invest*, 98: 785-792
- Shulman L (1974) Diffuse fasciitis with hypergammaglobulinemia and eosinophilia: a new syndrome? *Clinical Research*, 23: 443A
- Silman A, Jannini S, Symmons D, Bacon P (1988) An epidemiological study of scleroderma in the West Midlands. *Br J Rheumatol*, 27: 286-290
- Skobieranda K, Helm KF (1995) Decreased expression of the human progenitor cell antigen (CD34) in morphea. *Am J Dermatopathol*, 17: 471-475
- Soma Y, Fujimoto M (1998). Frontoparietal scleroderma (en coup de sabre) following Blaschko's lines. *J Am Acad Dermatol*, 38: 366-368
- Soma Y, Tamaki T, Kikuchi K, Abe M, Igarashi A, Takehara K, Ishibashi Y (1993) Coexistence of morphea and systemic sclerosis. *Dermatology*, 186: 103-105
- Stava Z, Kobikova M (1977) Salazopyrin in the treatment of scleroderma. *Br J Dermatol*, 96: 541-544
- Stefanec T (2000) Endothelial apoptosis: could it have a role in the pathogenesis and treatment of disease? *Chest*, 117: 841-854
- Stege H, Berneburg M, Humke S, Klammer M, Grewe M, Grether-Beck S, Boedeker R, Diepgen T, Dierks K, Goerz G, Ruzicka T, Krutmann J (1997) High-dose UVA1 radiation therapy for localized scleroderma. *J Am Acad Dermatol*, 36: 938-944
- Steger JW, Matthews JH (1999) UVA therapy for scleroderma. *J Am Acad Dermatol*, 40: 787-788
- Stone J, Franks AJ, Guthrie JA, Johnson MH (2001). Scleroderma "en coup de sabre": pathological evidence of intracerebral inflammation. *J Neurol Neurosurg Psychiatry*, 70: 382-385
- Su WP, Person JR (1981) Morphea profunda. A new concept and a histopathologic study of 23 cases. *Am J Dermatopathol*, 3: 251-260
- Su WP, Greene SL (1986) Bullous morphea profunda. *Am J Dermatopathol*, 8: 144-147
- Takehara K, Moroi Y, Nakabayashi Y, Ishibashi Y (1983) Antinuclear antibodies in localized scleroderma. *Arthritis Rheum*, 26: 612-616
- Taveira M, Selores M, Costa V, Massa A (1999) Generalized morphea and lichen sclerosus et atrophicus successfully treated with sulphasalazine. *J Eur Acad Dermatol Venereol*, 12: 283-284

- Todd DJ, Askari A, Ektaish E (1998) PUVA therapy for disabling pansclerotic morphea of children. *Br J Dermatol*, 138: 201–202
- Torres JE, Sanchez JL (1998) Histopathologic differentiation between localized and systemic scleroderma. *Am J Dermatopathol*, 20: 242–245
- Tuffanelli DL (1998) Localized scleroderma. *Semin Cutan Med Surg*, 17: 27–33
- Uitto J, Santa Cruz DJ, Bauer EA, Eisen AZ (1980) Morphea and lichen sclerosus et atrophicus. Clinical and histopathologic studies in patients with combined features. *J Am Acad Dermatol*, 3: 271–279
- Umbert P, Winkelmann RK (1978) Concurrent localized scleroderma and discoid lupus erythematosus. Cutaneous 'mixed' or 'overlap' syndrome. *Arch Dermatol*, 114: 1473–1478
- Unterberger I, Trinkla E, Engelhardt K, Muigg A, Eller P, Wagner M, Sepp N, Bauer G (2003). Linear scleroderma "en coup de sabre" coexisting with plaque-morphea: neuro-radiological manifestation and response to corticosteroids. *J Neurol Neurosurg Psychiatry*, 74: 661–664
- Uziel Y, Krafchik BR, Feldman B, Silverman ED, Rubin LA, Laxer RM (1994). Serum levels of soluble interleukin-2 receptor. A marker of disease activity in localized scleroderma. *Arthritis Rheum*, 37: 898–901
- Uziel Y, Krafchik BR, Silverman ED, Thorner PS, Laxer RM (1994b) Localized scleroderma in childhood: a report of 30 cases. *Semin Arthritis Rheum*, 23: 328–340
- Uziel Y, Feldman BM, Krafchik BR, Yeung RS, Laxer RM (2000) Methotrexate and corticosteroid therapy for pediatric localized scleroderma. *J Pediatr*, 136: 91–95
- van Bergen BH, van Dooren-Greebe RJ, Fiselier TJ, Koopman RJ (1997) D-penicillamine in treatment of scleroderma "en coup de sabre". *Hautarzt*, 48: 42–44
- van den Hoogen FH, Boerbooms AM, Swaak AJ, Rasker JJ, van Lier HJ, van de Putte LB (1996) Comparison of methotrexate with placebo in the treatment of systemic sclerosis: a 24 week randomized double-blind trial, followed by a 24 week observational trial. *Br J Rheumatol*, 35: 364–372
- Venneker GT, Das PK, Naafs B, Tigges AJ, Bos JD, Asghar SS (1994) Morphea lesions are associated with aberrant expression of membrane cofactor protein and decay accelerating factor in vascular endothelium. *Br J Dermatol*, 131: 237–242
- Wach F, Ullrich H, Schmitz G, Landthaler M, Hein R (1995) Treatment of severe localized scleroderma by plasmapheresis – report of three cases. *Br J Dermatol*, 133: 605–609
- Wakelin SH, James MP (1995) Zosteriform atrophoderma of Pasini and Pierini. *Clin Exp Dermatol*, 20: 244–246
- Weedon D (1997) Disorders of collagen. In: *Skin Pathology*, Churchill Livingstone, HongKong, pp 288–293
- Weide B, Walz T, Garbe C (2000) Is morphea caused by *Borrelia burgdorferi*? A review. *Br J Dermatol*, 142: 636–644
- Whittaker SJ, Smith NP, Jones RR (1989) Solitary morphea profunda. *Br J Dermatol*, 120: 431–440
- Winkelmann RK, Connolly SM, Doyle JA (1982) Carpal tunnel syndrome in cutaneous connective tissue disease: generalized morphea, lichen sclerosus, fasciitis, discoid lupus erythematosus, and lupus panniculitis. *J Am Acad Dermatol*, 7: 94–99
- Winkelmann R (1985) Localized cutaneous scleroderma. *Seminars in Dermatology*, 4: 90–103
- Wlaschek M, Briviba K, Stricklin GP, Sies H, Scharffetter-Kochanek K (1995) Singlet oxygen may mediate the ultraviolet A-induced synthesis of interstitial collagenase. *J Invest Dermatol*, 104: 194–198
- Wollenberg A, Baumann L, Plewig G (1995) Linear atrophoderma of Moulin: a disease which follows Blaschko's lines. *Br J Dermatol*, 135: 277–279
- Wollina U, Looks A, Schneider R, Maak B (1998) Disabling morphea of childhood-beneficial effect of intravenous immunoglobulin therapy. *Clin Exp Dermatol*, 23: 292–293
- Wuthrich RC, Roenigk HH, Steck WD (1975) Localized scleroderma. *Arch Dermatol*, 111: 98–100
- Yamaguchi K, Takeuchi I, Yoshii N, Gushi A, Kanekura T, Kanzaki T (1998) The discrepancy in hardness between clinical and histopathological findings in localized scleroderma treated with PUVA. *J Dermatol*, 25: 544–546
- Yamanaka CT, Gibbs NF (1999) Trauma-induced linear scleroderma. *Cutis*, 63: 29–32



- Yamane K, Ihn H, Kubo M, Yazawa N, Kikuchi K, Soma Y, Tamaki K (2000) Increased serum levels of soluble vascular cell adhesion molecule 1 and E-selectin in patients with localized scleroderma. *J Am Acad Dermatol*, 42: 64–69
- Young EM, Jr, Barr RJ (1985) Sclerosing dermatoses. *J Cutan Pathol*, 12: 426–441
- Zheng XY, Zhang JZ, Tu P, Ma SQ (1998) Expression of platelet-derived growth factor B-chain and platelet-derived growth factor beta-receptor in fibroblasts of scleroderma. *J Dermatol Sci*, 18: 90–97

## **4.2 Progressive Systemic Scleroderma**

*Nicolas Hunzelmann and Thomas Krieg*

### **Introduction**

Systemic sclerosis (SSc) belongs to the group of "diffuse inflammatory connective tissue diseases" or "collagen vascular diseases" comprising a variety of severe, sometimes life-threatening systemic diseases which often have a chronic, debilitating course. SSc is characterized by the involvement of the skin and various internal organs (e.g. kidney, lung, heart). The inflammatory and fibrotic process destroys the normal architecture of the affected organs leading to dysfunction and failure. The disease activity is highly variable and often unpredictable. The severity of the disease process in SSc leads to a reduced lifespan, impaired mobility and loss of autonomy.

SSc mainly evolves along pathological changes of the vascular system, the immune system and of the extracellular matrix including its major cell type, the fibroblast. The resulting fibrosis leading to atrophy and failure of the affected organs largely determines the outcome of the disease process. However, despite intense research efforts the relationship and interaction between the pathophysiological processes affecting the vascular system, the immune system and the extracellular matrix are only incompletely understood.

### **Immune Dysregulation**

One of the hallmarks of SSc is a perturbed immunoregulation (resulting in the presence of autoantibodies), which appears to be influenced by additional factors such as genetic and exogenous factors. Autoimmunity in SSc is characterized by HLA gene restricted autoantibody responses against nuclear and nucleolar antigens. The mechanisms inducing the antibody production are unknown but clinical associations with autoantibody specificities suggest that these antigen-restricted responses are involved in disease specific pathology. These autoimmune phenomena are in a not well understood way related to the inflammatory process with lymphocytic perivascular infiltrates in the skin

and lung evident early on in the disease process and preceding the development of fibrosis. The similarity of the condition with some aspects of graft versus host disease has frequently been noted. Recently it was suggested that microchimerism, i.e. the persistence of foetal cells in the maternal bone marrow and other organs like the skin might be a risk factor, also explaining the female excess (Artlett et al. 1998; Evans et al. 1999). However, subsequent studies found similar frequencies of microchimerisms compared to normal controls but nevertheless an increased number of microchimeric fetal cells in patients (Burastero et al 2003).

### **Vascular Pathology**

The relationship between autoimmune responses and the vascular pathology is unclear, as Raynaud's syndrome and vascular abnormalities may be evident many years prior to the onset of disease (Blockmans et al. 1996). The morphological changes that can be observed on a ultrastructural level, i.e. basement membrane thickening, intimal hyperplasia and inflammatory cell infiltration have been interpreted as a sign indicating microvascular injury as a primary event in this disease (Prescott et al. 1992).

Depending on the study population and statistical methodology, between 5 and 20% of all individuals presenting with Raynaud's phenomenon are reported to subsequently develop SSc. A constellation of additional signs and symptoms indicative of microvascular damage separates SSc patients from others presenting with Raynaud's phenomenon. These include nailfold capillaroscopic changes (Maricq et al. 1980), hand/foot edema, digital ulcers, calcifications and teleangiectasia. The combination of a fibrotic microvascular and hyperreactive vasoconstrictor status is thought to represent the primary lesion responsible for the vasospastic episodes. Tissue hypoxia normally induces new blood vessel growth by induction of a variety of angiogenic factors. In SSc, loss of capillaries is a typical and early disease manifestation which has been related to an increase in angiostatic factors and programmed endothelial cell death (apoptosis) where a number of possible mechanisms have been proposed (Sgonc et al. 1996; Kahaleh and Fan 1997; Hebbbar et al, 2000). A recent study suggests that latent cytomegalovirus infection contributes to the known phenomenon of endothelial cell cytotoxicity of scleroderma serum by identifying IgG autoantibodies that bind a cytomegalovirus protein and induce apoptosis in human endothelial cells (Lunardi et al. 2000).

### **Dysregulation of Extracellular Matrix Synthesis**

The dysregulation of extracellular matrix synthesis is the third major pathophysiologic change, with the extent and progression of the fibrotic process

being important prognostic factors in the disease process. It has been well established by *in situ* hybridization and by fibroblast cultures obtained from involved tissue (e.g. skin or lung) that scleroderma fibroblasts display an activated phenotype producing increased amounts of various collagens and expressing adhesion molecules such as ICAM-1 (LeRoy et al. 1974; Uitto et al. 1979; Scharffetter et al. 1988; Majewski et al. 1995). The newly synthesized extracellular matrix is deposited particularly around skin appendages and at the border of the dermis to the subcutaneous tissue, partially replacing the latter (Perlish et al. 1985). The collagen bundles running parallel with the skin surface show swelling and variation in thickness. Although the biosynthesis of collagens has been investigated in detail, its metabolism and turnover *in vivo* is not yet fully understood. In physiological situations involving increased collagen synthesis, as e.g. in wound healing, the amount of collagen in the tissue is obviously tightly controlled by its similarly increased degradation. Similarly, in a fibrotic disease, the net gain of collagens must thus involve a disturbed balance between the synthetic and degradative processes. The most commonly used approach to study collagen degradation is the study of collagen degrading enzymes (Herrmann et al. 1991; Mauch et al. 1998). However, the results are difficult to interpret in terms of the *in vivo* situation, as a combination of several enzymes including the corresponding inhibitors are likely to be involved in the degradation of a single collagen fiber. A different approach to this question is to study the degradation products as they appear *in vivo*. Interestingly, we and others could demonstrate that increased levels of ICTP, a degradation product of cross-linked type I collagen, are common in patients with SSc (Heickendorff et al. 1995; Hunzelmann et al. 1998b). They correlate well with the skin score, a commonly used indicator of the severity of the disease (Subcommittee of the ARA 1980; Kahaleh et al. 1986). This indicates that the concentrations of circulating ICTP reflect the type I collagen load in this disease. We found the highest values in patients with very active and extensive disease. Recently, a study on the urinary excretion of two mature cross-links of collagen, hydroxylysyl and lysyl pyridinoline, also suggested that in SSc more fibrillar collagens are degraded than in the normal state (Stone et al. 1995). Furthermore these crosslinks can usually only be detected in bone, suggesting that occurrence of these crosslinks in the skin is related to the sclerotic process. Therefore these studies indicate that the increased deposition of type I collagen is accompanied by an increased turnover and altered crosslink formation of this molecule, indicating an even more complex derangement of synthetic and degradative processes in this disease than previously acknowledged.

The factors which finally lead to the activated phenotype of scleroderma fibroblasts are not entirely clear. Several studies suggest the contribution of transforming growth factor- $\beta$  (TGF- $\beta$ ) (Kulozik et al. 1990), a potent inducer of collagen synthesis, to the progression of skin sclerosis. This notion is further supported by the detection of connective tissue growth factor (CTGF) gene expression in skin biopsies of SSc patients (Igarashi et al. 1995) and SSc

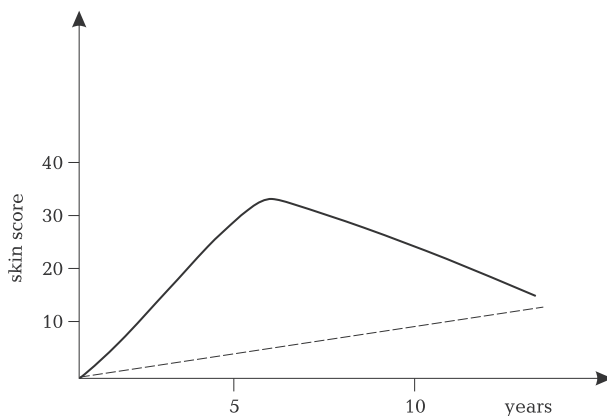
fibroblasts (Shi-Wen et al. 2000) as TGF- $\beta$  is also known to induce CTGF. Recent studies indicate that a deficiency in SMAD-7 an inhibitory protein in the TGF- $\beta$  signalling pathway is characteristic of scleroderma fibroblasts (Dong et al. 2002). The increased biosynthesis of collagen is accompanied by an elevation of the steady-state mRNA levels in vitro and in vivo of about 1.5–2x which appears to be due to both increased transcriptional activation as well as increased mRNA stability (Eckes et al. 1996; Jimenez and Saitta, 2000).

### **Clinical Appearance/Classification**

The incidence of SSc is reported to be 2–20/million population and the prevalence 4–290/million population. Based on distinct clinical aspects and courses of the disease an internationally accepted classification was established with two forms: limited cutaneous SSc (lSSc) and diffuse cutaneous SSc (dSSc). The disease is much commoner in females than males for reasons that are not entirely clear with a female-to-male ratio of 3–9:1. There are some populations at high risk as e.g. the Choctaw Indians from Oklahoma suggesting that genetic factors are critical. However, twin studies are inconclusive and familial aggregation is rare.

Both forms, however, lead to life threatening involvement of internal organs and large areas of the skin and are associated with marked excess mortality. The quality of life is severely reduced and the patients require continuous medical support. Institution of regular physical therapy as early as possible to prevent loss of function is mandatory. Patient support groups play an important role in helping these patients to cope with their difficult psychosocial situation. The two major clinical variants are distinguished primarily on the degree and extent of skin involvement. The term overlap syndrome is used when features commonly encountered in other connective tissue diseases are present such as polymyositis or systemic lupus erythematosus.

The hallmark of SSc is fibrosis of the skin resulting early on in oedema, often the first indication of SSc skin involvement, which is followed by fibrotic induration and finally atrophy. Several skin scoring methodologies have been developed with the modified Rodnan skin score having the broadest distribution (Kahaleh et al, 1986; Furst et al. 1998). It is assessed by palpation of skin using a 0–3 scale (normal, mild, moderate or severe thickening) at seventeen areas. Following the skin score and the distribution of cutaneous induration is of major clinical importance, as patients with diffuse cutaneous scleroderma are much more likely to have significant heart and/or renal disease than those with the limited form of SSc, furthermore early disability and premature mortality are observed in this group (Clements et al. 1990). The period when skin thickening is most rapidly is also a time in which decline in visceral function is most likely to occur (Seibold 1994) (*Fig. 1*).



**Fig. 1.** Longitudinal development of skin score in patients with diffuse systemic sclerosis (—) and limited systemic sclerosis (- - -)

### Diffuse Cutaneous SSc (dSSc)

dSSc is characterized by distal and proximal extremity and truncal skin thickening. Usually the elbows and knees are considered the dividing line. Leading symptoms of dSSc are: 1) onset of Raynaud's syndrome within 1 year of onset of skin changes (puffy or hidebound); 2) presence of tendon friction rubs; 3) early and significant incidence of interstitial lung disease, oliguric renal failure, diffuse gastrointestinal disease, and myocardial involvement; 4) absence of anti CENP-B antibodies; 5) nailfold capillary dilatation and capillary destruction; 6) anti-DNA-topoisomerase I antibodies (30%).

### Limited Cutaneous SSc (lSSc)

Leading symptoms of lSSc are the following: 1) Raynaud's syndrome for years (occasionally decades); 2) skin involvement limited to hands, face, and forearms (acral) or absent; 3) a significant late incidence of pulmonary hypertension, with or without interstitial lung disease; 4) a high incidence of anti centromer (CENP-B) antibodies (70–80%); 5) dilated nailfold capillary loops, usually without capillary dropout; 6) skin calcifications and teleangiectasia particularly affecting the face and hands; 7) occasional late development of small bowel mal absorption.

A recent study suggests that *systemic sclerosis sine scleroderma* is a subset of SSc which should be included into the spectrum of SSc with limited cutaneous involvement and should not be considered as a distinct disorder (Poormoghim et al. 2000). Except for the absence of skin thickening, the group of patients with *systemic sclerosis sine scleroderma* had no significant

differences in individual internal organ involvements, laboratory features, serum autoantibody type (e.g. anti-centromer) or survival rate compared with patients with lSSc. There was a tendency but no significant difference toward more pronounced pulmonary arterial hypertension and reduced carbon monoxide diffusing capacity (< 70% of predicted).

### **Scleroderma Overlap Syndromes**

The most common overlap syndromes are Mixed Connective Tissues Disease (MCTD), Scleromyositis (PM-Scl-associated) and the Synthetase Syndrome (Jo 1-associated). MCTD and the Synthetase Syndrome are more extensively dealt with in chapter 7.

Scleromyositis is a scleroderma/polymyositis or scleroderma/dermatomyositis overlap disorder associated with antibodies directed to the nucleolar PM-Scl complex and associated with HLA-DR3 (Genth et al. 1990). In a recent study of 108 cases, 83% of patients had characteristic manifestations (Jablonska and Blasczyk 1999). These findings include Raynaud's syndrome, scleroderma-like and dermatomyositis-like cutaneous changes of the face and hands including hyperkeratotic changes on the fingers, myalgia and arthritis. Pulmonary involvement occurs in about 30 to 60% of the patients (Marguerie et al. 1992). This syndrome is also a rather common subtype in children as about one third of the reported cases in the study of Jablonska (1999) are children with a mean age of onset at nine years. The course of this overlap syndrome is rather benign and usually responds to small or moderate doses of corticosteroids.

### **Environmentally Related Scleroderma-Like Syndromes**

A broad variety of environmental factors have been reported to induce scleroderma (reviewed in Straniero et al. 1989). However, with few exceptions (contaminated tryptophan, contaminated rape seed oil, vinyl chloride, trichlorethylene) these cases are likely to represent random occurrences. These scleroderma-like disorders often lack several features of SSc, in particular the autoimmune phenomena (autoantibody synthesis). In this respect, there has been much concern and publicity on the role of silicone (e.g. in the form of surgical implants) as a possible environmental factor for connective tissue diseases such as SSc, but despite several epidemiological studies, no link has been established (Janowsky et al. 2000).

In contrast, several studies indicate that silica dust-associated scleroderma can not be distinguished from SSc in terms of antibody profile and phenotype (Haustein and Andereg 1998). This is supported by experimental data suggesting that silica dust induces pathophysiological events similar to SSc (Haustein and Andereg 1998).

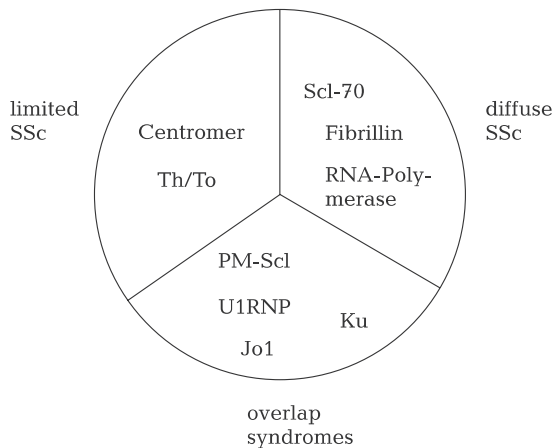
## Diagnosis

As in many other chronic diseases, diagnosis is in general readily performed once the illness has fully developed. Due to the often smoldering disease onset and the uncharacteristic changes occurring early on in SSc, including Raynaud's phenomenon, joint pain or swelling clinical diagnosis of SSc and the differentiation from other diffuse inflammatory connective tissue diseases (rheumatoid arthritis, systemic lupus erythematosus, polymyositis) or disorders characterised by abnormal extracellular deposition (e.g. amyloidosis) may be difficult if not impossible. Although each of the diffuse inflammatory connective tissue diseases are clinically distinct entities, they share some general analogies and often display a high level of clinical variability resulting not uncommonly in overlap syndromes which pose a particular diagnostic and therapeutic challenge.

Investigations related to the autoimmune phenomena and the vascular changes (e.g. capillaroscopy) are therefore necessary to perform. In some cases, follow up of the patient over time will indicate whether the patient finally develops inflammatory connective tissue disease, overlap syndrome etc. or may experience remission of an early flare up of autoimmune phenomena reflecting undifferentiated connective tissue disease (Williams et al. 1999).

### Autoantibody Profile

The identification of autoantibodies is helpful in establishing the correct diagnosis, indicating the prognosis and providing a guide to treatment and follow up (Fritzler 1993). In several studies, more than 95% of patients show



**Fig. 2.** Antibody profile and clinical classification of progressive systemic sclerosis and overlap syndromes



**Table 1.** Clinical Characteristics of Autoantibodies Associated with Progressive Systemic Sclerosis

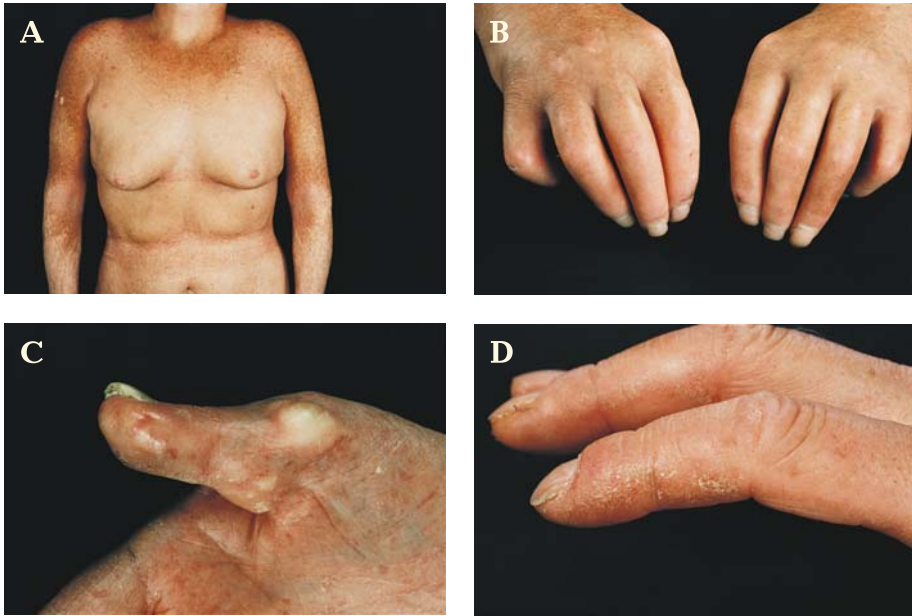
Antibody	Antigen	Comments	Frequency
Scl-70	DNA-topoisomerase I	increased risk for tumors	up to 70% of dSSc; 10 to 20% of SSs
U1 RNP	U1 small nuclear ribonucleoprotein	overlap syndrome to SLE	
Fibrillarin	U3 RNP	poor prognosis	10–20% of dSSc
RNA Polymerase I, III	sub units of RNA polymerase		20% of dSSc
centromere	kinetochores, CENP-A, B, C, E	limited disease	60–80% of ISSc; 15% of SSs
Th/To	Rnase P	limited disease	2%
PM-Scl	nuclear protein-complex	characteristic skin changes	15% of overlap syndromes
Ku	Nucleolar heterodimer	overlap syndrome	< 10% of overlap syndromes
Jo1	histidyl-tRNA synthetase	SSc/polymyositis overlap	10% of overlap syndromes

antinuclear antibodies (ANA) (Bunn et al. 1998), thus making the diagnosis of SSs in a patient without ANA quite unlikely. Although there is no antibody which can be related to disease activity like the presence of anti-dsDNA antibodies in systemic lupus erythematosus, patient classification according to serologic subsets can be meaningful. Nearly 85% of patients can be associated to one of seven SSs related antibodies (*Table 1*) and each of these antibodies describes a subset which to a different degree has characteristic clinical manifestations (*Fig. 2, 3*).

### Clinical Presentation

At clinical presentation, sclerodactily is present in about 95% of patients and Raynaud's syndrome is present in about 90%. If none of these features (including ANA) is present, the patient is likely to have a disorder other than SSs.

Differential diagnosis includes in particular the generalized form of localized scleroderma, eosinophilic fasciitis, scleromyxoedema, scleroderma adultorum Buschke, amyloidosis, porphyria cutanea tarda and acrodermatitis chronica



**Fig. 3.** Clinical phenotype of progressive systemic sclerosis and overlap syndromes. **A.** Diffuse systemic sclerosis: diffuse sclerosis with hyperpigmentation of the trunk. **B.** Sclerodactyly with contractures and atrophy of the fingers. **C.** Cutaneous calcinosis. **D.** PM-Scl overlap syndrome: mechanic hands with hyperkeratosis of the fingers

atrophicans in the inflammatory phase (*Table 2*) and rarely sclerodermiform genodermatoses. Furthermore, one has to be aware of the vast differential diagnoses of Raynaud's phenomenon in the patients presenting in the initial phase of the disease.

**Table 2.** Scleroderma-Like Disorders

I. Sclerotic disorders	Scleroderma adulatorum Buschke
	Scleroderma diabeticorum
	Scleroderma amyloidosum
	Scleromyxedema
	Environmentally related scleroderma-like syndromes
	Graft versus host disease
	Porphyria cutanea tarda
	Acrodermatitis chronica atrophicans
II. Sclerodermiform genodermatoses	Werner Syndrome
	Progeria
	Acrogeria/Metageria

## Associated Diseases

Association of SSc with other autoimmune diseases is relatively common including primary biliary cirrhosis, Sjogren-syndrome (including the detection of anti-Ro/La antibodies) and the subset of overlap syndromes, dermatomyositis and polymyositis.

## Therapy

The treatment of SSc is challenging due to the complex disease process and the difficulty to specifically treat distinct subgroups of this relatively rare disease. Thus in 1995, an American College of Rheumatology Committee published guidelines for the conduct of clinical trials in SSc (White et al. 1995). To date, there is no proven effective disease modifying treatment of SSc. Nevertheless, there have been significant breakthroughs in the treatment of several individual end-organ manifestations leading to improvements in patients longevity and quality of life. SSc poses a particular problem to the medical system due to the relative rarity of the disease requiring specialised care by the general practitioner. Therefore, diagnosis and care should be at least in part in the hands of specialists who have daily exposure to this disease and have access to a laboratory trained in autoimmune serology, to dermatohistopathology, and modern diagnostic radiologic procedures (e.g. CT, MRT, angiography). Cooperation with different subspecialties is often necessary to provide optimal care due to the nature of the disease affecting other organ systems than the skin (e.g. rheumatology, pulmonary medicine, nephrology, neurology). Specialized care should be provided in a setting where the outpatient facilities have also access to hospital beds to ensure timely and appropriate treatment for patients presenting with exacerbation of their disease. Physical therapy which has access to treatment facilities to prevent loss of function is another prerequisite for these specialised facilities. Although there are single medical centers often linked to research centers which can provide care along the guidelines cited above they are usually not embedded into the medical system in a way that ensures access for patients not living in regions where these centers exist. Patient support groups which to date in part make up for these shortcomings should play an important role in communicating the special needs of these patients to society. Internet based resources will play an increasing role for the information of patients and recruitment for ongoing studies in the future (e.g. [Http://www.sclero.org](http://www.sclero.org), [www.Sklerodermie.info](http://www.Sklerodermie.info)). Therefore an important future aim will be to develop competence and communication based networks which ensure participation of all levels involved in the care for these patients.

### **Immunosuppressive Agents**

D-penicillamine seems to affect both collagen and the immune system thus making it an ideal candidate to treat SSc. Interestingly, it took until the mid 90s to start a double blind randomized trial to investigate the effect of D-penicillamine in SSc. Unfortunately, no difference was found between a dose of 62.5 mg and 750 mg D-penicillamine daily indicating lack of efficacy (Clements et al. 1999). Also photopheresis (extracorporeal photochemotherapy) that has shown promise in several uncontrolled studies (Rook et al. 1992), failed in a recent crossover study to demonstrate a favourable effect (Enomoto et al. 1999). Several smaller trials investigated the use of cyclosporin A, which unfortunately was associated with considerable toxicity, especially nephropathy (Denton et al. 1994). Methotrexate, although its toxicity profile in patients with SSc was better than expected, produced inconsistent results in two controlled studies (van den Hoogen et al. 1996; Pope et al. 1998).

### **Antifibrotic Agents**

Interferon- $\gamma$  is the most potent cytokine known to inhibit collagen synthesis. Several uncontrolled studies applying the cytokine over up to one year have been performed to investigate the potential role of interferon- $\gamma$  in the treatment of SSc showing no major effect on the disease course (Hunzelmann et al. 1997). Interferon- $\alpha$  has also been shown to inhibit collagen synthesis (Duncan et al. 1995). However, a placebo controlled study of early diffuse SSc found no benefit for skin sclerosis and pulmonary function, but a greater mortality in the active treatment arm (Black et al. 1998). Relaxin is a pregnancy-related hormone that has tissue remodeling and antifibrotic effects. Relaxin has been tested in a phase 2 trial where in the low dose group a significant improvement of the modified Rodnan skin score was found ( $p = 0.049$ ) whereas in the high dose group no such effect was seen (Seibold et al. 2000).

### **Organ-Specific Therapies**

#### *Skin Involvement*

General measures include skin protection from cold and trauma, skin care with moistening creams, lymph drainage and active physiotherapy. Calcium channel blockers or angiotensin II receptor type 1 antagonists can be given to decrease symptoms of Raynaud's syndrome (Dziaio et al. 1999). In severe cases of finger tip ulcerations and impending digit amputation, intravenous prostacycline analogues may be of value (Zachariae et al. 1996; Pope et al. 2000). New agents as endothelin antagonists or phosphodiesterase-inhibitors are still under investigation. Ectopic calcifications or calcinosis when compromising

blood circulation or causing symptoms may be removed surgically or by the use of CO<sub>2</sub>-laser (Bottomly et al. 1996). Laser (i.e. argon or flashlamp pumped dye laser) therapy is the treatment of choice to remove teleangiectasias, which may also involve the mucosa.

UV radiation (UVA1 or bath-PUVA) with small patients numbers in uncontrolled studies has been reported to be beneficial. In localized scleroderma, evidence for the efficacy of UVA1 or bath-PUVA is increasing although no double blind prospective study is available (Kerscher et al. 1996). Recent studies have shown that UVA irradiation alone, and more so in conjunction with photosensitizing agents, increases the expression, synthesis and activation of metalloproteinases. In addition, a variety of cytokines and soluble factors *in vitro* and *in vivo* are modulated by UVA and can affect connective tissue remodeling (Scharffetter et al. 1991; Herrmann et al. 1993). Clinical and ultrasound evaluation revealed that the sclerotic lesions disappeared or markedly improved during PUVA bath photochemotherapy in 13 of the 17 enrolled patients within less than three months. We have additional experience in 14 patients suffering from localized scleroderma who improved substantially from bath PUVA therapy as monitored by skin score, cutaneous elastometry and evaluation of skin thickness by ultrasound analysis (Hunzelmann et al. 1998b). In a recent publication, the therapeutic potential of UVA1 therapy has been evaluated in localized scleroderma (Stege et al. 1998). This study corroborates and extends previous observations that *in vivo* UVA1 irradiation exposure of healthy human skin is associated with the induction of interstitial collagenase RNA expression *in situ* which may play a role in the remodelling of the fibrotic connective tissue.

### *Musculoskeletal Involvement*

Musculoskeletal involvement, arthralgia and musculoskeletal pain being the most frequent complaints, is common in scleroderma and may lead to secondary fibromyalgia. Muscle weakness and some increase in serum creatine kinase levels are quite common. Inflammatory arthritis can occur but raises the suspicion of the presence of an overlap syndrome and only rarely results in mutilating arthritis. Corticosteroids should be avoided due to their long term side effects and association with nephropathy in higher doses (Steen et al. 1998). Non steroidal anti-inflammatory agents should also be prudently chosen due to their potential side effects on renal function, blood pressure and gastrointestinal function. The superiority of the use of cyclo-oxygenase 2 inhibitors remains to be proven.

### *Renal Involvement*

Acute renal crisis is a serious and potentially fatal SSc complication associated with an acute reduction on cortical blood flow, hyperreninemia, hyper-

tension which occurs most likely in diffuse cutaneous scleroderma of less than four years duration. Thus regular control of blood pressure (at least twice a week) is recommended to detect acute renal involvement early on. Some patients will progress to renal failure and dialysis or renal transplantation. Chronic renal involvement is associated with a slowly progressive obliterative vasculopathy. Before the advent of ACE inhibitor therapy and other improvements in the management of advanced renal disease, survival for longer than 3–6 months was almost unknown. Particularly in acute renal crisis, ACE inhibitors are the mainstay of treatment significantly prolonging patient survival (Steen et al. 1990). Additional administration of intravenous prostacyclin may be considered. Nevertheless, prognosis of established renal crisis is still relatively poor with about one third of patients progressing to renal replacement therapy. Here, a five year kidney graft survival rate of 47% was reported comparable to that of patients with SLE (Chang and Spiera 1999).

### *Pulmonary Involvement*

Pulmonary fibrosis in SSc affects to different degrees the parenchymal and the vascular system. In early disease, inflammatory alveolitis may precede and/or accompany interstitial fibrosis leading to loss of pulmonary function as evidenced by decreased diffusing capacity and vital capacity. Bronchoalveolar lavage (in experienced hands) and high resolution chest computertomography will help to determine the degree of inflammation. Several studies indicate that alveolitis can be treated with cyclophosphamide (White et al. 2000).

Pulmonary hypertension may most prominently develop in patients with limited cutaneous scleroderma of long duration with relatively little interstitial disease determining the prognosis of these patients. Here infusion or inhalation of prostacycline analogues or endothelin antagonists may improve the outcome, which usually results in death within five years unless heart-lung transplantation is performed (Pigula et al. 1997; Badesch et al. 2000; Hoepfer et al. 2000; Rubin et al, 2002).

### *Gastrointestinal Involvement*

The gastrointestinal tract is frequently involved with a frequency for the oesophagus in about 80%, the stomach, small intestine and large intestine in about 40–70% (Sjogren 1996). The pathology is characterized both by atrophy of the smooth muscles that line the gastrointestinal tract and involvement of the myenteric nerve plexus. Main symptoms associated are heartburn, esophageal dysfunction in the upper gastrointestinal tract and diarrhoea due to bacterial overgrowth, fetal incontinence in the distal tract. Prokinetics (e.g. octreotide) are of limited use in severe constipation and recently, the prokinetic cisapride has been withdrawn from the market due to associated cardiac arrhythmias leading to death. Proton pump inhibitors and to a lesser extent

H<sub>2</sub>-blockers are effective in controlling reflux esophagitis apart from typical conservative measures (no late meals etc.). Bacterial overgrowth and fungal infections (e.g. candida esophagitis) can be dealt with by intermittent antimicrobial therapy and antimycotics. Rarely, teleangiectasias may also be present on the mucosa representing a potential source of occult intestinal bleeding.

### *Cardiac Involvement*

The nature and severity of cardiac disease depends on the extent of myocardial fibrosis, a primary component of this disorder, and on the extent to which concurrent fibrosis of the lung and thickening and fibrosis of the small pulmonary arteries place an additional burden on the circulation. Large perfusion abnormalities on thallium scans are predictive of shortened survival and an increased number of cardiac events (Steen et al. 1996). Also, intermittent vascular ischemia is observed which probably reflects similar pathophysiological changes as observed in the peripheral vasculature (Raynaud's syndrome). Arrhythmias are quite common in SSc but seldom meet the definition of severe arrhythmia.

### *Novel Therapeutic Perspectives*

A number of studies are currently performed or planned to investigate the effect of new therapeutic concepts. Due to the relative rarity of these diseases and distinct subgroups, however, national and international cooperative studies will be required to prove the efficacy of these new approaches. The role of collagen as an autoantigen in SSc is not entirely proven. However, in a recent study on the use of oral administration of bovine collagen a reduction of T cell reactivity to human collagen was found accompanied by significantly improved skin thickness score and carbon monoxide diffusing capacity (McKown et al. 2000).

Recombinant technology gives now rise to the development of recombinant cytokines and anti-cytokines that may have therapeutic potential, the principle of anti-TNF-alpha therapy in rheumatoid arthritis being the most prominent example. TGF-beta as a potent stimulus of collagen synthesis is thought to drive the fibrotic process. Recent studies in a mouse model (McCormick et al. 1999) and in human glaucoma in the human indicate a potential for the use of TGF-beta antibodies.

Studies have been recently initiated to evaluate the beneficial effect of autologous haemopoietic stem cell transplantation in systemic lupus erythematosus and SSc. Previous studies showed that patients with autoimmune disease who undergo bone marrow transplant for haemopoietic or other malignancy are frequently noted to experience a remission of their autoimmune disease (Clements et al. 1997; Tyndall et al. 1997). However, to date only uncontrolled studies have been reported with divergent effects.

## Summary

Despite intense research efforts and major advances in the understanding of particular aspects of the disease process, the etiology of SSc is still unknown and the pathogenesis only partly understood. Thus the concept that SSc evolves along pathological changes of the vascular system, the immune system and of the extracellular matrix has not significantly changed over the last twenty years. Nevertheless, survival has markedly improved over the past two decades, with a 5-year survival rate over 80%, although to date there is no proven effective disease-modifying treatment of SSc. This is due to significant breakthroughs in the treatment of several individual end-organ manifestations. Current therapies of SSc rely mainly on drugs directed to the major skin and visceral complications such as Raynaud's phenomenon, digital ulceration, nephropathy, gastrointestinal and pulmonary involvement. Although the introduction of drugs that treat these complications has changed markedly, the mortality and life quality of subgroups of SSc, the associated side effects and lack of efficacy in certain subgroups of organ involvement indicate that the available treatment options are often still unsatisfactory (e.g. digital ulceration, pulmonary fibrosis, kidney failure). Therefore, future treatments should specifically modulate distinct pathogenetic events in SSc.

## References

- Artlett CM, Smith CB, Jimenez SA (1998) Identification of fetal DNA and cells in skin lesions from women with systemic sclerosis. *N Engl J Med* 338: 1186–1191
- Badesch D, Tapson VF, McGoon MD (2000) Continuous intravenous epoprostenol for pulmonary hypertension due to the scleroderma spectrum of disease. *Ann Int Med* 132: 425–434
- Black CM, Silman SJ, Herrick AI (1998) Interferon-alpha does not improve outcome at one year in patients with diffuse cutaneous scleroderma: results of a randomized, double blind, placebo-controlled trial. *Arthritis Rheum* 42: 299–305
- Blockmans D, Beyens G, Verhaege R (1996) Predictive value of nailfold capillaroscopy in the diagnosis of connective tissue diseases. *Clin Rheumatol* 15: 148–153
- Bottomley WW, Goodfield MJ, Sheehan-Dare RA (1996) Digital calcification in systemic sclerosis: effective treatment with good tissue preservation using the carbon dioxide laser. *Br J Dermatol* 135: 302–302
- Bunn CC, Denton CP, Shi-Wen X, Knight C, Black CM (1998) Anti-RNA Polymerases and other autoantibody specificities in systemic sclerosis. *Br J Rheumatol* 37: 15–20
- Burastero SE, Galbiati S, Vassallo A, Sabbadini MG, Bellone M, Marchionni L et al. (2003) Cellular microchimerism as a lifelong physiologic status in parous women: an immunologic basis for its amplification in patients with systemic sclerosis. *Arthritis Rheum* 48: 1109–1116
- Chang YJ, Spiera H (1999) Renal transplantation in scleroderma. *Medicine* 78: 382–385
- Clements PJ, Lachenbruch PA, Ng SC (1990) Skin score. A semiquantitative measure of cutaneous involvement that improves prediction of prognosis in systemic sclerosis. *Arthritis Rheum* 33: 1256–1263
- Clements PJ, Furst DE (1997) Choosing appropriate patients with systemic sclerosis for treatment by autologous stem cell transplantation. *J Rheumatol* 24: 85–88
- Clements PJ, Furst DE, Wong WK (1999) High dose versus low dose D-penicillamine in early diffuse systemic sclerosis: analysis of a two year, double blind, randomized, controlled clinical trial. *Arthritis Rheum* 42: 1194–203



- Denton CP, Sweny P, Abdulla A, Black CM (1994) Acute renal failure occurring in scleroderma treated with cyclosporin A: a report of three cases. *Br J Rheumatol* 33: 90–92
- Dong C, Zhu S, Wang T, Yoon W, Li Z, Alvarez RJ et al. (2002) Deficient Smad 7 expression: a putative molecular defect in scleroderma. *PNAS* 99: 3908–13
- Duncan MR, Hasan A, Berman B (1995) Pentoxifylline, pentifylline and interferons decrease type I and III procollagen mRNA levels in dermal fibroblasts: evidence for mediation by nuclear factor 1 downregulation. *J Invest Dermatol* 104: 282–286
- Dziedzic M, Denton CP, Smith R (1999) Losartan therapy for Raynaud's phenomenon and scleroderma: clinical and biochemical findings in a fifteen-week, randomized, parallel group, controlled trial. *Arthritis Rheum* 42: 2646–2455
- Eckes B, Mauch C, Huppe G, Krieg T (1996) Differential regulation of transcription and transcript stability of pro  $\alpha 1(I)$  collagen and fibronectin in activated fibroblasts derived from patients with systemic sclerosis. *Biochem J* 315: 549–553
- Enomoto, Mekkes JR, Bossuyt PM (1999) Treatment of patients with systemic sclerosis with extracorporeal photochemotherapy (photopheresis). *J Am Acad Dermatol* 41: 915–922
- Evans PC, Lambert N, Maloney S (1999) Long term fetal microchimerism in peripheral blood mononuclear cell subsets in healthy women and women with scleroderma. *Blood* 93: 2033–2037
- Fritzler MJ (1993) Autoantibodies in scleroderma. *J Dermatol* 20: 257–268
- Furst DE, Clements PJ, Steen VD (1998) The modified Rodnan skin score is an accurate reflection of skin biopsy thickness in systemic sclerosis. *J Rheumatol* 25: 84–88
- Genth E, Mierau R, Genetzky P (1990) Immunogenetic associations of scleroderma-related antinuclear antibodies. *Arthritis Rheum* 33: 657–665
- Jablonska S, Blaszyk M (1999) Scleroderma Overlap Syndromes. *Adv Exp Med Biol* 455: 85–92
- Janowsky EC, Kupper LL, Hulka BS (2000) Meta-analyses of the relation between silicone breast implants and the risk of connective tissue. *N Engl J Med* 342: 781–790
- Haustein UF, Anderegg U (1998) Silica induced scleroderma – clinical and experimental aspects. *J Rheumatol* 25: 1917–1926
- Hebbar M, Peyrat JP, Homez L, Hatron PY, Hachulla E, Devulder B. (2000) Increased concentrations of the circulating angiogenesis inhibitor endostatin in patients with systemic sclerosis. *Arthritis Rheum* 43: 889–93
- Heickendorff L, Zachariae H, Bjerring P, Halkier-Sorensen L, Sondergaard K (1995) The use of serologic markers for collagen synthesis and degradation in systemic sclerosis. *J Am Acad Dermatol* 32: 584–588
- Herrmann K, Heckmann M, Kulozik M, Haustein UF, Krieg T (1991) Steady state mRNA levels of collagens I,III, fibronectin and collagenase in skin biopsies of systemic sclerosis patients. *J Invest Dermatol* 97: 219–225
- Herrmann G, Wlaschek M, Lange TS, Prenzel K, Goerz G, Scharffetter-Kochanek K (1993) UVA irradiation stimulates the synthesis of various matrix-metalloproteinases (MMPs) in cultured human fibroblasts. *Exp Dermatol* 2: 92–97
- Hoeper MM et al. (2000) Long term treatment of primary pulmonary hypertension with aerosolized iloprost, a prostacyclin analogue. *N Engl J Med* 342: 1866–70
- Hunzelmann N, Anders S, Fierlbeck G, Hein R, Herrmann K, Albrecht M, Bell S, Thur J, Muehe R, Adelman-Grill B, Wehner-Caroli J, Gaus W, Krieg T (1997) Systemic scleroderma: multicenter trial of one year treatment with recombinant interferon-gamma. *Arch Dermatol* 133: 609–613
- Hunzelmann N, Risteli J, Risteli L, Sacher C, Black CM, Krieg T (1998a) Increased circulating concentrations of the type I collagen specific degradation product ICTP in systemic sclerosis reflect the extent of skin involvement: A new serum marker for clinical severity in SSc patients. *Br J Dermatol* 139: 1020–1025
- Hunzelmann N, Scharffetter-Kochanek K, Hager C, Krieg T (1998b) Management of localized scleroderma. *Sem Cutan Med Surg* 17: 34–41
- Igarashi A, Nashiro K, Kikuchi K (1995) Significant correlation between connective tissue growth factor gene expression and skin sclerosis in tissue sections from patients with systemic sclerosis. *J Invest Dermatol* 105: 280–284

- Jimenez SA and Saitta B (2000) Alterations in the regulation of expression of the  $\alpha 1(I)$  collagen gene (COL1A1) in systemic sclerosis (scleroderma). *Springer Semin Immunopathol* 21: 397–414
- Kahaleh MB, Sultany GL, Smith EA, Huffstetter JE, Loadholt CB, LeRoy EC (1986) A modified scleroderma skin scoring method. *Clin Exp Rheumatol* 4: 367–369
- Kahaleh M, Fan PS (1997) Mechanism of serum mediated endothelial injury in scleroderma: identification of a granular enzyme in scleroderma skin and sera. *Clin Immunol Immunopathol* 83: 32–40
- Kerschner M, Meurer M, Sander C, Volkenandt M, Lehmann P, Plewig G, Röcken M (1996) PUVA bath photochemotherapy for localized scleroderma. *Arch Dermatol* 132: 1280–1282
- Kulozik M, Hogg A, Lankat-Buttgereit B, Krieg T (1990) Co-localization of transforming growth factor  $\beta 2$  with  $\alpha 1(I)$  procollagen mRNA in tissue sections of patients with systemic sclerosis. *J Clin Invest* 86: 917–921
- LeRoy EC (1974) Increased collagen synthesis by scleroderma fibroblasts in vitro. *J Clin Invest* 54: 880–889
- Lunardi C (2000) Systemic sclerosis immunoglobulin G autoantibodies bind the human cytomegalovirus late protein UL94 and induce apoptosis in human endothelial cells. *Nature Med* 6: 1183–1186
- Majewski S, Hunzelmann N, Johnson JP, Jung C, Mauch C, Ziegler-Heitbrock H, Riethmüller G, Krieg T (1991) Expression of intercellular adhesion molecule-1 (ICAM-1) on fibroblasts in the skin of patients with systemic sclerosis. *J Invest Dermatol* 97: 667–671
- Marguerie C (1992) The clinical and immunogenetic features of patients with autoantibodies to the nucleolar antigen PM-Scl. *Medicine* 71: 327–336
- Maricq H, LeRoy E, Dangelo W (1980) Diagnostic potential of in vivo capillary microscopy in scleroderma and related disorders. *Arthritis Rheum* 23: 183–189
- Mauch C (1998) Regulation of connective tissue turnover by cell-matrix interactions. *Arch Dermatol Res* 290: S30–36
- McCormick LL, Zhang Y, Tootell E, Gilliam AC (1999) Anti-TGF- $\beta$  treatment prevents skin and lung fibrosis in murine sclerodermatous graft-versus-host disease: a model for human scleroderma. *J Immunol* 163: 5693–5699
- McKown KM, Carbone LD, Bustillo J (2000) Induction of immune tolerance to human type I collagen in patients with systemic sclerosis by oral administration of bovine type I collagen. *Arthritis Rheum* 43: 1054–1061
- Perlsh JS, Lemlich G, Fleischmajer R (1988) Identification of collagen fibrils in scleroderma skin. *J Invest Dermatol* 90: 48–54
- Pigula FA, Griffith BP, Zenati MA (1997) Lung transplantation for respiratory failure resulting from systemic disease. *Ann Thorac Surg* 64: 1630–1634
- Poormoghim H, Lucas M, Fertig N, Medsger TA (2000) Systemic sclerosis sine scleroderma: demographic, clinical, and serologic features and survival in forty eight patients. *Arthritis Rheum* 43: 444–451
- Pope J, Bellamy N, Seibold J (1998) A controlled trial of methotrexate versus placebo in early diffuse scleroderma – preliminary analysis. *Arthritis Rheum* 41: S420
- Pope J, Fenlon D, Thompson A (2000) Iloprost and cisaprost for Raynaud's phenomenon in progressive systemic sclerosis. *Cochrane Database Syst Rev* 2: CD000953
- Prescott RJ, Freemont A, Jones C (1992) Sequential dermal microvascular and perivascular changes in the development of scleroderma. *J Pathol* 166: 255–263
- Rook AH, Freundlich B, Jegasothy BV (1992) Treatment of systemic sclerosis with extracorporeal photochemotherapy. Results of a multicenter trial. *Arch Dermatol* 128: 337–346
- Rubin LJ, Badesch DB, Barst RJ, Galie N, Black CM et al. (2002) Bosentan therapy for pulmonary hypertension. *NEJM* 346: 896–903
- Scharffetter K, Lankat-Buttgereit B, Krieg T (1988) Localization of collagen mRNA in normal and scleroderma skin by in situ hybridization. *Eur J Clin Invest* 18: 9–17
- Scharffetter K, Wlaschek M, Hogg A, Bolsen K, Schothorst A, Goerz G, Krieg T, Plewig G (1991) UVA irradiation induces collagenase in human dermal fibroblasts in vitro and in vivo. *Arch Dermatol Res* 283: 506–511
- Seibold J (1994) Systemic sclerosis. In: Klipped J, Dieppe P, Mosby St. Louis (Eds) *Rheumatology*, 8.1–8.14

- Seibold J, Korn J, Simms R (2000) Recombinant human relaxin in the treatment of scleroderma. A randomized, double blind, placebo-controlled study. *Ann Int Med* 132: 871–879
- Sgonc R, Gruschwitz M, Dietrich H (1996) Endothelial cell apoptosis is a primary pathogenetic event underlying skin lesions in avian and human scleroderma. *J Clin Invest* 98: 785–792
- Shi-Wen X, Pennington D, Holmes A (2000) Autocrine overexpression of CTGF maintains fibrosis: RDA analysis of fibrosis genes in systemic sclerosis. *Exp Cell Res* 25: 213–224
- Sjogren RW (1996) Gastrointestinal features of scleroderma. *Curr Opin Rheumatol* 8: 569–575
- Steen VD, Constantino JP, Shapiro AP, Medsger TA (1990) Outcome of renal crisis in systemic sclerosis: relation to availability of angiotensin converting enzyme (ACE) inhibitors. *Ann Int Med* 113: 352–357
- Steen VD, Follansbee WP, Conte CG, Medsger TA (1996) Thallium perfusion defects predict subsequent cardiac dysfunction in patients with systemic sclerosis. *Arthritis Rheum* 39: 677–681
- Steen VD, Medsger TA (1998) Case-control study of corticosteroids and other drugs that either precipitate or protect from the development of scleroderma renal crisis. *Arthritis Rheum* 41: 1613–1619
- Stege H, Berneburg M, Humke S (1997) High-dose UVA<sub>1</sub> radiation therapy for localized scleroderma. *J Am Acad Dermatol* 36: 938–944
- Stone PJ, Korn JH, North H, Lally EV, Miller LC, Tucker LB, Strongwater S, Snider GL, Franzblau C (1995): Cross-linked elastin and collagen degradation products in the urine of patients with scleroderma. *Arthritis Rheum* 38: 517–524
- Straniero NR, Furst DE (1989) Environmentally induced systemic sclerosis like illness. *Baillieres Clin Rheumatol* 3: 63–79
- Subcommittee for Scleroderma Criteria of the American Rheumatism Association Diagnosis and Therapeutic Criteria Committee (1980) Preliminary criteria for the classification of systemic sclerosis (scleroderma). *Arthritis Rheum* 23: 581–590
- Tyndall A, Black C, Finke J, Peter H, Gratwohl A (1997) Treatment of systemic sclerosis with autologous hemopoietic stem cell transplantation. *The Lancet* 349: 254–356
- Uitto J, Bauer EA, Eisen AZ (1979) Scleroderma. Increased biosynthesis of triple helical type I and type III procollagen associated with unaltered expression of collagenase by skin fibroblasts in culture. *J Clin Invest* 64: 921–930
- van den Hoogen FH, Boerbooms AM, Swaak AJ (1996) Comparison of methotrexate with placebo in the treatment of systemic sclerosis: a 24 week randomized double blind trial, followed by a 24 week observation trial. *Br J Rheumatol* 35: 364–372
- White B, Bauer EA, Goldsmith LA (1995) Guidelines for clinical trials in systemic sclerosis (scleroderma). I. disease modifying interventions. The American College of Rheumatology Committee on Design and Outcomes in Clinical Trials in Systemic sclerosis. *Arthritis Rheum* 38: 351–360
- White B, Moore WC, Wigley FM (2000) Cyclophosphamide is associated with pulmonary function and survival benefit in patients with scleroderma and alveolitis. *Ann Int Med* 132: 947–954
- Williams HJ, Alarcon GS, Joks R (1999) Early undifferentiated connective tissue disease. VI an inception cohort after 10 years: disease remissions and changes in diagnoses in well established and undifferentiated CTD. *J Rheumatol* 26: 816–825
- Zachariae H, Halkier-Sorensen L, Bjerring P, Heickendorff L (1996) Treatment of ischemic digital ulcers and prevention of gangrene with intravenous iloprost in systemic sclerosis. *Acta Derm Venereol* 76: 236–238

# 5 Lupus Erythematosus

## 5.1 Chronic Cutaneous Lupus Erythematosus

*Michael Sticherling*

### Introduction

The skin represents one of the major organs afflicted by lupus erythematosus (LE). LE was in fact first described as a skin disease in the mid and late 19<sup>th</sup> century (Talbot 1993) and denominated for the characteristic mutilations seen in subtypes of the disorder. Ever since in 1936 systemic manifestation without skin symptoms was appreciated as a disease entity, the subject has differentially been dealt with in the dermatological and rheumatological literature. Malar rash and discoid lesions are listed among the criteria defined by the American College of Rheumatology (ACR) for diagnosis of systemic lupus erythematosus (SLE) (Tan et al. 1982). Characteristic and defined entities encompassing various forms of acute, subacute and chronic cutaneous LE can be opposed to less characteristic skin manifestations like rashes and symptoms of cutaneous vasculitis. Both groups of symptoms may however be present at any stage of disease development. 20% of all SLE cases present with initial skin manifestations and 50–70% of all SLE patients will eventually show skin symptoms during the course of their disease (Sontheimer and Provost 1996).

### Classification

Chronic cutaneous lupus erythematosus (CCLE) comprises different clinical entities with discoid lupus erythematosus (DLE) as the most common form. In contrast to acute cutaneous LE (ACLE) and subacute cutaneous LE (SCLE), lesions are long-lasting for up to decades with occasional spontaneous

remissions. Disfiguring atrophy and scarring with emotional discomfort for patients as well as an increased risk to develop into squamous cell carcinoma in long-standing DLE pose distinct medical problems (Sontheimer and Provost 1996, Patel and Werth 2002). In many cases, symptoms are restricted to the skin without major systemic inflammatory or autoimmune manifestations. This used to be indiscriminately called DLE until twenty years ago when it was clearly dissected from other forms, especially from what is now referred to as SCLE. The term DLE should nowadays be restricted to subsets of CCLE with morphologically distinct plaques irrespective of systemic involvement.

In other, rather rare cases, DLE as well as further subsets of CCLE may present as first or intercurrent manifestations of SCLE and SLE and will eventually result in systemic disease. Exact epidemiological data of the different CCLE subtypes as well as their relation to SLE and SCLE are not available partly due to the different perception over the last couple of decades and within dermatology and rheumatology. CCLE may be underestimated within rheumatological literature and in case of absent systemic manifestations not be amply diagnosed at all. CCLE lesions, especially DLE lesions are found in up to 20% of SCLE patients and may predate manifestation of systemic disease. Further support of the relation as well as distinction of DLE and SLE is provided by the finding that DLE is present in 15–30% of SLE patients at any time during the disease course and is the prominent feature in 5–10% of such patients (Kanda et al. 1996; Parodi and Rebora 1997; Tebbe et al. 1997). Classical DLE as termed at the time of first diagnosis will progress into SLE in 5–10% of cases (Parodi and Rebora 1997; Tebbe et al. 1997). Such courses may account for different criteria of diagnosing SLE and varying medical check-up among different medical specialists. Generalized DLE and DLE associated with high autoantibody titers have a higher chance to develop into systemic disease. However, the overall incidence of DLE is ten-fold higher than that of SLE. At the same time, the female to male ratio of 3:2 to 3:1 for DLE is quite distinct from 9:1 in SLE indicating separate entities. Similarly, the age of disease manifestation (20–40 years) is slightly higher in DLE than in SLE. The other CCLE subtypes show varying correlations to SLE and will be discussed below (Sontheimer and Provost 1996).

The issue of CCLE being a distinct and separate entity at the benign end of a spectrum of LE or a limited stage or concurrent manifestation within the chronological evolution of SLE has to be further evaluated. Especially, characteristic etiopathogenetic factors as well as prognostic markers for CCLE remain to be elucidated. The final diagnosis of a distinct subset of LE can only be made following case history, clinical manifestations at the skin and other organs and laboratory findings encompassing the criteria defined by the American College of Rheumatology (ACR). Alternative criteria for cutaneous lesions have been suggested by the European Academy of Dermatology and Venereology (EADV). Being more specific, however less sensitive than the ACR criteria, they have not found their way into the rheumatologic literature (Parodi and Rebora 1997).

## Pathogenesis

*Various causes* and resulting *inflammatory and immunological processes* have been identified as relevant for the induction of cutaneous LE (reviewed by Norris et al. 1996). However, their particular role in individual clinical subsets of CCLE with respect to quantitative or qualitative differences has been barely clarified. Factors suspected to precipitate or aggravate cutaneous LE lesions are listed in *Table 1*. Regarding *genetic background*, various markers have been detected or suspected in LE. These include HLA antigens, complement factor polymorphisms or deficiencies, namely C4 and C5 in DLE (Asghar et al. 1991; Nousari et al. 1999), cytokine and receptor-polymorphisms (Jacob 1992), a deficiency of 21-hydroxylase-A with subsequent alterations of steroid homeostasis as well as genetically fixed varying responses to inflammatory stimuli regarding cytokine expression, ICAM-1 or stress protein expression (Jacob 1992; Middleton and Norris 1995). Recently, the impact of apoptosis-related molecules and receptors like bcl-2 or Fas in LE has been addressed (see below) (Casiano et al. 2000; Baima and Sticherling 2001). Their dysregulation in either keratinocytes (exaggerated apoptosis) or lymphocytes (decreased apoptosis with persistence of autoreactive lymphocytes) may be related to genetic factors as well. Regarding DLE, rather conclusive data have been found for a correlation to extended HLA phenotypes such as HLA-B7, Cw7, DR3 or HLA-Cw7, DR3, DQw1 as well as DQA1\*0102 with relative risks of 7.4 and 4.7, respectively. The role that genetic factors may play in the pathogenesis of DLE is stressed by the observed association of DLE with X-linked

**Table 1.** Pathogenetically Relevant Factors for CCLE

Genetics	HLA-antigens
	Cytokine-polymorphisms
	Cytokine-receptor-polymorphisms
	Complement deficiency
	Deficiency of 21-hydroxylase-A
	Overinduction of cytokines
	ICAM-1 expression
	Heat shock protein expression
	Apoptosis-related markers (e.g. bcl-2, Fas)
	Environmental
	UV-radiation
	Isomorphic phenomenon (Köbner phenomenon)
	Cigarette smoking
	Estrogen
	Certain drugs (questionable)

granulomatous disease, a disorder that is characterized by deficient or reduced NADPH oxidase (Rupec et al. 2000).

Evidence for virus infections as etiologic factors for LE is provided by the detection of viral material like alphavirus or paramyxovirus in skin lesions, the aggravation of LE following cytomegalovirus infections as well as a clinical, but probably accidental correlation of disseminated DLE lesions and SCLE with chronic hepatitis C. Altogether, evidence for viral induction is circumstantial and may in some cases be related to induction of pro-inflammatory cytokines like interferon- $\gamma$  and subsequent triggering of disease rather than direct involvement of virus (Jacob 1992).

In contrast to SLE and SCLE, distinct drugs do not seem to be relevant for the induction of CCLE lesions. However, the environmental factor smoking is associated to the persistence of DLE lesions as well as to a lack of therapeutic response to chloroquine (Gallego et al. 1999; Jewell and McCauliffe, 2000). A relation of CCLE to hormones like estrogen has been reported but seems to be less important than in SLE and SCLE. Nonspecific injury to the skin (*isomorphic response or Köbner phenomenon*) was found to induce DLE lesions similar to psoriasis and lichen planus and may explain manifestations at unusual locations.

A huge body of literature is in support of the influence of ultraviolet radiation in LE, the subsequent induction of inflammatory processes and its relation to autoantibody formation (Kind et al. 1993; Sontheimer and Provost 1996; Norris et al. 1996). As photosensitivity is a feature in up to 70% of SLE patients, UV sensitivity has been included as a criterion for diagnosis of SLE by the ACR. Regarding UV radiation and skin manifestations, 70% of SCLE patients are photosensitive and develop typical lesions after prolonged exposure to a combination of UVA and UVB (53%), UVB (33%) or UVA (14%) (Kind et al. 1993). Anti-Ro/SS-A antibodies have been associated with photosensitivity in SLE (Mond et al. 1989).

UV-light is able to induce pro-inflammatory cytokines like TNF- $\alpha$  and IL-1 in both keratinocytes and lymphocytes. This leads to induction of local inflammatory mediators like chemokines and lipid mediators to focus and amplify the subsequent inflammatory response to the local level. Both resident cells (endothelial cells, fibroblasts, mast cells) are activated as well as migratory cells like monocytes and lymphocytes attracted to the dermal and epidermal compartment through induction of different adhesion molecules in a characteristic sequence of events (Norris et al. 1996).

The central involvement of autoantibodies in the pathogenesis of LE like anti-Ro/SS-A has been fostered by recent results on the expression and/or release of intracellular antigens like the nucleoprotein SS-A on the keratinocyte surface upon UV radiation (Casciola-Rosen et al. 1995; Casiano et al. 2000). Alternatively, these antigens are expressed on keratinocytes undergoing apoptosis upon UV-irradiation (Norris et al. 1996). Our group has recently found that keratinocyte apoptosis correlated with local disease activity with a low rate in CDLE and a high rate in ACLE (Baima and Sticherling

2001). Consequently, keratinocytes are killed by antibody-dependent cellular cytotoxicity and the humoral immune response is triggered and boosted by antigenic challenge (Tan 1994; Norris et al. 1996; Casiano et al. 2000). Immune complex formation at the onset of LE seems to be of minor importance as immune complexes are detected at the dermo-epidermal junction only as late as six weeks after UV-irradiation. At that stage, influx of inflammatory cells like monocytes and other changes characteristic for LE have already taken place. According to this concept, inflammatory and immunological pathways are overreacting or insufficiently counterbalanced due to a variety of environmental or genetic factors or a combination of both.

However, the concept of a UV-induced pathogenesis elaborated for cutaneous LE like ACLE and SCLE seems less conclusive for CCLE and does not yet convincingly explain its clinical characteristics and distinction from other forms of cutaneous LE. In DLE, photosensitivity (predominantly to UVB, but also UVA radiation) is found in only 40% of the patients and anti-SS-A antibodies are rarely found. If positive, they may indicate incipient disease. Other antibody specificities and pathogenetic mechanisms have been suggested, but not yet been proven to be relevant. Only few studies address specific differences of CCLE to other forms of cutaneous LE. Immunohistochemical analysis of activated cutaneous lymphocytes has demonstrated a local T helper 2 response with the preferential activation of dermal T cells (Furukawa et al. 1996; Denfeld et al. 1997; Stein et al. 1997). Expression of various cellular and extracellular proteins like keratins (de Berker et al. 1995), adhesion molecules (Middleton and Norris 1995; Norris et al. 1996; Tebbe et al. 1997) and extracellular matrix proteins (de Jong et al. 1997) point to inflammatory processes common for chronic, hyperproliferative diseases with only partly distinction from other lichenoid skin reactions (McCauliffe 1998). The immunohistochemical demonstration of the membrane attack complex (C5b-9) may further subdivide different subsets of CCLE and suggests a pathogenic involvement (Magro et al. 1996). With respect to different subsets of inflammatory cells, CD4- and CD8-positive lymphocytes as well as macrophages constitute a major portion of the skin infiltrate in both SCLE and SLE (Hasan et al. 1999) whereas dermal Langerhans cells are absent in both entities (Sontheimer and Bergstresser 1982). However, the frequency of TCR $\gamma/\delta$ -positive T cells was elevated in DLE suggesting specific T-cell mediated epidermal cytotoxicity in this subtype (Volc-Platzer et al. 1993).

### **Clinical Appearance/Classification**

Several distinctly different clinical entities can be allocated to the group of CCLE (Table 2). They may be found as one and only manifestation or associated with other forms of CCLE, localized or disseminated, both with and without systemic manifestations and varying relation to SLE. The most common



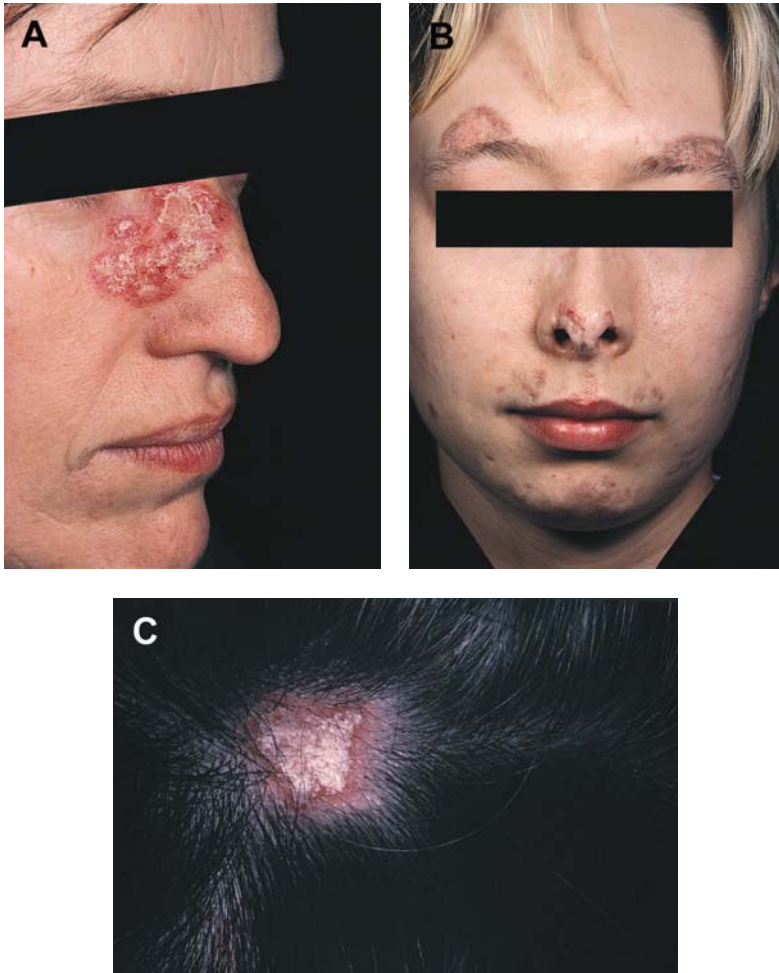
**Table 2.** Specific LE Skin Symptoms

Acute cutaneous lupus erythematosus (ACLE)	Localized Generalized
Subacute cutaneous lupus erythematosus (SCLE)	Annular Papulosquamous
Chronic cutaneous lupus erythematosus (CCLE)	Discoid (DLE) Localized (above neck) Generalized (above and below neck) follicular Hypertrophic DLE Mucosal LE Lupus panniculitis Lupus profundus (Panniculitis and DLE) Lupus tumidus Chilblain lupus Papulous mucinosis

form is chronic discoid lupus erythematosus (CDLE or DLE). It is characterized by persistent, sharply demarcated, elevated erythematous plaques with adherent scales which may rarely ulcerate (*Fig. 1A*). Early stages are characterized by erythema and *hyperpigmentation*. The characteristic painful sensation upon touching is caused by follicular plugging resulting in the so-called carpet-tack sign. Apart from that, atrophy and scarring can be found in the center of untreated lesions and may result in considerable disfiguration particularly when present in the face (*Fig. 1B*). A characteristic pitted, acneiform scarring is also a common residual feature of the perioral area including the lips.

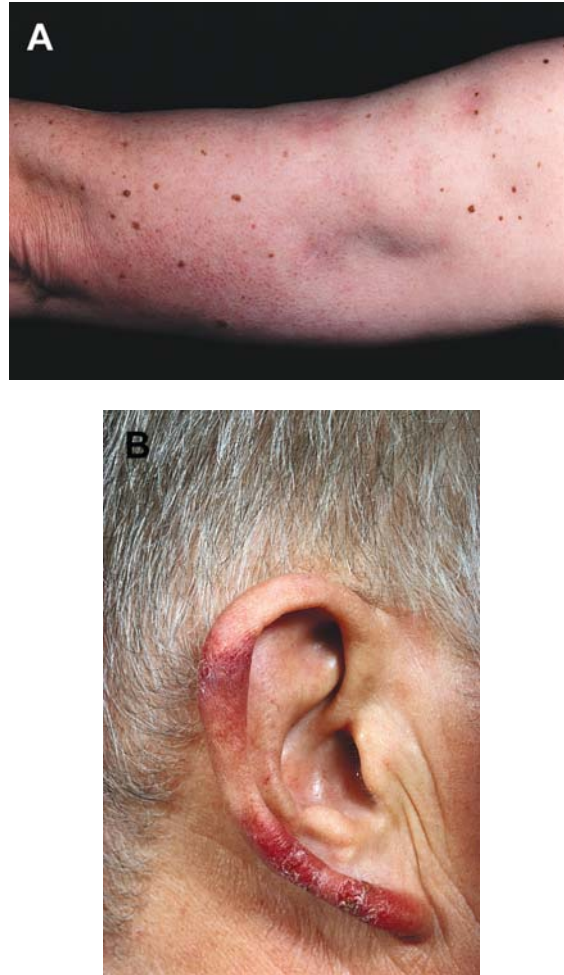DLE lesions predominantly occur in the light-exposed areas of skin like face, ears, neck and arms, but may be found in sun-protected areas as well as inguinal folds, palmo-plantar locations and the scalp. At the latter location, DLE may even be the only cutaneous manifestation in 10% of cases and thus presents a classical differential diagnosis of scarring alopecia. Altogether involvement of the scalp can be found in about 60% of DLE patients (Sontheimer and Provost 1996) (*Fig. 1C*). With a distribution above the neck, the so-called *localized form of DLE* can be separated from a *generalized DLE* if it is present above and below the neck. Small, follicularly orientated erythematous papules of less than 1 cm in diameter present as *follicular DLE* at the elbows, but may occur at any other part of the body as well. Precipitation of DLE lesions by physical trauma (Köbner phenomenon) has already been mentioned above and may explain occurrence at unusual locations.

If DLE lesions are distinctly proliferative, they are referred to as *hypertrophic or verrucous DLE*. They have to be separated from spinous cell carcinoma, keratoacanthoma and lichen planus by histology and immunohistochemistry (Perniciaro et al. 1995; Uy et al. 1999).



**Fig. 1.** **A.** Clinical presentation of chronic discoid lupus erythematosus. Typical sharply demarcated elevated erythematous plaque. **B.** Chronic atrophic lesions of the face lead to disfigurement. **C.** Involvement of the scalp leads to cicatricial alopecia

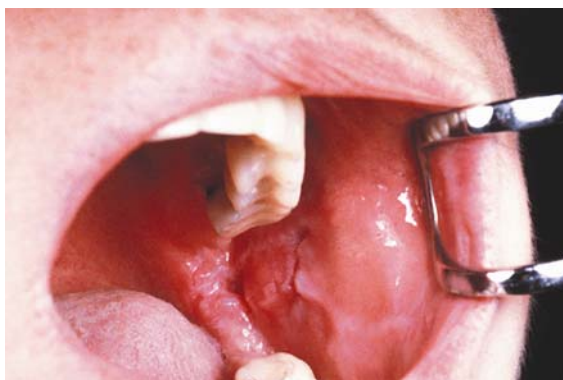Another rare manifestation of CCLE is *lupus profundus* or *lupus panniculitis*, also referred to as *Kaposi-Irgang disease* (Caproni et al. 1995; Watanabe and Tsuchida 1996; Kundig et al. 1997; Uy et al. 1999; Martens et al. 1999). It can be found in about 2% of SLE patients, but presents more commonly without further or only mild signs of systemic manifestation in about 50% of patients. Severe nephritis is an uncommon event. In contrast to DLE, mainly women are affected by painful, firm subcutaneous nodules of red-bluish colour and up to 1–3 cm diameter. Their main locations are the upper arms, buttocks and thighs, but chest, head and neck can be affected as well (*Fig. 2A*).



**Fig. 2. A.** Rare manifestations of chronic cutaneous lupus erythematosus. Lupus profundus or lupus panniculitis lead to saucer-like depressions resembling lipatrophy. **B.** Chilblain or perniosis is characterized by bluish-red patches and plaques located at the acra, such as the ears

The inflammatory process in the deeper dermis and subcutaneous tissue results in saucer-like depressions sometimes resembling lipatrophy. When DLE lesions are found on the overlying skin as is the case in 70% of patients, it is referred to as *lupus profundus*.

*Chilblain or perniosis* is characterized by bluish-red patches and plaques at acral locations like nose, ears, fingers, toes, knees and elbows (Su et al. 1994; Fisher and Everett 1996). These are painful upon pressure, especially when located at heels and knuckles where fissuring is quite common



**Fig. 3.** Ulcers of the buccal mucosa in chronic cutaneous lupus erythematosus

(Fig. 2B). It mainly occurs in cold climates and is possibly caused by a Köbner phenomenon. During further disease process, typical DLE lesions may appear and patches may ulcerate. As in lupus profundus, mild systemic symptoms like arthralgia can be found to fulfil three to four ACR criteria for diagnosis of SLE in up to 20% of patients. Due to its rare occurrence, no definite association to SLE can be made. The term lupus pernio is often used synonymously for this entity, should however be restricted to cutaneous sarcoidosis as an important differential diagnosis.

Another rare manifestation of CCLE, *lupus tumidus*, is characterized by excessive dermal mucin deposition resulting in urticarial plaques (Ruiz and Sanchez 1999; Dekle et al. 1999; Kühn et al. 2003). Compared to other CCLE types, it is characterized by distinct photosensitivity which explains its main occurrence at sun-exposed areas and induction of lesions upon photoprovocation. With a male preponderance its peak incidence is around the 30–40th year of age. Differential diagnosis to lymphocytic infiltration and polymorphous light eruption can be very difficult both clinically and histologically (Sontheimer and Provost 1996).

Mucous membrane involvement (*mucosal DLE*) can be found among CCLE patients in up to 25% (Burge et al. 1989; Botella et al. 1999). It does not necessarily reflect systemic manifestation, specific or high antibody titers or high disease activity. It is, however, included in the list of 11 diagnostic criteria for SLE defined by the ACR. Oral, mainly buccal manifestations are most common (Fig. 3), but nasal, conjunctival and anogenital mucous membranes may be affected as well. They present as painful erythematous patches which may ulcerate and cause atrophy in the long run. Sometimes mucosal DLE resembles lichen planus with honeycomb appearance. Squamous cell carcinoma as a long-term complication should be suspected and excluded in any case of asymmetrical induration of either mucosal or cutaneous lesions. Affliction of the lips (vermillion border, diffuse cheilitis especially of lower lip) can cause

considerable discomfort and disfiguration. Mucosal DLE of the nose may result in nasal septum perforation especially in association with SLE. Similarly, ocular affections which are mainly located at the palpebral conjunctiva and lower eyelids can cause permanent loss of eye lashes, ectropion and stromal keratitis (Uy et al. 1999).

*Annular erythema* has in the past been regarded as a rare manifestation of CCLE. It will not be dealt with in this chapter since it is generally associated with SCLE and Sjogren's syndrome (Watanabe et al. 1997).

*Papular mucinosis* may occur as early or only manifestation of CCLE and shows similarities to *lupus tumidus* in respect to dermal mucin deposition (Kanda et al. 1997; Williams and Ramos-Caro 1999, Sonntag et al. 2003, Kuhn et al. 2003). In contrast to *lupus tumidus*, more papular than plaque appearance and lack of inflammatory erythema can be found. Asymptomatic isolated or multiple lesions are located at the trunk, upper limbs and the face with less apparent photosensitivity than in *lupus tumidus*. Diagnosis may be only made upon immunohistochemical detection of linear or granular depositions of IgG, IgM and complement C3 at the dermo-epidermal junction whereas other histological traits of LE are absent. Accordingly, differential diagnosis to other cutaneous mucinoses can be difficult.

## Diagnosis

In contrast to skin manifestations associated with overt SCLE and SLE, patients with the different subtypes of CCLE will primarily present to dermatologists as long as systemic manifestations are missing. Once internal organ involvement has occurred, these patients will be referred to general practitioners or rheumatologists for analysis of systemic disease. Alternatively, general practitioners or rheumatologists may ask dermatologists to search for typical skin manifestations of LE in a suspected patient or to evaluate present skin symptoms as typical for or related to LE. In cases of CCLE, first line efforts will head at their definite diagnosis which as already outlined above may be sometimes difficult to establish.

Case history has to focus on LE-related symptoms like photosensitivity, arthralgia or arthritis, diffuse or areata-like alopecia, Raynaud's phenomenon, Sicca symptoms, morning stiffness of joints, thrombosis, spontaneous abortion, atypical pneumonia and carditis as well as neurological disorders. To support clinical diagnosis, histological as well as immunohistochemical examinations of skin lesions will be performed. Depending on the stage and acuity of LE, the typical histological findings include epidermal hyperkeratosis, epidermal atrophy, basal cell degeneration, thickening of the epidermal basement membrane, liquefaction degeneration and mononuclear cell infiltrate at the dermo-epidermal junction as well as around blood vessels and adnexial structures. The dermato-histological features of different LE types

(ACLE, SCLE, DLE) may be very similar (Sontheimer and Provost 1996; Ackerman 1997). Often these parameters do not allow to clearly distinguish the different entities apart from quantitative differences in epidermal or especially follicular hyperkeratosis which are characteristic for DLE. Special histological features can be found in *LE tumidus* with its characteristic abundant, partly focal deposition of mucin among collagenous fibers of the reticular dermis. *Lupus panniculitis* presents with a lobular pattern of perivascular and periadnexial mononuclear infiltration and partially necrobiotic changes of fatty tissue with fibrinoid deposits as well as focal calcinosis in the deep dermis.

### Direct Immunofluorescence

The characteristic findings of direct immunohistochemical examination of lesional skin are granular immune deposits of mostly IgG, IgM and complement factor C3 in a continuous line along the dermo-epidermal junction (so-called lesional *lupus band test*) (George et al. 1995; Cardinali et al. 1999). They will be only found in lesions of more than four to six weeks duration, an aspect which argues against their pathogenic relevance and the immediate involvement of immune complex mechanisms. Furthermore, the incidence of positive lupus band tests is higher in biopsies from upper body sites that is more likely in those from the face than in those from the trunk. However, neither does their absence exclude CCLE nor is their presence specific for LE. They may be found in sun-damaged skin, rosacea and polymorphic light eruption, often with deposits of IgM only. The significance of immune deposits in non-lesional skin (*non-lesional lupus band test*) is much debated (George et al. 1995; Cardinali et al. 1999) and seems specific for SLE when IgG and two additional immunoglobulin subtypes (IgG, IgM, IgA) are detected. Skin biopsies for non-lesional skin may be taken from the the inner aspect of the upper arm (sun-protected) and the extensor aspect of the forearm (sun-exposed). In CCLE with no extracutaneous manifestations these biopsies should be negative. The findings of the lupus band test have to be carefully interpreted together with other serological examinations. Epidermal dust-like particles in a specific fine speckled pattern which are generally associated with SCLE and anti-SS-A antibodies are rarely detected in DLE and may indicate more severe disease with progression to systemic manifestations (Sontheimer and Provost 1996; Norris et al. 1996). In patients with high titered anti-nuclear antibodies, especially anti-U1-RNP (which is typically associated with mixed connective tissue disease), positive epidermal nuclei can be found by direct immunofluorescence microscopy. This phenomenon most probably derives from in vitro binding of high titer or high affinity antibodies. In vivo penetrating the cell membrane autoantibodies may be found as well. However, their significance for disease manifestation as well as diagnostic procedures remains to be elucidated (Golan et al. 1997). Using specific monoclonal antibodies, the membrane attack complex (C5b-9) could be demonstrated in the

epidermis of different subsets of CCLE and may allow further distinction (Magro et al. 1996). In lupus profundus as well as in SLE granular deposits of IgG and C3 may be occasionally found in dermal vessel walls indicating immune complex vasculitis.

### Serological Tests

Serological tests are critical for the confirmation of CCLE. Antinuclear antibodies of high titers and characteristic specificity will rarely be found without systemic manifestation. They may however be present in cases of generalized DLE which in turn has a greater risk to progress to SLE. Anti-Ro(SS-A) antibodies can sometimes be detected by ELISA techniques, may however lack precipitating activity, i.e. immunodiffusion techniques are negative (Provost et al. 1996). Anti-DNA-antibodies are negative in classical DLE and other subsets of CCLE and if present indicate systemic disease (Watanabe et al. 1995; Provost et al. 1996; Sontheimer and Provost 1996; Tebbe et al. 1997). Anticardiolipin antibodies are mostly not detectable. They may be found in cases of lupus panniculitis and chilblain lupus indicating secondary antiphospholipid syndrome and progression to systemic disease (Ruffati et al. 1995). Similarly, tests for complement consumption (e.g. CH50 test), detection of complement fragments and circulating immune complexes will mostly be negative or only slightly altered and should only be performed in cases of suspected systemic disease. Serum levels of other serological molecules like soluble adhesion markers and soluble IL-2 receptor are related to disease activity (Sontheimer and Provost 1996), but have not yet been established as routine parameters.

Apart from the above examinations, basic clinical routine laboratory tests should be performed to exclude anemia, leukopenia, renal involvement (proteinuria, hematuria) and systemic inflammation. Accordingly, blood sedimentation rate (BSR), blood cell count, hepatic enzymes, urine sediment and serum immunoglobulins should be checked. Pathologic findings are substantiated by further tests if necessary. Clinical tests like chest X-ray and evaluation of organ involvement (e.g. in ophthalmology, neurology, cardiology) should be performed based on case history or pathologic results of physical or laboratory exams. The indication for routine testing of cutaneous sensitivity to ultraviolet light as well as photoprovocation is much debated in CCLE. However, the impact of these exams with regard to stringency of sun protection and consequences for life-style supports their usefulness in the clinical routine (Kind et al. 1993; Sontheimer and Provost 1996, Kuhn et al. 2001).

CCLE patients should be monitored at 6 to 12-months intervals for further signs of systemic disease, especially when anemia or leukopenia, persistent high ANA titers or elevated blood sedimentation rates are found. Based on these clinical and laboratory findings, disease activity can be quantitated using the Systemic Lupus Activity Measure (SLAM) (Parodi et al. 2000) which may be a valuable parameter to monitor the patients.

## Therapy

Many of the following drugs have been extensively used in SCLE which is different in respect to more pronounced inflammatory and less hyperproliferative activity (*Table 3*) (Callen 2002, Wallace 2002). They will accordingly be discussed in detail in the context of SCLE. Therapy regimens and their intensity will be dictated by the extent of cutaneous as well extracutaneous involvement and thus have to depend on ample diagnostic procedures as outlined above. The scarring potential of CCLE demands early and aggressive treatment to avoid cosmetically and emotionally disturbing and irreversible disfiguration (Sontheimer and Provost 1996; Drake et al. 1996). Individual cases may require combinations of different therapy regimens and frequently, disease relapses after lowering daily doses of drugs or stopping treatment.

In cases of solitary or only few DLE lesions and absent systemic manifestations local therapy may suffice (Ting and Sontheimer 2001, Callen 2002, Wallace 2002). This comprises local application of glucocorticosteroids (e.g.

**Table 3.** Therapeutic Options for CCLE

---

Local therapy	glucocorticosteroids
	retinoids
	macrolactames
	interferons
	laser
	cryotherapy
	cosmetic surgery
	camouflage
Systemic therapy	antimalarials
	glucocorticosteroids
	dapsone
	thalidomide
	retinoids
	interferons
	clofazimine
	gold
	methotrexate
	azathioprine
	cyclophosphamide
	ciclosporin
	sulfasalazine
	biologics
	intravenous immunoglobulins
	photopheresis

---



clobetasol propionate 0.05%, betamethasone dipropionate 0.05%, triamcinolone acetonide 0.1%, fluocinonide) twice daily for 10–14 days as ointment, fluid (propylenglykol), tape/occlusive dressing or focal infiltration. Recently, the successful local application of tazarotene has been reported in a case of DLE with distinct hyperproliferation (Edwards and Burke 1999). The macrolactame antibiotics pimecrolimus and tacrolimus have shown beneficial effects upon topical use in cases of discoid and subacute cutaneous lupus erythematosus (Chambers 2003, Walker et al. 2002, de la Rosa Carrillo and Christensen 2004).

In more severe cases, antimalarials have been successfully used either alone or in combination (hydroxychloroquine, chloroquine, quinacrine) especially in DLE (Drake et al. 1996; Sontheimer and Provost 1996) with a delayed effect after a treatment period of three to four weeks. Hydroxychloroquine is usually used first-line starting with 400 mg/d and tapered after four to eight weeks to 200 mg/d upon clinical improvement. In cases of insufficient response, it may be combined with 100 mg/d quinacrine, especially in lupus profundus and hypertrophicus. Alternatively, chloroquine may be used at 250 mg/d. Glucose-6-phosphate deficiency should be excluded prior to therapy to minimize the risk of idiosyncratic reactions. Otherwise, neurotoxicity as well as muscular and hepatic toxicity may occur. Retinal toxicity should be monitored by initial examination of the ocular fundus and thereafter every 6–12 months during therapy. Retinal toxicity is low at daily doses below 4 mg/kg/d hydroxychloroquine (6 mg/kg/d chloroquine) with no apparent maximal total life time dosis (Ochsendorf and Runne 1996). Recently, the inhibitory effect of cigarette smoking on the therapeutic efficacy of antimalarials has been demonstrated (Gallego et al. 1999; Jewell and McCauliffe 2000). This may be explained by induction of hepatic microsomal enzymes leading to accelerated metabolism of antimalarials. Initially, especially in cases of high inflammatory activity or generalized disease, antimalarials can be combined with oral glucocorticosteroids well below 1 mg/kg/d prednisolone-equivalent which should be tapered within two to three weeks. Classical CCLE will however seldomly require such a regimen.

Dapsone (diaminodiphenylsulfone) may be alternatively used at 100 mg/d (Drake et al. 1996; Sontheimer and Provost 1996; Wozel 1996). As with antimalarials, glucose-6-phosphate deficiency should be excluded. Regular monitoring for methemoglobinemia, hemolytic anemia as well as hepatic disturbances should be performed at two week intervals during the first three to six months of therapy. The incidence and severity of anemia can be reduced by adding cimetidin or vitamin C/E.

Thalidomide in a dose of 100 to 200 mg/d or even less, has been shown to be effective in DLE and especially lupus panniculitis (Drake et al. 1996; Sontheimer and Provost 1996; Warren et al. 1998; Georgala et al. 1998; Ordi-Ros et al. 2000; Kyriakis et al. 2000). Peripheral irreversible neuropathy and fatigue present limiting side-effects in up to 50% of the patients. Furthermore, amenorrhoea may occur (Ordi et al. 1998). Regarding the well-known teratogenic effects of thalidomide, strict contraception is mandatory. To avoid relap-

ses, slow reduction of therapeutic doses or longterm treatment with low doses are recommended.

Retinoids present another therapeutic option in cases of insufficient response to above mentioned approaches. All three available compounds (isotretinoin, etretinate, acitretin) have been used in LE, at a dosage of around 1 mg/kg/d (Marks 1995). The teratogenic effects limit their use in women at childbearing age and require strict contraceptive measures. Apart from that, dryness of mucous membranes as well as skin, peeling of palms and soles and transient hair loss especially following intake of etretinate, hepatic disturbances including drug-induced hepatitis, hypertriglyceridemia and hypercholesterinemia as well as phototoxic effects present common and therapy-limiting side effects.

Controversial results have been reported on the use of interferons in LE. Both local and systemic interferon- $\alpha$  2A has successfully been used in SCLE and DLE (Thivolet et al. 1990; Sontheimer and Provost 1996). However, interferon- $\alpha$  treatment of chronic inflammatory and malignant diseases resulted in precipitation or exacerbation of SLE (Garcia-Porrua et al. 1998). This potential adverse side effect stresses the importance to distinguish SLE from CCLE before starting the therapy.

Case reports demonstrated the beneficial effects of *clofazimine* (100 mg/d), oral or parenteral *gold* (cave: mucocutaneous toxicity, hematological, renal and pulmonary toxicity), *methotrexate* (Bottomley and Goodfield 1995, Kuhn et al. 2002), *cyclophosphamide* and *azathioprine*. Sulfasalazine at a dose of up to 2 g/d has also been used successfully (Sabbagh et al. 1997). Novel immunomodulatory substances like ciclosporin (Saeki et al. 2000), leflunomide (Furst 1999), systemic tacrolimus, fumaric acid, mycophenolate mofetil (Jayne 1999) or humanized antibodies (e.g. anti CD4) (Prinz et al. 1996) have only anecdotically been used in CCLE or in SLE only. As their efficacy still needs to be evaluated especially for CCLE they should be used only in cases of disseminated and refractory disease. The advent of "biologics" namely antibodies, fusion proteins and soluble receptors still need to be evaluated in the context of CCLE (Gescuk and Davis 2002, Isenberg and Leckie 2002). Intravenous immunoglobulins have been effective in recalcitrant CCLE as adjuvant therapy (Callen 2002, Wallace 2002). Recently, positive effects of extracorporeal photopheresis have been reported in widespread and recalcitrant DLE (Richter et al. 1998; Wollina and Looks 1999). The therapeutic use of UV exposure in lupus is still controversial regarding photosensitivity and should be restricted to individual cases (Millard and Hawk 2001).

UV protection should be performed in all cases of CCLE as supportive measure. Its stringency does not need to be enforced as strictly as in SCLE in all but cases of proven UV sensitivity. This includes avoidance of the sun especially during midday and summer months, wearing of sun-protective clothing and application of broad-spectrum sun-screen with high UV protection factor. Titanium dioxide containing sun-screens have become available as convenient and very efficient physical sun-protection.

In case of disfiguration camouflage is recommended. Alopecia may be hidden by ample hair dressing or hair pieces. Surgical approaches including hair transplantation or cosmetic surgery should only be initiated when inflammatory disease activity has totally subsided or was stopped by therapeutic measures. Different approaches with laser therapy (Nunez et al. 1996; Nurnberg et al. 1996; Walker and Harland 2000) and cryotherapy (Molin 1999) have been used with varying success. However, when therapeutically applying physical procedures, one has to take into account the possibility of isomorphic provocation and aggravation of cutaneous disease.

## Summary

Skin, to a similar extent as the joints, represents the most common organ involved in LE either as primary manifestation or during the course of disease. Nonspecific symptoms can be separated from the distinct and specific manifestations of acute, subacute and chronic cutaneous LE. The latter may present as a disease confined to the skin or as a manifestation of systemic disease. In several subtypes of CCLE, mild involvement of the internal organs may be present which does not suffice for diagnosing SLE. The risk of further development into systemic disease is, however, present in 5–10% of CCLE. The pathogenesis of the different CCLE entities is not as conclusive as for ACLE and SCLE. The impact of photosensitivity is relatively low as are evident systemic autoimmune phenomena like high titered antinuclear antibodies. Similar to systemic disease, lesional skin of CCLE is characterized by positive immune deposits at the dermo-epidermal junction. The six major subtypes of CCLE can present as solitary disease or combined with other subtypes. These are discoid lupus erythematosus (DLE), hypertrophic DLE, mucous membrane DLE, chilblain lupus, lupus tumidus and lupus panniculitis/profundus. In contrast to SCLE, lesions tend to show atrophy and scarring. Typical DLE lesions are represented by sharply demarcated erythematous plaques with hyperkeratosis and follicular plugging. In lupus panniculitis, deep inflammatory processes in the dermis and subcutis result in saucer-like defects often associated with typical overlying epidermal changes. Entities most intimately associated with systemic disease are chilblain lupus and lupus panniculitis. Diagnostic procedures have to substantiate cutaneous and to exclude underlying systemic disease. Histological and immunohistochemical examinations have to be combined with autoimmune serological tests as well as additional clinical laboratory tests depending on the findings of clinical exams. Accordingly, therapeutic measures depend on the extent of cutaneous involvement and the accompanying systemic manifestations. Early and aggressive treatment has to prevent irreversible scarring and disfiguration. Local therapy with glucocorticosteroids, retinoids, laser and cryotherapy may not suffice and has to be accompanied or substituted by systemic therapy. Antimalarial drugs,

possibly in combination with short term oral glucocorticosteroids, oral retinoids, dapsone, thalidomide and supportive UV protection are the most common regimens. Alternatively, clofazimine, gold, interferons, methotrexate and azathioprine may be used.

## References

- Ackerman AB (1997) Lupus erythematosus. In: Ackerman AB (ed) *Histologic diagnosis of inflammatory skin diseases*. 2nd ed. Williams & Wilkins, Baltimore pp 525–546
- Asghar SS, Venneker GT, van Meegen M, Meinardi MM, Hulsmans RF, de Waal LP (1991) Hereditary deficiency of C5 in association with discoid lupus erythematosus. *J Am Acad Dermatol* 24: 376–378
- Baima B, Sticherling M (2001) Apoptosis in different manifestations of cutaneous lupus erythematosus. *Br J Dermatol* 144: 958–966
- Botella R, Alfonso R, Silvestre JF, Ramon R (1999) Discoid lupus erythematosus-like lesions and stomatitis. *Arch Dermatol* 135: 847, 850
- Bottomley WW, Goodfield MJ (1995) Methotrexate for the treatment of discoid lupus erythematosus. *Br J Dermatol* 133: 655–656
- Burge SM, Frith PA, Juniper RP, Wojnarowska F (1989) Mucosal involvement in systemic and chronic cutaneous lupus erythematosus. *Br J Dermatol* 121: 727–741
- Callen JP (2002) Management of skin disease in patients with lupus erythematosus. *Best Pract Res Clin Rheumatol* 16: 245–264
- Caproni M, Palleschi GM, Papi C, Fabbri P (1995) Discoid lupus erythematosus lesions developed on lupus erythematosus profundus nodules. *Int J Dermatol* 34: 357–359
- Cardinali C, Caproni M, Fabbri P (1999) The utility of the lupus band test on sun-protected non-lesional skin for the diagnosis of systemic lupus erythematosus. *Clin Exp Rheumatol* 17: 427–432
- Casciola-Rosen LA, Anhalt G, Rosen A (1994) Autoantigens targeted in systemic lupus erythematosus are clustered in two populations of surface structures on apoptotic keratinocytes. *J Exp Med* 179: 1317–1330
- Casiano C, Wu X, Molinaro C (2000) Apoptosis, necrosis, and the genesis of antinuclear antibodies. in: Conrad K, Humbel RL, Meurer M, Shoenfeld Y, Tan EM (eds) *Autoantigens and autoantibodies: diagnostic tool and clues to understanding autoimmunity*. Pabst Science Publishers, Lengerich, pp 152–186
- Chambers CA (2003) Topical tacrolimus for cutaneous lupus erythematosus. *Br J Dermatol* 148: 829
- de Berker D, Dean D, Leigh IM, Burge S (1995) Keratin expression in discoid lupus erythematosus. *Exp Dermatol* 4: 350–356
- de Jong EM, van der Vleuten CJ, van Vlijmen-Willems IM (1997) Differences in extracellular matrix proteins, epidermal growth and differentiation in discoid lupus erythematosus, lichen planus and the overlap syndrome. *Acta Derm Venereol* 77: 356–360
- de la Rosa Carrillo D, Christensen OB (2004) Treatment of chronic discoid lupus erythematosus with topical tacrolimus. *Acta Derm Venereol* 84: 233–234
- Dekle CL, Mannes KD, Davis LS, Sanguenza OP (1999) Lupus tumidus. *J Am Acad Dermatol* 41: 250–253
- Denfeld RW, Kind P, Sontheimer RD, Schöpf E, Simon JC (1997) In situ expression of B7 and CD28 receptor families in skin lesions of patients with lupus erythematosus. *Arthritis Rheum* 40: 814–821
- Drake LA, Dinehart SM, Farmer ER, Goltz RW, Graham GF, Hordinsky MK, Lewis CW, Pariser DM, Skouge JW, Webster SB, Whitaker DC, Butler B, Lowery BJ, Sontheimer RD, Callen JP, Camisa C, Provost TT, Tuffanelli DL (1996) Guidelines of care for cutaneous lupus erythematosus. *American Academy of Dermatology. J Am Acad Dermatol* 34: 830–836

- Edwards KR, Burke WA (1999) Treatment of localized discoid lupus erythematosus with tazarotene. *J Am Acad Dermatol* 41: 1049–1050
- Fisher DA, Everett MA (1996) Violaceous rash of dorsal fingers in a woman. Diagnosis: chilblain lupus erythematosus (perniosis). *Arch Dermatol* 132: 459–462
- Furst DE (1999) Leflunomide, mycophenolic acid and matrix metalloproteinase inhibitors. *Rheumatology (Oxford)* 38: 14–18
- Furukawa F, Tokura Y, Matsushita K, Iwasaki-Inuzuka K, Onagi-Suzuki K, Yagi H, Wakita H, Takigawa M (1996) Selective expansions of T cells expressing V beta 8 and V beta 13 in skin lesions of patients with chronic cutaneous lupus erythematosus. *J Dermatol* 23: 670–676
- Gallego H, Crutchfield CE 3rd, Lewis EJ, Gallego HJ (1999) Report of an association between discoid lupus erythematosus and smoking. *Cutis* 63: 231–234
- Garcia-Porrúa C, Gonzales-Gay MA, Fernandez-Lamelo F, Paz-Carreira JM, Lavilla E, Gonzales-Lopez MA (1998) Simultaneous development of SLE-like syndrome and autoimmune thyroiditis following alpha-interferon treatment. *Clin Exp Rheumatol* 16: 107–108
- Georgala S, Katoulis AC, Hasapi V, Koumantaki-Mathioudaki E (1998) Thalidomide treatment for hypertrophic lupus erythematosus. *Clin Exp Dermatol* 23: 141
- George R, Kurian S, Jacob M, Thomas K (1995) Diagnostic evaluation of the lupus band test in discoid and systemic lupus erythematosus. *Int J Dermatol* 34: 170–173
- Gescuk BD, Davis JC Jr. (2002) Novel therapeutic agents for systemic lupus erythematosus. *Curr Opin Rheumatol* 14: 515–521
- Golan TD, Sigal D, Sabo E, Shemuel Z, Guedj D, Weinberger A (1997) The penetrating potential of autoantibodies into live cells in vitro coincides with the in vivo staining of epidermal nuclei. *Lupus* 6: 18–26
- Hasan T, Stephansson E, Ranki A (1999) Distribution of naive and memory T-cells in photoproved and spontaneous skin lesions of discoid lupus erythematosus and polymorphous light eruption. *Acta Derm Venereol* 79: 437–442
- Isenberg D, Leckie MJ (2002) Biological treatments for systemic lupus erythematosus. *Scand J Rheumatol* 31:187–191
- Jacob CO (1992) Tumor necrosis factor and interferon gamma: relevance for immune regulation and genetic predisposition to autoimmune disease. *Semin Immunol* 4: 147–154
- Jayne D (1999) Non-transplant uses of mycophenolate mofetil. *Curr Opin Nephrol Hypertens* 8: 563–567
- Jewell ML, McCauliffe DP (2000) Patients with cutaneous lupus erythematosus who smoke are less responsive to antimalarial treatment. *J Am Acad Dermatol* 42: 983–987
- Kanda N, Tsuchida T, Watanabe T, Tamaki K (1996) Clinical features of systemic lupus erythematosus in men. Characteristics of the cutaneous manifestations. *Dermatology* 193: 6–10
- Kanda N, Tsuchida T, Watanabe T, Tamaki K (1997) Cutaneous lupus mucinosus: a review of our cases and the possible pathogenesis. *J Cutan Pathol* 24: 553–558
- Kind P, Lehmann P, Plewig G (1993) Phototesting in lupus erythematosus. *J Invest Dermatol* 100: 53S–57S
- Kuhn A, Sonntag M, Richter-Hintz D, Oslislo C, Megahed M, Ruzicka T, Lehmann P (2001) Phototesting in lupus erythematosus: a 15-year experience. *J Am Acad Dermatol* 45: 86–95
- Kuhn A, Specker C, Ruzicka T, Lehmann P (2002) Methotrexate treatment for refractory subacute cutaneous lupus erythematosus. *J Am Acad Dermatol* 46: 600–603
- Kuhn A, Sonntag M, Ruzicka T, Lehmann P, Megahed M (2003) Histopathologic findings in lupus erythematosus tumidus: review of 80 patients. *J Am Acad Dermatol* 48: 901–908
- Kundig TM, Trueb RM, Krasovec M (1997) Lupus profundus/panniculitis. *Dermatology* 195: 99–101
- Kyriakis KP, Kontochristopoulos GJ, Panteleos DN (2000) Experience with low-dose thalidomide therapy in chronic discoid lupus erythematosus. *Int J Dermatol* 39: 218–222
- Magro CM, Crowson AN, Harrist TJ (1996) The use of antibody to C5b-9 in the subclassification of lupus erythematosus. *Br J Dermatol* 134: 855–862
- Marks R (1995) Lichen planus and cutaneous lupus erythematosus. in: Lowe N, Marks R (eds) *Retinoids. A clinician's guide*. Martin Dunitz, London, pp 113–117

- Martens PB, Moder KG, Ahmed I (1999) Lupus panniculitis: clinical perspectives from a case series. *J Rheumatol* 26: 68–72
- McCauliffe DP (1998) Distinguishing subacute cutaneous from other types of lupus erythematosus. *Lancet* 351: 1527–1528
- Middleton MH, Norris DA (1995) Cytokine-induced ICAM-1 expression in human keratinocytes is highly variable in keratinocyte strains from different donors. *J Invest Dermatol* 104: 489–496
- Millard TP, Hawk JLM (2001) Ultraviolet therapy in lupus. *Lupus* 10: 185–187
- Molin L (1999) Discoid lupus erythematosus lesions treated with cryosurgery. *Adv Exp Med Biol* 455: 375–376
- Mond CB, Peterson MG, Rothfield NF (1989) Correlation of anti-Ro antibody with photosensitivity rash in systemic lupus erythematosus patients. *Arthritis Rheum* 32: 202–204
- Norris DA, Bennion SD, David-Bajar K (1996) Pathomechanisms of cutaneous lupus erythematosus. In: Wallace DJ, Hahn BH (eds) *Dubois' Lupus Erythematosus*. 4th ed. Lea and Febiger, Philadelphia, pp 549–567
- Nousari HC, Kimyai-Asadi A, Provost TT (1999) Generalized lupus erythematosus profundus in a patient with genetic partial deficiency of C4. *J Am Acad Dermatol* 41: 362–364
- Nunez M, Boixeda P, Miralles ES, de Misa RF, Ledo A (1996) Pulsed dye laser treatment of teleangiectatic chronic erythema of cutaneous lupus erythematosus. *Arch Dermatol* 132: 354–355
- Numberg W, Algermissen B, Hermes B, Henz BM, Kolde G (1996) Erfolgreiche Behandlung des chronisch-diskoiden Lupus erythematoses mit dem Argon Laser. *Hautarzt* 47: 767–770
- Ochsendorf FR, Runne U (1996) Chloroquine: consideration of maximum daily dose (3.5 mg/kg ideal body weight) prevents retinopathy. *Dermatology* 192: 382–383
- Ordi J, Cortes F, Martinez N, Mauri M, De Torres I, Vilardell M (1998) Thalidomide induces amenorrhea in patients with lupus disease. *Arthritis Rheum* 41: 2273–2275
- Ordi-Ros J, Cortes F, Cucurull E, Mauri M, Bujan S, Vilardell M (2000) Thalidomide in the treatment of cutaneous lupus refractory to conventional therapy. *J Rheumatol* 27: 1429–1433
- Parodi A, Rebora A (1997) ARA and EADV criteria for classification of systemic lupus erythematosus in patients with cutaneous lupus erythematosus. *Dermatology* 194: 217–220
- Parodi A, Massone C, Cacciapuoti M, Aragone MG, Bondavalli P, Cattarini G, Rebora A (2000) Measuring the activity of the disease in patients with cutaneous lupus erythematosus. *Br J Dermatol* 142: 457–460
- Patel PP, Werth V (2002) Cutaneous lupus erythematosus: a review. *Dermatol Clin* 20: 373–385
- Perniciaro C, Randle HW, Perry HO (1995). Hypertrophic discoid lupus erythematosus resembling squamous cell carcinoma. *Dermatol Surg* 21: 255–257
- Prinz JC, Meurer M, Reiter C, Rieber EP, Plewig G, Riethmuller G (1996) Treatment of severe cutaneous lupus erythematosus with a chimeric CD4 monoclonal antibody, cM-T412. *J Am Acad Dermatol* 34: 244–252
- Provost TT, Watson R, Simmons-O'Brien E (1996) Significance of the anti-Ro (SS-A) antibody in evaluation of patients with cutaneous manifestations of a connective tissue disease. *J Am Acad Dermatol* 35: 147–169
- Richter HI, Krutmann J, Goerz G (1998) Extrakorporale Photopherese bei therapie-refraktärem disseminiertem diskoiden Lupus erythematoses. *Hautarzt* 49: 487–491
- Ruffatti A, Veller-Fornasa C, Patrassi GM, Sartori E, Tonello M, Tonetto S, Peserico A, Todesco S (1995) Anticardiolipin antibodies and antiphospholipid syndrome in chronic discoid lupus erythematosus. *Clin Rheumatol* 14: 402–404
- Ruiz H, Sanchez JL (1999) Tumid lupus erythematosus. *Am J Dermatopathol* 21: 356–360
- Rupec RA, Petropoulou T, Belohradsky BH, Walchner M, Liese JG, Plewing G, Messer G (2000) Lupus erythematosus tumidus and chronic discoid lupus erythematosus in carriers of X-linked chronic granulomatous disease. *Eur J Dermatol* 10: 184–189
- Sabbagh N, Delaporte E, Marez D, Lo-Guidice JM, Piette F, Broly F (1997) NAT2 genotyping and efficacy of sulfasalazine in patients with chronic discoid lupus erythematosus. *Pharmacogenetics* 7: 131–135
- Saeki Y, Ohshima S, Kurimoto I, Miura H, Suemura M (2000) Maintaining remission of lupus erythematosus profundus (LEP) with cyclosporin A. *Lupus* 9: 390–392

- Sonntag M, Lehmann P, Megahed M, Ruzicka T, Kuhn A (2003) Papulonodular mucinosis associated with subacute cutaneous lupus erythematosus. *Dermatology* 206: 326–329
- Sontheimer RD, Bergstresser PR (1982) Epidermal Langerhans cell involvement in cutaneous lupus erythematosus. *J Invest Dermatol* 79: 237–243
- Sontheimer RD, Provost TT (1996) Lupus erythematosus. in: Sontheimer RD, Provost TT: Cutaneous manifestations of rheumatic diseases. William & Wilkins, Baltimore, pp 1–71
- Stein LF, Saed GM, Fivenson DP (1997) T-cell cytokine network in cutaneous lupus erythematosus. *J Am Acad Dermatol* 36: 191–196
- Su WP, Perniciaro C, Rogers RS 3rd, White JW Jr (1994) Chilblain lupus erythematosus (lupus pernio): clinical review of the Mayo Clinic experience and proposal of diagnostic criteria. *Cutis* 54: 395–399
- Talbot JH (1993) Historical background of discoid and systemic lupus erythematosus. In: Wallace DJ, Hahn BH (eds) *Dubois' Lupus Erythematosus*. 4th ed. Lea and Febiger, Philadelphia, pp 3–12
- Tan EM, Cohen AS, Fries JF, Masi AT, McShane DJ, Rothfield NF, Schaller JG, Talal N, Winchester RJ (1982) The 1982 revised criteria for the classification of systemic lupus erythematosus. *Arthritis Rheum* 25: 1271–1277
- Tan EM (1994) Autoimmunity and apoptosis. *J Exp Med* 179: 1083–1086
- Tebbe B, Mansmann U, Wollina U, Auer-Grumbach P, Licht-Mbalyohere A, Arensmeier M, Orfanos CE (1997) Markers in cutaneous lupus erythematosus indicating systemic involvement. A multicenter study on 296 patients. *Acta Derm Venereol* 77: 305–308
- Thivolet J, Nicolas JF, Kanitakis J, Lyonnet S, Chouvet B (1990) Recombinant interferon alpha 2a is effective in the treatment of discoid and subacute cutaneous lupus erythematosus. *Br J Dermatol* 122: 405–409
- Ting WW, Sontheimer RD (2001) Local therapy for cutaneous and systemic lupus erythematosus: practical and theoretical considerations. *Lupus* 10: 171–184
- Uy HS, Pineda R 2nd, Shore JW, Polcharoen W, Jakobiec FA, Foster CS (1999) Hypertrophic discoid lupus erythematosus of the conjunctiva. *Am J Ophthalmol* 127: 604–605
- Volc-Platzer B, Anegg B, Milota S, Pickl W, Fischer G (1993) Accumulation of gamma delta T cells in chronic cutaneous lupus erythematosus. *J Invest Dermatol* 100: 84S–91S
- Walker SL, Harland CC (2000) Carbon dioxide laser resurfacing of facial scarring secondary to chronic discoid lupus erythematosus. *Br J Dermatol* 143: 1101–1102
- Walker SL, Kirby B, Chalmers RJ. (2002) The effect of topical tacrolimus on severe recalcitrant chronic discoid lupus erythematosus. *Br J Dermatol* 147: 405–6
- Wallace DJ (2002) Management of lupus erythematosus: recent insights. *Curr Opin Rheumatol* 14: 212–219
- Warren KJ, Nopper AJ, Crosby DL (1998) Thalidomide for recalcitrant discoid lesions in a patient with systemic lupus erythematosus. *J Am Acad Dermatol* 39: 293–295
- Watanabe T, Tsuchida T (1995) Classification of lupus erythematosus based upon cutaneous manifestations. Dermatological, systemic and laboratory findings in 191 patients. *Dermatology* 190: 277–283
- Watanabe T, Tsuchida T (1996) Lupus erythematosus profundus: a cutaneous marker for a distinct clinical subset? *Br J Dermatol* 134: 123–125
- Watanabe T, Tsuchida T, Ito Y, Kanda N, Ueda Y, Tamaki K (1997) Annular erythema associated with lupus erythematosus/Sjogren's syndrome. *J Am Acad Dermatol* 36: 214–218
- Williams WL, Ramos-Caro FA (1999) Acute periorbital mucinosis in discoid lupus erythematosus. *J Am Acad Dermatol* 41: 871–873
- Wollina U, Looks A (1999) Extracorporeal photochemotherapy in cutaneous lupus erythematosus. *J Eur Acad Dermatol Venereol*. 13: 127–130
- Wozel G (1996) *Dapson – Pharmakologie, Wirkmechanismus und klinischer Einsatz*. Thieme Stuttgart, New York 1996

## **5.2 Subacute Cutaneous and Systemic Lupus Erythematosus**

*Donna M. Pellowski, Jane E. Kihslinger, and  
Richard D. Sontheimer*

### **Definition and Classification**

Lupus erythematosus (LE) is a polyclonal T and B lymphocyte autoimmune disease thought to result from a complex interplay of genetic and environmental factors. Clinical expression of LE ranges in continuum from minor cutaneous lesions to life-threatening vital organ dysfunction. Throughout this continuum skin manifestations are variable and common. In 1981 Gilliam and Sontheimer developed a classification system that divides lesions into LE specific and LE non-specific cutaneous disease. LE specific cutaneous disease includes three clinically, immunologically and genetically distinct disorders: acute cutaneous LE (ACLE), subacute cutaneous LE (SCLE) and chronic cutaneous LE (CCLE). Histopathological differentiation between especially the first two disorders can be difficult.

This chapter focuses on the clinical features of SCLE and its management. SCLE is clinically characterized by nonscarring, nonindurated, erythematous, papulosquamous and/or annular skin lesions occurring in a symmetric, photodistributed pattern. Patients with SCLE tend to exhibit milder systemic symptoms than those with unselected systemic LE (SLE). Although not mandatory for diagnosis, the majority of SCLE patients produce anti-Ro/SSA autoantibodies.

### **Epidemiology**

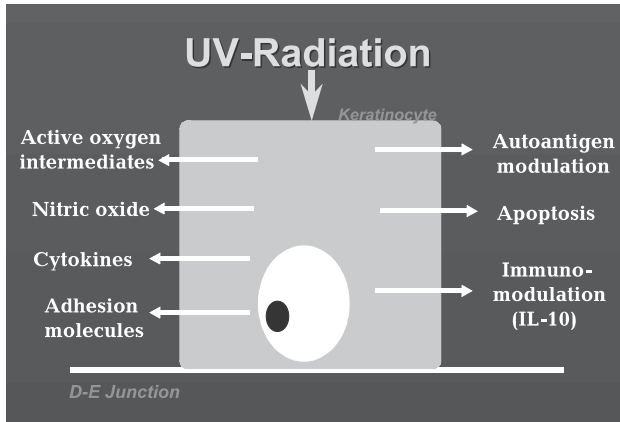
SCLE patients comprise approximately 3–32% of worldwide LE populations with the lowest reported rates in Korean and Chinese populations (Sontheimer



1989; Tebbe and Orfanos 1997; Lee 1998). SCLÉ is most frequent in young to middle-aged Caucasian females, but it can occur at any age and onset over age 60 years is possible (Chlebus et al. 1998). Seventy percent of the original SCLÉ cohort reported by Sontheimer et al. (1979) was female with a mean age of onset of 43.3 years and a range of 16–67 years. Eighty-five percent of the initial SCLÉ cohorts was Caucasian and 15% was African American or Hispanic, whereas the latter two groups comprised approximately 50% of the regional populations (Sontheimer et al. 1979). Other authors have reported similar demographic data (Callan and Klein 1988, Black et al. 2002). There have been five case reports of SCLÉ occurring in children 18 months to 9 years old (Buckley and Barnes 1995, Parodi et al. 2000, Siamopoulou-Mavridou et al 1989, Ciconte et al. 2002, Amato et al 2003).

### **Etiology and Pathomechanisms**

Programmed epidermal keratinocyte death in association with a lymphohistiocytic infiltrate is a hallmark histopathological feature of of -LE specific skin disease. Abnormally high rates of epidermal keratinocyte apoptosis occurs in patient with cutaneous LE when exposed to a precipitating environmental stressor such as ultraviolet light (Orteu et al. 2001). Abnormal exposure of autoantigens associated with apoptosis occurring with in a pro-inflammatory environment is thought to result in loss of immunological tolerance to such autoantigens. Cytokines, cytotoxic drugs, cytotoxic T cells and UV light can induce keratinocyte apoptosis (Millard and McGregor 2001). Apoptotic keratinocytes undergo programmed intracellular proteolysis and present Ro autoantigen, DNA, ribonucleoproteins, and calreticulin on surface membrane blebs as they disintegrate. (Millard and McGregor 2001; Racila et al. 2003). It has been proposed that anti-Ro/SSA and anti-La/SSB may bind to exposed autoantigen resulting in complement-mediated lysis or antibody-dependent cell-mediated cytotoxicity (ADCC) and cytotoxic T lymphocytes can induce keratinocyte lysis causing further release of epidermal cytokines. Partial/relative C1q deficiency may inhibit clearance of apoptotic debris and may lead to increased autoantibody production (Racila et al. 2003). The TNF- $\alpha$  G-308A polymorphism can lead to increased apoptosis and leukocyte migration into the skin and may promote the inflammatory pathway of apoptotic debris clearance. Inducible nitric oxide synthases in endothelial cells and keratinocytes may also be associated with dysregulated keratinocyte apoptosis and inflammation, but its role in the pathogenesis of photosensitive LE remains unclear (Orteu et al. 2001). Expression of the adhesion molecules ICAM-1, VCAM-1, E-selectin, and P-selectin is increased in cutaneous endothelial cells of LE patients (Kuhn et al. 2002a). Local T-cell and endothelial activation are possibly involved in the persistence and extension of lesions (Norris 1993). (*Fig. 1*).



**Fig. 1.** Potential factors involved in the pathogenesis of UV-induced cutaneous LE

## Immunogenetics

The earliest immunogenetic studies on SCLÉ patients suggested an association with several HLA class II phenotypes. HLA-DR3, a phenotype found in 25% of Caucasians in the US (Ahearn et al. 1982), was reported in some studies in at least half of SCLÉ patients (Sontheimer 1989; Vasquez-Doval et al. 1992), while others reported a lower frequency (Callen and Klein 1988; Drosos et al. 1990; Cohen and Crosby 1994). HLA-DR3 expression has been associated with annular more than papulosquamous SCLÉ lesions (Sontheimer et al. 1982; Herrero et al. 1988) and HLA class II phenotype expression has been even more closely associated with autoantibody production than with skin changes (Watson et al. 1991). HLA-DR3 and HLA-DR2 were first associated with the presence of anti-Ro/SSA antibody (Bell and Madisson 1980; Sontheimer et al. 1982; Watson et al. 1991), and subsequent work revealed that DQ alleles are the most frequent class II alleles associated with anti-Ro/SSA (Maddison 1999). Very high levels of anti-Ro/SSA production have been associated with the extended haplotype HLA-B8, DR3, DRw6, DQ2, DRw52 (Harley et al. 1986).

A distinct extended haplotype called the "high human immune responder" 8.1 ancestral haplotype (A\*01, B\*08, DRB1\*0301, DQB1\*0201, TNFAB\*a2b3, C2\*C) has also been linked with anti-Ro/SSA production (Price et al. 1999, Lio et al. 2001). Located on human chromosome 6, the 8.1 ancestral haplotype is in linkage disequilibrium with the gene for tumor necrosis factor- $\alpha$  (TNF- $\alpha$ ), an important proinflammatory mediator of the cutaneous innate immune response. A single nucleotide polymorphism in the promoter region of TNF- $\alpha$  G-308A, has been found to be associated with the SCLÉ phenotype (Werth et al. 2000, Millard et al. 2001a). Following exposure to UVB radiation in the presence of IL-1 $\alpha$ , this promoter polymorphism produced

exaggerated levels of TNF- $\alpha$  in human keratinocytes, which may have a priming effect on the adaptive component of the LE autoimmune response (Werth et al. 2000).

Inherited deficiencies of C1q, C2, C3, and C4 complement have also been associated with SCLE (Callen et al. 1987; Johansson-Stephansson et al. 1989; M van Hees et al. 1992). It has been shown that homozygous complete congenital deficiency of C1q is the strongest single genetic risk factor yet identified for the development of SLE (Korb and Ahearn 1997, Walport et al. 1998, Barilla-LaBarca and Atkinson 2000, Topaloglu et al. 2000, Fishelson et al. 2001). Approximately 93% of individuals with a congenital C1q deficiency have developed early onset severe SLE with photosensitive cutaneous forms of LE among the most common disease presentation. Racila et al. (2003) recently reported a highly significant association between a C1q coding region single nucleotide polymorphism (SNP), C1QA-Gly70<sub>GGA</sub>, and the SCLE phenotype. This SNP does not encode a different amino acid, but may alter C1q expression through an alternative splicing mechanism. Its presence correlates inversely with serum levels of C1q antigenic protein in SCLE patients. Since C1q binds calreticulin and is involved in clearance of cellular debris, C1q deficiency may result in decreased clearance of immunogenic material (Racila et al 2003).

## Environmental Factors

*Photosensitivity.* Photosensitivity is seen in the majority of SCLE patients. UV light can induce the release of inflammatory mediators such as IL-1, TNF- $\alpha$ , IL-10 and oxygen free radicals at the level of the epidermis and dermis. In addition to natural light, cutaneous LE lesions have been provoked by exposure to psoralen with UVA (Dowdy et al. 1989; McGrath et al. 1990), UVB via unshielded fluorescent light (Rihner and McGrath 1992; Kuhn et al. 2001), radiation therapy (Balabanova et al. 1997), and even photocopier light (Klein et al. 1995). In addition, many drugs which have been reported to induce SCLE lesions often have photosensitization as a side effect of their use. Several researchers have used standardized phototesting protocols which involve exposing specific patches of skin to precise amounts of UVR or natural light in order to demonstrate photosensitivity in these patients (Sanders et al. 2003; as reviewed in Kuhn et al. 2001). One such study was able to diagnose photosensitivity in 100% of SCLE patients despite the use of steroids, antimalarials, or methotrexate in several patients tested (Sanders et al. 2003). Their testing also demonstrated that the majority of skin reactions appeared after more than a 1-week delay, which the authors postulated, could explain why many patients who reported a negative history of photosensitivity were found to have a positive phototest. This evidence reaffirmed the need to encourage all SCLE patients to use photoprotective measures despite history.

**Table 1.** Medications that May Induce SCLE Lesions

<i>Diuretics</i>	Thiazides Spironolactone	<i>Antimicrobials</i>	Griseofulvin Terbinafine
<i>Calcium Channel Blockers</i>	Diltiazem Verapamil Nifedipine Nitrendipine	<i>Antihistamines</i>	Cinnarizine/ Thiethylperazine
<i>ACE inhibitors</i>	Captopril Cilazapril	<i>Sulfonylureas</i>	Glyburide
<i>Acid Blockers</i>	Ranitidine Omeprazole	<i>Chemotherapy</i>	Taxotere
<i>NSAIDS</i>	Naproxen Piroxicam	<i>Others</i>	Interferon beta-1a Interferon alfa Etanercept Phenytoin
<i>Beta Blockers</i>	Oxprenolol		Procainamide d-penicillamine
<i>Lipid-lowering</i>	Pravastatin Simvastatin		Psoralen-UVA Insecticides

*Drugs.* Several drugs are associated with the induction of SCLE lesions (Table 1). Thiazide diuretics (Reed et al. 1985; Fine 1989; Parodi et al. 1989; Brown and Deng 1995), calcium channel blockers (Crowson and Magro 1997; Gubinelli et al. 2003; Marzano et al. 2003a) and angiotensin-converting enzyme (ACE) inhibitors (Patri et al. 1985; Fernandez-Diaz et al. 1995) have most commonly been reported. Others include spironolactone (Leroy et al. 1987), interferon beta-1a (Nousari et al. 1998), procainamide (Sheretz 1988), d-penicillamine (Sontheimer 1989), sulfonylureas (Sontheimer 1989), terbinafine (Brooke et al. 1998; Callen et al. 2001; Bonsmann et al. 2001), oxprenolol (Gange and Levene 1979), griseofulvin (Miyogawa et al. 1994), naproxen (Parodi et al. 1992), piroxicam (Roura et al. 1991), phenytoin (Ross et al. 2002), etanercept (Bleumink et al. 2001) and PUVA (McGrath et al. 1990). The combination of the antihistamines cinnarizine and thiethylperazine was cited as the cause of annular SCLE lesions in one patient (Toll et al. 1998). Personal anecdotal experience has suggested acid inhibitors such as omeprazole and ranitidine may also be a trigger for SCLE (RDS). Some hypothesize that hormones play a significant enough role in SCLE and that it may be reasonable to recommend that cutaneous LE patients avoid estrogen-containing contraceptives (Tebbe and Orfanos 1997). However, no cases of SCLE have been reported as a result of oral estrogen use. A recent retrospective study showed an association between certain medications and the onset of disease in 15 of 70 patients with Ro positive cutaneous lupus (Srivastava et al. 2003). Antihy-

pertensives were most commonly identified as possible triggers, in addition to statins, interferon alfa, and interferon beta. In that review, clinical disease began between 4 and 20 weeks, and improved 6–12 weeks after discontinuation of the offending drug.

Drug-induced *SCLE* should be differentiated from classical drug-induced *SLE*. The former is associated with Ro/SSA autoantibodies and a characteristic photodistributed rash, whereas the latter is dominated by histone autoantibodies and systemic symptoms such as fever, arthritis, myalgias, and serositis (Brogan and Olsen 2003). A lupus-specific skin rash is rarely present in the drug-induced form of *SLE*, and is much more commonly seen in idiopathic *SLE* (Rubin 2002). The medications which typically trigger *SCLE* (*Table 1*) are distinct from those that trigger classical *SLE* (e.g., hydralazine, procainamide, isoniazid, minocycline, sulfasalazine, etanercept), with exceptions, probably reflecting different underlying disease mechanisms.

## Cutaneous Manifestations

Before Gilliam and Sontheimer classified it as a distinct entity, lesions of *SCLE* were referred to with varied nomenclature including symmetric erythema centrifugum, disseminated *DLE*, autoimmune annular erythema, subacute disseminated *LE*, superficial disseminated *LE*, psoriasiform *LE*, pityriasiform *LE*, and maculopapular photosensitive *LE* (Sontheimer et al. 1979).

Cutaneous lesions of *SCLE* typically begin with red macules or papules which evolve into psoriasiform and/or annular plaques on sun-exposed skin, characteristically the shoulders, upper back, extensor arms, V of the lower neck and upper chest, and back of the neck. The face is less commonly affected. Annular lesions tend to expand with central clearing and trailing scale. When active inflammation resolves, hypopigmentation is common, especially in the inactive centers of annular lesions. In Sontheimer's original cohort half presented with predominantly papulosquamous and half with predominantly annular lesions. Parodi reported similar findings (Parodi et al. 2000), whereas some cohorts have had a majority of annular lesions (Herrero et al. 1988; Chlebus et al. 1998; Black et al. 2002) and some have had a majority of papulosquamous lesions (Molad et al. 1987; Callen and Klein 1988; Cohen and Crosby 1994).

Atypical presentations of *SCLE* occur, including vesiculo-bullous forms. Well before the classification of *SCLE* as a subset of *LE*, Rowell et al. (1963), described EM-like (erythema multiforme) lesions in four so-called *DLE* patients who had a speckled ANA, rheumatoid factor and precipitating antibodies to the saline extract of human tissues (anti-Sj-T). Whereas EM and *DLE* can coexist, it has been suggested that Rowell's syndrome should now be reclassified as *SCLE* (Roustan et al. 2000). Lyon et al. (1998) reported two cases of delayed diagnosis of *SCLE* because of the clinical and histologic similarities

between SCLE and EM. Additional cases of EM-like SCLE lesions have been reported (Massone et al. 2000). In one patient the lesions developed changes similar to toxic epidermal necrolysis (Bielsa et al. 1987). Marginal vesicles were clinically evident in 38% of annular SCLE lesions that Herrero et al. observed (1988).

Rarer presentations of SCLE have also been reported including a morbiliform exanthem (Sontheimer 1985), exfoliative erythroderma (DeSpain and Clark 1988; Parodi et al. 2000), pityriasiform lesions (Sontheimer 1989; Parodi et al. 2000; Caproni et al. 2001), peculiar acral annular plaques (Scheinman 1994), progressive generalized poikiloderma (Pramatarov et al. 2000; Marzano et al. 2003b), sunlight induced papulonodular mucinosis (Sonntag et al. 2003), generalized erythroderma with acral bullae preceding SCLE (Mutasim, 2003) and annular SCLE lesions that were eventually replaced by morphea (Rao et al. 1990).

SCLE patients may have other LE specific skin lesions. Localized ACLE not uncommonly occurs in the setting of SCLE and is characterized by an erythematous, edematous malar rash in a butterfly pattern that usually spares the nasolabial folds (Sontheimer 1989). Localized ACLE is usually more transient than SCLE and usually heals without scarring or pigmentary changes. Sontheimer has anecdotally suggested that the individuals who developed ACLE following SCLE might be predisposed to eventually developing findings of SLE such as nephritis (Sontheimer 1989).

Classical DLE is the most common form of CCLE and may be seen in some SCLE patients. DLE lesions are more common on the scalp and face and have more hypopigmentation, hyperpigmentation, scarring, follicular plugging, and adherent scale than SCLE lesions. Induration was the most important clinical feature differentiating DLE from SCLE lesions (David-Bajar et al. 1992). Lupus panniculitis, often reported in association with DLE, has recently been reported in association with SCLE (Morgan & Callen 2001).

SCLE patients may also have LE nonspecific skin findings. The most common are diffuse alopecia, mucositis, livedo reticularis, periungual telangiectasias, small vessel vasculitis, Raynaud's phenomenon, cutaneous sclerosis (Sontheimer 1989), and red lunulae (Wollina et al. 1999). Dystrophic calcinosis cutis (Marzano et al. 1999), multiple HPV-11 cutaneous squamous cell carcinomas (Cohen et al. 1992), and erythema gyratum repens, a rare paraneoplastic eruption (Hochedez et al. 2001), have been case reported.

## Systemic Disease

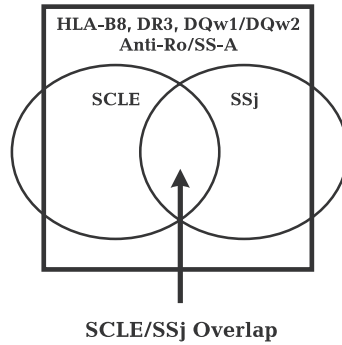
Thirty to 63% of SCLE patients have four or more American College of Rheumatology (ACR) diagnostic criteria for SLE (Sontheimer 1989; Chlebus et al. 1998; Parodi et al. 2000; Black et al. 2002). Musculoskeletal symptoms such as arthritis and arthralgias are the most common systemic manifestations

observed. Overall, most patients with SCLÉ tend to have mild systemic disease and it appears that isolated joint symptoms are a marker for milder disease. Some authors have reported musculoskeletal symptoms in 100 percent of their SCLÉ cohorts (Molad et al. 1987; Johansson-Stephansson et al. 1989). Renal and central nervous system (CNS) disease has been seen in 20% or less of SCLÉ cohorts (Cohen and Crosby 1994; Sontheimer 1989; Johansson-Stephansson et al. 1989; Chlebus et al. 1998; Parodi et al. 2000, Black et al. 2002). SCLÉ cohorts who have nephritis, papulosquamous lesions, high ANAs (>1:640), or who require high dose immunosuppressive therapy may have a worse prognosis (Sontheimer 1985, Cohen and Crosby 1994, Tebbe et al. 1997, Chlebus et al. 1998). Fatalities have rarely been reported in patients with severe systemic manifestations (Sontheimer 1989; Gunmundsen et al. 1992).

Sjogren's syndrome is the most common autoimmune disease associated with SCLÉ. The HLA-B8, DR3, DRw6, DQ2, and DRw52 extended haplotype is common to both Sjogren's syndrome and SCLÉ cohorts (Provost et al. 1988). The association with HLA-DR is probably more related to high circulating Ro/SS-A autoantibodies rather than to SCLÉ skin lesions. High Ro/SS-A antibody titers have also been associated in Sjogren's and LE patients with HLA-DQw1/DQw2 (Harley et al. 1986; Hamilton et al. 1988). (Fig. 2). In early studies twelve percent of SCLÉ cohorts developed Sjogren's syndrome. (Sontheimer et al. 1981). Subsequent studies with longer observation periods have reported the coincidence of Sjogren's syndrome to be as high as 43% (Black et al. 2002). In SCLÉ patients, the presentation of Sjogren's syndrome may be atypical. Rapidly progressive hypokalemic flaccid tetraparesis caused by a distal renal tubular acidosis was attributed to unrecognized Sjogren's syndrome in an SCLÉ patient (De Silva et al. 2001). Furthermore, annular erythema of Sjogren's syndrome is considered to be the Asian counterpart of SCLÉ in white persons. These patients have annular lesions similar to SCLÉ; however, they lack histopathologic findings at the dermal-epidermal junction of LE. It has been suggested that this is a subset of SCLÉ and that the relative absence of HLA DR3 in Japanese patients may account for the differences in disease expression (Haimowitz et al. 2000).

Other autoimmune disorders associated with SCLÉ include rheumatoid arthritis (Cohen et al. 1986; Sontheimer 1989, Pantoja et al. 2002), autoimmune thyroiditis (Sontheimer 1989; Ilan and Ben Yahuda 1991), hereditary angioedema (Gudat and Bork 1989), and autoimmune polyglandular syndrome type II (Schmidt's syndrome) (Wollina and Schreiber, 2003).

SCLÉ has been associated with various malignancies and some authors have suggested that SCLÉ is a paraneoplastic dermatosis (Brenner et al. 1997). Reported malignancies include lung, gastric, breast, uterine and hepatocellular carcinoma (Brenner et al. 1997, Ho et al. 2001), Hodgkin's disease (Castenet et al. 1995), malignant melanoma (Modley et al. 1989), and meningioma (Richardson and Cohen 2000). The significance of these anecdotal observations remains to be determined and the authors do not routinely screen new SCLÉ patients for occult malignancy.



**Fig. 2.** Immunogenetic associations of SCLE and Sjogren's syndrome

SCLE has been associated with a myriad of other diseases. Polymorphic light eruption (PLE), an inherited photosensitivity disorder, has frequently been associated with SCLE and they may have a common genetic predisposition (Millard et al. 2001b). Two-thirds of SCLE cohorts develop PLE and PLE cohorts have an increased relative risk of SCLE (Millard et al. 2001b). Case reports of porphyria cutanea tarda (Camp and Davis 1997), Sweet's syndrome (Goette 1985), Crohn's disease (Ashworth 1992), gluten sensitive enteropathy (Messenger and Church 1986), and X-linked Chronic Granulomatous Disease Carrier Status (Cordoba-Guijarro et al. 2000) have been associated with SCLE. Because of the infrequency of the latter reports, they may be incidental.

### Differential Diagnosis

The clinical diagnosis of SCLE is not always obvious. Annular lesions can be confused with erythema annulare centrifugum, granuloma annulare, erythema gyratum repens, autoinvolutive photoexacerbated tinea corporis (Dauden et al. 2001), or EM. Papulosquamous lesions may be confused with photosensitive psoriasis, lichen planus, eczema, pityriasis rubra pilaris, disseminated superficial actinic porokeratosis, contact dermatitis, tinea faciei (Meymandi et al. 2003) and dermatomyositis. Lesional photodistribution, characteristic histopathology and Ro/SS-A autoantibodies are useful in distinguishing SCLE from its differential diagnosis.

### Laboratory Findings

*Serology.* Whereas various autoantibodies have been found in SCLE cohorts, the Ro/SS-A autoantibody is the characteristic laboratory marker. Anti-Ro/



SSA is present in approximately 70% of SCLC cohorts by the classical Ouchterlony double immunodiffusion technique (Sontheimer 1989; Lee et al. 1994; Chlebus et al. 1998; Parodi et al. 2000) with its frequency ranging from 40–82% depending on the method of assay. ELISA (enzyme-linked immunosorbent assay) has been shown to be the most sensitive test for determining Ro/SS-A autoantibodies (Lee et al. 1994) and is the assay technique currently used in most clinical laboratories in the USA. Unfortunately, up to 10% of the normal population demonstrate Ro antibodies by such commercial ELISA techniques. Anti-La/SS-B usually occurs with less frequency and is seldom seen in the absence of anti-Ro/SS-A. Anti-nuclear antibody (ANA) tested with human substrate was found in 60–88% of SCLC cohorts and less frequent when animal substrate was used (Callen and Klein 1988; Herrero et al. 1988; Ng et al. 2000; Reichlin 2000). Other autoantibodies are present with varying frequencies in SCLC (*Table 2*).

*Miscellaneous laboratory.* Particularly if they have concomitant SLE, many SCLC patients have laboratory abnormalities including leukopenia, lymphocytopenia (Wenzel et al. 2002), thrombocytopenia, anemia, elevated erythrocyte sedimentation rate, elevated BUN and creatinine, hypergammaglobulinemia, proteinuria, hematuria, and urine casts. Complement levels may be depressed as a result of either genetic deficiency or consumption secondary to immune complex formation.

## Histopathology

The histopathologic features of LE specific skin disease include hyperkeratosis, epidermal atrophy, liquifactive vacuolar basal cell degeneration, and nodular perivascular and perifollicular mononuclear cell infiltrates. Some authors have reported degrees of LE specific features among LE subsets. SCLC has more epidermal atrophy, but less hyperkeratosis, basement membrane thickening, follicular plugging and inflammatory cell infiltrates when compared to DLE (Bangert et al. 1984; David-Bajar and Davis 1997). Since the histologic findings typically mirror the clinical findings, this is expected, and corresponds to the fine less adherent scale, lack of induration and less frequent alopecia of SCLC. Herrero et al biopsied the border of annular vesicular lesions in a SCLC cohort group with a high frequency of anti-Ro/SSA and the HLA DR3 phenotype (Herrero et al. 1988). Epidermal necrolysis was prominent and the authors suggested this immunophenotype may correlate with the histologic findings. However, other authors have reported variable success in differentiating LE subsets. Bangert et al. (1984) were unable to distinguish the histology between papulosquamous and annular SCLC lesions.

**Table 2.** Serological Findings in Patients with SCLE

Serology	Frequency range (percent)
ANA	60–88
Anti-Ro/SS-A	40–82
Anti-La/SS-B	12–71
Anti-dsDNA	1–33
Anti-U1RNP	0–53
Anti-Sm	0–12
Anticardiolipin	10–16
Rheumatoid factor	36–48
VDRL (false positive)	7–33
Antithyroid	18–44
Antilymphocyte	33

Data obtained from Sontheimer et al. (1982); Sontheimer (1989); Johansson-Stephensson et al. (1989); Marschalko et al. (1989); Konstadoulakis et al. (1993); Cohen and Crosby (1994); Chlebus et al. (1998); Parodi et al. (2000); Ng et al. (2000); Wenzel et al. (2000) and Black et al. (2002)

## Immunopathology

*Lesional skin.* Direct immunofluorescence (DIF) is an adjunctive diagnostic test for all subsets of LE. DIF of lesional skin shows immunoglobulins (IgG, IgA, IgM) and complement components in a granular band-like pattern at the epidermal basement membrane (DEJ). In the original cohort (Sontheimer et al. 1979), 40 percent of SCLE patients had a negative DIF. Therefore a positive DIF can help to confirm the diagnosis of LE, but a negative test cannot rule it out.

Nieboer et al. (1988) observed a distinctive “dust-like particle” pattern of IgG deposition near the DEJ of lesional skin in 30% of SCLE patients. Valeski et al. (1992) correlated this pattern with the presence of Ro/SSA autoantibodies. However, Lipsker et al (1998) retrospectively reviewed 4374 cutaneous DIF specimens and found a dust-like particle pattern in only 66 specimens from 60 individuals. Of those 60 persons 85% had some form of connective tissue disease, 53% had SCLE and 36% had Ro/SSA antibodies. Lipsker et al. concluded that whereas these particles are highly suggestive of connective tissue disease in general, the dust-like pattern is not specific for SCLE. Furthermore, since some investigators have not been able to appreciate this DIF pattern due probably to differences in immunofluorescence microscopy techniques, its meaning remain controversial (David-Bajar and Davis 1997).

*Nonlesional Lupus Band Test (LBT).* A 'positive' LBT shows a 'band' of immunoglobulin and complement reactants at the DEJ of nonlesional skin. The diagnostic and prognostic significance of the LBT is the subject of ongoing debate (Sontheimer and Provost 1996; David-Bajar and Davis 1997). Twenty-six percent of a SCLÉ cohort had a positive LBT when sun-protected flexor forearm skin was biopsied (Sontheimer and Gilliam 1979). When three or more immunoreactants are present in the LBT of sun-protected skin, the diagnostic specificity for SLE is very high (Velthuis et al. 1992) and a positive LBT correlates with a higher risk of lupus nephritis (Davis and Gilliam 1984). It is unclear if the LBT provides added value to more available, less invasive testing such as serologic assays for double-stranded DNA autoantibodies. The greatest utility of the LBT may be in patients with atypical clinical and laboratory presentations of SLE.

## Evaluation and Management

Effective management of SCLÉ patients relies upon adequate baseline evaluation and ongoing surveillance during treatment. The initial history and physical should include a comprehensive review of systems in order to uncover evidence of systemic disease. Additionally, laboratory workup should include a complete blood count with differential, platelet count, erythrocyte sedimentation rate, urinalysis, and blood chemistry profile. In addition to histopathology and ANA, Ro/SS-A autoantibodies, determination of C3, C4 and CH50 may also be helpful depending on clinical symptoms. Follow-up intervals for re-examination and laboratory monitoring should be customized to the individual patient as well as selected treatment modality.

Adequate patient education is essential. Disease-provoking factors such as sunlight, artificial ultraviolet (UV) exposure, photosensitizing drugs and even tobacco use are all modifiable factors, and alteration of these may be of value in the course of the disease. If possible, potentially offending drugs should be eliminated. Initial medical therapy should focus on maximizing local measures before systemic agents are introduced.

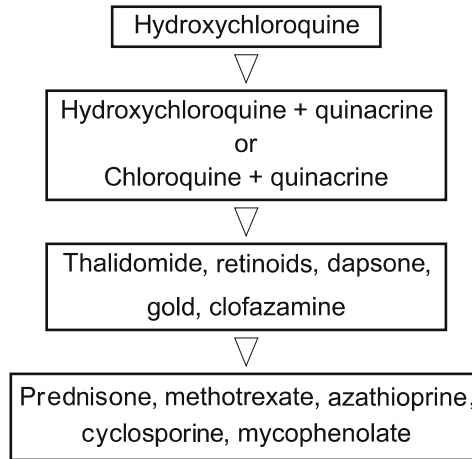
### Local Therapy

*Protection from UV exposure.* The importance of avoiding direct sunlight especially during midday hours and summer months should be stressed. A relatively lower danger from UV radiation while outdoors can be realized if one's shadow is longer than one is tall. SCLÉ patients should also be advised to avoid use of artificial tanning devices. Tightly woven clothing and broad-brimmed hats should be worn when outdoors. Specialty clothing lines which offer maximal UV protection are currently being marketed over the internet

for those anticipating prolonged sun exposure. Examples of internet sites include [www.sunprecautions.com](http://www.sunprecautions.com), [www.sunproof.com](http://www.sunproof.com) and [www.sunprotectiveclothing.com](http://www.sunprotectiveclothing.com).

In order to achieve maximal shielding from sunlight, broad spectrum sunscreens should be used in conjunction with photo-protective clothing. Water resistant or waterproof agents that block both UVA and UVB with a sun protection factor (SPF) of 30 or greater should be selected and generously applied. Since it has been shown that the amount of sunscreen that consumers put on is less than that applied under laboratory conditions when determining SPF ratings (Azurdia et al. 1999) it is important to use high SPF products to insure adequate protection under real-life conditions. Additionally, products with Parsol 1789 (avobenzone), zinc oxide or titanium dioxide provide broad UVA protection, offering a possible added value for SCLE patients (Callen et al. 1991a). Standardized testing to determine the best sunscreen for maximal protection in SCLE patients is needed. Stege et al. (2000) tested 3 commercially available sunscreens via photoprovocative testing with UVA and UVB and showed that while all three sunscreens tested were at least somewhat beneficial, they differed significantly in their abilities to protect against development of skin lesions and against the corresponding upregulation of ICAM-1 in exposed skin. These differences were found in spite of the fact that all 3 contained both Parsol 1789 and Titanium Dioxide. Sunscreens should be applied 30 min. before sun exposure and reapplied after bathing or significant perspiration. Stick-type sunscreens formulated for the lips may be better tolerated around the eyes than other sun blocking products. UV blocking films such as Llumar® UV Shield™ ([www.uv-shield.com](http://www.uv-shield.com)) should be placed over home and automobile windows. Plastic films or shields may be applied over fluorescent lighting, which can be a small source of UV irradiation. Corrective camouflage cosmetics such as Dermablend® ([www.dermablend.com](http://www.dermablend.com)) and Covermark® ([www.covermark.com](http://www.covermark.com)) offer the dual benefit of being highly effective physical sunscreens as well as aesthetically pleasing cosmetic masking agents which can provide great psychological benefit for these patients.

*Topical agents.* Superpotent topical class I agents are appropriate initial agents in the management of SCLE. Twice daily application to lesional skin for two weeks followed by a two week rest period is recommended in order to minimize the risk of steroid atrophy and telangiectasia. Intralesional steroids are not as effective in the treatment of SCLE as they are in DLE. Additionally, most SCLE patients have lesions that are too numerous to be managed in this manner. Topical tacrolimus may be of some benefit especially on the face and on skin lesions with less hyperkeratosis (Bohm et al. 2003), without the skin atrophy side effect seen with topical steroids. A speculative review concerning the utility in SCLE of new technology for defecting the stratum corneum barrier has recently been presented (Ting and Sontheimer 2001). Unfortunately, the majority of patients do not respond adequately to local therapy, and systemic therapy is usually required.



**Fig. 3.** Suggested algorithm for prescribing systemic medications in SCLL

### Systemic Therapy

*Antimalarials.* The aminoquinolone antimalarial agents have been the most efficacious of systemic agents used in the treatment of SCLL and represent first-line systemic therapy (see Fig. 3). Up to 75 percent of patients have responded to one or a combination of drugs within this class (Furner 1990a). Initial treatment should begin with hydroxychloroquine sulfate not to exceed a dose of 6 mg/kg lean body mass/day. It requires 6–8 weeks to achieve equilibrium blood levels. If an adequate clinical response is achieved, the dose can be decreased to 3 mg/kg lean body mass/day for maintenance for at least one year in order to minimize recurrence. If there is no significant improvement by 2 months, quinacrine hydrochloride 100 mg/day can be added (Feldman et al. 1994). If there is an inadequate response to this combination regimen after 4–6 weeks, chloroquine diphosphate 3 mg/kg lean body mass/day can be substituted for hydroxychloroquine while continuing quinacrine.

A rare, but well-known side effect of the antimalarial agents is retinal toxicity. When using either hydroxychloroquine or chloroquine, ophthalmologic evaluation is required. The current surveillance guidelines recommend follow-up ophthalmologic examination 5 years after an initial baseline exam in uncomplicated individuals on hydroxychloroquine. Complicated individuals (i.e. those who have taken antimalarials for greater than 5 years, those taking larger than recommended daily doses, those with high body fat levels, those greater than 60 years of age, and those with liver or kidney disease) should have yearly screening examinations. (Marmor et al 2002; Marmor 2003) Examination should include fundoscopic assessment, visual field testing (including central fields with a red object) and visual acuity testing. The use of an Amsler grid at home may allow early self-detection of visual field defects.

This is important since retinal changes may become irreversible if not found early. The risk of retinal toxicity may be minimized if certain daily doses of hydroxychloroquine (6 mg/kg/day) and chloroquine (3 mg/kg/day) are not exceeded (Lanham and Hughes 1982). Hydroxychloroquine and chloroquine should not be used together because of an enhanced risk of retinal toxicity. Quinacrine has not been shown to cause retinal toxicity. However, it is associated with a higher incidence of side effects than the others, including headaches, gastrointestinal intolerances, hematologic and dermatologic manifestations. Quinacrine is more likely to induce hemolysis in patients who are glucose-6-phosphate dehydrogenase (G6PD) deficient (Trenholme and Carson 1978).

All of the antimalarials have dermatologic side effects. Blue-black pigmentation of sun-exposed skin, the palatal mucosa and nails has been seen with these agents. They can rarely cause a bleaching of lightly pigmented hair. The antimalarials can also induce a lichenoid hypersensitivity drug reaction in the skin which can be confused with the appearance of true cutaneous LE lesions including SCLE. Thus, if new skin lesions appear in an SCLE patient on antimalarial therapy, one should consider the possibility of a superimposed lichenoid drug reaction. Quinacrine can cause diffuse reversible yellowing of the skin, especially in fair-skinned individuals. Other potential side effects of the antimalarials include hematologic (e.g. bone marrow suppression, aplastic anemia), neuropsychiatric (e.g. toxic psychosis, grand mal seizures), cardiac (e.g. arrhythmias, cardiomyopathy) and muscular. These are less common than in the past, when higher daily dosage regimens of antimalarials were used. Periodic laboratory monitoring of hematological and hepatic function is helpful in identifying any patient who might suffer an idiosyncratic reaction. Johansen and Gran (1998) reported two cases of ototoxicity associated with hydroxychloroquine. Hearing loss has been associated with chloroquine and quinine in the past, but this was the first report of such with hydroxychloroquine.

There is evidence that patients with cutaneous LE who smoke are less likely to respond to antimalarial therapy than nonsmokers (Rahman et al. 1998; Jewell and McCauliffe 2000). In addition to the well-known dangers of smoking, this represents another reason to strongly encourage tobacco cessation in the SCLE patient. Appropriate referrals should be made if counseling or drug therapy is needed to accomplish this goal.

*Thalidomide.* Thalidomide is a potent anti-inflammatory agent which acts in part via downregulation of TNF- $\alpha$ , a proinflammatory cytokine which may be involved in the pathogenesis of SCLE as discussed above. Treatment with 50–300 mg/day can be very effective in otherwise-refractory cutaneous LE (Stevens et al. 1997; Georgala et al. 1998; Warren et al. 1998; Duong et al. 1999; Ordi-Ros et al. 2000). In general, about 75 percent of cutaneous LE patients will respond to antimalarial monotherapy or combination therapy. It appears that thalidomide can be effective in 75 percent of antimalarial-refractory cutaneous LE. Because of the high rate (approximately 75 percent)

of relapse after withdrawal of the medication, it has been suggested that low maintenance doses for long periods of time may be necessary (Ordi-Ros et al. 2000). Alternatively, other forms of therapy such as antimalarials can be used to maintain thalidomide-induced remissions. Since thalidomide is a potent teratogen, special precautions must be taken when prescribing the drug. Other second-line drugs should be considered in females of child-bearing potential. Thalidomide is available in the United States under the name Thalomid. Physicians and pharmacies are required to register with the manufacturer, the Celgene Corporation. Once registered, Celgene will send the physician specially developed materials (System for Thalidomide Education and Prescribing Safety (STEPS)) to educate patients in the prevention of birth defects.

Another important adverse effect of thalidomide is sensory neuropathy, which is sometimes irreversible. Routine clinical assessment for neuropathy is the single most effective means to detect the early development of neuropathy (Duong et al. 1999). Nerve conduction tests are recommended at baseline and periodically during treatment, but the role of these is not well defined. Evidence of neuropathy, by either high clinical suspicion or by electrophysiologic data is an indication to withdraw the drug (Stevens et al. 1997). Other side effects of thalidomide include amenorrhea, drowsiness, weight gain, vomiting, constipation, migraine headaches, and skin eruptions. Some of these side effects are improved on lower daily doses and when the drug is given at bedtime. A case of toxic pustuloderma secondary to thalidomide was reported in a patient with refractory cutaneous LE (Rua-Figueroa et al. 1999). While clear evidence of thrombosis in SCLC patients on thalidomide is lacking, Piette et al. (2002) also warned about the potential thrombotic risk associated with thalidomide therapy. There are known cases of thrombosis in cancer, Bechet's syndrome, and SLE patients including one SCLC patient with antiphospholipid antibodies (Flageul et al. 2000) on thalidomide therapy. The authors emphasized the need for increased surveillance in SCLC patients treated with thalidomide. These concerns are especially valid since SCLC patients often have additional prothrombotic risk factors such as smoking, estrogen-containing contraceptive use, antiphospholipid antibodies, or stopping antimalarial therapy like hydroxychloroquine which has anti-thrombotic properties.

*Dapsone.* Dapsone (Diaminodiphenylsulfone) has been used successfully in some antimalarial-refractory SCLC cases (McCormack et al. 1984; Holtman et al. 1990; Neri et al. 1999) but overall experience with this agent for cutaneous LE has been disappointing (Sontheimer and Provost 1996; Callen 1997). An initial dose of 25 mg twice daily can be increased to 200–300 mg/day as needed. Frequent monitoring is required to evaluate for potential renal, hepatic, and hematologic toxicity, including hemolysis and/or methemoglobinemia that occur especially in patients deficient in G6PD enzyme activity.

*Retinoids.* The synthetic retinoids, isotretinoin and acitretin, have been shown to significantly improve SCLC lesions in doses of 1/2–1 mg/kg/day (Furner 1990b; Richardson and Cohen 2000). Their long-term use may be

limited by the potential for teratogenicity, mucocutaneous dryness, photosensitivity, hepatitis, hypertriglyceridemia, mood alteration, psuedotumor cerebri, and bony changes consistent with diffuse idiopathic skeletal hyperostosis (DISH) syndrome.

*Clofazimine and Gold.* Although these agents have been successfully used in the treatment of refractory cutaneous LE (Costner et al. 2004; Crovato 1981), they are both limited by their potential for toxic side effects.

*Systemic corticosteroids and other immunosuppressive agents.* These agents are usually reserved for those patients who have not responded to less toxic therapies. However, they may be needed before an adequate trial of less toxic drugs is completed in those patients with severe disease. Pulsed intravenous methylprednisolone at a dose of 1 g for three consecutive days provided improvement of SCLE patients in the presence of systemic LE (Goldberg and Lidsky 1984). The side effects of steroids, especially when used over long periods of time are worrisome. They are more appropriately used as adjunctive treatment and tapered off if possible. Steroid-sparing agents that may be of benefit in refractory SCLE include methotrexate (Boehm et al. 1998, Kuhn et al. 2002b), azathioprine (Callen et al. 1991b), cyclosporine, and mycophenolate. Mycophenolate is increasingly being reported as an effective option for refractory SCLE. Hanjani and Nousari (2002) reported one SCLE patient treated with 3 g/day of mycophenolate with complete resolution at 3 months and no flare by 10 months after failing multiple prednisone tapers and antimalarials. Schanz et al. (2002) presented two additional cases of antimalarial, azathioprine, and high dose steroid refractory SCLE which completely resolved within a few weeks on 2g/day of mycophenolate. In one patient this response was successfully maintained for over 24 months on a lower dose of at least 1 g/day. Mycophenolate offers a lower toxicity profile than some of the other immunosuppressants. A thorough understanding of potentially harmful side effects is imperative with all of these medications, and close monitoring is essential.

*Immune regulation.* Five patients, including one SCLE patient with refractory cutaneous LE, who received infusions of chimeric CD4 monoclonal antibody showed improvement and became more responsive to conventional treatments (Prinz et al. 1996). Intravenous immunoglobulin may lead to improvement of cutaneous LE lesions (Genereau et al. 1999; Goodfield et al. 2004), but its study and use is limited mostly by cost-prohibitiveness. Recombinant IFN- $\alpha$  2a, allowed a complete response in two of four SCLE patients (Thivolet et al. 1990). However, the use of IFN- $\alpha$  has also been associated with the induction and/or exacerbation of SCLE (Srivistava et al. 2003) and SLE. Caution should therefore be used in this setting.

Fautrel et al. (2002) reported the resolution of SCLE in a rheumatoid arthritis patient using etanercept, an anti-TNF $\alpha$  recombinant biologic agent. Etanercept and infliximab have both been associated with the development of anti-double-stranded DNA antibodies and a lupus-like syndrome in some RA and Crohn's patients. A small number of case reports suggests the possi-



bility of etanercept-induced SCLE (Bleumink et al. 2001). Thus, there is some concern regarding the induction or unmasking of cutaneous or systemic LE with the use of either of these agents in cutaneous LE. Rituximab (Rituxan), a recombinant monoclonal antibody which inhibits CD20 expressing B cells, has shown efficacy in small numbers of systemic and cutaneous LE patients (Kneitz et al 2002; Perotta et al 2002). Finally, other biologic drugs which inhibit antigen presenting cell-T cell interaction are speculated to be of benefit in SCLE, although more study is needed. Some examples include alefacept (Amevive), an inhibitor of the LFA3:CD2 interaction, and efalizumab (Raptiva), an inhibitor of the LFA-1:ICAM-1 interaction.

*Other.* Two antineoplastic drugs, cyclophosphamide and cytarabine, were beneficial in refractory SCLE (Schulz and Menter 1971; Yung and Richardson 1995). Although sulfasalazine, phenytoin, danazol, dehydroepiandrosterone sulfate (DHEAS) and cefuroxime axetil have all been suggested in the treatment of cutaneous lupus, they have not been effectively used by the authors.

*Ultraviolet A-1 phototherapy (UVA-1).* Finally, it has been suggested that cutaneous lupus patients may benefit from low doses of longer wavelength (340–400 nm) UV irradiation (Sonnichsen et al. 1993; McGrath 1997). According to McGrath (1997), this modality reduced the need for medication and attenuated autoimmune antibody levels. These results should be interpreted with caution. Conflicting data indicate that UVA, including long wave UVA, may play a role in cutaneous LE (Lehmann et al. 1990; Nived et al. 1993). Additionally, in an SLE murine model, UVA-1 irradiation was associated with increased renal disease and death (Cai et al. 2000).

### Prognosis

Because SCLE has been recognized for little over two decades, long-term outcomes of patients are not yet known. Most patients tend to have intermittent recurrent skin lesions without significant disease progression, while some may experience permanent remissions. Approximately 15 percent of patients developed active SLE in the original cohort. More recent studies addressing prognosis have revealed similar findings (Chlebus 1998). In addition, an informal long-term prospective follow-up study of SCLE patients who presented from 1971–1995 in the Department of Dermatology at UT Southwestern Medical Center in Dallas was initiated by one of the authors (RDS, unpublished observation). To date, 18 of 130 patients have been evaluated. Mean duration of follow-up was 12.6 years. Thirty-nine percent had inactive skin and systemic disease at follow-up. The most common complaints other than skin lesions and photosensitivity were fatigue, arthralgias and Raynaud's phenomenon. In addition, many patients had a subjective history of depression. Lesions were predominantly papulosquamous in this particular population. Facial involvement, hypopigmentation and telangiectasias were common, while true scarring rarely occurred. At least one, and possibly three, out of

130 died of causes related to SLE (pancreatic vasculitis). A larger number of SCLE patients needs to be examined in a prospective study to more firmly establish its course, ANA and Ro/SS-A prevalence, overlap with other connective tissue diseases, as well as prognosis.

## References

- Ahearn JM, Provost TT, Dorsch CA, Stevens MB, Bias WB, Arnett FC (1982) Interrelationships of HLA-DR, MB and MT phenotypes, autoantibody expression, and clinical features in systemic lupus erythematosus. *Arthritis Rheum* 25: 1031–1040
- Amato L, Coronella G, Berti S, Moretti S, Fabbri P (2003) Subacute cutaneous lupus erythematosus in childhood. *Pediatric Dermatology* 20(1):31–4
- Ashworth J (1992) Subacute cutaneous lupus erythematosus in a patient with Crohn's disease. *Clin Exp Dermatol* 17: 135–136
- Azurdia RM, Pagliaro JA, Diffey BL, Rhodes LE (1999) Sunscreen application by photosensitive patients is inadequate for protection. *Br J Dermatol* 140: 255–258
- Balbanova MB, Botev IN, Michailoba JI (1997) Subacute cutaneous lupus erythematosus induced by radiation therapy. *Br J Dermatol* 137: 648–649
- Bangert JL, Freeman RG, Sontheimer RD, Gilliam JN (1984) Comparative histopathology of subacute cutaneous lupus erythematosus and discoid lupus erythematosus. *Arch Dermatol* 120: 332
- Barilla-LaBarca ML, Atkinson JP (2000) Rheumatic syndromes associated with complement deficiency. *Current Opinion in Rheumatology* 15: 55–60
- Bell DA, Maddison PJ (1980) Serologic subsets in systemic lupus erythematosus. *Arthritis Rheum* 23: 1268–1273
- Bielsa I, Herrero C, Font J, Mascaro JM (1987) Lupus erythematosus and toxic epidermal necrolysis. *J Am Acad Dermatol* 16: 1265–1267
- Black DR, Hornung CA, Schneider PD, Callen JP (2002) Frequency and severity of systemic disease in patients with subacute cutaneous lupus erythematosus. *Arch Dermatol* 138(9): 1175–8
- Bleumink GS, ter Borg EJ, Ramselaar CG, Ch Stricker BH (2001) Etanercept-induced subacute cutaneous lupus erythematosus. *Rheumatology* 40(11): 1317–9
- Boehm IB, Boehm GA, Bauer R (1998) Management of cutaneous lupus erythematosus with low-dose methotrexate: indication for modulation of inflammatory mechanisms. *Rheumatol Int* 18: 59–62
- Bohm M, Gaubitz M, Luger TA, Metze D, Bonsmann G (2003) Topical tacrolimus as a therapeutic adjunct in patients with cutaneous lupus erythematosus – A report of three cases. *Dermatology* 207:381–385
- Bonsmann G, Schiller M, Luger TA, and Stander S (2001) Terbinafine-induced subacute cutaneous lupus erythematosus. *J Am Acad Dermatol* 44: 925–931.
- Brenner S, Golan H, Gat A, Bialy-Golan A (1997) Paraneoplastic subacute cutaneous lupus erythematosus: report of a case associated with cancer of the lung. *Dermatology* 194: 172–174
- Brogan BL, Olsen NJ (2003) Drug-induced rheumatic syndromes. *Curr Opin Rheumatol* 15(1):76–80.
- Brooke R, Coulson IH, al-Dawoud A (1998) Terbinafine-induced subacute cutaneous lupus erythematosus. *Br J Dermatol* 139: 1132–1133
- Brown CW, Jr. and Deng JS (1995) Thiazide diuretics induce cutaneous lupus-like adverse reaction. *J Toxicol Clin Toxicol* 33:729–733.
- Buckley D and Barnes L (1995) Childhood subacute cutaneous lupus erythematosus associated with homozygous complement 2 deficiency. *Pediatr. Dermatol.* 4: 327–30.
- Cai W, Maldonado M, Werth VP (2000) Differential effects of UVA1 and UVB on skin lesions of MRL/lpr lupus mice. (Abstract) *J Invest Dermatol* 114: 884

- Callen JP, Hodge SJ, Kulick KB, Stelzeer G, Buchino JJ (1987) Subacute cutaneous lupus erythematosus in multiple members of a family with C2 deficiency. *Arch Dermatol* 123: 66–70
- Callen JP, Klein J (1988) Subacute cutaneous lupus erythematosus. Clinical, serologic, immunogenetic, and therapeutic considerations in 72 patients. *Arthritis Rheum* 31: 1007–1013
- Callen JP, Roth DE, McGrath C, Dromgoole SH (1991a) Safety and efficacy of a broad-spectrum sunscreen in patients with discoid or subacute cutaneous lupus erythematosus. *Cutis* 47: 130–132, 135–136
- Callen JP, Spencer LV, Burruss JB, Holtman J (1991b) Azathioprine. An effective, corticosteroid-sparing therapy for patients with recalcitrant cutaneous lupus erythematosus or with recalcitrant cutaneous leukocytoclastic vasculitis. *Arch Dermatol* 127: 515–522
- Callen JP (1997) Management of antimalarial-refractory cutaneous lupus erythematosus. *Lupus* 6: 203–208
- Callen JP, Hughes AP, and Kulp-Shorten C (2001) Subacute cutaneous lupus erythematosus induced or exacerbated by terbinafine – A report of 5 cases. *Archives of Dermatology* 137:1196–1198.
- Camp PB, Davis LS (1997) Coexistence of subacute cutaneous lupus erythematosus and porphyria cutanea tarda: a case report [letter; comment]. *Cutis* 59: 216E
- Caproni M, Cardinali C, Salvatore E, Fabbri P (2001) Subacute cutaneous lupus erythematosus with pityriasis-like cutaneous manifestations *Int J Dermatol* 40(1): 59–62
- Castenet J, Taillon B, Lacour JP, Garnier G, Perrin C, Ortonne JP (1995) Subacute cutaneous lupus erythematosus associated with Hodgkin's disease. *Clin Rheumatol* 14: 692–694
- Chlebus E, Wolska H, Blaszczyk M, Jablonska S (1998) Subacute cutaneous lupus erythematosus versus systemic lupus erythematosus – Diagnostic criteria and therapeutic options. *J Am Acad Dermatol* 38: 405–412
- Ciconte A, Mills AE, Shipley A, Marks R (2002) Subacute cutaneous lupus erythematosus presenting in a child *Australasian J Dermatol* 43(1):62–4
- Cohen LM, Tyring SK, Rády P, Callen JP (1992) Human papillomavirus type II in multiple squamous cell carcinomas in a patient with subacute cutaneous lupus erythematosus. *J Am Acad Dermatol* 26 Suppl: 840–845
- Cohen MR, Crosby D (1994) Systemic disease in subacute cutaneous lupus erythematosus: A controlled comparison with systemic lupus erythematosus. *J Rheumatol* 21: 1665–1669
- Cohen S, Stastny P, Sontheimer RD (1986) Concurrence of subacute cutaneous lupus erythematosus and rheumatoid arthritis. *Arthritis Rheum* 29: 421–425
- Cordoba-Guijarro S, Feal C, Dauden E, Fraga J, Garcia-Diez A (2000) Lupus erythematosus-like lesions in a carrier of X-linked chronic granulomatous disease *J Euro Acad Dermatol & Venereol* 14(5): 409–11
- Costner MI, Provost TT, and Sontheimer RD (2004) Lupus erythematosus. Chapter 2. In, *Cutaneous Manifestations of Rheumatic Diseases*. 2nd edition. Lippincott Williams and Wilkins, Philadelphia.
- Crowson AN, Magro CM (1997) Subacute cutaneous lupus erythematosus arising in the setting of calcium channel blocker therapy. *Human Pathol* 28: 67–73
- Crovato F (1981) Clotazimine in the treatment of annular lupus erythematosus. *Arch Dermatol* 117: 249–250
- Dauden E, Bartolome B, Pascual M, Fraga J, Garcia-Diez A (2001) Autoinvolutive photoexacerbated tinea corporis mimicking a subacute cutaneous lupus erythematosus *Acta Dermatovenereologica* 81(2): 141–2
- David-Bajar KM, Bennion SD, DeSpain JD, Golitz LE, Lee LA (1992) The clinical, histologic and immunofluorescent distinctions between subacute cutaneous lupus erythematosus and discoid lupus erythematosus. *J Invest Dermatol* 99: 251–257
- David-Bajar KM, Davis BM (1997) Pathology, immunopathology and immunohistochemistry in cutaneous lupus erythematosus. *Lupus* 6: 145–157
- Davis BM, Gilliam JN (1984) Prognostic significance of subepidermal immune deposits in uninvolved skin of patients with systemic lupus erythematosus: a 10-year longitudinal study. *J Invest Dermatol* 83: 242–247
- De Silva BD, Plant W, Kemmett D (2001) Subacute cutaneous lupus erythematosus and life-threatening hypokalaemic tetraparesis: a rare complication *Br J Dermatol* 144(3): 622–4

- DeSpain J, Clark DP (1988) Subacute cutaneous lupus erythematosus presenting as erythroderma. *J Am Acad Dermatol* 19: 388–392
- Dowdy MJ, Nigra TP, Barth WF (1989) Subacute cutaneous lupus erythematosus during PUVA therapy for psoriasis: Case report and review of the literature. *Arthritis Rheum* 32: 343–346
- Drosos AA, Dimou GS, Siamopoulou-Mavridou A, Hatzis J, Moutsopoulos HM (1990) Subacute cutaneous lupus erythematosus in Greece. A clinical, serological and genetic study. *Ann Med Interne (Paris)* 141: 421–424
- Duong DJ, Spigel GT, Moxley RT, Gaspari AA (1999) American experience with low-dose thalidomide therapy for severe cutaneous lupus erythematosus. *Arch Dermatol* 135: 1079–1087
- Fautrel B, Foltz V, Frances C, Bourgeois P, Rozenberg S (2002) Regression of subacute cutaneous lupus erythematosus in a patient with rheumatoid arthritis treated with a biologic tumor necrosis factor alpha-blocking agent: comment on the article by Pisetsky and the letter from Aringer et al. *Arthritis & Rheumatism* 46(5): 1408–9
- Feldmann R, Salomon D, Saurat J-H (1994) The association of the two antimalarials chloroquine and quinacrine for treatment-resistant chronic and subacute cutaneous lupus erythematosus. *Dermatology* 189: 425–427
- Fernandez-Diaz ML, Herranz P, Suarez-Marrero MC, Borbujo J, Manzano R, Casado M (1995) Subacute cutaneous lupus erythematosus associated with cilzapril [letter]. *Lancet* 345: 398
- Fine RM (1989) Subacute cutaneous lupus erythematosus associated with hydrochlorothiazide therapy. *Int J Dermatol* 28: 375–376
- Fishelson Z, Attali G, Mevorach D (2001) Complement and apoptosis. *Molecular Immunol* 38: 207–219.
- Flageul B, Wallach D, Cavellier-Balloy B, Bachelez H, Carsuzaa F, Dubertret L (2000) Thalidomide and thrombosis *Annales de Dermatologie et de Venerologie* 127(2): 171–4
- Furner BB (1990a) Treatment of subacute cutaneous lupus erythematosus. *Int J Dermatol* 29: 542–547
- Furner BB (1990b) Subacute cutaneous lupus erythematosus response to isotretinoin. *Int J Dermatol* 29: 587–590
- Gange KW, Levene GM (1979) A distinctive eruption in patients receiving oxprenolol. *Clin Exp Dermatol* 4: 87–97
- Genereau T, Chosidow O, Danel C, Cherin P, Herson S (1999) High-dose intravenous immunoglobulin in cutaneous lupus erythematosus. *Arch Dermatol* 135: 1124–1125
- Georgala S, Katoulis AC, Hasapi V, Koumantaki-Mathioudaki E (1998) Thalidomide treatment for hypertrophic lupus erythematosus [letter]. *Clin Exp Dermatology*. 23: 141
- Gilliam JN, Sontheimer RD (1981) Distinctive cutaneous subsets in the spectrum of lupus erythematosus. *J Am Acad Dermatol* 4: 471–475
- Goette DK (1985) Sweet's syndrome in subacute cutaneous lupus erythematosus. *Arch Dermatol* 121: 789–791
- Goldberg JW, Lidsky MD (1984) Pulse methylprednisolone therapy for persistent subacute cutaneous lupus. *Arthritis Rheum*. 27: 837–838
- Goodfield M, Davison K, Bowden K (2004) Intravenous immunoglobulin (IVIg) for therapy-resistant cutaneous lupus erythematosus (LE). *J Dermatolog Treat*. 15(1):46–50.
- Gubinelli E, Cocuroccia B, and Girolomoni G (2003) Subacute cutaneous lupus erythematosus induced by nifedipine. *J Cutan Med Surg*. February 10
- Gudat W, Bork K (1989) Hereditary angioedema associated with subacute cutaneous lupus erythematosus. *Dermatologica* 179: 211–213
- Gundmundsen K, Otridge B, Murphy GM (1992) Fulminant fatal lupus erythematosus. *Br J Dermatol* 126: 303–304
- Gupta G, Roberts DT (1999) Pulsed dye laser treatment of subacute cutaneous lupus erythematosus. *Clin Exp Dermatol* 24: 498–499
- Haimowitz JE, McCauliffe DP, Seykora J, Werth V (2000) Annular erythema of Sjogren's syndrome in a white woman. *J Am Acad Dermatol* 42: 1069–1073
- Hamilton RG, Harley JB, Bias WB, Roebber M, Reichlin M, Hochberg MC, Arnett FC (1988) Two Ro (SS-A) autoantibody responses in systemic lupus erythematosus. Correlation of

- HLA-DR/DQ specificities with quantitative expression of Ro (SS-A) autoantibody. *Arthritis Rheum* 31(4):496–505
- Hanjani NM, Nousari CH (2002) Mycophenolate mofetil for the treatment of cutaneous lupus erythematosus with smoldering systemic involvement. *Arch Dermatol* 138(12): 1616–8
- Harley JP, Reichlin M, Arnett FC, Alexander EL, Bias WB, Provost TT (1986) Gene interaction at the HLA-DQ locus enhances autoantibody production in primary Sjogren's syndrome. *Science* 232: 1145–1147
- Herrero C, Bielsa I, Font J, Lozano F, Ericilla G, Lecha M, Ingelman M, Mascaro JM (1988) Subacute cutaneous lupus erythematosus: Clinical pathologic findings in 13 cases. *J Am Acad Dermatol* 19: 1057–1062
- Ho C, Shumack SP, Morris D (2001) Subacute cutaneous lupus erythematosus associated with hepatocellular carcinoma Australasian *J Dermatol* 42(2): 110–3
- Hochedez P, Vasseur E, Staroz F, Morelon S, Roudier Pujol C, Saiag P (2001) Subacute cutaneous lupus gyratus repens *Annales de Dermatologie et de Venereologie* 128(3 Pt1): 244–6
- Holtman JH, Neustadt DH, Klein J, Callen JP (1990) Dapsone is an effective therapy for the skin lesions of subacute cutaneous lupus erythematosus and urticarial vasculitis in a patient with C2 deficiency. *J Rheumatol* 17: 1222–1225
- Ilan Y, Ben Yehuda A (1991) Subacute cutaneous lupus associated with Hashimoto's thyroiditis. *Neth J Med* 39: 105–107
- Jewell M, McCauliffe DP (2000) Cutaneous lupus erythematosus patients that smoke are less responsive to antimalarial treatment. *J Am Acad Dermatol* 42: 983–987
- Johansen PB, Gran JT (1998) Ototoxicity due to hydroxychloroquine – report of two cases. *Clin Exper Rheumatol* 16: 472–474
- Johansson-Stephansson E, Koskimes S, Partanen J, Kariniemi AL (1989) Subacute cutaneous lupus erythematosus: Genetic markers and clinical and immunological findings in patients. *Arch Dermatol* 125: 791–796
- Klein LR, Elmets CA, Callen JP (1995) Photoexacerbation of cutaneous lupus erythematosus due to ultraviolet A emissions from a photocopier. *Arthritis Rheum* 38: 1152–1156
- Kneitz C, Wilhelm M, Tony HP (2002) Effective B cell depletion with rituximab in the treatment of autoimmune diseases. *Immunobiology* 206:519–27
- Konstadoulakis MM, Kroubouzos G, Tosca A, Marafelia P, Konstadoulakis M, et al. (1993) Thyroid autoantibodies in the subsets of lupus erythematosus: Correlation with other autoantibodies and thyroid function. *Thyroidol Clin Exp* 5: 1–7
- Korb LC, Ahearn JM (1997) C1q binds directly and specifically to surface blebs of apoptotic human keratinocytes – complement deficiency and systemic lupus erythematosus revisited. *J Immunol* 158: 4525–4528
- Kuhn A, Sonntag M, Richter-Hintz D, Oslislo C, Megahed M, Ruzicka T, Lehmann P (2001) Phototesting in lupus erythematosus: a 15-year experience. *J Am Acad Dermatol* 45(1): 86–95
- Kuhn A, Sonntag M, Lehmann P, Megahed M, Vestweber D, Ruzicka T (2002a) Characterization of the inflammatory infiltrate and expression of endothelial cell adhesion molecules in lupus erythematosus tumidus. *Arch Dermatol Res* 294:6–13.
- Kuhn A, Specker C, Ruzicka T, Lehmann P (2002b) Methotrexate treatment for refractory subacute cutaneous lupus erythematosus. *J Am Acad Dermatol* 46(4): 600–3
- Lanham JG, Hughes GRV (1982) Antimalarial therapy in SLE. *Clin Rheumat Disease* 8: 279–299
- Lee LA, Roberts CM, Frank MB, McCubbin VR, Reichlin M (1994) The autoantibody response to Ro/SSA in cutaneous lupus erythematosus. *Arch Dermatol* 130: 1262–1268
- Lee CW (1998) Prevalences of subacute cutaneous lupus erythematosus and epidermolysis bullosa acquisita among Korean/Oriental populations. *Dermatology* 197: 187
- Lehmann P, Holze E, Kind P, Goerz G, Plewig G (1990) Experimental reproduction of skin lesions in lupus erythematosus by UVA and UVB radiation [see comments]. *J Am Acad Dermatol* 22: 181–187
- Leroy DA, Dompmmartin A, Le Jean SGJLMJC, Deschamps P (1987) Toxidermie A L'aldactone a type d'erytheme annulaire centrifuge lupique. *Ann Dermatol Venereol* 114: 1237–1240

- Lio D, Candore G, Colombo A, et al. (2001) A genetically determined high setting of TNF- $\alpha$  influences immunologic parameters of HLA-B8, DR3 positive subjects: implications for autoimmunity. *Hum Immunol* 62: 705–713.
- Lipsker D, Dicesare MP, Cribier D, Grosshans E, Heid E (1998) The significance of the 'dust-like particles' pattern of immunofluorescence. *Br J Dermatol* 138: 1039–1042
- Lyon CC, Blewitt R, Harrison PV (1998) Subacute cutaneous lupus erythematosus: Two cases of delayed diagnosis. *Acta Derm Venereol* 78: 57–59
- M VanHees CL, Boom BW, Vermeer BJ, Daha MR (1992) Subacute cutaneous lupus erythematosus in a patient with inherited deficiency of the third component of complement. *Arch Dermatol* 128: 700–701
- Maddison PJ (1999) Nature and nurture in systemic lupus erythematosus. *Adv Exp Med Biol* 455: 7–13
- Marmor MF, Carr RE, Easterbrook M, et al. (2002) Recommendations on screening for chloroquine and hydroxychloroquine retinopathy: a report by the American Academy of Ophthalmology. *Ophthalmology* 190: 1377–82.
- Marmor, MF (2003) New American Academy of Ophthalmology recommendations on screening for hydroxychloroquine retinopathy. *Arthritis and Rheumatism* 48:1764
- Marschalko M, Dobozy E, Daroczy J, Gyimesi E, Horvath A (1989) Subacute cutaneous lupus erythematosus: A study of 15 cases. *Orvosi Hetilap* 130: 2623–2628
- Marzano AV, Kolesnikova LV, Gasparini G, Alessi E (1999) Dystrophic calcinosis cutis in subacute lupus. *Dermatology* 198: 90–92
- Marzano AV, Borghi A, Mercogliano M, Facchetti M, Caputo R (2003a) Nitrendipine-induced subacute cutaneous lupus erythematosus. *Eur. J. Dermatol.* 13:213–216.
- Marzano AV, Facchetti M, Alessi E (2003b) Poikilodermatous subacute cutaneous lupus erythematosus. *Dermatology* 207(3):285–90
- Massone C, Parodi A, Rebora A (2000) Erythema multiforme-like subacute cutaneous lupus erythematosus: a new variety? *Acta Dermato-Venereologica* 80(4):308–9
- McCormack LS, Elgart ML, Turner ML (1984) Annular subacute cutaneous lupus erythematosus responsive to Dapsone. *J Am Acad Dermatol* 11: 397–401
- McGrath H Jr, Scopelitis E, Nesbitt LT Jr (1990) Subacute cutaneous lupus erythematosus during psoralen ultraviolet A therapy [letter]. *Arthritis Rheum* 33: 302–303
- McGrath H (1997) Prospects for UV-A1 therapy as a treatment modality in cutaneous lupus erythematosus and systemic LE. *Lupus* 6: 209–217
- Messenger AG, Church RE (1986) Subacute cutaneous lupus erythematosus and malabsorption. *Br J Dermatol* 115 (supplement 30): 56–57
- Meymandi S, Wiseman MC, Crawford RI (2003) Tinea faciei mimicking cutaneous lupus erythematosus: a histopathologic case report. *J Am Acad Dermatol* 48(2 Suppl): S7–8
- Millard TP, McGregor JM (2001) Molecular genetics of cutaneous lupus erythematosus. *Clinical and Experimental Dermatol* 26: 184–91
- Millard TP, Kondeatis E, Cox A, Wilson AG, Grabczynska SA, Carey BS, Lewis CM, Khamashta MA, Duff GW, Hughes GR, Hawk JL, Vaughan RW, McGregor JM (2001a) A candidate gene analysis of three related photosensitivity disorders: cutaneous lupus erythematosus, polymorphic light eruption and actinic prurigo *Br J Dermatol* 145(2): 229–36
- Millard TP, Kondeatis E, Vaughan RW, Lewis CM, Khamashta MA, Hughes GR, Hawk JL, McGregor JM (2001b) Polymorphic light eruption and the HLA DRB1\*0301 extended haplotype are independent risk factors for cutaneous lupus erythematosus. *Lupus* 10(7): 473–9
- Miyagawa S, Okuchi T, Shiomi Y, Sakamoto K (1989) Subacute cutaneous lupus erythematosus lesions precipitated by griseofulvin. *J Am Acad Dermatol* 21: 343–346
- Modley C, Wood D, Horn T (1989) Metastatic malignant melanoma arising from a common blue nevus in a patient with subacute cutaneous lupus erythematosus. *Dermatologica* 178: 171–175
- Molad Y, Weinberger A, David M, Garty B, Wysenbeek AJ, Pinkas J (1987) Clinical manifestations and laboratory data of subacute cutaneous lupus erythematosus. *Isr J Med. Sci* 23: 278–280
- Morgan KW, Callen JP (2001) Calcifying lupus panniculitis in a patient with subacute cutaneous lupus erythematosus: response to diltiazem and chloroquine *J Rheumatol* 28(9): 2129–32

- Mutasim DF. (2003) Severe subacute cutaneous lupus erythematosus presenting with generalized erythroderma and bullae. *J Am Acad Dermatol* 48(6):947–9
- Neri R, Mosca M, Bernacchi E, Bombardieri S (1999) A case of SLE with acute, subacute and chronic cutaneous lesions successfully treated with Dapsone. *Lupus* 8: 240–243
- Ng PP, Tan SH, Koh ET, Tan T (2000) Epidemiology of cutaneous lupus erythematosus in a tertiary referral center in Singapore *Australasian J Dermatol* 41(4): 229–33
- Nieboer C, Tak-Diamand Z, VanLeeuwen-Wallau AG (1988) Dust-like particles: a specific direct immunofluorescence pattern in subacute cutaneous lupus erythematosus. *Br J Dermatol* 118: 725–734
- Nived O, Johansen PB, Sturfelt G (1993) Standardized ultraviolet-A exposure provokes skin reaction in systemic lupus erythematosus. *Lupus* 2: 247–250
- Norris DA (1993) Pathomechanisms of photosensitive lupus erythematosus. *J Invest Dermatol* 100: 58S–68S
- Nousari HC, Kimyai-Asadi A, Tausk FA (1998) Subacute cutaneous lupus erythematosus associated with beta interferon-1a. *Lancet* 352: 1825–1826
- Ordi-Ros J, Cortes F, Cucurull E, Mauri M, Bujan S, Vilardell M (2000) Thalidomide in the treatment of cutaneous lupus refractory to conventional therapy. *Journal of Phycolgy* 27: 1429–1433
- Orteu DH, Sontheimer RD, Dutz JP (2001) The pathophysiology of photosensitivity in lupus erythematosus. *Photodermatol Photoimmunol Photomed* 17:95–113.
- Pantoja L, Gonzalez-Lopez MA, Bouso M, Alija A, Ortiz-Saracho J (2002) Subacute cutaneous lupus erythematosus in a patient with rheumatoid arthritis. *Scandinavian J Rheumatol* 31(6): 377–9
- Parodi A, Caproni M, Cardinali C, Bernacchi E, Fuligni A, De Panfilis G, Zane C, Papini M, Veller FC, Vaccaro M, Fabbri P, Bader U, Banyai M, Boni R, Burg G, Hafner J (2000) Clinical, histological and immunopathological features of 58 patients with subacute cutaneous lupus erythematosus – A review by the Italian Group of Immunodermatology. *Dermatology* 200: 6–10
- Parodi A, Romagnoli M, Rebora A (1989) Subacute cutaneous lupus erythematosus-like eruption caused by hydrochlorothiazide. *Photodermatol* 6(2):100–2.
- Parodi A, Rivara G, Guarrera M (1992) Possible naproxen-induced relapse of subacute cutaneous lupus erythematosus. *JAMA* 268: 51–52
- Patri P, Nigro A, Rebora A (1985) Lupus erythematosus-like eruption from captopril. *Acta Derm Venereol* 65: 447–448
- Perrotta S, Locatelli F, La Manna A et al. (2002) Anti-CD20 monoclonal antibody (Rituximab) for life-threatening autoimmune haemolytic anaemia in a patient with systemic lupus erythematosus *Br J of Haematol* 116:465–7.
- Piette JC, Sbai A, Frances C (2002) Warning: thalidomide-related thrombotic risk potentially concerns patients with lupus *Lupus* 11(2): 67–70
- Pramatarov K, Vassileva S, Miteva L (2000) Subacute cutaneous lupus erythematosus presenting with generalized poiklioderma. *J Am Acad Dermatol* 42: 286–288
- Price P, Witt C, Allock D, et al. (1999) The genetic basis for the association of the 8.1 ancestral haplotype (A1, B8, DR3) with multiple immunopathological diseases. *Immunological Reviews*. 167: 257–74.
- Prinz JC, Meurer M, Reiter C, Rieber EP, Plewig G, Riethmuller G (1996) Treatment of severe cutaneous lupus erythematosus with a chimeric CD4 monoclonal antibody, cM-T412. *J Am Acad Dermatol* 34: 244–252
- Provost TT, Talal N, Bias W, Harley JB, Reichlin M, Alexander EL (1988) Ro/SS-A positive Sjogren's/lupus erythematosus overlap patients are associated with the HLA-DR3 and/or DRW6 phenotypes. *J Invest Dermatol* 91: 369–371
- Racila DM, Sontheimer CJ, Sheffield A, Wisnieski JJ, Racila E, Sontheimer RD, (2003) Homozygous single nucleotide polymorphism of the complement C1QA gene is associated with decreased levels of C1q in patients with subacute cutaneous lupus erythematosus. *Lupus* 12(2): 124–32
- Rahman P, Gladman DD, Urowitz MB (1998) Smoking interferes with efficacy of antimalarial therapy in cutaneous lupus. *J Rheumatol* 25: 1716–1719
- Rao BK, Coldiron BM, Freeman RF, Sontheimer RD (1990) Subacute cutaneous lupus erythematosus lesions progressing to morphea. *J Am Acad Dermatol* 23: 1019–1022

- Reed BJ, Huff JC, Jones SK, Orton DW, Lee LA, Norris DA (1985) Subacute cutaneous lupus erythematosus associated with hydrochlorothiazide therapy. *Ann Intern Med* 103: 49–51
- Reichlin M (2000) ANA negative systemic lupus erythematosus sera revisited serologically. *Lupus* 9(2): 116–9
- Richardson TT, Cohen PR (2000) Subacute cutaneous lupus erythematosus: report of a patient who subsequently developed a meningioma and whose skin lesions were treated with isotretinoin. *Cutis* 66: 183–188
- Rihner M, McGrath H, Jr. (1992) Fluorescent light photosensitivity in patients with systemic lupus erythematosus. *Arthritis Rheum* 35: 949–952
- Ross S, Dywer C, Ormerod AD, Herriot R, Roberts C (2002) Subacute cutaneous lupus erythematosus associated with phenytoin. *Clinical & Experimental Dermatology* 27:474–476
- Roura M, Lopez-Gil F, Umberto P (1991) Systemic lupus erythematosus exacerbated by piroxicam. *Dermatologica* 182:56–58.
- Roustan G, Salas C, Barbadillo C, Sanchez Yus E, Mulero J, Simon A (2000) Lupus erythematosus with an erythema multiforme-like eruption. *Eur J Dermatol* 10: 459–462
- Rowell NR, Swanson-Beck J, Anderson JR (1963) Lupus erythematosus and erythema multiforme-like lesions. *Arch Dermatol* 88: 176–180
- Rua-Figueroa I, Erasusquin C, Naranjo A, Carretero-Hernandez G, Rodriguez-Lozano C, De la RP (1999) Pustuloderma during cutaneous lupus treatment with thalidomide [letter]. *Lupus* 8: 248–249
- Rubin, RL (2002) Drug-Induced Lupus. In Dubois' *Lupus Erythematosus*. D.J.Wallace and B.H.Hahn, editors. Lippincott Williams and Wilkins, Philadelphia.
- Rudnicka L, Szymanska E, Walecka I, Slowinska M (2000) Long-term cefuroxime axetil in subacute cutaneous lupus erythematosus: a report of three cases. *Dermatology* 200: 129–131
- Sanders CJ, Van Weelden H, Kazzaz GA, Sigurdsson V, Toonstra J, Bruijnzeel-Koomen CA. (2003) Photosensitivity in patients with lupus erythematosus: a clinical and photobiological study of 100 patients using a prolonged phototest protocol. *Br J Dermatol* 149(1):131–7
- Schanz S, Ulmer A, Rassner G, Fierlbeck G (2002) Successful treatment of subacute cutaneous lupus erythematosus with mycophenolate mofetil. *Br J Dermatol* 147(1): 174–8
- Scheinman PL (1994) Acral subacute cutaneous lupus erythematosus: an unusual variant. *J Am Acad Dermatol* 30: 800–801
- Schulz EJ, Menter MA (1971) Treatment of discoid and subacute cutaneous lupus erythematosus with cyclophosphamide. *Br J Dermatol* 85: 60–65
- Sheretz EF (1988) Lichen planus following procainamide induced lupus erythematosus. *Cutis* 42: 51–53
- Siamopoulou-Mavridou A, Stefanou D, Dross AA (1989) Subacute lupus erythematosus childhood. *Clin. Rheum.* 8: 533–7.
- Sonnichsen N, Meffert H, Kunzelmann V, Audring H (1993) [UV-A-1 therapy of subacute cutaneous lupus erythematosus]. [German]. *Hautarzt* 44: 723–725
- Sonntag M, Lehmann P, Megahed M, Ruzicka T, Kuhn A. (2003) Papulonodular mucinosis associated with subacute cutaneous lupus erythematosus. *Dermatology* 206(4): 326–9
- Sontheimer RD, Gilliam JN (1979) A reappraisal of the relationship between subepidermal immunoglobulin deposits and DNA antibodies in systemic lupus erythematosus: a study using the *Crithidia luciliae* immunofluorescence anti-DNA assay. *J Invest Dermatol* 72: 29–32
- Sontheimer RD, Thomas JR, Gilliam JN (1979) Subacute cutaneous lupus erythematosus: a cutaneous marker for a distinct lupus erythematosus subset. *Arch Dermatol* 115: 1409–1415
- Sontheimer RD, Stastny P, Gilliam JN (1981) Human histocompatibility antigen associations in subacute cutaneous lupus erythematosus. *J Clin Invest* 67: 312–316
- Sontheimer RD, Maddison PJ, Reichlin M, Jordan RE, Stastny P, Gilliam JN (1982) Serologic and HLA associations in subacute cutaneous lupus erythematosus, a clinical subset of lupus erythematosus. *Ann Intern Med* 97: 644–671
- Sontheimer RD (1985) Clinical significance of subacute cutaneous lupus erythematosus skin lesions. *J Dermatol* 12: 205–212
- Sontheimer RD (1989) Subacute cutaneous lupus erythematosus: a decade's perspective. *Med Clin North Am* 73: 1073



- Sontheimer RD, Provost TT (1996) Lupus erythematosus. In Sontheimer RD, Provost TT (eds) *Cutaneous Manifestations of Rheumatic Diseases*. Williams and Wilkins, Baltimore, p 31
- Srivastava, M, Rencic A, Diglio G, Santana H, Bonitz P, Watson R, Ha E, Anhalt GJ, Provost TT, Nousari CH (2003) Drug-induced, Ro/SSA-positive cutaneous lupus erythematosus. *Arch Dermatol* 139:45–49.
- Stege H, Budde MA, Grether-Beck S, Krutmann J (2000) Evaluation of the capacity of sunscreens to photoprotect lupus erythematosus patients by employing the photoprovocation test *Photodermatol, Photoimmunol, & Photomed* 16(6): 256–9
- Stevens RJ, Andujar C, Edwards CJ, Ames PR, Barwick AR, Khamashta MA, Hughes GR (1997) Thalidomide in the treatment of the cutaneous manifestations of lupus erythematosus: experience in sixteen consecutive patients. *Br J Rheumatol* 36: 353–359
- Tebbe B, Orfanos CE (1997) Epidemiology and socioeconomic impact of skin disease in lupus erythematosus. *Lupus* 6: 96–104
- Tebbe B, Mansmann U, Wollina U, Auergumbach P, Lichtmbalyohere A, Arensmeier M, Orfanos CE (1997) Markers in cutaneous lupus erythematosus indicating systemic involvement – A multicenter study on 296 patients. *Acta Dermato-Venereol* 77: 305–308
- Thivolet J, Nicolas JF, Kanitakis J, Lyonnet S, Chouvet B (1990) Recombinant interferon  $\alpha 2a$  is effective in the treatment of discoid and subacute cutaneous lupus erythematosus. *Br J Dermatol* 122: 405–409
- Ting W, Sontheimer RD (2001) Local therapy for cutaneous LE and systemic LE: Practical and theoretical consideration. *Lupus* 10: 171–189
- Toll A, Campo-Pisa P, Gonzalez-Castro J, Campo-Voegeli A, Azon A, Iranzo P, Lecha M, Herrero C (1998) Subacute cutaneous lupus erythematosus associated with cinnarizine and thiethylperazine therapy. *Lupus* 7: 364–366
- Topaloglu R, Bakkaloglu A, Slingsby JH et al. (2000) Survey of Turkish systemic lupus erythematosus patients for a particular mutation of C1Q deficiency. *Clinical and Experimental Rheumatol* 18:75–77
- Trenholme GM, Carson PE (1978) Therapy and prophylaxis of malaria. *JAMA* 240: 2293–229
- Valeski JE, Kumar V, Forman AB, Beutner EH, Chorzelski TP (1992) *J Am Acad Derm* 27: 194–198
- Vasquez-Doval J, Ruiz de Erenchun F, Sanchz-Ibarrola A, Contrera F, Soto de Delas J, Quintanilla E (1992) Subacute cutaneous lupus erythematosus – clinical, histopathological and immunophenotypical study of five cases. *J Invest Allerg* 2: 27–32
- Velthuis PJ, Kater L, Van der Tweel I, Baart de la Faille H, Van Vloten WA (1992) Immunofluorescence microscopy of healthy skin from patients with systemic lupus erythematosus: More than just the lupus band. *Ann Rheum Dis* 51: 720–725
- Walport MJ, Davies KA, Botto M (1998) C1q and systemic lupus erythematosus. *Immunobiol* 199: 265–85
- Warren KJ, Nopper AJ, Crosby DL (1998) Thalidomide for recalcitrant discoid lesions in a patient with systemic lupus erythematosus. *J Am Acad Dermatol* 39: 293–295
- Watson RM, Talwar P, Alexander E, Bias WB, Provost TT (1991) Subacute cutaneous lupus erythematosus-immunogenetic associations. *J Autoimmun* 4: 73–85
- Wenzel J, Bauer R, Bieber T, Bohm I (2000) Autoantibodies in patients with lupus erythematosus: spectrum and frequencies *Dermatology* 201(3): 282–3
- Wenzel J, Bauer R, Uerlich M, Bieber T, Boehm I (2002) The value of lymphocytopenia as a marker of systemic involvement in cutaneous lupus erythematosus *Br J Dermatol* 146(5): 869–71
- Werth VP, Zhang W, Dortzbach K, Sullivan, K (2000) Association of a promoter polymorphism of tumor necrosis factor- $\alpha$  with subacute cutaneous lupus erythematosus and distinct photoregulation of transcription. *J Invest Dermatol* 115: 726–730
- Wollina U, Barta U, Uhlemann C, Oelzner P (1999) Lupus erythematosus-associated red lunula. *J Am Acad Dermatol* 41: 419–421
- Wollina U, Schreiber G (2003) Polyglandular autoimmune syndrome type II (Schmidt's syndrome) in patients with autoimmune connective tissue disorders. *J Eur Acad Derm Venereol* 17(3): 371–2
- Yung RL, Richardson BC (1995) Cytarabine therapy for refractory cutaneous lupus. *Arthritis Rheum* 38:1341–1343

## **6 Dermatomyositis**

*Jeffrey P. Callen*

### **Introduction**

Dermatomyositis (DM) is one of the idiopathic inflammatory myopathies (IIM) (Callen 2000; Plotz et al. 1995; Targoff 1991). In 1975, Bohan and Peter published a classical article that first suggested a set of criteria to aid in the diagnosis and classification of DM and polymyositis (PM). Four of the five criteria related to the muscle disease: 1) progressive proximal symmetrical weakness 2) elevated muscle enzymes, 3) an abnormal electromyogram and 4) an abnormal muscle biopsy, while the fifth was the presence of compatible cutaneous disease. It was felt that DM differed from PM only by the presence of cutaneous disease. Recent studies of the pathogenesis of the myopathy have been controversial, some suggesting that the myopathies in DM and PM are pathogenetically different with DM being due to a vascular inflammation (Kuru et al. 2000) while other studies of cytokines suggest that the processes are similar (Wanchu et al. 1999; Shimizu et al. 2000; Sugiura et al. 2000; Nyberg et al. 2000). There has been a renewed interest in the pathogenetic mechanisms involved in the myopathy with recent studies revealing abnormal levels of nitric oxide, elevation of circulating tumor necrosis factor receptors, elevated soluble CD40 expression, and increased expression of interleukin 1-alpha within the muscle. The pathogenesis of the cutaneous disease is poorly understood.

### **Classification and Clinical Appearance**

#### **Classification**

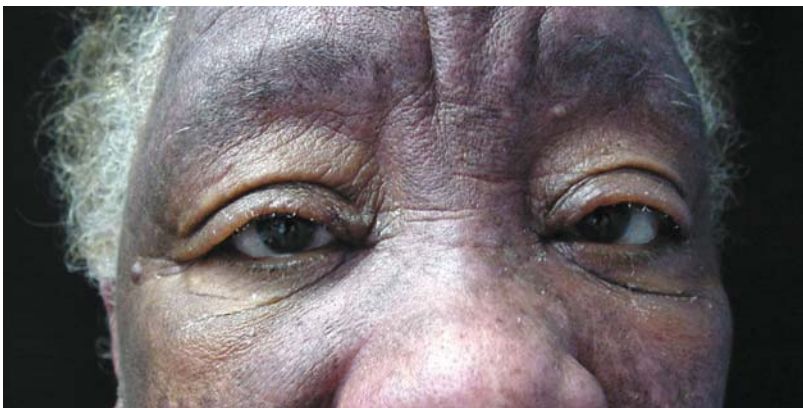Bohan and Peter (1975) suggested five subsets of myositis – DM, PM, myositis with cancer, childhood DM/PM, and myositis overlapping with another collagen-vascular disorder. In a subsequent publication, Bohan et al. (1977) noted

that cutaneous disease may precede the development of the myopathy, however it was only recently recognized that another subset of patients with disease that only affects the skin (amyopathic dermatomyositis) [ADM] or DM-sine myositis may occur (Euwer and Sontheimer 1991). A seventh subset known as inclusion body myositis (IBM) has more recently been recognized (Sayers et al. 1992). Perhaps there is an eighth group in which characteristic cutaneous disease is drug-induced (Dourmishev and Dourmishev 1999). Finally, Sontheimer has proposed another subset that classifies patients as hypomyopathic dermatomyositis when skin disease is present with subtle muscle disease evident with studies other than enzymatic analysis and a post-myopathic DM for those patients in whom the myositic component of the disease resolves while the skin disease remains active (Sontheimer 2002).

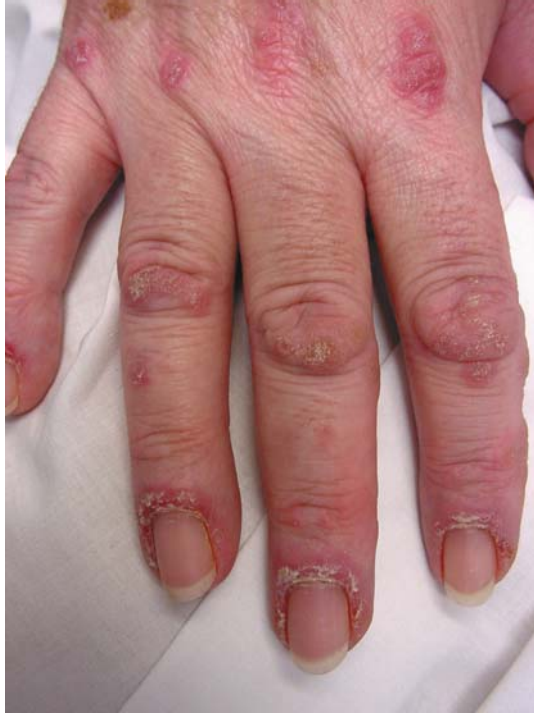### Cutaneous Manifestations

The characteristic and possibly pathognomonic cutaneous features of DM are the heliotrope rash and *Gottron's* papules. The heliotrope rash consists of a violaceous to dusky erythematous rash with or without edema in a symmetrical distribution involving periorbital skin (*Fig. 1*). Sometimes this sign is quite subtle and may involve only a mild discoloration along the eyelid margin. A heliotrope rash is rarely observed in lupus erythematosus (LE) and scleroderma. Occasionally patients may be felt to have angioedema or dermatitis.

*Gottron's* papules are found over bony prominences, particularly the metacarpophalangeal joints, the proximal interphalangeal joints, and/or the distal interphalangeal joints (*Fig. 2*). They may also be found overlying the elbows, knees and/or feet. The lesions consist of slightly elevated, violaceous papules and plaques. There may be a slight scale and on some occasions there is a



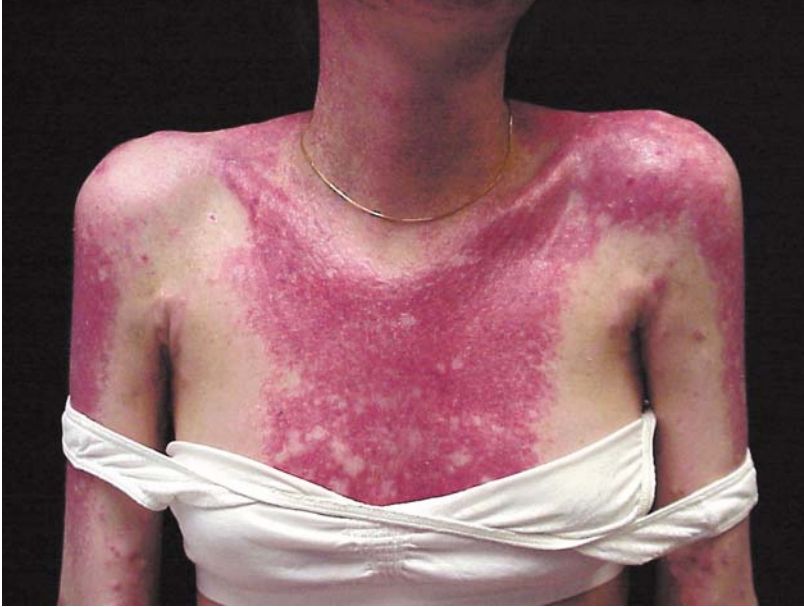**Fig. 1.** Facial erythema with periorbital edema are present in this woman with dermatomyositis. The periorbital changes represent the heliotrope eruption



**Fig. 2.** Gottron's papules. Erythematous scaly plaques are present on the dorsal hands, particularly over the bony prominences (MCP, PIP and DIP joints). There is also marked periungual telangiectasia and cuticular overgrowth

thick psoriasiform scale. Within the lesions, there is often telangiectasia. These lesions may be clinically confused with lesions of LE, or, at times, with papulosquamous disorders, such as psoriasis or lichen planus. Routine histopathological evaluation will aid in the differentiation from psoriasis or lichen planus, but cannot reliably distinguish the cutaneous lesions of DM from those of LE.

Several other cutaneous features are characteristic of the disease despite not being pathognomonic. They include malar erythema, poikiloderma in a photosensitive distribution, violaceous erythema on the extensor surfaces, and periungual and cuticular changes. Nailfold changes consist of periungual telangiectasia and/or a characteristic cuticular change with hypertrophy of the cuticle and small, hemorrhagic infarcts with this hypertrophic area. Periungual telangiectasia may be clinically apparent or may be appreciated only by capillary microscopy. Poikiloderma (the combination of atrophy, dyspigmentation and telangiectasia) may occur on exposed skin such as the extensor surfaces of the arm, the 'V' of the neck (*Fig. 3*) or the upper back (*Shawl sign*). Patients rarely complain of photosensitivity, despite the prominent photodis-



**Fig. 3.** Poikiloderma of the upper chest in a patient with dermatomyositis

tribution of the rash. This photosensitive poikilodermatous eruption may be difficult to differentiate from LE. Facial erythema may also occur in DM. This change must be differentiated from LE, rosacea, seborrheic dermatitis or atopic dermatitis. Scalp involvement in dermatomyositis is relatively common and is manifest by an erythematous to violaceous, psoriasiform dermatitis (Kasteler and Callen 1994). Clinical distinction from seborrheic dermatitis or psoriasis is occasionally difficult, but histopathologic evaluation is helpful. Nonscarring alopecia may occur in some patients and often follows a flare of the systemic disease. Lastly, recent reports have detailed the finding of gingival telangiectasia (Ghali et al. 1999) and angiokeratomas (Shannon and Ford 1999) in children with DM.

DM-sine myositis, also known as amyopathic DM (ADM), is diagnosed in patients with typical cutaneous disease in whom there is no evidence of muscle weakness and who repeatedly have normal serum muscle enzyme levels (Bohan et al. 1977; Rockerbie et al. 1989; Stonecipher 1993; Cosnes et al. 1995). Some patients with 'ADM' when studied will have an abnormal ultrasound, magnetic resonance imaging or muscle biopsy. These patients have muscle involvement, and may be better classified as hypomyopathic DM (Sontheimer 2002). Since many of the ADM patients are not evaluated beyond clinical and enzymatic studies, many feel that the ADM patient represents a systemic process requiring systemic therapies. There are also a fair number of patients whose myositis resolves following therapy, but whose skin disease

remains as an active, important feature of the disease. These patients are called Post-myopathic DM, and the skin is their major and often only manifestation of the disease. There is also a small subset of patients who never develop myositis, despite having prominent cutaneous changes, and it is these patients who can be classified as amyopathic DM assuming that they have not received systemic corticosteroids or immunosuppressive agents.

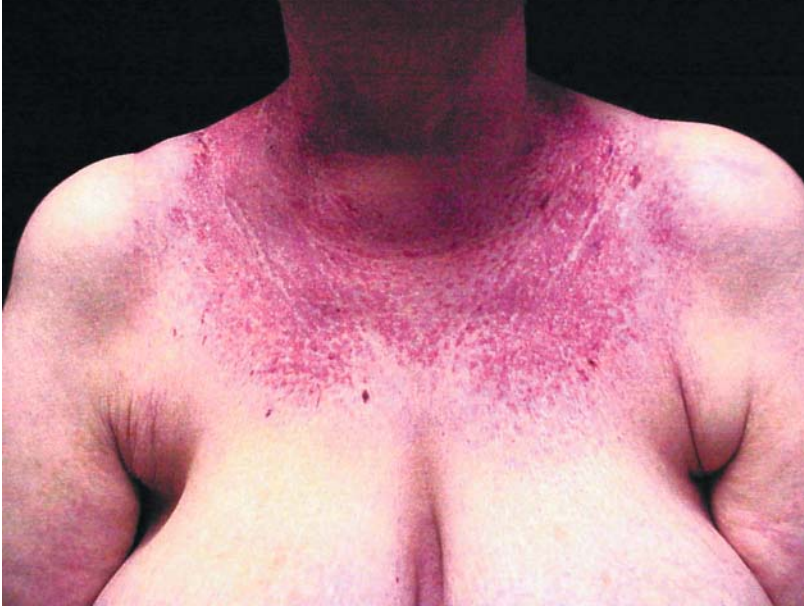Patients with DM are at times difficult to distinguish from patients with subacute cutaneous lupus erythematosus (SCLE). The lesions of DM differ slightly in their distribution, occurring more over bony prominences, and they are frequently accompanied by severe pruritus; whereas LE lesions tend to occur between the knuckles and are usually asymptomatic. Routine skin biopsy is not helpful in the distinction between LE and DM. Immunofluorescence microscopy (IF) should be negative in DM and positive in LE, however, about 50% of SCLE patients have a negative IF, and IF may be falsely positive on sun-exposed skin. Serologic testing is also imperfect, since only 25% of DM patients are Mi2 positive, and on a single testing only 60–70% of SCLE patients are Ro (SS-A) antibody positive.

The skin lesions of DM are probably photoaggravated despite the lack of symptoms suggestive of photosensitivity reported by patients (Cheong et al. 1994). Clinical observations suggest that not only is the skin disease exacerbated by light, but muscle disease may be worsened after sun exposure (Woo et al. 1985; Callen 1993; Zuber et al. 1996; Callen 1999). However, phototesting has not been able to reliably reproduce the skin lesions, thus, the wavelength of light that is responsible for the clinical manifestations (action spectrum) is not known.

Rare cutaneous manifestations include vesiculobullous lesions (McCullough and Cockerell 1998), an eruption that simulates pityriasis rubra pilaris (Requena et al. 1997), a flagellate erythema (Nousari et al. 1999), vasculitis, erosive lesions, as well as an exfoliative erythroderma. In small case series it has been suggested that some of these cutaneous manifestations may be more common in patients with an associated malignancy.

Skin lesions of DM may precede the development of myopathy and may persist well after the control and quiescence of the myositis. Patients skin lesions may flare with sun exposure, but only some of these patients will have a flare of their muscle involvement. Thus, in many instances the course of the skin lesions does not parallel that of the muscle disease.

A variety of other cutaneous lesions have been described in patients with DM or PM that do not reflect the interface changes observed histopathologically with the pathognomonic or characteristic lesions. These include panniculitis, plaque-like mucinosis (*Fig. 4*) (Abernethy et al. 1996; Kaufman et al. 1998), a flagellate eruption (Nousari et al. 1999), urticaria, as well as changes of hyperkeratosis of the palms known as mechanics hands. Lastly, children with DM may develop calcinosis, but in addition insulin-resistance and lipodystrophy has recently been reported as a relatively common complication despite adequate therapy (Heumer et al 2001).



**Fig. 4.** Papular mucinosis-like lesions in a patient with dermatomyositis. Prominent papular lesions are present within the poikilodermatous eruption. Histopathology revealed deposition of massive amounts of mucin in the dermis

### **Muscle Disease**

Clinical and laboratory abnormalities suggestive of muscle disease are characteristic features of DM (Wortmann 2000). The myopathy primarily affects the proximal muscles, is usually symmetrical and is slowly progressive over a period of weeks to months. Initial complaints including myalgias, fatigue, or weakness manifest as an inability to climb stairs, to raise the arms for actions like hair grooming or shaving, to rise from a squatting or sitting position, or a combination of these features. Tenderness upon palpation of the muscles is variable. An inability to swallow and symptoms of aspiration may reflect the involvement of striated muscle of the pharynx or upper esophagus. Dysphagia or dysphonia generally signifies a rapidly progressive course and may be associated with poor prognosis.

### **Systemic Features**

Dermatomyositis is a multisystem disorder (Spiera and Kagen 1998). Arthralgias and/or arthritis may be present in up to one fourth of patients with inflammatory myopathy. The usual picture is one of generalized arthralgias

accompanied by morning stiffness. The small joints of the hands, wrists, and ankles may be involved with a symmetrical nondeforming arthritis.

Esophageal disease as manifested by dysphagia is estimated to be present in 15% to 50% of patients with inflammatory myopathy. The dysphagia can be of two types: proximal dysphagia or distal dysphagia. Proximal dysphagia is caused by involvement of striated muscle in the pharynx or proximal esophagus. This involvement correlates well with the severity of the muscle disease and is steroid-responsive. Distal dysphagia is related to involvement of nonstriated muscle and appears to be more frequent in patients who have an overlap with scleroderma or another collagen vascular disorder. Dysphagia is associated with a poor prognosis and correlates with the presence of pulmonary involvement.

Pulmonary disease occurs in dermatomyositis and polymyositis in approximately 15% to 30% of patients (Marie et al. 1998). Interstitial pneumonitis is a primary process observed in DM/PM. It is more frequent in patients with esophageal involvement. Lung disease may also occur as a direct complication of the muscle disease, such as hypoventilation or aspiration in patients with dysphagia, or may be a result of treatment, as with opportunistic infections or drug-induced hypersensitivity pneumonitis. In a retrospective review of 70 patients with myositis associated interstitial lung disease seen at Mayo Clinic between 1990 and 1998, most of the patients presented with either symptoms of lung disease or symptoms of myositis alone, with only 15 in whom the involvement occurred simultaneously (Douglas et al 2001). In general, the lung disease was at first felt to be a pneumonitis that was antibiotic resistant. Biopsy of the lung revealed non-specific interstitial pneumonitis or diffuse alveolar damage in a majority of those who were biopsied. Only two patients had bronchiolitis obliterans organizing pneumonia (BOOP). It is unclear how many of the patients had dermatomyositis, but perhaps between 8 and 12. Therapy included corticosteroids with or without an immunosuppressive agent and the prognosis is poorer for these patients than unselected patients with myositis as demonstrated by a 5-year survival of 60.4%. Patients with Jo-1 antibodies (19 of 50 who were tested) had roughly the same features and prognosis as those who did not have this antibody.

Clinically symptomatic cardiac involvement in patients with DM or PM is uncommon, but when present it is associated with a poor prognosis (Gonzalez-Lopez et al. 1996). Various abnormalities have been described which include conduction defects, and rhythm disturbances primarily. Although congestive heart failure, pericarditis, and valvular disease may occur, they are much less frequent. Depending on the report, cardiac manifestations may occur in up to 50% of patients, but only a small proportion of these patients manifest symptoms. It is not known whether the identification of asymptomatic abnormalities has an effect on long-term outcome, or even if the findings are more prevalent in DM/PM than in an age-matched control group.

Calcinosis of the skin or muscle is unusual in adults but may occur in up to 40% of children or adolescents with DM. Calcinosis cutis is manifested by firm,



yellow or flesh-colored nodules, often over bony prominences. Occasionally, these nodules can extrude through the surface of the skin, in which case secondary infection may occur. Calcification of the muscles is often asymptomatic and may be seen only on radiological examination. In severe forms, the calcinosis can cause loss of function, and, rarely bone formation is possible.

### **Myositis and Malignancy**

The relationship of DM-polymyositis to malignancy has been recently clarified (Hill et al. 2001). The reported frequency of malignancy in dermatomyositis has varied from 6% to 60% with most large population-based cohort studies revealing a frequency of about 20–25%.

Several Scandinavian studies have documented the increased frequency of malignancy in DM over the general population (Siguregeirsson et al. 1992; Chow et al. 1995; Ario et al. 1995; Hill et al. 2001). While polymyositis patients had a slight increase in cancer frequency; it was not highly significant and could be explained by a more aggressive cancer search (known as diagnostic suspicion bias). These studies have not dealt with the amyopathic DM subset, but data from Mayo Clinic suggests that these patients may also have an associated malignancy (el-Azhary and Pakzad 2002). Malignancies may occur prior to the onset of myositis, concurrently with myositis, or after the onset of DM. In addition, the myositis may follow the course of the malignancy (a paraneoplastic course) or may follow its own course independent of the treatment of the malignancy. Studies demonstrating benefits of cancer surgery on myositis as well as those showing no relationship of the myositis to the malignancy have been reported.

A wide variety of malignancies have been reported in patients with DM. Gynecologic malignancy, in particular ovarian carcinoma may be overrepresented in DM (Whitmore et al. 1994; Hill et al. 2001). Asians with DM are often found to have nasopharyngeal cancer (Peng et al. 1995). In the recent analysis of combined data from Scandinavia, Hill et al. (2001) again noted the increased association of ovarian cancer, but also noted increases in lung, pancreatic, stomach, colorectal cancer and non-Hodgkin's lymphoma. Malignancy is more common in older patients (> 50 years) (Marie et al. 1998; Pautas et al. 2000), but reports of young adults and rarely even children with DM have appeared, suggesting that age alone should not dissuade the physician from a careful evaluation (see below). The site of malignancy can be predicted by the patient's age (e.g., malignancy in a young man is more often testicular cancer, whereas, in an elderly male, colon or prostate cancer would be more common). In the past, there was concern about whether the use of immunosuppressive therapies would predispose the patient to an excess cancer risk. This has not proven to be the case with most cancers being reported within the first three years following diagnosis.

### **Juvenile (Childhood) Dermatomyositis (JDMS)**

DM is much more common than polymyositis in children and adolescents (Pachman 1995). A fulminant course may be present, but most often the onset is indolent and children are first thought to have viral infections or dermatitis. Delayed diagnosis is more common in the non-white population. Often JDMS is characterized as a vasculitis, but the major difference of JDMS from adult DM is the greater potential for calcinosis. A recent report detailed the chronic nature of this disease in children, with many patients requiring therapy to suppress their disease activity more than three years after diagnosis (Huber et al. 2000). In addition, it was noted that the development of calcinosis was not related to initial therapy, but was associated with a lower score on an assessment instrument of physical function. Pachman et al. (2000) linked the presence of calcinosis and a prolonged course of disease with TNF-308A allele in their patients with juvenile DM.

### **Drug-Induced Dermatomyositis**

The etiology of most cases of DM is unknown, however, in a small number of patients, the cutaneous manifestations are due to, or are exacerbated by drugs. This has been best documented for hydroxyurea in which de-challenges and re-challenges have been performed (Daoud et al. 1997; Marie et al. 2000, Dacey and Callen 2003). However, quinidine, non-steroidal anti-inflammatory drugs, D-penicillamine, and HMG-CoA-reductase inhibitors have also been linked on occasion to DM (Dourmishev and Dourmishev 1999).

### **Diagnosis and Evaluation of the Patient with Dermatomyositis**

The diagnosis of DM is suspected in patients with clinically compatible cutaneous findings. Exclusion of other possible cutaneous conditions is aided by skin biopsy and the recognition of muscle involvement. In the absence of identifiable myopathy, the differentiation from cutaneous LE may be difficult. Muscle weakness may be caused by many other disorders including toxins, infections, metabolic abnormalities, and neurologic disorders (Wortmann 2000). However, the presence of characteristic skin lesions allows the diagnosis to be more firmly established.

Muscle involvement is suspected clinically. Enzymatic testing will reveal elevations of creatine kinase, aldolase, lactic dehydrogenase or ALT. The CK seems most specific and most widely available and is a useful test for following response to therapy. Additional testing including electromyography (EMG),

muscle biopsy, ultrasound or MR imaging may be ordered in patients in whom other tests are inconclusive (Garcia 2000).

Serologic tests are often ordered, but their clinical application is at best controversial. Antinuclear antibody testing is frequently positive in DM patients. Several myositis-specific antibodies (MSAs) have been recognized and correlate with certain subsets (Love et al. 1991). Most MSAs are described in PM patients and will not be further discussed here. Anti-Jo-1 antibody is predictive of pulmonary involvement, but rarely occurs in DM patients. Anti-Mi-2 occurs in roughly 25% of DM patients and although specific for DM, it is not sensitive. Recently Targoff et al. (2000) described a new antibody to a 155 kd antigen or Se antigen (90–95 kd) that appears to be a marker of amyopathic DM (16 of 18 patients studied). The anti-155 kd antibody may also be associated with juvenile DM and might predict a chronic course. Anti-Ro (SS-A) antibody may occur rarely. Perhaps as further studies are performed, serologic testing will become clinically useful. Until then, these tests are primarily reserved for investigation.

Once the diagnosis is confirmed, the patient should have a thorough evaluation. Evaluation has several purposes: assessment of severity, prediction of prognosis and identification of associated disorders. The severity of the myositis often correlates with enzyme levels and degree of weakness. Patients should be assessed for esophageal, pulmonary, and cardiac involvement with tests such as a barium swallow and/or esophageal motility studies, chest x-ray, pulmonary function studies including diffusion studies, and an electrocardiogram.

An evaluation of malignancy should be considered in all adult patients with DM (Callen 1982, Callen 2002). The type of evaluation is selected based upon the patient's age and sex. The likelihood of malignancy increases with age and the sites vary depending on the patient's age. Malignancy evaluation is repeated with new symptoms or annually for the first three-years following diagnosis. The over-representation of cancer in these patients seemingly approaches normal levels after three-years (Hill et al. 2001), thus, age-specific malignancy screening, along with evaluation of any abnormal symptoms or findings, are recommended for following patients more than three years after the initial diagnosis.

## **Course and Therapy**

Several general measures are helpful in treating patients with DM. Bedrest is often valuable in the individual with progressive weakness; however, this must be combined with a range-of-motion exercise program to prevent contractures. Patients who have evidence of dysphagia should have the head of their bed elevated and should avoid eating meals immediately before retiring.

## Corticosteroids and Immunosuppressive Agents

The mainstay of therapy for DM is the use of systemic corticosteroids. Traditionally, prednisone is given at a dose of 0.5 to 1 mg/kg daily as initial therapy. The treatment should continue for at least one month after the myositis has become clinically and enzymatically inactive. At this point, the dose is slowly tapered, generally over a period lasting one and a half to two times as long as the period of active treatment. Approximately 25% of patients with dermatomyositis will not respond to systemic corticosteroids, another 25–50% will develop significant steroid-related side effects. Therefore, early intervention with steroid-sparing agents primarily immunosuppressive agents, such as methotrexate, azathioprine, cyclophosphamide, mycophenolate mofetil, chlorambucil, or cyclosporin may be an effective means of inducing or maintaining a remission (Sinoway and Callen 1993; Villalba and Adams 1996; Gelber et al. 2000; Vencovsky et al. 2000). Roughly one-half to three fourths of patients treated with an immunosuppressive agent will respond with an increase in strength, a decrease in enzyme levels, or a reduction in corticosteroid dosage. However, there few double-blind, placebo-controlled studies that demonstrate the effectiveness of any of these agents.

## Additional Therapeutic Options

Patients who fail to respond to these immunosuppressives may respond to pulse methylprednisolone therapy (Callen et al. 1994; Sawhney et al. 2000; Al-Mayouf et al. 2000a) combination immunosuppressive therapy (Villalba et al. 1998), etanercept (Saadeh 2000), infliximab (Hengstman et al. 2000) or total body irradiation. Early enthusiasm for plasmapheresis was followed by a placebo-controlled study that failed to demonstrate effectiveness. (Miller et al. 1992). However, in a double-blind, placebo-controlled study, Dalakas and co-workers (1993) demonstrated the benefits of high dose intravenous immune globulin for recalcitrant DM. Further open-label studies have demonstrated similar results (Cherin et al 2002).

Therapy of cutaneous disease in patients with DM is often difficult because even though the myositis may respond to treatment with corticosteroids and/or immunosuppressive drugs, the cutaneous lesions often persist. Although cutaneous disease may be of minor importance in patients with serious fulminant myositis, in many patients, cutaneous disease becomes the most important aspect of their disorder. Most patients with cutaneous lesions are photosensitive; thus, the daily use of a broad-spectrum sunscreen with a high sun protective factor is recommended. Topical therapy with an appropriately selected corticosteroid or a non-steroidal immunomodulators such as tacrolimus or pimecrolimus may be useful adjunctive therapy (Hollar and Jorizzo 2004). Hydroxychloroquine HCL in dosages of 200 mg to 400 mg per day is effective in approximately 80% of patients treated as a steroid-sparing

agent (Woo et al. 1984). Patients who do not respond well to hydroxychloroquine can be switched to chloroquine phosphate 250 to 500 mg per day or can have quinacrine HCL 100 mg twice daily added to the regimen. Patients on continuous antimalarial therapy should have periodic ophthalmologic examinations and blood counts. It appears that patients with DM have a greater frequency of drug eruptions from antimalarials, thus patients should be warned about this possibility (Pelle and Callen 2002).

Methotrexate in doses of 15–35 mg per week has been reported to be useful for skin lesions of DM (Zieglschmid et al. 1995; Kasteler and Callen 1997). These studies, however, are uncontrolled, open-label observations. The need for routine liver biopsy in the DM patient treated with methotrexate is controversial, but patients who are obese, diabetic, or have abnormal liver function tests should probably have periodic liver biopsies.

Other immunosuppressive agents have not been systematically studied as treatment of cutaneous lesions of DM, but some anecdotes suggest that mycophenolate mofetil might be beneficial. Lastly, intravenous immune globulin administered monthly can result in clearing of patients with cutaneous lesions.

Calcinosis is a complication of disease in children and adolescents. This process may be prevented by aggressive early treatment. Preliminary analysis of the use of intravenous methylprednisolone suggested that this therapy might lessen the frequency and severity of this process (Callen et al. 1994). Others have suggested that immunosuppressives may similarly reduce the chance of calcinosis (Al-Mayouf et al. 2000b). Once established, calcinosis is difficult to treat. Although possible, spontaneous regression is unusual. Individual patients have been treated with low-dose warfarin or oral aluminum hydroxide, however, no studies have documented the usefulness in larger groups of patients. Recent reports of long-term administration of diltiazem are promising (Oliveri et al. 1996).

The prognosis of dermatomyositis varies greatly, depending on the series of patients studied. Factors that affect prognosis include the patient's age, the severity of myositis, the presence of dysphagia, the presence of cardiopulmonary involvement, the presence of an associated malignancy, and the response to corticosteroid therapy (Marie et al. 1999). It seems to be well established by retrospective reports that the use of corticosteroids and/or immunosuppressive therapies improves the prognosis.

## Summary

DM is a condition primarily of the skin and muscles, but other systemic features may occur. DM appears to be the predominant myopathy in children, whereas in adults many patients without skin disease occur (polymyositis or inclusion body myositis). The pathogenesis of the muscle disease is becoming

better understood, but the cutaneous disease mechanisms remain enigmatic. DM in adults is associated with malignancy and thus a careful evaluation of each patient should be part of their initial and followup assessments. Patients should also be evaluated for the presence of esophageal, pulmonary and cardiac disease. Calcinosis is more frequent in children with DM, and early aggressive therapy may limit the chance of this complication. Corticosteroids, immunosuppressives, biologic agents and/or immune globulin are effective therapies for the myopathy of DM, whereas the skin disease is best managed with sunprotection, topical corticosteroids, antimalarials, methotrexate and/or immune globulin. The prognosis is good except for patients with malignancy, those with severe weakness and those with cardiopulmonary dysfunction.

### References

- Abernethy ML, Arterberry JF, Callen JP (1996) Low-dose methotrexate as an adjunctive therapy with surgery for ectropion complicating dermatomyositis. *Dermatology* 192(2): 153–155
- Al-Mayouf SM, Laxer RM, Schneider R, Silverman ED, Feldman BM (2000a) Intravenous immunoglobulin therapy for juvenile dermatomyositis: efficacy and safety. *J Rheumatol* 27: 2498–2503
- Al-Mayouf S, Al-Mazyed A, Bahabri S (2000b) Efficacy of early treatment of severe juvenile dermatomyositis with intravenous methylprednisolone and methotrexate. *Clin Rheumatol* 19: 138–141
- Airio A, Pukkala E, Isomäki (1995) Elevated cancer incidence in patients with dermatomyositis: A population based study. *J Rheumatol* 22: 1300–1303
- Bohan A, Peter JB (1975) Polymyositis and dermatomyositis. *N Engl J Med* 292: 344–347 and 403–407 (two part article)
- Bohan A, Peter JB, Bowman RL, Pearson CM (1977) A computer-assisted analysis of 153 patients with polymyositis and dermatomyositis. *Medicine* 56: 255–286
- Callen AM, Pachman LM, Hayford J, Chung A, Ramsey-Goldman R (1994) Intermittent high dose intravenous methylprednisolone (IV pulse) prevents calcinosis and shortens disease course in juvenile dermatomyositis (JDMS). *Arth Rheum* 37: R10A
- Callen JP (1982) The value of malignancy evaluation in patients with dermatomyositis. *J Am Acad Dermatol* 6: 253–259
- Callen JP (1993) Photodermatitis in a 6-year-old child. *Arthritis Rheum* 36: 1483–1485
- Callen JP (1999) Photosensitivity in collagen vascular diseases. *Semin Cutan Med Surg* 18(4): 293–296
- Callen JP (2000) Dermatomyositis. *Lancet* 355: 53–57
- Callen JP (2000) When and how should the patient with dermatomyositis or amyopathic dermatomyositis be assessed for possible cancer? *Arch Dermatol* 138: 969–971
- Cheong W-K, Hughes GRV, Norris PG, Hawk JLM (1994) Cutaneous photosensitivity in dermatomyositis. *Brit J Dermatol* 131: 205–208
- Cherin P, Pelletier S, Teixeira A, Laforet P, Genereau T, Simon A, Maisonnobe T, Eymard B, Herson S (2002): Results and long-term followup of intravenous immunoglobulin infusions in chronic, refractory polymyositis. *Arthritis Rheum* 46: 467–74.
- Chow WH, Gridley G, Mellemkjaer L, McLaughlin JK, Olsen JH, Fraumeni JF Jr (1995) Cancer risk following polymyositis and dermatomyositis: A nationwide cohort study in Denmark. *Cancer Causes and Control* 5: 9–13
- Cosnes A, Amaudric F, Gherardi R, Verroust J, Wechsler J, Revuz J, Roujeau JC (1995) Dermatomyositis without muscle weakness. Long-term follow-up of 12 patients without systemic corticosteroids. *Arch Dermatol* 131: 1381–1385

- Dacey MJ, Callen JP (2003) Hydroxyurea-induced dermatomyositis-like eruption. *J Am Acad Dermatol* 48: 439-441.
- Dalakas MC, Illa I, Dambrosia JM, Soueidan SA, Stein DP, Otero C, Dinsmore ST, McCrosky S (1993) A controlled trial of high-dose intravenous immune globulin infusions as treatment for dermatomyositis. *N Engl J Med* 329: 1993-2000
- Dalakas MC (1998) Molecular immunology and genetics of inflammatory muscle diseases. *Arch Neurol* 54: 1509-1512
- Daoud MS, Gibson LE, Pittelkow MR (1997) Hydroxyurea dermatopathy. A unique lichenoid eruption complicating long-term therapy with hydroxyurea. *J Am Acad Dermatol* 36: 178-182
- Douglas WW, Tazelaar HD, Hartman TE, Hartman RP, Decker PA, Schroeder DR, Ryu JH (2001) Polymyositis-dermatomyositis-associated interstitial lung disease. *Am J Respir Crit Care Med*. 164: 1182-5.
- Dourmishev AL, Dourshimev LA (1999) Dermatomyositis and drugs. *Adv Exp Med Biol* 445: 187-191
- El-Azhary RA, Pakzad SY (2002) Amyopathic dermatomyositis: retrospective review of 37 cases. *J Am Acad Dermatol* 46: 560-565
- Euwer RL, Sontheimer RD (1991) Amyopathic DM (DM sine myositis). *J Am Acad Dermatol* 24: 959-966
- Garcia J (2000) MRI in inflammatory myopathies. *Skeletal Radiol* 29: 425-438
- Gelber AC, Nousari HC, Wigley FM (2000) Mycophenolate mofetil in the treatment of severe skin manifestations of dermatomyositis: a series of 4 cases. *J Rheumatol* 27: 1542-1545
- Ghali FE, Stein LD, Fine J-D, Burkes EJ, McCauliffe DP (1999) Gingival telangiectases. An underappreciated physical sign of juvenile dermatomyositis. *Arch Dermatol* 135: 1370-1374
- Gonzalez-Lopez L, Gamez-Nava JI, Sanchez L, Rosas E, Suarez-Almazor M, Cardona-Munoz C, Ramos-Remus C (1996) Cardiac manifestations in dermato-polymyositis. *Clin Exp Rheumatol* 14: 373-379
- Hengstman G, van den Hoogen F, van Engelen B, Barrera P, Netea M, van den Putte L (2000) Anti-TNF-blockade with infliximab (remicade) in polymyositis and dermatomyositis. *Arthritis Rheum* 43: S193A
- Hill CL, Zhang Y, Sigurgeirsson B, Pukkala E, Mellemkjaer L, Airio A, Evan SR, Felson DT (2001) Frequency of specific cancer types in dermatomyositis and polymyositis: A population-based study. *Lancet* 357: 96-100
- Huemer C, Kitson H, Malleson PN, Sanderson S, Huemer M, Cabral DA, Chanoine J-P, Petty RE (2001) Lipodystrophy in patients with juvenile dermatomyositis – evaluation of clinical and metabolic abnormalities. *J Rheumatol* 28: 610-615.
- Hollar CB, Jorizzo JL (2004) Topical tacrolimus 0.1% ointment for refractory skin disease in dermatomyositis: a pilot study. *J Dermatolog Treat* 15: 35-9.
- Huber AM, Lang B, LeBlanc CM, Birdi N, Bolaria RK, Malleson P (2000) Medium- and long-term functional outcomes in a multicenter cohort of children with juvenile dermatomyositis. *Arthritis Rheum* 43: 541-549
- Kasteler JS, Callen JP (1994) Scalp involvement in dermatomyositis. Often overlooked or misdiagnosed. *JAMA* 272: 1939-1941
- Kasteler JS, Callen JP (1997) Low-dose methotrexate administered weekly in an effective corticosteroid-sparing agent for the treatment of the cutaneous manifestations of dermatomyositis. *J Am Acad Dermatol* 36: 67-71
- Kaufmann R, Greiner D, Schmidt P, Wolter M (1998) Dermatomyositis presenting as plaque-like mucinosis. *Brit J Dermatol* 138: 889-892
- Kuru S, Inukai A, Liang Y, Doyu M, Takano A, Sobue G (2000) Tumor necrosis factor- $\alpha$  expression in muscles of polymyositis and dermatomyositis. *Acta Neuropathol* 99: 585-588
- Love LA, Leff RL, Fraser DD, Targoff IN, Dalakas M, Plotz PH, Miller FW (1991) A new approach to the classification of idiopathic inflammatory myopathy: Myositis-specific autoantibodies define useful homogeneous patient groups. *Medicine* 70(6): 360-374
- Lundberg IE, Nyberg P (1998) New developments in the role of cytokines and chemokines in inflammatory myopathies. *Curr Opin in Rheumatol* 10: 521-529

- Marie I, Hatron P-Y, Hachulla E, Wallaert B, Michon-Pasturel U, Devulder B (1998) Pulmonary involvement in polymyositis and in dermatomyositis. *J Rheumatol* 25: 1336-1343
- Marie I, Hatron PY, Levesque H, Hachulla E, Hellot MF, Michon-Pasturel U, Courtois H, Devulder B (1999) Influence of age on characteristics of polymyositis and dermatomyositis in adults. *Medicine* 78: 139-147
- Marie I, Joly P, Levesque H, Heron F, Courville P, Cailleux N, Courtois H (2000) Pseudo-dermatomyositis as a complication of hydroxyurea therapy. *Clin Exp Rheumatol* 18: 536-537
- McCullough ML, Cockerell CJ (1998) Vesiculo-Bullous Dermatomyositis. *Am J Dermatopathol* 20: 170-174
- Miller FW, Leitman SF, Cronin ME, Hicks JE, Leff RL, Wesley R, Fraser DD, Dalakas M, Plotz PH (1992) Controlled trial of plasma exchange and leukapheresis in polymyositis and dermatomyositis. *N Engl J Med* 326: 1380-1384
- Nousari HC, Ha VT, Laman SD, Provost TT, Tausk FA (1999) 'Centripetal Flagellate Erythema': A Cutaneous Manifestation Associated with Dermatomyositis. *J Rheumatol* 26: 692-695
- Nyberg P, Wikman A-L, Nennesmo I, Lundberg I (2000) Increased expression of Interleukin 1a and MHC class I in muscle tissue of patients with chronic, inactive polymyositis and dermatomyositis. *J Rheumatol* 27: 940-948
- Oliveri MB, Palermo R, Mautalen C, Hübscher O (1996) Regression of calcinosis during Diltiazem treatment of juvenile dermatomyositis. *J Rheumatol* 23: 2152-2155
- Pachman LM (1995) An update on juvenile dermatomyositis. *Curr Opin Rheumatol* 7: 437-441
- Pachman LM, Liotta-Davis MR, Hong DK, Kinsella TR, Mendez EP, Kinder JM, Chen EH (2000) TNFa-308A allele in juvenile dermatomyositis. *Arthritis Rheum* 43: 2368-2377
- Pautas E, Cherin P, Piette J-C, Pelletier S, Wechsler B, Cabane J, Herson S (2000) Features of polymyositis and dermatomyositis in the elderly: A case-control study. *Clin Exp Rheumatol* 18: 241-244
- Pelle MT, Callen JP (2002) Adverse cutaneous reactions to hydroxychloroquine are more common in patients with dermatomyositis than in patients with cutaneous lupus erythematosus. *Arch Dermatol* 138: 1231-1233
- Peng J-C, Sheem T-S, Hsu M-M (1995) Nasopharyngeal carcinoma with dermatomyositis. Analysis of 12 cases. *Arch Otolaryngol Head Neck Surg* 121: 1298-1301
- Plotz PH, Rider LG, Targoff IN, Raben N, O'Hanlon TP, Miller FW (1995) Myositis: Immunologic Contributions to Understanding Cause, Pathogenesis, and Therapy. *Ann Intern Med* 122: 715-724
- Requena L, Grilli R, Soriano L, Escalonilla P, Farina C, Martin L (1997) Dermatomyositis with a pityriasis rubra pilaris-like eruption: a little-known distinctive cutaneous manifestation of dermatomyositis. *Brit J Dermatol* 136: 768-771
- Rockerbie NR, Woo TY, Callen JP, Giustina T (1989) Cutaneous changes of dermatomyositis precede muscle weakness. *J Am Acad Dermatol* 20: 629-632
- Saadeh CK (2000) Etanercept is effective in the treatment of polymyositis/dermatomyositis which is refractory to conventional therapy including steroids and other disease modifying agents. *Arthritis Rheum* 43: S193A
- Sawhney S, Sidoti G, Woo P, Murray KJ (2000) Clinical characteristics and outcome of idiopathic inflammatory myositis (IIM) in childhood: A 2 year follow up. *Arthritis Rheum* 43: A
- Sayers ME, Chou SM, Calabrese LH (1992) Inclusion body myositis: Analysis of 32 cases. *J Rheumatol* 19: 1385-1389
- Shannon PL, Ford MJ (1999) Angiokeratomas in juvenile dermatomyositis. *Pediatr Dermatol* 16: 448-451
- Shimizu T, Tomita Y, Son K, Nishinarita S, Sawada S, Horie T (2000) Elevation of serum soluble tumor necrosis factor receptors in patients with polymyositis and dermatomyositis. *Clin Rheumatol* 19: 352-359
- Sontheimer RD (2002) Would a new name hasten the acceptance of amyopathic dermatomyositis (dermatomyositis sine myositis) as a distinctive subset within the idiopathic inflammatory dermatomyopathies spectrum of clinical illness? *J Am Acad Dermatol* 46: 626-636.
- Spiers R, Kagen L (1998) Extramuscular manifestations in idiopathic inflammatory myopathies. *Curr Opin in Rheumatol* 10: 556-561



- Sigureirsson B, Lindelöf B, Edhag O, Allander E (1992) Risk of cancer in patients with dermatomyositis or polymyositis. *N Engl J Med* 325: 363–367
- Sinoway PA, Callen JP (1993) Chlorambucil: An Effective Corticosteroid-Sparing Agent for Patients with Recalcitrant Dermatomyositis. *Arthritis Rheum* 36: 319–324
- Sugugiura T, Kawaguchi Y, Harigai M, Takagi K, Ohta S, Fukasawa C, Hara M, Kamatani N (2000) Increased CD40 expression on muscle cells of polymyositis and dermatomyositis: Role of CD40-CD40 ligand interaction in IL-6, IL-8, IL-5, and monocyte chemoattractant protein-1 production. *J Immunol* 164: 6593–6000
- Stonecipher MR, Jorizzo JL, White WL, Walker FO, Prichard E (1993) Cutaneous changes of dermatomyositis in patients with normal muscle enzymes: DM sine myositis? *J Am Acad Dermatol* 28: 951–956
- Targoff IN (1991) Dermatomyositis and polymyositis. *Curr Prob Dermatol* 3: 131–180
- Targoff IN, Trieu EP, Sontheimer RD (2000) Autoantibodies to 155 kd and Se antigens in patients with clinically-amyopathic dermatomyositis. *Arthritis Rheum* 43: S194A
- Vencovsky J, Jarosova K, Machacek S, Studynkova J, Kafvova J, Bartunkova J, Nemcova D, Charvat F (2000) Cyclosporine A versus methotrexate in the treatment of polymyositis and dermatomyositis. *Scand J Rheumatol* 29: 95–102
- Villalba L, Adams EM (1996) Update on therapy for refractory dermatomyositis and polymyositis. *Curr Opinion Rheumatol* 8: 544–551
- Villalba L, Hicks JE, Adams EM, Sherman JB, Gourley MF, Leff RL, Thornton BC, Burgess SH, Plotz PH, Miller FW (1998) Treatment of refractory myositis. A randomized crossover study of two new cytotoxic regimens. *Arthritis Rheum* 41(3): 392–399
- Wanchu A, Khullar M, Sud A, Bamberg P (1999) Nitric oxide production is increased in patient with inflammatory myositis. *Nitric Oxide* 3: 454–458
- Whitmore SE, Rosenshein NB, Provost TT (1994) Ovarian cancer in patients with dermatomyositis. *Medicine* 73: 153–160
- Woo TY, Callen JP, Voorhees JJ, Bickers DR, Hanno R, Hawkins C (1984) Cutaneous lesions of dermatomyositis are improved by hydroxychloroquine. *J Am Acad Dermatol* 10: 592–600
- Woo TR, Rasmussen J, Callen JP (1985) Recurrent photosensitive dermatitis preceding juvenile dermatomyositis. *Pediatr Dermatol* 2: 207–212
- Wortmann RL (2001) Idiopathic inflammatory diseases of muscle. In *Treatment of the Rheumatic Diseases*. Weisman ML, Weinblatt ME, Louie JS (eds) W. B. Saunders Co. pp 390–402
- Zieglschmid-Adams ME, Pandya AG, Cohen SB, Sontheimer RD (1995) Treatment of dermatomyositis with methotrexate. *J Am Acad Dermatol* 32: 754–757
- Zuber M, John S, Pfreundschuh M, Gause A (1996) A young woman with a photosensitive pruritic rash on her face and upper trunk. *Arthritis Rheum* 39: 1419–1422

## 7 Mixed Connective Tissue Disease

*Reiji Kasukawa*

### Introduction

Since Klemperer proposed a concept on diffuse collagen disease in 1942, diseases occurring in the connective tissue have been understood to reveal their clinical symptoms in various tissues and organs with a variety of findings. This concept consequently allowed us to believe in the presence of a disease appearing between two established diseases or being an overlapped or mixed form of two diseases.

Sharp had recognized a group of patients who have mixed clinical features of systemic lupus erythematosus (SLE), systemic sclerosis (SSc) and polymyositis (PM). All such patients had high titers of anti-extractable nuclear antigen (ENA) antibody and a good prognosis. In 1972, Sharp et al. published a group of these conditions as a new disease entity: mixed connective tissue disease (MCTD).

The independent feature of the clinical entity of MCTD, however, was criticized by several investigators including Reichlin et al. (1976), LeRoy et al. (1980) and Nimelstein et al. (1980) on the following two points. The clinical features of MCTD do not differ from those of anti-snRNP antibody-positive SLE patients and most MCTD patients progress to scleroderma during the observation period.

Nevertheless, MCTD has been a recognized disease all over the world having characteristic mixed clinical features of several connective tissue diseases and autoantibody to U1snRNP.

### Etiopathogenesis

#### *Anti-U1snRNP Autoantibodies*

The etiopathogenesis of MCTD is not clear, a fact true of other connective tissue diseases. However, the function of U1snRNP to which anti-U1snRNP

antibody reacts was clarified by Lerner and Steitz (1979) to be a splicing of the precursor of mRNA. Murakami et al. (2002) demonstrated recently a new conformational epitope generated by the binding of recombinant 70 kDa protein and U1 RNA to anti-U1 RNP antibody. All of 196 sera from patients with MCTD reacted with the U1-RNA-70 kDa protein complex. The mechanism underlying the production and pathogenic significance of anti-U1snRNP antibody has been studied by many investigators and clarified in part. Query et al. (1987) described a fact of molecular mimicry between RNP antigen and retroviral p30gag antigen. They demonstrated that 11 of 25 or 12 of 24 amino acids of the 70 kDa RNP antigen are homologous to those of Molony MuLV p30gag protein, and further observed that heteroimmune anti-p30gag antibody reacted to 70 kDa protein of RNP. Prokop and Jagodsinski (2004) found a retroviral conserved pol sequences at 90.9% in sera of patients with MCTD and suggested the development of anti-U1 70 kDa antibodies to this sequence. Alarcon-Segovia et al. (1978) presented the attractive phenomenon of sufficient penetration of the anti-U1snRNP antibody but little penetration of anti-DNA antibody into the living cells. In their recent publication (Alarcon-Segovia et al. 1996), they demonstrated that anti-U1snRNP antibody penetrated into human mononuclear cells and induced apoptosis of the autoreactive lymphocytes at a higher frequency of 7.70% than control IgG at 1.21%, with the higher frequency believed to induce subsequently autoimmune disease.

#### *Other Autoantibodies*

In addition to anti-U1snRNP antibody (Burdtt et al. 1999), several autoantibodies have been found in patients with MCTD. These autoantibodies and their frequencies in the sera of MCTD patients were presented in *Table 1*. The pathogenic and clinical significance of these autoantibodies, however, remains unclear, in the same manner as anti-U1snRNP antibody. Ikeda et al. (2003) found anti-TS1-RNA antibodies at 31.7% in patients with MCTD, which correlated with the disease activity of lupus-like features in patients with MCTD. Mairesse et al. (1993) tested serum samples from 18 patients with MCTD against human constitutive HSP 73 kDa protein and found a positive reaction with higher titers in all 18 patients, in contrast to the negative reaction of the sera of patients with rheumatoid arthritis (RA), SLE, SSc and PM. They concluded that anti-HSP 70kDa antibody could become a new diagnostic marker for MCTD. Anti-casein kinase II (CKII) antibody was found in 15% (8/52) of patients with MCTD, but in none of 52 healthy donors (Wiemann et al. 1993). The epitope of CKII was identified to be present in a subunit of the CKII molecule. However, they could not find any correlation between the occurrence of anti-casein kinase II antibody and anti-U1snRNP antibody. Anti-endothelial cell (EC) antibody was found in serum samples of 57% of patients with MCTD, and these antibody-positive patients were found to have higher levels of serum endothelin-1 at  $7.3 \pm 1.5$  pg/ml ( $n = 12$ ) by Filep et al. (1995).

**Table 1.** Immunological Aberrations of Patients with Mixed Connective Tissue Disease

A. Autoantibodies to	Frequency	Reference
U1snRNP	100%	Burdet et al. 1999
new epitope combined no kDa and U1 RNA	100%	Murakami et al. 2002
TS1-RNA	31,7%	Ikedo et al. 2003
73 kDa HSP	100%	Mairesse et al. 1993
Casein kinase	15%	Wiemann et al. 1993
Endothelial cells	57%	Filep et al. 1995
Spliceosome (A2/hn RNP)	38%	Hassfeld et al. 1995
Human endogenous retrovirus p30gag	33%	Hishikawa et al. 1997
Phospholipid	15%	Komatireddy et al. 1997
Fibrillin-1	34%	Tan et al. 1999
Nuclear matrix	100%	Sato et al. 2000
B. T cell characteristics		
CD4+CD45+RA	increased (p < 0.01)	Becker et al. 1992
TCR V $\beta$ 8/V $\beta$ 11/C $\beta$	decreased (p = 0.029)	Ikaeheimio et al. 1994
TCR V $\beta$ 1, 3, 4, 5.2, 14, 16	frequently used	Okubo et al. 1994
TCR AV CDR3 (common motif)	highly conserved (p < 0.03)	Talken et al. 1999
C. HLA class II specificity		
DR4	in American	increased Hoffmann et al. 1990
DR4 (B15, DR4)	in Finnish	increased (p < 0.05) Ruuska et al. 1992
DR2 or DR4	in English (UCTD)	increased (p = 0.007) Gendi et al. 1995
DRB4* 0101, DQA1* 03	in Japanese	increased (RR = 2.47, 2.25) Dong et al. 1993
DQB1* 0501	in Mexican	increased (p = 0.0051) Weckmann et al. 1999

U1snRNP: U1 small nuclear ribonucleoprotein, HSP: heat shock protein, hnRNP: heterogeneous nuclear ribonucleoprotein, TCR: T cell receptor, V $\beta$ : variable region of  $\beta$ -chain, AV: variable region of  $\alpha$ -chain, CDR: complementary determining region, UCTD: undifferentiated connective tissue disease

Both anti-EC antibody and endothelin-1 have been considered to participate in the process of vascular damage in MCTD patients. The antibody to spliceosome (A2/hn RNP) was first described by Hassfeld et al. (1995) in the sera of 38% of patients with MCTD, and this antibody was considered to interact with other hnRNP proteins. This antibody to heterogeneous nuclear ribonucleoprotein complex (hn RNP-A2) was found at almost an equivalent frequency in

the sera of patients with RA and SLE. However, in recent studies, an epitope difference between anti-A3/RA33 antibody in MCTD and those in RA or SLE was reported (Steiner et al. 1996; Skriner et al. 1997).

Anti-human endogenous retrovirus (HERV) p30gag antibody was detected in the sera of MCTD patients at a frequency of 33%, and also found at a similar frequency in the sera of SLE (48.3%) and Sjogren's syndrome (35.0%) patients (Hishikawa et al. 1997). Antiphospholipid antibodies were found in MCTD patients at 15% (7/48) with low titers and none of these antibody-positive patients demonstrated vascular lesions due to thromboembolisms including pulmonary embolism. This findings differed from the reported thromboembolism of antibody-positive SLE patients (Komarireddy et al. 1997). However, anticardiolipin antibody has been reported to be associated with pulmonary hypertension in patients with MCTD (Miyata et al. 1992, 1993). Anti-fibrillin-1 antibody was found by Tan et al. (1999) in the sera of 38% of MCTD patients. The fibrillin-1 is the major structural glycoprotein of connective tissue microfibrils, especially of elastic fibers. This antibody was similarly found in the sera of patients with diffuse SSc (37%) and CREST syndrome (51%). Similar results have been reported by Lundberg et al. (2000) on anti-fibrillin-1 antibody in MCTD and CREST syndrome. Recently, Sato et al. (2000) reported the presence of anti-nuclear matrix antibody in the sera of patients with anti-U1RNP antibody at a frequency of 100%. Higher titers of this antibody were detected in MCTD and SSc patients, and lower titers in SLE and undifferentiated connective tissue disease (UCTD) patients. They considered this antibody to be potentially useful in distinguishing MCTD or SSc from SLE or UCTD. This antibody to the nuclear matrix, a relatively insoluble component of the cell nucleus, was originally reported by Fritzler et al. (1984).

#### *Additional Immune Phenomena*

The T cell population of MCTD patients has been characterized by several investigators. Becker et al. (1992) reported an increased percentage of CD4+ CD29+ T cells in MCTD patients compared with controls ( $p < 0.01$  and  $p < 0.001$ , respectively). They considered this imbalance of the T cell population to likely enhance autoimmunity. A haplotype of TCR V $\beta$ 8/V $\beta$ 11/C $\beta$  was reported to be reduced in Finnish MCTD patients ( $p < 0.029$ ) compared to controls (Ikaeheimo 1994). On the other hand, an increased frequency of TCR V $\beta$ , 3, 4, 5.2, 14 and 16 in Japanese MCTD patients was reported by Okubo et al. (1994). Holyst et al. (1997) reported that T cells in MCTD patients responding to 70 kDa, B or D protein of RNP antigen produced a higher level of IL-4 and IFN $\gamma$ , but a lower level of IL-2 and IL-6. Bodolay et al. (2002) reported similarly that T cells of MCTD patients produce in higher values of both type 1 (1 IFN g) and type 2 cytokines (IL-4, IL-10). Talkin et al. (1999) reported that the T cell receptor reactive to U1 70 kDa snRNP has hold a highly conserved common motif in the CDR 3 region of the  $\alpha$  chain of the receptor.

The specificity of HLA class II antigen in MCTD patients has been investigated in several studies. An increased frequency of HLA-DR4 has been found in North American patients (Hoffman et al. 1990). Similarly, an increased frequency of DR4 (B15, DR4) was found in Finnish patients compared with controls ( $p < 0.05$ ) (Ruuska et al. 1992), and an increased association with DR2 or DR4 was found in the undifferentiated type of MCTD in English patients ( $p = 0.007$ , Gendi et al. 1995). An increased frequency of DRB4\*0101 and DQA1\*03 was observed in Japanese MCTD patients compared with SLE patients (RR = 2.47 and 2.25, respectively, Dong et al. 1993). Finally, an increased frequency of DQB1\*0501 was found in Mexican patients ( $p = 0.0051$ , Weckmann et al. 1999).

Increased serum levels of several proteins are present in MCTD patients. Filep et al. (1995) reported an increased level of serum endothelin-1. Moreover, patients with MCTD complicated by pulmonary hypertension showed increased serum levels of angiotensin converting enzymes (Ozawa et al. 1995), IL-1 and IL-6 (Okawa et al. 1994), and IL-6 and IgG anticardiolipin antibody (Nishimaki et al. 1999), tissue inhibitor of metalloproteinases 1 and 2 (Jinnin et al. 2002).

## Clinical Appearance

The clinical features of patients with MCTD vary and include those found in SLE, SSc, PM and occasionally RA. The frequency of each clinical findings differs slightly depending on the race of the patients studied and on the diagnostic criteria used. The frequencies of each findings observed in a multi-institutional study including 284 MCTD patients in Japan (Miyawaki et al. 1988) and those of a study involving 47 MCTD patients in the USA (Burdet et al. 1999) are presented in *Table 2*. As seen in this table, the findings observed at the highest frequency in both groups of patients were Raynaud's phenomenon, polyarthritis/arthralgia, swollen hands, sclerodactyly, pulmonary lesions and muscle symptoms. The second tier of the frequently observed findings include esophageal dysfunction, leukocytopenia or thrombocytopenia and pleuritis and pericarditis. Rarely found clinical findings were alterations of the nervous system, renal lesions and diffuse sclerosis in both groups. One of the characteristic features of MCTD patients is swollen fingers or hands, a symptom referred to "sausage-like fingers" (*Fig. 1*). No significant differences between MCTD and SLE in the features of facial erythema have been described. In *Fig. 2*, a photograph of the face of a MCTD patient with faded erythema and acrosclerosis is presented. Among these findings in MCTD patients, some show a tendency to diminish while others persist or increase during the observation period. A similar change in the clinical features of the patients during the observation period has been reported in several studies. The results of two studies done in Japan (Miyawaki et al. 1988) on 284 patients fol-

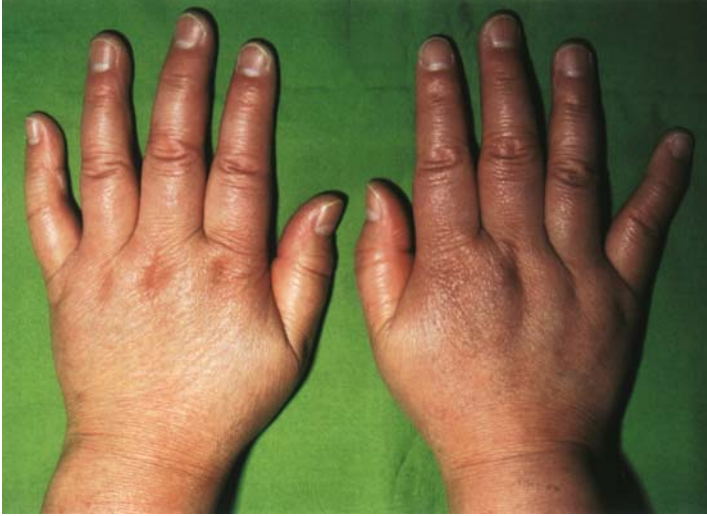**Table 2.** Clinical Findings of Patients with Mixed Connective Tissue Disease

	Japanese patients (Miyawaki et al. 1988) 284 cases	US patients (Burdet et al. 1999) 47 cases
Raynaud's phenomenon	97.9%	96%*
Swollen fingers or hands	73.9	66
Anti-U1snRNP antibody positive	96.6	100
Arthritis	69.5	96 (arthralgia)
Sclerodactyly	50.2	49
Reduced diffusion capacity	48.5	66 (pulmonary)
Pulmonary fibrosis	40.1	dysfunction
Restrictive changes of lung	33.5	
Pulmonary hypertension	4.5	23
Muscle weakness	39.3	51 (myositis)
Myogenic pattern on EMG	35.4	
Elevated muscle enzymes	31.0	
Leukocytopenia	37.7	53 (leukopenia/
Thrombocytopenia	8.9	lymphopenia)
Lymphadenopathy	29.2	-
Esophageal hypomotility or dilatation	27.7	66
Facial erythema	19.5	53 (skin rash)
Pleuritis	6.5	43 (pericarditis)
Pericarditis	5.7	
Anti-Sm antibody	11.5	22
Diffuse sclerosis	11.6	19
Proteinuria	7.8	11 (renal disease)
Urinary casts	1.8	

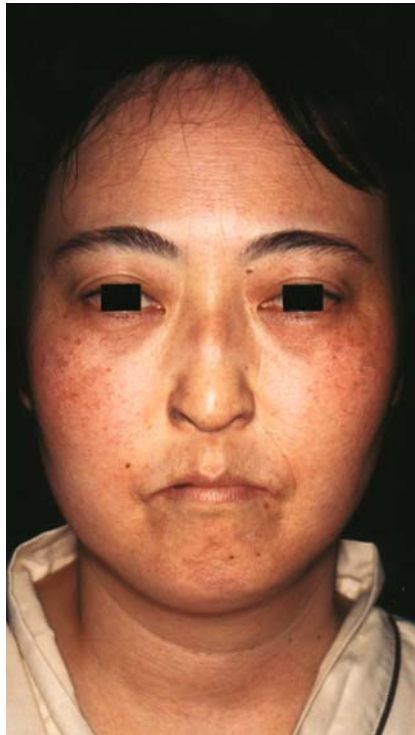\* Cumulative findings

lowed for a mean period of 6 years, and those of a study in the USA (Burdet et al. 1999) on 47 patients followed for a mean period of 15 years were very similar. Diminished symptoms included myositis, arthritis, facial erythema, pleuritis/pericarditis in both studies. On the other hand, persistent or increased symptoms were pulmonary lesions, scleroderma and esophageal dysfunction. Raynaud's phenomenon remained almost unchanged in both groups.

Pulmonary hypertension in MCTD patients had been recognized in the early 1980's by Esther et al. (1981), Graziano et al. (1983) and Sullivan et al. (1984). The prevalence of pulmonary hypertension in MCTD patients was reported to be 4% by Esther et al. (1981) and 3.9% by Miyawaki et al. (1988). Sharp stressed the clinical importance of pulmonary hypertension and included it in his diagnostic criteria as one of major symptoms (Sharp 1987). Pulmonary hypertension is the most critical symptom related to the prognosis



**Fig. 1.** Swollen fingers and hands of a 58-year-old woman with mixed connective tissue disease



**Fig. 2.** Face of a 32-year-old woman with mixed connective tissue disease. Discrete facial erythema and slightly sclerotic skin at the nose and around the mouth



of MCTD patients. Sawai et al. (1997) reported that the most frequent cause of death in MCTD patients is pulmonary hypertension, accounting for 11 of 32 (34%) autopsy cases with MCTD. In a comparison between MCTD patients and those with SLE and SSc, we reported that pulmonary hypertension in MCTD occurred more quickly and carried a shorter survival period than in other diseases (Kasukawa et al. 1990). Characteristic histopathological findings of pulmonary hypertension in MCTD patients include a marked intimal thickening of the pulmonary arteries especially in the distal portion, and the hypertensive pulmonary vascular change with plexiform lesions accompanied by or without pulmonary fibrosis (Hosoda et al. 1994; Sawai et al. 1997). The five-year survival rate of MCTD patients was reported to be 96.5% (Tojo et al. 1991).

## Diagnosis

Since Sharp reported MCTD to be a distinct disease entity in 1972, criticism has been raised over its supposed independent nature. The main thrust of the criticism can be summarized as follows: the first is the difficulty in distinguishing patients whose symptoms could simultaneously satisfy two criteria for MCTD and other connective tissue diseases such as SLE (Reichlin 1976) or SSc and the second is the shifting of clinical features of MCTD to those of other connective tissue diseases such as SSc or SLE during the observation period (LeRoy et al. 1980, Nimelstein et al. 1980; Black et al. 1992; van den Hoogen et al. 1994).

To address these problems, a classification criteria for MCTD was eagerly pursued. To date, three criteria for MCTD have been proposed: Alarcon-Segovia's criteria (1976; revised in 1987), Sharp's criteria (1987) and the criteria of The Research Committee of the Japanese Ministry of Health and Welfare for MCTD (JMHW, Kasukawa et al. 1987). The three sets of criteria for MCTD arranged by Smolen and Steiner (1998) are presented in *Table 3*. The reliability of the diagnostic criteria depends on their sensitivity and specificity when tested on patients with objective disease and control diseases. Few studies have been performed to test the sensitivity and specificity of the proposed criteria for MCTD. The results of the five reported studies are listed chronologically in *Table 4*. (Kasukawa et al. 1987; Alarcon-Segovia et al. 1989; Doria et al. 1991; Amigues et al. 1996; Smolen and Steiner 1998). The sensitivity and specificity of these three criteria were found to be satisfactorily high except for the study of Amigues et al. (1996). In general, the criteria of Alarcon-Segovia are simple and suitable for screening MCTD from various connective tissue diseases, whereas the criteria of Sharp and JMHW are suitable not only for classifying MCTD as a connective tissue disease but also for analyzing each of the clinical features of MCTD patients.

Table 3. Characteristics of 3 Sets of Criteria for the Classification of Mixed Connective Tissue Disease \*

Reference	Criteria	Requirements for diagnosis
Alarcon-Segovia and Villarreal (1987)	<p>A. Serologic</p> <ol style="list-style-type: none"> <li>1. Anti-RNP at a hemagglutination titer of <math>\geq 1:1,600</math></li> </ol> <p>B. Clinical</p> <ol style="list-style-type: none"> <li>1. Edema in the hands</li> <li>2. Synovitis</li> <li>3. Myositis</li> <li>4. Raynaud's phenomenon</li> <li>5. Acrosclerosis</li> </ol>	Serological criterion plus at least 3 clinical criteria, or including either synovitis myositis.
Kasukawa et al. (1987)	<p>A. Common symptoms</p> <ol style="list-style-type: none"> <li>1. Raynaud's phenomenon</li> <li>2. Swollen fingers or hands</li> </ol> <p>B. Anti-snRNP antibody positive</p> <p>C. Mixed symptoms</p> <ol style="list-style-type: none"> <li>1. SLE-like findings <ol style="list-style-type: none"> <li>a. Polyarthritis</li> <li>b. Lymphadenopathy</li> <li>c. Facial erythema</li> <li>d. Pericarditis or pleuritis</li> <li>e. Leuko- or thrombocytopenia</li> </ol> </li> <li>2. SSc-like findings <ol style="list-style-type: none"> <li>a. Sclerodactyly</li> <li>b. Pulmonary fibrosis, restrictive changes of lung, or reduced diffusion capacity</li> <li>c. Hypomotility or dilatation of esophagus</li> </ol> </li> <li>3. PM-like findings <ol style="list-style-type: none"> <li>a. Muscle weakness</li> <li>b. Elevated serum levels of muscle enzymes (CPK)</li> <li>c. Myogenic pattern on EMG</li> </ol> </li> </ol>	At least 1 of the 2 common symptoms plus positive for anti-snRNP plus 1 or more of the mixed symptoms in at least 2 of the 3 disease categories.
Sharp (1987)	<p>A. Major</p> <p>At least 4 major criteria plus anti-U1 RNP titer of at least</p> <ol style="list-style-type: none"> <li>1. Myositis, severe</li> <li>2. Pulmonary involvement <ol style="list-style-type: none"> <li>a. Diffusion capacity <math>&lt; 70\%</math> of normal values</li> <li>b. Pulmonary hypertension</li> <li>c. Proliferative vascular lesions on lung biopsy</li> </ol> </li> </ol>	1:4,000 (exclusion criterion: positivity for anti-Sm); Or, 2 major criteria from among criteria 1, 2, and 3 plus 2 minor criteria plus anti-U1 RNP titer of at least 1:1,000

**Table 3.** Characteristics of 3 Sets of Criteria for the Classification of Mixed Connective Tissue Disease \*

Reference	Criteria	Requirements for diagnosis
	2. Raynaud's phenomenon or esophageal hypomotility	
	4. Swollen hands or sclerodactyly	
	5. Anti-ENA $\geq$ 1:10,000 and anti-U1 RNP positive and anti-Sm negative	
	B. Minor	
	1. Alopecia	
	2. Leukopenia	
	3. Anemia	
	4. Pleuritis	
	5. Pericarditis	
	6. Arthritis	
	7. Trigeminal neuropathy	
	8. Malar rash	
	9. Thrombocytopenia	
	10. Mild myositis	
	11. History of swollen hands	

\* snRNP = small nuclear RNP; SLE = systemic lupus erythematosus; SSc = systemic sclerosis; PM = polymyositis; CPK = creatine phosphokinase; EMG = electromyogram; ENA = extractable nuclear antigen (Smolen and Steiner: Arthritis Rheum 1998)

## Therapy

Therapeutic regimens for treating MCTD patients are similar to those used for patients with SLE, SSc or PM. The main therapeutic approach is the administration of systemic corticosteroids. Nonsteroidal anti-inflammatory drugs (NSAID) and vasodilators are often used, and immunosuppressants are occasionally used. In our multi-institutional study done in Japan (Miyawaki et al. 1988) on 284 patients with MCTD, the therapeutic methods used were as follows: corticosteroids in 230 cases (81.0%), vasodilators in 123 (43.3%), NSAID in 109 (38.4%), prostaglandin or prostacyclin derivatives in 37 (13.0%), and immunosuppressants in 16 (5.6%). In the above study, the correlation between doses of prednisolone and prognosis was analyzed. Administration of 30 mg or more of prednisolone per day induced a better prognosis of MCTD patients ( $p < 0.05$ ) than doses of less than 30 mg of prednisolone per day according to Radit and Mann-Whitney tests (Table 5, Miyawaki et al. 1988). Aside from these drugs, several other therapeutic methods have been used for MCTD patients, including anticoagulants, plasma exchange and O<sub>2</sub> inhalation. Case

**Table 4.** Sensitivity and Specificity of Three Sets of Criteria for Mixed Connective Tissue Disease

Investigators	Year JMHW(22) studied	Objective disease (OD) and Control disease (CD)	No. of patients studied	Sensitivity and Specificity	Criteria of	
					Alarcon- Segovia and Villarreal 1987	Sharp 1987
Kasukawa et al.	1987	OD: MCTD	81	Sensi:		
		CD: SLE/SSc/PM/DM	261	Speci:		
Alarcon- Segovia and Cardiel	1989	OD: MCTD	80	Sensi:	100%	100%
		CD: SLE/SSc/RA- PM/DM/SS	518	Speci:	99-100%	55-100%
Doria et al.	1991	OD: MCTD	32	Sensi:		87%
Amigues et al.	1996	CD: SLE/SSc/PM	75	Speci:		94%
		OD: aRNP positive pts including control pts	45	Sensi:	62.5%	100%
Smolen and Steiner	1998	CD: RA/SLE/SSc/Ov	25	Speci:	86.2%	38%
		OD: MCTD	26	Sensi:	100%	70%

JMHW: Japanese Ministry of Health and Welfare, MCTD: mixed connective tissue disease, SLE: systemic lupus erythematosus, SSc: systemic sclerosis, PM: polymyositis, DM: dermatomyositis, RA: rheumatoid arthritis, SS: Sjogren's syndrome, aRNP: anti-U1snRNP antibody, pts: patients, Ov: overlap syndrome

**Table 5.** Correlation between Doses of Prednisolone used for 284 Patients with Mixed Connective Tissue Disease and their Prognosis for 6 Years at Mean (Miyawaki et al. 1988)

Doses	No. of patients	No. of patients who revealed the prognosis of				
		Remission 125 (45.0%)	Unchanged 124 (43.7%)	Worse 12 (4.2%)	Deceased 16 (5.6%)	Unknown 4 (1.4%)
		(%)				
Not used	69	15 (21.7)	48 (69.6)	3 (4.3)	2 (2.9)	1 (1.4) **
Used	215	113 (52.6)	76 (35.3)	9 (4.2)	14 (6.5)	3 (1.4)
Less than 20 mg	54	22 (40.7)	28 (51.9)	1 (1.9)	2 (3.7)	1 (1.9)
More than 20 mg	161	91 (56.5)	48 (29.8)	8 (5.0)	12 (7.5)	2 (1.2) ns
Less than 30 mg	88	36 (40.9)	46 (52.3)	1 (1.1)	3 (3.4)	2 (2.3) *
More than 30 mg	127	77 (60.6)	30 (23.6)	8 (6.3)	11 (8.7)	1 (0.8)

\*p < 0.05, \*\*p < 0.01, ns: not significant

reports of effectiveness of autologous peripheral blood stem cell transplantation (Myllykangas-Lousujarvi et al. 2000) and pulsed intravenous immunoglobulin (Ulmer et al. 2002) for patients with MCTD were presented.

Pulmonary hypertension in MCTD patients is the most critical factor affecting the prognosis of MCTD patients. Corticosteroids are occasionally effective during the early stage of the disease. Anticoagulants (warfarin potassium), antiplatelets (ticlopidine hydrochloride), and vasodilators (prostaglandin or prostacyclin derivatives, calcium antagonists) are used for the progressive stage of pulmonary hypertension. Digitalis products and diuretics are used to treat heart failure in the advanced stage of pulmonary hypertension. A combination of cyclophosphamide and cyclosporin A was reported to be effective against the pulmonary hypertension in MCTD patients (Dahl et al. 1992). However, to date no promising therapeutic methods have been established for both primary and secondary type of the pulmonary hypertension. Inhalation of NO in addition to O<sub>2</sub> is effective against pulmonary hypertension (Pepke-Zaba 1991).

## References

- Alarcon-Segovia D (1976) Symptomatic Sjogren's syndrome in mixed connective tissue disease. *J Rheumatol* 3: 191-195
- Alarcon-Segovia D, Villarreal M (1987) Classification and diagnostic criteria for mixed connective tissue disease. In: Kasukawa R, Sharp GC (eds) *Mixed Connective Tissue Disease and Antinuclear Antibodies*. Elsevier, Amsterdam, pp 33-40

- Alarcon-Segovia D, Cardiel MH (1989) Comparison between three diagnostic criteria for mixed connective tissue disease. Studies of 593 patients. *J Rheumatol* 16: 328–334
- Amigues JM, Cantagrel A, Abbal M, Mazieres B, and the Autoimmunity Group of the Hospitals of Toulouse (1996) Comparative study of 4 diagnosis criteria sets in mixed connective tissue disease in patients with anti-RNP antibodies. *J Rheumatol* 23: 2055–2062 (see comments)
- Becker H, Langrock A, Federlin K (1992) Imbalance of CD4+ lymphocyte subsets in patients with mixed connective tissue disease. *Clin Exp Immunol* 88: 91–95
- Black C, Isenberg DA (1992) Mixed connective tissue disease – goodbye to all that. *Br J Rheumatol* 31: 695–700 (see comments)
- Bodolay E, Aleksza M, Antal-Szalmás P, Vegh J, Szodoray P, Soltesz P, Szegedi A, Szekanecz Z (2002) Serum cytokine levels and type 1 and type 2 intracellular T cell cytokine profiles in mixed connective tissue disease. *J Rheumatol* 29: 2136–2142.
- Burdet MA, Hoffman RW, Dertscher SL, Wang GS, Johnson JC, Sharp GC (1999) Long-term outcome in mixed connective tissue disease: longitudinal clinical and serological findings. *Arthritis Rheum* 42: 899–909
- Dahl M, Chalmers A, Wade J, Calverley D, Munt B (1992) Ten year survival of a patient with advanced hypertension and mixed connective tissue disease treated with immunosuppressive therapy. *J Rheumatol* 19: 1807–1809
- Dong RP, Kimura A, Hashimoto H, Akizuki M, Nishimura Y, Sasazuki T (1993) Difference in HLA-linked genetic background between mixed connective tissue disease and systemic lupus erythematosus. *Tissue Antigens* 41: 21–25
- Doria A, Ghirardello A, de Zambiasi P, Ruffatti A, Gambari PF (1992) Japanese diagnostic criteria for mixed connective tissue disease in Caucasian patients. *J Rheumatol* 19: 259–264
- Esther JH, Sharp GC, Agia G, Hurst DJ, Maricq HR (1981) Pulmonary hypertension in a patient with connective tissue disease and antibody to nuclear ribonucleoprotein. *Arthritis Rheum* 24: 2105
- Filep JG, Bodolay E, Sipka S, Gyimesi E, Csipoe I, Szegedi G (1995) Plasma endothelin correlate with antiendothelial antibodies in patients with mixed connective tissue disease. *Circulation* 92: 2969–2974
- Fritzler MJ, Ali R, Tan EM (1984) Antibodies from patients with mixed connective tissue disease react with heterogeneous nuclear ribonucleoprotein or ribonucleic acid (hn RNP/RNA) of the nuclear matrix. *J Immunol* 132: 1216–1222
- Gendi NS, Welsh KI, van Venrooij WJ, Vancheeswaran R, Girloy J, Black CM (1995) HLA type as a predictor of mixed connective tissue disease differentiation: ten-year clinical and immunologic follow up of 46 patients. *Arthritis Rheum* 38: 259–266
- Graziano FM, Friedman LCV, Grossmaen J (1983) Pulmonary hypertension in a patient with mixed connective tissue disease. *Clin Exp Rheumatol* 1: 251–255
- Hassfeld W, Steiner G, Studinicka-Benke A, Skriner K, Graninger W, Fisher I, Smolen JS (1995) Autoimmune response to the spliceosome: an immunologic link between rheumatoid arthritis, mixed connective tissue disease, and systemic lupus erythematosus. *Arthritis Rheum* 38: 777–785
- Hishikawa T, Ogasawara H, Kaneko H, Shirasawa T, Matsuura Y, Sekigawa I, Takasaki Y, Hashimoto H, Hirose S, Handa S, Nagasawa R, Maruyama N (1997) Detection of autoantibodies to a recombinant gag protein derived from human endogenous retrovirus clone 4–1 in autoimmune diseases. *Viral Immunol* 10: 137–147
- Hoffman RW, Rettenmaier LJ, Takeda Y, Hewette JE, Pettersson I, Nyman U, Luger AM, Sharp GC (1990) Human autoantibodies against the 70-kd polypeptide of U1 small nuclear RNP are associated with HLA-DR 4 among connective tissue disease patients. *Arthritis Rheum* 33: 666–673
- Holyst MM, Hill DL, Hoch SO, Hoffman RW (1997) Analysis of human T cell and B cell response against U small nuclear ribonucleoprotein 70-kd, B, and D polypeptides among patients with systemic lupus erythematosus and mixed connective tissue disease. *Arthritis Rheum* 40: 1493–1503
- Hosoda Y (1994) Pathology of pulmonary hypertension: A human and experimental study. *Pathol Int* 44: 241–267

- Ikaeimo H, Tiilikainen AS, Hameenkorpi R, Silvennoinen-Kassinen SH (1994) Different distribution of T cell receptor beta-chain haplotypes in mixed connective tissue disease and systemic lupus erythematosus. *Ann Med* 26:129-132
- Ikeda K, Takasaki Y, Hirokawa K, Takeuchi K, Hashimoto H (2003) Clinical significance of antibodies to TS1-RNA in patients with mixed connective tissue disease. *J Rheumatol* 30: 998-1005
- Jinnin M, Ihn H, Yamane K, Asano Y, Yasava N, Tamaki K (2002) Serum levels of tissue inhibitor of metalloproteinases in patients with mixed connective tissue disease. *Clin Exp Rheumatol* 20: 539-542
- Kasukawa R, Tojo T, Miyawaki S, Yoshida H, Tanimoto K, Nobunaga M, Suzuki T, Takasaki Y, Tamura T (1987) Preliminary diagnostic criteria for classification of mixed connective tissue disease: In: Kasukawa R, Sharp GC (eds) *Mixed Connective Tissue Disease and Antinuclear Antibodies*. Elsevier, Amsterdam, pp 41-47
- Kasukawa R, Nishimaki T, Takagi T, Miyawaki S, Yokohari R, Tsunematsu T (1990) Pulmonary hypertension in connective tissue disease. Clinical study of sixty patients in multi-institutional study. *Clin Rheum* 9: 56-62
- Klemperer P, Pollack AD, Baehr G (1942) Diffuse collagen diseases, acute disseminated lupus erythematosus and diffuse scleroderma. *JAMA* 119: 331-332
- Komatireddy GR, Wang GS, Sharp GC, Hoffman RW (1997) Antiphospholipid antibodies among anti-U1-70 kda autoantibody positive patients with mixed connective tissue disease. *J Rheumatol* 24: 319-322 (see comments)
- Le Roy EC, Maricq HR, Kahaleh MB (1980) Undifferentiated connective tissue syndromes. *Arthritis Rheum* 23: 341-343
- Lerner MR, Steitz JA (1979) Antibodies to small nuclear RNAs complexed with proteins are produced by patients with systemic lupus erythematosus. *Proc Natl Acad Sci USA* 76: 5495-5499
- Lundberg I, Antohi S, Takeuchi K, Arnett F, Steiner G, Brumeanu TD, Klareskog L, Bona C (2000) Kinetics of anti-fibrillin-1 autoantibodies in MCTD and CREST syndrome. *J Autoimmun* 14: 267-274
- Mairesse N, Kahn MF, Appelboom T (1993) Antibodies to the constitutive 73-kd heat shock protein: A new marker for mixed connective tissue disease? *Am J Med* 95: 595-600
- Miyata M, Kida S, Kanno T, Suzuki K, Watanabe H, Kaise S, Nishimaki T, Hosoda Y, Kasukawa R (1992) Pulmonary hypertension in MCTD: Report of two cases with anticardiolipin antibody. *Clin Rheumatol* 11: 195-201
- Miyata M, Suzuki K, Sakuma F, Watanabe H, Kaise S, Nishimaki T, Kasukawa R (1993) Anticardiolipin antibodies are associated with pulmonary hypertension in patients with mixed connective tissue disease or systemic lupus erythematosus. *Int Arch Allergy Immunol* 100: 351-354
- Miyawaki S, Kasukawa R, Nishimaki T, Onodera H (1988) Treatment and prognosis of patients with mixed connective tissue disease. A multi-center co-operative study. In: Kasukawa R (ed) 1987 Annual Report of The Research Committee of Japanese Ministry of Health and Welfare for Mixed Connective Tissue Disease pp 31-41 (in Japanese, Abstract in English)
- Murakami A, Kojima K, Ohya K, Imamura K, Takasaki Y (2002) A new conformational epitope generated by binding of recombinant 70-kd protein and U1 RNA to anti U1 RNP autoantibodies in sera from patients with mixed connective tissue disease. *Arthritis Rheum* 46: 3273-3282
- Myllykangas-Lousujarvi R, Jantunen E, Kaipainen-Seppanen O, Mahlamaki E, Nousianen T (2000) Autologous peripheral blood stem cell transplantation in a patients with mixed connective tissue disease. *Scand J Rheumatol* 29: 326-327
- Nimelstein SH, Brody S, Mc Shane D, Holman HR (1980) Mixed connective tissue disease: a subsequent evaluation of the original 25 patients. *Medicine (Baltimore)* 59: 239-248
- Nishimaki T, Aotsuka S, Kondo H, Yamamoto K, Takasaki Y, Sumiya M, Yokohari R (1999) Immunological analysis of pulmonary hypertension in connective tissue disease. *J Rheumatol* 26: 2357-2362
- Okawa-Takatsuji M, Aotsuka S, Uwatoko M, Sumiya M, Yokohari R (1994) Enhanced synthesis of cytokines by peripheral blood monocytes cultured in the presence of auto-

- antibodies against U1-ribonucleoprotein and/or negatively charged molecules: implication in the pathogenesis of pulmonary hypertension in mixed connective tissue disease (MCTD). *Clin Exp Immunol* 98: 427–433
- Okubo M, Kurokawa M, Ohto H, Nishimaki T, Nishioka K, Kasukawa R, Yamamoto K (1994) Clonotype analysis of peripheral blood T cells and autoantigen-reactive T cells from patients with mixed connective tissue disease. *J Immunol* 153: 3784–3790
- Ozawa T, Ninomiya Y, Honma T, Kikuchi M, Sato T, Nakano M, Arakawa M (1995) Increased serum angiotensin-1 converting enzyme activity in patients with mixed connective tissue disease and pulmonary hypertension. *Scand J Rheumatol* 24: 38–43
- Pepke-Zaba J, Higenbottam TW, Dinh-Xuan AT, Stone D, Wallwork J (1991) Inhaled nitric oxide as a cause of selective pulmonary vasodilatation in pulmonary hypertension. *Lancet* 338: 1173–1174
- Prokop J, Jagodsinski PP (2004) Identification of retroviral conserved pol sequences in serum of mixed connective tissue disease and systemic sclerosis patients. *Biomed Pharmacother* 58: 61–64
- Query CC, Keene JD (1987) A human autoimmune protein associated with U1 RNA contains a region of homology that is cross reactive with retroviral p30gag antigen. *Cell* 51: 211–220
- Reichlin M (1976) Problems in differentiating SLE and mixed connective tissue disease. *N Engl J Med* 295: 1194–1195
- Ruuska P, Hameenkorpi R, Forsberg S, Julkunen H, Maekitalo R, Ilonen J, Tilikainen A (1992) Differences in HLA antigens between patients with mixed connective tissue disease and systemic lupus erythematosus. *Ann Rheum Dis* 51: 52–55
- Sato S, Hasegawa M, Ihn H, Kikuchi K, Takehara K (2000) Clinical significance of antinuclear matrix antibody in serum from patients with anti-U1 RNP antibody. *Arch Dermatol Res* 292: 55–59
- Sawai T, Murakami K, Kasukawa R, Kyogoku M (1997) Histopathological study of mixed connective tissue disease for 32 autopsy cases in Japan. *Jpn J Rheumatol* 7: 279–292
- Sharp GC, Irvin WS, Tan EM, Gould RG, Holman HR (1972) Mixed connective tissue disease: an apparently distinct rheumatic disease syndrome associated with a specific antibody to an extractable nuclear antigen (ENA). *Am J Med* 52: 148–159
- Sharp GC (1987) Diagnostic criteria for classification of MCTD. In: Kasukawa R, Sharp GC (eds) *Mixed Connective Tissue Disease and Antinuclear Autoantibodies*. Elsevier, Amsterdam, pp 23–32
- Skriner K, Sommergruber WH, Tremmel V, Fischer I, Barta A, Smolen JS, Steiner G (1997) Anti-A2/RA33 autoantibodies are directed to the RNA binding region of A2 protein of the heterogeneous nuclear ribonucleoprotein complex: differential epitope recognition in rheumatoid arthritis, systemic lupus erythematosus and mixed connective tissue disease. *J Clin Invest* 100: 127–135
- Smolen JS, Steiner G (1998) Mixed connective tissue disease. To be or not to be? *Arthritis Rheum* 41:768–777
- Steiner G, Skrinier K, Smolen JS (1996) Autoantibodies to the A/B proteins of the heterogeneous nuclear ribonucleoprotein complex: Novel tools for the diagnosis of rheumatic diseases. *Int Arch Allergy Immunol* 111: 314–319
- Sullivan WD, Hurst DJ, Harmon CE, Esther JH, Agia GA, Maltby JD, Lillard SB, Held CN, Wolfe JF, Sunderrajan EV, Maricq HR, Sharp GC (1984) Prospective evaluation emphasizing pulmonary involvement in patients with mixed connective tissue disease. *Medicine* 63: 92–107
- Talken BL, Lee DR, Caldwell CW, Quinn TP, Schaefermeyer KR, Hoffman RW (1999) Analysis of T cell receptors specific for U1–70 kD small nuclear ribonucleoprotein autoantigen: The alpha chain complementary determining region three is highly conserved among connective tissue disease patients. *Human Immunol* 60: 200–208
- Tan FK, Arnett FC, Antohi S, Saito S, Mirarchi A, Spiera H, Sasaki T, Shoichi O, Takeuchi K, Pandey JP, Silver RM, LeRoy C, Postlethwaite AE, Bona CA (1999) Autoantibodies to the extracellular matrix microfibrillar protein, fibrillin-1, in patients with scleroderma and other connective tissue diseases. *J Immunol* 163: 1066–1072
- Tojo T, Ogasawara T, Aotsuka S, Yokohari R (1991) Major causes of death and five year survival rates in mixed connective tissue disease. In: Yokohari R (ed) 1999 Annual Report of



- The Research Committee of Japanese Ministry of Health and Welfare for Mixed Connective Tissue Disease. Pp 10–13 (in Japanese, Abstract in English)
- Ulmer A, Kotter I, Pfaff AS, Fierbeck G (2002) Efficacy of pulsed intravenous immunoglobulin therapy in mixed connective tissue disease. *J Am Acad Dermatol* 46: 123–127
- van den Hoogen FH, Spronk PE, Boerbooms AM, Bootsma H, de Rooij DJ, Kallenberg CG, van de Putte LB (1994) Long-term follow up of 46 patients with anti-(U1) sn RNP antibodies. *Br J Rheumatol* 33: 1117–1120
- Weckmann AL, Granados J, Cardiel MH, Andrede F, Vargas-Alarcon G, Alcocer-Varela J, Alarcon-Segovia D (1999) Immunogenetics of mixed connective tissue disease in Mexican Mestizo population. *Clin Exp Rheumatol* 17: 91–94
- Wiemann C, Bodenbach L, Pyerin W (1993) Antibodies to casein kinase II in sera of patients with mixed connective tissue disease: Evaluation with recombinant protein. *Clin Chem* 39: 2492–2494

## **8 Sjogren's Syndrome**

*Robert I. Fox and Ichiro Saito*

### **Introduction**

The term Sjogren's syndrome (SS) refers to xerophthalmia and xerostomia due to lymphocytic infiltrates of lacrimal and salivary glands. The condition may exist as a primary entity (primary SS, 1° SS) or in association with other autoimmune disorders such as systemic lupus erythematosus (SLE), dermatomyositis, scleroderma or rheumatoid arthritis (in which the sicca symptoms are termed "secondary" SS, 2° SS). The criteria for diagnosis of primary SS has been controversial. The absence of a uniformly accepted criteria has led to confusion in clinical practice and in the research literature. For example, only 15% of patients that fulfill European (EEC) criteria for SS would fulfill the San Diego criteria. This difference in disease classification leads to difficulty in comparing clinical trials and in elucidating pathogenetic mechanisms, since different patient populations are evaluated. However, a new international criteria has been suggested and will be presented since the final version of this criteria is close to acceptance by rheumatologists and government agencies.

This chapter will concentrate on dermatologic manifestations of primary SS with emphasis on the ocular surface and oral manifestations of this disorder, since this information is spread throughout the rheumatologic, ophthalmologic and oral medicine literature. The differential diagnosis of SS is often difficult since patients with mild dryness, vague skin rashes and a low titer anti-nuclear antibody are often referred. The distinction between 1° SS, SLE, fibromyalgia, and medication side effects is difficult and rheumatologists will often turn to dermatologists for help in diagnosis, as well as for treatment options for their skin problems.

### **Pathogenesis of Sjogren's Syndrome**

The pathogenesis of SS involves several different but inter-related processes. Although a detailed discussion is beyond the scope of this article they include:

- a) initial changes in the glandular cells and vasculature that precede lymphocytic infiltration (Tapinos et al 1999);
- b) activation of the HLA-independent (innate) immune system that may respond to apoptotic products including RNA-protein complexes such as the SS-A contained particle (Manganelli et al 2003; Scofield et al 1999; Humphreys-Beher et al 1999; Tsusumi et al 2001)
- c) activation of the HLA-DR dependent (acquired) immune system, with a close correlation of the particular HLA-DR extended haplotype and the pattern of autoantibodies against antigens such as SS-A and SS-B (Bacman et al 1998)
- d) activation of metalloproteinases that degrade matrix of the salivary and lacrimal glands, leading to dysfunction of glandular function (Kontinen et al 1998)
- e) partial destruction of the gland by granzyme/perforin mechanisms (Alpert et al 1994)
- f) dysfunction of the residual gland (that constitutes about 50% of the original number of ducts and acini) due to the inflammatory cytokines (such as IL-1, TNF), autoantibodies (such as antibodies to muscarinic M3 receptor), and interruption of matrix glandular signaling by metalloproteinases. These factors lead to decreased release of neurotransmitters by residual neurons in the gland and decreased response to available neurotransmitter by residual glands (Fox et al 1999; Sternberg et al 2001).

These steps in pathogenesis are shown schematically in Figure 1 and several references to each step are presented in Table 1.

Each of these steps help explain the requirement for both genetic (ie. acquired immune system) and environmental factors (ie. HLA-independent innate immune system) that can lead to glandular dysfunction/destruction and lymphoproliferation. Also, SS provides an interesting example of the interaction of local mucosal inflammation and the central nervous system where sensations such as dryness are sensed. Indeed, the recognition that salivation/lacrimation is the result of a functional circuit has led to new approaches to therapy (Stern et al 1998; Fox et al 2002). For example, patients with Alzheimer's or multiple sclerosis frequently have significant dryness due to alterations in the subcortical white matter that participate in the functional circuit. This has led to the use of medications such as Cevimeline, originally developed as a muscarinic agonist for treatment of Alzheimer's disease, as a therapy for increasing salivation. This is discussed further, below, after outlining some of the histo-immuno-pathologic lessons learned from lacrimal and salivary gland biopsies. However, it is important to recognize that SS provides an opportunity to directly visualize with tissue biopsies an inflammatory site where the immune system influences neural function (Jonsson et al. 2003).

T-lymphocytes infiltrating the salivary glands (SG) exhibit CD4 (+), memory T-cell phenotype and cytokine profile similar to Th-1 cells (Fox et al. 1994; Ohyama et al. 1996). CD4+ T-cells eluted from the SG of SS patients are re-

**Table 1.** Selected References to Proposed Stages of Pathogenesis

Environmental Factors	Robinson et al. 1996
HLA-DR Independent (Innate) Immune System Activation of Vascular and Glandular Cells	Freemont et al. 1983; Edwards et al. 1993
Alteration of Glandular mucosa (chronic wound reaction manifest by cytokines and alteration in cellular structure/function)	Pflugfelder et al. 2000
Alteration of Vascular Endothelium (Chemokines/Receptors/iNOS), And	Fox et al. 1994; Koski et al. 1997; Hulkkonen et al. 2000; Koski et al. 2001
Alteration of Epithelial Cells (HLA-DR and other costimulatory molecules, cytokines, growth factors)	Boumba et al. 1995; Skopouli et al. 1995; Kizu et al. 1996; Tapinos et al. 1999
Focal Infiltration of Gland by Lymphocytes of HLA-dependent (Acquired) Immune System T-cell and B-cell repertoire	Adamson et al. 1983; Fox et al. 1986; Whitcher et al. 1994; Ohyama et al. 1995; Namekawa et al. 1995; Fredriksen et al. 1995; Murata et al. 1995; Ronci et al. 1995; Fox et al. 1998; Gellrich et al. 1999; Esch et al. 2000
Activation of Lymphocytes within the gland leading to: cytokines, autoantibodies, metalloproteinases	Fox et al. 1994; Nelson 1994; De Vita 1996; Kong et al. 1997
Partial Glandular Destruction (Granzyme A) Apoptosis and Impaired secretion due to glandular dysfunction including release/response to neurotransmitters, matrix gland signalling and aquaporin	Alpert et al. 1994; Nelson 1994; De Vita 1996; Matsumura et al. 1996; Kong et al. 1997; Pflugfelder et al. 2000; Ohlson et al. 2001; Bolstad et al. 2003
Chronic inflammatory changes in mucosal surface	Stern et al. 1998; Pflugfelder et al. 1999; Liu et al. 2000; Stern et al. 2002

sistant to apoptosis after stimulation by anti-CD3 or anti-Fas antibody stimulation (Fox 1997). This resistance may result from increased levels of bcl-2 (Kong et al. 1997) or bcl-x (large) (Fox 1998). Bcl-x is a member of the bcl-2 family that contains binding sites for proto-oncogenes that resist apoptosis (Kroemer 1997), while an alternatively spliced form (termed bcl-x short) lacks these binding sites and promotes apoptosis (Boise et al. 1993). The relative ratio of bcl-2 and bcl-x (large) in tissue lymphocytes reflects the contribution of tissue stromal cells in releasing factors such as IL-1 that preferentially upregulate bcl-x (large) (Akbar and Salmon 1997). Other factors important in regulating the levels of bcl-2 and related proteins include the level of intracellular glutathione (Hyde et al. 1997), growth factors and estrogen/androgen (Janz and van der Kraak 1997).

In contrast to the decreased apoptosis of SG T-cells, a significant proportion of acinar and ductal epithelial cells were found to exhibit apoptotic markers (Kong et al. 1997). T-cells may promote the apoptosis of glandular epithelial cells by secretion of TNF- $\alpha$  (Fox et al. 1994) as well as by production of granzyme A (Alpert et al. 1994). Local production of nitrous oxide may also contribute to apoptosis (Konttinen et al. 1996). Also, production of "protective" cytokines such as TGF- $\beta$  may be reduced in the SG of SS patients (Ogawa et al. 1996). This possibility is strengthened by the observation that a TGF- $\alpha$  knockout mouse develops SS-like lesions in its SG (Dang et al. 1995).

In comparison to the decreased "apoptosis" of SG T-cells, peripheral blood T-cells of SS patients have an increased rate of apoptosis in comparison to peripheral blood of normal controls (Ogawa et al. 1996); this rules out a "global" genetic defect leading to deficient apoptosis in all lymphocytes in SS patients, such as noted in the MRL/lpr mouse model of SS (Hayashi et al. 1994). This increased apoptosis of peripheral T-cells and salivary gland epithelial cells in SS patients may lead to increased levels of circulating Fas and Fas ligand in some SS patients (Nozawa et al. 1997) although lower than levels noted in SLE patients (Mountz et al. 1994).

The NOD mouse develops infiltrates of the lacrimal and salivary glands, providing an interesting animal model to look at different components of SS. Genetic studies using NOD mice have indicated that multiple "immune" as well as "non-immune" genes are involved in the pathogenesis of sialadenitis (Humphreys et al. 1996). An important role for "non-immune" genes in the sialadenitis of the NOD mouse is suggested by histologic abnormalities of lacrimal and salivary glands in NOD.SCID mice, a mouse lacking functional T- and B-cells (Robinson et al. 1996). Also of interest, the types of proteins found in the saliva of the NOD.SCID mice differ from proteins in saliva of normal mice; further, the NOD.SCID SG contain increased levels of metalloproteinases and parotid salivary proteins have undergone cleavage into novel products that may contribute to the formation of autoantigens (Robinson et al. 1997). However, the salivary flow rate in NOD mice is significantly diminished only when T-lymphocytes infiltrate the gland (Humphreys 1996). It is possible that cytokines released by these lymphocytes contribute to an early decrease in the neural innervation of the lacrimal gland epithelial (Walcott and Brink 1997) as well as decreased signal transduction in response to neural signals (Hu et al. 1994).

### **Autoantibodies and Autoantigens**

The association of SS with antibodies against the nuclear antigens SS-A and SS-B has always been puzzling, since these antigens are found in all nucleated cells. Thus, SS patients provide an opportunity to study the factors necessary for the failure of "tolerance" to a cellular antigen in a relatively organ specific disease. Antigen presentation to CD4(+) T-cells may occur by

"inflamed" epithelial cells (but not by normal epithelial cells) as a result of upregulation of HLA-DR, HLA-DM and invariant chain molecules (Hershberg et al. 1997). Further, co-stimulatory activities are required for antigen presentation by epithelial cells and can be provided by cell adhesion molecules such as I-CAM (Altmann et al. 1989). Each of these factors necessary for antigen presentation by epithelial cells has been demonstrated in the SS gland (reviewed in Fox 1996).

It has been proposed that SS-A and SS-B antigens may escape the normal "tolerance" processes by serving as cryptic antigens, ie. binding with relatively low affinity to self MHC molecules in the thymus and thus avoiding "negative" selection (Theofilopoulos 1995). SS-A and SS-B antigens are found in the blebs of apoptotic cells and do not undergo proteolysis during apoptosis (Casciola-Rosen et al. 1995; Casiano et al. 1996); this is in contrast to other autoantigens including fodrin (discussed below), poly (ADP-ribose) polymerase (PARP), or topoisomerase. It is possible that increased levels of cell death (either apoptotic or necrotic) or aberrant clearance and processing of antigens derived from dying cells, may lead to the accumulation of potentially immunogenic forms of autoantigens (Casiano and Tan 1996). These could, under the appropriate genetic background, amplify and maintain T-cell dependent responses by an autoimmunization processes. Alternative mechanisms that might expose immunocryptic epitopes in autoantigens include structural alterations caused by abnormal protein-protein interactions during aberrant cell death, mutations, and interactions with toxins, chemical or foreign antigens derived from microorganisms such as viruses.

The SS-A 52 kd antigen has an alternatively spliced form that is expressed on fetal heart from 14 to 18 weeks of development (Buyon et al. 1997) and that has been proposed as target for maternal anti-52 kd antibodies that cross the placenta (Buyon 1996). However, mothers who give birth to babies with heart block exhibit a similar pattern of antibody reactivity to antigenic epitopes on SS-A as SS mothers having normal infants (Buyon et al. 1994; Wagenmann et al. 1996). An altered form of SS-B has also been reported (Bachmann et al. 1997) and antibodies against SS-B (but not SS-A) cross react with laminin (Li and Tseng 1995), leading to proposal that anti-SS B antibody is a cause for congenital heart block (Horsfall et al. 1996). Complete heart block was reported to develop in an adult SS patient and attributed to anti-SS A antibodies (Lee et al. 1996). The elucidation of the initial pathogenetic epitope(s) for these antigens may be difficult to detect due to antigenic spreading from the original T-cell epitope to additional sites (Tseng et al. 1997).

It has been proposed that apoptotic cleavage of certain cellular proteins might reveal cryptic epitopes that can potentially stimulate an immunogenic response (Casciola-Rosen et al. 1995). For example, antibodies against a cleaved (120 kd) form of fodrin have been detected in the sera of patients with Sjogren's syndrome (Haneji et al. 1997). Fodrin (also known as brain spectrin) is a 250 kd membrane skeletal protein found in many tissues that serves to anchor proteins including tubulin, actin, ankyrin, E-cadherins and phospholipids

(Diakowski and Sikorski 1995; Piepenhagen et al. 1995). Fodrin is cleaved into a 150 kd and 120 kd form through apoptotic cleavage by calpains and ICE proteases (Martin et al. 1995; Cyrus et al. 1996) and redistribution in the cytoplasm (Blomgren et al. 1995). Although T-cell clones reactive against 120 kd fodrin were detected in a mouse model of SS (Haneji et al. 1997), it remains unclear if the reactivity to fodrin 120 kd fragment are a primary event in SS pathogenesis or even if antibodies to the fodrin 120 kd protein are specific to SS in comparison to other autoimmune disorders (unpublished observations). Antibodies to fodrin are known to occur at low titer in normals (apparently to promote opsonization and removal of cell debris) (Lutz et al. 1996), and in increased amounts after cellular injury such as stroke and in Alzheimer's disease (Vazquez et al. 1996). IgA antibodies against fodrin may help distinguish SS from multiple sclerosis (De Seze et al. 2003).

### **Environmental Agents**

Evidence to suggest an infectious agent as a co-factor in SS remains intriguing but unproven. Elevated antibody titers in SS patients have been reported for a variety of Epstein-Barr virus (EBV) antigens, including BHRF1 (the viral homologue of bcl-2) and BMRF1 (a EBV DNA binding protein) (Newkirk et al. 1996). EBV genomes in SS SG and lacrimal glands have been detected by *in situ* hybridization (Merne and Syrjanen 1996; Suzuki et al. 1996; Wen et al. 1996), by polymerase chain reaction methods (Saito et al. 1989; Pflugfelder et al. 1996) and by engraftment of SG tissue in SCID mice (Cannon et al. 1990). However, the frequency of EBV infected cells is low (approximately 1 infected cell per  $10^6$  uninfected cells, and some studies failed to detect EBV genomes in SS SG biopsies (Mariette et al. 1996). An endogenous retrovirus (retrovirus 3) has expression in fetal heart from 11 to 16 weeks and could be a possible target for immune reactions leading to congenital heart block (Li et al. 1996). A novel retrovirus (termed retrovirus 5) was originally isolated from a patient with RA plus SS (Griffiths et al. 1997), but subsequent studies have not detected this retrovirus in a significant proportion of SS patients. Past studies that detected antibodies in SS patients to retroviral gag proteins were probably detecting a cross cellular protein (Brookes et al. 1992; De Keyser et al. 1992). SG tissues from Caucasian SS patients were negative for HTLV-1 tax genes by DNA methods (Rigby et al. 1996) and thus negates earlier findings of reactivity of these tissue with a monoclonal anti-HTLV-1 antibody (Shattles et al. 1992). In comparison, genomic sequences homologous to HTLV-1 tax have been found in SS tissues in a subset of Japanese SS patients (Sumida et al. 1994). Although hepatitis C patients are considered as distinct from SS in the San Diego classification, these patients may provide clues to environmental agents responsible for SS since their minor SG biopsies may contain lymphoid infiltrates (Haddad et al. 1992) and animals with a hepatitis C transgene develop sialadenitis (Koike et al. 1997). Although an

initial study suggested an association with Parvovirus B19, a more recent study did not confirm the association (De Stefano et al. 2003)

## Epidemiology and Clinical Spectrum

In 1932, Henrik Sjogren reported the triad of keratoconjunctivitis sicca (KCS), xerostomia and rheumatoid arthritis. The clinical spectrum of SS as a systemic autoimmune disease was further defined by Bloch et al. (1956). In patients with extreme manifestations there is good agreement on diagnosis among clinicians, but the diagnosis in patients with milder sicca symptoms has remained controversial due to the absence of good non-invasive methods for documenting xerostomia. The demonstration of focal lymphocytic infiltrates on minor SG biopsy has remained the "gold" standard for the oral component of SS. A cluster of 50 or more lymphocytes is called a "focus" and an average focus score of 2 or more per 4 mm<sup>2</sup> fulfills the diagnosis of SS in the San Francisco criteria (Daniels et al. 1994). Multiple studies have shown that a positive SG biopsy is closely correlated with KCS and anti-nuclear antibodies directed against SS-A (Ro) and SS-B (La) antigens (Daniels et al. 1994). Another classification system is the San Diego criteria where patients have a) objective KCS and xerostomia; b) a characteristic minor SG biopsy or evidence of a systemic autoimmune disease as manifested by characteristic autoantibodies (Fox and Saito 1994). In comparison, the European (EEC) proposed criteria can be fulfilled without requirement for histologic or serologic abnormality (Vitali et al. 1994). Also, exclusions to diagnosis of SS differ in the San Diego and EEC criteria. For example, patients with sicca symptoms associated with hepatitis C infection (Haddad et al. 1992) are excluded from diagnosis as SS in the San Diego criteria (Fox 1994) but included in the EEC criteria where up to 20% of SS patients may have hepatitis C (Jorgensen et al. 1996). Comparison of SS patients fulfilling different criteria systems indicates that only about 15% of the patients fulfilling the EEC criteria would be diagnosed as SS using the San Diego criteria (Vitali et al. 1994). Therefore, it is difficult to compare studies published from Europe (where EEC criteria are frequently used) to studies published in US where other diagnostic criteria are often used. Also, basic research on pathogenetic mechanisms of SS relies on samples which clinicians provide to researchers. Thus, attempts to find better animal models or to test a particular molecular hypothesis for SS are difficult when there is no "gold" standard for clinical definition of the disease. Fortunately, a recent abstract from the EEC study group has suggested modification of the European criteria to require either a positive minor salivary gland biopsy (focus score 1 or greater) or positive antibody against SS-A antigen (Vitali et al. 1994). This revision of the EEC criteria will lead to much closer agreement between the San Diego and EEC criteria and has served as the basis for a new international criteria. Although this criteria is still in the



final stages of preparation for a collaborative study for validation, the final version will be similar to those presented in *Table 2*.

Primary Sjogren syndrome (SS) is very rare in childhood (Cimaz et al 2003; Nikitakis et al 2003). Cimaz et al recently collected a series of 40 primary pediatric SS cases (onset before age 16 years) from different centers. Almost all patients (35/40) were females, age at onset varied from 9.3 to 12.4 years (mean 10.7 years). Signs and symptoms at disease onset were mainly recurrent parotid swelling followed by sicca symptoms. Abnormal laboratory tests were found in the majority of cases. Regarding treatment, 22 patients were treated at some time with oral corticosteroids, seven with non-steroidal anti-inflammatory drugs, and five with hydroxychloroquine; two patients needed cyclosporine and one cyclophosphamide. Follow-up varied from 0 to 7.5 years from onset, without major complications in the majority of patients.

### **Ocular and Oral Mucosal Surface Abnormalities in SS**

The tear "film" is a hydrated "gel" containing water, proteins, growth factors, and mucins (mucopolysaccharides and mucoproteins). The mucins play a key role in maintaining the stability of the hydrated gel and "mechanical" functions such as allowing the upper lid to slide over the ocular surface. Therefore, it is not surprising that symptoms of discomfort are closely correlated with deficient mucin production (Pflugfelder et al. 1997; Saari et al. 1997). Ocular mucins include a transmembrane mucin (Inatomi et al. 1995) and mucins secreted by goblet cells, conjunctival (Inatomi et al. 1996) and corneal (Watanabe et al. 1995) epithelial cells that form the hydrated gel of tears (Hicks et al. 1995). Mucins play an important role in the oral cavity, where they provide "viscosity" to the hydrated gel that allows the tongue to slide past the teeth and elasticity to the mucosal tissues necessary for chewing and deglutition. At least 9 different mucins have been identified and the proportion of different types of mucin in the eye differs from that in the mouth, trachea and stomach (Slomiany et al. 1996). Abnormalities in mucin production may occur in SS patients as a result of the chronic inflammation of ocular surface in SS patients (Stern et al. 1998). Decreased mucin production is frequent in the elderly and contributes to sicca symptoms in the absence of a systemic autoimmune disease (Vissink et al. 1996).

Symptoms of dry eyes may also result from increased "evaporative" loss associated with Meibomian gland dysfunction (Lemp 1987). A common problem in differential diagnosis of SS patients is blepharitis (often associated with overuse of ocular lubricants by the patient) or with rosacea. Less commonly, processes such as pemphigoid may present with increased aqueous tear deficiency due to disruption of lipid or mucin production.

A common misconception about SS is that sicca symptoms result from the total immune destruction of the lacrimal or salivary gland. A minor SG biopsy from a SS patient is shown in *Fig. 1A*, which shows lymphocytic infiltrates in

**Table 2.** Extraglandular Manifestations of Sjogrens

Dermatologic	Raynaud's phenomena Leukocytoclastic vasculitis (palpable purpura) Urticarial vasculitis Subacute lupus Hyperglobulinemic purpura (nonpalpable purpura) Cryoglobulinemia Annular erythema Medication related rashes
Cardiovascular	Pericarditis and cardiomyopathy Accelerated rates of atherosclerotic disease Thrombotic complications due to circulating procoagulants such as anti-cardiolipin antibodies and hyperhomocysteinemia Autonomic cardiovascular neuropathy
Pulmonary	Pleural effusions Pulmonary Hypertension Interstitial pneumonitis
Gastrointestinal	Dysphagia, esophageal motility, gastroesophageal reflux Hepatitis and biliary cirrhosis Jejunitis due to microvasculitis Collagenous colitis
Otolaryngology	Hearing Sinusitis Laryngeal Tracheal reflux
Renal	Interstitial and mesangial nephritis including renal tubular acidosis, urolithiasis and hypokalemia periodic paralysis Glomerulonephritis including amyloidosis and mixed cryoglobulinemia Hypertension related to renovascular occlusion
Peripheral Neurologic	Peripheral neuropathy sensory and gangliopathy Peripheral motor Peripheral ataxic disorders Mononeuritis multiplex
Central Nervous System	Multiple sclerosis like manifestations Stroke-thrombotic and vasculitic Ischemic Optic and Choroid Neuropathy Autonomic neuropathy including Adie's pupil Trigeminal neuropathy Ataxia Neuropsychiatric Chronic fatigue and cognitive function
Hematologic and Neoplastic	Neutropenia Hemolytic anemia, Cryoglobulinemia Thrombocytopenia Anti-phospholipid syndrome Lymphadenopathy and pseudolymphoma Lymphoma

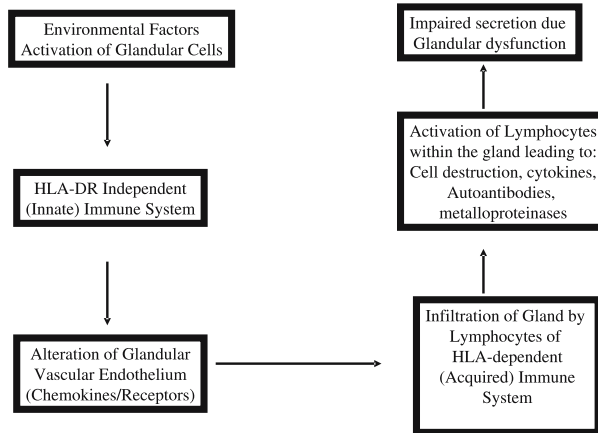
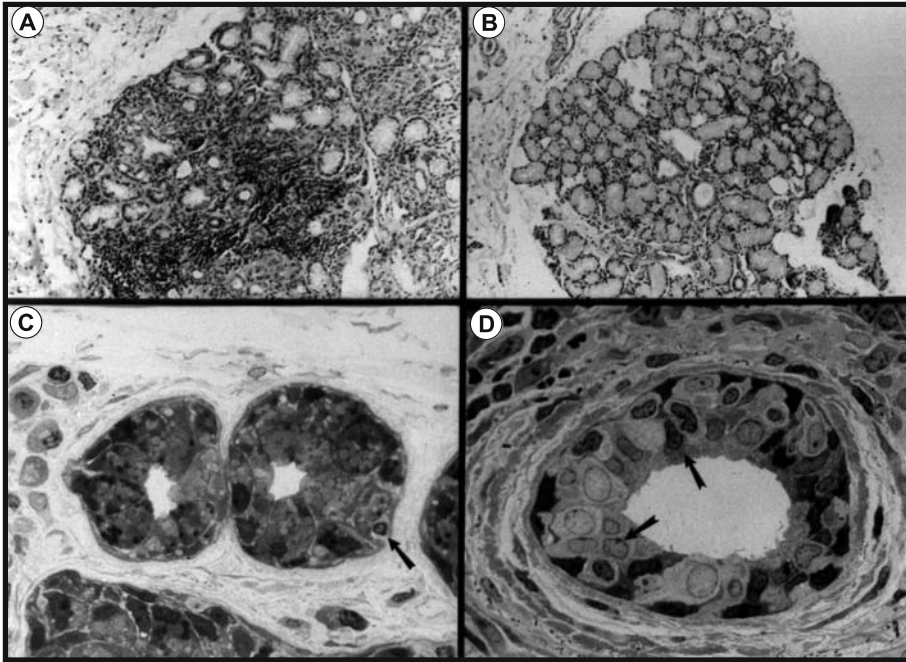


Fig. 1

the central region of the lobule; in comparison, a histologically normal minor SG biopsy is shown in *Fig. 1B*. Around the periphery of the lobule in *Fig. 1A*, acinar and ductal cells are still present even though this patient has had symptoms of severe sicca syndrome for over 10 years. This retention of almost half of the glandular epithelial cells in SS contrasts with other organ specific autoimmune disorders such as type I diabetes mellitus, where destruction of insulin producing epithelial cells occurs before clinical symptoms are apparent. Morphometric analysis of SS biopsies shows that almost half of the acinar cells remain histologically intact in patients with longstanding sicca symptoms (Andoh et al. 1993). The failure of residual acini in SS glands to function adequately may result partly from the loss of neural innervation, as indicated by decreased neural axon specific protein 9.5 and synaptophysin by immunohistologic methods (Konttinen et al. 1992). Acetylcholine is required for acinar secretion and VIP for glandular homeostasis (Ekstrom et al. 1989). The release of cytokines (particularly TNF- $\alpha$  and IL-1) may be toxic to local nerves or acini (Main et al. 1993; Lu et al. 1997). Cytokines IL-1 or TNF- $\alpha$  amounts similar to the levels found in SS glands or saliva are "toxic" to nerve cells grown in vitro (Soliven and Wang 1995) or in mice expressing these transgenes (Campbell 1995).

Normal lacrimal and salivary flow is regulated through feedback mechanisms shown schematically in *Fig. 2A*. The mucosal surfaces of the eye or mouth are heavily innervated by unmyelinated fibers that carry afferent signals to the lacrimatory or salivatory nuclei located in the medulla. These medullary nuclei, which are part of the autonomic nervous system, are influenced by higher cortical inputs including taste, smell, anxiety, and depression. The efferent neurons innervate both glandular cells and local blood vessels. The blood vessels provide not only water for tears and saliva, but also growth factors including hormones (eg. insulin) and matrix proteins (eg. fibronectin and



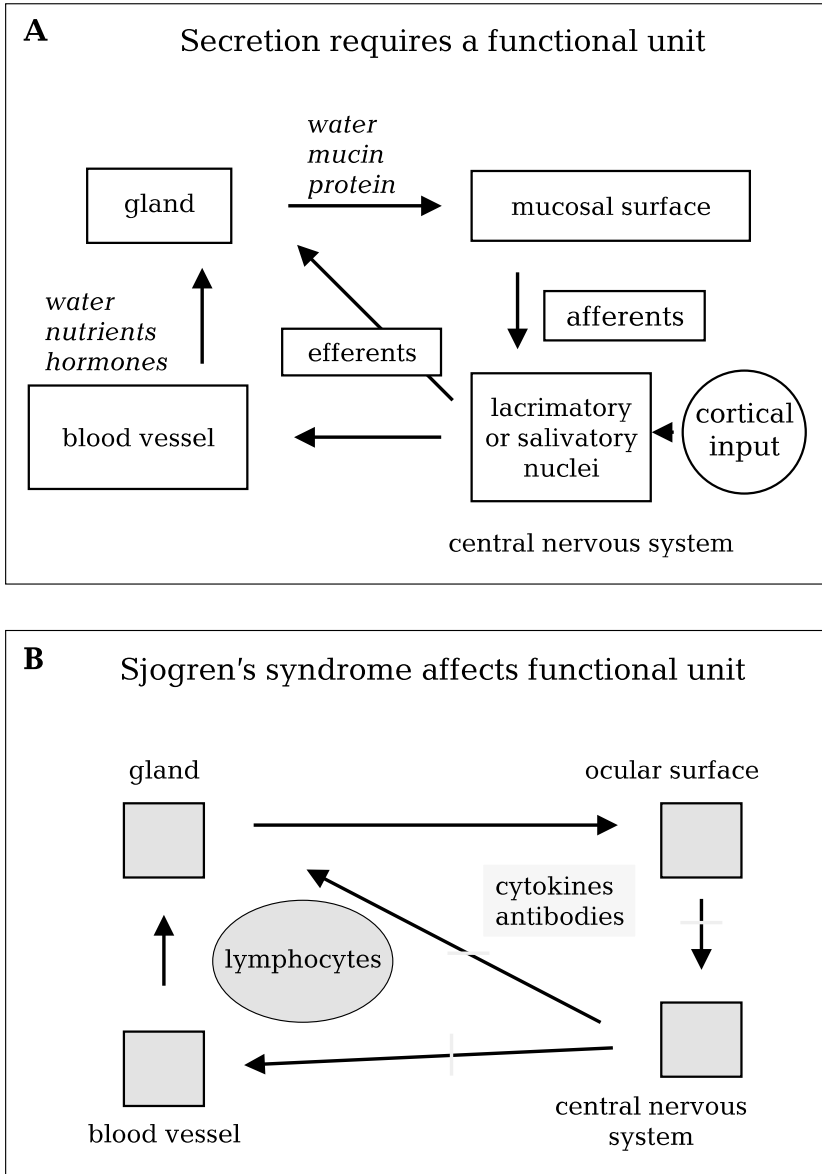
**Fig. 2.** Minor salivary gland biopsy from patients with Sjogren's syndrome (**A**) and (**B**) from a patient with fibromyalgia (a histologically normal biopsy). Higher power views of the Sjogren's biopsy are shown in **C** and **D**

vitronectin) in the perivascular space of the lacrimal and salivary glands. In response to neural stimulation through muscarinic M3 receptors and vasoactive intestinal peptide (VIP) receptors, glandular acinar and ductal cells secrete water, proteins, and mucopolysaccharides (mucins). This complex mixture forms a hydrated gel which lubricates the ocular surface (ie. tears) and the oral mucosa (ie. saliva).

In the simplest model of SS (*Fig. 2B*), the lacrimal or salivary gland is incapable of adequate response to neural signals as a consequence of local immune infiltrates and their derived cytokines. The actual processes in SS or autonomic neuropathy are more complicated than indicated in these schematic diagrams which are primarily designed to emphasize that salivation or lacrimation are part of a regulatory circuit involving the central nervous system (Stern et al. 1998).

### Cutaneous Manifestations of Sjogren's Syndrome

The overall approach to vasculitis and SS is similar to that in SLE. Rashes are generally divided into symmetric and asymmetric, grouped and discrete, photo-



**Fig. 3. A.** "Circuit" that controls normal tear flow or salivation and interruption of the circuit in patients with Sjogren's syndrome. The stimulation of the ocular or oral mucosal surface leads to afferent nerve signals that reach the lacrimal or salivatory nuclei in the medulla. Efferent neural signals stimulate both blood vessels and glandular epithelial cells. The medullary signal may be affected by cortical inputs that reflect stimuli such as taste, smell, anxiety, or depression. The efferent neural signal to the gland is mediated by acetylcholine. The gland contains receptors for acetylcholine of the muscarinic class, particularly M3 receptors (shown by arrow). **B.** In Sjogren's syndrome, lymphocytes infiltrate the gland and secrete cytokines that inhibit the release of neurotransmitters and the response of receptors that initiate glandular secretion

**Table 3.** Extraglandular Manifestations in Patients with Sjogren's Syndrome

Respiratory	Chronic bronchitis secondary to dryness of upper and lower airway with mucus plugging Lymphocytic interstitial pneumonitis Pseudolymphoma with nodular infiltrates Lymphoma Pleural effusions Pulmonary hypertension
Gastrointestinal	Dysphagia associated with xerostomia Atrophic gastritis Liver disease including biliary cirrhosis and sclerosing cholangitis
Skin and mucous membranes	Candida-oral and vaginal Vaginal dryness Hyperglobulinemic purpura Raynaud's phenomenon Vasculitis
Endocrine, neurologic, and muscular	Thyroiditis Peripheral neuropathy involvement of hands and/or feet Mononeuritis multiplex Myositis
Hematologic	Neutropenia, anemia, thrombocytopenia Pseudolymphoma Lymphadenopathy Lymphoma and myeloma
Renal	Tubular-interstitial nephritis (TIN) Glomerulonephritis, in absence of antibodies to DNA Mixed cryoglobulinemia Amyloidosis Obstructive nephropathy due to enlarged periaortic lymph nodes Lymphoma Renal artery vasculitis

exposed or non-exposed, macular, papular and vesicular. Other rashes may be associated with venous or arterial thrombosis. Rashes may be associated with visceral organ involvement, intercurrent infections or may be secondary to drug toxicity. These distinctions may require skin biopsy and immunofluorescence for differential diagnosis.

Hypergammaglobulemic purpura is relatively common in SS patients and may lead to sensory peripheral neuropathy (Gemignani et al. 1994; Hebbar et al. 1995; Cho et al. 1997). In comparison, among a large cohort of patients with hyperglobulinemic purpura, about 50% have SS (Kyle et al. 1971). The skin lesions are non-palpable and often associated with rheumatoid factor (esp. IgM- kappa monoclonal rheumatoid factor) containing VKIIIb subclass of light chains (Fox et al. 1986). The skin biopsies generally show ruptured blood vessels and deposition of complement. It has been assumed that immune

complexes become trapped at the bifurcation of small blood vessels, leading to complement activation by the immune complex. We have used hydroxychloroquine (5–7 mg/kg) in order to help decrease the hyperglobulinemia and the subsequent development of neuropathy (Fox et al. 1988).

Palpable purpura is also found in SS patients (Alexander and Provost 1983) with biopsies showing leukocytoclastic vasculitis (Ramos-Casals et al. 1998) and may be associated with central nervous system involvement (Alexander and Provost 1987; Provost et al. 1997) or pulmonary involvement (Konishi et al. 1997). The treatment of these patients needs to be more aggressive and may require higher dose corticosteroids or even cyclophosphamide. Mixed cryoglobulinemia also may be associated with leukocytoclastic vasculitis (Ferri et al. 1998) and should initiate a search for occult hepatitis C infection.

Patients with anti-neutrophil cytoplasmic antibodies (ANCA) are relatively uncommon in primary SS and when present are usually p-ANCA (perinuclear) antibodies. Caution must be used in interpreting the ANCA in SS patients since false positive results may result from the presence of other antinuclear antibodies (Merkel et al. 1997). Antibodies against endothelial cells have been found in a subset of SS patients, but are also detected in many other autoimmune disorders and are not closely associated with skin vasculitis (Navarro et al. 1997). Anticardiolipin antibodies are found in a subset of SS patients and are generally IgA isotype, with lower incidence of thrombosis than found in SLE patients (Asherson et al. 1992).

Additional cutaneous features include subcutaneous amyloid (Pablos et al. 1993) and anetoderma (Ricci et al. 1998). The presence of anetoderma has also been associated with B-cell lymphomas (Jubert et al. 1993). Among Japanese SS patients, annular erythema has been reported in a relatively high proportion of patients (Ruzicka et al. 1991; Watanabe et al. 1997), including those with childhood onset (Miyagawa et al. 1995). Urticarial vasculitis has been reported in association with SS (O'Donnell and Black 1995). Dryness of the skin in some patients has been associated with lymphocytic infiltrates in the eccrine glands (Sais et al. 1998).

Neonatal lupus may be found in the children of mothers with SS, SLE, and in a proportion of mothers bearing antibodies against SS-A and SS-B antigens but lacking clinical SS (Buyon et al. 1996).

In a recent study, Ramos-Casals and co-workers (Ramos-Casals, 2004) analyzed the different clinical and histologic types of cutaneous vasculitis in 558 consecutive patients with primary SS. All patients fulfilled 4 or more of the diagnostic criteria for SS proposed by the European Community Study Group in 1993. A total of 89 (16%) patients presented with cutaneous involvement (88 female patients and 1 male; mean age, 51.8 yr). The main cutaneous involvement was cutaneous vasculitis, present in 52 (58%) patients. There were 51 (98%) female patients and 1 (2%) male, with a mean age at diagnosis of cutaneous vasculitis of 51 years (range, 20–80 yr). Fourteen presented with cryoglobulinemic vasculitis, 11 with urticarial vasculitis, and the remaining 26, with cutaneous purpura not associated with cryoglobulins. A skin

biopsy specimen was obtained in 38 patients (73%). Involvement of small-sized vessels was observed in 36 (95%) patients (leukocytoclastic vasculitis), while the remaining 2 (5%) presented with medium-sized vessel vasculitis (necrotizing vasculitis). Patients with cutaneous vasculitis had a higher prevalence of articular involvement (50% vs 29), peripheral neuropathy (31% vs 4), Raynaud phenomenon (40% vs 15%), renal involvement (10% vs 0%), antinuclear antibodies (88% vs 60%), rheumatoid factor (78% vs 48%), anti-Ro/SS-A antibodies (70% vs 43%), and hospitalization (25% vs 4%) compared with SS patients without vasculitis. Six (12%) patients died, all of whom had multisystemic cryoglobulinemia. In conclusion, cutaneous involvement was detected in 16% of patients with primary SS, with cutaneous vasculitis being the most frequent process. The main characteristics of SS-associated cutaneous vasculitis were the overwhelming predominance of small versus medium vessel vasculitis and leukocytoclastic versus mononuclear vasculitis, with a higher prevalence of extraglandular and immunologic SS features. Small vessel vasculitis manifested as palpable purpura, urticarial lesions, or erythematous maculopapules, with systemic involvement in 44% of patients in association with cryoglobulins in 30%. Life-threatening vasculitis was closely related to cryoglobulinemia.

### **Extraglandular Organ Involvement**

Patients with SS develop extraglandular symptoms similar to those in patients with other rheumatic diseases, particularly SLE. They frequently develop arthralgias and myalgias (painful joints and muscles) that may become frank arthritis or myositis (objective signs of inflammation). In general, the arthritis is nonerosive (similar to patients with SLE) but may develop ulnar deviation. Also, there appears to be a higher incidence and earlier age of onset of aggressive (also known as "erosive") osteoarthritis involving hands and feet.

Internal organ involvement may include lung (pneumonitis), liver (association with primary biliary cirrhosis and sclerosing cholangiitis), nervous system (both peripheral and central), and kidney (interstitial nephritis and, less frequently, glomerulonephritis). Biopsies general show small perivascular lymphocytic infiltrates although non-caseating granulomas (sarcoid like) are occasionally found. The vasculitis tends to be small vessel, in contrast to the large vessel involvement found in Wegener's granulomatosis and polyarteritis. Hyperglobulinemic purpura involving the lower extremities appears to reflect the deposition of immune complexes and complement activation, rather than a classic leukocytoclastic vasculitis.

Hematopoietic manifestations frequently include leukopenia, thrombocytopenia and anemia. The leukopenia is not generally clinically significant but absolute neutrophil counts of less than 500 may predispose to infections. Of particular concern is the increased frequency of non-Hodgkin's lymphoma



(about 40 fold in patients with SS; Kassan et al. 1978). There is a particular increase in the frequency of lymphoma involving the lymph nodes of the neck. In patients with persistent swelling of the parotid or submandibular glands, imaging studies to look for associated adenopathy should be performed. Biopsy or excision of the parotid gland may be complicated by surgical damage to the facial nerve and thus caution in this surgery is indicated. However, the finding of persistent regional lymph adenopathy should lead to consideration of biopsy for lymphoma. There is great debate about the interpretation of parotid biopsies in terms of whether the infiltrates are lymphoma or part of the autoimmune process. The detection of t(14:18) translocations (Pisa et al. 1991) or p53 mutations (Tapinos et al. 1999) may be associated with the lymphoma.

The term pseudolymphoma has been used to describe a patient who has clinical features of lymphoma (night sweats, lymphadenopathy) but does not show frank lymphoma on biopsy. The lymphocytic infiltrates in most SS biopsies are predominantly T-cell, while the lymphomas are generally B-cell (Fox et al. 1983). However, small immunoglobulin gene rearrangements are frequently present in "benign" biopsies such as lymphoepithelial infiltrates (Fishleder et al. 1987; Freimark and Fox 1987).

A common symptom of SS is fatigue. The fatigue can be debilitating and often is not taken seriously by the patient's family or her physician. It is important to determine if the fatigue results from an inflammatory process, a hormonal imbalance, or from non-immune, non-hormonal problems. The fatigue may be related to active immune disease and is generally attributed to the central nervous action of cytokines such as IL-1 or TNF; thus, measurement of acute-phase reactants such as erythrocyte sedimentation rate or C-reactive protein made in response to these cytokines should suggest this cause. However, in other patients the fatigue may reflect an imbalance in the hypothalamic-pituitary-adrenal axis (Johnson et al. 2000). Also, patients with SS have a higher frequency of hypothyroidism as a hormonal cause (Perez et al. 1995).

Gynecologic problems include dyspareunia – difficult or painful intercourse. This problem is a relatively common complaint that is often not expressed to the physician because the woman is embarrassed. However, dyspareunia may be diminished with topical lubricants and topical estrogen (in the older patient). Because women are so often reluctant to bring up this subject, it is vital that the physician initiates this discussion.

In pregnant patients, a higher frequency of the fetal complication of congenital heart block has been noted. This may be due to antibodies against SS-A, since a novel spliced form of SS-A is expressed by the fetal heart from 8 to 12 weeks of gestation. Other autoantibodies have also been suggested as causative in fetal complications or the development of rash neonatal SLE in the newborn infant. In some patients, recurrent miscarriages or vascular thrombosis is associated with anti-cardiolipin antibodies, a false-positive RPR, lupus anticoagulants, or antibody to beta-2 glycoprotein I.

In addition to sensory peripheral neuropathy, SS patients may develop mononeuritis multiplex (Grant et al. 1997). Central nervous system involvement may include the spectrum of disorders found in SLE patients, ranging from vasculitis (Alexander et al. 1988) to neuropsychiatric manifestations (Spezialetti et al. 1993). The incidence of CNS lesions in SS patients has remained controversial, with the incidence at our center being similar to that found in SLE patients (Fox 1995). There has been controversy about the frequency of autonomic neuropathy in SS, but one recent study (Niemela 2003).

Other sites that may be involved with vasculitis include bladder (interstitial cystitis) which may be associated with an autoantibody against a novel 70 kd protein (Ochs et al. 1996). Abdominal and mesenteric vasculitis may occur, most commonly in patients with mixed cryoglobulemia (Singer et al. 1986; Mody and Cassim 1998). Nephritis is generally interstitial but glomerulonephritis may occur in primary SS patients (Fox and Wilson 1993); however, the occurrence of glomerulonephritis should stimulate a search for amyloid or SLE (Fox and Wilson 1993).

### Differential Diagnosis of Sjogren's Syndrome

The rheumatologist is often faced with the diagnostic difficulty of distinguishing primary 1° SS from 2° SS associated with SLE. These patients frequently share similar symptoms (arthralgias, myalgias, fatigue, rashes, and visceral involvement due to vasculitis) as well as laboratory tests including positive ANA and antibody to SS-A (Ro) (Smolen et al. 1997). Indeed, it has been argued that SLE represents a spectrum of patients where subsets are "artificially" subdivided on the basis of their serology and the serology (ie. antibody against SS-A, etc) correlates better with their genotype than with their clinical features (Harley et al. 1989; Arnett 1994). If one accepts the premise that patients with SLE constitute a heterogeneous group of patients in terms of pattern of organ involvement and anti-nuclear antibodies (Harley et al. 1989), then it reasonably can be argued that primary SS patients represent a *forme fruste* of SLE where patients have only 4 of the necessary 5 criteria for diagnosis of SLE (Fox 1994). The group of patients with 1° SS is genetically heterogeneous even among patients who have similar ethnic background. However, a significant proportion of Caucasian 1° SS patients have similar HLA associations (HLA- DR3 and particular DQ alleles) that are found in a subset of SLE patients (Guggenbuhl et al. 1998; Jean et al. 1998). Further, our experience with multiplex families (ie. one member with 1° SS and another member with autoimmune disease such as RA, SLE or scleroderma) in China (Kang et al. 1991) and in another study of a multiplex Caucasian family (Reveille et al. 1984), family members (siblings, mothers, daughters) of 1° SS patients had an almost equal frequency of 1° SS or SLE. Similarly, in a large multiplex family with multiple cases of SLE, family members with SS were noted (Sestak et al. 1999). Thus, it might be postulated that certain genetic factors

predispose to either 1° SS or a subset of SLE, while other environmental (or gene recombination events) then propel the genetically susceptible patient down the clinical pathway of either 1° SS or SLE. In this regard, the close overlap of clinical symptoms of 1° SS and a subset of SLE would be expected. I would propose that SS develops in those patients with a more lymphocyte aggressive disease, as manifest by the infiltration of lymphocytes (predominantly CD4+ T cells) into tissues normally lacking lymphoid infiltrates (ie. lacrimal and salivary glands, as well as lung or renal parenchyma). An extension of this hypothesis is the increased frequency of lymphoma in SS patients (Kassan et al. 1978). In comparison, many of the manifestations of SLE patients appear to result from pathogenic antibodies that lead to immune complex disease or specific antibodies against platelets or glomerular antigens. Although there is clearly a great deal of overlap in 1° SS and SLE in this regard, this is a relatively simple model for prognostically evaluating patients symptoms (ie. interstitial pneumonitis, interstitial nephritis or increased lymphoma) with features of SS or SLE.

At present, the label "Sjogren's syndrome" alerts the rheumatologist to the particular ocular and oral needs of the patient with sicca symptoms as well as to their particular problems of lymphoproliferative disorders. Thus, it is important for rheumatologists not to get bogged down in currently fashionable debates over classification criteria. The key point is that diseases are best classified by etiology and that the etiology of SLE and SS remains unknown; thus, we are left with classifying clusters of symptoms/signs and the key point is how to determine prognosis and treatment.

The pattern of rashes in 1° SS patients differs somewhat from those in most SLE patients. Malar rashes are more common in SLE, due to the presence of malar rash as serving as criteria for SLE. However, the malar rash of SLE must be distinguished from rosacea which can contribute to blepharitis and ocular symptoms mimicking 1° SS (Katayama et al. 1994). Patients with 1° SS have a relatively higher incidence of hyperglobulinemic purpura based on retrospective studies (Kyle et al. 1971); and the purpura may be associated with a type II mixed cryoglobulin (Ferri et al. 1998) containing a monoclonal rheumatoid factor with a particular idiotype (Fox et al. 1986). In Japanese patients, particular types of rashes such as erythema annulare (particularly with location on the face) are more common in SS than SLE patients (Ruzicka et al. 1991; Watanabe et al. 1997). In the past, a psoriaform skin rash was termed "subacute" lupus when associated with a negative ANA (done using mouse kidney substrate) and a positive anti-SS A antibody (Bangert et al. 1984). These patients had a high frequency of SS like symptoms. In recent years, a different substrate for detection of ANA's (Hep 2 cells) has been used and patients with "subacute lupus" now are shown to have a positive ANA (McCauliffe et al. 1996) and are frequently diagnosed as SS (Harper et al. 1982; Bielsa et al. 1994; Provost et al. 1997). A wide range of additional skin lesions are found in both SLE and SS, ranging from leukocytoclastic vasculitis to the purpura associated with low platelets (Magro et al. 1999).

**Table 4.** Therapeutic Principles

- 
1. Therapy includes topical replacement of lubrication (artificial tears and saliva), as well as preservation of tears by punctal occlusion.
  2. Local inflammation of the ocular surface may be treated by use of anti-inflammatory substances such as topical cyclosporin.
  3. The normal tear film or saliva lubricants contain mucins as well as saliva. Although current therapies can replace aqueous secretions, they are still deficient in replacement of the mucin components.
  4. New oral medications help stimulate muscarinic M3 secretion to lead to increased water content of secretions.
  5. The overall treatment program for SS is similar to SLE with the use of corticosteroids (that can be used for short intervals), nonsteroidal agents, slow acting anti-rheumatic drugs (hydroxychloroquine, methotrexate, and perhaps newer agents such as leflunomide or TNF inhibitors) for chronic management of extraglandular manifestations, and cytotoxic agents (i.e. cyclophosphamide) for life threatening vasculitis.
- 

Mouth (intraoral) lesions occur in both SS and SLE. However, the characteristic SLE lesion is an oral ulcer. The most common mouth lesion in SS patients is due to oral candida (Daniels and Fox 1992a). These lesions are recognized by the presence of angular cheilitis and erythematous patches (often resembling telangiectasias) on the hard palate (Daniels and Fox 1992b). The use of corticosteroids and antibiotics predisposes to oral candida in patients with decreased salivary flow. Also, oral lesions in patients on methotrexate may not be due to drug allergy but to oral candida.

### Therapy of Sjogren's Syndrome

The mainstay of treatment of dry eyes remains the use of artificial tears. In some patients, punctal occlusion may provide a longer retention time for instilled tears (Friedlaender and Fox 1998). In some patients, preservatives in commercial tears may contribute to the topical irritation although this is less common than in past years due to the new generation of "preservatives" and "preservative free" artificial tears now available (Whitcher et al. 1998). Recent studies have suggested a role for topical cyclosporin A eye drops (Sall et al. 2000) and topical androgen eye drops are being evaluated (Sullivan et al. 1999).

For dry mouth, special toothpastes that lack detergents (foaming agents) in regular toothpastes may be better tolerated. Also, artificial salivas are available that are useful to help in swallowing, talking and to prevent having to get up at night to get water (and the resulting nocturia). Topical fluoride (often applied at night) by trays may help retard progressive cariogenic disease (Daniels and Fox 1992b). Muscarinic agonists such as pilocarpine (Vivino et al. 1999)

and cevimeline (Fox 2000) have recently been approved for the treatment of symptoms of dry mouth.

The treatment of extra-glandular symptoms of SS remains similar to treatment of SLE. Symptoms of arthralgia may respond to nonsteroidal anti-inflammatory agents or antimalarials (Fox et al. 1996). Recent studies have suggested that tetracyclines may be effective in RA (Breedveld 1997) and in animal models of dental disease (Flemmig et al. 1996), perhaps due to their ability to inhibit metalloproteinases (Greenwalt 1994). In SS patients resistant to nonsteroidal anti-inflammatory agents, low dose methotrexate appears useful to control arthralgia and myalgia; no increase in lacrimal or salivary gland flow was detected in the methotrexate treated patients (Skopouli et al. 1996). Oral cyclosporin A has been effective in SLE (Manger et al. 1996; Yocum 1996) and animal models of SS (Jabs et al. 1996); however, controlled trials of cyclosporin A, FK-506, or rapamycin have not been performed in SS due to concerns about higher risks of renal toxicity (ie. increased pre-existent interstitial nephritis) and tendency towards lymphoma (Ferraccioli et al. 1996). The recent success with "biologic" agents (ie. anti-TNF antibody and TNF receptors) in RA and i.v. gammaglobulin in various autoimmune diseases initially suggested a potential role for these agents. However, now controlled multicenter trials have not demonstrated benefit from infliximab or etanercept (Mariette et al. 2003)

## References

- Adamson TC, III, RI Fox, DM Frisman, and FV Howell. 1983. Immunohistologic analysis of lymphoid infiltrates in primary Sjögren's syndrome using monoclonal antibodies. *J Immunol* 130: 203
- Akbar AN, Salmon M (1997) Cellular environments and apoptosis: tissue microenvironments control activated T-cell death. *Immunol Today* 18: 72-76
- Alexander EL, Provost TT (1983) Cutaneous manifestations of primary Sjögren's syndrome: a reflection of vasculitis and association with anti-Ro (SSA) antibodies. *J Invest Dermatol* 80: 386-391
- Alexander E, Provost TT (1987) Sjögren's syndrome. Association of cutaneous vasculitis with central nervous system disease. *Arch Dermatol* 123: 801-810
- Alexander EL, Beall SS, Gordon B, Selnes LA, Yannakakis GD, Patronas N, Provost TT, McFarland HF (1988) Magnetic resonance imaging of cerebral lesions in patients with the Sjögren's syndrome. *Annals of Internal Medicine* 108: 815-823
- Alpert S, Kang HI, Weissman I, Fox RI (1994) Expression of granzyme A in salivary gland biopsies from patients with primary Sjogren's syndrome. *Arthritis Rheum* 37: 1046-1054
- Altmann D, Hogg J, Trowsdale J, Wilkinson D (1989) Cotransfection of ICAM-1 and HLA-DR reconstitutes human antigen-presenting cell function in mouse L cells. *Nature* 338: 512-514
- Andoh Y, Shimura S, Sawai T, Sasaki H, Takishima T, Shirato K (1993) Morphometric analysis of secretory glands in Sjögren's syndrome. *Am Rev Respir Dis* 148: 1358-1362
- Arnett F (1994) Histocompatibility typing in the rheumatic diseases: diagnostic and prognostic implications. *Med Clin NA* 20: 371-387
- Asherson RA, Fei HM, Staub HL, Khamashta MA, Hughes GRV, Fox RI (1992) Antiphospholipid antibodies and HLA associations in primary Sjögren's syndrome. *Ann Rheum Dis* 51: 495-498

- Bachmann M, Grolz D, Bartsch H, Klein R, Troster H (1997) Analysis of expression of an alternative SS-B cDNA and localization of the encoded N and C terminal peptides. *Bioch Bioph Acta* 135: 53–63
- Bacman SR, A Berra, L Sterin-Borda, and ES Borda. 1998. Human primary Sjogren's syndrome autoantibodies as mediators of nitric oxide release coupled to lacrimal gland muscarinic acetylcholine receptors. *Curr Eye Res* 17: 1135
- Bangert JL, Freeman RG, Sontheimer RD, Gilliam JN (1984) Subacute cutaneous lupus erythematosus and discoid lupus erythematosus. Comparative histopathologic findings. *Arch Dermatol* 120: 332–337
- Bielsa I, Herrero C, Collado A, Cobos A, Palou J, Mascaro JM (1994) Histopathologic findings in cutaneous lupus erythematosus. *Arch Dermatol* 130: 54–58
- Bloch KJ, Buchanan WW, Wohl MJ, Bunim JJ (1956) Sjögren's syndrome: A clinical, pathological and serological study of 62 cases. *Medicine (Baltimore)* 44: 187–231
- Blomgren K, Kawashima S, Saido TC, Karlsson JO, Elmered A, Hagberg H (1995) Fodrin degradation and subcellular distribution of calpains after neonatal rat cerebral hypoxic-ischemia. *Brain Res* 684: 143–149
- Boise L, Gonzalez M, Postema C, Ding L, Lindsten T, Rurka L, Mao X, Nunez G, Thompson C (1993) bcl-x, a bcl-2 related gene that functions as a dominant regulator of apoptotic cell death. *Cell* 74: 599–608
- Bolstad AI, HG Eiken, B Rosenlund, ME Alarcon-Riquelme, and R Jonsson. 2003. Fas ligand, cytotoxic T lymphocyte-associated antigen 4, and programmed cell death 1 in primary Sjogren's syndrome. *Arthritis Rheum* 48: 174
- Boumba D, F Skopouli, and H Moutsopoulos. 1995. Cytokine mRNA expression in the labial salivary gland tissues from patients with primary Sjogren's syndrome. *Brit J Rheum* 34: 326
- Breedveld FC (1997) Minocycline in rheumatoid arthritis [editorial; comment]. *Arthritis Rheum* 40: 794–796
- Brookes SM, Pandolfino YA, Mitchell TJ, Venables PJ, Maini R (1992) The immune response to and expression of cross-reactive retroviral gag sequences in autoimmune disease. *Br J Rheumatol* 31: 735–742
- Buyon JP, Slade SG, Reveille JD, Hamel JC, Chan EK (1994) Autoantibody responses to the "native" 52-kDa SS-A/Ro protein in neonatal lupus syndromes, systemic lupus erythematosus, and Sjogren's syndrome. *J Immunol* 152: 3675–3684
- Buyon JP (1996) Neonatal lupus. *Curr Opin Rheumatol* 8: 485–490
- Buyon JP, Tseng CE, Di Donato F, Rashbaum W, Morris A, Chan EK (1997) Cardiac expression of 52beta, an alternative transcript of the congenital heart block-associated 52-kd SS-A/Ro autoantigen, is maximal during fetal development. *Arthritis Rheum* 40: 655–660
- Campbell IL (1995) Neuropathogenic actions of cytokines assessed in transgenic mice. *Int J Dev Neurosci* 13: 275–284
- Cannon MJ, Pisa P, Fox RI, Cooper NR (1990) Epstein-Barr virus induces aggressive lymphoproliferative disorders of human B cell origin in SCID/hu chimeric mice. *J Clin Invest* 85: 1333–1337
- Casciola-Rosen L, Anhalt G, Rosen A (1995) DNA dependent protein kinase is one of a subset of autoantigens specifically cleaved early during apoptosis. *J Exp Med* 182: 1625–1634
- Casiano CA, Martin SI, Green DR, Tan EM (1996a) Selective Cleavage of nuclear autoantigens during CD95 (Fas/Apo-1) mediated T-cell apoptosis. *J Exp Med* 184: 765–770
- Casiano CA, Tan EM (1996b) Recent developments in the understanding of antinuclear autoantibodies. *Int Arch Allergy Immunol* 111: 308–313
- Cho CS, Park SH, Min JK, Lee SH, Kim HY (1997) Clinical significances of antibodies to Ro/SS-A autoantigens and its subtypes in primary Sjogren's syndrome. *Korean J Intern Med* 12: 176–181
- Chimaz R, A Casadei, C Rose, J Bartunkova, A Sediva, F Falcini, P Picco, M Taglietti, F Zulian, R Ten Cate, FR Sztajnbnok, PV Voulgari, and AA Drosos. 2003. Primary Sjogren syndrome in the paediatric age: a multicentre survey. *Eur J Pediatr*
- Cyrus U, Bergeron L, Zho H, Li H, Yuan J (1996) Specific cleavage of Fodrin during Fas and tumor necrosis factor induced apoptosis is mediated by an ICE/CED-3 protease distinct from the poly (ADP-ribose) polymerase protease. *J Biol Chem* 271: 31277–31282

- Dang H, Geiser AG, Letterio JJ, Nakabayashi T, Kong L, Fernandes G, Talal N (1995) SLE-like autoantibodies and Sjogren's syndrome-like lymphoproliferation in TGF-beta knockout mice. *J Immunol* 155: 3205-3212
- Daniels T, Fox PC (1992a) Salivary and Oral Components of Sjogren's Syndrome. *Rheum Clinics NA* 18: 571-583
- Daniels T, Fox PC (1992b) Salivary and oral components of Sjogren's syndrome. *Rheum Dis Clin North Am* 18: 571-589
- Daniels T, Whitcher JP (1994) Association of patterns of labial salivary gland inflammation with keratoconjunctivitis sicca. Analysis of 618 patients with suspected Sjogren's syndrome. *Arthritis Rheum* 37: 869-877
- De Keyser F, Hoch SO, Takei M, Dang H, De Keyser H, Rokeach LA, Talal N (1992) Cross-reactivity of the B/B' subunit of the Sm ribonucleoprotein autoantigen with proline-rich polypeptides. *Clin Immunol Immunopathol* 62: 285-290
- De Seze J, S Dubucquoi, AL Fauchais, T Matthias, D Devos, G Castelnovo, T Stojkovic, D Ferriby, E Hachulla, P Labauge, D Lefranc, PY Hatron, P Vermersch, and T Witte. 2003. alpha-Fodrin autoantibodies in the differential diagnosis of MS and Sjogren syndrome. *Neurology* 61: 268
- De Stefano R, S Manganelli, E Frati, E Selvi, A Azzi, K Zakrzewska, and R Marcolongo. 2003. No association between human parvovirus B19 infection and Sjogren's syndrome. *Ann Rheum Dis* 62: 86
- De Vita S 1996. Ductal Fas antigen and the pathobiology of Sjogren's syndrome [editorial; comment]. *Clin Exp Rheumatol* 14: 231
- Diakowski W, Sikorski AF (1995) Interaction of brain spectrin (fodrin) with phospholipids. *Biochemistry* 34: 13252-13258
- Edwards JC, LS Wilkinson, P Speight, and DA Isenberg. 1993. Vascular cell adhesion molecule 1 and alpha 4 and beta 1 integrins in lymphocyte aggregates in Sjogren's syndrome and rheumatoid arthritis. *Ann Rheum Dis* 52: 806
- Ekstrom J (1989) Autonomic control of salivary secretion. *Proc Finn Dent Soc* 85: 323-331
- Esch TR, MV Jonsson, VA Levanos, JD Poveromo, and BC Sorkin. 2000. Leukocytes infiltrating the submandibular glands of NOD mice express E-cadherin. *J Autoimmun* 15: 387
- Ferraccioli GF, De Vita S, Casatta L, Damato R, Pegoraro I, Bartoli E (1996) Autoimmune connective tissue disease, chronic polyarthritides and B cell expansion: risks and perspectives with immunosuppressive drugs. *Clin Exp Rheumatol* 14 Suppl 14: S71-80
- Ferri C, La Civita L, Longombardo G, Zignego AL, Pasero G (1998) Mixed cryoglobulinaemia: a cross-road between autoimmune and lymphoproliferative disorders. *Lupus* 7: 275-279
- Fishleder A, Tubbs R, Hesse B, Levin H (1987) Immunoglobulin-gene rearrangement in benign lymphoepithelial lesions. *N Engl J Med* 316: 1118-1121
- Flemmig TF, Weinacht S, Rudiger S, Rumetsch M, Jung A, Klaiber B (1996) Adjunctive controlled topical application of tetracycline HCl in the treatment of localized persistent or recurrent periodontitis. Effects on clinical parameters and elastase-alpha1-proteinase inhibitor in gingival crevicular fluid. *J Clin Periodontol* 23: 914-921
- Fox RI, Adamson III TC, Fong S, Robinson CA, Morgan EL, Robb JA, Howell FV (1983) Lymphocyte phenotype and function of pseudolymphomas associated with Sjogren's syndrome. *J Clin Invest* 72: 52-62
- Fox RI, Carson DA, Chen P, Fong S (1986a) Characterization of a cross reactive idio type in Sjogren's syndrome. *Scand J Rheumatol* 561: 83-88
- Fox RI, Chen PP, Carson DA, Fong S (1986b) Expression of a cross reactive idio type on rheumatoid factor in patients with Sjogren's syndrome. *J Immunol* 136: 477-483
- Fox RI, Chan E, Benton L, Fong S, Friedlaender M, Howell FV (1988) Treatment of primary Sjogren's syndrome with hydroxychloroquine. *Amer J Med* 85: 62-67
- Fox RI, PP Chen, DA Carson, and S Fong (1986c) Expression of a cross reactive idio type on rheumatoid factor in patients with Sjogren's syndrome. *J Immunol* 136: 477
- Fox RI, Wilson C (1993) Sjogren's syndrome: The association of interstitial nephritis and keratoconjunctivitis. *Diseases affecting the eye and the kidney* 266-276
- Fox RI, Kang HI, Ando D, Abrams J, Pisa E (1994a) Cytokine mRNA expression in salivary gland biopsies of Sjogren's syndrome. *J Immunol* 152: 5532-5539

- Fox RI (1994) Classification Criteria for Sjogren's syndrome. *Rheumatic Disease Clinics of North America: Current Controversies in Rheumatology* 20: 391-407
- Fox R, Kang H, Pisa E (1994) Cytokine transcription in salivary gland biopsies of Sjögren's syndrome. *J Immunol* 151: 132-142
- Fox RI, Saito I (1994) Criteria for diagnosis of Sjogren's syndrome. *Rheum Dis Clin North Am* 20: 391-407
- Fox RI, HI Kang, D Ando, J Abrams, and E Pisa (1994) Cytokine mRNA expression in salivary gland biopsies of Sjogren's syndrome. *J Immunol* 152: 5532
- Fox RI (1995) Sjogren's syndrome. *Curr Opin Rheumatol* 7: 409-416
- Fox RI (1996) Clinical features, pathogenesis, and treatment of Sjogren's syndrome. *Curr Opin Rheumatol* 8: 438-445
- Fox RI, Dixon R, Guarrasi V, Krubel S (1996) Treatment of primary Sjogren's syndrome with hydroxychloroquine: a retrospective, open-label study. *Lupus* 5 Suppl 1: S31-36
- Fox R (1997) Sjogren's syndrome: Progress and controversies. *Med Clin NA* 17: 441-534
- Fox RI (1998) Sjogren's syndrome. Pathogenesis and new approaches to therapy. *Adv Exp Med Biol* 438: 891-902
- Fox RI, J Tornwall, T Maruyama, and M Stern (1998) Evolving concepts of diagnosis, pathogenesis, and therapy of Sjogren's syndrome. *Curr Opin Rheumatol* 10: 446
- Fox RI, J Tornwall, and P Michelson (1999) Current issues in the diagnosis and treatment of Sjogren's syndrome. *Curr Opin Rheumatol* 11: 364
- Fox RI (2000) Sjogren's syndrome: current therapies remain inadequate for a common disease. *Expert Opin Investig Drugs* 9: 2007-2016
- Fox RI, and M Stern (2002) Sjogren's syndrome: mechanisms of pathogenesis involve interaction of immune and neurosecretory systems. *Scand J Rheumatol Suppl*: 3
- Fredriksen C, AC Johannessen, and R Jonsson. 1995. T-cell receptor V-gene usage in Sjogren's syndrome. *Adv Exp Med Biol* 371B: 1203
- Freemont AJ, and CJP Jones. 1983. Endothelial specialization of salivary gland vessels for accelerated lymphocyte transfer in Sjögren's syndrome. *J Rheum.* 10: 801
- Freimark B, Fox RI (1987) Detection of Clonally Detected T and B Cells in Salivary Gland Biopsies of Sjogren's sjogren lacking myoepithelial islands. *N E J Med* 317: 1158
- Friedlaender MH, Fox RI (1998) Punctal occlusion for the treatment of dry eye. *Adv Exp Med Biol* 438: 1017-1020
- Gellrich S, S Rutz, A Borkowski, S Golembowski, E Gromnica-Ihle, W Sterry, and S Jahn. 1999. Analysis of V(H)-D-J(H) gene transcripts in B cells infiltrating the salivary glands and lymph node tissues of patients with Sjogren's syndrome. *Arthritis Rheum* 42: 240
- Gemignani F, Marbini A, Pavesi G, Di Vittorio S, Manganelli P, Cenacchi G, Mancina D (1994) Peripheral neuropathy associated with primary Sjogren's syndrome. *J Neurol Neurosurg Psychiatry* 57: 983-986
- Grant IA, Hunder GG, Homburger HA, Dyck PJ (1997) Peripheral neuropathy associated with sicca complex. *Neurology* 48: 855-862
- Greenwalt R, Golub L, Lavietas B, Ramamurthy N, Gruber B, Laskin R, McNamera T (1994) Tetracyclines inhibit human collagenase in vivo and in vitro. *J Rheum* 14: 28-32
- Griffiths DJ, Venables PJ, Weiss RA, Boyd MT (1997) A novel exogenous retrovirus sequence identified in humans. *J Virol* 71: 2866-2872
- Guggenbuhl P, Jean S, Jego P, Grosbois B, Chales G, Semana G, Lancien G, Veillard E, Pawlowsky Y, Perdriger A (1998) Primary Sjogren's syndrome: role of the HLA-DRB1\*0301-1501 heterozygotes. *J Rheumatol* 25: 900-905
- Haddad J, Deny P, Munz-Gotheil C, Ambrosini JC (1992) Lymphocytic sialadenitis of Sjögren's syndrome associated with chronic hepatitis C virus liver disease. *Lancet* 8: 321-323
- Haneji N, Nakamura T, Takio K, Yanagi K, Higashiyama H, Saito I, Noji S, Sugino H, Hayashi Y (1997) Identification of alpha-fodrin as a candidate autoantigen in primary Sjogren's syndrome. *Science* 276: 604-607
- Harley JB, Sestak AL, Willia LG, Fu SM, Hansen JA, Reichlin M (1989) A model for disease heterogeneity in systemic lupus erythematosus. *Arthritis Rheum* 32: 826-86
- Harper JI (1982) Subacute cutaneous lupus erythematosus (SCLE): a distinct subset of LE *Clin Exp Dermatol* 7: 209-212



- Hayashi Y, Haneji N, Hamano H (1994) Pathogenesis of Sjogren's syndrome-like autoimmune lesions in MRL/lpr mice. *Pathol Int* 44: 559–568
- Hebbar M, Hebbar-Savean K, Hachulla E, Brouillard M, Hatron PY, Devulder B (1995) Participation of cryoglobulinaemia in the severe peripheral neuropathies of primary Sjogren's syndrome. *Ann Med Interne* 146: 235–238
- Hershberg R, Framson P, Cho D, Lee L, Kovats S, Beitz J, Blum J, Nepom G (1997) Epithelial Cells use two distinct pathways for HLA Class II antigen processing. *J Clin Inv* 100: 204–215
- Hicks SJ, Carrington SD, Kaswan RL, Stern ME, Corfield AP (1995) Secreted and membrane bound ocular mucins from normal and dry eye dogs. *Biochem Soc Trans* 23: 537S
- Horsfall AC, Li JM, Maini RN (1996) Placental and fetal cardiac laminin are targets for cross-reacting autoantibodies from mothers of children with congenital heart block. *J Autoimmun* 9: 561–568
- Hu Y, Purushotham KR, Wang P, Dawson R, Jr, Humphreys-Beher MG (1994) Down-regulation of beta-adrenergic receptors and signal transduction response in salivary glands of NOD mice. *Am J Physiol* 266: G433–443
- Hulkkonen J, J Vilpo, L Vilpo, T Koski, and M Hurme (2000) Interleukin-1 beta, interleukin-1 receptor antagonist and interleukin-6 plasma levels and cytokine gene polymorphisms in chronic lymphocytic leukemia: correlation with prognostic parameters. *Haematologica* 85: 600
- Humphreys-Beher MG (1996) Animal models for autoimmune disease-associated xerostomia and xerophthalmia. *Adv Dent Res* 10: 73–75
- Humphreys-Beher MG, and AB Peck (1999) New concepts for the development of autoimmune exocrinopathy derived from studies with the NOD mouse model. *Arch Oral Biol* 44 Suppl 1: S21
- Hyde H, Borthwick NJ, Janossy G, Salmon M, Akbar AN (1997) Upregulation of intracellular glutathione by fibroblast-derived factor(s): enhanced survival of activated T cells in the presence of low Bcl-2. *Blood* 89: 2453–2460
- Inatomi T, Spurr-Michaud S, Tisdale AS, Gipson IK (1995) Human corneal and conjunctival epithelia express MUC1 mucin. *Invest Ophthalmol Vis Sci* 36: 1818–1827
- Inatomi T, Spurr-Michaud S, Tisdale AS, Zhan Q, Feldman ST, Gipson IK (1996) Expression of secretory mucin genes by human conjunctival epithelia. *Invest Ophthalmol Vis Sci* 37: 1684–1692
- Jabs DA, Burns WH, Prendergast RA (1996) Paradoxical effect of anti-CD4 therapy on lacrimal gland disease in MRL/Mp-lpr/lpr mice. *Invest Ophthalmol Vis Sci* 37: 246–250
- Janz DM, van der Kraak G (1997) Suppression of apoptosis by gonadotropin, 17beta-estradiol, and epidermal growth factor in rainbow trout preovulatory ovarian follicles. *Gen Comp Endocrinol* 105: 186–193
- Jean S, Quelvennec E, Alizadeh M, Guggenbuhl P, Birebent B, Perdriger A, Grosbois B, Pawlotsky PY, Semana G (1998) DRB1\*15 and DRB1\*03 extended haplotype interaction in primary Sjogren's syndrome genetic susceptibility. *Clin Exp Rheumatol* 16: 725–728
- Johnson EO, Skopouli FN, Moutsopoulos HM (2000) Neuroendocrine manifestations in Sjogren's Syndrome [In Process Citation]. *Rheum Dis Clin North Am* 26: 927–949
- Jonsson R, TP Gordon, and YT Kontinen. 2003. Recent advances in understanding molecular mechanisms in the pathogenesis and antibody profile of Sjogren's syndrome. *Curr Rheumatol Rep* 5: 311
- Jorgensen C, Legouffe MC, Perney P, Coste J, Tissot B, Segarra C, Bologna C, Bourrat L, Combe B, Blanc F, Sany J (1996) Sicca syndrome associated with hepatitis C virus infection. *Arthritis Rheum* 39: 1166–1171
- Jubert C, Cosnes A, Clerici T, Gaulard P, Andre P, Revuz J, Bagot M (1993) Sjogren's syndrome and cutaneous B cell lymphoma revealed by anetoderma. *Arthritis Rheum* 36: 133–134
- Kang HI, Fei H, Fox RI (1991) Comparison of genetic factors in Chinese, Japanese and Caucassoid patients with Sjögren's syndrome. *Arthritis & Rheum* 34: S41 (supplement)
- Kassan SS, Thomas TL, Moutsopoulos HM, Hoover R, Kimberly RP, Budman DR, Costa J, Decker JL, Chused TM (1978) Increased risk of lymphoma in sicca syndrome. *Ann Intern Med* 89: 888–892
- Katayama I, Koyano T, Nishioka K (1994) Prevalence of eyelid dermatitis in primary Sjogren's syndrome. *Int J Dermatol* 33: 421–424

- Kizu Y, H Sakurai, S Katagiri, N Shinozaki, M Ono, K Tsubota, and J Saito. 1996. Immunohistological analysis of tumour growth factor beta 1 expression in normal and inflamed salivary glands. *J Clin Pathol* 49: 728
- Koike K, Moriya K, Ishibashi K, Yotsuyanagi H, Shintani Y, Fujie H, Kurokawa K, Matura Y, Miyamaura T (1997) Sialadenitis histologically resembling Sjogren syndrome in mice transgenic for hepatitis C virus envelope genes. *Proc Nat Acad Sci* 94: 233–236
- Kong L, Ogawa N, Nakabayashi T, Liu GT, D'Souza E, McGuff HS, Guerrero D, Talal N, Dang H (1997) Fas and Fas ligand expression in the salivary glands of patients with primary Sjogren's syndrome. *Arthritis Rheum* 40: 87–97
- Konishi M, Ohosone Y, Matsumura M, Oyamada Y, Yamaguchi K, Kawahara Y, Mimori T, Ikeda Y (1997) Mixed-cryoglobulinemia associated with cutaneous vasculitis and pulmonary symptoms. *Intern Med* 36: 62–67
- Konttinen YT, Sorsa T, Hukkanen M, Segerberg M, et. (1992) Topology of innervation of labial salivary glands by protein gene product 9.5 and synaptophysin immunoreactive nerves in patients with Sjögren's syndrome. *J Rheumatol* 19: 30–37
- Konttinen YT, Tornwall J, Kempainen P, Uusitalo H, Sorsa T, Hukkanen M, Polak JM (1996) Neutral endopeptidase (EC 3.4.24.11) in labial salivary glands in healthy controls and in patients with Sjogren's syndrome. *Ann Rheum Dis* 55: 513–519
- Konttinen YT, Halinen S, R Hanemaaijer, T Sorsa, J Hietanen, A Ceponis, J W Xu, R Manthorpe, J Whittington, A Larsson, T Salo, L Kjeldsen, U H Stenman, and A Z Eisen (1998) Matrix metalloproteinase (MMP)-9 type IV collagenase/gelatinase implicated in the pathogenesis of Sjogren's syndrome. *Matrix Biol* 17: 335
- Koski H, A Janin, MG Humphreys-Beher, T Sorsa, M Malmstrom, and YT Konttinen (2001) Tumor necrosis factor-alpha and receptors for it in labial salivary glands in Sjogren's syndrome. *Clin Exp Rheumatol* 19: 131
- Koski H, YT Konttinen, J Hietanen, T Tervo, and M Malmstrom (1997) Epidermal growth factor, transforming growth factor-alpha, and epidermal growth factor receptor in labial salivary glands in Sjogren's syndrome. *J Rheumatol* 24: 1930
- Kroemer G (1997) The proto-oncogene bcl-2 and its role in regulating apoptosis. *Nature Medicine* 3: 614–620
- Kyle R et al. (1971) Benign hyperglobuliemic purpura of Waldenstrom. *Medicine (Baltimore)* 50: 113–123
- Lee LA, Pickrell MB, Reichlin M (1996) Development of complete heart block in an adult patient with Sjogren's syndrome and anti-Ro/SS-A autoantibodies. *Arthritis Rheum* 39: 1427–1429
- Lemp MA (1987) Tear film: new concepts and implications for the management of the dry eye. *Trans New Orleans Acad Ophthalmol* 35: 53–64
- Li DQ, Tseng SC (1995) Three patterns of cytokine expression potentially involved in epithelial-fibroblast interactions of human ocular surface. *J Cell Physiol* 163: 61–79
- Li JM, Fan WS, Horsfall AC, Anderson AC, Rigby S, Larsson E, Venables PJ (1996) The expression of human endogenous retrovirus-3 in fetal cardiac tissue and antibodies in congenital heart block. *Clin Exp Immunol* 104: 388–393
- Liu Z, M Carvajal, CA Carothers Carraway, KL Carraway, and SC Pflugfelder. 2000. Increased expression of the type 1 growth factor receptor family in the conjunctival epithelium of patients with keratoconjunctivitis sicca. *Am J Ophthalmol* 129: 472
- Lu G, Beuerman RW, Zhao S, Sun G, Nguyen DH, Ma S, Kline DG (1997) Tumor necrosis factor-alpha and interleukin-1 induce activation of MAP kinase and SAP kinase in human neurooma fibroblasts. *Neurochem Int* 30: 401–410
- Lutz HU, Pfister M, Hornig R (1996) Tissue homeostatic role of naturally occurring anti-band 3 antibodies. *Cell Mol Biol (Noisy-le-grand)* 42: 995–1005
- Magro CM, Crowson AN (1999) The cutaneous pathology associated with seropositivity for antibodies to SSA (Ro): a clinicopathologic study of 23 adult patients without subacute cutaneous lupus erythematosus. *Am J Dermatopathol* 21: 129–137
- Main C, Blennerhassett P, Collins SM (1993) Human recombinant interleukin 1 beta suppresses acetylcholine release from rat myenteric plexus. *Gastroenterology* 104: 1648–1654.
- Manganelli P, and P Fietta 2003 Apoptosis and Sjogren syndrome. *Semin Arthritis Rheum* 33: 49
- Manger K, Kalden JR, Manger B (1996) Cyclosporin A in the treatment of systemic lupus erythematosus: results of an open clinical study. *Br J Rheumatol* 35: 669–675

- Mariette X, Cazals-Hatem D, Agbalika F, Selimi F, Brunet M, Morinet F, Gluckman E (1996) Absence of cytomegalovirus and Epstein-Barr virus expression in labial salivary glands of patients with chronic graft-versus-host disease. *Bone Marrow Transplant* 17: 607–610
- Marriette X 2003. Lack of benefit of Infliximab in Sjogren's Syndrome. *Arth Rheum abstract* S19
- Martin SJ, O'Brien GA, Nishioka WK, McGahon AJ, Mahboubi A, Saido TC, Green DR (1995) Proteolysis of fodrin (non-erythroid spectrin) during apoptosis. *J Biol Chem* 270: 6425–6428
- Matsumura R, M Kagami, H Tomioka, E Tanabe, T Sugiyama, M Sueishi, A Nakajima, M Azuma, and K Okumura. 1996. Expression of ductal Fas antigen in sialoadenitis of Sjogren's syndrome [see comments]. *Clin Exp Rheumatol* 14: 309
- McCauliffe DP, Faircloth E, Wang L, Hashimoto T, Hoshino Y, Nishikawa T (1996) Similar Ro/SS-A autoantibody epitope and titer responses in annular erythema of Sjogren's syndrome and subacute cutaneous lupus erythematosus. *Arch Dermatol* 132: 528–531
- Merke PA, Polissone RP, Chang Y, Skates SJ, Niles JL (1997) Prevalence of antineutrophil cytoplasmic antibodies in a large inception cohort of patients with connective tissue disease. *Ann Intern Med* 126: 866–873
- Merne ME, Syrjanen SM (1996) Detection of Epstein-Barr virus in salivary gland specimens from Sjogren's syndrome patients. *Laryngoscope* 106: 1534–1539
- Miyagawa S, Iida T, Fukumoto T, Matsunaga T, Yoshioka A, Shirai T (1995) Anti-Ro/SSA-associated annular erythema in childhood. *Br J Dermatol* 133: 779–782
- Mody GM, Cassim B (1998) Rheumatologic manifestations of gastrointestinal disorders. *Curr Opin Rheumatol* 10: 67–72
- Mountz JD, Wu J, Cheng J, Zhou T (1994) Autoimmune disease. A problem of defective apoptosis. *Arthritis Rheum* 37: 1415–1420
- Murata H, Y Kita, A Sakamoto, I Matsumoto, R Matsumura, T Sugiyama, M Sueishi, K Takabayashi, I Iwamoto, Y Saitoh, and et al. (1995) Limited TCR repertoire of infiltrating T cells in the kidneys of Sjogren's syndrome patients with interstitial nephritis. *J Immunol* 155: 4084
- Namekawa T, K Kuroda, T Kato, K Yamamoto, H Murata, T Sakamaki, K Nishioka, I Iwamoto, Y Saitoh, and T Sumida (1995) Identification of Ro(SSA) 52 kDa reactive T cells in labial salivary glands from patients with Sjogren's syndrome. *J Rheumatol* 22: 2092
- Navarr M, Cervera R, Font J, Reverter JC, Monteagudo J, Escolar G, Lopez-Soto A, Ordinas A, Ingelmo M (1997) Anti-endothelial cell antibodies in systemic autoimmune diseases: prevalence and clinical significance. *Lupus* 6: 521–526
- Nelson JD (1994) Diagnosis of keratoconjunctivitis sicca. *Int Ophthalmol Clin* 34: 37
- Newkirk MM, Shiroky JB, Johnson N, Danoff D, Isenberg DA, Shustik C, Pearson GR (1996) Rheumatic disease patients, prone to Sjogren's syndrome and/or lymphoma, mount an antibody response to BHRF1, the Epstein-Barr viral homologue of BCL-2. *Br J Rheumatol* 35: 1075–1081
- Nikitakis NG, H Rivera, C Lariccia, JC Papadimitriou, and JJ Sauk (2003) Primary sjogren syndrome in childhood: report of a case and review of the literature. *Oral Surg Oral Med Oral Pathol Oral Radiol Endod* 96: 42
- Nozawa K, Kayagaki N, Tokano Y, Yagita H, Okumura K, Hasimoto H (1997) Soluble Fas (Apo-1, CD95) and Soluble Fas ligand in rheumatic diseases. *Arth Rheum* 40: 1126–1129
- O'Donnell B, Black AK (1995) Urticarial vasculitis. *Int Angiol* 14: 166–174
- Ochs RL, Stein TW jr, Chan EK, Ruutu M, Tan EM (1996) cDNA cloning and characterization of a novel nucleolar protein. *Mol Biol Cell* 7: 1015–1024
- Ogawa N, Dang H, Kong L, Anaya J, Liu G, Talal N (1996) Lymphocyte apoptosis and apoptosis-associated gene expression in Sjogren's syndrome. *Arth Rheum* 39: 1875–1886
- Ohlsson M, K Skarstein, AI Bolstad, AC Johannessen, and R Jonsson (2001) Fas-induced apoptosis is a rare event in Sjogren's syndrome. *Lab Invest* 81: 95
- Ohyama Y, S Nakamura, G Matsuzaki, M Shinohara, A Hiroki, M Oka, and K Nomoto (1995) T-cell receptor V alpha and V beta gene use by infiltrating T cells in labial glands of patients with Sjogren's syndrome. *Oral Surg Oral Med Oral Pathol Oral Radiol Endod* 79: 730
- Ohyama Y, Nakamura S, Matsuzaki G, Shinohara M, Hiroki A, Fujimura T, Yamada A, Itoh K, Nomoto K (1996) Cytokine messenger RNA expression in the labial salivary glands of patients with Sjogren's syndrome. *Arthritis Rheum* 39: 1376–1384

- Pablos JL, Cogolludo V, Pinedo F, Carreira PE (1993) Subcutaneous nodular amyloidosis in Sjögren's syndrome. *Scand J Rheumatol* 22: 250–251
- Perez B, Kraus A, Lopez G, Cifuentes M, Alarcon-Segovia D (1995) Autoimmune thyroid disease in primary Sjogren's syndrome. *Am J Med* 99: 480–484
- Pflugfelder S, Crouse C, Monroy D, Yen M, Rowe M, Atherton S (1993) EBV and the lacrimal gland pathology of Sjogrens syndrome. *Am J Path* 143: 49–64
- Pflugfelder SC, A Solomon, and ME Stern. 2000. The diagnosis and management of dry eye: a twenty-five-year review. *Cornea* 19: 644
- Pflugfelder SC, D Jones, Z Ji, A Afonso, and D Monroy (1999) Altered cytokine balance in the tear fluid and conjunctiva of patients with Sjogren's syndrome keratoconjunctivitis sicca. *Curr Eye Res* 19: 201.
- Pflugfelder SC, Tseng SC, Yoshino K, Monroy D, Felix C, Reis BL (1997) Correlation of goblet cell density and mucosal epithelial membrane mucin expression with rose bengal staining in patients with ocular irritation. *Ophthalmology* 104: 223–235
- Piepenhagen PA, Peters LL, Lux SE, Nelson WJ (1995) Differential expression of Na(+)-K(+)-ATPase, ankyrin, fodrin, and E-cadherin along the kidney nephron. *Am J Physiol* 269: C1417–1432
- Pisa EK, Pisa P, Kang HI, Fox RI (1991) High frequency of t(14;18) translocation in salivary gland lymphomas from Sjögren's syndrome patients. *J Exp Med* 174: 1245–1250
- Provost TT, Watson R, Simmons-O'Brien E (1997) Anti-Ro(SS-A) antibody positive Sjogren's/lupus erythematosus overlap syndrome. *Lupus* 6: 105–111
- Ramos-Casals M, Cervera R, Yague J, Garcia-Carrasco M, Trejo O, Jimenez S, Morla RM, Font J, Ingelmo M (1998) Cryoglobulinemia in primary Sjogren's syndrome: prevalence and clinical characteristics in a series of 115 patients. *Semin Arthritis Rheum* 28: 200–205
- Reveille J, Wilson R, Provost T, Bias W, Arnett F (1984) Primary Sjögren's syndrome and other autoimmune diseases in families. *Ann Intern Med* 101: 748
- Ricci RM, Meffert JJ, McCollough ML (1998) Primary anetoderma. *Cutis* 62: 101–103
- Rigby S, Cooke S, Weerasing D he, Venables P (1996) Absence of HTLV-1 tax in Sjogren's syndrome. *Arth Rheum* 39: 1609–1610
- Robinson C, Yamciuka S, Alford C, Cooper C, Pichardo E, Shah N, Peck M, Humphrey-Beher M (1997) Elevated levels of cysteine protease activity in saliva and salivary glands of NOD mouse model for Sjogren's syndrome. *Proc Nat Acad Sci* 94: 5767–5771
- Robinson CP, Yamamoto H, Peck AB, Humphreys-Beher MG (1996) Genetically programmed development of salivary gland abnormalities in the NOD (nonobese diabetic)-scid mouse in the absence of detectable lymphocytic infiltration: a potential trigger for sialoadenitis of NOD mice. *Clin Immunol Immunopathol* 79: 50–59
- Roncin S, L Guillevin, M Beaugrand, S Vallet, YL Pennec, J Colin, and P Youinou. 1995. Identification of the T cell antigen receptor V beta gene products in labial salivary glands from patients with primary Sjogren's syndrome. *Ann Med Interne (Paris)* 146: 226
- Ruzicka T, Faes J, Bergner T, Peter RU, Braun-Falco O (1991) Annular erythema associated with Sjogren's syndrome: a variant of systemic lupus erythematosus [see comments]. *J Am Acad Dermatol* 25: 557–560
- Saari H, Halinen S, Ganlov K, Sorsa T, Konttinen YT (1997) Salivary mucous glycoprotein MG1 in Sjogren's syndrome. *Clin Chim Acta* 259: 83–96
- Sais G, Admella C, Fantova MJ, Montero JC (1998) Lymphocytic autoimmune hidradenitis, cutaneous leucocytoclastic vasculitis and primary Sjogren's syndrome. *Br J Dermatol* 139: 1073–1076
- Saito I, Serenius B, Compton T, Fox RI (1989) Detection of Epstein-Barr virus DNA by polymerase chain reaction in blood and tissue biopsies from patients with Sjögren's syndrome. *J Exp Med* 169: 2191–2198
- Sall K, Stevenson OD, Mundorf TK, Reis BL (2000) Two multicenter, randomized studies of the efficacy and safety of cyclosporine ophthalmic emulsion in moderate to severe dry eye disease. *CsA Phase 3 Study Group. Ophthalmology* 107: 631–639
- Scofield RH, KM Kaufman, U Baber, JA James, JB Harley, and BT Kurien 1999. Immunization of mice with human 60-kd Ro peptides results in epitope spreading if the peptides are highly homologous between human and mouse. *Arthritis Rheum* 42: 1017

- Sestak AL, Shaver TS, Moser KL, Neas BR, Harley JB (1999) Familial aggregation of lupus and autoimmunity in an unusual multiplex pedigree. *J Rheumatol* 26: 1495-1499
- Shattles WG, Brookes SM, Venables PJ, Clark DA, Maini RN (1992) Expression of antigen reactive with a monoclonal antibody to HTLV-1 P19 in salivary glands in Sjögren's syndrome. *Clin Exp Immunol* 89: 46-51
- Singer DR, Venning MC, Lockwood CM, Pusey CD (1986) Cryoglobulinaemia: clinical features and response to treatment [published erratum appears in *Ann Med Interne (Paris)* 1986; 137(5): 436]. *Ann Med Interne* 137: 251-253
- Skopouli FN, and HM Moutsopoulos (1995) Cytokines in Sjögren's syndrome. *Ann Med Interne (Paris)* 146: 219
- Skopouli FN, Jagiello P, Tsfetaki N, Moutsopoulos HM (1996) Methotrexate in primary Sjögren's syndrome. *Clin Exp Rheumatol* 14: 555-558
- Slomiany BL, Murty VL, Piotrowski J, Slomiany A (1996) Salivary mucins in oral mucosal defense. *Gen Pharmacol* 27: 761-771
- Smolen JS, Butcher B, Fritzler MJ, Gordon T, Hardin J, Kalden JR, Lahita R, Maini RN, Reeves W, Reichlin M, Rothfield N, Takasaki Y, van Venrooij WJ, Tan EM (1997) Reference sera for antinuclear antibodies. II. Further definition of antibody specificities in international antinuclear antibody reference sera by immunofluorescence and western blotting. *Arthritis Rheum* 40: 413-418
- Soliven B, Wang N (1995) Tumor necrosis factor- $\alpha$  regulates nicotinic responses in mixed cultures of sympathetic neurons and nonneuronal cells. *J Neurochem* 64: 883-894
- Spezialetti R, Bluestein HG, Peter JB, Alexander EL (1993) Neuropsychiatric disease in Sjögren's syndrome: anti-ribosomal P and anti-neuronal antibodies. *Am J Med* 95: 153-160
- Stern ME, Beuerman RW, Fox RI, Gao J, Mircheff AK, Pflugfelder SC (1998a) A unified theory of the role of the ocular surface in dry eye. *Adv Exp Med Biol* 438: 643-651
- Stern ME, Beuerman RW, Fox RI, Gao J, Mircheff AK, Pflugfelder SC (1998b) The pathology of dry eye: the interaction between the ocular surface and lacrimal glands. *Cornea* 17: 584-589
- Stern ME, J Gao, TA Schwalb, M Ngo, DD Tieu, CC Chan, BL Reis, SM Whitcup, D Thompson, and JA Smith. 2002. Conjunctival T-cell subpopulations in Sjögren's and non-Sjögren's patients with dry eye. *Invest Ophthalmol Vis Sci* 43: 2609
- Sternberg EM 2001. Neuroendocrine regulation of autoimmune/inflammatory disease. *J Endocrinol* 169: 429
- Sullivan DA, Wickham LA, Rocha EM, Krenzer KL, Sullivan BD, Steagall R, Cermak JM, Dana MR, Ullman MD, Sato EH, Gao J, Rocha FJ, Ono M, Silveira LA, Lambert RW, Kelleher RS, Tolls DB, Toda I (1999) Androgens and dry eye in Sjögren's syndrome. *Ann NY Acad Sci* 876: 312-324
- Sumida T, Yonaha F, Maeda T, Kita Y, Yoshida S (1994) Expression of sequences homologous to HTLV-1 Tax gene in the labial salivary glands of Japanese patients with Sjögren's syndrome. *Arth Rheum* 37: 545-550
- Suzuki M, Nagata S, Hiramatsu K, Takagi I, Ito H, Kitao S, Ito M, Ohta N, Baba S (1996) Elevated levels of soluble Fc epsilon RII/CD23 and antibodies to Epstein-Barr virus in patients with Sjögren's syndrome. *Acta Otolaryngol Suppl (Stockh)* 525: 108-112
- Tapinos NI, M Polihronis, AG Tzioufas, and HM Moutsopoulos (1999) Sjögren's syndrome. Autoimmune epithelitis. *Adv Exp Med Biol* 455: 127
- Tapinos NI, Polihronis M, Moutsopoulos HM (1999) Lymphoma development in Sjögren's syndrome: novel p53 mutations. *Arthritis Rheum* 42: 1466-1472
- Theofilopoulos AN (1995) The basis of autoimmunity: Part I Mechanisms of aberrant self-recognition. *Immunol Today* 16: 90-98
- Tseng CE, Chan EK, Miranda E, Gross M, Di Donato F, Buyon JP (1997) The 52-kd protein as a target of intermolecular spreading of the immune response to components of the SS-A/Ro-SS-B/La complex. *Arthritis Rheum* 40: 936-944
- Tsutsumi A, K Sasaki, N Wakamiya, K Ichikawa, T Atsumi, K Ohtani, Y Suzuki, T Koike, and T Sumida. 2001. Mannose-binding lectin gene: polymorphisms in Japanese patients with systemic lupus erythematosus, rheumatoid arthritis and Sjögren's syndrome. *Genes Immun* 2: 99

- Vazquez J, Fernandez-Shaw C, Marina A, Haas C, Cacabelos R, Valdivieso F (1996) Antibodies to human brain spectrin in Alzheimer's disease. *J Neuroimmunol* 68: 39–44
- Vissink A, Spijkervet FK, Van Nieuw Amerongen A (1996) Aging and saliva: a review of the literature. *Spec Care Dentist* 16: 95–103
- Vitali C, Moutsopoulos HM, Bombardieri S (1994) The European Community Study Group on diagnostic criteria for Sjogren's syndrome. Sensitivity and specificity of tests for ocular and oral involvement in Sjogren's syndrome. *Ann Rheum Dis* 53: 637–647
- Vitali C, Bombardieri S (1997) The European classification criteria for Sjogren's syndrome (SS): proposal for modification of the rules for classification suggested by the analysis of the receiver operating characteristic (ROCS) curve of the criteria performance. *J Rheum* 24 (supplement): S18
- Vivino FB, Al-Hashimi I, Khan Z, LeVeque FG, Salisbury PL, 3rd, Tran-Johnson TK, Muscoplat CC, Trivedi M, Goldlust B, Gallagher SC (1999) Pilocarpine tablets for the treatment of dry mouth and dry eye symptoms in patients with Sjogren syndrome: a randomized, placebo-controlled, fixed-dose, multicenter trial. P92-01 Study Group. *Arch Intern Med* 159: 174–181
- Wagenmann A, Kato T, Yamamoto K, Nishoka K, Burmester G, Hiepe F (1996) Anti-52 kd SSa autoantibodies in different autoimmune diseases preferentially recognize epitopes on the central region of the antigen. *J Rheum* 23: 462–468
- Walcott B, Claros N (1998) Age related decrease in innervation density of the lacrimal gland in mouse models of Sjogren's syndrome. *Adv Exp Med Biol* 438: 917–923
- Watanabe H, Fabricant M, Tisdale AS, Spurr-Michaud SJ, Lindberg K, Gipson IK (1995) Human corneal and conjunctival epithelia produce a mucin-like glycoprotein for the apical surface. *Invest Ophthalmol Vis Sci* 36: 337–344
- Watanabe T, Tsuchida T, Ito Y, Kanda N, Ueda Y, Tamaki K (1997) Annular erythema associated with lupus erythematosus/Sjogren's syndrome. *J Am Acad Dermatol* 36: 214–218
- Wen S, Shimizu N, Yoshiyama H, Mizugaki Y, Shinozaki F, Takada K (1996) Association of Epstein-Barr virus (EBV) with Sjogren's syndrome: differential EBV expression between epithelial cells and lymphocytes in salivary glands. *Am J Pathol* 149: 1511–1517
- Whitcher JP, TE Daniels, and MD Sherman (1994) Correlation of labial salivary gland biopsies with ocular and oral findings in patients with Sjogren's syndrome. *Adv Exp Med Biol* 350: 667
- Whitcher JP jr, Gritz DC, Daniels TE (1998) The dry eye: a diagnostic dilemma. *Int Ophthalmol Clin* 38: 23–37
- Yocum DE (1996) Cyclosporine, FK-506, rapamycin, and other immunomodulators. *Rheum Dis Clin North Am* 22: 133–154

# 9 Psoriasis Vulgaris and Arthropathica

*Jörg Christoph Prinz*

## Introduction

Psoriasis vulgaris is an HLA-associated inflammatory disorder, which affects ~2% of the Caucasian population. It presents with a characteristic type of skin lesions which appear as sharply demarcated reddish plaques of variant size covered with intensive silvery scaling. In a significant proportion of patients psoriasis also involves the joints, sometimes leading to severe arthritis.

Psoriasis has been documented already in ancient times. The earliest descriptions are attributed to Celsus (25 a.c. to 50 p.c.) (Dirckx, 1983) and to the 3<sup>rd</sup> Book of Moses in the Book of Leviticus, chapter 13, of the Old Testament (Glickman, 1986). Here, psoriasis is assumed behind the term "zaraath". In 1801 psoriasis was clearly distinguished from leprosy by Robert Willan (1757–1812) (Leach and Beckwith, 1999). Since then, pathophysiology and therapy of psoriasis have remained an intellectual challenge.

## Epidemiology and Genetics of Psoriasis

The true incidence of psoriasis is difficult to determine. The prevalence varies in different parts of the world between 0.1% to 3%. In Western industrialized nations it is estimated to affect 1.5–2% of the population.

Psoriasis has a strong hereditary background. The concordance in monozygotic twins is 65 to 70% (Farber et al. 1974; Brandrup et al. 1982), compared to 15 to 20% in dizygotic twins. The risk of first-degree relatives to acquire psoriasis ranges from 8 to 23%. The inherited predisposition involves various gene loci. They include PSORS1 (psoriasis susceptibility locus) on chromosome 6p21.3, PSORS2 on 17q24-q25, PSORS3 on 4qter, PSORS4 on 1cen-q21, PSORS5 on 3q21, PSORS6 on 19p13, PSORS7p35-p34, PSORS8 on 16q12-q13, and PSORS9 on 4q31 (<http://www.ncbi.nlm.nih.gov/Omim>). Potential other psoriasis gene loci are 16q und 20p (Nair et al. 1997). Some of these gene loci are identical to gene loci of atopic childhood eczema (20p, PSORS2, PSORS4)

(Cookson et al. 2001). Psoriasis susceptibility is furthermore influenced by polymorphisms in various cytokine alleles (IL-1, IL-6, IL-10, IL12, TNF- $\alpha$ ) (Arias et al. 1997; Asadullah et al. 2001; Reich et al. 2002; Tsunemi et al. 2002).

PSORS1 and PSORS2 have been confirmed by more than one research group. They apparently carry the main risk alleles for psoriasis. PSORS1 contributes approximately 30–50% to the genetic predisposition (Trembath et al. 1997). It reflects the association of psoriasis with HLA-Cw6 that was identified as the first correlate of the genetic predisposition (Russel et al. 1972). In northern Europe and the U.S.A. two thirds of the psoriasis patients are HLA-Cw6 positive (Elder et al. 2001). Approximately 10% of the HLA-Cw6 positive individuals acquire psoriasis. Because of this relative association it remains uncertain whether HLA-Cw6 itself or a closely adjoining gene polymorphism represents the actual risk allele (Nair et al. 2000). HLA-Cw6 is inherited as a conserved set of genes (extended haplotype, EH57.1/I) that involves the HLA molecules Cw6-B57-DRB1\*0701-DQA1\*0201-DQB1\*0303 and particular alleles of corneodesmosin, MICA (class I major histocompatibility complex chain-related gene A), and HCR (Schmitt Egenolf et al. 1996; Tazi Ahnini et al. 1999; Gonzalez et al. 1999; Jenisch et al. 1999; Asumalahti et al. 2002). Each of these alleles has single nucleotide polymorphisms (SNP) that are associated with psoriasis and make them potential candidates for risk alleles.

For PSORS2 on 17q24-q25 the situation is much better defined. It carries a particular psoriasis-associated SNP that is located between *SLC9A3R1* (EBP50/ERM-binding phosphoprotein 50 kDa or NHERF1) and *NAT9* (Helms et al. 2003). The SNP affects a binding site for the transcription factor, RUNX1, and, at least experimentally, ablates RUNX1 binding and RUNX1-regulated expression of *SLC9A3R1*. *SLC9A3R1* codes for a linker protein that binds members of the ezrin-radixin-moesin family via a PDZ domain (Reczek et al. 1997). It is involved in both, epithelial membrane function and the formation of the immunologic synapse, and it mediates inhibitory signals during T cell activation (Itoh et al. 2002). Since *SLC9A3R1* is expressed in the upper epidermal layers and in resting T cells ablation of RUNX1 binding may contribute to both epidermal dysregulation and exaggerated T-cell activation of psoriatic skin lesions. An altered RUNX-mediated gene expression has also been suggested for lupus erythematosus and rheumatoid arthritis, making RUNX-related immune dysregulation a potential mechanism of autoimmunity (Prokunina et al. 2002; Tokuhiro et al. 2003).

### **HLA-Cw6 and Psoriasis-Subtypes**

The biologic role of HLA-Cw6 in psoriasis is still unknown. Yet, HLA-Cw6 as the major risk allele defines several clinical aspects of psoriasis. Acute-exanthematic, so-called guttate psoriasis shows a high prevalence for HLA-Cw6 (Mallon et al. 2000). Homozygosity for HLA-Cw6 confers a higher risk



for psoriasis than heterozygosity (Gudjonsson et al. 2003). HLA-Cw6 is furthermore associated with an early onset of the disease and a positive family history for psoriasis (Queiro et al. 2003).

Two subtypes of non-pustular psoriasis have been defined by the age of disease onset, HLA-expression and family history (Christophers and Henseler, 1985). Type 1 represents approximately two thirds of the psoriasis patients. It is characterized by the presence of HLA-Cw6, a positive family history for psoriasis, and an early disease manifestation usually before the age of 40 years, with a maximum of onset at the age of 16 (females) or 22 (males) years. Type 2 psoriasis is characterized by a late onset with a maximum at the age of 60 (females) or 57 (males) years, and by an overrepresentation of HLA-Cw2. Other HLA-alleles found more frequently in non-pustular psoriasis are A2, A24, B13, B27, B37, Cw7, Cw8 and Cw11 (Henseler, 1998). Unlike type 2 psoriasis, type 1 psoriasis is selectively associated with streptococcal throat infection as major environmental trigger of psoriasis onset (Weisenseel et al. 2002).

### **Histopathology**

The histopathologic picture of psoriasis depends on stage and localisation of the lesion. Early lesions display quite unspecific changes with dilatation of the papillary capillaries, oedema and a mononuclear infiltrate, from which fewer cells exocytose into the lower epidermis (Braun-Falco and Christophers, 1974). Only then, epidermal changes develop with parakeratosis (incomplete cornification) and disappearance of the granular layer. At this stage the phenomenon of the "squirting papillae" occurs, with release of neutrophilic granulocytes (Pinkus and Mehregan, 1966) from the dermal capillaries. They accumulate as Munro microabscesses within the parakeratotic layer or, intermingled with epidermal cells (Ragaz and Ackerman, 1979), as spongiform pustules of Kogoj beneath the parakeratotic stratum corneum (Gordon and Johnson, 1967). Increased numbers of mast cells are observed in the dermis.

The fully developed lesions are characterized by acanthosis (thickening of the epidermis), elongated rete ridges with often club-shaped dermal papillae and thinning of the suprapapillary layers of the epidermis. The granular layer is absent. Parakeratosis may be accompanied by ortho-hyperkeratosis. Only the intra-epidermal pustules or microabscesses, however, represent fully pathognomonic features of psoriasis. They become predominant in pustular psoriasis, with spongiform macropustules in a degenerated epidermis (Shelley and Kirschbaum 1961).

### **Gene Expression Analysis**

Large scale gene expression analysis of affected and unaffected psoriatic skin as well as skin from healthy individuals demonstrated that more than 1,300

genes are differentially expressed in psoriatic inflammation. These genes are particularly relevant for wound healing and epidermal regeneration, inflammation and immunity, epidermal proliferation and differentiation, the JAK-STAT-signalling cascade, neurogenesis, melanogenesis, and the pathogen defence. They reflect the different compartments involved in the pathogenic cascade (Bowcock et al. 2001; Zhou et al. 2003). Interestingly, gene expression revealed no difference between type 1 and type 2 psoriasis patients.

### **Environmental Factors**

Throat infections with group A  $\beta$ -haemolytic streptococci are the most frequent trigger of psoriasis onset, but may also induce relapses. Reports on the incidence of streptococcal throat infection preceding first psoriasis onset range from 56 to 97% (Norr lind, 1954; Tervaert and Esseveld, 1970). Elevated serum antibody titres against streptococcal antigens (Streptolysin O, DNase B) are found in ~ 50% of patients with chronic plaque psoriasis. Other triggering factors are drugs (mainly lithium,  $\beta$ -adrenergic blocking agents, antimalaria agents, IFN- $\alpha$ , Interleukin-2), withdrawal of steroids, alcohol, emotional stress and hypocalcaemia, to name the most frequent ones. These factors somehow seem to act on the genetic predisposition to turn the latent state into the full psoriatic phenotype.

### **Immune Mechanisms in the Pathogenesis of Psoriasis**

Several fully reversible features shape the clinical appearance of psoriasis. They include a strong increase in keratinocyte proliferation and epidermal turnover, accumulation of neutrophilic granulocytes, inflammatory changes with elongation of the papillary capillaries, and a mononuclear infiltrate with activated T cells.

Accordingly, the cause of psoriasis has been assumed in a disturbed growth regulation of keratinocytes, abnormal function and chemotaxis of neutrophilic granulocytes, or in defects in the cAMP-cascade or arachidonic acid metabolism, to name some of the former approaches. Intensive analysis of these compartments, however, did not reveal clues to explain the pathogenesis of psoriasis.

### **T Cell Activation in Psoriasis**

Recent progress in the understanding of psoriasis vulgaris has suggested that activation of the specific cellular immune system, particularly T cells, in

the skin is an essential step in disease manifestation, and that it is responsible for all the different lesional psoriatic changes including the increased keratinocyte proliferation (Valdimarsson et al. 1986). This role was first suggested in 1976 by the ability of cyclosporine A to clear psoriasis (Mueller and Hermann, 1976), but in order to convince of the pivotal position of T cells in the realisation of a genetic predisposition which includes HLA-association and – less stringently – other gene loci (Henseler, 1997; Trembath et al. 1997; Tomfohrde et al. 1994), further observations were necessary. They were based mainly on the therapeutic efficacy of other immunosuppressive regimens such as FK506 (Michel et al. 1996), monoclonal CD3 and CD4 antibodies (Weinshenker et al. 1989; Nicolas et al. 1991; Prinz et al. 1991), or a T cell-selective toxin, DAB<sub>389</sub>IL-2 (Gottlieb et al. 1995), but also of immunomodulatory cytokines such as IL-10 (Asadullah et al. 1998).

The T cells accused for mediating psoriasis constitute a dense inflammatory infiltrate in the papillary dermis and, to a much lesser degree, in the epidermis. The majority of the dermal T cells are CD4<sup>+</sup>, while CD8<sup>+</sup> T cells represent the majority of the epidermal T cell infiltrate (Bos et al. 1983). According to the expression of the low molecular isoform of the tyrosine-phosphatase CD45 (CD45RO) the lesional psoriatic T cells are memory T cells (Bos et al. 1989). Accumulation of these T cells within the psoriatic skin lesions is mediated by the interaction of various glycoprotein ligands and chemokine receptors on the T cell surface (cutaneous lymphocyte-associated antigen/CLA, intracellular adhesion molecule-1/ICAM-1, CD11a/LFA-1, chemokine receptor/CCR10) with various adhesion molecules on the vascular endothelium of the papillary venules (P-selectin, E-selectin, ICAM-1, chemokine CCL27) (Prinz 2003). CLA and CCR10 characterize T lymphocytes of inflammatory skin diseases. They mediate binding of T cells to the endothelium of the postcapillary venules and thus promote extravasation and migration into the dermal extracellular matrix.

In skin inflammation, P- and E-selectin are upregulated on endothelial cells and bind T cells via the P-selectin-glycoprotein-ligand 1 (PSGL-1). CLA results from glycosylation of PSGL-1. Lesional and non-lesional skin of psoriasis patients are characterized by an increased expression of various adhesion molecules such as E-Selectin und ICAM-1. The chemokine CCL27 is produced by basal keratinocytes of psoriatic skin lesions and other inflammatory skin diseases. It is secreted into the papillary dermis and becomes immobilized on both the extracellular matrix and on endothelial cells (Homey et al. 2002). Binding of CCR10 along the CCL27 gradient directs T-cell migration into inflammatory skin lesions, and neutralization of CCL27 in a mouse model of skin inflammation inhibits cutaneous T-cell recruitment.

Functional analysis of T cells isolated and cloned from these infiltrates revealed that a substantial proportion was capable of stimulating the proliferation of keratinocyte by the secretion of mediators (Prinz et al. 1994; Bata-Csorgo et al. 1995). Whether a particular hyperresponsiveness of psoriatic keratinocytes to growth promoting signals from T cells is involved in this effect is still

a matter of investigation. Studies on cytokine secretion furthermore suggested, that the lesional T cells represent a particular regulatory T cell subset. They produce a particular cytokine pattern that by its biological activities should be able to mediate the features of psoriasis (Vollmer et al. 1994; Kagi et al. 1994). It includes IL-3, IL-6, and GM-CSF which can enhance keratinocyte proliferation *in vitro*; IL-8 as a key chemotactic cytokine for neutrophilic granulocytes; IL-5 which in combination with IL-3 promotes expansion and activation of mast cells; and IFN $\gamma$ , TNF- $\alpha$  and TNF- $\beta$  which activate macrophages and enhance their microbicidal actions (Abbas et al. 1996). In addition, IFN $\gamma$  is involved in the mitogenic effect of T cells on keratinocytes (Prinz et al. 1994; Bata-Csorgo et al. 1995), TNF- $\alpha$  induces keratinocytes to produce IL-8 and beta-defensins both of which are found in high amount in psoriatic epidermis (Nickoloff et al. 1991; Schroder and Harder, 1999). By the production of IFN $\gamma$  and the lack of IL-4 the lesional psoriatic T cells yielded a predominantly Th1-pattern, which is usually associated with both, effective cellular immune responses against bacteria (Abbas et al. 1996; Schaible et al. 1999) and with T cell mediated autoimmune tissue injury (Abbas et al. 1996). The presence of IL-5 (Vollmer et al. 1994) argues for a particular differentiation within the Th1-T cell subset.

Molecular analysis of TCR usage in psoriatic skin lesions has provided strong evidence in favour of an antigen-driven lesional T cell response. The TCR usage within psoriatic skin lesions appears highly restricted, with repetitive TCR rearrangements being reflected by the presence of clonally expanded T cell populations (Chang et al. 1994; Menssen et al. 1995). The same clonally expanded T cell populations were associated with the lesional psoriatic immune response over prolonged periods of time and in relapsing disease (Menssen et al. 1995; Chang et al. 1997). Extensive cloning and sequencing of TCR rearrangements of several BV gene families in repetitive biopsies from the same patients indicated that the lesional T cell receptor usage is quite stable in general, with hardly any variations in the selected TCR rearrangements over time. These results emphasize that the psoriatic immune response involves a restricted subset of clonally expanded T cells. It is apparently induced against antigens, which are continuously present within the psoriatic skin lesions, and it shows no signs of epitope spreading. Instead, identification of a conserved T cell receptor  $\beta$ -chain (TCRB) CDR3-motif within multiple lesions from different patients suggested that the psoriatic immune response is not only preserved within individual patients but that a common psoriatic antigen may be driving responses in different patients (Prinz et al. 1999).

### **Search for the Psoriatic Autoantigens**

In search for an organ-specific causative psoriatic antigen, molecular mimicry between streptococcal and keratinocyte proteins has been a highly intriguing hypothesis (Valdimarsson et al. 1997). Molecular mimicry proposes

that infecting pathogens express peptides that are similar in structure or sequence to a particular self-component and thus induce cross-reactive immune responses between pathogen and host (Fujinami and Oldstone, 1985; Oldstone, 1987). The classical paradigm for antigen mimicry has been acute rheumatic fever induced by group A  $\beta$ -haemolytic streptococci. Immunologically relevant structural homologies of streptococcal M proteins, which are major streptococcal virulence factors, with various organ-specific proteins such as myosin have been identified by both cross-reacting serum antibodies and T cells from patients affected by rheumatic fever in numerous studies (Robinson and Kehoe, 1992).

Common epitopes are also shared between streptococcal antigens and keratinocyte proteins (Robinson and Kehoe, 1992). Based on several amino acid sequence homologies with streptococcal M proteins that were identified by database searches, keratin 6, but also other keratins, were formerly suggested as psoriatic autoantigens (Valdimarsson et al. 1986). And indeed, peripheral blood T cells of psoriasis patients showed increased reactivity to several synthetic peptides corresponding to these homologous regions, when tested *in vitro* (Sigmundsdottir et al. 1997; Gudmundsdottir et al. 1999). A particular relevance of these findings for the psoriatic T cell response is suggested by increased lesional frequencies of streptococci-specific T cells (Baker et al. 1991; Baker et al. 1992). Therefore, in a concept of molecular mimicry, streptococcal M-proteins might have the capacity to direct a primary anti-streptococcal T cell response towards homologous organ-specific keratin peptides presented on keratinocytes.

When integrated into a pathogenetic concept, psoriasis might therefore essentially be interpreted as an autoimmune skin reaction triggered by molecular mimicry. At least in a subset of patients it may be mediated by a particular population of cross-reactive regulatory T cells that were originally primed against bacterial – in this case streptococcal – antigens and become reactivated within the skin when they recognize homologous peptides from keratinocyte proteins. This fact might be able to explain the whole array of features of psoriasis. According to their original antibacterial functional differentiation these T cells should induce an antibacterial tissue reaction when reactivated. The excessive epithelial hyperplasia with intense desquamation may thus be considered as an expulsive mechanism of epithelial surfaces to combat microbial invasion (McCarty, 1973); human beta defensins are antibacterial, keratinocyte-derived peptides (Harder et al. 1997); mast cells (Harvima et al. 1989) are known to hold a pivotal position in bacterial defence reactions (Prodeus et al. 1997); and neutrophilic granulocytes function as antimicrobial phagocytes. Whether the HLA-association of psoriasis results from the particular capacity of HLA-Cw6 to present particularly the homologous peptides from M proteins and keratins remains to be determined (Prinz 2004).

## Clinical Manifestations of Psoriasis

### Acute Guttate and Chronic Plaque Psoriasis

Psoriasis presents with two major clinical forms of manifestation, acute guttate psoriasis and chronic plaque psoriasis, as well as several less frequent clinical variants, mainly pustular psoriasis, erythrodermic psoriasis, and psoriasis arthritis.

The classical psoriatic skin lesion is a well-defined sharply demarcated plaque of salmon pink colour covered with a variable amount of silvery scales (erythemato-squamous plaques). It is characteristic of *chronic plaque psoriasis*. Scratching off the scaling reveals a glossy, red, dry membrane that upon further removal develops small bleeding points from the elongated papillary capillaries (Auspitz sign). Chronic psoriatic plaques show mostly uniform appearance. They are usually symmetrically distributed with a preference for certain predilection sites: extensor side of joints (particularly knees and elbows), umbilicus, anal cleft, genital region, ears, and scalp. The extent may vary from a few small lesions to extensive confluent plaques that cover large areas of the body.

*Acute guttate psoriasis* shows small pinpoint lesions with often only little scaling that are tightly scattered over trunk and limbs, less frequently also on face and scalp. It develops as acute, exanthematic form particularly after streptococcal throat infections in first onset psoriasis, but also in acute psoriasis relapses.

#### Modification by Site

The *scalp* is often involved with inflammation and scaling that extends approximately 1 cm onto the forehead. *Taenia amiantacea* can be considered as the most severe form of shell-like, firmly adherent scales. Although hair loss is not a prevailing sign of scalp psoriasis, a diffuse reversible inflammatory effluvium may develop.

*Fingernails and toenails* may be affected in two different ways: psoriasis of nailbed and hyponychium leads to subungual hyperkeratosis, onycholysis, and yellow discoloration (oil drop). Small indentations (pitting), grooves and ridges of the nail result from psoriatic involvement of the nail matrix.

In *flexural psoriasis* skin lesions show an "inverse" distribution pattern. They affect mainly axillae, groins, and submammary folds. Due to maceration scaling is usually absent.

*Psoriasis of palms and soles* is characterized by scaling, hyperkeratotic erythemata or intra-epidermal yellow, later on brown pustules (see below).

#### Clinical Variants

Accumulation of neutrophilic granulocytes in small intra-epidermal micro-abscesses is a pathognomonic feature of psoriatic skin lesions. If this aspect

becomes more pronounced macroscopic visible sterile pustules develop on the skin, leading to *pustular psoriasis*. Two main forms are distinguished: psoriasis of early onset may develop into pustular psoriasis under certain circumstances such as withdrawal of internal steroids or external irritation or high eruption pressure (*psoriasis cum pustulatione, generalized pustular psoriasis von Zumbusch*). The second group of pustular psoriasis usually develops later in life, often shows an atypical (flexural, acral = inverse) distribution and may display pustulation from onset on (*palmoplantar pustular psoriasis, acrodermatitis continua suppurativa of Hallopeau, annular pustular psoriasis, generalized pustular psoriasis von Zumbusch*). In both groups localized or generalized forms are distinguished.

In *erythrodermic psoriasis* psoriatic inflammation has become generalized with highly inflammatory, exfoliative erythema and profuse scaling of the whole skin. Together with generalized pustular psoriasis it represents the most severe form of psoriasis and may become life-threatening.

*Psoriatic arthritis* is defined as the association of psoriasis with peripheral or spinal arthropathy and negative serological tests for rheumatoid arthritis. The incidence of arthritis in psoriasis patients ranges from ~ 5 to 40%, depending on the diagnostic criteria included. In 65% of psoriatic arthritis patients psoriatic skin lesions preceded arthritis, in 16% joint and skin affection appeared simultaneously, and in 19% skin lesions developed after arthritis onset. HLA-B27, but also HLA-A2, B38, and DR4 confer an increased risk for psoriatic arthritis.

The classification of Wright and Moll distinguishes five subgroups of psoriatic arthritis (Moll and Wright, 1973). *Peripheral asymmetric mono- or oligoarthritis* is most common (~70%). It preferentially affects single interphalangeal joints and usually is accompanied by a sausage-like digital swelling. *Distal interphalangeal arthritis* (~5–10%) involves the distal interphalangeal joints. In *mutilating psoriatic arthritis (arthritis mutilans, ~5%)* multiple interphalangeal joints and adjacent bone are destroyed by osteolysis with subsequent telescope-like shortening of the fingers, ankylosis and arthrogenic contractures. *Symmetric psoriatic polyarthritis* (~15%) is similar to rheumatoid arthritis, but usually less severe and rheumatoid factor-negative. *Psoriatic spondylarthritis* (~5%) is clinically similar to spondylitis ancylopoetica and affects spine and/or sacroiliac joints. As additional type *pustular arthroosteitis* is characterized by psoriasis pustulosa palmoplantaris and osteoarthritis of the sternocostoclavicular joints (Edlund et al. 1988).

### Course of Psoriasis

The course of psoriasis is unpredictable. After onset, approximately 60% of the patients suffer from chronic persistent or recurring psoriasis with frequent relapses. In the remaining 40% of patients complete and prolonged remission may develop.

## Diagnosis

The diagnosis of psoriasis is usually made on clinical grounds by the combination of erythematous plaques, affected predelection sites, nail changes, and a positive familiar history. Diagnostic difficulties of atypical manifestation such as in seborrheic or flexural psoriasis as well as in palmoplantar psoriasis may require histopathological support.

## Management of Psoriasis

Therapy should take into consideration that psoriasis often is a life long recurring but not life threatening disease. Due to the large clinical variability of psoriasis, therapy has to be adapted individually. The mode of therapy has to consider the individual extend, localisation, acuity and duration of psoriasis, sex and age of the patient, social and private aspects, and patient compliance.

### General Measures

Patients should occasionally be examined for inflammatory foci (otolaryngologic, dental) that may serve as constant triggers of relapses. Streptococcal throat infection should be treated antibiotically. Tonsillectomy may be beneficial particularly in early psoriasis triggered by streptococcal sore throat. Triggering drugs and alcohol should be avoided, whenever possible. The influence of diet is unclear. It might be advisory in severe and refractory psoriasis to avoid meat and sausages from cattle and pig because of the fatcontent in precursors of arachidonic acid that may fuel psoriatic inflammation unspecifically (Adam, 1995).

Therapy should address the different aspects of psoriatic skin lesions: it should suppress keratinocyte proliferation, be anti-inflammatory and immunosuppressive.

### Topical Therapy

Dithranol (anthralin) was introduced into psoriasis therapy by Unna and Galewsky in 1916 (Farber, 1992). It replaced chrysarobin, a natural tree-bark extract that was not available any more during the 1<sup>st</sup> world war. Dithranol still represents a kind of gold standard. Its mode of action involves a cytostatic effect. It may be used in combination with UVB light (Ingram regimen) or as short contact application. Since it is highly irritative it is used in low concentrations that during the course of treatment are cautiously increased. Dithranol formulations have to be protected from oxidation by the addition of



salicylic acid. As a disadvantage, dithranol stains the skin as well as cloth with a brownish discoloration.

Coal tars have been known for their antipsoriatic effects since long. They probably act cytostatically. Tars are mainly used as creams or ointments and as bath in combination with UV light (Goeckerman regimen). In experienced hands they represent an effective, although by now old-fashioned approach particularly for chronic plaque psoriasis. Because of the high content in potentially carcinogenic polycyclic aromatic hydrocarbons and occasional reports on the occurrence of skin cancer in tar-treated areas, tar should be used with care. It definitely is not the first line of treatment anymore.

Topical steroids are effective in clearing psoriatic skin lesions. The mode of action involves anti-inflammatory and immunosuppressive effects. In addition to the disadvantages of long-term use (atrophy, systemic resorption etc.), steroid treatment induces rebounds that are usually more recalcitrant to further treatment. In order to reduce side effects and enhance efficiency, steroids should be used in combination with other treatment modalities, such as topical vitamin D or A analogues.

Vitamin D analogues (calcipotriol, tacalcitol) inhibit proliferation and enhance differentiation of epithelial cells via binding to vitamin D-receptors. Furthermore, they suppress T cell activation. They are quite effective in reducing psoriasis activity, but may leave a residual erythema. Advantages are ease of application and the absence of staining. Because of the potential of calcium mobilization from bone their use should be restricted to a certain amount used for a certain area in a certain interval according to the manufacturers' advice. Efficacy is enhanced when combined with topical steroids, tazarotene, or phototherapy.

A topical vitamin A analogue is tazarotene. It is a retinoic acid receptor-specific acetylenic retinoid, which is effective for the topical treatment of patients with stable plaque psoriasis. The low systemic absorption and rapid systemic elimination of tazarotene results in limited systemic exposure. Topical application may produce reversible skin irritation. The efficacy of monotherapy can be greatly increased when combined with topical steroids, vitamin D analogues, UVB or photochemotherapy.

### **Phototherapy and Photochemotherapy**

Basically, two different modes of UV-light therapy are used in psoriasis treatment: UV-B therapy, and UV-A photochemotherapy. Both can be applied as partial or whole body therapy. A natural form of phototherapy is helio-/thalasso-therapy (climate therapy) in the Dead Sea area, which, however, seems to produce shorter remissions than office based UV-therapy (Koo and Lebwohl, 1999).

The most effective therapeutic UV-B spectrum for psoriasis lies between a wavelength of 304 and 314 nm. A lamp emitting a narrow UVB band at 311 nm

is available. Narrow band UV-B is superior to broadband UV-B in terms of efficacy and reduced carcinogenicity. UV-B efficacy is increased by combination with dithranol (Ingram regimen), vitamin D or A analogues.

Psoralen and UV-A (PUVA) therapy, also termed photochemotherapy, is mainly used as a combination of 8-methoxypsoralen (8-MOP) with subsequent UV-A-radiation. 8-MOP, while formerly given systemically, is now largely applied topically either as bath or as cream. Following photoactivation by UV-A in the skin 8-MOP induces crosslinking of DNA-strands and thus inhibits DNA-replication and RNA-transcription. Various studies demonstrated a tendency for PUVA being superior to narrowband UV-B. Because of the higher degree of cutaneous immunosuppression and long-term carcinogenic hazard, however, PUVA should be applied with caution. It remains the mainstay for psoriasis patients with high PASI scores who do not respond or that cannot be controlled adequately by narrowband UV-B. A history of skin cancer, exposure to treatment with arsenic or cyclosporine A are relative contraindications (Morison et al. 1998; Halpern et al. 2000).

According to a large survey of the literature by Koo and Lebwohl (Koo and Lebwohl, 1999), PUVA and Ingram-regimen seem to induce the longest remissions of all treatment modalities.

### Systemic Therapy

Systemic therapy is indicated particularly in patients with moderate to severe psoriasis. Rotation of available therapies should always be considered to minimize long-term toxicity and allow effective treatments to be maintained for many years.

Four drugs are mainly used in systemic therapy: Methotrexate, acitretin, cyclosporine A, and fumaric acid esters. Rarely used are hydroxyurea and 6-thioguanine. Mycophenolate mofetil, a novel lymphocyte-selective immunosuppressant, seems to be less potent than initially expected. Further studies are necessary to decide whether it is a therapeutic alternative for patients with psoriatic arthritis. FK506, although effective, has not yet gained a place in psoriasis therapy.

*Methotrexate* represents an efficient anti-psoriatic drug. It is a dihydrofolate reductase inhibitor and has anti-proliferative and immunosuppressive effects. It usually is given as bolus therapy once a week. When liver function is carefully monitored and additional hepatotoxic hazards are avoided (alcohol) methotrexate appears safe even in long-term usage (Roenigk, Jr. et al. 1998).

*Acitretin* is the active metabolite of the retinoid etretinate. It replaced etretinate because of its decreased lipophilicity and shorter elimination half life (50h versus 80 days). Yet, a minor fraction of acitretin is metabolised back into etretinate. Because of the teratogenic hazards of retinoids and the long-term storage of etretinate in subcutaneous fat, women have to avoid pregnancy for two years after acitretin therapy. Although acitretin has beneficial

effects on psoriasis as monotherapy, its main domain is the combination with UV-B or PUVA therapy (Re-UVB, Re-PUVA). In particular when started before onset of phototherapy, it can significantly enhance the efficiency of both UV-B and PUVA. Furthermore, it is often effective in stabilizing pustular psoriasis and acrodermatitis continua suppurativa Hallopeau.

*Cyclosporine A* can efficiently improve psoriasis, probably by its immunosuppressive effects on T cells, but also antigen-presenting cells such as dendritic cells or mast cells. Its use is limited by nephrotoxic side effects and subsequent arterial hypertension. Furthermore, it increases the risk of cutaneous malignancies in patients with previous extensive phototherapy. Short-term usage for a few months in order to induce remission in recalcitrant and severe psoriasis appears as the main indication of this drug (Lebwohl et al. 1998).

*Fumaric acid esters* were introduced into psoriasis therapy nearly 30 years ago. It has proved to be safe and effective in patients with severe chronic plaque psoriasis. At the moment it is licensed in Germany. It seems to act as immunomodulator that induces a Th1-Th2 shift, and it inhibits the formation of proinflammatory cytokines by blocking NF $\kappa$ B-mediating pathways. Former reports on renal toxicity ask for a close monitoring of renal function. Lymphopenia usually develops without clinical signs of immunosuppression. In some patients severe flushing and diarrhoea may impede further usage. No data are available on the use of fumaric acid esters in combination regimens (Mrowietz et al. 1999).

*Biologics.* Novel anti-psoriatic drugs have recently been developed on the basis of genetically engineered monoclonal antibodies or recombinant fusion proteins. Currently, some of them are already registered in various countries for the treatment of psoriasis or psoriasis arthritis. They aim mainly at the exaggerated lesional psoriatic immune response and offer novel, efficient approaches for the treatment of psoriasis. Among others they involve:

- monoclonal antibodies against TNF- $\alpha$  (such as Infliximab, Adalimumab, or Onercept) or soluble TNF- $\alpha$ -antagonists (etanercept);
- an antibody against LFA-1/CD11a (efalizumab);
- a genetically engineered recombinant fusion protein that interferes with T cell activation (LFA3TIP);
- immunomodulatory cytokines (IL-11, IL-10, IL-4) (Prinz 2003).

It is beyond the purpose of this chapter to review these drugs in more detail. It needs to be stressed, however, that these approaches have different efficiencies in controlling psoriatic inflammation. As compared to the established psoriasis treatment modalities they offer as a particular advantage a lack of organ toxicity and drug interference, and, from the current point of view, they have a good safety profile. By interfering at select steps of the psoriatic inflammatory cascade, they have clarified the pathogenesis of psoriasis much better, and they represent a revolution in the ability to control the disease in high need patients. Of course, they should be active also in mild to moderate

psoriasis, but according to the high costs of treatment their use will probably be limited to more severe indications.

### Psychological Aspects

A major aspect in psoriasis is the reduction in health related quality of life with reduction in physical and mental functioning. It is comparable to that seen in other severe diseases such as cancer, arthritis, hypertension, heart disease, diabetes, and depression (Rapp et al. 1999). Therefore, psychological intervention and support may be necessary in patients that are emotionally and socially handicapped.

### Summary

Psoriasis has only recently gained acceptance as T cell mediated disorder. Therefore, its presentation in a book on autoimmunity may still raise objections. On closer sight, however, psoriasis fulfils many criteria of an autoimmune disease: it has a hereditary background with a strong HLA-class I-association; microbial infections contribute to disease onset; and T cells apparently play an essential role in disease manifestation. Yet, only the identification of the putative autoantigens will finally prove its autoimmune nature.

### References

- Abbas AK, Murphy KM, and Sher A (1996) Functional diversity of helper T lymphocytes. *Nature*, 383: 787–793
- Adam O (1995) Anti-inflammatory diet in rheumatic diseases. *Eur J Clin Nutr*, 49: 703–717
- Arias A, Giles B, Eiermann T, Sterry W, and Pandey J (1997) Tumor necrosis factor-alpha gene polymorphism in psoriasis. *Exp Clin Immunogenet*, 14: 118–122
- Asadullah K, Sterry W, Stephanek K, Jasulaitis D, Leupold M, Audring H, Volk HD, and Docke WD (1998) IL-10 is a key cytokine in psoriasis. Proof of principle by IL-10 therapy: a new therapeutic approach. *J Clin Invest*, 101: 783–794
- Asadullah K, Eskdale J, Wiese A, Gallagher G, Friedrich M, and Sterry W (2001) Interleukin-10 promoter polymorphism in psoriasis. *J Invest Dermatol*, 116: 975–978
- Asumalahti K, Veal C, Laitinen T, Suomela S, Allen M, Elomaa O, Moser M, de Cid R, Ripatti S, Vorechovsky I, Marcusson J, Nakagawa H, Lazaro C, Estivill X, Capon F, Novelli G, Saarialho Kere U, Barker J, Trembath R, and Kere J (2002) Coding haplotype analysis supports HCR as the putative susceptibility gene for psoriasis at the MHC PSORS1 locus. *Hum Mol Genet*, 11: 589–597
- Baker BS, Powles AV, Malkani AK, Lewis H, Valdimarsson H, and Fry L (1991) Altered cell-mediated immunity to group A haemolytic streptococcal antigens in chronic plaque psoriasis. *Br J Dermatol*, 125: 38–42
- Baker BS, Bolith S, Powles AV, Valdimarsson H, and Fry L (1992) Streptococcal antigen-specific T lymphocytes in skin lesions of guttate psoriasis. *J Invest Dermatol*, 98: 535–538

- Bata-Csorgo Z, Hammerberg C, Voorhees JJ, and Cooper KD (1995) Kinetics and regulation of human keratinocyte stem cell growth in short-term primary ex vivo culture. Cooperative growth factors from psoriatic lesional T lymphocytes stimulate proliferation among psoriatic uninvolved, but not normal, stem keratinocytes. *J Clin Invest*, 95: 317–327
- Bos JD, Hulsebosch HJ, Krieg SR, Bakker PM, and Cormane RH (1983) Immunocompetent cells in psoriasis. In situ immunophenotyping by monoclonal antibodies. *Arch Dermatol Res*, 275: 181–189
- Bos JD, Hagenaars C, Das PK, Krieg SR, Voorn WJ, and Kapsenberg ML (1989) Predominance of “memory” T cells (CD4+, CDw29+) over “naive” T cells (CD4+, CD45R+) in both normal and diseased human skin. *Arch Dermatol Res*, 281: 24–30
- Bowcock A, Shannon W, Du F, Duncan J, Cao K, Aftergut K, Catier J, Fernandez Vina M, and Menter A (2001) Insights into psoriasis and other inflammatory diseases from large-scale gene expression studies. *Hum Mol Genet*, 10: 1793–1805
- Brandrup F, Holm N, Grunnet N, Henningsen K, and Hansen HE (1982) Psoriasis in monozygotic twins: variations in expression in individuals with identical genetic constitution. *Acta Derm Venereol*, 62: 229–236
- Braun-Falco O and Christophers E (1974) Structural aspects of initial psoriatic lesions. *Arch Dermatol Forsch*, 251: 95–110
- Chang JCC, Smith LR, Froning KJ, Schwabe BJ, Laxer JA, Caralli LL, Kurland HH, Karasek MA, Wilkinson DI, Carlo DJ, and Brostoff SW (1994) CD8<sup>+</sup> T cells in psoriatic lesions preferentially use T-cell receptor V $\beta$ 3 and/or V $\beta$ 13.1 genes. *Proc Natl Acad Sci USA*, 91: 9282–9286
- Chang JC, Smith LR, Froning KJ, Kurland HH, Schwabe BJ, Blumeyer KK, Karasek MA, Wilkinson DI, Farber EM, Carlo DJ, and Brostoff SW (1997) Persistence of T-cell clones in psoriatic lesions. *Arch Dermatol*, 133: 703–708
- Christophers E and Henseler T (1985) Characterization of disease patterns in nonpustular psoriasis. *Semin Dermatol*, 4: 271–275
- Cookson W, Ubhi B, Lawrence R, Abecasis G, Walley A, Cox H, Coleman R, Leaves N, Trembath R, Moffatt M, and Harper J (2001) Genetic linkage of childhood atopic dermatitis to psoriasis susceptibility loci. *Nat Genet*, 27: 372–373
- Dirckx JH (1983) Dermatologic terms in the De Medicina of Celsus. *Am J Dermatopathol*, 5: 363–369
- Edlund E, Johnsson U, Lidgren L, Pettersson H, Sturfelt G, Svensson B, Theander J, and Willen H (1988) Palmoplantar pustulosis and sternocostoclavicular arthro-osteitis. *Ann Rheum Dis*, 47: 809–815
- Elder J, Nair R, Henseler T, Jenisch S, Stuart P, Chia N, Christophers E, and Voorhees J (2001) The genetics of psoriasis 2001: the odyssey continues. *Arch Dermatol*, 137: 1447–1454
- Farber EM, Nall ML, and Watson W (1974) Natural history of psoriasis in 61 twin pairs. *Arch Dermatol*, 109: 207–211
- Farber EM (1992) History of the treatment of psoriasis. *J Am Acad Dermatol*, 27: 640–645
- Fujinami RS and Oldstone MB (1985) Amino acid homology between the encephalitogenic site of myelin basic protein and virus: mechanism for autoimmunity. *Science*, 230: 1043–1045
- Glickman FS (1986) Lepra, psora, psoriasis. *J Am Acad Dermatol*, 14: 863–866
- Gonzalez S, Martinez Borra J, Torre Alonso J, Gonzalez Rocas S, Sanchez del Rio J, Rodriguez Perez A, Brautbar C, and Lopez Larrea C (1999) The MICA-A9 triplet repeat polymorphism in the transmembrane region confers additional susceptibility to the development of psoriatic arthritis and is independent of the association of Cw\*0602 in psoriasis. *Arthritis Rheum*, 42: 1010–1016
- Gordon M and Johnson WC (1967) Histopathology and histochemistry of psoriasis. I. The active lesion and clinically normal skin. *Arch Dermatol*, 95: 402–407
- Gottlieb SL, Gilleaudeau P, Johnson R, Estes L, Woodworth TG, Gottlieb AB, and Krueger JG (1995) Response of psoriasis to a lymphocyte-selective toxin (DAB<sub>389</sub>IL-2) suggests a primary immune, but not keratinocyte, pathogenic basis. *Nature Med*, 1: 442–447
- Gudjonsson J, Karason A, Antonsdottir A, Runarsdottir E, Hauksson V, Upmanyu R, Gulcher J, Stefansson K, and Valdimarsson H (2003) Psoriasis patients who are homozygous for the HLA-Cw\*0602 allele have a 2.5-fold increased risk of developing psoriasis compared with Cw6 heterozygotes. *Br J Dermatol*, 148: 233–235

- Gudmundsdottir AS, Sigmundsdottir H, Sigurgeirsson B, Good MF, Valdimarsson H, and Jonsdottir I (1999) Is an epitope on keratin 17 a major target for autoreactive T lymphocytes in psoriasis? *Clin Exp Immunol*, 117: 580–586
- Halpern SM, Anstey AV, Dawe RS, Diffey BL, Farr PM, Ferguson J, Hawk JL, Ibbotson S, McGregor JM, Murphy GM, Thomas SE, and Rhodes LE (2000) Guidelines for topical PUVA: a report of a workshop of the British photodermatology group. *Br J Dermatol*, 142: 22–31
- Harder J, Bartels J, Christophers E, and Schroder JM (1997) A peptide antibiotic from human skin. *Nature*, 387: 861
- Harvima IT, Naukkarinen A, Harvima RJ, and Horsmanheimo M (1989) Enzyme- and immunohistochemical localization of mast cell tryptase in psoriatic skin. *Arch Dermatol Res*, 281: 387–391
- Helms C, Cao L, Krueger JG, Wijmsan EM, Chamian F, Gordon D, Heffernan M, Daw JAW, Robarge J, Ott J, Kwok P-Y, Menter A, and Bowcock AM (2003) A putative RUNX1 binding site variant between *SLC9A3R1* and *NAT9* is associated with susceptibility to psoriasis. *Nat Genet*, 35: 349–356
- Henseler T (1997) The genetics of psoriasis. *J Am Acad Dermatol*, 37: S1–11
- Henseler T (1998) Genetics of psoriasis. *Arch Dermatol Res*, 290: 463–476
- Homey B, Alenius H, Muller A, Soto H, Bowman E, Yuan W, McEvoy L, Lauerma A, Assmann T, Bunemann E, Lehto M, Wolff H, Yen D, Marxhausen H, To W, Sedgwick J, Ruzicka T, Lehmann P, and Zlotnik A (2002) CCL27-CCR10 interactions regulate T cell-mediated skin inflammation. *Nat Med*, 8: 157–165
- Itoh K, Sakakibara M, Yamasaki S, Takeuchi A, Arase H, Miyazaki M, Nakajima N, Okada M, and Saito T (2002) Cutting edge: negative regulation of immune synapse formation by anchoring lipid raft to cytoskeleton through Cbp-EBP50-ERM assembly. *J Immunol*, 168: 541–544
- Jenisch S, Koch S, Henseler T, Nair RP, Elder JT, Watts CE, Westphal E, Voorhees JJ, Christophers E, and Kronke M (1999) Corneodesmosin gene polymorphism demonstrates strong linkage disequilibrium with HLA and association with psoriasis vulgaris. *Tissue Antigens*, 54: 439–449
- Kagi MK, Wüthrich B, Montano E, Baradun J, Blaser K, and Walker C (1994) Differential cytokine profiles in peripheral blood lymphocyte supernatants and skin biopsies from patients with different forms of atopic dermatitis, psoriasis and normal individuals. *Int Arch Allergy Immunol*, 103: 332–340
- Koo J and Lebwohl M (1999) Duration of remission of psoriasis therapies. *J Am Acad Dermatol*, 41: 51–59
- Leach D and Beckwith J (1999) The founders of dermatology: Robert Willan and Thomas Bateman. *J R Coll Physicians Lond*, 33: 580–582
- Lebwohl M, Ellis C, Gottlieb A, Koo J, Krueger G, Linden K, Shupack J, and Weinstein G (1998) Cyclosporine consensus conference: with emphasis on the treatment of psoriasis [see comments]. *J Am Acad Dermatol*, 39: 464–475
- Mallon E, Bunce M, Savoie H, Rowe A, Newson R, Gotch F, and Bunker C (2000) HLA-C and guttate psoriasis. *Br J Dermatol*, 143: 1177–1182
- McCarty, M. 1973, Host-parasite relations in bacterial diseases: Davis, B. D., Dulbecco, R., Eisen, H. N., Ginsberg, H. S., Wood, W. B., and McCarty, M. v. 2nd, (22):p. 627–665. Microbiology. Harper & Row: Hagerstown, New York, Evanstown, San Francisco, London
- Menssen A, Trommler P, Vollmer S, Schendel D, Albert E, Gürtler L, Riethmüller G, and Prinz JC (1995) Evidence for an antigen-specific cellular immune response in skin lesions of patients with psoriasis vulgaris. *J Immunol*, 155: 4078–4083
- Michel G, Kémény L, Homey B, and Ruzicka T (1996) FK506 in the treatment of inflammatory skin disease: promises and perspectives. *Immunol Today*, 17: 106–108
- Moll JM and Wright V (1973) Psoriatic arthritis. *Semin Arthritis Rheum*, 3: 55–78
- Morison WL, Baughman RD, Day RM, Forbes PD, Hoenigsmann H, Krueger GG, Lebwohl M, Lew R, Naldi L, Parrish JA, Piepkorn M, Stern RS, Weinstein GD, and Whitmore SE (1998) Consensus workshop on the toxic effects of long-term PUVA therapy. *Arch Dermatol*, 134: 595–598
- Mrowietz U, Christophers E, and Altmeyer P (1999) Treatment of severe psoriasis with fumaric acid esters: scientific background and guidelines for therapeutic use. The German Fumaric Acid Ester Consensus Conference. *Br J Dermatol*, 141: 424–429

- Mueller W and Hermann B (1976) Cyclosporin A for psoriasis. *N Engl J Med*, 301: 355
- Nair RP, Henseler T, Jenisch S, Stuart P, Bichakjian CK, Lenk W, Westphal E, Guo SW, Christophers E, Voorhees JJ, and Elder JT (1997) Evidence for two psoriasis susceptibility loci (HLA and 17q) and two novel candidate regions (16q and 20p) by genome-wide scan. *Hum Mol Genet*, 6: 1349–1356
- Nair RP, Stuart P, Henseler T, Jenisch S, Chia NV, Westphal E, Schork NJ, Kim J, Lim HW, Christophers E, Voorhees JJ, and Elder JT (2000) Localization of psoriasis-susceptibility locus PSORS1 to a 60-kb interval telomeric to HLA-C. *Am J Hum Genet*, 66: 1833–1844
- Nickoloff BJ, Karabin GD, and Barker JNWN (1991) Localization of IL-8 and its inducer TNF- $\alpha$  in psoriasis. *Am J Pathol*, 138: 129–140
- Nicolas JF, Chamchick N, Thivolet J, Wijdenes J, Morel P, and Revillard P (1991) CD4 antibody treatment of severe psoriasis. *Lancet*, 338: 321
- Norrind R (1954) Significance of infections in origination of psoriasis. *Acta Rheum Scand*, 1: 135–140
- Oldstone MB (1987) Molecular mimicry and autoimmune disease. *Cell*, 50: 819–820
- Pinkus H and Mehregan AH (1966) The primary histologic lesion of seborrheic dermatitis and psoriasis. *J Invest Dermatol*, 46: 109–116
- Prinz JC, Braun-Falco O, Meurer M, Daddona P, Reiter C, Rieber EP, and Riethmüller G (1991) Chimeric CD4 monoclonal antibody in the treatment of generalized pustular psoriasis. *Lancet*, 338: 320–321
- Prinz JC, Gross B, Vollmer S, Trommler P, Strobel I, Meurer M, and Plewig G (1994) T cell clones from psoriasis skin lesions can promote keratinocyte proliferation in vitro. *Eur J Immunol*, 24: 593–598
- Prinz JC, Vollmer S, Boehncke W-H, Menssen A, Laisney I, and Trommler P (1999) Selection of conserved TCR-VDJ-rearrangements in chronic psoriatic plaques indicates a common antigen in psoriasis vulgaris. *Eur J Immunol*, 29: 3360–3368
- Prinz JC (2003) The role of T cells in psoriasis. *J Eur Ac Derm Venerol*, 17: 257–270
- Prinz JC (2004) Disease mimicry: A pathogenetic concept for T cell-mediated autoimmune disorders triggered by molecular mimicry? *Autoimmun Rev*, 3: 10–15
- Prodeus AP, Zhou X, Maurer M, Galli SJ, and Carroll MC (1997) Impaired mast cell-dependent natural immunity in complement C3-deficient mice. *Nature*, 390: 172–175
- Prokunina L, Castillejo Lopez C, Oberg F, Gunnarsson I, Berg L, Magnusson V, Brookes A, Tentler D, Kristjansdottir H, Grondal G, Bolstad A, Svenungsson E, Lundberg I, Sturfelt G, Jonsson A, Truedsson L, Lima G, Alcocer Varela J, Jonsson R, Gyllenstein U, Harley J, Alarcon Segovia D, Steinsson K, and Alarcon Riquelme M (2002) A regulatory polymorphism in PDCD1 is associated with susceptibility to systemic lupus erythematosus in humans. *Nat Genet*, 32: 666–669
- Queiro R, Torre J, Gonzalez S, Lopez Larrea C, Tinture T, and Lopez Lagunas I (2003) HLA antigens may influence the age of onset of psoriasis and psoriatic arthritis. *J Rheumatol*, 30: 505–507
- Ragaz A and Ackerman AB (1979) Evolution, maturation, and regression of lesions of psoriasis. New observations and correlation of clinical and histologic findings. *Am J Dermatopathol*, 1: 199–214
- Rapp SR, Feldman SR, Exum ML, Fleischer AB, Jr., and Reboussin DM (1999) Psoriasis causes as much disability as other major medical diseases. *J Am Acad Dermatol*, 41: 401–407
- Reczek D, Berryman M, and Bretscher A (1997) Identification of EBP50: A PDZ-containing phosphoprotein that associates with members of the ezrin-radixin-moesin family. *J Cell Biol*, 139: 169–179
- Reich K, Mossner R, König I, Westphal G, Ziegler A, and Neumann C (2002) Promoter polymorphisms of the genes encoding tumor necrosis factor-alpha and interleukin-1beta are associated with different subtypes of psoriasis characterized by early and late disease onset. *J Invest Dermatol*, 118: 155–163
- Robinson JH and Kehoe MA (1992) Group A streptococcal M proteins: virulence factors and protective antigens. *Immunol Today*, 13: 362–367
- Roenigk HH, Jr., Auerbach R, Maibach H, Weinstein G, and Lebwohl M (1998) Methotrexate in psoriasis: consensus conference. *J Am Acad Dermatol*, 38: 478–485

- Russel TJ, Schultes LM, and Kuban DJ (1972) Histocompatibility (HL-A) antigens associated with psoriasis. *N Engl J Med*, 287: 738–740
- Schaible UE, Collins HL, and Kaufmann SH (1999) Confrontation between intracellular bacteria and the immune system. *Adv Immunol*, 71: 267–377
- Schmitt Egenolf M, Eiermann TH, Boehncke WH, Stander M, and Sterry W (1996) Familial juvenile onset psoriasis is associated with the human leukocyte antigen (HLA) class I side of the extended haplotype Cw6-B57-DRB1\*0701-DQA1\*0201-DQB1\*0303: a population- and family-based study. *J Invest Dermatol*, 106: 711–714
- Schroder JM and Harder J (1999) Human beta-defensin-2. *Int J Biochem Cell Biol*, 31: 645–651
- Shelley WB and Kirschbaum JO (1961) Generalized pustular psoriasis. *Arch Dermatol*, 84: 73–78
- Sigmundsdottir H, Sigurgeirsson B, Troye Blomberg M, Good MF, Valdimarsson H, and Jonsdottir I (1997) Circulating T cells of patients with active psoriasis respond to streptococcal M-peptides sharing sequences with human epidermal keratins. *Scand J Immunol*, 45: 688–697
- Tazi Ahnini R, Camp NJ, Cork MJ, Mee JB, Keohane SG, Duff GW, and di Giovine FS (1999) Novel genetic association between the corneodesmosin (MHC S) gene and susceptibility to psoriasis. *Hum Mol Genet*, 8: 1135–1140
- Tervaert WC and Esseveld H (1970) A study of the incidence of haemolytic streptococci in the throat in patients with psoriasis vulgaris, with reference to their role in the pathogenesis of this disease. *Dermatologica*, 140: 282–290
- Tokuhiro A, Yamada R, Chang X, Suzuki A, Kochi Y, Sawada T, Suzuki M, Nagasaki M, Ohtsuki M, Ono M, Furukawa H, Nagashima M, Yoshino S, Mabuchi A, Sekine A, Saito S, Takahashi A, Tsunoda T, Nakamura Y, and Yamamoto K (2003) An intronic SNP in a RUNX1 binding site of *SLC22A4*, encoding an organic cation transporter, is associated with rheumatoid arthritis. *Nat Genet*, 35: 341–348
- Tomfohrde J, Silverman A, Barnes R, Fernandez Vina MA, Young M, Lory D, Morris L, Wuepper KD, Stastny P, Menter A, and et al (1994) Gene for familial psoriasis susceptibility mapped to the distal end of human chromosome 17q. *Science*, 264: 1141–1145
- Trembath RC, Clough RL, Rosbotham JL, Jones AB, Camp RD, Frodsham A, Browne J, Barber R, Terwilliger J, Lathrop GM, and Barker JN (1997) Identification of a major susceptibility locus on chromosome 6p and evidence for further disease loci revealed by a two stage genome-wide search in psoriasis. *Hum Mol Genet*, 6: 813–820
- Tsunemi Y, Saeki H, Nakamura K, Sekiya T, Hirai K, Fujita H, Asano N, Kishimoto M, Tanida Y, Kakinuma T, Mitsui H, Tada Y, Wakugawa M, Torii H, Komine M, Asahina A, and Tamaki K (2002) Interleukin-12 p40 gene (IL12B) 3'-untranslated region polymorphism is associated with susceptibility to atopic dermatitis and psoriasis vulgaris. *J Dermatol Sci*, 30: 161–166
- Valdimarsson H, Baker BS, Jonsdottir I, and Fry L (1986) Psoriasis: a disease of abnormal keratinocyte proliferation induced by T lymphocytes. *Immunol Today*, 7: 256–259
- Valdimarsson H, Sigmundsdottir H, and Jonsdottir I (1997) Is psoriasis induced by streptococcal superantigens and maintained by M-protein-specific T cells that cross-react with keratin? *Clin Exp Immunol*, 107 Suppl 1: 21–24
- Vollmer S, Menssen A, Trommler P, Schendel D, and Prinz JC (1994) T lymphocytes derived from skin lesions of patients with psoriasis vulgaris express a novel cytokine pattern that is distinct from that of T helper type 1 and T helper type 2 cells. *Eur J Immunol*, 24: 2377–2382
- Weinshenker BG, Bass BH, Ebers GC, and Rice GP (1989) Remission of psoriatic lesions with muromonab-CD3 (orthoclone OKT3) treatment. *J Am Acad Dermatol*, 20: 1132–1133
- Weisenseel P, Laumbacher B, Besgen P, Ludolph-Hauser D, Herzinger T, Roecken M, Wank R, and Prinz JC (2002) Streptococcal infection distinguishes different types of psoriasis. *J Med Genet*, 39: 767–768
- Zhou X, Krueger J, Kao M, Lee E, Du F, Menter A, Wong W, and Bowcock A (2003) Novel mechanisms of T-cell and dendritic cell activation revealed by profiling of psoriasis on the 63,100-element oligonucleotide array. *Physiol Genomics*, 13: 69–78



# **10 Chronic Urticaria as an Autoimmune Disease**

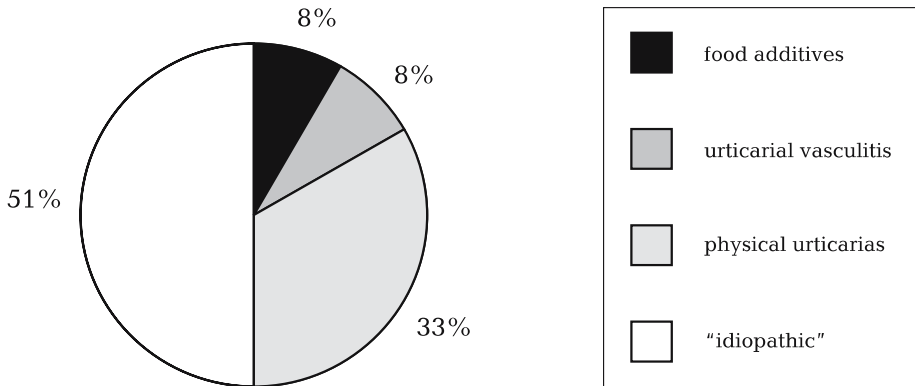
*Michihiro Hide, Malcolm W. Greaves*

## **Introduction**

Urticaria is conventionally classified as acute, intermittent and chronic (Greaves 2000a). Acute urticaria which frequently involves an IgE-mediated immunological mechanism, is common, its causes often recognised by the patient, and will not be considered further. Intermittent urticaria – frequent bouts of unexplained urticaria at intervals of weeks or months – will be discussed here on the same basis as ‘ordinary’ chronic urticaria. The latter is conventionally defined as the occurrence of daily or almost daily whealing for at least six weeks. The etiology of chronic urticaria is usually obscure. The different clinical varieties of chronic urticaria will be briefly considered here, and attention will be devoted to a newly emerged entity – autoimmune chronic urticaria, since establishing this diagnosis has conceptual, prognostic and therapeutic implications. Contact urticaria and angioedema without urticaria will not be dealt with in this account.

## **Classification of Chronic Urticaria**

The clinical subtypes of chronic urticaria are illustrated in the pie-chart of *Fig. 1*. The frequency of these subtypes is based upon the authors’ experience at the St John’s Institute of Dermatology in UK. Whilst there may well be minor differences, it is likely that the frequency distribution of these subtypes will be essentially similar in most centres in Europe and North America (Greaves 1995, 2000b). However, our experience suggests that the incidence of angioedema, especially that complicated by ordinary chronic urticaria is substantially lower in Japan and south Asian countries (unpublished observation).



**Fig. 1.** Chronic urticaria. Frequency of different subtypes in the authors' practices. The proportions are probably not very different elsewhere

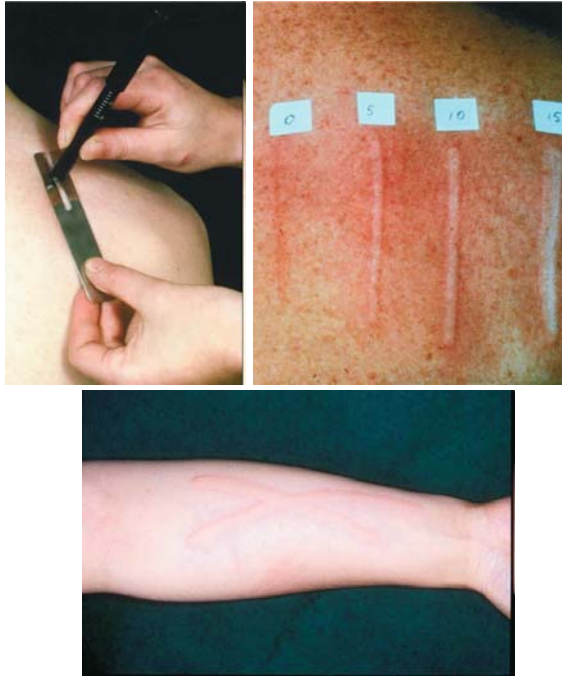
### Physical Urticarias

These comprise about one third to one fourth of all urticaria patients seen in the authors' services. The diagnosis is mainly made from careful history taking, appropriate clinical examination, and physical challenge testing is performed when necessary. It is important to identify patients in whom a physical urticaria is the main, if not the only, cause of the patient's symptoms. In this case, further investigation is not indicated, with rare exceptions (see below). Almost invariably, patients with this diagnosis are over-investigated by the time they are referred to the urticaria clinic. Skin prick testing, RAST (radio allerge sorbent tests), food exclusion diets, etc, are not normally indicated in patients with a physical urticaria with the exception of food-dependent exercise-induced urticaria, a rare variety of urticaria, which develops following exercise after food ingestion.

It is also important to appreciate that different physical urticarias can occur concurrently in the same patient; cold and cholinergic urticarias represent a well recognised example. Furthermore, chronic 'idiopathic' urticaria is often associated with dermographism or delayed pressure urticaria. The investigation and management of chronic urticaria should be influenced by establishing the relative contributions of coexisting forms of chronic urticaria to the patient's overall disability.

#### *Symptomatic Dermographism*

This common physical urticaria presents mainly in teenagers or adults of either sex. Like most physical urticarias, individual itchy wheals, produced by gentle stroking or rubbing of the skin, last less than 30 minutes before fading (*Fig. 2*). Angioedema and mucosal whealing do not occur and there are no

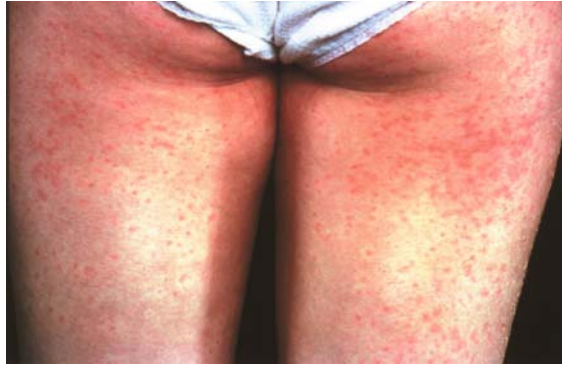

**Fig. 2.** Symptomatic Dermographism. Upper left hand panel: use of a graduated dermographometer to test for sensitivity to a dermographic stimulus. Upper right hand panel: graded wheal and flare response to a range of pressures. Lower panel: gentle stroking by round end of a pen rod with a certain pressure may readily disclose abnormal reaction of patients.

systemic symptoms but pruritus is troublesome. The etiology is unknown although skin reactivity can be passively transferred to non-human primates by intracutaneous injection of donor serum from a dermographic patient (Murphy et al. 1987). As with the majority of physical urticarias, investigations are pointless and any role for food items has not been substantiated. The prognosis is for eventual improvement in two to three years in most patients. Low sedation antihistamines such as loratidine 10 mg, cetirizine 10 mg or fexofenadine 120–180 mg are usually effective in relieving the itch, although additional treatment by a sedative antihistamine such as hydroxyzine 25 mg at night may also be useful. Combinations of  $H_1$ - and  $H_2$ - antihistamines may be useful.

### *Cholinergic Urticaria*

Cholinergic urticaria is common in children and young adults, although rare in the elderly. Historically, this type of urticaria has been classified as a physical urticaria. However, a recent consensus report for "definition, classification,



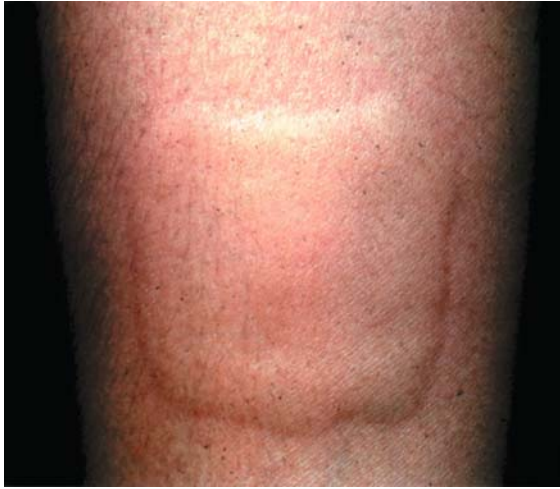**Fig. 3.** Cholinergic Urticaria. Typical monomorphic symmetrical maculopapular eruption evoked by heat or exertion or stress

and routine diagnosis of urticaria" (Zuberbier et al. 2001) for urticaria and angioedema classified this urticaria as a special type of urticaria, apart from physical urticarias. Symptoms of cholinergic urticaria, typically widespread pruritic monomorphic maculopapular lesions, develop in conditions causing sweating, such as exercise, hot bath taking, or emotional stimuli (Hirschmann et al. 1987) (*Fig. 3*). If the patient rests, cools off or relaxes, the eruption subsides in 15–45 minutes. Typical areas of predilection include the face, neck, fronts of elbows, wrists and popliteal fossae, although almost any area of the body can be involved. It may be accompanied by angioedema and systemic symptoms include wheezing or, rarely, anaphylactoid symptoms. Cholinergic urticaria can be disabling, especially when provoked by occupational or emotional triggers. The diagnosis is established by appropriate challenge testing (Commens et al. 1978) (exercise, a hot bath or mental arithmetic) and/or skin test with acetylcholine. No further investigations are indicated.

The prognosis is for gradual improvement over the course of months or years in most patients, although the authors have several patients in whom cholinergic urticaria remains unremitting. The condition normally responds reasonably well to avoidance of provoking factors, together with regular daily treatment by an  $H_1$ -antihistamine, especially in children.

Clinical variants include persistent cholinergic urticaria (Murphy et al. 1983), in which the rash is evident even at rest, and exercise-induced angioedema (Lawrence et al. 1981). Rarely patients may give a clear history of food provocation – either association of onset non-specifically with food intake, or specifically with certain food items (Zuberbier et al. 1993).

The pathomechanisms are incompletely understood. The local wheals can be blocked by atropinisation of the skin indicating involvement of acetylcholine, and histamine release has also been confirmed – presumably derived from mast cells (Herxheimer 1956). Wheal and flare reaction to autologous sweat and sweat-provoked histamine release from their basophils have been



**Fig. 4.** Cold Urticaria. Local whealing response to application of an ice cube for 10 min

demonstrated in some populations of patients with cholinergic urticaria (Adachi et al. 1994). These reactions have been suggested to be mediated by specific IgE, but the antigen in human sweat has not been identified yet.

### *Cold Urticaria*

This less common physical urticaria occurs in children and adults. Whealing is rapidly provoked by exposure to cold fluids or cold surfaces (*Fig. 4*). Angioedema of the oropharynx is common, e.g. after sucking an iced lolly. Systemic symptoms are common and may be severe – especially when provoked by extensive body immersion, as in sea-bathing. Cold urticaria is due to histamine release (Keahey et al. 1980), and cold-reactivity can be passively transferred to non-human primates by donor serum from affected individuals (Misch et al. 1983). The transferable factor has been variously attributed to IgE or IgM. Rarely cryoglobulins and cold agglutinin can be identified in sufferers' serum. These are usually sought routinely but positive results are exceptional. No other investigations are worth while.

In adults cold urticaria may be highly disabling especially in outdoor workers. It responds rather poorly to antihistamine treatment in all but the mildest cases and in children. Cold tolerance treatment (repeated cold exposure to induce a temporary refractory state) is effective but requires a highly motivated patient (Bentley-Phillips et al. 1976). Some remain crippled by cold sensitivity despite all these measures.

### *Delayed Pressure Urticaria*

This common and disabling physical urticaria is arguably not a true urticaria since the wheals characteristically are of more than 24 hours' duration (Lawlor et al. 1989a). As its name suggests, whealing occurs following a latent period of 2–4 hours after application of pressure perpendicular to the skin. Common examples of triggering factors include a tight waistband, tight footwear and golf club, tennis racquet, or steering wheel grips. Pain is more characteristic than itch although both may occur, and there is no angioedema and no mucosal involvement. A skin biopsy reveals an inflammatory infiltrate in which eosinophils are prominent but there is no vasculitis. Mild systemic symptoms are common including arthralgia and fatigue. The pathomechanisms in delayed pressure urticaria are unknown. In Caucasian populations about 40 per cent of patients with chronic 'idiopathic' urticaria have accompanying delayed pressure urticaria (Sabroe et al. 1999a), and it is doubtful if it ever occurs as an isolated clinical entity.

Treatment is very difficult. Early claims of the value of the antihistamine cetirizine have not been substantiated and antihistamines are usually poorly effective. Non-steroid anti-inflammatory agents are also usually disappointing and in severely disabled patients substantial dosage with oral steroids (e.g. prednisone 30–40 mg daily) may be necessary to control symptoms.

### *Other Physical Urticarias*

These are rare, and include solar urticaria (Ramsay 1977), aquagenic urticaria (Sibbald et al. 1981), vibratory angioedema (Lawlor et al. 1989b) and heat urticaria (Koro et al. 1986). Although it may be useful to determine the action spectrum needed to evoke solar urticaria, generally no further investigations are needed beyond establishing the diagnosis by appropriate challenge tests. Antihistamine therapy is helpful to varying degrees in members of this group, which will not be discussed further. The reader is referred to more detailed accounts of these physical urticarias published recently elsewhere (Black 2004).

### **Food Additive-Evoked Chronic Urticaria**

At some stage in the course of their disease, many patients with chronic urticaria believe they have an 'allergy' to food items, and this belief is often reinforced by gratuitous advice from relatives and friends, and even by health care professionals including dermatologists and allergists. In fact, a relationship between food and chronic urticaria can be substantiated infrequently. The gold standard should be placebo-controlled challenge testing (May 1985; Pastorello 1995). In our urticaria clinics chronic urticaria can be demonstrably attributable to a food additive in no more than five per cent of patients.

We ask patients to keep a diary and report fluctuations in severity of whealing and itching but daily measurements of plasma tryptase or urinary excretion of histamine and its metabolites can be used to provide a quantitative measure of exacerbations.

### **Urticarial Vasculitis**

A full description of the etiology, pathomechanisms, clinical presentation, investigation and treatment is outside the scope of this article. However, the subject has recently been comprehensively reviewed (O'Donnell and Black 1995). Only a very brief outline will be included here.

#### *Etiology*

In the majority of patients, no cause is evident but recognised etiological factors include virus infections (hepatitis B and C and HIV) and paraproteinaemia. Urticarial vasculitis may also be the first, or very early, clinical manifestation of autoimmune disease (lupus, Sjogren's syndrome) or ulcerative colitis or Crohn's disease. Drug hypersensitivity may also be an occasional cause.

#### *Clinical Presentation and Investigation*

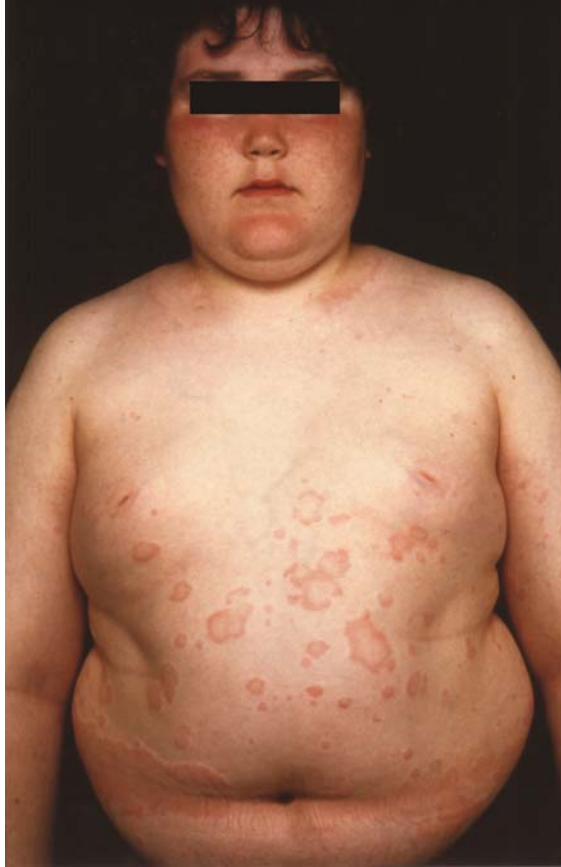In contrast with 'ordinary' urticaria, individual wheals are of duration greater than 24 hours. Itching is variable and may be less prominent than painful tenderness. Some staining of the skin may be evident due to purpura and wheals may show a predilection for pressure-bearing areas, such as the waistband. There may be associated systemic symptoms of which arthralgia is especially common. Urticarial vasculitis tends to pursue a chronic unremitting course.

#### *Treatment*

Urticarial vasculitis responds poorly to H<sub>1</sub>-antihistamines. Other drugs which have been proposed include dapsone, antimalarials and colchicine. Systemic steroids may be effective but, given the frequently prolonged duration of the disease, systemic complications are almost inevitable. Other measures worth considering in selected patients include intravenous immunoglobulin, parenteral gold injections and plasmapheresis.

### **Chronic 'Idiopathic' Urticaria**

This is conventionally defined as the daily, or almost daily, occurrence of wheals and itching for 6 weeks or more (Greaves 1995) (*Fig. 5*). The difference between acute urticaria that appears daily for a few days and chronic idiopathic



**Fig. 5.** Chronic “Idiopathic” Urticaria. This 11 year-old child was treated elsewhere with a prolonged course of systemic steroids. The child is clearly Cushingoid, and still has widespread urticaria

urticaria with disease duration for months is not clear, in terms of pathomechanism. The average duration of chronic idiopathic urticaria is two–three years, but most patients eventually move into remission.

### *Etiology*

If the small subgroup of patients substantiated to be reactive to a food additive is eliminated, then, at least until recently, the cause in the remainder was unknown. There have been several reports attempting to implicate local and/or systemic infections of viruses, bacteria, and fungi, such as hepatitis C virus (Kanazawa et al. 1996), *Helicobacter pylori* (*H.pylori*) (Wedi et al. 1998; Schnyder et al. 1999), and candida (Henz BM et al. 1998). However, they are



either anecdotal or may be exacerbatory rather than causative for some populations of patients. Aspirin is a recognized cause of flare-up of urticaria (Grattan 2003). In a study reported by one of us (MWG), although upwards 40 per cent of chronic urticaria patients had evidence of *H.pylori* infection, treatment of this produced no higher remission rate than when the same treatment was given to chronic urticaria patients who did not have evidence of *H.pylori* (Burova et al. 1998). Nevertheless it is feasible that *H.pylori* may have an indirect role in autoimmune chronic urticaria (Greaves 2001) (see below). Parasite infestation is not a cause in industrialized countries, but may be important in some developing countries (Wolfrom et al. 1995). Recently a subgroup of chronic idiopathic urticaria patients has proved to have a specific autoimmune basis (Hide et al. 1993) and this subset will be discussed in greater detail below.

### *Pathomechanisms*

Histamine is clearly implicated in the pathogenesis of the wheals and itch. Although histamine, derived from dermal mast cells, is a major contributor to the itch, its role in the wheals, which last several hours and are relatively poorly responsive to H-antihistamines, is less clear. Probably mast cell-derived cytokines, proteases and eicosanoids are also involved. Blood basophils and eosinophils are also prominent in skin biopsy material from wheals of all ages and may also be a source of vasoactive mediators (Sabroe et al. 1999b; Ying et al. 2002; Caproni et al. 2003).

The observation that histamine releasing activity could be demonstrated in the serum or plasma of some patients with chronic idiopathic urticaria (Grattan et al. 1986) eventually led to the recognition of autoimmune urticaria as the cause in an important subset of patients with this condition (Hide et al. 1993) (see below).

### *Clinical Features and Investigation*

Characteristically the wheals are intensely itchy, of less than 24 hours' duration individually and clear without marking the skin. Angioedema occurs in up to 50 per cent and affects skin and/or mucous membranes. Systemic symptoms are minimal. Delayed pressure urticaria occurs concurrently in up to 40 per cent of patients (Sabroe et al. 1999a). When delayed pressure urticaria is an accompanying feature, it is important to establish whether this physical urticaria or the accompanying spontaneous wheals and angioedema are the principal causes of the patient's disability, since if it is the former, as already indicated, no further investigations are worth while. The incidence of chronic idiopathic urticaria complicated with angioedema and delayed pressure urticaria, appears not so high in Japan and Asian countries according to the authors' experiences, although precise figures have not been reported.

Chronic idiopathic urticaria, with or without angioedema and delayed pressure urticaria, is a seriously disabling condition, causing occupational, social and personal disability of the same order as that consequent upon severe coronary artery disease (O'Donnell et al. 1997).

Patients with chronic urticaria are almost invariably over-investigated. No laboratory investigations are normally indicated in the first instance. Efforts should be directed at excluding urticarial vasculitis (by skin biopsy), food additive factors (by placebo-controlled challenge testing) and possibly a differential white blood cell count (for eosinophilia) in areas where parasite infestation is endemic. In severely affected patients, poorly responsive to H<sub>1</sub>-antihistamines, referral to a specialised unit for investigation for autoimmune chronic urticaria should be considered (see below).

### *Treatment*

General measures are important including a cool work and domestic environment, and avoidance of alcohol indulgence, aspirin, food additives such as preservatives and azo dyes, and wearing of tight clothes. Although almost inevitably associated with modern living, stress, fatigue and intercurrent virus infections should at least be recognised by patients as probable causes of occasional flare-ups of chronic urticaria.

H<sub>1</sub>-antihistamines are the mainstay of drug treatment. It is important to establish the diurnal periodicity of symptoms (itch occurs predominantly in the evening and at night) in timing the dosage. Most patients require an early morning dose of a low sedation antihistamine and supplementation in the evening with a further dose either of the same or, alternatively, a sedative antihistamine. If the latter is prescribed, it is important to draw the patient's attention to the possibility of significant impairment of cognitive function the next morning (Pirisi 2000). Topical application of 1% menthol in aqueous cream may be appreciated by patients as a rapid temporary relief from pruritus.

Oral steroids in short tapering courses can be useful in emergencies when rapid control is necessary. However, they are not recommended as a routine treatment of chronic urticaria, owing to the imbalance of efficacy and side effects (*Fig. 5*).

It has been proposed that H<sub>1</sub>-antihistamines may exert an 'anti-allergic' action independently of H<sub>1</sub> receptors (Hayashi and Hashimoto 1999). This consists of down-regulation of adhesion molecule expression leading to reduced eosinophil and neutrophil migration and possibly a mast cell 'stabilising' effect. However, such actions of H<sub>1</sub>-antihistamines, if substantiated, probably occur only with regimens involving well above the licensed dosages.

H<sub>2</sub>-antihistamines (e.g. cimetidine) do have a small statistically significant additive effect when combined with H<sub>1</sub>-antihistamines but it is probably not substantial enough to be clinically useful. Recently developed cysteinyl leukotriene receptor antagonists may be very effective in a certain population of

patients. The efficacy of montelukast by itself or in combination with H<sub>1</sub>-antihistamine has been shown by controlled trials (Pacor et al. 2001; Erbagci Z 2002.). On the other hand, others have proved negative (Reimers 2002). Aggravation of urticaria by aspirin in combination with other leukotriene antagonists has been reported (Ohnishi-Inoue et al. 1998).

### **Autoimmune Chronic Urticaria**

Between 30 and 50 per cent of patient with chronic 'idiopathic' urticaria have biologically functional autoantibodies against the high affinity IgE receptor or less commonly against IgE itself (Niimi et al. 1996). In these cases the antibody is deemed to be the cause of the disease. These patients are described as having autoimmune chronic urticaria (Hide et al. 1993; Hide et al. 1994).

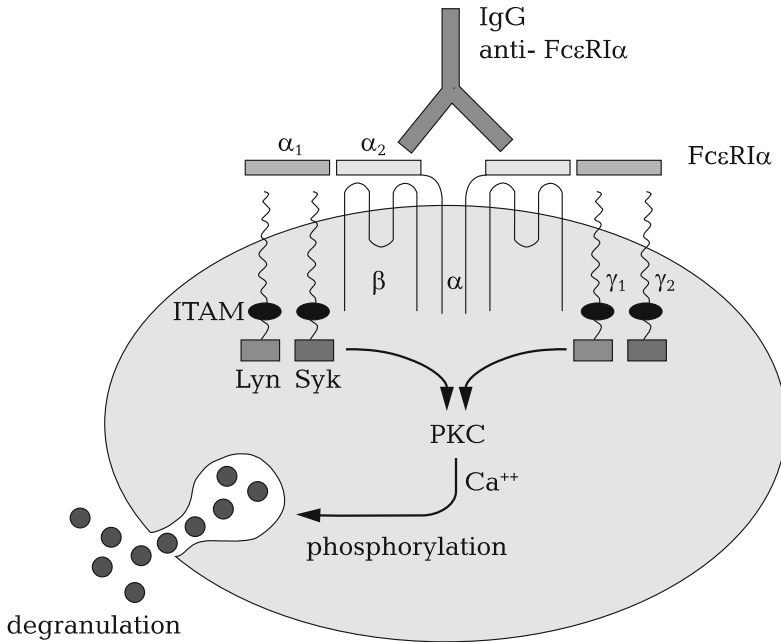
#### *Etiology*

The reason why these autoantibodies are present and causative in some patients with chronic urticaria and not others is unclear. Genetic factors are probably important. We have recently reported results of HLA class II associations in 100 patients with chronic urticaria (O'Donnell et al. 1999). Those whose sera were positive for anti-FcεRI or anti-IgE autoantibodies showed a highly significantly increased frequency of HLA DRB1\*04 (DR4) alleles. There is also a positive association with other autoimmune diseases, notably autoimmune thyroid disease in patients with autoimmune urticaria (Leznoff et al. 1983; Leznoff and Sussman 1989).

As mentioned above, a high incidence of *H.pylori* infection in patients with chronic idiopathic urticaria has already been remarked. One of us (MWG) has previously suggested that *H.pylori* infection could lead to development of anti-FcRI autoantibodies by molecular mimicry (Greaves 2001).

#### *Pathomechanisms*

Most patients with autoimmune chronic urticaria have IgG autoantibodies directed against the alpha-chain of the high affinity IgE receptors (FcRIα) expressed on dermal mast cells or blood basophils (Niimi et al. 1996). Histamine release evoked by these antibodies from basophil leucocytes of healthy donors can be inhibited by prior incubation with human recombinant alpha-chain. Some of them bind to FcRIα, regardless of the binding of IgE. However, the binding of most of these types of autoantibodies is interfered with competitively by IgE to various degrees (Hide et al. 1995). Removal of IgE (by lactic acid stripping) enables the autoantibody to release histamine but reconstituting the IgE on the surface of the basophils inhibits release (Niimi et al. 1996). Precise epitope mapping on FcRIα has not yet been carried out.



**Fig. 6.** Autoimmune Chronic Urticaria: Pathomechanisms. Schematic representation of a dermal mast cell. The high affinity IgE receptor (FcRI) is represented by  $\gamma_1$  and  $\gamma_2$ ,  $\beta$  and  $\alpha$  chains. The  $\alpha$  chain possesses two domains ( $\alpha_1$  and  $\alpha_2$ ). In this instance IgG anti-FcεRI binds to, and cross-links via  $\alpha_2$  domain. ITAM = Immunoreceptor Tyrosine Kinase Activation Motif. Lyn, Syk = protein kinases. PKC = protein kinase C

In about five per cent of patients with chronic idiopathic urticaria, the IgG autoantibody reacts with the Fc portion of IgE itself. These anti-IgE autoantibodies bind to the 4<sup>th</sup> domain of the IgE heavy chain (Grattan and Francis 1999). For histamine release to occur, either anti-FcRI $\alpha$  or anti-IgE autoantibodies normally cross-link adjacent high affinity IgE receptors through the  $\alpha$  chain or IgE respectively (Fig. 6).

The role of complement activation is controversial. Our own data, which indicated that the histamine-releasing activity of anti-FcRI $\alpha$  autoantibodies was heat-stable, argues against complement involvement. The heat-resistance of histamine releasing activity in sera of patients with chronic urticaria has also been observed by other authors (Zweiman et al. 1996; Tong et al. 1997). However, other authors, using specific inhibitors of complement components, decompemented sera and/or the reconstitution with C5, have reported evidence that in some circumstances the reaction between anti-FcRI $\alpha$  autoantibodies and dermal mast cells may be complement-dependent (Fiebiger et al. 1998; Fagiolo et al. 2000; Kikuchi and Kaplan 2002). Kikuchi and Kaplan (2001) showed the histamine release activity of serum IgG from 2 out of 6 patients was substantially enhanced by serum with complement, whereas that from

**Table 1.** Functional Properties of Anti-FcεRIα and Anti-IgE Autoantibodies

- 
1. Cause whealing in human skin following intradermal injection (see autologous serum skin test) (Sabroe et al. 1999c)
  2. Release histamine from dermal mast cells and blood basophils (Niimi et al. 1996)
  3. Reduce numbers of circulating blood basophils
  4. Serum levels are proportional to disease activity (Grattan et al. 1992, 2000; Zweiman B et al. 1996; O'Donnell BF et al. 1998)
  5. Removal by plasmapheresis results in remission of chronic urticaria in autoantibody positive patients (Grattan et al. 1992)
  6. Effectiveness of other immunomodulative therapies, such as cyclosporine-A and intravenous immunoglobulin (Grattan et al. 2000, O'Donnell BF et al. 1998)
- 

the other 4 patients was not, suggesting a heterogeneity of anti-FcεRI autoantibodies in terms of the complement dependency for histamine release. The population density of FcεRI on the surface of dermal mast cells and basophils, and/or the binding avidity of autoantibodies may be crucial – a low population density and a moderate binding avidity may allow monovalent binding of the autoantibodies with complement activation. The subclasses of IgG in autoimmune urticaria are predominantly IgG<sub>1</sub> and IgG<sub>3</sub>, which may readily activate complements (Fiebiger et al. 1998).

Subsequent intracellular events involve the activation of protein tyrosine kinases *lyn* and *syk* via immunoreceptor tyrosine kinase activation motifs located on the intracellular portions of the β and γ chains of FcεRI. (Rivera J 2002)

That these anti-FcεRI and anti-IgE autoantibodies are functional is indicated by evidence listed in *Table 1*.

Can autoimmune chronic urticaria be regarded as an autoimmune disease? Evidence includes the inverse relationship between blood basophil numbers and histamine content on the one hand and levels of serum anti-FcεRIα autoantibody on the other. Removal of the antibodies by plasmapheresis leads to remission of the urticaria (Grattan et al. 1992). The antibody also reproduces the urticarial wheal when introduced as an autologous serum injection into human skin, and causes histamine release from dermal mast cells and blood basophils (Niimi et al. 1996). Reproduction of urticaria in an animal model by sensitisation to the alpha-chain of FcεRI has not yet been carried out even with a transgenic mouse expressing FcεRIα (Fung-Leung 1996). However, it should be noted that urticarial eruptions are not apparently observed even in the systemic anaphylactic reactions induced by antigen in animals, such as rodents and guinea-pigs.

Increased histamine releasability from dermal mast cells and basophils is an important additional factor in the pathogenesis (Sabroe et al. 1998). Numerous previously published reports have shown that although mast cell numbers and histamine content of skin are essentially normal in chronic urticaria, various chemical histamine-releasing agents (codeine, compound 48/80) cause exaggerated whealing when injected into uninvolved skin of patients with

chronic urticaria (Juhlin and Michaelsson 1969, Smith CH et al 1992). This enhanced histamine releasability is probably due to the action of cytokines or neurokinines released locally. These cytokines also cause up-regulation of adhesion molecule expression, leading to the substantial leucocyte infiltrate characteristic of the histological appearances of autoimmune urticaria.

The organ selectivity of anti-Fc $\epsilon$ RI $\alpha$  autoantibodies is puzzling. Human lung mast cells express Fc $\epsilon$ RI $\alpha$  but patients with anti-Fc $\epsilon$ RI autoantibodies get urticaria without pulmonary symptoms. If complement is involved in evoked histamine release by anti-Fc $\epsilon$ RI $\alpha$  autoantibodies, then this anomaly is explicable since dermal but not lung mast cells express complement receptors. Alternatively, local cytokine and micro-circulatory differences between lung and skin may restrict access of the autoantibodies to tissue mast cells in the lungs. There is also functional heterogeneity between dermal and lung mast cells (Lowman et al. 1988). However, the reasons for fact that lung mast cells are evidently 'ring fenced' against Fc $\epsilon$ RI and anti-IgE autoantibodies remain obscure.

### *Clinical and Histological Features*

Detailed comparative reviews of the symptoms, clinical presentation and natural history of autoimmune and non-autoimmune chronic urticaria have failed to reveal differences sufficiently distinctive to be of diagnostic value (Sabroe et al. 1999a). However, the disease does tend to run a more aggressive and protracted course in patients who possess anti-Fc $\epsilon$ RI autoantibodies than those without an autoimmune etiology. Patients with autoimmune urticaria also tend to be less responsive to routine antihistamine treatment than non-autoimmune patients. Again, the difference is not so conspicuous as to be useful as a discriminating marker for an autoimmune etiology.

Sabroe et al. have also recently reported that the peripheral blood basophil leucocyte count is greatly reduced in patients with anti-Fc $\epsilon$ RI $\alpha$  autoantibodies compared with patients who did not have these antibodies (Sabroe et al. 1998). This is not an original observation; Rorsman (1961) noted almost 45 years' ago that chronic urticaria was associated with basopenia in some patients with chronic 'idiopathic' (but not physical) urticaria. The fate of the cells is of interest; degranulation or destruction in the peripheral blood is an obvious possibility. Indeed, Kaplan's group found the increase of basophils in skin of chronic idiopathic urticaria with or without autoantibodies as well as T cells, eosinophils and neutrophils (Ying et al. 2002). The alternative of redistribution into the lesional skin of chronic urticaria may account for the basopenia.

Sabroe (1999b) recently carried out a detailed histological study of skin biopsy material from patients with autoimmune and non-autoimmune urticaria. No significant differences were found apart from reduced numbers of activated eosinophils (EG2+) in lesional skin of autoimmune patients in which the wheal biopsied was more than 12 hours old. There is no vasculitis in autoimmune urticaria. More recently Kaplan's group also found no difference

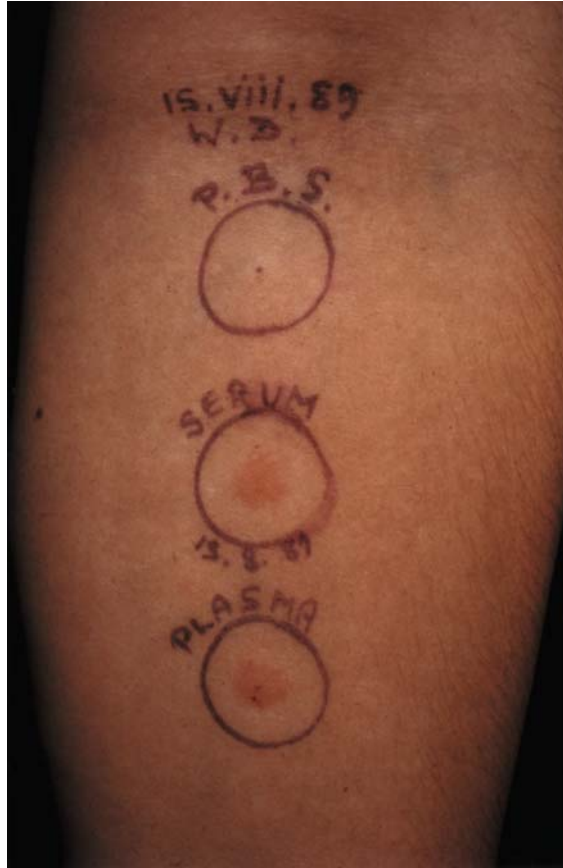
in either the numbers of inflammatory cells or the pattern of cytokine expressions between patients with and without autoantibody (Ying et al. 2002).

### Diagnosis

As pointed out above, there are no clinical or histological features which can be used as a paradigm in diagnosis (Sabroe et al. 1999a). The cornerstone of diagnosis is clearly detection of anti-Fc $\epsilon$ RI $\alpha$  or anti-IgE autoantibodies in serum of patients with chronic urticaria. However, we have found the autologous serum skin test to be a useful screening procedure. As recently described and characterised (Sabroe et al. 1999c), this test is based upon the original finding by Grattan (1986) that the serum of some patients with chronic 'idiopathic' urticaria would cause a red wheal upon autologous injection into the patient's uninvolved skin. This test has now been optimised for sensitivity and specificity (Sabroe et al. 1999c).

Autologous serum, collected during exacerbation of the chronic urticaria, is injected into uninvolved skin of the forearm in volume 0.05 ml. An equal volume of phosphate-buffered saline acts as a vehicle control. The local response is measured at 30 minutes and is deemed positive if the wheal is red in colour and at least 1.5 mm diameter greater than the saline control (*Fig. 7*). This autologous serum skin test (ASST) is positive in about 40 per cent of patients with chronic idiopathic urticaria (Table 2). In this test, false negative reactions are rare, but false positives may occasionally occur and some of the sera probably contain other wheal-producing mediators including the 'mast cell specific' factor. This non-immunoglobulin mediator retained by 3 KD ultrafiltration membranes was reported by us (Kermani et al. 1995) and appears to be present in about eight per cent of patients with chronic urticaria. It requires further characterisation. There is one study that showed no correlation between ASST and clinical features in chronic idiopathic urticaria, except for the frequency of complication with angioedema (Nettis et al. 2002). However, ASST shows a reasonable concordance with *in vitro* measurements of serum anti-Fc $\epsilon$ RI or anti-IgE autoantibodies, which also significantly correlated with clinical severities (Zweiman et al. 1996; Sabroe et al. 1999a).

A positive autologous serum skin screening test requires confirmation by *in vitro* analysis for anti-Fc $\epsilon$ RI $\alpha$  and anti-IgE autoantibodies. The current gold standard consists of demonstration by bioassay that either blood basophils or dermal mast cells release histamine or other mediators upon incubation with the patient's serum. Low IgE basophils predominantly detect anti-Fc $\epsilon$ RI autoantibodies, whereas high IgE basophils detect anti-IgE autoantibodies and anti-Fc $\epsilon$ RI autoantibodies that are non-competitive with IgE. Low IgE basophils may be directly obtained from low IgE (1 IU/ml) donors or prepared by lactic acid treatment of ordinary donors' leukocytes. To distinguish between the two types of autoantibody, it is desirable to carry out inhibition experiments utilising human recombinant  $\alpha$ -chain and monoclonal IgE. However, for practical



**Fig. 7.** Autologous Serum Skin Test. PBS = Phosphate-buffered saline; serum: undiluted 0.05 ml. Both serum and plasma show positive results at 30 min

purposes, this is usually unnecessary. In our hands, 25 per cent of chronic idiopathic urticaria sera can be confirmed to contain anti-Fc $\epsilon$ RI $\alpha$  autoantibodies, whereas about five per cent have anti-IgE autoantibodies (Niimi et al. 1996, Sabroe et al. 1999a).

As high as 76 per cent of chronic idiopathic urticaria patients were found to have anti-Fc $\epsilon$ RI $\alpha$  autoantibodies by Kaplan's group using a rat basophilic leukaemia cell line expressing  $\alpha$ -chain of human FcRI, which integrates chimeric Fc $\epsilon$ RI with endogenous rat  $\beta$  and  $\gamma$  chains of the receptor and using release of  $\beta$ -hexosaminidase as an indicator of cell degranulation (RBL-48) (Tong et al. 1997). This figure is even higher than that they observed by human basophils (52%). In our hands, however, the sensitivities of RBL-48 cell and other cell lines expressing human Fc $\epsilon$ RI $\alpha$  for anti-Fc $\epsilon$ RI $\alpha$  antibodies are not as high as human basophils obtained from healthy donors (unpublished



observation). Further studies with standardized conditions may be necessary to establish the usability of RBL cells expressing human FcεRIα.

Some investigators have used immunoassays (immunoblotting, ELISA, immunoprecipitation) (Fiebiger et al. 1995, 1998; Sabroe et al. 1998; Kikuchi and Kaplan 2001). These assays measure immunoreactive FcεRIα autoantibodies and show false positives when compared with bioassays. False positives are particularly prone to occur in autoimmune diseases including Sjögren's syndrome, dermatomyositis, pemphigus and pemphigoid (Fiebiger et al. 1998). However, unlike the anti-FcεRIα autoantibodies in urticaria which are of subtype IgG1 and IgG3, these antibodies are predominantly of the IgG2 and IgG4 subtypes. More important, they are non-functional, being inactive (non-histamine-releasing) against basophil leucocytes. Kikuchi and Kaplan (2001) showed no correlation between positive histamine release activity and immunoblotting in sera of patients with chronic urticaria. The ELISA, though initially promising, has not yet confirmed expectations in terms of specificity and demonstration of linearity between level of antibody and immunoreactivity. Horn et al (1999) detected substantial amount of anti-FcεRIα antibodies in sera from healthy donors and demonstrated that these antibodies are cross-reactive with tetanus toxoid by ELISA. He used recombinant protein consisting of two moieties of the extracellular part of human FcεRIα flanking one moiety of human serum albumin. Although the affinities of such autoantibodies against the recombinant FcεRIα were low ( $3.4 \times 10^{-6}$  and  $7.1 \times 10^{-7}$  M), healthy donor sera containing these autoantibodies showed histamine release activity as well as sera of patients with chronic idiopathic urticaria, using basophils treated with IL-3. They recently cloned anti-FcεRIα autoantibodies from healthy donors and patients with chronic idiopathic urticaria. Both autoantibodies had the same amino acid sequence and showed the activity of histamine release from basophils that were not occupied by IgE (Pachlopnik et al. 2004). On the other hand, immunoreactivity against FcεRIα in ELISA studied by Fiebiger et al (1998) and that in immunoblotting by the authors (Sabroe et al. 2002) were significantly correlated with basophil histamine release activities ( $p < 0.0001$ ,  $\chi^2$ ; data were re-calculated by the authors). Moreover, recent studies of IgE and FcεRIα revealed that cross linkage between FcεRI and FcγRII may inhibit histamine release from human mast cells and basophils (Tam et al. 2004) and binding of certain types of monomeric IgE could activate FcεRI by itself (Pandey et al. 2004). It is feasible that autoantibodies against FcεRI could mimic either of such functions. Taken together, the overall assessment of functional autoantibodies with histamine releasing assay using human basophils, or possibly mast cells, should be the gold standard for the detection of pathological autoantibodies.

Recently published values for anti-FcεRIα autoantibodies incidences and positive reactions in autologous serum skin test in chronic urticaria are listed in Table 2.

A better screening test than ASST is badly needed. Rapid flow cytophotometric methods for enumeration of circulating blood basophils offer prospects

**Table 2.** Prevalence of Anti-FcεRI Autoantibodies in Chronic Idiopathic Urticaria

	Skin test	Immunoassay	Bioassay
Grattian et al (1991)	ASST <sup>1)</sup> 20/25 (80%)		HBHR <sup>6</sup> 14/25 (56%)
Fiebiger et al (1995)		Western blot (sFcεRIα) 12/32 (37%)	
Niimi et al (1996)	ASST <sup>2)</sup> 98/163 (60%)		HBHR <sup>6)</sup> 47/163 (29%) anti-FcεRIα 38 (23%) anti-IgE 9 (6%)
Zweiman et al (1996)			HBHR <sup>6</sup> 21/70 (30%) anti-FcεRIα 12/13 anti-IgE 1/13
Tong et al (1997)			HBHR <sup>6</sup> 26/50 (52%) RBL cells 38/50 (76%)
Fiebiger et al (1998)		ELISA (sFcεRIα) 106/281 (38%)	HBHR (IL-3+) <sup>6)</sup> 39/86 (45%) 33/50 (66%) of autoAb+ 6/36 (17%) of autoAb-
Ferrer et al (1998)		Western blot (sFcεRIα) 34/53 (64%)	HBHR <sup>6</sup> foreskin-MC HR <sup>6</sup> 31/68 (48%) 28/65 (46%)
Sabroe et al (1999)	ASST <sup>3)</sup> 55/155 (35%)		HBHR <sup>6</sup> 54/155 (35%)
Horn et al (1999)		ELISA (sFcεRIα) 21/21 (100%) 5/21 (9.5%) <sup>8)</sup>	HBHR (IL-3+) <sup>6</sup> 1/21 (4.7%) <sup>9)</sup>
Asero et al (2001)	ASST <sup>4)</sup> 205/306 (67%)		HBHR <sup>6</sup> 20/121 (17%) 19/87 (22%) of ASST+

**Table 2.** Prevalence of Anti-FcεR1α Autoantibodies in Chronic Idiopathic Urticaria

	Skin test	Immunoassay	Bioassay
Kikuchi and Kaplan(2001)		Western blot (sFcεR1α)	HBHR <sup>6</sup>
		122/260 (47%)	111/260 (43%)
Nettis et al (2002)	ASST <sup>9)</sup>	42/102 (41.2%)	
Sabroe et al (2002)	ASST <sup>4)</sup>	27/78 (35%)	HBHR <sup>6</sup> skin slice- MC HR <sup>10)</sup>
		32/78 (41%) HR+ 20 HR- 12	27/78 (35%) 31/78 (40%)
Hide et al (unpublished results)	ASST <sup>5)</sup>	81/180 (45%)	HBHR <sup>6</sup>
			15/25 (60%) of ASST+ anti-FcεR1α 11/25 anti-IgE 4/25

<sup>1</sup> Determined as positive if wheal volume  $\geq 10 \text{ mm}^3$  than saline control at 60 min

<sup>2</sup> Determined as positive if diameter of wheal with flare is  $\geq 2 \text{ mm}$  than saline control at 30 min

<sup>3</sup> Determined as positive if diameter of wheal plus redness is  $\geq 1.5 \text{ mm}$  than saline control at 30 min. The condition was determined to obtain the optimal sensitivity and specificity for the identification of patients with histamine-releasing activity

<sup>4</sup> Determined as positive if wheal-and-flare area is  $\geq 50\%$  of the reaction induced by a prick test with 10 mg/ml histamine at 15 and 40 min

<sup>5</sup> Determined as positive if flare diameter is  $\geq 5 \text{ mm}$  than saline control OR serum-induced flare is larger than the flare induced by intradermal injection of 20  $\mu\text{l}$  of 10  $\mu\text{g/ml}$  histamine at 30 min

<sup>6</sup> Human basophil histamine release in the presence (if noted) or absence of IL-3

<sup>7</sup>  $\beta$ -hexosaminidase release from rat basophilic leukemia cell line transfected with human FcεR1α

<sup>8</sup> Histamine release from isolated foreskin mast cells

<sup>9</sup> When criteria for "positive" was set so as to exclude all data of all healthy controls

<sup>10</sup> Histamine release from skin slices

of an effective test, since basophil numbers are usually greatly reduced in antibody-positive patients (Sabroe et al. 1998).

### *Treatment of Autoimmune Urticaria*

The routine treatment of autoimmune chronic urticaria is essentially the same as that for non-autoimmune urticaria. All patients with chronic urticaria should receive antihistamines commencing with a low-sedation antihistamine such as loratidine 10 mg, cetirizine 10 mg, evastine 10 mg or fexofenadine 60 to 180 mg, (in Japan, fexofenadine is licensed for 120 mg; 60 mg each in morning and evening) usually administered in the morning. Since pruritus is mainly a problem in the evening and at night, it is useful to give a second dose of the same antihistamine in the evening or before retiring for the night. This represents a total daily dosage in excess of the licensed recommended dosage. In patients troubled by severe nocturnal pruritus, a sedative antihistamine such as hydroxyzine 25 mg may be indicated. However, patients should be warned that impairment of cognitive function may be a problem the following morning (Pirisi 2000).

Patients with autoimmune chronic urticaria may respond poorly to the above antihistamine regime. Systemic steroids are unsuitable as long term treatment for chronic urticaria although short tapering courses may be useful to meet specific contingencies. In patients with recalcitrant autoimmune chronic urticaria which is causing significant disability, cyclosporin may be effective (Grattan et al. 2000). The dosage for an average adult is 3–4 mg/kg/day and one of us (MWG) usually prescribe this dosage for two–three months. There is rarely a rebound withdrawal. About one-third of patients remain in remission after cyclosporin has been withdrawn; one-third relapse but only mildly and one-third relapse to their former pretreatment level of disease activity and may have to be recontinued on cyclosporin. Chronic autoimmune urticaria is not a licensed indication for cyclosporine and the usual precautions regarding renal function, blood pressure monitoring and unwanted interactions with other concurrently administered drugs metabolised via the cytochrome P450 enzyme pathway have to be considered.

We have previously reported positive results using more aggressive forms of immunotherapy including intravenous immunoglobulin (O'Donnell et al. 1998) and plasmapheresis (Grattan et al. 1992) in selected patients with autoimmune urticaria. We ought to emphasise that these treatment modalities are temporary symptom relieving rather than curative. Nevertheless, it is noteworthy that histamine releasing activities of the patients had decreased or diminished in accordance with urticarial symptoms after the treatments, endorsing the pathological role of autoantibodies and rationale for immunotherapies for chronic autoimmune urticaria.

More selective immunotherapeutic strategies are on the horizon. These include administration of humanised structure-based peptides representing the

antibody-binding sites on the  $\alpha$ -chain. This development will be dependent on epitope mapping, and should enable induction of desensitisation in anti-Fc $\epsilon$ RI-positive individuals. Alternatively down regulation of the Fc $\epsilon$ RI population density on mast cells could be achieved by administration of anti-IgE antibodies reactive with the C<sub>3</sub> domain of the IgE heavy chain (MacGlashan et al. 1987). Development of tolerance to the alpha chain of Fc $\epsilon$ RI might also be possible by oral administration (Weiner 1997).

## References

- Adachi J, Aoki T, Yamatodani A (1994) Demonstration of sweat allergy in cholinergic urticaria. *J Dermatol Sci* 7: 142–149
- Adams DD (1988) Long-acting thyroid stimulator: how receptor autoimmunity was discovered. *J Autoimmunity* 1: 3–9
- Asero R, Tedeschi A, Lorini M, Salimbeni R, Zanoletti T, Miadonna A (2001) Chronic urticaria: novel clinical and serological aspects. *Clin Exp Allergy* 31: 1105–1110
- Bentley-Phillips CB, Black AK, Greaves MW (1976) Induced tolerance in cold urticaria caused by cold-evoked histamine release. *Lancet* ii: 63–66
- Black AK, Lawlor F, Greaves MW (1996) Consensus meeting on the definition of physical urticarias and urticarial vasculitis. *Clin Exp Dermatol* 21: 424–426
- Black, AK, Physical and Cholinergic Urticarias. In: *Urticaria and Angioedema*. Eds Malcolm W Greaves, Allen P Kaplan. Marcel Dekker, New York, (2004) chapter 8, pp171 – 214
- Burova GP, Mallet AI, Greaves MW (1998) Is *Helicobacter pylori* a cause of chronic urticaria? *Br J Dermatol* 139 (Suppl): 42
- Caproni M, Volpi W, Macchia D, Giomi B, Manfredi M, Campi P, Cardinali C, D'Agata A, Fabbri P. (2003) Infiltrating cells and related cytokines in lesional skin of patients with chronic idiopathic urticaria and positive autologous serum skin test. *Exp Dermatol* 2: 621–628
- Commens CA, Greaves MW (1978) Tests to establish the diagnosis in cholinergic urticaria. *Brit J Dermatol* 98: 47–51
- Erbagci Z (2002) The leukotriene receptor antagonist montelukast in the treatment of chronic idiopathic urticaria: a single-blind, placebo-controlled, crossover clinical study. *J Allergy Clin Immunol* 110: 484–488
- Fagiolo U, Kricek F, Ruf C, Peserico A, Amadori A, Cancian M. (2000) Effects of complement inactivation and IgG depletion on skin reactivity to autologous serum in chronic idiopathic urticaria. *J Allergy Clin Immunol* 106: 567–572
- Ferrer M, Kinet JP, Kaplan AP (1998) Comparative studies of functional and binding assays for IgG anti-Fc $\epsilon$ RI $\alpha$  ( $\alpha$ -subunit) in chronic urticaria. *J Allergy Clin Immunol* 101: 672–676
- Fiebiger E, Maurer D, Holubar H, Reininger B, Hartmann G, Woisetschlager M, Stingl G (1995) Serum IgG autoantibodies directed against the alpha chain of Fc $\epsilon$ RI: a selective marker and pathogenetic factor for a distinct subset of chronic urticaria patients. *J Clin Invest* 96: 2606–2612
- Fiebiger E, Hammerschmid F, Stingl G, Maurer D (1998) Anti-Fc $\epsilon$ RI $\alpha$  autoantibodies in autoimmune-mediated disorders. *J Clin Invest* 101: 243–261
- Fung-Leung W-P, Sousa-Hitzien JD, Ishaque A (1996) Transgenic mice expressing the human high affinity immunoglobulin (Ig)E receptor  $\alpha$  chain, respond to human IgE in mast cell degranulation and allergic reactions. *J Exp Med* 183: 49–56
- Grattan CEH, Wallington TB, Warin RP (1986) A serological mediator in chronic idiopathic urticaria: a clinical immunological and histological evaluation. *Br J Dermatol* 114: 583–590
- Grattan CEH, Francis DM, Hide M, Greaves MW (1991) Detection of circulating histamine releasing autoantibodies with functional properties of anti-IgE in chronic urticaria. *Clin Exp Allergy* 21: 695–704

- Grattan CEH, Francis DM, Slater NGP, Greaves MW (1992) Plasmapheresis for severe unremitting chronic urticaria. *Lancet* 339: 1078–1080
- Grattan CEH, Francis DM (1999) Autoimmune urticaria. *Advances Dermatol* 15, 311–340
- Grattan CEH, O'Donnell BF, Francis DM, Niimi N, Barlow RJ, Seed PT, Black AK, Greaves MW (2000) Randomised double blind study of cyclosporin in chronic idiopathic urticaria. *Br J Dermatol* 143: 365–372
- Grattan CEH (2003) Aspirin sensitivity and urticaria. *Clin Exp Dermatol* 28: 123–127
- Greaves MW (1995) Current concepts in chronic urticaria. *New Eng J Med* 332: 1767–1772
- Greaves MW (2000a) Management of urticaria. *Hosp Med* 61: 463–469
- Greaves MW (2000b) Chronic urticaria. *J Allergy Clin Immunol* 105: 664–672
- Greaves MW (2001) Chronic idiopathic urticaria (CIU) and *Helicobacter pylori* – not directly causative, but could there be a link? *Allergy Clin Immunol Internat* 13: 23–26
- Hayashi S Hashimoto S (1999) Anti-inflammatory actions of new antihistamines. *Clin Exp Allergy* 29: 1593–1596
- Henz BM, Zuberbier T. Causes of urticaria. pp20–38. in *Urticaria* eds Henz BM, Zuberbier T, Grabbe J, Monroe E. Springer, Verlag Berlin Heidelberg 1998
- Herxheimer A (1956) The nervous pathway mediating cholinergic urticaria. *Clin Sci* 15: 195–205
- Hide M, Francis DM, Grattan CH, Greaves MW (1993) Autoantibodies against the high affinity IgE receptor as a cause for histamine release in chronic urticaria. *New Eng J Med* 328: 1599–1604
- Hide M, Francis DM, Grattan CEH, Barr RM, Winkelmann RK, Greaves MW (1994) The pathogenesis of chronic urticaria: new evidence suggests an autoimmune basis and implications for treatment. *Clin Exp Allergy* 24: 624–627
- Hide M, Francis DM, Barr RM and Greaves MW (1995). Skin mast cell activation by autoantibodies in urticaria and therapeutic implications. in *Biological and Molecular Aspects of Mast Cell and Basophil Differentiation and Function*. eds. Kitamura Y, Yamamoto S, Galli SJ, Greaves MW. pp183–192, Raven Press, New York
- Hirschmann JV, Lawlor F, English SJC, Lowback JB, Winkelmann RK, Greaves MW (1987) Cholinergic urticaria. *Arch Dermatol* 123: 462–467
- Holgate ST Bradding P Sampson AP (1996) Leukotriene antagonists and synthesis inhibitors: new directions in asthma therapy. *J Allergy Clin Immunol* 98: 1–13
- Horn MP, Gerster T, Ochensberger B, Derer T, Kricek F, Jouvin MH, Kinet JP, Tschernig T, Vogel M, Stadler BM, Miescher SM (1999) Human anti-FcepsilonR1alpha autoantibodies isolated from healthy donors cross-react with tetanus toxoid. *Eur J Immunol* 29: 1139–1148
- Juhlin L, Michaelsson G (1969) Cutaneous reactions to kallikrein, bradykinin and histamine in healthy subjects and in patients with urticaria. *Acta Derm Venereol (Stockh)* 49: 26–36
- Kanazawa K, Yaoita H, Tsuda F, Okamoto H. (1996) Hepatitis C virus infection in patients with urticaria. *J Am Acad Dermatol* 35: 195–198
- Keahey TM, Greaves MW (1980) Cold urticaria: dissociation of cold-evoked histamine release and urticaria following cold challenge. *Arch Dermatol* 116: 174–177
- Kermani F, Niimi N, Francis DM, Barr RM, Black AK, Greaves MW (1995) Characterisation of a novel mast cell-specific histamine-releasing activity in chronic idiopathic urticaria. *J Invest Dermatol* 105: 452
- Kikuchi Y, Kaplan AP (2001) Mechanisms of autoimmune activation of basophils in chronic urticaria. *J Allergy Clin Immunol* 107: 1056–1062
- Kikuchi Y, Kaplan AP (2002) A role for C5a in augmenting IgG-dependent histamine release from basophils in chronic urticaria. *J Allergy Clin Immunol* 109: 114–118
- Koro O, Dover JS, Francis DM, Black AK, Kelly RW, Barr RM, Greaves MW (1986) Release of prostaglandin D2 and histamine in a case of localised heat urticaria, and effect of treatment. *Br J Dermatol* 115: 721–728
- Lawlor F, Black AK, Milford Ward A, Morris R, Greaves MW (1989a) Delayed pressure urticaria: objective evaluation of a variable disease using a dermatographometer and assessment of treatment using colchicine. *Br J Dermatol* 120: 403–408
- Lawlor F, Black AK, Breathnach AS, Greaves MW (1989b) Vibratory angioedema: lesion induction, clinical features, ultrastructural findings and response to therapy. *Br J Dermatol* 120: 93–99

- Lawrence CM, Jorizzo JL, Black AK, Coutts A, Greaves MW (1981) Cholinergic urticaria associated with angioedema. *Br J Dermatol* 105: 543–550
- Leznoff A, Josse RG, Denburg J, Dolovich J (1983) Association of chronic urticaria and angioedema with thyroid autoimmunity. *Arch Dermatol* 119: 636–640
- Leznoff A, Sussman GL (1989) Syndrome of idiopathic chronic urticaria and angioedema with thyroid autoimmunity – a study of 90 patients. *J Allergy Clin Immunol* 84: 66–71
- Lowman MA, Rees PH, Benyon RC (1988) Human mast cell heterogeneity. Histamine release from mast cells dispersed from skin, lung, adenoids, tonsils and colon in response to IgE-dependent and non-immunological stimuli. *J Allergy Clin Immunol* 81: 590–597
- MacGlashan DW, Bochner BS, Adelman DC (1987) Down regulation of FcRI expression on human basophils during in vivo treatment of atopic human patients with anti-IgE antibody. *J Immunol* 158: 1438–1445
- May CD (1985) Are confusion and controversy about food hypersensitivity really necessary? *J Allergy Clin Immunol* 75: 329–333
- Misch K, Black AK, Greaves MW (1983) Almosauri T, Stanworth DR, Passive transfer of cold urticaria to monkeys. *Acta Derm Venereol (Stockh)* 63: 163–164
- Murphy GM, Black AK, Greaves MW (1983) Persisting cholinergic erythema – a variant of cholinergic urticaria. *Br J Dermatol* 109: 343–348
- Murphy GM, Zollman PE, Greaves MW, Winkelmann RK (1987) Symptomatic dermatographism (factitious urticaria) – passive transfer experiments from human to monkey. *Br J Dermatol* 116: 801–804
- Niimi N, Francis DM, Kermani F, Black AK, Barr RM, Grattan CEH, Greaves MW (1996) Dermal mast cell activation by autoantibodies against the high affinity IgE receptor in chronic urticaria. *J Invest Dermatol* 106: 1001–1006
- O'Donnell BF, Black AK (1995) Urticarial vasculitis. *Int Angiol* 14: 166–174
- O'Donnell BF, Lawlor F, Simpson J, Morgan M, Greaves MW (1997) The impact of chronic urticaria on quality of life. *Br J Dermatol* 136: 197–201
- O'Donnell BF, Barr RM, Black AK, Francis DM, Greaves MW (1998) Intravenous immunoglobulin in chronic autoimmune urticaria. *Br J Dermatol* 138: 101–6
- O'Donnell BF, O'Neill CM, Francis DM, Niimi N, Barr RM, Barlow RJ, Greaves MW, Welsh K (1999) Human leucocyte antigen class II associations in chronic idiopathic urticaria. *Br J Dermatol* 140: 853–858
- Ohnishi-Inoue Y, Mitsuya K, Horio T (1998) Aspirin-sensitive urticaria: provocation with a leukotriene receptor antagonist. *Br J Dermatol* 138: 483–485
- Ozkaya-Bayazit E, Demir K, Ozgaroglu E, Kaymakoglu S, Ozamagar G (1998) Helicobacter pylori eradication in patients with chronic urticaria. *Arch Dermatol* 314: 1165–1166
- Pachlopnik JM, Horn MP, Fux M, Dahinden M, Mandallaz M, Schneeberger D, Baldi L, Vogel M, Stadler BM, Miescher SM (2004) Natural anti-FcRI autoantibodies may interfere with diagnostic tests for autoimmune urticaria. *J Autoimmun* 22: 43–51
- Pacor ML, Di Lorenzo G, Corrocher R. (2001) Efficacy of leukotriene receptor antagonist in chronic urticaria. A double-blind, placebo-controlled comparison of treatment with montelukast and cetirizine in patients with chronic urticaria with intolerance to food additive and/or acetylsalicylic acid. *Clin Exp Allergy* 31: 1607–1614
- Pandey V, Mihara S, Fensome-Green A, Bolsover S, Cockcroft S (2004) Monomeric IgE stimulates NFAT translocation into the nucleus, a rise in cytosol  $Ca^{2+}$ , degranulation, and membrane ruffling in the cultured rat basophilic leukemia-2H3 mast cell line. *J Immunol* 172: 4048–4058
- Pastorello EA (1995) Evaluating new tests for the diagnosis of food allergy. *Allergy* 50: 289–291
- Pirisi A (2000) Antihistamines impair driving as much as alcohol. *Lancet* 355: 905
- Ramsay CA (1977) Solar urticaria treatment by inducing tolerance to artificial radiation and natural light. *Arch Dermatol* 113: 1222–1225
- Reimers A, Pichler C, Helbling A, Pichler WJ, Yawalkar N (2002) Zafirlukast has no beneficial effects in the treatment of chronic urticaria. *Clin Exp Allergy* 32: 1763–1768
- Rivera J (2002) Molecular adapters in FcεRI signaling and the allergic response. *Curr Opin Immunol* 14: 688–693
- Rorsman H (1961) Basopenia in urticaria. *Acta Allergol* 16: 185–215

- Sabroe RA, Francis DM, Barr RM, Black AK, Greaves MW (1998) Anti-FcεRI autoantibodies and basophil histamine release ability in chronic idiopathic urticaria. *J Allergy Clin Immunol* 102: 651–658
- Sabroe RA, Seed PT, Francis DM, Barr RM, Black AK, Greaves MW (1999a) Chronic idiopathic urticaria: comparison of clinical features of patients with or without anti-FcεRI or anti-IgE autoantibodies. *J Am Acad Dermatol* 40: 443–450
- Sabroe RA, Poon E, Orchard GE, Lane D, Francis DM, Barr RM, Black AK, Greaves MW (1999b) Cutaneous inflammatory cell infiltrate in chronic idiopathic urticaria: comparison of patients with and without anti-FcεRIα or anti-IgE autoantibodies. *J Allergy Clin Immunol* 103: 484–493
- Sabroe RA, Grattan CEH, Francis DM, Black AK, Barr RM, Greaves MW (1999c) The autologous serum skin test: a screening test for autoantibodies in chronic idiopathic urticaria. *Br J Dermatol* 140: 446–452
- Sabroe RA, Fiebiger E, Francis DM, Maurer D, Seed PT, Grattan CE, Black AK, Stingl G, Greaves MW, Barr RM (2002) Classification of anti-FcεRI and anti-IgE autoantibodies in chronic idiopathic urticaria and correlation with disease severity. *J Allergy Clin Immunol* 110: 492–499
- Schnyder B, Helbling A, Pichler WJ (1999) Chronic idiopathic urticaria: natural course and association with *Helicobacter pylori* infection. *Int Arch Allergy Immunol* 119: 60–63
- Sibbald RG, Black AK, Eady RAJ, James M, Greaves MW (1981) Aquagenic Urticaria: evidence of a cholinergic and histaminergic basis. *Br J Dermatol* 105: 297–302
- Smith CH, Atkinson B, Morris RW, Hayes N, Foreman JC, Lee TH. (1992) Cutaneous responses to vasoactive intestinal polypeptide in chronic idiopathic urticaria. *Lancet*. 339: 91–93
- Tam SW, Demissie S, Thomas D, Daeron M (2004) A bispecific antibody against human IgE and human FcRII that inhibits antigen-induced histamine release by human mast cells and basophils. *Allergy* 59: 772–780
- Tong LJ, Balakrishnan G, Kochan JP, Kinet J-P, Kaplan AP (1997) Assessment of autoimmunity in chronic urticaria. *J Allergy Clin Immunol* 99: 461–465
- Wedi B, Wagner S, Werfil T, Mann MP, Kapp A (1998) Prevalence of *Helicobacter pylori*-associated gastritis in chronic urticaria. *Int Arch Allergy Immunol* 116: 288–294
- Weiner HL (1997) Oral tolerance: immune mechanisms and treatment of autoimmune diseases. *Immunol Today* 18: 335–343
- Wolfrom E, Chene G, Boisseau H, Beylot C, Geniaux M, Taleb A (1995) Chronic urticaria and *Toxocara canis*. *Lancet* 345: 196
- Ying S, Kikuchi Y, Meng Q, Kay AB, Kaplan AP (2002) TH1/TH2 cytokines and inflammatory cells in skin biopsy specimens from patients with chronic idiopathic urticaria: comparison with the allergen-induced late-phase cutaneous reaction. *J Allergy Clin Immunol* 109: 694–700
- Zuberbier T, Bohm M, Czarnetski BM (1993) Food intake in combination with a rise in body temperature: a newly defined cause of angioedema. *J Allergy Clin Immunol* 91: 1226–1227
- Zweiman B, Valenzano M, Atkins PC, Tanus T, Getsy JA (1996) Characteristics of histamine-releasing activity in sera of patients with chronic idiopathic urticaria. *J Allergy Clin Immunol* 98: 89–98
- Zuberbier T, Greaves MW, Juhlin L, Kobza-Black A, Maurer D, Stingl G, Henz BM (2001) Definition, classification, and routine diagnosis of urticaria: a consensus report. *J Investig Dermatol Symp Proc*. 6: 123–127



# 11 Lichen Planus, Lichenoid Eruptions and Cutaneous Graft-Versus-Host-Reaction

*Miklós Simon Jr.*

## Introduction

Lichen planus (LP) is a noncontagious, inflammatory, pruritic, papular mucocutaneous disease of unknown etiology that most commonly affects middle-aged adults. In 1869 Erasmus Wilson described the cutaneous "leichen planus" in 50 case histories and recorded oral lesions in 3 of his patients (Wilson, 1869). Weyl and Wickham noted the surface markings on the papules and pointed out the importance of these marks in establishing the clinical diagnosis of LP (Weyl, 1885; Wickham, 1895). After Neumann, Weyl, Caspary, and Poór, Darier described the histopathology of LP (Darier, 1909), the only important addition has been the demonstration of "colloid bodies" at the dermoepidermal junction by Thyresson and Moberger (1957). The direct immunofluorescence findings in LP have been extensively studied for the first time by Barthelmes and Haustein (1970) and Baart de la Faille Kuyper and Baart de la Faille (1974), respectively.

LP has a worldwide distribution. The prevalence of LP in the general population is of the order of 0.9 to 1.2% (Scully & El-Kom, 1985). It appears initially during the fifth or sixth decade and affect women preferentially. LP of childhood is unusual, but familial cases have been observed (Copeman, 1978). A weak association with HLA-A3, B8, B16, B35 and a significantly increased HLA-DR1 (DRB1\* 0101) antigen frequency has been reported in patients with idiopathic LP (Simon jr et al, 1984; Powell et al, 1986; La Nasa et al, 1995). In addition, TNF- $\alpha$  and IFN $\gamma$  polymorphisms contributing to susceptibility to LP were described, very recently (Carrozzo et al, 2004).

The cause of LP is unknown. Evidence points to the possibility that an alteration of epidermal cell antigens (bacterial/viral infections, contact sensitizers, trauma etc.) induces a cell-mediated immune response similar to that seen in cutaneous graft-versus-host-reaction (cGVHR). Drugs may induce lichenoid eruptions (LDE). LDE (probably an allergic type IV reaction) produces

mucocutaneous lesions that are clinically and histologically indistinguishable from (idiopathic) LP. LDE usually appear as a symmetric eruption on the trunk and extremities and sometimes fail to exhibit classic Wickham striae. Medications commonly associated with the development of LDE are antimalarials, gold, penicillamine, methyldopa,  $\beta$ -blockers, angiotensin-converting enzyme inhibitors, spironolactone, lithium, cinnarizine, nonsteroidal anti-inflammatory drugs, thiazide, phenothiazine derivatives, allopurinol, tetracycline, and sulfonyleurea agents (Ellgehausen et al, 1998).

There have been several reports of patients with LP in association with autoimmune disorders, notably with systemic lupus erythematosus, thymoma, myasthenia gravis, dermatomyositis, ulcerative colitis, primary biliary cirrhosis, chronic active hepatitis, pemphigus vulgaris, dermatitis herpetiformis, bullous pemphigoid, alopecia areata, vitiligo, Sjögren's syndrome, morphea, and systemic sclerosis suggesting there may also be an immunological basis for classical LP (Simon jr, 1985).

### **Immune Pathogenesis**

Direct immunofluorescence studies of lesional and uninvolved skin in patients with LP demonstrated an irregular deposition of fibrin and complement along the dermoepidermal junction, especially in the dermal papillary region and around hair follicles, in the active papular lesions. The colloid bodies fluoresced brightly with IgM and with other immunoglobulins and complement components (Barthelmes & Haustein, 1970; Baart de la Faille-Kuyper & Baart de la Faille, 1974; Simon jr et al, 1983). In 1984, Olsen et al described an LP-specific antigen (LPSA) found by indirect immunofluorescence in the granular or spinous layer of the epidermis of lesional tissue (Olsen et al, 1984). The circulating anti-LPSA antibodies are more likely to be markers of the disease than to be causative.

In 1975 Touraine et al (1975) and Saurat et al (1975) reported a lichenoid eruption that occurred in two men who had received allogenic bone marrow transplants from their sisters. It now seems likely that this lichenoid tissue reaction is a later and more chronic manifestation of a GVHR in which the target appears to be the basal cell layer of the epidermis. The clinical picture and the histologic and direct immunofluorescence findings were essentially the same as those in idiopathic LP. Immunopathological investigations of lesional skin in these patients revealed intraepidermal a predominance of CD3<sup>+</sup>CD8<sup>+</sup>CD11a<sup>+</sup>CD16<sup>+</sup>CDw137<sup>+</sup>T-lymphocytes and a net-like specific positive staining when exposed to HLA-DR, CD54, CD36, CD21, CD16, and CD1 monoclonal antibodies, recently (Simon jr & Hunyadi, 1992; Anasetti, 2004). Cutaneous GVHR occurs most commonly in patients undergoing bone marrow transplantation, after solid organ transplant, but is also seen in fetuses ob-

taining maternal leukocytes via maternal-fetal transfusion and in blood transfusions transplanting immunocompetent cells into immunodeficient recipients. The precise pathophysiology of GVHR is not known. However, several studies demonstrate that acute GVHR occurring in humans is induced by donor T-lymphocytes reactive against recipient cells expressing different tissue antigens. On the other hand, T-cells recognizing host-specific antigens are present in the blood and the skin of patients with chronic GVHR (Aractingi & Chosidow, 1998). A significant association between polymorphism of TNF- $\alpha$ , IFN- $\gamma$ , IL-10, and IL-6 and the development of severe GVHR has been demonstrated, recently (Takahashi et al, 2000; Cavet et al, 2001).

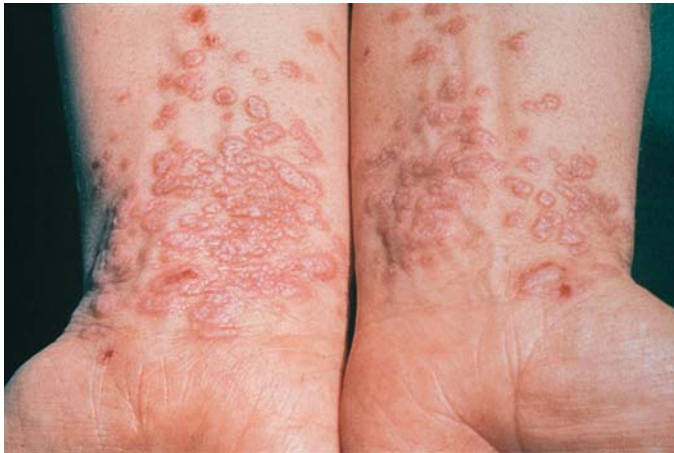The pathologic process in LP is a cell-mediated response localized to the dermoepidermal junction and characterized by degeneration of keratinocytes in the basal layer and disruption of the basement membrane. The basement membrane zone is an interface composed of epidermal basal cell surface glycoproteins, laminin, fibronectin, type IV collagen, and supporting mesenchymal extracellular proteoglycans. These proteins and oligosaccharides may be identified immunohistochemically by monospecific antibodies and high-affinity lectins, respectively.

The earliest features of LP are changes in, and close to the epidermal basal cell layer, which may occur in the absence of demonstrable changes in the dermis. Studies concerning the evolution of lesions of LP demonstrated, that one of the first observable changes is the appearance of Langerhans cells (Ragaz & Ackerman, 1981). Shortly after appearance of Langerhans cells basal keratinocytes undergo flattening and hydropic changes, their nuclei are injured at an early phase of the mitotic cycle. These basal cell changes in LP are accompanied by a dense mononuclear inflammatory T-lymphocyte infiltrate subepidermal and at the dermoepidermal interface, the location of which makes a relationship to the basal epithelial changes highly likely.

In the course of examining keratinocyte-lymphocyte interactions in vitro Nickoloff et al (1988) reported prominent adherence by both allogeneic and autologous T-lymphocytes and monocytes to cultured keratinocytes after pretreatment of keratinocytes with IFN $\gamma$ . The binding of these mononuclear cells to IFN $\gamma$ -treated keratinocytes involves the lymphocyte function-associated antigen-1 (LFA-1) molecule on T-cells and the intercellular adhesion molecule-1 (ICAM-1) induced by IFN $\gamma$  or TNF- $\alpha$  on keratinocytes (Griffiths et al, 1989). Biopsy specimens from lesional skin of LP patients exhibited intraepidermal specific positive staining when exposed to ICAM-1 (CD54), HLA-DR, NF-kappaB, CXCL9, 10, 11, CD1, and CD120a antibodies (Malmnäs Tjernlund, 1980; Simon jr, 1988; Griffiths et al, 1989; Simon jr & Gruschwitz, 1997; Iijima et al, 2003; Santoro et al, 2003). CD54 expression in lesional keratinocytes in LP, similar to that in various cutaneous inflammatory conditions (Lange Wantzin et al, 1988; Griffiths et al, 1989), may be an important initiator of keratinocyte-lymphocyte interaction, whereas HLA-DR expression in keratinocytes seems to be more important in postadherence antigenic recognition and/or presentation to activated T-lymphocytes (Messadi et al, 1988).

In LP, the cellular infiltrate is predominantly composed of T-lymphocytes and monocytes as detected by hetero- and monoclonal antibodies, nonspecific esterase, lysosyme, and, selectively by peanut agglutinin lectin (Walker, 1976). The role of these T-lymphocytes, probably antigen activated T-cells, is not quite clear, however, autoradiographic investigations revealed a three to four times higher lymphoblast proliferation rate in LP lesions than in psoriasis or contact dermatitis (Lachapelle & De la Brassine, 1973). Langerhans cells in the epidermis and subepidermal may also be identified with the use of light microscopy by formalin resistant sulfhydryl dependent nucleoside triphosphatase, ultrastructurally by the presence of Birbeck's granules, immunohistochemically by monoclonal antibodies or S-100 calf brain protein. Their participation in LP, and close vicinity to the T-lymphocytes, combined with local and systemic release of various cytokines (e.g.  $\text{TNF-}\alpha$ , IL-6,  $\text{IFN}\gamma$ ) both in the skin and in the serum, would seem to provide antigen processing activity and the induction of a hypersensitivity reaction (Giannotti et al, 1983; Soehnchen et al, 1992). In addition, soluble mediators of cell damage produced by T-cells may induce keratinocyte apoptosis and formation of colloid bodies.

Examinations of different lymphocyte subpopulations in cutaneous inflammatory infiltrate of active LP revealed the existence of T-lymphocytes of both the  $\text{CD4}^+$  and the  $\text{CD8}^+$  phenotype. In early phases of LP lesions the lymphocytes observed in close contact with large, non-lymphoid cells were identified as  $\text{CD4}^+$ T-cells (Bhan et al, 1982). In the late phases of LP lesions intraepidermal lymphocytes almost constantly exhibited CD8-positivity (Simon jr & Keller, 1984). The dermoepidermal interface, from the pathogenetic point of view probably the most important zone, showed a predominance of  $\text{HLA-DR}^+\text{CD25}^+\text{LFA-1}^+\text{TNF-R}^+\text{CCR5}^+\text{CXCR3}^+\text{CCL5}^+\text{CXCL10}^+\text{CD3}^+\text{CD8}^+\text{TCR}\gamma\delta^-$



**Fig. 1.** Typical purple polygonal papules of LP

T-lymphocytes (Malrnäs Tjernlund, 1980; Simon jr & von den Driesch, 1994; Gadenne et al, 1994; Simon jr & Gruschwitz, 1997; Iijima et al, 2003).

Immunological characterization of different T-lymphocyte subpopulations in peripheral blood of LP patients, by means of the indirect immunofluorescence technique using monoclonal antibodies, clearly documented a reduced percentage of the CD8<sup>+</sup>T-cell subset, normal pan T-, CD4<sup>+</sup>T-, and B-lymphocyte values as compared with the controls (Simon jr & Keller, 1984). The phytohemagglutinin response of lymphocytes from LP patients was in the same range as that of healthy controls (Cerni et al, 1976).

A markedly diminished, to the severity of the disease related natural killer cell activity against K562 target cells was revealed in patients with extensive erosive LP of oral mucosa, generalized acute eruptive and moderate cutaneous LP as compared with that of patients with non-erosive LP of oral mucosa and healthy controls. Interleukin-2 failed to restore completely reduced natural killer cell activities in all groups of patients investigated (Simon jr et al, 1989).

The in vitro effect of peripheral blood lymphocytes on syngeneic oral epithelial cells using a modified <sup>51</sup>Cr release macro-assay in patients with LP resulted as a substantial lymphocytotoxicity in comparison to the controls. This positive lymphocytotoxicity is probably generated by sensitized effector lymphocytes via specific recognition of foreign antigenic structures on syngeneic oral target cells (Simon jr et al., 1983). Similar results were found using CD8<sup>+</sup> T-cell lines and clones cultured from LP lesions against autologous lesional keratinocytes, recently (Sugerman et al, 2000). These findings may be regarded as a functional evidence for the pathogenetic role of CD8<sup>+</sup> cytotoxic T-cells in the course of LP.

## Clinical Features

### Lichen Planus, Lichenoid Eruptions

The cutaneous lesions of LP consist of pruritic faintly erythematous to violaceous, flat-topped, polygonal papules, occasionally showing central umbilication. A thin, transparent scale may be discerned atop the lesions. A network of fine white lines or puncta referred to as Wickham striae is present in many well-developed papules (*Fig. 1*).

LP lesions are usually distributed symmetrically, the disease tends to involve the flexural areas (wrists, arms, legs) preferentially. The thighs, lumbar area, trunk, neck, and the dorsal surfaces of the hands with the nails may also be affected. The face and scalp are usually spared in classic LP. Inverse LP affects the axillae, groin, and inframammary regions. Nail changes include longitudinal ridging and splitting of the nail plate, onycholysis, pterygium formation, or complete loss of the nail plate. Mucous membranes are in more than half of the patients additional sites of involvement. Erosive mucosal LP

is extremely painful often pursues a chronic course with little tendency to spontaneous resolution. It may predispose to squamous cell carcinoma, but the risk is fairly low. In generalized LP, the eruption often spreads within 1–3 month from onset of the disease. Koebner's isomorphic response (LP develops at the site of exogenous irritation) is common (Fox & Odom, 1985; Boyd & Neldner, 1991).

### Clinical Variants

Several distinctive variants of LP need to be recognized, since lack of characteristic skin changes in these cases makes the clinical diagnosis difficult. The prototypic papule of LP can be altered/modified in morphology, configuration or anatomic distribution.

**Linear LP.** Linear group of typical LP papules, usually on the extremities. The linear pattern may develop secondary to trauma, in zosteriform or segmental arrangement or even in the site of healed herpes zoster.

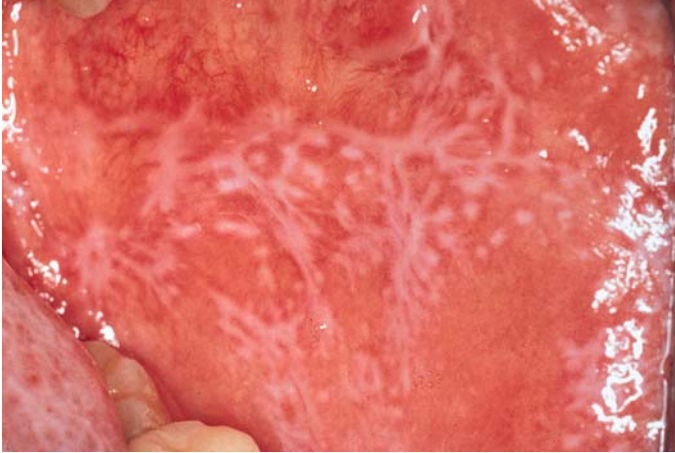**Annular LP.** Annular lesions develop from a ring of typical LP papules that progress peripherally and produce central clearing. Annular lesions are common on the penis and scrotum but may occur on the trunk or extremities.

**Bullous LP.** Rare variant of LP characterized by the development of bullae on preexisting LP papules. The bullae, which appear mostly on the extremities with mild constitutional symptoms, usually resolve in a few month. Bullae arising from normal skin in LP patients are more characteristic of lichen planus pemphigoides, which is a unique condition with circulating IgG autoantibodies reacting to 180- and/or 200-kDa antigen within the basement membrane zone.

**Erosive/ulcerative LP.** This is a very rare variant of LP presenting with chronic, painful bullae and ulcerations of the soles of the feet, and sometimes of the mucous membranes, associated with cicatricial alopecia of the scalp and permanent loss of the toenails. The lesions on the feet tend not to heal and have a definite risk of development of a squamous cell carcinoma in the chronic ulcerations.

**Hypertrophic LP.** The extensor sides of the shins and interphalangeal joints are preferentially affected with highly pruritic, lichenified, violaceous, or hyperpigmented plaques (LP verrucous). The lesions are often symmetric, sometimes show accentuated, elevated follicle swellings and chalky hyperkeratoses. Scarring occurs after healing of the lesions. Malignant degeneration is not uncommon.

**Atrophic LP.** In some cases, atrophy of LP papules may produce sharply demarcated, whitish, atrophic maculae. These lesions can coalesce and form larger plaques most common on the trunk or lower extremities. This LP variant is



**Fig. 2.** Reticular LP in buccal mucosa

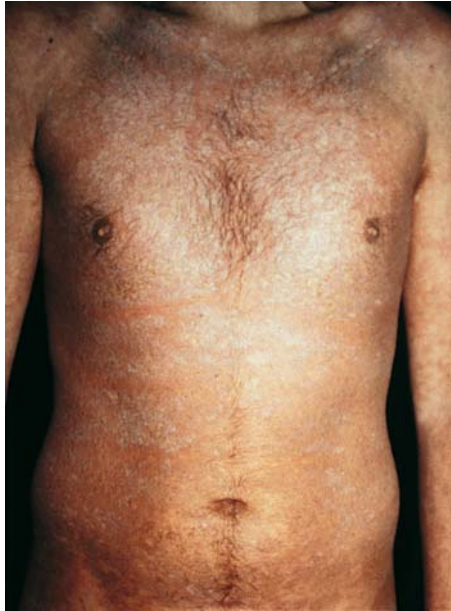rare and needs to be distinguished from lichen sclerosus et atrophicus and guttate morphea.

**Follicular LP.** This form of LP may occur alone or simultaneously with other mucocutaneous changes of LP. It forms isolated or aggregated, pinhead-sized, red papules, which carry a conical acuminated hyperkeratosis (LP acuminatus). Sites of predilection include the trunk, neck, sacral region, and the proximal extremities. Follicular LP of the scalp also occurs in an isolated form and leads to scarred alopecia (LP follicularis decalvans). This condition affects women more than men. Perifollicular erythema and acuminate keratotic plugs are characteristic features. The symptom combination of follicular LP on the trunk and on the scalp with nail dystrophy has been described as Lassueur-Graham-Little syndrome.

**Actinic LP.** This variant is more common in the tropics, especially in children and young adults, on sun-exposed parts of the body such as the face, the back of the hands, the lower forearms, and the chest. The extremely pruritic papular lesions are hyperpigmented with violaceous-brown color, which frequently show annular configuration. The course is subacute, and the condition tends to heal spontaneously.

**Mucosal LP.** LP can affect the mucosal sites of mouth, glans penis, vulva, vagina, collum uteri, anus, conjunctiva, nose, larynx, trachea, esophagus, stomach, urethra, bladder, and tympanic membrane.

Oral LP is present in some 60–70% of dermatological patients with LP. As the sole manifestation of the disease, it makes up 15% to 35% of the patient populace. The buccal mucosa (bilateral) and the tongue are most often affected



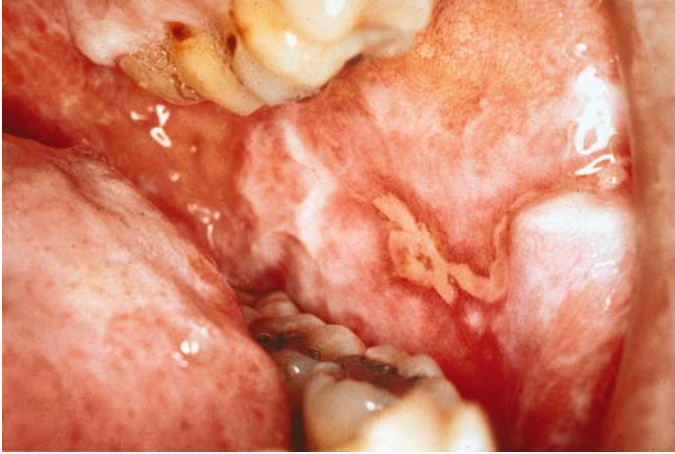
**Fig. 3.** Disseminated lichenoid GVHR

but the gums, floor of the mouth, palate, and lips have also been documented. The mucosal lesions consist of lacy, reticulated white streaks (*Fig. 2*), white papules and plaques, and erythematous, atrophic or ulcerated patches with painful, burning sensations.

Particular clinical forms are characteristic for certain regions of the oral mucosa. Reticular LP is the most common type. It affects the buccal mucosa predominantly. The margins of the tongue show generally lace-like and/or erosive LP, the dorsal surface exhibits usually round, white plaques or smooth atrophic areas. Most cases of carcinoma appear to arise in patients with long-standing erosive LP of the tongue or buccal mucosa. Gingival involvement of LP may potentially lead to the picture of desquamative gingivitis (Scully & El-Kom, 1985).

Lesions of the male genitalia are observed in about 25% of cases. The glans penis is most commonly affected, exhibiting annular lesions frequently. Similar changes can occur on the scrotal skin as well. Occasionally, the glans penis has erosive lesions and is the only site of LP involvement (Alinovi et al, 1983). The female genitalia demonstrate generally patches of leukoplakia or erythroplakia, with variable atrophy. Desquamative vaginitis is most commonly due to LP. The labia minora agglutinate and vaginal adhesions, in association with burning pain, may prevent sexual intercourse (Edwards & Friedrich jr, 1988; Soper et al, 1988).





**Fig. 4.** Erosive buccal lesions in a patient with lichenoid GVHR

### **Cutaneous Graft-Versus-Host-Reaction (cGVHR)**

Mucocutaneous lesions of GVHR occur in 20 to 80% of posttransplant cases after marrow infusion. There are two forms: in the acute form the cutaneous eruption begins between the fifth and fiftieth day, in the chronic form two to six months after grafting. Some patients experience both forms of cGVHR, sequentially (Harper, 1987).

In acute cGVHR the eruption generally begins with tender erythematous macules on the upper trunk, neck, hands, and feet. As a cGVHR evolves, the distribution of erythematous macules increases, becoming confluent over broad body surfaces. At later stages, erythroderma may ensue. Generalized erythroderma with bullae formation and desquamation portend a poor prognosis. The clinical picture of subepidermal bullae with a necrotic roof in these patients greatly resembles toxic epidermal necrolysis. Oral and/or ocular involvement in acute cGVHR may occur but are less common than in chronic cGVHR (Volc-Platzer, 1992; Aractingi & Chosidow, 1998).

The incidence of a chronic cGVHR, divided artificial into lichenoid and sclerodermoid forms, is roughly 25%. This two forms of chronic cGVHR clearly overlap in many patients.

In the lichenoid form, which may also occur soon after transplantation, erythematous to violaceous polygonal papules appear acrally and may be seen on the palms and soles. In addition, lichenoid cGVHR favors the ears, periorbital region, trunk, buttocks, hips, and thighs as well. In some cases lichenoid papules can occur around hair follicles. LP-like cGVHR can also affect the nails, with onychatrophia and pterygium. The disseminated lichenoid eruption in chronic cGVHR is clinically indistinguishable from LP (*Fig. 3*). Pruritus and

postinflammatory hyperpigmentation are also present. Oral involvement is typical, with white lacy patches and/or painful erosions on the tongue and buccal mucosa (*Fig. 4*).

The sclerodermoid form of a chronic cGVHR greatly resembles scleroderma with variably distributed, hyper- and/or hypopigmented, somewhat atrophic plaques. Some patients develop only few sclerodermoid plaques, other ones develop widespread disease associated with alopecia, chronic cutaneous ischemia with ulceration, joint contractures and debilitating fasciitis. Of note, acrosclerosis and Raynaud phenomenon are uncommon in chronic sclerodermatous GVHR, in contrast to systemic sclerosis. The mucosa of the gums, palate, and lips can become atrophic and occasionally ulcerate. Sicca symptoms often accompany the sclerodermoid form due to diminished salivary and lacrimal output (Volc-Platzer, 1992; Aractingi & Chosidow, 1998).

Despite the apparent simplicity of the traditional classification of GVHR into acute and chronic phases, defined as number of days after transplantation, this separation is not that precise. The lichenoid chronic GVHR may be observed as early as day 30 after transplantation and acute GVHR may appear/persist after day 100 in some cases. Moreover, atypical variants of cGVHR have been described that do not fit into this diagnostic classification either.

## Diagnosis

The diagnosis of LP, LDE, cGVHR rests on the combination of anamnestic data, clinical, histopathologic, and immunofluorescence/immunohistochemical findings. Special immunophenotypic and T-cell receptor genotypic analyses are sometimes required to define the underlying pathology manifesting as lichenoid dermatitis more precisely.

The clinical differential diagnosis of lichenoid dermatoses, depending on the manifestation of the disease, involves generalized granuloma annulare, psoriasis guttata, papular sarcoid, lichen amyloidosis, scabies, pityriasis rosea, pityriasis rubra pilaris, and papular secondary syphilis. Mucous membrane lesions may be confused with leukoplakia, mucous patches of syphilis, candidiasis, oral hairy leukoplakia, lupus erythematosus, chronic ulcerative stomatitis, paraneoplastic pemphigus, and cicatricial pemphigoid.

## Therapy

### Lichen Planus, Lichenoid Eruptions

Apart from the very rare instances of possible malignant transformation (ulcerative LP, LP verrucosus, erosive/atrophic mucosal LP), LP is a benign disease with spontaneous remissions and exacerbations. Consequently, any treatment

strategy must be safe and unlikely to aggravate the disease. Avoidance of potentially provocative medications (Ellgehausen et al, 1998), unless absolutely required, and minimizing trauma to skin and mucosal tissues are recommended. Patients with actinic LP must be protected by sunscreens. Oral erosive/atrophic LP lesions are painful and are frequently associated with poor oral hygiene. For these patients, good oral hygiene (the use of an antibacterial mouthwash e.g. chlorhexidine) and regular professional dental care need to be encouraged.

Evaluating the efficacy of different forms of treatment in cutaneous LP is difficult since LP tends to regress spontaneously after varying amounts of time. A large variety of topical and systemic therapies are available, and this range of options may be attributed to the chronicity, symptomatology, and variable responsiveness of the disease. In mild cases, treatment should be symptomatic: antihistamines for pruritus and topical glucocorticoids for their antipruritic and anti-inflammatory effects. Severe, acute cases may benefit from a tapered course of systemic glucocorticoids or retinoids for two to eight weeks. Relapses may occur, however, chronic systemic glucocorticoid use should be avoided. Narrowband UVB, ultraviolet A1, PUVA photochemotherapy (or bath PUVA) solely or combined with systemic retinoids may have beneficial effect in such cases. Systemic cyclosporine administration has many side effects, therefore it should be considered as a drug of last resort. Hypertrophic LP may also benefit from intralesional glucocorticoids, or topical glucocorticoids under occlusion, or tar preparations. Ulcerative and hypertrophic LP of the palms and soles is frequently disabling and uncomfortable. Use of split-thickness skin grafts to cover these lesions has been proved an effective way to manage such patients (Lendrum, 1974; Simon jr, 1990; Simon jr & Hunyadi, 1990; Simon jr & von den Driesch, 1994; Boyd, 2000; Saricaoglu et al, 2003; Polderman et al, 2004).

Non-erosive LP of mucous membranes generally does not need any treatment and may resolve spontaneously. Erosive oral and/or genital LP can be exceptionally difficult to control, but may respond to high potency topical glucocorticoids (in Orabase or intralesional), topical retinoic acid (tretinoin or isotretinoin gel), cyclosporine or tetracycline rinses, and topical tacrolimus (FK-506) (Hodgson et al, 2003). 308-nm UVB excimer laser showed encouraging results in these patients, recently (Kollner et al, 2003). Topical anaesthetics also provide symptomatic benefit for patients who have difficulty with eating and chewing. Newer antifungal agents may be useful in mucosal LP with evidence of *Candida* colonization.

Systemic treatment with oral glucocorticoids and retinoids may be considered for particularly severe erosive mucosal LP lesions, but remissions are short-lived and the risk of serious side-effects is high. Nevertheless, oral glucocorticoids may be of value in the management of acute episodes, when topical or intralesional glucocorticoids alone failed to achieve adequate control. In recalcitrant cases, steroid sparing agents such as azathioprine, mycophenolate mofetil, methotrexate or cyclosporine are generally added. Anecdotal

reports have suggested improvement in mucosal erosive LP with a number of systemic agents including griseofulvin, dapsone, hydroxychloroquine, low-molecular-weight heparin, and thalidomide. The administration of low dose cyclophosphamide for the treatment of severe oral LP, unresponsive to the aforementioned therapies, appears to induce remissions that are sustained. Extracorporeal photochemotherapy has recently been examined for the treatment of erosive LP, mainly involving oral and vulvar tissues. All patients experienced complete remission, and some have showed a durable response. Surgical excision, CO<sub>2</sub> laser, Nd: YAG laser, and cryotherapy have all been used for treatment of recalcitrant mucosal LP. In general, surgery is reserved for removal of dysplastic areas in patients at high risk. Patients under a great deal of stress frequently show improvement when their emotional environment is altered (Boyd, 2000; Setterfield et al, 2000).

### **Cutaneous Graft-Versus-Host-Reaction (cGVHR)**

The best way of treating (c)GVHR is to prevent it from occurring by irradiating blood products before transfusion. Patients receiving allogeneic transplants are placed on methotrexate, cyclosporine, or both before marrow infusion. Recent data indicate that FK-506 is more effective than cyclosporine in the prevention of GVHR when each drug is used in combination with methotrexate (Hiraoka et al, 2001).

If acute GVHR has already occurred, initial therapy usually includes systemic glucocorticoids. Anti-thymocyte globulin, azathioprine, mycophenolate mofetil, pentostatin, cyclosporine, FK-506, and monoclonal antibodies, directed against effector cell populations (CDw52, CD25) or cytokines (TNF- $\alpha$ ), may also be used separately or in combination. Narrowband UVB, PUVA or extracorporeal photochemotherapy may be useful in the treatment of patients with acute cGVHR. Keratinocytes treated with UV-A and UV-B are known to produce immunosuppressive cytokines. Depletion and morphologic alterations of dendritic cells also occur (Queen et al, 1989; Aubin et al, 1995; Hale et al, 1996; Richter et al, 1997; Dall'Amico & Zacchello, 1998; Grundmann-Kollmann et al, 2002).

Chronic GVHR is treated similar to acute GVHR. Glucocorticoids, cyclosporine, azathioprine, mycophenolate mofetil, and methotrexate are administered in various combinations, depending on the severity of the disease. Tacrolimus ointment, pimecrolimus cream or PUVA treatment generally control widespread lichenoid GVHR effectively (Volc-Platzer et al, 1990; Choi & Nghiem, 2001). Mucous membrane manifestations may improve with these therapies as well. It is unclear whether PUVA (or bath PUVA) is able to reverse the cutaneous changes in sclerodermatous GVHR (Aubin et al, 1995). Ultraviolet A1 phototherapy may be considered as an appropriate approach

for these patients (Calzavara Pinton et al, 2003). Extracorporeal photochemotherapy has also been reported as beneficial (Greinix et al, 2000).

## Summary

Lichenoid dermatoses encompass, based on the microscopic pattern of inflammation and skin response, a significant group of dermatologic conditions whose pathophysiologic mechanisms are unclear. Lichen planus (LP), the prototype, is an inflammatory disorder with characteristic purple, polygonal, pruritic papules of the skin and may be accompanied by mucosal lesions. There are many similar clinical variants described, ranging from lichenoid drug eruptions (LDE) to association with other diseases such as the cutaneous graft-versus-host-reaction (cGVHR). This chapter delineates some of the recent aspects of the etiopathogenesis, clinical manifestations and treatment modalities of LP, LDE, and cGVHR.

## References

- Alinovi A, Barella PA, Benoldi D (1983) Erosive lichen planus involving the glans penis alone. *Int J Dermatol*. 22: 37–38
- Anasetti C (2004) Advances in the prevention of graft-versus-host disease after hematopoietic cell transplantation. *Transplantation* 77: S79-S83
- Aractingi S, Chosidow O (1998) Cutaneous graft-versus-host disease. *Arch Dermatol* 134: 602–612
- Aubin F, Brion A, Deconinck E, Plouvier E, Herve P, Humbert P, Cahn JY (1995) Phototherapy in the treatment of cutaneous graft-versus-host disease. Our preliminary experience in resistant patients. *Transplantation* 59: 151–155
- Baart de la Faille-Kuyper EH, Baart de la Faille H (1974) An immunofluorescence study of lichen planus. *Br J Dermatol*. 90: 365–371
- Barthelmes H, Hausteil UF (1970) Nachweis von Fibrinablagerungen beim Lichen ruber planus mit Hilfe der Immunfluoreszenzhistologie. *Derm Mschr* 156: 85–96
- Bhan AK, Harrist TJ, Murphy GF, Mihm jr MC (1982) T cell subsets and Langerhans cells in lichen planus: In situ characterization using monoclonal antibodies. *Br J Dermatol* 105: 617–622
- Boyd AS, Neldner KH (1991) Lichen planus. *J Am Acad Dermatol* 25: 593–619
- Boyd AS (2000) New and emerging therapies for lichenoid dermatoses. *Dermatol Clin* 18: 21–29
- Calzavara Pinton P, Porta F, Izzi T, Venturini M, Capezzer R, Zane C, Notarangelo LD (2003) Prospects for ultraviolet A1 phototherapy as a treatment for chronic cutaneous graft-versus-host disease. *Haematologica* 88: 1169–1175
- Carrozzo M, Uboldi de Capei M, Dametto E, Fasano ME, Arduino P, Broccoletti R, Vezza D, Rendine S, Curtoni ES, Gandolfo S (2004) Tumor necrosis factor-alpha and interferon-gamma polymorphisms contribute to susceptibility to oral lichen planus. *J Invest Dermatol* 122: 87–94
- Cavet J, Dickinson AM, Norden J, Taylor PR, Jackson GH, Middleton PG (2001) Interferon-gamma and interleukin-6 gene polymorphisms associate with graft-versus-host disease in HLA-matched sibling bone marrow transplantation. *Blood* 98: 1594–1600
- Cerni C, Ebner H, Kokoschka E-M (1976) Allgemeiner Immunstatus bei Patienten mit generalisiertem Lichen ruber planus. *Arch Dermatol Res* 256: 13–22

- Choi CJ, Nghiem P (2001) Tacrolimus ointment in the treatment of chronic cutaneous graft-vs-host disease. A case series of 18 patients. *Arch Dermatol* 137: 1202–1206
- Copeman PWM, Tan RSH, Timlin D, Samman PD (1978) Familial lichen planus. *Br J Dermatol* 98: 573–577
- Dall'Amico R, Zacchello G (1998) Treatment of graft-versus-host disease with photopheresis. *Transplantation* 65: 1283–1284
- Darier J (1909) *Précis de Dermatologie*. Masson, p 118. Paris
- Edwards L, Friedrich jr EG (1988) Desquamative vaginitis: lichen planus in disguise. *Obstet Gynecol.* 71: 832–836
- Ellgehausen P, Elsner P, Burg G (1998) Drug-induced lichen planus. *Clin Dermatol* 16: 325–332
- Fox BJ, Odom RB (1985) Paposquamous diseases: A review. *J Am Acad Dermatol* 12: 597–624
- Gadenne AS, Strucke R, Dunn D, Wagner M, Bleicher P, Bigby M (1994) T-cell lines derived from lesional skin of lichen planus patients contain a distinctive population of T-cell receptor  $\gamma\delta$ -bearing cells. *J Invest Dermatol* 103: 347–351
- Giannotti B, De Panfilis G, Manara GC, Allegra F (1983) Macrophage-T-lymphocyte interaction in lichen planus. An electron microscopic and immunocytochemical study. *Arch Dermatol Res* 275: 35–40
- Greinix HT, Volc-Platzer B, Knobler RM (2000) Extracorporeal photochemotherapy in the treatment of severe graft-versus-host disease. *Leuk Lymphoma* 36: 425–434
- Griffiths CEM, Voorhees JJ, Nickoloff BJ (1989) Characterization of intercellular adhesion molecule-1 and HLA-DR expression in normal and inflamed skin: modulation by recombinant gamma-interferon and tumor necrosis factor. *J Am Acad Dermatol* 20: 617–629
- Grundmann-Kollmann M, Martin H, Ludwig R, Klein S, Boehncke WH, Hoelzer D, Kaufmann R, Podda M (2002) Narrowband UV-B phototherapy in the treatment of cutaneous graft versus host disease. *Transplantation* 74: 1631–1634
- Hale G, Waldmann H (1996) Recent results using CAMPATH-1 antibodies to control GVHD and graft rejection. *Bone Marrow Transplant* 17: 305–308
- Harper JI (1987) Cutaneous graft versus host disease. *Br Med J* 295: 401–402
- Hiraoka A, Ohashi Y, Okamoto S, Moriyama Y, Nagao T, Kodera Y, Kanamaru A, Dohy H, Masaoka T; Japanese FK506 BMT (Bone Marrow Transplantation) Study Group (2001) Phase III study comparing tacrolimus (FK506) with cyclosporine for graft-versus-host disease prophylaxis after allogeneic bone marrow transplantation. *Bone Marrow Transplant* 28: 181–185
- Hodgson TA, Sahni N, Kaliakatsou F, Buchanan JA, Porter SR (2003) Long-term efficacy and safety of topical tacrolimus in the management of ulcerative/erosive oral lichen planus. *Eur J Dermatol* 13: 466–470
- Iijima W, Ohtani H, Nakayama T, Sugawara Y, Sato E, Nagura H, Yoshie O, Sasano T (2003) Infiltrating CD8<sup>+</sup> T cells in oral lichen planus predominant express CCR5 and CXCR3 and carry respective chemokine ligands RANTES/CCL5 and IP-10/CXCL10 in their cytolytic granules: a potential self-recruiting mechanism. *Am J Pathol* 163: 261–268
- Kollner K, Wimmershoff M, Landthaler M, Hohenleutner U (2003) Treatment of oral lichen planus with the 308-nm UVB excimer laser. Early preliminary results in eight patients. *Lasers Surg Med* 33: 158–160
- La Nasa G, Cottoni F, Mulargia M, Carcassi C, Vacca A, Pizzati A, Ledda A, Montesu MA, Cerimele D, Contu L (1995) HLA antigen distribution in different clinical subgroups demonstrates genetic heterogeneity in lichen planus. *Br J Dermatol* 132: 897–900
- Lachapelle JM, De la Brassine M (1973) The proliferation of cells in the dermal infiltrate of lichen planus lesions. *Br J Dermatol* 89: 137–141
- Lange Wantzin G, Ralfkiaer E, Lisby S, Rothlein R (1988) The role of intercellular adhesion molecules in inflammatory skin reactions. *Br J Dermatol* 119: 141–145
- Lendrum J (1974) Surgical treatment of lichen planus of the soles. *Br J Plast Surg* 27: 171–175
- Malmnäs Tjernlund U (1980) Ia-like antigens in lichen planus. *Acta Derm Venereol (Stockholm)* 60: 309–314
- Messadi DV, Pober JS, Murphy GF (1988) Effects of recombinant gamma-interferon on HLA-DR and DQ expression by skin cells in short-term organ culture. *Lab Invest* 58: 61–67

- Nickoloff BJ, Reusch MK, Bensch K, Karasek MA (1988) Preferential binding of monocytes and Leu2<sup>+</sup>T-lymphocytes to interferon-gamma-treated cultured skin endothelial cells and keratinocytes. *Arch Dermatol Res* 280: 235–245
- Olsen RG, Du Plessis DP, Schulz EJ, Camisa C (1984) Indirect immunofluorescence microscopy of lichen planus. *Br J Dermatol* 110: 9–15
- Polderman MCA, Wintzen M, van Leeuwen RL, de Winter S, Pavel S (2004) Ultraviolet A1 in the treatment of generalized lichen planus: A report of 4 cases. *J Am Acad Dermatol* 50: 646–647
- Powell FC, Rogers RS, Dickson ER, Breannan Moore S (1986) An association between HLA-DR1 and lichen planus. *Br J Dermatol* 114: 473–478
- Queen C, Schneider WP, Selick HE, Payne PW, Landolfi NF, Duncan JF, Avdalovic NM, Levitt M, Junghans RP, Waldmann TA (1989) A humanized antibody that binds to the interleukin 2 receptor. *Proc Natl Acad Sci USA* 86: 10029–10033
- Ragaz A, Ackerman AB (1981) Evaluation, maturation and regression of lesions of lichen planus. *Am J Dermatopathol* 3: 1–4
- Richter HI, Stege H, Ruzicka T, Soehngen D, Heyll A, Krutmann J (1997) Extracorporeal photopheresis in the treatment of acute graft-versus-host disease. *J Am Acad Dermatol* 36: 787–789
- Santoro A, Majorana A, Bardellini E, Festa S, Sapelli P, Facchetti F (2003) NF-kappaB expression in oral and cutaneous lichen planus. *J Pathol* 201: 466–472
- Saricaoğlu H, Karadogan SK, Baskan EB, Tunali S (2003) Narrowband UVB therapy in the treatment of lichen planus. *Photodermatol Photoimmunol Photomed* 19: 265–267
- Saurat JH, Didierjean L, Gluckman E, Bussel A (1975) Graft-versus-host-reaction and lichen planus-like eruption in man. *Br J Dermatol* 92: 591–592
- Scully C, El-Kom M (1985) Lichen planus: Review and update on pathogenesis. *J Oral Pathol* 14: 431–458
- Setterfield JF, Black MM, Challacombe SJ (2000) The management of oral lichen planus. *Clin Exp Dermatol* 25: 176–182
- Simon jr M, Reimer G, Schardt M, Hornstein OP (1983) Lymphocytotoxicity for oral mucosa in lichen planus. *Dermatologica* 167: 11–15
- Simon jr M, Unterpaintner F, Reimer G (1983) Immunphänomene bei Lichen ruber – eine immunfluoreszenzmikroskopische Studie. *Z Hautkr* 58: 121–128
- Simon jr M, Djawari D, Schönberger A (1984) HLA antigens associated with lichen planus. *Clin Exp Dermatol* 9: 435
- Simon jr M, Keller J (1984) Subpopulations of T lymphocytes in peripheral blood and in skin lesions in lichen ruber planus. *Dermatologica* 169: 112–116
- Simon jr M (1985) Lichen ruber planus aus immunologischer Sicht. *Zbl Hautkr* 150: 699–708
- Simon jr M (1988) Lesional keratinocytes express OKM5, Leu-8 and Leu-11b antigens in lichen planus. *Dermatologica* 177: 152–158
- Simon jr M, Hunyadi J, Fickentscher H, Hornstein OP (1989) Basic and interleukin-2-augmented natural killer cell activity in lichen planus. *Dermatologica* 178: 141–144
- Simon jr M (1990) Immunopathological aspects of etretinate therapy in lichen planus. *J Dermatol (Tokyo)* 17: 282–286
- Simon jr M, Hunyadi J (1990) Etretinate suppresses ICAM-1 expression by lesional keratinocytes in healing cutaneous lichen planus. *Arch Dermatol Res* 282: 412–414
- Simon jr M, Hunyadi J (1992) Immunpathologische Untersuchungen bei Patienten mit chronischer kutaner Graft-versus-host-Reaktion. *Z Hautkr* 67: 900–903
- Simon jr M, Driesch von den P (1994) Expressionsmuster von Adhäsionsmolekülen bei PUVA-behandelten Lichen planus-Patienten. *Hautarzt* 45: 161–165
- Simon jr M, Gruschwitz MS (1997) In situ expression and serum levels of tumour necrosis factor alpha receptors in patients with lichen planus. *Acta Derm Venereol (Stockholm)* 77: 191–193
- Soehnchen RM, Kaudewitz P, Holler E (1992) Tumour necrosis factor- $\alpha$  is elevated in serum of patients with lichen planus. *Arch Dermatol Res* 284: 27
- Soper DE, Patterson JW, Hurt WG, Fantl JA, Blaylock WK (1988) Lichen planus of the vulva. *Obstet Gynecol.* 72: 74–76
- Sugerman PB, Satterwhite K, Bigby M (2000) Autocytotoxic T-cell clones in lichen planus. *Br J Dermatol* 142: 449–456

- Takahashi H, Furukawa T, Hashimoto S, Suzuki N, Kuroha T, Yamazaki F, Inano K, Takahashi M, Aizawa Y, Koike T (2000) Contribution of TNF-alpha and IL-10 gene polymorphisms to graft-versus-host disease following allo-haematopoietic stem cell transplantation. *Bone Marrow Transplant* 26: 1317–1323
- Thyresson N, Moberger G (1957) Cytologic studies in lichen ruber planus. *Acta Derm Venereol (Stockholm)* 37: 191–204
- Touraine R, Revuz J, Dreyfus B, Rochant H, Mannoni P (1975) Graft-versus-host-reaction and lichen planus. *Br J Dermatol* 92: 589
- Volc-Platzer B (1992) "Graft-versus-host disease" (GvHD). *Hautarzt* 43: 669–677
- Volc-Platzer B, Hönigsman H, Hinterberger W, Wolff K (1990) Photochemotherapy improves chronic cutaneous graft-versus-host disease. *J Am Acad Dermatol* 23: 220–228
- Walker DM (1976) Identification of subpopulations of lymphocytes and macrophages in the infiltrate of lichen planus lesions of skin and oral mucosa. *Br J Dermatol* 94: 529–534
- Weyl A (1885) Bemerkungen zum Lichen planus. *Dtsch Med Wschr* 11: 624–626
- Wickham LF (1895) Sur un signe pathognomonique du lichen de Wilson (lichen plan). *Stries et ponctuations grisâtres. Anns Derm Syph Paris* 6: 517–520
- Wilson E (1869) On leichen planus. *J Cut Med* 3: 117–132



## 12 Small Vessel Vasculitides

*Peter Lamprecht and Wolfgang L. Gross*

### Introduction

Vasculitis of small blood vessels of the skin, i.e. arterioles, capillaries and venules, is found in cutaneous leukocytoclastic vasculitis (CLA) as well as in systemic vasculitides. CLA is restricted to the skin, whereas ANCA-associated and several immune complex-mediated systemic vasculitides are characterized by an involvement of – predominantly – small vessels affecting various organs including the skin.

Primary systemic vasculitides, where no underlying disease or agent is known, are to be distinguished from secondary vasculitides, i.e. secondary to other diseases of either autoimmune or other origin. ANCA-associated and immune complex-mediated vasculitides are the major immunopathogenetic categories which involve small vessels (*Table. 1*) (for review: Gross 2003).

### Pathophysiology

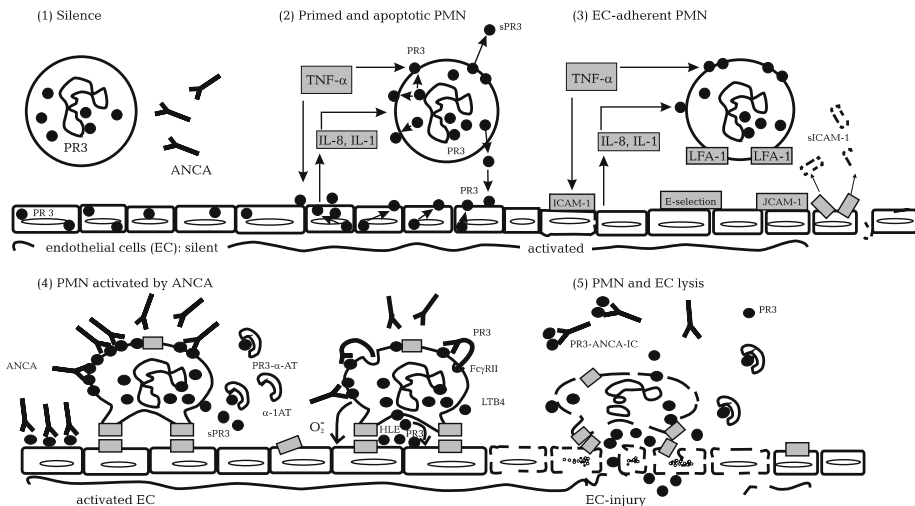
#### ANCA-Associated Vasculitides

Substantial evidence from *in vitro* experiments and animal models supports the view, that anti-neutrophil cytoplasmic antibodies (ANCA) have a role in the immunopathogenesis of *Wegener's granulomatosis (WG)* and *microscopic polyangiitis (MPA)*, giving rise to the "ANCA-cytokine sequence theory" (*Figure 1*) (Gross et al. 1991). The target autoantigens proteinase 3 (PR3) and myeloperoxidase (MPO) are expressed on the cell surface of neutrophil granulocytes and monocytes after priming with TNF- $\alpha$  or IL-1 (Falk et al. 1988, Jenne et al. 1990, Falk et al. 1990, Csernok et al. 1990). ANCA directed against these enzymes of neutrophil azurophilic granula (PR3-ANCA and MPO-ANCA) induce activation of primed neutrophil granulocytes, which degranulate and release reactive oxygen radicals and lytic enzymes subsequently. PR3- and

**Table 1.** Small vessel vasculitides affecting the skin

Primary systemic vasculitis	<p><i>ANCA-associated vasculitis</i></p> <ol style="list-style-type: none"> <li>1. Wegener's granulomatosis (WG)</li> <li>2. Microscopic vasculitis (MPA)</li> <li>3. Churg-Strauss syndrome</li> </ol> <p><i>Immune complex-mediated primary systemic vasculitis</i></p> <ol style="list-style-type: none"> <li>1. Cutaneous leukocytoclastic angiitis (CLA)</li> <li>2. Henoch-Schönlein purpura (HSP)</li> <li>3. Essential cryoglobulinemic vasculitis (ECV)</li> </ol>
Secondary systemic vasculitis	<p><i>Immune complex-mediated secondary systemic vasculitis</i></p> <ol style="list-style-type: none"> <li>1. Rheumatoid vasculitis (RV)</li> <li>2. HCV-associated CV</li> <li>3. Secondary vasculitis or CV in SLE, Sjögren's syndrome and other connective tissue diseases</li> <li>4. Secondary vasculitis or CV in infectious diseases, e.g. bacterial endocarditis</li> <li>5. Paraneoplastic vasculitis</li> </ol>

Abbreviations: ANCA = anti-neutrophil cytoplasmic antibody; HCV = hepatitis C virus; SLE = systemic lupus erythematosus



**Fig. 1.** ANCA-cytokine sequence theory: Cytokine primed polymorphonuclear leukocytes (PMN) translocate and express intracytoplasmic proteinase 3 (PR3) or myeloperoxidase (MPO) on their cell surface. PR3 or MPO become accessible to anti-neutrophil cytoplasmic antibodies (ANCA). ANCA bind via Fc and Fab proportions to PMN. Activated PMN adhere to endothelial cells via adhesion molecule interaction and release oxygen radicals (ROS) and other substances. As a consequence endothelial damage is found (update and review by Csernok and Gross 2000)

MPO-ANCA bind to surface-expressed PR3 or MPO via F(ab')<sub>2</sub> and Fc $\gamma$  receptor (Fc $\gamma$ RIIIa or Fc $\gamma$ RIIIb). Binding of ANCA to PR3 or MPO as well as to the Fc $\gamma$  receptor is necessary for full activation (Csernok et al. 1990, Porges et al. 1994, Kocher et al. 1998). ANCA-activated neutrophil granulocytes up-regulate gene expression of inflammatory mediators and release cytokines such as IL-8 and leukotrienes (Grimminger et al. 1996, Yang et al. 2002). Production of IL-8 by ANCA stimulated neutrophils and monocytes within the intravascular department and/or endothelial cells may frustrate transendothelial leukocyte migration and favor premature degranulation with subsequent endothelial damage (Cockwell et al. 1999). Moreover, ANCA also favor firm adhesion of rolling neutrophil granulocytes and promote their migration *in vitro* (Radford et al. 20001). Pauci-immune, necrotizing vasculitis is seen as a result of the complex interaction of ANCA, neutrophil granulocytes and endothelial cells. An *in vivo* animal model has provided further support of the pivotal role of ANCA and neutrophil granulocytes for the induction of vasculitis (Xiao et al. 2002).

The inciting agent(s) triggering the aforementioned pathophysiological cascade in ANCA-associated vasculitides are still unknown. *Staphylococcus aureus* nasal carriage is associated with the activity of WG in the upper respiratory tract. A prophylaxis with trimethoprim/sulfmethooxazole results in a significant reduction in the relapse rate (Stegeman et al. 1996). B-cell superantigens such as staphylococcal protein A might play a role in the expansion of autoreactive PR3 producing B-cells residing within granulomatous lesions of the respiratory tract (Voswinkel et al. 2002). One hypothesis suggests that a polypeptide translated from the antisense DNA strand of PR3 or to a mimic of this peptide may induce anti-idiotypic PR3-ANCA production (Pendergraft et al. 2004).

### **Granulomatous Lesions in WG and CSS**

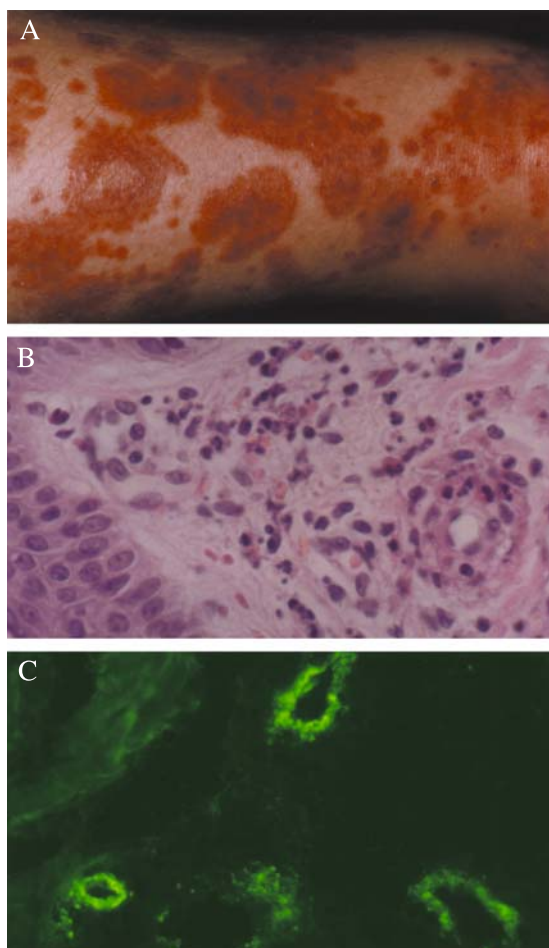
*Wegener's granulomatosis (WG)* and *Churg Strauss syndrome (CSS)* are characterized by small vessel vasculitis and necrotizing granulomatous lesions in the respiratory tract and other locations, e.g. the orbita and the skin (Lamprecht and Gross 2004). Granulomatous lesions in WG are made up of CD4<sup>+</sup> (-positive) and CD8<sup>+</sup> T-cells, monocyte derived tissue macrophages, giant cells, B-cells, and neutrophil granulocytes surrounding a necrotic center. Peripheral blood T-cells and monocytes produce Th1-type cytokines in WG, but they secrete higher amounts of IFN $\gamma$  during the initial disease stage (localized WG) as compared to generalized WG. A subset of circulating T-cells lacking the co-stimulatory molecule CD28 is expanded in WG. The expansion of CD28<sup>-</sup> T-cells is already evident in early disease, i.e. localized WG restricted to the respiratory tract (Lamprecht et al. 2003). The expansion of CD28<sup>-</sup> T-cells correlates with organ involvement. Circulating peripheral blood as well as CD4<sup>+</sup>CD28<sup>-</sup> T-cells within granulomatous lesions are a major source

of Th1-type cytokine secretion and may favor recruitment of T-cells and monocytes into granulomatous lesions (Komocsi et al. 2002, Lamprecht et al. 2003). Th1-type CD28<sup>-</sup> T-cells subset display features of effector memory T-cells (Lamprecht et al. 2003, Lamprecht et al. 2004). Moreover, a subset of autoreactive PR3-specific T-cells producing TNF- $\alpha$  can be detected in WG (Winek et al. 2004). These studies suggest that an aberrant Th1-type dominated immune response might play a role during initiation of WG, whereas additive Th2-type cytokine production may play a role during late disease stages (Komocsi et al. 2002, Sneller 2002, Lamprecht et al. 2003, Lamprecht and Gross 2004). Granulomatous lesions in CSS consist of lymphocytes, macrophages and eosinophils. A predominance of the Th2 cytokine profile is seen in Churg Strauss syndrome (Fujioka et al. 1998, Tsukadaira et al. 1999, Kiene et al. 2001).

### **Immune Complex-Mediated Vasculitides**

Deposition or in situ formation of immune complexes in the vessel wall may result in the subsequent evolution of vasculitis. Additional factors such as the size of the complexes, composition, charge, complement activation, hydrostatic pressure on the wall and efficiency or ineffectivity of reparative mechanisms determine, whether the initial lesion will eventually progress to a necrotizing vasculitis (for review: Gross 2003). Immune complexes formed in antigen excess circulate until the aforementioned factors contribute to their deposition in blood vessel walls. Activation of neutrophils, up-regulation of endothelial adhesion molecules and cytokine release facilitate further leukocyte recruitment. The membrane attack complex of complement plays a significant role in altering the endothelial cell membrane integrity. Activated neutrophils release proteolytic enzymes, especially collagenases and elastases, along with free oxygen radicals that further damage the vessel wall (Claudy 1998).

*Cryoglobulinemic vasculitis (CV)* is an immune complex-mediated vasculitis predominately affecting small vessels. Cryoglobulins are cold-precipitable monoclonal or polyclonal immunoglobulins. Cryoglobulins can induce cold-dependent activation of complement and hypocomplementemia, followed by leukocyte attraction and vessel damage (Wei et al. 1997). The skin is frequently involved. CV is usually found in the presence of type II cryoglobulinemia, i.e. mixed monoclonal IgM $\kappa$  and polyclonal IgG cryoglobulinemia. The monoclonal IgM component often (>75%) has rheumatoid factor activity (for review: Lamprecht et al. 1999). The non-enveloped HCV core protein is a constitutive component of type II cryoglobulins and might contribute to cryoprecipitation in hepatitis C virus (HCV)-associated CV. Binding of HCV core protein to the globular domain of the C1q receptor on the surface of both leukocytes and endothelial cells may favor the interaction of HCV core protein-containing type II cryoglobulin and endothelial cells (Sansonne et al. 2003).



**Fig. 2.** Immune complex vasculitis. **A.** Clinical presentation with petechial purpura of the lower legs. **B.** Histopathology with diapedesis of erythrocytes and fragmentation of neutrophil granulocytes. **C.** Deposits of immune complexes around dermal blood vessels detected by direct immunofluorescence microscopy

## Clinical Classification and Appearance

### Classification

ANCA-associated, pauci-immune vasculitides (WG, MPA, CSS) and immune complex-mediated vasculitides (CLA, HSP, ECV) comprise the group of primary systemic vasculitides affecting predominantly small vessels according to the definition of the Chapel Hill Consensus (CHC) conference (Jennette et al. 1994). Whereas the CHC nomenclature gives names and definitions of primary systemic vasculitides, the American College of Rheumatology (ACR)

classification criteria distinguish selected vasculitides from each other on the basis of criteria with high level sensitivity and specificity (Hunder et al. 1990). Neither the CHC nomenclature nor the ACR classification criteria can be taken as diagnostic criteria. Some authors consider the ACR classification of limited value for the diagnosis of vasculitis (Rao et al. 1998).

### **Clinical Appearance: Skin**

The typical aspect of CLA and skin involvement in systemic small vessel vasculitides is the *palpable purpura* (for review: Csernok and Gross 2000). Purpura is a manifestation mainly of postvenule capillary vasculitis. The lower limbs are most frequently affected by the palpable purpura due to the higher hydrostatic pressure in these vessels (Hautmann et al. 1999). Hydrostatic pressure may also account for the accentuation of the purpura during the day seen in some patients. *Petechiae* may occur secondary to widespread capillary damage. *Urticaria vasculitis* results from a progression of the small vessel vasculitis to fibrinoid necrosis of postcapillary venules, i.e. necrotizing vasculitis. Urticaria typically persists for more than 24 hours in these cases (Schur 1993).

Small hemorrhages with slightly nodular character at the tips of the fingers (*Osler's nodes*) and on the palms, especially on the thenar eminences (*Janeway lesions*) are seen in secondary immune complex-mediated small vessel vasculitides in infectious endocarditis. These lesions indicate an important differential diagnosis with regard to the etiology of vasculitis (Schur et al. 1993). *Pyoderma gangrenosum* or *dermatitis ulcerosa* may be encountered in several systemic diseases, e.g. inflammatory bowel diseases, and in small vessel vasculitides (Powell et al. 1985).

*Nailfold splinter hemorrhages and infarcts* are vasculitic manifestations mainly of arterioles and small arteries. The vasculitis may progress and include small arteries causing cutaneous ulcers and acral necrosis. Pathologic examination often reveals fibrinoid necrosis and thrombosis with little inflammatory infiltration. Vasospasm of dermal ascending arterioles with hyperperfusion of unaffected vessels gives rise to livedo reticularis. Progression to *livedo vasculitis* may result in purpura, cutaneous nodules and ulceration predominantly of the lower extremities (Schur 1993).

### **Clinical Appearance: Systemic Vasculitis**

Constitutional signs such as malaise, weight loss, fever, arthralgia and myalgia may precede other symptoms of systemic vasculitis. Multi-organ involvement may be found in every systemic small vessel vasculitis. However, mono- or oligosymptomatic courses may be encountered at times. Vasculitides differ with respect to the preferential involvement of distinct vascular areas (Table. 2): Pulmonary-renal syndrome is more likely in WG and MPA, whereas

**Table 2.** Typical aspects of ANCA-associated vasculitides (WG, MPA, CSS) and immune complex-mediated vasculitides (CLA, CV, sec. SVV in SLE, RV)

Vasculitis	Clinical findings	Laboratory findings	Histology
WG	Starts in the upper respiratory tract, pulm.-renal syndr.	Compl. $\leftrightarrow$ or $\uparrow$ , C-ANCA, PR3-ANCA	Granulomatous lesions, pauci-imm. vasc.
MPA	Pulm.-renal syndr.	Compl. $\leftrightarrow$ or $\uparrow$ , P-ANCA, MPO-ANCA	Pauci-imm. vasc.
CSS	Asthma, pulmonary infiltration, PNP, cardiac involvement	Eosinophilia, compl. $\leftrightarrow$ or $\uparrow$ , less often: ANCA	Pauci-imm. vasc., eosinophil infiltration
CLA	Purpura	Compl. $\leftrightarrow$ or $\downarrow$	Leukocyt. vasculitis
ECV, HCV-ass. CV	Purpura, arthralgia, weakness, PNP, GN	Compl. $\bar{}$ , RF, cryoglobulin, HCV-ab., HCV-RNA	Imm. compl. vasc.
Sec. vasculitis in SLE	Purpura, PNP, GN, cerebral vasculitis	Compl. $\bar{}$ , ANA, ds-DNA ab., anti-Sm ab.	Imm. compl. vasc.
RV	Purpura, ulcers, PNP	Compl. $\bar{}$ , RF	Imm. compl. vasc.
HSP	Purpura, arthralgia, GN, abdominal pain	Compl. $\bar{}$ , IgA $\bar{}$	Imm. compl. vasc. with IgA

ANCA = anti-neutrophil cytoplasmic antibody (Immunofluorescence patterns: C-ANCA = cytoplasmic pattern ANCA, P-ANCA = perinuclear pattern ANCA; ELISA: PR3-ANCA = proteinase 3 ANCA, MPO = myeloperoxidase ANCA), WG = Wegener's granulomatosis, MPA = microscopic polyangiitis, CSS = Churg Strauss syndrome, CLA = cutaneous leukocytoclastic angiitis, CV = cryoglobulinemic vasculitis (ECV = essential CV, HCV-ass. CV = hepatitis C virus associated CV), sec. = secondary, GN = glomerulonephritis, PNP = polyneuropathy, RA = rheumatoid arthritis, SVV = small vessel vasculitis, SLE = systemic lupus erythematosus, RV = rheumatoid vasculitis, ab. = antibody, Imm. compl. vasc. = immune complex-mediated vasculitis, Compl. = complement, ANA = antinuclear ab., ds-DNA ab. = double strand DNA ab, Leukocyt. vasc. = leukocytoclastic vasculitis, Immune compl.-med. vasc. = immune complex-mediated vasculitis

other diseases such as systemic lupus erythematosus (SLE) less often cause this syndrome. Purpura and renal involvement are common in CV, polyneuropathy and gastrointestinal vasculitis in CV and CSS, and cardiac involvement in CSS. Proceeding nasal obstruction, crusting, epistaxis and/or otitis media and mastoiditis is usually found in WG. Episcleritis is often seen in WG and MPA. Asthma bronchiale, eosinophilia and pulmonary infiltrations together with cardiac involvement and/or polyneuropathy are frequently seen in CSS. Severe renal disease is less frequent in CSS compared to WG and MPA. Neuropathy and cardiac disease are frequently encountered in severe CSS.

Coronary arteritis and myocarditis are the principle causes of morbidity and mortality in CSS (Jennette and Falk 1997; Savage et al. 1997). CSS may evolve over a period of time starting with allergic rhinitis, asthma bronchiale. Thereafter, a hypereosinophilic syndrome with infiltrative eosinophilic disease, e.g. eosinophilic pneumonia and gastroenteritis will ensue, and finally small vessel vasculitis with granulomatous lesions is seen in CSS (Lanham et al. 1984). The triad of arthralgia, purpura and weakness (so-called Meltzer's triad) is frequently seen in essential CV (ECV) and in HCV-associated CV. CV frequently involves the kidneys and peripheral nerves (Ferri et al. 1991). Purpura, cutaneous ulcers and polyneuropathy in a patient with long-standing rheumatoid arthritis (RA) is suggestive of rheumatoid vasculitis (RV). Purpura, arthritis, and abdominal pain in a child with a nephritic sediment is found in Henoch-Schönlein purpura (HSP). HSP has a peak incidence at the age of five years. The disease often begins after an upper respiratory tract infection (Jennette and Falk 1997; Savage et al. 1997).

Small vessel vasculitides may affect different structures within the same organ or body region giving rise to a variety of symptoms: Affection of the ear in WG may include sensorineural deafness due to vasculitis of the inner ear and/or cochlear nerve, otitis media, and mastoiditis. CSS and CV may cause abdominal pain due to gastro-intestinal vasculitis or vasculitis of the gall bladder. Renal involvement in immune complex-mediated vasculitis may result in mesangioproliferative and other forms of glomerulonephritis, whereas focal and segment necrotizing glomerulonephritis is more common in ANCA-associated vasculitis (Jennette and Falk 1997). Renal vasculitis of small and medium sized renal arteries is seen at least in one third of the patients with cryoglobulinemic glomerulonephritis (D'Amico 1998). Pulmonary small vessel vasculitis may result in dyspnoea, cough, hemoptysis due to either bronchial ulcerations or frank hemorrhagic alveolitis. Full-blown pulmonary-renal syndrome will cause renal and respiratory failure. Central nervous involvement may cause cranial nerve palsies, seizures, stroke and other symptoms. Cardiac involvement may be indicated by arrhythmias due to coronariitis or myocarditis, pericardial effusion, and angina pectoris (Savage et al. 1997).

Secondary vasculitides in SLE and other connective tissue diseases or rheumatoid arthritis are usually preceded by typical symptoms of their underlying autoimmune disease. Thus, rheumatoid vasculitis is usually encountered after previous long-lasting rheumatoid arthritis. In case of unusual symptom constellations paraneoplastic vasculitis, secondary vasculitis in infectious diseases such as bacterial endocarditis, and drug-induced vasculitides should be excluded. It has to be kept in mind, that small vessel vasculitides are also seen in primary immunodeficiencies, e.g. bare lymphocyte syndrome (TAP-deficiency and others), CVID, hyperimmunoglobulinemia D and periodic fever syndrome (HIDS), and tumor necrosis factor receptor-associated periodic syndrome (TRAPS) (Sais et al. 1996, Moins-Teisserenc et al. 1999, Lamprecht et al. 2004).



## Diagnosis

### Clinical Parameters

A detailed patient history, physical examination and focused laboratory investigation are vital in diagnosing vasculitic disorders. The goals of the work-up include identification of a cause of the disease and/or the underlying immunopathogenetic mechanism, classification of the disease, and determination of the disease activity and extent. The latter is all the more important as stage-adapted therapy and assessment of the treatment's efficacy are only possible if there are uniform and reproducible measures of the extent and activity of organ involvement in the vasculitic disease. A prerequisite for this is a standardized evaluation of the clinical, radiological and laboratory findings by an interdisciplinary team of expert physicians (internal medicine, neurology, ophthalmology, dermatology, radiology etc.) (Gross et al. 2000).

A detailed patient history and physical examination should give rise to a preliminary diagnosis. CLA requires a detailed drug history as drugs cause ca. 10% of vasculitic skin lesions. Drugs that have been implicated are penicillins, aminopenicillins, sulfonamides, allopurinol, thiazides, hydantoins and propylthiouracil (Jennette and Falk 1997).

### Laboratory Tests

Laboratory tests are used to ascertain the type of vasculitis. Erythrocyte sedimentation rate (ESR) and C-reactive protein (CRP) indicate inflammation. Low complement levels are seen in immune complex-mediated vasculitides including CV, whereas normal or elevated complement levels are found in ANCA-associated vasculitides (Gross et al. 2000). Furthermore, low complement levels may indicate hereditary complement deficiencies, which may cause SLE-like diseases with secondary vasculitides. C-ANCA are strongly associated with "classic" WG. The principle target antigen for C-ANCA in WG is PR3 (Csernok et al. 1990, Jenne et al. 1990). Only few WG patients (<5%) have a P-ANCA with MPO specificity. In PR3-ANCA positive WG a higher disease extent is seen as compared to MPO-ANCA positive WG (Schönermarck et al. 2000). ANCA-negative WG is rarely encountered (Lamprecht et al. 2000). Combining the detection of C-ANCA resp. P-ANCA in IFT and PR3-ANCA resp. MPO-ANCA in ELISA yields a high sensitivity and specificity for WG and MPA (Hagen et al. 1998). Despite their high sensitivity and specificity, C-ANCA and PR3-ANCA may be found in other diseases than WG, e.g. subacute bacterial endocarditis or severe CV (Choi et al. 2000). RF may be found in various conditions such as RV, CV and endocarditis. Auto-antibodies, e.g. ANA, ds-DNA antibodies, anti Sm, anti SSA, anti-SSB etc., will be seen in secondary vasculitides in SLE, Sjögren's syndrome and other

connective tissue diseases. Low level autoantibodies such as ANA may also be found in CV. ANA may be seen in RV and a variety of other diseases. Serum levels of IgA are elevated in half of the patients with HSP. As infections may cause secondary vasculitis, HBV, HCV, HIV, and bacterial infections should be excluded. Serial blood cultures may be necessary (Gross et al. 2000). ALT and AST may not necessarily be elevated in HCV-associated CV (Lamprecht et al. 1999). Procalcitonin may help to differentiate between autoimmune diseases and bacterial infections and sepsis (Moosig et al. 1998).

### **Additional Diagnostics**

Echocardiography should rule out vegetations on the leaves. Primary immunodeficiencies also have to be considered. Quantitative assessment of immunoglobulin classes including IgD, lymphocyte subpopulations, standardized cutaneous tests for various T-cell specific antigens, complement levels, MHC-class I and II expression, tests for the assessment of the functional status of various neutrophils, lymphocytes etc., and molecular genetic analysis of mutations of the MEFV-gene (Familial Mediterranean fever), MVK-gene (HIDS), or TNFRSF1A-gene (TRAPS) may be necessary in selected patients (Baumert et al. 1992, Moins-Teisserenc et al. 1999, Lamprecht et al. 2004).

Arteriograms are helpful in identifying vasculitis of medium-sized arteries, e.g. renal, coronar or intestinal vessels, or even larger arteries. These vascular areas may sometimes be involved in addition to the small vessel vasculitis. The definite diagnosis of vasculitis is dependent on the demonstration of vascular involvement by biopsy. Biopsy specimen should be obtained from clinically involved tissue. Applying immunohistochemistry is helpful in distinguishing immune complex mediated from pauci-immune (ANCA-associated) vasculitides (Gross et al. 2000).

## **Therapy**

### **Cutaneous Leukocytoclastic Vasculitis (CLA)**

CLA is usually limited to a single episode that resolves spontaneously within weeks or a few months. Approximately 10% will have recurrent disease at intervals of months to years. Drugs that could cause the disease should be stopped. Oral corticosteroid therapy is indicated in severe cutaneous disease. Progressive, steroid resistant CLA is rarely encountered and may necessitate additional immunosuppressive therapy such as azathioprine. Critical reevaluation of the diagnosis should also take place in such cases (Jennette and Falk 1997).

### ANCA-Associated Vasculitis

Induction of remission is achieved with combined oral corticosteroids and oral cyclophosphamide in life threatening conditions and severe, progressive vasculitis in WG, MPA and CSS. Oral cyclophosphamide at 2mg/kg/day is preferentially used in severe conditions ("Fauci's scheme" or "NIH standard"), whereas cyclophosphamide i.v. (15mg/kg every 3 weeks) may only be expected as a successful alternative in less severe disease (Reinhold-Keller et al. 1994). Reduction of the corticosteroid dose should be started carefully as cyclophosphamide therapy becomes effective after 7–10 days. Tapering of corticosteroids is aimed at reaching the lowest effective dose after having achieved a stable remission for more than three months. Doses should at least range below the so-called "Cushing" level at this time in order to prevent adverse effects (Savage et al. 1997).

About 5% of patients remain resistant to "Fauci's scheme". A transient increase of the cyclophosphamide dose to 4mg/kg for approximately two weeks and subsequent reduction on the basis of the patients leukocyte count may overcome the initial therapy resistance in some patients (Schmitt and Gross 1998). In cases resistant to conventional therapy high dose intravenous immunoglobulin may be effective (Jayne et al 2000). T-cell directed biologicals, such as anti-thymocyte globulin (ATG) and humanized monoclonal antibodies to CD4 and CD52 have been reported to induce remission in small case series, but adverse effects may be substantial (Schmitt et al. 2004). 15-deoxyspergualin proved to be efficient in the treatment of refractory WG in another small case series (Birck et al. 2003). Both the chimeric monoclonal anti-TNF- $\alpha$  antibody infliximab and the human soluble p75 TNF- $\alpha$  receptor fusion protein etanercept have been successfully applied in patients with refractory WG (Stone et al. 2000; Lamprecht et al. 2002).

Corticosteroids and cyclophosphamide predispose patients to serious adverse effects. Cyclophosphamide causes premalignant hemorrhagic cystitis, ovarian and testicular failure and myelodysplastic syndrome (Hoffman et al. 1992; Reinhold-Keller et al. 2000). Mesna is beneficial in avoiding hemorrhagic cystitis (Reinhold-Keller et al. 2000). Less toxic treatment is highly desirable. However, only patients with non-life threatening WG or MPA may be treated safely with methotrexate (0,3 mg/kg/week i.v.) and corticosteroids for the induction of remission (Langford et al 2000). Azathioprine can be used for the maintenance of remission after induction of remission with cyclophosphamide (Jayne et al. 2003). Methotrexate and leflunomide may be alternatives for the maintenance of remission in WG and MPA (deGroot et al. 1996, Metzler et al. 2004). Nasal *S. aureus* carriage is associated with activity of WG in the upper respiratory tract. A prophylaxis with trimethoprim/sulfamethoxazole results in a significant reduction in the relapse rate (Stegeman et al. 1996). Mupirocin ointment is also used for the reduction of nasal *S. aureus* carriage.

CSS is often controlled with high-dose corticosteroid treatment. Refractory and relapsing disease may require addition of a cytotoxic drug similar to

the treatment of WG and MPA (Jennette and Falk 1997). Interferon- $\alpha$  (IFN- $\alpha$ ) therapy has been reported to induce remission in CSS and substantial reduction of the prednisolone requirement in patients who had attained incomplete remission with cyclophosphamide or methotrexate. The mechanism of action of IFN- $\alpha$  in CSS has not been clearly established, but switch in the cytokine profile as well as down-regulation of IgE receptors on eosinophils and lymphocytes may be relevant (Tatsis et al. 1998; Metzler et al. 2000).

### **Cryoglobulinemic Vasculitis**

Essential CV, i.e. non-infection or other disease related CV, is treated similar to the treatment protocol for WG and MPA. Plasma pheresis has been recommended in life-threatening conditions, progressive glomerulonephritis and polyneuropathy (Lamprecht et al. 1999). Severe, progressive vasculitis and life-threatening conditions of HCV-associated CV may also be treated with oral cyclophosphamide and corticosteroids ("Fauci's scheme") for the induction of remission. Plasmapheresis may be added (D'Amico 1998). The monoclonal anti-CD20 antibody rituximab targeting B-cells has been shown to be efficacious in severe HCV-associated CV (Zaja et al. 2003). IFN- $\alpha$  and ribavirin are applied in less severe disease in order to attempt HCV elimination (Donada et al. 1998). However, caution is recommended for the treatment of polyneuropathy with IFN- $\alpha$  (Ferri et al. 1993). Addition of corticosteroids may be beneficial in controlling cutaneous vasculitis despite the risk of delayed virus elimination and easier evolution of escape-mutants from immune surveillance (Dammacco et al 1994). Secondary CV in infectious endocarditis should be controlled by antibiotic treatment and valve replacement if indicated. Transient addition of corticosteroids may be necessary in order to control vasculitic manifestations, e.g. glomerulonephritis (Choi et al. 2000).

### **Henoch-Schönlein Purpura**

HSP has a good prognosis in general. Pulmonary disease, rapidly progressive renal failure and peripheral polyneuropathy are uncommon (Jennette and Falk 1997). Adult onset HSP is rare. Corticosteroids and azathioprine may be beneficial in patients with progressive renal insufficiency (Bergstein et al. 1998).

### **Miscellaneous Secondary Vasculitides**

RV shows histopathological similarities to polyarteritis nodosa and requires equally aggressive therapy. Intermittent intravenous bolus cyclophosphamide plus methylprednisolone for the induction of remission has been demonstrated to improve healing of vasculitic lesions including leg ulcers and neuropathy.

Bolus therapy result in a lower incidence of relapse and a lower mortality compared with other treatments. Comparatively high doses of cyclophosphamide (15–20mg/kg per bolus) and short treatment intervals (14 and 21 days) are necessary to control the often aggressive course of the disease (Scott and Bacon 1984). Although there are no controlled studies for the maintenance of remission in RV, practical considerations suggest to treat the patient with DMARDS used in RA, preferably methotrexate.

Secondary vasculitis in SLE is treated with intermittent intravenous bolus cyclophosphamide and corticosteroids according to the Austin's scheme. The original Austin's scheme included monthly intermittent intravenous bolus cyclophosphamide (0,5–1,0g/m<sup>2</sup> body surface area) plus low-dose oral prednisolone (starting with up to 0,5mg/kg per day) (Austin et al. 1986; Boumpas et al. 1991). Secondary vasculitides in other connective tissue diseases are treated analogous to the Austin's scheme in SLE.

Secondary vasculitis in bacterial endocarditis is treated similar to secondary CV due to endocarditis (see 12.4.3). Paraneoplastic vasculitis may require treatment similar to the treatment protocol for WG and MPA for the vasculitic manifestations, e.g. cutaneous ulcers, acral necrosis, or polyneuropathy. Therapy of the underlying neoplasm is essential for the control of the vasculitis. Rheumatic symptoms and vasculitis secondary to primary immunodeficiencies may improve upon intravenous immunoglobulin administration in some disease conditions, e.g. CVID (Sais et al. 1996; Gause et al. 2000) and in TAP deficiency (Gadola et al. 2000).

## Summary

Small vessel vasculitides affecting the skin are seen in primary systemic vasculitides, i.e. the ANCA-associated vasculitides (WG, MPA, CSS) and the immune complex-mediated vasculitides (ECV, HSP, CLA). Secondary immune complex-mediated vasculitides, e.g. in SLE and other connective tissue diseases, paraneoplastic conditions, and in infectious diseases, also frequently involve small vessels of the skin. Diagnosis is made upon a detailed patient history, physical examination, focused laboratory investigation, and demonstration of vasculitis by biopsy. Stage-adopted therapy aims at inducing and maintaining remission of the respective vasculitis. Treatment of underlying diseases may be necessary in secondary vasculitides.

## References

- Austin HA 3d, Klippel JH, Balow JE, le Riche NG, Steinberg AD, Plotz PH, Decker JL (1986) Therapy of lupus nephritis. Controlled trial of prednisone and cytotoxic drugs. *N Engl J Med* 314: 614–619

- Bergstein J, Leiser J, Andreoli SP (1998) Response of crescentic Henoch-Schoenlein purpura nephritis to corticosteroid and azathioprine therapy. *Clin Nephrol* 49: 9–14
- Birck R, Warnatz K, Lorenz HM, Choi M, Haubitz M, Grunke M, Peter HH, Kalden JR, Gobel U, Drexler JM, Hotta O, Nowack R, Van der Woude FJ (2003) 15-Deoxyspergualin in patients with refractory ANCA-associated systemic vasculitis: A six-month open-label trial to evaluate safety and efficacy. *J Am Soc Nephrol* 14, 440–447
- Boumpas DT, Yamada H, Patronas NJ, Scott D, Klippel JH, Balow JE (1991) Pulse cyclophosphamide for severe neuropsychiatric lupus. *Q J Med* 81: 975–984
- Baumert E, Schlesier M, Wolff-Vorbeck G, Peter HH (1992) Alterations in lymphocyte subsets in variable immunodeficiency syndrome. *Immun Infekt* 20: 73–75
- Choi HK, Lamprecht P, Niles JL, Gross WL, Merkel PA (2000) Subacute bacterial endocarditis with positive C-ANCA and antiproteinase 3 antibodies. *Arthritis Rheum* 43: 226–231
- Claudy A (1998) Pathogenesis of leukocytoclastic vasculitis. *Eur J Dermatol* 8: 75–79
- Cockwell P, Brooks CJ, Adu D, Savage COS (1999) Interleukin-8: pathogenetic role in anti-neutrophil cytoplasmic autoantibody-associated glomerulonephritis. *Kidney Int* 55: 852–863
- Csernok E, Lüdemann J, Gross WL, Bainton DF (1990) Ultrastructural localization of proteinase 3, the target antigen of anticytoplasmic antibodies circulating in Wegener's granulomatosis. *Am J Pathol* 137: 1113–1120
- Csernok E, Trabandt A, Müller A, Wang GC, Moosig F, Paulsen J, Schnabel A, Gross WL (1999) Cytokine profiles in Wegner's granulomatosis. Predominance of type 1 (Th1) in the granulomatous inflammation. *Arthritis Rheum* 42: 742–750
- Csernok E, Gross WL (2000) Primary vasculitides and vasculitis confined to the skin: clinical features and new pathogenic aspects. *Arch Dermatol Res* 292: 427–436.
- Dammacco F, Sansonno D, Han JH, Shyamala V, Cornacchiulo V, Iacobelli AR, Lauletta G, Rizzi R (1994) Natural interferon-alpha versus its combination with 6-methyl-prednisolone in the therapy of type II mixed cryoglobulinemia: a long-term, randomized, controlled study. *Blood* 84: 3336–3343
- D'Amico G (1998) Renal involvement in hepatitis C infection: cryoglobulinemic glomerulonephritis. *Kidney Int* 54: 650–671
- deGroot K, Reinhold-Keller E, Tatsis E, Paulsen J, Heller M, Nolle B, Gross WL (1996) Therapy for the maintenance of remission in sixty-five patients with generalized Wegener's granulomatosis. Methotrexate versus trimethoprim/sulfamethoxazole. *Arthritis Rheum* 39: 2052–2061
- deGroot K, Haubitz M, Haller H (2000) ANCA-assozierte Vaskulitiden. Neue Konzepte und Strategien in der Therapie. *Internist* 41: 1112–1119
- Donada C, Crucitti A, Donadon V, Chemello L, Alberti A (1998) Interferon  $\alpha$  and ribavirin combination therapy in patients with chronic hepatitis C and mixed cryoglobulinemia. *Blood* 92: 2983–2984
- Falk RJ, Jennette JC (1988) Anti-neutrophil cytoplasmic autoantibodies with specificity for myeloperoxidase in patients with systemic vasculitis and idiopathic necrotizing and crescentic glomerulonephritis. *N Engl J Med* 318: 1651–1657
- Falk RJ, Terrell RS, Charles LA, Jennette JC (1990) Anti-neutrophil cytoplasmic autoantibodies induce neutrophils to degranulate and produce oxygen radicals in vitro. *Proc Natl Acad Sci USA* 87: 4115–4119
- Ferri C, Greco F, Longombardo G, Palla P, Moretti A, Marzo E, Fosella PV, Pasero G, Bombardieri (1991) Antibodies to hepatitis C virus in patients with mixed cryoglobulinemia. *Arthritis Rheum* 34: 1606–1610
- Ferri C, Marzo E, Longombardo G, Lombardini F, La Civita L, Vanacore R, Liberati AM, Gerli R, Greco F, Moretti A (1993) Interferon-alpha in mixed cryoglobulinemia patients: a randomized, crossover-controlled trial. *Blood* 81: 1132–1136
- Fujioka A, Yamamoto T, Takasu H, Kawano K, Masuzawa M, Katsuoka K, Jinno S (1998) The analysis of mRNA expression of cytokines from skin lesions in Churg-Strauss syndrome. *J Dermatol* 25:171–177
- Gadola SD, Moins-Teisserenc HT, Trowsdale J, Gross WL, Cerundolo V (2000) TAP deficiency syndrome. *Clin Exp Immunol* 121: 173–178
- Gause A, Inderrieden DC, Laas R, Arlt AC, Gross WL (2000) Common variable immunodeficiency (CVID) and inclusion body myositis. *Immunobiology* 202: 199–203

- Grimminger F, Hattar K, Papavassilis C, Temmesfeld B, Csernok E, Gross WL, Seeger W, Sibelius U (1996) Neutrophil activation by anti-proteinase 3 antibodies in Wegener's granulomatosis: role of exogenous arachidonic acid and leukotrien B<sub>4</sub> generation. *J Exp Med* 184: 1567–1572
- Gross WL, Csernok E, Schmitt WH (1991) Antineutrophil cytoplasmic autoantibodies: immunobiological aspects. *Klin Wochenschr* 69: 558–566
- Gross WL, Trabandt A, Reinhold-Keller E (2000) Diagnosis and evaluation of vasculitis. *Rheumatology* 39: 245–252
- Gross WL (2003) Immunopathogenesis of vasculitis. In: Klippel JH, Dieppe PA (eds) *Rheumatology*. 3<sup>rd</sup> ed. Mosby, London, chapter 7.19, p. 1–8
- Hagen EC, Daha MR, Hermans J, Andrassy K, Csernok E, Gaskin G, Lesavre P, Ludemann J, Rasmussen N, Sinico RA, Wiik A, van der Woude FJ (1998) Diagnostic value of standardized assays for anti-neutrophil cytoplasmic antibodies in idiopathic systemic vasculitis. EC/BCR Project for ANCA Assay Standardization. *Kidney Int* 53: 743–753
- Hautmann G, Campanile G, Lotti TM (1999) The many faces of cutaneous vasculitis. *Clin Dermatol* 17: 515–531
- Hoffman GS, Kerr GS, Leavitt RY, Hallahan CW, Lebovics RS, Travis WD, Rottem M, Fauci AS (1992) Wegener granulomatosis: an analysis of 158 patients. *Ann Intern Med* 116: 488–498
- Hunder GG, Arend WP, Bloch DA, Calabrese LH, Fauci AS, Fries JF, Leavitt RY, Lie JT, Lightfoot RW Jr, Masi AT, McShane DJ, Michel BA, Mills JA, Stevens MB, Wallace SL, Zvaifler NJ (1990) The American College of Rheumatology 1990 criteria for the classification of vasculitis. Introduction. *Arthritis Rheum* 33: 1065–1067
- Jayne DR, Chapel H, Adu D, Misbah S, O'Donoghue D, Scott D, Lockwood CM (2000) Intravenous immunoglobulin for ANCA-associated systemic vasculitis with persistent disease activity. *QJM* 93: 433–439
- Jayne D, Rasmussen N, Andrassy K, Bacon PA, Cohen Tervaert JW, Dadonieni J, Ekstrand A, Gaskin G, Gregorini G, deGroot K, Gross WL, Hagen EC, Mirapeix E, Pettersson E, Siegert C, Sinico A, Tesar V, Westman K, Pusey C, for the European Vasculitis Study Group (2003) A randomized trial of maintenance therapy for vasculitis associated with antineutrophil autoantibodies. *N Engl J Med* 349: 36–44
- Jenne DE, Tschoop J, Lüdemann J, Utech B, Gross WL (1990) Wegener's autoantigen deduced. *Nature* 346: 520.
- Jennette JC, Falk RJ, Andrassy K, Bacon PA, Churg J, Gross WL, Hagen EC, Hoffman GS, Hunder GG, Kallenberg CG, McCluskey RT, Sinico A, Rees AJ, van Es LA, Waldherr R, Wiik A (1994) Nomenclature of systemic vasculitides. Proposal of an international consensus conference. *Arthritis Rheum* 37: 187–192
- Jennette JC, Falk R. (1997) Small-vessel vasculitis. *N Engl J Med* 337: 1512–1523
- Kallenberg CG, Cohen Tervaert JW (2000) New treatments of ANCA-associated vasculitis. *Sarcoidosis Vasc Diffuse Lung Dis* 17: 125–129
- Kiene M, Csernok E, Müller A, Metzler C, Trabandt A, Gross WL (2001) Elevated IL-4 and IL-13 production by T-cell lines in Churg-Strauss syndrome. *Arthritis Rheum* 44: 469–473
- Kocher M, Edberg JC, Fleit HB, Kimberly RP (1998) Antineutrophil cytoplasm antibodies preferentially engage Fc gammaRIIIb on human neutrophils. *J Immunol* 161: 6909–6914
- Komocsi A, Lamprecht P, Csernok E, Müller A, Holl-Ulrich K, Seitzer U, Moosig F, Schnabel A, Gross WL (2002) Peripheral blood and granuloma CD4<sup>+</sup>CD28<sup>-</sup> T-cells are a major source of IFN $\gamma$  and TNF- $\alpha$  in Wegener's granulomatosis. *Am J Pathol* 160: 1717–1724
- Langford CA, Talar-Williams C, Sneller MC. Use of methotrexate and glucocorticoids in the treatment of Wegener's granulomatosis. Long-term renal outcome in patients with glomerulonephritis. *Arthritis Rheum* 43: 1836–1840
- Lamprecht P, Gause A, Gross WL (1999). Cryoglobulinemic vasculitis. *Arthritis Rheum* 42: 2507–2516
- Lamprecht P, Trabandt A, Gross WL (2000) Clinical and immunological aspects of Wegener's granulomatosis (WG) and other syndromes resembling WG. *Isr Med Assoc J* 2: 621–626
- Lamprecht P, Voswinkel J, Lilienthal T, Nölle B, Heller M, Gross WL, Gause A (2002) Effectiveness of TNF- $\alpha$  blockade with infliximab in refractory Wegener's granulomatosis. *Rheumatology* 41: 1303–1307

- Lamprecht P, Erdmann A, Müller A, Csernok E, Reinhold-Keller E, Holl-Ulrich K, Feller AC, Brühl H, Gross WL (2003a) Heterogeneity of CD4<sup>+</sup> and CD8<sup>+</sup> memory T cells in localized and generalized Wegener's granulomatosis. *Arthritis Res Ther* 5: R25-R31
- Lamprecht P, Brühl H, Erdmann A, Holl-Ulrich K, Csernok E, Seitzer U, Mack M, Feller AC, Reinhold-Keller E, Gross WL, Müller A (2003b) Differences in CCR5 expression on peripheral blood CD4<sup>+</sup>CD28<sup>+</sup> T-cells and in granulomatous lesions between localized and generalized Wegener's granulomatosis. *Clin Immunol* 108: 1-7
- Lamprecht P, Gross WL (2004) Wegener's granulomatosis. *Herz* 29: 47-56
- Lamprecht P, Müller A, Gross WL (2004a) CD28<sup>+</sup> T-cells display features of effector memory T-cells in Wegener's granulomatosis. *Kidney Int* 65:1113.
- Lamprecht P, Moosig F, Adam-Klages S, Mrowietz U, Csernok E, Kirrstetter M, Ahmadi-Simab K, Schröder JO, Gross WL (2004b) Small vessel vasculitis and relapsing panniculitis in tumor necrosis factor receptor-associated periodic syndrome (TRAPS). *Ann Rheum Dis* in press
- Lanham JG, Elkon KB, Pusey CD, Hughes GR (1984) Systemic vasculitis with asthma and eosinophilia: a clinical approach to the Churg-Strauss syndrome. *Medicine (Baltimore)* 63: 65-81
- Ludviksson BJ, Sneller MC, Chua KS, Talar-Williams C, Langford CA, Ehrhardt RO, Fauci AS, Strober W (1998) Active Wegener's granulomatosis is associated with HLA-DR+CD4+ T cells exhibiting an unbalanced Th1-type T cell cytokine pattern: reversal with IL-10. *J Immunol* 160: 3602-3609
- Metzler C, Tatsis E, Gause A, Gross WL (2000) Long-term treatment of Churg-Strauss syndrome with interferon- $\alpha$ . *Arthritis Rheum* 43 (Suppl): S369
- Metzler C, Fink C, Lamprecht P, Gross WL, Reinhold-Keller E (2004) Maintenance of remission with leflunomid in Wegener's granulomatosis. *Rheumatology* 43: 315-320
- Moins-Teisserenc HT, Gadola SD, Cella M, Dunbar PR, Exley A, Blake N, Baycal C, Lambert J, Bigliardi P, Willemsen M, Jones M, Buechner S, Colonna M, Gross WL, Cerundolo V (1999) Association of a syndrome resembling Wegener's granulomatosis with low surface expression of HLA class-I molecules. *Lancet* 354: 1598-1603
- Moosig F, Csernok E, Reinhold-Keller E, Schmitt W, Gross WL (1998) Elevated procalcitonin levels in active Wegener's granulomatosis. *J Rheumatol* 25: 1531-1533
- Müller A., Trabandt A, Glöckner-Hofmann K, Seitzer U, Csernok E, Schönermarck U, Feller AC, Gross WL (2000) Localized Wegener's granulomatosis: predominance of CD26 and IFN $\gamma$  expression. *J Pathol* 192: 113-120
- Pendergraft WE, Preston GA, Shah R, Tropsha A, Carter CW, Jennette JC, Falk RJ (2004) Autoimmunity is triggered by cPR3(105-201), a protein complementary to human autoantigen proteinase 3. *Nature Med* 10: 72-79
- Porges AJ, Redecha PB, Kimberly WT, Csernok E, Gross WL, Kimberly RP (1994) Antineutrophil cytoplasmic antibodies engage and activate human neutrophils via Fc gamma RIIa. *J Immunol* 153: 1271-1280
- Powell FC, Schroeter AL, Su WPD, Perry HO (1985) Pyoderma gangrenosum: A review of 86 patients. *Q J Med* 55: 173-82
- Radford DJ, Luu NT, Hewins P, Nash GB, Savage CO (2000) Antineutrophil cytoplasmic antibodies stabilize adhesion and promote migration of flowing neutrophils on endothelial cells. *Arthritis Rheum* 44: 2851-2861
- Rao JK, Allen NB, Pincus T (1998) Limitations of the 1990 American College of Rheumatology classification criteria in the diagnosis of vasculitis. *Ann Intern Med* 129: 345-352
- Reinhold-Keller E, Kekow J, Schnabel A, Schmitt WH, Heller M, Beigel A, Duncker G, Gross WL (1994) Influence of disease manifestation and antineutrophil cytoplasmic antibody titer on the response to pulse cyclophosphamide therapy in patients with Wegener's granulomatosis. *Arthritis Rheum* 37: 919-924
- Reinhold-Keller E, Beuge N, Latza U, de Groot K, Rudert H, Nolle B, Heller M, Gross WL (2000) An interdisciplinary approach to the care of patients with Wegener's granulomatosis: long-term outcome in 155 patients. *Arthritis Rheum* 43: 1021-1032
- Sais G, Vidaller A, Servitje O, Jucgla A, Peyri J (1996) Leukocytoclastic vasculitis and common variable immunodeficiency: successful treatment with intravenous immune globulin. *J Allergy Clin Immunol* 98: 232-233.



- Sansonno D, Lauletta G, Nisi L, Gatti P, Pesola F, Pansini N, Dammacco F (2003) Non-enveloped HCV core protein as constitutive antigen of cold-precipitable immune complex in type II mixed cryoglobulinemia. *Clin Exp Immunol* 133: 275–282
- Savage COS, Harper L, Adu D (1997) Primary systemic vasculitis. *Lancet* 349: 553–558
- Schmitt WH, Gross WL (1998) Vasculitis in the seriously ill patient: diagnostic approaches and therapeutic options in ANCA-associated vasculitis. *Kidney Int Suppl* 64: S39–44
- Schmitt WH, Hagen EC, Neumann I, Nowack R, Flores-Suarez LF, Van der Woude FJ, for the European Vasculitis Group (2004) Treatment of refractory Wegener's granulomatosis with antithymocyte globulin (ATG): An open study in 15 patients. *Kidney Int* 65: 1440–1448
- Schönermarck U, Lamprecht P, Csernok E, Gross WL (2000) Prevalence and spectrum of rheumatic diseases associated with PR3-ANCA and MPO-ANCA. *Rheumatology* in press.
- Schur PH (1993) Clinical features of SLE. In: Kelley WN, Harris ED Jr, Ruddy S, Sledge CB (eds) *Textbook of Rheumatology, Volume 2*. WB Saunders Company, Philadelphia London Toronto Montreal Sydney Tokyo, pp 1017–1042
- Scott DG, Bacon PA (1984) Intravenous cyclophosphamide plus methylprednisolone in treatment of systemic rheumatoid vasculitis. *Am J Med* 76: 377–384
- Sneller MC (2002) Granuloma formation, implications for the pathogenesis of vasculitis. *Cleveland Clin J Med* 69(Suppl. 2): SII-40-SII43
- Stegeman CA, Cohen Tervaert JW, de Jong PE, Kallenberg CGM (1996) Trimethoprim-sulfamethoxazole (Co-trimoxazole) for the prevention of relapses in Wegener's granulomatosis. *N Engl J Med* 335: 16–20
- Stone JH for the WGET investigators (2000) Etanercept in Wegener's granulomatosis (WG): Design of a randomized, multi-center trial. *Clin Exp Immunol* 120 (Suppl 1): 72
- Tatsis E, Schnabel A, Gross WL (1998) Interferon-alpha treatment of four patients with the Churg-Strauss syndrome. *Ann Intern Med* 129: 370–374
- Tsukadaira A, Okubo Y, Kitano K, Horie S, Momose T, Takashi S, Suzuki J, Isobe M, Sekiguchi M (1999) Eosinophil active cytokines and surface analysis of eosinophils in Churg-Strauss syndrome. *Allergy Asthma Proc* 20: 39–44
- Voswinkel J, Müller A, Lamprecht P, Gause A, Gross WL (2002) Does ANCA formation result from an antigen-triggered immune response in Wegener's endonasal inflamed tissue? (Abstract) *Cleveland Clin. J. Med.* 69-Supl.2: SII-159.
- Wei G, Yano S, Kuroiwa T, Hiromura K, Maezawa A (1997) Hepatitis C virus (HCV)-induced IgG-IgM rheumatoid factor (RF) complex may be the main causal factor for cold-dependent activation of complement in patients with rheumatic disease. *Clin Exp Immunol* 107:83–88.
- Winek J, Müller A, Csernok E, Gross WL, Lamprecht P (2004) Frequency of proteinase 3 (PR3)-specific autoreactive T-cells determined by cytokine flow cytometry in Wegener's granulomatosis. *J Autoimmun* 22: 79–85
- Xiao H, Heeringa P, Hu P, Liu Z, Zhao M, Aratani Y, Maeda N, Falk RJ, Jennette JC (2002) Antineutrophil cytoplasmic autoantibodies specific for myeloperoxidase cause glomerulonephritis and vasculitis in mice. *J Clin Invest* 110: 955–963
- Yang JJ, Preston GA, Alcorta DA, Waga I, Munger WE, Hogan SL, Sekura SB, Phillips BD, Thomas RP, Jennette JC, Falk RJ (2002) Expression profile of leukocyte genes activated by anti-neutrophil cytoplasmic autoantibodies (ANCA). *Kidney Int* 62: 1638–1649.
- Zaja F, De Vita S, Mazzaro C, Sacco S, Damiani D, De Marchi G, Michelutti A, Baccarani M, Fanin R, Ferraccioli G (2003). Efficacy and safety of rituximab in type II mixed cryoglobulinemia. *Blood* 101: 3827–3834

## **13 Vitiligo**

*Karin U. Schallreuter*

### **Introduction**

Vitiligo (from vitula (latin) = calf, vitium (latin) = mistake) is an acquired idiopathic epidermal pigment loss which can occur anywhere on the body. The cause of this ancient disease is still unknown.

The incidence of vitiligo worldwide has not been accurately determined, but studies in Europe indicate that 0.5% of the population may be affected, meanwhile in India reports of 4–8% have been suggested (Ortonne and Bose 1993). Even if the lower value is correct, vitiligo must be regarded as one skin disease confronting Dermatologists worldwide (Ortonne and Bose 1993). This disabling depigmentation disorder was recognised thousands of years ago. Several hypotheses have been put forward for the depigmentation process but none of them can conclusively explain the plethora of clinical and basic scientific data (Ortonne and Bose 1993, LePoole et al. 1993a). The clinical signature of the disease is the loss of constitutive pigment from the skin, and most publications account for this by either showing a decreased number of functioning melanocytes or the complete absence of these cells in the depigmented epidermis (Ortonne and Bose 1993, LePoole et al. 1993a, LePoole et al. 1993b, Xie et al. 1999). A recent study by Tobin et al proved that melanocytes are still present, even in long standing vitiligo (Tobin et al. 2000). There has been much debate over, how melanocytes lose their functionality and viability, and certainly the most popular hypothesis is still selective autoimmunity to melanocytes.

### **Clinical Picture and Classification**

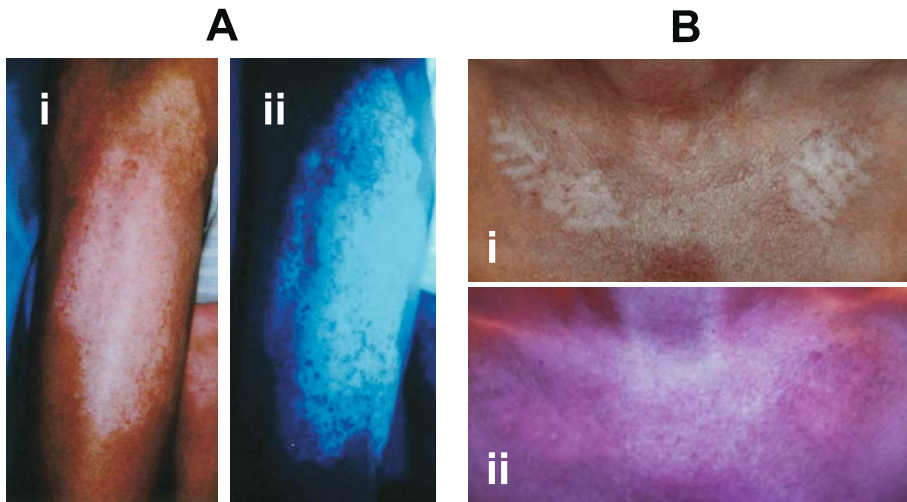
The typical lesion of vitiligo has a chalk white colour without any other epidermal changes and varies in size and location.

Vitiligo can be diagnosed by demonstrating a distinct fluorescence in the depigmented epidermis when it is exposed to Wood's light (UVA 351 nm), whereas leucodermas of other origin do not fluoresce (Schallreuter et al. 1994a). A comparison of vitiligo and a laser induced leucoderma is shown in *Figure 1*.

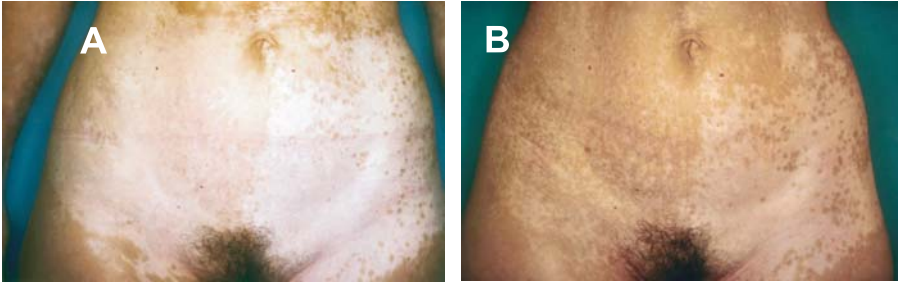
The disease has several characteristic patterns but can involve the entire skin surface.

- Focal vitiligo is characterised by the appearance of one or more isolated macules anywhere on the body.
- Segmental vitiligo is characterised by unilateral appearance in dermatomal or almost dermatomal distribution. Rarely this form can be mixed with generalised vitiligo (*Figure 2*).
- Generalised vitiligo (vitiligo vulgaris) is characterised by symmetrical distribution of white areas anywhere on the integument.
- Acrofacial vitiligo involves distal digits and acrofacial as well as genito-anal areas.
- Universal vitiligo describes depigmentation in > 80% of the entire integument.

The disease can involve mucosal surfaces as well as palms and soles. Active vitiligo is often associated with pruritus in the freshly depigmenting skin (Schallreuter, unpublished results). Koebnerisation has been observed in more than 40% of patients (Ortonne and Bose 1993).



**Fig. 1.** Differential diagnosis of clinical leucoderma upon WOOD's light (351 nm) examination **A.** Vitiligo vulgaris: i. Clinical picture; ii. N.B. Presence of bluish fluorescence is characteristic for vitiligo. **B.** Laser induced leucoderma: i. Clinical picture; ii. N.B. Absence of any fluorescence under WOOD's light



**Fig. 2.** Segmental vitiligo mixed with generalised vitiligo (vulgaris). **A.** Before treatment. **B.** After treatment with low dose narrowband UVB activated pseudocatalase (PC-KUS). NB: The repigmentation of segmental vitiligo is considerably slower!

## Pathomechanisms –a Critical Analysis

### I. Autoimmunity in Vitiligo

Over the past, a variety of techniques have been used in the detection of antibodies to melanocytes in patients with vitiligo. These include indirect immunofluorescence, immunoprecipitation, immunoblotting and complement-dependent cytolysis of melanocytes (Naughton et al. 1983a, Naughton et al. 1983b, Naughton et al. 1986a, Naughton et al. 1986b, Galbraith et al. 1988, Norris et al. 1988, Harning et al. 1991, Cui et al. 1992, Cui et al. 1993). These antibodies are believed to be important in the progress of the disease, because they have been found to be cytotoxic to melanocytes under *in vitro* conditions (Norris et al. 1988, Cui et al. 1993). The presence of anti-melanocyte antibodies has been correlated with the activity of skin depigmentation (Naughton et al. 1986a, Harning et al. 1991). Recent work has focused on attempts to identify specific antibodies against melanocytes in vitiligo (Cui et al. 1992). Since several of the antigens are not specific and can cross-react, most attention has been given to antibodies reacting with proteins specific for melanocytes. In this context, research has focused on the detection of antibodies against tyrosinase and tyrosinase related proteins 1 and 2 (TRP-1 and TRP-2) (Song et al. 1994, Baharav et al. 1996, Kemp et al. 1997a, Kemp et al. 1997b, Kemp et al. 1998 and Okamoto et al. 1998). Since tyrosinase is a glycoprotein which is extremely stable to proteolytic digestion, it appeared to be a good candidate for the elicitation of an immune response (Wood and Schallreuter 1991, Laskin and Piccinini 1996). In addition, tyrosinase, TRP-1 and TRP-2 are regarded as melanosome specific as well as being key proteins in the control of pigmentation. TRP-1 is a melanosomal membrane associated protein which has 43% sequence homology to tyrosinase and it controls both the activity and stability of this key enzyme in melanogenesis (Halaban and Moellmann 1990, Orlow et al. 1993). Halaban and Moellmann were the first to demonstrate

that TRP-1 has catalase/peroxidase activities and these authors suggested that it functions by protecting tyrosinase from oxidative degradation (Halaban and Moellmann 1990). In this context, it has been established that  $H_2O_2$  is a potent competitive inhibitor of human tyrosinase and that superoxide anion radical is a preferred substrate for this enzyme compared to molecular oxygen (Wood and Schallreuter 1991). Thus, melanogenesis has been considered as anti-oxidant defence mechanism protecting the melanocyte against oxidative stress (Wood et al. 1999). Jimbow et al reported that melanocytes established from the perilesional skin of patients with vitiligo expressed a TRP-1 containing 11 additional amino acids at the C-terminal end of its sequence and this sequence was identical to murine TRP-1 (Jimbow et al. 2001). The initial transcript for human and murine TRP-1 shows 93% sequence homology (Boissy et al. 1998). However, post-translational processing via an unidentified protease occurs in the human system producing a protein lacking 11 residues from the C-terminal. It has been proposed that this protease appears to be either lost, inhibited or inactivated in vitiligo (Jimbow et al. 2001). Interestingly, in vitiliginous melanocytes the murine form of TRP-1 is expressed and this protein loses its function for protecting melanosome integrity due to defective interactions with both tyrosinase as well as the melanosome chaperone calnexin (Manga et al. 2000, Jimbow et al. 2001). Animal models lacking active TRP-1 develop an adaptive autoimmune response to melanocytes, thus providing an example to support a potential role for  $H_2O_2$  in fostering an immune response (Austin and Boissy 1995, Rutault et al. 1999).

To date the results obtained on tyrosinase antibodies in vitiligo are controversial. Xie et al could not confirm the presence of antibodies to tyrosinase in 54 patients' sera (Xie et al. 1999). These authors reported a non-specific protein comigrating with tyrosinase at 62 kD (Xie et al. 1999). Therefore, it was concluded that this protein most likely gave false positive results as reported by Song et al (Song et al. 1994, Xie et al. 1999). Very recently Kemp et al have re-examined the antibodies and this group delineated epitope regions on tyrosinase reacting with these antibodies (Kemp et al. 1999). Accordingly, three epitope regions were found in the centre of the tyrosinase molecule (i.e. amino acids 240–255, 289–294 and 295–300) and two others towards the C-terminal end (i.e. amino acids 435–447 and 461–479). The centrally located epitopes had sequence homology with regions of TRP-1 and TRP-2, which consequently could explain the cross reactivity observed for these closely related proteins (Kwon 1993, Yokoyama et al. 1994). Two of the five patients examined cross-reacted with both TRP-1 and TRP-2 and one patient reacted only with the 289–294 and 295–300 regions of tyrosinase (Kemp et al. 1999). Two patients reacted only with tyrosinase 435–447 and 461–479 and did not recognise TRP-1 or TRP-2 (Kemp et al. 1999). Based on these results, it can be concluded that multiple autoantibodies to tyrosinase occur in vitiligo. However, the frequency of tyrosinase antibody expression in this disease remains extremely low (i.e. = 5%). Whether these anti-tyrosinase antibodies can account for the progress of vitiligo in these few patients remains currently

unanswered. Similar low frequencies for TRP-1 and TRP-2 were found in vitiligo patients (i.e. 3 out of 53) (Kemp et al. 1997, Kemp et al. 1998). Based on this low expression, it is very likely that tyrosinase, TRP-1 and TRP-2 antibodies do not play a major role in vitiligo and that other melanocyte autoantigens must be more significant targets. It should be recognised that during the period from 1994 to 1999 autoantibodies to tyrosinase in vitiligo have lost their scientific significance from 61% down to 0–5% (Song et al. 1994, Kemp et al. 1999, Xie et al. 1999). In conclusion, it seems unconvincing that autoantibodies to tyrosinase, TRP-1 and TRP-2 account for the loss of functioning melanocytes in this disease. Moreover, recently three membrane associated antigens have been detected at the cell surface of melanocytes with molecular weights of 90, 75 and 40 kD, in addition to the non-specific 62 kD protein that comigrates with tyrosinase (Xie et al. 1999). However, the structure/function of these proteins and their specificity to the melanocyte requires more rigorous examination before they can be unambiguously proved to be part of the postulated autoimmune response in vitiligo. A critical analysis of all data published and a reevaluation of 320 patients with vitiligo failed to support the involvement of classical autoimmunity in vitiligo. However, there are indeed increased thyroid peroxidase (TPO) antibody levels compared to controls. A very recent study failed to link these results to the clinical outcome of vitiligo and to autoimmune thyroiditis (M Hashimoto) (J Diehle, Medical Thesis, U of Hamburg, 2004).

Hence, the question remains "Are there specific autoantigens in the depigmentation disorder vitiligo?"

## II. The Neural Hypothesis

It is believed that neurochemical mediators released from nerve endings can cause destruction of MC's. It has been proposed that some intermediates or end products of catecholamines destroy the pigment (reviewed in Nordlund et al. 1988). Neural factors were thought to be involved in 30% of patients with vitiligo.

## III. The Self Destruction Hypothesis

Based on both laboratory and clinical experiments melanin precursor toxicity was implicated for the loss of pigment cells. The melanocyte synthesises melanin by the oxidation of L-tyrosine via L-dopa to L-dopaquinone.

Subsequently, L-dopaquinone oxidises through several steps into a variety of indoles and free radicals. These phenolic compounds can damage MC's *in vitro* and *in vivo* (Boissy and Manga 2004).

#### IV. Virus and Vitiligo

Recently Grimes et al have proposed a viral aetiology for this disease (Grimes et al. 1996, Grimes et al. 1999). Using PCR techniques, cytomegalovirus (CMV) and Epstein Barr virus (EBV) have been detected in the epidermis of patients with this disorder. Based on these findings, the authors suggested a viral induced patho-mechanism. Since this study was undertaken in California the direct association of CMV with vitiligo is difficult to assess, since 85% of the population in California test positive for CMV but the incidence of vitiligo is only approximately 0.5%. A recent study re-examined the hypothesis of viral induced disease on 72 patients with vitiligo compared to healthy controls (n = 70). The outcome showed no direct evidence for CMV, Herpes virus I/II and varicella virus using PCR techniques in skin biopsies as well as in the serum from these patients (Würfel et al. 2000). However, even these findings cannot exclude a viral involved 'hit/run' mechanism, despite there is no direct evidence for virus detection *in loco* or in serum. In fact, it has been shown in animal models that virus infection can trigger an autoimmune response due to molecular mimicry of viral peptide sequences activating subsets of T-cells. This hypothesis could support viral induced T-cells as a target against melanocytes. In these models the virus causing autoimmunity escapes detection after the onset of the disease (Herrath and Oldstone 1996, Morse et al. 1999). In this context, it is noteworthy that viruses can attract an infiltrate of leukocytes and macrophages leading to the 'oxygen burst' concomitant with the production of reactive oxygen species (ROS), such as superoxide anion radical ( $O_2^-$ ) and hydrogen peroxide ( $H_2O_2$ ).

#### V. Oxidative Stress in Vitiligo

Nowadays there is accumulating evidence that vitiligo is a disease affecting the entire epidermis, although most of the studies have concentrated on the melanocyte (Schallreuter et al. 1999a, Schallreuter 1999b). In addition to the loss of functioning melanocytes, the keratinocytes and Langerhans cells are disturbed in this disease (Nordlund and Ortonne 1992, Tobin et al. 2000). It has been demonstrated by various investigators that the entire epidermis of patients shows signs for oxidative stress yielding various degrees of vacuolation in all epidermal cells including dilation of the rough endoplasmic reticulum in melanocytes (Moellmann et al. 1982, Bhawan and Bhutani 1983, Boissy et al 1991, Nordlund and Ortonne 1992, Schallreuter et al, 1999a, Schallreuter 1999b, Tobin et al 2000). This oxidative stress can continue even in melanocytes and keratinocytes cultured under *in vitro* conditions unless these cultures are protected by anti-oxidant enzymes for instance catalase (Medrano and Nordlund 1990, Schallreuter et al. 1999a). The proof of oxidative stress in vitiligo has been accomplished '*in vivo*' by measuring hydrogen peroxide ( $H_2O_2$ ) directly in the depigmented epidermis by non-invasive Fourier Transform

(FT) Raman spectroscopy, where  $\text{H}_2\text{O}_2$  yields a distinctive peak due to the O–O stretch at  $875\text{ cm}^{-1}$  (Schallreuter et al. 1999a). This epidermal  $\text{H}_2\text{O}_2$  can be removed by a synthetic catalyst that oxidises  $\text{H}_2\text{O}_2$  to  $\text{O}_2$  and  $\text{H}_2\text{O}$ , thus mimicking the reaction catalysed by natural catalase. The active catalyst is a narrow band UVB-activated bis  $\text{Mn}_{\text{III}}$  (EDTA) $^2$  ( $\text{HCO}_3^-$ ) $^2$  complex and has been named 'pseudocatalase' (Schallreuter et al. 1995a). Pseudocatalase can arrest the progress of the disease in 95% of all patients and initiates repigmentation in approximately 60% of those treated topically with this modality (Schallreuter et al. 1995a, Schallreuter 1999a). The biochemical basis for the accumulation of  $\text{H}_2\text{O}_2$  in patients with vitiligo has been the target of much research. Initially it was shown that these patients have low levels of catalase in their entire epidermis (Schallreuter et al. 1991). However, although catalase levels are decreased, the expression of catalase mRNA remains unaltered in these patients (Schallreuter et al. 2004). These early data were confirmed, showing that melanocytes established from the non-lesional skin of these patients contained lower than normal catalase activities (Maresca et al. 1997). These *in vitro* results were in agreement with increased epidermal  $\text{H}_2\text{O}_2$  levels (mM range) *in vivo*. Under these conditions this reactive oxygen species can inactivate catalase by degradation of the porphyrin active site after concentrations exceeding  $V_{\text{max}}$  levels (Aronoff 1965). In the presence of low catalase levels, glutathione peroxidase functions as a back up enzyme for the efficient removal of  $\text{H}_2\text{O}_2$ . In this context, it has been shown that these enzyme activities are also compromised in this patient group (Beazley et al. 1999).

Several investigators have reported the presence of a cellular infiltrate in the perilesional skin of patients with vitiligo (Ortonne and Bose 1993). The presence of this infiltrate indicates the likelihood of the biological 'oxygen burst' leading to the generation of superoxide anion radical ( $\text{O}_2^-$ ) from  $\text{O}_2$  via NADPH-oxidase (Darr and Fridovich 1994, Marks et al. 1996, Stark 1998). In a normal inflammatory reaction  $\text{O}_2^-$  concentrations increase up to 20 fold. After disproportionation this concentration would produce a 10 fold increase in  $\text{H}_2\text{O}_2$  (Darr and Fridovich 1994). The perilesional border in vitiligo frequently contains an infiltrate but the numbers of infiltrating neutrophils and macrophages as well as T-cells are usually very low or even absent in long lasting disease. Therefore, it is very difficult to assess the  $\text{H}_2\text{O}_2$  contribution deriving from this perilesional infiltrate. Indeed, cells in the perilesional epidermis in vitiligo show the same degree of vacuolation (i.e. lipid peroxidation) as cells in both lesional and non-lesional skin (Schallreuter et al. 1999a, Tobin et al. 2000). However, recently it has been shown that  $\text{H}_2\text{O}_2$  can activate peripheral blood dendritic cells by upregulating surface markers known to be involved in T-cell interactions (Rutault et al. 1999). This  $\text{H}_2\text{O}_2$  driven process promotes interaction with MHC class II molecules (DQ and DR) as well as costimulatory molecules CD 40 and CD 86 (Rutault et al. 1999). After exposing dendritic cells in culture to  $\text{H}_2\text{O}_2$  these cells promote T-cell proliferation compared to untreated controls lacking  $\text{H}_2\text{O}_2$  exposure (Rutault et al. 1999). The effect of  $\text{H}_2\text{O}_2$  can be blocked *in vitro* upon the addition of the anti-



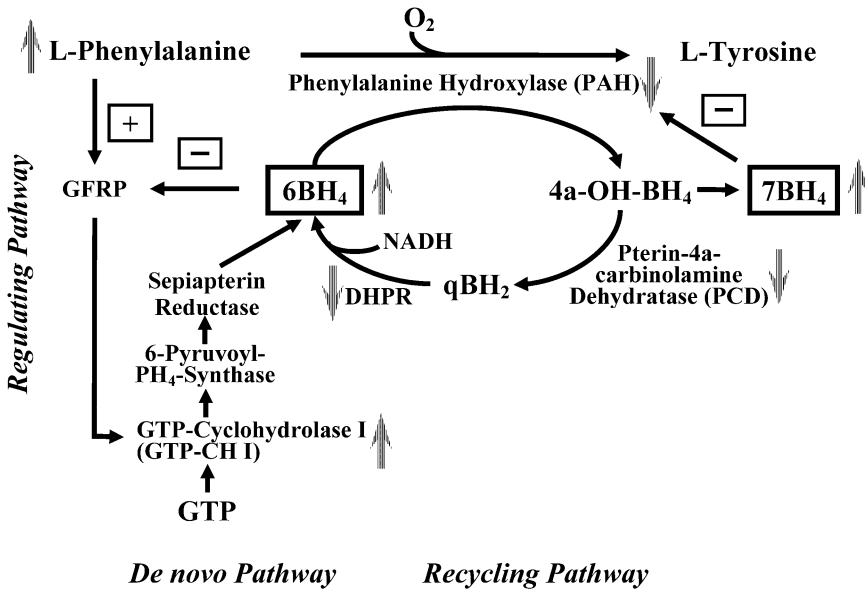
oxidant N-acetyl cysteine (Rutault et al. 1999). In the same context, it has been shown that solar simulated irradiation upregulates epidermal Langerhans cell B7.1 and B7.2 costimulatory molecules (Laihia and Jansen 1997). It has been shown *in vivo* and *in vitro* that  $H_2O_2$  is generated by UVB (311 nm) and UVA using FT-Raman spectroscopy (Schallreuter et al. 1999a). Therefore it can be concluded that  $H_2O_2$  could modulate the response of epidermal Langerhans cells and other dendritic cells in vitiligo (Laihia and Jansen 1997, Schallreuter et al. 1999a, Tobin et al. 2000). These data could directly link oxidative stress from  $H_2O_2$  to the onset of an adaptive immune response (Laihia and Jansen 1997). Moreover, these results may also be a rationale that the immune response in vitiligo is most likely a secondary event linked to oxidative stress with an overproduction of  $H_2O_2$  in the skin.

To date a plethora of studies have recognised several sources and consequences of  $H_2O_2$  in vitiligo:

1. Defective *de novo* synthesis/recycling and regulation of the essential cofactor (6R)-L-erythro 5,6,7,8 tetrahydrobiopterin (Schallreuter et al. 1994a, Schallreuter et al. 1994b).
  - Induction of GTP-CH1 (rate limiting step for *de novo* 6BH<sub>4</sub> synthesis (Shimizu et al. 2003).
  - Deactivation of pterin-4a-carbinolamine dehydratase (PCD) and dihydropteridine reductase (DHPR). (Both enzymes are involved in 6BH<sub>4</sub> recycling). (Schallreuter et al. 2001, Hasse et al. 2004).
2. Increased epidermal monoamine oxidase A activities (Schallreuter et al. 1996a).
3. Increased NADPH-oxidase activities from the activation of neutrophils and macrophages that can sometimes be observed in the perilesional infiltrate in vitiligo (Darr and Fridovich 1994).
4. Increased TNF $\alpha$  production (Moretti et al. 2002).
5. Photo-oxidation of epidermal 6-biopterin and sepiapterin (Rokos et al. 2002).
6. Increased inducible nitric oxide synthase (Schallreuter et al. 1999b).
7. Deactivation of acetylcholinesterase (Schallreuter et al. 2004).
8. Oxidation of epidermal albumin (Rokos et al. 2004).

## VI. Pteridines in Vitiligo

In 1994 it was finally discovered that the fluorescent compounds present in vitiliginous epidermis were oxidised pterins (Schallreuter et al. 1994a, Schallreuter et al. 1994b) (*Figure 1*). This accumulation of oxidised pterins arose from the recognition that these patients have a defective *de novo* synthesis/recycling/regulation of the essential cofactor (6R)-L-erythro 5,6,7,8 tetrahydrobiopterin (6BH<sub>4</sub>) (Schallreuter et al. 1994a, Schallreuter et al. 1994b) (*Figure 3*). Defective recycling of 6BH<sub>4</sub> causes accumulation of its abiogenic isomer



**Fig. 3.** Defective 6BH<sub>4</sub> synthesis leading to 7BH<sub>4</sub> production in vitiligo. Both epidermal melanocytes and keratinocytes have the full capacity for de novo synthesis/recycling of 6BH<sub>4</sub> (Schallreuter et al. 1994a, Schallreuter et al. 1994b). The rate limiting step for the de novo synthesis of 6BH<sub>4</sub> is GTP-cyclohydrolase I (GTP-CH-I) which is regulated by H<sub>2</sub>O<sub>2</sub> (Shimizu et al. 2003). This enzyme is also controlled by L-phenylalanine (positive feedback) via the GTP-CH-I feedback regulatory protein (GFRP), as well as several cytokines (TNF $\alpha$ , IL-2, IFN $\gamma$ , MGF). 6BH<sub>4</sub> down regulates GTP-CH-I via GFRP. Furthermore, 6BH<sub>4</sub> is the essential cofactor (a) for phenylalanine hydroxylase to metabolise L-phenylalanine to L-tyrosine in melanocytes and keratinocytes, and (b) for tyrosine hydroxylase to convert L-tyrosine to L-dopa in catecholamine biosynthesis in epidermal keratinocytes and melanocytes. It is also a regulator of tyrosinase activity in melanocytes, inhibiting the enzyme by an allosteric mechanism. The recycling of 6BH<sub>4</sub> is catalysed by the rate-limiting pterin-4a-carbinolamine dehydratase (PCD) via quinonoid dihydropterin (qBH<sub>2</sub>) and its reduction by dihydropteridine reductase (DHPR) in the presence of NADH. If 6BH<sub>4</sub> is overproduced, as in vitiligo, then 4a-hydroxy-BH<sub>4</sub> is non-enzymatically converted to high levels of 7BH<sub>4</sub>, which in turn inhibit phenylalanine hydroxylase, yielding a compromised L-tyrosine supply

7BH<sub>4</sub> and it was shown that molar concentrations of 7BH<sub>4</sub> inhibit phenylalanine hydroxylase (PAH) thus preventing the turnover of L-phenylalanine to L-tyrosine resulting in a build up of L-phenylalanine in the epidermis (Davis et al. 1992). This build up has been indeed demonstrated *in vivo* by FT-Raman Spectroscopy (Schallreuter et al. 1998). Only recently it has been discovered that H<sub>2</sub>O<sub>2</sub> deactivates the rate limiting recycling enzyme pterin-4a-carbinolamine dehydratase (PCD) because H<sub>2</sub>O<sub>2</sub> alters directly the structure of this bifunctional protein (Schallreuter et al. 2001). The deactivation of PCD by H<sub>2</sub>O<sub>2</sub> as observed *in vivo* and *in vitro* could contribute to the immune response considering that lymphocytes and dendritic cells do express PCD and produce H<sub>2</sub>O<sub>2</sub> themselves via NADPH oxidase (Darr and Fridovich 1994,

Marks et al. 1996 and Stark 1998). Consequently, the build up of  $H_2O_2$  would be autocatalytic. Furthermore, it should be noted that  $H_2O_2$  rapidly oxidises  $6BH_4$  to 6-biopterin and this oxidation product has been shown to be cytotoxic to melanocytes with an  $LC_{50} = 10^{-7}$  M (Schallreuter et al. 1994c). Further investigation demonstrated the presence of pterin 6-carboxylic acid as the final oxidation product of 6-biopterin and other pterins. This photo-oxidation coincides with the generation of  $H_2O_2$  (Rokos et al. 2002). Hence, defective pterin synthesis coupled to oxidative stress can directly influence melanocyte populations and integrity in vitiligo primarily due to the cytotoxicity of 6-biopterin and other oxidised pterins. Only very recently it was demonstrated that epidermal  $H_2O_2$  travels to the vascular system and there it can influence the cholinergic pathway via acetylcholine esterase (Schallreuter et al. 2004). It also has been shown that dihydropteridine reductase, the last step in  $6BH_4$  recycling, can be deactivated in peripheral blood cells by  $H_2O_2$  in the  $\mu$ molar range (Hasse et al. 2004).

## VII. Catecholamines in Vitiligo

The presence of increased levels of  $6BH_4$  and low levels of L-tyrosine in vitiligo provides ideal conditions for increased activity of tyrosine hydroxylase (TH), the key enzyme for catecholamine biosynthesis (Schallreuter et al. 1995b). Both keratinocytes and melanocytes express TH isoform I, the most active of the four different isoforms of this enzyme (Schallreuter et al. 1995b, Marles et al. 2003). In this context it has been reported that patients with active vitiligo have elevated levels of noradrenaline in skin and plasma, as well as high levels of catecholamine metabolites in their urine (Schallreuter et al. 1994b, Morrone et al. 1992). Increased noradrenaline synthesis in the epidermis of these patients causes the induction of the catecholamine degrading enzymes monoamine oxidase A (MAO-A) and catecholamine-O-methyltransferase (COMT) (LePoole et al. 1994, Schallreuter et al. 1996a). MAO-A produces  $H_2O_2$  as a reaction product from the oxidation of noradrenaline, and therefore the increased expression of epidermal MAO-A yields severe oxidative stress (Schallreuter et al. 1996a).

## VIII. Calcium Homeostasis and Oxidative Stress in Vitiligo

The influence of oxidative stress on calcium uptake/efflux has been known for a long time (Marks et al 1996). Earlier studies on the transport of isotopically labelled calcium with keratinocytes and melanocytes established from the depigmented epidermis of patients with vitiligo revealed a significant decrease in the rates for calcium uptake in these cells (Schallreuter et al. 1988, Schallreuter et al. 1996b). Several investigators have shown that the extracellular concentration of calcium, which controls the kinetics for its uptake

and efflux, strongly influences melanogenesis in melanosomes. Recently it has been confirmed that L-phenylalanine transport and its intracellular turnover to L-tyrosine is a calcium dependent process in normal human melanocytes (Schallreuter et al. 1999c). This essential amino acid is actively transported in these cells via the well established L-phenylalanine/sodium/calcium ATP-ase antiporter system described previously for the active transport of neutral amino acids (Schallreuter et al. 1999c). Since the majority of eumelanin is synthesised in melanocytes from the autocrine conversion of L-phenylalanine to L-tyrosine via PAH, then the perturbation of calcium homeostasis in these cells from these patients could also play a crucial role in the loss of pigment in vitiliginous melanocytes (Schallreuter et al. 1996b, Schallreuter et al. 1999c). In this context it is noteworthy that epidermal calcium homeostasis also relies on both the adrenergic and cholinergic signal transduction. Only recently it was shown that acetylcholinesterase, the degrading step for acetylcholine is also deactivated by  $H_2O_2$  (Schallreuter et al. 2004).

### IX. Genetic and/or Environmental Factors in Vitiligo

The application of FT-Raman spectroscopy for *in vivo* analysis of the depigmented epidermis indicates that all untreated patients contain higher than normal levels of  $H_2O_2$  by following the peak at  $875\text{ cm}^{-1}$  (Schallreuter et al. 1999a). In addition, all patients have more total phenylalanine in their depigmented skin at  $1004\text{ cm}^{-1}$ , measured also *in vivo* by the same method, compared to their pigmented skin (Schallreuter et al. 1998). This defect in phenylalanine metabolism has been recognised also in the systemic turnover of L-phenylalanine in this patient group ( $n > 1000$ ) after receiving an oral loading with this essential amino acid (Schallreuter et al. 1998). Interestingly all patients showed a normal rate for the phenylalanine turnover compared to controls, but 40% of the patients tested, revealed pathological L-phe/L-tyr ratios similar to phenylketonurea heterozygotes (Schallreuter et al. 1998). In this context, it is interesting that approximately 35–40% of the patients have a positive family history for vitiligo, strongly suggesting a genetic predisposition for this disease (Ortonne and Bose 1993). However, to date there is no evidence for any mutation on the PAH gene in vitiligo. The defective recycling of  $6BH_4$  via pterin 4a-carbinolamine dehydratase (PCD) suggested the possibility of a polymorphism in this gene (Schallreuter et al. 1994a, Schallreuter et al. 1994b), but recent studies have shown that PCD is directly deactivated by  $H_2O_2$  (Schallreuter et al. 2001). Examination of the sequence of the PCD gene revealed only wild type enzyme (Schallreuter et al. 2001). Another report on vitiligo suggested that this disease is caused by a mutation in GTP-cyclohydrolase I (GTP-CH-I), the rate limiting enzyme for  $6BH_4$  synthesis (De la Fuente-Fernandez 1997), but this result could not be substantiated (Blau et al. 1996, Schallreuter and Blau 1997). An attempt to search for a possible mutation in the regulatory protein GFRP revealed wild type sequence for the  $6BH_4$  binding

domain (KUS, unpublished results). Whether the polymorphism in the catalase gene of affected individuals can account for vitiligo needs to be substantiated (Casp et al. 2002). Only recently the involvement of chromosome 17 has been invoked where special autoimmunity alleles are implicated (Spritz et al. 2004). However, so far this finding was only shown in one family.

Therefore a genetic analysis may be more feasible for those patients who have both autoimmune disorders and vitiligo indicating a true subset of the disease. In our hands the majority of the patients (> 4000) only have vitiligo.

### **No Increased Risk for Skin Cancer in Vitiligo**

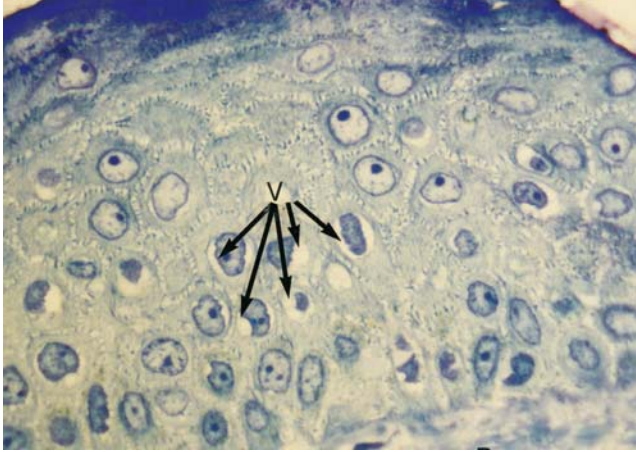
It is generally accepted that the cutaneous pigment protects against the development of skin cancers despite the sun protection factor (SPF) for this melanin is only ranging between 2–5. Since patients with vitiligo lack this protective mechanism, it would be anticipated that affected individuals run a higher risk for skin cancer. Surprisingly, these patients even with long standing vitiligo (>47 years duration) have no evidence for increased photodamage such as actinic keratosis and solar elastosis as well as increased numbers of basal cell and squamous cell carcinoma (Calanchini–Postizzi and Frenk 1987, Schallreuter et al. 2002).

The reason for this paradox response in vitiligo is still unknown. Recently an increased epidermal functioning p53 has been detected, but this increased p53 is not associated with apoptosis in these patients (Schallreuter et al. 2003). In this context it should be noted that p53 can be induced by  $\mu$ molar levels of  $H_2O_2$  (Vile GF 1997). Hence, this scenario could be valid in vitiligo. The question remains, whether p53 is induced as a direct protective mechanism in prevention of skin cancer in this disease which could be an interesting new concept to explain the observed paucity of solar induced damage and skin cancer. Further work is needed to gain more insight into these interesting observations.

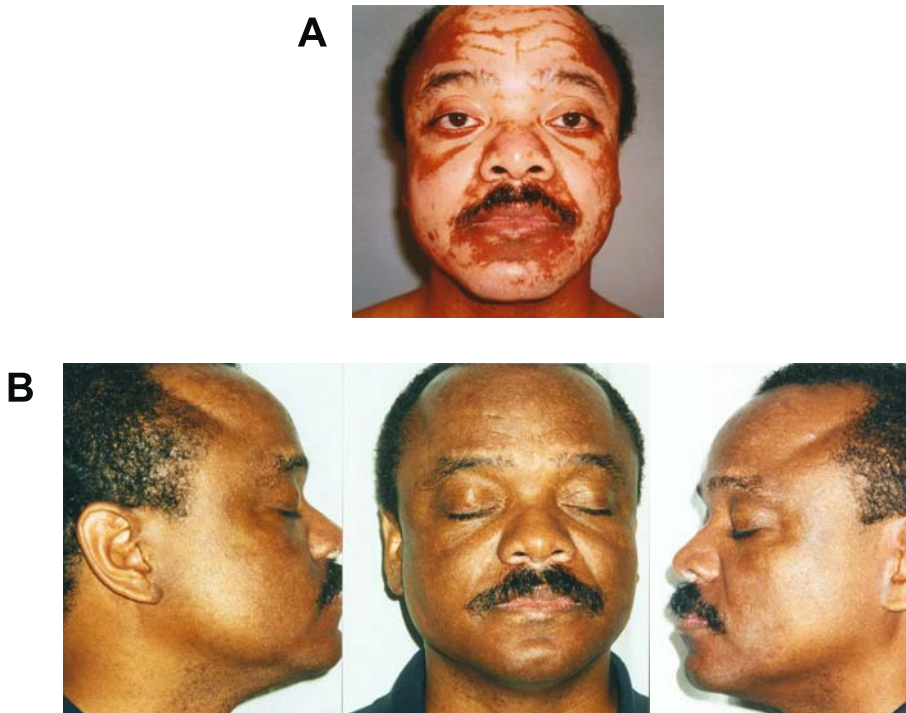### **Newer Treatment Concepts**

Based on the evidence provided there is no doubt that epidermal generation/accumulation of  $H_2O_2$  plays a central role in vitiligo.

This concept is in agreement with the clinical observation where patients with this disorder, regardless of the time of onset and duration of the disease, age, gender and skin phototype respond to a topically applied pseudocatalase (PC-KUS) with a loss of epidermal and systemic  $H_2O_2$  accumulation concomitant with repigmentation (Schallreuter et al. 1999a; Schallreuter et al. 2001, Hasse et al. 2004; Schallreuter et al. 2004) (*Figure 5*).



**Fig. 4.** Epidermal oxidative stress in acute vitiligo. Toluidine blue staining. NB: The extensive vacuolation (V) is based on lipid peroxidative damage due to  $H_2O_2$  (Tobin et al. 2000)



**Fig. 5.** Extensive facial vitiligo in skin phototype VI (Fitzpatrick Classification). **A.** Before treatment. **B.** After treatment with low dose narrowband UVB activated pseudocatalase (PC-KUS)

If vitiligo would fit the criteria of an autoimmune disease, one would expect that the treatment is more successful after the introduction of topical or systemic immunosuppressive drugs. However, the published clinical results are rather disappointing. Even the use of systemic as well as local corticosteroids failed to control the disease in the majority of patients. Topical application of tacrolimus and pimecrolimus as recent local treatment modalities are effective in the repigmentation of facial vitiligo but fail the management of other body areas. Apart from pseudocatalase (PC-KUS) the most promising treatment at the present time seems to be the use of narrowband UVB (311nm) with increasing doses twice or 3 times per week at least over 1 year. The precise mechanism of action remains to be established (Westerhof et al. 1999, Hamzavi et al. 2004).

## Summary

What did we learn? Despite autoimmunity is still the favoured hypothesis for vitiligo, the evidence to date does not support that vitiligo belongs into the group of primary autoimmune diseases. The low frequency of vitiligo antibodies specific for melanocytes could most likely be caused by the influence of  $H_2O_2$  on the immune system as a secondary response. To date there is accumulating evidence that other autoimmune phenomena in association with vitiligo are a rather random event.

In the light of epidermal and systemic  $H_2O_2$  accumulation, it is tempting to speculate that environmental (exogenous) or systemic (endogenous) trigger factors could be the mechanisms for the 'hit' that increases  $H_2O_2$  production via NADPH-oxidase in the microenvironment. This could tip the balance and cause the initial loss of constitutive pigmentation due to the generation of hydroxyl radicals ( $OH^\bullet$ ) from  $H_2O_2$  via the UV-catalysed Haber-Weiss reaction (Darr and Fridovich 1994). However, in the subsequent process of the disease, the origin of  $H_2O_2$  derives from various sources, which could well foster the 'run' mechanism, where  $H_2O_2$  activates T-cell proliferation with consequent activation of T-cell clones (Rutault et al. 1999, LePoole et al. 2004). A cellular infiltrate in the perilesional skin in active vitiligo can contribute to a temporary oxygen burst yielding  $H_2O_2$ . However, vacuolation/lipid peroxidation, expected to be exacerbated by the oxygen burst, is not different in the perilesional skin compared to lesional skin and the normally pigmented epidermis. All compartments can have the same extent of vacuolation (Tobin et al. 2000) (*Figure 4*). Moreover, many of the described mechanisms are perturbed and are observed in both the lesional and non lesional skin of patients with vitiligo indicating that the entire skin participates in the depigmentation process.

Despite that our knowledge on vitiligo has improved, there is still no complete concept in understanding of those factors underlying the initiation of this disease. Future work is needed to get a better picture which allows the

development of a more effective treatment or even cure of this ancient disfiguring disease.

## References

- Aronoff S (1965) Catalase: kinetics of photo-oxidation. *Science* 150: 72–73
- Austin LM, Boissy RE (1995) Mammalian tyrosinase related protein-1 is recognised by autoantibodies from vitiliginous Smyth chickens. *Am J Pathol* 146:1529–1541
- Baharav E, Merimski O, Shoenfeld Y, Zigelman R, Gilbrud B, Yechezkel G, Youinou P, Fishman P (1996) Tyrosinase as an autoantigen in patients with vitiligo. *Clin Exp Immunol* 105: 84–88
- Beazley WD, Gaze DC, Panske A, Panzig E, Schallreuter KU (1999) Serum selenium levels and glutathione peroxidase activities in vitiligo. *Br J Dermatol* 141: 301–303
- Bhawan J, Bhutani LK (1983) Keratinocyte damage in vitiligo. *J Cutaneous Pathol* 10: 207–212
- Blau N, Barnes I, Dhondt JL (1996) International database of tetrahydrobiopterin deficiencies. *J Inher Metab Dis* 19: 8–14
- Boissy R, Liu YY, Medrano EE, Nordlund JJ (1991) Structural aberration of the rough endoplasmic reticulum and melanosome compartmentalisation in long term cultures of melanocytes from vitiligo patients. *J Invest Dermatol* 97: 395–404
- Boissy RE, Sakai C, Zhao H, Kobayashi T, Hearing VJ (1998) Human tyrosinase related protein-1 (TRP-1). *Exp Dermatol* 7: 198–204
- Boissy RE, Manga P (2004) On the etiology of contact/occupational vitiligo. *Pigment Cell Res* 17: 208–14
- Calanchini-Postizzi E, Frenk E (1987) Long-term actinic damage in sun-exposed vitiligo and normally pigmented skin. *Dermatologica* 174: 266–71
- Casp CB, She JX, McCormack WT (2002) Genetic association of the catalase gene (CAT) with vitiligo susceptibility. *Pigment Cell Res* 15: 62–6
- Cui J, R Harning, M Henn, J-C Bystryn (1992) Identification of pigment cells antigens defined by vitiligo antibodies. *J Invest Dermatol* 98: 162–165
- Cui J, Arita Y, Bystryn J-C (1993) Cytolytic antibodies to melanocytes in vitiligo. *J Invest Dermatol* 100: 812–815
- Cui J, Chen D, Misfeldt ML, Swinfard RW, Bystryn J-C (1995) Antimelanoma antibodies in swine with spontaneously regressing melanoma. *Pigment Cell Res* 8: 60–63
- Darr D, Fridovich I (1994) Free radicals in cutaneous biology. *J Invest Dermatol* 102: 671–675
- Davis MD, Ribeiro P, Tipper J, Kaufman S (1992) 7-Tetrahydrobiopterin, a naturally occurring analogue of tetrahydrobiopterin, is a cofactor for and a potential inhibitor of the aromatic amino acid hydrolases. *Proc Natl Acad Sci USA* 89: 10108–10113
- De la Fuente-Fernandez R (1997) Mutations in GTP-cyclohydrolase I gene and vitiligo. *Lancet* 350: 640
- Diehle J (2004) Med Thesis, University of Hamburg, Germany
- Galbraith GM, Miller D, Emerson DL (1988) Western blot analysis of serum antibody reactivity with human melanoma cell antigens in alopecia areata and vitiligo. *Clin Immunol Immunopathol* 48: 317–324
- Grimes PE, Sevall JS, Vojdani A (1996) Cytomegalovirus DNA identified in skin biopsy specimens of patients with vitiligo. *J Am Acad Dermatol* 1996; 35:21–26
- Grimes PE, Elkadi T, Sanders, J (1999) Epstein-Barr virus infection in patients with vitiligo (abstr). *J Invest Dermatol* 112: 604
- Halaban R, Moellmann GE (1990) Murine and human b-locus pigmentation genes encode a glycoprotein (gp75) with catalase activity. *Proc Nat Acad Sci USA* 1990 87:4809–4813
- Hamzavi I, Jain H, Mclean D, Shapiro J, Zeng H, Lui H (2004) Parametric modelling of narrowband UVB phototherapy for vitiligo using a novel quantitative tool: the Vitiligo Area Scoring Index. *Arch Dermatol* 140: 677–83
- Harning R, Cui J, Bystryn J-C (1991) Relation between the incidence and level of pigment cell antibodies and disease activity in vitiligo. *J Invest Dermatol* 97: 1078–1080



- Hasse S, Gibbons NC, Rokos H, Marles LK, Schallreuter KU (2004) Perturbed 6-tetrahydrobiopterin recycling via decreased dihydropteridine reductase in vitiligo: more evidence for H<sub>2</sub>O<sub>2</sub> stress. *J Invest Dermatol* 122: 307–313
- Herrath MG, Oldstone MB (1996) Virus induced autoimmune disease. *Curr Opin Immunol* 8: 878–885
- Jimbow K, Chen H, Park JS, Thomas P (2001) Increased sensitivity of melanocytes to oxidative stress and abnormal expression of tyrosinase related protein in vitiligo. *Br J Dermatol* 144: 55–65
- Kemp EH, Gawkrödger DJ, MacNeil S, Watson PF, Weetman AP (1997a) Detection of tyrosinase autoantibodies in vitiligo patients using 35S-labelled recombinant human tyrosinase in a radioimmunoassay. *J Invest Dermatol* 109: 69–73
- Kemp EH, Gawkrödger DJ, Watson PF, Weetman AP (1997b) Immunoprecipitation of melanogenic enzyme autoantigens with vitiligo sera: evidence for cross-reactive autoantibodies to tyrosinase and tyrosinase-related protein-2 (TRP-2). *Clin Exp Immunol* 109: 495–500
- Kemp EH, Waterman, Gawkrödger DJ, Watson PF, Weetman AP (1998) Autoantibodies to tyrosinase-related protein-1 (TRP-1) detected in the sera of vitiligo patients using a quantitative radiobinding assay. *Br J Dermatol* 139: 798–805
- Kemp EH, Waterman EA, Gawkrödger DJ, Watson PF, Weetman AP (1999) Identification of epitopes on tyrosinase which are recognised by autoantibodies from patients with vitiligo. *J Invest Dermatol* 113: 267–271
- Kwon BS (1993) Pigmentation genes: the tyrosinase gene family and the pmel17 gene family. *J Invest Dermatol* 100: 134S–140S
- Laihia JK, Jansen CT (1997) Upregulation of human epidermal Langerhans cell B7–1 and B7–2 costimulatory molecules *in vivo* by solar stimulating irradiation. *Eur J Immunol* 27: 984–989
- Laskin JD, Piccinini LA (1986) Tyrosinase isozyme heterogeneity in differentiating B16/C3 melanoma. *J Biol Chem* 261: 16626–16635
- LePoole IC, Das PK, van den Wijngaard RM, Bos JD, Westerhof W (1993a) Review of the etiopathomechanism of vitiligo: A convergence theory. *Exp Dermatol* 2: 146–153
- LePoole IC, van dan Wijngaard RM, Westerhof W, Dutrieux RP, Das PK (1993b) Presence or absence of melanocytes in vitiligo lesions: an immunohistochemical investigation. *J Invest Dermatol* 100: 816–822
- LePoole C, Wijngaard Van den, Smit NPM, Oosting J, Westerhof W, Pavel S (1994) Catechol-O-methyl transferase in vitiligo. *Arch Dermatol Res* 286: 81–86
- Le Poole IC, Wankowicz-Kalinska A, van der Wijngaard RMJGJ, Nickoloff BJ, Das PK (2004) Autoimmune aspects of depigmentation in vitiligo. *J Invest Dermatol Symp Proc* 9: 68–72
- Manga P, Sato K, Ye L, Beerman F, Lamoreux ML, Orlov SJ (2000). Mutational analysis of the modulation of tyrosinase by tyrosinase related proteins 1 and 2 *in vitro*. *J Pigment Cell Res* 13: 364–374
- Maresca V, Roccella M, Roccella F, Camera E, Del Porto G, Passi S, Grammatico P, Picardo M (1997) Increased sensitivity to peroxidative agents as a possible pathogenic factor of melanocyte damage in vitiligo. *J Invest Dermatol* 109: 310–313
- Marks DB, Marks AD, Smith CM (1996) Oxygen metabolism and oxygen toxicity. In: *Basic Medical Biochemistry: A Clinical Approach*. Baltimore: Williams and Wilkins 327–340
- Marles LK, Peters EM, Tobin DJ, Hibberts NA, Schallreuter KU (2003) Tyrosine hydroxylase isoenzyme I is present in human melanosomes: a possible novel function in pigmentation. *Exp Dermatol* 12: 61–70
- Medrano EE and Nordlund JJ (1990) Successful culture of adult human melanocytes obtained from normal and vitiligo donors. *J Invest Dermatol* 95: 441–445
- Moellmann G, Klein-Angerer S, Scollay DA, Nordlund JJ, Lerner AB (1982) Extracellular granular material and degeneration of keratinocytes in the normally pigmented epidermis of patients with vitiligo. *J Invest Dermatol* 79: 321–330
- Moretti S, Spallanzani A, Amato L et al. (2002) New insights into the pathogenesis of vitiligo: imbalance of epidermal cytokines at sites of lesions. *Pigment Cell Res* 15: 87–92
- Morrone A, Picardo M, De Luca C, Terminali O, Passi S, Ippolito F (1992) Catecholamines and vitiligo. *Pigment Cell Res* 5: 58–62

- Morse SS, Sakaguchi N, Sakaguchi S (1999) Virus and autoimmunity: induction of autoimmune disease in mice by mouse T-lymphotropic virus (MTLV) destroying CD4 and T cells. *J Immunol* 162: 5309–5316
- Naughton GK, Eisinger M, Bystryn J-C (1983a) Antibodies to normal human melanocytes in vitiligo. *J Exp Med* 158: 246–251
- Naughton GK, Eisinger M, Bystryn J-C (1983b) Detection of antibodies to melanocytes in vitiligo by specific immunoprecipitation. *J Invest Dermatol* 81: 540–542
- Naughton GK, Reggiardo MD, Bystryn J-C (1986a) Correlation between vitiligo antibodies and extent of depigmentation in vitiligo. *J Am Acad Dermatol* 15: 978–981
- Naughton GK, Mahaffey M, Bystryn J-C (1986b) Antibodies to surface antigens of pigment cells in animals with vitiligo. *Proc Soc Exp Biol Med* 181: 423–426
- Nordlund JJ, Ortonne JP (1992) Vitiligo and depigmentation. *Curr Prob Dermatol* 4: 3–30
- Nordlund JJ, Boissy RE, Hearing VJ, King RA, Ortonne JP (eds) (1998) *The pigmentary system. Physiology and Pathophysiology*. Oxford University Press, Oxford
- Norris DA, Kissinger RM, Naughton GK, Bystryn J-C (1998) Evidence for immunologic mechanisms in human vitiligo: patients' sera induce damage to human melanocytes *in vitro* by complement-mediated damage and antibody-dependent cellular toxicity. *J Invest Dermatol* 90: 783–789
- Okamoto T, Irie RF, Fujii S, Huang SKS, Nizze AJ, Morton DL, Hoon DSB (1998) Anti-tyrosinase related protein-2 immune response in vitiligo patients and melanoma patients receiving active-specific immunotherapy. *J Invest Dermatol* 111: 1034–1039
- Orlow SJ, Boissy RE, Moran D, Pifka-Hinst S (1993) Subcellular distribution of tyrosinase and tyrosinase related protein 1: Implications for melanosomal biogenesis. *J Invest Dermatol* 100:55–64
- Ortonne JP, Bose SK (1993) Vitiligo: Where do we stand? *Pigment Cell Res* 8: 61–72
- Rokos H, Beazley WD, Schallreuter KU (2002) Oxidative stress in vitiligo: photo-oxidation of pterins produces H<sub>2</sub>O<sub>2</sub> and pterin-6-carboxylic acid. *Biochem Biophys Res Commun* 292: 805–811
- Rokos H, Moore J, Hasse S, Gillbro JM, Wood JM, Schallreuter KU (2004) *In vivo* Fluorescence Excitation Spectroscopy and *in vivo* FT-Raman Spectroscopy in human skin: Evidence of H<sub>2</sub>O<sub>2</sub> oxidation of epidermal albumin in patients with vitiligo. *J Raman Spectrosc* 35: 125–130
- Rutault K, Alderman C, Chain BM, Katz DR (1999) Reactive oxygen species activate human peripheral blood dendritic cells. *Free Radic Biol Med* 26: 232–238
- Schallreuter KU, Pittelkow MR (1988) Defective calcium uptake in keratinocyte cell cultures from vitiliginous skin. *Arch Dermatol Res* 280: 137–139
- Schallreuter KU, Wood JM, Berger J (1991) Low catalase levels in the epidermis of patients with vitiligo. *J Invest Dermatol* 97: 1081–1085
- Schallreuter KU, Wood JM, Pittelkow MR, Gütlich M, Lemke KR, Rödl W, Swanson NN, Hitzemann K, Ziegler I (1994a) Regulation of melanin biosynthesis in the human epidermis by tetrahydrobiopterin. *Science* 263: 1444–1446
- Schallreuter KU, Wood JM, Ziegler I, Lemke KR, Pittelkow MR, Lindsey NJ, Gütlich M (1994b) Defective tetrahydrobiopterin and catecholamine biosynthesis in the depigmentation disorder vitiligo. *Biochim Biophys Acta* 1226: 181–192
- Schallreuter KU, Büttner G, Pittelkow MR, Wood JM, Swanson NN, Körner C (1994c) Cytotoxicity of 6-biopterin to human melanocytes. *Biochem Biophys Res Commun* 204: 43–48
- Schallreuter KU, Wood JM, Lemke KR, Levenig C (1995a) Treatment of vitiligo with a topical application of pseudocatalase and calcium in combination with short-term UVB exposure: a case study on 33 patients. *Dermatol* 190: 223–229
- Schallreuter KU, Lemke KR, Pittelkow MR, Wood JM, Körner C, Malik R (1995b) Catecholamines and keratinocyte differentiation. *J Invest Dermatol* 104: 953–957
- Schallreuter KU, Wood JM, Pittelkow MR, Büttner G, Swanson NN, Körner C, Ehrke C (1996a) Increased monoamine oxidase A activity in the epidermis of patients with vitiligo. *Arch Dermatol Res* 288: 14–18
- Schallreuter KU, Pittelkow MR, Swanson NN (1996b) Defective calcium transport in vitiliginous melanocytes. *Arch Dermatol Res* 288: 11–13

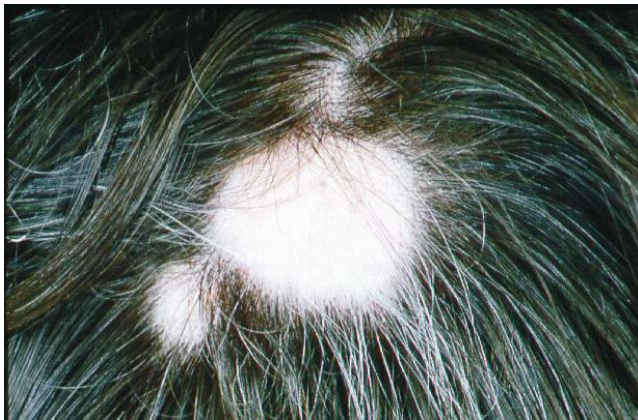- Schallreuter KU, Blau N (1997) GTP-cyclohydrolase and vitiligo. *Lancet* 350: 1254
- Schallreuter KU, Zschiesche M, Moore J, Panske A, Hibberts NA, Herrmann FH, Metelmann HR, Sawatzki J (1998) *In vivo* evidence for compromised phenylalanine metabolism in vitiligo. *Biochem Biophys Res Commun* 243: 395–399
- Schallreuter KU, Moore J, Wood JM, Beazley WD, Gaze DC, Tobin DJ, Marshall HS, Panske A, Panzig E, Hibberts NA (1999a) *In vivo* and *in vitro* evidence for hydrogen peroxide ( $H_2O_2$ ) accumulation in the epidermis of patients with vitiligo and its successful removal by a UVB-activated pseudocatalase. *J Invest Dermatol Symp Proc* 4: 91–96
- Schallreuter KU (1999b). Successful treatment of oxidative stress in vitiligo. *Skin Pharmacol Appl Skin Physiol* 12: 132–138
- Schallreuter KU, Wood JM (1999c) The importance of L-phenylalanine transport and its autocrine turnover to L-tyrosine for melanogenesis in human epidermal melanocytes. *Biochem Biophys Res Commun* 262: 423–428
- Schallreuter KU, Moore J, Wood JM, Beazley WD, Peters EMJ, Marles LK, Behrens-Williams SC, Dummer R, Blau N, Thöny B (2001) Epidermal  $H_2O_2$  accumulation alters tetrahydrobiopterin ( $6BH_4$ ) recycling in vitiligo: Identification of a general mechanism in regulation of all  $6BH_4$  dependent processes? *J Invest Dermatol* 116: 167–74
- Schallreuter KU, Tobin DJ, Panske A (2002) Decreased photodamage and low incidence of non-melanoma skin cancer in 136 sun-exposed caucasian patients with vitiligo. *Dermatology* 204: 194–201
- Schallreuter KU, Behrens-Williams S, Khaliq TP et al. (2003) Increased epidermal functioning wild-type p53 expression in vitiligo. *Exp Dermatol* 12: 268–277
- Schallreuter KU, Elwary SM, Gibbons NC, Rokos H, Wood JM (2004) Activation/deactivation of acetylcholinesterase by  $H_2O_2$ : more evidence for oxidative stress in vitiligo. *Biochem Biophys Res Commun* 315: 502–508
- Shimizu S, Shiota K, Yamamoto S et al. (2003) Hydrogen peroxide stimulates tetrahydrobiopterin synthesis through the induction of GTP-cyclohydrolase I and increases nitric oxide synthase activity in vascular endothelial cells. *Free Radic Biol Med* 34: 1343–52
- Song Y, Connor E, Li Y, Zorovich B, Balducci P, Maclaren N (1994) The role of tyrosinase in autoimmune vitiligo. *Lancet* 344: 1049–1052
- Spritz RA, Gowan K, Bennett DC, Fain PR (2004) Novel vitiligo susceptibility loci on chromosomes 7 (AIS2) and 8 (AIS3), confirmation of SLEV1 on chromosome 17, and their roles in an autoimmune diathesis. *Am J Hum Genet* 74: 188–91
- Stark JM(1998) Immunological adjuvance of metabolic origin: oxidative stress, postulated impaired function of thiol proteases and immunogenicity. *Scand J Immunol* 48: 475–479
- Tobin DJ, Swanson NN, Pittelkow MR, Peters EMJ, Schallreuter KU (2000) Melanocytes are not absent in lesional skin of long duration vitiligo. *J Pathol* 2000 191: 407–416
- Vile GF (1997) Active oxygen species mediate the solar ultraviolet radiation-dependent increase in the tumour suppressor protein p53 in human skin fibroblasts. *FEBS Lett* 412: 70–74
- Westerhof W, Nieuweboer-Krobotova L, Mulder PG, Glazenburg EJ (1999) Left-right comparison study of the combination of fluticasone propionate and UVA vs either fluticasone propionate or UVA alone for the long term treatment of vitiligo. *Arch Dermatol* 135: 1061–6
- Wood JM, Schallreuter KU (1991) Studies on the reactions between human tyrosinase, superoxide anion, hydrogen peroxide and thiols. *Biochim Biophys Acta* 1074: 378–385
- Wood JM, Jimbow K, Boissy RE, Slominski A, Plonka PM, Slawinski J, Wortsman J, Tosk J (1999) What's the use of generating melanin? *Exp Dermatol* 8: 133–164
- Würfel F, Panske A, Schallreuter KU (2000) Are viral infections a possible cause for the manifestation of vitiligo? *J Pigment Cell Res* 13: 404
- Xie Z, Chen D, Jiao D, Bystryjn J-C (1999) Vitiligo antibodies are not directed to tyrosinase. *Arch Dermatol* 135: 417–422
- Yohn JJ, Norris DA, Yrastorza G, Buno IJ, Leff JA, Hake SS, Repine JE (1991) Disparate antioxidant enzyme activities in cultured human cutaneous fibroblasts, keratinocytes and melanocytes. *J Invest Dermatol* 97: 405–409
- Yokoyama K, Suzuki H, Yasumoto K, Tomita Y, Shibahara S (1994) Molecular cloning and functional analysis of a cDNA coding for human DOPachrome tautomerase/tyrosinase-related protein-2. *Biochim Biophys Acta* 1217: 317–321

# 14 Alopecia areata

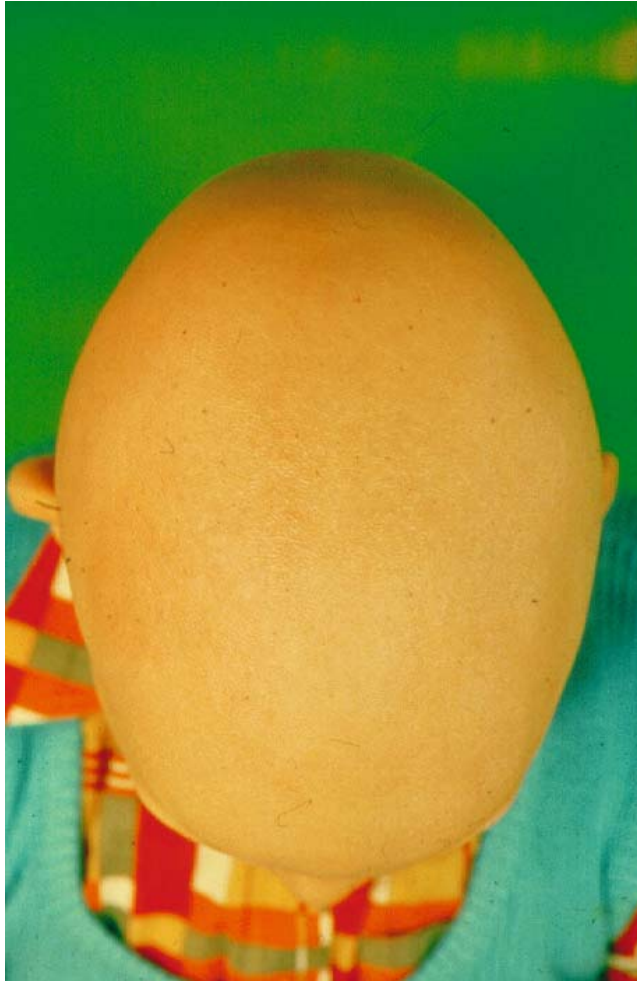
*Pia Freyschmidt-Paul, Kevin McElwee and Rolf Hoffmann*

## Classification and Clinical Appearance

Alopecia areata (AA) is the symptomless loss of hair in either small circumscribed patches (*Fig. 1*), which may remain discrete or may expand into total loss of all scalp (*Fig. 2*) and even body hairs. AA is a common human disease with a lifetime risk of 1.7% in the general population. It is characterized by a reversible patchy hair loss most commonly involving the scalp although other regions of the head, including eyelashes and beard, may also be affected. The typical patient with AA notes the sudden appearance of circular patch of hair loss. Areas of activity in the lesion may be indicated by the presence of "exclamation mark" hairs (*Fig. 3*) which are usually 2–4mm long and may have a dark expanded tip and a depigmented root. The disease may sometimes lead to complete scalp baldness (Alopecia areata totalis) or even total body hair loss (Alopecia areata universalis). AA of the neck is called the ophiasis



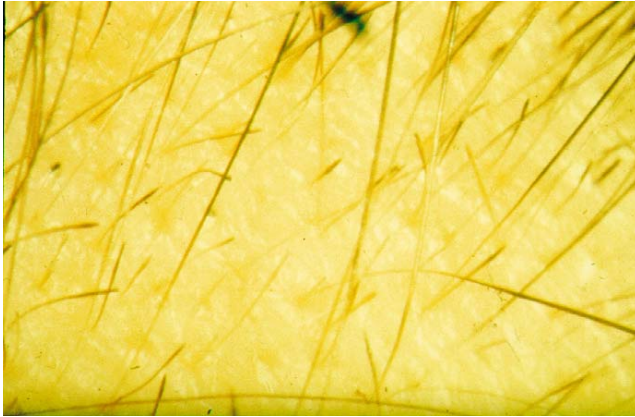
**Fig. 1.** Patchy alopecia areata: two small round bald patches in a child



**Fig. 2.** Alopecia areata totalis. In this example the whole scalp is affected

type. AA may be observed at any age with no sex predominance. AA is more likely to occur in adolescents. AA is not life-threatening but rather psychologically and socially disturbing.

The course of AA is unpredictable and typically characterized by phases of acute hair loss followed by spontaneous hair regrowth and waxing and waning of the lesions. However, in severe forms hair loss can persist for many years. Very often AA shows a mild clinical course with only few small bald patches, and hair regrowth after some weeks or months. However, the severe forms are usually chronic. The prognosis for AA is defined by the age at disease onset, duration, nails signs, the extent of hair loss and the presence



**Fig. 3.** Exclamation mark hairs at advancing edge of patch of alopecia areata

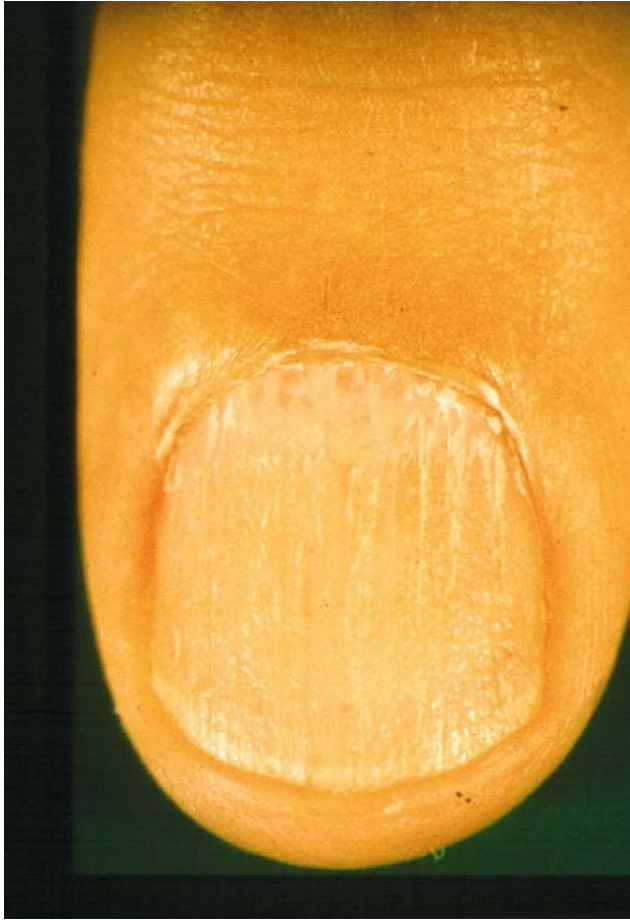
of atopic dermatitis. This means that a patient with AA universalis for many years, with a first episode of AA during childhood, associated nail changes and atopic dermatitis has only a small chance to experience hair regrowth.

Except the nails, which may show typical signs of AA such as small pits, red spotted lunulae or vertical ridging (*Fig.4*), no other organs are affected by this disease. Sometimes small nail pits are the first signs of a developing AA and hair loss may occur later. Only exceptionally nails may fall off (Onychomadesis) due to a severe nail AA. Sometimes all nails are affected. Nail involvement is usually associated with wide spread AA. There are some publications which describe the association of AA with other autoimmune diseases such as Vitiligo or Type 1 diabetes mellitus. However, there is considerable debate about the practical value of those observations. In our view only Hashimoto's thyroiditis tends to be more common in AA.

As hair loss is sudden, hair regrowth occurs without any indicators. The initial hair regrowth after an episode of AA is often white due to a delay in repigmentation of hairs. Interestingly, the last hairs to be affected by AA are white hairs, explaining how scalp hair can appear to become white overnight.

## Diagnosis

The clinical history of abrupt onset of patchy hair loss, the lack of infection, black dots, exclamation mark hairs, are all suggestive of the diagnosis of AA and in most cases the diagnosis of AA can be made clinically. There is no blood test to confirm or to rule out the diagnosis. In rare cases differential diagnosis such as chronic discoid lupus erythematosus, Lichen planopilaris, syphilis, traction alopecia, metastasis to the scalp, mycosis fungoides or alopecia

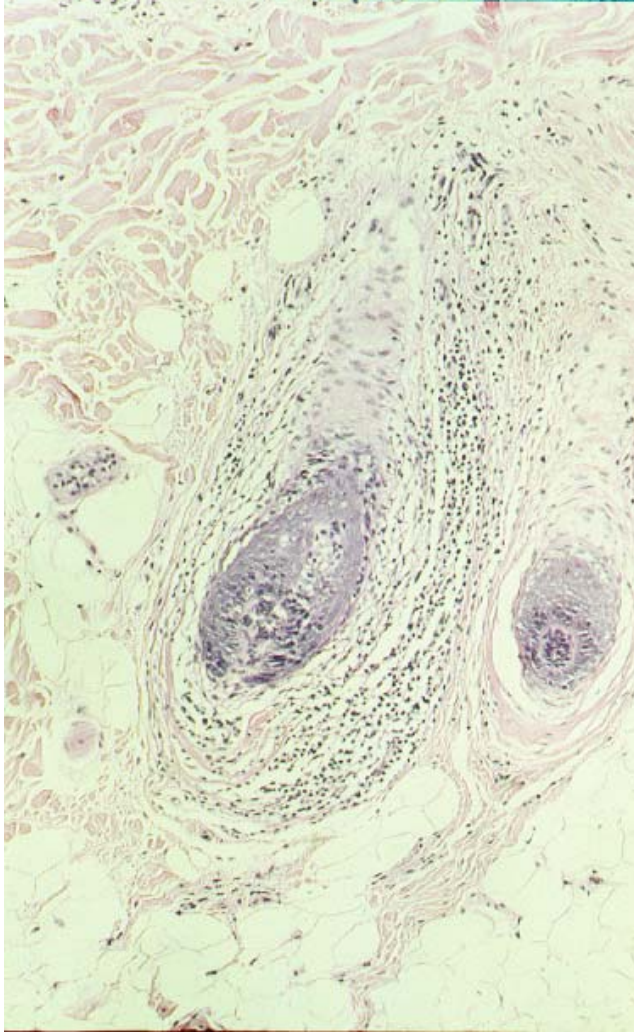


**Fig. 4.** Mild nail dystrophy in alopecia areata with pitting and ridging

mucinosi must be taken into consideration. Especially in AA of the diffuse type it might be difficult to make the diagnosis. Then a scalp biopsy is indicated.

### **Histopathology**

Histopathological features of AA include peri- and intrafollicular lymphocytic infiltrates involving only anagen hair follicles with subsequent miniaturization of these follicles. The lymphocytic infiltrate is located around the hair bulb with some lymphocytes invading the hair follicle (*Fig. 5*). Destruction of hair follicles or scarring usually does not occur in AA and therefore hair regrowth is possible at any timepoint of the disease, either spontaneously or



**Fig. 5.** Histology of alopecia areata. Lymphocytes are clustered around the hair bulb and extend into the dermal papilla (LM x 100)

due to a successful treatment. The process usually involves terminal hairs but can affect vellus hairs as well.

### **Molecular Genetics –the Present Knowledge**

AA has been proposed to be an autoimmune disease based on several indirect observations in humans and animal models of the disease (McElwee et al.



1999c). Genetic influence has been clearly demonstrated in most other autoimmune diseases and one would expect that AA is no exception. AA is clearly a complex disease, it does not segregate according to the rules of Mendelian inheritance (Van der Steen et al. 1992a; Shellow et al. 1992; Colombe et al. 1995; Sharma et al. 1996a). As with other autoimmune diseases, AA is most likely a polygenic disorder where susceptibility is dictated by several major genes and the phenotype may be modified by numerous minor genes.

## Rodent Models

Isolated examples of AA have been identified in several species. However, the limited characterization or availability of these examples restricts their usefulness in any genetic research for AA (McElwee et al. 1998b). Two rodent models have been developed and characterized for use in AA research, the Dundee experimental bald rat (DEBR) and the C3H/HeJ mouse (Michie et al. 1991; Sundberg et al. 1994). Both models are inbred strains. Despite their inbred nature, rodents may have a wide variety of hair loss presentations from isolated patches, or diffuse AA, to near universal hair loss. AA in both rodent models has been shown to be an autosomal polygenic trait with partial phenotype penetrance by analysis of breeding programs.

The DEBR, originally a hybrid between BDIX and Wistar rats, has been intercrossed for over 35 generations. Two separate inbred DEBR sub-strains exist, one black hooded and the other brown, but with similar AA phenotype properties. Hair loss is associated with a primarily CD4<sup>+</sup> and CD8<sup>+</sup> lymphocyte cell infiltrate of anagen stage hair follicles and production of hair follicle specific antibodies (Zhang and Oliver 1994, McElwee et al. 1996). Spontaneous expression of AA develops in 42% of individuals with onset from 7 months of age in both males and females. Hair loss typically first develops in symmetrical bald patches on the flanks. Multiple patches may develop to affect the head, dorsal and ventral skin with approximately 15% of affected individuals reaching a near universal hair loss state. DEBR have been cross bred with PVG/OlaHsd rats yielding 21% affected F1 offspring (Oliver, personal communication) suggesting PVG/OlaHsd rats contain few AA susceptibility genes. PVG/OlaHsd rats may be one of several strains suitable for use in an intercross or backcross breeding strategy to identify AA susceptibility and severity modifying genes by linkage disequilibrium.

C3H/HeJ mice have existed as a unique inbred strain at the Jackson Laboratory since 1947, but onset of the AA phenotype was first observed in several individuals of a C3H/HeJ mouse colony in 1993. The mouse breeding pattern permitted tracing the genetic history of the affected mice to a single breeding pair at generation F198 (Sundberg et al. 1994), suggesting a genetic modification of the strain in one parent. The frequency of spontaneous AA expression in aged mice, up to 18 months old, increased to approximately 20%

in 3–4 generations for over 300 mice evaluated (Sundberg et al. 1994). Both males and females are affected with initially ventral hair loss typically developing in females from 6 months and in males from 10 months of age. Hair loss may progress to the dorsal surface and reach near universal loss in 10% of affected individuals. Histopathology shows all affected anagen stage hair follicles to be affected by non-scarring focal inflammation of primarily CD4<sup>+</sup> and CD8<sup>+</sup> lymphocytes and hair follicle specific autoantibodies are present at a high titer (Tobin et al. 1997; Freyschmidt-Paul et al. 1999).

Recent studies have demonstrated that all adult C3H/HeJ mice are susceptible to AA. Grafting skin from spontaneous AA affected mice to normal haired C3H/HeJ mice consistently promotes onset of AA 8–10 weeks after grafting (McElwee et al. 1998a). Skin grafts from AA affected mice to the histocompatible C3H/OuJ and C3HeB/FeJ inbred strains promotes AA onset with a similar phenotype and pathology, but in only 40% of graft recipients (McElwee et al. 1998a). Crosses between C3H/HeJ mice with AA and mice from the closely related strain with no history of age associated alopecia, yielded F1 and subsequent generation mice with an AA expression frequency of 10–12% (Sundberg et al. 1994). The AA induction technique suggests that while inbred C3H/HeJ mice may all be genetically susceptible, the AA phenotype must be activated. It is possible that the environment provides a trigger for initial disease onset. The apparent reduced susceptibility of the C3H/OuJ and C3HeB/FeJ strains to AA suggest that these strains carry fewer AA susceptibility genes as compared to the C3H/HeJ strain. The segregation pattern of phenotypes suggests that AA in laboratory mice is under the control of one or more dominant gene alleles.

A preliminary backcross study between C3H/HeJ mice and C57BL6/J mice suggested a tentative locus for susceptibility on mouse Chromosome 6 (37cM, 1 recombinant/24 alleles with D6MIT230 is 4.2 cM,  $p = 3 \cdot 10^{-6}$ , 95% confidence interval of the distance is 0.1–21.1 cM) (McElwee et al. 1999a). Within this region are numerous immunoglobulin genes, a gene for cytokine TGF $\alpha$ , as well as genes for the lymphocyte surface markers CD8 and Ly36. The mouse locus corresponds to human chromosome region 2p13. Thus, this region may be worthy of close attention within a genome wide screen. C3H/HeJ mice cross bred with C57/BL6J mice yield 7% of affected F1 generation mice (10% affected females, 2% affected males) and intercross studies with C57BL6/J mice are in progress with up to 13 candidate gene loci under investigation supporting the hypothesis that AA is a polygenic disease (Sundberg et al. 2003).

## Human Epidemiology

There is a higher incidence of AA in genetically related individuals. This suggests that at least some people are genetically predisposed to develop AA. The triggers for the onset of AA may be environmental, but the resistance of

the AA lesion to treatment, its persistence and regression, and its extent over the body may be influenced by the presence and interaction of multiple genes. Several studies suggest that AA has a genetic basis (Van der Steen et al. 1992a; Colombe et al. 1995). AA with similar times of onset or similar hair loss patterns has been reported in monozygotic twins (Hendren 1949; Weidman et al. 1956; Bonjean et al. 1968; Stankler 1979; Cole and Herzlinger 1984; Scerri and Pace 1992; Alsaleh et al. 1995). Families with several generations of AA affected individuals also suggest AA may be a genetically determined disease (Shelton and Hollander 1942; Goldshtein and Chipizhenko 1978; Hordinsky et al. 1984; Valsecchi et al. 1985; Van der Steen et al. 1992a; Sharma et al. 1996a; Sharma et al. 1996b).

Epidemiological studies provide basic evidence for AA susceptibility genes. Numerous studies suggest AA may be more frequently expressed in genetically related individuals. Typically, 10 to 20% of patients with AA

**Table 1.** Incidence of alopecia areata in reported epidemiological studies

Percentage with family history	Geographic location	Source
3%	UK	Barber 1921
20%	UK	Brown 1929
20%	France	Sabouraud 1929
19%	UK	Anderson 1950
10%	USA	Muller and Winkelmann 1963
3.4%	Italy	Olivetti and Bubola 1965
6.3%	Portugal	Bastos Araujo and Poiares Baptista 1967
25%	UK	Cunliffe et al. 1969
17%	Sweden	Gip et al. 1969
27%	USA	Sauder et al. 1980
24%	UK	Friedmann 1981
11%	Belgium	De Weert et al. 1984
6.6%	Germany	Lutz and Bauer 1988
18%	Netherlands	De Waard 1989
11.4%	Germany	Gollick and Orfanos 1990
16%	Germany	Van der Steen et al. 1992
42%	USA	Shellow et al. 1992
11.5%	Korea	Ro Bi 1995
9%	India	Sharma et al. 1996a
12.4%*	India	Sharma et al. 1996b

\* Children aged 16 or younger

indicate at least one other affected family member (*Table 1*). In contrast, the lifetime risk of AA expression in the general population has been suggested to be 1.7% (Safavi et al. 1995). Familial incidence may be significantly higher than reported in epidemiological studies as the marked psycho-social consequences of hair loss inhibit some individuals from seeking diagnosis. In addition, some may not be aware of their hair loss if it is limited or develops in an area not immediately visible to the individual.

A strong association has been observed between AA and trisomy 21 (Down's syndrome). In 1000 patients and 1000 control subjects, Du Vivier and Munro observed 60 cases of trisomy 21 individuals with AA versus 1 control (Du Vivier and Munro 1975). Carter and Jegasothy identified 19 cases of AA in 214 trisomy 21 affected patients and the statistical relationship is further supported in other studies (Wunderlich and Braun-Falco 1965; Carter and Jegasothy 1976). The genetic mutation for autoimmune polyendocrinopathy syndrome type 1 (AIRE, autoimmune regulator gene) (Finnish-German APECED Consortium 1997) is also associated with a 29 to 37% prevalence of AA (Betterle et al. 1998). These studies suggest that candidate gene loci for AA susceptibility may be present on human chromosome 21.

Associations of AA with other autoimmune diseases have also been reported. Between 7% and 27% of AA affected patients may also have a thyroid disease, including goiter presence, myxedema and Hashimoto's thyroiditis (Cunliffe et al. 1969; Milgraum et al. 1987; Shellow et al. 1992; Puavilai et al. 1994). Co-expression of vitiligo and AA has also been reported at between 4% and 9% (Muller and Winkelmann 1963; Main et al. 1975). However, the statistical significance of these disease associations when compared to appropriate control populations has been disputed elsewhere (Salamon et al. 1971; Gollick and Orfanos 1990; Schallreuter et al. 1994). Numerous case reports detail concordant presence of AA with other autoimmune diseases, such as diabetes and myasthenia gravis, although the statistical significance is unknown (McElwee et al. 1998b).

## HLA Genes

Human leukocyte antigen (HLA) genes on human chromosome 6 code for the major histocompatibility complex (MHC) proteins that are important in presentation of antigens and self recognition by immune cells. MHC class I antigens comprise the HLA-B, HLA-C and HLA-A loci in this order. MHC class II is coded by genes in the HLA-D region that is subdivided into gene clusters HLA-DP, HLA-DQ, and HLA-DR (Vogel and Motulsky 1997). MHC class I antigens are expressed on almost all nucleated cells. CD8<sup>+</sup> lymphocytes have the capacity to recognize cellular antigens presented in association with MHC class I via their T cell receptors. In contrast, MHC class II antigens are normally expressed on antigen presenting cells (APCs), such as macrophages

and Langerhans' cells, and expression may be induced on other nucleated cells during inflammatory processes such as AA (Messenger and Bleehen 1985; Bröcker et al. 1987). CD4<sup>+</sup> lymphocytes may recognize antigen plus MHC class II complexes on APCs. Different MHC proteins may have superior presenting properties for particular antigens compared to other MHC complexes and consequently some antigen plus MHC complexes will be more effective in their activation of lymphocytes than others. In part, this may determine the ability of lymphocytes to respond to the hair follicle antigen(s) targeted in AA and may define how potent an immune response against a particular antigen will be.

Genetic research into other autoimmune diseases has shown HLA encoding alleles to segregate with specific disease phenotypes. However, inconsistent results have been found with analysis of HLA class I haplotypes of the A and B series and AA. Some studies report statistically significant associations, but other studies found no HLA class I association (Kuntz et al. 1977; Zlotogorski et al. 1990). HLA-A2, B40 and Aw32, B18 have each been reported as associated with AA (Hordinsky et al. 1984; Valsecchi et al. 1985). Associations between HLA-B12 in Finnish patients, HLA-B18 in Israelis, B13 and B27 in Russians have also been suggested (Kianto et al. 1977; Hacham-Zadeh et al. 1981; Averbakh and Pospelov 1986).

Genetic analysis studies in AA have primarily focused on the HLA-D genes (MHC class II encoding) as the most likely region for genes that regulate susceptibility, severity of, or resistance to disease (Duvic et al. 1991). Consistent associations have been observed between class II haplotypes and AA including DR4 (Friedman 1985; Frentz et al. 1986; Orecchia et al. 1987; Duvic et al. 1991; de Andrade et al. 1999), DR5 (Friedman 1985; Frentz et al. 1986; Orecchia et al. 1987), DR6 (de Andrade et al. 1999), DR7 (Averbakh and Pospelov 1986) and broad antigen DQ3 (Welsh et al. 1994; Colombe et al. 1995; Colombe et al. 1999). More recent research has shown allele DRB1\*1104 (DR11) to be present with significant increased expression in patients with AA (Colombe et al. 1995; Colombe et al. 1999) and this was confirmed in other studies (Morling et al. 1991; Welsh et al. 1994; Duvic et al. 1995). Allele DRB1\*0401 (DR4) was strongly associated with AA totalis and universalis subgroups (Colombe et al. 1999). DQB1\*0301 (DQ7 by serology) was also significantly expressed only in association with AA totalis and universalis (Colombe et al. 1995; Duvic et al. 1995; Colombe et al. 1999). Other studies implicate other DQB1 alleles, DQB1\*302, DQB1\*601, and DQB1\*603, in AA (de Andrade et al. 1999). The current consensus is that AA in humans has a genetic basis, but is not always in a familial aggregation (Van der Steen et al 1992; Colombe et al. 1995).

It has been suggested that the HLA gene products, the MHC antigens, could be important for the presentation of an unknown AA antigen. Aberrant expression of MHC proteins within AA affected hair follicles is frequently found, but the question of its true significance remains (Messenger and Bleehen 1985; Bröcker et al. 1987). There are many more alleles that code for other factors within, and outside of, the immune system that may be vital in the development of AA.

## Non HLA Genes

The HLA gene region is likely to be only one of several gene loci involved in AA, but limited research has been conducted in other areas of the genome. One investigation has shown an association between AA and allele 2 polymorphism for the IL-1 $\alpha$  gene on human chromosome 2 that codes for the IL-1 receptor antagonist (Tarlow et al. 1994). Results indicated allele 2 was present in 41% of controls versus 44% in individuals with patchy AA, 66% of those with alopecia totalis and 77% of alopecia universalis affected individuals (Tarlow et al. 1994). Allele 2 is known to influence IL-1 $\beta$  production. Galbraith et al. identified the IL-1 $\beta$ -1,2 genotype as significantly increased in frequency for individuals with extensive, but not patchy, AA further suggesting that the severe form of disease may be associated with increased IL-1 $\beta$  production (Galbraith et al. 1999).

Genes for immunoglobulin heavy (Gm) and light (Km) chain genotypes on human chromosome 14 have also been implicated in AA susceptibility (Galbraith et al. 1984; Galbraith and Pandey 1989) with the suggestion that IL-1 $\beta$  (IL-1 $\beta$ -1,2) and light chain (KM-1,3) genotypes may interact to increase AA susceptibility (Galbraith et al. 1999). TNF $\alpha$  gene polymorphisms, or adjacent genes in the HLA region may also influence AA susceptibility (Galbraith and Pandey 1995; Cork et al. 1996). Involvement of all these gene loci, as susceptibility or severity modifying genes, is consistent with an autoimmune pathogenesis of AA.

## Conclusions

Rodent model research has shown that AA is an immune mediated disease and strongly suggests that the mechanism is autoimmune in nature (McElwee et al. 1999c). It is probable that AA susceptibility and severity modifying genes will primarily be involved in the immune system, but other susceptibility genes may control hair follicle function. From observation in humans and animal models, AA can be described as a polygenic disease with a variable spectrum of severity. While previous research studies have understandably focused on the HLA region and identification of marker genes segregating with the AA phenotype, there is a clear need for genome wide analysis to define further candidate susceptibility, severity modifying, and possibly resistance gene loci. Human population analysis suggests potential gene loci may be located on chromosomes 2, 6, 14, and 21 (Du Vivier and Mundo 1975; Colombe et al. 1995; Duvic et al. 1995; Galbraith et al. 1999). Careful categorization of DNA samples based on phenotypic presentation of hair loss in the individual will be important for defining sub-categories of AA. It might be possible to define specific alleles with association to particular AA phenotypes such as patchy AA, AA totalis, or AA universalis.

## Therapy

Various methods to treat AA have been described, but for many of them only anecdotal reports exist and the alleged treatment success might be attributed to spontaneous remission. Because of the high rate of spontaneous hair regrowth in AA, the only treatments that can be regarded as evidence-based are those proven to be effective either after exclusion of spontaneous remission by treating every patient on one half of the scalp only or in a double-blind, placebo controlled study including a very large number of patients. Furthermore, studies evaluating treatments for AA should preferably include patients with AA totalis, AA universalis and extensive patchy AA (> 25% scalp hair loss) persisting longer than 3 months, because these patients have a worse prognosis than patients with limited patchy AA. These patients are also the ones who are most in need of an effective treatment. Any treatment has to be suitable for long-term therapy, because AA is a disease that can persist for many years or even life. Hence, all therapeutic approaches showing severe side-effects are inappropriate for AA in the long run.

### Immunosuppressive Treatments

#### Corticosteroids

Topical, intralesional, and systemic corticosteroids have been used for the treatment of AA with different rates of success and side effects.

##### *Topical Corticosteroids*

Topical treatment of AA with corticosteroid creams, ointments or lotions is frequently used. However, only two placebo-controlled studies reported a treatment response (Pascher et al. 1970; Leyden and Kligman 1972), but both studies do not fulfill the criteria for evidence based treatment of AA (40% of drop outs in the first study, patients with only limited AA in the second study). Furthermore, both studies were performed in the 1970s and they have not been confirmed by others over the last 30 years (Weitgasser 1968; Verbov 1973; Lehnert 1974; Montes 1977). Only one placebo-controlled study with an appropriate number of patients has been performed to date, but the rate of treatment success was not statistically significant (Charuwichitratana et al. 2000).

The failure of topical corticosteroids is most likely due to the insufficient penetration of topically applied drugs dissolved in ointments, creams or lotions to the hair bulb. Improved penetration by occlusive treatment has been tried without success (Lehnert 1974) or with a response rate of only 17,8%

(Tosti et al. 2003). Considering the lack of treatment response and the side effects of topically applied corticosteroids, we conclude that topical corticosteroids are not an effective method of treating AA.

### *Intralesional Corticosteroids*

Intralesional injections of corticosteroid crystal suspensions, primarily triamcinolone acetonide, have been used for the treatment of AA for more than 40 years (Kalkoff and Macher 1958). Several studies reported hair regrowth at the site of injection in the majority of cases (Kalkoff and Macher 1958; Orentreich et al. 1960; Porter and Burton 1971; Fülöp and Vajda 1971; Abell and Munro 1973; Frenz 1977). Most of these studies tried to exclude spontaneous hair regrowth by comparing the injected sites of the scalp with non-injected areas, especially in alopecia totalis. However, in practice it is impossible to treat the whole scalp by intralesional injections of corticosteroids and so this treatment is only indicated in patchy AA with longstanding bald areas. Apart from the sometimes painful procedure of injection, permanent skin atrophy can occur after injection. Taken together, intralesional injection of corticosteroids is a reasonable treatment in exceptional, selected cases of longstanding small patches of AA, but has potentially significant side effects.

### *Systemic Corticosteroids*

AA has been treated with systemic corticosteroids since 1952 (Dillaha and Rothman 1952). Whereas initially corticosteroids were applied orally daily or every other day for several months, this approach is obsolete today. The doses that are required to maintain hair regrowth in AA are between 30 and 150 mg prednisolone daily, giving rise to unacceptable side effects such as hypertension, diabetes, immunosuppression, osteoporosis and susceptibility to thrombosis.

Since 1975 several authors have performed pulsed administration of corticosteroids in single doses, given once monthly in order to reduce the side effects of corticosteroids to an acceptable level, but all studies which noted hair regrowth, were uncontrolled and the majority of patients had patchy AA (Perriard-Wolfensberger et al. 1993; Sharma 1996; Friedli et al. 1998; Sharma and Muralidhar 1998; Seiter et al. 2001). Moreover, other studies reported a treatment failure after corticosteroid pulse therapy (Burton and Shuster 1975; Schulz et al. 1996). Controlled studies should be conducted to prove the efficacy and long-term value of this treatment. In particular, the efficacy in interrupting acute phases of rapid hair loss by pulsed administration of oral corticosteroids should be investigated. According to the data currently available, pulsed administration of corticosteroids for AA cannot be recommended.



## **PUVA**

Several studies have been performed on the treatment of AA with PUVA using either oral application of 8-methoxypsoralen (8-MOP) with ultraviolet A radiation (UVA) of the scalp or the whole body, or topical application of 8-MOP and UVA radiation on the scalp, including one study with topical application of psoralen via the PUVA-turban (Larkö and Swanbeck 1983; Claudy and Gagnaire 1983; Lassus et al. 1984; Mitchell and Douglass 1985; Healy and Rogers 1993; Taylor and Hawk 1995; Behrens-Williams et al. 2001). Some investigations seemed to show good results (Claudy and Gagnaire 1983; Lassus et al. 1984; Healy and Rogers 1993; Taylor and Hawk 1995; Behrens-Williams et al. 2001, Whitmont and Cooper 2003), but there were no controls in any of the studies. Moreover, there were a high number of AA recurrences in most of the studies (between 30% and 50% of successfully treated patients) after initial hair regrowth that strongly decreases the efficacy of PUVA treatment for AA (Claudy and Gagnaire 1983; Lassus et al. 1984; Healy and Rogers 1993; Taylor and Hawk 1995). This high number of relapses is most likely due to the fact that regrown hair inhibits the UVA light from reaching the skin. Technical improvement such as a comb emitting UVA light have been tried, but so far no results have been reported. Unfortunately, a continuous hair regrowth after the initial response has to be actively maintained for several years in most cases of AA. With regard to the increased risk of skin malignancies after long-term PUVA therapy, PUVA therapy cannot be recommended for AA even if technical improvement like a UVA-comb should ultimately prove to be effective.

## **Immunomodulatory Treatments**

### **Diphenylcyclopropenone and Squaric Acid Dibutylester**

AA has been treated with contact sensitizers for more than 25 years. Dinitrochlorobenzene (DNCB) was the first sensitizer that was used for the treatment of AA (Happle and Echternacht 1977), but because it has been shown to be mutagenic in the Ames test, it can no longer be used (Happle 1979, 1985). Today diphenylcyclopropenone (DCP) or squaric acid dibutylester (SADBE), that are not mutagenic in the Ames test, are widely used in European states and in Canada.

### *Treatment*

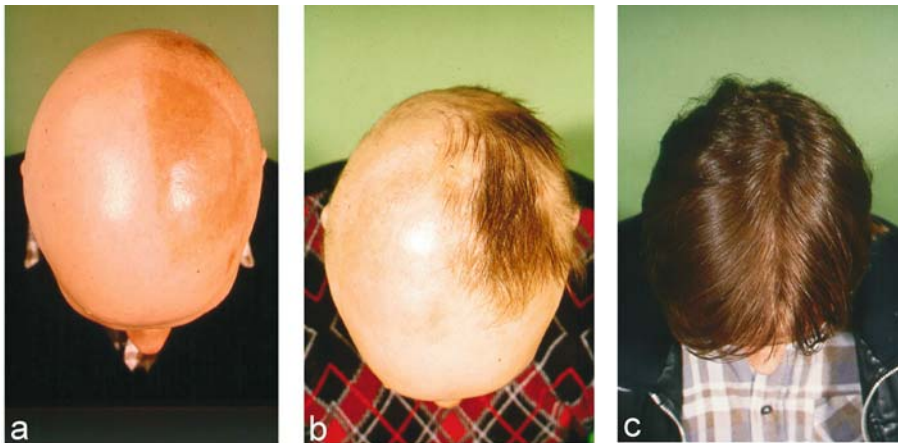Treatment with contact sensitizers is preceded by sensitization of the patient with 2% DCP solution on a small area of the scalp. Two weeks later, treatment is initiated by application of a 0.001% DCP solution, followed by weekly

application of increasing concentrations of DCP until a mild eczematous reaction is obtained. In this way, an appropriate eliciting concentration of DCP for each patient is identified. This concentration has to be applied once a week to induce a mild eczematous reaction that is characterized by itching and erythema, without blistering or oozing. SADBE is used in those patients who become tolerant to DCP. It is applied in the same way and shows a similar rate of response.

Initial hair regrowth is usually visible after 8–12 weeks. Treatment has to be continued once weekly until complete hair regrowth is obtained. Treatment intervals are then decreased and eventually treatment may be discontinued. However, if a relapse occurs after discontinuation of therapy, treatment can be restarted immediately to stop further progression of AA and induce renewed hair growth. Treatment should initially always be applied on one half of the scalp and the other side left untreated to exclude a spontaneous hair regrowth coincidental to treatment initiation. Treatment is continued on both sides only after the treated side has shown a response in the form of better hair growth on the treated side (*Fig. 1*).

### *Side Effects*

A mild eczematous reaction and enlargement of retroauricular lymph nodes are desired reactions and inherent to treatment. They are usually well tolerated if the patients are informed that these reactions are desirable for the therapeutic effect. Undesired side effects are noted in 2–5% of patients (Hoffmann and Happle 1996). Vesicular or bullous reactions sometimes occur at the



**Fig. 6.** Treatment of AA with a contact sensitizer: Unilateral contact dermatitis after application of a contact sensitizer on the left side of the scalp (a); unilateral hair growth on the treated side (b); complete hair growth after treatment of both sides (c)

beginning of treatment before the individual appropriate concentration has been determined. Dissemination of allergic contact dermatitis, urticarial or erythema multiforme-like reactions may occur (Perret et al. 1990) but can be successfully treated with topical corticosteroids. Pigmentary disturbances such as postinflammatory hyperpigmentation with spotty hypopigmentation ("dyschromia in confetti") have been observed, especially in patients with dark skin, but resolved within 1 year after discontinuation of treatment in most cases (van der Steen and Happle 1992; Hoffmann and Happle 1996). Apart from these acute and subacute side effects, no long-term side effects have been reported after 20 years of DCP (23 years of SADBE) treatment worldwide of about 10,000 patients, including children. However, it should be borne in mind that DCP and SADBE are not approved therapeutic substances.

### *Studies*

More than 25 studies have been performed to test the efficacy of AA treatment with a contact sensitizer. The most significant controlled studies are listed in *Table 2*. In contrast to corticosteroid and PUVA treatment studies, the majority of contact sensitizer treatment studies were controlled, most of them using an untreated side of the scalp as a control. When comparing the rates of response obtained in various therapeutic modalities, one should bear in mind that spontaneous regrowth is excluded in these controlled, within-patient studies, but not in the uncontrolled ones. The response rate of treatment with a contact sensitizer varies between 29% and 78% (see *Table 1*). The differences may be explained in part by the different extent and duration of AA prior to treatment in the patients of each study, and in part by differences in the method of treatment. However, the median response rate of all studies is 49%, rendering contact sensitizers an effective therapeutic tool for AA.

### *Mode of Action*

The mode of action of the treatment with contact sensitizers is so far poorly understood. It has been shown that treatment with a contact sensitizer changes the composition and localization of the perifollicular infiltrate in humans and in the C3H/HeJ mouse-model for AA (Happle et al. 1986; Freyschmidt-Paul et al. 1999). In both, mice and men, the localization of the inflammatory infiltrate shows a shift from peribulbar before treatment to the upper dermis after therapy. However, in human AA the CD4:CD8 ratio changes from 4:1 before to 1:1 after therapy, while in mice successful treatment with a contact sensitizer is associated with an increase in the number of CD4<sup>+</sup> cells and a decrease in the number of CD8<sup>+</sup> cells. Hoffmann et al. demonstrated that after treatment with a contact sensitizer the mRNA-expression of IFN $\gamma$  is reduced while the expression of IL-10 is increased (Hoffmann et al. 1994). Whether this is due

**Table 2.** Treatment of AA with Contact Sensitizers, Controlled Studies Including Patients with Severe, Longstanding AA

Reference	Contact Sensitizer	Clinical form of AA (number of patients)			Controlled study	Number of patients	Cosmetically acceptable hair regrowth
		Patchy AA	AA totalis	AA universalis			
Happle et al., 1983	DCP	5	22	0	Yes (ULT)	27	68%
Happle et al., 1984	DCP	8	37	0	Yes (ULT)	45	58%
Ochsendorf et al., 1988	DCP	18	8	1	Yes (ULT)	27	37%
Macdonald Hull and Norris, 1988	DCP	8	20	0	Yes (ULT)	28	29%
Monk, 1989	DCP	0		14	Yes (ULT)	14	43%
Steen van der, et al., 1991	DCP	78	32	29	Yes (ULT)	139	50.4%
Macdonald Hull et al., 1991	DCP	4	8	0	Yes (ULT)	12 children	33%
Macdonald Hull et al., 1991	DCP	33	45	0	Yes (ULT)	78	55%
Hofing et Boehm, 1992	DCP	11	20	14	Yes (ULT)	45	51%
Gordon et al., 1996	DCP	12	36	0	Yes (ULT)	48	38%
Schuttelaar et al., 1996	DCP	10	16	0	Yes (ULT)	26 children	32%
Weise et al., 1996	DCP	43	22	40	Yes (ULT)	105	48%
Cotellessa et al., 2001	DCP	14	42	0	Yes (ULT)	56	48%
Wiseman et al., 2001	DCP	113	35	0	Yes (ULT)	148	77.9%
Happle et al., 1980	SADBE	26	27	0	Yes (ULT)	53	70%
Case et al., 1984	SADBE	11	10		Yes (ULT)	21	52%
Casario 1987	SADBE	2	5	7	Yes (ULT)	14	29%
Micali et al., 1996	SADBE	129	8	0	Yes (ULT)	137	64%

ULT, unilateral treatment, untreated side serves as control

to a Th1-Th2 shift or whether it is caused by the introduction of regulatory T-cells with a type 2 cytokine profile is the object of current investigations. Immunohistochemical studies furthermore have shown in humans and in the C3H/HeJ mouse-model of AA, that treatment with a contact sensitizer reduces the aberrant expression of MHC-I and MHC-II molecules on the lower hair follicle epithelium (Bröcker et al. 1987; Freyschmidt-Paul et al. 1999). From these data it can be concluded that treatment with a contact sensitizer restores the immune privilege of the lower hair follicle epithelium.

## **Other Treatments**

### **Irritant Contact Dermatitis –Anthralin**

While treatment of AA with an allergic contact dermatitis has been proven to be effective, treatment of AA with an irritant contact dermatitis has never been shown to be successful in a controlled study. In a half-side controlled study, using 0.1% anthralin that resulted in a mild irritant contact dermatitis, no difference between treated and untreated side was observed (Nelson and Spielvogel 1985). Therefore, anthralin cannot be recommended for the treatment of AA.

### **Minoxidil**

Because the antihypertensive agent minoxidil causes hypertrichosis as a side-effect, Weiss et al. attempted to use it as a treatment for various forms of hair loss, including alopecia areata (Weiss et al. 1984). But all studies that claim successful treatment of AA with minoxidil did not fulfill the criteria of evidence based treatment of AA (Weiss et al. 1984, Fiedler-Weiss et al. 1986, Price 1987a, b; Ranchoff et al. 1989)

Six other placebo-controlled studies performed by various groups did not show a statistically significant difference between the hair growth of patients treated with the placebo or with minoxidil (Frentz 1984; Maitland et al. 1984; Vanderveen et al. 1984; White and Friedmann 1985; Vestey and Savin 1986; Fransway and Muller 1988). In three of these studies cosmetically acceptable hair regrowth was not even observed in any patient (Vanderveen et al. 1984; White and Friedmann 1985; Fransway and Muller 1988). In summary, minoxidil is not useful in the treatment of AA.

## **Summary**

Alopecia areata is regarded as a T-cell mediated autoimmune disease that is directed against a so far unknown autoantigen of the hair follicle. There is a

genetic predisposition to develop alopecia areata, whereas environmental triggers have not yet been identified. The diagnosis can be established by characteristic clinical features including severe forms such as alopecia areata totalis and universalis. Nail changes may help confirm the diagnosis. In some cases histopathological examination may be necessary, whereas other laboratory investigations are unnecessary. Because of the high rate of spontaneous remission, the efficacy of a rational treatment for AA has to be proven in controlled studies. An ideal treatment should be highly effective but associated with only minor side effects. According to the rules of evidence-based medicine, treatment with a contact sensitizer is at present the most effective treatment of alopecia areata showing only mild side effects. However, it is a time-consuming and in some cases ineffective therapeutic approach, which is why it is necessary to develop new, more specific forms of treatment.

## Pathogenesis

The complete pathogenesis picture for AA has yet to be determined. However, recent research has made much progress in our understanding of the disease mechanism. There is numerous circumstantial evidence in support of the notion that AA is fundamentally an inflammation driven disease and may be autoimmune in nature. Observation of a peri- and intra-follicular inflammation of the target anagen hair follicle primarily by T lymphocytes in both humans and animal models is the most compelling morphological evidence (Perret et al. 1984; Ranki et al. 1984; Zhang et al. 1994; Sundberg et al. 1994). In addition to a lymphocytic infiltrate there is increased presence of antigen presenting cells such as macrophages and particularly Langerhans cells around, and sometimes within, dystrophic hair follicles (Wiesner-Menzel and Happle, 1984; Zhang et al. 1994). Furthermore, inflammatory markers include up regulation of ICAM and ELAM expression on the endothelium of blood vessels closely associated with affected hair follicles (Nickloff and Griffiths 1991; McDonagh et al. 1993; Zhang et al. 1994). Changes in cytokine levels, particularly activating cytokines such as IL-2 and IFN $\gamma$ , have been noted during AA inflammation with corresponding alteration of cytokine concentrations after successful topical counter irritant therapy (Hoffmann et al. 1994). MHC class I and II expression on hair follicle epithelial structures normally devoid of MHC expression is associated with hair follicle inflammation and AA (Bröcker et al. 1987; McDonagh et al. 1993). Certain MHC class II haplotypes seem to be associated with predisposal of the individual towards AA, a common observation in autoimmune diseases (Duvic et al. 1991; Colombe et al. 1999). Hair follicle specific IgG autoantibodies have been found in increased concentrations in the peripheral blood of AA affected individuals compared to normal, non-affected humans (Tobin et al. 1994a, Tobin et al. 1994b). AA may respond to a range of immunomodulatory treatments (Hoffmann and Happle, 1999). All these and other circumstantial evidence (McElwee et al. 1999c; McElwee et al. 2002b) are of some assistance in understanding the pathogenesis of AA. However, detailed characterization and functional studies are required to demonstrate the significance of these circumstantial observations and to elucidate disease mechanisms. Primarily due to ethical limitations, functional studies cannot readily be conducted in humans. Consequently, animal models of human AA are required.

## Immune System Targets

AA is generally believed to have an autoimmune pathogenesis (Paus et al. 1993; McDonagh and Messenger, 1996). While the evidence in support of this idea is compelling, the primary requirement to prove the autoimmune

nature of AA, to identify a self antigen as the primary target that can initiate the disease mechanism and lead to development of the phenotype, has yet to be proven. Without this evidence, AA can only be described as a putative autoimmune disease. Using a SCID-human model of AA, Gilhar et al claimed melanogenesis related antigens to be inciting agents for the activation of pathogenic cells involved in AA (Gilhar et al. 2001). Circumstantially, there are several claimed cases of selective pigmented hair loss and white hair survival in AA affected individuals (Plinck et al. 1993; Messenger and Simpson, 1997; Camacho, 1997). Much has been made of this observed phenomenon in defining potential targets of inflammation in AA. However, there are many more unreported examples of AA affected individuals losing both pigmented and non-pigmented hair and in a mouse model of AA white hair can be successfully targeted by inflammatory cells (McElwee et al. 2001a).

While it is quite possible for melanocyte derived antigens to be involved in AA, they need not be the primary agents in precipitating disease onset. Downstream of the disease activation event it is likely that the phenomena of epitope spreading (Chan et al. 1998) results in the targeting of numerous antigenic epitopes from diverse sources within the hair follicles. Logically, one would expect the primary target for follicular inflammation to be a key component in hair fiber production, the targeting of which would lead to growth cessation. While follicular dermal papilla cells may be a candidate source of the primary antigenic target for inflammatory cells (Nutbrown et al. 1996), the most likely source of the primary inciting agent are follicular keratinocytes. Circumstantial evidence in support of this view includes the identification of hair follicle specific autoantibodies which target keratinocyte derived epitopes and that intra-follicular penetrating inflammatory cells in humans and animal models primarily take up residence in keratinocyte comprised root sheath and matrix locations (McElwee et al. 2003b). However, beyond these speculations, little is known about the nature of the antigenic targets on which inflammatory cells focus in AA. It is quite possible that different clinical AA presentations may be associated with different antigenic epitope targeting patterns.

### **The Humoral Immune System in AA**

Autoantibodies against hair follicle antigens have been identified in both humans and animal models of AA with significantly increased frequency compared to the general population. Tobin et al, demonstrated production of antibodies with heterogeneous targeting of hair follicle structures and similar heterogeneity of morphological targeting has been found in mouse and rat models of AA (McElwee et al. 1996a; Tobin et al. 1997). Trichohyalin and specific keratins, have been defined as targets for some of the antibodies (Tobin et al. 2003). The diversity of autoantibody production with no consistent



structure targeting observed in serum samples from different patients, suggests autoantibodies are not the dominant factor in AA development. Other evidence also supports this view with time line evaluation studies on a mouse model for AA indicating cellular targeting for the follicle occurs prior to an upregulation in genes associated with antibody production (Carroll et al. 2002). Transfer of serum from AA patients to skin in a SCID-human model also failed to regenerate the disease phenotype (Gilhar et al. 1992). However, this does not invalidate antibody investigation. Autoantibodies in serum from AA patients may hold important clues to the targets for cellular inflammation in AA. Autoantibodies may yet be shown to play a secondary role in the disease pathogenesis. One small study involving the transfer of equine AA-derived antibodies to normal haired mice promoted an increase in telogen state hair follicles, although no apparent development of cellular inflammation was induced and systemic AA did not develop (Tobin et al. 1998). Autoantibodies then may play a secondary role accentuating the chronic disease state but it seems unlikely they are the primary mediators of AA.

### The Cellular Immune System in AA

In many autoimmune diseases and animal models of autoimmune disease lymphocytes are identified as the primary disease mediator. Most commonly, CD4<sup>+</sup> lymphocytes have been identified as the primary pathogenic cell subset retaining the ability to transfer many autoimmune diseases, but other subsets including CD8<sup>+</sup> cells have also been identified as important in disease pathogenesis (eg. Ablamunits et al. 1999; Huseby et al. 2001). The predominantly CD4<sup>+</sup> and CD8<sup>+</sup> lymphocyte inflammation of hair follicles suggests these cells to be the primary instigators of the disease phenotype in AA. Depleting the inflammatory cell number with immunosuppressive therapies reinforces the general view that these cells hold the key to hair growth inhibition in AA (Freyschmidt-Paul et al. 2001). In rodent models this has been taken a step further with the selective removal of CD4<sup>+</sup> or CD8<sup>+</sup> cells by injections monoclonal antibodies. Depletion of one or other lymphocyte population permits hair regrowth, but with replacement of the depleted cell population the AA phenotype redevelops (McElwee et al. 1996b; McElwee et al. 1999b; Carroll et al. 2002).

Recent cell subset transfer studies have further characterized the importance of CD4<sup>+</sup> and CD8<sup>+</sup> lymphocytes in AA. Human AA-affected, skin-derived cells have been shown to reinduce inflammatory hair loss in xenografts of previously AA affected skin grafted to *scid/scid* mice (Gilhar et al. 1998). Separation of CD4<sup>+</sup> and CD8<sup>+</sup> cell subsets and their transfer to this model suggested each cell type alone was not capable of reinducing hair loss, but in combination hair loss redeveloped (Gilhar et al. 2002). In C3H/HeJ mice subcutaneous injection of CD8<sup>+</sup> cells led to the rapid development of localized

hair loss at the site of injection but no further development of hair loss. In contrast, injection of CD4<sup>+</sup>/CD25<sup>-</sup> cells resulted in little localized hair loss but successful transfer of the disease systemically with the development of multiple alopecia patches (McElwee et al. in press). Thus, it is the CD4<sup>+</sup>/CD25<sup>-</sup> cell population in the C3H/HeJ mouse model that retains the capacity to transfer the systemic AA phenotype to naive hosts and most likely promotes AA via promotion of APC activity and subsequent stimulation of hair follicle autoreactive CD8<sup>+</sup> cells. This pathogenic activity defines the CD4<sup>+</sup>/CD25<sup>-</sup> cell population as a key component of AA and a prime target for the development of therapeutic strategies. CD8<sup>+</sup> cells, although apparently the primary effectors of the actual hair loss phenotype, are largely under the control of CD4<sup>+</sup>/CD25<sup>-</sup> cells.

### **Mechanisms of Cellular Action on the Hair Follicle**

It seems then that the cellular immune system is the principal promoter of AA. The question remains how might leukocytes act on hair follicles to promote hair loss. Studies so far implicate a combination of mechanisms. Cytotoxicity may be mediated through Fas – Fas ligand (FasL) interaction. The binding of Fas expressed on target cells by FasL on activated lymphocytes leads to apoptosis of the Fas expressing cell. This mechanism of tissue destruction is not MHC restricted and has the potential to damage innocent bystander cells not directly targeted by the pathogenic lymphocyte clones. Fas – FasL signaling is also believed to promote antigen presentation (Siegel et al. 2000). In the C3H/HeJ mouse model for AA, Fas and FasL are significantly differentially expressed in skin infiltrating lymphocytes and Fas is highly expressed on human and mouse dystrophic hair follicle keratinocytes (Bodemer et al. 2000; McElwee et al. 2002a; Freyschmidt-Paul et al. 2003). Histocompatible mice deficient in Fas or FasL are comparatively resistant to the induction of AA. This resistance was in part localized to the skin as Fas and FasL deficient skin transplanted to AA affected mice resisted immune activity and continued to grow hair (Freyschmidt-Paul et al. 2003). The possibility of an autocrine and paracrine action of Fas and FasL within and between hair follicle keratinocytes may add to the action of the inflammatory infiltrate and may explain why FasL deficient hair follicles were also relatively resistant to AA.

Perforin, produced by cytotoxic cells, is a potent mediator of cell lysis (Russell and Ley, 2002). For perforin induced lysis of target cells to occur, the T cell receptor of an autoreactive cell must ligand with the relevant antigenic peptide presented in conjunction with MHC on the target cell. Whether perforin mediated cell destruction occurs in AA is unknown, but the presence of highly activated CD8<sup>+</sup> cells within dystrophic hair follicles and the high expression of MHC molecules on hair follicle keratinocytes circumstantially suggests MHC restricted, perforin mediated, tissue damage could occur. Granzymes,

that may gain access to target cells via perforin or induce apoptosis independent of perforin through binding cell surface receptors (Motyka et al. 2000), have been identified as highly expressed in human AA (Bodemer et al. 2000; Carroll et al. 2002). Inducible nitric oxide synthase expression is apparent during mouse AA development which may suggest a role for nitric oxide in disease pathogenesis (McElwee, personal observations).

Lymphocytes need not have close contact with hair follicle keratinocytes to exert an effect. Cytokines such as TNF $\alpha$  may have a negative impact on the survival of hair follicle keratinocytes in AA (Janssen et al. 2003). IFN $\gamma$  may inhibit cell proliferation and promote keratinocyte expression of MHC molecules that will aid other inflammatory mechanisms (Schroder et al. 2004). Other cytokines may negatively regulate keratinocyte cell proliferation and encourage hair follicles to truncate their growth cycle and enter a telogen resting state (Randall, 2001). Overall, cytokines may be significant modulators of hair follicle disruption.

### **Disease Modulating Factors**

While the fundamental mechanism of AA is essentially self contained it is likely there are exterior factors that influence the disease course. Thus far various, candidate genetic influences have been identified in human and rodent model AA (described elsewhere). In addition, epigenetic factors are also probably involved in determining an individual's susceptibility to AA. Epigenetic factors may be both susceptibility and severity modifiers of AA and act in two ways: They may modify an individual's general susceptibility to a disease activation event. Alternatively, they may be involved in determining the future prognoses for hair loss in terms of extent, hair loss pattern, duration or chronicity of disease, and/or resistance to treatment, once onset of overt hair loss has been initiated.

Recently, using the C3H/HeJ mouse model, interferon gamma (IFN $\gamma$ ) has been identified as a key player in precipitating onset of hair loss (Freyschmidt-Paul et al. 2004). Injecting IFN $\gamma$  into mice known to be genetically susceptible to AA brings forward the time at which AA onset develops and increases the frequency of mice expressing the AA while transgenic knockout mice genetically deficient in IFN $\gamma$  are incapable of developing AA. In the real world, IFN $\gamma$  expression is increased in response to a variety of insults, particularly infectious agents (Schroder et al. 2004). It is generally accepted that an infectious agent might promote autoimmune disease onset through mimicry of antigenic epitopes (Wucherpfennig, 2001). If an infectious agent expresses antigens that are similar to self antigens found naturally in hair follicles then exposure to the pathogen may elicit a cross reactivity to the hair follicle located antigens. However, the knowledge that IFN $\gamma$  is involved in disease development suggests that there need not be a specific relationship between

pathogen-expressed antigens and hair follicle antigens. Rather, responses to the general "viral load" might play a key role in AA for some (Stewart and Smoller, 1993; Kissler et al. 2001). It is conceivable then that an individual genetically susceptible to AA might experience onset of hair loss subsequent to infectious agent exposure or exposure to any other factor that promotes an increase in IFN $\gamma$ . Chronic exposure or cumulative exposure to multiple pathogens may increase the level of susceptibility to disease onset.

Increased levels of IFN $\gamma$  alone are unlikely to induce AA onset in any one individual. If this were true, AA would be expressed with a much higher frequency within the population than is the case. It is likely that multiple genetic and epigenetic factors must interact correctly for actual disease onset to occur. Rodent model research has shown that hormones can influence the degree of susceptibility to AA induction. Ovariectomized mice had a relatively reduced rate of AA development compared to estradiol supplemented mice. In contrast mice supplemented with testosterone were fully resistant to AA development compared to gonadectomized mice (McElwee et al. 2001b). Hormonal influence in humans is suggested by old case reports asserting temporary hair growth in AA affected women during the late stages of pregnancy or improvement with onset of menopause (Sabouraud 1913, Lévy-Franckel 1925, Walker 1950). Model research has also shown that increased dietary soy oil content can reduce AA susceptibility (McElwee et al. 2003a). While this is of little practical value in understanding human AA, it demonstrates the potential influence of environmental factors on AA susceptibility.

To protect against inappropriate immune system activation, and to calm down activated immune cells after a pathogenic challenge has been cleared, immune regulatory mechanisms are exploited. CD4<sup>+</sup>/CD25<sup>+</sup> cells have been identified as one of probably several lymphocyte regulatory cell subsets that can restrain pathogenic cell activity. CD4<sup>+</sup>/CD25<sup>+</sup> cells are essential for maintaining homeostasis, are able to suppress the induction of autoimmune disease, suppress CD4<sup>+</sup>/CD25<sup>-</sup> cells, and can inhibit the effector function of autoreactive CD8<sup>+</sup> cells (Suri-Payer et al. 1998; Gao et al. 1999; Annacker et al, 2001). Little is currently known about immune regulatory mechanisms in human AA. Recent studies in the skin graft induced AA mouse model revealed that CD4<sup>+</sup>/CD25<sup>+</sup> cell levels drop significantly on activation of AA and prior to the onset of overt hair loss (Zöller et al. 2002). In contrast, sham grafted mice are able to maintain CD4<sup>+</sup>/CD25<sup>+</sup> cell numbers and quickly recover normal inflammatory cell numbers after injury. This apparent active depression of regulatory cells in AA challenged mice may be a key factor in AA susceptibility. CD4<sup>+</sup>/CD25<sup>-</sup> cells or CD8<sup>+</sup> cells from AA affected mice transferred to unaffected mice can induce some form of AA, but if CD4<sup>+</sup>/CD25<sup>+</sup> cells are added to the mixture the disease onset is partially inhibited (McElwee et al. in press). This indicates the potential importance of regulatory cell failure in AA development. Why regulatory cells fail to appropriately restrain onset of AA is not known but further examination of CD4<sup>+</sup>/CD25<sup>+</sup> cells and other regulatory cells may reveal significant insights into AA susceptibility and development.

There are likely other epigenetic factors that modulate AA. Stress has been suggested as a potential instigator of autoimmune diseases possibly through glucocorticoid modulation of inflammatory cytokine expression (Elenkov and Chrousos, 2002). Stress has also been postulated as a potential influence on AA development although the evidence is only circumstantial (Mehlman and Griesemer, 1968; Colon et al. 1991; Liakopoulou et al, 1997; Kavak et al, 2002). AA frequency and severity is apparently associated with a greater frequency of allergies as compared to the general population (Muller and Winkelmann, 1963; Ikeda, 1965; Penders, 1968; De Waard-van der Spek et al. 1989; Weise et al. 1996). Whether there is a direct relationship whereby an allergic response is capable of increasing immune system sensitivity and instability such that AA susceptibility increases, or whether the increased frequency of allergies in AA patients is merely a reflection of genetically determined immune system sensitivity remains to be determined. Other promoters of the immune system in autoimmune diseases may include drugs and toxins (Bigazzi, 1994; Elkayam et al. 1999; Holsapple, 2002). In principle, one or more of these factors may modulate the immune system in AA, but in practice little is known about the effects of environmental stimuli on AA in rodent models or humans.

With time and changes in epigenetic factors that may influence AA, so the degree of susceptibility to AA will fluctuate. While an individual may have a genetic susceptibility to AA that may be regarded as an unmovable baseline, additional epigenetic factors may increase or depress overall AA susceptibility. Only if an individual receives multiple signals that cumulatively increase the susceptibility to disease above a threshold level for expression will an episode of AA actually develop. This may also help explain why the presentation of the AA phenotype is so varied. Individuals with chronic extensive AA, versus those with an isolated AA patch, may have a dominant genetic susceptibility to disease and relatively minor epigenetic modification of this genetic susceptibility. In others who whose AA waxes and wanes, or who present with multiple episodes of AA expression and remission may be more greatly impacted by epigenetic factors and their changing influence with time.

## **Disease Initiation**

We still do not know the disease phenotype precipitating event, but one hypothesis is that AA develops in susceptible individuals due to a failure in hair follicle immunoprotection. Anagen stage hair follicles are regarded as immune privileged sites (Westgate et al. 1991; Paus et al. 1999), but follicle immunoprotection is likely only transient due to the nature of the hair follicle cycle. Research suggests the onset of catagen is associated with an infiltration of immune cells, candidate antigen presenting cells (Parakkal, 1969; Westgate

et al. 1991; Paus, 1996; Eichmüller et al. 1998). Regression of the hair follicle in catagen involves high levels of apoptosis and significant remodeling of the lower transient portion of the hair follicle (Weedon and Strutton, 1981; Lindner et al. 1997). It is possible then that the immune system is constantly exposed to low levels of hair follicle derived antigens as hair follicles cycle through catagen and given the ability of dendritic cells to present apoptosis derived antigens. Autoimmune disease is not regarded as an all or nothing event. Rather, there are degrees of autoreactivity and a threshold level above which overt autoimmune disease is induced (Ludewig et al. 2001; McElwee et al. 2001b). A reflection of this may be the low level of hair follicle specific antibodies found in some humans and rodents in the absence of overt AA (Tobin et al. 1994a; Tobin et al. 1994b; Tobin et al. 1997). If however, catagen regression became disordered and the immune cell infiltrate associated with catagen inappropriately presented antigenic peptides in association with expression of costimulatory molecules, antigen presentation to the immune system might breach the threshold for stimulation of autoreactive cells. In a genetically susceptible individual, resident in a permissible environment, AA might follow.

## Summary

Overall, we still cannot claim AA is an autoimmune disease with complete confidence, but all the evidence produced so far points in that direction and provides compelling supporting evidence. Circumstantial evidence from observing the state of humans with AA has been supplemented with indirect, functional evidence from a variety of animal models. In the near future, animal model and human genome screening will likely define loci involved in AA susceptibility and resistance. With further research, the contribution of specific genes to the disease onset may provide much information on the disease pathogenesis.

## References

- Abell E, Munro DD (1973) Intralesional treatment of alopecia areata with triamcinolone acetonide by jet injector. *Br J Dermatol* 88: 55–9
- Ablamunits V, Elias D, Cohen IR (1999) The pathogenicity of islet-infiltrating lymphocytes in the non-obese diabetic (NOD) mouse. *Clin Exp Immunol* 115: 260–7
- Alsaleh QA, Nanda A, al-Hasawi F, el-Kashlan M (1995) Concurrent appearance of alopecia areata in siblings. *Pediatr Dermatol* 12: 285–6
- Anderson I (1950) Alopecia areata: A clinical study. *Br Med J* 2: 1250–2.
- Andrade M de, Jackow CM, Dahm N, Hordinsky M, Reveille JD, Duvic M (1999) Alopecia areata in families: Association with the HLA locus. *J Invest Dermatol Symp Proc* 4: 220–3
- Annacker O, Pimenta-Araujo R, Burlen-Defranoux O, Barbosa TC, Cumano A, Bandeira A (2001) CD25+ CD4+ T cells regulate the expansion of peripheral CD4 T cells through the production of IL-10. *J Immunol* 166: 3008–18

- Averbakh EV, Pospelov LE (1986) HLA antigens in patients with alopecia areata. *Vestn Dermatol Venerol* 1: 24–6
- Barber HW (1921) Alopecia areata. *Br J Dermatol and Syph* 33: 1–14
- Bastos Araujo A, Poiaras Baptista A (1967) Algumas consideracoes sobre 300 casos de pelada. *Trabalhos da Sociedade Portuguesa de Dermatologia e Venereologia* 25: 135–41
- Behrens-Williams S, Leiter U, Schiener R, Weidmann M, Peter RU, Kerscher M (2001) The PUVA-turban as a new option of applying a dilute psoralen solution selectively to the scalp of patients with alopecia areata. *J Am Acad Dermatol* 44: 248–252
- Betterle C, Greggio NA, Volpato M (1998) Clinical review 93 Autoimmune polyglandular syndrome type 1. *J Clin Endocrinol Metab* 83: 1049–55
- Bigazzi PE (1994) Autoimmunity and heavy metals. *Lupus* 3:449–53
- Bodemer C, Peuchmaur M, Fraitag S, Chatenoud L, Brousse N, De Prost Y (2000) Role of cytotoxic T cells in chronic alopecia areata. *J Invest Dermatol* 114: 112–6
- Bonjean M, Prime A, Avon P. Pelade chez deux jumeaux homozygotes (sic) (1968) *Lyon Med* 219: 1852–3
- Bröcker EB, Echternacht-Happle K, Hamm H, Happle R (1987) Abnormal expression of class I and class II major histocompatibility antigens in alopecia areata: Modulation by topical immunotherapy. *J Invest Dermatol* 88: 564–8
- Brown WH (1929) The aetiology of alopecia areata and its relationship to vitiligo and possibly scleroderma. *Br J Dermatol and Syph* 41: 299–323
- Burton JL, Shuster S (1975) Large doses of glucocorticoid in the treatment of alopecia areata. *Acta Derm Venereol (Stockh)* 55: 493–6
- Camacho F Anagenic and telogenic effluvia (1997) In: *Trichology: Diseases of the pilosebaceous follicle*, Camacho F, Montagna W, eds.; Aula Medica Group: Madrid pp. 387–96
- Carroll JM, McElwee KJ, E King L, Byrne MC, Sundberg JP (2002) Gene array profiling and immunomodulation studies define a cell-mediated immune response underlying the pathogenesis of alopecia areata in a mouse model and humans. *J Invest Dermatol* 119: 392–402
- Carter DM, Jegasothy BV (1976) Alopecia areata and Down syndrome. *Arch Dermatol* 112: 1397–9
- Case PC, Mitchell AJ, Swanson NA, Vanderveen EE, Ellis CN, Headington JT (1984) Topical therapy of alopecia areata with squaric acid dibutylester. *J Am Acad Dermatol* 10:447–51
- Casario RJ (1987) Treatment of alopecia areata with squaric acid dibutylester. *Arch Dermatol* 123: 1036–41
- Chan LS, Vanderlugt CJ, Hashimoto T, Nishikawa T, Zone JJ, Black MM, Wojnarowska F, Stevens SR, Chen M, Fairley JA, Woodley DT, Miller SD, Gordon KB (1998) Epitope spreading: lessons from autoimmune skin diseases. *J Invest Dermatol* 110: 103–9
- Charuwichitratana S, Wattanakrai P, Tanrattanakorn S (2000) Randomized double-blind placebo-controlled trial in the treatment of alopecia areata with 0.25% desoximetasone cream. *Arch Dermatol* 136: 1276–1277
- Claudy AL, Gagnaire D (1983) PUVA treatment of alopecia areata. *Arch Dermatol* 119: 975–8
- Cole GW, Herzlinger D (1984) Alopecia universalis in identical twins. *Int J Dermatol* 23: 283
- Colombe BW, Price VH, Khoury EL, Garovoy MR, Lou CD (1995) HLA class II antigen associations help define two types of alopecia areata. *J Am Acad Dermatol* 33: 757–64
- Colombe BW, Lou CD, Price VH (1999) The genetic basis of alopecia areata: HLA associations with patchy alopecia areata versus alopecia totalis and alopecia universalis. *J Invest Dermatol Symp Proc* 4: 216–9
- Colon EA, Popkin MK, Callies AL, Dessert NJ, Hordinsky MK (1991) Lifetime prevalence of psychiatric disorders in patients with alopecia areata. *Compr Psychiatry* 32: 245–51
- Cork MJ, Crane AM, Duff GW (1996) Genetic control of cytokines: Cytokine gene polymorphisms in alopecia areata. *Dermatol Clin* 14: 671–8
- Cotellessa C, Peris K, Caracciolo E, Mordenti C, Chimenti S (2001) The use of topical diphenylcyclopropenone for the treatment of extensive alopecia areata. *J Am Acad Dermatol* 44: 73–6
- Cunliffe WJ, Hall R, Stevenson CJ, Weightman D (1969) Alopecia areata, thyroid disease and autoimmunity. *Br J Dermatol* 81: 877–81

- De Waard-van der Spek FB, Oranje AP, De Raeymaecker DM, Peereboom-Wynia JD (1989) Juvenile versus maturity-onset alopecia areata – a comparative retrospective clinical study. *Clin Exp Dermatol* 14:429–33
- De Weert J, Temmerman L, Kint A (1984) Alopecia areata: A clinical study. *Dermatologica* 168: 224–9
- Dillaha CJ, Rothman S (1952) Therapeutic experiments in alopecia areata with orally administered cortisone. *J Am Med Ass* 150:546–50
- Du Vivier A, Munro DD (1975) Alopecia areata, autoimmunity, and Down's syndrome. *Br Med J* 1: 191–2
- Duvic M, Hordinsky MK, Fiedler VC, O'Brien WR, Young R, Reveille JD (1991) HLA-D locus associations in alopecia areata. *Arch Dermatol* 127: 64–8
- Duvic M, Welsh EA, Jackow C, Papadopoulos E, Reveille JD, Amos C (1995) Analysis of HLA-D locus alleles in alopecia areata patients and families. *J Invest Dermatol* 104(suppl): 5S-6S
- Eichmüller S, van der Veen C, Moll I, Hermes B, Hofmann U, Muller-Rover S, Paus R (1998) Clusters of perifollicular macrophages in normal murine skin: physiological degeneration of selected hair follicles by programmed organ deletion. *J Histochem Cytochem* 46: 361–70
- Elenkov IJ, Chrousos GP (2002) Stress hormones, proinflammatory and antiinflammatory cytokines, and autoimmunity. *Ann N Y Acad Sci* 966: 290–303
- Elkayam O, Yaron M, Caspi D (1999) Minocycline-induced autoimmune syndromes: an overview. *Semin Arthritis Rheum* 28: 392–7
- Fiedler-Weiss VC, West DP, Buys CM, Rumsfield JA (1986) Topical minoxidil dose-response effect in alopecia areata. *Arch Dermatol* 122:180–82
- Finnish-German APECED Consortium (1997) An autoimmune disease, APECED, caused by mutations in a novel gene featuring two PHD-type zinc-finger domains. *Nature Genet* 17: 399–403
- Fransway AF, Muller SA (1988) 3 percent topical minoxidil compared with placebo for the treatment of chronic severe alopecia areata. *Cutis* 41: 431–435
- Frentz G (1977) Topical treatment of extended alopecia. *Dermatologica* 155: 147–154
- Frentz G (1985) Topical minoxidil for extended areate alopecia. *Acta Derm Venereol* 65: 172–175
- Frentz G, Thomsen K, Jakobsen BK, Svejgaard A (1986) HLA-DR4 in alopecia areata. *J Am Acad Dermatol* 14: 129–30
- Freyschmidt-Paul P, Sundberg JP, Happle R, McElwee KJ, Metz S, Boggess D, Hoffmann R (1999) Successful treatment of alopecia areata-like hair loss with the contact sensitizer squaric acid dibutylester (SADBE) in C3H/HeJ mice. *J Invest Dermatol* 113: 61–8
- Freyschmidt-Paul P, Hoffmann R, Levine E, Sundberg JP, Happle R, McElwee KJ (2001) Current and potential agents for the treatment of alopecia areata. *Curr Pharm Des* 7: 213–30
- Freyschmidt-Paul P, McElwee KJ, Botchkarev V, Kissling S, Wenzel E, Sundberg JP, Happle R, Hoffmann R (2003) Fas-deficient C3.MRL-Tnfrsf6(lpr) mice and Fas ligand-deficient C3H/HeJ-Tnfrsf6(gld) mice are relatively resistant to the induction of alopecia areata by grafting of alopecia areata-affected skin from C3H/HeJ mice. *J Invest Dermatol Symp Proc* 8:104–8
- Freyschmidt-Paul P, Zoeller M, McElwee KJ, Sundberg JP, Hoffmann R (2004) Th-1 cytokines in alopecia areata pathogenesis: IFN $\gamma$  is essentially involved while IL-2 plays a minor role. *J Invest Dermatol* 122, A8
- Friedli A, Labarthe MP, Engelhardt E, Feldman R, Salomon D, Saurat JH (1998) Pulse methylprednisolone therapy for severe alopecia areata: an open prospective study of 45 patients. *J Am Acad Dermatol* 39: 597–602
- Friedmann PS (1981) Alopecia areata and autoimmunity. *Br J Dermatol* 105: 153–157
- Friedman PS (1985) Clinical and immunologic association of alopecia areata. *Semin Dermatol* 4: 9–15
- Fülöp E, Vajda Z (1971) Experimentelle Untersuchungen über die therapeutische und schädigende Wirkung der intrafokalen Steroidbehandlung. *Dermatol Monatsschr* 157: 269–77
- Galbraith GM, Thiers BH, Pandey JP (1984) Gm allotype associated resistance and susceptibility to alopecia areata. *Clin Exp Immunol* 56: 149–52



- Galbraith GM, Pandey JP (1989) Km1 allotype association with one subgroup of alopecia areata. *Am J Hum Genet* 44: 426–8
- Galbraith GM, Pandey JP (1995) Tumor necrosis factor alpha (TNF-alpha) gene polymorphism in alopecia areata. *Hum Genet* 96: 433–6
- Galbraith GM, Palesch Y, Gore EA, Pandey JP (1999) Contribution of interleukin 1beta and KM loci to alopecia areata. *Hum Hered* 49: 85–9
- Gao Q, Rouse TM, Kazmerzak K, Field EH (1999) CD4+CD25+ cells regulate CD8 cell anergy in neonatal tolerant mice. *Transplant* 68:1891–7
- Gilhar A, Pillar T, Assay B, David M (1992) Failure of passive transfer of serum from patients with alopecia areata and alopecia universalis to inhibit hair growth in transplants of human scalp skin grafted on to nude mice. *Br J Dermatol* 126:166–71
- Gilhar A, Ullmann Y, Berkutzki T, Assay B, Kalish RS (1998) Autoimmune hair loss (alopecia areata) transferred by T lymphocytes to human scalp explants on SCID mice. *J Clin Invest* 101: 62–7
- Gilhar A, Landau M, Assay B, Shalaginov R, Serafimovich S, Kalish RS (2001) Melanocyte-associated T cell epitopes can function as autoantigens for transfer of alopecia areata to human scalp explants on Prkdc(scid) mice. *J Invest Dermatol* 117:1357–62
- Gilhar A, Landau M, Assay B, Shalaginov R, Serafimovich S, Kalish RS (2002) Mediation of alopecia areata by cooperation between CD4+ and CD8+ T lymphocytes: transfer to human scalp explants on Prkdc(scid) mice. *Arch Dermatol* 138:916–922
- Gip L, Lodin A, Molin L (1969) Alopecia areata: A follow-up investigation of outpatient material. *Acta Derm Venereol* 49: 180–8.
- Goldshtein LM, Chipizhenko VA (1978) Familial alopecia areata. *Vestn Dermatol Venerol* 10: 36–8
- Gollick H, Orfanos CE (1990) Alopecia areata: pathogenesis and clinical picture. In: Orfanos CE, Happle R, eds. *Hair and Hair Diseases*. Berlin: Springer-Verlag, 529–69
- Gordon PM, Aldridge RD, McVittie E, Hunter JAA (1996) Topical diphencyprone for alopecia areata: evaluation of 48 cases after 30 months' follow up. *Br J Dermatol* 134: 869–71
- Hacham-Zadeh S, Brautbar C, Cohen C, Cohen T (1981) HLA and alopecia areata in Jerusalem. *Tissue Antigens* 18: 71–4
- Happle R (1979) Hinweis zur DNCB-Therapie bei Alopecia areata. *Hautarzt* 30: 556
- Happle R, Echternacht K (1977) Induction of hair growth in alopecia areata with D.N.C.B. *Lancet* 2:1002–3
- Happle R, Kalveram KJ, Büchner U, Echternacht-Happle K, Göggelmann W, Summer KH (1980) Contact allergy as a therapeutic tool for alopecia areata: application of squaric acid dibutylester. *Dermatologica* 161: 289–97
- Happle R, Hausen BM, Wiesner-Menzel L (1983) Diphencyprone in the treatment of alopecia areata. *Acta Derm Venereol* (Stockh) 63: 49–52
- Happle R, Perret C, Wiesner-Menzel L (1984) Treatment of alopecia areata with diphencyprone induces hair regrowth and affects the composition of peribulbar infiltrates. In *Immunodermatology* MacDonald, DM Ed.; Butterworth: London pp.279–86
- Happle R (1985) The potential hazards of dinitrochlorobenzene. *Arch Dermatol* 121: 330–331
- Happle R, Klein HM, Macher E (1986) Topical immunotherapy changes the composition of the peribulbar infiltrate in alopecia areata. *Arch Dermatol Res* 278: 214–8
- Healy E, Rogers S (1993) PUVA treatment for alopecia areata: does it work? A retrospective review of 102 cases. *Br J Dermatol* 129:42–4
- Hendren S (1949) Identical alopecia areata in identical twins. *Arch Dermatol* 60: 793–5
- Hoffmann R, Wenzel E, Huth A, van der Steen P, Schäufele M, Henninger HP, Happle R (1994) Cytokine mRNA levels in Alopecia areata before and after treatment with the contact allergen diphenylcyclopropenone. *J Invest Dermatol* 103: 530–3
- Hoffmann R, Happle R (1996) Topical immunotherapy in alopecia areata: what, how, and why? *Dermatol Clin* 14: 739–44
- Hoffmann R, Happle R (1999) Alopecia areata. 1: Clinical aspects, etiology, pathogenesis. *Hautarzt* 50: W222–31
- Holsapple MP (2002) Autoimmunity by pesticides: a critical review of the state of the science. *Toxicol Lett* 127: 101–9
- Hordinsky MK, Hallgren H, Nelson D, Filipovich AH (1984) Familial alopecia areata. HLA antigens and autoantibody formation in an American family. *Arch Dermatol* 120: 464–8

- Hoting E, Boehm A (1992) Therapy of alopecia areata with diphencyprone. *Br J Dermatol* 127: 625–9
- Huseby ES, Liggitt D, Brabb T, Schnabel B, Ohlen C, Goverman J (2001) A pathogenic role for myelin-specific CD8(+) T cells in a model for multiple sclerosis. *J Exp Med* 194: 669–676
- Ikedo T (1965) A new classification of alopecia areata. *Dermatologica* 131: 421–45
- Jansen BJ, van Ruissen F, Cerneus S, Cloin W, Bergers M, van Erp PE, Schalkwijk J (2003) Tumor necrosis factor related apoptosis inducing ligand triggers apoptosis in dividing but not in differentiating human epidermal keratinocytes. *J Invest Dermatol* 121: 1433–9
- Kalkoff KW, Macher E (1958) Über das Nachwachsen der Haare bei der Alopecia areata und maligna nach intracutaner Hydrocortisoninjektion. *Hautarzt* 9: 441–51
- Kavak A, Yesildal N, Parlak AH (2002) Effect of two consecutive earthquakes on outbreaks of alopecia areata. *J Dermatol* 29: 414–8
- Kianto U, Reunala T, Karvonen J, Lassus A, Tiilikainen A (1977) HLA-B12 in alopecia areata. *Arch Dermatol* 113: 1716
- Kissler S, Anderton SM, Wraith DC (2001) Antigen-presenting cell activation: a link between infection and autoimmunity? *J Autoimmun* 16: 303–8
- Kuntz BM, Selzle D, Braun-Falco O (1977) HLA antigens in alopecia areata. *Arch Dermatol* 113: 1717
- Larkö O, Swanbeck G (1983) PUVA treatment for alopecia totalis. *Acta Derm Venereol (Stockh)* 63: 546–9
- Larsson M, Fonteneau JF, Bhardwaj N (2001) Dendritic cells resurrect antigens from dead cells. *Trends Immunol* 22: 141–8
- Lassus A, Eskelinen A, Johansson E (1984) Treatment of alopecia areata with three different PUVA modalities. *Photodermatology* 1: 141–4
- Lehnert W Zur Lokalbehandlung schwerer Formen der Alopecia areata mit Kortikosteroid-salbe (1974) *Dermatol Monatsschr* 160: 396–8
- Lévy-Franckel A, Juster E La pelade (1925) *J de Medecine de Paris* 44: 631–5
- Leyden JJ, Kligman AM (1972) Treatment of alopecia areata with steroid solution. *Arch Derm* 106: 924
- Liakopoulou M, Alifieraki T, Katideniou A, Kakourou T, Tselalidou E, Tsiantis J, Stratigos J (1997) Children with alopecia areata: psychiatric symptomatology and life events. *J Am Acad Child Adolesc Psychiatry* 36: 678–84
- Lindner G, Botchkarev VA, Botchkareva NV, Ling G, van der Veen C, Paus R (1997) Analysis of apoptosis during hair follicle regression (catagen). *Am J Pathol* 151:1601–17
- Ludewig B, Junt T, Hengartner H, Zinkernagel RM (2001) Dendritic cells in autoimmune diseases. *Curr Opin Immunol* 13: 657–62
- Lutz G, Bauer R (1988) Autoimmunity in alopecia areata: An assessment in 100 patients. *Hautarzt* 39: 5–11.
- Macdonald Hull S, Cunliffe WJ (1991) Successful treatment of alopecia areata using the contact allergen diphencyprone. *Br J Dermatol* 124: 212–3
- Macdonald Hull S, Norris JF (1988) Diphencyprone in the treatment of long-standing alopecia areata. *Br J Dermatol* 119: 367–74
- Macdonald Hull S, Pepall L, Cunliffe WJ (1991) Alopecia areata in children: response to treatment with diphencyprone. *Br J Dermatol* 125: 164–8
- Main RA, Robbie RB, Gray ES, Donald D, Horne CH (1975) Smooth muscle antibodies and alopecia areata. *Br J Dermatol* 92: 389–93
- Maitland JM, Alridge RD, Main RA, White MI, Ormerod AD (1984) Topical minoxidil in the treatment of alopecia areata. *Br Med J* 288: 794
- McDonagh AJ, Messenger AG (1996) The pathogenesis of alopecia areata. *Dermatol Clin* 14: 661–70
- McElwee KJ, Pickett P, Oliver RF (1996a) The DEBR rat, alopecia areata and autoantibodies to the hair follicle. *Br J Dermatol* 134: 55–63
- McElwee KJ, Spiers EM, Oliver RF (1996b) In vivo depletion of CD8+ T cells restores hair growth in the DEBR model for alopecia areata. *Br J Dermatol* 135: 211–7
- McElwee KJ, Boggess D, King LE Jr, Sundberg JP (1998a) Experimental induction of alopecia areata-like hair loss in C3H/HeJ mice using full-thickness skin grafts. *J Invest Dermatol* 111: 797–803

- McElwee KJ, Boggess D, Olivry T, Oliver RF, Whiting D, Tobin DJ, Bystryń JC, King LE Jr, Sundberg JP (1998b) Comparison of alopecia areata in human and nonhuman mammalian species. *Pathobiology* 66: 90–107
- McElwee KJ, Bristol IJ, Boggess D, Leiter EH, King LE Jr, Elson CO, Cong Y, Sundberg JP (1999a) A common disease susceptibility gene locus for development of alopecia areata and/or colitis in C3H/HeJ mice. *J Invest Dermatol Symp Proc* 4: 249
- McElwee KJ, Spiers EM, Oliver RF (1999b) Partial restoration of hair growth in the DEBR model for Alopecia areata after in vivo depletion of CD4+ T cells. *Br J Dermatol* 140: 432–7
- McElwee KJ, Tobin DJ, Bystryń JC, King LE Jr, Sundberg JP (1999c) Alopecia areata: An autoimmune disease? *Exp Dermatol* 8: 371–9
- McElwee K, Freyschmidt-Paul P, Ziegler A, Happle R, Hoffmann R (2001a) Genetic susceptibility and severity of alopecia areata in human and animal models. *Eur J Dermatol* 11: 11–6
- McElwee KJ, Silva K, Beamer WG, King LE Jr, Sundberg JP (2001b) Melanocyte and gonad activity as potential severity modifying factors in C3H/HeJ mouse alopecia areata. *Exp Dermatol* 10: 420–429
- McElwee KJ, Hoffmann R (2002a) Alopecia areata – animal models. *Clin Exp Dermatol* 27: 414–21
- McElwee KJ, Hoffmann R, Freyschmidt-Paul P, Wenzel E, Kissling S, Sundberg JP, Zöller M (2002b) Resistance to alopecia areata in C3H/HeJ mice is associated with increased expression of regulatory cytokines and a failure to recruit CD4+ and CD8+ cells. *J Invest Dermatol* 119: 1426–33
- McElwee KJ, Niiyama S, Freyschmidt-Paul P, Wenzel E, Kissling S, Sundberg JP, Hoffmann R (2003a) Dietary soy oil content and soy-derived phytoestrogen genistein increase resistance to alopecia areata onset in C3H/HeJ mice. *Exp Dermatol* 12: 30–6
- McElwee KJ, Silva K, Boggess D, Bechtold L, King LE Jr, Sundberg JP (2003b) Alopecia areata in C3H/HeJ mice involves leukocyte-mediated root sheath disruption in advance of overt hair loss. *Vet Pathol* 40: 643–50
- McElwee KJ, Freyschmidt-Paul P, Hoffmann R, Kissling S, Hummel S, Vitacolonna M, Zöller M Transfer of CD8+ cells induce localized hair loss while CD4+/CD25- cells promote systemic alopecia areata and CD4+/CD25+ cells blockade disease onset in the C3H/HeJ mouse model. *J Invest Dermatol* (in press)
- Mehlman RD, Griesemer RD (1968) Alopecia areata in the very young. *Am J Psychiatry* 125: 605–14
- Messenger AG, Bleehen SS (1985) Expression of HLA-DR by anagen hair follicles in alopecia areata. *J Invest Dermatol* 85: 569–72
- Messenger AG, Simpson NB (1997) Alopecia areata. In: *Diseases of the hair and scalp*. Dawber R, ed.; Blackwell Science Oxford pp.338–69
- Micali G, Cicero RL, Nasca MR, Sapuppo A (1996) Treatment of alopecia areata with squaric acid dibutylester. *Int J Dermatol* 35: 52–6
- Michie HJ, Jahoda CA, Oliver RF, Johnson BE (1991) The DEBR rat: An animal model of human alopecia areata. *Br J Dermatol* 125: 94–100
- Milgraum SS, Mitchell AJ, Bacon GE, Rasmussen JE (1987) Alopecia areata, endocrine function, and autoantibodies in patients 16 years of age or younger. *J Am Acad Dermatol* 17: 57–61
- Mitchell AJ, Douglass MC (1985) Topical photochemotherapy for alopecia areata. *J Am Acad Dermatol* 12: 644–9
- Monk B (1989) Induction of hair growth in alopecia totalis with diphenylprone sensitization: *Clin Exp Dermatol* 14: 154–7
- Montes LF (1977) Topical halcinonide in alopecia areata and in alopecia totalis. *J Cut Pathol* 4: 47–50
- Morling N, Frenzt G, Fugger L, Georgsen J, Jakobsen B, Odum N, Svejgaard A (1991) DNA polymorphism of HLA class II genes in alopecia areata. *Dis Markers* 9: 35–42
- Motyka B, Korbitt G, Pinkoski MJ, Heibei JA, Caputo A, Hobman M, Barry M, Shostak I, Sawchuk T, Holmes CF, Gauldie J, Bleackley RC (2000) Mannose 6-phosphate/insulin-like growth factor II receptor is a death receptor for granzyme B during cytotoxic T cell-induced apoptosis. *Cell* 103: 491–500

- Muller SA, Winkelmann RK (1963) Alopecia areata: An evaluation of 736 patients. *Arch Dermatol* 88: 290–7
- Nelson DA, Spielvogel RL (1985) Anthralin therapy fo alopecia areata. *Int J Dermatol* 24: 606–7
- Nutbrown M, MacDonald Hull SP, Baker TG, Cunliffe WJ, Randall VA (1996) Ultrastructural abnormalities in the dermal papillae of both lesional and clinically normal follicles from alopecia areata scalps. *Br J Dermatol* 135: 204–10
- Ochsendorf FR, Mitrou G, Milbradt R (1988) Therapie der Alopecia Areata mit Diphenylcyclopropenone. *Z Hautkr* 63: 94–100
- Olivetti L, Bubola D (1965) Clinical observations on 160 cases of "area celsi". *It Dermatol Minerva Dermatol* 106: 367–72.
- Orecchia G, Belvedere MC, Martinetti M, Capelli E, Rabbiosi G (1987) Human leukocyte antigen region involvement in the genetic predisposition to alopecia areata. *Dermatologica* 175: 10–14
- Orentreich N, Sturm HM, Weidman AI, Pelzig A (1960) Local Injection of steroids and hair regrowth in alopecias. *Arch Dermatol* 82: 894–902
- Parakkal PF (1969) Role of macrophages in collagen resorption during hair growth cycle. *J Ultrastruct Res* 29: 210–7
- Pascher F, Kurtin S, Andrade R (1970) Assay of 0.2% fluocinolone acetonide cream for alopecia areata and totalis. *Dermatologica* 141: 193–202
- Paus R, Slominski A, Czarnetzki BM (1993) Is alopecia areata an autoimmune-response against melanogenesis-related proteins, exposed by abnormal MHC class I expression in the anagen hair bulb? *Yale J Biol Med* 66: 541–54
- Paus R (1996) Control of the hair cycle and hair diseases as cycling disorders. *Curr Opin Dermatol* 3: 248–58
- Paus R, Christoph T, Muller-Rover S (1999) Immunology of the hair follicle: a short journey into terra incognita. *J Investig Dermatol Symp Proc* 4: 226–34
- Penders AJ (1968) Alopecia areata and atopy. *Dermatologica* 136: 395–9
- Perret C, Wiesner-Menzel L, Happle R (1984) Immunohistochemical analysis of T-cell subsets in the peribulbar and intrabulbar infiltrates of alopecia areata. *Acta Derm Venereol* 64: 26–30
- Perret CM, Steijlen PM, Happle R (1990) Erythema multiforme-like eruptions: a rare side effect of topical immunotherapy with diphenylcyclopropenone. *Dermatologica* 180: 5–7
- Perriard-Wolfensberger J, Pasche-Koo F, Mainetti C, Labarthe MP, Salomon D, Saurat J (1993) Pulse of methylprednisolone in alopecia areata. *Dermatology* 187: 282–5
- Plinck E P, Peereboom-Wynia J D, Vuzevski V D, Westerhof W, Stolz E (1993) Turning white overnight, is it possible? *Ned Tijdschr Geneesk* 137: 207–10
- Porter D, Burton JL (1971) A comparison of intra-lesional triamcinolone hexacetonide and triamcinolone acetonide in alopecia areata. *Br J Dermatol* 85: 272
- Price VH (1987a) Double-blind, placebo-controlled evaluation of topical minoxidil in extensive alopecia areata. *J Am Acad Dermatol* 16: 730–36
- Price VH (1987b) Topical minoxidil (3%) in extensive alopecia areata, including long-term efficacy. *J Am Acad Dermatol* 16: 737–44
- Puavilai S, Puavilai G, Charuwichitratana S, Sakuntabhai A, Sriprachya-Anunt S. (1994) Prevalence of thyroid diseases in patients with alopecia areata. *Int J Dermatol* 33: 632–3
- Ranchoff RE, Bergfeld WF, Steck WD, Subichin SJ (1989) Extensive alopecia areata. Results of treatment with 3% topical minoxidil. *Cleve Clin J Med* 56: 149–154
- Randall VA (2001) Is alopecia areata an autoimmune disease? *Lancet* 358: 1922–24
- Ranki A, Kianto U, Kanerva L, Tolvanen E, Johansson E (1984) Immunohistochemical and electron microscopic characterization of the cellular infiltrate in alopecia (areata, totalis, and universalis). *J Invest Dermatol* 83: 7–11
- Ro BI (1995) Alopecia areata in Korea (1982–1994) *J Dermatol* 22: 858–64.
- Russell JH, Ley TJ (2002) Lymphocyte-mediated cytotoxicity. *Annu Rev Immunol* 20: 323–70
- Sabouraud R (1913) Nouvelles recherches sur l'étiologie de la pelade (pelade et ménopause). *Annales de Dermatologie et de syphiligraphie* 5: 88–97
- Sabouraud R (1896) Sur les origines de la pelade. *Annales de Dermatologie et syphiligraphie* 3: 253–77

- Sabouraud R (1929) Sur l'étiologie de la pelade Arch Dermatol-Syphiligr Clin Hop St Louis 1: 31-49
- Safavi KH, Muller SA, Suman VJ, Moshell AN, Melton LJ 3<sup>rd</sup> (1995) Incidence of alopecia areata in Olmsted County, Minnesota, 1975 through 1989. Mayo Clin Proc 70: 628-33
- Salamon T, Musafija A, Milicevic M (1971) Alopecia areata and diseases of the thyroid gland. Dermatologica 142: 62-3
- Sauder DN, Bergfeld WF, Krakauer RS (1980) Alopecia areata: An inherited autoimmune disease. In: Hair, trace elements and human disease Brown AC, Crouse AG eds. New York: Praeger, 343.
- Scerri L, Pace JL (1992) Identical twins with identical alopecia areata. J Am Acad Dermatol 27: 766-7
- Schallreuter KU, Lemke R, Brandt O, Schwartz R, Westhofen M, Montz R, Berger J (1994) Vitiligo and other diseases: coexistence or true association? Hamburg study on 321 patients. Dermatology 188: 269-75
- Schroder K, Hertzog PJ, Ravasi T, Hume DA (2004) Interferon-gamma: an overview of signals, mechanisms and functions. J Leukoc Biol 75: 163-89
- Schulz A, Hamm H, Weiglein U, Axt M, Bröcker EB (1996) Dexamethasone pulse therapy in severe long-standing alopecia areata: a treatment failure. Eur J Dermatol 6: 26-9
- Schuttelaar M-LA, Hamstra JJ, Plinck E.P, Peereboom-Wynia JDR, Vuzevski VD, Mulder PGH, Oranje AP (1996) Alopecia areata in children: treatment with diphencyprone. Br J Dermatol 135: 581-5
- Seiter S, Ugurel S, Tilgen W, Reinhold U (2001) High-Dose pulse corticosteroid therapy in the treatment of severe alopecia areata. Dermatology 202: 230-234
- Sharma VK (1996) Pulsed administration of corticosteroids in the treatment of alopecia areata. Int J Dermatol 35: 133-136
- Sharma VK, Dawn G, Kumar B (1996a) Profile of alopecia areata in Northern India. Int J Dermatol 35: 22-7
- Sharma VK, Kumar B, Dawn G (1996b) A clinical study of childhood alopecia areata in Chandigarh, India. Pediatr Dermatol 13: 372-7
- Sharma VK, Muralidhar S (1998) Treatment of widespread alopecia areata in young patients with monthly oral corticosteroid pulse. Pediatr Dermatol 15: 313-317
- Shellow WV, Edwards JE, Koo JY (1992) Profile of alopecia areata: A questionnaire analysis of patient and family. Int J Dermatol 31: 186-9
- Shelton JM, Hollander L (1942) Alopecia totalis in father and daughter. Arch Dermatol Syph 46: 137-8
- Siegel RM, Chan FK, Chun HJ, Lenardo MJ (2000) The multifaceted role of Fas signaling in immune cell homeostasis and autoimmunity. Nat Immunol 1: 469-74
- Stankler L (1979) Synchronous alopecia areata in two siblings: a possible viral aetiology. Lancet 1: 1303-4
- Stewart MI, Smoller BR (1993) Alopecia universalis in an HIV-positive patient: possible insight into pathogenesis. J Cutan Pathol 20:180-3
- Sundberg JP, Boggess D, Silva KA, McElwee KJ, King LE, Li R, Churchill G, Cox GA (2003) Major locus on mouse chromosome 17 and minor locus on chromosome 9 are linked with alopecia areata in C3H/HeJ mice. J Invest Dermatol. 120: 771-5
- Sundberg JP, Cordy WR, King LE Jr. (1994) Alopecia areata in aging C3H/HeJ mice. J Invest Dermatol 102: 847-56
- Suri-Payer E, Amar AZ, Thornton AM, Shevach EM (1998) CD4+CD25+ T cells inhibit both the induction and effector function of autoreactive T cells and represent a unique lineage of immunoregulatory cells. J Immunol 160: 1212-8
- Tarlow JK, Clay FE, Cork MJ, Blakemore AI, McDonagh AJ, Messenger AG, Duff GW. (1994) Severity of alopecia areata is associated with a polymorphism in the interleukin-1 receptor antagonist gene. J Invest Dermatol 103: 387-90
- Taylor CR, Hawk JLM (1995) PUVA treatment of alopecia areata partialis, totalis and universalis: audit of 10 years' experience at St John's Institute of Dermatology. Br J Dermatol 133: 914-8
- Tobin DJ, Orentreich N, Bystryn JC (1994a) Autoantibodies to hair follicles in normal individuals. Arch Dermatol 130: 395-6

- Tobin DJ, Orentreich N, Fenton DA, Bystryn JC (1994b) Antibodies to hair follicles in alopecia areata. *J Invest Dermatol* 102: 721–4
- Tobin DJ, Sundberg JP, King LE Jr, Boggess D, Bystryn JC (1997) Autoantibodies to hair follicles in C3H/HeJ mice with alopecia areata-like hair loss. *J Invest Dermatol* 109: 329–33
- Tobin DJ, Alhaidari Z, Olivry T (1998) Equine alopecia areata autoantibodies target multiple hair follicle antigens and may alter hair growth. A preliminary study. *Exp Dermatol* 7: 289–97
- Tobin DJ (2003) Characterization of hair follicle antigens targeted by the anti-hair follicle immune response. *J Invest Dermatol Symp Proc* 8: 176–81
- Tosti A, Piraccini B, Pazzaglia M, Vincenzi C (2003) Clobetasol propionate 0.05% under occlusion in the treatment of alopecia totalis/universalis. *J Am Acad Dermatol* 49: 96–98
- Valsecchi R, Vicari O, Frigeni A, Foidadelli L, Naldi L, Cainelli T (1985) Familial alopecia areata – genetic susceptibility or coincidence? *Acta Derm Venereol* 65: 175–7
- Van der Steen PH, Baar van JMJ, Perret C, Happle R (1991) Treatment of alopecia areata with diphenylcyclopropenone. *J Am Acad Dermatol* 24: 253–7
- Van der Steen P, Traupe H, Happle R, Boezeman J, Strater R, Hamm H (1992a) The genetic risk for alopecia areata in first degree relatives of severely affected patients. *Acta Derm Venereol (Stockh)* 72: 373–5
- Van der Steen PH, Happle R (1992b) Dyschromia in confetti as a side effect of topical immunotherapy with diphenylcyclopropenone. *Arch Dermatol* 128: 518–20
- Van der Veen EE, Ellis CN, Kang S, Case P, Headington JT, Voorhees JJ, Swanson NA (1984) Topical minoxidil for hair regrowth. *J Am Acad Dermatol* 11: 416–421
- Verbov J (1973) Steroid solution treatment of alopecia areata. *Arch Derm* 108:135
- Vestey JP, Savin JA (1986) A trial of 1% minoxidil used topically for severe alopecia areata. *Acta Derm Venereol (Stockh)* 66: 179–80
- Vogel F, Motulsky AG (1997) *Human Genetics: Problems and Approaches*. 3rd ed. Berlin: Springer-Verlag, 223–6
- Walker SA, Rothman S (1950) Alopecia areata. A statistical study and consideration of endocrine influences. *J Invest Dermatol* 14: 403–413
- Weedon D, Strutton G (1981) Apoptosis as the mechanism of the involution of hair follicles in catagen transformation. *Acta Derm Venereol* 61: 335–9
- Weidman AI, Zion LS, Mamelok AE (1956) Alopecia areata occurring simultaneously in identical twins. *Arch Dermatol* 74: 424–6
- Weise K, Kretzschmar L, John SM, Hamm H (1996) Topical immunotherapy in alopecia areata: anamnestic and clinical criteria of prognostic significance. *Dermatology* 192: 129–133
- Weiss VC, West DP, Fu TS, Robinson LA, Cook B, Cohen RL, Chambers DA (1984) Alopecia areata treated with topical minoxidil. *Arch Dermatol* 120: 457–63
- Weitgasser H (1968) Erfahrungen mit einer Triamcinolon-Tinktur bei entzündlichen Dermatosen. *Z Hautkr* 43: 505–8
- Welsh EA, Clark HH, Epstein SZ, Reveille JD, Duvic M (1994) Human leukocyte antigen-DQB1\*03 alleles are associated with alopecia areata. *J Invest Dermatol* 103: 758–63
- Westgate GE, Craggs RI, Gibson WT (1991) Immune privilege in hair growth. *J Invest Dermatol* 97: 417–420
- White SI, Friedmann PS (1985) Topical minoxidil lacks efficacy in alopecia areata. *Arch Dermatol* 121: 591
- Whitmont K, Cooper A (2003) PUVA treatment of alopecia areata totalis and universalis: a retrospective study. *Australas J Dermatol* 44: 106–109
- Wiseman MC, Shapiro J, MacDonald N, Lui H (2001) Predictive model for immunotherapy of alopecia areata with diphenylcyclopropenone. *Arch Dermatol* 137: 1063–1068
- Wucherpfennig KW (2001) Mechanisms for the induction of autoimmunity by infectious agents. *J Clin Invest* 108: 1097–104
- Wunderlich C, Braun-Falco O (1965) Mongolismus und Alopecia areata. *Med Welt* 10: 477–81
- Zandman-Goddard G, Shoenfeld Y (2002) HIV and autoimmunity. *Autoimmun Rev* 1: 329–37
- Zhang JG, Oliver RF (1994) Immunohistological study of the development of the cellular infiltrate in the pelage follicles of the DEBR model for alopecia areata. *Br J Dermatol* 130: 405–14

- Zlotogorski A, Weinrauch L, Brautbar C (1990) Familial alopecia areata: No linkage with HLA. *Tissue Antigens* 36: 40–1
- Zöller M, McElwee KJ, Engel P, Hoffmann R (2002) Transient CD44 variant isoform expression and reduction in CD4(+)/CD25(+) regulatory T cells in C3H/HeJ mice with alopecia areata. *J Invest Dermatol* 118: 983–92

# **15 Novel Therapeutic Approaches in Autoimmune Skin Disorders**

*Sybille Thoma-Uszynski and Rüdiger Eming*

## **Introduction**

The medical management of autoimmune skin disorders is complex. At present, the mainstay of therapy of most of the previously characterized autoimmune skin diseases is based on mid- to long-term administration of immunosuppressive drugs. Although therapeutic immunosuppression took away the fatality of many autoimmune skin disorders, there are several pitfalls associated with longterm immunosuppression. Under this light, there is an urgent need to incorporate novel efficient therapeutic applications which harbor fewer side effects in the medical management of autoimmune skin diseases.

Immunological tolerance and breakdown of or escape from self-tolerance are incompletely understood. Deeper insight into immune mechanisms of self-tolerance should extend the possibilities for specific therapeutic interventions in autoimmune diseases. Principally, therapeutic strategies are targeted to distinct steps in the sequence of events which lead to a imbalance in immune function and/or break of tolerance and eventually to overt autoimmune disease. These include bone marrow ablation, general immunosuppression, modulating autoantigen recognition, cytokine function, autoantibody production and degradation, gene transcription or inhibiting cellular immune responses. During the past several years the development of biologic agents (biologics) interfering with key steps in the immunopathogenesis of autoimmune diseases have profoundly changed the way of treating autoimmune disorders. This chapter reviews the most recent developments and the corresponding clinical applications.

## **Immunomodulatory Drug Development**

Recent drug development extended the spectrum of anti-inflammatory and/or immunosuppressive pharmaceuticals.



## **Mycophenolic Acid**

Mycophenolic acid (MPA), an immunosuppressive agent that blocks lymphocyte purine synthesis (Lipsky 1996), had been introduced into the management of psoriasis, but now becomes increasingly popular for other clinical applications, including autoimmune bullous skin disorders, such as pemphigus vulgaris (PV) and bullous pemphigoid (BP) (Bohm et al. 1997; Enk and Knop 1999; Grundmann-Kollmann et al. 1999). One recent study applied it as monotherapy in PV and BP and disease activity was successfully suppressed (Grundmann-Kollmann et al. 1999). Mimouni et al. conducted a historical prospective study including 31 patients with PV and 11 pemphigus foliaceus (PF)-patients, evaluating the role of MPA as a corticosteroid-sparing agent (Mimouni et al. 2003). Complete remission was achieved in 71% and 45% of the patients with PV and PF, respectively. The authors considered MPA as an effective and well tolerated adjuvant in the treatment of patients with pemphigus (Mimouni et al. 2003). Powell et al. confirmed these conclusions by evaluating the efficacy and safety of mycophenolate mofetil (MMF) combined with glucocorticosteroids in a group of 17 pemphigus patients (Powell et al. 2003). In this study, treatment with MMF was an effective steroid-sparing immunosuppressant to 12 of the 17 patients (Powell et al. 2003). Recent studies demonstrate good responses to treatment with MMF in various nephrological autoimmune disorders. Filler et al. reported effective treatment of pediatric patients with vasculitis and connective tissue disease involving the kidney, i.e. SLE, antiphospholipid antibody syndrome or Wegener granulomatosis (Filler et al. 2003). Contreras et al. showed that for patients with proliferative lupus nephritis maintenance therapy with MMF or azathioprine (AZA) seems to be more efficacious and safer than i.v.-cyclophosphamide treatment (Contreras et al. 2004). A recent study by Budde et al. with renal transplant patients demonstrated that MMF can safely be converted to enteric-coated mycophenolate sodium without compromising the safety and efficacy of the drug (Budde et al. 2004). This enteric-coated formulation reduces the adverse effects in the upper gastrointestinal tract compared to MPA. The current status of MPA as a promising compound in the dermatological field is reviewed by Frieling and Luger (Frieling and Luger 2002).

## **Immunosuppressive Macrolides**

Immunosuppressive macrolides represent a new class of substances which modulate inflammatory processes. They can be topically applied and are potential alternatives to corticosteroid therapy.

### *Tacrolimus (FK506)*

The macrolide lactone tacrolimus (FK506), introduced into transplantation medicine for prevention of allograft rejection, is now also applied for treat-

ment of inflammatory skin disorders such as atopic eczema, psoriasis, pyoderma gangrenosum, Behcet's disease, alopecia areata and lichen planus (Assmann et al. 2000). Functionally similar, but structurally different to cyclosporin A, FK506 binds to immunophilins and this complex specifically inhibits calcineurine phosphatase and early gene expression after T cell stimulation, but with a 10 to 100 fold stronger immunosuppressive potency than cyclosporin A (Sawada et al. 1987).

It has been shown that topical application of FK506 has a wide spectrum of effects including reduced expression of costimulatory molecules on immunocompetent cells and cytokine production in the skin (Homey et al. 1998). It has been used to treat patients with systemic sclerosis with moderate success (Morton and Powell 2000). A cohort of recent case reports demonstrated the successful topical treatment of different autoimmune blistering disorders with tacrolimus, including vesicular pemphigoid (Chuh et al. 2004), cases of localized pemphigoid (Chu et al. 2004; Ko et al. 2004) and labial pemphigus as reported by Hodgson et al. (2003). Vecchietti et al. reported the case of a patient with CD20+ follicular non Hodgkin's lymphoma developing paraneoplastic pemphigus with severe stomatitis and painful ulceration on the dorsum of the tongue (Vecchietti et al. 2003). In addition to treatment with monoclonal anti-CD20 antibody (Rituximab®), the patient was given an oral suspension of tacrolimus 0,03%, three 5-min rinses per day. The mucosal lesion cleared within six weeks and relapses of mucosal ulcerations responded well to reintroduction of a two week course of topical tacrolimus. (Vecchietti et al. 2003). Furthermore, effective topical treatment of Hailey-Hailey's disease (Rabeni et al. 2003; Sand et al. 2003) and recalcitrant chronic discoid lupus erythematosus (CDLE) (Walker et al. 2003) with tacrolimus have recently been described. Thus the current results may prove tacrolimus a useful adjunct in the topical treatment of a variety of cutaneous autoimmune disorders.

### *Sirolimus (Rapamycin)*

*Sirolimus (Rapamycin)* is another macrolide which also binds to immunophilins. In contrast to cyclosporin A and tacrolimus, the sirolimus FKBP12 complex inhibits the mammalian target of rapamycin and interferes with cell cycling events.

### *Ascomycin (ASM 981)*

Another related macrolactam derivative, *ASM 981* or *ascomycin* has been specifically developed for the treatment of inflammatory skin diseases. It inhibits via complex formation with FKBP12 calcineurin phosphatase and gene transcription. Thereby, it suppresses Th1 and Th2 cytokine production, downmodulates release of proinflammatory mast cell mediators and of note, also decreases the release of the proinflammatory cytokine, TNF- $\alpha$  (Grassberger et al. 1999).

This new generation of macrolid derivatives represents a class of T cell-dependent immunosuppressive agents. Their application in dermatology holds great potential to more specifically influence immune dysregulation in distinct autoimmune disorders and warrants controlled clinical trials.

### **Leflunomide**

Leflunomide is a new immunomodulatory drug which had been approved for treatment of rheumatoid arthritis (RA) (Prakash and Jarvis 1999). The specific mode of action is not clear; it presumably inhibits the mitochondrial enzyme dihydro-orotate dehydrogenase and subsequently, pyrimidine biosynthesis with suppressive effects on cytotoxic T cells and antibody production. In addition, leflunomide exerts an antiinflammatory action through inhibition of leucotriene B<sub>4</sub> (LTB<sub>4</sub>) formation and chemotaxis (Chong et al. 1999). Furthermore, it is an antiproliferative agent (Kurtz et al. 1995). One recent study suggests that it also blocks TNF- $\alpha$  receptor signaling (Manna et al. 2000). Leflunomide has been successfully applied and shown to be of particular value in critical situations where steroids are contraindicated and other steroid-sparing agents are not tolerated (Nousari and Anhalt 2000). Its efficacy and safety profile make it a potential agent for hyperproliferative and inflammatory dermatoses (Herrmann et al. 2000). Lately, however, reports on substantial liver toxicity contributed to concerns regarding its handling, particular if applied as part of a combination therapy with potential additive or synergistic toxic effects (Weinblatt et al. 2000; Emery et al. 2000). Lately, also cystic macular edema has been reported as a severe adverse event after administration of leflunomide (Barak et al. 2004).

## **Antigen Specific Approaches for Therapy of Autoimmune Diseases**

The ideal treatment for autoimmune diseases would be to induce long lasting autoantigen specific tolerance. A precondition for such treatment is that the disease-associated autoantigens are well characterized. This holds true for only few, mostly organ-specific autoimmune diseases such as myasthenia gravis (MG), Hashimoto's disease, autoimmune diabetes mellitus or the autoimmune skin diseases BP and PV (Stanley 1989; Patrick 1990).

### **Therapy by Autoantigen Administration**

Several experimental animal models of autoimmune disease are established. In these models, autoantigens are used to induce the autoimmune disease

such as MBP for experimental autoimmune encephalitis (EAE), insulin for autoimmune diabetes mellitus, acetylcholine receptor (AChR) for experimental autoimmune myasthenia gravis (EAMG), and thyroglobulin for experimental autoimmune thyroiditis, and others. Depending on the dose and route of administration, exogenous administration of proteins that usually represent self-antigens can lead to tolerance induction and prevention of autoimmune disease. This paradoxical use of self-antigens to treat autoimmune disease has been verified in the aforementioned experimental animal models as well.

The antigen is delivered either via a tolerizing route, e.g. via oral/intestinal or nasal mucosa, or in a tolerogenic form, e.g. as soluble peptide MHC complex. Systemic administration (intraperitoneal, intravenous or subcutaneous injection) of high dose peptide or monomeric protein can induce clonal deletion, clonal anergy or immune deviation (Liblau et al. 1997). Examples of systemic antigen immunotherapy in experimental autoimmune disease are reviewed by Liblau and colleagues (Liblau et al. 1997).

Experimental proof of that principle had been brought about by Chen et al. who tolerized mice via oral administration of myelin basic protein (MBP). Isolated T cell clones from the mesenteric lymph nodes showed a Th2-type cytokine pattern and induced suppression of EAE. Thus mucosa-associated regulatory T cells are generated upon an oral vaccination approach (Chen et al. 1994).

Distinct mechanisms are involved during antigen-induced tolerance. High dose antigen administration leads to antigen-induced T cell apoptosis via FasL- or TNF- $\alpha$ -dependent pathways. Continuous presence of antigen can lead to T cell hyporesponsiveness or clonal anergy. Low dose antigen administration can induce regulatory T cells which secrete anti-inflammatory cytokines, such as IL-4, IL-10 or TGF- $\beta$  and suppress APC and/or effector T cell function and possibly compete with effector T cells for antigen presentation.

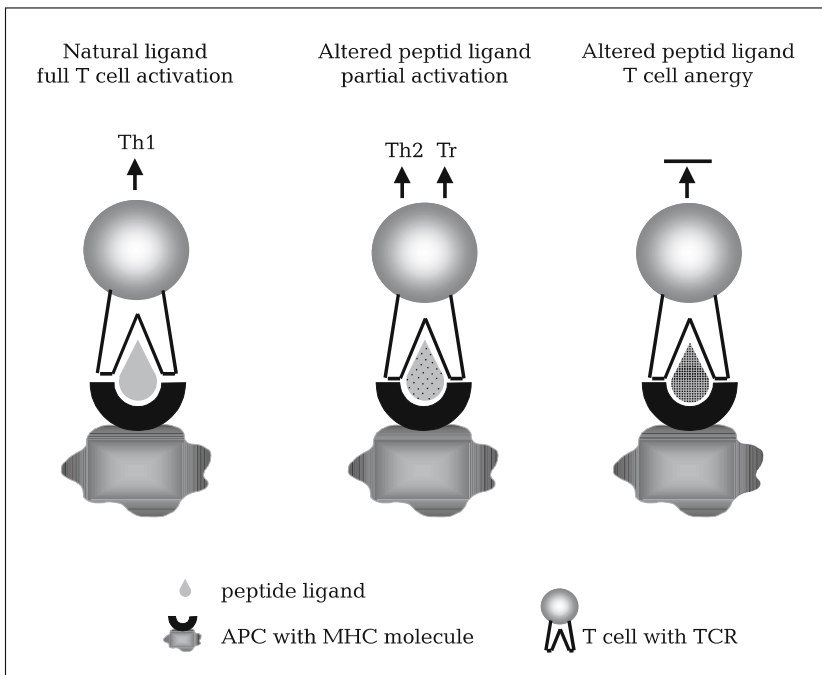
The administration of the random peptide copolymer glatiramer acetate (Copaxone) is another related approach. Previously shown to be partially effective in multiple sclerosis (MS) it was thought to suppress autoreactive T cells specifically (Johnson et al. 2000). A recent study, however, revealed that the T cell receptor (TCR) is engaged in a degenerate, antigen-non specific way and immune function is altered by induction of cross-reactive regulatory Th2 responses with bystander suppressor effects on APC and/or effector T cells in MS patients (Duda et al. 2000). Although shown in MS, it could be a potent agent also for other autoimmune diseases which are alleviated upon a Th2 shift.

Antigen-specific immune therapy has not made it yet to broad clinical application. Although neither significant toxicity nor exacerbation of autoimmune disease had overshadowed recent and ongoing clinical trials, a clear clinical efficacy could not yet been demonstrated (Faria and Weiner 1999).

## Modified Antigens to Induce Tolerance

### *Altered Peptide Ligands*

The TCR interacts with the peptide MHC-complex with high specificity. The on/off time of such interaction determines which co-stimulatory molecules participate in the immunologic synapse with functional consequences on subsequent T cell activation. According to this "strength of signal theory" there is either full T cell activation, partial activation or T cell anergy. Full vs. partial T cell activation may lead to an opposite cytokine profile, e.g. Th1 vs. Th2, a phenomenon called immune deviation. An altered peptide ligand (APL) has slightly changed residues of an immunodominant self-epitope which impair the T cell strength of signal (*Fig. 1*). Thus a single TCR can productively recognize a large continuum of related ligands (Kersh and Allen 1996a). This flexibility is crucial for T cell development and harbors the possibility for both beneficial and harmful effects on peripheral T cells (Kersh and Allen 1996b).



**Fig. 1.** Natural peptide ligands and altered peptide ligands (APL). The T cell receptor of an autoreactive T cell is fully stimulated by its natural ligand. Slight modification of the natural peptide ligand results in an APL. Interaction of an APL with the autoreactive T cell can lead to partial activation with a possible shift of the cytokine profile or to T cell anergy, both desired effects regarding therapeutic intervention in states of autoimmunity

The APL strategy has been applied in several animal models of autoimmune diseases, and EAE being a well established animal model of MS in particular: A single TCR antagonistic peptide has been shown to inhibit EAE (Kuchroo et al. 1994). A single amino acid shift of a myelin basic protein peptide produced an APL which mediated immune deviation by changing the cytokine profile towards a protective Th2 or Th0 pattern while retaining cross-reactivity to the native peptide (Nicholson et al. 1995).

Recently, first phase II clinical trials in humans applied the APL approach. One study compared the APL of MBP to placebo. The APL-treated group was clinically stable and fine analysis revealed that lesions were reduced in volume and number. The APL induced a regulatory type 2 T helper cell response that cross-reacted with the native peptide (Kappos et al. 2000). The second phase II clinical trial to treat MS with an MBP peptide (aa 83–99)-derived APL induced an exacerbation of the disease in three individuals, and the trial had therefore to be halted (Bielekova et al. 2000). In two of the three patients, clinical worsening could be attributed to the APL as immunological studies demonstrated the encephalitogenic potential of the APL peptide (aa 83–99).

Although principally appealing to modulate the fine tuning of the immunologic synapse by APL, severe considerations arise from these first clinical experiences. In light of an individual T cell repertoire in the outbred human population, the functional effects of APLs seem unpredictable and problematic.

### *Complementary Peptides*

According to the molecular recognition theory, peptides encoded by the antisense RNA are designated as complementary or antisense peptides, can interact with the natural peptide due to their hydrophobic complementarity (Blalock 1990). Antibodies raised against complementary peptides of a ligand can recognize its receptor, thus antibodies against complementary peptides possess the ability to bind antibodies against sense or natural peptides (Araga et al. 1996). Proof of principle had been given by animal models of AMG and EAE (Araga and Blalock 1994; Araga et al. 1996, 1999, 2000). These studies showed that a complementary peptide vaccine approach resulted in T cell anergy and blocking of T cell help in particular (Araga et al. 1999, 2000). The complementary peptide approach has also been shown to alter B cell-mediated autoimmune diseases by induction of anti-idiotypic antibodies to pathogenic autoantibodies (Smith et al. 1987; Araga and Blalock 1994). One recent study based on the molecular recognition theory aimed to develop a complementary peptide vaccine to BP (Nie et al. 1999). Choosing the extracellular non-collagenous immunodominant NC16A domain of BP180, the putative major BP autoantigen, to derive complementary peptides from, failed however to demonstrate binding to the natural peptides. Thus the targeted epitope was

not eligible for complementary peptide vaccine development for BP (Nie et al. 1999). This result does not preclude that other yet undefined BP180 epitopes can be targeted using the complementary peptide approach.

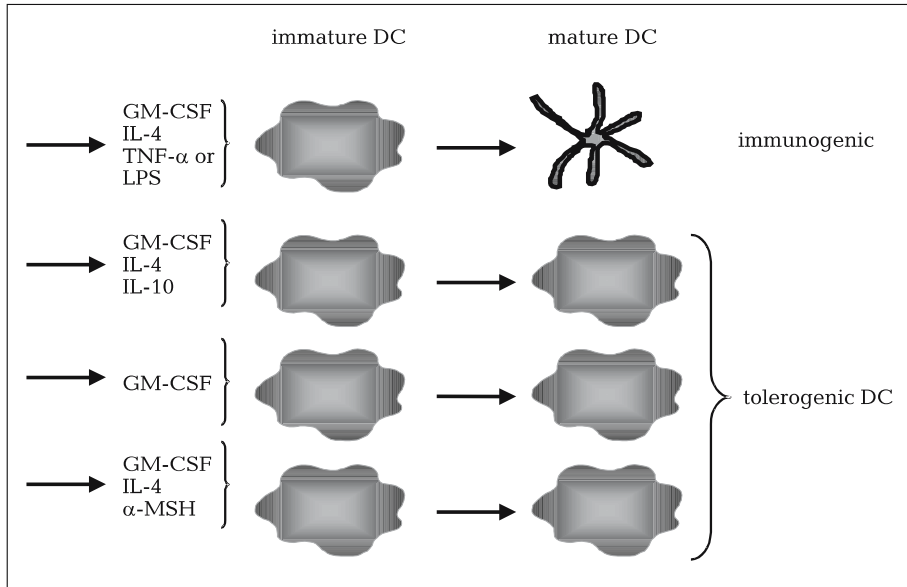
### Tolerogenic Dendritic Cells

Dendritic cells (DC) are the most powerful antigen presenting cells and initiate immune responses after uptake, processing and presentation of foreign antigen. In addition to their eminent role in host defense, DC are also held responsible in triggering autoimmune diseases by presenting autoantigens to autoreactive T cells (Ludewig et al. 1998, 1999; Link et al. 1999; Drake-smith et al. 2000). Several immuntherapeutic strategies utilize the antigen presenting capacity of DC, such as DC vaccine for treatment of cancer or infection. Recent attempts included also to modify DC function such that subsequent T cell activation would be inhibited or downregulated. For instance, monocyte-derived human DC cultured in the absence of IL-4 and in the presence of low concentrations of GM-CSF were maturation-resistant and induced hyporesponsiveness of T cells and prolonged cardiac allograft survival (Lutz et al. 2000).

Appropriate cytokine treatment can convert immunogenic into tolerogenic DC (Drakesmith et al. 2000). IL-10-treated DC had a reduced allostimulatory capacity and induced a state of T cell anergy (Steinbrink et al. 1997, 1999). In contrast to cytokine treatment which halts DC maturation, it has been shown recently that also fully mature DC are able to induce anergy in T cell clones reactive with thyroid peroxidase antigen and are able to process and present an immunodominant epitope with antagonistic altered peptide features (Quaratino et al. 2000). Recently, DC that take up apoptotic cells were described to induce peripheral tolerance to self antigens (Huang et al. 2000; Sauter et al. 2000).

More and more functional properties are ascribed to cytokines, chemokines and other factors within the network of immune regulation. One such factor is the neuropeptide alpha-melanocyte stimulating hormone ( $\alpha$ -MSH) which has been shown to exert anti-inflammatory effects by antagonizing IL-1, IL-6 and TNF- $\alpha$  (Becher et al. 1999).  $\alpha$ -MSH signals via the melanocortin receptor 1 (MC-1R) which is present on both monocytes and DC. Indicative for the potentially anti-inflammatory and/or immunosuppressive role of  $\alpha$ -MSH is the observation that it downregulates the expression of the co-stimulatory molecules CD86 and CD40 on monocyte-derived DC (Becher et al. 1999).

Although the term DC defines a heterogeneous population with different functional properties ranging from powerful to poor T cell activators, there are therapeutic possibilities emerging to functionally modulate DC into mediators of tolerance in T cell-dependent autoimmune diseases (*Fig. 2*).



**Fig. 2.** Immunogenic and tolerogenic dendritic cells (DC). Immunogenic DC can be derived from monocytes by in vitro culture in the presence of a cytokine cocktail, usually containing GM-CSF and IL-4. Addition of TNF- $\alpha$  or LPS induces complete maturation. Variations of the cytokine cocktail in terms of content and concentration of the cytokines can modify the resulting DC regarding maturation state and immunogenicity. Depicted are cytokine combinations in the presence of which tolerogenic DC have been generated

## Modulating the Effector Phase of Autoimmune Diseases

Since many autoimmune diseases share common effector pathways of inflammation it is a rational strategy to target this effector phase. Attempts to neutralize proinflammatory cytokines in conditions where these cytokines represent pathogenic key elements, are promising and most clinical experience has been collected regarding TNF- $\alpha$ .

### Inhibition of TNF- $\alpha$ Synthesis

TNF- $\alpha$  mediates inflammatory effects by acting on multiple target cells and by inducing cascades of other cytokines such as IL-1, IL-6 and IL-8 facilitating leukocyte chemotaxis and angiogenesis. Elevated serum levels are detectable in many autoimmune diseases including RA, Crohn's disease and MS. Ways to neutralize a cytokine include alteration of cytokine transcription/translation, administration of monoclonal antibodies against the cytokine or cytokine receptor, soluble cytokine receptors or nonactivating cytokine antagonists. In humans, TNF- $\alpha$  neutralization has been accomplished by in-



**Table 1.** Immunomodulatory and Anti-Inflammatory Mode of Action of Thalidomide

---

Inhibition of TNF- $\alpha$ production by monocytes/macrophages
Reduced TNF- $\alpha$ mRNA half-life
Inhibition of IL-12 production
Inhibition of leukocyte chemotaxis
Reduced phagocytosis by polymorphonuclear granulocytes
Increased IL-4 and IL-5 synthesis by mononuclear cells
Inhibition of IFN- $\gamma$ production by mononuclear cells

---

**Table 2.** Dermatological Disorders that are Responsive to Treatment with Thalidomide

---

Disorder	Initial therapeutic daily dose	Reference
Erythema nodosum leprosum	400 mg	Iyer et al. 1971
Stomatitis aphthosa	200–400 mg	Brodthagen 1985, Grinspan 1985
Behcet's disease	100–400 mg	Ghate and Jorizzo 1999
Cutaneous lupus erythematosus	100–400 mg	Ordi-Ros et al. 2000, Kyriakis et al. 2000
Systemic lupus erythematosus	100–400 mg	Khamashta et al. 2000
Prurigo nodularis	400 mg	Warren et al. 1998, Daly and Shuster 2000
Pyoderma gangrenosum	200–400 mg	Federman and Federman 2000
HIV-associated symptoms	200–400 mg	Berger et al. 1995, Herranz et al. 1998

---

hibitors of cytokine production, monoclonal antibodies and genetically engineered soluble TNF-receptors.

Thalidomide, a sedative drug originally introduced for sleep disorders has been among the first drugs known to exert anti-inflammatory action by inhibition of TNF- $\alpha$  synthesis (Calabrese and Fleischer 2000). There are additional effects exerted by thalidomide on immune function that are still incompletely understood (*Table 1*). Thalidomide reduces neutrophil phagocytosis and inhibits monocyte phagocytosis. A major immunomodulatory effect of thalidomide is the selective, but incomplete inhibition of TNF- $\alpha$  production by human monocytes. This effect is presumably the consequence of a significantly reduced half-life of TNF- $\alpha$  mRNA (Moraes et al. 2000).

Since TNF- $\alpha$  is a major proinflammatory cytokine, the inhibition of this cytokine by thalidomide may explain its effectiveness in a variety of inflammatory disorders. Conditions such as lepromatous leprosy which are highly responsive to thalidomide (FDA approval for this indication) are character-

ized by elevated serum TNF- $\alpha$  levels. Relief of the symptoms is accompanied by a decrease of serum TNF- $\alpha$  levels. There are, however, disastrous examples that demonstrate that thalidomide does not always reduce overall TNF- $\alpha$  synthesis. A double-blinded randomized study in drug-induced toxic epidermal necrolysis, a condition characterized by most severe epidermolysis of skin and mucosa and elevated TNF- $\alpha$  concentrations in skin lesions and serum showed that treatment with thalidomide significantly increased the risk of a fatal outcome of this disorder. Patients with toxic epidermal necrolysis had even elevated TNF- $\alpha$  serum levels upon treatment with thalidomide (Wolkenstein et al. 1998).

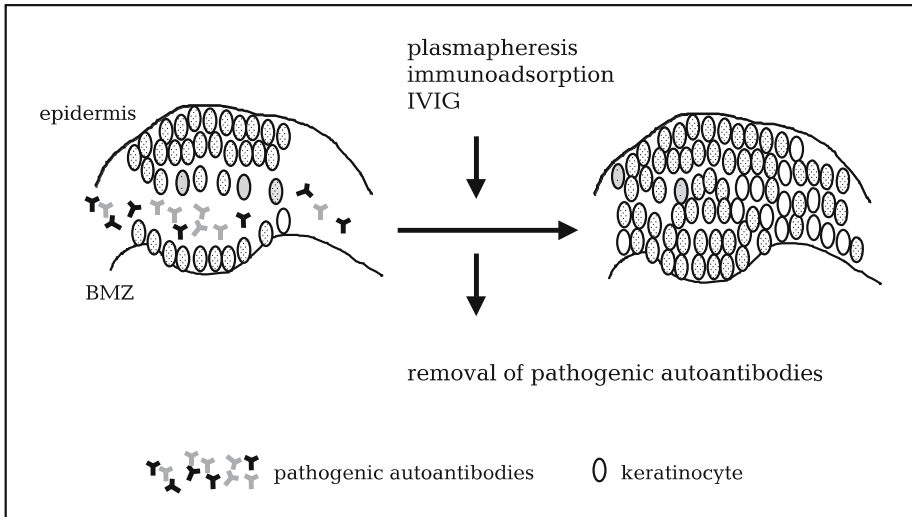
Apart from leprosy, thalidomide has been successfully applied in Behcet's disease and HIV-associated aphthosis, cutaneous and systemic lupus erythematosus and prurigo syndromes (*Table 2*).

### **Removal or Inhibition of Pathogenic Autoantibodies**

A key feature and pathogenetic hallmark of many autoimmune skin disorders is the formation of autoantibodies that interfere with the function of the target antigen. Autoimmune bullous skin disorders, such as pemphigus vulgaris (PV) and bullous pemphigoid (BP), are well characterized by the presence of distinct disease-precipitating antibodies. Removal of pathogenic autoantibodies contributes to reduced disease activity. PV as a paradigmatic disorder of antibody-mediated autoimmunity correlates in intensity with the concentration of circulating autoantibodies. Moreover, transfer of the patients' autoantibodies into mice reproduces the characteristic pathology of this disorder (Amagai et al. 1994, 1995). For more than 25 years, attempts have been made to reduce levels of circulating autoantibodies as a therapeutic strategy (*Fig. 3*).

### **Plasmapheresis**

Plasmapheresis has been one of the mainstays in the treatment of pemphigus for several years but has not yet developed into a first-line therapy of autoimmune diseases. This is greatly due to limited patient numbers which do not allow the appropriate conduction of controlled clinical trials to confirm a statistically proven benefit (Schneider 1996). Plasmapheresis has been applied to treat a series of autoimmune diseases: In PV, BP, and severe epidermolysis bullosa acquisita (EBA), plasmapheresis led to a substantial steroid sparing effect of immunosuppressive therapy (Sondergaard et al. 1995, 1997; Yamada et al. 1997; Egan et al. 2000; Turner et al. 2000). Plasmapheresis has proven beneficial in systemic lupus erythematosus, particularly in lupus nephritis (Wallace 1999; Braun et al. 2000), and also in systemic sclerosis (Dau and Callahan 1994) and dermatomyositis (Bennington and Dau 1981; Dau 1994). Unfortunately, plasmapheresis does not only remove pathogenic antibodies but also causes a significant loss of additional plasma components.



**Fig. 3.** Mechanism of action of intravenous immunoglobulin (IVIg) therapy. The intracellular FcRn receptor in endothelial cells binds pinocytosed IgG at acid pH in the endosome and redirects it to the neutral pH at the cell surface. Unbound IgG is degraded in the lysosome. In states of hypergammaglobulinemia, FcRn becomes saturated, and lysosomal degradation is increased. This IgG depleting mechanisms contributes to degradation of pathogenic IgG (autoantibodies) during high dose IVIg therapy. Therapeutic approaches targeting the FcRn with either synthetic ligands or neutralizing mAb would predict the same IgG depleting catabolism without the risks and costs associated with IVIg therapy. Figure adapted from Yu and Lennon 1999

### Immunoadsorption

Several models demonstrated that selective adsorption of pathogenic autoantibodies may prevent the experimental induction of autoimmune bullous skin disorders of the pemphigus group. Amagai et al. demonstrated that pemphigus sera can be depleted from IgG reactive with the autoantigens of PV, desmoglein 3 and pemphigus foliaceus, desmoglein 1, by preadsorption of the sera over immobilized protein A (Amagai et al. 1994, 1995). The IgG autoantibody-depleted sera no longer induced pemphigus-like blisters upon passive transfer into newborn mice.

Immunoadsorption is a novel therapeutic strategy aimed at removing distinct protein components from the patient's plasma. Similarly to leukapheresis, peripheral blood from the patient is collected and separated by centrifugation into plasma and cellular components. The plasma fraction is then subjected to passage over an affinity column coated with protein A sepharose, peptides with IgG binding capacity, tryptophane-PVA or phenylalanine-PVA. The most important advantages of adsorption apheresis over unselective plasma exchange (i.e. plasmapheresis) are:

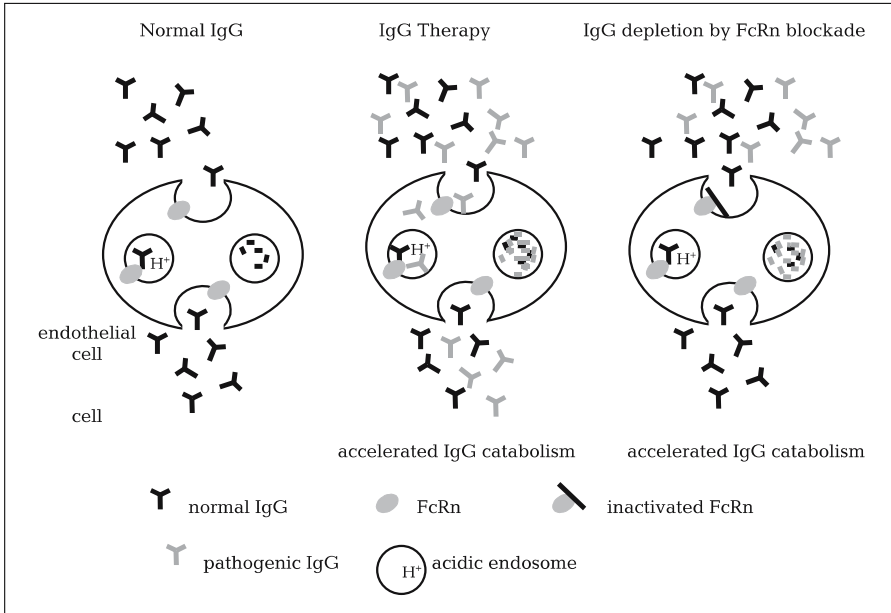
- Selective removal of pathogenic plasma proteins (i.e. antibodies, cytokines)
- No loss of essential plasma proteins
- No requirement for adequate protein replacement

The tremendous costs of immunoadsorption, however, exceed those of unselective plasma exchange by a factor greater than 2. The different adsorbents currently available for therapeutic trials have distinct adsorption profiles and may be selectively utilized to remove distinct antibody subtypes (Ikonomov et al. 1992). Immunoadsorption has been successfully employed for the removal of circulating autoantibodies in systemic lupus erythematosus (Kutsuki et al. 1998; Gaubitz et al. 1998). Recently, immunoadsorption has been successfully employed in the treatment of recalcitrant pemphigus vulgaris and pemphigus foliaceus (Luftl et al. 2003; Eming et al. [submitted]). Single yet unpublished case reports suggest a beneficial effect of immunoadsorption in severe pemphigoid gestationis and EBA.

### High Dose Intravenous Immunoglobulins

Modifying the immune system by repeated intravenous administration of high dose intravenous immunoglobulins has become an attractive therapeutic option to treat cases of autoimmune disorders that are resistant to conventional immunosuppressive drug regimens. The underlying mechanism of such treatment, however, remained obscure until recently. Immunoglobulins may exert immunomodulatory effects by several ways. These include Fc receptor blockade, regulatory capacity of anti-idiotypic antibodies or cytokine modulation via effectors on cytokine synthesis (Yu and Lennon 1999). An accelerated rate of IgG catabolism has been proposed to be the most likely mechanism in mediating the beneficial action of intravenous immunoglobulins in antibody-dependent autoimmune disorders (Ghetie and Ward 1997; Yu and Lennon 1999). A specialized intracellular Fc receptor, FcRn, is abundantly expressed in endothelial cells and binds pinocytosed IgG in a pH-dependent manner, namely only in the acidic endosome. IgG is released when endosomal transport vesicles reach the neutral pH of the cell surface. Unbound IgG is transferred to lysosomes for rapid degradation. FcRn becomes saturated in states of hypergammaglobulinemia, resulting in an increased rate of IgG catabolism. IgG depletion via FcRn receptor saturation convincingly explains the temporary benefit of intravenous immunoglobulin therapy in antibody-mediated autoimmune diseases. Based on this mechanism, a therapeutic strategy would be to target FcRn, e.g. by neutralizing antibodies or synthetic ligands to decrease levels of circulating pathogenic autoantibodies (Yu and Lennon 1999). These fundamental insights into IgG catabolism harbor great potential for therapeutic intervention at the effector level (*Fig. 4*).

Intravenous immunoglobulins have been highly beneficial in restoring therapeutic responsiveness to standard immunosuppressive treatment in disorders that were otherwise refractory (*Table 3*). Intravenous immunoglobulins



**Fig. 4.** Therapeutic effect of infliximab (anti-TNF- $\alpha$ ) in an inflammatory skin disorder. A patient with recalcitrant subcorneal pustular dermatosis (Sneddon-Wilkinson) responded promptly to infliximab therapy. Shown are pre-(left) and posttreatment (right) photographs of the patient's neck. Disseminated pustules completely resolved after a single course of treatment and the patient remained in stable remission for several months (provided by Dr. C. Voigtländer, Erlangen, Germany)

may be highly effective in therapy-refractory PV, linear IgA bullous dermatosis (incl. chronic bullous disease of childhood), EBA and mucous membrane pemphigoid. In drug-induced toxic epidermal necrolysis, a condition characterized by extensive and uncontrolled epidermal necrolysis of large skin areas, immediate treatment with intravenous immunoglobulins resulted in a dramatic beneficial response in some patients (Viard et al. 1998). This effect seems to be mediated by the anti-apoptotic action of anti-Fas IgG in the immunoglobulin preparations preventing apoptotic keratinocyte death.

## Targeting Immune Cells in Autoimmune Diseases

### Biologics

Biologic agents or "biologics" represent a new group of substances including monoclonal antibodies, fusion and recombinant proteins possessing biological activity. These proteins can either be isolated from animal tissues or nowa-

**Table 3.** Dermatological Disorders Treated with Intravenous Immunoglobulins

Disorder	Therapeutic Trial	Reference
Dermatomyositis	Double-blind, placebo-controlled	Dalakas 1998
Pemphigus vulgaris	Open	Harman and Black 1999; Sibaud et al. 2000
Epidermolysis bullosa	Open	Kofler et al. 1997
Bullous Pemphigoid	Open	Harman and Black 1999
Linear IgA bullous dermatosis	Open	Letko et al. 2000
Mucous Membrane Pemphigoid	Open	Foster and Ahmed 1999
Toxic epidermal necrolysis	Open	Viard et al. 1998
Chronic (autoimmune) urticaria	Open	O'Donnell et al. 1998
Lupus erythematosus	Open	Hundt et al. 2000; Viertel et al. 2000; Enk and Knop 2000
Morphea	Open	Wollina et al. 1998
Systemic sclerosis	Open	Levy et al. 2000
Pyoderma gangrenosum	Single case	Dirschka et al. 1998
Vasculitides	Open	Jayne et al. 2000; Ong and Benson 2000

days commonly be synthesized by biotechnological methods, i.e. recombinant DNA techniques. The use of biologics in other specialties, i.e. hematooncology (erythropoietin, GM-CSF) or organ transplantation (anti-CD25-antibodies) has been known for years. The more defined understanding of the pathophysiology of autoimmune diseases has led to the therapeutical use of biologics in chronic inflammatory disorders like RA or Crohn's disease (Feldman et al. 1998). More recently, in the dermatological field psoriasis serves as a model for a chronic, T cell mediated (auto-) immune disease which has been an important subject for new therapeutic strategies using biologics (Gottlieb and Bos 2002). With regard to the immunopathophysiology of psoriasis the immunologic strategies of biologics aim at inhibition of T cell activation, depletion of activated T cells, inhibition of T cell adhesion and inhibition of proinflammatory cytokines. Regarding therapy of inflammatory autoimmune diseases antibodies which target B cells and autoantibody-producing plasma cells are of particular interest.

Most of the listed biologics are being investigated in clinical trials (phase I-III) for the treatment of moderate to severe plaque psoriasis. Alefacept and efalizumab are approved for the treatment of moderate to severe plaque psoriasis, whereas infliximab is approved for psoriatic arthritis, Crohn's disease

**Table 4.** Biologic therapies and their sites of action

Substances	Target	Type	Company
<b>Inhibition of T cell activation</b>			
Alefacept (LFA3TIP)	CD2-LFA-3-interaction	fusion protein	Biogen IDEC
CTLA4-Ig (BMS 188667)	CD80/CD86 costimulation	chimeric fusion protein	Bristol Myers Squibb
IDEC 114	CD80 costimulation	primatized mAb	Biogen IDEC
<b>Inhibition of T cell migration</b>			
Efalizumab (hu1124)	CD11a (LFA-1-ICAM-interaction)	humanized IgG <sub>1</sub> mAb	Genentech/XOMA
CDP 850	E-selectin	humanized mAb	Celltech
Bimosiamose (TBC-1269)	anti-pan-selectin	small molecule	Encysive
Efomycine M	P- and E-selectin	small molecule	
<b>Reduction of activated T cells</b>			
DAB398IL-2 (denileukin diftitox)	IL-2R	fusion protein	Ligand
Siplizumab/MEDI-507	CD2	humanized mAb	Medimmune
OKT3	CD3	murine IgG <sub>2a</sub> mAb	Cilag Lab.
Visilizumab	CD3	humanized mAb	PDL
HuMax-CD4	CD4	human mAb	Genmab A/S
OKTcdr4a	CD4	humanized IgG <sub>1</sub> mAb	IMUCLONE
Basiliximab	CD25	chimeric IgG <sub>1</sub> mAb	Novartis
Daclizumab	CD25	humanized IgG <sub>1</sub> mAb	Roche
<b>Depletion of B cells</b>			
Rituximab	CD20	chimeric IgG <sub>1</sub> mAb	Roche
<b>Depletion of lymphocytes</b>			
Campath-1H/Alemtuzumab	CD52	humanized IgG <sub>1</sub> mAb	ILEX
<b>Blocking the activity of inflammatory cytokines</b>			
Infliximab	TNF $\alpha$	chimeric IgG <sub>1</sub> mAb	Centocor/Essex
Atlizumab	IL-6R	humanized mAb	Roche/Chugai
Etanercept	TNF $\alpha$	fusion protein	Wyeth
ABX-IL8	IL-8	human mAb	Abgenix
HuZAF/Fontolizumab	IFN $\gamma$	humanized mAb	PDL

and rheumatoid arthritis and etanercept is approved for the treatment of psoriatic and rheumatoid arthritis. Basiliximab and daclizumab are indicated for the prophylaxis of acute organ rejection in patients receiving renal transplants. Rituximab is being used for the treatment of low-grade B cell non-Hodgkin's lymphoma. For simplification, each substance is listed in one category only. Note that some biologics have multiple effects, i.e. efalizumab also inhibits T cell activation.

### *Inhibition of T cell activation*

#### Alefacept

Alefacept is a fully human, recombinant fusion protein consisting of the extracellular domain of the leucocyte function-associated antigen type 3 (LFA-3) fused to the Fc-portion of human IgG<sub>1</sub>. It is produced by recombinant DNA technology in a Chinese Hamster Ovary (CHO) mammalian expression system (Biogen IDEC 2003). By effectively blocking the interaction between CD2 which is highly expressed on memory effector T cells and LFA-3 expressed on APC, alefacept inhibits the activation of effector T cells. Treatment with alefacept also reduces the number of CD4/CD45 RO-positive memory T cells through binding of its Fc-portion to Fc $\gamma$ III-receptors on natural killer cells (NK cells) or macrophages. This leads to the induction of a granzyme B-mediated apoptosis preferentially in CD4/CD45 RO-positive memory T cells (Ellis et al., 2001). Recent studies by Gordon et al. revealed a relationship between the decrease in circulating CD4+ memory T lymphocytes and the improvement of the psoriatic skin lesions (Gordon et al. 2003). Since January 2003, alefacept is approved by the FDA for the treatment of moderate to severe plaque psoriasis. The treatment regimen is a course of 12 weekly injections (15 mg i.m./week) followed by a 12 week treatment free observation period (Biogen Idec 2003). The results of two phase III trials show that after two i.v.- or i.m.-alefacept courses, respectively about 40% of the patients showed a  $\geq 75\%$  reduction in their PASI-scores (Krueger et al. 2002; Lebwohl et al. 2003). The response to alefacept was durable, since the median duration of a  $> 50\%$  reduction in PASI was 216 days for patients who initially achieved a 75% reduction in PASI (Krueger and Callis 2003). Alefacept is reported to be well tolerated both by i.v. and i.m. administration with a consistent safety profile in the clinical trials (Gordon et al. 2003). Commonly reported infections in patients treated with alefacept were similar to those in patients receiving placebo. In both phase III studies there did not appear to be a correlation between infections and CD4+ cell counts below 250 cells/ $\mu$ l (Ortonne 2003 and Krueger et al. 2003). Kraan et al reported that alefacept treatment in psoriatic arthritis shows promising results (Kraan et al. 2002).

#### Efalizumab

Efalizumab (hu 1124, anti-CD11a) is a humanized IgG<sub>1</sub> version of the murine anti-human CD11a monoclonal antibody MHM24 (Werther et al. 1996). CD11a and CD18 are subunits of the lymphocyte  $\beta$ 2-integrin LFA-1 that primarily binds to the intercellular adhesion molecules ICAM-1 ICAM-2 and ICAM-3 expressed on leukocytes, epithelial cells including keratinocytes and endothelial cells (Janeway et al. 2001). The main function of integrins on the cell surface of T lymphocytes is to mediate cell adhesion with APC, endothelial



cells and extracellular matrix. In vitro studies by Werther et al. showed that by blocking the LFA-1–ICAM-1 interaction, efalizumab inhibits key pathogenic steps in psoriasis like T cell activation, T cell extravasation and T cell adhesion to keratinocytes (Werther et al. 1996). In two recent phase III trials with s.c. administered efalizumab nearly 1100 psoriatic patients had been randomized to treatment with an initial conditioning dose of 0,7 mg/kg in week one followed by weekly doses of efalizumab 1 mg/kg or 2 mg/kg or placebo. Compared to the placebo group, in which 3,4% achieved PASI 75, 29% of the patients in the 1 mg/kg group and 28% in the 2 mg/kg group achieved a  $\geq 75\%$  reduction in their PASI-score (Gordon et al. 2002). The clinical improvement correlated with sustained efalizumab levels in the serum, T cell CD11a saturation and down modulation, decreased epidermal and dermal T cell counts, histologic improvement and increased counts of circulating lymphocytes (Menter et al. 2001). FDA approved efalizumab for the treatment of moderate to severe psoriasis in October 2003. At present, safety data for 2762 patients treated during 13 clinical trials are available, showing a good safety profile for efalizumab (Leonardi et al. 2004). Long term results based on treatment for up to 24 months revealed no new common ( $\geq 5\%$  of the patients) adverse events. The incidence of serious infection or malignancy in efalizumab-treated patients was low and similar to the placebo group (Leonardi et al. 2004).

#### CTLA-4Ig/IDEC-114

In addition to antigen-induced signals, the proliferation and differentiation of T cells requires a second signal provided by costimulatory molecules on APC. A well characterized costimulatory pathway includes CD28 on T cells binding to the costimulatory molecules B7–1 (CD80)/B7–2 (CD86) on activated APC. Another T cell surface receptor for CD80/CD86, CTLA-4 (CD152) inhibits T cell activation (Abbas et al. 2000). CTLA-4Ig and IDEC-114 are biologicals targeting these costimulatory signals by binding to CD80 and CD86 on APC, thus inhibiting T cell activation. IDEC-114 is a primatized anti-human CD80 monoclonal antibody blocking the CD28–CD80 ligation without affecting the CD80–CTLA-4–interaction (Schopf 2001). Gottlieb et al. presented data on a single-dose phase I/II trial with 24 psoriatic patients who were administered IDEC-114 in i.v.-doses ranging from 0,05–15 mg/kg. IDEC-114 demonstrated mild clinical and histologic improvements in patients of the higher-dose groups (Gottlieb et al. 2000). A follow-up study (multiple dose, phase I/II) showed a PASI 50% reduction in 40% of the observed patients. The maximal clinical effect was observed 12 weeks after the last infusion (IDEC 2001). CTLA-4 Ig is a fusion protein composed of the extracellular domain of CTLA-4 (CD152) and the Fc domain of human IgG<sub>1</sub>. In an open phase I/II dose escalation trial CTLA-4Ig showed a dose dependent improvement in psoriatic patients. In the high dose group (50 mg/kg) about 90% of the study patients experienced a 50% PASI reduction (Abrams et al. 2000). An

earlier study by Abrams et al. indicated a decreased ability of the treated patients to mount T cell dependent antibody responses (Abrams et al. 1999). Currently, CTLA-4Ig is being investigated in other inflammatory disorders such as rheumatoid arthritis or organ transplantation (Gottlieb and Bos 2002).

### *Depletion of Activated T Lymphocytes*

#### Interleukin-2

Interleukin-2 (IL-2) is the principal cytokine which is secreted by antigen-activated T lymphocytes in the early phase of antigen recognition. IL-2 functions as an autocrine growth and differentiation factor for the T cells. Its high affinity receptor consists of the three non-covalently associated subunits IL-2R $\alpha$  (CD25), IL-2R $\beta$  (CD122) and IL-2R $\gamma$  (CD132). The TCR-dependent activation of naive T cells leads to the upregulation of the  $\alpha$  chain (CD25) which then enables T cells to respond to low concentration of IL-2 through their high affinity receptor. Therefore, CD25 is also considered an early activation marker for T cells. This is the rationale for using anti-CD25 monoclonal antibodies or denileukin diftotox (DAB<sub>389</sub>IL-2) which is composed of recombinant IL-2 and part of diphtheria toxin. All three substances aim at eliminating pathogenic T cells.

#### Basiliximab

Basiliximab is a chimeric monoclonal antibody consisting of the heavy and light chain of the variable region of the murine anti-human CD25 antibody RFT5 and the heavy chain and  $\kappa$ -light chain of the Fc region of human IgG<sub>1</sub>. Basiliximab specifically binds to the IL-2 receptor (IL-2R) with high affinity (Amlot et al. 1995). Binding of basiliximab to the IL-2R prevents further binding of IL-2 to the receptor. This way basiliximab inhibits IL-2-dependent proliferation of antigen-activated T cells (Onrust et al. 1999). Since May 1998 basiliximab is approved for the prevention of acute organ rejection after allogeneic renal transplantation. It is combined with other immunosuppressive drugs as cyclosporin or corticosteroids. So far, in different case reports basiliximab has been reported to treat severe recalcitrant psoriasis in combination with cyclosporin (Owen et al. 2000; Bell et al. 2002). Kaegi and Heyer demonstrated the successful treatment of a 29-year old patient with severe atopic dermatitis with two i.v.-infusions of basiliximab (20 mg/infusion) together with low-dose cyclosporin (150 mg/d) (Kaegi and Heyer 2001).

#### Daclizumab

Daclizumab is the humanized variant of the murine anti-human CD25 monoclonal antibody MAT (murine anti TAC). In vitro studies demonstrated a high

affinity of daclizumab for the alpha chain (CD25) of the human IL-2R (Queen et al. 1989; Junghans et al. 1990). Daclizumab shows a dose dependent inhibition of the IL-2-dependent proliferation of human T cells. An open phase II clinical trial by Krueger et al. included 19 psoriatic patients who underwent treatment with four cycles of daclizumab, initially 2 mg/kg and 1 mg/kg, respectively at weeks 2, 4, 8 and 12 (Krueger et al. 2000). Daclizumab showed a moderate clinical improvement with a mean PASI reduction of 30%. In a study by Willenbacher et al. daclizumab was used to treat 16 patients with grade III-IV graft-vs.-host disease (GvHD) (Willenbacher et al. 2001). As only nine patients showed a clinical response and three patients died of serious infections, daclizumab demonstrated a limited effectiveness when used as a monotherapy.

#### Denileukin diftitox (DAB<sub>389</sub>-IL-2)

This recombinant fusion protein contains human IL-2 linked to a portion of the diphtheria toxin molecule. Activated T lymphocytes expressing the high affinity IL-2R internalize denileukin diftitox by receptor mediated endocytosis. The intracellular release of the diphtheria toxin blocks the protein-synthesis of the T cells and finally leads to cell death (Martin et al. 2001). Currently denileukin diftitox is approved for the treatment of cutaneous T cell lymphoma. Martin et al. demonstrated results of a dose-escalation trial with 35 psoriatic patients who were given 12 infusions of denileukin diftitox over a period of eight weeks. Seven out of 15 patients in the high dose group (5 µg/kg) showed a minimal PASI reduction of 50% (Martin et al. 2001). The dose dependent adverse effects included fever/chills, asthenia, myalgia and rash.

#### Siplizumab (Medi-507)

CD2 is a 50 kD glycoprotein containing two extracellular Ig domains and it is expressed on more than 90% of mature T cells, NK cells and up to 70% of thymocytes (Abbas et al. 2000). Binding of CD2 to its principal ligand LFA-3 (CD58) on APC increases the strength of adhesion between T lymphocytes and APC. There is further evidence that the CD2-LFA-3 interaction enhances TCR-mediated activation of T cells (Abbas et al. 2000). Siplizumab (Medi-507) is a humanized anti-CD2 monoclonal IgG<sub>1</sub> antibody which is currently investigated for its efficacy in the treatment of moderate to severe psoriasis. In three phase I/II trials, siplizumab was administered as a single i.v.-dose, eight weekly i.v.-infusions or as 12 weekly s.c.-doses (Langley et al. 2001). In the high dose groups (5–7 mg in the s.c.-group or 40 mg/kg in the i.v.-study) more than 55% of the patients showed at least a 50% reduction in PASI, while 33% of the patients experienced a 75% PASI reduction (Langley et al. 2001). With a maximum 12h post-dose, the number of circulating T lymphocytes in the peripheral

blood decreased by 50%. Siplizumab was considered generally safe and well tolerated. The side effects included fever/chills and flu-like symptoms (MedImmune, R&D pipeline, available at <http://www.medimmune.com>).

### *Depletion of B Lymphocytes*

#### Rituximab

Arising from haematopoietic stem cells, B lymphocytes pass through different maturation steps. Finally, mature B cells give rise to plasma cells producing immunoglobulins. The surface markers CD19 and CD20 appear early in the B cell development and remain present until the stage of mature B cells. Rituximab (anti-CD20) is a chimeric IgG<sub>1k</sub> monoclonal antibody with murine variable region and human constant regions, recognizing human CD20. In 1997 rituximab was the first mAb to be approved for the treatment of relapsed or refractory, low-grade B cell follicular non-Hodgkin's lymphoma (NHL) by the FDA. In lymphoma patients receiving the standard regimen with four weekly treatments of 375 mg/m<sup>2</sup>, profound B cell depletion is observed and sustained for 6–9 months (Gorman et al. 2003). Thus rituximab seems to be promising for the treatment of antibody-mediated autoimmune diseases. In patients with systemic lupus erythematosus (SLE) significant B cell depletion correlated with clinical improvement (Anolik et al. 2003). In an open study including five patients with refractory dermatomyositis, all patients reported marked improvement in both muscle strength and dermatitis within 1–3 months. The clinical improvement sustained for at least six months (Levine 2003). There are several recent reports indicating successful treatment of autoimmune bullous disorders with rituximab. Cooper et al. (2003) and Herrmann et al. (2003) reported good clinical responses in patients with severe PV upon treatment with rituximab (Coopet et al. 2003; Herrmann et al. 2003). Borradori et al reported the rapid improvement of paraneoplastic pemphigus in a 61-year-old woman with CD20+ follicular non Hodgkin's lymphoma grade I, after a regimen with rituximab 375 mg/m<sup>2</sup> once a week for four weeks (Borradori et al. 2001). Another case report showed rapid clinical response to rituximab in a patient with treatment-resistant pemphigus foliaceus (Goebeler et al. 2003).

### *Inhibition of Lymphocyte Migration and Extravasation*

To eliminate (auto-) antigens in the effector phase of an (auto-) immune response, memory and effector T cells home to the sites of inflamed peripheral tissues, i.e. to inflamed dermis. Among the adhesion molecules which are important for leukocyte recruitment, selectins (E- and P-selectin) are expressed on activated endothelium and initiate leukocyte recruitment by binding to oligosaccharides (sialyl Lewis<sup>x</sup>) on the cells surface of circulating leukocytes. Therefore selectins are considered as crucial targets for interrupting the

initiation and perpetuation of a T cell mediated, inflammatory (auto-) immune response.

#### CDP850

CDP 850 is a humanized anti-E-selectin monoclonal antibody. Bhushan et al. performed a randomized clinical trial including nine psoriatic patients with moderate to severe chronic plaque psoriasis. While nine patients received 20 mg/kg CDP850 as a single i.v. infusion, four control patients received placebo infusions (Bhushan et al. 2002). Eight weeks post infusion, there was no significant reduction in PASI from baseline for the CDP850 treated group compared to the placebo group. These results demonstrate that blockade of E-selectin alone does not have sufficient impact on the treatment of psoriasis, probably due to alternative pathways for leukocyte adherence to endothelium (Bhushan et al. 2002).

#### Bimosiamose (TBC1269)/Efomycine M

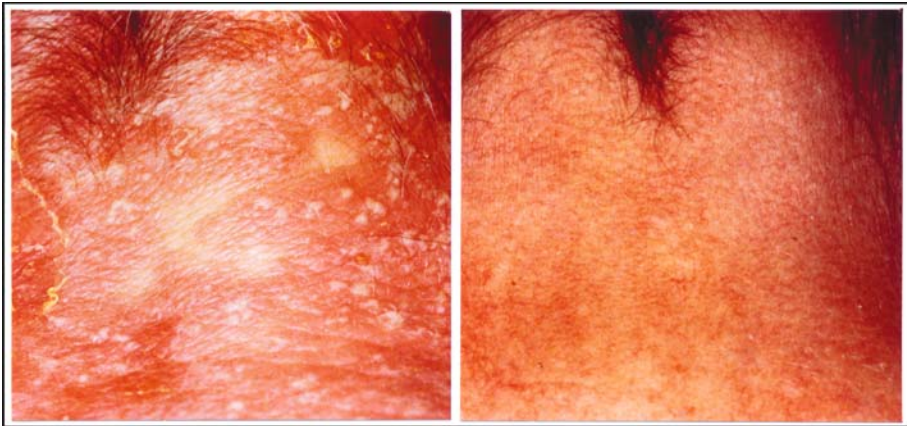
Both compounds are so called small molecules and as anti-pan-selectins they may overcome the ineffectiveness of monoclonal antibodies directed against single adhesion molecules. Preliminary data from recent clinical pilot studies on psoriatic patients treated with bimosiamose strongly suggest an effective role in the treatment of psoriasis (Friedrich et al. 2003). Schon et al. presented data in the psoriasis-SCID-mouse model showing that efomycine M effectively inhibits leukocyte recruitment and thus alleviates cutaneous inflammatory responses (Schon et al. 2002). This substance is currently in further clinical development.

#### *Neutralization of TNF- $\alpha$ by Monoclonal Antibodies*

Recently, several recombinant antibodies and receptor agonists have been introduced to block bioactive TNF- $\alpha$  in rheumatological disorders and inflammatory bowel disease. In fact, these antibodies have contributed to the recent renaissance of antibody therapy in general. Infliximab, a chimeric mouse-human IgG<sub>1</sub> monoclonal antibody (mAb) against TNF- $\alpha$  has been proven highly effective in several clinical trials in RA (Elliott et al. 1994a; Elliott et al. 1994b). The Crohn's disease study group demonstrated that anti-TNF- $\alpha$  was a potent therapy in gastrointestinal and cutaneous Crohn's disease (Targan et al. 1997; Geyer et al. 2000). Recent studies evaluated infliximab for treatment of ankylosing spondylitis and found significant improvement of clinical and laboratory parameters (Van den Bosch et al. 2000a, 2000b; Brandt et al. 2000).

Etanercept is a dimeric molecule consisting of two human p75 sTNFR extracellular domains attached to the Fc portion of human IgG1. By now, extensive experience has been collected with etanercept in the treatment of adult RA (Weinblatt et al. 1999). It has been demonstrated that particularly early phase treatment is clinically very effective in preventing irreversible bone destruction (Bathon et al. 2000). In addition, the pediatric rheumatology collaborative study group recently reported that anti-TNF- $\alpha$  therapy with etanercept in children with polyarticular juvenile RA is a safe and efficient therapy with a high clinical response rate (Lovell et al. 2000).

Potential dermatological indications for treatment with anti-TNF- $\alpha$  antibodies include recalcitrant psoriasis arthritis (Maini et al. 1999) and plaque psoriasis where first clinical trials are initiated, pyoderma gangraenosum and other conditions with elevated TNF- $\alpha$  levels. A recent study demonstrated that infliximab was highly efficient in the treatment of psoriatic plaques that were otherwise unresponsive to concomitant treatment with methotrexate (Oh et al. 2000; Ogilvie et al. 2001). Infliximab was also highly effective in recalcitrant subcorneal pustular dermatosis (Sneddon-Wilkinson) (*Fig. 5*), a skin disorder characterized by disseminated pustules which is associated with RA and inflammatory bowel disease (Voigtländer et al. 2001). Pyoderma gangrenosum is yet another disorder that may be highly responsive to treatment with anti-TNF- $\alpha$  antibodies as observed in a single case with a chronic re-



**Fig. 5.** Immune intervention in autoantibody-mediated skin disorders. Circulating pathogenic autoantibodies cause loss of integrity of the skin by interfering with adhesion molecule function in autoimmune blistering diseases of the pemphigus and pemphigoid group. Removal of these antibodies by several techniques allows reconstitution of epidermal or dermal/epidermal adhesion. These therapeutical approaches may be also useful to remove autoantibodies or proinflammatory cytokines in other skin autoimmune diseases such as systemic scleroderma, lupus erythematosus and dermatomyositis

fractory course (Jenne et al. 2004). Recently, the administration of infliximab was highly effective in chronic disseminated granuloma annulare (Hertl et al. 2005) and a case of therapy-refractory pemphigus vulgaris. Jacobi et al. reviewed the current therapeutic applications for the two TNF $\alpha$  inhibitors infliximab and etanercept in inflammatory skin disorders (Jacobi et al. 2003).

### *Inhibition of Other Pro-Inflammatory Cytokines*

Attempts to neutralize other proinflammatory cytokines included IL-1 (Campion et al. 1996; Bresnihan et al. 1998; Jiang et al. 2000) and IL-6 (Yoshizaki et al. 1998) with encouraging results for RA.

Since TNF- $\alpha$  blockade also affects circulating levels of TNF-dependent cytokines such as IL-1 and IL-6 it seems currently superior to inhibit this key cytokine to stop autoaggressive inflammatory responses.

To modulate inflammatory responses, other anti-inflammatory cytokines have been administered with therapeutic intention: IL-10 has been used successfully in psoriasis (Asadullah et al. 1998, 1999). Although IL-10 leads to a significant clinical response rate, its use may be restricted to severe forms of psoriasis due to potential immunosuppressive side effects of systemic IL-10 administration. The immunomodulatory cytokine IL-11 had been administered to patients in Crohn's disease (Sands et al. 1999). The clinical response rate was moderate in this short term trial, the therapeutic potential of IL-11 appears limited due to its thrombocytopoietic properties. In an open-label phase I dose-escalation clinical trial, Trepicchio et al. reported significant improvement in seven out of twelve psoriasis patients treated with oprelevkin (recombinant humanized IL-11). There was a correlation between the clinical response and a decrease in proinflammatory cytokines (Trepicchio et al. 1999). Peptide T is an octapeptide from the V2 region of gp120 of HIV. Raychaudhuri et al. demonstrated its immunomodulatory effects leading to an upregulation of IL-10 and a decrease of IFN $\gamma$  and IL-2 production (Raychaudhuri et al. 1999). Due to this anti-inflammatory effect, peptide T showed clinical improvement in psoriatic patients in several clinical trials (Gulliver et al. 1999). Moreover, Talme et al. demonstrated by immunohistology that peptide T treated psoriasis patients showed decreased dermal lymphocytic infiltrates (Talme et al. 1995). Keratinocyte-derived IL-8 is involved in leukocyte recruitment to inflamed dermis (Barker et al. 1991; Biasi et al. 1998) and angiogenesis which is also a prominent characteristic of chronically inflamed skin (Nickoloff et al. 1994). ABX-IL8 is a fully humanized anti-IL-8 IgG<sub>2</sub> monoclonal antibody that has been used for treating psoriasis patients (Lohner et al. 1999). In dose-escalating clinical trials ABX-IL8 was well tolerated and generally safe. So far its clinical efficacy in improving psoriasis is moderate so that its further clinical development in the field of psoriasis had been discontinued. IL-4 is considered the principal cytokine promoting the develop-

ment of Th2-type effector T cells. Its capacity to counterbalance Th1-dominated, proinflammatory immune responses led to the use of IL-4 in clinical trials. Recently, twenty psoriasis patients divided into five groups received increasing doses of IL-4 over six weeks. 18 patients receiving higher doses of IL-4 showed a statistically significant PASI reduction of 60 to 80% in this study (Ghoreschi et al. 2003).

### **Extracorporeal Photopheresis**

Photopheresis is a leukapheresis-based therapy with ultraviolet A (UVA) irradiation of ex-vivo isolated peripheral blood mononuclear cells (PBMC) plus systemically administered 8-methoxypsoralen (8-MOP). After UVA-irradiation, the PBMC are re-infused into the patients. The ECP procedure consists of several steps: first, a portion of PBMC is collected and secondly, incubated with 8-MOP; alternatively, 8-MOP is administered systemically and third, followed by UVA irradiation. Fourth, the UVA-irradiated PBMC are reinfused intravenously (Andreu et al. 1994). ECP is usually well tolerated with only minor side effects (Perotti et al. 1999; Salvaneschi et al. 2000). The molecular mode of action of 8-MOP/UVA is the formation of DNA and RNA photo adducts (i.e. thymidine dimers) leading to an alteration of DNA and protein synthesis. The immunological basis for the responses of patients to photopheresis is presumably due to the induction of anti-clonotypic immunity directed against pathogenic clonal T cell populations. Treatment-induced apoptosis of pathogenic T cells and activation of antigen presenting cells may be critical in this therapeutic process (Rook et al. 1999).

In addition to cutaneous T cell lymphoma (CTCL) (Bisaccia et al. 2000), the treatment modality of ECP has been applied to several autoimmune diseases (*Table 5*), including RA, systemic sclerosis (Schwartz et al. 1997), SLE (Knobler 1994) and PV (Wollina et al. 1999). Several case reports and case series suggest efficacy of ECP, but few controlled studies have been conducted to test this hypothesis (Owsianowski et al. 1996).

### **Immunoablation and Stem Cell Transplantation**

Immunoablation and subsequent autologous or allogenic hematopoietic stem cell transplantation (HSCT) has emerged as a recent treatment modality for severe autoimmune diseases (Marmont 2000). Insight into a response of autoimmune disorders to immunoablation and subsequent stem cell transplantation comes from animal models and patient cases with concomitant malignancies (Passweg et al. 1999).



**Table 5.** Extracorporeal Photopheresis in Dermatological Disorders

Disorder	Trial	Reference
Chronic graft versus host disease	Open	Dall'Amico et al.1997
PV, BP	Open	Wollina et al. 1999
Epidermolysis bullosa acquisita	Open	Gordon et al. 1997
SLE	Open	Richter et al. 1998
Systemic sclerosis	Open	Krasagakis et al. 1998
MS	Double-blind, placebo-controlled	Rostami et al. 1999

First clinical trials or cases have been reported for progressive MS (Fassas et al. 2000; Burt et al. 1998), systemic lupus erythematosus (SLE) (Burt et al. 1999a, 2000), RA (Burt et al. 1999b; Snowden et al. 1999) and chronic autoimmune thrombocytopenia (Pavletic 1997; Skoda et al. 1997). The mechanism of remission of autoimmune disease is not entirely clear. There is ongoing debate whether dose-intense immunosuppression, as performed with non-myeloablative conditioning is sufficient to induce remission. Under current view, although autologous stem cell transplants are associated with a lower complication rate, allogeneic stem cell grafts seem preferable for treatment of autoimmune diseases in order not to reintroduce the autoimmunity into the recipient (Burt and Traynor 1999b). An allograft provides a new stem cell source, and a controlled graft versus host effect could further contribute to modulation and eradication of autoreactive lymphocytes.

Overall, immunoablation followed by HSCT is an aggressive treatment and should be reserved for a carefully selected patient collective. Precise pre- and posttransplant assessment of the immune system should unravel further details on tolerance and immunity. It remains to be determined whether this therapy can induce true long-term peripheral tolerance and whether the curative efficacy weighs out the treatment-associated risks.

## Summary and Conclusions

Tremendous progress has been made in understanding autoimmune processes and autoimmune diseases. Novel therapies begin to emerge and techniques in use for some time have been refined and enrich the spectrum of treatment modalities. New immunomodulatory drugs currently help to reduce corticosteroid induced morbidity, but are also applied as monotherapy. These include mycophenolic acid, immunosuppressive macrolides and leflunomide.

Antigen specific immunotherapy includes oral, mucosal or systemic auto-antigen delivery and tolerance induction. Modified antigens are administered in form of altered peptide ligands or complementary peptides. As antigen-specific therapy in perfection appears the use of tolerogenic dendritic cells as mediators of specific tolerance induction.

The effector phase of an autoimmune disease involves production of auto-antibodies and release of proinflammatory cytokines. Therapeutic approaches are aimed at removing these compounds from the circulation and include plasmapheresis, immunoadsorption, high dose intravenous immunoglobulin therapy, and most potently, TNF- $\alpha$  blockade.

Dysregulated cellular immune responses in autoimmune diseases are targeted by antibody therapy to eliminate distinct cell populations, by extracorporeal photopheresis and, most aggressively, by immunoablation followed by hematopoietic stem cell transplantation. In this scenario, the use of biologics will help to more specifically modulate crucial events in the effector phase of an inflammatory autoimmune response. This can be achieved by the inhibition of proinflammatory cytokines such as TNF- $\alpha$  and costimulatory molecules required for T cell activation.

Based on increasing knowledge about tolerance and immunity, new horizons for therapeutic intervention are visible.

## References

- Adair JR, Athwal DS, Bodmer MW, Bright SM, Collins AM, Pulito VL, Rao PE, Reedman R, Rothermel AL, Xu D (1994) Humanization of the murine anti-human CD3 monoclonal antibody OKT3. *Hum Antibodies Hybridomas* 5: 41-47
- Amagai M, Hashimoto T, Shimizu N, Nishikawa T (1994) Absorption of pathogenic auto-antibodies by the extracellular domain of pemphigus vulgaris antigen (Dsg3) produced by baculovirus. *J Clin Invest* 94: 59-67
- Amagai M, Hashimoto T, Green KJ, Shimizu N, Nishikawa T (1995) Antigen-specific immunoadsorption of pathogenic autoantibodies in pemphigus foliaceus. *J Invest Dermatol* 104: 895-901
- Andreu G, Leon A, Heshmati F, Tod M, Menkes CJ, Baudelot J, Laroche L (1994) Extracorporeal photochemotherapy: evaluation of two techniques and use in connective tissue disorders. *Transfus Sci* 15: 443-454
- Aragá S, Blalock JE (1994) Use of complementary peptides and their antibodies in B-cell-mediated autoimmune disease: prevention of experimental autoimmune myasthenia gravis with a peptide vaccine. *Immunomethods* 5: 130-135
- Aragá S, Galin FS, Kishimoto M, Adachi A, Blalock JB (1996) Prevention of experimental autoimmune myasthenia gravis by a monoclonal antibody to a complementary peptide for the main immunogenic region of the acetylcholine receptors. *J Immunol* 157: 386-392
- Aragá S, Kishimoto M, Doi S, Nakashima K (1999) A complementary peptide vaccine that induces T cell anergy and prevents experimental allergic neuritis in Lewis rats. *J Immunol* 163: 476-482
- Aragá S, Xu L, Nakashima K, Villain M, Blalock JE (2000) A peptide vaccine that prevents experimental autoimmune myasthenia gravis by specifically blocking T cell help. *FASEB J* 14: 185-196
- Asadullah K, Sterry W, Stephanek K, Jasulaitis D, Leupold M, Audring H, Volk HD, Docke WD (1998) IL-10 is a key cytokine in psoriasis. Proof of principle by IL-10 therapy: a new therapeutic approach. *J Clin Invest* 101: 783-794

- Asadullah K, Docke WD, Ebeling M, Friedrich M, Belbe G, Audring H, Volk HD, Sterry W (1999) Interleukin 10 treatment of psoriasis: clinical results of a phase 2 trial. *Arch Dermatol* 135: 187–192
- Barak A, Morse LS, Schwab I (2004) Leflunomide (Arava)-induced cystoid macular oedema. *Rheumatology (Oxford)*. 43(2):246–8
- Assmann T, Homey B, Ruzicka T (2000) Applications of tacrolimus for the treatment of skin disorders. *Immunopharmacology* 47: 203–213
- Bathon JM, Martin RW, Fleischmann RM, Tesser JR, Schiff MH, Keystone EC, Genovese MC, Wasko MC, Moreland LW, Weaver AL, Markenson J, Finck BK (2000) A Comparison of etanercept and methotrexate in patients with early rheumatoid arthritis. *N Engl J Med* 343: 1586–1593
- Becher E, Mahnke K, Brzoska T, Kalden DH, Grabbe S, Luger TA (1999) Human peripheral blood-derived dendritic cells express functional melanocortin receptor MC-1R. *Ann N Y Acad Sci* 885: 188–195
- Bennington JL, Dau PC (1981) Patients with polymyositis and dermatomyositis who undergo plasmapheresis therapy. Pathologic findings. *Arch Neurol* 38: 553–560
- Berger TG, Hoffman C, Thieberg MD (1995) Prurigo nodularis and photosensitivity in AIDS: treatment with thalidomide. *J Am Acad Dermatol* 33: 837–838
- Bielekova B, Goodwin B, Richert N, Cortese I, Kondo T, Afshar G, Gran B, Eaton J, Antel J, Frank JA, McFarland HF, Martin R (2000) Encephalitogenic potential of the myelin basic protein peptide (amino acids 83–99) in multiple sclerosis: results of a phase II clinical trial with an altered peptide ligand. *Nat Med* 6: 1167–1175
- Bisaccia E, Gonzalez J, Palangio M, Schwartz J, Klainer AS (2000) Extracorporeal photochemotherapy alone or with adjuvant therapy in the treatment of cutaneous T-cell lymphoma: a 9-year retrospective study at a single institution. *J Am Acad Dermatol* 43: 263–271
- Blalock JE (1990) Complementarity of peptides specified by 'sense' and 'antisense' strands of DNA. *Trends Biotechnol* 8: 140–144
- Bohm M, Beisert S, Schwarz T, Metz D, Luger T (1997) Bullous pemphigoid treated with mycophenolate mofetil [letter]. *Lancet* 349: 541
- Borradori L, Lombardi T, Samson J et al. (2001) Anti-CD20 monoclonal antibody (Rituximab) for refractory erosive stomatitis secondary to CD20+ follicular lymphoma-associated paraneoplastic pemphigus. *Arch Dermatol* 137: 269–72
- Brandt J, Haibel H, Cornely D, Golder W, Gonzalez J, Reddig J, Thriene W, Sieper J, Braun J (2000) Successful treatment of active ankylosing spondylitis with the anti-tumor necrosis factor alpha monoclonal antibody infliximab. *Arthritis Rheum* 43: 1346–1352
- Braun N, Erley C, Klein R, Kotter I, Saal J, Risler T (2000) Immunoabsorption onto protein A induces remission in severe systemic lupus erythematosus [In Process Citation]. *Nephrol Dial Transplant* 15: 1367–1372
- Bresnihan B, Alvaro-Gracia JM, Cobby M, Doherty M, Domljan Z, Emery P, Nuki G, Pavelka K, Rau R, Rozman B, Watt I, Williams B, Aitchison R, McCabe D, Musikic P (1998) Treatment of rheumatoid arthritis with recombinant human interleukin-1 receptor antagonist. *Arthritis Rheum* 41: 2196–2204
- Brink I, Thiele B, Burmester GR, Trebeljahr G, Emmrich F, Hiepe F (1999) Effects of anti-CD4 antibodies on the release of IL-6 and TNF-alpha in whole blood samples from patients with systemic lupus erythematosus. *Lupus* 8: 723–730
- Brodthagen H (1985) Significant response of oral aphthosis to thalidomide treatment. *J Am Acad Dermatol* 13: 509
- Budde K, Glander P, Diekmann F, Waiser J, Fritsche L, Dragun D, Neumayer HH (2004) Review of the immunosuppressant enteric-coated mycophenolate sodium. *Expert Opin Pharmacother*. 5(6):1333–45.
- Burt RK, Traynor AE, Cohen B, Karlin KH, Davis FA, Stefoski D, Terry C, Lobeck L, Russell EJ, Goolsby C, Rosen S, Gordon LI, Keever-Taylor C, Brush M, Fishman M, Burns WH (1998) T cell-depleted autologous hematopoietic stem cell transplantation for multiple sclerosis: report on the first three patients. *Bone Marrow Transplant* 21: 537–541
- Burt RK, Traynor A, Burns W (1999a) Hematopoietic stem cell transplantation of multiple sclerosis, rheumatoid arthritis, and systemic lupus erythematosus. *Cancer Treat Res* 101: 157–184

- Burt RK, Traynor AE (1999b) Hematopoietic stem cell transplantation: a new therapy for autoimmune disease. *Stem Cells* 17: 366–372
- Burt RK, Marmont A, Schroeder J, Rosa R, Traynor AE (2000) Intense immune suppression for systemic lupus – the role of hematopoietic stem cells. *J Clin Immunol* 20: 31–37
- Calabrese L, Fleischer AB (2000) Thalidomide: current and potential clinical applications. *Am J Med* 108: 487–495
- Campion GV, Lebsack ME, Lookabaugh J, Gordon G, Catalano M (1996) Dose-range and dose-frequency study of recombinant human interleukin-1 receptor antagonist in patients with rheumatoid arthritis. The IL-1Ra Arthritis Study Group. *Arthritis Rheum* 39: 1092–1101
- Casadevall A (1999) Passive antibody therapies: progress and continuing challenges. *Clin Immunol* 93: 5–15
- Chen Y, Kuchroo VK, Inobe J, Hafler DA, Weiner HL (1994) Regulatory T cell clones induced by oral tolerance: suppression of autoimmune encephalomyelitis. *Science* 265: 1237–1240
- Chong AS, Huang W, Liu W, Luo J, Shen J, Xu W, Ma L, Blinder L, Xiao F, Xu X, Clardy C, Foster P, Williams JA (1999) In vivo activity of leflunomide: pharmacokinetic analyses and mechanism of immunosuppression. *Transplantation* 68: 100–109
- Chu J, Bradley M, Marinkovich MP (2003) Topical tacrolimus is a useful adjunctive therapy for bullous pemphigoid. *Arch Dermatol* 139(6): 813–5
- Chuh AA (2004) The application of topical tacrolimus in vesicular pemphigoid. *Br J Dermatol* 150(3):622–3
- Contreras G, Pardo V, Leclercq B, Lenz O, Tozman E, O’Nan P, Roth D.: Sequential therapies for proliferative lupus nephritis. (2004) *N Engl J Med* 350(10):971–80
- Cooper N, Stasi R, Cunningham-Rundles S, Feuerstein MA, Leonard JP, Amadori S, Bussel JB (2004) The efficacy and safety of B-cell depletion with anti-CD20 monoclonal antibody in adults with chronic immune thrombocytopenic purpura. *Br J Haematol* 125(2): 232–9
- Costes V, Magen V, Legouffe E, Durand L, Baldet P, Rossi JF, Klein B, Brochier J (1999) The Mi15 monoclonal antibody (anti-syndecan-1) is a reliable marker for quantifying plasma cells in paraffin-embedded bone marrow biopsy specimens. *Hum Pathol* 30: 1405–1411
- Dalakas MC (1998) Controlled studies with high-dose intravenous immunoglobulin in the treatment of dermatomyositis, inclusion body myositis, and polymyositis. *Neurology* 51: S37–S45
- Dall’Amico R, Rossetti F, Zulian F, Montini G, Murer L, Andreetta B, Messina C, Baraldi E, Montesco MC, Dini G, Locatelli F, Argioli F, Zacchello G (1997) Photopheresis in paediatric patients with drug-resistant chronic graft- versus-host disease. *Br J Haematol* 97: 848–854
- Daly BM, Shuster S (2000) Antipruritic action of thalidomide. *Acta Derm Venereol* 80: 24–25
- Dau PC (1994) Immunomodulation during treatment of polymyositis with plasmapheresis and immunosuppressive drugs. *J Clin Apheresis* 9: 21–25
- Dau PC, Callahan JP (1994) Immune modulation during treatment of systemic sclerosis with plasmapheresis and immunosuppressive drugs. *Clin Immunol Immunopathol* 70: 159–165
- Dirschka T, Kastner U, Behrens S, Altmeyer P (1998) Successful treatment of pyoderma gangrenosum with intravenous human immunoglobulin. *J Am Acad Dermatol* 39: 789–790
- Drakesmith H, Chain B, Beverley P (2000) How can dendritic cells cause autoimmune disease? *Immunol Today* 21: 214–217
- Duda PW, Schmied MC, Cook SL, Krieger JI, Hafler DA (2000) Glatiramer acetate (Copa-xone) induces degenerate, Th2-polarized immune responses in patients with multiple sclerosis. *J Clin Invest* 105: 967–976
- Egan CA, Meadows KP, Zone JJ (2000) Plasmapheresis as a steroid saving procedure in bullous pemphigoid. *Int J Dermatol* 39: 230–235
- Elliott MJ, Maini RN, Feldmann M, Long-Fox A, Charles P, Bijl H, Woody JN (1994a) Repeated therapy with monoclonal antibody to tumour necrosis factor alpha (cA2) in patients with rheumatoid arthritis. *Lancet* 344: 1125–1127
- Elliott MJ, Maini RN, Feldmann M, Kalden JR, Antoni C, Smolen JS, Leeb B, Breedveld FC, Macfarlane JD, Bijl H (1994b) Randomised double-blind comparison of chimeric monoclonal antibody to tumour necrosis factor alpha (cA2) versus placebo in rheumatoid arthritis. *Lancet* 344: 1105–1110
- Emery P, Breedveld FC, Lemmel EM, Kaltwasser JP, Dawes PT, Gomor B, Van den BF, Nordstrom D, Bjerneboe O, Dahl R, Horslev-Petersen K, Rodriguez DLS, Molloy M, Tikly

- M, Oed C, Rosenberg R, Loew-Friedrich I (2000) A comparison of the efficacy and safety of leflunomide and methotrexate for the treatment of rheumatoid arthritis. *Rheumatology (Oxford)* 39: 655–665
- Eming R, Rech J, Kalden JR, Schuler G, Harrer T, Hertl M Highly effective removal of autoantibodies in severe pemphigus by immunoadsorption (submitted)
- Enk AH, Knop J (1999) Mycophenolate is effective in the treatment of pemphigus vulgaris [see comments]. *Arch Dermatol* 135: 54–56
- Enk AH, Knop J (2000) [Successful management of systemic lupus erythematosus with IgM enriched immunoglobulins]. *Hautarzt* 51: 416–418
- Faria AM, Weiner HL (1999) Oral tolerance: mechanisms and therapeutic applications. *Adv Immunol* 73: 153–264
- Fassas A, Anagnostopoulos A, Kazis A, Kapinas K, Sakellari I, Kimiskidis V, Smias C, Eleftheriadis N, Tsimourto V (2000) Autologous stem cell transplantation in progressive multiple sclerosis – an interim analysis of efficacy. *J Clin Immunol* 20: 24–30
- Federman GL, Federman DG (2000) Recalcitrant pyoderma gangrenosum treated with thalidomide. *Mayo Clin Proc* 75: 842–844
- Filler G, Hansen M, LeBlanc C, Lepage N, Franke D, Mai I, Feber J (2003) Pharmacokinetics of mycophenolate mofetil for autoimmune disease in children. *Pediatr Nephrol.* 18(5): 445–9. Epub 2003 Apr 08
- Foster CS, Ahmed AR (1999) Intravenous immunoglobulin therapy for ocular cicatricial pemphigoid: a preliminary study. *Ophthalmology* 106: 2136–2143
- Frieling U, Luger TA (2002) Mycophenolate mofetil and leflunomide: promising compounds for the treatment of skin diseases. *Clin Exp Dermatol.* 27(7):562–70
- Gaubitz M, Seidel M, Kummer S, Schotte H, Perniok A, Domschke W, Schneider M (1998) Prospective randomized trial of two different immunoadsorbents in severe systemic lupus erythematosus. *J Autoimmun* 11: 495–501
- Geyer AS, Anhalt GJ, Nousari HC (2000) Effectiveness of infliximab in the treatment of refractory perineal cutaneous Crohn disease. *Arch Dermatol* 136: 459–460
- Ghate JV, Jorizzo JL (1999) Behcet's disease and complex aphthosis. *J Am Acad Dermatol* 40: 1–18
- Ghetie V, Ward ES (1997) FcRn: the MHC class I-related receptor that is more than an IgG transporter. *Immunol Today* 18: 592–598
- Gordon KB, Chan LS, Woodley DT (1997) Treatment of refractory epidermolysis bullosa acquisita with extracorporeal photochemotherapy. *Br J Dermatol* 136: 415–420
- Gorman C, Leandro M, Isenberg D (2003) B cell depletion in autoimmune disease. *Arthritis Res Ther* 5(Suppl 4): S17–S21
- Gottlieb AB, Lebwohl M, Shirin S, Sherr A, Gilleaudeau P, Singer G, Solodkina G, Grossman R, Gisoldi E, Phillips E, Neisler HM, Krueger JG (2000) Anti-CD4 monoclonal antibody treatment of moderate to severe psoriasis vulgaris: results of a pilot, multicenter, multiple-dose, placebo-controlled study. *J Am Acad Dermatol* 43: 595–604
- Grassberger M, Baumruker T, Enz A, Hiestand P, Hultsch T, Kalthoff F, Schuler W, Schulz M, Werner FJ, Winiski A, Wolff B, Zenke G (1999) A novel anti-inflammatory drug, SDZ ASM 981, for the treatment of skin diseases: in vitro pharmacology. *Br J Dermatol* 141: 264–273
- Grinspan D (1985) Significant response of oral aphthosis to thalidomide treatment. *J Am Acad Dermatol* 12: 85–90
- Grundmann-Kollmann M, Korting HC, Behrens S, Kaskel P, Leiter U, Krahn G, Kerscher M, Peter RU (1999) Mycophenolate mofetil: a new therapeutic option in the treatment of blistering autoimmune diseases. *J Am Acad Dermatol* 40: 957–960
- Harman KE, Black MM (1999) High-dose intravenous immune globulin for the treatment of autoimmune blistering diseases: an evaluation of its use in 14 cases [see comments]. *Br J Dermatol* 140: 865–874
- Herranz P, Pizarro A, De Lucas R, Arribas JR, Garcia-Tobaruela A, Pena JM, Casado M (1998) Treatment of AIDS-associated prurigo nodularis with thalidomide. *Clin Exp Dermatol* 23: 233–235
- Herrmann ML, Schleyerbach R, Kirschbaum BJ (2000) Leflunomide: an immunomodulatory drug for the treatment of rheumatoid arthritis and other autoimmune diseases. *Immunopharmacology* 47: 273–289

- Hertl MS, Haendle I, Schuler G, Hertl M (2005) Rapid improvement of recalcitrant disseminated granuloma annulare upon treatment with the tumor necrosis factor-alpha inhibitor, infliximab *Br. J. Dermatol* (in press)
- Hiepe F, Volk HD, Apostoloff E, von Baehr R, Emmrich F (1991) Treatment of severe systemic lupus erythematosus with anti-CD4 monoclonal antibody. *Lancet* 338: 1529–1530
- Hodgson TA, Malik F, Hegarty AM, Porter SR (2003) Topical tacrolimus: a novel therapeutic intervention for recalcitrant labial pemphigus vulgaris. *Eur J Dermatol.* 13(2):142–4.
- Homey B, Assmann T, Vohr HW, Ulrich P, Lauerma AI, Ruzicka T, Lehmann P, Schuppe HC (1998) Topical FK506 suppresses cytokine and costimulatory molecule expression in epidermal and local draining lymph node cells during primary skin immune responses. *J Immunol* 160: 5331–5340
- Huang FP, Platt N, Wykes M, Major JR, Powell TJ, Jenkins CD, MacPherson GG (2000) A discrete subpopulation of dendritic cells transports apoptotic intestinal epithelial cells to T cell areas of mesenteric lymph nodes. *J Exp Med* 191: 435–444
- Hundt M, Manger K, Dorner T, Grimbacher B, Kalden P, Rascu A, Weber D, Burmester GR, Peter HH, Kalden JR, Schmidt RE (2000) Treatment of acute exacerbation of systemic lupus erythematosus with high-dose intravenous immunoglobulin. *Rheumatology (Oxford)* 39: 1301–1302
- Ikonomov V, Samtleben W, Schmidt B, Blumenstein M, Gurland HJ (1992) Adsorption profile of commercially available adsorbents: an in vitro evaluation. *Int J Artif Organs* 15: 312–319
- Isaacs JD, Burrows N, Wing M, Keogan MT, Rebello PR, Watts RA, Pye RJ, Norris P, Hazelman BL, Hale G, Waldmann H (1997) Humanized anti-CD4 monoclonal antibody therapy of autoimmune and inflammatory disease. *Clin Exp Immunol* 110: 158–166
- Iyer CG, Languillon J, Ramanujam K, Tarabini-Castellani G, las Aguas JT, Bechelli LM, Uemura K, Martinez D, V, Sundaresan T (1971) WHO co-ordinated short-term double-blind trial with thalidomide in the treatment of acute lepra reactions in male lepromatous patients. *Bull World Health Organ* 45: 719–732
- Jacobi A, Manger B, Schuler G, Hertl M (2003) Therapeutic application of TNF-alpha inhibitors infliximab and etanercept in inflammatory skin disorders. *JDDG* 1(4): 259–272
- Jayne DR, Chapel H, Adu D, Misbah S, O'Donoghue D, Scott D, Lockwood CM (2000) Intravenous immunoglobulin for ANCA-associated systemic vasculitis with persistent disease activity. *QJM* 93: 433–439
- Jenne L, Sauter B, Thumann P, Hertl M, Schuler G (2004) Successful treatment of therapy-resistant chronic vegetating pyoderma gangrenosum with infliximab (chimeric antitumor necrosis factor antibody). *Br J Dermatol.* 150 (2): 380–2
- Jiang Y, Genant HK, Watt I, Cobby M, Bresnihan B, Aitchison R, McCabe D (2000) A multicenter, double-blind, dose-ranging, randomized, placebo-controlled study of recombinant human interleukin-1 receptor antagonist in patients with rheumatoid arthritis: radiologic progression and correlation of Genant and Larsen scores. *Arthritis Rheum* 43: 1001–1009
- Johnson KP, Brooks BR, Ford CC, Goodman A, Guarnaccia J, Lisak RP, Myers LW, Panitch HS, Pruitt A, Rose JW, Kachuck N, Wolinsky JS (2000) Sustained clinical benefits of glatiramer acetate in relapsing multiple sclerosis patients observed for 6 years. *Copolymer 1 Multiple Sclerosis Study Group. Mult Scler* 6: 255–266
- Kappos L, Comi G, Panitch H, Oger J, Antel J, Conlon P, Steinman L, et al. (2000) Induction of a non-encephalitogenic type 2 T helper-cell autoimmune response in multiple sclerosis after administration of an altered peptide ligand in a placebo-controlled, randomized phase II trial. *Nat Med* 6: 1176–1182
- Kersh GJ, Allen PM (1996a) Structural basis for T cell recognition of altered peptide ligands: a single T cell receptor can productively recognize a large continuum of related ligands. *J Exp Med* 184: 1259–1268
- Kersh GJ, Allen PM (1996b) Essential flexibility in the T-cell recognition of antigen. *Nature* 380: 495–498
- Khamashta MA, Ruiz-Irastorza G, Hughes GR (2000) Therapy of systemic lupus erythematosus: new agents and new evidence. *Expert Opin Investig Drugs* 9: 1581–1593
- Knobler RM (1994) Extracorporeal photochemotherapy for the treatment of lupus erythematosus: preliminary observations. *Springer Semin Immunopathol* 16: 323–325

- Ko MJ, Chu CY (2003) Topical tacrolimus therapy for localized bullous pemphigoid. *Br J Dermatol.* 149(5):1079–81
- Kofler H, Wambacher-Gasser B, Topar G, Weinlich G, Schuler G, Hintner H, Romani N, Fritsch P (1997) Intravenous immunoglobulin treatment in therapy-resistant epidermolysis bullosa acquisita. *J Am Acad Dermatol* 36: 331–335
- Kraan MC, van Kuijk AW, Dinant HJ, Goedkoop AY, Smeets TJ, de Rie MA, Dijkmans BA, Vaishnav AK, Bos JD, Tak PP (2002) Alefacept treatment in psoriatic arthritis: reduction of the effector T cell population in peripheral blood and synovial tissue is associated with improvement of clinical signs of arthritis. *Arthritis Rheum.* 46 (10): 2776–84
- Krasagakis K, Dippel E, Ramaker J, Owsianowski M, Orfanos CE (1998) Management of severe scleroderma with long-term extracorporeal photopheresis. *Dermatology* 196: 309–315
- Kuchroo VK, Greer JM, Kaul D, Ishioka G, Franco A, Sette A, Sobel RA, Lees MB (1994) A single TCR antagonist peptide inhibits experimental allergic encephalomyelitis mediated by a diverse T cell repertoire. *J Immunol* 153: 3326–3336
- Kurtz ES, Bailey SC, Arshad F, Lee AA, Przekop PA (1995) Leflunomide: an active anti-inflammatory and antiproliferative agent in models of dermatologic disease. *Inflamm Res* 44 Suppl 2: S187–S188
- Kutsuki H, Takata S, Yamamoto K, Tani N (1998) Therapeutic selective adsorption of anti-DNA antibody using dextran sulfate cellulose column (Selesorb) for the treatment of systemic lupus erythematosus. *Ther Apher* 2: 18–24
- Kyriakis KP, Kontochristopoulos GJ, Panteleos DN (2000) Experience with low-dose thalidomide therapy in chronic discoid lupus erythematosus. *Int J Dermatol* 39: 218–222
- Letko E, Bhol K, Foster CS, Ahmed AR (2000) Linear IgA bullous disease limited to the eye: a diagnostic dilemma: response to intravenous immunoglobulin therapy. *Ophthalmology* 107: 1524–1528
- Levy Y, Sherer Y, Langevitz P, Lorber M, Rotman P, Fabrizzi F, Shoenfeld Y (2000) Skin score decrease in systemic sclerosis patients treated with intravenous immunoglobulin – a preliminary report. *Clin Rheumatol* 19: 207–211
- Liblau R, Tisch R, Bercovici N, McDevitt HO (1997) Systemic antigen in the treatment of T-cell-mediated autoimmune diseases. *Immunol Today* 18: 599–604
- Link H, Huang YM, Xiao BG (1999) Dendritic cells in experimental allergic encephalomyelitis and multiple sclerosis. *J Neuroimmunol* 100: 102–110
- Lipsky JJ (1996) Mycophenolate mofetil. *Lancet* 348: 1357–1359
- Lovell DJ, Giannini EH, Reiff A, Cawkwell GD, Silverman ED, Nocton JJ, Stein LD, Gedalia A, Ilowite NT, Wallace CA, Whitmore J, Finck BK (2000) Etanercept in children with polyarticular juvenile rheumatoid arthritis. *Pediatric Rheumatology Collaborative Study Group. N Engl J Med* 342: 763–769
- Ludewig B, Odermatt B, Landmann S, Hengartner H, Zinkernagel RM (1998) Dendritic cells induce autoimmune diabetes and maintain disease via de novo formation of local lymphoid tissue. *J Exp Med* 188: 1493–1501
- Ludewig B, Odermatt B, Ochsenbein AF, Zinkernagel RM, Hengartner H (1999) Role of dendritic cells in the induction and maintenance of autoimmune diseases. *Immunol Rev* 169: 45–54
- Luft M, Stauber A, Mainka A, Klingel R, Schuler G, Hertl M (2003) Successful removal of pathogenic autoantibodies in pemphigus by immunoabsorption with a tryptophan-linked polyvinylalcohol adsorber. *Br J Dermatol* 149: 598–605
- Lutz MB, Suri RM, Niimi M, Ogilvie AL, Kukutsch NA, Rossner S, Schuler G, Austyn JM (2000) Immature dendritic cells generated with low doses of GM-CSF in the absence of IL-4 are maturation resistant and prolong allograft survival in vivo. *Eur J Immunol* 30: 1813–1822
- Maini R, St Clair EW, Breedveld F, Furst D, Kalden J, Weisman M, Smolen J, Emery P, Harriman G, Feldmann M, Lipsky P (1999) Infliximab (chimeric anti-tumour necrosis factor alpha monoclonal antibody) versus placebo in rheumatoid arthritis patients receiving concomitant methotrexate: a randomised phase III trial. ATTRACT Study Group. *Lancet* 354: 1932–1939
- Manna SK, Mukhopadhyay A, Aggarwal BB (2000) Leflunomide suppresses TNF-induced cellular responses: effects on NF- $\kappa$ B, activator protein-1, c-Jun N-terminal protein kinase, and apoptosis. *J Immunol* 165: 5962–5969

- Marmont AM (2000) New horizons in the treatment of autoimmune diseases: immunoblation and stem cell transplantation. *Annu Rev Med* 51: 115–134
- Moraes MO, Sarno EN, Teles RM, Almeida AS, Saraiva BC, Nery JA, Sampaio EP (2000) Anti-inflammatory drugs block cytokine mRNA accumulation in the skin and improve the clinical condition of reactional leprosy patients. *J Invest Dermatol* 115: 935–941
- Moreau T, Coles A, Wing M, Thorpe J, Miller D, Moseley I, Issacs J, Hale G, Clayton D, Scolding N, Waldmann H, Compston A (1996) CAMPATH-1H in multiple sclerosis. *Mult Scler* 1: 357–365
- Morel P, Revillard JP, Nicolas JF, Wijdenes J, Rizova H, Thivolet J (1992) Anti-CD4 monoclonal antibody therapy in severe psoriasis. *J Autoimmun* 5: 465–477
- Morton SJ, Powell RJ (2000) Cyclosporin and tacrolimus: their use in a routine clinical setting for scleroderma. *Rheumatology (Oxford)* 39: 865–869
- Nicholson LB, Greer JM, Sobel RA, Lees MB, Kuchroo VK (1995) An altered peptide ligand mediates immune deviation and prevents autoimmune encephalomyelitis. *Immunity* 3: 397–405
- Nie Z, Garrod DR, Chan LS, Hashimoto T (1999) Complementary peptides against the major epitope in the NC16A domain of BP180 show no specificity as vaccines to bullous pemphigoid. *J Dermatol Sci* 21: 157–164
- Nousari HC, Anhalt GJ (2000) Bullous pemphigoid treated with leflunomide: A novel immunomodulatory agent. *Arch Dermatol* 136: 1204–1205
- O'Donnell BF, Barr RM, Black AK, Francis DM, Kermani F, Niimi N, Barlow RJ, Winkelmann RK, Greaves MW (1998) Intravenous immunoglobulin in autoimmune chronic urticaria. *Br J Dermatol* 138: 101–106
- Ogilvie ALJ, Antoni CH, Dechant C et al. (2001) Treatment of psoriatic arthritis with anti-TNF-alpha antibody clears skin lesions of psoriasis resistant to treatment with methotrexate. *Br J Dermatol* 144: 587–589
- Oh CJ, Das KM, Gottlieb AB (2000) Treatment with anti-tumor necrosis factor alpha (TNF-alpha) monoclonal antibody dramatically decreases the clinical activity of psoriasis lesions. *J Am Acad Dermatol* 42: 829–830
- Ong CS, Benson EM (2000) Successful treatment of chronic leucocytoclastic vasculitis and persistent ulceration with intravenous immunoglobulin. *Br J Dermatol* 143: 447–449
- Ordi-Ros J, Cortes F, Cucurull E, Mauri M, Bujan S, Vilardell M (2000) Thalidomide in the treatment of cutaneous lupus refractory to conventional therapy. *J Rheumatol* 27: 1429–1433
- Owsianowski M, Garbe C, Ramaker J, Orfanos CE, Gollnick H (1996) [Therapeutic experiences with extracorporeal photopheresis. Technical procedure, follow-up and clinical outcome in 31 skin diseases]. *Hautarzt* 47: 114–123
- Passweg J, Gratwohl A, Tyndall A (1999) Hematopoietic stem cell transplantation for autoimmune disorders. *Curr Opin Hematol* 6: 400–405
- Patrick CC (1990) Organ-specific autoimmune diseases. *Immunol Ser* 50: 435–448
- Pavletic ZS (1997) Treatment of chronic immune thrombocytopenic purpura. *Ann Intern Med* 127: 572
- Perotti C, Torretta L, Viarengo G, Roveda L, Bernuzzi S, Carbone S, Del Fante C, La Torre R, Locatelli F, Bonetti F, Gabba P, Bellosta M, Salvaneschi L (1999) Feasibility and safety of a new technique of extracorporeal photochemotherapy: experience of 240 procedures. *Haematologica* 84: 237–241
- Powell AM, Albert S, Al Fares S, Harman KE, Setterfield J, Bhogal B, Black MM (2003) An evaluation of the usefulness of mycophenolate mofetil in pemphigus. *Br J Dermatol* 149(1):138–45.
- Prakash A, Jarvis B (1999) Leflunomide: a review of its use in active rheumatoid arthritis. *Drugs* 58: 1137–1164
- Pulito VL, Roberts VA, Adair JR, Rothermel AL, Collins AM, Varga SS, Martocello C, Bodmer M, Jolliffe LK, Zivin RA (1996) Humanization and molecular modeling of the anti-CD4 monoclonal antibody, OKT4A. *J Immunol* 156: 2840–2850
- Pusiol A, Cesaro S, Nocerino A, Picco G, Zanesco L, Bisogno G (2004) Successful treatment with the monoclonal antibody rituximab in two children with refractory autoimmune thrombocytopenia. *Eur J Pediatr* Mar 23 (Epub ahead of print)
- Qi Y, Berg R, Singleton MA, Debrick JE, Staerz UD (1996) Hybrid antibody mediated veto of cytotoxic T lymphocyte responses. *J Exp Med* 183: 1973–1980



- Qi Y, Staerz UD (1998) Specific inhibition of CD4+ T lymphocytes by a hybrid antibody. *Nat Biotechnol* 16: 271–275
- Quarantino S, Duddy LP, Londei M (2000) Fully competent dendritic cells as inducers of T cell anergy in autoimmunity. *Proc Natl Acad Sci USA* 97: 10911–10916
- Rabeni EJ, Cunningham NM (2002) Effective treatment of Hailey-Hailey disease with topical tacrolimus. *J Am Acad Dermatol* 47(5):797–8.
- Richter HI, Krutmann J, Goerz G (1998) [Extracorporeal photopheresis in therapy-refractory disseminated discoid lupus erythematosus]. *Hautarzt* 49: 487–491
- Rook AH, Suchin KR, Kao DM, Yoo EK, Macey WH, DeNardo BJ, Bromely PG, Geng Y, Junkins-Hopkins JM, Lessin SR (1999) Photopheresis: clinical applications and mechanism of action. *J Investig Dermatol Symp Proc* 4: 85–90
- Rostami AM, Sater RA, Bird SJ, Galetta S, Farber RE, Kamoun M, Silberberg DH, Grossman RI, Pfohl D (1999) A double-blind, placebo-controlled trial of extracorporeal photopheresis in chronic progressive multiple sclerosis. *Mult Scler* 5: 198–203
- Saleh MN, Gutheil J, Moore M, Bunch PW, Butler J, Kunkel L, Grillo-Lopez AJ, LoBuglio AF (2000) A pilot study of the anti-CD20 monoclonal antibody rituximab in patients with refractory immune thrombocytopenia. *Semin Oncol* 27: 99–103
- Salvaneschi L, Perotti C, Torretta L (2000) Adverse effects associated with extracorporeal photochemotherapy. *Transfusion* 40: 121
- Sand C, Thomsen HK (2003) Topical tacrolimus ointment is an effective therapy for Hailey-Hailey disease. *Arch Dermatol* 139(11):1401–2
- Sands BE, Bank S, Sninsky CA, Robinson M, Katz S, Singleton JW, Miner PB, Safdi MA, Galandiuk S, Hanauer SB, Varilek GW, Buchman AL, Rodgers VD, Salzberg B, Cai B, Loewy J, DeBruin MF, Rogge H, Shapiro M, Schwertschlag US (1999) Preliminary evaluation of safety and activity of recombinant human interleukin 11 in patients with active Crohn's disease. *Gastroenterology* 117: 58–64
- Sauter B, Albert ML, Francisco L, Larsson M, Somersan S, Bhardwaj N (2000) Consequences of cell death: exposure to necrotic tumor cells, but not primary tissue cells or apoptotic cells, induces the maturation of immunostimulatory dendritic cells. *J Exp Med* 191: 423–434
- Sawada S, Suzuki G, Kawase Y, Takaku F (1987) Novel immunosuppressive agent, FK506. In vitro effects on the cloned T cell activation. *J Immunol* 139: 1797–1803
- Schneider M (1996) *Pl. Z Rheumatol* 55: 90–104
- Schulze-Koops H, Davis LS, Haverty TP, Wacholtz MC, Lipsky PE (1998) Reduction of Th1 cell activity in the peripheral circulation of patients with rheumatoid arthritis after treatment with a non-depleting humanized monoclonal antibody to CD4. *J Rheumatol* 25: 2065–2076
- Schwartz J, Gonzalez J, Palangio M, Klainer AS, Bisaccia E (1997) Extracorporeal photochemotherapy in progressive systemic sclerosis: a follow-up study. *Int J Dermatol* 36: 380–385
- Sibaud V, Beylot-Barry M, Doutre MS, Beylot C (2000) [Successful treatment of corticoid-resistant pemphigus with high-dose intravenous immunoglobulins]. *Ann Dermatol Venerol* 127: 408–410
- Skoda RC, Tichelli A, Tyndall A, Hoffmann T, Gillessen S, Gratwohl A (1997) Autologous peripheral blood stem cell transplantation in a patient with chronic autoimmune thrombocytopenia. *Br J Haematol* 99: 56–57
- Smith LR, Bost KL, Blalock JE (1987) Generation of idiotypic and anti-idiotypic antibodies by immunization with peptides encoded by complementary RNA: a possible molecular basis for the network theory. *J Immunol* 138: 7–9
- Snowden JA, Biggs JC, Milliken ST, Fuller A, Brooks PM (1999) A phase I/II dose escalation study of intensified cyclophosphamide and autologous blood stem cell rescue in severe, active rheumatoid arthritis. *Arthritis Rheum* 42: 2286–2292
- Sondergaard K, Carstens J, Jorgensen J, Zachariae H (1995) The steroid-sparing effect of long-term plasmapheresis in pemphigus. *Acta Derm Venereol* 75: 150–152
- Sondergaard K, Carstens J, Zachariae H (1997) The steroid-sparing effect of long-term plasmapheresis in pemphigus: an update. *Ther Apher* 1: 155–158
- Staerz UD, Qi Y (1999) Treatment of an autoimmune disease with "classical" T cell veto: a proposal. *J Clin Immunol* 19: 195–202

- Staerz UD, Lee DS, Qi Y (2000) Induction of specific immune tolerance with hybrid antibodies. *Immunol Today* 21: 172–176
- Stanley JR (1989) Pemphigus and pemphigoid as paradigms of organ-specific, autoantibody-mediated diseases. *J Clin Invest* 83: 1443–1448
- Steinbrink K, Wolfli M, Jonuleit H, Knop J, Enk AH (1997) Induction of tolerance by IL-10-treated dendritic cells. *J Immunol* 159: 4772–4780
- Steinbrink K, Jonuleit H, Muller G, Schuler G, Knop J, Enk AH (1999) Interleukin-10-treated human dendritic cells induce a melanoma-antigen-specific anergy in CD8(+) T cells resulting in a failure to lyse tumor cells. *Blood* 93: 1634–1642
- Targan SR, Hanauer SB, van Deventer SJ, Mayer L, Present DH, Braakman T, DeWoody KL, Schaible TF, Rutgeerts PJ (1997) A short-term study of chimeric monoclonal antibody cA2 to tumor necrosis factor alpha for Crohn's disease. Crohn's Disease cA2 Study Group. *N Engl J Med* 337: 1029–1035
- Treon SP, Raje N, Anderson KC (2000) Immunotherapeutic strategies for the treatment of plasma cell malignancies. *Semin Oncol* 27: 598–613
- Turner MS, Sutton D, Sauder DN (2000) The use of plasmapheresis and immunosuppression in the treatment of pemphigus vulgaris. *J Am Acad Dermatol* 43: 1058–1064
- van den Bosch F, Kruithof E, De Vos M, De Keyser F, Mielants H (2000a) Crohn's disease associated with spondyloarthritis: effect of TNF- $\alpha$  blockade with infliximab on articular symptoms. *Lancet* 356: 1821–1822
- van den Bosch F, Kruithof E, Baeten D, De Keyser F, Mielants H, Veys EM (2000b) Effects of a loading dose regimen of three infusions of chimeric monoclonal antibody to tumour necrosis factor alpha (infliximab) in spondyloarthritis: an open pilot study. *Ann Rheum Dis* 59: 428–433
- van Oosten BW, Lai M, Barkhof F, Miller DH, Moseley IF, Thompson AJ, Hodgkinson S, Polman CH (1996) A phase II trial of anti-CD4 antibodies in the treatment of multiple sclerosis. *Mult Scler* 1: 339–342
- van Oosten BW, Lai M, Hodgkinson S, Barkhof F, Miller DH, Moseley IF, Thompson AJ, Rudge P, McDougall A, McLeod JG, Ader HJ, Polman CH (1997) Treatment of multiple sclerosis with the monoclonal anti-CD4 antibody cM-T412: results of a randomized, double-blind, placebo-controlled, MR-monitored phase II trial. *Neurology* 49: 351–357
- Vecchiotti G, Kerl K, Hügli A, Samson J, Borradori L (2003) Topical tacrolimus (FK506) for relapsing erosive stomatitis in paraneoplastic pemphigus. *Br J Dermatol* 148: 823–842
- Viard I, Wehrli P, Bullani R, Schneider P, Holler N, Salomon D, Hunziker T, Saurat JH, Tschopp J, French LE (1998) Inhibition of toxic epidermal necrolysis by blockade of CD95 with human intravenous immunoglobulin. *Science* 282: 490–493
- Viertel A, Weidmann E, Wigand R, Geiger H, Mondorf UF (2000) Treatment of severe systemic lupus erythematosus with immunoadsorption and intravenous immunoglobulins. *Intensive Care Med* 26: 823–824
- Voigtländer C, Lüftl M, Schuler G, Hertl M (2001) Infliximab (anti-TNF- $\alpha$  antibody), a novel highly effective treatment of recalcitrant subcorneal pustular dermatosis (Sneddon-Wilkinson). *Arch Dermatol* 137 (12): 1571–4
- Walker SL, Kirby B, Chalmers RJ (2002) The effect of topical tacrolimus on severe recalcitrant chronic discoid lupus erythematosus. *Br J Dermatol* 147(2):405–6.
- Wallace DJ (1999) Apheresis for lupus erythematosus. *Lupus* 8: 174–180
- Warren KJ, Nopper AJ, Crosby DL (1998) Thalidomide for recalcitrant discoid lesions in a patient with systemic lupus erythematosus. *J Am Acad Dermatol* 39: 293–295
- Weinblatt ME, Kremer JM, Bankhurst AD, Bulpitt KJ, Fleischmann RM, Fox RI, Jackson CG, Lange M, Burge DJ (1999) A trial of etanercept, a recombinant tumor necrosis factor receptor:Fc fusion protein, in patients with rheumatoid arthritis receiving methotrexate. *N Engl J Med* 340: 253–259
- Weinblatt ME, Dixon JA, Falchuk KR (2000) Serious liver disease in a patient receiving methotrexate and leflunomide. *Arthritis Rheum* 43: 2609–2611
- Wendling D, Racadot E, Wijdenes J (1993) Treatment of severe rheumatoid arthritis by anti-interleukin 6 monoclonal antibody. *J Rheumatol* 20: 259–262
- Wendling D, Racadot E, Toussiot E, Wijdenes J (1996) Combination therapy of anti-CD4 and anti-IL6 monoclonal antibodies in a case of severe spondylarthritis. *Br J Rheumatol* 35: 1330

- Wendling D, Racadot E, Wijdenes J, Sibia J, Flipo RM, Cantagrel A, Miossec P, Eschard JP, Macro M, Bertin P, Liote F, Debais F, Juvin R, Le Goff P, Masson C (1998) A randomized, double blind, placebo controlled multicenter trial of murine anti-CD4 monoclonal antibody therapy in rheumatoid arthritis. *J Rheumatol* 25: 1457–1461
- Wolkenstein P, Latarjet J, Roujeau JC, Duguet C, Boudeau S, Vaillant L, Maignan M, Schuhmacher MH, Milpied B, Pilorget A, Bocquet H, Brun-Buisson C, Revuz J (1998) Randomised comparison of thalidomide versus placebo in toxic epidermal necrolysis. *Lancet* 352: 1586–1589
- Wollina U, Looks A, Schneider R, Maak B (1998) Disabling morphea of childhood-beneficial effect of intravenous immunoglobulin therapy. *Clin Exp Dermatol* 23: 292–293
- Wollina U, Lange D, Looks A (1999) Short-time extracorporeal photochemotherapy in the treatment of drug-resistant autoimmune bullous diseases. *Dermatology* 198: 140–144
- Yamada H, Yaguchi H, Takamori K, Ogawa H (1997) Plasmapheresis for the treatment of pemphigus vulgaris and bullous pemphigoid. *Ther Apher* 1: 178–182
- Yocum DE, Solinger AM, Tesser J, Gluck O, Cornett M, O'Sullivan F, Nordensson K, Dallaire B, Shen CD, Lipani J (1998) Clinical and immunologic effects of a primatized anti-CD4 monoclonal antibody in active rheumatoid arthritis: results of a phase I, single dose, dose escalating trial. *J Rheumatol* 25: 1257–1262
- Yoshizaki K, Nishimoto N, Mihara M, Kishimoto T (1998) Therapy of rheumatoid arthritis by blocking IL-6 signal transduction with a humanized anti-IL-6 receptor antibody. *Springer Semin Immunopathol* 20: 247–259
- Yu Z, Lennon VA (1999) Mechanism of intravenous immune globulin therapy in antibody-mediated autoimmune diseases. *N Engl J Med* 340: 227–228

## Subject Index

- Acantholysis 47  
Acanthosis 293  
ACE inhibitors 177, 207  
Acetylcholine esterase 376  
Acid Blockers 207  
Acitretin 218, 302  
Acral annular plaques 209  
Acrodermatitis chronica atrophicans 173  
Acrodermatitis continua suppurativa hallopeau 303  
Acrosclerosis 249  
Acute cutaneous lupus erythematosus 183, 188  
Acute guttate psoriasis 298  
Acute urticaria 309  
Adenocarcinomas 78  
Alefacept 220, 436, 437  
Allergic contact dermatitis 400, 402  
Allergic rhinitis 356  
Alopecia areata 145, 385, 420  
– totalis 385–386, 395  
– universalis 385, 395  
Alopecia mucinosa 387  
Altered peptide ligand (APL) 426  
American College of Rheumatology 174, 184, 209, 353  
Amyloidosis 172  
Anagen hair follicle 404  
ANCA-associated vasculitides 351, 355, 357, 361  
ANCA-associated vasculitis 359  
ANCA-cytokine sequence theory 350  
Anchoring fibrils 109, 117, 119  
Anemia 196  
Anetoderma 274  
Angioedema 310, 313, 317, 329  
Angiokeratomas 232  
Annular erythema 208, 274  
Anthralin 300, 402  
Anti-Fc $\epsilon$ RI $\alpha$  autoantibodies 321–323  
Antibiotics 74  
Antibodies 193, 246, 369, 380  
Antibody-antigen complexes 80  
Antibody-dependent cellular cytotoxicity 187, 204  
Anticardiolipin antibodies 201, 213, 248, 274  
Anticentromere antibodies 145  
Anticoagulants 256  
Anti-Cytokines 178  
Anti-DNA-antibodies 194  
Anti-double-stranded DNA antibodies 213, 219  
Anti-endomysium autoantibodies 97  
Anti-Fc $\epsilon$ RI autoantibodies 321, 324–325  
Anti-fibrillin-1 antibody 248  
Antigen specific immunotherapy 425, 447  
Antigen spreading 49  
Antihistamines 311, 328  
Anti-IgE autoantibodies 320, 321, 322  
Anti-La/SSB 204, 213  
Antimalarials 144, 152, 196, 206, 217, 240  
Anti-melanocyte antibodies 369  
Anti-neutrophil cytoplasmic antibodies (ANCA) 274, 350, 355  
Antinuclear antibodies 1, 172, 193, 198, 212, 238, 267, 275, 277–278  
Antinuclear matrix antibody 248  
Antiphospholipid antibodies 145, 218, 248  
Antiphospholipid antibody syndrome 422  
Antiplatelets 256  
Anti-Ro/SS-A antibodies 194, 204, 213, 265, 278  
Anti-Scl 70, 145  
Anti-Sm 213  
Anti-TNF- $\alpha$  antibodies 17, 303, 443  
Anti-U1 RNP antibody 213, 246  
Aplastic anemia 144, 217  
Apoptosis 186, 263  
Arteriogramms 358  
Arthralgias 145, 209, 356  
Arthritis 170, 209–210  
Arthropod reaction 77  
Ascomycin (ASM 981) 423  
Asthma bronchiale 356

- Atopic childhood eczema 291  
 Atopic dermatitis 387, 423  
 Atrophoderma 140  
 Atrophy 165, 168  
 Atypical pneumonia 192  
 Auspitz sign 298  
 Autoantibodies 1, 6, 13, 16, 46, 71, 80, 110, 123, 127, 138, 146, 165, 212, 246, 325, 328, 431–433  
 Autoantigens 10, 424  
 Autoimmune bullous diseases 95, 122  
 Autoimmune bullous skin disorders 95, 122, 119, 422, 431–432  
 Autoimmune diabetes 425  
 Autoimmune pathogenesis 404  
 Autoimmune polyendocrinopathy syndrome type 1 210, 393  
 Autoimmune thrombocytopenia 74, 446  
 Autoimmune thyroiditis 100, 210, 371  
 Autoimmune urticaria 309, 320, 322, 328  
 Autologous serum skin test 321  
 Autoreactive B cells 1, 9  
 Autoreactive lymphocytes 8, 13  
 Autoreactive T cells 9, 74, 81, 425–426, 428  
 Azathioprine 79, 197, 219, 239, 358
- B cell dysregulation 138  
 B cell receptor 2  
 B cell tolerance 10  
 B Lymphocytes 441  
 $\beta$ 4 integrin 78  
 Basement membrane zone 71, 102, 119, 124  
 Basiliximab 436, 439  
 Bath-PUVA 176  
 Behcet's disease 431, 450  
 Beta Blockers 207  
 $\beta$ -haemolytic streptococci 294, 297  
 Biologics 421, 434  
 Biopsy 358  
 Biostatistics 25  
 Blaschko's lines 142  
 Bone marrow 2, 166  
 Bone marrow transplant 178  
 BP188 1, 57, 76, 78, 81, 84  
 BP238 76, 78, 81, 84  
 Breast Implants 34–35  
 Brunsting-Perry pemphigoid 109  
 Bullous morphea 141  
 Bullous pemphigoid 39, 71, 102, 109, 122, 422, 431, 435, 446  
 Bullous SLE 116  
 C3H/HeJ mouse-model 400  
 Calcinosis 235, 240–241  
 Calcitriol 150  
 Calcium channel blockers 175, 207  
 Calcium Homeostasis 376  
 Captopril 57, 74  
 Cardiac involvement 355  
 Catalase 373  
 Catecholamines 376  
 CD11 $\alpha$  437  
 CD4+/CD25+ cells 409  
 Celiac disease 105  
 Cell-mediated cytotoxicity 204  
 Cell-substrate adhesion 85  
 Cellular infiltrate 373  
 CENP antibodies 169, 172  
 Central Tolerance 3  
 Chapel Hill Consensus 353  
 Chemokine receptors 295  
 Chemotaxis 424  
 Chilblain lupus 190, 198  
 Chlorambucil 79, 239  
 Chloroquine 196, 216, 240  
 Cholinergic Urticaria 312  
 Chronic active hepatitis 11  
 Chronic bullous disease of childhood 115, 434  
 Chronic cutaneous lupus erythematosus 183–187, 188, 190–191, 196–197  
 Chronic cutaneous lupus erythematosus
  - ACR criteria 191
  - American College of Rheumatology 183
  - ANA 194
  - Annular erythema 192
  - Anti-SS-A antibodies 187, 193
  - Antinuclear antibodies 194
  - Antiphospholipid syndrome 194
  - Anti-Ro/SS-A 186
  - Arthralgia 191–192
  - Autoantibodies 186
  - CDLE 186, 188
  - Chilblain 190
  - Chilblain lupus 194
  - Classification 183
  - Clinical Appearance 187
  - Cytokines 186
  - Diagnosis 186, 192
  - Direct Immunofluorescence 193
  - ELISA 194
  - Generalized DLE 188, 194
  - Hypertrophic DLE 188
  - Kaposi-Irgang disease 189
  - Keratinocyte apoptosis 186
  - Lipatrophy 190
  - Localized form of DLE 188
  - Lupus band test 193
  - Lupus panniculitis 189, 194
  - Lupus pernio 190–191
  - Lupus profundus 189–190
  - Lupus tumidus 191–192
  - Mucous membrane involvement 191

- Nephritis 189
- Papular mucinosis 192
- Pathogenesis 185
- Photosensitivity 186–187, 191–192
- Polymorphous light eruption 191
- Raynaud's phenomenon 192
- SCLE 183–184, 186–187, 195
- Serological Tests 194
- T helper 2 response 187
- Therapeutic options 195
- Ultraviolet radiation 186
- Chronic discoid lupus erythematosus 189, 387, 423
- Chronic graft versus host disease 344, 446
- Chronic idiopathic urticaria 316–317, 318, 320, 325–326, 329
- Chronic plaque psoriasis 294, 298, 303
- Chronic ulcerative stomatitis 342
- Chronic urticaria 310, 319, 323
- Chronic urticaria
  - Anti-FcεRIα autoantibodies 320–324
  - Aquagenic urticaria 314
  - Arthralgia 314
  - Autoantibodies 319
  - Autoimmune chronic urticaria 319
  - Autologous Serum Skin Test 324
  - Cholinergic urticaria 312–313
  - Classification 309
  - Cold agglutinin 313
  - Cold urticaria 313
  - Cryoglobulins 313
  - Delayed pressure urticaria 314
  - Dermographism 310
  - Eosinophils 314
  - Food additive-evoked 314
  - Food provocation 312
  - H1-antihistamines 318
  - Helicobacter pylori 317, 319
  - High affinity IgE receptors 319
  - Histamine 317
  - Oral steroids 318
  - Physical urticaria 310, 314
  - Solar urticaria 314
  - Systemic steroids 328
  - Treatment 328
  - Urticaria vasculitis 310, 315
  - Vibratory angioedema 314
- Churg Strauss syndrome 351–352
- Cicatricial pemphigoid 74, 78, 102, 109
- Ciclosporine 79
- Clofazimine 197
- Clonal anergy 425
- Coal tars 301
- Cochrane review 27
- Colchicine 104, 126
- Collagen 149, 178
  - bundles 135, 167
  - degradation 167
  - metabolism 138
  - synthesis 153, 167
  - vascular diseases 165
  - collagenase I 149
  - collagenous domain 112
- Colloid bodies 334, 336
- Complement 137, 206, 320
- Complementary peptides 427
- Congenital heart block 265, 276
- Connective tissue growth factor 167
- Contact dermatitis 77
- Contact sensitizers 398, 400–401
- Contact urticaria 309
- Contraceptives 73
- Corticosteroid pulse therapy 397
- Corticosteroids 16, 144, 176, 219, 235, 241, 256, 359
- C-reactive protein 357
- CREST syndrome 248
- Crohn's disease 117, 211, 442
- Cryoglobulin 278, 352
- Cryoglobulinemic vasculitis 274, 352, 360
- Cryptic epitopes 265
- Cutaneous calcinosis 173
- Cutaneous Graft-Versus-Host-Reaction 333, 343, 344
- Cutaneous leukocytoclastic vasculitis 349, 358
- Cutaneous lupus erythematosus 183, 187, 204, 217, 430
- Cutaneous sclerosis 209
- Cutaneous T cell lymphoma (CTCL) 445
- Cutaneous vasculitis 274
- Cyclophosphamide 79, 177, 197, 239, 256, 268, 359–360
- Cyclosporin A 104, 127, 153, 175, 219, 239, 256, 279–280, 302
- Cytolysis of melanocytes 369
- Cytomegalovirus infection 166, 372
- Cytotoxic T cells 204
  
- Daclizumab 436, 439
- Dapsone 102, 104, 196
- Deep morphea 143
- Delayed pressure urticaria 310
- Dendritic cells 428
- Denileukin diftitox 440
- Depigmentation process 367
- Dermal capillaries 293
- Dermal-epidermal junction 95, 102, 212
- Dermatitis herpetiformis Dühring 77, 96–95
  - Autoantibodies 102
  - Autoimmune disorders 100
  - Celiac disease 95, 97

- Clinical presentation 95, 100
- Diagnosis 100
- Direct immunofluorescence microscopy 100
- Endomysium 97, 99
- Gluten 97, 100, 105
- Histopathology 101
- IgA 99–100, 102, 105
- Immunofluorescence microscopy 100, 102
- Neutrophils 102
- Therapy 102
- Tissue transglutaminase 97
- Dermatomyositis 34, 45, 74, 170, 174, 230, 234, 236, 239, 242, 261, 325, 432, 435, 441
- Amyopathic dermatomyositis 230, 232, 236
- Anti-Ro (SS-A) 238
- Arthralgias 234
- Calcinosis 235
- Cardiopulmonary involvement 235, 238, 240
- Classification 229
- Corticosteroids 239
- Cutaneous Manifestations 230
- Cytokines 229
- Diagnosis 237
- Drug-Induced DM 237
- Dysphagia 234
- Electromyography 237
- Facial erythema 230
- Gottron's papules 230–231
- Heliotrope rash 230
- Immunofluorescence microscopy 233
- Immunosuppressive agents 239–240
- Intravenous immune globulin 239
- Malignancy 236, 238, 240
- Muscle involvement 234, 237
- Myopathy 229, 233
- Myositis 229, 239
- Myositis-specific antibodies (MSAs) 238
- Photosensitivity 231, 233
- Polymyositis 229, 233, 235
- Pulmonary involvement 235
- Systemic corticosteroids 239
- Systemic Features 234
- Therapy 239
- Dermoepidermal basement membrane 57, 60
- Dermographism 310
- Desmogleins 1, 3, 14, 46, 49–50, 57, 432
- Desquamation 297
- Diabetes 393
- Digital ulceration 179
- Dihydrofolate reductase 302
- Dinitrochlorobenzene 398
- Diphenylcyclopropanone 398
- Direct immunofluorescence microscopy 75, 334
- Discoid lupus erythematosus 198
- Disease Modulating Factors 408
- Distal dysphagia 235
- Distal interphalangeal arthritis 299
- Dithranol 300
- Diuretics 207
- DNA-topoisomerase I 172
- Down's syndrome 393
- D-penicillamine 57, 74, 152, 237
- Drug-induced lupus erythematosus 145, 208
- Drug-induced pemphigus 45–46
- Drug-induced toxic epidermal necrolysis 434
- Dyshidrosiform pemphigoid 72
- Echocardiography 358
- Efalizumab 220, 303, 436–437
- Efomycine 442
- Electromyogram 229
- Endothelial adhesion molecules 352
- Endothelin-1 175, 249
- Endothelium 137, 166, 351
- Enteropathy 97
- Environmental factors 170, 206, 294, 377
- Envoplakin 50
- Enzyme linked immunosorbent assays 76, 123
- Eosinophil pneumonia 356
- Eosinophilia 144–146, 355
- Eosinophilic fasciitis 144, 172
- Eosinophils 82
- Eotaxin 82
- Epidemiology 25–27, 39, 133, 203, 391
  - Analytic 25–26
  - Autoimmune skin disorders 25
  - BP 39
  - Bullous pemphigoid 38
  - Case series 25
  - Case-control studies 36, 38, 40, 50
  - Case-control study 26, 31
  - Chronic discoid lupus erythematosus 28–29
  - Cohort studies 26
  - Control group 26
  - Controlled trials 27
  - Cross-sectional studies 26
  - Dermatomyositis 36
  - Descriptive 25–26, 28
  - Etiology 25
  - Evidence Based Medicine 27
  - Incidence 26, 28, 32, 38
  - Morbidity 26

- Morphea 32
- Mortality 26
- Odds-ratio 26
- Ordinary review 27
- Population 26
- Prevalence 26, 28, 32–33, 38
- Risk Factors 25–26, 29, 32, 38
- Smoking 31
- SSc 33–34, 36–37
- Systematic review 27
- Systemic lupus erythematosus 28–29, 32, 34, 36
- Systemic sclerosis 32–33
- Epidermal atrophy 212
- Epidermal cell antigens 333
- Epidermal keratinocytes 46, 48, 63
- Epidermal transglutaminase 101
- Epidermal-dermal junction 100
- Epidermolysis bullosa acquisita 77, 102, 109, 131, 435, 446
- Anchoring fibrils 109–110, 112–113, 117–118, 120
- Autoantibodies 112, 115, 117–119, 122–123
- Basement membrane zone 109
- BP-like presentation 114
- Brunsting-perry pemphigoid 115
- Bullous SLE 111, 116–117, 122–123, 128
- Classical EBA 114
- Clinical manifestations 113
- Clinical presentation 113, 119
- Colchicine 126
- Collagen 109
- CP 115
- Crohn's disease 117
- Diagnosis 118
- Direct immunofluorescence 118
- Direct salt split skin immunofluorescence 121
- EBA 109–110, 112–113, 115–116, 118–120, 122, 125–126, 434
- Electron microscopy 119
- ELISA 119, 123
- Etiology 110
- Hemidesmosomes 110
- Histology 119
- IgA 115–116
- Immune adsorption 127
- Immunoblot analysis 123
- Immunoelectron microscopy 120
- Immunoglobulins 127
- Immunosuppressive agents 126
- Incidence 110
- Indirect immunofluorescence 119
- LABD-like presentation 115
- Lamina densa 110, 125
- Lamina lucida 118
- Pathogenesis 110–111, 118
- Photopheresis 127
- Salt-split skin 121
- Suction split immunofluorescence 125
- Systemic glucocorticoids 126
- Therapy 125
- Type VII collagen 110–113, 115–117, 122–125, 127
- Western blot analysis 122
- Epithelial hyperplasia 297
- Epitope 81, 405
- Epstein Barr virus 266, 372
- Erythema 188
- Erythema annulare centrifugum 211, 278
- Erythema gyratum repens 209, 211
- Erythema multiforme 56, 208, 400
- Erythematous plaques 298
- Erythematous papules 95
- Erythroderma 72, 209
- Erythrodermic psoriasis 299
- Esophageal dysfunction 249
- Esophageal involvement 145
- Etanercept 219, 436, 443
- Exclamation mark hairs 385, 387
- Experimental autoimmune encephalitis 425
- Experimental autoimmune myasthenia gravis 425
- Experimental autoimmune thyroiditis 425
- Extracellular matrix synthesis 139,166
- Extracorporeal photochemotherapy 127, 153, 175, 344
- Extracorporeal photopheresis 445–446
- Extraglandular symptoms 275
- Facial erythema 249
- Fas ligand 407
- Fauci's scheme 359–360
- Fc receptor 433
- FcεRI 321, 324, 329
- FcRn 433–434
- Fibrillar collagens 167
- Fibrillarin 172
- Fibrillin 1 146, 248
- Fibroblasts 138
- Fibronectin 112
- Fibrotic process 168, 178
- Finger tip ulcerations 175
- Fingernails 298
- Fixed urticaria 77
- Flexural psoriasis 298
- Fluorescent overlay antigen mapping 125
- Focal vitiligo 368
- Fodrin 265
- Follicular inflammation 404
- Follicular plugging 209



- Foxp3 6  
 Free oxygen radicals 352  
 Fumaric acid esters 302–303
- Gastrointestinal vasculitis 355  
 Gene loci 291  
 Generalised vitiligo 368–369  
 Generalized disease 196  
 Generalized morphea 134, 137, 141  
 Generalized pustular psoriasis von Zumbusch 299  
 Genetics 291  
 Gestational pemphigoid 73  
 Gingival involvement 340  
 Gingival telangiectasia 232  
 Glandular cells 262  
 Glatiramer acetate 425  
 Glomerulonephritis 360  
 Glucocorticosteroids 195  
 Glucose-6-phosphate deficiency 196  
 Glucose-6-phosphate dehydrogenase 217  
 Gluten 105  
 Gluten sensitive enteropathy 211  
 Gluten-free diet 105–106  
 Gold 197  
 Graft-versus-Host-Reaction 344  
 Granular IgA deposits 100  
 Granuloma annulare 211, 444  
 Granulomatous lesions 351, 356  
 Granzyme 262  
 Gutatte psoriasis 292  
 Guttate morphea 139
- H2-blockers 178  
 Haemopoetic stem cell 178  
 Hair follicle 404, 407  
 Hair follicle antigens 405, 409  
 Hair regrowth 396–397  
 H-antihistamines 317  
 Hashimoto's thyroiditis 74, 145, 393  
 Helicobacter pylori 316  
 Hemidesmosomes 84, 120  
 Hemifacial atrophy 143  
 Hemolytic anemia 196  
 Hemorrhagic cystitis 359  
 Henoch-Schönlein purpura 360  
 Hereditary angioedema 210  
 Herpes gestationis 73  
 High affinity IgE receptor 320  
 High dose intravenous immunoglobulins 62, 433  
 HIV-associated aphthosis 431  
 HLA class II alleles 45–46, 74, 205, 319, 394  
 Human leukocyte antigen 393  
 Hydroxychloroquine 153, 196, 216, 239
- Hypereosinophilic syndrome 356  
 Hypergammaglobulinemia 146, 433  
 Hyperglobulinemic purpura 273, 275, 278  
 Hyperpigmentation 188  
 Hypertension 177  
 Hypertrophic DLE 198  
 Hypothyroidism 276
- Idiopathic inflammatory myopathies 229  
 IgA antibodies 105  
 IgA gammopathies 58  
 IgE-mediated diseases 17  
 IgE receptor 320  
 IgG catabolism 433  
 Ignorance 5, 7  
 Immune complex-mediated vasculitides 349, 352–353, 361  
 Immune deviation 425–426  
 Immune pathogenesis 334  
 Immune phenomena 248  
 Immunoablation 445  
 Immunoabsorption 62, 432–433  
 Immunodominant 81, 426  
 Immunoglobulin 1–2, 7, 9–10, 14–15, 120  
 Immunohistochemistry 358  
 Immunological tolerance 421  
 Immunomodulatory treatments 86, 398, 404, 421  
 Immunopathogenesis 213, 421  
 Immunophilins 423  
 Immunosuppression 147, 254, 301, 421  
 Immunosuppressive macrolides 422  
 Immunosuppressive therapy 62, 150, 241, 396  
 Immunotherapy 425  
 Incidence 26, 28, 134  
 Inclusion body myositis 230, 240  
 Indirect immunofluorescence 75  
 Infectious agents 10  
 Inflammatory alveolitis 177  
 Inflammatory bowel disease 117, 126, 442  
 Inflammatory infiltrate 166, 295  
 Infliximab 436, 442–444  
 Inhibition of pathogenic autoantibodies 431  
 Insulin-resistance 233  
 $\alpha 6\beta 4$  integrin 85  
 Intercellular adhesion molecule-1 335  
 Interferon- $\alpha$  175  
 Interferon- $\gamma$  7, 153  
 Interferons 197  
 Interleukin-1 52  
 Interleukin-2 439  
 Interleukin-8 102  
 Intermittent urticaria 309  
 Interstitial pneumonitis 235

- Intimal hyperplasia 166  
 Intra-epidermal microabscesses 298  
 Intrafollicular lymphocytic infiltrates 388  
 Intralesional corticosteroids 397  
 Intrathymic selection 4  
 Intravenous immunoglobulin 127, 219, 328, 359, 433–434  
 Irritant contact dermatitis 402  
 Ischemic injury 136  
 Isotretinoin 218
- Jo-1 antibodies 172, 235  
 Joint contractures 144  
 Junctional adhesion complexes 84  
 Juvenile DM 237–238
- Keratinocyte 186, 204, 294–295, 297, 336  
 Keratoacanthoma 188  
 Keratoconjunctivitis sicca 267  
 Kidney failure 179  
 Koebner's isomorphic response 186, 188, 191, 338, 368
- LABD antigen 78, 116  
 Laboratory tests 357  
 Lamina densa 125  
 Lamina lucida 102, 120–122  
 Laminin 265  
 Laminin-5 78, 81, 85, 122  
 Laminin-6 78  
 Langerhans cells 335, 372, 374, 404  
 Leflunomide 359, 424  
 Leucocyte function-associated antigen type 3 437  
 Leucoderma 368  
 Leukaemia 144  
 Leukocyte attraction 352  
 Leukocytoclastic vasculitis 274–275, 278  
 Leukopenia 212  
 Lichen planopilaris 387  
 Lichen planus 11, 145, 188, 231, 333, 337, 342, 423  
 Lichen sclerosus 139, 145  
 Lichenoid dermatoses 244, 334, 342, 345  
 Light microscopy 75  
 Lilac ring 139, 142  
 Linear IgA bullous dermatosis 77, 95, 97, 110, 434  
 Linear morphea 142, 145  
 Lipatrophy 190  
 Lipodystrophy 233  
 Lipopolysaccharides 12  
 Livedo vasculitis 354  
 Local inflammation 82
- Localized morphea 148  
 Localized scleroderma 133, 135, 151, 172, 176  
 Low complement levels 357  
 L-phenylalanine 375  
 Lupus 315  
 Lupus band test 193, 214  
 Lupus erythematosus 74, 100, 145, 183, 203, 230, 245, 435
  - Lupus nephritis 422, 431
  - Lupus panniculitis 190, 193, 196, 198, 209
  - Lupus profundus 190
  - Lupus-like syndrome 219
 Lyme borreliosis 136  
 Lymph drainage 175  
 Lymphocytic infiltrate 191, 267–268, 404  
 Lymphocytic perivascular infiltrates 165  
 Lymphoma 105  
 Lysyl pyridinoline 167  
 Lytic enzymes 349
- Macrolides 422  
 Malar erythema 231  
 Malar rash 183, 278  
 Mast cells 15, 322  
 Matrix metalloproteinase 82  
 MCTD 245, 249, 252  
 Mechanic hands 173  
 Mechanobullous disease 114, 126  
 Melanocyte autoantigens 371  
 Melanogenesis 370  
 Melanosome 370, 377  
 Meltzer's triad 356  
 Membrane thickening 166  
 Memory T cells 1  
 Metalloproteinases 176, 262  
 Methemoglobinemia 196  
 Methotrexate 79, 150, 152, 197, 206, 219, 239–240, 302, 359–361, 443  
 8-Methoxypsoralen 302, 398  
 Methylprednisolone 219  
 MHC class II 110, 404  
 Microchimerism 166  
 Microscopic polyangiitis 349  
 Microvascular injury 166  
 Milia formation 114  
 Mimicry 408  
 Minoxidil 402  
 Mixed connective tissue disease 245, 247, 250, 255  
 Mixed connective tissue disease (MCTD)
  - Alarcon-Segovia's criteria 252
  - Anticardiolipin antibody 248
  - Anti-casein kinase II (CKII) antibody 246

- Anti-DNA antibody 246
- Anti-EC antibody 247
- Anti-HSP 70kDa antibody 246
- Anti-human endogenous retrovirus (HERV) p30gag ant 248
- Anti-U1snRNP autoantibodies 245
- Arthritis 250
- Autoantibodies 246–301
- Classification 252–254
- Clinical appearance 249–250
- CREST syndrome 248
- Criteria 252–255
- Diagnostic criteria 250, 252
- Endothelin-1 247
- Esophageal dysfunction 249
- Etiopathogenesis 245
- HLA class II 247, 249
- Immunological aberrations 247
- Leukocytopenia 249
- Myositis 250
- Nonsteroidal anti-inflammatory drugs 254
- Pericarditis 249
- Pleuritis 249
- Prognosis 256
- Pulmonary hypertension 248, 250, 256
- Raynaud's phenomenon 250
- Sausage-like fingers 249
- Sharp's criteria 252
- Survival rate 252
- Systemic corticosteroids 254
- T cell characteristics 247
- The Research Committee of the Japanese Ministry 252
- Therapy 254
- Thrombocytopenia 249
- Mixed cryoglobulinemia 274
- Molecular mimicry 11, 246, 296, 372
- Monoamine oxidase A 374
- Monocytes 349
- Monozygotic twins 392
- Morbilloform exanthem 209
- Morning stiffness 192
- Morphea 133, 136, 150, 152, 154, 435
- Morphea en plaque 134
- Mucocutaneous lesions 48, 341
- Mucosal inflammation 262
- Mucous membrane pemphigoid 434–435
- Multiple sclerosis 425
- Munro microabscesses 293
- Muscle biopsy 229
- Muscle disease 234
- Muscle weakness 176
- Mutilating psoriatic arthritis 299
- Myalgia 170
- Myasthenia gravis 393
- Mycophenolate mofetil 79, 127, 219, 239, 302
- Mycophenolic acid 422
- Myelin basic protein (MBP) 425
- Myelodysplastic syndrome 359
- Myeloperoxidase 349
- Myenteric nerve plexus 177
- Myocardial fibrosis 178
- Myopathy 230, 240
- Myositis 236, 240
- Myxedema 393
- Nail involvement 387–388
- Nail pits 387
- Nailfold capillary dilatation 169
- Nailfold splinter hemorrhages 354
- Nasolabial folds 209
- Necrotizing vasculitis 351
- Neonatal lupus 274, 276
- Nephropathy 152, 175, 210
- Neurological disorders 192
- Neutrophil elastase 82
- Neutrophilic granulocytes 293, 298, 349, 351
- Non HLA genes 395
- Non steroidal anti-inflammatory agents 176, 207
- Nuclear antigens 264
- Oedema 168
- Oesophagus 177
- Onychomadesis 387
- Ophiasis 385
- Oral cavity 72
- Ortho-hyperkeratosis 293
- Overlap syndrome 172, 174, 176
- Oxidative stress 370, 372, 376, 379
- Palmoplantar pustular psoriasis 299
- Palpable purpura 274, 354
- Panniculitis 233
- Pansclerotic morphea 144
- Papillary dermis 102, 295
- Papular mucinosis-like lesions 234
- Parakeratosis 293
- Paraneoplastic dermatosis 210
- Paraneoplastic pemphigus 45, 77, 342, 441
- Paraneoplastic vasculitis 356
- Parry–Romberg syndrome 143
- Passive transfer 52
- Patchy hair loss 385
- Pathogenesis 187, 294
- Pathogen associated molecular pattern 7
- Pathogenic autoantibodies 431
- Pauci-immune vasculitides 353, 358
- PBL-SCID mouse model 53

- Pemphaxin 49
- Pemphigoid 325
- Pemphigoid gestationis 73, 110
- Pemphigoid nodularis 72
- Pemphigus 45, 325, 431–432
- Pemphigus
  - $\alpha 9$  acetylcholine receptor 50
  - Acantholysis 46, 48, 52, 57, 63
  - Animal models 52–53
  - Antinuclear Ab 58
  - Auto-Ab 56
  - Autoantigens 61
  - Autoreactive B cells 51, 53
  - Autoreactive T cells 51–52
  - Azathioprin 62
  - B cell lymphoma 56
  - BP238 50, 57
  - Castleman's tumor 56
  - CD4+ T lymphocytes 51
  - Cholinergic receptor 50
  - Clinical phenotype 53, 54
  - Cyclophosphamide 62
  - Cyclosporin A 62
  - Desmocollins 47, 50, 58
  - Desmoglein 3-deficient mouse 52
  - Desmoplakins I 50, 57
  - Direct Immunofluorescence microscopy 57, 60
  - Drug-induced pemphigus 57
  - Dsg1 53, 55, 57, 61, 63
  - Dsg3 47–48, 51, 53, 55, 57, 61
  - ELISA 58, 61
  - Envoplakin 57
  - Epidemiology 45
  - Epitopes 48
  - Etiopathogenesis 46
  - Fogo selvagem 55
  - Gastrointestinal disease 58
  - Glucocorticoids 61
  - Hallopeau type 60
  - HD1/plektin 50, 57
  - Histopathology 60
  - HLA-DQ $\beta$ 1\*0503 51
  - HLA-DR $\beta$ 1\*0410 46, 51
  - HLA-DR $\beta$ 1\*1409 46
  - IgA pemphigus 58
  - Immunological diagnosis 59
  - Immunosuppression 62
  - Immunosuppressive agents 62
  - Immunosuppressive therapy 62
  - Incidence 45
  - Indirect immunofluorescence microscopy 60
  - Interferon- $\gamma$  57
  - Intraepidermal neutrophilic dermatosis 58
  - Intravenous immunoglobins 62
  - Lung epithelium 56
  - Lymphoma 45
  - Methotrexate 62
  - Monoclonal IgA gammopathies 58
  - Mucosal involvement 54, 58
  - Mycophenolate mofetil 62
  - Nuclear antigens 50
  - Oral lesions 54, 57
  - Paraneoplastic pemphigus 56
  - Pathogenic auto-Ab 51
  - PBL-SCID Mouse 53
  - Pemphaxin 50
  - Pemphigus erythematosus (Senear Usher) 58
  - Pemphigus foliaceus 54, 56
  - Pemphigus herpetiformis 58
  - Pemphigus sebor rhoicus 56
  - Pemphigus vegetans 58
  - Pemphigus vulgaris 54, 56
  - Penicillamine 45
  - Periplakin 50, 57
  - Plasmapheresis 62
  - Rare pemphigus variants 58
  - Subcorneal pustular dermatosis 58
  - Therapy 61
  - Thymoma 56
  - Type Neumann 58
- Pemphigus erythematosus 50
- Pemphigus foliaceus 45, 432, 441
- Pemphigus variants 61
- Pemphigus vulgaris 14, 16, 45, 52, 422, 435
- Penicillin 153
- Peptide MHC complex 425–426
- Perforin 262, 407
- Pericarditis 250
- Perifollicular infiltrate 400
- Peripheral tolerance 3, 5, 428
- Periplakin 50
- Perniotic lupus 190
- Phenylalanine metabolism 375, 377
- Phenytoin 153
- Phosphodiesterase-inhibitors 175
- Phospholipase C 48
- Photochemotherapy 301–302
- Photodynamic therapy 153
- Photopheresis 175
- Photo-protective clothing 215
- Photoprovocation 194
- Photosensitivity 192, 206, 214
- Phototherapy 301
- Physiotherapy 175
- Pimecrolimus 196, 380
- Pityriasiform lesions 209
- Plaque morphea 134, 137, 139, 147
- Plaque psoriasis 435, 443
- Plaque-like mucinosis 233
- Plasmapheresis 127, 152, 321, 431

- Plasminogen activator 48, 82–83  
 Plectin 81, 85  
 Pleuritis 249  
 PM-Scl complex 170, 172  
 PM-Scl overlap syndrome 173  
 Poikiloderma 231–232  
 Polymorphic light eruption 211  
 Polymyositis 170–171, 174, 236–237, 240, 245  
 Polyneuropathy 355, 360  
 Porphyria cutanea tarda 114, 172, 211  
 Postinflammatory hyperpigmentation 400  
 PR3-specific T-cells 352  
 Precursor T cells 2  
 Prednisolone 254  
 Pregnancy 73  
 Pretibial pemphigoid 72  
 Prevalence 26, 34, 133  
 Prognostic markers 80  
 Progressive systemic sclerosis  
   – Alveolitis 177  
   – ANA 172  
   – Anti-centromer (CENP-B) antibodies 169  
   – Anti-DNA-topoisomerase I antibodies 169  
   – Anti-ds DNA antibodies 172  
   – Antifibrotic agents 175  
   – Arthralgia 176  
   – Autoantibodies 165, 171–172  
   – Autoantibody profile 171  
   – Calcinosis 175  
   – Cardiac involvement 178  
   – Clinical presentation 168, 172  
   – Collagen synthesis 167, 175, 178  
   – Collagens 167, 175, 180  
   – Dermatohistopathology 174  
   – Diagnosis 171  
   – Diffuse cutaneous SSc (dSSc) 168–169  
   – D-penicillamine 175  
   – Extracellular matrix 166–167  
   – Gastrointestinal Involvement 177  
   – HLA gene 165  
   – Immune dysregulation 165  
   – Immunosuppressive agents 175  
   – Incidence 168  
   – Interferon- $\gamma$  175  
   – Limited cutaneous SSc (lSSc) 168–169  
   – Methotrexate 175  
   – Mixed connective tissues disease (MCTD) 170  
   – Musculoskeletal involvement 176  
   – Overlap syndromes 170  
   – Physical therapy 174  
   – Pulmonary involvement 170, 175, 177  
   – Quality of life 168  
   – Raynaud's syndrome 166, 169–170, 172, 175, 178  
   – Renal involvement 176  
   – Sclerodactily 172  
   – Scleroderma-like syndromes 170, 173  
   – Scleromyositis (PM-Scl-associated) 170  
   – Skin involvement 175  
   – Synthetase syndrome 170  
   – Systemic lupus erythematosus 172, 178  
   – Systemic sclerosis sine scleroderma 169  
   – TGF-beta 167, 178  
   – Therapy 174, 178  
   – UV radiation 176  
   – Vascular pathology 166  
 Propanolol 57  
 Prostacycline 175, 177, 254  
 Prostaglandin 254  
 Proteases 48, 104  
 Proteinase 3 349  
 Proton pump inhibitors 177  
 Prurigo 77  
 Pruritic eruption 95  
 Pseudocatalase 373  
 Pseudolymphoma 276  
 Psoralens 149, 302  
 Psoriasis 17, 231, 298, 423, 435, 444  
   – Psoriasis arthritis 443  
   – Psoriasis cum pustulatione 299  
   – Psoriasis vulgaris 291  
   – Psoriasis-subtypes 292  
   – Psoriatic arthritis 299  
   – Psoriatic autoantigens 296  
   – Psoriatic skin lesions 295–296  
   – Psoriatic spondylarthritis 299  
   – PSORS1 292  
   – PSORS2 292  
   – Psychosocial situation 168  
 Pteridines 374  
 Pulmonary embolism 248  
 Pulmonary fibrosis 179  
 Pulmonary hypertension 250  
 Pulmonary involvement 56, 177  
 Pulse methylprednisolone therapy 239  
 Purpura 278, 355–356  
 Pustular arthroostitis 299  
 Pustular psoriasis 299, 303  
 PUVA 149, 176  
 Pyoderma gangrenosum 354, 423, 430, 435, 443  
  
 Quinacrine hydrochloride 216  
  
 Radiation 136  
 Rashes 278

- Raynaud's phenomenon 133, 166, 171, 342  
 Raynaud's syndrome 169  
 Receptor type 1 antagonists 175  
 Regulatory T cell 6, 17, 296  
 Relaxin 175  
 Renal involvement 176, 355  
 Repigmentation 378  
 Respiratory failure 56  
 Retinoids 197  
 Retrovirus 248  
 Rheumatoid arthritis 74, 145, 171, 178, 210, 219, 246, 267, 424, 447  
 Rheumatoid factor 213, 275, 352  
 Rheumatoid vasculitis 356  
 Risk factor 29, 31  
 Rituximab 220, 360, 436, 441  
 RNA Polymerase I, III 172  
 Ro autoantigen 204  
 Ro/SS-A 211, 214  
 Rodnan skin score 146, 168, 175
- Salicylic acid 301  
 Salivary glands 261–262, 264  
 Salt split skin immunofluorescence 121  
 Scabies 77  
 Scl-70 172  
 SCLÉ 192–193, 204, 208–209, 211, 213–216, 233  
 Scleroderma 133, 138, 170, 176, 230, 250, 261, 342
  - Scleroderma adutorum Buschke 172
  - Scleroderma overlap syndromes 170
  - Sclerodermiform genodermatoses 173
  - Scleromyositis 170
  - Scleromyxoedema 172
  - Sclerosis 136, 142, 144
  - Sclerotic lesions 142
  - Secondary immune complex-mediated vasculitides 356, 361
- Secondary epitopes 81  
 Segmental vitiligo 368–369  
 Self antigens 428  
 Self MHC molecules 265  
 Self-tolerance 421  
 Self-antigens 4, 11  
 Self-reactive T and B Cells 9  
 Shulman Syndrome 144  
 Sicca symptoms 192, 268, 270  
 Silica dust 170  
 Siplizumab 440  
 Sirolimus (Rapamycin) 423  
 Sjogren's syndrome 100, 192, 210–211, 248, 261, 265, 271–273, 278–280, 281, 283, 285, 287, 289
  - Antibodies 265
  - Anti-cardiolipin antibodies 276
  - Apoptosis of glandular epithelial cells 264
  - Arthralgia 275, 280
  - Arthralgias
  - Arthritis 275
  - Autoantibodies 264, 267, 276
  - Autoantigens 264
  - Central nervous system involvement 274
  - Complete heart block 265
  - Cutaneous manifestations 271
  - Differential diagnosis 277
  - Dyspareunia 276
  - Environmental agents 266
  - Epidemiology 267
  - European (EEC) criteria 261, 267
  - Extraglandular manifestations 273, 275
  - Extra-glandular symptoms 280
  - Fatigue 276
  - Genetic factors 277
  - Hepatitis C infection 274
  - HLA associations 277
  - Hypergammaglobulemic purpura 273
  - Lacrimal glands 266
  - Leukopenia 275
  - Lymphoma 278
  - Mucosal surface abnormalities 268
  - Myalgias 275
  - Myositis 275
  - Nephritis 277–278
  - Pathogenesis 261
  - Peripheral neuropathy 273
  - Pulmonary involvement 274
  - Salivary gland 264, 271
  - San Diego criteria 261
  - Sialadenitis 264
  - Sicca symptoms 267, 278
  - SS-A 264, 276
  - SS-B 264
  - Therapeutic principles 279
  - T-lymphocytes 262
  - Vasculitis 277
  - Xerostomia 267
- Sjogren's syndrome 34, 174, 315  
 Skin cancer 378  
 Skin fragility 112, 114, 117  
 Skin involvement 137  
 Skin prick testing 310  
 Skin sclerosis 146  
 Skin thickness 149  
 Skin-infiltrating T cells 149  
 SLE 110, 177, 183, 191, 197, 209, 220, 248, 252, 277–279, 446  
 Small vessel vasculitides 209, 361  
 Soluble CD4 receptor 137  
 Spinous cell carcinoma 188

- Spliceosome 247
- Squaric acid dibutylester 398
- SS-A 265, 267, 274
- SS-A antigens 265
- SS-B 267, 267, 274
- SSc 165–166, 168, 171–172, 175–178, 248, 252
- Staphylococcus aureus 351
- Stem Cell transplantation 445
- Steroids 206
- Stomach 177
- Stratified epithelia 71
- Streptococcal antigens 294, 297
- Streptococcal infections 11
- Subacute cutaneous lupus erythematosus 188, 196, 233
  - ACLE 203, 209
  - ACR 209
  - Acute cutaneous LE 203
  - Alopecia 209
  - ANA 212, 221
  - Antimalarials 216
  - Autoantibodies 204, 212
  - CCLE 203
  - Chronic cutaneous LE 203
  - Clofazimine 219
  - Cutaneous manifestations 208
  - Dapsone 218
  - Definition 203
  - Differential diagnosis 211
  - Direct immunofluorescence 213
  - DLE 208–209
  - Environmental factors 206
  - Epidemiology 203
  - Etiology 204
  - Exfoliative erythroderma 209
  - Histopathology 212
  - HLA-DR3 205
  - Immunoglobulin 219
  - Immunoglobulins 213
  - La/SS-B autoantibodies 212
  - Laboratory findings 211
  - Livedo reticularis 209
  - Local corticosteroids 215
  - Local therapy 214
  - Nephritis 209
  - Nonlesional lupus band test 214
  - Photosensitivity 206
  - Prognosis 220
  - Progressive generalized poikiloderma 209
  - Raynaud's phenomenon 209
  - Retinoids 218
  - Ro/SS-A autoantibody 211, 213, 221
  - Serological findings 213
  - SLE 220
  - Smoking 217
  - Systemic corticosteroids 219
  - Systemic disease 209
  - Systemic therapy 216
  - Thalidomide 217
  - Ultraviolet A-1 phototherapy 220
  - UV light 204
  - UVA protection 215
- Subcorneal pustular dermatosis (Sneddon-Wilkinson) 443
- Subcutaneous amyloid 274
- Subcutaneous morphea 143
- Subepidermal bullous diseases 102, 118, 122, 341
- Sublamina densa zone 118–121
- Sulfmethooxazole 351, 359
- Sulphapyridine 104
- Sulphasalazine 153
- Sun protection factor 215
- Sunlight induced papulonodular mucinosis 209
- Superantigens 3
- Superficial morphea 141
- Susceptibility haplotypes 46
- Sweet's syndrome 211
- Symmetric psoriatic polyarthritis 299
- Systemic disease 194
- Systemic glucocorticoids 63, 152, 343, 397
- Systemic lupus erythematosus 13, 171, 183, 203, 261, 334, 355, 446, 430–431, 433, 441
- Systemic sclerosis 33, 133–134, 146, 165, 172, 245, 423, 431, 435, 445–446
- Systemic therapy 302
- Systemic vasculitides 349, 353–354, 361
  
- T cell anergy 426, 428
- T cell epitopes 11
- T cell receptor (TCR) 1, 4, 425–426
- T cells 404, 425
- T helper (Th) cells 8
- Tacrolimus (FK506) 153, 196, 380, 422
- Tazarotene 301
- T-B cell Interactions 2, 16
- TCR 265, 296
- Telangiectasia 231
- Th1 cytokines 82
- Th2 cytokines 82
- Thalidomide 196, 430–431
- Therapy 79, 279
- Throat infection 294, 300
- Thrombocytopenia 144, 212
- Thromboembolisms 248
- Thrombosis 192, 218
- Thymic maturation 2
- Thymus 2, 265

- Tissue hypoxia 166  
Tissue injury 296  
TNF- $\alpha$  353, 429, 442  
TNF- $\alpha$  gene polymorphisms 395  
TNF- $\alpha$  receptor 424, 430  
TNF- $\alpha$ -antagonists 303  
Tobacco use 214  
Toenails 298  
Tolerance 3, 10, 16, 264, 421, 424–426  
Tolerogenic dendritic cells (DC) 428–429  
Toll-like receptors 7  
Tonsillectomy 300  
Topical calcipotriol 150  
Topical corticosteroids 79, 147, 396  
Topical tacrolimus 215  
Topical therapy 300  
Topoisomerase 265  
Toxic pustuloderma 218  
Traction alopecia 387  
Transforming growth factor- $\beta$  167  
Transglutaminase 97, 105  
Trauma-induced blisters 112  
Trichohyalin 405  
Trimethoprim 351, 359  
Tumor necrosis factor- $\alpha$  52  
Tumor necrosis factor- $\beta$ , 356  
Type I collagen 167  
Type I diabetes mellitus 100, 270  
Type VII collagen 78, 109–112, 115, 117–118, 122–123  
Type XVII collagen 76  
Tyrosinase 369  
Tyrosinase antibodies 370  
U1-RNA-70 kDa protein complex 172, 246  
Ultraviolet A radiation 147, 398  
Universal vitiligo 368  
Urticaria 309  
Urticarial plaques 97  
Urticarial vasculitis 274, 315, 318, 354  
UV exposure 214  
UV light 204  
UVA1 176  
UV-B spectrum 301  
Vascular inflammation 229  
Vascular system 165  
Vasculitis 77, 275, 277, 349, 357–358, 435  
Vasodilators 254, 256  
Verrucous DLE 188  
Vessel damage 352  
Virus infections 186  
Vitamin D analogues 150, 301  
Vitiligo 100, 145, 367, 383  
– acrofacial 368  
Vulvar pemphigoid 72  
Weakness 356  
Wegener's granulomatosis 349, 351, 422  
Wickham striae 337  
Xerophthalmia 261  
Xerostomia 261, 267  
X-linked chronic granulomatous disease 211
-



## *Springer and the Environment*

WE AT SPRINGER FIRMLY BELIEVE THAT AN INTERNATIONAL science publisher has a special obligation to the environment, and our corporate policies consistently reflect this conviction.

WE ALSO EXPECT OUR BUSINESS PARTNERS – PRINTERS, paper mills, packaging manufacturers, etc. – to commit themselves to using environmentally friendly materials and production processes.

THE PAPER IN THIS BOOK IS MADE FROM NO-CHLORINE pulp and is acid free, in conformance with international standards for paper permanency.