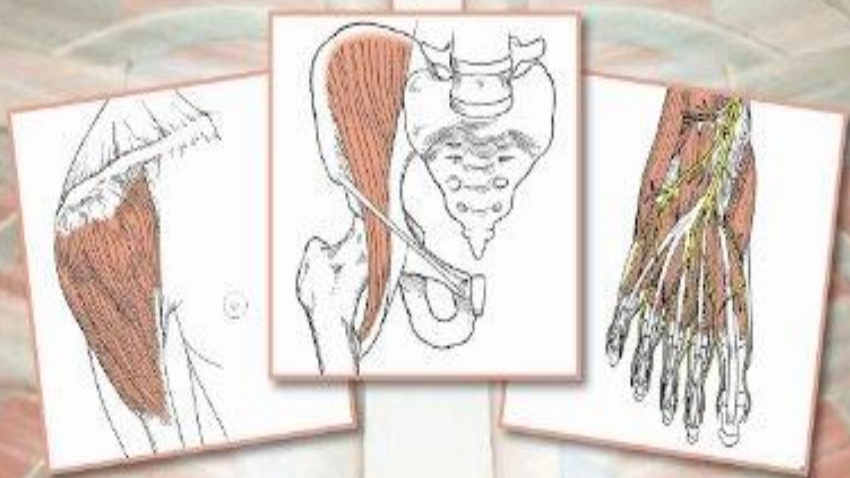


An Illustrated Atlas of the Skeletal Muscles

• THIRD EDITION •



*Bradley S. Bowden
& Joan M. Bowden*

CONTENTS

PREFACE ix

CHAPTER ONE **THE SKELETON** 1

- Skull—lateral view 2
- Skull—lateral, posterior, anterior views 3, 4
- Skull—inferior (basal) view 4
- Skull to humerus—lateral view 5
- Skull to sternum—anterior view 6
- Rib cage, pectoral girdle, upper arm—anterior view 7
- Skeleton—posterior view 8
- Right arm—posterior view 9
- Right arm and right hand—anterior views 10
- Lumbar and pelvic region—anterior view 11
- Pelvic girdle to knee—lateral view 12
- Thoracic to pelvic region—lateral view 12
- Pelvic girdle—posterior view 13
- Pelvic girdle and upper leg—three-quarter posterior view 13
- Pelvic girdle to leg—anterior view 14
- Pelvic girdle to leg—posterior view 15
- Right leg and right foot—anterolateral views 16
- Right leg—posterior view 17
- Right foot—plantar view 18

CHAPTER TWO MOVEMENTS **OF THE BODY** 19

- Anatomical position 20
- Median or midsagittal plane 20
- Coronal (frontal) planes 20
- Transverse planes (cross sections) 20
- Flexion, extension, hyperextension 21
- Lateral flexion 21
- Abduction, adduction 21
- Medial rotation, lateral rotation 21
- Movements of the scapula
 - elevation* 22
 - depression* 22
 - protraction* 22
 - retraction* 22
 - rotation* 22
- Movements of the hand and forearm
 - pronation, supination* 23

radial flexion (abduction), ulnar flexion (adduction) 23

abduction 23

adduction 23

opposition 23

Movements of the foot

dorsiflexion, plantar flexion 24

eversion 24

inversion 24

CHAPTER THREE MUSCLES **OF THE FACE AND HEAD** 25

Scalp

epicranius—occipitalis 26

epicranius—frontalis 26

temporoparietalis 27

Ear

auricularis anterior 28

auricularis superior 28

auricularis posterior 28

Eyelids

orbicularis oculi 29

levator palpebrae superioris 30

corrugator supercilii 31

Nose

procerus 32

nasalis 33

depressor septi 34

Mouth

orbicularis oris 35

levator labii superioris—angular head 36

levator labii superioris—infraorbital head 36

levator anguli oris 37

zygomaticus major 38

zygomaticus minor 39

risorius 40

depressor labii inferioris 41

depressor anguli oris 42

mentalis 43

buccinator 44

Mastication

temporalis 45

masseter 46

pterygoideus medialis 47

pterygoideus lateralis 48

CHAPTER FOUR MUSCLES OF THE NECK 49

- sternocleidomastoideus* 50
- platysma* 51
- Suprahyoid muscles
 - digastricus* 52
 - stylohyoideus* 53
 - mylohyoideus* 54
 - geniohyoideus* 55
- Infrahyoid muscles
 - sternohyoideus* 56
 - sternothyroideus* 57
 - thyrohyoideus* 58
 - omohyoideus* 59
- Anterior vertebral muscles
 - longus colli* 60
 - longus capitis* 61
 - rectus capitis anterior* 62
 - rectus capitis lateralis* 63
- Lateral vertebral muscles
 - scalenus anterior* 64
 - scalenus medius* 65
 - scalenus posterior* 66
- Suboccipital neck muscles
 - rectus capitis posterior major* 67
 - rectus capitis posterior minor* 68
 - obliquus capitis inferior* 69
 - obliquus capitis superior* 70

CHAPTER FIVE MUSCLES OF THE TRUNK 71

- splenius capitis* 72
- splenius cervicis* 73
- Erector spinae
 - iliocostalis lumborum* 74
 - iliocostalis thoracis* 74
 - iliocostalis cervicis* 74
 - longissimus thoracis* 75
 - longissimus cervicis* 75
 - longissimus capitis* 75
 - spinalis thoracis* 76
 - spinalis cervicis* 76
 - spinalis capitis* 76
- Transversospinalis
 - semispinalis thoracis* 77
 - semispinalis cervicis* 77
 - semispinalis capitis* 77
 - multifidis* 78
 - rotatores* 79
 - interspinales* 80

- Intertransversarii
 - intertransversarii anteriores* 81
 - intertransversarii posteriores* 81
 - intertransversarii laterales* 81
 - intertransversarii mediales* 81
- Thoracic muscles
 - intercostales externi* 82
 - intercostales interni* 83
 - subcostales* 84
 - transversus thoracis* 85
 - levatores costarum* 86
 - serratus posterior superior* 87
 - serratus posterior inferior* 88
 - diaphragm* 89
- Abdominal muscles
 - obliquus externus abdominis* 90
 - obliquus internus abdominis* 91
 - cremaster* 92
 - transversus abdominis* 93
 - rectus abdominis* 94
 - abdominal muscle group* 95
 - quadratus lumborum* 96

CHAPTER SIX MUSCLES OF THE SHOULDER AND ARM 97

- Anterior compartment (flexors)—shoulder and arm
 - pectoralis major* 98
 - pectoralis minor* 99
 - subclavius* 100
 - coracobrachialis* 101
 - biceps brachii* 102
 - brachialis* 103
- Posterior compartment (extensors)—attaching to trunk
 - anterior chest and arm group* 104
 - trapezius* 105
 - latissimus dorsi* 106
 - levator scapulae* 107
 - rhomboideus major* 108
 - rhomboideus minor* 109
 - serratus anterior* 110
- Posterior compartment (extensors)—shoulder
 - deltoideus* 111
 - supraspinatus* 112
 - infraspinatus* 113
 - teres minor* 114
 - subscapularis* 115
 - teres major* 116
- Posterior compartment (extensors)—arm
 - triceps brachii* 117
 - anconeus* 118
 - posterior back, shoulder and arm group* 119

CHAPTER SEVEN MUSCLES OF THE FOREARM AND HAND 121

Anterior

- pronator teres* 122
- flexor carpi radialis* 123
- palmaris longus* 124
- flexor carpi ulnaris* 125
- anterior wrist group* 126
- flexor digitorum superficialis* 127
- flexor digitorum profundus* 128
- flexor pollicis longus* 129
- flexors of the fingers group* 130
- pronator quadratus* 131

Posterior

- brachioradialis* 132
- extensor carpi radialis longus* 133
- extensor carpi radialis brevis* 134
- extensor digitorum communis* 135
- extensor digiti minimi* 136
- extensor carpi ulnaris* 137
- supinator* 138
- abductor pollicis longus* 139
- extensor pollicis brevis* 140
- extensor pollicis longus* 141
- extensors of the thumb* 142
- extensor indicis* 143

Hand

- palmaris brevis* 144
- abductor pollicis brevis* 145
- flexor pollicis brevis* 146
- opponens pollicis* 147
- adductor pollicis* 148
- abductor digiti minimi* 149
- flexor digiti minimi brevis* 150
- opponens digiti minimi* 151
- lumbricales* 152
- palmar interossei* 153
- dorsal interossei* 154

CHAPTER EIGHT MUSCLES OF THE HIP AND THIGH 155

Hip

- psoas major* 156
- iliacus* 157

Lateral rotators

- piriformis* 158
- obturator internus* 159
- gemellus superior* 160

- gemellus inferior* 161
- obturator externus* 162
- quadratus femoris* 163

Gluteal

- gluteus maximus* 164
- gluteus medius* 165
- gluteus minimus* 166
- hip group* 167
- tensor fasciae latae* 168

Anterior thigh

- sartorius* 169
- quadriceps femoris—rectus femoris* 170
- quadriceps femoris—vastus lateralis* 171
- quadriceps femoris—vastus medialis* 172
- quadriceps femoris—vastus intermedius* 173
- anterior thigh group* 174

Posterior thigh

- biceps femoris* 175
- semitendinosus* 176
- semimembranosus* 177
- hamstring muscles group* 178

Medial thigh

- gracilis* 179
- pectineus* 180
- adductor longus* 181
- adductor brevis* 182
- adductor magnus* 183
- hip flexors and adductors group* 184

CHAPTER NINE MUSCLES OF THE LEG AND FOOT 185

Anterior leg

- tibialis anterior* 186
- extensor hallucis longus* 187
- extensor digitorum longus* 188
- peroneus tertius* 189
- anterior and lateral group* 190

Posterior superficial leg

- gastrocnemius* 191
- soleus* 192
- plantaris* 193
- muscles of the calf group* 194

Posterior deep leg

- popliteus* 195
- flexor hallucis longus* 196
- flexor digitorum longus* 197
- tibialis posterior* 198
- deep posterior group* 199

Lateral leg

- peroneus longus* 200
- peroneus brevis* 201

Dorsal foot
extensor digitorum brevis 202

Plantar—first layer
abductor hallucis 203
flexor digitorum brevis 204
abductor digiti minimi 205

Plantar—second layer
quadratus plantae 206
lumbricales 207

Plantar—third layer
flexor hallucis brevis 208
adductor hallucis 209
flexor digiti minimi brevis 210

Plantar—fourth layer
dorsal interossei 211
plantar interossei 212

ALPHABETICAL LISTING OF MUSCLES 213

INDEX 215

PREFACE

This book is a study guide and reference for the anatomy and actions of human skeletal muscles. It is designed for use by students of anatomy, physical education and health-related fields. It also serves as a compact reference for the practicing professional.

The first chapter presents labeled line drawings of the skeleton, which include all structures that are used in describing origins and insertions in the later chapters. A master numbering system is used so that each structure is labeled with the same number in all drawings.

The second chapter describes the various movements of the body.

In chapters 3 through 9 the origin, insertion, action and innervation of the skeletal muscles are described and each muscle is presented on a separate page with a line drawing.

The spinal cord levels of the nerve fibers that innervate each muscle are included in parentheses after the name of each nerve.

Labeled drawings of major muscle groups are presented throughout chapters 3 to 9. Notes and relationships among muscles have been included on many pages.

The drawings include the following important features:

1. Bones and cartilage containing muscle attachment sites are shaded.
2. Adjacent structures are shown.

3. Muscle fibers are drawn by direction.
4. Muscle fibers are shown on the undersurface of bone and cartilage as dashed lines.
5. Tendons and aponeuroses are shown.
6. Labeled muscle groups are included.

These features aid in visual orientation and understanding of the action of the muscles. We have noticed that many students find it useful to color the illustrations.

Notes have been included on many pages to show how muscles are used. Relationships among many of the muscles have also been indicated where appropriate. Many more of these have been included in the third edition.

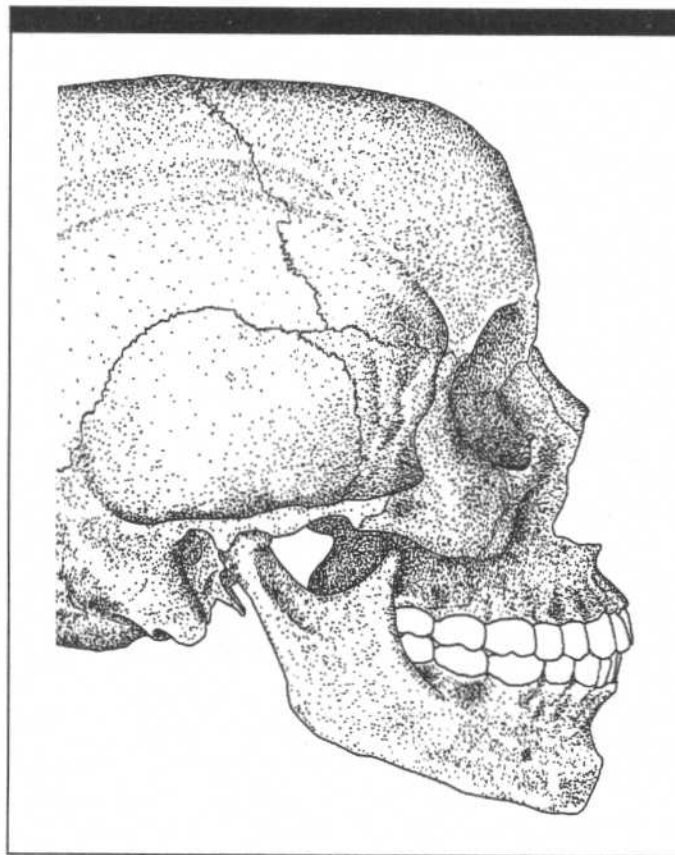
Since our primary goal is to describe the muscles moving the skeleton, we have not described the muscles of the perineum, eye, tympanic cavity, tongue, larynx, pharynx, or palate.

We extend our appreciation to Mr. George Boykin, who was for many years the jolly proprietor of the gross anatomy laboratories at the Health Sciences Center of the State University of New York at Stony Brook, for his help and encouragement. We also thank Mr. Vincent Verdisco and Ms. Diane Chandler for their technical advice with the artwork and Ms. Katherine Juner for her secretarial services.

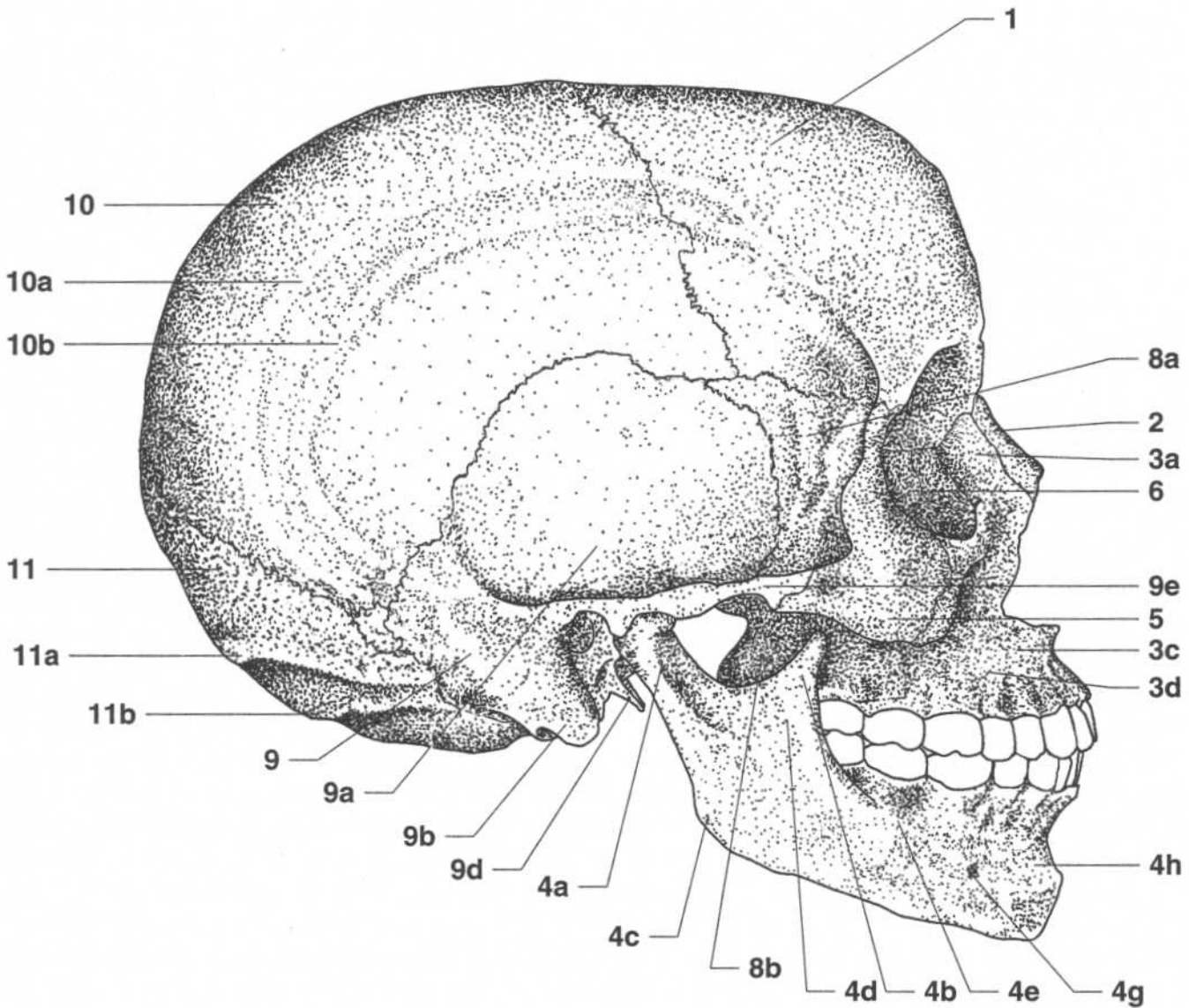
Robert J. Stone

Judith A. Stone

CHAPTER ONE
THE SKELETON



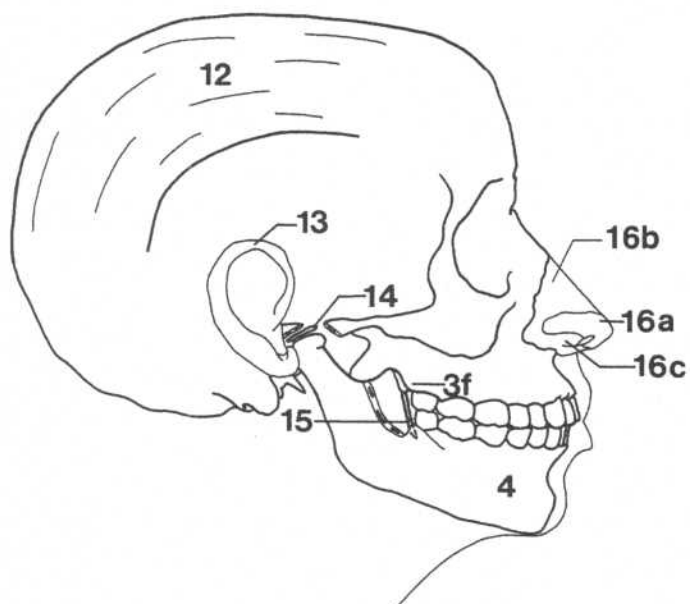
SKULL—LATERAL VIEW



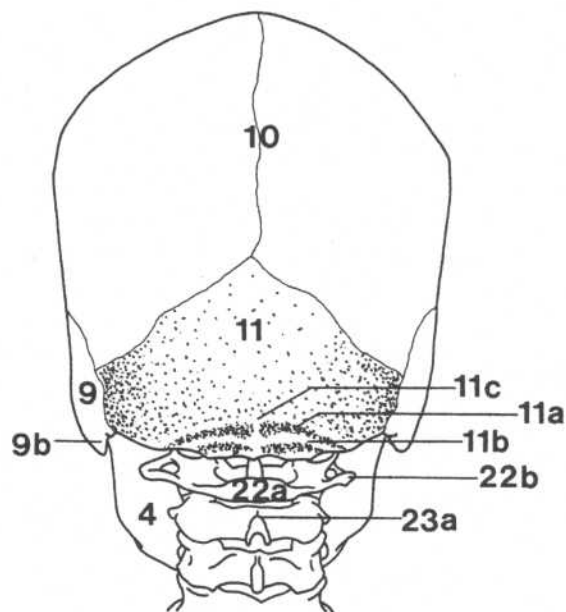
- 1.** Frontal bone
- 2.** Nasal bone
- 3a.** Frontal process (maxilla)
- 3c.** Incisive fossa of maxilla
- 3d.** Canine fossa (maxilla)
- 4a.** Neck of condyle (mandible)
- 4b.** Coronoid process (mandible)
- 4c.** Angle of the mandible
- 4d.** Ramus (mandible)
- 4e.** Oblique line (mandible)
- 4g.** Mental foramen (mandible)
- 4h.** Incisive fossa of mandible
- 5.** Zygomatic bone
- 6.** Lacrimal bone
- 8a.** Greater wing of sphenoid bone

- 8b.** Lateral pterygoid plate
- 9.** Temporal bone
- 9a.** Temporal fossa
- 9b.** Mastoid process (temporal bone)
- 9d.** Styloid process (temporal bone)
- 9e.** Zygomatic process (temporal bone)
- 10.** Parietal bone
- 10a.** Superior temporal line
- 10b.** Inferior temporal line
- 11.** Occipital bone
- 11a.** Superior nuchal line (occipital bone)
- 11b.** Inferior nuchal line (occipital bone)

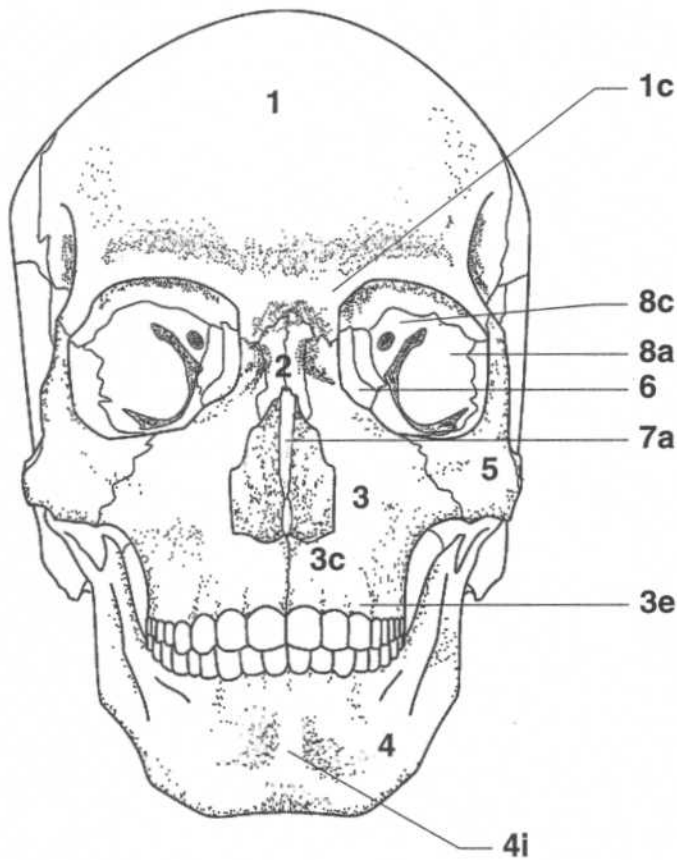
Note: The zygomatic arch is formed by the zygomatic process of the temporal bone meeting the zygomatic bone.

SKULL—LATERAL VIEW**SKULL—POSTERIOR VIEW**

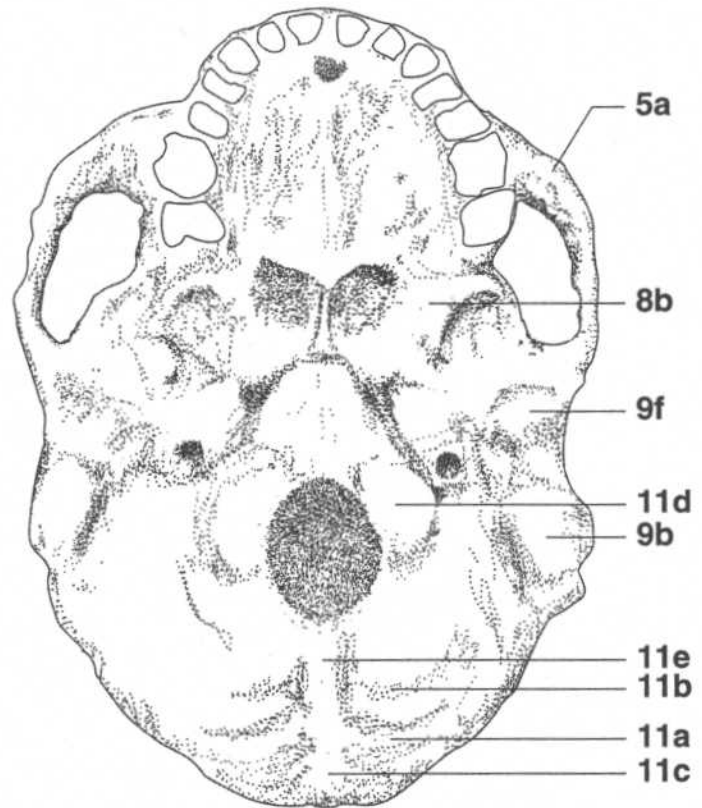
- 3f.** Tuberosity of maxilla
- 4.** Mandible
- 12.** Galea aponeurotica
- 13.** Helix of ear
- 14.** Articular disk of temporomandibular joint
- 15.** Pterygomandibular raphe
- 16a.** Greater alar cartilage
- 16b.** Nasal cartilage
- 16c.** Ala



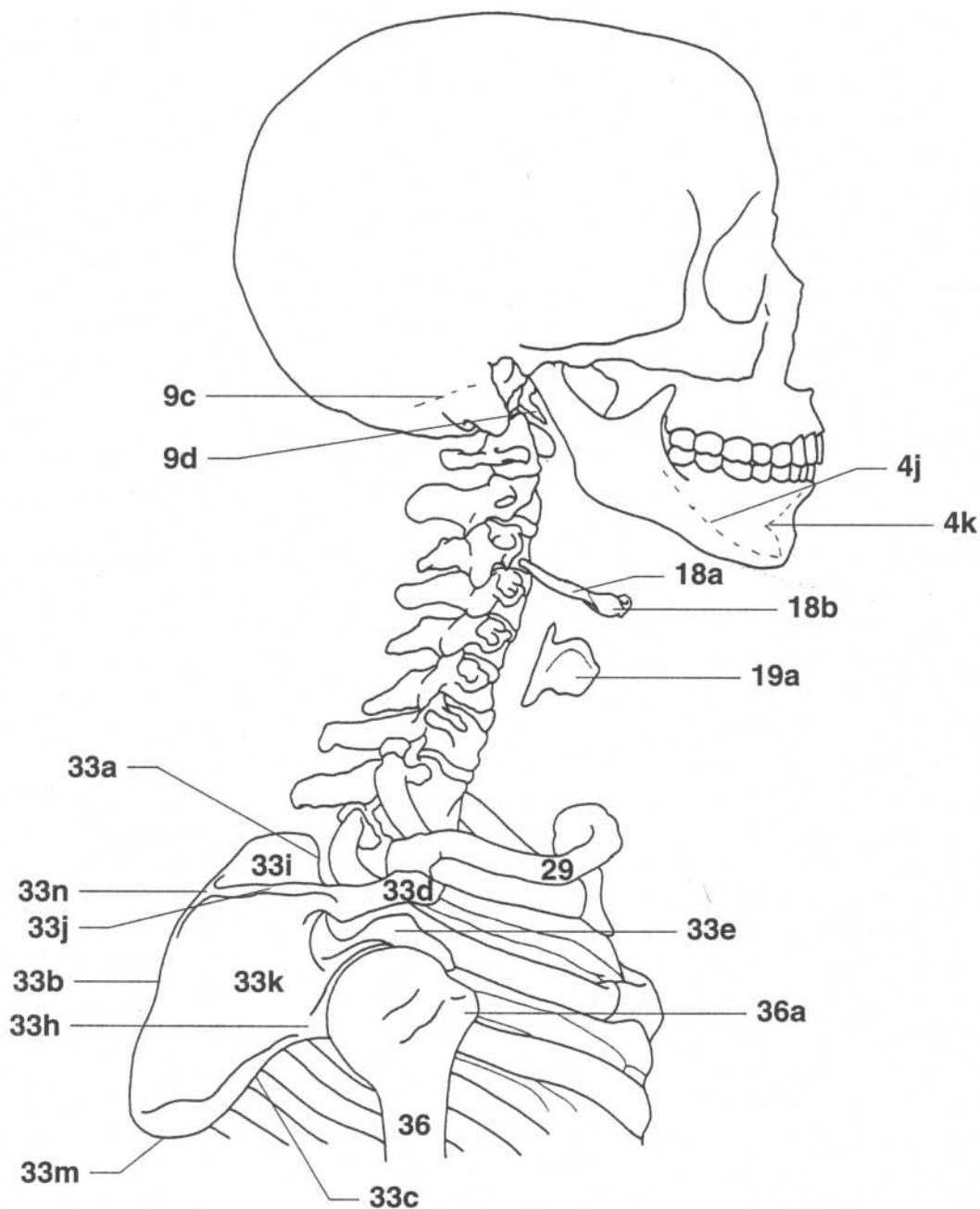
- 4.** Mandible
- 9.** Temporal bone
- 9b.** Mastoid process (temporal bone)
- 10.** Parietal bone
- 11.** Occipital bone
- 11a.** Superior nuchal line (occipital bone)
- 11b.** Inferior nuchal line (occipital bone)
- 11c.** External occipital protuberance
- 22a.** Posterior arch of atlas
- 22b.** Transverse process of atlas
- 23a.** Spinous process of axis

SKULL—ANTERIOR VIEW

- 1.** Frontal bone
- 1c.** Superciliary arch (frontal bone)
- 2.** Nasal bone
- 3.** Maxilla
- 3c.** Incisive fossa of maxilla
- 3e.** Alveolar border of maxilla
- 4.** Mandible
- 4i.** Symphysis of mandible
- 5.** Zygomatic bone
- 6.** Lacrimal bone
- 7a.** Nasal septum (ethmoid bone)
- 8a.** Greater wing of sphenoid bone
- 8c.** Lesser wing of sphenoid bone

SKULL—INFERIOR (BASAL) VIEW

- 5a.** Zygomatic arch
- 8b.** Lateral pterygoid plate
- 9b.** Mastoid process (temporal bone)
- 9f.** Mandibular process (temporal bone)
- 11a.** Superior nuchal line (occipital bone)
- 11b.** Inferior nuchal line (occipital bone)
- 11c.** External occipital protuberance (occipital bone)
- 11d.** Occipital condyle (occipital bone)
- 11e.** External occipital crest (occipital bone)

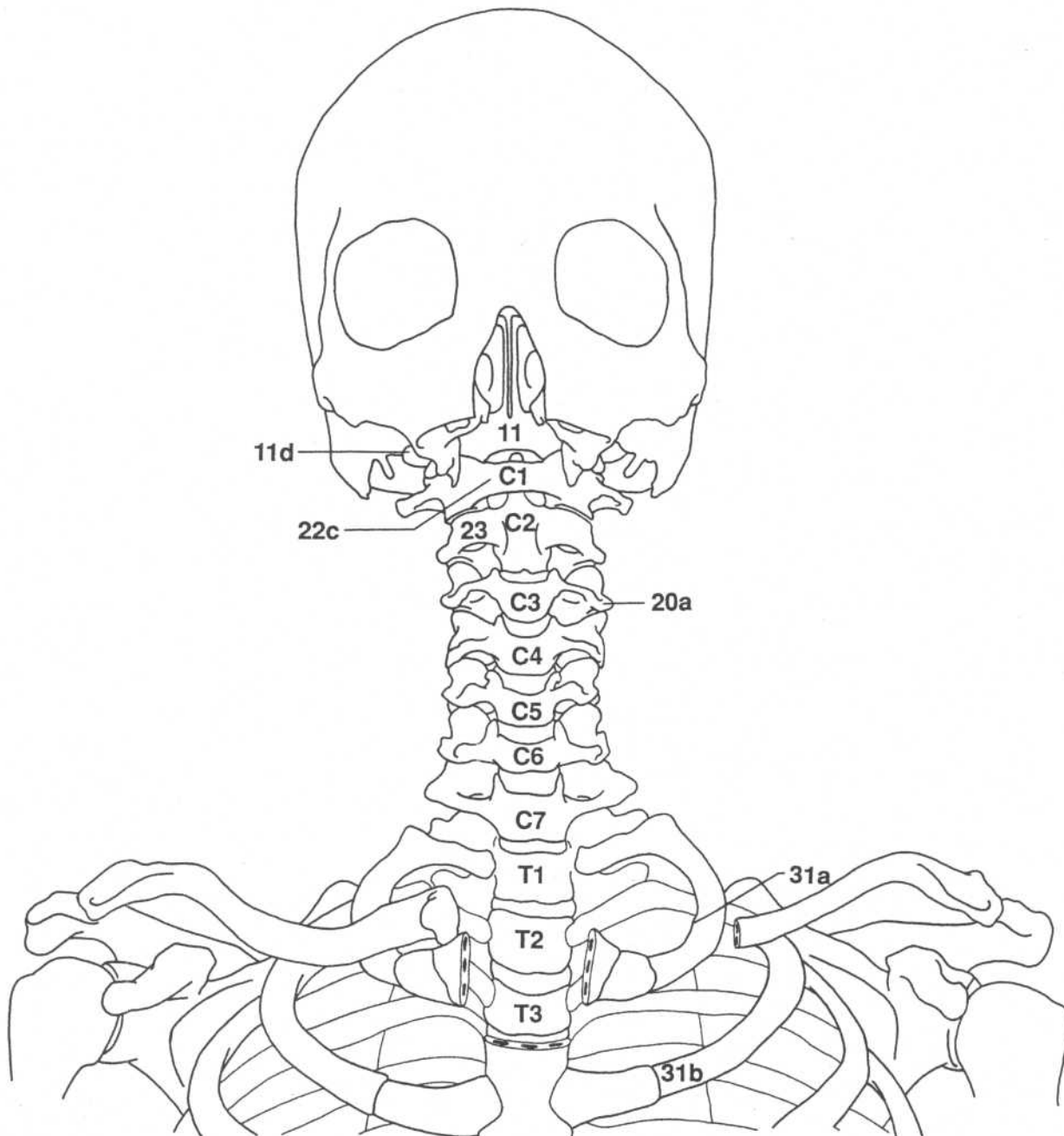
SKULL TO HUMERUS—LATERAL VIEW

- 4j.** Mylohyoid line (medial surface of mandible)
- 4k.** Inferior mental spine (inner surface of mandible)
- 9c.** Mastoid notch (medial surface of temporal bone)
- 9d.** Styloid process (temporal bone)
- 18a.** Greater cornu of hyoid
- 18b.** Body of hyoid
- 19a.** Lamina of thyroid cartilage
- 29.** Clavicle
- 33a.** Superior border of scapula
- 33b.** Vertebral (medial) border of scapula
- 33c.** Axillary (lateral) border of scapula

- 33d.** Acromion (scapula)
- 33e.** Coracoid process (scapula)
- 33h.** Infraglenoid tubercle (scapula)
- 33i.** Supraspinous fossa (scapula)
- 33j.** Crest of spine (scapula)
- 33k.** Infraspinous fossa (scapula)
- 33m.** Inferior angle of scapula
- 33n.** Root of spine (scapula)
- 36.** Humerus
- 36a.** Greater tuberosity of humerus

SKULL TO STERNUM—ANTERIOR VIEW

(Mandible and maxilla removed)

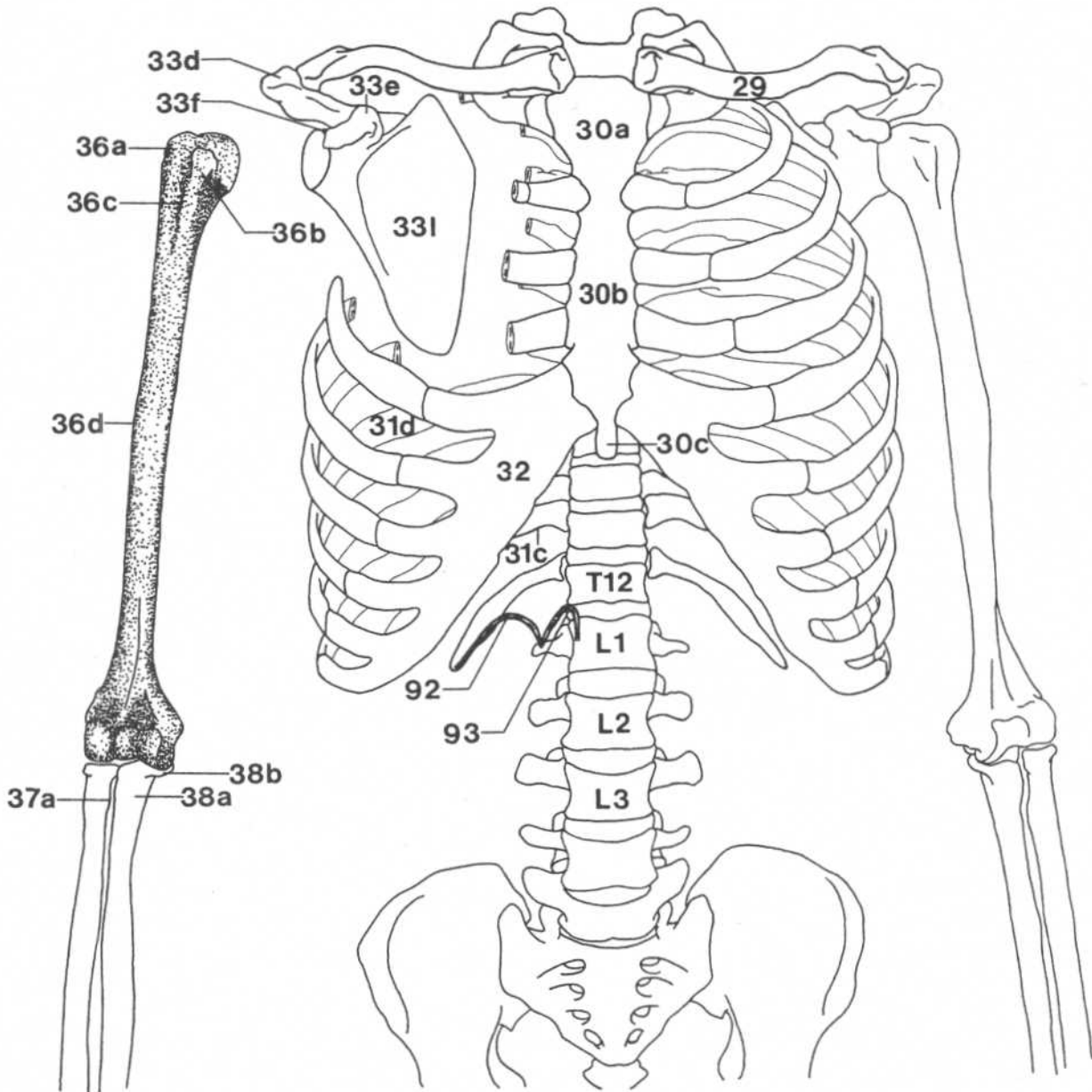


- 11.** Occipital bone
- 11d.** Jugular process of occipital bone
- 20a.** Transverse process of vertebra
- 22c.** Anterior arch of atlas

- 23.** Axis
- 31a.** Scalene tubercle of first rib
- 31b.** Second rib

RIB CAGE, PECTORAL GIRDLE, UPPER ARM—ANTERIOR VIEW

(Ribs partially removed, right arm disarticulated)



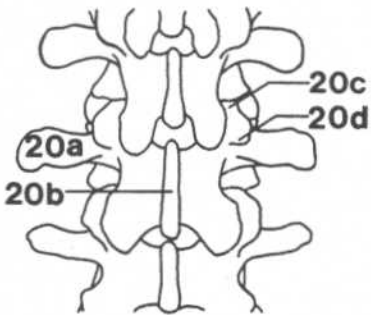
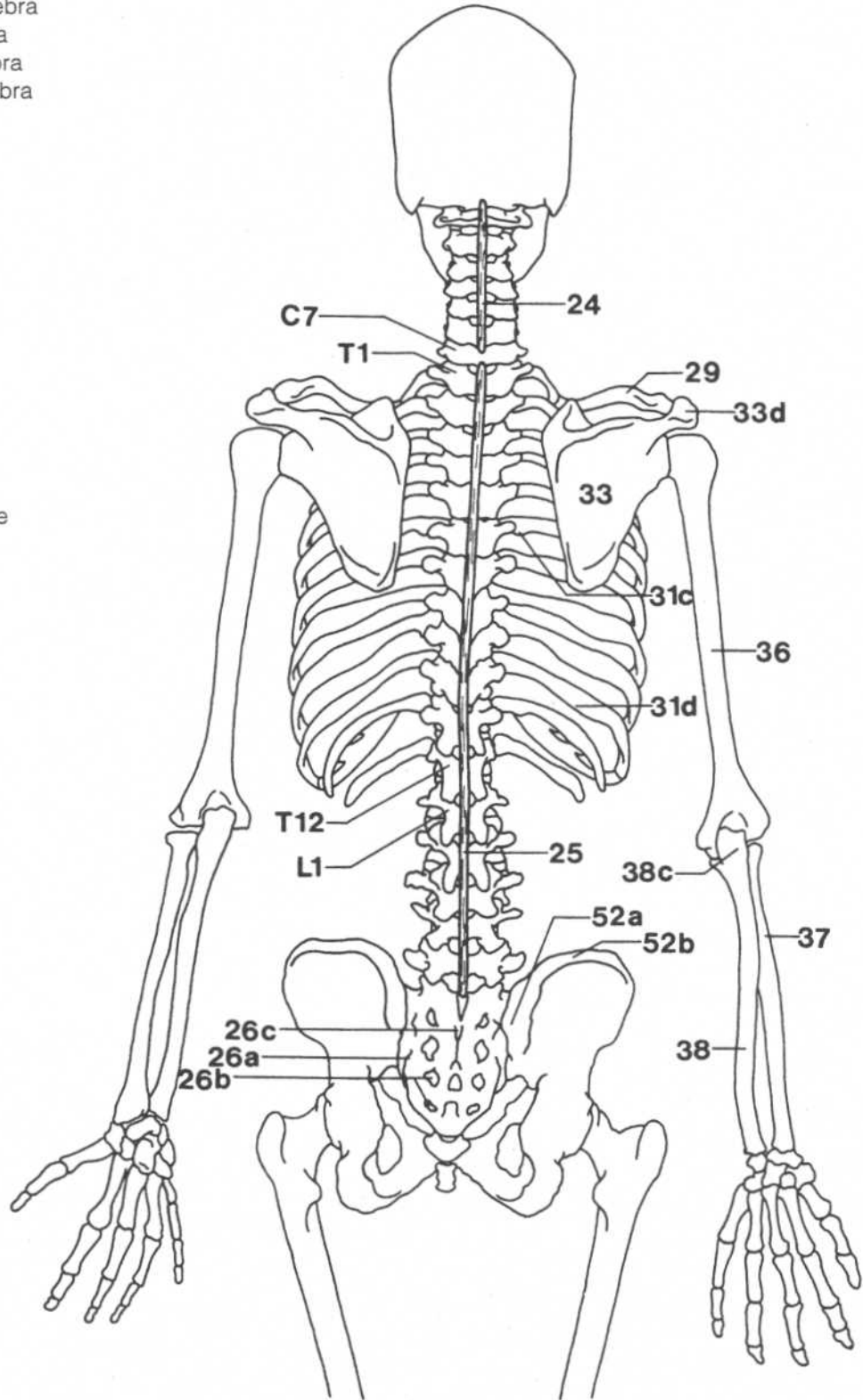
- 29.** Clavicle
- 30a.** Manubrium (sternum)
- 30b.** Body (sternum)
- 30c.** Xiphoid process (sternum)
- 31c.** Tubercle of rib
- 31d.** Angle of rib
- 32.** Costal cartilage
- 33d.** Acromion (scapula)
- 33e.** Coracoid process (scapula)
- 33f.** Supraglenoid tubercle (scapula)
- 33l.** Subscapular fossa (scapula)
- 36a.** Greater tuberosity (tubercle) of humerus
- 36b.** Lesser tuberosity of humerus
- 36c.** Intertubercular (bicipital) groove (humerus)
- 36d.** Deltoid tuberosity (humerus)
- 37a.** Radial tuberosity (radius)
- 38a.** Ulnar tuberosity (ulna)
- 38b.** Coronoid process (ulna)
- 92.** Lateral lumbocostal arch (lateral arcuate ligament)*
- 93.** Medial lumbocostal arch (medial arcuate ligament)

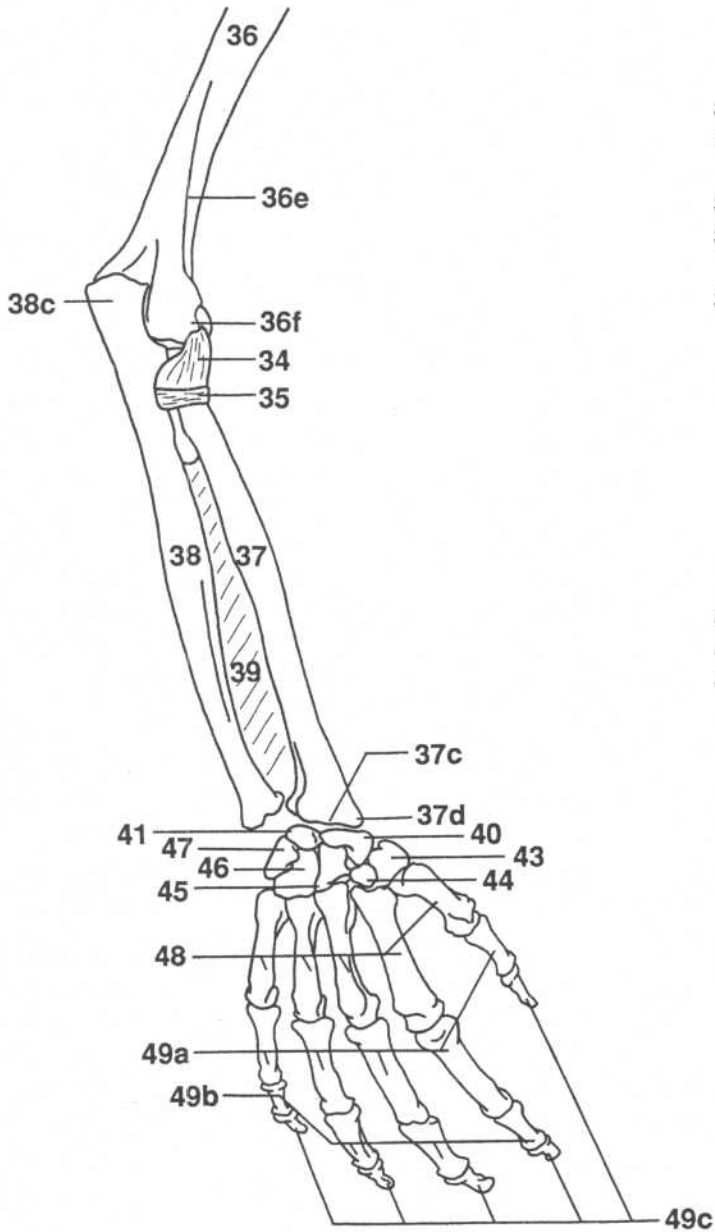
*See p. 89.

SKELETON—POSTERIOR VIEW

(Enlargement of lumbar vertebrae)

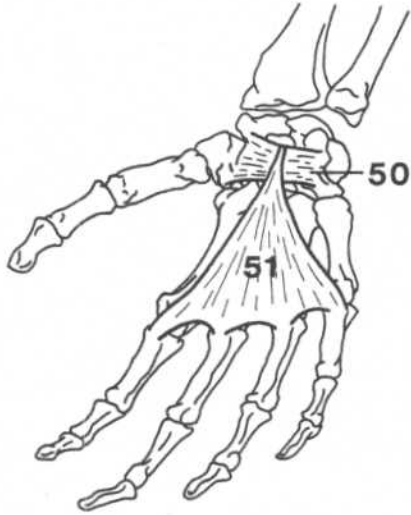
- 20a. Transverse process of vertebra
- 20b. Spinous process of vertebra
- 20c. Mamillary process of vertebra
- 20d. Accessory process of vertebra
- 24. Ligamentum nuchae
- 25. Supraspinous ligaments
- 26a. Lateral sacral crest
- 26b. Sacral foramina
- 26c. Medial sacral crest
- 29. Clavicle
- 31c. Tubercle of rib
- 31d. Angle of rib
- 33. Scapula
- 33d. Acromion (scapula)
- 36. Humerus
- 37. Radius
- 38. Ulna
- 38c. Olecranon process (ulna)
- 52a. Posterior superior iliac spine
- 52b. Iliac crest



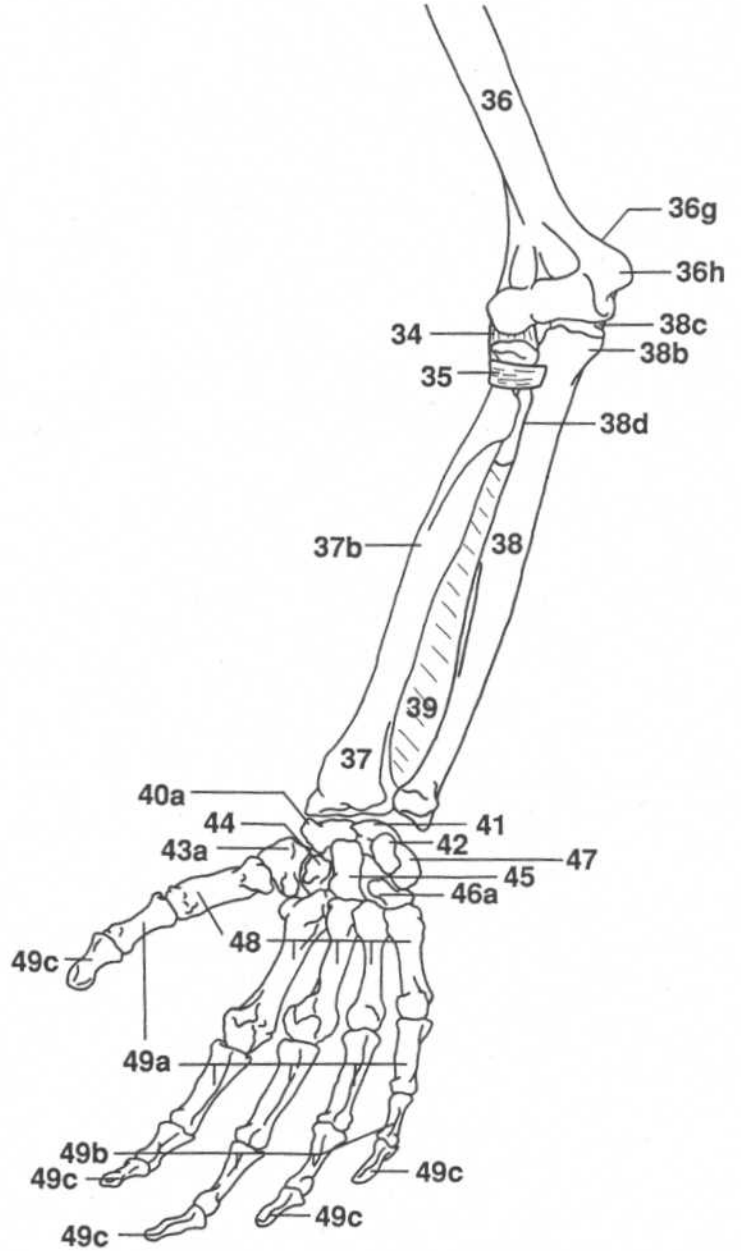
RIGHT ARM—POSTERIOR VIEW

- 34.** Radial collateral ligament
- 35.** Annular ligament
- 36.** Humerus
- 36e.** Lateral supracondylar ridge (humerus)
- 36f.** Lateral epicondyle (humerus)
- 37.** Radius
- 37c.** Dorsal tubercle (radius)
- 37d.** Styloid process (radius)
- 38.** Ulna
- 38c.** Olecranon process (ulna)
- 39.** Interosseous membrane
- 40.** Scaphoid (navicular)
- 41.** Lunate
- 43.** Trapezium
- 44.** Trapezoid
- 45.** Capitate
- 46.** Hamate
- 47.** Triquetrum
- 48.** Metacarpals
- 49a.** Proximal phalanges
- 49b.** Middle phalanges
- 49c.** Distal phalanges

RIGHT HAND— ANTERIOR VIEW

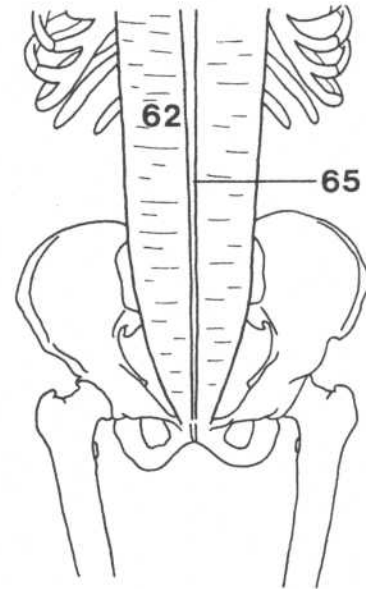
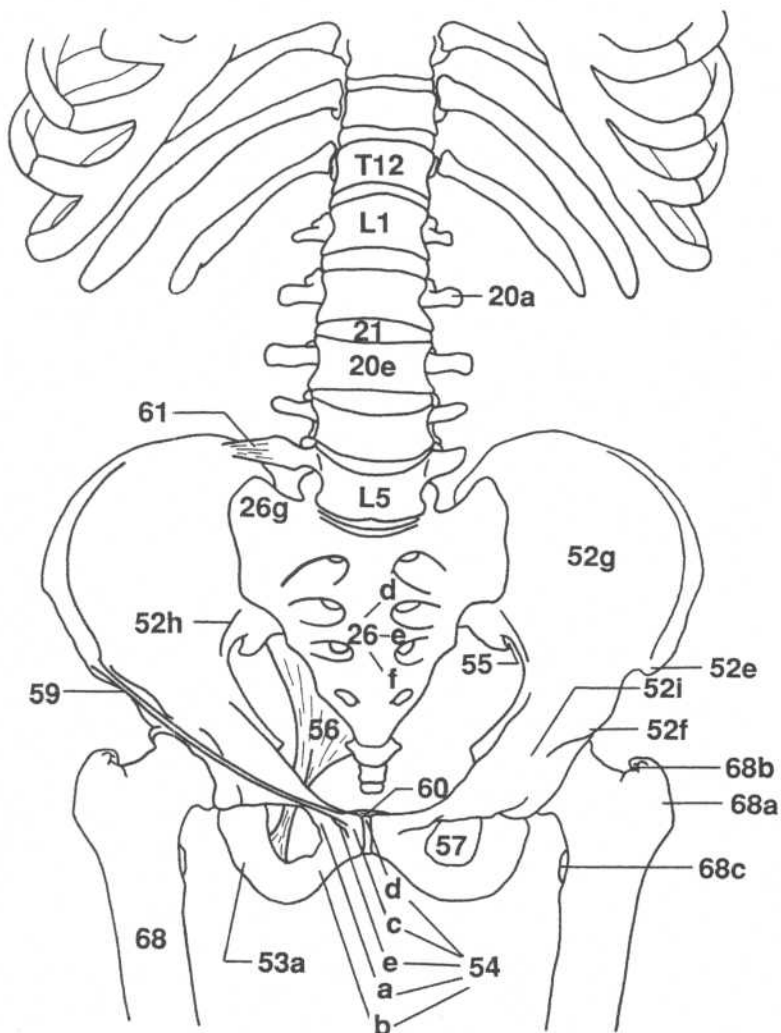


RIGHT ARM— ANTERIOR VIEW



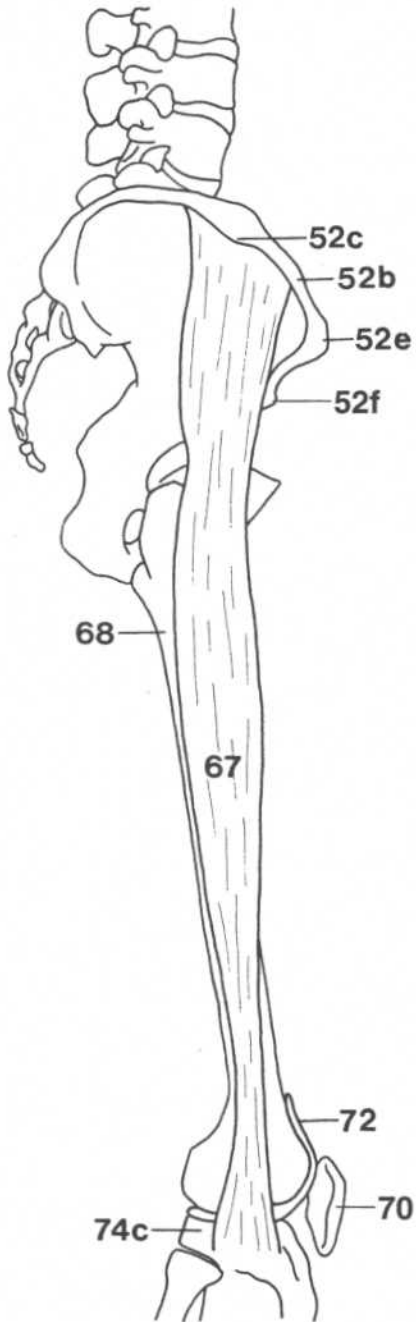
- 34. Radial collateral ligament
- 35. Annular ligament
- 36. Humerus
- 36g. Medial supracondylar ridge (humerus)
- 36h. Medial epicondyle (humerus)
- 37. Radius
- 37b. Pronator tuberosity (radius)
- 38. Ulna
- 38b. Coronoid process (ulna)
- 38c. Olecranon process (ulna)
- 38d. Supinator crest (ulna)
- 39. Interosseous membrane
- 40a. Tubercle of scaphoid (navicular)
- 41. Lunate
- 42. Pisiform
- 43a. Tubercle of trapezium
- 44. Trapezoid
- 45. Capitate
- 46a. Hook of hamate
- 47. Triquetrum
- 48. Metacarpals
- 49a. Proximal (first) phalanges
- 49b. Middle (second) phalanges
- 49c. Distal (third) phalanges
- 50. Flexor retinaculum
- 51. Palmar aponeurosis

LUMBAR AND PELVIC REGION—ANTERIOR VIEW



- 20a.** Transverse process of vertebra
- 20e.** Body of vertebra
- 21.** Intervertebral disk
- 26d.** Second sacral vertebra
- 26e.** Third sacral vertebra
- 26f.** Fourth sacral vertebra
- 26g.** Ala of sacrum
- 52e.** Anterior superior iliac spine
- 52f.** Anterior inferior iliac spine
- 52g.** Iliac fossa
- 52h.** Arcuate line (ilium)
- 52i.** Iliopectineal eminence (ilium)
- 53a.** Ramus of ischium
- 54a.** Superior ramus of pubis
- 54b.** Inferior ramus of pubis
- 54c.** Pubic crest
- 54d.** Pubic symphysis
- 54e.** Pubic tubercle
- 55.** Greater sciatic notch
- 56.** Sacrotuberous ligament
- 57.** Obturator foramen
- 59.** Inguinal ligament
- 60.** Superior pubic ligament
- 61.** Iliolumbar ligament
- 62.** Rectus sheath
- 65.** Linea alba
- 68.** Femur
- 68a.** Greater trochanter (femur)
- 68b.** Trochanteric fossa (femur)
- 68c.** Lesser trochanter (femur)

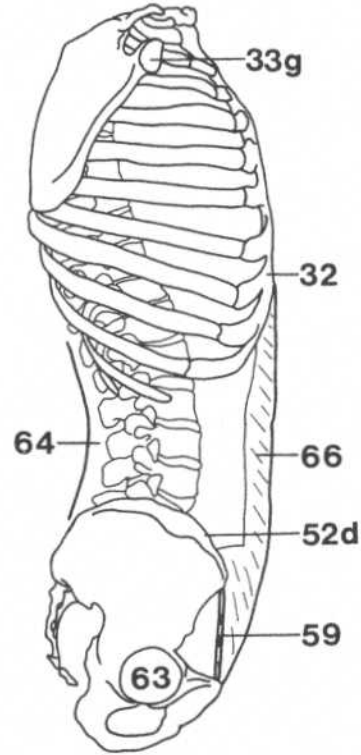
PELVIC GIRDLE TO KNEE— LATERAL VIEW



- 52b.** Iliac crest
- 52c.** Iliac tubercle
- 52e.** Anterior superior iliac spine
- 52f.** Anterior inferior iliac spine
- 67.** Iliotibial tract
- 68.** Femur
- 70.** Patella
- 72.** Synovial membrane of knee joint
- 74c.** Lateral condyle of tibia

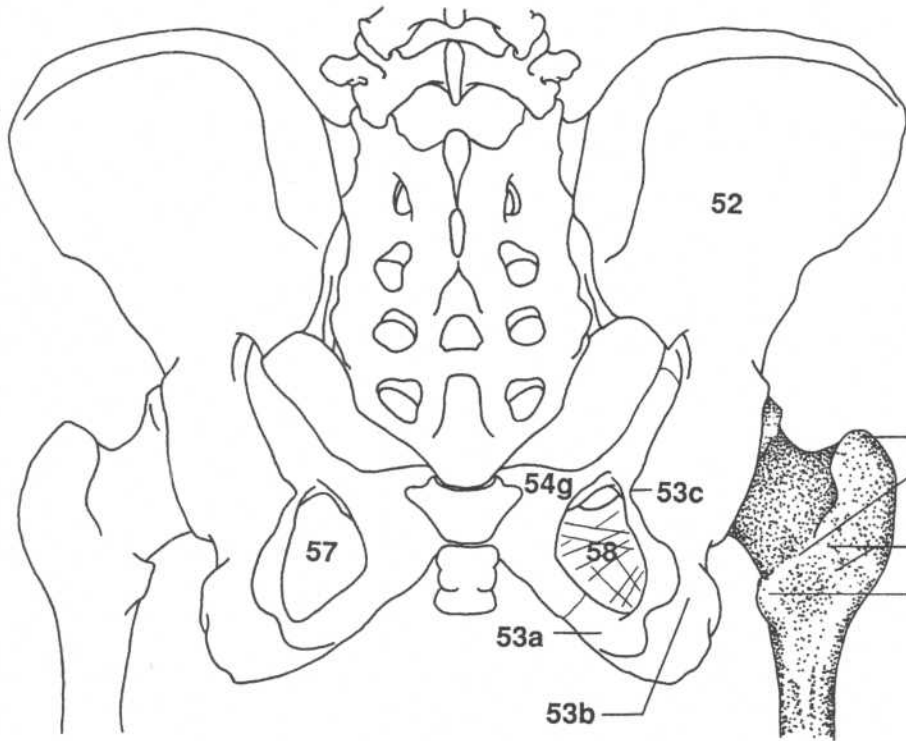
THORACIC TO PELVIC REGION—LATERAL VIEW

(Arm and leg removed)



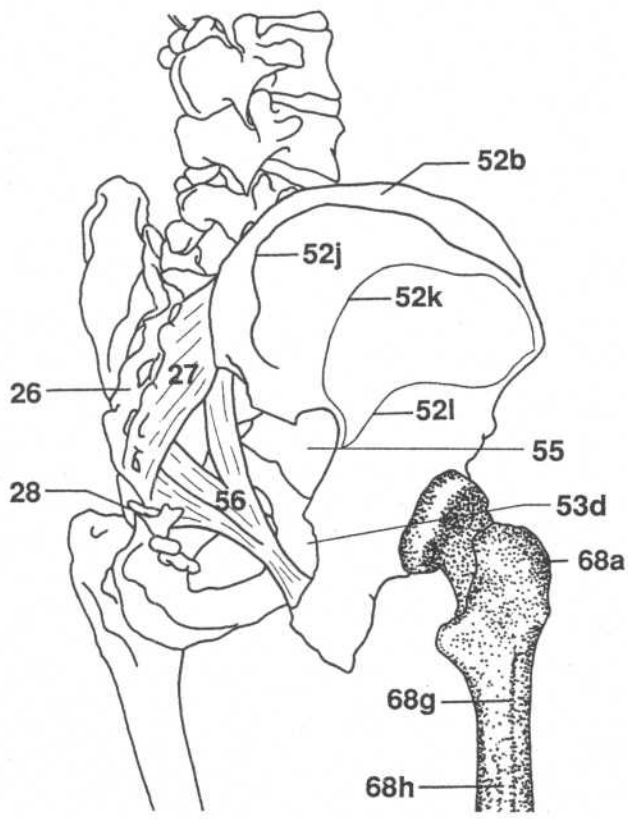
- 32.** Costal cartilage
- 33g.** Glenoid cavity (scapula)
- 52d.** Anterior iliac crest
- 59.** Inguinal ligament
- 63.** Acetabulum
- 64.** Thoracolumbar fascia
- 66.** Abdominal aponeurosis

PELVIC GIRDLE—POSTERIOR VIEW



- 52. Ilium
- 53a. Ramus of ischium
- 53b. Ischial tuberosity
- 53c. Spine of ischium
- 54g. Body of pubis
- 57. Obturator foramen
- 58. Obturator membrane
- 68a. Greater trochanter (femur)
- 68c. Lesser trochanter (femur)
- 68d. Intertrochanteric crest (femur)
- 68f. Quadrato line (femur)

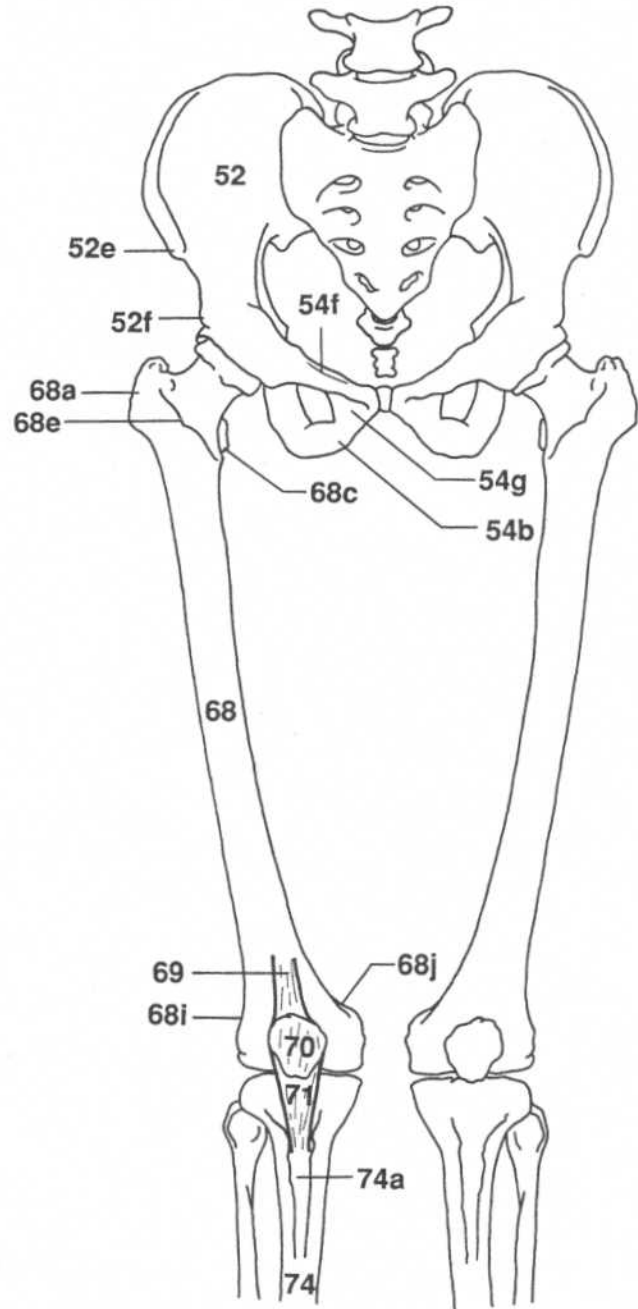
PELVIC GIRDLE AND UPPER LEG—THREE-QUARTER POSTERIOR VIEW

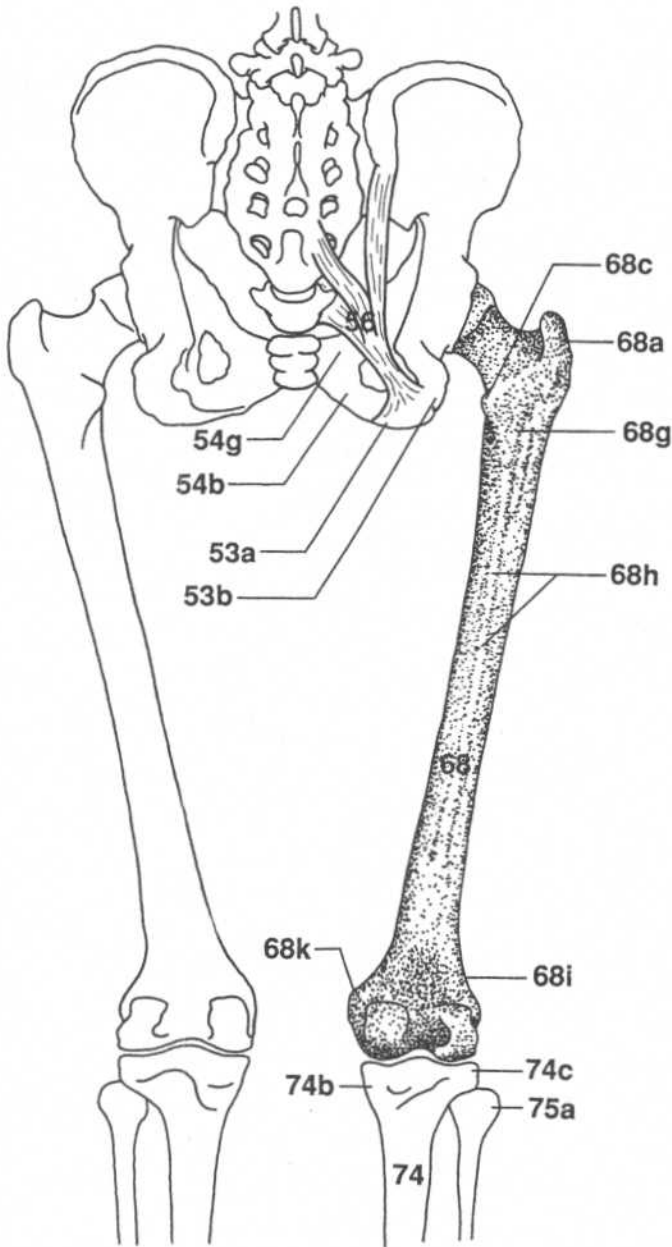


- 26. Sacrum
- 27. Aponeurosis of erector spinae
- 28. Coccyx
- 52b. Iliac crest
- 52j. Posterior gluteal line (ilium)
- 52k. Middle (anterior) gluteal line (ilium)
- 52l. Inferior gluteal line (ilium)
- 53d. Lesser sciatic notch
- 55. Greater sciatic foramen
- 56. Sacrotuberous ligament
- 68a. Greater trochanter (femur)
- 68g. Gluteal tuberosity (femur)
- 68h. Linea aspera (femur)

PELVIC GIRDLE TO LEG—ANTERIOR VIEW

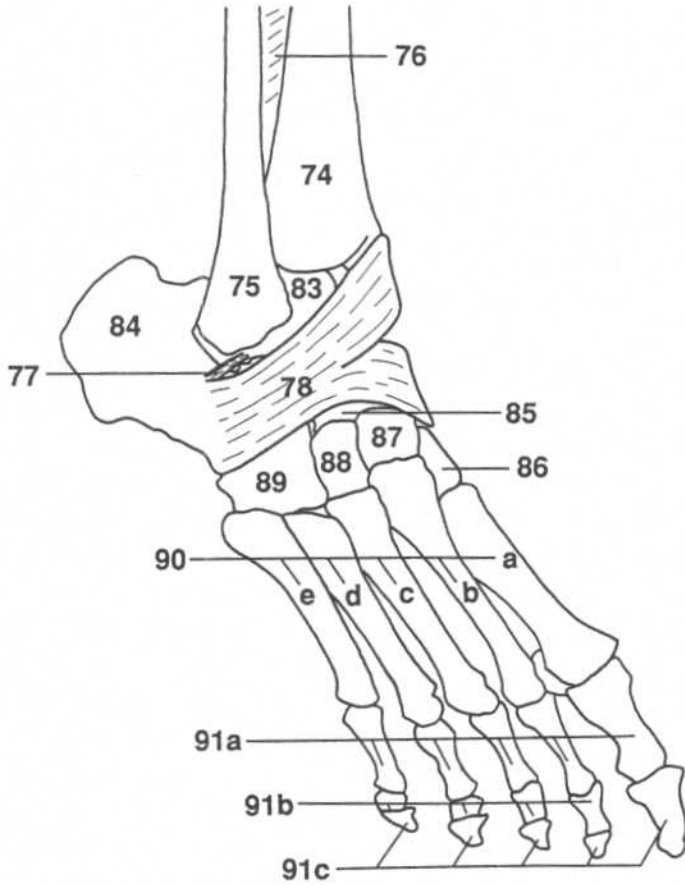
- 52.** Ilium
- 52e.** Anterior superior iliac spine
- 52f.** Anterior inferior iliac spine
- 54b.** Inferior ramus of pubis
- 54f.** Pectineal line (pubis)
- 54g.** Body of pubis
- 68.** Femur
- 68a.** Greater trochanter (femur)
- 68c.** Lesser trochanter (femur)
- 68e.** Intertrochanteric line (femur)
- 68i.** Lateral supracondylar line (femur)
- 68j.** Medial supracondylar line (femur)
- 69.** Quadriceps tendon
- 70.** Patella
- 71.** Patellar ligament
- 74.** Tibia
- 74a.** Tuberosity of tibia



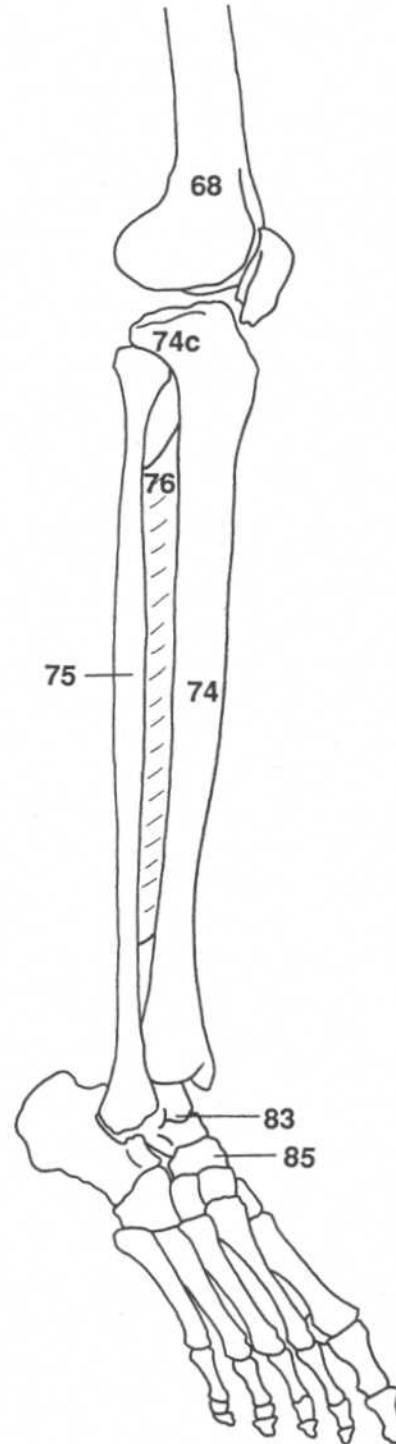
PELVIC GIRDLE TO LEG—POSTERIOR VIEW

- 53a.** Ramus of ischium
- 53b.** Ischial tuberosity
- 54b.** Inferior ramus of pubis
- 54g.** Body of pubis
- 56.** Sacrotuberous ligament
- 68.** Femur
- 68a.** Greater trochanter (femur)
- 68c.** Lesser trochanter (femur)
- 68g.** Gluteal tuberosity (femur)
- 68h.** Linea aspera (femur)
- 68i.** Lateral supracondylar line (femur)
- 68k.** Adductor tubercle (femur)
- 74.** Tibia
- 74b.** Medial condyle of tibia
- 74c.** Lateral condyle of tibia
- 75a.** Head of fibula

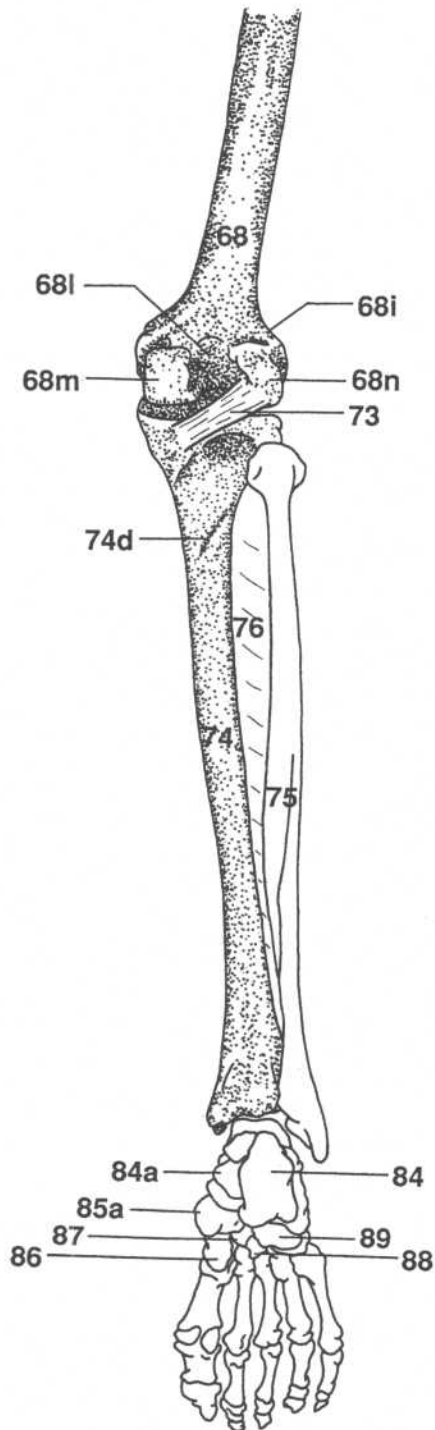
RIGHT FOOT— ANTEROLATERAL VIEW



RIGHT LEG— ANTEROLATERAL VIEW

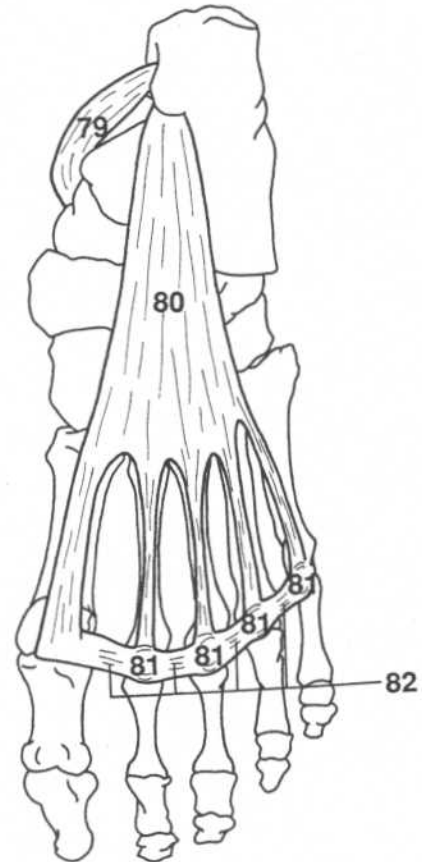
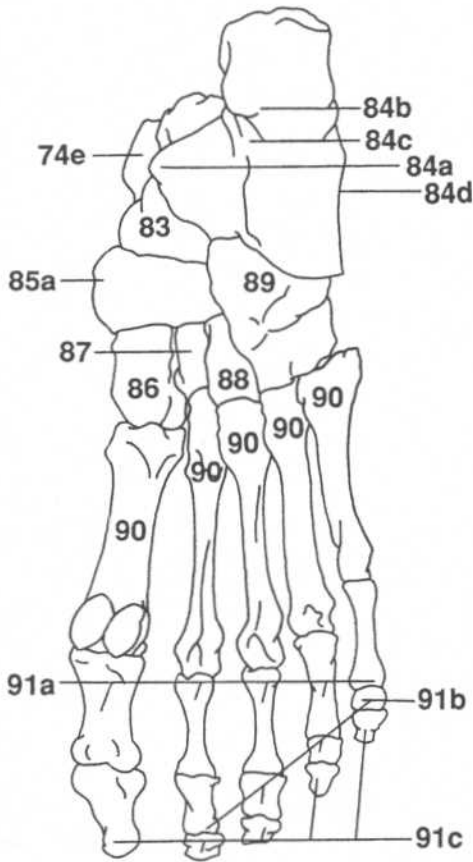


- 68. Femur
- 74. Tibia
- 74c. Lateral condyle of tibia
- 75. Fibula
- 76. Interosseous membrane
- 77. Lateral talocalcaneal ligament
- 78. Inferior extensor retinaculum
- 83. Talus
- 84. Calcaneus
- 85. Navicular
- 86. Medial cuneiform
- 87. Intermediate cuneiform
- 88. Lateral cuneiform
- 89. Cuboid
- 90. Metatarsal bones
- 90a. First metatarsal
- 90b. Second metatarsal
- 90c. Third metatarsal
- 90d. Fourth metatarsal
- 90e. Fifth metatarsal
- 91a. Proximal phalanges
- 91b. Middle phalanges
- 91c. Distal phalanges

RIGHT LEG—POSTERIOR VIEW

- 68.** Femur
- 68i.** Lateral supracondylar line (femur)
- 68l.** Popliteal surface (femur)
- 68m.** Medial condyle (femur)
- 68n.** Lateral condyle (femur)
- 73.** Oblique popliteal ligament
- 74.** Tibia
- 74d.** Soleal line (tibia)
- 75.** Fibula
- 76.** Interosseous membrane
- 84.** Calcaneus
- 84a.** Sustentaculum tali of calcaneus
- 85a.** Tuberosity of navicular
- 86.** Medial cuneiform
- 87.** Intermediate cuneiform
- 88.** Lateral cuneiform
- 89.** Cuboid

RIGHT FOOT—PLANTAR VIEW

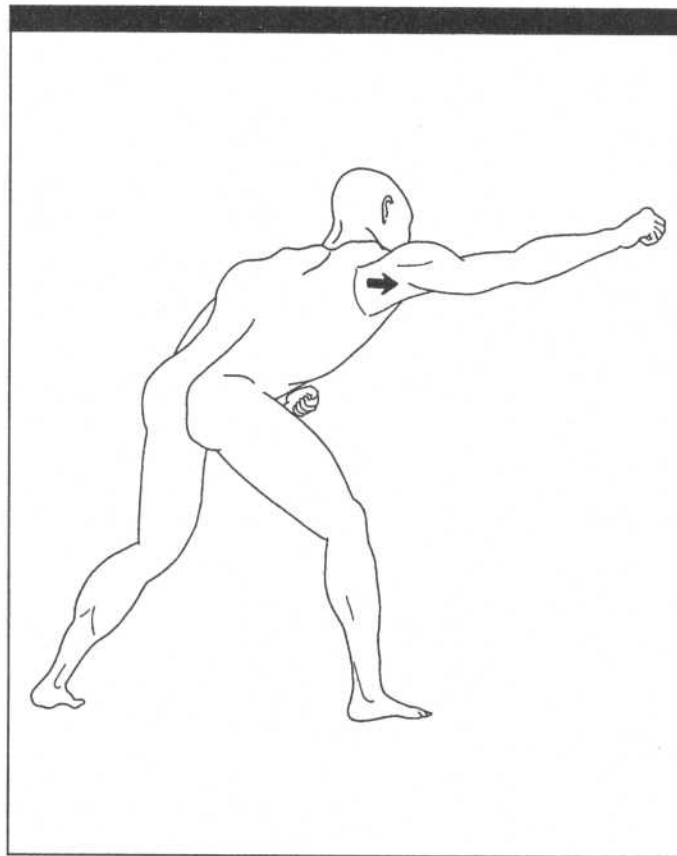


- 74e.** Medial malleolus of tibia
- 79.** Flexor retinaculum
- 80.** Plantar aponeurosis
- 81.** Plantar metatarsophalangeal ligaments
- 82.** Transverse metatarsal ligaments
- 83.** Talus
- 84a.** Sustentaculum tali of calcaneus
- 84b.** Tuberosity of calcaneus
- 84c.** Medial border of calcaneus
- 84d.** Lateral border of calcaneus

- 85a.** Tuberosity of navicular
- 86.** Medial cuneiform
- 87.** Intermediate cuneiform
- 88.** Lateral cuneiform
- 89.** Cuboid
- 90.** Metatarsal bones
- 91a.** Proximal phalanges
- 91b.** Middle phalanges
- 91c.** Distal phalanges

CHAPTER TWO

MOVEMENTS OF THE BODY



Anatomical position—A subject in the anatomical position is standing erect with the head, eyes, and toes facing forward and the arms hanging straight at the sides with the palms of the hands facing forward.

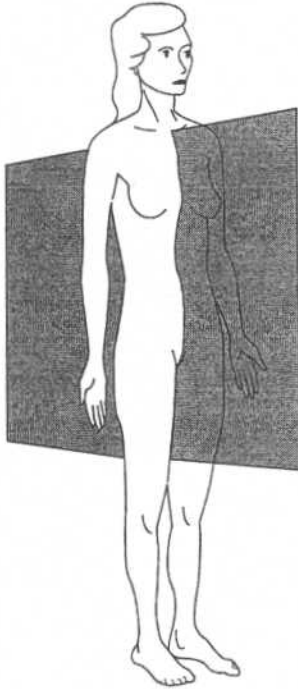


Figure 2.1

Median or midsagittal plane—Passes vertically through the body from anterior (front) to posterior (back). It divides the body into right and left sides. Other sagittal planes are parallel to this plane.

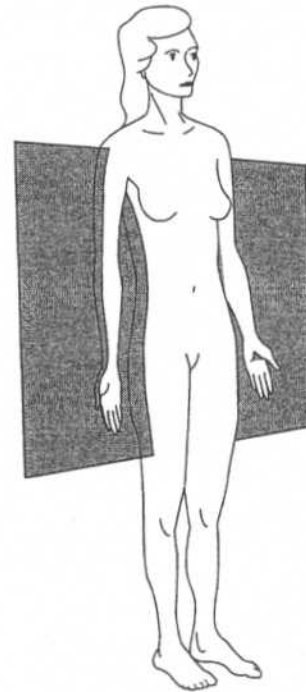


Figure 2.2

Coronal (frontal) planes—Pass vertically through the body from side to side. They divide the body from front to back.

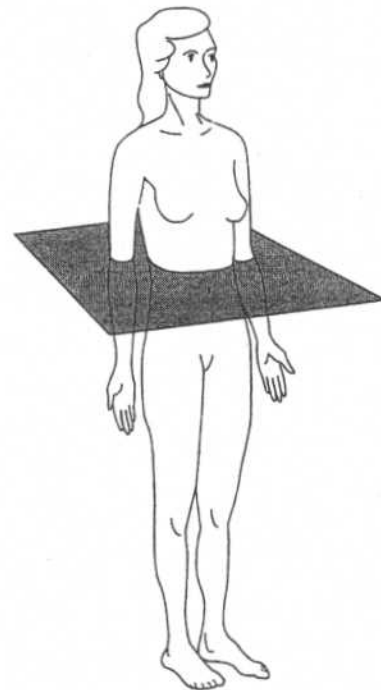
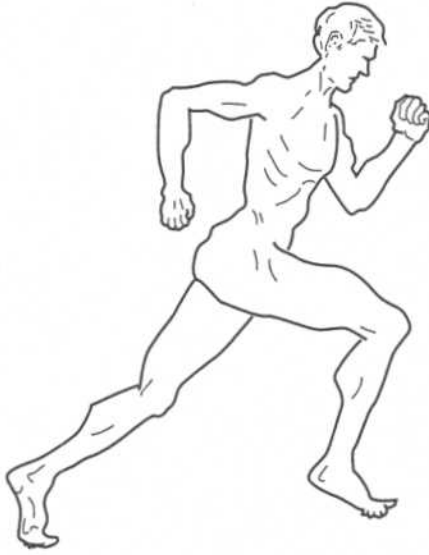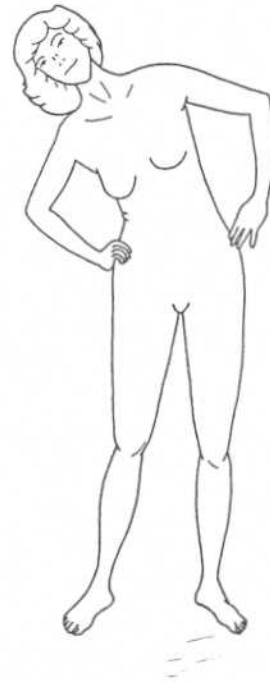


Figure 2.3

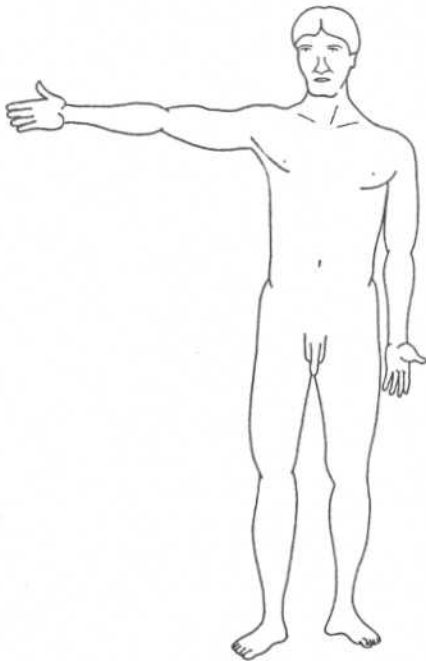
Transverse planes (cross sections)—Pass horizontally through the body parallel to the ground.

**Figure 2.4**

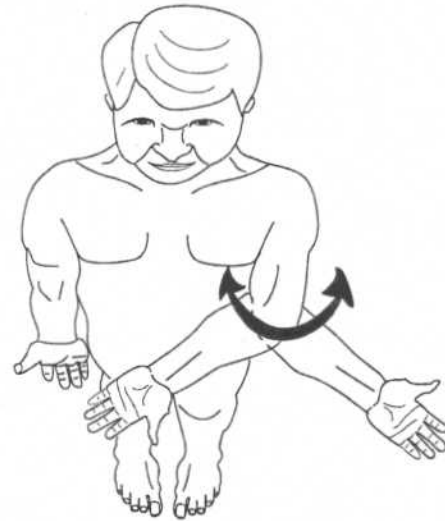
Flexion—The left arm, forearm, and right thigh are drawn forward in sagittal planes. The right knee is also flexed.
 Extension—The left thigh and knee are extended.
 Hyperextension—The right arm is hyperextended at the shoulder.

**Figure 2.5**

Lateral flexion—The torso (or head) bends laterally in the coronal plane.

**Figure 2.6**

Abduction—The right arm is drawn laterally in the coronal plane.
 Adduction—The left arm is returned from abduction to the anatomical position.

**Figure 2.7**

Medial rotation—The anterior of the arm (or thigh) is moved toward the median plane.
 Lateral rotation—The anterior of the arm (or thigh) is moved away from the median plane.

MOVEMENTS OF THE SCAPULA

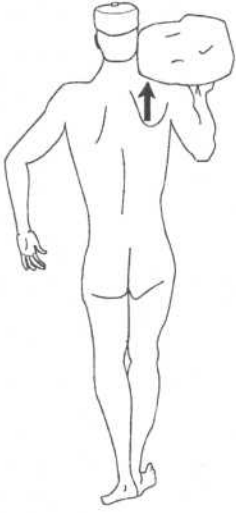


Figure 2.8
Elevation—The right scapula of this figure is drawn superiorly.

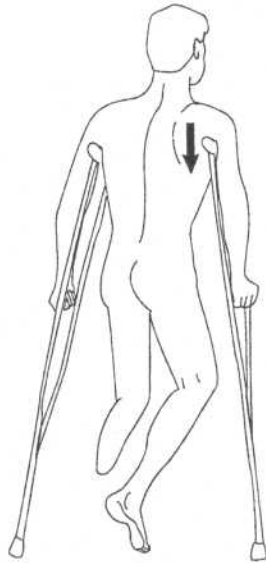


Figure 2.9
Depression—The right scapula of this figure is pushing the arm inferiorly.

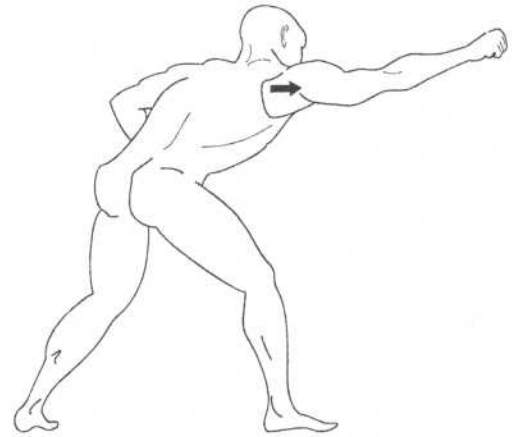


Figure 2.10
Protraction—The scapula pushes the arm forward in a sagittal plane.

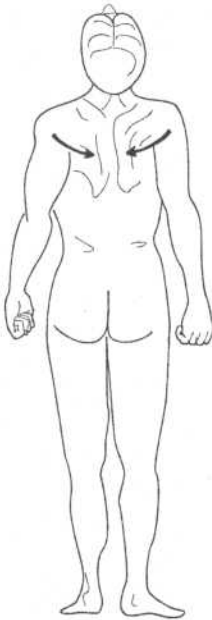


Figure 2.11
Retraction—The scapula is pulled back from protraction in a sagittal plane. Since the scapula slides around the ribs toward the median plane, it becomes adduction.

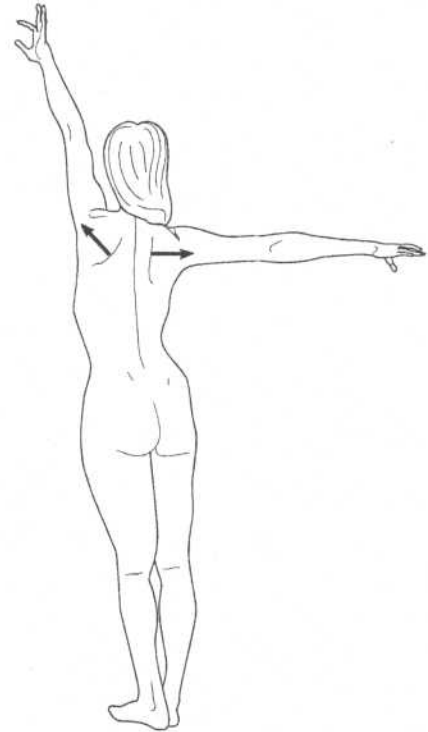


Figure 2.12
Rotation—For abduction of the arm to continue above the height of the shoulder, the scapula must rotate on its axis so that the glenoid fossa turns upward.

MOVEMENTS OF THE HAND AND FOREARM

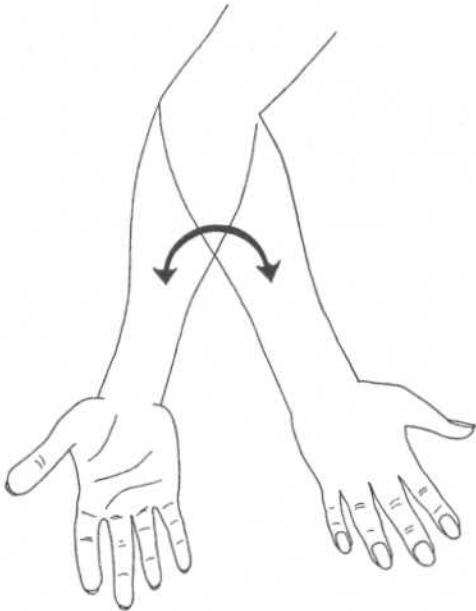


Figure 2.13

Pronation—The forearm is rotated away from the anatomical position so that the palm turns medially then posteriorly. If the forearm is flexed at the elbow, then the palm turns inferiorly.

Supination—The forearm is rotated so that the palm turns anteriorly (or superiorly if the forearm is flexed).

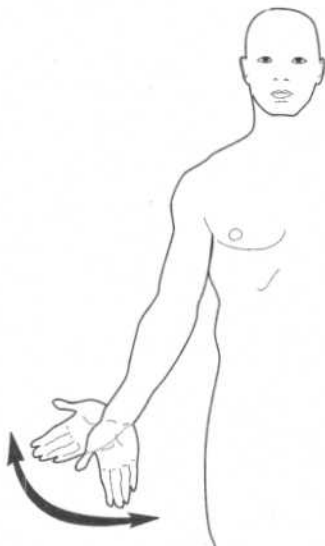


Figure 2.15

Radial flexion (abduction)—The hand, at the wrist, is drawn away from the body in a coronal plane.

Ulnar flexion (adduction)—The hand, at the wrist, is drawn toward the body in a coronal plane.

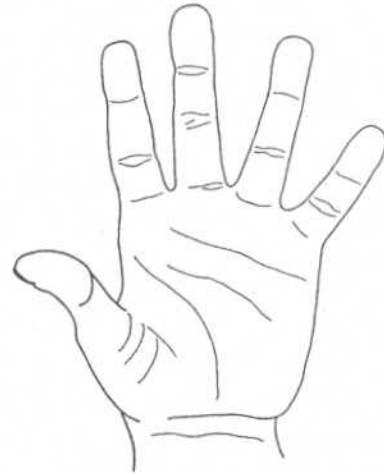


Figure 2.14

Abduction—The fingers are moved away from the midline of the hand.

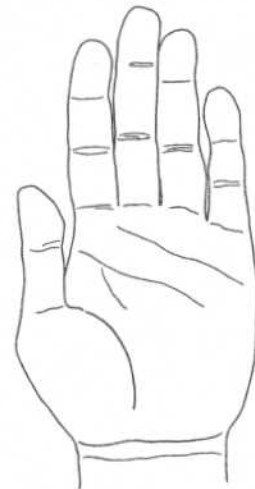

Figure 2.16

Adduction—The fingers are moved toward the midline of the hand.

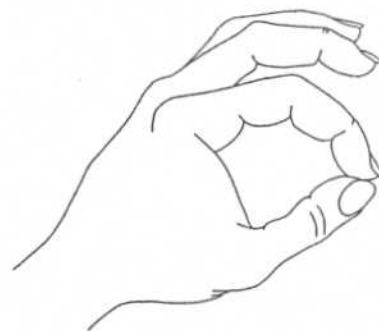

Figure 2.17

Opposition—The thumb is rotated so its anterior pad can touch the anterior pads of the four fingers.

MOVEMENTS OF THE FOOT

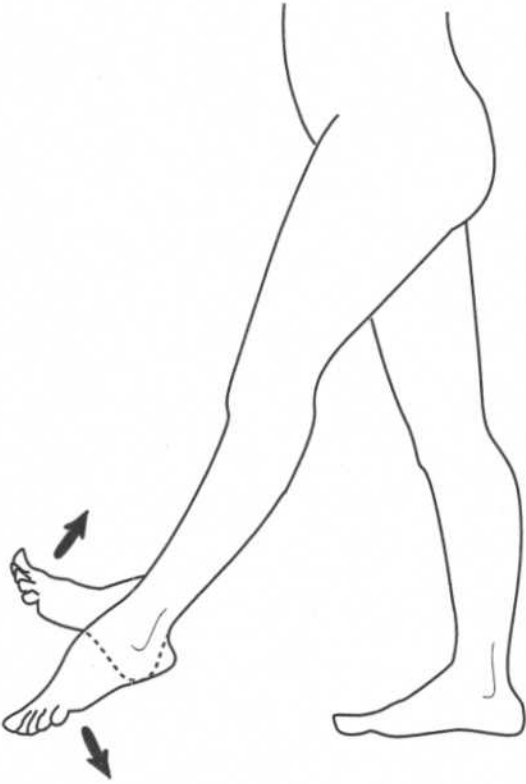


Figure 2.18

Dorsiflexion—The ankle flexes, moving the foot superiorly.
Plantar Flexion—The ankle extends, moving the foot inferiorly.

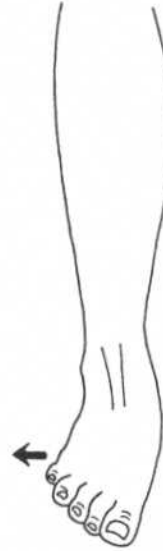

Figure 2.19

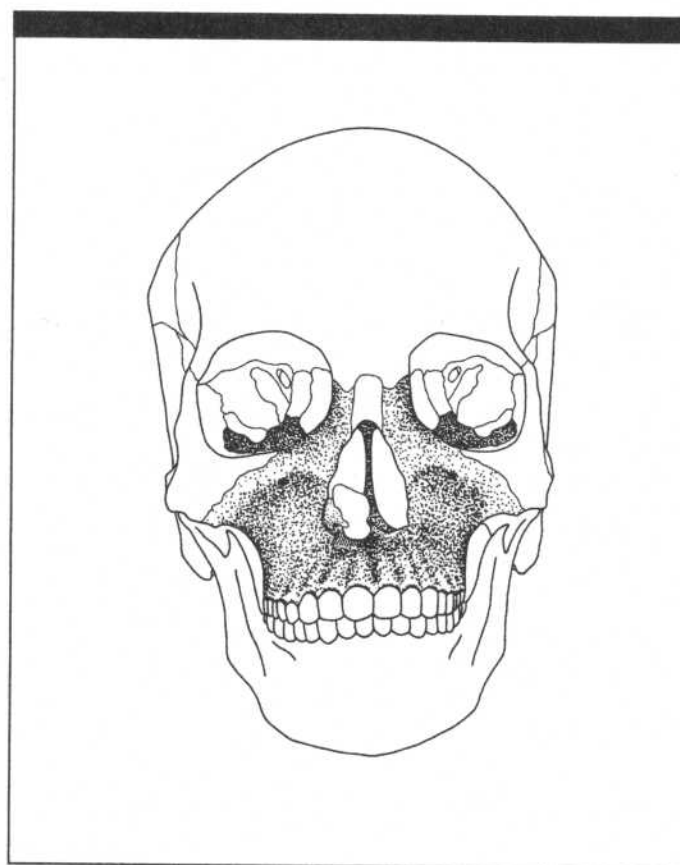
Eversion—The front of the foot moves laterally away from the midline (abduction), and the sole turns outward.

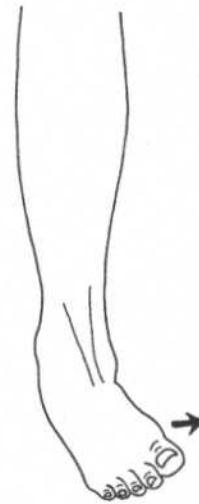

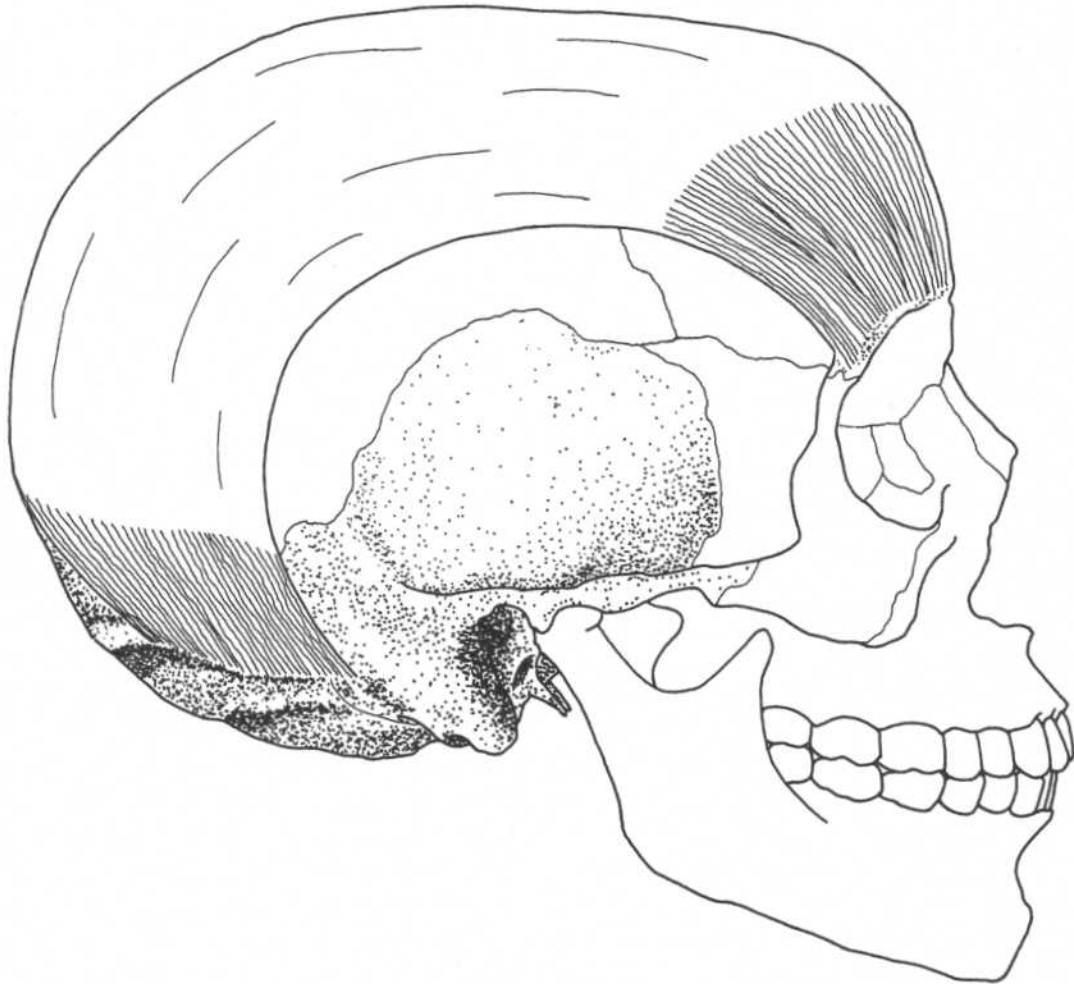
Figure 2.20

Inversion—The front of the foot moves medially toward the midline (adduction), and the sole turns inward.

CHAPTER THREE
MUSCLES OF THE FACE AND HEAD



EPICRANIUS



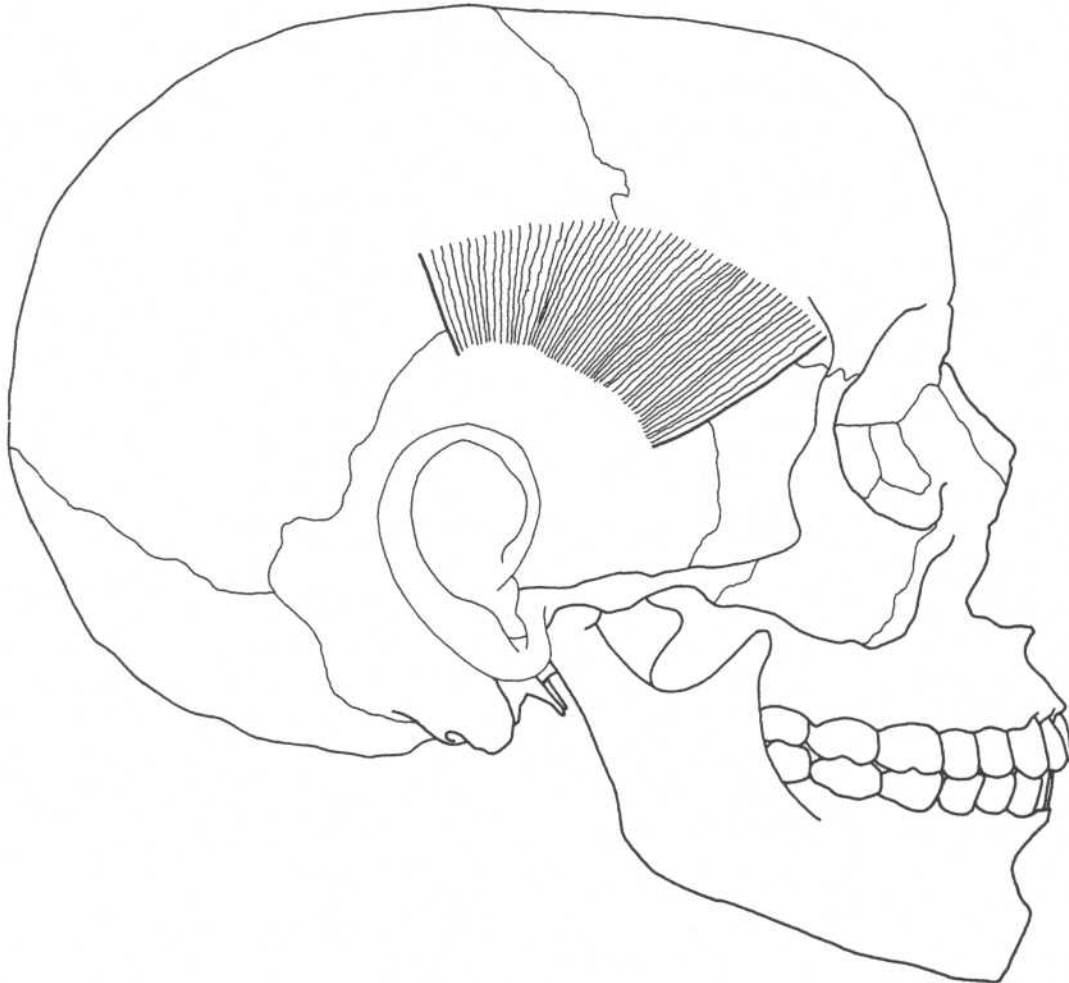
Skull—lateral view

Occipital belly (*occipitalis*)

Origin	Lateral two-thirds of superior nuchal line of occipital bone, mastoid process of temporal bone
Insertion	Galea aponeurotica (an intermediate tendon leading to frontal belly)
Action	Draws back scalp, aids frontal belly to wrinkle forehead and raise eyebrows
Nerve	Posterior auricular branch of facial nerve

Frontal belly (*frontalis*)

Origin	Galea aponeurotica
Insertion	Fascia of facial muscles and skin above nose and eyes
Action	Draws back scalp, wrinkles forehead, raises eyebrows
Nerve	Temporal branches of facial nerve

TEMPOROPARIETALIS**Skull—lateral view****Origin**

Fascia over ear

Insertion

Lateral border of galea aponeurotica

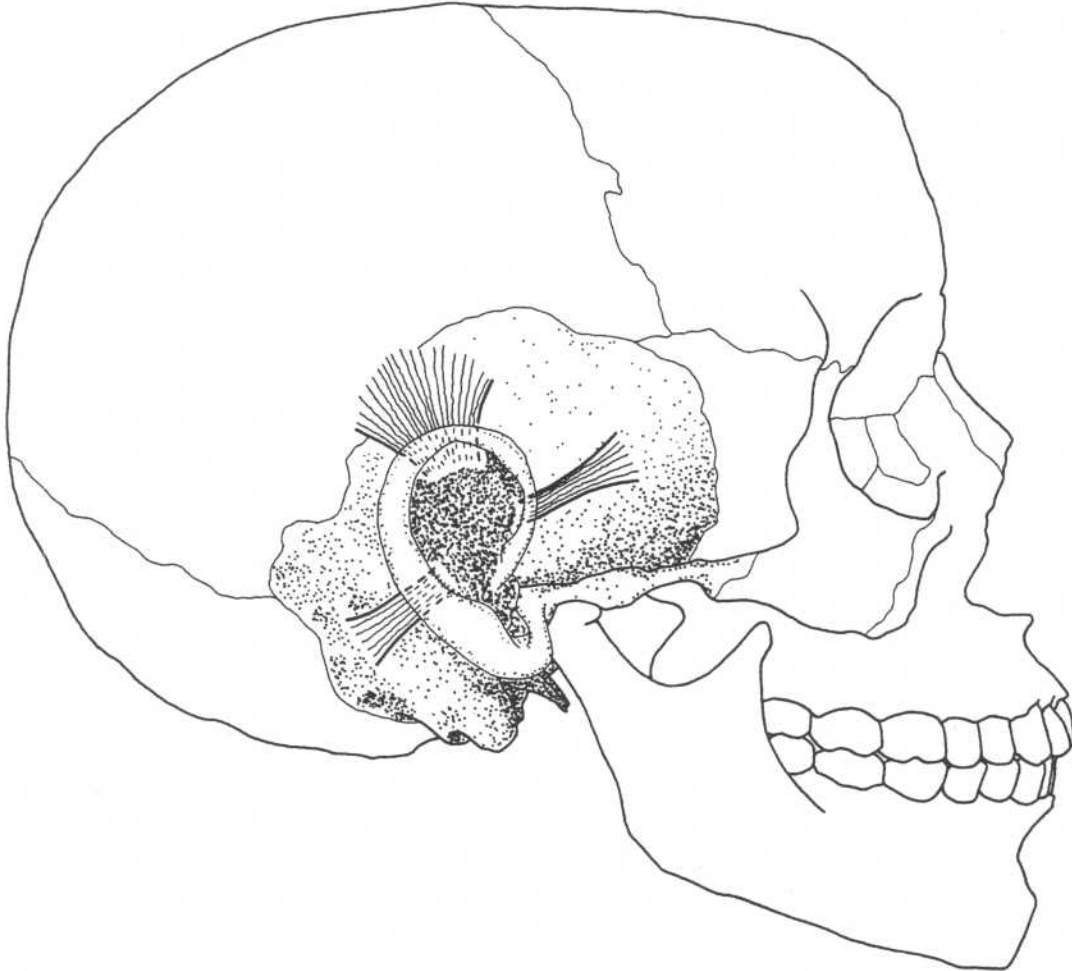
Action

Raises ears, tightens scalp

Nerve

Temporal branch of facial nerve

AURICULARIS ANTERIOR, SUPERIOR, POSTERIOR



Skull—lateral view

Auricularis anterior

Origin	Fascia in temporal region
Insertion	Anterior to helix of ear
Action	Draws ear forward in some individuals, moves scalp*
Nerve	Temporal branch of facial nerve

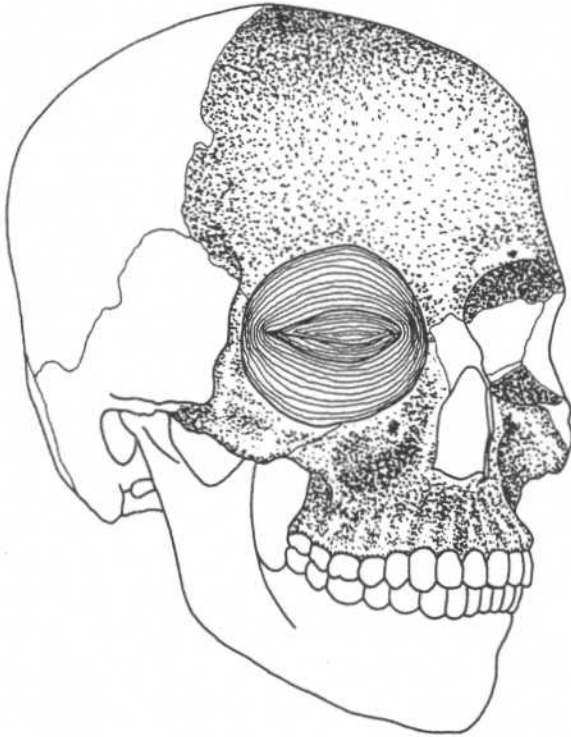
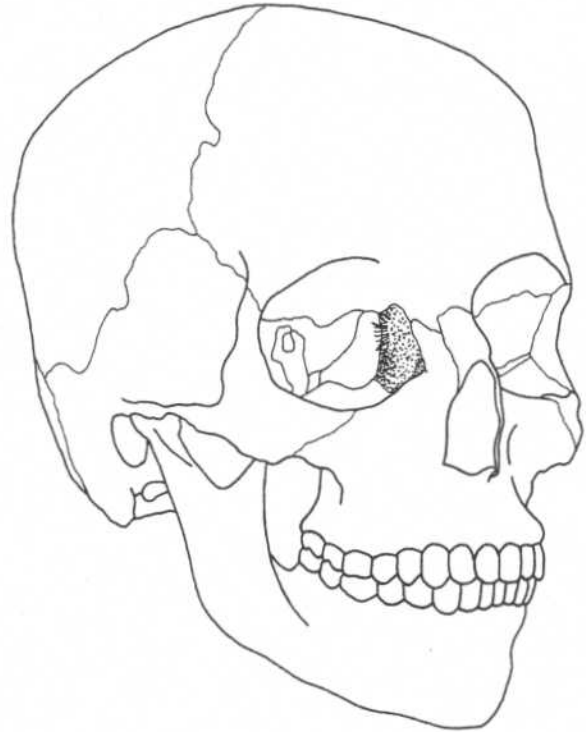
Auricularis superior

Origin	Fascia in temporal region
Insertion	Superior part of ear
Action	Draws ear upward in some individuals, moves scalp*
Nerve	Temporal branch of facial nerve

Auricularis posterior

Origin	Mastoid area of temporal bone
Insertion	Posterior part of ear
Action	Draws ear upward in some individuals*
Nerve	Posterior auricular branch of facial nerve

*This muscle is nonfunctional in most people.

ORBICULARIS OCULI**ORBITAL AND PALPEBRAL PARTS****LACRIMAL PART****Skull—three-quarter anterior view****Orbital part**

Origin	Frontal bone, maxilla (medial margin of orbit)
Insertion	Continues around orbit and returns to origin
Action	Strong closure of eyelids
Nerve	Temporal and zygomatic branches of facial nerve

Lacrimal part (*behind medial palpebral ligament and lacrimal sac*)

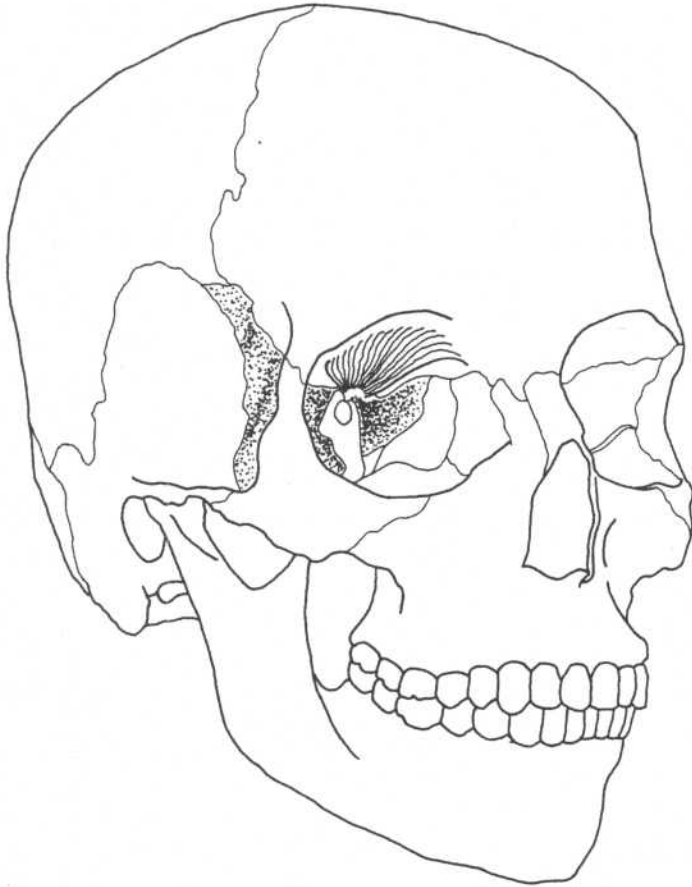
Origin	Lacrimal bone
Insertion	Lateral palpebral raphe
Action	Draws lacrimal canals onto surface of eye
Nerve	Temporal and zygomatic branches of facial nerve

Palpebral part (*in eyelids*)

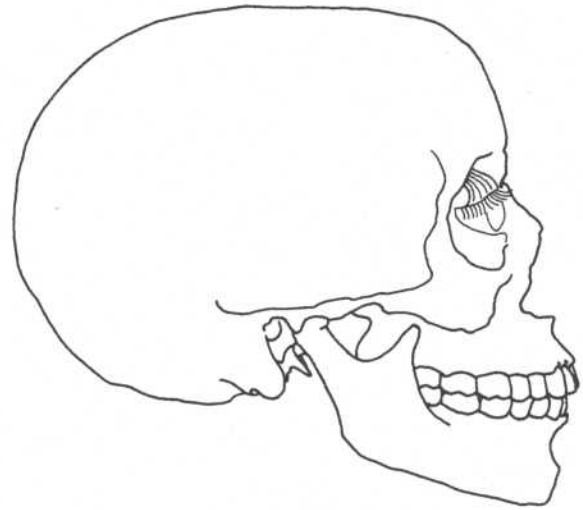
Origin	Medial palpebral ligament
Insertion	Lateral palpebral ligament into zygomatic bone
Action	Gentle closure of eyelids
Nerve	Temporal and zygomatic branches of facial nerve

LEVATOR PALPEBRAE SUPERIORIS

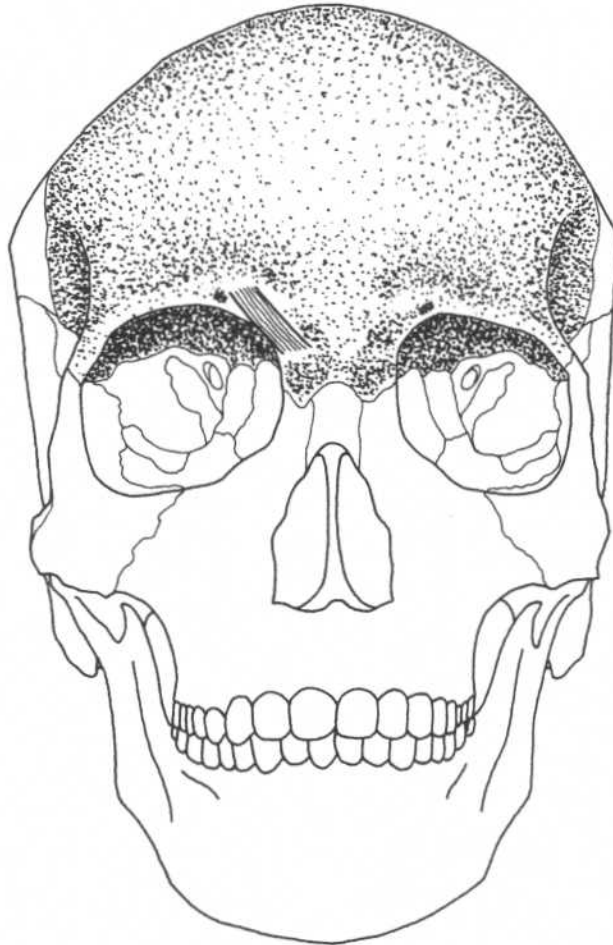
Origin	Inferior surface of lesser wing of sphenoid
Insertion	Skin of upper eyelid
Action	Raises upper eyelid
Nerve	Oculomotor nerve



Skull—three-quarter anterior view



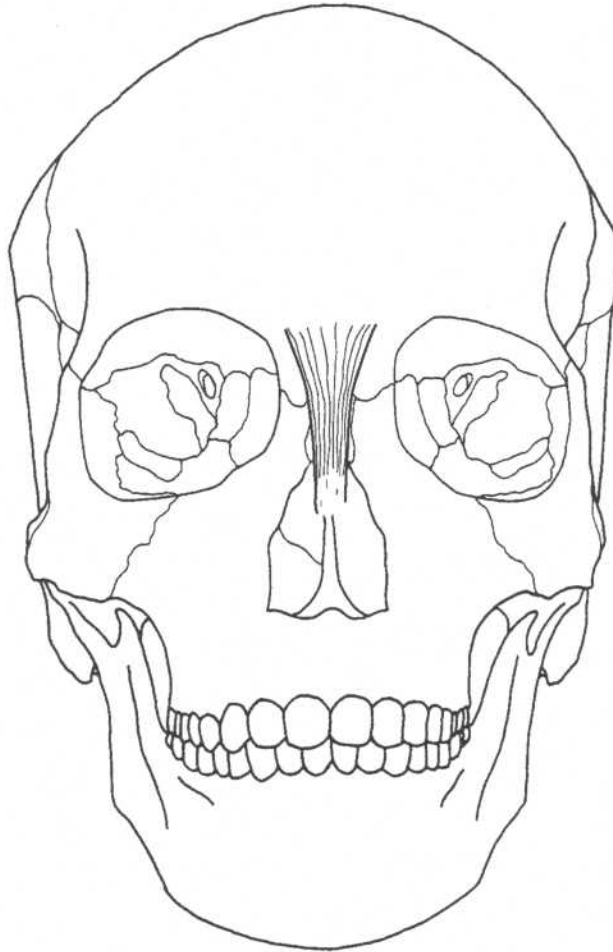
Skull—lateral view

CORRUGATOR SUPERCILII**Skull—anterior view****Origin**
Insertion

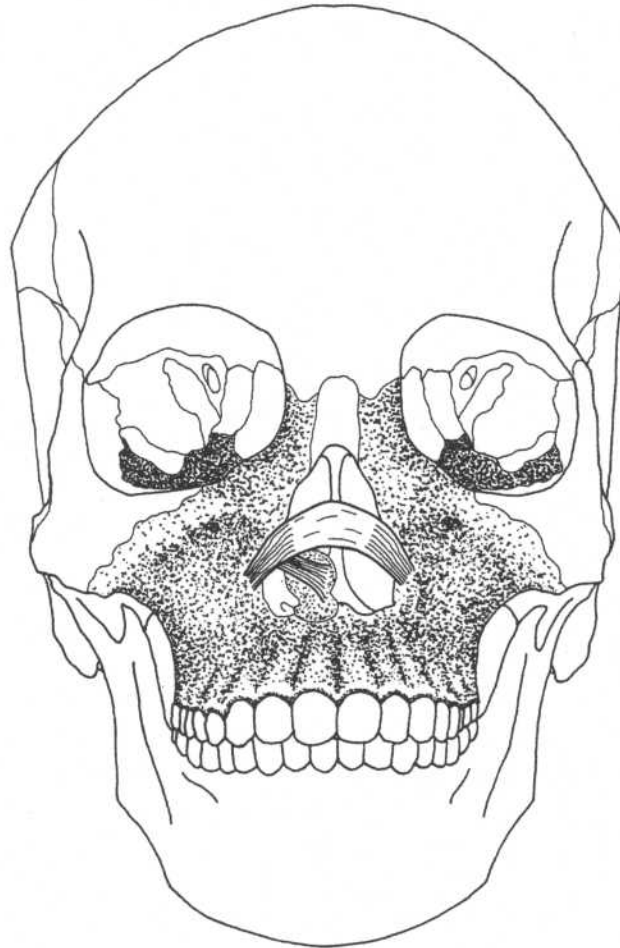
Medial end of superciliary arch
Deep surface of skin under medial
portion of eyebrows

Action
Nerve

Draws eyebrows downward and
medially
Temporal branch of facial nerve

PROCERUS**Skull—anterior view**

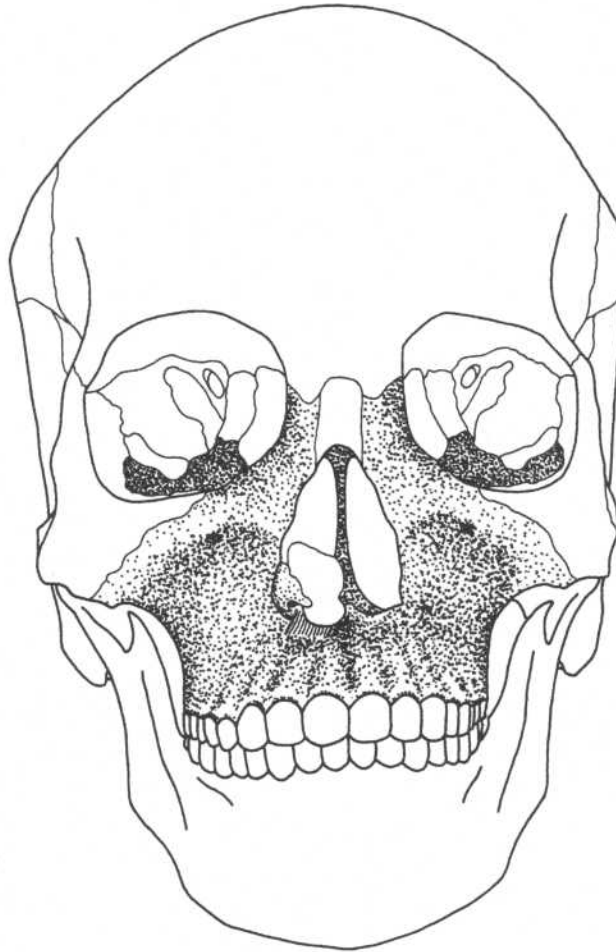
Origin	Fascia over nasal bone and lateral nasal cartilage	Action	Draws down medial part of eyebrows, wrinkles nose
Insertion	Skin between eyebrows	Nerve	Buccal branches of facial nerve

NASALIS**Skull—anterior view****Transverse part**

Origin Middle of maxilla
Insertion Muscle of opposite side over bridge of nose

Alar part

Origin Greater alar cartilage, skin on nose
Insertion Skin at point of nose
Action Both parts maintain opening of external nares during forceful inspiration
Nerve Buccal branches of facial nerve

DEPRESSOR SEPTI**Skull—anterior view****Origin**

Incisive fossa of maxilla

Insertion

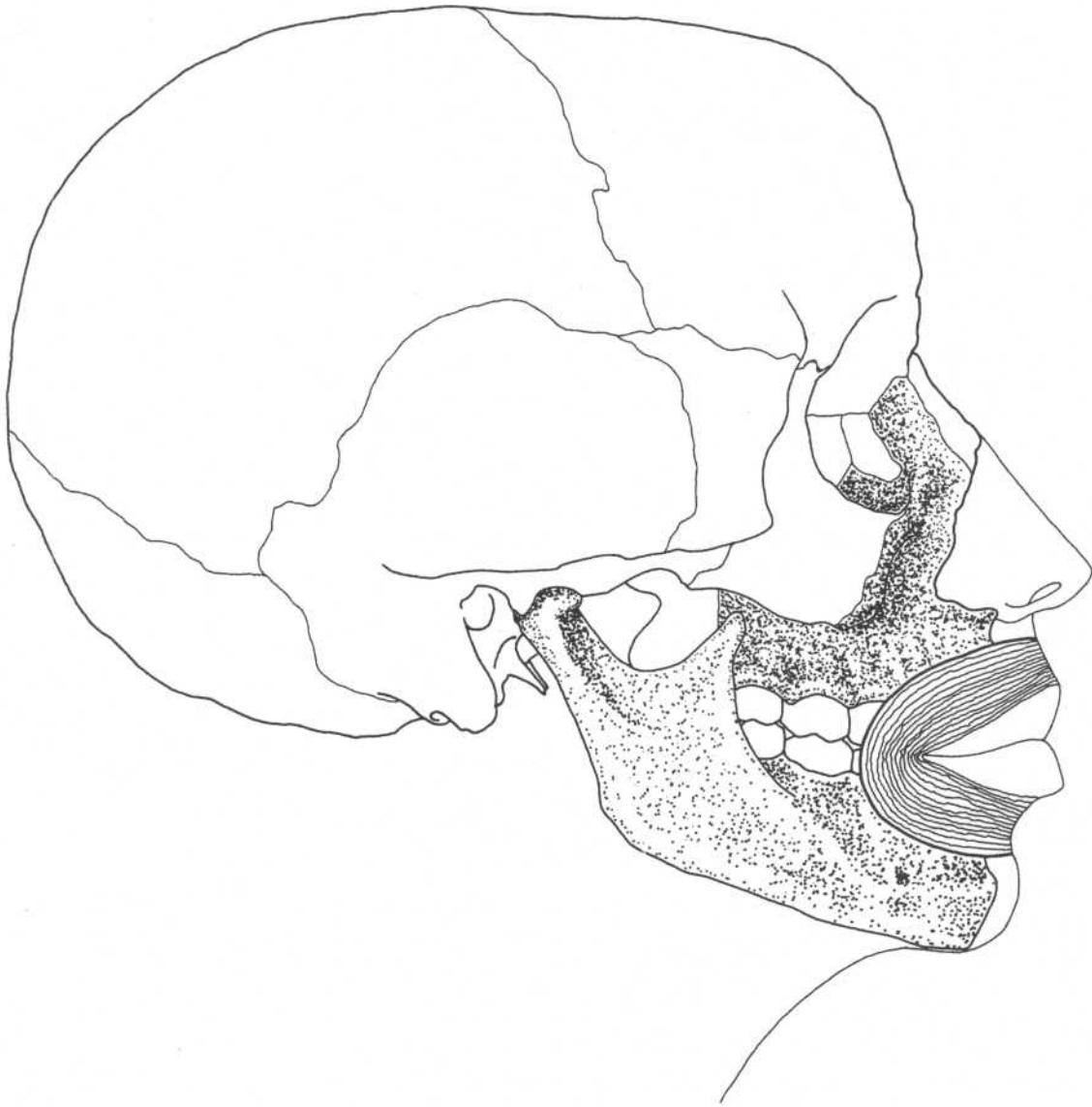Nasal septum and ala

Action

Constricts nares

Nerve

Buccal branches of facial nerve

ORBICULARIS ORIS**Skull—lateral view****Origin**

Lateral band—alveolar border of maxilla
 Medial band—septum of nose
 Inferior portion—lateral to midline of mandible

Insertion

Becomes continuous with other muscles at angle of mouth

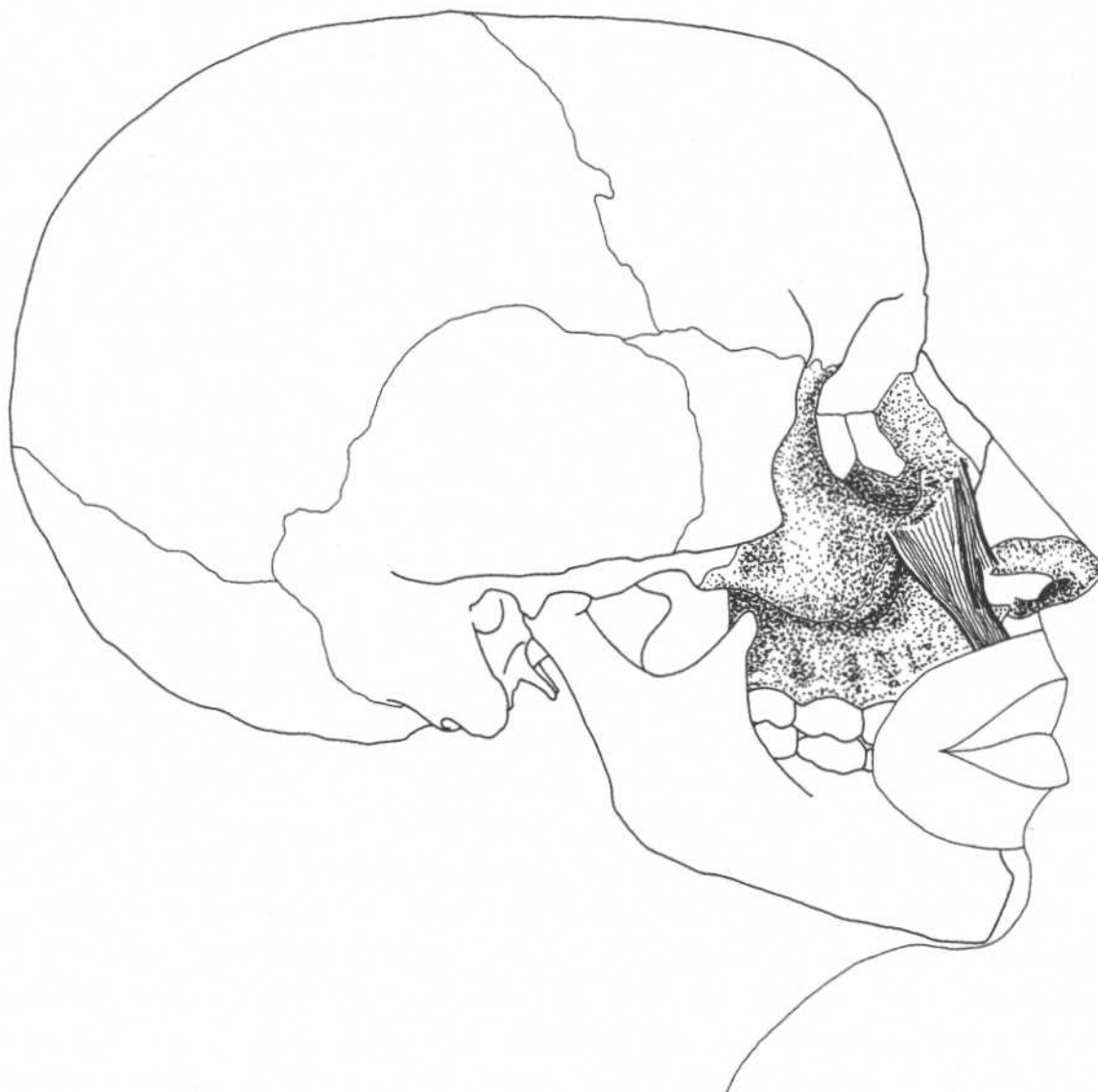
Action

Closure and protrusion of lips

Nerve

Buccal and mandibular branches of facial nerve

LEVATOR LABII SUPERIORIS



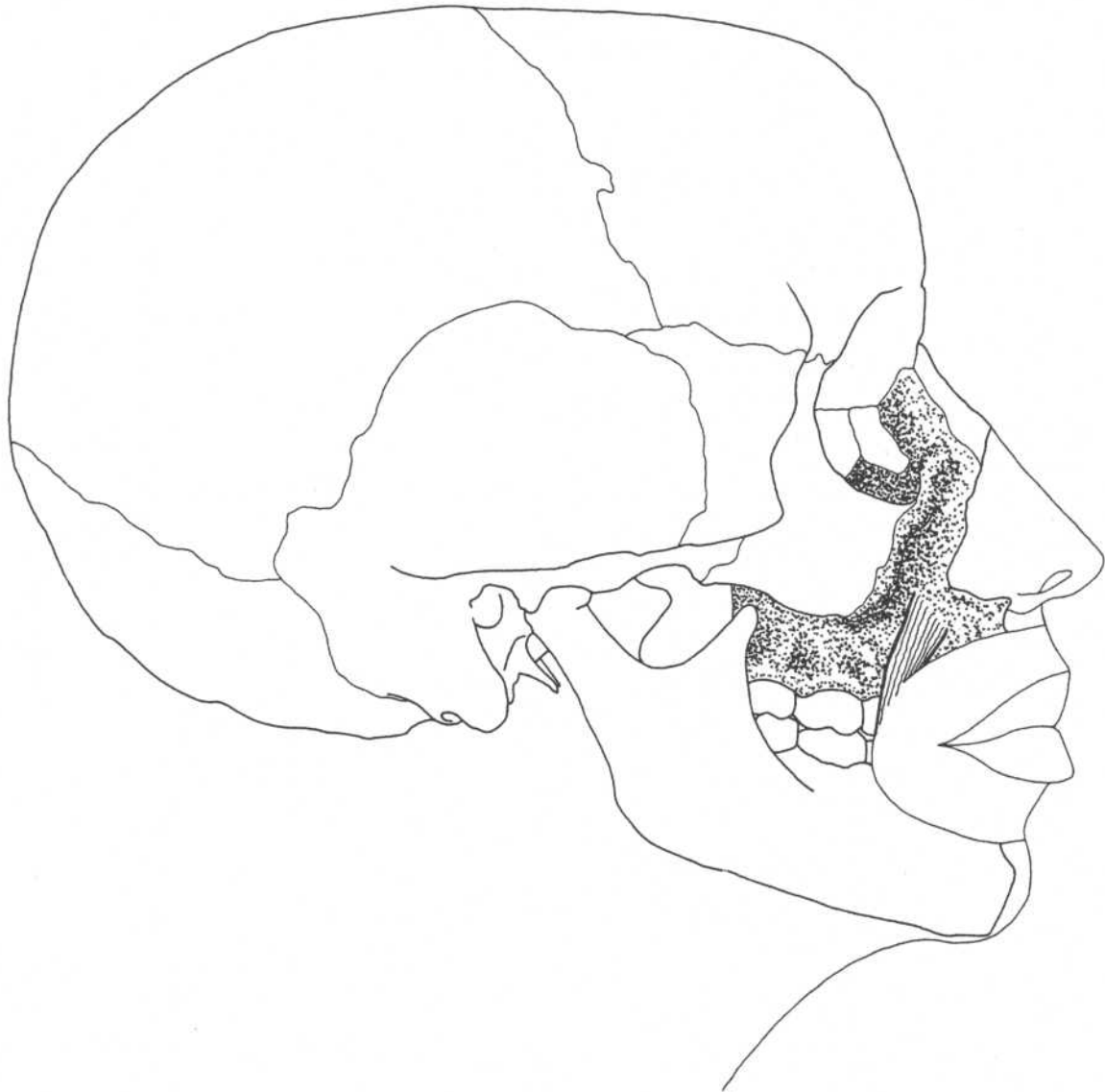Skull—lateral view

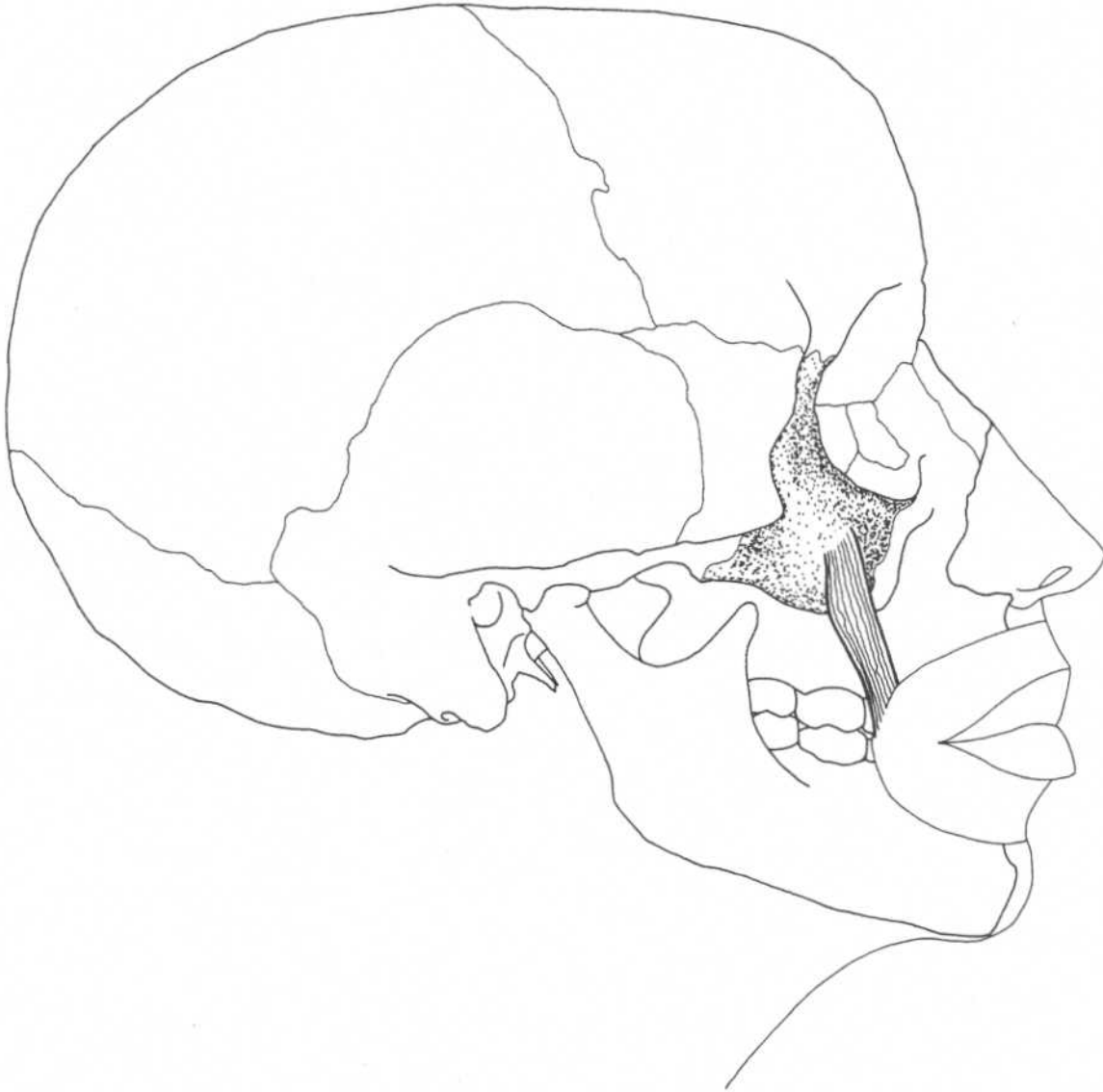Angular head

Origin	Frontal process of maxilla and zygomatic bone
Insertion	Greater alar cartilage and skin of nose, upper lip
Action	Elevates upper lip, dilates nares, forms nasolabial furrow
Nerve	Buccal branches of facial nerve

Infraorbital head

Origin	Lower margin of orbit
Insertion	Muscles of upper lip
Action	Elevates upper lip
Nerve	Buccal branches of facial nerve

LEVATOR ANGULI ORIS**Skull—lateral view****Origin**
InsertionCanine fossa of maxilla
Angle of mouth**Action**
NerveElevates corner (angle) of mouth
Buccal branches of facial nerve

ZYGOMATICUS MAJOR**Skull—lateral view**

Origin
Insertion

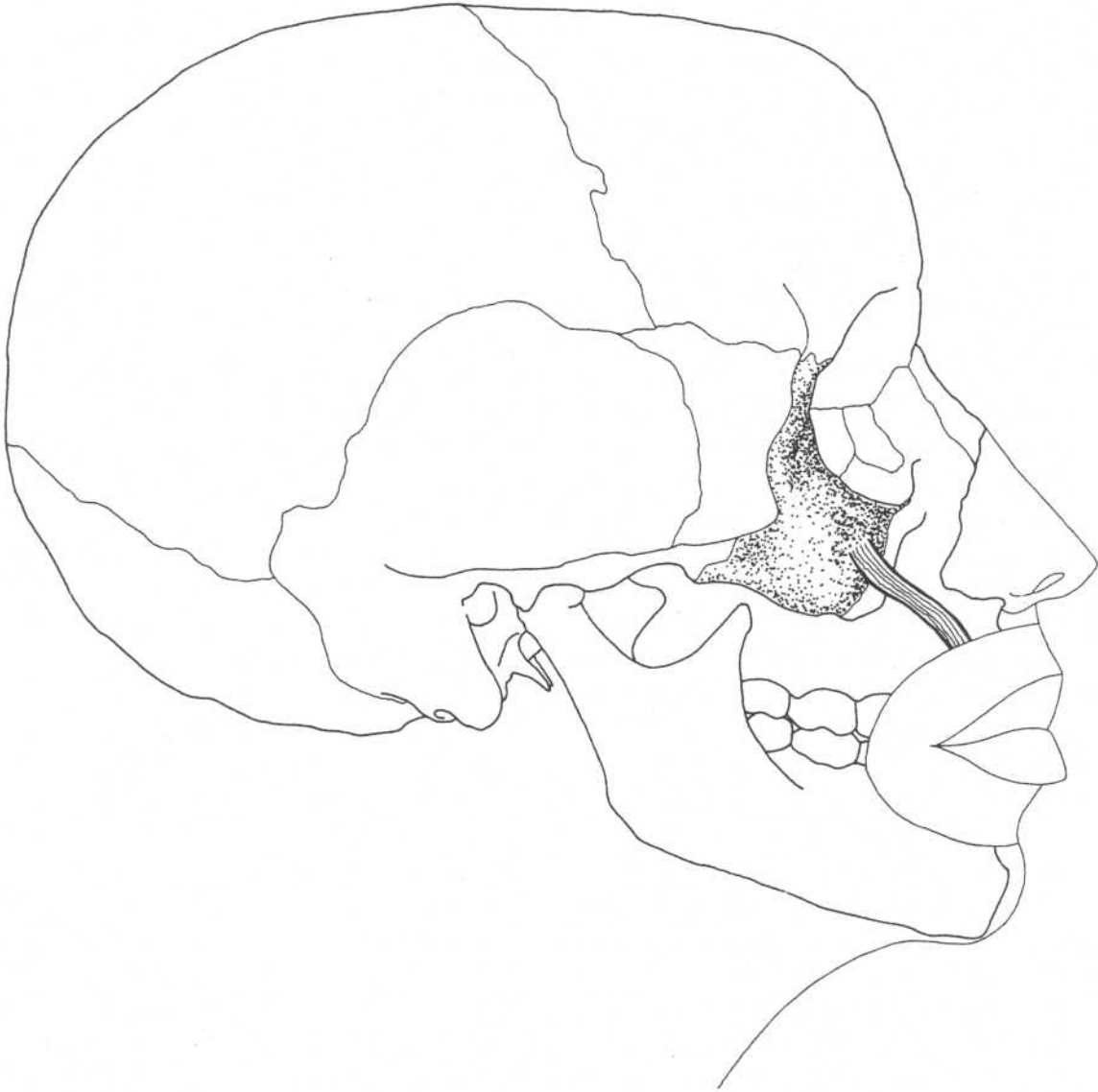Zygomatic bone
Angle of mouth

Action

Draws angle of mouth upward and backward (laughing)

Nerve

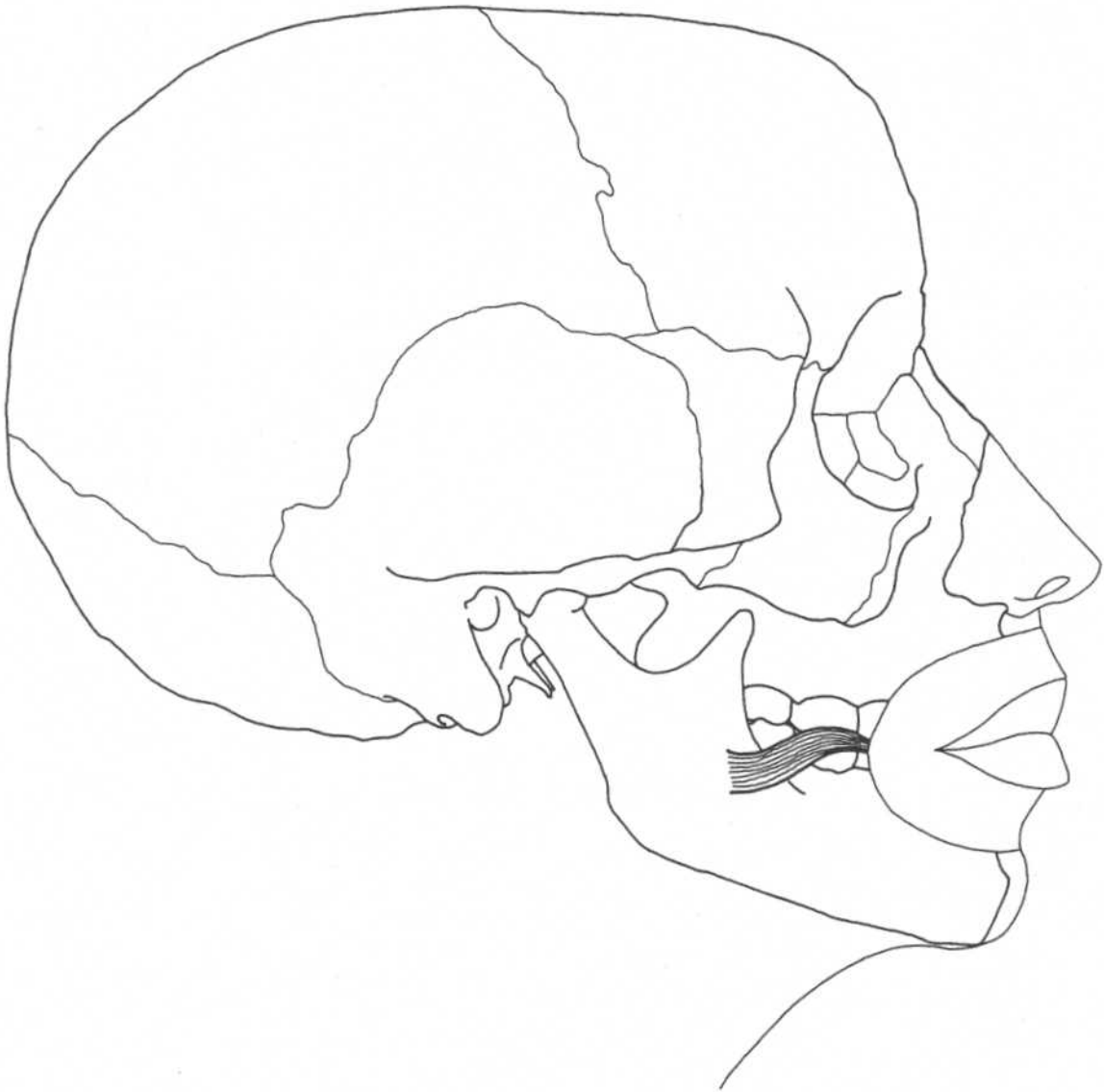
Buccal branches of facial nerve

ZYGOMATICUS MINOR**Skull—lateral view****Origin**
Insertion

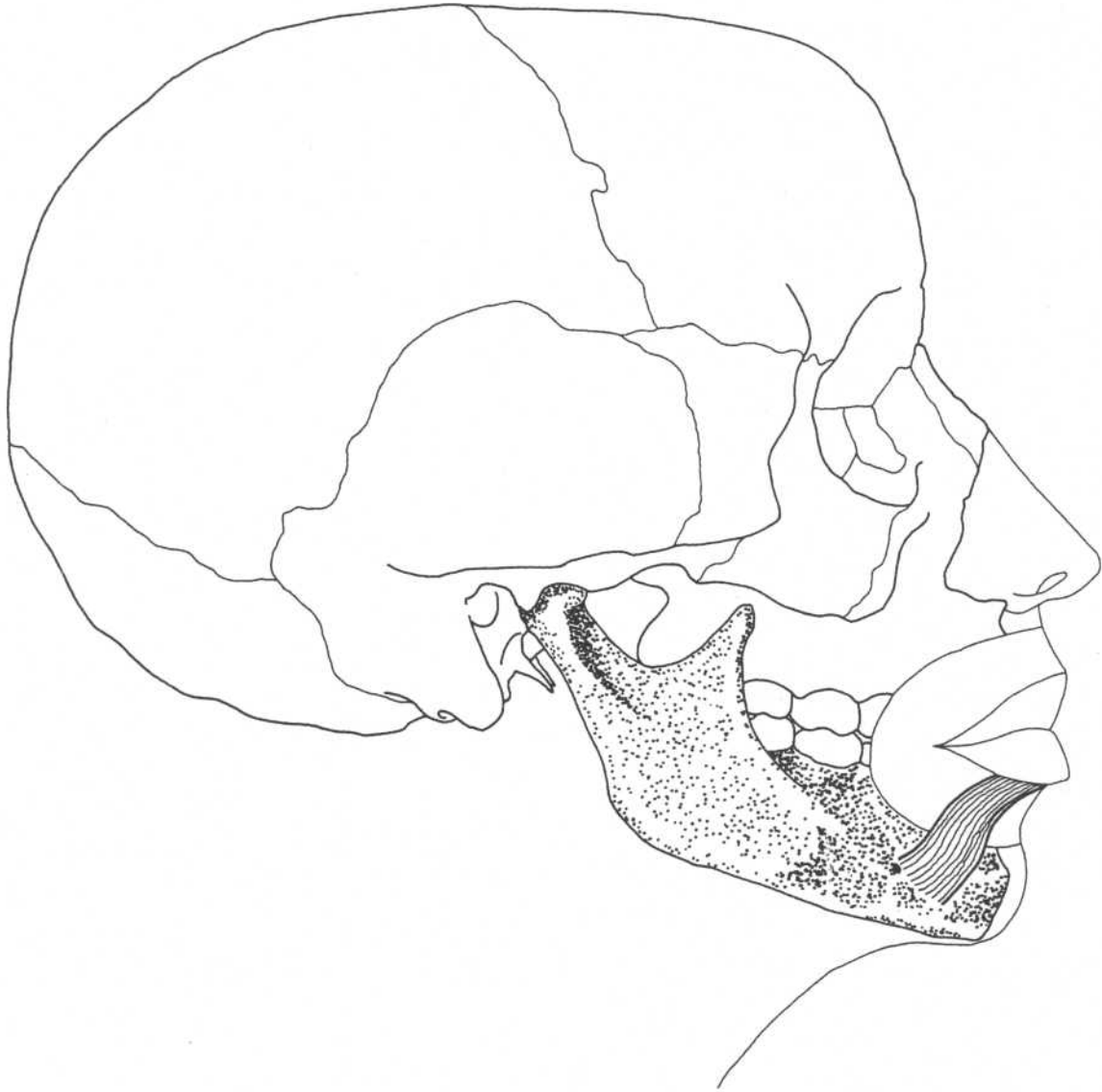
Zygomatic bone
Upper lip lateral to levator labii
superioris

Action
Nerve

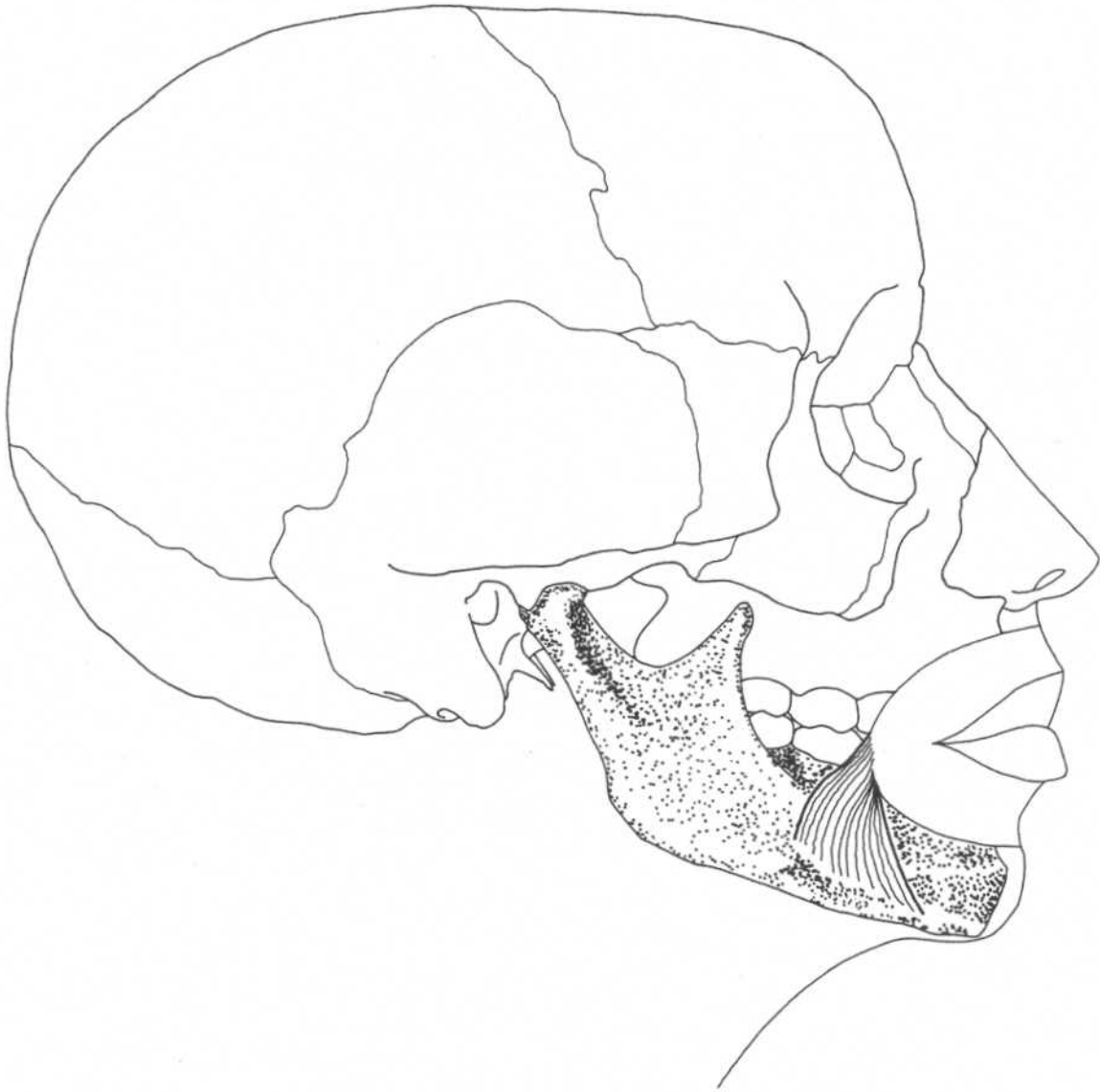Forms nasolabial furrow
Buccal branches of facial nerve

RISORIUS**Skull—lateral view**

Origin	Fascia over masseter	Action	Retracts angle of mouth, as in grinning
Insertion	Skin at angle of mouth	Nerve	Buccal branches of facial nerve

DEPRESSOR LABII INFERIORIS**Skull—lateral view**

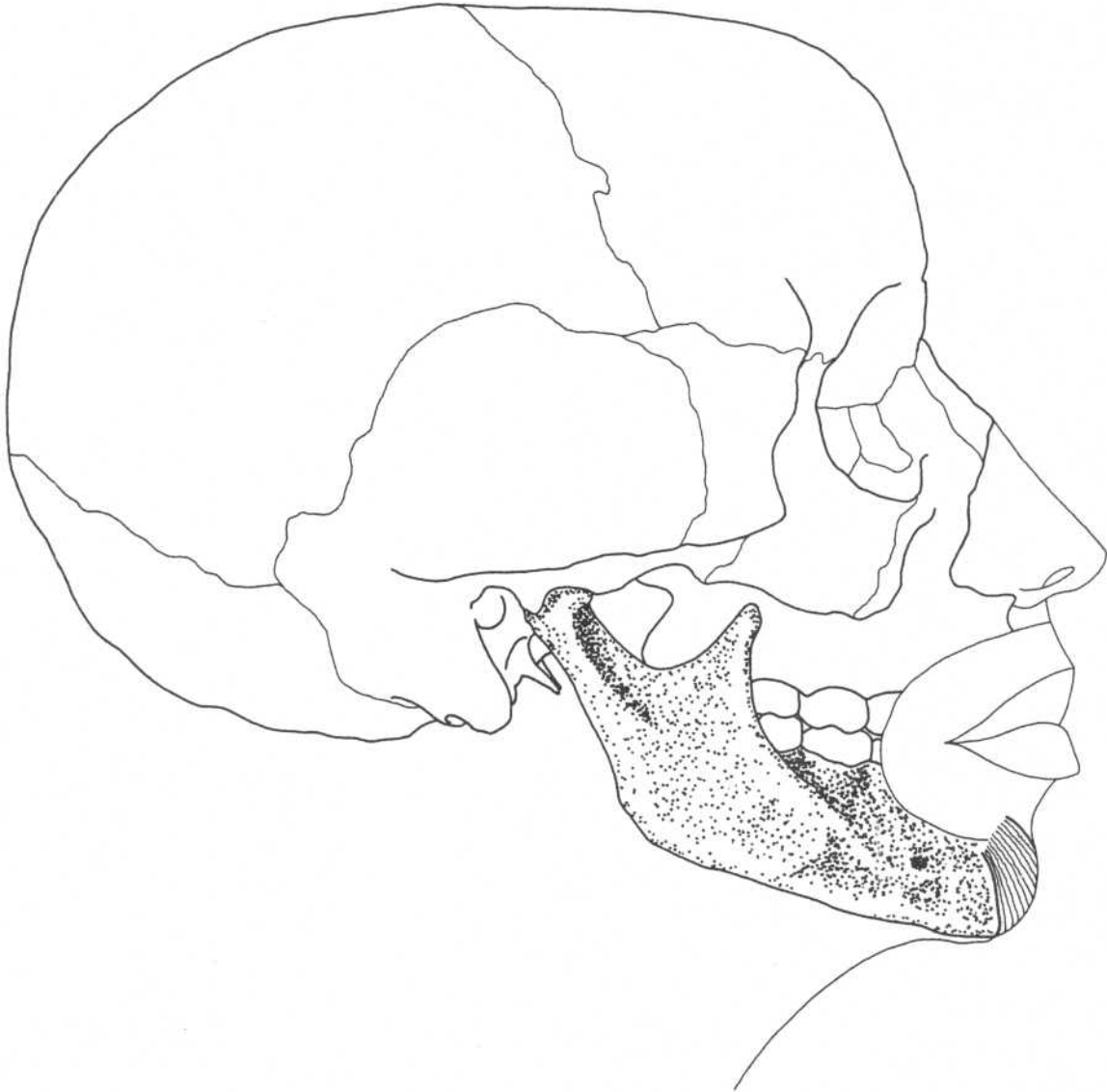
Origin	Mandible, between symphysis and mental foramen	Action	Draws lower lip downward and laterally
Insertion	Skin of lower lip	Nerve	Mandibular branch of facial nerve

DEPRESSOR ANGULI ORIS**Skull—lateral view****Origin**
Insertion

Oblique line of the mandible
Angle of the mouth

Action
Nerve

Depresses angle of mouth, as in
frowning
Mandibular branch of facial nerve

MENTALIS**Skull—lateral view****Origin**
Insertion

Incisive fossa of mandible
Skin of chin

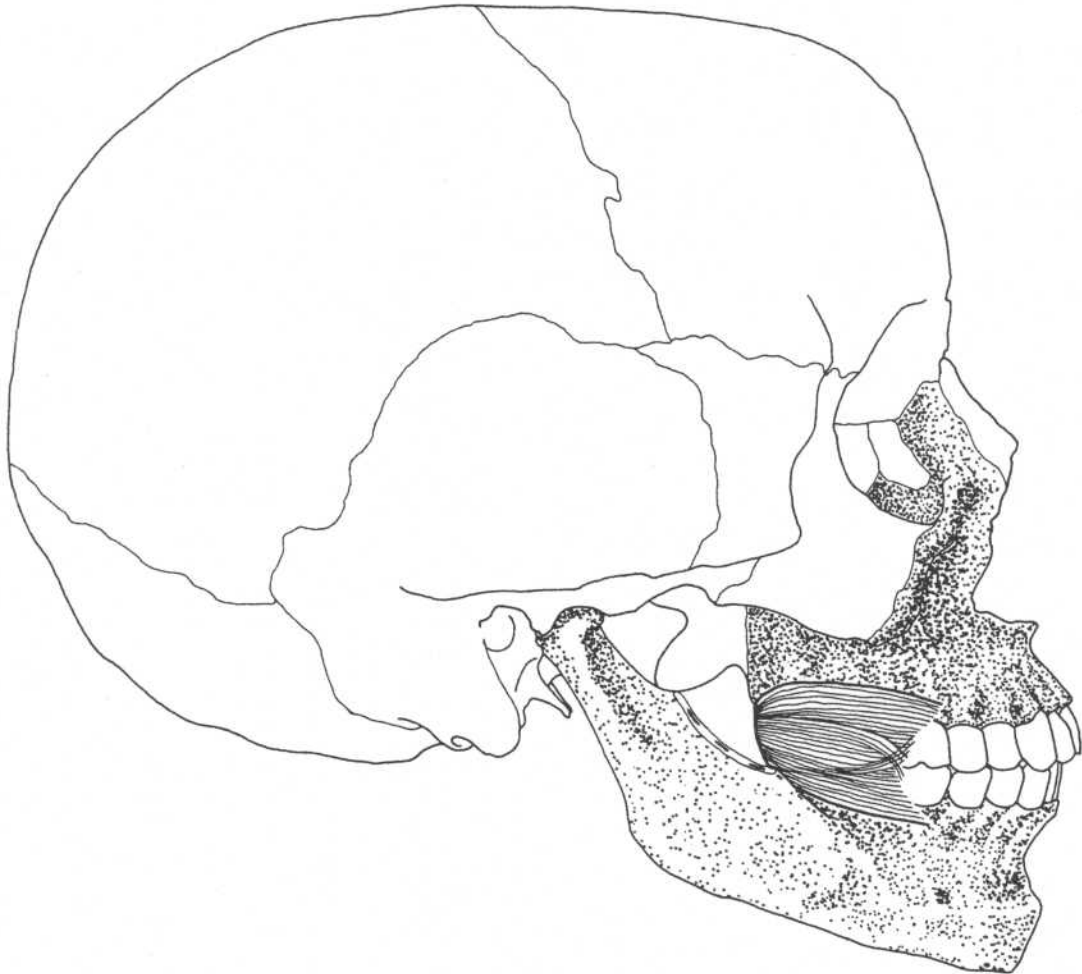
Action

Raises and protrudes lower lip,
wrinkles skin of chin

Nerve

Mandibular branch of facial nerve

BUCCINATOR



Skull—lateral view

Origin

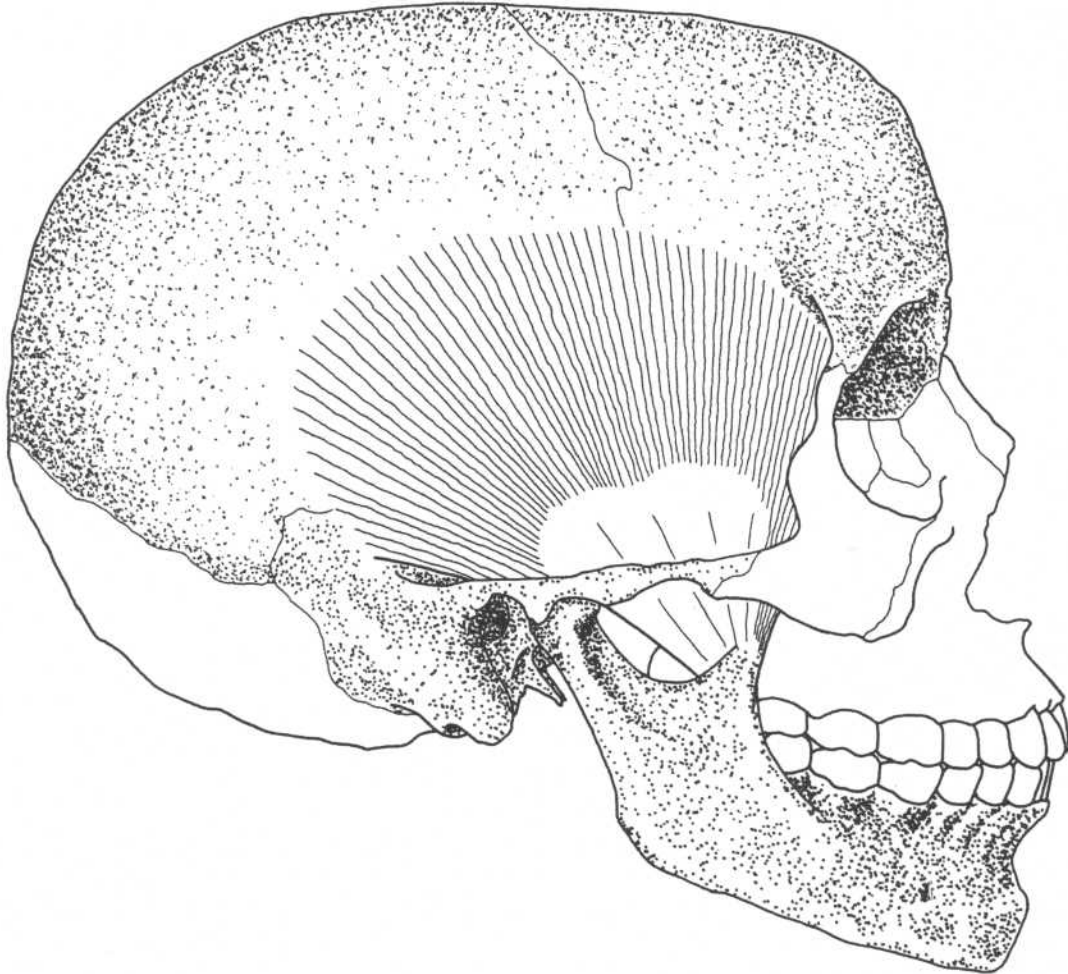
Outer surface of alveolar processes of maxilla and mandible over molars and along pterygomandibular raphe

Insertion

Deep part of muscles of lips

**Action
Nerve**

Compresses cheek
Buccal branches of facial nerve

TEMPORALIS**Skull—lateral view****Origin**

Temporal fossa including frontal, parietal, and temporal bones

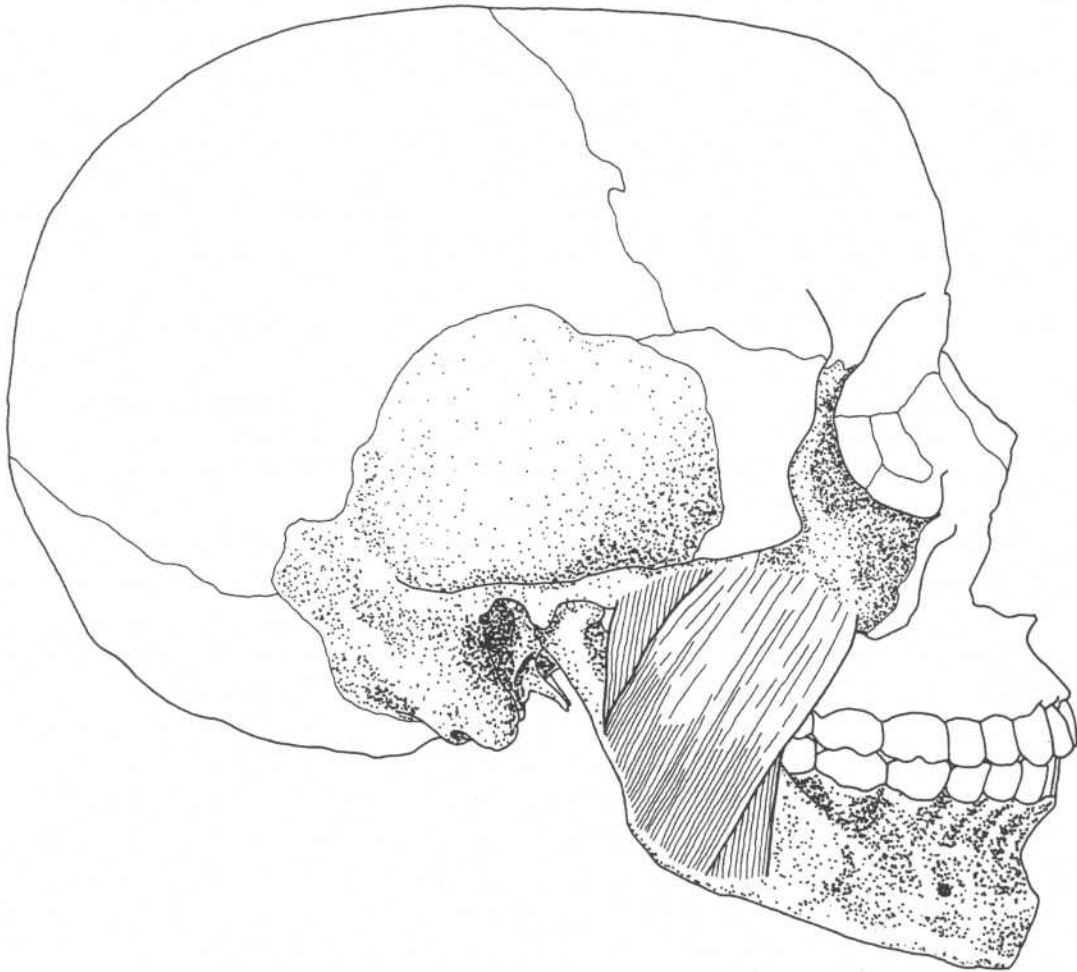
Insertion

Coronoid process and anterior border of ramus of mandible

**Action
Nerve**

Closes lower jaw, clenches teeth
Mandibular division of trigeminal nerve

MASSETER



Skull—lateral view

Origin

Zygomatic process of maxilla, medial and inferior surfaces of zygomatic arch

Insertion

Angle and ramus of mandible, lateral surface of coronoid process of mandible

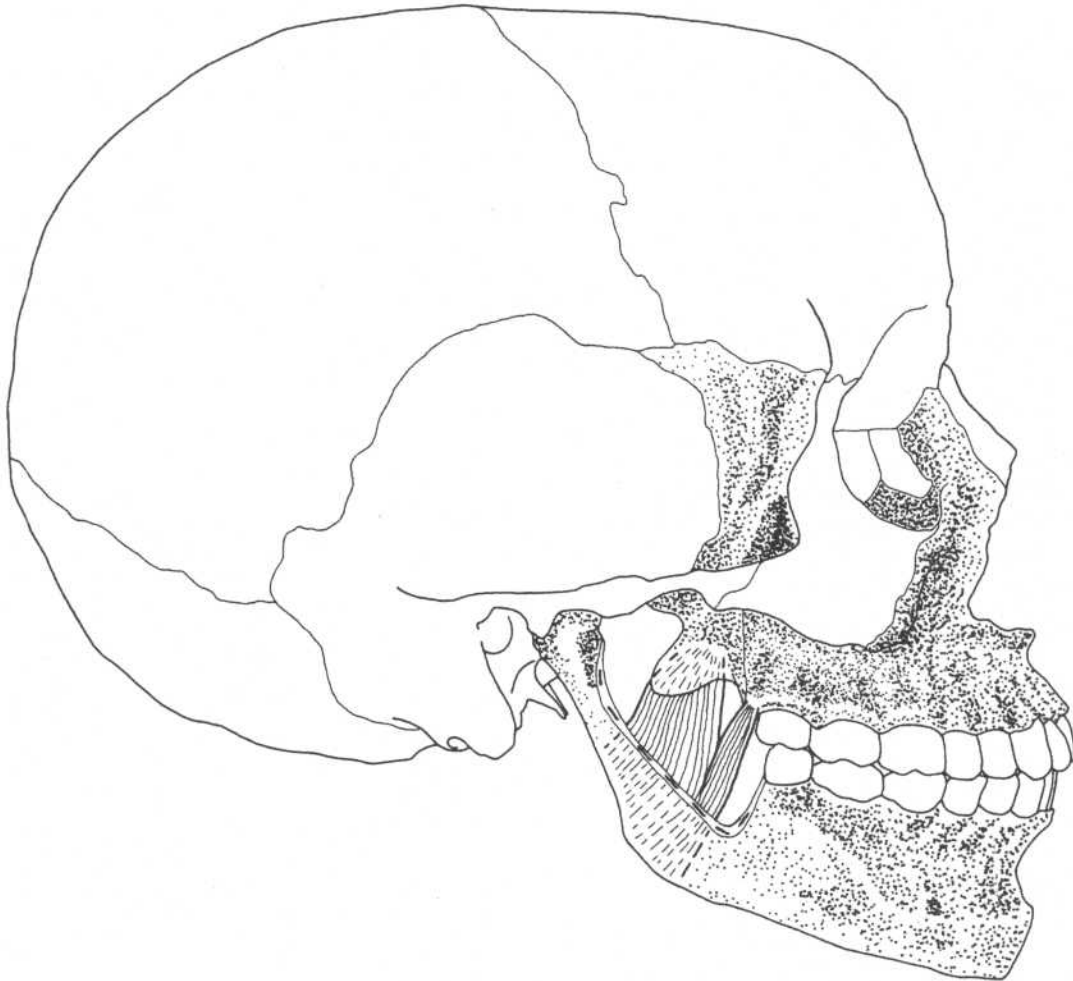
Action

Closes lower jaw, clenches teeth

Nerve

Mandibular division of trigeminal nerve

Note: Superficial fibers slightly protract jaw (see lateral pterygoid).

PTERYGOIDEUS MEDIALIS*(Medial Pterygoid)***Skull—lateral view***(Part of mandible cut away)***Origin**

Medial surface of lateral pterygoid plate of sphenoid bone, palatine bone, and tuberosity of maxilla

**Action
Nerve**

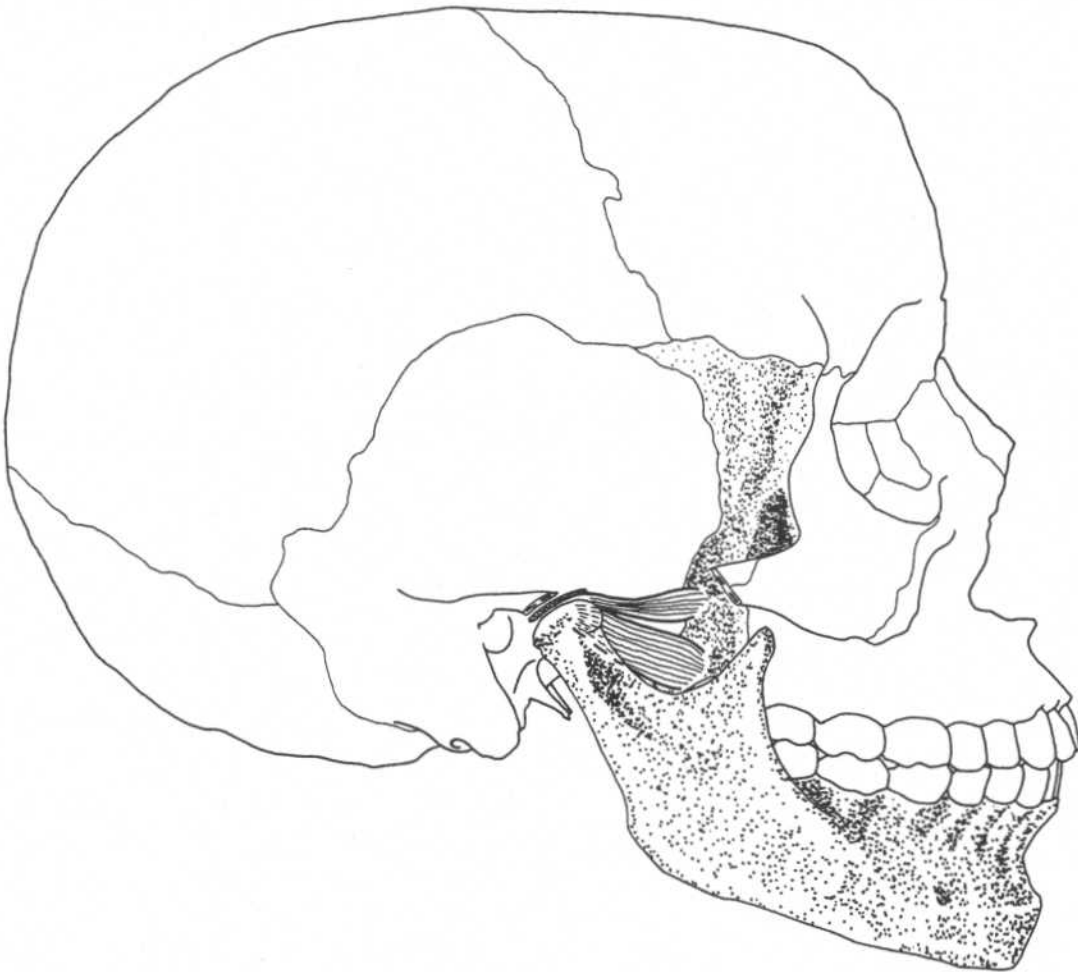
Closes lower jaw, clenches teeth
Mandibular division of trigeminal nerve

Insertion

Medial surface of ramus and angle of mandible

PTERYGOIDEUS LATERALIS*

(Lateral Pterygoid)



Skull—lateral view

Origin Superior head*—lateral surface of greater wing of sphenoid
Inferior head—lateral surface of lateral pterygoid plate

Insertion Condyle of mandible, temporomandibular joint

Action Opens jaws, protrudes mandible, moves mandible sideways

Nerve Mandibular division of trigeminal nerve

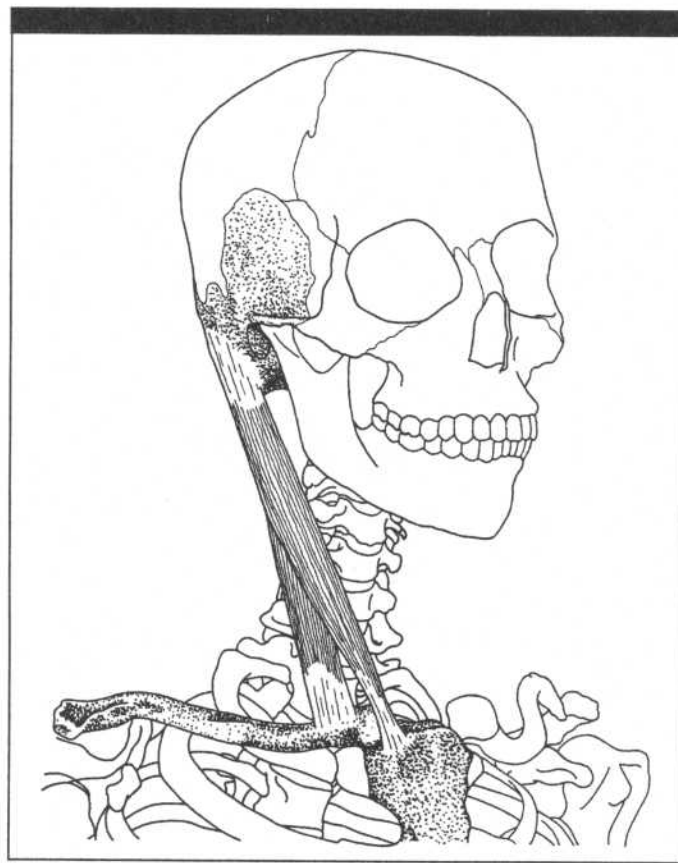
Note: This sideward movement, aided by superficial fibers of masseter, causes chewing movements.

*Stern calls this a separate muscle: superior pterygoid.

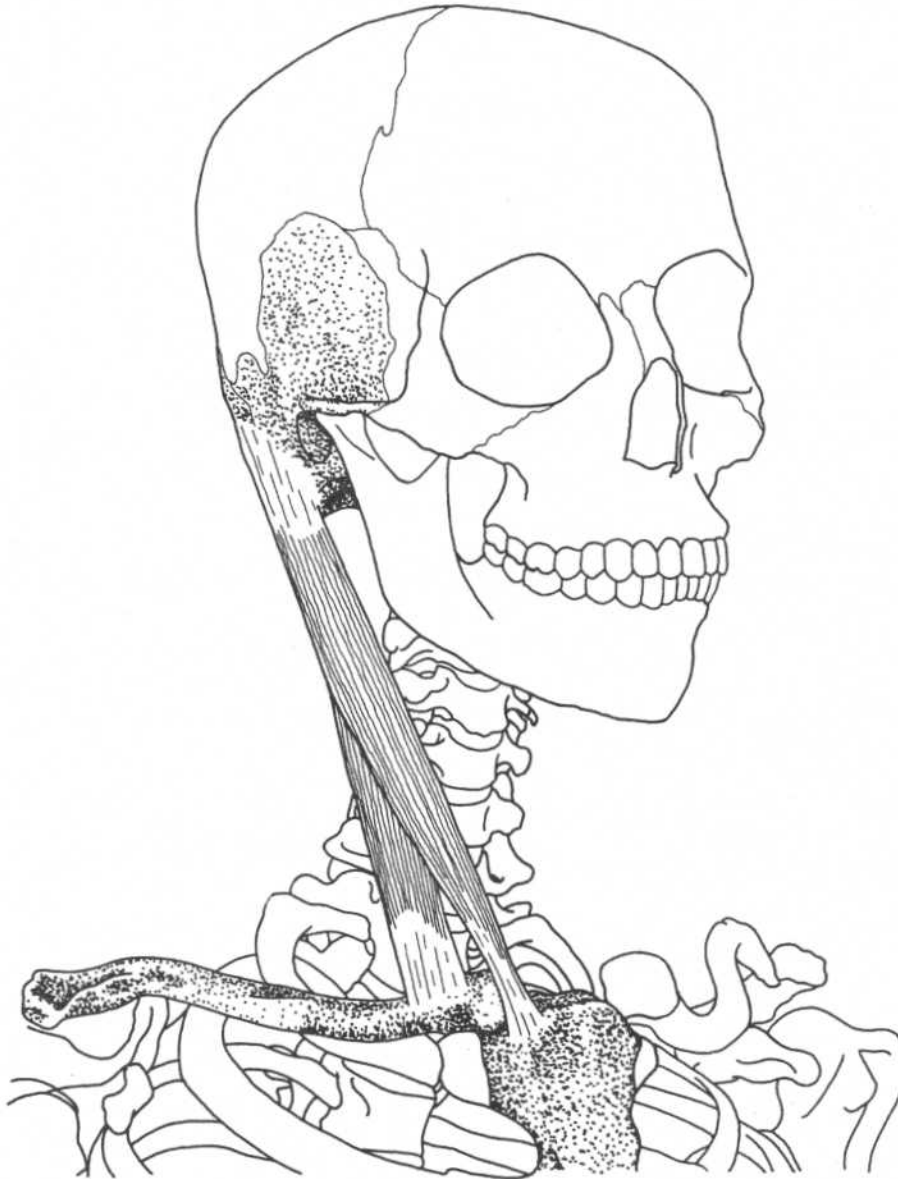
Reference: Stern, JT: *Essentials of Gross Anatomy*, F. A. Davis Company, Philadelphia, 1988.

CHAPTER FOUR

MUSCLES OF THE NECK

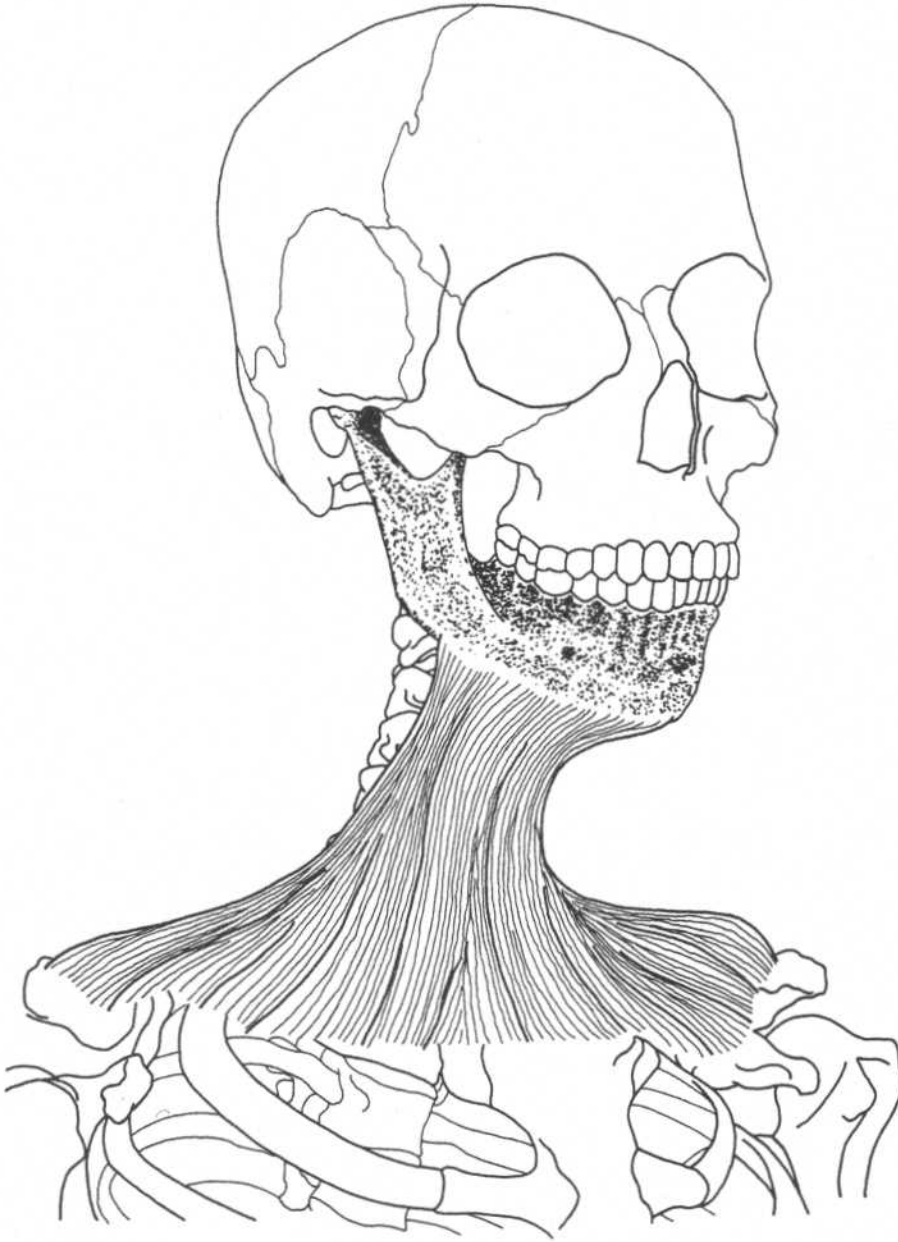


STERNOCLEIDOMASTOIDEUS



Three-quarter frontal view

Origin	Sternal head—manubrium of sternum Clavicular head—medial part of clavicle	Action	One side—bends neck laterally, rotates head to opposite side Both sides together—flexes neck, draws head ventrally and elevates chin, draws sternum superiorly in deep inspiration
Insertion	Mastoid process of temporal bone, lateral half of superior nuchal line of occipital bone	Nerve	Spinal part of accessory nerve (C2, C3)

PLATYSMA**Three-quarter frontal view****Origin**

Subcutaneous fascia of upper one-fourth of chest

Action

Depresses and draws lower lip laterally, draws up skin of chest

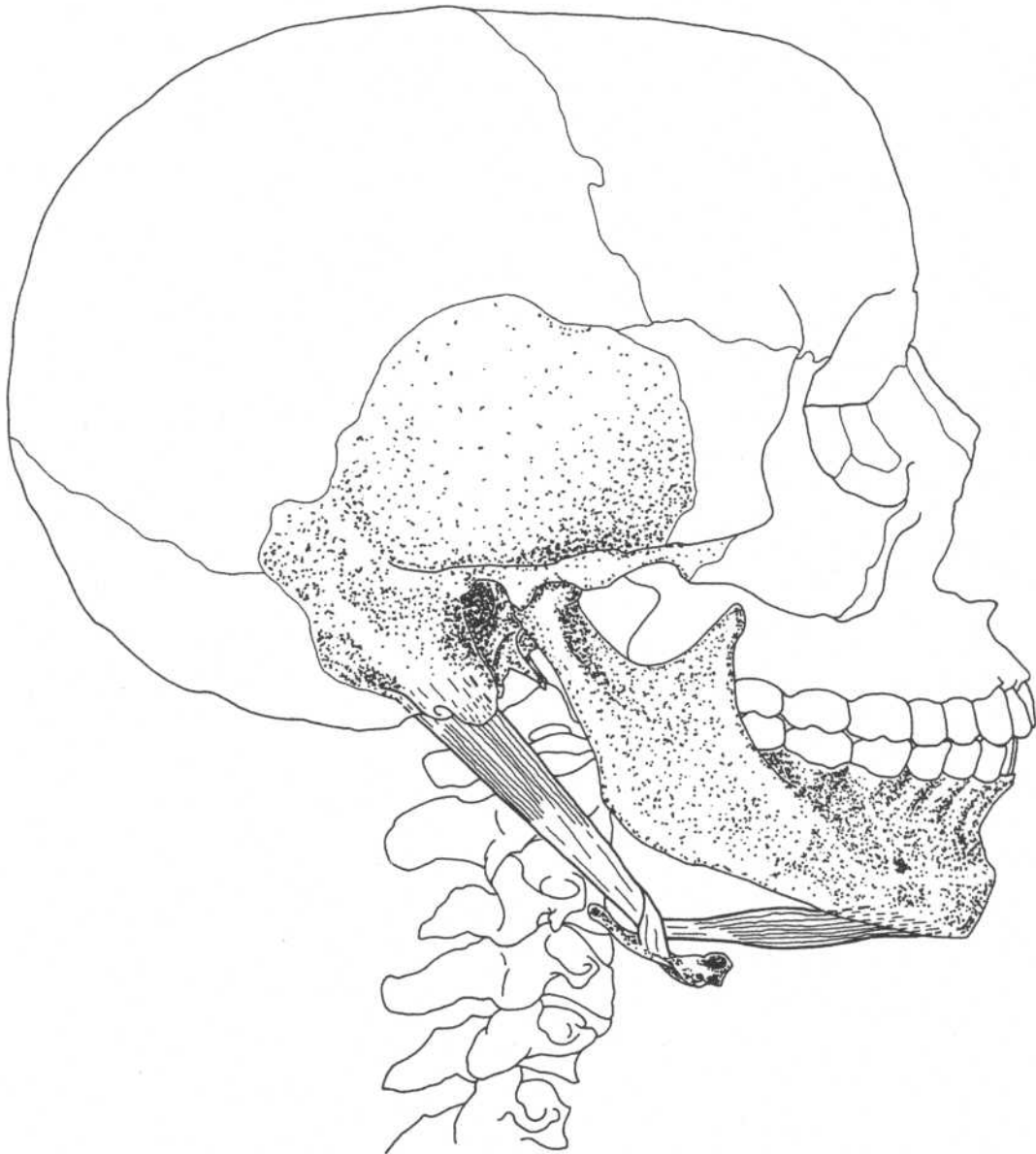
Insertion

Subcutaneous fascia and muscles of chin and jaw, mandible

Nerve

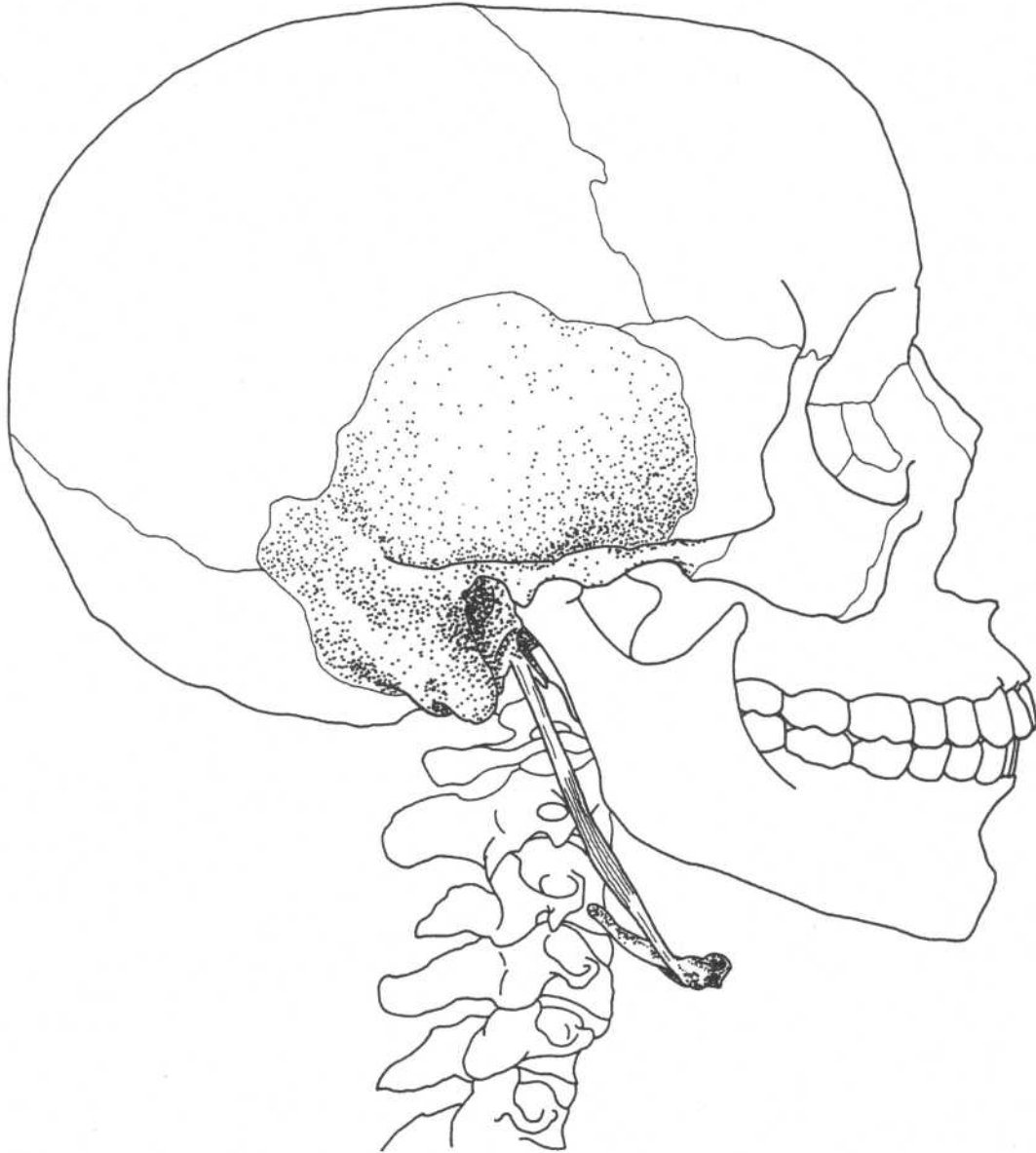
Cervical branch of facial nerve

DIGASTRICUS



Lateral view

Origin	Posterior belly—mastoid notch of temporal bone Anterior belly—inner side of inferior border of mandible near symphysis	Action	Raises hyoid bone, assists in opening jaws, moves hyoid forward or backward
Insertion	Intermediate tendon attached to hyoid bone	Nerve	Anterior belly—mandibular division of trigeminal Posterior belly—facial nerve

STYLOHYOIDEUS**Lateral view****Origin**
Insertion

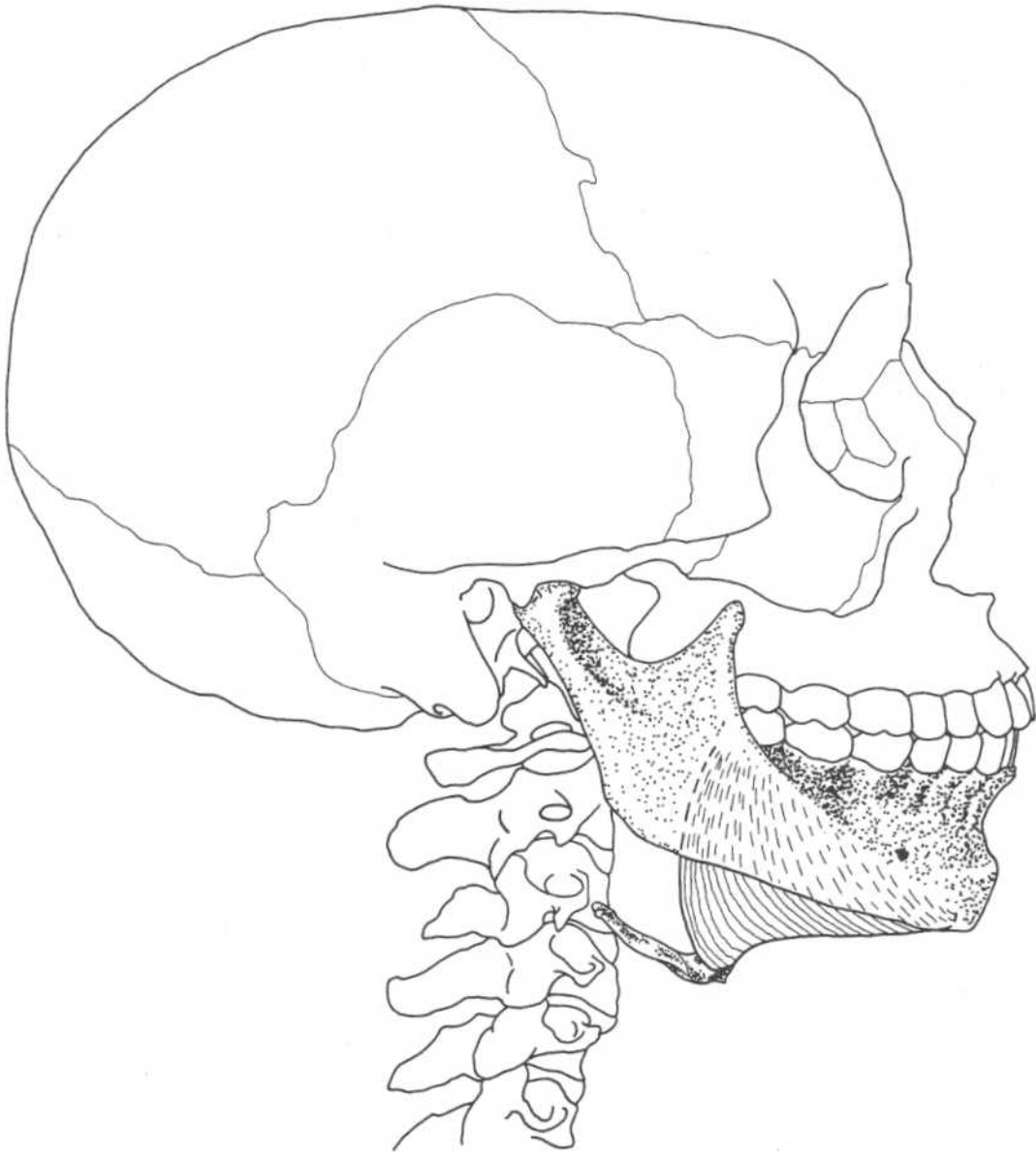
Styloid process of temporal bone
Hyoid bone

Action

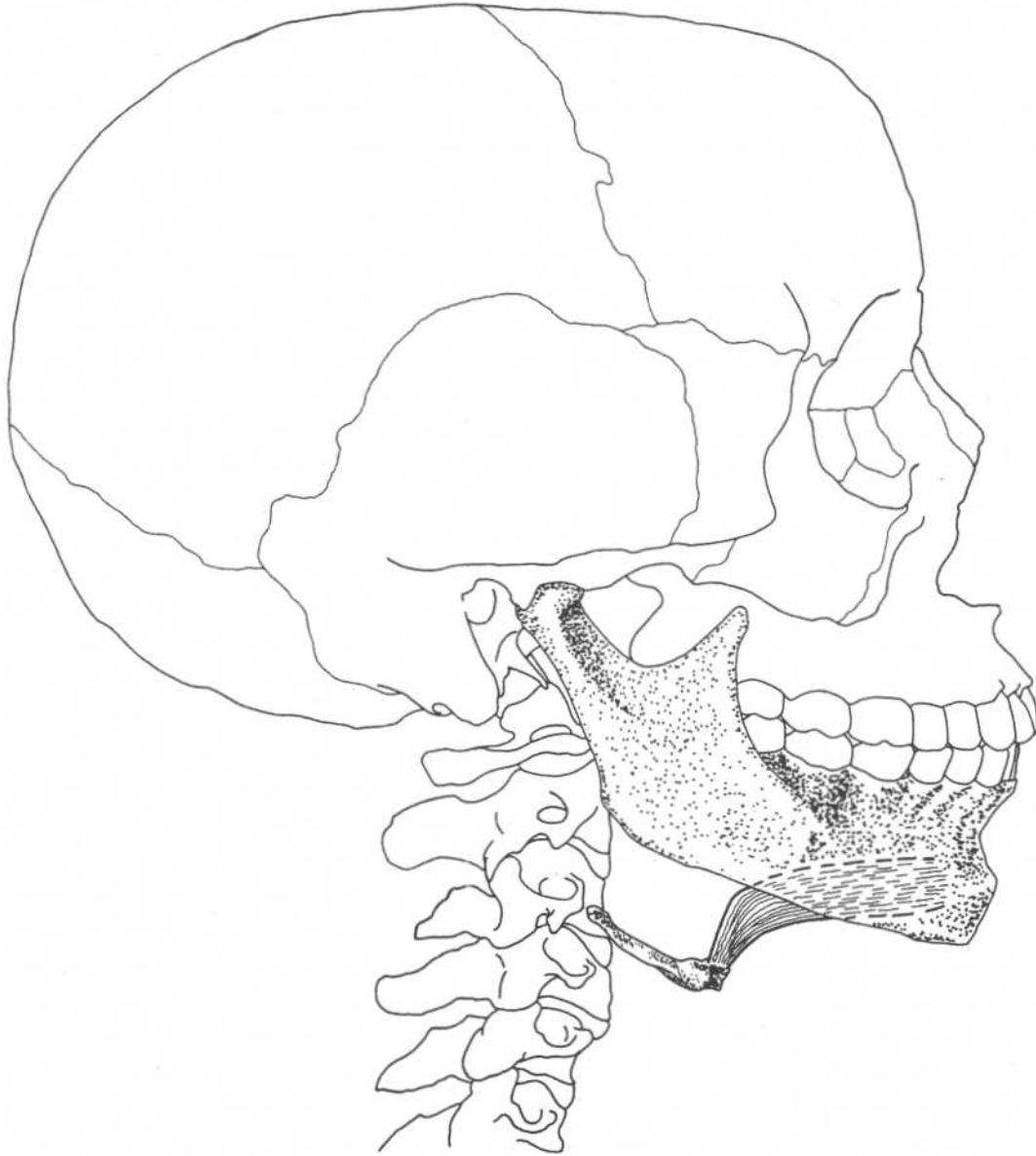
Draws hyoid bone backward,
elevates tongue

Nerve

Facial nerve

MYLOHYOIDEUS**Lateral view**

Origin	Inside surface of mandible from symphysis to molars (mylohyoid line)	Action	Elevates hyoid bone, raises floor of mouth and tongue
Insertion	Hyoid bone	Nerve	Mandibular division of trigeminal nerve

GENIOHYOIDEUS**Lateral view****Origin**

Inferior mental spine on interior
medial surface of mandible

Action

Protrudes hyoid bone and tongue

Insertion

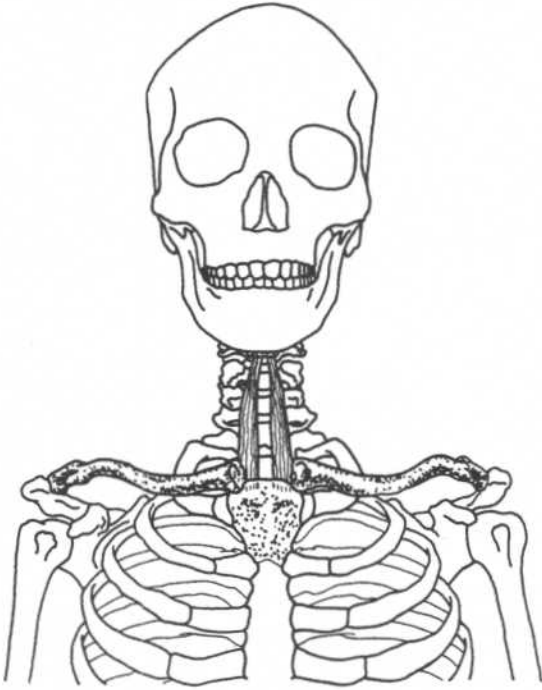
Body of hyoid bone

Nerve

Branch of C1 through hypoglossal
nerve

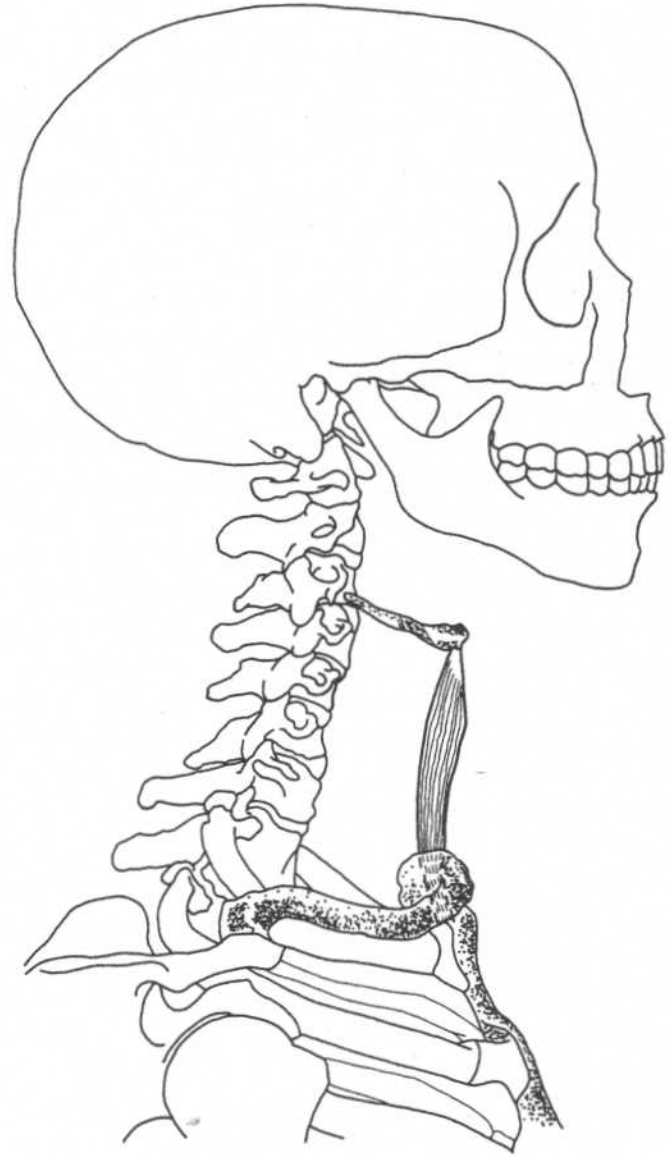
SOUTHMEAD
LIBRARY &
INFORMATION SERVICE

STERNOHYOIDEUS

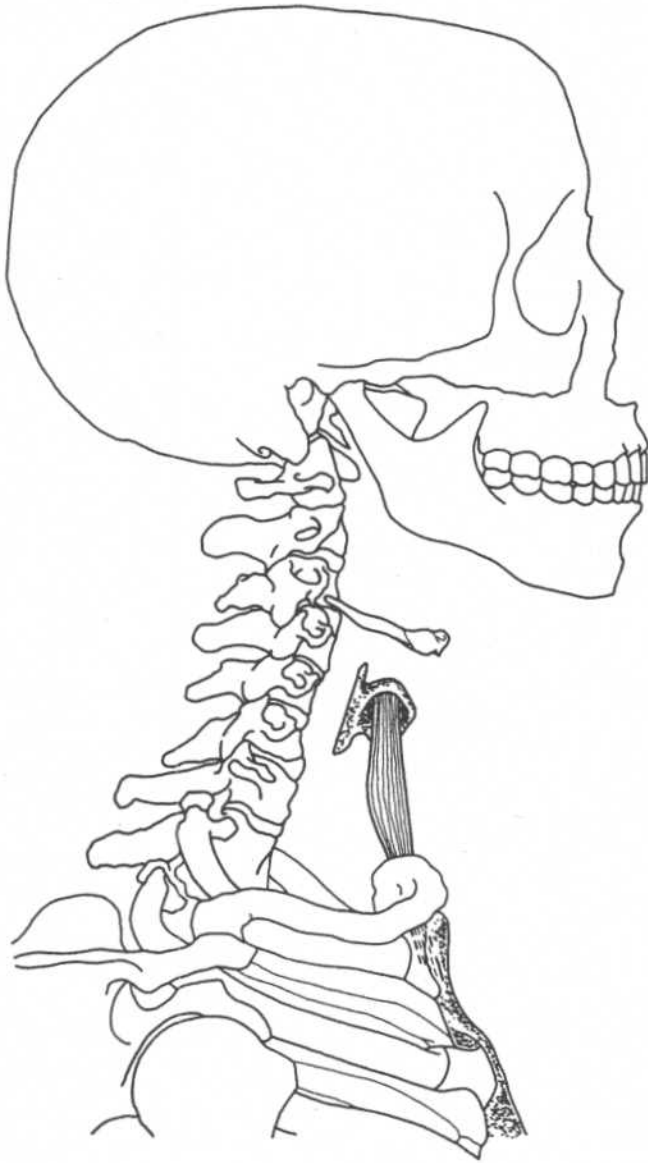
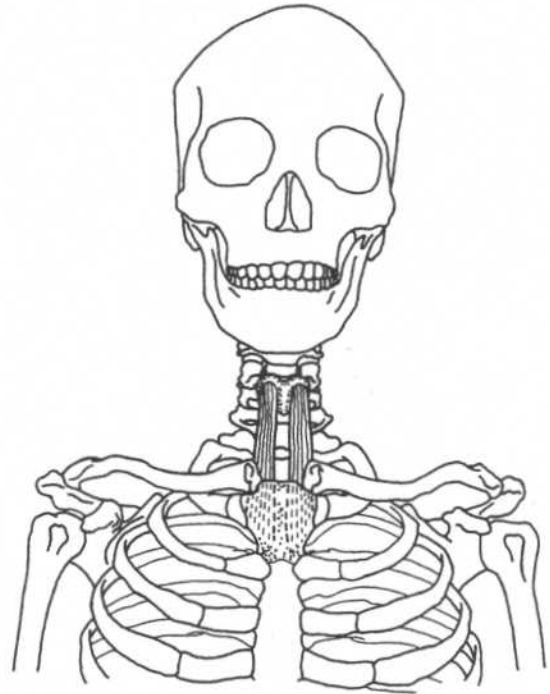


Frontal view

Origin	Medial end of clavicle, manubrium of sternum
Insertion	Body of hyoid bone
Action	Depresses hyoid bone
Nerve	Ansa cervicalis (C1–C3)

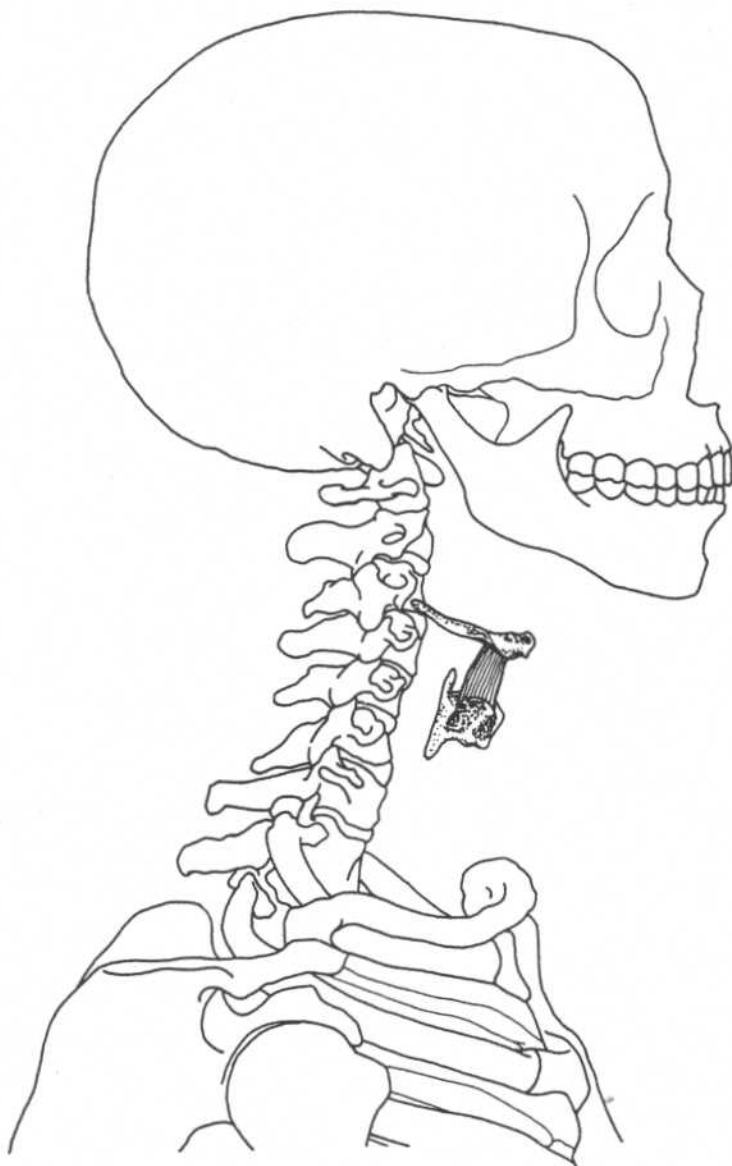


Lateral view

STERNOTHYROIDEUS**Lateral view****Frontal view**

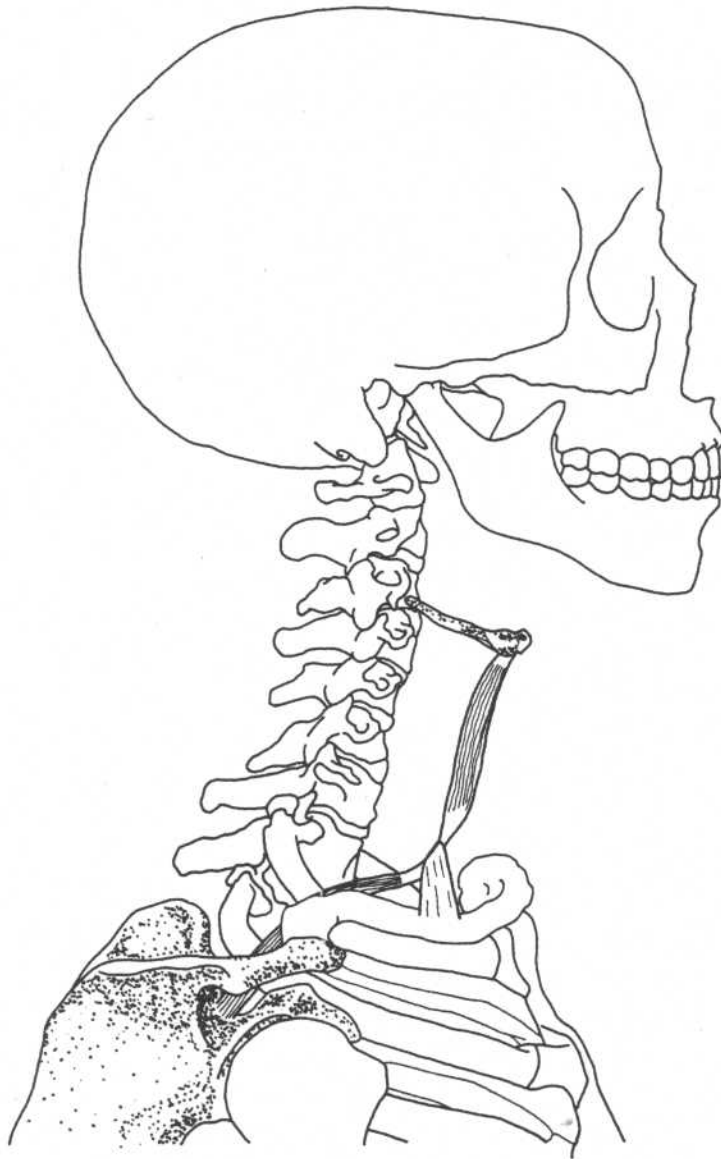
Origin	Dorsal surface of manubrium of sternum
Insertion	Lamina of thyroid cartilage
Action	Depresses thyroid cartilage
Nerve	Ansa cervicalis (C1-C3)

THYROHYOIDEUS



Lateral view

Origin	Lamina of thyroid cartilage	Action	Depresses hyoid or raises thyroid
Insertion	Greater cornu of hyoid bone	Nerve	C1 through hypoglossal nerve

OMOHYOIDEUS**Lateral view****Origin**

Superior border of scapula

Insertion

Inferior belly—bound to clavicle by central tendon

Superior belly—continues to body of hyoid bone

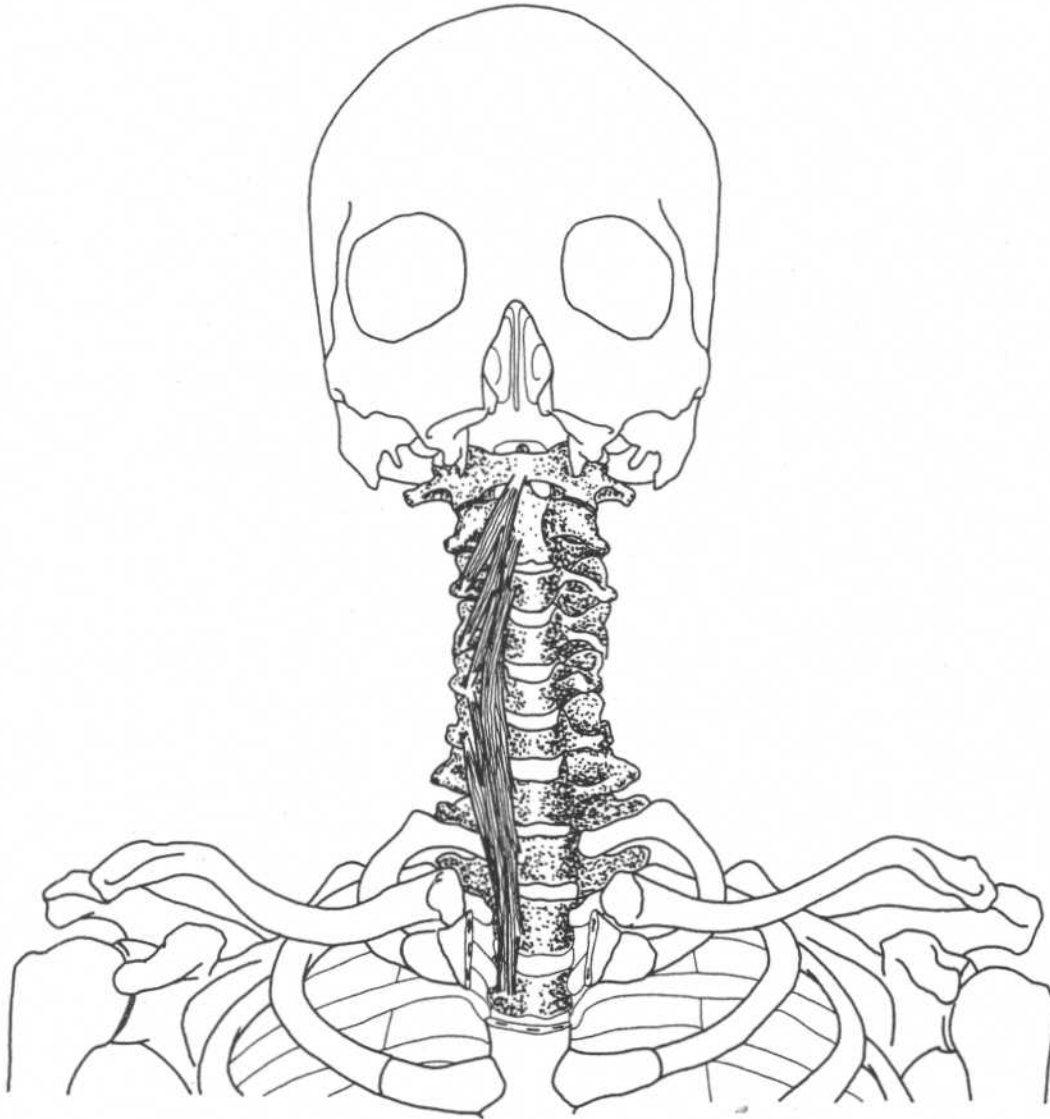
Action

Depresses hyoid bone

Nerve

Ansa cervicalis (C2, C3)

LONGUS COLLI



Frontal view

(Mandible and part of maxilla removed)

Superior oblique part

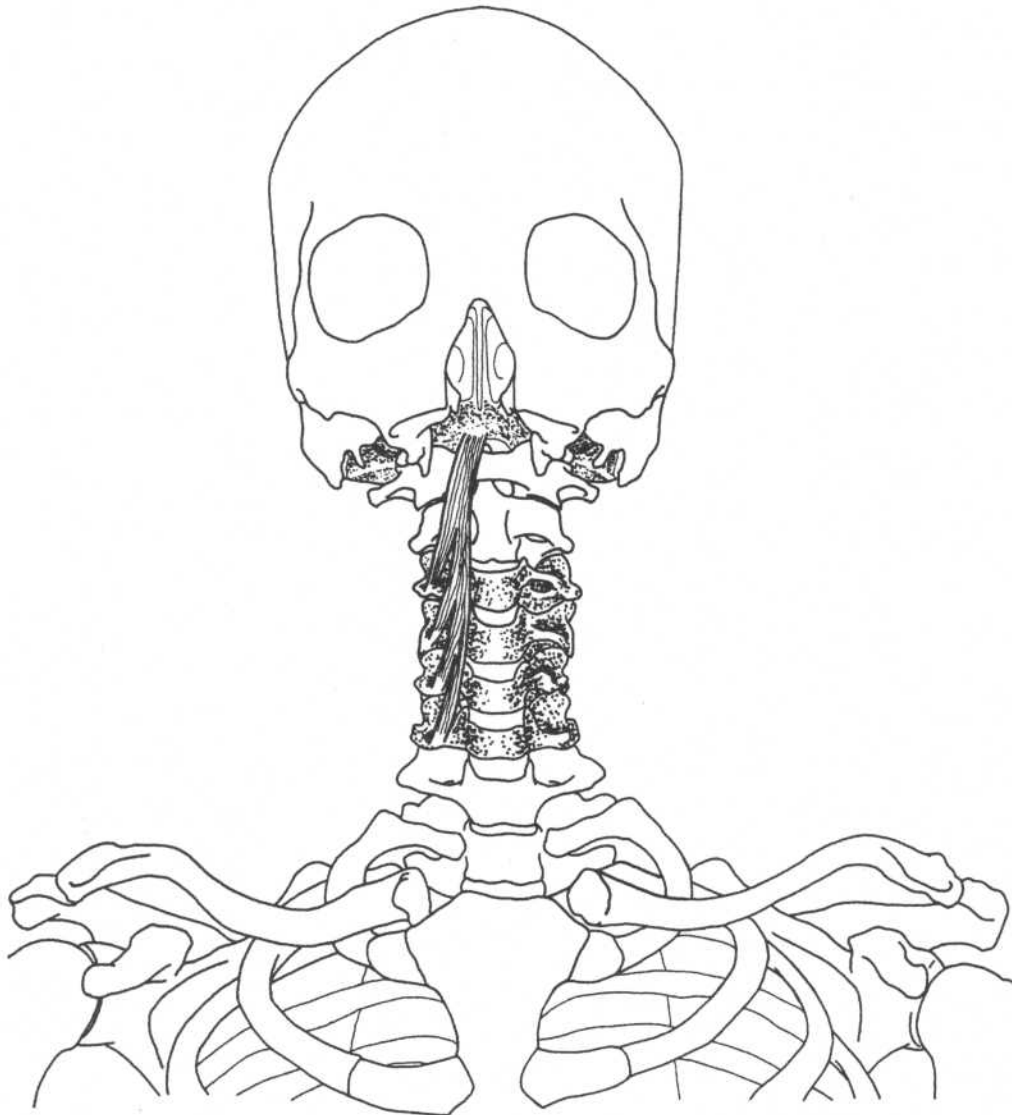
Origin Transverse processes of third, fourth, and fifth cervical vertebrae
Insertion Anterior arch of atlas

Inferior oblique part

Origin Anterior surface of bodies of first two or three thoracic vertebrae
Insertion Transverse processes of fifth and sixth cervical vertebrae

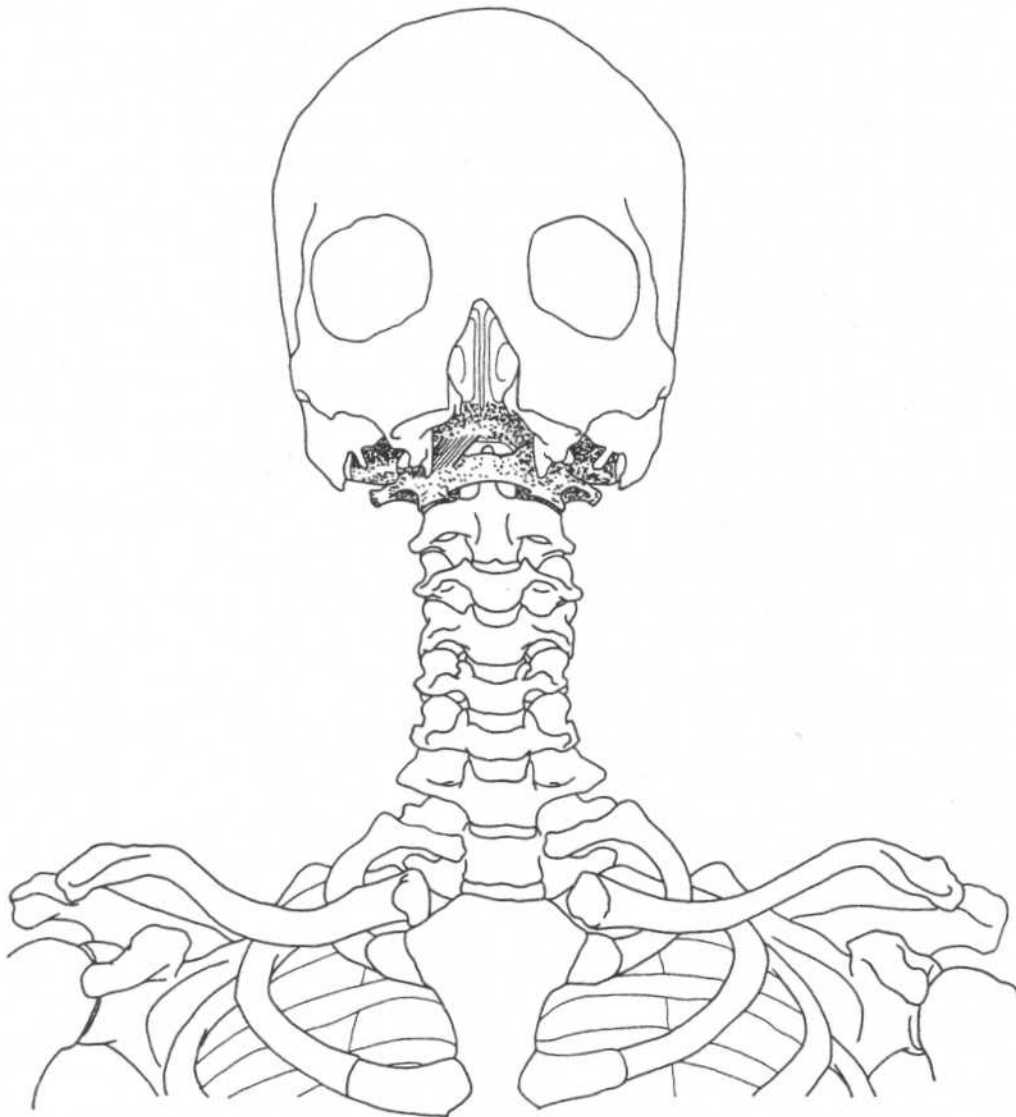
Vertical part

Origin Anterior surfaces of bodies of upper three thoracic and lower three cervical vertebrae
Insertion Anterior surfaces of the second, third, and fourth cervical vertebrae
Action All three parts flex cervical vertebrae
Nerve C2–C7

LONGUS CAPITIS**Frontal view**

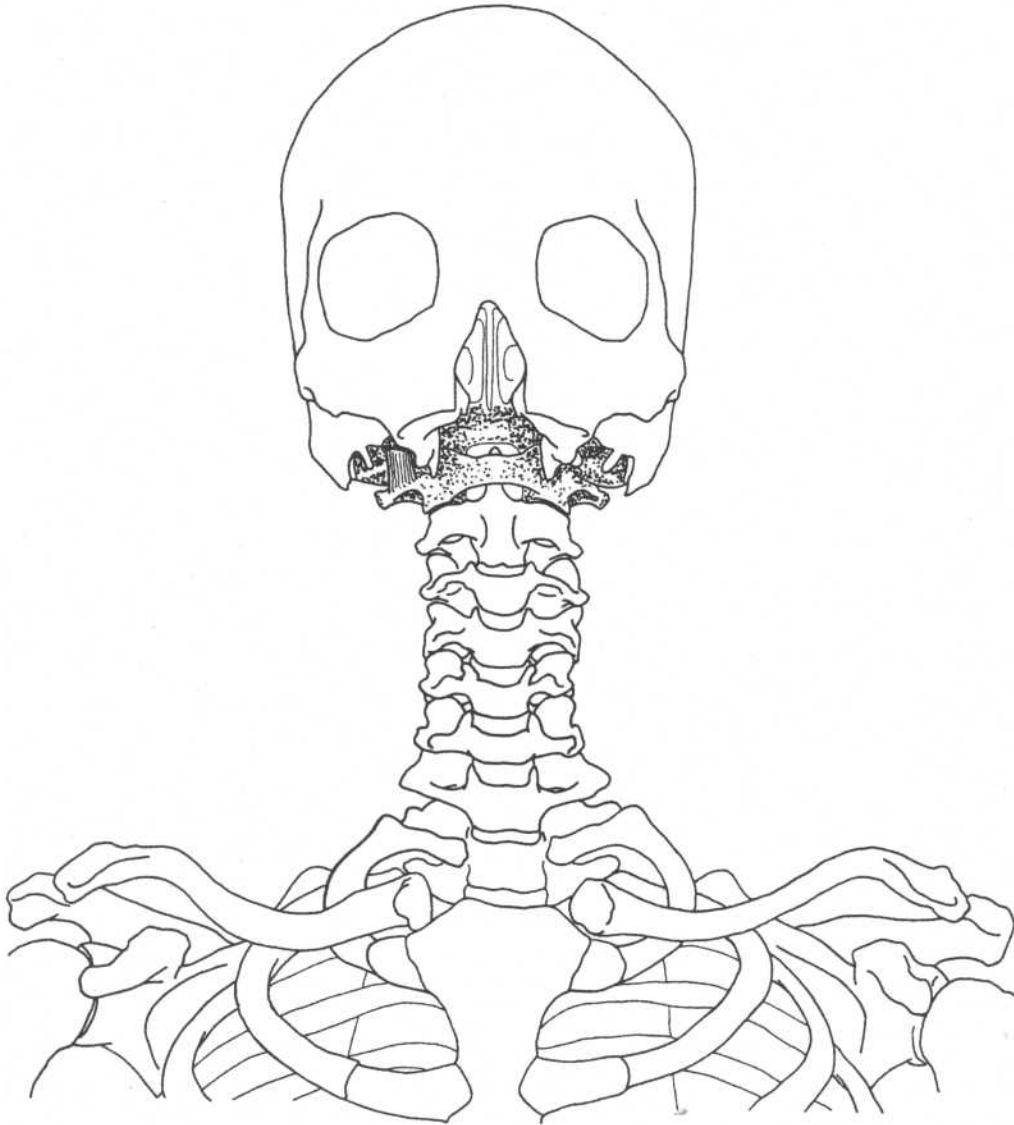
(Mandible and part of maxilla removed)

Origin	Transverse processes of third through sixth cervical vertebrae	Action	Flexes head
Insertion	Occipital bone anterior to foramen magnum	Nerve	C1-C3

RECTUS CAPITIS ANTERIOR**Frontal view**

(Mandible and part of maxilla removed)

Origin	Anterior base of transverse process of atlas	Action	Flexes head
Insertion	Occipital bone anterior to foramen magnum	Nerve	C2, C3

RECTUS CAPITIS LATERALIS**Frontal view**

(Mandible and part of maxilla removed)

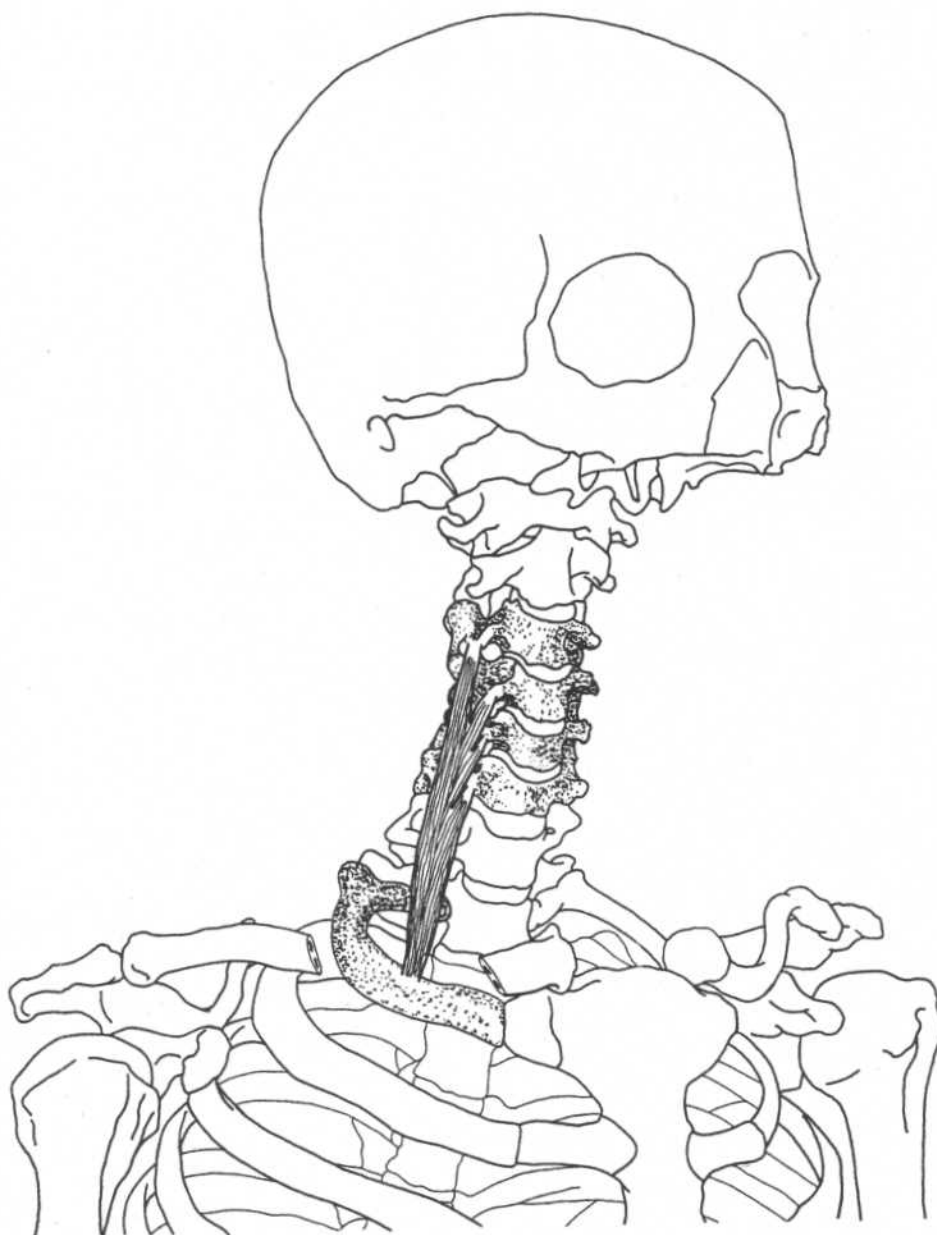
Origin
Insertion

Transverse process of atlas
Jugular process of occipital bone

Action
Nerve

Bends head laterally
C2, C3

SCALENUS ANTERIOR

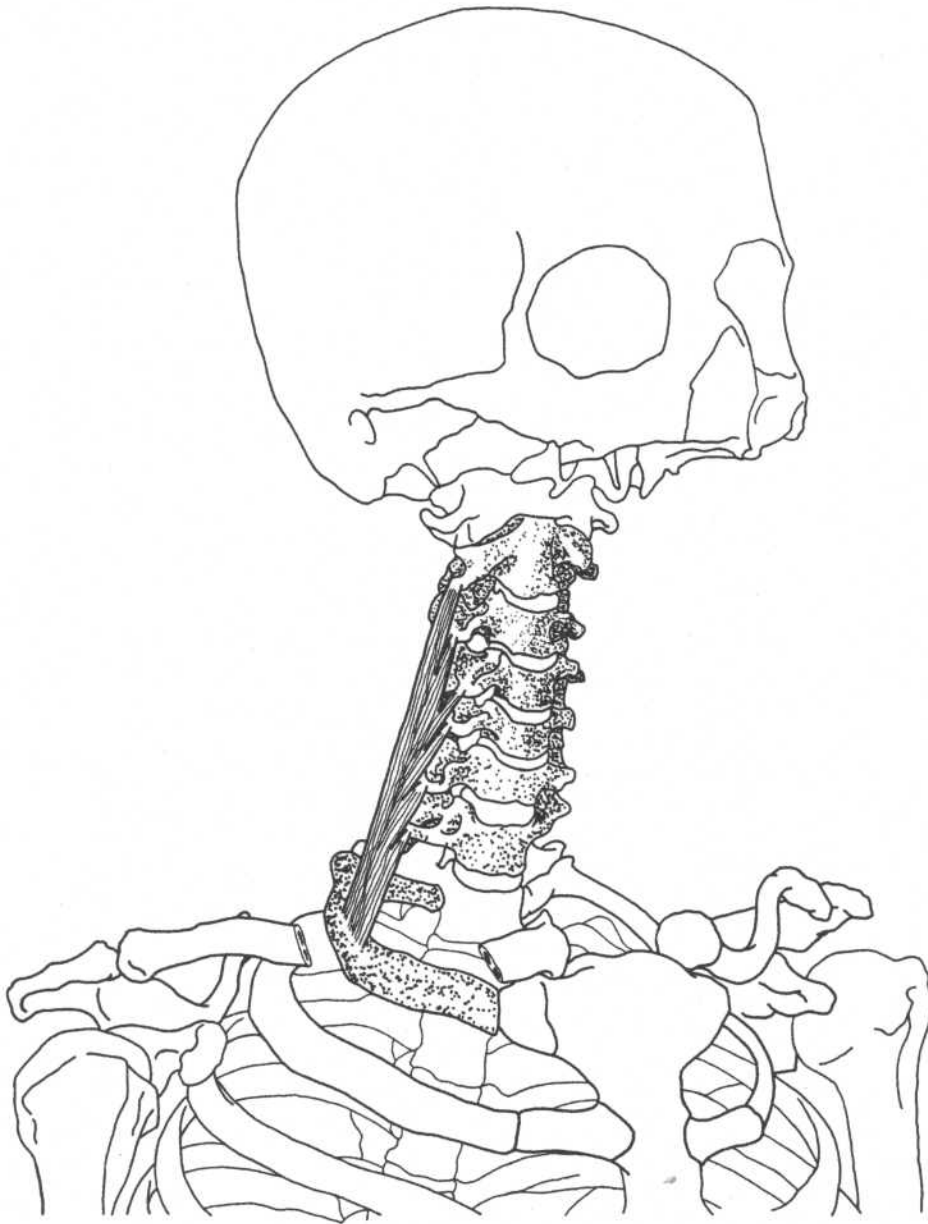


Three-quarter frontal view

(Mandible and part of maxilla removed)

Origin	Transverse processes of third through sixth cervical vertebrae	Action	Raises first rib (respiratory inspiration); acting together, they flex neck; acting on one side, they laterally flex, rotate neck
Insertion	Inner border of first rib (scalene tubercle)	Nerve	Ventral rami of cervical nerves

SCALENUS MEDIUS

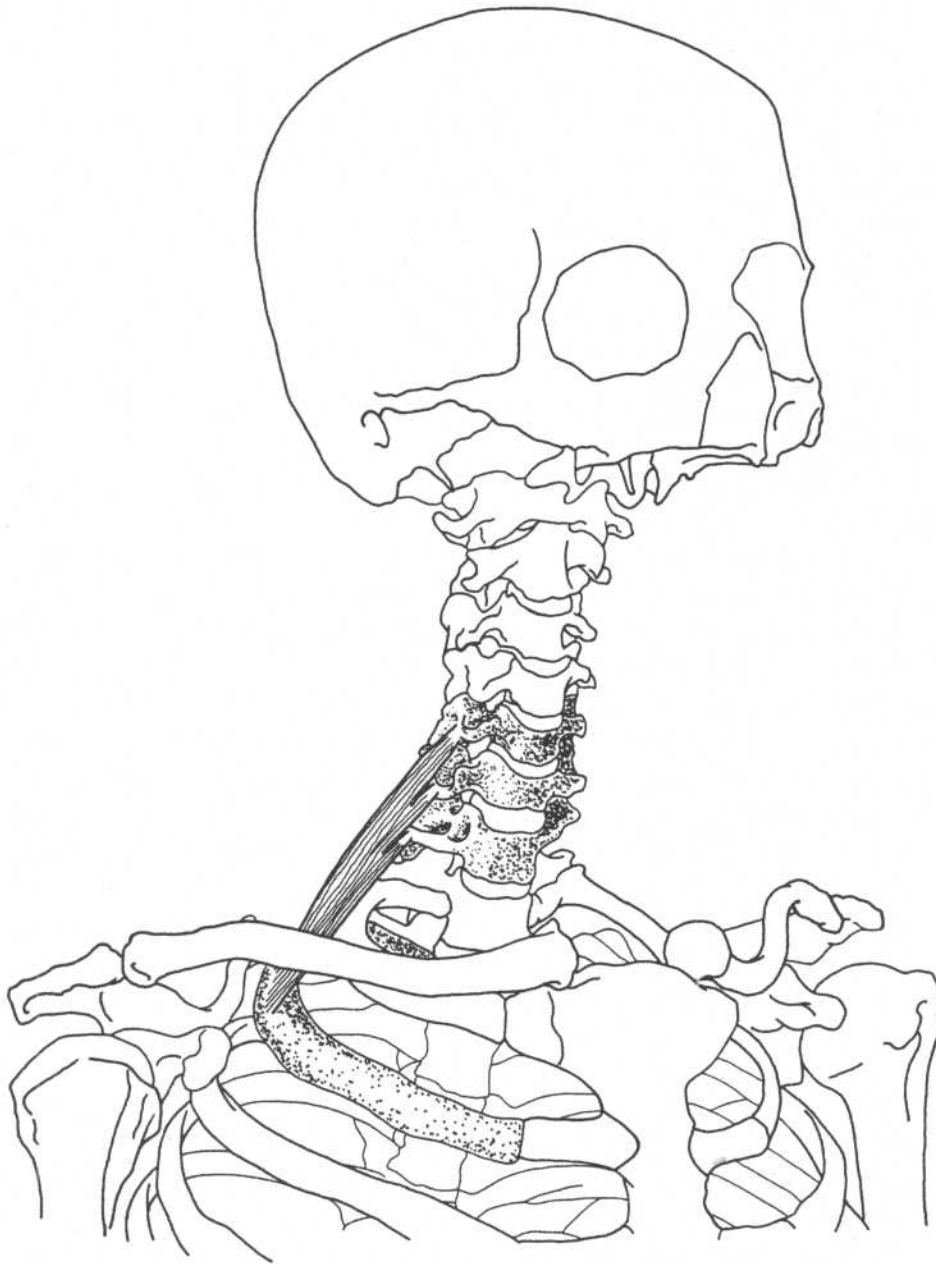


Three-quarter frontal view

(Mandible and part of maxilla removed)

Origin	Transverse processes of lower six cervical vertebrae (C2–C7)	Action	Raises first rib (respiratory inspiration); acting together, they flex neck; acting on one side, they laterally flex, rotate neck
Insertion	Upper surface of first rib	Nerve	Ventral rami of cervical nerves

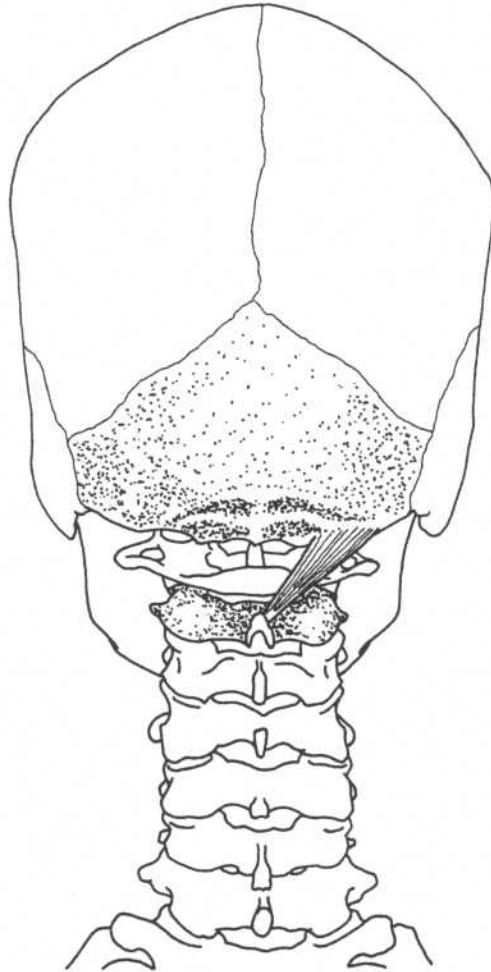
SCALENUS POSTERIOR



Three-quarter frontal view

(Mandible and part of maxilla removed)

Origin	Transverse processes of lower two or three cervical vertebrae (C5–C7)	Action	Raises second rib (respiratory inspiration); acting together, they flex neck; acting on one side, they laterally flex, rotate neck
Insertion	Outer surface of second rib	Nerve	Ventral rami of lower cervical nerves

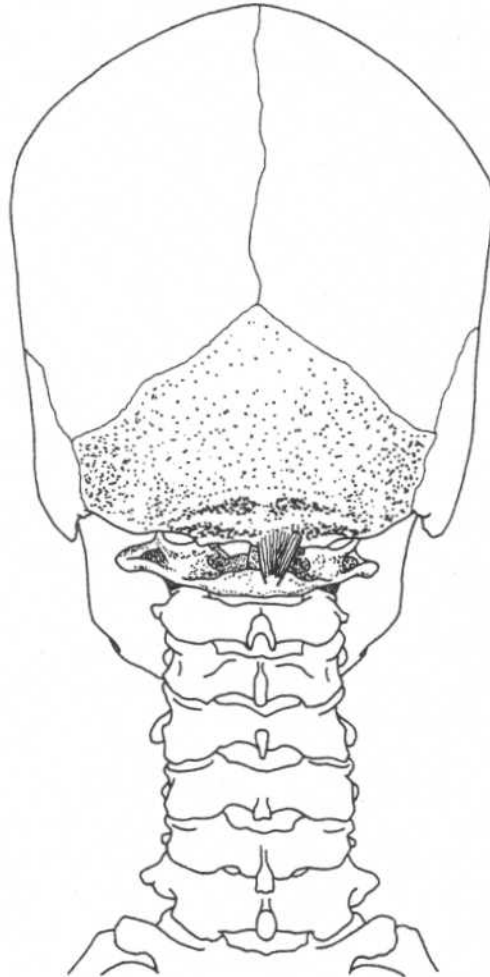
RECTUS CAPITIS POSTERIOR MAJOR**Posterior skull and cervical vertebrae****Origin**
Insertion

Spinous process of axis
Lateral portion of inferior nuchal line
of occipital bone

Action
Nerve

Extends and rotates head
Suboccipital nerve

RECTUS CAPITIS POSTERIOR MINOR



Posterior skull and cervical vertebrae

Origin

Posterior arch of atlas

Action

Extends head

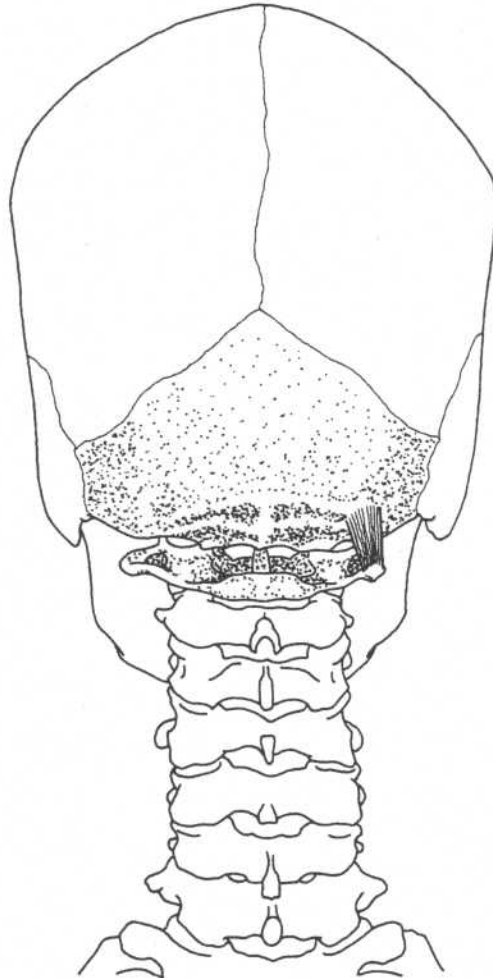
Insertion

Medial portion of inferior nuchal line
of occipital bone

Nerve

Suboccipital nerve

OBLIQUUS CAPITIS SUPERIOR



Posterior skull and cervical vertebrae

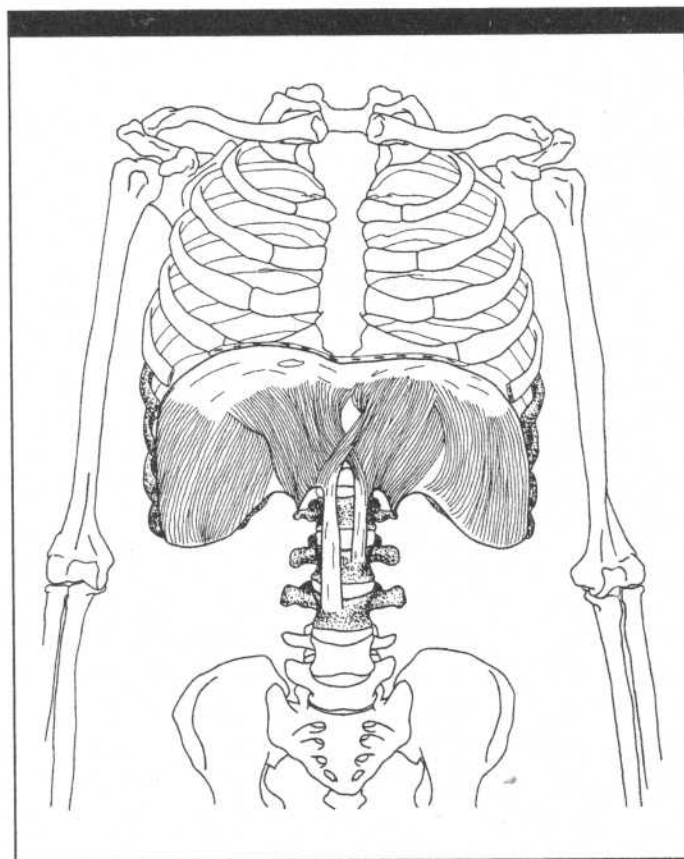
Origin
Insertion

Transverse process of atlas
Occipital bone between inferior and
superior nuchal lines

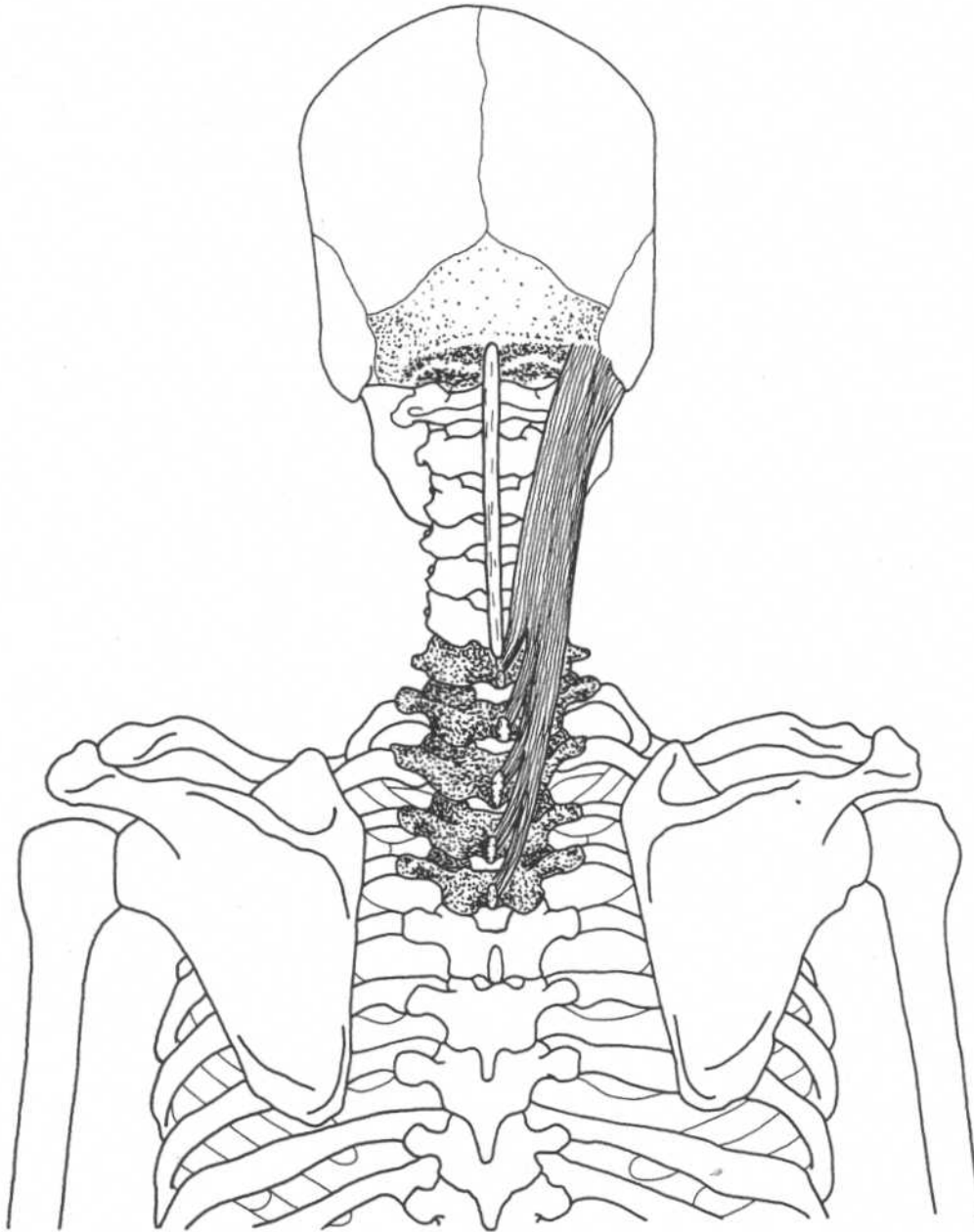
Action
Nerve

Extends and bends head laterally
Suboccipital nerve

CHAPTER FIVE
MUSCLES OF THE TRUNK

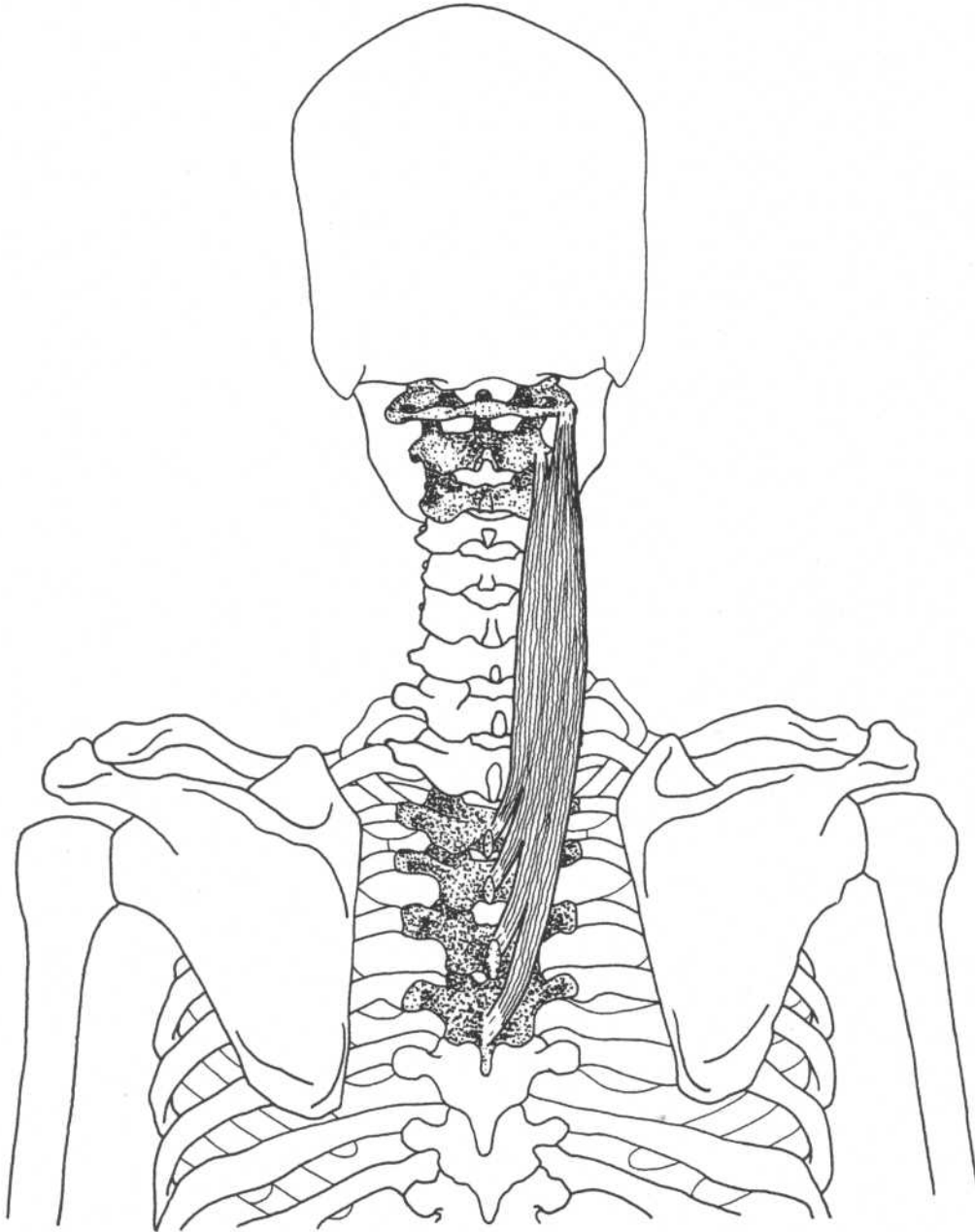


SPLENIUS CAPITIS



Posterior skull, neck, and back

Origin	Lower part of ligamentum nuchae, spinous processes of seventh cervical vertebra (C7) and upper three or four thoracic vertebrae (T1–T4)	Action	Acting together, they extend, hyperextend head, neck; acting on one side, they laterally flex, rotate head, neck
Insertion	Mastoid process of temporal bone and lateral part of superior nuchal line	Nerve	Lateral branches of dorsal primary divisions of middle and lower cervical nerves

SPLenius CERVICIS**Posterior skull, neck, and back****Origin**

Spinous processes of third through sixth thoracic vertebrae (T3–T6)

Insertion

Transverse processes of upper two or three cervical vertebrae (C1–C3)

Action

Acting together, they extend, hyperextend head, neck; acting on one side, they laterally flex, rotate head, neck

Nerve

Lateral branches of dorsal primary divisions of middle and lower cervical nerves

ERECTOR SPINAE*

ILIOCOSTALIS LUMBORUM

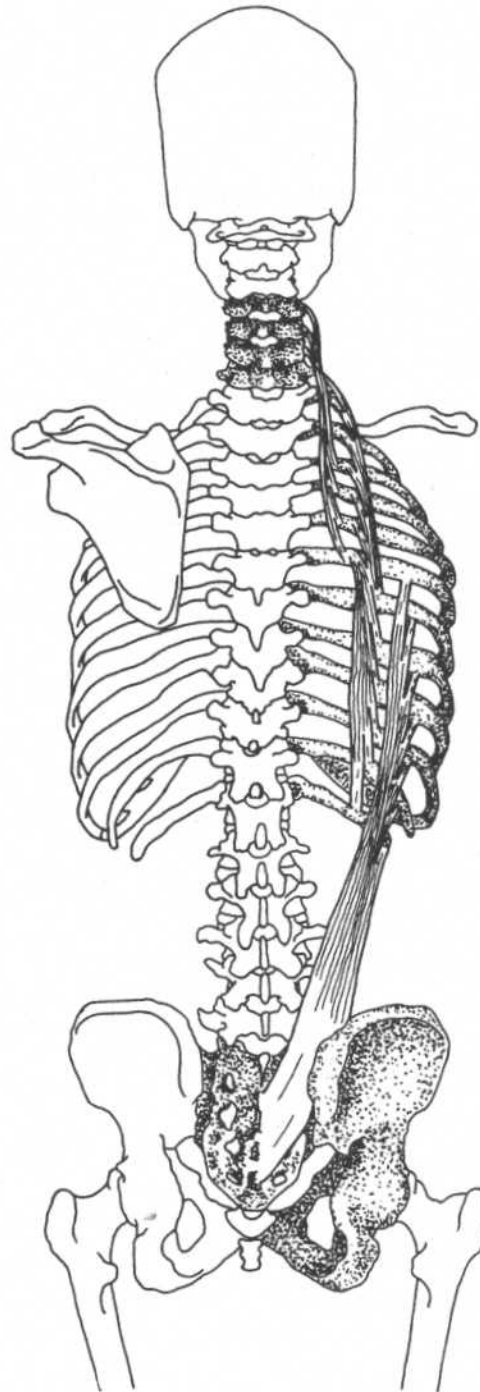
Origin	Medial and lateral sacral crests and medial part of iliac crests
Insertion	Angles of lower six ribs
Action	Extension, lateral flexion of vertebral column, rotates ribs for forceful inspiration
Nerve	Dorsal primary divisions of spinal nerves

ILIOCOSTALIS THORACIS

Origin	Angles of lower six ribs medial to iliocostalis lumborum
Insertion	Angles of upper six ribs and transverse process of seventh cervical vertebra
Action	Extension, lateral flexion of vertebral column, rotates ribs for forceful inspiration
Nerve	Dorsal primary divisions of spinal nerves

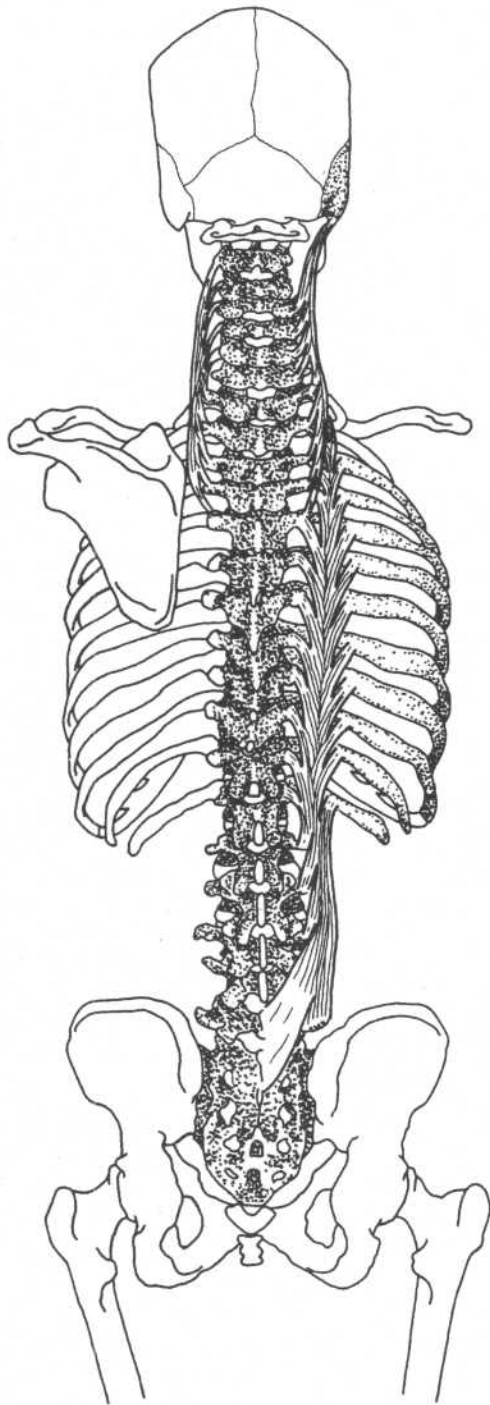
ILIOCOSTALIS CERVICIS

Origin	Angles of third through sixth ribs
Insertion	Transverse processes of fourth, fifth, and sixth cervical vertebrae
Action	Extension, lateral flexion of vertebral column
Nerve	Dorsal primary divisions of spinal nerves



Trunk—dorsal view

*The erector spinae (sacrospinalis) is a complex of three sets of muscles: iliocostalis, longissimus, and spinalis. The origin of this group is the medial and lateral sacral crests, the medial part of iliac crests, and the spinous processes and supraspinal ligament of lumbar and eleventh and twelfth thoracic vertebrae.



Trunk—dorsal view

ERECTOR SPINAE

LONGISSIMUS THORACIS

Origin	Medial and lateral sacral crests, spinous processes and supraspinal ligament of lumbar and eleventh and twelfth thoracic vertebrae, and medial part of iliac crests
Insertion	Transverse processes of all thoracic vertebrae, between tubercles and angles of lower nine or ten ribs
Action	Extension, lateral flexion of vertebral column, rotates ribs for forceful inspiration
Nerve	Dorsal primary divisions of spinal nerves

LONGISSIMUS CERVICIS

Origin	Transverse processes of upper four or five thoracic vertebrae (T1–T5)
Insertion	Transverse processes of second through sixth cervical vertebrae
Action	Extension, lateral flexion of vertebral column
Nerve	Dorsal primary divisions of spinal nerves

LONGISSIMUS CAPITIS

Origin	Transverse processes of upper five thoracic vertebrae (T1–T5), articular processes of lower three cervical vertebrae (C5–C7)
Insertion	Posterior part of mastoid process of temporal bone
Action	Extends and rotates head
Nerve	Dorsal primary divisions of middle and lower cervical nerves

ERECTOR SPINAE

SPINALIS THORACIS

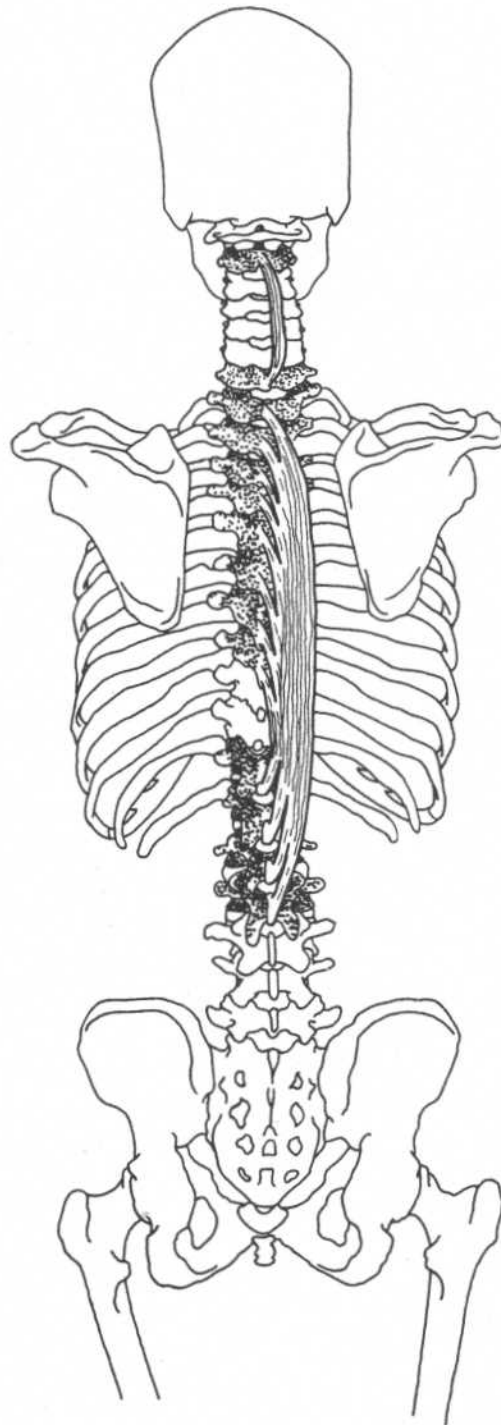
Origin	Spinous processes of lower two thoracic (T11, T12) and upper two lumbar (L1, L2) vertebrae
Insertion	Spinous processes of upper thoracic vertebrae (T1–T8)
Action	Extends vertebral column
Nerve	Dorsal primary divisions of spinal nerves

SPINALIS CERVICIS

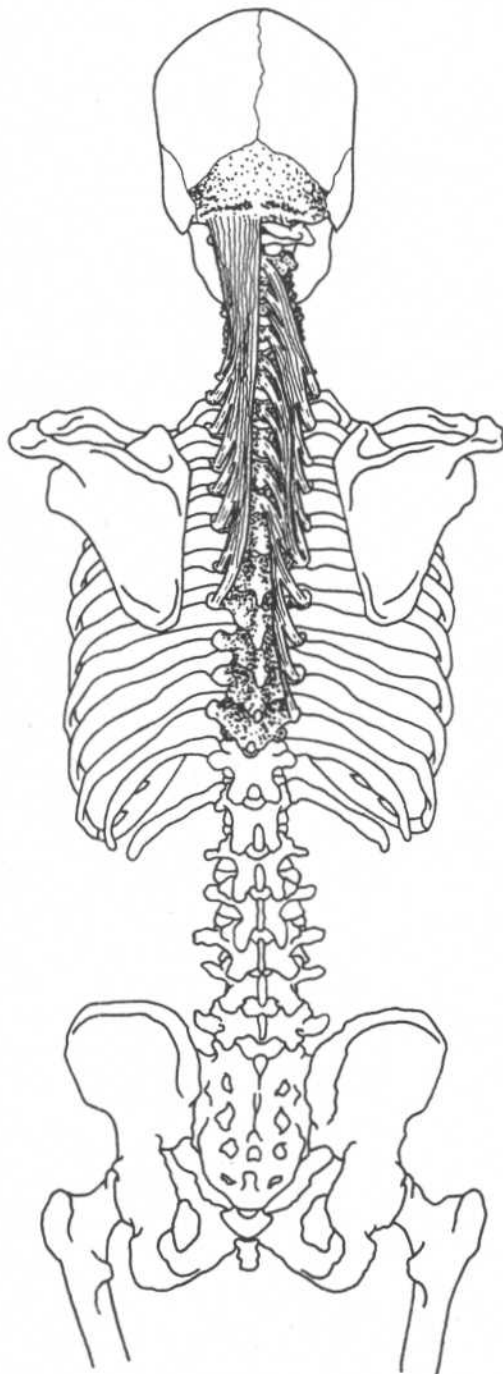
Origin	Ligamentum nuchae, spinous process of seventh cervical vertebra
Insertion	Spinous process of axis
Action	Extends vertebral column
Nerve	Dorsal primary divisions of spinal nerves

SPINALIS CAPITIS

(Medial part of semispinalis capitis)



Trunk—dorsal view



Trunk—dorsal view

TRANSVERSOSPINALIS*

SEMISPINALIS THORACIS

Origin	Transverse processes of the sixth through tenth thoracic vertebrae (T6–T10)
Insertion	Spinous processes of the lower two cervical (C6, C7) and upper four thoracic (T1–T4) vertebrae
Action	Extends and rotates vertebral column
Nerve	Dorsal primary divisions of spinal nerves

SEMISPINALIS CERVICIS

Origin	Transverse processes of upper five or six thoracic vertebrae (T1–T6)
Insertion	Spinous processes of second to fifth cervical vertebrae (C2–C5)
Action	Extends and rotates vertebral column
Nerve	Dorsal primary divisions of spinal nerves

SEMISPINALIS CAPITIS

(Medial part is spinalis capitis)

Origin	Transverse processes of lower four cervical (C4–C7) and upper six or seven thoracic (T1–T7) vertebrae
Insertion	Between superior and inferior nuchal lines of occipital bone
Action	Extends and rotates head
Nerve	Dorsal primary divisions of spinal nerves

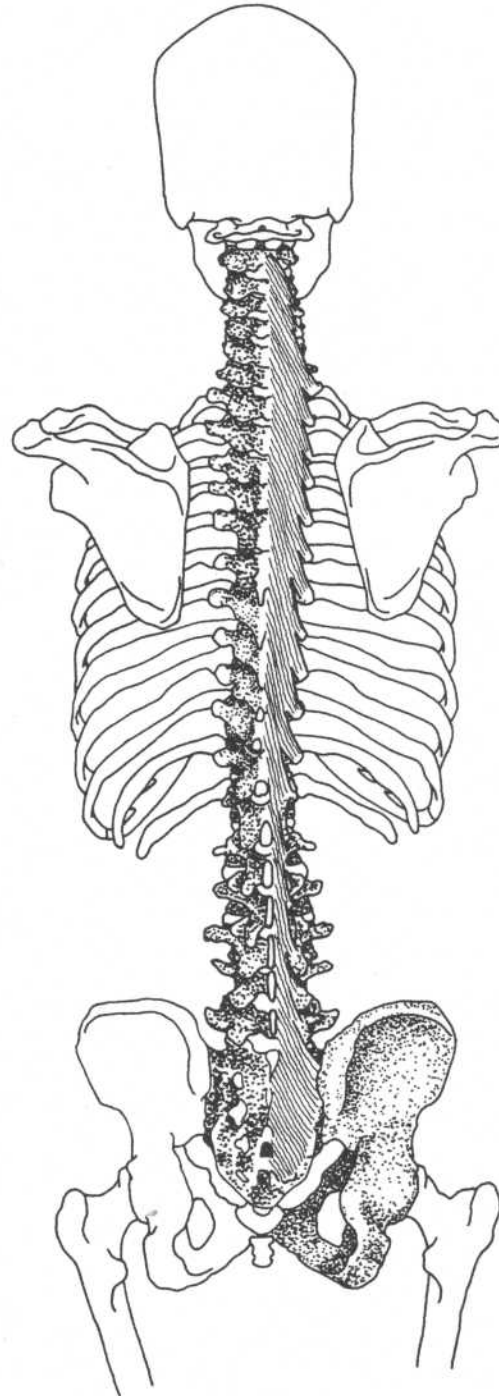
*The transversospinalis is composed of groups of small muscles generally extending upward from transverse processes to spinous processes of higher vertebrae. They are deep to erector spinae. They include semispinalis, multifidi, and rotatores.

MULTIFIDIS*

Origin	Sacral region—along sacral foramina up to posterior superior iliac spine Lumbar region—mamillary processes† of vertebrae Thoracic region—transverse processes Cervical region—articular processes of lower four vertebrae (C4–C7)
Insertion	Spinous process two to four vertebrae superior to origin
Action	Extend and rotate vertebral column
Nerve	Dorsal primary division of spinal nerves

*Part of transversospinalis.

†Posterior border of superior articular process.



Trunk—dorsal view

ROTATOIRES***Origin**

Transverse process of each vertebra

Insertion

Base of spinous process of next vertebra above

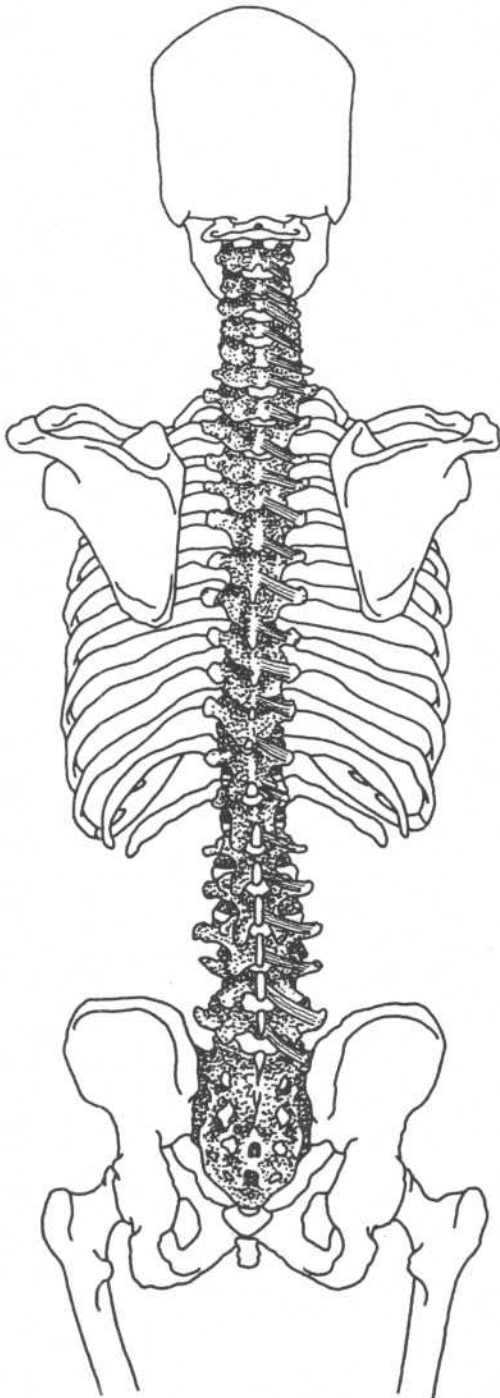
Action

Extend and rotate vertebral column

Nerve

Dorsal primary division of spinal nerves

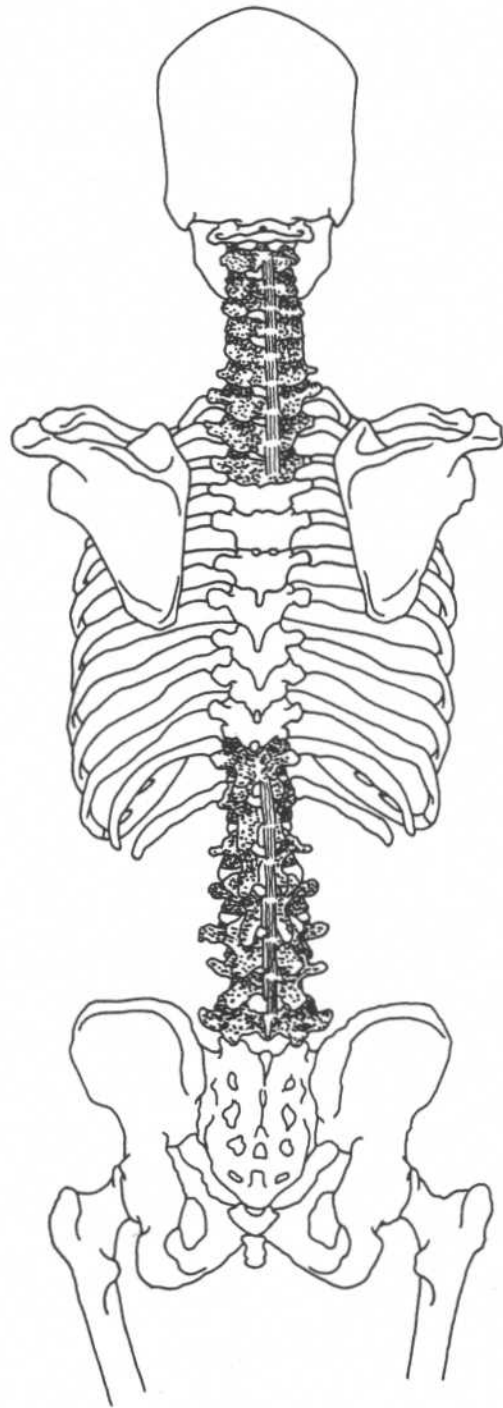
*Part of transversospinalis.

**Trunk—dorsal view**

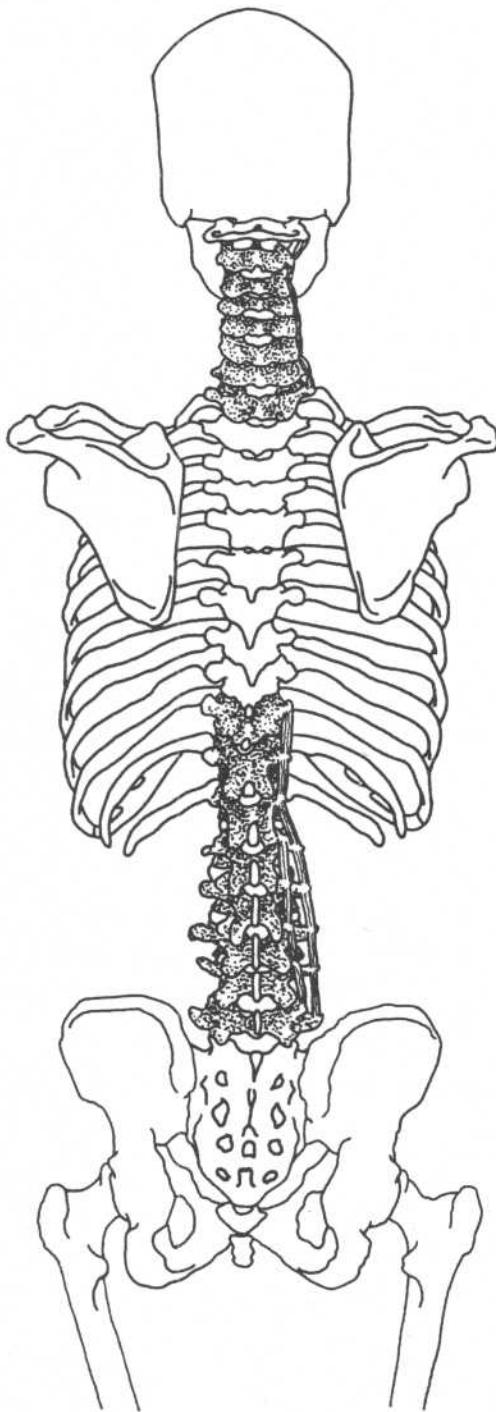
INTERSPINALES

(Paired on either side of interspinal ligament)

Origin	Cervical region—spinous processes of third to seventh cervical vertebrae (C3–C7) Thoracic region—spinous processes of second to twelfth thoracic vertebrae (T2–T12) Lumbar region—spinous processes of second to fifth lumbar vertebrae (L2–L5)
Insertion	Spinous process of next vertebra superior to origin
Action	Extend vertebral column
Nerve	Dorsal primary division of spinal nerves



Trunk—dorsal view



Trunk—dorsal view

INTERTRANSVERSARI

Cervical region

INTERTRANSVERSARI ANTERIORES

Origin	Anterior tubercle of transverse processes of vertebrae from first thoracic to axis
Insertion	Anterior tubercle of next superior vertebra
Action	Lateral flexion of vertebral column
Nerve	Ventral primary division of spinal nerves

INTERTRANSVERSARI POSTERIORES

Origin	Posterior tubercle of transverse processes of vertebrae from first thoracic to axis
Insertion	Posterior tubercle of next superior vertebra

Thoracic region

Origin	Transverse processes of first lumbar to eleventh thoracic vertebrae
Insertion	Transverse processes of next superior vertebra

Lumbar region

INTERTRANSVERSARI LATERALES

Origin	Transverse processes of lumbar vertebrae
Insertion	Transverse process of next superior vertebra
Action	Lateral flexion of vertebral column
Nerve	Ventral primary division of spinal nerves

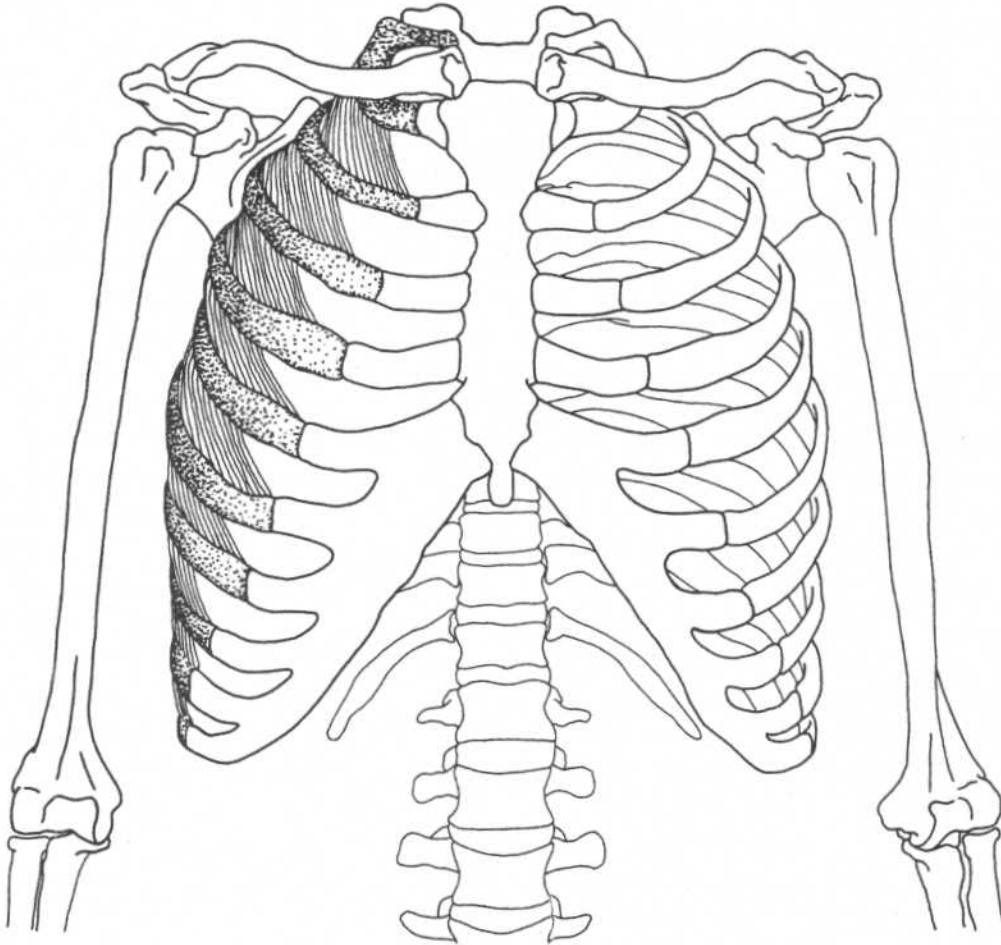
INTERTRANSVERSARI MEDIALES

Origin	Mamillary process [†] of each lumbar vertebra
Insertion	Accessory process of the next superior lumbar vertebra
Action	Lateral flexion of vertebral column
Nerve	Dorsal primary division of spinal nerves

[†]Posterior border of superior articular process.

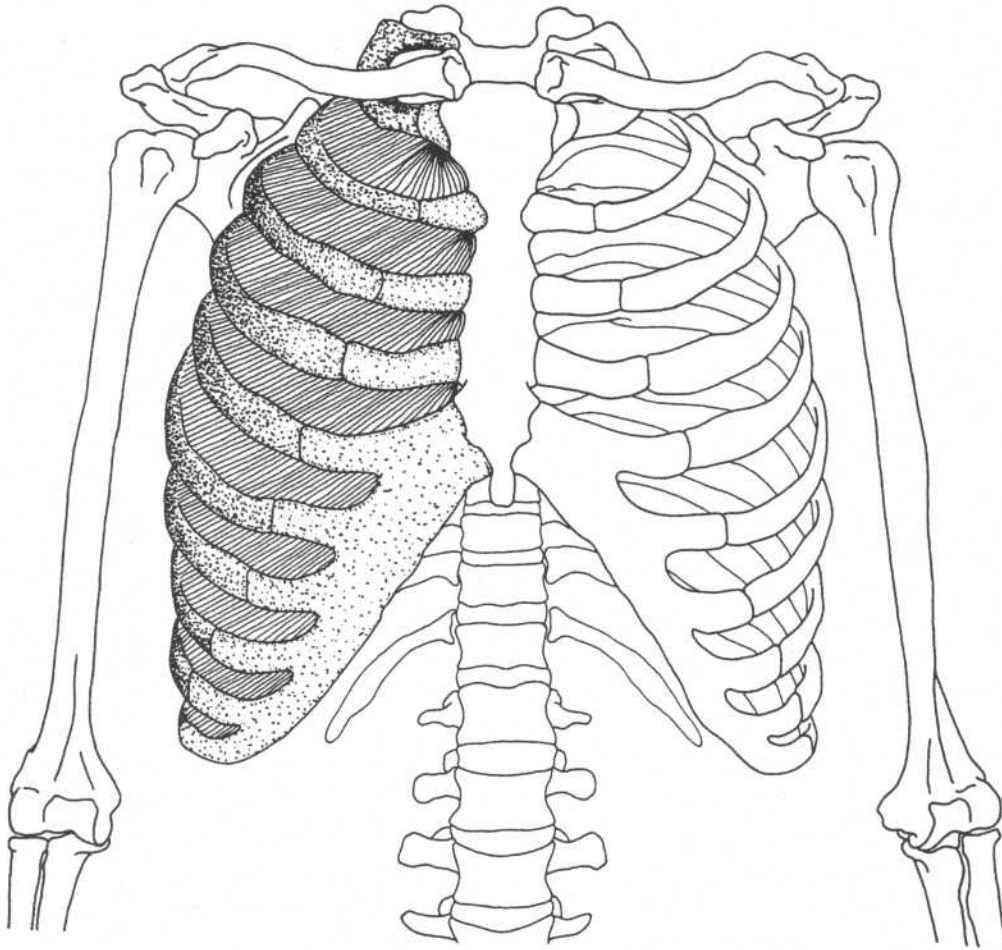
INTERCOSTALES EXTERNI

(External Intercostal)



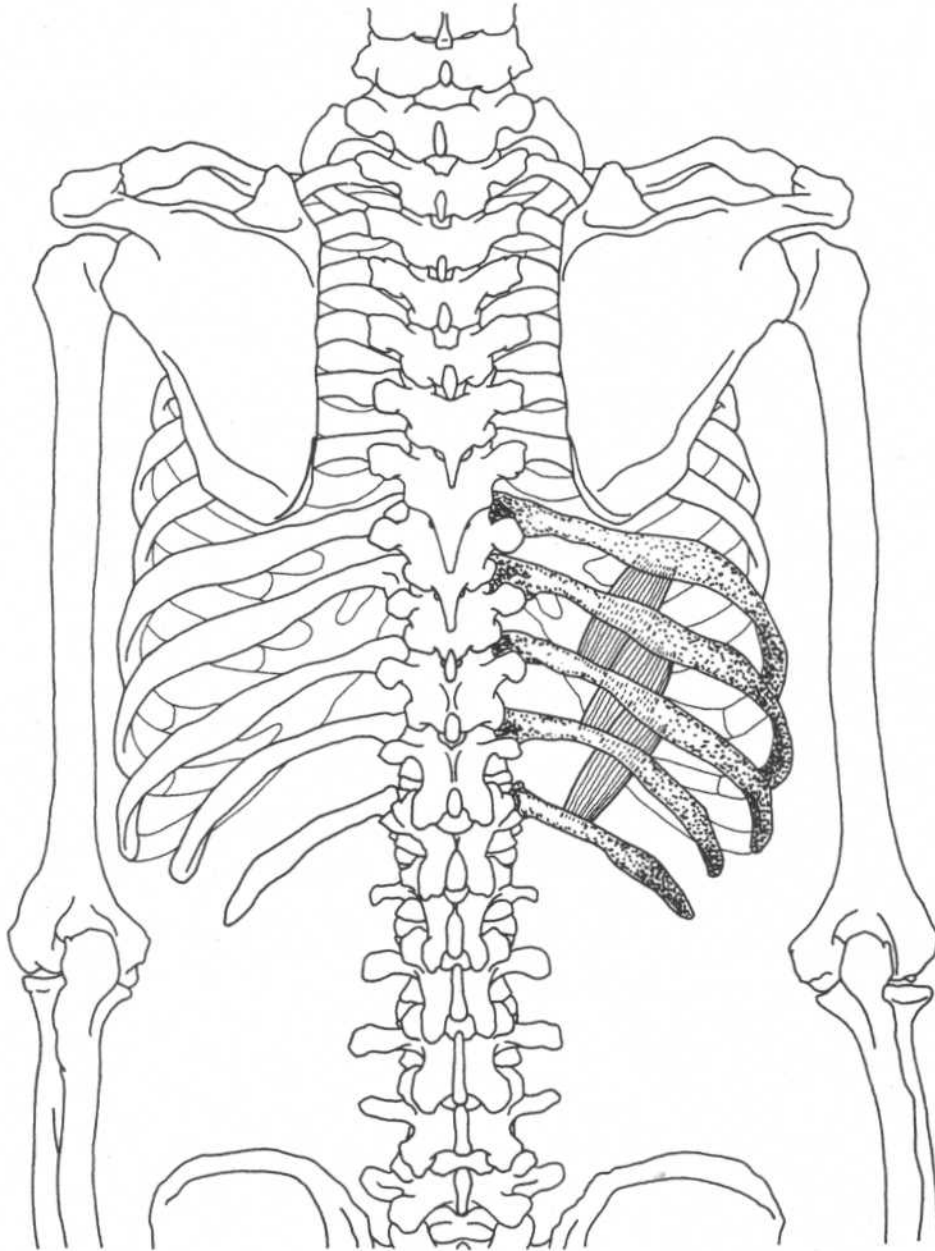
Trunk—anterior view

Origin	Lower margin of upper eleven ribs	Action	Draw ventral part of ribs upward, increasing the volume of the thoracic cavity for inspiration
Insertion	Superior border of rib below (each muscle fiber runs obliquely and inserts toward the costal cartilage)	Nerve	Intercostal nerves

INTERCOSTALES INTERNI*(Internal Intercostal)***Trunk—anterior view**

Origin	From the cartilages to the angles of the upper eleven ribs	Action	Draw ventral part of ribs downward, decreasing the volume of the thoracic cavity for expiration
Insertion	Superior border of the rib below (each muscle fiber runs obliquely and inserts away from the costal cartilage)	Nerve	Intercostal nerves

SUBCOSTALES



Trunk—dorsal view

Origin Inner surface of each rib near its angle

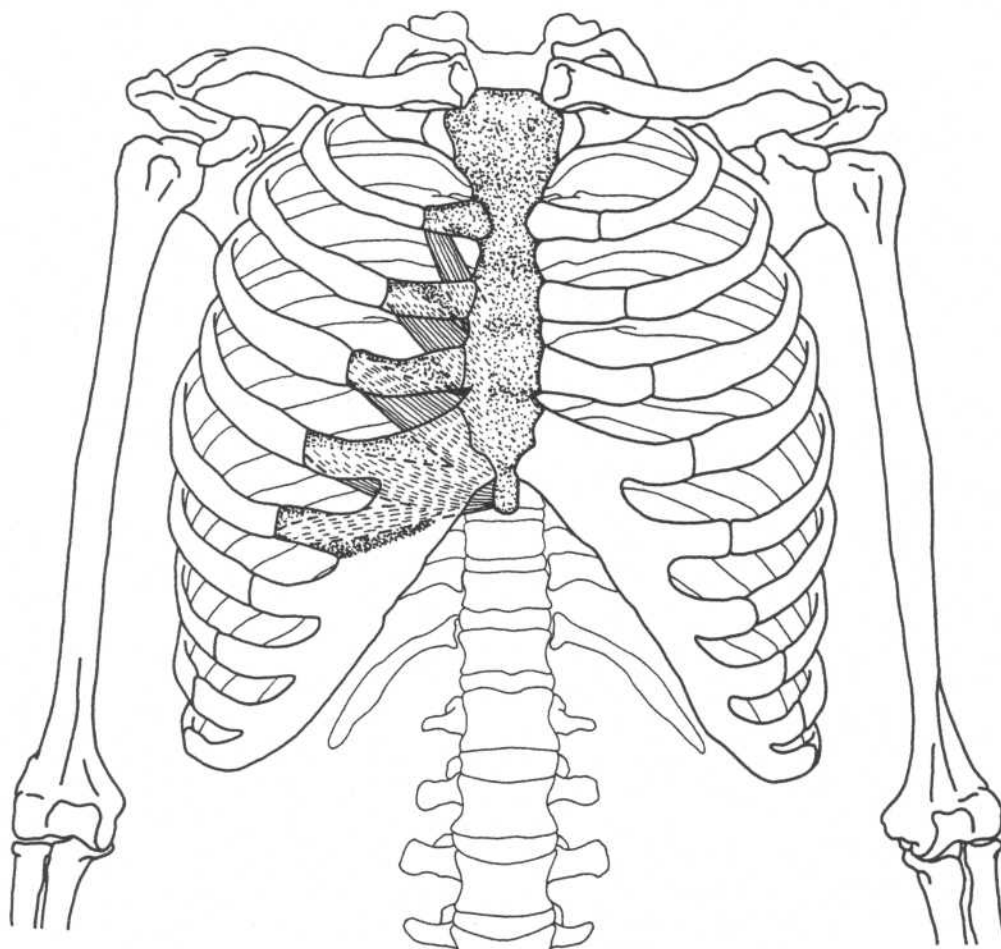
Insertion Medially on the inner surface of second or third rib below

Action Draw ventral part of ribs downward, decreasing the volume of the thoracic cavity for forceful expiration

Nerve Intercostal nerves

Note: These muscles are deep to the internal intercostals. They continue distally between single ribs, where they are known as innermost intercostal muscles.

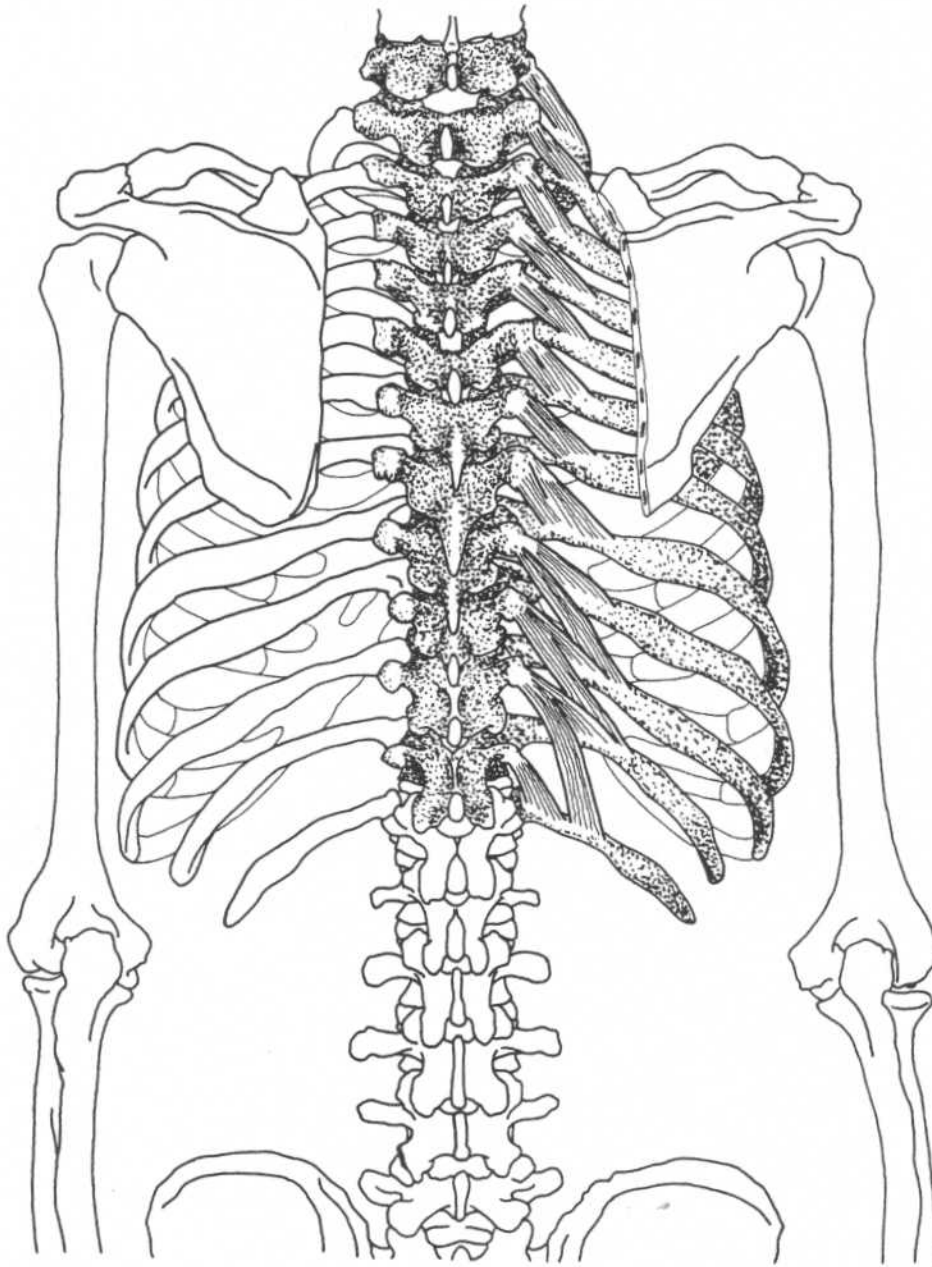
TRANSVERSUS THORACIS



Trunk—anterior view

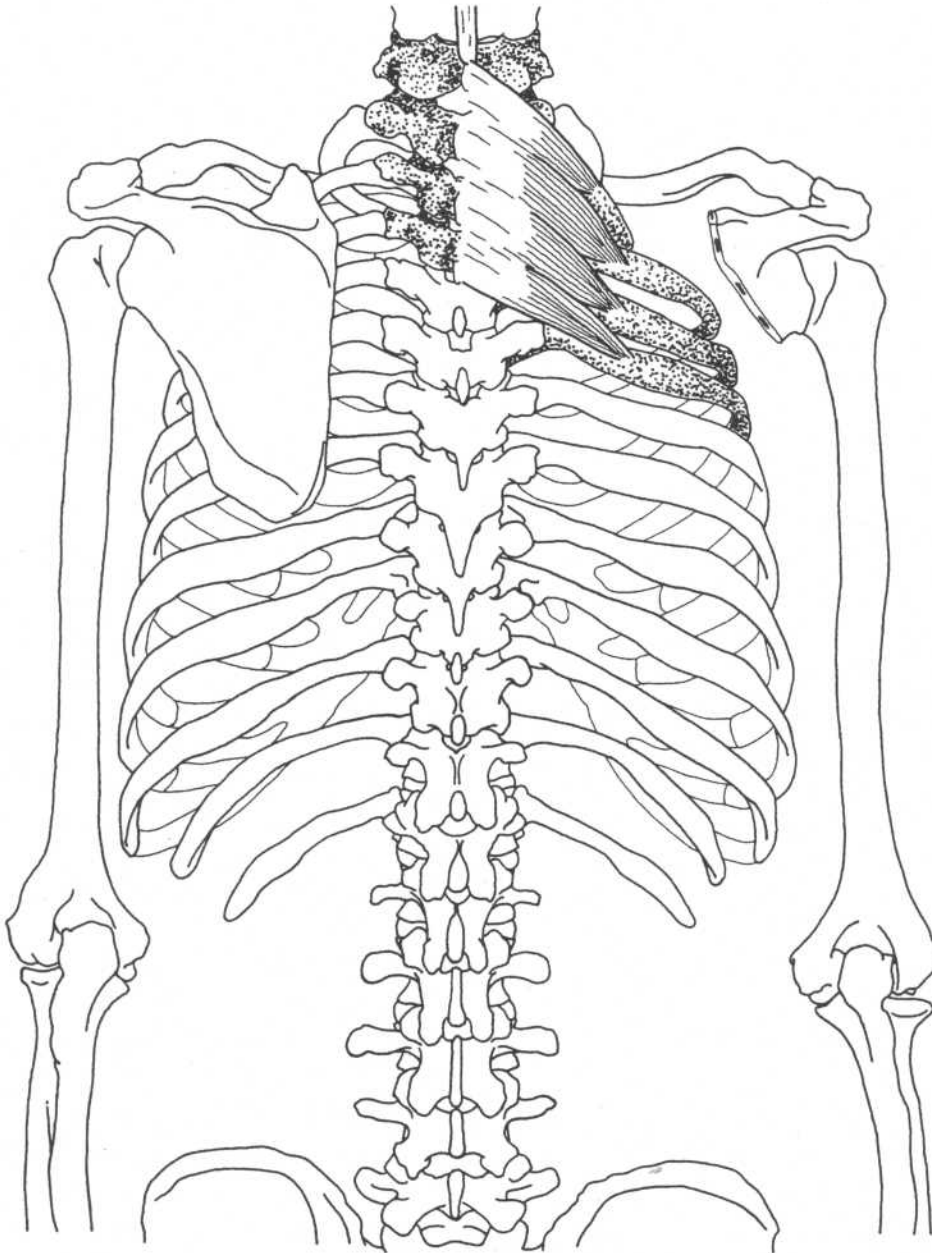
Origin	Inner surface of lower portion of sternum and adjacent costal cartilages	Action	Draws ventral part of ribs downward, decreasing the volume of the thoracic cavity for forceful expiration
Insertion	Inner surfaces of costal cartilages of the second through sixth ribs	Nerve	Intercostal nerves
		Note: These muscles are deep to the internal intercostal muscles.	

LEVATORES COSTARUM



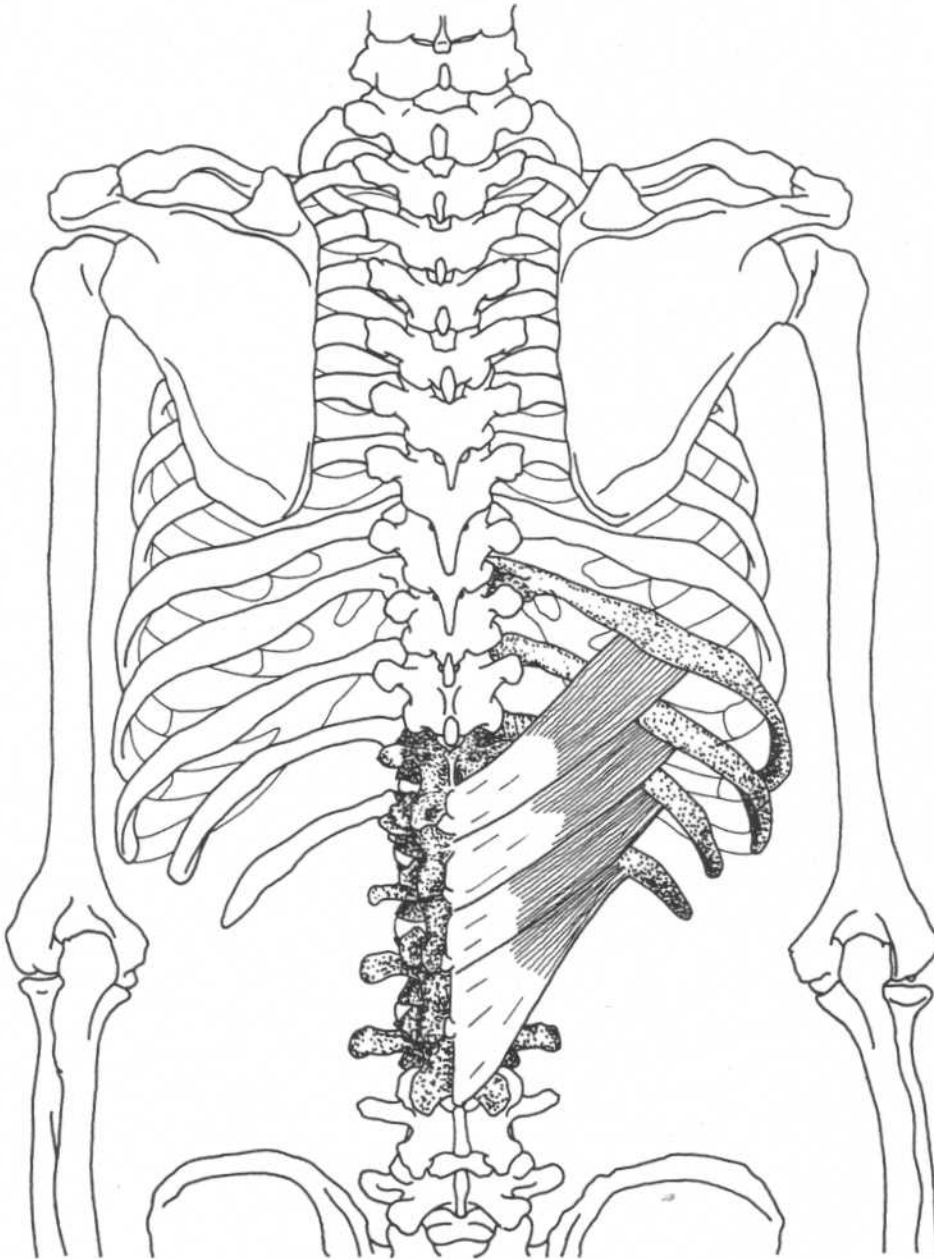
Trunk—dorsal view

Origin	Transverse processes of the seventh cervical and the upper eleven thoracic vertebrae	Action	Raises ribs; extends, laterally flexes, and rotates vertebral column
Insertion	Laterally to outer surface of next lower rib (lower muscles may cross over one rib)	Nerve	Intercostal nerves

SERRATUS POSTERIOR SUPERIOR**Trunk—dorsal view**

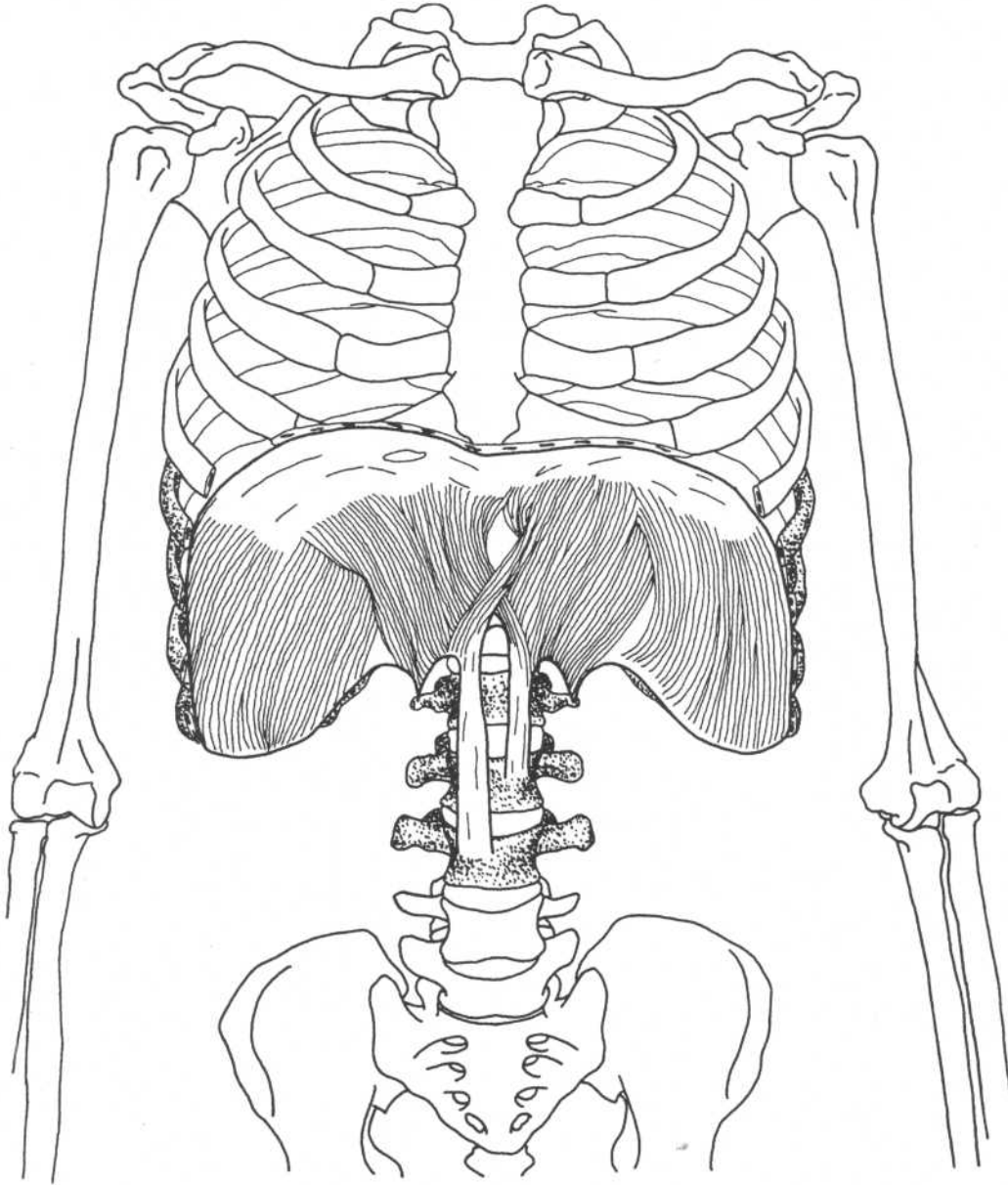
Origin	Ligamentum nuchae, spinous processes of seventh cervical and first few thoracic vertebrae	Action	Raises ribs in inspiration
Insertion	Upper borders of the second through fifth ribs lateral to their angles	Nerve	T1–T4

SERRATUS POSTERIOR INFERIOR



Trunk—dorsal view

Origin	Spinous processes of the lower two thoracic and the upper two or three lumbar vertebrae	Action	Pulls ribs down, resisting pull of diaphragm
Insertion	Lower borders of bottom four ribs	Nerve	T9–T12

DIAPHRAGM

Trunk—anterior view
(Lower costal cartilages removed)

Origin

Sternal part—inner part of xiphoid process
 Costal part—inner surfaces of lower six ribs and their cartilages
 Lumbar part—upper two or three lumbar vertebrae and lateral and medial lumbocostal arches*

Insertion

Fibers converge and meet on a central tendon

Action

Draws central tendon inferiorly

Nerve

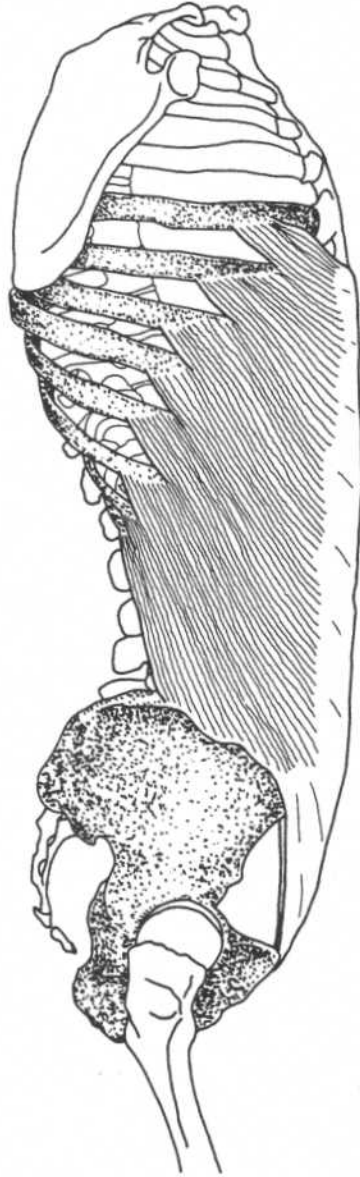Phrenic nerve (C3–C5)

Note: This muscle inserts upon itself. Its action is to change the volume of the thoracic and abdominal cavities.

*These tendinous structures, also known as the medial and lateral arcuate ligaments, allow the diaphragm to bridge the upper parts of the psoas major and quadratus lumborum muscles.

OBLIQUUS EXTERNUS ABDOMINIS

(External Oblique)



Trunk—lateral view

Origin

Lower eight ribs

Insertion

Anterior part of iliac crest, abdominal aponeurosis to linea alba

Action

Compresses abdominal contents, laterally flexes and rotates vertebral column

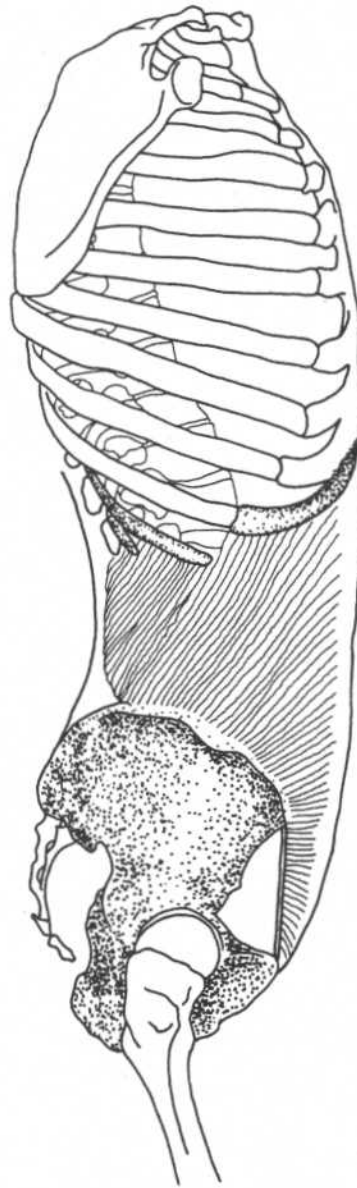
Nerve

Eighth to twelfth intercostal, iliohypogastric, ilioinguinal nerves

Relationships

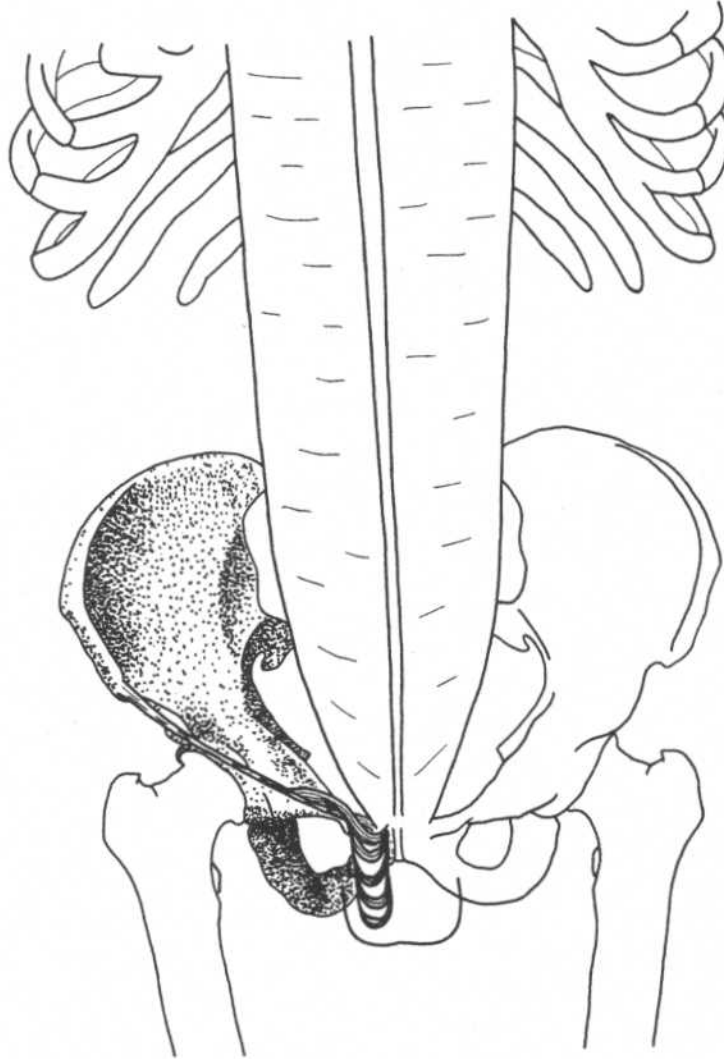
Most superficial of the three lateral abdominal muscles

Note: Important in forced expiration, coughing, sneezing.

OBLIQUUS INTERNUS ABDOMINIS*(Internal Oblique)***Trunk—lateral view**

Origin	Lateral half of inguinal ligament, iliac crest, thoracolumbar fascia	Nerve	Eighth to twelfth intercostal, iliohypogastric, ilioinguinal nerves
Insertion	Cartilage of bottom three or four ribs, abdominal aponeurosis to linea alba	Relationships	Middle layer of the three lateral abdominal muscles
Action	Compresses abdominal contents, laterally flexes and rotates vertebral column		Note: Important in forced expiration, coughing, sneezing.

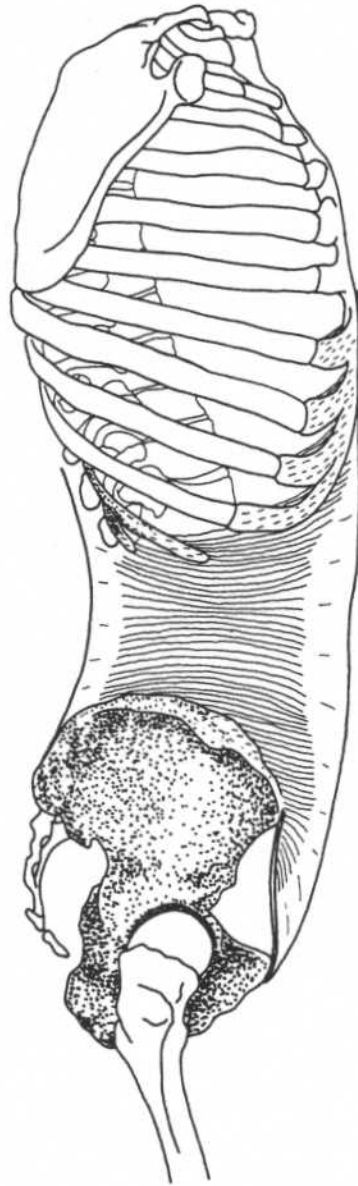
CREMASTER



Trunk—anterior view

Origin	Inguinal ligament	Action	Pulls testes toward body
Insertion	Pubic tubercle, crest of pubis, sheath of rectus abdominis	Nerve	Genital branch of genitofemoral nerve

Note: The cremaster regulates the temperature of the testes, which is important for spermatogenesis.

TRANSVERSUS ABDOMINIS**Trunk—lateral view**

Origin	Lateral part of inguinal ligament, iliac crest, thoracolumbar fascia, cartilage of lower six ribs	Action	Compresses abdomen
Insertion	Abdominal aponeurosis to linea alba	Nerve	Seventh to twelfth intercostal, iliohypogastric, ilioinguinal nerves
		Relationships	Deepest of the three lateral abdominal muscles

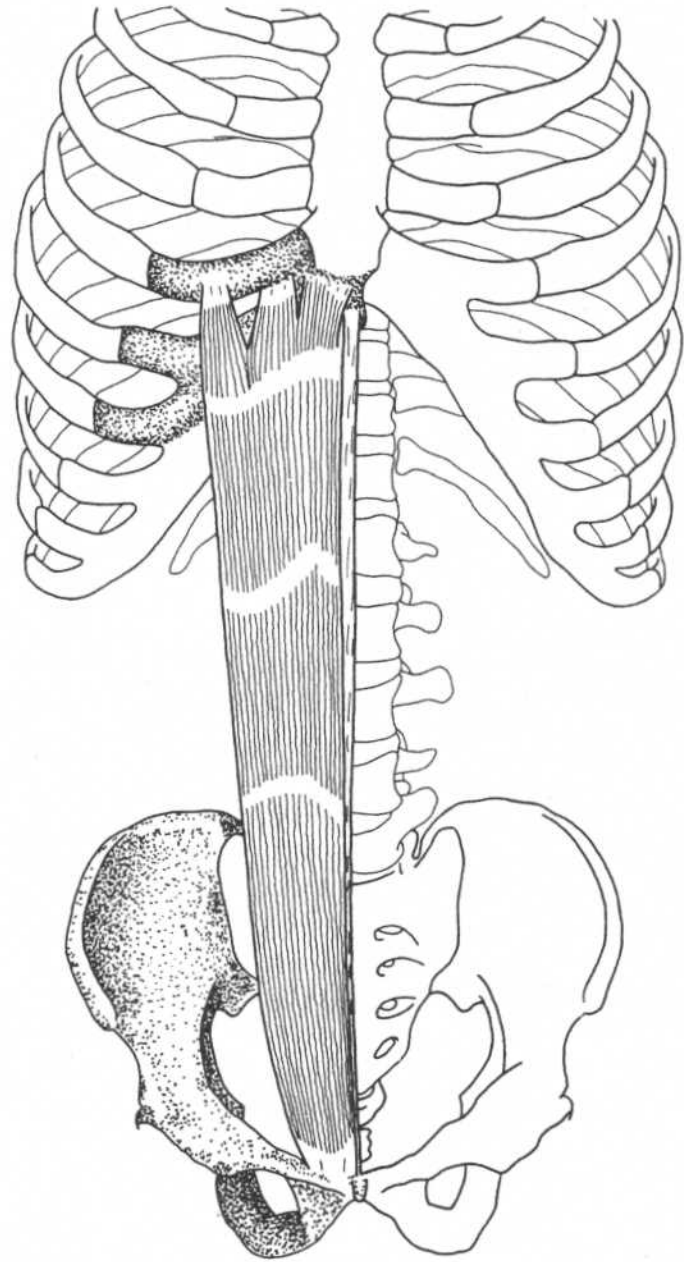
Note: Important in forced expiration, coughing, sneezing.

RECTUS ABDOMINIS*

Origin	Crest of pubis, pubic symphysis
Insertion	Cartilage of fifth, sixth, and seventh ribs, xiphoid process
Action	Flexes vertebral column, compresses abdomen
Nerve	Seventh through twelfth intercostal nerves

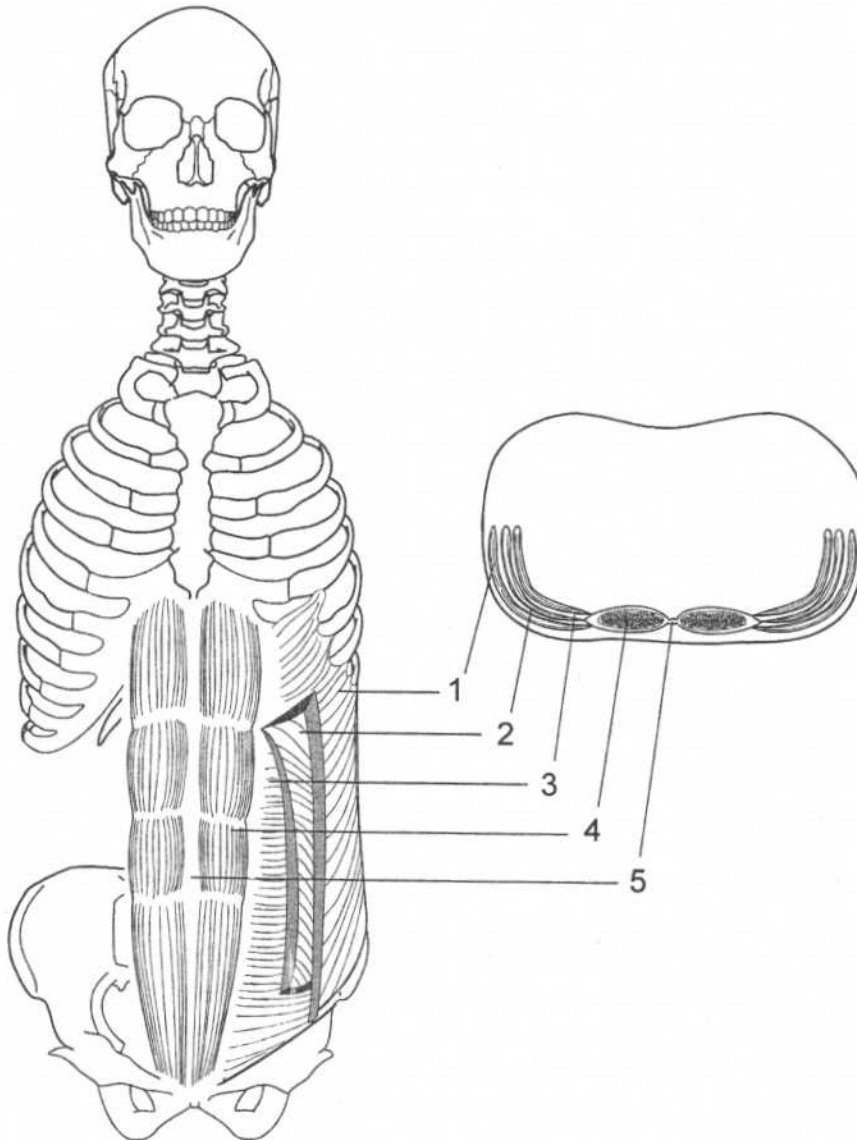
*Tendinous bands divide each rectus into three or four bellies. Each rectus is sheathed in aponeurotic fibers from the lateral abdominal muscles. These fibers meet centrally to form the linea alba.

Note: The pyramidalis is a small, unimportant muscle that extends from the ventral surface of the pubis to the lower part of the linea alba. It is frequently absent.



Trunk—anterior view

ABDOMINAL MUSCLES



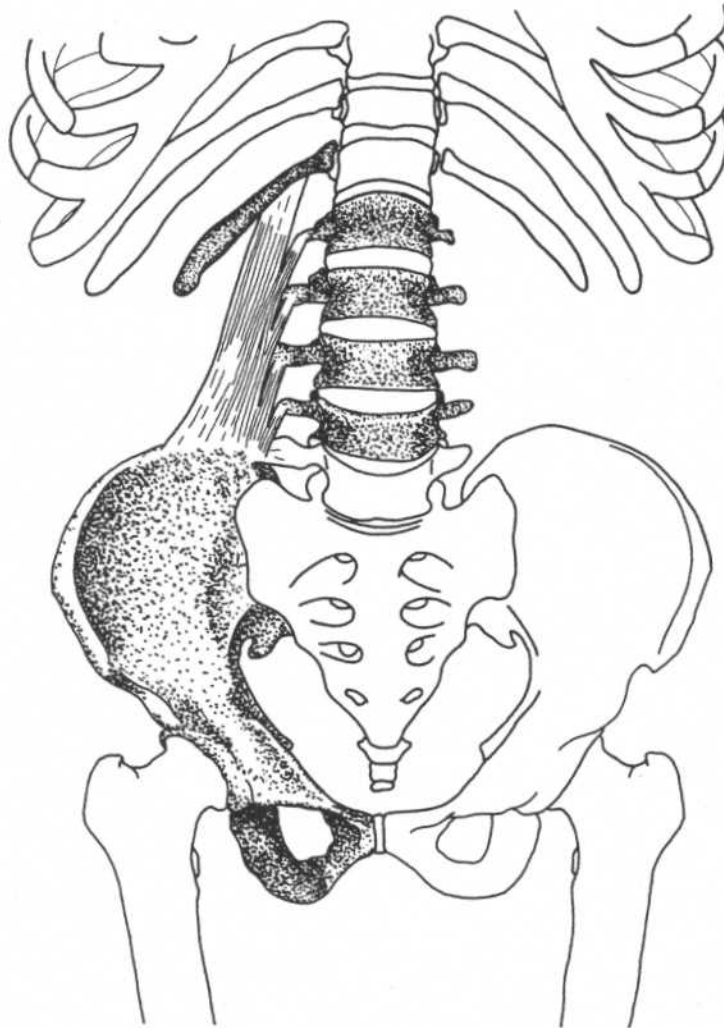
Trunk—anterior and cross-sectional views

1. Obliquus externus abdominis
2. Obliquus internus abdominis
3. Transversus abdominis

4. Rectus abdominis
5. Linea alba

Note: The aponeuroses (tendons) of the three lateral abdominal muscles join to form the fascial sheath surrounding the rectus abdominis.

QUADRATUS LUMBORUM



Lower trunk—anterior view

Origin

Iliolumbar ligament, iliac crest

Insertion

Twelfth rib, transverse processes of upper four lumbar vertebrae

Action

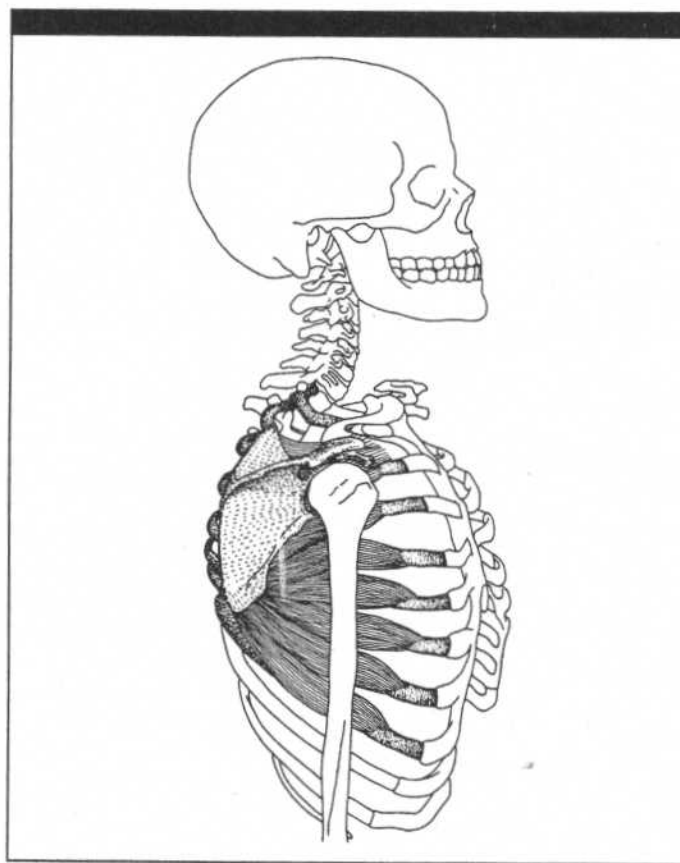
Laterally flexes vertebral column, fixes ribs for forced expiration

Nerve

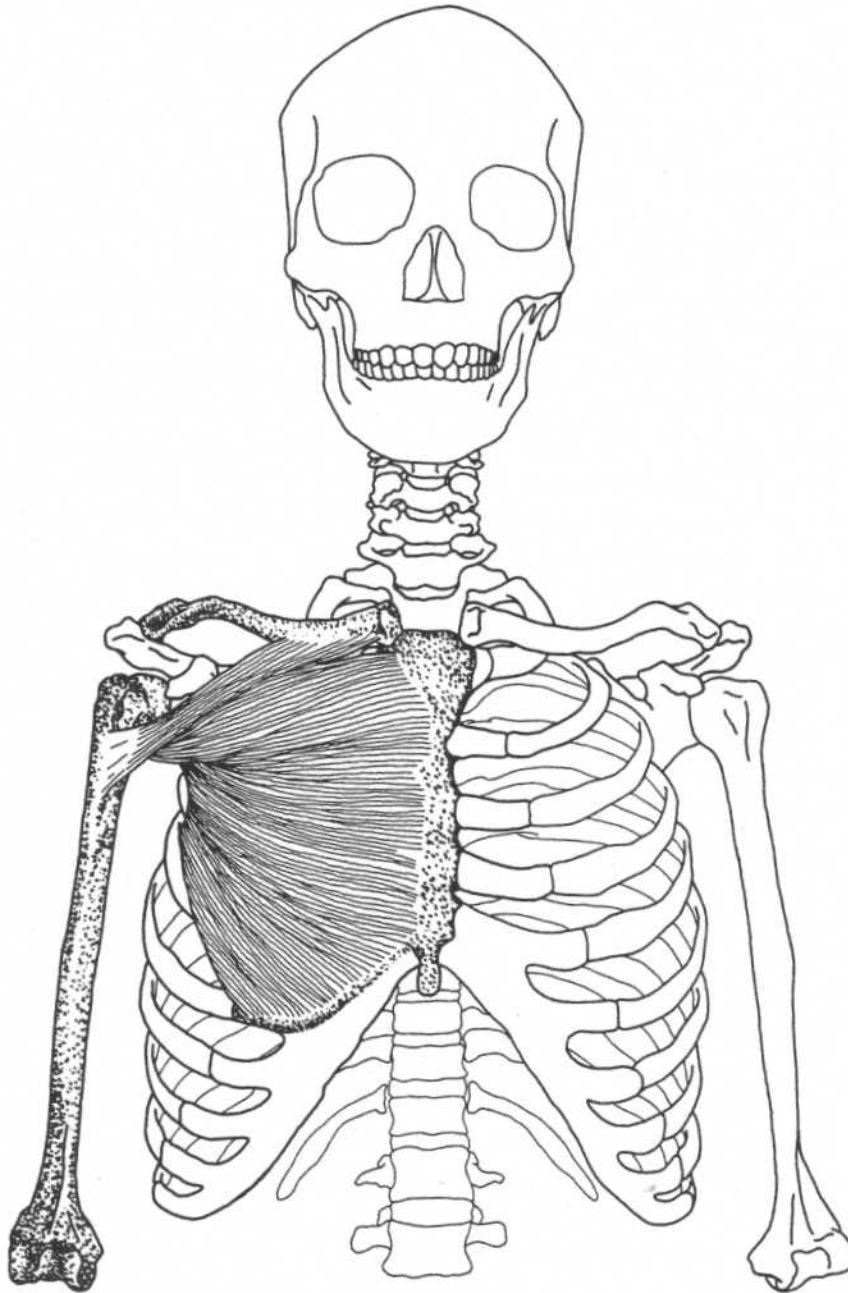
T12, L1

Note: Fixation of the ribs may provide a stable attachment of the diaphragm for voice control in singers.

CHAPTER SIX
MUSCLES OF THE
SHOULDER AND ARM

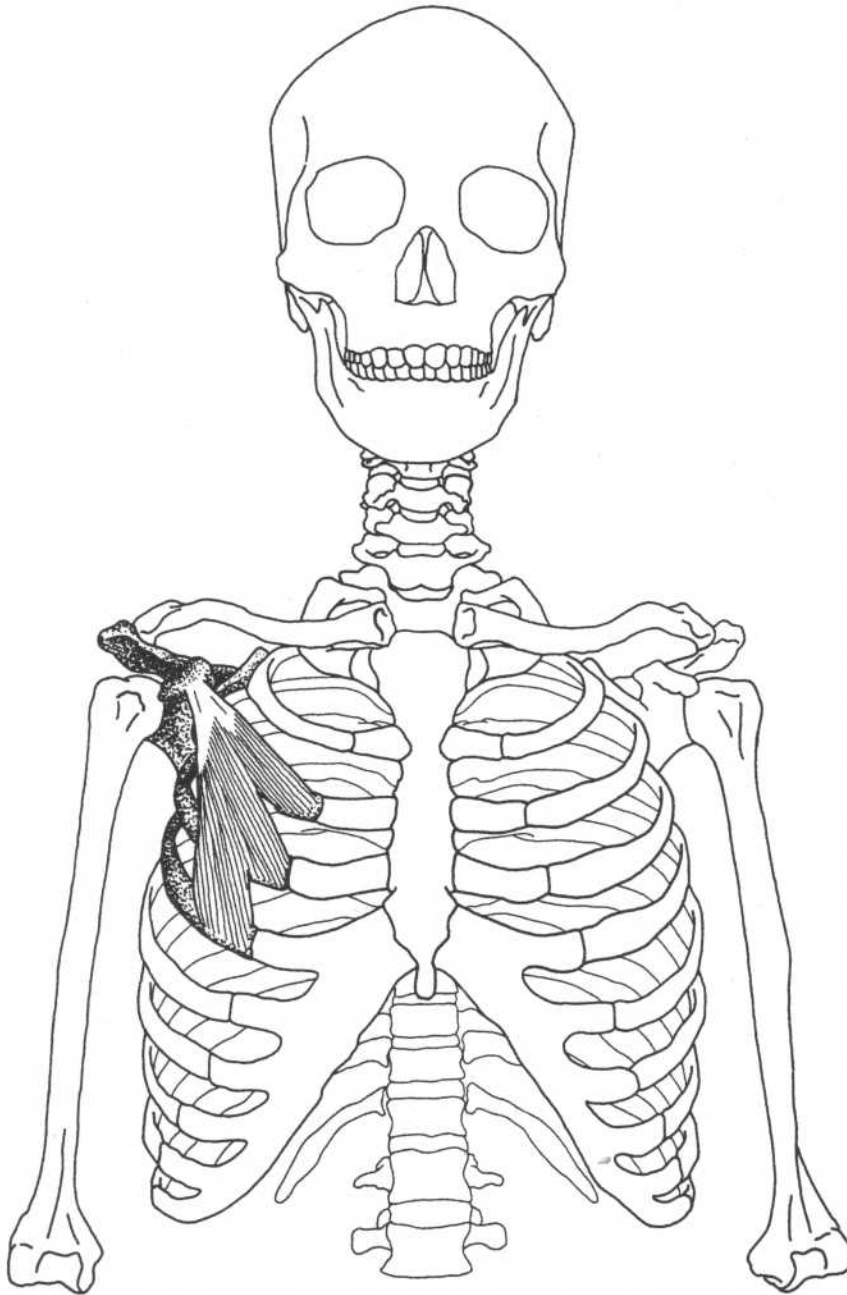


PECTORALIS MAJOR



Anterior view

Origin	Clavicular part—medial half of the clavicle Sternocostal part—sternum, upper six costal cartilages, aponeurosis of external oblique	Action	Both parts adduct, medially rotate arm; clavicular part flexes arm from full extension; sternocostal part extends the flexed arm
Insertion	Lateral lip of intertubercular (bicipital) groove of humerus, crest below greater tubercle of the humerus	Nerve	Medial and lateral pectoral nerves (C5–C8, T1)

PECTORALIS MINOR**Anterior view****Origin**

External surfaces of the third, fourth, and fifth ribs

Insertion

Coracoid process of the scapula

Action

Draws scapula forward and downward, raises ribs* in forced inspiration

Nerve

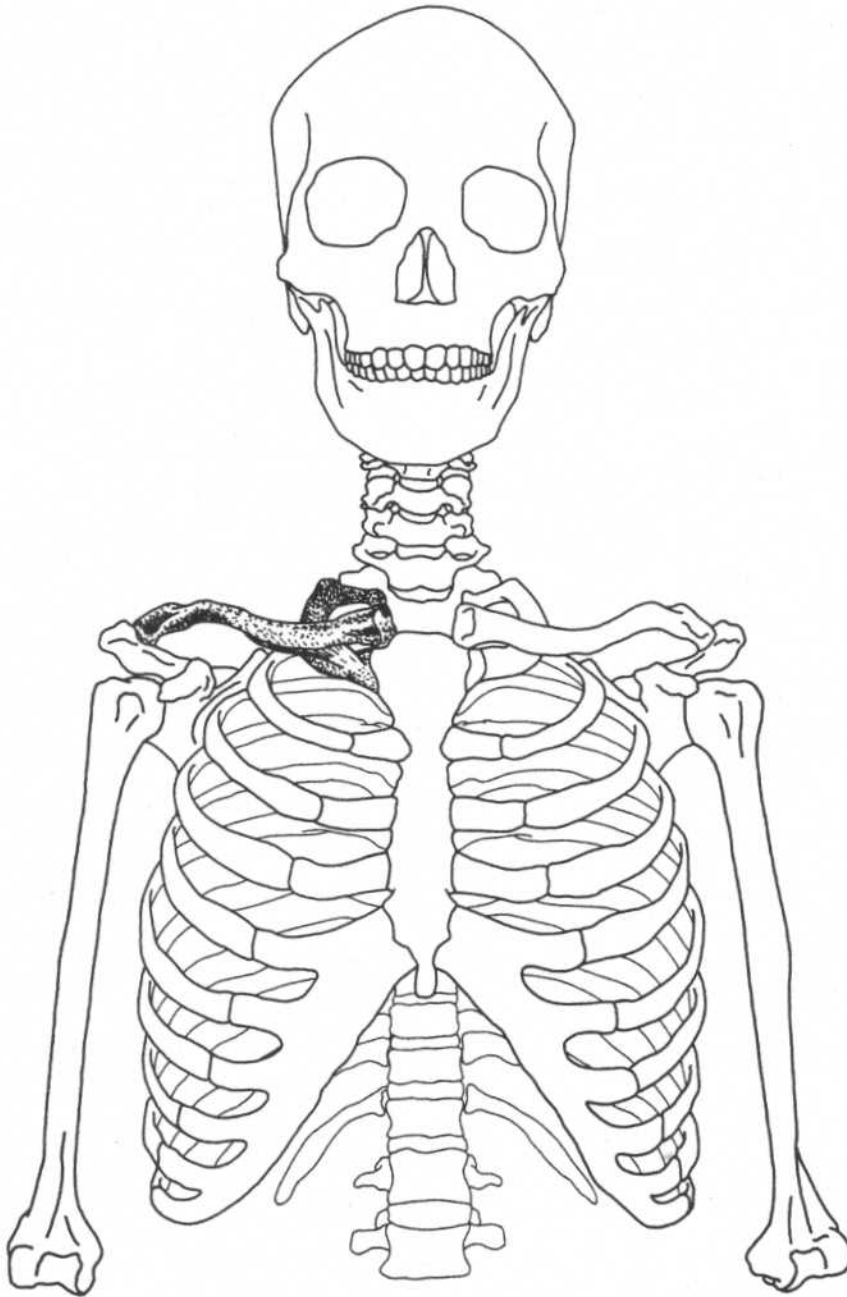
Medial pectoral nerve (C8, T1)

Relationships

Deep to pectoralis major

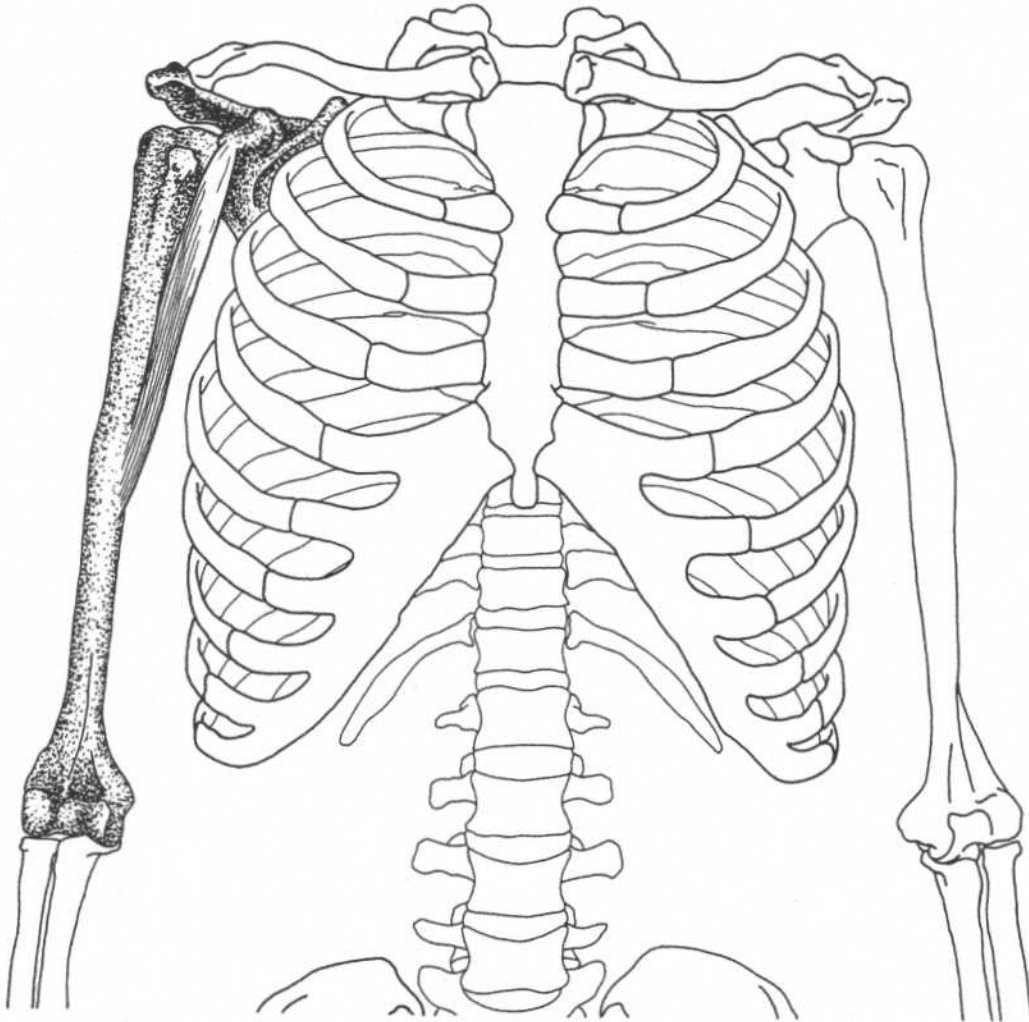
*Raising the ribs requires stabilization of the scapula by the rhomboids and trapezius.

SUBCLAVIUS



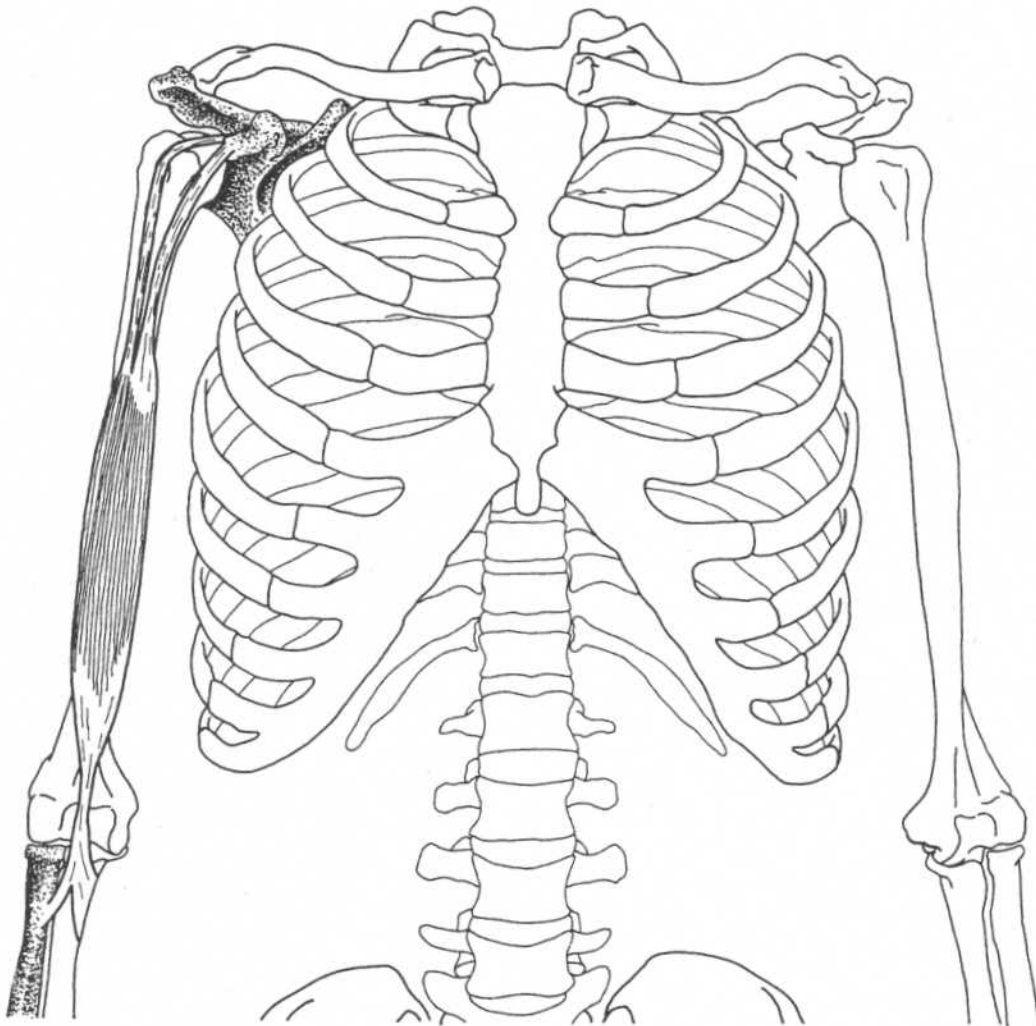
Anterior view

Origin	Junction of the first rib with its costal cartilage	Action	Depresses clavicle, draws shoulder forward and downward, steadies clavicle during movements of shoulder girdle
Insertion	Groove on the inferior (lower) surface of the clavicle	Nerve	C5, C6

CORACOBRACHIALIS**Anterior view**

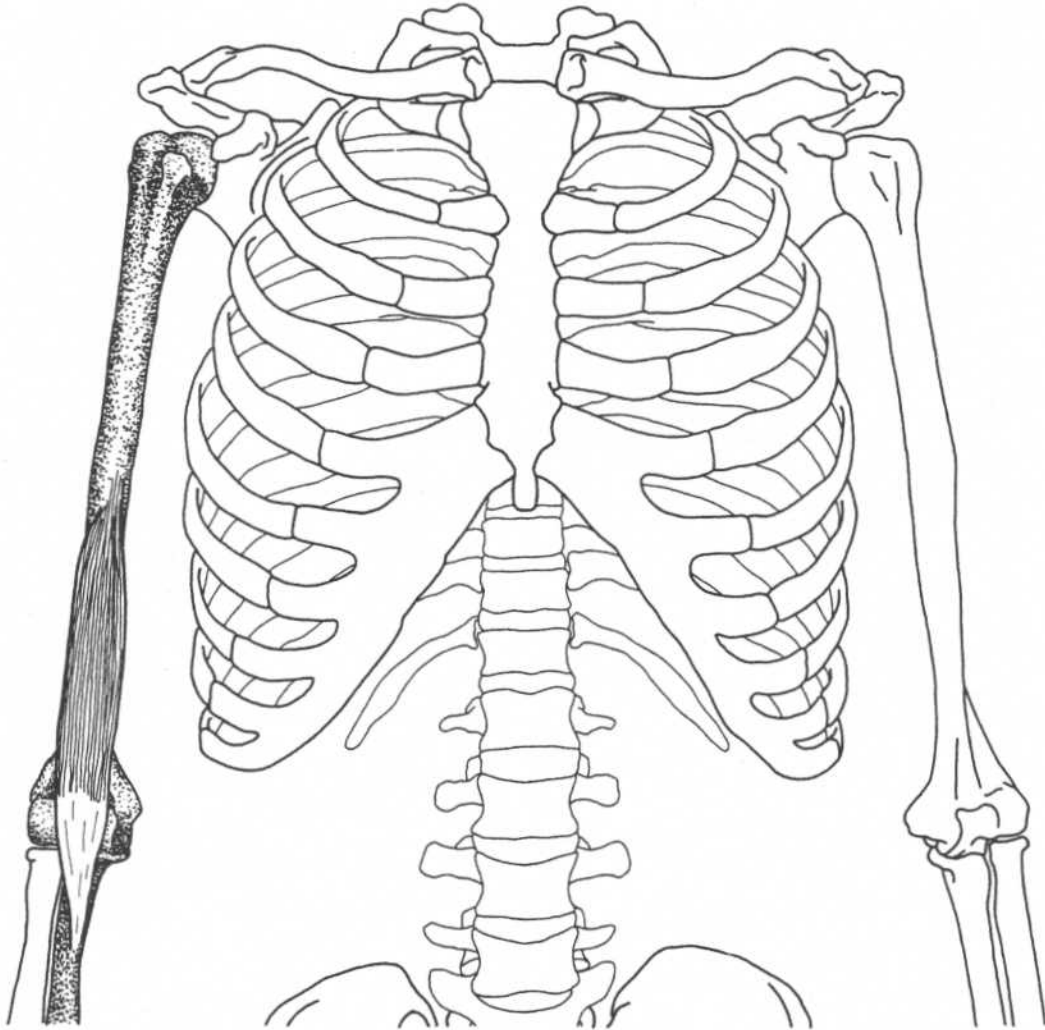
Origin	Tip (apex) of the coracoid process of scapula	Nerve	Musculocutaneous nerve (C6, C7)
Insertion	Middle third of the medial surface and border of the humerus	Relationships	Deep to short head of biceps
Action	Weakly adducts arm (flexion unsubstantiated), aids in stabilizing humerus		

BICEPS BRACHII



Anterior view

Origin	Long head—supraglenoid tubercle of scapula Short head—coracoid process of scapula	Action	Supinates forearm, flexes forearm, weakly flexes arm at shoulder
Insertion	Tuberosity of radius, bicipital aponeurosis into deep fascia on medial part of forearm	Nerve	Musculocutaneous nerve (C5, C6)
		Relationships	Long head passes through intertubercular (bicipital) groove, then inside glenohumeral joint capsule

BRACHIALIS**Anterior view****Origin**

Anterior of lower half of humerus

Insertion

Coronoid process of ulna, tuberosity of ulna

Action

Flexes forearm

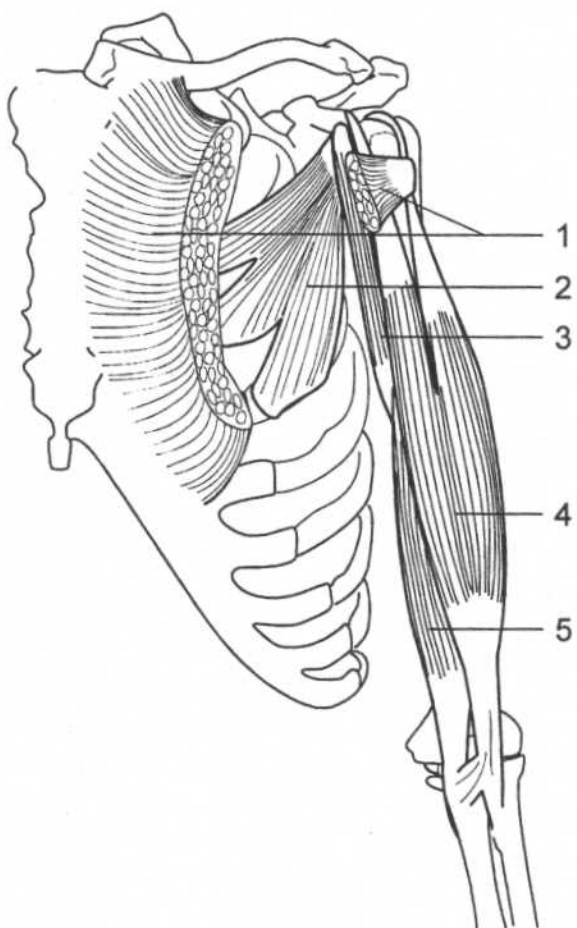
Nerve

Musculocutaneous nerve (C5, C6)

Relationships

Deep to biceps brachii

MUSCLES OF THE ANTERIOR CHEST AND ARM

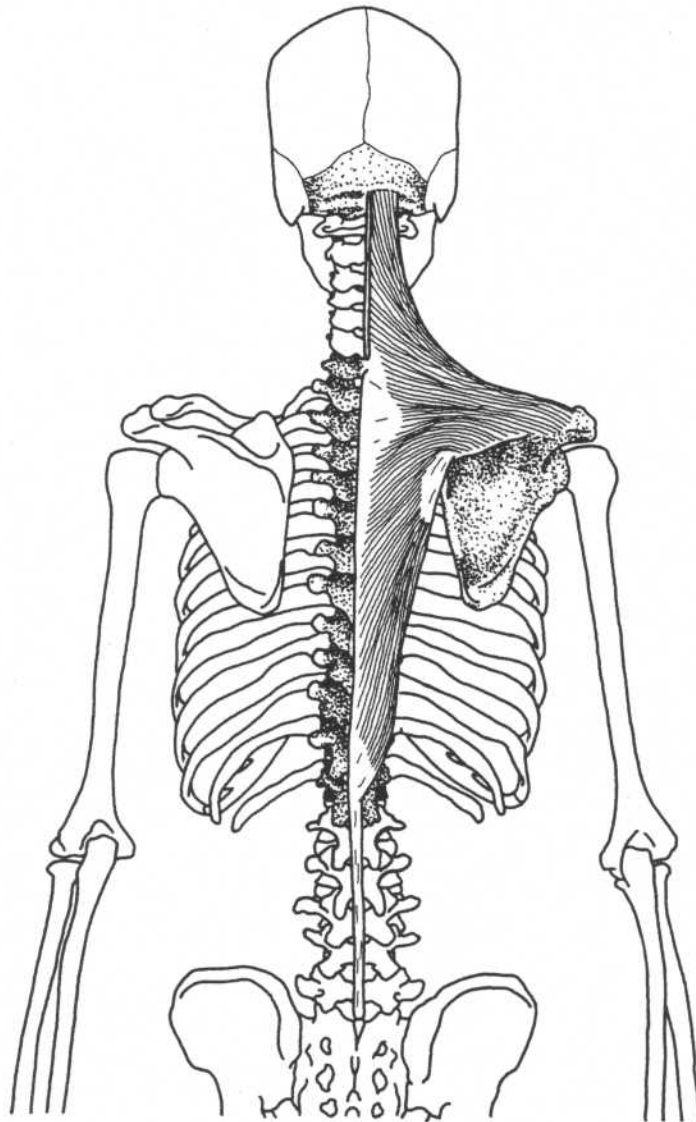


Shoulder—anterior view

- 1. Pectoralis major (cut)
- 2. Pectoralis minor
- 3. Coracobrachialis

- 4. Biceps brachii
- 5. Brachialis

TRAPEZIUS

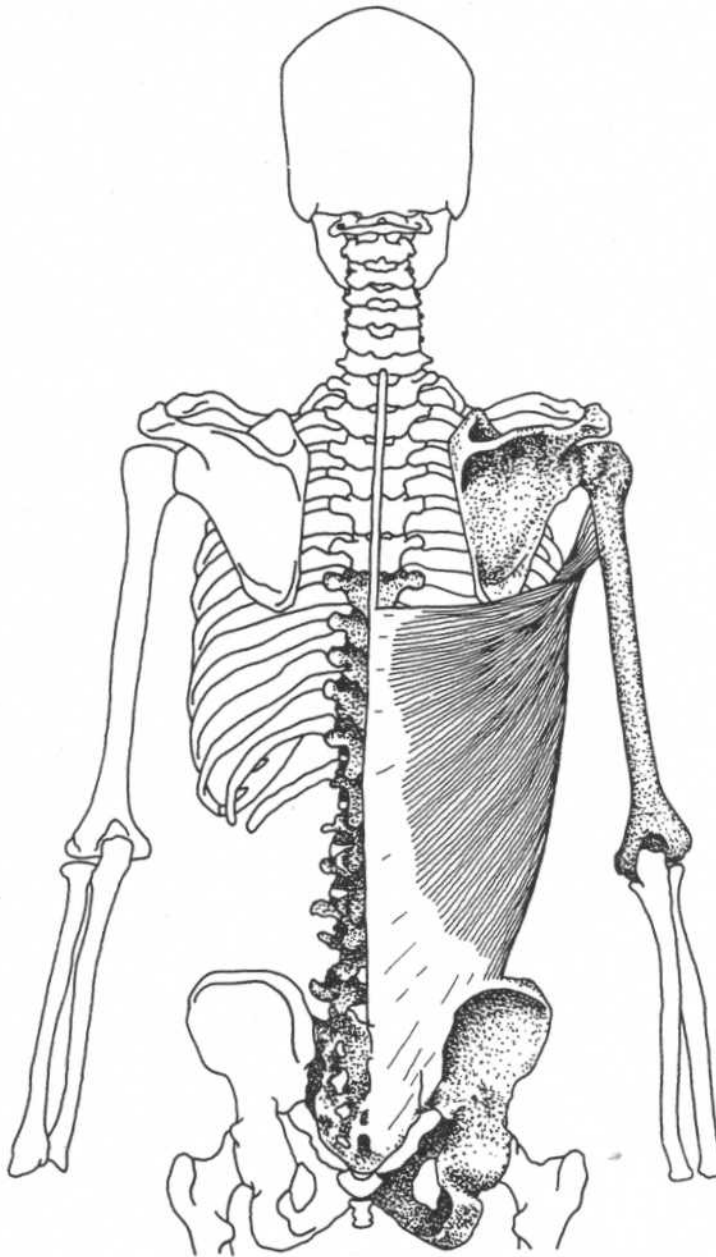


Posterior view

Origin	Medial third of superior nuchal line, external occipital protuberance, ligamentum nuchae, spinous processes and supraspinous ligaments of seventh cervical and all thoracic vertebrae	Action	Upper part elevates scapula,* middle part retracts (adducts) scapula, lower part depresses scapula, upper and lower parts together rotate scapula (important in elevating arm)
Insertion	Upper part—lateral third of clavicle Middle part—acromion and crest of spine of scapula Lower part—medial portion of crest of spine of scapula (tubercle)	Nerve	Accessory (eleventh cranial), C3, C4
		Relationships	Most superficial muscle of back

*Upper part stabilizes scapula against downward rotation, as when weight is carried in the hand.

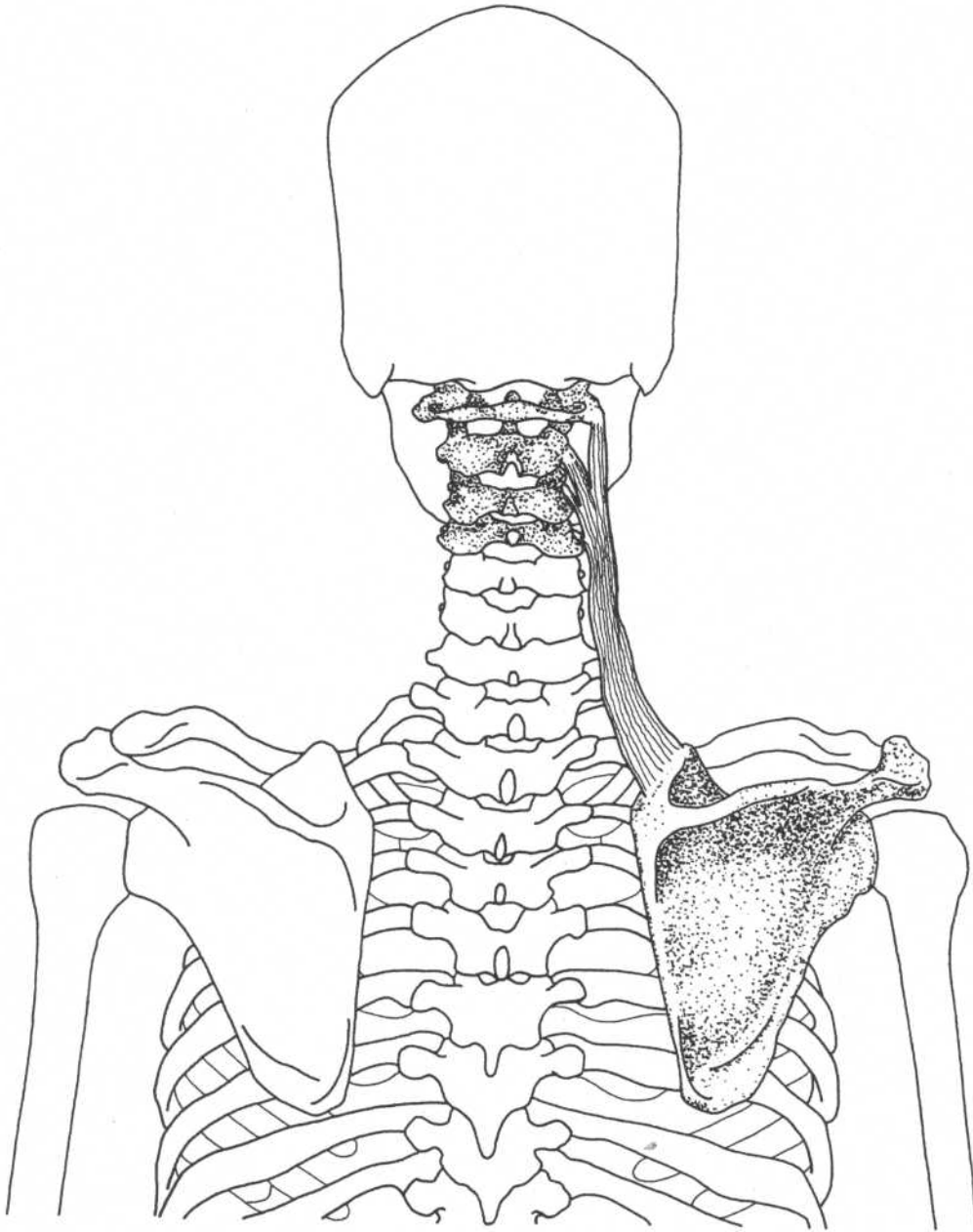
LATISSIMUS DORSI



Posterior view

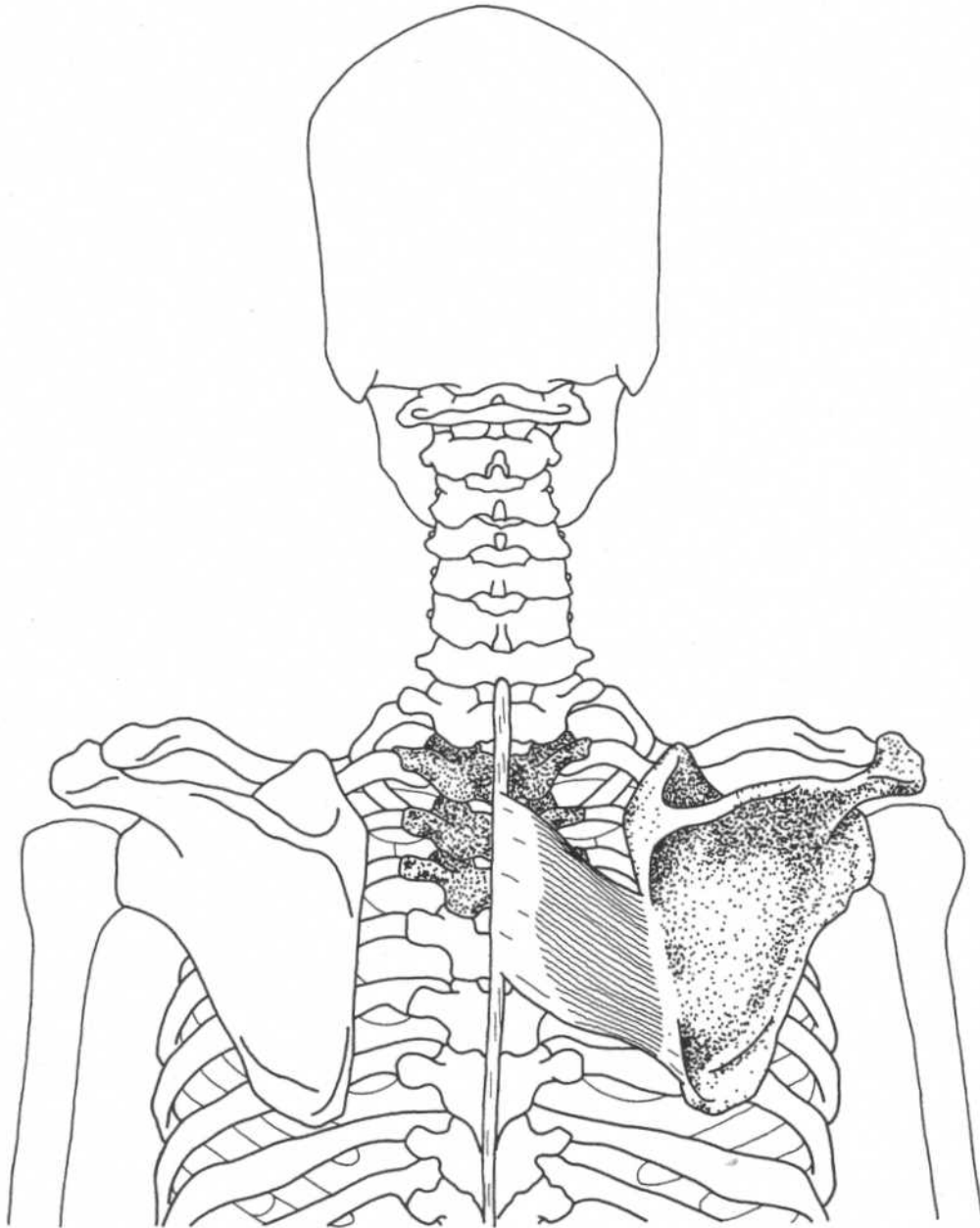
Origin	Spinous processes of the lower six thoracic vertebrae, lumbar vertebrae, sacral vertebrae, supraspinal ligament, and posterior part of the iliac crest through the lumbar (thoracolumbar) fascia, lower three or four ribs, inferior angle of the scapula	Action	Extends, adducts, and medially rotates the arm, draws the shoulder downward and backward, keeps inferior angle of scapula against the chest wall, accessory muscle of respiration
Insertion	Floor (bottom) of the bicipital groove of humerus	Nerve	Thoracodorsal nerve (C6–C8)

Note: This muscle is used for the crawl stroke in swimming.

LEVATOR SCAPULAE**Posterior view**

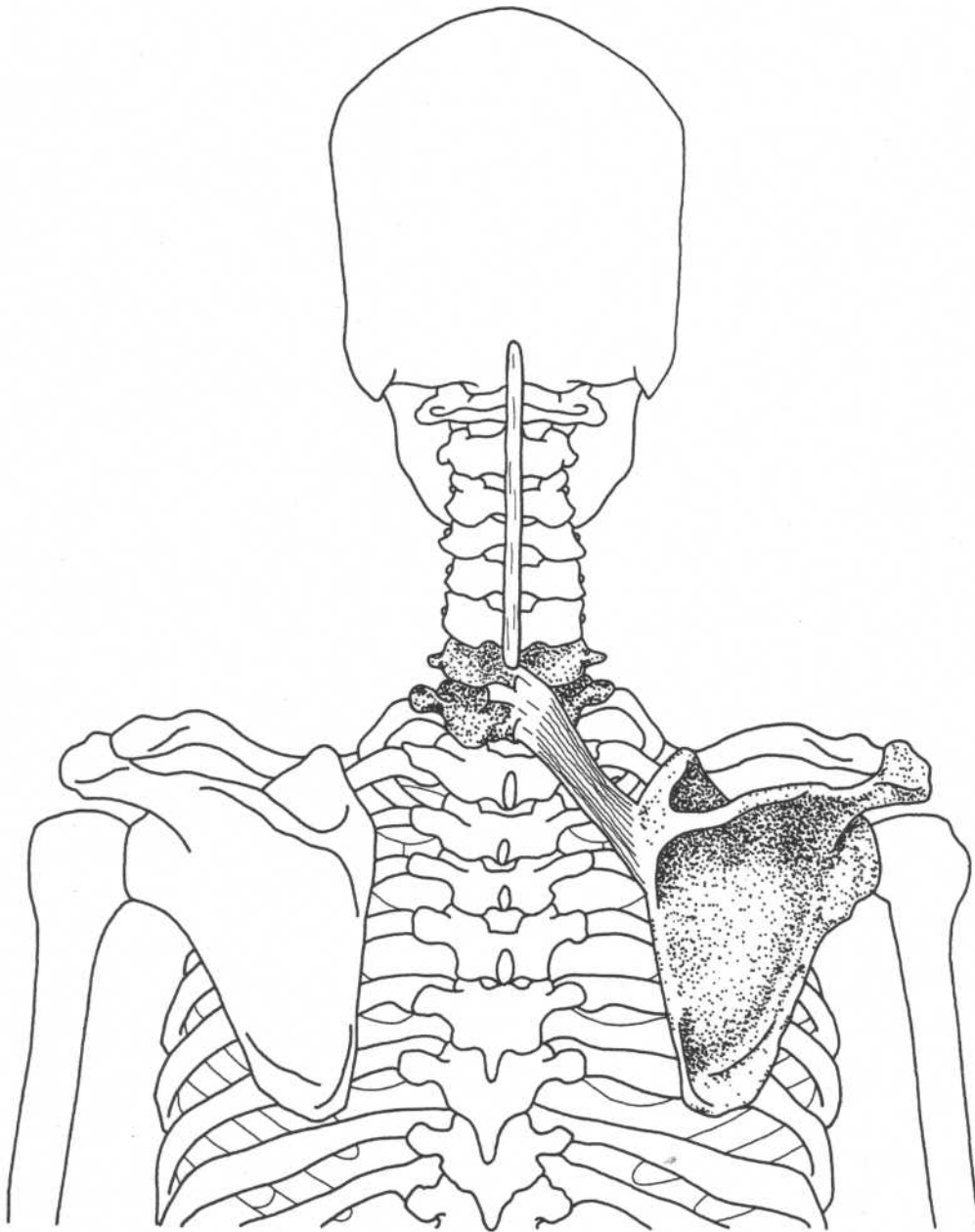
Origin	Posterior tubercles of the transverse processes of the first four cervical vertebrae	Action	Elevates medial border of scapula, rotates scapula to lower the lateral angle, acts with trapezius and rhomboids to pull scapula medially and upward, bends neck laterally
Insertion	Vertebral (medial) border of the scapula at and above the spine	Nerve	Dorsal scapular nerve (C5)

RHOMBOIDEUS MAJOR



Posterior view

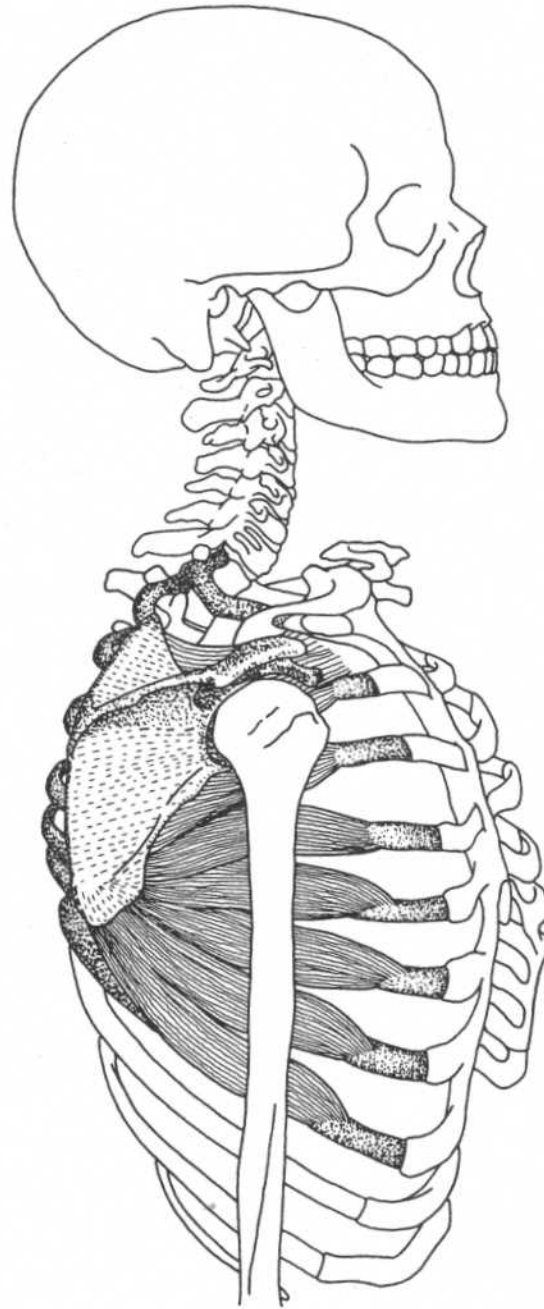
Origin	Spines of the second to fifth thoracic vertebrae, supraspinous ligament	Action	Retracts and stabilizes scapula, elevates the medial border of the scapula causing downward rotation, assists in adduction of arm
Insertion	Medial border of the scapula below the spine	Nerve	Dorsal scapular nerve (C5)

RHOMBOIDEUS MINOR**Posterior view**

Origin	Spines of the seventh cervical and first thoracic vertebrae, lower part of the ligamentum nuchae	Action	Retracts and stabilizes scapula, elevates the medial border of the scapula, rotates the scapula to depress the lateral angle (assists in adduction of arm)
Insertion	Medial border of the scapula at the root of the spine	Nerve	Dorsal scapular nerve (C5)

SERRATUS ANTERIOR

Origin	Outer surfaces and superior borders of first eight or nine ribs, and fascia covering first intercostal space
Insertion	Anterior surface (costal surface) of the medial border of the scapula
Action	Rotates scapula for abduction and flexion of arm, protracts scapula
Nerve	Long thoracic nerve (C5–C7)
Relationships	Serratus anterior and rhomboids both insert on the medial border of scapula; they are antagonists causing protraction and retraction



Lateral view

DELTOIDEUS

Origin

Anterior portion—anterior border and superior surface of the lateral third of the clavicle

Middle portion—lateral border of the acromion process

Posterior portion—lower border of the crest of the spine of the scapula

Insertion

Deltoid tuberosity, on the middle of the lateral surface of the shaft of the humerus

Action

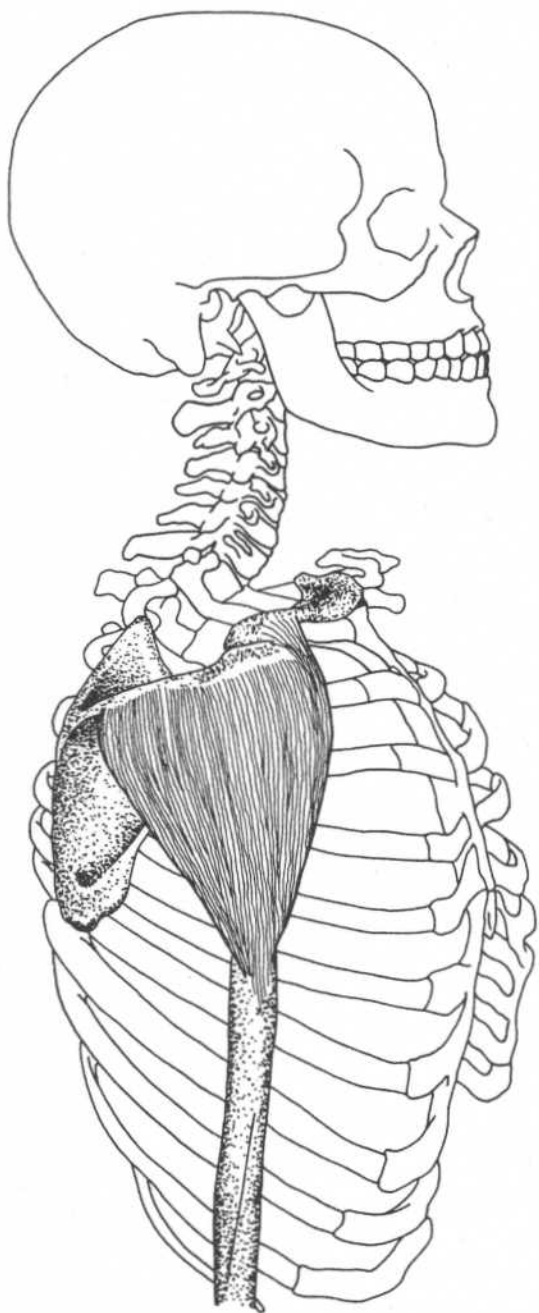
Anterior portion—flexes and medially rotates arm

Middle portion—abducts arm

Posterior portion—extends and laterally rotates arm

Nerve

Axillary nerve (C5, C6)



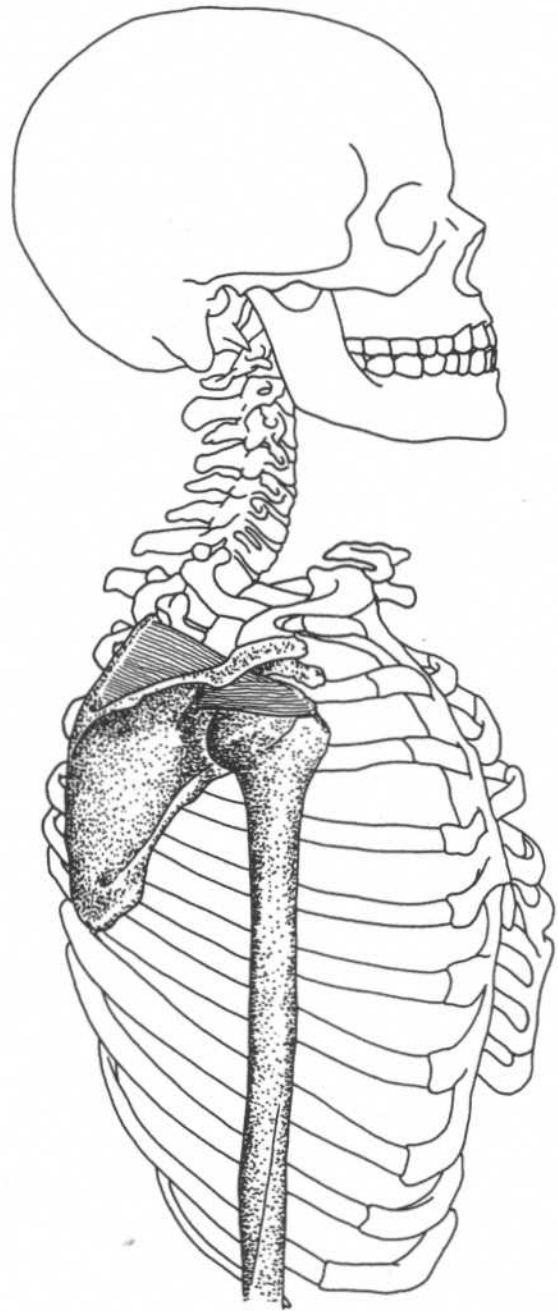
Lateral view

SUPRASPINATUS

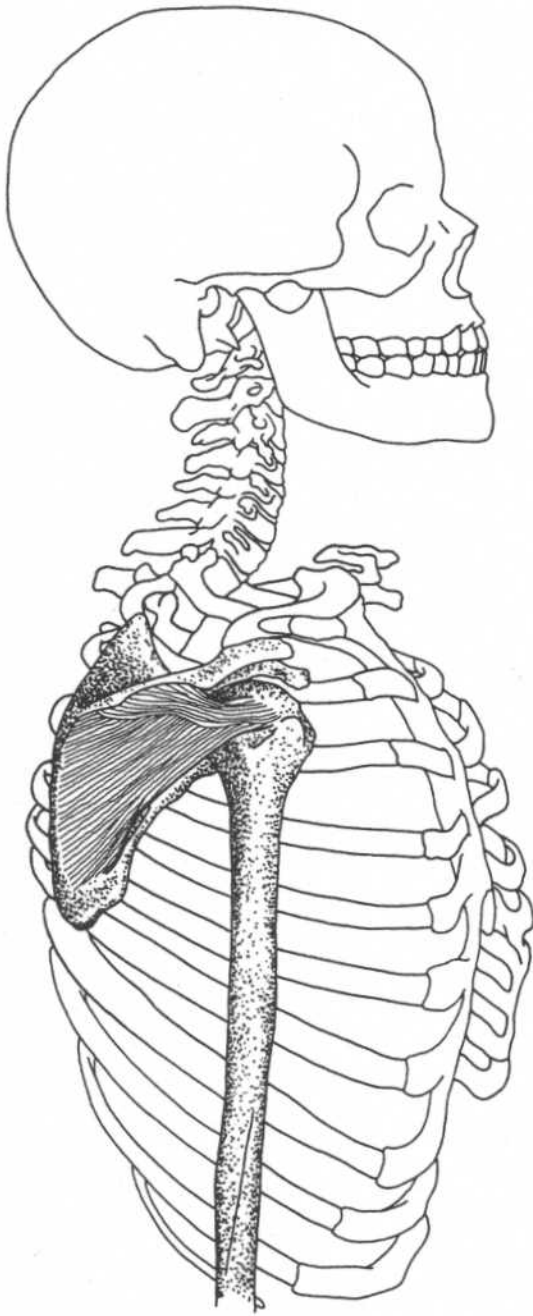
(Rotator cuff)*

Origin	Supraspinous fossa of scapula
Insertion	Upper part of the greater tuberosity of the humerus, capsule of the shoulder joint
Action	Aids deltoid in abduction of arm, draws humerus toward glenoid fossa preventing deltoid from forcing humerus up against acromion, weakly flexes arm
Nerve	Suprascapular nerve (C5)

*Supraspinatus, infraspinatus, teres minor, and subscapularis together are called the rotator cuff. They prevent the larger muscles from dislocating the humerus during their actions.



Lateral view

**Lateral view**

INFRASPINATUS

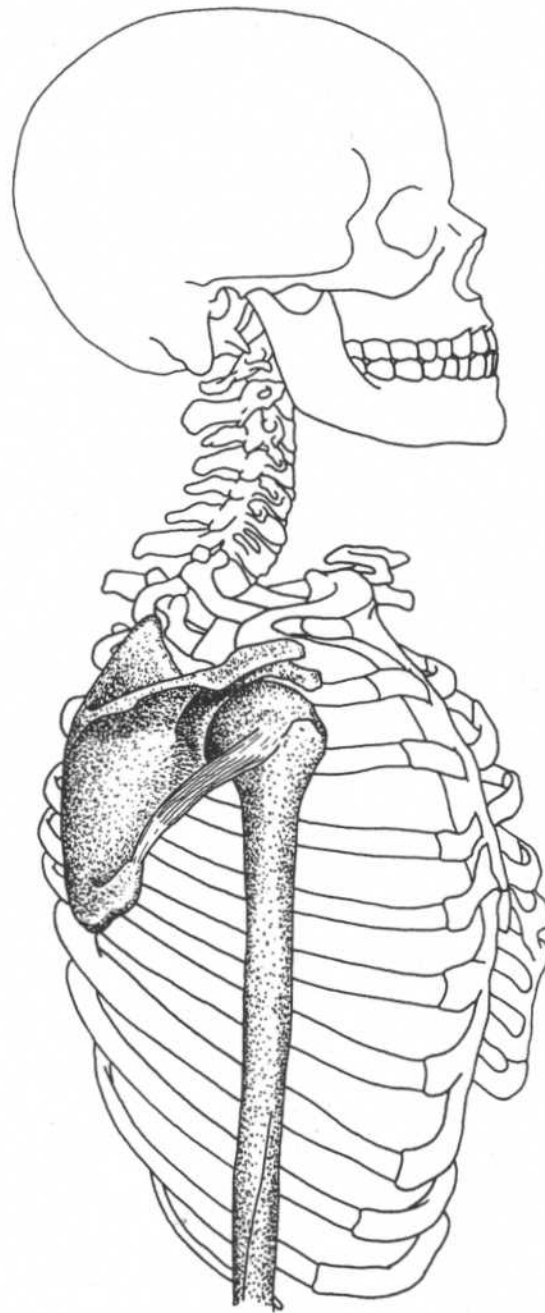
(Rotator cuff)

Origin	Infraspinous fossa of the scapula
Insertion	Middle facet of the greater tuberosity of the humerus, capsule of the shoulder joint
Action	Draws humerus toward glenoid fossa thus resisting posterior dislocation of arm, as in crawling; laterally rotates; abducts arm
Nerve	Suprascapular nerve (C5, C6)

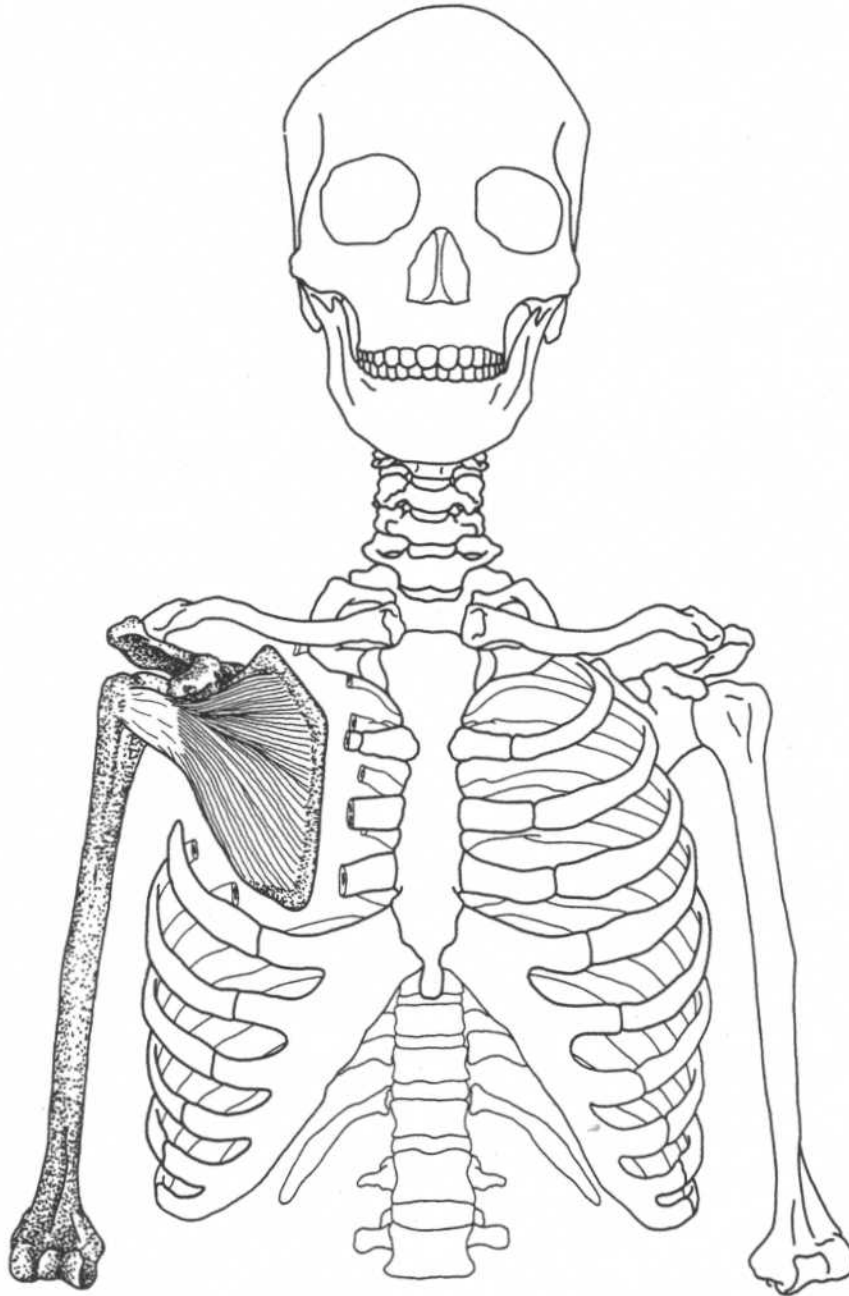
TERES MINOR

(Rotator cuff)

Origin	Upper two-thirds of the dorsal surface of the axillary border of the scapula
Insertion	The capsule of the shoulder joint, the lower facet of the greater tuberosity of the humerus
Action	Laterally rotates arm, weakly adducts arm, draws humerus toward glenoid fossa
Nerve	Axillary nerve (C5)

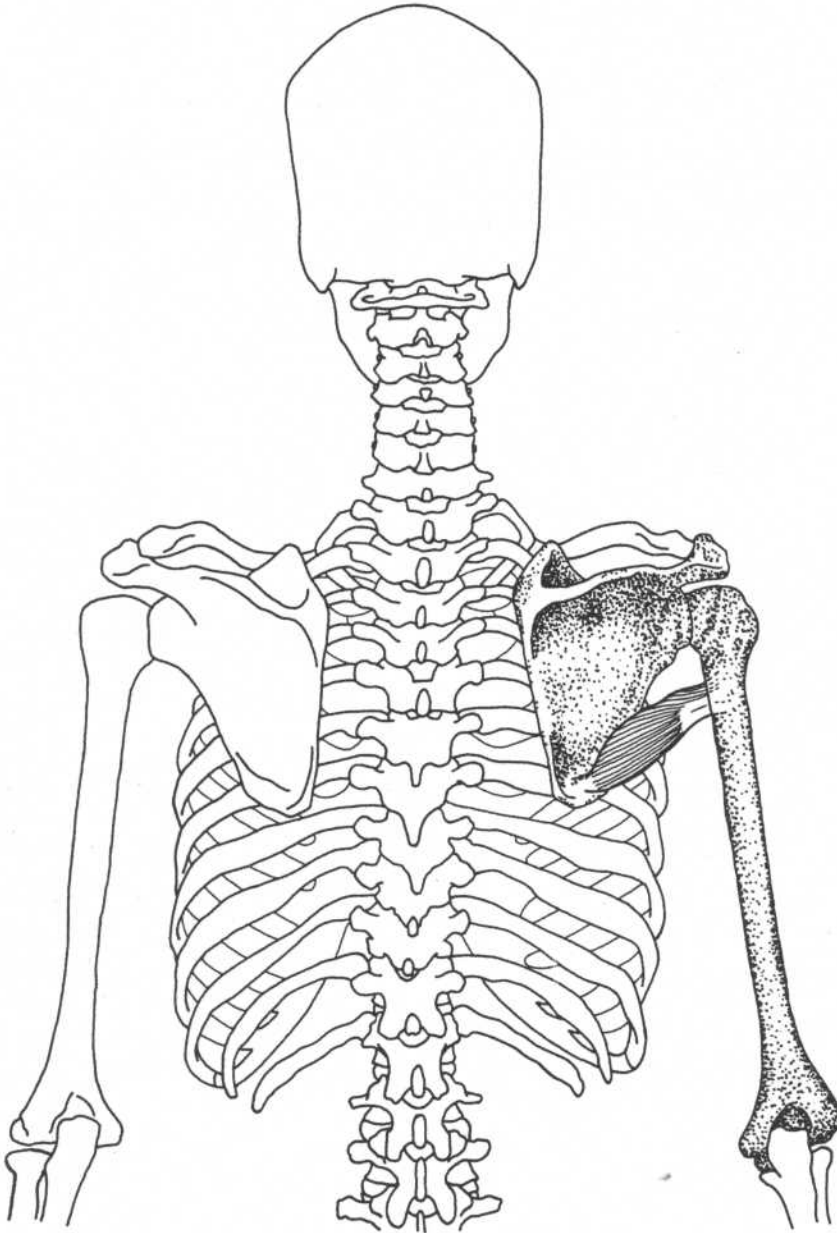


Lateral view

SUBSCAPULARIS*(Rotator cuff)***Anterior view***(Upper ribs cut away)*

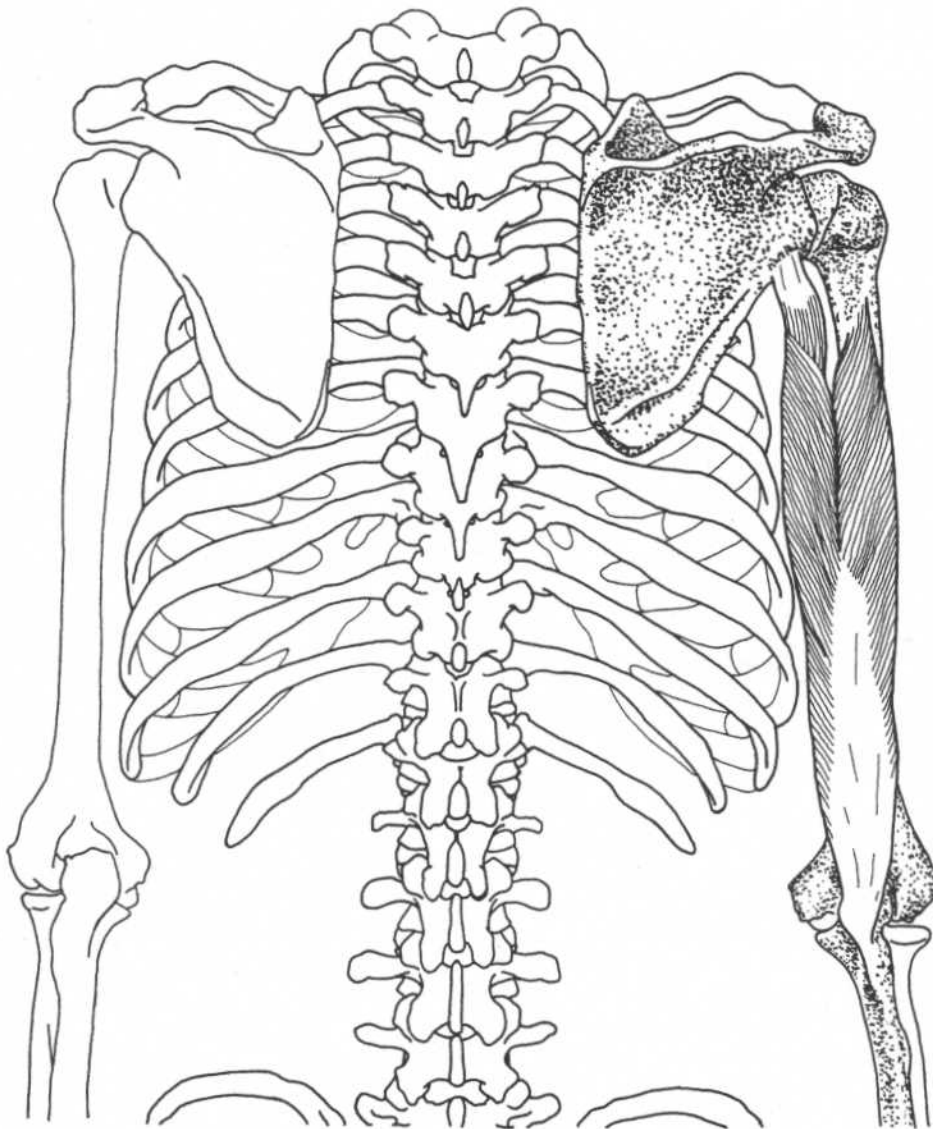
Origin	Subscapular fossa on the anterior surface of scapula	Action	Medially rotates arm, stabilizes glenohumeral joint
Insertion	Lesser tuberosity of the humerus, ventral part of the capsule of the shoulder joint	Nerve	Upper and lower subscapular nerves (C5, C6)

TERES MAJOR



Posterior view

Origin	Lower third of the posterior surface of the lateral border of the scapula, near the inferior angle	Action	Medially rotates arm, adducts arm, extends arm
Insertion	Medial lip of the bicipital groove of the humerus	Nerve	Lower subscapular nerve (C5, C6)

TRICEPS BRACHII**Posterior view****Origin**

Long head—infraglenoid tubercle of the scapula

Lateral head—upper half of the posterior surface of the shaft of the humerus

Medial head—posterior surface of the lower half of the shaft of the humerus

Insertion

Posterior part of olecranon process of the ulna

Action

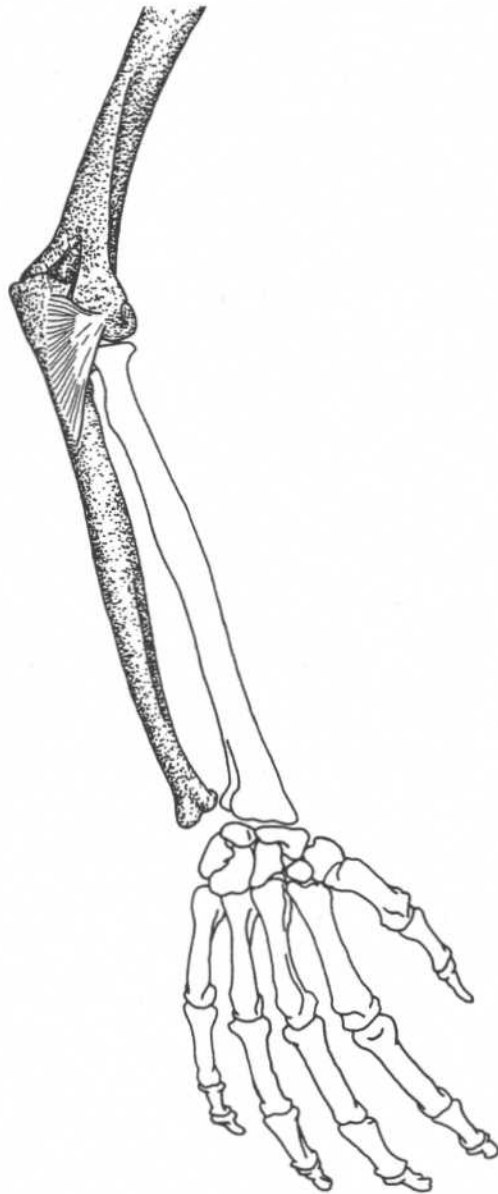
Extends forearm, long head aids in adduction if arm is abducted

Nerve

Radial nerve (C7, C8)

Note: The radial nerve comes from the axilla (armpit) and passes along the humerus between the medial and lateral heads. Because of its position, it is the most commonly injured peripheral nerve.

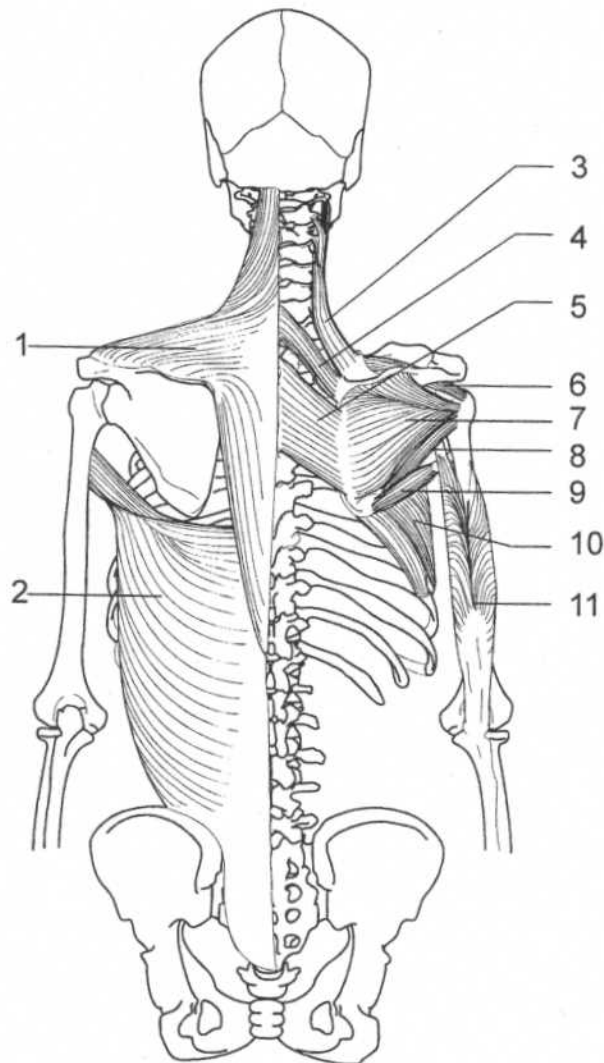
ANCONEUS



Posterior view of arm

Origin	Posterior part of lateral epicondyle of the humerus	Action	Extends forearm (assists triceps)
Insertion	Lateral surface of the olecranon process and posterior surface of ulna	Nerve	Radial nerve (C7, C8)

POSTERIOR BACK, SHOULDER, AND ARM MUSCLES



Trunk—dorsal view

Superficial layer

1. Trapezius
2. Latissimus dorsi

Deep layer

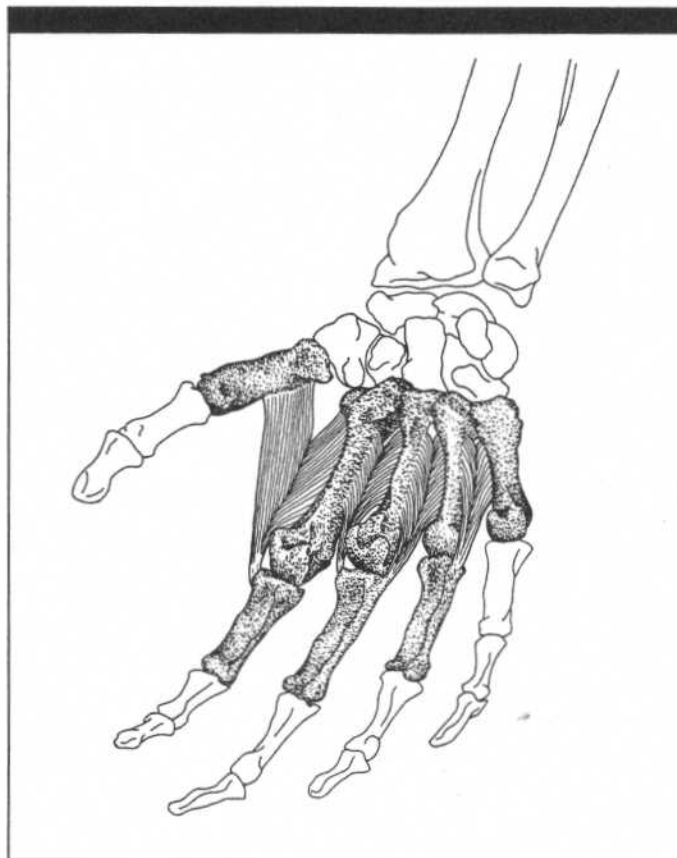
3. Levator scapulae
4. Rhomboideus minor
5. Rhomboideus major

6. Supraspinatus (rotator cuff)
7. Infraspinatus (rotator cuff)
8. Teres minor (rotator cuff)
9. Teres major
10. Serratus anterior

Posterior arm

11. Triceps brachii

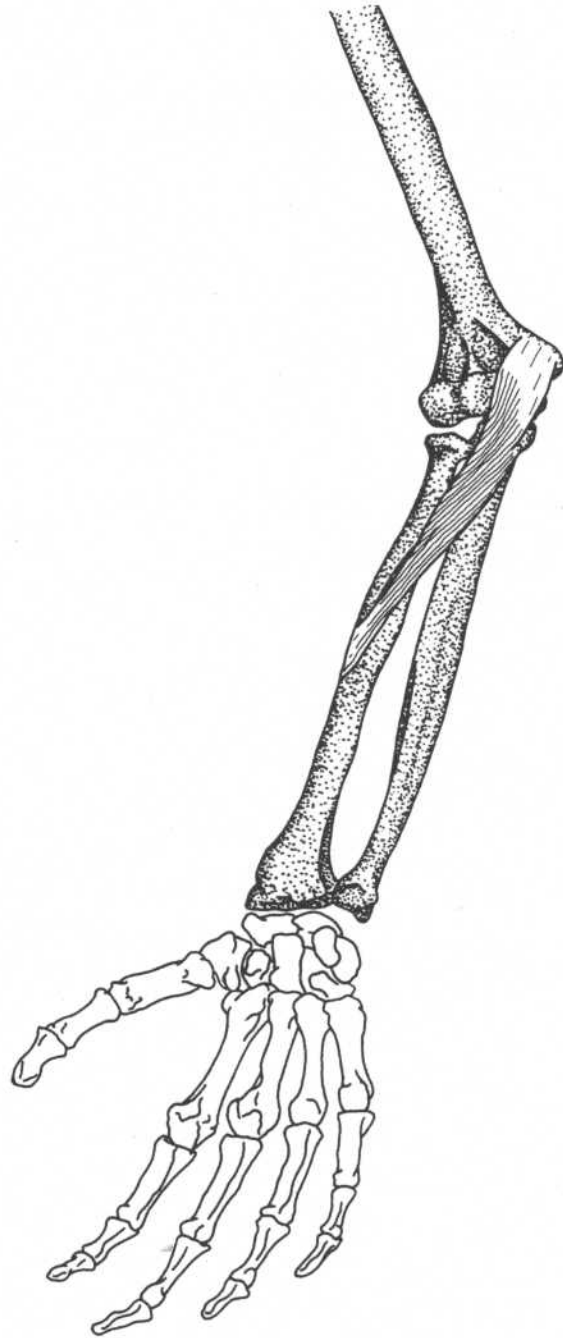
CHAPTER SEVEN
MUSCLES OF THE FOREARM
AND HAND



PRONATOR TERES

(Superficial group)

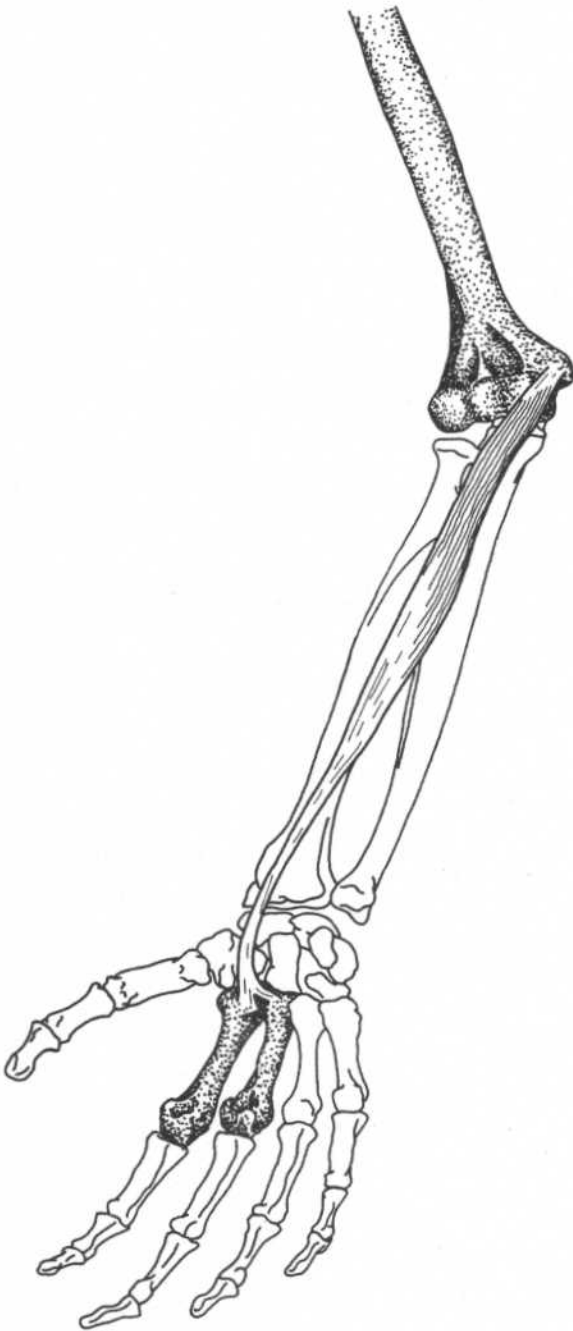
Origin	Humeral head—medial supracondylar ridge and medial epicondyle of the humerus Ulnar head—medial border of the coronoid process of the ulna
Insertion	Middle of lateral surface of the radius (pronator tuberosity)
Action	Pronates and flexes forearm
Nerve	Median nerve (C6, C7)



Forearm—anterior view

FLEXOR CARPI RADIALIS*(Superficial group)*

Origin	Medial epicondyle of the humerus through the common tendon
Insertion	Front of the bases of the second and third metacarpal bones
Action	Flexes hand, synergist in abduction with extensor carpi radialis longus and brevis
Nerve	Median nerve (C6, C7)

**Forearm—anterior view**

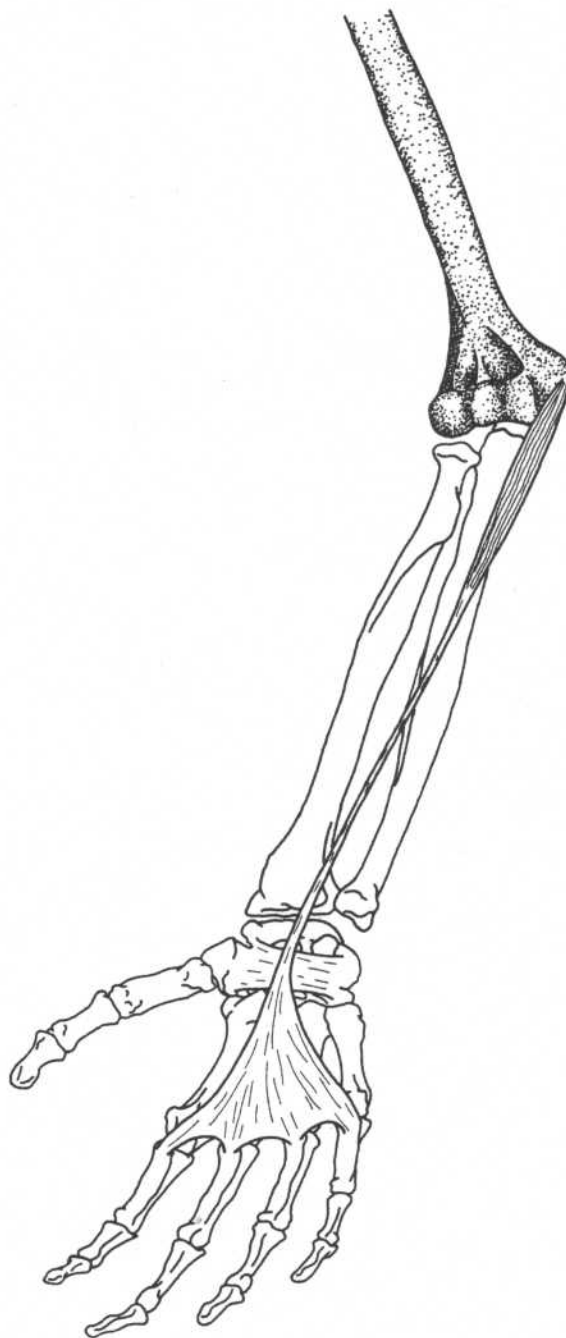
PALMARIS LONGUS

(Superficial group)

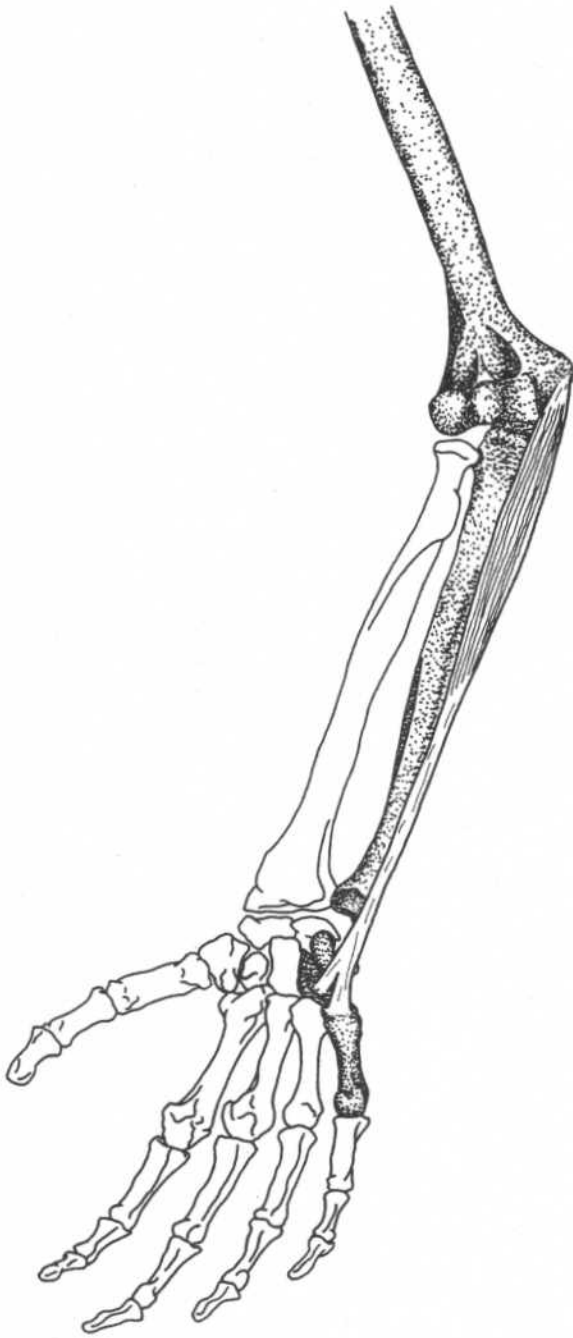
Origin	Medial epicondyle of the humerus through the common tendon
Insertion	Front (central part) of the flexor retinaculum and apex of the palmar aponeurosis
Action	Flexes the hand
Nerve	Median nerve (C6, C7)

Note: This muscle is absent in about 14% of limbs.

Reference: Agur, Amr: *Grant's Atlas of Anatomy*, 9th ed. Williams & Wilkins, Baltimore, 1991.



Forearm—anterior view

FLEXOR CARPI ULNARIS*(Superficial group)***Origin**

Humeral head—medial epicondyle of the humerus through the common tendon

Ulnar head—medial margin of olecranon process of ulna, dorsal border of shaft of the ulna

Insertion

Pisiform bone, hook of the hamate, and base of the fifth metacarpal bone

Action

Flexes hand, synergist in adduction of hand with extensor carpi ulnaris

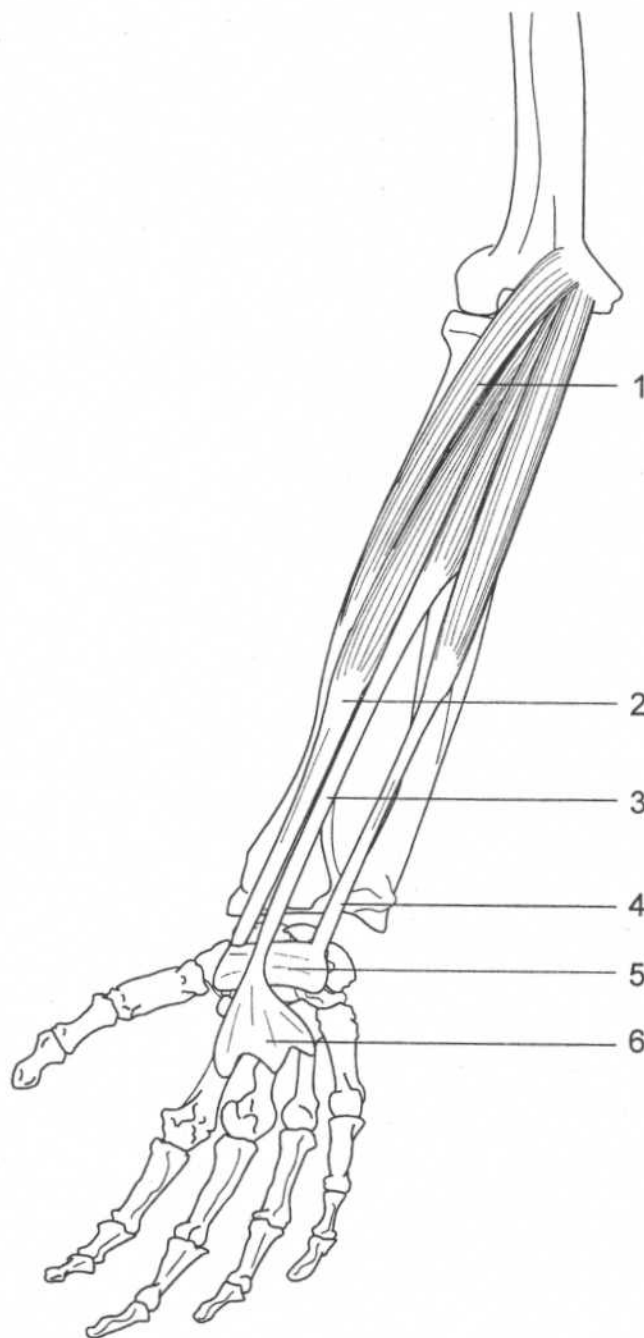
Nerve

Ulnar nerve (C8, T1)

Forearm—anterior view

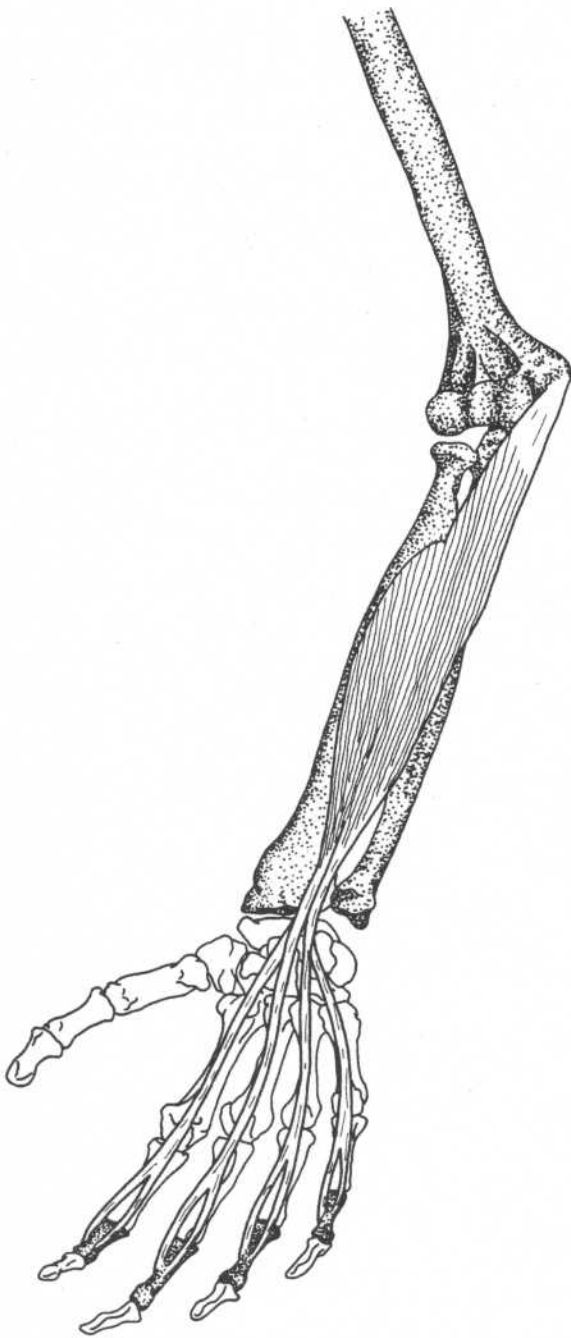
MUSCLES OF THE WRIST

1. Pronator teres
2. Flexor carpi radialis
3. Palmaris longus
4. Flexor carpi ulnaris
5. Flexor retinaculum
6. Palmar aponeurosis



Forearm—anterior view

FLEXOR DIGITORUM SUPERFICIALIS



Origin

Humeroulnar head—medial epicondyle of the humerus through common tendon,* medial margin of the coronoid process of ulna
 Radial head—anterior surface of shaft of radius

Insertion

Four tendons divide into two slips each, slips insert into the sides (margins of the anterior surfaces) of the middle phalanges of four fingers

Action

Flexes the middle phalanges of the fingers

Nerve

Median nerve (C7, C8, T1)

Relationships

Deep to superficial flexors

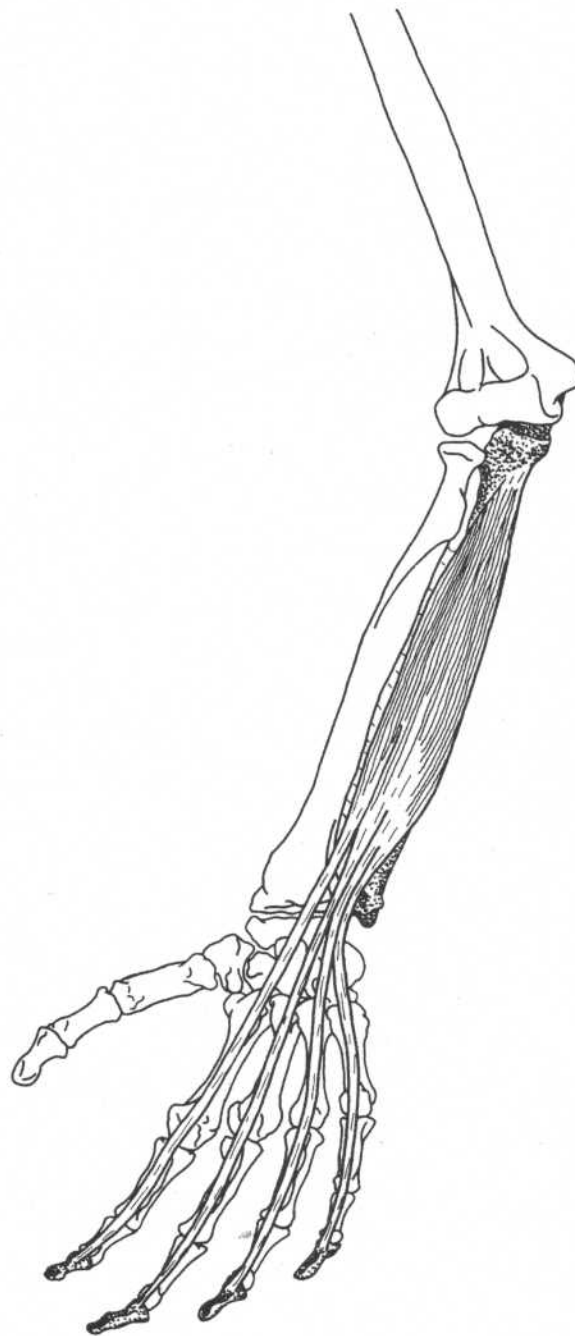
*See superficial flexors.

Forearm—anterior view

FLEXOR DIGITORUM PROFUNDUS

- Origin** Upper three-fourths of anterior and medial surfaces of shaft of ulna and medial side of the coronoid process, interosseous membrane
- Insertion** Front of base of distal phalanges of fingers
- Action** Flexes distal phalanges
- Nerve** Ulnar nerve supplies the medial half of the muscle (going to the little and ring fingers) (C8, T1)
Anterior interosseous branch of median nerve supplies lateral half (going to index and middle fingers) (C8, T1)
- Relationships** Deep to flexor digitorum superficialis

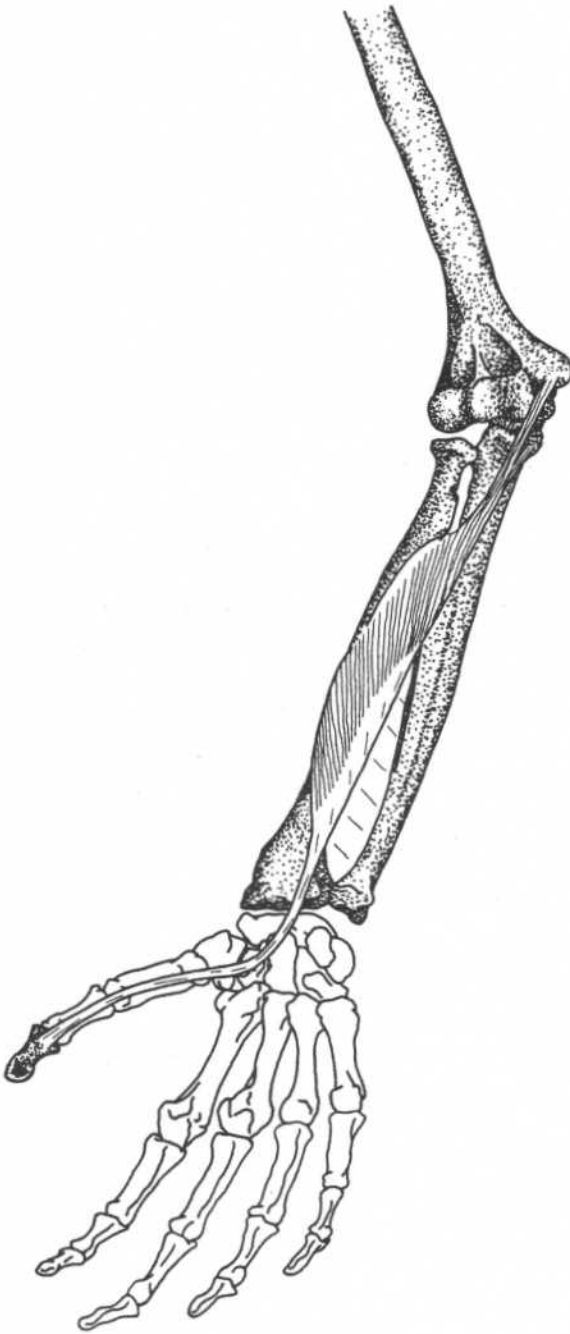
Note: Both flexor digitorum muscles and the median nerve pass under the flexor retinaculum (page 10) in the wrist. When irritated, the synovial sheaths of these muscles can compress the median nerve, causing the sensory and motor deficits known as carpal tunnel syndrome.



Forearm—anterior view

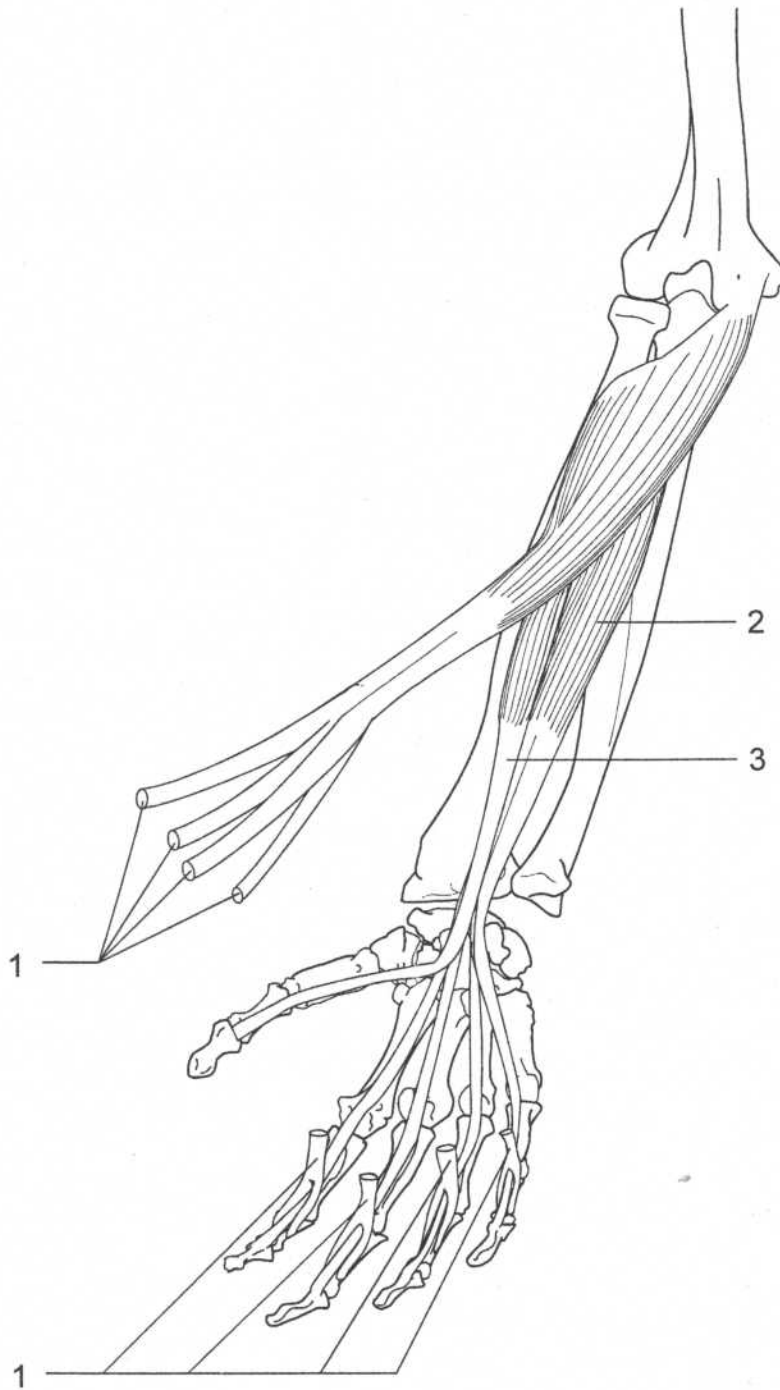
FLEXOR POLLICIS LONGUS

Origin	Middle of anterior surface of shaft of radius, interosseous membrane, medial epicondyle of humerus, and often coronoid process of ulna
Insertion	Palmar aspect of base of the distal phalanx of thumb
Action	Flexes the thumb
Nerve	Anterior interosseous branch of median nerve (C8, T1)



Forearm—anterior view

FLEXORS OF THE FINGERS



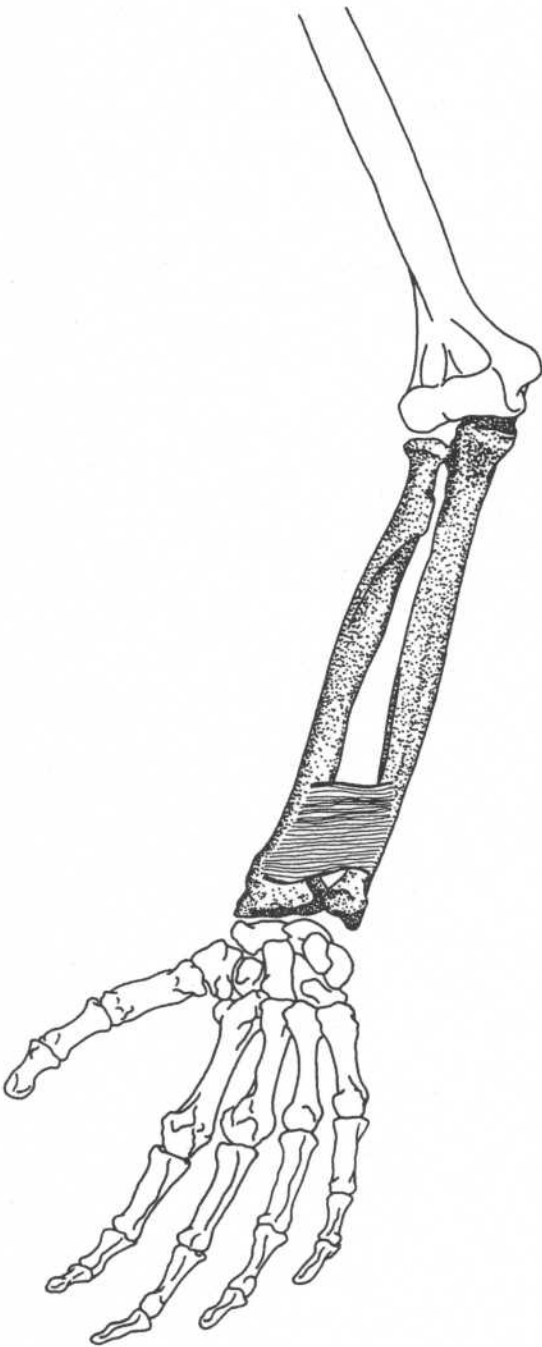
Forearm—anterior view

1. Flexor digitorum superficialis (cut)
2. Flexor digitorum profundus
3. Flexor pollicis longus

Note: The tendons of flexor digitorum superficialis split and attach to the middle phalanx. The tendons of flexor digitorum profundus pass through this split and continue to the distal phalanx.

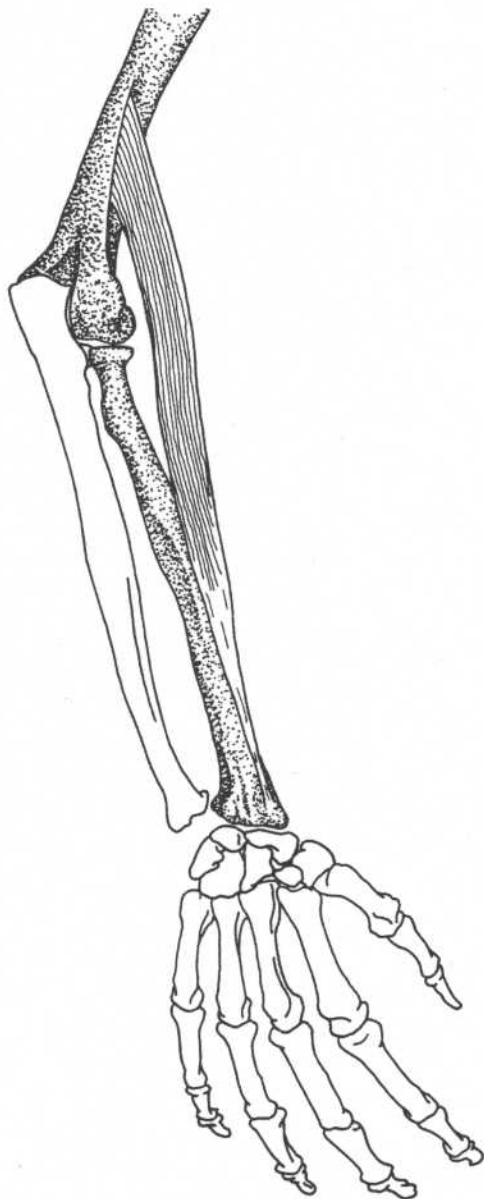
PRONATOR QUADRATUS

- Origin** Anterior surface of distal part of shaft of ulna
- Insertion** Lower portion of anterior surface of shaft of radius, distal part of lateral border of radius
- Action** Pronates forearm and hand
- Nerve** Anterior interosseous branch of median nerve (C8, T1)
- Relationships** Deepest forearm muscle



Forearm—anterior view

BRACHIORADIALIS



Forearm—dorsal view

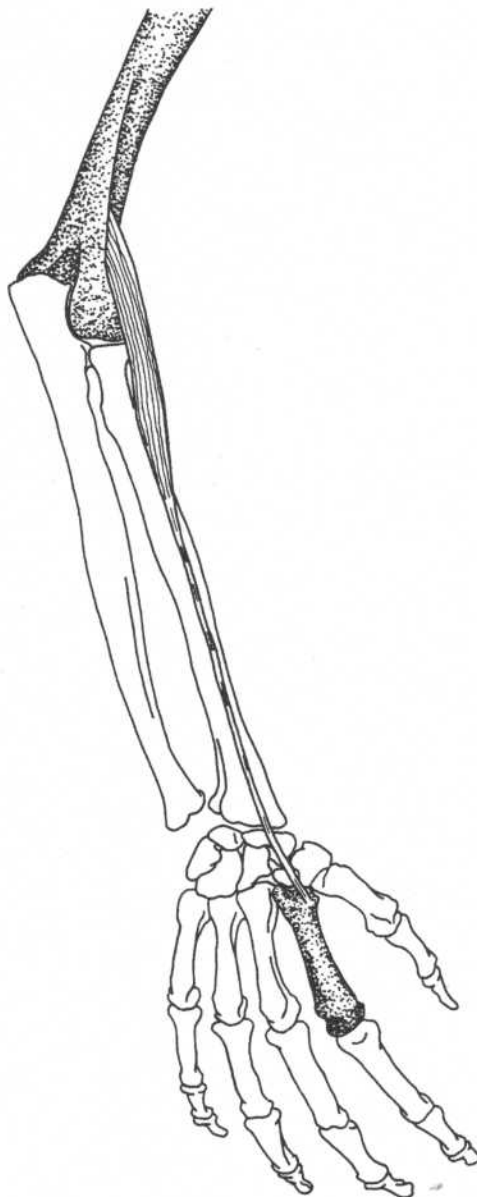
Origin
Insertion

Upper two-thirds of lateral supracondylar ridge of humerus
 Base of styloid process and lateral surface of radius

Action
Nerve

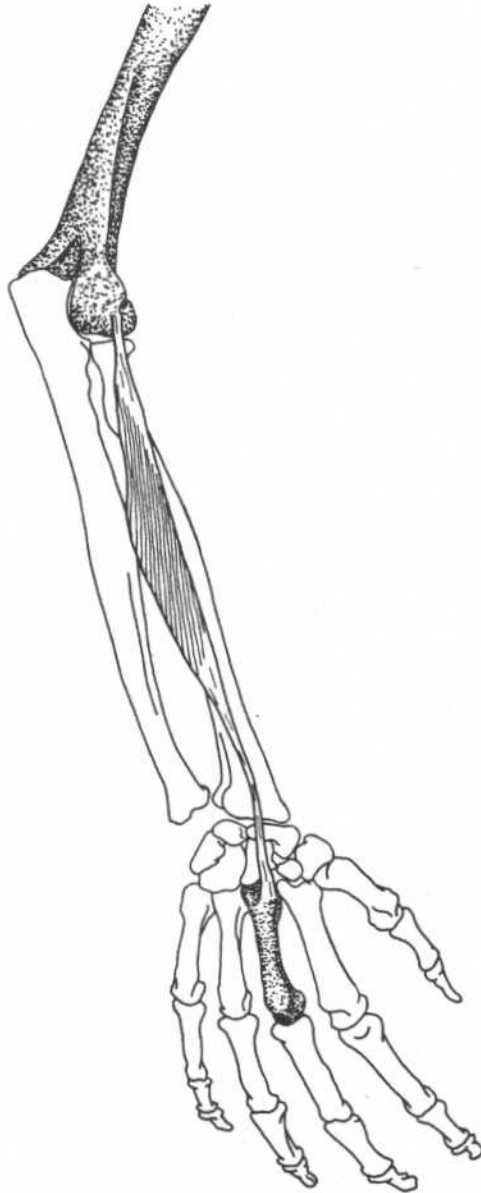
Flexes forearm
 Radial nerve (C5, C6)

O
In

EXTENSOR CARPI RADIALIS LONGUS**Forearm—dorsal view**

Origin	Lower third of lateral supracondylar ridge of humerus	Action	Extends hand, synergist in abduction of hand with flexor carpi radialis
Insertion	Dorsal surface of the base of the second metacarpal bone	Nerve	Radial nerve (C6, C7)

EXTENSOR CARPI RADIALIS BREVIS



Forearm—dorsal view

Origin

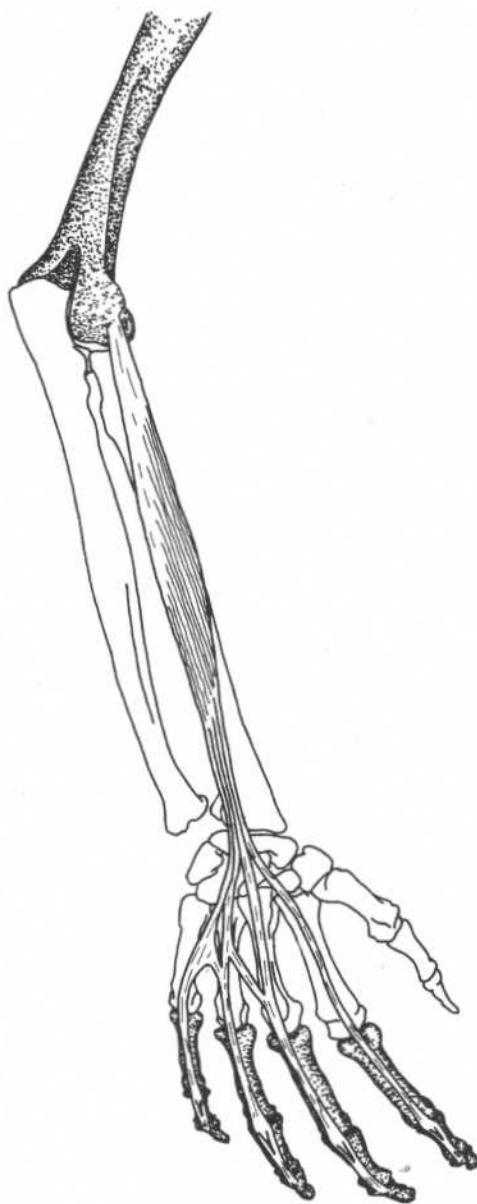
Lateral epicondyle of humerus
Dorsal surface of third metacarpal bone

Action

Extends hand, synergist in abduction of hand with flexor carpi radialis

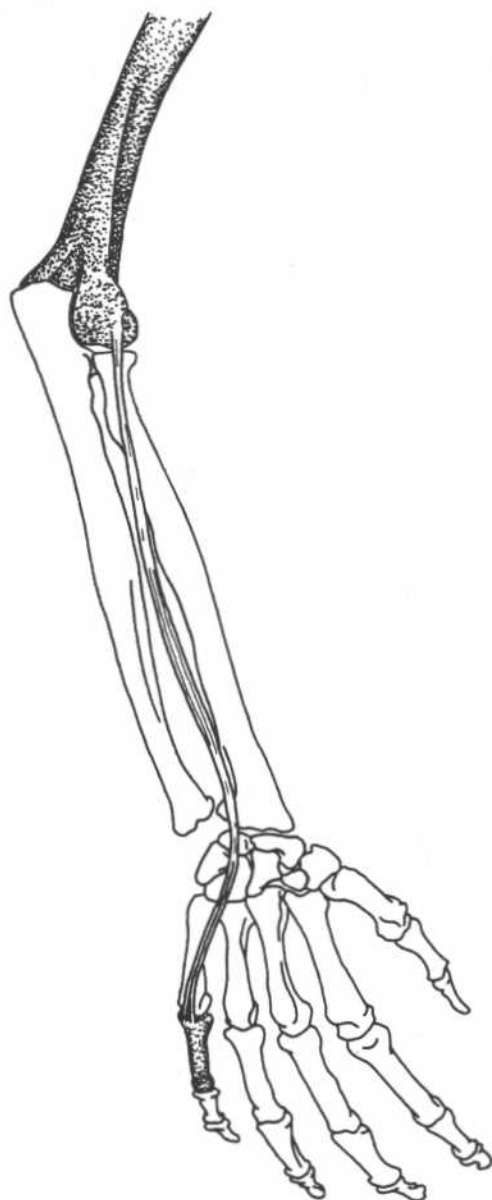
Nerve

Radial nerve (C6, C7)

EXTENSOR DIGITORUM COMMUNIS**Forearm and hand—dorsal view**

Origin	Common tendon attached to lateral epicondyle of humerus	Nerve	Deep branch of radial nerve (C6–C8)
Insertion	Lateral and dorsal surfaces of all the phalanges of the four fingers	Relationships	Tends to hyperextend the metacarpophalangeal joint causing "claw hand"; its action is balanced by the lumbricales and interossei
Action	Extends the fingers and wrist		

EXTENSOR DIGITI MINIMI



Forearm and hand—dorsal view

Origin

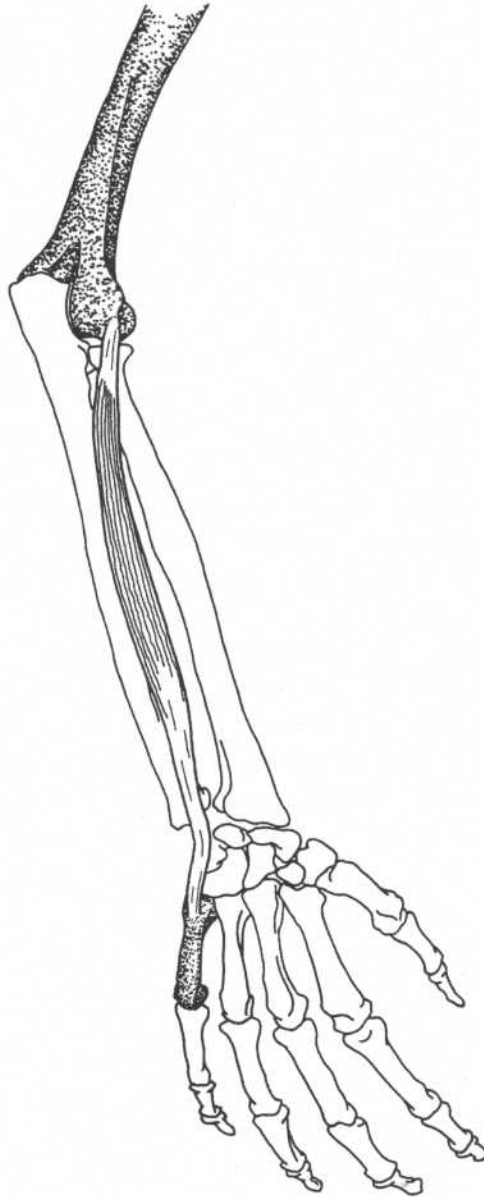
Common tendon attached to lateral epicondyle of humerus

Insertion

Dorsal surface of base of first phalanx of fifth finger

Action
Nerve

Extends fifth finger
Radial nerve (C6–C8)

EXTENSOR CARPI ULNARIS**Forearm and hand—dorsal view**

Origin	Common tendon attached to lateral epicondyle of humerus	Action	Extends hand, synergist in adduction of hand with flexor carpi ulnaris
Insertion	Dorsal surface of base of fifth metacarpal bone	Nerve	Radial nerve (C6–C8)

SUPINATOR

Origin

Lateral epicondyle of humerus, lateral ligament (radial collateral) of elbow, annular ligament of superior radioulnar joint, supinator crest of ulna

Insertion

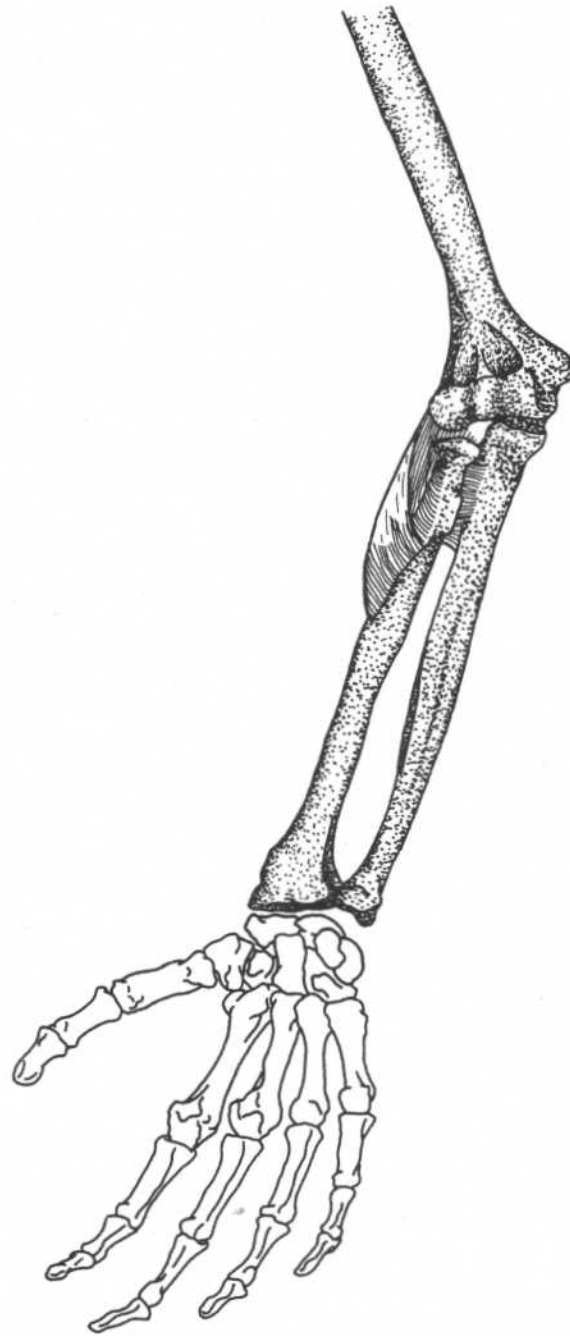
Dorsal and lateral surfaces of upper third of radius

Action

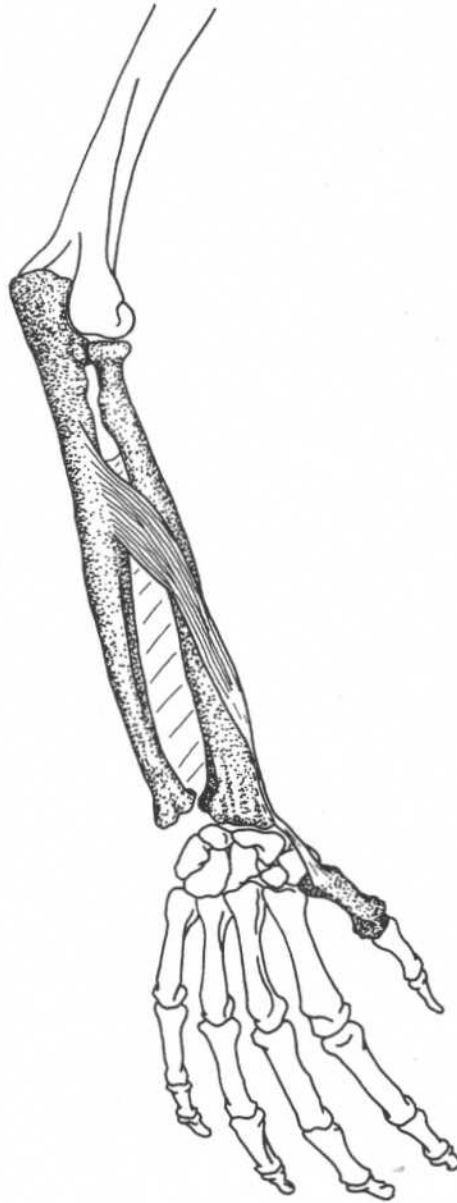
Supinates forearm

Nerve

Radial nerve (C6)

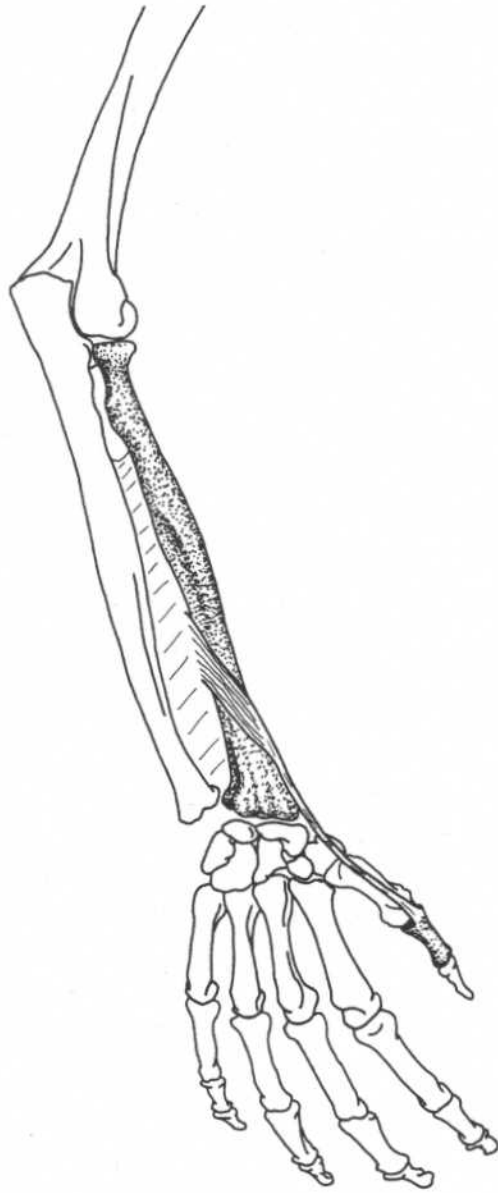


**Forearm and hand—
anterior view**

ABDUCTOR POLLICIS LONGUS**Forearm and hand—dorsal view**

Origin	Posterior (dorsal) surface of shaft of radius, ulna, interosseous membrane	Action	Abducts, laterally rotates, and extends thumb; abducts wrist
Insertion	Dorsal surface of base of first metacarpal bone	Nerve	Radial nerve (C6, C7)

EXTENSOR POLLICIS BREVIS



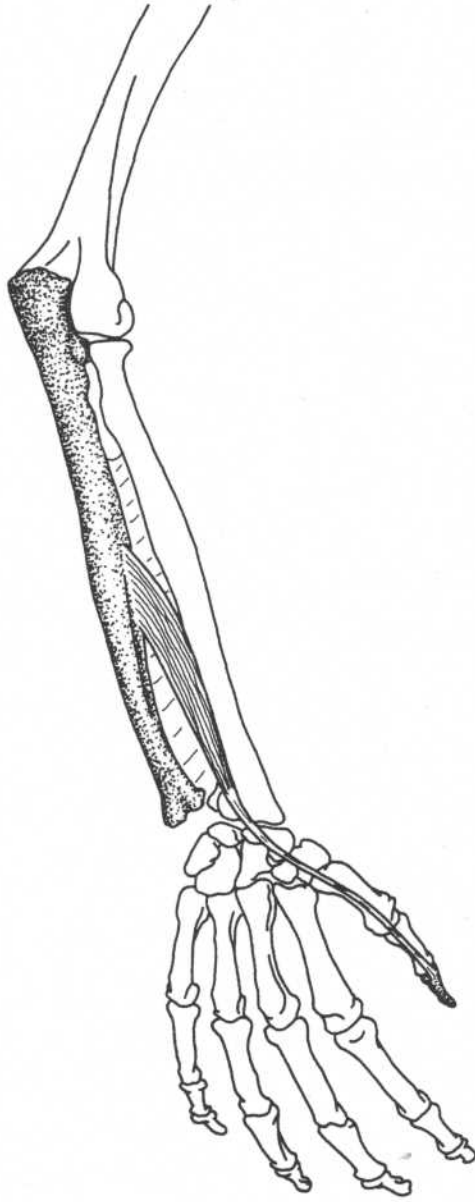
Forearm and hand—dorsal view

Origin
Dorsal surface of radius, adjacent part of interosseous membrane
Base of proximal phalanx of thumb

Action
Nerve

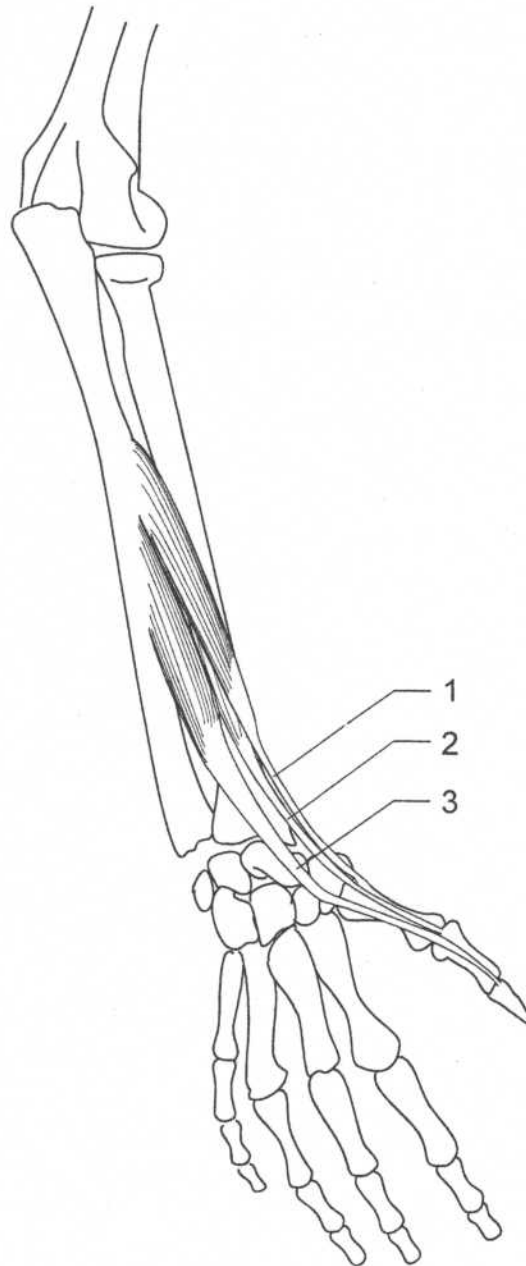
Extends thumb, abducts hand
Radial nerve (C6, C7)

O
I

EXTENSOR POLLICIS LONGUS**Forearm and hand—dorsal view**

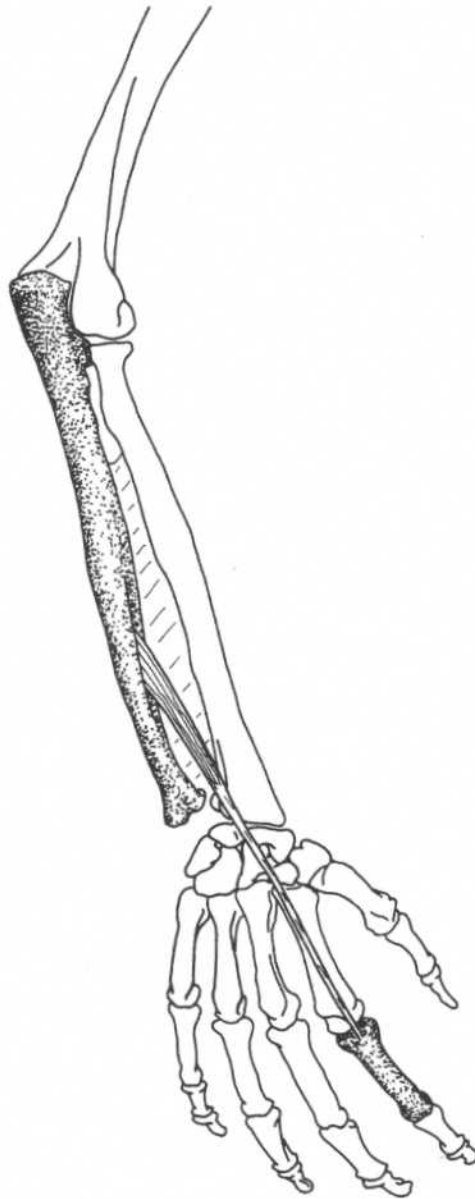
Origin	Middle third of dorsal surface of ulna, interosseous membrane	Action	Extends thumb
Insertion	Base of distal phalanx of thumb	Nerve	Radial nerve (C6–C8)

EXTENSORS OF THE THUMB



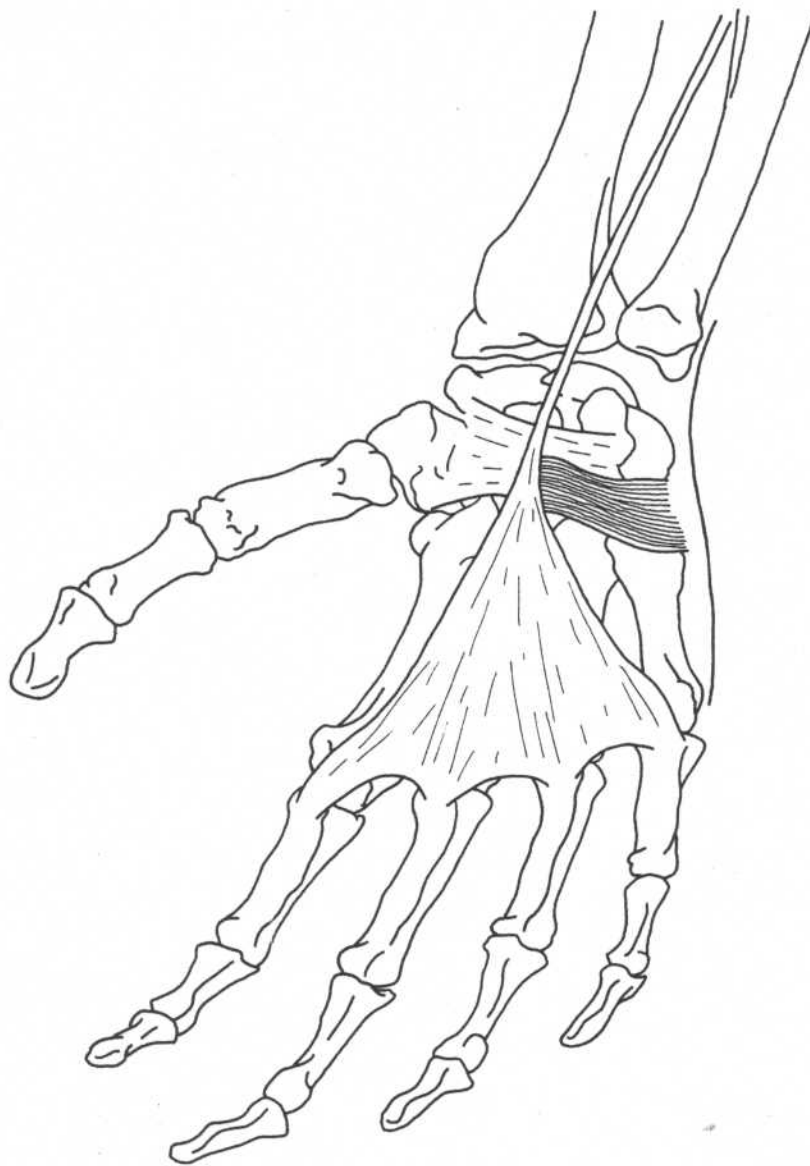Forearm—posterior view

1. Abductor pollicis longus
2. Extensor pollicis brevis
3. Extensor pollicis longus

EXTENSOR INDICIS**Forearm and hand—dorsal view**

Origin	Posterior surface of ulna and adjacent part of interosseous membrane	Action	Extends index finger
Insertion	Extensor expansion on dorsal surface of proximal phalanx of index finger	Nerve	Radial nerve (C6–C8)

PALMARIS BREVIS



Hand—palmar view

Origin

Flexor retinaculum, palmar aponeurosis

Insertion

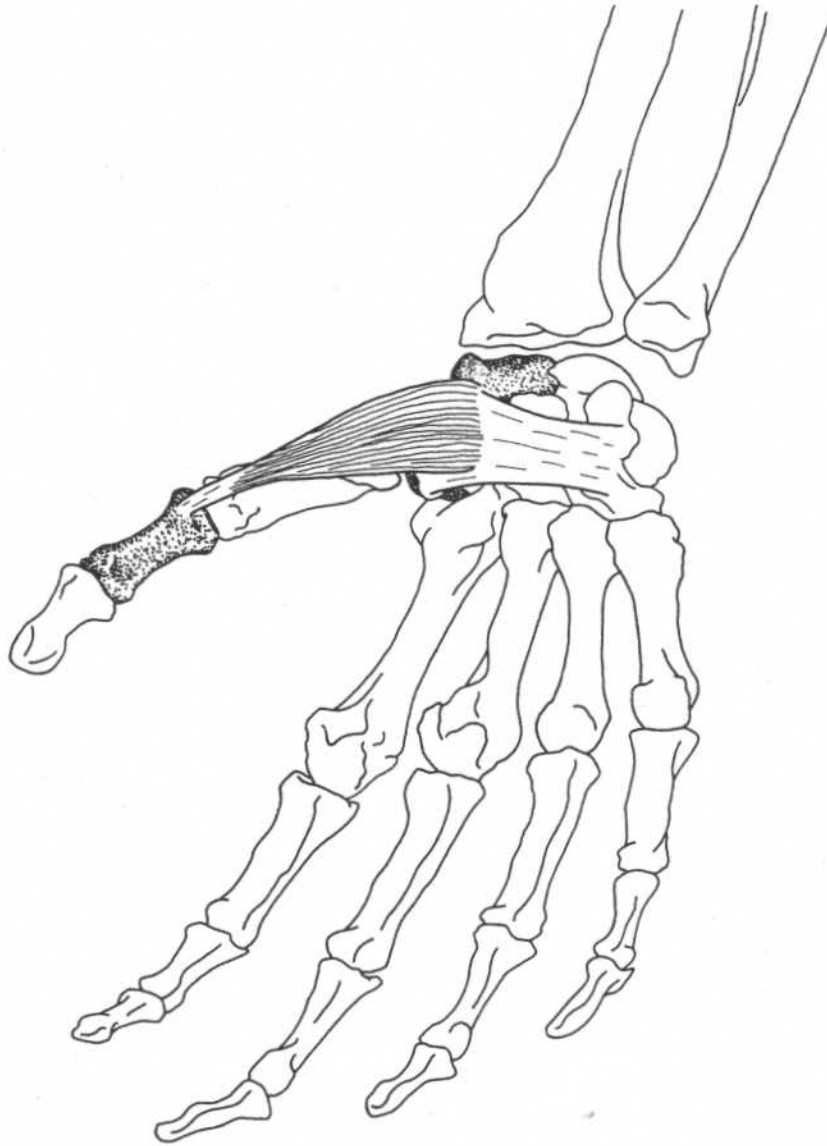
Skin of the palm

Action
Nerve

Corrugates skin of palm
Ulnar nerve (C8)

ABDUCTOR POLLICIS BREVIS

(Thenar eminence)



Hand—palmar view

Origin Tubercle of scaphoid, tubercle of trapezium, flexor retinaculum

Insertion Base of proximal phalanx of thumb

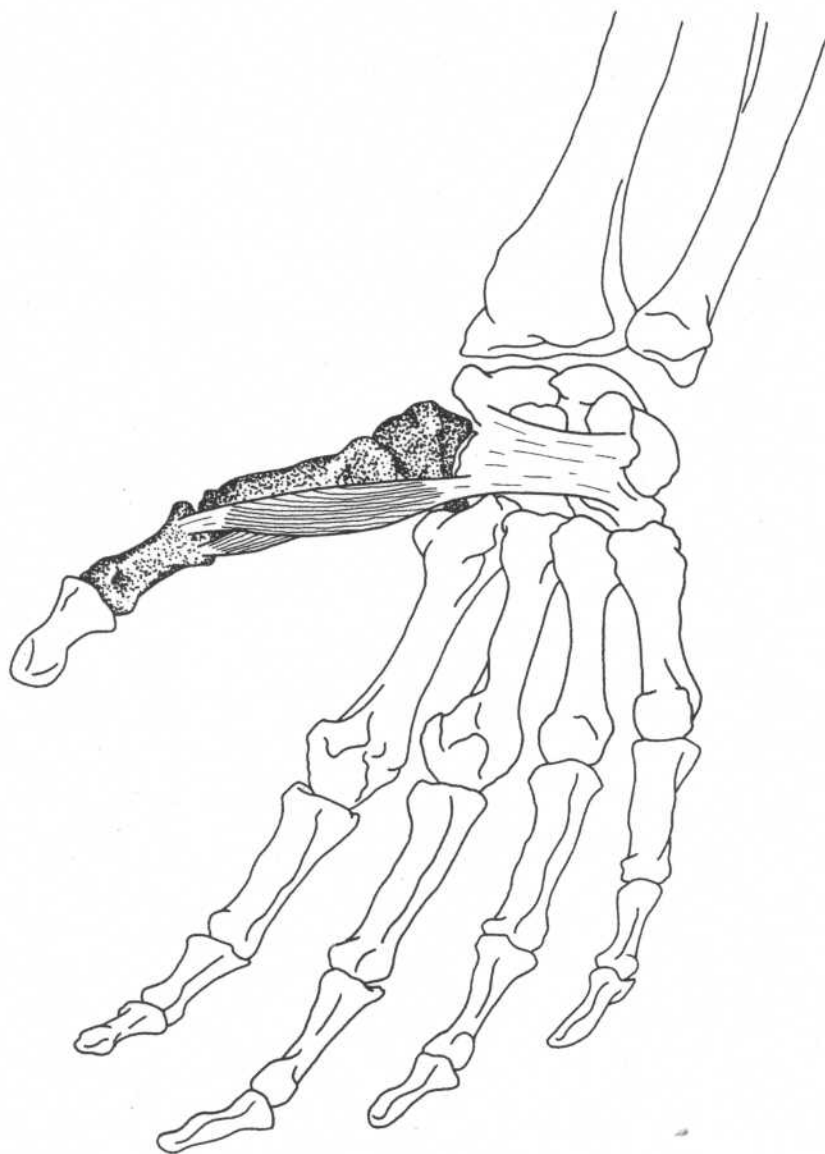
Action Abducts thumb and moves it anteriorly, acts together with other muscles of thenar eminence to oppose thumb to other fingers

Nerve Median (C6, C7)

Note: The abductor pollicis brevis, flexor pollicis brevis, and opponens pollicis form the thenar eminence at the base of the thumb.

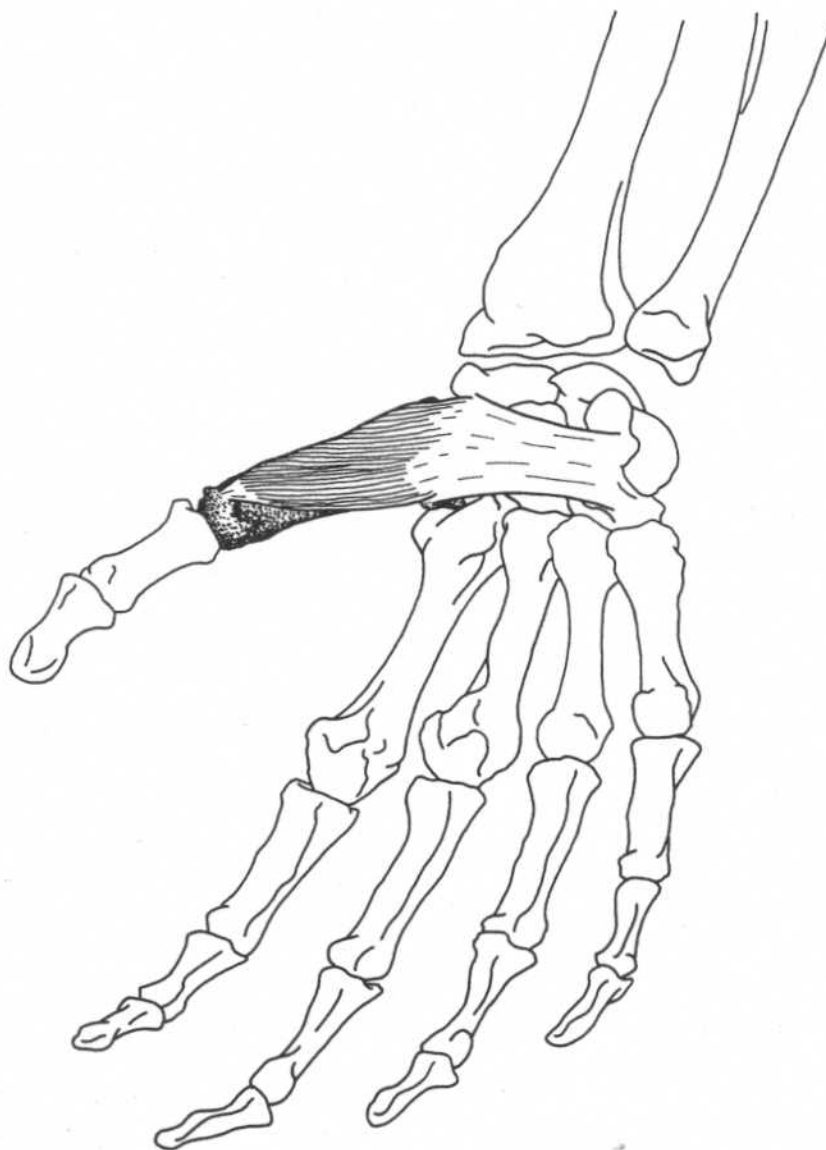
FLEXOR POLLICIS BREVIS

(Thenar eminence)



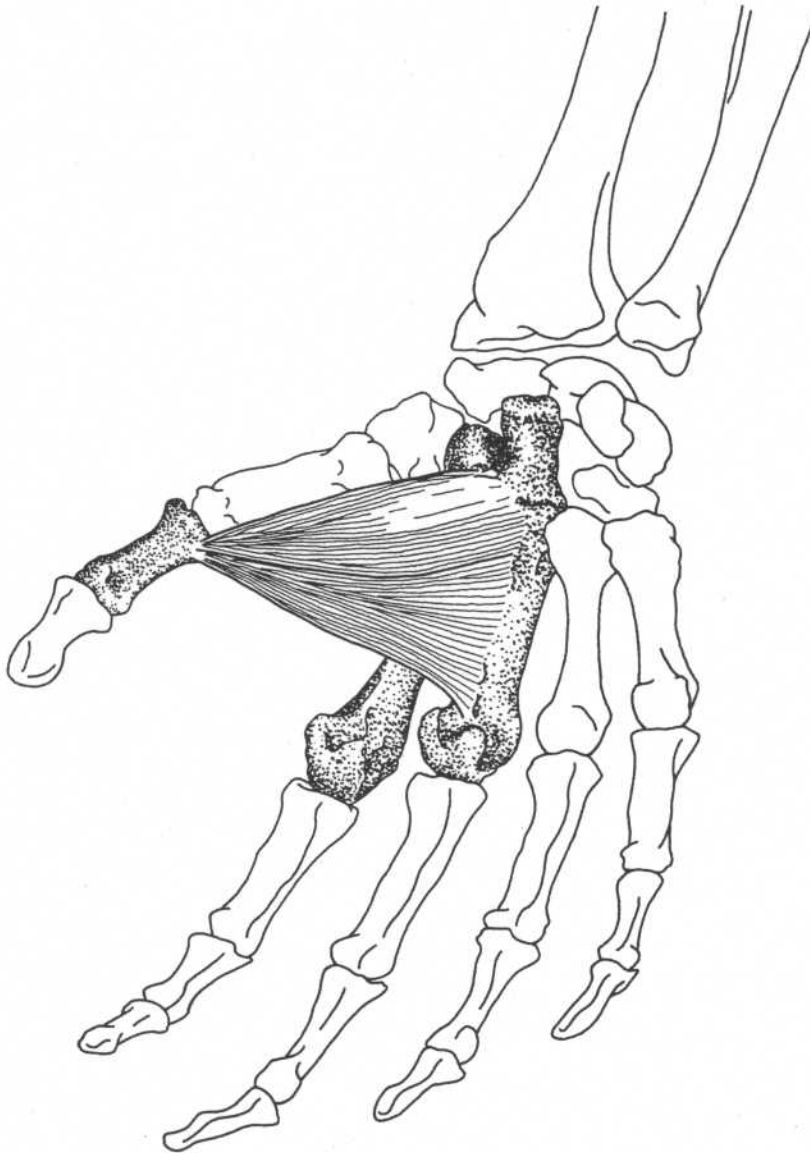
Hand—palmar view

Origin	Flexor retinaculum and trapezium, and first metacarpal bone	Action	Flexes metacarpophalangeal joint of thumb, assists in abduction and rotation of thumb, acts together with other muscles of thenar eminence to oppose thumb to other fingers
Insertion	Base of proximal phalanx of thumb	Nerve	Lateral portion—median nerve (C6, C7) Medial portion—ulnar nerve (C8, T1)

OPPONENS POLLICIS*(Thenar eminence)***Hand—palmar view**

Origin	Flexor retinaculum, tubercle of trapezium	Action	Rotates thumb into opposition with fingers, acts together with other muscles of thenar eminence to oppose thumb to other fingers
Insertion	Lateral border of first metacarpal bone	Nerve	Median nerve (C6, C7)

ADDUCTOR POLLICIS



Hand—palmar view

Origin

Oblique head—anterior surfaces of second and third metacarpals, capitate, trapezoid
Transverse head—anterior surface of third metacarpal bone

Insertion

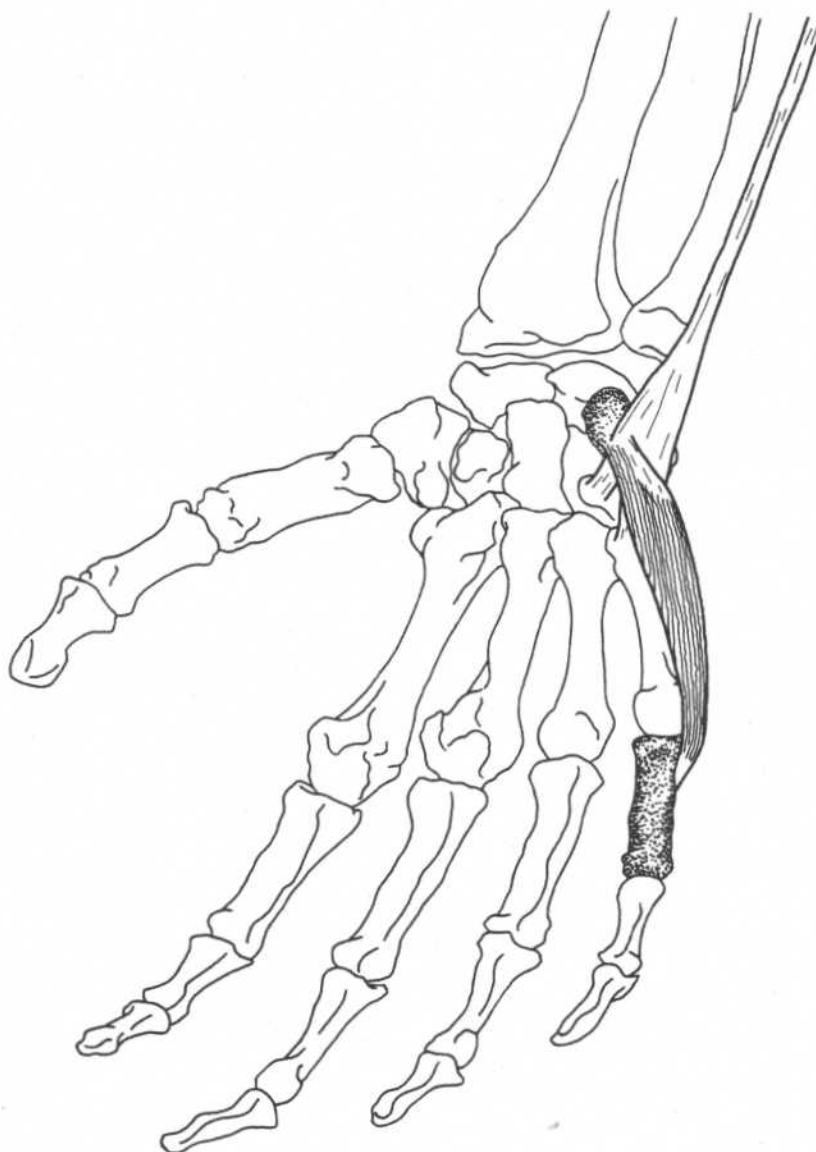
Medial side of base of proximal phalanx of the thumb

Action

Adducts thumb

Nerve

Ulnar nerve (C8, T1)

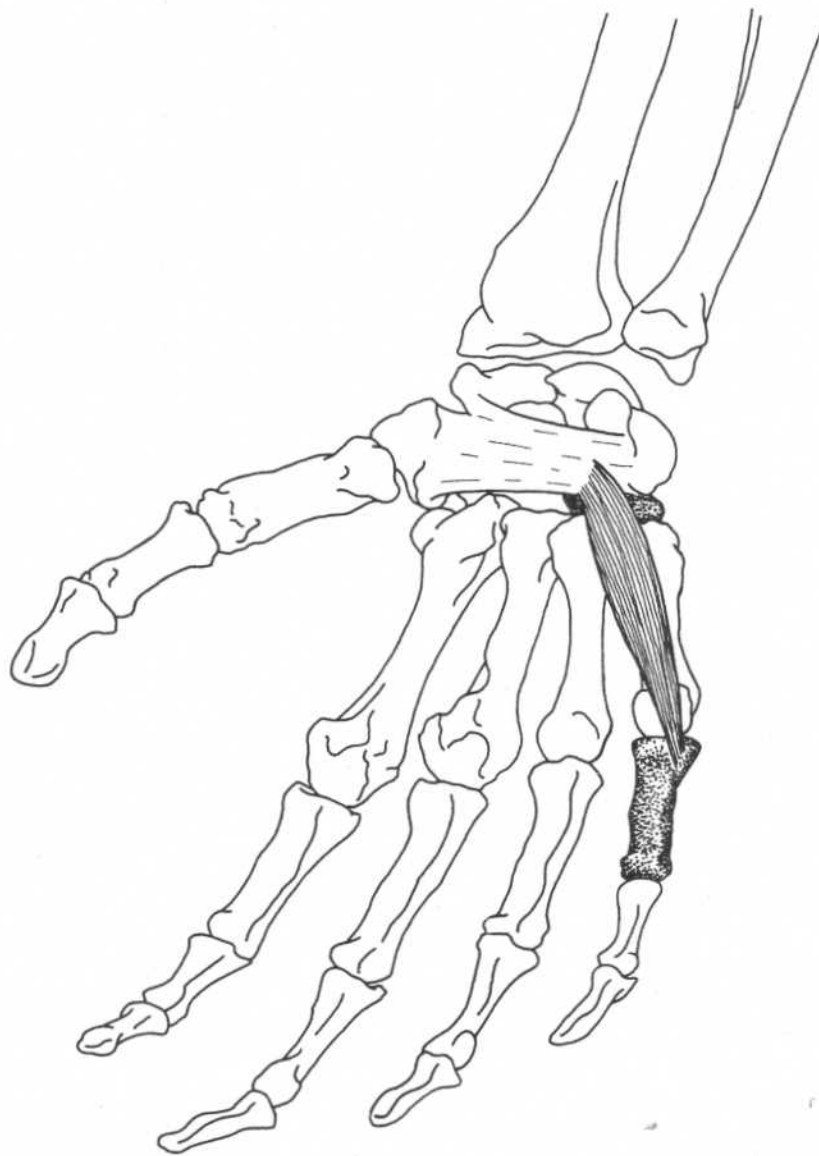
ABDUCTOR DIGITI MINIMI*(Hypothenar eminence)***Hand—palmar view**

Origin	Pisiform bone, tendon of flexor carpi ulnaris	Action	Abducts fifth finger
Insertion	Medial side of base of proximal phalanx of fifth finger	Nerve	Ulnar nerve (C8, T1)

Note: The hypothenar eminence is less prominent than the thenar eminence, and the fifth finger obviously cannot oppose the other digits.

FLEXOR DIGITI MINIMI BREVIS

(Hypothenar eminence)



Hand—palmar view

Origin

Anterior surface of flexor retinaculum,
hook of hamate

Action

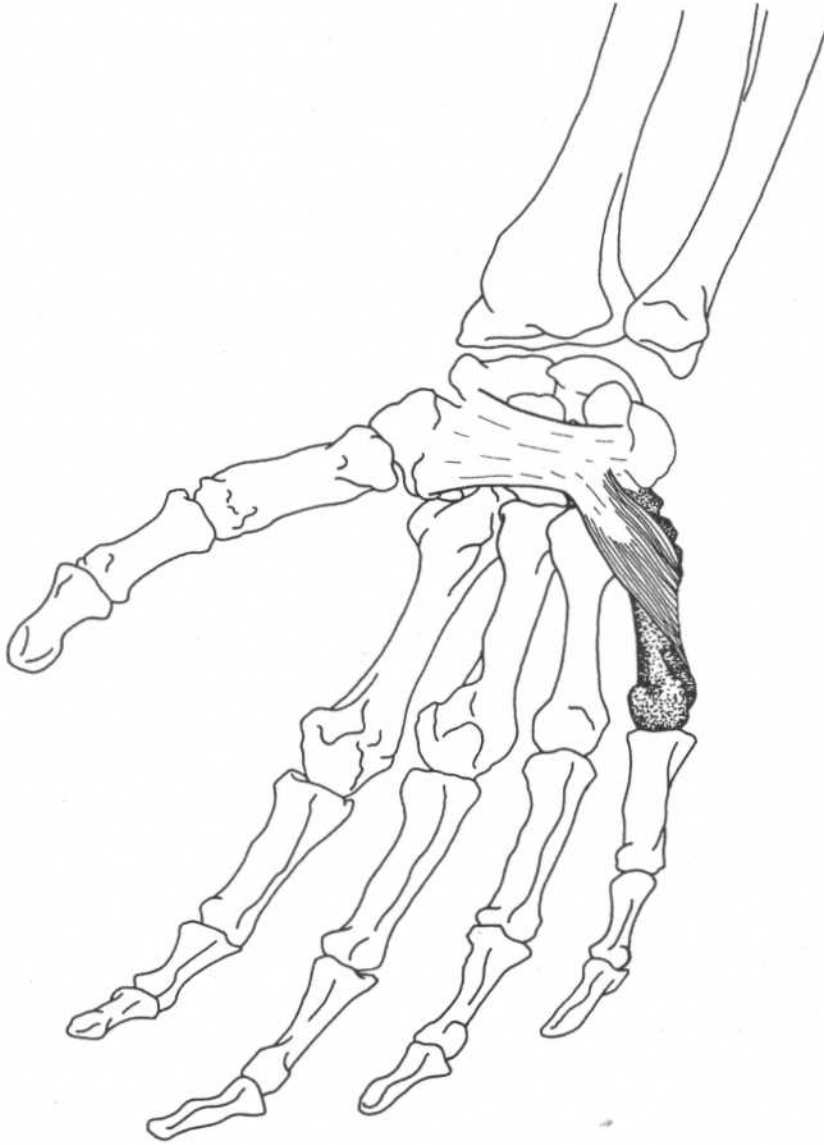
Flexes fifth finger at
metacarpophalangeal joint

Insertion

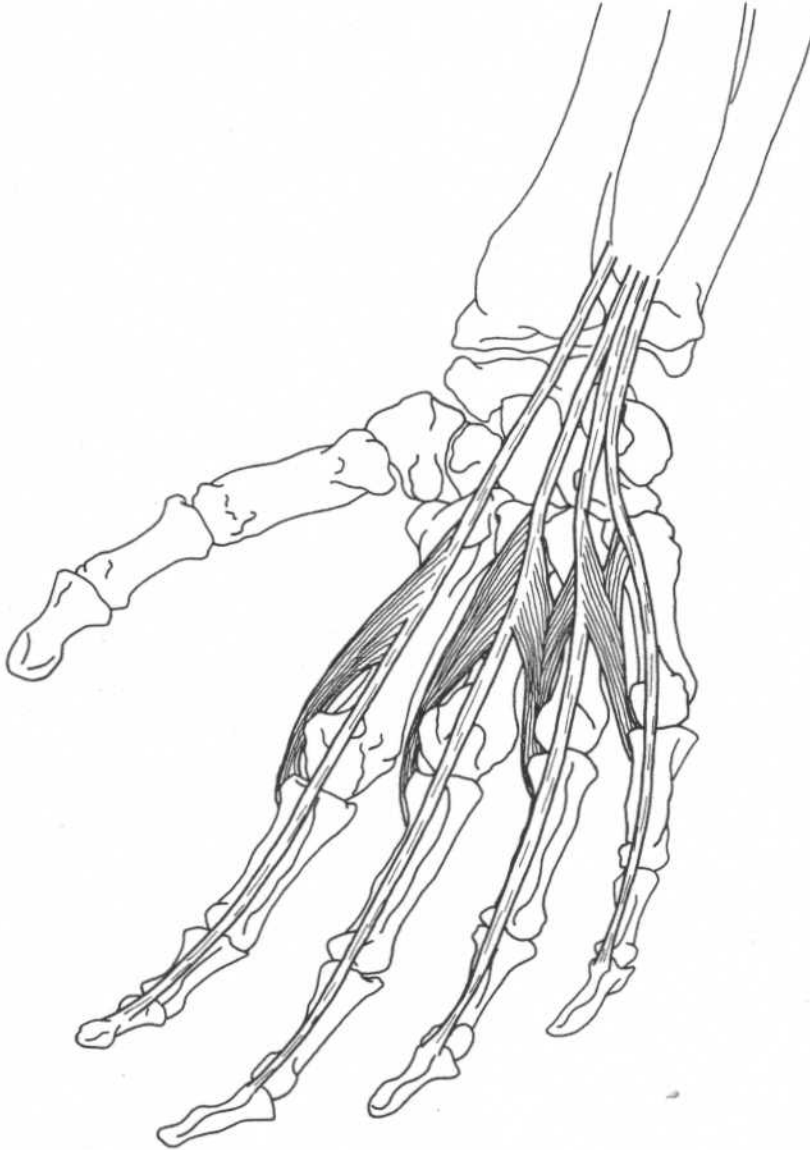
Medial side of base of proximal
phalanx of fifth finger

Nerve

Ulnar nerve (C8, T1)

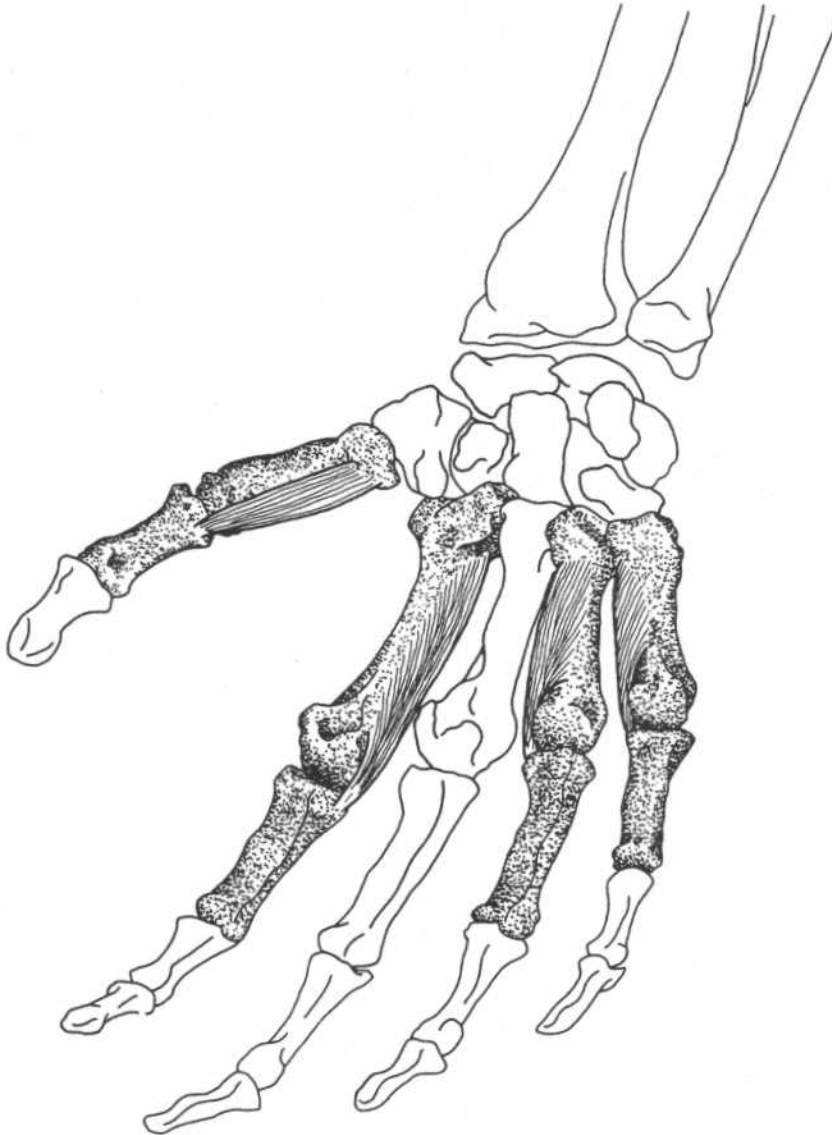
OPPONENS DIGITI MINIMI*(Hypothenar eminence)***Hand—palmar view**

Origin	Anterior surface of flexor retinaculum, hook of hamate	Action	Rotates fifth metacarpal bone, draws fifth metacarpal bone forward, assists flexor digiti minimi brevis in flexing carpometacarpal joint of fifth finger
Insertion	Whole length of medial border of fifth metacarpal bone	Nerve	Ulnar nerve (C8, T1)

LUMBRICALES**(Four muscles)***Hand—palmar view**

Origin	Tendons of flexor digitorum profundus in palm	Nerve	Lateral lumbricals (first and second)—median nerve (C6, C7) Medial lumbricals (third and fourth)—ulnar nerve (C8)
Insertion	Lateral side of corresponding tendon of extensor digitorum on fingers	Relationships	Assist extensor digitorum communis in extending fingers without hyperextension at the metacarpophalangeal joints
Action	Extend fingers at interphalangeal joints, weakly flex fingers at metacarpophalangeal joints		

*Associated with the tendons of flexor digitorum profundus.

PALMAR INTEROSSEI**Hand—palmar view****Origin**

First—medial side of base of first metacarpal bone
 Second, third, and fourth—anterior surfaces of second, fourth, and fifth metacarpal bones

Insertion

First—medial side of base of proximal phalanx of thumb
 Second—medial side of base of proximal phalanx of index finger
 Third and fourth—lateral side of proximal phalanges of ring finger and fifth finger

Action

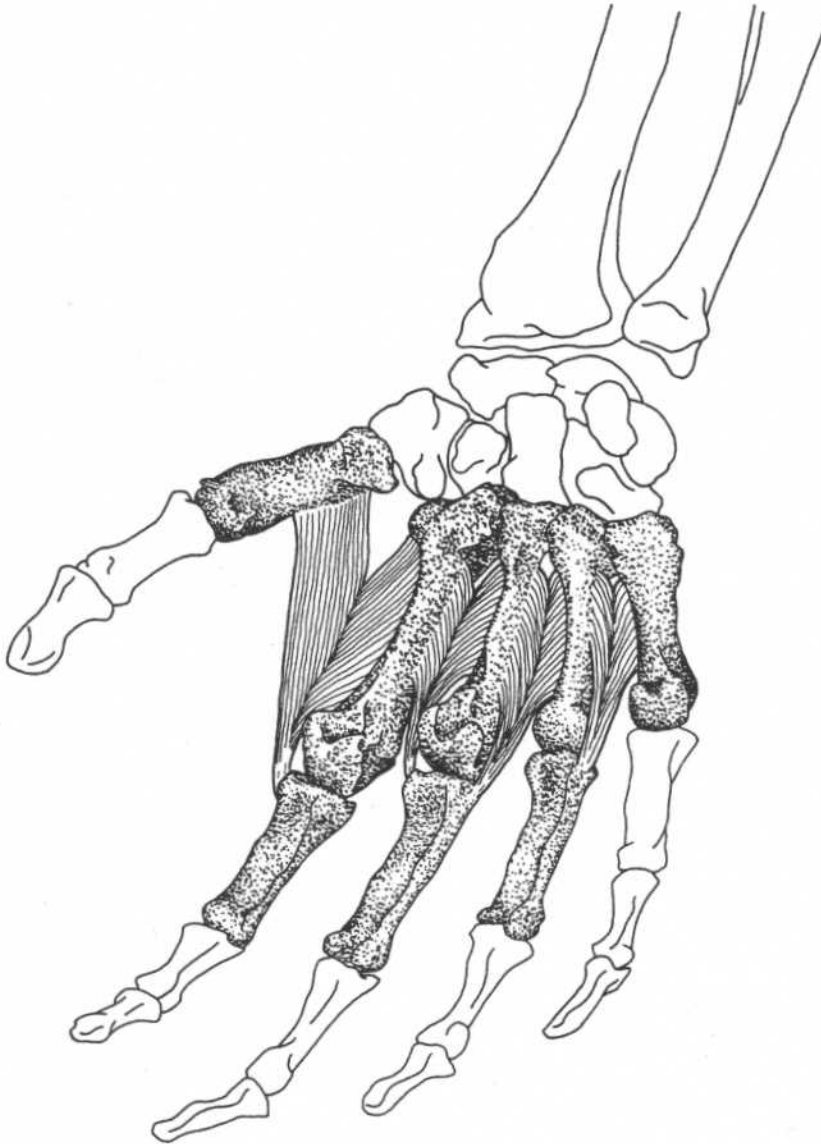
Adduct fingers toward center of third finger at metacarpophalangeal joints, assist in flexion of fingers at metacarpophalangeal joints

Nerve

Ulnar nerve (C8, T1)

Note: The palmar interosseus of the thumb, called the palmar interosseus of Henle, is usually absent.

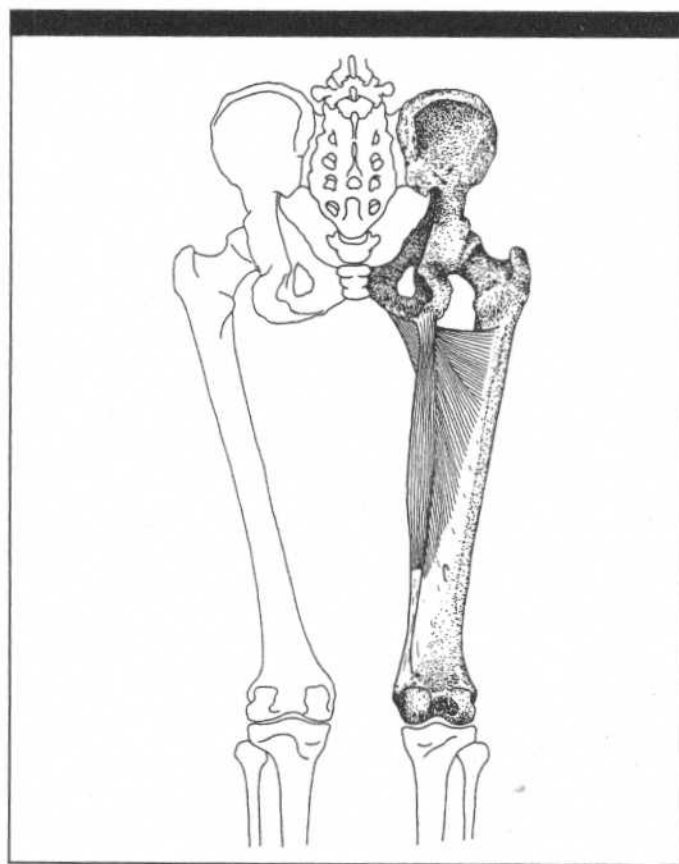
DORSAL INTEROSSEI



Hand—palmar view

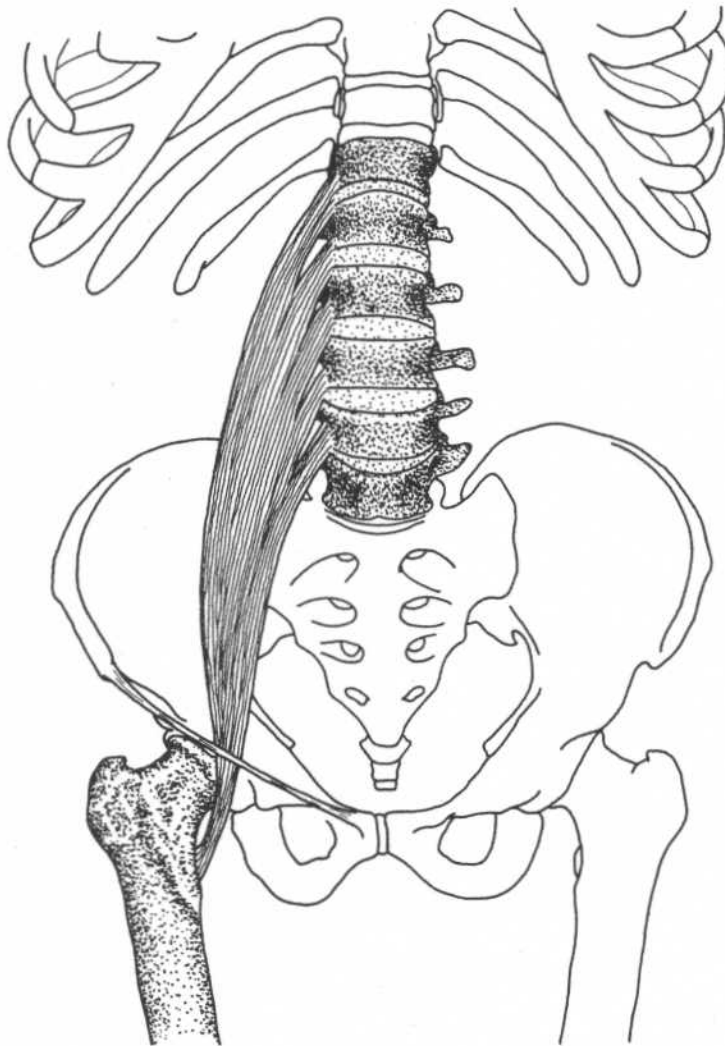
Origin	By two heads from adjacent sides of first and second, second and third, third and fourth, and fourth and fifth metacarpal bones		
Insertion	First—lateral side of base of proximal phalanx of index finger Second—lateral side of base of proximal phalanx of middle finger	Action	Third—medial side of base of proximal phalanx of middle finger Fourth—medial side of base of proximal phalanx of ring finger Abduct fingers away from center of third finger at metacarpophalangeal joints, assist in flexion of fingers at metacarpophalangeal joints
		Nerve	Ulnar nerve (C8, T1)

CHAPTER EIGHT
MUSCLES OF THE HIP AND THIGH



PSOAS MAJOR

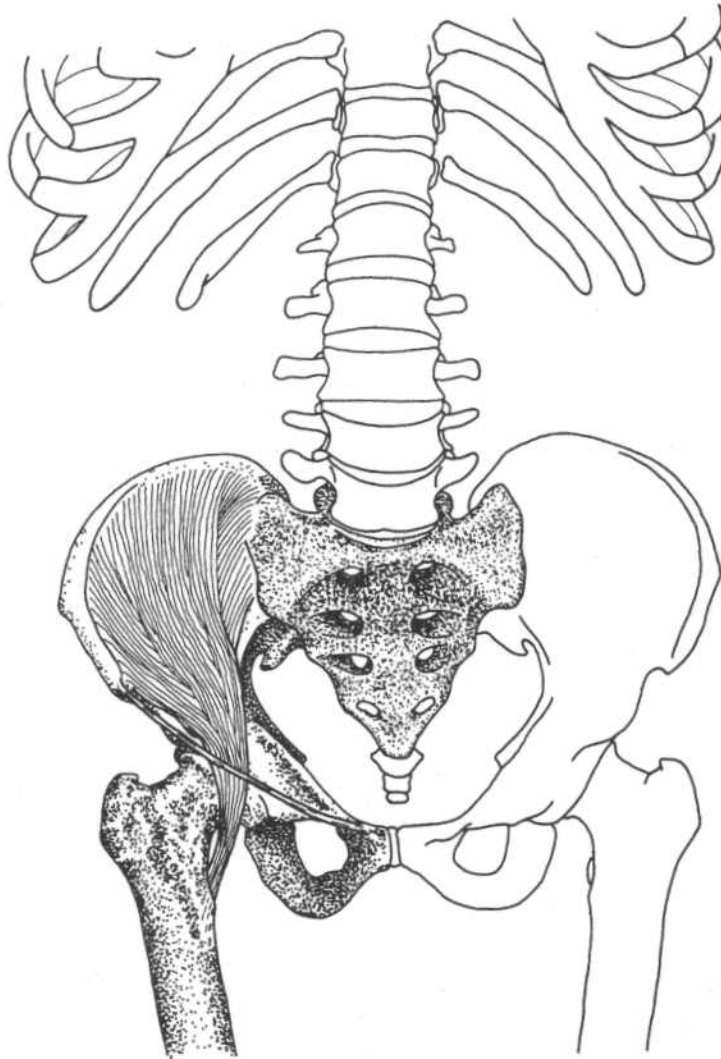
(Part of iliopsoas)



Lumbar region, hip, and thigh—anterior view

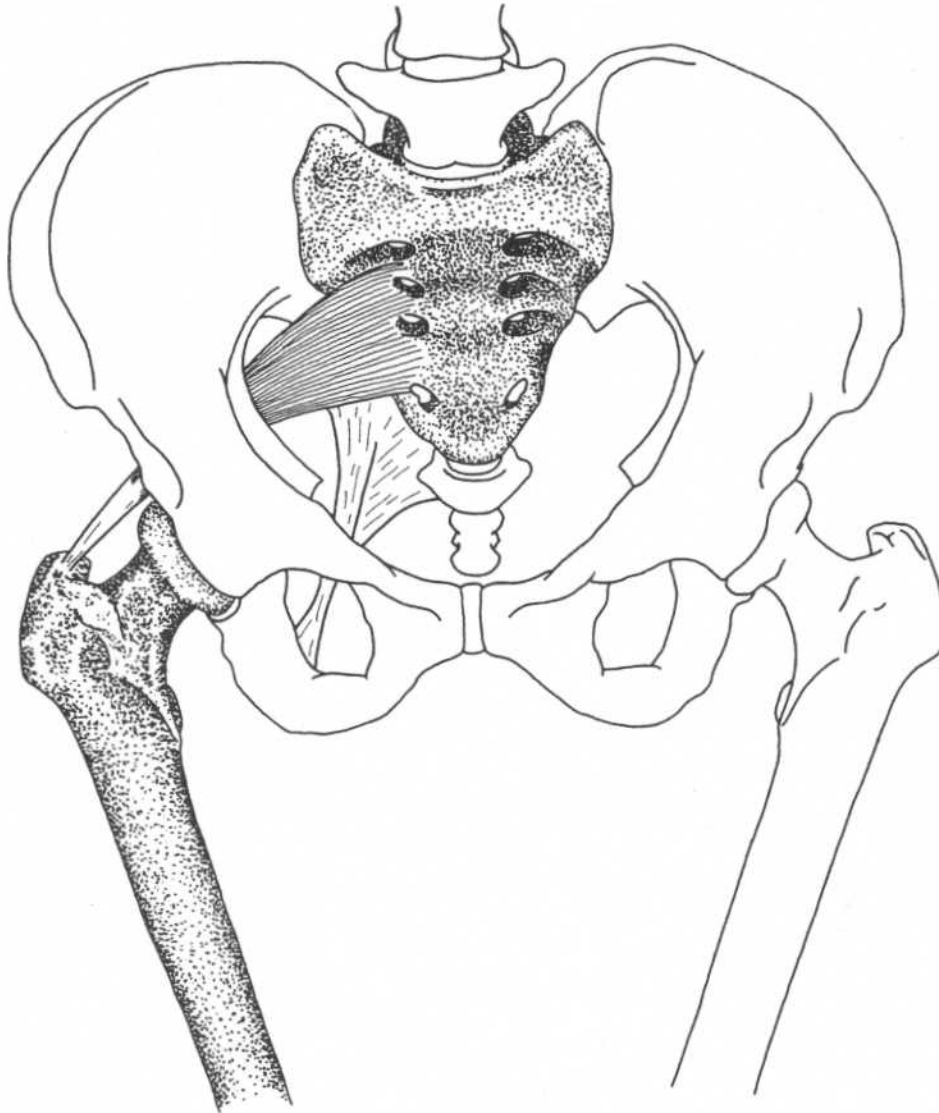
Origin	Bases of transverse processes of all lumbar vertebrae, bodies of twelfth thoracic and all lumbar vertebrae, intervertebral disks above each lumbar vertebra	Insertion	Lesser trochanter of femur
		Action	Flexes thigh at hip joint, flexes vertebral column
		Nerve	Branches from lumbar plexus (L2, L3) and sometimes L1 or L4

Note: Some upper fibers insert onto the hip bone from the arcuate line to the iliopectineal eminence to form the *psaos minor*. This muscle has little function and is frequently absent.

ILIACUS*(Part of iliopsoas)***Lumbar region, hip, and thigh—anterior view**

Origin	Upper two-thirds of iliac fossa, ala of sacrum and adjacent ligaments, anterior inferior iliac spine	Action	Flexes thigh at hip joint
Insertion	Onto tendon of psoas major, which continues into lesser trochanter of femur (together the two muscles form the iliopsoas)	Nerve	Femoral nerve (L2, L3)
			Note: The iliacus brings swinging leg forward in walking or running.

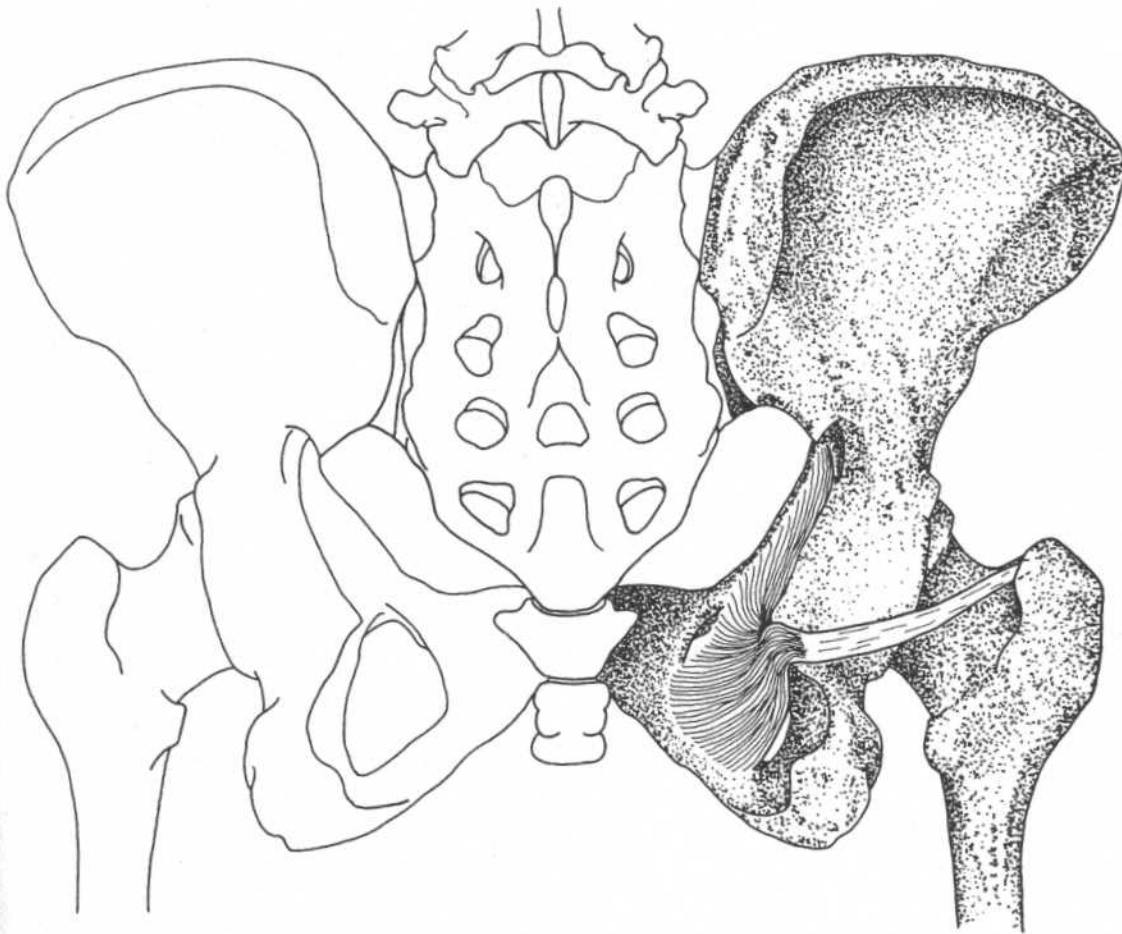
PIRIFORMIS



Hip and thigh—anterior view

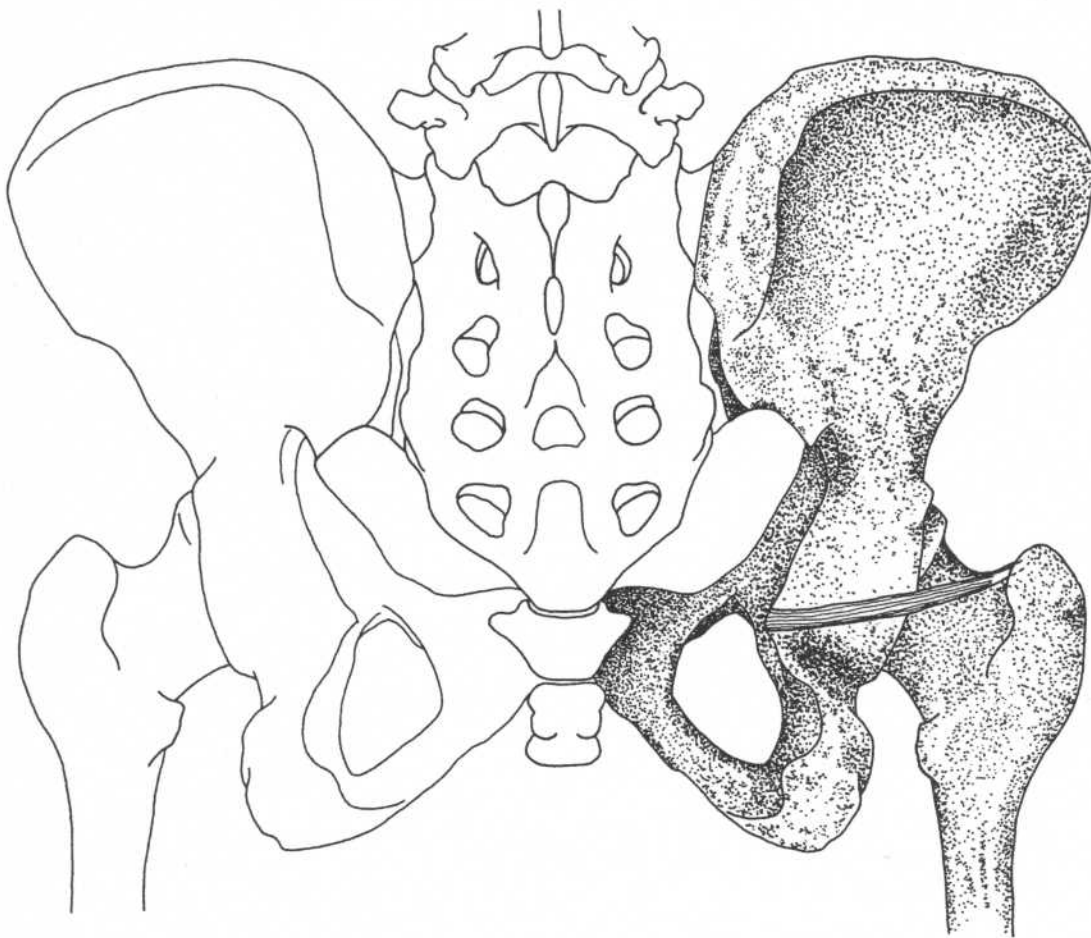
Origin	Internal surface of sacrum, sacrotuberous ligament	Action	Laterally rotates thigh at hip joint, abducts thigh
Insertion	Upper border of greater trochanter	Nerve	Anterior rami of first and second sacral nerves

Note: The common peroneal part of the sciatic nerve may emerge through the belly of the piriformis instead of below its inferior border along with the tibial part.

OBTURATOR INTERNUS**Hip—posterior view**

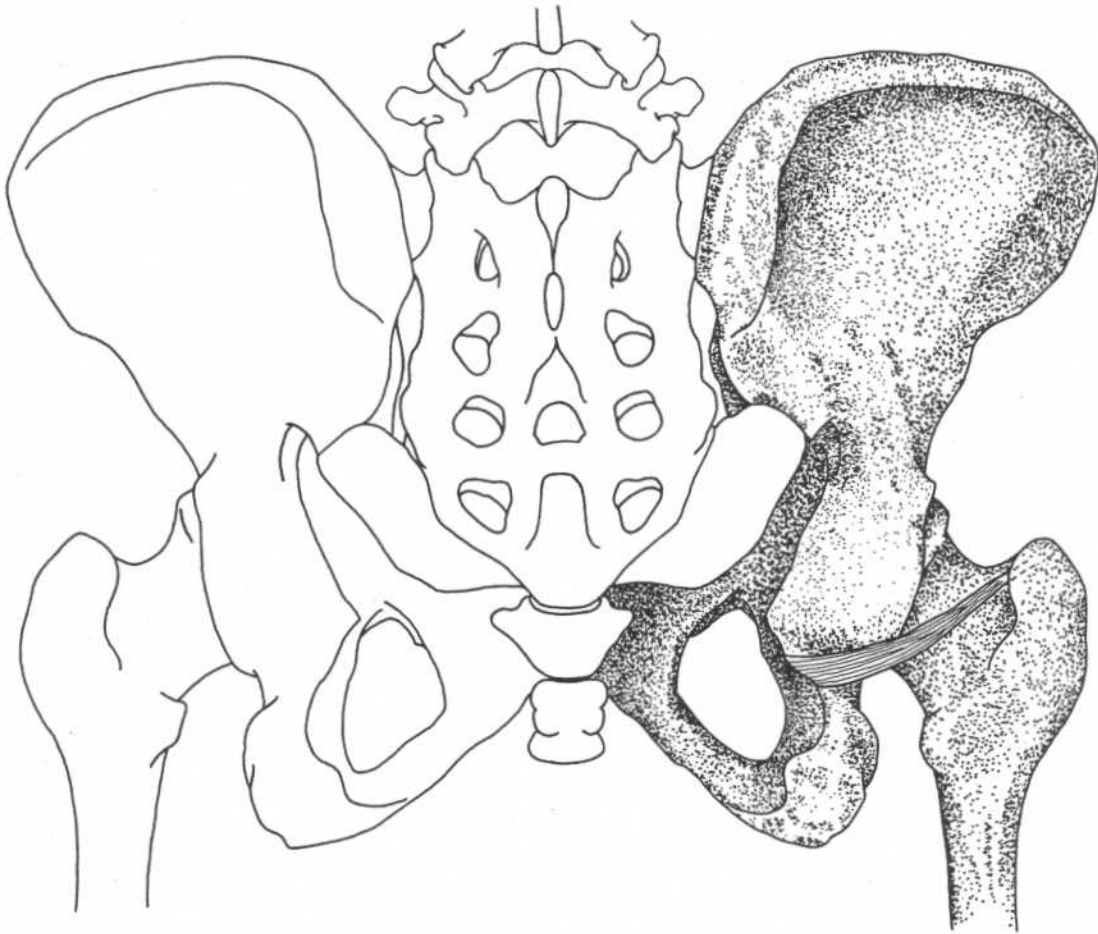
Origin	Pelvic surface of obturator membrane and surrounding bones (ilium, ischium, pubis)	Action	Laterally rotates thigh at hip joint
Insertion	Common tendon with superior and inferior gemelli to medial surface of greater trochanter	Nerve	Nerve from sacral plexus (L5, S1–S3)

GEMELLUS SUPERIOR



Hip—posterior view

Origin	Spine of ischium	Action	Laterally rotates thigh at hip joint
Insertion	With tendon of obturator internus into upper border of greater trochanter	Nerve	Branch of nerve to obturator internus from sacral plexus

GEMELLUS INFERIOR**Hip—posterior view****Origin**

Upper margin of ischial tuberosity

Insertion

With tendon of obturator internus into upper border of greater trochanter

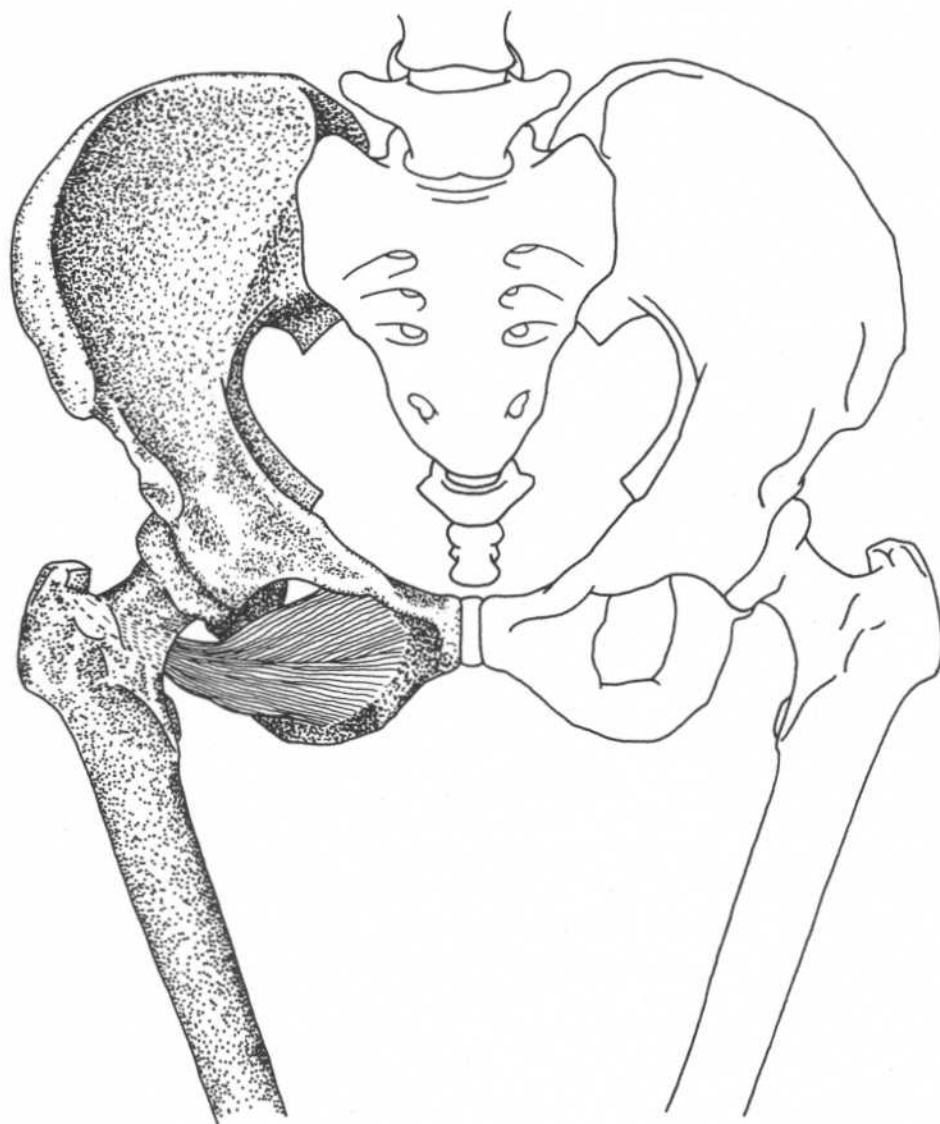
Action

Laterally rotates thigh at hip joint

Nerve

Branch of nerve to quadratus femoris from sacral plexus

OBTURATOR EXTERNUS



Hip and thigh—anterior view

Origin

Outer surface of superior and inferior rami of pubis and ramus of ischium surrounding obturator foramen

Insertion

Trochanteric fossa of femur

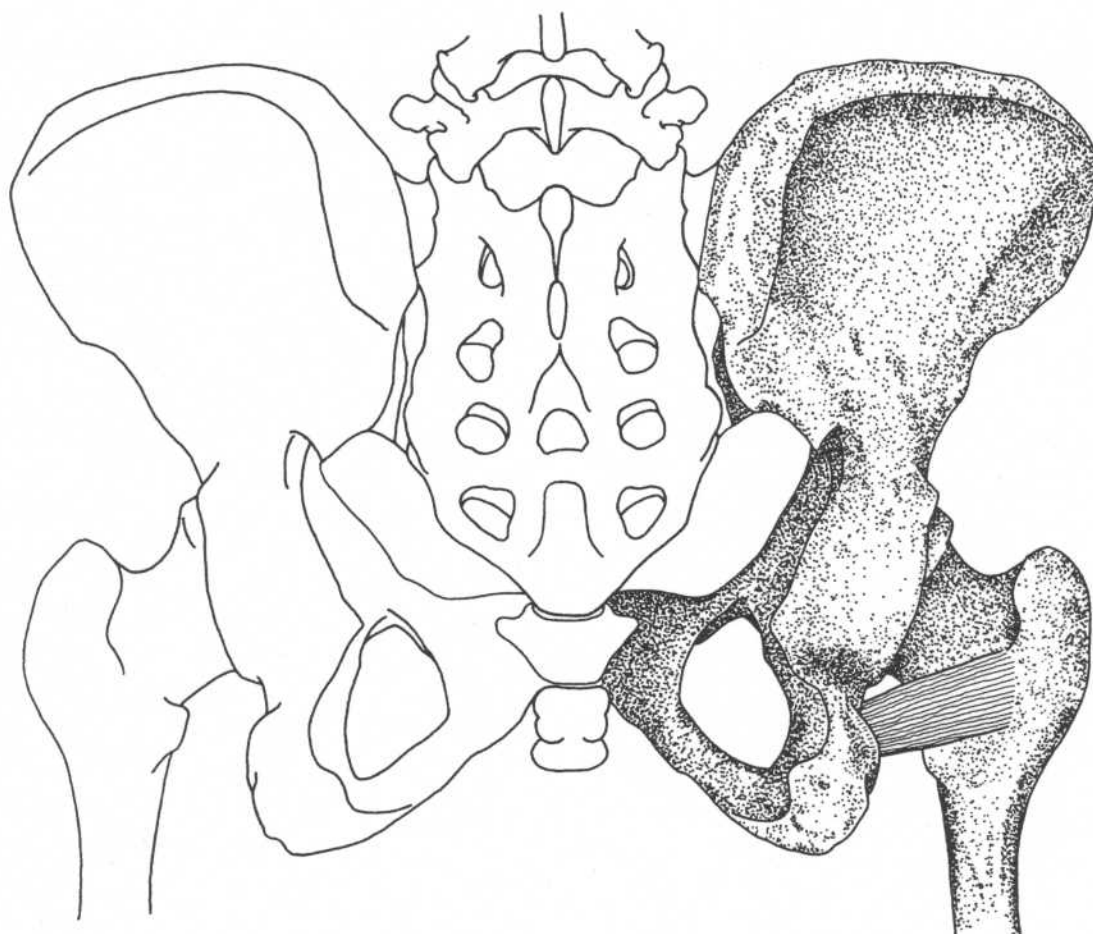
Action

Laterally rotates thigh

Nerve

Obturator nerve (L3, L4)

Note: Part of this muscle can be seen posteriorly by separating the gemellus inferior and quadratus femoris. It is deep within this cleft.

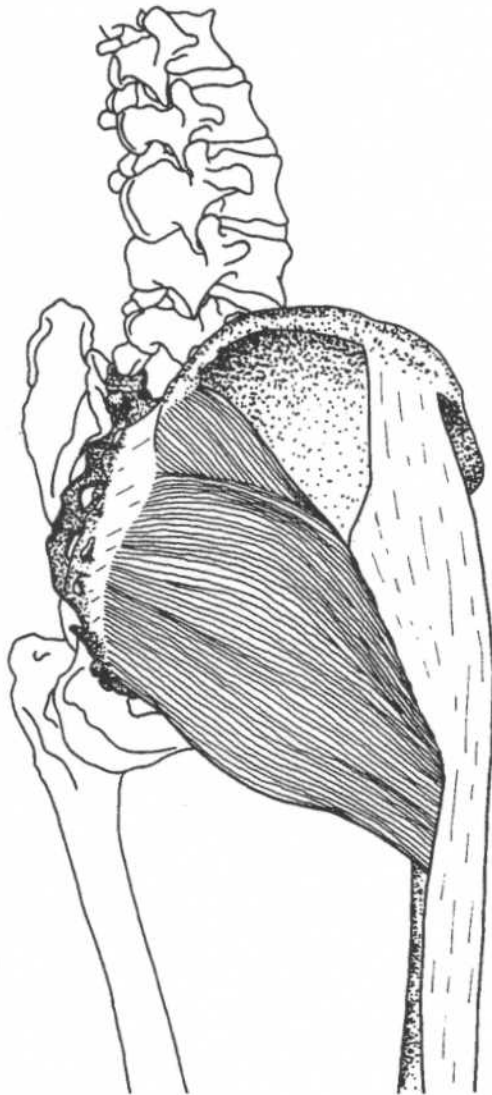
QUADRATUS FEMORIS**Hip and thigh—posterior view****Origin**
Insertion

Lateral border of ischial tuberosity
Below intertrochanteric crest
(quadrate line)

Action
Nerve

Laterally rotates thigh at hip joint
Branch from sacral plexus (L5, S1)

GLUTEUS MAXIMUS



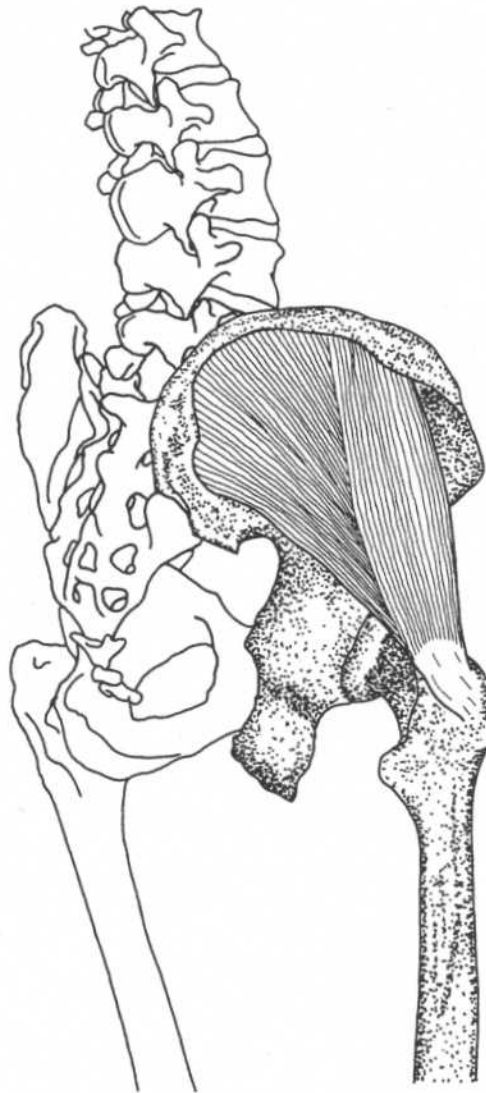Hip and thigh—lateral view

Origin
 Outer surface of ilium behind posterior gluteal line, adjacent posterior surface of sacrum and coccyx, sacrotuberous ligament, aponeurosis of erector spinae (sacrospinalis)
 Iliotibial tract of fascia lata, gluteal tuberosity of femur

Action
 Upper part—abducts, laterally rotates thigh
 Lower part—extends, laterally rotates thigh, extends trunk, assists in adduction of thigh

Nerve
 Inferior gluteal nerve (L5, S1, S2)

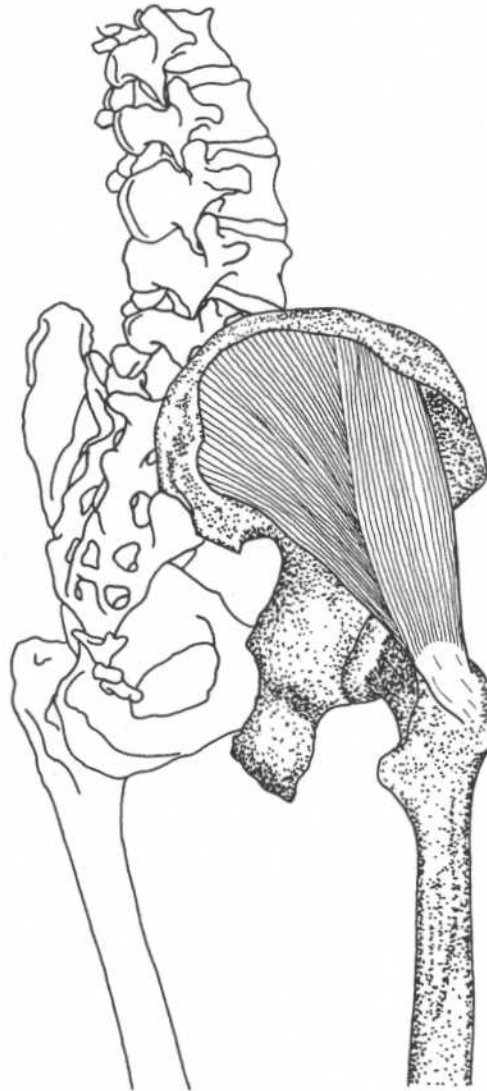Note: This is not a postural muscle; it is not used in walking but only in forceful extension, as in running, climbing, or rising from a seated position.

GLUTEUS MEDIUS**Hip and thigh—lateral view**

Origin	Outer surface of ilium inferior to iliac crest	Action	Abducts femur at hip joint and rotates thigh medially
Insertion	Lateral surface of greater trochanter	Nerve	Superior gluteal nerve (L4, L5, S1)

Note: In locomotion, this muscle (along with the gluteus minimus) prevents the pelvis from dropping (adduction of thigh) toward the opposite swinging leg.

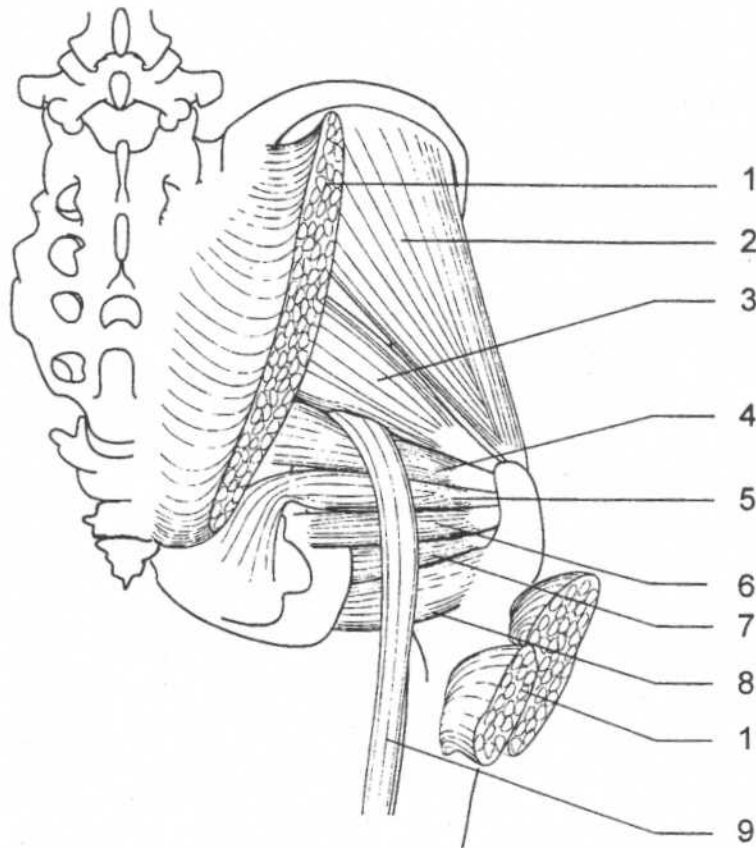
GLUTEUS MINIMUS



Hip and thigh—lateral view

Origin	Outer surface of ilium between middle (anterior) and inferior gluteal lines	Action	Abducts femur at hip joint and rotates thigh medially
Insertion	Anterior surface of greater trochanter	Nerve	Superior gluteal nerve (L4, L5, S1)

Note: See note on gluteus medius.

MUSCLES OF THE HIP**Hip—posterior view**

1. Gluteus maximus (cut)
2. Gluteus medius
3. Piriformis
4. Gemellus superior
5. Obturator internus

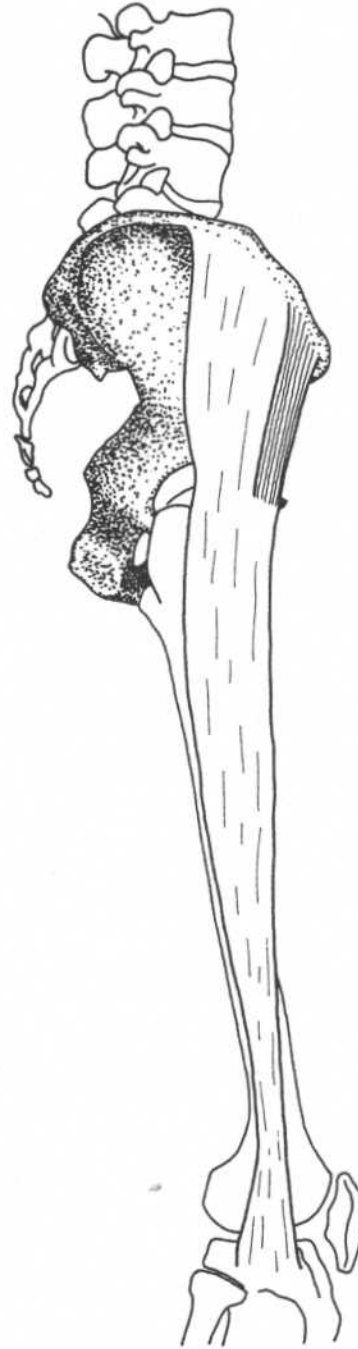
6. Gemellus inferior
7. Obturator externus
8. Quadratus femoris
9. Sciatic nerve

Note: Gemellus inferior and quadratus femoris have been shown separated to expose the deeply placed obturator externus.

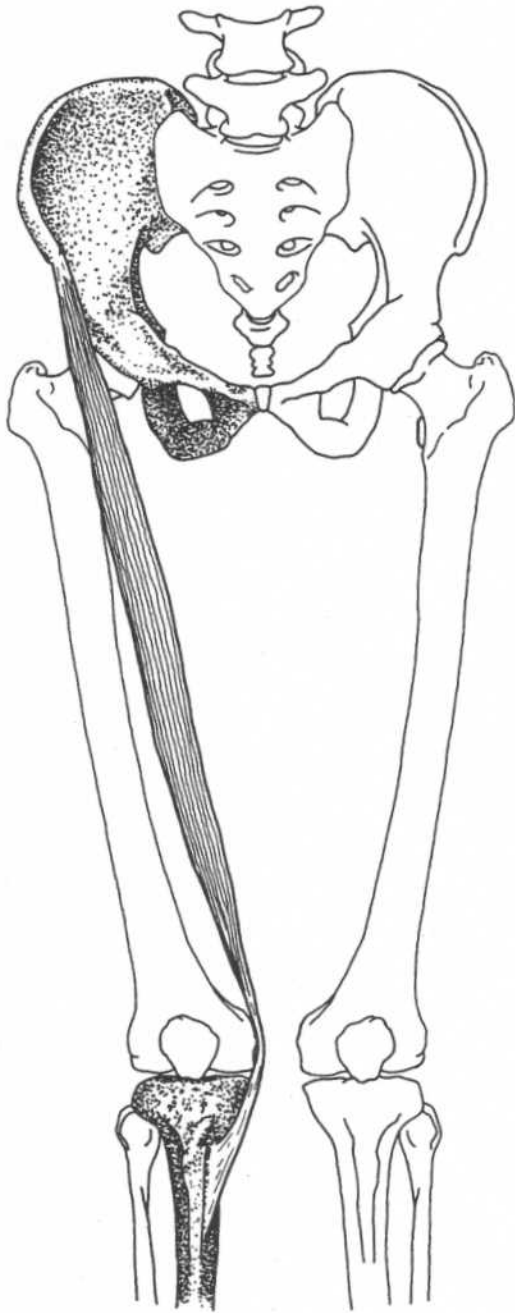
TENSOR FASCIAE LATAE

Origin	Outer edge of iliac crest between anterior superior iliac spine and iliac tubercle
Insertion	Iliotibial tract on upper part of thigh
Action	Flexes, abducts thigh
Innervation	Superior gluteal nerve (L4, L5, S1)

Notes: This muscle, along with gluteus maximus, draws the iliac fascia lata upward, stabilizing the knee.



Hip and thigh—lateral view



**Hip, thigh, and leg—
anterior view**

SARTORIUS

Origin	Anterior superior iliac spine and area immediately below it
Insertion	Upper part of medial surface of shaft of tibia
Action	Flexes, abducts, and laterally rotates thigh at hip joint, flexes and slightly medially rotates leg at knee joint after flexion
Nerve	Femoral nerve (L2, L3)
Relationships	Insertions of sartorius, gracilis, and semitendinosus fuse on the medial tibia; these tendons, called the pes anserinus (goose foot), give medial support to the knee

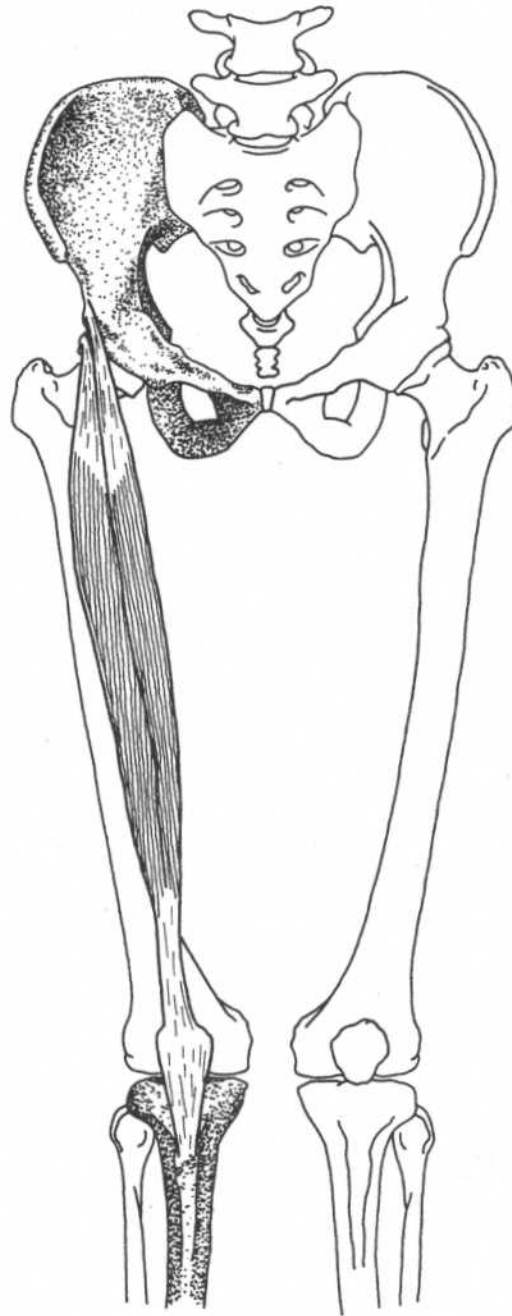
Note: This muscle is used to bring swinging leg forward in walking and running.

RECTUS FEMORIS

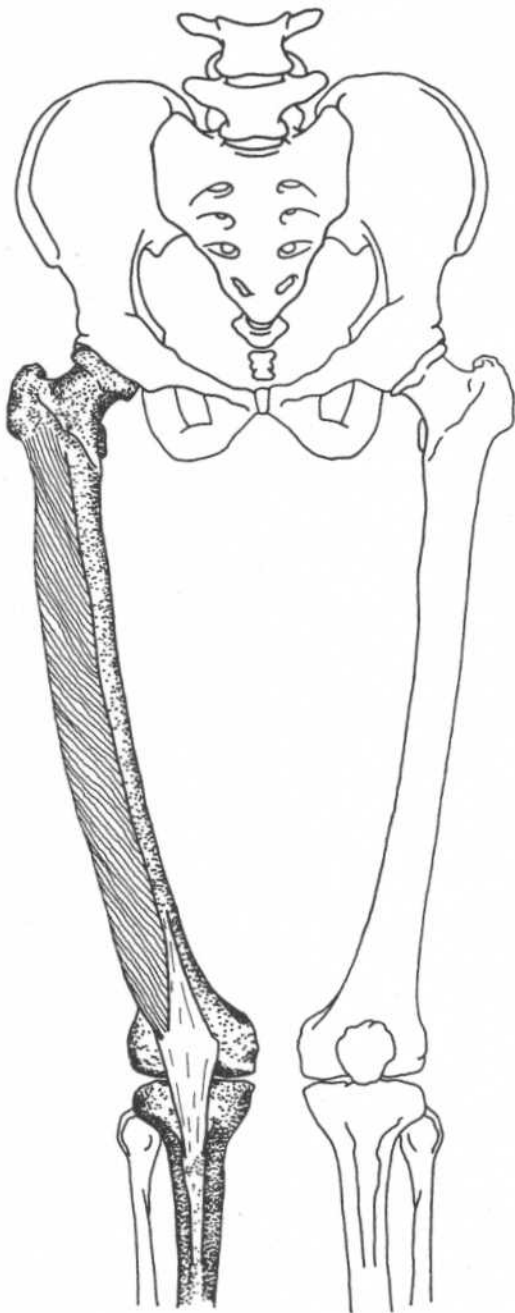
(One of quadriceps femoris)

Origin	Anterior head—anterior inferior iliac spine Posterior head—ilium above acetabulum
Insertion	Patella, then by patellar ligament to tuberosity of the tibia
Action	Extends leg at knee joint, flexes thigh at hip joint
Nerve	Femoral nerve (L2–L4)

Note: This muscle is used when thigh flexion and leg extension are needed together, such as in kicking a football. In walking, the quadriceps prevent the knee from flexing during heel strike and early support phase.



**Hip, thigh, and leg—
anterior view**

VASTUS LATERALIS*(One of quadriceps femoris)***Origin**

Intertrochanteric line, inferior border of greater trochanter, gluteal tuberosity, lateral lip of linea aspera of femur

Insertion

Lateral margin of patella, then by patellar ligament to tuberosity of tibia

Action

Extends leg at knee joint

Nerve

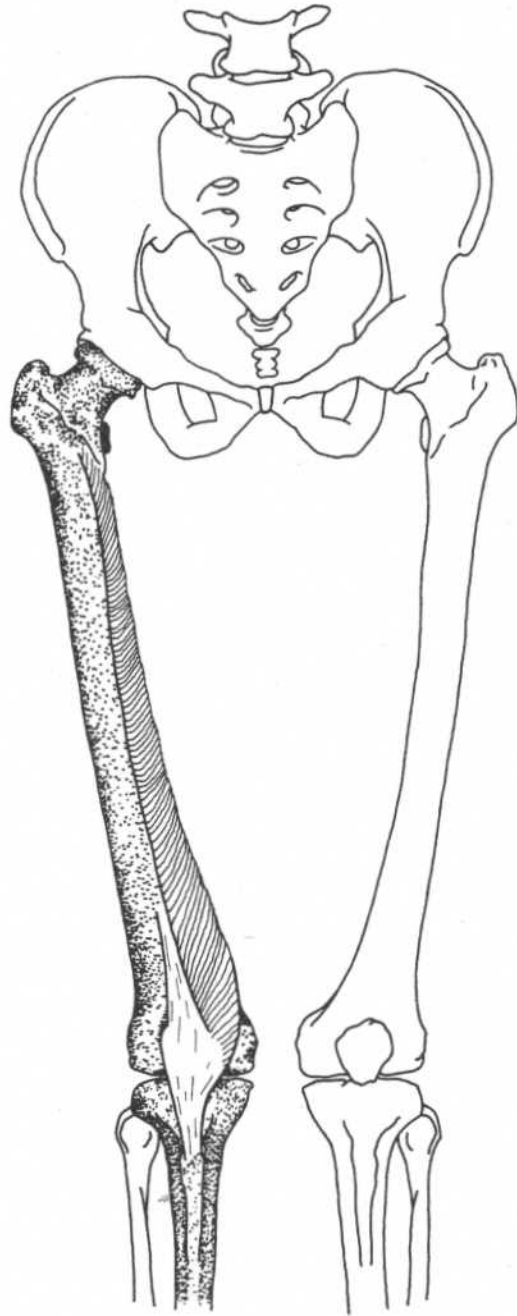
Femoral nerve (L2–L4)

**Hip, thigh, and leg—
anterior view**

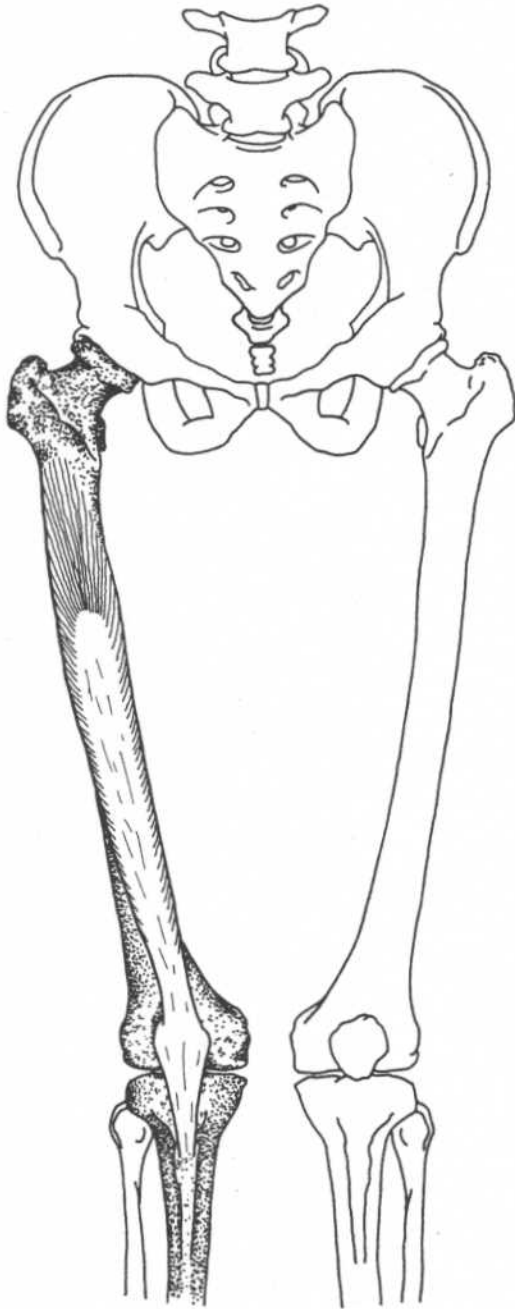
VASTUS MEDIALIS

(One of quadriceps femoris)

Origin	Intertrochanteric line, medial lip of linea aspera of femur, medial intermuscular septum, medial supracondylar line
Insertion	Medial border of the patella, then by patellar ligament into tibial tuberosity, medial condyle of tibia
Action	Extends leg at knee joint
Nerve	Femoral nerve (L2–L4)



**Hip, thigh, and leg—
anterior view**

VASTUS INTERMEDIUS*(One of quadriceps femoris)*

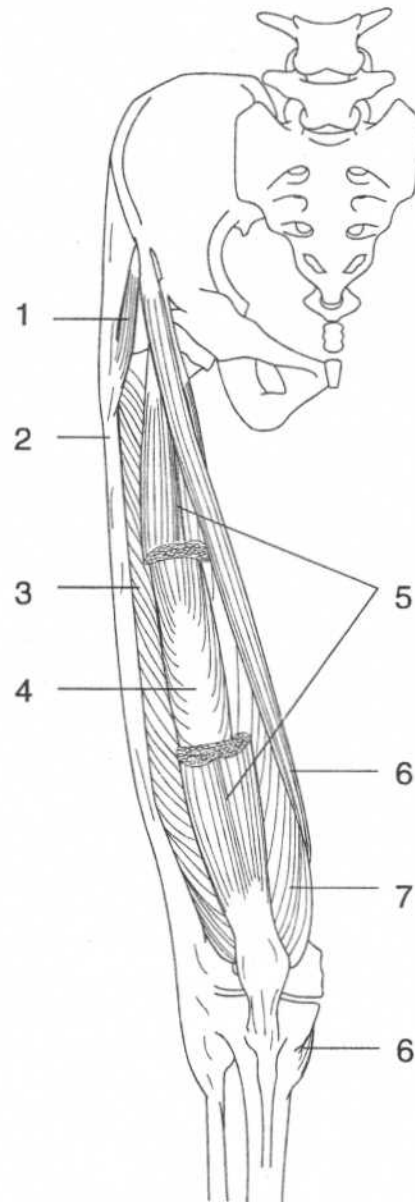
Origin	Anterior and lateral surfaces of upper two-thirds of femur, lateral intermuscular septum, linea aspera, lateral supracondylar line
Insertion	Deep aspect of quadriceps tendon, then through patella to tibial tuberosity
Action	Extends leg at knee joint
Nerve	Femoral nerve (L2–L4)

Note: A few bundles of fibers from this muscle insert onto the upper part of the joint capsule of the knee. They probably draw the capsule superiorly during extension of the leg, preventing it from binding in the joint. They are called *articularis genuis*.

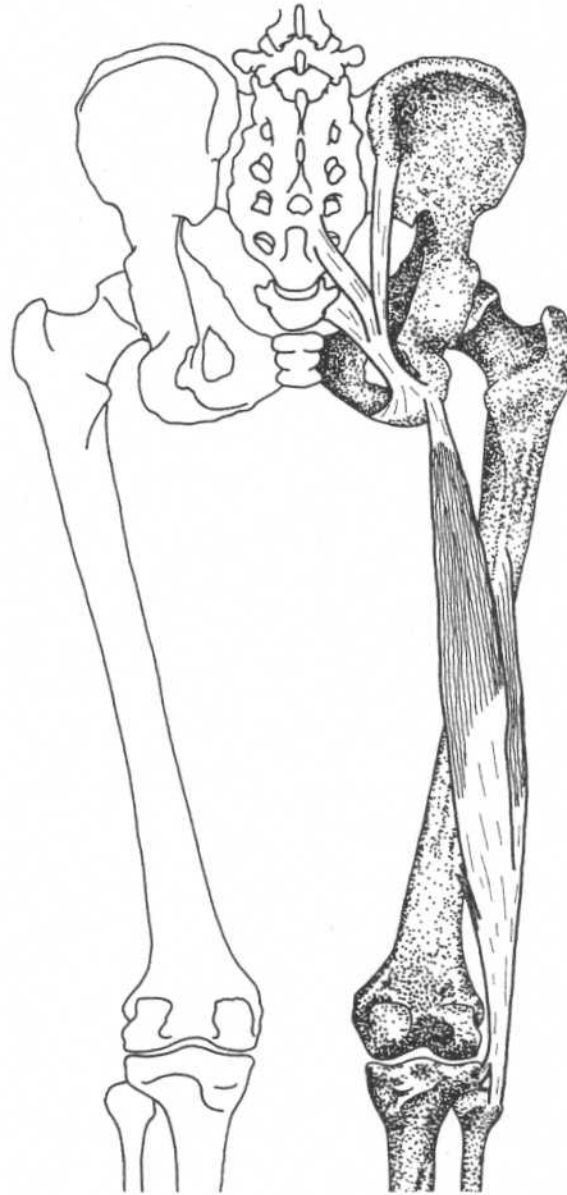
**Hip, thigh, and leg—
anterior view**

MUSCLES OF THE ANTERIOR THIGH

1. Tensor fasciae latae
2. Iliotibial tract
3. Vastus lateralis (quadriceps femoris)
4. Vastus intermedius (quadriceps femoris)
5. Rectus femoris (cut) (quadriceps femoris)
6. Sartorius
7. Vastus medialis (quadriceps femoris)



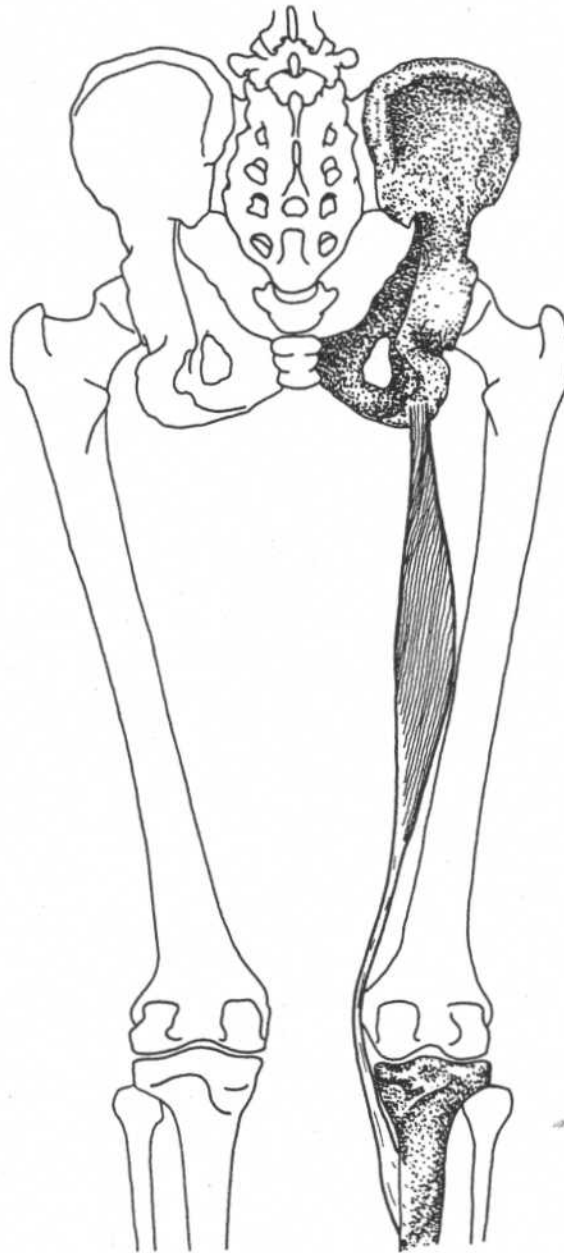
Hip and thigh—anterior view

BICEPS FEMORIS*(Part of hamstrings)***Hip and thigh—posterior view**

Origin	<p>Long head—ischial tuberosity, sacrotuberous ligament</p> <p>Short head—linea aspera, lateral supracondylar ridge, lateral intermuscular septum</p>	Nerve	<p>Long head—tibial part of sciatic nerve (S1–S3)</p> <p>Short head—common peroneal part of sciatic nerve (L5, S1, S2)</p>
Insertion	Lateral side of head of fibula and lateral condyle of tibia	<p>Note: During walking or running, the hamstrings are used to slow down the leg at the end of its swing and prevent the trunk from flexing at the hip. They are susceptible to being strained by resisting the momentum of these body parts.</p>	
Action	Flexes leg at knee joint, long head also extends thigh at hip joint		

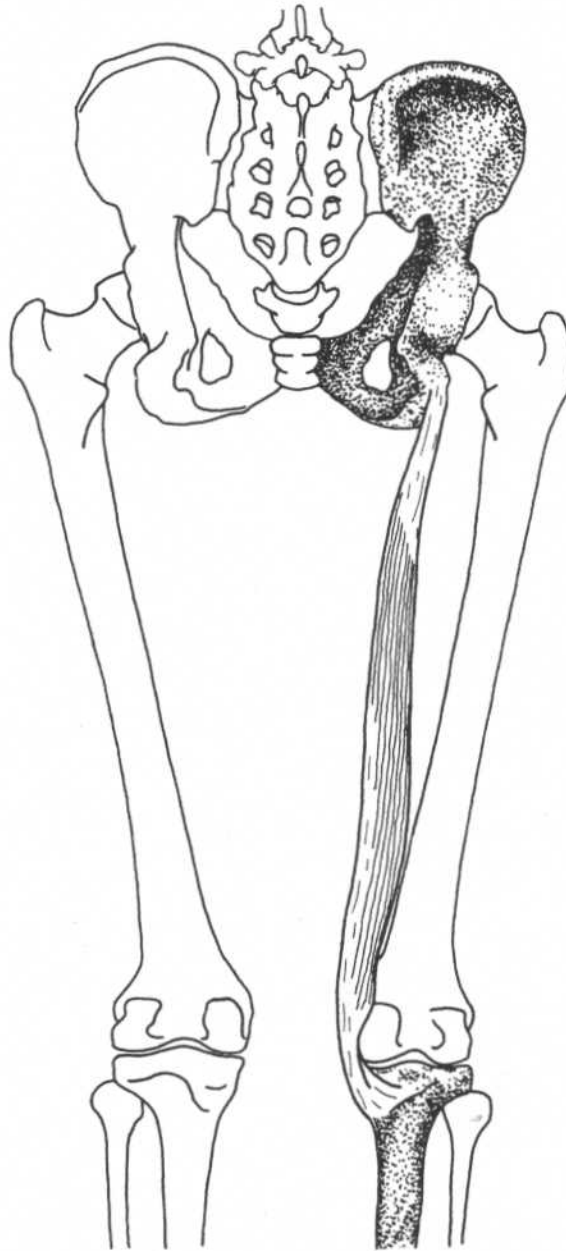
SEMITENDINOSUS

(Part of hamstrings)



Hip and thigh—posterior view

Origin	Ischial tuberosity	Nerve	Tibial portion of sciatic nerve (L5, S1, S2)
Insertion	Medial surface of shaft of tibia		
Action	Flexes and slightly medially rotates leg at knee joint after flexion, extends thigh at hip joint	Note: See note on biceps femoris and Relationships section on sartorius.	

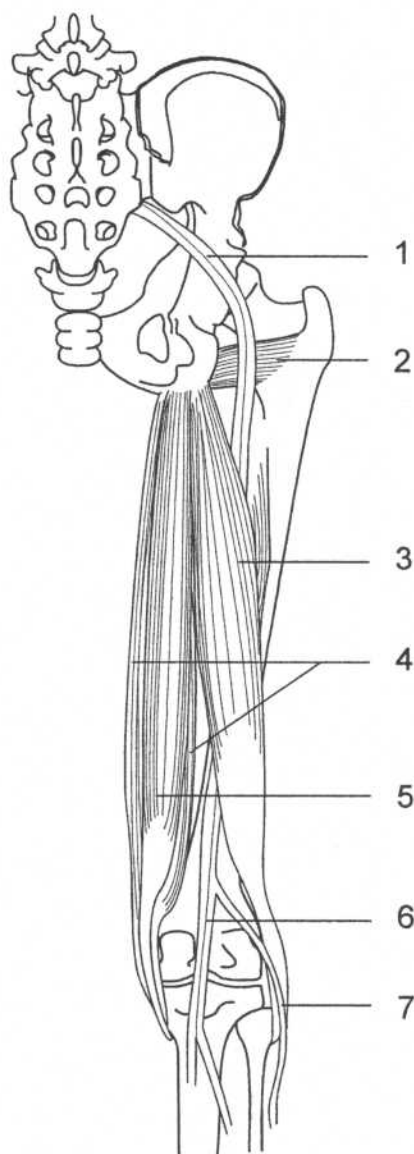
SEMIMEMBRANOSUS*(Part of hamstrings)***Hip and thigh—posterior view**

Origin	Ischial tuberosity	Nerve	Tibial portion of sciatic nerve (L5, S1, S2)
Insertion	Posterior part of medial condyle of tibia		
Action	Flexes and slightly medially rotates leg at knee joint after flexion, extends thigh at hip joint	Note: See note on biceps femoris.	

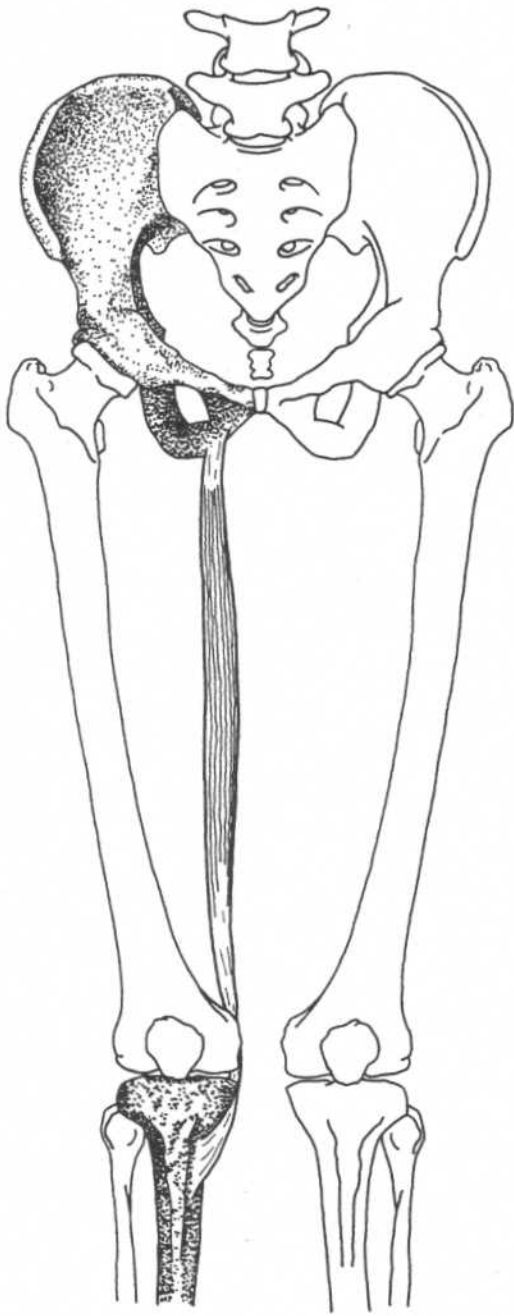
HAMSTRING MUSCLES

1. Sciatic nerve
2. Quadratus femoris
3. Biceps femoris
4. Semimembranosus
5. Semitendinosus
6. Tibial nerve
7. Common peroneal nerve

Note: The common peroneal nerve is exposed to compression and damage as it passes over the head of the fibula. The quadratus femoris, a lateral rotator, is included for reference.



**Hip and thigh—
posterior view**



GRACILIS

Origin	Lower margin of body and inferior ramus of pubis
Insertion	Upper part of medial surface of shaft of tibia
Action	Adducts thigh at hip joint and flexes leg at knee joint; with leg flexed, assists in medial rotation
Nerve	Obturator nerve (L3, L4)

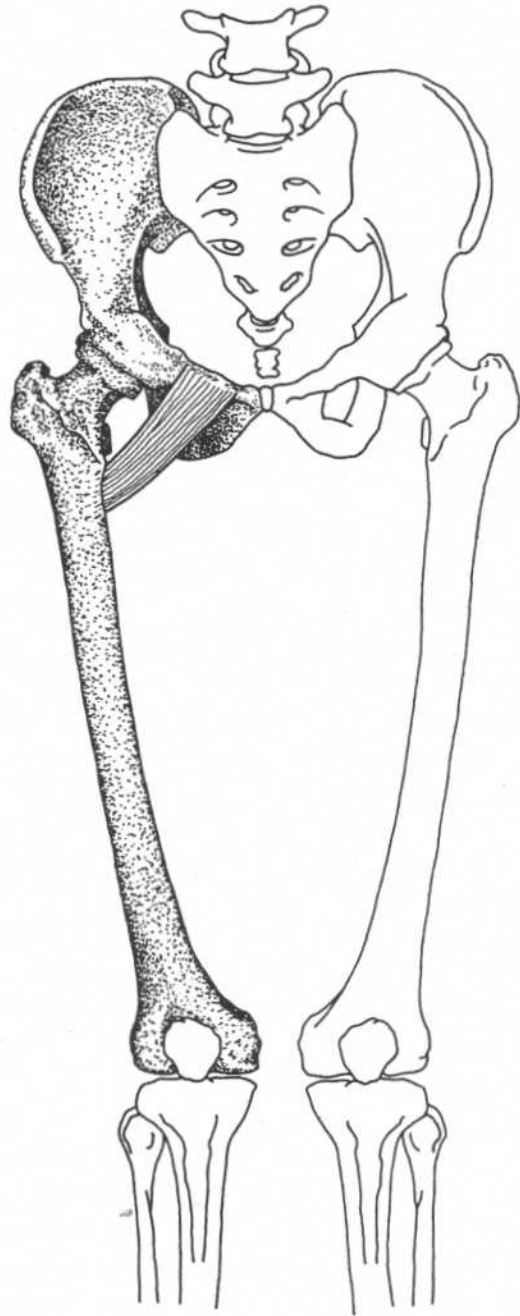
Note: See Relationships section on sartorius.

Hip and thigh—anterior view

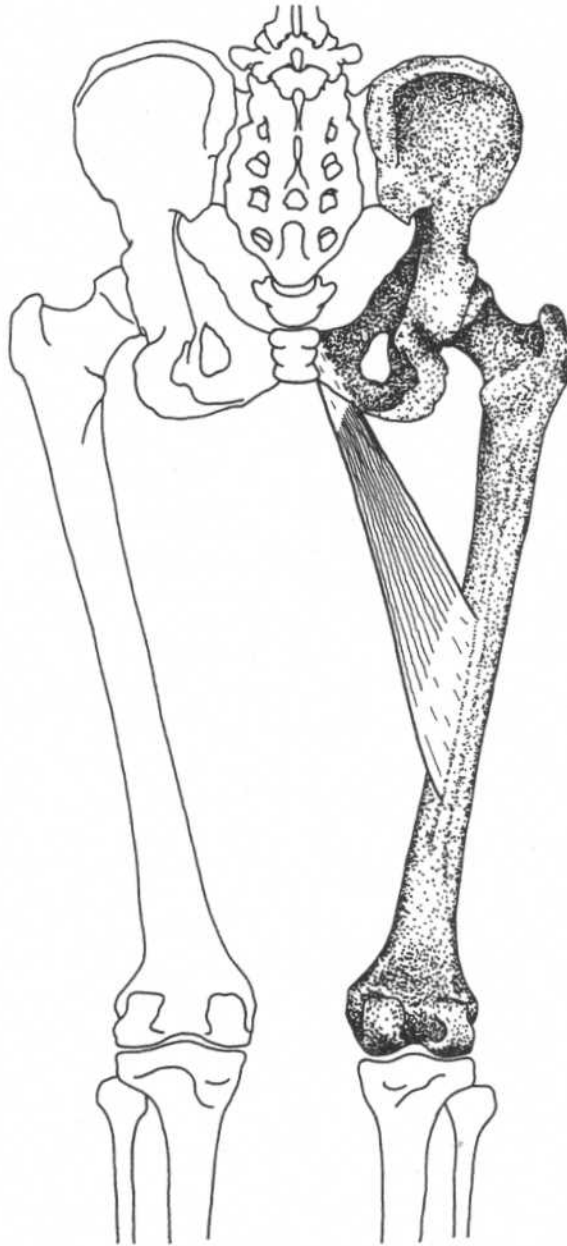
PECTINEUS

Origin	Pectineal line on superior ramus of pubis
Insertion	From lesser trochanter to linea aspera of femur
Action	Flexes thigh, assists in adduction when hip is flexed
Nerve	Femoral nerve (L2–L4), (sometimes a branch of obturator nerve)

Note: The rotating function of this and other hip muscles is controversial and probably depends on whether the hip is flexed or extended and adducted or abducted.



Hip and thigh—anterior view

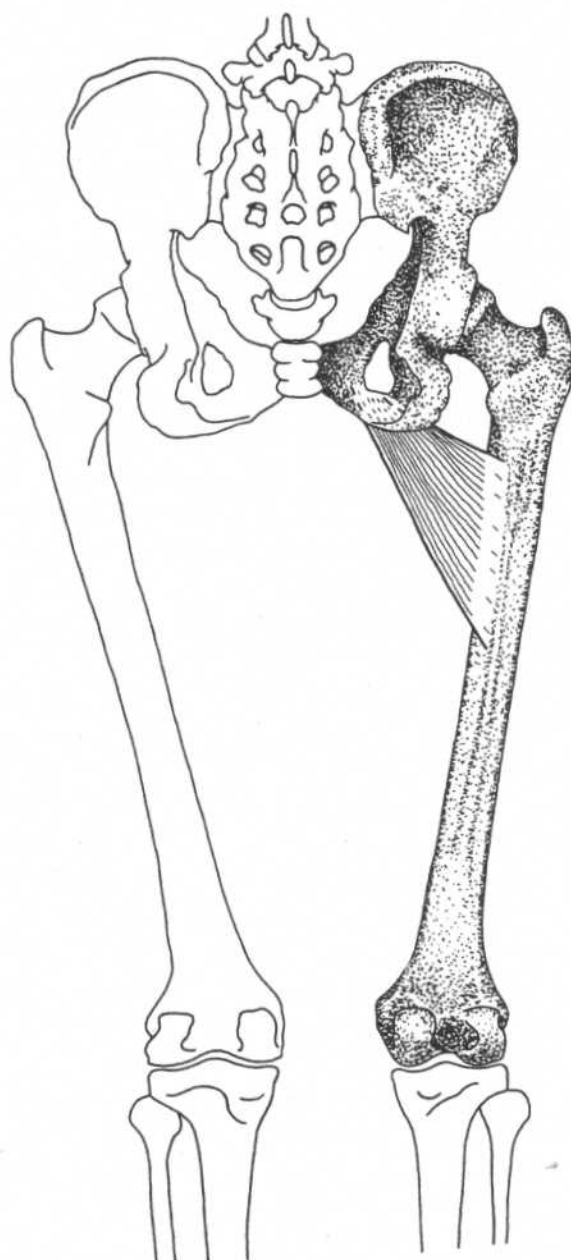
ADDUCTOR LONGUS**Hip and thigh—posterior view****Origin**
Insertion

Anterior of body of pubis
Medial lip of linea aspera

Action
Nerve

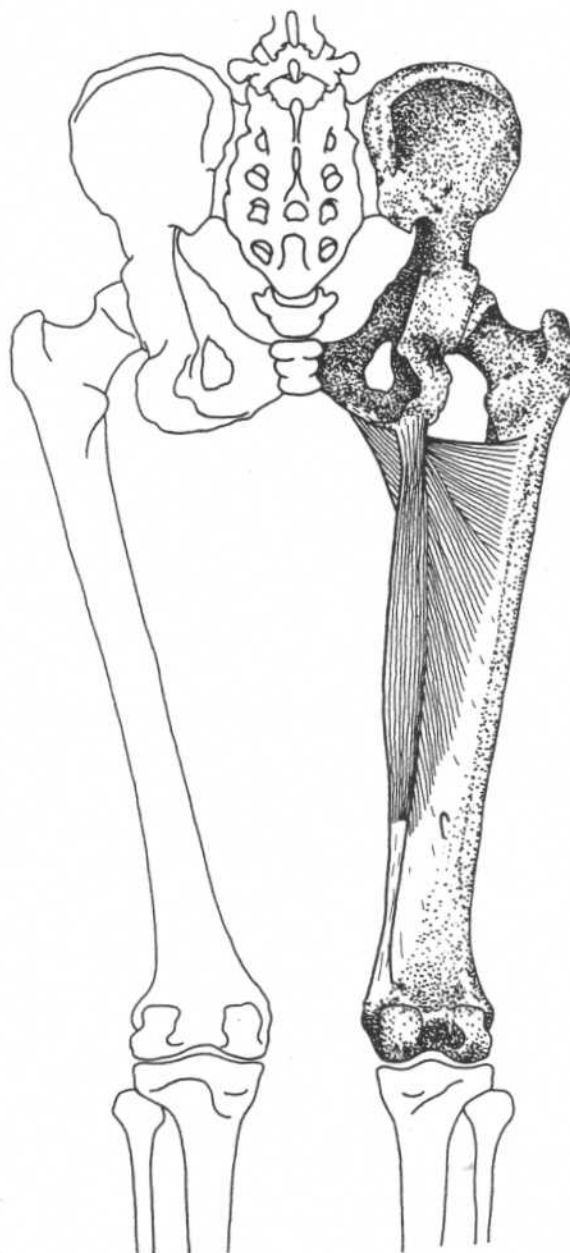
Adducts, flexes thigh, assists in
medial rotation
Obturator nerve (L3, L4)

ADDUCTOR BREVIS



Hip and thigh—posterior view

Origin	Outer surface of inferior ramus of pubis	Action	Adducts thigh, assists in flexion, medial rotation
Insertion	From below lesser trochanter to linea aspera and into proximal part of linea aspera	Nerve	Obturator nerve (L3, L4)

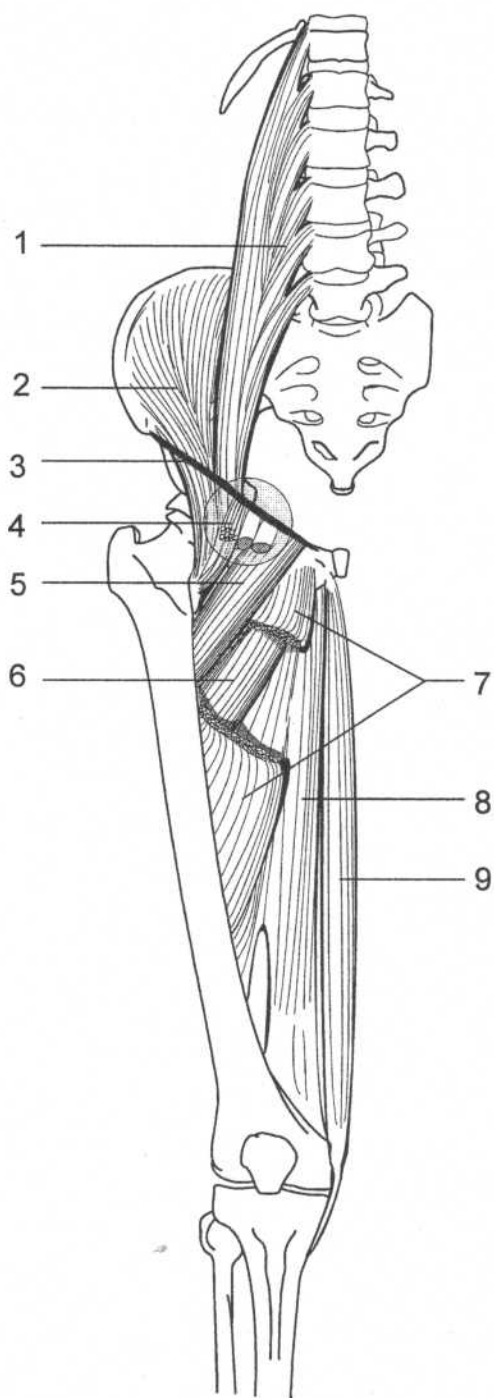
ADDUCTOR MAGNUS**Hip and thigh—posterior view**

Origin	Inferior ramus of pubis, and ramus and lower part of tuberosity of ischium	Action	Adducts, extends thigh, lower portion (adductor tubercle insertion) assists in medial rotation
Insertion	Linea aspera, adductor tubercle of femur	Nerve	Obturator nerve (L3, L4), sciatic nerve

Note: The linea aspera insertion may assist in lateral rotation.

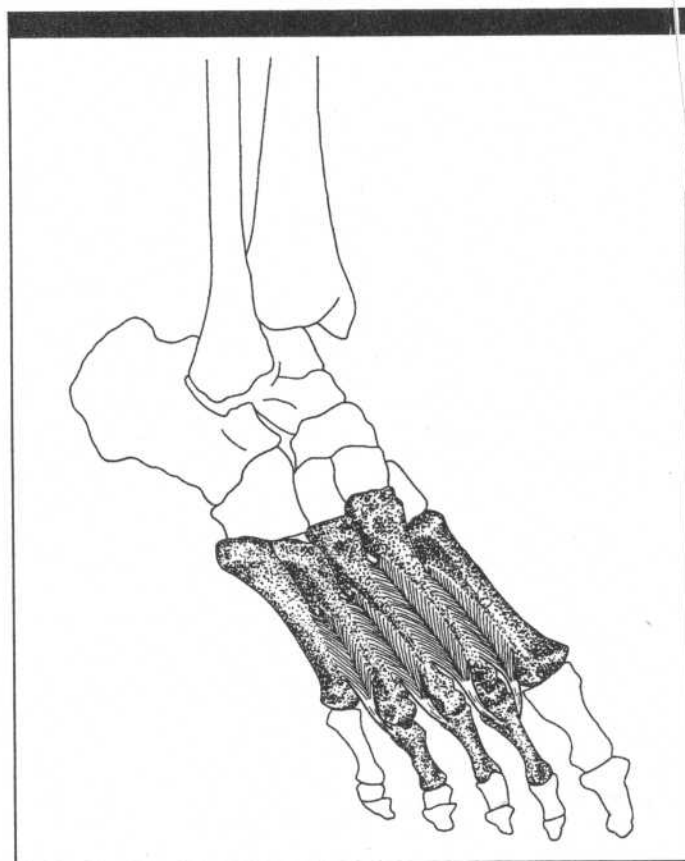
HIP FLEXORS AND ADDUCTORS

- Psoas major
- Iliacus
- Inguinal ligament
- Femoral nerve, vein, artery
- Pectineus
- Adductor brevis
- Adductor longus (cut)
- Adductor magnus
- Gracilis



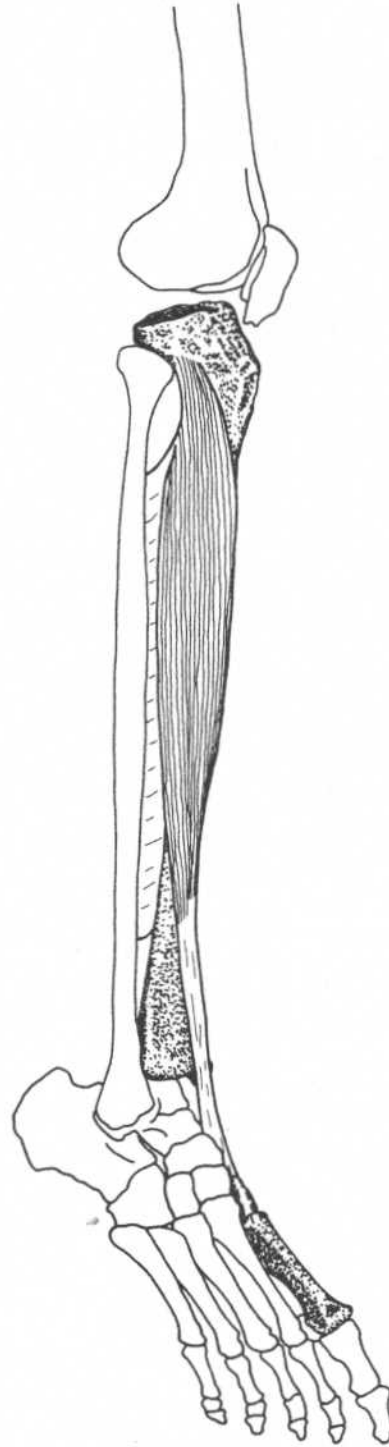
Hip and thigh—anterior view

CHAPTER NINE
MUSCLES OF THE LEG AND FOOT

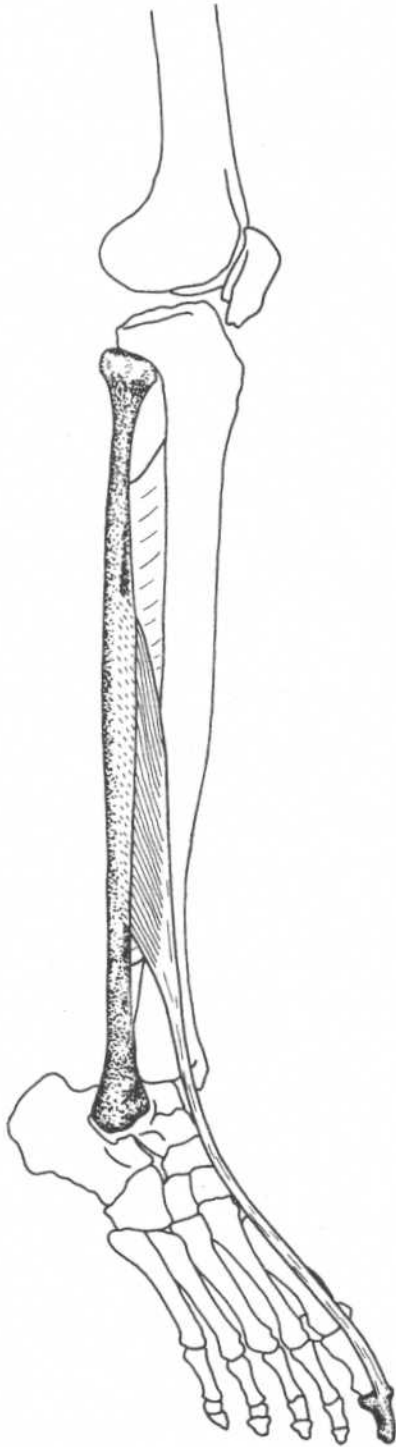


TIBIALIS ANTERIOR

Origin	Lateral condyle of tibia, upper half of lateral surface of tibia, interosseous membrane
Insertion	Medial side and plantar surface of medial cuneiform bone, and base of first metatarsal bone
Action	Dorsiflexes foot at ankle joint, inverts (supinates) foot
Nerve	Deep peroneal nerve (L4, L5, S1)



Leg—anterolateral view

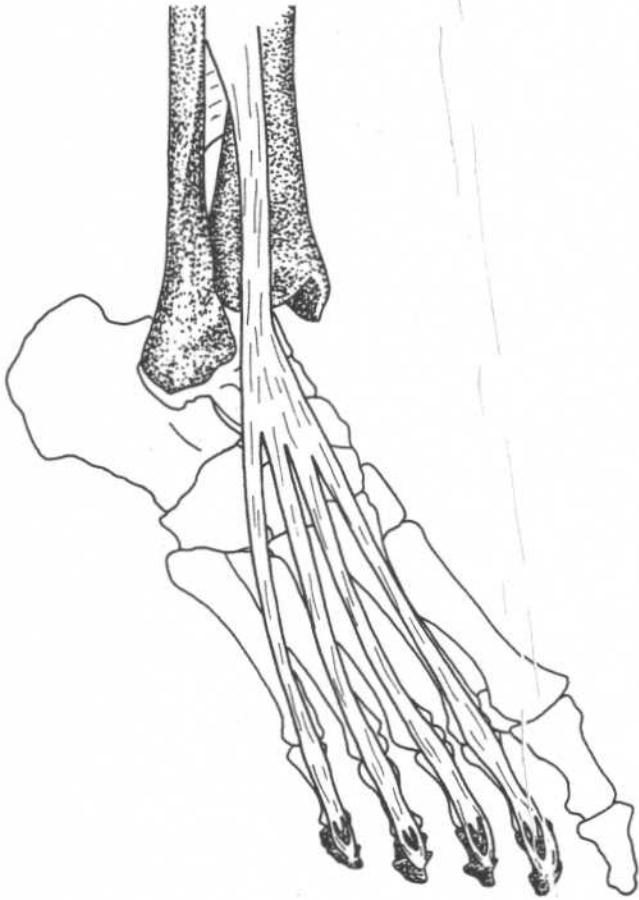


Leg—anterolateral view

EXTENSOR HALLUCIS LONGUS

Origin	Middle half of anterior surface of fibula and interosseous membrane
Insertion	Base of distal phalanx of great toe
Action	Extends, hyperextends great toe, dorsiflexes and inverts (supinates) foot
Nerve	Deep peroneal nerve (L4, L5, S1)

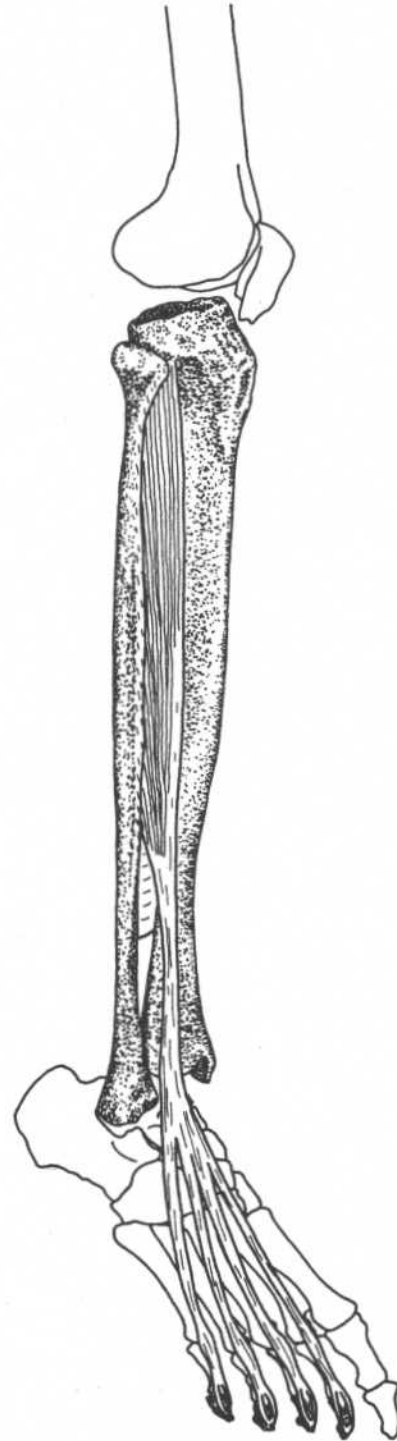
EXTENSOR DIGITORUM LONGUS



Foot—anterolateral view

Origin	Upper two-thirds of anterior surface of fibula, interosseous membrane, lateral condyle of tibia
Insertion	Along dorsal surface of four lateral toes, and then to bases of middle and distal phalanges
Action	Extends toes, dorsiflexes foot at ankle, everts foot
Nerve	Deep peroneal nerve (L4, L5, S1)

Note: The lower lateral part of this muscle makes a separate insertion onto the dorsal surface of the fifth metatarsal and is called *peroneus tertius*.

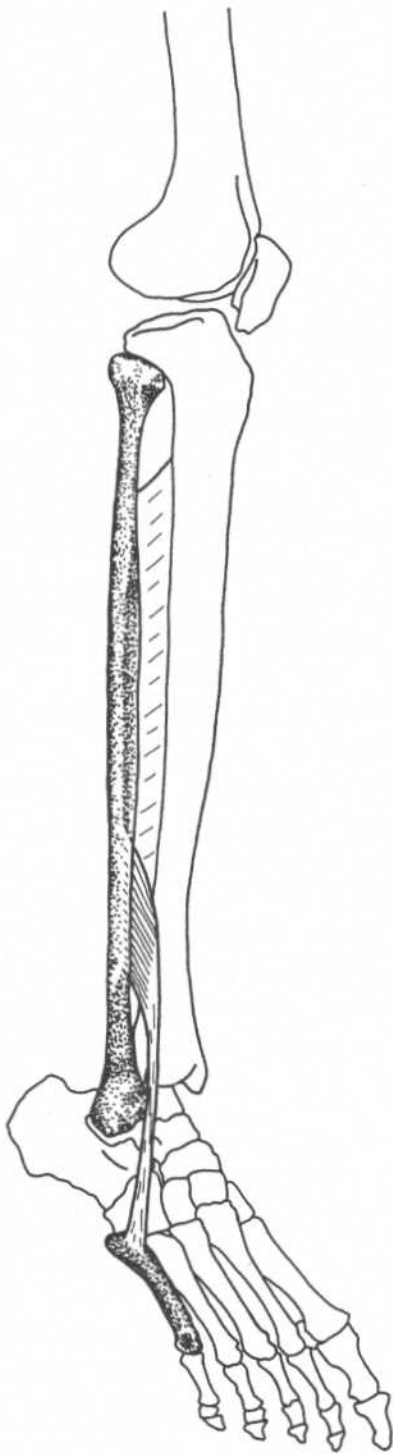


Leg—anterolateral view

PERONEUS TERTIUS

(Lower lateral part of extensor digitorum longus)

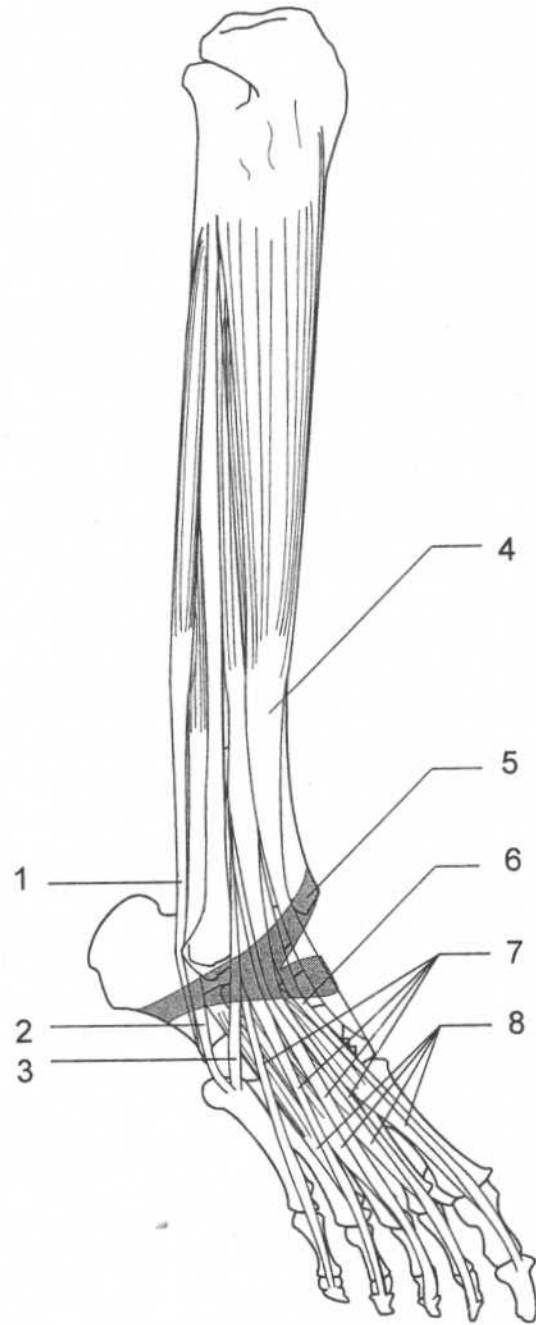
Origin	Lower third of anterior surface of fibula and interosseous membrane
Insertion	Dorsal surface of base of fifth metatarsal bone
Action	Dorsiflexes and everts foot
Nerve	Deep peroneal nerve (L4, L5, S1)



Leg—anterolateral view

ANTERIOR AND LATERAL LEG MUSCLES

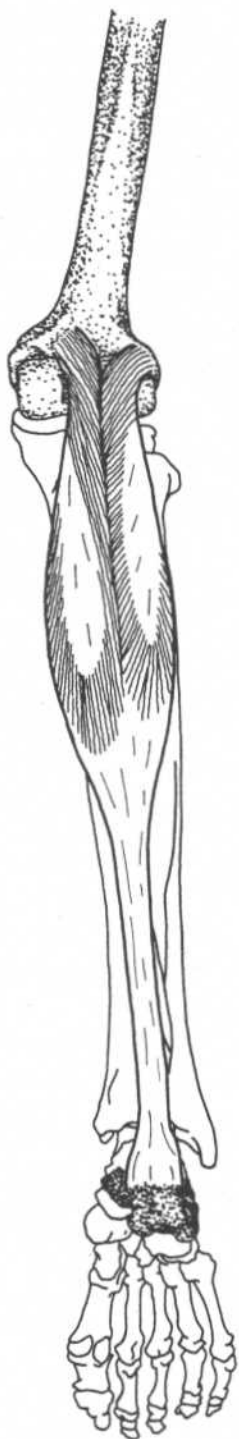
1. Peroneus longus
2. Peroneus brevis
3. Peroneus tertius
4. Tibialis anterior
5. Extensor retinaculum
6. Extensor hallucis longus
7. Extensor digitorum longus
8. Extensor digitorum brevis



Leg—anterolateral view

GASTROCNEMIUS*(Part of triceps surae)*

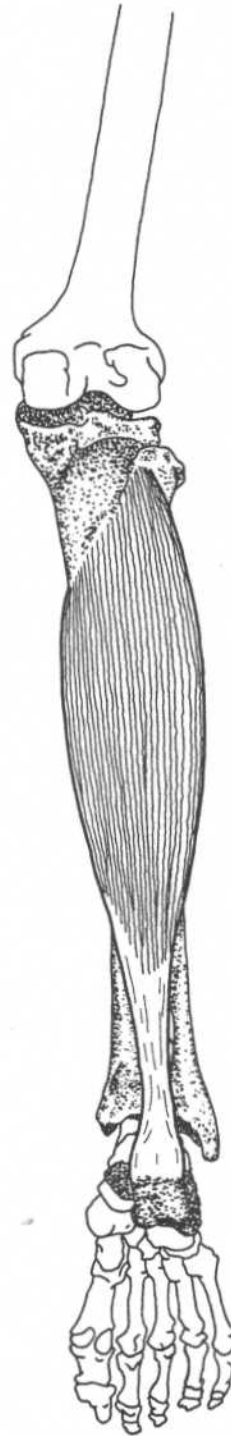
Origin	Lateral head—lateral condyle and posterior surface of femur Medial head—popliteal surface of femur above medial condyle
Insertion	Posterior surface of the calcaneus
Action	Plantar flexes foot, flexes leg at knee
Nerve	Tibial nerve (S1, S2)

**Leg—posterior view**

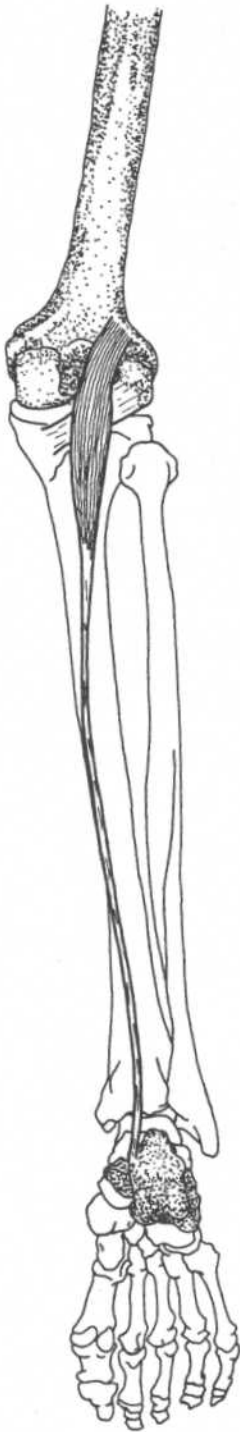
SOLEUS

(Part of triceps surae)

Origin	Posterior surface of the tibia (soleal line), upper third of posterior surface of fibula, fibrous arch between tibia and fibula
Insertion	Posterior surface of the calcaneus
Action	Plantar flexes foot
Nerve	Tibial nerve (S1, S2)



Leg—posterior view



Leg—posterior view

PLANTARIS

Origin

Lateral supracondylar ridge of femur,
oblique popliteal ligament

Insertion

Posterior surface of the calcaneus

Action

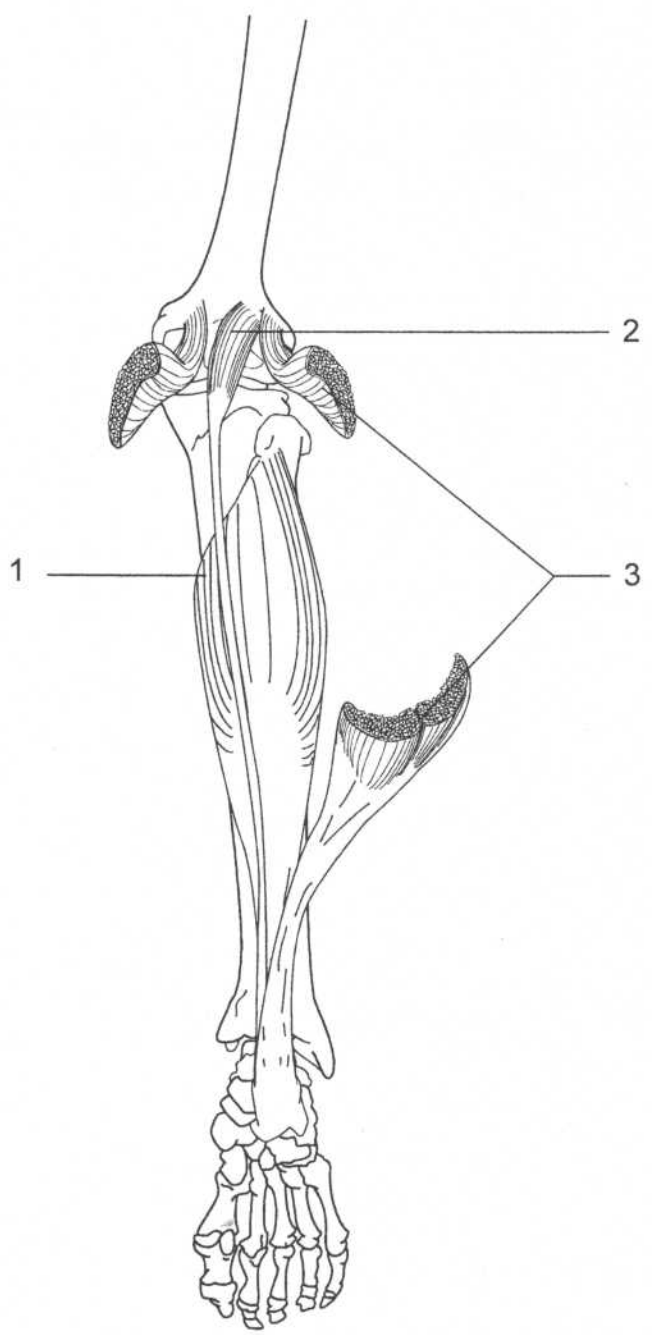
Plantar flexes foot, flexes leg

Nerve

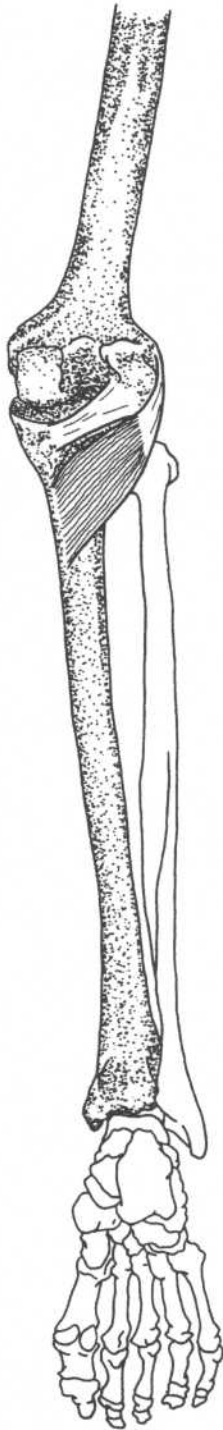
Tibial nerve (L4, L5, S1)

MUSCLES OF THE CALF

- 1. Soleus
- 2. Plantaris
- 3. Gastrocnemius (cut)



Leg—posterior view



Leg—posterior view

POPLITEUS

Origin	Lateral surface of lateral condyle of femur
Insertion	Upper part of posterior surface of tibia
Action	Rotates leg medially, flexes leg
Nerve	Tibial nerve (L4, L5, S1)

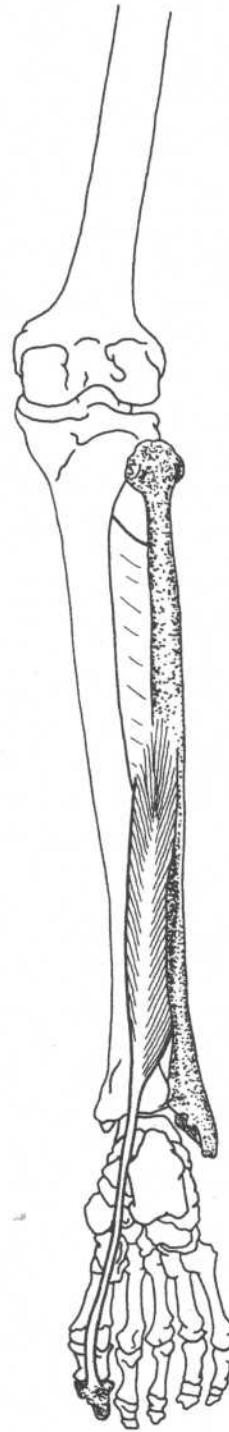
Note: Stern contends that this muscle stabilizes the knee by preventing lateral rotation of the tibia during medial rotation of the thigh while the foot is planted.

Reference:
Stern, JT: *Essentials of Gross Anatomy*, F. A. Davis Company, Philadelphia, 1988.

FLEXOR HALLUCIS LONGUS

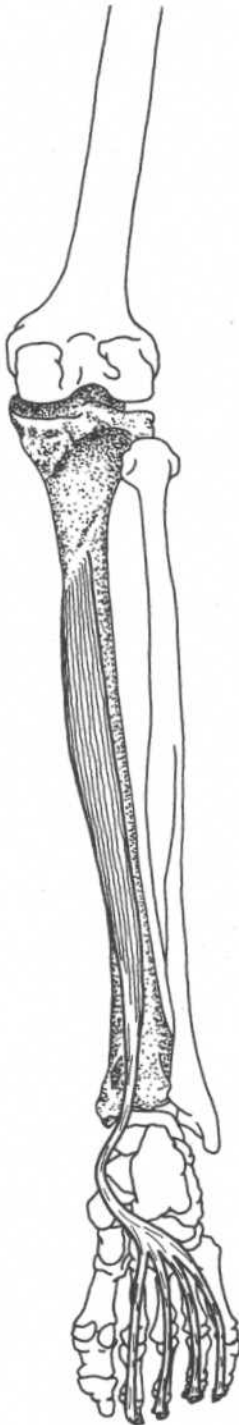
Origin	Lower two-thirds of posterior surface of shaft of fibula, posterior intermuscular septum, interosseous membrane
Insertion	Base of distal phalanx of great toe
Action	Flexes distal phalanx of great toe, assists in plantar flexing foot, inverts foot
Nerve	Tibial nerve (L5, S1, S2)

Note: This muscle is important in pushing off the surface in walking, running, jumping.

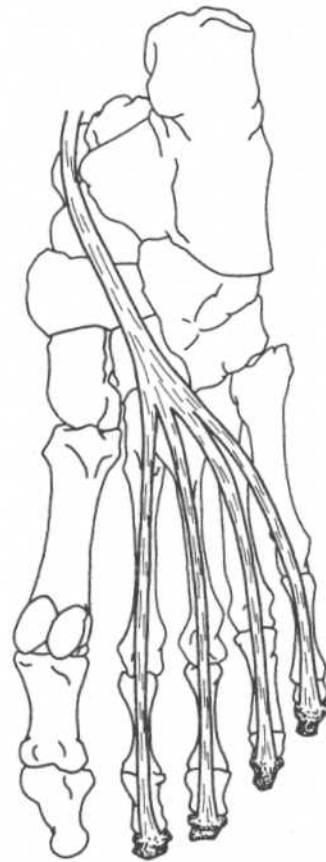


Leg—posterior view

FLEXOR DIGITORUM LONGUS



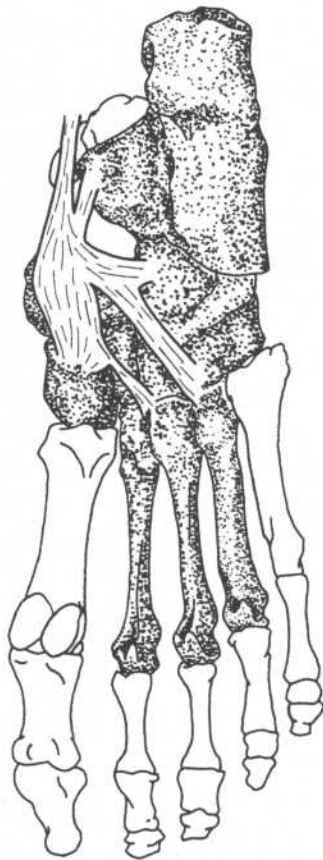
Leg—posterior view



Foot—plantar view

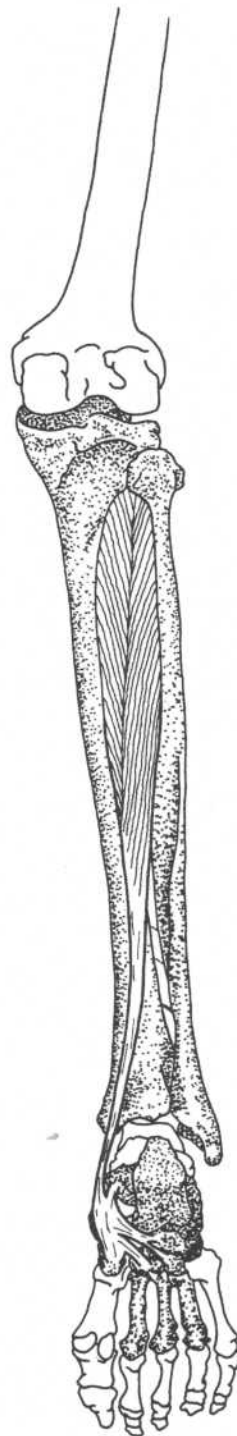
Origin	Medial part of posterior surface of tibia
Insertion	Bases of distal phalanges of second, third, fourth, and fifth toes
Action	Flexes distal phalanges of lateral four toes, assists in plantar flexing foot, inverts foot
Nerve	Tibial nerve (L5, S1)

TIBIALIS POSTERIOR



Foot—plantar view

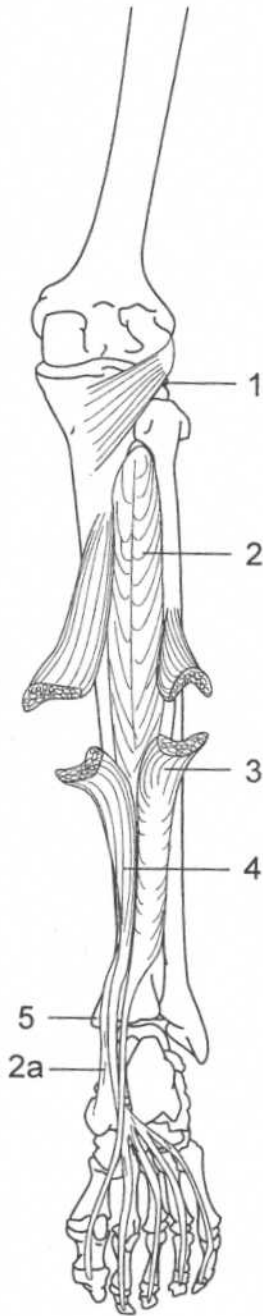
Origin	Lateral part of posterior surface of tibia, interosseous membrane, proximal half of posterior surface of fibula
Insertion	Tuberosity of navicular bone, cuboid, cuneiforms, second, third, and fourth metatarsals, sustentaculum tali of calcaneus
Action	Plantar flexes, inverts foot
Nerve	Tibial nerve (L5, S1)



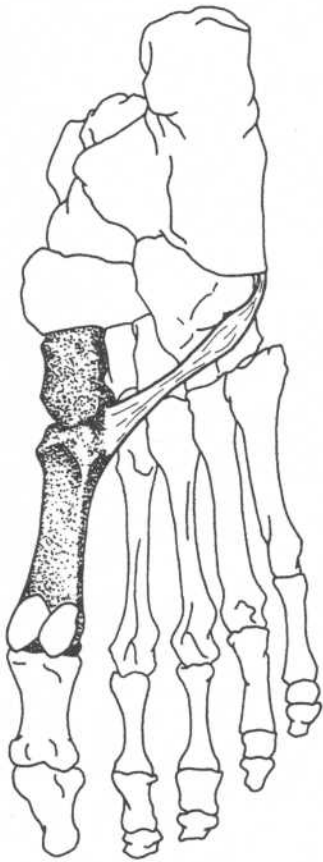
Leg—posterior view

**DEEP POSTERIOR
LEG MUSCLES**

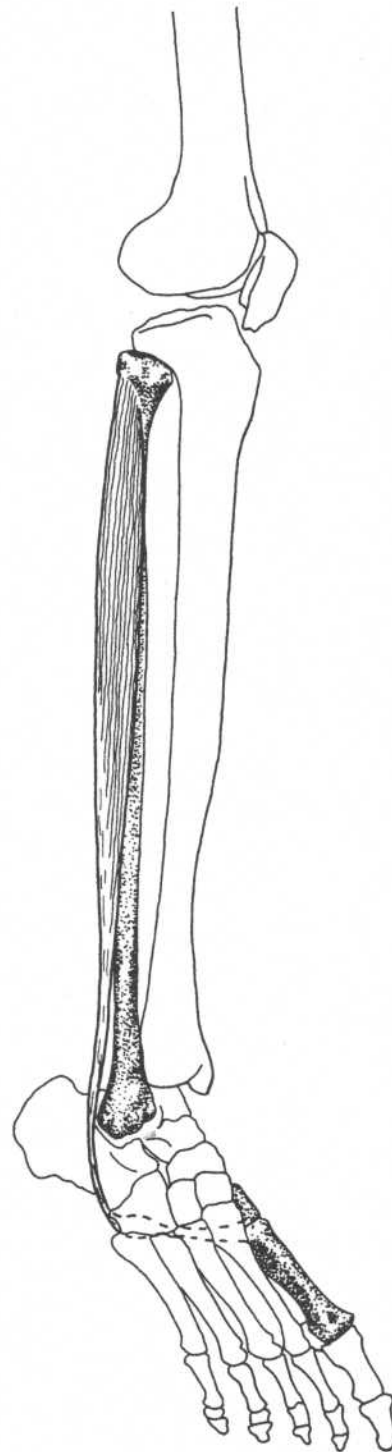
1. Popliteus
2. Tibialis posterior
- 2a. Tendon of tibialis posterior
3. Flexor hallucis longus (cut)
4. Flexor digitorum longus (cut)
5. Medial malleolus

**Leg—posterior view**

PERONEUS LONGUS



Foot—plantar view

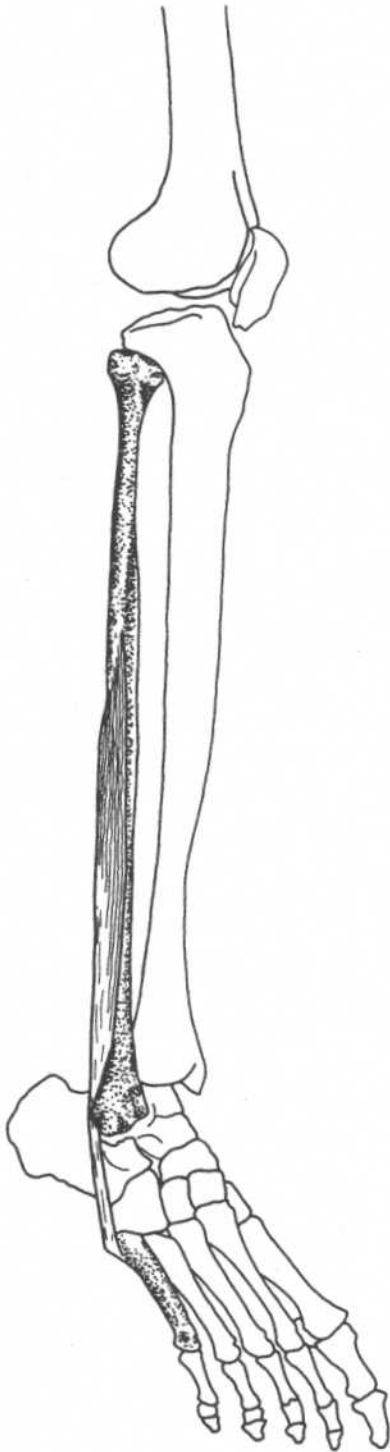


Leg—anterolateral view

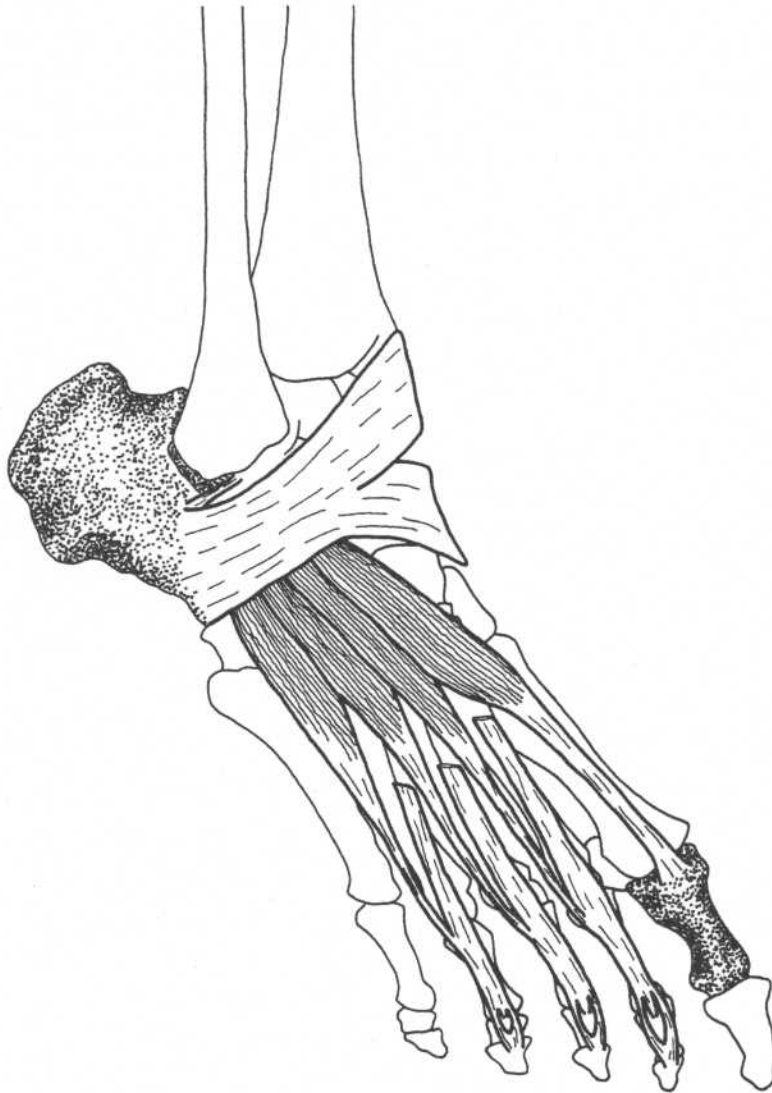
- | | |
|--------------------|--|
| Origin | Upper two-thirds of lateral surface of fibula |
| Insertion | Lateral side of medial cuneiform, base of first metatarsal |
| Action | Plantar flexes, everts foot |
| Innervation | Superficial peroneal nerve (L4, L5, S1) |

PERONEUS BREVIS

Origin	Lower two-thirds of lateral surface of fibula
Insertion	Lateral side of base of fifth metatarsal bone
Action	Everts, plantar flexes foot
Nerve	Superficial peroneal nerve (L4, L5, S1)

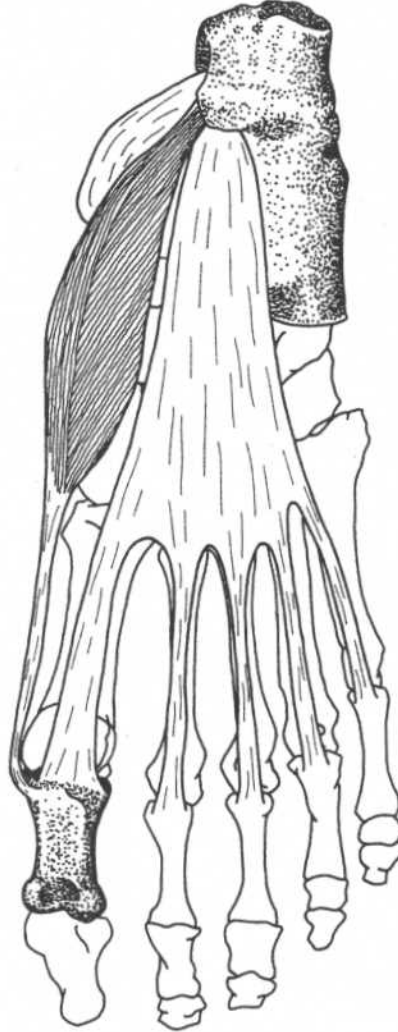
**Leg—anterolateral view**

EXTENSOR DIGITORUM BREVIS



Foot—anterolateral view

Origin	Anterior and lateral surfaces of calcaneus, lateral talocalcaneal ligament, inferior extensor retinaculum	Action	Extends the four toes
Insertion	Into base of proximal phalanx of great toe, into lateral sides of tendons of extensor digitorum longus of second, third, and fourth toes	Nerve	Deep peroneal nerve (L5, S1)

ABDUCTOR HALLUCIS*(First layer)***Foot—plantar view**

Origin	Tuberosity of calcaneus, flexor retinaculum, plantar aponeurosis
Insertion	Medial side of base of proximal phalanx of great toe
Action	Abducts great toe
Nerve	Medial plantar nerve (L4, L5)

Note: The muscles of the sole of the foot can be divided into four layers (from superficial to deep):

First layer—abductor hallucis, flexor digitorum brevis, abductor digiti minimi

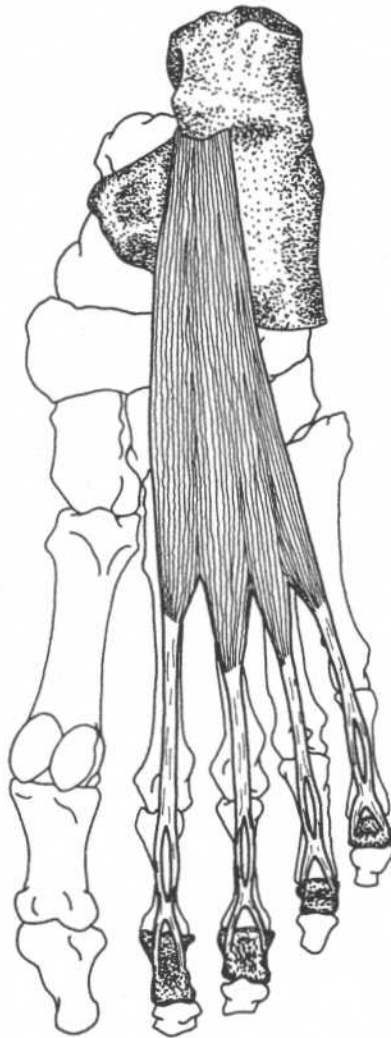
Second layer—quadratus plantae, lumbricales (tendons of flexor hallucis longus and flexor digitorum longus pass through this layer)

Third layer—flexor hallucis brevis, adductor hallucis, flexor digiti minimi brevis

Fourth layer—interossei (tendons of tibialis posterior and peroneus longus pass through this layer)

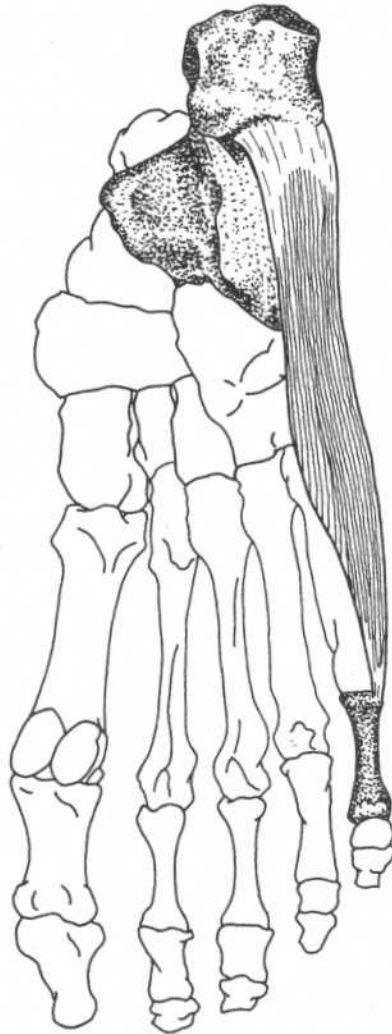
FLEXOR DIGITORUM BREVIS

(First layer)



Foot—plantar view

Origin	Tuberosity of calcaneus, plantar aponeurosis	Action	Flexes proximal phalanges and extends distal phalanges of second through fifth toes
Insertion	Sides of middle phalanges of second to fifth toes	Nerve	Medial plantar nerve (L4, L5)

ABDUCTOR DIGITI MINIMI*(First layer)***Foot—plantar view****Origin**

Tuberosity of calcaneus, plantar aponeurosis

Insertion

Lateral side of proximal phalanx of fifth toe

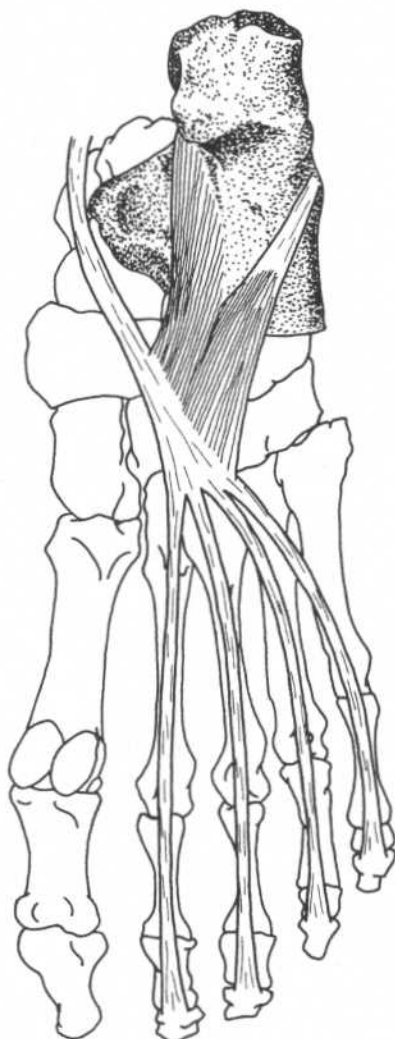**Action
Nerve**

Abducts fifth toe

Lateral plantar nerve (S1, S2)

QUADRATUS PLANTAE

(Second layer)



Foot—plantar view

Origin

Medial head—medial surface of calcaneus

Lateral head—lateral border of inferior surface of calcaneus

Insertion

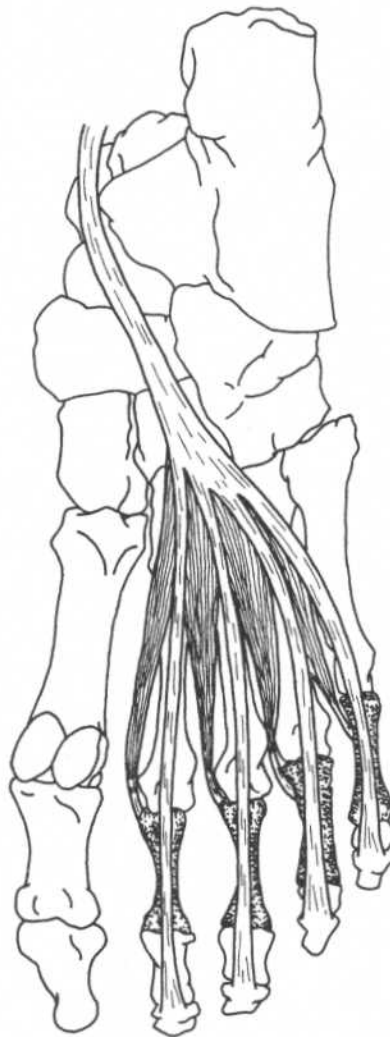Lateral margin of tendon of flexor digitorum longus

Action

Flexes terminal phalanges of second through fifth toes

Nerve

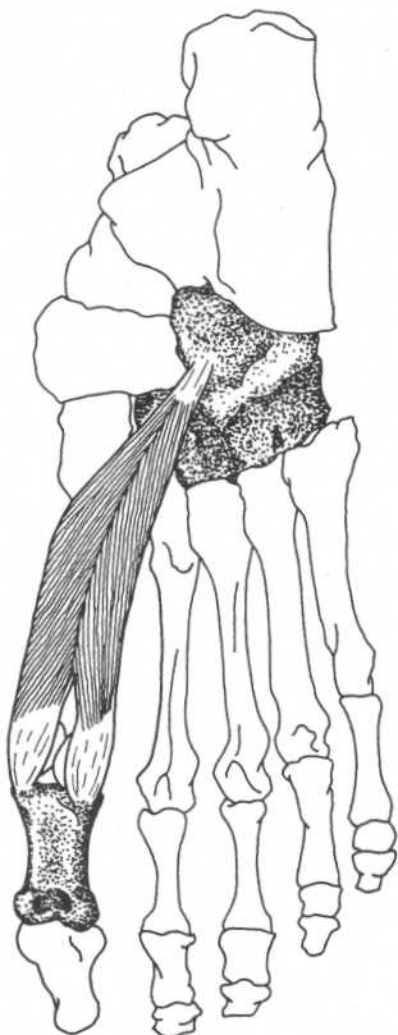
Lateral plantar nerve (S1, S2)

LUMBRICALES*(Second layer)***Foot—plantar view**

Origin	Tendons of flexor digitorum longus	Nerve	First lumbricalis—medial plantar nerve (L4, L5)
Insertion	Dorsal surfaces of proximal phalanges		Second through fifth lumbricales—lateral plantar nerve (S1, S2)
Action	Flex proximal phalanges of second through fifth toes		

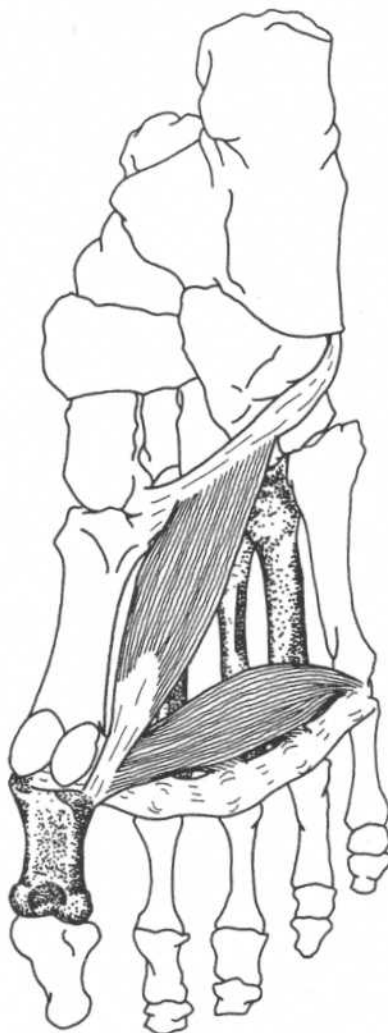
FLEXOR HALLUCIS BREVIS

(Third layer)



Foot—plantar view

Origin	Cuboid bone, lateral cuneiform bone	Action	Flexes proximal phalanx of great toe
Insertion	Medial part—medial side of base of proximal phalanx of great toe Lateral part—lateral side of base of proximal phalanx of great toe	Nerve	Medial plantar nerve (L4, L5, S1)

ADDUCTOR HALLUCIS*(Third layer)***Foot—plantar view****Origin**

Oblique head—second, third, and fourth metatarsal bones, and sheath of peroneus longus tendon
 Transverse head—plantar metatarsophalangeal ligaments of third, fourth, and fifth toes, and transverse metatarsal ligaments

Insertion

Lateral side of base of proximal phalanx of great toe

Action

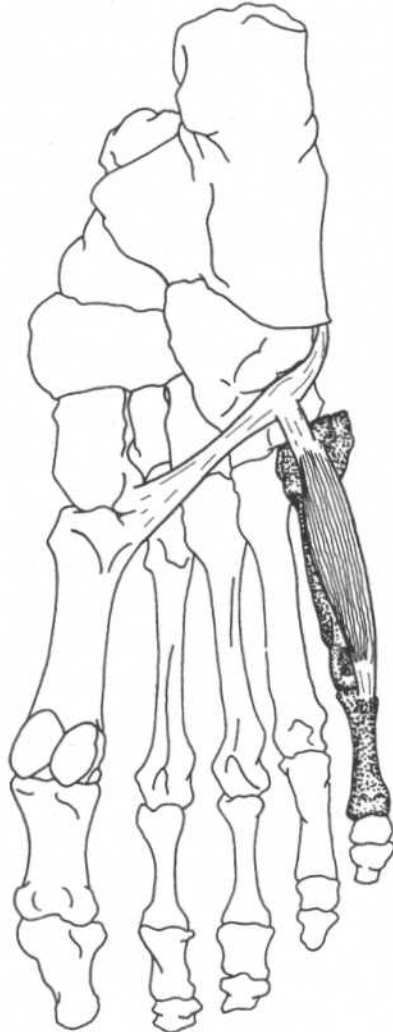Adducts great toe

Nerve

Lateral plantar nerve (S1, S2)

FLEXOR DIGITI MINIMI BREVIS

(Third layer)



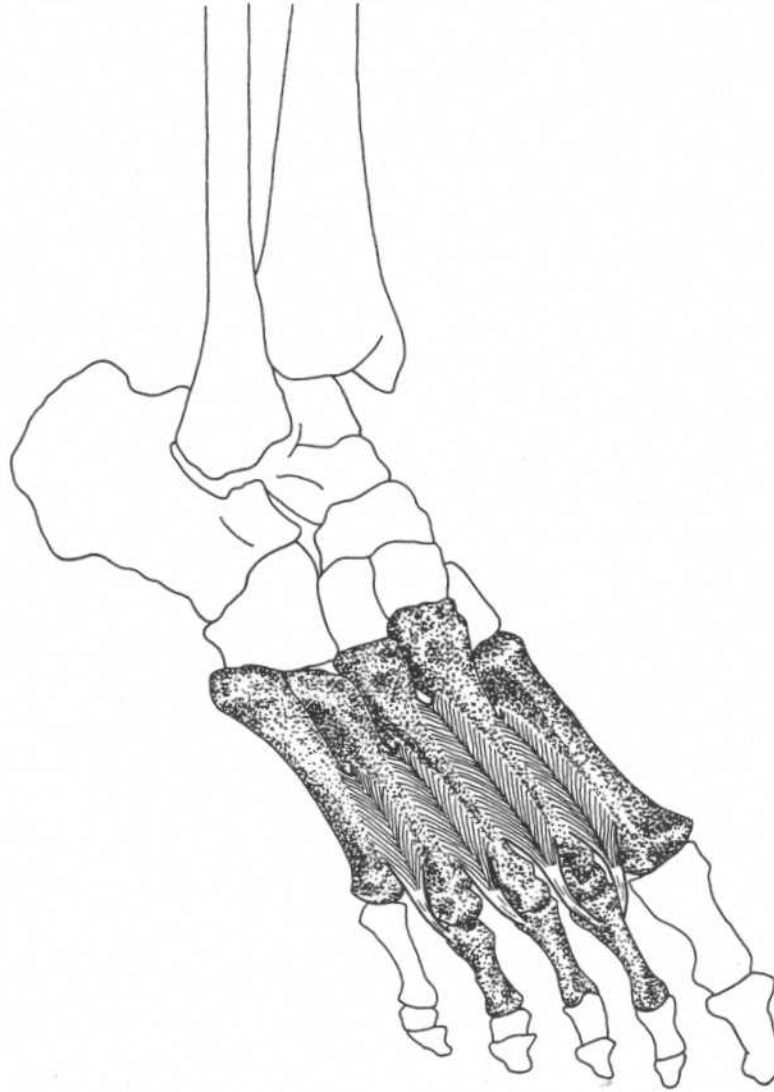
Foot—plantar view

Origin
Insertion

Base of fifth metatarsal, sheath of peroneus longus tendon
 Lateral side of base of proximal phalanx of fifth toe

Action
Nerve

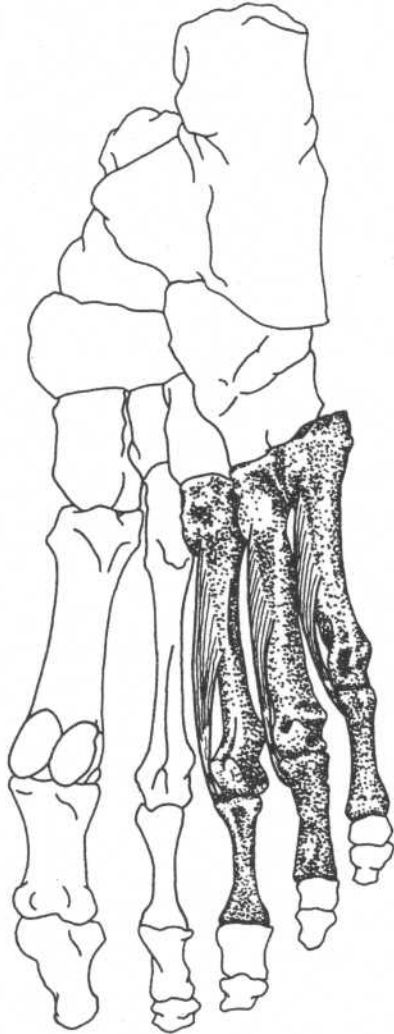
Flexes proximal phalanx of fifth toe
 Lateral plantar nerve (S1, S2)

DORSAL INTEROSSEI*(Fourth layer; four muscles)***Foot—anterolateral view**

Origin	Adjacent sides of metatarsal bones	Action	Abduct toes, flex proximal phalanges
Insertion	Bases of proximal phalanges First—medial side of proximal phalanx of second toe Second, third, fourth—lateral sides of proximal phalanges of second, third, and fourth toes	Nerve	Lateral plantar nerve (S1, S2)

PLANTAR INTEROSSEI

(Fourth layer; three muscles)



Foot—plantar view

Origin	Bases and medial sides of third, fourth, and fifth metatarsal bones	Action	Adduct toes, flex proximal phalanges
Insertion	Medial sides of bases of proximal phalanges of same toes	Nerve	Lateral plantar nerve (S1, S2)

Alphabetical Listing of Muscles

A

Abductor digiti minimi
of foot, 205
of hand, 149
Abductor hallucis, 203
Abductor pollicis brevis, 145
Abductor pollicis longus, 139
Adductor brevis, 182
Adductor hallucis, 209
Adductor longus, 181
Adductor magnus, 183
Adductor pollicis, 148
Anconeus, 118
Auricularis
anterior, superior, posterior, 28

B

Biceps brachii, 102
Biceps femoris, 175
Brachialis, 103
Brachioradialis, 132
Buccinator, 44

C

Coracobrachialis, 101
Corrugator supercillii, 31
Cremaster, 92

D

Deltoideus, 111
Depressor
anguli oris, 42
labii inferioris, 41
septi, 34
Diaphragm, 89
Digastricus, 52
Dorsal interossei
of foot, 211
of hand, 154

E

Epicranium
frontal belly (frontalis), 26
occipital belly (occipitalis), 26
Erector spinae, 74–76
Extensor carpi radialis brevis, 134
Extensor carpi radialis longus, 133

Extensor carpi ulnaris, 137
Extensor digiti minimi, 136
Extensor digitorum brevis, 202
Extensor digitorum communis, 135
Extensor digitorum longus, 188
Extensor hallucis longus, 187
Extensor indicis, 143
Extensor pollicis brevis, 140
Extensor pollicis longus, 141

F

Flexor carpi radialis, 123
Flexor carpi ulnaris, 125
Flexor digiti minimi, 145, 146
Flexor digiti minimi brevis, 150, 210
Flexor digitorum brevis, 204
Flexor digitorum longus, 197
Flexor digitorum profundus, 128
Flexor digitorum superficialis, 127
Flexor hallucis brevis, 208
Flexor hallucis longus, 196
Flexor pollicis brevis, 146
Flexor pollicis longus, 129
Frontalis. *See* Epicranium

G

Gastrocnemius, 191
Gemellus
inferior, 161
superior, 160
Geniohyoideus, 55
Gluteus
maximus, 164
medius, 165
minimus, 166
Gracilis, 179

I

Iliacus, 157
Iliocostalis
cervicis, 74
lumborum, 74
thoracis, 74
Iliopsoas, 154
Infraspinatus, 113
Intercostales
externi, 82
interni, 83

Interossei

of foot, 211–212
of hand, 153–154
Interspinales, 80
Intertransversarii, 81

L

Latissimus dorsi, 106
Levator anguli oris, 37
Levator labii superioris, 36
Levator palpebrae superioris, 30
Levator scapulae, 107
Levatores costarum, 86
Longissimus, 75
capitis, 75
cervicis, 75
thoracis, 75
Longus
capitis, 61
colli, 60
Lumbricales
of foot, 207
of hand, 152

M

Masseter, 46
Mentalis, 43
Multifidus, 78
Muscle Groups
abdominal muscles, 95
muscles of anterior chest and arm, 104
posterior back, shoulder and arm
muscles, 119
muscles of the wrist, 126
flexors of the fingers, 130
extensors of the thumb, 142
muscles of the hip, 167
muscles of the anterior thigh, 174
hamstring muscles, 178
hip flexors and adductors, 184
anterior and lateral leg muscles, 190
muscles of the calf, 194
deep posterior leg muscles, 199
Mylohyoideus, 54

N

Nasalis
alar part, 33
transverse part, 33

O

Obliquus capitis
 inferior, 69
 superior, 70
 Obliquus externus abdominis, 90
 Obliquus internus abdominis, 91
 Obturator
 externus, 162
 internus, 159
 Occipitalis. *See* Epicranius
 Omohyoideus, 59
 Opponens digiti minimi, 151
 Opponens pollicis, 147
 Orbicularis oculi, 29
 Orbicularis oris, 35

P

Palmar interossei, 153
 Palmaris
 brevis, 144
 longus, 124
 Pectineus, 180
 Pectoralis
 major, 98
 minor, 99
 Peroneus
 brevis, 201
 longus, 200
 tertius, 189
 Piriformis, 158
 Plantar interossei, 212
 Plantaris, 193
 Platysma, 51
 Popliteus, 195
 Procerus, 32
 Pronator
 quadratus, 131
 teres, 122
 Psoas
 major, 156
 minor, 156
 Pterygoideus
 lateralis, 48
 medialis, 47
 Pyramidalis, 95

Q

Quadratus
 femoris, 163
 lumborum, 96
 plantae, 206
 Quadriceps femoris
 rectus femoris, 170
 vastus intermedius, 173
 vastus lateralis, 171
 vastus medialis, 172

R

Rectus abdominis, 94
 Rectus capitis
 anterior, 62
 lateralis, 63
 posterior major, 67
 posterior minor, 68
 Rectus femoris. *See* Quadriceps femoris
 Rhomboideus
 major, 108
 minor, 109
 Risorius, 40
 Rotatores, 79

S

Sacrospinalis. *See* Erector spinae
 Sartorius, 169
 Scalenus
 anterior, 64
 medius, 65
 posterior, 66
 Semimembranosus, 177
 Semispinalis
 capitis, 77
 cervicis, 77
 thoracis, 77
 Semitendinosus, 176
 Serratus
 anterior, 110
 posterior inferior, 88
 posterior superior, 87
 Soleus, 192
 Spinalis, 74
 capitis, 76

cervicis, 76
 thoracis, 76

Splenius
 capitis, 72
 cervicis, 73
 Sternocleidomastoideus, 50
 Sternohyoideus, 56
 Sternothyroideus, 57
 Stylohyoideus, 53
 Subclavius, 100
 Subcostales, 84
 Subscapularis, 115
 Supinator, 138
 Supraspinatus, 112

T

Temporalis, 45
 Temporoparietalis, 27
 Tensor fasciae latae, 168
 Teres
 major, 116
 minor, 114
 Thyrohyoideus, 58
 Tibialis
 anterior, 186
 posterior, 198
 Transversospinalis, 77
 Transversus
 abdominis, 93
 thoracis, 85
 Trapezius, 105
 Triceps brachii, 117

V

Vastus
 intermedius. *See* Quadriceps femoris
 lateralis. *See* Quadriceps femoris
 medialis. *See* Quadriceps femoris

Z

Zygomaticus
 major, 38
 minor, 39

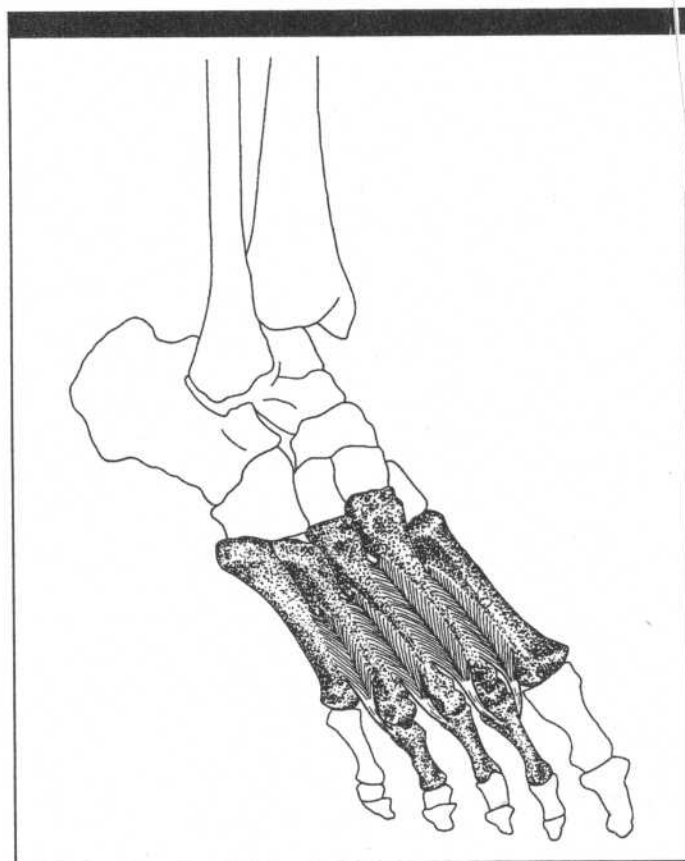
Index

- A**
- Abdominal aponeurosis, 12, 90, 91, 93
 - Abduction, 21, 23, 24
 - Accessory nerve (11th cranial)
 - cranial part, 105
 - spinal part, 50
 - Accessory process of vertebra, 8
 - Acetabulum, 12, 170
 - Acromion, 5, 7, 8
 - Adduction, 21–24
 - Adductor tubercle of femur, 15
 - Ala, 3
 - of nose, 3, 34
 - of sacrum, 11, 157
 - Alar cartilage, 3, 33, 36
 - Alveolar border (process)
 - of maxilla, 4
 - Anatomical position, 20, 21, 23
 - Annular ligament of radius, 9, 10, 138
 - Ansa cervicalis, 56, 57, 59
 - Anterior iliac crest, 12
 - Anterior iliac spine
 - inferior, 11, 14, 157
 - superior, 11, 12, 14
 - Arcuate ligament
 - lateral, 7, 89
 - medial, 7, 89
 - Arcuate line of ilium, 11, 156
 - Articular disk
 - temporomandibular joint, 3
 - Atlas
 - anterior arch, 6, 60
 - posterior arch, 3, 68
 - transverse process, 3, 62, 63, 69, 70
 - Axillary nerve, 111, 114
 - Axis, 6
 - spinous process of, 3, 67, 69, 76
- B**
- Bicipital aponeurosis, 102
 - Bicipital (intertubercular) groove
 - of humerus, 7, 102
- C**
- Calcaneus, 16, 191–193, 202, 206
 - sustinaculum tali, 17, 18, 198
 - tuberosity, 18, 203–205
 - Canine fossa of maxilla, 2
 - Capitate bone, 9, 10, 148
 - Carpometacarpal joint, 151
 - Cervical nerves
 - dorsal primary divisions, 72, 73, 75
 - ventral rami, 64–66
 - Clavicle, 5, 7, 8, 50, 59, 98, 100, 105, 111
 - Coccyx, 13, 164
 - Common peroneal nerve, 175, 178
 - Coracoid process of scapula, 5, 7
 - Coronal (frontal) planes, 20, 21, 23
 - Costal cartilage, 7, 12, 82, 83, 89, 93, 94, 98, 100
 - Cuboid bone, 16–18, 198, 208
 - Cuneiform bones, 16–18, 186, 198, 200
- D**
- Deep peroneal nerve, 186–189, 202
 - Deltoid tuberosity of humerus, 7, 11
 - Depression of scapula, 22
 - Dorsal scapular nerve, 107–109
 - Dorsiflexion of ankle joint, 24
- E**
- Ear
 - helix, 3
 - Elevation of scapula, 22
 - Ethmoid bone
 - nasal septum, 4, 34, 35
 - Eversion, 24
 - Extension, 21, 24
 - Extensor expansion, 143
 - Extensor retinaculum, 16, 190, 202
 - External occipital protuberance, 3, 4
- F**
- Facial nerve, 52, 53
 - auricular branch (posterior), 26, 28
 - buccal branches, 32–40, 44
 - cervical branch, 51
 - mandibular branch, 35, 41–43
 - temporal branch, 26–29, 31
 - zygomatic branch, 29
 - Fascia lata. *See* iliotibial tract
 - Femoral nerve, 157, 169–173, 180, 184
 - Femur, 11, 12, 14–17
 - adductor tubercle, 15, 183
 - condyles, 17, 191, 195
 - gluteal tuberosity, 13, 15, 164, 171
 - greater trochanter, 11, 13–15, 158–161, 165, 166, 171
 - intertrochanteric crest, 13, 163
 - intertrochanteric line, 14, 171, 172
 - lateral supracondylar ridge (line), 14, 15, 17, 173, 175, 193
 - lesser trochanter, 11, 14, 15, 156, 157, 180, 182
 - linea aspera, 13, 15, 171–173, 175, 180–183
 - medial supracondylar (ridge) line, 14, 172
 - popliteal surface, 17, 191
 - quadrate line, 13, 163
 - supracondylar ridge (line), 14, 15, 17, 172, 175
 - trochanteric fossa, 11
 - Fibula, 16, 17, 187–189, 192, 196, 198, 200, 201
 - head, 15
 - Flexion, 21, 23, 24
 - Flexor retinaculum
 - of foot, 18, 203
 - of hand, 10, 24, 126, 144–147, 150, 151
 - Foramen magnum, 61, 62
 - Frontal bone, 2, 4, 29, 45
 - superciliary arch, 4
 - Frontal (coronal) planes, 20, 21, 23
 - Frontal process of maxilla, 2
- G**
- Galea aponeurotica, 3, 26
 - Genitofemoral nerve, genital branch, 92
 - Glenoid cavity of scapula, 12
 - Gluteal nerve
 - inferior, 164
 - superior, 165, 166, 168
- H**
- Hamate bone, 9, 10, 150, 151
 - hook, 10, 125
 - Humerus, 8, 101, 103
 - condyles, 9
 - deltoid tuberosity, 7, 111
 - greater tuberosity (tubercle), 5, 7, 98, 112–114
 - intertubercular (bicipital) groove, 7, 98, 102, 106, 116
 - lateral epicondyle, 9, 118, 134–138
 - lateral supracondylar ridge, 9, 132, 133
 - lesser tuberosity, 7, 115
 - medial epicondyle, 10, 122–125, 127, 129
 - medial supracondylar ridge, 10, 122
 - Hyoid bone, 5, 52–56, 58, 59
 - greater cornu, 5
 - Hyperextension, 21
 - Hypoglossal nerve, 55, 58
 - Hypothenar eminence, 149
- I**
- Iliohypogastric nerve, 91, 93
 - Ilioinguinal nerves, 90, 91, 93
 - Iliolumbar ligament, 11, 95
 - Iliopectineal eminence, 11, 156
 - Iliotibial tract, 112, 164, 168, 174

- Ilium**
 arcuate line, 11
 crest of, 8, 12, 13, 74, 75, 90, 91, 93
 fossa of, 11, 157
 gluteal lines
 inferior, 13, 166
 middle (anterior), 13, 166
 posterior, 13, 164
 iliopectineal eminence, 11
 spines
 anterior inferior, 11, 14, 170
 anterior superior, 11, 12, 168, 169
 posterior superior iliac, 8, 78
 tubercle, 12, 168
 Inguinal ligament, 11, 12, 91-93, 184
 Intercostal nerves, 82-86, 90, 91, 93, 94
 Intercostal space, 83
 Interosseous membrane
 radioulnar, 9, 10, 128, 129,
 139-141, 143
 tibiofibular, 16, 17, 186-189, 196, 198
 Intervertebral disks, 11, 156
 Inversion, 24
 Ischium
 greater sciatic notch, 13
 lesser sciatic notch, 13
 ramus, 11, 13, 15, 162, 183
 spine, 13, 160
 tuberosity, 13, 15, 161, 163, 175-177
- L**
 Lacrimal bone, 2, 4, 29
 Lateral cuneiform bone, 16-18
 Ligamentum nuchae, 8, 72, 76, 87,
 105, 109
 Linea alba, 11, 12, 90, 91, 93, 95
 Lumbar (thoracolumbar) fascia, 12
 Lumbar plexus, 156
 Lumbar vertebrae. *See* vertebra
 Lumbocostal arch(es), 7, 89
 Lunate bone, 9, 10
- M**
 Mammillary process of vertebrae, 8, 78, 81
 Mandible, 2-5, 35, 51, 52, 55
 alveolar process (border), 44
 angle, 2, 46, 47
 condyle, 2, 48
 coronoid process, 2, 45, 46
 incisive fossa, 2, 43
 inferior mental spine, 5
 mental foramen, 2, 41
 mylohyoid line, 5, 54
 oblique line, 2
 ramus, 2, 45-47
 symphysis, 4, 5, 41, 52
 Maxilla, 2, 4
 alveolar process (border), 4, 35, 44
 canine fossa, 2, 37
 frontal process, 2, 36
 incisive fossa, 2, 4
 tuberosity, 3, 47
 zygomatic process, 46
 Medial cuneiform bone, 16-18
 Median (midsagittal plane), 20-22
 Median nerve, 122-124, 127, 145-147, 152
 anterior interosseous branch, 128-131
 Metacarpal bones, 9, 10, 123, 125, 133,
 134, 137, 139, 146-148, 151,
 153, 154
 Metacarpophalangeal joint, 135, 146, 150,
 152-154
 Metatarsal bones, 16, 18, 186, 188, 189,
 198, 200, 201, 209-212
 Muscles. *See* pages 213, 214
 Musculocutaneous nerve, 101-103
- N**
 Nasal bone, 2, 4
 Nasal cartilage, 3
 Nasal septum (ethmoid bone), 4, 34, 35
 Nasolabial furrow, 36, 39
 Navicular bone, 9, 16
 tubercle of, 10
 tuberosity of, 17, 18, 198
- O**
 Oblique popliteal ligament, 17, 183
 Obturator foramen, 11, 13, 162
 Obturator membrane, 13, 159
 Obturator nerve, 162, 179, 180-183
 Occipital bone, 2, 3, 4, 6
 external occipital crest, 4
 external occipital protuberance, 3,
 4, 105
 foramen magnum, 61, 62
 inferior nuchal line, 2, 3, 4, 67, 68, 70
 jugular process, 6
 superior nuchal line, 2, 3, 4, 70, 72, 105
 Oculomotor nerve, 30
 Opposition, 23
- P**
 Palatine bone, 47
 Palmar aponeurosis, 10, 124, 126, 144
 Palpebral ligament
 lateral (raphe), 29
 medial, 29
 Parietal bone, 3
 inferior temporal line, 2
 superior temporal line, 2
 Patella, 14, 170-173
 Patellar ligament, 14, 170-172
 Pectoral nerves
 lateral, 98
 medial, 98, 99
 Peroneal nerves
 common, 175
 deep, 186-188, 202
 superficial, 200, 201
 Pes anserinus, 169
 Phalanges
 of foot, 16, 18, 187, 188, 196, 197,
 202-212
 of hand, 9, 10, 127-129, 135, 136, 140,
 141, 143, 145-147
 Phrenic nerve, 89
 Pisiform bone, 10, 125, 149
 Plantar aponeurosis, 18, 203-205
 Plantar flexion, 24
 Plantar metatarsophalangeal ligaments,
 18, 209
 Plantar nerves
 lateral, 205-207, 209-212
 medial, 203, 204, 207, 208
 Pronation of scapula, 23
 Protraction of scapula, 22
 Pterygoidomandibular raphe, 3, 44
 Pubic ligament, 11
 Pubic symphysis, 11, 94
 Pubis
 body, 13-15
 crest, 11
 inferior ramus, 11, 14, 15, 162, 179,
 182, 183
 pectineal line, 14, 180
 superior ramus, 11, 162
 tubercle, 11
- Q**
 Quadriceps tendon, 14, 173
- R**
 Radial collateral ligament, 9, 10, 138
 Radial nerve, 117, 118, 132-143
 deep branch, 135
 Radius
 dorsal tubercle, 9
 tuberosity, 10, 122
 styloid process, 9, 132
 Retraction of scapula, 22
 Rib(s)
 angle, 7, 8
 scalene tubercle, 6
 tubercle, 7, 8, 75
 Rotation, 21
 Rotator cuff, 112-115
- S**
 Sacral nerves, 158
 Sacral plexus, 159-161
 Sacral vertebrae. *See* Vertebra
 Sacrotuberous ligament, 11, 13, 15, 158,
 164, 175
 Sacrum, 13, 158, 164
 ala, 11, 159
 crests, 8, 74, 75
 foramina, 8, 78
 Sagittal plane, 20-22
 Scalp, 26-28
 Scaphoid bone, 9
 tubercle, 10, 145
 Scapula, 8
 acromion, 5, 7, 8, 105, 111, 112
 angle, inferior, 5, 106, 116
 coracoid process, 5, 7, 99, 101, 102
 glenoid cavity (fossa), 12, 112-114
 infraglenoid tubercle, 5, 117
 infraspinous fossa, 5, 113
 movements, 22
 spine, 5, 105, 107-109, 111
 subscapular fossa, 7, 115

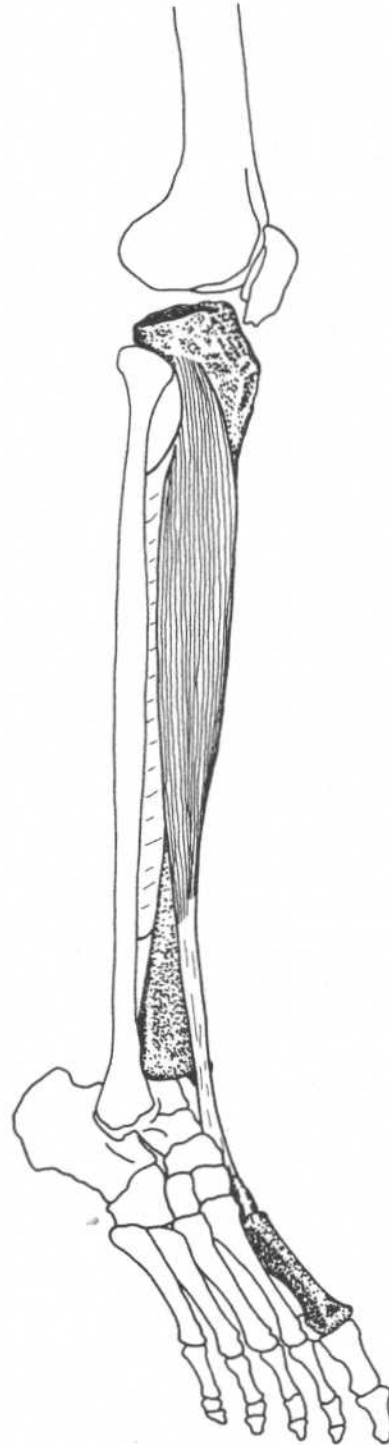
- supraglenoid tubercle, 7, 102
 supraspinous fossa, 5, 112
 Sciatic foramen, 11
 Sciatic nerve, 167, 178, 183
 common peroneal part, 175
 tibial part, 175-177
 Sphenoid bone, 2
 greater wing, 2, 4, 48
 lesser wing, 4, 30
 pterygoid plate, lateral, 2, 4, 47, 48
 Spinal nerves
 dorsal primary division, 74-81
 ventral primary division, 81
 Sternum, 7, 85, 98
 body, 7
 manubrium, 5, 7, 50, 56, 57
 xiphoid process, 7, 89, 94
 Suboccipital nerve, 67-70
 Superficial peroneal nerve, 200, 201
 Supination, 23
 Suprascapular nerve, 112, 113
 Supraspinous ligament, 8, 75, 105,
 106, 108
 Synovial membrane of knee, 12
- T**
- Talocalcaneal ligament, 16, 202
 Talus, 16, 18
 Teeth, 44-47, 54
 Temporal bone, 2, 3, 45
 mandibular process, 4
 mastoid notch, 5, 52
 mastoid process, 2, 3, 4, 26, 50, 72, 75
 styloid process, 2, 5
 zygomatic process, 2
 Temporal fossa, 2, 45
 Temporomandibular joint, 48
 articular disk, 4
 Testes, 92
 Thoracic nerves
 dorsal, 106
 long, 110
 Thoracolumbar (lumbar) fascia, 12, 91,
 93, 106
 Thyroid cartilage
 lamina, 5, 57, 58
 Tibia
 condyles, 12, 15, 16, 172, 175, 177,
 186, 188
 medial malleolus, 18
 soleal line, 17, 199
 tuberosity of, 14, 170-173
 Tibial nerve, 178, 191-198
 Transverse metatarsal ligaments, 18, 209
 Transverse planes (cross sections), 20
 Trapezium bone, 9, 146
 tubercle, 10, 145, 147
 Trapezoid bone, 9, 10, 148
 Trigeminal nerve
 mandibular division, 45-48, 52, 54
 Triquetrum bone, 9, 10
- U**
- Ulna, 8
 coronoid process, 7, 10, 103, 122,
 127-129
 olecranon process, 8-10, 117, 118, 125
 supinator crest, 10, 136
 tuberosity, 7, 103
 Ulnar flexion, 23
 Ulnar nerve, 125, 128, 144, 146, 148-154
- V**
- Vertebra
 accessory process, 8, 81
 anterior tubercle, 81
 articular process, 75, 78
 body, 11
 mammillary process, 8, 78
 posterior tubercle, 81, 107
 spinous process, 8, 72, 73, 75-80, 87,
 105, 108
 transverse process, 6, 8, 11, 60, 64-66,
 73-81, 86, 88, 96, 156
- Z**
- Zygomatic arch, 2, 46
 Zygomatic bone, 2, 4, 29, 36, 38, 39

CHAPTER NINE
MUSCLES OF THE LEG AND FOOT

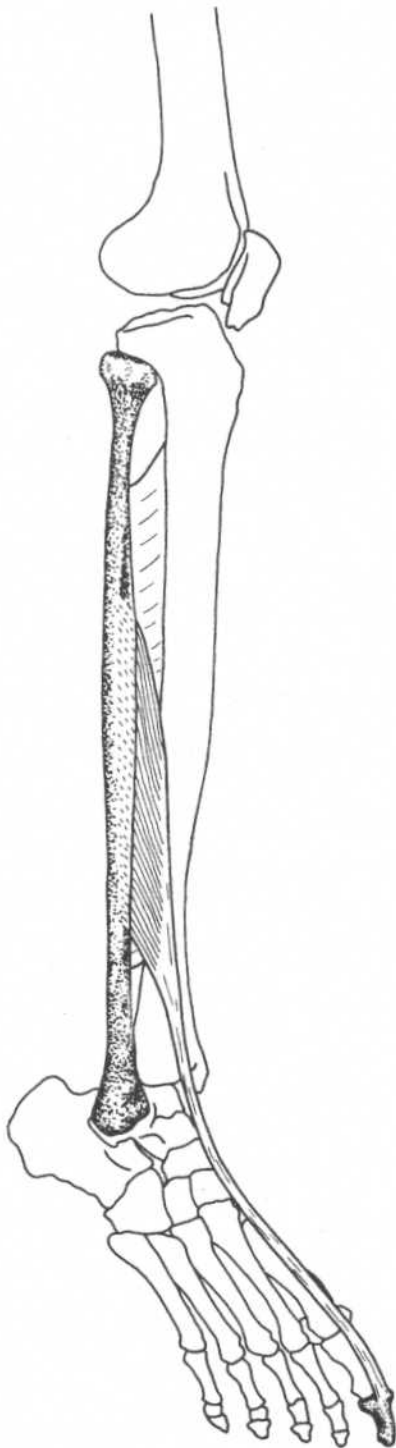


TIBIALIS ANTERIOR

Origin	Lateral condyle of tibia, upper half of lateral surface of tibia, interosseous membrane
Insertion	Medial side and plantar surface of medial cuneiform bone, and base of first metatarsal bone
Action	Dorsiflexes foot at ankle joint, inverts (supinates) foot
Nerve	Deep peroneal nerve (L4, L5, S1)



Leg—anterolateral view

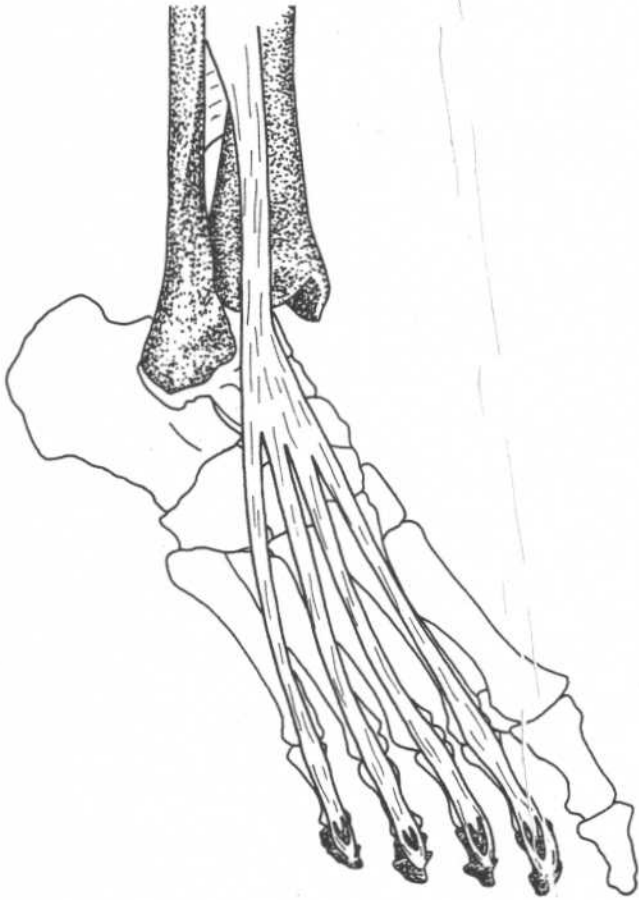


Leg—anterolateral view

EXTENSOR HALLUCIS LONGUS

Origin	Middle half of anterior surface of fibula and interosseous membrane
Insertion	Base of distal phalanx of great toe
Action	Extends, hyperextends great toe, dorsiflexes and inverts (supinates) foot
Nerve	Deep peroneal nerve (L4, L5, S1)

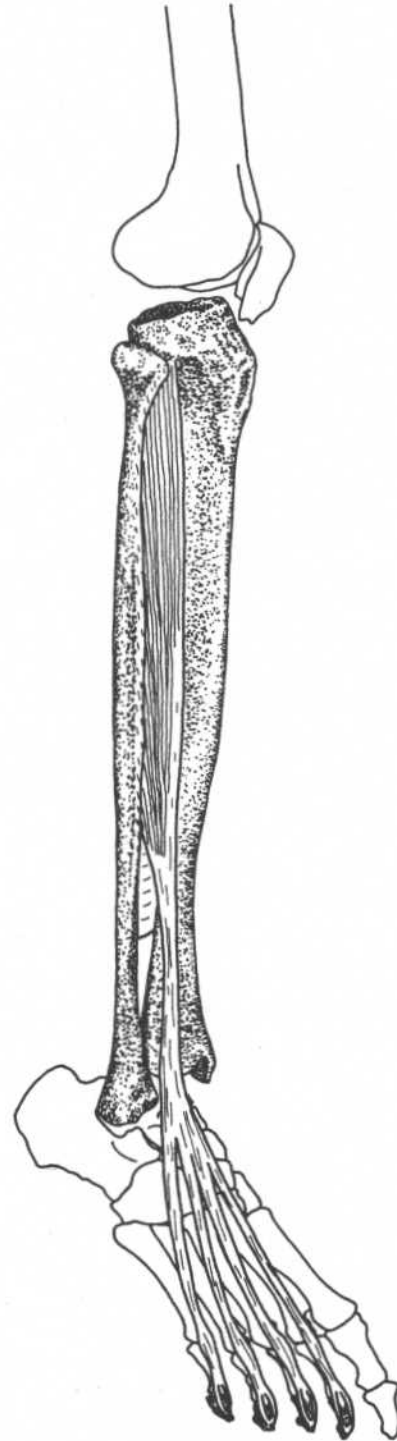
EXTENSOR DIGITORUM LONGUS



Foot—anterolateral view

Origin	Upper two-thirds of anterior surface of fibula, interosseous membrane, lateral condyle of tibia
Insertion	Along dorsal surface of four lateral toes, and then to bases of middle and distal phalanges
Action	Extends toes, dorsiflexes foot at ankle, everts foot
Nerve	Deep peroneal nerve (L4, L5, S1)

Note: The lower lateral part of this muscle makes a separate insertion onto the dorsal surface of the fifth metatarsal and is called *peroneus tertius*.

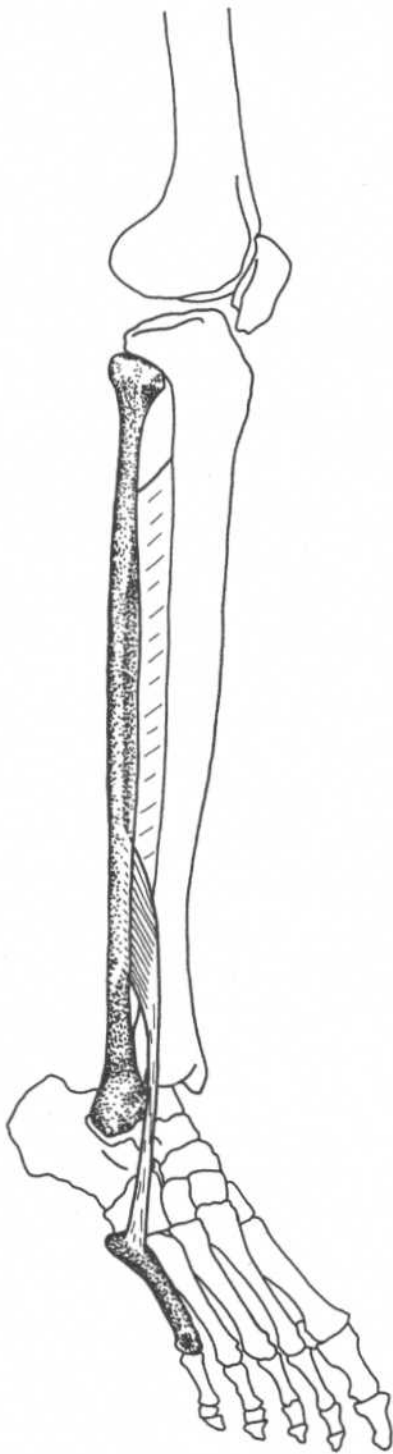


Leg—anterolateral view

PERONEUS TERTIUS

(Lower lateral part of extensor digitorum longus)

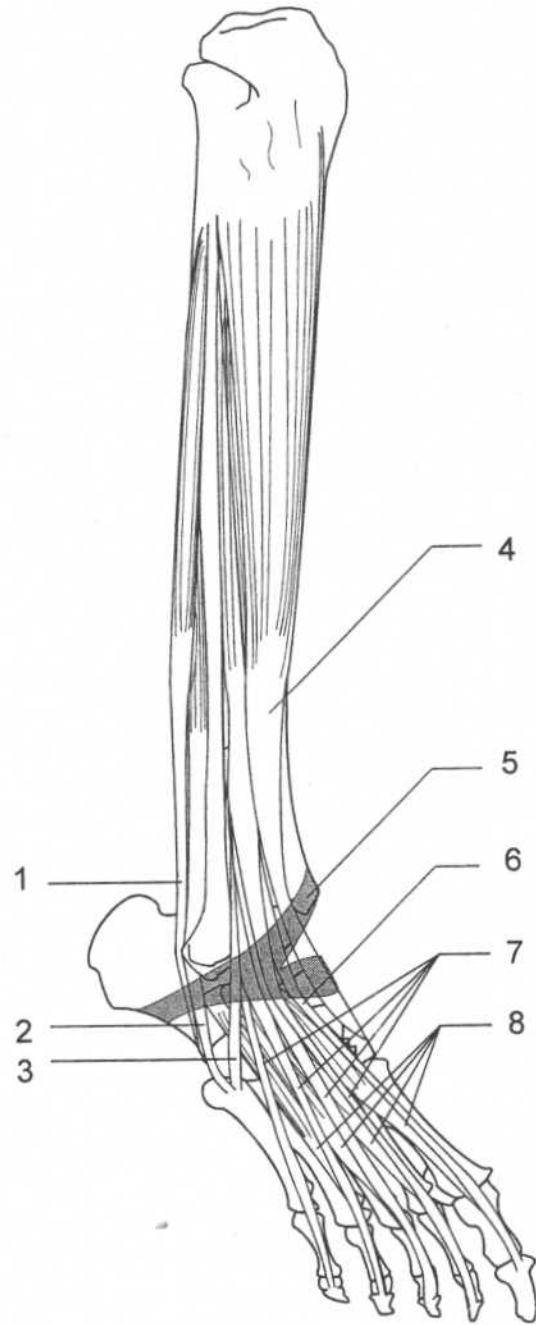
Origin	Lower third of anterior surface of fibula and interosseous membrane
Insertion	Dorsal surface of base of fifth metatarsal bone
Action	Dorsiflexes and everts foot
Nerve	Deep peroneal nerve (L4, L5, S1)



Leg—anterolateral view

ANTERIOR AND LATERAL LEG MUSCLES

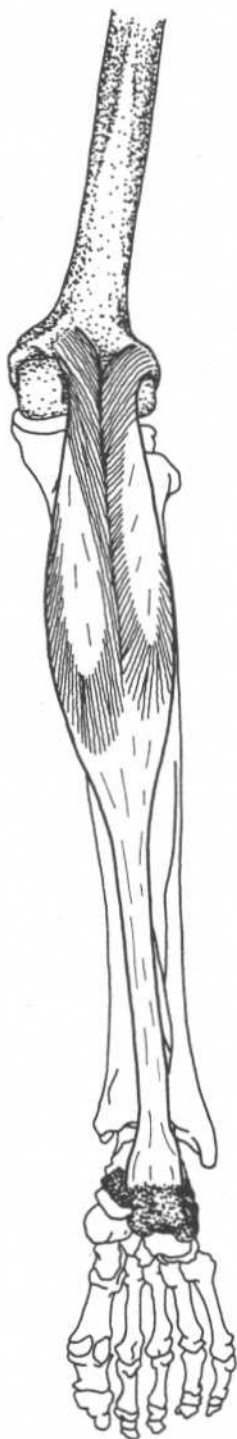
1. Peroneus longus
2. Peroneus brevis
3. Peroneus tertius
4. Tibialis anterior
5. Extensor retinaculum
6. Extensor hallucis longus
7. Extensor digitorum longus
8. Extensor digitorum brevis



Leg—anterolateral view

GASTROCNEMIUS*(Part of triceps surae)*

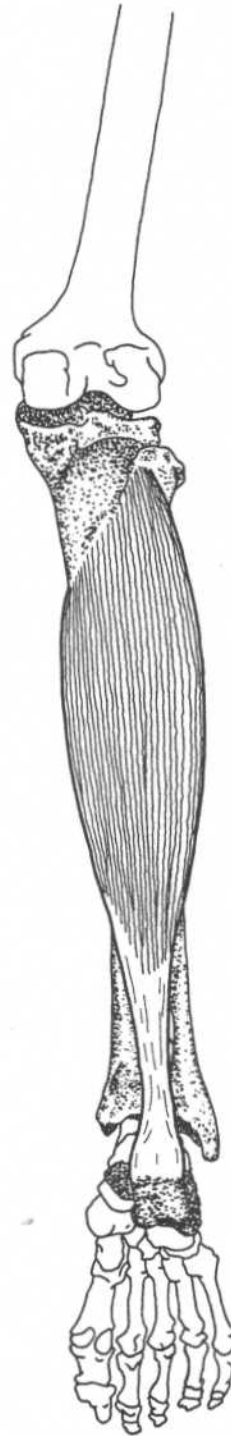
Origin	Lateral head—lateral condyle and posterior surface of femur Medial head—popliteal surface of femur above medial condyle
Insertion	Posterior surface of the calcaneus
Action	Plantar flexes foot, flexes leg at knee
Nerve	Tibial nerve (S1, S2)

**Leg—posterior view**

SOLEUS

(Part of triceps surae)

Origin	Posterior surface of the tibia (soleal line), upper third of posterior surface of fibula, fibrous arch between tibia and fibula
Insertion	Posterior surface of the calcaneus
Action	Plantar flexes foot
Nerve	Tibial nerve (S1, S2)



Leg—posterior view



Leg—posterior view

PLANTARIS

Origin

Lateral supracondylar ridge of femur,
oblique popliteal ligament

Insertion

Posterior surface of the calcaneus

Action

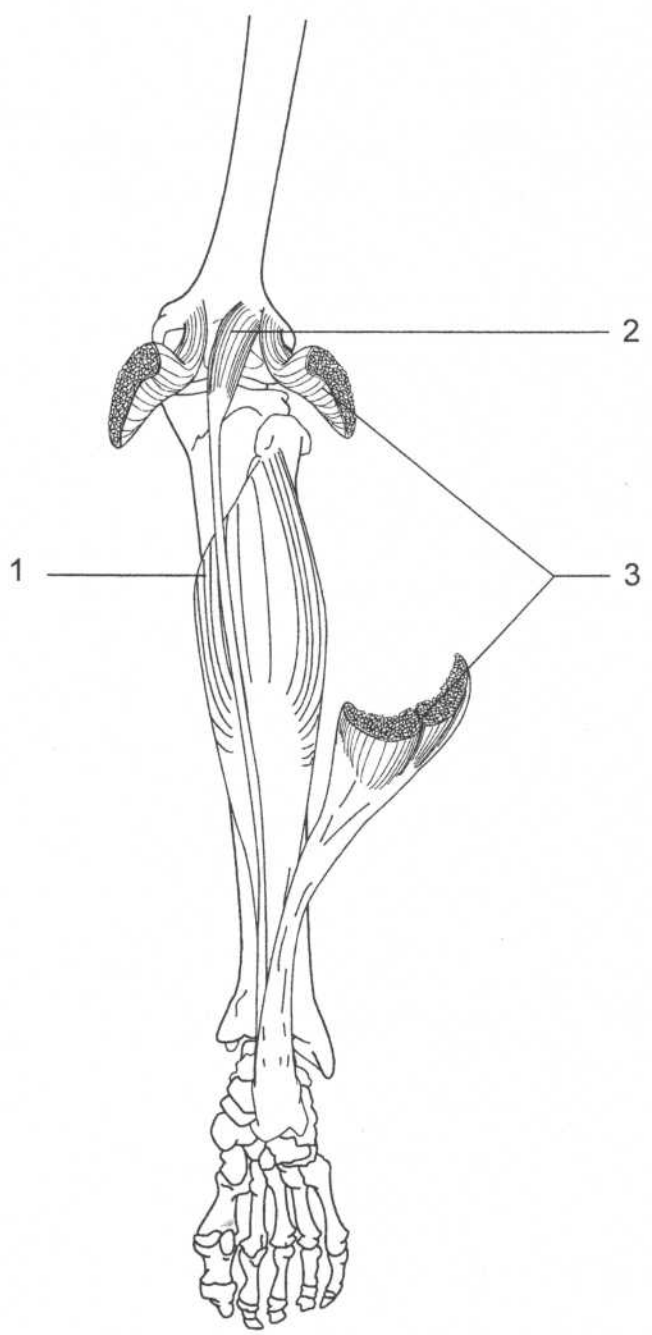
Plantar flexes foot, flexes leg

Nerve

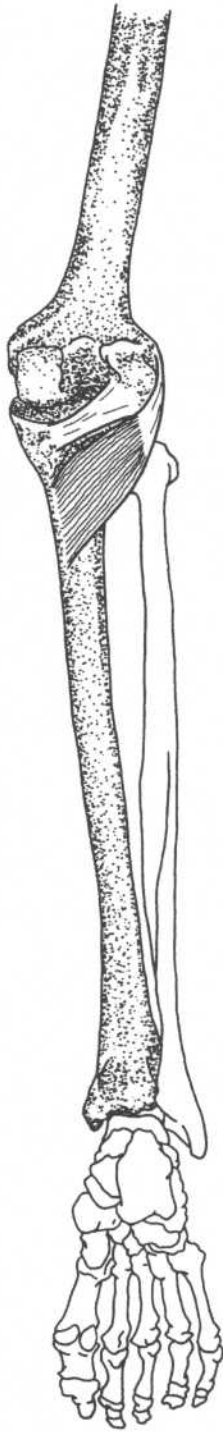
Tibial nerve (L4, L5, S1)

MUSCLES OF THE CALF

- 1. Soleus
- 2. Plantaris
- 3. Gastrocnemius (cut)



Leg—posterior view



Leg—posterior view

POPLITEUS

Origin	Lateral surface of lateral condyle of femur
Insertion	Upper part of posterior surface of tibia
Action	Rotates leg medially, flexes leg
Nerve	Tibial nerve (L4, L5, S1)

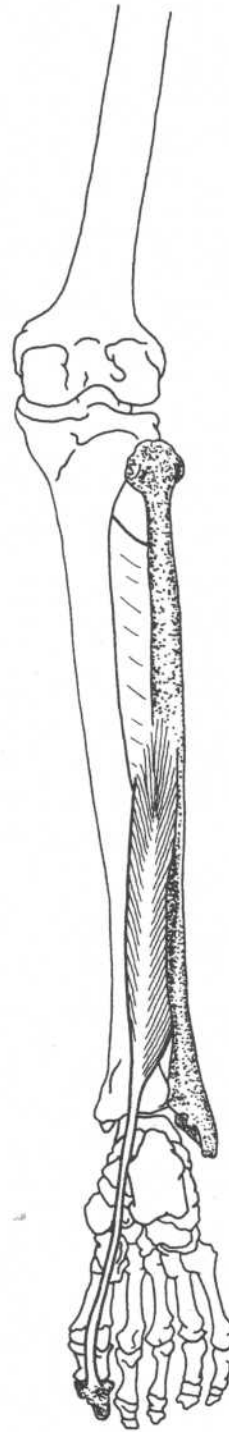
Note: Stern contends that this muscle stabilizes the knee by preventing lateral rotation of the tibia during medial rotation of the thigh while the foot is planted.

Reference:
Stern, JT: *Essentials of Gross Anatomy*, F. A. Davis Company, Philadelphia, 1988.

FLEXOR HALLUCIS LONGUS

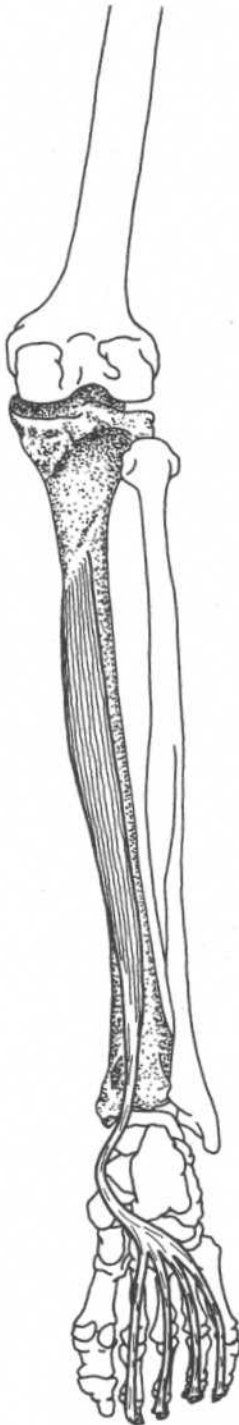
Origin	Lower two-thirds of posterior surface of shaft of fibula, posterior intermuscular septum, interosseous membrane
Insertion	Base of distal phalanx of great toe
Action	Flexes distal phalanx of great toe, assists in plantar flexing foot, inverts foot
Nerve	Tibial nerve (L5, S1, S2)

Note: This muscle is important in pushing off the surface in walking, running, jumping.

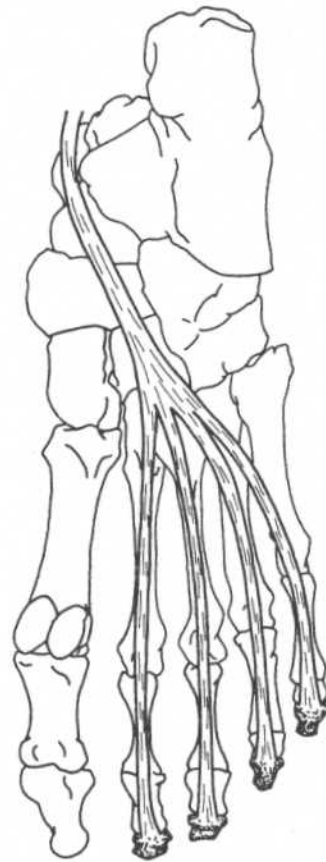


Leg—posterior view

FLEXOR DIGITORUM LONGUS



Leg—posterior view



Foot—plantar view

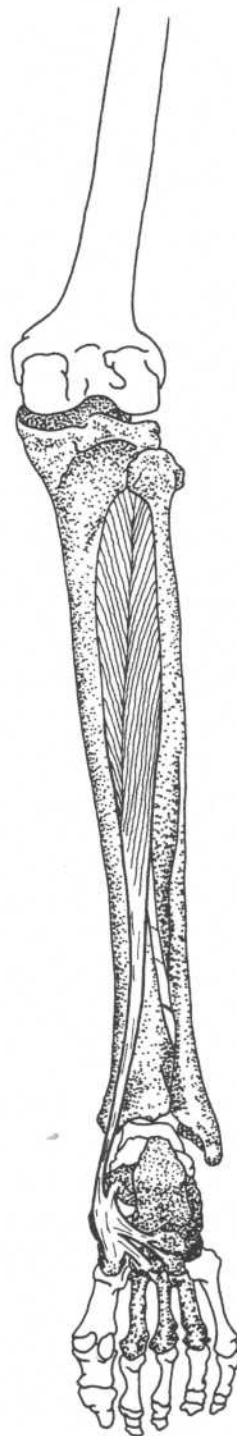
Origin	Medial part of posterior surface of tibia
Insertion	Bases of distal phalanges of second, third, fourth, and fifth toes
Action	Flexes distal phalanges of lateral four toes, assists in plantar flexing foot, inverts foot
Nerve	Tibial nerve (L5, S1)

TIBIALIS POSTERIOR



Foot—plantar view

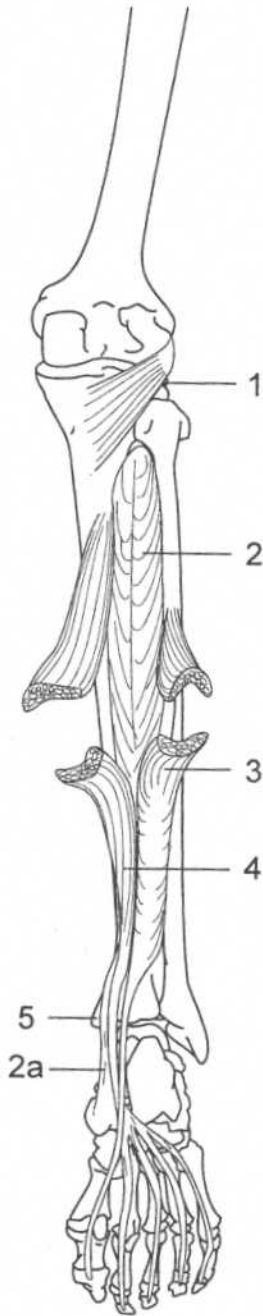
Origin	Lateral part of posterior surface of tibia, interosseous membrane, proximal half of posterior surface of fibula
Insertion	Tuberosity of navicular bone, cuboid, cuneiforms, second, third, and fourth metatarsals, sustentaculum tali of calcaneus
Action	Plantar flexes, inverts foot
Nerve	Tibial nerve (L5, S1)



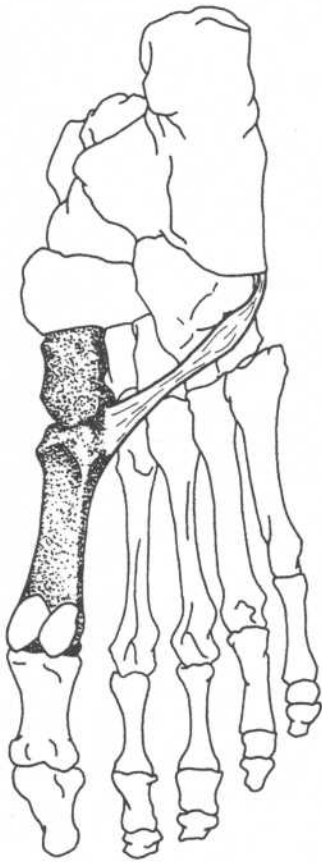
Leg—posterior view

**DEEP POSTERIOR
LEG MUSCLES**

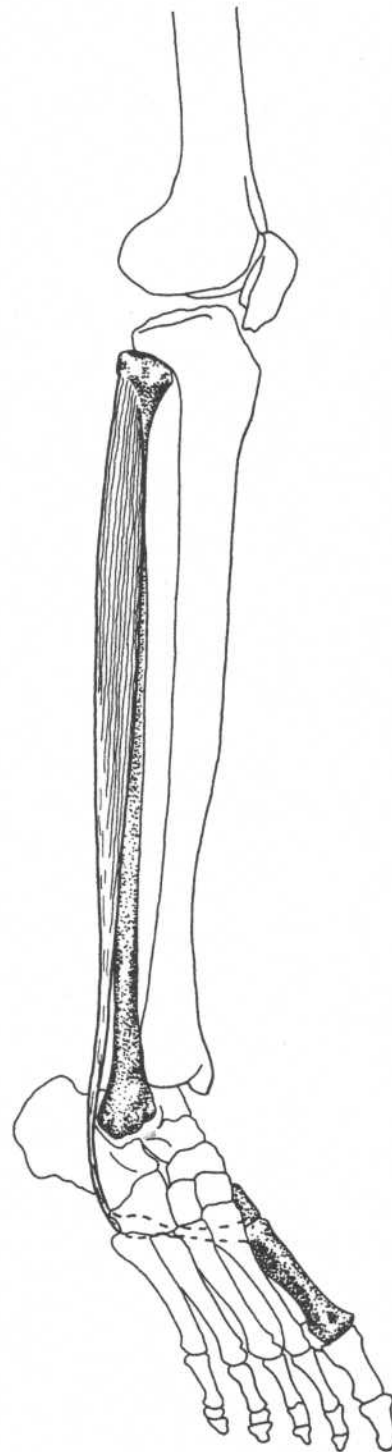
1. Popliteus
2. Tibialis posterior
- 2a. Tendon of tibialis posterior
3. Flexor hallucis longus (cut)
4. Flexor digitorum longus (cut)
5. Medial malleolus

**Leg—posterior view**

PERONEUS LONGUS



Foot—plantar view

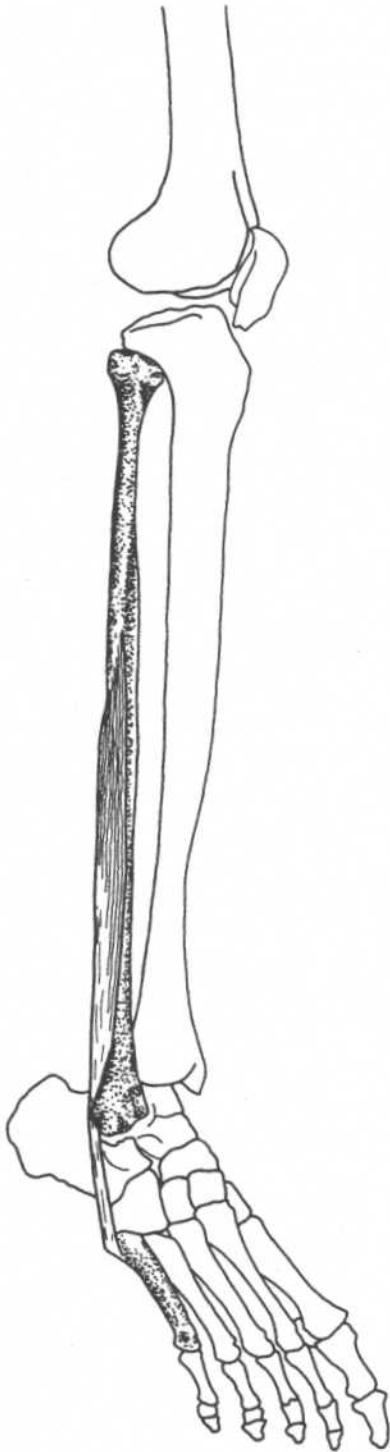


Leg—anterolateral view

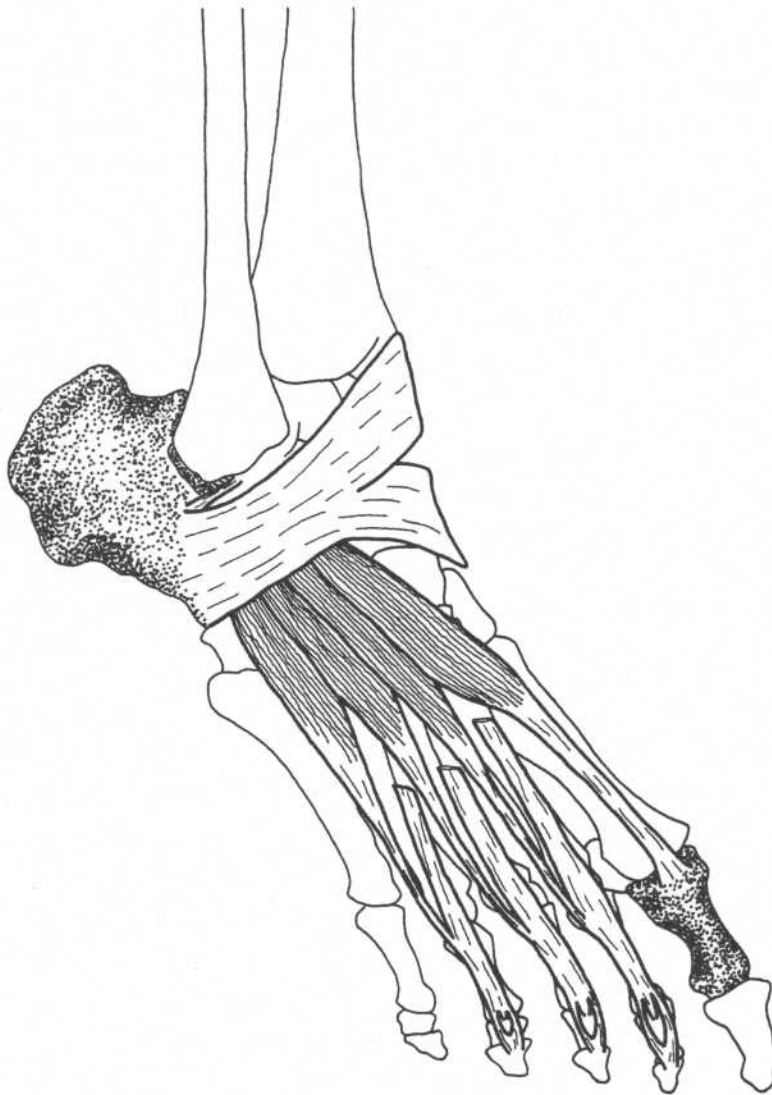
- | | |
|--------------------|--|
| Origin | Upper two-thirds of lateral surface of fibula |
| Insertion | Lateral side of medial cuneiform, base of first metatarsal |
| Action | Plantar flexes, everts foot |
| Innervation | Superficial peroneal nerve (L4, L5, S1) |

PERONEUS BREVIS

Origin	Lower two-thirds of lateral surface of fibula
Insertion	Lateral side of base of fifth metatarsal bone
Action	Everts, plantar flexes foot
Nerve	Superficial peroneal nerve (L4, L5, S1)

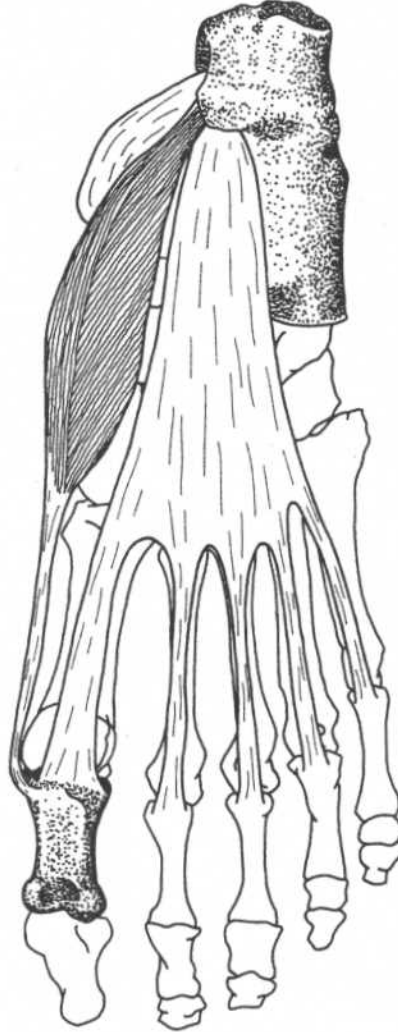
**Leg—anterolateral view**

EXTENSOR DIGITORUM BREVIS



Foot—anterolateral view

Origin	Anterior and lateral surfaces of calcaneus, lateral talocalcaneal ligament, inferior extensor retinaculum	Action	Extends the four toes
Insertion	Into base of proximal phalanx of great toe, into lateral sides of tendons of extensor digitorum longus of second, third, and fourth toes	Nerve	Deep peroneal nerve (L5, S1)

ABDUCTOR HALLUCIS*(First layer)***Foot—plantar view**

Origin	Tuberosity of calcaneus, flexor retinaculum, plantar aponeurosis
Insertion	Medial side of base of proximal phalanx of great toe
Action	Abducts great toe
Nerve	Medial plantar nerve (L4, L5)

Note: The muscles of the sole of the foot can be divided into four layers (from superficial to deep):

First layer—abductor hallucis, flexor digitorum brevis, abductor digiti minimi

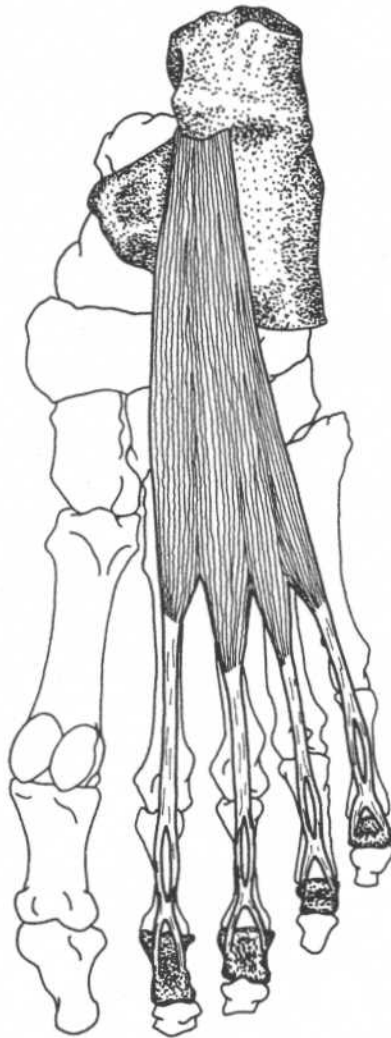
Second layer—quadratus plantae, lumbricales (tendons of flexor hallucis longus and flexor digitorum longus pass through this layer)

Third layer—flexor hallucis brevis, adductor hallucis, flexor digiti minimi brevis

Fourth layer—interossei (tendons of tibialis posterior and peroneus longus pass through this layer)

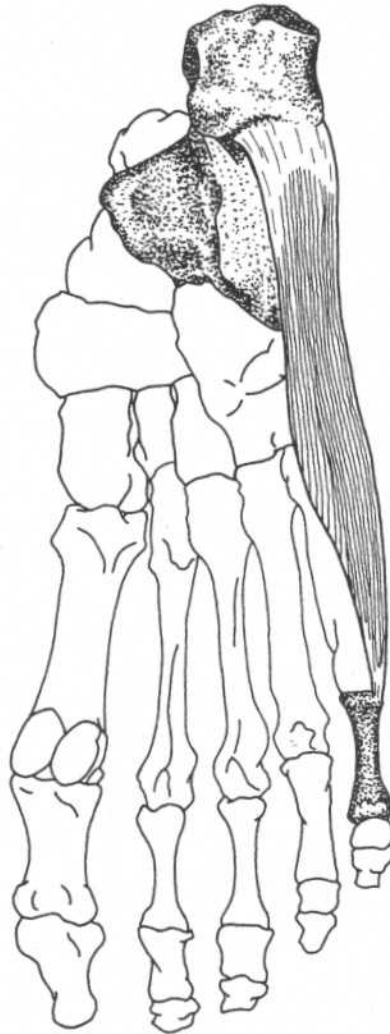
FLEXOR DIGITORUM BREVIS

(First layer)



Foot—plantar view

Origin	Tuberosity of calcaneus, plantar aponeurosis	Action	Flexes proximal phalanges and extends distal phalanges of second through fifth toes
Insertion	Sides of middle phalanges of second to fifth toes	Nerve	Medial plantar nerve (L4, L5)

ABDUCTOR DIGITI MINIMI*(First layer)***Foot—plantar view****Origin**

Tuberosity of calcaneus, plantar aponeurosis

Insertion

Lateral side of proximal phalanx of fifth toe

**Action
Nerve**

Abducts fifth toe

Lateral plantar nerve (S1, S2)

QUADRATUS PLANTAE

(Second layer)



Foot—plantar view

Origin

Medial head—medial surface of calcaneus

Lateral head—lateral border of inferior surface of calcaneus

Insertion

Lateral margin of tendon of flexor digitorum longus

Action

Flexes terminal phalanges of second through fifth toes

Nerve

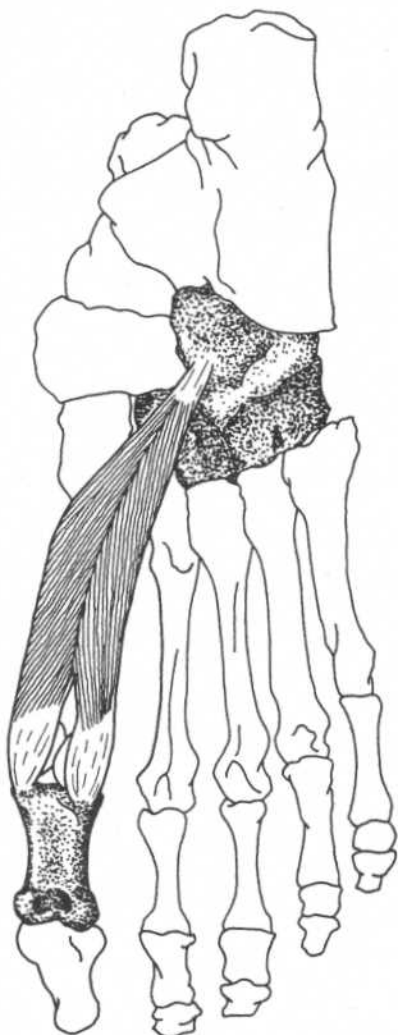
Lateral plantar nerve (S1, S2)

LUMBRICALES*(Second layer)***Foot—plantar view**

Origin	Tendons of flexor digitorum longus	Nerve	First lumbricalis—medial plantar nerve (L4, L5)
Insertion	Dorsal surfaces of proximal phalanges		Second through fifth lumbricales—lateral plantar nerve (S1, S2)
Action	Flex proximal phalanges of second through fifth toes		

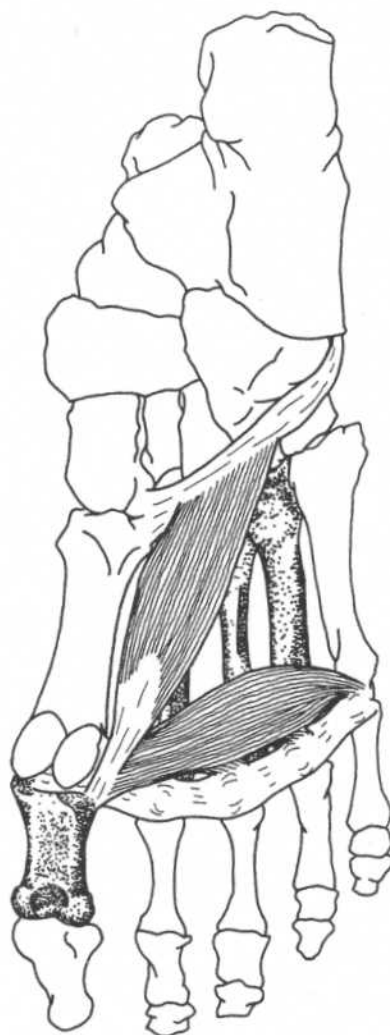
FLEXOR HALLUCIS BREVIS

(Third layer)



Foot—plantar view

Origin	Cuboid bone, lateral cuneiform bone	Action	Flexes proximal phalanx of great toe
Insertion	Medial part—medial side of base of proximal phalanx of great toe Lateral part—lateral side of base of proximal phalanx of great toe	Nerve	Medial plantar nerve (L4, L5, S1)

ADDUCTOR HALLUCIS*(Third layer)***Foot—plantar view****Origin**

Oblique head—second, third, and fourth metatarsal bones, and sheath of peroneus longus tendon
 Transverse head—plantar metatarsophalangeal ligaments of third, fourth, and fifth toes, and transverse metatarsal ligaments

Insertion

Lateral side of base of proximal phalanx of great toe

Action

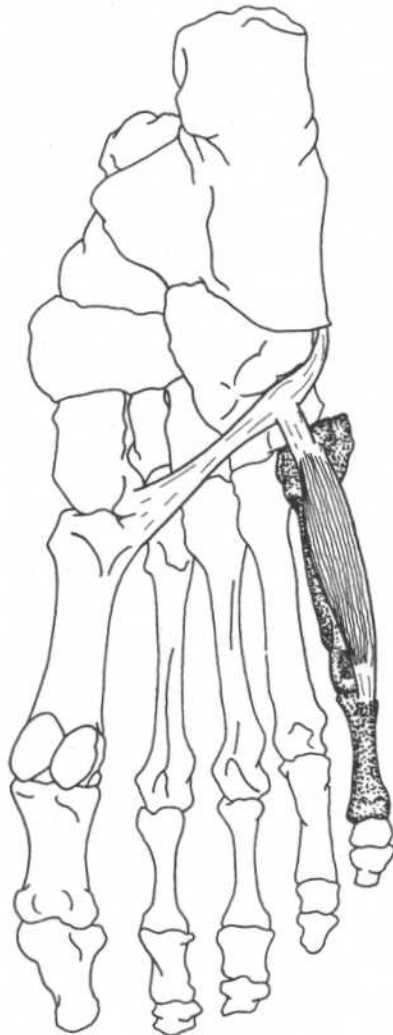
Adducts great toe

Nerve

Lateral plantar nerve (S1, S2)

FLEXOR DIGITI MINIMI BREVIS

(Third layer)



Foot—plantar view

Origin Base of fifth metatarsal, sheath of peroneus longus tendon

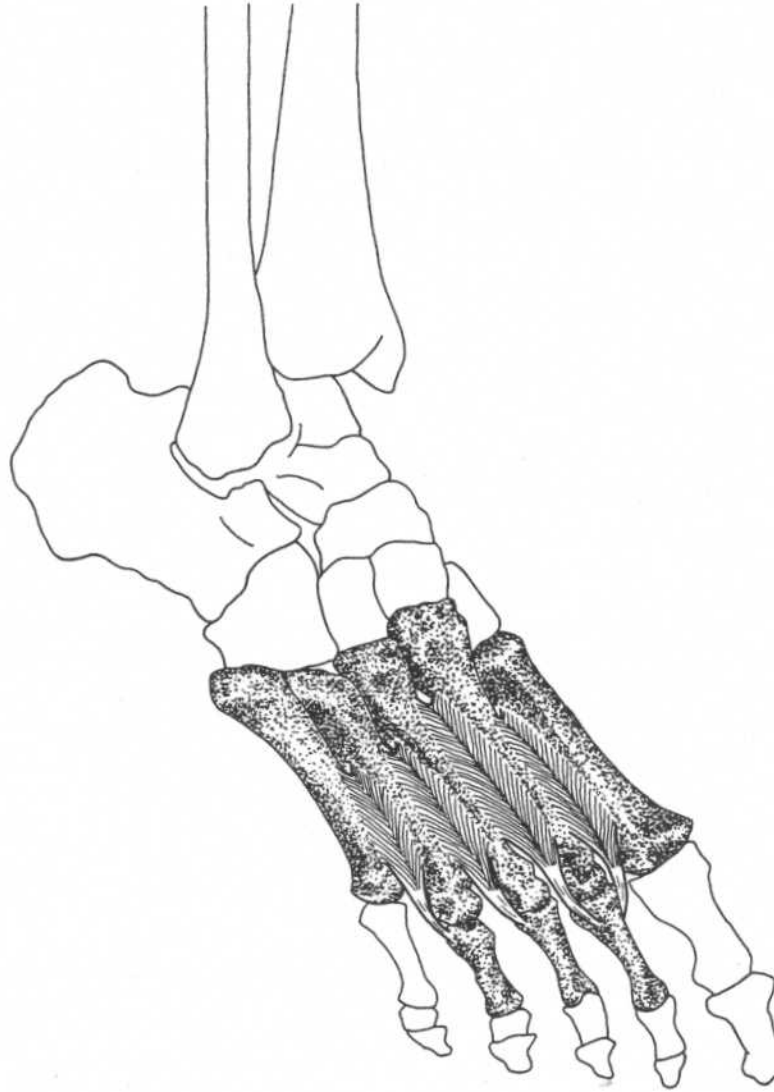
Insertion Lateral side of base of proximal phalanx of fifth toe

Action

Nerve

Flexes proximal phalanx of fifth toe

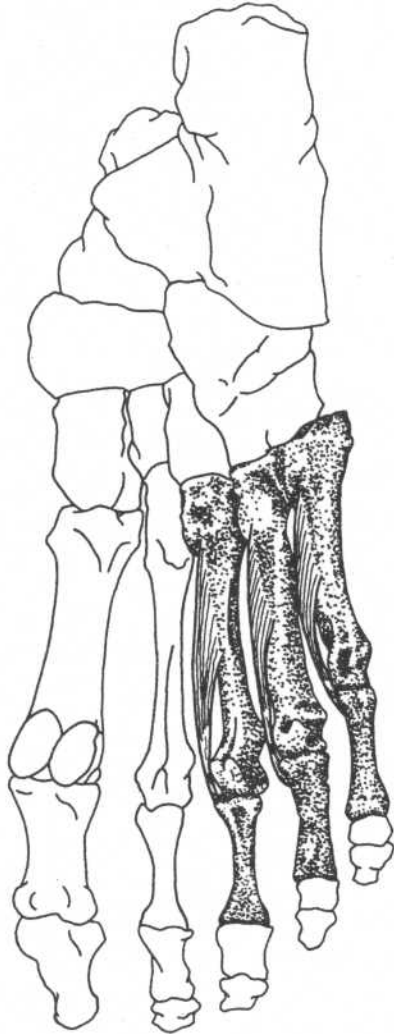
Lateral plantar nerve (S1, S2)

DORSAL INTEROSSEI*(Fourth layer; four muscles)***Foot—anterolateral view**

Origin	Adjacent sides of metatarsal bones	Action	Abduct toes, flex proximal phalanges
Insertion	Bases of proximal phalanges First—medial side of proximal phalanx of second toe Second, third, fourth—lateral sides of proximal phalanges of second, third, and fourth toes	Nerve	Lateral plantar nerve (S1, S2)

PLANTAR INTEROSSEI

(Fourth layer; three muscles)



Foot—plantar view

Origin	Bases and medial sides of third, fourth, and fifth metatarsal bones	Action	Adduct toes, flex proximal phalanges
Insertion	Medial sides of bases of proximal phalanges of same toes	Nerve	Lateral plantar nerve (S1, S2)

Alphabetical Listing of Muscles

A

Abductor digiti minimi
of foot, 205
of hand, 149
Abductor hallucis, 203
Abductor pollicis brevis, 145
Abductor pollicis longus, 139
Adductor brevis, 182
Adductor hallucis, 209
Adductor longus, 181
Adductor magnus, 183
Adductor pollicis, 148
Anconeus, 118
Auricularis
anterior, superior, posterior, 28

B

Biceps brachii, 102
Biceps femoris, 175
Brachialis, 103
Brachioradialis, 132
Buccinator, 44

C

Coracobrachialis, 101
Corrugator supercillii, 31
Cremaster, 92

D

Deltoideus, 111
Depressor
anguli oris, 42
labii inferioris, 41
septi, 34
Diaphragm, 89
Digastricus, 52
Dorsal interossei
of foot, 211
of hand, 154

E

Epicranius
frontal belly (frontalis), 26
occipital belly (occipitalis), 26
Erector spinae, 74–76
Extensor carpi radialis brevis, 134
Extensor carpi radialis longus, 133

Extensor carpi ulnaris, 137
Extensor digiti minimi, 136
Extensor digitorum brevis, 202
Extensor digitorum communis, 135
Extensor digitorum longus, 188
Extensor hallucis longus, 187
Extensor indicis, 143
Extensor pollicis brevis, 140
Extensor pollicis longus, 141

F

Flexor carpi radialis, 123
Flexor carpi ulnaris, 125
Flexor digiti minimi, 145, 146
Flexor digiti minimi brevis, 150, 210
Flexor digitorum brevis, 204
Flexor digitorum longus, 197
Flexor digitorum profundus, 128
Flexor digitorum superficialis, 127
Flexor hallucis brevis, 208
Flexor hallucis longus, 196
Flexor pollicis brevis, 146
Flexor pollicis longus, 129
Frontalis. *See* Epicranius

G

Gastrocnemius, 191
Gemellus
inferior, 161
superior, 160
Geniohyoideus, 55
Gluteus
maximus, 164
medius, 165
minimus, 166
Gracilis, 179

I

Iliacus, 157
Iliocostalis
cervicis, 74
lumborum, 74
thoracis, 74
Iliopsoas, 154
Infraspinatus, 113
Intercostales
externi, 82
interni, 83

Interossei

of foot, 211–212
of hand, 153–154
Interspinales, 80
Intertransversarii, 81

L

Latissimus dorsi, 106
Levator anguli oris, 37
Levator labii superioris, 36
Levator palpebrae superioris, 30
Levator scapulae, 107
Levatores costarum, 86
Longissimus, 75
capitis, 75
cervicis, 75
thoracis, 75
Longus
capitis, 61
colli, 60
Lumbricales
of foot, 207
of hand, 152

M

Masseter, 46
Mentalis, 43
Multifidus, 78
Muscle Groups
abdominal muscles, 95
muscles of anterior chest and arm, 104
posterior back, shoulder and arm
muscles, 119
muscles of the wrist, 126
flexors of the fingers, 130
extensors of the thumb, 142
muscles of the hip, 167
muscles of the anterior thigh, 174
hamstring muscles, 178
hip flexors and adductors, 184
anterior and lateral leg muscles, 190
muscles of the calf, 194
deep posterior leg muscles, 199
Mylohyoideus, 54

N

Nasalis
alar part, 33
transverse part, 33

O

Obliquus capitis
 inferior, 69
 superior, 70
 Obliquus externus abdominis, 90
 Obliquus internus abdominis, 91
 Obturator
 externus, 162
 internus, 159
 Occipitalis. *See* Epicranium
 Omohyoideus, 59
 Opponens digiti minimi, 151
 Opponens pollicis, 147
 Orbicularis oculi, 29
 Orbicularis oris, 35

P

Palmar interossei, 153
 Palmaris
 brevis, 144
 longus, 124
 Pectineus, 180
 Pectoralis
 major, 98
 minor, 99
 Peroneus
 brevis, 201
 longus, 200
 tertius, 189
 Piriformis, 158
 Plantar interossei, 212
 Plantaris, 193
 Platysma, 51
 Popliteus, 195
 Procerus, 32
 Pronator
 quadratus, 131
 teres, 122
 Psoas
 major, 156
 minor, 156
 Pterygoideus
 lateralis, 48
 medialis, 47
 Pyramidalis, 95

Q

Quadratus
 femoris, 163
 lumborum, 96
 plantae, 206
 Quadriceps femoris
 rectus femoris, 170
 vastus intermedius, 173
 vastus lateralis, 171
 vastus medialis, 172

R

Rectus abdominis, 94
 Rectus capitis
 anterior, 62
 lateralis, 63
 posterior major, 67
 posterior minor, 68
 Rectus femoris. *See* Quadriceps femoris
 Rhomboideus
 major, 108
 minor, 109
 Risorius, 40
 Rotatores, 79

S

Sacrospinalis. *See* Erector spinae
 Sartorius, 169
 Scalenus
 anterior, 64
 medius, 65
 posterior, 66
 Semimembranosus, 177
 Semispinalis
 capitis, 77
 cervicis, 77
 thoracis, 77
 Semitendinosus, 176
 Serratus
 anterior, 110
 posterior inferior, 88
 posterior superior, 87
 Soleus, 192
 Spinalis, 74
 capitis, 76

cervicis, 76
 thoracis, 76

Splenius
 capitis, 72
 cervicis, 73
 Sternocleidomastoideus, 50
 Sternohyoideus, 56
 Sternothyroideus, 57
 Stylohyoideus, 53
 Subclavius, 100
 Subcostales, 84
 Subscapularis, 115
 Supinator, 138
 Supraspinatus, 112

T

Temporalis, 45
 Temporoparietalis, 27
 Tensor fasciae latae, 168
 Teres
 major, 116
 minor, 114
 Thyrohyoideus, 58
 Tibialis
 anterior, 186
 posterior, 198
 Transversospinalis, 77
 Transversus
 abdominis, 93
 thoracis, 85
 Trapezius, 105
 Triceps brachii, 117

V

Vastus
 intermedius. *See* Quadriceps femoris
 lateralis. *See* Quadriceps femoris
 medialis. *See* Quadriceps femoris

Z

Zygomaticus
 major, 38
 minor, 39

Index

- A**
- Abdominal aponeurosis, 12, 90, 91, 93
 - Abduction, 21, 23, 24
 - Accessory nerve (11th cranial)
 - cranial part, 105
 - spinal part, 50
 - Accessory process of vertebra, 8
 - Acetabulum, 12, 170
 - Acromion, 5, 7, 8
 - Adduction, 21–24
 - Adductor tubercle of femur, 15
 - Ala, 3
 - of nose, 3, 34
 - of sacrum, 11, 157
 - Alar cartilage, 3, 33, 36
 - Alveolar border (process)
 - of maxilla, 4
 - Anatomical position, 20, 21, 23
 - Annular ligament of radius, 9, 10, 138
 - Ansa cervicalis, 56, 57, 59
 - Anterior iliac crest, 12
 - Anterior iliac spine
 - inferior, 11, 14, 157
 - superior, 11, 12, 14
 - Arcuate ligament
 - lateral, 7, 89
 - medial, 7, 89
 - Arcuate line of ilium, 11, 156
 - Articular disk
 - temporomandibular joint, 3
 - Atlas
 - anterior arch, 6, 60
 - posterior arch, 3, 68
 - transverse process, 3, 62, 63, 69, 70
 - Axillary nerve, 111, 114
 - Axis, 6
 - spinous process of, 3, 67, 69, 76
- B**
- Bicipital aponeurosis, 102
 - Bicipital (intertubercular) groove
 - of humerus, 7, 102
- C**
- Calcaneus, 16, 191–193, 202, 206
 - sustinaculum tali, 17, 18, 198
 - tuberosity, 18, 203–205
 - Canine fossa of maxilla, 2
 - Capitate bone, 9, 10, 148
 - Carpometacarpal joint, 151
 - Cervical nerves
 - dorsal primary divisions, 72, 73, 75
 - ventral rami, 64–66
 - Clavicle, 5, 7, 8, 50, 59, 98, 100, 105, 111
 - Coccyx, 13, 164
 - Common peroneal nerve, 175, 178
 - Coracoid process of scapula, 5, 7
 - Coronal (frontal) planes, 20, 21, 23
 - Costal cartilage, 7, 12, 82, 83, 89, 93, 94, 98, 100
 - Cuboid bone, 16–18, 198, 208
 - Cuneiform bones, 16–18, 186, 198, 200
- D**
- Deep peroneal nerve, 186–189, 202
 - Deltoid tuberosity of humerus, 7, 11
 - Depression of scapula, 22
 - Dorsal scapular nerve, 107–109
 - Dorsiflexion of ankle joint, 24
- E**
- Ear
 - helix, 3
 - Elevation of scapula, 22
 - Ethmoid bone
 - nasal septum, 4, 34, 35
 - Eversion, 24
 - Extension, 21, 24
 - Extensor expansion, 143
 - Extensor retinaculum, 16, 190, 202
 - External occipital protuberance, 3, 4
- F**
- Facial nerve, 52, 53
 - auricular branch (posterior), 26, 28
 - buccal branches, 32–40, 44
 - cervical branch, 51
 - mandibular branch, 35, 41–43
 - temporal branch, 26–29, 31
 - zygomatic branch, 29
 - Fascia lata. *See* iliotibial tract
 - Femoral nerve, 157, 169–173, 180, 184
 - Femur, 11, 12, 14–17
 - adductor tubercle, 15, 183
 - condyles, 17, 191, 195
 - gluteal tuberosity, 13, 15, 164, 171
 - greater trochanter, 11, 13–15, 158–161, 165, 166, 171
 - intertrochanteric crest, 13, 163
 - intertrochanteric line, 14, 171, 172
 - lateral supracondylar ridge (line), 14, 15, 17, 173, 175, 193
 - lesser trochanter, 11, 14, 15, 156, 157, 180, 182
 - linea aspera, 13, 15, 171–173, 175, 180–183
 - medial supracondylar (ridge) line, 14, 172
 - popliteal surface, 17, 191
 - quadrate line, 13, 163
 - supracondylar ridge (line), 14, 15, 17, 172, 175
 - trochanteric fossa, 11
 - Fibula, 16, 17, 187–189, 192, 196, 198, 200, 201
 - head, 15
 - Flexion, 21, 23, 24
 - Flexor retinaculum
 - of foot, 18, 203
 - of hand, 10, 24, 126, 144–147, 150, 151
 - Foramen magnum, 61, 62
 - Frontal bone, 2, 4, 29, 45
 - superciliary arch, 4
 - Frontal (coronal) planes, 20, 21, 23
 - Frontal process of maxilla, 2
- G**
- Galea aponeurotica, 3, 26
 - Genitofemoral nerve, genital branch, 92
 - Glenoid cavity of scapula, 12
 - Gluteal nerve
 - inferior, 164
 - superior, 165, 166, 168
- H**
- Hamate bone, 9, 10, 150, 151
 - hook, 10, 125
 - Humerus, 8, 101, 103
 - condyles, 9
 - deltoid tuberosity, 7, 111
 - greater tuberosity (tubercle), 5, 7, 98, 112–114
 - intertubercular (bicipital) groove, 7, 98, 102, 106, 116
 - lateral epicondyle, 9, 118, 134–138
 - lateral supracondylar ridge, 9, 132, 133
 - lesser tuberosity, 7, 115
 - medial epicondyle, 10, 122–125, 127, 129
 - medial supracondylar ridge, 10, 122
 - Hyoid bone, 5, 52–56, 58, 59
 - greater cornu, 5
 - Hyperextension, 21
 - Hypoglossal nerve, 55, 58
 - Hypothenar eminence, 149
- I**
- Iliohypogastric nerve, 91, 93
 - Ilioinguinal nerves, 90, 91, 93
 - Iliolumbar ligament, 11, 95
 - Iliopectineal eminence, 11, 156
 - Iliotibial tract, 112, 164, 168, 174

- Ilium**
 arcuate line, 11
 crest of, 8, 12, 13, 74, 75, 90, 91, 93
 fossa of, 11, 157
 gluteal lines
 inferior, 13, 166
 middle (anterior), 13, 166
 posterior, 13, 164
 iliopectineal eminence, 11
 spines
 anterior inferior, 11, 14, 170
 anterior superior, 11, 12, 168, 169
 posterior superior iliac, 8, 78
 tubercle, 12, 168
 Inguinal ligament, 11, 12, 91-93, 184
 Intercostal nerves, 82-86, 90, 91, 93, 94
 Intercostal space, 83
 Interosseous membrane
 radioulnar, 9, 10, 128, 129,
 139-141, 143
 tibiofibular, 16, 17, 186-189, 196, 198
 Intervertebral disks, 11, 156
 Inversion, 24
 Ischium
 greater sciatic notch, 13
 lesser sciatic notch, 13
 ramus, 11, 13, 15, 162, 183
 spine, 13, 160
 tuberosity, 13, 15, 161, 163, 175-177
- L**
 Lacrimal bone, 2, 4, 29
 Lateral cuneiform bone, 16-18
 Ligamentum nuchae, 8, 72, 76, 87,
 105, 109
 Linea alba, 11, 12, 90, 91, 93, 95
 Lumbar (thoracolumbar) fascia, 12
 Lumbar plexus, 156
 Lumbar vertebrae. *See* vertebra
 Lumbocostal arch(es), 7, 89
 Lunate bone, 9, 10
- M**
 Mammillary process of vertebrae, 8, 78, 81
 Mandible, 2-5, 35, 51, 52, 55
 alveolar process (border), 44
 angle, 2, 46, 47
 condyle, 2, 48
 coronoid process, 2, 45, 46
 incisive fossa, 2, 43
 inferior mental spine, 5
 mental foramen, 2, 41
 mylohyoid line, 5, 54
 oblique line, 2
 ramus, 2, 45-47
 symphysis, 4, 5, 41, 52
 Maxilla, 2, 4
 alveolar process (border), 4, 35, 44
 canine fossa, 2, 37
 frontal process, 2, 36
 incisive fossa, 2, 4
 tuberosity, 3, 47
 zygomatic process, 46
 Medial cuneiform bone, 16-18
 Median (midsagittal plane), 20-22
 Median nerve, 122-124, 127, 145-147, 152
 anterior interosseous branch, 128-131
 Metacarpal bones, 9, 10, 123, 125, 133,
 134, 137, 139, 146-148, 151,
 153, 154
 Metacarpophalangeal joint, 135, 146, 150,
 152-154
 Metatarsal bones, 16, 18, 186, 188, 189,
 198, 200, 201, 209-212
 Muscles. *See* pages 213, 214
 Musculocutaneous nerve, 101-103
- N**
 Nasal bone, 2, 4
 Nasal cartilage, 3
 Nasal septum (ethmoid bone), 4, 34, 35
 Nasolabial furrow, 36, 39
 Navicular bone, 9, 16
 tubercle of, 10
 tuberosity of, 17, 18, 198
- O**
 Oblique popliteal ligament, 17, 183
 Obturator foramen, 11, 13, 162
 Obturator membrane, 13, 159
 Obturator nerve, 162, 179, 180-183
 Occipital bone, 2, 3, 4, 6
 external occipital crest, 4
 external occipital protuberance, 3,
 4, 105
 foramen magnum, 61, 62
 inferior nuchal line, 2, 3, 4, 67, 68, 70
 jugular process, 6
 superior nuchal line, 2, 3, 4, 70, 72, 105
 Oculomotor nerve, 30
 Opposition, 23
- P**
 Palatine bone, 47
 Palmar aponeurosis, 10, 124, 126, 144
 Palpebral ligament
 lateral (raphe), 29
 medial, 29
 Parietal bone, 3
 inferior temporal line, 2
 superior temporal line, 2
 Patella, 14, 170-173
 Patellar ligament, 14, 170-172
 Pectoral nerves
 lateral, 98
 medial, 98, 99
 Peroneal nerves
 common, 175
 deep, 186-188, 202
 superficial, 200, 201
 Pes anserinus, 169
 Phalanges
 of foot, 16, 18, 187, 188, 196, 197,
 202-212
 of hand, 9, 10, 127-129, 135, 136, 140,
 141, 143, 145-147
 Phrenic nerve, 89
 Pisiform bone, 10, 125, 149
 Plantar aponeurosis, 18, 203-205
 Plantar flexion, 24
 Plantar metatarsophalangeal ligaments,
 18, 209
 Plantar nerves
 lateral, 205-207, 209-212
 medial, 203, 204, 207, 208
 Pronation of scapula, 23
 Protraction of scapula, 22
 Pterygoidomandibular raphe, 3, 44
 Pubic ligament, 11
 Pubic symphysis, 11, 94
 Pubis
 body, 13-15
 crest, 11
 inferior ramus, 11, 14, 15, 162, 179,
 182, 183
 pectineal line, 14, 180
 superior ramus, 11, 162
 tubercle, 11
- Q**
 Quadriceps tendon, 14, 173
- R**
 Radial collateral ligament, 9, 10, 138
 Radial nerve, 117, 118, 132-143
 deep branch, 135
 Radius
 dorsal tubercle, 9
 tuberosity, 10, 122
 styloid process, 9, 132
 Retraction of scapula, 22
 Rib(s)
 angle, 7, 8
 scalene tubercle, 6
 tubercle, 7, 8, 75
 Rotation, 21
 Rotator cuff, 112-115
- S**
 Sacral nerves, 158
 Sacral plexus, 159-161
 Sacral vertebrae. *See* Vertebra
 Sacrotuberous ligament, 11, 13, 15, 158,
 164, 175
 Sacrum, 13, 158, 164
 ala, 11, 159
 crests, 8, 74, 75
 foramina, 8, 78
 Sagittal plane, 20-22
 Scalp, 26-28
 Scaphoid bone, 9
 tubercle, 10, 145
 Scapula, 8
 acromion, 5, 7, 8, 105, 111, 112
 angle, inferior, 5, 106, 116
 coracoid process, 5, 7, 99, 101, 102
 glenoid cavity (fossa), 12, 112-114
 infraglenoid tubercle, 5, 117
 infraspinous fossa, 5, 113
 movements, 22
 spine, 5, 105, 107-109, 111
 subscapular fossa, 7, 115

- supraglenoid tubercle, 7, 102
 supraspinous fossa, 5, 112
 Sciatic foramen, 11
 Sciatic nerve, 167, 178, 183
 common peroneal part, 175
 tibial part, 175-177
 Sphenoid bone, 2
 greater wing, 2, 4, 48
 lesser wing, 4, 30
 pterygoid plate, lateral, 2, 4, 47, 48
 Spinal nerves
 dorsal primary division, 74-81
 ventral primary division, 81
 Sternum, 7, 85, 98
 body, 7
 manubrium, 5, 7, 50, 56, 57
 xiphoid process, 7, 89, 94
 Suboccipital nerve, 67-70
 Superficial peroneal nerve, 200, 201
 Supination, 23
 Suprascapular nerve, 112, 113
 Supraspinous ligament, 8, 75, 105,
 106, 108
 Synovial membrane of knee, 12
- T**
 Talocalcaneal ligament, 16, 202
 Talus, 16, 18
 Teeth, 44-47, 54
 Temporal bone, 2, 3, 45
 mandibular process, 4
 mastoid notch, 5, 52
 mastoid process, 2, 3, 4, 26, 50, 72, 75
 styloid process, 2, 5
 zygomatic process, 2
 Temporal fossa, 2, 45
 Temporomandibular joint, 48
 articular disk, 4
 Testes, 92
 Thoracic nerves
 dorsal, 106
 long, 110
 Thoracolumbar (lumbar) fascia, 12, 91,
 93, 106
 Thyroid cartilage
 lamina, 5, 57, 58
 Tibia
 condyles, 12, 15, 16, 172, 175, 177,
 186, 188
 medial malleolus, 18
 soleal line, 17, 199
 tuberosity of, 14, 170-173
 Tibial nerve, 178, 191-198
 Transverse metatarsal ligaments, 18, 209
 Transverse planes (cross sections), 20
 Trapezium bone, 9, 146
 tubercle, 10, 145, 147
 Trapezoid bone, 9, 10, 148
 Trigeminal nerve
 mandibular division, 45-48, 52, 54
 Triquetrum bone, 9, 10
- U**
 Ulna, 8
 coronoid process, 7, 10, 103, 122,
 127-129
 olecranon process, 8-10, 117, 118, 125
 supinator crest, 10, 136
 tuberosity, 7, 103
 Ulnar flexion, 23
 Ulnar nerve, 125, 128, 144, 146, 148-154
- V**
 Vertebra
 accessory process, 8, 81
 anterior tubercle, 81
 articular process, 75, 78
 body, 11
 mammillary process, 8, 78
 posterior tubercle, 81, 107
 spinous process, 8, 72, 73, 75-80, 87,
 105, 108
 transverse process, 6, 8, 11, 60, 64-66,
 73-81, 86, 88, 96, 156
- Z**
 Zygomatic arch, 2, 46
 Zygomatic bone, 2, 4, 29, 36, 38, 39

Alphabetical Listing of Muscles

A

Abductor digiti minimi
of foot, 205
of hand, 149
Abductor hallucis, 203
Abductor pollicis brevis, 145
Abductor pollicis longus, 139
Adductor brevis, 182
Adductor hallucis, 209
Adductor longus, 181
Adductor magnus, 183
Adductor pollicis, 148
Anconeus, 118
Auricularis
anterior, superior, posterior, 28

B

Biceps brachii, 102
Biceps femoris, 175
Brachialis, 103
Brachioradialis, 132
Buccinator, 44

C

Coracobrachialis, 101
Corrugator supercillii, 31
Cremaster, 92

D

Deltoideus, 111
Depressor
anguli oris, 42
labii inferioris, 41
septi, 34
Diaphragm, 89
Digastricus, 52
Dorsal interossei
of foot, 211
of hand, 154

E

Epicranius
frontal belly (frontalis), 26
occipital belly (occipitalis), 26
Erector spinae, 74–76
Extensor carpi radialis brevis, 134
Extensor carpi radialis longus, 133

Extensor carpi ulnaris, 137
Extensor digiti minimi, 136
Extensor digitorum brevis, 202
Extensor digitorum communis, 135
Extensor digitorum longus, 188
Extensor hallucis longus, 187
Extensor indicis, 143
Extensor pollicis brevis, 140
Extensor pollicis longus, 141

F

Flexor carpi radialis, 123
Flexor carpi ulnaris, 125
Flexor digiti minimi, 145, 146
Flexor digiti minimi brevis, 150, 210
Flexor digitorum brevis, 204
Flexor digitorum longus, 197
Flexor digitorum profundus, 128
Flexor digitorum superficialis, 127
Flexor hallucis brevis, 208
Flexor hallucis longus, 196
Flexor pollicis brevis, 146
Flexor pollicis longus, 129
Frontalis. *See* Epicranius

G

Gastrocnemius, 191
Gemellus
inferior, 161
superior, 160
Geniohyoideus, 55
Gluteus
maximus, 164
medius, 165
minimus, 166
Gracilis, 179

I

Iliacus, 157
Iliocostalis
cervicis, 74
lumborum, 74
thoracis, 74
Iliopsoas, 154
Infraspinatus, 113
Intercostales
externi, 82
interni, 83

Interossei

of foot, 211–212
of hand, 153–154
Interspinales, 80
Intertransversarii, 81

L

Latissimus dorsi, 106
Levator anguli oris, 37
Levator labii superioris, 36
Levator palpebrae superioris, 30
Levator scapulae, 107
Levatores costarum, 86
Longissimus, 75
capitis, 75
cervicis, 75
thoracis, 75
Longus
capitis, 61
colli, 60
Lumbricales
of foot, 207
of hand, 152

M

Masseter, 46
Mentalis, 43
Multifidus, 78
Muscle Groups
abdominal muscles, 95
muscles of anterior chest and arm, 104
posterior back, shoulder and arm
muscles, 119
muscles of the wrist, 126
flexors of the fingers, 130
extensors of the thumb, 142
muscles of the hip, 167
muscles of the anterior thigh, 174
hamstring muscles, 178
hip flexors and adductors, 184
anterior and lateral leg muscles, 190
muscles of the calf, 194
deep posterior leg muscles, 199
Mylohyoideus, 54

N

Nasalis
alar part, 33
transverse part, 33

O

Obliquus capitis
 inferior, 69
 superior, 70
 Obliquus externus abdominis, 90
 Obliquus internus abdominis, 91
 Obturator
 externus, 162
 internus, 159
 Occipitalis. *See* Epicranius
 Omohyoideus, 59
 Opponens digiti minimi, 151
 Opponens pollicis, 147
 Orbicularis oculi, 29
 Orbicularis oris, 35

P

Palmar interossei, 153
 Palmaris
 brevis, 144
 longus, 124
 Pectineus, 180
 Pectoralis
 major, 98
 minor, 99
 Peroneus
 brevis, 201
 longus, 200
 tertius, 189
 Piriformis, 158
 Plantar interossei, 212
 Plantaris, 193
 Platysma, 51
 Popliteus, 195
 Procerus, 32
 Pronator
 quadratus, 131
 teres, 122
 Psoas
 major, 156
 minor, 156
 Pterygoideus
 lateralis, 48
 medialis, 47
 Pyramidalis, 95

Q

Quadratus
 femoris, 163
 lumborum, 96
 plantae, 206
 Quadriceps femoris
 rectus femoris, 170
 vastus intermedius, 173
 vastus lateralis, 171
 vastus medialis, 172

R

Rectus abdominis, 94
 Rectus capitis
 anterior, 62
 lateralis, 63
 posterior major, 67
 posterior minor, 68
 Rectus femoris. *See* Quadriceps femoris
 Rhomboideus
 major, 108
 minor, 109
 Risorius, 40
 Rotatores, 79

S

Sacrospinalis. *See* Erector spinae
 Sartorius, 169
 Scalenus
 anterior, 64
 medius, 65
 posterior, 66
 Semimembranosus, 177
 Semispinalis
 capitis, 77
 cervicis, 77
 thoracis, 77
 Semitendinosus, 176
 Serratus
 anterior, 110
 posterior inferior, 88
 posterior superior, 87
 Soleus, 192
 Spinalis, 74
 capitis, 76

cervicis, 76
 thoracis, 76

Splenius
 capitis, 72
 cervicis, 73
 Sternocleidomastoideus, 50
 Sternohyoideus, 56
 Sternothyroideus, 57
 Stylohyoideus, 53
 Subclavius, 100
 Subcostales, 84
 Subscapularis, 115
 Supinator, 138
 Supraspinatus, 112

T

Temporalis, 45
 Temporoparietalis, 27
 Tensor fasciae latae, 168
 Teres
 major, 116
 minor, 114
 Thyrohyoideus, 58
 Tibialis
 anterior, 186
 posterior, 198
 Transversospinalis, 77
 Transversus
 abdominis, 93
 thoracis, 85
 Trapezius, 105
 Triceps brachii, 117

V

Vastus
 intermedius. *See* Quadriceps femoris
 lateralis. *See* Quadriceps femoris
 medialis. *See* Quadriceps femoris

Z

Zygomaticus
 major, 38
 minor, 39

Index

- A**
- Abdominal aponeurosis, 12, 90, 91, 93
 - Abduction, 21, 23, 24
 - Accessory nerve (11th cranial)
 - cranial part, 105
 - spinal part, 50
 - Accessory process of vertebra, 8
 - Acetabulum, 12, 170
 - Acromion, 5, 7, 8
 - Adduction, 21–24
 - Adductor tubercle of femur, 15
 - Ala, 3
 - of nose, 3, 34
 - of sacrum, 11, 157
 - Alar cartilage, 3, 33, 36
 - Alveolar border (process)
 - of maxilla, 4
 - Anatomical position, 20, 21, 23
 - Annular ligament of radius, 9, 10, 138
 - Ansa cervicalis, 56, 57, 59
 - Anterior iliac crest, 12
 - Anterior iliac spine
 - inferior, 11, 14, 157
 - superior, 11, 12, 14
 - Arcuate ligament
 - lateral, 7, 89
 - medial, 7, 89
 - Arcuate line of ilium, 11, 156
 - Articular disk
 - temporomandibular joint, 3
 - Atlas
 - anterior arch, 6, 60
 - posterior arch, 3, 68
 - transverse process, 3, 62, 63, 69, 70
 - Axillary nerve, 111, 114
 - Axis, 6
 - spinous process of, 3, 67, 69, 76
- B**
- Bicipital aponeurosis, 102
 - Bicipital (intertubercular) groove
 - of humerus, 7, 102
- C**
- Calcaneus, 16, 191–193, 202, 206
 - sustinaculum tali, 17, 18, 198
 - tuberosity, 18, 203–205
 - Canine fossa of maxilla, 2
 - Capitate bone, 9, 10, 148
 - Carpometacarpal joint, 151
 - Cervical nerves
 - dorsal primary divisions, 72, 73, 75
 - ventral rami, 64–66
 - Clavicle, 5, 7, 8, 50, 59, 98, 100, 105, 111
 - Coccyx, 13, 164
 - Common peroneal nerve, 175, 178
 - Coracoid process of scapula, 5, 7
 - Coronal (frontal) planes, 20, 21, 23
 - Costal cartilage, 7, 12, 82, 83, 89, 93, 94, 98, 100
 - Cuboid bone, 16–18, 198, 208
 - Cuneiform bones, 16–18, 186, 198, 200
- D**
- Deep peroneal nerve, 186–189, 202
 - Deltoid tuberosity of humerus, 7, 11
 - Depression of scapula, 22
 - Dorsal scapular nerve, 107–109
 - Dorsiflexion of ankle joint, 24
- E**
- Ear
 - helix, 3
 - Elevation of scapula, 22
 - Ethmoid bone
 - nasal septum, 4, 34, 35
 - Eversion, 24
 - Extension, 21, 24
 - Extensor expansion, 143
 - Extensor retinaculum, 16, 190, 202
 - External occipital protuberance, 3, 4
- F**
- Facial nerve, 52, 53
 - auricular branch (posterior), 26, 28
 - buccal branches, 32–40, 44
 - cervical branch, 51
 - mandibular branch, 35, 41–43
 - temporal branch, 26–29, 31
 - zygomatic branch, 29
 - Fascia lata. *See* iliotibial tract
 - Femoral nerve, 157, 169–173, 180, 184
 - Femur, 11, 12, 14–17
 - adductor tubercle, 15, 183
 - condyles, 17, 191, 195
 - gluteal tuberosity, 13, 15, 164, 171
 - greater trochanter, 11, 13–15, 158–161, 165, 166, 171
 - intertrochanteric crest, 13, 163
 - intertrochanteric line, 14, 171, 172
 - lateral supracondylar ridge (line), 14, 15, 17, 173, 175, 193
 - lesser trochanter, 11, 14, 15, 156, 157, 180, 182
 - linea aspera, 13, 15, 171–173, 175, 180–183
 - medial supracondylar (ridge) line, 14, 172
 - popliteal surface, 17, 191
 - quadrate line, 13, 163
 - supracondylar ridge (line), 14, 15, 17, 172, 175
 - trochanteric fossa, 11
 - Fibula, 16, 17, 187–189, 192, 196, 198, 200, 201
 - head, 15
 - Flexion, 21, 23, 24
 - Flexor retinaculum
 - of foot, 18, 203
 - of hand, 10, 24, 126, 144–147, 150, 151
 - Foramen magnum, 61, 62
 - Frontal bone, 2, 4, 29, 45
 - superciliary arch, 4
 - Frontal (coronal) planes, 20, 21, 23
 - Frontal process of maxilla, 2
- G**
- Galea aponeurotica, 3, 26
 - Genitofemoral nerve, genital branch, 92
 - Glenoid cavity of scapula, 12
 - Gluteal nerve
 - inferior, 164
 - superior, 165, 166, 168
- H**
- Hamate bone, 9, 10, 150, 151
 - hook, 10, 125
 - Humerus, 8, 101, 103
 - condyles, 9
 - deltoid tuberosity, 7, 111
 - greater tuberosity (tubercle), 5, 7, 98, 112–114
 - intertubercular (bicipital) groove, 7, 98, 102, 106, 116
 - lateral epicondyle, 9, 118, 134–138
 - lateral supracondylar ridge, 9, 132, 133
 - lesser tuberosity, 7, 115
 - medial epicondyle, 10, 122–125, 127, 129
 - medial supracondylar ridge, 10, 122
 - Hyoid bone, 5, 52–56, 58, 59
 - greater cornu, 5
 - Hyperextension, 21
 - Hypoglossal nerve, 55, 58
 - Hypothenar eminence, 149
- I**
- Iliohypogastric nerve, 91, 93
 - Ilioinguinal nerves, 90, 91, 93
 - Iliolumbar ligament, 11, 95
 - Iliopectineal eminence, 11, 156
 - Iliotibial tract, 112, 164, 168, 174

- Ilium**
 arcuate line, 11
 crest of, 8, 12, 13, 74, 75, 90, 91, 93
 fossa of, 11, 157
 gluteal lines
 inferior, 13, 166
 middle (anterior), 13, 166
 posterior, 13, 164
 iliopectineal eminence, 11
 spines
 anterior inferior, 11, 14, 170
 anterior superior, 11, 12, 168, 169
 posterior superior iliac, 8, 78
 tubercle, 12, 168
 Inguinal ligament, 11, 12, 91-93, 184
 Intercostal nerves, 82-86, 90, 91, 93, 94
 Intercostal space, 83
 Interosseous membrane
 radioulnar, 9, 10, 128, 129,
 139-141, 143
 tibiofibular, 16, 17, 186-189, 196, 198
 Intervertebral disks, 11, 156
 Inversion, 24
 Ischium
 greater sciatic notch, 13
 lesser sciatic notch, 13
 ramus, 11, 13, 15, 162, 183
 spine, 13, 160
 tuberosity, 13, 15, 161, 163, 175-177
- L**
 Lacrimal bone, 2, 4, 29
 Lateral cuneiform bone, 16-18
 Ligamentum nuchae, 8, 72, 76, 87,
 105, 109
 Linea alba, 11, 12, 90, 91, 93, 95
 Lumbar (thoracolumbar) fascia, 12
 Lumbar plexus, 156
 Lumbar vertebrae. *See* vertebra
 Lumbocostal arch(es), 7, 89
 Lunate bone, 9, 10
- M**
 Mammillary process of vertebrae, 8, 78, 81
 Mandible, 2-5, 35, 51, 52, 55
 alveolar process (border), 44
 angle, 2, 46, 47
 condyle, 2, 48
 coronoid process, 2, 45, 46
 incisive fossa, 2, 43
 inferior mental spine, 5
 mental foramen, 2, 41
 mylohyoid line, 5, 54
 oblique line, 2
 ramus, 2, 45-47
 symphysis, 4, 5, 41, 52
 Maxilla, 2, 4
 alveolar process (border), 4, 35, 44
 canine fossa, 2, 37
 frontal process, 2, 36
 incisive fossa, 2, 4
 tuberosity, 3, 47
 zygomatic process, 46
 Medial cuneiform bone, 16-18
 Median (midsagittal plane), 20-22
 Median nerve, 122-124, 127, 145-147, 152
 anterior interosseous branch, 128-131
 Metacarpal bones, 9, 10, 123, 125, 133,
 134, 137, 139, 146-148, 151,
 153, 154
 Metacarpophalangeal joint, 135, 146, 150,
 152-154
 Metatarsal bones, 16, 18, 186, 188, 189,
 198, 200, 201, 209-212
 Muscles. *See* pages 213, 214
 Musculocutaneous nerve, 101-103
- N**
 Nasal bone, 2, 4
 Nasal cartilage, 3
 Nasal septum (ethmoid bone), 4, 34, 35
 Nasolabial furrow, 36, 39
 Navicular bone, 9, 16
 tubercle of, 10
 tuberosity of, 17, 18, 198
- O**
 Oblique popliteal ligament, 17, 183
 Obturator foramen, 11, 13, 162
 Obturator membrane, 13, 159
 Obturator nerve, 162, 179, 180-183
 Occipital bone, 2, 3, 4, 6
 external occipital crest, 4
 external occipital protuberance, 3,
 4, 105
 foramen magnum, 61, 62
 inferior nuchal line, 2, 3, 4, 67, 68, 70
 jugular process, 6
 superior nuchal line, 2, 3, 4, 70, 72, 105
 Oculomotor nerve, 30
 Opposition, 23
- P**
 Palatine bone, 47
 Palmar aponeurosis, 10, 124, 126, 144
 Palpebral ligament
 lateral (raphe), 29
 medial, 29
 Parietal bone, 3
 inferior temporal line, 2
 superior temporal line, 2
 Patella, 14, 170-173
 Patellar ligament, 14, 170-172
 Pectoral nerves
 lateral, 98
 medial, 98, 99
 Peroneal nerves
 common, 175
 deep, 186-188, 202
 superficial, 200, 201
 Pes anserinus, 169
 Phalanges
 of foot, 16, 18, 187, 188, 196, 197,
 202-212
 of hand, 9, 10, 127-129, 135, 136, 140,
 141, 143, 145-147
 Phrenic nerve, 89
 Pisiform bone, 10, 125, 149
 Plantar aponeurosis, 18, 203-205
 Plantar flexion, 24
 Plantar metatarsophalangeal ligaments,
 18, 209
 Plantar nerves
 lateral, 205-207, 209-212
 medial, 203, 204, 207, 208
 Pronation of scapula, 23
 Protraction of scapula, 22
 Pterygoidomandibular raphe, 3, 44
 Pubic ligament, 11
 Pubic symphysis, 11, 94
 Pubis
 body, 13-15
 crest, 11
 inferior ramus, 11, 14, 15, 162, 179,
 182, 183
 pectineal line, 14, 180
 superior ramus, 11, 162
 tubercle, 11
- Q**
 Quadriceps tendon, 14, 173
- R**
 Radial collateral ligament, 9, 10, 138
 Radial nerve, 117, 118, 132-143
 deep branch, 135
 Radius
 dorsal tubercle, 9
 tuberosity, 10, 122
 styloid process, 9, 132
 Retraction of scapula, 22
 Rib(s)
 angle, 7, 8
 scalene tubercle, 6
 tubercle, 7, 8, 75
 Rotation, 21
 Rotator cuff, 112-115
- S**
 Sacral nerves, 158
 Sacral plexus, 159-161
 Sacral vertebrae. *See* Vertebra
 Sacrotuberous ligament, 11, 13, 15, 158,
 164, 175
 Sacrum, 13, 158, 164
 ala, 11, 159
 crests, 8, 74, 75
 foramina, 8, 78
 Sagittal plane, 20-22
 Scalp, 26-28
 Scaphoid bone, 9
 tubercle, 10, 145
 Scapula, 8
 acromion, 5, 7, 8, 105, 111, 112
 angle, inferior, 5, 106, 116
 coracoid process, 5, 7, 99, 101, 102
 glenoid cavity (fossa), 12, 112-114
 infraglenoid tubercle, 5, 117
 infraspinous fossa, 5, 113
 movements, 22
 spine, 5, 105, 107-109, 111
 subscapular fossa, 7, 115

- supraglenoid tubercle, 7, 102
 supraspinous fossa, 5, 112
 Sciatic foramen, 11
 Sciatic nerve, 167, 178, 183
 common peroneal part, 175
 tibial part, 175-177
 Sphenoid bone, 2
 greater wing, 2, 4, 48
 lesser wing, 4, 30
 pterygoid plate, lateral, 2, 4, 47, 48
 Spinal nerves
 dorsal primary division, 74-81
 ventral primary division, 81
 Sternum, 7, 85, 98
 body, 7
 manubrium, 5, 7, 50, 56, 57
 xiphoid process, 7, 89, 94
 Suboccipital nerve, 67-70
 Superficial peroneal nerve, 200, 201
 Supination, 23
 Suprascapular nerve, 112, 113
 Supraspinous ligament, 8, 75, 105,
 106, 108
 Synovial membrane of knee, 12
- T**
 Talocalcaneal ligament, 16, 202
 Talus, 16, 18
 Teeth, 44-47, 54
 Temporal bone, 2, 3, 45
 mandibular process, 4
 mastoid notch, 5, 52
 mastoid process, 2, 3, 4, 26, 50, 72, 75
 styloid process, 2, 5
 zygomatic process, 2
 Temporal fossa, 2, 45
 Temporomandibular joint, 48
 articular disk, 4
 Testes, 92
 Thoracic nerves
 dorsal, 106
 long, 110
 Thoracolumbar (lumbar) fascia, 12, 91,
 93, 106
 Thyroid cartilage
 lamina, 5, 57, 58
 Tibia
 condyles, 12, 15, 16, 172, 175, 177,
 186, 188
 medial malleolus, 18
 soleal line, 17, 199
 tuberosity of, 14, 170-173
 Tibial nerve, 178, 191-198
 Transverse metatarsal ligaments, 18, 209
 Transverse planes (cross sections), 20
 Trapezium bone, 9, 146
 tubercle, 10, 145, 147
 Trapezoid bone, 9, 10, 148
 Trigeminal nerve
 mandibular division, 45-48, 52, 54
 Triquetrum bone, 9, 10
- U**
 Ulna, 8
 coronoid process, 7, 10, 103, 122,
 127-129
 olecranon process, 8-10, 117, 118, 125
 supinator crest, 10, 136
 tuberosity, 7, 103
 Ulnar flexion, 23
 Ulnar nerve, 125, 128, 144, 146, 148-154
- V**
 Vertebra
 accessory process, 8, 81
 anterior tubercle, 81
 articular process, 75, 78
 body, 11
 mammillary process, 8, 78
 posterior tubercle, 81, 107
 spinous process, 8, 72, 73, 75-80, 87,
 105, 108
 transverse process, 6, 8, 11, 60, 64-66,
 73-81, 86, 88, 96, 156
- Z**
 Zygomatic arch, 2, 46
 Zygomatic bone, 2, 4, 29, 36, 38, 39