

Nicola Maffulli  
Mark Easley  
*Editors*

# Minimally Invasive Forefoot Surgery in Clinical Practice

 Springer

# Minimally Invasive Forefoot Surgery in Clinical Practice



Nicola Maffulli • Mark Easley  
Editors

# Minimally Invasive Forefoot Surgery in Clinical Practice



Springer

*Editors*

Nicola Maffulli  
Centre for Sport  
and Exercise Medicine  
Mile End Hospital  
London  
UK

Mark Easley  
Duke Health Center  
Durham  
North Carolina  
USA

ISBN 978-1-4471-4488-5      ISBN 978-1-4471-4489-2 (eBook)  
DOI 10.1007/978-1-4471-4489-2  
Springer London Heidelberg New York Dordrecht

Library of Congress Control Number: 2012951636

© Springer-Verlag London 2013

This work is subject to copyright. All rights are reserved by the Publisher, whether the whole or part of the material is concerned, specifically the rights of translation, reprinting, reuse of illustrations, recitation, broadcasting, reproduction on microfilms or in any other physical way, and transmission or information storage and retrieval, electronic adaptation, computer software, or by similar or dissimilar methodology now known or hereafter developed. Exempted from this legal reservation are brief excerpts in connection with reviews or scholarly analysis or material supplied specifically for the purpose of being entered and executed on a computer system, for exclusive use by the purchaser of the work. Duplication of this publication or parts thereof is permitted only under the provisions of the Copyright Law of the Publisher's location, in its current version, and permission for use must always be obtained from Springer. Permissions for use may be obtained through RightsLink at the Copyright Clearance Center. Violations are liable to prosecution under the respective Copyright Law.

The use of general descriptive names, registered names, trademarks, service marks, etc. in this publication does not imply, even in the absence of a specific statement, that such names are exempt from the relevant protective laws and regulations and therefore free for general use.

While the advice and information in this book are believed to be true and accurate at the date of publication, neither the authors nor the editors nor the publisher can accept any legal responsibility for any errors or omissions that may be made. The publisher makes no warranty, express or implied, with respect to the material contained herein.

Printed on acid-free paper

Springer is part of Springer Science+Business Media ([www.springer.com](http://www.springer.com))

# Preface

Many of our patients hate their feet. Actually, it is not true: they hate their forefeet. It is the reason why so many procedures have been proposed to address deformities of the hallux and of the lesser toes! For example, just for hallux valgus some 140 operations have been described to correct it. The truth, when so many procedures are possible, is that none of them is fool proof. Also, traditional surgical techniques involve large incisions, and subsequent ugly scarring. Here come minimally invasive surgical correction techniques for forefoot problems. They have been around for a while, and have been popular in some parts of the world. They are becoming increasingly popular, and, while there is no evidence that they are 'better' than 'traditional' ones, they seem to be comparable. In this book, we describe a few of the better established and studied ones. But remember: we still need to be able to perform the traditional procedures!



# Contents

<b>1 Arthroscopy of the First Metatarsophalangeal Joint</b> .....	1
Tun Hing Lui	
<b>2 Minimally Invasive Management of Hallux Rigidus</b> .....	25
Mariano De Prado, Pedro-Luis Ripoll, and Pau Golanó	
<b>3 Percutaneous First Metatarso-Phalangeal Joint Fusion</b> .....	43
Thomas Bauer	
<b>4 The Reverdin-Isham Procedure for the Correction of Hallux Valgus: A Distal Metatarsal Osteotomy Procedure Using Minimal Invasive Technique</b> .....	55
Stephen A. Isham and Orlando E. Nunez	
<b>5 Arthroscopic Assisted Correction of Hallux Valgus Deformity</b> .....	73
Tun Hing Lui	
<b>6 Minimally Invasive Hallux Valgus Correction</b> .....	93
Francesco Oliva, Umile Giuseppe Longo, and Nicola Maffulli	
<b>7 Minimally Invasive Modified Wilson Osteotomy for the Treatment of Hallux Valgus</b> .....	105
Sheldon Nadal	



<b>8 Percutaneous Surgery for Static Metatarsalgia</b> .....	139
Thomas Bauer	
<b>9 Percutaneous Treatment of Static Metatarsalgia with Distal Metatarsal Mini-invasive Osteotomy</b> .....	149
J.Y. Coillard, Olivier Laffenetre, Christophe Cermolacce, Patrice Determe, Stéphane Guillo, and ChristopededeLavigne, GRECMIP (Groupe de Recherche et d'Etude en Chirurgie Mini-Invasive du Pied)	
<b>10 Isham Hammertoe Procedures for the Correction of Lesser Digital Deformities: Phalangeal Osteotomy Procedures</b> .....	161
Stephen A. Isham and Orlando E. Nunez	
<b>11 Minimally Invasive Management of Dorsiflexion Contracture at the Metatarsophalangeal Joint and Plantarflexion Contracture at the Proximal Interphalangeal Joint of the Fifth Toe</b> .....	181
Mariano de Prado, Pedro-Luis Ripoll, Pau Golanó, Javier Vaquero, Filippo Spiezia, and Nicola Maffulli	
<b>12 Arthroscopic Assisted Correction of Lesser Toe Deformity</b> .....	193
Tun Hing Lui	
<b>13 Percutaneous Fixation of Proximal Fifth Metatarsal Fractures</b> .....	205
Aaron T. Scott and James A. NunleyII	
<b>Index</b> .....	227

# Chapter 1

## Arthroscopy of the First Metatarsophalangeal Joint

**Tun Hing Lui**

### 1.1 Introduction

Arthroscopy of the first metatarsophalangeal joint (MTP-1) was originally described by Watanabe [1] in 1972. Advancements in small joint instrumentation and arthroscopic technique have expanded the application of arthroscopy in the management of the first metatarsophalangeal joint pathology. Although the use of the arthroscopy in the MTP-1 has not been as popular as in the knee or the shoulder, its value continues to grow in the management of various pathologies from traumatic to degenerative and reconstruction.

### 1.2 Anatomy/Pathoanatomy

The MTP-1 is composed of the first metatarsal head and neck, proximal phalangeal base, medial and lateral sesamoids. It has two compartments: metatarsophalangeal and metatarsos-sesamoid compartments. The metatarsophalangeal compartment composes of the oval, concave proximal phalanx articular surface and the convex metatarsal head articular

---

T.H. Lui, MBBS (HK), FRCS (Edin), FHKAM, FHKCOS  
Department of Orthopaedics and Traumatology, North District Hospital,  
9 Po Kin Road, Sheung Shui, NT Hong Kong SAR, China  
e-mail: luithderek@yahoo.co.uk

N. Maffulli, M. Easley (eds.), *Minimally Invasive Forefoot Surgery in Clinical Practice*, DOI 10.1007/978-1-4471-4489-2\_1, © Springer-Verlag London 2013

surface. The proximal phalanx articular surface is smaller than the corresponding articular surface of the metatarsal head. The metatarso-sesamoid compartment composes of the articular surfaces of the sesamoid bones and the plantar articular surface which is separated into two sloped surfaces by a small crista.

The articular surface of each sesamoid is convex in the coronal plane and concave in the sagittal plane and fits well with the corresponding trochlear surface. The dorsomedial aspect of the joint contains a sizable synovial fold with the average width of 7 mm covering 29 % of the joint. At the level of the MTP-1, the distribution of the cutaneous nerve is highly variable, but usually the dorsomedial and dorsolateral cutaneous branches originate from the medial dorsal cutaneous branch of the superficial peroneal nerve and the deep peroneal nerve, respectively.

The plantar medial and plantar lateral branches originate from the medial plantar nerve. The dorsomedial cutaneous nerve is in proximity of the dorsomedial portal and is on average 13.1 mm medial to the extensor hallucis longus tendon [2] but has been reported to be 2–5 mm from it [3]. The plantar medial hallucal nerve is on average 10.6 mm plantar to the midline, which is the location for the medial portal [4]. Given the variations of the nerves in the foot, all the arthroscopic portals should be handled with care assuming that a nerve is located directly underneath.

## 1.3 Arthroscopic Technique

### 1.3.1 Positioning

We undertake arthroscopy of the MTP-1 with the patient supine and both hips abducted so that the surgeon will have a 360° access to the forefoot. I prefer to sit at the lateral side of the operated foot with the monitor at the end of the bed. Plantar portals, if needed, can be approached with the surgeon sitting between the patient's legs.

### *1.3.2 Traction*

Manual traction is usually sufficient to visualize the metatarsal head and the base of the proximal phalanx. We do not routinely use the finger trap traction. Joint distraction, while opening the space between the articular facets, makes the intraarticular gutters obliterated and decreases the maneuverability of the arthroscope and instruments. However, it may be useful in the access to some osteochondral lesions and in arthroscopy-assisted arthrodesis which requires passing instruments between the joint facets. The finger trap traction can be attached to a 3–5 kg weight, or the limb can be suspended from a pole so that it is just off the operating table.

### *1.3.3 Instruments*

Either 1.9 or 2.7 mm 30° small joint arthroscopy is used for most arthroscopic visualization of the MTP-1. The 1.9 mm arthroscope is used in tight joints or when no traction is applied, but should be handled with care due to its fragility. A long 2.7 or 4 mm 30° arthroscope which provides wider field of view and easier orientation is helpful in periarticular endoscopy, such as in endoscopic distal soft tissue release and gouty tophi excision. Gravity driven inflow is usually adequate, and an arthroscopic pump is generally not required.

### *1.3.4 Portals*

The dorsomedial portal is at the level of joint line just medial to the extensor hallucis longus tendon joint. The dorsolateral portal is at the same level but just lateral to the extensor hallucis longus tendon. The dorsomedial and dorsolateral hallucal nerves can be directly beneath or send off a branch in close proximity to the dorsal portals. The medial portal is

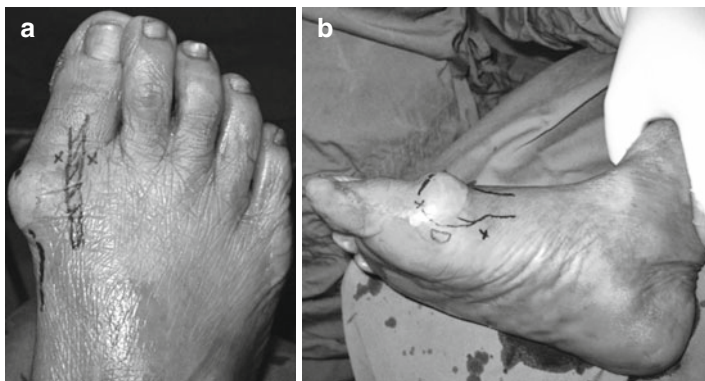


FIGURE 1.1 (a) Dorsolateral and dorsomedial portals at the lateral and medial aspects of the tendon of extensor hallucis longus. (b) Medial portal and proximal medial portal

through the thick medial capsule at the level of joint line at the equator of the joint, and is away from neurovascular structures [2]. The plantar medial portal [5] described for the instrumentation in the metatarso-sesamoid compartment is located 4 cm proximal to the joint line between the abductor hallucis tendon and the medial head of the flexor hallucis brevis (Fig. 1.1).

An easy way to introduce instruments through the medial portal without traction is firstly introducing the instrument to the adjacent dorsal capsular gutter and then “swapped” into the metatarsophalangeal compartment (Fig. 1.2).

We use the dorsolateral and medial portals for arthroscopy of the metatarso-phalangeal compartment because of the wider distance between the portals can reduce crowding of the instruments (Fig. 1.3).

The proximal medial portal is in line with the medial portal but is just proximal to the medial eminence. This portal is used for the medial exostectomy [6, 7]. The toe web portal and the plantar portal [6, 7] are required for the endoscopic lateral release of the hallux valgus correction. The toe web portal is just dorsal to the first web space. The plantar portal is approximately 4–5 cm proximal to the web space produced

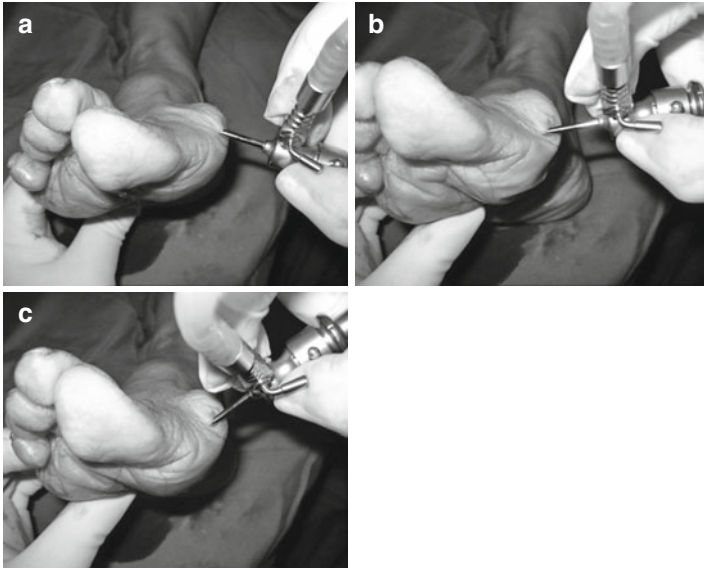


FIGURE 1.2 (a) The cannula and trocar is inserted into the dorsal capsular gutter. (b) The cannula and trocar are swapped into the metatarsophalangeal compartment for arthroscopy of the metatarsophalangeal compartment. (c) The cannula and trocar are swapped into the metatarso-sesamoid compartment for arthroscopy of the metatarso-sesamoid compartment

using an inside-out technique with a Wissinger rod from the toe web portal passing underneath the intermetatarsal ligament. The toe web portal is relatively safe from the neurovascular structures but the plantar portal is in the vicinity of the branches from the medial plantar nerve.

The 2.0 mm probe is used to palpate the cartilage surface to detect softening, crevices, delamination, or osteochondral lesions. Loose bodies are removed with small straight hemostats which are preferable over the graspers due to the suction effect pulling the loose body to the jaws when opened. At times, a tight joint may require manual manipulation to enhance visualization such as plantarflexion to open the metatarso-sesamoid compartment.

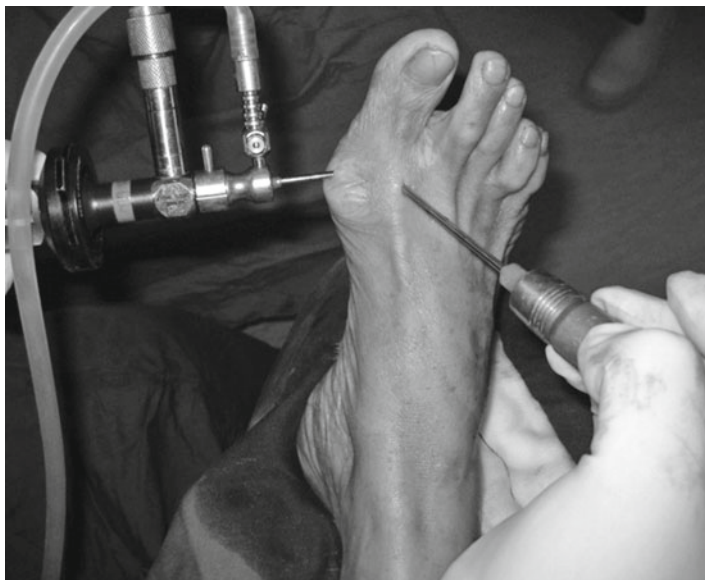

FIGURE 1.3 Metatarso-phalangeal compartment arthroscopy with the dorsolateral and middle portals

## 1.4 Arthroscopic Examination

The joint line is identified by a puckering with straight traction of great toe and by direct palpation.

The dorsolateral portal is established at the previously described location by making a longitudinal 3 mm incision followed by blunt dissection with a curved hemostat. The medial portal placement can be assisted by arthroscopic localization with a 21 gauge needle. Through the dorsolateral portal, the medial gutter, distal part of the sesamoid apparatus and the plantar plate, the middle and distal part of the lateral gutter, the medial part of the dorsal gutter and the middle and distal part of the articular surfaces of the metatarso-phalangeal compartment can be examined. Through the medial portal, the metatarso-sesamoid compartment (except the most lateral part of the compartment especially in case of

severe hallux valgus deformity), the lateral and dorsal gutters and the lateral and central part of the articular surfaces of metatarso-phalangeal compartment can be examined.

## 1.5 Arthroscopic Synovectomy

Synovitis of the first metatarso-phalangeal joint (Fig. 1.4) can arise from metabolic, e.g. gouty arthritis; inflammatory, e.g. rheumatoid arthritis; infective causes, and can be associated with abnormal mechanical stress, e.g. hallux valgus. The management of synovitis should be according to the underlying cause. Arthroscopic synovectomy is indicated once conservative treatment fails to control the disease. However, it should be supplemented with appropriate medical treatment if indicated e.g. in case of rheumatoid arthritis.

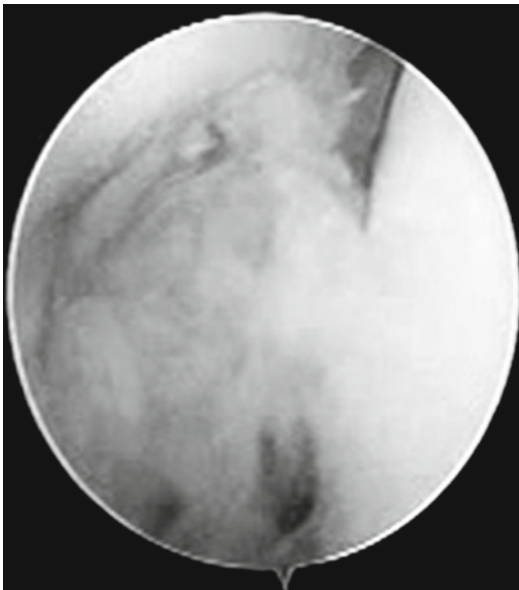

FIGURE 1.4 Synovitis of the first metatarso-phalangeal joint



### 1.5.1 Technique

Arthroscopic synovectomy can usually be performed with the dorsolateral and the medial portals. If complete synovectomy of the metatarso-sesamoid compartment, a portal 4 cm proximal to the joint and between the abductor hallucis and flexor hallucis brevis tendons can be made to complete the synovectomy around the sesamoid bones (Fig. 1.5).

Alternatively, the synovectomy of the metarso-sesamoid compartment can be performed together with the endoscopic distal soft tissue procedure through the medial and the toe web portal in patients with first metatarso-phalangeal synovitis associated with hallux valgus [7, 8]. Visualization of the, occasional enlarged, dorsomedial synovial fold is easier performed through the dorsolateral portal. Thorough debridement of the inflamed synovial tissue which is usually a major pain generator can be performed with a 3.0 full-radius shaver [9]. Traction is typically not required for a synovectomy. Suction is kept at minimum given the limited inflow from the small arthroscopic cannula.

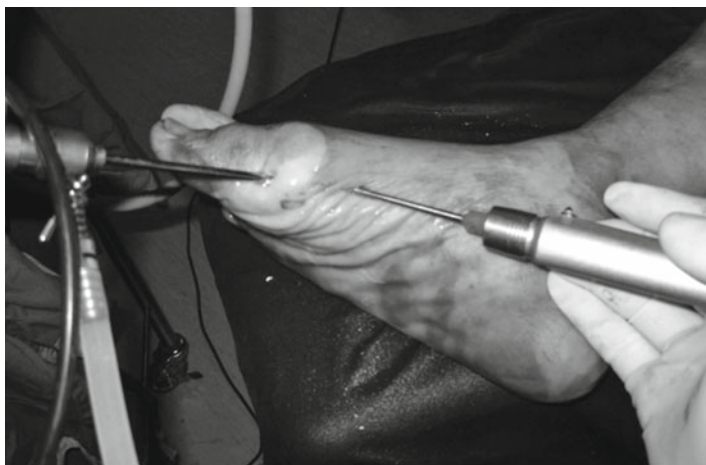

FIGURE 1.5 Metatarso-sesamoid compartment arthroscopy with medial and plantar medial portals

### 1.5.1.1 Endoscopic Resection of Gouty Tophus Around the First Metatarso-Phalangeal Joint

Gouty arthritis is one of the commonest type of arthritides faced by orthopedic surgeon. The commonest joint involved is the first metatarso-phalangeal joint. Tophi formation around the first metatarso-phalangeal joint will affect shoe-wear. Moreover, ulceration of the tophus will lead to persistent discharge and chronic ulceration which will take a long time to heal. Secondary infection is common. Wound breakdown, skin necrosis and impaired healing are common after open resection of the tophus. Minimally invasive decompression of the tophus minimizes wound complications [10]. However, this is mainly a blind percutaneous procedure, and the completeness of the resection cannot be ascertained. Also, protection of the digital nerve is difficult. The endoscopic approach [11] allows resection of the tophus under direct visualization and arthroscopic examination of the first metatarso-phalangeal joint [11, 12]. In addition to the advantage of minimization of wound complication, this can ensure complete resection without damage to the normal tissue.

The patient is supine with a thigh tourniquet. Two portals are established at the proximal and distal ends of the gouty tophus. A tunnel is produced between the two portals with the cannula and trocar. The two portals are switched as the visualization and working portals and the tophaceous materials are removed under arthroscopic visualization starting from the tunnel and proceed to the periphery of the tophus. The pockets of tophaceous materials are removed until the pseudo-capsule is reached. Great care is performed to avoid injury to the dorsomedial hallucal nerve superficial to the pseudocapsule (Fig. 1.6). After adequate decompression of the tophus, the overlying skin will be loose enough to allow free mobilization of the portals to plantar and dorsal directions to remove the plantar and dorsal extension of the tophus. Moreover, the distal portal can be mobilized to the position of the medial portal of first metatarso-phalangeal joint and the intra-articular condition can be examined with

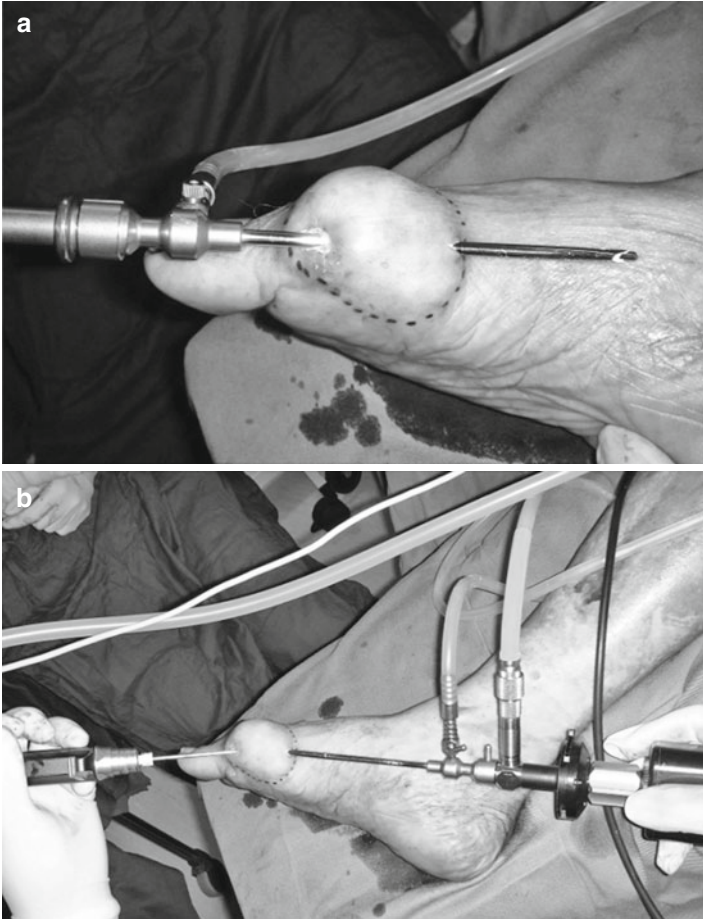


FIGURE I.6 (a) Cannula and trocar pass through the proximal and distal portals. (b) Endoscopic resection of gouty tophus

a 1.9 mm 30° arthroscope. If synovitis or tophaceous material is present, a dorsolateral portal is established to complete the debridement. The use of warm irrigation fluid is recommended to increase the solubility of the urate thus preventing clogging of the system [10]. Post-surgical gout attacks can be prevented by pre-surgical control of serum uric acid and prophylactic perioperative administration of colchicine.

Post-operatively, the patient is allowed to weight bearing walking with wooden based sandal.

### 1.5.1.2 Endoscopic Distal Soft Tissue Procedure for Hallux Valgus Correction

Endoscopic distal soft tissue procedure employs the same principle of open procedure [6, 7]. The lateral soft tissue release is performed through the toe web and plantar portals. The medial exostectomy and medial capsular plication are performed through the proximal and distal bunion portals. The distal bunion portal is the same as the medial portal of first metatarso-phalangeal arthroscopy, and the proximal portal is at the proximal pole of the bunion. The reduction of the sesamoid apparatus can be assessed arthroscopically through the toe web and distal bunion portals. The intermetatarsal space is then closed up manually and held with a positioning screw bridging the two metatarsals. This endoscopic approach is indicated in hallux valgus with incongruent metatarso-phalangeal joint and no significant bony abnormality e.g. severe hallux valgus interphalangeus or abnormal distal metatarsal articular angle. However, it is contra-indicated if the intermetatarsal angle cannot be closed up manually e.g. presence of os intermetatarsium. First metatarso-phalangeal arthrosis, deformity secondary to neuromuscular condition are other contra-indications of this procedure. It has the advantages of better assessment of the sesamoid reduction, better cosmetic result and avoids the need of metatarsal osteotomy. This approach will be discussed in another chapter.

## 1.6 Arthroscopic Dorsal Cheilectomy for Dorsal Impingement Syndrome

Dorsal impingement syndrome of the first metatarso-phalangeal joint is due to impingement of the dorsal osteophytes during dorsiflexion. Dorsal cheilectomy is indicated when conservative treatment has failed [13]. Dorsomedial

and dorsolateral portals are made at the medial and lateral corner of the dorsal osteophytes, which is further away from the tendon of extensor hallucis longus than the usual dorsal portals described above. This can avoid the crowding of the instruments. The two portals can be interchanged as the visualization and instrumentation portals and the dorsal impinging bony prominence can be removed with arthroscopic burr under arthroscopic visualization. Stripping of the dorsal capsule from the phalangeal and metatarsal insertions can improve the “working space” for bone shaving. Small osteophytes can be easily removed with a bone cutting shaver, and the round-tip abradar is reserved for large osteophytes or unusually hard bone. For an arthroscopic cheilectomy, the dorsal metatarsal head including a small amount of articular cartilage is decompressed until 50–70° of dorsiflexion is achieved. If there is any question regarding the amount of the decompression, fluoroscopy can be utilized. The prominent osteophyte on the proximal phalangeal base should be evaluated and adequately decompressed (Fig. 1.7).

## 1.7 Osteoarthritis

Mild to moderate osteoarthritis of the MTP-1 with pain, arising mainly from synovitis is an appropriate indication for arthroscopic management, especially when the arthrodesis or arthroplasty is not yet indicated. However, patients with advanced osteoarthritis with midrange pain have not shown a lasting benefit from arthroscopic debridement. Large osteophytes (>5 mm) may obliterate the dorsal joint space. This can be addressed arthroscopically by firstly stripping the dorsal capsule with a small periosteal elevator through the dorsal portals to increase the working space. Moreover, the placement of the dorsal portals at the dorsomedial and the dorsolateral corners of the joint allows debridement of the osteophytes in the dorsal, medial and lateral gutters. For example, the medial osteophytes can be debrided with the dorsolateral portal as visualization portal and the dorsomedial

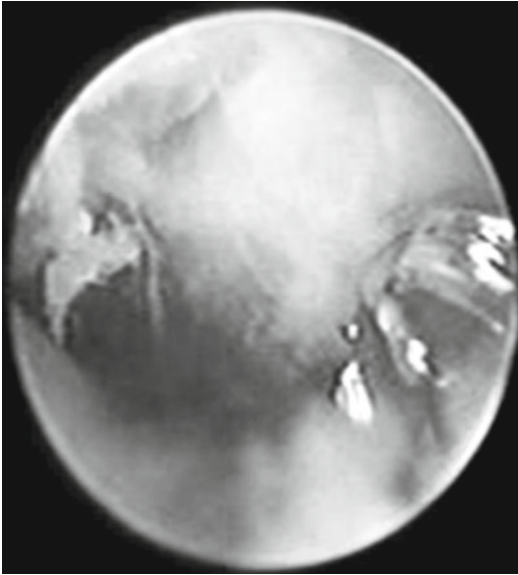


FIGURE 1.7 Dorsal cheilectomy of the phalangeal base

portals as the instrumentation portals. If adequate debridement is not possible arthroscopically, it can be converted to open debridement.

Arthroscopic assisted arthrodesis [14, 15] has been described for end stage disease (Fig. 1.8) without gross deformity or bone loss. It is contraindicated in patients with marked bone deformity or if shortening of the first ray is required, as in correction of deformity of the forefoot in rheumatoid patients. Dorsomedial and medial portals are used, and continuous traction with a finger trap is usually not required. Residual cartilage is debrided using curettes, shavers, or abraders. The preserved subchondral bone is microfractured using small chondral picks.

The position of fusion is in 15 degrees of valgus and 20 degrees of dorsiflexion. If the positioning of the joint is affected by contracted capsular structure, the capsule can be released through the corresponding portal wound. If the

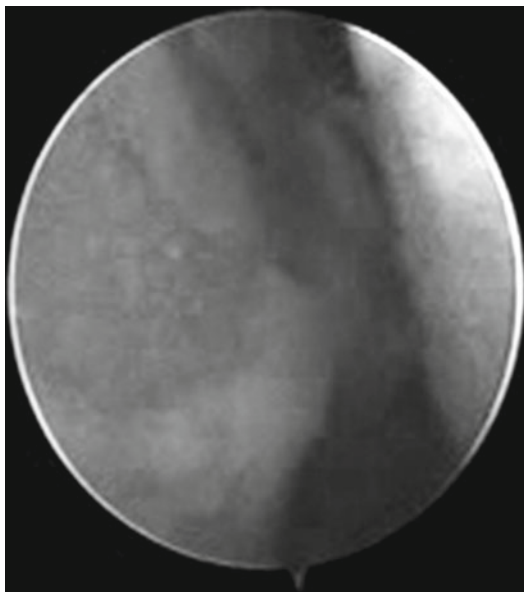


FIGURE 1.8 Advanced degeneration of the first metatarso-phalangeal joint

positioning is affected by bony impingement, the impinging bone can be removed with the 2 mm Isham straight flute burr through the corresponding portal. Provisional fixation is made with a Kirschner wire, and the position confirmed with fluoroscopy. When the foot is placed flat on a metal tray, the interphalangeal joint should be slightly elevated from the surface. Crossed 4.0 mm cannulated screws are inserted under fluoroscopic guidance.

## 1.8 Chondral and Osteochondral Lesions

Chondral and osteochondral lesions have been successfully managed arthroscopically with the benefits of less pain, stiffness, and reduced rehabilitation time. In patients with cartilage lesions, the aims are to remove the source of pain,

stimulate fibrocartilage production, and eliminate mechanical symptoms. Partial thickness cartilage injury can be treated with the radiofrequency probe to provide smooth edges. We recommend microfracture technique using a small joint microfracture probe or a Kirschner wire for a full thickness cartilage loss or an osteochondral defect. For osteochondral lesions *in situ*, the overlying cartilage may look deceptively normal but with careful palpation with a probe, the lesion can be identified. A curette can be used to remove the osteochondral fragments, but the 2.0 mm probe is less traumatic to the surrounding tissue. Softened cartilage can be easily penetrated and cut with the tip of the probe. The probe can then be used as a hook to pull the fragment loose. The fragment can be debrided with a shaver or removed with hemostats. The defect is further debrided until fresh cancellous surface is reached (Fig. 1.9). Microfracture is then performed (Fig. 1.10). The joint is mobilized through the range of motion,

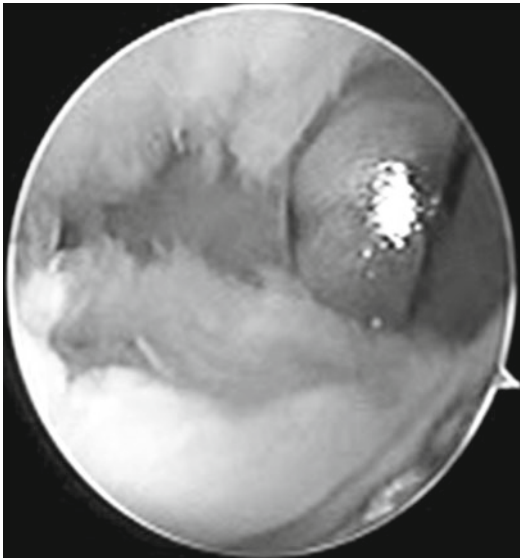


FIGURE 1.9 Debridement of the osteochondral lesion of metatarsal head



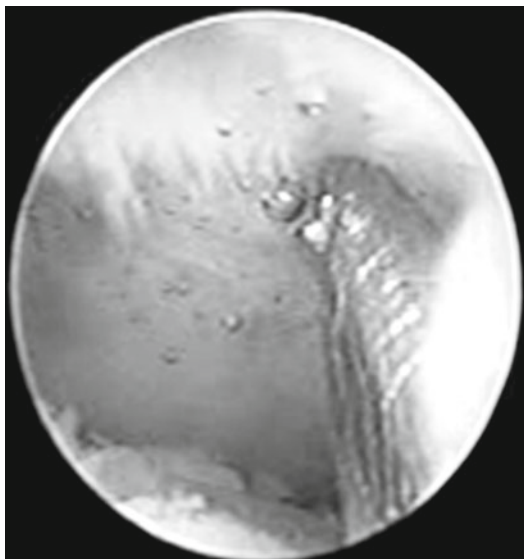


FIGURE 1.10 Microfracture of the osteochondral lesion

and any potential area that can produce mechanical catching are smoothed with a radiofrequency probe. The corresponding kissing lesion that can present on the proximal phalangeal base should be managed concurrently [16].

## 1.9 Arthroscopic Sesamoidectomy for Sesamoid Pathology

First metatarso-phalangeal sesamoidectomy is well-established for sesamoiditis, osteochondritis resistant to conservative management, infection secondary to diabetic neuropathy, and in non-union of sesamoid fractures. Open surgical procedure uses a standard medial arthrotomy approach, opening up the capsule and retracting it plantarward until the articular surface of the sesamoid can be visualized. The potential complications of open surgical approach included the risk of damage to the lateral digital nerve, which is just at the lateral side of fibular

sesamoid. Excessive soft tissue dissection during open procedure may result in post-operative stiffness. Moreover, deformities such as hallux varus and cock-up deformity may result from open procedure, because of the disruption of ligamentous and tendinous structures around the sesamoids. The use of arthroscopy may decrease surgical morbidity and complications associated with open procedures. Arthroscopy also provides thorough assessment of the intra-articular status of the metatarso-phalangeal joint.

Arthroscopic medial bipartite sesamoidectomy [17] had been described for the management of bipartite medial sesamoid. Arthroscopic lateral sesamoidectomy [18] has also been described for the management of chronic osteomyelitis of the lateral sesamoid bone.

The medial sesamoid has been removed using the dorsolateral portal for visualization and the medial portal for instrumentation. The lateral sesamoid can be removed using the medial and plantar medial portals. The toe web and plantar portals may be needed in case of severe hallux valgus. The sesamoid can be excised in piecemeal with a pituitary rongeur or a 2.0 mm round abrader. The ligamentous attachments are preserved.

## 1.10 Arthroscopic Assisted Plantar Plate Tenodesis for First Metatarso-Phalangeal Instability

Injuries to the first metatarso-phalangeal can range from a mild sprain to a frank dislocation. Late complication can occur depending the types and severity of the injury, the initial treatment and rehabilitation. The commonest late complications are joint stiffness and pain with athletic activity. Other complications include arthrofibrosis, different types of deformity e.g. hallux valgus, cock up deformity, and chronic instability. Plantar plate repair and abductor hallucis transfer are the treatment of choice for plantar plate insufficiency. However, the procedure requires extensive soft tissue dissection. Plantar plate tenodesis is first described as an arthroscopic assisted technique for correction of lesser toe deformity. It stabilizes the plantar plate by

connecting the plantar plate to the long extensor tendon with a figure-of-eight of suture. The pull of the extensor tendon will redirect plantarly to stabilize the plantar plate. This technique can also be used to stabilize the plantar plate in instability of the first metatarso-phalangeal joint. This technique is feasible if the plantar plate is disrupted at the metatarsal side or the inter-sesamoid ligament is torn, because the figure of eight construct of the suture can close up the inter-sesamoid distance and the plantar plate is shifted proximally to its proximal insertion. It is not feasible if the plantar plate is disrupted at its phalangeal insertion. Plantar plate tenodesis [19] has the advantage of accurate arthroscopic examination of the first metatarso-phalangeal joint and assessment of status of the plantar plate before plantar plate reconstruction. Plantar plate tenodesis is performed through the arthroscopic portal wounds if the phalangeal insertion of the plantar plate is intact. This minimizes the degree of soft tissue dissection.

### *1.10.1 Technique*

Arthroscopy of the first metatarso-phalangeal joint is performed through the dorsomedial and dorsolateral portals. After examination of the joint, plantar plate tenodesis is performed through the portal wounds. A PDS 1 suture is passed through the lateral part of the plantar plate and the plantar skin with a straight eyed needle through the dorsolateral portal. The suture is then retrieved from the plantar surface of the plantar plate through the medial side of the metatarsal to the proximal dorsal wound at the mid shaft of the metatarsal using of a curved hemostat. The other limb of the suture is passed from the dorsolateral portal to the dorsomedial portal deep inside the joint. It is then passed through the medial part of the plantar plate via the dorsomedial portal. The suture is then retrieved through the lateral side of the metatarsal to the proximal wound. The suture is anchored to the tendon of extensor hallucis longus. Then, a figure of eight configuration of the suture, connecting the plantar plate to the tendon of extensor digitorum longus, is constructed.

## 1.11 Arthroscopic Release for First Metatarso-Phalangeal Arthrofibrosis

Arthrofibrosis of the first metatarso-phalangeal joint occurs in patients following bunion surgery or trauma to the hallux. In patients with functional limitation who do not respond to conservative management, surgery is indicated. Patient should be carefully evaluated clinically and radiographically to plan the surgical strategy. First ray deformity, e.g. hallux elevatus, and first metatarso-phalangeal joint osteoarthritis should be managed accordingly. In patient with first metatarso-phalangeal joint arthrofibrosis, surgical soft tissue release is indicated. However, open release has a high chance of recurrence. Early post-operative vigorous mobilization is allowed after arthroscopic release [20] because of the minimal wound pain.

### 1.11.1 Technique

The patient is supine with a thigh pneumatic tourniquet. No traction of the joint is applied. A 1.9 mm 30° arthroscope is used. First, the dorsolateral and dorsomedial portals are using as the visualization and working portals for the dorsal gutter. The dorsal portals should be placed in the dorsomedial and dorsolateral corners of the joint as in arthroscopic dorsal cheilectomy (Fig. 1.11). At the initial portal placement, the trocar should be used to free up the dorsal fibrotic tissue by sweeping it back and forth. The fibrosis in the dorsal gutter is cleared up, and the dorsal fibrosis can be stripped from the metatarsal head using an arthroscopic shaver and a small periosteal elevator. This produces an intra-articular working space for the subsequent procedures.

Secondly, the lateral gutter of the joint is cleared with the dorsomedial portal as the visualization portal and the dorsolateral portal as the working portal Fig. 1.12. Fibrous bands at the lateral gutter can then be debrided. Beware not to strip the lateral capsule from the metatarsal head because of the potential risk of hallux varus deformity.

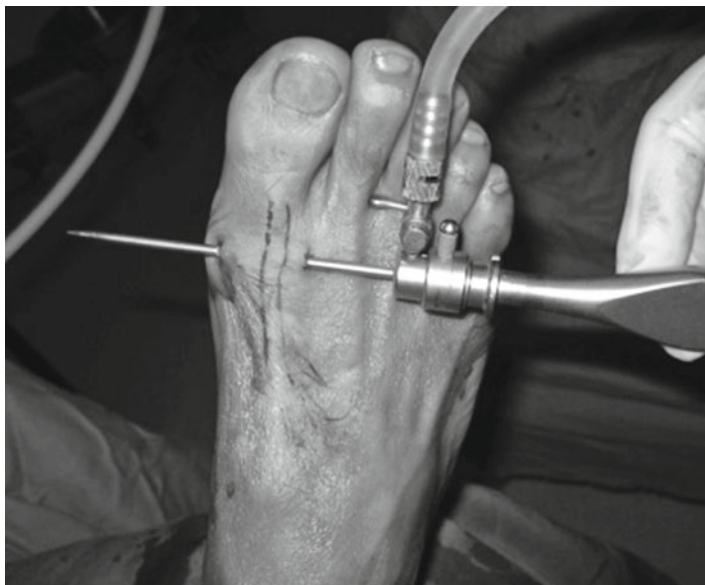

FIGURE 1.11 The dorsal portals should be at the dorsomedial and dorsolateral corners of the joint

After clearance of the lateral gutter, the medial gutter is visualized through the dorsolateral portal. Medial gutter fibrosis can be cleared using an arthroscopic shaver through the dorsomedial portal. The medial capsule can be stripped from the metatarsal head in case of over-plication of the medial capsule during bunion surgery.

Finally, the metatarso-sesamoid compartment can be visualized through the medial portal. The fibrous adhesions of the compartment can be debrided through the plantar medial portal. Manipulation to achieve maximum range of motion is usually performed after the release. After release of the dorsal capsule and clearance of the medial and lateral gutters, the first metatarso-phalangeal joint can be plantarflexed to allow easier instrumentation.

The circumference of the joint can then be released arthroscopically without excessive soft tissue dissection.

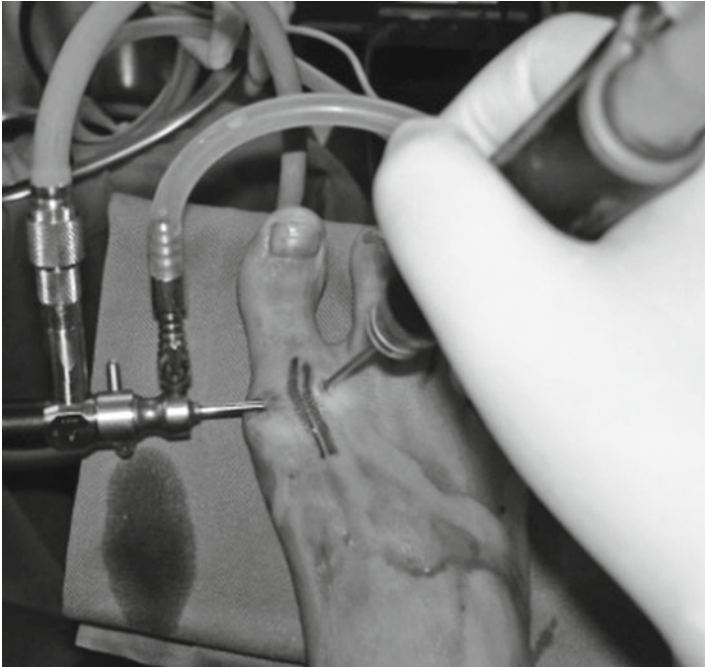


FIGURE 1.12 The lateral gutter of the joint is cleared with the dorso-medial portal as the visualization portal and the dorsolateral portal as the working portal

Active and passive mobilization of the first metatarso-phalangeal joint is started on the first post-operative day.

### 1.12 Arthroscopic Assisted Reduction and Fixation of Intra-articular Fracture of the First Metatarsal Head

In case of intra-articular fracture of the metatarsal head, first metatarso-phalangeal arthroscopy can assist the reduction of the intra-articular fragment (Fig. 1.13) and the fracture can be stabilized with percutaneous screw fixation (Fig. 1.14).

FIG. 1.13 Intra-articular fracture of the metatarsal head

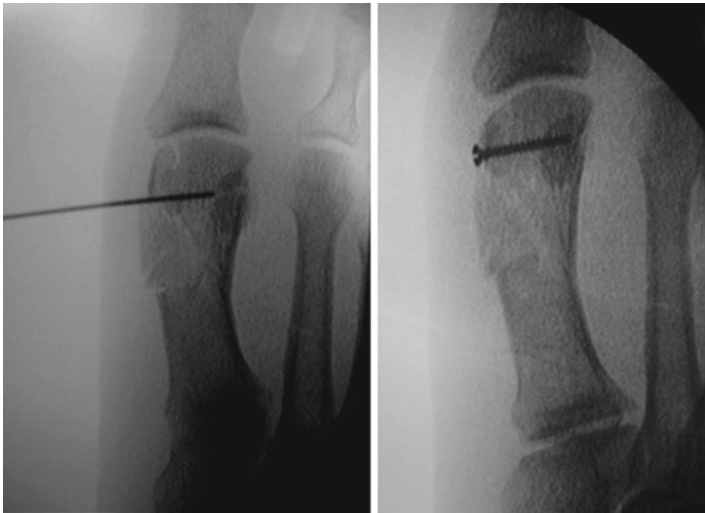
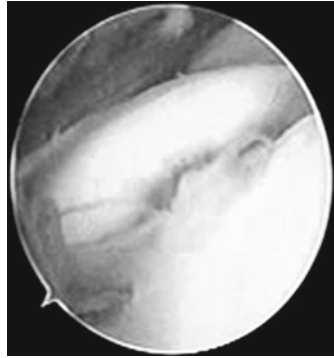

FIGURE 1.14 Percutaneous screw fixation

## References

1. Watanabe M. Selfox-arthroscope (Wantantabe No. 24 arthroscope). Tokyo: Teishin Hospital; 1972.
2. Solan MC, Lemon M, Bendall SP. The surgical anatomy of the dorso-medial cutaneous nerve of the hallux. *J Bone Joint Surg Br.* 2001;83(2):250-2.

3. Ferkel R. Great-toe arthroscopy. In: Whipple T, editor. *Arthroscopic surgery: the foot & ankle*. Philadelphia: Lippincott-Raven; 1996. p. 255–72.
4. Phisitkul P, et al. The surgical anatomy of the plantar medial hallux nerve in relation to the medial approach of the first metatarsophalangeal joint. *Foot Ankle Int*. 2009;30(6):558–61.
5. van Dijk CN, Veenstra KM, Nuesch BC. Arthroscopic surgery of the metatarsophalangeal first joint. *Arthroscopy*. 1998;14(8):851–5.
6. Lui TH, Ng S, Chan KB. New technique: endoscopic distal soft tissue procedure in hallux valgus. *Arthroscopy*. 2005;21(11):1403.e1–7.
7. Lui TH, et al. Arthroscopy-assisted correction of hallux valgus deformity. *Arthroscopy*. 2008;24(8):875–80.
8. Lui TH. First metatarsophalangeal joint arthroscopy in patients with hallux valgus. *Arthroscopy*. 2008;24(10):1122–9.
9. Lidtke RH, George J. Anatomy, biomechanics, and surgical approach to synovial folds within the joints of the foot. *J Am Podiatr Med Assoc*. 2004;94(6):519–27.
10. Lee SS, et al. The soft-tissue shaving procedure for deformity management of chronic tophaceous gout. *Ann Plast Surg*. 2003;51(4):372–5.
11. Lui TH. Endoscopic resection of the gouty tophi of the first metatarsophalangeal joint. *Arch Orthop Trauma Surg*. 2008;128(5):521–3.
12. Wang CC, et al. Arthroscopic elimination of monosodium urate deposition of the first metatarsophalangeal joint reduces the recurrence of gout. *Arthroscopy*. 2009;25(2):153–8.
13. Iqbal MJ, Chana GS. Arthroscopic cheilectomy for hallux rigidus. *Arthroscopy*. 1998;14(3):307–10.
14. Carro LP, Vallina BB. Arthroscopic-assisted first metatarsophalangeal joint arthrodesis. *Arthroscopy*. 1999;15(2):215–7.
15. Stroud CC. Arthroscopic arthrodesis of the ankle, subtalar, and first metatarsophalangeal joint. *Foot Ankle Clin*. 2002;7(1):135–46.
16. Bartlett DH. Arthroscopic management of osteochondritis dissecans of the first metatarsal head. *Arthroscopy*. 1988;4(1):51–4.
17. Perez Carro L, Echevarria Llata JI, Martinez Agueros JA. Arthroscopic medial bipartite sesamoidectomy of the great toe. *Arthroscopy*. 1999;15(3):321–3.
18. Chan PK, Lui TH. Arthroscopic fibular sesamoidectomy in the management of the sesamoid osteomyelitis. *Knee Surg Sports Traumatol Arthrosc*. 2006;14(7):664–7.
19. Lui TH. Stabilization of first metatarsophalangeal instability with plantar plate tenodesis. *J Foot Ankle Surg*. 2008;14(4):211–4. Epub 2008 Jun 30.
20. Lui TH. Arthroscopic release of first metatarsophalangeal arthrofibrosis. *Arthroscopy*. 2006;22(8):906.e1–4.



# Chapter 2

## Minimally Invasive Management of Hallux Rigidus

**Mariano De Prado, Pedro-Luis Ripoll, and Pau Golanó**

### 2.1 Introduction

Hallux rigidus is the clinical expression of osteoarthritis of the metatarso-phalangeal joint of the hallus. Hallux rigidus presents with limited joint mobility, especially in extension, and pain, with osteophytes on the dorsal aspect of the head of the first metatarsal (Fig. 2.1) and of the base of the proximal phalanx of the hallux. It has a prevalence of 2 % of the population between 30 and 60 years of age.

Davies-Colley, in 1887, first described the condition, calling it hallux flexus, and a few months later, Cotterill's referred to it as hallux rigidus, a term that seems more accurate and which is now widespread.

---

M. De Prado, M.D. (✉) • P. Ripoll, M.D.  
Department of Orthopaedics, Hospital USP San Carlos,  
Murcia, Spain  
e-mail: deprado@hospitalsancarlos.net

P. Golanó, M.D.  
Department Pathology and Experimental Therapeutics,  
(Human Anatomy Unit)  
University of Barcelona,  
Barcelona, Spain

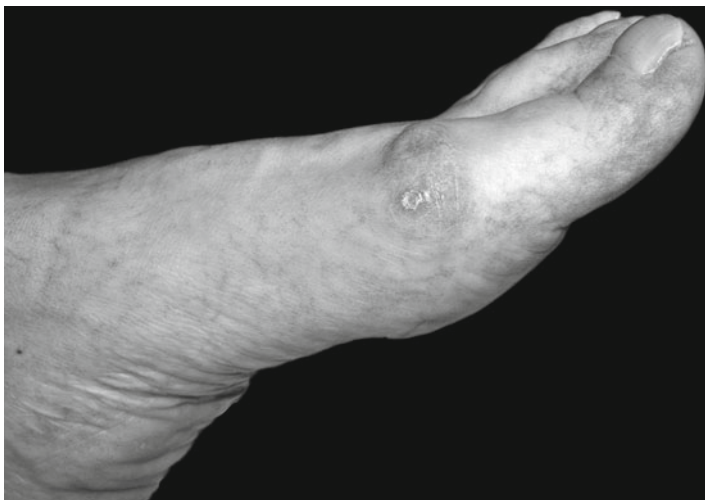


FIGURE 2.1 Hallux rigidus presents with visible osteophytes on the dorsal aspect of the head of the first metatarsal

## 2.2 Pathogenesis

### 2.2.1 *Intrinsic Causes*

The presence of a long hallux, either secondary to a long first metatarsal (plus index), or a foot that, despite having a formula index or index plus minus, has a large phalanx of the hallux will impose abnormal strain to the metatarso-phalangeal joint of the hallux.

Another factor is a relatively flattened shape of the head of the first metatarsal. This alters the normal mobility of this joint, favoring degenerative joint disease. Flattening of the first metatarsal head changes the angle of incidence of the first metatarsal to the ground, which impacts the lower half of the metatarso-phalangeal joint during walking. Also, the upper half of the metatarso-phalangeal joint will be subjected to abnormal contact with the articular surface of the proximal phalanx of the hallux.

Osteochondritis of the head of the first metatarsal, by producing a cartilage lesion, promotes early osteoarthritis.

Pronation of the foot can also be associated with hallux rigidus.

Systemic diseases that cause arthritis localized to the metatarso-phalangeal are gout and rheumatoid arthritis.

### 2.2.2 *Extrinsic Causes*

Repetitive microtrauma to the hallux from sporting endeavors or work promote the development of hallux rigidus. Osteochondral fractures of the metatarsal head or base of the proximal phalanx, with irreversible damage to the cartilage, with use of inappropriate footwear are also associated with the condition.

## 2.3 Clinical

Patient normally report pain and decreased mobility of the first metatarso-phalangeal joint during gait, especially in the push off, with a progressive dorsal deformity. This limits normal activities, and produces skin irritation. Often patients use flat shoes with a stiff sole. In more advanced stages, the mobility of first metatarso-phalangeal joint is very limited, and exostoses develop both dorsally and medially. The patient will walk with the foot externally rotated and the forefoot supinated to compensate for the lack of mobility.

The metatarso-phalangeal joint of the hallux is larger than normal, both dorsally and medially, with local limited inflammation and possibly bursitis. The interphalangeal joint may be in hyperextension, with a plantar callus at the base of the distal phalanx (Fig. 2.2) and another on the head of the fifth metatarsal.

Palpation elicits dorsal tenderness, with crepitus. Flexion is painful, and the rubbing of the dorsal osteophytes with the

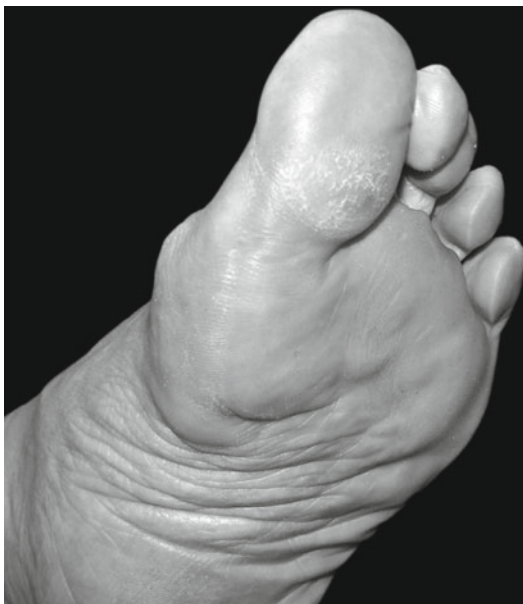


FIGURE 2.2 The interphalangeal joint may be in hyperextension, with a plantar callus at the base of the distal phalanx

sheath of the extensor tendons of the hallux may cause mechanical synovitis. Clinically, two distinct stages can be identified:

- Stage 1 (hallux dolorosus). The metatarso-phalangeal joint pain is virtually the only symptom, sometimes accompanied by discomfort in the lateral aspect of the foot. Pain is elicited on extension of the metatarso-phalangeal joint, which shows limited range of motion.
- Stage 2 (hallux limitus). Mobility is almost blocked. There are callosities of the fifth metatarsal head and the base of the proximal phalanx of the hallux. The patient walks with external rotation of the foot, to avoid dorsiflexion of the first metatarso-phalangeal joint.

## 2.4 Imaging and Further Investigations

Radiographs of both feet should include weight bearing dorso-plantar and lateral views, and oblique views. Radiographs show arthritis with osteophytes, sclerosis, subchondral cysts, etc. Regnault described three radiographic stages

- Stage 1. slight narrowing of the joint with small osteophytes over the lateral aspect of the first metatarsal head. Small osteophytes are also dorsally (Fig. 2.3).
- Stage 2. Osteophytes develop on both sides of the joint. The metatarsal head is flattened, with lateral subchondral sclerosis (Fig. 2.4).
- Stage 3. Total loss of joint space, with florid osteophytes and irregularities of the articular surface, alternating with areas of intense sclerosis (Fig. 2.5).

We do not recommend any other investigations, but in some patients in whom there may be suspicion of associated injuries magnetic resonance (MRI), computed tomography (CT), bone scans can be used.

### 2.4.1 Surgery

In patients with marked pain, an active life and in whom conservative management (rocker bottom shoes, insoles, steroid injections) has not provided sufficient relief of symptoms and functional impairment, surgery should be considered.

Contraindications for surgery are vascular problems and local infection.

In the remaining part of this chapter, we describe our minimally invasive technique.

### 2.4.2 Instruments

- A general orthopedic set is necessary.
- Beaver Knife 64.

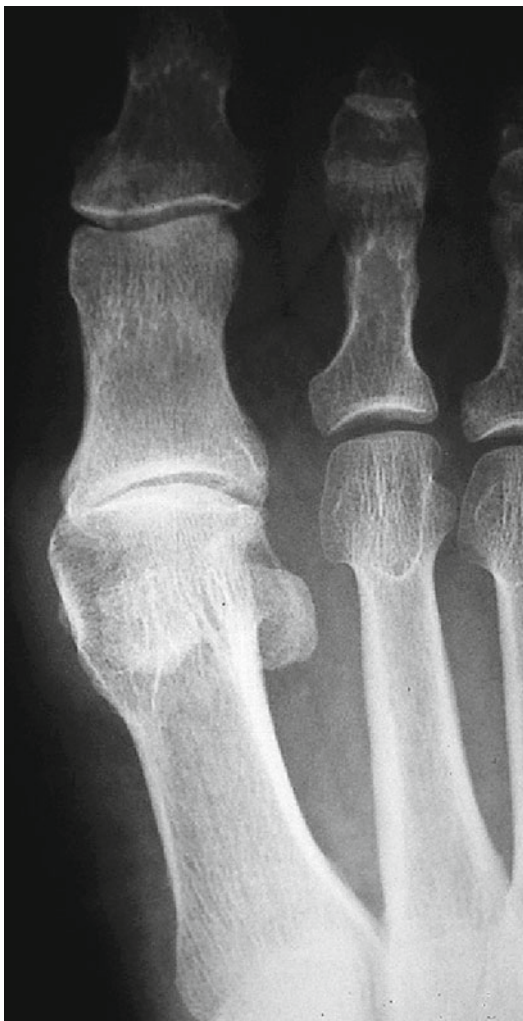

FIGURE 2.3 Slight narrowing of the joint with small osteophytes over the lateral aspect of the first metatarsal head. Small osteophytes are also seen dorsally

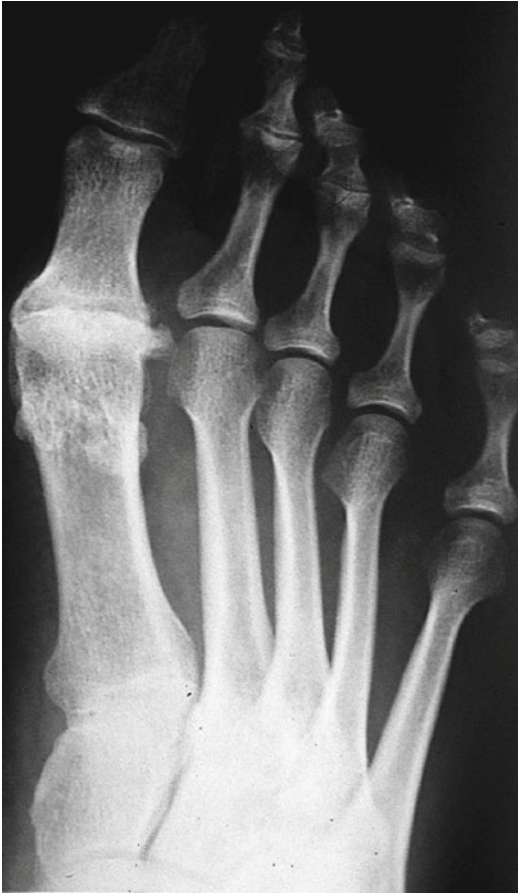

FIGURE 2.4 Osteophytes develop on both sides of the joint. The metatarsal head is flattened, with lateral subchondral sclerosis

- A 44 long Shannon Burs, X-Mass Tree Wedge Burrs 3.1 and 4.1, and a Brophy Burr.

### 2.4.3 *Anesthesia*

We use a peripheral ankle block, but some patients may prefer general anesthesia.

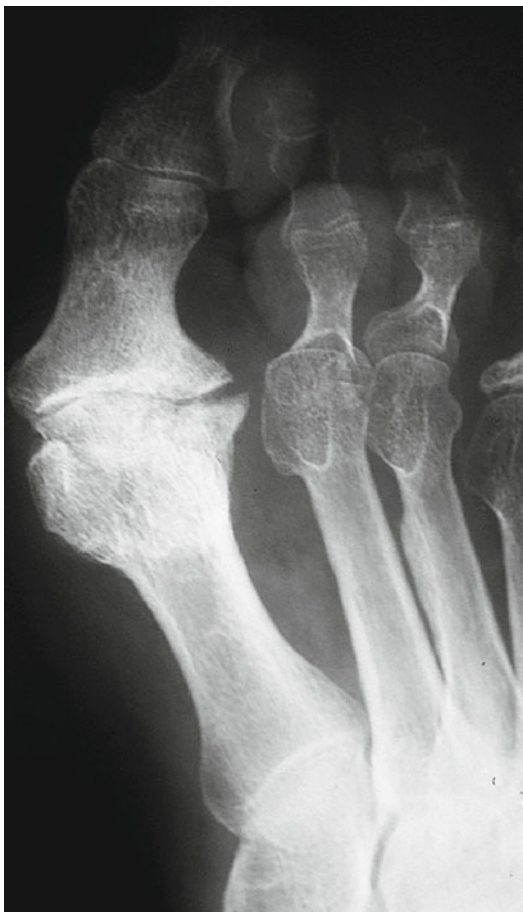

FIGURE 2.5 Total loss of joint space, with flurid osteophytes and irregularities of the articular surface, alternating with areas of intense sclerosis

#### 2.4.4 *Cheilectomy*

A 0.5 cm incision is made in the dorsal medial forefoot, just behind the metatarsal neck and under the dorsal digital nerve with Beaver blade 64 (Figs. 2.6 and 2.7). The incision is





FIGURE 2.6 A percutaneous cheilectomy procedure starts with a 0.5 cm incision in the dorsal medial forefoot, just behind the metatarsal neck and under the dorsal digital nerve with Beaver blade 64

deepened, accommodating the blade on the medial exostosis at the level of its dorsal aspect, and goes under the capsule covering the exostosis, both medially and dorsally. A rasp is introduced to remove the fibrous remains of the exostosis, and to produce a working space between the dorsal and medial exostosis below and above the joint capsule. We introduce the small triangular bur to abrade the exostosis (Fig. 2.8). One should be very aggressive to the dorsal exostosis. In some patients, it is necessary to proceed with the exostosectomy to the dorsal base of the proximal phalanx. At times, it can be difficult to reach the lateral portion of the dorsal exostosis. In these instances, a new 0.5 cm incision, also at the level of the metatarso-phalangeal joint, should be produced, parallel to the tendon of the extensor hallucis longus. In this case, the joint capsule and the insertion of abductor tendon at

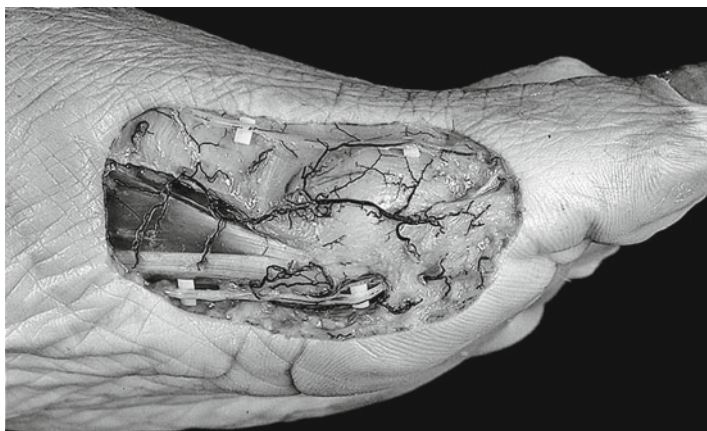


FIGURE 2.7 The incision is deepened, accommodating the blade on the medial exostosis at the level of its dorsal aspect, and goes under the capsule covering the exostosis, both medially and dorsally

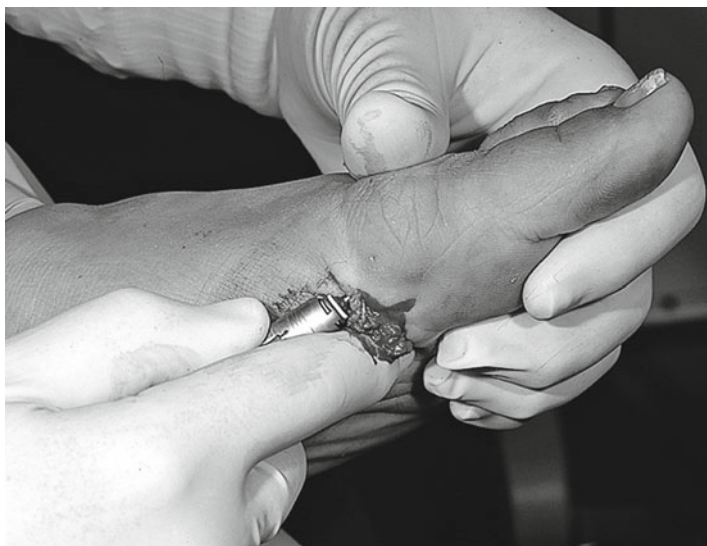

FIGURE 2.8 A small triangular burr to abrade the exostosis

the base of the proximal phalanx should be spared not to destabilize the joint.

Once the cheilectomy has been completed, great care should be exerted to make sure that the bone spur is thoroughly extruded.

#### 2.4.5 *Distal First Metatarsal Osteotomy*

A long Shanon 44 burr is used on the medial aspect of the metatarsal neck, angled 45° from dorsal distal to plantar proximal, starting just proximal to the articular surface of the metatarsal head, and ending immediately above the sesamoid (Figs. 2.9 and 2.10). The cutting should start on the medial cortex, and the osteotomy should proceed severing the dorsal

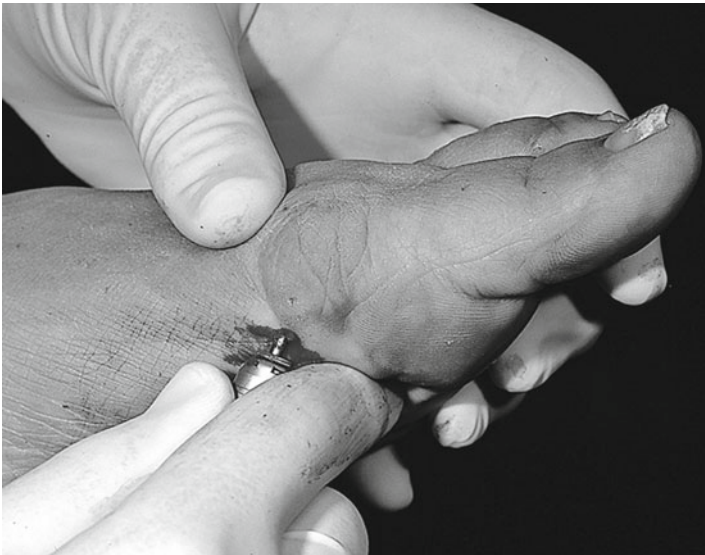

FIGURE 2.9 A long Shanon 44 burr is used on the medial aspect of the metatarsal neck, angled 45° from dorsal distal to plantar proximal, starting just proximal to the articular surface of the metatarsal head, and ending immediately above the sesamoid

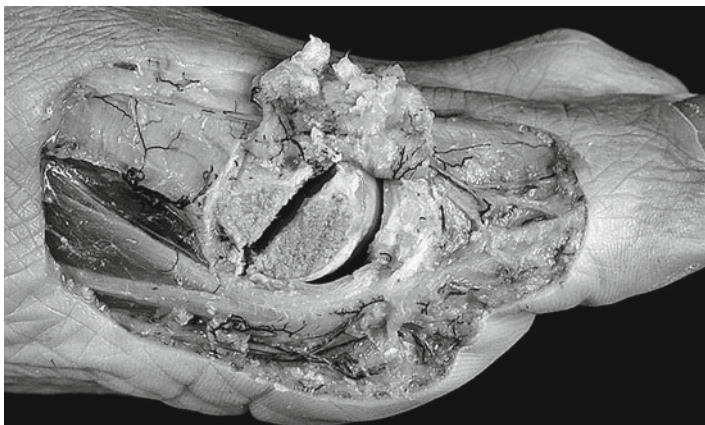


FIGURE 2.10 A long Shanon 44 burr is used on the medial aspect of the metatarsal neck starting just proximal to the articular surface of the metatarsal head, and ending immediately above the sesamoid

cortex, then the lateral cortex. In this way, a dorsal closing wedge is designed, and the plantar cortex undergoes manual osteoclasis (Figs. 2.11 and 2.12).

#### 2.4.6 *Osteotomy of the Base of the Proximal Phalanx*

The base of the proximal phalanx is approached medial to the tendon of the extensor hallucis longus, producing a working space in the usual fashion. A long Shanon 44 strawberry burr rests on the medial aspect of the base of the phalanx, and the osteotomy is started (Figs. 2.13 and 2.14), sparing the last few millimeters of bone from the plantar aspect of the phalanx. The osteotomy is completed on both the lateral and dorsal aspect, designing a dorsal closing wedge. The osteotomy is completed by osteoclasis. This completes the plantar osteotomy once achieved the wedge in the right way. The three entry portals used sutured in a routine fashion (Figs. 2.15 and 2.16). A bandage similar to that used in hallux valgus will aim to keep the first ray in dorsiflexion.

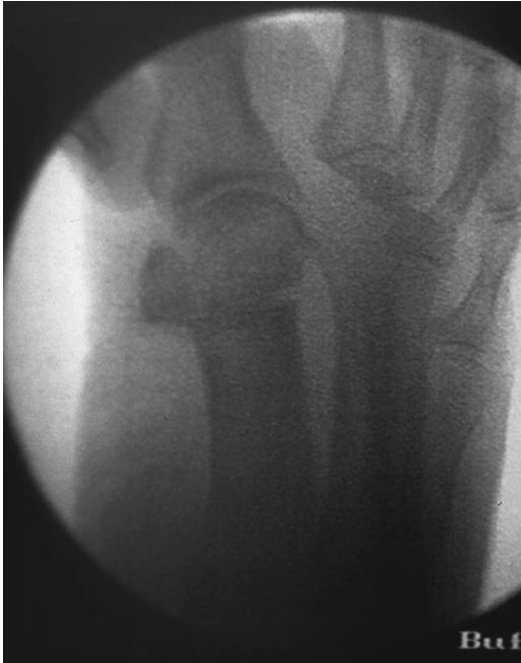

FIGURE 2.11 Cutting should start on the medial cortex, and the osteotomy should proceed severing the dorsal cortex, then the lateral cortex. In this way, a dorsal closing wedge is designed, and the plantar cortex undergoes manual osteoclasis. This is illustrated in Figures 2.11 and 2.12

#### 2.4.7 *Postoperative Care*

Weight bearing is allowed with a stiff soled boot. Patients are reviewed 7 days after surgery, when the stitches removed. A 3 mm toe separator is placed between the hallux and the second toe, aiming to close the wedge in the proximal phalanx. Patients are instructed to change the bandage every day, and are reviewed at 3 weeks, when new radiographs are taken. If the closing wedges continue to stay closed, gentle mobilization is initiated, and the bandages are kept until the sixth post-operative week. Normal walking is usually restored after 2 months, and sports and physical activity are allowed 4–6 months post-operatively (Fig. 2.17a–c).

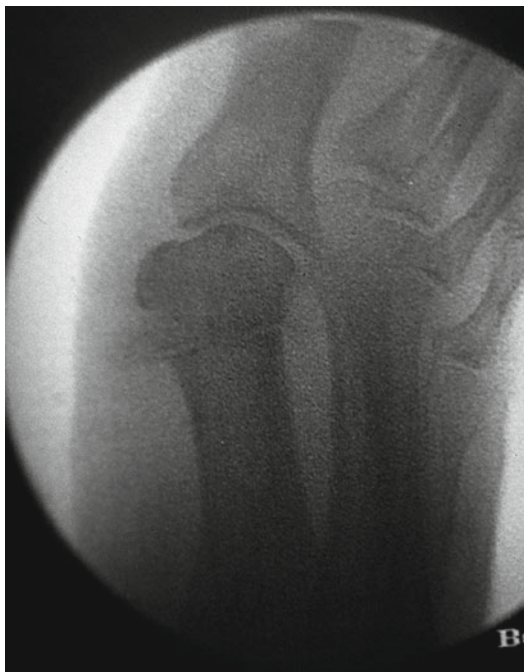

FIGURE 2.12 Cutting should start on the medial cortex, and the osteotomy should proceed severing the dorsal cortex, then the lateral cortex. In this way, a dorsal closing wedge is designed, and the plantar cortex undergoes manual osteoclasis. This is illustrated in Figures 2.11 and 2.12

## 2.5 Surgical Indications

### 2.5.1 *Cheilectomy*

A cheilectomy on its own is indicated in elderly patients with little pain and no functional limitation on their usual activities.

### 2.5.2 *Cheilectomy Plus Metatarsal Osteotomy and the Phalanx*

It is indicated in young patients or those with marked pain, functional limitations to their usual activities.

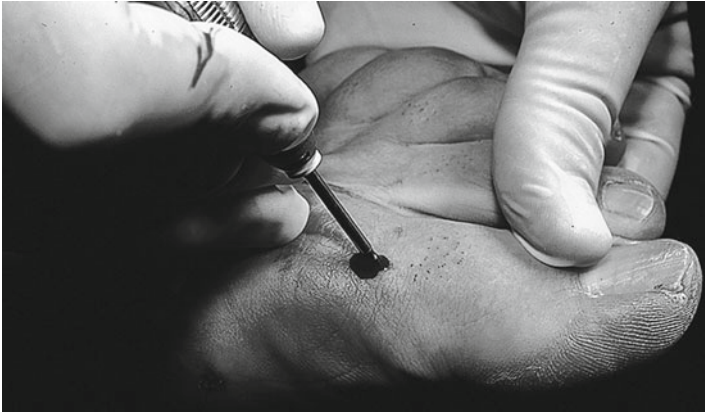

FIGURE 2.13 The base of the proximal phalanx is approached medial to the tendon of the extensor hallucis longus, producing a working space in the usual fashion. A long Shanon 44 strawberry burr rests on the medial aspect of the base of the phalanx, and the osteotomy is started. Intra-operative appearance

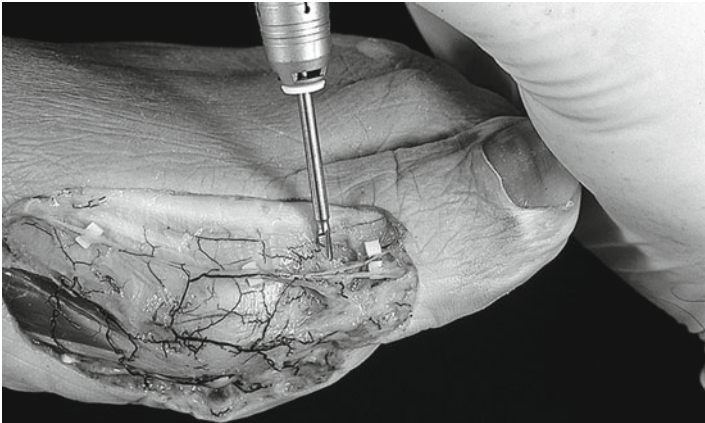


FIGURE 2.14 The base of the proximal phalanx is approached medial to the tendon of the extensor hallucis longus, producing a working space in the usual fashion. A long Shanon 44 strawberry burr rests on the medial aspect of the base of the phalanx, and the osteotomy is started. Anatomical appearance

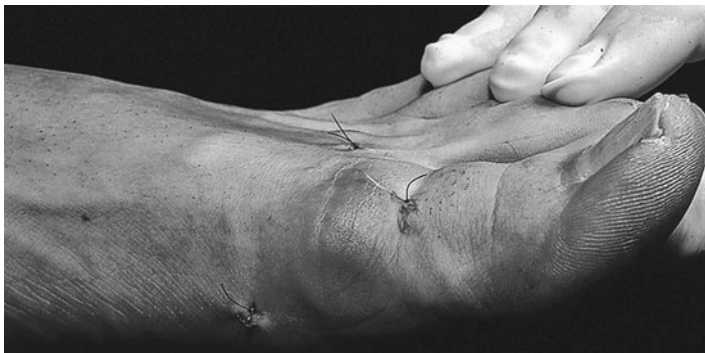

FIGURE 2.15 The three entry portals used are sutured in a routine fashion

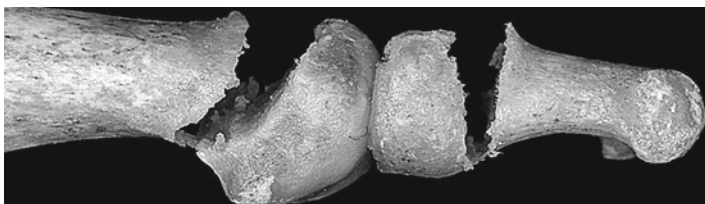


FIGURE 2.16 Patients are reviewed 7 days after surgery, when the stitches removed. A 3 mm toe separator is placed between the hallux and the second toe, aiming to close the wedge in the proximal phalanx

### 2.5.3 *Metatarso-Phalangeal Arthrodesis*

In our hands, it is indicated after failure of previous surgery.



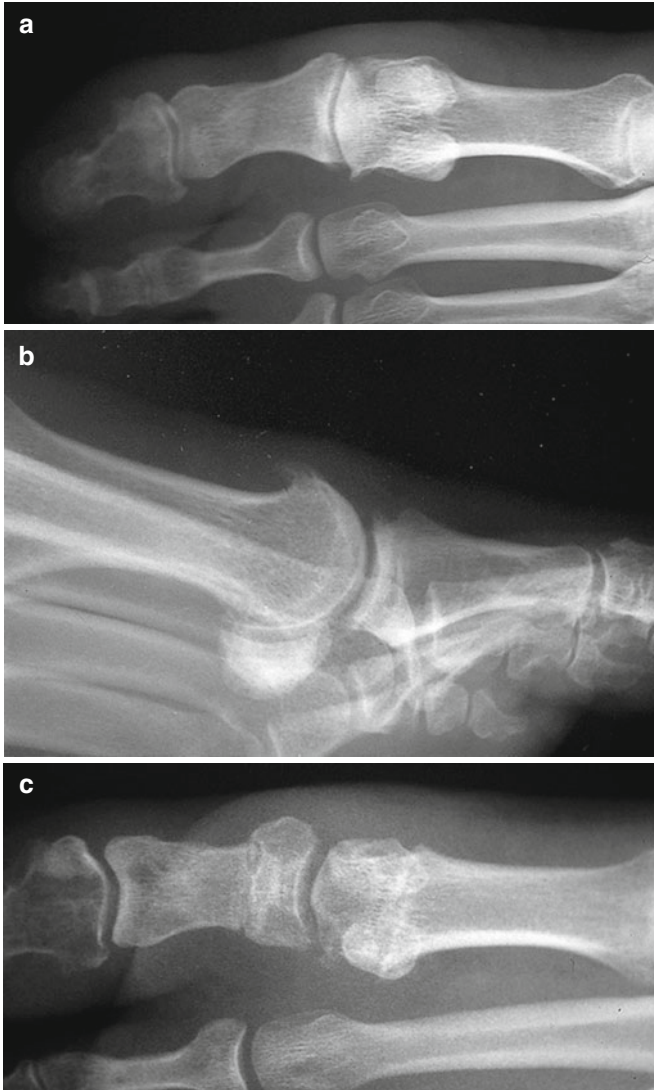


FIGURE 2.17 (a) Preoperative antero-posterior view of a mild hallux rigidus. (b) Preoperative lateral view of a mild hallux rigidus. (c) Postoperative AP view showing dorsally based closing wedge osteotomy of the distal portion of the first metatarsal and of the base of the proximal phalanx of the hallux

## Bibliography

- Beeson P, Phillips C, Corr S, Ribbans W. Classification systems for hallux rigidus: a review of the literature. *Foot Ankle Int.* 2008;29(4):407–14.
- Bonney G, Macnab I. Hallux valgus and hallux rigidus: a critical survey of operative results. *J Bone Joint Surg Br.* 1952;34:366–85.
- Cotterill JM. Stiffness of the great toe in adolescents. *BMJ.* 1888;1:1158.
- Davies-Colley MR. Contraction of the metatarsophalangeal joint of the great toe. *BMJ.* 1887;1:728.
- De Prado M, Ripoll PL, Golanó P. *Cirugía percutánea del pie.* Barcelona: Elsevier (masson); 2003.
- De Prado M, Ripoll PL, Golanó P. *Minimally invasive foot surgery.* Barcelona: AYH; 2009.
- DuVries HL. Hallux rigidus (hallux limitus). In: DuVries HL, editor. *Surgery of the foot.* St. Louis: Mosby; 1959. p. 392–9.
- Easley ME, Anderson RB. Hallux rigidus in the adult and adolescent. In: Adelaar RS, editor. *Disorders of the great toe.* Rosemont: American Academy of Orthopaedic Surgeons; 1997. p. 23–32.
- Haddad SL. The use of osteotomies in the treatment of hallux limitus and hallux rigidus. *Foot Ankle Clin.* 2000;5:629–62.
- Keiserman LS, Sammarco VJ, Sammarco GJ. Surgical treatment of the hallux rigidus. *Foot Ankle Clin.* 2005;10(1):75–96.
- Mann RA, Coughlin MJ, DuVries HL. Hallux rigidus: a review of the literature and a method of treatment. *Clin Orthop.* 1979;142:57–63.
- Mesa-Ramos M, Mesa-Ramos F, Carpintero P. Evaluation of the treatment of hallux rigidus by percutaneous surgery. *Acta Orthop Belg.* 2008;74(2):222–6.
- Moberg E. A simple operation for hallux rigidus. *Clin Orthop.* 1979;142:55–6.
- Pittman SR, Burns DE. The Wilson bunion procedure modified for improved clinical results. *J Foot Surg.* 1984;23:314–20.
- Waterann H. Die arthritis deformans Grosszehen-Grundgelenkes. *Orthop Chir.* 1927;48:346–55.
- Yee G, Lau J. Current concepts review: hallux rigidus. *Foot Ankle Int.* 2008;29(6):637–46.
- Zgonis T, Jolly GP, Garbalosa JC, Cindric T, Godhania V, York S. The value of radiographic parameters in the surgical treatment of hallux rigidus. *J Foot Ankle Surg.* 2005;44(3):184–9.

# Chapter 3

## Percutaneous First Metatarso-Phalangeal Joint Fusion

**Thomas Bauer**

### 3.1 Introduction

Fusion of the first metatarso-phalangeal (MTP1) joint is a useful procedure in forefoot surgery, and is still considered the gold standard for the management of severe painful hallux rigidus. Normal walking and running are possible after MTP1 fusion, as the interphalangeal (IP) joint develops compensatory hypermobility in dorsi-flexion (Mann [1], DeFrino [2]). The main difficulty in this procedure is the 3D positioning of the arthrodesis that should be adapted to global foot anatomy, daily activity and shoe wearing habits of each patient (Conti [3], Harper [4], Alexander [5], Kelikian [6], Womack [7]). Another non specific difficulty is linked to the primary stability of the fusion depending on both technique for fusion site preparation and type of internal fixation (Kelikian [6], Womack [7], Chana [8], Wu [9], Curtis [10], Rongstad [11], Watson [12], Goucher [13]). Several open or arthroscopically assisted procedures for MTP1 arthrodesis have been described, with fusion rates from 90 to 100 %. The authors present a percutaneous procedure for MTP1 fusion with details on the surgical technique, first results and discussion of the benefits and indications.

---

T. Bauer, M.D.

Department of Orthopaedic Surgery,  
Ambroise Paré Hospital, West Paris University,  
9 av Charles de Gaulle, 92100, Boulogne, France  
e-mail: thomas.bauer@apr.aphp.fr

## 3.2 Operative Technique

**Instruments:** Surgical tools for percutaneous MTP1 fusion are identical to those used for all percutaneous forefoot surgical procedures including a conic burr, a Beaver<sup>®</sup> blade, elevators, rasps, low speed and high torque drill and a fluoroscope. We normally internally fix the fusion with cannulated 3.0 mm compression screws, but other percutaneous fixation systems can be used.

**Patient set up:** The patient is supine, under regional or local anesthesia, with the foot free over the end of the table to allow antero-posterior and lateral fluoroscopic control.

**Portals:** Percutaneous MTP1 fusion is performed with one main portal and two accessory portals (Fig. 3.1). The main portal is medial at the MTP1 joint line level, and is used for the preparation of bony areas. Two accessory portals can be useful in some patients: one proximal medial and plantar portal at the level of the first metatarsal head, and one distal

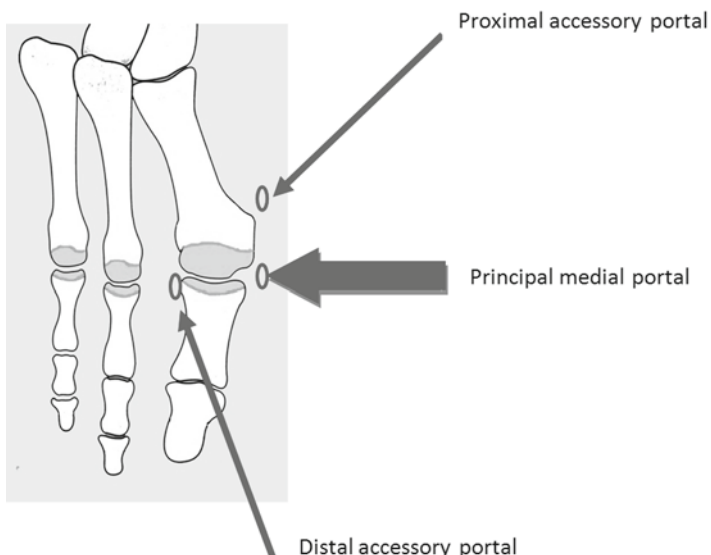


FIGURE 3.1 Portals

lateral and dorsal portal at the level of the first phalanx (P1) basis. The accessory proximal medial portal is used for dorsal and medial osteophytes removal and the accessory distal lateral portal is used for dorsal and lateral osteophytes removal and for lateral MTP1 joint capsule and ligaments release.

**Method of fusion site preparing:** The procedure begins with the removal of metatarsal or phalangeal osteophytes. The resection is performed through the two accessory portals with the large conic burr after periosteal peeling off with the elevators to create a working area and avoid soft tissue damages. Bone debris is carefully evacuated with rasps, and the resection site is abundantly cleaned with normal saline. The quantity and quality of osteophytes removal must be assessed under fluoroscopic control; this resection must be adapted to patient's symptoms (dorsal and medial osteophytes often create impingement with shoes but lateral osteophytes are rarely symptomatic). Excessive resection with risk of bone loss (most often on the first metatarsal head) must be avoided not to interfere with the stability of the arthrodesis.

Preparation of the site of arthrodesis is a most important step, and is performed through the principal medial portal (Fig. 3.2). The conic burr is placed in the MTP1 joint with traction on the hallux. Cartilage resection and bony areas preparation are performed with the burr under fluoroscopic

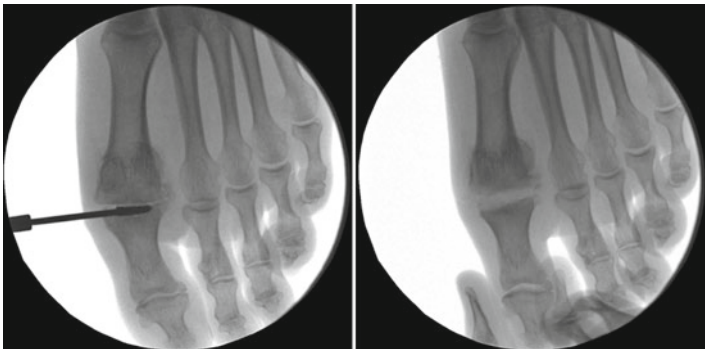


FIGURE 3.2 Preparation of the bone surfaces

control to assess both quantity and quality of bone resection. In this technique the fusion site is prepared by cutting two flat and parallel surfaces. The preparation of this area is the most difficult step of this procedure and the main risk is to have an asymmetrical resection. Some pitfalls must be avoided:

- excessive metatarsal bone resection: the bone of the proximal phalanx is more dense than the bone of the metatarsal head, and the burr will tend to remove the weakest bone, on the metatarsal side. The risk is to obtain an excessive bone resection on the metatarsal head with first metatarsal shortening, loss of primary stability, metatarsus elevatus positioning of the arthrodesis with an increased risk of transfer metatarsalgia. It is thus important to control the burr and press more on the proximal phalanx than on the metatarsal head and assess the progression of the resection with fluoroscopic control.
- excessive dorsal resection: it is often more difficult to reach the plantar part of the MTP1 joint than the dorsal part, and again the burr will tend to remove the bone easiest to reach, on the dorsal portion of the joint. The risk is to obtain an asymmetrical V-shaped bone resection from excessive dorsal resection with loss of primary stability and positioning of the arthrodesis with excessive dorsal flexion of P1. Bone preparation with the burr must be performed with continuous gentle traction on the hallux to open the MTP1 joint, to facilitate the access on the plantar part, to control bone resection and have parallel cuts on lateral fluoroscopic view.

After bone resection, the bone debris are evacuated with rasps and the arthrodesis site is abundantly washed with normal saline to avoid prolonged inflammation.

**MTP1 arthrodesis positioning:** Contact between P1 and M1 is obtained by pressure in the axis of the first ray and the position is maintained with an oblique Kirschner wire. The positioning of the arthrodesis is assessed clinically and under fluoroscopic control:

- on AP view (Fig. 3.3): first ray alignment or slight valgus, first ray length, metatarso-phalangeal bone contact, no subluxation.

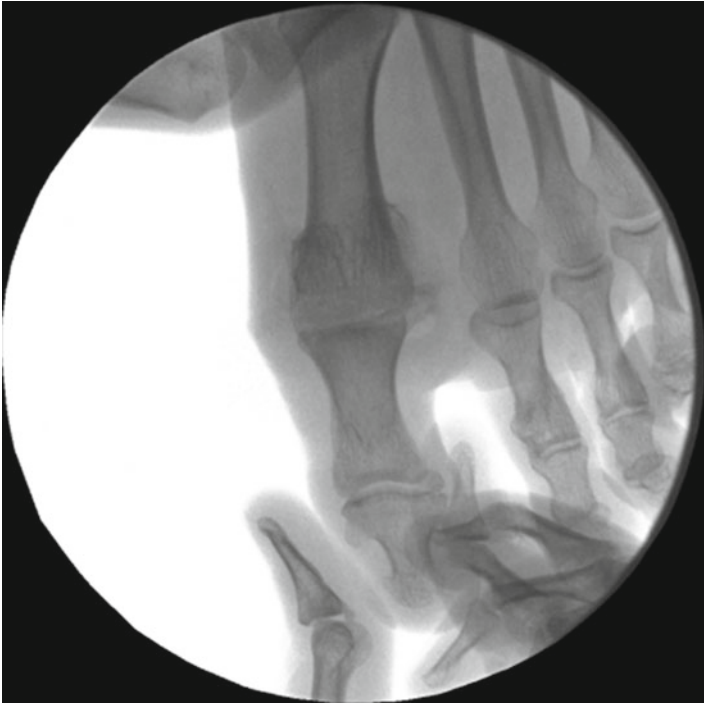

FIGURE 3.3 Arthrodesis positioning on antero-posterior view

- on lateral view (Fig. 3.4): P1 position is assessed using a flat metal tray applied on the sole of the foot. P1 must be parallel to the floor plane with good bone contact and no plantar-flexion.

**Arthrodesis fixation:** the percutaneous MTP1 fusion is fixed with two cannulated compression screws (Fig. 3.5). The first Kirschner wire is oblique from P1 to M1 (from medial-distal to lateral-proximal), and the second is oblique from M1 to P1 and crosses the first Kirschner wire at the level of the first metatarsal head. The two cannulated screws are inserted and compression is obtained alternately on each screw. The stability of the MTP1 arthrodesis in dorsal and plantar flexion is then controlled and all the portals are closed (Fig. 3.6).

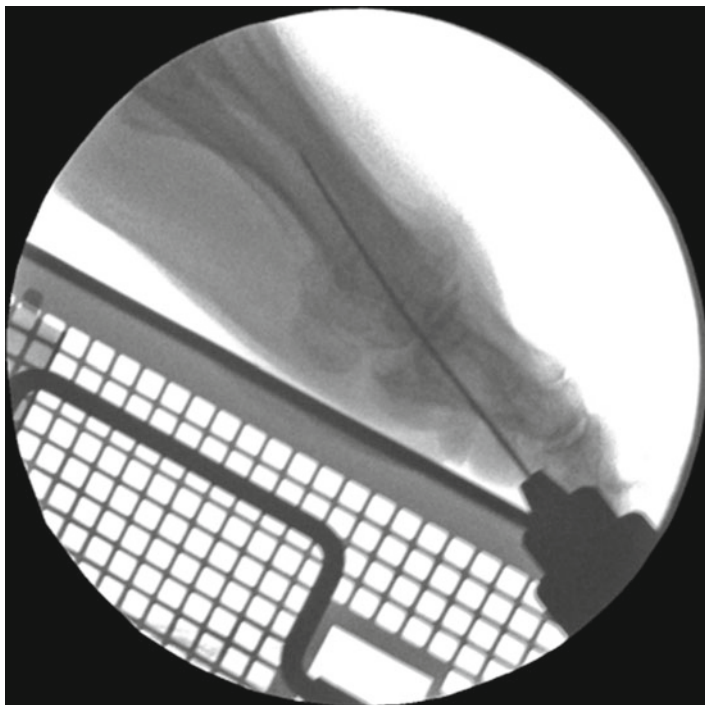


FIGURE 3.4 Arthrodesis positioning on lateral view

### 3.3 Post-operative Care

Percutaneous MTP1 fusion is performed in outpatients. The first dressing is changed after 10 days, and then a less bulky dressing is applied with a cohesive bandage. Immediate full weight bearing is authorized with a post-operative shoe with a flat and rigid insole. Radiographs are taken after 10 days and 1 month. Normal shoes are worn after 1 month according to clinical and radiographic findings.

### 3.4 Indications – Results

The indications for percutaneous MTP1 fusion are basically the same as for open MTP1 fusion. This procedure is mainly performed for the treatment of severe and painful hallux



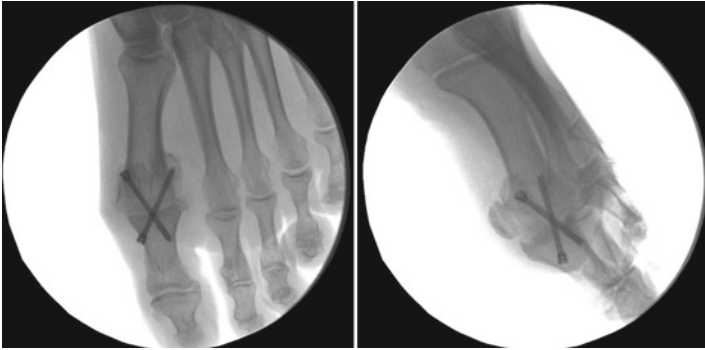


FIGURE 3.5 Arthrodesis fixation

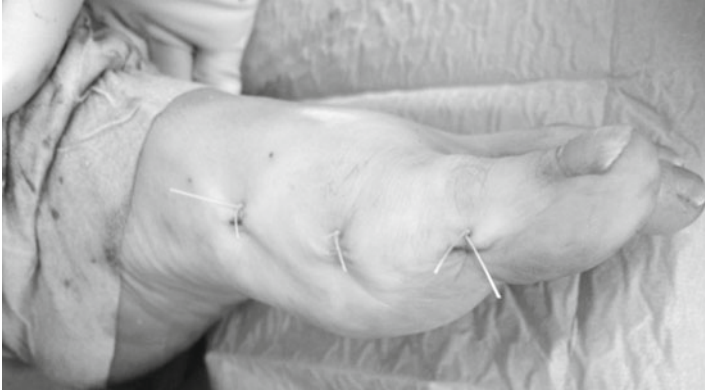

FIGURE 3.6 Post-operative view after skin suture

rigidus and functional improvement is better and faster achieved in case of painful and stiff hallux rigidus with a compensatory hypermobility of the IP joint. Without a pre-operative IP joint hypermobility return to normal walking and shoe wearing can be slow due to the progressive adaptation of the IP joint. Percutaneous MTP1 fusion can be performed for severe hallux valgus deformity, symptomatic hallux varus, complex forefoot deformities (in case of rheumatoid arthritis) or for failed previous forefoot surgery. The main limit for a percutaneous MTP1 fusion is the presence of an extensive bone loss with a short first ray and indication for a bone graft.

Thirty-two percutaneous MTP1 joint fusions were analysed in a prospective continuous series including 30 patients with an average age of 66. The indications for MTP1 joint fusion were symptomatic hallux rigidus or hallux rigidus-valgus in most of the cases. All the patients underwent the same percutaneous procedure, in 1-day surgery for 26 cases. Clinical results were assessed with the functional AOFAS forefoot scoring system pre-operatively and at the latest follow-up. Radiographic analysis focused on the positioning and quality of bone fusion of the procedure. No patient was lost at a mean follow up of 18 months. The functional AOFAS score improved in all patients from a mean 36/100 pre-operatively to a mean 80/100 post-operatively ( $p=0.02$ ). Thirty patients were satisfied or very satisfied with the final outcome of the procedure, one patient was disappointed, and one was not satisfied. For the satisfied or very satisfied patients, normal shoe wearing was achieved after a mean 50 days. At plain radiography, fusion was obtained in 31 cases on 32. Post-operative mean dorsal flexion of the MTP1 joint fusion was  $21^\circ$  (range 15–35°).

### 3.5 Discussion

Percutaneous MTP1 fusion is a simple and quick procedure which can achieve functional results comparable to those obtained with open MTP1 fusion with more than 90 % of patients satisfied (Womack [7], Goucher [13], Coughlin [14], Flavin [15], Brodsky [16], Yee [17]).

In open MTP1 fusion, the method of bone preparing requires a large approach with a risk of post-operative prolonged pain and swelling or wound healing difficulties (Kelikian [6], Womack [7]). One of the benefits of the percutaneous MTP1 fusion is the decreased morbidity, with few patients reporting pain and scar problems, and the procedure can be performed on an outpatient basis with immediate full weight bearing.

Bone preparation is a crucial step of this procedure, and requires experience in percutaneous forefoot surgery. In this

technique, bone cuts are flat and any mistake on the preparation will have an impact on the positioning of the arthrodesis. Bone resection with the burr must be controlled to avoid any bone loss or asymmetrical resection that would affect primary stability and bone contact of the arthrodesis. A cup-and-cone configuration of bone preparation is more sound than flat bone cuts either for biomechanical reasons and for the arthrodesis positioning that is simpler without first ray shortening (Curtis [10], Goucher [13]). However, this method of preparing the fusion site cannot be undertaken percutaneously.

Arthrodesis positioning is perhaps the most critical of all the technical considerations. It is not only a problem of alignment of the hallux in terms of valgus/varus, dorsal flexion/plantar flexion or medial rotation/lateral rotation, but also a question of metatarsus varus, metatarsal length, hindfoot positioning (valgus flatfoot, pes cavus), forefoot symptoms (metatarsalgias, lesser toes deformities) and shoe wear habits (flat shoes or high heel shoes) (Conti [3], Harper [4], Alexander [5], Kelikian [6], Womack [7]). Arthrodesis positioning is easy to perform percutaneously, and the various stages of the procedures can be followed clinically and with fluoroscopy. A flat metallic tray to reproduce the effect of weight bearing is useful to judge accurately the appropriate position of the hallux (Kelikian [6], Womack [7]).

The fixation with cannulated compression crossed screws is a very simple technique but is not biomechanically the most stable technique. It is therefore important to assess with accuracy the position of the screws (Womack [7]).

### 3.6 Conclusion

Percutaneous MTP1 fusion is a simple procedure providing comparable results to fusions performed with open techniques. Post-operative care is simplified, with immediate full weight bearing on rigid flat shoes and quick return to normal walking. Bone preparation is an important step and requires an experience in percutaneous forefoot surgery. Arthrodesis

positioning and fixation with this percutaneous procedure are simple to verify clinically radiographically. The indications for percutaneous MTP1 fusion are those of the open procedure, and only severe bone loss or osteoporosis can be, in our hands, relative contraindications to use this technique.

## References

1. Mann RA, Oates JC. Arthrodesis of the first metatarsophalangeal joint. *Foot Ankle*. 1980;1(3):159–66.
2. DeFrino PF, Brodsky JW, Pollo F, et al. First metatarsophalangeal arthrodesis: a clinical, pedobarographic and gait analysis study. *Foot Ankle Int*. 2002;23(6):496–502.
3. Conti SF, Dhawan S. Arthrodesis of the first metatarsophalangeal and interphalangeal joints of the foot. *Foot Ankle Clin North Am*. 1996;1:33–53.
4. Harper MC. Positioning of the hallux for first metatarsophalangeal joint arthrodesis. *Foot Ankle Int*. 1997;18:827.
5. Alexander IJ. Hallux metatarsophalangeal joint arthrodesis. In: Kitaoka HB, editor. *Masters techniques in foot and ankle surgery*. 2nd ed. Philadelphia: Lippincott Williams and Wilkins; 2002. p. 45–60.
6. Kelikian AS. Technical considerations in hallux metatarsophalangeal arthrodesis. *Foot Ankle Clin North Am*. 2005;10:167–90.
7. Womack JW, Ishikawa SN. First metatarsophalangeal arthrodesis. *Foot Ankle Clin North Am*. 2009;14:43–50.
8. Chana GS, Andrew TA, Cotterill CP. A simple method of arthrodesis of the first metatarsophalangeal joint. *J Bone Joint Surg Br*. 1984;66:703–5.
9. Wu KK. Fusion of the metatarsophalangeal joint of the great toe with Herbert screws. *Foot Ankle*. 1993;14:165–9.
10. Curtis MJ, Myerson M, Jinnah RH, et al. Arthrodesis of the first metatarsophalangeal joint: a biomechanical study of internal fixation techniques. *Foot Ankle Int*. 1993;14:395–9.
11. Rongstad DJ, Miller GJ, Vadergriend RA, et al. A biomechanical comparison of four fixation methods of first metatarsophalangeal joint arthrodesis. *Foot Ankle Int*. 1994;15:415–9.
12. Watson AD, Kelikian AS. Cost-effectiveness comparison of three methods of internal fixation for arthrodesis of the first metatarsophalangeal joint. *Foot Ankle Int*. 1998;19:304–10.
13. Goucher NR, Coughlin MJ. Hallux metatarsophalangeal joint arthrodesis using dome-shaped reamers and dorsal plate fixation: a prospective study. *Foot Ankle Int*. 2006;27:869–76.

14. Coughlin MJ, Shurnas PS. Hallux rigidus: grading and long-term results of operative treatment. *J Bone Joint Surg Am.* 2003; 85A(11):2072–88.
15. Flavin R, Stephens MM. Arthrodesis of the first metatarsophalangeal joint using a dorsal titanium contoured plate. *Foot Ankle Int.* 2004;25(11):783–7.
16. Brodsky JW, Passmore RN, Pollo FE, et al. Functional outcome of arthrodesis of the first metatarsophalangeal joint using parallel screw fixation. *Foot Ankle Int.* 2005;26:140–6.
17. Yee G, Lau J. Current concepts review: hallux rigidus. *Foot Ankle Int.* 2008;29(6):637–46.

# Chapter 4

## The Reverdin-Isham Procedure for the Correction of Hallux Valgus: A Distal Metatarsal Osteotomy Procedure Using Minimal Invasive Technique

**Stephen A. Isham and Orlando E. Nunez**

Hallux valgus is perhaps one of the most challenging of all forefoot deformities facing the surgeon today. More than 150 procedures have been developed during the last century to correct hallux valgus deformity. The first metatarso-phalangeal joint supports 125 % of the weight of a walking person during the propulsive phase of gait, and must perform this function 1,000 of times a day for a lifetime.

The minimally invasive Reverdin-Isham procedure is highly effective in a wide range of bunion deformities. The definition, cause, and classification of hallux valgus, the Reverdin-Isham procedure with its preoperative criteria, the techniques of

---

S.A. Isham, M.D., DPM, DrHC (✉)  
Department of Minimally Invasive Foot Surgery,  
San Francisco Hospital, Sanatorio San Francisco, Mexico DF, Mexico  
e-mail: drisham@frontier.com

O.E. Nunez, M.D., DPM  
Department of Foot Surgery, del Cesar Clinic,  
Valledupar – Cesar, Colombia

Coeur d'Alene Foot & Ankle Surgery Center,  
Coeur d'Alene, ID, USA

operation, postoperative management, and the advantages and disadvantages are presented.

## 4.1 Definition

Hallux valgus is a combination of a transverse and frontal plane deformity of the hallux on the first metatarso-phalangeal head. This frequent deformity exists with progressive abduction and pronation of the first phalanx, abduction, pronation, and elevation of the first metatarsal with lateral capsule retraction of this joint. This results in the hallux being laterally deviated toward the lesser digits, and rotated into pronation with its dorsal surface more medially. Most bunions, mild, moderate, or severe, contain some combination of these deformities. These deformities involve both soft tissue and osseous components, producing, respectively, positional and structural deformities.

## 4.2 Etiology

The primary cause of hallux valgus is a congenitally abnormal foot structure, which is exposed to abnormal pronatory forces resulting in hypermobility of the joints of the foot and an overdependence on soft tissues for stability during weight bearing, especially during the last phase of the propulsive stage of gait. The severity of hallux valgus is proportional to the severity of the abnormal pronatory forces present.

Other causes of hallux valgus deformities are systemic disease, such as gouty or rheumatoid arthritis, neurologic disorders, and trauma causing permanent osseous or soft-tissue damage to the first metatarso-phalangeal joint. The progression and severity of hallux valgus increase when more than one cause is present. Footwear, although not a primary cause, can aggravate the symptoms of the deformity.

## 4.3 Classification

Appropriate classification of the deformities enables the surgeon to select or modify a procedure to achieve the best results for a given patient. To classify the severity of a hallux valgus deformity, we use the following measurements: hallux abductus angle, distal articular set angle, proximal articular set angle, first intermetatarsal angle, and first metatarsophalangeal joint position.

### 4.3.1 *Hallux Abductus Angle*

The hallux abductus angle (HA angle) is formed by the bisection of the longitudinal axis of the first proximal phalanx and the longitudinal axis of the first metatarsal. The normal angle formed by these lines is between  $5^{\circ}$  and  $15^{\circ}$ .

### 4.3.2 *Distal Articular Set Angle*

The distal articular set angle (DASA) is formed by the bisection of the longitudinal axis of the proximal phalanx and the line drawn perpendicular to the articular surface of the base of the proximal phalanx.

### 4.3.3 *Proximal Articular Set Angle*

The proximal articular set angle (PASA) is formed by the bisection of the longitudinal axis of the first metatarsal and the active cartilage of the head of the first metatarsal (DMMA).

### 4.3.4 *First Intermetatarsal Angle*

The first intermetatarsal angle is formed by the bisection of the line of the longitudinal axis of the first and second metatarsals. Normal range is between  $6^{\circ}$  and  $8^{\circ}$ .



### 4.3.5 *First Metatarso-Phalangeal Joint Position*

The first metatarso-phalangeal joint (MTPJ) position has three components:

- Congruous – The articular surface of the first MTPJ is parallel or equal.
- Deviated – The articular surface of the first MTPJ is unequal. The lines of intersection fall outside the joint.
- Subluxed – The articular surface of the first MTPJ is unequal with lines of intersection intersecting inside of the MTPJ.

The presence of a deviated or subluxed joint position is evidence of the presence of increased positional deformity (Fig. 4.1).

## 4.4 Classification of Hallux Valgus

Hallux valgus deformity is classified into three classes: mild, moderate, and severe.

### 4.4.1 *Mild Hallux Valgus*

In these patients, there is a hallux abductus angle of 5–20°, and a first intermetatarsal angle of 6–8°. The MTPJ surface is generally congruous (Fig. 4.2).

### 4.4.2 *Moderate Hallux Valgus*

Patients with moderate hallux valgus exhibit a hallux abductus angle between 20° and 40°, and a first intermetatarsal angle of 8° and 15°. The first MTPJ is generally deviated (Fig. 4.3).

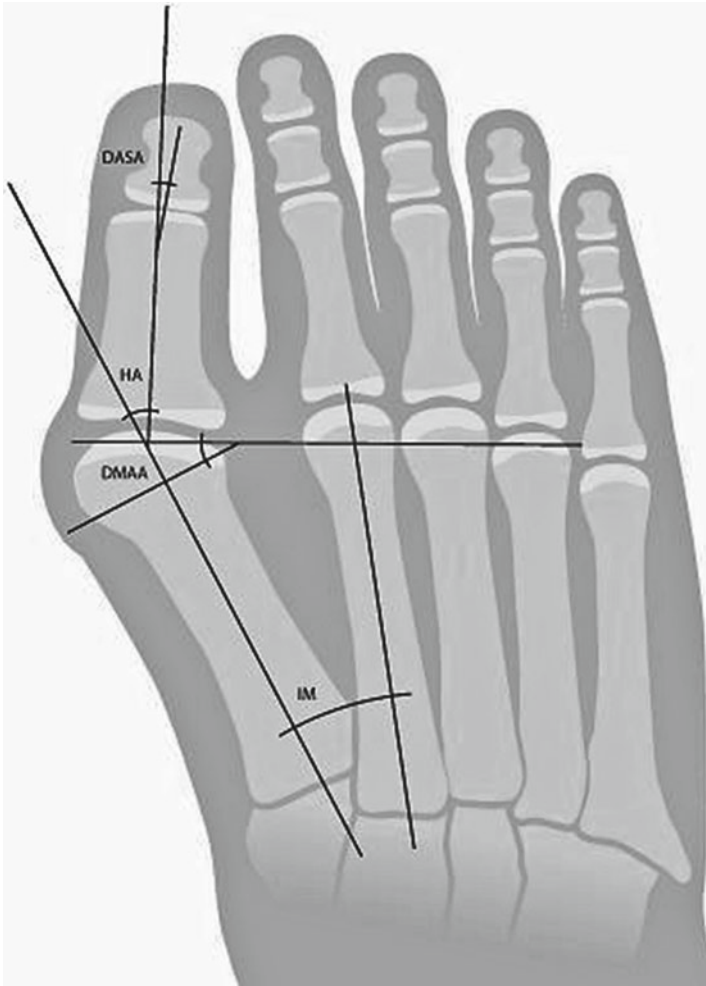


FIGURE 4.1 The presence of a deviated or subluxed joint position is evidence of the presence of increased positional deformity

### 4.4.3 Severe Hallux Valgus

Deformities of severe hallux valgus contain a hallux abductus angle of  $40^\circ$  or greater. The first intermetatarsal angle is  $15^\circ$  or greater. The MTPJ is usually subluxed (Fig. 4.4).

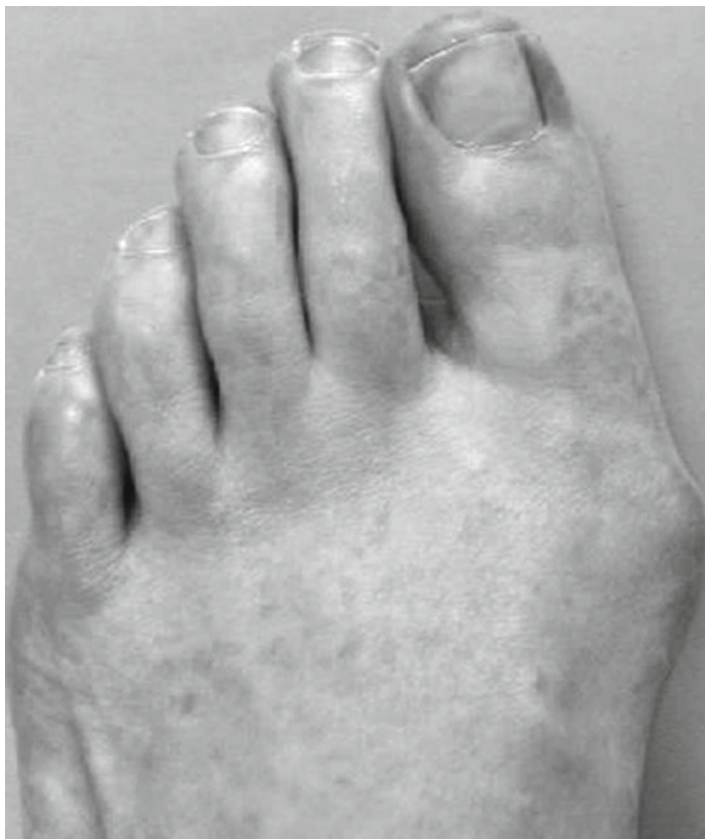

FIGURE 4.2 The MTPJ surface in mild hallux valgus is generally congruous

#### 4.5 Reverdin-Isham Procedure

Prior to 1985, minimal incision hallux valgus corrective procedures available to the surgeon, with the exception of a Wilson bunionectomy, although highly effective, were a compromise and failed to take into consideration the importance of the proximal articular set angle. An increased proximal articular set angle in the HAV deformity results in instability

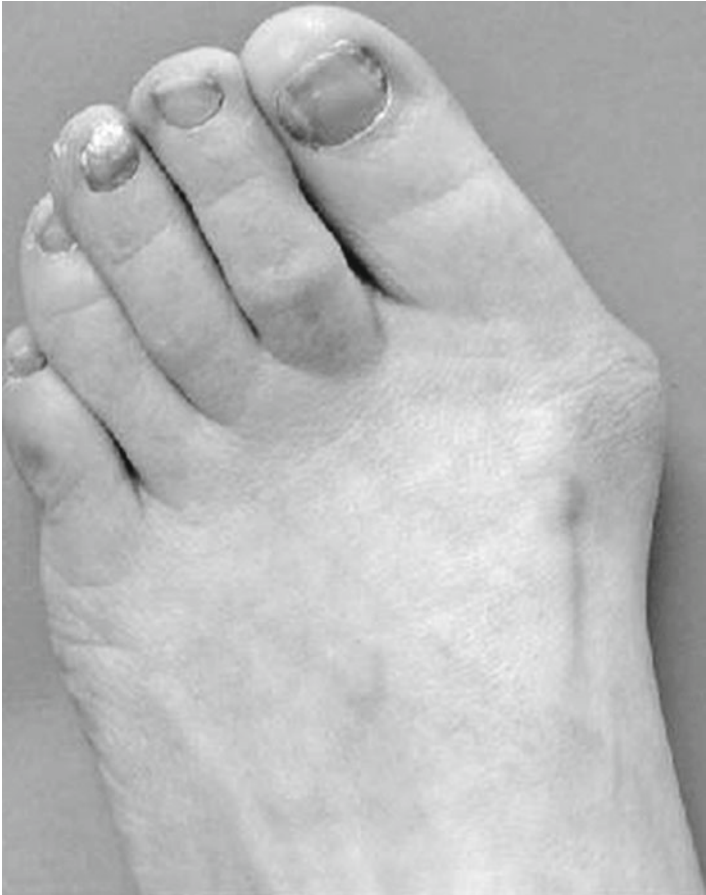

FIGURE 4.3 The first MTPJ is generally deviated in moderate hallux valgus

of the MTPJ and increased structural and positional forces that increase the first intermetatarsal angle and the hallux abductus angles. From a structural view point, a joint that is straight on a metatarsal bone is more stable than one that is set at an angle. This confirms the importance of the PASA (DMMA) in producing a hallux valgus deformity, and the need to reduce it in hallux valgus corrective surgery.

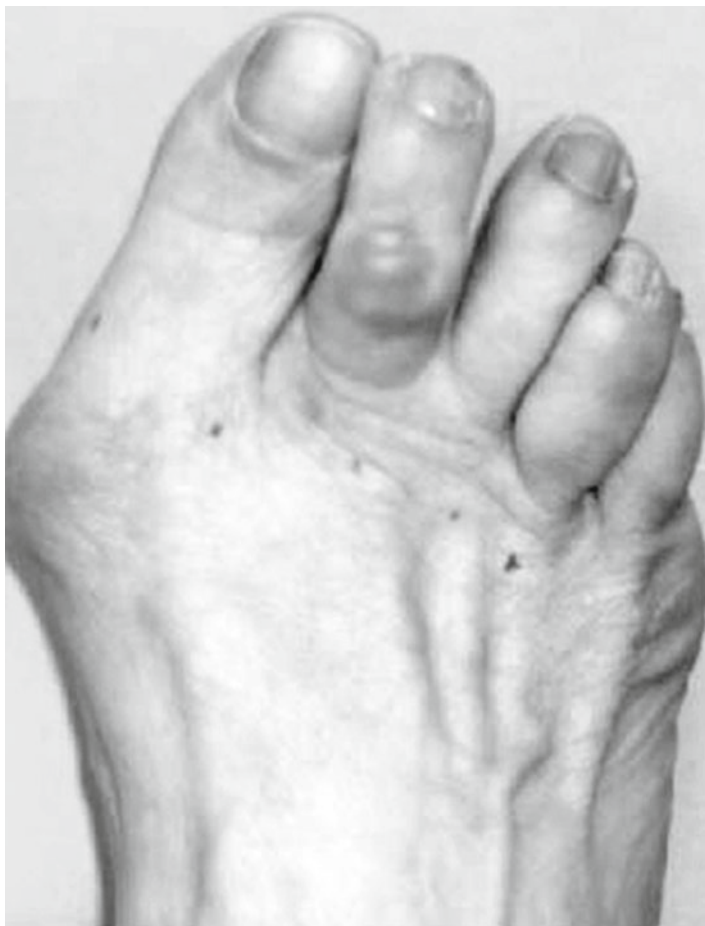

FIGURE 4.4 The MTPJ is usually subluxed in severe hallux valgus

In the early 1980's, Isham perfected the hallux valgus corrective procedure using minimally invasive surgery. Using minimal incision techniques, Reverdin bunionectomies were performed. These minimal incision Reverdin bunionectomies proved to be superior to previously used procedures in the correction of the involved structural positional components

of HAV disorders. As with large incision Reverdin bunionectomy procedures, in which a medial wedge osteotomy was performed through the first metatarsal head dorsal to plantar perpendicular to the weight-bearing surface of the first metatarsal, degenerative joint disease resulted when the osteotomy was placed through the articular surface on the plantar aspect of the head of the first metatarsal. The osteotomy interfered with the normal function of the sesamoid bones, resulting in decreased range of motion at the MTPJ.

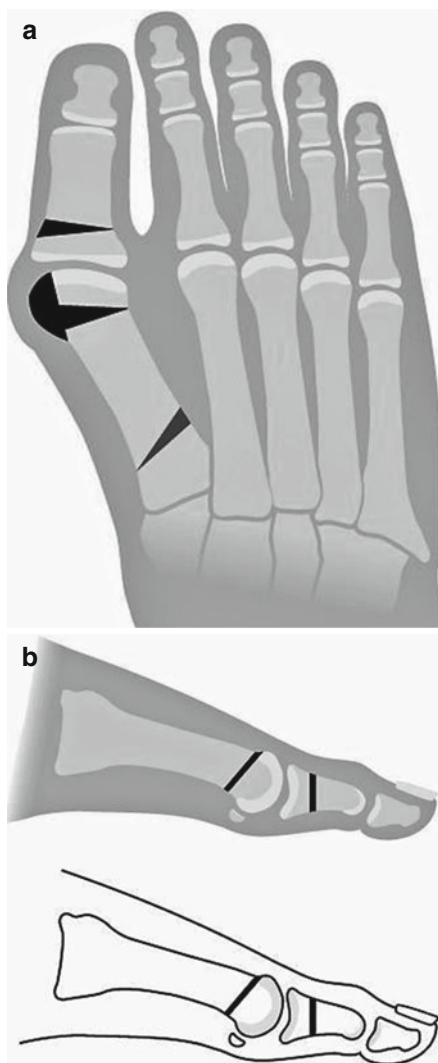
The author modified the Reverdin osteotomy with the Isham osteotomy by performing the medial wedge osteotomy in the head of the first metatarsal at an angle from dorsal distal, just proximal to the articular surface on the dorsal aspect of the head, to plantar proximal to a point just proximal to the articular surface on the plantar aspect of the first metatarsal head (Fig. 4.5a, b). This placement of the Isham osteotomy preserves and repositions the articular surface, corrects the proximal articular set angle, and redirects and stabilizes the structural forces at the first metatarso-phalangeal head. The placement of the osteotomy inside the joint capsule in the cancellous bone of the first metatarsal head was highly stable, and eliminated the need for internal fixation. As hoped, the post operative management proved to be the same as is needed for the minimal incision Silver-Akin procedure or modified McBride-Akin. No increased pain or disability was noted. Marked improvement of short and long term results were immediately apparent.

## 4.6 Preoperative Criteria

This procedure is directed at the structural correction of the deformities of HAV that are manifested at the metatarsal head. Specific criteria for the Reverdin-Isham procedure are;

- A symptomatic medial bunion deformity.
- A good range of motion for the first MTPJ; no pain, no crepitus, and no degenerative changes.

FIG. 4.5 (a) Schematics of the osteotomies in antero-posterior view. (b) Schematics of the osteotomies in lateral view



- A congruous deviated joint.
- An intermetatarsal angle of  $20^\circ$  or less for straight foot and  $16^\circ$  or less for an adducted foot.
- An increased PASA.

- A normal DASA.
- HA angle measurements that are from slightly too highly abnormal.
- A hallux axial rotation that is mild or absent.
- Relative metatarsal protrusion that is normal to positive.

If the DASA is abnormal, then the Reverdin-Isham procedure should be combined with an Akin procedure. A plantarflexed first metatarsal may or may not be present. Another procedure to correct a plantarflexed metatarsal is not needed.

## 4.7 Operative Technique

The Reverdin-Isham procedure is performed by combining several minimally invasive procedures. The first being an exostectomy of the dorsal medial aspect of the first metatarsal head, a distal metatarsal osteotomy, a Reverdin-Isham, an adductor release, and finally an Akin phalangeal osteotomy.

## 4.8 Minimally Invasive Technique

A 0.5–1 cm longitudinal incision is made on the plantar medial aspect of the first metatarsal head. The incision is carried deep through subcutaneous tissue to expose the capsule of the first MTPJ. A capsulotomy is performed, and the dorsal medial aspect of the head is freed of the capsule and ligamentous attachments. The medial eminence is then resected using a bone reducing Burr 3.1 wedge (Vilex, 111 Moffitt Street, McMinnville, TN 37110, USA). The dorsal eminence and the tibial sesamoid is palpated and identified through the skin. A bone cutting instrument (e.g. Isham Straight Flute, Burr, Vilex, 111 Moffitt Street, McMinnville, TN 37110, USA) is inserted into the incision, and an angular medial wedge osteotomy is performed from dorsal distal to plantar proximal in the metaphyseal portion of the head



of the first metatarsal. Care must be taken to preserve the lateral cortex and the articular surface of the hallux sesamoids and the dorsal articular surface of the head. The use of a fluoroscope facilitates placement of the osteotomy and indicates the amount of bone to be removed. The hallux is then rotated into adductus, and the osteotomy is compressed and closed. Remaining osseous structures are rasped smooth.

Attention is then directed to the lateral aspect of the first MTPJ, where a 0.5 cm oblique incision is made over the first MTPJ. The incision is deepened, a lateral capsulotomy and an adducto hallucis tenotomy is performed (Fig. 4.6). Skin edges are approximated using 4-0 nonabsorbable suture. If indicated by an increased distal articular set angle, an Akin procedure is performed. An Akin procedure is indicated in most patients. The wound is dressed, and a position is maintained with a sterile splint dressing of the surgeon's choice.

## 4.9 Postoperative Management

The patient is given a surgical shoe and discharged. The patient is allowed to increase weight bearing as tolerated. Postoperative pain, as with most ambulatory procedures, may require minimal amounts of pain control medication. Many patients take none.

The dressing is changed on day 2 or 3 after surgery, and the sutures are removed at this time. A splint dressing is reapplied. The second dressing change occurs 1 week after surgery, and a removable splint dressing is applied and changed daily by the patient. Bathing is then permitted. The patient is allowed to ambulate in the self surgical shoe or a supportive athletic-type shoe until normal shoes can be worn. Postoperative radiographs are taken on the first redressing and again 3–4 weeks after surgery for evaluation of healing. It should be noted that, as with an Austin-type bunionectomy, a minimal amount of bony callous formation is expected.

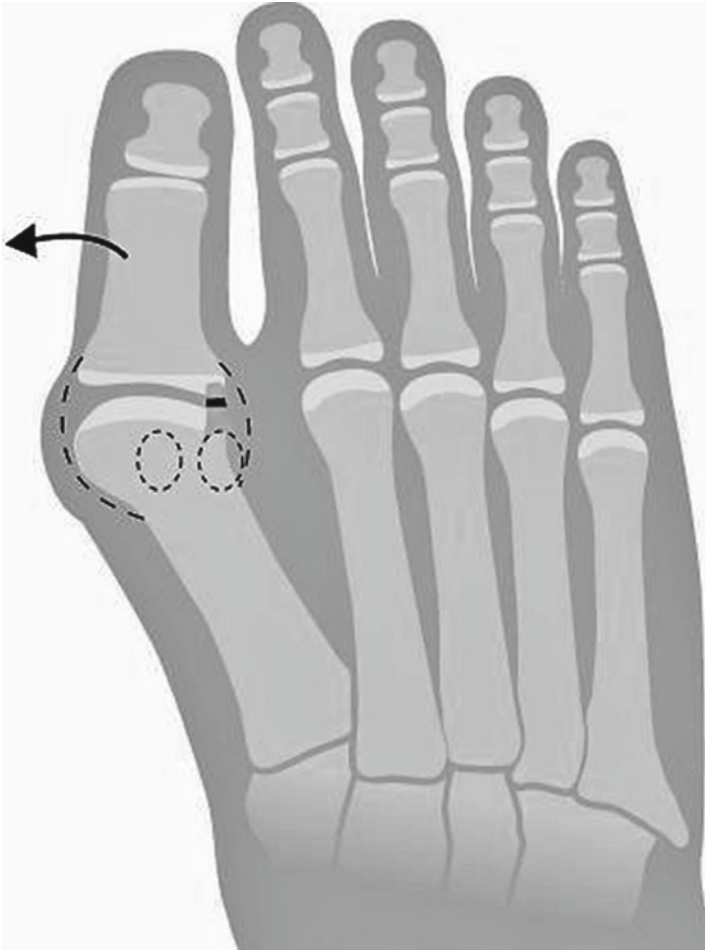


FIGURE 4.6 The lateral aspect of the first MTPJ, where a 0.5 cm oblique incision is made over the first MTPJ. The incision is deepened, a lateral capsulotomy and a tenotomy of the adductor hallucis is performed

#### 4.10 Postoperative Bandaging

Minimal incision procedures, by design, are very atraumatic, with a minimal amount of soft-tissue disruption. A second metatarsal, for example, has seven tendons passing over the

MTPJ. These tendons pass over the dorsal, medial, plantar, and lateral aspects of the MTPJ. The head of the second metatarsal is also stabilized by a strong intermetatarsal ligament, attached to the third, fourth, and fifth metatarsals. A properly performed osteotomy at the proximal aspect of the metatarsal head does not disrupt these soft-tissue structures. These structures, during the initial postoperative healing phase of the first 3–6 weeks, contract and stabilize the osteotomy site. We call this contracture of the soft tissues “intrinsic fixation.” Although internal fixation is not required, external splinting is required to enable the patient to bear weight.

Postoperative splint dressings in minimal incision foot surgery should stabilize the surgical site in its corrected position, be a comfort to the patient that is easy to apply, and maintain a sterile barrier.

Postoperative dressings are presented in two phases. The first phase represents the type of dressing used during the first postoperative week. These dressings are applied by the surgeon. The second phase of the dressings consists of splint dressings used for the following 4 weeks. Figure 4.7a–c depict phase one dressing, and Fig. 4.8 depicts phase two dressing. The phase two dressings are initially applied by the surgeon and are changed daily by the patients after they have been instructed in their application. Bathing is permitted on a daily basis after the first postoperative week.

#### 4.11 Advantages of the Reverdin-Isham Procedure

- Good healing as the osteotomy is performed in metaphyseal bone.
- Minimal fixation (internal or external) is required because the procedure is intracapsular and compressed by the retrograde force of the hallux.
- It provides biplane correction of the structural deformity with improved positions of sesamoids.

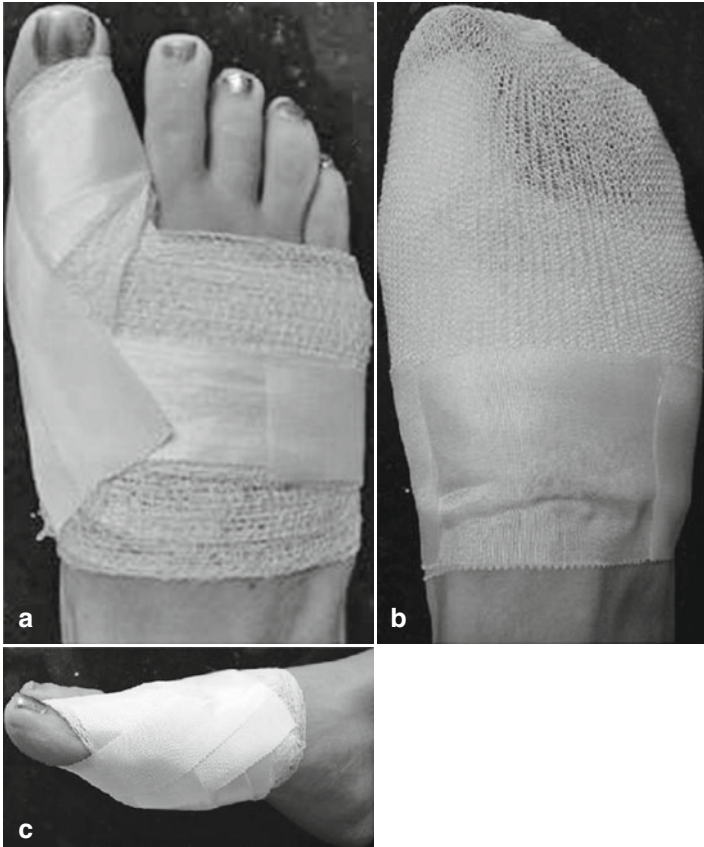

FIGURE 4.7 (a) Phase one: Basic dressing following the osteotomy. (b) Phase one: The dressing can be covered with tubinet. (c) Phase two: Detail of the dressing

- It involves minimal amount of postoperative disability, similar to the minimal incision Silver-Akin procedure.
- It can be performed on children prior to epiphyseal closure because the epiphysis is located at the metatarsal base.
- It can be performed in the presence of uncontrollable pronatory forces.
- The average reduction of the intermetatarsal angle of  $7^\circ$  has been noted, especially when the procedure is performed with the Akin procedure.

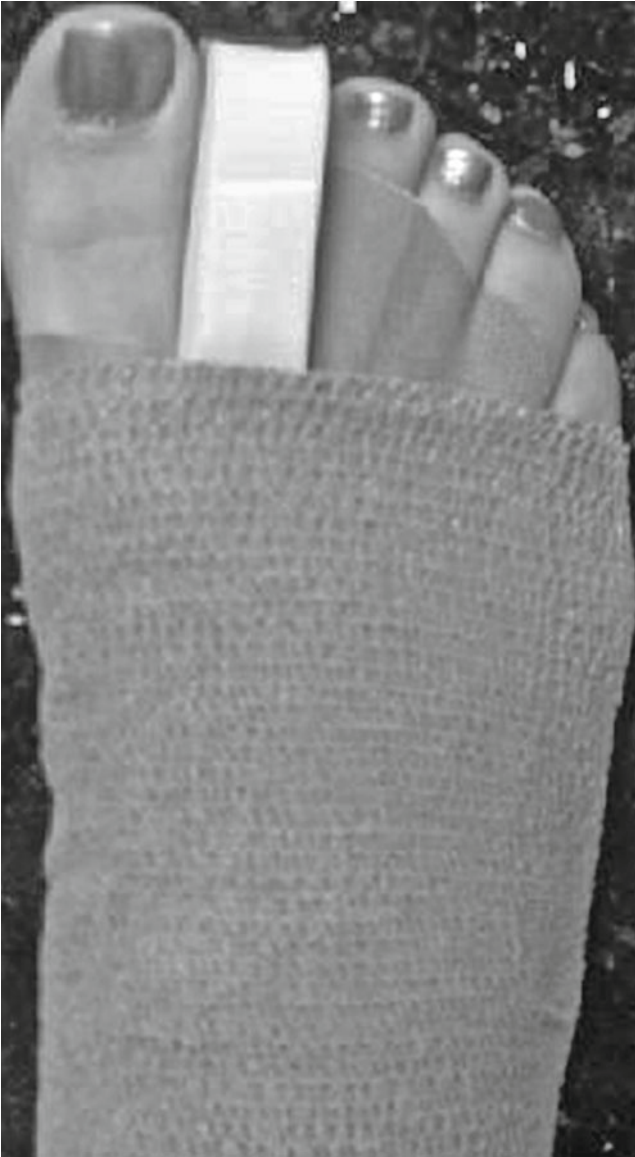

FIGURE 4.8 Postoperative dressings are presented in two phases: phase two dressing

## 4.12 Disadvantages of the Reverdin-Isham Procedure

- The sagittal plane deformity may not be corrected, however, with reduction of the first intermetatarsal angle; relative sagittal plane correction is noted. With a modified Reverdin-Isham, in which the head is slid laterally, the sagittal plane correction is obtained when indicated.
- An average shortening of the first metatarsal of 5 mm should be expected. If poor healing at the osteotomy site occurs, greater shortening of the first metatarsal is possible.

## 4.13 Summary

The Reverdin-Isham procedure is a distal metatarsal osteotomy procedure that has stood the test of time. If the PASA needs to be corrected, the Reverdin-Isham procedure will involve an osteotomy of the lateral cortex, allowing the metatarsal head to be shifted laterally, directly reducing the intermetatarsal angle. Another option is a closing wedge osteotomy of the first metatarsal base. Using one or more of these modifications, the surgeon can correct severe hallux valgus deformities.

## Suggested Reading

Akin OF. The treatment of hallux valgus: a new operative procedure and its results. *Med Sent.* 1925;33:678–9.

Colloff B, Weitz EN. Proximal phalangeal osteotomy and hallux valgus. *Clin Orthop.* 1967;54:105.

Funk FJ Jr, Wells RE. Bunionectomy—with distal osteotomy. *Clin Orthop Relat Res.* 1972;85:71–4.

Gerbert J. *Textbook of bunion surgery.* New York: Futura Publishing Co; 1981.

Gerbert J, Melillo T. A modified Akin procedure for the correction of hallux valgus. *J Am Podiatric Assoc.* 1971;61:132.

Gertbert J, Mercado OA, Sokoloff TH. The surgical treatment of hallux abducto-valgus and allied deformities. In: *Podiatric medicine*

and surgery, Monograph series. New York: Futura Publishing Co; 1973.

Isham SA. The Reverdin-Isham procedure for the correction of hallux valgus. *Curr Podiatr Med.* 1985;7:11-3.

Kelikian H. Hallux valgus, allied deformities of the forefoot and metatarsalgia. Philadelphia: W.B. Saunders Co; 1965.

Maffulli N. Minimally invasive surgery in orthopedic surgery. *Orthop Clin North Am.* 2009;40:441-568.

Peabody CW. Surgical cure of hallux valgus. *J Bone Joint Surg.* 1931;13A:273.

Podiatrics Sino-American conference on foot disorders. October 1987, Beijing.

# Chapter 5

## Arthroscopic Assisted Correction of Hallux Valgus Deformity

**Tun Hing Lui**

Endoscopic assisted distal soft-tissue correction for hallux valgus deformity follows the same principle of the open procedure [1–3]. This approach is indicated with symptomatic hallux valgus with an incongruent metatarsophalangeal joint and no significant bony abnormality (e.g., severe hallux valgus interphalangeus or abnormal distal metatarsal articular angle). It is contraindicated if the intermetatarsal angle cannot be corrected manually (e.g., presence of os intermetatar-seum). Sometimes, the correction may be obstructed by the dislocated fibular sesamoid bone in the web space. This is not a contraindication of the procedure, since the sesamoid can be reduced after lateral release and the intermetatarsal space can then be closed up. Osteoarthritis of the first metatarsophalangeal joint and deformity resulting from neuromuscular conditions are other contraindications.

Endoscopic assisted distal soft-tissue correction for hallux valgus deformity has the advantages of better assessment of sesamoid reduction, and avoids the need for metatarsal osteotomy. The potential complications are similar to those of the open procedure, including recurrence of deformity, digital nerve injury, and implant failure.

---

T.H. Lui, MBBS (HK), FRCS (Edin), FHKAM, FHKCOS  
Department of Orthopaedics and Traumatology, North District Hospital,  
9 Po Kin Road, Sheung Shui, NT Hong Kong SAR, China  
e-mail: luithderek@yahoo.co.uk

N. Maffulli, M. Easley (eds.), *Minimally Invasive Forefoot Surgery in Clinical Practice*, DOI 10.1007/978-1-4471-4489-2\_5,  
© Springer-Verlag London 2013



## 5.1 Technique of Endoscopic Distal Soft Tissue Procedure

The patient is supine with an ipsilateral thigh tourniquet on the spread leg table. We use a 2.7 mm 30° arthroscope, an arthroscopic shaver and burr, retrograde knife and straight needle. The procedure has four steps. The first is lateral soft tissue release, the second is medial bunionectomy, and the third is reduction of the 1,2 intermetatarsal angle and fixation of the 1,2 metatarsals. The final step is plication of medial capsule.

### 5.1.1 *Lateral Soft Tissue Release*

There are two approaches of the lateral soft tissue release: ligament sacrificing [1–3] and ligament preserving [4] approaches. The difference is whether the intermetatarsal ligament is cut or not.

#### 5.1.1.1 Ligament Sacrificing Approach

For the lateral release, two portals are made, the plantar portal and the toe web portal. The toe web portal is established by a stab incision over the dorsum of the first web space, followed by blunt dissection of the subcutaneous tissue using a hemostat until the plantar surface of the intermetatarsal ligament is felt (sensation of hitting a wash board). The 2.7 mm arthroscopic cannula together with the trocar are passed through the toe web portal, and advanced proximally underneath the ligament. The plantar aponeurosis is then reached and pierced by the trocar. There should be minimal resistance before the plantar aponeurosis is reached. The trocar should be advanced gently to avoid injury to the plantar neurovascular structures, especially the medial digital nerve to the second toe. The plantar portal should be just proximal to the penetration point of the plantar aponeurosis to maximize the “working length” of the portal tract.

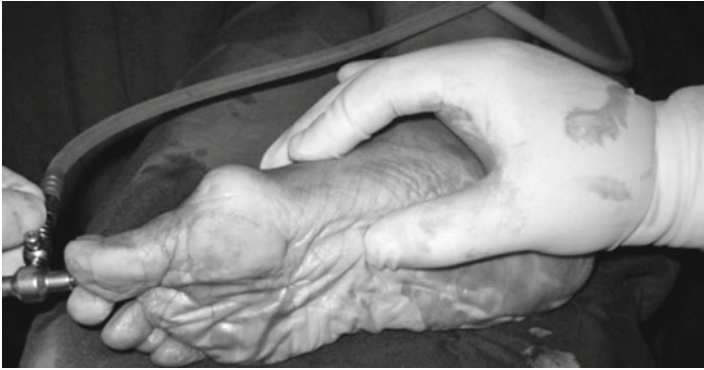

FIGURE 5.1 The plantar portal is established immediate after the trocar has passed through the plantar aponeurosis at the level of tarso-metatarsal joint

To have adequate working length, the plantar portal should be at the level of the tarso-metatarsal joint (Fig. 5.1). If the plantar portal is too distal, there will be inadequate working length. The cannula and the trocar are retrieved, and only the trocar is reinserted into the toe web portal and exits through the plantar portal. The arthroscopic cannula is then introduced through the plantar portal and exited through the toe web portal along the trocar (Fig. 5.2).

The trocar is then removed, and a 2.7 mm 30° arthroscope is introduced. The retrograde knife is then passed through the toe web portal under arthroscopic guidance until it reaches the proximal edge of the intermetatarsal ligament, the proximal edge of which is relatively easy to identify by probing with the retrograde knife. The ligament is then released using the retrograde knife (Fig. 5.3).

After the ligament is released, the arthroscope is moved slightly dorsally through the cut ends of the ligament, and is turned 90° towards the hallux to visualise the insertion of the tendon of adductor hallucis (Fig. 5.4).

The insertion is released with the retrograde knife, and the fibular sesamoid bone can then be seen. The lateral capsule release is started a bit proximal to the fibular sesamoid bone

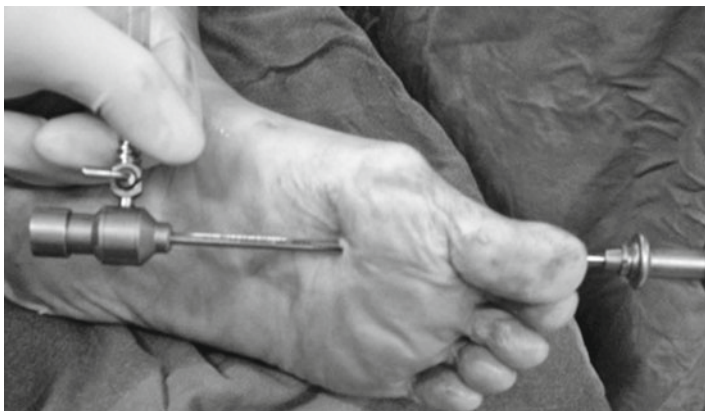

FIGURE 5.2 The trocar is used as a guide rod for the introduction of the cannula through the plantar portal

and at the midpoint of metatarsal neck to avoid injury to the lateral digital nerve to the hallux. The release is progressed distally just dorsal to the fibular sesamoid bone to the base of proximal phalanx. This can release the metatarsal sesamoidal suspensory ligament and preserve the metatarso-phalangeal collateral ligament. To ensure that the phalangeal insertional band is released, the retrograde knife should be shifted slightly laterally when it hits the base of the proximal phalanx and finished the release of the band. This is important for the reduction of the sesamoid bones to the corresponding metatarsal grooves. However, it should be kept in mind that sudden “give way” after the release of the band may lead to accidental extension of the toe web portal wound.

After completion of the lateral release, the hallux valgus deformity and the sesamoid apparatus can be reduced by abducting and supinating the proximal phalanx. The lateral part of the metatarso-phalangeal joint and metatarso-sesamoid compartment can be examined by the arthroscope through the toe web portal (Fig. 5.5). During the lateral release, the instruments should be kept away from the fat tissue plantar to the intermetatarsal ligament to minimize the risk of injury to the digital nerve.

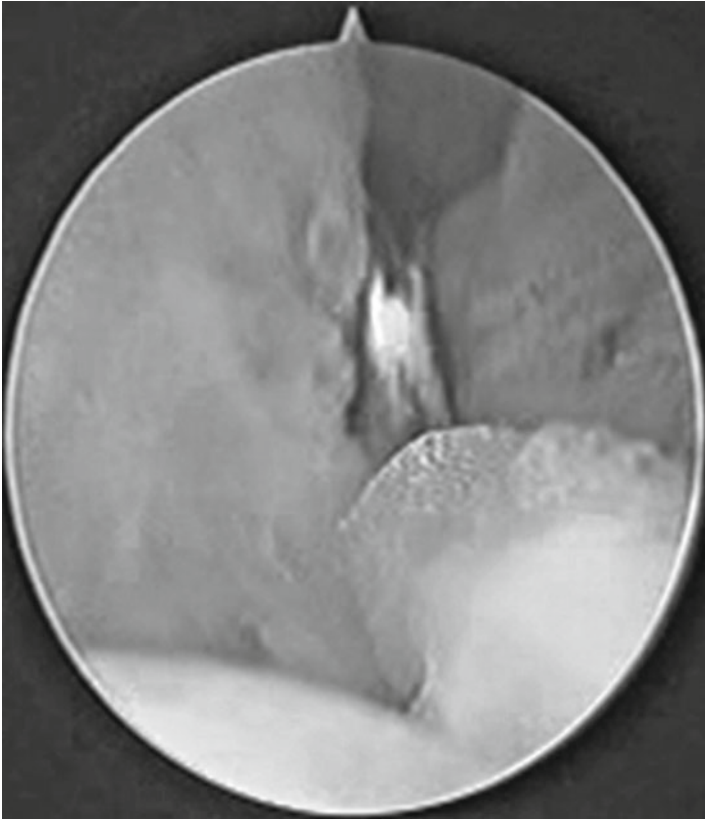


FIGURE 5.3 Release of the intermetatarsal ligament by retrograde knife

#### 5.1.1.2 Ligament Preserving Approach

It is similar to the standard procedure except that the arthroscope is passed just dorsal to the intermetatarsal ligament. The intermetatarsal ligament is left intact, and only the insertion of the tendon of the adductor hallucis and the lateral capsular structures are released. This is technically more difficult, and may not have a protective role to the neurovascular structure [4].

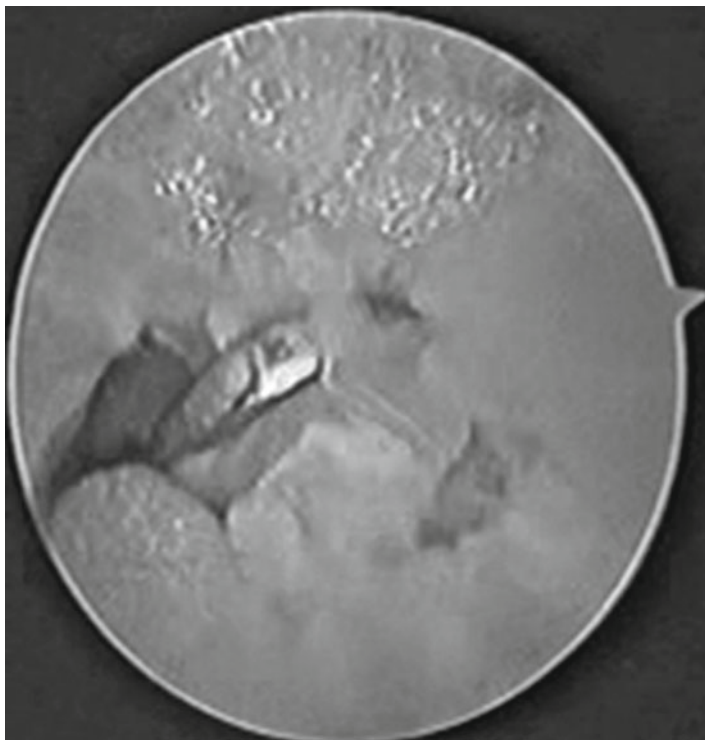


FIGURE 5.4 The tendon of adductor hallucis insertion is released

The degree of correction of the deformity can be checked by abducting and supinating the hallux and closing the intermetatarsal space manually. In case of total dislocation of the fibular sesamoid, it is useful to plantar flex the first metatarsophalangeal joint to relax the plantar capsule and pass a hemostat through the toe web portal into the metatarsosesamoid interval to reduce the fibular sesamoid. The correction can usually be maintained by closing the intermetatarsal space alone if the lateral release is adequate (Fig. 5.6). If the correction is suboptimal, it may arise from inadequate lateral release, inadequate closure of the intermetatarsal space or excessive pronation of the first metatarsal. If the intermetatarsal space cannot be

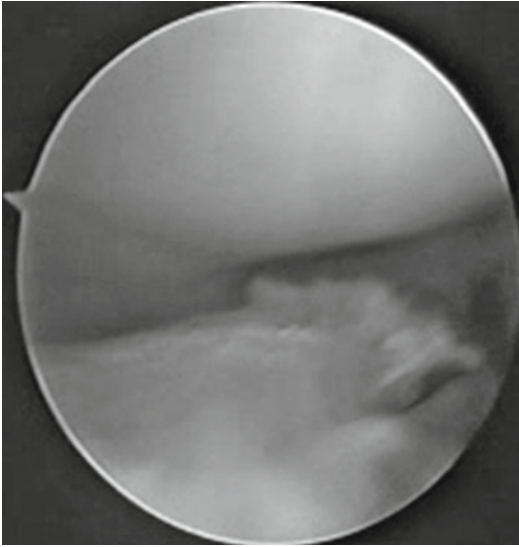


FIGURE 5.5 Reduction of the fibular sesamoid to the corresponding metatarsal groove can be accessed through the toe web portal

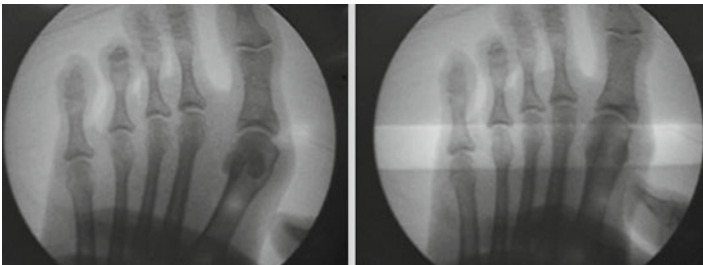


FIGURE 5.6 After adequate lateral release, the sesamoid bones and the metatarso-phalangeal joint can be reduced by closure of the intermetatarsal space

closed manually even after adequate lateral soft tissue release, a metatarsal osteotomy is indicated. In case of excessive metatarsal pronation, derotation of the metatarsal is needed before insertion of the positioning screw.

### 5.1.2 Medial Exostectomy

It relies on two portals on the medial aspect of the foot. The distal bunion portal is located at the mid-point of the medial side of the first metatarso-phalangeal joint, as the medial portal of the first metatarso-phalangeal arthroscopy. The proximal portal is at the level of the proximal pole of the bunion. They can be both viewing and working portals, depending on the stage of the procedure (Fig. 5.7). The first metatarso-phalangeal joint is examined through the distal bunion portal using a 1.9 mm arthroscope. An arthroscopic synovectomy is performed through the dorsolateral portal if synovitis is present and the patient complained of first metatarso-phalangeal joint pain with joint line tenderness [3, 5].

The medial capsule is first stripped from the bony bunion using a small periosteal elevator through the proximal and distal portals. The bony prominence can be removed using arthroscopic burr under direct arthroscopic visualization, removing more bone dorsally. The adequacy of the exostectomy can be checked with fluoroscopy.

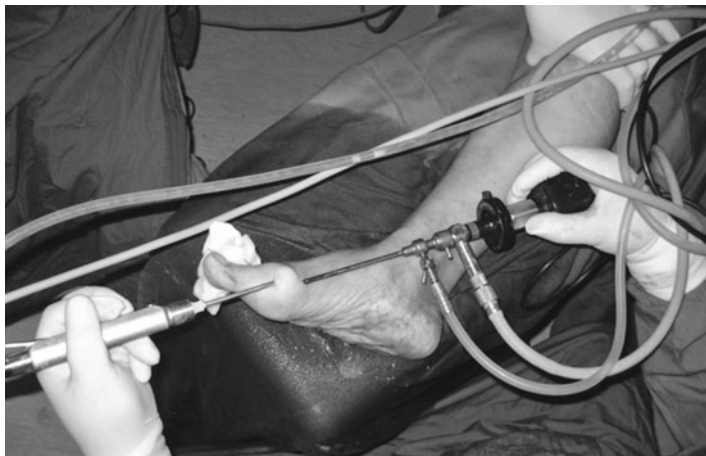

FIGURE 5.7 Medial exostectomy through the proximal and distal bunion portals

### 5.1.3 *Reduction and Fixation of Intermetatarsal Angle*

A 2 mm bone tunnel of the neck of the first metatarsal is made through the proximal bunion portal. A long small catheter is passed through the bone tunnel, and the tip is caught with a hemostat through the toe web portal. The needle is removed, and the tip of the cannula is retrieved through the toe web portal and a double-stranded PDS 1 suture is passed from the proximal bunion portal to the toe web portal through the angiocath cannula to the toe web portal. The suture is then wrapped around the second metatarsal neck using an aneurysmal needle through the toe web portal. The suture is retrieved to the proximal bunion portal with a hemostat. The suture should be deep to the extensor tendons of both hallux and second toe and dorsal nerve and superficial to the dorsal capsule of the first metatarso-phalangeal joint (Fig. 5.8). The first intermetatarsal space is closed manually and held with a 4.0 mm cannulated positioning screw bridging the bases of the two metatarsals [6]. The intermetatarsal sutures are then tied.

### 5.1.4 *Plication of the Medial Capsule*

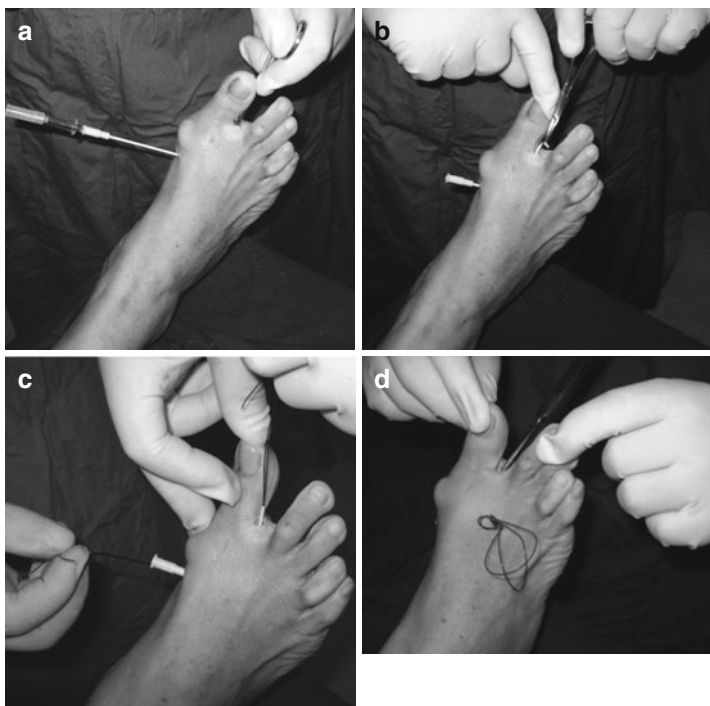
The PDS-1 sutures with a cutting-tip curved eyed needle are prepared to plicate the medial capsule. The aim of medial capsular plication is to anchor the distal plantar corner of medial capsule to the proximal dorsal corner, to provide adduction and supination force to proximal phalanx [1]. The needle is introduced through the distal bunion portal to pierce the plantar capsular flap and come out through the skin in an inside out fashion. Then, the skin is retracted with a skin hook, and the surface of the capsule is cleared with a hemostat until the suture is seen. The suture is retrieved at the surface of the capsule, making sure that the digital nerve is not entrapped. The suture is then passed through the plantar capsular flap again under direct visualization to avoid trapping the digital nerve, through the joint lastly, and finally above the dorsal capsule and through the skin, in an outside in fashion.



The suture is retrieved from the joint through the distal bunion portal. The suture is passed to the proximal portal deep to the capsule. The needle is introduced through the proximal portal to pierce the dorsal capsular flap and comes out through the skin in an inside out fashion. The sutures are retrieved at the surface of the capsule, as described above (Fig. 5.9).

The medial capsular suture should be inserted before tying the intermetatarsal space. The medial capsular suture is tied with the hallux held in the reduced position, and should be tied after tying the intermetatarsal suture.

Post-operatively, the foot is put in a bulky dressing for 2 weeks, when the dressing is changed to a light dressing, and active toe mobilization is allowed with a dynamic hallux valgus splint (Fig. 5.10). The screw transfixing the first and second metatarsal is removed under local anesthesia 8 weeks after the operation.



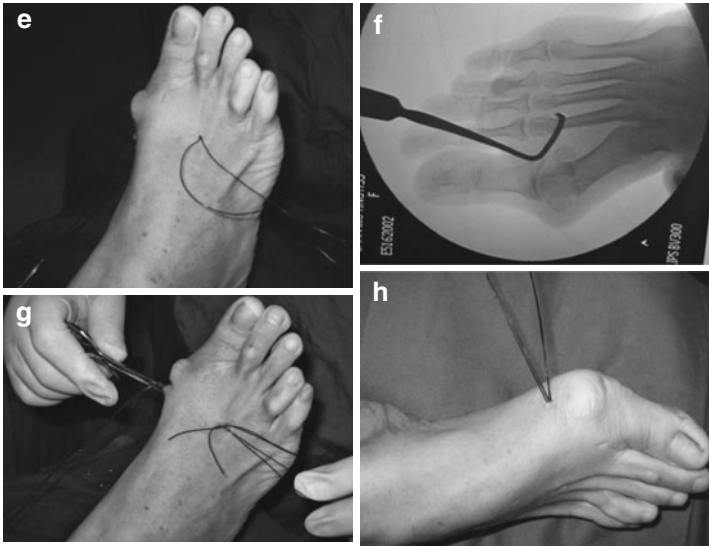


FIGURE 5.8 (a) A long angiocath is passed through the bone tunnel and the tip is caught by a hemostat through the toe web portal. (b) The needle is removed and the tip of the cannula is retrieved through the toe web portal. (c) A double-stranded PDS 1 suture is passed from the proximal bunion portal to the toe web portal through the angiocath cannula to the toe web portal. (d–f) The suture is then wrapped around the second metatarsal neck using an aneurysmal needle through the toe web portal. (g, h) The suture is retrieved from the proximal bunion portal with a hemostat. The suture should be deep to the extensor tendons of both hallux and second toe and dorsal nerve, and superficial to the dorsal capsule of the first metatarso-phalangeal joint

## 5.2 Adjunct Procedures

### 5.2.1 Derotation of the First Metatarsal

If the apparent sesamoid subluxation in the dorsolateral radiograph arises from excessive pronation of the first metatarsal rather than true sesamoid subluxation, it can be detected using sesamoid view preoperatively. The sesamoid

bones are seated into the corresponding groove of the metatarsal head, and the sesamoid grooves are facing plantarlaterally in sesamoid view. Intra-operatively, excessive metatarsal pronation should be suspected if the reduction of a sesamoid is suboptimal even after complete lateral soft tissue release. Arthroscopic examination of the metatarso-sesamoid compartment through the distal bunion portal and the toe web portal will show that the sesamoid bones seated in the corresponding grooves. In a study of metatarso-phalangeal

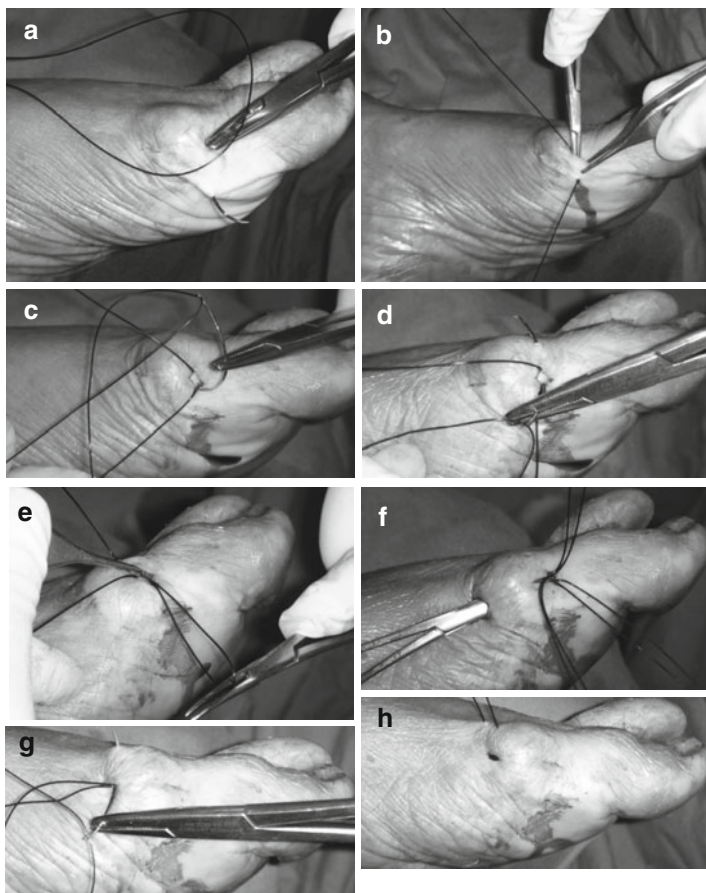

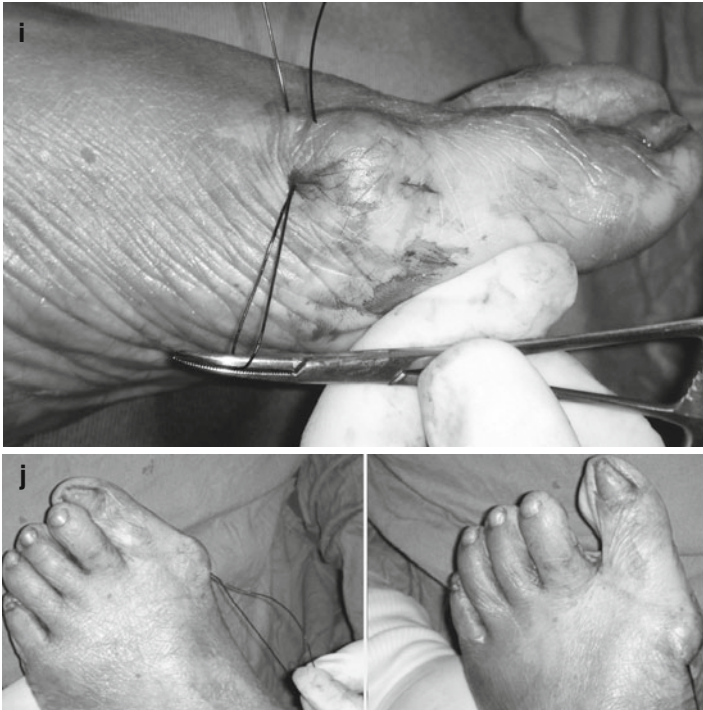


FIGURE 5.9 (a) The needle is introduced through the distal bunion portal to pierce the plantar capsular flap and come out through the skin in an inside out fashion. (b) The surface of the capsule is cleared with a hemostat until the suture is seen. The suture is retrieved at the surface of the capsule, making sure that the digital nerve is not entrapped. (c, d) The suture is then passed through the plantar capsular flap again under direct visualization to avoid trapping the digital nerve, through the joint lastly, and finally above the dorsal capsule and through the skin in an outside in fashion. (e) The suture is retrieved from the joint through the distal bunion portal. (f) The suture is passed to proximal portal deep to the capsule. (g, h) The needle is introduced through the proximal portal to pierce the dorsal capsular flap and come out through the skin in an inside out fashion. (i) The sutures are retrieved at the surface of the capsule and deep to the extensor tendon and digital nerve. (j) The hallux valgus deformity can be corrected by tensioning the medial capsular placcation suture

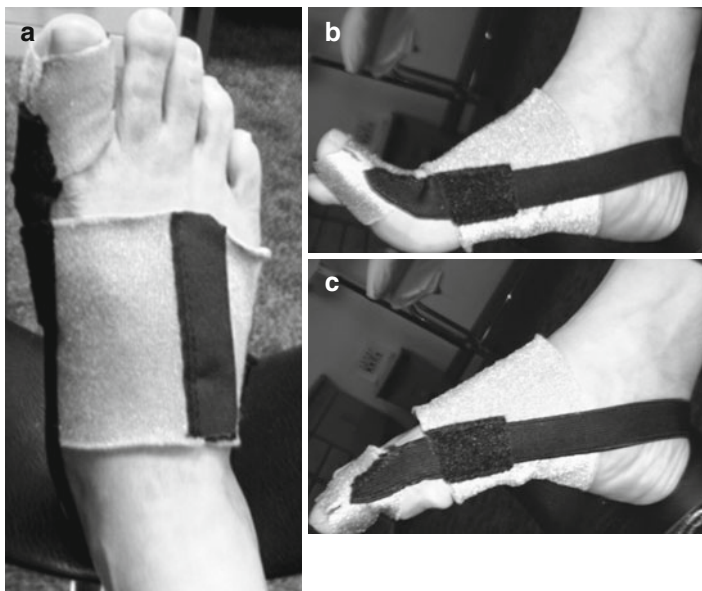


FIGURE 5.10 (a) From above. (b) From the side, with the hallux in dorsi-flexion. (c) From the side, with the hallux in plantar-flexion

arthroscopy in patients with hallux valgus, there was a high chance of cartilage degeneration of the metatarso-sesamoid compartment because of the joint incongruity as a result of sesamoid subluxation. If there is no cartilage degeneration of the metatarso-sesamoid compartment, metatarsal pronation should be suspected. The first metatarsal is de-rotated with a Kirschner wire before insertion of the proximal fixation screw (Fig. 5.11) [3].

#### 5.2.1.1 Arthroscopic First Tarso-Metatarsal (Lapidus) Arthrodesis

A Lapidus arthrodesis is indicated in patients with hypermobility of the medial cuneiform metatarsal joint. Stability of the first ray may be restored after surgical correction of

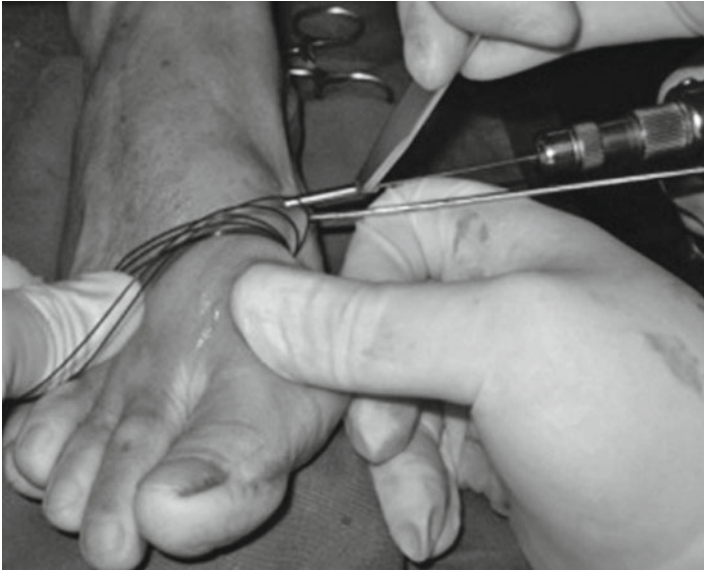

FIGURE 5.11 The first metatarsal is supinated and plantarflexed, and the intermetatarsal space is closed by the surgeon's right hand while the assistant is inserting the guide wire

the hallux valgus deformity despite leaving the capsule of the first tarso-metatarsal joint undisturbed [7]. Preoperatively, we establish the need for the arthroscopic Lapidus procedure by performing the relocation drawer test [2]. We perform the drawer test with the hallux valgus deformity reduced manually. We believe that first tarso-metatarsal arthrodesis is indicated only if the first tarso-metatarsal joint hypermobility persists during the relocation drawer test. The open procedure has been criticized for its prolonged healing and high nonunion rate, as well as the tendency for dorsal angulation of the first metatarsal. Arthroscopic Lapidus arthrodesis [8] has the advantage of more thorough preparation of the fusion site with minimal bone removal and better control of the arthrodesis position with less chance of malunion because of preservation of soft tissue around the joint.

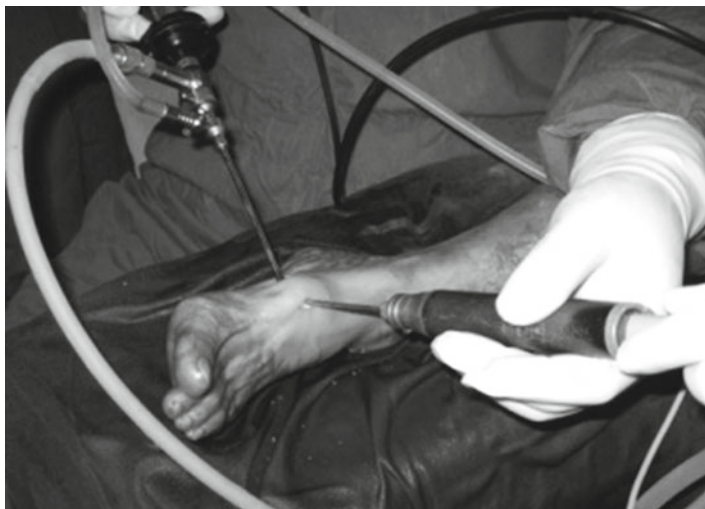

FIGURE 5.12 First tarso-metatarsal arthroscopy

#### 5.2.1.2 Technique

With the patient supine and a pneumatic thigh tourniquet and no distraction, the first tarso-metatarsal is located and arthroscopy (Fig. 5.12) is performed through the plantar medial and dorsomedial portals at the plantar medial and dorsomedial corners of the joint which can be located with a G21 needle.

The instruments used are 2.7 mm 30° arthroscope, small periosteal elevator, arthroscopic osteotome and arthroscopic awl. The articular cartilage using an arthroscopic osteotome and a small periosteal elevator, leaving the subchondral bone intact. Micro-fracture of the subchondral bone is then performed by means of arthroscopic awls (Fig. 5.13). The intermetatarsal angle is closed manually, and the first metatarsal is held in plantarflexion via dorsiflexion of the first metatarsophalangeal joint. A 4.0 mm cannulated screw is inserted from a proximal dorsal direction to a distal plantar direction across the joint. Finally, a 4.0 mm positioning screw is inserted from the first metatarsal base to the second metatarsal base. The

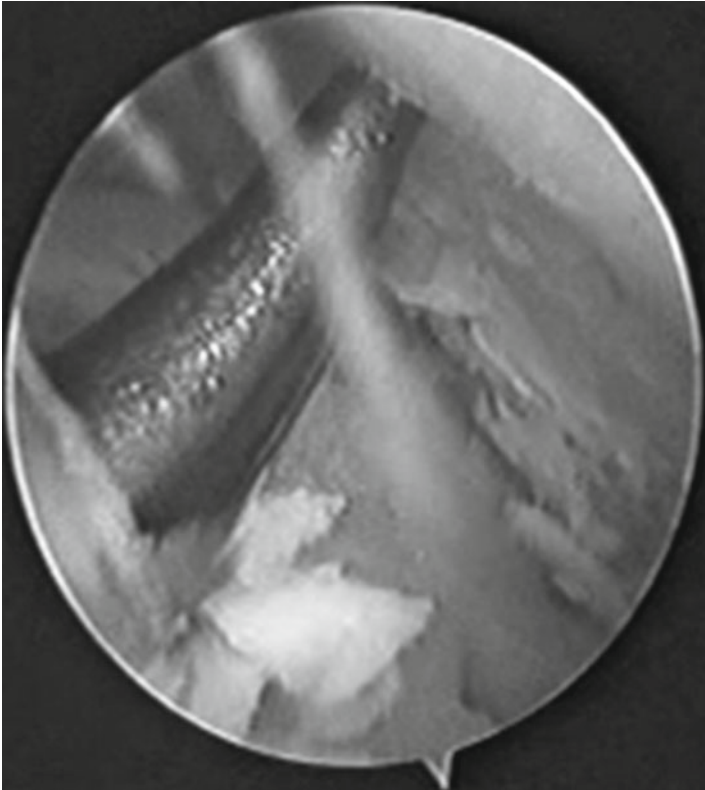


FIGURE 5.13 Micro-fragmentation of the subchondral bone with arthroscopic awl

patient is given an ankle foot orthosis (AFO) and kept non weight bearing. The positioning screw is removed 12 weeks later.

### 5.2.2 Endoscopic Assisted Lengthening of the Extensor Hallucis Longus Tendon

Extensor hallucis longus contracture can occur in patients with severe deformity with long duration. Endoscopic



Z-lengthening of the tendon [9] is indicated if there is hyperextension deformity of the interphalangeal joint at times associated metatarso-phalangeal joint after correction of the hallux valgus deformity. It should be used in caution as active extension of the hallux will be markedly impaired after the procedure.

### 5.2.2.1 Technique

Along the course of the extensor hallucis longus tendon at the foot dorsum, two portals are established. At the distal portal, at the level of the metatarsal neck, the medial half of the extensor hallucis longus tendon is cut and stripped proximally with a tendon stripper to the proximal portal at the level of the navicular bone. The lateral half of the tendon is cut at the proximal portal. Stay stitches are applied to the tendon ends. With the ankle in plantar flexion and the hallux kept in a position similar to the lesser toes, the stay stitches are sutured to the opposing tendon segments. The potential advantage of the procedure is less scarring around the extensor tendon, and better hallux motion is expected. The tendon repair is less secure as compared with the open procedure, and the risk of rupture of the repair is greater.

## References

1. Lui TH, Ng S, Chan KB. New technique: endoscopic distal soft tissue procedure in hallux valgus. *Arthroscopy*. 2005;21(11):1403.e1–7.
2. Lui TH. Current concepts: foot and ankle arthroscopy and endoscopy: indications of new technique. *Arthroscopy*. 2007;23(8):889–902.
3. Lui TH, Chan KB, Chow HT, Ma CM, Chan PK, Ngai WK. Arthroscopy-assisted correction of hallux valgus deformity. *Arthroscopy*. 2008;24:875–80.
4. Lui TH, Chan KB, Chan LK. Lateral release of endoscopic distal soft tissue procedure in treatment of hallux valgus: a cadaveric study. *Arthroscopy* (in press).
5. Lui TH. First metatarsophalangeal arthroscopy in patients with hallux valgus. *Arthroscopy*. 2008;14(10):1122–9.

6. Friscia DA. Distal soft tissue correction for hallux valgus with proximal screw fixation of the first metatarsal. *Foot Ankle Clin.* 2000;5(3):581–9.
7. Coughlin MJ, Jones CP, Viladot R, Glano P, Grebing BR, Kennedy MJ. Hallux valgus and first ray mobility: a cadaveric study. *Foot Ankle Int.* 2004;25(8):537–44.
8. Lui TH, Chan KB, Ng S. Technical note: arthroscopic ligidus arthrodesis. *Arthroscopy.* 2005;21(12):1516.e1–4.
9. Lui TH. Arthroscopically assisted Z-lengthening of the extensor hallucis longus tendon. *Arch Orthop Trauma Surg.* 2007;127(9):855–7.

# Chapter 6

## Minimally Invasive Hallux Valgus Correction

**Francesco Oliva, Umile Giuseppe Longo,  
and Nicola Maffulli**

### 6.1 Introduction

There is an increasing concern among orthopedists towards the potentials of minimally invasive procedures. Applied to foot surgery, minimally invasive surgery (MIS) can be accomplished in shorter time respect of a conventional surgery, together with less distress and problems to the soft tissues. In addition, the operation can be done bilaterally, it allows use of distal anesthetics blocks and early weight-bearing [1].

In 1986, Van Enoo defined the minimum-incision surgery as an operation done through the smallest incision required for a proper procedure, and the percutaneous surgery as that

---

F. Oliva, M.D., Ph.D.

Department of Trauma and Orthopaedic Surgery,  
University of Rome “Tor Vergata”,  
Viale Oxford 81, Rome, Italy

U.G. Longo, M.D.

Department of Trauma and Orthopaedic Surgery,  
University Campus Biomedico of Rome,  
Via Alvaro del Portillo 200, Rome, Italy

N. Maffulli, M.D., M.S., Ph.D., FRCS(Orth) (✉)

Centre for Sports and Exercise Medicine Queen Mary  
University of London, Barts and The London School of Medicine  
and Dentistry, Mile End Hospital,  
275 Bancroft Road, London, E1 4DG, UK  
e-mail: n.maffulli@qmul.ac.uk

performed within the smallest possible working incision in a closed fashion [2].

A percutaneous MIS requires the use of dedicated instruments and frequently a fluoroscopy. Lui and other colleagues from Hong Kong have described arthroscopic and endoscopic assisted correction of hallux valgus deformities [3, 4]. Morton Polokoff, a podiatric physician, in 1945 tried to use fine chisels, rasps and spears to perform subdermal surgery. Years later, Leonard Britton accomplished the first osteotomy on bunion deformities with percutaneous exposure of the first metatarsal, a closing wedge osteotomy, and the Akin procedure [5].

North American podiatrists started to adopt MIS of the foot in 1970 [6]. The technique percutaneous surgery for hallux valgus correction that we use derives from that described by Lamprecht-Kramer-Bösch in 1982 [7–9]. These authors based the procedure on the subcapital metatarsal linear osteotomy of Hohmann [10]. In 1991, Isham described a minimally invasive distal metatarsal osteotomy without implantation [11]. The results of recent French studies showed that patients treated with minimally invasive surgery for hallux valgus needed less hospitalization time and recovered earlier [12].

Minimum incision techniques, by allowing limb safety with reduced damage of soft tissue or bones trauma should be a first choice indication to patients at high risk of ulceration [13–16].

Recurrence of the deformity is the most frequent complication related to the use of MIS to foot deformity correction. Recurrence can arise from inadequate correction, or incorrect application of the technique, or incorrect estimation of the healing time of the [12, 17, 18]. European orthopedic foot surgeons [17, 19, 20] seem to show more interest in minimally invasive surgery than their North American counterparts [18].

### 6.1.1 *Indications*

We have considered minimally invasive procedures to correct hallux valgus deformity when the hallux valgus angle (HVA) is up to 40°, and the intermetatarsal angle (IMA) is up to 20°. In

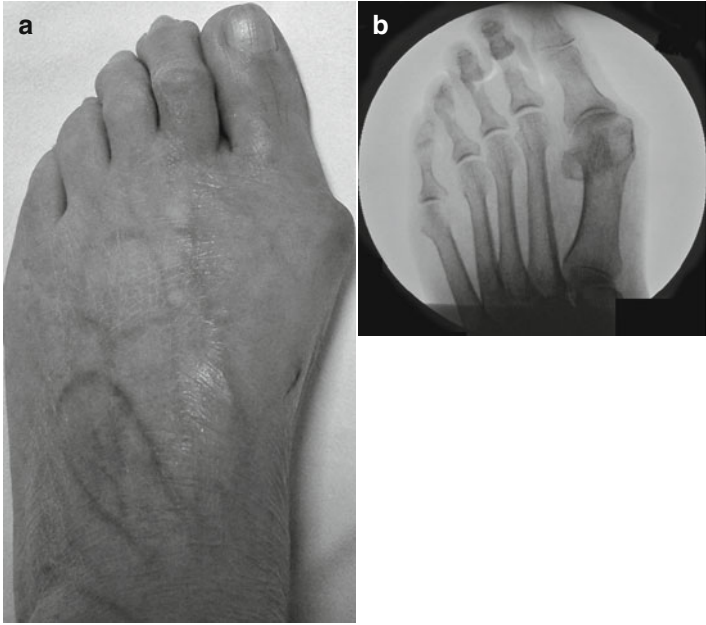


FIGURE 6.1 (a) Clinical view of a left hallux valgus with a second toe deformity. (b) Intraoperative antero-posterior radiograph

the presence of congruency of the metatarso-phalangeal joint, the procedure has been indicated in patients showing significant increase of the distal metatarsal articular angle (DMAA), and in patients with mild degenerative arthritis of the metatarso-phalangeal joint (Fig. 6.1a, b). We do not recommend this approach in patients with severe deformity with IMA greater than  $20^\circ$ , severe degenerative disease or stiffness of the metatarso-phalangeal joint and when metatarso-cuneiform or the metatarso-phalangeal joint are highly unstable [20].

According other authors, percutaneous surgical correction of hallux valgus is indicated in patients with painful primary mild-to-moderate hallux valgus with IMA between  $10^\circ$  to  $20^\circ$  and HVA of less than  $40^\circ$ , in juvenile hallux valgus deformities with an increased distal metatarsal articular angle and some hallux valgus interphalangeous deformity. The technique

is not indicated in hallux rigidus and in patients in whom a Keller's procedure unsuccessful [21, 22]. Giannini et al. apply MIS to correction of mild to moderate deformities with a HVA up to 40°, and an IMA up to 20° [23].

## 6.2 Surgical Technique

With the patient supine with the desired anesthesia, a calf tourniquet is applied. The foot is exsanguinated and prepared in the usual fashion. Soft tissue release, though not necessary given the large lateral shift of the metatarsal head, can be undertaken through a stab wound if desired. If there is stiffness of the metatarso-phalangeal joint, we perform a manual stretch of the adductor hallucis to force the hallux into some varus before incising the skin. A 2 cm medial incision is made just proximal to the bunion. The incision is deepened through skin and subcutaneous tissue, until the medial aspect of the first metatarsal is exposed. The soft tissues are retracted plantarly and dorsally. A linear osteotomy is performed with a standard 5 × 2 × 0.4 mm blade saw (STRYKER, USA) (Fig. 6.2a). A small osteotome is used to mobilize the head of the first metatarsal. A 2 mm Kirschner wire is inserted from the medial portion of the tip of the hallux, close to the nail. The wire is advanced in the soft tissues of the hallux, in a distal to proximal direction parallel to longitudinal axis of the hallux. The head of the metatarsal is displaced laterally, and the Kirschner wire penetrates the medullary canal of the first metatarsal (Fig. 6.2b).

If required, a slight varus position of the toe (up to 10°) can be forced after stabilization of the Kirschner wire (Fig. 6.3a, b). The operation ends with a standard skin suture. The protruding Kirschner wire is bent and cut. Recently, we have added a second Kirschner wire inserted in a proximal-to-distal and medial-to-lateral directions from the shaft of the first metatarsal towards the head. This second wire provides stability to the osteotomy by preventing dorsal translation of the metatarsal head in the post-operative stages. This second Kirschner wire is removed 2 weeks from the operation (Fig. 6.3c, d).

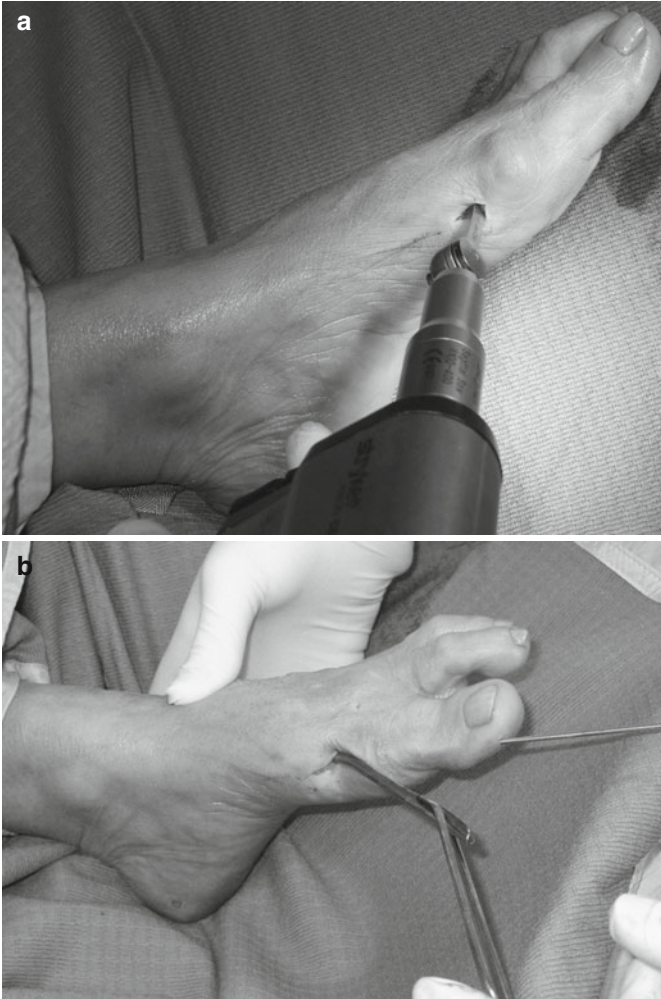


FIGURE 6.2 Surgical technique. **(a)**: Skin incision. The size of the incision is 2 cm, sufficient for insertion of the saw blade. The metatarsal osteotomy is performed using a standard oscillating saw. **(b)** Insertion of the Kirschner wire in the soft tissues of the hallux along the longitudinal axis, in a distal to proximal direction. A grooved device has been inserted at the osteotomy site. The Kirschner wire will be guided through the device groove

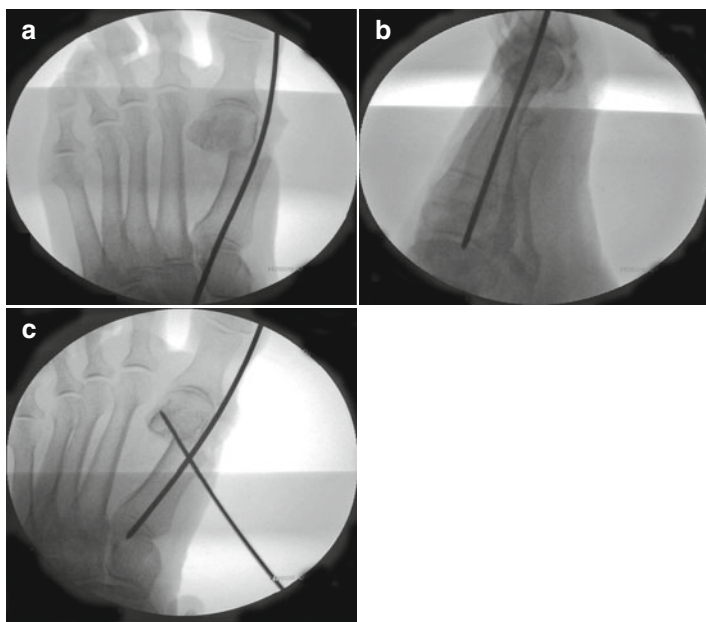


FIGURE 6.3 (a) Intraoperative fluoroscopy: antero-posterior view. (b) Intraoperative fluoroscopy: lateral view. (c) Intraoperative fluoroscopy: the second Kirschner wire is inserted proximally to distally

### 6.3 Postoperative Care

The foot is kept with a compressive bandage, and plain radiographs of the foot (anteroposterior, lateral and oblique views) are taken.

Patients can walk immediately in a flat, rigid sole postoperative shoe, which allows not to put weight through the osteotomy, though in the beginning they are advised to walk for short times only, and to rest with the foot raised while supine or sitting.. The longitudinal Kirschner wire remains *in situ* for 6 weeks from the date of surgery. At that time, it is



removed in the outpatient department, and other plain radiographs are taken [20].

At this point, patients are recommended to cycle and swim, and to wear comfortable plain shoes for 3–6 months, after which they can gradually return to their usual footwear. The patients have their next clinical and radiographic check in 3 months. Subsequent follow up varies depending on the patient.

Some authors prefer to remove the Kirschner wire 4 weeks after the operation, applying a corrective bandage around the hallux to be renewed once a week for the next 6 weeks. In this method, the bandage should apply a moderate hypercorrection to the hallux [21].

## 6.4 Discussion

Recurrence of the deformity due to incorrect choice of technique is the most frequent complication of the type of surgery. Since the literature collects reports of only case series and there are not randomized studies that compare conventional open with mini invasive surgical techniques applied to hallux valgus, we do not have adequately powered level one evidence studies [24].

In Weil's work there are descriptions of tendon, vascular and nerves injuries from minimal incision surgeries [25].

De Prado recorded such rates as 0.2 % of infections and 1 % of phlebitis. He also described shortening of the first metatarsal in 100 % of cases, osteotomy displacement in 3 %, and delayed union in 8 %. Soft tissue complications occurred, especially skin complications related to portal placement. There were also neuro-vascular complications. Portal and skin complications were mainly burns (3 %). Nervous complications related to nerves were transient in 12 % of cases, and permanent in 0.5 %. Vascular complications were bleeding and hematomas, with no records of ischemic complications. Other type of complications recorded were reduced mobility (4 %) and persistent pain (3 %) [11].

Magna and colleagues observed that 49 % of patients with dorsiflexion presented plantar displacement subsequent to surgery, while recurrence of the deformity occurred in 3 of the 118 ft [21]. The clinical significance of these morphological features are unclear.

Weimberg and colleagues performed a study of 301 percutaneous non-internally fixed first metatarsal surgery for correction of hallux valgus. Their study showed a moderate metatarsal shortening of the metatarsal between 2.6 and 5.8 mm, 47 (15.6 %) cases of malunions, 11 (3.7 %) infections, seven stress fractures of the second metatarsal (2.3 %), four (1.2 %) delayed unions, and one (0.3 %) hallux varus [26].

Giannini, in a 4 years study on 190 patients treated with MIS, found only nine cases that were scored lower than 60 in the AOFAS satisfaction level scale. Portaluri in a retrospective clinical and radiographic evaluation of 182 Bosch procedures with a mean follow-up of  $16.4 \pm 2.4$  months reported eight superficial infections (4.4 %), two ulcerations around the hallux pin site (1.1 %), and two dorsal malunions (1.1 %) [24].

Sanna and Ruiu, in a retrospective review of 52 ft that had percutaneous distal-first metatarsal osteotomies over a period of 31.5 months, found four (7.4 %) superficial infections and three (5.8 %) ulcerations by the hallux pin site, one (2 %) recurrent deformity, one (2 %) permanent anesthesia around the hallux, and one (2 %) over lengthening of the first metatarsal [27].

Pique-Vidal's prospective evaluation of 94 percutaneous, non-internally fixed first metatarsal and Akin osteotomy type, similar to the Bocsh procedure, reported four delayed unions (4.3 %) but no infections, nonunions, or avascular necrosis [28].

De Giorgi et. al. studied 27 consecutive patients receiving a Bosch technique, who were followed up for an average of 19 months (range 6 months to 5 years). The technique appeared give very satisfactory results, but the radiographs

taken during after a few years showed some loss of correction. However, the patients were clinically satisfied. Only one non union was recorded [29].

Baieta and colleagues studied 98 percutaneous distal osteotomies of the first metatarsal, with an average follow up of 76.2 months, obtaining an AOFAS score of 89.9, with 96 % of patients satisfied. Four superficial infections around the wire were reported, two recurrences of hallux valgus, one hallux rigidus, and five metatarsalgias [30].

Among the 94 patient undergoing arthroscopy-assisted hallux valgus deformity corrections with percutaneous screw fixation, there were three symptomatic recurrences which required revision [4].

Using MIS techniques, the osteotomy healing time is of the highest importance as it can interfere with the procedure's definitive outcome. Lopez and colleagues believe that the healing time should be shorter than healing time required in conventional surgery of the type. Their hypothesis is based on two reasons: (a) the percutaneous technique produces minimal injury to vessels and surrounding soft tissues (b) the bone detritus ("bone mush") at the osteotomy site acts as internal bone graft [31].

In the interval between the removal of the proximal Kirschner wire, after 2 weeks, and the removal of the main Kirschner wire after 6 weeks, the foot is exposed to chances of superficial infection. However, this second wire allows better stability to the transverse osteotomy to prevent dorsal migration and/or angulation of the capital fragment (Fig. 6.4a–c).

Provided that the indications are adequate and that sufficient experience has been matured with the used of dedicated instruments, MIS is a suitable surgical choice for the correction of mild to moderate hallux valgus deformities [32]. There is still need of randomized prospective clinical trials to enable valuable comparison of MIS applications with conventional open procedures.

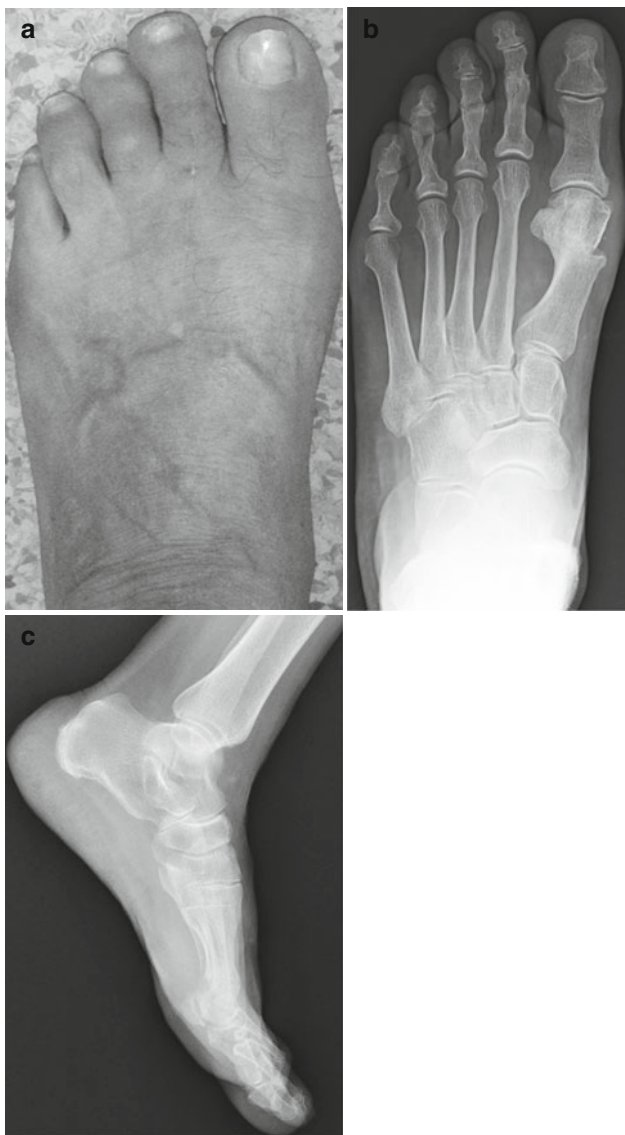

FIGURE 6.4 (a) Clinical picture 12 months after the procedure. (b, c) Plain antero-posterior and lateral radiographs after 6 months showing healing of the osteotomy

## References

1. David C, Sammarco G, James G. Minimum incision surgery. *Foot Ankle Int.* 1992;13(3):157–60.
2. Van Enoo RE, Cane EM. Minimal incision surgery: a plastic technique or a cover-up? *Clin Podiatr Med Surg.* 1986;3(2):321–35.
3. Lui TH, Ng S, Chan KB. Endoscopic distal soft tissue procedure in hallux valgus surgery. *Arthroscopy.* 2005;21:1403.e1–7.
4. Lui TH, Chan KB, Chow HT, et al. Arthroscopy-assisted correction of hallux valgus deformity. *Arthroscopy.* 2008;24(8):875–80.
5. Hymes L. Introduction: brief history of the use of minimum incision surgery (MIS). In: Fielding MD, editor. *Forefoot minimum incision in podiatric medicine: a handbook on primary corrective procedures on the human foot using minimum incisions with minimum trauma.* New York: Futura Pub Co; 1977. p. 1–2.
6. De Lavigne C, Guillo S, Laffenêtre O, De Prado M. The treatment of hallux valgus with the mini-invasive technique. *Interact Surg.* 2007; 2:31–7.
7. Bösch P, Markowski H, Rannicher V. Technik und erste Ergebnisse der subkutanen distalen Metatarsale-I-Osteotomie. *Orthop Praxis.* 1990;26:51–6.
8. Hohmann G. Symptomatische oder physiologische Behandlung des Hallux valgus. *Munch Med Wochenschr.* 1921;68:1042–5.
9. Lamprecht E, Kramer J. Die Metatarsale-I-Osteotomie nach Kramer zur Behandlung des Hallux valgus. *Orthop Prax.* 1982;28:635–45.
10. Bösch P, Wanke S, Legenstein R. Hallux valgus correction by the method of Bösch: a new technique with a seven-to-ten year follow-up. *Foot Ankle Clin.* 2000;5:485–98.
11. Isham SA. The Reverdin-Isham procedure for the correction of hallux abducto valgus. A distal metatarsal osteotomy procedure. *Clin Podiatr Med Surg.* 1991;8:81–94.
12. Leemrijse T, Valtin B, Besse JL. Hallux valgus surgery in 2005. Conventional, mini-invasive or percutaneous surgery? Uni- or bilateral? Hospitalisation or one-day surgery? *Rev Chir Orthop Reparatrice Appar Mot.* 2008;94:111–27.
13. Roukis TS. Central metatarsal head-neck osteotomies: indications and operative techniques. *Clin Podiatr Med Surg.* 2005;22(2): 197–222.
14. Roukis TS. The Tailor's bunionette deformity: a field guide to surgical correction. *Clin Podiatr Med Surg.* 2005;22(2):223–45.
15. Weitzel S, Trnka H-J, Petroutsas J. Transverse medial slide osteotomy for bunionette deformity: long-term results. *Foot Ankle Int.* 2007;28(7):794–8.
16. Roukis TS, Schade VL. Minimum-incision metatarsal osteotomies. *Clin Podiatr Med Surg.* 2008;25:587–607.

17. De Prado M, Ripoll PL, Vaquero J, Golano P. Tratamiento quirúrgico per cutáneo del hallux mediante osteotomias múltiples. *Rev Orthop Traumatol.* 2003;47:406–16.
18. Kadakia AR, Smerek JP, Myerson MS. Radiographic results after percutaneous distal metatarsal osteotomy for correction of hallux valgus deformity. *Foot Ankle Int.* 2007;28:355–60.
19. De Prado M, Ripoll PL, Golano P. *Cirugía percutánea del pie.* Barcelona: Ed. Masson; 2003.
20. Maffulli N, Oliva F, Coppola C, et al. Minimally invasive hallux valgus correction: a technical note and a feasibility study. *J Surg Orthop Adv.* 2005;14:193–8.
21. Magnan B, Bortolazzi R, Samaila E, et al. Percutaneous distal metatarsal osteotomy for correction of hallux valgus. *Surgical technique. J Bone Joint Surg Am.* 2006;88:135–48.
22. Magnan B, Samaila E, Viola G, Bortolazzi P. Minimally invasive retrocapital osteotomy of the first metatarsal in hallux valgus deformity. *Oper Orthop Traumatol.* 2008;20:89–96.
23. Giannini S, Vannini F, Faldini C, et al. The minimally invasive hallux valgus correction (S.E.R.I.). *Interact Surg.* 2007;2:17–23.
24. Portoluri M. Hallux valgus correction by the method of Bosch: a clinical evaluation. *Foot Ankle Clin.* 2000;5(3):499–511.
25. Weil LS. Minimal invasive surgery of the foot and ankle. *J Foot Ankle Surg.* 2001;40:61.
26. Weinberger BH, Fulp JM, Falstrom P, et al. Retrospective evaluation of percutaneous bunionectomies and distal osteotomies without internal fixation. *Clin Podiatr Med Surg.* 1991;8(1):111–36.
27. Sanna P, Ruiu GA. Percutaneous distal osteotomy of the first metatarsal (PDO) for the surgical treatment of hallux valgus. *Chir Organi Mov.* 2005;90(4):365–9.
28. Pique-Vidal C. The effect of temperature elevation during discontinuous use of rotator burrs in the correction of hallux valgus. *J Foot Ankle Surg.* 2005;44(5):336–44.
29. De Giorgi S, Mascolo V, Losito A. The correction of hallux valgus by Bösch technique (PDO – Percutaneous Distal Osteotomy). *GIOT.* 2003;29:161–4.
30. Baietta D, Perusi M. Cassini Hallux valgus surgical treatment with Bosch technique: clinical evaluation and surgical consideration after 5 years. *GIOT.* 2007;33:107–13.
31. González LJJ, Rodríguez RS, Cadena ML. Functional, esthetic and radiographic results of treatment of hallux valgus with minimally invasive surgery. *Acta Ortop Mex.* 2005;19:42–6.
32. Guillo S, Laffenêtre O, De Prado M. The treatment of hallux valgus with the mini-invasive technique. *Interact Surg.* 2007;2:31–7.

# Chapter 7

## Minimally Invasive Modified Wilson Osteotomy for the Treatment of Hallux Valgus

**Sheldon Nadal**

### 7.1 Introduction

The modified Wilson osteotomy is a V-shaped osteotomy of the first metatarsal neck made in the sagittal plane with the apex of the V pointed proximally (Fig. 7.1). This osteotomy allows the head of the first metatarsal to be displaced laterally to reduce the intermetatarsal angle. The V-shape contributes stability. The best results are obtained when the procedure is performed on a foot with a mild to moderate hallux valgus deformity, a flexible first metatarsal phalangeal joint, and a mild to moderately increased metatarsus primus varus angle.

The procedure can be performed on an outpatient basis, under local anesthesia. Given the minimally invasive nature of the technique, patients can walk immediately after surgery and casts are not necessary. Most patients do not require crutches or medication stronger than a mild analgesic or non-steroidal anti-inflammatory.

---

S. Nadal, B.Sc., D.P.M. (✉)

586 Eglinton Avenue East, Suite 501, Podiatrist Toronto,  
ON M4P 1P2, Canada

Academy of Ambulatory Foot and Ankle surgery,

Philadelphia, PA, USA

e-mail: shel14@rogers.com

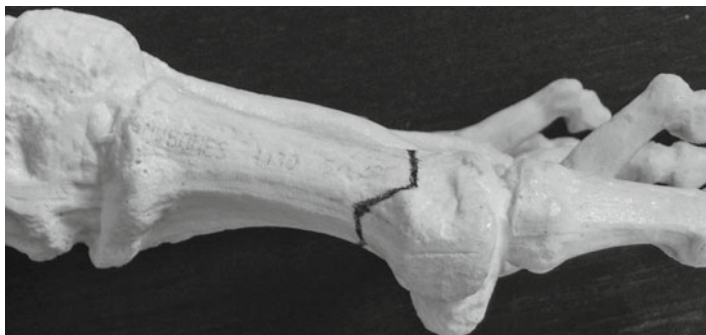

FIGURE 7.1 The modified Wilson osteotomy

## 7.2 History

The original Wilson osteotomy was described by J. N. Wilson in 1963 patients with juvenile hallux valgus [1]. This was an oblique osteotomy, performed in the distal third of the first metatarsal, beginning just proximal to the medial bony eminence. The osteotomy was performed by Dr. Wilson using a 3/8 in. wide osteotome at 45° from distal medial to proximal lateral. The osteotomy was also combined with remodeling of the medial eminence of the first metatarsal head. The osteotomy was non-fixated and kept in a below knee plaster cast with the great toe over-corrected for 2 weeks. The over-correction was then reduced to a more neutral position and was followed by 6 weeks in a walking cast.

The idea of performing a minimally invasive Wilson osteotomy was originally suggested to Seymour Kesler, D.P.M., Abram Plon, D.P.M., and Marvin Arnold, D.P.M. by Lowell Weil Sr., D.P.M. of Chicago in the 1970's (Abe Plon, D.P.M., retired from private practice, Elkins Park, now deceased, personal communication).

Dr. Kesler performed an oblique osteotomy through a small dorsal incision using a Shannon 44 burr. The osteotomy was made from dorsal distal to plantar proximal, and relied on ground reactive forces to prevent the first metatarsal head from shifting plantarly and proximally (David Zuckerman, D.P.M., private practice, Woodbury, personal communication).



Doctors Plon and Arnold modified the osteotomy into a V-shaped osteotomy performed through a medial incision (Abe Plon, D.P.M. and Marvin Arnold, D.P.M., retired from private practice, West Palm Beach, personal communication). They first made a fail-safe hole at the neck of the first metatarsal running from medial to lateral, midway between the dorsal and plantar cortices. The dorsal arm of the V was then angled distally and superiorly from the fail-safe hole at approximately a 45° angle to the long axis of the first metatarsal. The plantar cut was made, beginning at the fail-safe hole, and angled plantarly at approximately a 90° angle to the long axis of the first metatarsal. The osteotomy was not fixated and the foot was taped firmly by the clinician for 3 weeks and an additional 3 weeks by the patient. The author angles the plantar cut so that it is perpendicular to the supporting surface or, on some occasions, aimed slightly more distal to reduce the chance of the head of the metatarsal slipping plantarly and proximally.

### 7.3 Anesthesia

The modified Wilson osteotomy was designed to be performed under local anesthesia, in an office based setting. This can be accomplished using an ankle block or by using a modified Mayo block adding local infiltration between the first and second metatarsal heads and at the medial aspect of the first metatarsal head and neck using a mixture of 1 % lidocaine mixed with 0.5 % bupivacaine in equal quantities. Epinephrine and an ankle tourniquet are not used, allowing bleeding of the surgical site. Bleeding will reduce the possibility of thermal necrosis during the bone cutting process.

### 7.4 Instrumentation

The following instruments may be used to perform the procedure.

1. A number 15 blade.
2. A Locke elevator or similar instrument [2] (Fig. 7.2).

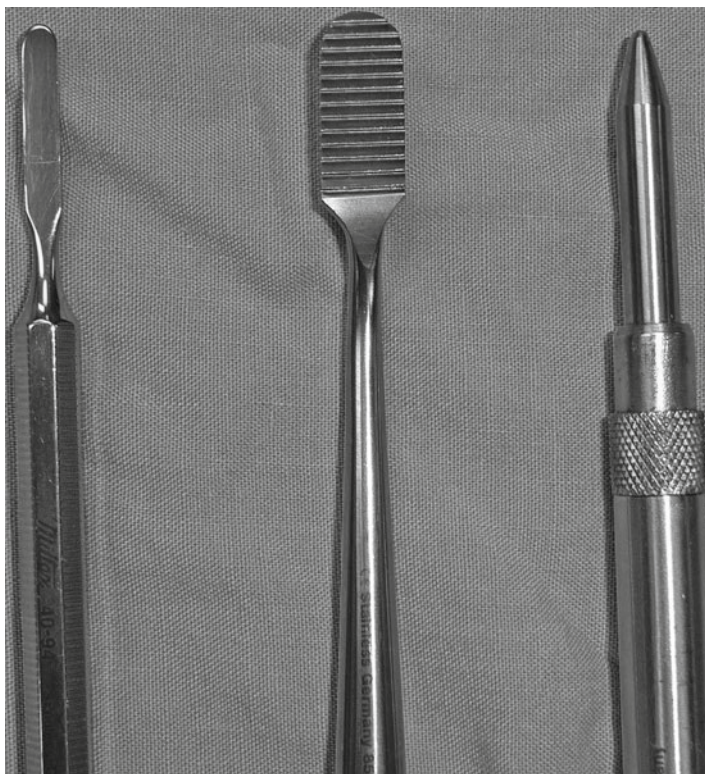


FIGURE 7.2 *Left to right:* Locke elevator, rasp, eye magnet

3. Three medium Shannon 44 burs, 2 mm in diameter [3] (Fig. 7.3).
4. One short Shannon 44 burr, 2 mm in diameter [3] (Fig. 7.3).
5. A 3 mm diameter wedge burr [3] (Fig. 7.3).
6. A 7.5 in. Lewis nasal rasp, or similar instrument (Fig. 7.2).
7. Best results will be obtained by using some manner of intra-operative fluoroscopy. The author utilizes a XI-Scan unit, model 1000-1 [4] (Fig. 7.4).
8. A high torque, low speed drill such as the Osada PEDO [5] unit with the 2:7:1 reduction speed hand piece (Fig. 7.5a, b).




FIGURE 7.3 *Left to right:* Short Shannon 44 burr, medium Shannon 44 burr, 3 mm wedge burr

## 7.5 Technique

The surgical site is prepped and draped in the usual sterile manner.



FIGURE 7.4 Xi-Scan portable fluoroscope, model 1000-1

With the number 15 blade, a 5 mm longitudinal skin incision is made and then deepened to bone at the medial aspect of the first metatarsal (Fig. 7.6), just proximal to the medial eminence, midway between the dorsal and plantar cortices. At the incision, using a Shannon 44, a fail-safe hole is created (Fig. 7.7). The purpose of the fail-safe hole is to create a reference point from which the dorsal and plantar osteotomy cuts begin. The fail-safe hole is drilled from the medial cortex to and through the lateral cortex (Fig. 7.8), parallel to the supporting surface (Fig. 7.9) at a 90° angle to the long axis of the second metatarsal (Fig. 7.10a). This angle will allow the metatarsal head to shift laterally without undue shortening of the first metatarsal. The fail-safe hole can be angled slightly from proximal medial to distal lateral to further reduce shortening (Fig. 7.10b). In this instance, however, the surgeon may find it more difficult to displace the metatarsal head laterally.

The fail-safe hole may also be angled slightly from dorsal medial to plantar lateral to shift the head of the metatarsal plantarly and laterally to decrease the chance of producing excessive pressure under the second metatarsal head during




FIGURE 7.5 (a) Osada PEDO drill. (b) Close up of Osada 2:7:1 reduction speed handpiece

midstance. Care must be taken not to shift the metatarsal head more than slightly plantarly, otherwise this may cause the hallux to elevate dorsally or cause excessive pressure under the tibial sesamoid.

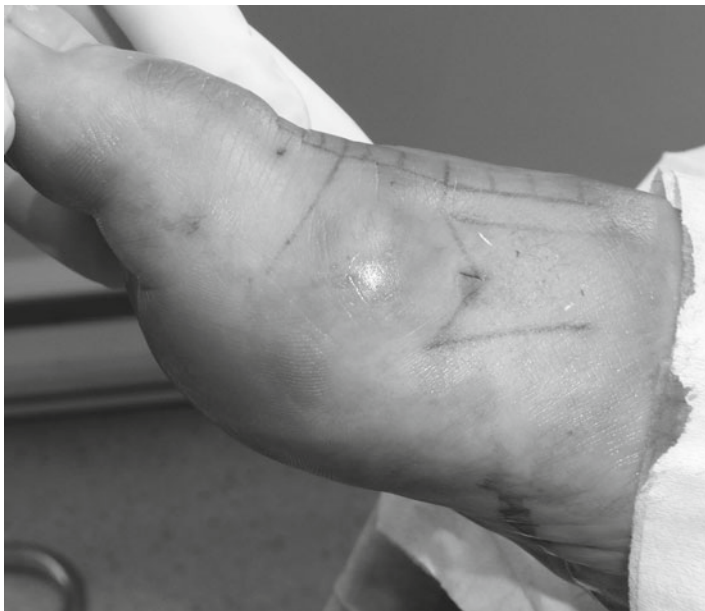

FIGURE 7.6 Skin incision used to produce the fail-safe hole from which the modified Wilson osteotomy will be performed

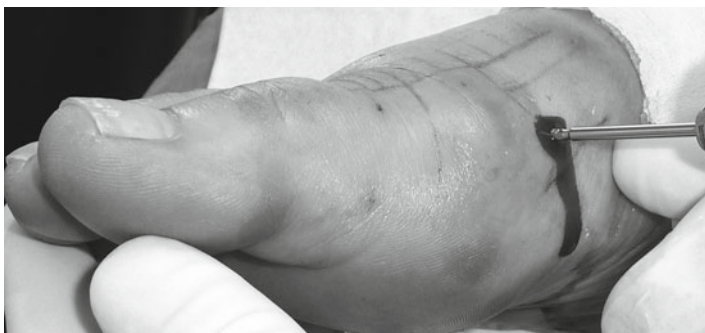

FIGURE 7.7 Creating the fail-safe hole

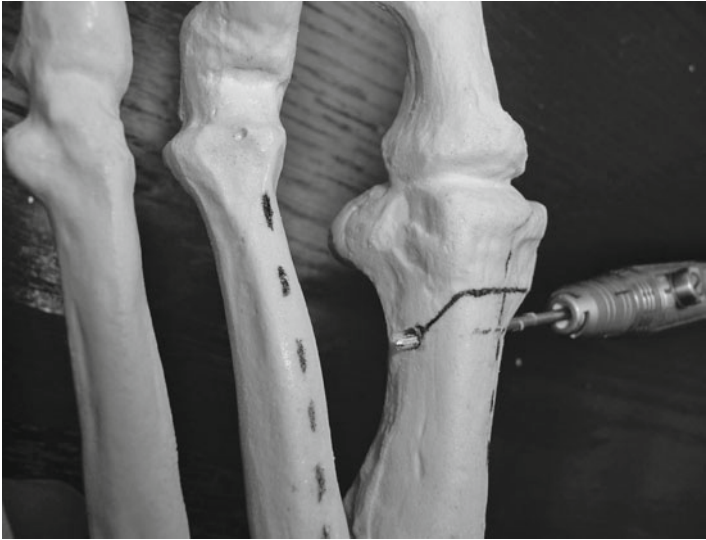


FIGURE 7.8 The fail-safe hole is drilled from medial to lateral mid-way between the dorsal and plantar cortices

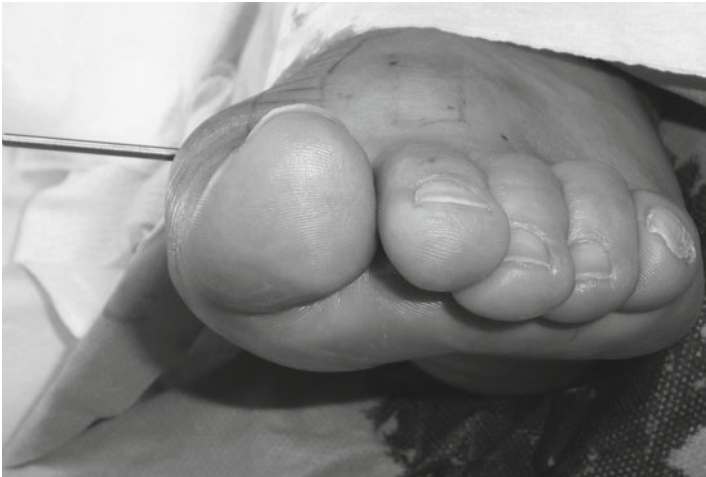

FIGURE 7.9 The fail-safe hole is made parallel to the supporting surface. It may be angled slightly from dorsal medial to plantar lateral

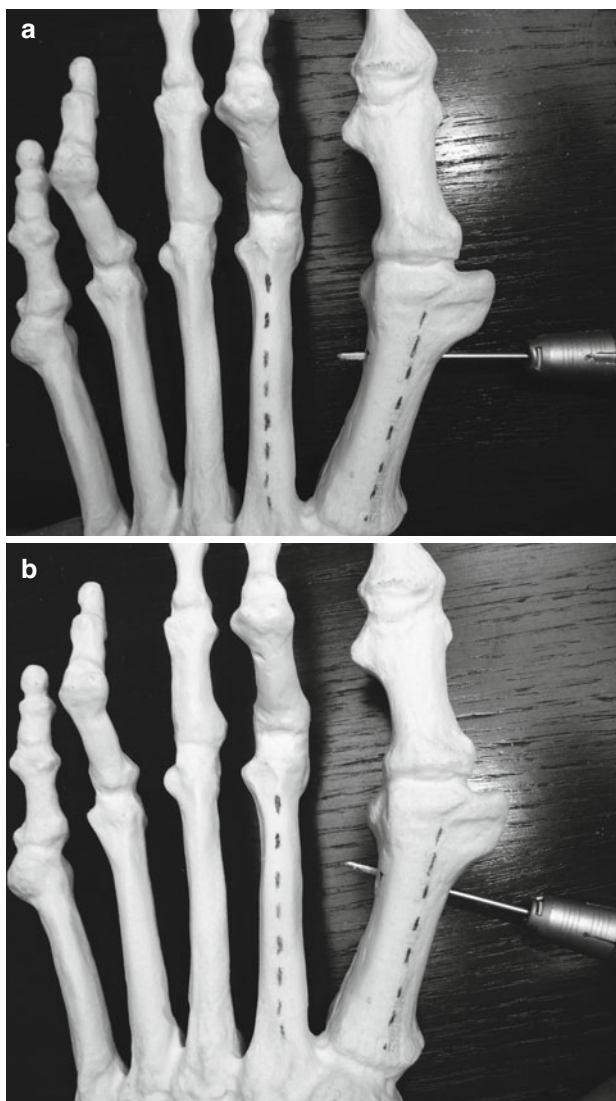


FIGURE 7.10 (a) The fail-safe hole is drilled from medial to lateral at a  $90^\circ$  angle to the long axis of the second metatarsal. (b) The fail-safe hole may be angled slightly from proximal medial to distal lateral to further reduce shortening



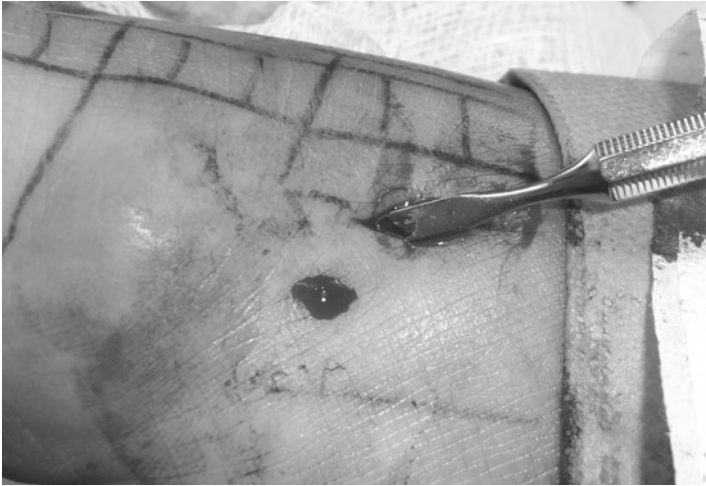

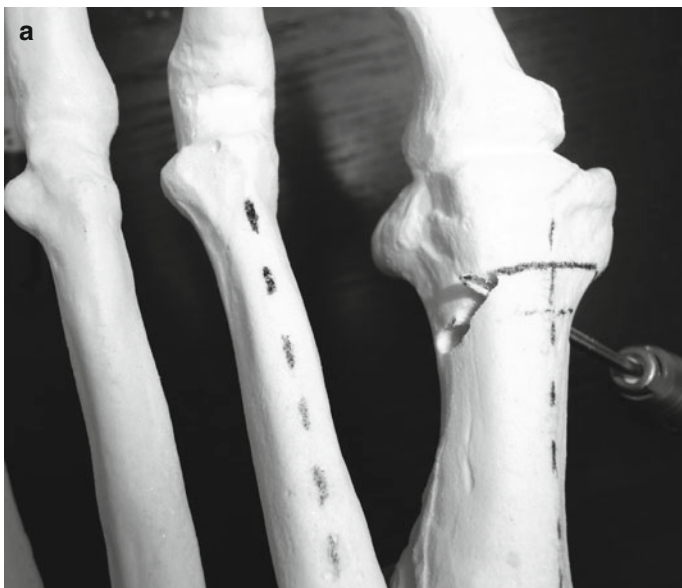
FIGURE 7.11 A Locke elevator separates the capsule from the medial eminence of the first metatarsal head

A second longitudinal skin incision is now made 5 or 6 mm dorsal to the original skin incision and slightly posterior to it and deepened to bone. This incision may be 2 or 3 mm longer than the first incision to facilitate the entry of the rasp later in the procedure. A Locke elevator is then inserted into the second incision and is used to separate the capsule from the medial eminence of the first metatarsal head (Fig. 7.11).

A second Shannon 44 burr is then introduced into the fail-safe hole and the dorsal arm of the osteotomy is begun. The cutting surface of the Shannon follows a path beginning at the lateral aspect of the neck of the metatarsal, midway between the dorsal and plantar surfaces (Fig. 7.8), and slowly cuts in a distal dorsal direction through the dorsal half of the lateral cortex until it reaches the dorsal lateral surface of the metatarsal neck, proximal to the articular cartilage (Fig. 7.12a). The cutting surface of the Shannon 44 burr then cuts through the dorsal cortex of the metatarsal from dorsal lateral to dorsal medial, parallel to the angle made by the fail-safe hole to the second metatarsal (Fig. 7.12b). The dorsal arm of the osteot-

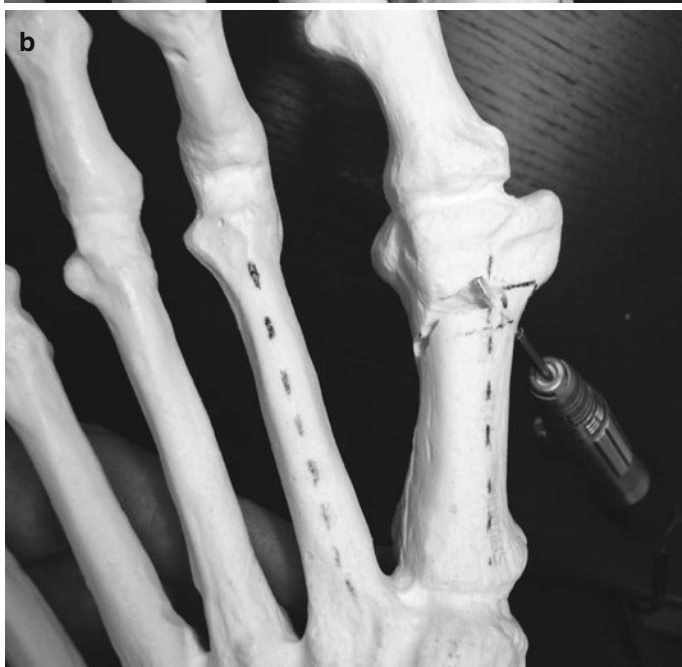

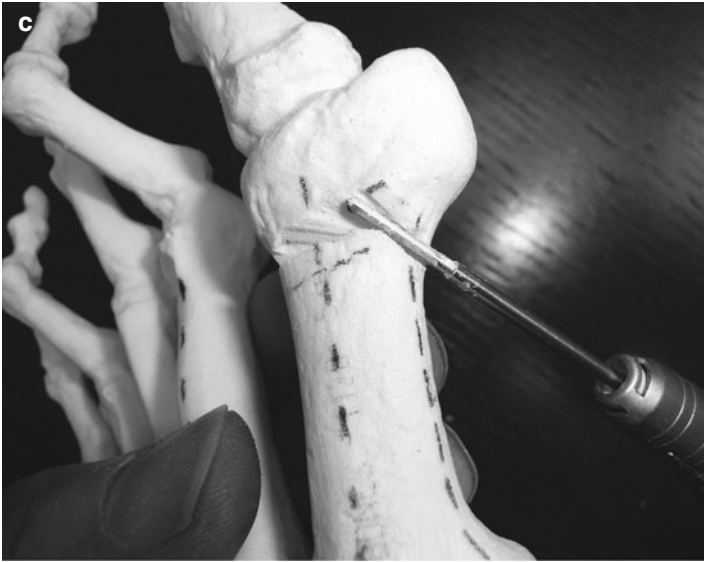


FIGURE 7.12 (a-c) The dorsal arm of the osteotomy is created

omy is then completed as the burr cuts through the dorsal half of the medial cortex of the first metatarsal (Fig. 7.12c).

A third Shannon 44 is then inserted into the fail-safe hole to produce the plantar arm of the osteotomy. The cutting surface follows a path beginning at the lateral aspect of the first metatarsal, midway between the dorsal and plantar cortices (Fig. 7.13a), through the plantar half of the lateral cortex, toward the plantar lateral surface of the first metatarsal neck at an angle such that the plane of the osteotomy will be  $90^\circ$  to the supporting surface (Fig. 7.13b) or, according to the surgeon's discretion, angled slightly more distal. The cutting surface of the burr then goes from plantar lateral to plantar medial through the plantar cortex (Fig. 7.13c), again at an angle parallel to the fail-safe hole and perpendicular to the supporting surface. When making the plantar cut, the surgeon should take care to stay proximal to the crista and the sesamoid bones. The osteotomy is then carried through the plantar half of the medial cortex of the first metatarsal neck, thus completing the V-shaped osteotomy (Fig. 7.14).

FIG. 7.13 (a-c) The plantar arm of the osteotomy is created

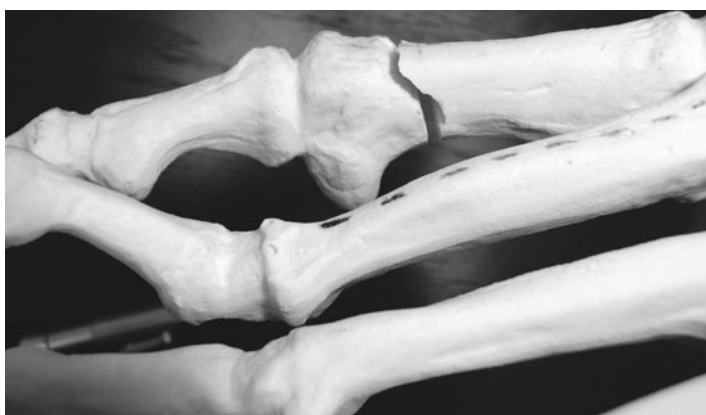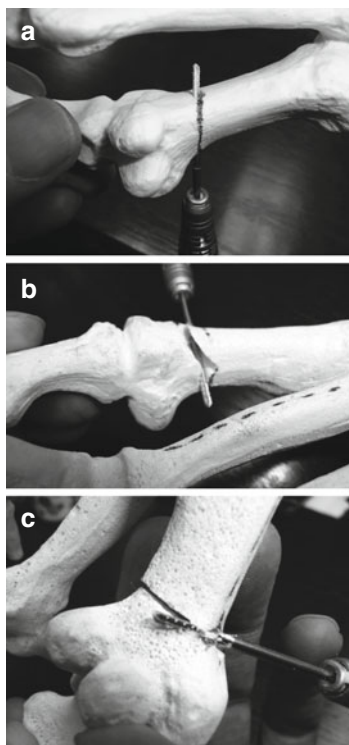


FIGURE 7.14 The completed osteotomy

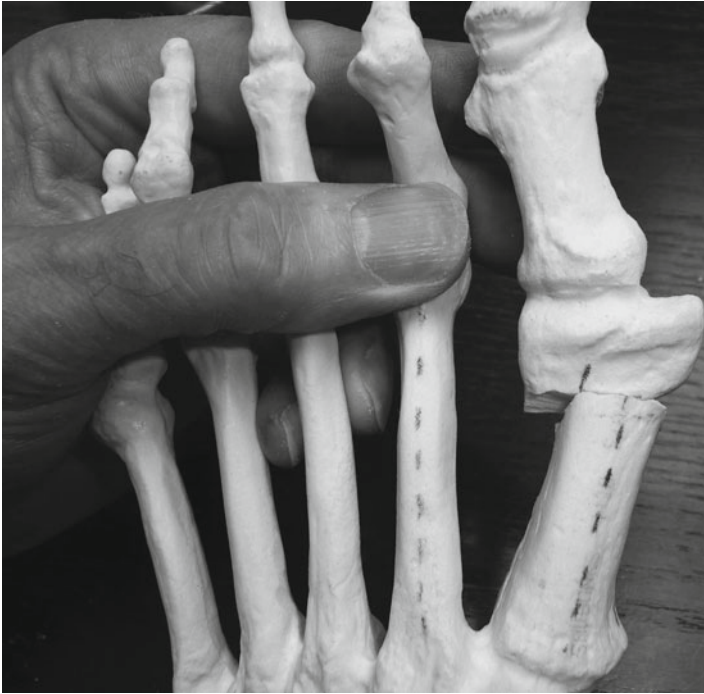

FIGURE 7.15 The head of the first metatarsal is displaced laterally and impacted against the metatarsal shaft

The capital fragment is then distracted and displaced laterally. If necessary, a Locke elevator can be used to distract and displace the osteotomy. Once the metatarsal head has been shifted laterally, it then is impacted proximally against the metatarsal shaft (Fig. 7.15).

## 7.6 Remodeling the Medial Side of the First Metatarsal Head

It may be technically easier to remodel the metatarsal head prior to completing the metatarsal osteotomy, since the metatarsal head is more stable, but we recommend to remodel the

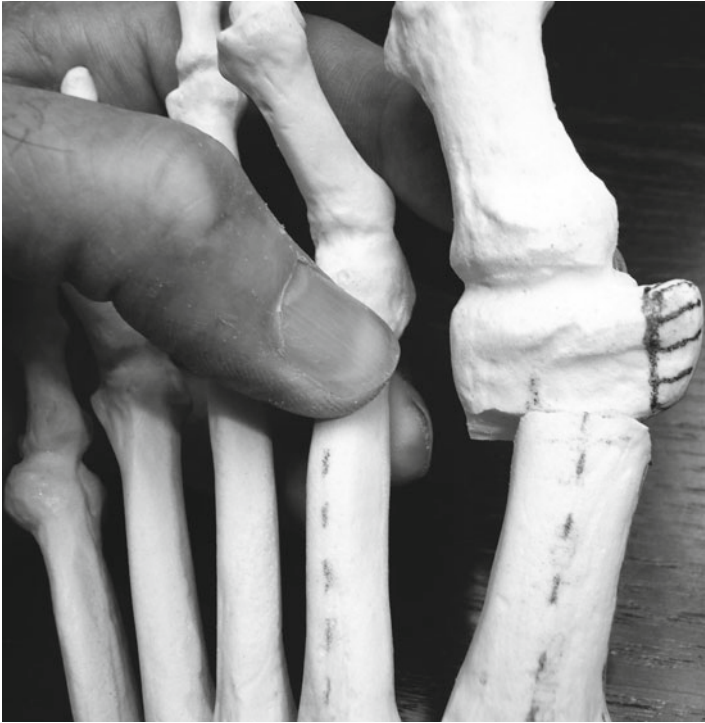

FIGURE 7.16 Medial eminence to be removed after lateral displacement of the metatarsal head

metatarsal head after the osteotomy is completed. The advantage of remodeling the head after performing the osteotomy is that less of the medial eminence will need to be removed after the head of the metatarsal has been displaced laterally (Fig. 7.16) and the surgeon may be able to increase the lateral displacement of the metatarsal head and thus further reduce the intermetatarsal angle while still maintaining good bony apposition at the medial aspect of the osteotomy site.

The metatarsal head can be remodeled through the initial incision but the surgeon may find it easier to use the second more dorsal incision to obtain a better angle of approach. This will also make it easier to remodel the medial aspect of

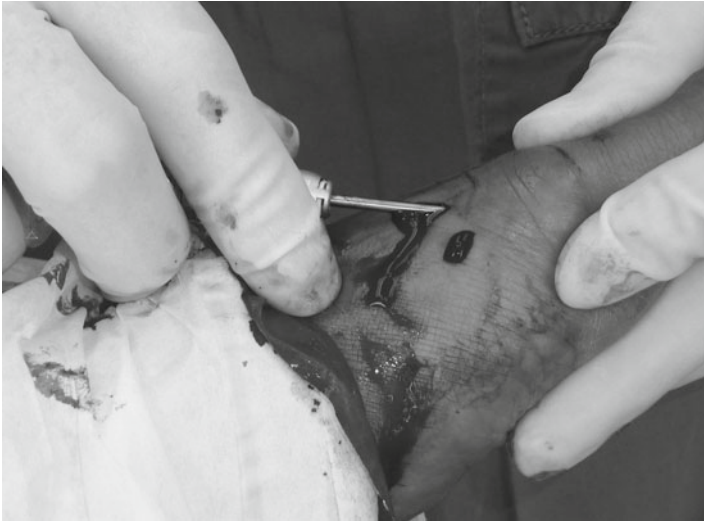

FIGURE 7.17 Reducing the medial eminence of the first metatarsal head

the first metatarsal just proximal to the osteotomy site, if a palpable osseous prominence is present one the head has been displaced.

A Shannon 44 burr is then introduced into the dorsal incision, deep and under the capsule and a small amount of the bone is removed from the medial aspect of the metatarsal head (Fig. 7.17). This creates room to introduce the 3 mm wedge burr which is used to reduce the majority of the unwanted medial eminence. Care should be taken not to entangle the soft tissue around the rotating burrs. The rasp, or a similar instrument, may then be introduced to smoothen any remaining bony projections. Subcapsular debris should then be removed using the rasp, with the teeth aimed toward the capsule. Bone paste and fragments are thus expressed. The surgeon may also choose to flush out any remaining debris with sterile saline solution.

If the surgeon deems it necessary, the osteotomy can be fixed percutaneously using Kirschner wires, although this

increases the chance of fracturing the dorsal ledge. A 0.45 gauge Kirschner wire is inserted proximal to the osteotomy site at the dorsal aspect of the shaft of the first metatarsal carefully avoiding the Extensor Hallucis Longus tendon, and drilled in a distal and plantar direction into the head of the first metatarsal while holding the head firmly against the shaft of the metatarsal (Fig. 7.18a). A second Kirschner wire, 0.45 gauge for a lighter patient or 0.62 for a heavier patient, is then inserted into the medial aspect of the first metatarsal shaft, proximal to the osteotomy site, and drilled in a distal lateral direction into the head of the first metatarsal, again while holding the head in position against the shaft (Fig. 7.18b). Care should be taken not to introduce the Kirschner wires too close to the osteotomy to avoid fracturing the dorsal shelf during weight bearing. The surgeon can reduce the chance of such a fracture, especially in a patient with reduced bone density, by incorporating a Dancer's pad made of 1/8–1/4 in. felt to the plantar surface of the postoperative dressing to reduce dorsiflexion pressure on the first metatarsal head (Fig. 7.19).

If a palpable medial bony prominence is produced just proximal to the osteotomy site at the neck of the first metatarsal (Fig. 7.20), it can now be remodeled using a medium or short Shannon 44 through the dorsal incision. The two incisions can then be closed using one or two nylon sutures. At this point, it is up to the discretion of the surgeon whether to use any combination of proximal phalanx osteotomy, adductor tenotomy, lateral capsulotomy, and Extensor Hallucis Longus tendon lengthening to further reduce the deformity. These procedures can also be performed using minimally invasive techniques.

The foot is then dressed with a sterile, non-adhering dressing such as Adaptic [6], as well as gauzes, topical povidine-iodine solution, and 2 in. conforming rolled stretch gauze (Fig. 7.21a). The proximal phalanx should be over-corrected in adduction to keep pressure on the medial portion of the osteotomy site. If percutaneous fixation is not used, the distal fragment should be taped into position firmly using 1 in. Durapore tape [7] (Fig. 7.21b).



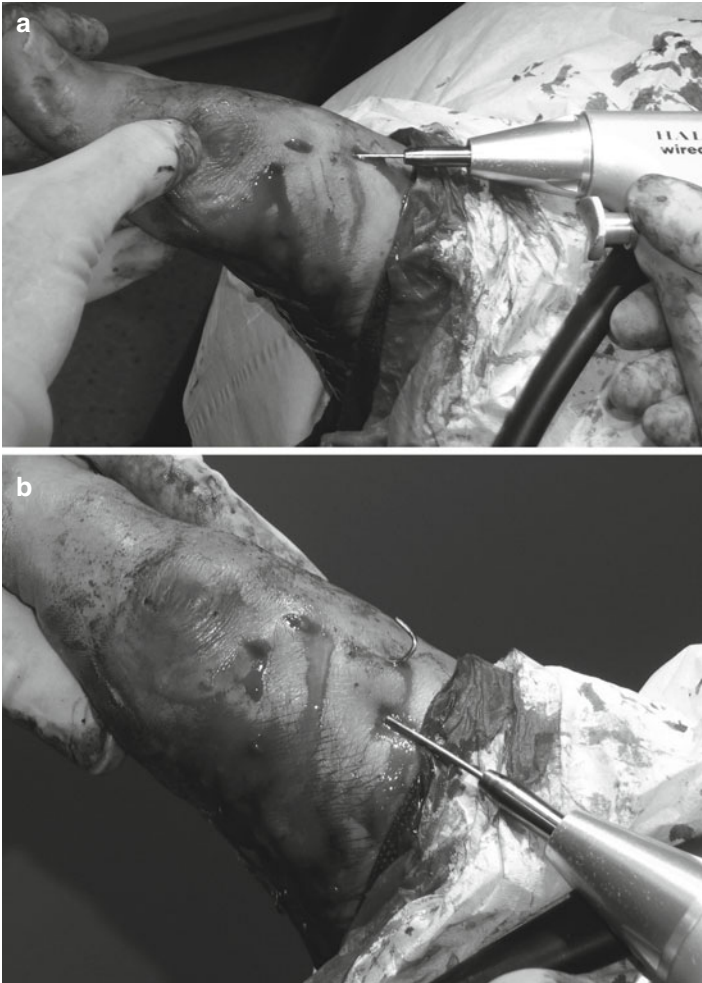


FIGURE 7.18 (a, b) Optional percutaneous fixation using Kirschner wires

If percutaneous fixation is used, it is not necessary to tape the metatarsal head as firmly. Folded gauzes should be placed just proximal and distal to the Kirschner wires (Fig. 7.22a) to avoid skin irritation from excessive pressure on the wires

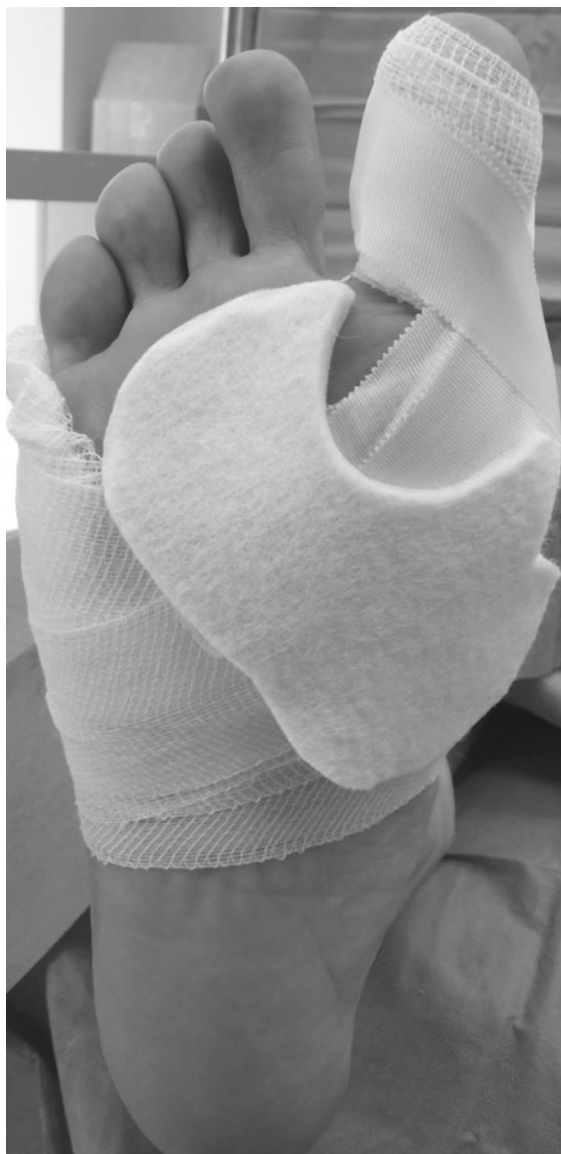

FIGURE 7.19 Felt Dancer's pad which may be used to reduce dorsiflexory pressure on the first metatarsal head

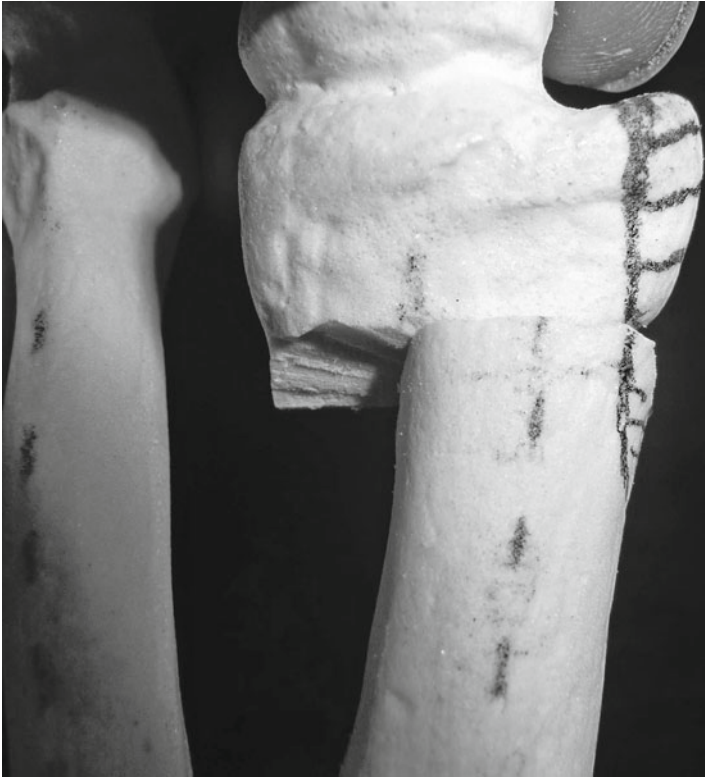

FIGURE 7.20 Medial osseous prominence just proximal to the metatarsal eminence. If the prominence is palpable, it should be reduced to avoid shoe irritation

from the dressing or taping. The practitioner can then use 1 in. Durapore or 3 in. adhesive backed stretch tape to cover the dressing (Fig. 7.22b). The patient is given a surgical sandal to wear when walking for as long as the foot is taped.

The foot is taped for 6 weeks. If Kirschner wire fixation is not used, the foot should be taped firmly for 6 weeks. The taping does not have to be as firm for the first 3 weeks if Kirschner wires are in place. The foot should be taped firmly for 3 weeks after the wires have been removed.

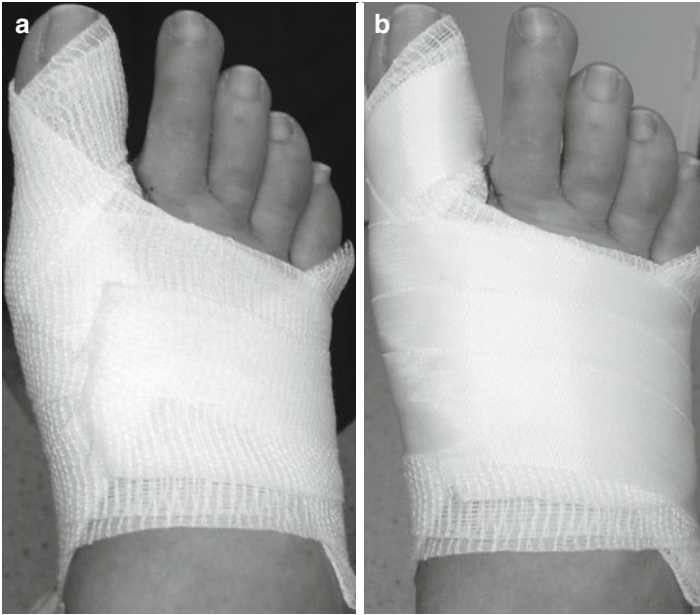

FIGURE 7.21 (a) The foot is wrapped with 2 in. conforming rolled stretch gauzes placed at the first and fifth metatarsal heads. (b) The dressing is reinforced with 1 in. Durapore tape

The patient should be seen in 4 or 5 days post-operatively to change the dressing, rule out infection, and check the alignment of the osteotomy. If the alignment is incorrect, the Kirschner wires should be removed and the metatarsal head should be manipulated into place and firmly redressed. The patient is then seen 1 week later to change the dressing and to remove sutures. The patient is then seen 3 weeks post-operatively to change the dressing and to remove the Kirschner wires, if fixation was used. The patient should now begin passive range of motion exercises at the first metatarsal phalangeal joint using their contralateral hand (Fig. 7.23a, b). The patient can then be instructed on home taping of the foot for an additional 3 weeks, or the practitioner may choose to do this for the patient weekly in the office. The patient should be encouraged to walk weight bearing as tolerated, but excessive walking should be avoided for 6 weeks following surgery.



FIGURE 7.22 (a) If Kirschner wires are used, gauzes are placed proximal and distal to the wires to avoid skin irritation. (b) The dressing is covered with 3 in. three adhesive backed stretch tape

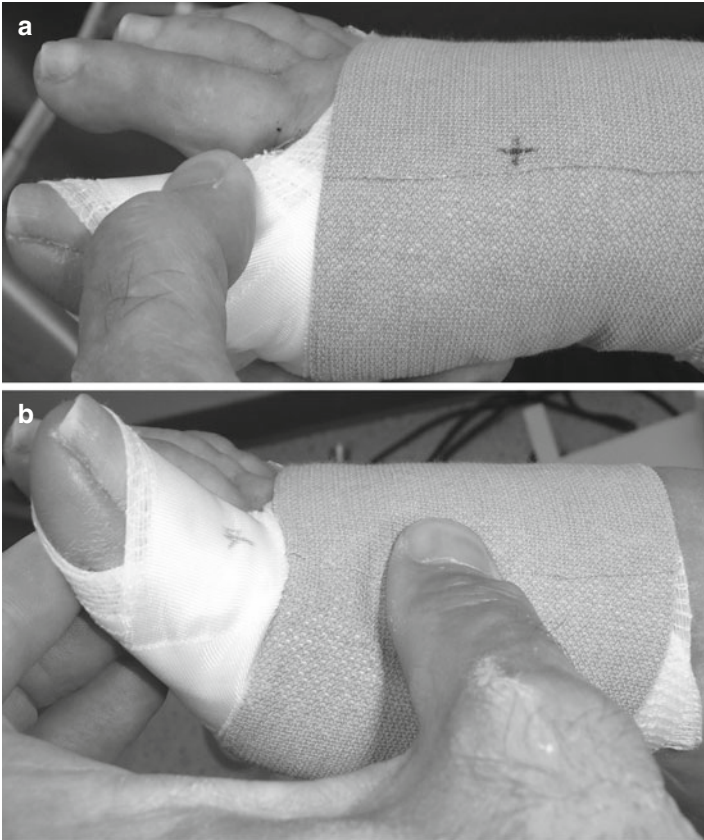


FIGURE 7.23 The patient should begin range of motion exercises. Begin 3 weeks post-operatively and continue until there is adequate range of motion at the first metatarsal phalangeal joint. (a) Plantarflexion. (b) Dorsiflexion

## 7.7 Additional Suggestions

When first performing this procedure, the surgeon may find it helpful to draw landmarks on the foot prior to surgery. These landmarks may include the plantar medial, dorsal medial and dorsal lateral cortices of the first metatarsal, the medial and

dorsal aspect of the osteotomy itself, the first metatarsal phalangeal joint, and the Extensor Hallucis Longus tendon (Fig. 7.24). The surgeon may also choose to confirm the location of the initial skin incision for the fail-safe hole by placing a sterile, 7/8 in. needle at the proposed location of the incision and checking it under fluoroscopy (Figs. 7.25, 7.26, 7.27, 7.28, 7.29, 7.30, 7.31, and 7.32).

When performing the osteotomy, to avoid thermal necrosis, the surgeon should avoid running the burrs at excessive speed, three Shannon 44 burrs should be used and the burrs should be sharp. Dull burrs should be discarded. Also, avoid applying undue pressure on the burrs to reduce the change of burr breakage.

In case of burr breakage, if part of the fragment is protruding from the bone, the surgeon may use a hemostat or a needle driver to grasp the fragment, and pull it out, while using an unscrewing motion.

If the burr is unreachable inside a partially performed osteotomy, the surgeon should complete the osteotomy using another Shannon 44 burr to free up the burr fragment. An eye-magnet [2] can then be inserted into the osteotomy site, under fluoroscopy if available. In most instances, if the eye-magnet makes contact with the loose fragment, the surgeon will be able to remove it with little difficulty.

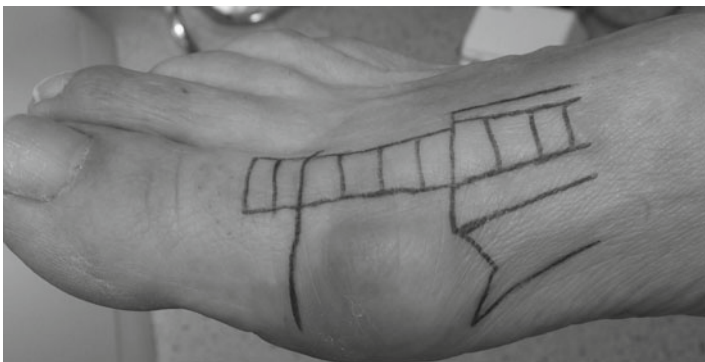


FIGURE 7.24 Landmarks may be drawn prior to beginning surgery

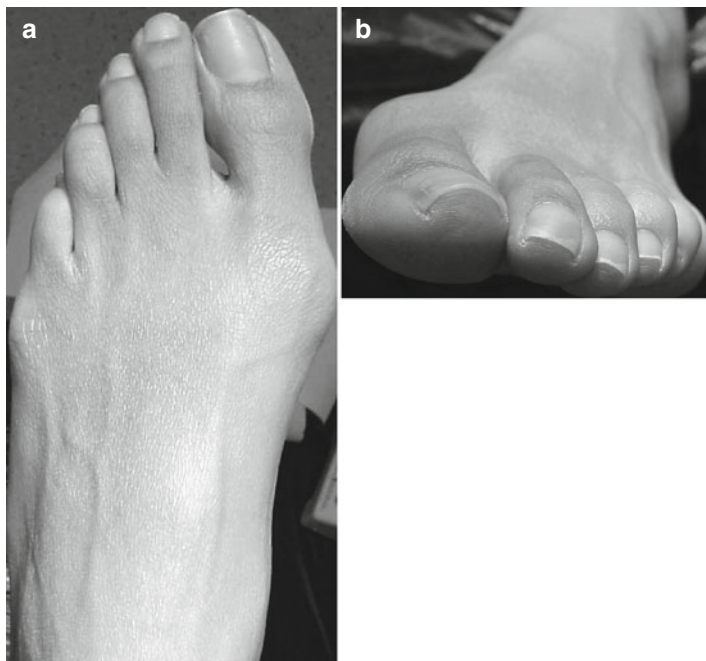


FIGURE 7.25 (a, b) Pre-operative photographs

If the surgeon has difficulty shifting the metatarsal head laterally following the completion of the osteotomy, it may be necessary to again run the Shannon 44 inside the osteotomy to remove an additional small amount of bone.

It is not necessary to surgically revise the redundant skin in the area of the first metatarsal head. This will shrink on its own.



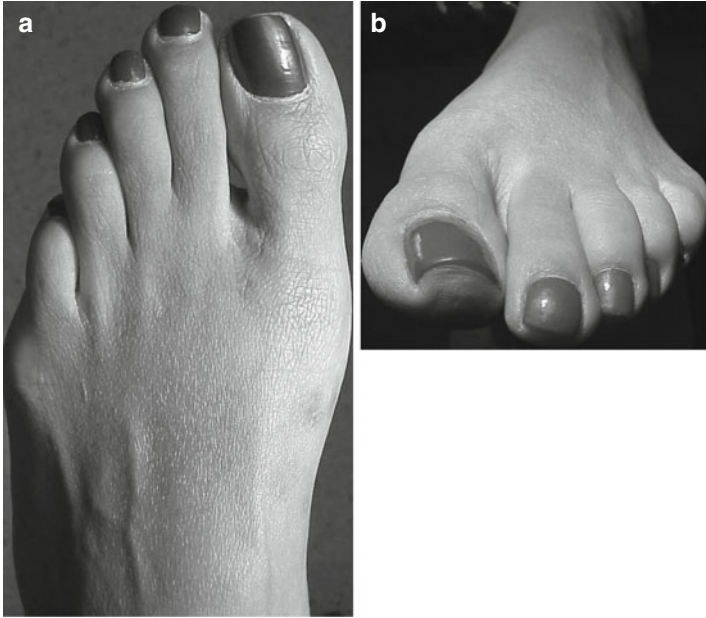

FIGURE 7.26 (a, b) Post-operative photographs

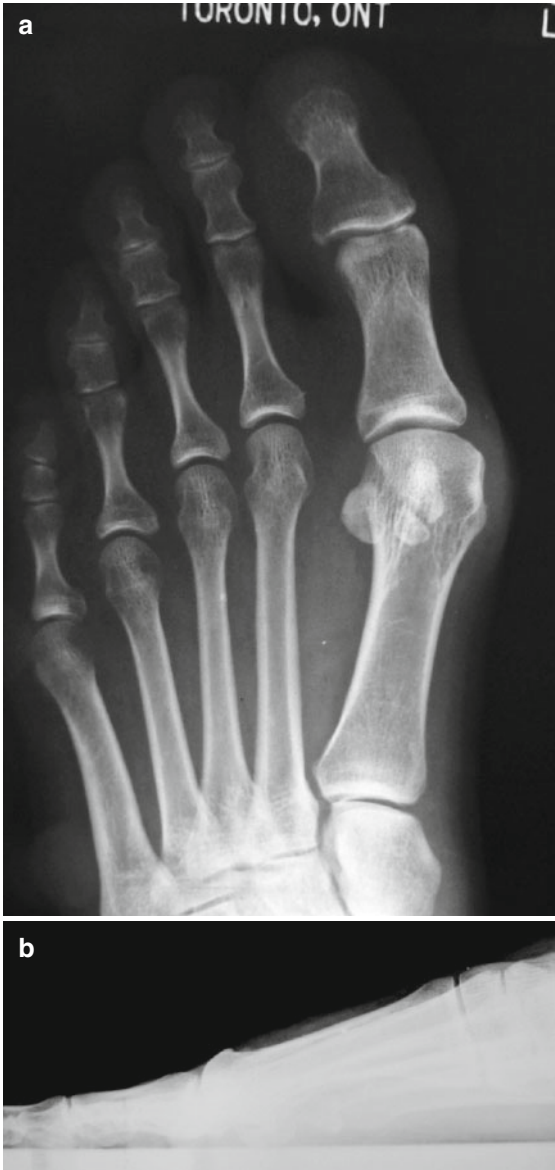

FIGURE 7.27 (a, b) Pre-operative radiographs

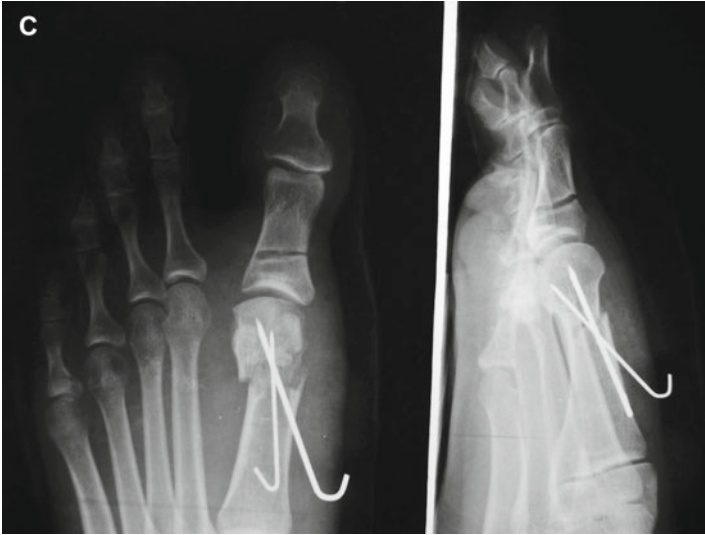

FIGURE 7.28 (a-c) Immediate post-operative radiographs

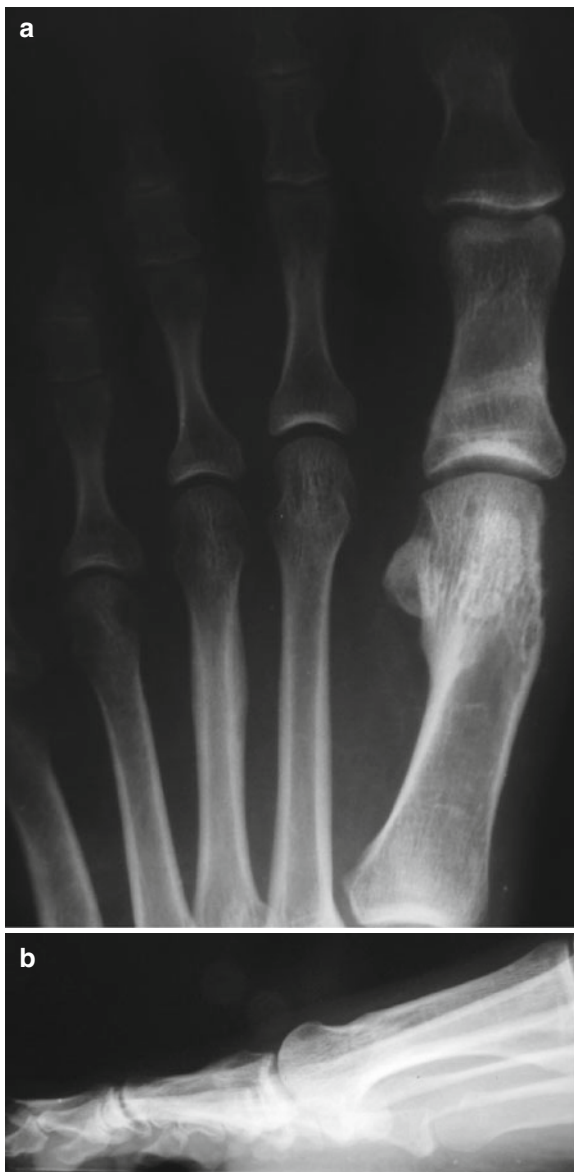

FIGURE 7.29 (a, b) One year post-operative radiographs

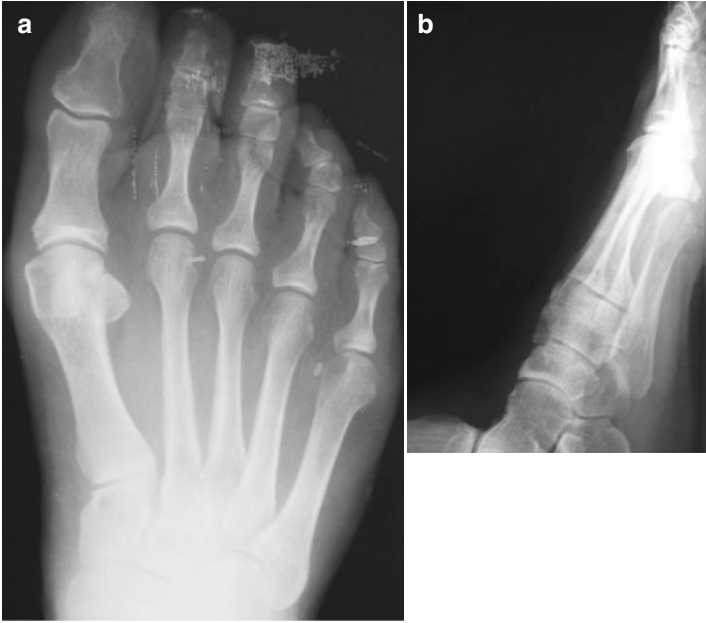


FIGURE 7.30 (a, b) Pre-operative radiographs

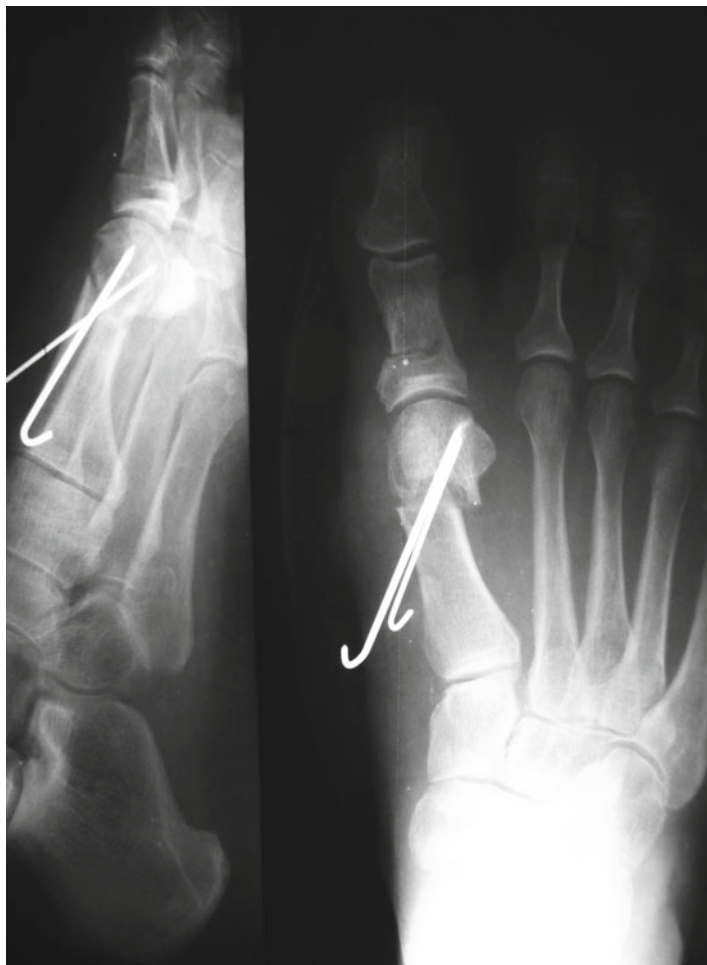

FIGURE 7.3I Immediate post-operative radiographs

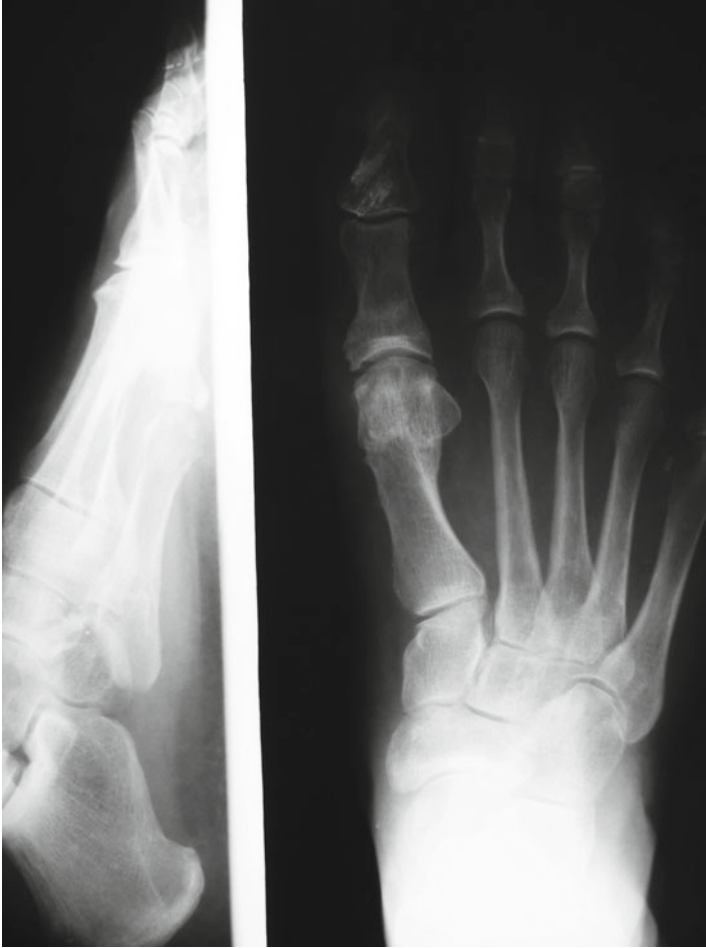

FIGURE 7.32 One year post-operative radiographs

## References

1. Wilson JN. Oblique displacement osteotomy for hallux valgus. *J Bone Joint Surg.* 1963;45B:552–6.
2. Miltex Inc. York, Pennsylvania.
3. Vilex in Tennessee Inc., McMinnville, Tennessee.
4. Xi-Tec, Inc., East Windsor, Connecticut, company no longer in operation.
5. Osada, Inc., Los Angeles, California.
6. Johnson and Johnson Medical Limited, Gargrave, Skipton, U.K.
7. 3M Health Care, St. Paul Minnesota.



# Chapter 8

## Percutaneous Surgery for Static Metatarsalgia

**Thomas Bauer**

### 8.1 Introduction

Metatarsalgias with plantar hyperkeratosis under the metatarsal heads of the lateral rays is very prevalent. Conservative management with insoles often provides a complete or partial relief of the symptoms. In case of failure of non-operative modalities, surgery can be indicated, and several metatarsal osteotomies have been described. Their aim is to shorten and to raise the metatarsals to decrease the pressure under the metatarsal heads of the lateral rays to provide relief of the symptoms [1–12]. The Weil osteotomy is the most popular distal metatarsal osteotomy and is still the gold standard treatment for metatarsalgia [5]. However, metatarso-phalangeal joint stiffness is a very frequent complication after Weil osteotomy, and difficulties with fixation or restoration of the distal metatarsal arch can be experienced. We present a percutaneous procedure for the treatment of metatarsalgias with details on the surgical technique, first results and discussion of the benefits and indications [13, 14].

---

T. Bauer, M.D.

Department of Orthopaedic Surgery,  
Ambroise Paré Hospital, West Paris University,  
9 av Charles de Gaulle, 92100, Boulogne, France  
e-mail: thomas.bauer@apr.aphp.fr

## 8.2 Operative Technique

**Instruments:** The surgical tools required to perform a distal metatarsal mini-invasive osteotomy (DMMO) are those used for percutaneous forefoot procedures, including a straight burr, a Beaver<sup>®</sup> blade, elevators, rasps, low speed and high torque drill and a fluoroscope.

**Patient set up:** The patient is supine, under regional or local anesthesia, with the foot free over the end of the table to allow fluoroscopic control.

**Portals:** A small skin incision (1 or 2 mm) is made with the Beaver<sup>®</sup> blade next to the metatarsal head, parallel to the extensor tendon (Fig. 8.1). The portal can be more distal, at the level of the metatarso-phalangeal joint in case of dorsal release of this joint.

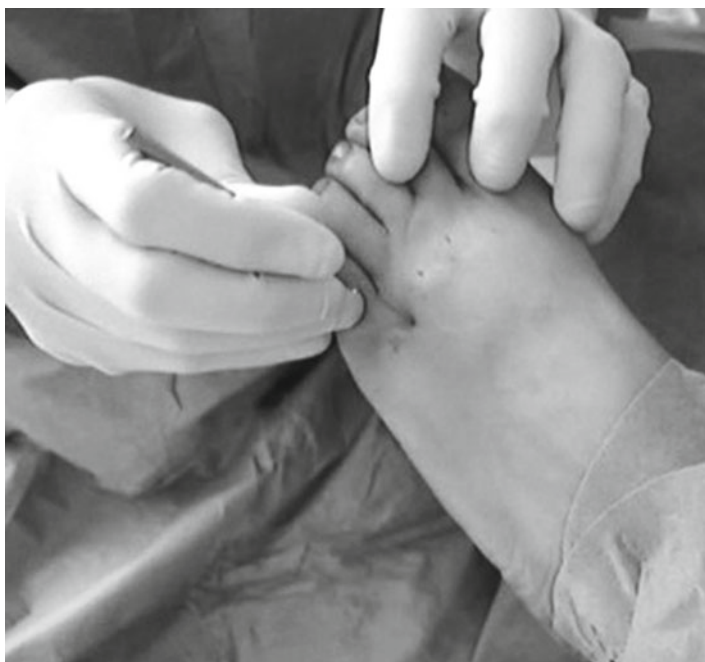

FIGURE 8.1 Portals for DMMO of the 2nd, 3rd and 4th metatarsals

**Distal Metatarsal Mini-invasive Osteotomy (DMMO):**

After subcutaneous dissection, an elevator is introduced with a 45° direction from dorsal distal to plantar proximal and is sliding down the lateral cortex of the metatarsal shaft just proximal to the head. This produce a working area avoiding soft tissue damages with the burr. The straight burr is then introduced in the same direction in contact with the bone (Fig. 8.2). The osteotomy is more proximal than the Weil osteotomy and is extra-articular. The osteotomy is in a 45° direction from dorsal distal to plantar proximal (Fig. 8.3). During the osteotomy, a circular movement of the burr is made around a fixed axis at the level of the skin incision. The osteotomy is begun on the lateral cortex 2–3 mm proximal from the

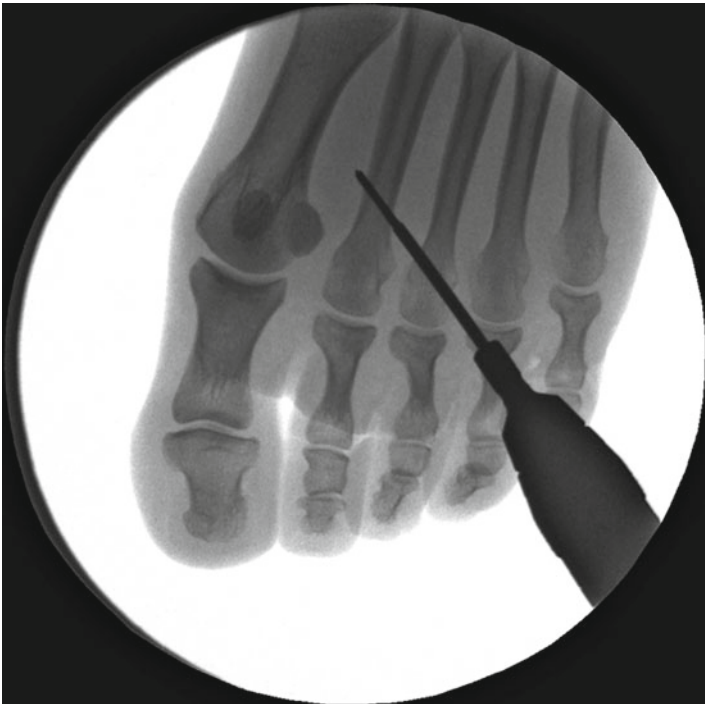

FIGURE. 8.2 Positioning of the burr

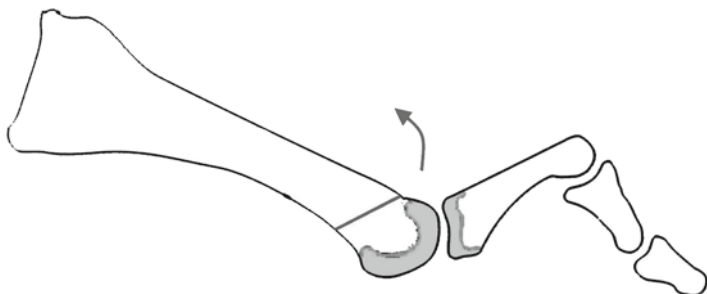


FIGURE 8.3 Principles of the DMMO

articular surface with the burr parallel to the shaft and then the plantar and medial cortices are cut (Fig. 8.4). The osteotomy ends on the dorsal cut with the burr perpendicular with the metatarsal shaft (Fig. 8.5). The toe is then pulled and pushed to check the osteotomy is complete and to release periosteal attachments that would prevent the shortening and rising up of the distal metatarsal fragment (Fig. 8.6). The same procedure is performed for each ray needing an osteotomy.

### 8.3 Post-operative Care

The portals are not closed. A post-operative dressing with specific bandage is made to keep the good alignment of the different toes. The dressing is changed after 10 days and a cohesive bandage is applied for 1 month (Fig. 8.7). Immediate full weight bearing is allowed in a shoe with a complete flat and rigid insole. Radiographs are taken after 10 days and 1 month from the operation. Normal shoe wearing is begun after 1 month according to the clinical and radiographic control.

### 8.4 Indications – Results

The indications for DMMO are basically all static metatarsalgias of the lateral rays with plantar hyperkeratosis after failure of conservative treatment for 6 months. These are very

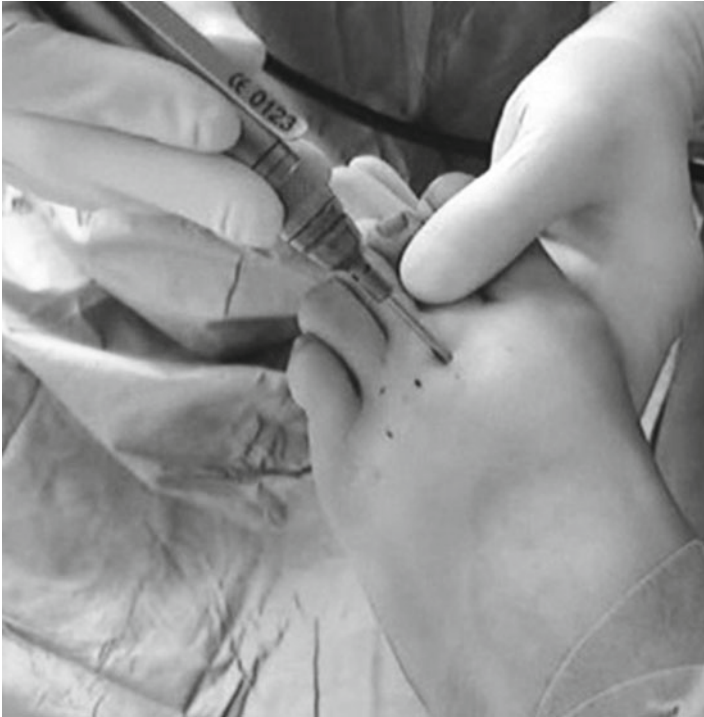

FIGURE. 8.4 DMMO: beginning of the osteotomy (the burr is parallel to the metatarsal)

frequent with or without first ray deformity, after failed previous surgery or in chronic inflammatory diseases.

One hundred and eighteen cases of metatarsalgias in whom a DMMO had been performed were studied prospectively with a mean follow up of 26 months. Plantar hyperkeratosis and metatarsalgias disappeared in all the cases within 2.5 months. The overall functional AOFAS forefoot score significantly improved from a mean 60/100 pre-operatively to a mean 94/100 post-operatively ( $p < 0.001$ ). Two patients had marked stiffness ( $ROM < 30^\circ$ ) of the metatarsophalangeal joint of one ray: in both patients, the osteotomy was intra-articular, and was revised. In 4 patients in whom DMMO were performed only on the second and third ray, a transfer metatarsalgia appeared under the 4th ray after the

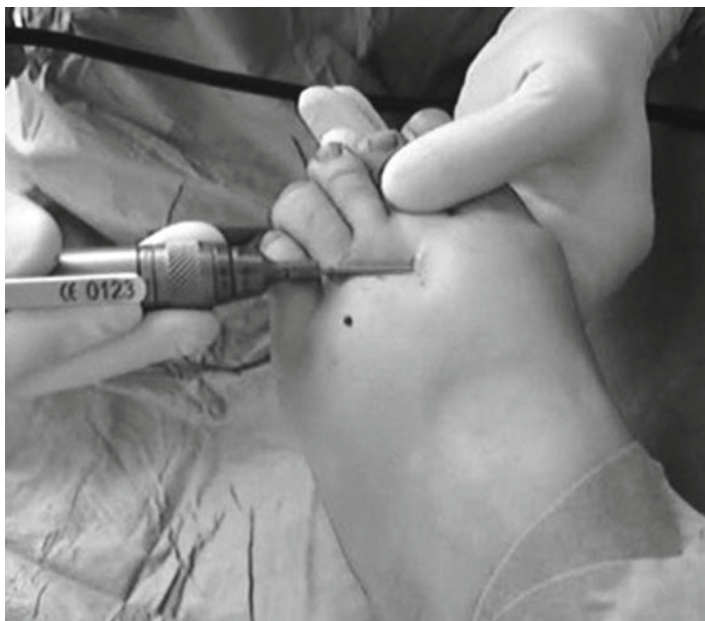

FIGURE. 8.5 DMMO: end of the osteotomy (the burr is perpendicular to the metatarsal)

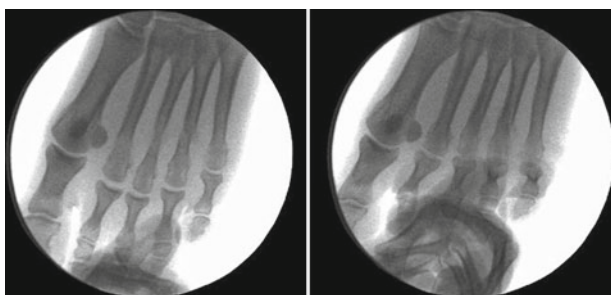


FIGURE. 8.6 Mobilization of the toes after DMMO

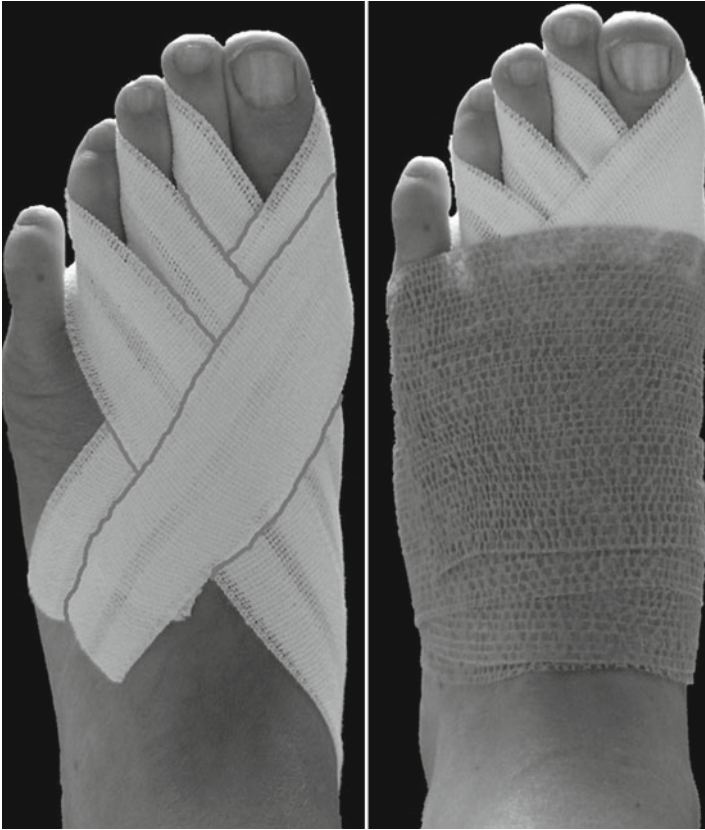

FIGURE. 8.7 Post-operative dressing with cohesive bandage

post-operative month. A prolonged swelling of 2 months was often seen. Bone healing was achieved in all but one case with a very variable delay (6 weeks to 18 months). The only patient with one metatarsal non-union was still asymptomatic after 4 years. Antero-posterior radiographs showed shortening of the metatarsal with a lining up of the metatarsal heads from the first to the fifth metatarsal.

## 8.5 Discussion

Percutaneous surgery for metatarsalgia using the DMMO is simple, effective and reproducible. Complications are rare, and can be avoided if appropriate care is exerted:

- the risk of skin burn decreases with the experience and learning curve in percutaneous forefoot surgery.
- metatarso-phalangeal joint stiffness is avoided by performing a more proximal extra-articular osteotomy at the level of the distal third of the metatarsal shaft.
- transfer metatarsalgia is avoided by performing simultaneous DMMO on the 2nd, 3rd and 4th metatarsal to obtain an harmonic lining up of the central metatarsal heads with an automatic adjustment with full weight bearing.

## References

1. Feibel JB, Tisdell CL, Donley BD. Lesser metatarsal osteotomies. A biomechanical approach to metatarsalgia. *Foot Ankle Clin.* 2001;6(3):473–89.
2. Leventen EO, Pearson SW. Distal metatarsal osteotomy for intractable plantar keratosis. *Foot Ankle Int.* 1987;10:247–51.
3. Gauthier G. Maladie de Freiberg ou deuxième maladie de Koehler Propositions d'un traitement de reconstruction au stade évolué de l'affection (34 cas traités). *Rev Chir Orthop.* 1974;60(suppl II):337–41.
4. Kitaoka HB, Patzer GL. Chevron osteotomy of lesser metatarsals for intractable plantar callosities. *J Bone Joint Surg Br.* 1998; 80:516–8.
5. Leemrijse T. Ostéotomie de Weil. In: *Chirurgie de l'avant-pied, Cahiers d'enseignement de la SOFCOT.* 2nd ed. Paris: Elsevier; 2005. p. 126–41.
6. Wolf MD. Metatarsal osteotomy for the relief of painful metatarsal callosities. *J Bone Joint Surg Am.* 1973;55:1760–2.
7. Helal B. Metatarsal osteotomy for metatarsalgia. *J Bone Joint Surg Br.* 1975;57:187–92.
8. Giannestras NJ. Plantar keratosis treatment by metatarsal shortening. *J Bone Joint Surg Am.* 1966;48:72–6.
9. Giannestras NJ. Shortening of the metatarsal shaft in the treatment of plantar keratosis. An end-result study. *Foot Ankle Int.* 1995; 16:529–34.



10. Delagoutte JP, Jarde O. Ostéotomies métatarsiennes à l'exception de la technique de Weil. In: Chirurgie de l'avant-pied, Cahiers d'enseignement de la SOFCOT. 2nd ed. Paris: Elsevier; 2005. p. 149–52.
11. Denis A, Huber-Levernieux C, Goutallier D. Notre expérience de l'ostéotomie métatarsienne dans le traitement des métatarsalgies statiques. *Méd Chir Pied*. 1984;1:85–8.
12. Toullec E, Barouk LS, Rippstein P. Ostéotomie de relèvement basal métatarsienne BRT. In: Chirurgie de l'avant-pied, Cahiers d'enseignement de la SOFCOT. 2nd ed. Paris: Elsevier; 2005. p. 142–8.
13. De Prado M, Ripoll PL, Golano P. Metatarsalgias. In: *Cirurgia percutanea del pie*. Barcelona: Masson SA; 2003. p. 167–82.
14. Coillard JY, Laffenetre O, Cermolacce C, et al. Traitement chirurgical des métatarsalgies statiques par technique percutanée. In: *Chirurgie de l'avant-pied, Cahiers d'enseignement de la SOFCOT*. 2nd ed. Paris: Elsevier; 2005. p. 153–7.

# Chapter 9

## Percutaneous Treatment of Static Metatarsalgia with Distal Metatarsal Mini-invasive Osteotomy

**J.Y. Coillard, Olivier Laffenetre, Christophe Cermolacce,  
Patrice Determe, Stéphane Guillo, and Christophe Lavigne,  
GRECMIP (Groupe de Recherche et d'Etude en Chirurgie  
Mini-Invasive du Pied)**

---

J.Y. Coillard (✉)

Department of Orthopaedic Surgery, Division of Foot Surgery,  
Clinique du Parc 86, Boulevard des Belges, 69006, Lyon, France  
e-mail: jy.coillard@cliniqueduparclyon.com

O. Laffenetre, M.D.

Department of Orthopaedic Surgery, Division of Foot Surgery,  
Victor Ségalen Bordeaux-2 University, Bordeaux cedex, France

Department of Orthopaedic Surgery, Division of Foot Surgery,  
Pellegrin University Hospital, Place Amélie Raba Léon,  
33076, Bordeaux cedex, France

Department of Orthopaedic Surgery, Division of Foot Surgery,  
ICP Paris, 8 rue Lacépède, 75005, Paris, France

C. Cermolacce, M.D.

Department of Orthopaedic Surgery, Division of Foot Surgery,  
L'Institut de Chirurgie Orthopédique et Sportive,  
118 Rue Jean Mermoz, 13008, Marseille, France

P. Determe, M.D.

Department of Orthopaedic Surgery, Division of Foot Surgery,  
ICP Paris, 8 rue Lacépède, 75005, Paris, France

Department of Orthopaedic Surgery, Division of Foot Surgery,  
Clinique du Parc, 105 rue Achille Viadieu, 31400, Toulouse, France

S. Guillo, M.D.

Department of Orthopaedic Surgery, Division of Foot Surgery,  
ICP Paris, 8 rue Lacépède, 75005, Paris, France

Department of Orthopaedic Surgery, Division of Foot Surgery,  
Research and Study Group for Mini-invasive Surgery of the Foot,  
9 rue Jean Moulin, 33700, Mérignac, France

C. deLavigne, M.D.

Department of Orthopaedic Surgery, Division of Foot Surgery,  
Sport Medical Center, Merignac, France

## 9.1 Introduction

Metatarsalgia is frequent. Most patients respond to 6–12 months of conservative management. At times, usually from structural abnormalities of the foot, especially first-ray shortening, surgery provides considerable benefit. Historically, the first osteotomies described to manage metatarsalgia were diaphyseal (Meisenbach 1916; Giannestras 1954; Helal 1975), then proximal metaphyseal (Mau 1940; Sgarlata 1979; Delagoutte 1990), and finally distal (Borrgreve 1949; Davidson 1969; Gauthier 1970). In 1991, Weil [1] described a technique, still widely used in Europe, which enables perfect control of the planned proximal migration of the metatarsal head. Consolidation is ensured by appropriate internal fixation. The technique, however, involves penetrating the metatarso-phalangeal joint, and frequently causes stiffening of the metatarso-phalangeal joint.

A minimally invasive distal metatarsal osteotomy [2, 3] avoids these disadvantages, and is recommended in these patients [4].

## 9.2 Aims and Principles

As in open surgery, the minimally invasive procedure which we describe aims to shorten the operated metatarsal and raise the metatarsal heads via a minimally invasive approach to limit dorsal fibrosis, avoiding to penetrate the joint to

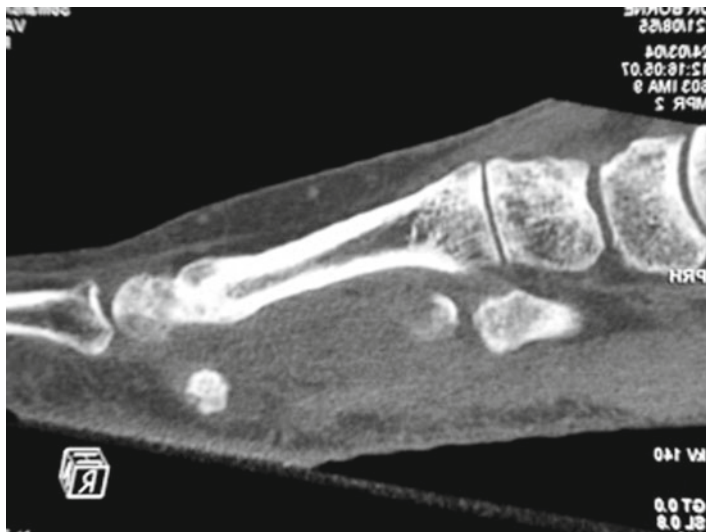


FIGURE 9.1 Lateral view of CT scan showing malunion of the osteotomy, with dorsiflexion deformity

prevent stiffening, and without internal fixation to ensure appropriate bony callus in optimal weight-bearing position.

The aim is to shorten and dorsiflex the relevant metatarsal (Figs. 9.1, 9.2, and 9.3). The indications for surgery are basically clinical, although antero-posterior weight-bearing forefoot radiographs also provides precious information about the metatarsal formula, acknowledging that it does not take into account sagittal metatarsal mobility. There is no pre-operative planning of the sort required, for example, when undertaking a Weil osteotomy. The osteotomized metatarsal heads find their own positions when weight-bearing postoperatively.

### 9.3 Materials

To undertake minimally invasive surgery, a dedicated instrumentation, an image intensifier and a dedicated mini-motor are necessary.

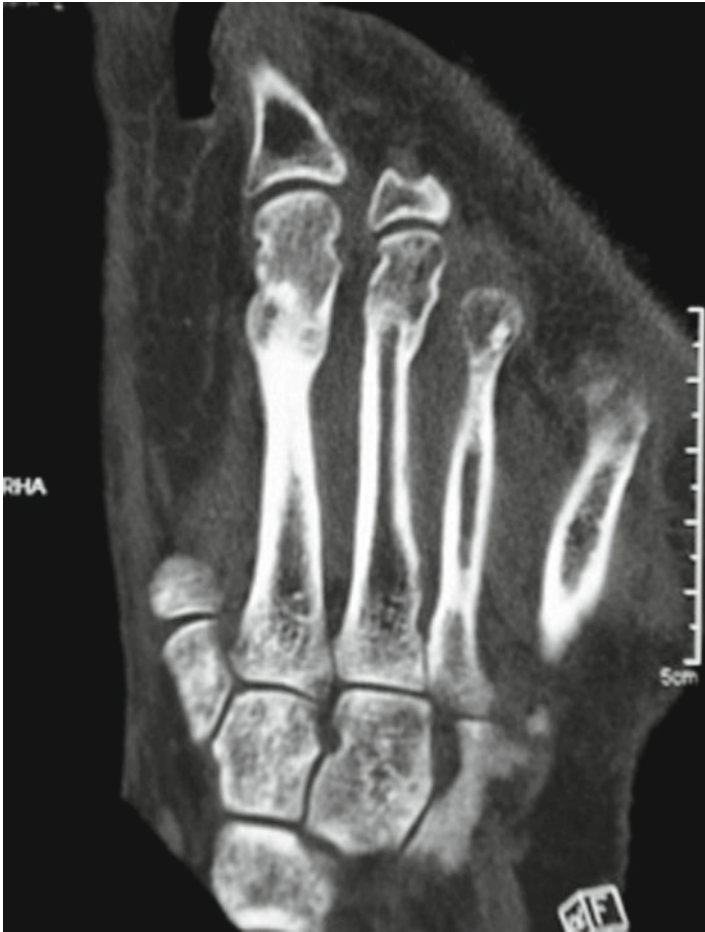

FIGURE 9.2 Anteroposterior view of CT scan showing malunion of the osteotomy

The following are recommended:

- (a) Beaver® type scalpel
- (b) A small periosteal elevator

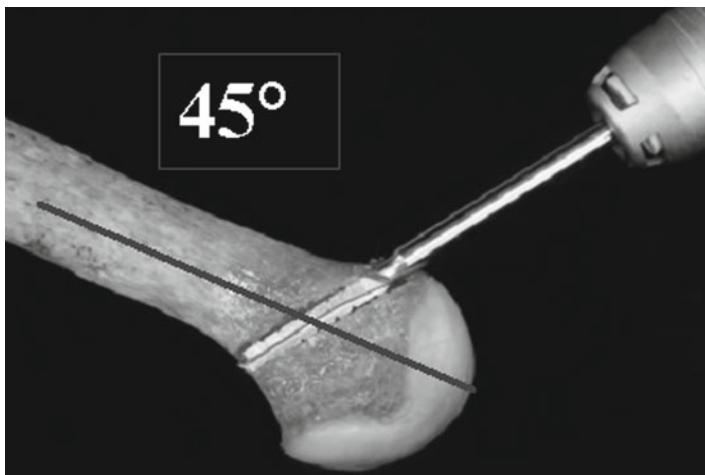


FIGURE 9.3 Place of the burr in contact with the metatarsal cortex at 45°

- (c) Rasp (little used in this indication)
- (d) Slow rotation (<15,000 rpm) mini-motor
- (e) Long or wide Shannon 44 burr
- (f) Low radiation an image intensifier

## 9.4 Surgical Technique

### 9.4.1 *Anesthesia*

We normally use a popliteal or posterior tibial block supplemented by extensor brevis and anterior coronal midfoot block.

### 9.4.2 *Patient positioning*

Appropriate positioning of the patient depends on how the first ray is to be realigned. Perioperative control radiographs should, however, be planned.

### 9.4.3 *Osteotomy*

A small incision using the beaver knife is performed in the inter-metatarsal space just next to the head (to the right, for a right-handed surgeon) parallel to the extensor tendons. The scalpel is pointed at 45° to the metatarsal neck. The elevator is then introduced, to prepare the subcapital edge of the metatarsal neck and avoid soft tissue damage. Radiographs allow to check the most appropriate position for the osteotomy. The wide or long Shannon 44 burr is then introduced through the incision, in direct contact with the metatarsal cortex. During the osteotomy, the burr is maintained at 45°, milling a clear cortical groove to prevent any error in angulation or displacement of the burr. With a rotational movement, the medial, then planar, then lateral and finally dorsal cortex are osteotomized, with the burr at 45° throughout.

It is also possible to proceed by a simple lateral movement of the burr, without rotation around the metatarsal axis, but there is a greater risk of soft tissue injury. At this point, a further radiographic check can be made, together with clinical assessment that the metatarsal head is freely mobile.

The number of osteotomies depends on the pattern of plantar hyperkeratosis: when this lies exclusively under the second metatarsal head, the second and third metatarsals are osteotomized. If the plantar hyperkeratosis is located under the second and third metatarsal heads, the second, third and fourth metatarsals are osteotomized. The fifth ray is very mobile, and it seldom requires an osteotomy.

Finally, the wound is closed, with one suture per incision, and dressed with gauze compresses orienting the operated heads towards the hallux; this is especially important in patients in whom hallux valgus correction is associated with the distal metatarsal osteotomy of the lesser metatarsals, so that the deviation of the lesser toes caused by the hallux valgus deformity is corrected as the osteotomies consolidate.

## 9.5 Post-operative Follow-Up

Surgery may be performed on an out-patient basis or with overnight admission. Patient are allowed to weight bear immediately in a stiff-soled shoe, but should walk as little as possible during the first 3 weeks, to avoid pain and post-surgical edema. The patients are recommended to spend as much time as possible with the foot raised during the day. When surgery to the first ray is associated, the dressing can be left unchanged for a week if the procedure was entirely minimally invasive; after that, the dressing is renewed, taking care that the bandage is fashioned so that the toes are pushed towards the hallux for 3 weeks to prevent mal-union (Fig 9.4).



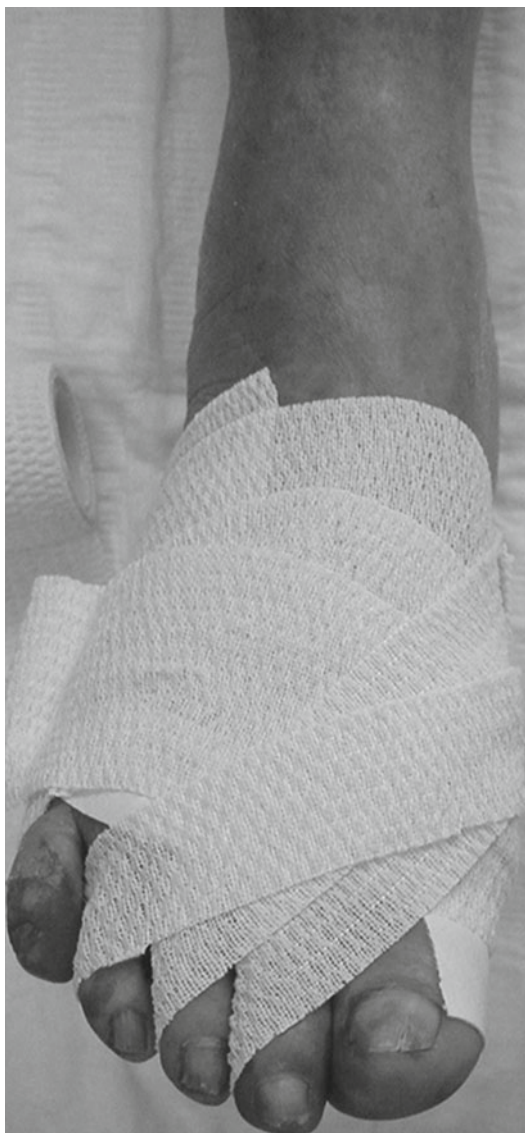

FIGURE 9.4 Specific cohesive bandaging of the toes towards the hallux to prevent mal-union an oedema

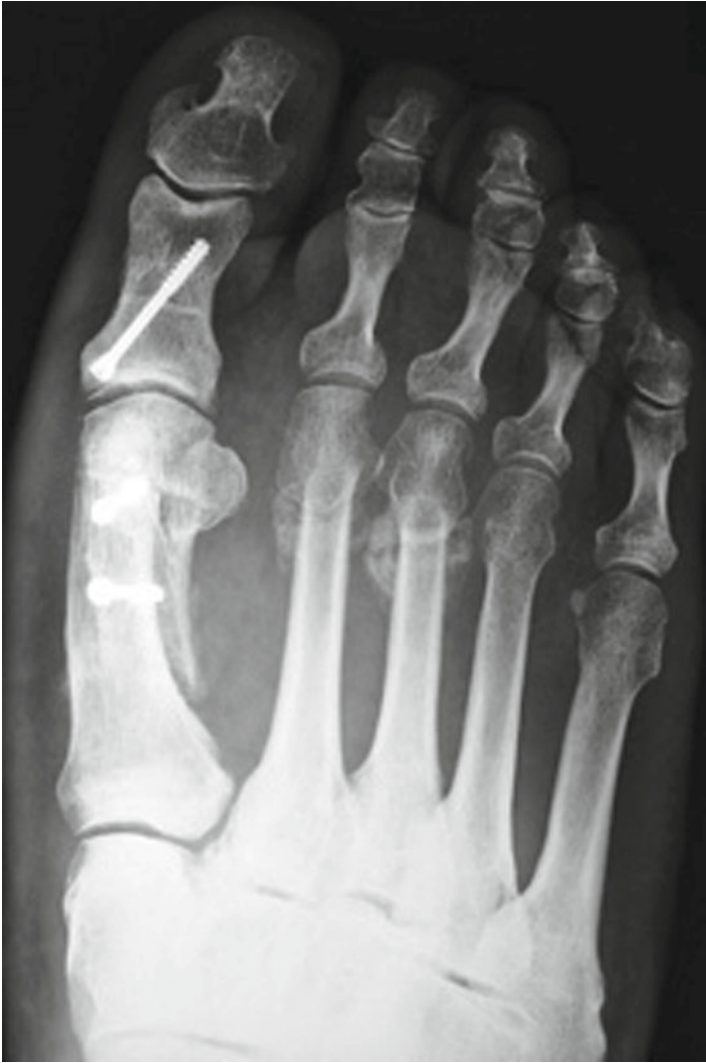

FIGURE 9.5 Normal aspect of callus after 2 months for 2nd and 3rd shafts

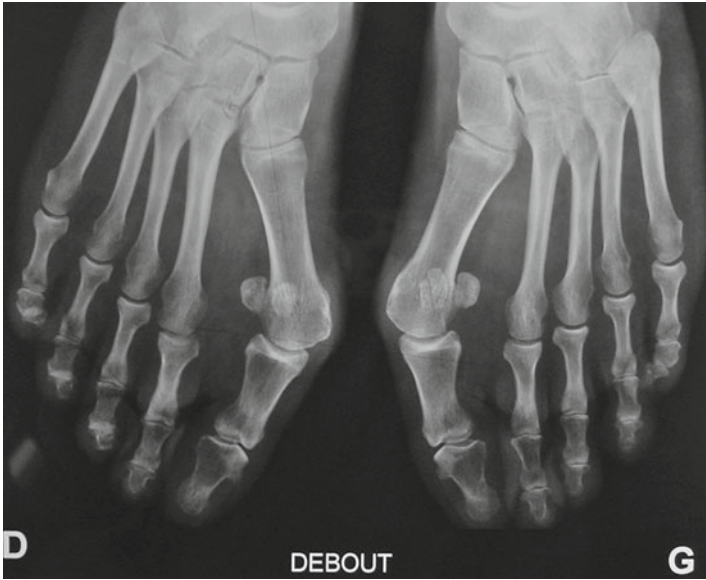

FIGURE 9.6 Preoperative radiograph prior to hybrid mini invasive surgery

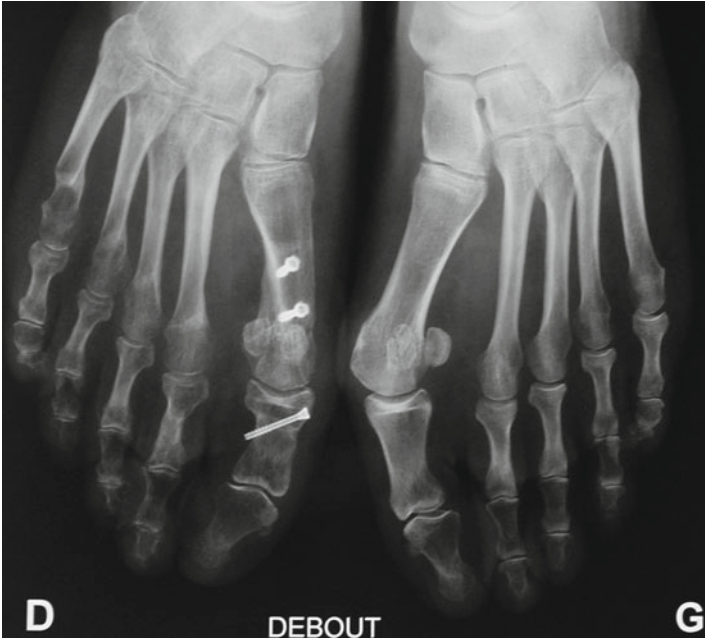

FIGURE 9.7 Hybrid mini invasive surgery which has combined DMMO 2–5, percutaneous Akin osteotomy and classical scarf osteotomy. Post-operative (18 months follow-up) aspect

A second postoperative check is made at 4 weeks to counsel about shoe wear, then at 3 or 4 months for consolidation. The fibrous callus forms as of week 3, limiting pain and mobility in the metatarsal heads, and a hypertrophic bony callus can be seen from the second post-operative month (Figs. 9.5, 9.6, and 9.7).

## 9.6 Conclusion

Minimally invasive distal osteotomy for static metatarsalgia provides satisfactory clinical and anatomical results avoiding the medium-term stiffness and pain typical of open surgery.

## References

1. Barouk LS. Weil's metatarsal osteotomy in the treatment of metatarsalgia. *Orthopade*. 1996;25(4):338-44. German.
2. De Prado M, Ripoll PL, Golano P. Cirugia percutanea del pie. Barcelona: Masson; 2003. p. 165-74. Part 4 Capitulo 10, métatarsalgias.
3. Coillard JY, Laffenetre O, Cermolacce C, Determe P, Guillo S, Jambou S, de Lavigne C. Traitement chirurgical des métatarsalgies statiques par technique mini-invasive. *Conférences d'Enseignement de la Sofcot*. 2 ed. 2005;89. Paris: Elsevier. p. 153-7.
4. Darcel V, Villet L, Chauveaux D, Grecmip Group, Laffenetre O. Treatment of static metatarsalgia using distal percutaneous metatarsal osteotomy: a prospective study of 222 feet. *Rev Chir Orthop*. 2009;5:229-42.

# Chapter 10

## Isham Hammertoe Procedures for the Correction of Lesser Digital Deformities: Phalangeal Osteotomy Procedures

**Stephen A. Isham and Orlando E. Nunez**

These Minimal Invasive surgical (MIS) procedures are utilized for the treatment of a variety of hammertoe deformities. Performing transverse, combination, or wedge osteotomies in the proximal or middle phalanges of the deformed digits preserve the functional articular surfaces of the metatarsal phalangeal and interphalangeal joint resulting in the correction of the structural deformity of lesser digits. Performing percutaneous tenotomies and capsulotomies will result in correction of the soft tissue deformities of this pathology. MIS permits the surgeon to utilize different surgical procedures to address the different components of a given deformity.

These surgical procedures are reserved for surgeons with experience, not only in minimal invasive, but also traditional surgery. These surgical procedures are performed

---

S.A. Isham, M.D. DPM, DrHC (✉)

Department of Minimally Invasive Foot Surgery,  
San Francisco Hospital, Sanatorio San Francisco, Mexico DF, Mexico  
e-mail: drisham@frontier.com

O.E. Nunez, M.D., DPM

Department of Foot Surgery, del Cesar Clinic,  
Valledupar – Cesar, Colombia

Coeur d'Alene Foot & Ankle Surgery Center,  
Coeur d'Alene, ID, USA

through a very small incision. If the surgeon is not precise, important structures can be damaged and lead to predicted complications.

## 10.1 Definition

Hammertoe, including claw toe and mallet toe, deformities are a combination of one or more deformities of the digits at the metatarsal phalangeal joints (MPJ) and interphalangeal joint (IPJ). These deformities can be in sagittal, transverse, and frontal planes. Most commonly, the deformed digit is dorsal flexed at the metatarsal phalangeal joint and plantarflexed at the middle interphalangeal joints or distal phalangeal joints. These deformities contain both soft tissue and osseous components called positional and structural deformities.

## 10.2 Etiology

One of the most common manifestations of biomechanical functional abnormalities of the foot is expressed in painful deformities of the lesser digits. This manifestation can be expressed by soft tissue and structural components caused by normal adaptive changes on soft tissue and osseous structures. Digital deformity can occur at the MPJ joint, the proximal IPJ joint, and the distal IPJ joint of the involved digit.

The primary cause of hammertoe deformities is the abnormal foot structure which, as dictated by genetic code, is exposed to abnormal pronatory forces. This results in hypermobility of the osseous structures and over dependence on soft tissue structure for stability during weight bearing and in particular during the last phase of the propulsive stage of gait. The severity of the hammertoes is proportionate to the severity of the abnormal pronatory forces present and how long the deformity has existed. Other causes of hammertoe deformities are systemic diseases such as gout, rheumatoid arthritis,

neurological disorders, or trauma causing permanent osseous or soft tissue damage to the digit. Footwear, though not a primary cause, can definitely aggravate the symptoms of the deformity. When more than one cause is present the surgeon can expect the progression and the severity of the deformity to increase.

### 10.3 Classification

The classification of deformities is a tool that enables the surgeon to select or modify procedures to achieve the best results for each patient. To classify the severity of hammertoe deformities, the following observations are commonly used by the author. Most deformed digits that we are called upon to correct have been long term enough to have both structural and soft tissue components. The component of the deformity is the result of adaptive changes taking place at the involved joint or joints of the digits. The longer period of time the contracture exists, the more adaptive changes will occur. The classifications are *flexible, semi-rigid, and rigid*.

The aim of the Isham Hammertoe Procedures is directed at correcting the soft tissue structures by doing soft tissue releases of the extensor and flexor tendons and a capsulotomy at the metatarsal phalangeal joint, if indicated, and correcting the structural deformities while conserving the articulation and utilizing the adaptive changes that are occurring at these joint structures. By using conservative osteotomy and soft tissue procedures, we can redirect the biomechanical function and improve the appearance and symptoms of the deformed digit.

### 10.4 Phalangeal Osteotomy Procedures

Development of surgical procedures is an evolution based on the work of previous surgeons. Diaphyseal osteotomy procedures of the phalanx have been utilized for years for the correction of hammertoe deformities. The author has modified



these procedures by using a transverse, combination, and wedge osteotomies at the base of the proximal phalanx, in conjunction when indicated with a combination osteotomy of the middle phalanx and a wedge osteotomy when indicated along with exostectomies and soft tissue corrections.

*Transverse osteotomy* is an osteotomy performed in the diaphysis or metaphysis completely severing the phalanx thereby shortening the osseous structure.

*Wedge osteotomy* is an osteotomy procedure where a wedge is performed in the diaphysis or metaphysis whereby a cortical or periosteal hinge is conserved redirecting or realigning the osseous structures on an anatomical guideline.

*Combination osteotomy* is an osteotomy procedure in the diaphysis or metaphysis of the bone where a transverse bone shortening osteotomy is performed through the cortex and periosteum but also wedged to realign the osseous structures and improve function.

## 10.5 Isham Hammertoe Procedures

I-1 procedure. This procedure is a combination osteotomy at the base of the proximal phalanx with soft tissue releases of the two extensor and flexor tendons and, if necessary, a capsulotomy on the dorsal aspect of the metatarsal phalangeal joint. This procedure is indicated in a semi-flexible hammertoe deformity where a majority of the deformity takes place at the metatarsal phalangeal joint (MPJ) (Fig. 10.1).

I-2 procedure. This procedure is a combination osteotomy performed on the base of the proximal phalanx and an exostectomy performed on the dorsal aspect of the head of the proximal phalanx along with extensor and flexor soft tissue releases. This is indicated in a semi-flexible or semi-rigid hammertoe deformity at the metatarsal phalangeal joint (MPJ) with an exostosis on the head of the proximal phalanx (Fig. 10.2).

I-3 procedure. This procedure is a combination osteotomy at the base of the proximal phalanx, an exostectomy on the dorsal aspect of the head of the proximal phalanx, and a dorsal

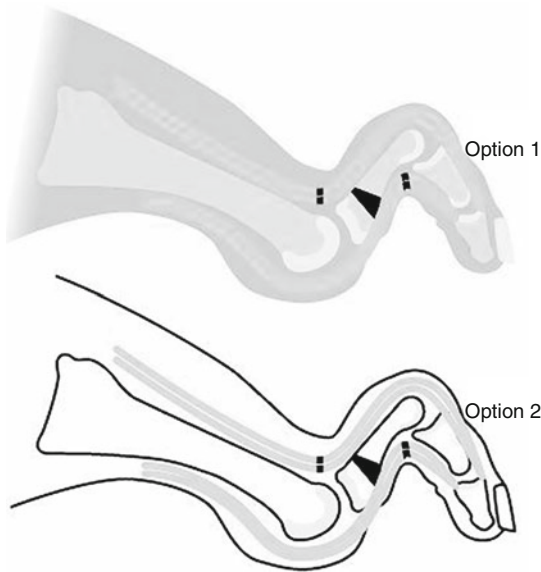


FIGURE 10.1 Isham Hammertoe procedure I-1. This procedure is a combination osteotomy at the base of the proximal phalanx with soft tissue releases of the two extensor and flexor tendons and, if necessary, a capsulotomy on the dorsal aspect of the metatarsal phalangeal joint

wedge osteotomy through the head of the proximal phalanx with extensor and flexor soft tissue releases resulting in a realignment and straightening of the articular surface of the proximal interphalangeal joint (PIPJ). This is indicated for a semi-rigid or rigid deformity with a long phalanx at the metatarsal phalangeal joint (MPJ) and proximal interphalangeal joint (PIPJ) (Fig. 10.3).

I-4 procedure. This procedure is a combination osteotomy at the base of the proximal phalanx and a combination osteotomy procedure in the diaphysis of the middle phalanx with associated extensor and flexor releases. This is indicated for semi-flexible or semi-rigid hammertoe deformities where the deformity is not only at the metatarsal phalangeal joint (MPJ), but also at the proximal and distal interphalangeal joints (IPJ). This hammertoe procedure is most commonly utilized by the author (Fig. 10.4).

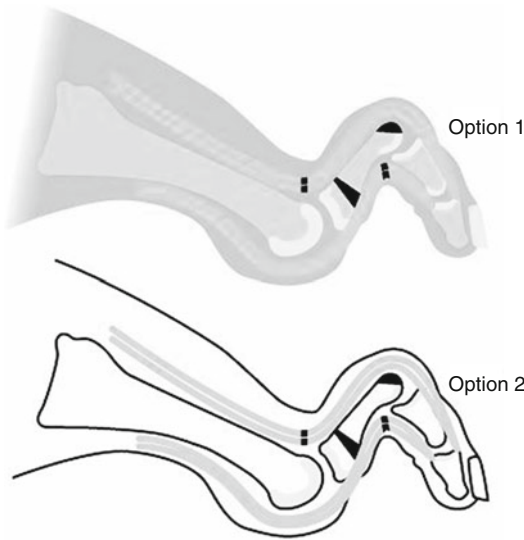


FIGURE 10.2 Isham Hammertoe procedure I-2 procedure. This procedure is a combination osteotomy performed at the base of the proximal phalanx and an exostectomy performed on the dorsal aspect of the head of the proximal phalanx along with extensor and flexor soft tissue releases

I-5 procedure. This procedure is a combination osteotomy at the base of the proximal phalanx and an exostectomy at the hypertrophied exostosis on the dorsal aspect of the proximal phalanx and a combination osteotomy of the middle phalanx. This is indicated for semi-flexible or semi-rigid hammertoe deformity where the deformity is not only at the metatarsal phalangeal joint (MPJ), but also at the proximal and distal interphalangeal joints (IPJ) with an exostosis on the dorsal aspect of the proximal phalanx (Fig. 10.5).

I-6 procedure. This procedure is a combination osteotomy at the base of the proximal phalanx, an exostectomy on the dorsal aspect of the head of the proximal phalanx, a dorsal wedge osteotomy through the head of the proximal phalanx, and a combination osteotomy at the diaphysis of the middle phalanx. This is indicated for a rigid deformity of the digits when the

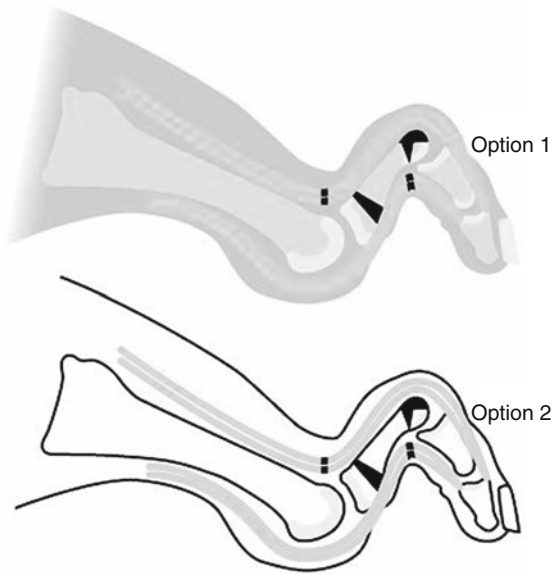


FIGURE 10.3 Isham Hammertoe procedure I-3 procedure. This procedure is a combination osteotomy at the base of the proximal phalanx, an exostectomy on the dorsal aspect of the head of the proximal phalanx, and a dorsal wedge osteotomy through the head of the proximal phalanx with extensor and flexor soft tissue releases resulting in a realignment and straightening of the articular surface of the proximal interphalangeal joint (*PIPJ*)

deformities exist at the metatarsal phalangeal joint (MPJ) and both interphalangeal joints (IPJ's) with exostosis of the dorsal aspect of the proximal phalanx. This procedure is mostly seen to be needed in a second digit deformity (Fig. 10.6).

## 10.6 Non-hammertoe Lesser Digit Deformities

Digital deformities may be associated with biomechanical or non-biomechanical deformities, such as congenital or acquired deformities. In a laterally or medially deviated digit the

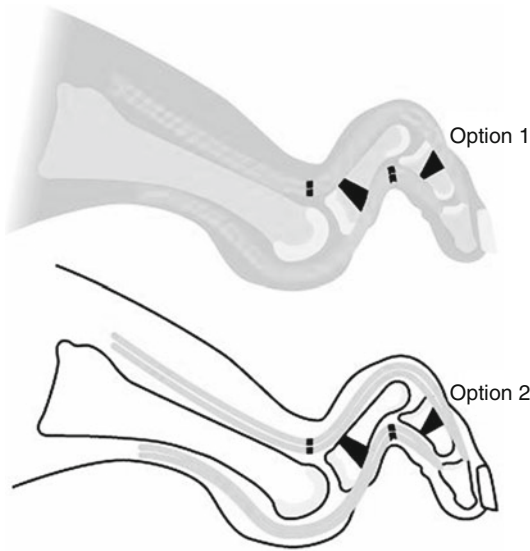


FIGURE 10.4 Isham Hammertoe procedure I-4 procedure. This procedure is a combination osteotomy at the base of the proximal phalanx and a combination osteotomy procedure in the diaphysis of the middle phalanx with associated extensor and flexor releases

PASA is affected either positively or negatively at the metatarsal phalangeal joint (MPJ). It is often noticed with hallux valgus deformities where the lesser digit is deviated also laterally or medially overlapping the hallux. This medial deviation is caused by a plantarflexed metatarsal resulting in over stress of the metatarsal phalangeal joint (MPJ). A lateral deviation is very common in arthritic conditions such as rheumatoid arthritis.

If the digital deformity is associated strictly with a deformity at the metatarsal phalangeal joint (MPJ) and there is no metatarsal deformity, keratosis or symptomatology on the metatarsal, then a wedge phalangeal osteotomy may be performed to straighten the digit. This procedure is performed without or in conjunction with soft tissue releases, as needed.

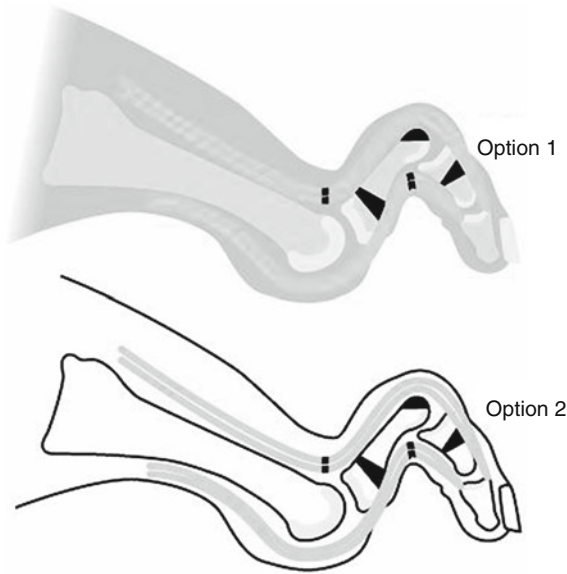


FIGURE 10.5 Isham Hammertoe procedure I-5 procedure. This procedure is a combination osteotomy at the base of the proximal phalanx and an exostectomy at the hypertrophied exostosis on the dorsal aspect of the proximal phalanx and a combination osteotomy of the middle phalanx

A wedge osteotomy procedure may be performed to straighten out a laterally deviated or medially deviated digit conjunction with a Modified Isham Osteotomy through the head or neck of the metatarsal correcting the PASA as well as elevating the metatarsal head for a painful lesion underneath the metatarsal head area. Again, soft tissue procedures are infrequent and only performed when indicated (Fig. 10.7a, b)

On congenital deformities of the fifth digit, an overlapping fifth digit to the fourth digit has proven to be a challenge for many years to regarding correction of this deformity. This deformity may be corrected by doing a combination osteotomy at the base of the proximal phalanx in conjunction with

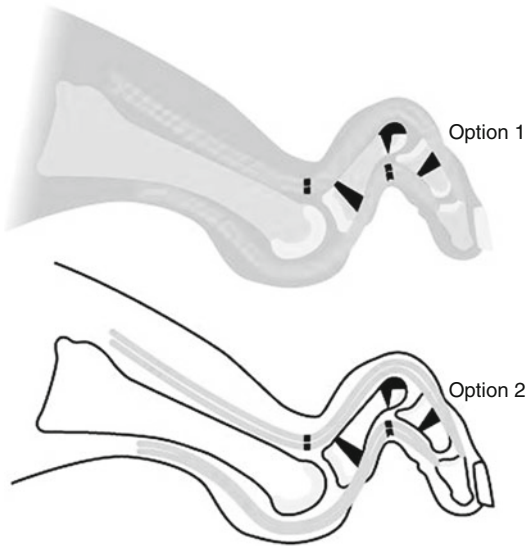


FIGURE 10.6 Isham Hammertoe procedure I-6 procedure. This procedure is a combination osteotomy at the base of the proximal phalanx, an exostectomy on the dorsal aspect of the head of the proximal phalanx, a dorsal wedge osteotomy through the head of the proximal phalanx, and a combination osteotomy at the diaphysis of the middle phalanx

an extensor tenotomy and capsulotomy releases. On occasion, should the adaptive cartilage of the fifth digit be significantly dorsal at the metatarsal phalangeal joint (MPJ) on the metatarsal head, a combination osteotomy is needed on the metatarsal plantarly in order to re-position the adaptive cartilage more towards normal function position directly in front of the metatarsal head (Fig. 10.8).

Exostosis excisions may be performed using percutaneous incisions on any hyperostosis on the phalanx such as on the distal aspect of the digit, at the distal interphalangeal joint (IPJ), the proximal interphalangeal joint (IPJ) either dorsal, medial, or lateral (Figs. 10.9 and 10.10).

For a congenitally long digit that has no deformity factors at either the interphalangeal joint (IPJ) or metatarsal phalangeal

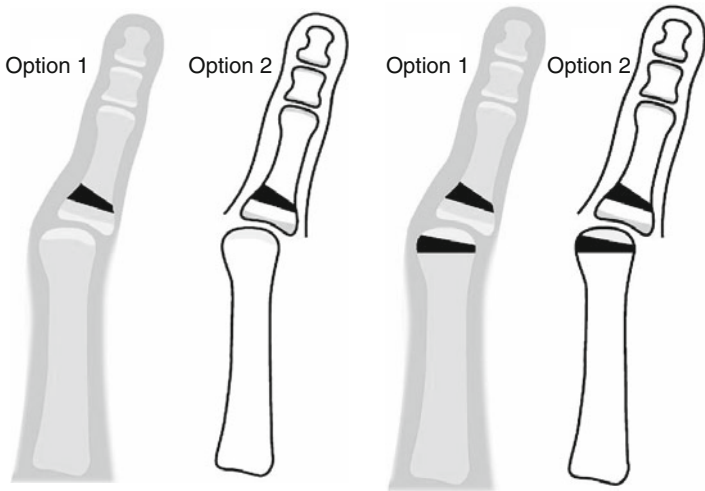


FIGURE 10.7 A wedge osteotomy procedure may be performed to straighten out a laterally deviated or medially deviated digit together with a modified Isham osteotomy through the head or neck of the metatarsal correcting the PASA as well as elevating the metatarsal head for a painful lesion underneath the metatarsal head area

joint (MPJ), a shortening osteotomy procedure may be performed in both the base of the proximal phalanx and in the middle phalanx without soft tissue releases in order to render the digit a more normal length (Fig. 10.11).

### 10.6.1 Operative Technique

The Isham Hammertoe Procedures are performed using 2 mm percutaneous incisions. These portals are performed using an MIS 64 or MIS 67 blade (BD Beaver Blades, Becton Dickinson, 1 Becton Drive, Franklin Lakes, NJ 07417). The first procedure is the release the soft tissue structures. A 2 mm incisions is made over the dorsal aspect of the metatarsal phalangeal joint (MPJ) over the extensor tendon apparatus. Tenotomy of the extensor longus is performed, and if



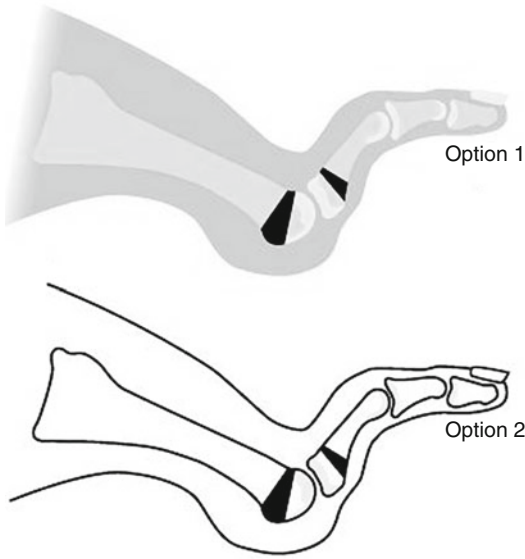
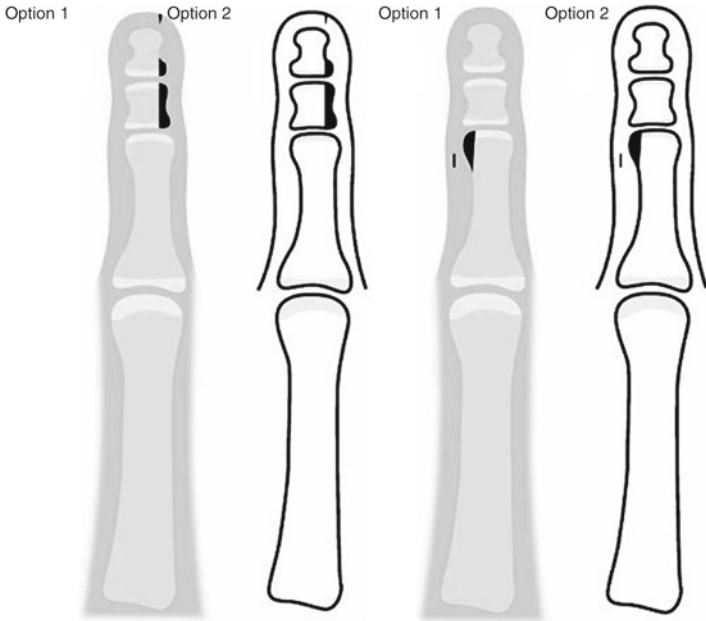


FIGURE 10.8 A fifth digit overlapping on the fourth digit may be corrected by a combination osteotomy at the base of the proximal phalanx together with an extensor tenotomy and capsulotomy releases

necessary, the extensor brevis and a deeper capsulotomy may also be performed if indicated. On the plantar aspect of the involved digit 2 mm incisions are also performed using the same instrumentation. These incisions are performed to allow passage of a bone cutting instrument, a rotary burr (Isham Short by Vilex). These incisions are centered on the phalanx plantarly, extended deep allowing a channel for the cutting instrument. Through the same or separate incisions a percutaneous tenotomy of both the flexor brevis and longus is performed.

The author utilizes a combination osteotomy on the proximal and middle phalanxes when indicated to correct the majority of hammertoe deformities. The combination osteotomy permits the surgeon to correct the angle of a deformity and reposition the digit in its correct position, following the laws of Wolff (Fig. 10.12a–c, Preoperative and Postoperative)



FIGS. 10.9 AND 10.10 Exostosis excisions can be performed using percutaneous incisions on any hyperostosis on the phalanx such as on the distal aspect of the digit, at the distal interphalangeal joint (IPJ), the proximal interphalangeal joint (IPJ) either dorsal, medial, or lateral

### 10.6.2 Post Operative Bandaging

Minimal invasive procedures by design are very atraumatic with minimal amount of soft tissue disruption. Although internal fixation is not required, external splinting is required to maintain the correction and enable the patient to bare weight.

Post operative dressings in minimal invasive foot surgery should stabilize the surgical site in its correct position, be comfortable to the patient and easy to apply and while maintaining a sterile barrier.

My post operative dressings present in phases. The first phase represents the type of dressing used during the first post operative 3 days. These dressings are applied by the surgeon.

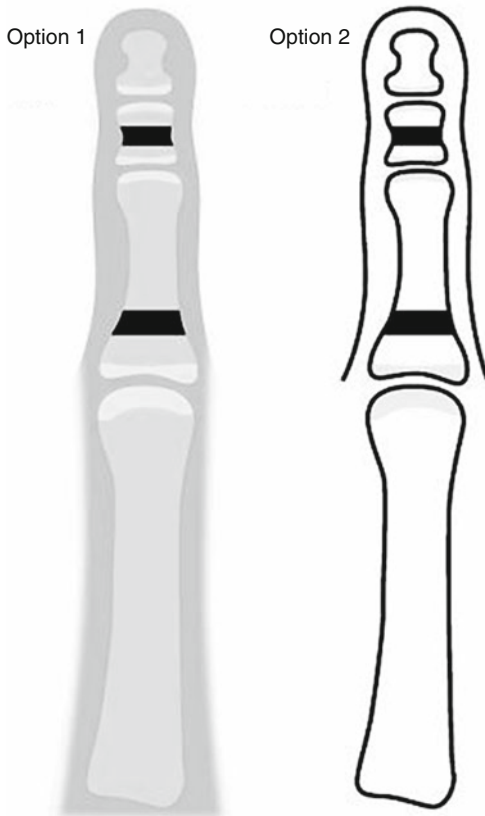


FIGURE 10.11 A shortening osteotomy procedure may be performed in a congenitally long digit that has no deformity factors at either the interphalangeal joint (*IPJ*) or metatarsal phalangeal joint (*MPJ*)

The second phase of the dressings are splint dressings that are used for the following 2 weeks. Figure 10.13a–c represents phase one dressing and (Fig. 10.14a, b) represents phase two dressing. The phase two dressings are initially applied by the surgeon and changed daily by the patients after they have been instructed in their application. Bathing is permitted on a daily basis after the first post operative week if the incisions are healed.

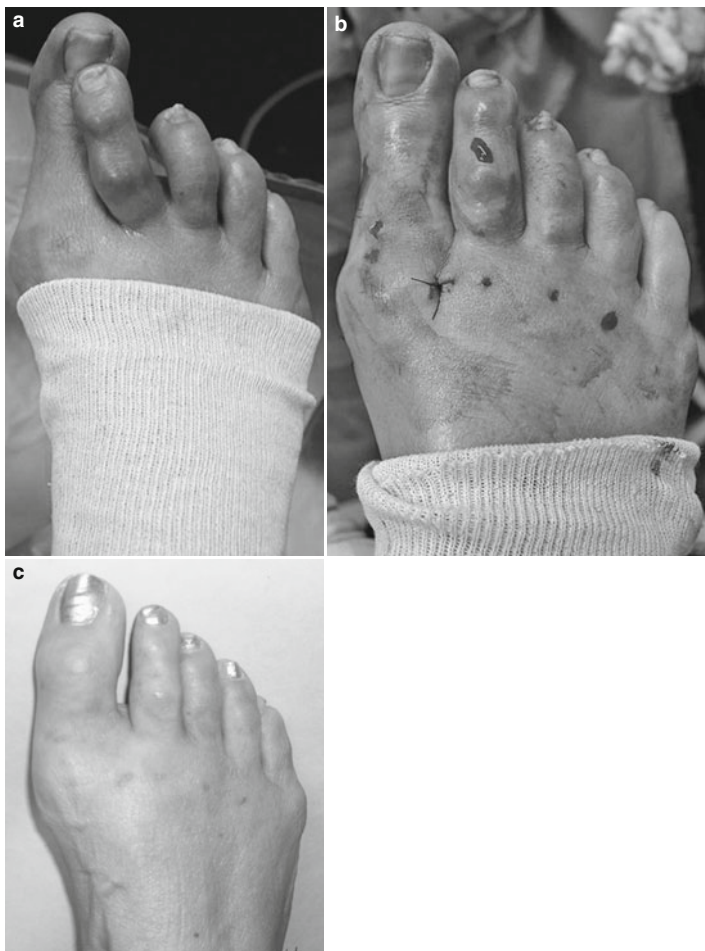

FIGURE 10.12 Combination osteotomy on the proximal and middle phalanges can be performed to correct most hammertoe deformities. The combination osteotomy allows to correct the deformity and reposition the digit in its correct position: pre-operative, post-operative and 19 weeks post-operative.

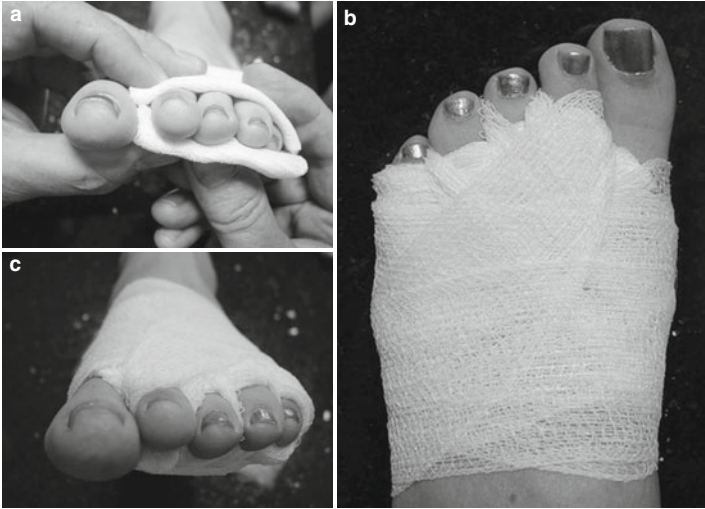


FIGURE 10.13 Post-operative dressings present in phases: the first phase represents the type of dressing used during the first post-operative 3 days

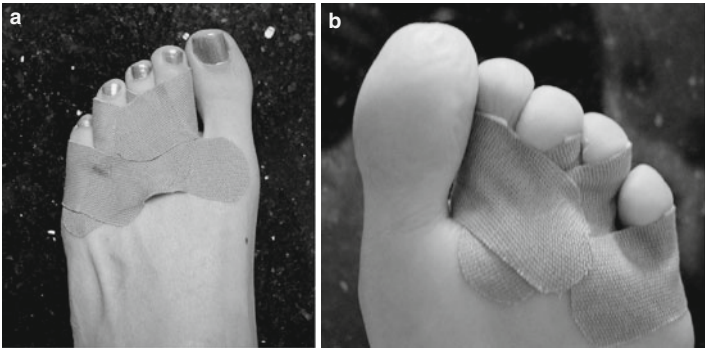


FIGURE 10.14 Post-operative dressings present in phases: the second phase of the dressings are splint dressings that are used for the following 2 weeks

### Advantages of the Isham Hammertoe Procedures

- Good healing due to minimal soft tissue trauma.
- Minimal fixation required because the procedure is minimally traumatic and neurovascular structures are intact resulting in shortened healing time.
- Tri-plane correction of the structural deformity is provided.
- Minimal amount of post-operative complication and disability. The patient remains ambulatory and productive.

### Disadvantages of the Isham Hammertoe Procedures

- Limitation of flexion at the proximal interphalangeal joint (IPJ) occurs in approximately 20 % of the procedures performed; this is associated with fibrous adhesions around the joint structures. These are almost always asymptomatic and do not interfere with normal function during gait.
- Failure to adequately release the soft tissue structures in semi-rigid and rigid deformities may result in telescoping of the osseous segments at the osteotomy site. This will result in slower healing times and possibly malposition or malunion at the osteotomy site.
- Fibrous clinical union occurs quite rapidly in less than 3 weeks at the osteotomy sites. However, due to lack of highly vascularized soft tissue structures bony ossification is approximately twice as long as with metatarsal osteotomies. This is an asymptomatic finding.
- The goal of the procedure is to functionally realign the osseous segment and not realign the osseous segment anatomically. Should symptomatic failure of the procedure occur, then a traditional or Minimal Invasive Arthroplasty or partial head resection may be performed using percutaneous procedures.

## 10.7 Summary

Correction of lesser digital deformities using percutaneous procedures using exostectomy but primarily combination osteotomies with soft tissue releases correct the vast majority

of digital pathology. These procedures are very conservative however, and should we have a rare failure, the use of traditional hammertoe procedures would be a viable option. In most cases, however, a repetition or modification of the original Isham Hammertoe Procedure is effective.

## Bibliography

Akin OF. The treatment of hallux valgus: a new operative and its results. *Med Sent.* 1925;33:678–9.

Collof B, Weitz EN. Proximal phalangeal osteotomy and hallux valgus. *Clin Orthop.* 1967;54:105.

De Prado M, Ripoll P, Golano P. *Cirugia percutanea del pie.* Barcelona: Masson; 2003.

Funk JF, Wells R. Bunionectomy with distal osteotomy. *Clin Orthop Relat Res.* 1972.

Garcia NE. *Techniques of minimal incision.* Madrid: Mileto Ediciones; 2004.

Garcia NE. *Estructuras Anatomicas Implicadas en la Practica de la Cirugia de Minima Incision del Pie.* Barcelona: Editorial Glosa, S.L; 2009.

Gerbert J. *Textbook of bunion surgery.* Mount Kisco/New York: Futura Publishing Co; 1981.

Gerbert J, Mercado OA, Sokoloff TH. The surgical treatment of hallux abducto-valgus and allied deformities. In: Fielding MD, editor. *Podiatric medicine and surgery: monograph series.* Mount Kisco/New York: Futura Publishing; 1973.

Gorman J, Plon M. Minimal incision surgery and laser surgery in podiatry. 1983.

Isham SA. The Reverdin-Isham procedure for the correction of hallux abducto-valgus. *Curr Podiatr Med.* 1985;7:11–3.

Kelikian H. *Hallux valgus, allied deformities of the forefoot and metatarsalgia.* Philadelphia: W.B. Saunders Co.; 1965.

Peabody CW. Surgical cure of hallux valgus. *J Bone Joint Surg.* 1931;13a:273.

Podiatrics Sino-American Conference on Foot Disorders. October, 1987, Beijing.

Sanchez Pulgar JA. *El Tratamiento Percutaneo Del Hallux Valgus Con La Tecnica De Reverdin-Isham.* Tesis Doctoral; 2007.

Teatino JA. Cirugia por minima incision en los dedos medios-(II). Podoscopio 2 Epoca. 1995;I(21).

Teatino JA. Cirugia por minima incision en los dedos medios-(III). Podoscopio 2 Epoca. 1995;I(22).

Teatino JA. Cirugia por minima incision en los dedos medios-I. Podoscopio 2 Epoca. 1995;I(20).

Viladot A. Deformaciones de los dedos. Patologia del antepie. Capitulo X, 1984;181-9.

Watson A, Anderson R, Hodges W. Deformaciones de los dedos menores. In: Kelikian AS, editor. Tratamiento quirurgico de pie y tobillo. Cap 8. Madrid: McGraw-Hill Interamericana; 1999. p. 97-113.



# Chapter 11

## Minimally Invasive Management of Dorsiflexion Contracture at the Metatarsophalangeal Joint and Plantarflexion Contracture at the Proximal Interphalangeal Joint of the Fifth Toe

**Mariano de Prado, Pedro-Luis Ripoll, Pau Golanó, Javier Vaquero, Filippo Spiezia, and Nicola Maffulli**

---

M. de Prado, M.D. (✉) • P. Ripoll, M.D.  
Department of Orthopaedics, Hospital USP San Carlos,  
Murcia, Spain  
e-mail: deprado@hospitalsancarlos.net

P. Golanó, M.D.  
Department of Pathology and Experimental Therapeutics  
(Human Anatomy Unit), Universidad de Barcelona,  
Barcelona, Spain

J. Vaquero, M.D., Ph.D.  
Department of Orthopaedics,  
Hospital General Universitario Gregorio Marañón,  
Madrid, Spain

F. Spiezia, M.D.

Department of Orthopaedic and Trauma Surgery,  
Campus Biomedico University,  
Via Alvaro del Portillo Trigatoria, Rome, Italy

N. Maffulli, M.D., Ph.D., FRCS (Orth)

Centre for Sports and Exercise Medicine,  
Barts and The London School of Medicine and Dentistry,  
Mile End Hospital,  
London, UK

## 11.1 Introduction

Surgical management of persistent dorsiflexion contracture at the metatarsophalangeal joint and plantarflexion contracture at the proximal interphalangeal joint of the fifth toe is indicated in patients with marked rigidity and pain, following failure of conservative management with appropriate orthoses and shoes with a wide toe box.

In this chapter we describe procedure of Augustine and Jacobs [1] to correct this deformity of the fifth toe using a minimally invasive approach. This technique consists of a plantar closing wedge osteotomy of the fifth toe at the base of its proximal phalanx associated with an exostosectomy of the head of the proximal phalanx and at the base of the middle phalanx. Lastly, a complete tenotomy of the deep and superficial flexor tendons and of the tendon of the extensor digitorum longus is undertaken (Fig. 11.1a, b).

## 11.2 Surgical Technique

The procedure can be performed under regional nerve block either at the level of the ankle or of the fifth metatarsal. The patient is supine with the foot to be operated overhanging the end of the operating table. It is not necessary to use a tourniquet.

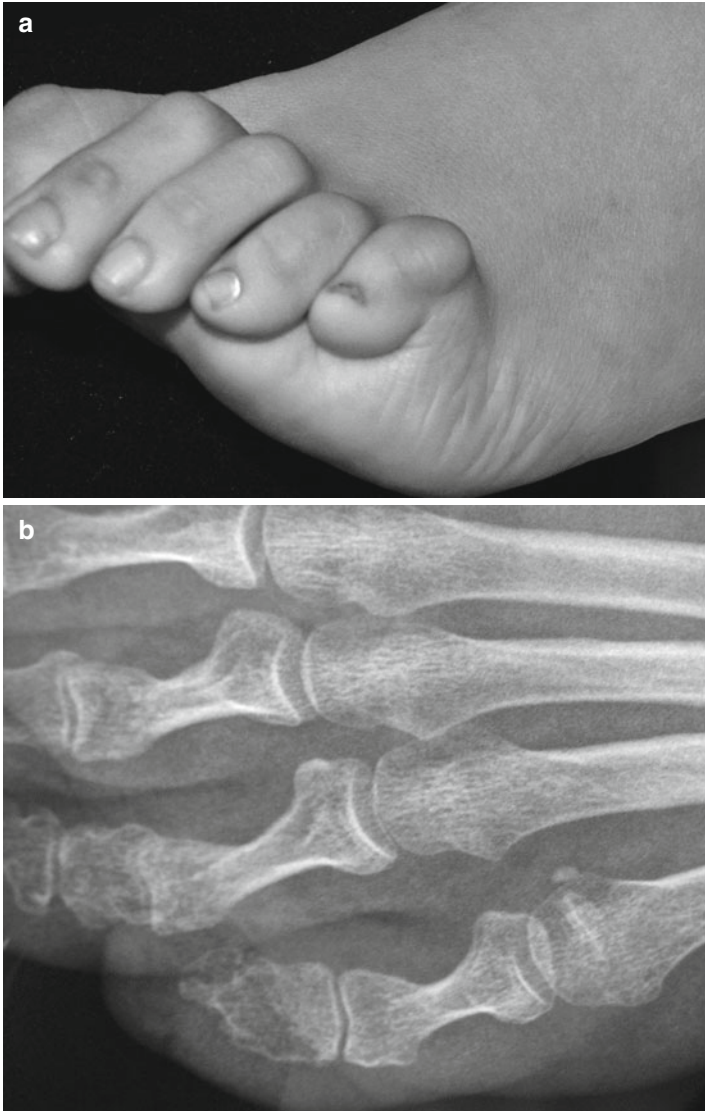


FIGURE 11.1 (a) Clinical and (b) radiographical appearance 12 months after the procedure, showing stable correction of the deformity

1. Tenotomy of the tendon of extensor digitorum longus to the fifth toe

A 2 mm incision is performed just above the extensor tendon and parallel to it at the level of the metatarsophalangeal joint. The patient is then asked to extend the fifth toe, allowing to better locate the tendon, which is fully tenotomised (Fig. 11.2a, b).

2. Dorsal metatarsophalangeal capsulotomy

In patients with severe rigidity, capsulotomy of the metatarsophalangeal joint is performed, releasing only the superior portion of the capsule and the extensor sling. Correction of the hyperextension is remarkable.

3. Lateral condylectomy

If the hyper-flexion of the interphalangeal joints is difficult to correct, there often is an exostosis at the lateral condyle of the proximal phalanx of the fifth toes and at the base of the middle phalanx. If this is the case, a lateral condylectomy is indicated. A 2 mm incision is made over the dorso-lateral aspect of the fifth toe. The blade is introduced until it touches the underlying bone. The periosteum is detached from the bone with a rasp, and the exostosis is removed with the short Shannon 44 burr (Fig. 11.3a, b) at slow speed with gentle oscillating movements.

4. Tenotomy of the flexor tendons

A 2 mm incision is performed just proximal to the plantar fold of the toe, just medial to the toe itself. The surgeon extends the fifth toe to tense the flexor tendon, which is severed with the tip of the scalpel. It should then be possible to appreciate the loss of resistance to extension in the proximal and distal interphalangeal joints.

5. Osteotomy of the proximal phalanx

A rasp is introduced through the same incision used for the tenotomy of the flexor tendons, and the periosteum is detached from the lateral aspect of the phalanx. A plantar based closing wedge osteotomy is performed (Fig. 11.4a, b) using the short Shannon 44 burr. Complete correction of deformity is thereby achieved (Fig. 11.5a, b).

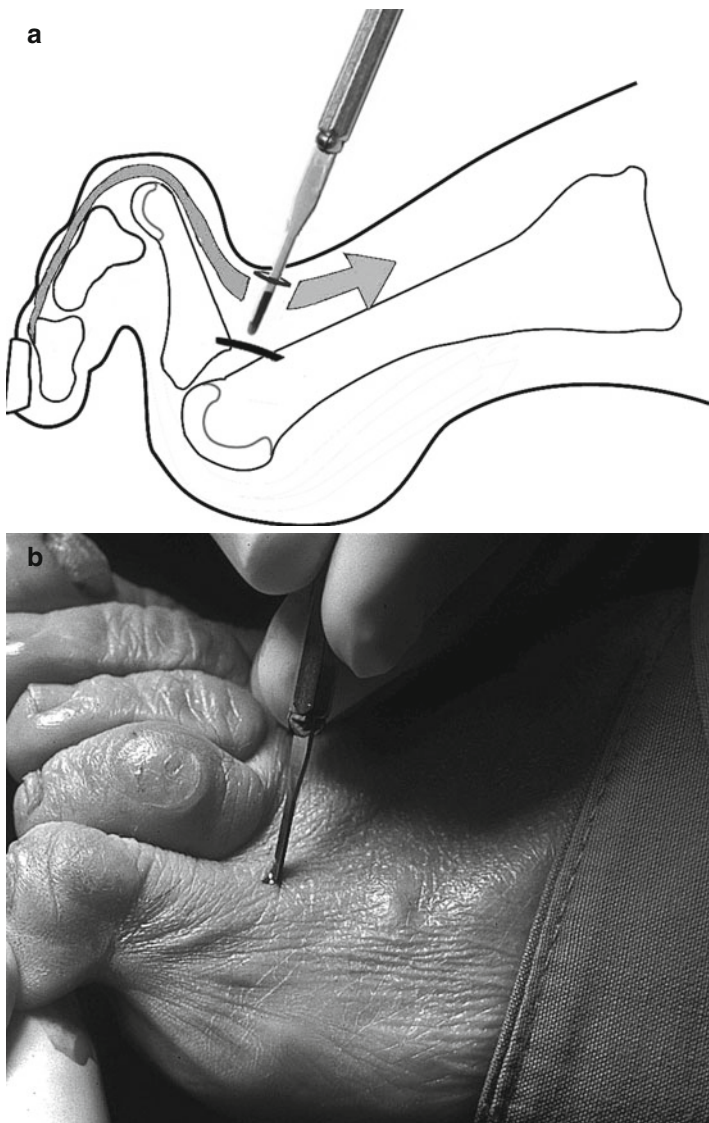


FIGURE 11.2 (a) Schematic representation, and (b) and clinical picture of the tenotomy of the tendon of extensor digitorum longus through a 2 mm incision

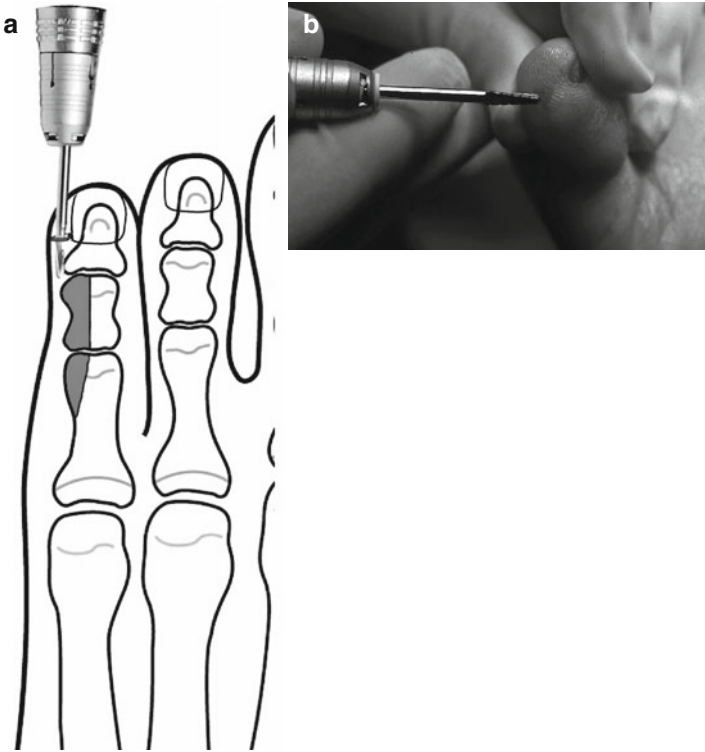


FIGURE 11.3 (a) Schematic representation, and (b) clinical picture of the condylectomy performed with a short Shannon 44 drill using a 2 mm lateral approach

The skin is sutured using a 4.0 monofilament suture. A bandage is put in place placing a strip of gauze to keep the proximal phalanx of the fifth toe in flexion. Another strip of gauze is applied to keep the interphalangeal joint in extension. Both dressings are joined by a bandage placed behind the interdigital pleats acting as a metatarsal spacer.

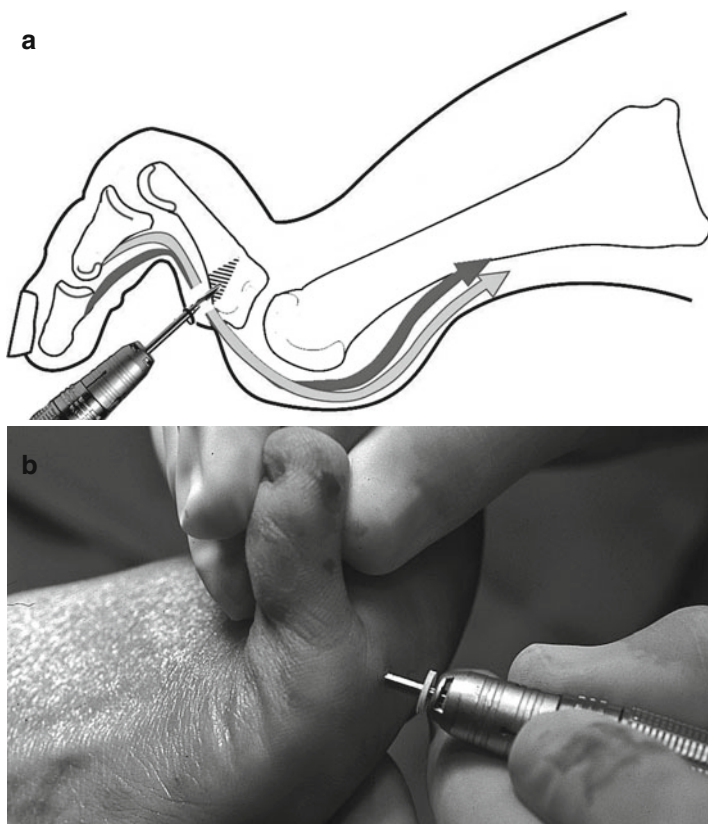


FIGURE 11.4 (a) Schematic representation, and (b) clinical picture of the plantar based closing wedge osteotomy at the base of the proximal phalanx to correct the hyperextension deformity

### 11.3 Postoperative Management

Immediate mobilization is encouraged, wearing an orthopedic shoe for 7 days, when the stitches are removed and an adhesive bandage put in place, taking care to keep the deformity reduced. Patients are taught how to change the bandage,

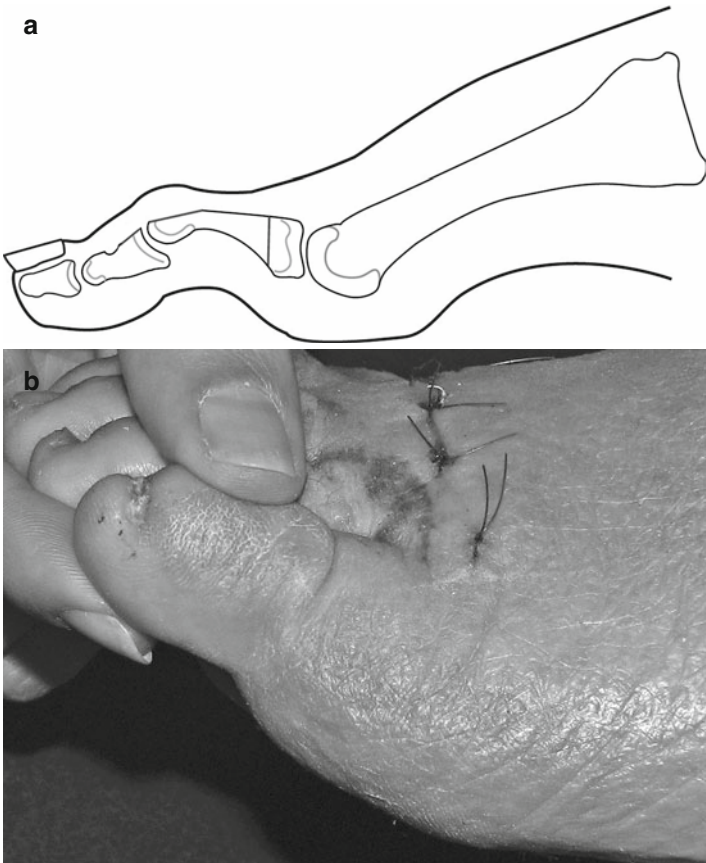


FIGURE 11.5 (a) Schematic representation, and (b) clinical picture of the correction obtained

and told to change it every day after washing the foot for the following 6 weeks.

Around that time, complete consolidation of the osteotomies is achieved and the use of comfortable footwear is recommended.



## 11.4 Discussion

Several surgical options have been described to manage persistent dorsiflexion contracture at the metatarsophalangeal joint and plantarflexion contracture at the proximal interphalangeal joint of the fifth toe.

This technique consists in a plantar closing wedge osteotomy of the fifth toe at the base of its proximal phalanx associated with a lateral condylectomy of the head of the proximal phalanx and at the base of the middle phalanx. Lastly, a complete tenotomy of the deep and superficial flexor tendons and of the tendon of the extensor digitorum longus is undertaken.

Possible complications of this procedure are iatrogenic bunionette, a floppy toe, extensive shortening of the fifth toe and subsequent hammertoe deformity of the fourth toe. In addition, some techniques involve the excision of an elliptical portion of the plantar skin is excised, a possible cause of vascular impairment of the fifth toe and hypertrophic scarring [2, 3].

This technique permits correction of the deformity using a minimally invasive approach without interfering with the joint surface and producing only minimal shortening of the fifth toe, and no vascular or skin compromise (Fig. 11.6).

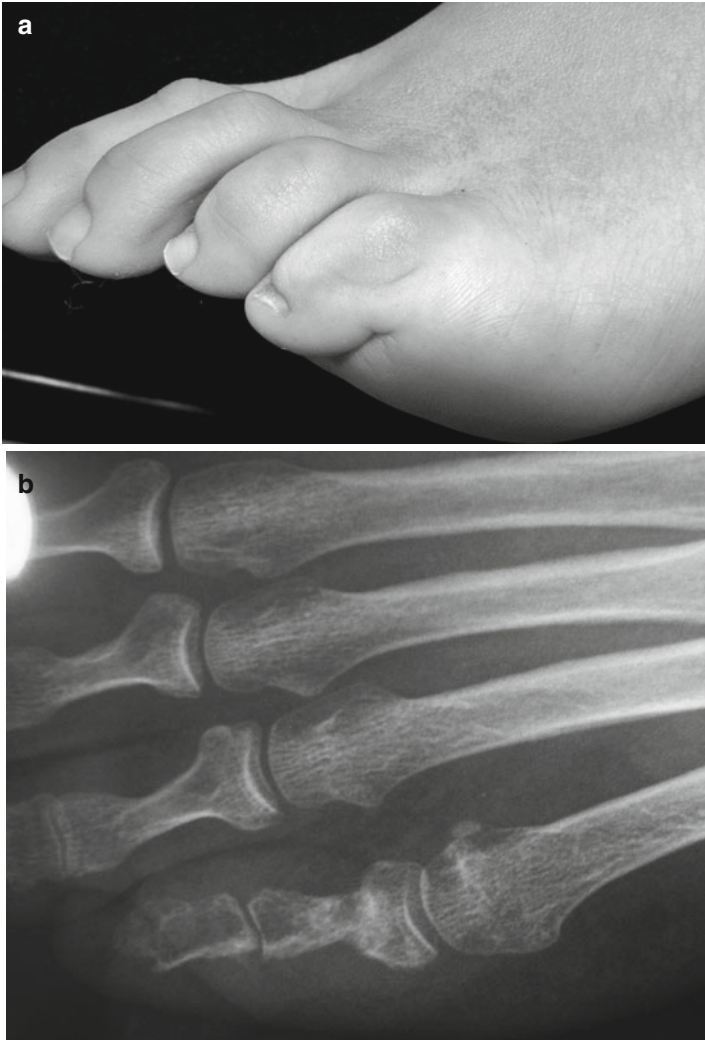


FIGURE 11.6 (a) Clinical and (b) radiographical appearance of cock-up deformity of the fifth toe. Note the dorsiflexion of the metatarsophalangeal joint and the flexion of the interphalangeal joint

## References

1. Augustine DF, Jacobs JF. Restoration of toe function with minimal traumatic procedures including advanced diaphysectomy. *Clin Podiatry*. 1985;2:457-70.
2. Dyal CM, Davis WH, Thompson FM, et al. Clinical evaluation of the Ruiz-Mora procedure: long-term follow-up. *Foot Ankle Int*. 1997;18:94-7.
3. Janecki Jr CJ. Triggering of the finger caused by flexor-tendon laceration. *J Bone Joint Surg Am*. 1976;58:1174-5.

# Chapter 12

## Arthroscopic Assisted Correction of Lesser Toe Deformity

**Tun Hing Lui**

### 12.1 Introduction

Claw toe deformity is common. Hyperextension of the metatarsophalangeal joint is the key component of this deformity. The proximal and distal interphalangeal joints remain flexed. The plantar plate is one of the structures responsible for the stability of the metatarsophalangeal joint [1–4]. The plantar plate experiences extension forces imposed by toe-off. The weak attachment of the plantar plate at the metatarsal neck attenuates or ruptures, allowing the plate to subluxate distally and dorsally, until rupture of the thin proximal synovial attachment occurs and the metatarsophalangeal joint dislocates. The intrinsic axis alters and the intrinsic muscles fail to act as efficient flexors of the metatarsophalangeal joint [5–7]. Painful callosity of the overlying the proximal interphalangeal joint and beneath the metatarsal head are thus presentation. Conservative management consists of taping, padding, footwear modification or insoles. All may help to relieve the symptoms, but do not correct the deformity. Surgical options can be divided into soft tissue [8–12] and bony [13–17] procedures. Flexor tendon transfer has been reported as the most consistently successful treatment in stabilizing the metatarsophalangeal joint and

---

T.H. Lui, MBBS (HK), FRCS (Edin), FHKAM, FHKCOS  
Department of Orthopaedics and Traumatology, North District Hospital,  
9 Po Kin Road, Sheung Shui, NT, Hong Kong SAR, China  
e-mail: luithderek@yahoo.co.uk

N. Maffulli, M. Easley (eds.), *Minimally Invasive Forefoot Surgery in Clinical Practice*, DOI 10.1007/978-1-4471-4489-2\_12, © Springer-Verlag London 2013

correcting the flexible claw toe deformity. It works as a static tenodesis. However, the function of the tendon of flexor digitorum longus is lost and patient satisfaction has been limited due to stiffness and residual discomfort at the metatarsophalangeal joint. A shortening osteotomy, such as Weil's osteotomy, can be another option. It is indicated if the joint cannot be adequately decompressed by soft tissue release. However, a stiff toe commonly results. Resection arthroplasty or arthrodesis will result in loss of the joint integrity. Plantar plate tenodesis tackles the primary pathology of plantar plate attenuation. Postoperative stiffness and discomfort should be less of a factor if the stabilization is addressed at the level of the plantar plate rather than performing a tendon transfer [18]. Moreover, early toe mobilization is allowed and this can minimize the risk of toe stiffness.

In claw toe deformity, the attenuation or rupture of the plantar plate is usually at the proximal end or the middle grooved area, while the phalangeal insertion is usually intact. We anchor the distal central part of the plantar plate and suture to the extensor digitorum longus tendon in figure of eight pattern. By this configuration, the middle central grooved area is closed up and the plantar plate is shifted proximally to its proximal insertion. Moreover, the tension produced by the extensor digitorum longus is redirected plantarward to move the plantar plate and the proximal phalanx proximally. The tension of the extensor digitorum longus distal to the suture is relieved. This, together with the arthroscopic dorsal capsular release, will release the hyperextension deforming force of the metatarsophalangeal joint. The joint is kept in neutral and the interosseous tendons become plantar to the axis of rotation of the metatarsal head. The intrinsic minus toe will then be corrected [19, 20].

In overriding toe deformity, there is medial deviation deformity of the toe in addition to the sagittal plane deformity of claw toe. Both the plantar plate and the collateral ligaments are involved. The plantar plate is deformed and displaced dorsomedially and the flexor tendons are medially displaced [21]. Under direct arthroscopic guidance, the

contracted medial capsule and collateral ligament are released, and the lateral capsule is plicated. With the flexor tendon sheath attachment to the plantar plate, release of the collateral ligament will not recenter the subluxed plate and pull the flexor tendons back into alignment [21]. The figure of eight configuration of the “plantar plate tenodesis” suture will realign and centralize the plantar plate to the longitudinal axis of the metatarsal. Hopefully, this will reduce the risk of recurrence of the overriding toe deformity.

This procedure is indicated in case of claw toe or overriding toe deformity without complete dislocation of the metatarsophalangeal joint. It is contraindicated in patients in whom the plantar plate is attenuated at the phalangeal insertion, in rigid deformity, in the presence of arthrosis of the involved metatarsophalangeal joint, or deformity resulting from a neuromuscular condition or polyarthritis. It is relatively contraindicated in lateral deviation deformity of the second toe and overriding toe with predominant medial deviation deformity. In case of lateral deviation deformity, we use the extensor digitorum brevis tendon graft to reconstruct the medial collateral ligament of the second metatarsophalangeal joint. Modified extensor digitorum brevis transfer [22] is the treatment of choice to correct the transverse plane deformity in patients with overriding toe predominant medial deviation deformity and mild clawed toe component.

Potential problems include digital nerve injury, tethering of the flexor tendon by the suture or the weakening of the suture by the hemostat. The hemostat should stay subperiosteally and deep to the flexor tendon and the segment of the suture that was crushed by the hemostat should not be left in the figure of eight construct.

### *12.1.1 Technique of Plantar Plate Tenodesis*

The patient is positioned supine, with a pneumatic tourniquet applied to the thigh. Metatarsophalangeal arthroscopy is performed through the dorsomedial and dorsolateral portals at

the medial and lateral sides of the extensor tendons. The metatarsophalangeal joint is then examined with a 1.9 mm 30° arthroscope. Intra-articular pathology can be addressed. The distal part of the plantar plate can be examined. Plantar plate tenodesis can be performed if the phalangeal insertion of the plantar plate is intact. The dorsal capsule is stripped from the metatarsal neck with a small soft tissue stripper (Kokubun dissector) under arthroscopic guidance (Fig. 12.1).

In case of overriding toe deformity, the medial capsule and the medial collateral ligament are stripped from the medial side of the metatarsal head under arthroscopic guidance.

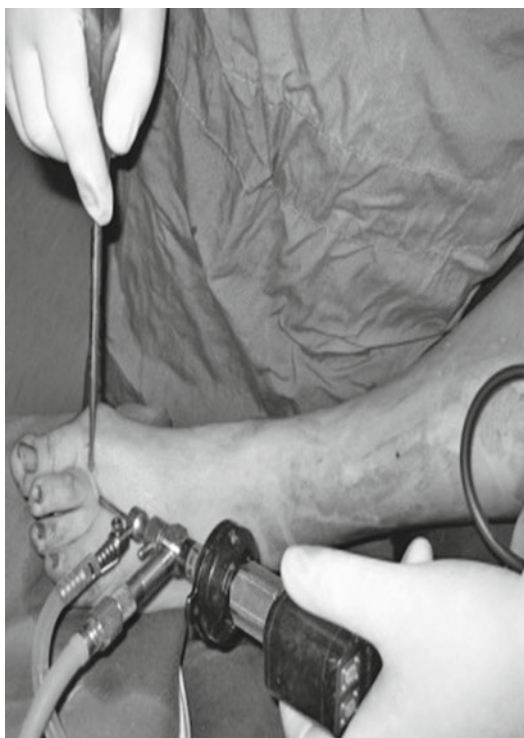

FIGURE 12.1 The dorsal capsule is stripped from the metatarsal neck with a small soft tissue stripper (Kokubun dissector) under arthroscopic guidance

With the arthroscope in the dorsolateral portal, a PDS 1 suture is passed through the medial part of the plantar plate with a straight eyed needle. The needle should be pointed slightly towards the midline of the joint just after the penetration of plantar plate to ensure the suture is kept within the boundary of the fibrous flexor tendon sheath. Finally, the needle is passed through the skin of the plantar aspect of the toe (Fig. 12.2).

The suture is then retrieved from the plantar surface of plantar plate through the lateral side of the metatarsal to a proximal dorsal wound with a curved hemostat at the level of mid shaft of the second metatarsal (Fig. 12.3).

The other limb of the suture is passed from the dorsomedial portal to the dorsolateral portal deep inside the joint (Fig. 12.4).

The suture is then passed through the lateral part of the plantar plate via the dorsolateral portal with the arthroscope in the dorsomedial portal. The suture is then retrieved through the medial side of the metatarsal to the proximal wound. It is important to maintain a loop of suture so that tension can be applied to the suture to aid the retrieval of the suture to the proximal wound (Fig. 12.5).

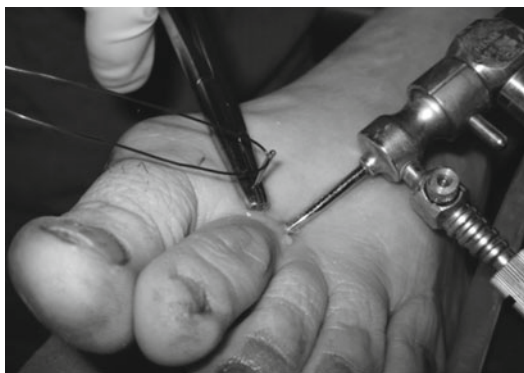

FIGURE 12.2 With the arthroscope in the dorsolateral portal, a PDS 1 suture is passed through the medial part of the plantar plate with a straight needle



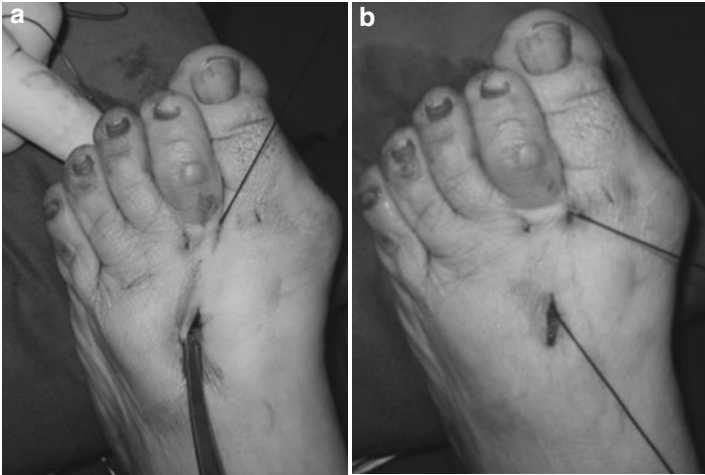


FIGURE 12.3 (a, b) The retrieval of suture to the proximal wound

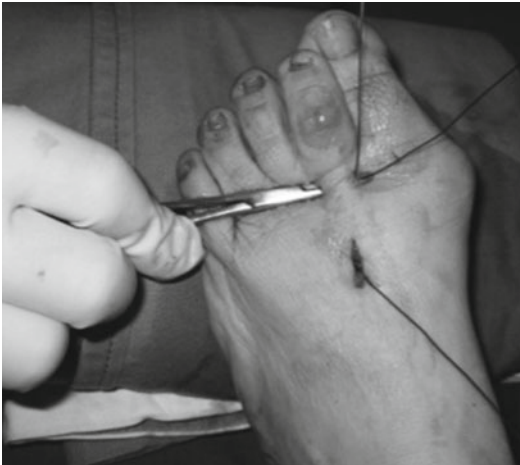

FIGURE 12.4 The suture is retrieved to the dorsolateral portal

The suture is anchored to the extensor digitorum longus tendon to the affected toe. Then a figure of 8 configuration of suture connecting plantar plate to extensor digitorum longus

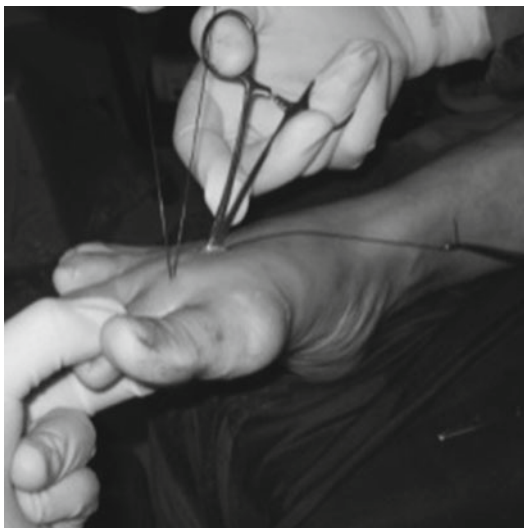

FIGURE 12.5 The suture is then retrieved through the medial side of the metatarsal to the proximal wound. It is important to maintain a loop of suture so that tension can be applied to the suture to aid the retrieval of the suture to the proximal wound

is constructed. The suture is then tensioned with the ankle in neutral, so that the affected metatarsophalangeal joint is reduced spontaneously, and suture is tied over the long extensor tendon.

In case of overriding toe correction, the lateral capsule of the metatarsophalangeal joint is plicated with a PDS 1 suture in a figure of eight pattern. The distal limb of the figure of eight suture is inserted close to the base of proximal phalanx through the dorsolateral portal with the arthroscope in the dorsomedial portal. The distal limb of the figure of eight is inserted close to the metatarsal head origin of the medial collateral ligament and exit through the proximal wound. The suture is then retrieved back to the dorsolateral portal. It is important to tension the “plantar plate tenodesis” suture before the lateral capsule suture is tied. This can prevent the correction of medial

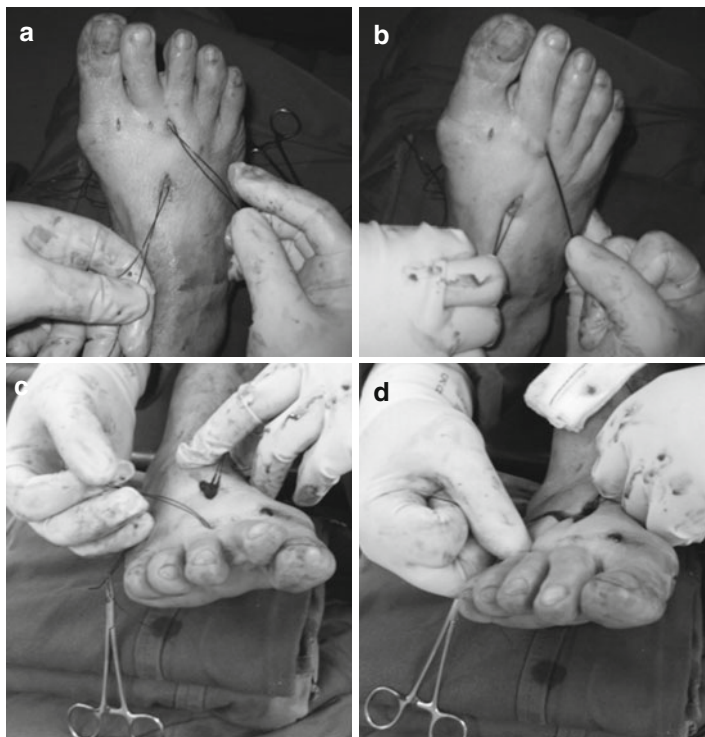


FIGURE 12.6 (a–d) the overriding toe deformity can be corrected by tensioning of the lateral placcation suture and the plantar plate tenodesis suture

deviation deformity with the toe in hyperextension position. Finally, fine adjustment of tension of the “plantar plate tenodesis” suture and tired over the long extensor tendon to achieve full correction of the overriding toe deformity (Fig. 12.6).

The day after the operation, patients are advised on active toe mobilization and passive plantar mobilization of the affected metatarsophalangeal joint. Weight bearing walking with post-operative sandal is allowed.

## 12.2 Modified Plantar Plate Tenodesis

Because of the confined space of the fibrous flexor tendon sheath and the presence of the flexor tendons within the sheath, it can be difficult to retrieve the suture at the surface of the plantar plate. Extensive blunt dissection may be needed to retrieve the suture. This may disrupt the extra-osseous arterial blood supply to the metatarsal head [23, 24].

### 12.2.1 *Technique*

Dorsomedial and dorsolateral stab wounds are produced at the sides of the extensor tendon at the level of the joint line of the second metatarsophalangeal joint. The dorsal capsule is stripped from the metatarsal neck with a small periosteal elevator. A PDS 1 suture is passed through the lateral part of the plantar plate with a straight needle through the dorsolateral wound. The needle should point slightly away from the midline of the joint to avoid the pass the suture through the flexor tendon. Finally, the needle pieces through the fibrous flexor tendon sheath and the plantar skin. The second toe is dorsiflexed passively with the suture kept in tension to make sure that the suture has not tethered the flexor tendon. Another dorsal longitudinal incision is made at the level of mid shaft of the metatarsal. A curved hemostat is introduced on the medial side of the metatarsal to the plantar aspect of the distal portion of the metatarsal deep to the interosseous muscles and the flexor tendons, and then to the lateral side of the fibrous tendon sheath. The suture is kept in tension and the plantar skin together with the suture is squeezed from distal to proximal to bring the plantar segment of the suture proximally. This will allow easy retrieval of the suture to the dorsal wound without extensive plantar dissection. The other limb of the suture is passed from the dorsolateral wound to the dorsomedial wound and is then passed through the medial part of the plantar plate. The suture is retrieved

through the lateral side of the metatarsal to the proximal wound. It is important to maintain a loop of suture so that tension can be applied to the suture to aid the retrieval of the suture from the proximal wound.

The suture is sutured to the extensor digitorum longus tendon at the proximal dorsal wound. The suture is tensioned with the ankle in neutral, so that the affected metatarsophalangeal joint is reduced spontaneously, and suture is tied over the long extensor tendon. A figure of 8 configuration of suture connecting the plantar plate-flexor tendon sheath complex to extensor digitorum longus is constructed.

The postoperative rehabilitation is along the same lines described for the original technique.

## References

1. Deland JT, Lee KT, Sobei M, DiCarlo EF. Anatomy of the plantar plate and its attachments in the lesser metatarsal phalangeal joint. *Foot Ankle Int.* 1995;16:480-6.
2. Green DR, Brekke M. Anatomy, biomechanics and pathomechanics of lesser digital deformities. *Clin Podiatr Med Surg.* 1996;13:179-200.
3. Johnston RB, Smith J, Daniels T. The plantar plate of the lesser toes: an anatomical study in human cadavers. *Foot Ankle Int.* 1994;15:276-82.
4. Stainsby GD. Pathological anatomy and dynamic effect of the displaced plantar plate and the importance of the integrity of the plantar plate-deep transverse metatarsal ligament tie-bar. *Ann R Coll Surg Engl.* 1997;79:58-68.
5. Coughlin MJ. Subluxation and dislocation of the second metatarsophalangeal joint. *Orthop Clin North Am.* 1989;20:539-51.
6. Coughlin MJ. Crossover second toe deformity. *Foot Ankle.* 1987;8:29-39.
7. Coughlin MJ. Lesser toe deformities. *Orthopedics.* 1987;10:63-75.
8. Barbari SG, Brevig K. Correction of clawtoes by the Girdlestone-Taylor flexor-extensor transfer procedure. *Foot Ankle.* 1984;5:67-73.
9. Feeney MS, Williams RL, Stephens MM. Selected lengthening of the proximal flexor tendon in the management of acquired claw toes. *J Bone Joint Surg.* 2001;83B:335-8.
10. Frank GR, Johnson WM. The extensor shift procedure in the correction of clawtoe deformities in children. *South Med J.* 1966;59:889-96.

11. Kuwuda GT, Dockery GL. Modification of the flexor tendon transfer procedure for the correction of flexible hammertoes. *J Foot Surg.* 1980;19:38–40.
12. Thompson FM, Deland JT. Flexion tendon transfer for metatarsophalangeal instability of the second toe. *Foot Ankle.* 1993;14:385–8.
13. Berens TA. Laterally closing metatarsal head osteotomy in the correction of a medially overlapping digit. *Clin Podiatr Med Surg.* 1996;13:293–307.
14. Caterini R, Farsetti P, Tatantino U, Potenza V, Ippolito E. Arthrodesis of the toe joints with an intramedullary cannulated screw for correction of hammertoe deformity. *Foot Ankle Int.* 2004;25:256–61.
15. Karlock LG. Second metatarsophalangeal joint fusion: a new technique for crossover hammertoe deformity. A preliminary report. *J Foot Ankle Surg.* 2003;42:178–82.
16. O’Kane C, Kilmartin T. Review of proximal interphalangeal joint excisional arthroplasty for the correction of second hammer toe deformity in 100 cases. *Foot Ankle Int.* 2005;26:320–5.
17. Miller SJ. Hammer toe correction by arthrodesis of the proximal interphalangeal joint using a cortical bone allograft pin. *J Am Podiatr Med Assoc.* 2002;92:563–9.
18. Ford LA, Collins KB, Christensen JC. Stabilization of the subluxed second metatarsophalangeal joint: flexor tendon transfer versus primary repair of the plantar plate. *J Foot Ankle Surg.* 1998;37:217–22.
19. Lui TH. Arthroscopic-assisted correction of claw toe or overriding toe deformity: plantar plate tenodesis. *Arch Orthop Trauma Surg.* 2007;127:855–7.
20. Lui TH. Current concept: arthroscopy and endoscopy of the foot and ankle: indications for new techniques. *Arthroscopy.* 2007;23:889–902.
21. Deland JT, Sung II-H. The medial crossover toe: a cadaveric dissection. *Foot Ankle Int.* 2000;21:375–8.
22. Lui TH, Chan KB. Modified extensor digitorum brevis tendon transfer for crossover second toe correction. *Foot Ankle Int.* 2007;28:521–3.
23. Bayliss NC, Klenerman L. Avascular necrosis of lesser metatarsal heads following forefoot surgery. *Foot Ankle Int.* 1989;10:124–8.
24. Peterson WJ, Lankes JM, Paulsen F, Hassenpflug J. The arterial supply of the lesser metatarsal heads: a vascular injection study in human cadavers. *Foot Ankle Int.* 2002;23:491–5.

# Chapter 13

## Percutaneous Fixation of Proximal Fifth Metatarsal Fractures

**Aaron T. Scott and James A. NunleyII**

### 13.1 Introduction

Fractures of the fifth metatarsal base have garnered a significant amount of attention since Sir Robert Jones' classic description of his own such fracture suffered while dancing [10]. Despite numerous publications on the topic, controversy continues to exist regarding nomenclature, classification, indications for surgery, and optimal surgical technique.

Stewart is credited with publishing the first anatomic classification scheme [30], but the three zone classification system devised by Lawrence and Botte [16] is currently the most commonly cited anatomic classification system for proximal fifth metatarsal fractures (Fig. 13.1). In this system, Zone I injuries are tuberosity avulsion fractures. Zone II injuries are considered "true Jones fractures", and have previously been defined by Stewart [30] as transverse fractures occurring at the level of the metaphyseal-diaphyseal junction with medial extension of the fracture line into the fourth-fifth

---

A.T. Scott, M.D. (✉)

Department of Orthopaedic Surgery,  
Wake Forest University, Baptist Medical Center,  
Winston-Salem, NC, USA  
e-mail: aascott@wfubmc.edu

J.A. NunleyII, M.D.

Department of Orthopaedic Surgery,  
Duke University Medical Center, Durham, NC, USA

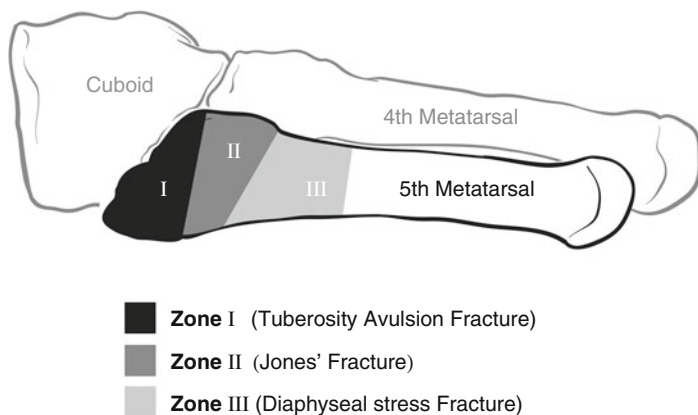


FIGURE 13.1 Lawrence and Botte classification of proximal fifth metatarsal fractures

intermetatarsal joint. The third zone in this classification is represented by the proximal diaphyseal stress fracture. In yet another classification system, Torg et al. [31] used radiographic criteria to divide fractures distal to the tuberosity into acute fractures, delayed unions, and non-unions. Acute fractures displayed a narrow fracture line and no intramedullary sclerosis, delayed unions a widened fracture line and a variable degree of intramedullary sclerosis, while the nonunions were characterized by a complete obliteration of the medullary canal. This radiographic classification has prognostic implication, and when combined with the anatomic classification of Lawrence and Botte, provides a basis for treatment recommendations [24].

Lewis Carp in 1927 was the first to describe the fifth metatarsal's propensity for problematic healing when he reported four nonunions in his subset of 12 fifth metatarsal base fractures that returned for follow-up, a finding that he attributed to this bone's tenuous blood supply [2]. Although Stewart [30] was the first to suggest a differing prognosis for tuberosity avulsion fractures and true Jones fractures, Dameron [5] is credited with presenting the first large series of fifth metatarsal fractures that showed a clear-cut difference in healing



rates based on anatomic location (in fractures treated non-operatively). Of the 100 tuberosity fractures in this series, all but one demonstrated a radiographic union at final follow-up and even this nonunion was asymptomatic. In contrast to the overwhelmingly successful non-operative treatment of tuberosity fractures, Dameron observed five nonunions in the 20 patients who were treated conservatively for fractures occurring within the proximal 1.5 cm of the shaft. In addition to these five nonunions which were later treated surgically, three other patients in this group required greater than 12 months to achieve osseous union radiographically. Unacceptably high rates of delayed unions and nonunions following the conservative management of fractures distal to the tuberosity have also been reported by Clapper et al. [4], Zelko et al. [36], Josefsson et al. [11], and Kavanaugh et al. [12]. When successful union has been achieved with conservative measures, it has been done so in the setting of acute fractures with a non-weightbearing regimen [31], or with weightbearing at the expense of time (average 3.5 months for bony union in Zone II injuries and 4.8 months for Zone III fractures in a retrospective study by Konkkel et al. [14]). These results have provided the impetus for the surgical management of fifth metatarsal base fractures in select circumstances.

A variety of methods have been used in the surgical management of acute and chronic fifth metatarsal base fractures, including open pinning [30], percutaneous pinning [1], tension band wiring [27], inlay bone grafting [17, 31], sliding bone grafts [5], and intramedullary screw fixation [7, 8, 11, 12, 15, 18–20, 22–26, 32, 35]. Kavanaugh et al. [12] were the first to advocate intramedullary screw fixation in competitive athletes and in non-athletes with delayed unions or re-fracture following non-operative management. In their 13 patients who underwent this procedure, there was a 100 % union rate and no re-fractures at a mean follow-up of 3.5 years. Lending further support to this method of treatment, DeLee et al. [7] used a percutaneous intramedullary screw in the treatment of ten athletes with fifth metatarsal stress fractures. In these patients, they were able to achieve clinical union, radiographic union, and return to sports at 4.5, 7.5, and 8.5 weeks, respectively.

There were no refractures or nonunions, and pain at the screw head or metatarsal head in seven of the ten patients was successfully managed with local shoe modifications. Other authors [18, 21–23] have reported similar rates of success with clinical and radiographic union rates approaching 100 %, early return to sports, and no re-fractures.

Despite the success of intramedullary screw fixation, re-fractures, delayed unions, and nonunions [8, 15, 35] have been reported and have prompted a closer look at screw diameter, screw type, and post-operative protocols. Wright et al. [35] presented six re-fractures following intramedullary screw fixation and found that all of their re-fractures occurred in patients who were fixed with screws with a diameters of 4.5 mm or less. In a retrospective review, Larson et al. [15] noted four re-fractures and two symptomatic nonunions following intramedullary screw fixation. In their failure group, the authors found a higher proportion of elite athletes, and found that patients in the failure group returned to full activity at 6.8 weeks following surgery versus 9 weeks in the non-failure group, prompting them to recommend postponing return to sports until radiographic union is confirmed. A myriad of biomechanical studies have been conducted to evaluate the various screws available [9, 13, 21, 25, 28, 29, 33]. In the biomechanical arm of a combined clinical and biomechanical study by Reese et al. [25], it was shown that screws greater than 6.5 mm in diameter were superior to those under 4.0 mm, that stainless steel screws were superior to titanium screws, and that solid screws were superior to cannulated screws in terms of resistance to fatigue failure with a cyclic three-point bending protocol. In other studies, the 6.5 partially threaded lag screw was shown to have greater pull-out strength than the 5.0 mm partially threaded lag screw [13] and 4 mm leading thread-5 mm trailing thread tapered, variable pitch screw [29], despite the lack of a significant difference in terms of bending stiffness. In yet another study, Horst et al. [9] showed that 5.0 and 6.5 mm screws provided equal torsional rigidity. However, to achieve stability equal to that of the 6.5 mm screw, the 5.0 mm screw required a length sufficient enough to gain purchase in the distal fragment

which subsequently had a tendency to straighten out the normally curved fifth metatarsal, thus creating a gap at the lateral aspect of the fracture site. These findings have led to the current recommendations for selecting the ideal screw.

## 13.2 Surgical Indications

Percutaneous intramedullary screw fixation is indicated in the competitive athlete with a Zone II or Zone III fracture of the proximal fifth metatarsal. Other indications include the non-athlete with a delayed union or a non-union, or any patient with a recurrent fracture. When attempting to decide between operative and non-operative intervention, there is no need to distinguish between the “true Jones” (Zone II) and proximal diaphyseal (Zone III) fractures [3]. Contraindications for operative fixation include: active sepsis, skin infection or other cutaneous lesions in the vicinity of the skin incision, medical comorbidities that would prohibit a surgical procedure, and Charcot arthropathy [19, 20, 32].

If surgery is not indicated or if the patient elects for non-operative management, we prefer to manage Zone II and Zone III fractures non-weightbearing in a short leg cast, bearing in mind that the time to union may be prolonged. In patients unwilling to comply with casting and a non-weightbearing status, we have used an in-shoe orthotic device that elevates and unloads the base of the fifth metatarsal as described by Dameron [6] (Fig. 13.2a, b). Despite anecdotal success, we are unaware of any published results regarding the use of this type of orthosis. We continue to manage Zone I fractures with weightbearing as tolerated in a hard-soled shoe.

## 13.3 Pre-operative Work-Up

Thorough physical examination of the injured foot with an emphasis on hindfoot alignment is essential. The presence of hindfoot varus, whether congenital or acquired, must be

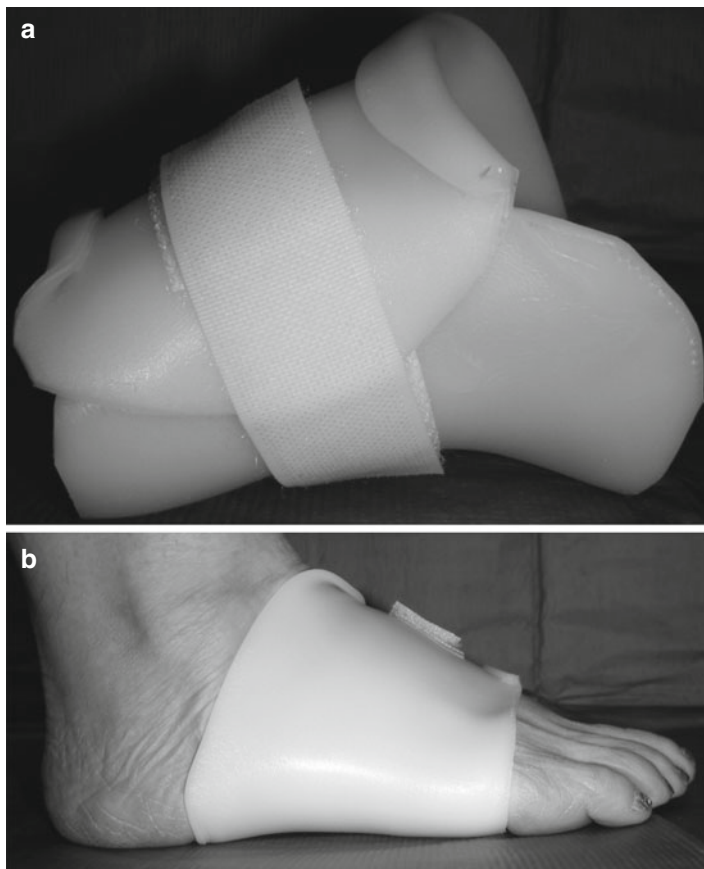


FIGURE 13.2 (a, b) Dameron-type orthosis

identified pre-operatively and corrected at the same time as the fifth metatarsal base fracture to prevent lateral column overload and subsequent non-union or refracture. Following physical examination, high quality radiographs of the foot are obtained in the anterior-posterior (AP), lateral, and oblique planes (Fig. 13.3a–c). Although pre-operative templating has been described [32], we do not routinely do this, nor do we feel that it is necessary. In general, screw length and diameter

are chosen intra-operatively based on fluoroscopic imaging and torque resistance of the cannulated tap.

Female athletes deserve special consideration. The combination of disordered eating, amenorrhea, and osteoporosis has been termed the “female athlete triad” [34], and is a serious syndrome which has been associated with an increased risk of stress fractures. Following fixation of the fracture in a patient with the signs and symptoms of this condition, a multi-disciplinary approach to this complex, multi-faceted condition is warranted.

## 13.4 Surgical Technique

The procedure is performed under regional anesthesia, and we use either an ankle or a calf tourniquet. Perioperative antibiotics are optional.

The patient is positioned supine with a bump under the ipsilateral greater trochanter to internally rotate the operative extremity, thereby permitting the foot to be placed plantigrade on the image intensifier platform of a standard fluoroscopy unit when the knee is flexed. The foot and ankle are prepped and draped in a standard, sterile fashion and the tourniquet is inflated after Esmarch exsanguination. With the knee flexed, the foot is positioned flat on the fluoroscopy platform and a free guide pin is placed on the dorsolateral skin overlying the intramedullary canal of the fifth metatarsal shaft (Fig. 13.4). Proper alignment is confirmed with fluoroscopy and a line is drawn along the path of the guide pin (Fig. 13.5a, b). This procedure is repeated in the lateral plane giving two lines that correspond to the trajectory of the metatarsal shaft, thus giving the surgeon an external reference for subsequent guide pin placement (Fig. 13.6a, b).

A 1.5 cm longitudinal incision is produced 2 cm proximal to the fifth metatarsal base, taking great care to identify and protect both the sural nerve and the distal extent of the peroneus brevis tendon (Fig. 13.7a, b). Utilizing a tissue protector (sleeve), a guide pin is placed in the dorsomedial quadrant

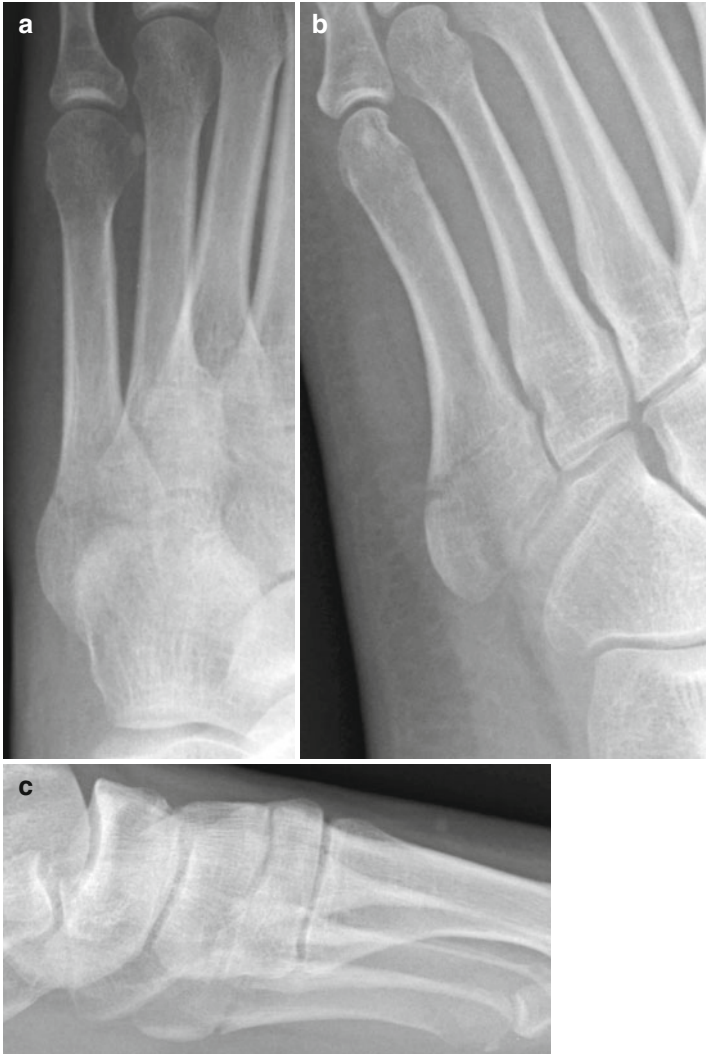

FIGURE 13.3 (a-c) Pre-operative plain radiographs demonstrating a Zone II fracture of the proximal fifth metatarsal

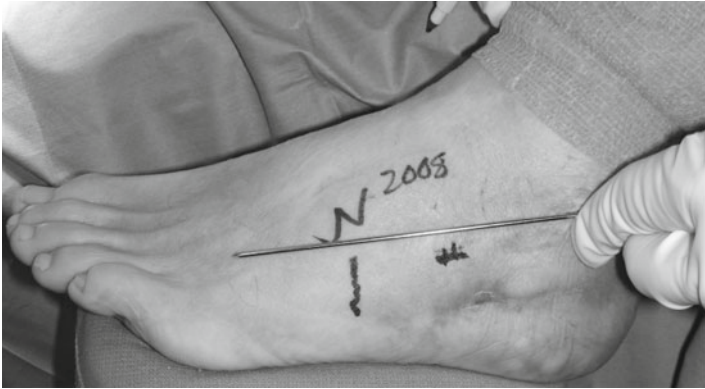


FIGURE 13.4 Foot flat on the image intensifier and free guide pin placed along dorsal aspect of fifth metatarsal shaft

(“high and inside” position) of the fifth metatarsal base. Under fluoroscopic guidance, this guide pin is then advanced within the center of the medullary canal confirming proper position in the AP, lateral, and oblique planes (Fig. 13.8a, b). Throughout its advancement, the pin must lie against the lateral skin overlying the calcaneus to avoid penetration of the medial cortex of the shaft. The guide pin is advanced until its tip is approximately 2 cm beyond the fracture line, and then is overdrilled using a 3.2 mm drill bit under fluoroscopic guidance (Fig. 13.9). The drill is withdrawn, and a 4.5 mm cannulated tap is advanced over the guide pin (Fig. 13.10). Tapping proceeds under fluoroscopic guidance across the fracture site to the curved portion of the fifth metatarsal shaft, but not beyond this region (Fig. 13.11). Sequential tapping with the 4.5, 5.5, and 6.5 mm taps is performed until a substantial amount of resistance is encountered within the medullary canal. When the surgeon observes external rotation of the right fifth metatarsal or internal rotation of the left fifth metatarsal with the final half-turn of the tap, the tap diameter corresponds to the desired screw diameter. It is essential throughout the process of drilling and tapping that a soft tissue protector is used to prevent inadvertent damage

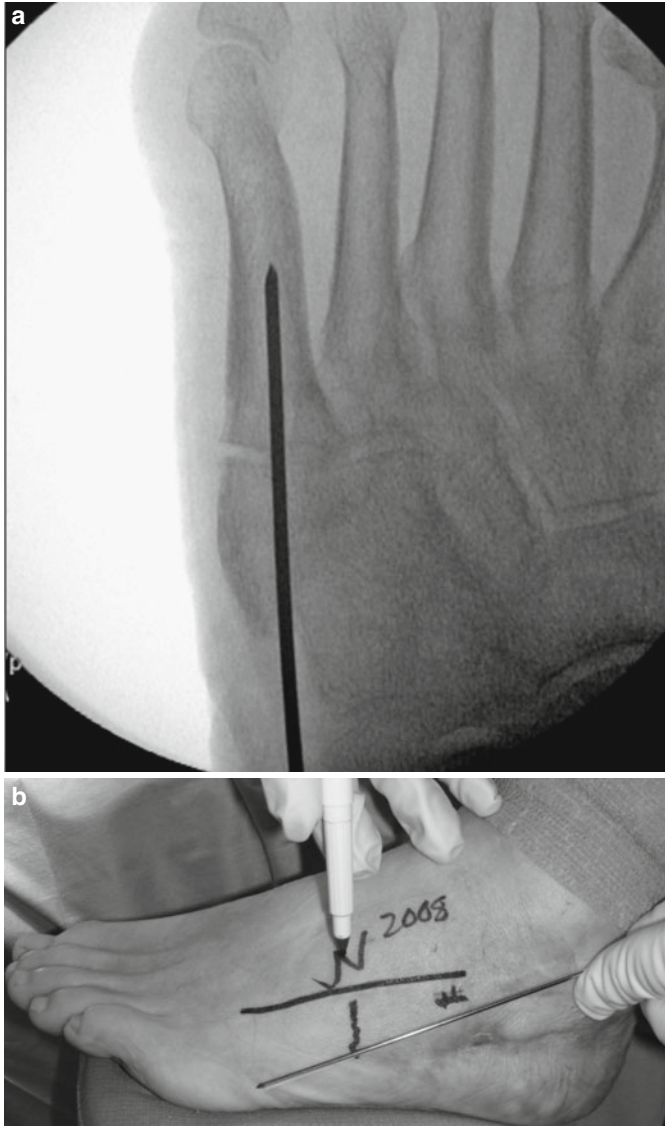


FIGURE 13.5 (a) Fluoroscopic image demonstrating alignment of guide pin along metatarsal shaft. (b) Line drawn on the skin corresponding to the alignment obtained in Fig. 13.5a



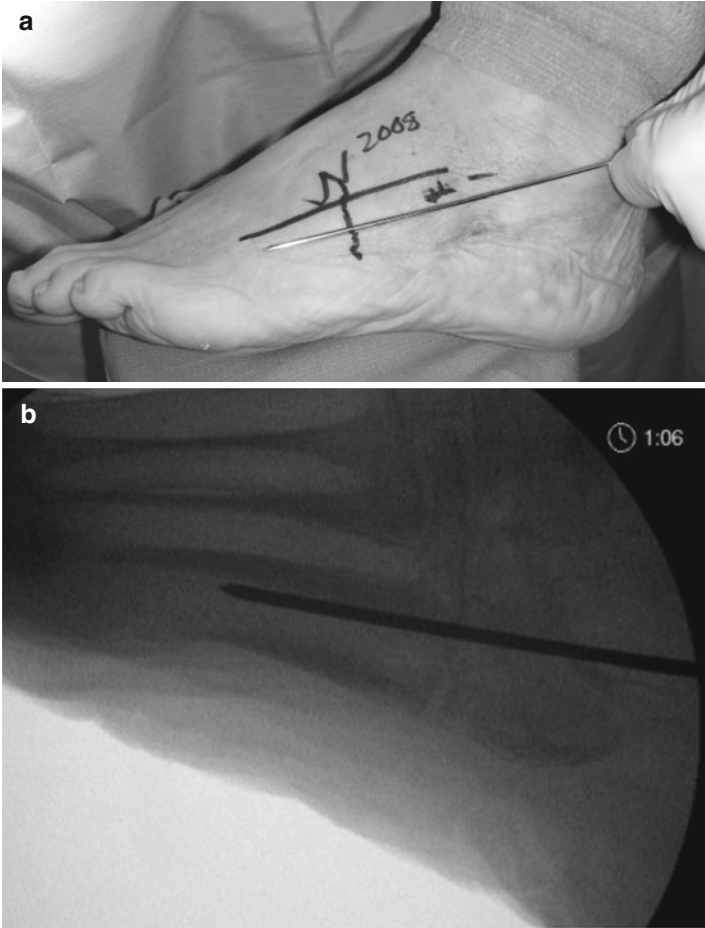


FIGURE 13.6 (a, b) Intra-operative photograph and corresponding fluoroscopic image demonstrating correct alignment in the sagittal plane

to the sural nerve, peroneus brevis tendon, or the surrounding skin. Once the canal has been tapped to the desired diameter, screw length is measured using a cannulated depth gauge (Fig. 13.12) and double-checked by placing a screw of the measured length on the lateral aspect of the foot and

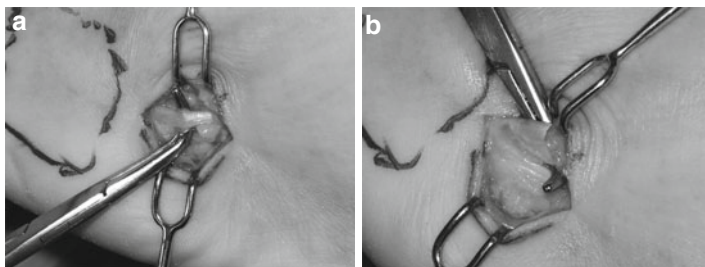


FIGURE 13.7 (a) Sural nerve identified within the surgical wound. (b) Peroneus brevis tendon identified within the surgical wound

taking an oblique fluoroscopic image (Fig. 13.13). The ideal screw should be long enough that all of the threads lie beyond the fracture line, yet not so long that its tip enters the curved portion of the medullary canal. If the screw is too long, it will have a tendency to straighten out this normally curved bone, thus distracting the fracture site laterally. After determining the correct screw diameter and length, the guide pin is withdrawn, and immediately replaced with a solid, partially-threaded, stainless steel screw (Fig. 13.14). The screw is fully seated, and final fluoroscopic images are obtained (Fig. 13.15).

The wound is irrigated and then closed using 4-0 nylon horizontal mattress sutures. A sterile dressing is applied, and the extremity is placed in a well padded short leg plaster splint or cast boot (Fig. 13.16).

### 13.5 Post-operative Protocol

Following rigid fixation, patients are kept non-weightbearing in their post-operative splint. At 2 weeks, sutures are removed and the patient is fashioned with an in-shoe clamshell orthosis as described by Dameron [6]. At the 4-week mark, three plain radiographic views of the operative foot are obtained and, if early bony healing is noted, the patient is allowed to commence weightbearing as tolerated in a CAM Walker with

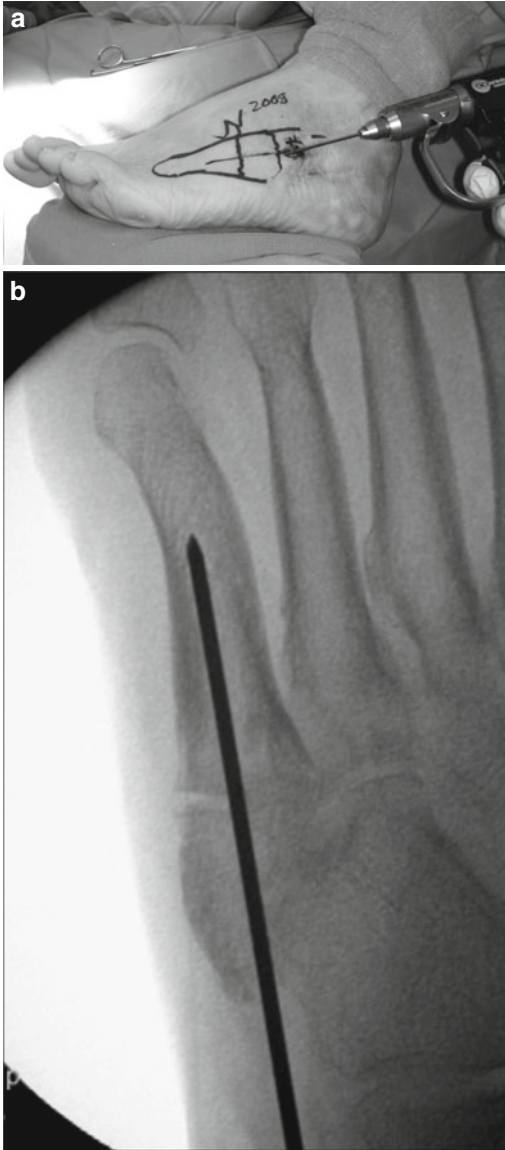

FIGURE 13.8 (a, b) Correct guide pin placement is confirmed fluoroscopically

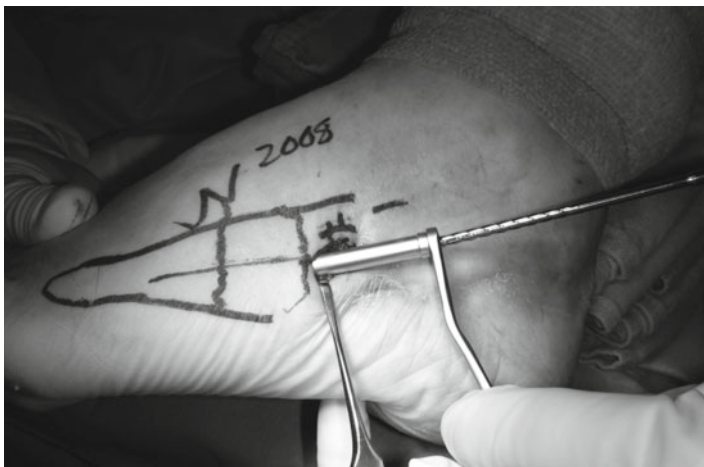

FIGURE 13.9 Overdrilling of the proximal fifth metatarsal with the 3.2 mm drill bit using a tissue protector sleeve



FIGURE 13.10 Sequential tapping of the fifth metatarsal through the protective sleeve

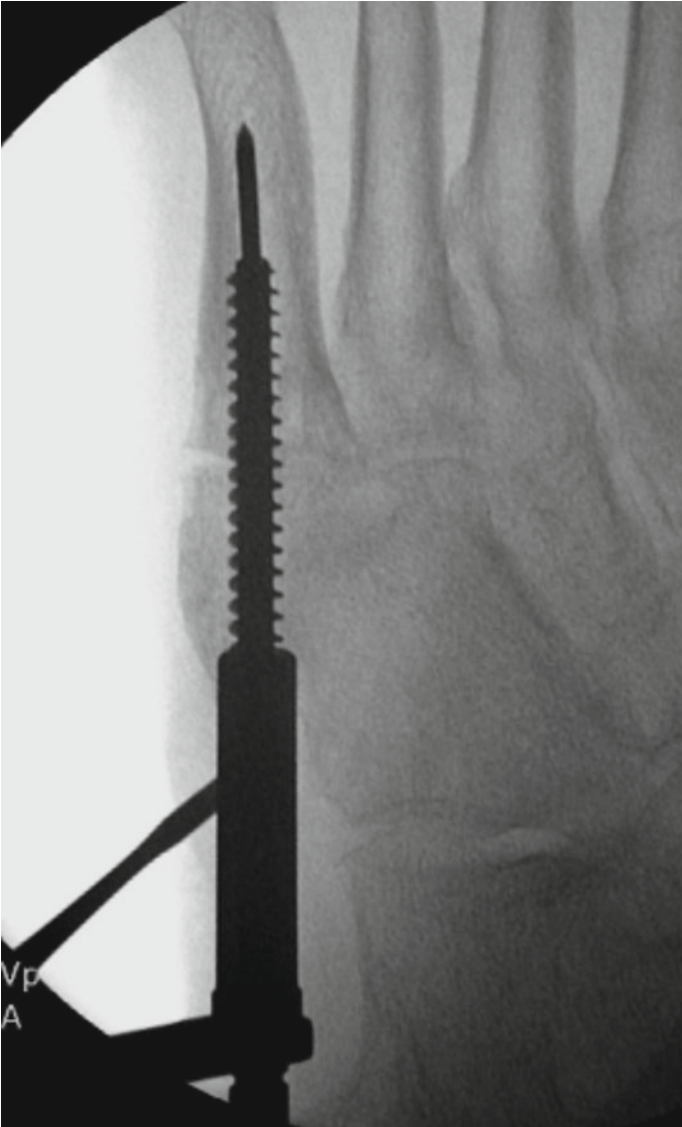


FIGURE 13.11 Verification of the correct depth of the cannulated tap. Tapping proceeds across the fracture site and stops just proximal to the curved portion of the shaft

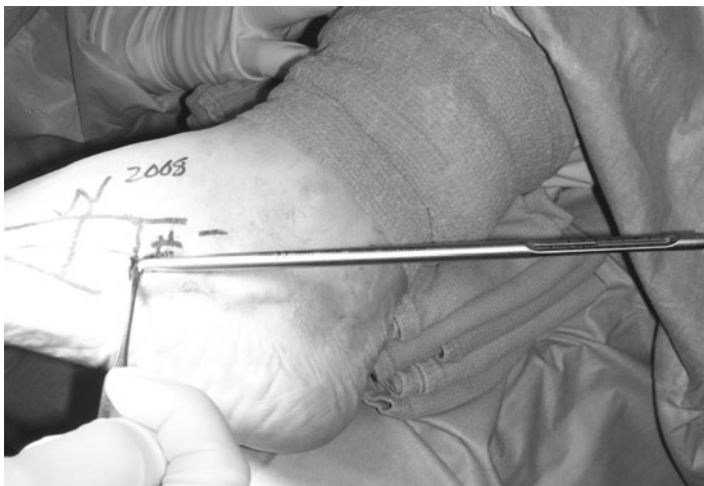


FIGURE 13.12 Length of the proper screw is measured using a cannulated depth gauge

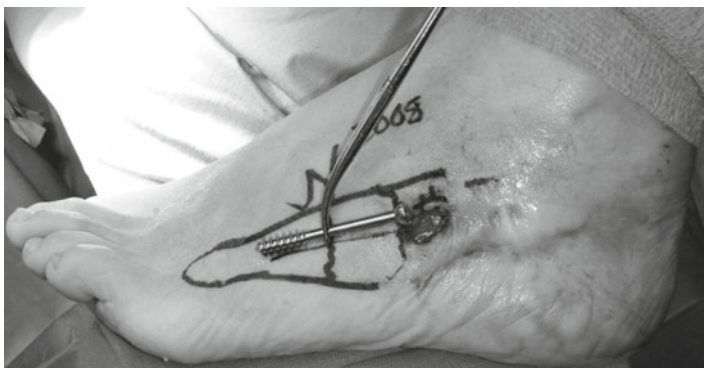

FIGURE 13.13 The appropriate length of the screw may alternatively be checked by placing a screw of the projected length on the skin, and verifying its selection fluoroscopically. The appropriate length screw should have all of its threads distal to the fracture line, and its tip should not enter the curved portion of the medullary canal

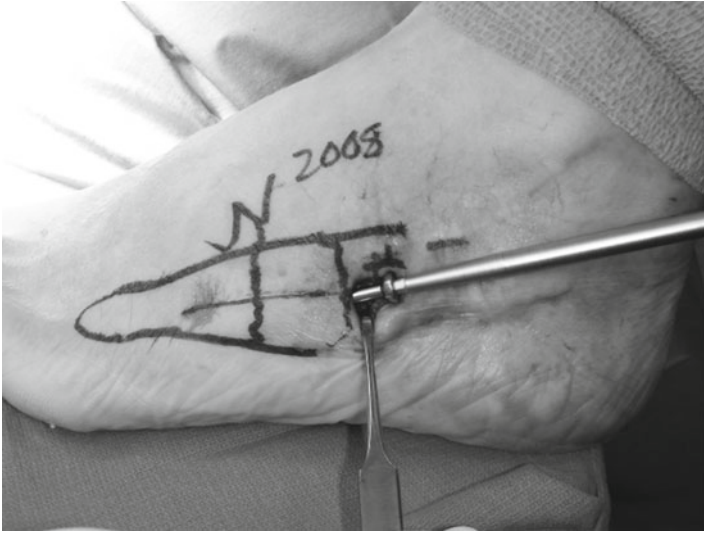


FIGURE 13.14 After removal of the guide pin, the solid, partially threaded, stainless steel screw is inserted

their orthotic device. At 6 weeks, the CAM Walker is exchanged for a regular tennis shoe (with the orthosis), and, if full radiographic healing is noted at the 12-week visit, the orthosis may be discontinued.

In the competitive athlete, the post-operative protocol parallels that of the non-athlete with a few exceptions. In these patients, we routinely employ a bone stimulator and begin upper body conditioning at the 2-week mark. At 3 weeks, partial weightbearing in the CAM Walker with clamshell orthosis is commenced, as well as a daily regimen of 30 min on the stationary bike. If radiographs taken at the 6 weeks follow-up appointment show adequate fracture healing, the patient starts progressive on-field work-out. Full, unrestricted return to sports is allowed at 8-weeks postoperatively, barring any set-backs.

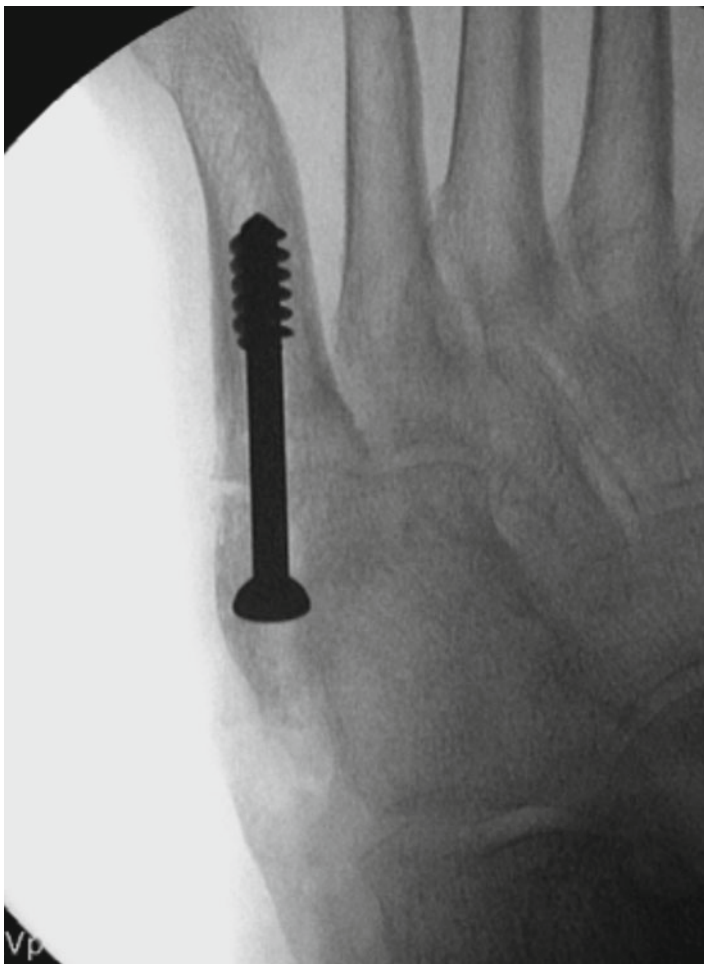

FIGURE 13.15 Final fluoroscopic images are obtained

### 13.6 Complications

Delayed union, nonunion, and refracture have all been reported following an otherwise successful percutaneous fixation of a fifth metatarsal base fracture [8, 11, 15, 25, 35, 36], and are generally the result of a technical or diagnostic error.





FIGURE 13.16 At the completion of the procedure, the patient is placed in a cast boot or short leg splint

Common technical errors include: failure to fully cross the fracture site with the screw threads, placement of a screw that lacks an adequate diameter to gain solid purchase in the distal fragment, or insertion of a screw that is too long and subsequently straightens the curved fifth metatarsal thereby distracting the lateral aspect of the fracture site [20]. From a diagnostic standpoint, failure to identify an associated hind-foot varus may lead to the development of a delayed union, nonunion, or refracture, and should therefore be addressed with a simultaneous Dwyer calcaneal osteotomy or other corrective procedure [20]. In thin athletes, irritation of the peroneus brevis tendon by the screw head may be observed [20]. However, given the significant risk of refracture following screw removal [11], we do not recommend removal until the athlete has completed their competitive careers.

Two other potential complications include injury to the sural nerve or peroneus brevis tendon [20]. These important structures must be identified during this limited percutaneous approach and protected throughout the entire procedure. The importance of gentle retraction with the use of the soft tissue protector sleeve cannot be overstated.

## References

1. Arangio G. Transverse proximal diaphyseal fracture of the fifth metatarsal: a review of 12 cases. *Foot Ankle*. 1992;13:547–9.
2. Carp L. Fracture of the fifth metatarsal bone with special reference to delayed union. *Ann Surg*. 1927;86:308–20.
3. Chuckpaiwong B, Queen RM, Easley ME, Nunley JA. Distinguishing Jones and proximal diaphyseal fractures of the fifth metatarsal. *Clin Orthop Relat Res*. 2008;466(8):1966–70.
4. Clapper MF, O'Brien TJ, Lyons PM. Fractures of the fifth metatarsal: analysis of a fracture registry. *Clin Orthop Relat Res*. 1995;315:238–41.
5. Dameron TB. Fractures and anatomical variations of the proximal portion of the fifth metatarsal. *J Bone Joint Surg*. 1975;57-A:788–92.
6. Dameron TB. Fractures of the proximal fifth metatarsal: selecting the best treatment option. *J Am Acad Orthop Surg*. 1995;3:110–4.
7. DeLee JC, Evans JP, Julian J. Stress fracture of the fifth metatarsal. *Am J Sports Med*. 1983;11:349–53.
8. Glasgow MT, Naranja RJ, Glasgow SG, Torg JS. Analysis of failed surgical management of fractures of the base of the fifth metatarsal distal to the tuberosity: the Jones fracture. *Foot Ankle Int*. 1996;17:449–57.
9. Horst F, Gilbert BJ, Glisson RR, Nunley JA. Torque resistance after fixation of Jones fractures with intramedullary screws. *Foot Ankle Int*. 2004;25:914–9.
10. Jones R. Fracture of the base of the fifth metatarsal bone by indirect violence. *Ann Surg*. 1902;35:697–700.
11. Josefsson PO, Karlsson M, Redlund-Johnell I, Wendeberg B. Jones fracture: surgical versus nonsurgical treatment. *Clin Orthop Relat Res*. 1994;299:252–5.
12. Kavanaugh JH, Brower TD, Mann RV. The Jones fracture revisited. *J Bone Joint Surg*. 1978;60-A:776–82.
13. Kelly IP, Glisson RR, Fink C, Easley ME, Nunley JA. Intramedullary screw fixation of Jones fractures. *Foot Ankle Int*. 2001;22:585–9.
14. Konkel KF, Menger AG, Retzlaff SA. Nonoperative treatment of fifth metatarsal fractures in an orthopaedic suburban private multi-specialty practice. *Foot Ankle Int*. 2005;26:704–7.
15. Larson CM, Almekinders LC, Taft TN, Garrett WE. Intramedullary screw fixation of Jones fractures: analysis of failure. *Am J Sports Med*. 2002;30:55–60.
16. Lawrence SJ, Botte MJ. Foot Fellow's review: Jones' fractures and related fractures of the proximal fifth metatarsal. *Foot Ankle*. 1993;14:358–65.
17. Lehman RC, Torg JS, Pavlov H, DeLee JC. Fractures of the base of the fifth metatarsal distal to the tuberosity: a review. *Foot Ankle*. 1987;7:245–52.

18. Mindrebo N, Shelbourne D, Van Meter CD, Rettig AC. Outpatient percutaneous screw fixation of the acute Jones fracture. *Am J Sports Med.* 1993;21:720–3.
19. Nunley JA. Fractures of the base of the fifth metatarsal: the Jones fracture. *Orthop Clin North Am.* 2001;32:171–80.
20. Nunley JA. Jones fracture technique. *Tech Foot Ankle Surg.* 2002;1: 131–7.
21. Pietropaoli MP, Wnorowski DC, Werner FW, Fortino MD. Intramedullary screw fixation of Jones fractures: a biomechanical study. *Foot Ankle Int.* 1999;20:560–3.
22. Porter DA, Duncan M, Meyer SJF. Fifth metatarsal Jones fracture fixation with a 4.5-mm cannulated stainless steel screw in the competitive and recreational athlete: a clinical and radiographic evaluation. *Am J Sports Med.* 2005;33:726–33.
23. Portland G, Kelikian A, Kodros S. Acute surgical management of Jones' fractures. *Foot Ankle Int.* 2003;24:829–33.
24. Quill GE. Fractures of the proximal fifth metatarsal. *Orthop Clin North Am.* 1995;26:353–61.
25. Reese K, Litsky A, Kaeding C, Pedroza A, Shah N. Cannulated screw fixation of Jones fractures: a clinical and biomechanical study. *Am J Sports Med.* 2004;32:1736–42.
26. Rosenberg GA, Sferra JJ. Treatment strategies for acute fractures and nonunions of the proximal fifth metatarsal. *J Am Acad Orthop Surg.* 2000;8:332–8.
27. Sarimo J, Rantanen J, Orava S, Alanen J. Tension-band wiring for fractures of the fifth metatarsal located in the junction of the proximal metaphysis and diaphysis. *Am J Sports Med.* 2006;34:476–80.
28. Shah SN, Knoblich GO, Lindsey DP, Kreshak J, Yerby SA, Chou LB. Intramedullary screw fixation of proximal fifth metatarsal fractures: a biomechanical study. *Foot Ankle Int.* 2001;22:581–4.
29. Sides SD, Fetter NL, Glisson R, Nunley JA. Bending stiffness and pull-out strength of tapered, variable pitch screws, and 6.5-mm cancellous screws in acute Jones fractures. *Foot Ankle Int.* 2006;27: 821–5.
30. Stewart IM. Jones's fracture: fracture of the base of the fifth metatarsal. *Clin Orthop.* 1960;16:190–8.
31. Torg JS, Balduini FC, Zelko RR, Pavlov H, Peff TC, Das M. Fractures of the base of the fifth metatarsal distal to the tuberosity: classification and guidelines for non-surgical and surgical management. *J Bone Joint Surg.* 1984;66-A:209–14.
32. Tsaknis R, Leumann A, Valderrabano V, Pagenstert G, Hintermann B. Fixation of proximal fifth metatarsal fractures. *Tech Foot Ankle Surg.* 2008;7:115–9.
33. Vertullo CJ, Glisson RR, Nunley JA. Torsional strains in the proximal fifth metatarsal: implications for Jones and stress fracture management. *Foot Ankle Int.* 2004;25:650–6.

34. West RV. The female athlete: the triad of disordered eating, amenorrhea, and osteoporosis. *Sports Med.* 1998;26:63–71.
35. Wright RW, Fischer DA, Shively RA, Heidt RS, Nuber GW. Refracture of proximal fifth metatarsal (Jones) fracture after intramedullary screw fixation in athletes. *Am J Sports Med.* 2000;28:732–6.
36. Zelko RR, Torg JS, Rachun A. Proximal diaphyseal fractures of the fifth metatarsal – treatment of the fractures and their complications in athletes. *Am J Sports Med.* 1979;7:95–101.

# Index

## A

### Adjunct procedures

- derotation, first metatarsal
  - arthroscopic examination, 84
  - dorsolateral radiograph and sesamoid subluxation, 83
- first tarso-metatarsal
  - arthrodesis (*see* First tarso-metatarsal arthrodesis)
- intermetatarsal space, 86, 87
- metatarso-sesamoid compartment, 86
- sesamoid bones, 83–84
- sesamoid subluxation, 86
- extensor hallucis longus tendon (*see* Extensor hallucis longus tendon)

### American Orthopaedic Foot and Ankle Society (AOFAS)

- metatarso-phalangeal joint, 143
- radiographic analysis, 50
- satisfaction level scale, 100

### Anesthesia

- modified Wilson osteotomy, 107
- surgical technique, 153

### AOFAS. *See* American Orthopaedic Foot and Ankle Society (AOFAS)

### Arthrodesis

- dorsal flexion, 46
- fixation, 47, 49
- fluoroscopy, 51

- global foot anatomy, 43
- MTP1 positioning, 46–48
- primary stability and bone contact, 51
- risk, bone loss, 45
- site preparation of, 45
- transfer metatarsalgia, 46

### Arthrofibrosis

- MTPJ, 19–20
- MTP-1 joint, 19–21

### Arthroscopic assisted correction,

- hallux valgus deformity adjunct procedures (*see* Adjunct procedures)
- description, 73
- distal soft-tissue correction, 73
- endoscopic distal soft tissue procedure (*see* Endoscopic distal soft tissue)
- osteoarthritis, 73

### Arthroscopic synovectomy, MTPJ

- endoscopic distal soft tissue procedure, 11
- gouty tophus endoscopic resection, 9–11
- metatarso-sesamoid compartment, 8
- synovitis, 7

### Arthroscopic technique

- anatomy/pathoanatomy, 1–2
- chondral and osteochondral lesions, 14–16
- defined, 1

- Arthroscopic technique (*cont.*)  
 dorsal impingement syndrome, 11–13  
 dorsolateral portal, 6  
 instruments, 3  
 intra-articular fracture, metatarsal head, 21–22  
 osteoarthritis (*see* Osteoarthritis, MTPJ)  
 plantar plate tenodesis, 17–18  
 portals (*see* Portals, arthroscopic technique)  
 positioning, 2  
 release, arthrofibrosis, 19–21  
 sesamoidectomy, sesamoid pathology, 16–17  
 synovectomy (*see* Arthroscopic synovectomy, MTPJ)  
 technique (*see* Arthroscopic technique)  
 traction, 3
- B**  
 Bosch technique, 100–101
- C**  
 Cheilectomy  
 bone slur, 35  
 description, 32  
 dorsal medial forefoot, Beaver blade 64, 32, 33  
 exostosis capsule cover, 32, 34  
 plus metatarsal osteotomy and phalanx, 38  
 proximal phalanx, 33  
 surgical indications, 38  
 triangular burr, abrade exostosis, 33, 34  
 Chondral and osteochondral lesions  
 cartilage lesions, 14–15  
 debridement, metatarsal head, 15  
 microfracture, 15, 16
- Computed tomography (CT), 150–152  
 CT. *See* Computed tomography (CT)
- D**  
 DASA. *See* Distal articular set angle (DASA)  
 Digital deformities  
 classification, 163  
 description, 161–162  
 etiology, 162–163  
 Isham Hammertoe procedures (*see* Isham Hammertoe procedures)  
 non-Hammertoe lesser digit deformities (*see* Non-Hammertoe lesser digit deformities)  
 phalangeal osteotomy procedures (*see* Phalangeal osteotomy procedures)  
 Distal articular set angle (DASA), 57  
 Distal first metatarsal osteotomy  
 dorsal closing wedge, 36–38  
 Shanon 44 burr, 35  
 Distal metatarsal mini-invasive osteotomy (DMMO)  
 anesthesia, 153  
 CT, 150–152  
 description, 150  
 materials, 151–152  
 mobilization, toes, 142, 144  
 osteotomy, 153–154  
 osteotomy beginning and end, 142–144  
 patient positioning, 153  
 place, burr, 150, 153  
 positioning, burr, 141  
 post-operative (*see* Post-operation, DMMO)  
 principles, 141, 142  
 Weil osteotomy, 151

- Distal metatarsal osteotomy. *See* Reverdin-Isham procedure
- DMMO. *See* Distal metatarsal mini-invasive osteotomy (DMMO)
- Dorsal impingement syndrome  
cheilectomy, phalangeal base, 12, 13  
defined, 11–12
- Dorsal metatarsophalangeal capsulotomy, 184
- Dorsiflexion contracture. *See* Proximal interphalangeal joint, fifth toe
- E**
- Endoscopic distal soft tissue procedure  
hallux valgus, 11  
ligament preserving approach (*see* Ligament preserving approach)  
ligament sacrificing approach (*see* Ligament sacrificing approach)  
medial exostectomy, 80  
plication, medial capsule, 81–82  
reduction and fixation, intermetatarsal angle, 81–83
- Extensor hallucis longus tendon, 89–90
- F**
- “Female athlete triad”, 211
- First metatarso phalangeal joint (MTP-1). *See also* Proximal interphalangeal joint, fifth toe  
AOFAS score, 50  
arthrodesis (*see* Arthrodesis)  
arthroscopy (*see* Arthroscopic technique)  
bone preparation, 50–51  
cannulated compression, 51  
compensatory hypermobility, IP joint, 49  
description, 43  
dorsi-flexion, 43  
forefoot surgery, 49  
global foot anatomy, 43  
IP, 43  
operative technique, 44–47  
post-operative care, 48  
post-operative prolonged pain and swelling, 50  
symptomatic hallux rigidus/hallux rigido-valgus, 50  
treatment, hallux rigidus, 48–49
- First metatarso-phalangeal joint (MTPJ) position  
congruous, 58  
deviated, subluxed joint position, 58, 59  
subluxed, 58
- First tarso-metatarsal arthrodesis  
advantages, 87  
description, 86–87  
hallux valgus deformity, 87  
open procedure, 87  
technique, 88–89
- G**
- Gouty tophus endoscopic resection, MTPJ  
cannula and trocar, 9, 10  
synovitis/tophaceous material, 10  
two portals, 9
- H**
- Hallux abducto-valgus (HAV) deformity, 60–61  
disorders, 62–63  
HA angle, 57
- Hallux abductus (HA) angle, 57
- Hallux dolorosus, 28

- Hallux limitus, 28
- Hallux rigidus
- anesthesia, 31
  - cheilectomy (*see* Cheilectomy)
  - description, 25
  - distal first metatarsal osteotomy, 35–36
  - dolorosus, 28
  - extrinsic causes, 27
  - flexion, 27–28
- Hallux rigidus (*cont.*)
- instruments, 29, 31
  - interphalangeal joint, distal phalanx, 26, 27
  - intrinsic causes, 26–27
  - limitus, 28
  - metatarsal osteotomy, cheilectomy and phalanx, 38
  - metatarso-phalangeal arthrodesis, 40
  - osteochondritis, first metatarsal, 27
  - osteotomy, base of proximal phalanx (*see* Osteotomy)
  - postoperative care, 37, 41
  - radiographic stages, 29
  - small osteophytes, first metatarsal head, 29, 30
  - subchondral sclerosis, 29, 31
  - surgery, 29
  - total loss of joint space, florid osteophytes and articular surface, 29, 32
  - visible osteophytes, first metatarsal, 25, 26
- Hallux valgus
- advantages, Reverdin-Isham procedure, 68–69
  - bunion deformities, 55
  - classification, 58–60
  - correction (*see* Reverdin-Isham procedure)
  - DASA (*see* Distal articular set angle (DASA))
  - definition, 56
  - deformity, 55
  - disadvantages, Reverdin-Isham procedure, 71
  - etiology, 56
  - first intermetatarsal angle, 57
  - HA angle (*see* Hallux abductus (HA) angle)
  - management, postoperative, 66
  - measurements, 57
  - minimally invasive technique (*see* Minimally invasive technique, hallux valgus)
  - MTPJ, 58
  - operative technique, 65
  - PASA, 57
  - postoperative bandaging (*see* Postoperative bandaging)
  - preoperative criteria, 63–65
  - Reverdin-Isham procedure (*see* Reverdin-Isham procedure)
- Hallux valgus angle (HVA), 94–96
- Hallux valgus correction
- defined, 93–94
  - distal osteotomies, 100, 101
  - metatarsal shortening, 100
  - metatarso-phalangeal joint, 94–95
  - osteotomy healing time, 101
  - postoperative care, 98–99
  - recurrence, deformity, 99
  - surgical technique, 96–98
  - transverse osteotomy, 101, 102
- Hallux valgus deformity
- arthroscopic assisted correction (*see* Arthroscopic assisted correction, hallux valgus deformity)
  - mild, 58, 60
  - moderate, 58, 61
  - severe, 59, 62
- HAV. *See* Hallux abducto-valgus (HAV)
- HVA. *See* Hallux valgus angle (HVA)



**I**

- IMA. *See* Intermetatarsal angle (IMA)
- Instrumentation, modified Wilson osteotomy
- Locke elevator, rasp and eye magnet, 107, 108
  - Osada PEDO unit, reduction speed handpiece, 108, 111
  - Shannon and wedge burrs, 108, 109
  - Xi-scan portable fluoroscope, model 1000-1, 108, 110
- Intermetatarsal angle (IMA), 94–96
- Interphalangeal joint (IPJ). *See also* Metatarsal phalangeal joints (MPJ)
- compensatory hypermobility, 49
  - dorsi-flexion, 43
  - normal walking and shoe wearing, 49
- IPJ. *See* Interphalangeal joint (IPJ)
- Isham Hammertoe procedures
- advantages and disadvantages, 177
  - I-1 procedure, 164, 165
  - I-2 procedure, 164, 166
  - I-3 procedure, 164–165, 167
  - I-4 procedure, 165, 168
  - I-5 procedure, 166, 169
  - I-6 procedure, 166–167, 170
- Isham osteotomy, 63, 64

**L**

- Lapidus arthrodesis. *See* First tarso-metatarsal arthrodesis
- Lateral condylectomy, 184, 186
- Lawrence and Botte classification, 205–206
- Ligament preserving approach
- closure, intermetatarsal space, 78, 79

- degree of correction, deformity, 78
  - description, 77
  - metatarsal osteotomy, 79
- Ligament sacrificing approach
- description, 74
  - fibular sesamoid, toe web portal, 76, 79
  - intermetatarsal ligament, retrograde knife, 75, 77
  - metatarsal sesamoidal suspensory ligament, 76
  - metatarso-phalangeal collateral ligament, 76
  - plantar aponeurosis, 74
  - plantar portal, tarso-metatarsal joint, 75
  - tendon, adductor hallucis insertion, 75, 78
  - toe web portal, 74
  - trocár, plantar portal, 75, 76

**M**

- Medial capsule plication
- distal bunion portal, 82
  - dynamic hallux valgus splin, 82, 86
  - medial capsular suture, 82
  - PDS-1 sutures, 81
- Metatarsal fractures
- acute and chronic, 207
  - Dameron-type orthosis, 209, 210
  - “female athlete triad”, 211
  - Lawrence and Botte classification, 205–206
  - post-operative protocol, 216, 221
  - pre-operative plain radiographs, 210, 212
  - re-fractures, 207–208
  - surgical technique, 211–216
  - technical errors, 223
  - thin athletes, 223
  - tuberosity fractures, 206–207

- Metatarsalgia. *See* Distal metatarsal mini-invasive osteotomy (DMMO)
- Metatarsal head remodeling  
 Dancer's pad, dorsiflectory pressure reduction, 122, 124  
 folded gauzes, 123, 125, 127  
 foot dressing, 122, 126  
 medial eminence removal, 119, 120  
 optional percutaneous fixation, Kirschner wires, 122, 123  
 palpable medial bony prominence, 122, 125  
 plantarflexion and dorsiflexion, 126, 128  
 Shannon 44 burr, 121
- Metatarsal phalangeal joints (MPJ). *See also* Isham Hammertoe procedures  
 definition, 162  
 etiology, 162
- Metatarsal spacer, 186
- Metatarso-phalangeal arthrodesis, 40
- Microfracture technique, 15
- Mild hallux valgus, 58, 60
- Minimally invasive technique, hallux valgus  
 bone cutting instrument, 65  
 Burr 3.1 wedge, 65  
 capsulotomy, 65  
 hallux sesamoids and dorsal articular surface, 66  
 oblique incision, first MTPJ, 66, 67
- Minimum incision techniques, 94
- Moderate hallux valgus, 58, 61
- Modified Wilson osteotomy, hallux valgus treatment  
 anesthesia, 107  
 description, 106–107  
 dorsal arm, 115, 117  
 fail-safe hole, 110, 112–114  
 instrumentation, 107–111  
 landmarks drawn, beginning surgery, 129  
 Locke elevator, 115  
 plantar arm, 117, 118  
 pre and post operative photographs, 129–131  
 pre and post operative radiographs, 129, 132–137  
 remodeling, metatarsal head (*see* metatarsal head remodeling)  
 skin incision, 110, 112  
 V-shaped, 117, 118
- N**
- Non-hammertoe lesser digit deformities  
 congenital deformities, 169–170  
 description, 167–168  
 exostosis excisions, 170, 173  
 extensor tenotomy and capsulotomy releases, 170, 172  
 IPJ, 170  
 MPJ, 168  
 operative technique, 171–172  
 post operative bandaging, 173–174  
 shortening osteotomy procedure, 171, 174  
 wedge osteotomy procedure, 169, 171
- O**
- Operative technique  
 first metatarso phalangeal joint (MTP-1)  
 arthrodesis fixation, 47  
 arthrodesis positioning, 46–47  
 fusion site preparation, 45–46  
 instruments, 44  
 patient set up, 44  
 portals, 44–45

- non-hammertoe lesser digit deformities
  - bone cutting instrument, 172
  - combination osteotomy, 172, 175
  - Isham Hammertoe procedures, 171
  - MPJ, 171–172
- Osteoarthritis, MTPJ
  - defined, 12–13
  - degeneration, 13, 14
- Osteotomy
  - burr, at 45°, 154
  - cheilectomy plus metatarsal, 38
  - distal first metatarsal (*see* Distal first metatarsal osteotomy)
  - hallux valgus correction, 154
  - inter-metatarsal space, 153
  - plantar hyperkeratosis, 154
  - proximal phalanx (*see* Proximal phalanx)
- P**
- PASA. *See* Proximal articular set angle (PASA)
- Percutaneous surgery, static metatarsalgia
  - antero-posterior radiographs, 145
  - AOFAS forefoot score, 143
  - description, 139
  - indications, DMMO, 142
  - operative technique, 140
  - plantar hyperkeratosis, 143
  - post-operative care, 142, 145
  - Weil osteotomy, 139
- Phalangeal osteotomy procedures
  - combination, 164
  - hammertoe deformities, 163
  - transverse, 164
  - wedge, 164
- Plantarflexion contracture. *See* Proximal interphalangeal joint, fifth toe
- Plantar plate tenodesis
  - defined, 17–18
  - dorsal capsule, 196
  - dorsomedial portal, 199
  - modified, 201–202
  - overridden, toe deformity, 200
  - PDS 1 suture, 18, 197
  - suture retrieval, 197–199
- Portals, arthroscopic technique
  - cannula and trocar, 4, 5
  - dorsolateral and medial portals, MTP-1 compartment, 4, 6
  - plantar medial portal, 4
  - probe, 5
- Post-operation, DMMO
  - callus, 154, 157
  - cohesive bandaging, toes, 154, 156
  - description, 154
  - hybrid mini invasive surgery, 154, 159
  - radiograph prior, hybrid mini invasive surgery, 154, 158
- Postoperative bandaging
  - hallux valgus
    - description, 67–68
    - head, second metatarsal, 68
    - phase one dressing, 68, 69
    - phase two dressing, 68, 70
    - splint dressings, 68
  - non-Hammertoe lesser digit deformities
    - description, 173
    - first and second phases, 174, 176
    - minimal invasive procedures, 173
- Proximal articular set angle (PASA), 57
- Proximal interphalangeal joint, fifth toe
  - correction, deformity, 189
  - description, 182

Proximal interphalangeal joint,  
 fifth toe (*cont.*)  
 dorsiflexion,  
   metatarsophalangeal  
   joint and flexion, IPJ,  
   189, 190  
 plantar closing wedge  
   osteotomy, 189  
 postoperative management,  
 187–188  
 stable correction, deformity,  
 182, 183  
 surgical technique, 184–188  
 Proximal phalanx  
 articular surface, metatarsal  
   head, 26, 35  
 exostosectomy, 33  
 extensor hallucis longus, 39  
 3 mm toe separator, 40  
 osteochondral fractures, 27  
 osteotomy, 36

**R**

Reverdin-Isham procedure  
 advantages, 68–69  
 bunion deformities, 55  
 description, 60  
 disadvantages, 71  
 HAV deformity, 60–61  
 HAV disorders, 62–63  
 medial wedge osteotomy, 63, 64  
 metatarsal bone, 61  
 minimally invasive procedures  
   (*see* Minimally invasive  
   technique, hallux valgus)  
 minimally invasive surgery, 62  
 operative technique, 65  
 PASA, 61  
 postoperative bandaging (*see*  
   Postoperative bandaging)  
 postoperative management, 66  
 preoperative criteria, 63–65  
 proximal articular set angle, 60  
 Silver-Akin procedure/modified  
   McBride-Akin, 63  
 Reverdin osteotomy, 63, 64

**S**

Severe hallux valgus, 59, 62  
 Surgical technique  
   hallux valgus correction  
     intraoperative fluoroscopy,  
     96, 98  
     skin incision and Kirschner  
     wire insertion, 96, 97  
 metatarsal fractures  
   alignment, fluoroscopy  
     and guide pin, 211, 214  
   cannulated tap depth  
     verification, 213, 219  
   cast boot/short leg splint,  
   216, 223  
   fluoroscopic images,  
   216, 222  
   foot flat, 211, 213  
   guide pin placement,  
   213, 217  
   guide pin replacement,  
   216, 221  
   overdrilling, guide pin,  
   213, 218  
   sagittal plane alignment,  
   211, 215  
   screw length, 215–216, 220  
   sequential tapping,  
     protective sleeve,  
     213, 218  
   sural nerve and peroneus  
     brevis tendon  
     identification, 211, 216  
 proximal interphalangeal joint,  
 fifth toe  
 dorsal metatarsophalangeal  
   capsulotomy, 184  
 lateral condylectomy,  
 184, 186  
 metatarsal spacer, 186  
 osteotomy, proximal  
   phalanx, 184, 187–188  
 tenotomy, flexor  
   tendons, 184  
 tenotomy, tendon of  
   extensor digitorum  
   longus, 184, 185

**T**

## Tenotomy

- flexor tendons, 184
- tendon of extensor digitorum longus, 184, 185

## Toe deformity, arthroscopy

- flexor tendon transfer, 193–194
- lateral deviation deformity, 195
- plantar plate tenodesis, 195–202
- tension, extensor digitorum longus, 194

**V**

- V-shaped osteotomy, 105, 107, 117

**W**

- Wilson bunionectomy, 60

**X**

- Xi-scan portable fluoroscope, model 1000–1, 108, 110