

Developments in Ophthalmology

Editor: W. Behrens-Baumann

Vol. 29

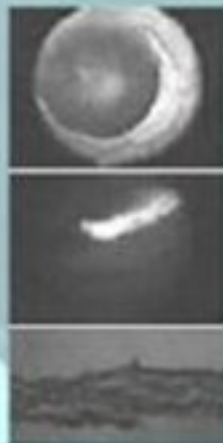Macular and Retinal Diseases

Recent Advances in Diagnosis and Therapy

Editors

P. Wiedemann

L. Kohen



KARGER

.....

Macular and Retinal Diseases

.....

Developments in Ophthalmology

Vol. 29

Series Editor

W. Behrens-Baumann, Magdeburg

KARGER

Basel · Freiburg · Paris · London · New York ·
New Delhi · Bangkok · Singapore · Tokyo · Sydney

.....

Macular and Retinal Diseases

Recent Advances

in Diagnosis and Therapy

Volume Editors *P. Wiedemann, Leipzig*
L. Kohen, Leipzig

30 figures, 4 in color and 7 tables, 1997

KARGER

Basel · Freiburg · Paris · London · New York ·
New Delhi · Bangkok · Singapore · Tokyo · Sydney

.....
Peter Wiedemann, Leon Kohen

Universitätsklinikum, Klinik und Poliklinik für Augenheilkunde
Liebigstrasse 14, D 04103 Leipzig

Continuation of 'Bibliotheca Ophthalmologica', 'Advances in Ophthalmology', and 'Modern Problems in Ophthalmology'

Founded 1926 as 'Abhandlungen aus der Augenheilkunde und ihren Grenzgebieten' by C. Behr, Hamburg and J. Meller, Wien

Former Editors: A. Bruckner, Basel (1938–1959); H. J. M. Wewe, Utrecht (1938–1962); H. M. Dekking, Groningen (1954–1966); E. B. Streiff, Lausanne (1954–1979); J. François, Gand (1959–1979); J. van Doesschate, Utrecht (1967–1971); M. J. Roper-Hall, Birmingham (1966–1980); H. Sautter, Hamburg (1966–1980); W. Straub, Marburg a. d. Lahn (1981–1993)

Library of Congress Cataloging-in-Publication Data

Macular and retinal diseases: recent advances in diagnosis and therapy / volume editors, P. Wiedemann, L. Kohen.

(Developments in ophthalmology; vol. 29)

Based on a symposium titled New approaches in the diagnosis and therapy of macular and retinal diseases, held Nov. 1996 in Leipzig, Germany.

Includes bibliographical references and indexes.

1. Macula lutea—Diseases—Atlases. 2. Retina—Diseases—Atlases.

I. Wiedemann, Peter. II. Kohen, L. (Leon) III. Series.

[DNLM: 1. Retinal Diseases—congresses. 2. Macula Lutea—congresses.

W1 DE998NG v.29 1998WW 270 M17515 1997]

RE661.M3M332 1997

617.7'35-dc21

ISBN 3-8055-6553-4 (hardcover: alk. paper)

Bibliographic Indices. This publication is listed in bibliographic services, including Current Contents® and Index Medicus.

Drug Dosage. The authors and the publisher have exerted every effort to ensure that drug selection and dosage set forth in this text are in accord with current recommendations and practice at the time of publication. However, in view of ongoing research, changes in government regulations, and the constant flow of information relating to drug therapy and drug reactions, the reader is urged to check the package insert for each drug for any change in indications and dosage and for added warnings and precautions. This is particularly important when the recommended agent is a new and/or infrequently employed drug.

All rights reserved. No part of this publication may be translated into other languages, reproduced or utilized in any form or by any means electronic or mechanical, including photocopying, recording, microcopying, or by any information storage and retrieval system, without permission in writing from the publisher.

© Copyright 1997 by S. Karger AG, P. O. Box, CH-4009 Basel (Switzerland)

Printed in Switzerland on acid free paper by Reinhardt Druck, Basel

ISBN 3-8055-6553-4

.....

Contents

VII Preface

- 1 Recent Developments in Scanning Laser Ophthalmoscopy**
Wolf, S. (Aachen)
- 8 Multifocal ERG Recording by the VERIS Technique and its Clinical Applications**
Kretschmann, U.; Gendo, K.; Seeliger, M.; Zrenner, E. (Tubingen)
- 15 Advances in the Management of Vitreomacular Traction Syndrome and Macular Hole**
Koerner, F.; Garweg, J. (Berne)
- 30 Use of Autologous Platelet Concentrate in Macular Hole Surgery: Report of 77 Cases**
Gaudric, A.; Paques, M.; Massin, P.; Santiago, P. Y.; Dosquet, C. (Paris)
- 36 Autologous Platelet Concentrate in the Surgical Management of Macular Holes**
Minihan, M.; Cleary, P. E. (Cork)
- 44 Hemorrhagic Macular Cysts in Terson's Syndrome and Its Implications for Macular Surgery**
Morris, R. (Birmingham, Ala.); Kuhn, F. (Birmingham, Ala./Pécs); Witherspoon, C. D. (Birmingham, Ala.); Mester, V. (Pécs); Dooner, J. (Birmingham, Ala.)
- 55 Complications in the Removal of the Posterior Vitreous Cortex**
Ripandelli, G.; Coppé, A. M.; Falsini, B.; Fedeli, R.; Stirpe, M. (Rome)
- 61 Epiretinal Macular Membranes: Pathogenesis and Treatment**
Miller, B. (Haifa)

- 64 Local Therapy of CMV Retinitis: A New Therapeutical Approach**
Fuchs, A.V.; Scheider, A.; Klauss, V.; Kampik, A. (Munich)
- 69 A Retained Catheter for Retrobulbar Administration of Interferon for Age-Related Macular Degeneration**
Lincoff, H. (New York, N. Y.); Kreissig, I.; Gelisken, F. (Tubingen); Stanga, P. (New York, N. Y.)
- 78 Experimental Therapies for Age-Related Macular Degeneration**
Soubrane, G.; Coscas, G. (Créteil)
- 85 Evaluation of Macular Therapy**
Blach, R. K. (London)
- 95 Author Index**
- 96 Subject Index**

.....

Preface

On the occasion of the construction of the New University Eye Hospital in Leipzig, Germany, a symposium was held in November 1996, under the title 'New approaches in the diagnosis and therapy of macular and retinal diseases'. The aim of the symposium was for internationally recognized experts to inform the participants regarding the status, goals and perspectives of macular and retinal research.

The symposium was a success due to the great efforts of the speakers and we are grateful for their excellent presentations. In order to share some of the ideas and knowledge presented in Leipzig, we collected most of the papers.

New diagnostic techniques are presented by Wolf and Kretschmann. Different experiences in the surgery of macular holes are described by Körner, Cleary and Gaudric. Surgery of Terson's syndrome is presented by Kuhn and Morris, and epiretinal membrane surgery by Miller. Stirpe refers to complications in the removal of the posterior vitreous cortex. The use of an intraocular implant for drug delivery is explained by Kampik group. Kreissig and Lincoff introduce the therapeutic balloon for the treatment of AMD, while Soubrane gives a review of current experimental therapies for AMD. Blach points out the problems of macular therapy and evaluates the treatment strategies.

Transplantation into the subretinal space, gene therapy of retinal diseases, molecular-based diagnosis, retina implant, and cellular and biochemical aspects of retinal diseases will be published in *Ophthalmic Research*.

We are very grateful to the editors of *Developments in Ophthalmology* and to the publisher for the opportunity to present these subjects in their book series.

Peter Wiedemann, Leipzig
Leon Kohen, Leipzig

.....

Recent Developments in Scanning Laser Ophthalmoscopy

Sebastian Wolf

Augenlinik der Medizinischen Fakultät der RWTH Aachen
(Director: Prof. B. Kirchhof), Aachen, Germany

The scanning laser technique employs a new electro-optical principle that does not require optical image formation [1, 2]. This allows not only imaging of the retina with different wavelength [3] but permits a variety of new applications like angiography [4, 5], blood flow measurement [6, 7], reflectometry [8], retinal densitometry [9], microperimetry [10–12], and other functional testings [13–15]. Currently, several instruments for retinal imaging or functional testings using the scanning laser technique are commercial available from different companies.

Methods and Materials

The scanning laser technique has been described previously in detail [1, 2]. In short, for illumination a scanning laser ophthalmoscope uses a laser beam, focused by the optical system of the eye to a small moving spot, that is swept across the retina to form a rectangular raster. The light returning from the retina is converted by a high sensitivity solid state detector into an electronic signal from which a two dimensional image is constructed electronically [16]. From this electronic signal a standard video signal can be created and recorded with a video recorder. Furthermore, the electronic signal can be directly digitized and stored on a computer. Since in scanning laser systems only a small point of the retina is illuminated, only a very small area of the pupil is used for illumination and the rest is available for light collection. Therefore, scanning laser systems are highly light efficient and reduce light intensities for illumination of the retina for imaging by a factor of 100 1,000. This permits recording of a very high

number of images without reaching the maximum permissible light level for retinal irradiance [17, 18].

Additionally, the optical principal of scanning laser systems allows different imaging modes. In the direct imaging mode the photodetector in the scanning laser systems accepts all light collected by the instrument. These nonconfocal images suffer from reduction of contrast due to light which is returned to the detector after being scattered or reflected by layers from outside the optical plane. In the confocal imaging mode a pinhole, which is conjugate to the laser focus, is placed in front of the detector [16]. The size of the pinhole determines the degree of confocality of the image, a small pinhole produces a highly confocal image. In the confocal mode the depth of field is very small producing optical sections of the fundus. Using an annular aperture instead of the small pinhole in front of the detector all light reflected from the focal plane is blocked and only stray light produces the image. This mode is called the indirect mode.

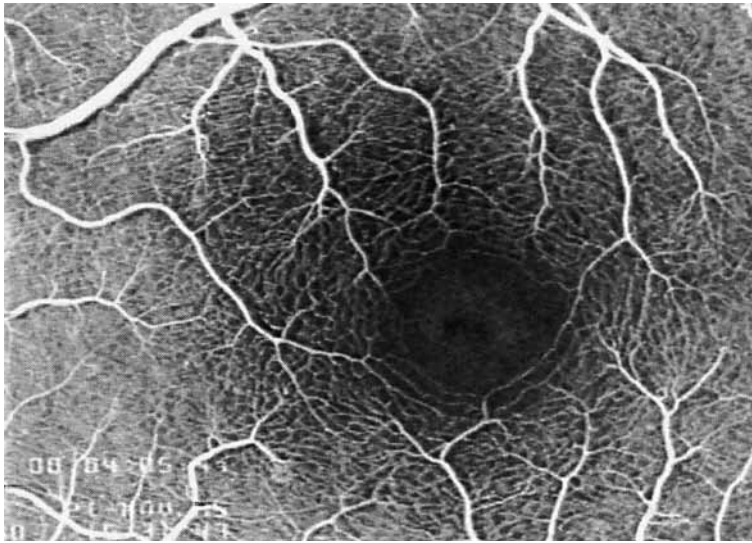
Another important feature of scanning laser systems is the ability to modulate the intensity of the illumination by varying the laser power by means of an acousto optic modulator. This allows to produce a graphic design on a patient's retina that is simultaneously viewed by the patient and observed on the fundus on the electronic image. Controlling the acousto optic modulator by a computer a variety of psychophysical test can be performed.

Depending on the application different lasers are used as light source in scanning laser systems. For fluorescein angiography an Argon laser (wavelength 488 and 514 nm) is used. Additionally, autofluorescence images can be recorded with this laser [19]. For indocyanine green angiography and infrared imaging diode infrared lasers (wavelength: 788 and 820 nm) are used. Microperimetry is usually performed with HeNe laser illumination (wavelength 633 nm).

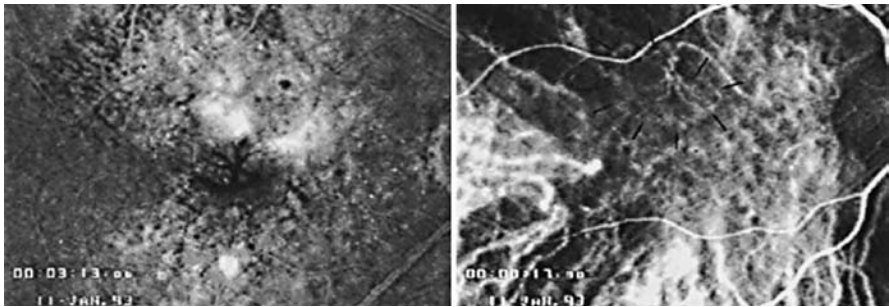
Results

Fluorescence Angiography

The distinctive features of scanning laser imaging improve the signal-to-noise ratio and thus enhance the contrast of the image as compared with standard imaging techniques. Beside the high quality of the fluorescence angiographic images (fig. 1, 2), the high frame rate (up to 60 Hz) allows a detailed analysis of the blood flow dynamics during angiography. The improved resolution of scanning laser angiograms made the acquisition of capillary flow velocities and the assessment of capillary density in the perifoveal network possible [7]. In various diseases and under varying physiological conditions capillary flow velocities and capillary density in the perifoveal network have been assessed [20–22]. These studies have shown that capillary density and flow velocity are reduced in patients with diabetes mellitus even without diabetic retinopathy [21]. Similar results were found in patients with systemic hypertension [22].



1



2

Fig. 1. Fluorescein angiographic image (20° field; SLO 101, Rodenstock) of the perifoveal capillary network in a patient with arterial hypertension.

Fig. 2. Fluorescence angiographic study (40° field; SLO 101, Rodenstock) in a patient with occult CNV. Left: Fluorescein angiogram; right: ICG angiogram with visible CNV (arrows).

Autofluorescence Imaging

We used a standard confocal scanning laser ophthalmoscope (HRA, Heidelberg Engineering) for visualization and mapping of retinal autofluorescence. For excitation the argon laser blue line (wavelength 488 nm) was used at maximal intensity (300 $\mu\text{W}/\text{cm}^2$). In the detection pathway an interference filter (band pass with >90 % transmission for 505–700 nm) and a confocal stop were inserted. The images were digitally recorded. We

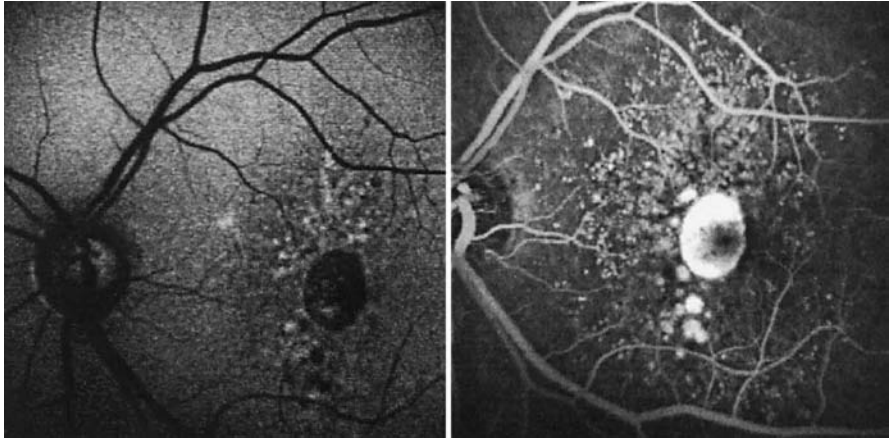


Fig. 3. Autofluorescence image (left) and fluorescein angiographic study (right) (30° field; HRA, Heidelberg Engineering) in a patient with geographic atrophy secondary to AMD. Note the decreased autofluorescence in the area of atrophy.

have analyzed the autofluorescence images of patients with age related macular degeneration (AMD). Areas of hyperpigmentation at the level of the RPE showed increased autofluorescence, whereas areas of depigmentation appeared hypofluorescent in the autofluorescent images in all cases (fig. 3). Patients with AMD demonstrated focal accumulation of fluorescent material – most likely lipofuscin. Thus, the scanning laser technique combined with an image analyzing system may help to identify eyes at risk for the development of exudative AMD.

Microperimetry

Currently, only the scanning laser ophthalmoscope (SLO-101, Rodenstock Instr., Germany) can be used for fundus perimetry. For retinal imaging an infrared diodelaser (780 nm) is used. Background illumination and stimuli are generated with a HeNe laser (633 nm) modulated by an acousto-optic modulator (AOM). The AOM is controlled by a microcomputer. In our system we use an Image Technology FG100-AT board. Our current software for fundus controlled perimetry allowed for static automatic microperimetry by means of a suprathreshold staircase strategy [10]. Light intensities could be varied between 0 and 27.9 dB above background. For clinical studies the first stimulus is presented with 10 dB, thereafter light intensities are increased by 4 dB after a correct answer and decreased by 2 dB, if the stimulus is not seen. During the test procedure a fixation cross

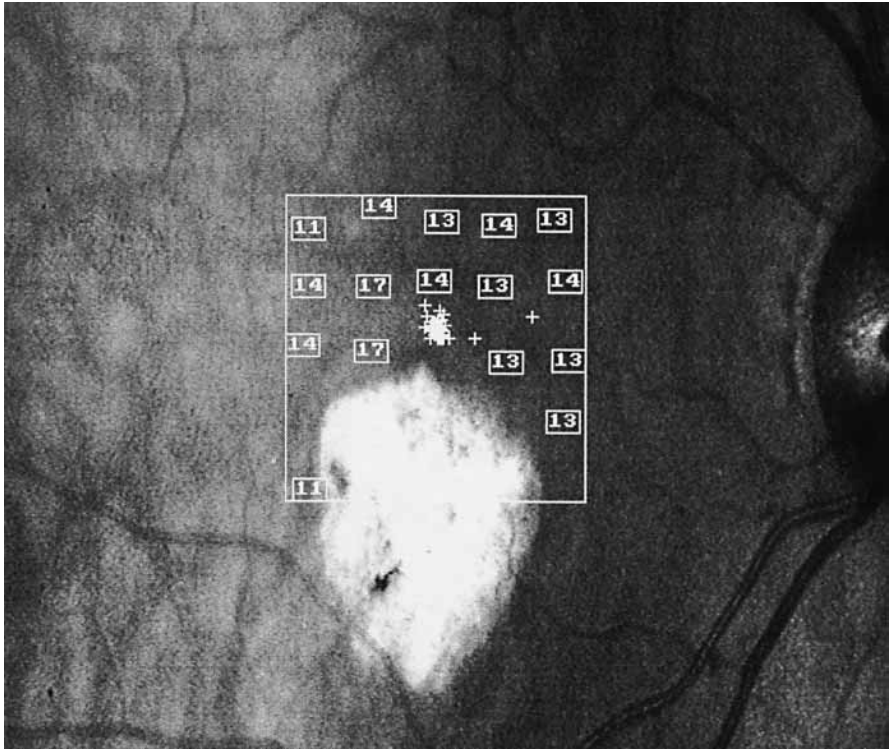


Fig. 4. Result of a microperimetry in a patient with an extrafoveal laser scar after laser photocoagulation for a well defined choroidal neovascularization. The numbers indicate the local retinal sensitivity expressed in dezibel.

(size: 36×36 min arc; contrast: 0 dB) is presented. Fixation and eye movements are controlled by manual fundus tracking. Therefore, it is possible to calculate the circle area that would encompass 75 % of all fixation points and the center of fixation. The radius of this circle is given to quantify fixation stability. Figure 4 shows the result of a microperimetry in a patient with AMD after laser photocoagulation for an extrafoveal CNV.

Discussion

The scanning laser ophthalmoscope provides excellent fluorescein and indocyanine green angiographic images [23, 24]. The high frame rate allows not only morphologic analysis of the angiograms but permits additionally the assessment of retinal hemodynamics [20–22]. Recently, visuali-

zation and mapping of fundus autofluorescence with the scanning laser ophthalmoscope have demonstrated the possibility to assess the metabolic activity of the RPE [19]. This technique may add a great deal of information about the correlation between accumulation of autofluorescent material in the RPE and the progression of AMD. Equally significant for the clinical assessment of macular diseases is the ability of the scanning laser technique to provide complex static or dynamic testing for identifying the retinal loci of functional deficits.

Additional clinical applications with scanning laser systems are currently under investigation. Further technical improvement will expand the clinical use of the scanning laser technique in the future.

References

- 1 Klingbeil U, Plesch A, Bille J, Käfer O: Meßverfahren in der Augenhintergrundsdiagnostik mit Laserscannern. *Fortschr Ophthalmol* 1982;79:275-277.
- 2 Webb RH, Hughes GW, Pomerantzeff O: Flying spot TV ophthalmoscope. *Appl Opt* 1980;19:2991-2997.
- 3 Elsner AE, Burns SA, Weiter JJ, Delori FC: Infrared imaging of subretinal structures in the human ocular fundus. *Vision Res* 1996;1:191-205.
- 4 Gabel VP, Birngruber R, Nasemann J: Fluorescein angiography with the scanning laser ophthalmoscope (SLO). *Lasers Light Ophthalmol* 1988;2:35-40.
- 5 Scheider A, Schroedel C: High resolution indocyanine green angiography with a scanning laser ophthalmoscope. *Am J Ophthalmol* 1989;108:458-459.
- 6 Tanaka T, Muraoka K, Shimizu K: Fluorescein fundus angiography with scanning laser ophthalmoscope: Visibility of leukocytes and platelets in perifoveal capillaries. *Ophthalmology* 1991;98:1824-1829.
- 7 Wolf S, Arend O, Toonen H, Bertram B, Jung F, Reim M: Retinal capillary blood flow measurement with a scanning laser ophthalmoscope. Preliminary results. *Ophthalmology* 1991;98:996-1000.
- 8 Elsner AE, Burns SA, Huges GW, Webb RH: Quantitative reflectometry with a scanning laser ophthalmoscope. *Appl Opt* 1992;31:3697-3710.
- 9 van Norren D, vd Kraats, J: Imaging retinal densitometry with a confocal scanning laser ophthalmoscope. *Vis Res* 1989;29:1825-1830.
- 10 Toonen F, Remky A, Janssen V, Wolf S, Reim M: Microperimetry in patients with central serous retinopathy. *German J Ophthalmol* 1995;4:311-314.
- 11 Timberlake GT, Mainster MA, Webb RH, Hughes GW, Trempe CL: Retinal localization of scotoma by scanning laser ophthalmoscopy. *Invest Ophthalmol Vis Sci* 1982;22:91-97.
- 12 Sunness JS, Schuchard RA, Shen N, Rubin GS, Bagnelie G, Haselwood DM: Landmark driven fundus perimetry using the scanning laser ophthalmoscope. *Invest Ophthalmol Vis Sci* 1995;36:1863-1874.
- 13 Rohrschneider K, Becker M, Kruse FE, Fendrich T, Voelcker HE: Stability of fixation: results of fundus controlled examination using the scanning laser ophthalmoscope. *German J Ophthalmol* 1995;4:197-202.
- 14 Culham LE, Fitzke FW, Timberlake Gt, Marshall J: Use of scrolled text in a scanning laser ophthalmoscope to assess reading performance at different retinal locations. *Ophthalm Physiol Opt* 1992;12:282-286.
- 15 Teping C, Wolf S, Schippers V, Plesch A, Silny J: Anwendung des Scanning Laser Ophthalmoskops zur Registrierung des Muster-ERG und VECF. *Klin Mbl Augenheilk* 1989;195:203-206.

- 16 Webb RH, Hughes GW, Delori FC: Confocal scanning laser ophthalmoscope. *Appl Opt* 1987; 26:1492 1499.
- 17 Delori FC, Parker JS, Mainster MA: Light levels in fundus photography and fluorescein angiography. *Vis Res* 1980;20:1099 1104.
- 18 Klingbeil U: Safety aspects of laser scanning ophthalmoscopes. *Health Phys* 1986;51:81 93.
- 19 von Rückmann A, Fitzke FW, Bird AC: Distribution of fundus autofluorescence with a scanning laser ophthalmoscope. *Br J Ophthalmol* 1995;79:407 412.
- 20 Arend O, Wolf S, Jung F, et al: Retinal microcirculation in patients with diabetes mellitus: dynamic and morphologic analysis of perifoveal capillary network. *Br J Ophthalmol* 1991;75:514 518.
- 21 Wolf S, Arend O, Toonen H, Bertram B, Reim M: Measurement of retinal micro and macrocirculation in patients with diabetes mellitus with scanning laser ophthalmoscopy. *Clin Vision Sci* 1992;7:461 469.
- 22 Wolf S, Arend O, Schulte K, Ittel TH, Reim M: Quantification of retinal capillary density and flow velocity in patients with essential hypertension. *Hypertension* 1994;23:464 467.
- 23 Scheider A, Kaboth A, Neuhauser L: Detection of subretinal neovascular membranes with indocyanine green and an infrared scanning laser ophthalmoscope. *Am J Ophthalmol* 1992; 113:45 51.
- 24 Wolf S, Wald KJ, Elsner AE, Staurengi G: Indocyanine green choroidal videoangiography: A comparison of imaging analysis with the scanning laser ophthalmoscope and the fundus camera. *Retina* 1993;13:266 269.

Priv. Doz. Dr. Ing., Dr. med. S. Wolf, Augenklinik der Medizinischen Fakultät der RWTH Aachen,
Pauwelsstrasse 30, D 52057 Aachen (Germany)
Fax: (02 41) 8 88 84 08

.....

Multifocal ERG Recording by the VERIS Technique and Its Clinical Applications

Ulf Kretschmann, Krisna Gendo, Mathias Seeliger, Eberhart Zrenner

Department of Pathophysiology of Vision and Neuro Ophthalmology,
University Eye Hospital Tübingen, Germany

The multifocal ERG [1] using a m-sequence stimulation technique allows simultaneous electroretinographic mapping of the central retina of both eyes with a high resolution in a considerably short time. It is therefore considered to be a promising diagnostic tool in retinal diseases [2–5]. The VERIS (visual-evoked response imaging system) Scientific program has already made use of the scalar product method to visualize the spatial distribution of the response density. However, it was difficult to relate this ERG topography directly to normative data. Additional time-consuming procedures were necessary for the comparison between patient results and normal values, which have limited the value of the system in a clinical setting.

For such applications, VERIS Clinic™ was developed to provide an immediate comparison of a patient's multifocal ERG with the values of a normal collective. It requires the examination of a group of normal volunteers, under the same conditions as those, for patient recordings prior to its use. The local ERGs of the normals are combined to form an average focal ERG, which is then used as an appropriate template in the calculation of a patient's scalar product of the same region.

The aim of the present study was to test the clinical applicability of the VERIS Clinic system in patients with maculopathies of different etiology and hereditary photoreceptor degenerations.

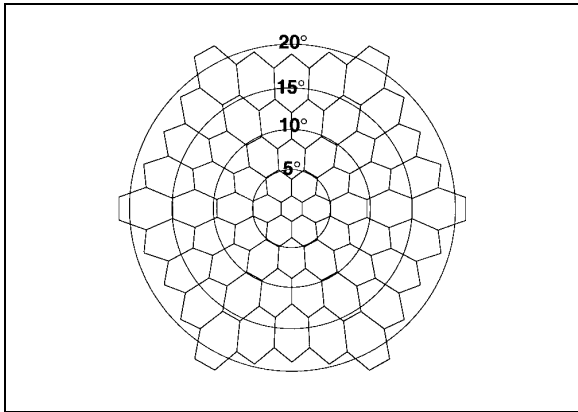


Fig. 1. The geometry of the stimulus is shown. Additionally to the 61 hexagons of the stimulus their position within the visual field is indicated by isopters.

Table 1. Summary of the clinical data of the patients presented here

Patient	Age	Sex	Diagnosis	Visual acuity	Visual field	Ganzfeld ERG
P1	44	male	M. Stargardt	0.08/0.4	central scotoma	normal
P2	26	male	retinopathia solaris	0.3/0.6	central scotoma	normal
P3	35	male	RCS	1.0/0.6	OS: central scotoma	normal
P4	30	female	RP	1.25/1.25	ring scotoma	scotopic and photopic reduced
P5	11	female	cone dystrophy	0.05/0.05	central scotoma	photopic reduced

Subjects and Methods

The clinical characteristics of 5 patients are summarized in table 1. Fifty normal volunteers, aged 22–55 (median 34 years), were used as a control group. Inclusion criteria were a visual acuity of 1.0 (20/20) or better, refractive errors of less than ± 6.0 dpt (spherical equivalent), and no history of relevant eye diseases.

The stimulus was presented on a bright black and white 17" monitor with a frame rate of 75 Hz (Chuomusen, model MD B 1700, Japan). A stimulus field consisting of 61 hexagons within a 22° visual field was used (fig. 1). The diameter of the central hexagon

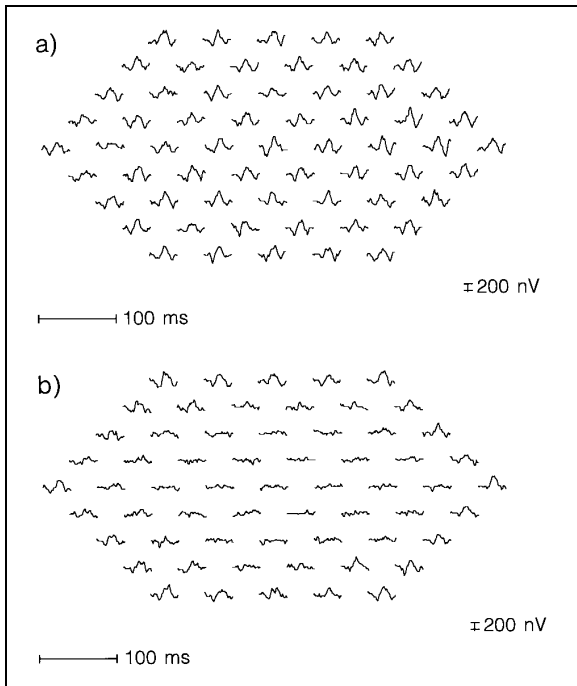


Fig. 2. 61 focal ERGs from the left eye of a normal volunteer (a) and patient 1 (b) are plotted.

was 3.2° . The array was scaled with eccentricity, so that the most eccentric areas were 4.7 times larger than the central area. A grey central fixation point was used. Each element, which was either black (3.0 cd/m^2) or white (200.0 cd/m^2 , 97 % contrast), changed following a binary m sequence independently from other elements. The mean luminance was 101.5 cd/m^2 .

Both eyes were dilated with tropicamide (0.5 %) and phenylephrine (5 %), and the refractive errors were corrected. The distance between monitor and subject was adjusted according to an implemented nomogram to ensure a similar retinal magnification of the stimulus image regardless of the individual refraction. In case of emmetropia, a correction lens of +3.0 dptr was used and the distance set to 33 cm. The ERG responses were recorded by means of DTL fiber electrodes (Tomey, Japan), positioned on the conjunctiva directly beneath the cornea and attached with its two ends at the lateral and nasal canthus, respectively. The reference and ground skin electrodes were attached to the ipsi lateral temple and forehead, respectively. The subjects position was central in front of the monitor and the fixation and recording was binocular. An exception was made in the case of squinting problems, where fixation and recording was monocular.

The evoked potential was amplified ($\times 100,000$) and filtered (10 300 Hz; Grass amplifier, model 12, Quincy, USA). The sampling rate of the AD converter was 16 samples per frame, yielding a temporal resolution of 0.83 ms.

The overall duration of a recording session was about 5 7 min, which included 16 recording segments, during which the subjects were not allowed to blink or move.




Fig. 3. Data sheet of patient 1 with M. Stargardt (OS). Figure 3*a* shows the three dimensional graph of response density. For comparison, the average response density distribution of the 50 normal volunteers is presented in figure 3*b*. In 3*c* the deviation between patient and normal response density is presented.

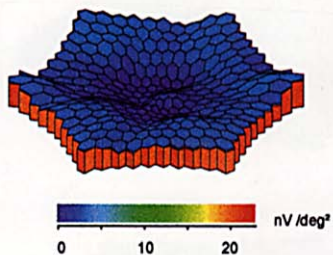
The local ERG responses from the 61 stimulated areas were analyzed with a fast m transform algorithm [6, 7]. To evaluate the function of the outer retina, the first order kernel was calculated (VERIS Clinic program for the power Macintosh, EDI, San Francisco, Tomey, Nagoya, Japan).

For each subject, a trace array containing all 61 focal ERGs was obtained. A three dimensional ERG topography visualizing the response density calculated by the scalar product method [1] was generated from this data. Additionally, a distribution of the difference between the ERG topography of the patients and the average of the 50 normal volunteers, was calculated and visualized in three dimensional graphs.

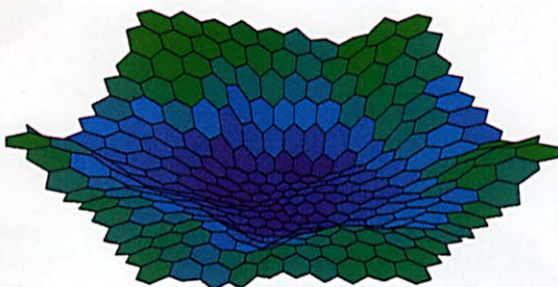
Results

In the 3 patients with maculopathies, the central focal ERGs were not recordable or strongly attenuated, whereas peripheral responses were normal. There was, however, a difference in the area affected. In both eyes of patient 1 with Stargardt's disease, valid signals were obtained from the


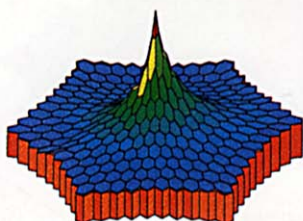
a) Patient / Normal Projection



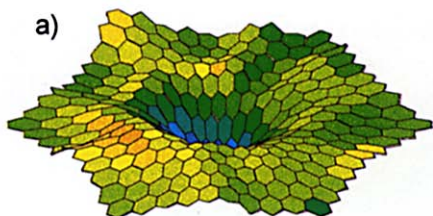
b) Patient / Normal Deviation



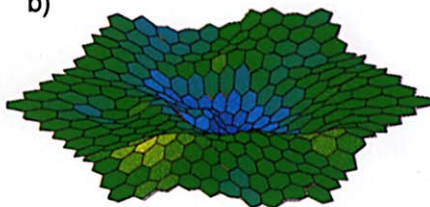
c) Normal Reference



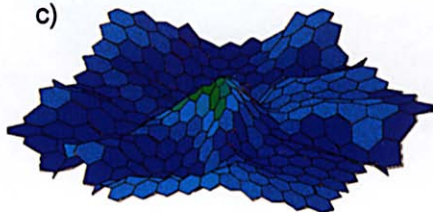
a)





b)



c)



d)






Fig. 4. The response density deviation plots of patient 2 with retinopathia solaris (a), patient 3 with RCS (b), patient 4 with RP (c), and patient 5 with cone dystrophy (d).

outermost ring only (figs. 2, 3). In the patients with solar and central serous retinopathy (RCS), the area of subnormal response densities was much smaller (fig. 4a, b). In the RCS patient, the defect was unilateral.

The reverse pattern is typical for retinitis pigmentosa (RP), where, as in patient 4, only macular responses were within the normal range. In the deviation plot (fig. 4c), this is indicated by the central green area surrounded by low-response density. Reduced response density values in the entire test field as in figure 4d are typical for cone dystrophies.

Discussion

With multi-input stimulation techniques [1, 8], numerous focal ERGs can be recorded simultaneously in a considerably short time. The cross-correlation algorithm of Sutter allows one to obtain 61 to 241 focal ERG responses per eye within 4–16 min recording time. Studies comparing mul-

tifocal and Ganzfeld ERG [9] have demonstrated the close relationship between the first order kernel response of the multifocal ERG and the a-wave-b-wave complex, as well as oscillatory potentials of the flash ERG.

This new method will certainly help to elucidate local dysfunction in patients where the Ganzfeld ERG response is unchanged, as in localized maculopathies.

Generalized receptor dystrophies can usually be detected by Ganzfeld ERG according to ISCEV standards [10]. Multifocal ERG can, however, add more detailed information about the topography – and potentially the progression – of dysfunctional areas. In retinitis pigmentosa (RP), a concentric constriction of the responsive areas was found early in the course of the disease [5]. Additionally, the association between amplitudes and implicit times was found to vary among different diseases. In RP, amplitude reduction and implicit time rise are directly correlated, whereas in Stargardt’s disease, this is not true.

Using the VERIS technique, 61 local ERGs from each eye can be obtained in a 4 min recording session. The VERIS dataset with 122 ERG waveforms is much more complex than a Ganzfeld ERG with its 2×5 mandatory waveforms according to the ISCEV standard and therefore needs an easy-to-be-grasped presentation.

The deviation plot of the VERIS Clinic gives a satisfactory summary of this complex information that can, because of its similarity to common reports of visual field tests, be evaluated by an ophthalmologist without special training. Furthermore, normal ERG response density and psychophysical light sensitivity are both maximal in the fovea, with a decrease towards the periphery and a minimum in the area of the blind spot. However, it should be mentioned that in some special cases a review of the original data (i. e. the trace array) appears advisable, since due to the nature of data reduction procedures, some of the information is lost.

Reference

- 1 Sutter EE, Tran D: The field topography of ERG components in man. I. The photopic luminance response. *Vis Res* 1992;32:433 446.
- 2 Kondo M, Miyake Y, Horiguchi M, Suzuki S, Tanikawa A: Clinical evaluation of multifocal electroretinogram. *Invest Ophthalmol Vis Sci* 1995;36:2146 2150.
- 3 Bearnse MA, Sutter EE: Imaging localized retinal dysfunction with the multi focal electroretinogram. *Opt Soc Am J A* 1996;13:634 640.
- 4 Kretschmann U, Rütther K, Usui T, Zrenner E: ERG campimetry using a multi input stimulation technique for mapping of retinal function in the central visual field. *Ophthalmic Res* 1996;160:303 311.
- 5 Seeliger MW, Kretschmann UH, Rütther RW, Apfelstedt Sylla E, Zrenner E: ERG campimetry in retinitis pigmentosa. *Invest Ophthalmol Vis Sci* 1996;37:S341.

- 6 Sutter EE: The fast m transform: A fast computation of cross correlations with binary m sequences. *Siam J Comput* 1991;20:686-694.
- 7 Sutter EE: A deterministic approach to nonlinear systems analysis; in Printer RB, Nabet B (eds): *Nonlinear Vision: Determination of Neutral Receptive Fields, Function, and Networks*. Boca Raton, CRC Press, 1992;pp. 171-220.
- 8 Usui S, Nagasaka E: Spatial distribution of local flash ERG by multi input stimulation. *Doc Ophthalmol* 1994;88:57-63.
- 9 Hood DC, Seiple W, Holopigian K, Greenstein V: A comparison of the components of the multi focal and full field ERGs. *Vis Neurosci*, 1997;14:533-544.
- 10 Marmor MF, Zrenner E: Standard for clinical electroretinography (1994 upgrade). *Doc Ophthalmol* 1995;89:199-210.

U. Kretschmann, Department of Pathophysiology of Vision and Neuro Ophthalmology,
University Eye Hospital, Schleichstraße 12-16, D 72076 Tübingen (Germany)
Fax (07071) 29 50 38

.....

Advances in the Management of Vitreomacular Traction Syndrome and Macular Hole

Fritz Koerner, Justus Garweg

Department of Ophthalmology, University of Bern, Switzerland

The management of macular holes, with or without retinal detachment, has benefited considerably from the biomicroscopic and histopathologic identification of changes at the vitreomacular interface, as well as from advances in vitreoretinal surgery, generally.

Idiopathic macular holes are a major cause of impairments in visual function, particularly in older women. And in the United States alone, their incidence has been estimated at around 100,000 people [1].

Pathogenesis of Macular Holes

Idiopathic macular holes are distinct from retinal detachment with macular hole, which latter condition is often associated with myopia. In a consecutive series of 80 eyes which had undergone surgery for macular hole, retinal detachment was extant in 66 cases (82.5%), and among these, myopia and high myopia (>10 diopters) were prevalent (table 1).

Shrinkage of the epimacular vitreous cortex has been recognized as the basic mechanism underlying the pathogenesis of macular holes [2-5]. Neither the development of macular cysts and impending holes nor their progression to full-thickness lesions depend on posterior vitreous detachment [6, 7]; indeed, early-stage macular holes may even regress if the posterior vitreous has detached [7].

Four stages in the clinical development of macular holes may be distinguished [2]: Dehiscence of the foveal receptor layer is defined as im-

Table 1. Prevalence of myopia and proliferative vitreoretinopathy (PVR) in cases of idiopathic macular hole and in those with retinal detachment and macular hole

	Idiopathic macular hole		Macular hole with retinal detachment	
	n	%	n	%
Total number of cases	14		66	
Myopia (≤ 10 D)	1	7	9	14
High myopia (> 10 D)	0	0	31	47*
PVR	5	35 ¹	19	29

* $p < 0.001$ (Fisher exact p , two tailed test).

¹ Epimacular membrane present.

pending macular hole (stage 1). Stage 2 is characterized by the manifestation of small – and stage 3 by that of larger – full-thickness macular holes *without* posterior vitreous detachment, in association with which there is usually a cuff of subfoveal fluid. Stage 4 is attained when complete detachment of the vitreous has occurred. The biomicroscopic manifestation of prefoveal opacification has been suspected of bespeaking a contracted condensation of premacular vitreous cortex [8], and histopathologic analyses of such regions have borne out this impression: these pseudo-opercula are not comprised of retinal tissue [9–11].

Certain cases in which macular pucker or epimacular membrane occur in association with pseudoholes may be falsely diagnosed as true macular holes, but they should be considered as distinct entities [12–15] and not confused with the latter. On the other hand, full-thickness macular holes may, in certain cases, be caused by tangential traction of epiretinal membranes [16], and an association between cystoid macular edema and idiopathic macular holes has been demonstrated histologically [16, 17].

A clinical distinction between pseudo- and full-thickness macular holes may be facilitated by use of a laser aiming-beam test [18], and laser biomicroscopy is known to aid the identification of vitreomacular separation [19]. Optical coherence tomography (OCT) is a new sophisticated technique which permits macular cysts and impending holes to be distinguished from full-thickness ones; it also renders possible a visualization of

vitreo-macular separation and measurement of macular hole diameter [20].

Conventional Surgical Methods for the Treatment of Retinal Detachment with Associated Macular Holes

Retinal detachment in association with a macular hole has in the past been treated by posterior scleral indentation either with diathermy, photocoagulation or cryopexy. Posterior scleral indentation was achieved either by use of a radial [21–24] or absorbable fibrin sponge [25], by creating a scleral pocket [26], by subchoroidal implantation of hyaluronic acid [27], or by a silver clip [28–30].

A review of 277 cases, published before 1982, reveals that reattachment was achieved in 74 % of cases [21, 25, 31–34]. According to recent retrospective studies, vitrectomy in conjunction with gas-injection yielded better visual results than did macular diathermy and/or buckling [35, 36]. Aspiration of liquid vitreous followed by intravitreal gas-injection alone, i. e. without effecting scleral buckling and macular coagulation, has been reported to be successful in 16 of 19 cases [37].

Vitrectomy and Fluid-Gas Exchange for Retinal Detachment with Macular Hole

Gonvers and Machemer [38] proposed in 1982 the performance of vitrectomy for the treatment of eyes with retinal detachment and macular holes. The rationale behind a direct vitreoretinal approach was the release of vitreoretinal traction which is recognized as the principal cause of macular holes. Initially, a vitrectomy was combined with coagulation of the macular hole in about 20 % of the cases, hyaluronic acid, gases like sulfur hexafluoride and perfluoropropane, air, or silicone oil [39–42] being used as tamponades. But it subsequently became apparent that this coagulation step was unnecessary, a review of 213 cases published between 1982 and 1986 disclosing the reattachment rate to be as high as 82 % when vitrectomy was performed without macular coagulation [38, 43–54].

Although early macular redetachment after initial surgery may still occur in about 20 % of instances, a final reattachment of the macula is now being achieved in an average of 90 % of cases which have undergone vitrectomy and gas injection [36].

Autologous Blood and Tissue Adhesives for Macular Hole Surgery in Eyes with Retinal Detachment

Early postoperative reopening of macular holes is always a potential threat, especially in highly myopic eyes, and in an endeavor to minimize this risk, various adjunctive measures have been proposed to facilitate macular adhesion.

Since 1985, we began to use autologous blood as a sealant during vitrectomy, particularly in highly myopic eyes which were suspected of having reduced macular adhesion properties owing to posterior chorioretinal atrophy [55]. In a recent retrospective study [unpubl.], we analyzed the postoperative reattachment rate and visual function in 80 consecutive eyes which had undergone vitrectomy for macular holes either in association with or without retinal detachment. Autologous blood was applied to the macular hole after vitrectomy and fluid/air exchange in 40 cases, whilst the other 40 eyes served as controls (no adjunctive treatment with autologous blood). A significant postoperative increase in mean visual acuity occurred only in those eyes which had received topical autologous blood treatment, this being especially so in myopic eyes.

Autologous blood has also been shown to facilitate separation of the posterior vitreous cortex from the macular area [56].

Cyanoacrylate tissue sealants have also proved to be beneficial in improving macular adhesion after vitrectomy. In one study comprised of 9 such cases, 8 of which had previously undergone unsuccessful vitreoretinal surgery, complete reattachment was achieved in 8 instances [57]. And in another series employing such a sealant, visual improvement was reported in 76 % of the instances (n = 15) [58].

Vitrectomy for Impending and Idiopathic Full-Thickness Macular Holes

In recent years, eyes with idiopathic macular holes at stages 2–4 as well as impending ones (stages 1 A and 1 B), have been increasingly considered as candidates for vitreoretinal surgery [59].

Special techniques have been described for the suctioning and peeling away of vitreous cortex, which is often firmly attached to the posterior pole, macular region and optic disc in stage 1–3 macular holes [60, 61]. We have found that the localization and subsequent peeling of adherent vitreous cortex, under indirect ophthalmoscopic control or by use of the operating microscope, may be considerably facilitated by intraoperative

automatic air infusion. And intravitreal injection of autologous blood also helps to identify the epimacular vitreous cortex [62].

Conflicting opinions exist on the use of vitreoretinal surgery for impending macular holes. In a randomized multicenter trial, the benefit of vitrectomy for stage 1 macular holes was not borne out: 37 % of operated cases progressed to full-thickness holes compared with 40 % in eyes randomized for observation [63]. But in another study [13], a lower rate of progression occurred in 26 % of the instances. Visual improvement after vitrectomy for stage 1 macular holes has been reported in over 80 % of the cases [12, 61] and appears to be more commonly achieved in such eyes than in those with full-thickness holes.

Albeit so, vitreoretinal surgery is being increasingly undertaken in the latter instances (stages 2–4). Criteria for anatomical success include closure of the hole, i. e. reattachment of the cuff of subretinal fluid, and prevention of subsequent retinal detachment. And on this basis, success is currently being achieved in 58–97 % of the instances [64–73].

Adjunctive Agents Used to Facilitate Healing of Macular Holes

In a series of 23 cases of macular hole with associated retinal detachment, vitrectomy was performed in conjunction with topical application of autologous blood [55]; 57 % of the eyes were highly myopic. Final reattachment of the retina was achieved in 87 % of the instances, and a visual improvement in 78 %. In a larger series of 80 eyes, application of autologous blood to the hole yielded a significantly higher rate of visual improvement than did vitrectomy without such adjunctive treatment (see above; fig. 1).

Human [74] or bovine thrombin, the latter in combination with autologous fibrinogen [75], as well as autologous serum, have been employed as adjuncts both in humans [76–78] and experimental animals [79, 80]. And it has been argued that certain serum cytokines such as those known to act in the capacity of growth factors, could conceivably induce fibrocellular proliferation and thus also facilitate chorioretinal adhesion at the site of a macular hole.

TGF- β 2, with its capacity to promote wound healing, appears to be a particularly effective adjunct in macular hole surgery, as evidenced by the high rates of closure and visual improvement achieved [81–85] when it is employed at sufficiently high doses [81]. By use of this agent, it is even possible to avoid peeling of epimacular membranes [83]. And reopened macular holes have also been successfully retreated with TGF- β 2 [82, 84, 85]. However, the limited availability and high costs of this substance thwart its general use in macular hole surgery.

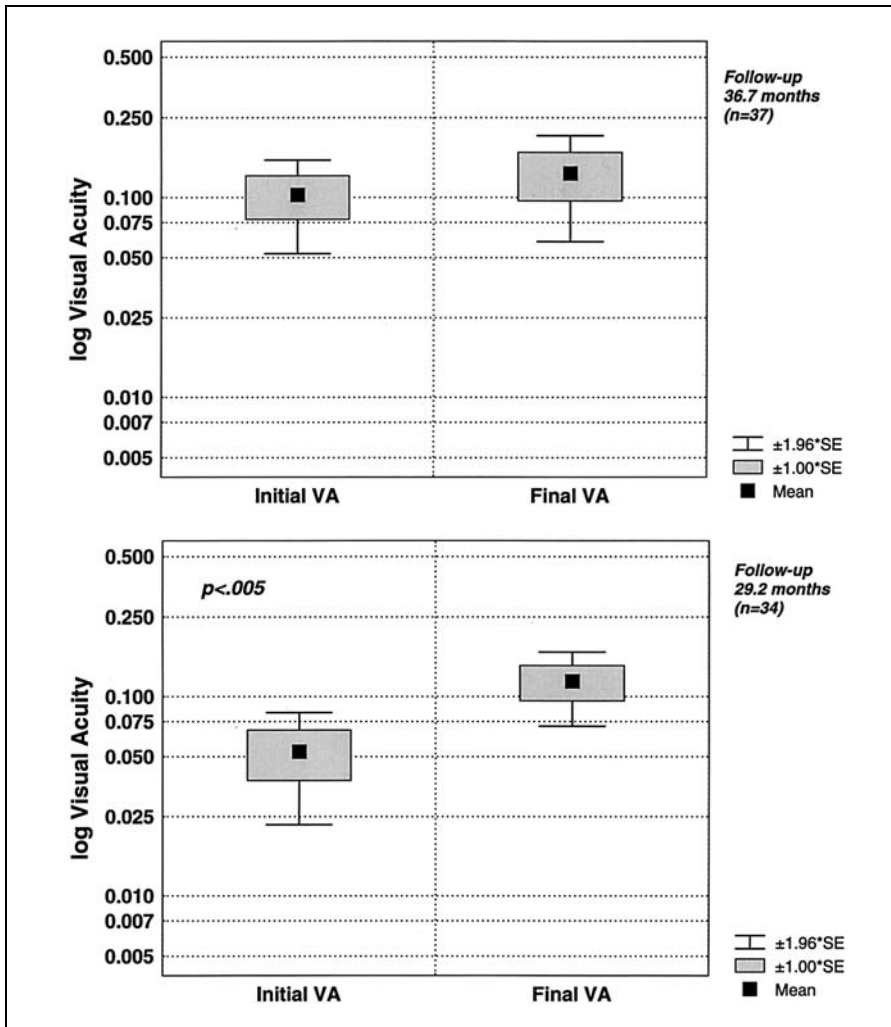


Fig. 1. Initial and final visual acuity (VA) in 37 eyes which had undergone vitrectomy and air or sulfur hexafluoride gas injection and in 34 eyes which had additionally received adjunctive application of autologous blood to the macular hole. Five eyes of group 1, and 2 in group 2, had an impending macular hole; all other cases had full thickness ones. Retinal detachment was present in 73 and 88 % of the instances in groups 1 and 2, respectively. Nine amblyopic eyes were excluded from the total of 80.

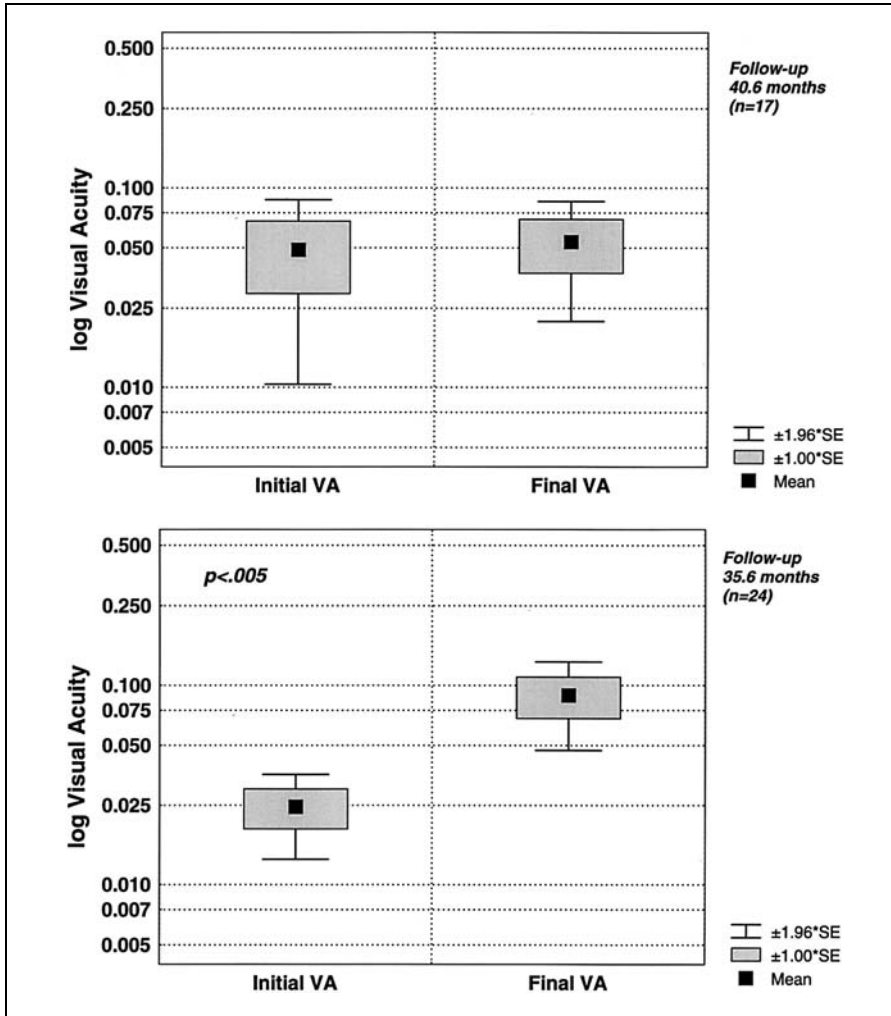


Fig. 2. Initial and final visual acuity (VA) in 17 myopic eyes which had undergone vitrectomy and air or sulfur hexafluoride gas injection and in 24 myopic eyes which had additionally received adjunctive application of autologous blood to the macular hole. Retinal detachment was associated with the macular hole in 40 of the 41 eyes.

In two recent studies [71, 73], autologous platelet concentrates were used as adjuncts in the treatment of full-thickness macular holes, flattening of the affected areas being achieved in 95 and 85.7 % of the cases, respectively. In another investigation [71], similar treatment elicited reattachment in 19 of 20 eyes, as against 13 of the 20 which received no such ad-

Table 2. Adjunctive agents currently used to facilitate the healing of macular holes (together with the pertinent literature references)

Adjunctive agent used in vitreoretinal surgery	Reference
Autologous blood	55, 56
Human thrombin	74
Bovine thrombin together with autologous fibrinogen	75
Autologous serum	78 80
TGF β 2	81 85
Platelet concentrate	71, 73

unctive therapy ($p < 0.05$). Preliminary personal observations indicate that comparable anatomical success rates may be achieved by use of either platelet concentrate or autologous blood. The use of autologous serum, blood and platelet concentrates all have the advantages of easy preparation, and low cost, and their use does not carry the risk of precipitating unwanted immunological reactions (table 2).

Functional Results of Macular Hole Surgery

The visual results currently achieved by macular hole surgery are encouraging, albeit that we are still fairly ignorant of the long-term functional outcome of the untreated condition. Indeed, we are not aware of any prospective study which has been undertaken to compare visual function after vitreoretinal surgery for macular holes with that in a control group of eyes over long observation periods.

Elimination of vitreoretinal traction in stage 1 impending macular holes improves visual function in about 90 % of the cases [12, 13, 61]. And closure of a full-thickness ones also improves visual acuity in most instances [72], superior results being obtained in patients with symptoms of less than 6- to 12-months' duration [66, 69, 70]. Interestingly, bilateral visual function after macular hole surgery in one eye appears to be markedly better in patients with near-normal – than in those with reduced – visual acuity of the fellow eye [86].

Adjunctive application of an appropriate dose of TGF- β 2 to idiopathic or traumatic full-thickness macular holes after vitrectomy has been

Table 3. Pre and postoperative visual acuity in 66 eyes with macular holes and retinal detachment

Visual acuity	PPV with autologous blood		PPV without autologous blood	
	n	%	n	%
Better	23	63.9	9	30.0
Same	7	19.4	14	46.7
Worse	6	16.7	7	23.3
Total number of cases	36		30	

Significantly higher rates of visual improvement were achieved when autologous blood was applied to the macular hole ($p < 0.02$) after pars plana vitrectomy (PPV).

shown to elicit an increase in visual acuity by two lines or more in 40–70 % of the cases [81, 84, 85]. Scanning laser ophthalmoscopic microperimetry of patients with macular hole has revealed absolute scotomata in the region of neurosensory defect as well as relative ones in the zone of perifoveal detachment, and there exists a good correlation between central visual field defects and visual acuity [87]. After vitrectomy with adjunctive TGF- β 2, absolute scotomata disappeared and relative ones at least partially resolved [88].

In a personal study of 66 cases, application of autologous blood to the macular holes after vitrectomy for retinal detachment elicited significantly better visual results than did surgery in the absence of such adjunctive treatment (table 3; fig. 1). A similarly favorable functional result was obtained in myopic eyes (fig. 2). Autologous blood contains a variety of growth factors, including TGF- β 2, and it seems not unlikely that some of these may play a role in wound healing after vitrectomy, and perhaps incite a regenerative response by the receptor layer and/or retinal pigment epithelium.

Complications

The development of progressive nuclear cataracts is a well-known side effect of vitreoretinal surgery, and their manifestation after macular hole surgery is therefore not surprising; increasing rates of cataract have been

reported to occur in up to 76 % of the cases 2 or more years after vitrectomy and instillation of long-acting gases [89].

A specific and so far unexplained complication of macular hole surgery appear to be a visual field defects, particularly in the lower periphery of the field, and in some of these cases an optic-disc pallor may also be observed [90, 91]. Whether these deleterious changes are attributable to surgical manipulation at the epipapillary vitreous cortex, or to the use of long-acting gases, or indeed whether other as yet unknown factors are responsible, remains to be clarified.

Postoperative progression of stage 2 macular holes to the stage 3 or 4 condition has been reported in 20 % of the cases, as against an incidence of 71 % of untreated eyes observed for 12 months or more [92].

The risk of a postoperative increase in intraocular pressure is usually limited to the first two weeks after surgery. If TGF- β 2 is employed as an adjunct, then a markedly higher risk (39 %) of increasing intraocular pressure is associated with the recombinant – than with the bovine – form [93].

Postoperative infections or immunological reactions to adjunctive agents have not been reported, although hypopyon-development has been reported in 8 [74] to 28 % [75] of the cases treated topically with bovine thrombin.

Posterior-segment complications have become less frequently in recent years, owing to improvements in vitreoretinal surgical techniques. Formerly, retinal hemorrhaging was commonly observed when using macular buckling procedures [94]. Nowadays, peripheral retinal breaks and/or rhegmatogenous detachment [95] or retinal dialysis [65] are more likely to occur, and these conditions are usually precipitated by remote traction on the vitreous base during aspiration of the nondetached vitreous cortex. Reported rates of late macular hole reopening and recurrent retinal detachment vary between 5 and 15 %, depending on the anatomical situation and surgical technique used [37, 38, 40, 43, 96–98]. Reoperation using an air tamponade, TGF- β 2 or silicone oil have proved to be successful in most cases.

Postoperative damage to the retinal pigment epithelium in the macular area [99, 100] is to be expected in eyes with large full-thickness macular holes, retinal detachment and high myopia. And a swelling as well as mottling of this layer may persist after peeling away epimacular membranes and sheets of vitreous cortex [101].

Conclusion

A better insight into the pathogenesis of macular holes has substantially influenced our surgical approach during the past 15 years. It is now known that adherent vitreous cortex and/or epimacular membranes exert centrifugal traction on the inner perifoveal layers. But the cause of the adhesive forces which prevent posterior vitreous detachment in these patients remains to be elucidated.

Initial symptoms of the vitreomacular traction syndrome include loss of visual acuity and metamorphopsia, and their early recognition permits surgical removal of vitreous cortex and epimacular membranes before the development of a full-thickness macular hole. The functional results of vitrectomy for impending macular holes are particularly good.

Closure of full-thickness macular holes is achieved by vitrectomy and air or gas tamponade in a substantial number of cases. And the adjunctive application of autologous blood, serum, transforming growth factor or a platelet concentrate to the macular hole yields a surprisingly high rate of visual improvement. The same holds true for similarly treated cases of retinal detachment with associated macular holes, although the final visual acuity remains at lower levels, owing to morphological changes in the macular region, in these frequently myopic and sometimes amblyopic eyes.

In general, anatomic and functional success rates justify the application of vitreoretinal surgery in conjunction with agents known to facilitate chorioretinal wound healing at the site of a macular hole.

References

- 1 Woods DO: Idiopathic macular hole. *Ophthalmic Nurs Technol* 1995;14:57 58, 60, 62 66.
- 2 Gass JD: Idiopathic senile macular hole: Its early stages and pathogenesis. *Arch Ophthalmol* 1988;106:629 639.
- 3 Johnson RN, Gass JD: Idiopathic macular holes: Observations, stages of formation, and implications for surgical intervention. *Ophthalmology* 1988;95:917 924.
- 4 Gass JD: Das altersabhängige idiopathische Makulaforamen. Aktuelle Vorstellungen von der Pathogenese, Diagnose und Behandlung. *Ophthalmologie* 1995;92:617 625.
- 5 Bresgen M, Heimann K: Das idiopathische Makulaforamen: Neue Aspekte zur Stadieneinteilung und mögliche Therapiekonzepte. *Klin Monatsbl Augenheilkd* 1995;206:2 212.
- 6 Akiba J, Quiroz MA, Trempe CL: Role of posterior vitreous detachment in idiopathic macular holes. *Ophthalmology* 1990;97:1610 1613.
- 7 Akiba J, Yoshida A, Trempe CL: Risk of developing a macular hole. *Arch Ophthalmol* 1009;108:1088 1090.
- 8 Gass JD: Reappraisal of biomicroscopic classification of stages of development of a macular hole. *Am J Ophthalmol* 1995;119:752 759.
- 9 Madreperla SA, Geiger GL, Funata M, de la Cruz Z, Green WR: Clinicopathologic correlation of a macular hole treated by cortical vitreous peeling and gas tamponade. *Ophthalmology* 1994;101:682 686.

- 10 Madreperla SA, McCuen BW, Hickingbotham D, Green WR: Clinicopathologic correlation of surgically removed macular hole opercula. *Am J Ophthalmol* 1995;120:197 207.
- 11 Yooh HS, Brooks HL, Jr, Capone A, Jr, L'Hernault NL, Grossniklaus HE: Ultrastructural features of tissue removed during idiopathic macular hole surgery. *Am J Ophthalmol* 1996;122:67 75.
- 12 Margherio RR, Trese MT, Margherio AR, Cartright K: Surgical management of vitreomacular tractions syndromes. *Ophthalmology* 1989;96:1437 1445.
- 13 Smiddy WE, Michels RG, Green WR: Morphology, pathology, and surgery of idiopathic vitreoretinal macular disorders: A review. *Retina* 1990;10:288 296.
- 14 Dralands L, Leys A, Kerremans D: Syndromes interface vitréomaculaire. *Bull Soc Belge Ophthalmol* 1991;240:107 117.
- 15 Fish RH, Anand R, Izbrand DJ: Macular pseudoholes: Clinical features and accuracy of diagnosis. *Ophthalmology* 1992;99:1665 1670.
- 16 Guyer DR, Green WR, de Bustros S, Fine SL: Histopathologic features of idiopathic macular holes and cysts. *Ophthalmology* 1990;97:1045 1051.
- 17 Frangieh GT, Green WR, Engel HM: A histopathologic study of macular cysts and holes. *Retina* 1981;1:311 336.
- 18 Martinez J, Smiddy WE, Kim J, Gass JD: Differentiating macular holes from macular pseudoholes. *Am J Ophthalmol* 1994;117:762 767.
- 19 Kiruy J, Shahidi M, Ogura Y, Blair NP, Zeimer R: Illustration of the stages of idiopathic macular holes by laser biomicroscopy. *Arch Ophthalmol* 1995;113:1156 1160.
- 20 Hee MR, Puliafito CA, Wong C, Duker JS, Reichel E, Schuman JS, Swanson EA, Fujimoto JG: Optical coherence tomography of macular holes. *Ophthalmology* 1995;102:748 756.
- 21 Liesenhoff H: Die vertikale Halberclage, eine neue Methode zur Operation desparater Netzhautablösungen mit Makulaforamen. *Büch Augenarztes* 1970;53:70 75.
- 22 Theodossiadis GP: Eine vereinfachte Technik der chirurgischen Behandlung von Netzhautablösungen infolge von Maculalöchern. *Klin Monatsbl Augenheilkd* 1973;162:719 728.
- 23 Theodossiadis GP: Treatment of retinal detachment arising from macular holes. *Mod Probl Ophthalmol* 1974;12:322 329.
- 24 Theodossiadis GP, Damanakis AG, Koutsandrea CN: Abnahme der Myopie nach Operation makulalochbedingter Netzhautablösungen. *Klin Monatsbl Augenheilkd* 1986;189:289 292.
- 25 Wollensak J, Engels T: Operation der Netzhautablösung bei Makulaforamen mit resorbierbarer Plombe. *Klin Monatsbl Augenheilkd* 1977;171:278 282.
- 26 Bonnet M: Poche sclérale sur le pôle postérieur et traitement des décollements de la rétine provoqués par un trou maculaire. *J Fr Ophtalmol* 1982;5:505 513.
- 27 Orduna F: Indentation choroidienne resorbable. *J Fr Ophtalmol* 1983;6:895 900.
- 28 Klöti R: Eine Operationsmethode für makulaloch bedingte Netzhautablösungen. *Ophthalmologica* 1964;148:42 56.
- 29 Klöti R: Silver clip for central retinal detachments with macular hole. *Mod Probl Ophthalmol* 1974;12:330 336.
- 30 Gloor BP: Operation der Netzhautablösung bei Löchern im Bereich des hinteren Pols mit ein facher, lang verträglicher Silberspanne und Cerclage. *Klin Monatsbl Augenheilkd* 1977;171:271 277.
- 31 Alexandridis E, Kohl Eisenhut H: Treatment of retinal detachment with macular hole. *Graefes Arch Clin Exp Ophthalmol* 1986;224:11 12.
- 32 Meyer Schwickeradt G: Makulaloch mit Netzhautablösung. *Ber Dtsch Ophthalmol Ges* 1962;64:249 253.
- 33 Klöti R: Erfahrungen mit der Silberklemme bei makulalochbedingten Netzhautablösungen. *Ophthalmologica* 1970;161:210 216.
- 34 Margherio RR, Schepens CL: Macular breaks. II. Management. *Am J Ophthalmol* 1972;74:233 240.
- 35 Matsumura M, Kuriyama S, Harada T, Ishigooka H, Ogino N: Surgical techniques and visual prognosis in retinal detachment due to macular hole. *Ophthalmologica* 1992;204:122 133.
- 36 Kuriyama S, Matsumura H, Harada T, Ishijooka H, Ogino N: Surgical techniques and reattachment rates in retinal detachment due to macular hole. *Arch Ophthalmol* 1990;108:1559 1561.

- 37 Blankenship GW, Ibanez Langlois S: Treatment of myopic macular hole and detachment. *Intra vitreal gas exchange. Ophthalmology* 1987;94:333-336.
- 38 Gonvers M, Machermer R: A new approach to treating retinal detachment with macular hole. *Am J Ophthalmol* 1982;94:468-472.
- 39 Haut J, Van Effenterre G, Ullern M, Chermet M: Traitement chirurgical des décollements de rétine avec trou maculaire par la technique de la vitrectomie associée à l'injection de silicone liquide. *J Fr Ophthalmol* 1980;3:115-118.
- 40 Roussat B, Ruellan YM: Traitement du décollement de rétine par vitrectomie et injection d'huile de silicone. Résultats à long terme et complications dans 105 cas. *J Fr Ophthalmol* 1984;7:11-18.
- 41 Heimann K, Dimopoulos S, Paulmann H: Silikonölinjektion in der Behandlung komplizierter Netzhautablösungen. *Klin Monatsbl Augenheilkd* 1984;185:505-508.
- 42 Gao R, Lu L, Zhang S, Tang S, Liu Q, Hu Z: Study on application of the silicone oil in the reattachment of complicated retinal detachment. *Yen Ko Hsueh Pao* 1993;9:146-148.
- 43 Laqua H: Die Behandlung der Ablatio mit Makulaforamen nach der Methode von Gonvers und Machermer. *Klin Monatsbl Augenheilkd* 1985;186:13-17.
- 44 Binder S, Riss B: Advances in intraocular techniques in the treatment of retinal detachment arising from holes of the posterior pole. *Br J Ophthalmol* 1983;67:147-149.
- 45 Tittarelli R, Benedetti S: Su di una modificazione tecnica nel trattamento microchirurgico del distacco di retina da foro maculare: Nota preliminare. *Boll Oculist* 1983;62:793-797.
- 46 Rossi P, Lai S, Selis G, Ciurlo G: Una nova metodica per il trattamento dei distacchi retinici con foro maculare. *Boll Oculist* 1984;63 (suppl. 5-6): 341-345.
- 47 De Molfetta V, Arpa P, De Casa N, Lunetti M, Moretti C, Vinciguerra P, Zenoni S: La vitrectomia via pars plana nel trattamento del distacco della retina da foro maculare. *Ann Ottalmol Clin Ocul* 1984;110:311-325.
- 48 Billington BM, Chignell AH: Treatment of rhegmatogenous retinal detachment uncomplicated by massive preretinal proliferation by pars plana vitrectomy. *Trans Ophthalmol Soc UK* 1985;104:120-122.
- 49 Yamagishi K, Nishimura S, Ogino N, Nagata M: Outcome of vitrectomy with gas tamponade for retinal detachment with macular hole. *Jpn J Clin Ophthalmol* 1985;39:613-617.
- 50 Brasseur G, Charlin JF, Gruber D, Langlois J: Macular hole induced retinal detachment. Vitrectomy and internal tamponade in seven cases. *Bull Soc Ophthalmol Fr* 1985;85:67-69.
- 51 Tavakolian U, Heimann K, Lemmen D: Zur chirurgischen Behandlung von Amotiones mit zentralen Foramina bei hoher Myopie. *Fortschr Ophthalmol* 1985;82:553-555.
- 52 Chignell AH, Billington BM: The treatment of macular holes by pars plana vitrectomy and internal air/SF6 exchange. *Graefes Arch Clin Exp Ophthalmol* 1986;224:67-68.
- 53 Vallat M: Surgical treatment of retinal detachment from macular hole. *Graefes Arch Clin Exp Ophthalmol* 1986;224:238-239.
- 54 Harris MJ, De Bustros S, Michels RG: Treatment of retinal detachments due to macular hole. *Retina* 1994;4:144-147.
- 55 Koerner F: Retinal detachment with macular hole: Vitrectomy and controlled hematotamponade of posterior breaks. *Klin Monatsbl Augenheilkd* 1987;190:326-331.
- 56 Ryan EA, Lee S, Chern S: Use of intravitreal autologous blood to identify posterior cortical vitreous in macular hole surgery. *Arch Ophthalmol* 1995;113:822-823.
- 57 Sheta SM, Hida T, McCuen BW: Cyanoacrylate tissue adhesive in the management of recurrent retinal detachment caused by macular hole. *Am J Ophthalmol* 1990;109:28-32.
- 58 Tilanus MA, Deutman AF: Full thickness macular holes treated with vitrectomy and tissue glue. *Int Ophthalmol* 1994;18:355-358.
- 59 Freeman WR: Vitrectomy surgery for full thickness macular holes (editorial). *Am J Ophthalmol* 1993;116:233-235.
- 60 Mein CE, Flynn HW Jr: Recognition and removal of the posterior cortical vitreous during vitreoretinal surgery for impending macular hole. *Am J Ophthalmol* 1991;111:611-613.
- 61 Chambers RB, Davidorf FH, Gresak P, Stief WC 4th: Modified vitrectomy for impending macular holes. *Ophthalmic Surg* 1991;22:730-734.

- 62 Ryan EA, Lee S, Chern S: Use of intravitreal autologous blood to identify posterior cortical vitreous in macular hole surgery. *Arch Ophthalmol* 1995;113:822 823.
- 63 de Bustros S: Vitrectomy for prevention of macular holes. Results of a randomized multicenter clinical trial: Vitrectomy for Prevention of Macular Hole Study Group. *Ophthalmology* 1994;101:1055 1059.
- 64 Kelly NE, Wendel RT: Vitreous surgery for idiopathic macular holes: Results of a pilot study. *Arch Ophthalmol* 1991;109:654 659.
- 65 Orellana J, Lieberman RM: Stage III macular hole surgery. *Br J Ophthalmol* 1993;77:555 558.
- 66 Wendel RT, Patel AC, Kelly NE, Salzano TC, Wells JW, Novack GD: Vitreous surgery for macular holes. *Ophthalmology* 1993;100:1671 1676.
- 67 Ruby AJ, Williams DF, Grand MG, Thomas MA, Meredith TA, Boniuk I, Olk RJ: Pars plana vitrectomy for treatment of stage 2 macular holes. *Arch Ophthalmol* 1994;112:359 364.
- 68 Thompson JT, Glaser MB, Sjaarda RN, Murphy RP, Hanham A: Effects of intraocular bubble duration in the treatment of macular holes by vitrectomy and transforming growth factor beta 2. *Ophthalmology* 1994;101:1195 1200.
- 69 Ryan EH Jr, Gilbert HD: Results of surgical treatment of recent onset full thickness idiopathic macular holes. *Arch Ophthalmol* 1994;112:1545 1553.
- 70 Ogino N: Results of macular hole surgery. *Nippon Ganka Gakkai Zasshi* 1995;99:938 944.
- 71 Gaudric A, Massin P, Paques M, Santiago PY, Guez JE, Le Gargasson JF, Mundler O, Drouet L: Autologous platelet concentrate for the treatment of full thickness macular holes. *Graefes Arch Clin Exp Ophthalmol* 1995;233:549 554.
- 72 Maeno T, Hattori T, Ninomiya Y, Takenaka H, Mitsuda H, Fujikado T, Mano T, Tano Y: Visual functional changes in idiopathic macular holes treated by vitrectomy. *Nippon Ganka Gakkai Zasshi* 1996;100:40 45.
- 73 Korobelnik JF, Hannouche D, Belayachi N, Branger M, Guez JE, Hoang Xuan T: Autologous platelet concentrate as an adjunct in macular hole healing: A pilot study. *Ophthalmology* 1996;103:590 594.
- 74 Vine AK, Johnson MW: Thrombin in the management of full thickness macular holes. *Retina* 1996;16:474 478.
- 75 Olsen TW, Sternberg P, Martin DF, Capone A Jr, Lim JJ, Aaberg TM: Postoperative hypopyon after intravitreal bovine thrombin for macular hole surgery. *Am J Ophthalmol* 1996;121:575 577.
- 76 Christas NJ, Skolik SA, Howard MA, Saito Y, Barnstable CJ, Liggett PE: Treatment of retinal breaks with autologous serum in an experimental model. *Ophthalmology* 1995;102:263 271.
- 77 Monin C, Barale PO, Harrabi S, Haut J: Traitement chirurgical par vitrectomie et serum autologue de trente six trous maculaires idiopathiques. *J Fr Ophtalmol* 1996;19:341 348.
- 78 Wells JA, Gregor ZJ: Surgical treatment of full thickness macular holes using autologous serum. *Eye* 1996;10:593 599.
- 79 Coleman DJ, Lucas BC, Fleischmann JA, Dennis PH Jr, Chang S, Iwamoto T, Nalbandian RM: A biologic tissue adhesive for vitreoretinal surgery. *Retina* 1988;8:250 256.
- 80 Liggett PE, Skolik SA, Horio B, Saito Y, Alfaro V, Mieler W: Human autologous serum for the treatment of full thickness macular holes. *Ophthalmology* 1995;102:1071 1076.
- 81 Glaser BM, Michels RG, Kuppermann BD, Sjaarda RN, Pena RA: Transforming growth factor beta 2 for the treatment of full thickness macular holes. A prospective randomized study. *Ophthalmology* 1992;99:1162 1172.
- 82 Smiddy WE, Glaser BM, Thompson JT, Sjaarda RN, Flynn HW, Jr Hanham A, Murphy RP: Transforming growth factor beta 2 significantly enhances the ability to flatten the rim of subretinal fluid surround macular holes: Preliminary anatomic results of a multicenter prospective randomized study. *Retina* 1993;13:296 301.
- 83 Lansing MB, Glaser BM, Liss H, Hanham A, Thompson JT, Sjaarda RN, Gordon AJ: The effect of pars plana vitrectomy and transforming growth factor beta 2 without epiretinal membrane peeling on full thickness macular holes. *Ophthalmology* 1993;100:868 871.
- 84 Ie D, Glaser BM, Thompson JT, Sjaarda RN, Gordon LW: Retreatment of full thickness macular holes persisting after prior vitrectomy: A pilot study. *Ophthalmology* 1993;100:1787 1793.

- 85 Rubin JS, Glaser BM, Thompson JT, Sjaarda RN, Pappas SS, Jr Murphy RP: Vitrectomy, fluid gas exchange and transforming growth factor beta 2 for the treatment of traumatic macular holes. *Ophthalmology* 1995;102:1840-1845.
- 86 Polk TG, Smiddy WE, Flynn HW Jr: Bilateral visual function after macular hole surgery. *Ophthalmology* 1996;103:422-426.
- 87 Sjaarda RN, Frank DA, Glaser BM, Thompson JT, Murphy RP: Assessment of vision in idiopathic macular holes with macular microperimetry using the scanning laser ophthalmoscope. *Ophthalmology* 1993;100:1513-1518.
- 88 Sjaarda RN, Frank DA, Glaser BM, Thompson JT, Murphy RP: Resolution of an absolute scotoma and improvement of relative scotomata after successful macular hole surgery. *Am J Ophthalmol* 1993;116:129-139.
- 89 Thompson JT, Glaser BM, Sjaarda RN, Murphy RP: Progression of nuclear sclerosis and long term visual results of vitrectomy with transforming growth factor beta 2 for macular holes. *Am J Ophthalmol* 1995;119:48-54.
- 90 Kerrison JB, Haller JA, Elman M, Miller NR: Visual field loss following vitreous surgery. *Arch Ophthalmol* 1996;114:564-569.
- 91 Pendergast SD, McCuen BW 2nd: Visual field loss after macular hole surgery. *Ophthalmology* 1996;103:1069-1077.
- 92 Kim JW, Freeman WR, Azen SP, el Haig W, Klein DJ, Bailey IL: Prospective randomized trial of vitrectomy or observation for stage 2 macular holes. Vitrectomy for Macular Hole Study Group. *Am J Ophthalmol* 1996;121:605-614.
- 93 Thompson JT, Sjaarda RN, Glaser BM, Murphy RP: Increased intraocular pressure after macular hole surgery. *Am J Ophthalmol* 1996;121:615-622.
- 94 Anemiya T, Iida T: Results and complications of surgery of retinal detachment with a macular hole. *Ophthalmologica* 1980;181:88-92.
- 95 Parks SS, Marcus DM, Duker JS, Pesavento RD, Topping TM, Frederick AR Jr, D'Amico DJ: Posterior segment complications after vitrectomy for macular hole. *Ophthalmology* 1995;102:775-781.
- 96 Rashed O, Sheta S: Evaluation of the functional results after different techniques for treatment of retinal detachment due to macular holes. *Graefes Arch Clin Exp Ophthalmol* 1989;27:508-512.
- 97 Bonnet M, Semiglia R: Late recurrences after successful surgery for retinal detachment with macular hole. *Graefes Arch Clin Exp Ophthalmol* 1993;31:347-350.
- 98 Duker JS, Wendel R, Patel AC, Puliafito CA: Late re opening of macular holes after initially successful treatment with vitreous surgery. *Ophthalmology* 1994;101:1373-1378.
- 99 Charles S: Retinal pigment epithelial abnormalities after macular hole surgery (letter). *Retina* 1993;13:176.
- 100 Duker JS: Retinal pigment epitheliopathy after macular hole surgery (letter). *Ophthalmology* 1993;100:1604-1605.
- 101 Poliner LS, Tornambe PE: Retinal pigment epitheliopathy after macular hole surgery. *Ophthalmology* 1992;99:1671-1677.

Prof. Fritz Koerner, MD, University of Bern, Department of Ophthalmology, Inselspital, CH 3010 Bern (Switzerland)

.....

Use of Autologous Platelet Concentrate in Macular Hole Surgery: Report of 77 Cases

*Alain Gaudric^a, Michel Paques^a, Pascale Massin^a, Pierre-Yves Santiago^a,
Christine Dosquet^b*

^a Service d'Ophthalmologie, Hôpital Lariboisière, ^b Site Transfusionnel,
Lab. Cytokines, Hôpital Saint Louis, Assistance Publique Hôpitaux de Paris,
Université Paris 7, France

Since 1989, when Kelly and Wendel [1] published the first series of surgically treated macular holes, comprising 52 cases, the results of macular hole surgery have improved fast and are especially good in cases operated early. Initially, this operation had an anatomical success rate of 58 % [1]. The operative technique has remained essentially the same, but several refinements have been introduced. Five years later the above authors obtained an anatomic success rate of 89 % due to their increased experience on a series of 227 eyes [2]. The operation consisted of removal of the vitreous body and posterior hyaloid, as well as any epimacular substance present around the hole and then applying a gas tamponade for several days. During the same period, Glaser et al. [3] used bovine extract transforming growth factor- β 2 (TGF- β 2) in addition to vitreous surgery to try to improve macular hole closure [3]. In 1993, they published an anatomic success rate of 96 % and their study opened the way to further research on biological healing adjuvants in retinal surgery [4]. As we, like many others, were unable to reproduce the high anatomical success rate obtained by Wendel and coworkers without the addition of any biological substance, we have been using autologous platelet concentrate (APC) as an adjuvant in macular hole surgery since July 1993 [5].

Patients and Methods

From July 1993 to October 1995, 77 eyes of 72 patients were operated on with autologous platelets. We excluded from this series subjects with posttraumatic and highly myopic macular holes. The mean age of patients was 65 years. There were 7 stage 2 holes, 51 stage 3 holes, 11 stage 4 holes and 8 reoperations after the failure of a first operation without platelets. The mean duration of macular holes was 9.5 months. Fifteen of them (19 %) lasted more than 1 year. The mean follow up period after surgery was 10 months.

Before surgery, each patient underwent a standard clinical examination that included testing visual acuity (VA) with the best optical correction measured on a decimal chart, fluorescein angiography, and scanning laser ophthalmoscope (SLO) examination, which allowed us to check for the presence of a central scotoma [6 10].

The platelet concentrate was prepared at the beginning of the operation from the patient's blood, as follows [5]: just before the operation 16 ml of venous blood is collected into a syringe containing 4 ml of acid citrate dextrose formula A (ACD A) and the two are gently mixed. The syringe containing this blood sample is then brought to the blood bank and treated under sterile conditions. The blood is transferred into a tube and immediately centrifuged for 15 min at room temperature (20 °C) and at 150 g. The platelet rich plasma (PRP) devoided of red blood cells is depleted and mixed with 1/8 volume ACD A (4 ml PRP + 0,5 ml ACD A) and again centrifuged for 10 min at room temperature (20 °C) at 1.500 g. The supernatant platelet poor plasma (PPP) is drawn off and the packed platelets are gently mixed with 0.6 ml of isotonic sodium chloride to obtain a platelet suspension devoid of agglutinates. This suspension is then brought back to the operating room about 1 h after blood sampling.

Surgery consisted first of 3 port pars plana vitrectomy; then, for stage 3 holes, the posterior hyaloid was detached by grasping the Weiss ring with an aspirating forceps, and vitrectomy was completed, as near as possible to the vitreous base [11]. If an epiretinal membrane was present around the hole, it was removed. We found such a membrane around the hole in only 25 % of stage 3 macular holes, but in 80 % of stage 4 holes. A complete fluid gas exchange was then performed, followed by a 10 min pause, after which the residual fluid was aspirated. 0.1 ml of autologous platelet concentrate was then injected over the posterior pole. Lastly, the vitreous cavity was filled with a mixture of 17 % C2F6 and air. The patients lay on their backs for the first 12 h after surgery and were then asked to remain face down 20 h a day for 12 days.

To measure the platelet content of growth factors, we analyzed the remnants of 70 samples of APC used for macular hole surgery. These samples were lysed by 5 cycles of freeze thawing and the lysates were assayed by ELISA for TGF β 1 and 2, bFGF, PDGF, and EGF. The usual controls were applied.

Results

Our *autologous platelet concentrate* contained a mean of 75×10^6 platelets per 0.1 ml. There was a relatively small range of platelet counts, as 95 % of them ranged from 70 to 80×10^6 . TGF- β 1 and PDGF were the

most abundant factors found. There was traces of TGF- β 2. We found that a sample of 0.1 ml of APC contained mean amounts of 9.88 ng of TGF- β 1 (± 0.97), 0.037 ng of TGF- β 2 (± 0.029), 8.93 ng of PDGF (± 0.005) and 0.081 ng of EGF (± 0.034). Only a small proportion (8 %) of TGF- β 1 and -2 was present in the active state. Only traces of PDGF were found in the plasma-poor platelets, thus confirming that no noticeable platelet lysis occurred during APC preparation [results presented at the 1997 ARVO meeting].

The overall *anatomical success rate* was 93 % (72/77 cases). Anatomical success was defined as either flattening of the edge of the hole, or its complete disappearance. The hole closed in 46 of the 48 holes of less than 6 months' duration (96 %), in 14 of the 14 holes of 7–12 months' duration (100 %), and in 12 of the 15 holes which had been present for more than a year (80 %). In most cases the hole completely closed and became undetectable, even with a high magnification of the biomicroscope.

Postoperative best corrected *visual acuity* was 0.4 or more in 72 % of the patients, compared to 5 % preoperatively. For holes of less than 6 months' duration, mean VA improved of 0.17 to 0.52. For holes of 7–12 months' duration, it improved from 0.13 to 0.37, and for holes which had lasted for more than a year, it improved from 0.16 to 0.44.

On SLO examination of the successfully operated eyes, the eccentric preferred locus of fixation became central in 87 % of the cases, microscotoma disappeared in 72 % and the line was seen to be continuous in 75 % of the cases.

Complications which were rare, included intraoperative retinal breaks (9 %), postoperative retinal detachment (1.6 %), transient high intraocular pressure (53 %), visual field defects (23 %), noncontractile thin epimacular membrane (16 %), cataract (60 % at 1 year) and late reopening of the hole (4 %) at a mean of 15 months after vitrectomy, in most cases after cataract extraction. None of these complications could be specifically attributed to the use of platelets. However, in 2 cases, fibrin condensation occurred over the macula, probably due to incorrect platelet preparation.

Discussion

A review of the literature tends to indicate that the use of healing adjuvants is beneficial during macular hole surgery, although no controlled trial has yet been completed, except for TGF- β [12]. The adjunctive agents used so far include TGF- β [3, 12], autologous serum or plasma [13–15], Tissucol[®] [16], and thrombin [17–19].

In the series described here, we confirmed, on a larger sample of patients, the high anatomical and functional success rate which we had already published [5] and compares favorably with the results published by others using different adjunctive agents.

The rationale for the use of platelets is that they contain many growth factors, including PDGF, bFGF, TGF- β 1 and -2 or EGF which are known to promote wound healing. They have already been used for the stimulation of experimental and clinical dermal healing [20–22].

In addition, some of these growth factors have been shown to stimulate glial cell chemotaxis and proliferation [23], and, on the other hand, postmortem studies have shown that in some cases, localized glial proliferation was sealing the hole [24–26]. PDGF, like TGF- β , might therefore be useful to stimulate retinal healing.

However, the amount of growth factors contained in 0.1 ml of APC, and especially TGF- β , is relatively small, compared, for instance, to the 330 ng or more of the TGF- β used by Glaser and coworkers [3, 4], but perhaps several growth factors could act in synergy. In APC, most of the TGF- β is in an inactive state. It is not clear whether it becomes activated during platelet aggregation.

Of course, we do not claim to have measured the concentration of every growth factor in the platelets, and molecules other than those mentioned here, may also be of interest.

Since growth factors are known to promote glial cell proliferation, it is possible that this proliferation forms a kind of glial cork sealing the hole, and postmortem studies have indeed shown that in 4 cases reported, a localized glial proliferation sealed the hole [24–26]. Growth factors are also known to promote glial cell chemotaxis [23], thus allowing the formation of an epiretinal membrane, which may eventually contract and close the hole. However, we did not observe such membrane formation developing during the first 3 postoperative months.

The consequences of platelet administration for the retina are not yet clear. We only observed that our success rate increased when we began to use platelets, and that there were no serious complications such as proliferative vitreoretinopathy or epiretinal membrane formation.

A randomized clinical trial is mandatory to confirm that platelets are beneficial as an adjuvant. We have initiated such a trial in 4 centers in France. The patients included have stage 3 and 4 idiopathic macular holes of less than 3 years' duration. They have been divided into two groups: those with holes of less than 1 year's duration, and between 1 and 3 years' duration, respectively. At the end of fluid-gas exchange, patients are randomly assigned to receive an autologous platelet concentrate or not. The

main endpoints are the comparative rates of hole closure, and improvement of the ETDRS visual acuity score. Secondary criteria are the quality of hole closure, the near vision score, and functional testing, assessed by SLO. Complications such as hypertony, visual field defects, retinal detachment, and cataract are also recorded. This trial has been completed by the first trimester of 1997.

Conclusion

We operated 77 idiopathic macular holes using autologous platelet concentrate. The mean duration of the hole was 9.5 months. The anatomical success rate was 93 %, and postoperative visual acuity was at least 20/50 in 72 % of the patients. Our anatomical and functional success rates compare favorably with other results in the literature, and suggest that the use of autologous platelet concentrate could be beneficial in macular hole surgery. To confirm these results we have completed a randomized clinical trial, in which more than 120 patients have been enrolled in 4 centers in France.

References

- 1 Kelly N, Wendel R: Vitreous surgery for idiopathic macular holes: Results of a pilot study. *Arch Ophthalmol* 1991;109:654-659.
- 2 Patel AC, Wendel RT: Vitrectomy for macular hole. *Semin Ophthalmol* 1994;9:47-55.
- 3 Glaser BM, Michels RG, Kuppermann BD, Sjaarda RN, Pena RA: Transforming growth factor beta 2 for the treatment of full thickness macular holes: A prospective randomized study. *Ophthalmology* 1992;99:1162-1172.
- 4 Lansing MB, Glaser BM, Liss H et al: The effect of pars plana vitrectomy and transforming growth factor beta 2 without epiretinal membrane peeling on full thickness macular holes. *Ophthalmology* 1993;100:868-871.
- 5 Gaudric A, Massin P, Paques M et al: Autologous platelet concentrate for the treatment of full thickness macular holes. *Graefes's Arch Clin Exp Ophthalmol* 1995;233:549-554.
- 6 Acosta F, Lashkari K, Reynaud X, Jalkh AE, Van dVF, Chedid N: Characterization of functional changes in macular holes and cysts. *Ophthalmology* 1991;98:1820-1823.
- 7 Legargasson JF, Guez JE, Goberville M et al: Anatomical and functional examination of full thickness macular holes with an SLO. *Invest Ophthalmol Vis Sci* 1994;35:2136.
- 8 Legargasson JF, Rigaudière F, Guez JE, Gaudric A, Grall Y: Contribution of scanning laser ophthalmoscope (SLO) to the functional investigation of subject with a macular hole. *Doc Ophthalmol* 1994;86:227-238.
- 9 Sjaarda RN, Frank DA, Glaser BM, Thompson JT, Murphy RP: Assessment of vision in idiopathic macular holes with macular microperimetry using the scanning laser ophthalmoscope. *Ophthalmology* 1993;100:1513-1518.
- 10 Sjaarda RN, Frank DA, Glaser BM, Thompson JT, Murphy RP: Resolution of an absolute scotoma and improvement of relative scotomata after successful macular hole surgery. *Am J Ophthalmol* 1993;116:129-139.

- 11 Gaudric A, Massin P, Chen Q: An aspirating forceps to remove the posterior hyaloid in the surgery of full thickness macular holes. *Retina* 1996;16:261 263.
- 12 Smiddy WE, Glaser BM, Thompson JT et al: Transforming growth factor beta 2 significantly enhances the ability to flatten the rim of subretinal fluid surrounding macular holes: Preliminary anatomic results of a multicenter prospective randomized study. *Retina* 1993;13:296 301.
- 13 Monin C, Barale PO, Harrabi S, Haut J: Surgical treatment by vitrectomy and autologous serum of 36 idiopathic macular holes. *J Fr Ophthalmol* 1996;19:341 348.
- 14 Wells JA: surgical treatment of full thickness macular holes using autologous serum. *Eye* 1996;10:593 599.
- 15 Liggett PE, Skolik SA, Horio B, Saito Y, Alfaro V, Mieler W: Human autologous serum for the treatment of full thickness macular holes. *Ophthalmology* 1995; 102:1071 1076.
- 16 Tilanus M, Deutman AF: Full thickness macular holes treated with vitrectomy and tissue glue. *Int Ophthalmol* 1994;18:355 358.
- 17 Johnson MW, Vine AK: Use of thrombin as mitogen therapy in macular hole surgery. *Invest Ophthalmol Vis Sci* 1995;36:4849.
- 18 Vine KW, Johnson MW: Thrombin in the management of full thickness macular holes. *Retina* 1996;16:474 478.
- 19 Blumenkranz MS, Coll GE, Chang S, Morse LS: Use of autologous plasma thrombin mixture as adjuvant therapy for macular hole. *Ophthalmology* 1994;101:769.
- 20 Steed DL, Goslen JB, Holloway GA, Malone JM, Bunt TJ, Webster MW: Randomized prospective double blind trial in treating chronic diabetic foot ulcer CT 102 activated platelet supernatant, topical versus placebo. *Diabetes Care* 1992;15:1598 1604.
- 21 Hitaizumi Y, Transfeldt EE, Kawahara N, Sung JH, Knighton D, Fiegel VD: In vitro angiogenesis by platelet derived wound healing formula in injured spinal cord. *Brain Res Bull* 1993;30:353 357.
- 22 Ksander GA, Sawamura S, Ogawa Y, Sundsmo J, McPherson J: The effect of platelet release on wound healing in animal models. *J AM Acad Dermatol* 1990;22:781 791.
- 23 Uchiyori Y, Puro D: Mitogenic and chemotactic effects of platelet derived growth factor on human retinal glial cells. *Invest Ophthalmol Vis Sci* 1991;32:2689 2695.
- 24 Funata M, Wendel RT, de ICZ, Green WR: Clinicopathologic study of bilateral macular holes treated with pars plana vitrectomy and gas tamponade. *Retina* 1992;12:289 298.
- 25 Madreperla SA, Geiger GL, Funata M, de ICZ, Green WR: Clinicopathologic correlation of a macular hole treated by cortical vitreous peeling and gas tamponade. *Ophthalmology* 1994;101:682 686.
- 26 Rosa R, Glaser B, de la Cruz Z, Green W: Clinicopathologic correlation of an untreated macular hole and a macular hole treated by vitrectomy, transforming growth factor β 2, and gas tamponade. *Am J Ophthalmol* 1996;122:853 863.

Prof. Alain Gaudric, Service d'Ophthalmologie, Hôpital Lariboisière, 2, rue Ambroise Paré, FA 75475 Paris cedex 10 (France)
 Tel. (01) 49 95 64 88, Fax (01) 49 95 64 83, E Mail alain.gaudric@lrb.ap.hop.paris.fr

.....

Autologous Platelet Concentrate in the Surgical Management of Macular Holes

Miriam Minihan, Philip E. Cleary

Ophthalmology Department of University College Cork, and
Cork University Hospital, Cork, Ireland

Macular holes are believed to be caused by tractional forces on the retina, especially in a tangential manner, by pre-foveal vitreous, and by epiretinal membranes, causing a dehiscence of the retina at the macula [1]. Reduction in visual acuity occurs due to dehiscence at the umbro, loss of retinal tissue in the hole and detachment of the neurosensory retina surrounding the hole.

The goal of surgical therapy for macular holes is to achieve flattening of the neurosensory retinal detachment around the hole, thereby improving visual acuity and diminishing symptoms of metamorphosia. Vitrectomy, and gas tamponade has now achieved widespread use in the management of macular holes. First described by Kelly and Wendel [2], vitrectomy and gas tamponade are now often combined with other treatment modalities to improve anatomic and visual results. Wound healing substances are believed to increase the success rate of macular hole surgery by promoting chorioretinal adhesion at the margins of the hole [3], and also possibly by having a growth-promoting effect on photoreceptors [4]. Glaser et al. [3] first reported the results of adjunctive therapy in the treatment of macular holes. They found that the use of the cytokine transforming growth factor-beta-2 (TGF- β 2) enhanced the closure of macular holes [5]. Others have used different growth-promoting substances, and pilot studies have reported encouraging results using adjuncts such as serum [6], and platelets [7].

We report the results of a prospective study of 50 eyes which underwent vitrectomy, 16 % C3F8 gas tamponade and autologous platelet concentrate, for the treatment of full thickness macular holes.

Materials and Methods

We describe 50 procedures on 48 patients, 2 were reoperations for previously failed surgery (1 previously treated with platelet concentrate, the other with SF6 gas). Patients ranged in age from 33 to 85 years (median 69), 39 (81 %) were female and 9 (19 %) were male. Patients were included in the study if they had a visual acuity of 6/18 or worse, no other significant ocular disease, and had a duration of symptoms for less than 1 year.

Preoperatively, a complete ocular examination was performed, including best corrected Snellen visual acuity, slit lamp biomicroscopy, intraocular pressure measurement, assessment of lens clarity, contact lens fundus examination, fundus fluorescein angiography, and suprathreshold Humphrey's visual field examination. Macular holes were staged according to the criteria outlined by Gass [1, 8], and this staging was confirmed at surgery. There were 13 (26 %) stage 2, 27 (54 %) stage 3, and 10 (20 %) stage 4 macular holes.

Three port trans pars plana vitrectomy was performed in each case. In stage 2 and 3 holes, the posterior hyaloid was detached and vitreous removed as far out to the periphery as possible. In stage 4 holes, posterior vitreous detachment was confirmed using a sili cone tipped needle. No attempt was made to drain fluid through the macular hole, to peel fine epiretinal membranes, or to interfere with the fovea in any way. All patients underwent careful examination of the peripheral fundus, prior to air/fluid exchange, to discover any induced retinal tears. After air/fluid exchange, 10 min were allowed for fluid to drain posteriorly. This fluid was then aspirated.

The autologous platelet concentrate was prepared immediately prior to the procedure in the manner described by Gaudric et al. [7]. 40 ml of venous blood was taken from the patient and gently mixed with 6 ml of acid citrate dextrose (ACD). The mixture was centrifuged at 280 g for 15 min and the platelet rich plasma decanted. This plasma was mixed with 1/8 volume of ACD, and further centrifuged at 1,000 g for 10 min. The packed platelets were then mixed with 0.6 ml of sodium chloride to achieve a platelet suspension. The preparation of platelets was performed entirely in the operating theatre. Each patient had an injection into the vitreous cavity of 0.1 ml of autologous platelet concentrate. 16 % C3F8 gas was then injected. Patients remained supine for 6 h post operatively, and postured face down for 2–4 weeks.

Postoperative assessment occurs at 1, 3 and 6 months. This includes complete ocular examination, best corrected Snellen visual acuity, slit lamp examination, assessment of intraocular pressure and lens clarity, contact lens fundus examination, and visual field testing.

Results

Postoperatively, there was mild anterior chamber activity, intraocular pressure never rose to a level higher than 30 mm Hg and resolved on medical management within one week. A white 'coagulum' was present over the posterior pole, and covering the hole in most cases. This material slowly disappeared over the subsequent 1–2 weeks.

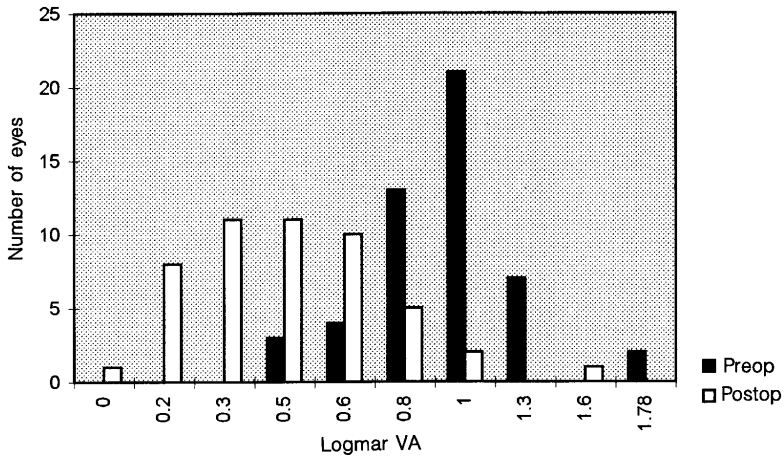


Fig. 1. Pre vs. postoperative logmar visual acuity.

Cases were deemed an anatomic success if the subretinal fluid surrounding the hole resolved and the retina flattened. The macular hole was closed in 48 (96 %) of eyes. Twelve (92 %) of the stage 2 holes, 26 (96 %) of the stage 3 holes, and 10 (100 %) of the stage 4 holes were an anatomic success. There was no significant difference in anatomic success rate between the different stages.

Postoperative visual acuity ranged from 6/6 to 3/60. Mean postoperative visual acuity (fig. 1) was significantly better than preoperative visual acuity ($p < 0.001$). Sixty-three percent of patients had a final visual acuity of 6/18 or better, and 40 % had 6/12 or better. Of successful cases, stage 2 holes are more likely than either stage 3 ($p = 0.03$), or stage 4 holes ($p = 0.03$) to achieve a final visual acuity of 6/9 or better. Snellen visual acuity improved by 2 lines or more in 37 (74 %) eyes, and 4 lines or more in 20 (41 %). Visual acuity improved by 2 lines or more in 8 (61 %) of stage 2, 21 (78 %) stage 3, and 8 (80 %) stage 4 holes (table 1).

Two procedures were reoperations for previously failed surgery. One was successful, the other was not. Final visual acuity in the successful eye was 6/24.

Six eyes (12 %) developed retinal tears treated intraoperatively. One (2 %) developed retinal detachment. Significant cataracts have developed in 20 (40 %) eyes. We experienced a number of macular abnormalities in eyes which were an anatomic success. In 17 (34 %) eyes, a focal epithelial pigmentary hypertrophy occurred at the site of the macular hole. Surrounding this pigment spot, the hole was closed and the retina flat. Eleven

Table 1. Visual outcome of different staged holes

Stage	6/12 or better		6/18 or better		VA increase			
					2 lines or more		4 lines or more	
	n	%	n	%	n	%	n	%
2	8	66	10	83	7	58	4	33
3	11	41	17	63	21	78	12	44
4	1	11	3	33	8	80	4	40

Stage 2 significantly more likely than stage 3 ($p = 0.003$) or stage 4 ($p = 0.003$) to achieve 6/9.

Table 2. Visual outcome in eyes with macular abnormalities

Macular Abnormality	6/12 or better		6/18 or better		VA increase			
					2 lines or more		4 lines or more	
	n	%	n	%	n	%	n	%
Pigment spot	8	47	12	70	134	82	11	65
No pigment spot	12	37	19	59	23	69	9	28
Radial folds	2	18	7	63	8	73	3	27
No radial folds	18	47	24	63	29	74	17	44

(22 %) eyes had fine radial folds emanating from the closed hole. These tended to disappear at about 6 weeks after surgery. There was no significant difference in visual outcome in eyes with and without a pigment spot, but eyes without radial folds were more likely to achieve a final visual acuity of 6/12 or better than those with radial folds ($p = 0.017$) (table 2). Five (10 %) eyes developed fine epiretinal membranes. One required vitrectomy for removal, but none of the others caused traction on the macula or distortion of vision. Sixteen (32 %) eyes have developed postoperative temporal or inferotemporal visual field loss. Four of these had stage 2 holes, 9 had stage 3, and 3 had stage 4 holes.

Discussion

When performing surgery for macular holes, the aim is to achieve flattening of the neurosensory retinal detachment surrounding the hole, leading to visual improvement. As the macula is a vision-sensitive area, it is important to achieve this flattening with minimal damage to retinal tissue. Kelly and Wendel (2) first described vitrectomy, gas tamponade, and post-operative posturing for the treatment of macular holes. Some advocate the aggressive peeling of fine epiretinal membranes and/or the internal limiting membrane (ILM) during this procedure. We avoid such contact with the macula, and we peel ERMs only if clearly visible or causing traction. We achieved a high anatomic success rate despite avoiding foveal manipulation.

There have been suggestions [9] that longer gas tamponade may be associated with a higher success rate. We use C3F8 gas, and ask patients to posture for 2–4 weeks. Each patient receives an information leaflet pre-operatively, and the importance of posturing is reiterated during their inpatient stay and after discharge.

Adjunctive therapy was introduced to the surgical management of macular holes by Glaser and coworkers [4], in an attempt to improve the anatomic and visual outcome. The cytokine TGF- β 2 has been shown to induce chorioretinal adhesion of the margins of a retinal tear in an animal model [10]. Used in the treatment of macular holes, the cytokine induces chorioretinal adhesion at the margins of the hole, increasing the anatomic success and thereby improving visual outcome. It has also been suggested [4] that TGF- β 2 has a growth-promoting effect on the photoreceptors of the macula improving the visual result. Other sources of cytokines such as serum [6] and platelets [7] have been used with success in the treatment of macular holes.

We attained an anatomic success rate of 96 %. In Kelly and Wendel's initial study, an anatomic success rate of 58 % was reported. This had improved to 90 % in a larger series of patients [11]. Glaser et al. [3] achieved 100 % success rate using 1,330 ng of TGF- β 2. Liggett et al. [6] found 100 % anatomic success in 11 eyes treated with autologous human serum. Gaudric et al. [7] reported 95 % anatomic success in 20 eyes treated with autologous platelet concentrate, and Korobelnik et al. [12] reported 87.5 % hole closure in 11 eyes also using autologous platelet concentrate. Our study with 50 eyes seems to support a high success rate with autologous platelet concentrate.

In this study, 74 % of patients had an improvement in visual acuity of 2 lines or more. Most authors have used the two-line criterion as a mea-

sure of visual success. In Kelly and Wendel's [2] initial study, 42 % of cases were a visual success. This improved to 55 % in their follow-up study [11]. Glaser's group [3] achieved 85 % visual success using TGF- β 2. Fine [13] suggested an arbitrary figure of 6/12 as a target for the successful treatment of macular holes, and it is perhaps actual visual acuity which is more important than lines of improvement. In this study, 40 % of patients had a final visual acuity of 6/12 or better, and 63 % had visual acuity of 6/18 or better.

Platelets are a rich source of cytokines [14], and this property has been exploited to promote wound healing [15]. Platelets are believed to enhance the surgical success of macular hole treatment by releasing cytokines which stimulate chorioretinal adhesion at the margin of the macular hole. We inject 0.1 ml of a platelet solution containing 10^6 platelets per ml into the eye. For the following 1–2 weeks, most patients have the appearance of a white 'coagulum' over the posterior pole. This may be merely clumping of the platelets, or the material may contain some of the clotting factors, for example fibrin. Others working with platelets have also noted this appearance [Gaudric, pers. commun.]. This white material may have a beneficial effect by enhancing closure of the macular hole by mechanical means, perhaps providing a scaffold for cell proliferation, but it is also possible that it has a deleterious effect on the retinal tissue. A number of eyes, despite having successfully closed holes, had one of a variety of macular abnormalities. Seventeen have focal retinal pigment hypertrophy at the site of the macular hole, occurring about 6 weeks postoperatively. Surrounding this pigment spot, the macular hole was closed, with no edge visible. The presence of a pigment spot did not appear to effect visual outcome as there was no significant difference in visual outcome between eyes with and without this pigment abnormality ($p = 0.5$). We noted radial striae emanating from the closed macular hole in 11 eyes postoperatively. They present 4–6 weeks postoperatively and then gradually disappear. The retina remains thickened at the fovea for several weeks postoperatively in some eyes in which the macular hole has closed and these striae may represent the effects of centripetal contraction on hole closure. Radial striae in the retina have been reported to be present in some macular holes preoperatively and their presence has been correlated with a better visual outcome [16]. We found that eyes without radial folds were significantly more likely to achieve a final visual acuity of 6/12 or better than those with radial folds ($p = 0.017$).

We have experienced a number of complications similar to those reported by others [17, 18]. Significant cataracts have developed in 20 eyes. Six eyes developed retinal tears, treated intraoperatively, and one had a

retinal detachment. In 1 patient a previously closed macular hole reopened. A second procedure was undertaken and this was successful. Sixteen eyes have been found to have temporal or inferotemporal visual field defects. This phenomenon has recently been described in association with macular hole surgery [19–21], but the incidence has not been documented previously. A number of factors may be responsible and it has been suggested that it is due to trauma to the optic nerve during posterior hyaloid stripping. However, in our series 3 eyes with field loss did not require this procedure (i. e. were stage 4 holes). The exact aetiology of this visual field loss is still unclear. Pendergast and McCuen [21] have suggested a number of possible causes including nocturnal hypotension, ocular compression due to face down posturing, elevated intraocular pressure postoperatively, and retinal toxicity due to the intraocular gas bubble. It has also been suggested [19] that direct trauma to the optic nerve may result from vigorous fluid aspiration near the optic disc. We perform fluid aspiration using a silicone-tipped cannula, so such trauma is unlikely.

We have had no case of surgical endophthalmitis but infection is an obvious concern when injecting any substance into the vitreous cavity. To avoid this devastating complication, we prepare our platelet concentrate under sterile conditions within the operating theatre. We avoid transport of the blood products to and from laboratories, thus reducing the risk of bacterial and viral contamination.

We are encouraged by our high rate of anatomic and visual success in the treatment of macular holes using vitrectomy, gas tamponade, and autologous platelet concentrate. Most patients experience visual improvement, some achieving visual acuities of 6/9 or even 6/6. The decision of when, and if, to operate is still not clear [22, 23], but a recent study [24] has shown that bilateral visual function does improve following macular hole surgery, especially if vision in the fellow eye is subnormal. This study supports the effectiveness of platelet concentrate as adjunctive therapy, but has the limitations of not being a controlled trial. One of the main difficulties for patients is the prolonged posturing, and our efforts are now directed to reduce the length of time required to posture while maintaining a high success rate.

References

- 1 Gass JDM: Idiopathic macular hole: its early stages and pathogenesis. *Arch Ophthalmol* 1988;106:629–639.
- 2 Kelly NE, Wendel RT: Vitreous surgery for macular holes: Results of a pilot study. *Arch Ophthalmol* 1991;109:654–659.

- 3 Glaser BM, Michaels RG, Kupperman BD, Sjaarda RN, Pena RA: Transforming growth factor beta2 for the treatment of full thickness macular holes: A prospective randomised study. *Ophthalmology* 1992;99:1162 1172.
- 4 Lansing MB, Glaser BM, Liss H, Hanham A, Thompson JT, Sjaarda RN, Gordon AJ: The effect of pars plana vitrectomy without epiretinal membrane peeling on full thickness macular holes. *Ophthalmology* 1993;100:868 872.
- 5 Smiddy WE, Glaser BM, Thompson JT, Sjaarda RN, Flynn HW, Hanham A, Murphy RP: Transforming growth factor beta 2 significantly enhances the ability to flatten the rim of subretinal fluid surrounding macular holes: Preliminary results of a multicenter prospective randomised study. *Retina* 1993;13:296 301.
- 6 Liggett PE, Skolik DSA, Horio B, Saito Y, Alfaro V, Mieler W: Human autologous serum for the treatment of full thickness macular holes: A preliminary study. *Ophthalmology* 1995; 102:1071 1076.
- 7 Gaudric A, Massin P, Paques M, Santiago PY, Guez JE, Le Gargasson JF, Mundler O, Drouet L: Autologous platelet concentrate for the treatment of full thickness macular holes. *Graefe's Arch Clin Exp Ophthalmol* 1995;233:549 554.
- 8 Gass JDM: Reappraisal of biomicroscopic classification of development of a macular hole. *AJO* 1995;119:752 759.
- 9 Thompson JT, Glaser BM, Sjaarda RN, Murphy RP, Hanham A: Effects of intraocular gas bubble duration in the treatment of macular holes by vitrectomy and transforming growth factor beta 2. *Ophthalmology* 1994;101:1195 1200.
- 10 Smiddy WE, Glaser BM, Green WR, Concor TB, Roberts AB, Lucas R, Sporn MB: Transforming growth factor beta: A biologic chorioretinal glue. *Arch Ophthalmol* 1989;107:577 580.
- 11 Wendel RT, Patel RC, Kelly NE, Salzano TG, Wells JW, Novack GD: Vitreous surgery for macular holes. *Ophthalmology* 1993;100:1671 1676.
- 12 Korobelnik JF, Hannouche D, Belayachi N, Branger M, Guez JE, Hoang Xuan T: Autologous platelet concentrate as an adjunct in macular hole healing: A pilot study. *Ophthalmology* 1996;103:590 594.
- 13 Fine SL: Discussion on ref. [4]. *Ophthalmology* 1993;100:871 872.
- 14 *British Medical Bulletin*.
- 15 Steed DL, Gosler JB, Holloway GA, Malone JM, Bunt TJ, Webster MW: Randomised double blind trial in treating chronic diabetic foot ulcers with CT102 activated platelet supernatant, topical versus placebo. *Diabetes Care* 1992;15:1598 1604.
- 16 Yoshida A, Ishiko S, Akiba J: Radiating retinal folds detected by scanning laser ophthalmoscope in idiopathic macular holes. Report at Club Jules Gonin Meeting, September 1996.
- 17 Thompson JT, Glaser BM, Sjaarda RN, Murphy RP: Progression of nuclear sclerosis and long term visual results of vitrectomy with transforming growth factor beta 2 for macular holes *AJO* 1995;119:48 54.
- 18 Park SS, Marcus DM, Duker JS, Pesavento RD, Topping TM, Frederick AR, D'Amico DJ: Posterior segment complications after vitrectomy for macular hole. *Ophthalmology* 1995;102:775 781.
- 19 Melberg NS, Thomas MA: Visual field loss after pars plana vitrectomy with air/fluid exchange. *AJO* 1995;120:386 388.
- 20 Ezra E, Arden GB, Riordan Eva P, Aylward GW, Gregor ZJ: Visual field loss following vitrectomy for stage 2 and 3 macular holes. *BJO* 1996;80:519 525.
- 21 Prendergast SD, McCuen BW: Visual field loss after macular hole surgery. *Ophthalmology* 1996;103:1069 1077.
- 22 Barrie T: Macular holes (editorial). *BJO* 1995;79:511 512.
- 23 Fine SL: Vitreous surgery for macular hole in perspective: Is there an indication? *Arch Ophthalmol* 1991;109:635 636.
- 24 Polk TD, Smiddy WE, Flynn HW: Bilateral visual function after macular hole surgery. *Ophthalmology* 1996;103:422 426.

Ms. Miriam Minihan, FRCOphth, Department of Ophthalmology, Cork University Hospital, Wilton, Cork (Ireland)

.....

Hemorrhagic Macular Cysts in Terson's Syndrome and Its Implications for Macular Surgery

*Robert Morris^a, Ferenc Kuhn^{a, b}, C. Douglas Witherspoon^a,
Viktória Mester^b, James Dooner^a*

^a Helen Keller Eye Research Foundation, Birmingham, Ala., USA;

^b Department of Ophthalmology, University of Pécs, Hungary

First reported in 1881 [1], Terson's syndrome is characterized by vitreous hemorrhage secondary to subarachnoid or subdural hemorrhage [2–4]. It is bilateral in more than half of the cases [5]. In approximately one-third of these eyes, an accumulation of blood ('hemorrhagic macular cyst, HMC', see below) may also be found [6]. Persistence of a dense preretinal or intraretinal hemorrhage at the fovea can be detrimental [7, 8].

Vitrectomy allows prompt HMC removal. We present our experience with removal of 13 such cysts. Based on the excellent visual recovery in adult eyes and the lack of complications during long-term follow-up, we confirm our earlier suggestion [6] that intentional removal of the macular internal limiting membrane (ILM) to treat traction maculopathies is reasonable.

Subjects and Methods

Thirty three eyes of 27 patients with Terson's syndrome underwent standard vitrectomy between December 1978 and April 1996. All epiretinal membranes and HMCs were removed completely. The single exception was the first patient, an infant with bilateral cysts. While the HMC was removed from the right eye, the HMC in the fellow eye was left intact initially.

The removed cyst wall from case 2 was placed in 10% buffered formalin and submitted for histologic examination. 7 µm thick sections were prepared from a paraffin block, stained (hematoxylin eosin), and evaluated by light microscopy. A portion of the aspirate from the macular cyst in case 5 was stained (May Grunwald Giemsa) and then benzidine peroxidase reaction was performed. A separate portion of this specimen underwent polarization microscopic examination following toluidine blue and picosirius

staining [9, 10]. Immunohistochemical (polyclonal acidic glial fibrillar protein antibody) reaction was also performed [11]. Transmission electron microscopy was performed on the specimen from case 8.

Results

A HMC (fig. 1, 2) was found in 13 of the 33 eyes (39%). One patient had bilateral cysts. Four of the 12 patients were children. Most eyes underwent vitrectomy at ≤ 3 months after the occurrence of the hemorrhage with the cyst still containing blood remnants. In the 2 eyes with vitrectomy at 15 and 23 months (cases 2 and 6), both cysts had collapsed, and the blood had completely resolved. The anterior cyst wall, appearing as a loose epimacular membrane, remained visible in both eyes.

Two types of HMCs were found. In 9 eyes, the HMC was beneath the ILM (submembranous HMC). Removal of the ILM in was confirmed clinically, histologically (case 2), and electron microscopically (case 8) by several independent observers (fig. 3, 6).

In 3 eyes, although it appeared during vitrectomy that the HMC had an anterior wall behind the detached posterior vitreous face, no membrane was encountered. In these eyes with preretinal HMC, simple aspiration was sufficient to restore normal macular anatomy. Demonstrating glial or collagen membranes, or basement membrane material in the specimen from case 5 was unsuccessful.

Table 1 summarizes the clinical data on the 13 eyes with HMC. In the 9 eyes with submembranous HMC, the average follow-up was 27 months. Of the 6 adult eyes with macular ILM removal, 5 (83%) reached and maintained $\geq 20/25$ visual acuity. One eye sustained a retinal detachment involving the macula; the retina was subsequently reattached, but visual improvement was limited. Cataract developed in 2 eyes. In children, visual acuity measurement was difficult, impossible, or influenced by amblyopia or brain damage, but clinically obvious maculopathy was not observed.

Biomicroscopic examination at various times during the follow-up period of eyes with submembranous HMC was performed by several independent observers. They repeatedly confirmed the presence of scrolled residual edges of the partially excised ILM and the absence of the usual retinal sheen in the cyst bed. Loss of the normal macular sheen is evident when the cyst bed is compared to the extramacular retinal (ILM) reflex in the same eye or to the macular appearance in the fellow eye in (fig. 5a, b).

Comment

Most cases of vitreous hemorrhage do not require surgery because of spontaneous resorption. Individuals with Terson's syndrome, however, are mostly young with a usually healthy vitreous gel that slows clearing [12]. The hemorrhage has been reported to persist after as long as 6 years [13]. Vitrectomy cannot only prevent blood-related secondary complications, it is also able to achieve rapid visual rehabilitation in these often desperate patients [5, 6]. As a low-risk procedure, vitrectomy is a reasonable alternative to observation in nonclearing vitreous hemorrhages in adults who can give informed consent. Surgery should be indicated as early as possible in infants to prevent deep amblyopia.

Numerous publications have reported on the accumulation of blood in the macular area in Terson's syndrome [4, 5, 14–27]. It is not uncommon to see a retinal fold [28] around the border of the blood. HMCs have been referred to as subretinal swelling [23], intraretinal or preretinal hemorrhage [24–26], subhyaloid hemorrhage [15, 21], macular hematoma [19], mushroom-like white glistening tumor [17], and retinoschisis [20].

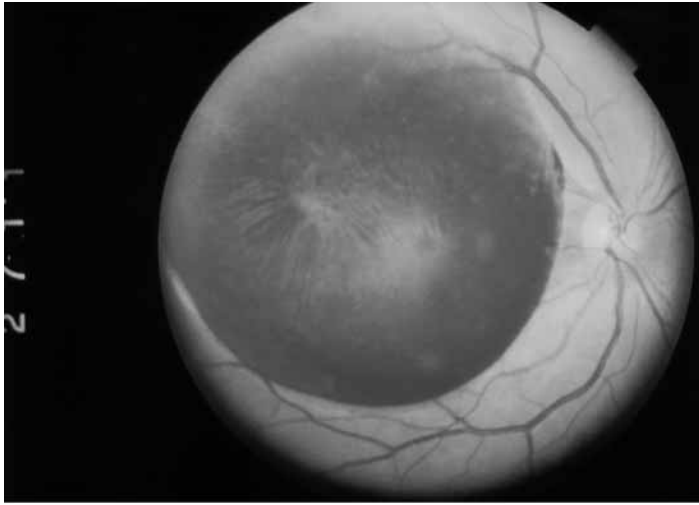
Careful analysis of the published case reports reveals that most articles fail to accurately localize the position of the blood with respect to the retina [15–17, 19, 21, 23–26, 29]. Misclassification of the ILM is surprisingly frequent: since this structure is part of the retina, a hemorrhage located beneath the membrane obviously cannot be called 'preretinal' [30].

Based on the blood's relation to the ILM, two types of HMCs can be distinguished. A HMC is preretinal if the blood is located anterior to all layers of the retina, and submembranous if the blood pooled beneath the ILM (fig. 2). The anterior cyst wall may initially be formed by the posterior hyaloid face and later by proliferation. This newly formed membrane is sometimes still present even if blood from the cyst has cleared [4]. In rare instances, there is no visible or exciseable anterior cyst wall. It is likely that in such cases the degenerated red blood cells 'stick' together; their walls are known to have a strong tendency to adhere to each other [31].

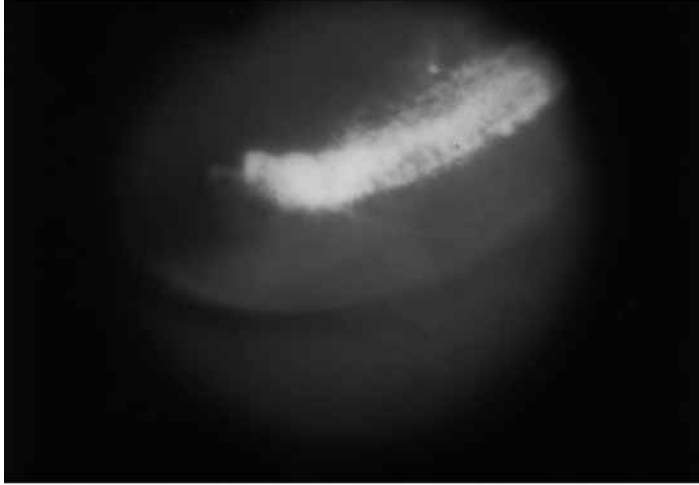
Fig. 1. Typical appearance of a fresh submembranous hemorrhagic macular cyst seen in Terson's syndrome. Note the round shape of the lesion and the striae showing stress on the internal limiting membrane.

Fig. 2. Case 1, right eye. Intraoperative view of cyst edge. Linear reflection of fiberoptic light on convex cyst surface.

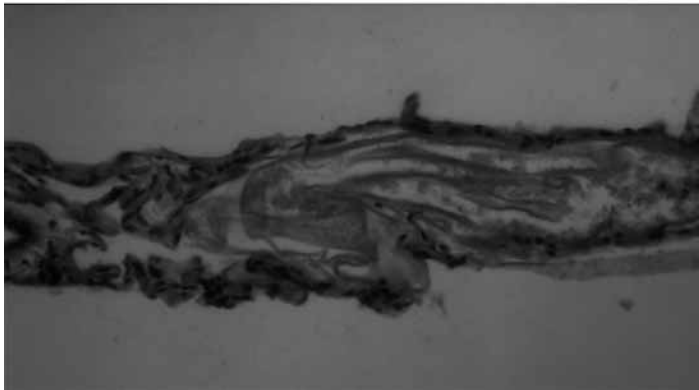
Fig. 3. Hematoxylin eosin stain of anterior cyst wall (case 2). Thick, scrolled, well formed basement membrane consistent with retinal internal limiting membrane.



1



2



3

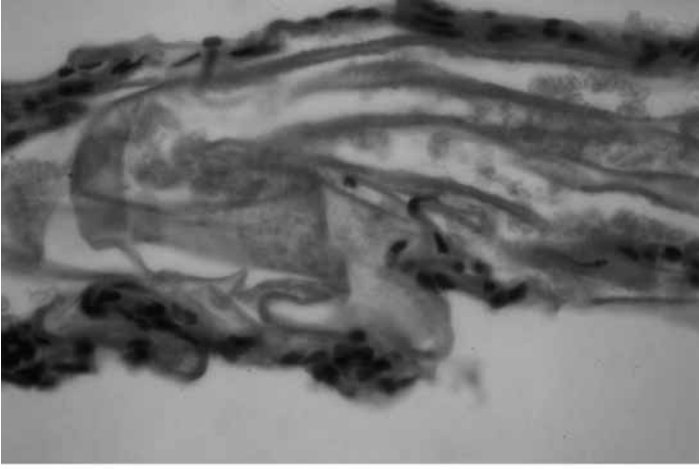
The term ‘hemorrhagic macular cyst’ is proposed based on the clinical and echographic appearance of these characteristic macular lesions. On ultrasonography, the careful observer may notice a nonmobile, convex, fluid-containing mass in front of the macula. The mass is clearly distinguishable from the blood-stained vitreous. During surgery, the surgeon finds a cyst-like lesion overlying the retina and obscuring the macula. The appearance of the cyst depends on the duration of the lesion. For a few weeks after the bleeding, one usually finds that the cyst contains red blood. With time, the contents’ color changes to white or yellow as the blood degenerates. Finally, with absorption or leakage of the cyst’s contents, the anterior wall may collapse and appear as a loose epiretinal membrane. We therefore think that ‘cyst’ defined as similar to a bladder (‘an abnormal sac containing gas, fluid, or semisolid material’) or to a vesicle (‘any hollow structure... containing a serous fluid’) [32] is an appropriate term. Though the lesion may give the appearance of a hematoma when it is fresh, in most cases breakdown of the blood has already occurred by the time the surgeon actually observes it. At this stage the color of the cyst is neither red nor blue, therefore the term ‘hematoma’ may be misleading.

Though detachment of the ILM has been stated as probably uncommon in Terson’s syndrome [4], several cases of submembranous HMC have been reported [15, 19, 21, 25–27], and were more prevalent than pre-retinal HMCs in this series. Blood pooling beneath the ILM in the posterior pole is facilitated by the fact that the ILM thickens here and its attachment plaques to the retina disappear; the extravasated blood is under tension, leading to the typical dome shape of the lesion [33]. It is likely that the ‘epimacular proliferation’, described in the literature in many eyes after clearing of the vitreous hemorrhage, is not a new membrane but represents the anterior wall of a collapsed submembranous HMC, as seen in the left eye of case 1. Whether a hemorrhage will hydrodissect the ILM and result in a submembranous cyst, or will (immediately or subsequently) break through the ILM and/or posterior hyaloid face, is determined by, among other factors, the extravasatum’s pressure and the resistance of the ILM [15, 16, 34]. We have observed 1 patient in whom blood from a HMC

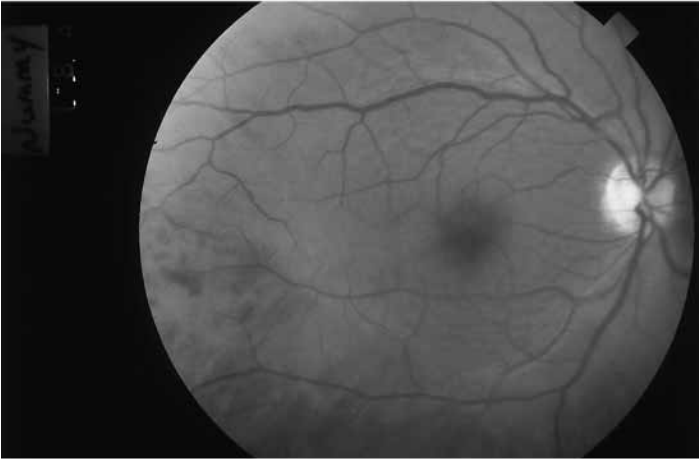
Fig. 4. High magnification view of specimen in figure 2.

Fig. 5. a Case 2, fundus photograph 65 months after removal of internal limiting membrane. Visual acuity is 20/25. Note dull macular reflex and persistent internal limiting membrane edge scrolled over 12 o’clock arterial bifurcation (arrow).

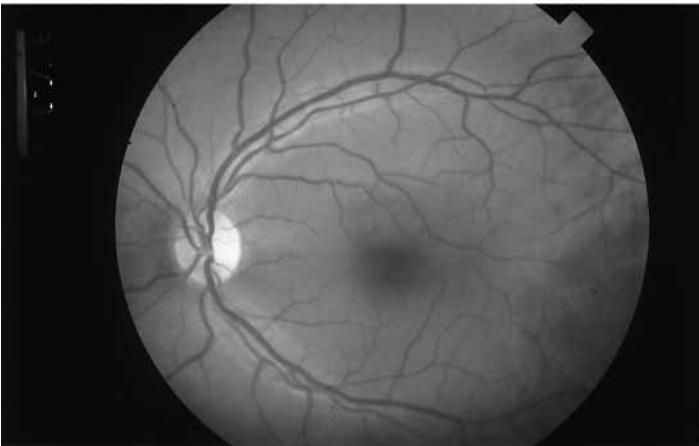
b Case 2, fundus photograph of fellow eye. Normal, smooth macula with healthy ILM reflex in this 21 year old male.



4



5a



5b

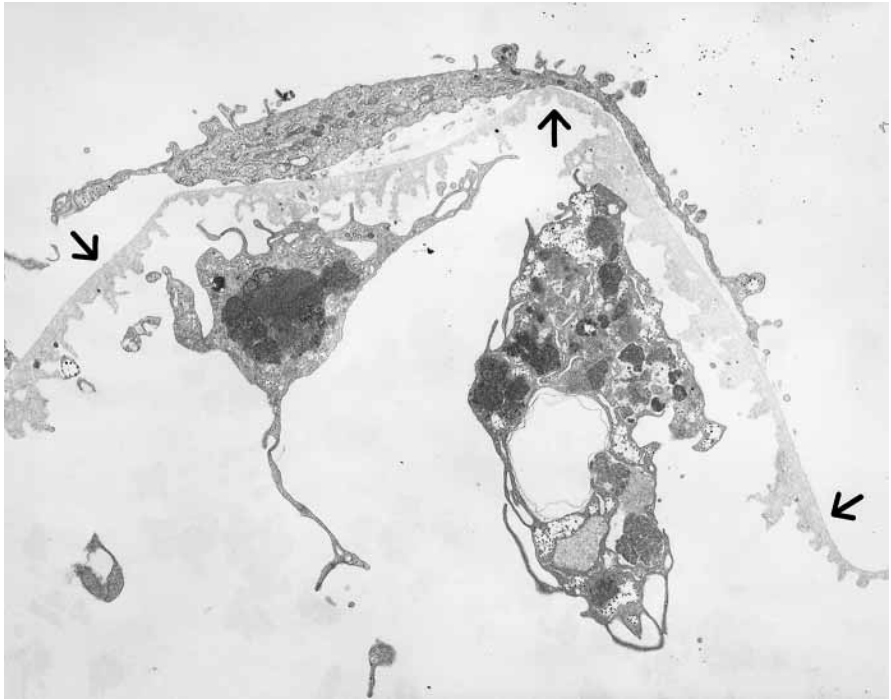


Fig. 6. Electron micrograph of the removed specimen from case 8. Smooth vitreal surface (against a fibrocyte) of the contiguous internal limiting membrane (arrows), as opposed to the irregular retinal surface (against macrophages).

broke into the previously clear vitreous a few days after the cerebrovascular incident.

To allow for early rehabilitation of macular function and to prevent blood-related complications, we advocate complete cyst removal, i. e. contents and anterior wall, regardless of cyst type.

Inadvertent ILM removal during epimacular proliferation surgery is fairly common [35, 36]. The literature is controversial as to whether loss of the foveal ILM permits good visual recovery. While most authors reported excellent visual improvement despite partial ILM removal [36, 37], a recent study found a significant difference in visual outcome between two groups of eyes undergoing surgery for epimacular proliferation. Of 11 eyes whose removed specimen contained ILM, none achieved >20/60 final vision, versus 41% of eyes with retained ILM [38].

Table 1. Selected clinical data of 13 eyes with hemorrhagic macular cyst

Case, eye (age)	Time to PPV	Follow up	Preoperative visual acuity	Final visual acuity	Comments
1 R (<1)	1	96	NP	20/60	SDH; HMC/SM
1 L (<1)	1	96	NP	20/400	HMC/SM
2 R (21)	15	65	HM	20/25	SDH; HMC/SM
3 L (<1)	2	10	P	NP	SDH; HMC/SM
4 R (47)	3	13	CF	20/25	HMC/PR
5 R (36)	3	8	HM	20/20	HMC/SM
6 L (5)	23	27	20/400	20/200	SDH; HMC/PR; amblyopia
7 L (54)	1	8	HM	20/20	HMC /PR; cataract
8 L (32)	3	6	20/200 to 20/60 ¹	20/20	HMC/SM
9 L (34)	4	1	HM	20/20	HMC/SM
10 L (48)	3	6	LP	6/200	HMC/SM; RD, cataract
11 R (<1)	1	6	NP	NP	HMC/PR; SDH
12 R 24	3	5	HM	20/20	SDH; HMC/SM

PPV = Pars plana vitrectomy; R = right eye; NP = not possible; SDH = subdural hemorrhage; HMC = emorrhagic macular cyst; SM = submembranous; L = left eye; HM = hand motion; CF = count fingers; PR = preretinal; LP = light perception; RD = retinal detachment. The intracranial hemorrhage subarachnoid unless indicated differently.

¹ Depending on how much 'peephole' vision the mobile vitreous hemorrhage permitted.

As reported in 1993 [6], we found that spontaneous detachment and subsequent surgical excision of the entire macular ILM did not interfere with excellent visual recovery and was not associated with clinical significant reparative proliferation during long-term follow-up. We also concluded that as a result of this finding, 'similar atraumatic mechanical stripping of the ILM during vitrectomy in certain cases of traction maculopathy might be more logically endorsed'.

Surgery to close macular holes, a previously untreatable condition, is now widely accepted. Various techniques are used to relieve anteroposterior and tangential traction, and removal of the frequently wrinkled ILM

is certainly a reasonable option. It is especially effective in reoperation after an initially unsuccessful hole closure surgery [39].

Removal of the still adherent ILM is a surgical maneuver that requires experience. For years we have used a technique we call 'ILM maculorhexis' (rhexis: breaking forth; bursting; the rupture of an organ; capsulorhexis: a method of creating a smooth-edged, continuous tear capsulotomy [40]). Following careful incision of the ILM by a bent microvitreoretinal blade in a selected macular quadrant, the flap is grasped by an end-gripping forceps, and the membrane is slowly torn in a circular motion concentric with the fovea. Vertical scissors may also be used for lifting and/or intermittent cutting. If necessary, the ILM is excised by retina-parallel scissors if the ILM does not spontaneously release from the fovea. As an alternative to peeling across the fovea, we feel that maculorhexis assures minimum foveal traction. Our yet unpublished results with ILM maculorhexis in macular hole surgery are encouraging. In a consecutive series of 32 eyes with idiopathic holes of ≤ 2 years of duration, a 97% closure rate was achieved; no significant intraoperative complication was seen. The vision improved ≥ 2 Snellen lines in 91% of eyes, and 41% of eyes reached $\geq 20/40$ vision at last follow-up.

Conclusion

Although most patients with Terson's syndrome require no surgical intervention, vitrectomy is a safe and effective alternative to observation, offering immediate visual rehabilitation. If a HMC is encountered, its complete removal is recommended, regardless of cyst type. Our results show that removal of the macular ILM seems neither to initiate clinically significant proliferation nor to prevent excellent and stable visual recovery.

These findings have important implications for other macular disorders related to traction. Frequently, the ILM has been colonized by contractile cells which use the ILM as a scaffold, producing foveal traction. Although not an easy surgical maneuver, removal of the ILM rarely leads to complications and may be necessary for adequate release of foveal traction. Macular hole surgery appears to be the most important indication for intentionally excising the ILM to relieve tangential traction and to prevent reopening of the hole. Results, reported at recent scientific meetings by various authors, are encouraging, and we recommend the technique we call 'ILM maculorhexis'.

Acknowledgment

The authors wish to thank J. Donald M. Gass, MD, Hans E. Grossniklaus, MD W. Richard Green, MD, Árpád Németh, MD, † and James Powell, MD for specimen evaluation, and Harold Skalka, MD, for the electrophysiologic testings.

References

- 1 Litten M: Über einige vom allgemein klinischen Standpunkt aus interessante Augenveränderungen. *Berl Klin Wochenschr* 1881;18:23 27.
- 2 MacDonald AE: Ocular lesions caused by intracranial hemorrhage. *Trans Am Ophthalmol Soc* 1931;29:418 432.
- 3 Terson A: De l'hémorragie dans le corps vitré au cours de l'hémorragie cérébrale. *Clin Ophthalmol* 1900;6:309 312.
- 4 Weingeist TA, Goldman EJ, Folk JC, Packer JA, Ossoinig KC: Terson's syndrome: Clinicopathologic correlations. *Ophthalmology* 1986;93:1435 1442.
- 5 Schultz PN, Sobol WM, Weingeist TA: Long term visual outcome in Terson syndrome. *Ophthalmology* 1991;98:1814 1819.
- 6 Morris R, Kuhn F, Witherspoon C: Hemorrhagic macular cysts. *Ophthalmology* 1993;100:1.
- 7 Hanley GP, Cany CL: Diabetic dense premacular hemorrhage: A possible indication for prompt vitrectomy. *Ophthalmology* 1985;92:507 511.
- 8 Stempels N, Tassinon MJ, Worst J: Les hémorragies dans la bourse prémaculaire traitées par le Q switched Nd YAG laser. *Ophthalmologie* 1990;4:314 316.
- 9 Puchter H, Waldrop F, Valentine LS: Polarization microscopic studies of connective tissue stained with picosirius red F3BA. *Beitr Pathol* 1973;150:174 187.
- 10 Romhányi G, Bukovszky A, Deak G: Sulfatation as a collagen specific reaction. The ultrastructure of sulfate collagen, basement membranes as shown by topo optical reactions. *Histochemie* 1973;36:123 138.
- 11 Kumpulainen I, Dahl D, Korhonen JK, Nylstrom SHM: Immunolabelling of carbonic anhydrase isoenzyme C and glial fibrillary acidic protein in paraffin embedded tissue sections of human brain and retina. *J Histochem Cytochem* 1983;31:879 887.
- 12 Benson WE, Spalter HF: Vitreous hemorrhage: A review of experimental and clinical investigations. *Surv Ophthalmol* 1971;15:297 311.
- 13 Clarkson JG, Flynn HW, Daily MJ: Vitrectomy in Terson's syndrome. *Am J Ophthalmol* 1980;90:540 552.
- 14 Ballantyne AJ: The ocular manifestations of spontaneous subarachnoid haemorrhage. *Br J Ophthalmol* 1943;27:383 414.
- 15 Vanderlinden RG, Chisholm LD: Vitreous hemorrhages and sudden increased intracranial pressure. *J Neurosurg* 1974;41:167 176.
- 16 Shaw JHE, Landers MB: Vitreous hemorrhage after intracranial hemorrhage. *Am J Ophthalmol* 1975;80:207 213.
- 17 Van Rens H, Bos PJM, van Dalen JTW: Vitrectomy in two cases of bilateral Terson syndrome. *Doc Ophthalmol* 1983;56:155 159.
- 18 Werry H, Brewitt H: Pars plana Vitrektomie beim Terson Syndrom. *Fortschr Ophthalmol* 1983;79:424 427.
- 19 Toosi SH, Malton M: Terson's syndrome: Significance of ocular findings. *Ann Ophthalmol* 1987;19:7 12.
- 20 Greenwald MJ, Weiss A, Oesterle CS, Friendly DS: Traumatic retinoschisis in battered babies. *Ophthalmology* 1986;93:618 625.
- 21 Hollenhorst RW, Stein HA: Ocular signs and prognosis in subdural and subarachnoid bleeding in young children. *Arch Ophthalmol* 1958;60:187 192.

- 22 Timberlake WH, Kubik CS: Follow up report with clinical and anatomical notes on 280 patients with subarachnoid hemorrhage. *Trans Am Neurol Assoc* 1952;77:26 30.
- 23 White WH: Two cases of intracranial aneurysm in young adults unaffected with malignant endocarditis or syphilis. *Trans Clin Soc Lond* 1895;28:5 9.
- 24 Greear JN Jr: Rupture of aneurysm of circle of Willis: Relationship between intraocular and intracranial hemorrhage. *Arch Ophthalmol* 1943;30:312 319.
- 25 Drews LC, Minckler J: Massive bilateral preretinal type of hemorrhage associated with subarachnoidal hemorrhage of the brain: With case report and pathologic findings. *Am J Ophthalmol* 1944;27:1 15.
- 26 Miller AJ, Cuttino JT: On the mechanism of production of massive preretinal hemorrhage following rupture of a congenital medial defect intracranial aneurysm. *Am J Ophthalmol* 1948; 31:15 24.
- 27 Morris DA, Henkind P: Relationship of intracranial optic nerve sheath and retinal hemorrhage. *Am J Ophthalmol* 1967;64:853 859.
- 28 Keithahn AZ, Bennett SR, Cameron D, Mieler WF: Retinal folds in Terson syndrome. *Ophthalmology* 1993;100:1187 1190.
- 29 Walsh FB, Hoyt WF: *Clinical Neuro Ophthalmology*. Baltimore, William & Wilkins, 1969, pp 1787 1791.
- 30 Foos RY: Subhyaloid hemorrhage illustrating a mechanism of macular hole formation. *Arch Ophthalmol* 1992;110:598.
- 31 Marchesi V, Steers E, Tillack T: Some properties of spectrin; in Jamieson G, Greenwalt I (eds): *Red Cell Membrane*. Philadelphia, Lippincott, 1969, p 119.
- 32 *Stedman's Medical Dictionary*: Baltimore, Williams & Wilkins Co., 1972, p 313.
- 33 Foos RF: Vitreoretinal juncture: Topographical variations. *Invest Ophthalmol* 1972;10:801 808.
- 34 Kashiwara K, Yamashita T, Ito H, Higashi S, Yamamoto S: Enlarging fundal hemorrhage in Terson's syndrome. *Ann Ophthalmol* 1989;21:59 64.
- 35 Kampik A, Green WR, Michels RG: Ultrastructural features of progressive idiopathic epiretinal membrane removed by vitreous surgery. *Am J Ophthalmol* 1980;90:797 809.
- 36 Trese M, Chandler DB, Machemer R: Macular pucker: Ultrastructure. *Graefe's Arch Clin Exp Ophthalmol* 1983;22:16 26.
- 37 de Bustros S, Rice T, Michels R, et al: Vitrectomy for macular pucker: use after treatment of retinal tears or retinal detachment. *Arch Ophthalmol* 1988;106:758 760.
- 38 Sivalingam A, Eagle RC, Duker JS, Brown GC, Benson E, Annesley WH, Federman J: Visual prognosis correlated with the presence of internal limiting membrane in histopathologic specimens obtained from epiretinal membrane surgery. *Ophthalmology* 1990;97:1549 1552.
- 39 Brooks HL: ILM peeling in full thickness macular hole surgery. *Vitreoret Surg Technol* 1995; 7:1.
- 40 Charlton JD, Weinstein GW: *Ophthalmic Surgery Complications*. Philadelphia, Lippincott: 1995, p 99.

Dr. Robert Morris, 700 18th Street South, Suite 601, Birmingham, AL 35233 (USA)
Tel. (205) 933 93 89, Fax (205) 933 13 41, E Mail: rkuhn@uab.edu

.....

Complications in the Removal of the Posterior Vitreous Cortex

*Guido Ripandelli^a, Andrea-Maria Coppé^a, Benedetto Falsini^b,
Romolo Fedeli^a, Mario Stirpe^a*

^a Fondazione G. B. Bietti per lo Studio e la Ricerca in Oftalmologia, and

^b Department of Ophthalmology, Catholic University, Rome, Italy

In selected cases a radical removal of the posterior vitreous cortex increases the possibility of successful surgery and lowers the risk of postoperative proliferative complications [1]. The present report focuses on 3 cases, from a series of 16, of unexplained postoperative visual impairment, after vitrectomy with removal of the posterior vitreous cortex; the patients complained of a dramatic postoperative decrease of visual acuity, with peripheral visual field defects, confirmed on VF testing. No recovery followed after a minimum follow-up of 12 months. In an attempt to determine the retinal dysfunction site(s) in these patients (i. e. those with unexplained visual loss after surgery, see above), macular and full-field ERGs were recorded in response to sinusoidally flickering light (flicker ERGs). It has previously been shown that fundamental and second harmonic components of the 8-Hz flicker ERG [2] are dominated by the activity of distal and proximal retinal layers, respectively. Results suggested that the inner retina was the major dysfunction site responsible for visual loss.

Patients and Methods

In a retrospective study we selected the medical records of 16 patients (9 males, 7 females, mean age 49.25 ± 7.23 years) operated on with a standard pars plana vitrectomy and posterior vitreous cortex removal for different pathologies between January 1993 and December 1995. The selected patients had seven idiopathic macular holes, five cellophane maculopathies with progressive visual reduction, and four double perforating injuries with attached retina. In all cases, after the removal of a first layer of vitreous cortex by means of a silicone tipped cannula, a second layer of epiretinal tissue has been en-

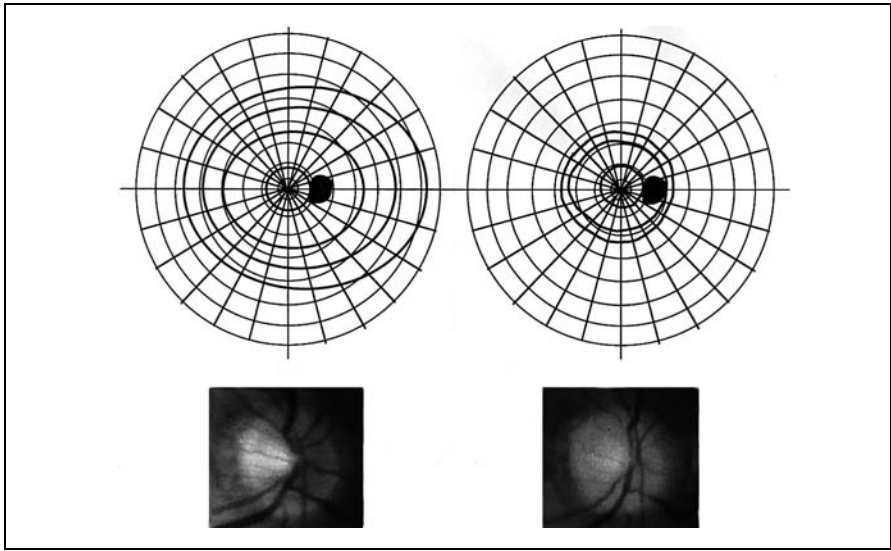


Fig. 1. Patient 2 (thick macular cellophane). Left: Preoperatively, the visual field revealed no damages and the optic disk has a normal appearance. Right: 6 months postoperatively, the visual field shows narrowing of peripheral isopters and the optic disk is pale, with marked reduction of neural rim.

gaged and removed; a complete fluid air exchange was then performed in all patients. Three of the 16 patients, 1 for each diagnostic group (2 females, 1 male, mean age 56.33 ± 9.86 years), complained of an abrupt, remarkable, postoperative visual acuity decrease (mean VA decrease 0.23 ± 0.23) with narrowing of the visual field, followed by optic disk whitening. Major visual outcome measures included visual acuity, pre and post operative biomicroscopy, perimetry and SLO microperimetry [3, 4].

The preoperative mean macular sensitivity and VA were not statistically different in the patients with postoperative complications in comparison with the control group (patients without complications); mean macular sensitivity (study group: 8.15 ± 8.30 dB, control group: 7.44 ± 1.80 dB; $t = 0.66$, $p = 0.51$), VA (study group: 0.3 ± 0.07 , control group: 0.28 ± 0.2 ; $t = 0.164$, $p = 0.87$). The objective assessment of visual function after surgery was performed by means of a flicker ERG with Fourier analysis of the responses [2, 5-7].

Results

Common alterations in all cases were (1) narrowing of the peripheral isopters of the visual field (fig. 1); (2) decrease of macular sensitivity assessed with SLO microperimetry (fig. 2); (3) late optic disk whitening (fig. 1) in some cases associated with late narrowing of retinal arterioles.

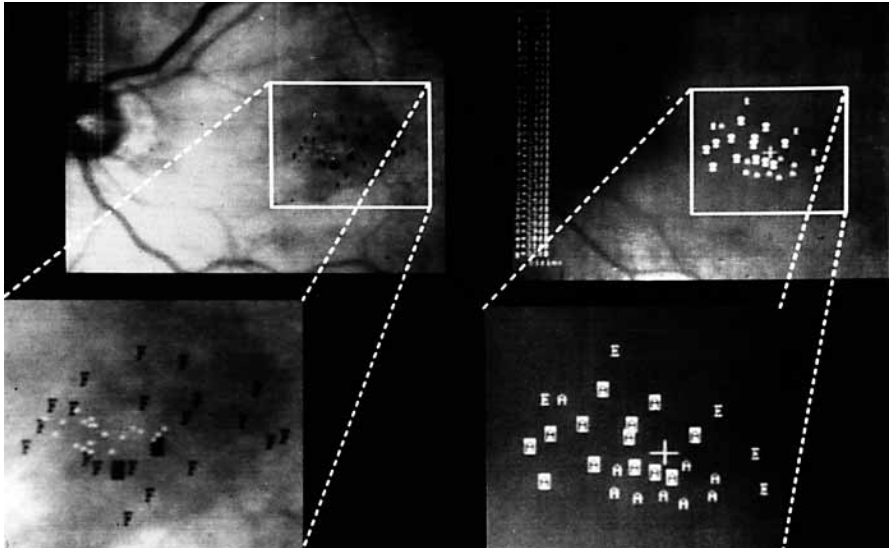
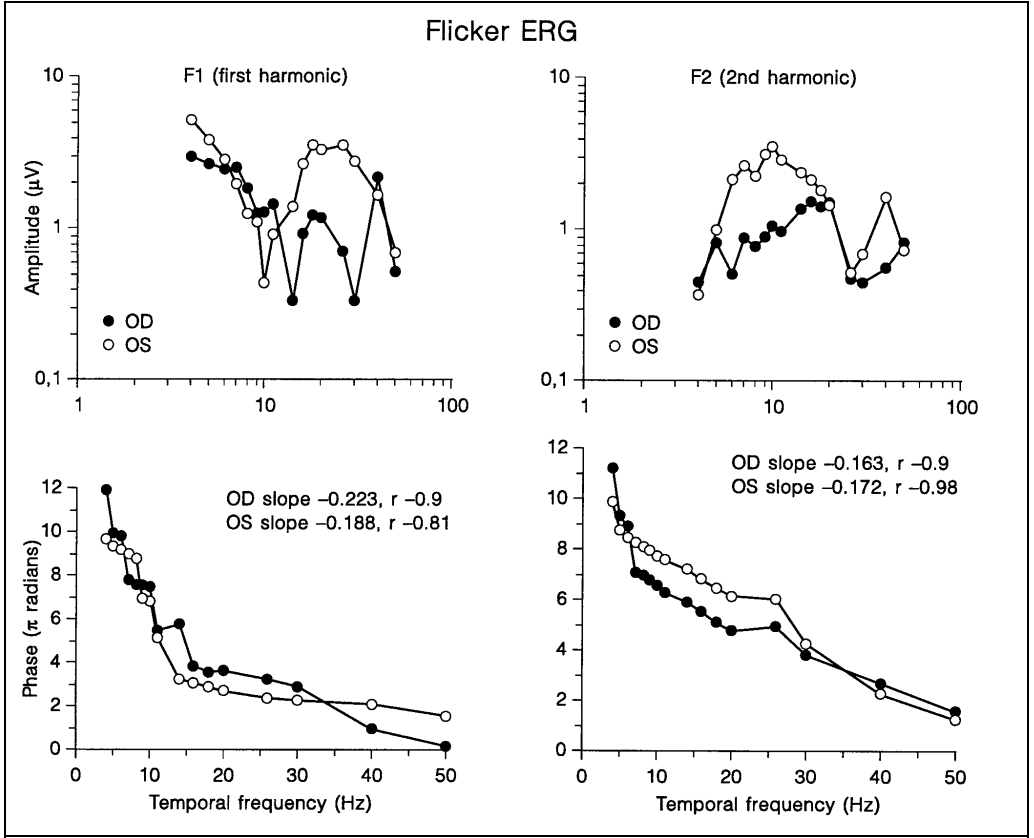
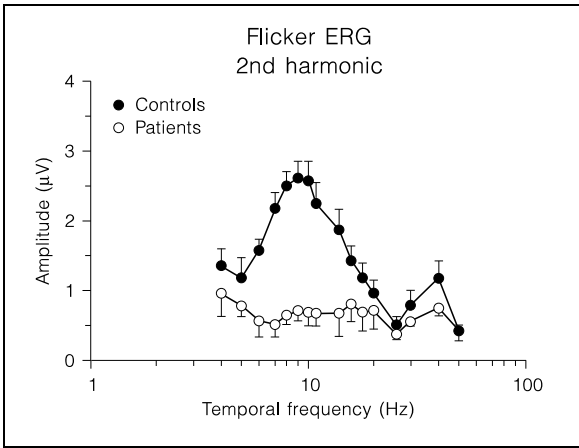


Fig. 2. Patient 2. Left: Preoperative SLO microperimetry shows a slight reduction in the macular sensitivity with a small paracentral scotoma. Right: 3 months postoperatively SLO microperimetry revealed an enlargement of the central scotoma, with further reduction of retinal sensitivity in the surrounding area.

The histological study, performed on 11 patients in the series, revealed the presence of the ILM in specimens of epiretinal tissue in 7 eyes, including 2 of the 3 cases with visual deficit. F-ERG analysis showed all layers of the retina to be damaged (fig. 3) in the patient with perforating injury (No. 3), whereas in the 2 remaining patients (No. 1, 2), with thick and taut epiretinal membrane and with the macular hole, only the inner retinal layers were damaged (fig. 4). The electrophysiological findings of an all-layer retinal damage in patient 3 is consistent with the intense macular edema that occurred intraoperatively during the removal of the vitreous cortex. A macular edema occurred in all patients in whom a second layer of epiretinal tissue was removed from the macular region, but the entity of this edema was different in the other 2 patients. Although in patient 3 both fundamental and second harmonics were reduced in amplitude as compared to the control values, second harmonic losses were significantly greater than those of the fundamental. In the remaining 2 patients, the fundamental flicker ERG component was normal in amplitude, whereas the second harmonic was profoundly depressed. Taken together, these data support the hypothesis that the proximal retina is the major dysfunction site responsible for postoperative visual loss in this patients.



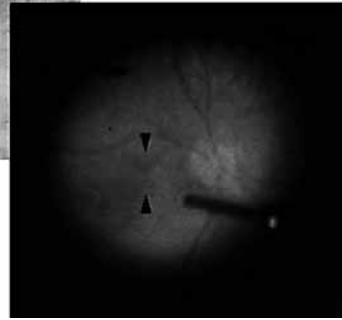
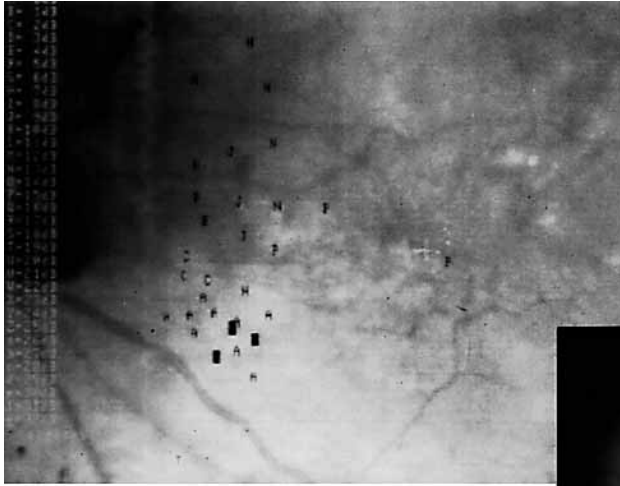
3



4

Fig. 3. Patient 3. Postoperative (6 months) flicker ERG, reduction in the amplitude of I and II armonic components.

Fig. 4. Patients 1 and 2. Postoperative (6 months) flicker ERG, marked reduction in the amplitude of II armonic component.



macular region.

Discussion

The electrophysiological study of retinal function taken layer by layer allowed us to detect the most common site of postoperative damage in the inner retinal layers. This finding, with the postoperative narrowing and sheathing of retinal arterioles, is consistent with ischemic alterations of the inner retinal circulation, as hypothesized by other researchers [8, 9]. We think that the region between the macula and the optic disk is a risk area for the removal of the vitreous cortex (fig. 5). In predisposed subjects, with stronger vitreoretinal adhesions in this area, tractions caused by the surgical maneuvers can damage the inner retinal layers and/or the retinal arterioles. Further removal of the vitreous cortex, if needed (i. e. macular hole with PVC adherent to the edge of the hole), should be limited only to the perilésional area.

In our series, the preoperative evaluation of the visual function was limited to the assessment of visual acuity and macular sensitivity; unfortunately, the electrophysiological tests were only performed postoperatively. Since we have found, after vitrectomy with removal of a further layer of posterior vitreous cortex, similar but less severe alterations in several subjects of a wider unpublished series, we think that a prospective study, with

preoperative electrophysiological evaluation and, eventually, OCT imaging of the macular region [10, 11] is needed to help in the preoperative detection of patients with stronger vitreoretinal adhesions, at risk of this kind of complications.

References

- 1 Ripandelli G, Stirpe M: Posterior vitreoretinal surgery in PFCL. Communication presented at the Retina Society 28th Annual Scientific Meeting, Santa Fe, 1995.
- 2 Baker CL, Hes RF: Linear and non linear components of human electroretinogram. *J Neurophysiol* 1984;51:952-967.
- 3 Van der Velde FJ, Timberlake GT: Static SLO microperimetry in macular disease. *Invest Ophthalmol Vis Sci* 1989;30:367-376.
- 4 Acosta F, Lashkari K: Characterization of functional changes in macular holes and cysts. *Ophthalmol* 1981;98:1820-1823.
- 5 Falsini B, Iarossi G, Porciatti V, Merendino E, Fadda A, Cermola F, Buzzonetti L: Postreceptor al contribution to macular dysfunction in retinitis pigmentosa. *Invest Ophthalmol Vis Sci* 1994;35:4282-4290.
- 6 Burns FA, Elfner AE, Kreitz MR: Analysis of non linearities in the flicker electroretinogram. *Optom Vis Sci* 1992;69:95-105.
- 7 Porciatti V, Falsini B: Inner retina contribution to the flicker electroretinogram. *Clin Vis Sci* 1993;8:435-447.
- 8 Pendergast SD, McCuen BW: Visual field loss after macular hole surgery. *Ophthalmology* 1996;103:1069-1077.
- 9 Boldt HC, Munden PM, Folk JC, Mehaffey M: Visual field defects after macular hole surgery. *Am J Ophthalmol* 1996;3:371-381.
- 10 Puliafito C, Hee MR, Lin P, Reichel E, Schuman JS, Duker JS, Izatt JA, Swanson EA, Fujimoto JG: Imaging of macular diseases with optical coherence tomography. *Ophthalmology* 1995;102:217-229.
- 11 Hee MR, Puliafito C, Wong C, Duker JS, Reichel E, Schuman JS: Optical coherence tomography of macular holes. *Ophthalmology* 1995;102:749-755.

Dr. Andrea Maria Coppé, Piazza Sassari, 5, I 00161 Rome (Italy)
Tel. (06)4 40 44 59, Fax (06)4 40 38 00

.....

Epiretinal Macular Membranes: Pathogenesis and Treatment

Benjamin Miller

Department of Ophthalmology, Rambam Medical Center, and
Bruce Rappaport Faculty of Medicine, Technion Israel Institute of Technology,
Haifa, Israel

Epiretinal macular membranes (ERMMS) may cause cellophane maculopathy or surface-wrinkling retinopathy when the membranes are thin and only the inner retina is affected, and macular pucker when the membranes are thick and full thickness retinal folds are created. The main components of ERMMS are glial cells, retinal pigment epithelial (RPE) cells, extensions of Müller cell processes, fibroblasts, myofibroblasts, macrophages and collagen fibers.

Epiretinal membranes are regarded as an extended scar tissue on the retinal surface representing overstimulated wound healing of an injured retina. In order to challenge this theory we undertook a series of experiments.

In the first series of experiments we inflicted full thickness retinal wounds just inferior to the optic disk and medullary rays of the rabbit's eye. Within 3 weeks these wounds healed, attracting macrophages during the first week of healing and eventually creating a very limited scar tissue at the surface of the retina. The scar tissue consisted of Müller cell extensions and fibroblasts.

In the next series of experiments we created a larger break in the rabbit retina by carefully peeling a piece of neuroretina off the RPE. These large wounds never healed and the RPE layer remained as a monolayer. There was no RPE proliferation outside the retinal holes, and no epiretinal membranes were observed anywhere on the surface of the retina.

Injection of red blood cells (RBCs) into the vitreous cavity of a rabbit eye created within a week typical microscopic breaks in the internal limiting membrane (ILM) through which Müller cell extensions grew out to

the vitreoretinal interface, surrounded at the beginning by a large number of macrophages proliferating and eventually creating a thick epiretinal membrane which contracted and threw the retina into full-thickness retinal folds.

This experiment suggests that a retinal wound is not enough to induce epiretinal membranes and that a most important factor in this induction is the inflammatory response at the vitreoretinal junction initiated in our experiment by the injection of RBCs into the vitreous cavity.

In another series of experiments we measured the protein level in the vitreous of the rabbit eye following injection of deactivated horse serum, trying to correlate the protein level with the morphological changes at the vitreoretinal interface. On the first day following injection the protein level was naturally very high. This level diminished within 1 week, yet at 4 weeks it again, spontaneously, reached high levels in the vitreous. At the same time (4 weeks after horse serum injection) typical epiretinal membranes appeared at the vitreoretinal junction pulling on the retina and eventually causing retinal detachment.

We thus believe that biochemical changes in the vitreous precede morphological changes at the retinal surface and that the cascade of events starts with the reactive inflammation induced here by the horse serum, leading within a few weeks to blood-ocular barrier breakdown, leakage of blood proteins into the vitreous, and epiretinal membrane growth following this leakage.

Based on these series of experiments we stress the importance of the inflammatory response in the vitreous cavity in the pathogenesis of epiretinal membranes. A retinal injury is necessary, yet an inflammatory response has to follow for the glial cells of the retina to emerge and to grow into thick epiretinal membrane once they reach the retinal surface.

Clinically, thick ERMMs may appear following the rhegmatogenous retinal detachment surgery. They are composed mainly of RPE cells that reach the retinal surface via the retinal holes. Thin idiopathic membranes, on the other hand, are composed mainly of glial cells, reaching the surface of the retina via ILM breaks; they also contain some RPE cells originating from transformation or transretinal migration. Most membranes, however, are mixed.

The most important events that may initiate epiretinal membrane growth are retinal breaks, treatment of retinal breaks, trauma, retinal vascular diseases, intraocular inflammation, and vitreous hemorrhage. Often, however, these membranes are idiopathic.

ERMMs after retinal detachment surgery are, in fact, a localized form of proliferative vitreoretinopathy. RPE cell proliferation stimulates glial

migration and proliferation, followed by membrane contraction and collagen secretion.

Biochemical substances that probably promote epiretinal membrane growth once they reach the vitreoretinal junction are vitronectin, cellular adhesion molecules, and fibronectin. Macrophages play an important role in the pathogenesis of these membranes by their capability of intercellular regulation.

Most patients with macular puckers are suffering from mild and non-progressive symptoms. In such patients treatment is not indicated; yet when significant symptoms appear and visual acuity deteriorates, surgical treatment including pars plana vitrectomy and membrane peeling is necessary. As the membranes are often multilayered, sequential peeling to prevent residual membranes is important.

The most important complications following surgery are accelerated nuclear sclerosis, peripheral retinal breaks, recurrence of membranes, and posterior retinal breaks.

The main prognostic indicators are the preoperative visual acuity and the duration of symptoms.

As not much improvement is achieved when preoperative visual acuity is relatively good and as complications may follow surgery, we recommend to wait for substantial symptoms and to operate only when visual acuity drops below 6/20 accompanied by metamorphopsia.

Prof. Benjamin Miller, Department of Ophthalmology Technion
45 Ivory Coast St., Haifa (Israel)

.....

Local Therapy of CMV Retinitis: A New Therapeutical Approach

Anne V. Fuchs, Andreas Scheider, Volker Klauss, Anselm Kampik

Eye Hospital of the Ludwig Maximilians University, Munich, Germany

A number of chronic ophthalmological diseases need long-term therapy. When administered systemically therapeutica show systemic side effects. However, intraocular drug concentrations are limited by tight junctions between retinal pigmented epithelial cells and between the endothelial cells of retinal capillaries [1].

Topical administration is hindered by barriers of cornea, lens and aqueous turnover, because intraocular drug concentration does not reach therapeutical effects. Intraocular injections as long-term treatment is not appropriate because of its risk of endophthalmitis and retinal detachment. It can also lead to cataract formation and macular edema [2].

In our clinic a study was performed treating cytomegalovirus-retinitis in AIDS locally with an intraocular implanted ganciclovir sustained-release device.

Patients and Methods

In our clinic 34 HIV positive patients with CMV retinitis received 54 ganciclovir implants. 19 patients were involved unilateral, 15 bilateral. Extraocular CMV manifestation must not be present since systemic treatment is to be discontinued from the day of operation. Furthermore, patients were included into the study only, if ganciclovir showed to be effect during initial systemic treatment and led to scarring of the lesion. All patients were treated systemically when newly diagnosed with either ganciclovir or foscarnet.

Before surgery a full systemic evaluation is performed by the physician. At the day of operation patients come as out patients and undergo a complete ophthalmologic evaluation that include determination of best corrected visual acuity, slit lamp biomicro

scopy and binocular indirect funduscopy. All involved areas are photodocumented. If there is monocular involvement systemic therapy is discontinued at the day of operation, if both eyes are involved systemic treatment continues until the operation day of the second eye.

Operation time takes about 20 min. It is performed under local anesthesia.

After routine facial and retrobulbar block a conjunctival incision is made in the superiotemporal quadrant at the limbus. Hemostasis is achieved using diathermy. Next the intraocular device is prepared by trimming the base of the anchoring strut of the device. A 8.0 nylon suture is passed through the strut. Now a micro vitreoretinal blade is used to enter the sclera 4 mm from the limbus at the length of 6 mm circumferentially. Using an automated vitrectomy device any prolapsed vitreous is excised. The device is then grasped with smooth bladed forceps and inserted into the eye; now the pellet is tight to either side of the sclera incision. It is closed by a running 8.0 nylon suture, then the conjunctiva adaptation follows [17]. Postoperatively no severe complications were noted. All patients complained about transient blurred vision due to iatrogenic astigmatism of 1.0 dptr on average (4.25 0) and postoperative anterior chamber cells, but these changes were self limiting. In 18 cases we found mild vitreous hemorrhage, in 4 of these visual acuity dropped to hand movement. In one of these patients surgery was inevitable because hemorrhage developed due to a retinal detachment. However, this patient underwent vitrectomy before because of retinal detachment. Re vitrectomy was performed with silicone oil injection. In all other cases visual acuity improved spontaneously. In 35 eyes there was no difference in visual acuity 4 weeks postoperatively compared to preoperative findings. In 8 cases it had improved by 1.4 lines and in 7 cases it was 2.3 lines below the preoperative results. In 4 patients visual acuity could not be done.

In all patients the intraocular device showed to be effective in preventing further progression of CMV retinitis. Since the time when CMV retinitis was first diagnosed patients remained relapse free for 15.1 months (1 31). In 3 cases we observed reactivation of retinitis 9.3 months (4 13) after surgery. In one patient resistance to ganciclovir was suspected, in the other eyes it was due to an empty device. These 2 patients received a second pellet in the superionasal quadrant. The first device was not removed. No additional systemic treatment was needed to stop further progression of retinitis. The third patient was treated with foscarnet systemically.

In 6 patients (18%) an extraocular CMV infection developed. In 5 cases the gastrointestinal tract was involved, in 1 case combined with skin lesions. A CMV pneumonitis was observed once. These patients needed systemic treatment to resolve the symptoms. In 6 eyes of 19 patients with primarily unilateral involvement CMV retinitis was diagnosed in the fellow eye. Without complications a pellet was also implanted in the contralateral eye and retinitis resolved.

Discussion

Multiple ocular diseases like CMV retinitis or uveitis need long-term treatment. Topical administration does not achieve intraocular therapeutic drug concentration because of insufficient penetration, so that systemic treatment is required. Systemic side effects, however, limit their use. For

example, treatment of CMV retinitis with ganciclovir leads to low granulocyte cell counts in an already immunosuppressed patient [3, 4]. Local therapy by intraocular injections provides sufficient intraocular drug concentration after injection, decreasing, however, until the next injection to very low.

To improve local therapy of CMV retinitis an intravitreal implantable device was developed, releasing ganciclovir slowly into the vitreous cavity. As proved in other studies it is effective in preventing further progression of retinitis and in prolonging the relapse free interval [5–8]. In our investigation, patients with an implant have so far shown no reactivation of retinitis within 15.1 months after diagnosis on average. This is probably due to linear drug release into the vitreous without great fluctuation of drug levels.

Severe complications were not observed. The iatrogen-induced astigmatism resolved spontaneously within 4 weeks after surgery. Endophthalmitis as described by other authors after pellet implantation did not occur [6–8]. One retinal detachment was diagnosed postoperatively. The risk for retinal detachment is not higher in patients treated with an implant than with systemic administration [8]. Unfortunately, CMV causes a systemic infection and it is not restricted to the eye in all cases. In 6 cases, extraocular infections developed and needed systemic treatment. In 6 patients we diagnosed CMV in the fellow eye which primarily showed unilateral involvement.

However, this method of administering drugs seems to have of few complications and is effective in treatment.

There are several other ocular diseases that need long-term therapy. Uveitis associated with autoimmune diseases such as sarcoidosis [9], rheumatoid arthritis, Reiter's syndrome, Behcet's disease or inflammatory bowel disease [10] need steroid therapy. Symptoms can resolve with topical steroids, but recur after discontinuation of treatment [11]. Steroid eye drops can lead to toxicity to the corneal epithelium, impaired wound healing and increased intraocular pressure [12]. Systemic therapy shows wide-ranged side effects.

Cyclosporin A is used to treat some forms of uveitis and in high-risk keratoplasty. Being administered systemically it can lead to severe nephrotoxicity [13]. When applied topically, there is some controversial discussion about penetration of the drug into the aqueous [14, 15]. No one has ever reported on the drug levels delivered into the vitreous [16].

A study was done implanting subconjunctival devices containing 5-FU after glaucoma filtering surgery showing good results [17]. Failed filters are usually due to proliferation of fibroblasts leading to scarring and subsequent blockage of the filter. Inhibition of proliferation of fibroblasts

therefore should improve success rates of filtering surgery [18]. 5-FU was also used experimentally in rabbits to inhibit proliferative vitreoretinopathy (PVR) after retinal surgery [19]. PVR remains a leading cause for failure in retinal detachment surgery. Some RPE cells liberated into the vitreous undergo transformation into fibrocytes producing collagen and macrophages. Fixed folds due to preretinal retraction and periretinal proliferation as well as opacification and retraction of the vitreous body are named PVR. Again inhibition of proliferation of transformed fibroblasts may inhibit the PVR reaction and make vitreoretinal surgery more successful.

All the conditions mentioned above need treatment over a long period of time. The drugs to be used are mostly not effective when applied locally and also not tolerable when applied systemically because of unpleasant side effects. As we could show with the ganciclovir sustained-release implants this therapeutic method is highly effective and has few complications. Their usefulness for other therapeutic agents needs further investigation.

References

- 1 Bito LZ: Transport functions of the blood ocular and blood brain barriers, and the microenvironment of neuronal and non neuronal tissues; in Segal MB (ed): Barriers and Fluids of Eye and Brain. Boca Raton, CRC Press, 1992, pp 14 23.
- 2 Harris ML, Mathalone MBR: Intravitreal ganciclovir in CMV retinitis: Case report. *Br J Ophthalmol* 1989;73:382 384.
- 3 Henderly DE; Freemann WR, Causey DM, Rao NA: Cytomegalovirus retinitis and response to therapy with ganciclovir. *Ophthalmology* 1987;94:425 424.
- 4 Holland GN, Sidikaro Y, Kreiger AE, Hardy D, Sakamota MS, Frenkel LM, Winston DJ, Gottlieb MS, Bryson YJ, Champlin RE, Ho WG, Winters RE, Wolfe PR, Cherry JD: Treatment of cytomegalovirus retinopathy with ganciclovir. *Ophthalmology* 1997;94:815 823.
- 5 Anand R, Font RL, Fish RH, Nightingale SD: Pathology of cytomegalovirus retinitis treated with sustained release ganciclovir. *Ophthalmology* 1993;100:1032 1037.
- 6 Anand R, Nightingale SD, Fish RH, Smith TJ, Ashton P: Control of cytomegalovirus retinitis using sustained release ganciclovir. *Arch Ophthalmol* 1993;111:223 227.
- 7 Sanborn GE, Anand R, Torti RE, Nightingale MD, Cal SX: Sustained release ganciclovir therapy for treatment of cytomegalovirus retinitis. *Arch Ophthalmol* 1992;110:188 195.
- 8 Martin DF, Parks DJ, Mellow FL, Ferris FL, Walton RC, Remaley NA, Chew EY, Ashton P, Davis MD, Nussenblatt RB: Treatment of cytomegalovirus retinitis with an intraocular sustained release ganciclovir implant. *Arch Ophthalmol* 1994;112:1531 1539.
- 9 Blagojevic M, Parunovic J, Nicoloc J, Mladenovic V: L'aspect clinique et immunitaire des irido cyclites rhumatismalis. *Bull Soc Ophthalmol Fr* 1970;83:71 76.
- 10 Lurhuma AZ, Cambiaso CL, Masson PL, Heremans JF: Detection of circulating antigen antibody complexes by their inhibitory effect on agglutination of IgG coated particles of rheumatoid factor or C1q. *Clin Exp Immunol* 1976;25:212 226.
- 11 Leopold IH, Gaster RN: Ocular inflammation and anti inflammatory drugs; in Kaufmann HE, Barron BA, McDonald MB, Waltman SR (eds): *The Cornea*. New York, Churchill Livingstone, 1988, p 70.

- 12 Gilman AG: The Pharmacological Basis of Therapeutics. In Gilman AG, Rall TW, Nies AS, Taylor P (eds): New York, Pergamon Press 1990, pp 1431-1462.
- 13 Trowler HMA, Cliffe AM, Whittning PH, Forrester JV: Low dose cyclosporin A therapy in chronic posterior uveitis. *Eye* 1989;3:282-287.
- 14 BenEzra D, Maftzir G: Ocular penetration of cyclosporin A in the rat eye. *Arch Ophthalmol* 1990;108:584-587.
- 15 Kaswan RL, Kaplan HJ: Comparison of the efficacy of unilateral, bilateral, and oral cyclosporine in the experimental immunogenic uveitis in rabbits. *Transplant Proc* 1988;20(suppl 4):149-157.
- 16 Nussenblatt RB: The use of cyclosporin in ocular inflammatory disorders. *Transplant Proc* 1988;20(suppl 4):114-121.
- 17 Lee DA, Leong KW, Panek WC, Eng CT, Glasgow BJ: The use of bioerodible polymers and 5-fluorouracil in glaucoma filtration surgery. *Invest Ophthalmol Vis Sci* 1988;29:1692-1697.
- 18 Gressel MG, Heuer DK, Parrish RK: Trabeculectomy in young patients. *Ophthalmology* 1984;91:1242-1246.
- 19 Borhani H, Peyman G, Rahimi M, Thompson H: Suppression of experimental proliferative vitreoretinopathy by sustained intraocular delivery of 5-FU. *Int Ophthalmol* 1995;19:43-49.
- 20 Abrams G, Glazer L: Proliferative vitreoretinopathy; in Freeman W (ed): *Practical Atlas of Retinal Diseases*. New York, Raven Press, 1993, pp 279-297.

Dr. A. V. Fuchs, University Eye Hospital, Klinikum Innenstadt, Mathildenstrasse 8,
D 80336 Munich (Germany)

.....

A Retained Catheter for Retrobulbar Administration of Interferon for Age-Related Macular Degeneration

Harvey Lincoff^a, Ingrid Kreissig^b, Faik Gelisken^b, Paulo Stanga^a

^a Department of Ophthalmology, The New York Hospital Cornell Medical Center, New York, N. Y., USA;

^b Department of Ophthalmology III, University of Tübingen, Germany

A first-phase study in a rabbit model demonstrated that injections of human recombinant interferon (IFN α -2 a) into a retrobulbar depot yielded concentrations in the choroid more than 600 times higher than could be obtained by equal subcutaneous injections [1].

The serum levels of IFN α -2 a from a retrobulbar depot were less than 1 % of the choroidal levels and were equal to the serum levels from subcutaneous injections. The results of the animal study suggested that if sequential injections into a retrobulbar depot were tolerated by patients, it presented a unique opportunity to test the effect of IFN α -2 a on subfoveal choroidal neovascularization (cnv).

With the approval of the Institutional Review Board of Cornell University Medical College, a clinical study (second phase) was begun in September 1992 at the New York Hospital and subsequently with approval of the Ethics Committee at the Eye Hospital of the University of Tübingen. The dose approved was 1×10^6 IU of IFN α -2 a per day. This amount in a retrobulbar depot was expected to yield a therapeutic concentration in the choroid with minimum systemic toxicity.

The preliminary findings in 11 patients who were followed for 17–39 months are being reported because of the interest shown in the study and because some negative results, as well as some complications, have already become evident.

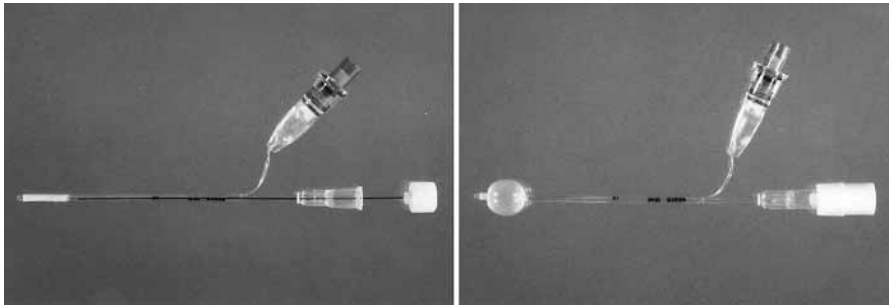


Fig. 1. The double lumen catheter with fiberoptic stylette (left) and with the balloon expanded (right). (Cornell University has patented the double lumen catheter.)

Materials and Methods

The 11 patients who were selected were older than 50 years and had had a recent onset of diminished central vision caused by subfoveal cnv. Visual acuity ranged from 20/40 to 20/200. One patient was experiencing a recurrence of a parafoveal lesion after laser treatment. Four patients were referred from the study on the effect of subcutaneous IFN α 2a on cnv because the entry medical examination concluded that they might not tolerate the larger dose to be administered.

A sensory detachment of the macula was present in all of the patients, 7 of them had a streak of blood in the macula at the edge of a pigment epithelial detachment. Eight patients had classic cnv demonstrated by fluorescein angiography. Two patients had occult cnv defined by fluorescein and indocyanine green angiography. One patient had both classic and occult features.

Patients were examined by a hematologist oncologist who obtained and evaluated a blood profile, chemistries, a urine analysis and an EKG before deciding that they were suitable candidates for the administration of IFN α 2a 1×10^6 IU daily for 50 days. The internist re examined the patients at 2, 4, and 7 weeks. Informed consent was obtained before treatment in every patient.

Human recombinant IFN α 2a was obtained in vials containing 16,000,000 IU. The powder was diluted with 1.6 ml of normal saline so that each 0.1 ml contained 1,000,000 IU. The solutions were kept refrigerated at 5 °C.

The double lumen catheter for injecting IFN α 2a into the retrobulbar space was similar to the one developed to carry a fiberoptic stylette in a second lumen for the localization of retinal breaks [2]. For the IFN α 2a project, the lumen carrying the stylette was opened at its distal end so that it could deliver medication into the orbit [3] (fig. 1).

The catheter was inserted under retrobulbar anesthesia through a 2 mm incision in the conjunctiva and Tenon's capsule. The incision was made 15 mm from the limbus at the superior edge of the lateral rectus muscle. A blunt, curved probe (Kreissig depressor) was inserted first and advanced under ophthalmoscopic observation to a position 1 disc diameter superior and temporal to the fovea (fig. 2). After the probe was with



Fig. 2. This blunt, curved probe (Kreissig depressor) with two curved ends correlating with the curvature of the globe) is first inserted in the parabulbar space and advanced under ophthalmoscopic observation to a position one disc diameter superior and temporal to the fovea.

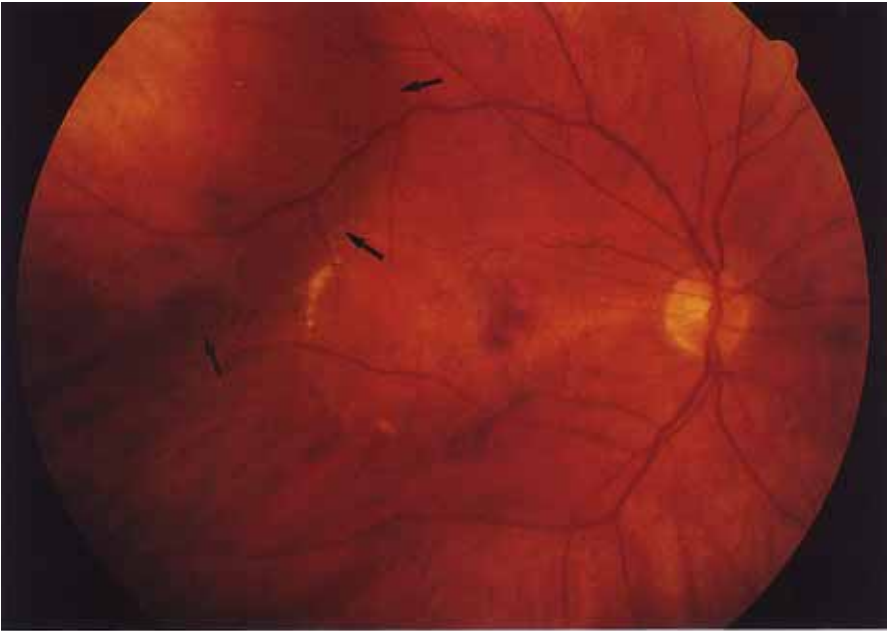
drawn, the balloon tipped catheter was inserted along the same pathway and the balloon expanded with 0.6 ml of sterile water. The balloon retains the catheter in position without sutures. The indentation of the expanded balloon can usually be discerned with the indirect ophthalmoscope (fig. 3). To further confirm its position, a fiberoptic was inserted into the lumen and its passage into the balloon observed through an unlighted binocular ophthalmoscope. When the fiberoptic entered the balloon, its glow outlined the balloon (fig. 4). If the balloon was not in a correct position, it was maneuvered accordingly. When the position was satisfactory, the stylette was withdrawn and 0.1 ml of IFN α 2a was injected into the catheter followed by 0.2 ml of air. The catheter had a volume of 0.16 ml and the air moved the medication into the retrobulbar space. The external part of the catheter and the valves were taped to the temple (fig. 5) and covered with sterile gauze.

The patients came for the supplemental injections six days a week. With the patient sitting in an ophthalmic examination chair, the gauze cover was removed and the valves, the skin of the temple and forehead cleaned with an alcohol pledget.

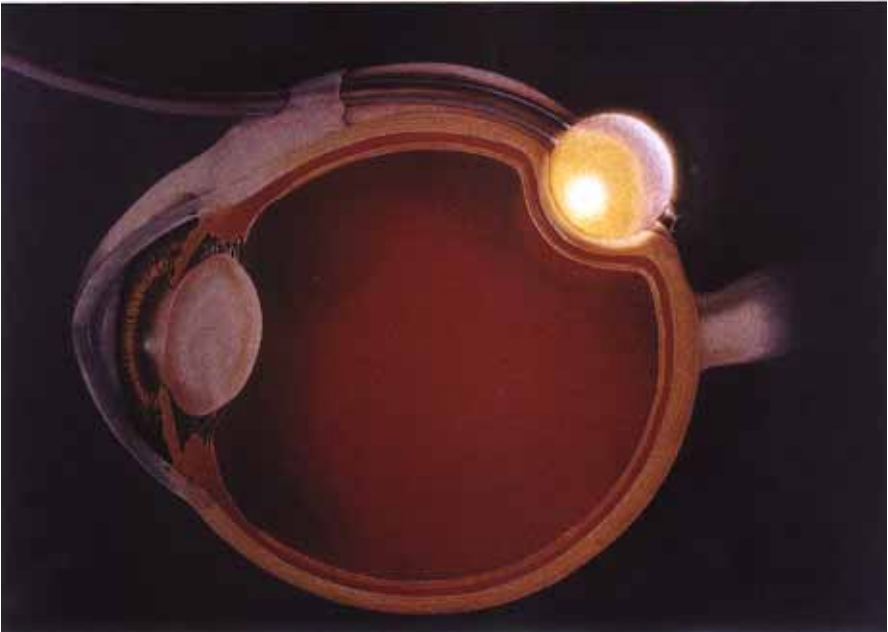
IFN α 2a (0.1 ml) was drawn into a tuberculin syringe. The solution at the open end of the syringe was touched with a sterile fluorescein strip. The fluorescein stained solution was barely perceptible under white light, but was apparent under blue light. Injecting under blue light enabled us to monitor the flow of interferon through the catheter and to ascertain that the air that followed it emptied the catheter.

At each visit, prior to injecting, the corrected visual acuity was tested with the same retroilluminated Snellen chart that had been used in the initial examination. The pupil of the eye being treated was dilated and the fundus examined by slit lamp biomicroscopy through a +78 dptr lens. Significant changes such as new blood were documented with photographs. Fluorescein angiograms were obtained at 2, 4, and 7 weeks and a second in docyanine green angiogram was obtained at 7 weeks. If lid edema developed, or the patient complained of pain or discomfort, 0.3 ml of sterile saline was injected and then withdrawn from the catheter and the sample cultured.

The indentation of the balloon diminished during the first week, but its position could be ascertained and its volume measured by ultrasonography (fig. 6). After 23 50



3



4

Fig. 3. Fundus photo showing the indentation of the balloon (arrows) supero-temporal to the fovea.

Fig. 4. Drawing of the balloon catheter adjacent to the posterior pole. The fiberoptic stylette is illuminating the balloon.

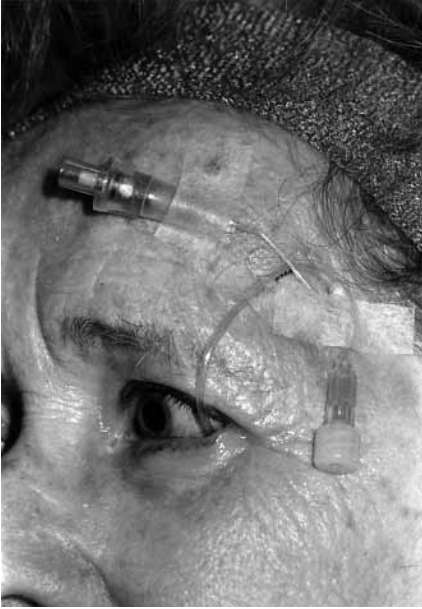

Fig. 5. The catheter and the valves are taped to the temple of the patient.

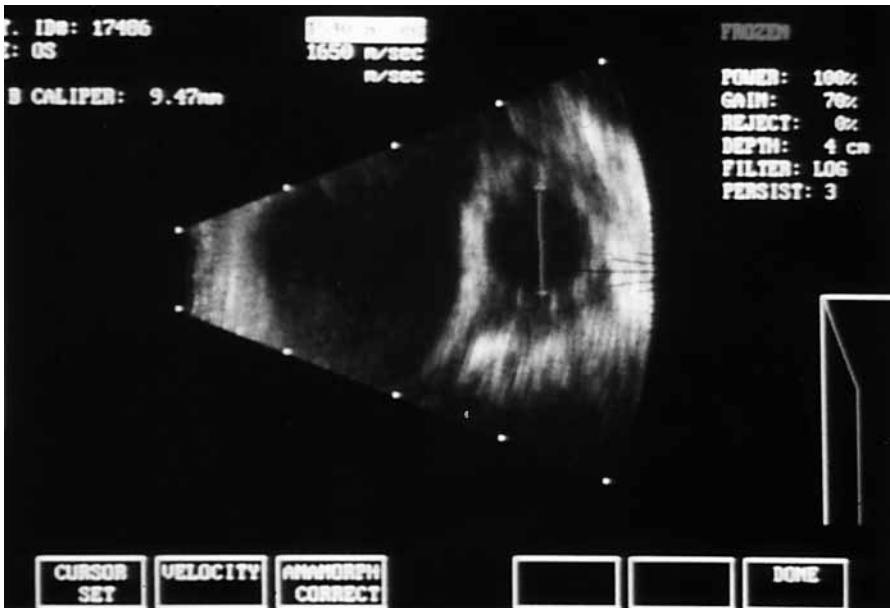


Fig. 6. An ultrasonogram to confirm the position of the balloon. The diameter of the balloon (vertical line) is 9.47 mm.

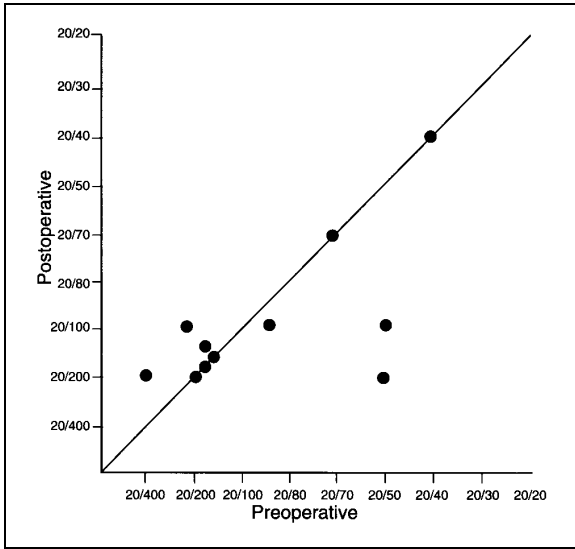


Fig. 7. Scattergram of last recorded visual acuity of 11 patients with subfoveal cnv treated with 23 50 injections of retrobulbar $IFN\alpha 2a$ followed for 17 39 months.

injections, the balloon was deflated and the catheter removed under topical anesthesia. Follow up examinations were done at 1, 3, 6, 12, 18, and 24 months. The follow up examinations consisted of corrected visual acuity, biomicroscopy, photography, and, if indicated by the clinical examination, a fluorescein or indocyanine green angiography.

Results

The first patient, by design, had 23 daily injections of $IFN\alpha-2a$. The first injection was 300,000 IU; the second, 600,000 IU; then 1,000,000 IU were injected daily for 21 days. The patient experienced 5 days of moderate lid and conjunctival edema beginning on the 8th day. A culture was without growth and the edema receded with topical prednisolone acetate 1% q.i.d. A fluorescein angiogram at 23 days failed to demonstrate regression of the cnv, so it was decided to increase the number of injections for subsequent patients to 50, unless regression was observed after a lesser number.

Patient 2 and patients 5–11 received 50 injections on a 6-day-per-week schedule. Patients 6 and 7 experienced brief periods of conjunctival and lid edema. Cultures of the lumen of their catheters were without growth

and the edema regressed with topical prednisolone. Patient 3 complained of discomfort and patient 4 of pain after 32 and 33 injections, respectively. Both patients were reluctant to continue so their catheters were withdrawn and cultured. The cultures were without growth and both patients were asymptomatic within a day.

In most patients, there was regurgitation part-way through the injection after the first week. Under blue light, the fluorescein-stained solution of IFN α -2a was immediately apparent at the margin of the lower lid. Interrupting the injection for 15 min enabled the remainder to be accepted without additional regurgitation.

The size of the cnv, as demonstrated by a fluorescein angiogram, was diminished in 2 patients and unchanged in 5. The cnv in patient 1, who had received 23 injections, grew to twice its original size after the treatment was discontinued. The cnv enlarged about 50 % over 12 months in patient 4, who received 33 injections, and in patient 11, who received 50 injections. The cnv in patient 7, who also received 50 injections, enlarged about 30 % after 6 months and then became stable. No growth was observed in any patient while they were receiving IFN α -2a.

The visual results are displayed in the scattergram (fig. 7): Of the 11 patients treated with 23–50 injections of retrobulbar IFN α -2a, visual acuity diminished in 3 patients, remained unchanged in 5 and improved in 3 patients.

Discussion

The retrobulbar injection of 1×10^6 IU of IFN α -2a was free of any of the toxic side effects reported upon from trials in which 3 or 6×10^6 IU were injected subcutaneously [4–9]. No patient complained of fatigue or depression. On the contrary, despite their age and the distance that some of them were required to travel each day, all but 2 patients were enthusiastic about their treatment and collectively missed only 2 of 488 appointments.

While no serious complications occurred as a result of the catheter in the first 11 patients, 2 patients who entered the study later, 1 in New York and 1 in Tübingen, were discontinued on the 4th and 12th days, respectively, because their catheters became infected. Lid edema and proptosis were the presenting signs. Cultures from both patients grew *Staphylococcus aureus* coagulase positive. Computer tomography and ultrasonography indicated that the infection was confined to the capsule around the balloon. Neither patient displayed evidence of ocular extension. In the first

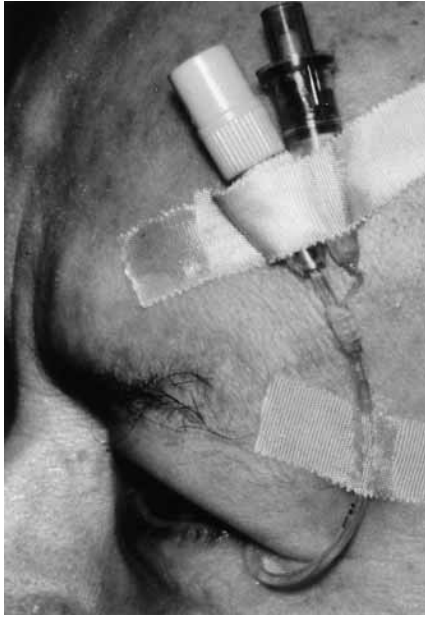


Fig. 8. The injection valve of the retained catheter is now closed with a plug containing a rubber dam (left valve).

patient, the catheter was withdrawn and the infection responded promptly to intravenous antibiotic therapy. In the second patient, the catheter was left in place for another 5 days and the patient was treated with local injections of antibiotics via the catheter in addition to intravenous medication with an equally good response. The supplemental injections through the catheter did not hasten the response. The visual acuity of these two patients was unchanged following the episode for 5 and 16 weeks, respectively, but subsequently deteriorated consistent with the natural history of the disorder [10, 11].

This incidence of infection of patients who entered the study later, was unexpected. Up to 1996, there have been only 2 infections in more than 2,000 insertions of balloon catheters for the treatment of retinal detachment in Tübingen and in New York [12]. It is apparent that sequential injections of medication through a catheter add additional risk. To avert subsequent infections, the injection valve, which has a female end, has been closed with a plug containing a rubber dam (fig. 8) similar to that which is employed for retained intravenous catheters, that are left in place for sequential injections.

From this second-phase study, we have concluded that sequential retrobulbar injections through a retained catheter are tolerated and are a potential route for medications that might be used to treat disorders of the

posterior segment. The higher concentration of IFN α -2a in the choroid obtained by depositing the medication in the retrobulbar space did not cause regression of classic or occult cnv after 50 injections. The most favorable interpretation is that IFN α -2a may have stopped the growth of cnv in 7 (6 of them had received 50 injections) of 11 patients for 17–39 months. A larger series of patients that will include randomized controls is required to reach a meaningful conclusion about whether IFN α -2a can arrest the growth of cnv.

References

- 1 Lincoff H, Stanga P, Movshovich A, et al: The choroidal concentration of interferon after retrobulbar injection. *Invest Ophthalmol Vis Sci* 1996;in press.
- 2 Lincoff H, Stergiou P, Kreissig I: A fiberoptic stylette for localizing the balloon buckle. *Arch Ophthalmol* 1990;180:607.
- 3 Lincoff H, Kreissig, I: A catheter to deliver retrobulbar medication. *Arch Ophthalmol* 1996;114:634 635.
- 4 Guyer DR, Tiedeman J, Yannuzzi LA, et al: Interferon associated retinopathy. *Arch Ophthalmol* 1993;111:350 356.
- 5 Thomas MA, Ibanez HE: Interferon alpha 2a in the treatment of subfoveal choroidal neovascularization. *Am J Ophthalmol* 1993;115:563 568.
- 6 Tholen A, Kain H, Messmer E: Treatment of age associated macular degeneration with interferon alpha 2 a. *Ophthalmology* 1993;90:279 282.
- 7 Poliner LS, Tornambe PE, Michelson, et al: Interferon alpha 2a for subfoveal neovascularization in age related macular degeneration. *Ophthalmology* 1993;100:1417 1424.
- 8 Gillies MC, Sarks JP, Beaumont PE, et al: Treatment of choroidal neovascularization in age related macular degeneration with interferon alpha 2 a and alpha 2 b. *Br J Ophthalmol* 1993; 77:759 765.
- 9 Kirkpatrick JNP, Dick AD, Forrester JV: Clinical experience with interferon alpha 2 a for exudative age related macular degeneration. *Br J Ophthalmol* 1993;77:766 770.
- 10 Bressler SB, Bressler NM, Fine SL, et al. Natural cause of choroidal neovascular membranes within the foveal avascular zone in senile macular degeneration. *Am J Ophthalmol* 1982; 93:157 163.
- 11 Guyer DR, Fine SL, Maguire MG, et al: Subfoveal choroidal neovascular membranes in age related macular degeneration: visual prognosis in eyes with relatively good initial visual acuity. *Arch Ophthalmol* 1986;104:702 705.
- 12 Kreissig I, Failer J, Lincoff H, Ferrari F: Results of a temporary balloon buckle in the treatment of 500 retinal detachments and a comparison with pneumatic retinopexy. *Am J Ophthalmol* 1989;107:381 389.

Prof. Dr. med. I. Kreissig, Augenheilkunde III, Universitäts Augenklinik, Schleichstrasse 12,
D 72076 Tübingen (Germany)
Tel. (07071) 29 29 68, Fax (07071) 29 37 46

.....

Experimental Therapies for Age-Related Macular Degeneration

Gisèle Soubrane, Gabriel Coscas

Clinique Ophtalmologique, Universitaire de Créteil, France

The goal of experimental therapies for age-macular degeneration (AMD) can be twofold: prevention of the occurrence of macular complications or treatment of the already arisen macular complications (central geographic atrophy or choroidal neovascularization).

Prevention of the Occurrence of Macular Complications

Gene therapy can only be considered as a treatment for AMD when the responsible gene(s) have been identified or by an effect on the gene of apoptosis BCL2.

Unless that therapy is possible, the preventive approach can concern the risk factors identified in numerous epidemiological studies. The personal and environmental factors increasing the frequency of AMD identified in the studies are systemic hypertension [1], coronary artery disease [2], smoking [3], nutrition [4], and light exposure [5].

Antioxidants

Certain nutrients may counteract the oxidative process. Vitamins and minerals that have antioxidant potential include vitamins E and C, carotenoids, selenium, zinc and a number of enzymes involved in the oxidative process [6]. When considering the nutrition influence, the measurements of the plasma levels of antioxidants are only markers of dietary habits. In some epidemiological studies, these markers have been assessed [7]. High levels of carotenoids for example are associated with decreased risk of

severe exudative AMD [8]. Vitamin C increases the risk of dry AMD [9].

A second approach considers antioxidant supplementation. Beta-carotene and alpha-tocopherol supplementation have been studied in a Finnish population of 941 patients, 65 years of age or more. The patients have been randomly assigned to alpha-tocopherol alone or associated with beta-carotene and compared to placebo-treated patients. After 5–8 years of daily supplementation, no positive effects was observed on AMD [10]. These results are contradictory with a previous pilot study published where a combination of vitamin C and E, β -carotene and selenium was found to halt or improve AMD [11]. One of the possible reason for these contradictory results is that the population concerned in the Finnish study is smokers. The deleterious effect of smoking on the oxidative process is well known.

In our department in Creteil, supplementation with 250 mg of *zinc* once a day was compared with placebo in 140 high-risk second eyes. After a follow-up period of at least 2 years, and mostly up to 5 years, there was no difference between the treated and untreated groups for the development of CNVs: 21.84 % of treated v. 20.69 % of untreated eyes developed CNVs. This study confirms at long-term the previous short-term published results [12].

Photocoagulation of Drusen

Laser photocoagulation of soft drusen, known to be the drusen at high risk of development of CNVs, is at present considered. It has been reported in observational cases that photocoagulation results in the disappearance of these precursors [13–15]. Numerous trials are underway dealing with either direct mild coagulation on the drusen directly or treatment at distance. In a spanish study their disappearance occurred in a mean period of 3.5 months and the drusen at distance disappeared in a 8.5 months period [16]. However, the spontaneous disappearance of soft drusen is evaluated to be between 10 and 13.9 % in a 5 year period. That spontaneous disappearance occurs mainly in the oldest population (mean age 79 years) [17].

At present, the only available result is that laser treatment of soft drusen has no iatrogenic effect. But, coagulation replaces an area of soft drusen by an atrophic scar. The scar expansion has been extensively describes in the litterature, not only in myopes but even after grid photocoagulation for cystoid macular edema [18]. The main concern remains that there is no proof that drusen disappearance will prevent the neovascular ingrowth and modify the natural course of AMD.

Therapy of Macular Complications

Central Geographic Atrophy

The only approach available at present is the equipment with low vision aids.

Future treatment can include RPE and/or photoreceptors transplantations. Experimental RPE transplantations [19–21] have already shown that transplanted cells rescue photoreceptors at long-term in the RCS rats [22, 23]. Recently, it has even been demonstrated that in electron microscopy, the photoreceptors build up outer segment when located next to the transplanted cells [24]. The trophic effect is observed not only in the immediate vicinity of the transplanted cells but also at distance, suggesting the secretion of a diffusible trophic factor [25]. The first clinical human RPE cell transplantations were performed in end stages of geographic atrophy [26]. No visual improvement was noted postoperatively although the cells remained viable for 3 months. Moreover, photoreceptors transplants seem necessary in geographic atrophy as these cells are already destroyed. Experimental implantation into the subretinal space results in the establishment of synapses [27]. The ‘en bloc’ transplantation of RPE and photoreceptor cells would probably be the most adapted strategy in this form of AMD.

An other approach is the microphotodiodes implants, some of which have been presented at this meeting [28].

Choroidal New Vessels

Until today, laser photocoagulation is the only therapeutic approach that has demonstrated its efficacy for well-defined CNVs on fluorescein angiography [29–32]. The availability of ICG angiography allows the precise identification and localization of occult new vessels in some eyes [33]. However, the results of ICG guided photocoagulation have not yet been proven of statistical benefit [34] and a clinical trial is underway.

Selective laser therapy is at present under evaluation using benzoporphyrin as a photosensitizer and a 692-nm laser as a means of infralimnar treatment [35]. The goal of that selective therapy is to decrease the retinal damage, especially to the photoreceptor layer.

Surgical ablation is technically possible. It was considered in order to minimize the visual loss. The results published in the litterature are very disappointing in AMD [36], even when associating RPE transplantations. This attempt has been performed some years ago with adult RP cells and more recently with fetal cells [26]. Both attempts did not result in an increase of visual fonction. At present a trial is underway in the United

States in order to evaluate the effectiveness of surgical ablation in well-defined new vessels. However, this method should be compared with sub-[32] of perifoveal [37] photocoagulation which have demonstrated a statistical benefit in randomized clinical trials.

Pharmacologic anti-angiogenic interventions hold great promises for treating this devastating condition. Effective drug therapies would enable us to avoid laser induced damage. A number of anti-angiogenic therapies are also at present under evaluation. Systemic interferon- α 2a the rationale of which was scientifically very strong, has shown to be of no benefit in 500 patients randomized all over the world. At 1 year, the visual acuity in the treated patients was worse than in the nontreated eyes.

However, at present, the delivery in situ of interferon- α 2a at the posterior pole of the affected eyes with the modified Lincoff balloon might be of benefit. The effects of systemic interferon- β is at present studied as well as thalidomide, intravitreal steroids and other drugs. All these approaches need of course after a pilot study to be tested in a randomized clinical trial.

Radiotherapy is considered as an anti-angiogenic and anti-inflammatory means. Multiple pilot studies suggest an efficacy of radiation [38–40]. However, all these studies are not comparable. The inclusion criteria are very different. They concerned either well-defined CNVs or occult CNVs or occult associated with well-defined CNVs. The treatment regimen are different in nearly all studies. No study has a control group and of course no randomisation procedure. The evaluation of the outcome is highly subjective. In fact, a critical analysis shows that visual acuity decreased nearly always although the period of follow-up is mostly short (around 3–6 months, and rarely 12 months). As a result of these numerous attempts a number of randomized trials are at present in progress.

Treatment of End Stages of AMD

In the presence of subretinal hemorrhages, attempts have been performed to drain the hematoma associated or not to tissue plasminogen activator [41] and to ablation of the neovascular membrane. These attempts have not evidenced a visual improvement. A number of postoperative complications were reported in the literature.

The injection of intravitreal gas when the hemorrhage is recent [42] might allow the displacement from the blood and result in a possible visualization of the responsible CNV on fluorescein or on ICG angiography performed rapidly after the injection. That might be a less traumatic approach than ablation.

In conclusion, laser photocoagulation remains the gold standard for the 15 % of well-defined CNVs. The other approaches must be compared to it. For isolated occult CNVs and vascularized pigment epithelium detachments, no effective treatment is at the horizon. For geographic atrophy the only hope is at present RPE and photoreceptors transplantation.

Numerous studies are underway in order to evaluate the effects of prevention of oxydative damage on the ingrowth of CNV. Laser photocoagulation is refined. All types of anti-angiogenic therapies are studied.

Future approaches might deal with the inhibition of the different steps of angiogenesis: proliferation, migration, and differentiation of endothelial cells. Specific inhibitors of the various angiogenic factors as well as antagonists to their receptors are certainly a way to go. Inhibition of extra-cellular matrix synthesis could impede the migration of the endothelial cells. In addition, the level of inhibitory factors physiologically present in the retina and choroid could be increased. The critical issues of experimental therapies for AMD remain the choice of a precise strategy to use, its evaluation in a clinically relevant animal model and the determination of the required end points. The efficient time duration of the angiogenesis blockade is not determined.

References

- 1 Sperduto RD, Hiller R: Systemic hypertension and age related maculopathy in the Framingham Study. Arch Ophthalmol 1986;104:216 219.
- 2 Hyman L, He O, Grimson, et al: Risk factors for age related maculopathy. Invest Ophthalmol Vis Sci 1992;33(suppl):801.
- 3 Klein R, Klein BEK, Linton KLP, De Mets DL: The Beaver Dam Eye Study: The relation of age related maculopathy to smoking. Am J Epidemiol 1993;137:190 200.
- 4 Eye Disease Case Control Study Group: Risk factors for neovascular age related macular degeneration. Arch Ophthalmol 1992;110:1701 1708.
- 5 Cruickshanks KJ, Klein R, Klein BEK: Sunlight and age related macular degeneration: The Beaver Dam Eye Study. Arch Ophthalmol 1993;111:514 518.
- 6 West S, Vitale S, Hallfrisch J, Munoz B, Muller D, Bressler SB, Bressler NM: Antioxidants and supplements: protective for age related macular degeneration. Arch Ophthalmol 1994;112:222 227.
- 7 Tsang NCK, Penfold PL, Snitch PJ, Billson F: Serum levels of antioxidants and age related macular degeneration. Doc Ophthalmol 1992;81:387 400.
- 8 Eye Disease Case Control Study Group: Antioxidant status and neovascular age related macular degeneration. Arch Ophthalmol 1993;111:104 109.
- 9 Goldberg J, Flowerdew G, Smith E, Brody JA, Tso MOM: Factors associated with age related macular degeneration: An analysis of data from the first National Health and Nutrition Examination Survey. Am J Epidemiol 1988;128:700 710.
- 10 Laatikainen L, Teikari JM, Virtamo J, Haukka J, Rautahiti M, Liesto K, Heinonen OP: Alpha tocopherol and beta carotene in age related maculopathy: A placebo controlled clinical trial. Macular Workshop, Bath, June 1996.

- 11 Gary E: Anti oxydant treatment of macular degeneration of the aging and macular edema in diabetic retinopathy. *South Med J* 1987;80:38.
- 12 Stur M, Tittl M, Reitner A, Meisinger V: Oral zinc and the second eye in age related macular degeneration. *Invest Ophthalmol Vis Sci* 1996;37:1225 1235.
- 13 Gass JDM: Drusen and disciform macular detachment and degeneration. *Arch Ophthalmol* 1973;90:206 217.
- 14 Wetzig PC: Treatment of drusen related aging macular degeneration by photocoagulation. *Trans Am Ophthalmol Soc* 1988;86:276 290.
- 15 Sigelman J: Foveal drusen resorption one year after perifoveal laser photocoagulation. *Ophthalmology* 1991;98:1379 1383.
- 16 Figueroa MS, Reguerras A, Bertrand J: Laser photocoagulation to treat macular soft drusen in age related macular degeneration. *Retina* 1994;14:391 396.
- 17 France DMLA Study Group: Case control study of risk factors for age related macular degeneration. *Arch Ophthalmol*, submitted.
- 18 Schatz H, Madeira D, McDonald R, Johnson R: Progressive enlargement of laser scars following grid laser photocoagulation for diffuse diabetic macular edema. *Arch Ophthalmol* 1991; 109:1549 1551.
- 19 Del Cerro M, Notter MFD, Cerro C, Wiegand SJ, Grover DA, Lazar E: Intraretinal transplantation for rod cell replacement in light damaged retinas. *J Neural Transplant* 1989;1:1 10.
- 20 Gouras P, Flood MT, Kjeldbye H: Transplantation of cultured human retinal cells to monkey retina. *Ann Acad Brazil Cienc* 1984;56:431 443.
- 21 Aramant R, Seiler M, Ehinger B, Bergstrom A, Gustavii B, Brundin P, Adolph AR: Transplantation of human embryonic retina to adult rat retina. *Restorative Neurol Neurosci* 1990;2:9 22.
- 22 Li L, Turner JE: Inherited retinal dystrophy in the RCS rat: Prevention of photoreceptor degeneration by pigment epithelial cell transplantation. *Exp Eye Res* 1988;47:911 917.
- 23 Li L, Sheedlo HJ, Turner JE: Long term rescue of photoreceptor cells in the retinas of RSC dystrophic rats by RPE cell transplant. *Prog Brain Res* 1990;82:179 185.
- 24 Lin N, Fan W, Sheedlo HJ, Aschenbrenner JE, Turner JE: Photoreceptor repair in response to RPE transplants in RSC rats: Outer segment regeneration. *Curr Eye Res* 1996;15:1069 1077.
- 25 Steinberg RG: Survival factors regulating retinal degenerations. *Curr Opin Neurobiol* 1994; 4:515 524.
- 26 Algere P, Berglin R, Gouras P, Sheng Y: Transplantation of fetal retinal pigment epithelium in age related macular degeneration with subfoveal neovascularization. *Graefes Arch Clin Exp Ophthalmol* 1994;32:707 716.
- 27 Silverman MS, Hughes SE, Valentino TL, Liut Y: Photoreceptor transplantation: anatomic, electrophysiologic and behavioral evidence for the functional reconstruction of retinas lacking photoreceptors. *Exp Neurol* 1992;115:87 94.
- 28 Humayun MS, De Juan E, Dagnelie G, Greenberg RJ, Propst RH, Phillips H: Visual perception elicited by electrical stimulation of retina in blind humans. *Arch Ophthalmol* 1996;114:40 46.
- 29 Coscas G, Soubrane G: Photocoagulation des néovaisseaux sous rétinien dans la dégénérescence maculaire sénile par laser à argon: Résultats de l'étude randomisée de 60 cas. *Bull Mem Soc Fr Ophthalmol* 1983;94:149 154.
- 30 Macular Photocoagulation Study Group: Krypton laser photocoagulation for neovascular lesions of age related macular degeneration: Results of a randomized clinical trial. *Arch Ophthalmol* 1990;108:816 824.
- 31 Macular Photocoagulation Study Group: Argon laser photocoagulation for neovascular maculopathy: five years results from randomized clinical trials. *Arch Ophthalmol* 1991;109:1109 1114.
- 32 Macular Photocoagulation Study Group: Laser photocoagulation of subfoveal neovascular lesions in age related macular degeneration: Results of a randomized clinical trial. *Arch Ophthalmol* 1991;109:1220 1231.
- 33 Guyer D, Yannuzzi L, Slakter J: Digital indocyanine green videoangiography of occult choroidal neovascularization. *Ophthalmology* 1994;101:1727 1737.
- 34 Slakter J, Yannuzzi L, Sorenson J: A pilot study of indocyanine green videoangiography guided laser photocoagulation of occult choroidal neovascularization in age related macular degeneration. *Arch Ophthalmol* 1994;112:465 472.

- 35 Kramer M, Miller JW, Michaud N, Moulton RS, Hasan T, Flotte TJ, Gragoudas ES: Liposomal benzoporphyrin derivative verteporfin photodynamic therapy: Selective treatment of choroidal neovascularization in monkeys. *Ophthalmology* 1996;103:427 438.
- 36 Thomas MA, Dickinson JD, Melberg NS, et al: Visual results following the surgical removal of subfoveal choroidal neovascularization. *Ophthalmology* 1994;101:1384 1394.
- 37 Coscas G, Soubrane G, Ramahefasolo C, Fardeau C: Perifoveal laser treatment for subfoveal choroidal new vessels in age related degeneration: Results of a randomized clinical trial. *Arch Ophthalmol* 1991;109:1258 1265.
- 38 Chakravarthy U, Houston RF, Archer DB: Treatment of age related subfoveal neovascular membranes by teletherapy: A pilot study. *Br J Ophthalmol* 1993;77:265 273.
- 39 Bergink GJ, Deutman AF, van den Broek JF, van Vaal WAG, van der Maazen RNM: Radiation therapy for subfoveal choroidal neovascular membranes in age related macular degeneration: A pilot study. *Graefes Arch Clin Exp Ophthalmol* 1994;232:591 598.
- 40 Finger PT, Berson A, Sherr D, Riley R, Balkin RA, Bosworth JL: Radiation therapy for subretinal neovascularization. *Ophthalmology* 1996;103:878 889.
- 41 Lewis H: Intra operative fibrinolysis of submacular hemorrhage with tissue plasminogen activator and surgical drainage. *Am J Ophthalmol* 1994;118:559 568.
- 42 Heriot WJ: Intravitreal gas and TPA: An outpatient procedure for submacular hemorrhage. *Vi treoretinal Frontiers*, Chicago, 1996.

Gisèle Soubrane, Clinique Ophtalmologique, Universitaire de Créteil, 40, avenue de Verdun, F 94010 Créteil (France)

.....

Evaluation of Macular Therapy

R. K. Blach

King's College Hospital, London

It may be generally observed that the more effective the therapy, the less complex its evaluation needs to be. Does it therefore follow that the less effective the therapy, the more abstract and tortuous its evaluation?

The underlying theme of this symposium has been to consider advances in knowledge that can be of potential use in the alleviation of macular (and retinal) disease and to evaluate their scientific worth in a quantitative manner. Unique to this conference and most stimulating has been the promotion of therapy at the conceptual, preclinical, level. However, the extrapolation of new scientific knowledge to individual patients also requires a qualitative assessment, a more complex and less exact evaluation.

Leipzig, as it happens, is a most appropriate location for a consideration of the evaluation of ocular therapy, for it is in this city that its most illustrious son, Johann Sebastian Bach, suffered at the hands of that infamous itinerant ophthalmologist and charlatan, Chevalier John Taylor. The Chevalier Taylor arrived in Leipzig in great splendour on 27th March 1750 and Kapellmeister Bach immediately became his patient. In March 1750, at the age of 66, he was operated upon for his blindness, requiring further surgery within days and a course of debilitating medical therapy prevalent at that time. His ophthalmologist pronounced the treatment a great success but Bach suffered very much and became completely blind. He died a few months later without a proper evaluation of his ophthalmic treatment [1].

Nature of Evaluation

Traditionally, the evaluation of therapy has concentrated on its effects on the individual. In macular therapy the parameters concern functional and structural outcomes and these can often be measured by clear, quantitative methods. More difficult, but just as important to the patient, is evaluation in terms of individual and social adaptation, 'the quality of life'. Increasingly, as well as individual measurements, epidemiological assessments are required using qualitative as well as quantitative methods.

Quantitative evaluation prefers numeric expression against accepted norms and within a static environment. Qualitative evaluation requires a holistic approach often measured against variable norms in a changing environment. The weakness of qualitative evaluation is its inexactitude, which has its most disturbing manifestation in the intellectual flabbiness of much social science and of complimentary medicine such as herbal medicine [2]. Nevertheless, it is important to find reliable yardsticks for the evaluation and measurement of the clinical outcomes of therapy.

The problem of therapeutic evaluation is becoming more acute with the proliferation of new technologies. In many western countries the compulsory evaluation of drugs and some medical devices has not been followed by the compulsory evaluation and control of other novel therapeutic procedures such as laparoscopic surgery, with serious consequences in many branches of medicine. This is now beginning to be tackled in the UK [3]. In future, as already foreshadowed at this meeting, the evaluation of gene therapy and neurological processing will become even more challenging [4].

Specific Parameters for Evaluation

We may consider the evaluation of macular therapy within the following parameters: (1) structure; (2) function; (3) epidemiology; (4) substitutions; (5) adaptation; (6) 'quality of life'.

Structure

Structural outcomes of macular therapy are assessed in vivo traditionally by ophthalmoscopic and photographic means although increasingly, as we have seen, sophisticated techniques such as scanning laser ophthalmoscopy and optical coherence tomography are being used. The measurement of structural change becomes more accurate with built-in quality

control of instrumentation. However, the interpretation of such change often depends on human skills which are very variable.

The opportunity for accessing the best talents for this task is becoming available through the development of telemedicine. There is no doubt that the scientific, educational and clinical benefits of, for example, fluorescein conferences using the techniques of telemedicine are enormous. The radiologists have already shown us the way with Picture Archiving and Communications Systems (PACS) [5]. Distance projection of fluorescein angiograms, allowing for their interpretation by the most experienced and sophisticated practitioners, obviously has tremendous advantages (the New England Medical Centre already has such a telemedicine web site), although commercial exploitation of such services will require academic control.

Surgical intervention will usually be assessed initially by structural measurement. However, the professionalisation of surgical evaluation, associated with *in vitro* training of surgeons, will become increasingly important. The report on the recent clinical trial of the surgical treatment of stage 2 macular holes emphasises the importance and sophistication of surgical technique in assessing therapeutic outcome [6]. The evaluation of surgical skills in training using virtual reality is already being introduced, although only now are surgeons beginning to catch up with airline pilots in the responsibility of their training. Flight simulators and personal assessment of pilots have been standard for many years!

Function

One of the rewards of ophthalmology, and especially macular work, is the numeric clarity with which the benefits of treatment can be evaluated although this does not apply to qualitative effects. Moreover, the conventional statistical evaluation of clinical results has recently become suspect. In dealing with clinical results traditionally we use a statistical on/off response, results are either significant or not significant. However, in the actual clinical situation, in which many factors precede a clinical trial and perhaps develop during it, we are much more likely to be dealing with incremental probabilities. These can be assimilated by using Bayesian statistics which are mathematically more complex but whose use is now greatly simplified by the appropriate computer software [7].

Numeric evaluation does not always correspond to the patient's perception of improvement. This is partly because visual acuity is only one functional measurement and various other electro-physiological tests may come closer to expressing a patient's actual experience, as in the assessment of photodynamic therapy reported at this meeting. For example, in

assessing the effects of laser treatment on central serous retinopathy, different outcomes are obtained in terms of Snellen's visual acuity from other psychophysical tests such as fine matrix mapping. This technique, used in combination with the scanning laser ophthalmoscope, measures retinal function on a 'microscopic' scale not evident on conventional testing [8].

Although quantitative methods of assessing function are increasingly sophisticated, the patient's qualitative experience is just as important to him or her. Thus elderly people may complain bitterly of their vision and yet are able to read 6/9. Their complaints are often true. It is just that they are more sensitive to their own receptor loss than the tests to which we choose to expose them. However, qualitative evaluation can be confusing. Have we not seen cases of retinitis pigmentosa return from Moscow? And is it for us to destroy a patient's genuine illusions?

Epidemiology

Epidemiology is the study of disease in populations. Since macular disease is such a common and increasingly important condition in our ageing population, it requires an epidemiological approach. The complex interrelationships of genetic and environmental factors in macular disease are increasingly being delineated by epidemiological studies [9].

Therapy may be evaluated from descriptive studies, in case-controlled studies, in cohorts, by clinical trials or by clinical audit. The development of evidence-based medicine and clinical audit are leading to the evolution of guidelines in many areas of clinical medicine. This represents a welcome restriction to so-called 'clinical freedom' which, according to Hampton [10], is often merely a cloak for clinical ignorance. It does, however, require a definition of 'evidence'.

Clinical evidence itself is usually classified into [11]:

- (i) class 1: from properly controlled randomised clinical trials;
- (ii) class 2: from case controlled and cohort studies, and
- (iii) class 3: from expert opinion, non-randomised studies with historical controls, and case reports.

Guidelines (recommendations on management) are based: specifically on (i); on direct evidence from (ii); or on a strong consensus from (iii).

In any therapeutic evaluation, the natural history of a disease process has to be well documented and it is perhaps in the untreated control group of Phase 3 clinical trials, that we find a trial's greatest value. In a recent editorial of the journal *Ophthalmology* clinical trials were advocated as the gold standard for therapeutic evaluation [12]. However, the criteria

set for the perfect trial were so demanding that it implied that many actual trials were not sufficiently rigorous and therefore misleading.

Important as they are, there are some serious shortcomings to phase 3 clinical trials:

- (a) The ethics are complex. Placebos are a form of patient deception and in invasive procedures control groups are difficult, if not impossible, to obtain.
- (b) Clinical trials are artificial because they need to control their variables. Therefore they need to be undertaken in an artificially simple framework with limited criteria for assessment. In the real (clinical) world therapy is judged on unlimited criteria so that clinical judgement is often more sophisticated than a clinical trial [13].
- (c) Objectivity is difficult to obtain unless third parties report the actual trial and interpret the findings (a triple blind trial). Raw data, which could now be easily published electronically, is often difficult to obtain by non-participants. Clinical trials do not make empirical treatments scientific.
- (d) Often there is a lack of common sense:

Positive results may be obvious from pilot studies (e.g. penicillin, vitamin C).

Negative results need publishing (statistically they are rarer than expected).

Useless results tend often to come out positive because of bias sometimes reinforced by meta-analysis.

This is not to say that clinical trials are useless. Indeed, they are essential where similar drugs and procedures are compared, where practitioners are influenced by non-clinical issues (such as self-advancement or commerce), where prejudice and ignorance are rife (as in complimentary medicine), or, perhaps, where the benefits of treatment are marginal (implying, conversely, that they are hardly needed for therapy that really works!). Clinical trials test not so much the *quality* of therapy as its *reliability* which can be difficult to test by other means.

However, with the increasing use of information technology to provide total information on clinical activity, and the practice of clinical audit (defined as the 'systematic, critical analysis of the quality of medical care, including procedures used for diagnosis and treatment, the use of resources and the resulting outcome and quality of life of the patient'), clinical trials will become increasingly less important to many areas of retinal therapy.

Substitutions

Mechanical. Some of the oldest and the newest forms of macular therapy involve substitute mechanisms. Simple optical aids hardly need clinical trials to advertise their usefulness. However, complex optical appliances, while often enabling an elderly patient to perform to the ophthalmologist's satisfaction, depend for their successful employment in everyday life on patient motivation, concentration and energy. Among the elderly, low vision aids often satisfy the prescriber rather than the patient and qualitative assessment is important.

Electro-mechanical aids, as we have seen in the exciting contributions to this meeting, have a realistic future. Cochlear implants have already reached the stage of alleviating profound deafness in adults and young children and are being evaluated as an exercise in health technology assessment [14], but ophthalmologists still have a long way to go [15] (the optic/auditory nerve fibres alone by a factor of 33).

Biological. There are two areas where evaluation of substitute mechanisms will be particularly difficult in the future, namely gene therapy and neurological processing. The basic standards used for conventional measurements and some ethical dimensions will need to be reviewed in view of the complex effects that gene and neurological replacement may have on normal tissues. Gene therapy in Tay-Sachs disease [16] and neurological stimulation of axonal growth of retinal ganglion cells and retinal grafting may well become realities [17].

Adaptation

Much of medical and macular therapy is concerned, not with returning the patient to the normal state, but with learning to adapt to a given situation:

Where aspects of macular or retinal function have never developed, as in red/green colour blindness, environmental restriction may be easily contained. Where visual acuity deteriorates from an early age, as in some hereditary macular degenerations, the early establishment of biological norms and consequent life-styles makes adaptation more difficult. Where 'blindness' from age-related macular degeneration occurs, specific problems develop. The quality of adaptation is probably diminished by the very ageing process affecting the whole patient. The reduced learning capability of old age is only partially mitigated by reduced needs and demands, although the compensatory mechanisms of the elderly should not be underestimated.

Incidentally, macular blindness, although classified as 'blind' in epidemiological studies, does not amount to blindness in the lay sense of the term.

We may classify vision into [18]: (i) normal vision, with normal acuity, normal navigational vision and social independence; (ii) central visual loss (macular blindness) with a good peripheral field and therefore good navigational vision allowing a good deal of social independence; (iii) central and peripheral visual loss, with loss of both detailed and navigational vision leading to social dependence.

The differences between (i) and (ii) are probably less than between (ii) and (iii) and, in our classification of blindness, it may be misleading to include (ii) and (iii) in the same category. If social policy is to be based on epidemiological input, the present classifications of blindness are misleading.

Biological organisms thrive by means of adaptation either to their external environment or to their own inherent or changing circumstances. Such adaptation may be 'instinctive' or may be helped by training (e.g. learning to use eccentric fixation by patients with macular scotomata). Adaptation to blindness can probably never be complete. However, there are some remarkable historical examples usually dependent on exceptional help from others. Perhaps one of the greatest is that of John Milton, the English poet who, in spite of developing complete blindness, became Cromwell's Foreign Secretary. He describes his blindness in one of the world's greatest poems, 'Paradise Lost', written in 1667 [19].

Milton also demonstrated the role and responsibility of society in the process of successful adaptation. Society can provide the environmental changes that allow such adaptation, a factor to be considered in the overall evaluation of macular therapy. Such action should not be seen as charity but as behaviour in the interests and for the dignity of society as a whole. It was Milton's family and helpers who allowed his unique talents to become manifest.

'Quality of Life'

Attempts to measure the effects of macular therapy on the general quality of life of affected patients have been made both by vision specific quality of life instruments and by generic questionnaires.

To express such studies in abstract mathematical terms may give a false impression of exactitude to such multi-factorial situations. Qualitative measurements take as their yardstick not an arbitrary biological scale derived from widespread objective data but the relative standards derived from the patient's own requirements and expectations, comparing his performance not to a biological average but to his own past performance and

to others in his own environment. Such 'relative' as opposed to 'objective' criteria, however, require rigorous and unsentimental standards from the ophthalmologist who is the auditor.

In Belfast there is a cross-sectional study of patients with macular degeneration and age-matched controls using (a) vision specific, and (b) generic quality-of-life questionnaires:

- (a) The vision specific questionnaire consisted of 33 items involving daily living tasks dependent on vision. These related to acuity, peripheral fields, contrast sensitivity and dark adaptation.
- (b) The 36 generic questions referred to 8 general dimensions of health (physical and social function, role limitation due to physical and emotional problems, mental health, energy, pain, general health perception).

The results showed that the vision-specific rather than the generic questionnaires appeared to relate to the impact of therapeutic intervention in macular degeneration [Chakravarty, pers. commun.].

Proposals

Many ideas have been aired in this talk and a number of specific proposals may be considered. The means by which they might be achieved include telemedicine, information processing, audit, therapeutic evaluation, therapeutic guidelines and societal guidelines. The ends to be considered are summarised.

Integration of Skills

Accurate diagnosis, upon which effective therapy depends, can be improved on a universal scale by means of telemedicine, particularly useful in the interpretation of structural change such as in fluorescein angiograms. In training, methods similar to those used for airline pilots are beginning to be introduced at least into general surgery.

Total Information and Audit

The quality of therapy and reliability of functional results can be improved by audit and the total input of clinical information with the help of information technology. Such an approach may obviate the need for phase 3 clinical trials in certain circumstances, although their need in areas such as comparative studies remains.

Extrapolation of Scientific Data to Clinical Practice

The extrapolation of scientific and epidemiological data to the needs of the individual patient often presents difficult problems. The quantitative evaluation of macular therapy, if not overwhelmingly in its favour, should have a qualitative assessment to judge its clinical worth. The conventional statistical tools used to assess significance may need to be modified to take account of incremental probabilities. An epidemiological approach can often assess the reliability of a therapeutic intervention but this does not necessarily translate into patient welfare. The evaluation of gene therapy and neurological processing will require new parameters of judgement that concern their influence on normal biological processes as well as disease mechanisms.

Qualitative Evaluation

The qualitative assessment of macular therapy is at an early stage but will eventually be the end-point in any evaluation. Unfortunately the methods used in sociology are not yet incisive because of the variable and multifactorial bases of measurement. Nevertheless, the complexities of qualitative measurement are not beyond the capabilities of information processing. In other words, it is the patient's welfare, not just the abstract mathematical response of his macula, which is the concern of the ophthalmologist.

Adaptation

Finally, the evaluation of macular therapy does not stop at treatment. The adaptation of the patient to society and, equally important, of society to the patient should also properly be the concern of the therapist. This opens doors for the development of intriguing modern therapies for example, in terms of neuronal plasticity and learning, and societal adaptation.

Finale

Lastly, we return to Johann Sebastian Bach. He wrote an organ chorale initially entitled 'Wenn wir in höchsten Nöten sein' ('When we are in most dire need'). Shortly before he died in Leipzig in 1750, and perhaps with some premonition of his own death, he changed the title to 'Vor Deinen Thron tret' ich' ('Before Thy throne I tread'). Bach did not have the opportunity to evaluate his disastrous therapy before it was administered. We should consider macular therapy today with the same humility and adaptability that made Bach change the title of his final organ chorale (BWV 668).

References

- 1 Baer KA: Johann Sebastian Bach (1685 1750). *Bull Med Libr Assoc* 1951;39:206.
- 2 Linde K, Ramirez G, Mulrow CD, et al: St John's wort for depression: An overview and meta analysis of randomised clinical trials. *Br Med J* 1996;313:253.
- 3 Sheldon TA, Faulkner A: Vetting new technologies (editorial). *Br Med J* 1996;313:508.
- 4 Smith KT, Shepherd AJ, Boyd JE, et al: Gene delivery systems for use in gene therapy, an overview of quality assurance and safety issues. *Gene Ther* 1996;3:190.
- 5 Strickland NH, Allison DJ: Default display arrangements of images on PACS monitors. *Br J Radiol* 1995;68:252.
- 6 Kim JW, Freeman WR, Azen SP, et al: Prospective randomized trial of vitrectomy for stage 2 macular holes. *Am J Ophthal* 1996;121:605.
- 7 Lilford RJ, Braunholtz D: The statistical basis of public policy: a paradigm shift overdue. *Br Med J* 1996;313:603.
- 8 Fitzke FW: Recent developments in psychophysics; in Jay B, Kirkness C: *Recent Advances in Ophthalmology*, Edinburgh, Churchill Livingstone, 1995, vol. 9. p. 258.
- 9 Evans K, Bird AC: The genetics of complex disorders. *Br J Ophthal* 1996;80:763.
- 10 Hampton JR: The end of clinical freedom. *Br Med J* 1983;287:1237.
- 11 Report of Quality Standard Subcommittee of the American Academy of Neurology: Practice Parameter: A guideline for discontinuing antiepileptic drugs in seizure free patients. Summary statement. *Neurology* 1996;47:600.
- 12 Meinert CL: Clinical trials: The gold standard for the evaluation of therapy. *Ophthalmology* 1996;103:869.
- 13 Wong D, Blach RK: Clinical trials versus intuition in evaluating the results of laser photocoagulation. *Int Ophthalmol*, 1986;9:71.
- 14 Summerfield AQ, Marshall DH: Cochlear implantation in the UK 1990 1994 Report by the MRC Institute of Hearing Research on the Evaluation of the National Cochlear Implant Programme, Nottingham, 1995.
- 15 Humayun MS, de Juan E, Dagnelie G, et al: Visual perception elicited by electrical stimulation in blind humans. *Arch Ophthal* 1996;114:40.
- 16 Akei S, Guidott J E, Vigue E, et al: Restoration of hexosamine A activity in human Tay Sachs fibroblasts via adenoviral vector mediated gene transfer. *Gene Ther* 1996;3:769.
- 17 Lund RD, Coffey PJ: Visual information processing by intracerebral retinal transplants in rats. *Eye* 1994;8:263.
- 18 Blach RK: Blindness and its prevention in proliferative diabetic retinopathy; in Lim Siew Ming A: *World's Major Blinding Conditions*, ed., 2 XXVI Int Congr Ophthalmology, Singapore, 1990, p 162.
- 19 Milton J: *Paradise Lost*. 1667, vol 3, pp 1 55.

R. K. Blach, FRS, FRCOph, Lister House, 11 Wimpole Street, London W1, England

.....

Author Index

- Blach, R. K. 85
Cleary, Ph. E. 36
Coppé, A. M. 55
Coscas, G. 78
Dooner, J. 44
Dosquet, Ch. 30
Falsini, B. 55
Fedeli, R. 55
Fuchs, A.V. 64
Garweg, J. 15
Gaudric, A. 30
Gelisken, F. 69
Gendo, K. 8
- Kampik, A. 64
Klauss, V. 64
Koerner, F. 15
Kohen, L. VII
Kreissig, I. 69
Kretschmann, U. 8
Kuhn, F. 44
Lincoff, H. 69
Massin, P. 30
Mester, V. 44
Miller, B. 61
Minihan, M. 36
Morris, R. 44
- Paques, M. 30
Ripandelli, G. 55
Santiago, P. Y. 30
Scheider, A. 64
Seeliger, M. 8
Soubrane, G. 78
Stanga, P. 69
Stirpe, M. 55
Wiedemann, P. VII
Witherspoon, C. D. 44
Wolf, S. 1
Zrenner, E. 8

.....

Subject Index

- Acquired immunodeficiency syndrome, *see* Cytomegalovirus retinitis
- Adaptation, macular therapy evaluation 90, 91, 93
- Age related macular degeneration
antioxidant therapy 78, 79
autofluorescence imaging 4
gene therapy 78
interferon $\alpha 2$ therapy
catheters for local administration
complications 74 76
dose regimen 74
insertion 70, 71
outcomes 75 77
types 70
ultrasound imaging 71, 74
follow up examination 74
patient selection 70
rationale 69, 81
photocoagulation of drusen 79, 81, 82
therapy of complications
central geographic atrophy 80
choroidal new vessels 80, 81
subretinal hemorrhage 81
- Antioxidant therapy, age related macular degeneration 78, 79
- Audit, clinical information 92
- Autofluorescence imaging, scanning laser ophthalmoscopy 3, 4, 6
- Choroidal new vessels, *see* Age related macular degeneration
- Cytomegalovirus retinitis, local ganciclovir therapy
difficulty 64
intraocular implant
complications 66
efficacy 65, 66
patient evaluation 64, 65
surgery 65
systemic side effects 65, 66
- Electro mechanical aids, ophthalmology 90
- Electroretinogram
flicker evaluation of posterior vitreous cortex removal 55 57, 59, 60
multifocal recording and VERIS Clinic system evaluation
comparison to Ganzfeld
electroretinogram 12, 13
patient selection 9
recording 10, 12
response density deviation responses
in various diseases 11 13
stimulus 9, 10
study design 8
topographic mapping 11
- Epidemiology, macular therapy evaluation 88, 89, 93

- Epiretinal macular membranes
 - complications 63
 - components 61
 - pathogenesis 61 63
 - prognostic indicators 63
 - rabbit models 61, 62
 - symptoms 63
- Fluorescence angiography
 - archives 87
 - scanning laser ophthalmoscopy 2, 5
- Functional evaluation, macular therapy 87, 88
- Ganciclovir, *see* Cytomegalovirus retinitis
- Gene therapy
 - age related macular degeneration 78
 - applications 90
- Glaucoma, local 5 fluorouracil therapy 66, 67
- Hemorrhagic macular cyst, Terson's syndrome
 - classification 45, 46
 - histology 44, 45
 - internal limiting membrane removal in treatment 44, 45 52
 - morphology 48
 - prevalence 44
 - ultrasonography 48
 - vitrectomy 44, 46 50
- Interferon $\alpha 2$, age related macular degeneration treatment
 - catheters for local administration
 - complications 74 76
 - dose regimen 74
 - insertion 70, 71
 - outcomes 75 77
 - types 70
 - ultrasound imaging 71, 74
 - follow up examination 74
 - patient selection 70
 - rationale 81
- Internal limiting membrane, removal in hemorrhagic macular cyst treatment 44, 45 52
- Laser, *see* Photocoagulation, Scanning laser ophthalmoscopy
- Macular hole
 - incidence 15
 - optical coherence tomography 16
 - pathogenesis and developmental stages 15, 16, 25, 36
 - radial folds and prognosis 41
 - surgical treatment of retinal detachment
 - autologous blood application 18, 19, 22, 23, 25
 - autologous platelet application
 - growth factors and mechanism of action 31 33, 41
 - outcomes 21, 22, 25, 32 34, 37 40, 42
 - preparation of concentrate 31, 37
 - complications 23, 24, 32, 41, 42
 - conventional outcomes 17
 - tissue adhesives 18
 - transforming growth factor $\beta 2$
 - application 19, 22, 23, 30, 32, 36, 40, 41
 - vitrectomy and fluid gas exchange 17, 25, 31, 36, 37, 40
 - vitreoretinal surgery outcomes 18, 19, 22
- Microperimetry, scanning laser ophthalmoscopy 4, 5
- Optical coherence tomography
 - evaluation of macular therapy 86
 - macular hole 16
- Photocoagulation, drusen in age related macular degeneration 79, 81
- Platelet, autologous application in macular hole surgery
 - growth factors and mechanism of action 31 33, 41
 - outcomes 21, 22, 25, 32 34, 37 40, 42
 - preparation of concentrate 31, 37
- Posterior vitreous cortex, evaluation of complications in removal 55 57, 59, 60
- Proliferative vitreoretinopathy, local 5 fluorouracil therapy 67

- Qualitative evaluation, macular therapy 86
- Quality of life, macular therapy evaluation 91, 92
- Quantitative evaluation, macular therapy 86, 88

- Retinitis pigmentosa, multifocal electroretinogram recording 12, 13

- Scanning laser ophthalmoscopy
 - acousto optic modulator 2
 - autofluorescence imaging 3, 4, 6
 - fluorescence angiography 2, 5
 - lasers 2
 - microperimetry 4, 5
 - modes of imaging 2
 - principle 1, 2
 - sensitivity 1

- Terson's syndrome, *see* Hemorrhagic macular cyst

- Transforming growth factor β 2, application in macular hole surgery 19, 22, 23, 30, 32, 36, 40, 41

- Uveitis, local therapy 66

- VERIS Clinic system, evaluation
 - electroretinogram recording 10, 12
 - patient selection 9
 - response density deviation responses in various diseases 11 13
 - stimulus 9, 10
 - study design 8
 - topographic mapping 11

- Virtual reality, evaluation of surgical skills 87, 92