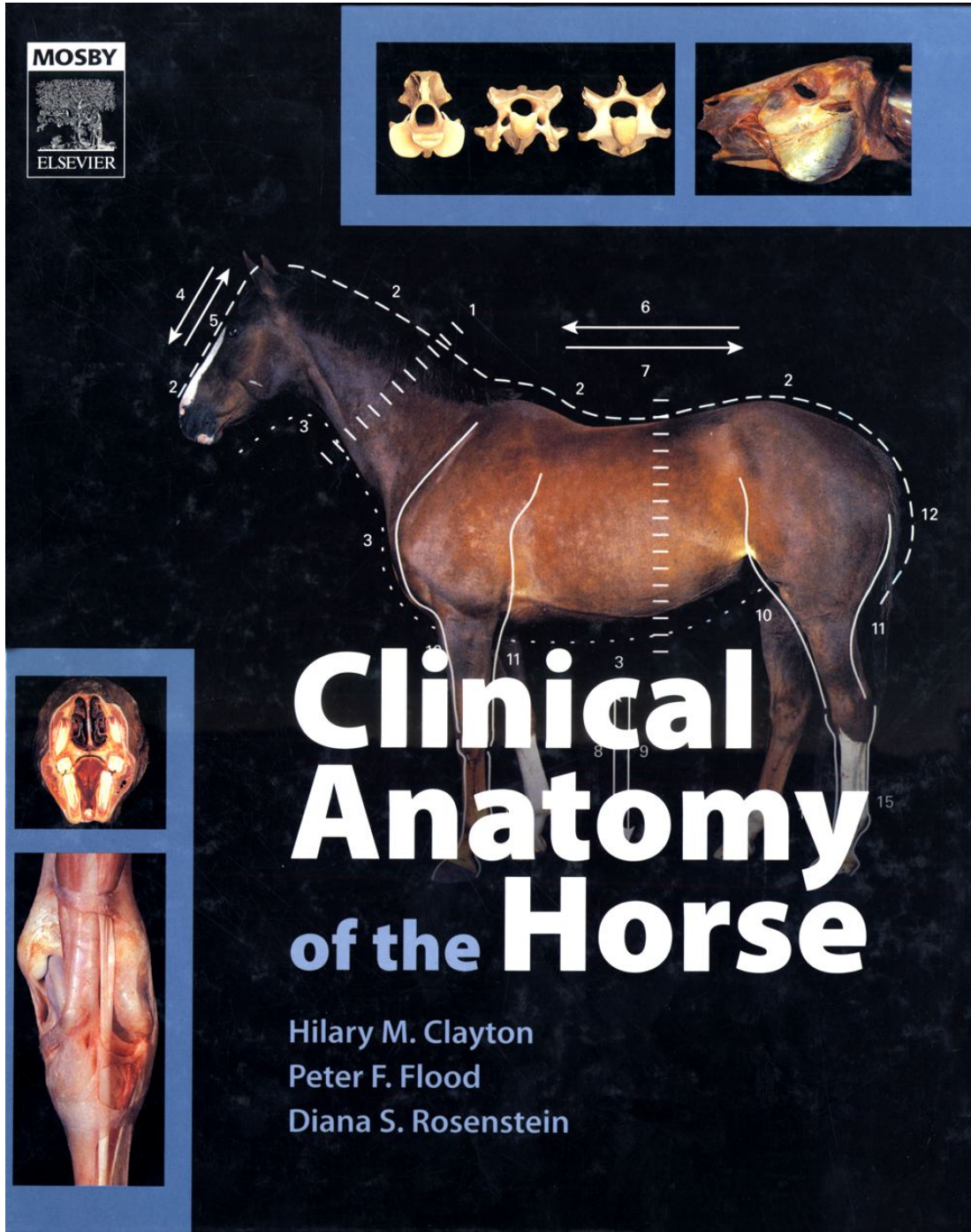

Clinical Anatomy of the Horse

Clinical Anatomy of the Horse

iii

1st ed.

Hilary M. Clayton, BVMS PhD MRCVS

Mary Anne McPhail Dressage Chair in Equine Sports Medicine, College of Veterinary Medicine, Michigan State University, East Lansing MI 48824-1314, USA

Peter F. Flood, BVSc MSc PhD MRCVS

Professor Emeritus of Veterinary Anatomy, Western College of Veterinary Medicine, University of Saskatchewan, 52 Campus Drive, Saskatoon, Saskatchewan, S7N 5B4, Canada

Diana S. Rosenstein, DVM, MS, DipACVR

Associate Professor of Large Animal Clinical Sciences, College of Veterinary Medicine, Michigan State University, East Lansing MI 48824-1314, USA

David Mandeville

Division of Media Technology, University of Saskatchewan, 28 Campus Drive, Saskatoon, Saskatchewan, S7N 0X1, Canada

0-7234-3302-X

iii

MOSBY ELSEVIER

iv

An affiliate of Elsevier Limited

© Elsevier Limited 2005. All rights reserved.

No part of this publication may be reproduced, stored in a retrieval system, or transmitted in any form or by any means, electronic, mechanical, photocopying, recording or otherwise, without either the prior permission of the publishers or a licence permitting restricted copying in the United Kingdom issued by the Copyright Licensing Agency, 90 Tottenham Court Road, London W1T 4LP. Permissions may be sought directly from Elsevier's Health Sciences Rights Department in Philadelphia, USA: phone: (+1) 215 238 7869, fax: (+1) 215 238 2239, e-mail: healthpermissions@elsevier.com. You may also complete your request on-line via the Elsevier Science homepage (<http://www.elsevier.com>), by selecting 'Customer Support' and then 'Obtaining Permissions'.

First edition 2005

ISBN 07234 3302 X

British Library Cataloguing in Publication Data

A catalogue record for this book is available from the British Library

Library of Congress Cataloging in Publication Data

Clinical Anatomy of the Horse

A catalog record for this book is available from the Library of Congress

Note

Veterinary knowledge and best practice in this field are constantly changing. As new research and experience broaden our knowledge, changes in practice, treatment and drug therapy may become necessary or appropriate. Readers are advised to check the most current information provided (i) on procedures featured or (ii) by the manufacturer of each product to be administered, to verify the recommended dose or formula, the method and duration of administration, and contraindications. It is the responsibility of the practitioner, relying on their own experience and knowledge of the patient, to make diagnoses, to determine dosages and the best treatment for each individual patient, and to take all appropriate safety precautions. To the fullest extent of the law, neither the publisher nor the authors assume any liability for any injury and/or damage.

Commissioning Editor: Joyce Rodenhuis

Senior Development Editors: Zoë A Youd, Rita Demetriou-Swanwick

Project Manager: Andrew Palfreyman

Design Direction: Stewart Larking

Printed in China

	Front Matter	iv
1	1 Introduction	1
2	2 Head	5
3	3 Spinal Column	25
4	4 Forelimb and Digit	35
5	5 Hindlimb	65
6	6 Thoracic Viscera	89
7	7 Abdominal and Pelvic Viscera	97

Clinical Anatomy of the Horse

¹ 1 Introduction

The illustrations in this atlas include photographs of skeletal preparations, dissections and endoscopic views as well as images obtained by radiology, ultrasonography and computerized tomography. These techniques contribute in different but complementary ways to our understanding of the anatomy of the horse (*Equus caballus*). The atlas is not intended to be a comprehensive anatomical reference book, of which there are several; instead, it is an illuminating companion to these texts. Our intent is to portray those aspects of equine anatomy that are particularly relevant to clinical practice as well as to students of anatomy.

Modern photographic and color printing techniques have been used to provide the best possible images of prepared bones and rapidly dissected, unfixed tissues, giving detailed conceptual information that cannot be readily obtained by other means. Some structures, such as the abdominal viscera, deteriorate rapidly in the fresh state, and in these cases we have given high priority to the accurate portrayal of color and texture.

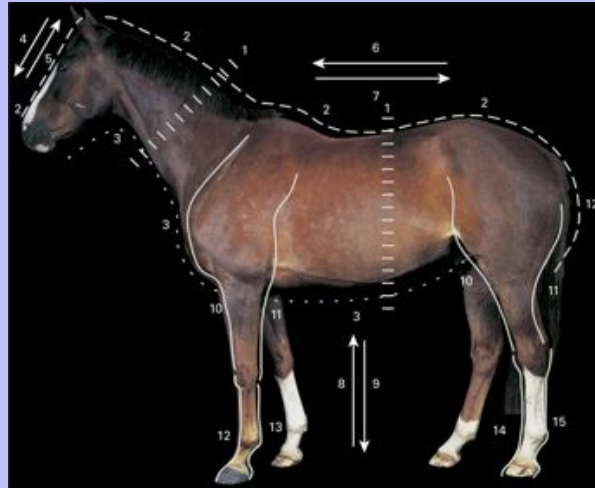
Anatomy concerns the form and relationships of the parts of the body. Communication between anatomists is facilitated by the use of agreed standardized terms and a list of these has been developed and periodically revised by the International Committee on Veterinary Anatomical Nomenclature. The list, which forms a small book known as the *Nomina Anatomica Veterinaria*¹ (NAV), provides general descriptive terms applicable to all vertebrates, and specific terms related to the structure of the horse. During the preparation of the NAV, every effort has been made to maximize conformity between the human and domestic animal nomenclatures, but because veterinary terminology must be based on the normal quadrupedal stance, rather than the erect human position, there are distinct differences in the terms used for direction. The veterinary terms are related to parts of the body, thus blood that flows towards the head is said to be moving cranially and that flowing towards the tail moves caudally. The directional terms are described in detail in this chapter through annotated photographs of a horse.

The NAV uses Latin to identify anatomical structures. Anatomists are encouraged to translate the original Latin terms into their own languages unless this leads to obvious ambiguity. In general, anglicized terms have been used in this atlas, though the Latin terms have been retained for most muscles. When a structure has a synonym or well-known name in common usage, it is shown in brackets.

1

Clinical Anatomy of the Horse

1.1 Live horse, lateral view. Topographic terms.

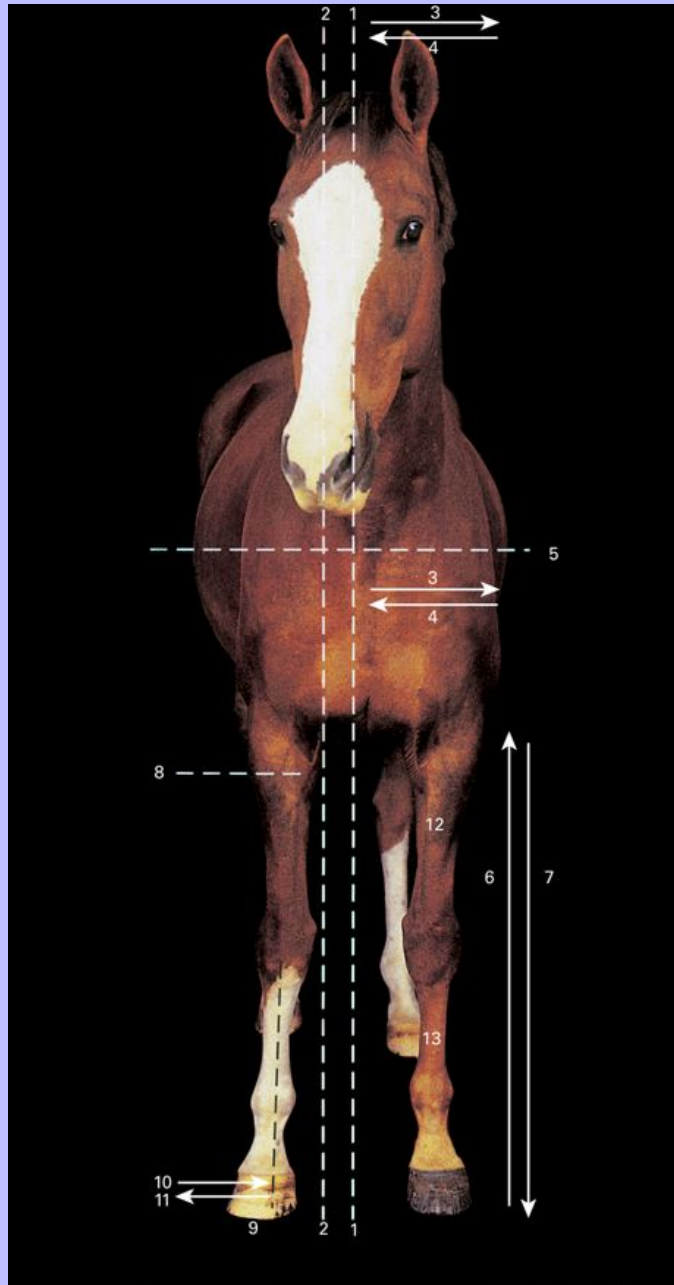


- 1 Transverse plane – neck, trunk
- 2 Dorsal – head, neck, trunk, tail
- 3 Ventral – head, neck, trunk, tail
- 4 Rostral – head
- 5 Caudal – head
- 6 Cranial – neck, trunk, tail
- 7 Caudal – neck, trunk, tail
- 8 Proximal – limb
- 9 Distal – limb
- 10 Cranial – proximal limb
- 11 Caudal – proximal limb
- 12 Dorsal – carpus and digit
- 13 Palmar – carpus and digit
- 14 Dorsal – tarsus and digit
- 15 Plantar – tarsus and digit

Clinical Anatomy of the Horse

1.2 Live horse, frontal view. Topographic terms.

3



Head, neck, trunk
1 Median plane

Clinical Anatomy of the Horse

2 Sagittal plane

3 Lateral

4 Medial

5 Dorsal plane

Limbs

6 Proximal

7 Distal

8 Transverse plane

9 Axial plane

10 Axial

11 Abaxial

12 Cranial

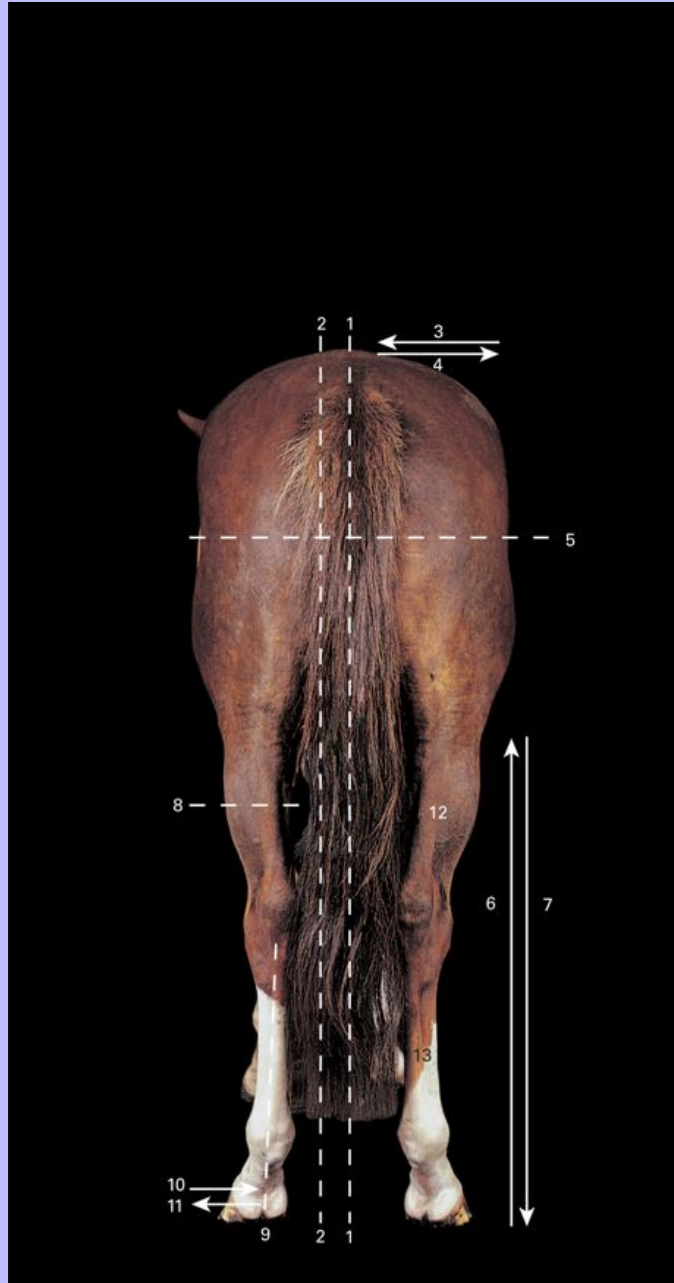
13 Dorsal

3

Clinical Anatomy of the Horse

1.3 Live horse, caudal view. Topographic terms.

4



Head, neck, trunk
1 Median plane

Clinical Anatomy of the Horse

2 Sagittal plane

3 Medial

4 Lateral

5 Dorsal plane

Limbs

6 Proximal

7 Distal

8 Transverse plane

9 Axial plane

10 Axial

11 Abaxial

12 Caudal

13 Plantar

1 *Nomina Anatomica Veterinaria* (1983, 3rd edition). International Committee on Veterinary Gross Anatomical Nomenclature, Ithaca, New York.

Clinical Anatomy of the Horse

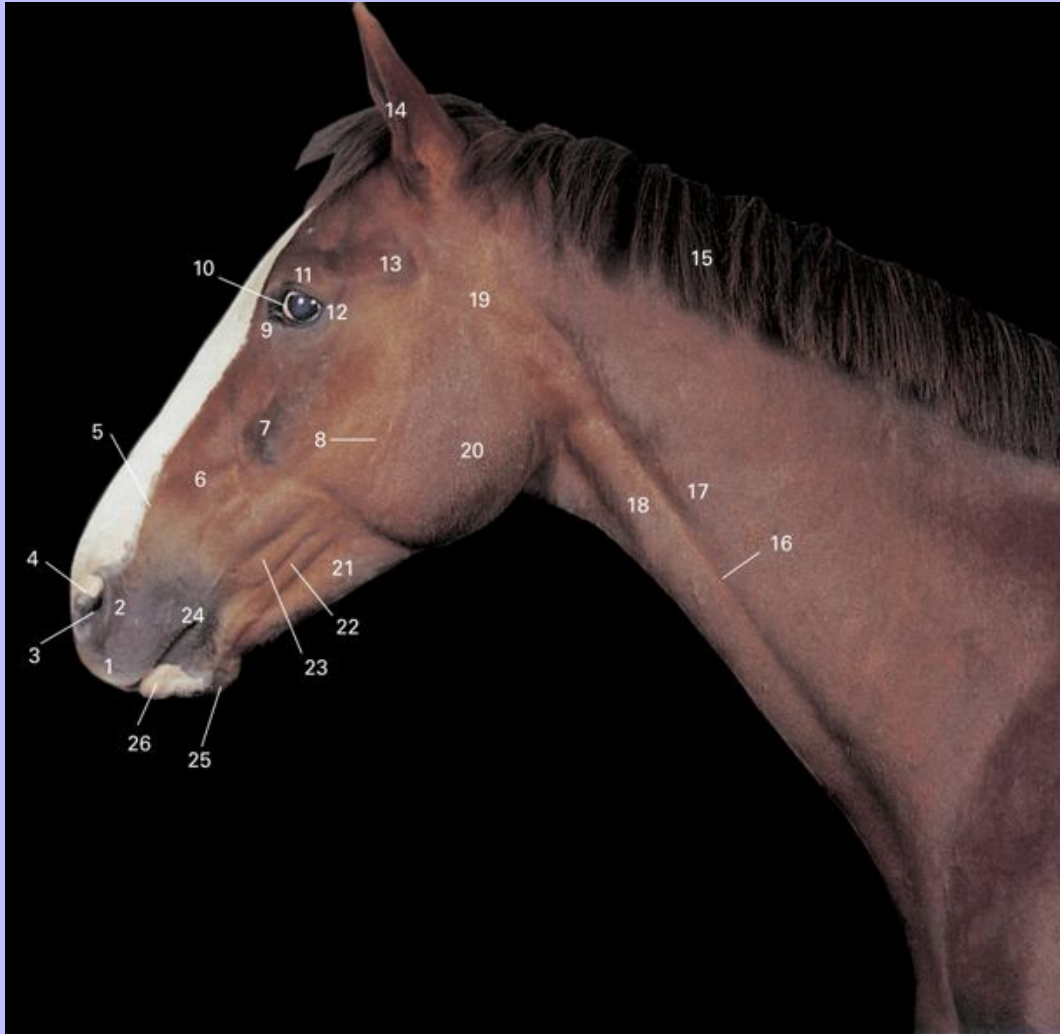2 Head

5

In this chapter palpable landmarks are indicated on photographs of live animals, osteological features are shown on bone specimens and radiographs, and soft-tissue structures are revealed using a series of prepared dissections, endoscopic views, radiographs and computed tomographic images. Topographical relationships between the bones and soft-tissue structures are clarified using specimens that have been sectioned in various orientations and accompanying images.

Clinical Anatomy of the Horse

2.1 Head and neck of live horse, lateral view, demonstrating visible and/or palpable landmarks.



- 1 Upper lip
- 2 Cornu of alar cartilage
- 3 Nostril
- 4 Lamina of alar cartilage
- 5 Nasoincisive notch

Clinical Anatomy of the Horse

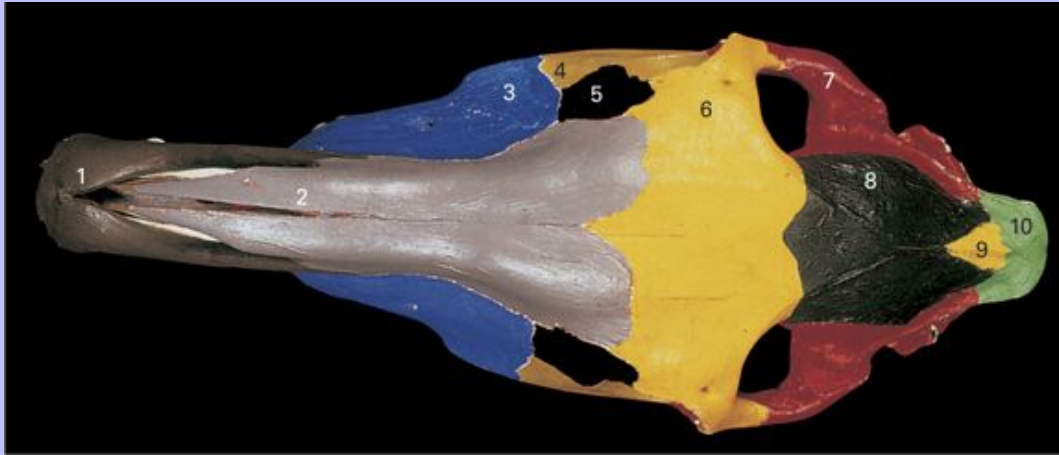
- 6 Infraorbital foramen
- 7 Facial crest
- 8 Facial nerve (VII)
- 9 Medial commissure of eyelids
- 10 Sclera (unpigmented in this horse)
- 11 Zygomatic process
- 12 Lateral commissure of eyelids
- 13 Zygomatic arch
- 14 Pinna
- 15 Mane
- 16 Jugular groove
- 17 M. brachiocephalicus
- 18 M. sternocephalicus
- 19 Parotid gland
- 20 M. masseter
- 21 Mandible
- 22 M. depressor labii inferioris
- 23 M. zygomaticus
- 24 Commissure of lips
- 25 Chin
- 26 Lower lip

5

Clinical Anatomy of the Horse

2.2 Bones of skull, dorsal view.

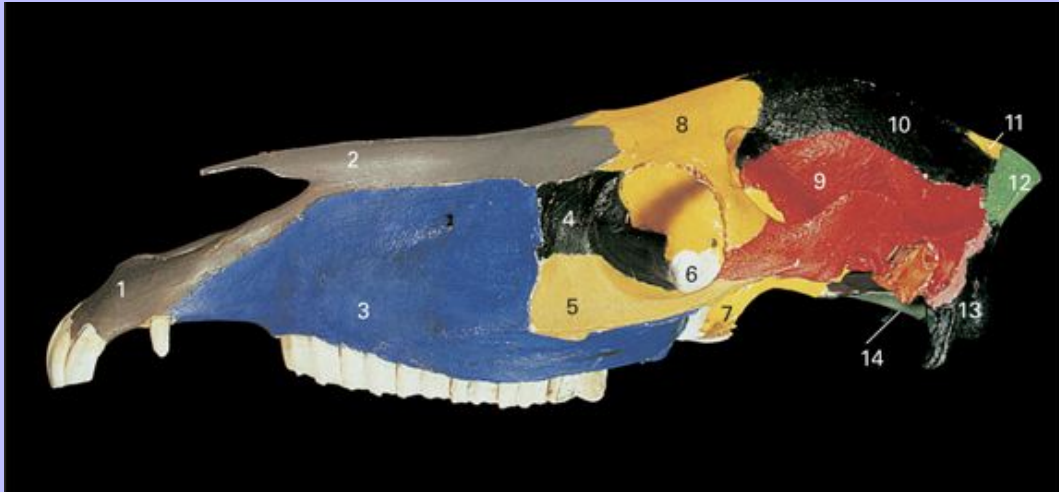
6



- 1 Incisive bone
- 2 Nasal bone
- 3 Maxilla
- 4 Zygomatic bone
- 5 Lacrimal bone
- 6 Frontal bone
- 7 Temporal bone
- 8 Parietal bone
- 9 Interparietal bone
- 10 Occipital bone, squamous part

Clinical Anatomy of the Horse

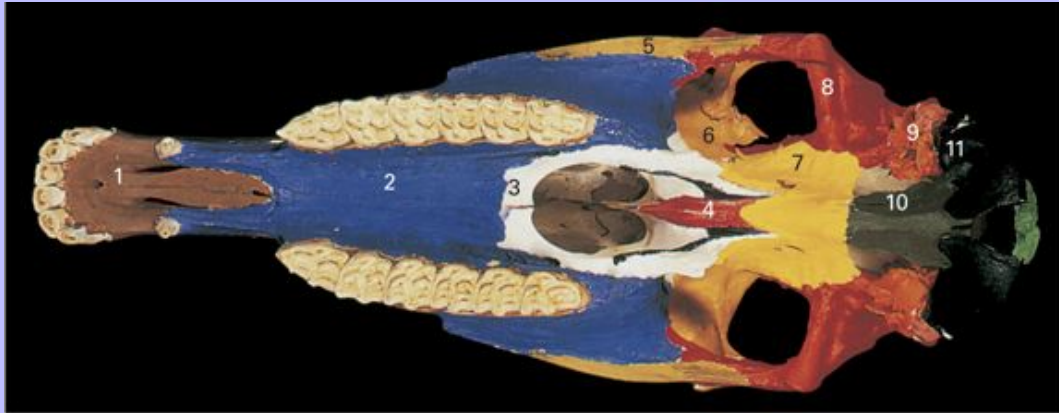
2.3 Bones of skull, lateral view.



- 1 Incisive bone
- 2 Nasal bone
- 3 Maxilla
- 4 Lacrimal bone
- 5 Zygomatic bone
- 6 Palatine bone, perpendicular plate
- 7 Presphenoid bone
- 8 Frontal bone
- 9 Temporal bone
- 10 Parietal bone
- 11 Interparietal bone
- 12 Occipital bone, squamous part
- 13 Occipital bone, lateral part
- 14 Occipital bone, basilar part

Clinical Anatomy of the Horse

2.4 Bones of skull, ventral view.

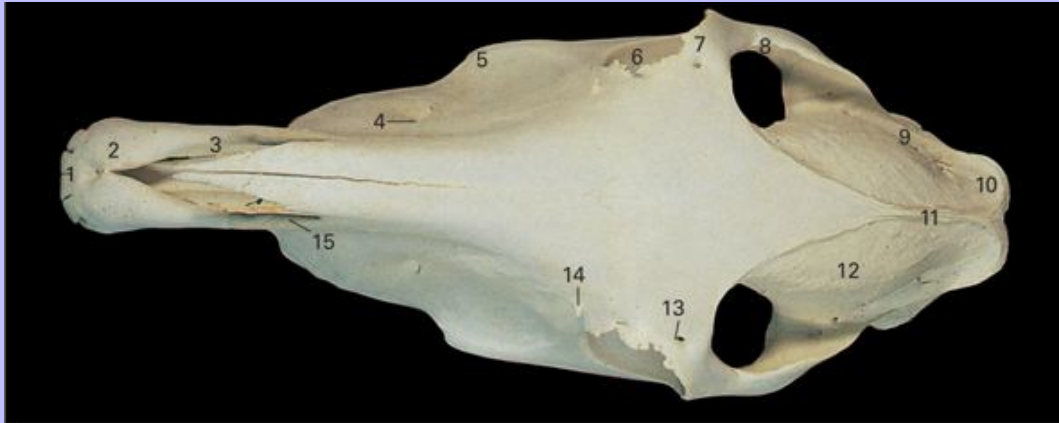


- 1 Incisive bone
- 2 Maxilla
- 3 Palatine bone
- 4 Vomer
- 5 Zygomatic bone
- 6 Frontal bone
- 7 Sphenoid bone
- 8 Temporal bone, squamous part
- 9 Temporal bone, tympanic and petrous parts
- 10 Occipital bone, basilar part
- 11 Occipital bone, lateral part

6

Clinical Anatomy of the Horse

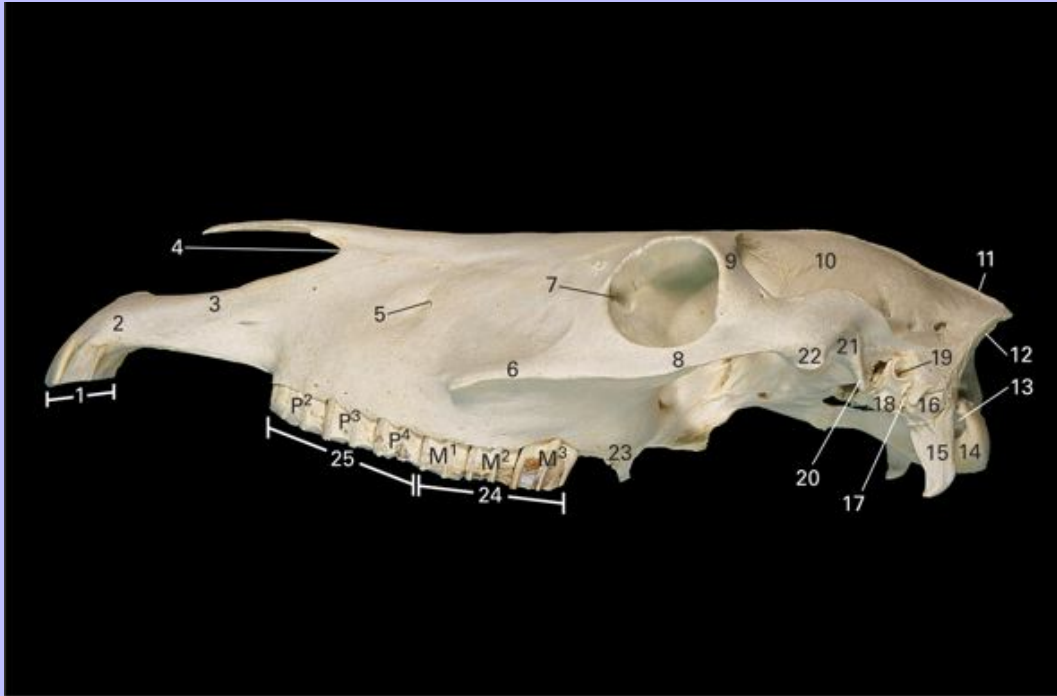
2.5 Bony features of skull, dorsal view.



- 1 Interincisive canal
- 2 Body of incisive bone
- 3 Nasal process of incisive bone
- 4 Infraorbital foramen
- 5 Facial crest
- 6 Orbit
- 7 Zygomatic process of frontal bone
- 8 Zygomatic arch
- 9 Temporal line
- 10 Nuchal crest
- 11 External sagittal crest
- 12 Temporal fossa
- 13 Supraorbital foramen
- 14 Rostral lacrimal process
- 15 Nasoincisive notch

Clinical Anatomy of the Horse

2.6 Bony features of skull, lateral view.



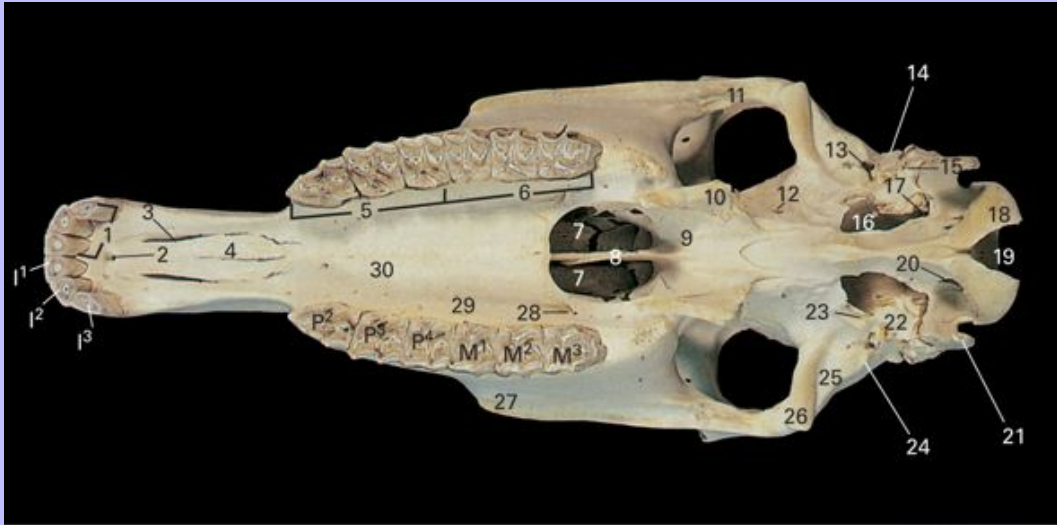
- 1 Incisor teeth
- 2 Body of incisive bone
- 3 Nasal process of incisive bone
- 4 Nasoincisive notch
- 5 Infraorbital foramen
- 6 Facial crest
- 7 Fossa for lacrimal sac
- 8 Zygomatic arch
- 9 Zygomatic process of frontal bone
- 10 Temporal fossa
- 11 External sagittal crest
- 12 Nuchal crest

Clinical Anatomy of the Horse

- 13 Condylod fossa
- 14 Occipital condyle
- 15 Jugular process
- 16 Mastoid process
- 17 Stylomastoid foramen
- 18 Styloid process
- 19 External acoustic meatus
- 20 Retroarticular process
- 21 Mandibular fossa
- 22 Articular tubercle
- 23 Condylar process
- 24 Molar teeth (M^1 , M^2 , M^3)
- 25 Premolar teeth (P^2 , P^3 , P^4)

Clinical Anatomy of the Horse

2.7 Skull of mare, ventral view.



- 1 Incisor teeth (I¹, I², I³)
- 2 Interincisive canal
- 3 Palatine fissure
- 4 Palatine process of incisive bone
- 5 Premolar teeth (P², P³, P⁴)
- 6 Molar teeth (M¹, M², M³)
- 7 Choanae
- 8 Vomer
- 9 Wings of vomer
- 10 Hamulus of pterygoid bone
- 11 Zygomatic arch
- 12 Caudal alar foramen
- 13 Petrotympenic fissure
- 14 External acoustic meatus

Clinical Anatomy of the Horse

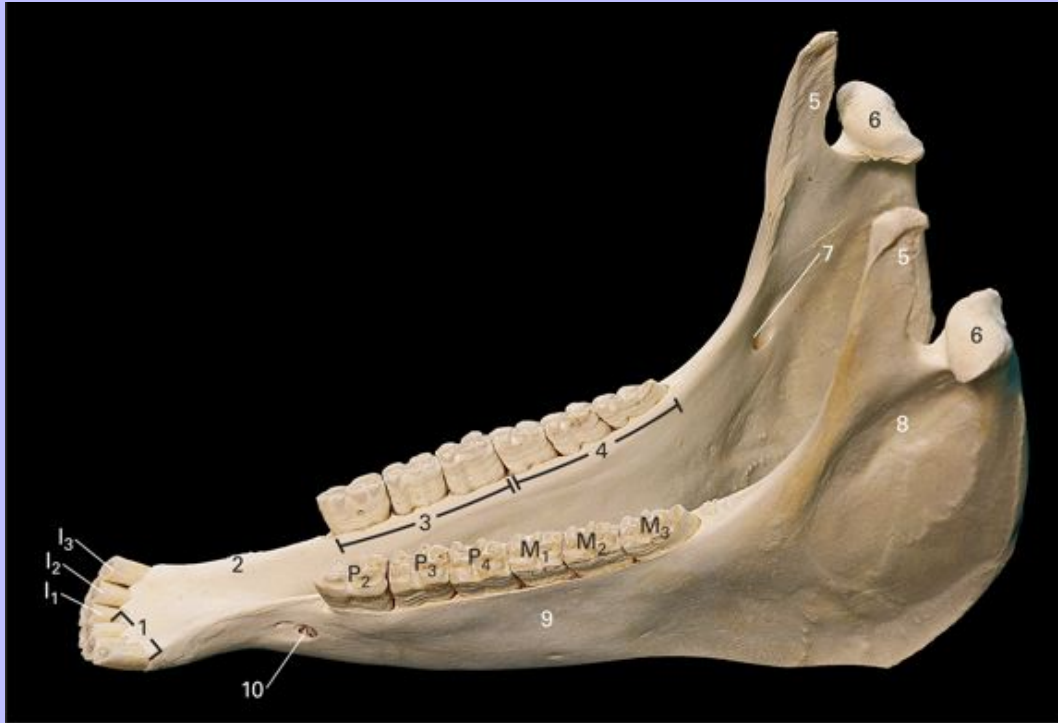- 15 Stylomastoid foramen
- 16 Foramen lacerum
- 17 Jugular foramen
- 18 Occipital condyle
- 19 Foramen magnum
- 20 Hypoglossal canal
- 21 Jugular process
- 22 Tympanic bulla
- 23 Osseous part of auditory tube
- 24 Retroarticular process
- 25 Mandibular fossa
- 26 Articular tubercle
- 27 Rostral end of facial crest
- 28 Major palatine foramen
- 29 Palatine groove
- 30 Palatine process of maxilla

7

Clinical Anatomy of the Horse

2.8 Mandible of mare, dorsal oblique view. Canine teeth are absent.

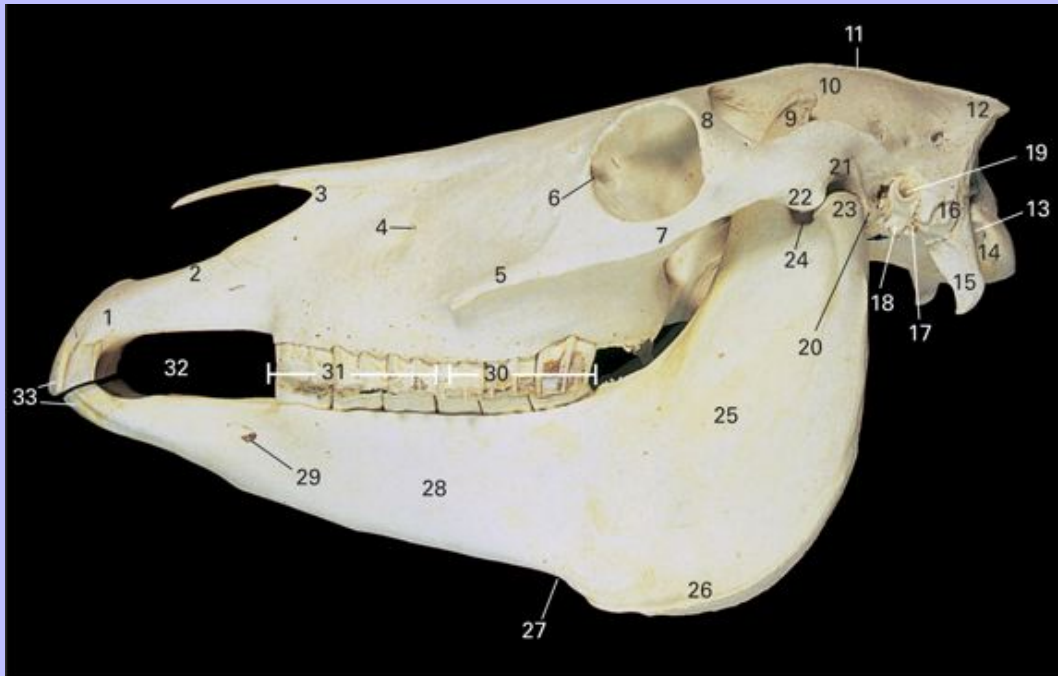
8



- 1 Incisor teeth (I_1 , I_2 , I_3)
- 2 Inter-alveolar border
- 3 Premolar teeth (P_2 , P_3 , P_4)
- 4 Molar teeth (M_1 , M_2 , M_3)
- 5 Coronoid process
- 6 Condylar process
- 7 Mandibular foramen
- 8 Ramus of mandible
- 9 Body of mandible
- 10 Mental foramen

Clinical Anatomy of the Horse

2.9 Skull and mandible of female horse, lateral view.



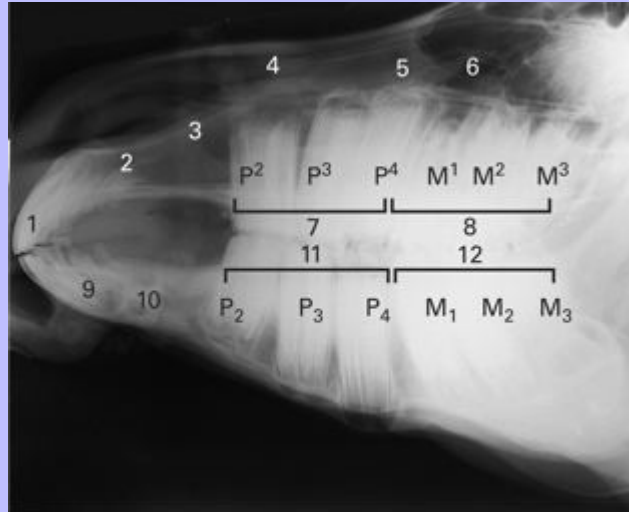
- 1 Body of incisive bone
- 2 Nasal process of incisive bone
- 3 Nasoincisive notch
- 4 Infraorbital foramen
- 5 Facial crest
- 6 Fossa for lacrimal soc
- 7 Zygomatic arch
- 8 Zygomatic process of frontal bone
- 9 Coronoid process
- 10 Temporal fossa
- 11 External sagittal crest
- 12 Nuchal crest
- 13
- 14
- 15
- 16
- 17
- 18
- 19
- 20
- 21
- 22
- 23
- 24
- 25
- 26
- 27
- 28
- 29
- 30
- 31
- 32
- 33

Clinical Anatomy of the Horse

- 13 Condylloid fossa
- 14 Occipital condyle
- 15 Jugular process
- 16 Mastoid process
- 17 Stylomastoid foramen
- 18 Styloid process
- 19 External acoustic meatus
- 20 Retroarticular process
- 21 Mandibular fossa
- 22 Articular tubercle
- 23 Condylar process
- 24 Mandibular notch
- 25 Ramus of mandible
- 26 Angle of mandible
- 27 Notch for facial vessels
- 28 Body of mandible
- 29 Mental foramen
- 30 Molar teeth
- 31 Premolar teeth
- 32 Inter-alveolar border
- 33 Incisor teeth

Clinical Anatomy of the Horse

2.10 Lateral view radiograph of horse head.



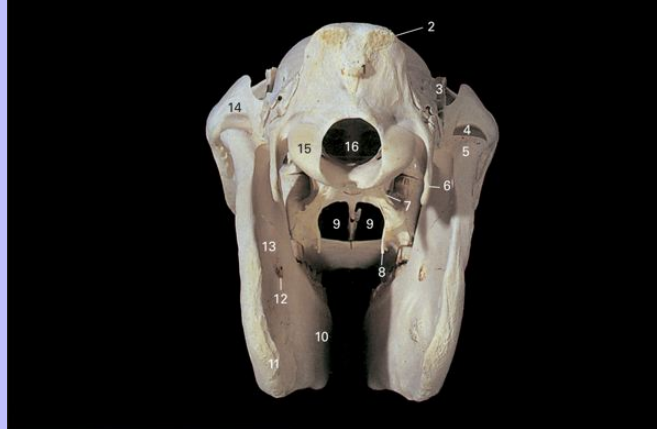
- 1 Upper incisor teeth
- 2 Incisive bone
- 3 Nasal process of incisive bone
- 4 Nasoincisive notch
- 5 Maxilla
- 6 Rostral compartment of maxillary sinus
- 7 Upper premolar teeth (P^2 , P^3 , P^4)
- 8 Upper molar teeth (M^1 , M^2 , M^3)
- 9 Lower incisor teeth
- 10 Mandible
- 11 Lower premolar teeth (P_2 , P_3 , P_4)
- 12 Lower molar teeth (M_1 , M_2 , M_3)

8

Clinical Anatomy of the Horse

9

2.11 Skull and mandible, caudal view.



- 1 External occipital protuberance
- 2 Nuchal crest
- 3 Coronoid process
- 4 Mandibular fossa
- 5 Condylar process
- 6 Jugular process
- 7 Caudal alar foramen
- 8 Hamulus of pterygoid
- 9 Choanae
- 10 Body of mandible
- 11 Angle of mandible
- 12 Mandibular foramen
- 13 Ramus of mandible
- 14 Zygomatic arch
- 15 Occipital condyle
- 16 Foramen magnum

Clinical Anatomy of the Horse

Deciduous dentition of horse

$$2\{Di\frac{3}{3} Dp\frac{3}{3}\}$$

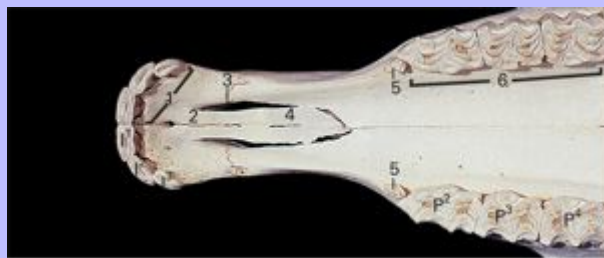Permanent dentition of horse

$$\text{Male } 2\{I\frac{3}{3} C\frac{1}{1} P\frac{3\text{ or }4}{3} M\frac{3}{3}\}$$

$$\text{Female } 2\{I\frac{3}{3} C\frac{0}{0} P\frac{3\text{ or }4}{3} M\frac{3}{3}\}$$

The second, third and fourth premolars are consistently present in the upper and lower jaws in male and female horses. The presence of the first upper premolar (wolf tooth) is variable; it is usually absent in both sexes, but may be present in vestigial form in horses of either sex. When present, it forms part of the permanent dentition. Canine teeth are present in male horses (stallions and geldings), but are usually absent, or small and poorly developed in mares.

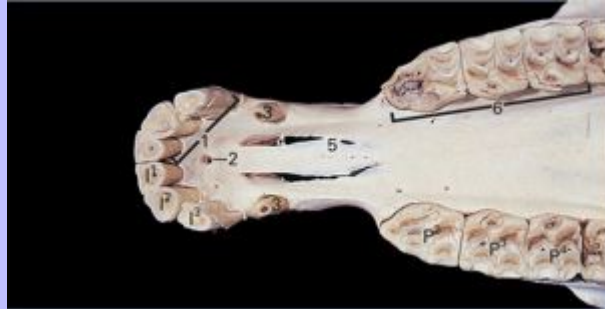2.12 Rostral part of skull of mare, ventral view, showing the position of the first premolar (wolf) tooth.



- 1 Incisor teeth (I^1, I^2, I^3)
- 2 Interincisive canal
- 3 Palatine fissure
- 4 Palatine process of incisive bone
- 5 First upper premolar (wolf) tooth (P^1)
- 6 Premolar teeth (P^2, P^3, P^4)

Clinical Anatomy of the Horse

2.13 Rostral part of skull of male horse with canine teeth, ventral view.



1 Incisor teeth (I^1, I^2, I^3)

2 Interincisive canal

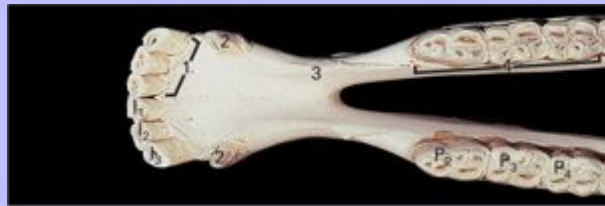3 Canine tooth

4 Palatine fissure

5 Palatine process

6 Premolar teeth (P^2, P^3, P^4)

2.14 Rostral part of mandible of male horse with canine teeth, dorsal view.



1 Incisor teeth (I_1, I_2, I_3)

2 Canine tooth

3 Interalveolar border

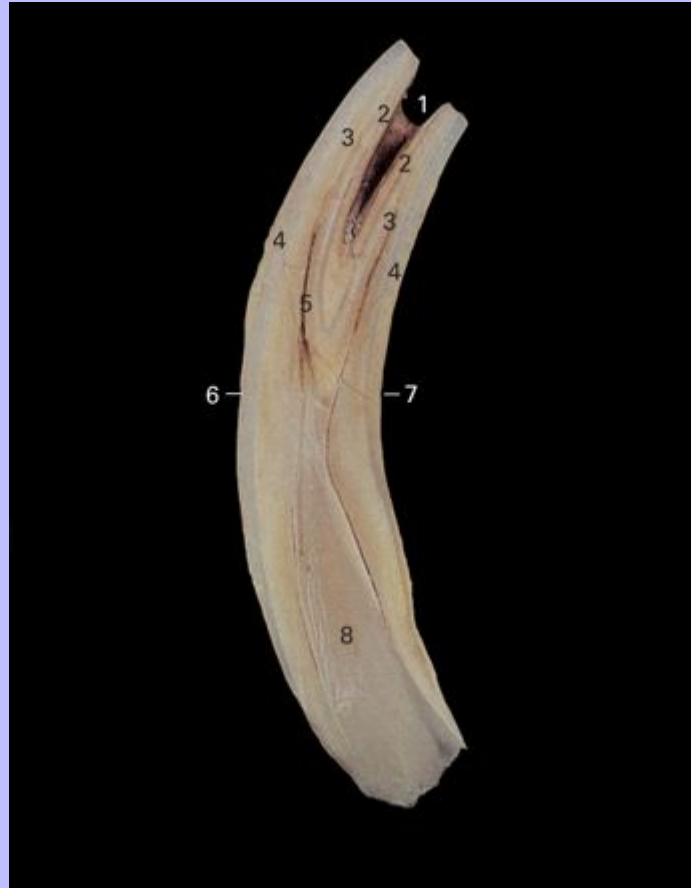4 Premolar teeth (P_2, P_3, P_4)

9

Clinical Anatomy of the Horse

2.15 Incisor tooth of young horse cut in longitudinal section.

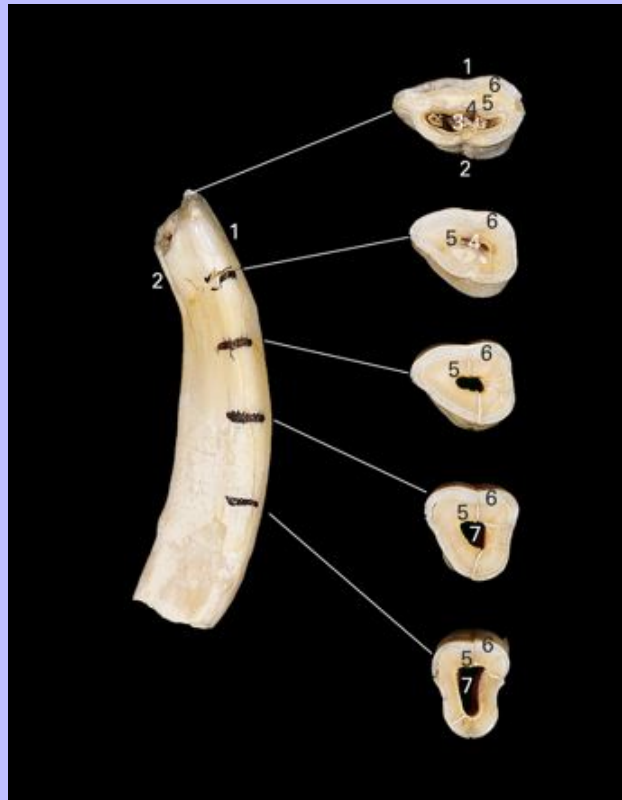10



- 1 Infundibulum
- 2 Central enamel
- 3 Dentin
- 4 Peripheral enamel
- 5 Secondary dentin will appear as the dental star
- 6 Rostral (buccal) surface
- 7 Caudal (lingual) surface
- 8 Pulp cavity

Clinical Anatomy of the Horse

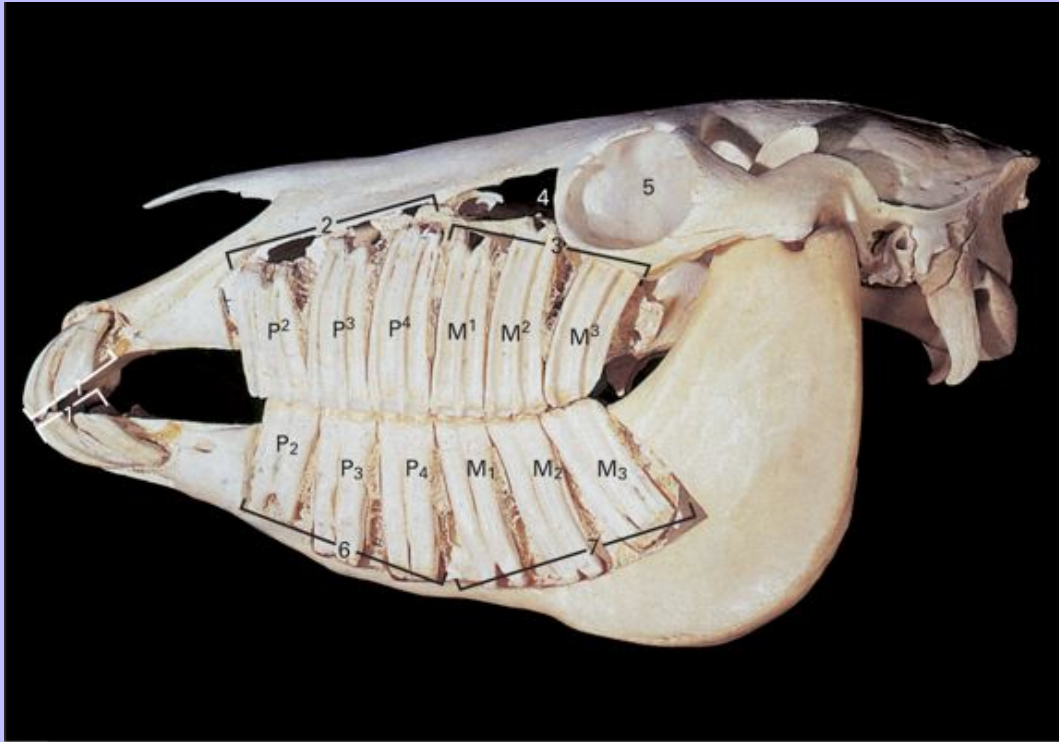
2.16 Incisor tooth cut in transverse section at the levels shown, which correspond approximately with ages 3 years, 9 years, 15 years, 20 years, 25 years. As the horse ages, the shape and contours of the table change. The pulp cavity fills with secondary dentin, which is darker than primary dentin, and appears on the table as the dental star.



- 1 Rostral (buccal) surface
- 2 Caudal (lingual) surface
- 3 Infundibulum
- 4 Central enamel
- 5 Dentin
- 6 Peripheral enamel
- 7 Pulp cavity

Clinical Anatomy of the Horse

2.17 Skull of young adult horse, lateral view. The bones have been sculptured to show the extent of the reserve crowns of the incisors, premolars and molars.



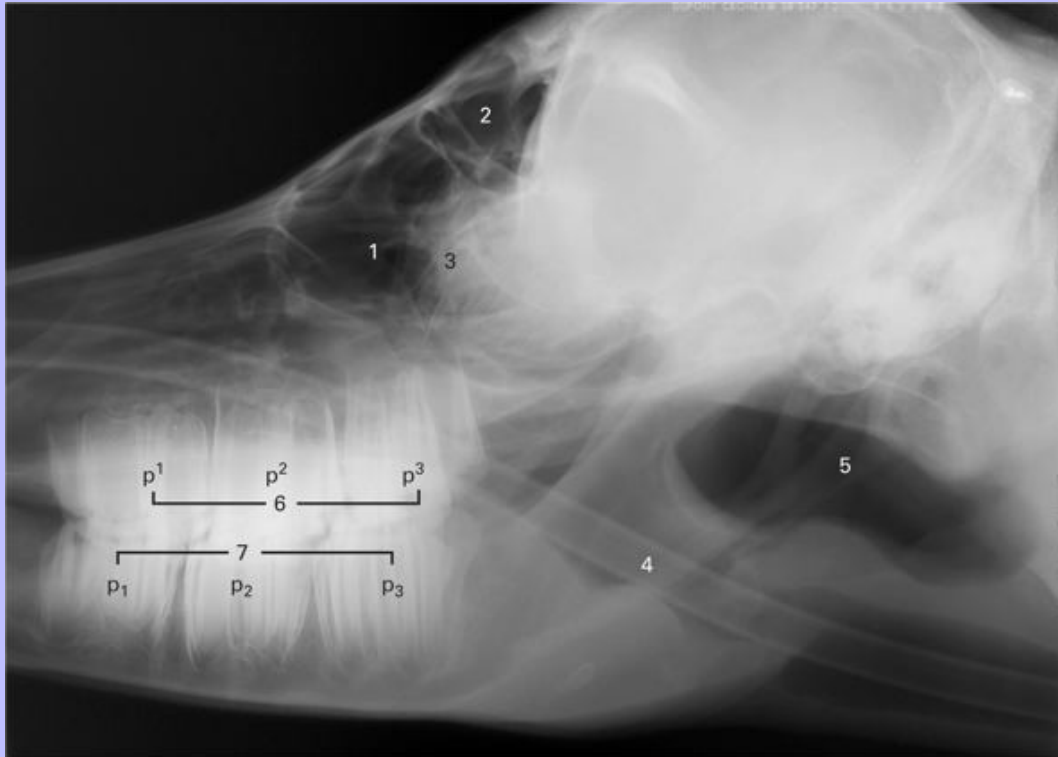
- 1 Incisor teeth
- 2 Upper premolar teeth (P², P³, P⁴)
- 3 Upper molar teeth (M¹, M², M³)
- 4 Maxillary sinus
- 5 Orbit
- 6 Lower premolar teeth (P₂, P₃, P₄)
- 7 Lower molar teeth (M₁, M₂, M₃)

10

Clinical Anatomy of the Horse

2.18 Lateral view radiograph of head of 1-day-old foal.

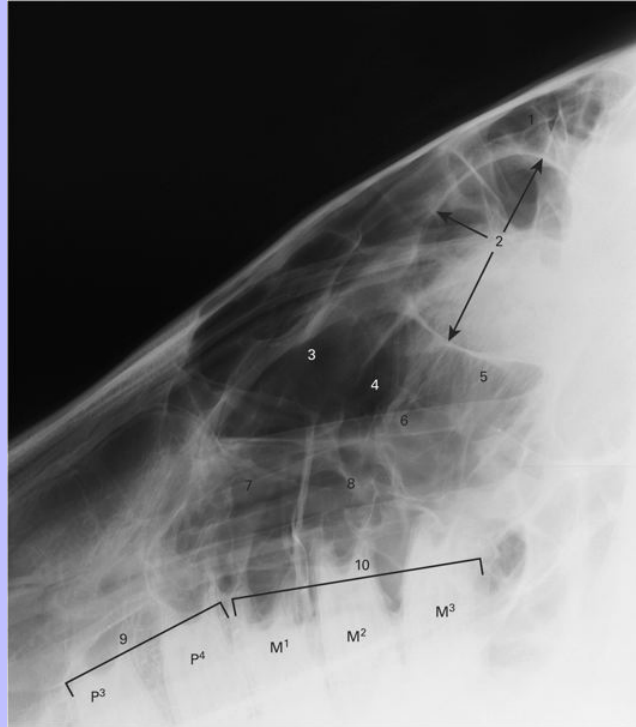
11



- 1 Maxillary sinus
- 2 Frontal sinus
- 3 Ethmoid turbinates
- 4 Nasotracheal oxygen tube
- 5 Auditory tube diverticulum
- 6 Upper deciduous premolar teeth (P^1 , P^2 , P^3)
- 7 Lower deciduous premolar teeth (P_1 , P_2 , P_3)

Clinical Anatomy of the Horse

2.19 Lateral view radiograph of maxillary tooth roots and paranasal sinuses of mature horse.

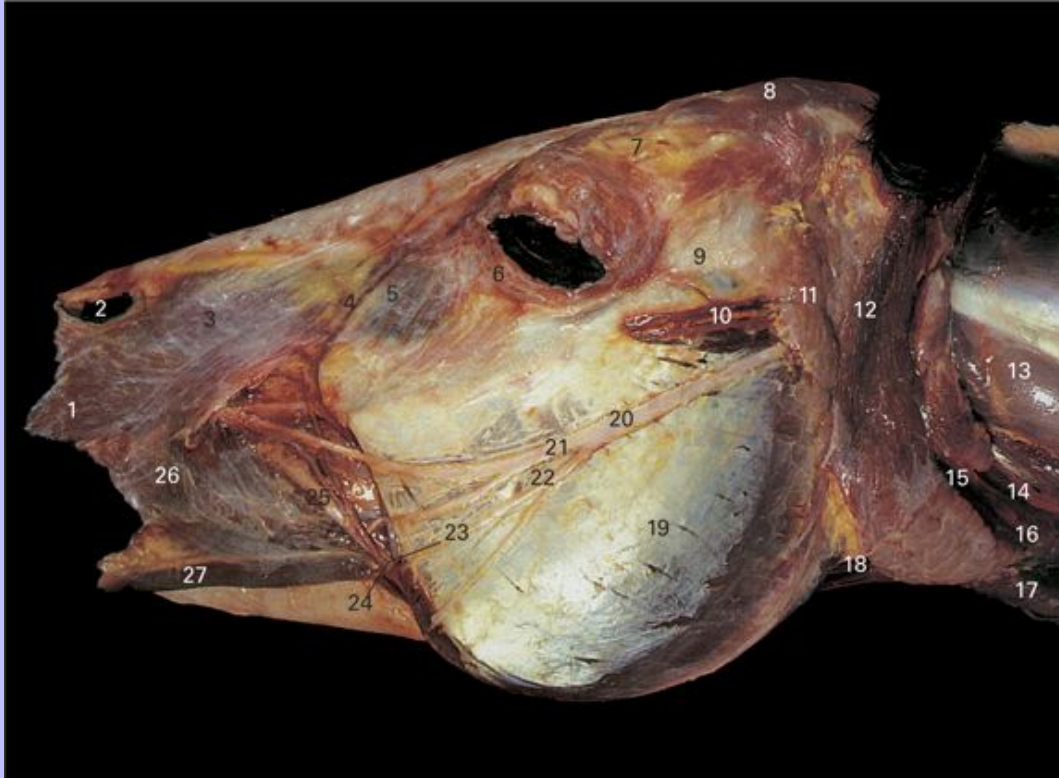


- 1 Frontal sinus
- 2 Orbit
- 3 Dorsal conchal frontal sinus
- 4 Caudal compartment of maxillary sinus
- 5 Ethmoid turbinates
- 6 Infraorbital canal
- 7 Rostral compartment of maxillary sinus
- 8 Ventral conchal sinus
- 9 Upper premolar teeth (P³, P⁴)
- 10 Upper molar teeth (M¹, M², M³)

Clinical Anatomy of the Horse

2.20 Superficial dissection of head, lateral view. Cutaneous muscles have been removed.

12



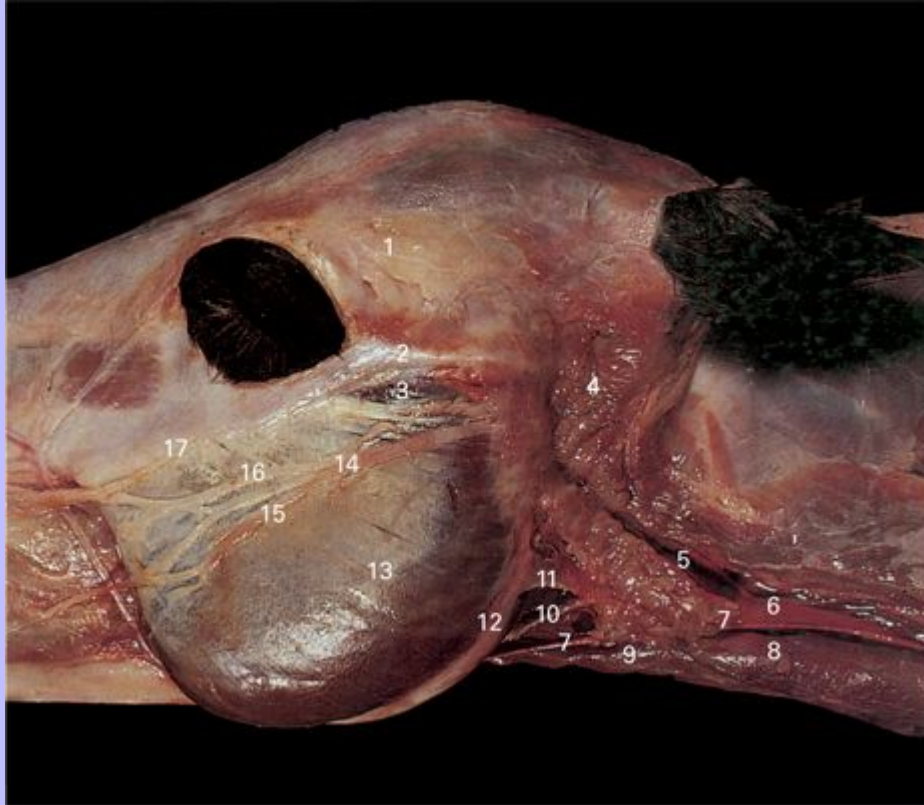
- 1 M. caninus
- 2 Nasal diverticulum
- 3 M. levator nasolabialis
- 4 Angular vein of eye
- 5 M. levator labii superioris
- 6 M. orbicularis oculi
- 7 Supraorbital fat pad
- 8 M. temporalis
- 9 Zygomatic arch
- 10 Transverse facial vessels
- 11 M. zygomaticus
- 12 M. masseter
- 13 M. pterygoid
- 14 M. digastric
- 15 M. geniohyoid
- 16 M. hyoglossus
- 17 M. stylohyoid
- 18 M. stapedius
- 19 M. tensor velum palatini
- 20 M. palatopharyngeus
- 21 M. palatoglossus
- 22 M. palatobuccinator
- 23 M. buccinator
- 24 M. buccopharyngeus
- 25 M. buccinervus
- 26 M. buccinervus
- 27 M. buccinervus

Clinical Anatomy of the Horse

- 11 Parotid gland
- 12 M. parotidoauricularis
- 13 M. brachiocephalicus
- 14 Common carotid artery
- 15 Maxillary vein
- 16 Jugular vein
- 17 M. sternocephalicus
- 18 M. sternohyoideus
- 19 M. masseter
- 20 Facial nerve (VII)
- 21 Dorsal buccal branch of facial nerve
- 22 Ventral buccal branch of facial nerve
- 23 Facial vein
- 24 Facial artery
- 25 Parotid duct
- 26 M. buccinator
- 27 M. depressor labii inferioris

Clinical Anatomy of the Horse

2.21 Superficial dissection of caudal mandibular region, lateral view. Cutaneous muscles and M. parotidoauricularis have been removed.



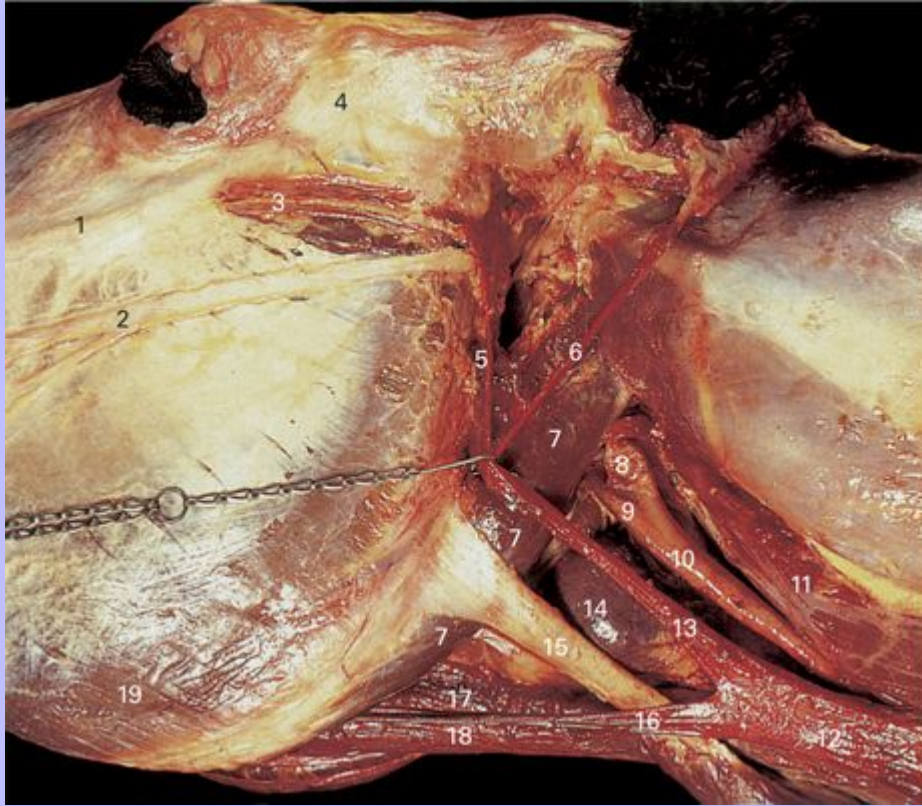
- 1 Supraorbital fat pad
- 2 Zygomatic arch
- 3 Transverse facial vessels
- 4 Parotid gland
- 5 Maxillary vein
- 6 External jugular vein
- 7 Linguofacial vein
- 8 M. sternocephalicus
- 9 M. sternohyoideus and M. omohyoideus

Clinical Anatomy of the Horse

- 10 Parotid duct
- 11 Tendon of M. sternocephalicus
- 12 Edge of mandible
- 13 M. masseter
- 14 Facial nerve (VII)
- 15 Ventral buccal branch of facial nerve
- 16 Dorsal buccal branch of facial nerve
- 17 Facial crest

Clinical Anatomy of the Horse

2.22 Deep dissection of caudal mandibular region, ventrolateral view. The M. parotidoauricularis, the parotid gland and the mandibular gland have been removed. The maxillary vein has been retracted rostrally.



- 1 Facial crest
- 2 Buccal branch of facial nerve
- 3 Transverse facial vessels and nerve
- 4 Zygomatic arch
- 5 Superficial temporal vein
- 6 Caudal auricular vein
- 7 M. digastricus
- 8 Carotid sinus on internal carotid artery

Clinical Anatomy of the Horse

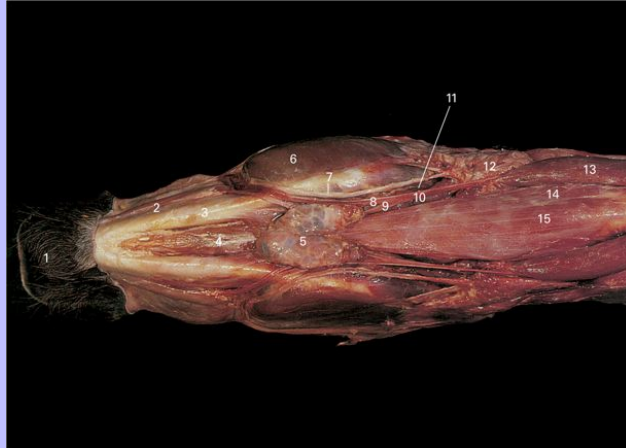
- 9 External carotid artery
- 10 Common carotid artery
- 11 M. omotransversarius
- 12 External jugular vein
- 13 Maxillary vein
- 14 Thyroid gland
- 15 Tendon of M. sternocephalicus
- 16 Linguofacial vein
- 17 M. sternothyroideus
- 18 M. omohyoideus and M. sternohyoideus
- 19 M. masseter

12

Clinical Anatomy of the Horse

13

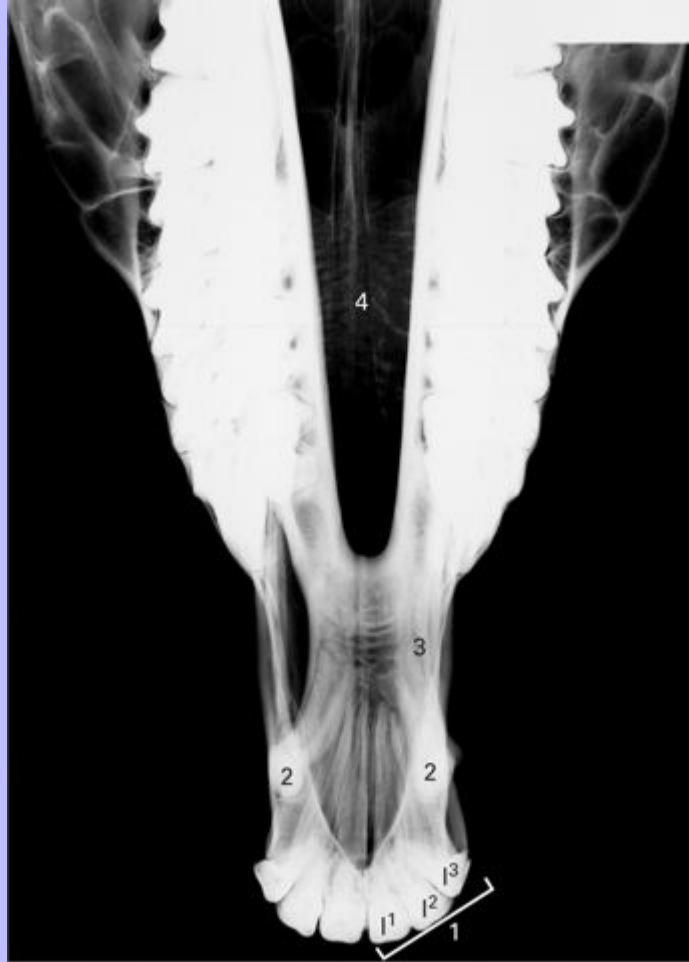2.23 Superficial dissection of head of horse, ventral view. Cutaneous muscles have been removed.



- 1 Chin
- 2 M. depressor labii inferioris
- 3 Mandible
- 4 M. mylohyoideus
- 5 Mandibular lymph node
- 6 M. masseter
- 7 Parotid duct
- 8 Facial vein
- 9 Lingual vein
- 10 Linguofacial vein
- 11 Facial artery
- 12 Parotid gland
- 13 M. sternocephalicus
- 14 M. omohyoideus
- 15 M. sternohyoideus

Clinical Anatomy of the Horse

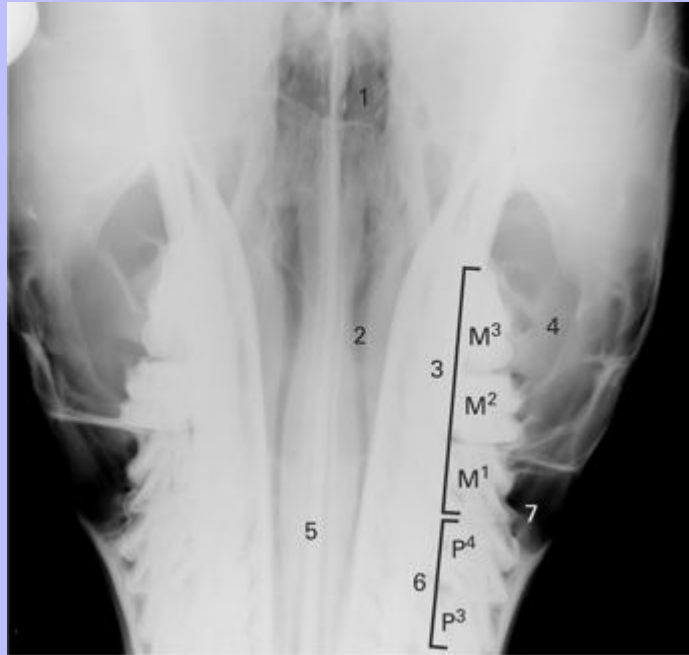
2.24 Dorsoventral view radiograph of rostral horse head.



- 1 Upper incisor teeth (I¹, I², I³)
- 2 Upper canine teeth
- 3 Inter-alveolar space
- 4 Nasal passages

Clinical Anatomy of the Horse

2.25 Dorsoventral view radiograph of caudal horse head.



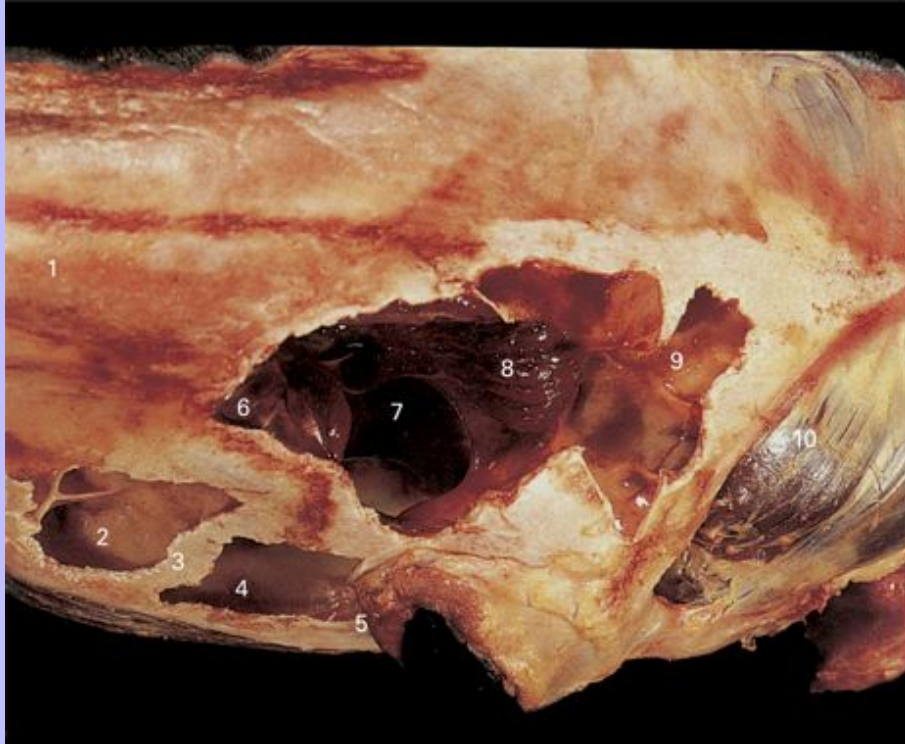
- 1 Ethmoidal conchae
- 2 Nasal passages
- 3 Upper molar teeth (M¹, M², M³)
- 4 Caudal compartment of maxillary sinus
- 5 Nasal septum
- 6 Upper premolar teeth (P³, P⁴)
- 7 Rostral compartment of maxillary sinus

13

Clinical Anatomy of the Horse

14

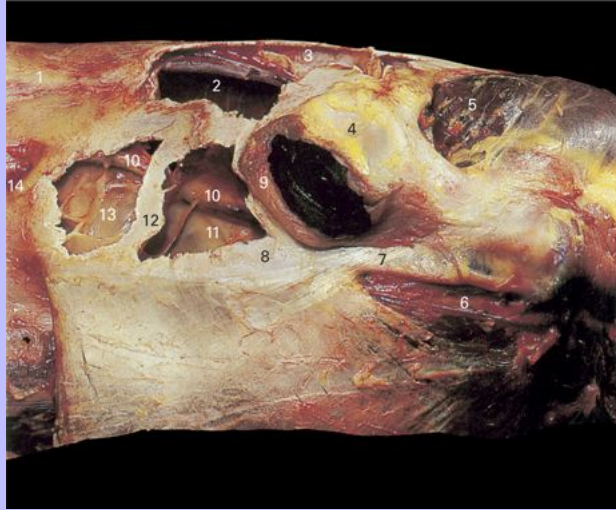2.26 Dissection of frontal and maxillary region of head, dorsal view. Overlying bone has been removed to expose the interior of the frontal and maxillary sinuses.



- 1 Nasal bone
- 2 Rostral maxillary sinus
- 3 Maxillary sinus septum
- 4 Caudal maxillary sinus
- 5 M. obicularis oculi
- 6 Conchal part of frontal sinus
- 7 Frontomaxillary opening
- 8 Ethmoidal conchae in frontal sinus
- 9 Frontal sinus
- 10 M. temporalis

Clinical Anatomy of the Horse

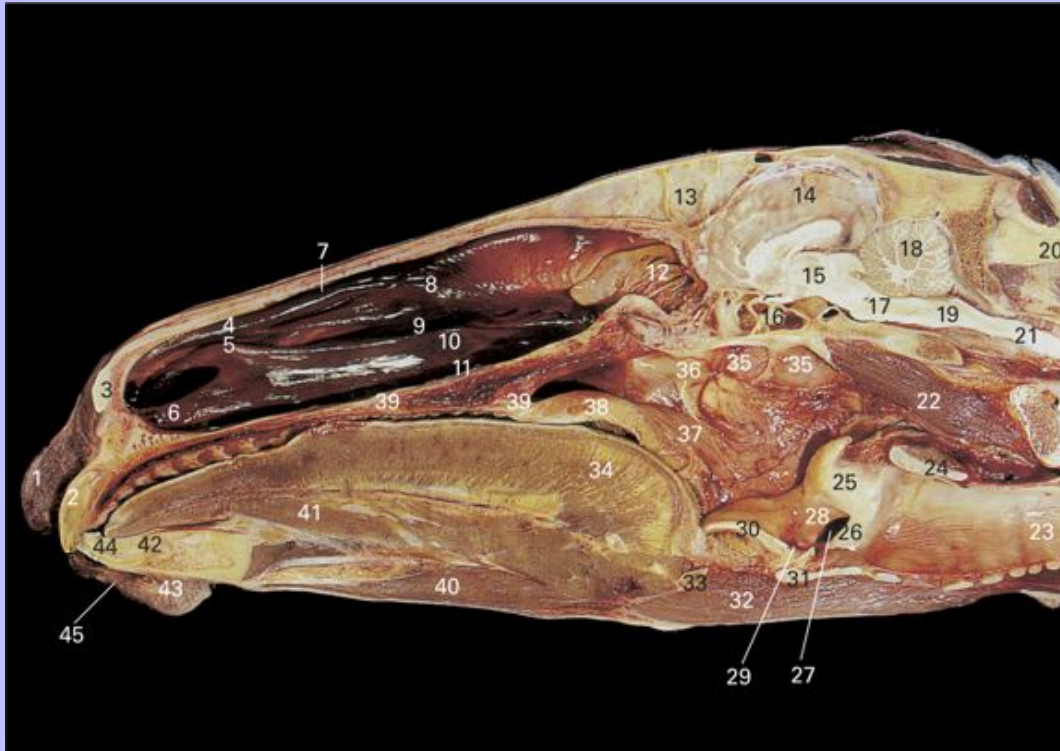
2.27 Dissection of frontal and maxillary region of head, lateral view. Overlying bone has been removed to expose the interior of the frontal and maxillary sinuses.



- 1 Nasal bone
- 2 Conchal part of frontal sinus
- 3 Frontal sinus
- 4 Supraorbital fat pad
- 5 M. temporalis
- 6 Transverse facial vessels
- 7 Zygomatic arch
- 8 Facial crest
- 9 M. orbicularis oculi
- 10 Infraorbital canal
- 11 Caudal maxillary sinus
- 12 Maxillary sinus septum
- 13 Rostral maxillary sinus
- 14 Infraorbital foramen

Clinical Anatomy of the Horse

2.28 Paramedian section through head. Nasal septum has been removed.



- 1 Upper lip
- 2 Incisor tooth (I^1)
- 3 Alar cartilage
- 4 Straight fold
- 5 Alar fold
- 6 Basal fold
- 7 Dorsal meatus
- 8 Dorsal nasal concha
- 9 Middle meatus
- 10 Ventral nasal concha
- 11 Ventral meatus

Clinical Anatomy of the Horse

- 12 Ethmoidal conchae
- 13 Septum separating left and right frontal sinuses
- 14 Cerebral hemisphere
- 15 Cerebral crura
- 16 Sphenopalatine sinus
- 17 Pons
- 18 Cerebellum
- 19 Medulla oblongata
- 20 Nuchal ligament
- 21 Spinal cord
- 22 M. longus capitis
- 23 Trachea
- 24 Cricoid cartilage
- 25 Arytenoid cartilage
- 26 Vocal fold
- 27 Lateral laryngeal ventricle
- 28 Vestibular fold
- 29 Median laryngeal ventricle
- 30 Epiglottis
- 31 Thyroid cartilage
- 32 M. sternohyoideus
- 33 Basihyoid bone
- 34 M. genioglossus
- 35 Mucosa separating left and right auditory tube diverticulae
- 36 Opening of auditory tube
- 37 Nasopharynx

Clinical Anatomy of the Horse

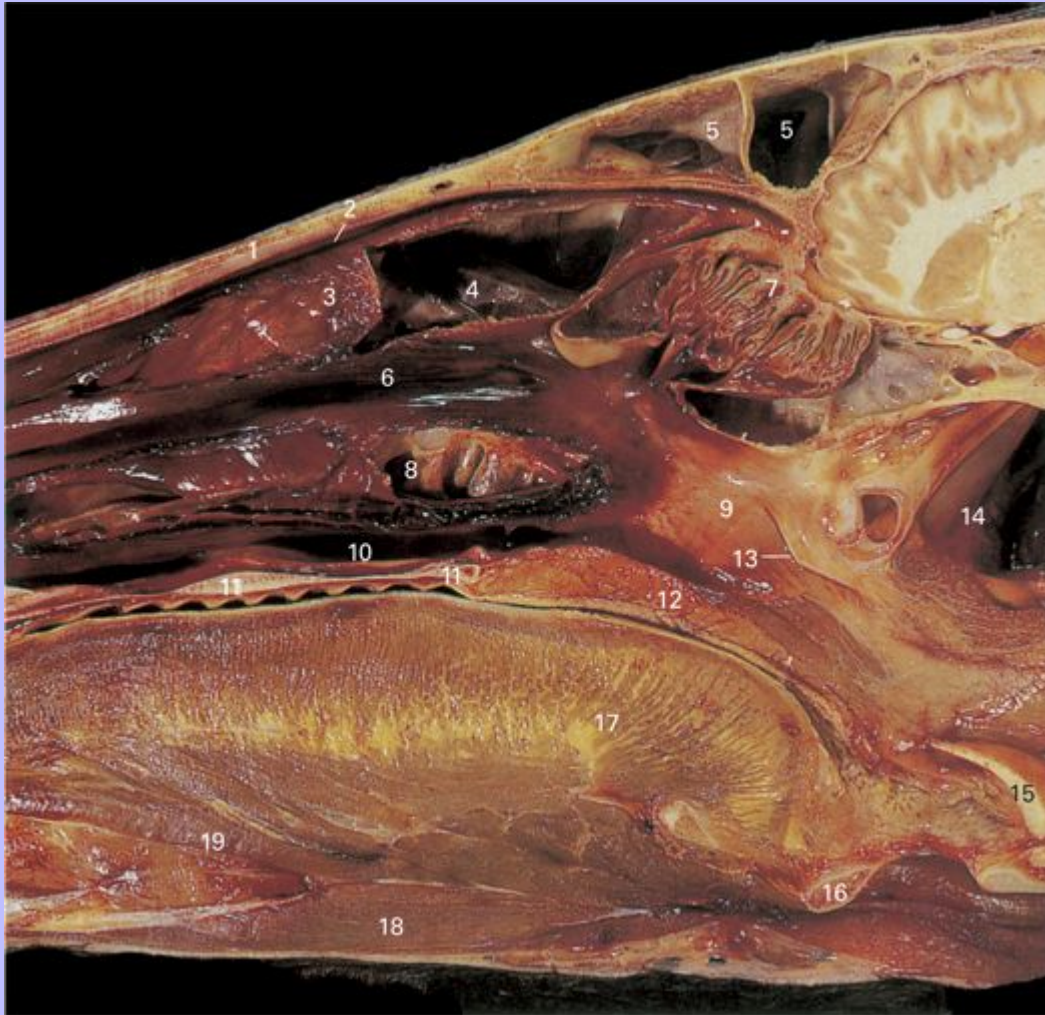- 38 Soft palate
- 39 Hard palate
- 40 M. geniohyoideus
- 41 M. styloglossus
- 42 Mandible
- 43 Chin
- 44 Incisor tooth (I₁)
- 45 Lower lip

14

Clinical Anatomy of the Horse

2.29 Paramedian section through head. The medial walls of the dorsal and ventral conchae have been removed.

15



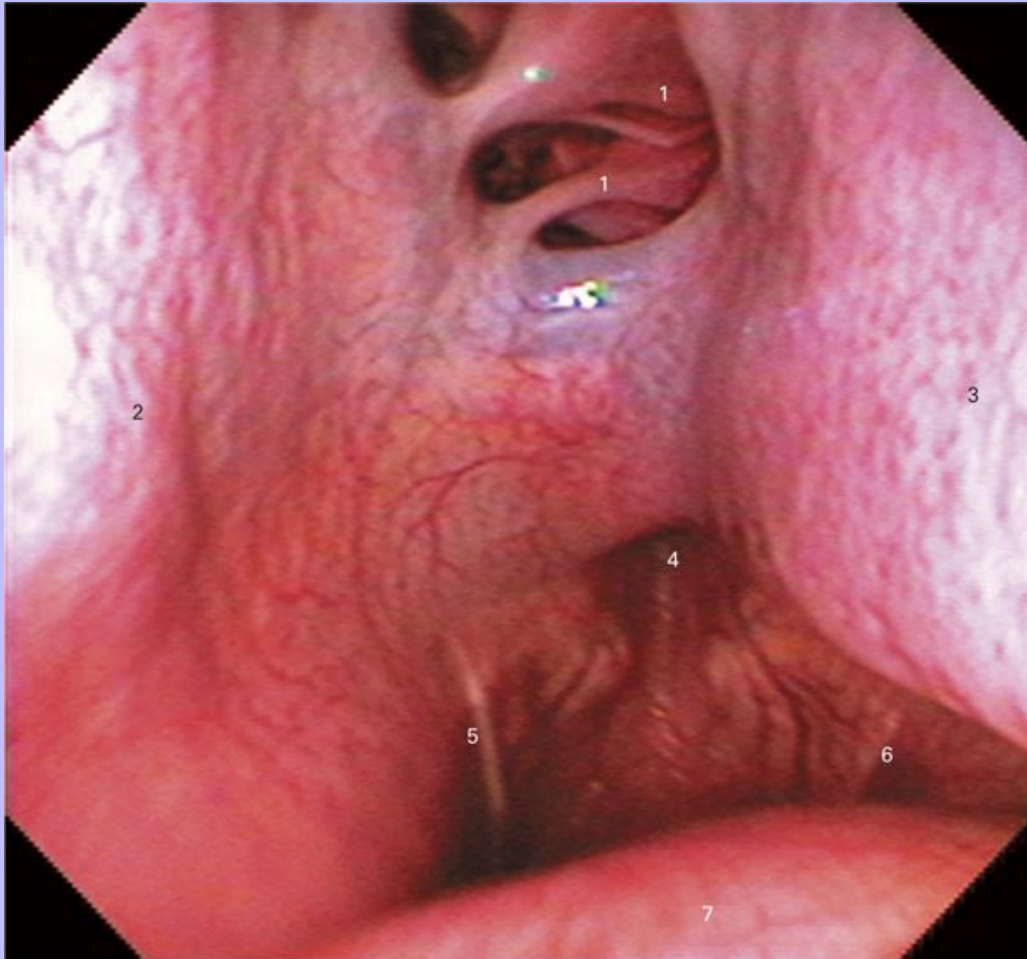
- 1 Nasal bone
- 2 Dorsal meatus
- 3 Scrolled portion of dorsal nasal concha
- 4 Conchal portion of frontal sinus
- 5 Frontal sinus
- 6 Middle meatus

Clinical Anatomy of the Horse

- 7 Ethmoidal conchae
- 8 Conchal portion of rostral maxillary sinus
- 9 Nasopharynx
- 10 Ventral meatus
- 11 Hard palate
- 12 Soft palate
- 13 Opening of auditory tube
- 14 Auditory tube diverticulum (guttural pouch)
- 15 Epiglottis
- 16 Basihyoid bone
- 17 Tongue
- 18 M. geniohyoideus
- 19 M. hyoglossus

Clinical Anatomy of the Horse

2.30 Endoscopic view of caudal nasal cavity and nasopharynx.

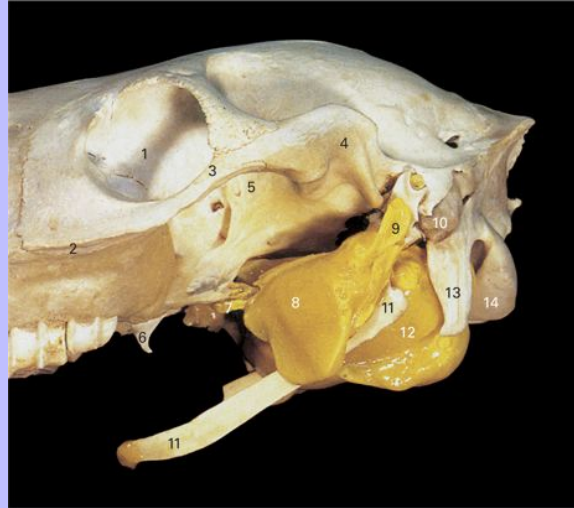

- 1 Ethmoidal conchae
- 2 Ventral nasal concha
- 3 Nasal septum
- 4 Nasopharyngeal recess
- 5 Opening of right auditory tube
- 6 Opening of left auditory tube
- 7 Soft palate

Clinical Anatomy of the Horse

16

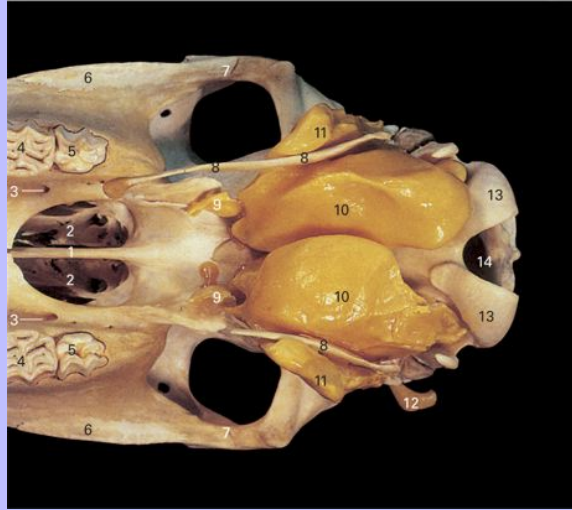
2.31 Skull of horse, lateral view. The external auditory canals, auditory tubes and auditory tube diverticulae (guttural pouches) have been filled with yellow latex.



- 1 Orbit
- 2 Facial crest
- 3 Zygomatic arch
- 4 Mandibular fossa
- 5 Pterygopalatine fossa
- 6 Hamulus of pterygoid bone
- 7 Auditory tube
- 8 Lateral compartment of auditory tube diverticulum
- 9 External acoustic meatus
- 10 Mastoid process
- 11 Stylohyoid bone
- 12 Medial compartment of auditory tube diverticulum
- 13 Paracondylar process
- 14 Occipital condyle

Clinical Anatomy of the Horse

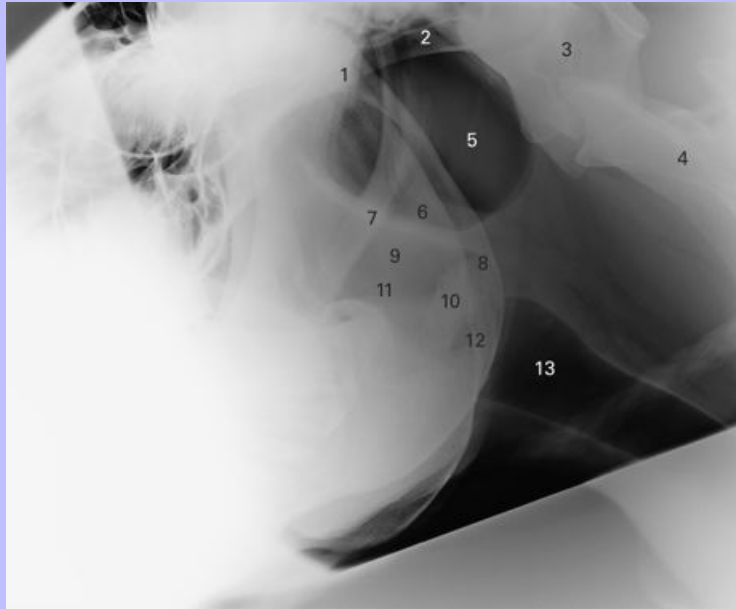
2.32 Skull of horse, ventral view. The external auditory canals, auditory tubes and auditory tube diverticulae (guttural pouches) have been filled with yellow latex.



- 1 Vomer
- 2 Choana
- 3 Major palatine foramen
- 4 Second upper molar
- 5 Third upper molar
- 6 Facial crest
- 7 Zygomatic arch
- 8 Stylohyoid bone
- 9 Auditory tube
- 10 Medial compartment of auditory tube diverticulum
- 11 Lateral compartment of auditory tube diverticulum
- 12 External auditory canal
- 13 Occipital condyle
- 14 Foramen magnum

Clinical Anatomy of the Horse

2.33 Lateral view radiograph of head showing auditory tube diverticulae.

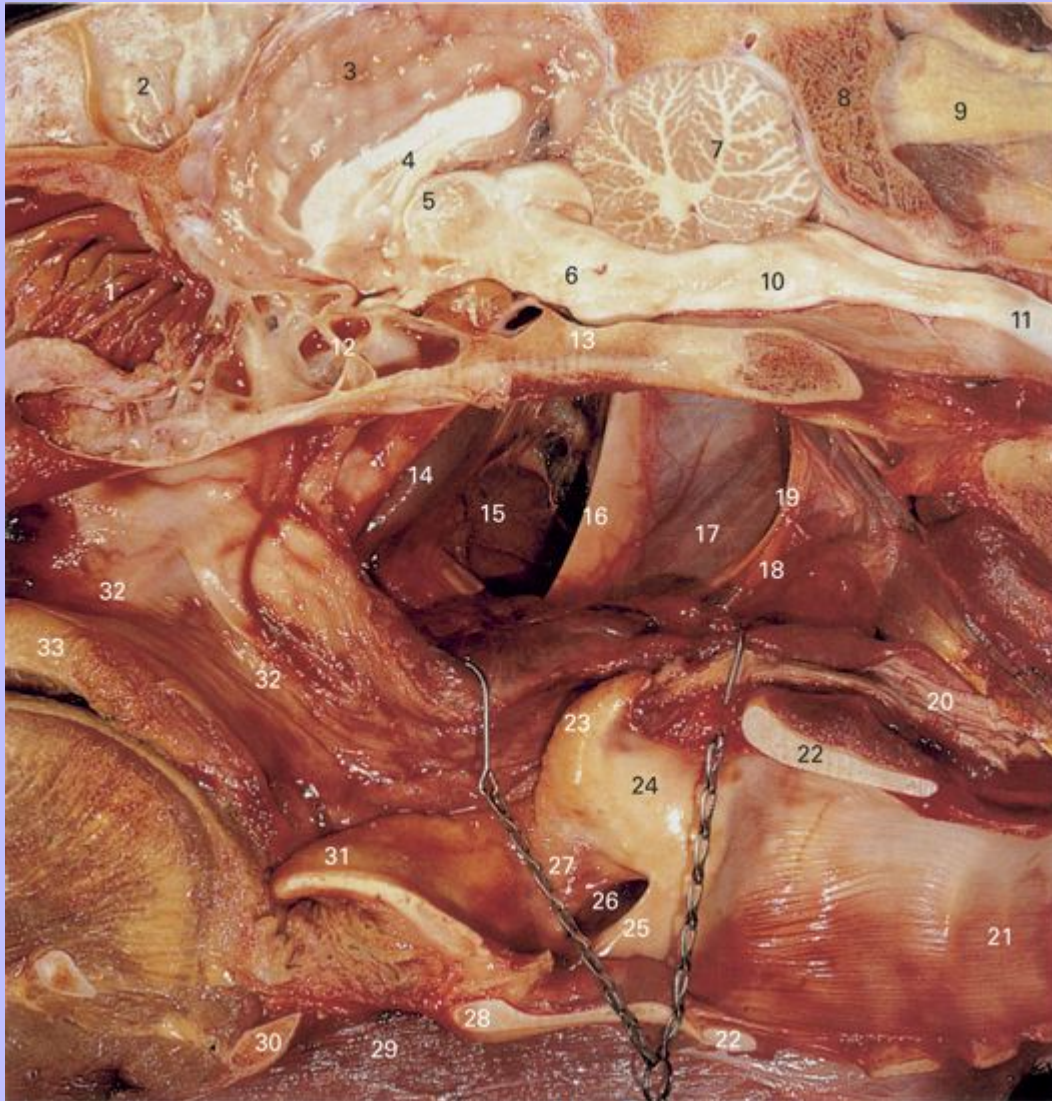

- 1 Basisphenoid bone
- 2 Basioccipital bone
- 3 Atlas (C1)
- 4 Axis (C2)
- 5 Auditory tube diverticulum, lateral compartment
- 6 Auditory tube diverticulum, medial compartment
- 7 Stylohyoid bone
- 8 Ramus of mandible
- 9 Nasopharynx
- 10 Arytenoid cartilage
- 11 Epiglottis
- 12 Laryngeal ventricle
- 13 Trachea

Clinical Anatomy of the Horse

2.34 Paramedian section through pharynx and larynx. The floor of the auditory tube diverticulum has been retracted ventrally to reveal its interior.

17



- 1 Ethmoidal conchae
- 2 Midline septum between left and right frontal sinuses
- 3 Cerebral hemisphere
- 4 Corpus callosum

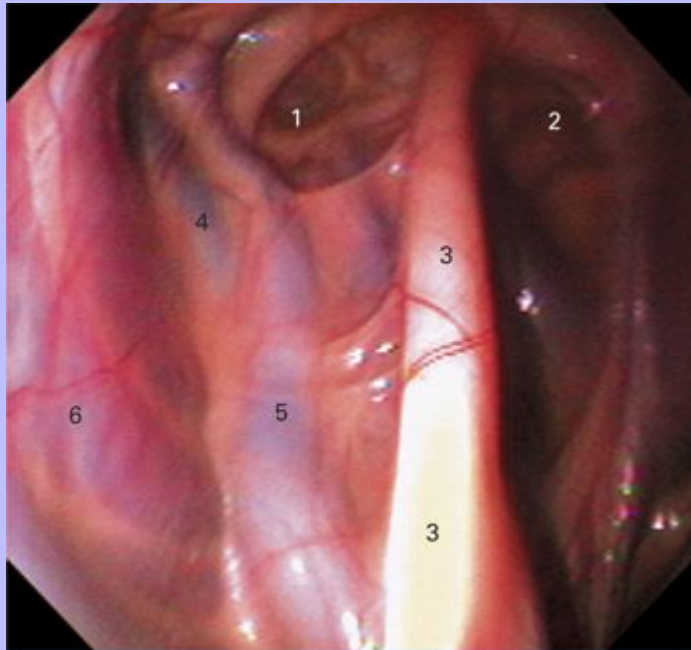
Clinical Anatomy of the Horse

- 5 Interthalamic adhesion
- 6 Mesencephalon
- 7 Cerebellum
- 8 Occipital bone
- 9 Nuchal ligament
- 10 Medulla oblongata
- 11 Spinal cord
- 12 Sphenoidal sinus
- 13 Basisphenoid and presphenoid bones
- 14 Auditory tube
- 15 Medial compartment of auditory tube diverticulum
- 16 Stylohyoid bone
- 17 Lateral compartment of auditory tube diverticulum
- 18 Glossopharyngeal nerve (IX)
- 19 Hypoglossal nerve (XII)
- 20 Esophagus
- 21 Trachea
- 22 Cricoid cartilage
- 23 Corniculate process
- 24 Arytenoid cartilage
- 25 Vocal fold
- 26 Laryngeal ventricle
- 27 Vestibular fold
- 28 Thyroid cartilage
- 29 M. sternohyoideus and M. omohyoideus
- 30 Basihyoid bone

Clinical Anatomy of the Horse

- 31 Epiglottis
- 32 Nasopharynx
- 33 Soft palate

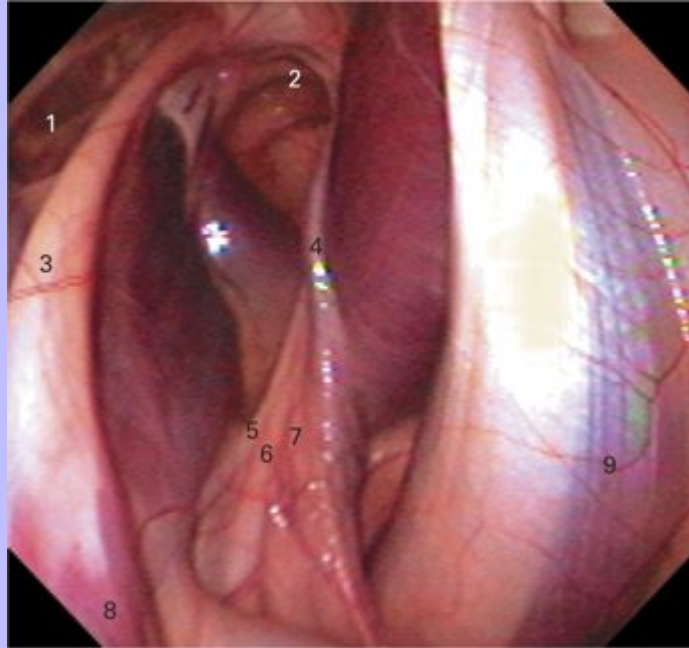
2.35 Endoscopic view of the lateral compartment of the right auditory tube diverticulum.



- 1 Lateral compartment of auditory tube diverticulum
- 2 Medial compartment of auditory tube diverticulum
- 3 Stylohyoid bone
- 4 Maxillary vein
- 5 External carotid artery
- 6 M. digastricus

Clinical Anatomy of the Horse

2.36 Endoscopic view of the medial compartment of the right auditory tube diverticulum.



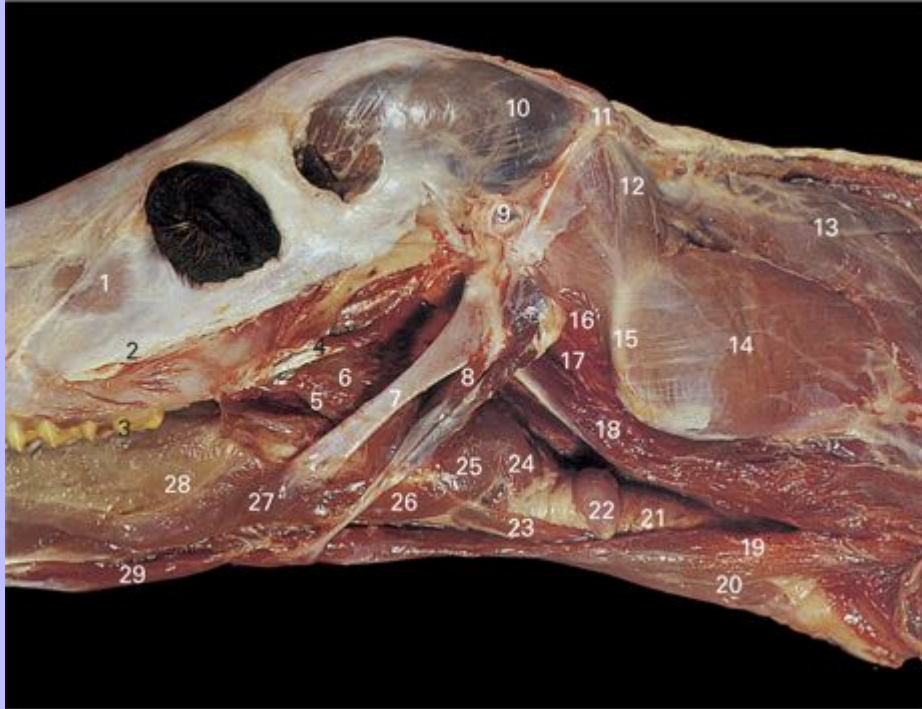- 1 Lateral compartment of auditory tube diverticulum
- 2 Medial compartment of auditory tube diverticulum
- 3 Stylohyoid bone
- 4 Internal carotid artery
- 5 Glossopharyngeal nerve (IX)
- 6 Hypoglossal nerve (XII)
- 7 Vagus nerve (X)
- 8 M. stylopharyngeus
- 9 M. longus capitis

17

Clinical Anatomy of the Horse

18

2.37 Deep dissection of caudal mandibular region of foal. Left mandible has been removed.



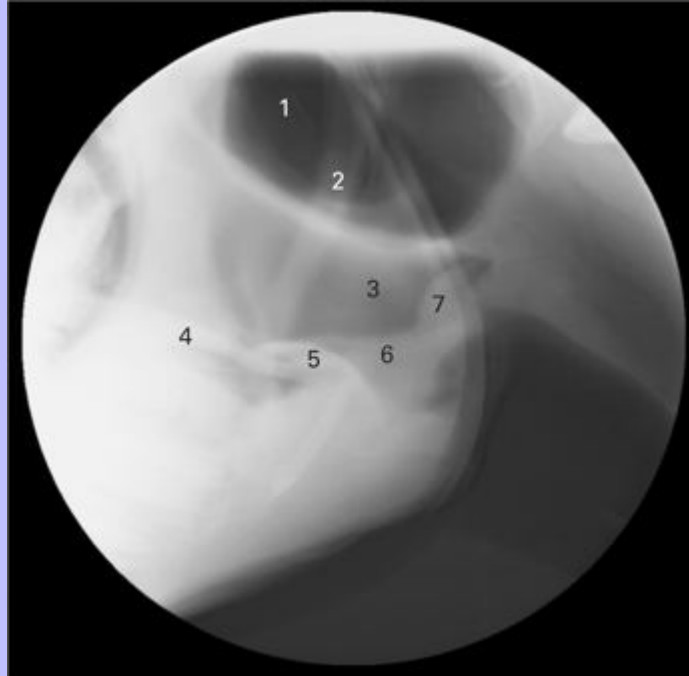- 1 M. levator labii superioris
- 2 Facial crest
- 3 First upper molar tooth (m^1)
- 4 M. tensor veli palatini
- 5 M. palatopharyngeus
- 6 M. pterygopharyngeus
- 7 Stylohyoid bone
- 8 M. stylohyoideus
- 9 External auditory canal
- 10 M. temporalis
- 11 Nuchal crest

Clinical Anatomy of the Horse

- 12 M. obliquus capitis cranialis
- 13 M. splenius
- 14 M. brachiocephalicus
- 15 Wing of atlas
- 16 M. rectus capitis lateralis
- 17 M. rectus capitis ventralis
- 18 M. longus capitis
- 19 M. omohyoideus
- 20 M. sternohyoideus
- 21 Trachea
- 22 Thyroid gland
- 23 M. sternothyroideus
- 24 M. cricopharyngeus
- 25 M. thyropharyngeus
- 26 M. thyrohyoideus
- 27 M. styloglossus
- 28 Tongue
- 29 M. geniohyoideus

Clinical Anatomy of the Horse

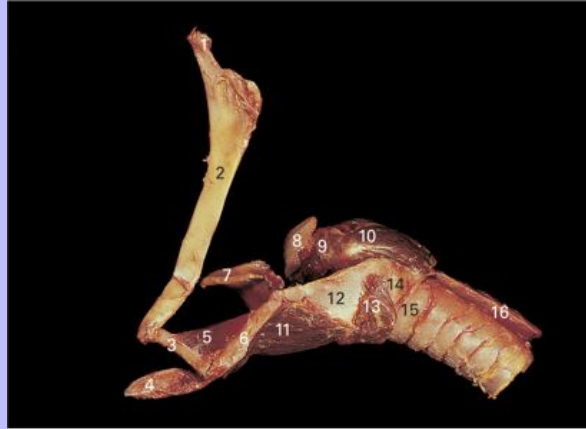2.38 Lateral view radiograph of head, laryngeal region.



- 1 Auditory tube diverticulum
- 2 Stylohyoid bone
- 3 Nasopharynx
- 4 Soft palate
- 5 Epiglottis
- 6 Aryepiglottic fold
- 7 Arytenoid cartilage

Clinical Anatomy of the Horse

2.39 Larynx and hyoid bones, lateral view.

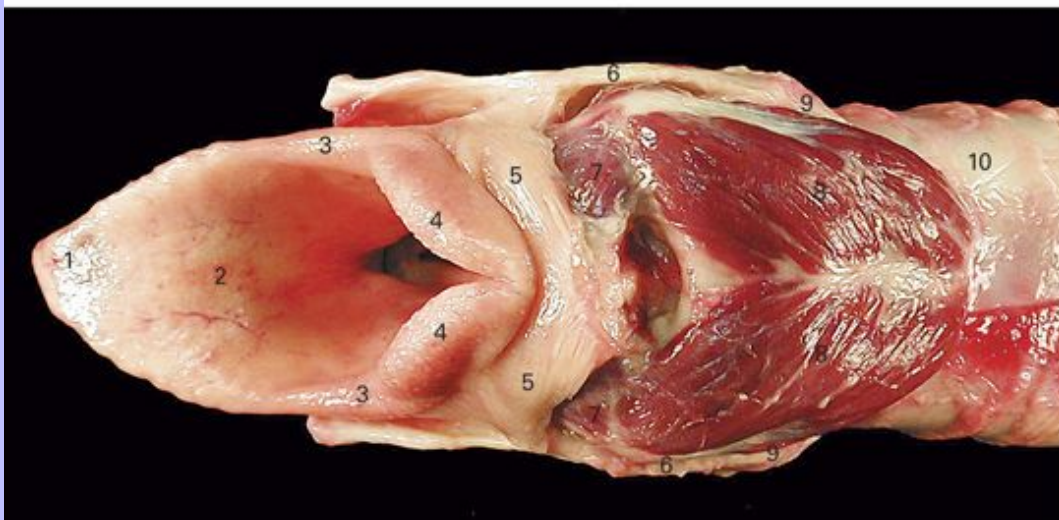
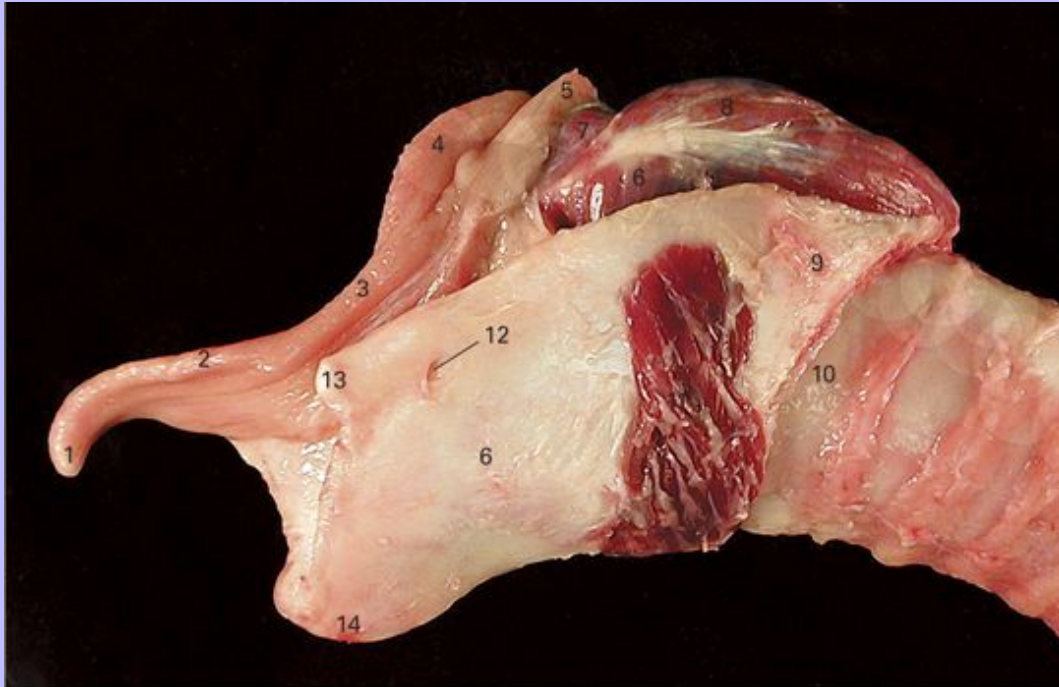


- 1 Tympanohyoid bone
- 2 Stylohyoid bone
- 3 Ceratohyoid bone
- 4 Lingual process
- 5 M. ceratohyoideus
- 6 Thyrohyoid bone
- 7 Epiglottis
- 8 Arytenoid cartilage
- 9 M. arytenoideus transversus
- 10 M. cricoarytenoideus dorsalis
- 11 M. thyrohyoideus
- 12 Thyroid cartilage
- 13 M. cricothyroideus
- 14 Cricoid cartilage
- 15 First tracheal ring
- 16 Esophagus

Clinical Anatomy of the Horse

19

2.40 Laryngeal cartilages and intrinsic musculature, lateral view (above) and dorsal view (below).



1 Apex of epiglottis

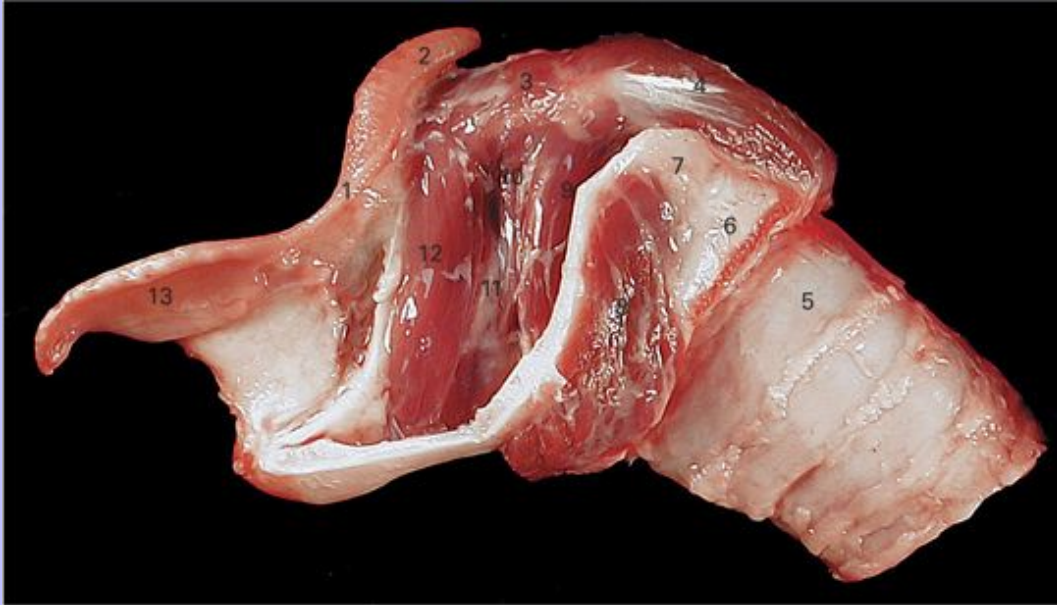2 Epiglottis

Clinical Anatomy of the Horse

- 3 Aryepiglottic fold
- 4 Arytenoid
- 5 Palatopharyngeal arch
- 6 Thyroid
- 7 M. arytenoideus transversus
- 8 M. cricoarytenoideus dorsalis
- 9 Cricoid
- 10 First tracheal ring
- 11 M. cricothyroideus
- 12 Foramen for cranial laryngeal nerve
- 13 Cranial cornu of thyroid
- 14 Laryngeal prominence

Clinical Anatomy of the Horse

2.41 Left lateral view of larynx after removal of the wing of the thyroid cartilage.

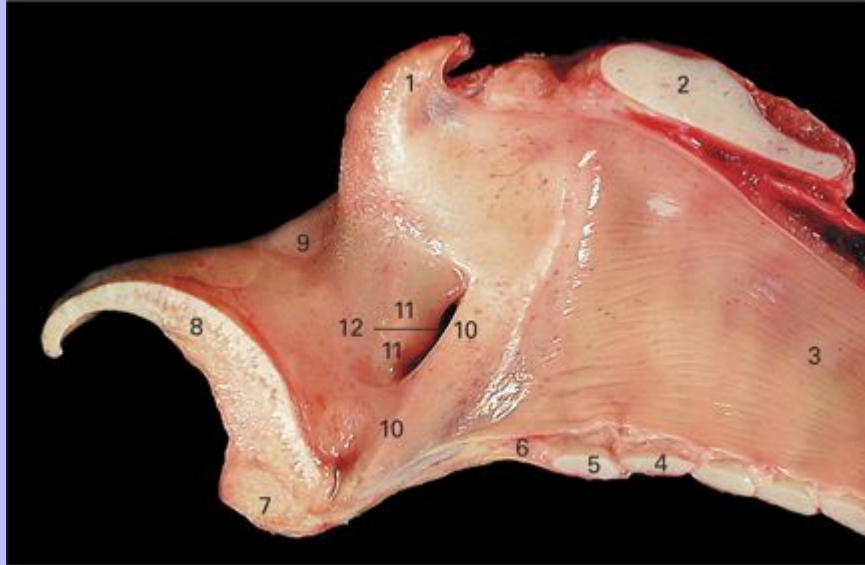


- 1 Aryepiglottic fold
- 2 Arytenoid cartilage
- 3 M. arytenoideus transversus
- 4 M. cricoarytenoideus dorsalis
- 5 First tracheal ring
- 6 Cricoid cartilage
- 7 Thyroid cartilage
- 8 M. cricothyroideus
- 9 M. cricoarytenoideus lateralis
- 10 M. vocalis
- 11 Laryngeal ventricle
- 12 M. ventricularis
- 13 Epiglottis

Clinical Anatomy of the Horse

20

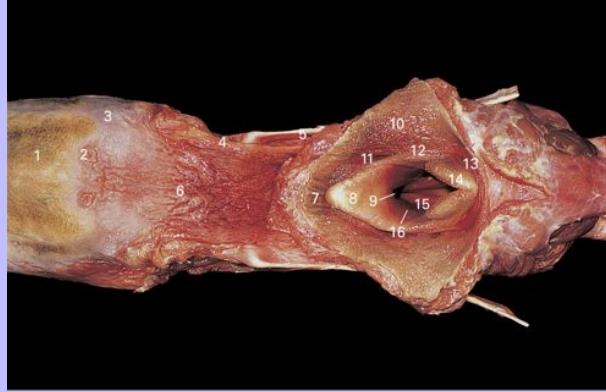
2.42 Median section through larynx.



- 1 Corniculate process of arytenoid cartilage
- 2 Lamina of cricoid cartilage
- 3 Tracheal mucosa
- 4 First tracheal ring
- 5 Ring of cricoid
- 6 Cricothyroid ligament
- 7 Thyroid cartilage
- 8 Epiglottis
- 9 Aryepiglottic fold
- 10 Vocal fold
- 11 Vestibular fold
- 12 Laryngeal ventricle

Clinical Anatomy of the Horse

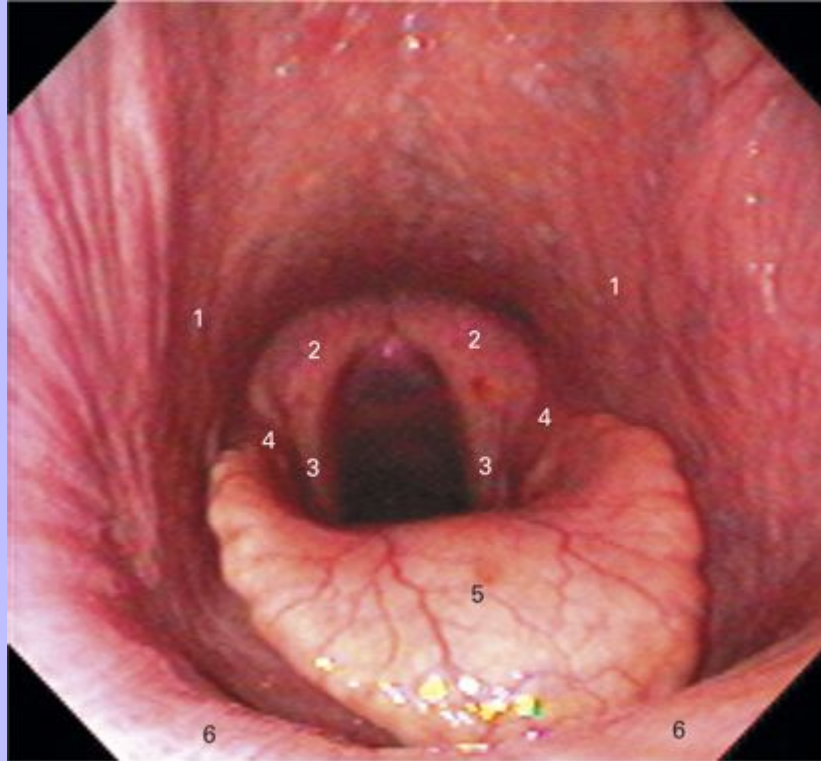2.43 Tongue and larynx. The aditus laryngis has been exposed by opening the pharynx dorsally.



- 1 Dorsum of tongue
- 2 Vallate papilla
- 3 Foliate papilla
- 4 Palatoglossal fold
- 5 Stylohyoid bone
- 6 Root of tongue
- 7 Caudal extremity of soft palate
- 8 Epiglottis
- 9 Median ventricle of larynx
- 10 Wall of pharynx
- 11 Piriform recess (lateral food channel)
- 12 Aryepiglottic fold
- 13 Dorsal part of palatopharyngeal arch
- 14 Corniculate process of arytenoid cartilage
- 15 Vocal fold
- 16 Laryngeal ventricle

Clinical Anatomy of the Horse

2.44 Endoscopic view of larynx.



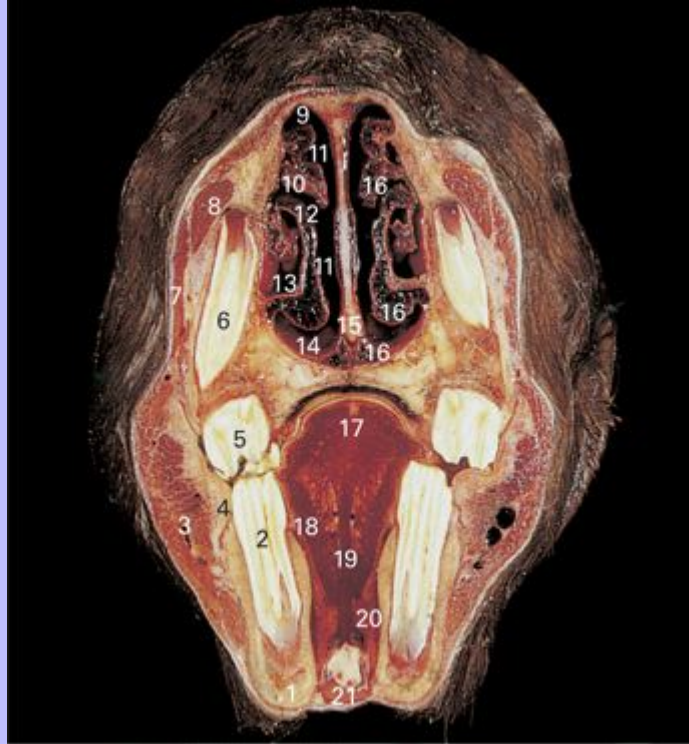
- 1 Palatopharyngeal arch
- 2 Arytenoid cartilage
- 3 Vocal fold
- 4 Aryepiglottic fold
- 5 Epiglottis
- 6 Soft palate

20

Clinical Anatomy of the Horse

21

2.45 Transverse section through head at third premolar tooth.



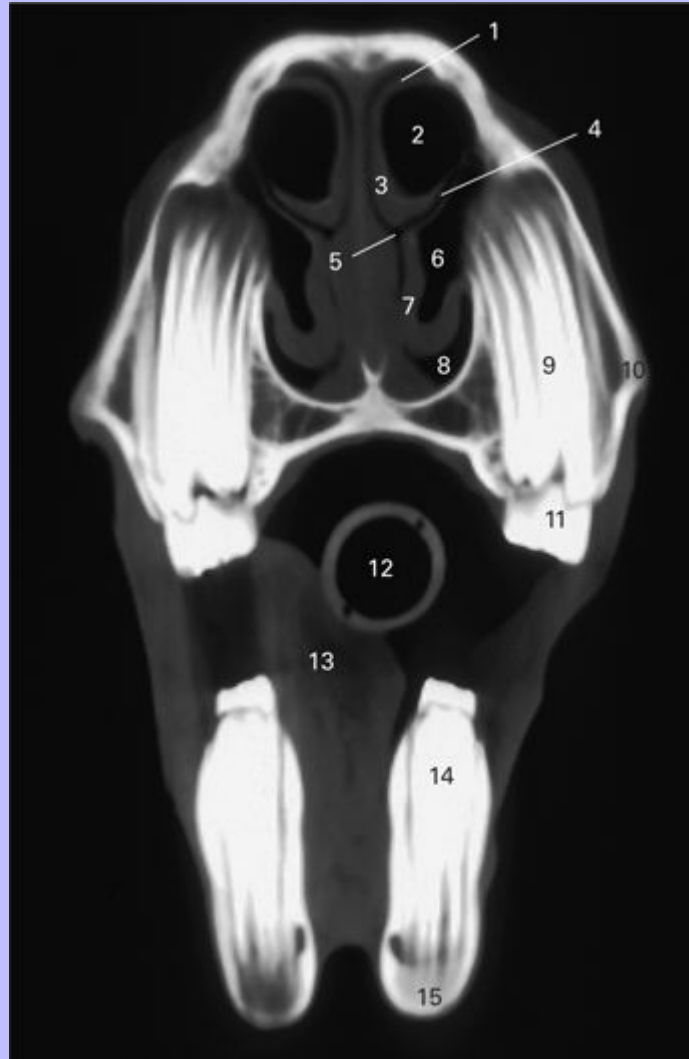
- 1 Mandible
- 2 Lower third premolar (P_3)
- 3 M. masseter
- 4 Buccal glands
- 5 Upper third premolar (P^3)
- 6 Reserve crown and root of upper second premolar (P^2)
- 7 M. levator nasolabialis
- 8 M. levator labii superioris
- 9 Dorsal nasal meatus
- 10 Dorsal nasal concha

Clinical Anatomy of the Horse

- 11 Common nasal meatus
- 12 Middle nasal meatus
- 13 Ventral nasal concha
- 14 Ventral nasal meatus
- 15 Nasal septum
- 16 Nasal venous plexus
- 17 Body of tongue
- 18 M. hyoglossus
- 19 M. genioglossus
- 20 Sublingual gland
- 21 M. geniohyoideus

Clinical Anatomy of the Horse

2.46 Computed tomographic image of head at third premolar tooth.



- 1 Dorsal nasal meatus
- 2 Dorsal conchal sinus
- 3 Dorsal concha
- 4 Middle nasal meatus
- 5 Common nasal meatus

Clinical Anatomy of the Horse

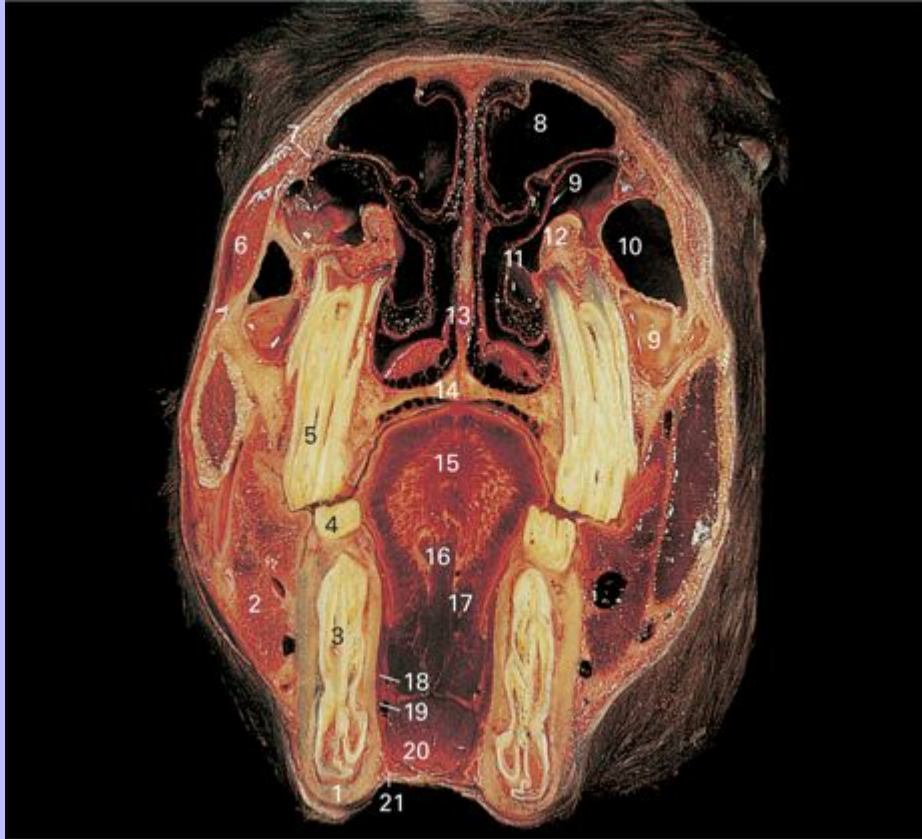- 6 Ventral conchal sinus
- 7 Ventral concha
- 8 Ventral nasal meatus
- 9 Upper third premolar (permanent)
- 10 Maxilla
- 11 Cap of upper deciduous third premolar
- 12 Endotracheal tube
- 13 Tongue
- 14 Lower third premolar
- 15 Mandible

21

Clinical Anatomy of the Horse

22

2.47 Transverse section through head at third molar tooth.



- 1 Mandible
- 2 M. masseter
- 3 Reserve crown and root of lower second premolar (P_2)
- 4 Lower third premolar (P_3)
- 5 Upper third premolar (P^3)
- 6 M. levator labii superioris and M. levator nasolabialis
- 7 Nasolacrimal duct
- 8 Conchofrontal sinus
- 9 Rostral part of maxillary sinus

Clinical Anatomy of the Horse

10 Caudal part of maxillary sinus

11 Conchal part of maxillary sinus

12 Infraorbital canal

13 Nasal septum

14 Hard palate

15 Body of tongue

16 M. genioglossus

17 M. hyoglossus

18 Mandibular duct

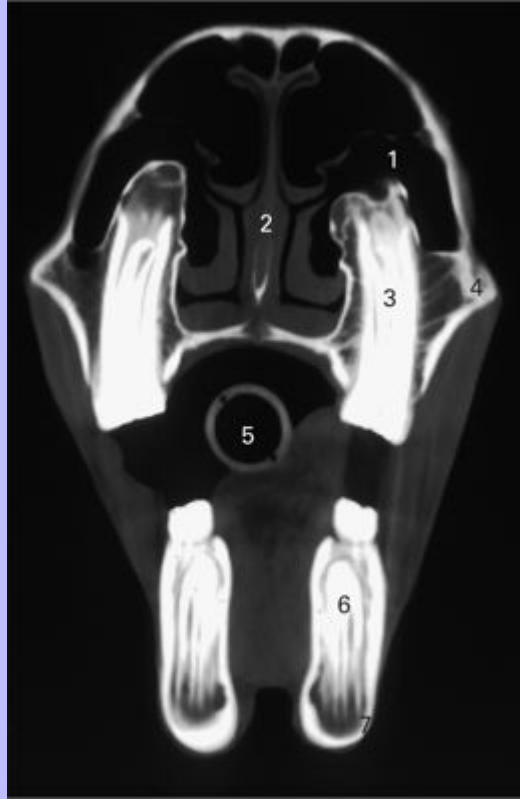
19 Sublingual vessels

20 M. geniohyoideus

21 M. mylohyoideus

Clinical Anatomy of the Horse

2.48 Computed tomographic image of head at third molar tooth.



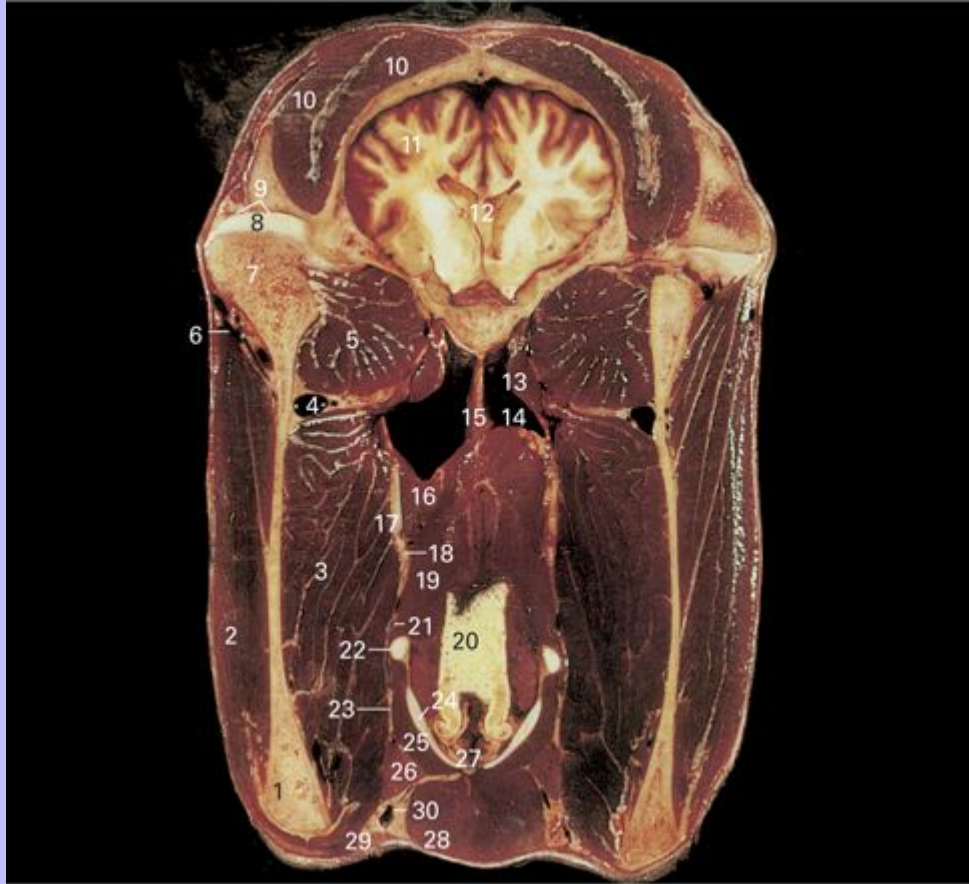- 1 Maxillary sinus
- 2 Nasal septum
- 3 Upper third molar (M^3)
- 4 Maxilla
- 5 Endotracheal tube
- 6 Lower third molar (M_3)
- 7 Mandible

22

Clinical Anatomy of the Horse

23

2.49 Transverse section through head at temporomandibular joint.



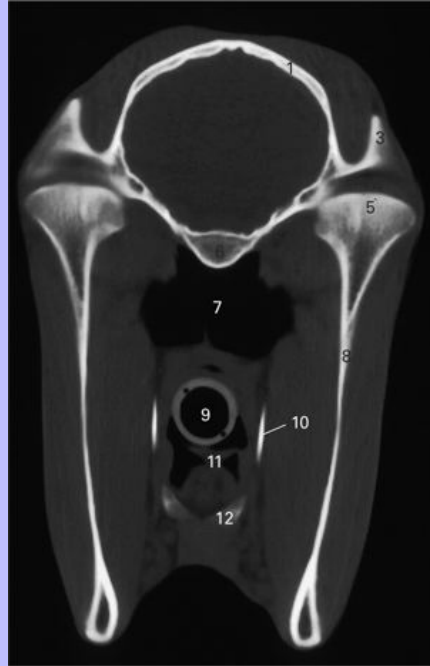- 1 Mandible
- 2 M. masseter
- 3 M. pterygoideus medialis
- 4 Maxillary vein
- 5 M. pterygoideus lateralis
- 6 Transverse facial vessels
- 7 Mandibular condyle
- 8 Articular disk

Clinical Anatomy of the Horse

- 9 Mandibular fossa
- 10 M. temporalis
- 11 Cerebral hemisphere
- 12 Lateral ventricle of brain
- 13 M. tensor veli palatini
- 14 Auditory tube diverticulum (guttural pouch)
- 15 Midline septum
- 16 M. stylopharyngeus
- 17 Stylohyoid bone
- 18 Lingual artery and nerve
- 19 M. hyopharyngeus
- 20 Epiglottis
- 21 Facial artery
- 22 Rostral cornu of thyroid cartilage
- 23 Tendon of M. digastricus
- 24 Thyroid cartilage
- 25 M. thyrohyoideus
- 26 Mandibular gland
- 27 Median ventricle of larynx
- 28 M. omohyoideus and M. sternohyoideus
- 29 M. cutaneus fasciei
- 30 Linguofacial vein

Clinical Anatomy of the Horse

2.50 Computed tomographic image of head at temporomandibular joint.

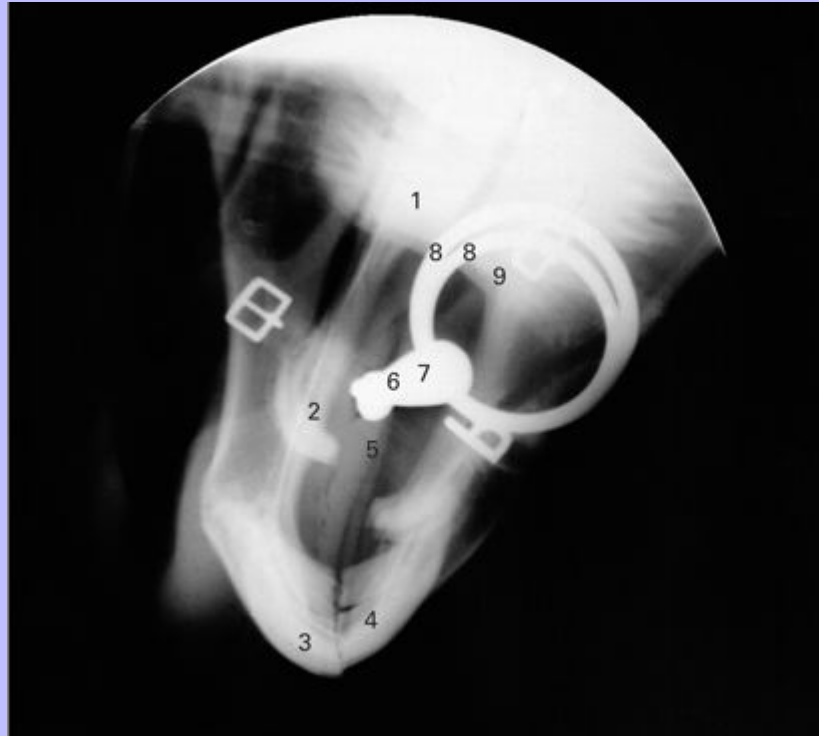


- 1 Temporal bone
- 2 Cerebrum
- 3 Zygomatic process of temporal bone
- 4 Temporomandibular joint
- 5 Condylar process of mandible
- 6 Basioccipital bone
- 7 Auditory tube diverticuli
- 8 Vertical ramus of mandible
- 9 Endotracheal tube
- 10 Stylohyoid bone
- 11 Epiglottis
- 12 Basihyoid bone

Clinical Anatomy of the Horse

24

2.51 Radiograph showing the position of a jointed snaffle bit in the horse's oral cavity, lateral view.



- 1 Second upper premolar tooth (P²)
- 2 Hard palate
- 3 Upper incisor teeth
- 4 Lower incisor teeth
- 5 Tongue
- 6 Joint of bit
- 7 Mouthpiece of bit
- 8 Rings of bit
- 9 Second lower premolar tooth (P₂)

Clinical Anatomy of the Horse

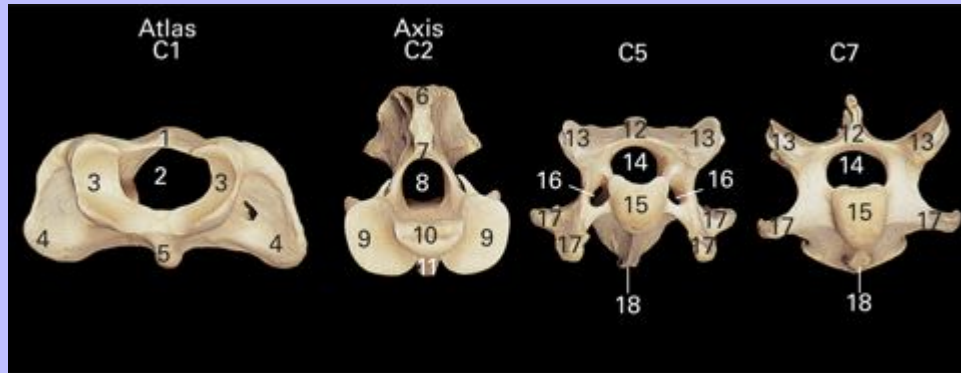
³ 3 Spinal Column

25

The osteology of the vertebral column is illustrated using bone specimens and the associated musculature is shown on dissected specimens.

Clinical Anatomy of the Horse

3.1 Atlas (C1), axis (C2), fifth (C5) and seventh (C7) cervical vertebrae, cranial view.



Atlas (C1)

- 1 Dorsal arch
- 2 Vertebral foramen
- 3 Cranial articular cavities
- 4 Transverse process (wing)
- 5 Ventral tubercle

Axis (C2)

- 6 Spinous process
- 7 Arch
- 8 Vertebral foramen
- 9 Cranial articular process
- 10 Dens
- 11 Ventral crest

C5, C7

- 12 Spinous process
- 13 Cranial articular process
- 14 Vertebral foramen

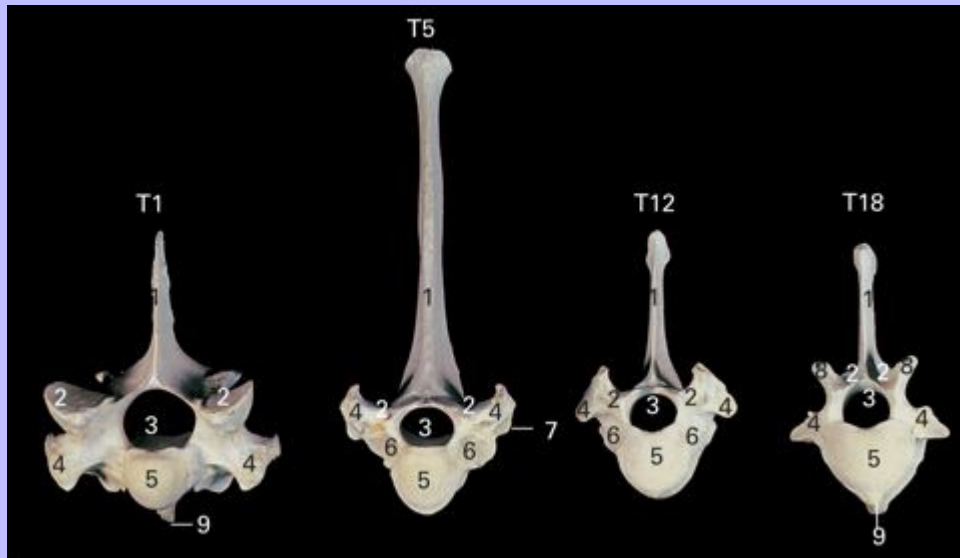Clinical Anatomy of the Horse

15 Body

16 Transverse foramen

17 Transverse process

3.2 First (T1), fifth (T5), twelfth (T12) and eighteenth (T18) thoracic vertebrae, cranial view.



1 Spinous process

2 Cranial articular process

3 Vertebral foramen

4 Transverse process

5 Body

6 Cranial costal fovea

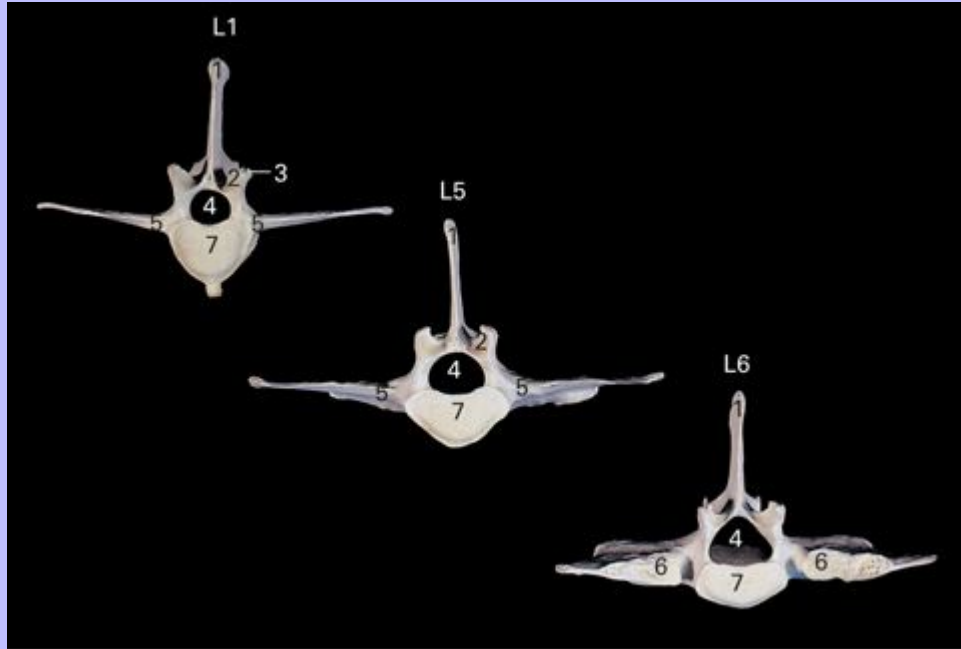
7 Facet for tubercle of rib

8 Mamillary process

9 Ventral tubercle

Clinical Anatomy of the Horse

3.3 First (L1), fifth (L5) and sixth (L6) lumbar vertebrae, cranial view.



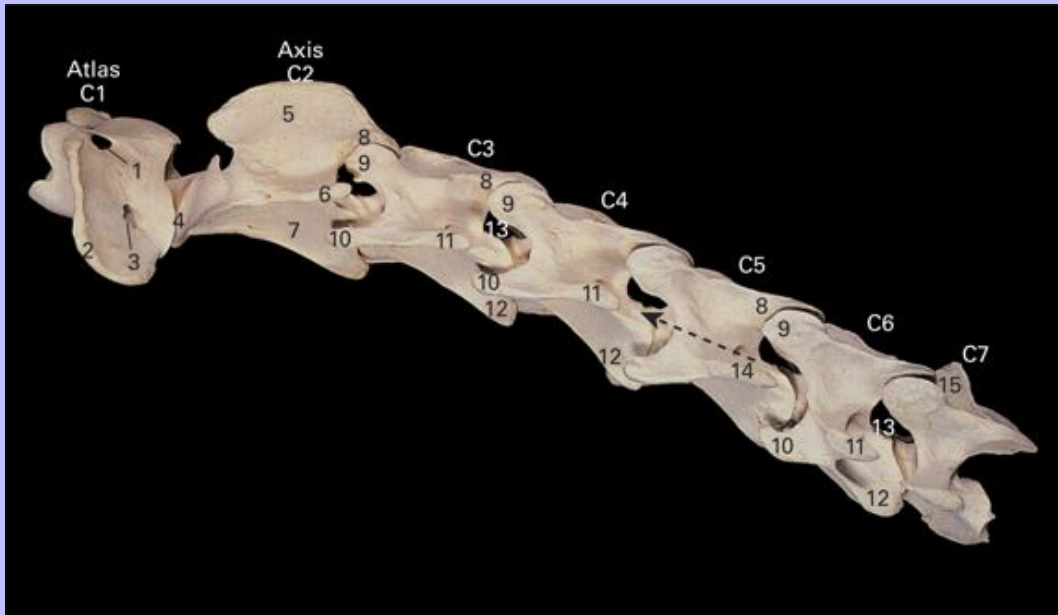
- 1 Spinous process
- 2 Cranial articular process
- 3 Mamillary process
- 4 Vertebral foramen
- 5 Transverse process
- 6 Articular surface of transverse process
- 7 Body

25

Clinical Anatomy of the Horse

26

3.4 Cervical vertebrae (C1–C7), lateral view.



Atlas (C1)

- 1 Alar foramen
- 2 Transverse process (wing)
- 3 Transverse foramen
- 4 Cranial articular process

Axis (C2)

- 5 Spinous process
- 6 Transverse process
- 7 Body

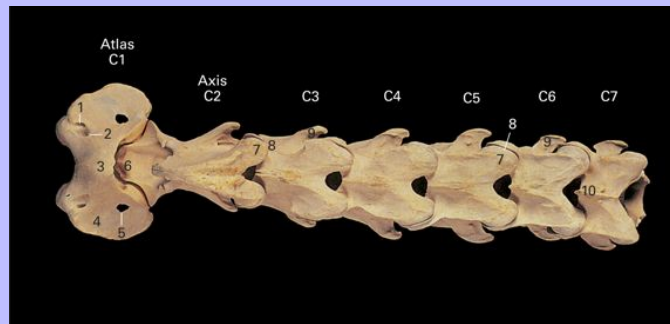
C3–C7

- 8 Caudal articular process
- 9 Cranial articular process
- 10 Ventral tubercle of transverse process

Clinical Anatomy of the Horse

- 11 Dorsal tubercle of transverse process
- 12 Ventral crest
- 13 Intervertebral foramen
- 14 Transverse foramen
- 15 Spinous process

3.5 Cervical vertebrae (C1–C7), dorsal view.



Atlas (C1)

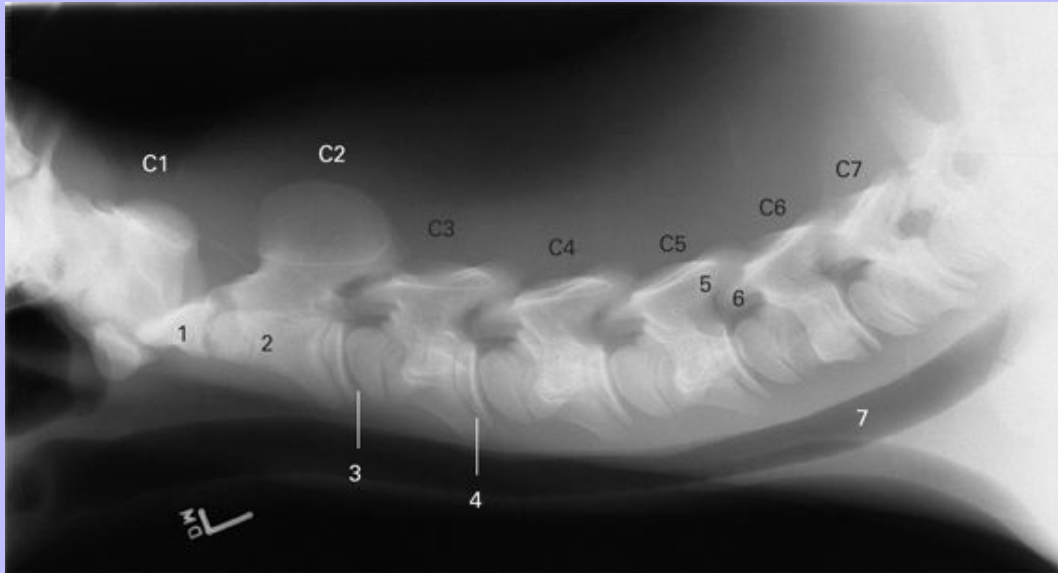
- 1 Alar foramen
- 2 Lateral vertebral foramen
- 3 Dorsal arch
- 4 Transverse process (wing)
- 5 Transverse foramen

C2–C7

- 6 Dens (odontoid process) of axis
- 7 Caudal articular process
- 8 Cranial articular process
- 9 Transverse process
- 10 Spinous process

Clinical Anatomy of the Horse

3.6 Lateral view radiograph of the neck of a 1-day-old foal.



Atlas (C1)

Axis (C2)

1 Dens (odontoid process of axis)

2 Body

C3–C7

3 Cranial physis of C3

4 Caudal physis of C3

5 Caudal articular process of C5

6 Cranial articular process of C6

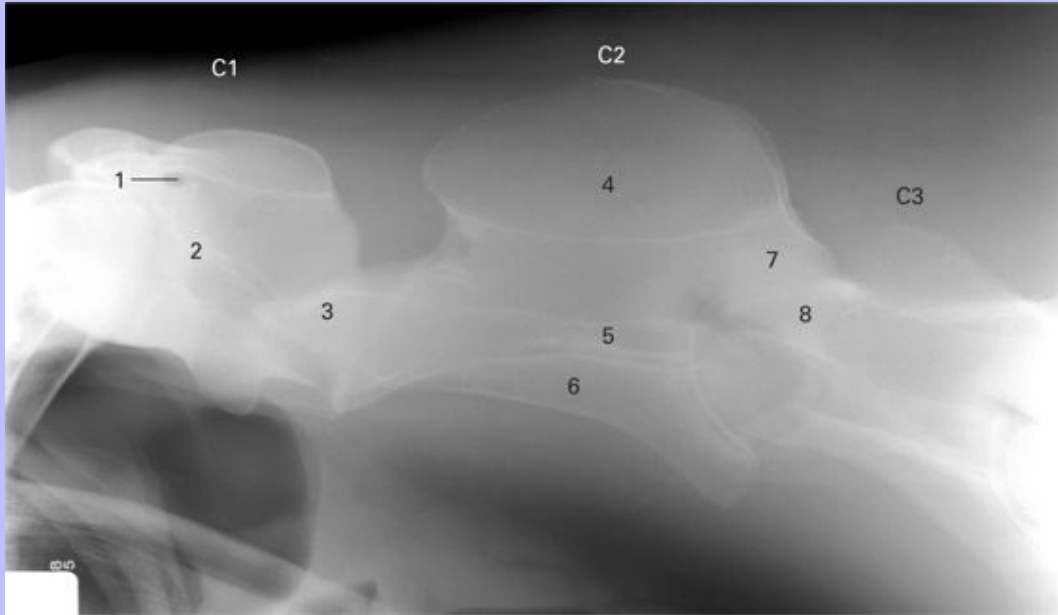
7 Trachea

26

Clinical Anatomy of the Horse

27

3.7 Lateral view radiograph of cranial cervical vertebrae of mature horse.



Atlas (C1)

- 1 Alar foramen
- 2 Transverse process

Axis (C2)

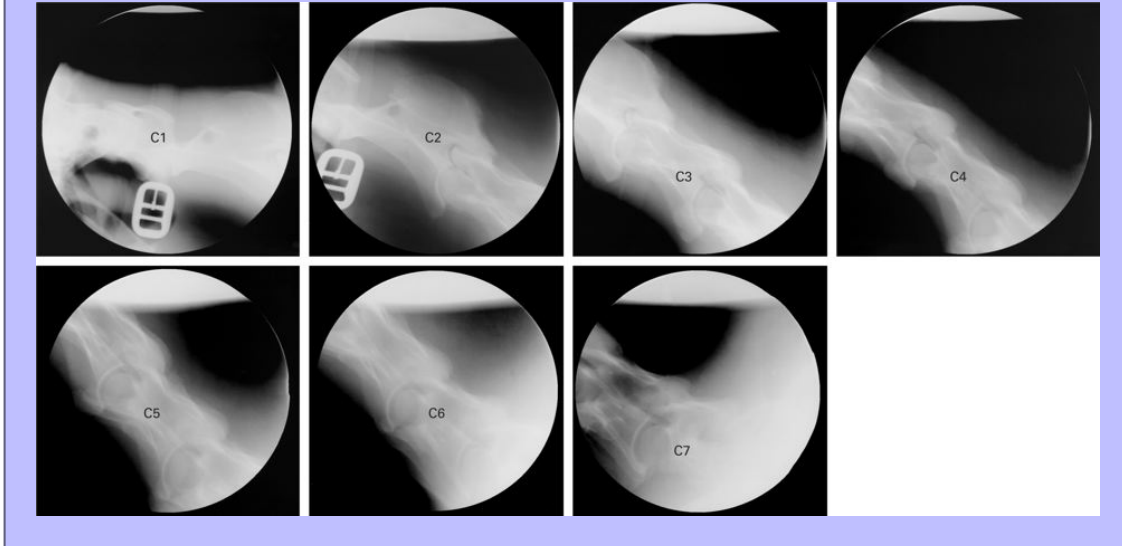
- 3 Dens (odontoid process of axis)
- 4 Spinous process
- 5 Transverse process
- 6 Body
- 7 Caudal articular process

C3

- 8 Cranial articular process

Clinical Anatomy of the Horse

3.8 Lateral view radiographs of neck showing individual cervical vertebrae (C1–C7).

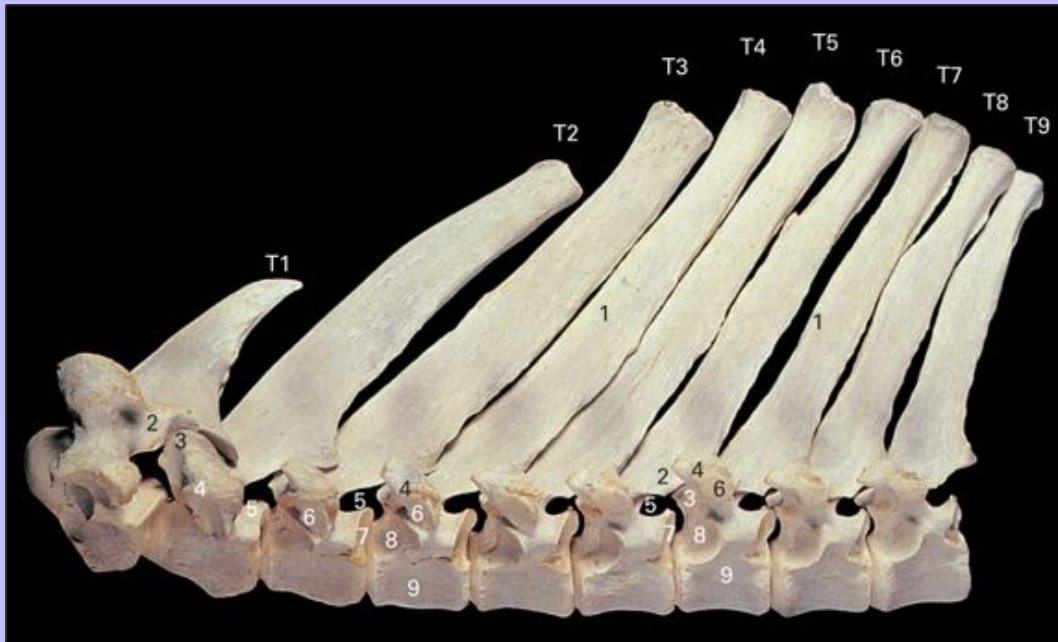


27

Clinical Anatomy of the Horse

28

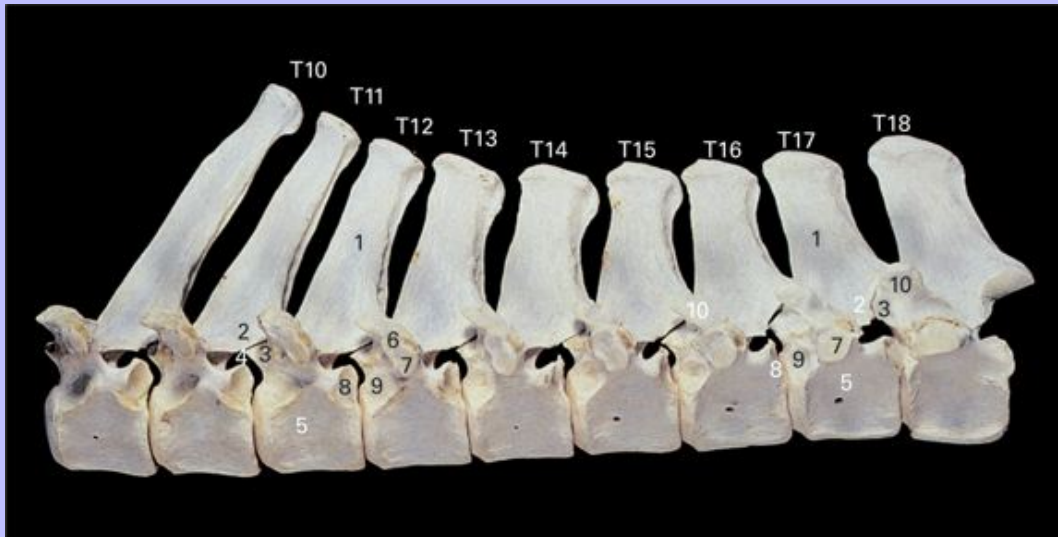
3.9 First to ninth thoracic vertebrae (T1–T9), lateral view.



- 1 Spinous process
- 2 Caudal articular process
- 3 Cranial articular process
- 4 Transverse process
- 5 Intervertebral foramen
- 6 Facet for tubercle of rib
- 7 Cranial costal fovea
- 8 Caudal costal fovea
- 9 Body

Clinical Anatomy of the Horse

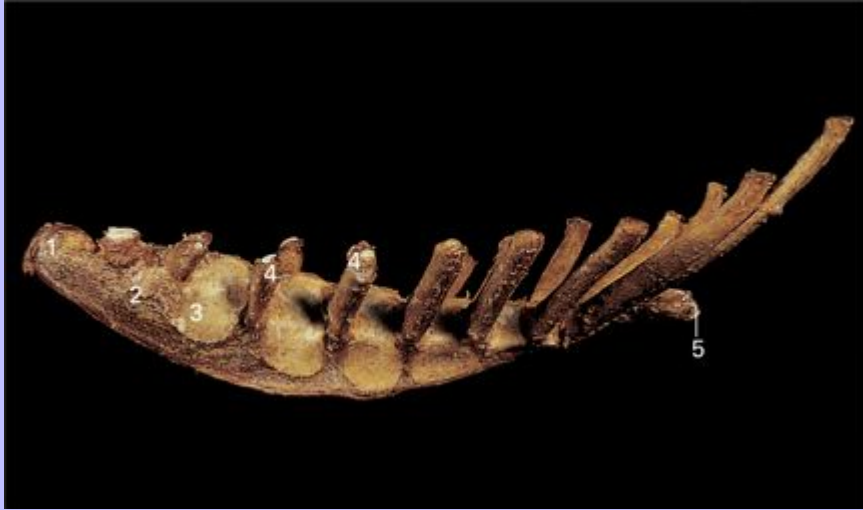3.10 Tenth to eighteenth thoracic vertebrae (T10–T18), lateral view.



- 1 Spinous process
- 2 Caudal articular process
- 3 Cranial articular process
- 4 Mamillary process
- 5 Transverse process
- 6 Intervertebral foramen
- 7 Facet for tubercle of rib
- 8 Cranial costal fovea
- 9 Caudal costal fovea
- 10 Body

Clinical Anatomy of the Horse


3.11 Sternum, lateral view.



- 1 Cartilage of manubrium
- 2 Manubrium
- 3 Second sternebra
- 4 Costal cartilage
- 5 Xiphoid cartilage

Clinical Anatomy of the Horse

3.12 Left eighth rib, cranial view.




- 1 Costal groove
- 2 Head
- 3 Neck
- 4 Tubercle
- 5 Sternal extremity

28

Clinical Anatomy of the Horse

29


3.13 Lateral view radiograph of thoracic vertebral spinous processes (T2–T7).



1 Physis

2 Separate center of ossification

3.14 Lateral view radiograph of thoracic spine.



1 Thoracic vertebral body

2 Rib

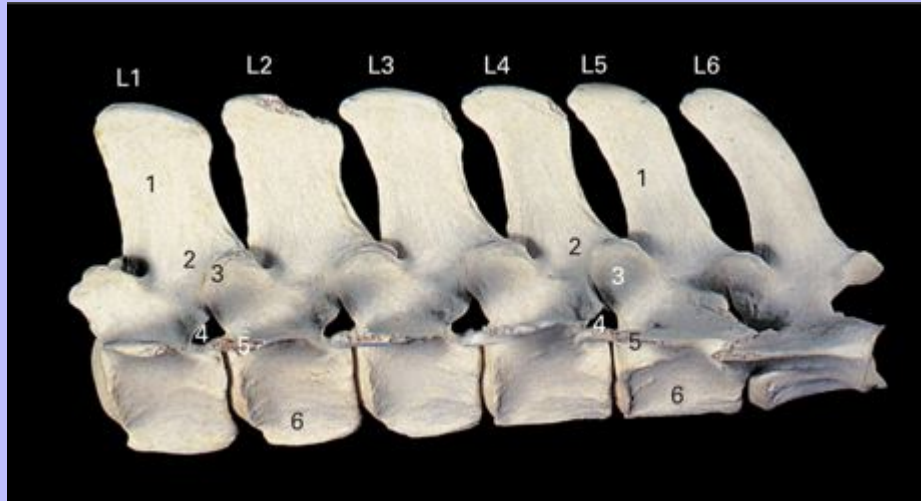
3 Pulmonary vessels

29

Clinical Anatomy of the Horse

30

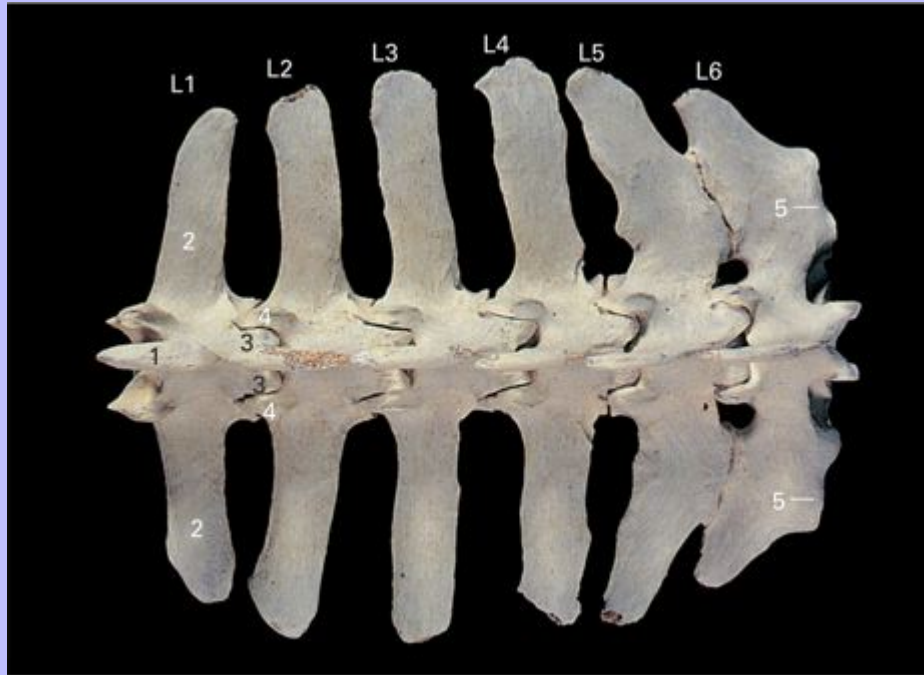
3.15 Lumbar vertebrae (L1–L6), lateral view.



- 1 Spinous process
- 2 Caudal articular process
- 3 Cranial articular process
- 4 Intervertebral foramen
- 5 Transverse process
- 6 Body

Clinical Anatomy of the Horse

3.16 Lumbar vertebrae (L1–L6), dorsal view. Note fusion of transverse processes of fifth and sixth lumbar vertebrae.



- 1 Spinous process
- 2 Transverse process
- 3 Caudal articular process
- 4 Cranial articular process
- 5 Surface of transverse process for articulation with wing of sacrum

Clinical Anatomy of the Horse

3.17 Lateral view radiograph of the lumbar spine.



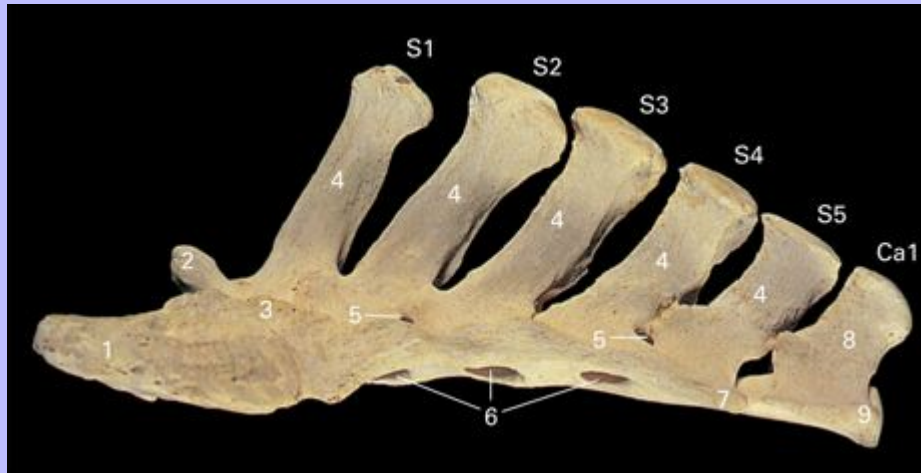
- 1 Body
- 2 Transverse process
- 3 Caudal articular process
- 4 Cranial articular process

30

Clinical Anatomy of the Horse

31

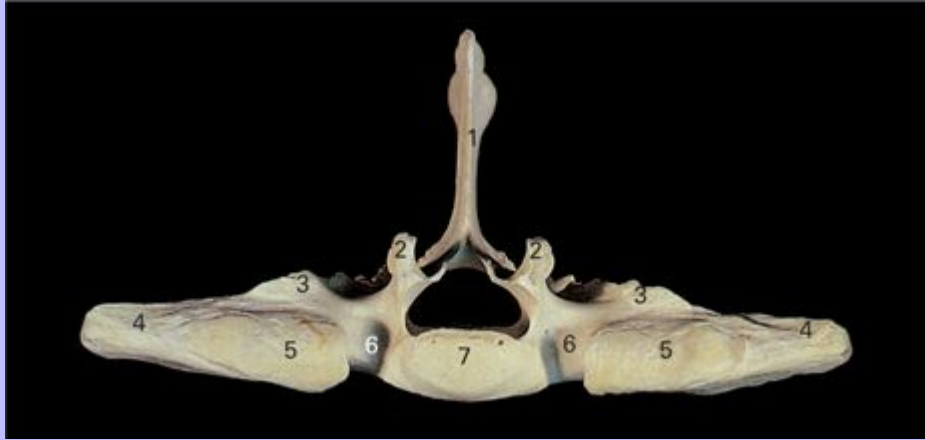3.18 Sacrum (S1–S5) and first caudal (Ca1) vertebra, lateral view.



- 1 Auricular surface
- 2 Articular process
- 3 Wing
- 4 Spinous process of sacral vertebra
- 5 Dorsal sacral foramen
- 6 Ventral sacral foramen
- 7 Transverse process of sacrum
- 8 Spinous process of first caudal vertebra
- 9 Transverse process of first caudal vertebra

Clinical Anatomy of the Horse

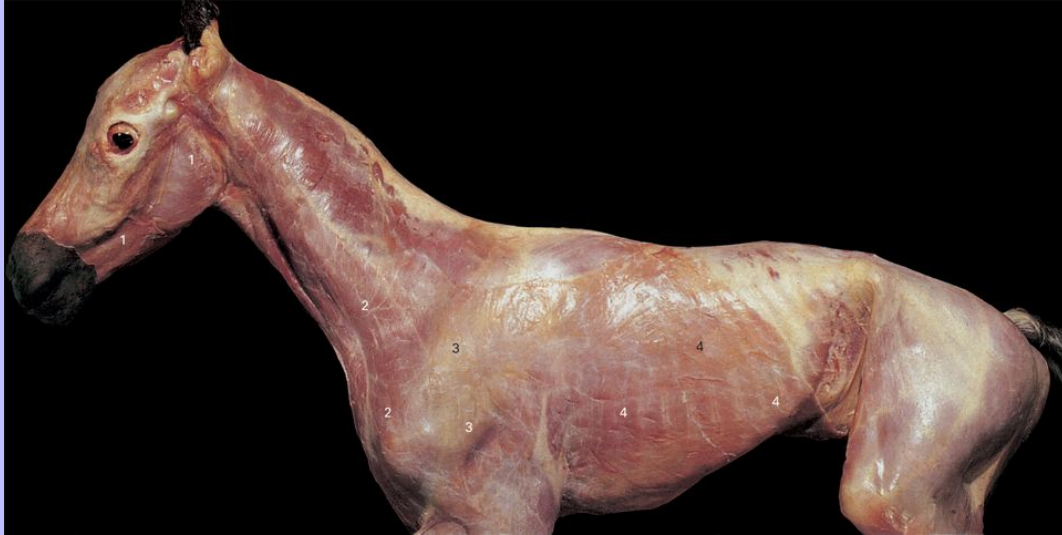3.19 Sacrum, cranial view.



- 1 Spinous process
- 2 Articular process
- 3 Lateral crest
- 4 Wing
- 5 Articular surface of wing
- 6 Notch
- 7 Body

Clinical Anatomy of the Horse

3.20 Cutaneous musculature of foal, lateral view.



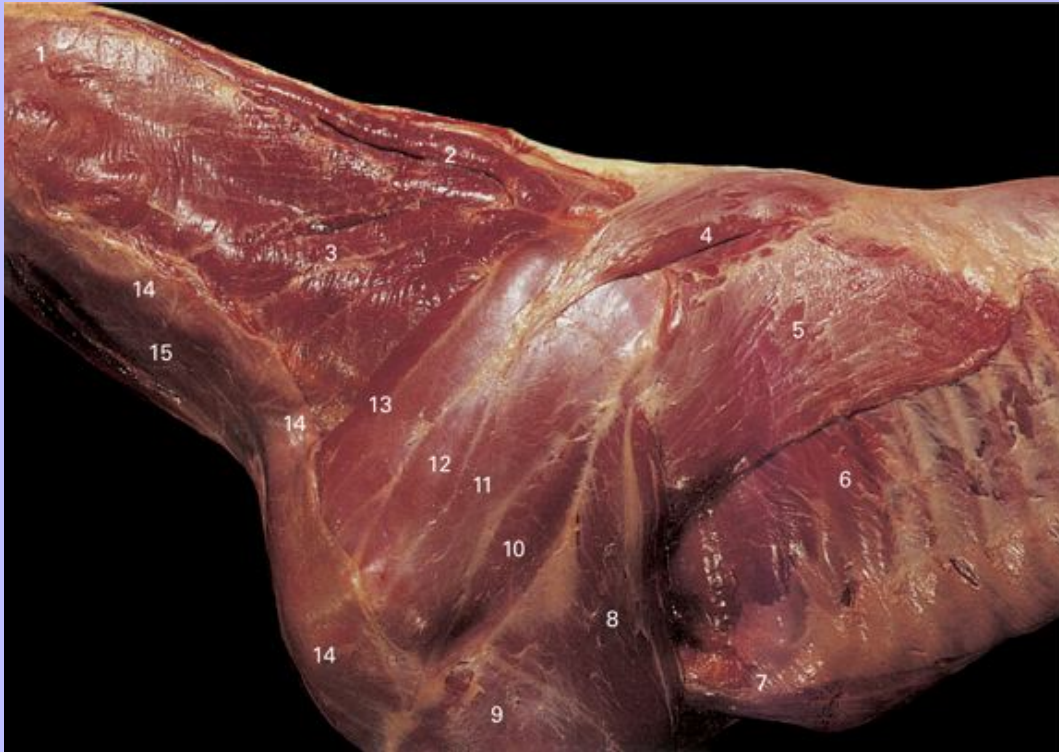- 1 M. cutaneus fasciei, part of M. platysma
- 2 M. cutaneus colli, part of M. platysma
- 3 M. cutaneus omobrachialis
- 4 M. cutaneus trunci

31

Clinical Anatomy of the Horse

32

3.21 Superficial dissection of musculature of neck, shoulder, and thoracic wall of foal, lateral view. The cutaneous muscles and cervical part of the M. trapezius have been removed.



- 1 M. splenius
- 2 M. rhomboideus cervicis
- 3 M. serratus ventralis cervicis
- 4 M. trapezius, thoracic part
- 5 M. latissimus dorsi
- 6 M. intercostales externi
- 7 M. pectoralis ascendens
- 8 M. triceps brachii, long head
- 9 M. triceps brachii, lateral head

Clinical Anatomy of the Horse

10 M. deltoideus

11 M. infraspinatus

12 M. supraspinatus

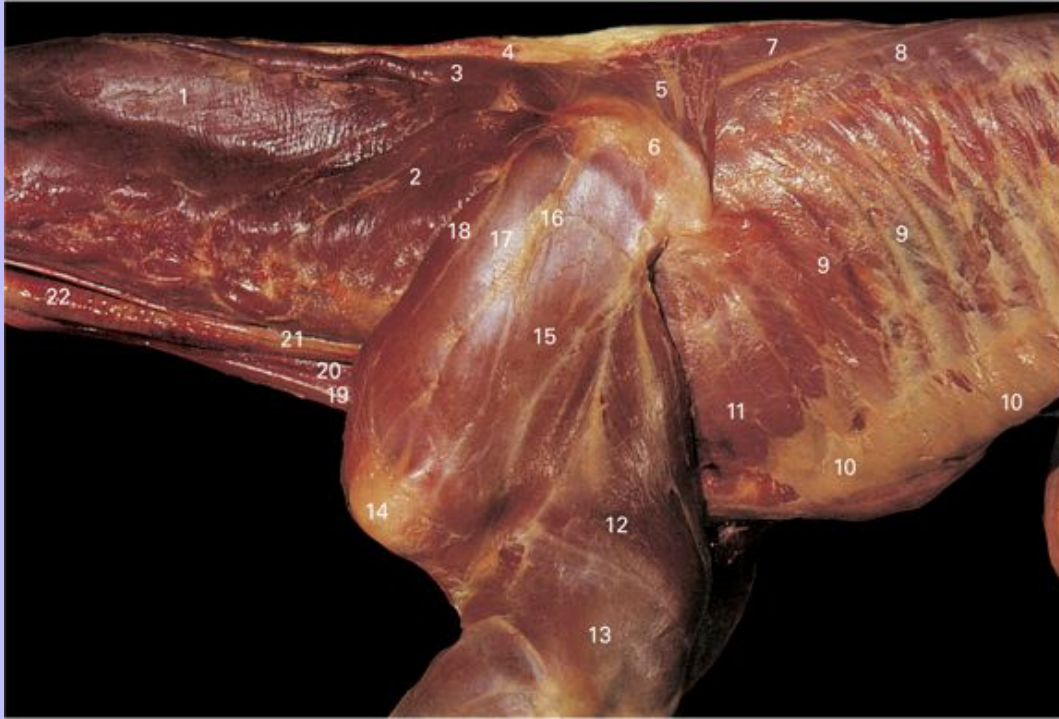13 M. subclavius

14 M. brachiocephalicus

15 M. sternocephalicus

Clinical Anatomy of the Horse

3.22 Deep dissection of musculature of neck, shoulder, and thoracic wall of foal, lateral view. The cutaneous muscles, M. trapezius, M. brachiocephalicus and M. sternocephalicus have been removed.



- 1 M. splenius
- 2 M. serratus ventralis cervicis
- 3 M. rhomboideus cervicis
- 4 Nuchal ligament
- 5 M. rhomboideus thoracis
- 6 Scapular cartilage
- 7 M. spinalis thoracis
- 8 M. longissimus thoracis
- 9 M. intercostales externi
- 10 M. obliquus externus abdominis

Clinical Anatomy of the Horse

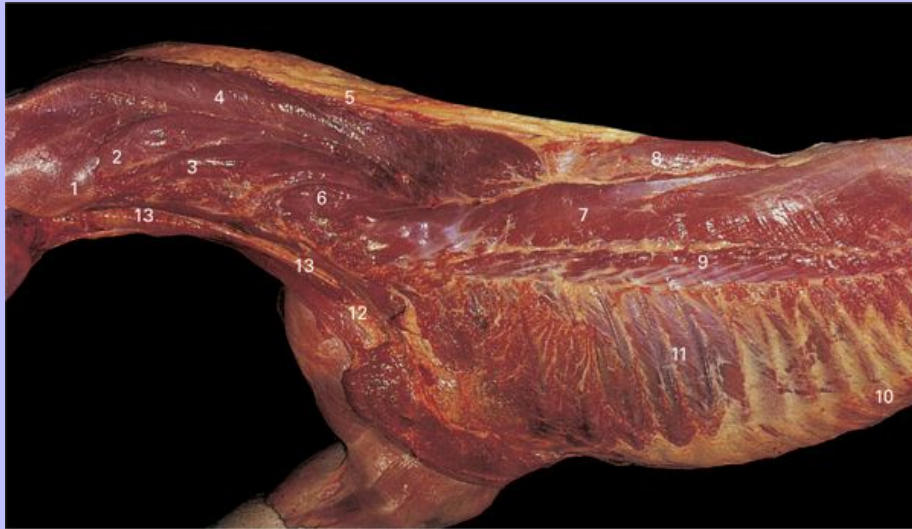- 11 M. serratus ventralis thoracis
- 12 M. triceps brachii, long head
- 13 M. triceps brachii, lateral head
- 14 Greater tubercle of humerus
- 15 M. infraspinatus
- 16 Spine of scapula
- 17 M. supraspinatus
- 18 M. subclavius
- 19 M. sternohyoideus
- 20 M. sternothyroideus
- 21 Esophagus
- 22 Trachea

32

Clinical Anatomy of the Horse

33

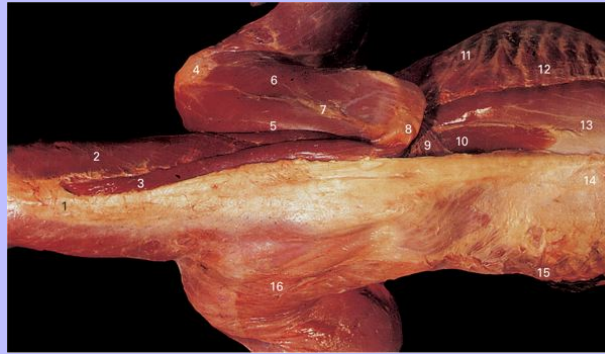
3.23 Deep dissection of musculature of neck and thoracic wall of foal, lateral view. The left front limb has been removed with the M. serratus dorsalis, M. serratus ventralis, M. trapezius, and M. rhomboideus.



- 1 M. obliquus capitis caudalis
- 2 Cut edge of M. longissimus capitis
- 3 M. longissimus atlantis
- 4 M. semispinalis capitis
- 5 Nuchal ligament, funicular part
- 6 M. longissimus cervicis
- 7 M. longissimus thoracis
- 8 M. spinalis thoracis
- 9 M. iliocostalis thoracis
- 10 M. obliquus externus abdominis
- 11 M. intercostales externi
- 12 M. sternohyoideus and M. sternothyroideus
- 13 Trachea

Clinical Anatomy of the Horse

3.24 Superficial (left side) and deep (right side) dissections of musculature of neck and trunk of foal, dorsal view. The cutaneous muscles, M. trapezius, and M. latissimus dorsi have been removed on the right side.

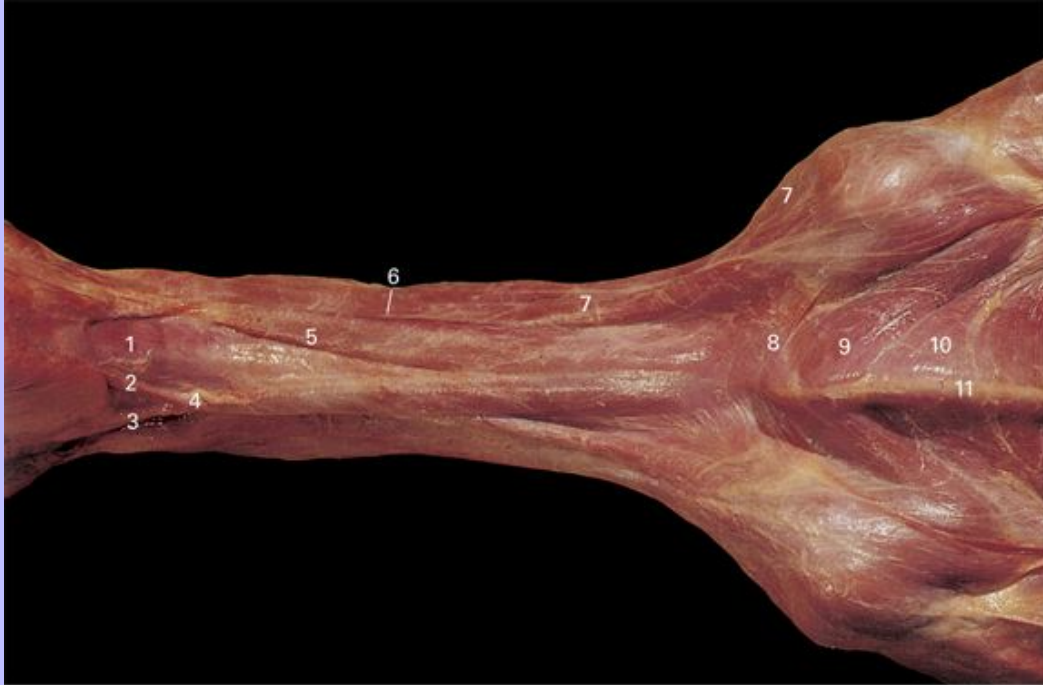


- 1 Funicular part of ligamentum nuchae
- 2 M. splenius
- 3 M. rhomboideus cervicis
- 4 Greater tubercle of humerus
- 5 M. supraspinatus
- 6 M. infraspinatus
- 7 Spine of scapula
- 8 Cartilage of scapula
- 9 M. rhomboideus thoracis
- 10 M. spinalis thoracis
- 11 M. intercostales externi
- 12 M. serratus dorsalis caudalis
- 13 M. longissimus thoracis
- 14 Lumbodorsal fascia
- 15 M. cutaneus trunci
- 16 M. cutaneus omobrachialis

Clinical Anatomy of the Horse

34

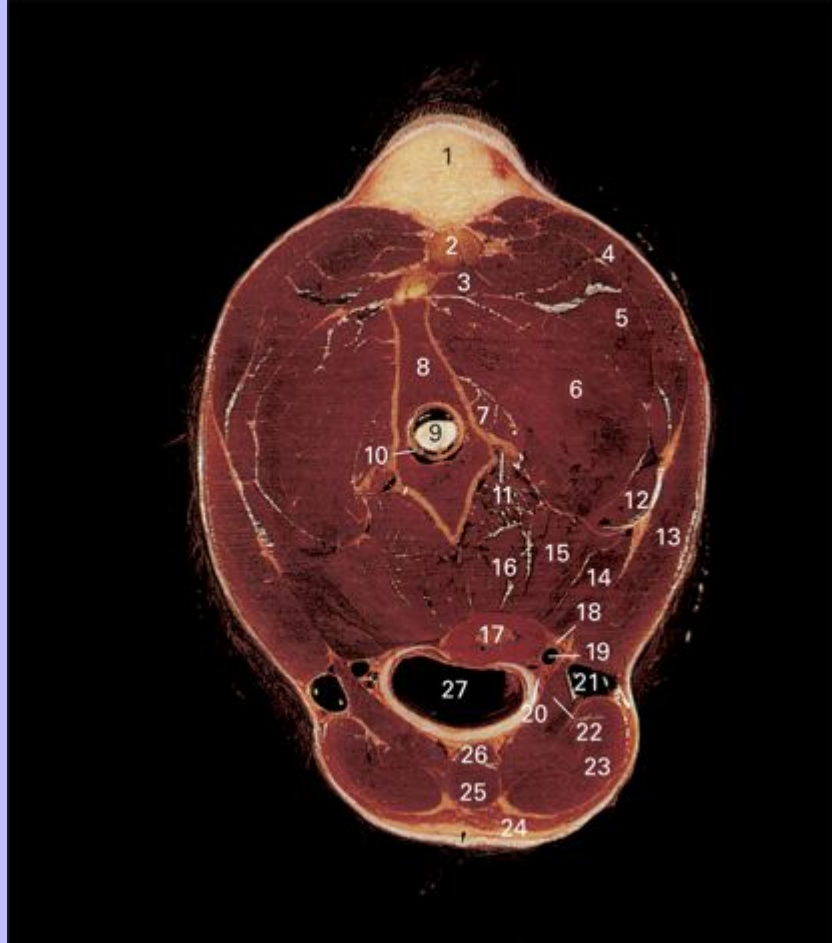
3.25 Superficial dissection of musculature of neck and pectoral region of foal, ventral view.



- 1 M. sternohyoideus and M. omohyoideus
- 2 Maxillary vein
- 3 Linguofacial vein
- 4 External jugular vein
- 5 M. sternocephalicus
- 6 Jugular groove
- 7 M. brachiocephalicus
- 8 M. cutaneus colli
- 9 M. pectoralis transversus
- 10 M. pectoralis descendens
- 11 Sternum

Clinical Anatomy of the Horse

3.26 Transverse section through neck of horse at the level of the second cervical vertebra, cranial view. The vertebra is slightly twisted.



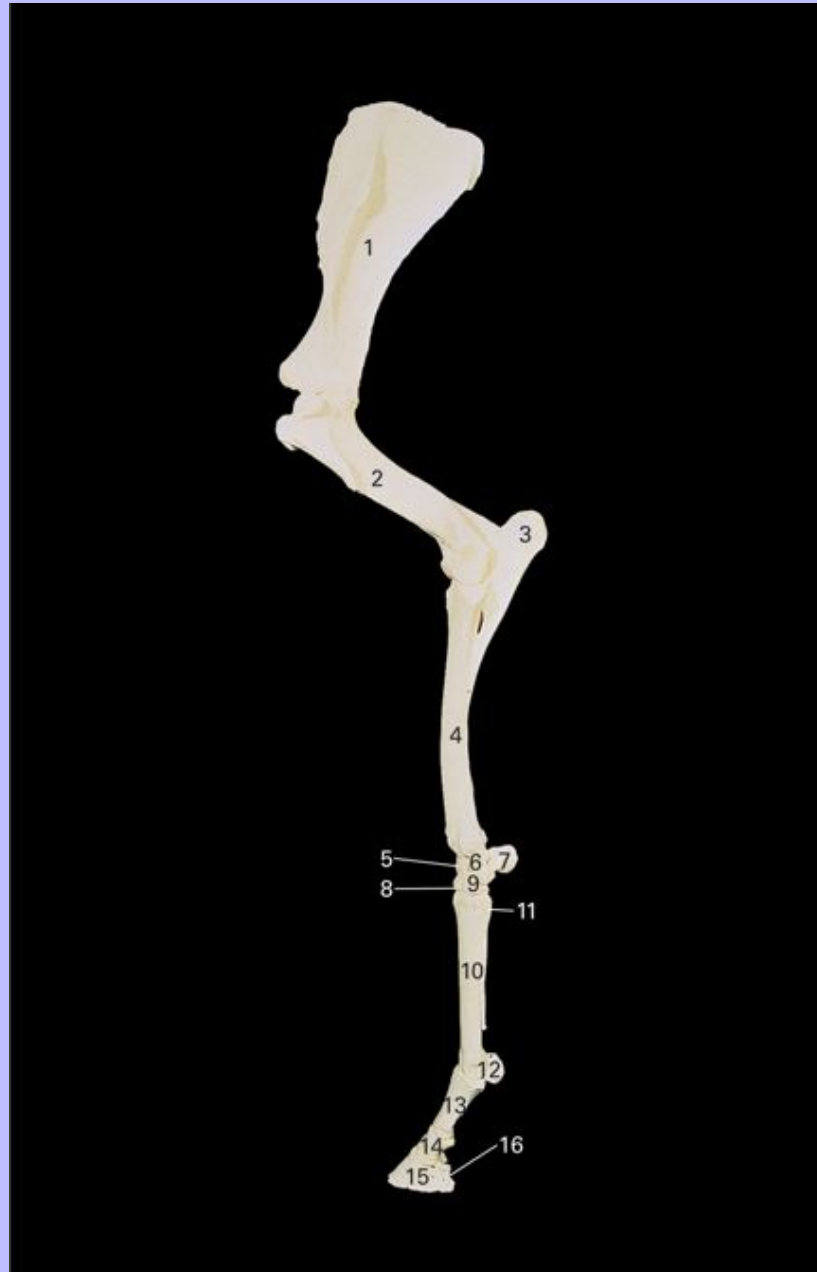
- 1 Nuchal adipose body (crest)
- 2 Nuchal ligament, funicular part
- 3 M. rectus capitis dorsalis major
- 4 M. splenius
- 5 M. semispinalis capitis
- 6 M. obliquus capitis dorsalis
- 7 M. multifidus cervicis

Clinical Anatomy of the Horse

- 8 Second cervical vertebra (axis)
- 9 Spinal cord
- 10 Internal vertebral plexus
- 11 Vertebral artery and vein
- 12 M. longissimus capitis
- 13 M. brachiocephalicus
- 14 M. longissimus atlantis
- 15 M. longus capitis
- 16 M. longus colli
- 17 Oesophagus
- 18 Vagosympathetic trunk
- 19 Common carotid artery
- 20 Recurrent laryngeal nerve
- 21 External jugular vein
- 22 M. omohyoideus
- 23 M. sternocephalicus
- 24 M. cutaneus colli
- 25 M. sternohyoideus
- 26 M. sternothyroideus
- 27 Trachea

4 Forelimb and Digit

4.1 Skeleton of left forelimb, lateral view.



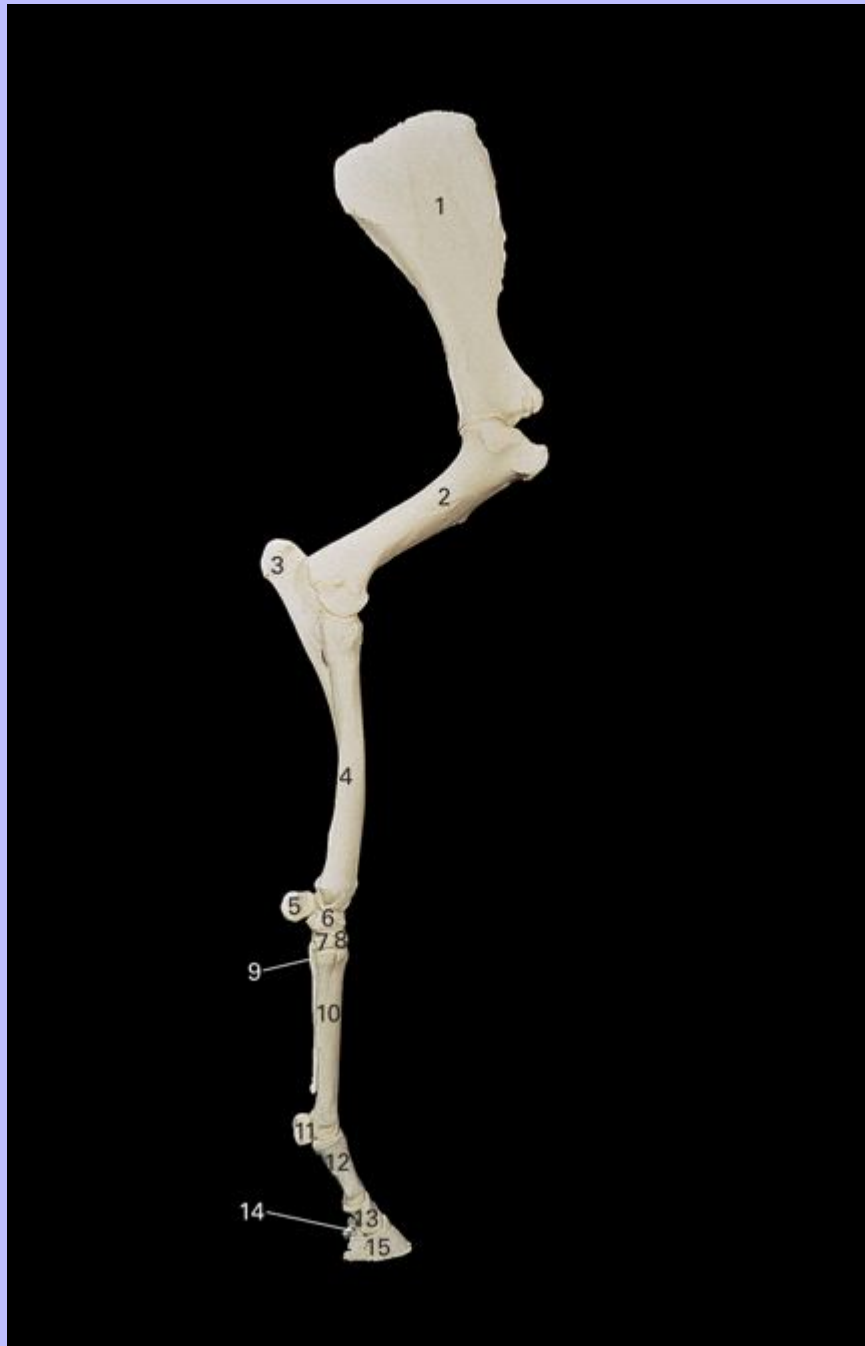1 Scapula

Clinical Anatomy of the Horse

- 2 Humerus
- 3 Ulna
- 4 Radius
- 5 Intermediate carpal bone
- 6 Ulnar carpal bone
- 7 Accessory carpal bone
- 8 Third carpal bone
- 9 Fourth carpal bone
- 10 Metacarpal III (cannon bone)
- 11 Metacarpal IV (lateral splint bone)
- 12 Lateral proximal sesamoid bone
- 13 Proximal phalanx (P1, long pastern bone)
- 14 Middle phalanx (P2, short pastern bone)
- 15 Distal phalanx (P3, coffin bone, pedal bone)
- 16 Distal sesamoid (navicular) bone

Clinical Anatomy of the Horse

4.2 Skeleton of left forelimb, medial view.



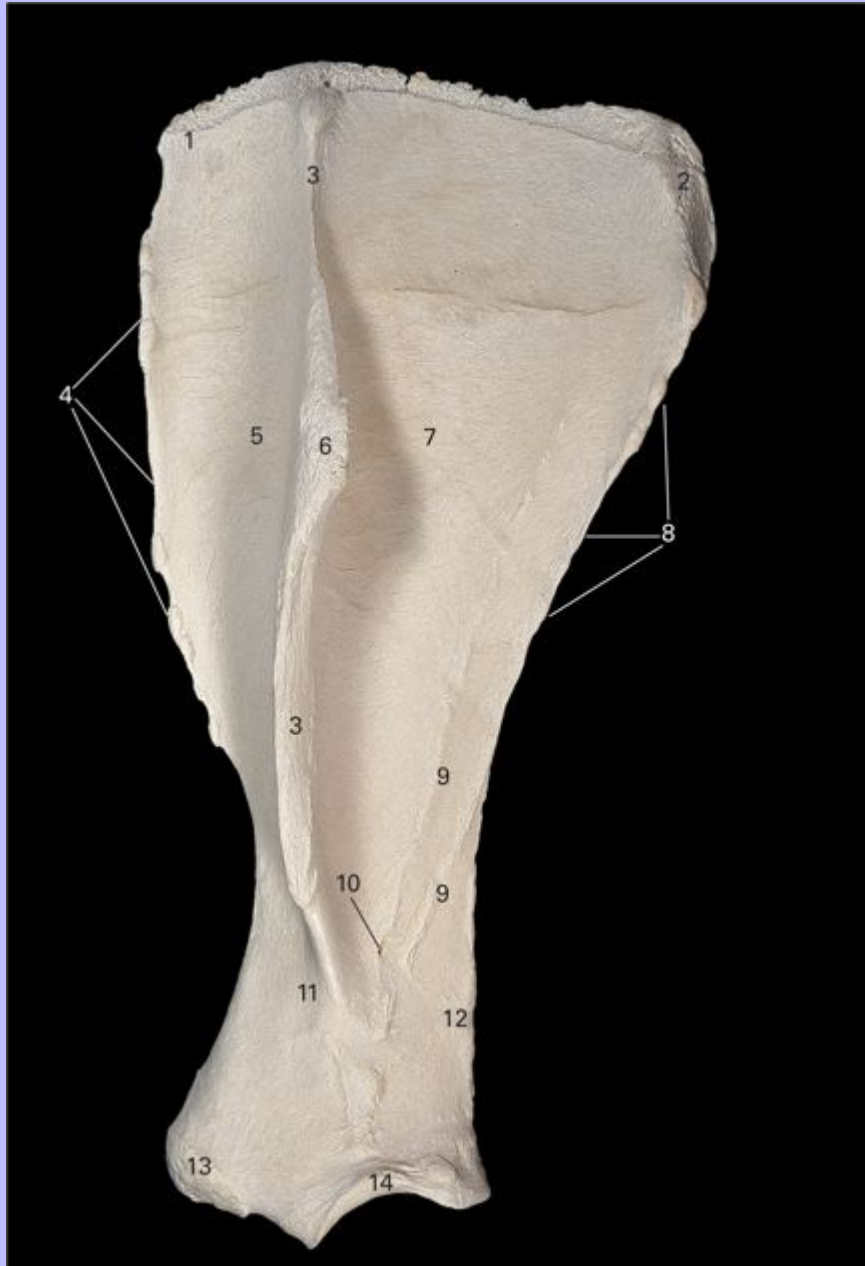
1 Scapula

Clinical Anatomy of the Horse

- 2 Humerus
- 3 Ulna
- 4 Radius
- 5 Accessory carpal bone
- 6 Radial carpal bone
- 7 Second carpal bone
- 8 Third carpal bone
- 9 Metacarpal II (medial splint bone)
- 10 Metacarpal III (cannon bone)
- 11 Medial proximal sesamoid bone
- 12 Proximal phalanx (P1, long pastern bone)
- 13 Middle phalanx (P2, short pastern bone)
- 14 Distal sesamoid (navicular) bone
- 15 Distal phalanx (P3, coffin bone, pedal bone)

35

4.3 Left scapula, lateral view.



1 Cranial angle

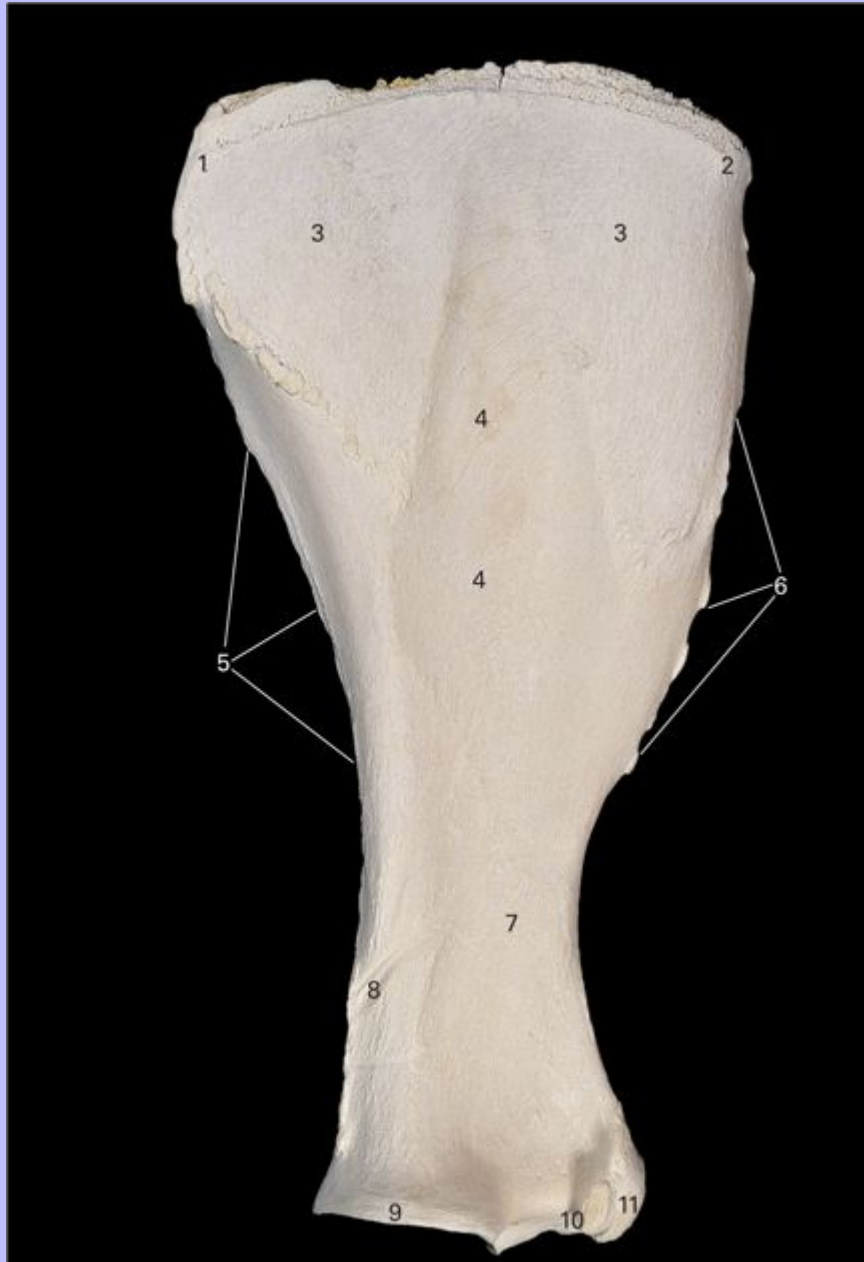2 Caudal angle

Clinical Anatomy of the Horse

- 3 Spine of scapula
- 4 Cranial border
- 5 Supraspinous fossa
- 6 Tuber of scapular spine
- 7 Infraspinous fossa
- 8 Caudal border
- 9 Muscular lines
- 10 Nutrient foramen
- 11 Neck
- 12 Vascular groove
- 13 Supraglenoid tubercle
- 14 Glenoid cavity

Clinical Anatomy of the Horse


4.4 Left scapula, medial view.



1 Caudal angle

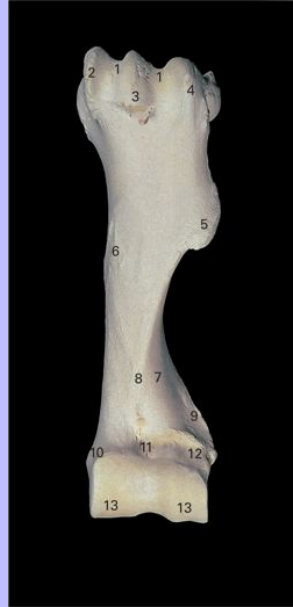2 Cranial angle

Clinical Anatomy of the Horse

- 
- 3 Facies serrata
 - 4 Subscapular fossa
 - 5 Caudal border
 - 6 Cranial border
 - 7 Neck
 - 8 Vascular groove
 - 9 Glenoid cavity
 - 10 Coracoid process
 - 11 Supraglenoid tubercle

36

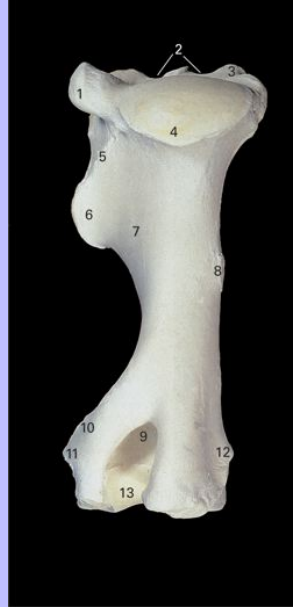4.5 Left humerus, cranial view.



- 1 Intertuberal groove
- 2 Lesser tubercle
- 3 Intermediate tubercle
- 4 Greater tubercle
- 5 Deltoid tuberosity
- 6 Teres major tuberosity
- 7 Groove for M. brachialis (musculospiral groove)
- 8 Humeral crest
- 9 Lateral epicondyloid crest
- 10 Medial epicondyle
- 11 Radial fossa
- 12 Lateral epicondyle
- 13 Trochlea

Clinical Anatomy of the Horse

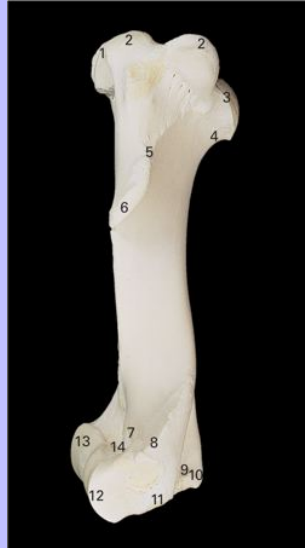4.6 Left humerus, caudal view.



- 1 Greater tubercle
- 2 Intertuberal groove
- 3 Lesser tubercle
- 4 Head
- 5 Tricipital line
- 6 Deltoid tuberosity
- 7 Groove for M. brachialis (musculospiral groove)
- 8 Teres major tuberosity
- 9 Olecranon fossa
- 10 Lateral epicondyloid crest
- 11 Lateral epicondyle
- 12 Medial epicondyle
- 13 Trochlea

Clinical Anatomy of the Horse

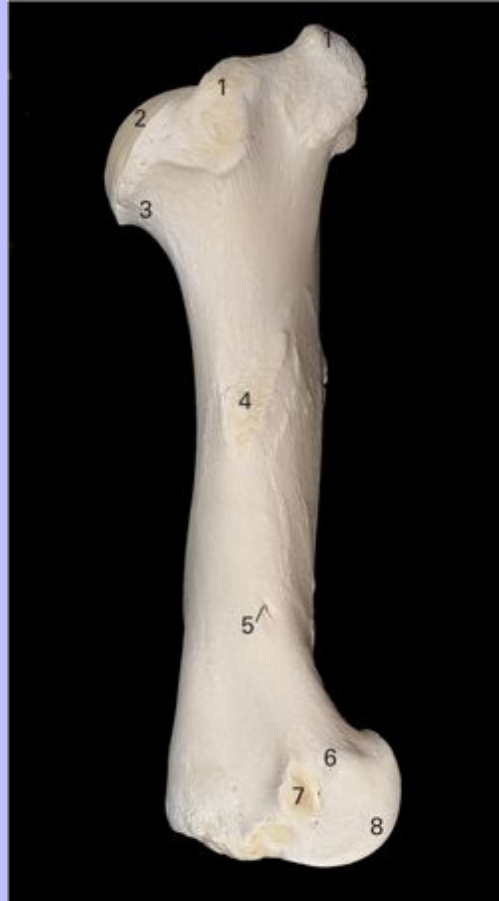4.7 Left humerus, lateral view.



- 1 Intertuberal groove
- 2 Greater tubercle
- 3 Head
- 4 Neck
- 5 Tricipital line
- 6 Deltoid tuberosity
- 7 Radial fossa
- 8 Lateral epicondyloid crest
- 9 Olecranon fossa
- 10 Medial epicondyle
- 11 Lateral epicondyle
- 12 Capitulum
- 13 Trochlea
- 14 Coronoid fossa

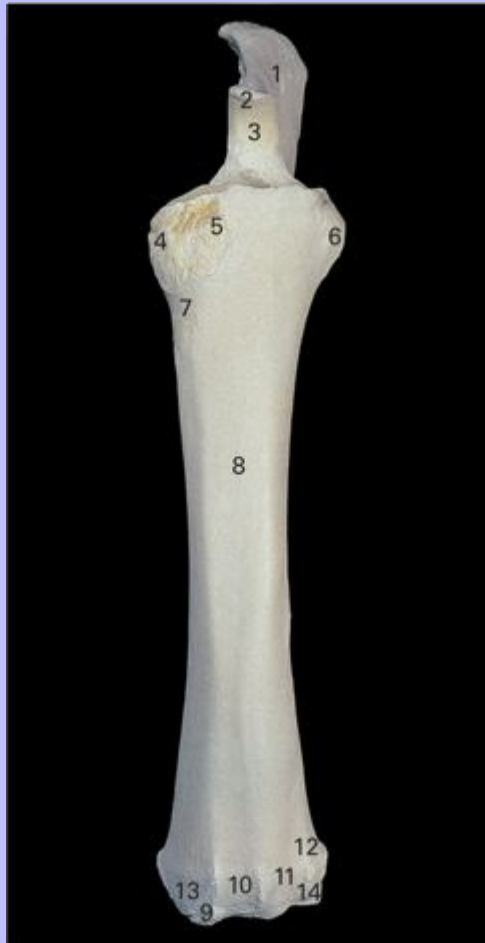Clinical Anatomy of the Horse

4.8 Left humerus, medial view.



- 1 Lesser tubercle
- 2 Head
- 3 Neck
- 4 Teres major tuberosity
- 5 Nutrient foramen
- 6 Medial epicondyle
- 7 Tubercle for attachment of medial collateral ligament
- 8 Trochlea

4.9 Left radius and ulna, cranial view.



Ulna

- 1 Olecranon tuberosity
- 2 Anconeal process
- 3 Trochlear notch

Radius

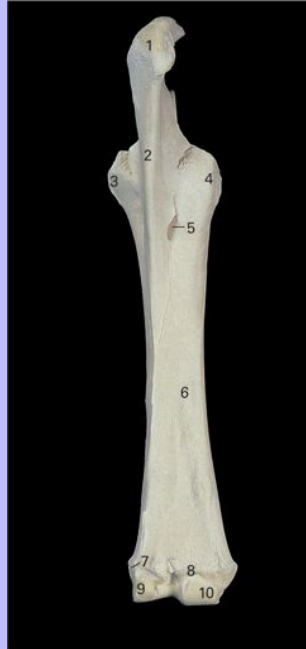- 4 Medial tuberosity
- 5 Radial tuberosity

Clinical Anatomy of the Horse

- 6 Lateral tuberosity
- 7 Groove for M. brachialis
- 8 Body
- 9 Groove for tendon of M. abductor digiti I longus
- 10 Groove for tendon of M. extensor carpi radialis
- 11 Groove for tendon of M. extensor digitorum communis
- 12 Groove for tendon of M. extensor digitorum lateralis
- 13 Medial styloid process
- 14 Lateral styloid process

Clinical Anatomy of the Horse

4.10 Left radius and ulna, caudal view.



Ulna

1 Olecranon tuberosity

2 Body

Radius

3 Lateral tuberosity

4 Medial tuberosity

5 Interosseous space

6 Body

7 Groove for tendon of M. extensor digitorum lateralis

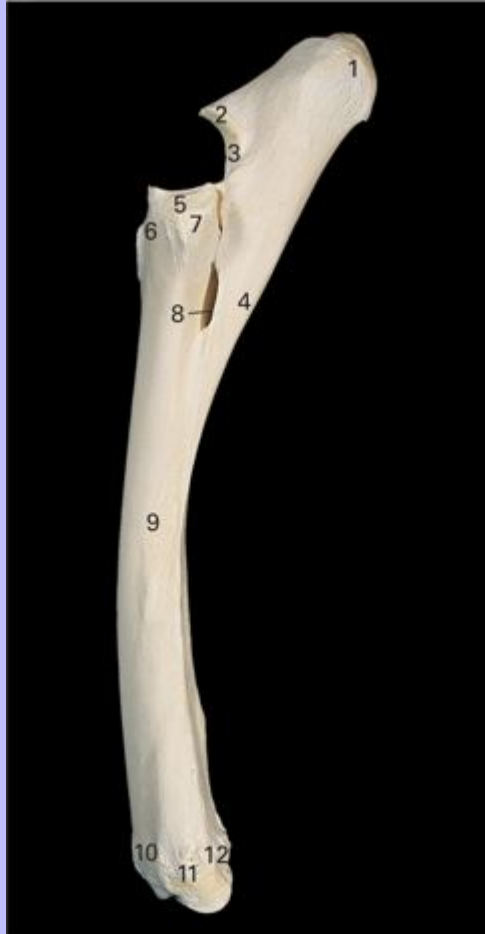8 Transverse crest

9 Lateral styloid process

10 Medial styloid process

Clinical Anatomy of the Horse

4.11 Left radius and ulna, lateral view.



Ulna

- 1 Olecranon tuberosity
- 2 Anconeal process
- 3 Trochlear notch
- 4 Shaft of ulna

Radius

- 5 Capitular fovea

Clinical Anatomy of the Horse

6 Radial tuberosity

7 Lateral tuberosity for attachment of lateral collateral ligament of elbow and M. extensor digitorum communis

8 Interosseous space

9 Shaft of radius

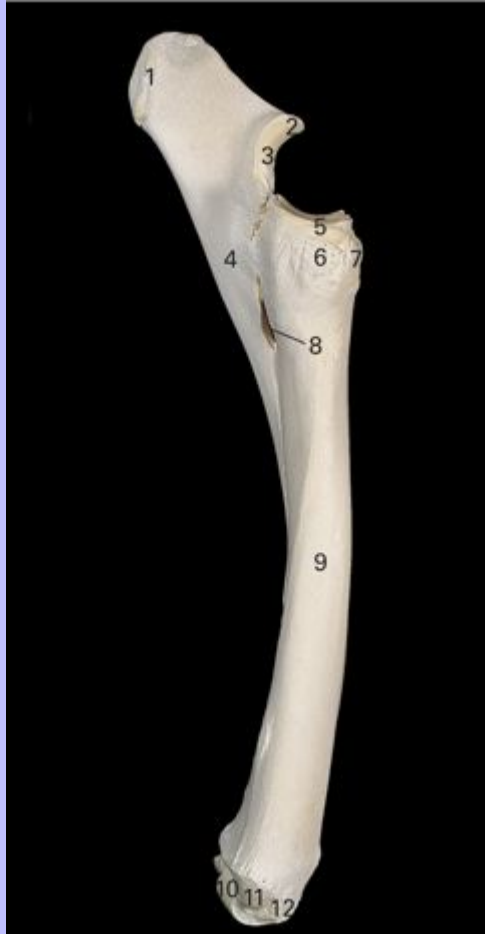10 Groove for tendon of M. extensor digitorum communis

11 Tuberosity for attachment of lateral collateral ligament of carpus

12 Groove for tendon of M. extensor digitorum lateralis

Clinical Anatomy of the Horse

4.12 Left radius and ulna, medial view.



Ulna

- 1 Olecranon tuberosity
- 2 Anconeal process
- 3 Trochlear notch
- 4 Shaft of ulna

Radius

- 5 Capitular fovea

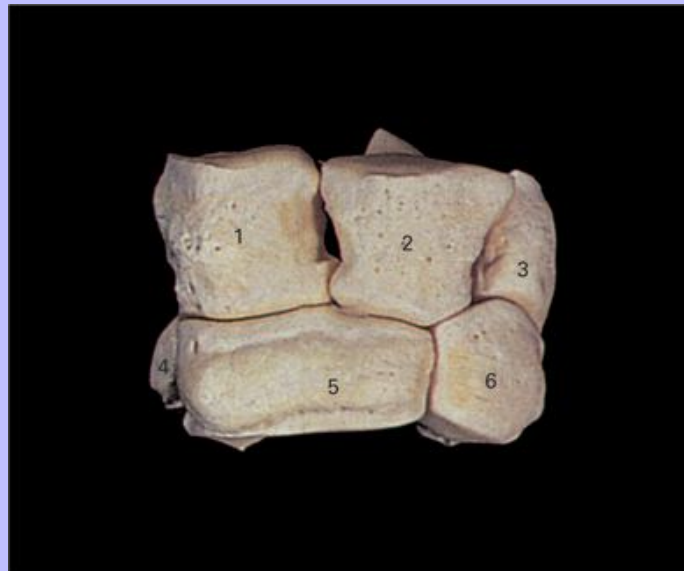Clinical Anatomy of the Horse

- 6 Medial tuberosity for attachment of short part of medial collateral ligament of elbow
- 7 Radial tuberosity
- 8 Interosseous space
- 9 Shaft of radius
- 10 Carpal articular surface
- 11 Medial tuberosity for attachment of carpal medial collateral ligament
- 12 Oblique groove for tendon of M. abductor digiti I longus

38

4.13 Left carpal bones, dorsal view.

39



- 1 Radial carpal bone
- 2 Intermediate carpal bone
- 3 Ulnar carpal bone
- 4 Second carpal bone
- 5 Third carpal bone
- 6 Fourth carpal bone

Clinical Anatomy of the Horse

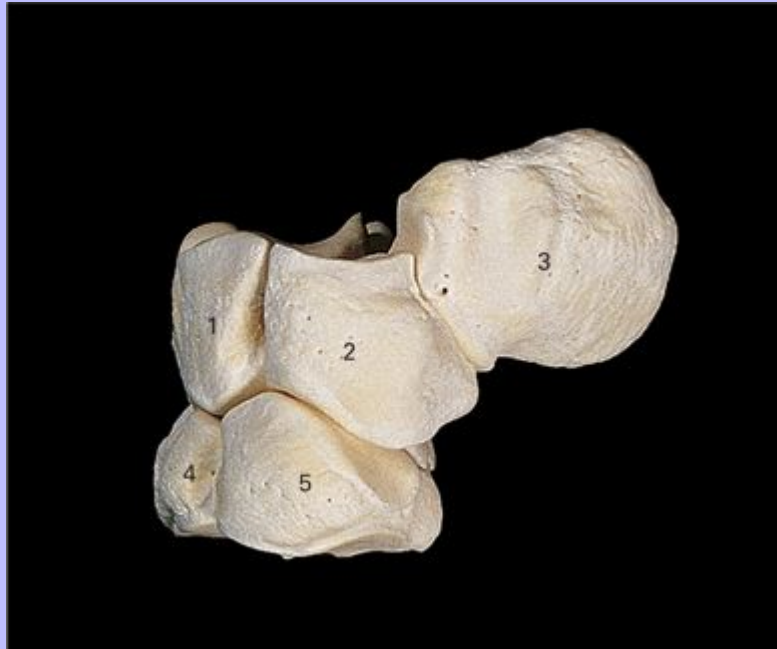4.14 Left carpal bones, palmar view.



- 1 Accessory carpal bone
- 2 Ulnar carpal bone
- 3 Intermediate carpal bone
- 4 Radial carpal bone
- 5 Fourth carpal bone
- 6 Third carpal bone
- 7 Second carpal bone
- 8 First carpal bone (inconstant)

Clinical Anatomy of the Horse

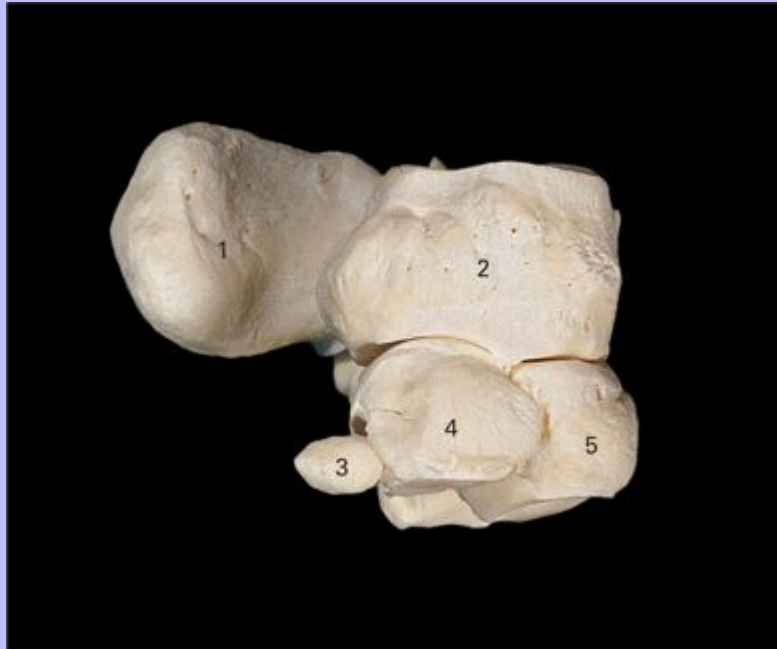4.15 Left carpal bones, lateral view.



- 1 Intermediate carpal bone
- 2 Ulnar carpal bone
- 3 Accessory carpal bone
- 4 Third carpal bone
- 5 Fourth carpal bone

Clinical Anatomy of the Horse

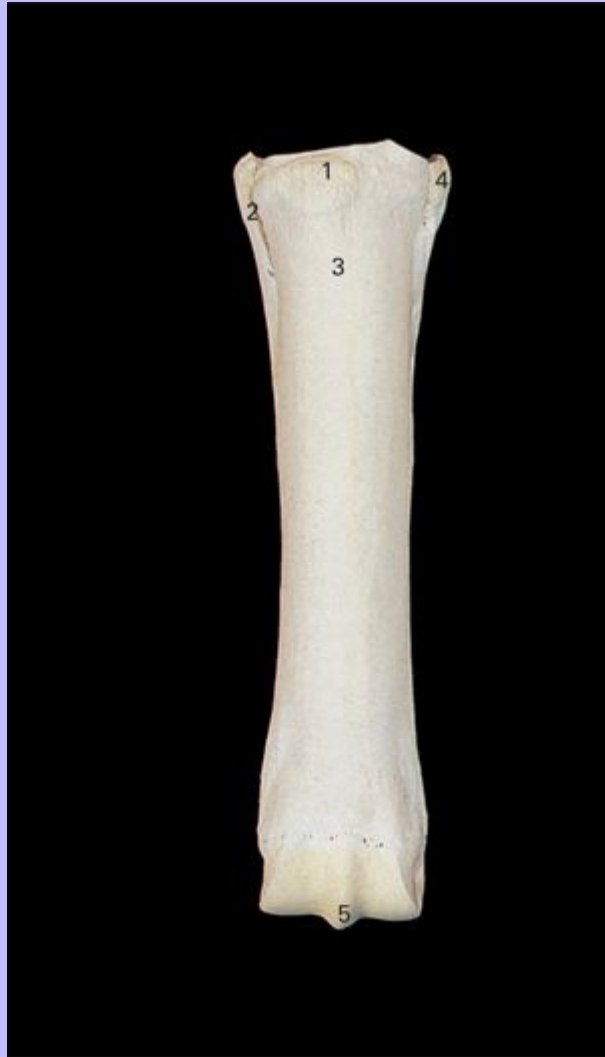4.16 Left carpal bones, medial view.



- 1 Accessory carpal bone
- 2 Radial carpal bone
- 3 First carpal bone (inconstant)
- 4 Second carpal bone
- 5 Third carpal bone

39

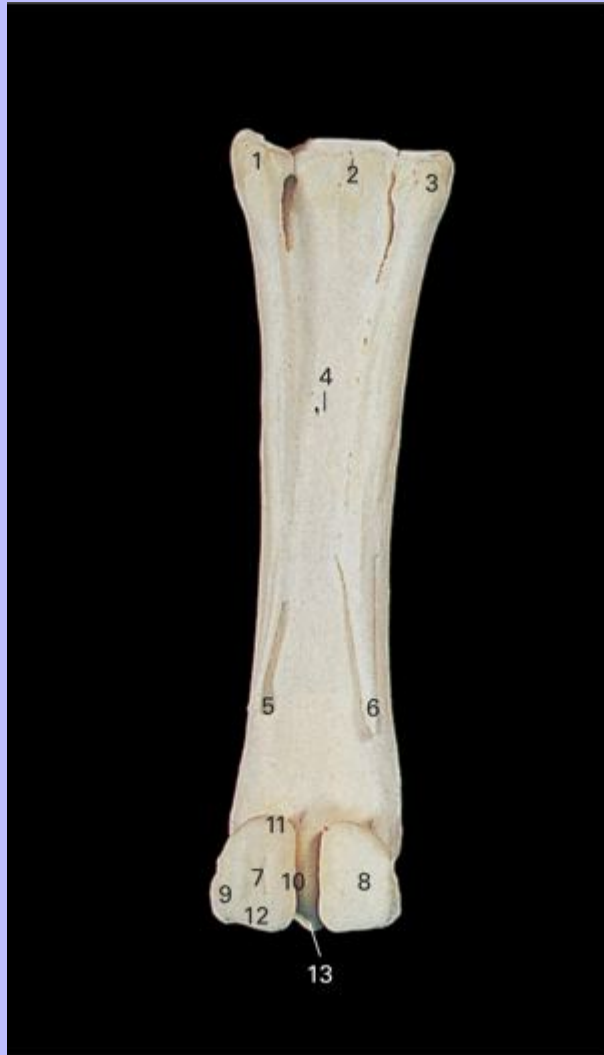4.17 Left metacarpal bones, dorsal view.



- 1 Metacarpal tuberosity
- 2 Metacarpal II (medial splint bone)
- 3 Metacarpal III (cannon bone)
- 4 Metacarpal IV (lateral splint bone)
- 5 Sagittal ridge

Clinical Anatomy of the Horse

4.18 Left metacarpal and proximal sesamoid bones, palmar view.



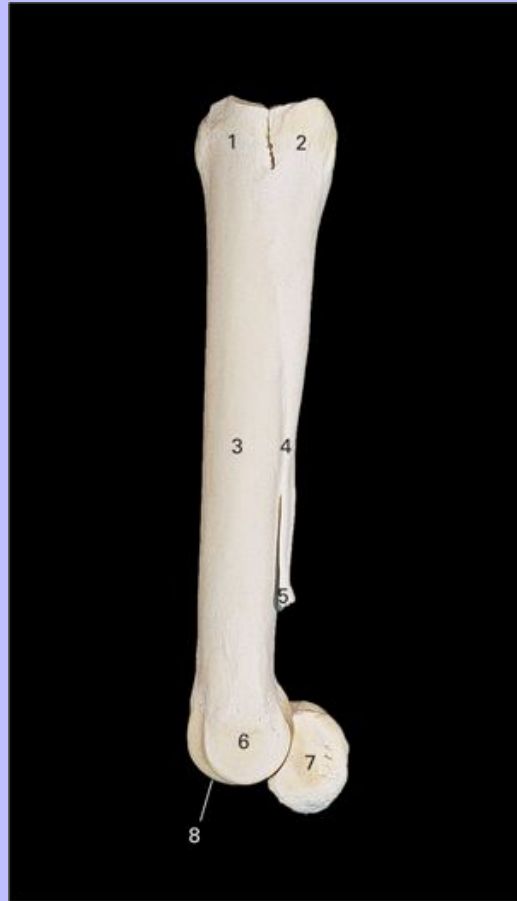- 1 Metacarpal IV (lateral splint bone)
- 2 Metacarpal III (cannon bone)
- 3 Metacarpal II (medial splint bone)
- 4 Nutrient foramen
- 5 Metacarpal IV, distal extremity (button)
- 6 Metacarpal II, distal extremity (button)

Clinical Anatomy of the Horse

- 7 Lateral proximal sesamoid bone
- 8 Medial proximal sesamoid bone
- 9 Abaxial surface
- 10 Axial surface
- 11 Apex
- 12 Base
- 13 Sagittal ridge

Clinical Anatomy of the Horse

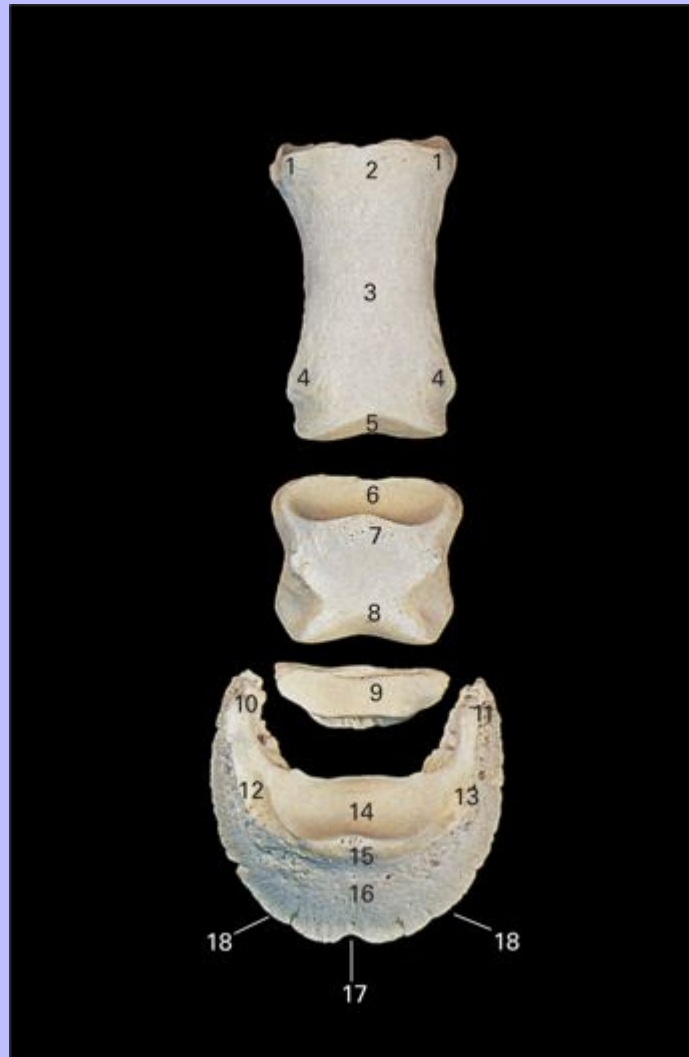4.19 Left metacarpal and proximal sesamoid bones, lateral view.



- 1 Metacarpal tuberosity
- 2 Base (head) of metacarpal IV (lateral splint bone)
- 3 Shaft of metacarpal III (cannon bone)
- 4 Shaft of metacarpal IV
- 5 Distal extremity (button) of metacarpal IV
- 6 Fossa for attachment of metacarpophalangeal lateral collateral ligament
- 7 Lateral proximal sesamoid bone
- 8 Sagittal ridge

40

4.20 Bones of left digit, dorsal view.



Proximal phalanx

- 1 Eminences for attachment of collateral ligaments of metacarpophalangeal joint
- 2 Eminence for attachment of digital extensor tendons
- 3 Body
- 4 Eminences for attachment of collateral ligaments of proximal interphalangeal joint

Clinical Anatomy of the Horse

5 Distal articular surface

Middle phalanx

6 Proximal articular surface

7 Extensor process

8 Distal articular surface

Distal sesamoid (navicular) bone

9 Articular surface

Distal phalanx

10 Medial palmar process

11 Lateral palmar process

12 Medial parietal sulcus

13 Lateral parietal sulcus

14 Articular surface

15 Extensor process

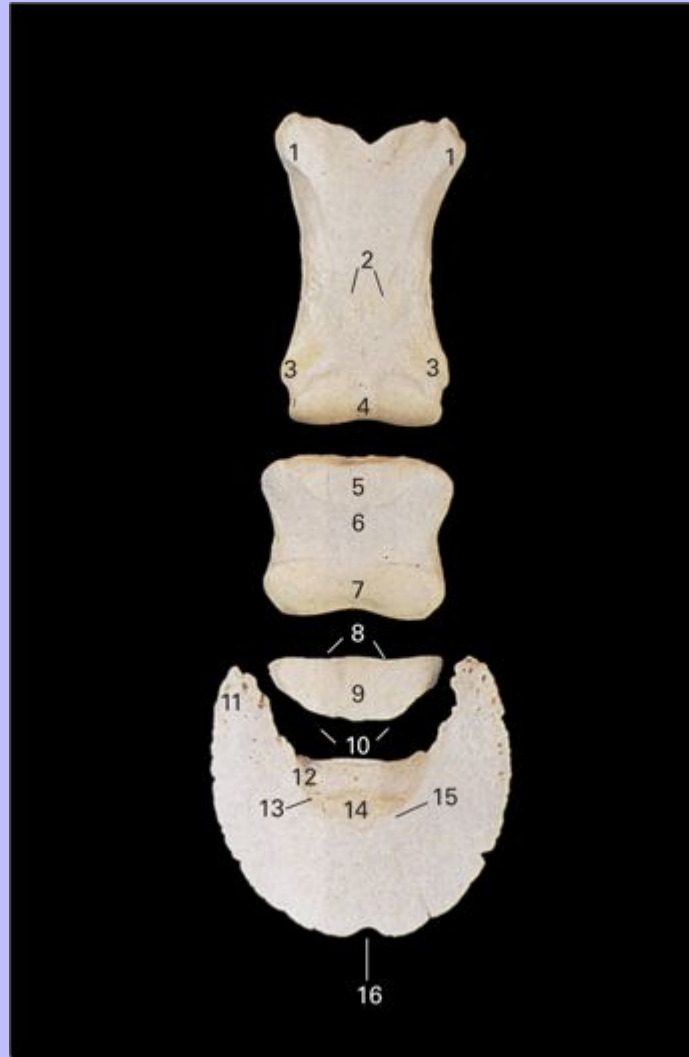
16 Parietal surface

17 Crena

18 Solar border

Clinical Anatomy of the Horse

4.21 Bones of left digit, palmar view.



Proximal phalanx

- 1 Eminences for attachment of collateral ligaments of metacarpophalangeal joint
- 2 Triangular rough area
- 3 Eminences for attachment of collateral ligaments of proximal interphalangeal joint
- 4 Condyle

Clinical Anatomy of the Horse

Middle phalanx

5 Articular fovea

6 Flexor tuberosity

7 Condyle

Distal sesamoid (navicular) bone

8 Proximal border

9 Flexor surface

10 Distal border

Distal phalanx

11 Lateral palmar process

12 Lateral solar groove

13 Lateral solar foramen

14 Flexor surface

15 Semilunar line

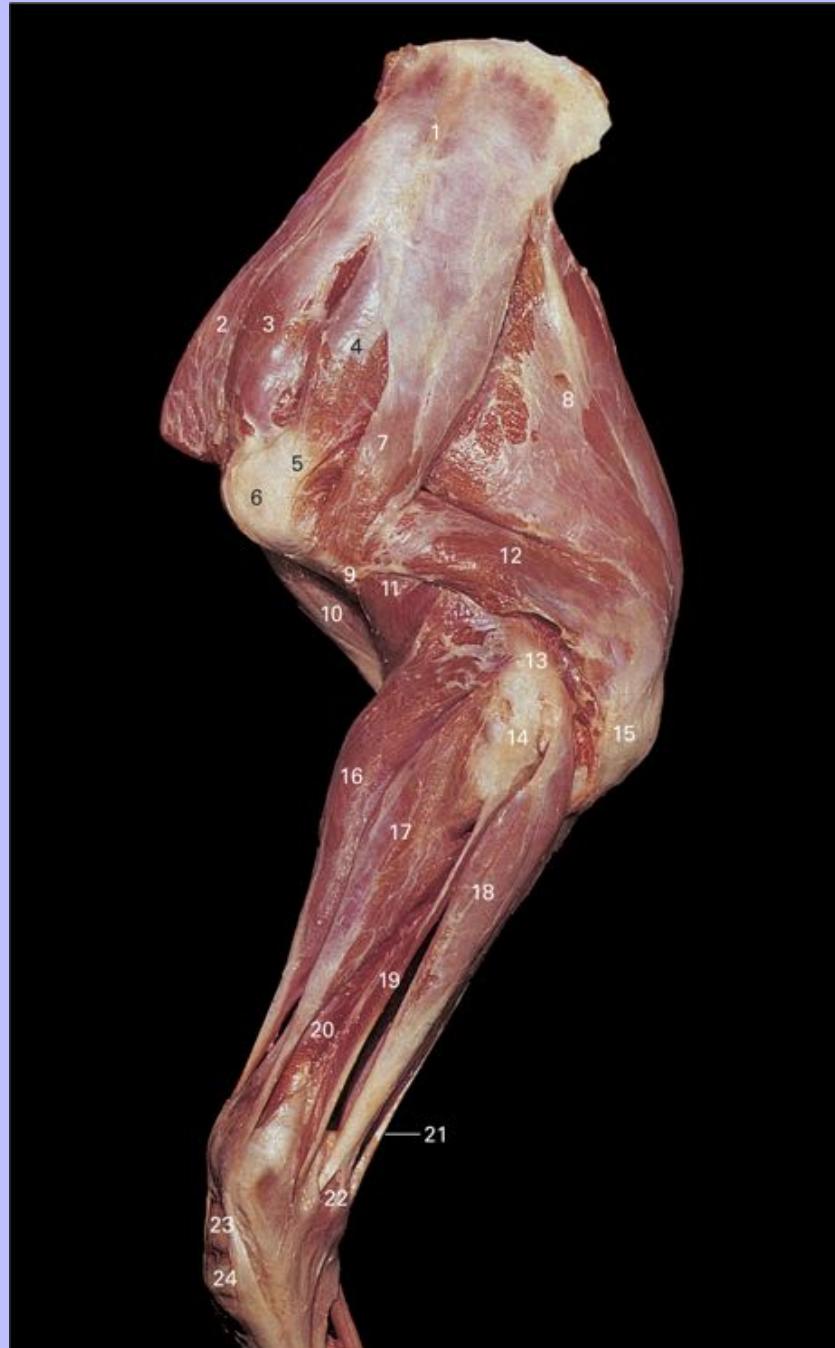16 Crena

41

Clinical Anatomy of the Horse

4.22 Superficial dissection of musculature of left forelimb, lateral view.

42



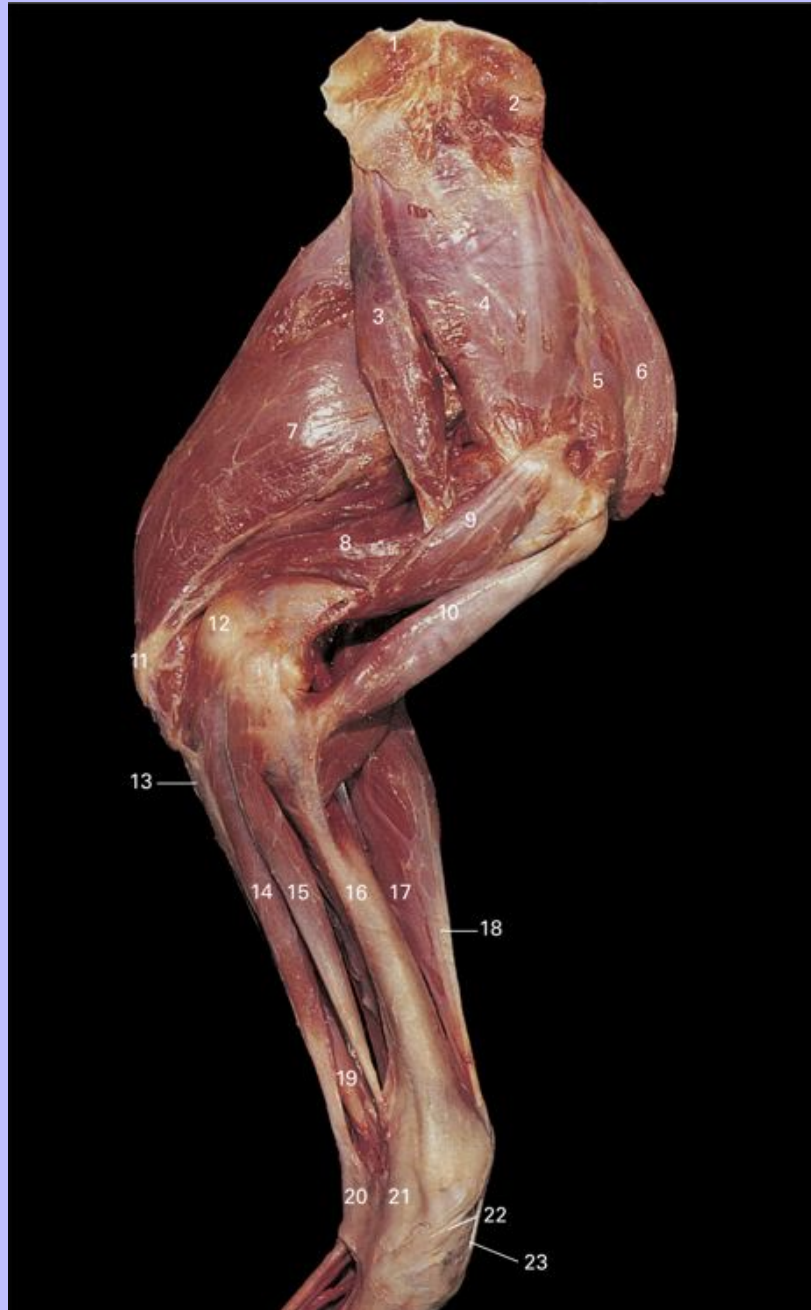
1 Spine of scapula

Clinical Anatomy of the Horse

- 2 M. subclavius
- 3 M. supraspinatus
- 4 M. infraspinatus
- 5 Tendon of M. infraspinatus
- 6 Greater tubercle of humerus
- 7 M. deltoideus
- 8 M. triceps brachii, long head
- 9 Deltoid tuberosity
- 10 M. biceps brachii
- 11 M. brachialis
- 12 M. triceps brachii, lateral head
- 13 Lateral epicondyle of humerus
- 14 Olecranon
- 15 Olecranon tuberosity
- 16 M. extensor carpi radialis
- 17 M. extensor digitorum communis
- 18 M. extensor carpi ulnaris (M. ulnaris lateralis)
- 19 M. extensor digitorum lateralis
- 20 M. abductor digiti I longus
- 21 M. flexor carpi ulnaris
- 22 Accessory carpal bone
- 23 Intermediate carpal bone
- 24 Third carpal bone

Clinical Anatomy of the Horse

4.23 Dissection of musculature of left forelimb, medial view. The M. tensor fascia antebrachii has been removed.



1 Attachment of M. rhomboideus

Clinical Anatomy of the Horse

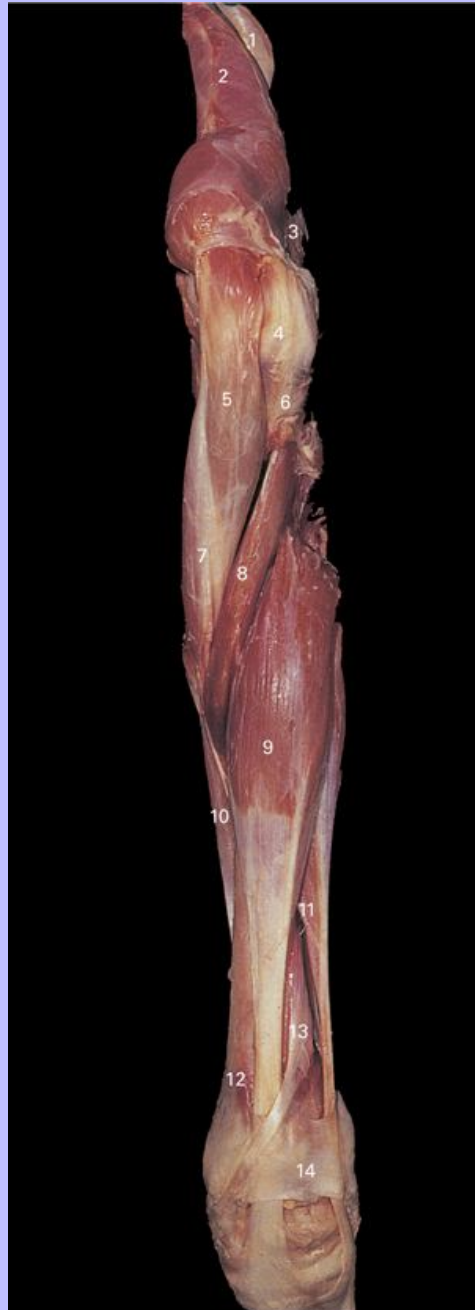- 2 Attachment of M. serratus ventralis
- 3 M. teres major
- 4 M. subscapularis
- 5 M. supraspinatus
- 6 M. subclavius
- 7 M. triceps brachii, long head
- 8 M. triceps brachii, medial head
- 9 M. coracobrachialis
- 10 M. biceps brachii
- 11 Olecranon tuberosity
- 12 Medial epicondyle
- 13 M. flexor digitorum profundus, ulnar head
- 14 M. flexor carpi ulnaris
- 15 M. flexor carpi radialis
- 16 Radius
- 17 M. extensor carpi radialis
- 18 Lacertus fibrosus
- 19 M. flexor digitorum superficialis
- 20 Carpal flexor retinaculum
- 21 Medial collateral carpal ligament
- 22 Tendon of M. abductor digiti I longus
- 23 Tendon of M. extensor carpi radialis

42

Clinical Anatomy of the Horse

43

4.24 Superficial dissection of musculature of left forelimb, cranial view. The pectoral muscles and M. subclavius have been removed.



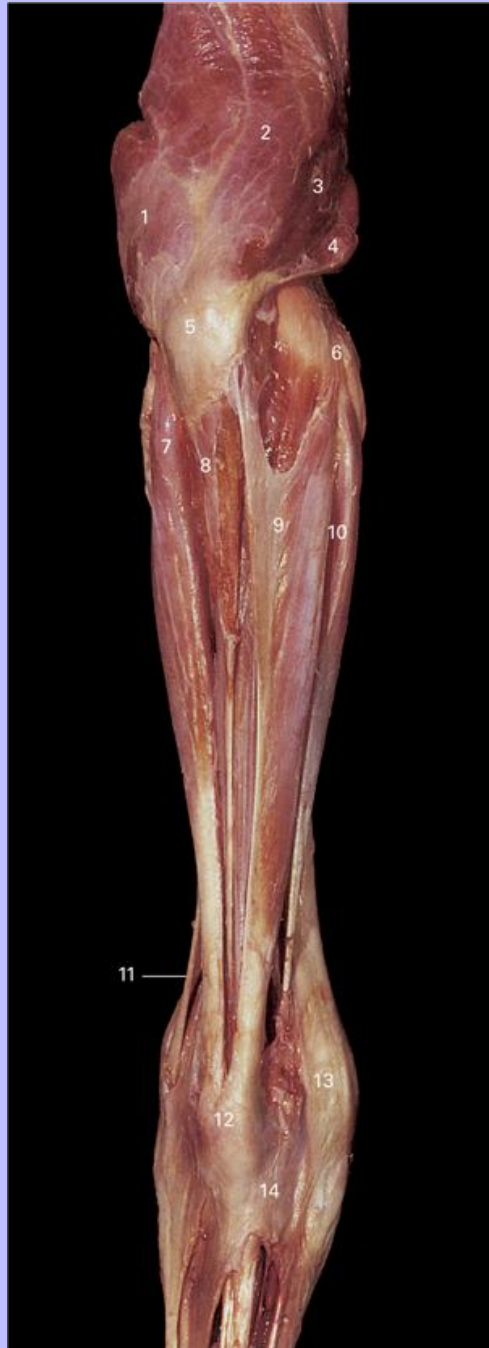1 Scapular cartilage

Clinical Anatomy of the Horse

- 2 M. supraspinatus
- 3 M. deltoideus
- 4 Greater tubercle of humerus
- 5 M. biceps brachii
- 6 Deltoid tuberosity
- 7 Tendinous intersection of M. biceps brachii
- 8 M. brachialis
- 9 M. extensor carpi radialis
- 10 M. flexor carpi radialis
- 11 M. extensor digitorum communis
- 12 Radius
- 13 M. abductor digiti I longus
- 14 Extensor retinaculum of carpus

Clinical Anatomy of the Horse

4.25 Superficial dissection of musculature of left forelimb, caudal view.



1 M. triceps brachii, lateral head

Clinical Anatomy of the Horse

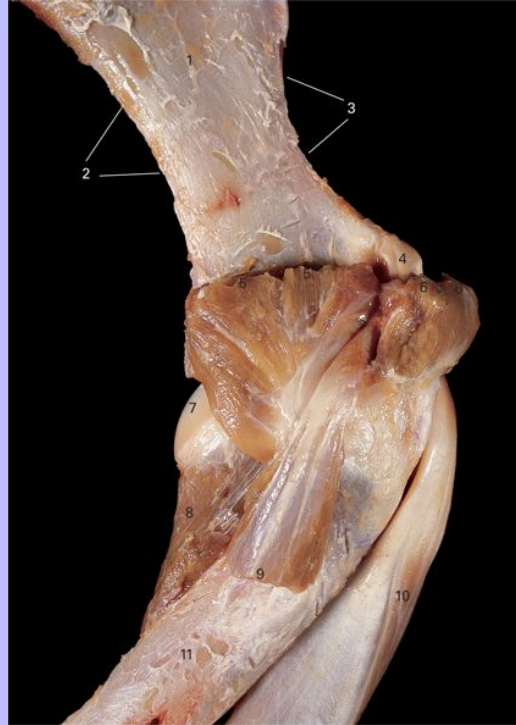- 2 M. triceps brachii, long head
- 3 M. triceps brachii, medial head
- 4 M. tensor fascia antebrachii
- 5 Olecranon tuberosity
- 6 M. flexor carpi radialis
- 7 M. extensor carpi ulnaris (M. ulnaris lateralis)
- 8 M. flexor digitorum profundus, ulnar head
- 9 M. flexor carpi ulnaris
- 10 M. flexor carpi radialis
- 11 Tendon of M. extensor digitorum lateralis
- 12 Accessory carpal bone
- 13 Medial collateral carpal ligament
- 14 Carpal flexor retinaculum

43

Clinical Anatomy of the Horse

44

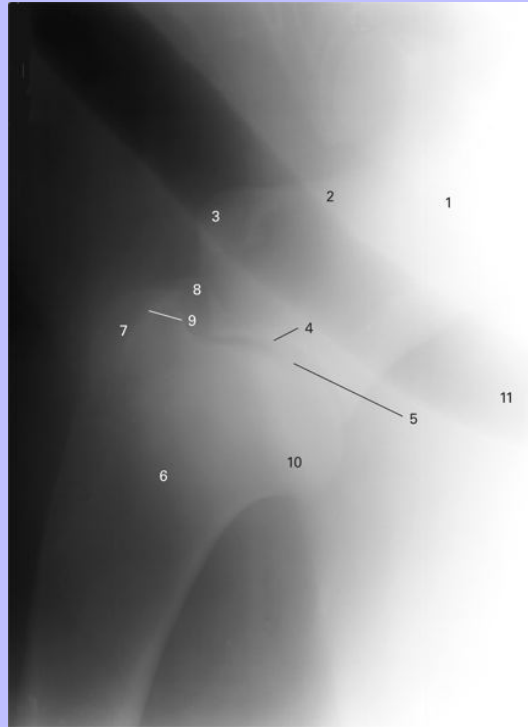
4.26 Deep dissection of left shoulder joint, medial view.



- 1 Subscapular fossa
- 2 Caudal border of scapula
- 3 Cranial border of scapula
- 4 Supraglenoid tubercle
- 5 Cut edge of M. subscapularis
- 6 Cut edge of M. supraspinatus
- 7 Head of humerus
- 8 M. articularis humeri
- 9 Cut edge of M. coracobrachialis
- 10 M. biceps brachii
- 11 Humerus

Clinical Anatomy of the Horse

4.27 Lateromedial view radiograph of shoulder joint.

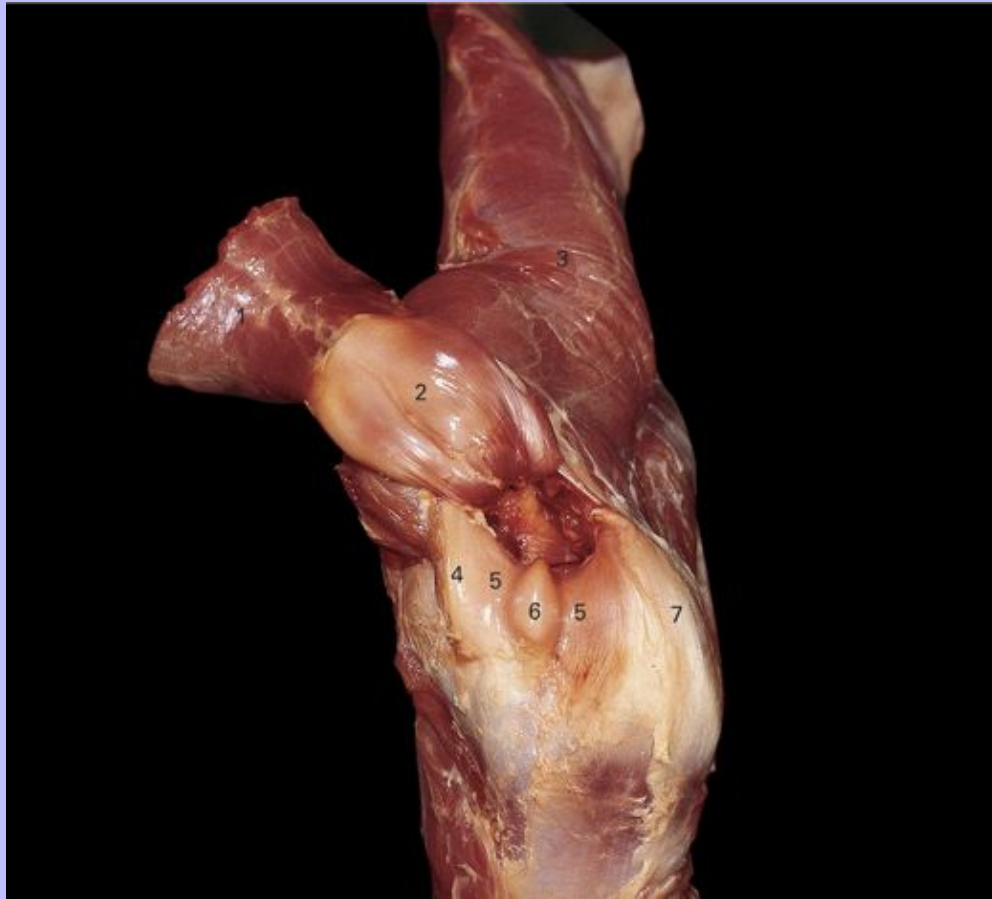


- 1 Scapula
- 2 Neck
- 3 Supraglenoid tubercle
- 4 Glenoid cavity
- 5 Scapulohumeral (shoulder) joint
- 6 Humerus
- 7 Greater tubercle
- 8 Lesser tubercle
- 9 Intertuberal groove
- 10 Head
- 11 Trachea

Clinical Anatomy of the Horse

45


4.28 Deep dissection of left shoulder joint, cranial view.



- 1 M. biceps brachii, sectioned and reflected craniomedially from its origin on the supraglenoid tubercle
- 2 Tendon of M. biceps brachii covered by synovial membrane of the bicipital bursa where it runs through the intertuberal groove
- 3 M. brachiocephalicus
- 4 Lesser tubercle
- 5 Inter-tuberal groove
- 6 Intermediate tubercle
- 7 Greater tubercle

Clinical Anatomy of the Horse

4.29 Proximocranial-distocranial view radiograph of proximal humerus.



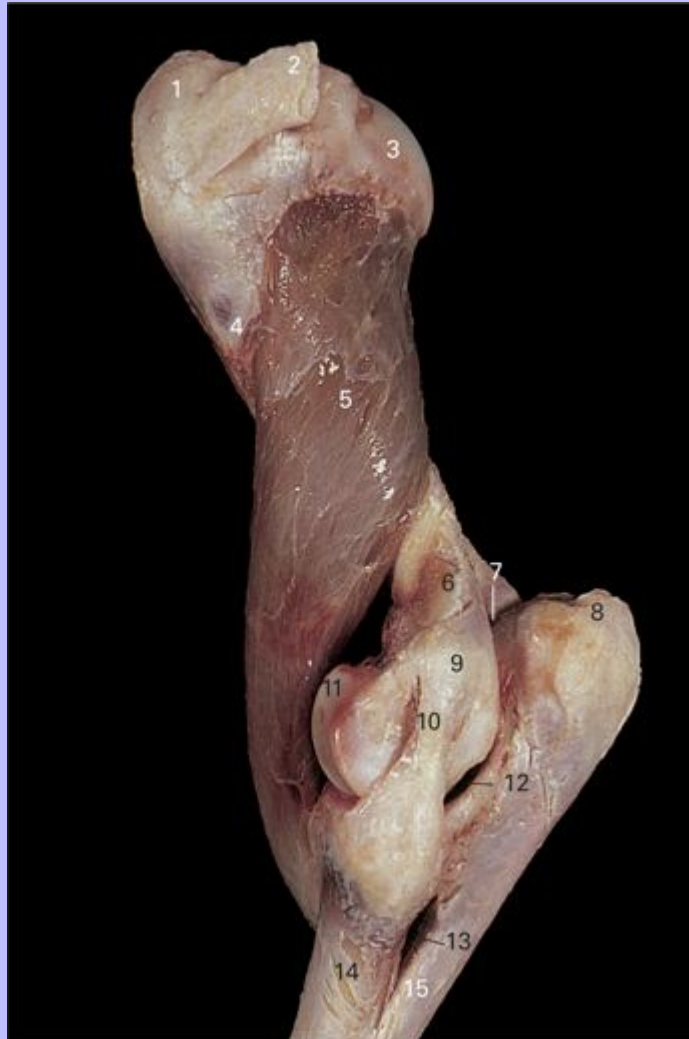- 1 Greater tubercle
- 2 Intermediate ridge
- 3 Lesser tubercle
- 4 Intertuberal groove

45

Clinical Anatomy of the Horse

46

4.30 Deep dissection of left cubital (elbow) joint, lateral view.



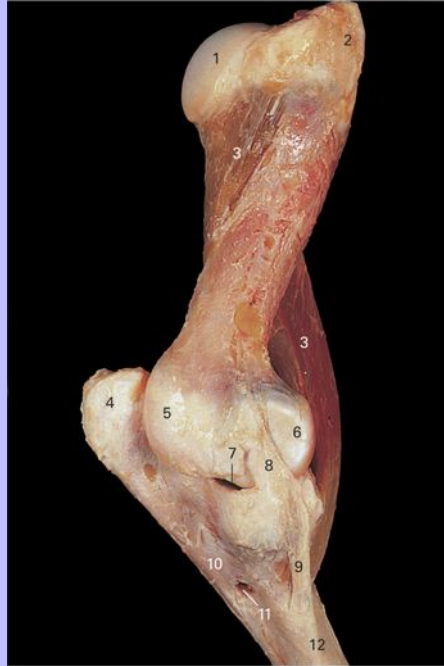- 1 Greater tubercle
- 2 Tendon of M. infraspinatus
- 3 Head of humerus
- 4 Deltoid tuberosity
- 5 M. brachialis
- 6 Lateral epicondyloid crest

Clinical Anatomy of the Horse

- 7 Olecranon fossa
- 8 Olecranon tuberosity
- 9 Lateral epicondyle
- 10 Lateral collateral ligament
- 11 Trochlea
- 12 Trochlear notch of ulna
- 13 Interosseous space
- 14 Radius
- 15 Ulna

Clinical Anatomy of the Horse

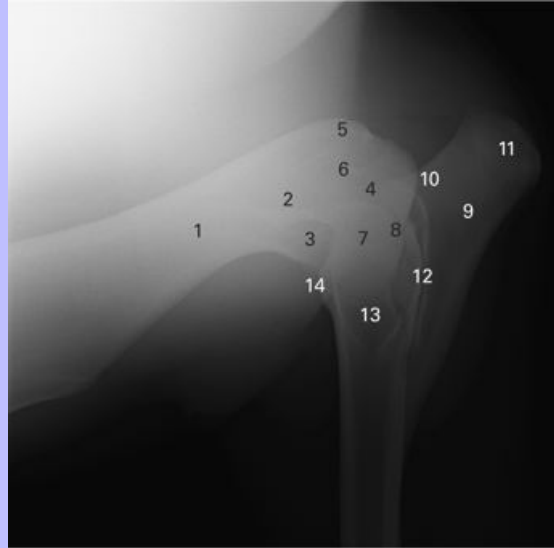
4.31 Deep dissection of left cubital (elbow) joint, medial view.



- 1 Head of humerus
- 2 Lesser tubercle
- 3 M. brachialis
- 4 Olecranon tuberosity
- 5 Medial epicondyle
- 6 Trochlea
- 7 Capitular fovea
- 8 Short part of medial collateral ligament
- 9 Long part of medial collateral ligament
- 10 Ulna
- 11 Interosseous space
- 12 Radius

Clinical Anatomy of the Horse

4.32 Lateromedial view radiograph of cubital (elbow) joint.

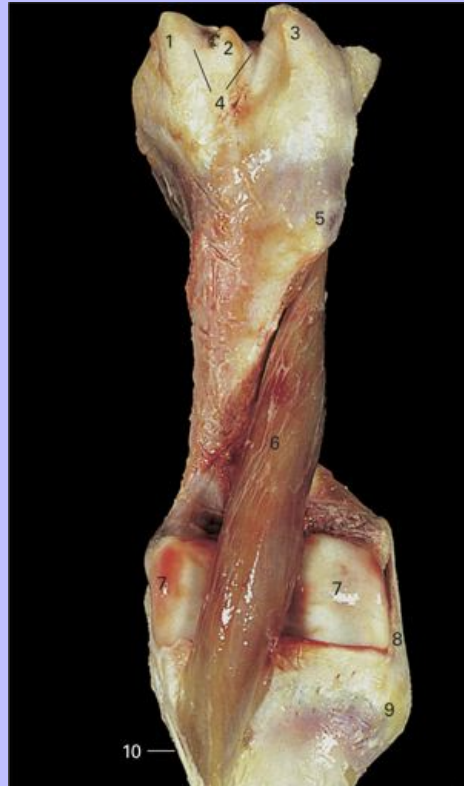

- 1 Humerus
- 2 Lateral supracondyloid crest
- 3 Radial fossa
- 4 Olecranon fossa
- 5 Medial epicondyle
- 6 Lateral epicondyle
- 7 Condyles
- 8 Cubital joint
- 9 Ulna
- 10 Anconeal process
- 11 Olecranon tuberosity
- 12 Interosseous space
- 13 Radius
- 14 Radial tuberosity

Clinical Anatomy of the Horse

47

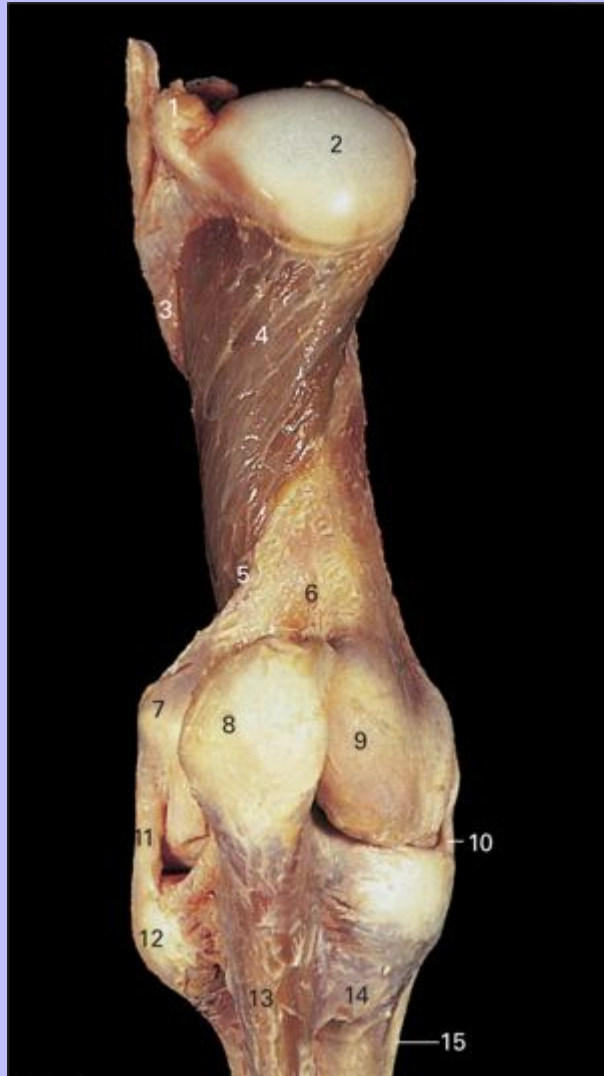4.33 Deep dissection of left cubital (elbow) joint, cranial view.



- 1 Lesser tubercle
- 2 Intermediate tubercle
- 3 Greater tubercle
- 4 Intertuberal groove
- 5 Deltoid tuberosity
- 6 M. brachialis
- 7 Trochlea
- 8 Lateral collateral ligament
- 9 Attachment site of M. extensor digitorum communis and M. extensor digitorum lateralis
- 10 Long part of medial collateral ligament

Clinical Anatomy of the Horse

4.34 Deep dissection of left cubital (elbow) joint, caudal view.



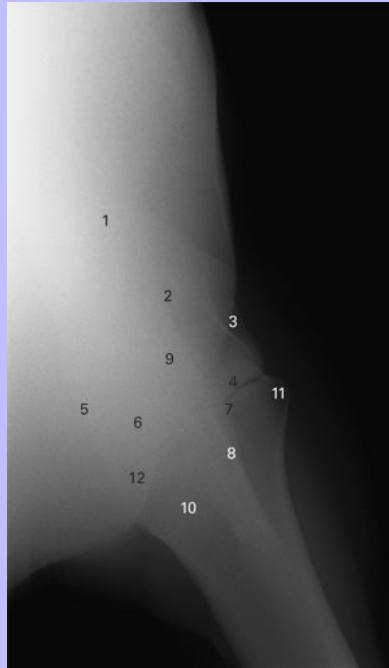
- 1 Greater tubercle
- 2 Head of humerus
- 3 Deltoid tuberosity
- 4 M. brachialis
- 5 Lateral epicondyloid crest

Clinical Anatomy of the Horse

- 6 Olecranon fossa
- 7 Lateral epicondyle
- 8 Olecranon tuberosity
- 9 Medial epicondyle
- 10 Short part of medial collateral ligament
- 11 Lateral collateral ligament
- 12 Attachment site of M. extensor digitorum communis and M. extensor digitorum lateralis
- 13 Ulna
- 14 Radius
- 15 Long part of medial collateral ligament

Clinical Anatomy of the Horse

4.35 Craniocaudal view radiograph of cubital (elbow) joint.

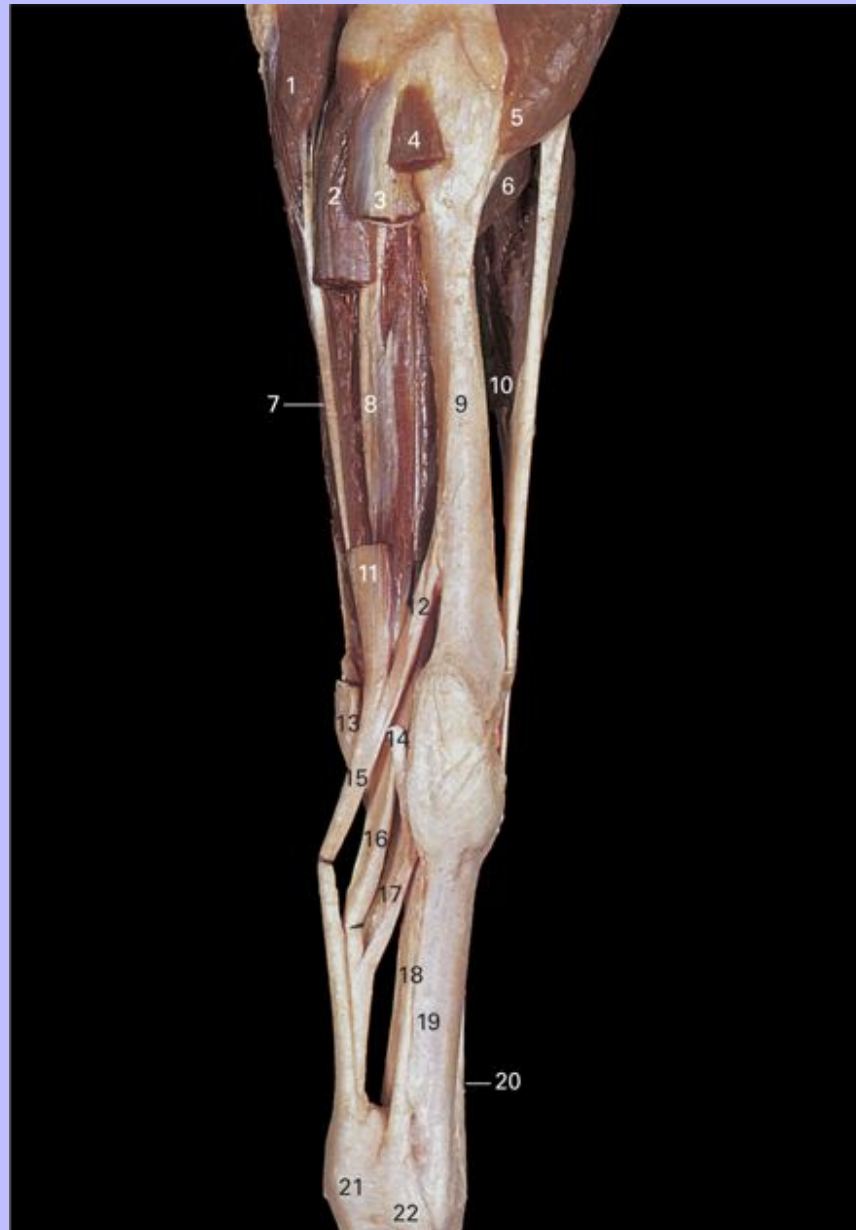

- 1 Humerus
- 2 Olecranon fossa
- 3 Lateral epicondyle
- 4 Lateral condyle
- 5 Medial epicondyle
- 6 Medial condyle
- 7 Cubital joint
- 8 Ulna
- 9 Olecranon tuberosity
- 10 Radius
- 11 Lateral tuberosity
- 12 Medial tuberosity

Clinical Anatomy of the Horse

48

4.36 Deep dissection of left forelimb, medial view. The M. flexor carpi radialis, M. flexor carpi ulnaris and M. flexor digitorum superficialis have been removed. The tendons of the M. flexor digitorum superficialis and M. flexor digitorum profundus have been retracted to expose the accessory ligaments.



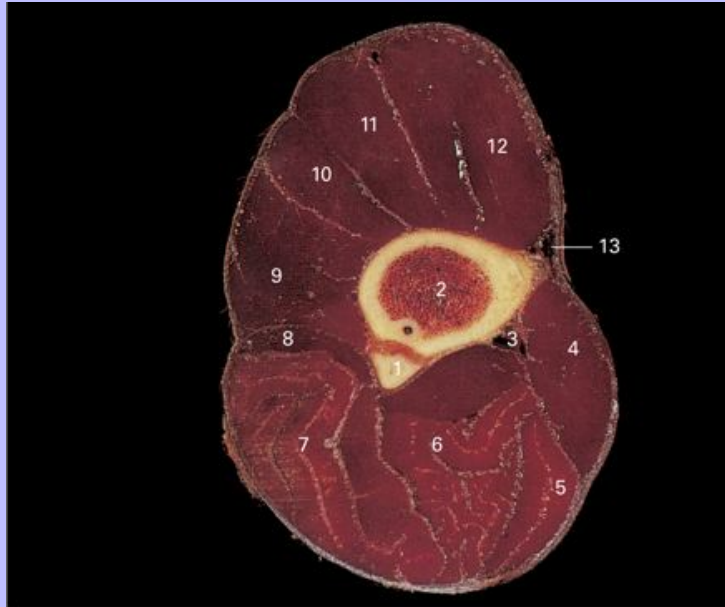1 M. flexor digitorum profundus, ulnar head

Clinical Anatomy of the Horse

- 2 Stump of M. flexor digitorum superficialis
- 3 Stump of M. flexor carpi ulnaris
- 4 Stump of M. flexor carpi radialis
- 5 M. biceps brachii
- 6 M. brachialis
- 7 Tendon of M. flexor digitorum profundus, ulnar head
- 8 M. flexor digitorum profundus, humeral head
- 9 Radius
- 10 M. extensor carpi radialis
- 11 Tendon of M. flexor digitorum superficialis
- 12 Accessory ligament of M. flexor digitorum superficialis (proximal check ligament)
- 13 Accessory carpal bone
- 14 Cut edge of tendon of M. flexor carpi radialis
- 15 Tendon of M. flexor digitorum superficialis
- 16 Tendon of M. flexor digitorum profundus
- 17 Accessory ligament of M. flexor digitorum profundus (distal check ligament)
- 18 M. interosseus medius (suspensory ligament)
- 19 Metacarpal III (cannon bone)
- 20 Tendon of M. extensor digitorum communis
- 21 Superficial transverse metacarpal ligament (palmar annular ligament)
- 22 Medial extensor branch of M. interosseus medius to tendon of M. extensor digitorum communis

Clinical Anatomy of the Horse

4.37 Transverse section through left antebrachium, distal view.

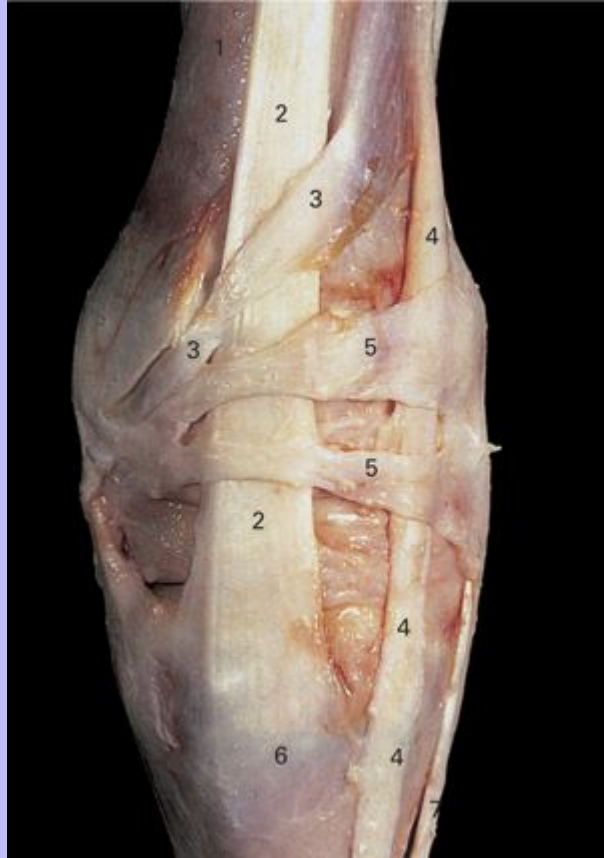

- 1 Ulna
- 2 Radius
- 3 Median vessels and nerve
- 4 M. flexor carpi radialis
- 5 M. flexor carpi ulnaris
- 6 M. flexor digitorum superficialis
- 7 M. flexor digitorum profundus, humeral head
- 8 M. flexor digitorum profundus, ulnar head
- 9 M. extensor carpi ulnaris (M. ulnaris lateralis)
- 10 M. extensor digitorum lateralis
- 11 M. extensor digitorum communis
- 12 M. extensor carpi radialis
- 13 Cephalic vein

Clinical Anatomy of the Horse

49

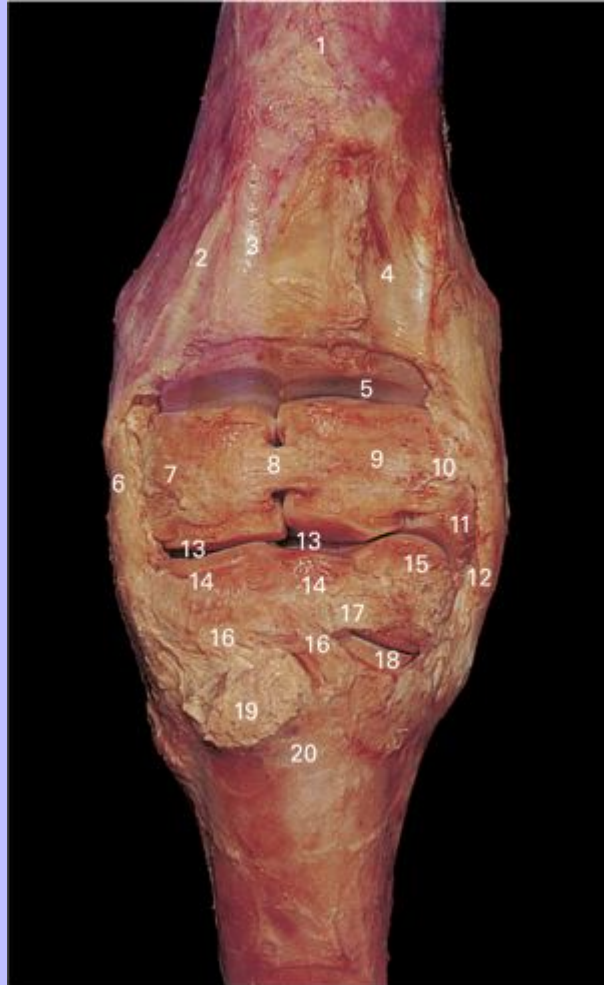
4.38 Superficial dissection of left carpus, dorsal view.



- 1 Radius
- 2 Tendon of M. extensor carpi radialis
- 3 Tendon of M. abductor digiti I longus
- 4 Tendon of M. extensor digitorum communis
- 5 Extensor retinaculum
- 6 Metacarpal tuberosity
- 7 Tendon of M. extensor digitorum lateralis

Clinical Anatomy of the Horse

4.39 Deep dissection of left carpus, dorsal view.



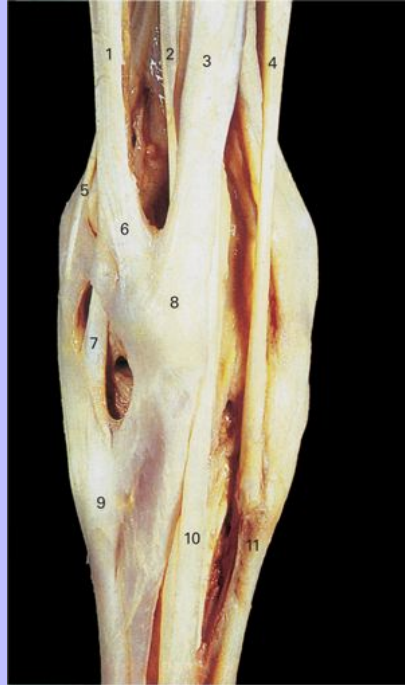
- 1 Radius
- 2 Groove for tendon of M. abductor digiti I longus
- 3 Groove for tendon of M. extensor carpi radialis
- 4 Groove for tendon of M. extensor digitorum communis
- 5 Antebrachio-carpal joint
- 6 Medial collateral carpal ligament
- 7 Radial carpal bone

Clinical Anatomy of the Horse

- 8 Dorsal intercarpal ligament between radial and intermediate carpal bones
- 9 Intermediate carpal bone
- 10 Dorsal intercarpal ligament between intermediate and ulnar carpal bones
- 11 Ulnar carpal bone
- 12 Lateral collateral carpal ligament
- 13 Intercarpal joint
- 14 Third carpal bone
- 15 Fourth carpal bone
- 16 Dorsal metacarpal ligament
- 17 Dorsal intercarpal ligament between third and fourth carpal bones
- 18 Carpometacarpal joint
- 19 Metacarpal tuberosity
- 20 Metacarpal III (cannon bone)

Clinical Anatomy of the Horse

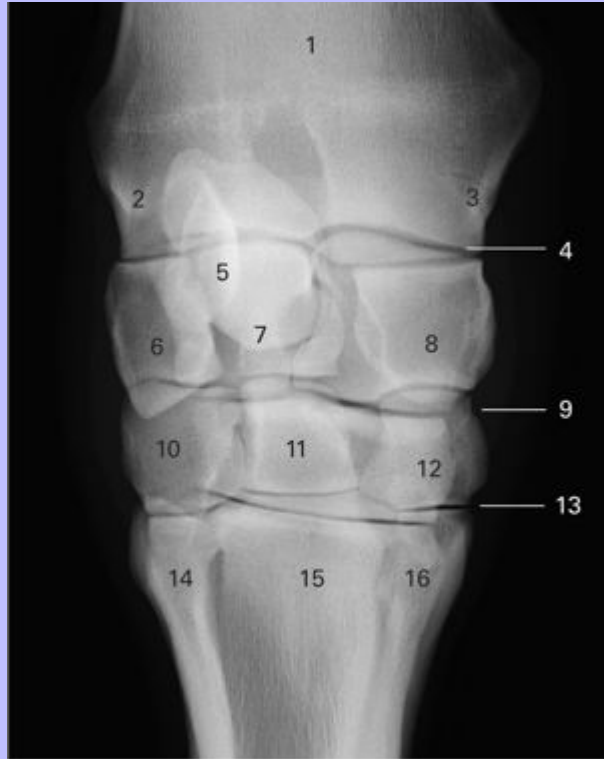4.40 Superficial dissection of left carpus, palmar view. Flexor retinaculum has been removed.



- 1 Tendon of M. extensor carpi ulnaris (M. ulnaris lateralis)
- 2 Tendon of M. flexor digitorum profundus
- 3 Tendon of M. flexor carpi ulnaris
- 4 Tendon of M. flexor carpi radialis
- 5 Tendon of M. extensor digitorum lateralis
- 6 Tendon of M. extensor carpi ulnaris to accessory carpal bone
- 7 Tendon of M. extensor carpi ulnaris to metacarpal IV
- 8 Accessory carpal bone
- 9 Metacarpal IV (lateral splint bone)
- 10 Tendon of M. flexor digitorum superficialis
- 11 Metacarpal II (medial splint bone)

Clinical Anatomy of the Horse

4.41 Dorsopalmar view radiograph of the carpus.



- 1 Radius
- 2 Lateral styloid process
- 3 Medial styloid process
- 4 Antebrachiocarpal (radiocarpal) joint
- 5 Accessory carpal bone
- 6 Ulnar carpal bone
- 7 Intermediate carpal bone
- 8 Radial carpal bone
- 9 Intercarpal joint
- 10 Fourth carpal bone
- 11 Third carpal bone

Clinical Anatomy of the Horse

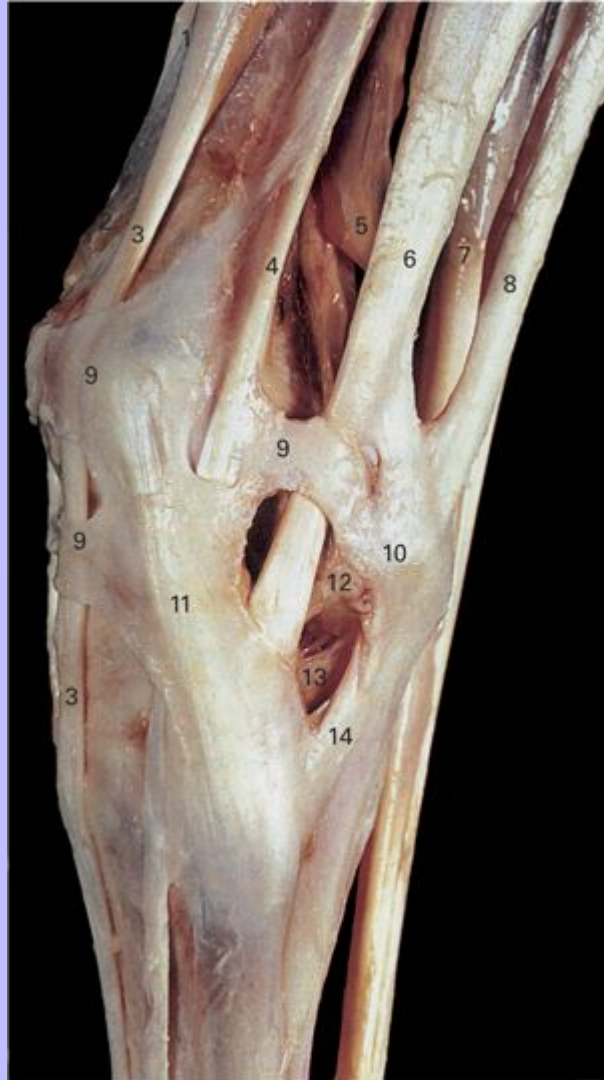
- 12 Second carpal bone
- 13 Carpometacarpal joint
- 14 Metacarpal IV (lateral splint bone)
- 15 Metacarpal III (cannon bone)
- 16 Metacarpal II (medial splint bone)

49

Clinical Anatomy of the Horse

50

4.42 Superficial dissection of left carpus, lateral view.



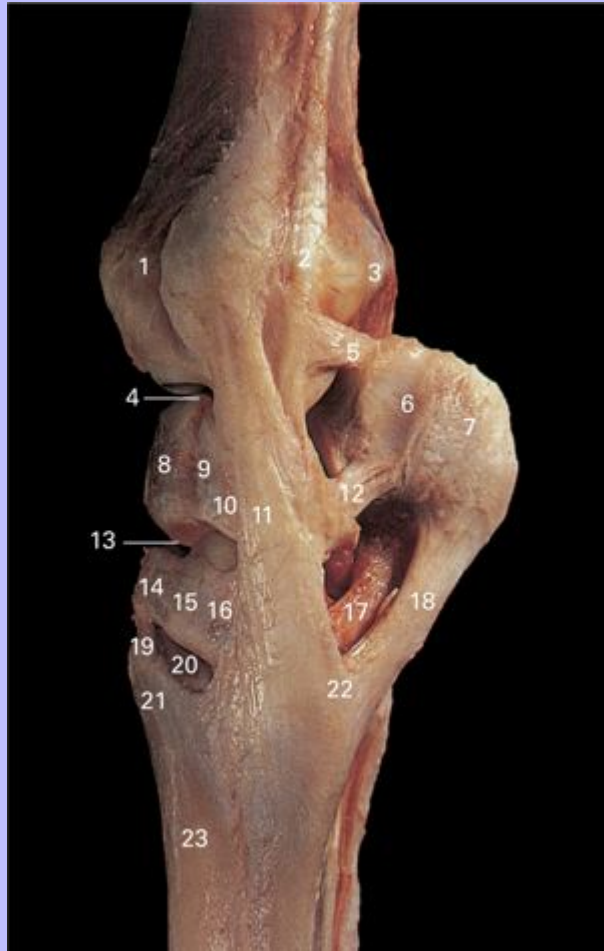
- 1 Tendon of M. extensor carpi radialis
- 2 M. abductor digiti I longus
- 3 Tendon of M. extensor digitorum communis
- 4 Tendon of M. extensor digitorum lateralis
- 5 M. flexor digitorum profundus, humeral head

Clinical Anatomy of the Horse

- 6 Tendon of M. extensor carpi ulnaris (M. ulnaris lateralis)
- 7 M. flexor digitorum profundus, ulnar head
- 8 Tendon of M. flexor carpi ulnaris
- 9 Extensor retinaculum
- 10 Accessory carpal bone
- 11 Lateral collateral carpal ligament
- 12 Accessoriocarpoulnar ligament
- 13 Accessorioquartal ligament
- 14 Accessoriometacarpal ligament

Clinical Anatomy of the Horse

4.43 Deep dissection of left carpus, lateral view.



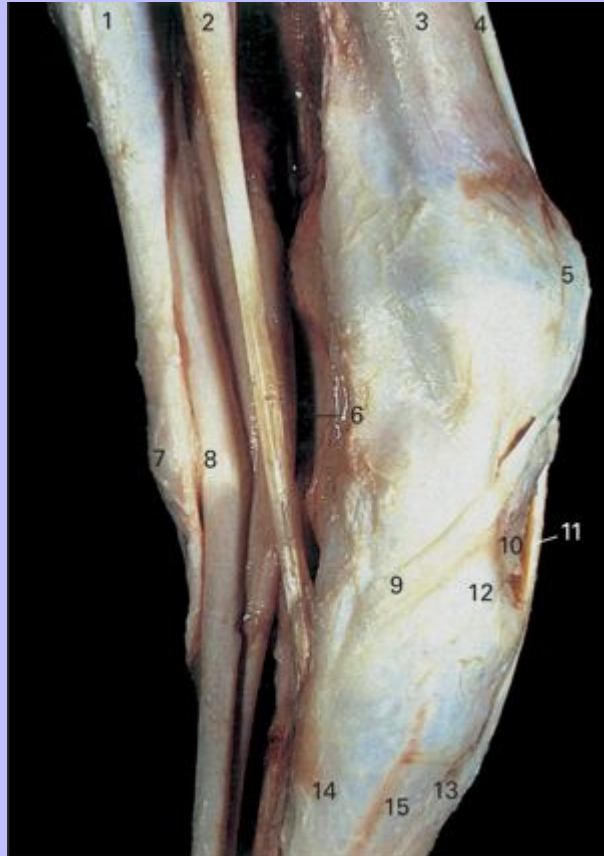- 1 Groove for tendon of M. extensor digitorum communis
- 2 Tendon of M. extensor digitorum lateralis
- 3 Transverse crest of radius
- 4 Antebrachio-carpal joint
- 5 Accessorioulnar ligament
- 6 Groove for tendon of M. ulnaris lateralis
- 7 Accessory carpal bone

Clinical Anatomy of the Horse

- 8 Intermediate carpal bone
- 9 Dorsal intercarpal ligament between intermediate and ulnar carpal bones
- 10 Ulnar carpal bone
- 11 Lateral collateral carpal ligament
- 12 Accessoriocarpoulnar ligament
- 13 Intercarpal joint
- 14 Third carpal bone
- 15 Dorsal intercarpal ligament between third and fourth carpal bones
- 16 Fourth carpal bone
- 17 Accessorioquartal ligament
- 18 Accessoriometacarpal ligament
- 19 Dorsal metacarpal ligament
- 20 Carpometacarpal joint
- 21 Metacarpal tuberosity
- 22 Base of metacarpal IV (lateral splint bone)
- 23 Metacarpal III (cannon bone)

Clinical Anatomy of the Horse

4.44 Superficial dissection of left carpus, medial view. Flexor retinaculum has been removed to expose contents of the carpal canal.



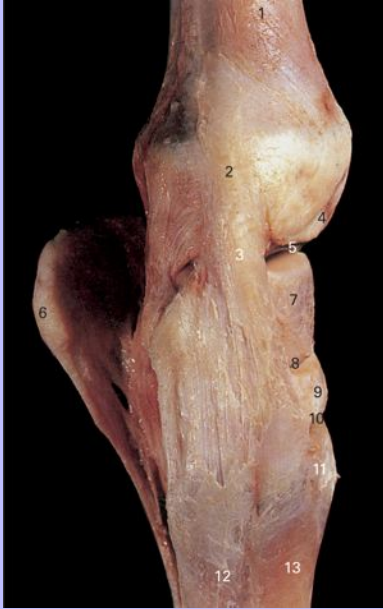- 1 M. flexor carpi ulnaris
- 2 M. flexor carpi radialis
- 3 Radius
- 4 M. extensor carpi radialis
- 5 Extensor retinaculum of carpus
- 6 Cut edge of flexor retinaculum
- 7 Accessory carpal bone
- 8 Tendon of M. flexor digitorum superficialis passing through carpal canal

Clinical Anatomy of the Horse

- 9 Tendon of M. extensor digiti I longus
- 10 Third carpal bone
- 11 Tendon of M. extensor carpi radialis
- 12 Medial collateral carpal ligament
- 13 Metacarpal tuberosity
- 14 Metacarpal II (medial splint bone)
- 15 Metacarpal III (cannon bone)

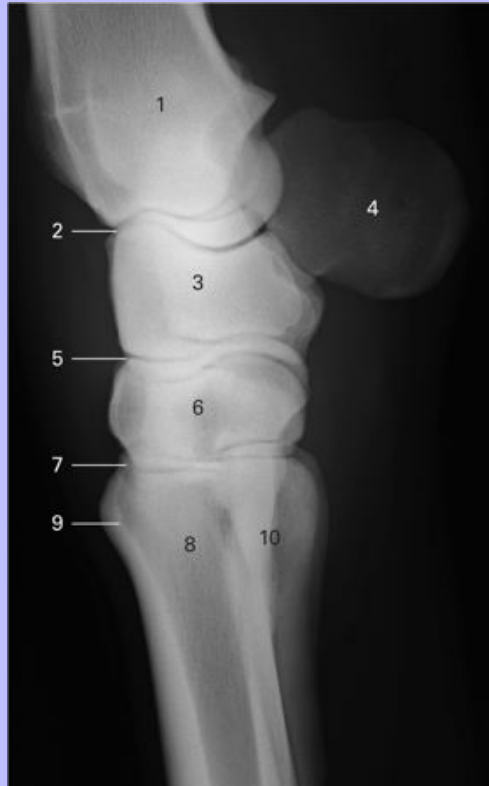Clinical Anatomy of the Horse

4.45 Deep dissection of left carpus, medial view.



- 1 Radius
- 2 Medial styloid process
- 3 Medial collateral carpal ligament
- 4 Groove for tendon of M. abductor digiti I longus
- 5 Antebrachio-carpal joint
- 6 Accessory carpal bone
- 7 Radial carpal bone
- 8 Intercarpal joint
- 9 Third carpal bone
- 10 Carpometacarpal joint
- 11 Metacarpal tuberosity
- 12 Metacarpal II (medial splint bone)
- 13 Metacarpal III (cannon bone)

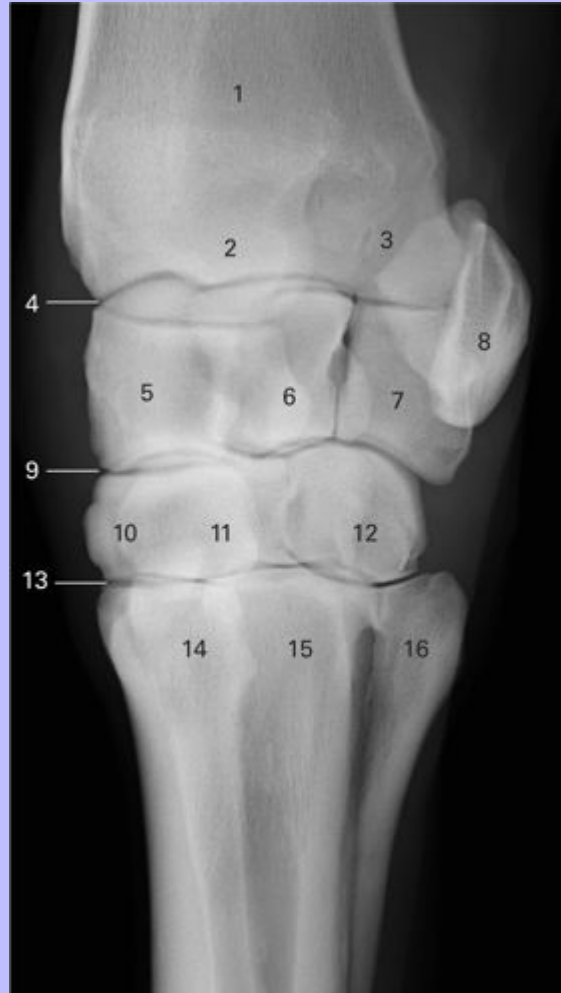
4.46 Lateromedial view radiograph of carpus.



- 1 Radius
- 2 Antebrachiocarpal (radiocarpal) joint
- 3 Radial, intermediate and ulnar carpal bones
- 4 Accessory carpal bone
- 5 Intercarpal joint
- 6 Second, third and fourth carpal bones
- 7 Carpometacarpal joint
- 8 Metacarpal III (cannon bone)
- 9 Metacarpal tuberosity
- 10 Metacarpals II and IV (medial and lateral splint bones)

Clinical Anatomy of the Horse

4.47 Dorsolateral-palmaromedial oblique view radiograph of carpus.



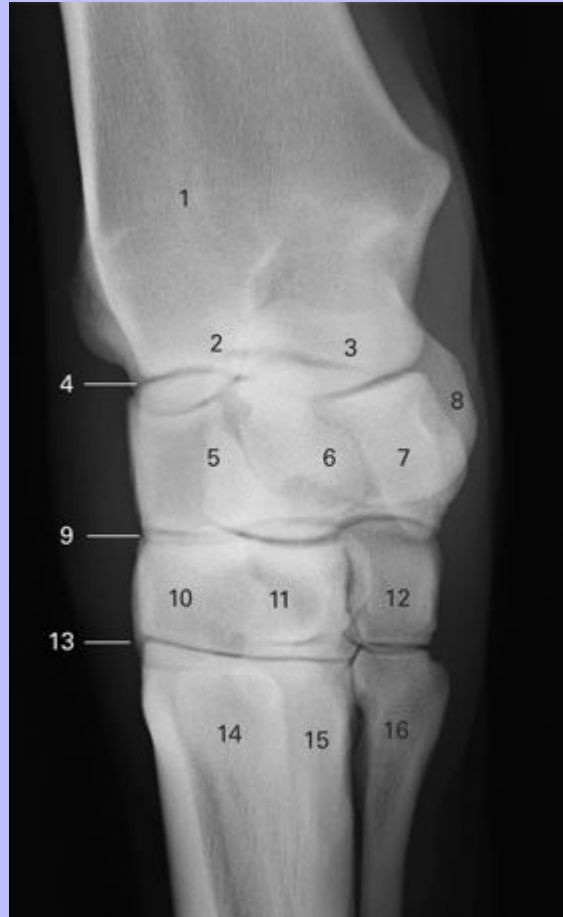
- 1 Radius
- 2 Medial styloid process
- 3 Lateral styloid process
- 4 Antebrachiocondylar (radiocarpal) joint
- 5 Radial carpal bone
- 6 Intermediate carpal bone
- 7 Ulnar carpal bone

Clinical Anatomy of the Horse

- 8 Accessory carpal bone
- 9 Intercarpal joint
- 10 Third carpal bone
- 11 Second carpal bone
- 12 Fourth carpal bone
- 13 Carpometacarpal joint
- 14 Metacarpal II (medial splint bone)
- 15 Metacarpal III (cannon bone)
- 16 Metacarpal IV (lateral splint bone)

Clinical Anatomy of the Horse

4.48 Dorsomedial-palmarolateral oblique view radiograph of carpus.



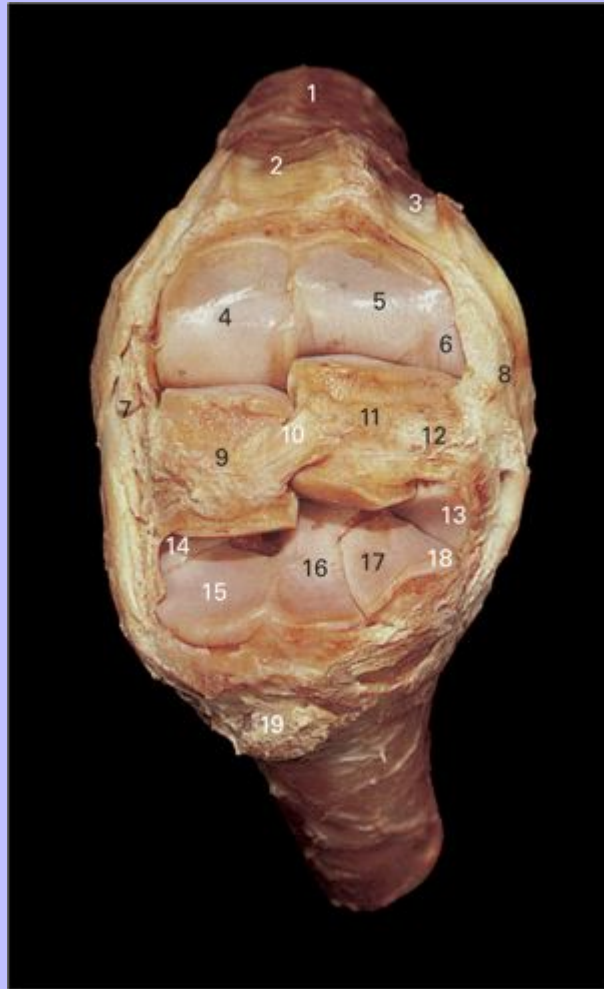
- 1 Radius
- 2 Lateral styloid process
- 3 Medial styloid process
- 4 Radiocarpal (antebrachiocarpal) joint
- 5 Ulnar carpal bone
- 6 Intermediate carpal bone
- 7 Radial carpal bone
- 8 Accessory carpal bone

Clinical Anatomy of the Horse

- 9 Intercarpal joint
- 10 Third carpal bone
- 11 Fourth carpal bone
- 12 Second carpal bone
- 13 Carpometacarpal joint
- 14 Metacarpal IV (lateral splint bone)
- 15 Metacarpal III (cannon bone)
- 16 Metacarpal II (medial splint bone)

51

4.49 Deep dissection of left carpus, flexed dorsal view.



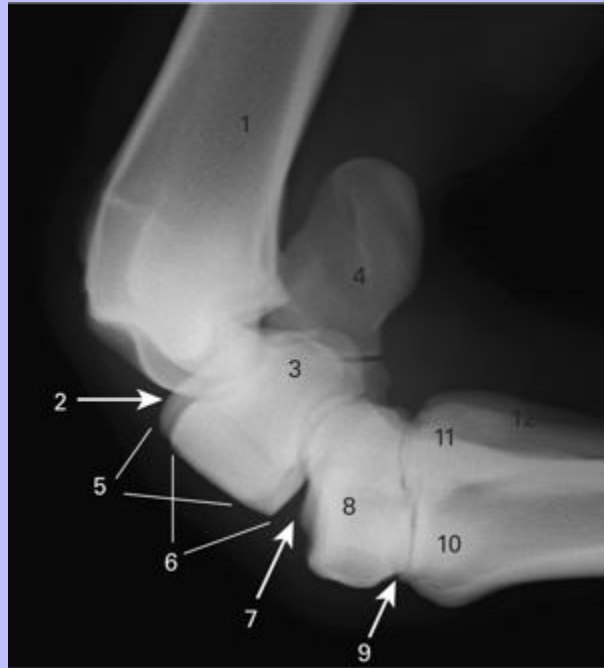
- 1 Radius
- 2 Groove for tendon of M. extensor carpi radialis
- 3 Groove for tendon of M. extensor digitorum lateralis
- 4 Facet on radius for articulation with radial carpal bone
- 5 Facet on radius for articulation with intermediate carpal bone
- 6 Facet on lateral styloid process for articulation with ulnar carpal bone
- 7 Medial collateral carpal ligament

Clinical Anatomy of the Horse

- 8 Lateral collateral carpal ligament
- 9 Radial carpal bone
- 10 Dorsal intercarpal ligament between radial and intermediate carpal bones
- 11 Intermediate carpal bone
- 12 Dorsal intercarpal ligament between ulnar and intermediate carpal bones
- 13 Facet on ulnar carpal bone for articulation with fourth carpal bone
- 14 Facet on second carpal bone for articulation with radial carpal bone
- 15 Facet on third carpal bone for articulation with radial carpal bone
- 16 Facet on third carpal bone for articulation with intermediate carpal bone
- 17 Facet on fourth carpal bone for articulation with intermediate carpal bone
- 18 Facet on fourth carpal bone for articulation with ulnar carpal bone
- 19 Metacarpal tuberosity

Clinical Anatomy of the Horse

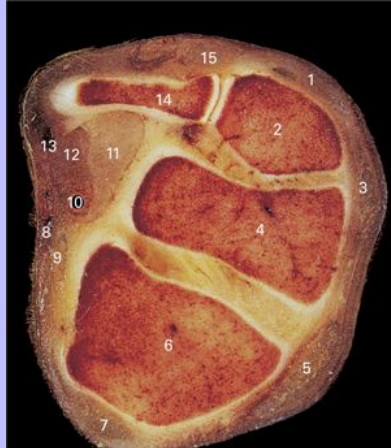
4.50 Flexed lateromedial view radiograph of carpus.



- 1 Radius
- 2 Antebrachiocarpal (radiocarpal) joint
- 3 Ulnar carpal bone
- 4 Accessory carpal bone
- 5 Intermediate carpal bone
- 6 Radial carpal bone
- 7 Intercarpal joint
- 8 Second, third and fourth carpal bones
- 9 Carpometacarpal joint
- 10 Metacarpal III (cannon bone)
- 11 Metacarpal II (medial splint bone)
- 12 Metacarpal IV (lateral splint bone)

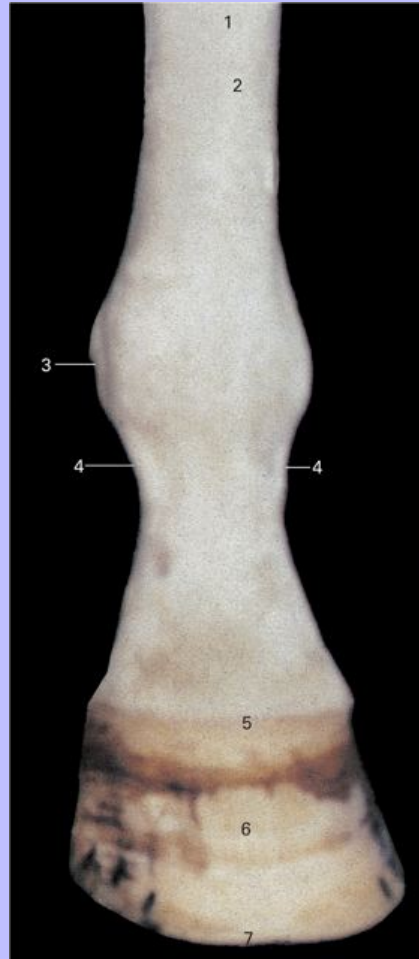
Clinical Anatomy of the Horse

4.51 Transverse section through left carpus at level of proximal row of carpal bones, distal view.



- 1 Tendon of M. extensor digitorum lateralis
- 2 Ulnar carpal bone
- 3 Tendon of M. extensor digitorum communis
- 4 Intermediate carpal bone
- 5 Tendon of M. extensor carpi radialis
- 6 Radial carpal bone
- 7 Tendon of M. abductor digiti I longus
- 8 Medial palmar vein
- 9 Tendon of M. flexor carpi radialis
- 10 Medial palmar artery and nerve
- 11 Tendon of M. flexor digitorum profundus
- 12 Tendon of M. flexor digitorum superficialis
- 13 Lateral palmar vessels and nerve
- 14 Accessory carpal bone
- 15 Tendon of M. extensor carpi ulnaris

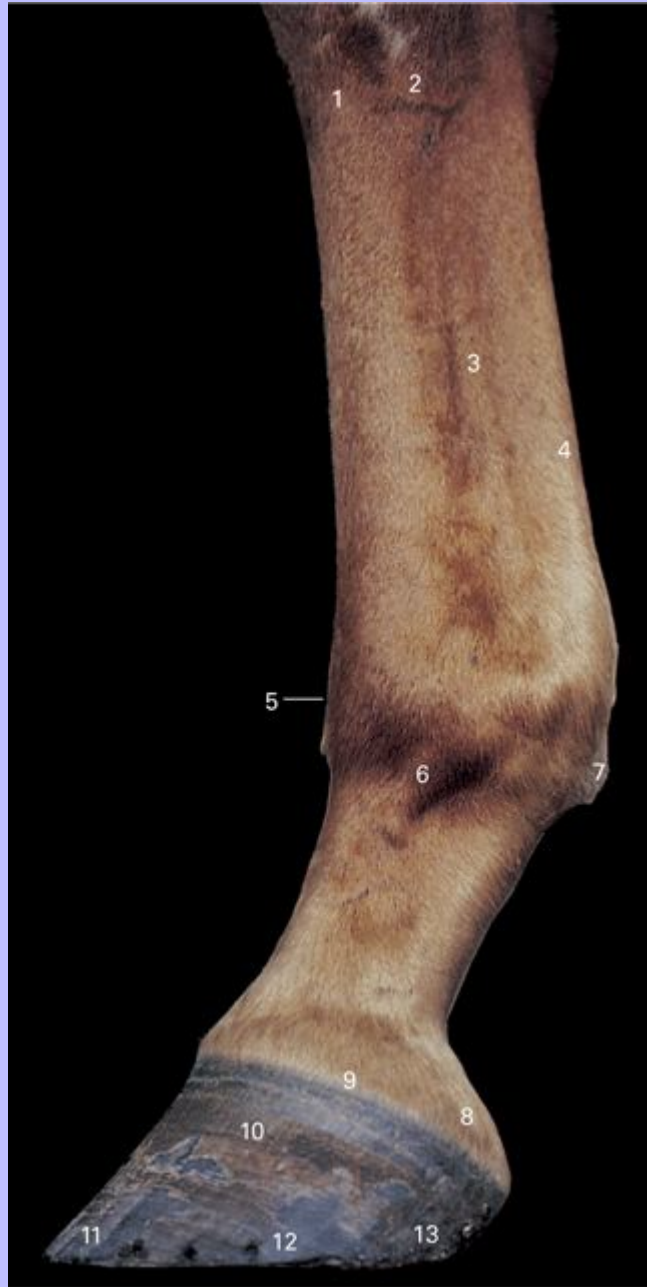4.52 Left manus, dorsal view.



- 1 Metacarpal region
- 2 Tendon of M. extensor digitorum communis
- 3 Level of metacarpophalangeal (fetlock) joint
- 4 Extensor branches of M. interosseus medius to tendon of M. extensor digitorum communis
- 5 Coronet
- 6 Wall of hoof
- 7 Toe

Clinical Anatomy of the Horse

4.53 Left manus, lateral view.



1 Metacarpal III (cannon bone)

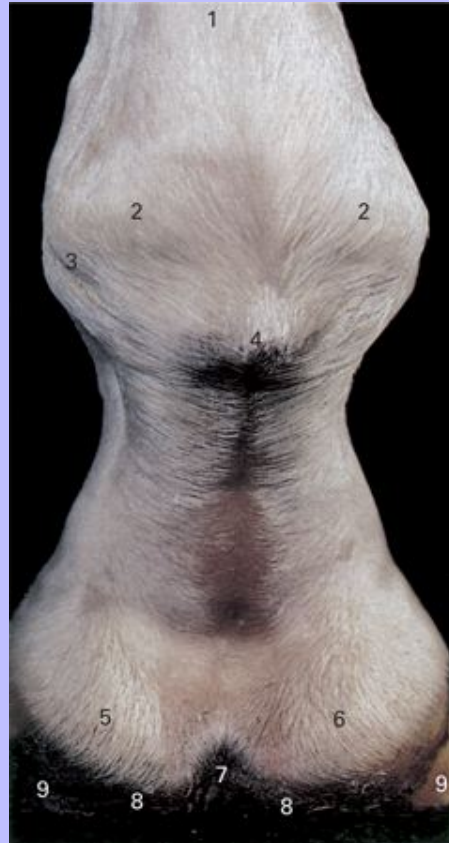2 Metacarpal IV (lateral splint bone)

Clinical Anatomy of the Horse

- 3 M. interosseus medius (suspensory ligament)
- 4 Tendons of M. flexor digitorum superficialis and M. flexor digitorum profundus
- 5 Level of metacarpophalangeal (fetlock) joint
- 6 Lateral extensor branch of M. interosseus medius
- 7 Ergot
- 8 Lateral cartilage of distal phalanx
- 9 Coronet
- 10 Wall of hoof
- 11 Toe
- 12 Quarter
- 13 Heel

Clinical Anatomy of the Horse

4.54 Left manus, palmar view.

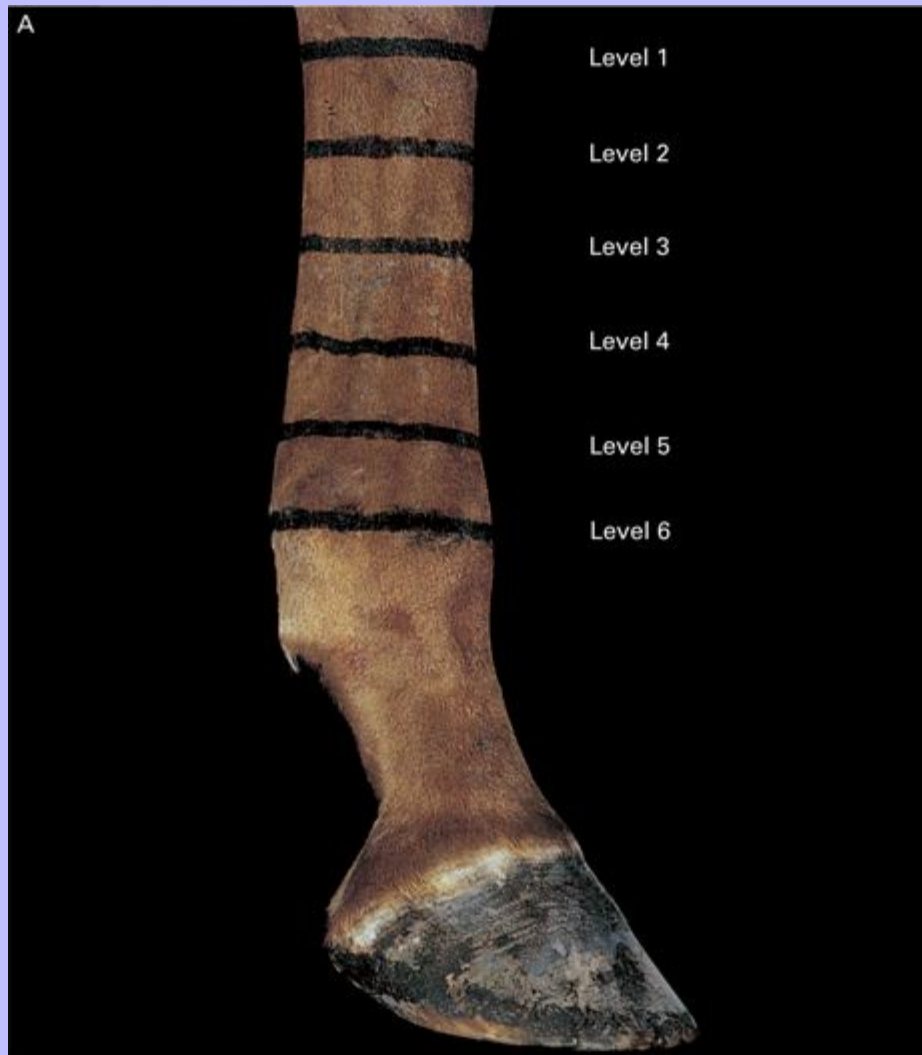


- 1 Metacarpal region
- 2 Proximal sesamoid bones
- 3 Level of metacarpophalangeal (fetlock) joint
- 4 Ergot
- 5 Lateral cartilage of distal phalanx
- 6 Medial cartilage of distal phalanx
- 7 Cleft of frog
- 8 Bulbs of heels
- 9 Hoof wall

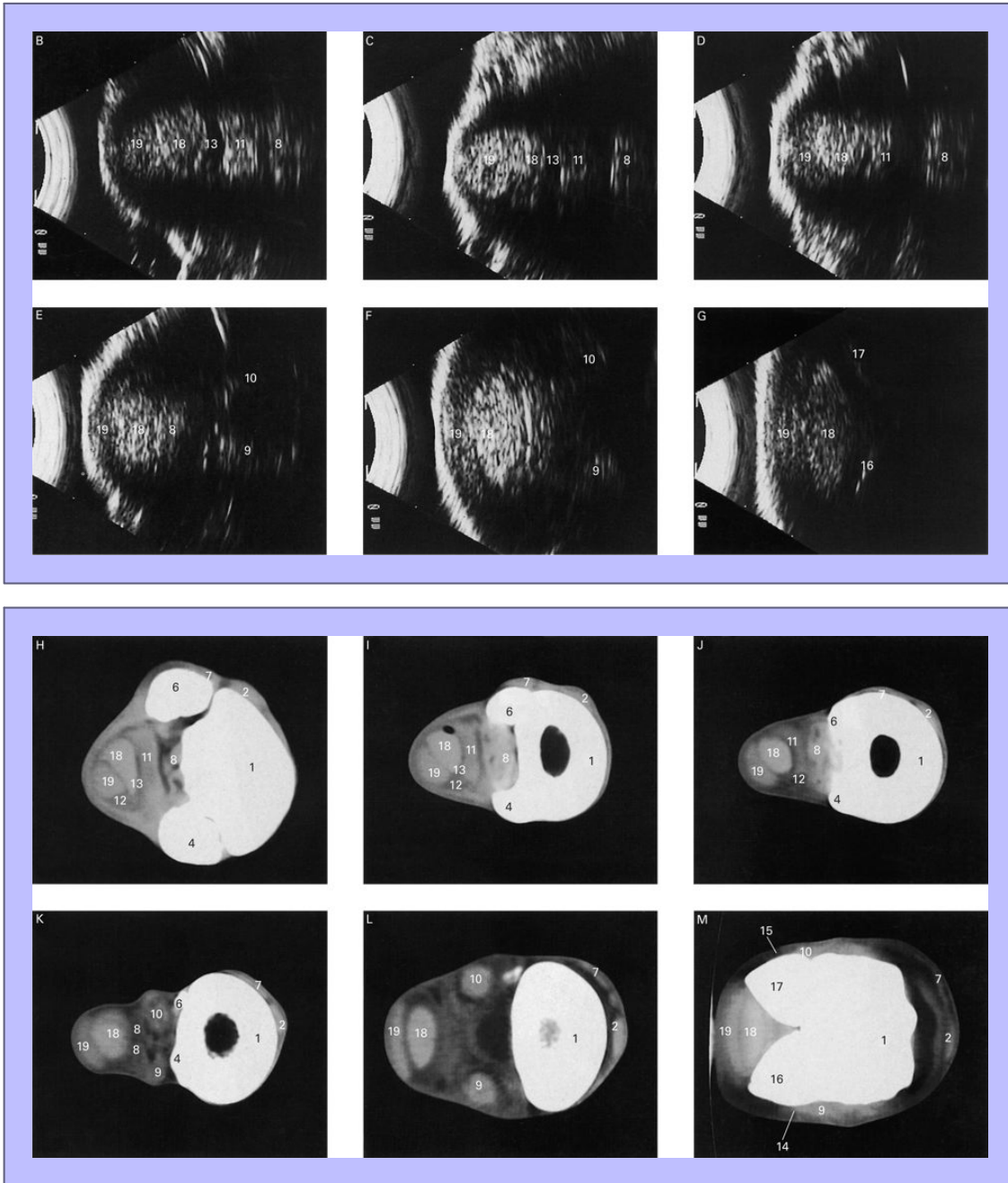
Clinical Anatomy of the Horse

54

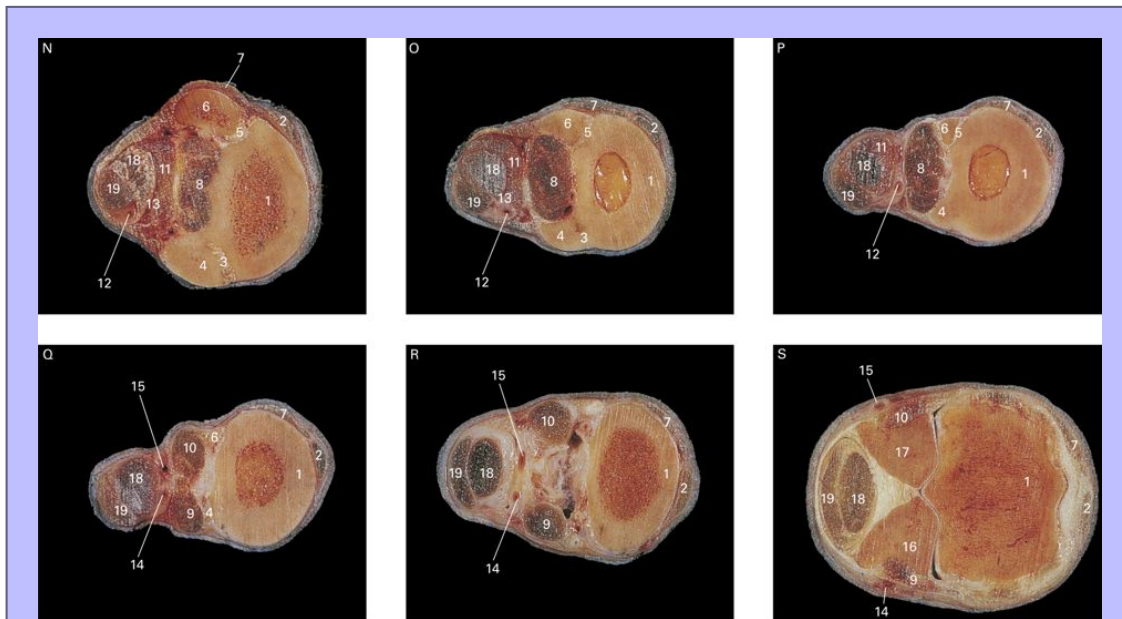
4.55 Left manus (A) showing six levels at which images were made using a 7.5 MHz ultrasound sector scanner with standoff pad (pictures B–G), and computed tomography (pictures H–M). The leg was then sectioned at the six levels (pictures N–S).



Clinical Anatomy of the Horse



Clinical Anatomy of the Horse



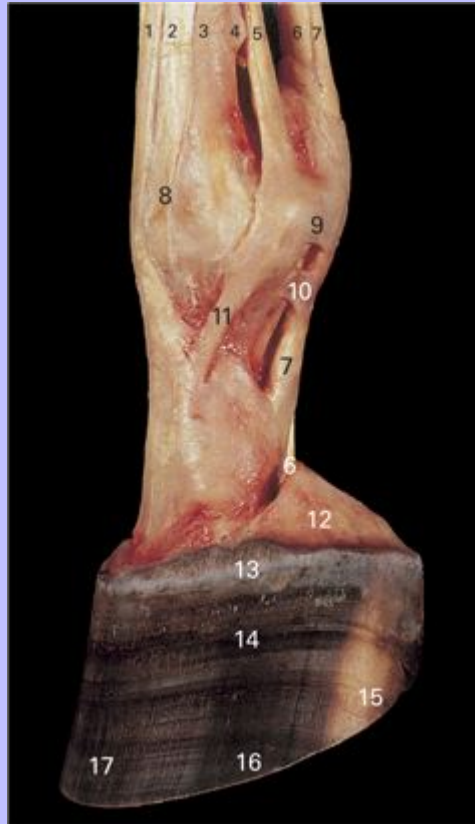
- 1 Metacarpal III (cannon bone)
- 2 Tendon of M. extensor digitorum communis
- 3 Interosseus metacarpal ligament between metacarpals II and III
- 4 Metacarpal II (medial splint bone)
- 5 Interosseus metacarpal ligament between metacarpals III and IV
- 6 Metacarpal IV (lateral splint bone)
- 7 Tendon of M. extensor digitorum lateralis
- 8 M. interosseus medius (suspensory ligament)
- 9 Medial extensor branch of M. interosseus medius
- 10 Lateral extensor branch of M. interosseus medius
- 11 Accessory ligament of M. flexor digitorum profundus (distal check ligament)
- 12 Medial palmar artery
- 13 Carpal sheath
- 14 Medial palmar digital artery

Clinical Anatomy of the Horse

- 15 Lateral palmar digital artery
- 16 Medial proximal sesamoid bone
- 17 Lateral proximal sesamoid bone
- 18 Tendon of M. flexor digitorum profundus
- 19 Tendon of M. flexor digitorum superficialis

54

4.56 Superficial dissection of digit of left forelimb, lateral view.



- 1 Tendon of M. extensor digitorum communis
- 2 Tendon of M. extensor digitorum lateralis
- 3 Metacarpal III (cannon bone)
- 4 Metacarpal IV (lateral splint bone)
- 5 M. interosseus medius (suspensory ligament)
- 6 Tendon of M. flexor digitorum profundus
- 7 Tendon of M. flexor digitorum superficialis
- 8 Attachment of tendon of M. extensor digitorum lateralis
- 9 Superficial transverse metacarpal ligament (palmar annular ligament)

Clinical Anatomy of the Horse

10 Vagina fibrosa (proximal digital annular ligament)

11 Lateral extensor branch of M. interosseus medius

12 Lateral cartilage of distal phalanx

13 Coronet

14 Wall of hoof

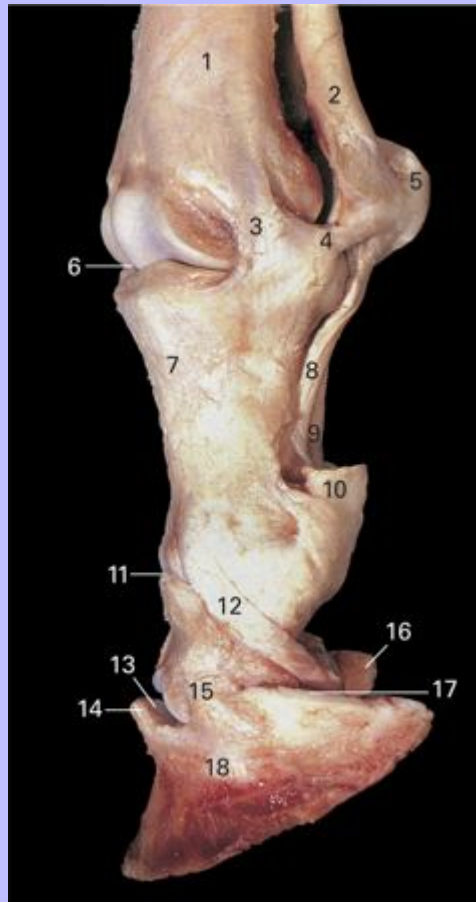
15 Heel

16 Quarter

17 Toe

Clinical Anatomy of the Horse

4.57 Deep dissection of digit of left forelimb, lateral view. The following structures have been removed: transverse metacarpal ligament; vagina fibrosa; tendons of the M. extensor digitorum communis, M. extensor digitorum lateralis, M. flexor digitorum superficialis and M. flexor digitorum profundus; lateral extensor branch of M. interosseus medius; wall, sole and frog of the hoof.



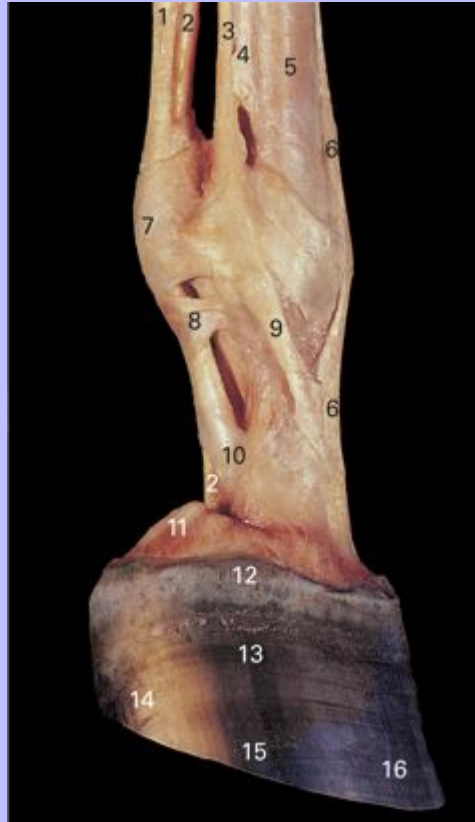- 1 Metacarpal II (medial splint bone)
- 2 M. interosseus medius (suspensory ligament)
- 3 Lateral collateral metacarpophalangeal ligament
- 4 Lateral collateral sesamoidean ligament
- 5 Lateral proximal sesamoid bone

Clinical Anatomy of the Horse

- 6 Metacarpophalangeal (fetlock) joint
- 7 Proximal phalanx
- 8 Oblique sesamoidean ligament
- 9 Straight sesamoidean ligament
- 10 Cut edge of tendon of M. flexor digitorum superficialis
- 11 Proximal interphalangeal (pastern) joint
- 12 Lateral collateral ligament of distal sesamoid bone (suspensory navicular ligament)
- 13 Distal interphalangeal (coffin) joint
- 14 Extensor process of distal phalanx
- 15 Lateral collateral ligament of distal interphalangeal joint
- 16 Medial process of distal phalanx
- 17 Cut edge of lateral cartilage of distal phalanx
- 18 Distal phalanx (coffin bone)

Clinical Anatomy of the Horse

4.58 Superficial dissection of digit of left forelimb, medial view.



- 1 Tendon of M. flexor digitorum superficialis
- 2 Tendon of M. flexor digitorum profundus
- 3 M. interosseus medius (suspensory ligament)
- 4 Metacarpal II (medial splint bone)
- 5 Metacarpal III (cannon bone)
- 6 Tendon of M. extensor digitorum communis
- 7 Superficial transverse metacarpal ligament (palmar annular ligament)
- 8 Vagina fibrosa (proximal digital annular ligament)
- 9 Medial extensor branch of M. interosseus medius

Clinical Anatomy of the Horse

10 Vagina fibrosa (distal digital annular ligament)

11 Medial cartilage of distal phalanx

12 Coronet

13 Wall of hoof

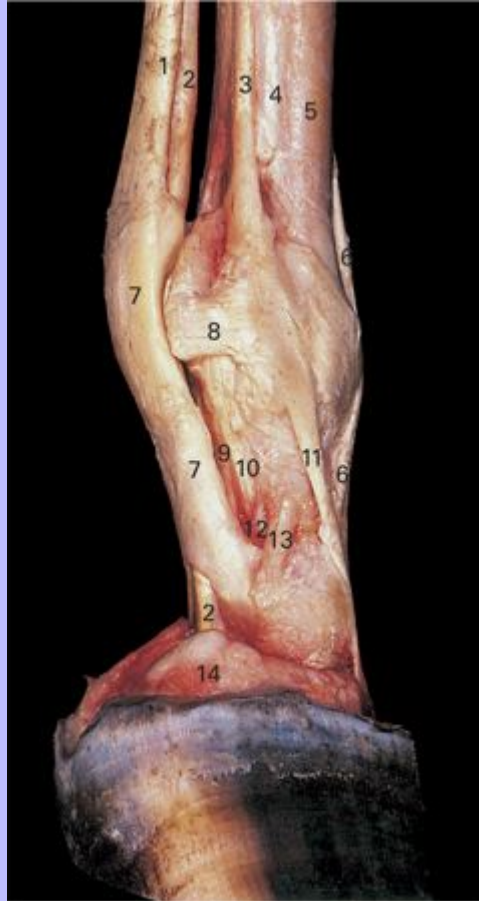
14 Heel

15 Quarter

16 Toe

Clinical Anatomy of the Horse

4.59 Deep dissection of digit of left forelimb, medial view. The superficial transverse metacarpal ligament and the vagina fibrosa have been removed.



- 1 Tendon of M. flexor digitorum superficialis
- 2 Tendon of M. flexor digitorum profundus
- 3 M. interosseus medius (suspensory ligament)
- 4 Metacarpal II (medial splint bone)
- 5 Metacarpal III (cannon bone)
- 6 Tendon of M. extensor digitorum communis
- 7 Manica flexoria

Clinical Anatomy of the Horse

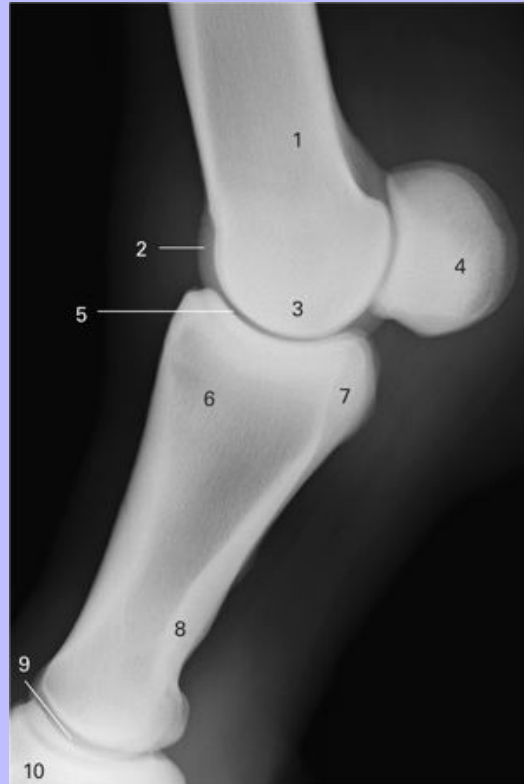- 8 Medial collateral sesamoidean ligament
- 9 Straight sesamoidean ligament
- 10 Oblique sesamoidean ligament
- 11 Medial extensor branch of M. interosseus medius
- 12 Palmar ligament of proximal interphalangeal joint
- 13 Medial collateral ligament of proximal interphalangeal joint
- 14 Medial cartilage of distal phalanx

56

Clinical Anatomy of the Horse

57

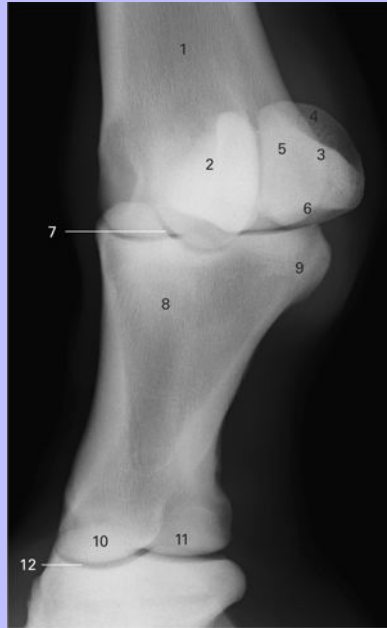
4.60 Lateromedial view radiograph of metacarpophalangeal (fetlock) joint.



- 1 Metacarpal III (cannon bone)
- 2 Sagittal ridge
- 3 Medial and lateral condyles
- 4 Medial and lateral proximal sesamoid bones
- 5 Metacarpophalangeal (fetlock) joint
- 6 Proximal phalanx (P1, long pastern bone)
- 7 Palmar tubercles (eminences)
- 8 Eminence for attachment of distal sesamoidean ligaments
- 9 Proximal interphalangeal (pastern) joint
- 10 Middle phalanx (P2, short pastern bone)

Clinical Anatomy of the Horse

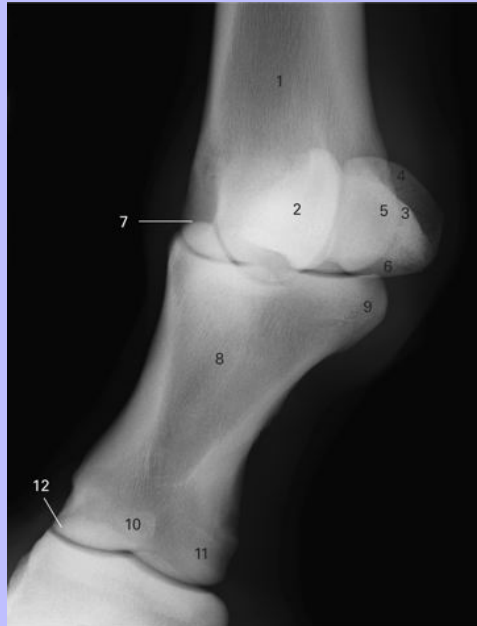4.61 Dorsolateral-palmaromedial oblique view radiograph of metacarpophalangeal (fetlock) joint.



- 1 Metacarpal III (cannon bone)
- 2 Medial proximal sesamoid bone
- 3 Lateral proximal sesamoid bone
- 4 Apex
- 5 Articular surface
- 6 Base
- 7 Metacarpophalangeal (fetlock) joint
- 8 Proximal phalanx (P1, long pastern bone)
- 9 Lateral palmar tubercle (eminence)
- 10 Medial condyle
- 11 Lateral condyle
- 12 Proximal interphalangeal (pastern) joint

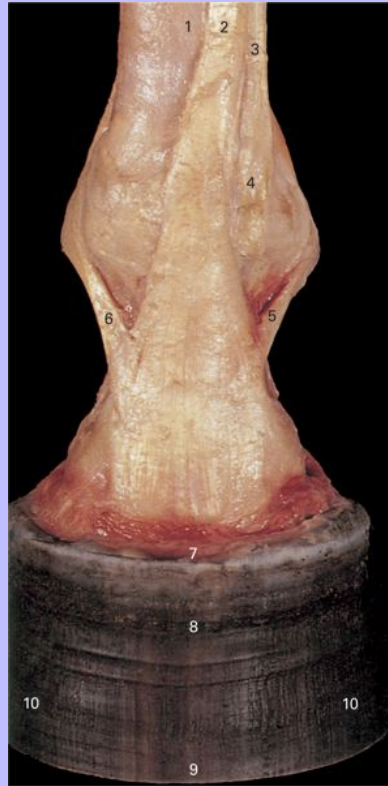Clinical Anatomy of the Horse

4.62 Dorsomedial-palmarolateral oblique view radiograph of metacarpophalangeal (fetlock) joint.



- 1 Metacarpal III (cannon bone)
- 2 Lateral proximal sesamoid bone
- 3 Medial proximal sesamoid bone
- 4 Apex
- 5 Articular surface
- 6 Base
- 7 Metacarpophalangeal (fetlock) joint
- 8 Proximal phalanx (P1, long pastern bone)
- 9 Medial palmar tubercle (eminence)
- 10 Lateral condyle
- 11 Medial condyle
- 12 Proximal interphalangeal (pastern) joint

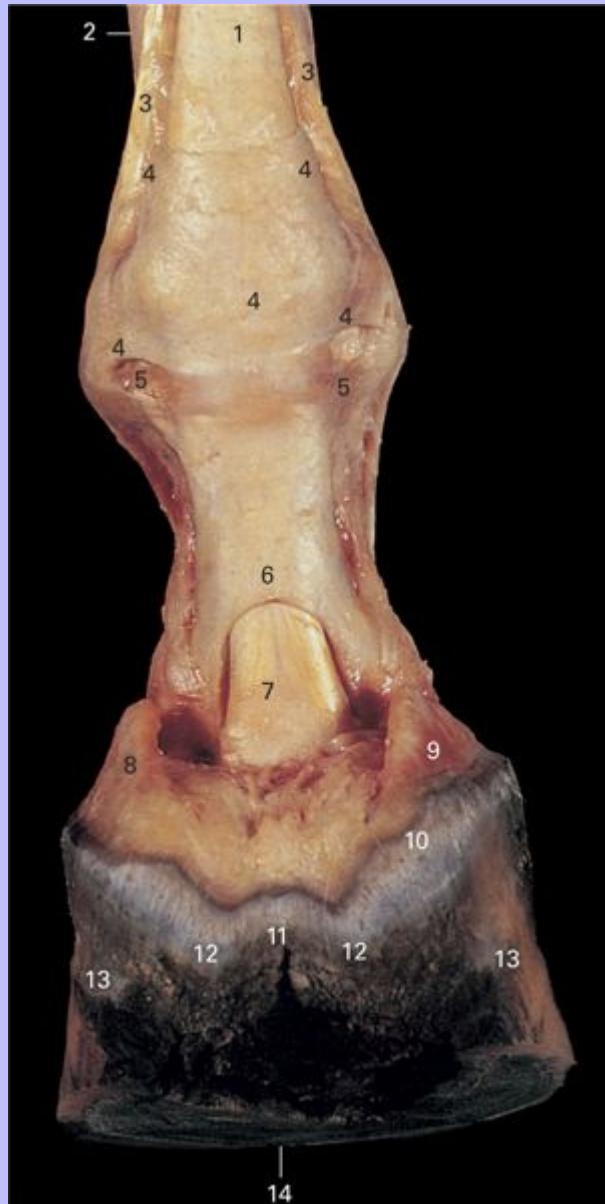4.63 Superficial dissection of left manus, dorsal view.



- 1 Metacarpal III (cannon bone)
- 2 Tendon of M. extensor digitorum communis
- 3 Tendon of M. extensor digitorum lateralis
- 4 Distal attachment of tendon of M. extensor digitorum lateralis
- 5 Lateral extensor branch of M. interosseus medius
- 6 Medial extensor branch of M. interosseus medius
- 7 Coronet
- 8 Wall of hoof
- 9 Toe
- 10 Quarters

Clinical Anatomy of the Horse

4.64 Superficial dissection of left manus, palmar view.



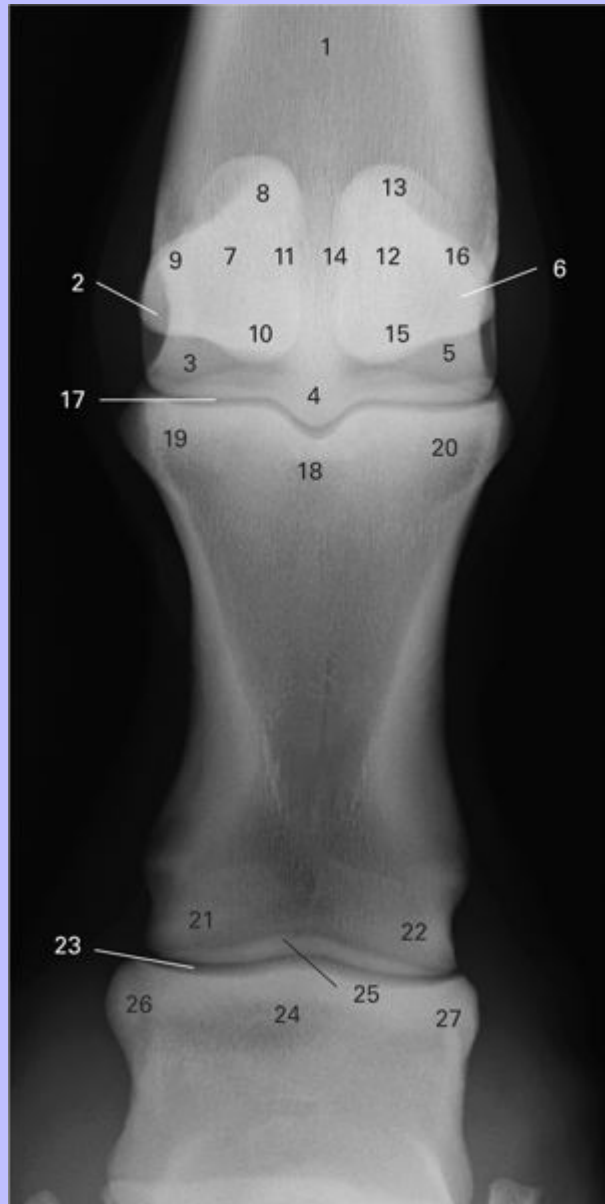
- 1 Tendon of *M. flexor digitorum superficialis*
- 2 Tendon of *M. extensor digitorum lateralis*
- 3 *M. interosseus medius* (suspensory ligament)

Clinical Anatomy of the Horse

- 4 Superficial transverse metacarpal ligament (palmar annular ligament)
- 5 Vagina fibrosa (proximal digital annular ligament)
- 6 Manica flexoria
- 7 Tendon of *M. flexor digitorum profundus*
- 8 Lateral cartilage of distal phalanx
- 9 Medial cartilage of distal phalanx
- 10 Coronet
- 11 Cleft of frog
- 12 Bulbs of heel
- 13 Wall of hoof
- 14 Sole of hoof

Clinical Anatomy of the Horse

4.65 Dorsopalmar view radiograph of metacarpophalangeal (fetlock) joint.



1 Metacarpal III (cannon bone)

2 Lateral epicondyle

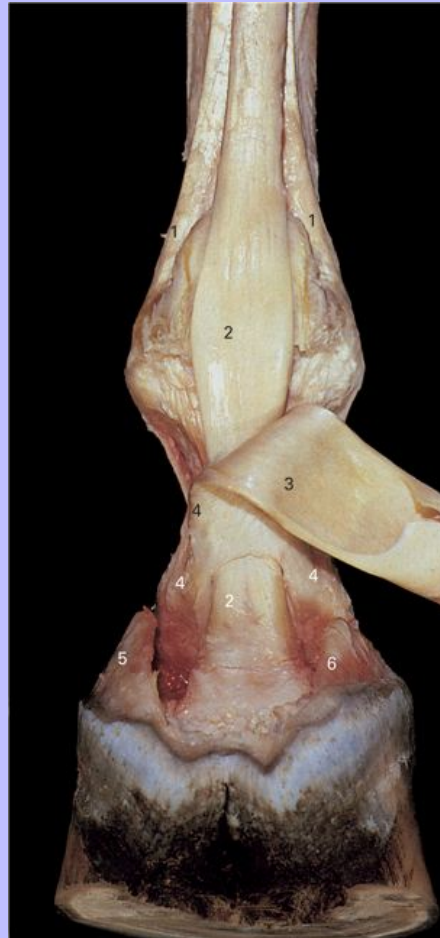
3 Lateral condyle

Clinical Anatomy of the Horse

- 4 Sagittal ridge
- 5 Medial condyle
- 6 Medial epicondyle
- 7 Lateral proximal sesamoid bone
- 8 Apex
- 9 Abaxial margin
- 10 Base
- 11 Axial margin
- 12 Medial proximal sesamoid bone
- 13 Apex
- 14 Axial margin
- 15 Base
- 16 Abaxial margin
- 17 Metacarpophalangeal (fetlock) joint
- 18 Proximal phalanx (P1, long pastern bone)
- 19 Lateral proximal tubercle
- 20 Medial proximal tubercle
- 21 Lateral condyle
- 22 Medial condyle
- 23 Proximal interphalangeal (pastern) joint
- 24 Middle phalanx (P2, short pastern bone)
- 25 Extensor process
- 26 Lateral eminence of proximal P2
- 27 Medial eminence of proximal P2

58

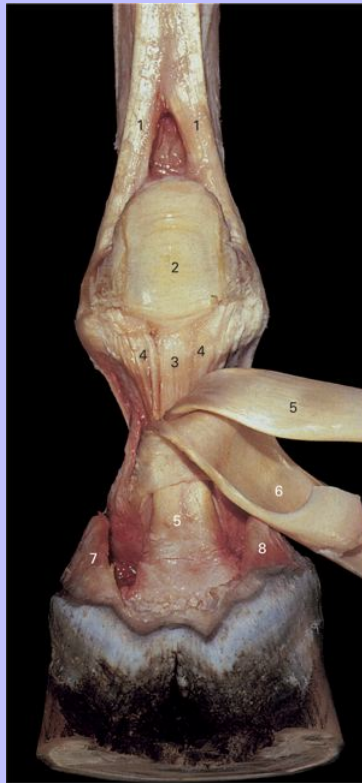
4.66 Deep dissection of digit of left forelimb, palmar view. The superficial transverse metacarpal ligament and the vaginae fibrosae have been removed. The tendon of the M. flexor digitorum superficialis has been reflected.



- 1 Extensor branches of M. interosseus medius
- 2 Tendon of M. flexor digitorum profundus
- 3 Tendon of M. flexor digitorum superficialis (reflected)
- 4 Manica flexoria
- 5 Lateral cartilage of distal phalanx
- 6 Medial cartilage of distal phalanx

Clinical Anatomy of the Horse

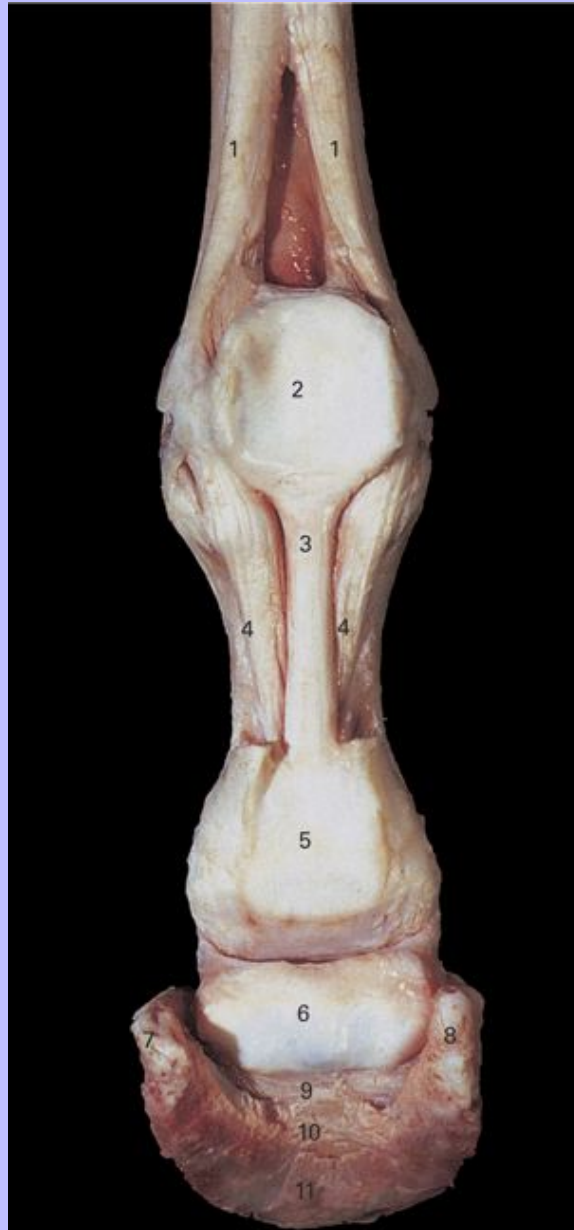4.67 Deep dissection of digit of left forelimb, palmar view. The superficial transverse metacarpal ligament and the vaginae fibrosae have been removed. The tendons of the M. flexor digitorum superficialis and M. flexor digitorum profundus have been reflected.



- 1 Extensor branches of M. interosseus medius
- 2 Palmar (intersesamoidean) ligament
- 3 Straight sesamoidean ligament
- 4 Oblique sesamoidean ligament
- 5 Tendon of M. flexor digitorum profundus
- 6 Tendon of M. flexor digitorum superficialis
- 7 Lateral cartilage of distal phalanx
- 8 Medial cartilage of distal phalanx

Clinical Anatomy of the Horse

4.68 Deep dissection of digit of left forelimb, palmar view. The superficial transverse metacarpal ligament, vagina fibrosa, tendon of the M. flexor digitorum superficialis, and tendon of the M. flexor digitorum profundus have been removed. The wall, sole and frog of the hoof have been removed.



1 Extensor branches of M. interosseus medius

Clinical Anatomy of the Horse

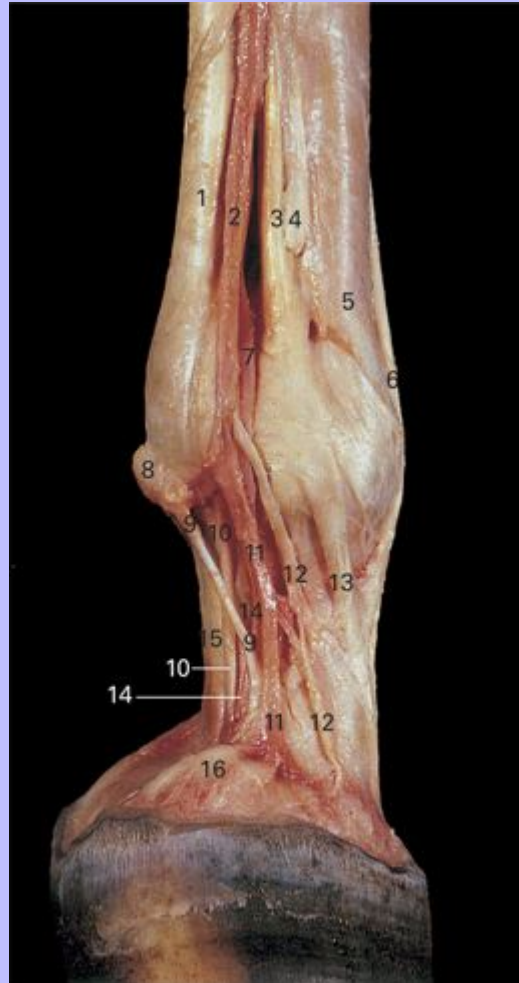
- 2 Palmar (intersesamoidean) ligament
- 3 Straight sesamoidean ligament
- 4 Oblique sesamoidean ligament
- 5 Fibrocartilaginous plate
- 6 Flexor surface of distal sesamoid bone
- 7 Lateral cartilage of hoof
- 8 Medial cartilage of hoof
- 9 Flexor surface of distal phalanx
- 10 Semilunar line
- 11 Solar surface of distal phalanx

59

Clinical Anatomy of the Horse

60

4.69 Dissection of nerves and vessels of distal left limb, medial view.



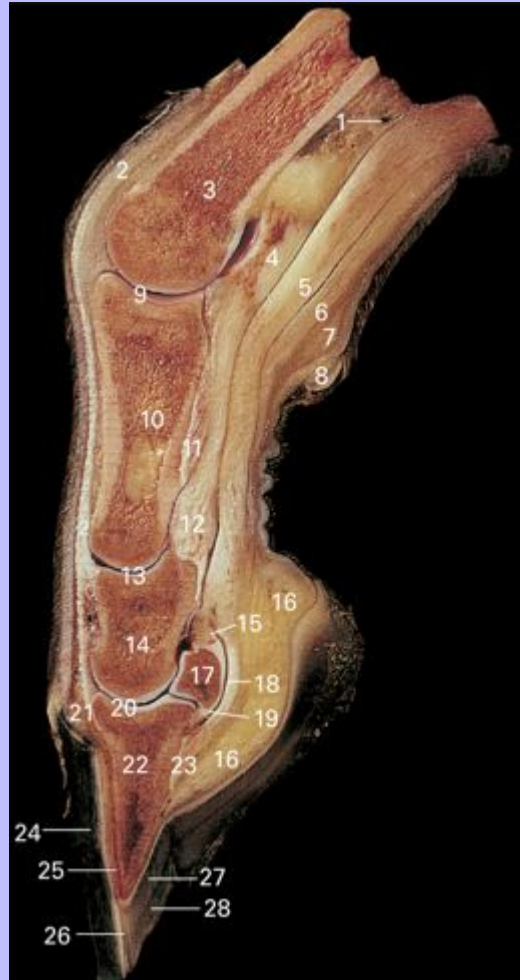- 1 Tendon of *M. flexor digitorum superficialis*
- 2 Medial palmar vein
- 3 *M. interosseus medius* (suspensory ligament)
- 4 Distal end of metacarpal II (button of medial splint bone)
- 5 Metacarpal III (cannon bone)
- 6 Tendon of *M. extensor digitorum communis*
- 7 Medial palmar artery

Clinical Anatomy of the Horse

- 8 Ergot
- 9 Ligament of ergot
- 10 Medial palmar digital nerve
- 11 Medial palmar digital vein
- 12 Dorsal branch of medial palmar digital nerve
- 13 Medial extensor branch of M. interosseus medius
- 14 Medial palmar digital artery
- 15 Tendon of M. flexor digitorum profundus
- 16 Medial cartilage of distal phalanx

Clinical Anatomy of the Horse

4.70 Median section through digit of left forelimb.



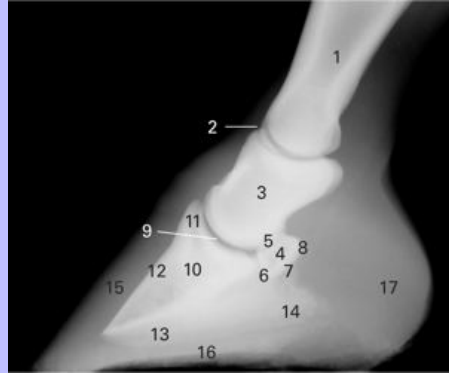- 1 Proximal extent of digital synovial sheath
- 2 Tendon of M. extensor digitorum communis
- 3 Metacarpal III (cannon bone)
- 4 Palmar ligament
- 5 Tendon of M. flexor digitorum profundus
- 6 Tendon of M. flexor digitorum superficialis
- 7 Fibrous tissue underlying ergot

Clinical Anatomy of the Horse

- 8 Ergot
- 9 Metacarpophalangeal (fetlock) joint
- 10 Proximal phalanx (P1, long pastern bone)
- 11 Oblique sesamoidean ligament
- 12 Straight sesamoidean ligament
- 13 Proximal interphalangeal (pastern) joint
- 14 Middle phalanx (P2, short pastern bone)
- 15 Collateral sesamoidean (suspensory navicular) ligament
- 16 Digital cushion
- 17 Distal sesamoid (navicular) bone
- 18 Podotrochlear (navicular) bursa
- 19 Distal sesamoid impar ligament
- 20 Distal interphalangeal (coffin) joint
- 21 Coronary corium
- 22 Distal phalanx (P3, coffin bone, pedal bone)
- 23 Insertion of tendon of M. flexor digitorum profundus
- 24 Wall of hoof
- 25 Laminae
- 26 White zone
- 27 Sole corium
- 28 Sole of hoof

Clinical Anatomy of the Horse

4.71 Lateromedial view radiograph of foot.

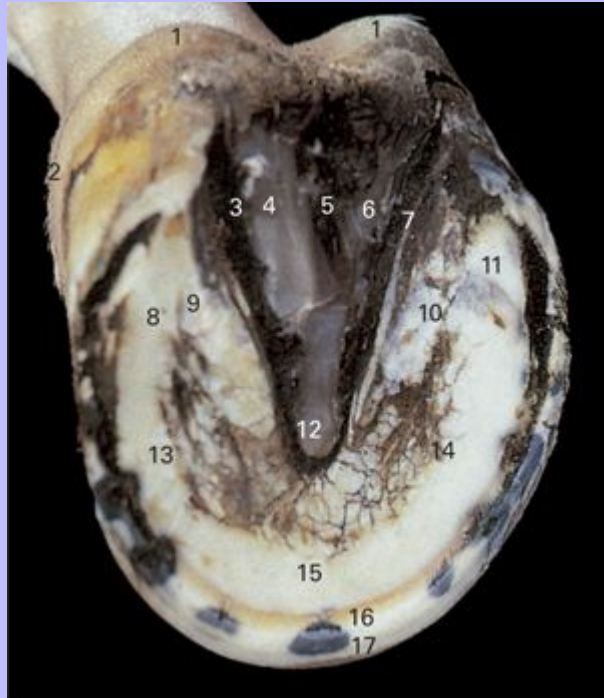

- 1 Proximal phalanx (P1, long pastern bone)
- 2 Proximal interphalangeal (pastern) joint
- 3 Middle phalanx (P2, short pastern bone)
- 4 Distal sesamoid (navicular) bone
- 5 Articular margin
- 6 Distal margin
- 7 Flexor surface
- 8 Proximal margin
- 9 Distal interphalangeal (coffin) joint
- 10 Distal phalanx (P3)
- 11 Extensor process
- 12 Dorsal margin
- 13 Solar margin
- 14 Palmar processes
- 15 Hoof wall
- 16 Sole
- 17 Bulbs

Clinical Anatomy of the Horse

61

4.72 Left hoof, solar view.



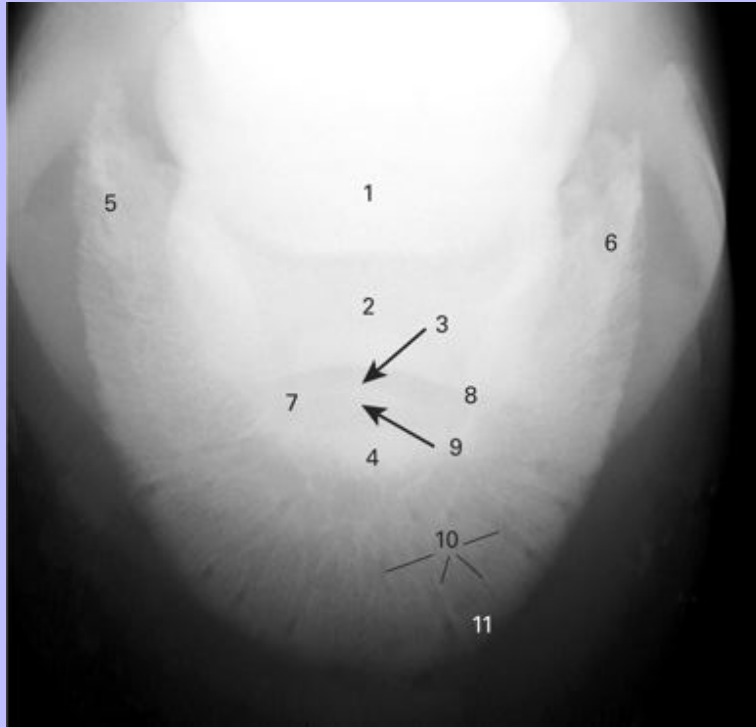
- 1 Bulbs of heel
- 2 Coronet
- 3 Lateral paracuneal sulcus
- 4 Lateral crus of frog
- 5 Central sulcus of frog
- 6 Medial crus of frog
- 7 Medial paracuneal sulcus
- 8 Lateral angle of sole
- 9 Lateral bar of hoof wall
- 10 Medial bar of hoof wall
- 11 Medial angle of sole
- 12 Apex of frog

Clinical Anatomy of the Horse

- 13 Lateral crus of sole
- 14 Medial crus of sole
- 15 Central part of sole
- 16 White zone
- 17 Hoof wall (stratum medium)

Clinical Anatomy of the Horse

4.73 Dorsopalmar view radiograph of distal phalanx.

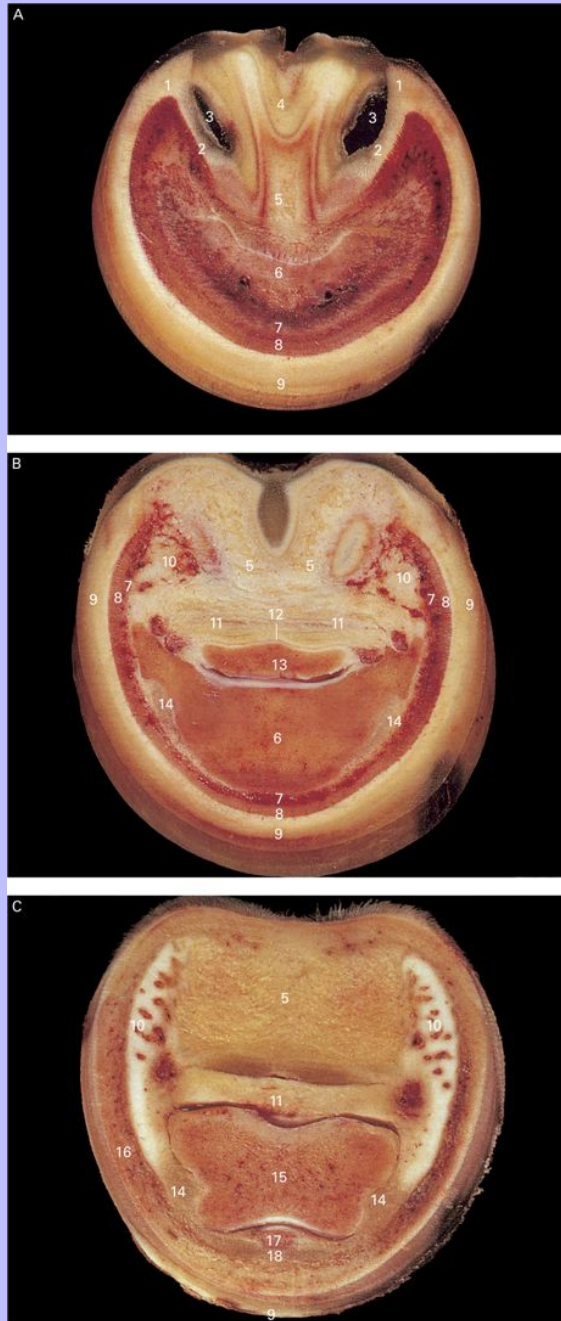


- 1 Distal sesamoid (navicular) bone
- 2 Middle phalanx (P2, short pastern bone)
- 3 Distal interphalangeal (coffin) joint
- 4 Distal phalanx (P3, coffin bone, pedal bone)
- 5 Lateral palmar process
- 6 Medial palmar process
- 7 Lateral parietal sulcus
- 8 Medial parietal sulcus
- 9 Extensor process
- 10 Vascular channels
- 11 Solar margin

Clinical Anatomy of the Horse

62

4.74 Transverse section through foot, distal view. Sections are cut parallel to the coronary border: A, three fourths of the distance from the coronet to the distal border of the hoof wall; B, midway between the coronet and distal border of the hoof wall; C, just distal to the coronet.



Clinical Anatomy of the Horse

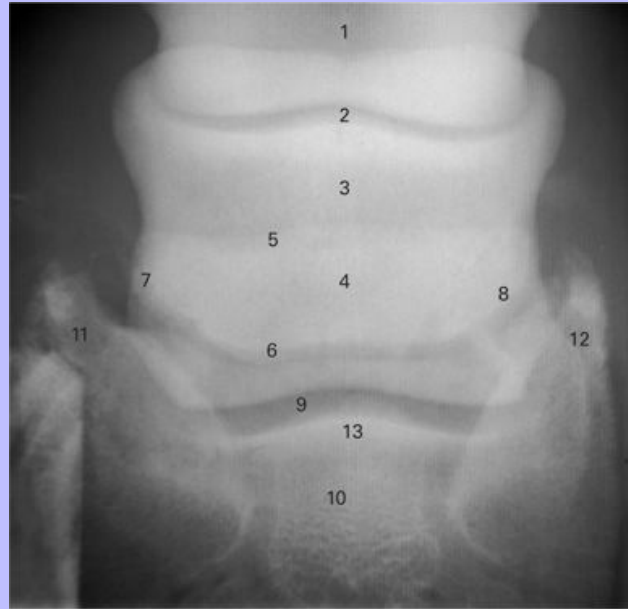
- 1 Angle
- 2 Bar
- 3 Space between frog and bar
- 4 Frog
- 5 Digital cushion
- 6 Distal phalanx (P3, coffin bone, pedal bone)
- 7 Lamellar corium (dermal lamellae)
- 8 Lamellae of wall (epidermal lamellae)
- 9 Wall
- 10 Cartilage of distal phalanx and associated vascular plexus
- 11 Tendon of M. flexor digitorum profundus
- 12 Podotrochlear (navicular) bursa
- 13 Distal sesamoid (navicular) bone
- 14 Collateral ligament of distal interphalangeal (coffin) joint
- 15 Middle phalanx (P2, short pastern bone)
- 16 Coronary corium
- 17 Extensor process of distal phalanx
- 18 Tendon of M. extensor digitorum communis

62

Clinical Anatomy of the Horse

63

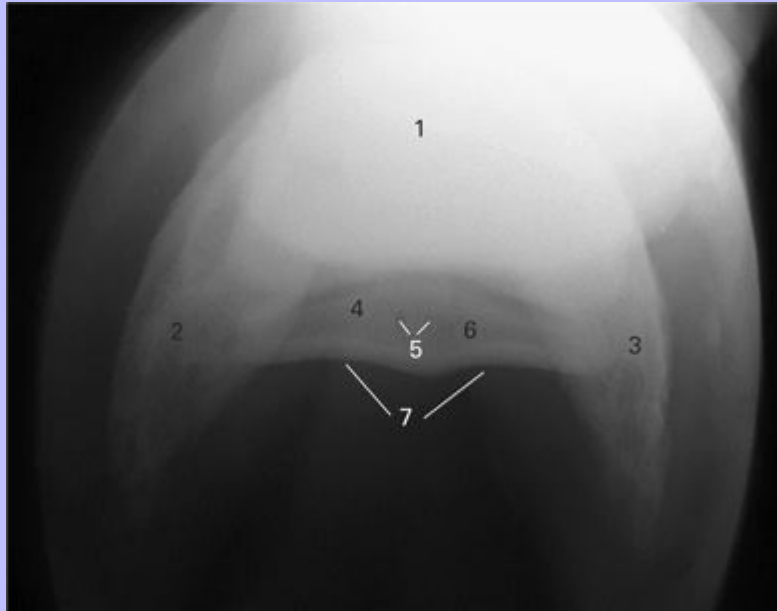
4.75 Dorsopalmar view radiograph of distal sesamoid (navicular) bone.



- 1 Proximal phalanx (P1, long pastern bone)
- 2 Proximal interphalangeal (pastern) joint
- 3 Middle phalanx (P2, short pastern bone)
- 4 Distal sesamoid (navicular) bone
- 5 Proximal margin
- 6 Distal margin
- 7 Lateral margin
- 8 Medial margin
- 9 Distal interphalangeal (coffin) joint
- 10 Distal phalanx (P3, coffin bone, pedal bone)
- 11 Lateral palmar process
- 12 Medial palmar process
- 13 Extensor process

Clinical Anatomy of the Horse

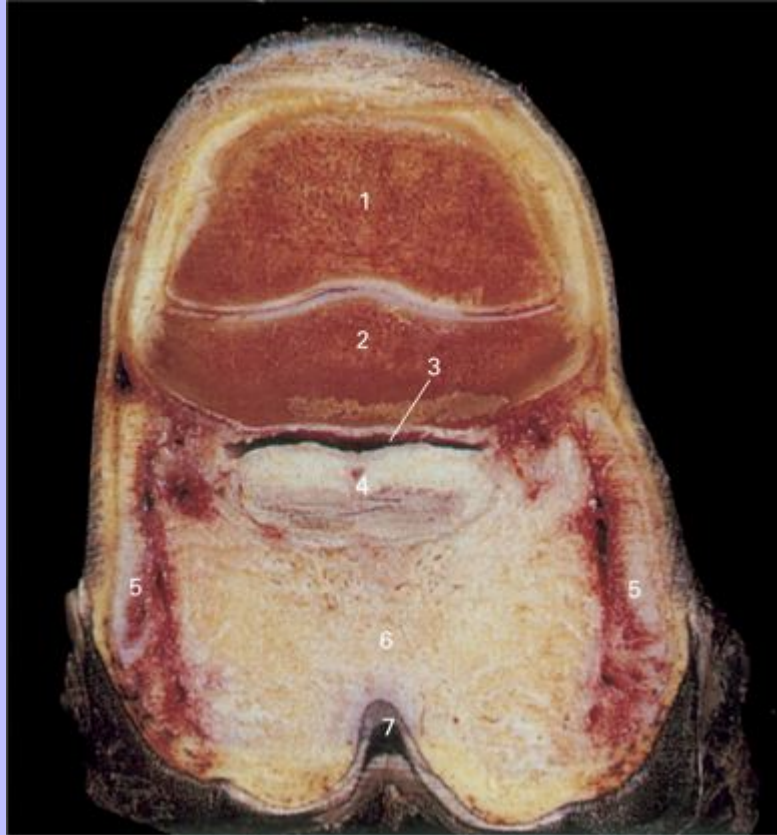
4.76 Proximopalmar-distopalmar view radiograph of the distal sesamoid (navicular) bone.



- 1 Distal phalanx (P3, coffin bone, pedal bone)
- 2 Lateral palmar process
- 3 Medial palmar process
- 4 Distal sesamoid (navicular) bone
- 5 Vascular channels
- 6 Medullary cavity
- 7 Flexor surface

Clinical Anatomy of the Horse

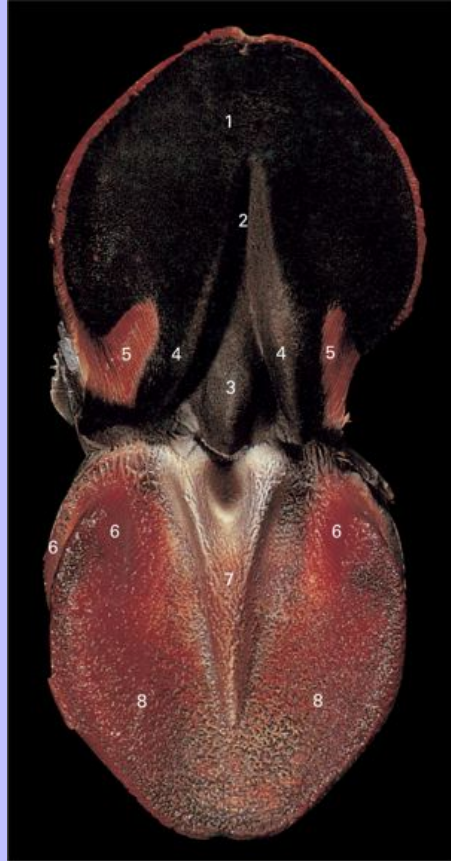4.77 Frontal section of left hoof, palmar view. Section is cut through the heels.



- 1 Middle phalanx (P2, short pastern bone)
- 2 Distal sesamoid (navicular) bone
- 3 Podotrochlear (navicular) bursa
- 4 Tendon of M. flexor digitorum profundus
- 5 Cartilages of distal phalanx with associated vascular plexus
- 6 Digital cushion
- 7 Cleft of frog

63

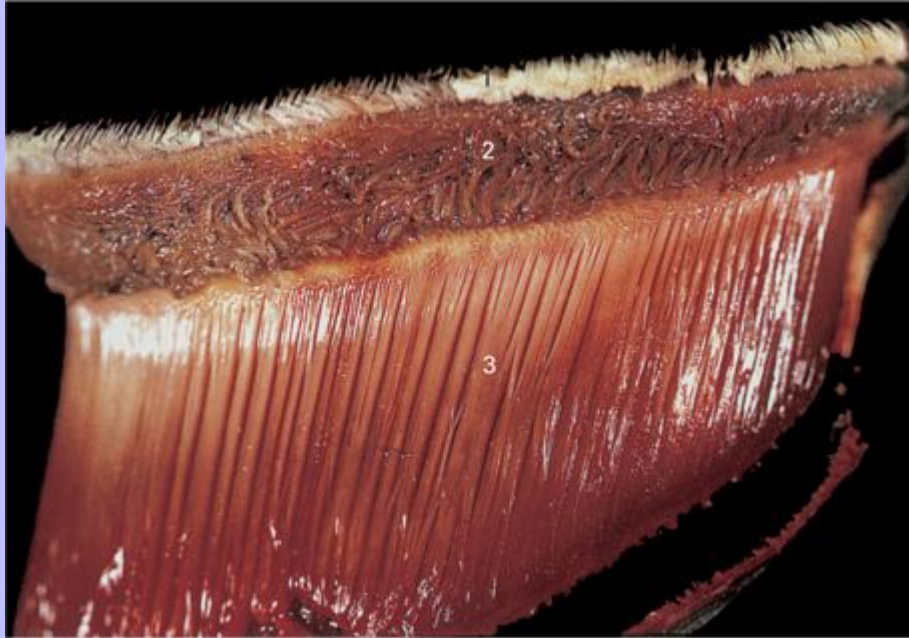
4.78 Foot, solar view. The epidermal tissues have been reflected upwards. The wall and epidermal lamellae have been removed.



- 1 Dorsal surface of sole
- 2 Central furrow over apex of frog
- 3 Spine of frog (frog stay)
- 4 Junction of frog and bar
- 5 Lamellae of bar
- 6 Lamellar corium
- 7 Corium of frog
- 8 Corium of sole

Clinical Anatomy of the Horse

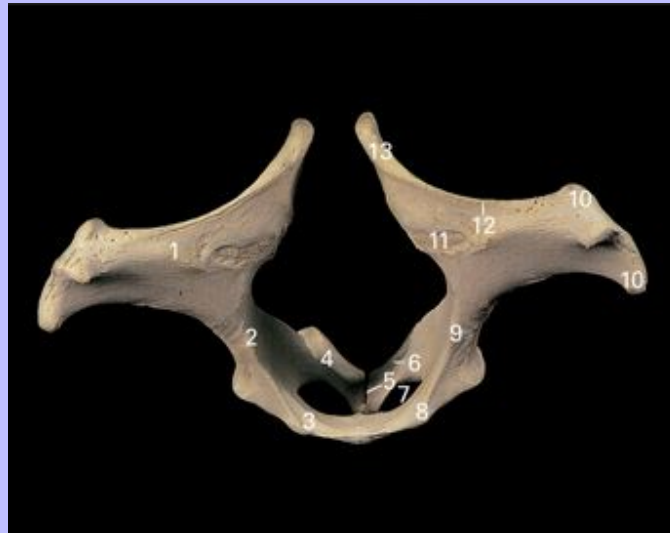4.79 Corium of foot, lateral view. The wall and epidermal lamellae have been removed.



- 1 Corium of periople
- 2 Coronary corium
- 3 Lamellar corium (dermal lamellae)

5 Hindlimb

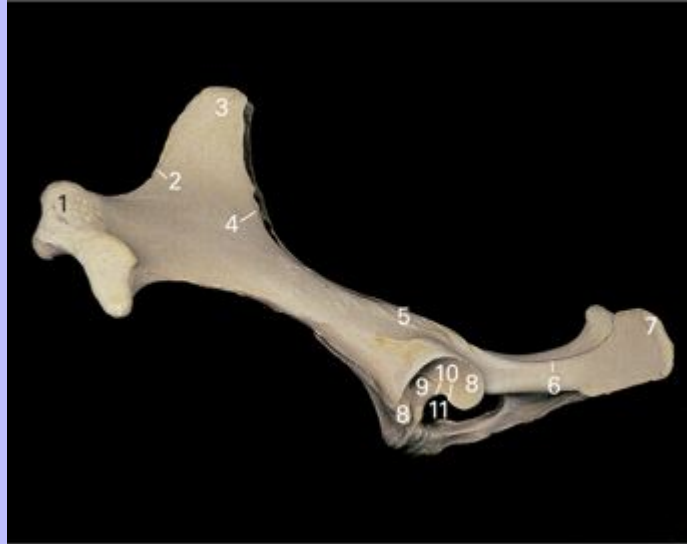5.1 Ossa coxarum, craniodorsal view.



- 1 Wing of ilium
- 2 Body of ilium
- 3 Pubis
- 4 Ischium
- 5 Pelvic symphysis, ischiatic part
- 6 Ischiatic arch
- 7 Obturator foramen
- 8 Pubic tubercle
- 9 Arcuate (iliopectineal) line
- 10 Coxal tuberosity
- 11 Auricular surface
- 12 Iliac crest
- 13 Sacral tuberosity

Clinical Anatomy of the Horse

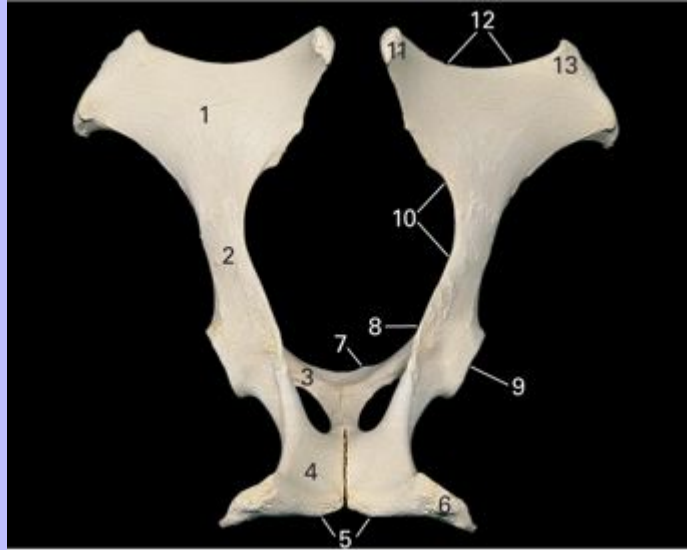
5.2 Ossa coxarum, left lateral view.



- 1 Coxal tuberosity
- 2 Crest of ilium
- 3 Sacral tuberosity
- 4 Greater ischiatic notch
- 5 Ischiatic spine
- 6 Lesser ischiatic notch
- 7 Ischiatic tuberosity
- 8 Articular surface of acetabulum
- 9 Acetabular fossa
- 10 Acetabular notch
- 11 Obturator foramen

Clinical Anatomy of the Horse

5.3 Ossa coxarum, dorsal view.

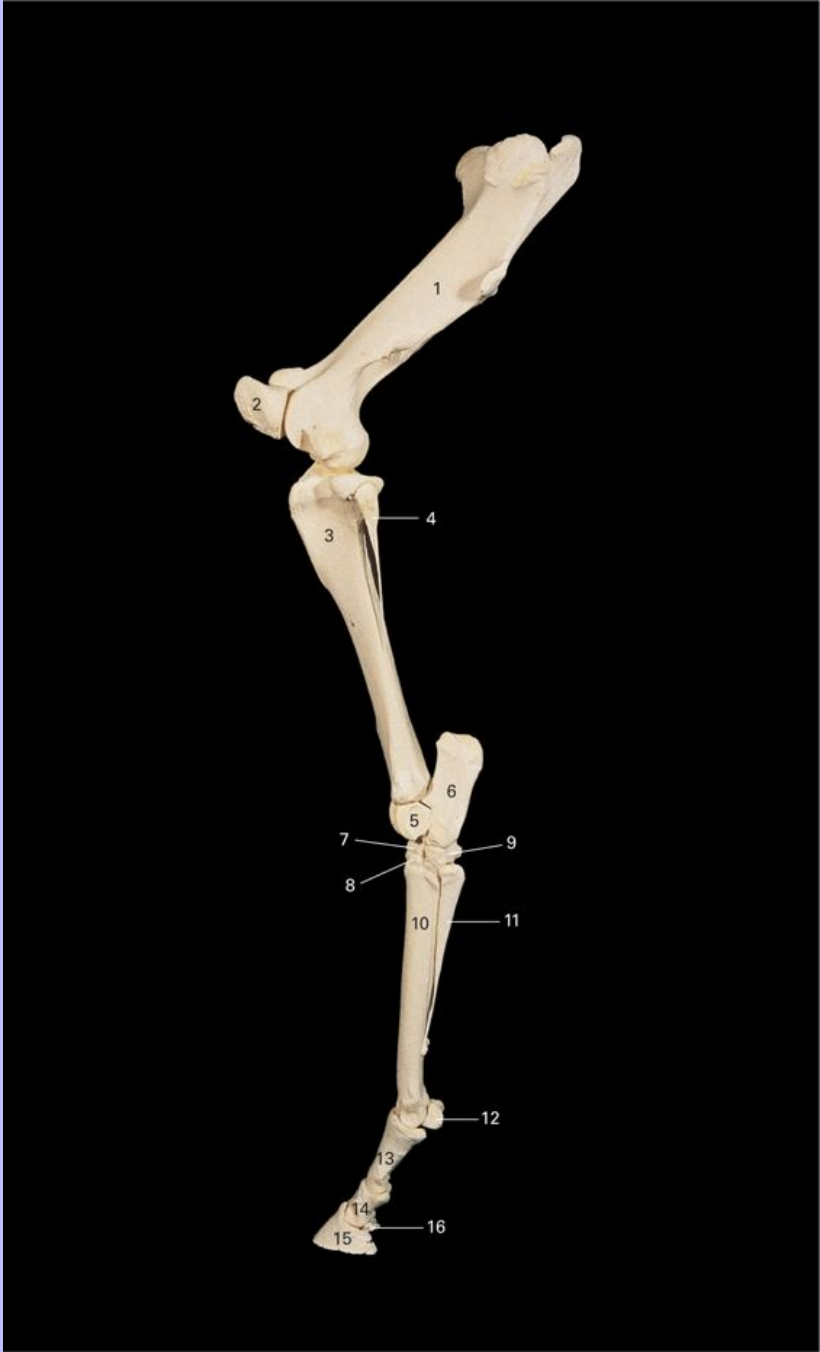


- 1 Wing of ilium
- 2 Body of ilium
- 3 Pubis
- 4 Ischium
- 5 Ischial arch
- 6 Ischiatic tuberosity
- 7 Pubic tubercle
- 8 Ischiatic spine
- 9 Acetabulum
- 10 Greater ischiatic notch
- 11 Sacral tuberosity
- 12 Crest of ilium
- 13 Coxal tuberosity

65

Clinical Anatomy of the Horse

5.4 Skeleton of left hindlimb, lateral view.



1 Femur

Clinical Anatomy of the Horse

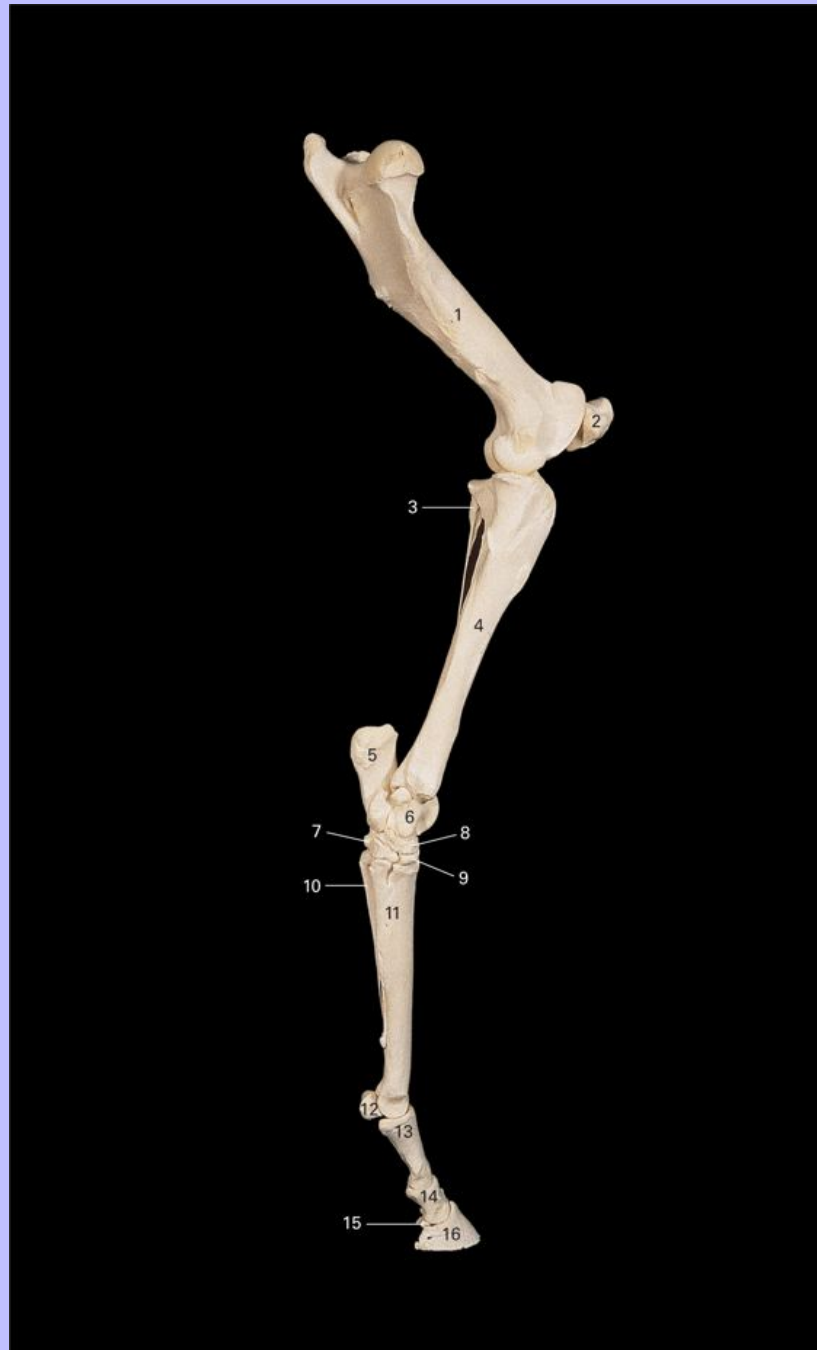- 2 Patella
- 3 Tibia
- 4 Fibula
- 5 Talus
- 6 Calcaneus
- 7 Central tarsal bone
- 8 Third tarsal bone
- 9 Fourth tarsal bone
- 10 Metatarsal III (cannon bone)
- 11 Metatarsal IV (lateral splint bone)
- 12 Lateral proximal sesamoid bone
- 13 Proximal phalanx (P1, long pastern bone)
- 14 Middle phalanx (P2, short pastern bone)
- 15 Distal phalanx (P3, coffin bone, pedal bone)
- 16 Distal sesamoid (navicular) bone

66

Clinical Anatomy of the Horse

67

5.5 Skeleton of left hindlimb, medial view.



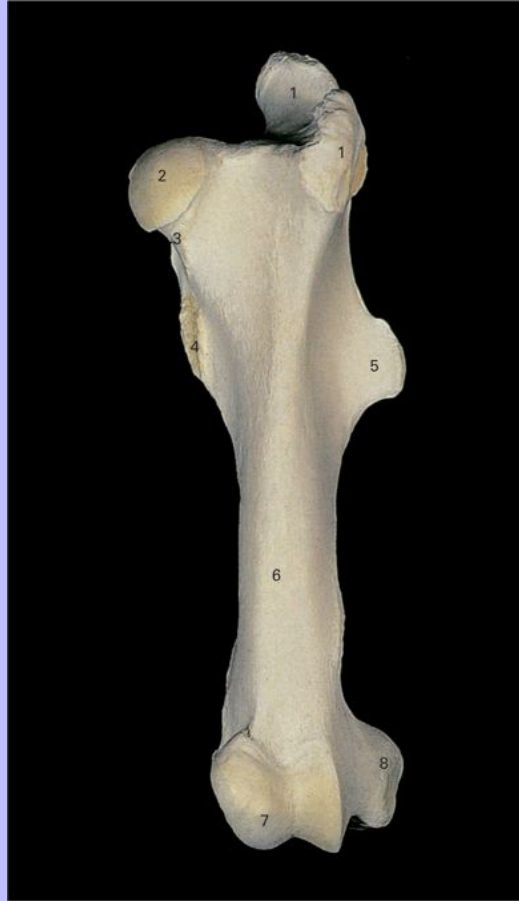1 Femur

Clinical Anatomy of the Horse

- 2 Patella
- 3 Fibula
- 4 Tibia
- 5 Calcaneus
- 6 Talus
- 7 First and second tarsal bone (fused)
- 8 Central tarsal bone
- 9 Third tarsal bone
- 10 Metatarsal II (medial splint bone)
- 11 Metatarsal III (cannon bone)
- 12 Proximal sesamoid bone
- 13 Proximal phalanx (P1, long pastern bone)
- 14 Middle phalanx (P2, short pastern bone)
- 15 Distal sesamoid (navicular) bone
- 16 Distal phalanx (P3, coffin bone, pedal bone)

67

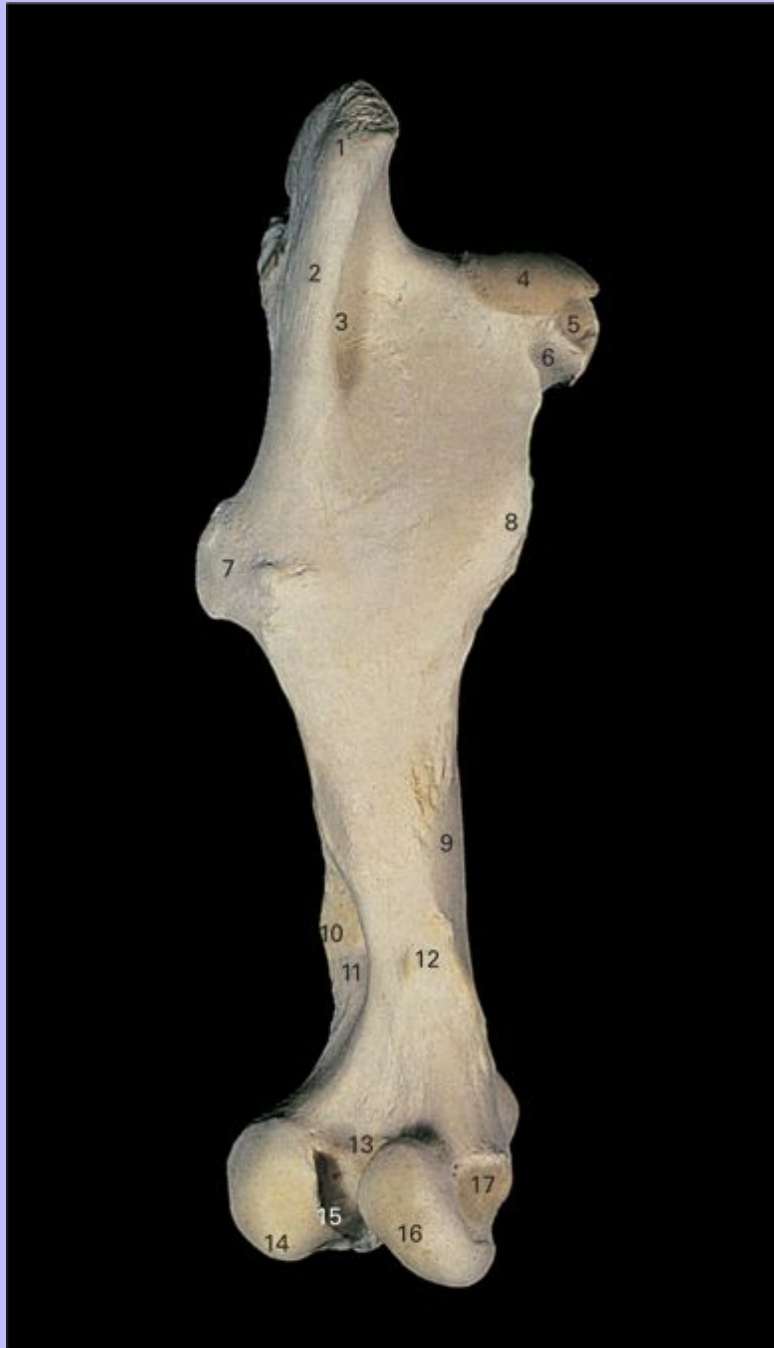5.6 Left femur, cranial view.



- 1 Greater trochanter
- 2 Head
- 3 Neck
- 4 Lesser trochanter
- 5 Third trochanter
- 6 Body
- 7 Trochlea
- 8 Lateral epicondyle

Clinical Anatomy of the Horse

5.7 Left femur, caudal view.



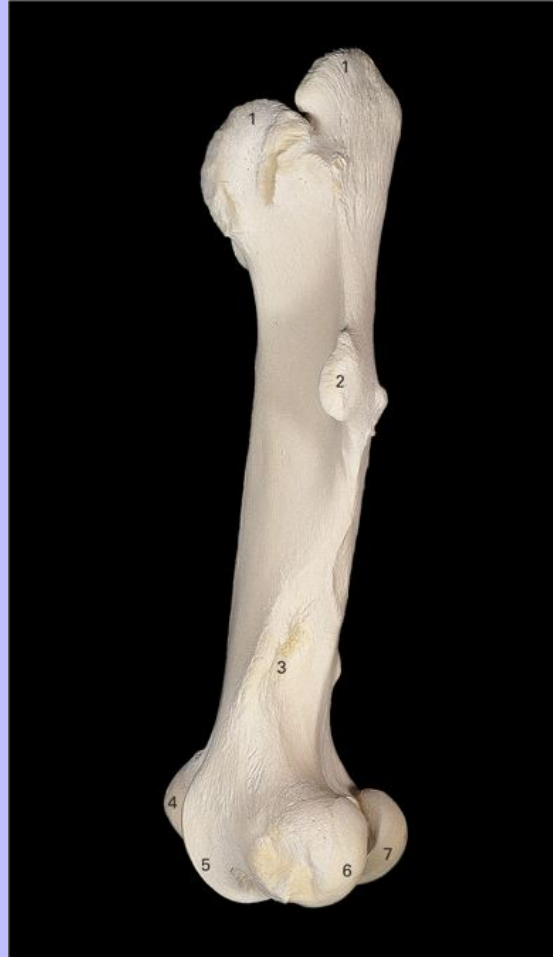1 Greater trochanter

Clinical Anatomy of the Horse

- 2 Intertrochanteric crest
- 3 Trochanteric fossa
- 4 Head
- 5 Fovea
- 6 Neck
- 7 Third trochanter
- 8 Lesser trochanter
- 9 Groove for femoral vessels
- 10 Lateral supracondyloid tuberosity
- 11 Supracondyloid fossa
- 12 Medial supracondyloid tuberosity
- 13 Intercondylar line
- 14 Lateral condyle
- 15 Intercondylar fossa
- 16 Medial condyle
- 17 Medial epicondyle

68

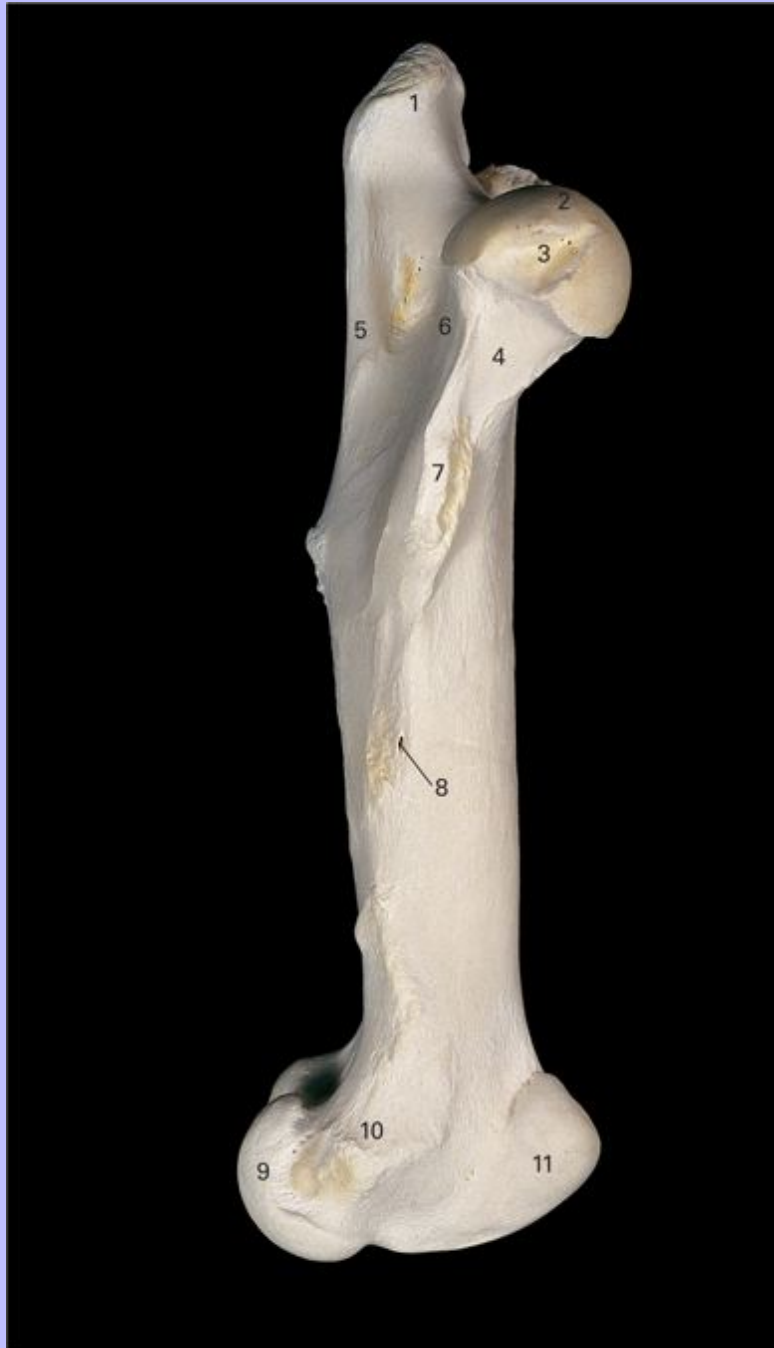5.8 Left femur, lateral view.



- 1 Greater trochanter
- 2 Third trochanter
- 3 Supracondyloid fossa
- 4 Medial ridge of trochlea
- 5 Lateral ridge of trochlea
- 6 Lateral condyle
- 7 Medial condyle

Clinical Anatomy of the Horse

5.9 Left femur, medial view.



1 Greater trochanter

Clinical Anatomy of the Horse

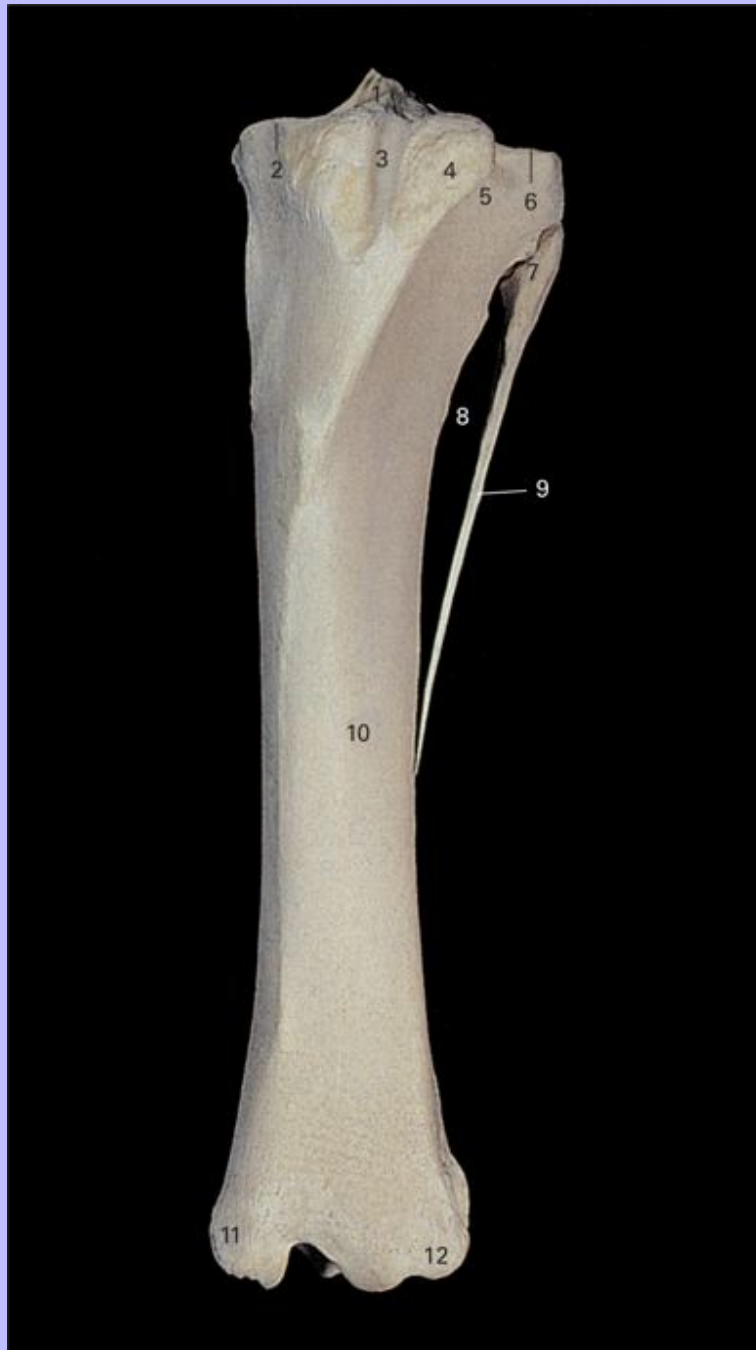
- 2 Head
- 3 Fovea
- 4 Neck
- 5 Intertrochanteric crest
- 6 Trochanteric fossa
- 7 Lesser trochanter
- 8 Nutrient foramen
- 9 Medial condyle
- 10 Medial epicondyle
- 11 Trochlea

69

Clinical Anatomy of the Horse

5.10 Left tibia and fibula, cranial view.

70



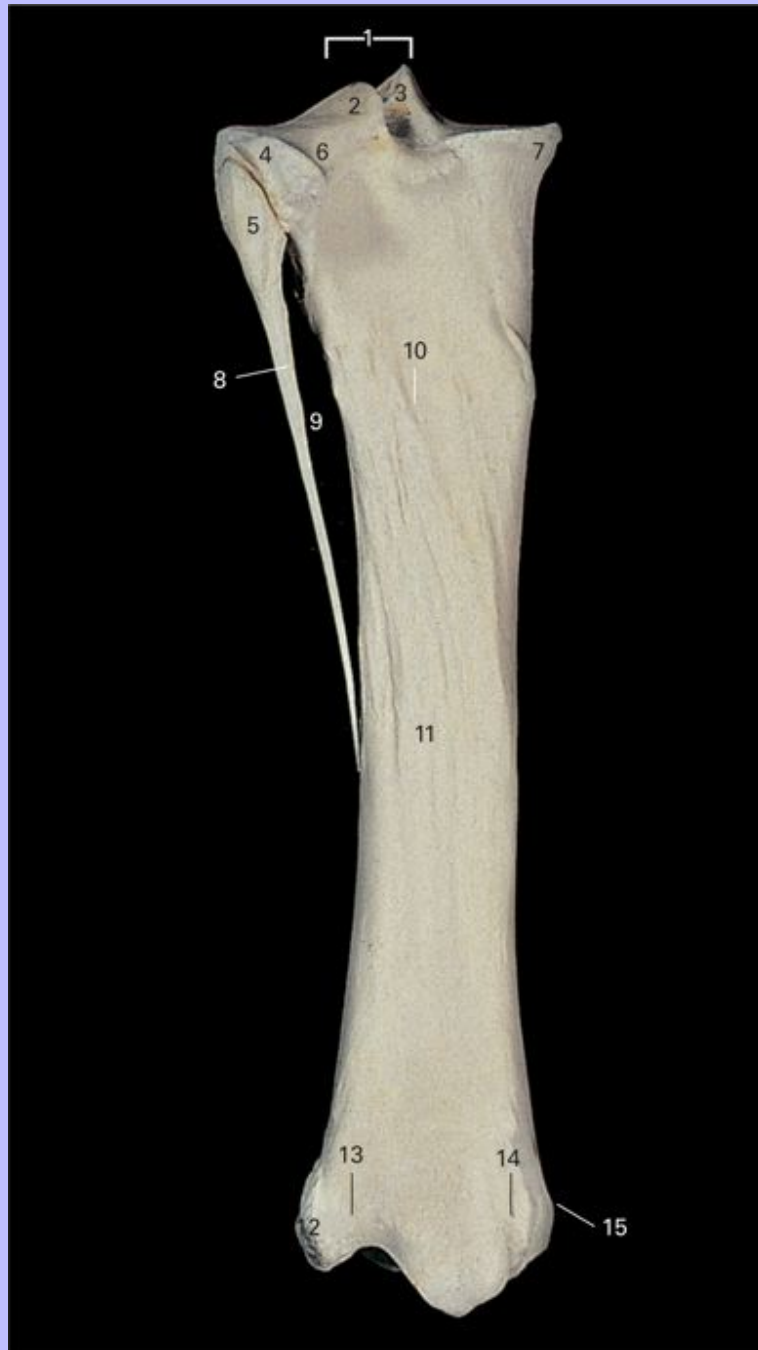1 Intercondylar eminence

Clinical Anatomy of the Horse

- 2 Medial condyle
- 3 Groove for middle patellar ligament
- 4 Tuberosity
- 5 Extensor sulcus
- 6 Lateral condyle
- 7 Head of fibula
- 8 Interosseous space
- 9 Body of fibula
- 10 Body of tibia
- 11 Medial malleolus
- 12 Lateral malleolus

Clinical Anatomy of the Horse

5.11 Left tibia and fibula, caudal view.



1 Intercondylar eminence

Clinical Anatomy of the Horse

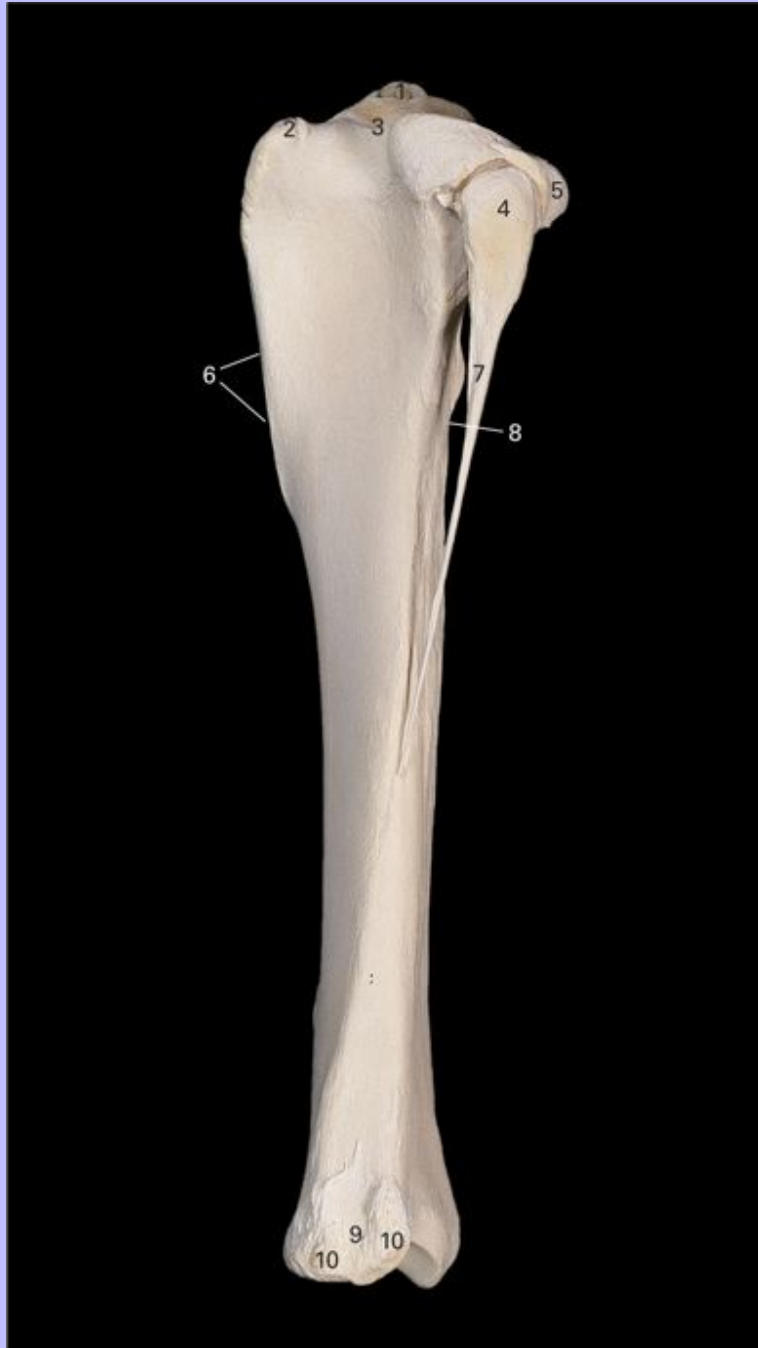
- 2 Lateral intercondylar tubercle
- 3 Medial intercondylar tubercle
- 4 Lateral condyle
- 5 Head of fibula
- 6 Popliteal notch
- 7 Medial condyle
- 8 Body of fibula
- 9 Interosseous space
- 10 Nutrient foramen
- 11 Body of tibia
- 12 Lateral malleolus
- 13 Groove for tendon of M. extensor digitorum lateralis
- 14 Groove for tendon of M. flexor digitorum longus
- 15 Medial malleolus

70

Clinical Anatomy of the Horse

5.12 Left tibia and fibula, lateral view.

71



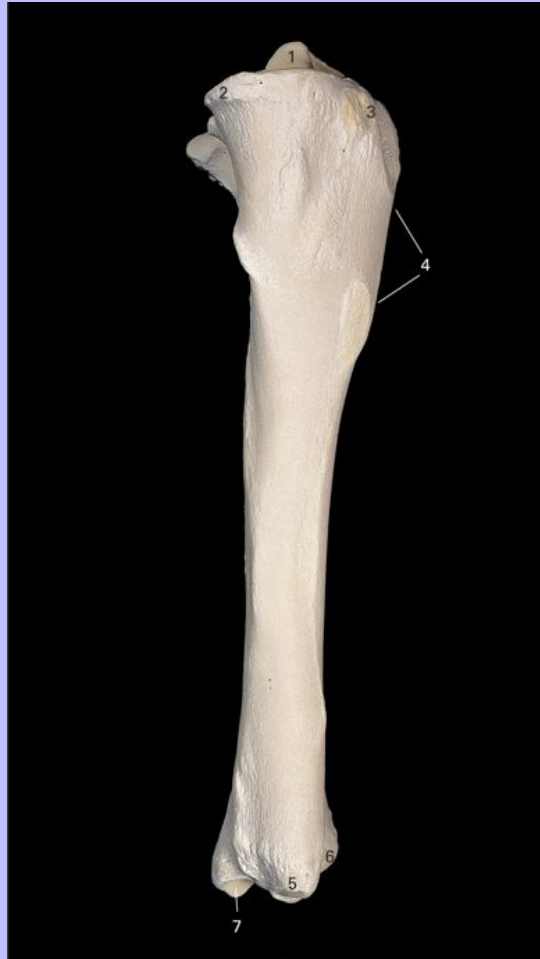1 Intercondylar eminence

Clinical Anatomy of the Horse

- 2 Tibial tuberosity
- 3 Extensor sulcus
- 4 Head of fibula
- 5 Lateral condyle
- 6 Cranial border
- 7 Shaft of fibula
- 8 Interosseous space
- 9 Groove for tendon of M. extensor digitorum lateralis
- 10 Lateral malleolus

Clinical Anatomy of the Horse

5.13 Left tibia and fibula, medial view.

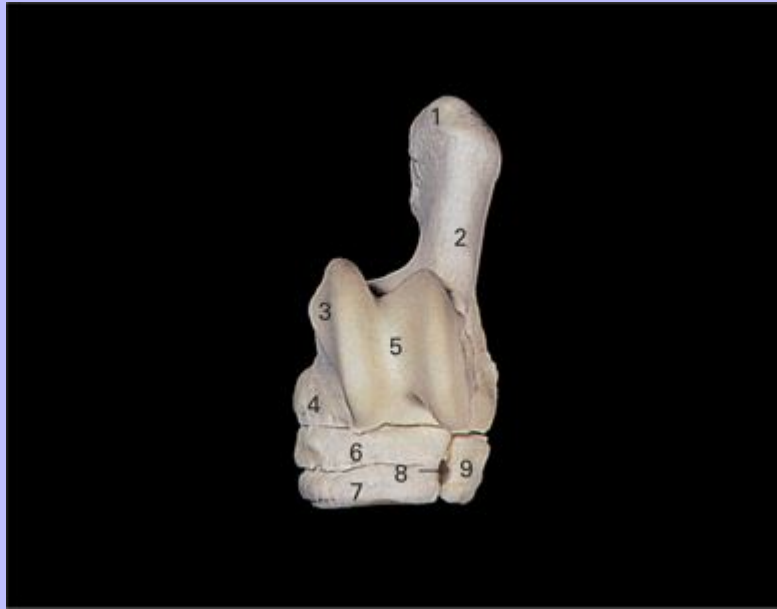

- 1 Intercondylar eminence
- 2 Lateral condyle
- 3 Tibial tuberosity
- 4 Cranial border
- 5 Medial malleolus
- 6 Lateral malleolus
- 7 Articular surface

Clinical Anatomy of the Horse

72

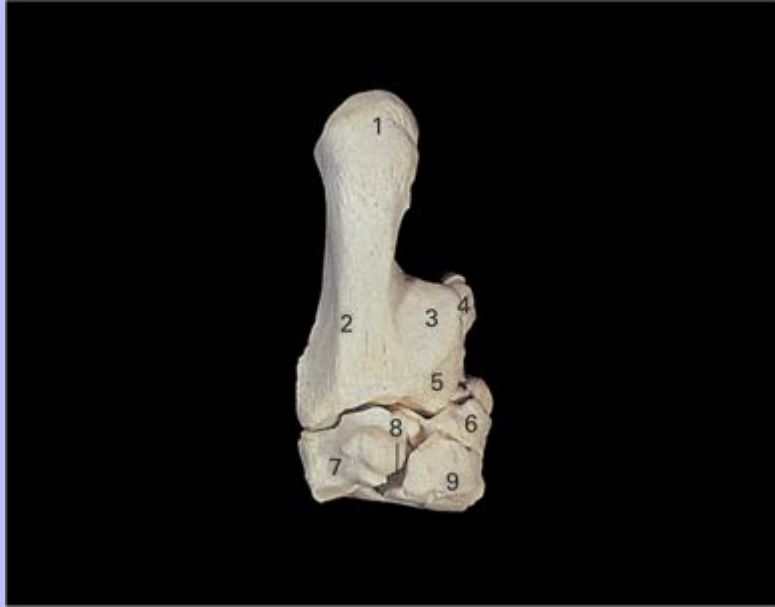5.14 Left tarsal bones, dorsal view.



- 1 Calcaneal tuber
- 2 Calcaneus
- 3 Talus
- 4 Distal tuberosity of talus
- 5 Trochlea
- 6 Central tarsal bone
- 7 Third tarsal bone
- 8 Vascular canal
- 9 Fourth tarsal bone

Clinical Anatomy of the Horse

5.15 Left tarsal bones, plantar view.



- 1 Calcaneal tuber
- 2 Calcaneus
- 3 Tarsal groove for tendon of M. flexor digitorum profundus
- 4 Talus
- 5 Sustentaculum tali
- 6 Central tarsal bone
- 7 Fourth tarsal bone
- 8 Vascular canal
- 9 First and second tarsal bones (fused)

Clinical Anatomy of the Horse

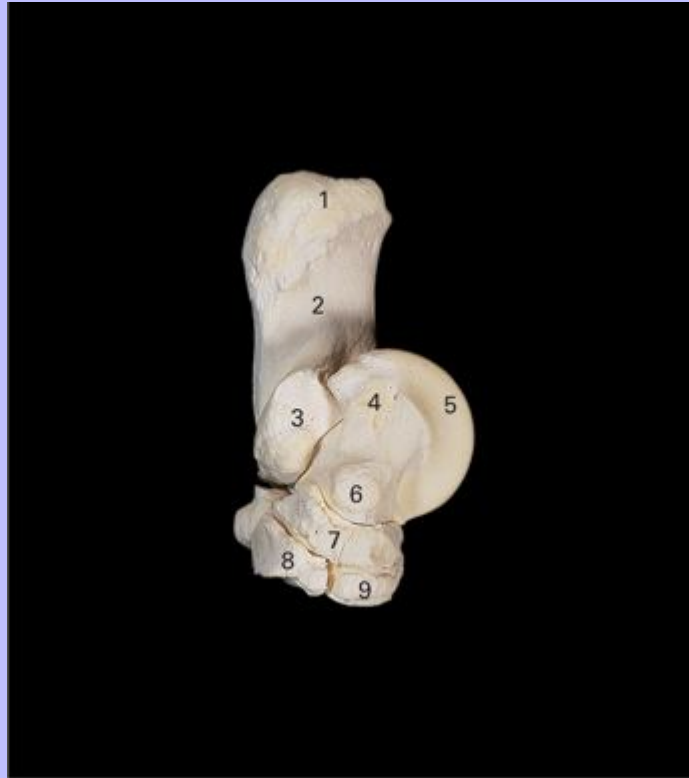5.16 Left tarsal bones, lateral view.



- 1 Calcaneal tuber
- 2 Calcaneus
- 3 Coracoid process
- 4 Talus
- 5 Depression for attachment of tarsal lateral collateral ligament
- 6 Central tarsal bone
- 7 Third tarsal bone
- 8 Fourth tarsal bone

72

5.17 Left tarsal bones, medial view.



- 1 Calcaneal tuber
- 2 Calcaneus
- 3 Sustentaculum
- 4 Proximal tuberosity of talus
- 5 Talus
- 6 Distal tuberosity of talus
- 7 Central tarsal bone
- 8 First and second tarsal bones (fused)
- 9 Third tarsal bone

Clinical Anatomy of the Horse

5.18 Left patella, cranial view



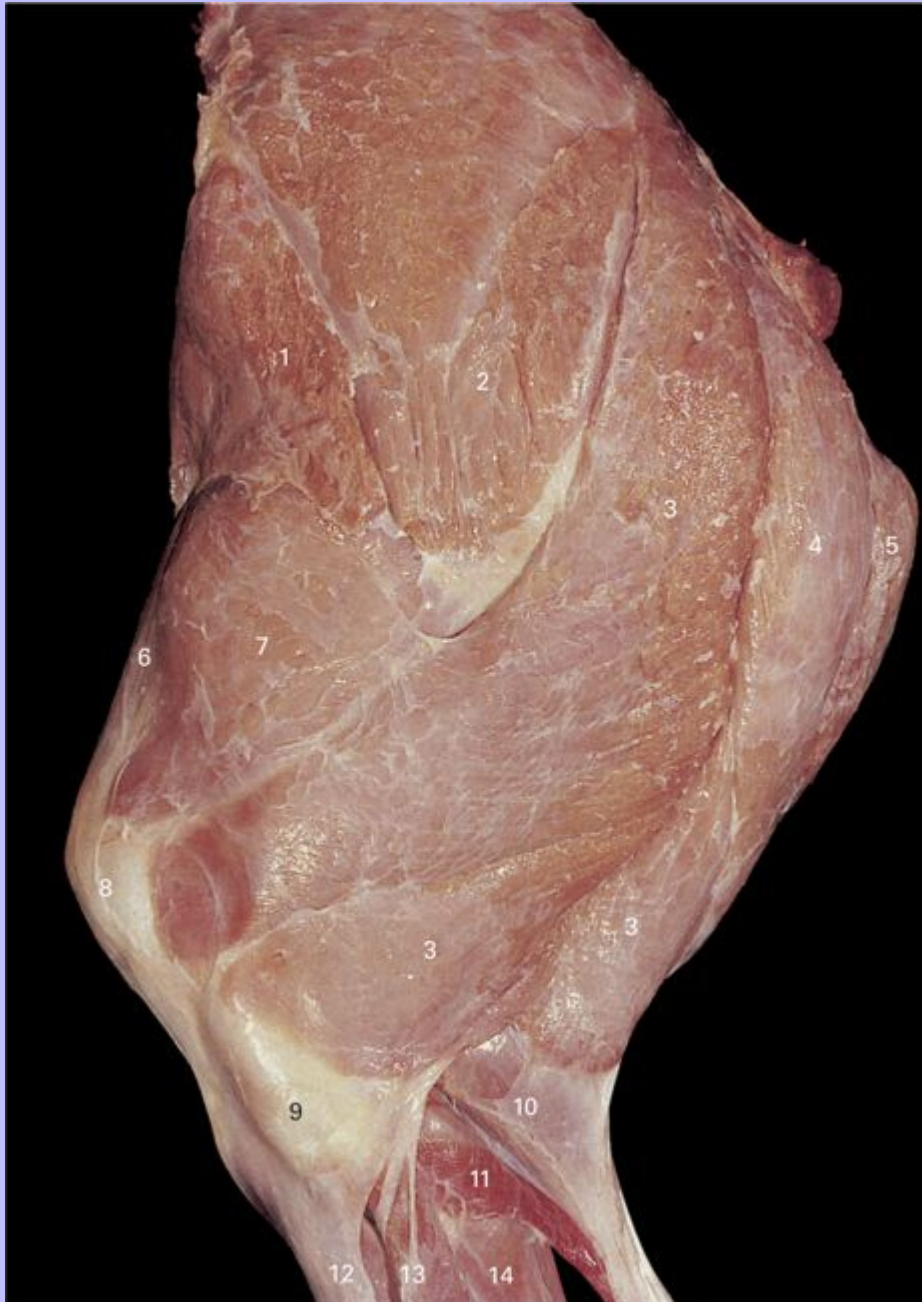- 1 Base
- 2 Medial border
- 3 Attachment area of middle patellar ligament
- 4 Attachment area of lateral patellar ligament
- 5 Lateral border
- 6 Apex

73

Clinical Anatomy of the Horse

74

5.19 Superficial dissection of left pelvis and thigh of foal, lateral view. Fascia lata has been removed to show M. rectus femoris and M. vastus lateralis.



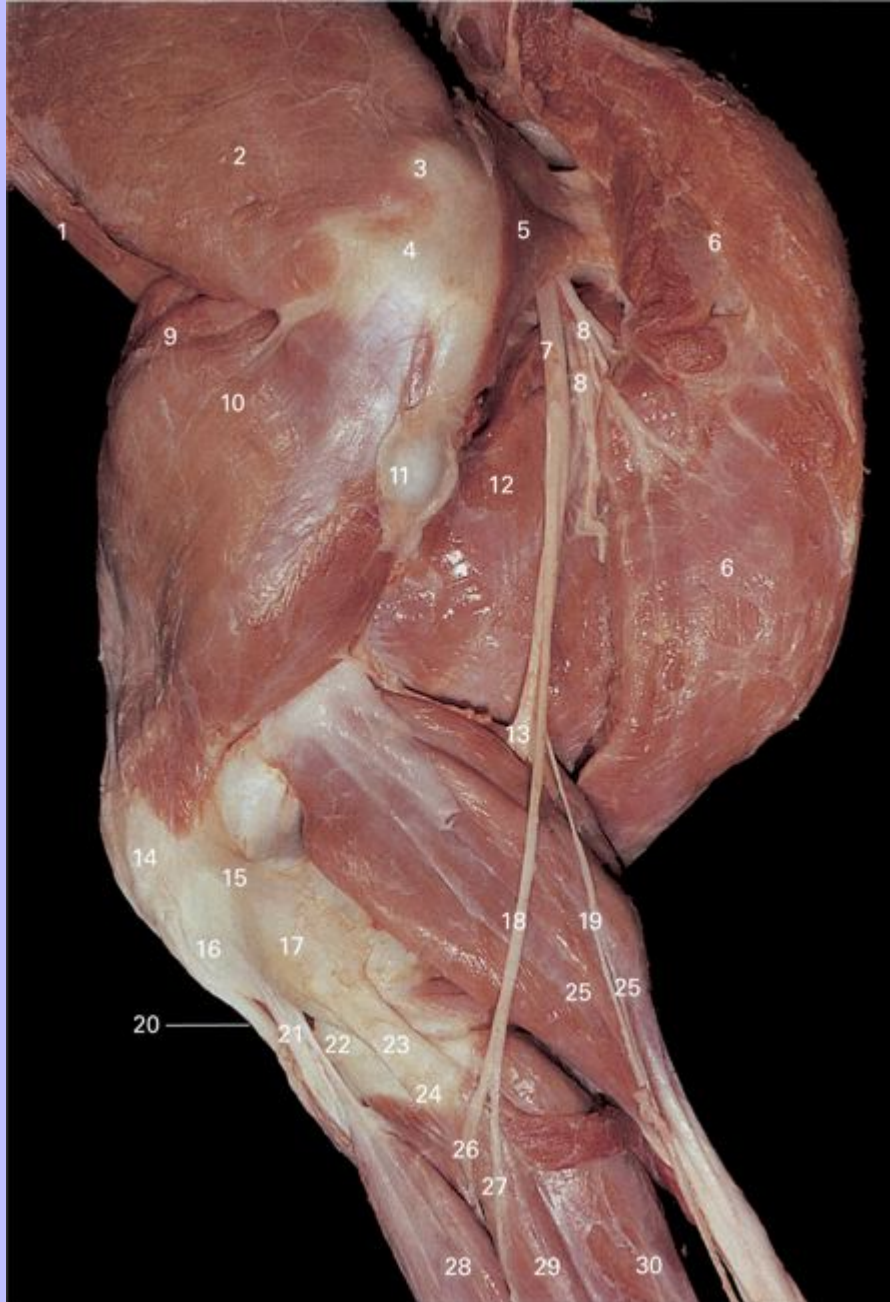
1 M. tensor fascia lata

Clinical Anatomy of the Horse

- 2 M. gluteus superficialis
- 3 M. biceps femoris
- 4 M. semitendinosus
- 5 M. semimembranosus
- 6 M. rectus femoris
- 7 M. vastus lateralis
- 8 Patella
- 9 Lateral condyle of tibia
- 10 M. gastrocnemius, lateral head
- 11 M. soleus
- 12 M. extensor digitorum longus
- 13 M. extensor digitorum lateralis
- 14 M. flexor digitorum profundus

Clinical Anatomy of the Horse

5.20 Deep dissection of left pelvis and thigh of foal, lateral view. M. tensor fascia lata, M. gluteus superficialis and M. biceps femoris have been removed.



1 M. iliacus

Clinical Anatomy of the Horse

- 2 M. gluteus medius
- 3 Trochanteric bursa
- 4 Greater trochanter
- 5 M. piriformis
- 6 M. semimembranosus
- 7 Ischiatic nerve
- 8 Muscular branches of tibial nerve
- 9 M. rectus femoris
- 10 M. vastus lateralis
- 11 Third trochanter
- 12 M. adductor
- 13 Tibial nerve
- 14 Common peroneal (fibular) nerve
- 15 Caudal cutaneous sural nerve
- 16 Patella
- 17 Lateral epicondyle of femur
- 18 M. soleus
- 19 M. gastrocnemius, lateral head
- 20 Middle patellar ligament
- 21 Lateral patellar ligament
- 22 Lateral meniscus
- 23 Lateral collateral femorotibial ligament
- 24 Lateral condyle of tibia
- 25 M. flexor digitorum profundus
- 26 Deep peroneal (fibular) nerve
- 27 Superficial peroneal (fibular) nerve

Clinical Anatomy of the Horse

28 M. extensor digitorum longus

29 M. extensor digitorum lateralis

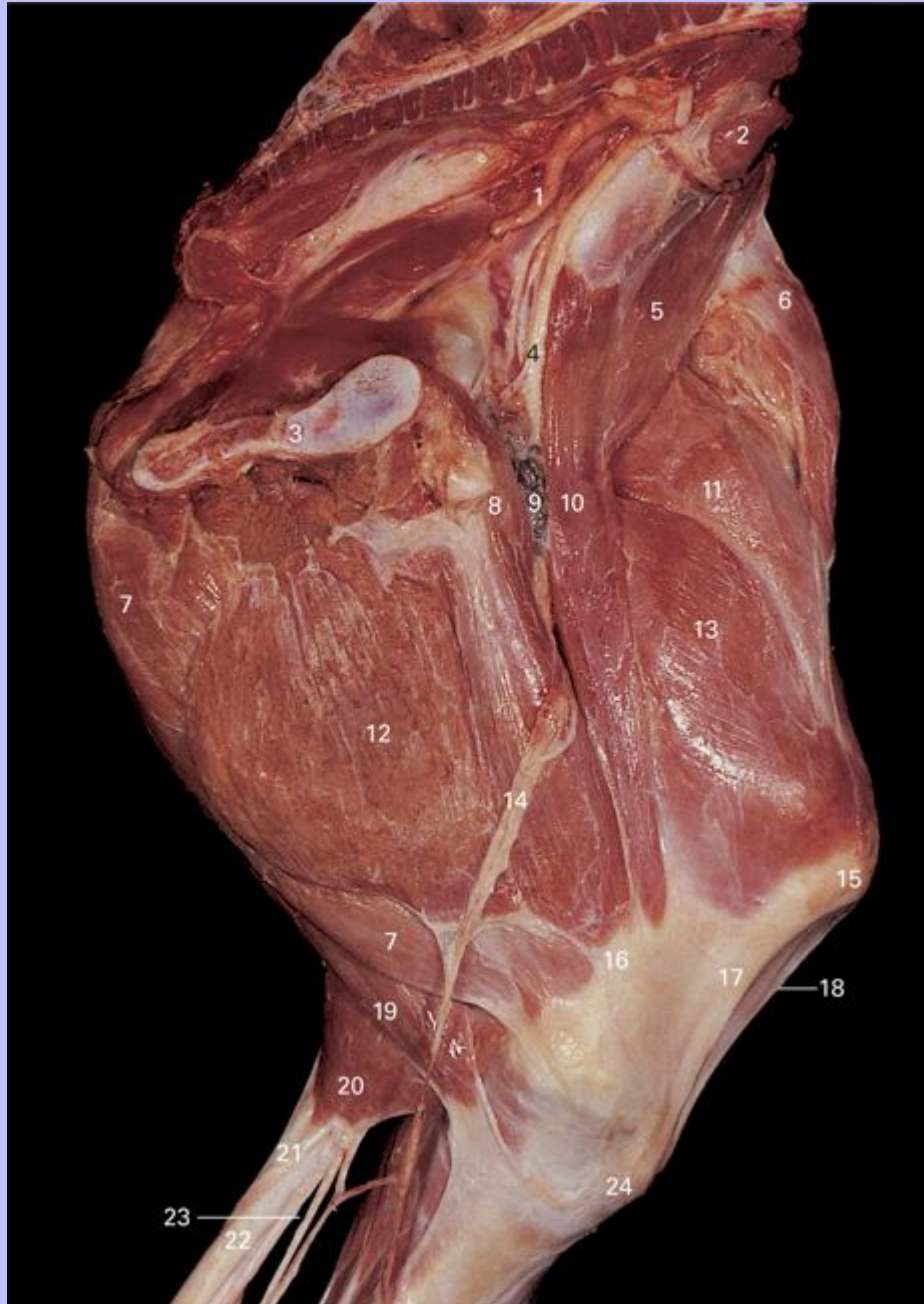
30 M. flexor digitorum profundus

74

Clinical Anatomy of the Horse

75

5.21 Superficial dissection of left pelvis and thigh of foal, medial view. The trunk has been sectioned in a median plane, and the viscera removed.



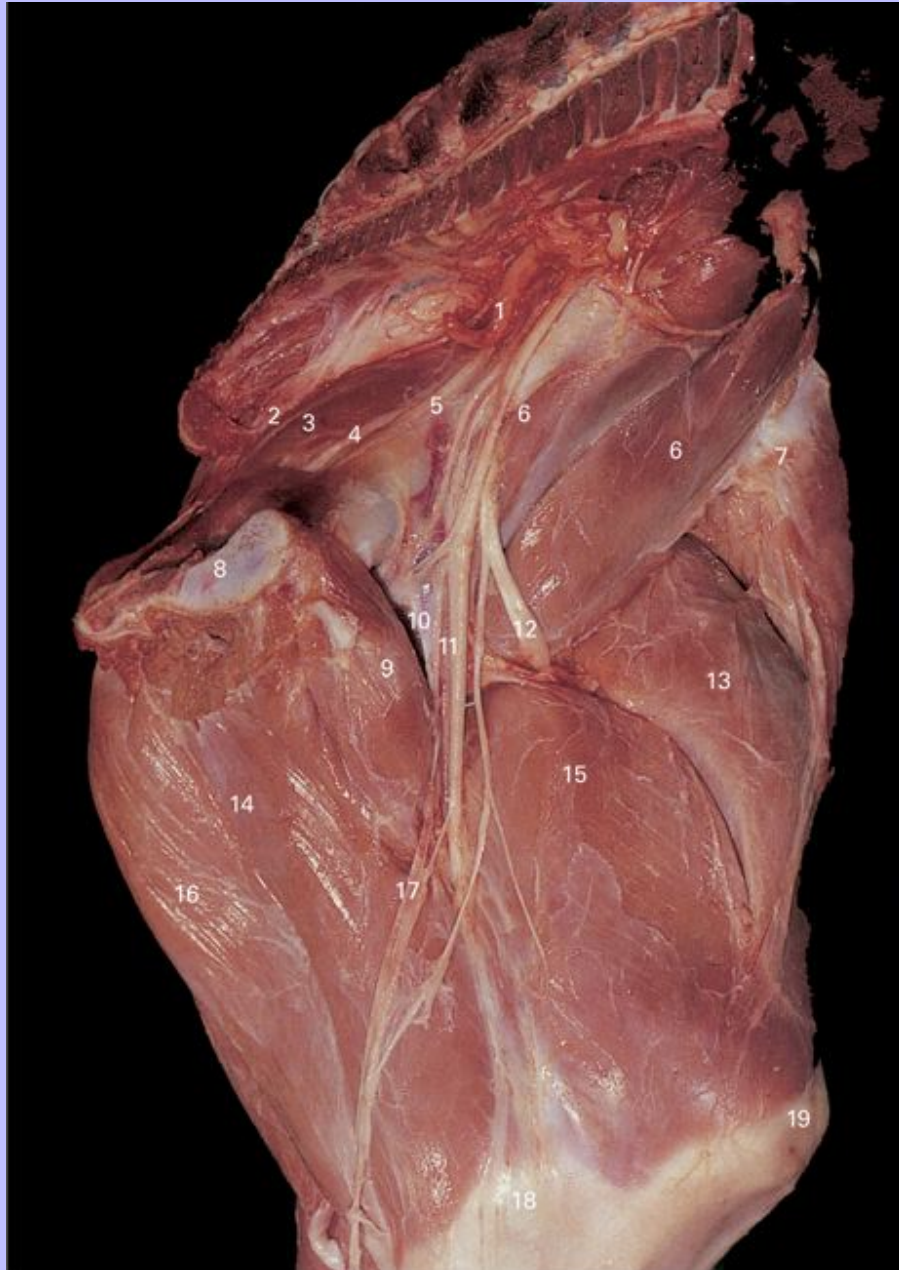1 Umbilical artery (cut)

Clinical Anatomy of the Horse

- 2 M. psoas minor
- 3 Pubis
- 4 Femoral nerve
- 5 M. iliopsoas
- 6 M. tensor fascia lata
- 7 M. semimembranosus
- 8 M. pectineus
- 9 Deep inguinal lymph nodes
- 10 M. sartorius
- 11 M. rectus femoris
- 12 M. gracilis
- 13 M. vastus medialis
- 14 Saphenous vessels and nerve
- 15 Patella
- 16 Medial epicondyle of femur
- 17 Medial patellar ligament
- 18 Middle patellar ligament
- 19 M. semitendinosus
- 20 M. gastrocnemius, medial head
- 21 Common calcaneal tendon
- 22 M. flexor digitorum superficialis
- 23 Tibial nerve
- 24 Medial condyle of tibia

Clinical Anatomy of the Horse

5.22 Deep dissection of left pelvis and thigh of foal, medial view. The trunk has been sectioned in a median plane and the viscera removed. The deep inguinal lymph nodes, M. gracilis, and M. sartorius have been removed.



1 Umbilical artery (cut)

Clinical Anatomy of the Horse

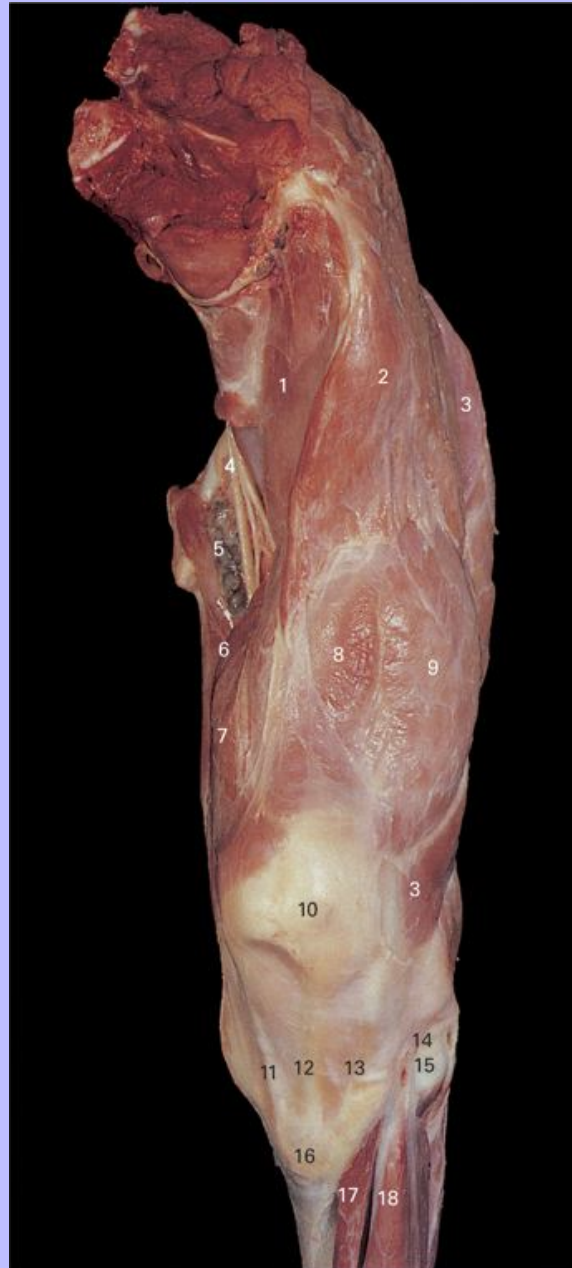- 2 Internal iliac artery
- 3 M. obturator internus
- 4 Obturator artery
- 5 Obturator nerve
- 6 M. iliopsoas
- 7 M. tensor fascia lata
- 8 Pubis
- 9 M. pectineus
- 10 Femoral vessels
- 11 Saphenous nerve
- 12 Femoral nerve
- 13 M. rectus femoris
- 14 M. adductor
- 15 M. vastus medialis
- 16 M. semimembranosus
- 17 Saphenous vessels
- 18 Medial epicondyle of femur
- 19 Patella

75

Clinical Anatomy of the Horse

76

5.23 Superficial dissection of left pelvis and thigh of foal, cranial view. The trunk has been sectioned in a median plane and the viscera removed. The fascia lata has been removed to expose M. rectus femoris and M. vastus lateralis.



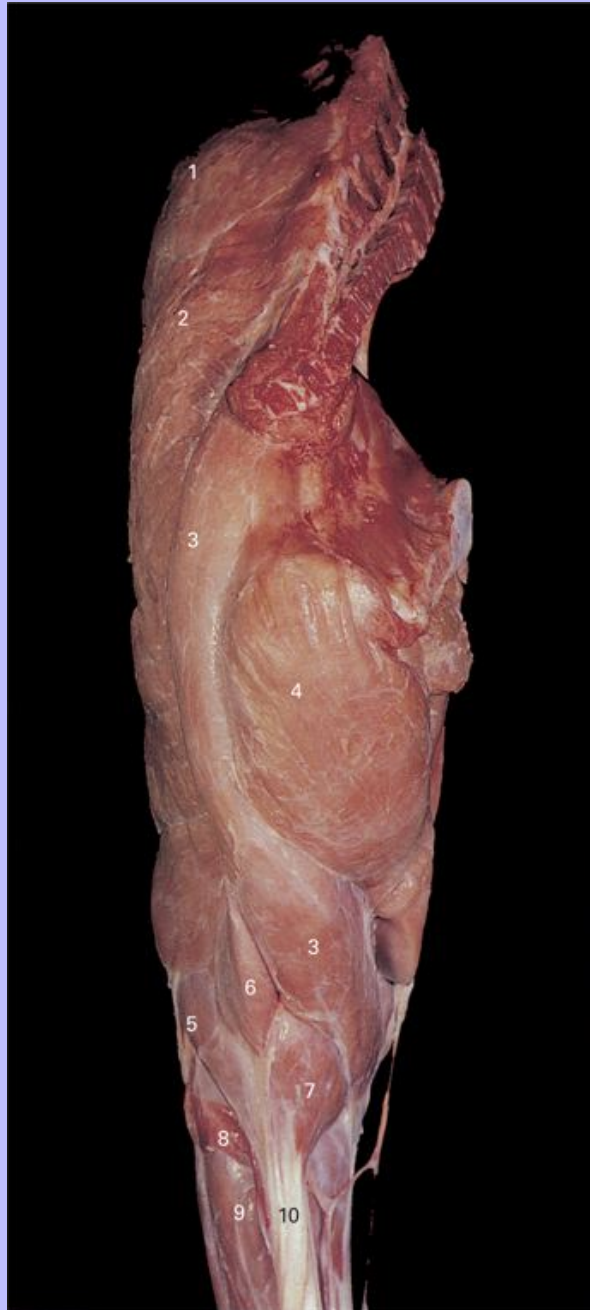1 M. iliopsoas

Clinical Anatomy of the Horse

- 2 M. tensor fascia lata
- 3 M. biceps femoris
- 4 Femoral nerve
- 5 Deep inguinal lymph nodes
- 6 M. sartorius
- 7 M. vastus medialis
- 8 M. rectus femoris
- 9 M. vastus lateralis
- 10 Patella
- 11 Medial patellar ligament
- 12 Middle patellar ligament
- 13 Lateral patellar ligament
- 14 Lateral meniscus
- 15 Lateral condyle of tibia
- 16 Tibial tuberosity
- 17 M. tibialis cranialis
- 18 M. extensor digitorum longus

Clinical Anatomy of the Horse

5.24 Superficial dissection of left pelvis and thigh of foal, caudal view. The trunk has been sectioned in a median plane, and the viscera removed.



1 M. gluteus superficialis

Clinical Anatomy of the Horse

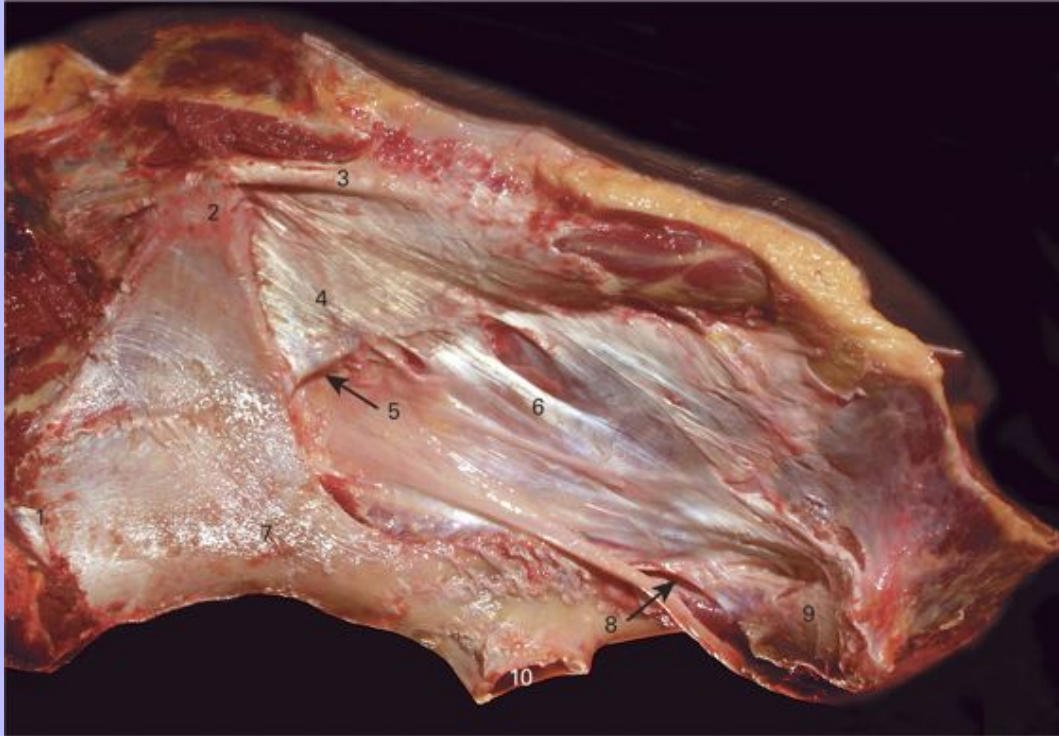- 2 M. biceps femoris
- 3 M. semitendinosus
- 4 M. semimembranosus
- 5 M. gastrocnemius, lateral head
- 6 M. flexor digitorum superficialis
- 7 M. gastrocnemius, medial head
- 8 M. soleus
- 9 M. flexor digitorum longus
- 10 Common calcaneal tendon

76

Clinical Anatomy of the Horse

77

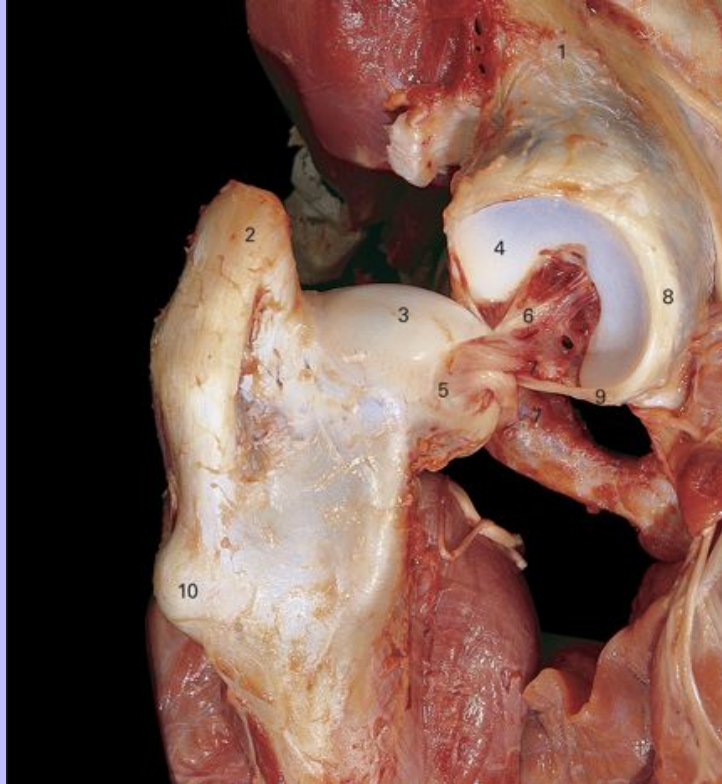
5.25 Deep dissection of pelvic ligaments on left side, lateral view.



- 1 Coxal tuberosity
- 2 Sacral tuberosity
- 3 Dorsal sacroiliac ligament
- 4 Lateral sacroiliac ligament
- 5 Greater ischiatic foramen
- 6 Sacrosciatic ligament
- 7 Shaft of ilium
- 8 Lesser ischiatic foramen
- 9 Ischial tuberosity
- 10 Acetabulum

Clinical Anatomy of the Horse

5.26 Deep dissection of left hip joint, caudal view.

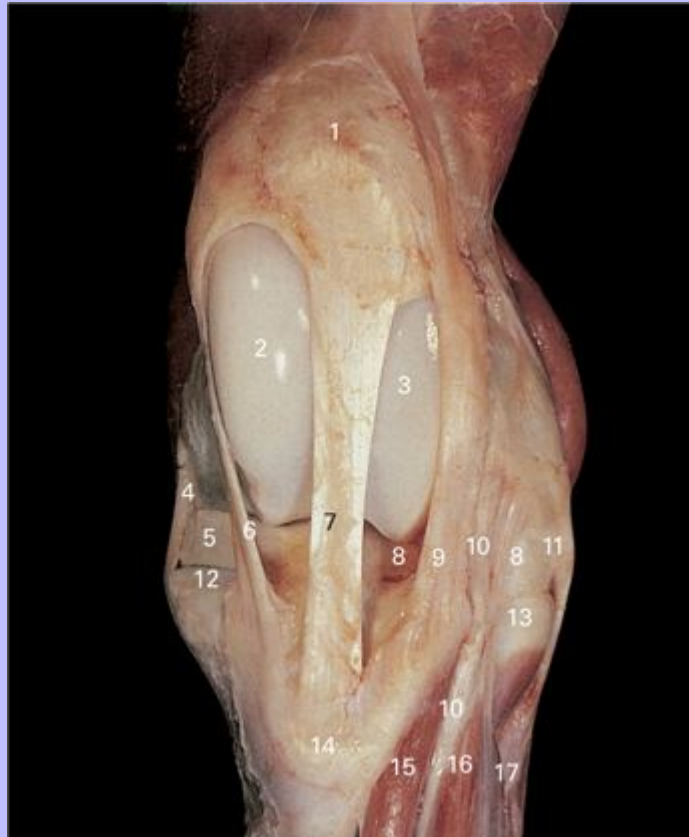

- 1 Body of ilium
- 2 Greater trochanter
- 3 Head of femur
- 4 Acetabulum
- 5 Fovea
- 6 Ligament of the head of the femur (round ligament)
- 7 Accessory ligament
- 8 Labrum
- 9 Transverse acetabular ligament
- 10 Third trochanter

Clinical Anatomy of the Horse

78

5.27 Deep dissection of left femorotibial joint, cranial view. The joint is extended with the medial femoral condyle engaged between the middle and medial patellar ligaments.



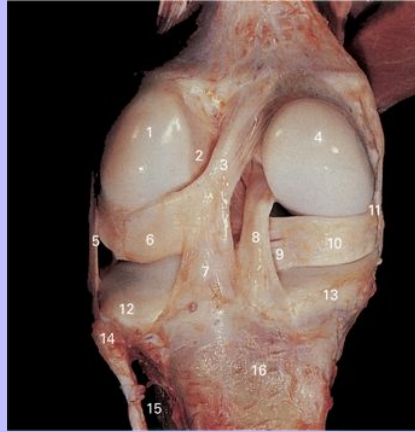- 1 Patella
- 2 Medial trochlear ridge of femur
- 3 Lateral trochlear ridge of femur
- 4 Medial collateral femorotibial ligament
- 5 Medial meniscus
- 6 Medial patellar ligament
- 7 Middle patellar ligament
- 8 Lateral meniscus

Clinical Anatomy of the Horse

- 9 Lateral patellar ligament
- 10 Tendon of M. peroneus (fibularis) tertius
- 11 Lateral collateral femorotibial ligament
- 12 Medial condyle of tibia
- 13 Lateral condyle of tibia
- 14 Tibial tuberosity
- 15 M. tibialis cranialis
- 16 M. extensor digitorum longus
- 17 M. extensor digitorum lateralis

Clinical Anatomy of the Horse

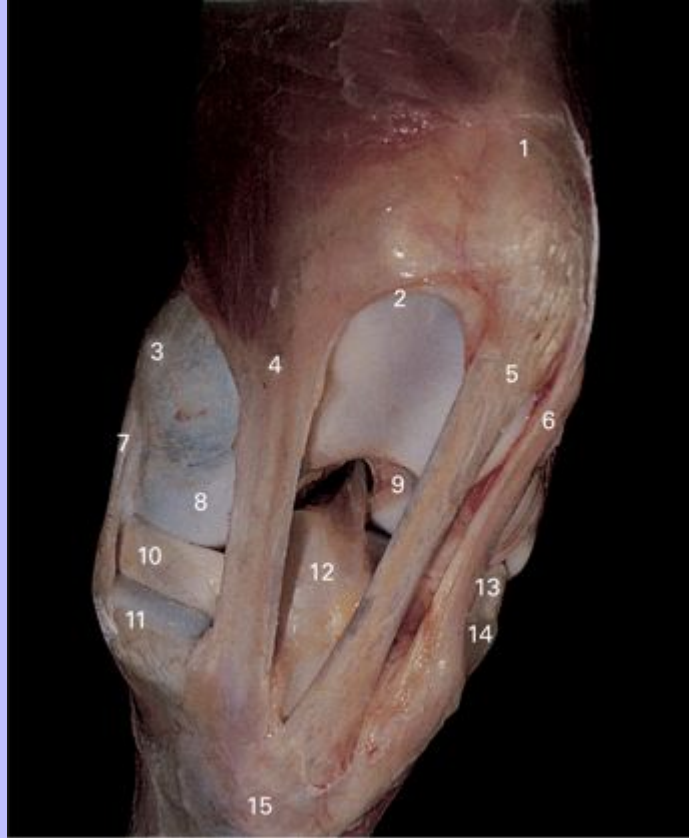5.28 Deep dissection of left femorotibial joint, caudal view.



- 1 Lateral condyle of femur
- 2 Cranial cruciate ligament
- 3 Menisofemoral ligament of lateral meniscus
- 4 Medial condyle of femur
- 5 Lateral collateral femorotibial ligament
- 6 Lateral meniscus
- 7 Caudal ligament of lateral meniscus
- 8 Caudal cruciate ligament
- 9 Caudal ligament of medial meniscus
- 10 Medial meniscus
- 11 Medial collateral femorotibial ligament
- 12 Lateral condyle of tibia
- 13 Medial condyle of tibia
- 14 Head of fibula
- 15 Interosseous space
- 16 Tibia

Clinical Anatomy of the Horse

5.29 Deep dissection of left femorotibial joint, dorsomedial view. The joint is partially flexed.



- 1 Patella
- 2 Medial trochlear ridge
- 3 Medial epicondyle of femur
- 4 Medial patellar ligament
- 5 Middle patellar ligament
- 6 Lateral patellar ligament
- 7 Medial collateral femorotibial ligament
- 8 Medial condyle of femur
- 9 Intercondyloid fossa of femur

Clinical Anatomy of the Horse

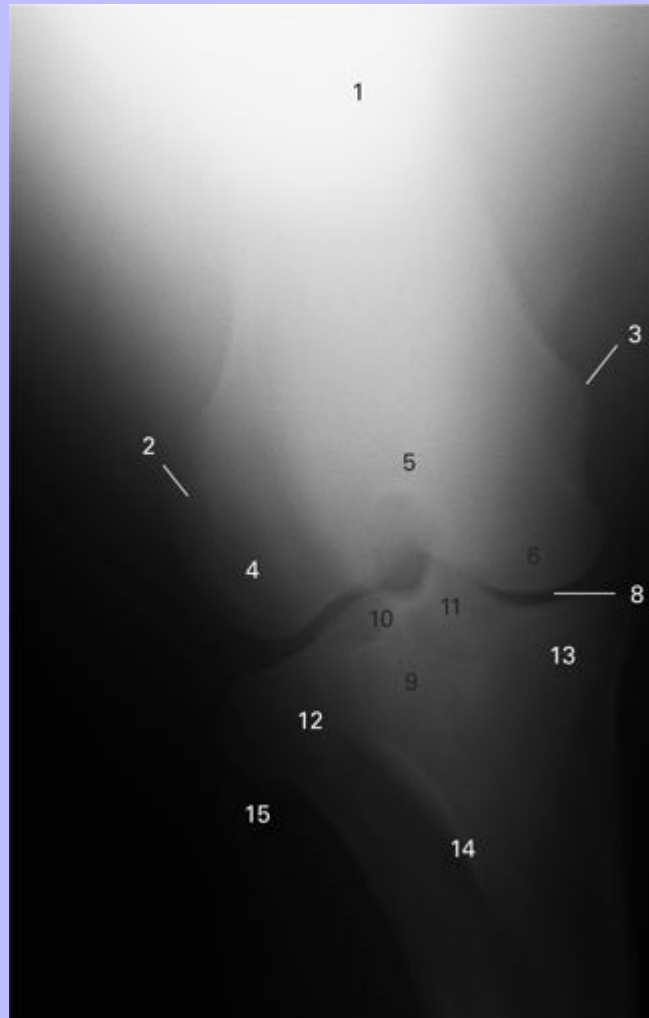
- 10 Medial meniscus
- 11 Medial condyle of tibia
- 12 Cranial cruciate ligament
- 13 Lateral meniscus
- 14 Lateral condyle of tibia
- 15 Tibial tuberosity

78

Clinical Anatomy of the Horse

79

5.30 Caudocranial view radiograph of genual (stifle) joint.



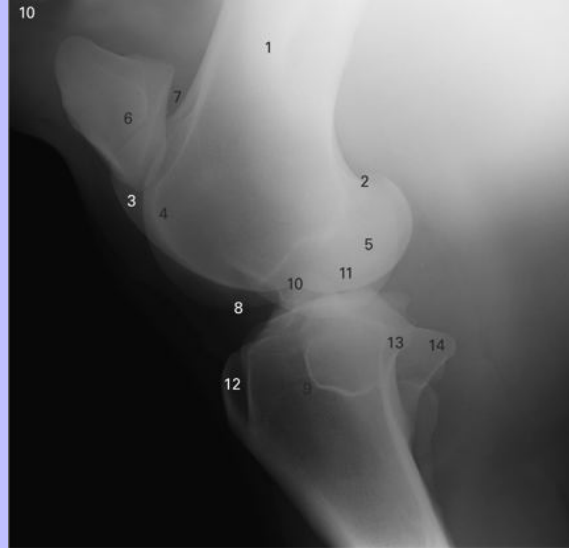
- 1 Femur
- 2 Lateral epicondyle
- 3 Medial epicondyle
- 4 Lateral condyle
- 5 Intercondylar fossa
- 6 Medial condyle

Clinical Anatomy of the Horse

- 7 Lateral femorotibial joint
- 8 Medial femorotibial joint
- 9 Tibia
- 10 Lateral intercondylar tubercle (eminence)
- 11 Medial intercondylar tubercle (eminence)
- 12 Lateral condyle
- 13 Medial condyle
- 14 Tibial tuberosity
- 15 Fibula

Clinical Anatomy of the Horse

5.31 Lateromedial view radiograph of genu (stifle) joint.

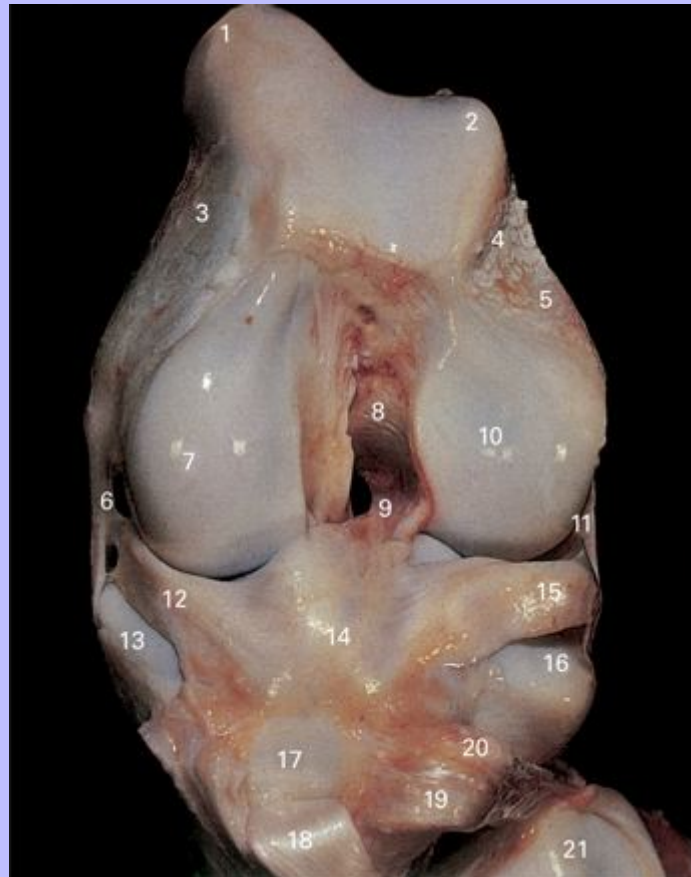


- 1 Femur
- 2 Supracondyloid fossa
- 3 Medial trochlea
- 4 Lateral trochlea
- 5 Medial and lateral condyles
- 6 Patella
- 7 Femoropatellar joint
- 8 Femorotibial joint
- 9 Tibia
- 10 Medial intercondylar tubercle
- 11 Lateral intercondylar tubercle
- 12 Tibial tuberosity
- 13 Medial condyle
- 14 Lateral condyle

Clinical Anatomy of the Horse

80

5.32 Deep dissection of left femorotibial joint, cranial view. The cranial cruciate ligament has been removed, and the patellar ligaments have been cut and reflected distally. The joint is fully flexed to show the distal extremity of the femur.



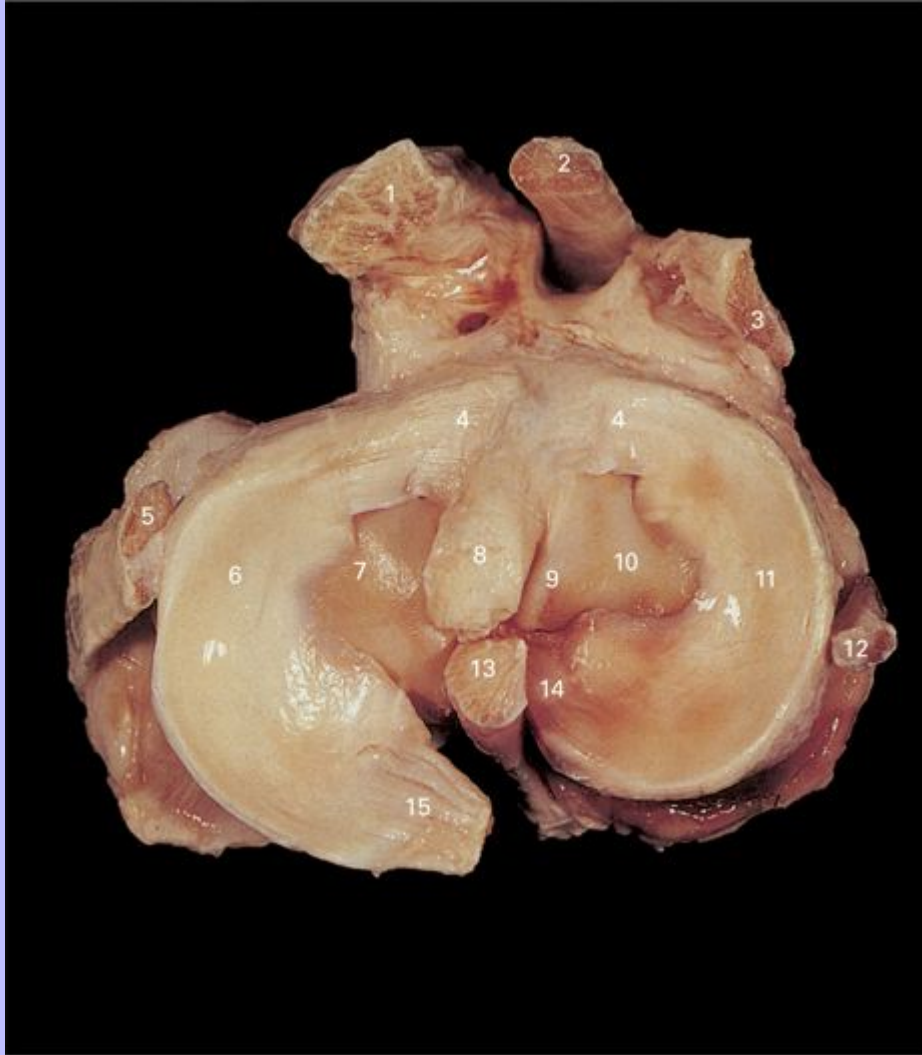- 1 Medial trochlear ridge of femur
- 2 Lateral trochlear ridge of femur
- 3 Medial epicondyle
- 4 Extensor fossa
- 5 Lateral epicondyle
- 6 Medial collateral femorotibial ligament
- 7 Medial condyle of femur

Clinical Anatomy of the Horse

- 8 Intercondyloid fossa
- 9 Caudal cruciate ligament
- 10 Lateral condyle of femur
- 11 Lateral collateral femorotibial ligament
- 12 Medial meniscus
- 13 Medial condyle of tibia
- 14 Cranial ligaments of menisci
- 15 Lateral meniscus
- 16 Lateral condyle of tibia
- 17 Tibial tuberosity
- 18 Medial patellar ligament (reflected)
- 19 Middle patellar ligament (reflected)
- 20 Lateral patellar ligament (reflected)
- 21 Articular face of patella

Clinical Anatomy of the Horse

5.33 Left tibia and menisci, proximal view.



- 1 Lateral patellar ligament
- 2 Middle patellar ligament
- 3 Medial patellar ligament
- 4 Cranial ligaments of menisci
- 5 Lateral collateral femorotibial ligament
- 6 Lateral meniscus

Clinical Anatomy of the Horse

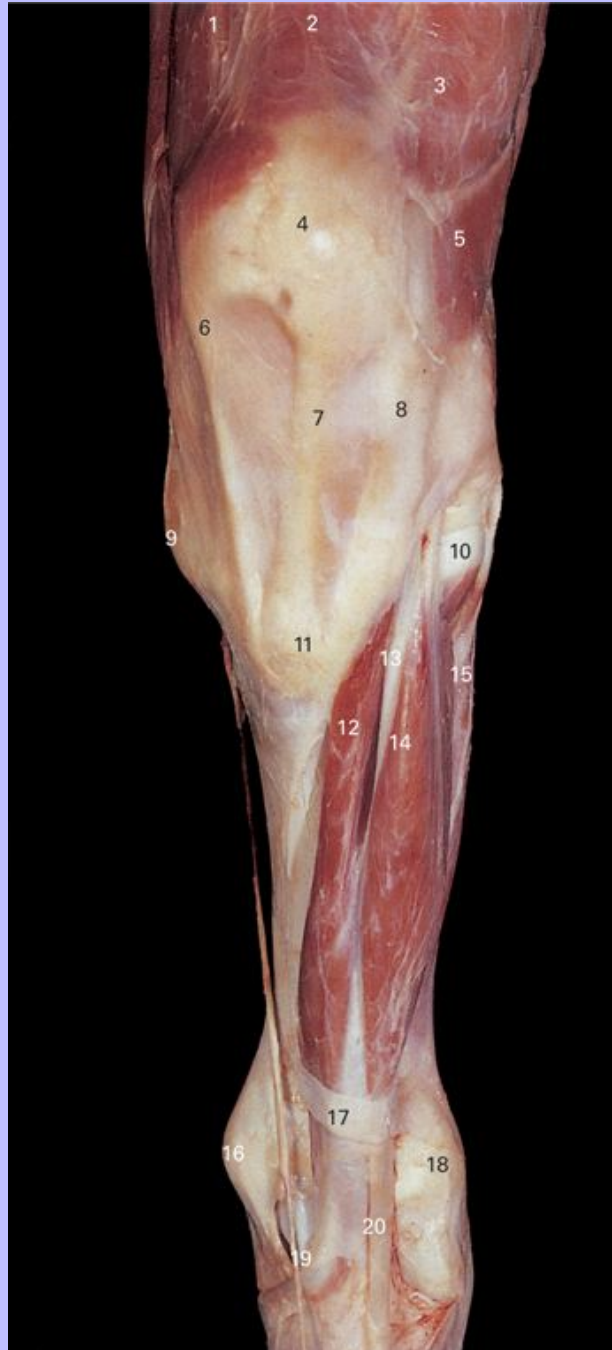
- 7 Lateral condyle of tibia
- 8 Cranial cruciate ligament
- 9 Spine of tibia
- 10 Medial condyle of tibia
- 11 Medial meniscus
- 12 Medial collateral femorotibial ligament
- 13 Caudal cruciate ligament
- 14 Caudal ligament of medial meniscus
- 15 Menisconfemoral ligament of lateral meniscus

80

Clinical Anatomy of the Horse

5.34 Superficial dissection of left crus, cranial view.

81



1 M. vastus medialis

Clinical Anatomy of the Horse

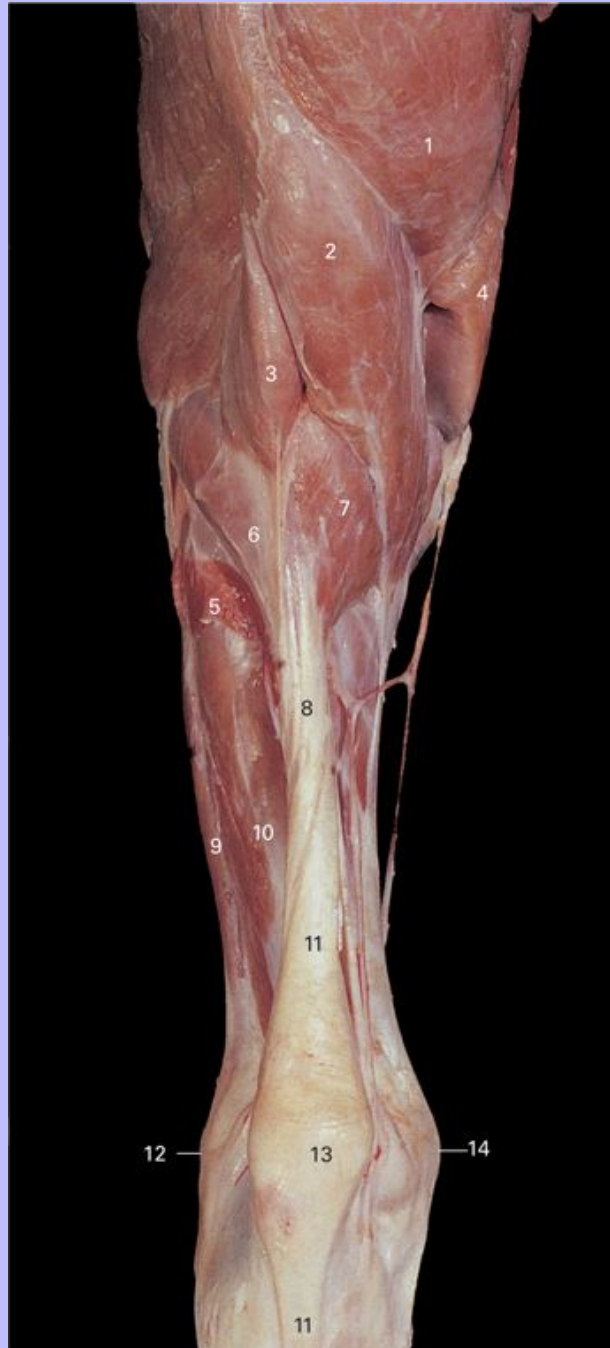- 2 M. rectus femoris
- 3 M. vastus lateralis
- 4 Patella
- 5 M. biceps femoris
- 6 Medial patellar ligament
- 7 Middle patellar ligament
- 8 Lateral patellar ligament
- 9 Medial condyle of tibia
- 10 Lateral condyle of tibia
- 11 Tibial tuberosity
- 12 M. tibialis cranialis
- 13 Tendon of M. peroneus (fibularis) tertius
- 14 M. extensor digitorum longus
- 15 M. extensor digitorum lateralis
- 16 Medial malleolus
- 17 Proximal extensor retinaculum of tarsus
- 18 Lateral malleolus
- 19 Medial tendon of M. tibialis cranialis (cunean tendon)
- 20 Tendon of M. extensor digitorum longus

81

Clinical Anatomy of the Horse

82

5.35 Superficial dissection of left crus, caudal view.



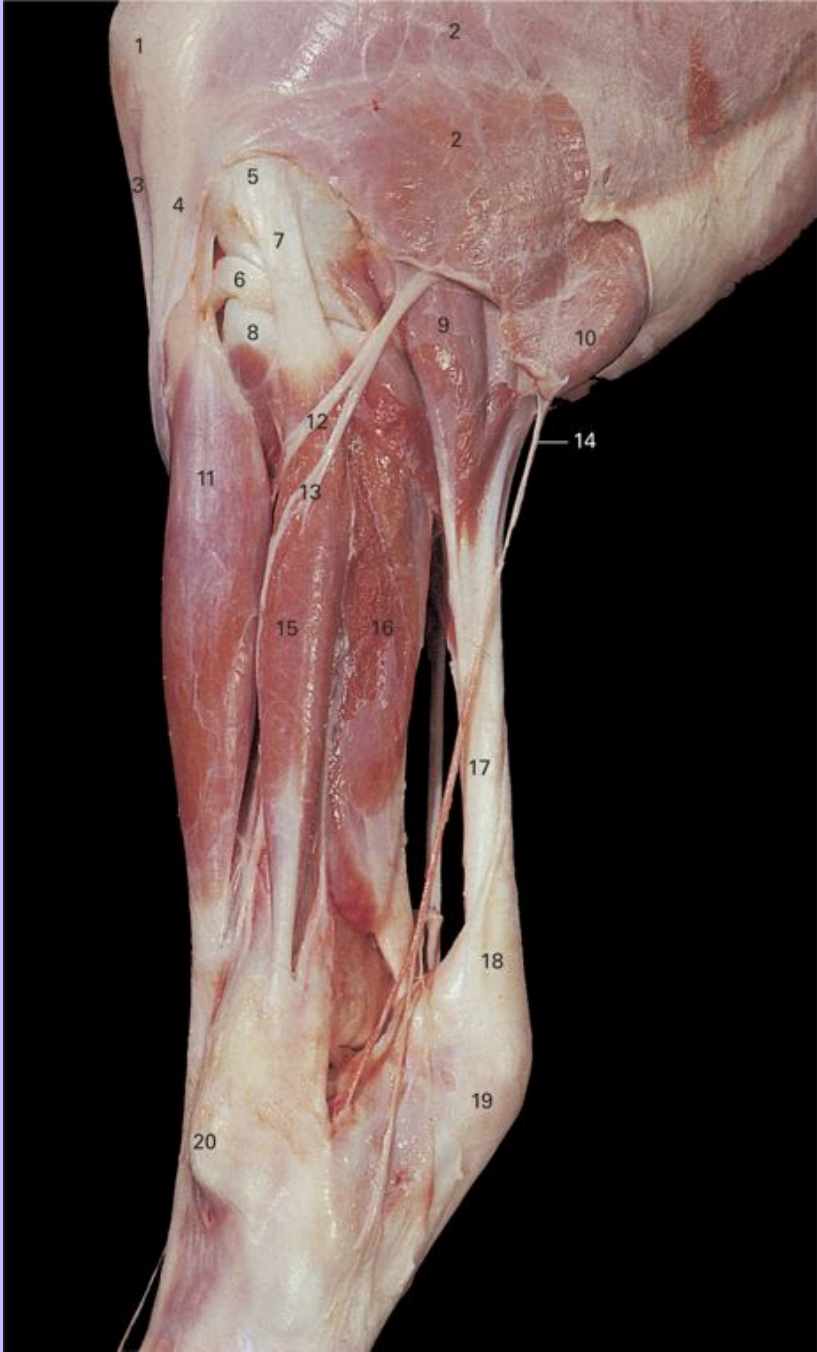1 M. semimembranosus

Clinical Anatomy of the Horse

- 2 M. semitendinosus
- 3 M. biceps femoris
- 4 M. gracilis
- 5 M. soleus
- 6 M. gastrocnemius, medial head
- 7 M. gastrocnemius, lateral head
- 8 Common calcaneal tendon
- 9 M. extensor digitorum lateralis
- 10 M. flexor digitorum profundus
- 11 Tendon of M. flexor digitorum superficialis
- 12 Lateral malleolus
- 13 Calcaneal tuber
- 14 Medial malleolus

Clinical Anatomy of the Horse

5.36 Superficial dissection of left crus, lateral view.



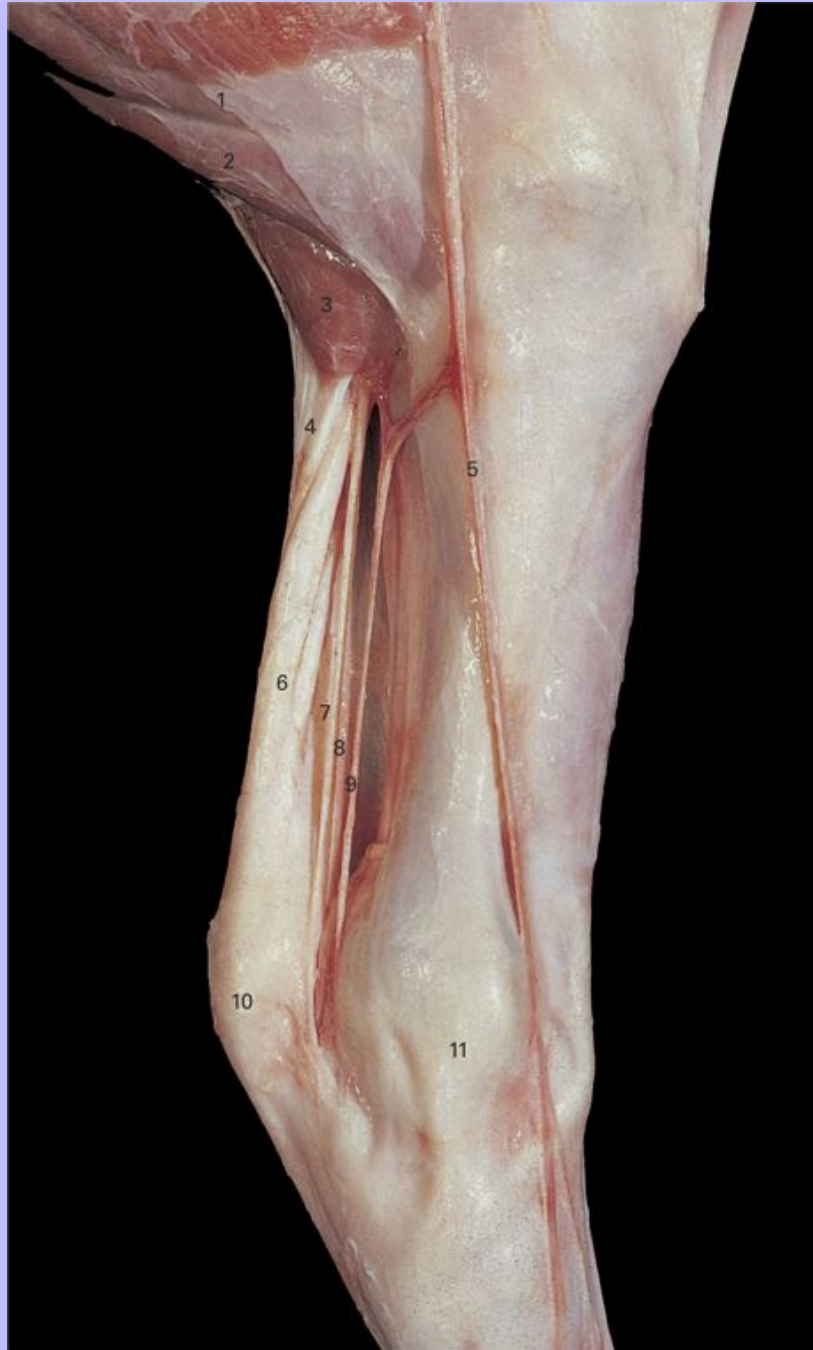1 Patella

Clinical Anatomy of the Horse

- 2 M. biceps femoris
- 3 Middle patellar ligament
- 4 Lateral patellar ligament
- 5 Lateral epicondyle of femur
- 6 Lateral meniscus
- 7 Lateral collateral femorotibial ligament
- 8 Lateral condyle of tibia
- 9 M. gastrocnemius, lateral head
- 10 M. semitendinosus
- 11 M. extensor digitorum longus
- 12 Deep peroneal (fibular) nerve
- 13 Superficial peroneal (fibular) nerve
- 14 Caudal cutaneous sural nerve
- 15 M. extensor digitorum lateralis
- 16 M. flexor digitorum profundus
- 17 Common calcanean tendon
- 18 Tendon of M. flexor digitorum superficialis
- 19 Calcaneal tuber
- 20 Lateral malleolus

82

5.37 Superficial dissection of left crus, medial view.



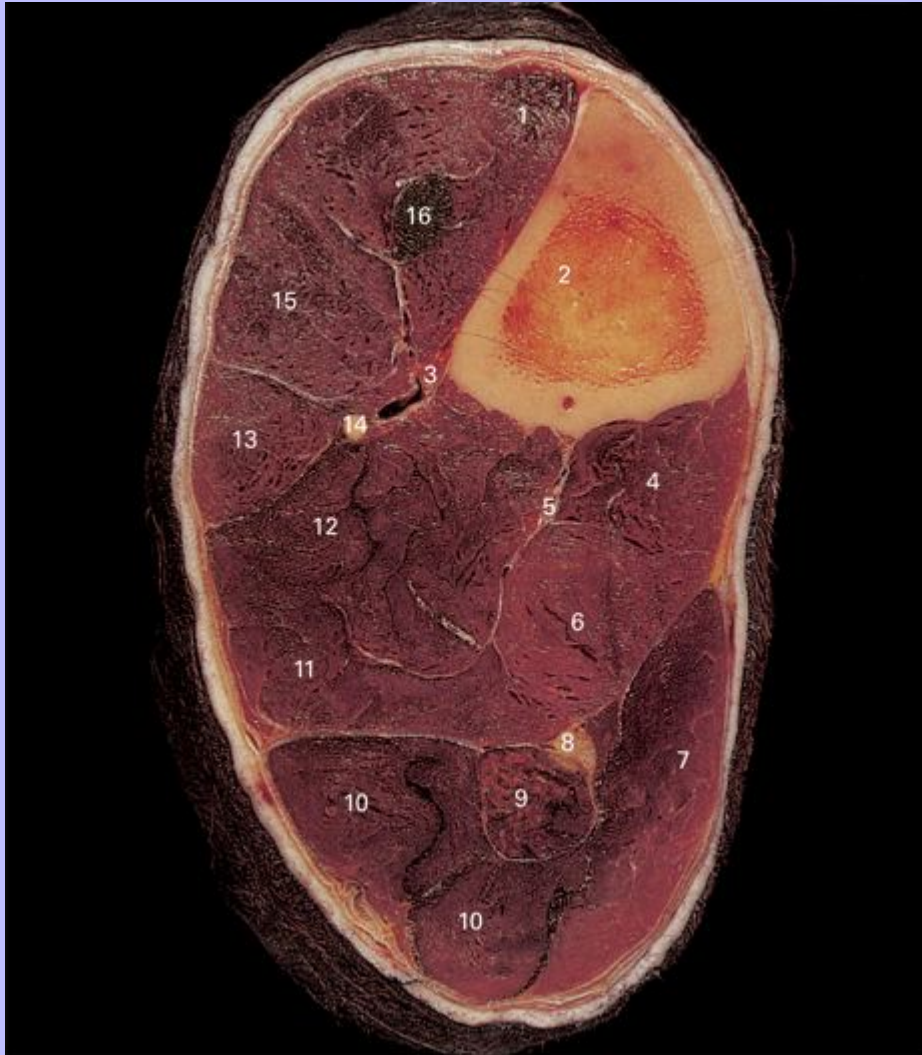
1 M. semimembranosus

Clinical Anatomy of the Horse

- 2 M. semitendinosus
- 3 M. gastrocnemius, medial head
- 4 Common calcanean tendon
- 5 Medial saphenous vein, cranial branch
- 6 Tendon of M. flexor digitorum superficialis
- 7 Tibial nerve
- 8 Saphenous artery
- 9 Medial saphenous vein, caudal branch
- 10 Calcaneal tuber
- 11 Medial malleolus

Clinical Anatomy of the Horse

5.38 Transverse section through left crus at the level of the junction between the proximal and middle third, distal view.



- 1 M. tibialis cranialis
- 2 Tibia
- 3 Cranial tibial vessels
- 4 M. popliteus
- 5 Caudal tibial vessels

Clinical Anatomy of the Horse

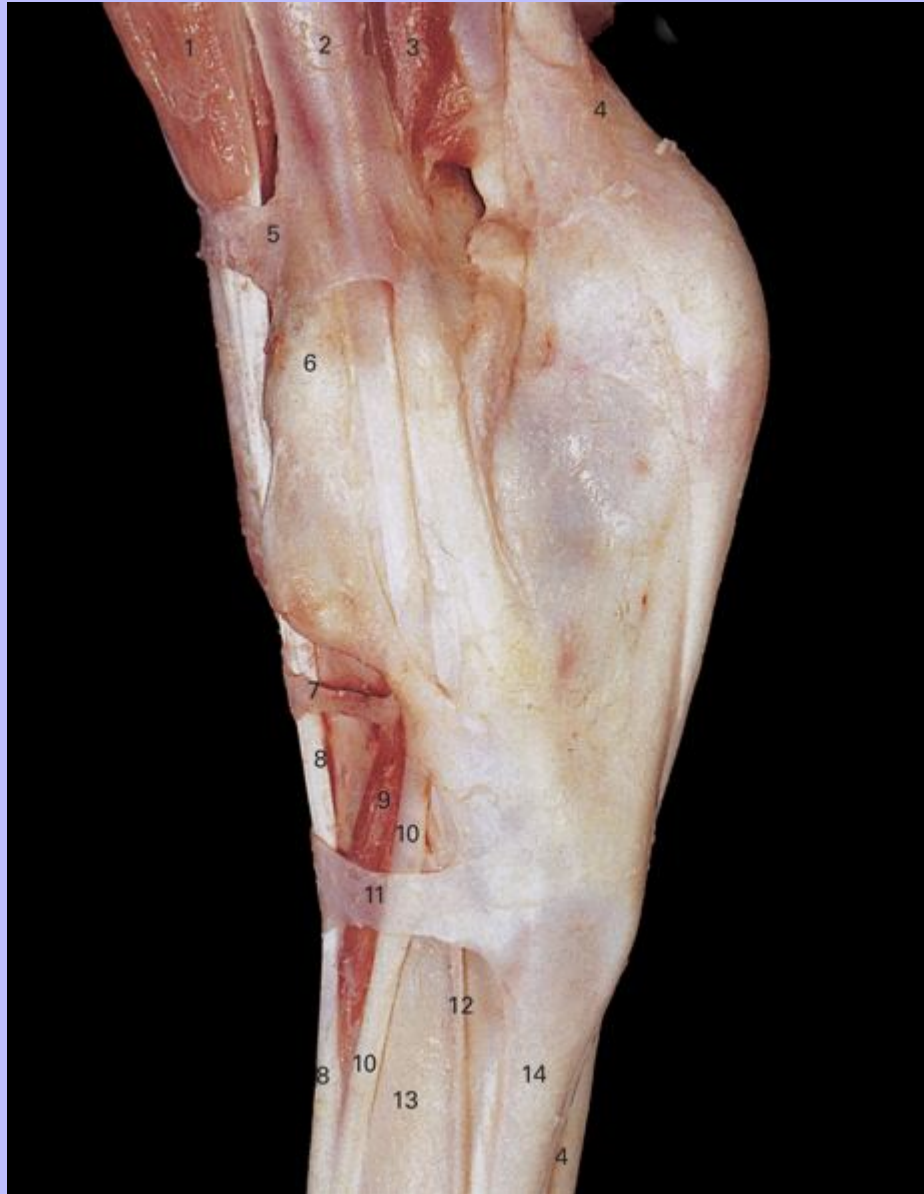- 6 M. flexor digitorum longus
- 7 M. gastrocnemius, medial head
- 8 Tibial nerve
- 9 M. flexor digitorum superficialis
- 10 M. gastrocnemius, lateral head
- 11 M. tibialis caudalis
- 12 M. flexor digitorum profundus
- 13 M. extensor digitorum lateralis
- 14 Fibula
- 15 M. extensor digitorum longus
- 16 M. peroneus (fibularis) tertius

83

Clinical Anatomy of the Horse

84

5.39 Superficial dissection of left tarsus, lateral view.



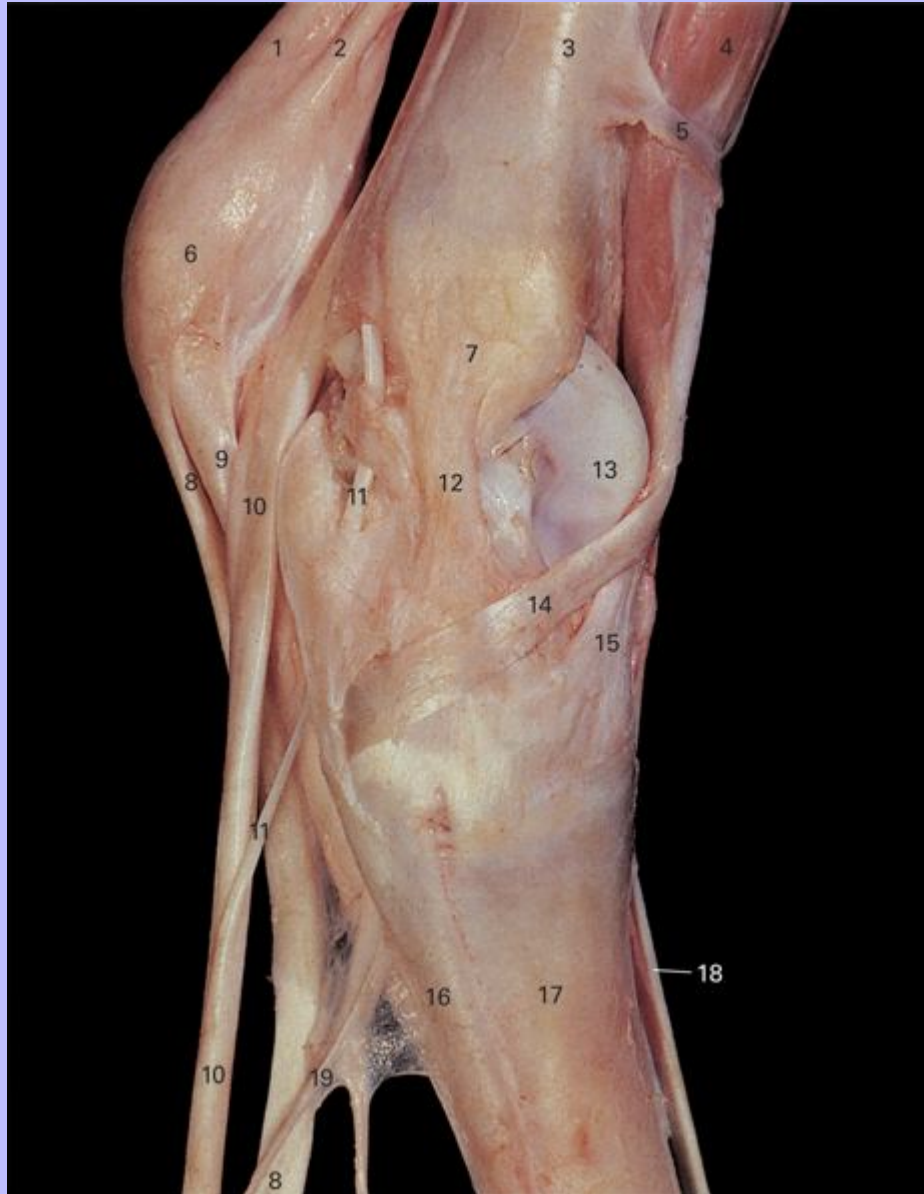
- 1 M. tibialis cranialis
- 2 M. extensor digitorum lateralis
- 3 M. flexor digitorum profundus

Clinical Anatomy of the Horse

- 4 Tendon of *M. flexor digitorum superficialis*
- 5 Proximal extensor retinaculum
- 6 Lateral malleolus
- 7 Middle extensor retinaculum
- 8 Tendon of *M. extensor digitorum longus*
- 9 *M. extensor digitorum brevis*
- 10 Tendon of *M. extensor digitorum lateralis*
- 11 Distal extensor retinaculum
- 12 Dorsal metatarsal artery III
- 13 Metatarsal III (cannon bone)
- 14 Metatarsal IV (lateral splint bone)

Clinical Anatomy of the Horse

5.40 Superficial dissection of left tarsus, medial view. Tendons of *M. flexor digitorum profundus* and *M. flexor digitorum superficialis* have been retracted in a plantar direction in the metatarsal region.



1 Tendon of *M. flexor digitorum superficialis*

2 Tendon of *M. gastrocnemius*

Clinical Anatomy of the Horse

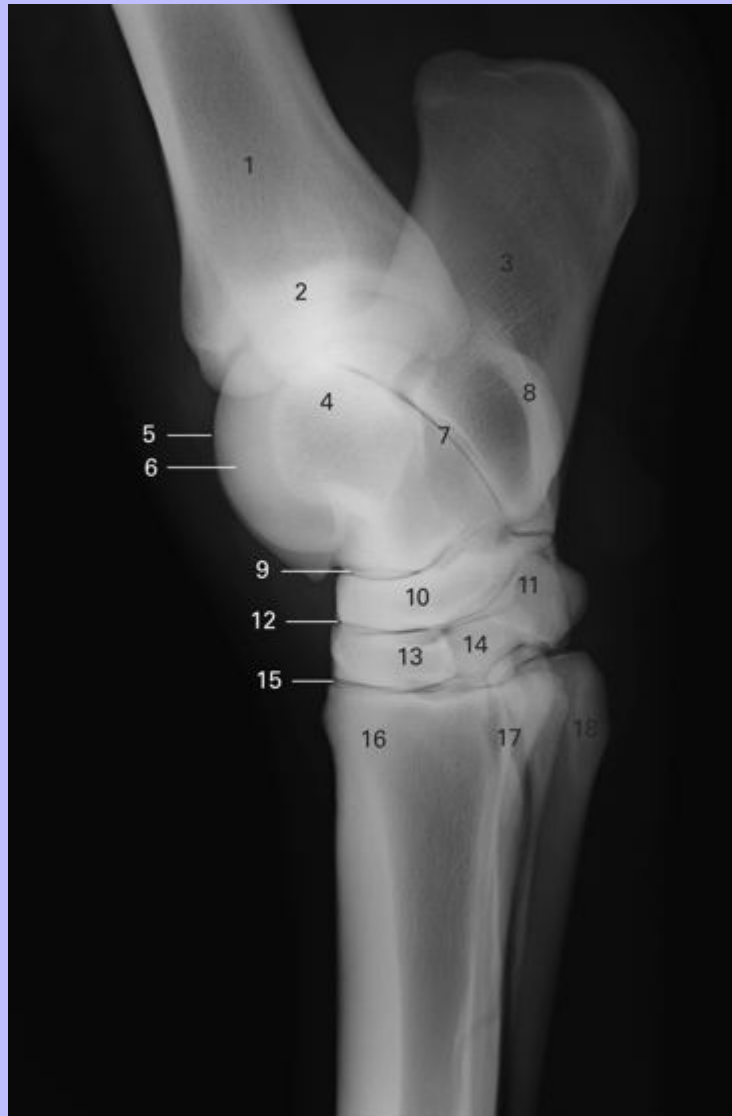
- 3 Tibia
- 4 M. tibialis cranialis
- 5 Proximal extensor retinaculum
- 6 Calcaneal tuber
- 7 Lateral malleolus
- 8 Tendon of M. flexor digitorum superficialis
- 9 Plantar ligament
- 10 Tendon of M. flexor digitorum profundus
- 11 Tendon of M. flexor digitorum longus
- 12 Medial collateral tarsal ligament
- 13 Trochlea of talus
- 14 Medial tendon of M. tibialis cranialis (cunean tendon)
- 15 Dorsal tendon of M. peroneus (fibularis) longus
- 16 Metatarsal II (medial splint bone)
- 17 Metatarsal III (cannon bone)
- 18 Tendon of M. extensor digitorum longus
- 19 Accessory ligament of M. extensor digitorum profundus (distal check ligament)

84

Clinical Anatomy of the Horse

85

5.41 Lateromedial view radiograph of tarsal joint.



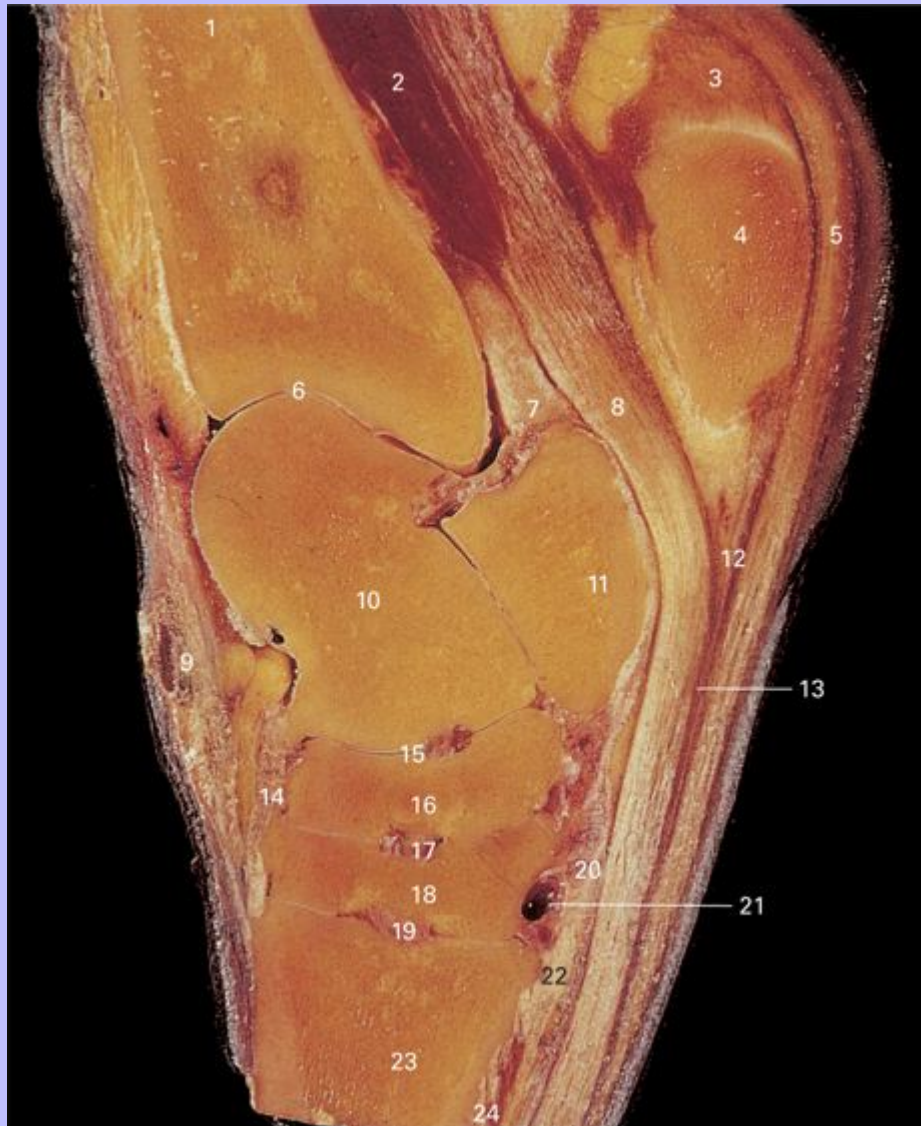- 1 Tibia
- 2 Tarsocrural joint
- 3 Calcaneus
- 4 Talus

Clinical Anatomy of the Horse

- 5 Lateral trochlea
- 6 Medial trochlea
- 7 Talocalcaneal joint
- 8 Sustentaculum tali
- 9 Proximal intertarsal joint
- 10 Central tarsal bone
- 11 Fourth tarsal bone
- 12 Distal intertarsal joint
- 13 Third tarsal bone
- 14 First and second tarsal bone (fused)
- 15 Tarsometatarsal joint
- 16 Metatarsal III (cannon bone)
- 17 Metatarsal II (medial splint bone)
- 18 Metatarsal IV (lateral splint bone)

Clinical Anatomy of the Horse

5.42 Sagittal section through left tarsus.



- 1 Tibia
- 2 M. flexor digitorum profundus
- 3 Tendon of M. gastrocnemius
- 4 Calcaneal tuber

Clinical Anatomy of the Horse

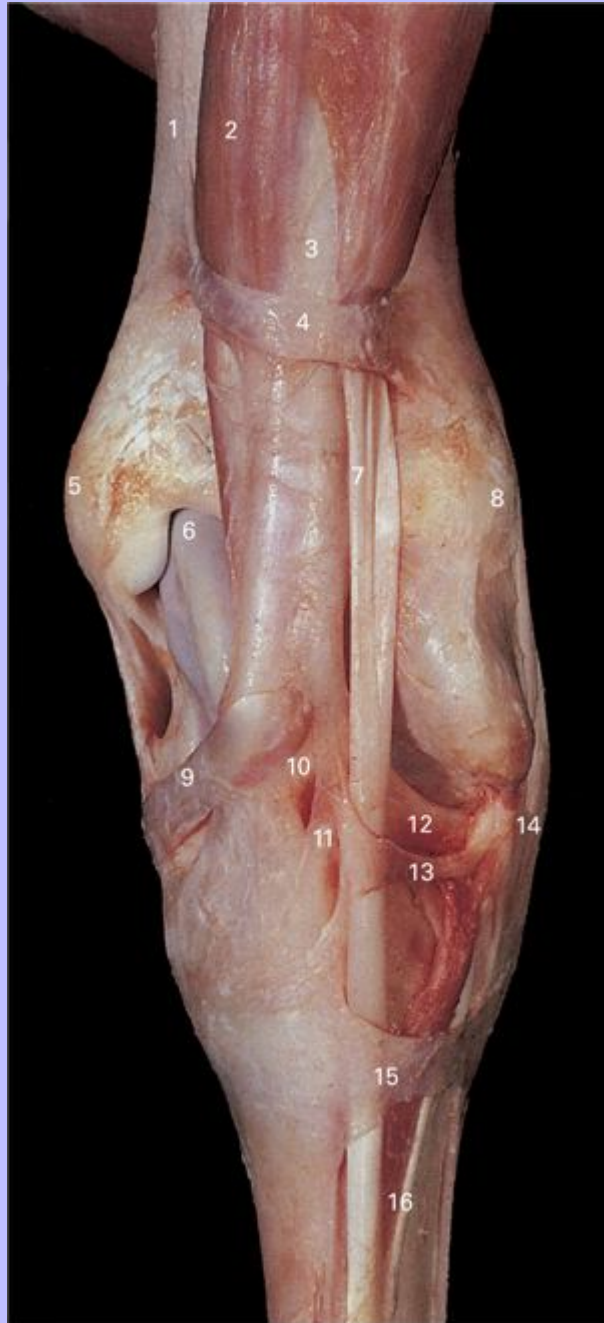
- 5 Tendon of M. flexor digitorum superficialis
- 6 Tibiotarsal joint
- 7 Thick part of joint capsule
- 8 Tendon of M. flexor digitorum profundus
- 9 Medial tendon of M. tibialis cranialis (cunean tendon)
- 10 Talus
- 11 Sustentaculum tali
- 12 Long plantar ligament
- 13 Flexor retinaculum
- 14 Fibrous joint capsule
- 15 Proximal intertarsal joint
- 16 Central tarsal bone
- 17 Distal intertarsal joint
- 18 Third tarsal bone
- 19 Tarsometatarsal joint
- 20 Joint capsule (tarsometatarsal ligament)
- 21 Proximal perforating tarsal vein
- 22 Accessory ligament of M. flexor digitorum profundus (distal check ligament)
- 23 Metatarsal III (cannon bone)
- 24 M. interosseus medius (suspensory ligament)

85

Clinical Anatomy of the Horse

5.43 Superficial dissection of left tarsus, dorsal view.

86



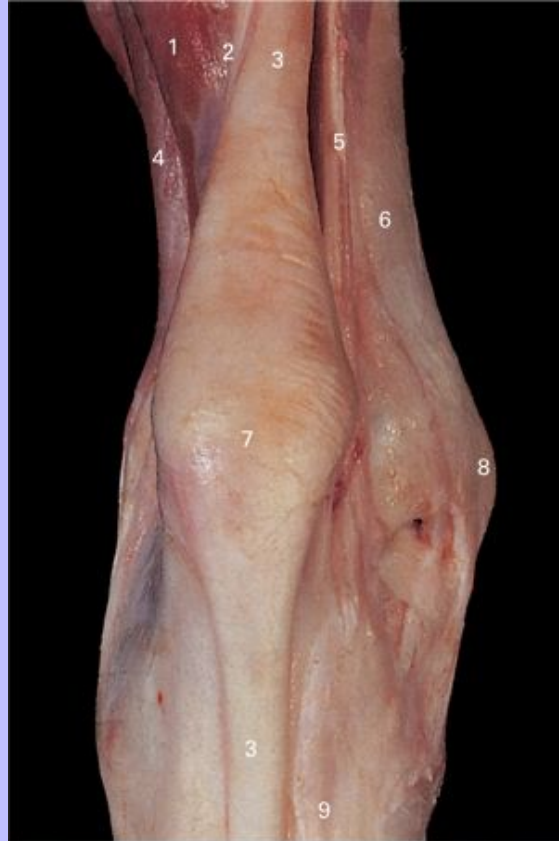1 Tibia

Clinical Anatomy of the Horse

- 2 M. tibialis cranialis
- 3 Tendon of M. peroneus (fibularis) tertius
- 4 Proximal extensor retinaculum
- 5 Medial malleolus
- 6 Trochlea of talus
- 7 Tendon of M. extensor digitorum longus
- 8 Lateral malleolus
- 9 Medial tendon of M. tibialis cranialis (cunean tendon)
- 10 Dorsal tendon of M. peroneus (fibularis) tertius
- 11 Dorsal tendon of M. tibialis cranialis
- 12 Lateral tendon of M. peroneus (fibularis) tertius
- 13 Middle extensor retinaculum
- 14 Long lateral collateral tarsal ligament
- 15 Distal extensor retinaculum
- 16 Tendon of M. extensor digitorum lateralis

Clinical Anatomy of the Horse

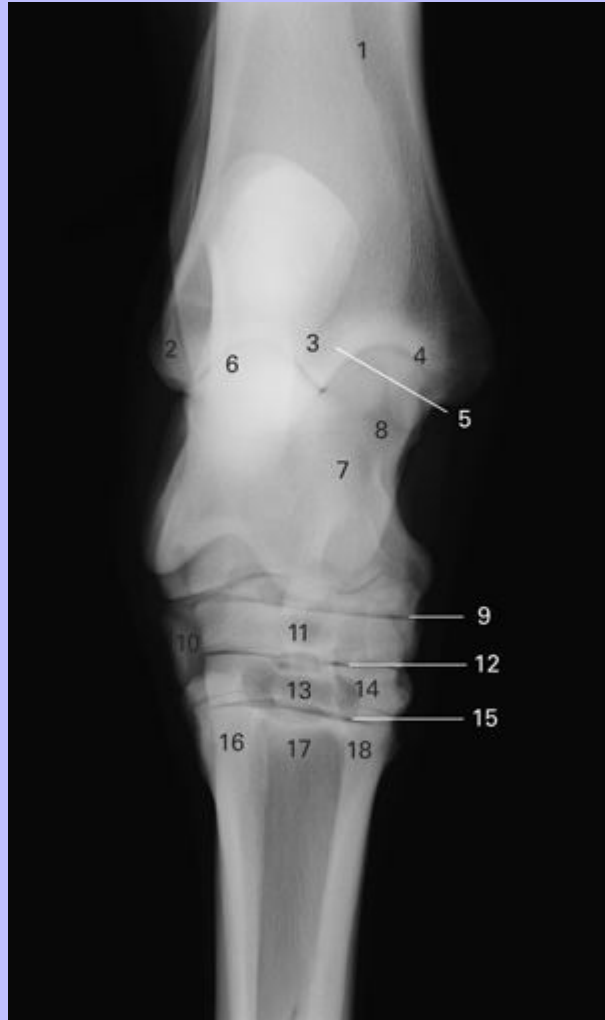5.44 Superficial dissection of left tarsus, caudal view.



- 1 M. flexor digitorum profundus, superficial head
- 2 Tendon of M. gastrocnemius
- 3 Tendon of M. flexor digitorum superficialis
- 4 M. extensor digitorum lateralis
- 5 M. flexor digitorum profundus, medial head
- 6 Tibia
- 7 Calcaneal tuber
- 8 Medial malleolus
- 9 Tendon of M. flexor digitorum profundus

Clinical Anatomy of the Horse

5.45 Dorsoplantar view radiograph of tarsal joint.



- 1 Tibia
- 2 Lateral malleolus
- 3 Sagittal ridge
- 4 Medial malleolus
- 5 Tarsocrural joint
- 6 Calcaneus

Clinical Anatomy of the Horse

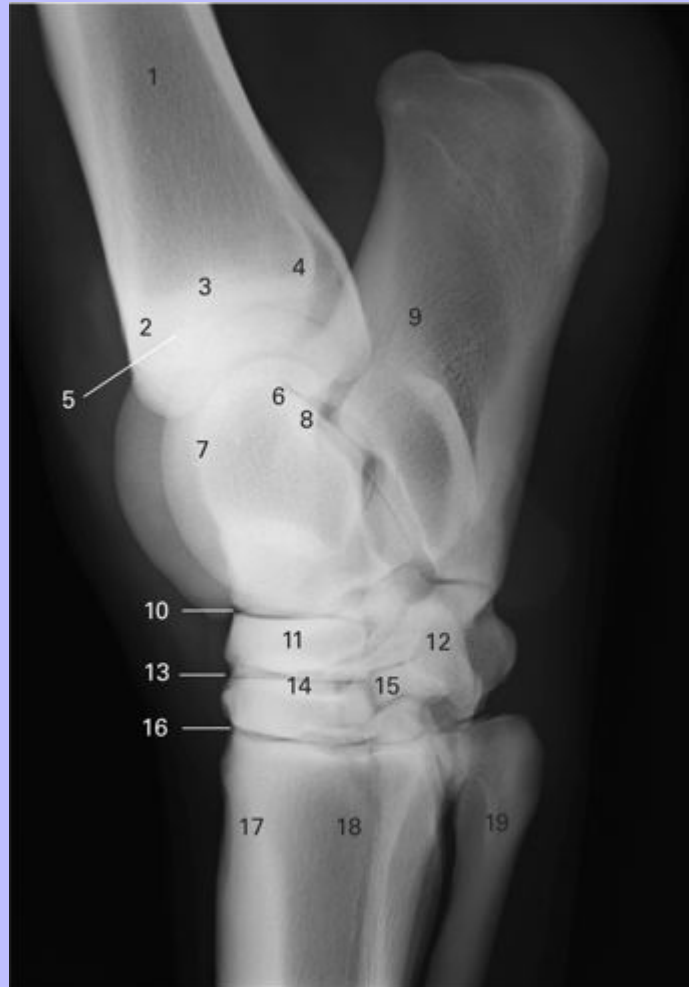- 7 Talus
- 8 Medial trochlea
- 9 Proximal intertarsal joint
- 10 Fourth tarsal bone
- 11 Central tarsal bone
- 12 Distal intertarsal joint
- 13 Third tarsal bone
- 14 First and second tarsal bone (fused)
- 15 Tarsometatarsal joint
- 16 Metatarsal IV (lateral splint bone)
- 17 Metatarsal III (cannon bone)
- 18 Metatarsal II (medial splint bone)

86

Clinical Anatomy of the Horse

87

5.46 Dorsolateral-plantaromedial oblique view radiograph of tarsal joint.



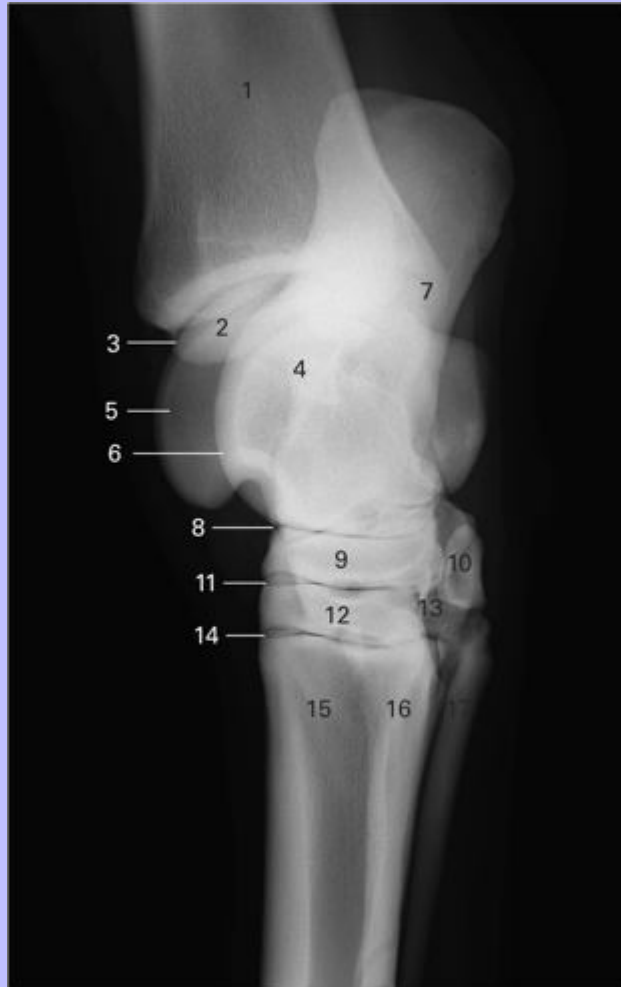
- 1 Tibia
- 2 Medial malleolus
- 3 Medial groove
- 4 Lateral groove
- 5 Tarsocrural joint
- 6 Talus
- 7 Medial trochlea

Clinical Anatomy of the Horse

- 8 Lateral trochlea
- 9 Calcaneus
- 10 Proximal intertarsal joint
- 11 Central tarsal bone
- 12 Fourth tarsal bone
- 13 Distal intertarsal joint
- 14 Third tarsal bone
- 15 First and second tarsal bone (fused)
- 16 Tarsometatarsal joint
- 17 Metatarsal III (cannon bone)
- 18 Metatarsal II (medial splint bone)
- 19 Metatarsal IV (lateral splint bone)

Clinical Anatomy of the Horse

5.47 Dorsomedial-plantarolateral oblique view radiograph of tarsal joint.



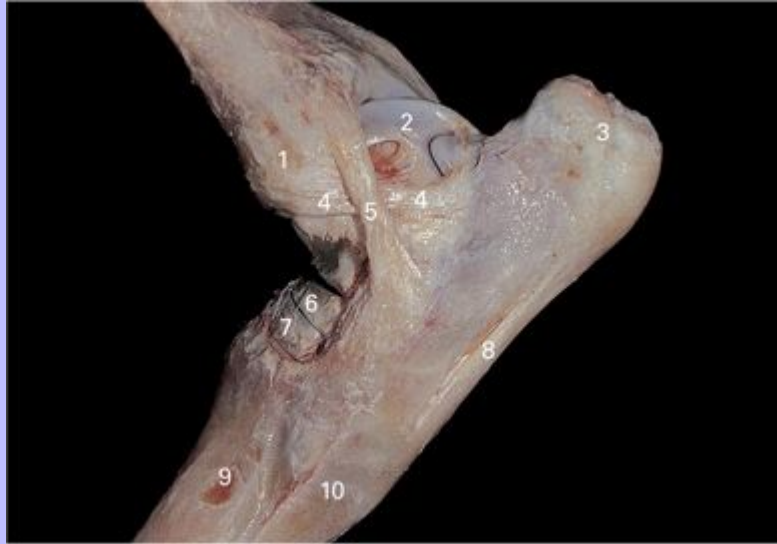- 1 Tibia
- 2 Sagittal ridge
- 3 Tarsocrural joint
- 4 Talus
- 5 Lateral trochlea
- 6 Medial trochlea
- 7 Calcaneus

Clinical Anatomy of the Horse

- 8 Proximal intertarsal joint
- 9 Central tarsal bone
- 10 Fourth tarsal bone
- 11 Distal intertarsal joint
- 12 Third tarsal bone
- 13 First and second tarsal bone (fused)
- 14 Tarsometatarsal joint
- 15 Metatarsal III (cannon bone)
- 16 Metatarsal IV (lateral splint bone)
- 17 Metatarsal II (medial splint bone)

Clinical Anatomy of the Horse

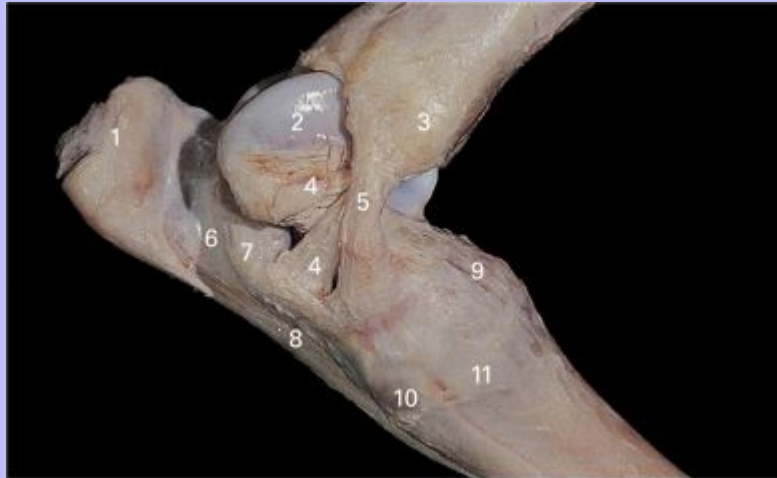
5.48 Deep dissection of left tarsal joint, flexed lateral view.



- 1 Lateral malleolus
- 2 Trochlea of talus
- 3 Calcaneal tuber
- 4 Short lateral collateral tarsal ligament
- 5 Long lateral collateral tarsal ligament
- 6 Central tarsal bone
- 7 Third tarsal bone
- 8 Long plantar ligament
- 9 Metatarsal III (cannon bone)
- 10 Metatarsal IV (lateral splint bone)

Clinical Anatomy of the Horse

5.49 Deep dissection of left tarsal joint, flexed medial view.



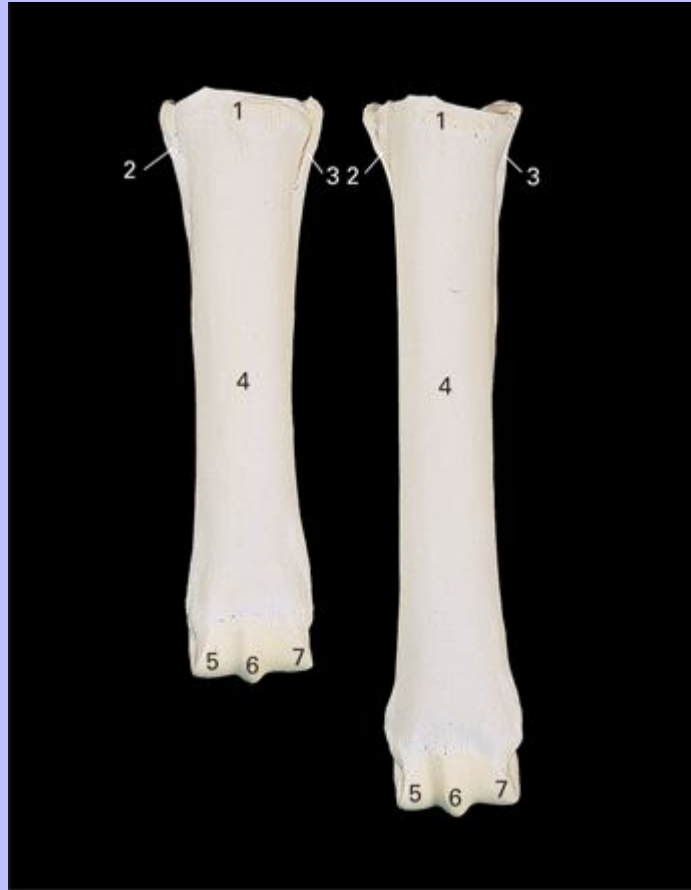- 1 Calcaneal tuber
- 2 Trochlea of talus
- 3 Medial malleolus
- 4 Short medial collateral tarsal ligament
- 5 Long medial collateral tarsal ligament
- 6 Groove for tendon of M. flexor digitorum profundus
- 7 Sustentaculum tali
- 8 Long plantar ligament
- 9 Dorsal tarsal ligament
- 10 Metatarsal II (medial splint bone)
- 11 Metatarsal III (cannon bone)

87

Clinical Anatomy of the Horse

88

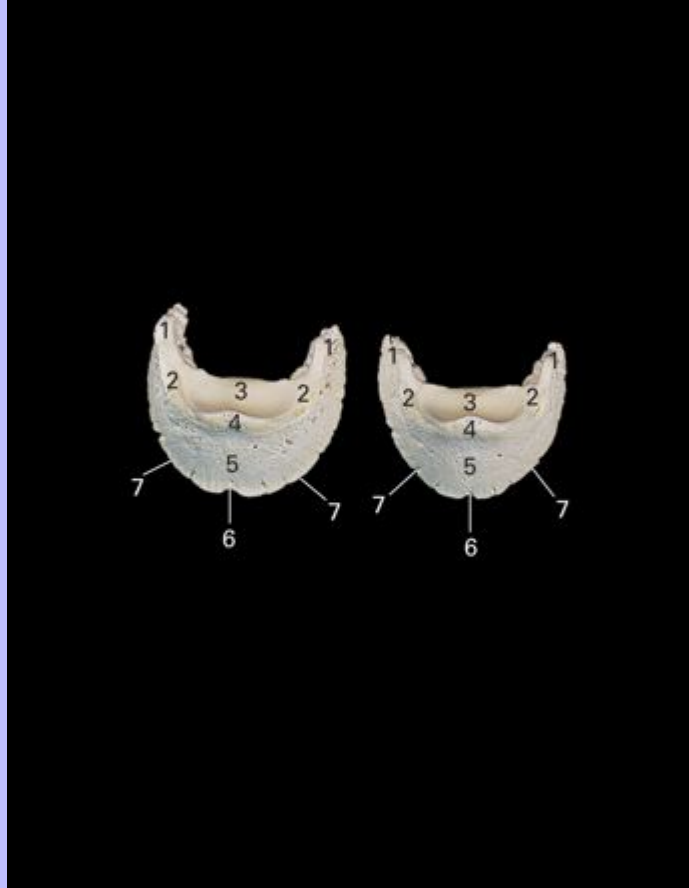
5.50 Metacarpal (left) and metatarsal (right) bones.



- 1 Metacarpal/metatarsal tuberosity
- 2 Second metacarpal/metatarsal bone
- 3 Fourth metacarpal/metatarsal bone
- 4 Third metacarpal/metatarsal bone
- 5 Medial condyle
- 6 Sagittal ridge
- 7 Lateral condyle

Clinical Anatomy of the Horse

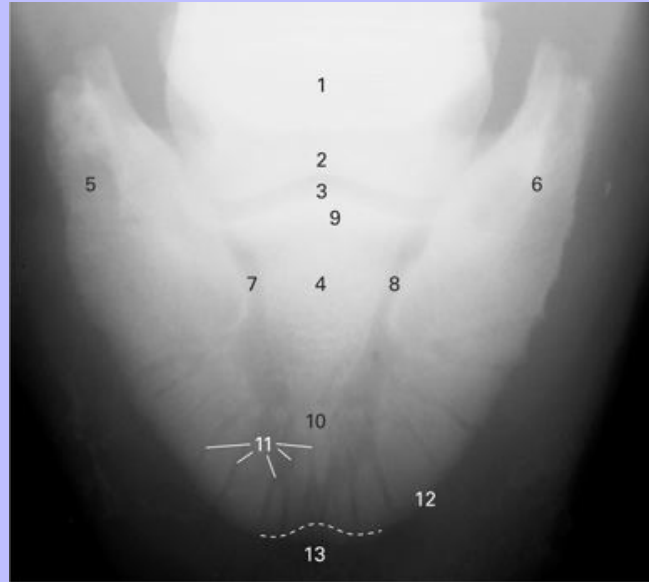
5.51 Distal phalanx of forelimb (left) and hindlimb (right), dorsal view.



- 1 Palmar process
- 2 Parietal sulcus
- 3 Articular surface
- 4 Extensor process
- 5 Parietal surface
- 6 Crena
- 7 Solar border

Clinical Anatomy of the Horse

5.52 Dorsoplantar view radiograph of hind distal phalanx.

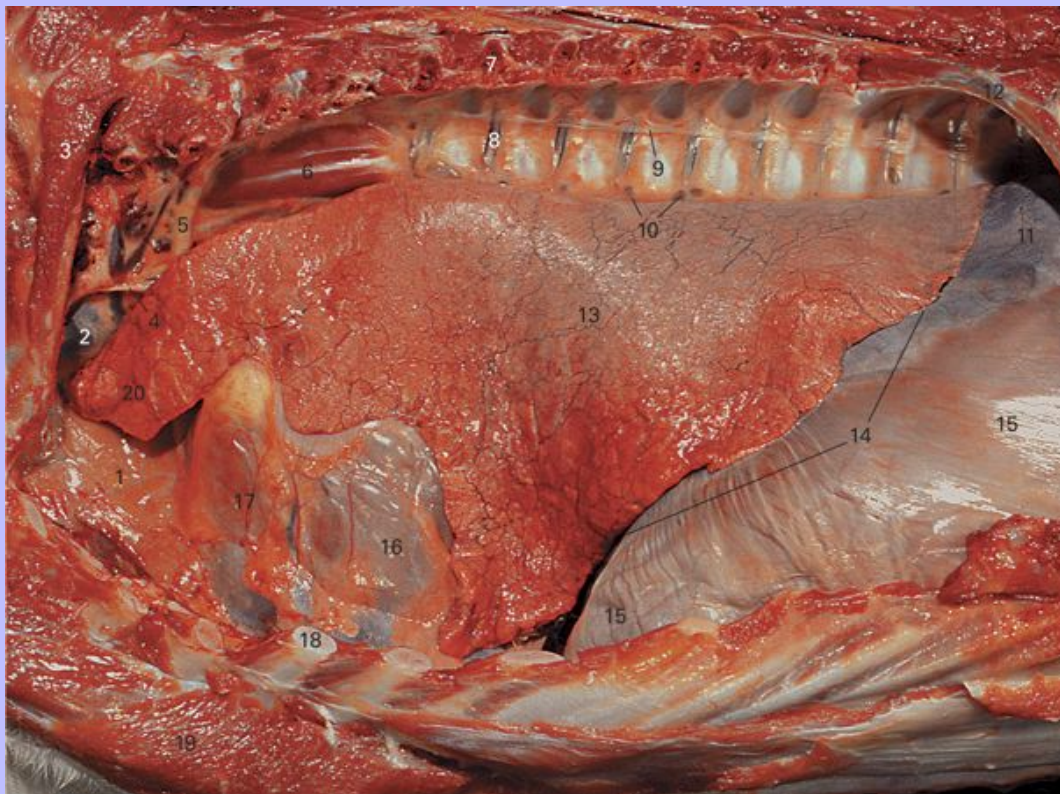


- 1 Distal sesamoid (navicular) bone
- 2 Middle phalanx (P2, short postern bone)
- 3 Distal interphalangeal (coffin) joint
- 4 Distal phalanx (P3, coffin bone, pedal bone)
- 5 Lateral plantar process
- 6 Medial plantar process
- 7 Lateral parietal sulcus
- 8 Medial parietal sulcus
- 9 Extensor process
- 10 Solar canal
- 11 Vascular channels
- 12 Solar margin
- 13 Crena

Clinical Anatomy of the Horse

6 Thoracic Viscera

6.1 Left view of the thorax. Ribs 2-12 and the associated soft tissues have been removed to expose the thoracic viscera. The pericardium is still in place.



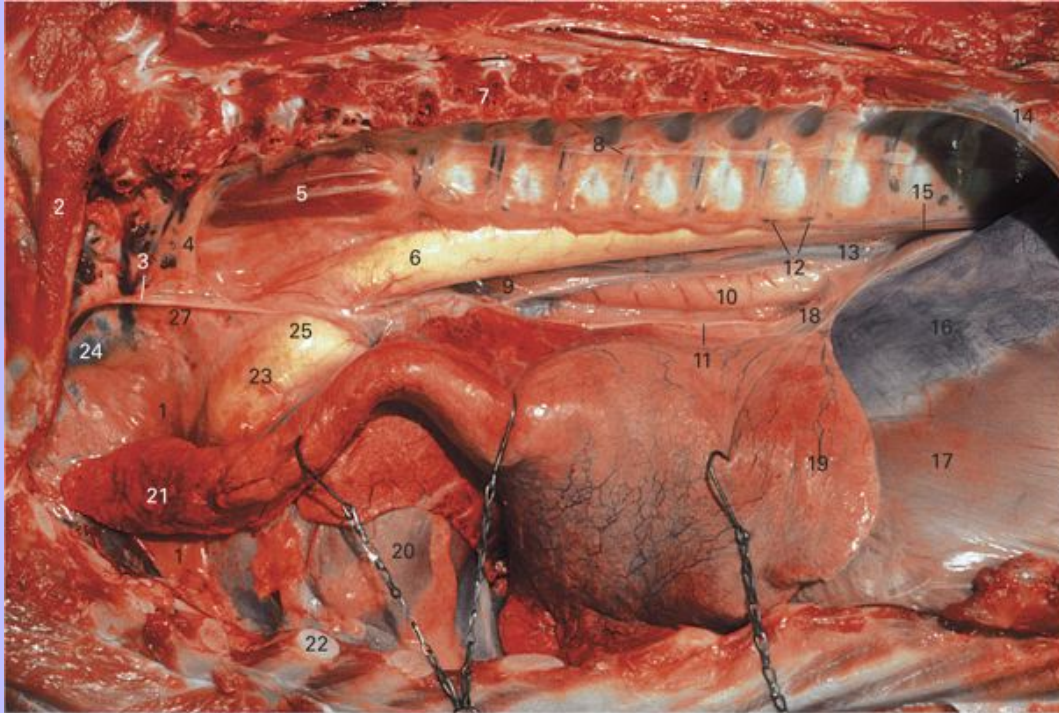- 1 Thymus
- 2 Cranial vena cava
- 3 Rib 1 with some overlying muscle
- 4 Vagosympathetic trunk
- 5 Costocervical trunk
- 6 M. longus colli
- 7 Cut dorsal end of rib 7
- 8 Origin of the intercostal vessels that will come to lie caudal to rib 7

Clinical Anatomy of the Horse

- 9 Sympathetic trunk
- 10 Aortic lymph nodes
- 11 Tendinous center of the diaphragm
- 12 Rib 13
- 13 Costal surface of the caudal lobe of the left lung
- 14 Basal border of the left lung
- 15 Costal part of the diaphragm
- 16 Left ventricle seen through the pericardium
- 17 Right ventricle seen through the pericardium
- 18 Cut cartilage of rib 5
- 19 Cut pectoral muscles
- 20 Costal surface of the cranial lobe of the left lung

Clinical Anatomy of the Horse

6.2 Left view of the thorax. Ribs 2-12 and the associated soft tissues have been removed to expose the thoracic viscera. The left lung has been reflected ventrally.



- 1 Thymus
- 2 Rib 1 with some overlying muscle
- 3 Vagosympathetic trunk
- 4 Costocervical trunk
- 5 M. longus colli
- 6 Aorta
- 7 Cut dorsal end of rib 7
- 8 Sympathetic trunk
- 9 Dorsal trunk of the vagus nerve
- 10 Esophagus

Clinical Anatomy of the Horse

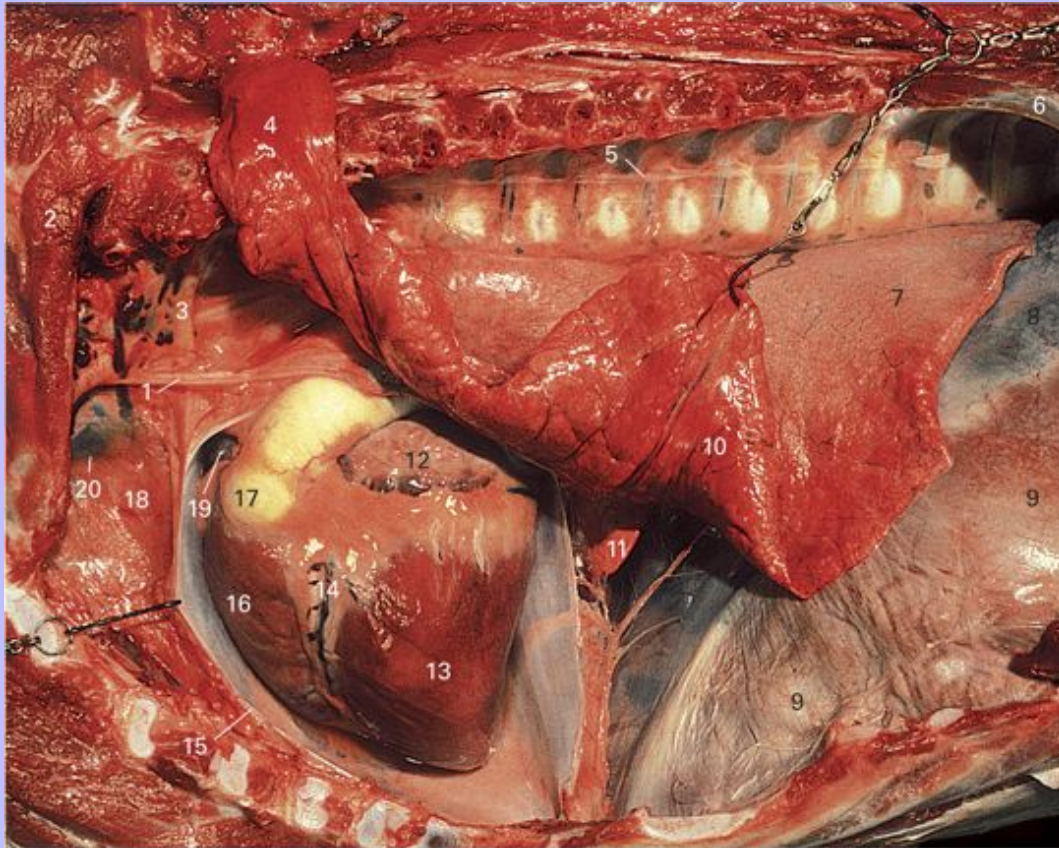
- 11 Ventral trunk of the vagus nerve
- 12 Aortic lymph nodes
- 13 Caudal mediastinum
- 14 Rib 13
- 15 Left crus of the diaphragm
- 16 Tendinous center of the diaphragm
- 17 Costal part of the diaphragm
- 18 Ligament of the lung
- 19 Caudal lobe of the left lung
- 20 Heart lying in the cardiac notch of the lung and surrounded by the pericardium
- 21 Reflected cranial lobe of the left lung
- 22 Cut costal cartilage of rib 5
- 23 Pulmonary trunk
- 24 Cranial vena cava
- 25 Arterial ligament

89

Clinical Anatomy of the Horse

90

6.3 Left view of the thorax. Ribs 2-12 and the associated soft tissues have been removed to expose the thoracic viscera. The left side of the pericardial sac has been removed and the lung has been reflected dorsally.



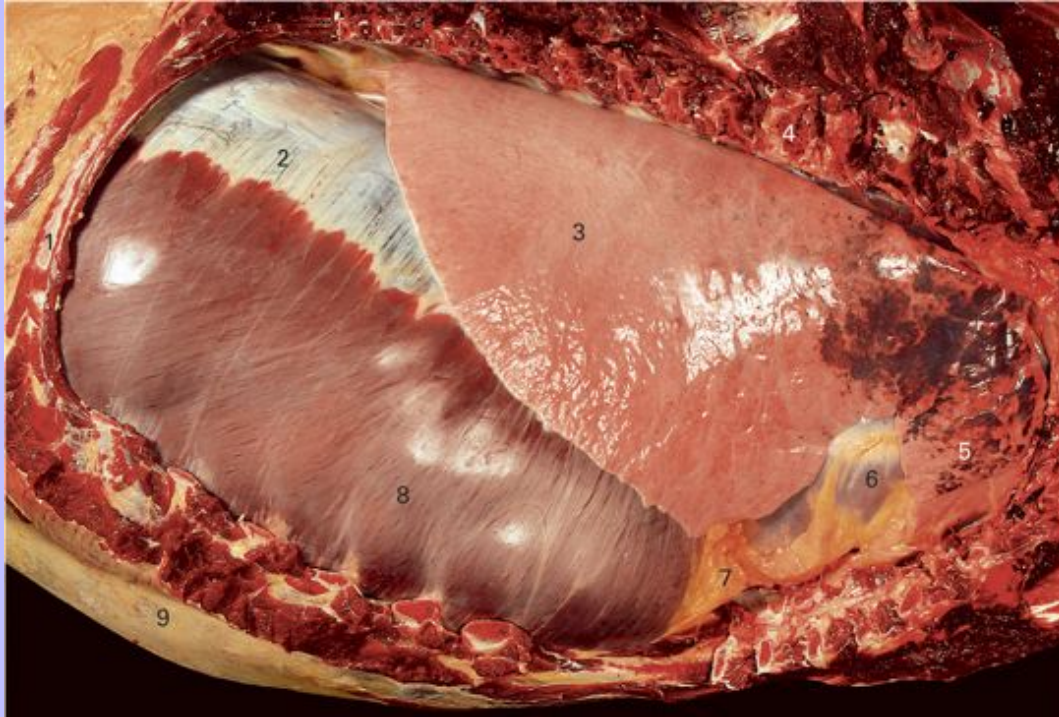- 1 Vagosympathetic trunk
- 2 Rib 1 with some overlying muscle
- 3 Costocervical trunk
- 4 Reflected cranial lobe of the left lung
- 5 Sympathetic trunk
- 6 Rib 13
- 7 Caudal lobe of the left lung
- 8 Tendinous center of the diaphragm

Clinical Anatomy of the Horse

- 9 Costal part of the diaphragm
- 10 Diaphragmatic surface of the reflected caudal lobe of the left lung
- 11 Accessory lobe of the right lung seen through the caudal mediastinum
- 12 Left auricle
- 13 Left ventricle
- 14 Paraconal interventricular groove
- 15 Cut edge of the pericardial sac
- 16 Right ventricle
- 17 Beginning of the pulmonary trunk
- 18 Thymus
- 19 Left extremity of the right auricle
- 20 Cranial vena cava

Clinical Anatomy of the Horse

6.4 The thoracic cavity seen from the right side. Ribs 1-13 and the associated soft tissues have been removed.



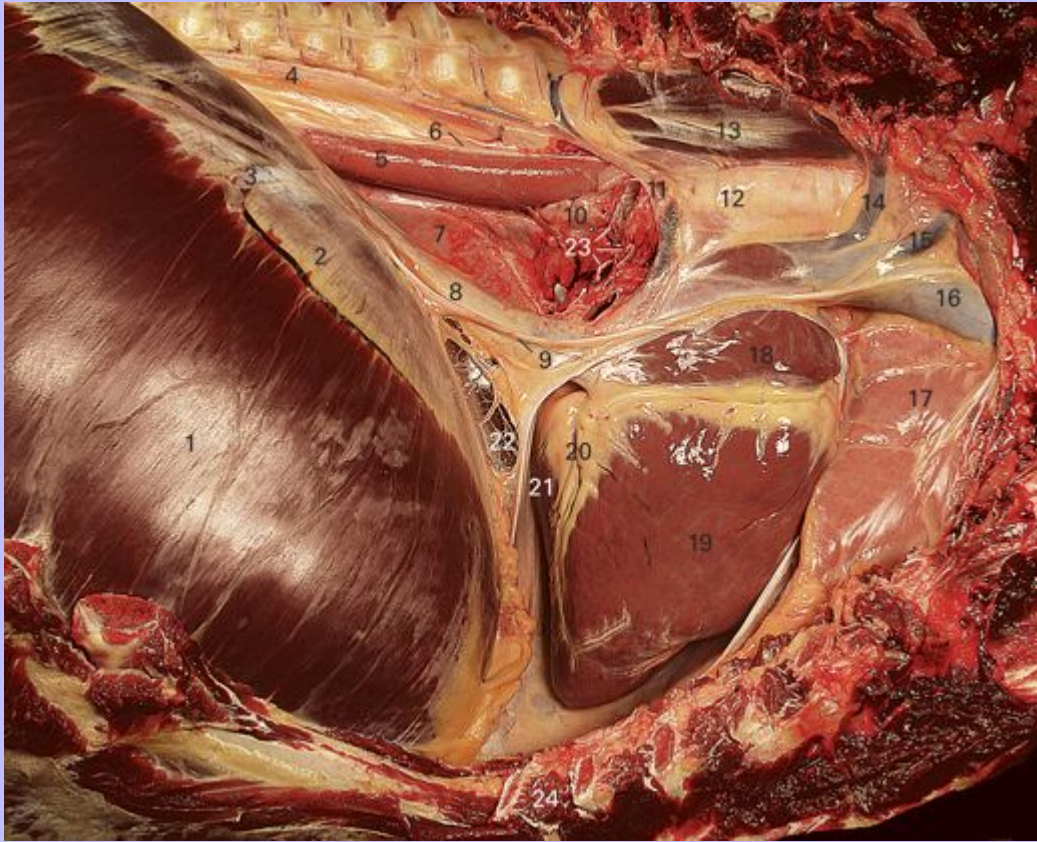- 1 Rib 14
- 2 Tendinous center of the diaphragm
- 3 Costal surface of the caudal lobe of the right lung
- 4 Cut proximal end of rib 4
- 5 Costal surface of the cranial lobe of the right lung (discolored by aspirated blood)
- 6 Right ventricle seen through the pericardium
- 7 The caval fold of the pleura containing abundant fat
- 8 Costal part of the diaphragm
- 9 Tunica flava abdominis overlying the abdominal muscles

90

Clinical Anatomy of the Horse

91

6.5 Right view of the mediastinum and associated structures in a 2-year-old quarter horse. The right side of the pericardium has been removed.



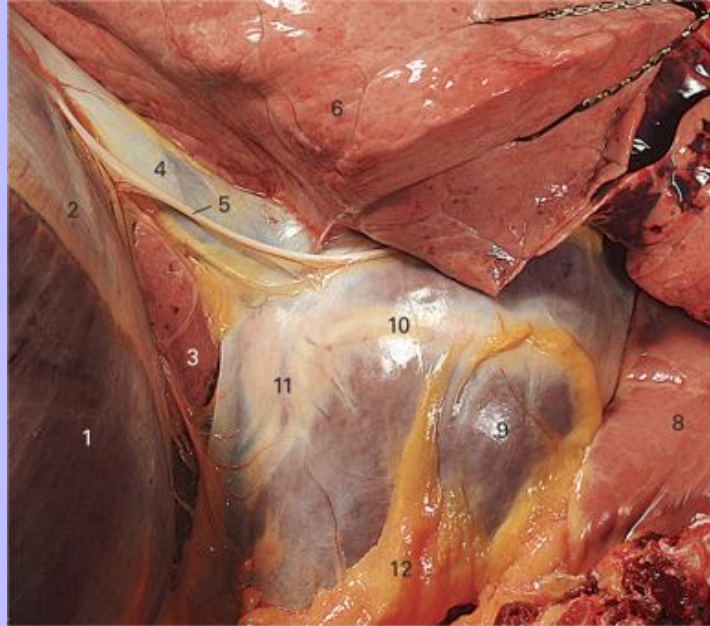
- 1 Costal part of the diaphragm
- 2 Tendinous center of the diaphragm
- 3 Right cranial phrenic vein
- 4 Thoracic duct
- 5 Esophagus
- 6 Dorsal trunk of the vagus
- 7 Left lung seen through the caudal mediastinum
- 8 Caudal vena cava (partially drained of blood)
- 9 Right phrenic nerve

Clinical Anatomy of the Horse

- 10 Tracheobronchial lymph node
- 11 Azygos vein (partially drained of blood)
- 12 Trachea
- 13 M. longus colli
- 14 Costocervical vein
- 15 Deep cervical vein
- 16 Cranial vena cava
- 17 Thymus
- 18 Right atrium with the coronary groove lying ventral to it
- 19 Right ventricle
- 20 Subsinoosal interventricular groove
- 21 Left ventricle
- 22 Caval fold of pleura
- 23 Structures in the root of the right lung. From dorsal to ventral: principal bronchus, pulmonary artery, pulmonary veins
- 24 Cut cartilage of rib 6

Clinical Anatomy of the Horse

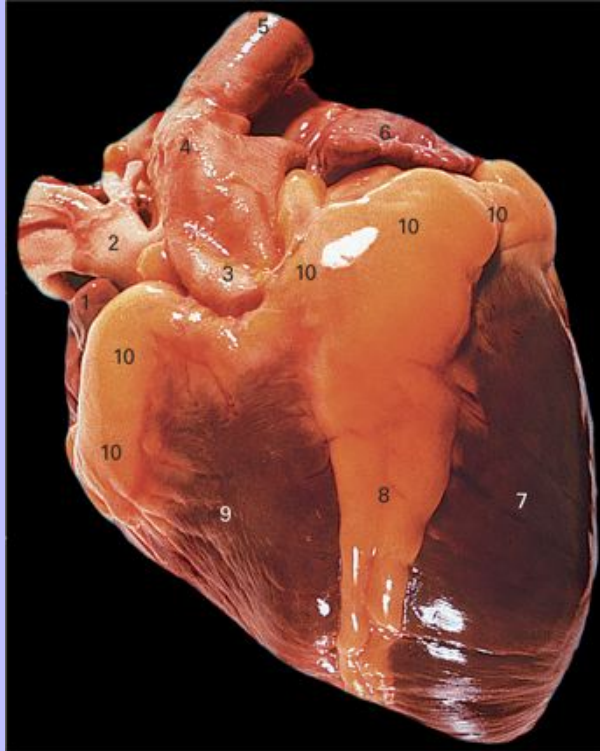
6.6 Detail of the ventral part of the mediastinum in a 2-year-old quarter horse. Right view.



- 1 Costal part of the diaphragm
- 2 Tendinous center of the diaphragm
- 3 Accessory lobe of the right lung seen through the delicate caval fold of pleura
- 4 Caudal vena cava (partially drained of blood)
- 5 Right phrenic nerve covered by a narrow fold of pleura
- 6 Diaphragmatic surface of the caudal lobe of the right lung
- 7 Right atrium seen through the pericardium
- 8 Thymus within the cranial mediastinum
- 9 Right ventricle seen through the pericardium
- 10 Coronary groove seen through the pericardium
- 11 Subsinuosal interventricular groove seen through the pericardium
- 12 Fat beneath the pericardial pleura

Clinical Anatomy of the Horse

6.7 Left view of the heart showing the auricular surface.

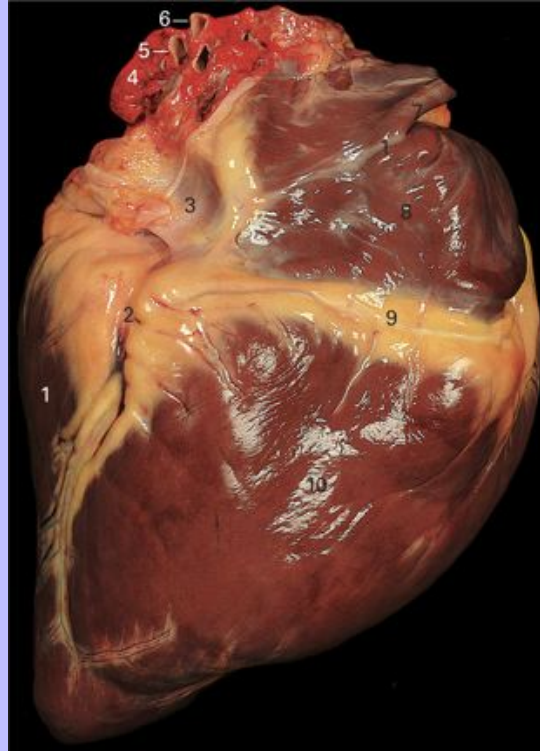


- 1 Right auricle
- 2 Brachiocephalic trunk
- 3 Pulmonary trunk
- 4 Arterial ligament
- 5 Aorta
- 6 Left auricle
- 7 Left ventricle
- 8 Paraconal interventricular groove containing abundant fat in this specimen as well as the paraconal interventricular branches of the left coronary artery and the great cardiac vein
- 9 Right ventricle
- 10 Coronary groove containing abundant fat in this specimen as well as the coronary vessels

Clinical Anatomy of the Horse

92

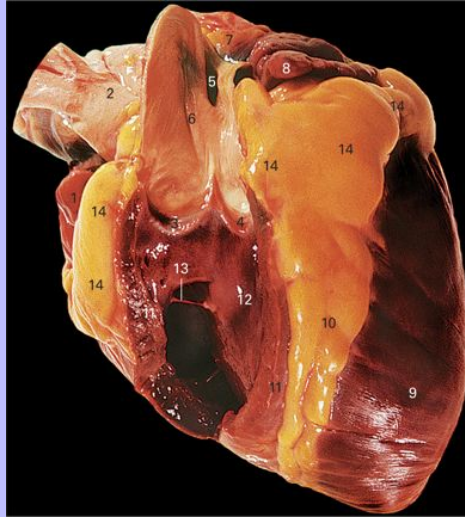
6.8 Right view of the heart showing the atrial surface.



- 1 Left ventricle
- 2 Subsinuosal interventricular groove containing the interventricular branch of the right coronary artery and the middle cardiac vein
- 3 Terminal part of the caudal vena cava (collapsed)
- 4 Remnants of lung tissue adherent to the dorsal aspect of the left atrium
- 5 One of several cut pulmonary veins
- 6 Cut pulmonary artery
- 7 Terminal part of the cranial vena cava
- 8 Right atrium
- 9 Coronary groove containing the right coronary artery
- 10 Right ventricle

Clinical Anatomy of the Horse

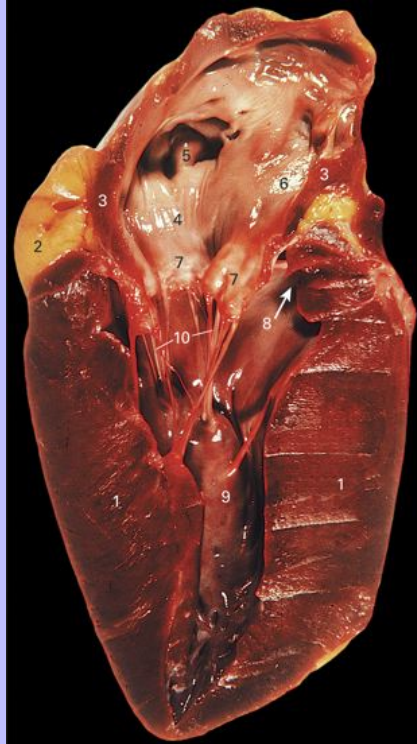6.9 Left view of the heart with part of the wall of the right ventricle removed.



- 1 Right auricle
- 2 Brachiocephalic trunk
- 3 Intermediate cusp of the pulmonary valve
- 4 Right cusp of the pulmonary valve
- 5 Depression marking the attachment of the arterial ligament to the outside of the pulmonary trunk
- 6 Pulmonary trunk
- 7 Part of the left atrium
- 8 Left auricle
- 9 Left ventricle
- 10 Paraconal interventricular groove
- 11 Wall of the right ventricle
- 12 Interventricular septum
- 13 Septomarginal band
- 14 Coronary groove

Clinical Anatomy of the Horse

6.10 The heart sectioned transversely through the left atrioventricular valve. The specimen is viewed from the caudal aspect.

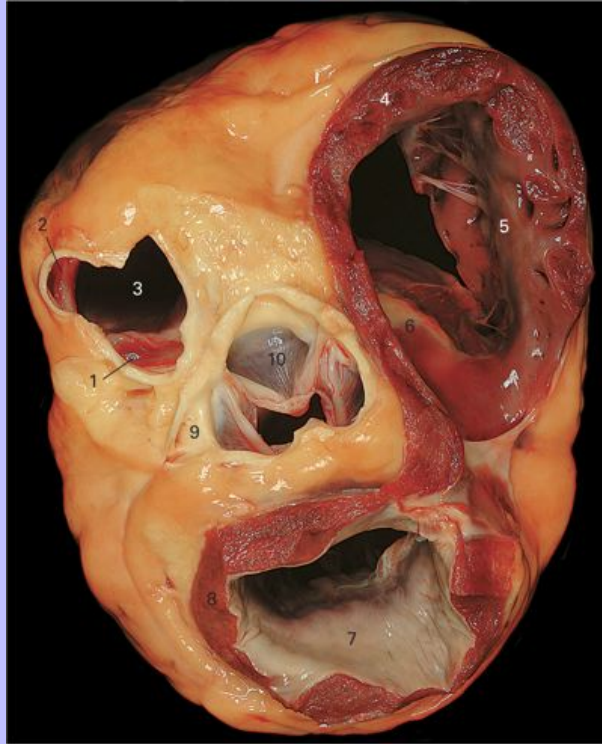


- 1 Cut wall of the left ventricle
- 2 Fat filling the coronary groove on the left side
- 3 Cut wall of the left atrium
- 4 Interior of the left atrium
- 5 Interior of the left auricle showing pectinate muscles
- 6 Part of the interatrial septum
- 7 Septal cusp of the left atrioventricular valve
- 8 Arrow pointing towards the aortic valve
- 9 Tendinous cords
- 10 Papillary muscle

Clinical Anatomy of the Horse

93

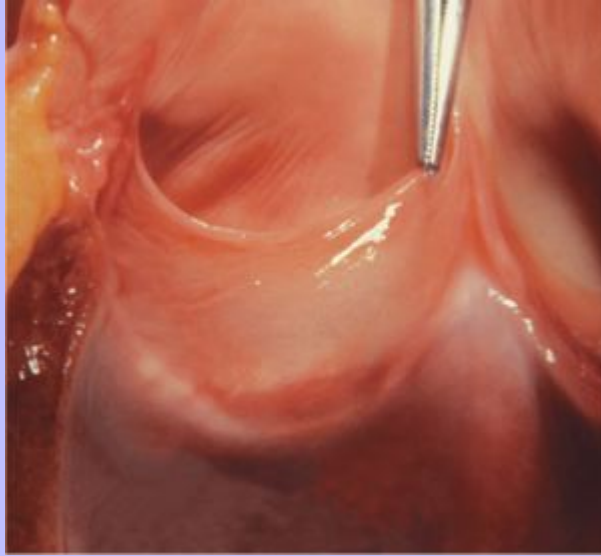
6.11 Dorsal view of the base of the heart. The atria and great vessels have been removed. The cranial aspect is towards the top of the page.



- 1 Left semilunar cusp of the pulmonary valve
- 2 Intermediate semilunar cusp of the pulmonary valve
- 3 Opening into the pulmonary trunk
- 4 Cut wall of the right atrium
- 5 Parietal cusp of the right atrioventricular valve
- 6 Septal cusp of the right atrioventricular valve
- 7 Parietal cusp of the left atrioventricular valve
- 8 Cut wall of the left atrium
- 9 Beginning of the left coronary artery
- 10 Right semilunar cusp of the aortic valve

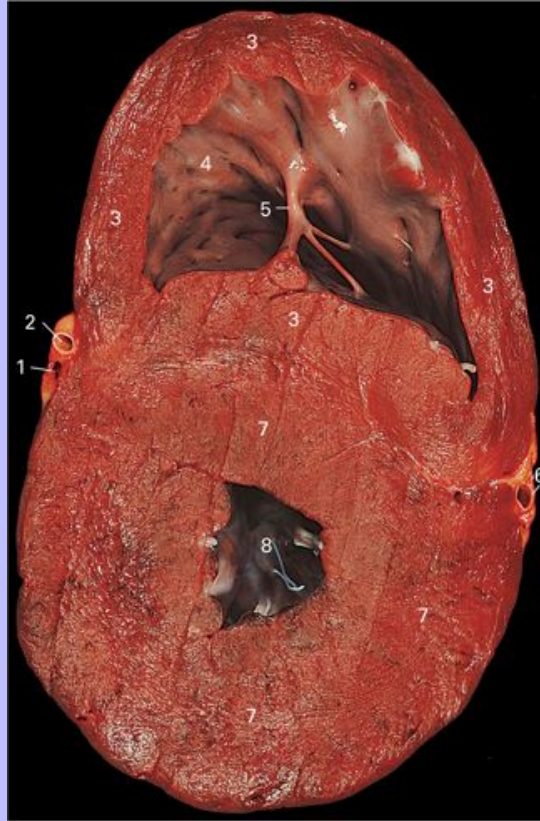Clinical Anatomy of the Horse

6.12 The aortic valve opened to show detail of the right semilunar cusp. The artery forceps are attached to the free edge of the cusp and are used to direct it somewhat towards the closed position.



Clinical Anatomy of the Horse

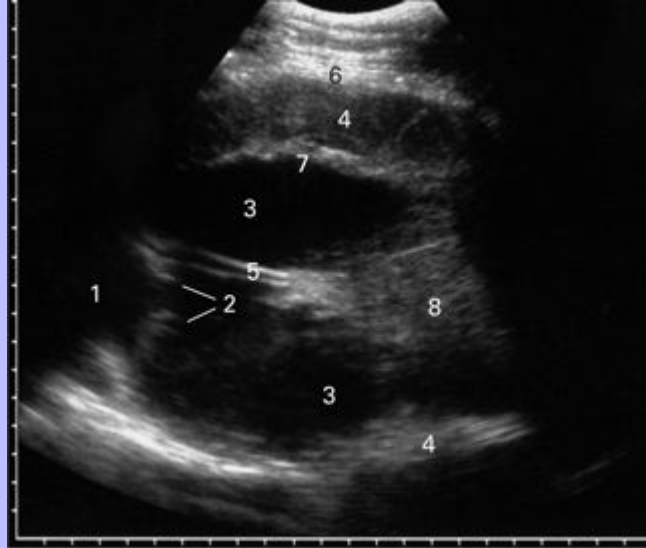6.13 Dorsal section of the ventricles of the heart midway between the coronary groove and the apex. The specimen is viewed from the dorsal aspect and its cranial part is towards the top of the page.



- 1 Paraconal interventricular vein in section
- 2 Paraconal interventricular branch of the left coronary artery in section
- 3 Right ventricular myocardium
- 4 Endocardium of the right ventricle
- 5 Septomarginal band
- 6 Subsinoasal interventricular branch of the right coronary artery in section
- 7 Left ventricular myocardium
- 8 Lumen of the left ventricle

Clinical Anatomy of the Horse

6.14 Ultrasound image of the heart made with a 5MHz sector scanner placed just behind the caudal border of the triceps brachii on the left side.



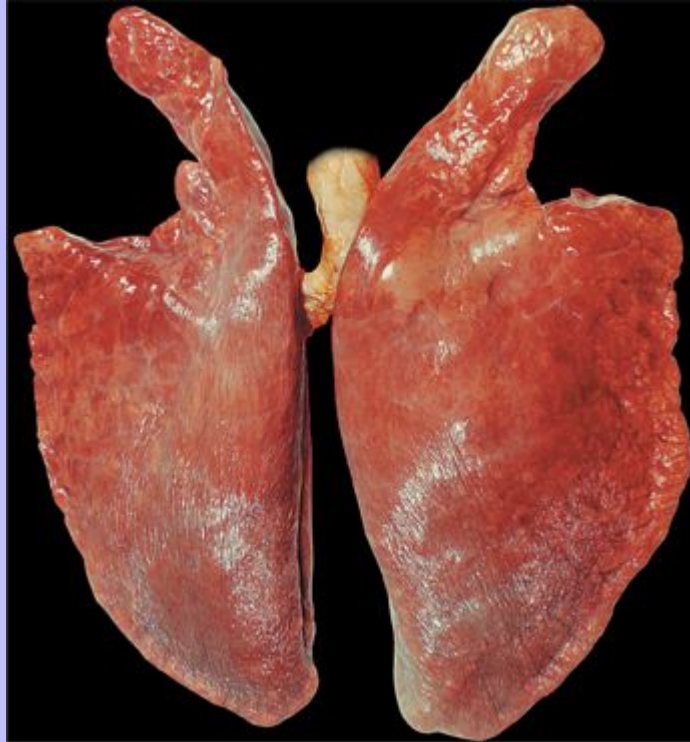- 1 Lumen of the left atrium
- 2 Left atrioventricular valve
- 3 Lumen of the left ventricle
- 4 Myocardium
- 5 Tendinous cords
- 6 Pericardium
- 7 Endocardium
- 8 Papillary muscle

93

Clinical Anatomy of the Horse

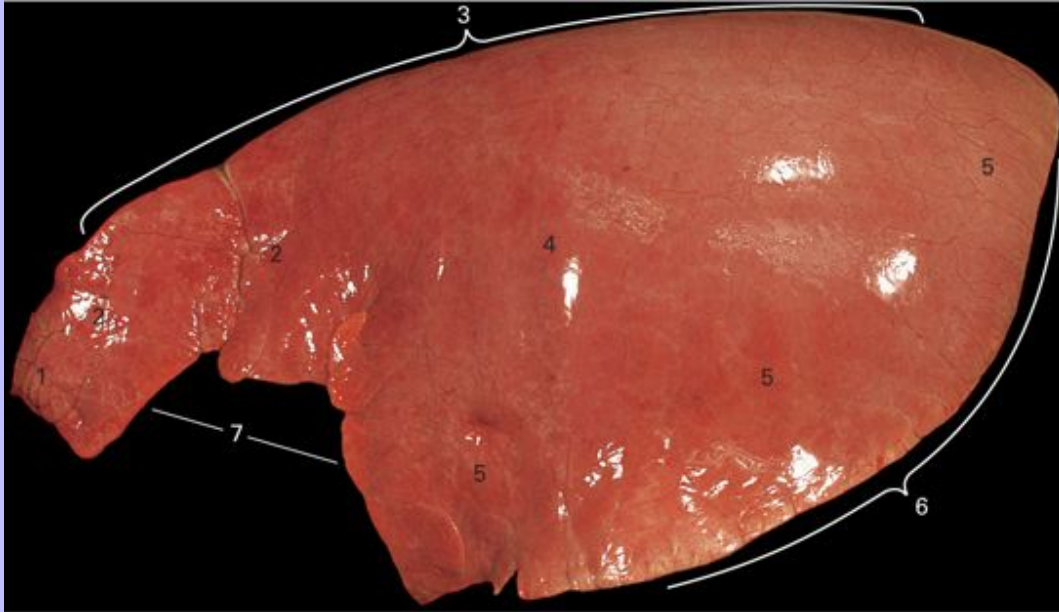
94

6.15 Both lungs attached to the bronchi and the terminal part of the trachea. They have been laid out so that the costal surfaces are uppermost. Note the larger size of the right lung and the larger cardiac notch on the left.



Clinical Anatomy of the Horse

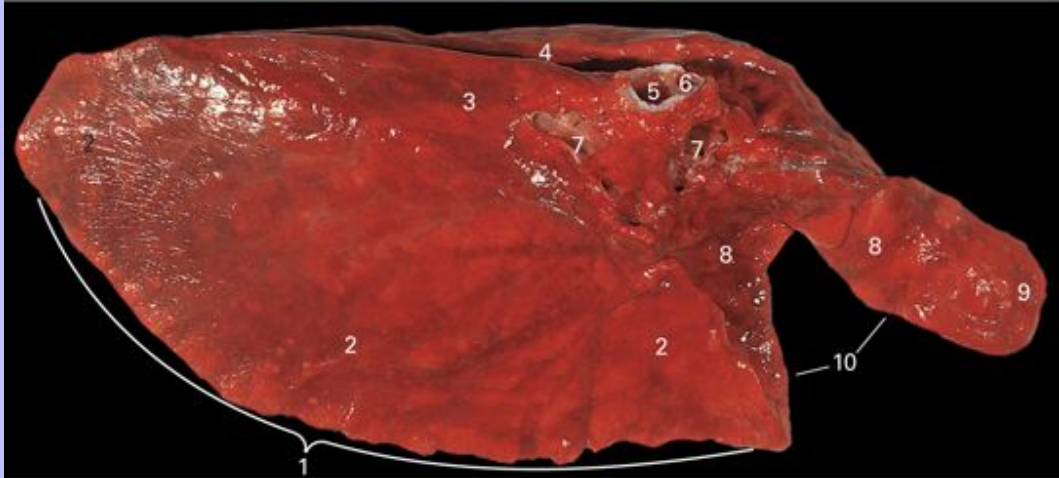
6.16 Lateral view of the left lung. This animal had longstanding recurrent airway obstruction so the lung has retained the shape and dimensions of the pleural cavity without collapsing in the normal manner.



- 1 Apex of the lung
- 2 Cranial lobe
- 3 Dorsal border
- 4 Costal surface
- 5 Caudal lobe
- 6 Basal border
- 7 Cardiac notch

Clinical Anatomy of the Horse

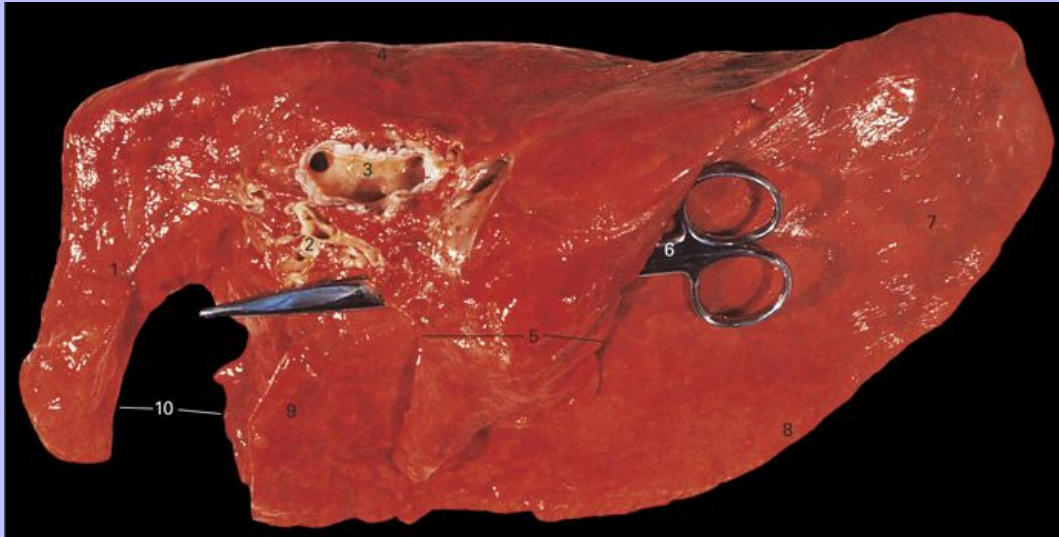
6.17 Medial view of the left lung.



- 1 Basal border
- 2 Diaphragmatic surface
- 3 Medial surface
- 4 Aortic impression
- 5 Lobar bronchus supplying the caudal lobe
- 6 Lobar bronchus supplying the cranial lobe
- 7 Pulmonary blood vessels
- 8 Cardiac impression
- 9 Apex of the lung
- 10 Cardiac notch

94

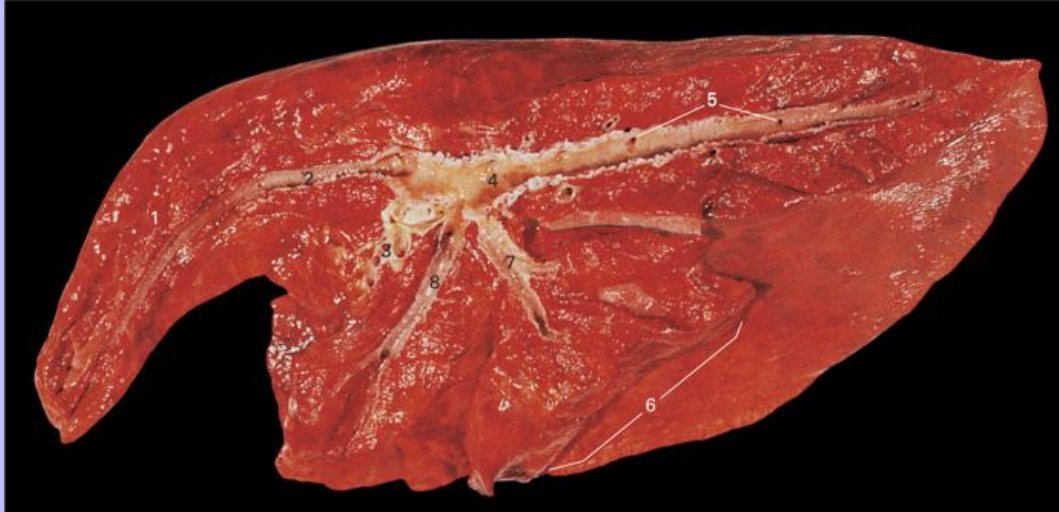
6.18 Medial view of the right lung.



- 1 Cranial lobe
- 2 Pulmonary arteries
- 3 Right principal bronchus with its medial wall removed
- 4 Dorsal border
- 5 Accessory lobe
- 6 Scissors indicating the course followed by the caudal vena cava
- 7 Diaphragmatic surface of the caudal lobe
- 8 Basal border
- 9 Part of cranial lobe caudal to the cardiac notch
- 10 Cardiac notch bounded by the ventral border of the lung

Clinical Anatomy of the Horse

6.19 Medial view of the right lung dissected to show the lobar bronchi.



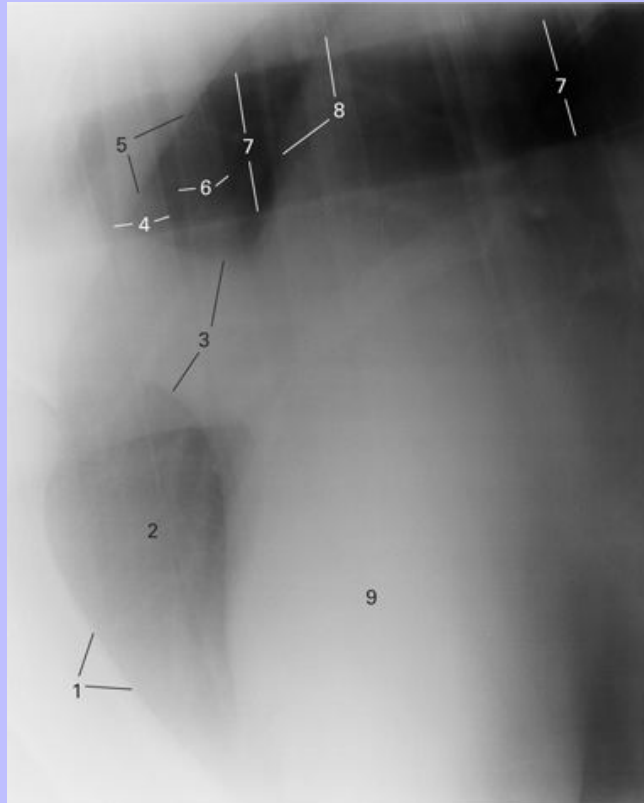
- 1 Cranial lobe
- 2 Cranial lobar bronchus
- 3 Pulmonary arteries
- 4 Caudal lobar bronchus
- 5 Segmental bronchi leaving the caudal lobar bronchus
- 6 Accessory lobe
- 7 Accessory lobar bronchus
- 8 Segmental bronchus supplying the part of the caudal lobe that is homologous with the middle lobe of other species

95

Clinical Anatomy of the Horse

96

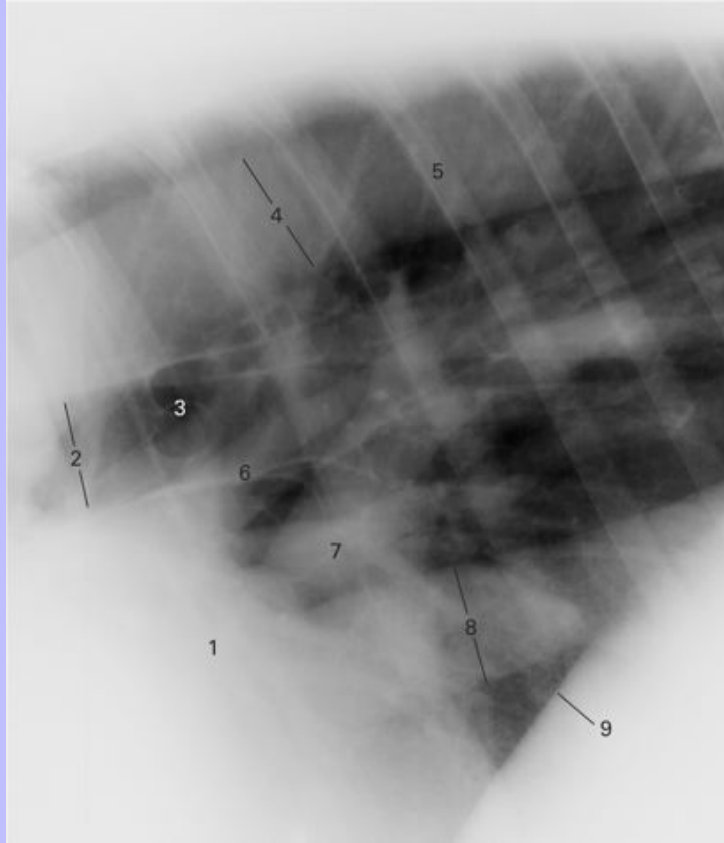
6.20 Lateral radiograph of the cranial thorax immediately caudal to the shoulder joint.



- 1 Caudal border of the humerus
- 2 Cranial lobes of the lungs including shadows of the pulmonary vessels
- 3 Cranial vena cava
- 4 Rib 2, left side
- 5 Caudal border of the neck of the scapula
- 6 Rib 2, right side
- 7 Trachea
- 8 Cranial border of the aortic arch
- 9 Ventricles

Clinical Anatomy of the Horse

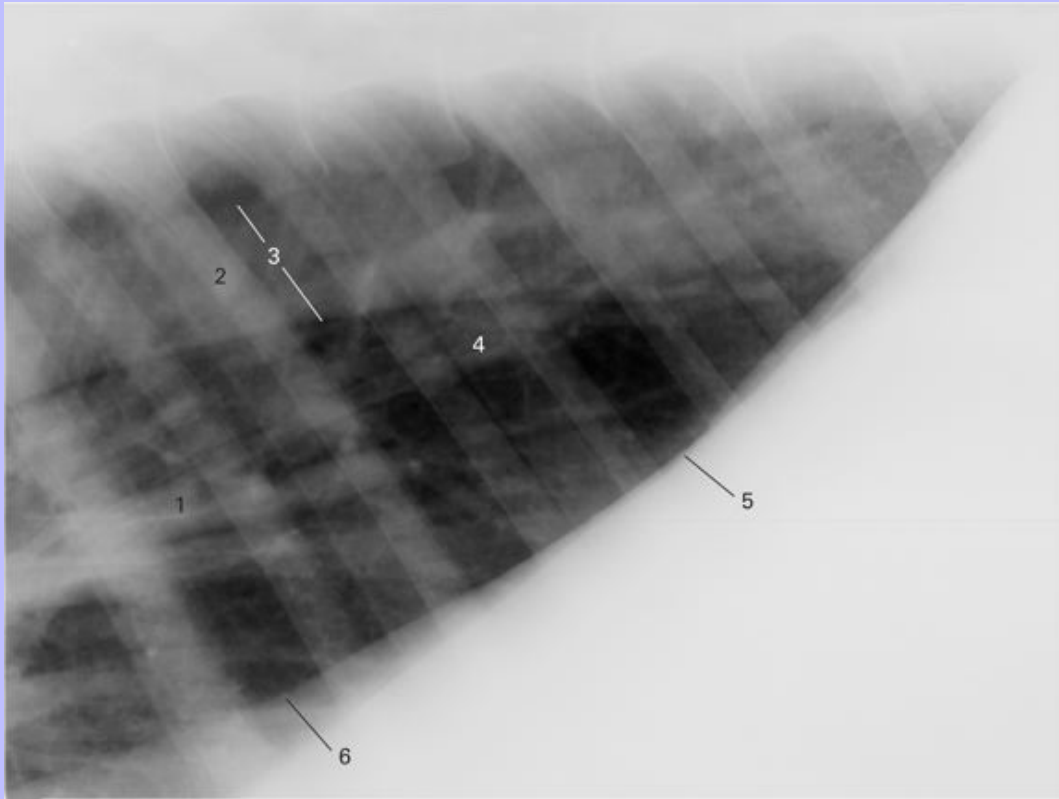
6.21 Lateral radiograph of the mid-thorax immediately caudal to the heart.



- 1 Left atrium
- 2 Trachea
- 3 Bifurcation of the trachea and the two principal bronchi
- 4 Descending aorta
- 5 Rib 8 on both sides superimposed
- 6 Mainly pulmonary arteries entering the lung
- 7 Mainly pulmonary veins leaving the lung
- 8 Caudal vena cava
- 9 Dome of the diaphragm

Clinical Anatomy of the Horse

6.22 Lateral radiograph of the caudal part of the thoracic region.

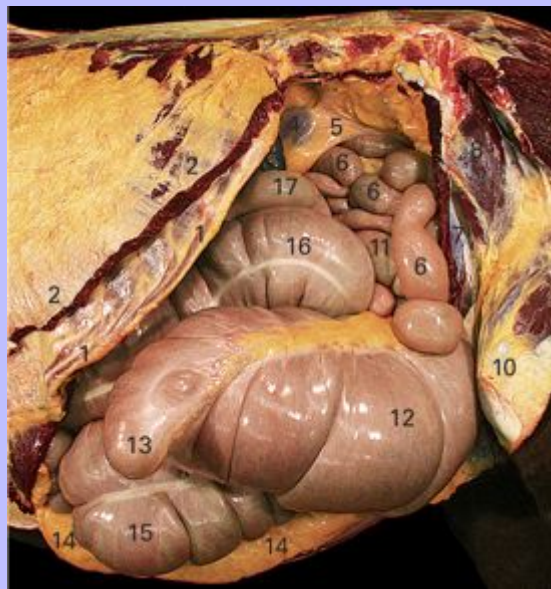


- 1 Pulmonary vessels
- 2 Rib 9 of each side partially superimposed
- 3 Descending aorta
- 4 Caudal lobes of the lungs
- 5 Dorsocranial surface of the diaphragm
- 6 Dorsal edge of the caudal vena cava

Clinical Anatomy of the Horse

7 Abdominal and Pelvic Viscera

7.1 Left view of the abdominal contents of a mature gelding with the costal arch intact.



- 1 Conjoined costal cartilages forming the costal arch
- 2 Cut origin of M. abdominis obliquus externus (covered by the tunica flava abdominis)
- 3 Most caudal part of the dorsal end (base) of the spleen
- 4 Caudal pole of the left kidney
- 5 Perirenal fat
- 6 Loops of small intestine
- 7 Caudal part of M. abdominis obliquus internus
- 8 M. tensor fasciae latae
- 9 M. gluteus medius
- 10 Stifle joint
- 11 Loop of descending colon
- 12 Body of the cecum
- 13 Cecocolic junction
- 14 Cecocolic junction
- 15 Cecocolic junction
- 16 Cecocolic junction
- 17 Cecocolic junction

Clinical Anatomy of the Horse

13 Apex of the cecum

14 Retroperitoneal fat

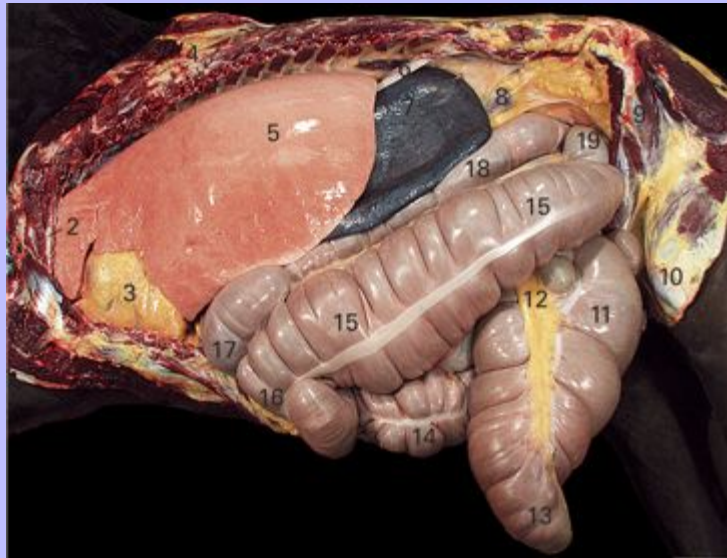
15 Right ventral colon

16 Left ventral colon

17 Left dorsal colon

Clinical Anatomy of the Horse

7.2 The abdominal and thoracic viscera exposed by removal of the left body wall (with the exception of rib 1) and the left half of the diaphragm. Left view. This animal had longstanding recurrent airway obstruction so the lung has retained a shape and size that are probably close to those of a normal living horse.



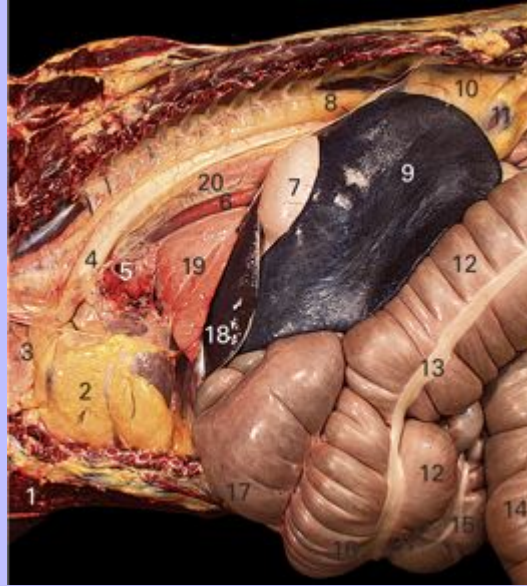- 1 Cut pectoral musculature
- 2 Rib 1
- 3 Pericardium (there is much fat in the loose connective tissue overlying the fibrous pericardium)
- 4 Rib 8 (cut)
- 5 Costal surface of the left lung
- 6 Remnant of the diaphragm
- 7 Spleen
- 8 Caudal pole of the left kidney
- 9 M. tensor fasciae latae
- 10 Stifle joint
- 11 Body of the cecum
- 12 Ileocecal fold (only partially exposed)

Clinical Anatomy of the Horse

- 13 Apex of the cecum
- 14 Right ventral colon
- 15 Left ventral colon (with prominent lateral free muscular band)
- 16 Sternal flexure
- 17 Diaphragmatic flexure
- 18 Left dorsal colon
- 19 Pelvic flexure

Clinical Anatomy of the Horse

7.3 The contents of the thorax and cranial abdomen after removal of the body wall, the left lung and the left half of the diaphragm. Left view.



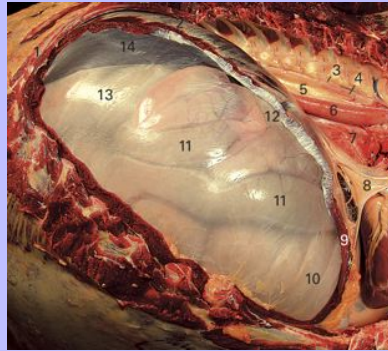
- 1 Cut pectoral musculature
- 2 Pericardium (there is much fat in the loose connective tissue overlying the fibrous pericardium)
- 3 Left phrenic nerve
- 4 Aortic arch
- 5 Left principal bronchus (cut)
- 6 Esophagus
- 7 Parietal surface of the blind sac (fundus) of the stomach
- 8 Cut edge of the diaphragm
- 9 Spleen (the ventral extremity is hidden behind the liver)
- 10 Perirenal fat
- 11 Caudal pole of the kidney
- 12 Left ventral colon
- 13 Lateral free muscular band of the left ventral colon

Clinical Anatomy of the Horse

- 14 Body of the cecum
- 15 Right ventral colon
- 16 Sternal flexure
- 17 Diaphragmatic flexure
- 18 Left lateral lobe of the liver
- 19 Accessory lobe of the lung visible through the mediastinal pleura
- 20 Dorsal part of the mediastinum

Clinical Anatomy of the Horse

7.4 The contents of the cranial abdomen seen through the diaphragmatic peritoneum on the right side. The thoracic wall was excised as far caudally as rib 13, the right lung was removed and the costal part of the diaphragmatic musculature was dissected away leaving the peritoneum (and the immediately associated connective tissue) retaining the abdominal viscera in place. Structures 10–14 are, therefore, seen through the peritoneum.

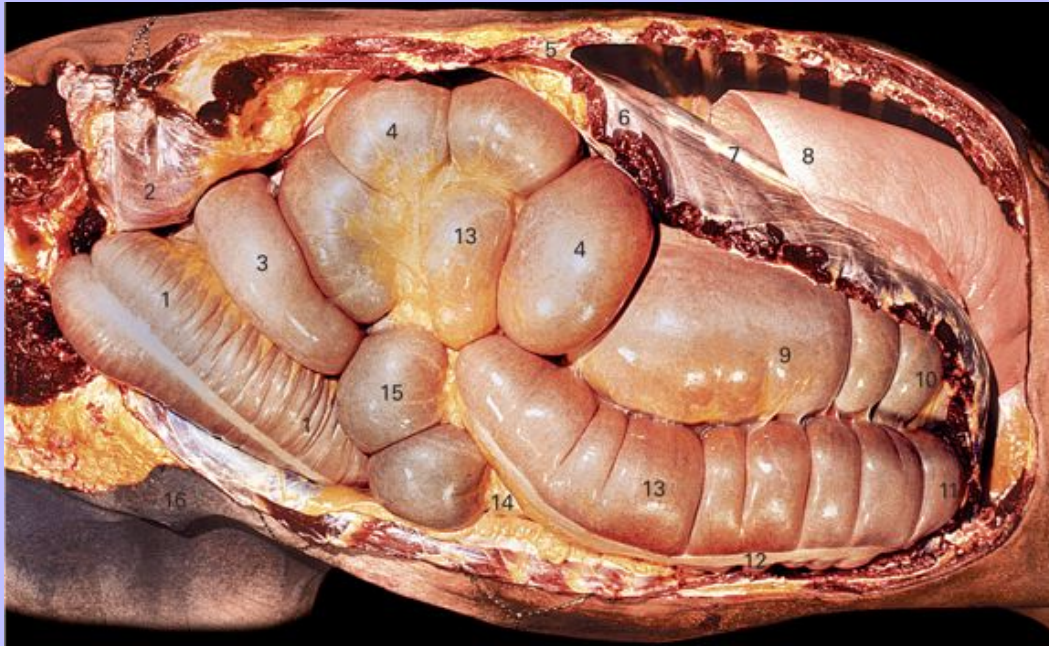


- 1 Rib 14
- 2 Tendinous center of the diaphragm
- 3 Azygos vein
- 4 Thoracic duct
- 5 Descending aorta
- 6 Esophagus
- 7 Caudal mediastinum
- 8 Caval fold containing the right phrenic nerve
- 9 Cut edge of the sternal part of the diaphragm
- 10 Sternal flexure of the ascending colon
- 11 Loops of small intestine overlying the ascending colon
- 12 Diaphragmatic flexure of the ascending colon
- 13 Right dorsal colon
- 14 Right lobe of the liver

Clinical Anatomy of the Horse

98

7.5 The contents of the abdomen and caudal thorax of a large horse seen from the right side after removal of the body wall. The undisturbed viscera were photographed as soon as the abdomen was opened. The colon and cecum are distended by enteric gas and the pelvic flexure of the colon has moved across the pelvic inlet to the right and is now tucked behind the body of the cecum.

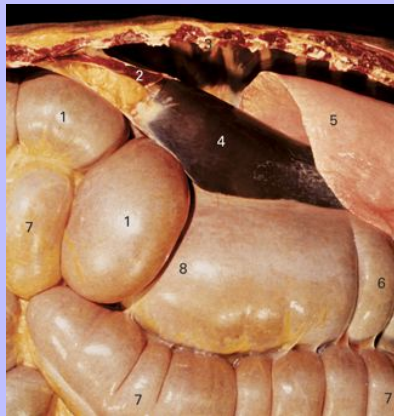

- 1 Left ventral part of the ascending colon
- 2 M. abdominis obliquus internus, reflected and seen from the medial aspect through the peritoneum
- 3 Left dorsal part of the ascending colon
- 4 Base of the cecum
- 5 Cut dorsal end of rib 18
- 6 Costal part of the diaphragm
- 7 Tendinous center of the diaphragm
- 8 Costal surface of the right lung
- 9 Right dorsal part of the ascending colon

Clinical Anatomy of the Horse

- 10 Diaphragmatic flexure of the ascending colon
- 11 Sternal flexure of the ascending colon
- 12 Lateral free muscular band of the left ventral colon
- 13 Right ventral part of the ascending colon
- 14 Cecocolic fold
- 15 Body of the cecum (the apex lies behind the right ventral part of the colon)
- 16 Mammary gland

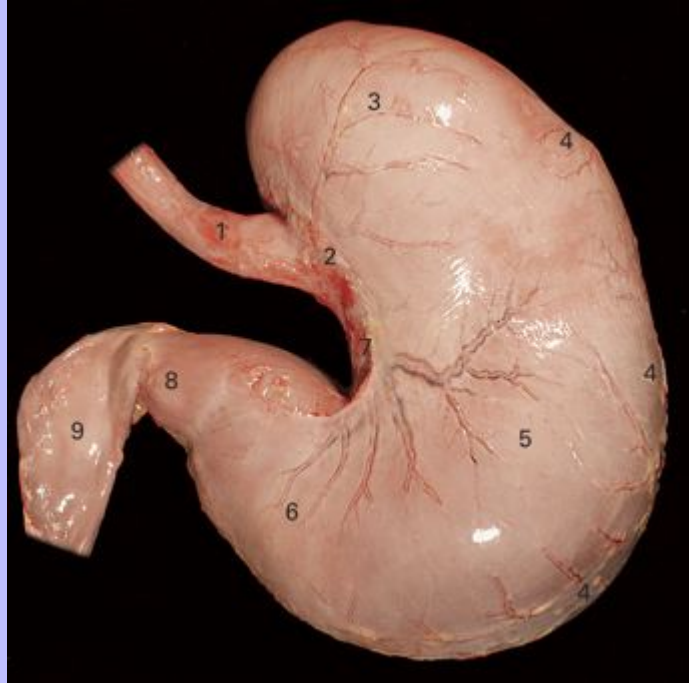
7.6 Detail from Fig. 7.5 after removal of the right half of the diaphragm to reveal part of the liver.



- 1 Base of the cecum
- 2 Right crus of the diaphragm seen in paramedian section
- 3 Cut dorsal end of rib 16
- 4 Right lobe of the liver
- 5 Costal surface of the caudal lobe of the right lung
- 6 Right dorsal part of the ascending colon
- 7 Right ventral part of the ascending colon
- 8 Right extremity of the transverse colon

Clinical Anatomy of the Horse

7.7 The parietal surface of the stomach. The parietal branches of the left gastric artery, and their satellite veins, can be seen ramifying over the surface.



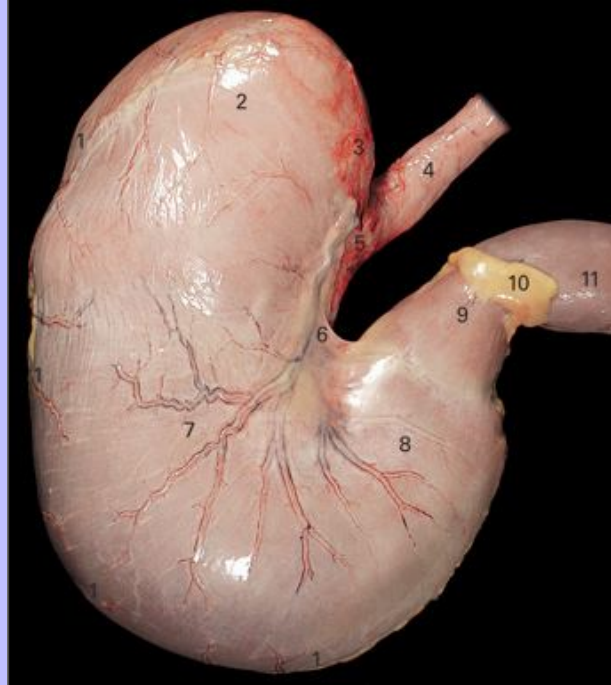
- 1 Esophagus
- 2 Cardia
- 3 Fundus (blind sac)
- 4 Greater curvature (attachment of the greater omentum)
- 5 Body of the stomach
- 6 Pyloric region of the stomach
- 7 Lesser curvature (attachment of the lesser omentum)
- 8 Pylorus
- 9 Duodenum

98

Clinical Anatomy of the Horse

99

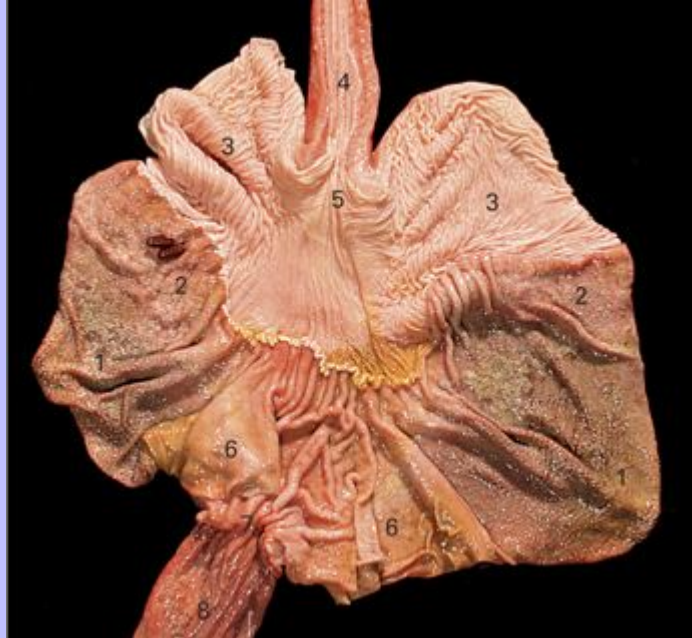7.8 The visceral surface of the stomach. The visceral branches of the left gastric artery, and their satellite veins, can be seen ramifying over the surface.



- 1 Greater curvature (attachment of the greater omentum)
- 2 Fundus (blind sac)
- 3 Area of direct adhesion to the diaphragm
- 4 Esophagus
- 5 Cardia
- 6 Lesser curvature (attachment of the lesser omentum)
- 7 Body of the stomach
- 8 Pyloric region of the stomach
- 9 Pylorus
- 10 Attachment of the greater omentum crossing the duodenum
- 11 Duodenum

Clinical Anatomy of the Horse

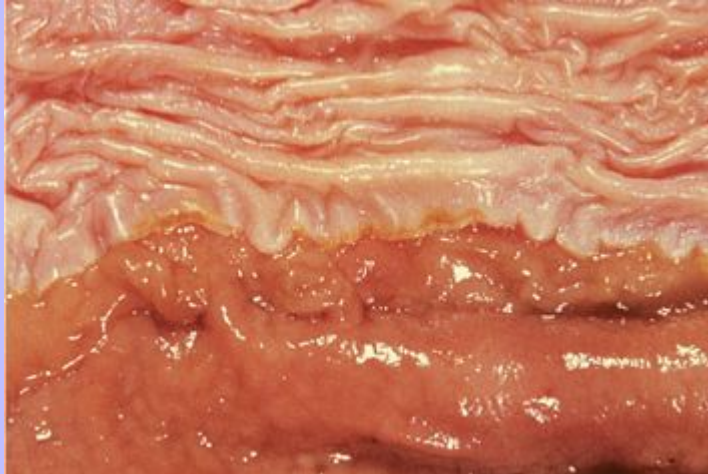7.9 The stomach, with part of the esophagus and duodenum, opened and laid flat to show the mucosa. The stomach was opened along the greater curvature.



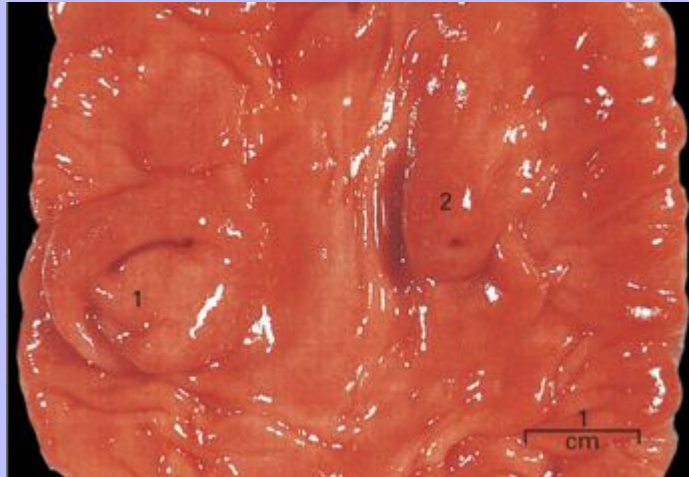
- 1 Proper gastric gland area
- 2 Cardiac gland area (with two *Gastrophilus* larvae attached)
- 3 Nonglandular part of the stomach lined by keratinized squamous epithelium
- 4 Esophagus
- 5 Cardia
- 6 Pyloric gland area
- 7 Pylorus
- 8 Duodenum

Clinical Anatomy of the Horse

7.10 Detail of the gastric mucosa showing the junction of the nonglandular part (top) and the cardiac gland area (bottom). The raised edge of the keratinized epithelium is known as the margo plicatus.



7.11 Part of the duodenal mucosa showing the duodenal papillae.



1 Major duodenal papilla (opening of the bile duct and pancreatic duct)

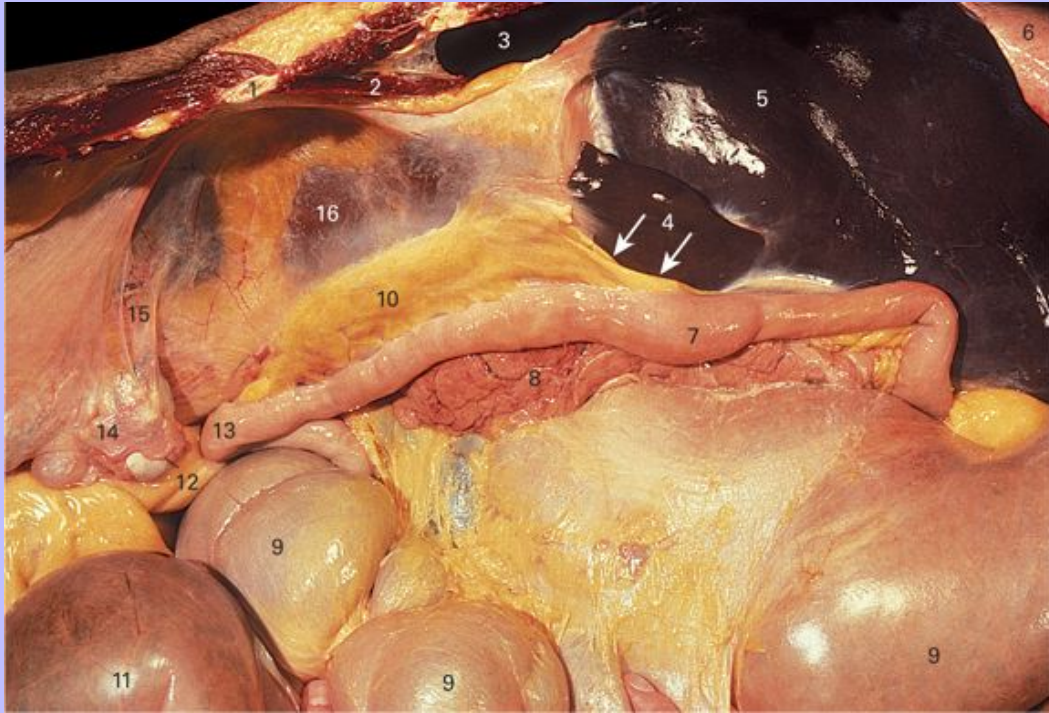
2 Minor duodenal papilla (opening of the accessory pancreatic duct)

99

Clinical Anatomy of the Horse

100

7.12 Ventrolateral view of the right dorsal part of the abdomen showing the region of the omental foramen. The right lobe of the liver has been reflected dorsally and the base of the cecum has been compressed and drawn ventrally.

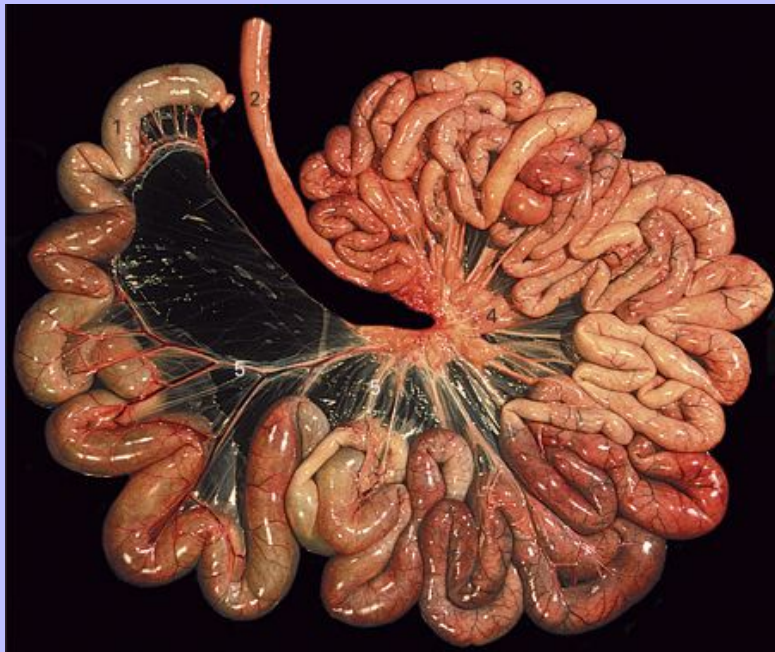

- 1 Cut dorsal end of rib 18
- 2 Right crus of the diaphragm in paramedian section
- 3 Caudodorsal part of the pleural cavity
- 4 Caudate lobe of the liver [the arrows indicate the opening of the omental (epiploic) foramen]
- 5 Visceral surface of the right lobe of the liver
- 6 Caudal part of the right lung
- 7 Duodenum
- 8 Right lobe of the pancreas
- 9 Base of the cecum
- 10 Mesoduodenum

Clinical Anatomy of the Horse

- 11 Loop of the left dorsal part of the ascending colon
- 12 Uterine tube (oviduct)
- 13 Duodenal flexure
- 14 Ovary
- 15 Suspensory ligament of the ovary
- 16 Ventral surface of the right kidney

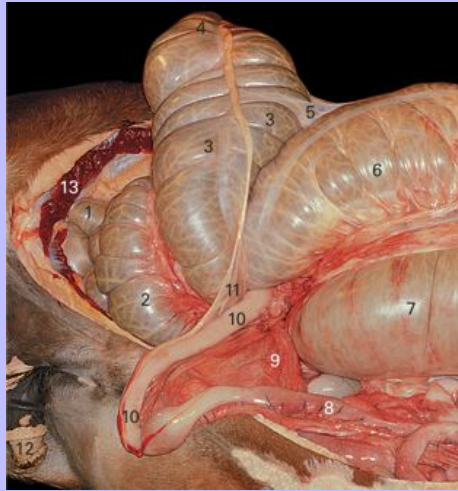
7.13 The small intestine of a 4-month-old foal removed from the abdomen and spread out as much as the mesentery will allow.



- 1 Terminal part of the ileum
- 2 Terminal part of the ascending duodenum
- 3 Beginning of the jejunum
- 4 Mesenteric lymph nodes
- 5 Jejunal blood vessels traversing the (great) mesentery

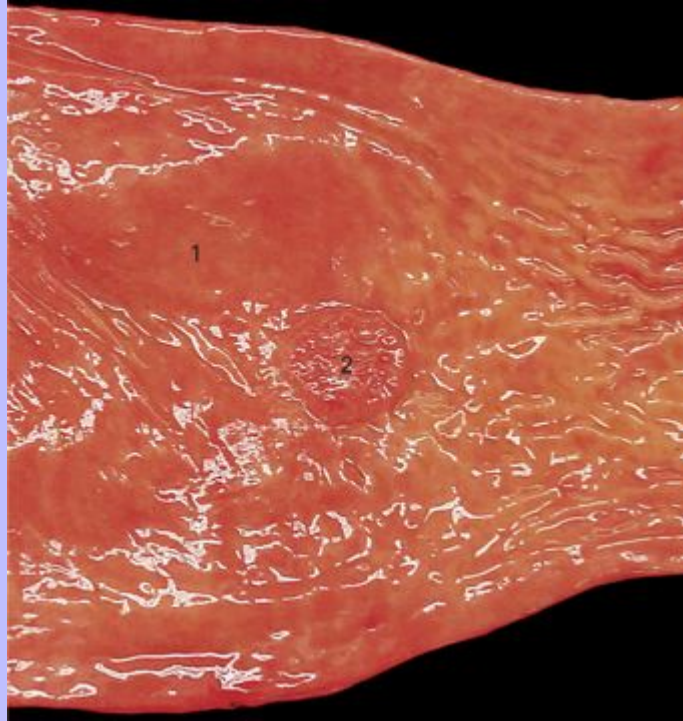
Clinical Anatomy of the Horse

7.14 The abdomen dissected to show the termination of the ileum. Both the body of the cecum and the ascending colon have been lifted out of the abdomen and reflected dorsally and to the right but none of their attachments have been cut.



- 1 Loop of descending colon
- 2 Left side of the cecal base
- 3 Body of the cecum
- 4 Apex of the cecum
- 5 Edge of the cecocolic fold
- 6 Left side of the beginning of the right ventral part of the ascending colon
- 7 Right dorsal part of the ascending colon at its junction with the transverse colon
- 8 Jejunum near its termination
- 9 Mesentery
- 10 Ileum
- 11 Ileocecal fold
- 12 Penis
- 13 Cut surface of M. obliquus internus abdominis

7.15 Section of jejunum opened along the mesenteric side.

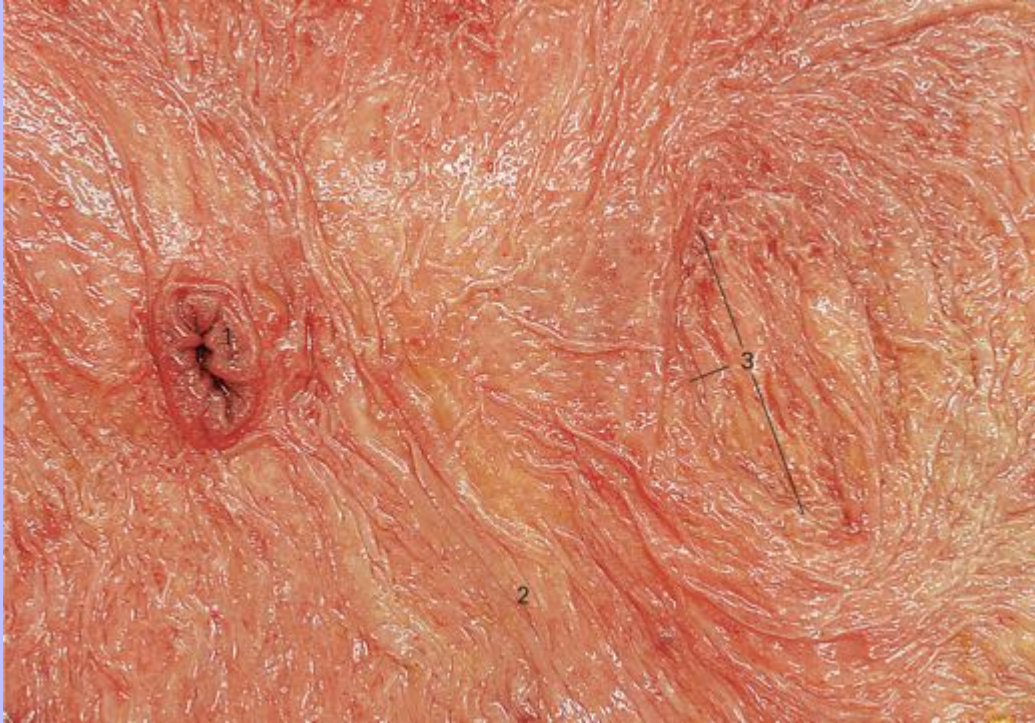


1 Mucosal surface

2 Aggregated lymphatic nodule (Peyer's patch)

Clinical Anatomy of the Horse

7.16 The base of the cecum opened from the dorsal side to show the mucosa and the openings into the ileum and the right ventral colon.



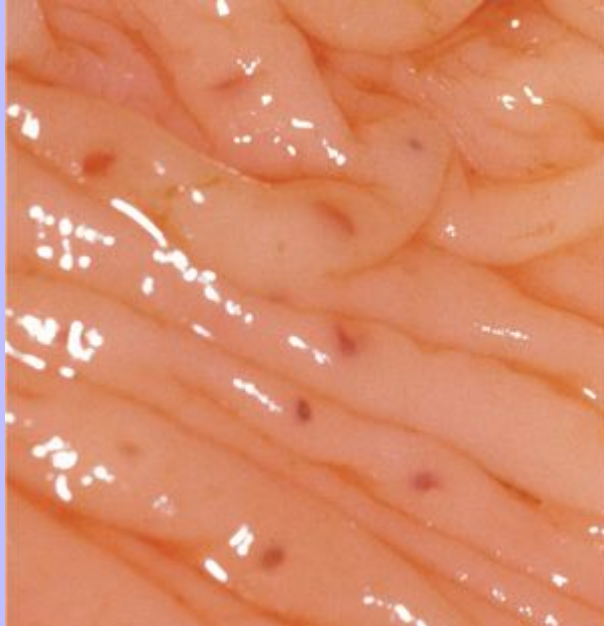
1 Ileocecal orifice on a low projection

2 Mucosa of the cecum

3 The cecocolic orifice. This is a wide and ill-defined slit with no change in the appearance of the mucosa

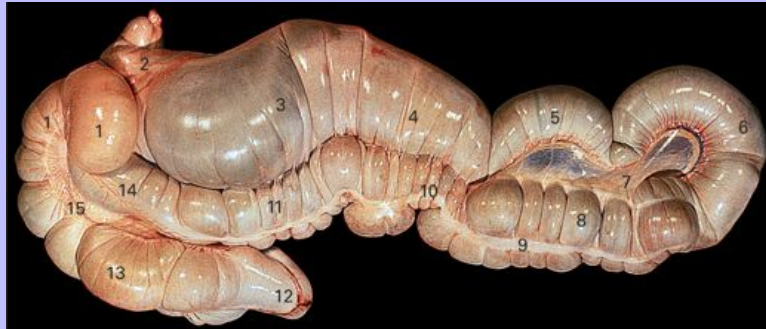Clinical Anatomy of the Horse

7.17 Detail of the cecal mucosa showing solitary lymphatic nodules (oval grayish areas).



Clinical Anatomy of the Horse

7.18 The cecum and ascending colon of a 4-month-old foal. The organs have been removed from the abdomen and the sternal and diaphragmatic flexures have been straightened. The surfaces shown are normally lateral; thus the part on the left of the photograph lies against the right flank, and that on the right lies against the left flank.

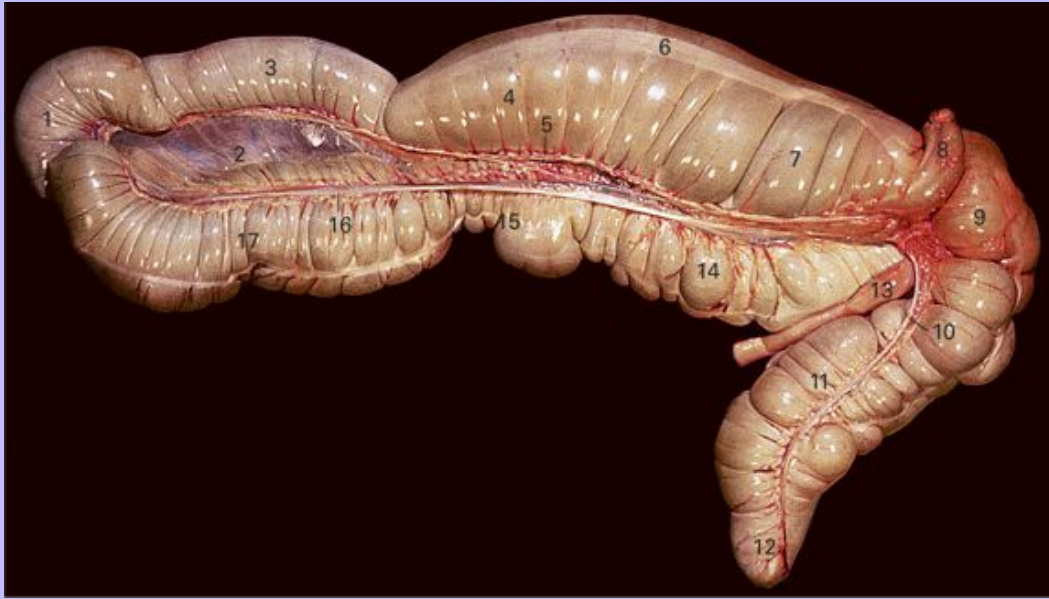

- 1 Base of the cecum
- 2 Transverse colon
- 3 Right dorsal part of the ascending colon
- 4 Diaphragmatic flexure
- 5 Left dorsal part of the ascending colon
- 6 Pelvic flexure
- 7 Mesocolon
- 8 Left ventral part of the ascending colon
- 9 Lateral free muscular band
- 10 Sternal flexure
- 11 Right ventral part of the ascending colon
- 12 Apex of the cecum
- 13 Body of the cecum
- 14 Beginning of the right ventral part of the ascending colon
- 15 Cecocolic fold

Clinical Anatomy of the Horse

102

7.19 The cecum and ascending colon of a 4-month-old foal. The organs have been removed from the abdomen and the sternal and diaphragmatic flexures have been straightened. The surfaces shown normally face medially and are related to each other or to loops of the small intestine or descending colon.

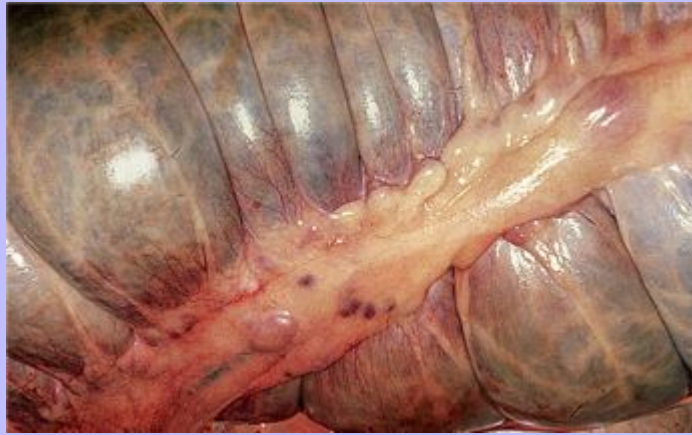

- 1 Pelvic flexure
- 2 Mesocolon
- 3 Left dorsal part of the ascending colon
- 4 Diaphragmatic flexure
- 5 Right colic artery
- 6 Medial free muscular band
- 7 Right dorsal part of the ascending colon close to the junction with the transverse colon
- 8 Junction of the transverse and descending colon
- 9 Left side of the base of the cecum
- 10 Medial cecal artery
- 11 Body of the cecum

Clinical Anatomy of the Horse

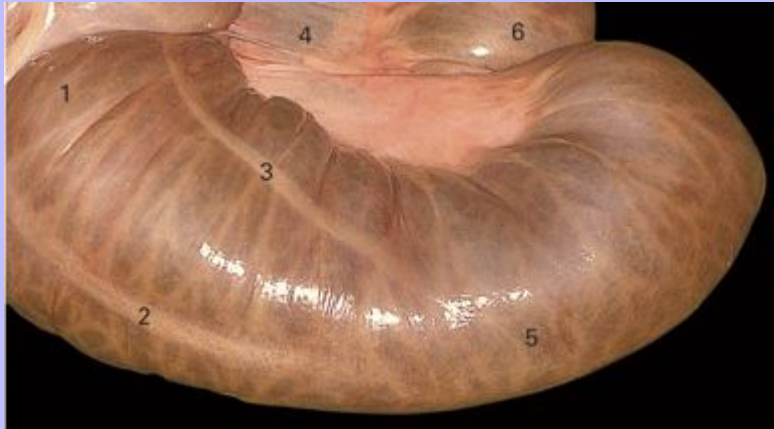
- 12 Apex of the cecum
- 13 Terminal part of the ileum
- 14 Right ventral part of the ascending colon
- 15 Sternal flexure
- 16 Colic branch of the ileocolic artery
- 17 Left ventral part of the ascending colon

7.20 Groove overlying the medial free muscular band of the cecum. It contains abundant fat and large numbers of lymph nodes.



Clinical Anatomy of the Horse

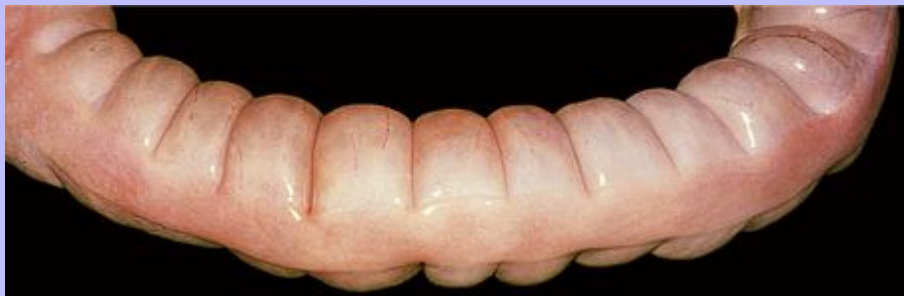7.21 The pelvic flexure of the ascending colon seen from the lateral and distal aspect.



- 1 End of the ventral part of the ascending colon
- 2 End of the lateral free muscular band
- 3 End of the lateral mesocolic muscular band (no longer mesocolic at this point)
- 4 Mesocolon
- 5 Pelvic flexure
- 6 Beginning of the dorsal part of the ascending colon

102

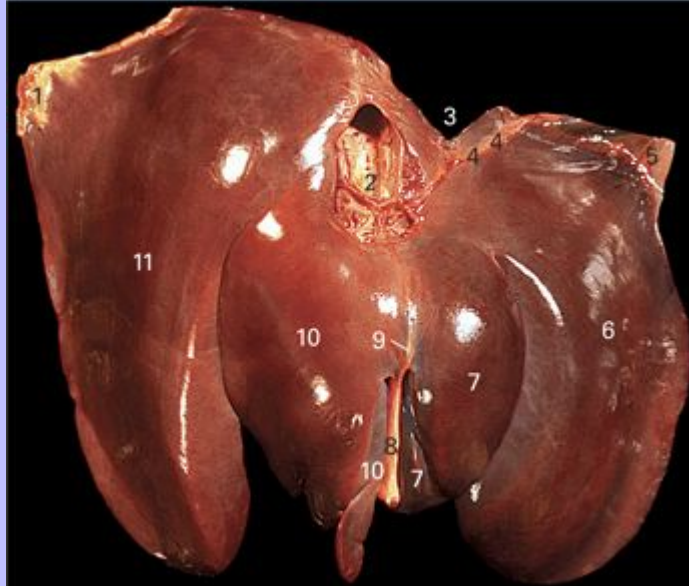
7.22 A short segment of the descending colon taken from near its distal end. The mesocolon has been removed from the concave side. The outlines of successive fecal balls and the wide antimesenteric muscular band are evident.



103

Clinical Anatomy of the Horse

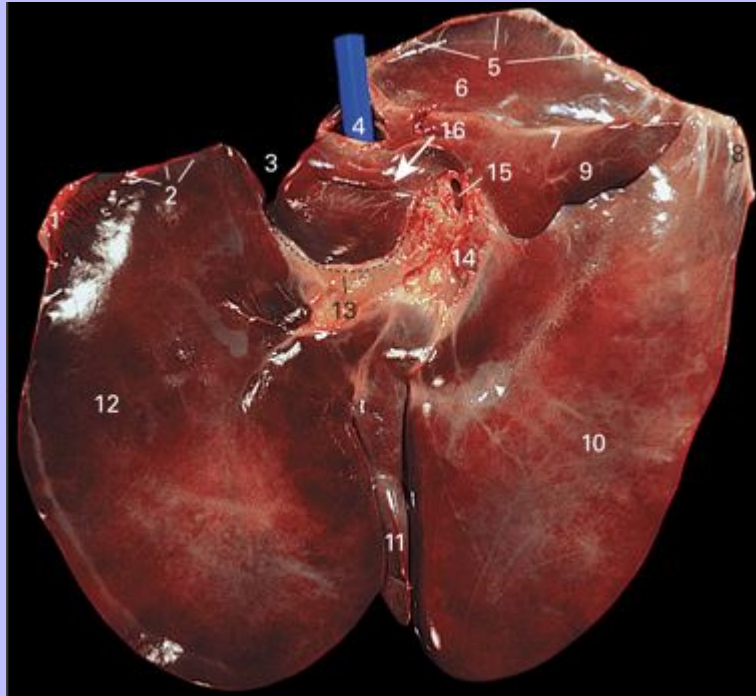
7.23 The parietal surface of the liver of a 4-month-old foal.



- 1 Right triangular ligament
- 2 Caudal vena cava passing cranioventrally through the liver; numerous hepatic veins of various sizes can be seen joining it
- 3 Esophageal notch
- 4 Left coronary ligament
- 5 Left triangular ligament
- 6 Left lateral lobe
- 7 Left medial lobe
- 8 Falciform ligament containing the remnant of the umbilical vein in its free edge
- 9 Line of attachment of the narrow part of the falciform ligament connecting the liver to the diaphragm
- 10 Quadrato lobe
- 11 Right lobe

Clinical Anatomy of the Horse

7.24 The visceral surface of the liver of a 4-month-old foal. A blue plastic rod has been inserted into the caudal vena cava to make its position clear.

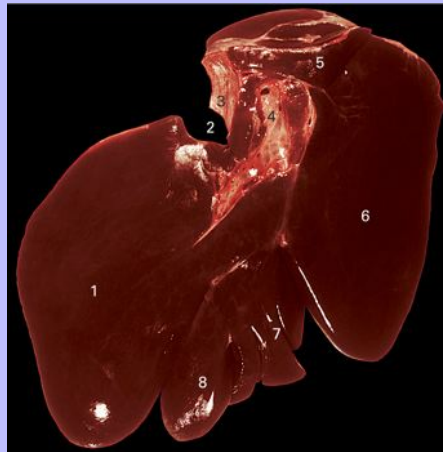


- 1 Left triangular ligament
- 2 Left coronary ligament
- 3 Esophageal notch
- 4 Plastic rod lying in the caudal vena cava
- 5 Right coronary ligament
- 6 Renal impression
- 7 Hepatorenal ligament
- 8 Right triangular ligament
- 9 Caudate lobe
- 10 Right lobe
- 11 Quadrate lobe

Clinical Anatomy of the Horse

- 12 Left lateral lobe
- 13 Line of attachment of the lesser omentum
- 14 Hepatic lymph nodes at the porta of the liver
- 15 Portal vein entering the liver
- 16 Path of the omental (epiploic) foramen

7.25 The visceral surface of the liver of a mature horse showing the change in shape with age when compared with Fig. 7.24. This change is much more extreme in old animals. The caudal vena cava and the portal vein have been dissected to show a little of their interior.

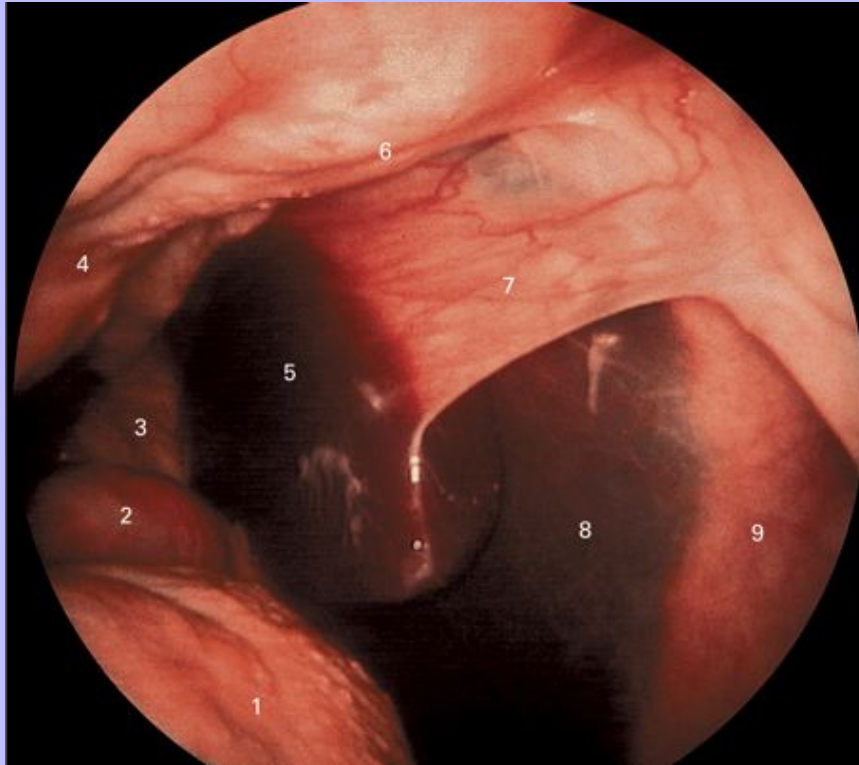


- 1 Left lateral lobe
- 2 Esophageal notch
- 3 Inner surface of the caudal vena cava
- 4 Portal vein opened to show part of its course within the liver
- 5 Caudate lobe
- 6 Right lobe
- 7 Quadrate lobe with small subdivisions
- 8 Left medial lobe

Clinical Anatomy of the Horse

104

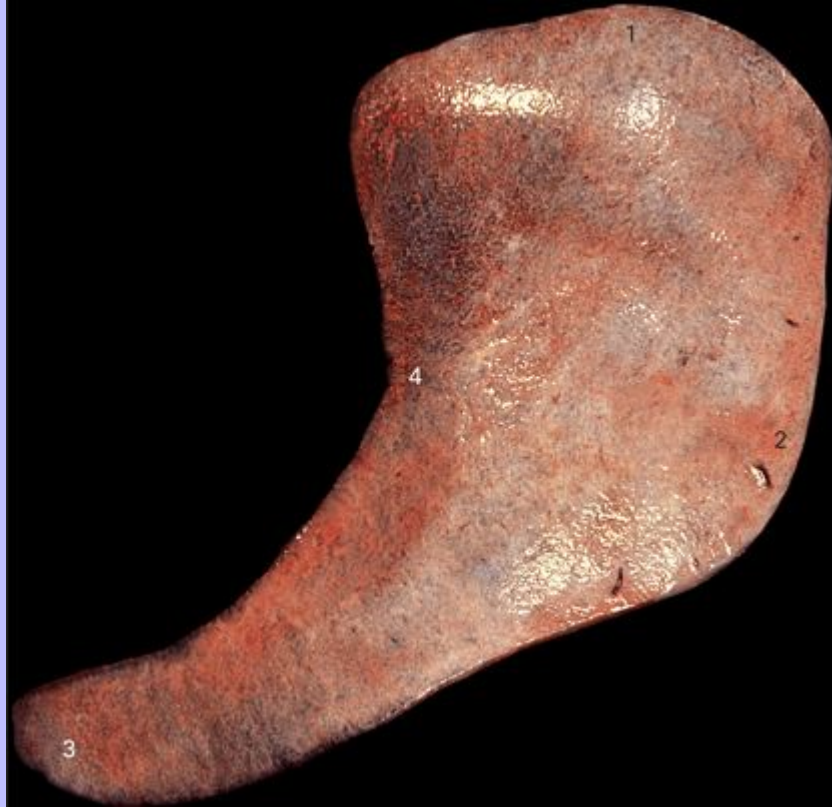7.26 Endoscopic view of the right triangular ligament. The endoscope was inserted through the right flank and directed cranially in a standing horse. (Image kindly supplied by Dr. D. G. Wilson.)



- 1 Right side of the base of the cecum
- 2 Duodenum
- 3 Mesoduodenum
- 4 Perirenal fat
- 5 Caudolateral angle of the right lobe of the liver
- 6 Phrenicorenal fold
- 7 Right triangular ligament
- 8 Tendinous center of the diaphragm
- 9 Right costal part of the diaphragm

Clinical Anatomy of the Horse

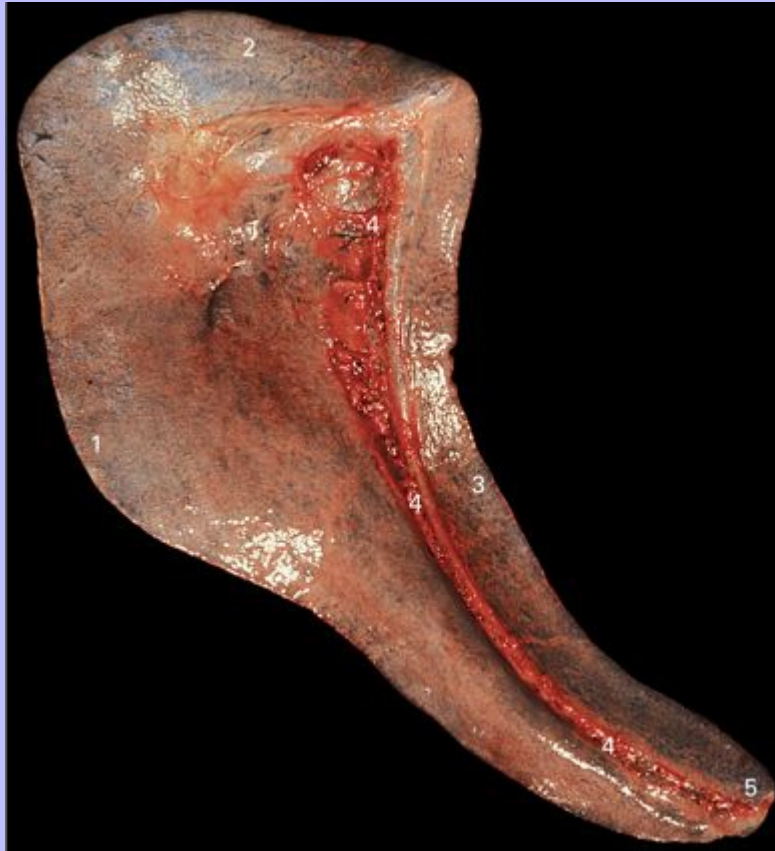7.27 Parietal surface of the spleen.



- 1 Dorsal end
- 2 Caudal border
- 3 Ventral end
- 4 Cranial border

Clinical Anatomy of the Horse

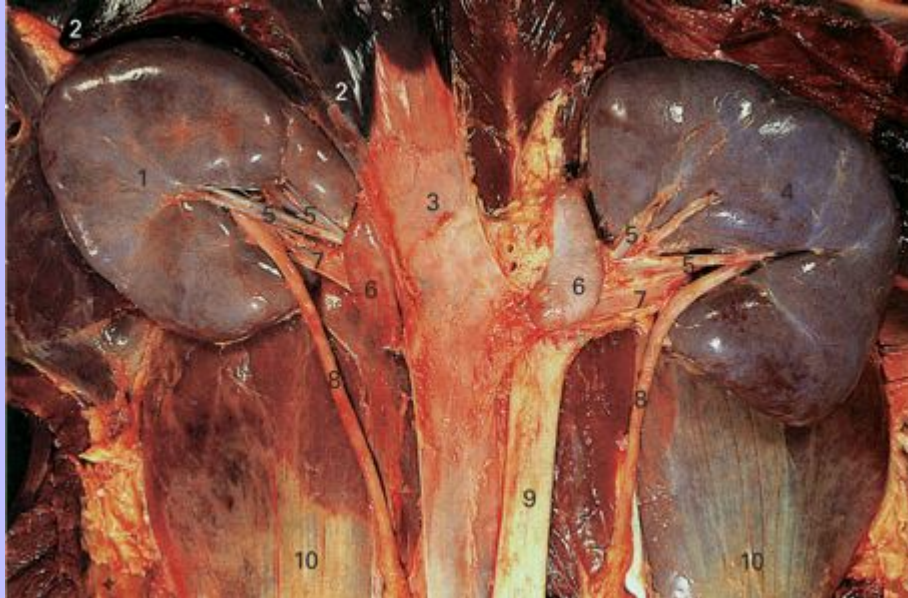
7.28 Visceral surface of the spleen.



- 1 Caudal border
- 2 Dorsal end
- 3 Cranial border
- 4 Hilus
- 5 Ventral end

Clinical Anatomy of the Horse

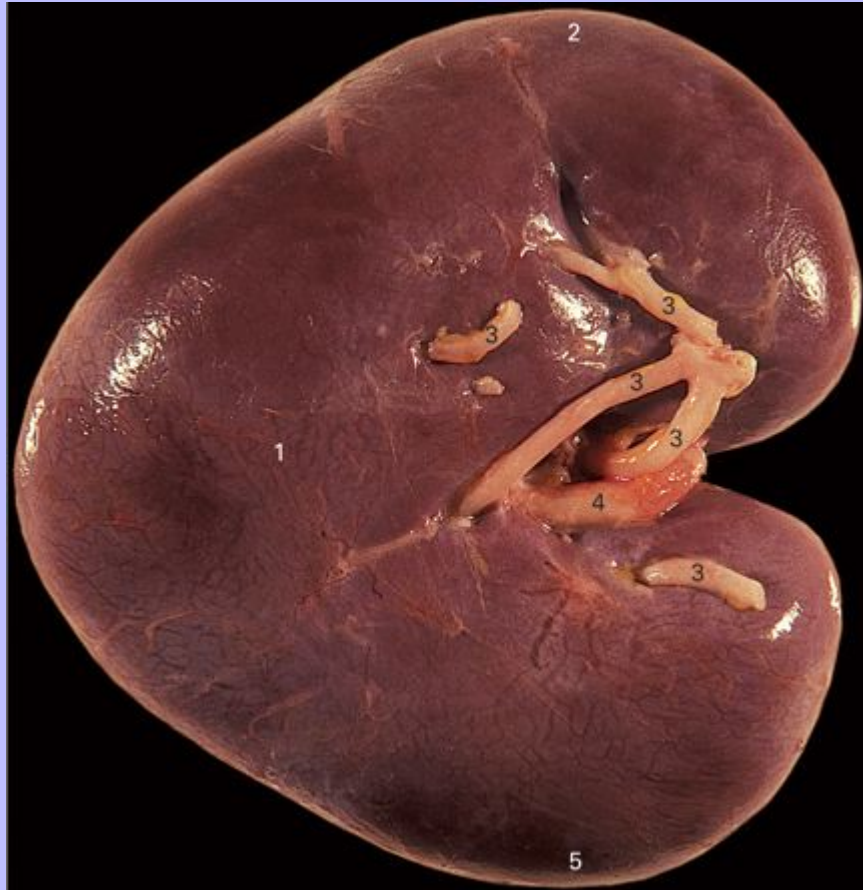7.29 Ventral view of the kidneys and related structures. Cranial is towards the top.



- 1 Ventral surface of the right kidney
- 2 Most caudal part of the caudate lobe of the liver
- 3 Caudal vena cava
- 4 Ventral surface of the left kidney
- 5 Renal arteries
- 6 Adrenal glands
- 7 Renal veins
- 8 Ureter
- 9 Aorta
- 10 M. iliopsoas

104

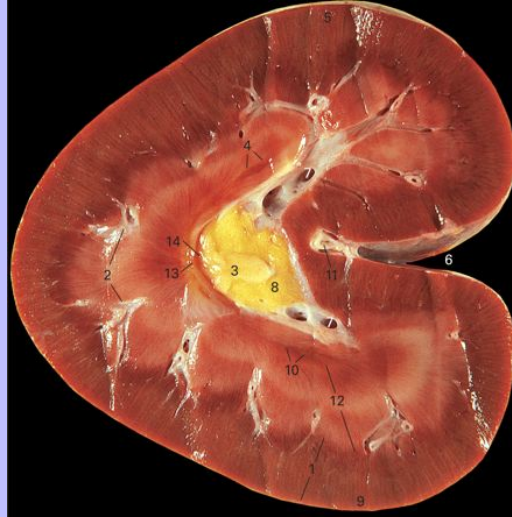
7.30 The right kidney seen from the ventral aspect.



- 1 Ventral surface
- 2 Cranial pole
- 3 Branches of the renal artery entering the kidney
- 4 Beginning of the ureter
- 5 Caudal pole

Clinical Anatomy of the Horse

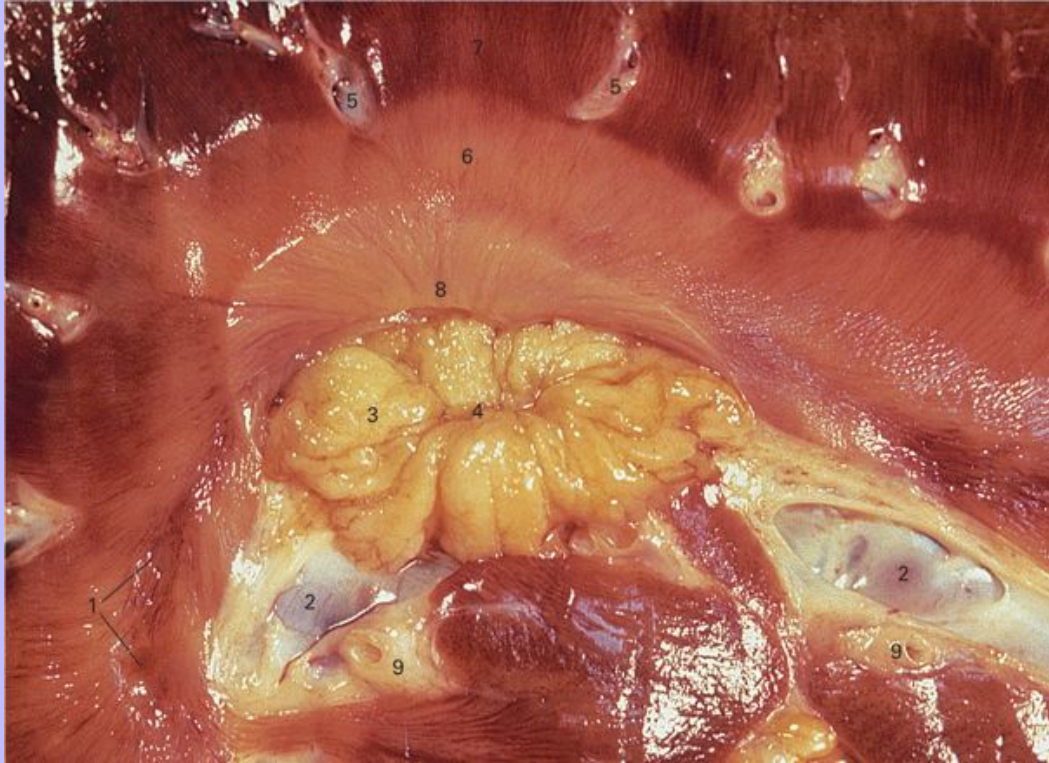
7.31 A dorsal section of the right kidney seen from the ventral aspect.



- 1 Renal cortex
- 2 Lobar vessels seen in section
- 3 Mucosa lining the renal pelvis and ureter
- 4 Oblique section of the terminal recess of the cranial pole surrounded by the pale striated tissue of the inner medulla
- 5 Cranial pole
- 6 Renal hilus
- 7 Renal veins seen in section leaving the renal tissue
- 8 Fat lying in the renal sinus
- 9 Caudal pole
- 10 Terminal recess of the caudal pole
- 11 Branch of the renal artery entering the kidney
- 12 Renal medulla
- 13 Renal crest
- 14 Renal pelvis

Clinical Anatomy of the Horse

7.32 Detail of the renal pelvis. The kidney is sectioned in dorsal plane and is seen from the dorsal side. This section passes just dorsal to the renal crest.



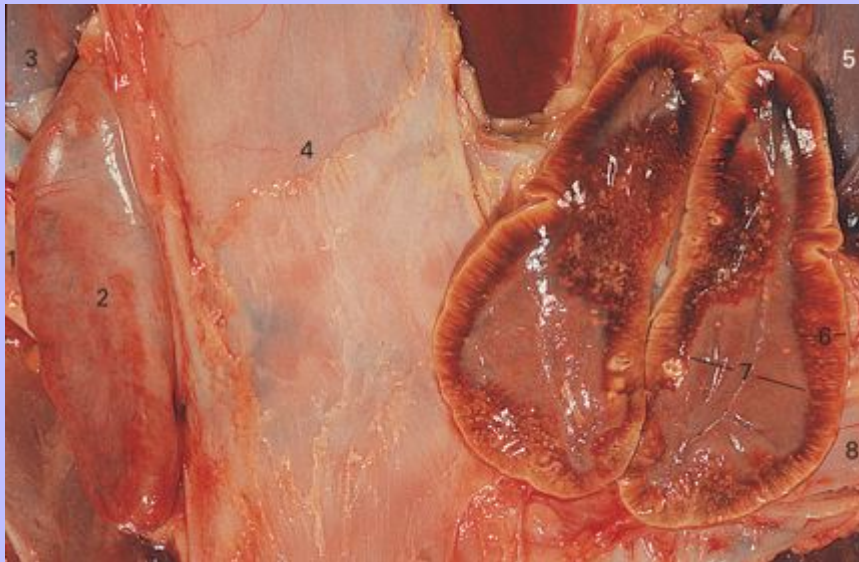
- 1 One of the terminal recesses cut obliquely
- 2 Branches of the renal vein in longitudinal section
- 3 Mucosa of the renal pelvis
- 4 Opening into the ureter
- 5 Lobar vessels seen in section
- 6 Pale inner medulla
- 7 Dark outer medulla
- 8 Renal crest
- 9 Branches of the renal artery

105

Clinical Anatomy of the Horse

106

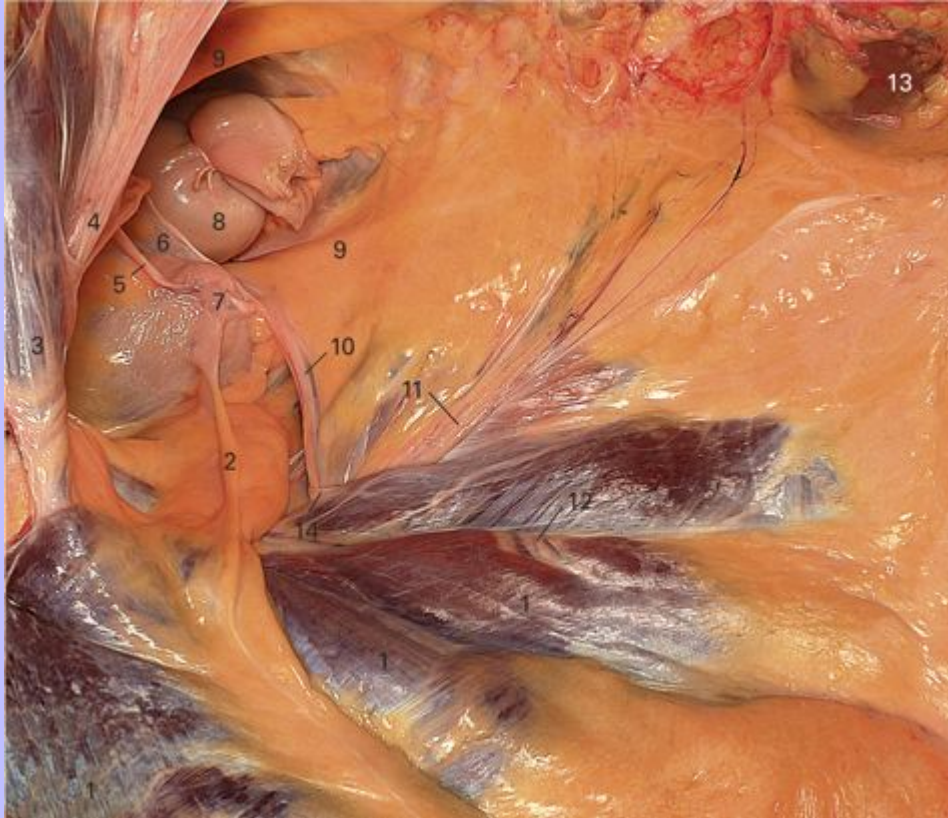7.33 Ventral view of the adrenal glands. The left gland has been sectioned in a dorsal plane and the ventral half of the gland has been reflected towards the animal's right (the left of the photograph) so that both halves are shown. Cranial is towards the top.



- 1 Right renal vein
- 2 Right adrenal gland
- 3 Medial border of the cranial part of the right kidney
- 4 Ventral surface of the caudal vena cava
- 5 Medial border of the cranial part of the left kidney
- 6 Adrenal cortex
- 7 Adrenal medulla
- 8 Left renal vein

Clinical Anatomy of the Horse

7.34 Cranial, lateral and ventral view of the pelvic inlet in a stallion. The rectum has been ligated and largely removed.



- 1 M. rectus abdominis
- 2 Middle ligament of the bladder
- 3 M. obliquus internus abdominis
- 4 The ductus deferens together with the testicular vessels and nerves of the right side entering the vaginal process, and thence the deep inguinal ring
- 5 The cranial border of the right lateral ligament of the bladder containing the right round ligament of the bladder
- 6 Genital fold
- 7 Apex of the bladder
- 8 Rectum

Clinical Anatomy of the Horse

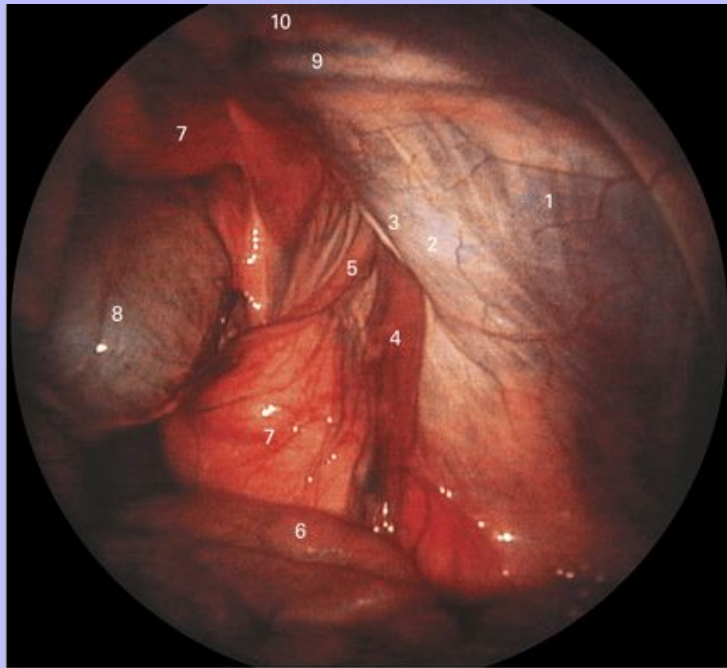
- 9 Fat-filled folds of peritoneum containing the ureters
- 10 Left deferent duct and the associated artery
- 11 Testicular vessels and nerves
- 12 Caudal epigastric vessels
- 13 Ventral surface of the left kidney
- 14 Peritoneal fold forming the medial entrance to the vaginal process

106

Clinical Anatomy of the Horse

107

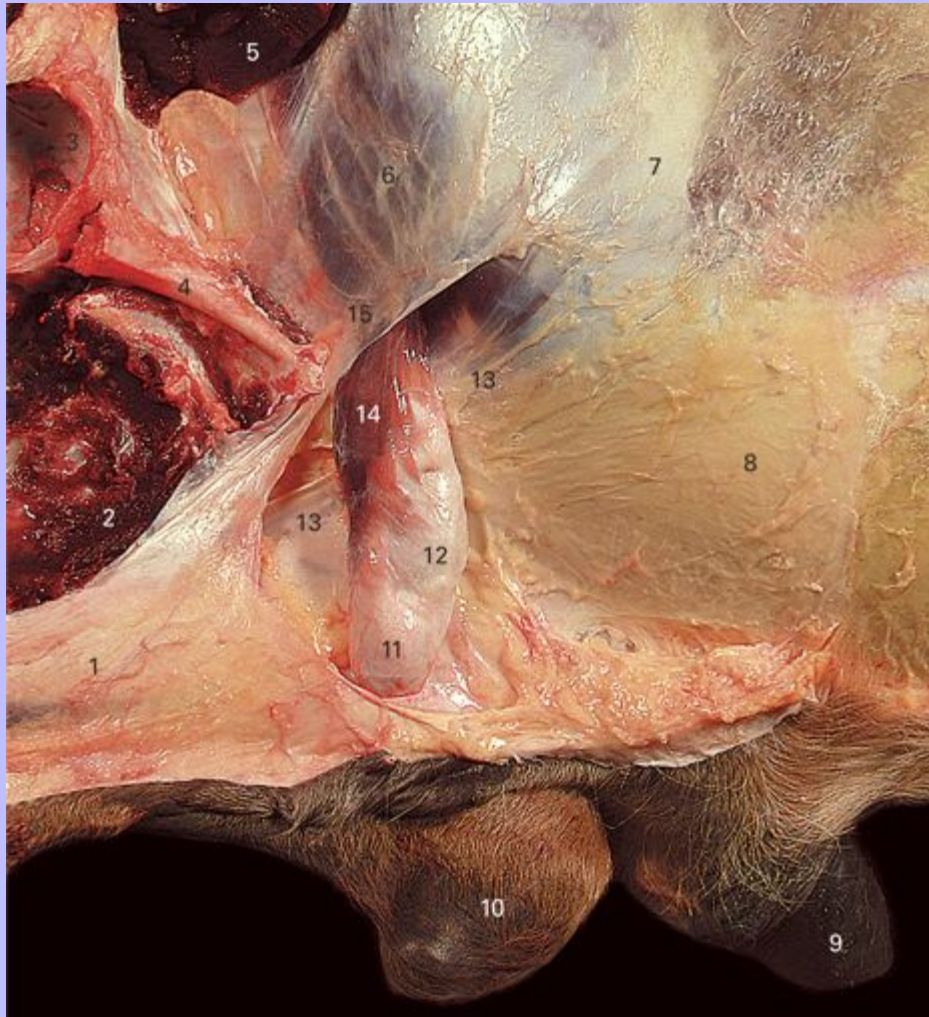
7.35 Endoscopic view of the deep inguinal region in a normal stallion. The horse was anesthetized and placed on its back. The endoscope was inserted into the peritoneal cavity through the right flank and directed caudally. Ventral is towards the top. (Image kindly supplied by Dr D. G. Wilson.)



- 1 M. transversus abdominis
- 2 Caudal edge of the M. obliquus internus abdominis
- 3 Craniomedial border of the deep inguinal ring
- 4 Testicular vessels
- 5 Ductus deferens
- 6 Loops of intestine
- 7 Pelvic fat seen through the peritoneum
- 8 Bladder
- 9 Caudal epigastric vessels
- 10 M. rectus abdominis

Clinical Anatomy of the Horse

7.36 The left inguinal region of a cryptorchid stallion. The right testis is abnormally small and situated high in the inguinal region, but just outside the superficial inguinal ring. Its long axis runs dorsoventrally unlike the normally descended testis in the horse in which it runs craniocaudally. Lateral view.



- 1 Loose connective tissue lying over the body of the penis
- 2 Cut adductor muscles
- 3 Acetabulum
- 4 Accessory ligament of the hip joint lying cranioventral to the pubis

Clinical Anatomy of the Horse

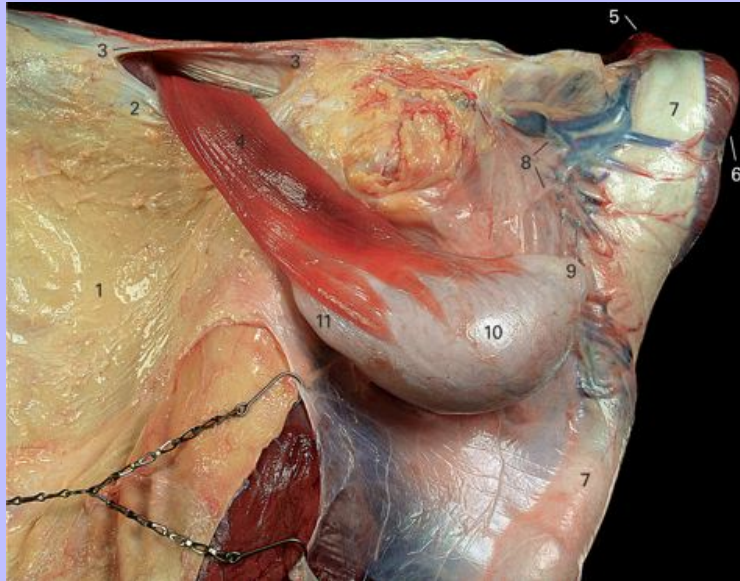
- 5 Cut iliopsoas muscle
- 6 M. obliquus internus abdominis visible through the aponeurosis of M. obliquus externus abdominis
- 7 The aponeurosis of M. obliquus externus abdominis
- 8 Tunica flava abdominis (layer of elastic fascia)
- 9 Exposed preputial fold
- 10 Hemiscrotum of the left side containing the normally descended left testis
- 11 Cauda epididymis visible through the spermatic fascia
- 12 Testis visible through the spermatic fascia
- 13 Medial crus of the aponeurosis of M. obliquus externus abdominis forming the medial boundary of the superficial inguinal ring
- 14 Cremaster muscle seen emerging from superficial inguinal ring and inserting on the spermatic fascia
- 15 Lateral crus of the aponeurosis of M. obliquus externus abdominis (inguinal ligament) forming the lateral boundary of the superficial inguinal ring

107

Clinical Anatomy of the Horse

108

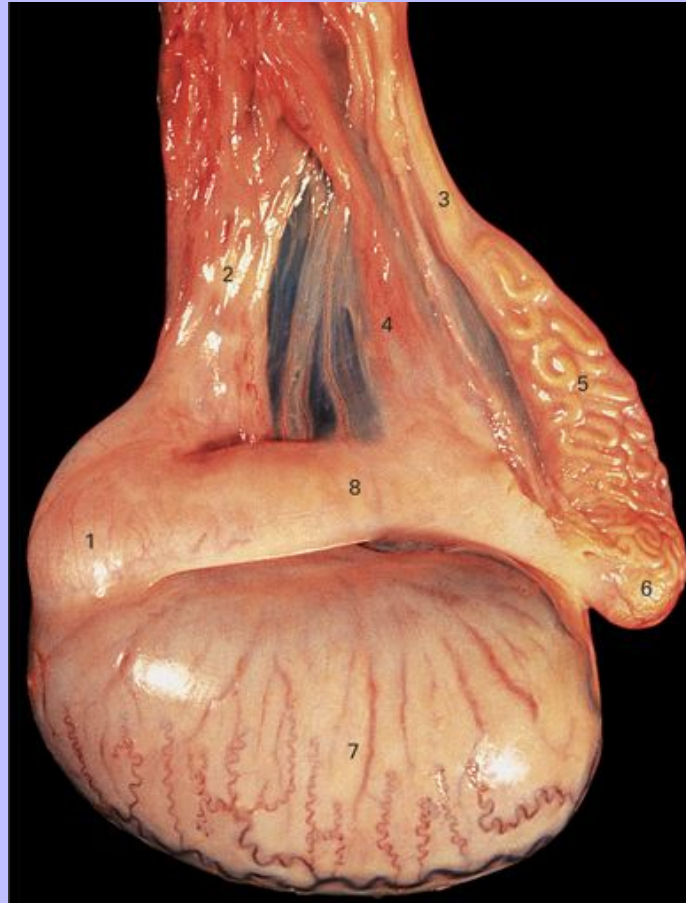7.37 The left testis within the spermatic fascia, and related structures. Ventral view. The testis and penis have been reflected towards the right giving a direct view of the exit from the inguinal canal.



- 1 Tunica flava abdominis overlying the aponeurosis of M. obliquus externus abdominis
- 2 Medial crus of the aponeurosis of M. obliquus externus abdominis forming the medial boundary of the superficial inguinal ring
- 3 Lateral crus of the aponeurosis of M. obliquus externus abdominis (inguinal ligament) forming the lateral boundary of the superficial inguinal ring
- 4 Cremaster muscle inserting on the spermatic fascia
- 5 Ischiocavernosus muscle covering the left crus of the penis
- 6 Bulbospongiosus muscle
- 7 Body of the penis enclosed in loose connective tissue
- 8 Part of the extensive vasculature lying dorsal to the penis
- 9 Cauda epididymis beneath the spermatic fascia
- 10 Testis beneath the spermatic fascia
- 11 Caput epididymis beneath the spermatic fascia

Clinical Anatomy of the Horse

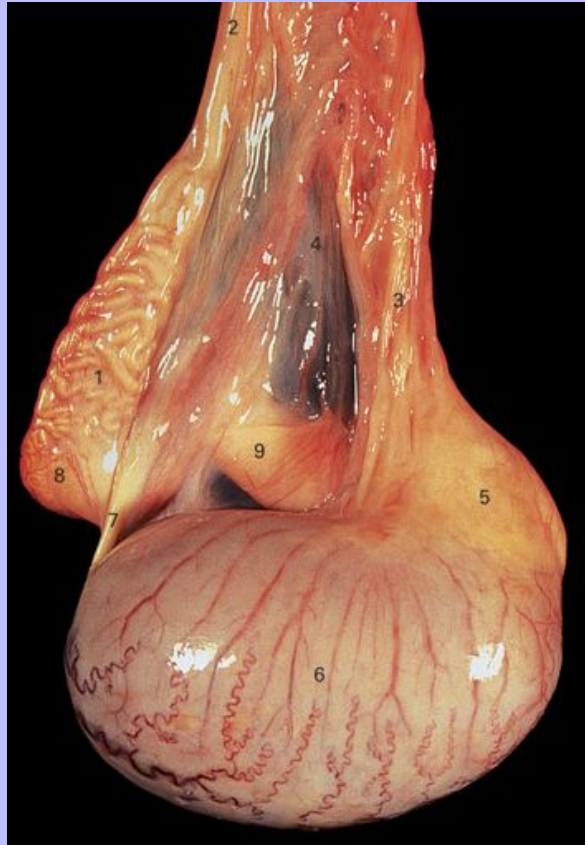7.38 Lateral view of the left testis. Cranial is towards the left.



- 1 Head of the epididymis consisting mainly of efferent ductules
- 2 Vascular cone of the testis; individual vessels cannot be seen through the connective tissue
- 3 Beginning of the straight part of the deferent duct
- 4 Mesorchium
- 5 Convoluted part of the deferent duct
- 6 Tail of the epididymis
- 7 Lateral surface of the testis
- 8 Body of the epididymis

Clinical Anatomy of the Horse

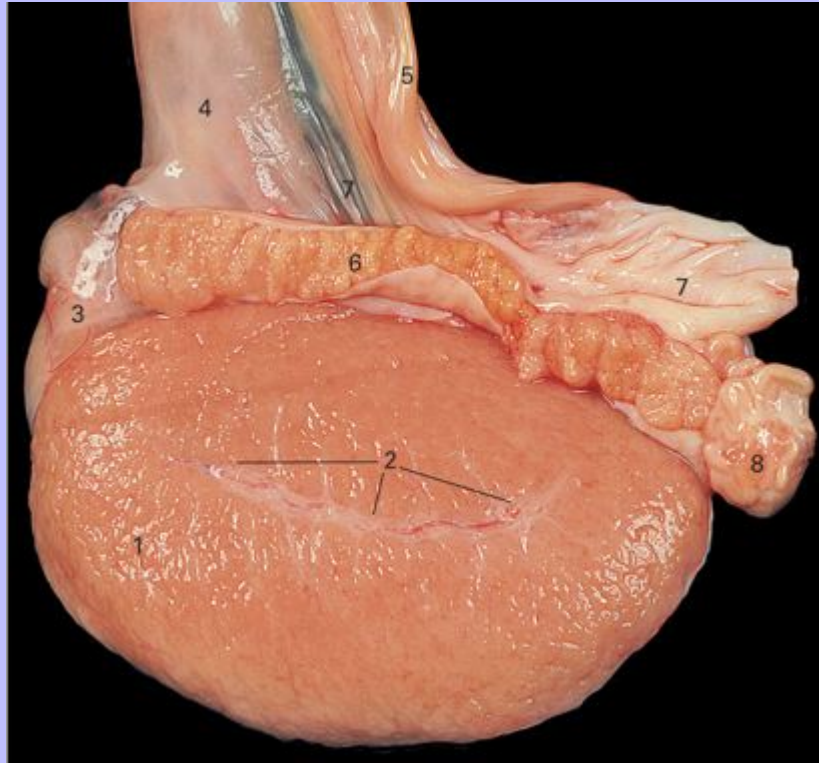
7.39 Medial view of the left testis. Cranial is towards the right.



- 1 Convoluted part of the deferent duct
- 2 Beginning of the straight part of the deferent duct
- 3 Vascular cone of the testis; individual vessels cannot be seen through the connective tissue
- 4 Mesorchium
- 5 Head of the epididymis consisting mainly of efferent ductules
- 6 Medial surface of the testis
- 7 Ligament of the tail of the epididymis
- 8 Tail of the epididymis
- 9 Body of the epididymis seen through the mesorchium

108

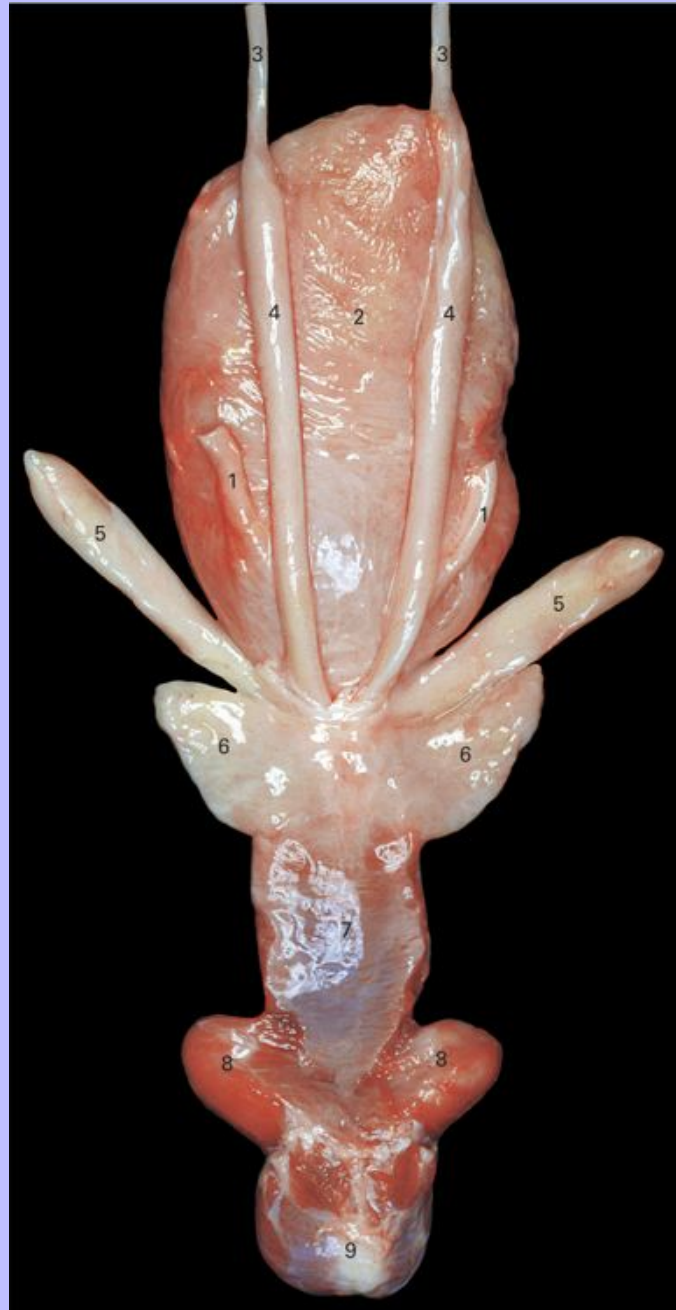7.40 The left testis and the body of the epididymis sectioned in a sagittal plane passing through the middle of the testis.



- 1 Testicular tissue
- 2 Mediastinum testis containing the rete testis
- 3 Head of the epididymis
- 4 Vascular cone of the testis; individual vessels cannot be seen through the connective tissue
- 5 Deferent duct
- 6 Body of the epididymis in section
- 7 Mesorchium
- 8 Tail of the epididymis in section showing the large diameter of the epididymal tubule in this region

Clinical Anatomy of the Horse

7.41 Dorsal view of the bladder, pelvic urethra and accessory genital glands in a 2-year-old stallion.



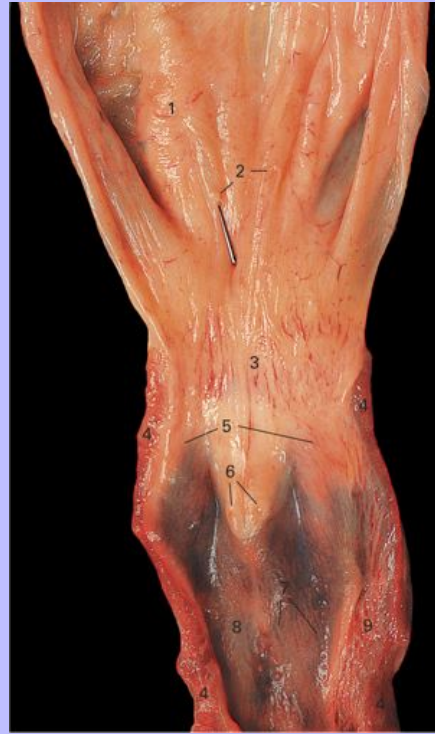
1 Ureters

Clinical Anatomy of the Horse

- 2 Bladder, partially filled
- 3 Deferent ducts
- 4 Ampullae of the deferent ducts
- 5 Vesicular glands (seminal vesicles)
- 6 Left and right lobes of the prostate gland
- 7 Pelvic part of the urethra surrounded by the urethral muscle
- 8 Left and right bulbourethral glands; almost all of the surrounding urethral muscle has been removed
- 9 Bulbospongiosus muscle surrounding the bulb of the penis

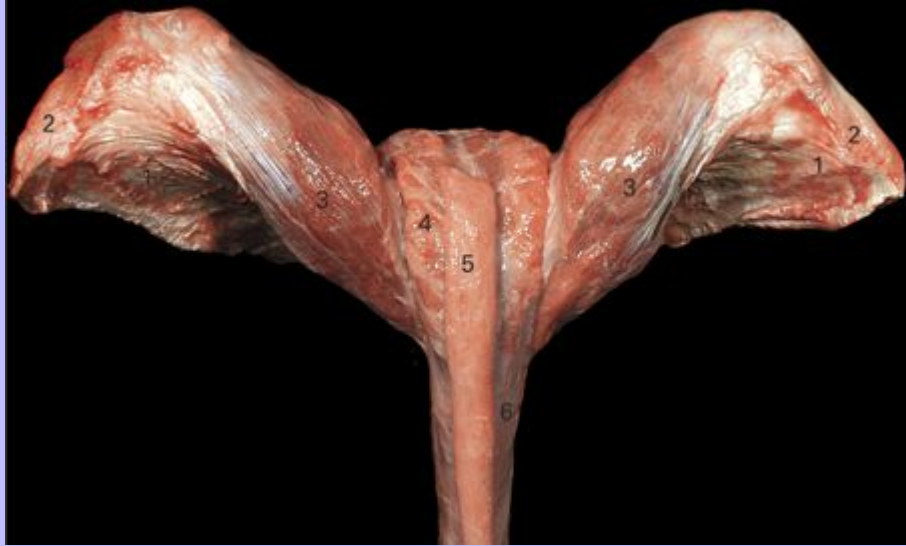
Clinical Anatomy of the Horse

7.42 The bladder and pelvic urethra opened from the ventral aspect in a 2-year-old stallion. The tip of a probe can be seen emerging from the opening of the right ureter.



- 1 Mucosa of the bladder
- 2 Openings of the ureters
- 3 Neck of the bladder (internal urethral orifice)
- 4 Cut urethral muscle
- 5 Areas where the prostatic ducts open; the openings themselves are not readily visible in the photograph
- 6 Openings of the ejaculatory ducts on the summit of the colliculus seminalis
- 7 Lateral and medial openings of the bulbourethral ducts
- 8 Mucosa of the pelvic urethra
- 9 Layer of erectile tissue surrounding the pelvic urethra

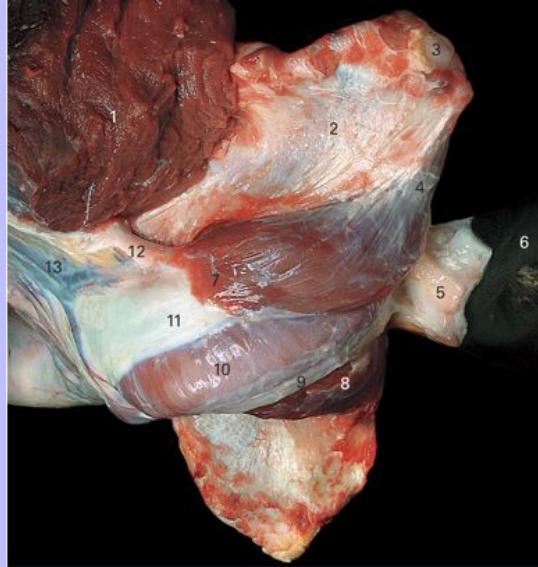
7.43 Caudal view of the root of the penis in a gelding.



- 1 Ventral surfaces of the ischia
- 2 Ischial tuberosities
- 3 Ischiocavernosus muscles surrounding the crura of the penis
- 4 Bulbospongiosus muscle surrounding the bulb of the penis
- 5 Retractor penis muscle (severed just below the terminal part of the rectum)
- 6 Body of the penis composed of the tunica albuginea enclosing the corpus cavernosum

Clinical Anatomy of the Horse

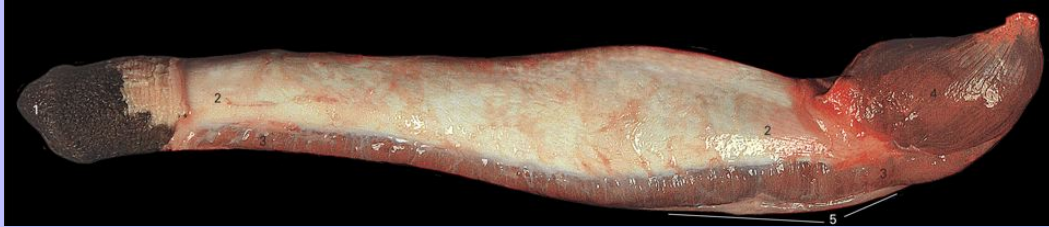7.44 Ventrolateral view of the root of the penis in a 2-year-old stallion. The distal end of the penis is deflected to the right.



- 1 Adductor muscles (cut)
- 2 Ventral surface of the left ischium
- 3 Left ischial tuberosity
- 4 Origin of the left ischiocavernosus muscle
- 5 Connective tissue surrounding the distal part of the rectum
- 6 Skin overlying the external anal sphincter
- 7 Insertion of the left ischiocavernosus muscle onto the body of the penis
- 8 Right ischiocavernosus muscle
- 9 Retractor penis muscle
- 10 Bulbospongiosus muscle extending beneath the body of the penis
- 11 Body of the penis
- 12 Suspensory ligament of the penis
- 13 Part of the extensive vasculature lying dorsal to the penis

Clinical Anatomy of the Horse

7.45 The penis in a 2-year-old stallion. The skin has been removed except at the distal end. Left lateral view.



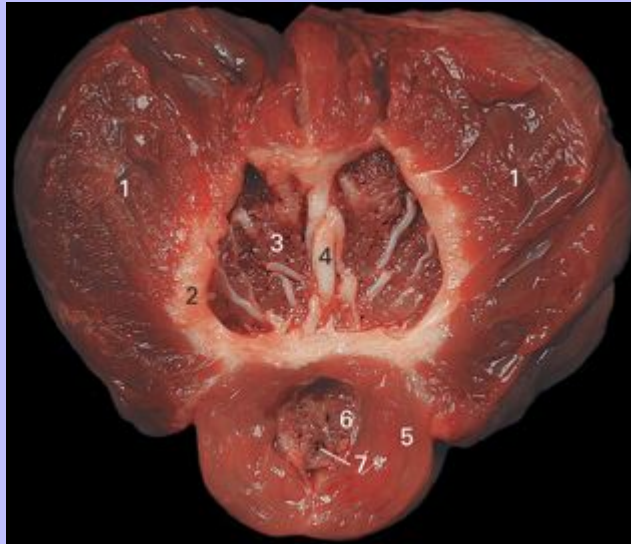- 1 Skin overlying the glans
- 2 Tunica albuginea covering the corpus cavernosum
- 3 Bulbospongiosus muscle; in horses this extends to the tip of the penis
- 4 Ischiocavernosus muscle
- 5 Retractor penis muscle

110

Clinical Anatomy of the Horse

111

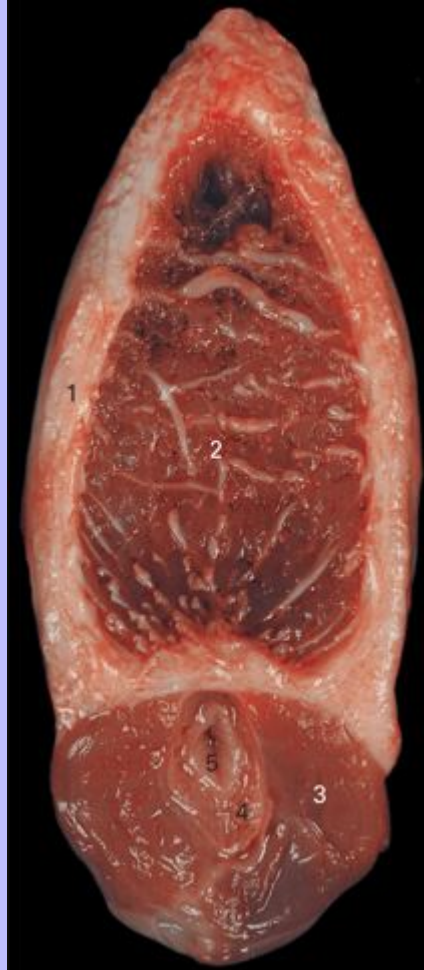7.46 Dorsal section of the penis of a stallion at the level of the ischial arch. The section is seen from the dorsal aspect and cranial is towards the top. At this level the left and right crura have just fused to form the corpus cavernosum.



- 1 Ischiocavernosus muscle
- 2 Tunica albuginea
- 3 Corpus cavernosum
- 4 Fibrous trabeculae within the corpus cavernosum
- 5 Bulbospongiosus muscle
- 6 Corpus spongiosum
- 7 Urethra

Clinical Anatomy of the Horse

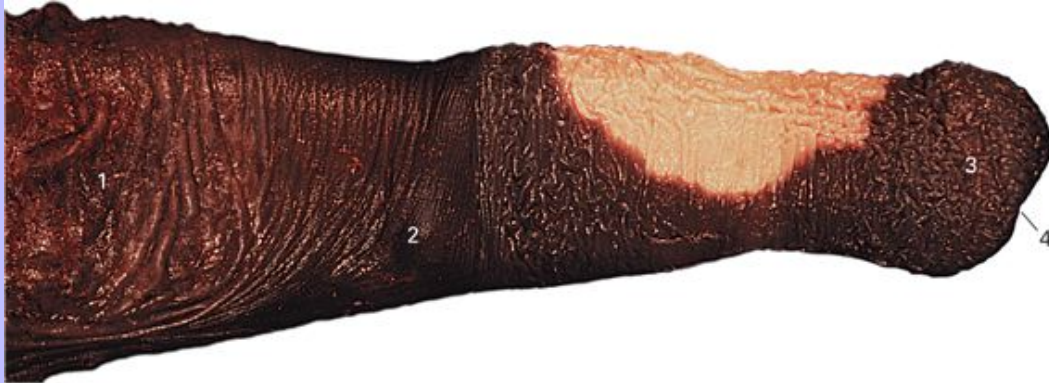7.47 Transverse section of the body of the penis.



- 1 Tunica albuginea
- 2 Corpus cavernosum
- 3 Bulbospongiosus muscle
- 4 Corpus spongiosum
- 5 Urethra

Clinical Anatomy of the Horse

7.48 Lateral view of the distal end of the penis when drawn out of the prepuce.



- 1 Preputial skin lining the part of the preputial cavity outside the preputial fold; it is frequently associated with large amounts of smegma
- 2 Skin forming the edge of the preputial fold that becomes evident when the penis is retracted; it bears the vestigial nipples of the male
- 3 Edge of the corona (crown) of the glans
- 4 Position of the urethral opening

Clinical Anatomy of the Horse

7.49 The glans penis seen from the ventral aspect.



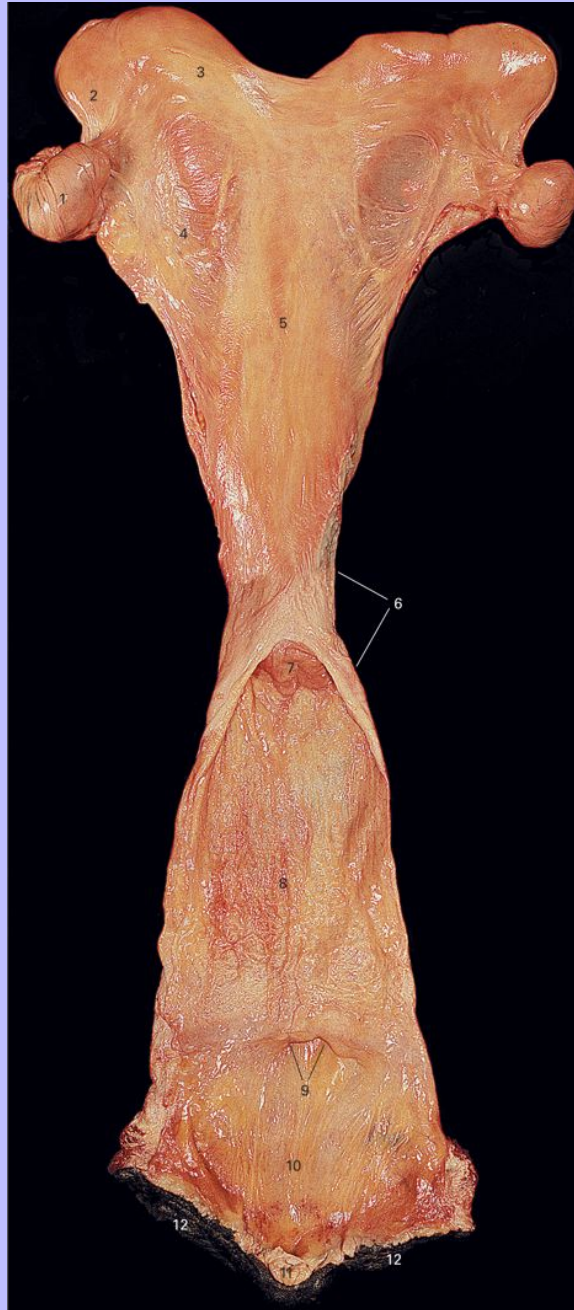- 1 Preputial skin lining the part of the preputial cavity inside the preputial fold
- 2 Corona (crown) of the glans
- 3 Fossa glandis
- 4 Urethral process
- 5 Urethral opening

111

Clinical Anatomy of the Horse

112

7.50 Dorsal view of the female reproductive tract. The vagina and vestibule have been opened from the dorsal side.



1 Ovary

Clinical Anatomy of the Horse

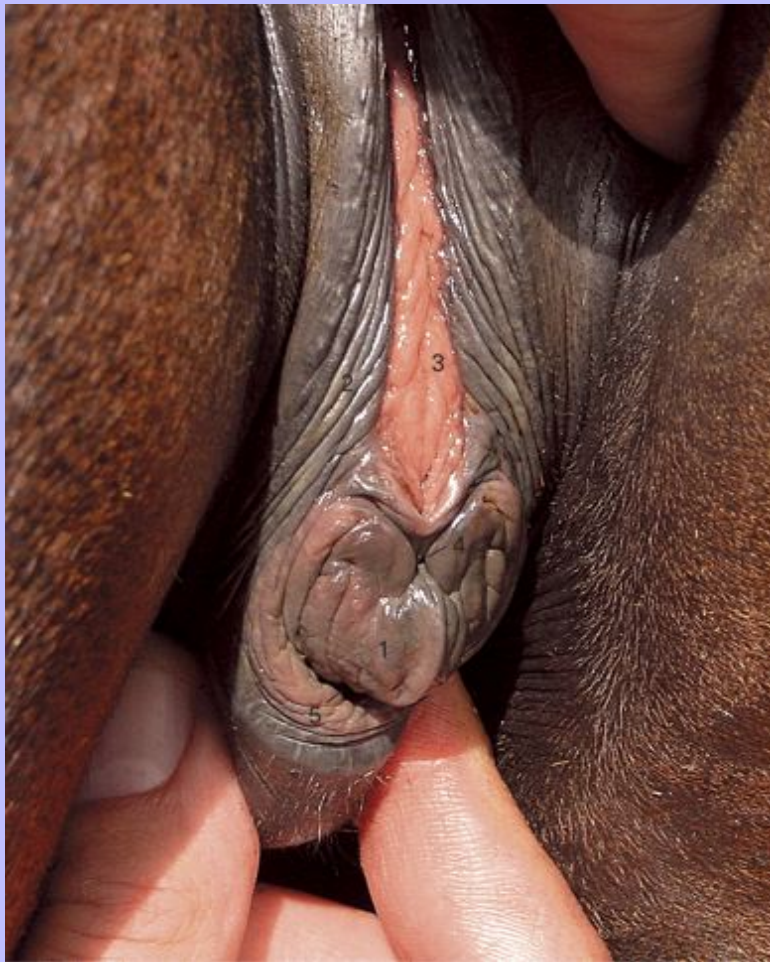- 2 Tip of the left uterine horn
- 3 Left uterine horn
- 4 Broad ligament
- 5 Body of the uterus
- 6 Position of the cervix
- 7 External opening of the cervix
- 8 Vagina
- 9 Urethral opening
- 10 Vestibule
- 11 Clitoris
- 12 Vulva

112

Clinical Anatomy of the Horse

113

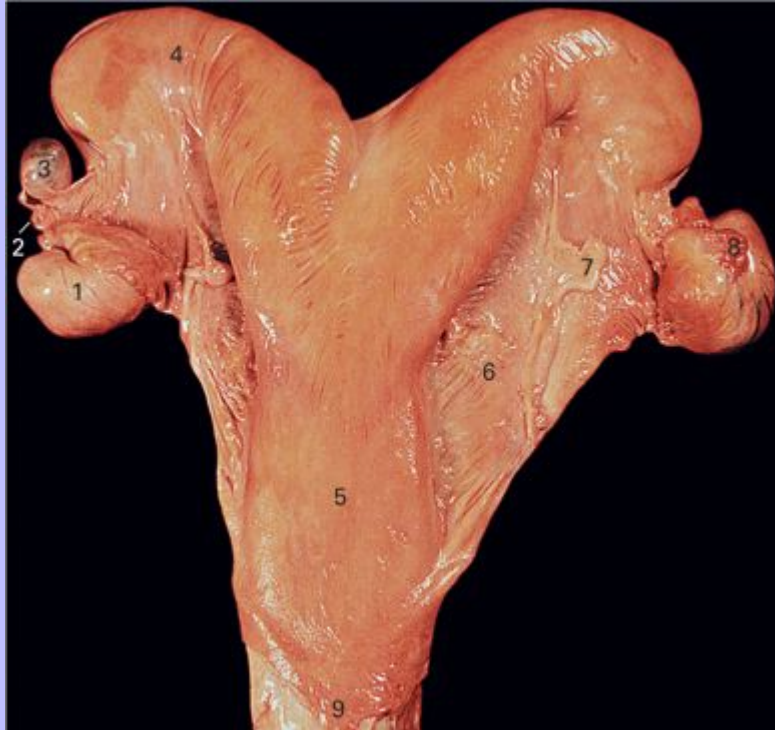7.51 The ventral commissure of the vulva of a mare everted to show the clitoris. The rim of the clitoridal fossa surrounds the glans of the clitoris. The clitoris is incompletely extruded from the fossa so that only the distal surface of the glans is revealed.



- 1 Glans of the clitoris
- 2 Skin of the vulva
- 3 Mucosa of the vestibule
- 4 Position of the opening of the clitoridal sinus
- 5 Ventral part of the clitoridal fossa

Clinical Anatomy of the Horse

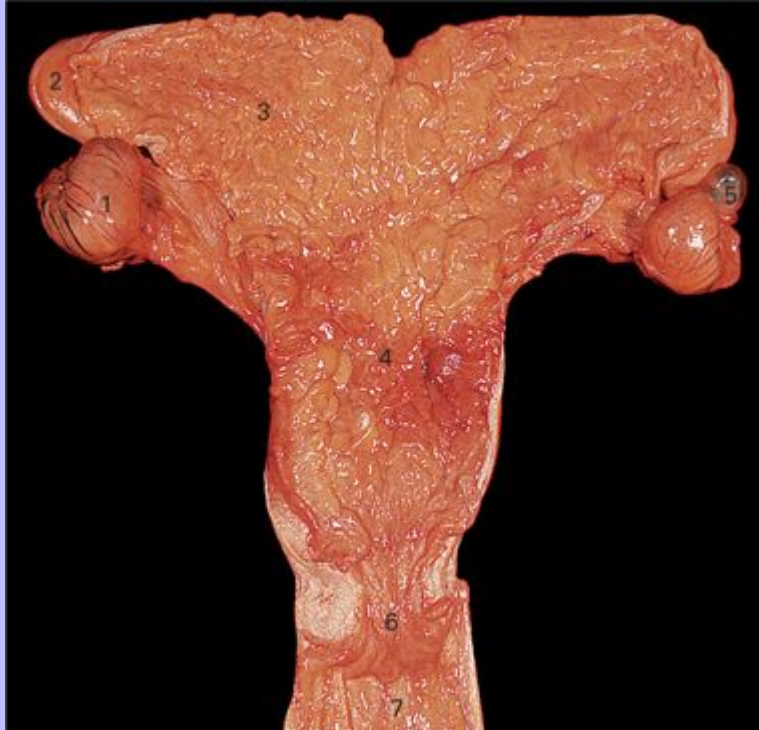7.52 Ventral view of the uterus and related structures.



- 1 Ovary
- 2 Uterine tube (oviduct)
- 3 Para-ovarian cyst, a common and innocuous abnormality
- 4 Right horn of the uterus
- 5 Body of the uterus
- 6 Broad ligament
- 7 Round ligament of the uterus
- 8 Fimbria of the uterine tube (oviduct)
- 9 Position of the cervix

Clinical Anatomy of the Horse

7.53 Dorsal view of the uterus opened from the dorsal side.



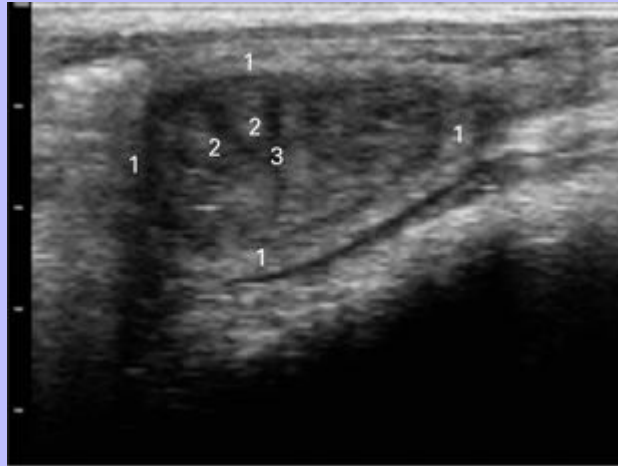- 1 Ovary
- 2 Tip of the left uterine horn
- 3 Mucosa of the left uterine horn
- 4 Mucosa of the body of the uterus
- 5 Para-ovarian cyst, a common and innocuous abnormality
- 6 Cervix
- 7 Vagina

113

Clinical Anatomy of the Horse

114

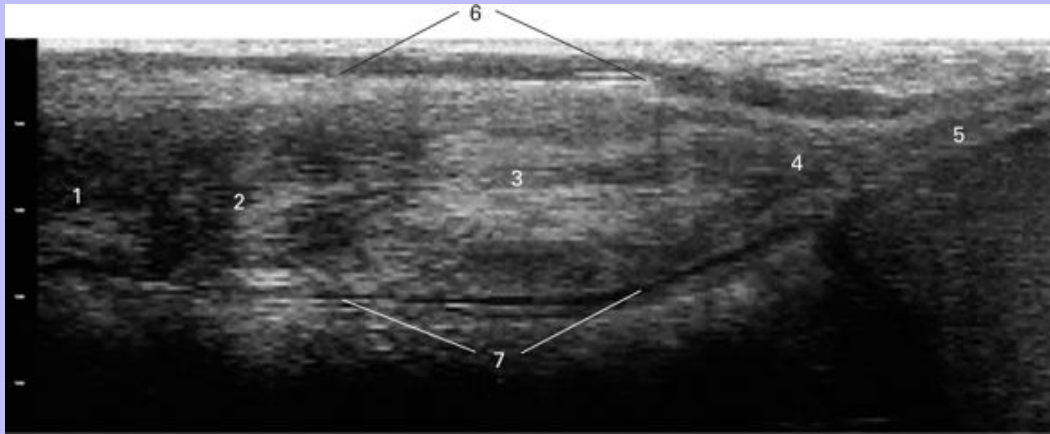
7.54 Ultrasound image of the uterus showing a transverse section of one of the horns. (The 7 MHz probe lies at the top of the image; the scale on the left shows centimeters. Image kindly supplied by Dr G. P. Adams.)



- 1 Myometrium
- 2 Endometrial folds
- 3 Uterine lumen

Clinical Anatomy of the Horse

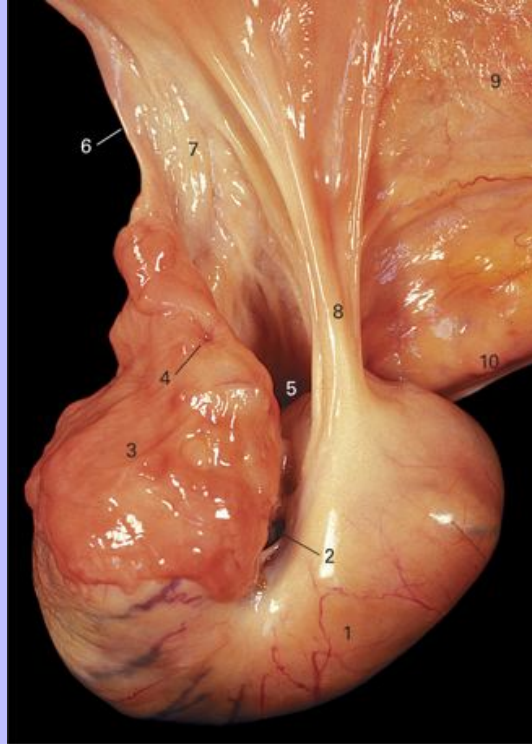
7.55 Ultrasound image of the cervix showing a median section in which the uterine end is towards the left. (The image was produced by combining two fixed frames. The 7 MHz probe lies at the top of the image; the scale on the left shows centimeters. Image kindly supplied by Dr G. P. Adams.)



- 1 Body of the uterus sectioned longitudinally
- 2 Internal end of the cervical canal
- 3 Cervical canal
- 4 External end of the cervical canal protruding into the vagina
- 5 Lumen of the vagina
- 6 Dorsal surface of the cervix
- 7 Ventral surface of the cervix

Clinical Anatomy of the Horse

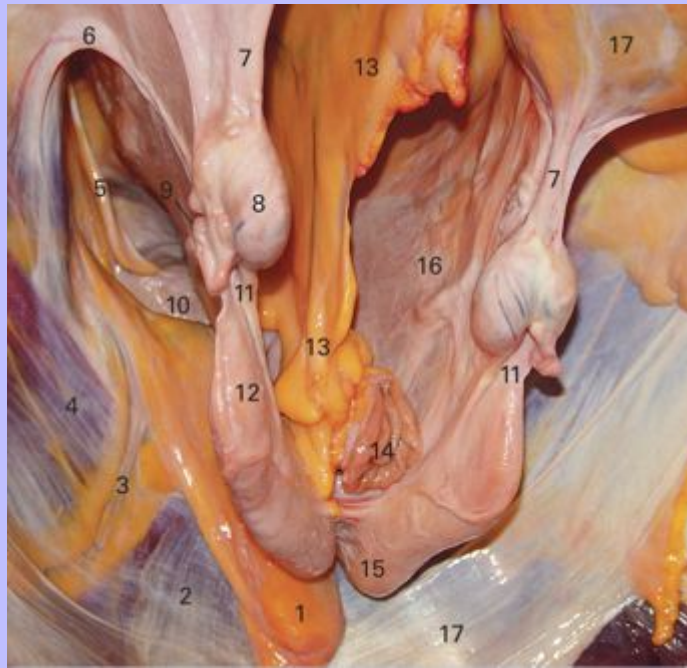7.56 The left ovary rotated to show the entrance to the ovarian bursa.
Ventromedial view. Cranial is towards the right.



- 1 Ovarian surface covered by peritoneum
- 2 Ovarian (ovulation) fossa
- 3 Everted infundibulum of the uterine tube edged by the fimbriae
- 4 Entrance to the ampulla of the uterine tube
- 5 Ovarian bursa
- 6 Uterine tube (oviduct)
- 7 Mesosalpinx
- 8 Proper ligament of the ovary
- 9 Medial surface of the broad ligament
- 10 Suspensory ligament of the ovary (free border of the broad ligament)

Clinical Anatomy of the Horse

7.57 The female reproductive tract, and related structures, suspended from the abdominal and pelvic roof. The animal is in the standing position. The intestines have been removed with the exception of the terminal part of the descending colon. The observer is looking caudally and a little to the left.



- 1 Fat lying in the ventral ligament of the bladder
- 2 M. rectus abdominis seen through the transverse fascia
- 3 Caudal epigastric vessels
- 4 M. obliquus internus abdominis
- 5 Round ligament of the bladder lying in the cranial border of the lateral ligament of the bladder
- 6 Round ligament of the uterus
- 7 Suspensory ligament of the ovary
- 8 Right ovary
- 9 Uterine tube (oviduct)
- 10 Apex of the bladder

Clinical Anatomy of the Horse

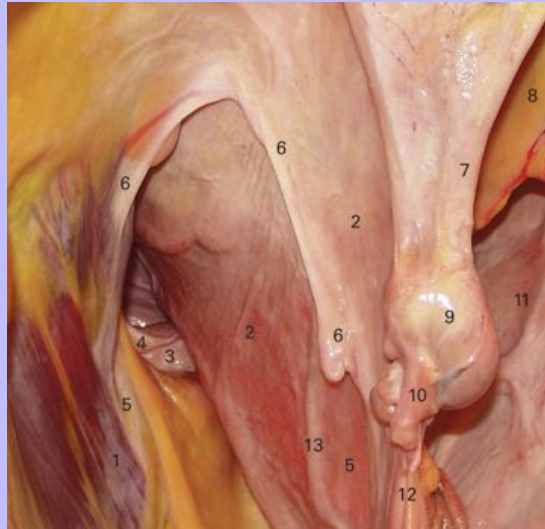- 11 Proper ligament of the ovary
- 12 Tip of the right uterine horn
- 13 Mesocolon
- 14 Cut descending colon
- 15 Base of the left uterine horn
- 16 Left broad ligament of the uterus
- 17 Transverse fascia

114

Clinical Anatomy of the Horse

115

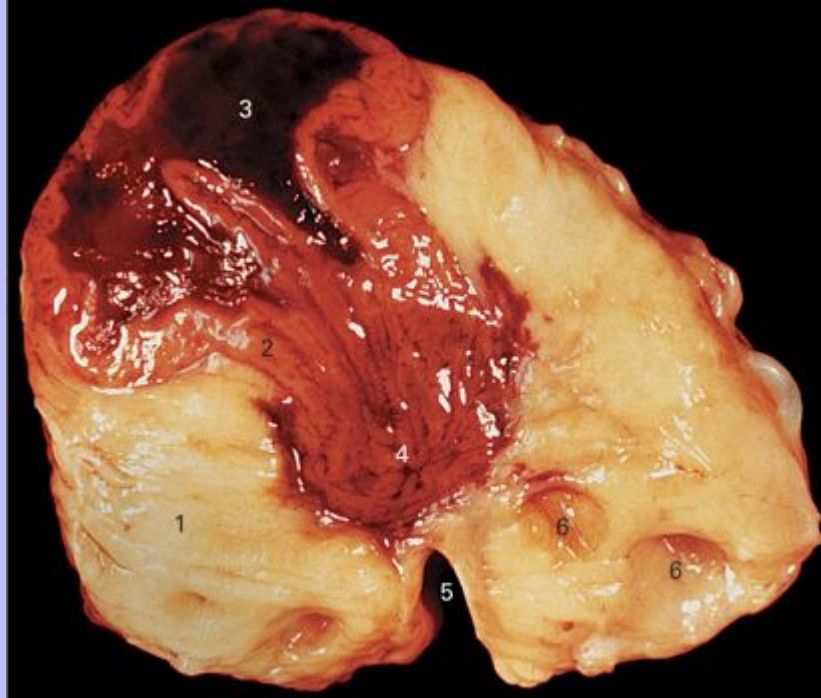
7.58 The caudal abdomen and pelvis of a mare held in the standing position. The intestines have been removed with the exception of the terminal part of the descending colon. The observer is looking caudally and to the left.



- 1 M. obliquus internus abdominis
- 2 Right broad ligament of the uterus
- 3 Apex of the bladder
- 4 Lateral ligament of the bladder
- 5 Location of the deep inguinal ring
- 6 Round ligament of the uterus
- 7 Suspensory ligament of the ovary
- 8 Mesocolon
- 9 Right ovary
- 10 Infundibular part of the uterine tube (oviduct)
- 11 Left broad ligament of the uterus
- 12 Proper ligament of the ovary
- 13 Uterine artery

Clinical Anatomy of the Horse

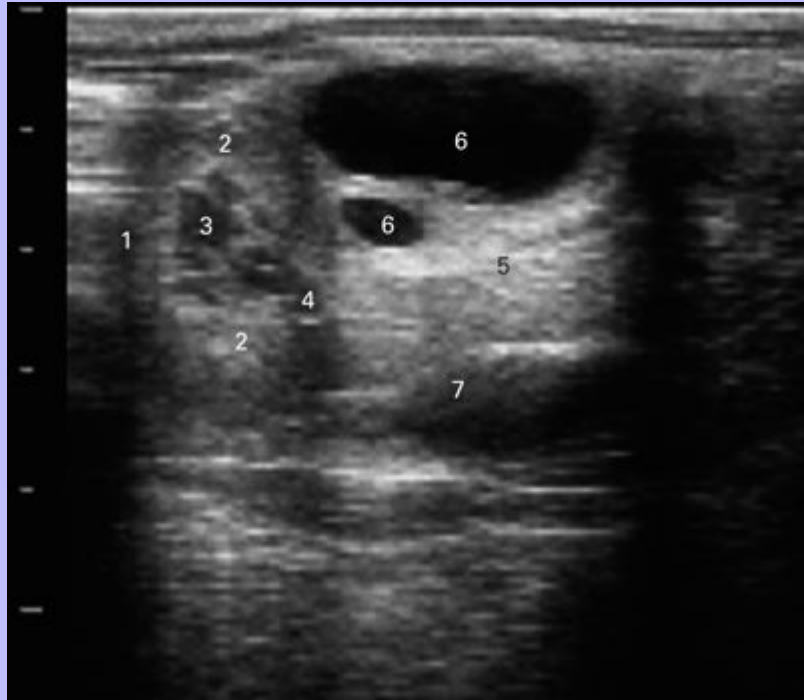7.59 An equine ovary sectioned from the convex mesovarial border to the free concave border bearing the ovarian (ovulation) fossa.



- 1 Interstitial tissue of the ovary
- 2 Luteal tissue
- 3 Central clot in a recently formed corpus luteum
- 4 Tongue of luteal tissue extending towards the ovarian fossa indicating the route followed at ovulation
- 5 Ovarian fossa (ovulation) fossa
- 6 Small ovarian follicles

Clinical Anatomy of the Horse

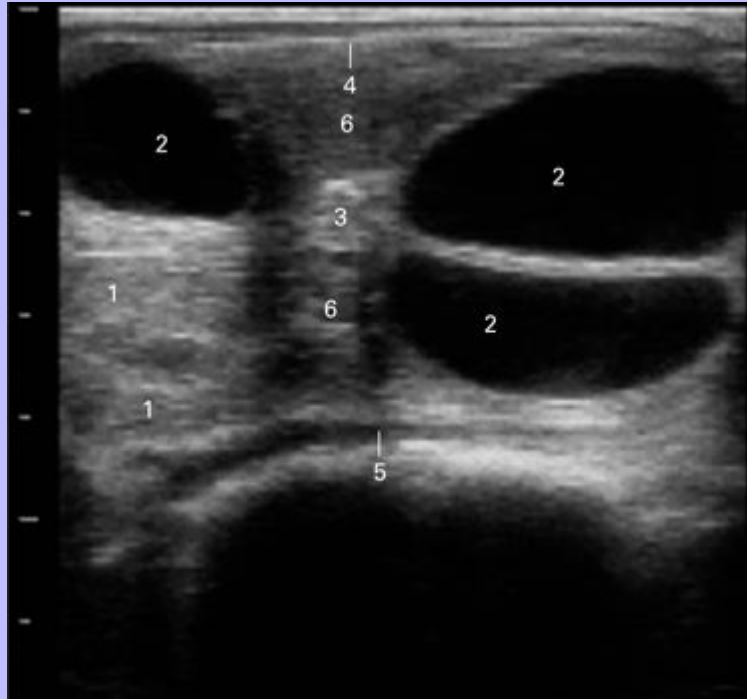
7.60 Ultrasound image of the ovary showing an oblique section including both a young corpus luteum and two medium-sized follicles. (The 7 MHz probe lies at the top of the image; the scale on the left is in centimeters. Image kindly supplied by Dr G. P. Adams.)



- 1 The position of the cranial pole of the ovary
- 2 Luteal tissue
- 3 Central blood clot beginning to organize
- 4 Tongue of the corpus luteum extending towards the ovarian fossa indicating the path followed at ovulation
- 5 Interstitial tissue of the ovary
- 6 Medium-sized follicles
- 7 Depression in the ovarian surface close to the ovarian (ovulation) fossa

Clinical Anatomy of the Horse

7.61 Ultrasound image of the ovary showing a plane passing through both poles and perpendicular to the plane extending from the attachment of the mesovarium to the ovulation fossa. In this case neither pole is within the confines of the image. (The 7 MHz probe lies at the top of the image; the scale on the left is in centimeters. Image kindly supplied by Dr G. P. Adams.)



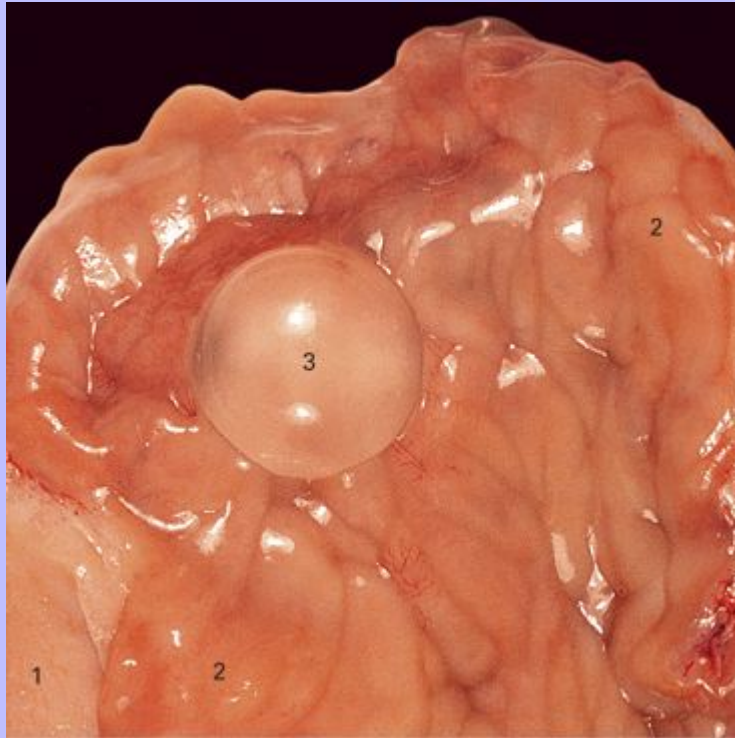
- 1 Tissue of a regressing corpus luteum
- 2 Large follicles with their points converging on the ovarian (ovulation) fossa
- 3 Dense ovarian tissue adjacent to the ovarian (ovulation) fossa
- 4 Surface of the ovary closest to the probe
- 5 Surface of the ovary farthest from the probe
- 6 Interstitial tissue of the ovary

115

Clinical Anatomy of the Horse

116

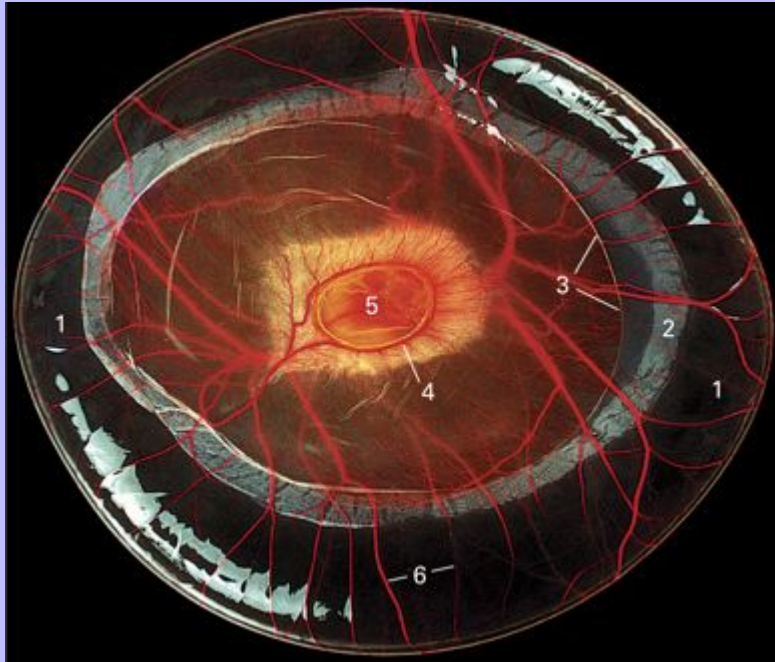
7.62 Dorsal view of the uterus of a pregnant mare 13 days after ovulation. It has been opened from the dorsal side.



- 1 Unopened part of the uterine horn
- 2 Endometrium
- 3 Encapsulated embryo lying on the endometrium (2 cm in diameter)

Clinical Anatomy of the Horse

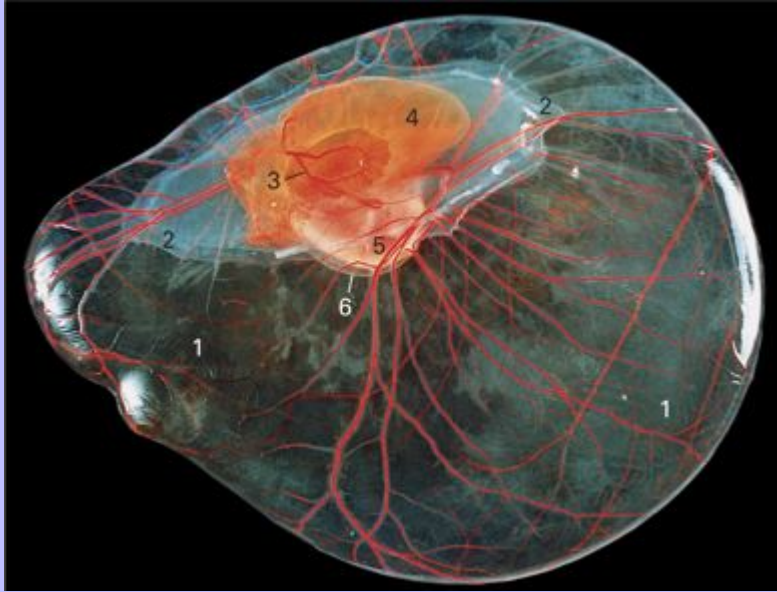7.63 A 34-day-old conceptus seen from the mesometrial aspect. It is about 8 cm in diameter.



- 1 Undifferentiated allantochorion
- 2 Chorionic girdle
- 3 Margin of the yolk sac
- 4 Sinus terminalis
- 5 Remnant of the bilaminar omphalopleure
- 6 Allantoic vessels

Clinical Anatomy of the Horse

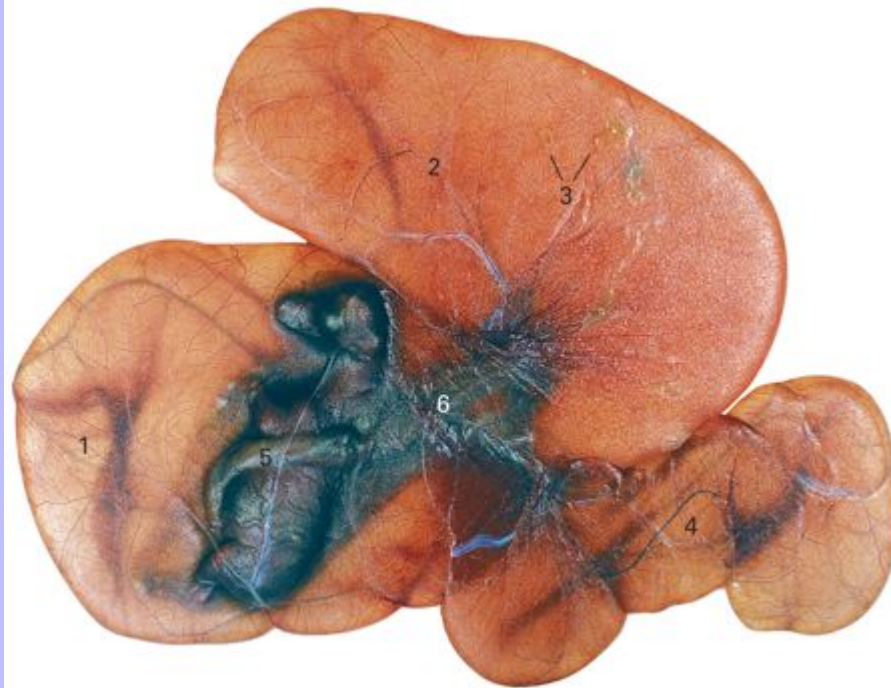7.64 A 39-day-old conceptus with the yolk sac uppermost. The embryo proper is 2 cm in length.



- 1 Undifferentiated allantochorion
- 2 Position of the chorionic girdle; the girdle cells have now invaded the endometrium
- 3 Sinus terminalis
- 4 Yolk sac
- 5 Embryo proper
- 6 Amnion

Clinical Anatomy of the Horse

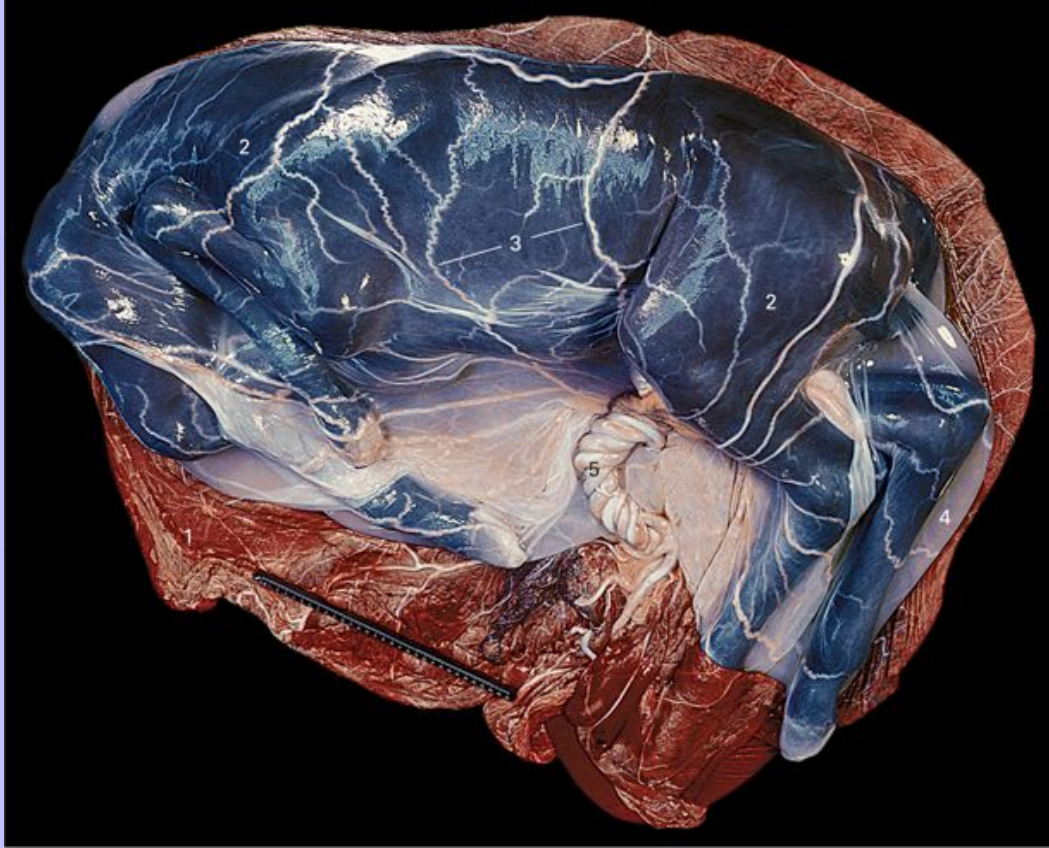7.65 A 98-day-old conceptus with the yolk sac uppermost. The fetus is 20 cm in length.



- 1 Part of the allantochorion occupying the body of the uterus
- 2 Part of the allantochorion occupying the horn of the uterus in which the conceptus originally attached
- 3 Parts of the allantochorion lacking microvilli because of their proximity to the endometrial cups
- 4 Part of the allantochorion occupying the horn of the uterus in which the conceptus did not originally attach
- 5 Amniotic portion of the umbilical cord visible through the fetal membranes
- 6 Allantoic portion of the umbilical cord visible through the allantochorion

116

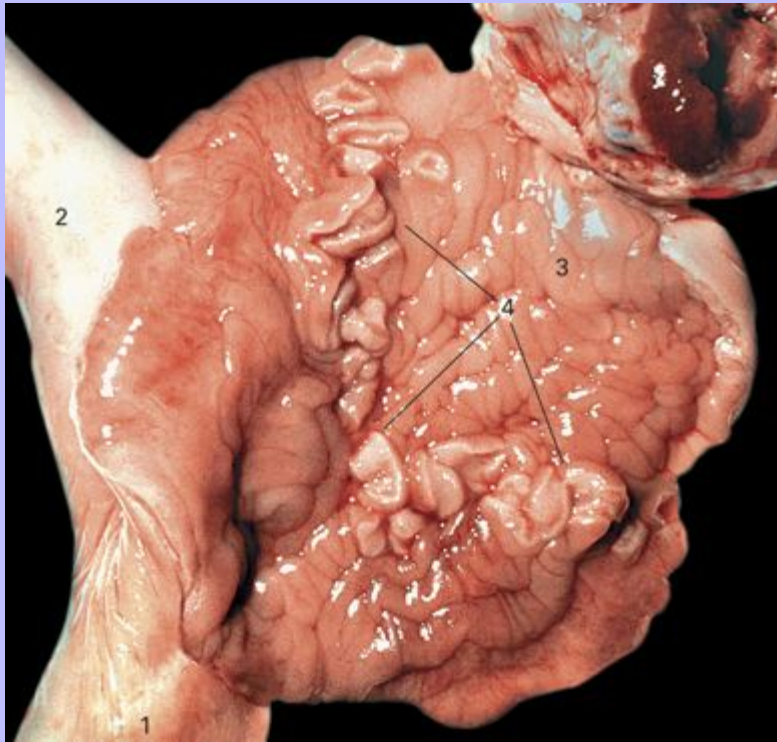
7.66 A near-term foal and its membranes. The allantochorion has been opened to show the fetus within the amnion.



- 1 Inner surface of the allantochorion
- 2 Amnion overlying the fetus
- 3 Branches of the allantoic vessels supplying the amnion
- 4 Part of the amnion containing amniotic fluid
- 5 Allantoic part of the umbilical cord

Clinical Anatomy of the Horse

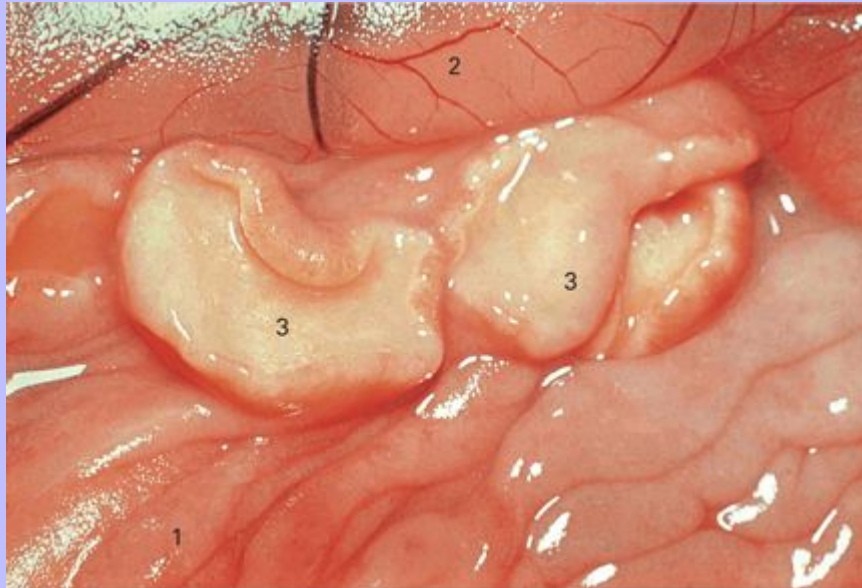
7.67 The gravid horn of the uterus of a 63-day-pregnant mare opened to show the endometrial cups. The fetus and its membranes have been removed. The line of endometrial cups would have formed an almost complete circle before the uterus was opened. (Photo kindly supplied by Professor W. R. Allen.)



- 1 Body of the uterus
- 2 Non-gravid horn of the uterus
- 3 Endometrium of the gravid horn
- 4 Endometrial cups forming an arc

Clinical Anatomy of the Horse

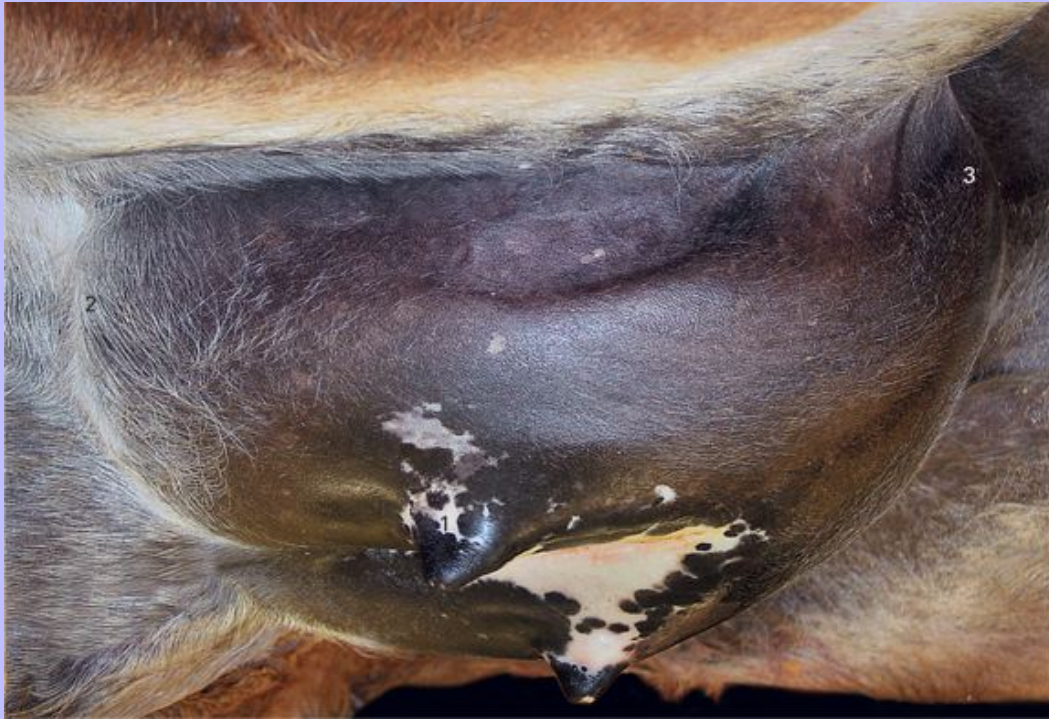7.68 Detail of the endometrial cups and related structures at 84 days' gestation. The allantochorion has been lifted away from the cups and towards the top of the photograph to reveal the cups. (Photo kindly supplied by Professor W. R. Allen.)



- 1 Endometrial surface
- 2 Allantochorion
- 3 Endometrial cups

117

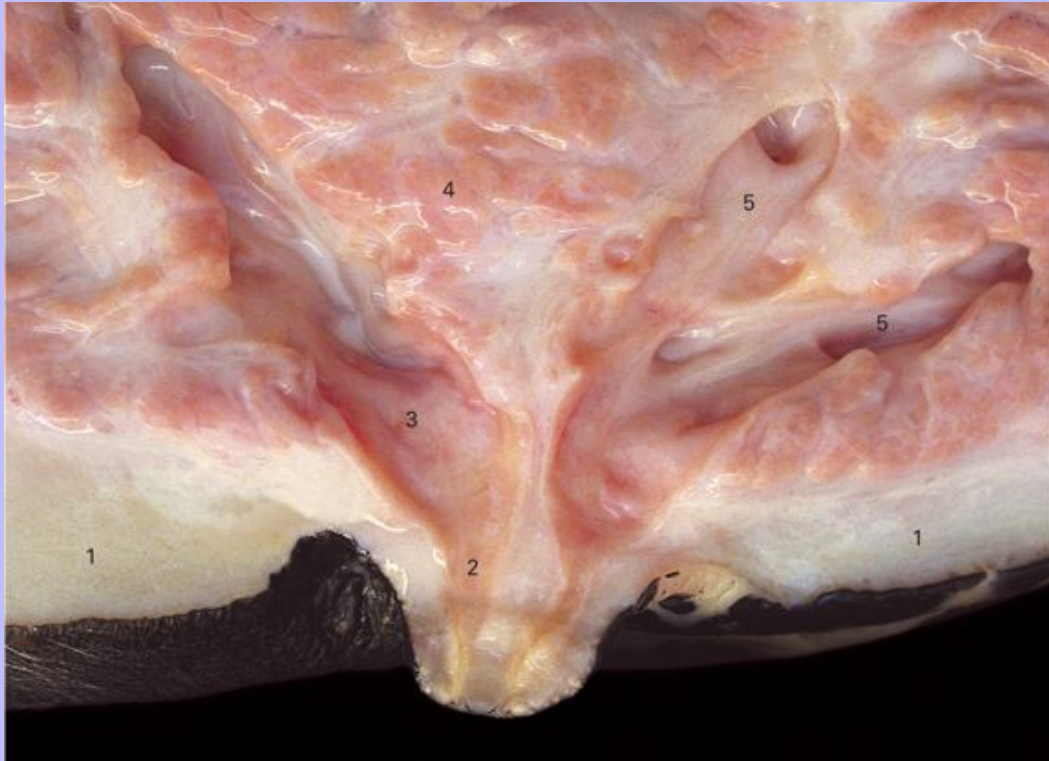7.69 The udder of a lactating mare seen from a ventral, caudal and lateral viewpoint.



- 1 Left teat: the openings of both papillary ducts are visible at its tip
- 2 Cranial extremity of the udder
- 3 Caudal extremity of the udder

Clinical Anatomy of the Horse

7.70 The left teat and the adjacent part of the udder of a lactating mare cut in sagittal section.



- 1 Subcutaneous connective tissue; it is somewhat edematous in this case
- 2 Papillary part of the more cranial of the two lactiferous sinuses; the much narrower teat canal can be seen at the tip of the teat
- 3 Glandular part of the more cranial of the two lactiferous sinuses
- 4 Secretory tissue
- 5 Lactiferous ducts