

Flexibook

Pocket Atlas of Sectional Anatomy

f

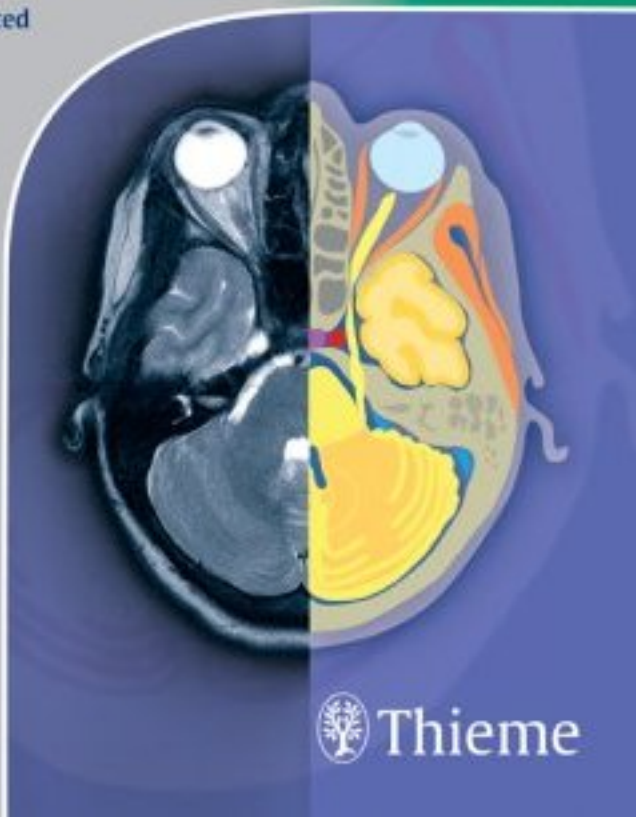
Computed Tomography and
Magnetic Resonance Imaging

T. B. Moeller
E. Reif

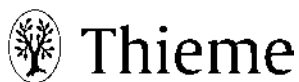Volume I: Head and Neck

3rd edition,
revised and updated

basic sciences



Thieme



Pocket Atlas of Sectional Anatomy

Computed Tomography
and Magnetic Resonance Imaging

Volume I
Head and Neck

Torsten B. Moeller, MD
Department of Radiology
Caritas Hospital
Dillingen, Germany

Emil Reif, MD
Department of Radiology
Caritas Hospital
Dillingen, Germany

Third edition, revised and updated

413 illustrations

Thieme
Stuttgart · New York

Library of Congress Cataloging-in-Publication Data is available from the publisher.

This book is an authorized and revised translation of the German 3rd edition published and copyrighted 2005 by Georg Thieme Verlag, Stuttgart, Germany. Title of the German edition: Taschenatlas der Schnittbildanatomie. Computertomographie und Kernspintomographie. Band I: Kopf, Hals

Translator: Barbara Herzberger, MD, Munich, Germany

Illustrator: Barbara Gay, Stuttgart, Germany

1st German edition 1993
 1st English edition 1994
 1st Japanese edition 1994
 1st Greek edition 1995
 1st Spanish edition 1995
 1st German edition 1997
 1st French edition 1999
 2nd English edition 2000
 2nd Japanese edition 2000
 2nd French edition 2001
 2nd Spanish edition 2001
 2nd Greek edition 2002
 1st Portuguese edition (for Brazil) 2002
 3rd German edition 2005

© 2007 Georg Thieme Verlag KG
 Rüdigerstraße 14,
 70469 Stuttgart, Germany
<http://www.thieme.de>
 Thieme New York, 333 Seventh Avenue,
 New York, NY 10001, USA
<http://www.thieme.com>

Cover design: Thieme Verlagsgruppe
 Typesetting by primustype R. Hurler GmbH,
 73274 Notzingen
 Printed in Germany by Appl Aprinta Druck,
 Wemding

ISBN 10: 3-13-125503-x (GTV)
 ISBN 13: 978-3-13-125503-7 (GTV)
 ISBN 10: 1-58890-475-x (TNY)
 ISBN 13: 978-1-58890-475-1 (TNY)

1 2 3 4 5 6

Important note: Medicine is an ever-changing science undergoing continual development. Research and clinical experience are continually expanding our knowledge, in particular our knowledge of proper treatment and drug therapy. Insofar as this book mentions any dosage or application, readers may rest assured that the authors, editors, and publishers have made every effort to ensure that such references are in accordance with **the state of knowledge at the time of production of the book.**

Nevertheless, this does not involve, imply, or express any guarantee or responsibility on the part of the publishers in respect to any dosage instructions and forms of applications stated in the book.

Every user is requested to examine carefully the manufacturers' leaflets accompanying each drug and to check, if necessary in consultation with a physician or specialist, whether the dosage schedules mentioned therein or the contraindications stated by the manufacturers differ from the statements made in the present book. Such examination is particularly important with drugs that are either rarely used or have been newly released on the market. Every dosage schedule or every form of application used is entirely at the user's own risk and responsibility. The authors and publishers request every user to report to the publishers any discrepancies or inaccuracies noticed. If errors in this work are found after publication, errata will be posted at www.thieme.com on the product description page. Some of the product names, patents, and registered designs referred to in this book are in fact registered trademarks or proprietary names even though specific reference to this fact is not always made in the text. Therefore, the appearance of a name without designation as proprietary is not to be construed as a representation by the publisher that it is in the public domain.

This book, including all parts thereof, is legally protected by copyright. Any use, exploitation, or commercialization outside the narrow limits set by copyright legislation, without the publisher's consent, is illegal and liable to prosecution. This applies in particular to photostat reproduction, copying, mimeographing, preparation of microfilms, and electronic data processing and storage.

**Dedicated in love and gratitude
to our parents,
Alfred and Friedel Moeller and
Emil and Edith Reif.**

Preface

This book presents the basic anatomy needed to interpret modern sectional images.

In making a diagnosis from sectional images, even experienced diagnosticians must adapt their thinking to the sectional portrayal of anatomic features. The *Pocket Atlas of Sectional Anatomy* aims to facilitate this process by presenting the two modalities that have the greatest practical importance in modern sectional imaging: computed tomography and magnetic resonance imaging.

The importance of these modalities rests partly on their high resolution. So many of the images were produced with 3-tesla instruments. We wish to express our gratitude to the manufacturers, Siemens and Philips.

We have attempted to provide vivid, comprehensive coverage of sectional anatomic details while still making the book compact and easy to use. The four-color illustrations were considered an essential part of this goal to maintain clarity despite the quantity of information.

The contents of the three volumes (I: Head and Neck, II: Chest and Abdomen, and III: Musculoskeletal System), which comprise a unit, follow a strict format in which each CT or MR image is accompanied by a correlative color diagram and a reduced-scale schematic drawing indicating the level of the section. This format conveys maximum information in a minimum of space.

All the images were obtained in patients or volunteers. We wish to express our special gratitude for the production of the images to our radiologic technologists, Monika Baumann, Silke Koehl, Sabine Mattil, Stefanie Mueller, Heike Philippi, Brigitte Schild, and Petra Weber, as well as to Birgit Reuter and Marion Hellinger from the Siemens manufacturing center. We sincerely thank our fellow physicians, Nadine Dillinger, Heike Ringling, Sigrid Roth, and especially Simone Zenner, for their helpful discussions and suggestions.

Torsten B. Moeller
Emil Reif

Contents

Cranial CT

Cranial CT—Axial (Canthomeatal)	2
Cranial CT—Vascular Territories (Axial)	26
Cranial CT—Neurofunctional Systems (Axial)	28
CT of the Petrous Part of Temporal Bone—Axial.....	30
Cranial CT—Coronal	36
Spaces in the Facial Skeleton—Coronal.....	42

Cranial MRI

Cranial MRI—Axial (Horizontal Plane).....	44
Cranial MRI—Vascular Territories (Axial).....	78
Cranial MRI—Sagittal	84
Cranial MRI—Vascular Territories (Sagittal)	110
Cranial MRI—Coronal	112
Cranial MRI—Vascular Territories (Coronal).....	148
Cranial MRI—Neurofunctional Systems (Coronal).....	150
Cranial MR Angiography—Arterial.....	152
Cranial MR Angiography—Venous.....	158

Neck

Neck—Axial.....	162
Cervical Lymph Nodes—Axial	198
Cervical Spaces—Axial	200
Larynx—Axial	202
Neck—Sagittal.....	210
Cervical Spaces—Sagittal	222
Neck—Coronal.....	224
Bibliography.....	248
Index.....	249

Cranial CT—Axial

Cranial CT—Coronal

Cranial MRI—Axial

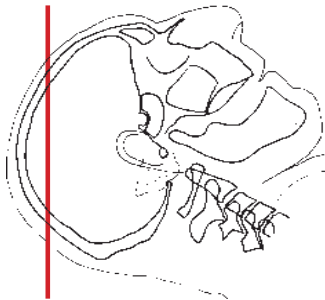
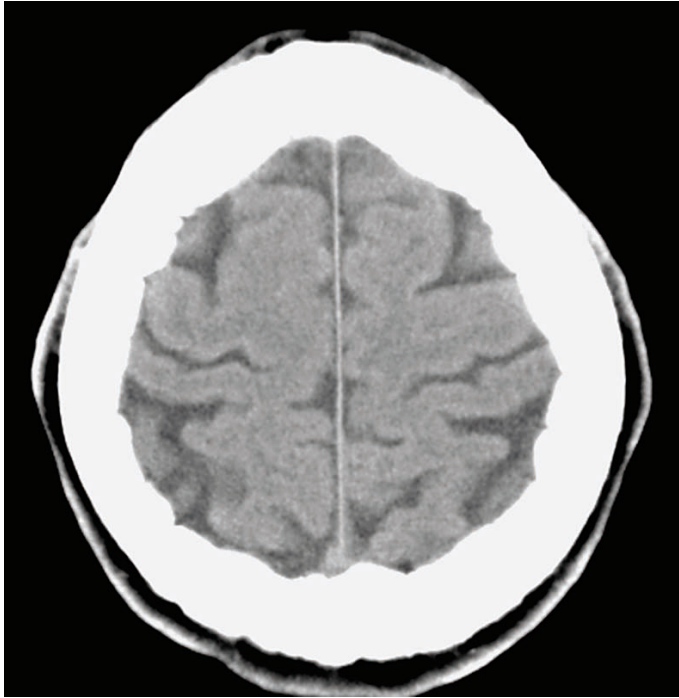
Cranial MRI—Sagittal

Cranial MRI—Coronal

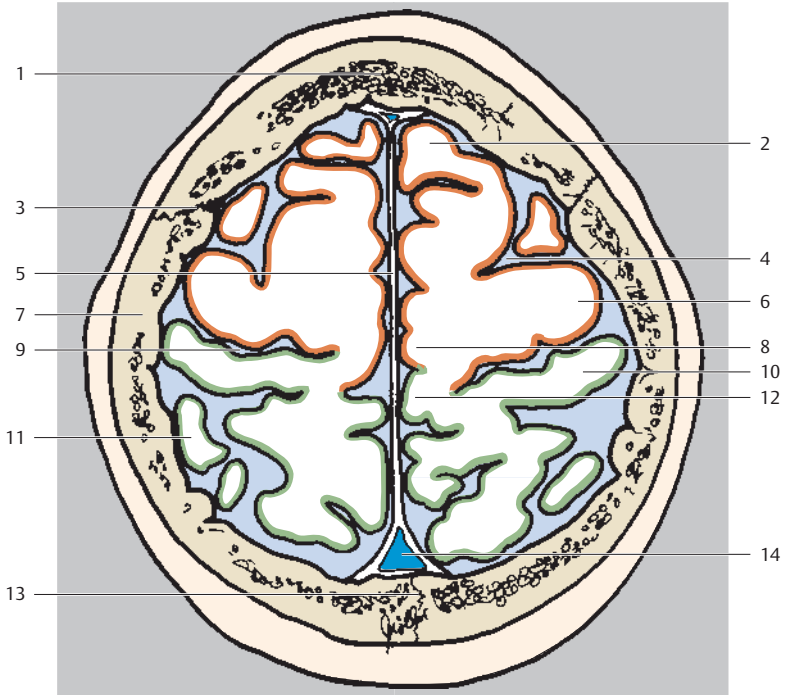
Neck—Axial

Neck—Sagittal

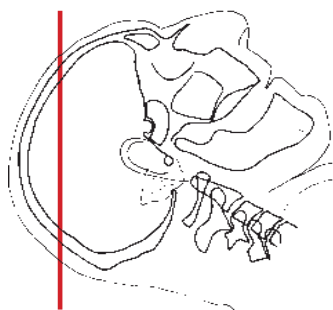
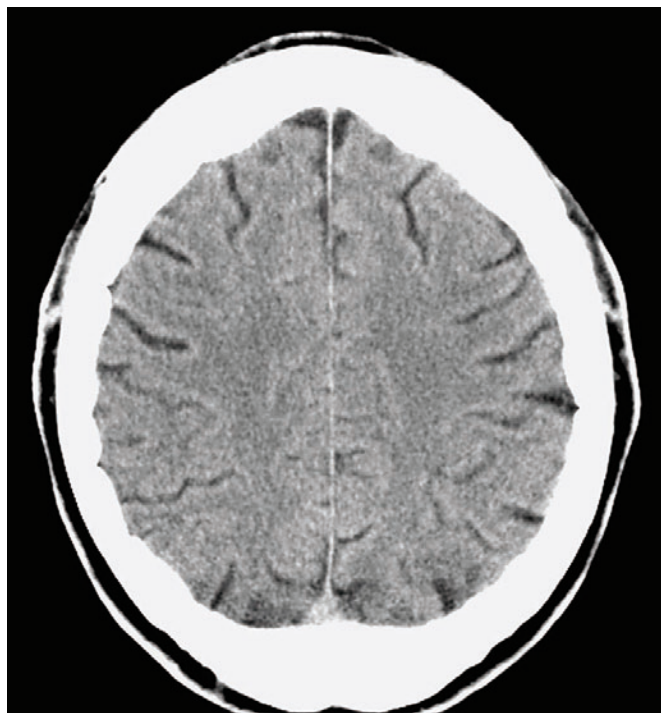
Neck—Coronal



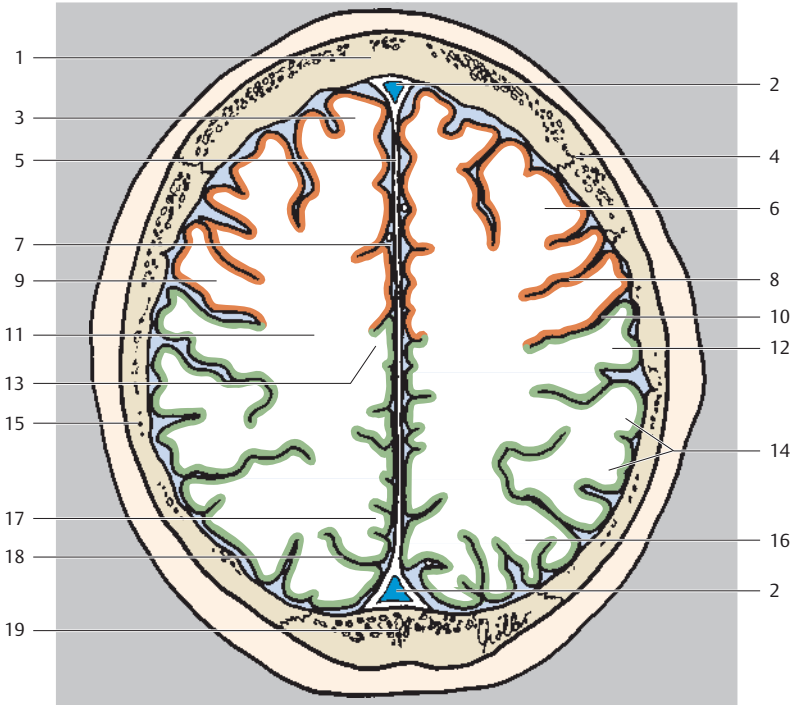
- Frontal lobe
- Parietal lobe



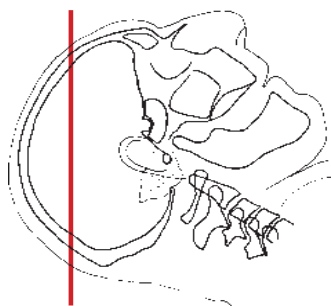
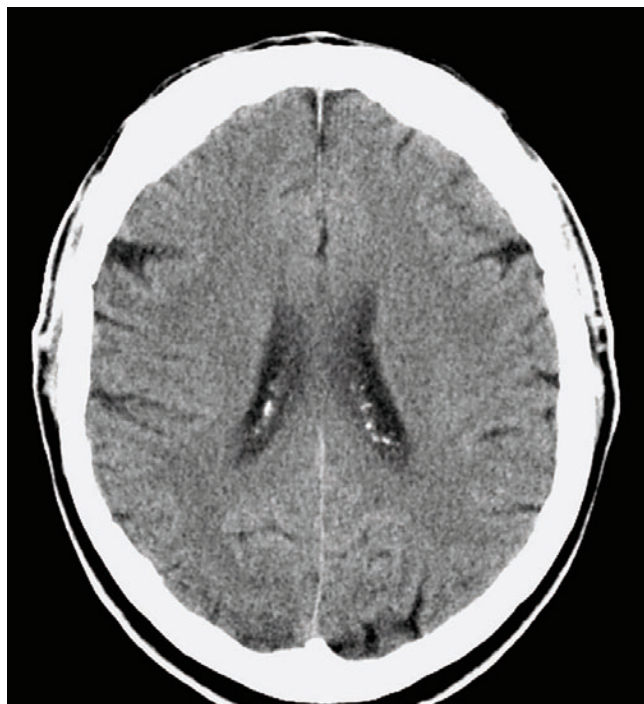- | | |
|--------------------------|-----------------------------|
| 1 Frontal bone | 8 Paracentral lobule |
| 2 Superior frontal gyrus | 9 Central sulcus |
| 3 Coronal suture | 10 Postcentral gyrus |
| 4 Precentral sulcus | 11 Superior parietal lobule |
| 5 Falx cerebri | 12 Precuneus |
| 6 Precentral gyrus | 13 Sagittal suture |
| 7 Parietal bone | 14 Superior sagittal sinus |



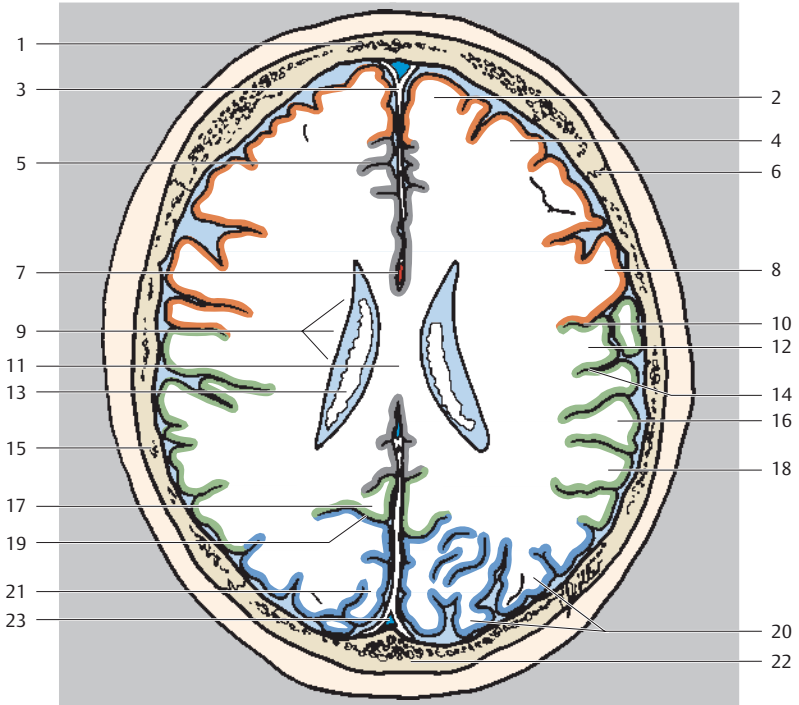
- Frontal lobe
- Parietal lobe



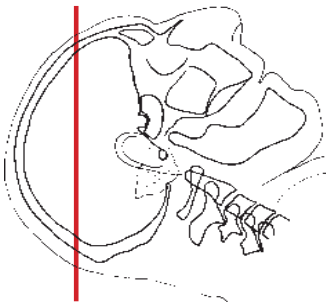
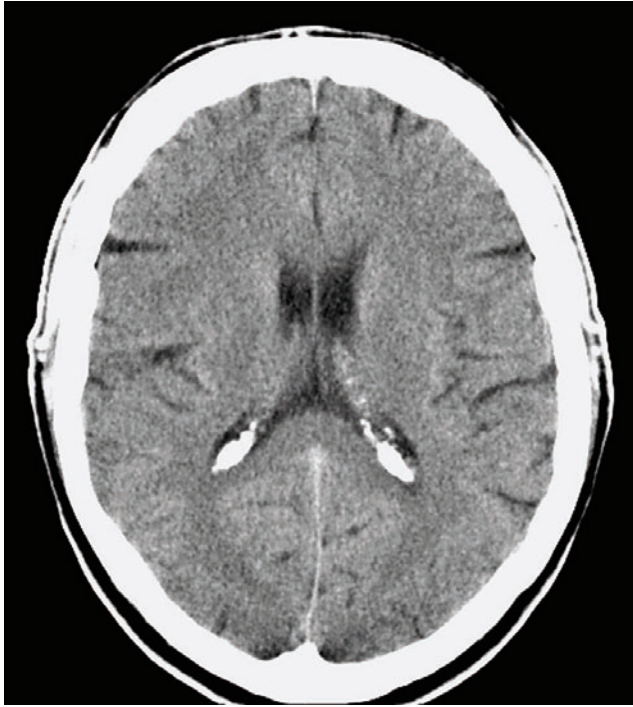- | | |
|---------------------------------|--|
| 1 Frontal bone | 11 Cerebral white matter (semioval center) |
| 2 Superior sagittal sinus | 12 Postcentral gyrus |
| 3 Superior frontal gyrus | 13 Paracentral lobule |
| 4 Coronal suture | 14 Supramarginal gyrus |
| 5 Falx cerebri | 15 Parietal bone |
| 6 Middle frontal gyrus | 16 Inferior parietal lobule |
| 7 Longitudinal cerebral fissure | 17 Precuneus |
| 8 Precentral sulcus | 18 Parieto-occipital sulcus |
| 9 Precentral gyrus | 19 Occipital bone |
| 10 Central sulcus | |



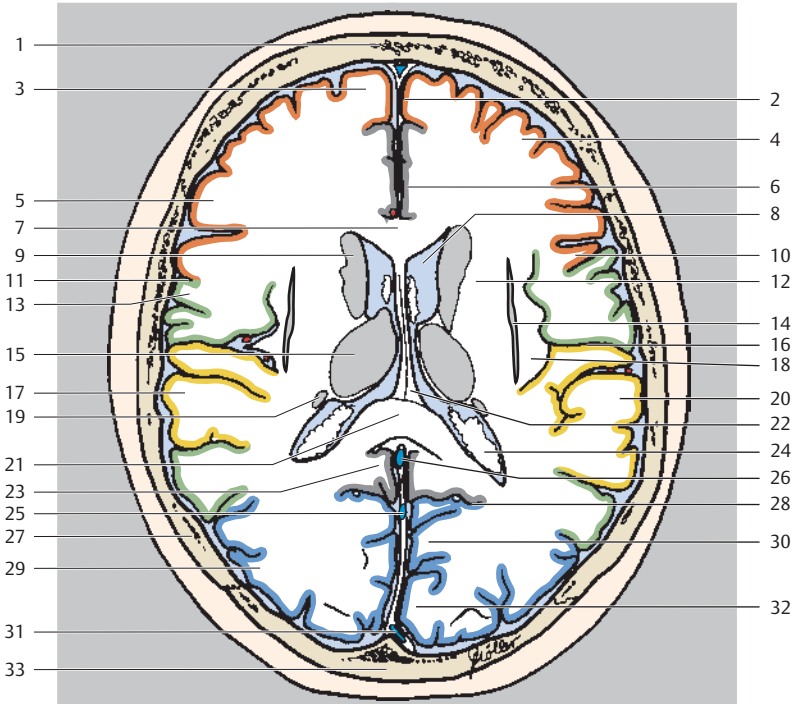
- Frontal lobe
- Parietal lobe
- Occipital lobe



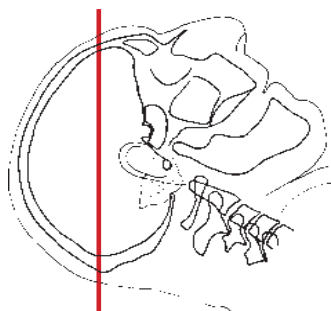
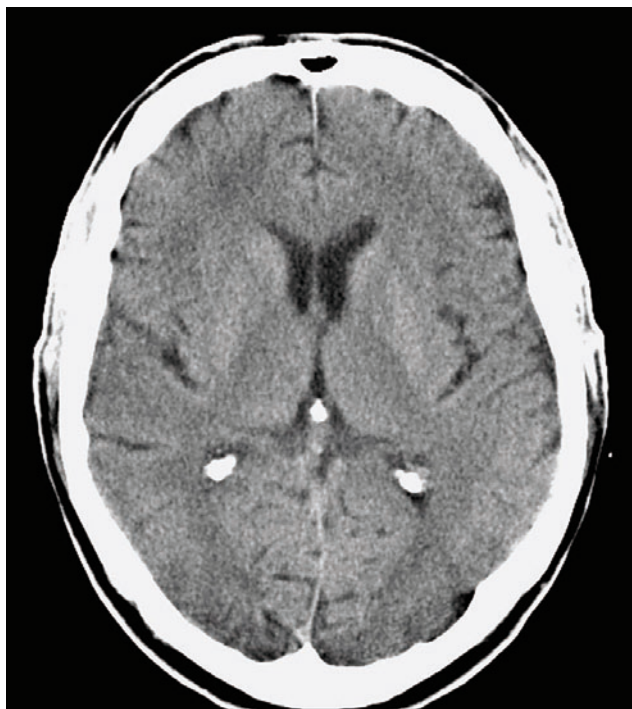- | | |
|--------------------------|---------------------------------------|
| 1 Frontal bone | 12 Postcentral gyrus |
| 2 Superior frontal gyrus | 13 Lateral ventricle (choroid plexus) |
| 3 Falx cerebri | 14 Postcentral sulcus |
| 4 Middle frontal gyrus | 15 Parietal bone |
| 5 Cingulate sulcus | 16 Supramarginal gyrus |
| 6 Coronal suture | 17 Precuneus |
| 7 Pericallosal artery | 18 Angular gyrus |
| 8 Precentral gyrus | 19 Parieto-occipital sulcus |
| 9 Corona radiata | 20 Occipital gyri |
| 10 Central sulcus | 21 Cuneus |
| 11 Corpus callosum | 22 Occipital bone |
| | 23 Superior sagittal sinus |








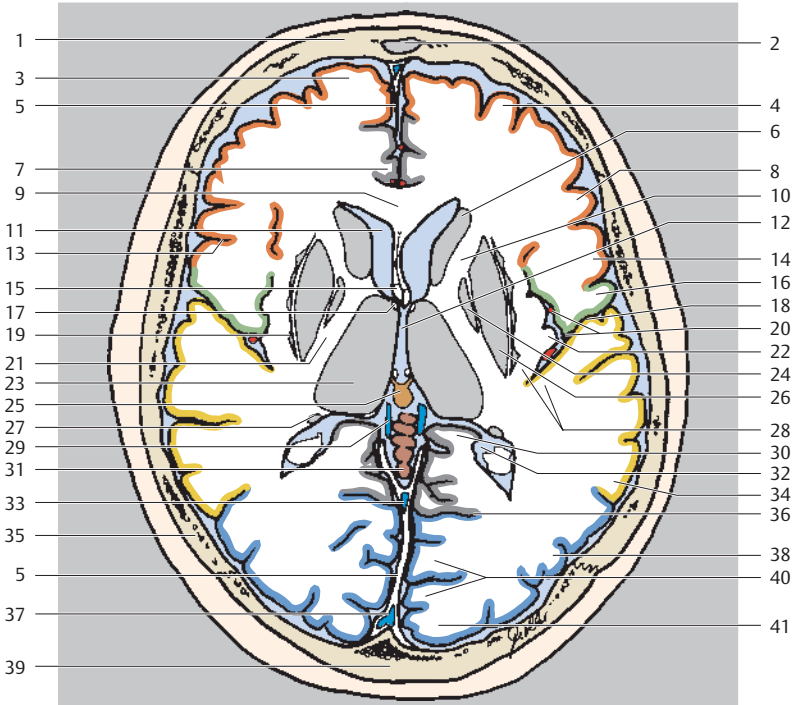
- Frontal lobe
- Temporal lobe
- Parietal lobe
- Occipital lobe



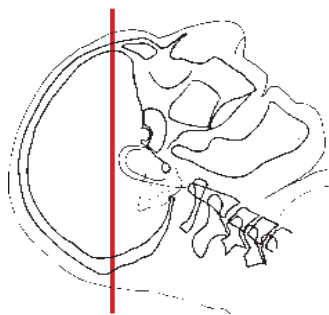
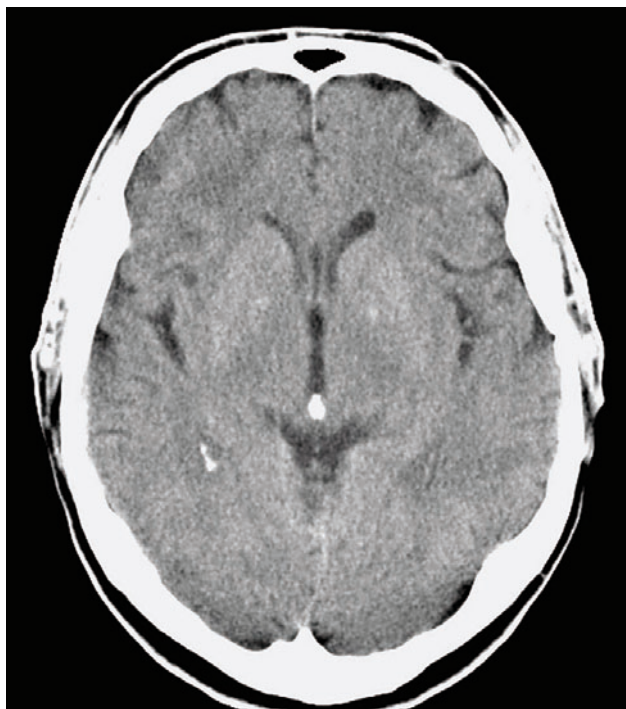- | | |
|-------------------------------------|---|
| 1 Frontal bone | 18 Insula |
| 2 Falx cerebri | 19 Caudate nucleus (tail) |
| 3 Superior frontal gyrus | 20 Superior temporal gyrus |
| 4 Middle frontal gyrus | 21 Corpus callosum (splenium) |
| 5 Inferior frontal gyrus | 22 Fornix |
| 6 Cingulate gyrus | 23 Cingulum |
| 7 Corpus callosum (trunk) | 24 Lateral ventricle (collateral trigone, choroid plexus) |
| 8 Lateral ventricle (anterior horn) | 25 Straight sinus |
| 9 Caudate nucleus (head) | 26 Great cerebral vein (vein of Galen) |
| 10 Precentral gyrus | 27 Parietal bone |
| 11 Central sulcus | 28 Parieto-occipital sulcus |
| 12 Corona radiata | 29 Occipital gyri |
| 13 Postcentral gyrus | 30 Cuneus |
| 14 Claustrum | 31 Superior sagittal sinus |
| 15 Thalamus | 32 Striate cortex |
| 16 Lateral sulcus | 33 Occipital bone |
| 17 Temporal operculum | |



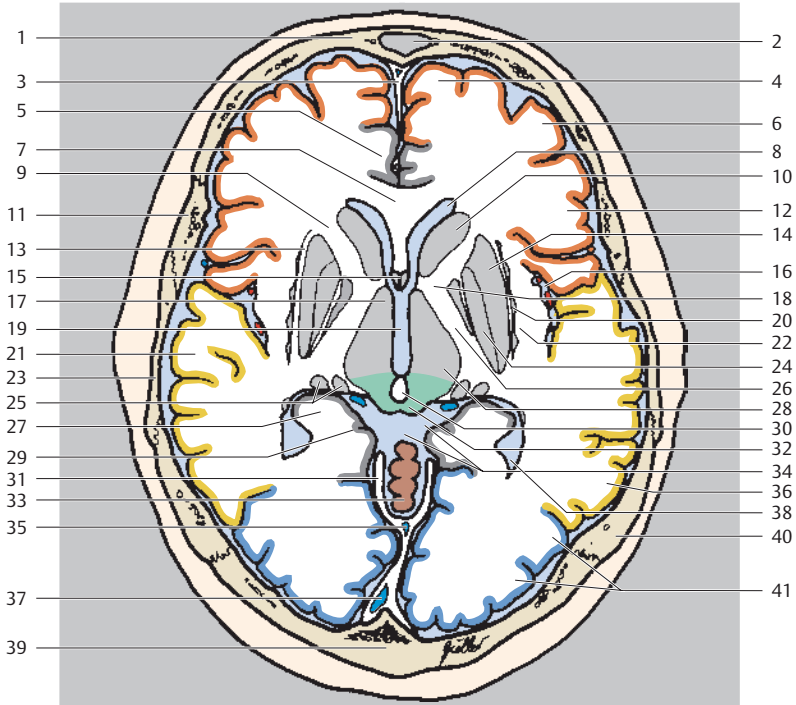
-  Frontal lobe
-  Temporal lobe
-  Parietal lobe
-  Occipital lobe
-  Cerebellum



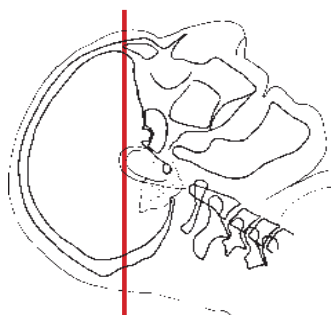
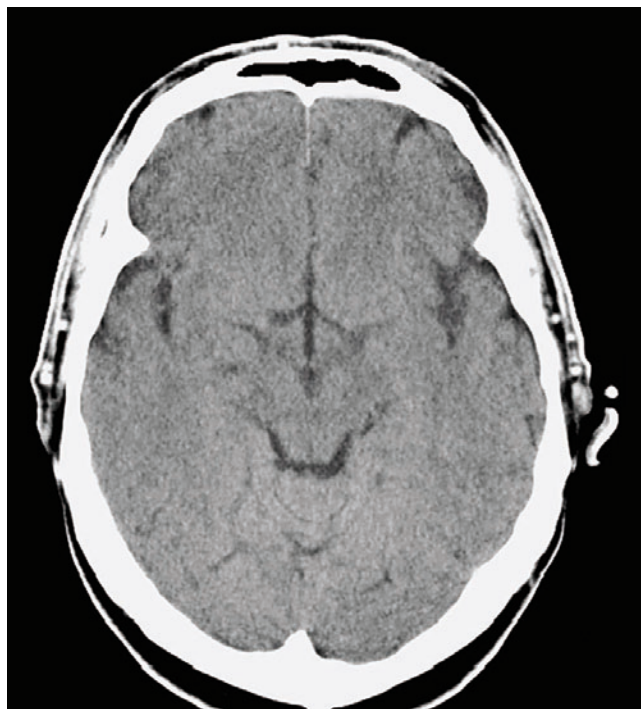- | | |
|--|--|
| 1 Frontal bone | 21 Internal capsule (posterior limb) |
| 2 Frontal sinus | 22 Insula |
| 3 Superior frontal gyrus | 23 Thalamus |
| 4 Middle frontal gyrus | 24 Globus pallidus (pallidum) |
| 5 Falx cerebri | 25 Pineal gland |
| 6 Caudate nucleus (head) | 26 Putamen |
| 7 Cingulate gyrus | 27 Caudate nucleus (tail) |
| 8 Inferior frontal gyrus | 28 Transverse temporal gyrus |
| 9 Corpus callosum (genu) | 29 Internal cerebral vein |
| 10 Internal capsule (anterior limb) | 30 Hippocampus |
| 11 Lateral ventricle (anterior horn) | 31 Vermis of cerebellum |
| 12 Third ventricle | 32 Lateral ventricle (trigone with choroid plexus) |
| 13 Central sulcus | 33 Straight sinus |
| 14 Precentral gyrus | 34 Middle temporal gyrus |
| 15 Fornix | 35 Parietal bone |
| 16 Postcentral gyrus | 36 Parieto-occipital sulcus |
| 17 Interventricular foramen (foramen of Monro) | 37 Superior sagittal sinus |
| 18 Lateral sulcus | 38 Occipital gyri |
| 19 Claustrum | 39 Occipital bone |
| 20 Insular arteries in the cistern of lateral cerebral fossa (insular cistern) | 40 Striate cortex |
| | 41 Occipital pole |








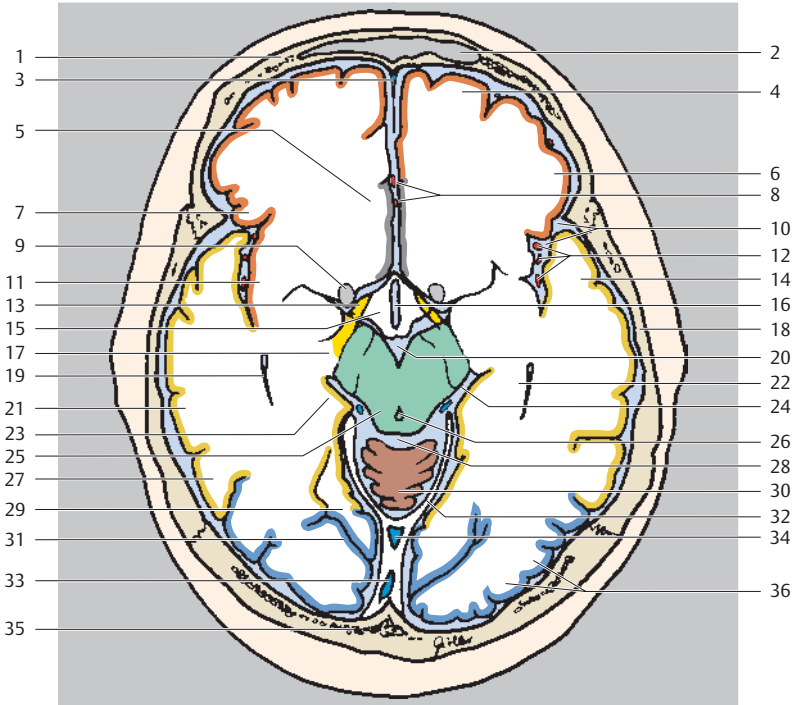
- Frontal lobe
- Temporal lobe
- Occipital lobe
- Cerebellum
- Mesencephalon



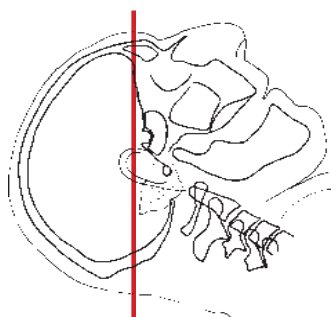
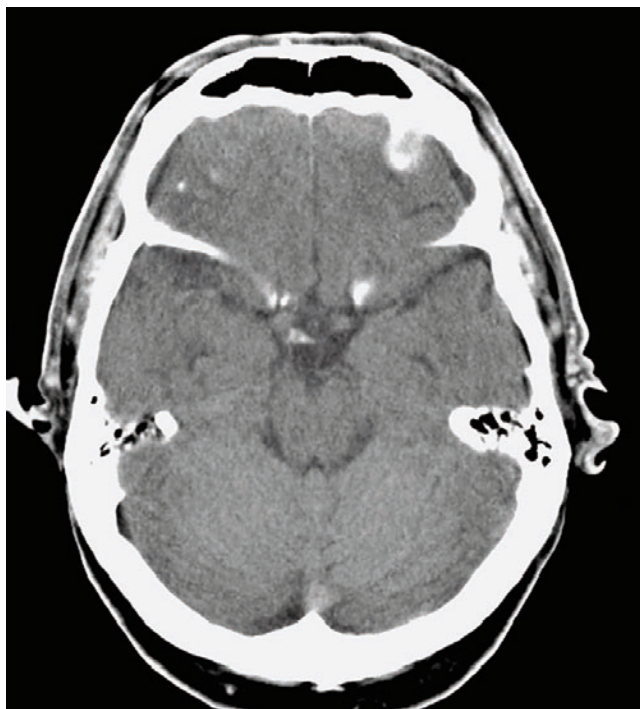- | | |
|--|---------------------------------------|
| 1 Frontal bone | 21 Superior temporal gyrus |
| 2 Frontal sinus | 22 Extreme capsule |
| 3 Falx cerebri | 23 Temporal bone |
| 4 Superior frontal gyrus | 24 Globus pallidus (pallidum) |
| 5 Cingulate gyrus | 25 Geniculate body |
| 6 Middle frontal gyrus | 26 Internal capsule (posterior limb) |
| 7 Corpus callosum (genu) | 27 Hippocampus |
| 8 Lateral ventricle (anterior horn) | 28 Thalamus |
| 9 Internal capsule (anterior limb) | 29 Parahippocampal gyrus |
| 10 Caudate nucleus (head) | 30 Pineal gland (calcified) |
| 11 Parietal bone | 31 Tentorium cerebelli |
| 12 Inferior frontal gyrus | 32 Quadrigeminal plate (colliculus) |
| 13 External capsule | 33 Vermis of cerebellum |
| 14 Putamen | 34 Quadrigeminal and ambient cisterns |
| 15 Septum verum (precommissural septum) | 35 Straight sinus |
| 16 Cistern of lateral cerebral fossa (insular cistern) | 36 Middle temporal gyrus |
| 17 Hypothalamus | 37 Superior sagittal sinus |
| 18 Internal capsule (genu) | 38 Lateral ventricle (trigone) |
| 19 Third ventricle | 39 Occipital bone |
| 20 Claustrum | 40 Parietal bone |
| | 41 Occipital gyri |







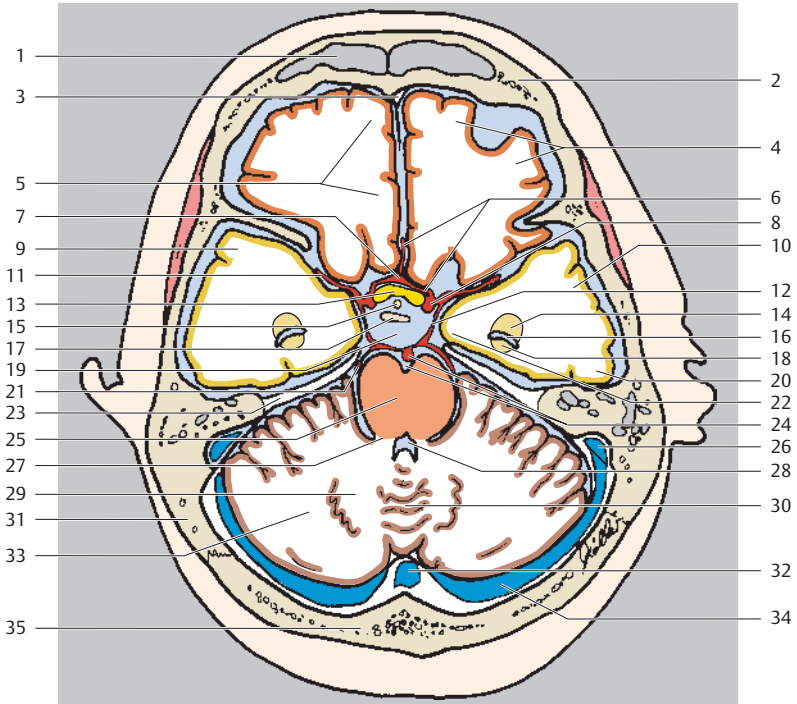
-  Frontal lobe
-  Temporal lobe
-  Occipital lobe
-  Cerebellum
-  Mesencephalon



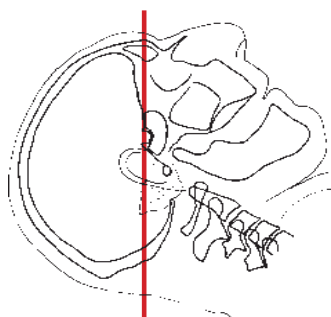
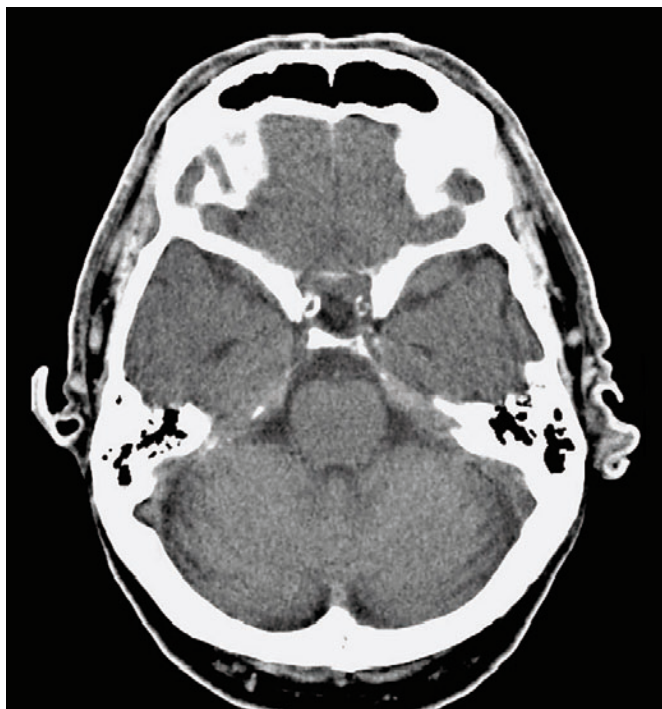- | | |
|--------------------------------------|--|
| 1 Frontal bone | 20 Interpeduncular cistern |
| 2 Frontal sinus | 21 Middle temporal gyrus |
| 3 Falx cerebri | 22 Hippocampus |
| 4 Superior frontal gyrus | 23 Parahippocampal gyrus |
| 5 Cingulate gyrus | 24 Ambient cistern |
| 6 Middle frontal gyrus | 25 Mesencephalon (quadrigeminal plate) |
| 7 Inferior frontal gyrus | 26 Aqueduct |
| 8 Anterior cerebral artery | 27 Inferior temporal gyrus |
| 9 Striatum (inferior portion) | 28 Quadrigeminal cistern |
| 10 Lateral sulcus (insular cistern) | 29 Lateral occipitotemporal gyrus |
| 11 Insula | 30 Vermis of cerebellum (superior portion) |
| 12 Insular arteries | 31 Parieto-occipital sulcus |
| 13 Optic tract | 32 Tentorium cerebelli |
| 14 Superior temporal gyrus | 33 Superior sagittal sinus |
| 15 Hypothalamus | 34 Straight sinus |
| 16 Third ventricle | 35 Occipital bone |
| 17 Cerebral peduncle | 36 Occipital gyri |
| 18 Parietal bone | |
| 19 Lateral ventricle (temporal horn) | |







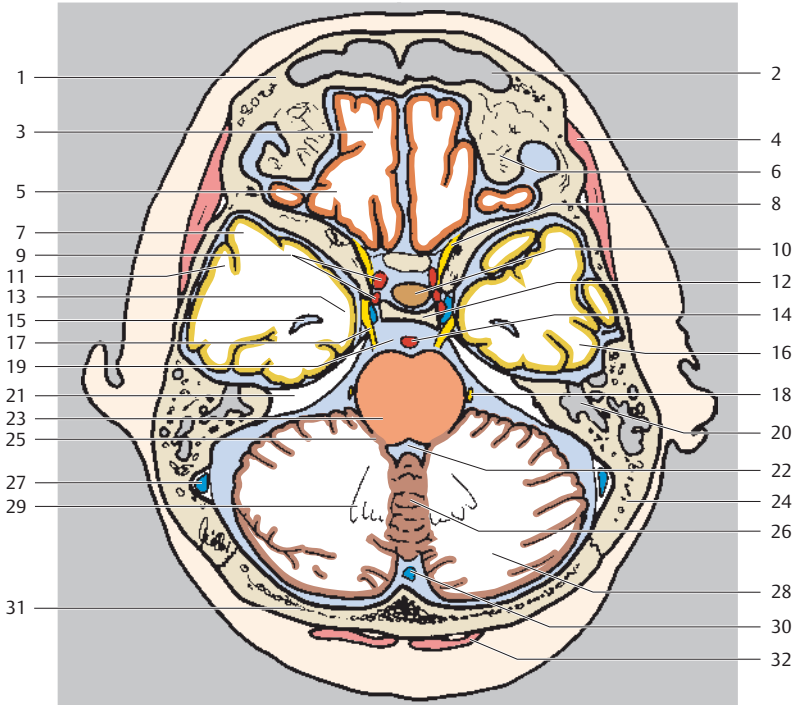
-  Frontal lobe
-  Temporal lobe
-  Cerebellum
-  Pons



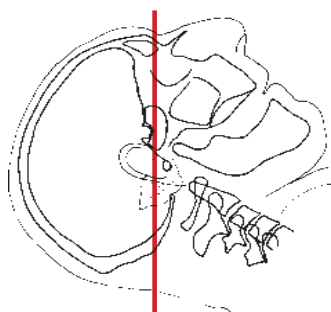
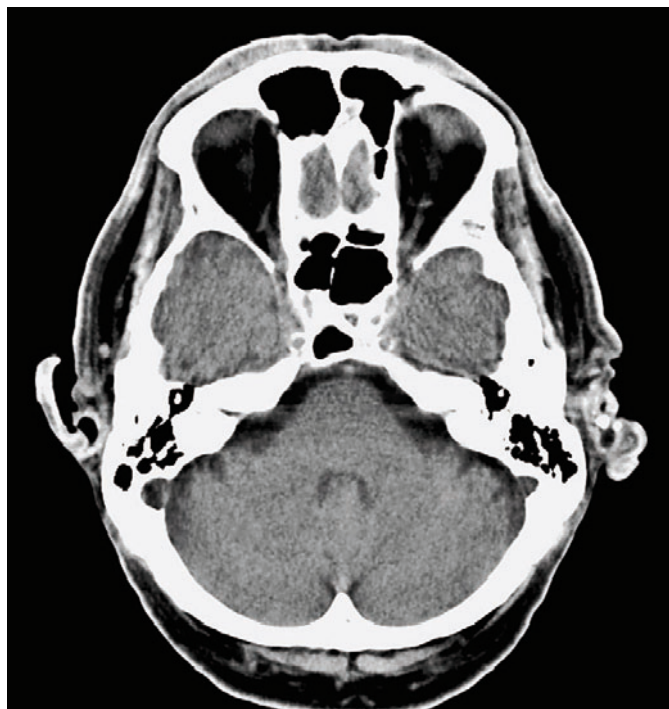- | | |
|--------------------------------------|---|
| 1 Frontal sinus | 18 Hippocampus |
| 2 Frontal bone | 19 Pentagon of basal cisterns |
| 3 Falx cerebri | 20 Inferior temporal gyrus |
| 4 Orbital gyri | 21 Posterior cerebral artery |
| 5 Straight gyrus | 22 Parahippocampal gyrus |
| 6 Anterior cerebral artery | 23 Tentorium cerebelli |
| 7 Anterior communicating artery | 24 Basilar artery and basal sulcus |
| 8 Internal carotid artery | 25 Pons |
| 9 Superior temporal gyrus | 26 Sigmoid sinus |
| 10 Middle temporal gyrus | 27 Cerebellar peduncle (middle) |
| 11 Middle cerebral artery | 28 Fourth ventricle |
| 12 Posterior communicating artery | 29 Dentate nucleus |
| 13 Optic chiasm | 30 Vermis of cerebellum (superior part) |
| 14 Amygdaloid body | 31 Temporal bone |
| 15 Pituitary stalk | 32 Confluence of the sinuses |
| 16 Lateral ventricle (temporal horn) | 33 Cerebellar hemisphere |
| 17 Dorsum sellae | 34 Transverse sinus |
| | 35 Occipital bone |







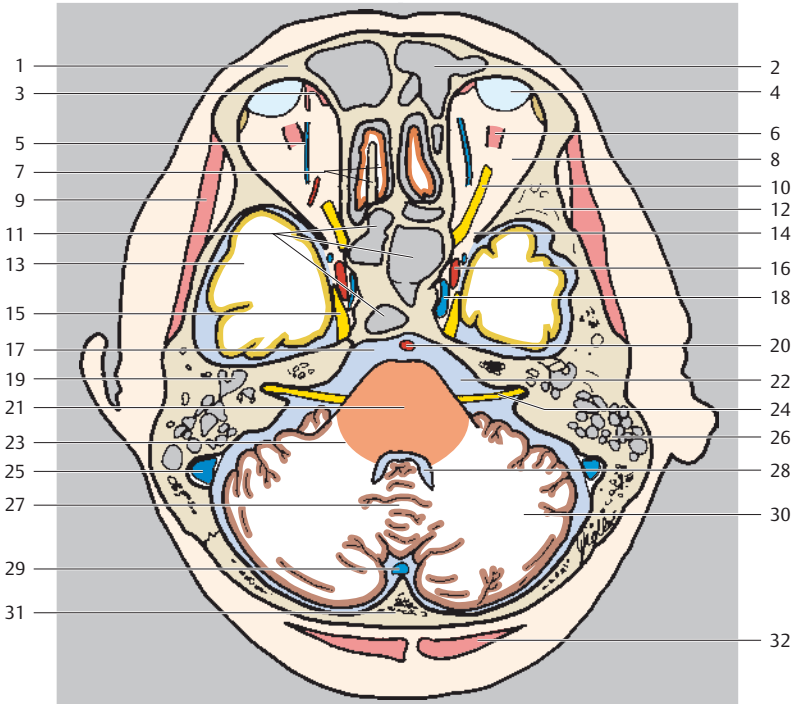
-  Frontal lobe
-  Temporal lobe
-  Cerebellum
-  Pons



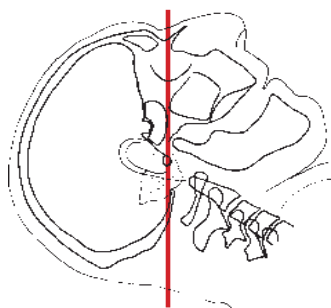
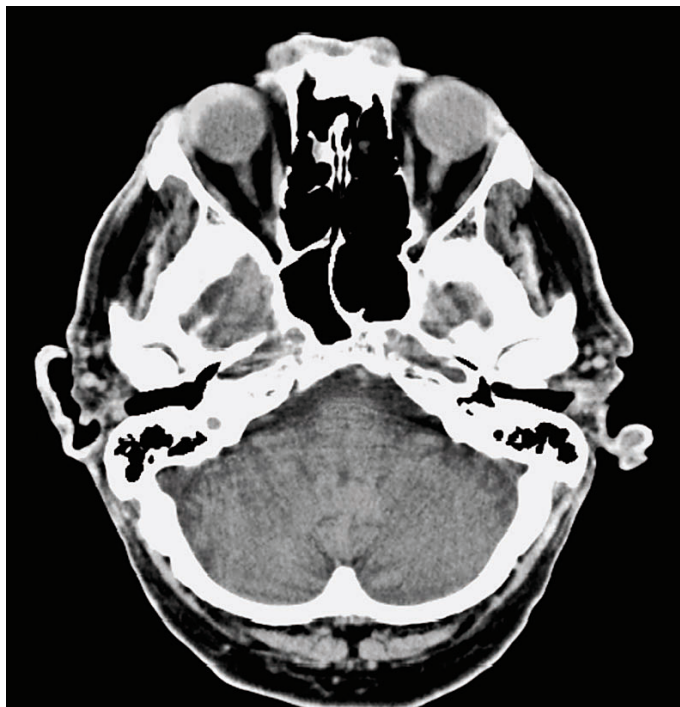
- | | |
|--------------------------------------|--------------------------------|
| 1 Frontal bone | 17 Trigeminal nerve (V) |
| 2 Frontal sinus | 18 Trochlear nerve |
| 3 Straight gyrus | 19 Pontine cistern |
| 4 Temporal muscle | 20 Mastoid antrum |
| 5 Orbital gyri | 21 Tentorium cerebelli |
| 6 Roof of orbit | 22 Fourth ventricle |
| 7 Superior temporal gyrus | 23 Pons |
| 8 Optic nerve | 24 Temporal bone |
| 9 Internal carotid artery | 25 Cerebellar peduncle |
| 10 Pituitary gland | 26 Vermis of cerebellum |
| 11 Middle temporal gyrus | 27 Sigmoid sinus |
| 12 Dorsum sellae | 28 Cerebellar hemisphere |
| 13 Parahippocampal gyrus | 29 Dentate nucleus |
| 14 Basilar artery | 30 Occipital sinus |
| 15 Lateral ventricle (temporal horn) | 31 Occipital bone |
| 16 Inferior temporal gyrus | 32 Semispinalis capitis muscle |







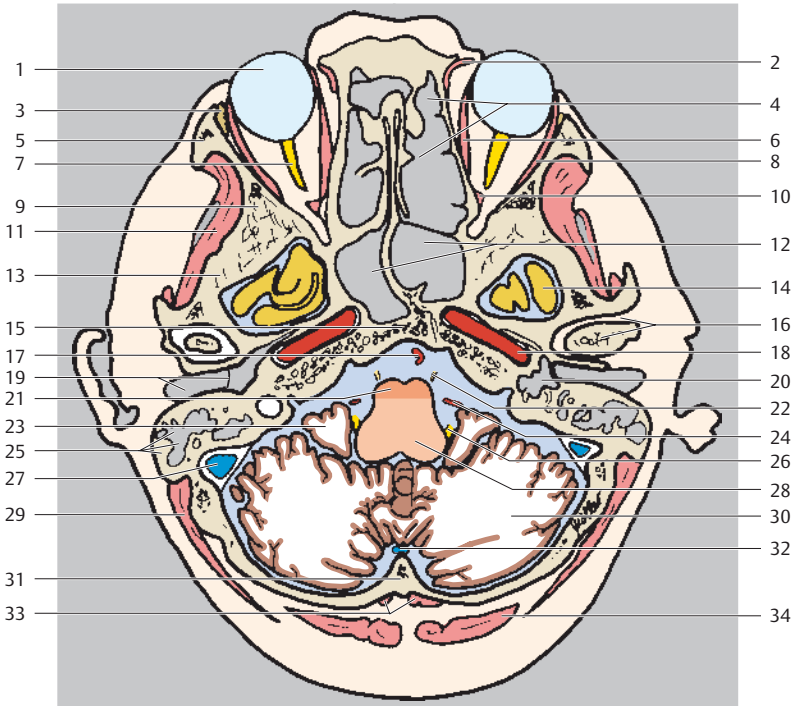
-  Frontal lobe
-  Temporal lobe
-  Cerebellum
-  Pons



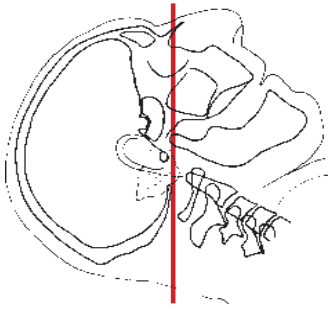
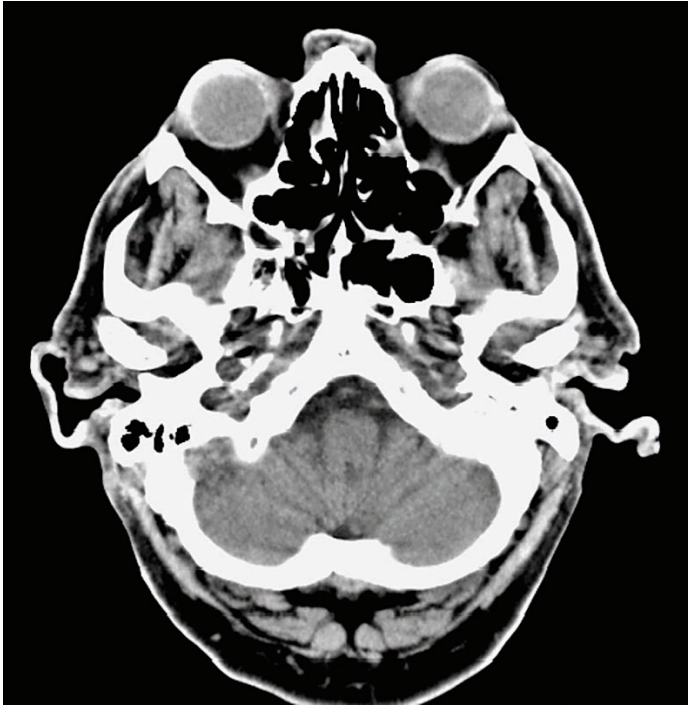
- | | |
|-------------------------------------|--|
| 1 Frontal bone | 18 Cavernous sinus |
| 2 Frontal sinus | 19 Mastoid antrum |
| 3 Superior oblique muscle | 20 Basilar artery |
| 4 Eyeball | 21 Pons |
| 5 Ophthalmic vein | 22 Pontocerebellar cistern |
| 6 Superior rectus muscle | 23 Middle and inferior cerebellar peduncle |
| 7 Straight gyrus and olfactory bulb | 24 Internal auditory meatus with facial (VII) and vestibulocochlear/acoustic (VIII) nerves |
| 8 Retro-orbital fatty tissue | 25 Sigmoid sinus |
| 9 Temporal muscle | 26 Mastoid process with mastoid cells |
| 10 Optic nerve | 27 Vermis of cerebellum |
| 11 Sphenoidal sinus | 28 Fourth ventricle |
| 12 Sphenoidal bone | 29 Occipital sinus |
| 13 Inferior temporal gyrus | 30 Cerebellar hemisphere |
| 14 Superior orbital fissure | 31 Occipital bone |
| 15 Trigeminal nerve (ganglion) | 32 Semispinalis capitis muscle |
| 16 Internal carotid artery | |
| 17 Pontine cistern | |



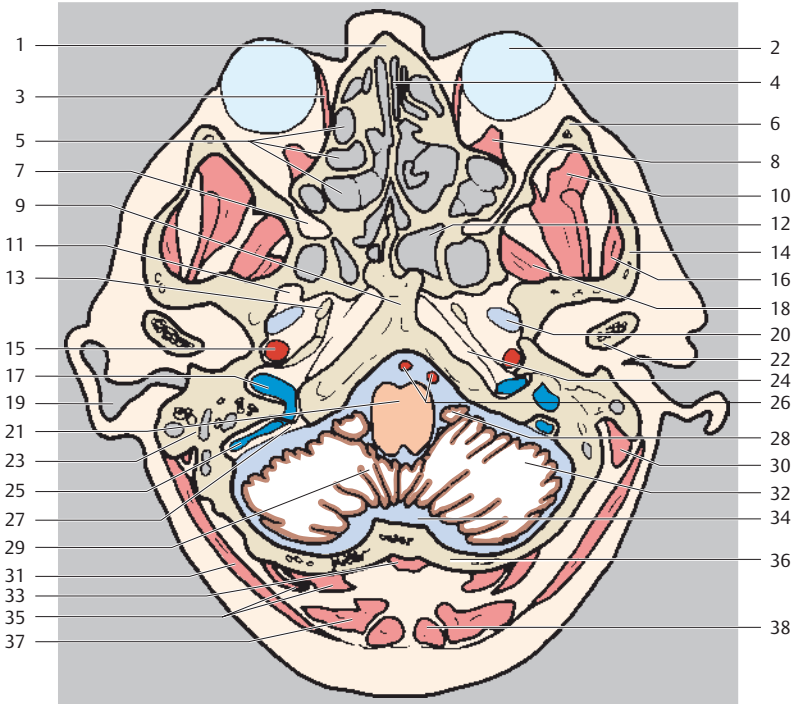
-  Frontal lobe
-  Temporal lobe
-  Cerebellum
-  Pons



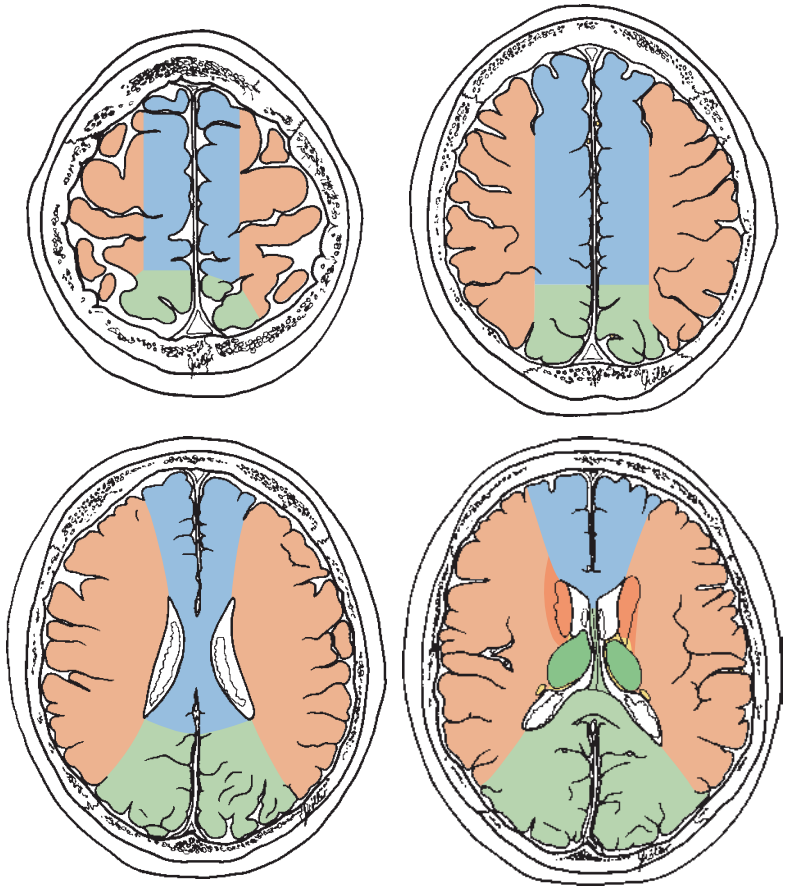
- | | |
|---|---|
| 1 Eyeball | 19 External auditory meatus and eardrum (tympanic membrane) |
| 2 Superior oblique muscle | 20 Tympanic cavity |
| 3 Lacrimal gland | 21 Pons |
| 4 Ethmoidal cells | 22 Abducent nerve (VI) |
| 5 Zygomatic bone | 23 Flocculus |
| 6 Medial rectus muscle | 24 Anterior inferior cerebellar artery |
| 7 Optic nerve | 25 Mastoid process and mastoid cells |
| 8 Lateral rectus muscle of eyeball | 26 Glossopharyngeal (IX) and vagus (X) nerves |
| 9 Sphenoidal bone | 27 Sigmoid sinus |
| 10 Superior rectus muscle | 28 Medulla oblongata (myelencephalon) |
| 11 Temporal muscle | 29 Splenius capitis muscle |
| 12 Sphenoidal sinus | 30 Cerebellar hemisphere |
| 13 Temporal bone | 31 Occipital bone |
| 14 Temporal lobe (base) | 32 Occipital sinus |
| 15 Clivus | 33 Rectus capitis posterior minor muscle |
| 16 Temporomandibular joint and head of mandible | 34 Semispinalis capitis muscle |
| 17 Basilar artery | |
| 18 Internal carotid artery | |



- Cerebellum
- Medulla oblongata

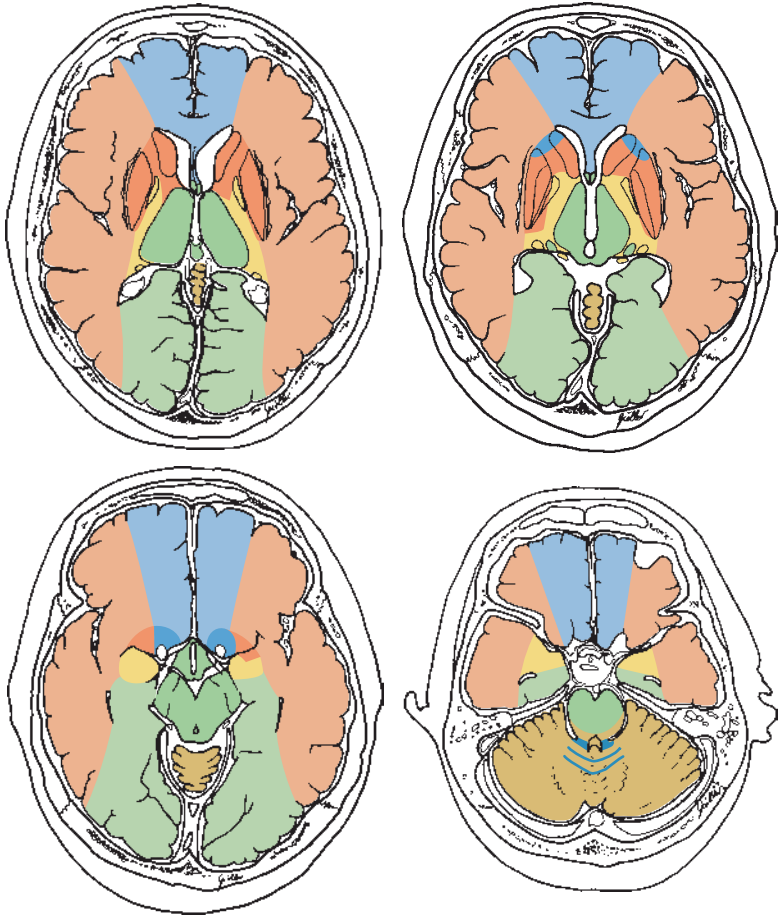


- | | |
|--|---|
| 1 Nasal bone | 19 External auditory meatus |
| 2 Eyeball | 20 Auditory tube |
| 3 Medial rectus muscle | 21 Medulla oblongata |
| 4 Nasal septum | 22 Head of mandible |
| 5 Ethmoidal cells | 23 Mastoid process |
| 6 Zygomatic bone | 24 Foramen lacerum |
| 7 Pterygopalatine fossa | 25 Sigmoid sinus |
| 8 Inferior rectus muscle | 26 Vertebral arteries |
| 9 Occipital bone (basilar part) | 27 Petro-occipital fissure |
| 10 Temporal muscle | 28 Flocculus |
| 11 Foramen ovale with mandibular nerve | 29 Cerebellar tonsil |
| 12 Sphenoidal sinus | 30 Digastric muscle |
| 13 Temporal bone (apex of the petrous pyramid) | 31 Splenius capitis muscle |
| 14 Zygomatic arch | 32 Cerebellar hemisphere (caudal lobe) |
| 15 Internal carotid artery | 33 Rectus capitis posterior minor muscle |
| 16 Masseter muscle | 34 Cisterna magna (posterior cerebello-medullary cistern) |
| 17 Jugular vein (bulb) | 35 Rectus capitis posterior major muscle |
| 18 Lateral pterygoid muscle (superior head) | 36 Occipital bone |
| | 37 Semispinalis capitis muscle |
| | 38 Trapezius muscle |





- Anterior cerebral artery**
 - Terminal branches
- Middle cerebral artery**
 - Terminal branches
 - Central branches (striate branches)



- Posterior cerebral artery**
 - Terminal branches
 - Central branches (including the posterior communicating artery)
- Anterior choroidal artery**





Anterior cerebral artery





-  Terminal branches
-  Central branches (striate branches)

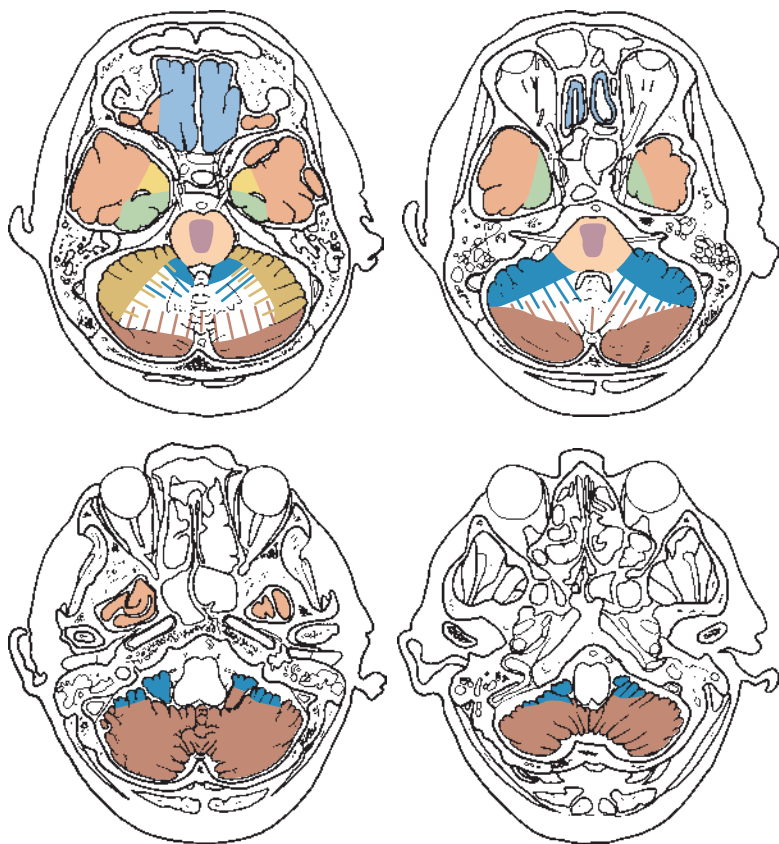
Middle cerebral artery

-  Terminal branches
-  Central branches (striate branches)

Posterior cerebral artery

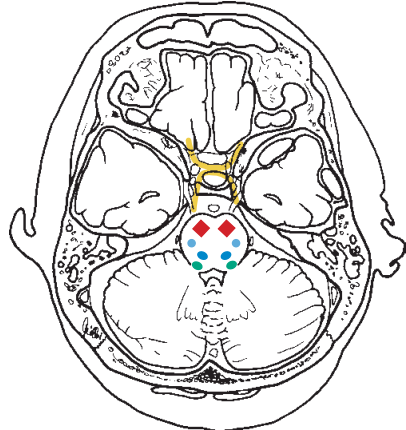
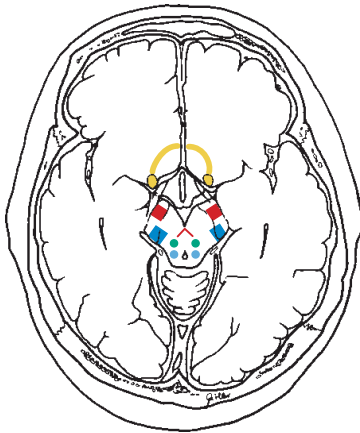
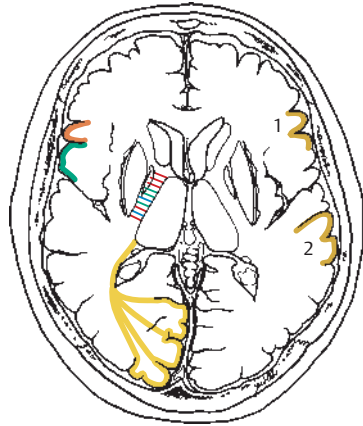
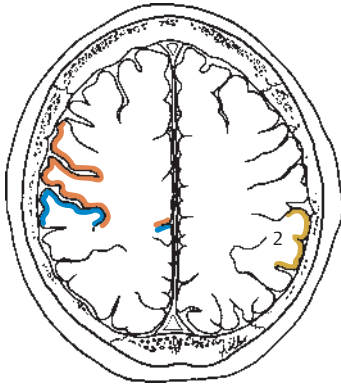
-  Terminal branches
-  Central branches (including the posterior communicating artery)

-  Anterior choroidal artery
-  Superior cerebellar artery
-  Anterior inferior cerebellar artery
-  Border region



- Anterior cerebral artery**
- Terminal branches
- Middle cerebral artery**
- Terminal branches
- Posterior cerebral artery**
- Terminal branches
- Anterior choroidal artery

- Basilar artery**
- Anteromedial and anterolateral paramedian branches
- Circumferential arteries and lateral and dorsal paramedian branches
- Superior cerebellar artery
- Anterior superior cerebellar artery
- Border region
- Posterior inferior cerebellar artery



Motor system

Sensory system

Medial lemniscal tract

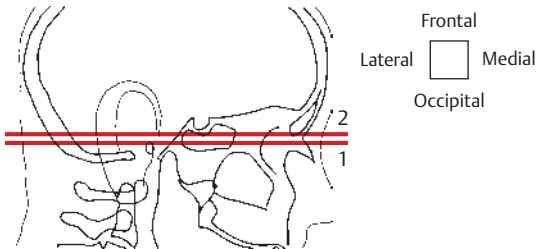
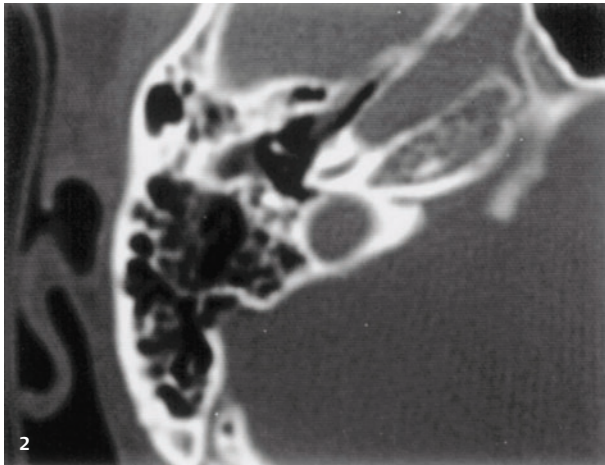
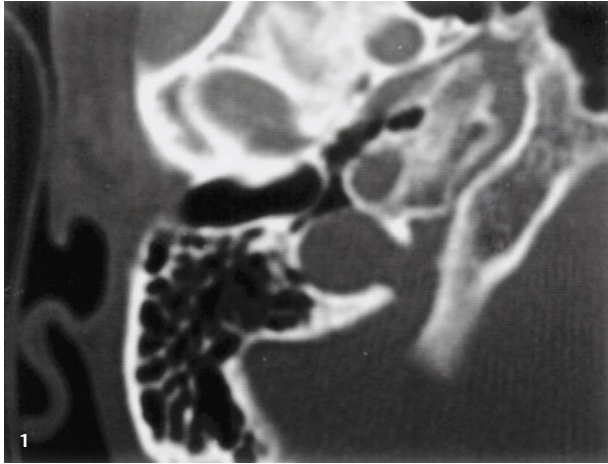Spinothalamic tract

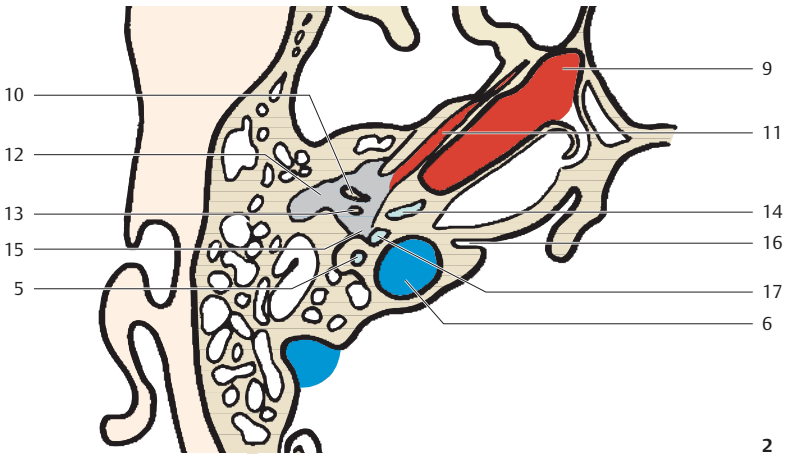
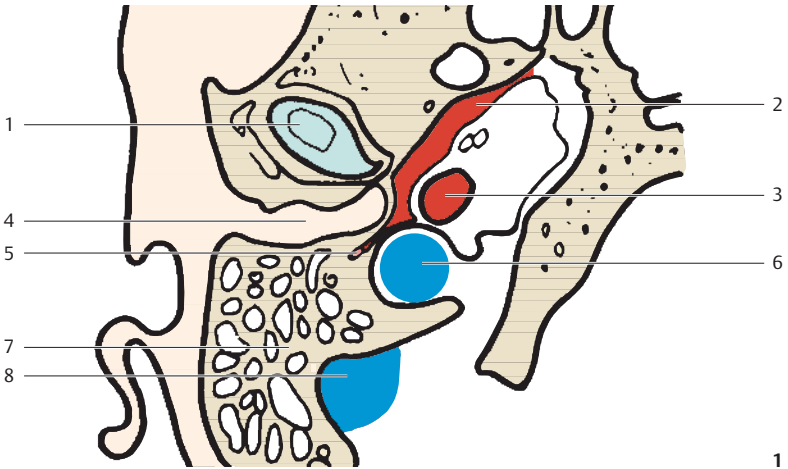
Mesencephalic nucleus of trigeminal nerve

Oculomotor nucleus and pathways

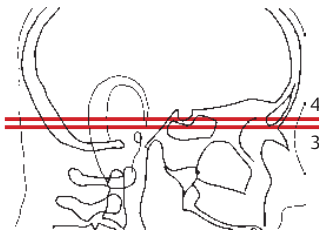
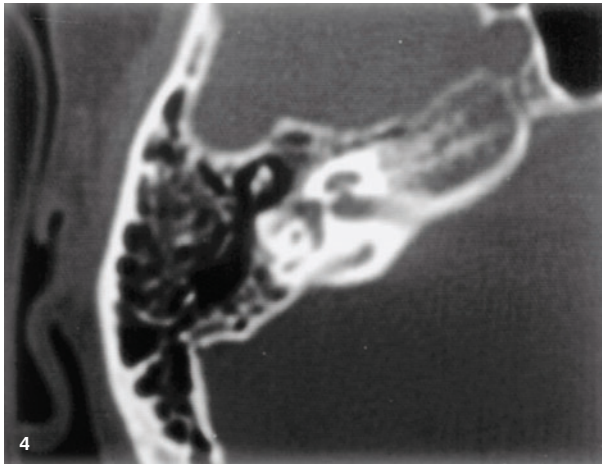
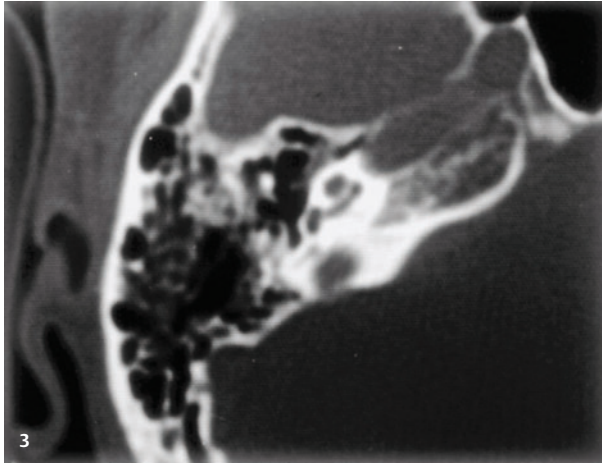
Optic tract

Speech center
(1 = motor, 2 = sensory)

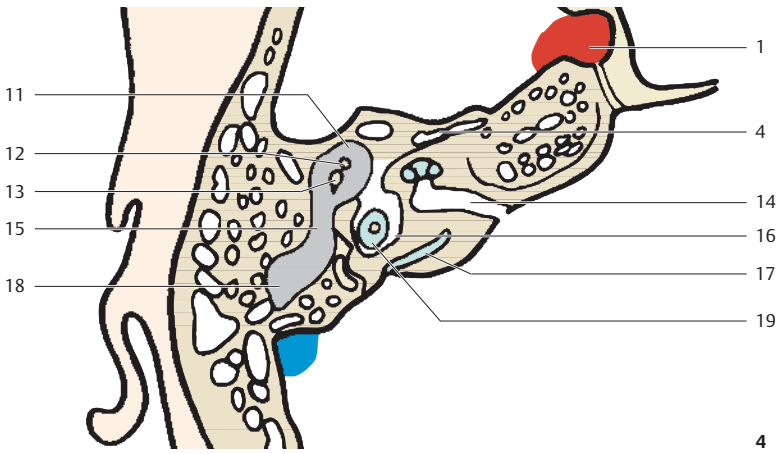
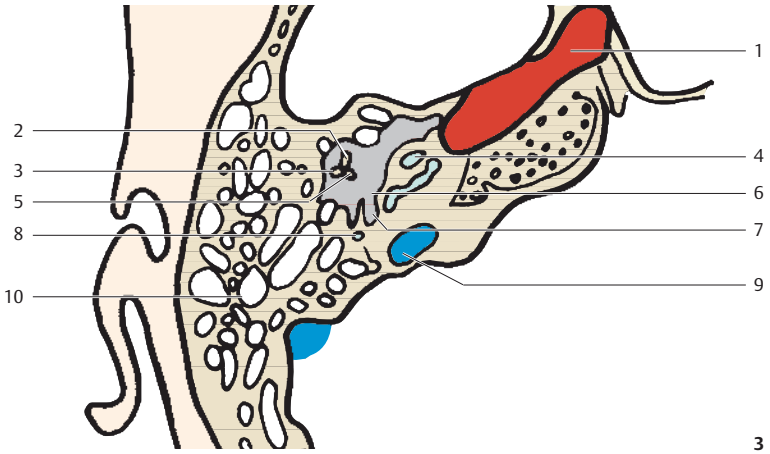




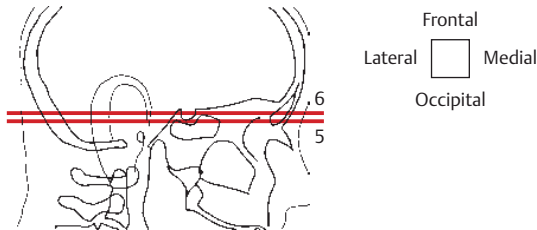
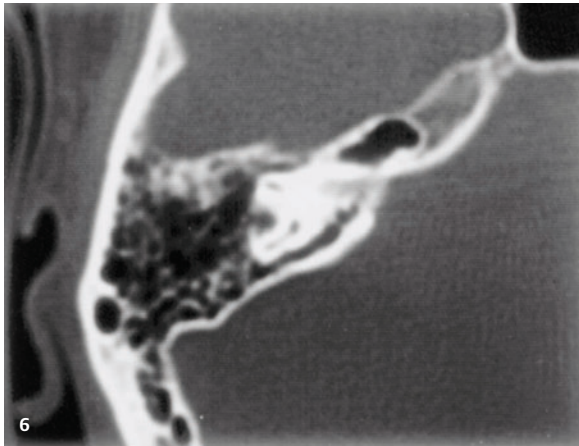
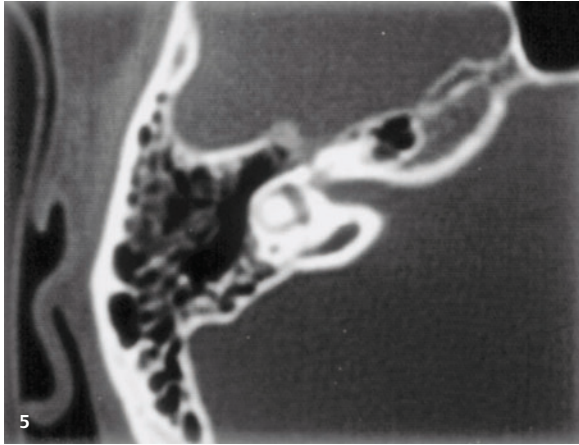
- | | | | |
|---|---|----|-------------------------------|
| 1 | Temporomandibular joint (glenoid roof and articular disc) | 9 | Carotid canal |
| 2 | Pharyngotympanic tube (auditory tube) | 10 | Malleus (handle) |
| 3 | Internal carotid artery | 11 | Tensor tympani muscle (canal) |
| 4 | External acoustic meatus | 12 | Middle ear |
| 5 | Facial canal | 13 | Incus (long limb) |
| 6 | Internal jugular vein | 14 | Cochlea (basal turn) |
| 7 | Mastoid process | 15 | Sinus tympani |
| 8 | Sigmoid sinus | 16 | Vestibular aqueduct |
| | | 17 | Round window |

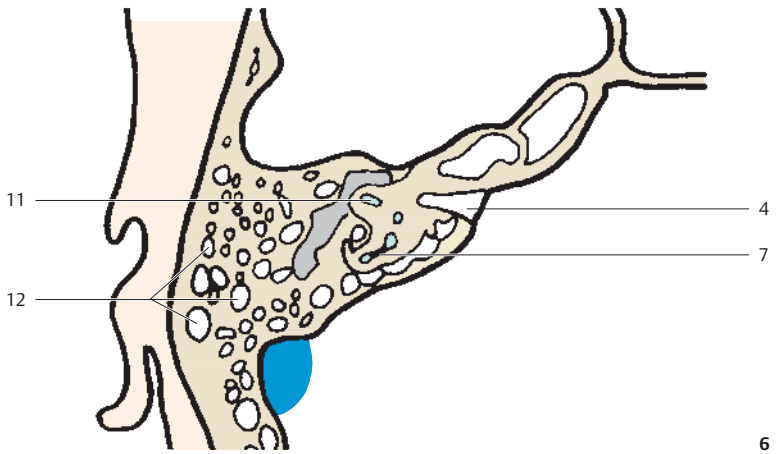
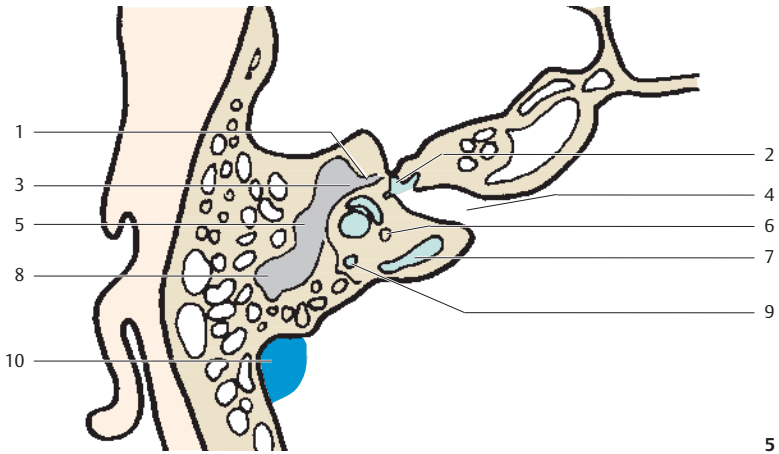


Frontal
Lateral Medial
Occipital

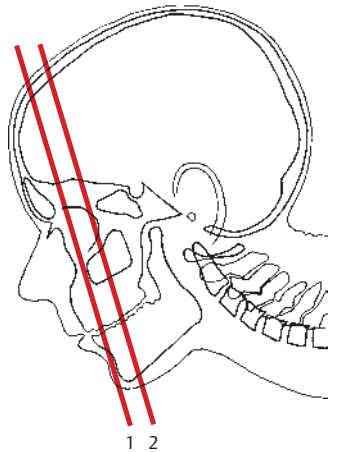
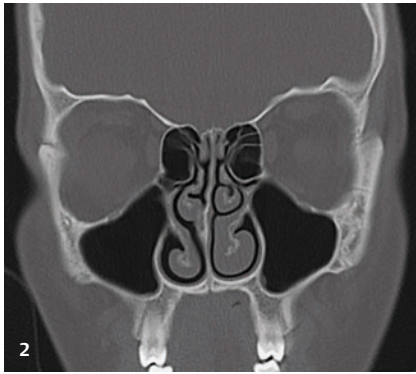
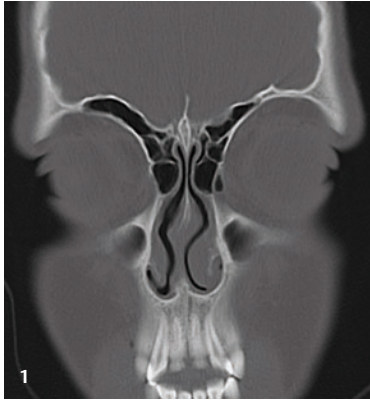

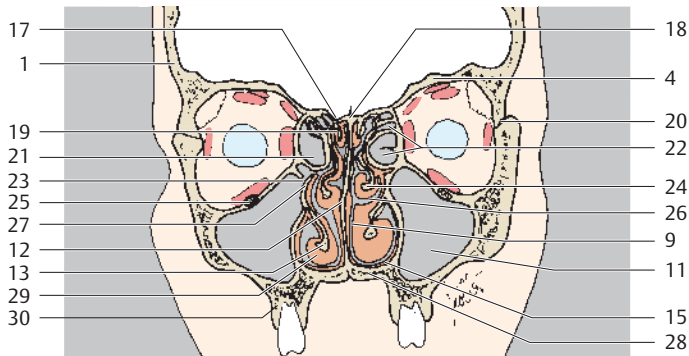
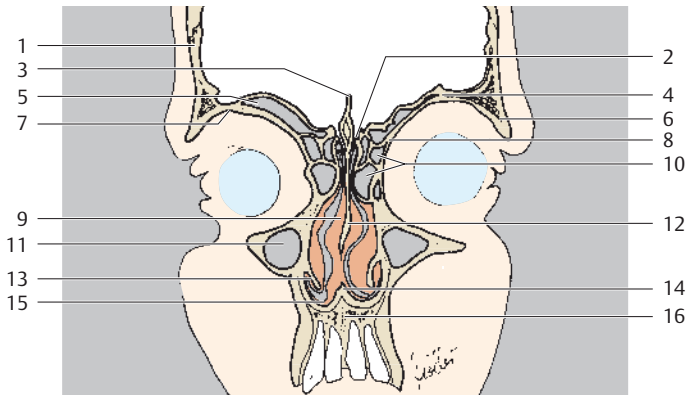
- | | |
|-----------------------------------|---------------------------------|
| 1 Internal carotid artery (canal) | 11 Epitympanic recess |
| 2 Malleus (handle) | 12 Malleus (head) |
| 3 Incus (long limb) | 13 Incus (short limb) |
| 4 Cochlea | 14 Internal acoustic meatus |
| 5 Stapes | 15 Aditus to mastoid antrum |
| 6 Oval window | 16 Vestibule |
| 7 Sinus tympani | 17 Posterior semicircular canal |
| 8 Facial canal | 18 Mastoid antrum |
| 9 Internal jugular vein (bulb) | 19 Lateral semicircular canal |
| 10 Mastoid | |



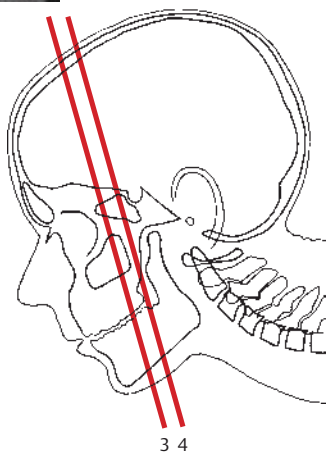
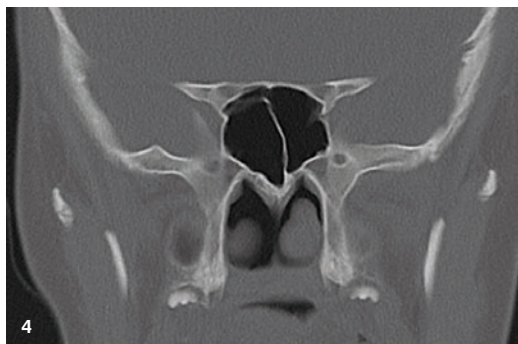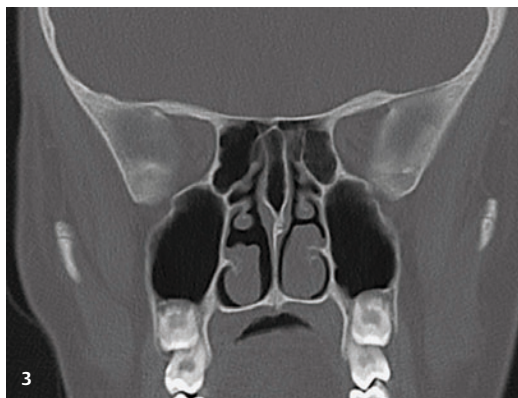


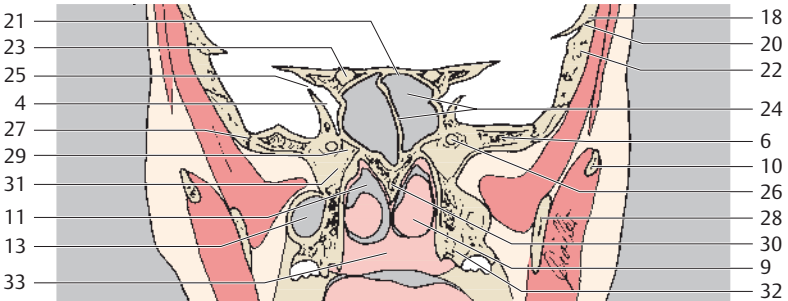
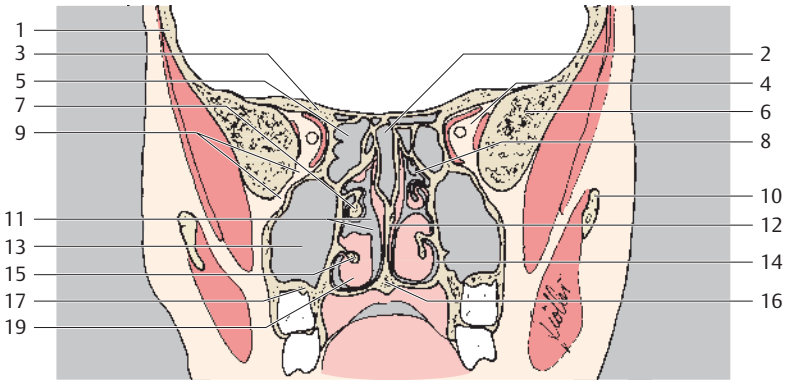
- | | |
|------------------------------|---|
| 1 Geniculate ganglion | 7 Posterior semicircular canal |
| 2 Facial nerve (first part) | 8 Mastoid antrum |
| 3 Facial nerve (second part) | 9 Lateral semicircular canal |
| 4 Internal acoustic meatus | 10 Sigmoid sinus |
| 5 Tympanic cavity | 11 Anterior (superior) semicircular canal |
| 6 Vestibule | 12 Mastoid cells |



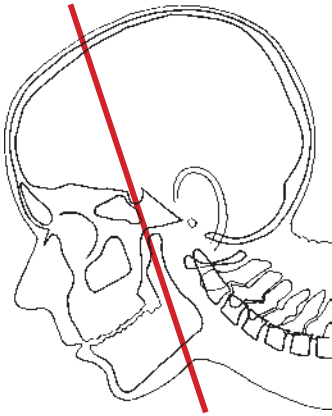
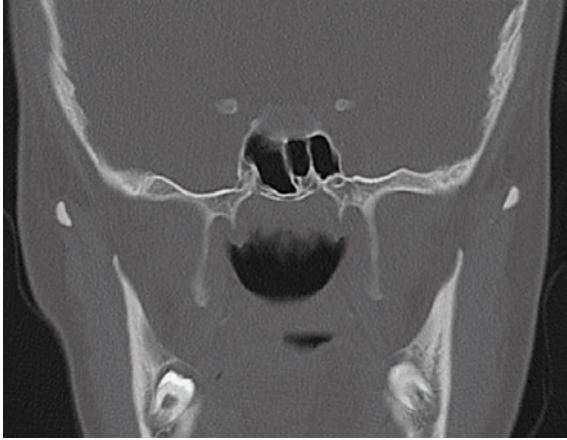


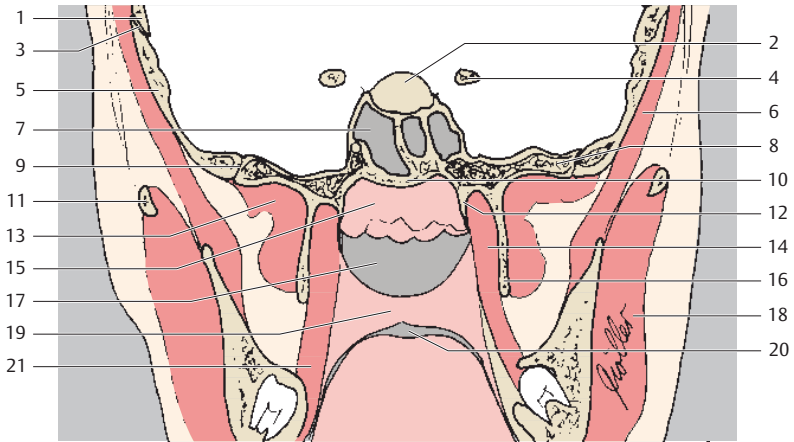
- | | |
|-----------------------------|---|
| 1 Frontal bone | 16 Alveolar process of maxilla |
| 2 Cribriform plate | 17 Ethmoidal notch |
| 3 Crista galli | 18 Ethmoidal bone (cribriform plate) |
| 4 Roof of orbit | 19 Superior nasal concha |
| 5 Frontal sinus | 20 Frontozygomatic suture |
| 6 Zygomatic process | 21 Orbital plate of ethmoidal labyrinth |
| 7 Supraorbital notch | 22 Ethmoidal cells (middle) |
| 8 Orbital plate | 23 Maxillary hiatus |
| 9 Nasal cavity | 24 Middle nasal concha |
| 10 Anterior ethmoidal cells | 25 Infraorbital foramen |
| 11 Maxillary sinus | 26 Middle nasal meatus |
| 12 Nasal septum | 27 Uncinate process |
| 13 Inferior nasal concha | 28 Hard palate |
| 14 Vomer | 29 Inferior nasal concha |
| 15 Inferior nasal meatus | 30 Maxilla (alveolar process) |



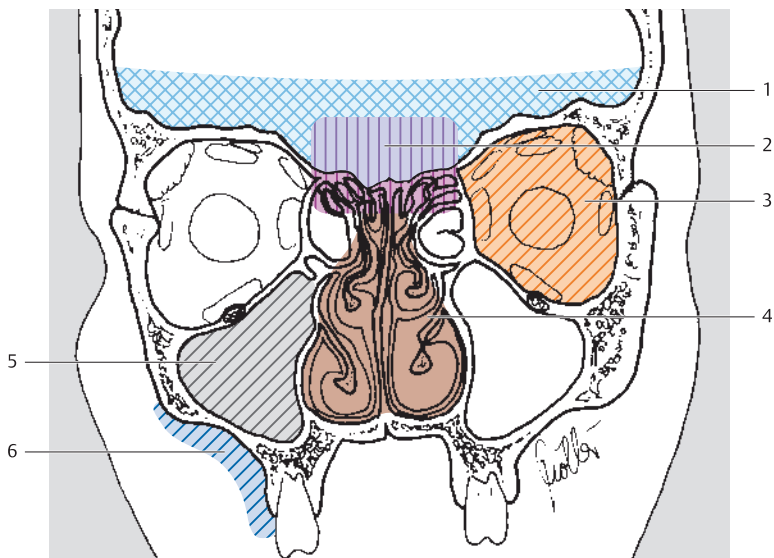








- | | |
|--|---|
| 1 Frontal bone | 18 Parietal bone |
| 2 Sphenoidal sinus (recess) | 19 Inferior nasal concha (cavernous body) |
| 3 Sphenoidal bone (lesser wing) | 20 Squamous suture |
| 4 Infundibulum of orbit | 21 Sphenoid bone (roof of sphenoid sinus) |
| 5 Ethmoidal cells (posterior) | 22 Temporal bone (squamous part) |
| 6 Sphenoidal bone (greater wing) | 23 Optic canal |
| 7 Middle nasal concha | 24 Sphenoidal sinus with septum |
| 8 Superior nasal concha | 25 Superior orbital fissure |
| 9 Inferior orbital fissure | 26 Foramen rotundum of sphenoidal bone |
| 10 Zygomatic bone | 27 Sphenosquamous suture |
| 11 Nasal cavity (common nasal meatus) | 28 Mandible (body and ramus) |
| 12 Nasal septum (perpendicular palate) | 29 Pterygoid canal |
| 13 Maxillary sinus | 30 Ethmoidal bone (nasal septum) |
| 14 Inferior nasal meatus | 31 Pterygopalatine fossa |
| 15 Inferior nasal concha | 32 Pterygoid process |
| 16 Palatine bone (horizontal plane) | 33 Soft palate |

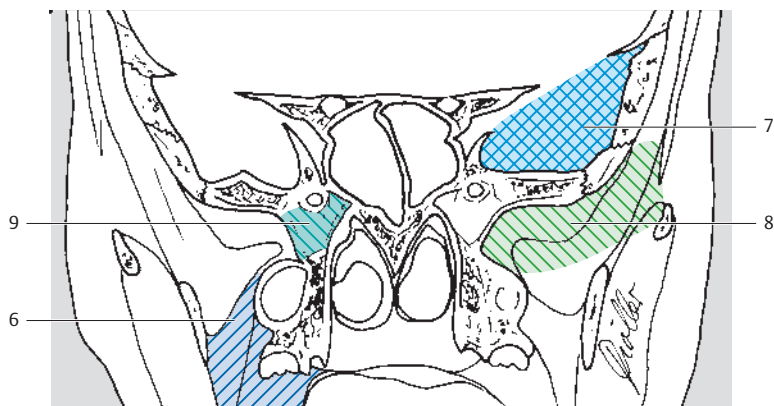
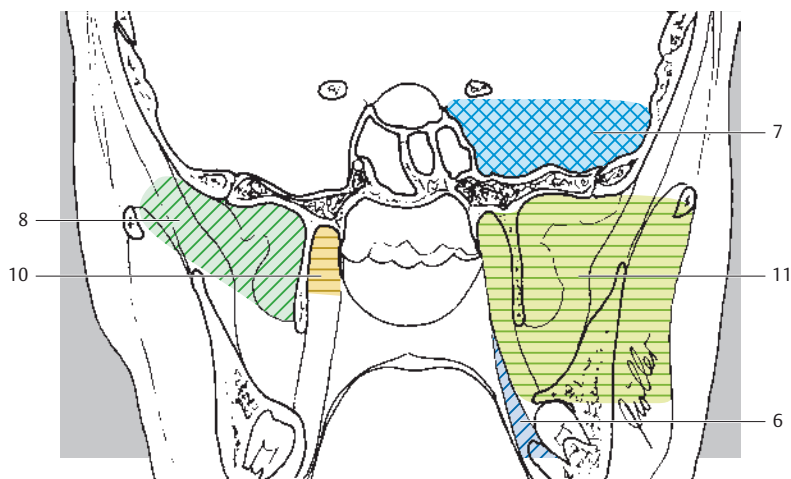







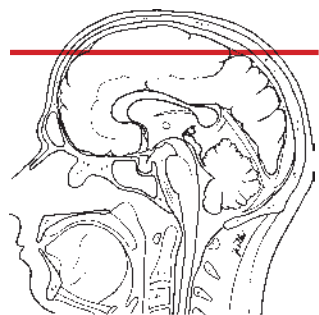
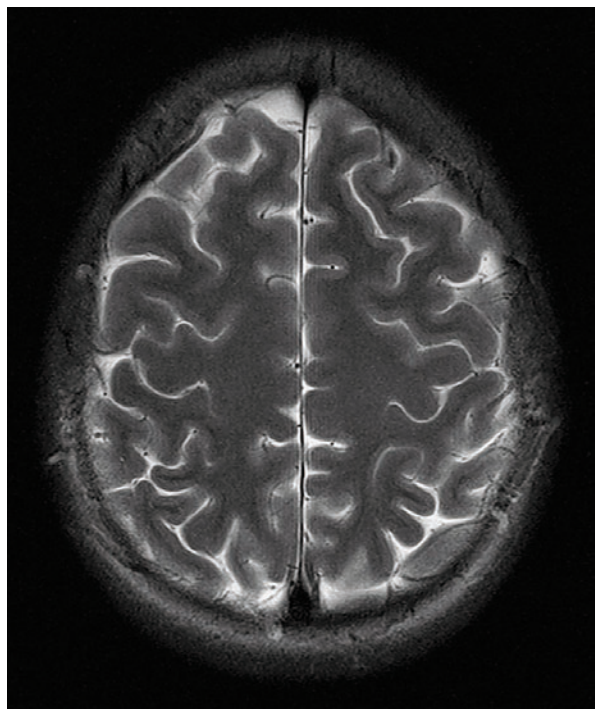
- | | |
|---|--------------------------------------|
| 1 Parietal bone | 10 Sphenoidal bone |
| 2 Sella turcica | 11 Zygomatic arch |
| 3 Squamous suture | 12 Pterygoid process (medial plate) |
| 4 Anterior clinoid process
(sphenoidal bone) | 13 Lateral pterygoid muscle |
| 5 Temporal bone (squamous
part) | 14 Pterygoid fossa |
| 6 Temporal muscle | 15 Pharyngeal tonsil |
| 7 Sphenoidal sinus | 16 Pterygoid process (lateral plate) |
| 8 Temporal bone (with articular
tubercle) | 17 Nasopharynx |
| 9 Sphenosquamous suture | 18 Masseter muscle |
| | 19 Soft palate |
| | 20 Oropharynx (isthmus of fauces) |
| | 21 Medial pterygoid muscle |



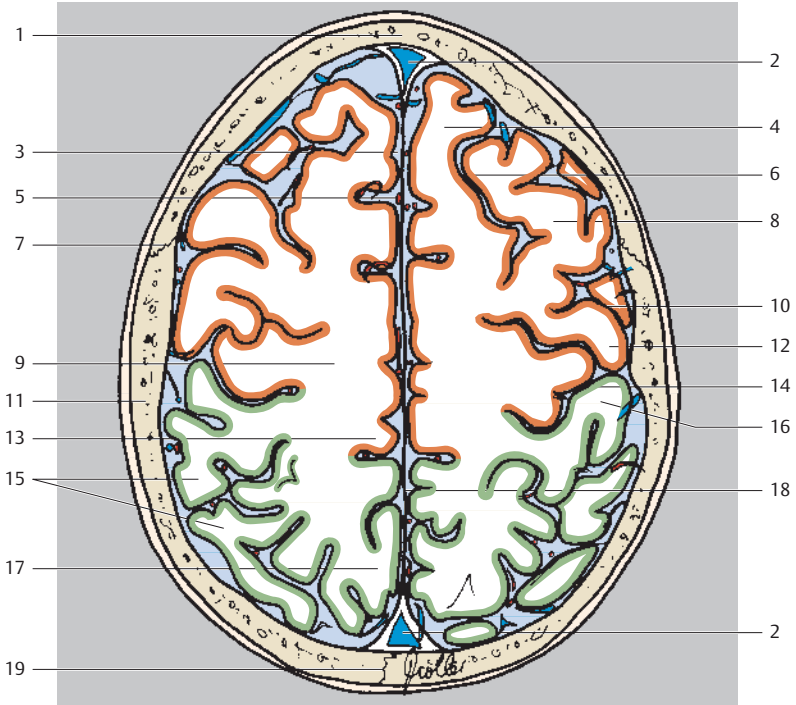
-  1 Anterior cranial fossa
-  2 Base of the nose
-  3 Orbital cavity
-  4 Nasal cavity
-  5 Maxillary sinus
-  6 Buccal space



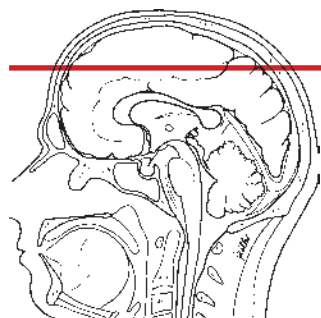
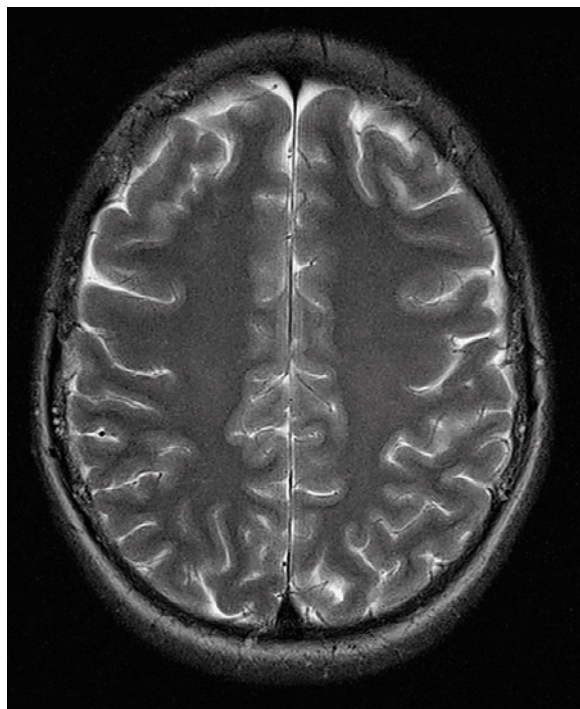
-  6 Buccal space
-  7 Middle cranial fossa
-  8 Infratemporal fossa
-  9 Pterygopalatine fossa
-  10 Pterygoid fossa
-  11 Masticatory space



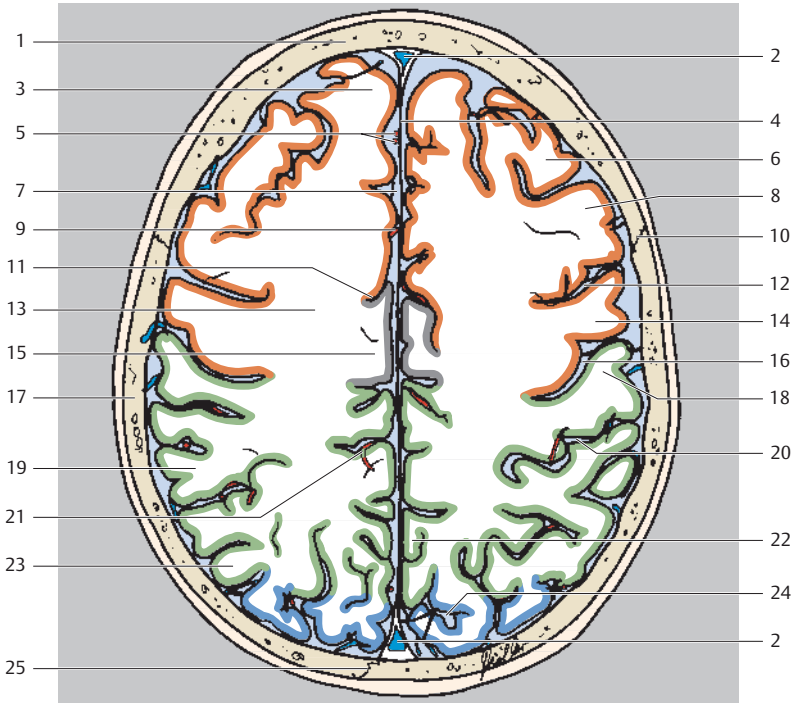
- Frontal lobe
- Parietal lobe



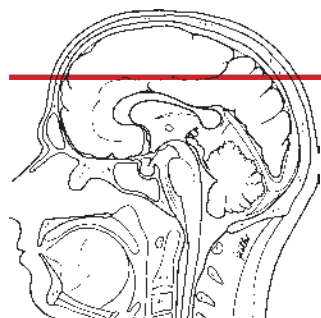
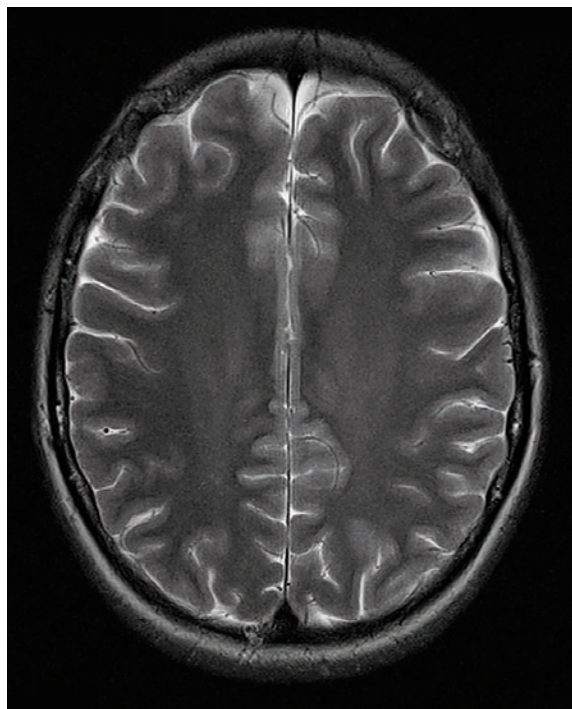
- | | |
|---|-----------------------------|
| 1 Frontal bone | 10 Precentral sulcus |
| 2 Superior sagittal sinus | 11 Parietal bone |
| 3 Longitudinal cerebral fissure | 12 Precentral gyrus |
| 4 Superior frontal gyrus | 13 Paracentral lobule |
| 5 Supratrochlear artery (postero-medial) | 14 Central sulcus |
| 6 Superior frontal sulcus | 15 Superior parietal lobule |
| 7 Coronal suture | 16 Postcentral gyrus |
| 8 Middle frontal gyrus | 17 Precuneus |
| 9 Cerebral white matter (semioval center) | 18 Falx cerebri |
| | 19 Sagittal suture |



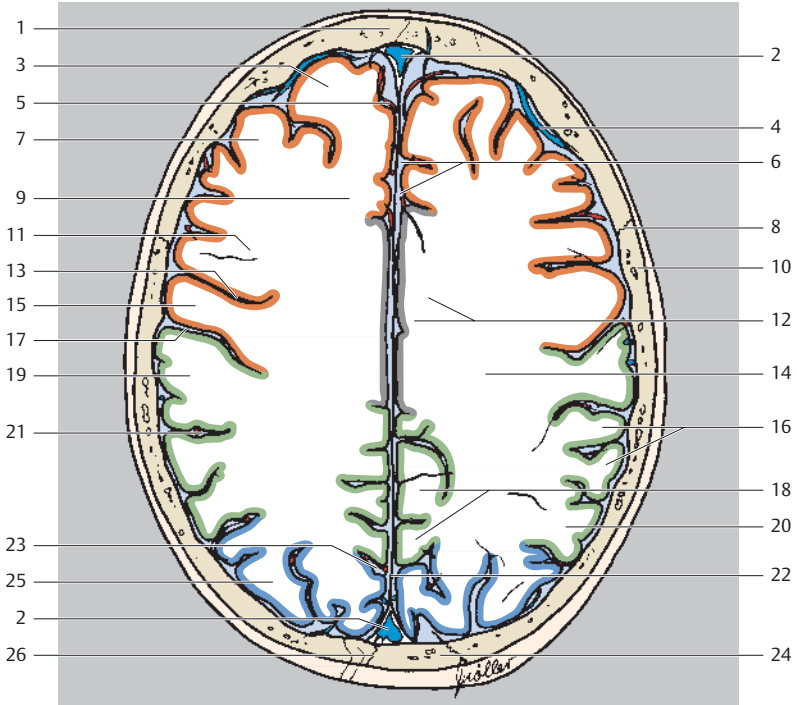
- Frontal lobe
- Parietal lobe
- Occipital lobe



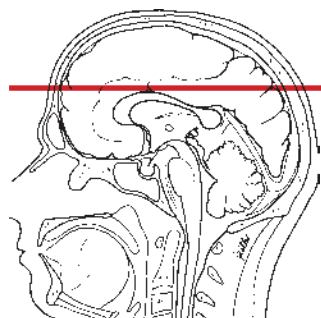
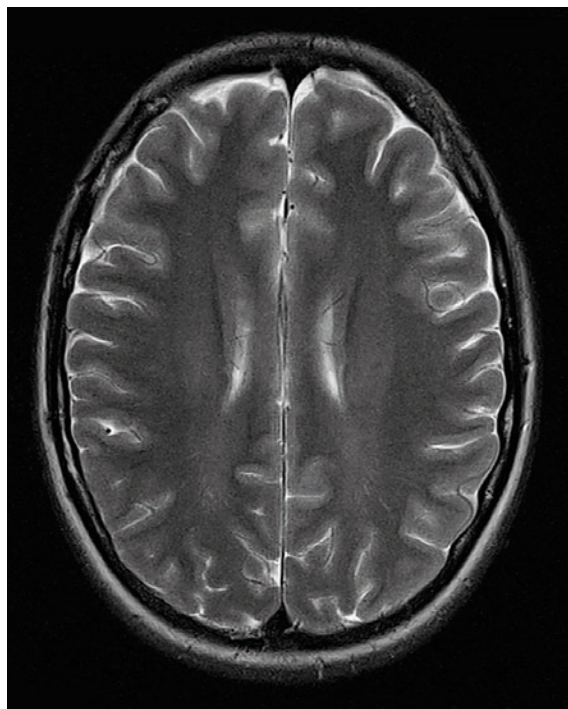
- | | |
|--|---|
| 1 Frontal bone | 14 Precentral gyrus |
| 2 Superior sagittal sinus | 15 Cingulate gyrus and cingulum |
| 3 Superior frontal gyrus | 16 Central sulcus (fissure of Rolando) |
| 4 Falx cerebri | 17 Parietal bone |
| 5 Supratrochlear artery (mediomedial) | 18 Postcentral gyrus |
| 6 Middle frontal gyrus | 19 Supramarginal gyrus |
| 7 Longitudinal cerebral fissure | 20 Postcentral sulcus |
| 8 Inferior frontal gyrus | 21 Paracentral branches of callosomarginal artery |
| 9 Callosomarginal artery | 22 Precuneus |
| 10 Coronal suture | 23 Angular gyrus |
| 11 Cingulate sulcus | 24 Parieto-occipital sulcus |
| 12 Precentral sulcus | 25 Sagittal suture |
| 13 Cerebral white matter (semioval center) | |



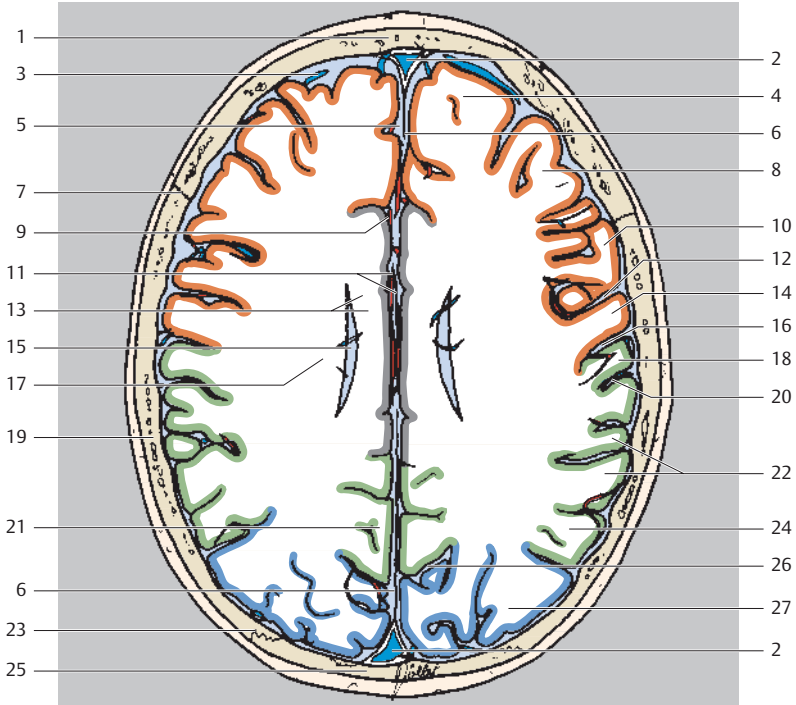
- Frontal lobe
- Parietal lobe
- Occipital lobe



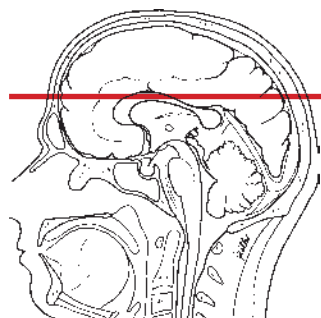
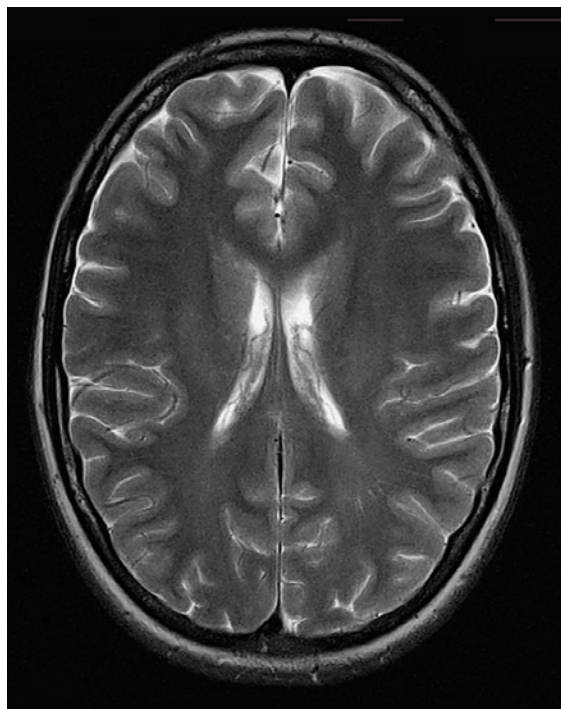
- | | |
|---------------------------------------|--|
| 1 Frontal bone | 14 Cerebral white matter (semioval center) |
| 2 Superior sagittal sinus | 15 Precentral gyrus |
| 3 Superior frontal gyrus | 16 Supramarginal gyrus |
| 4 Superior cerebral vein | 17 Central sulcus |
| 5 Supratrochlear (mediomedial) artery | 18 Precuneus |
| 6 Longitudinal cerebral fissure | 19 Postcentral gyrus |
| 7 Middle frontal gyrus | 20 Angular gyrus |
| 8 Coronal suture | 21 Postcentral sulcus |
| 9 Callosomarginal artery | 22 Falx cerebri |
| 10 Parietal bone | 23 Parieto-occipital sulcus |
| 11 Inferior frontal gyrus | 24 Occipital bone |
| 12 Cingulate gyrus and cingulum | 25 Occipital gyri |
| 13 Precentral sulcus | 26 Lambdoid suture |



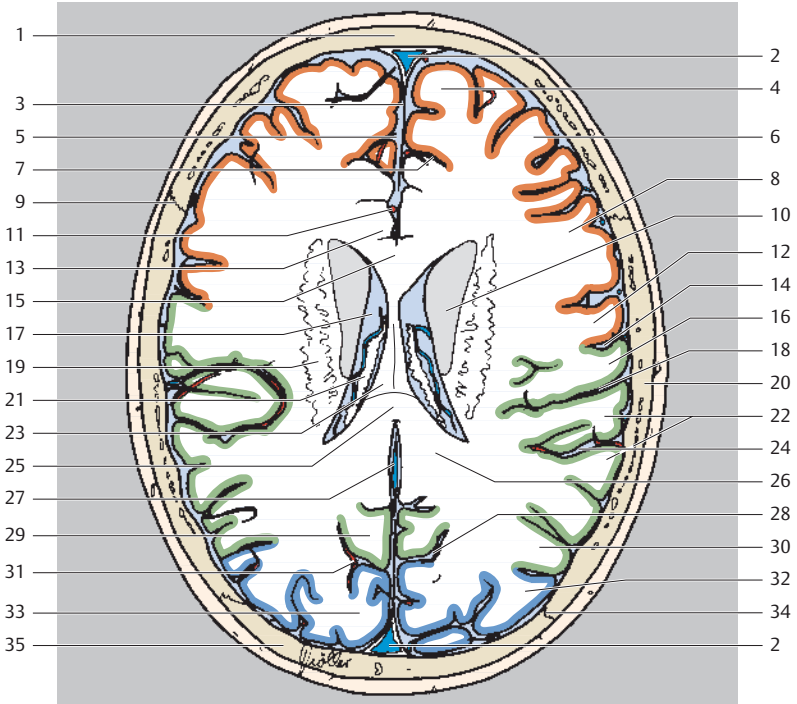
- Frontal lobe
- Parietal lobe
- Occipital lobe



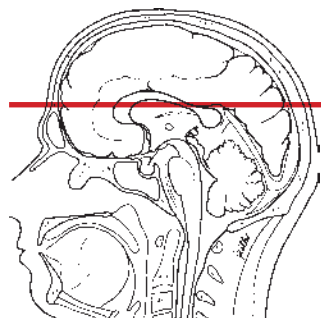
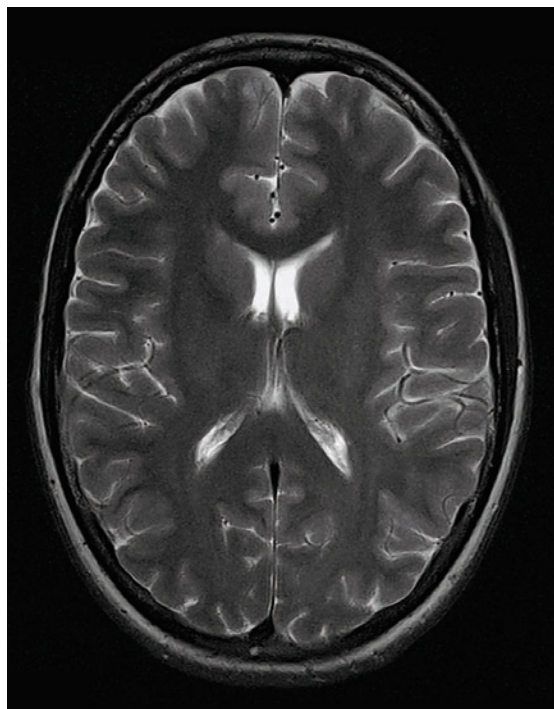
- | | |
|---------------------------------|-------------------------------------|
| 1 Frontal bone | 15 Lateral ventricle (central part) |
| 2 Superior sagittal sinus | 16 Central sulcus |
| 3 Superior cerebral vein | 17 Corona radiata |
| 4 Superior frontal gyrus | 18 Postcentral gyrus |
| 5 Longitudinal cerebral fissure | 19 Parietal bone |
| 6 Falx cerebri | 20 Postcentral sulcus |
| 7 Coronal suture | 21 Precuneus |
| 8 Middle frontal gyrus | 22 Supramarginal gyrus |
| 9 Callosomarginal artery | 23 Lambdoid suture |
| 10 Inferior frontal gyrus | 24 Angular gyrus |
| 11 Pericallosal artery | 25 Occipital bone |
| 12 Precentral sulcus | 26 Parieto-occipital sulcus |
| 13 Cingulate gyrus and cingulum | 27 Occipital gyri |
| 14 Precentral gyrus | |



- Frontal lobe
- Parietal lobe
- Occipital lobe

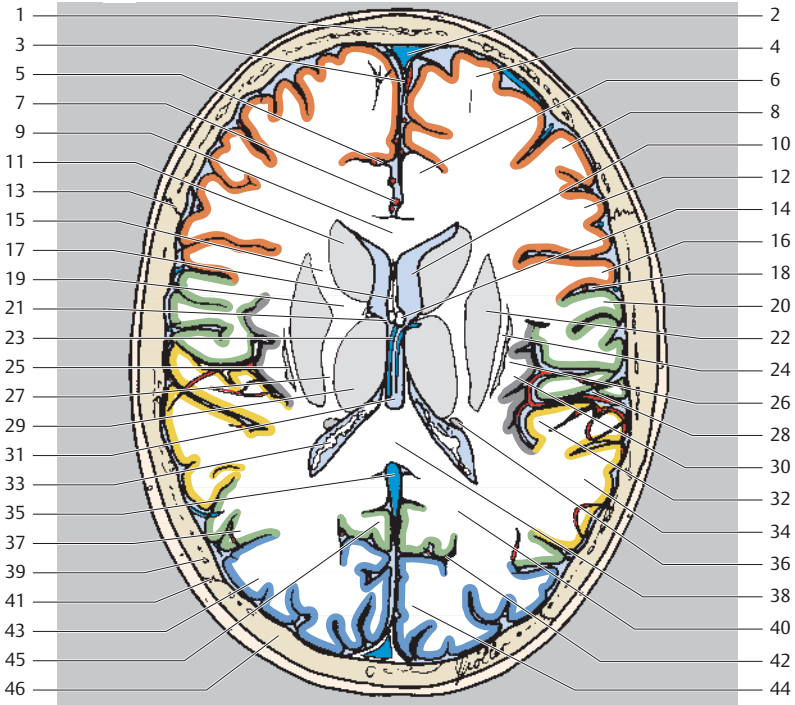


- | | |
|----------------------------|--------------------------------------|
| 1 Frontal bone | 19 Corona radiata |
| 2 Superior sagittal sinus | 20 Parietal bone |
| 3 Falx cerebri | 21 Choroid plexus |
| 4 Superior frontal gyrus | 22 Supramarginal gyrus |
| 5 Longitudinal cerebral | 23 Fornix |
| 6 Middle frontal gyrus | 24 Lateral sulcus (posterior ramus) |
| 7 Cingulate sulcus | 25 Corpus callosum, splenium |
| 8 Inferior frontal gyrus | 26 Major forceps (occipital forceps) |
| 9 Coronal suture | 27 Inferior sagittal sinus |
| 10 Head of caudate nucleus | 28 Parieto-occipital sulcus |
| 11 Pericallosal artery | 29 Precuneus |
| 12 Precentral gyrus | 30 Angular gyrus |
| 13 Cingulate gyrus | 31 Parieto-occipital artery |
| 14 Central sulcus | 32 Occipital gyri |
| 15 Corpus callosum (genu) | 33 Cuneus |
| 16 Postcentral gyrus | 34 Lambdoid suture |
| 17 Lateral ventricle | 35 Occipital bone |
| 18 Lateral sulcus | |

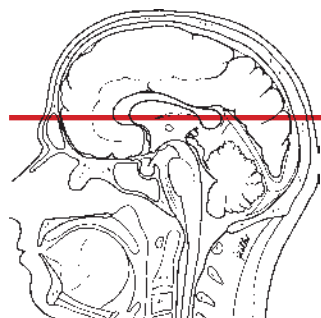
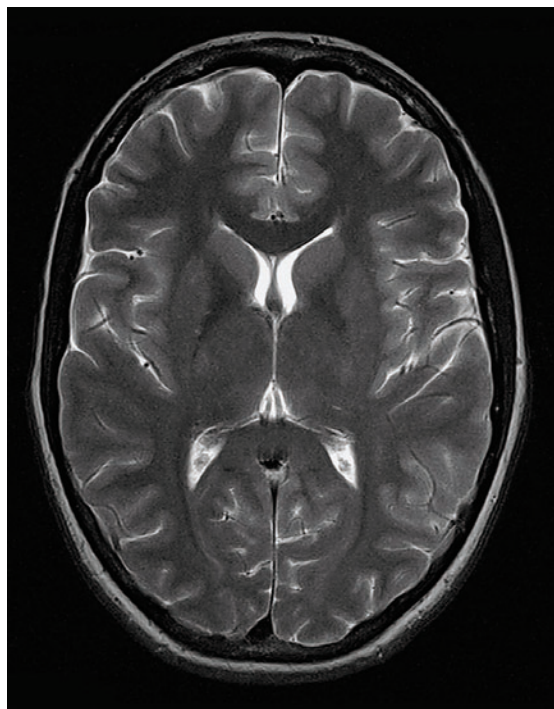


- Frontal lobe
- Temporal lobe
- Parietal lobe
- Occipital lobe

- | | |
|---------------------------|-------------------------------------|
| 1 Frontal bone | 7 Pericallosal artery |
| 2 Superior sagittal sinus | 8 Middle frontal gyrus |
| 3 Falx cerebri | 9 Corpus callosum (genu) |
| 4 Superior frontal gyrus | 10 Lateral ventricle (frontal horn) |
| 5 Cingulate sulcus | 11 Head of caudate nucleus |
| 6 Cingulate gyrus | 12 Inferior frontal gyrus |

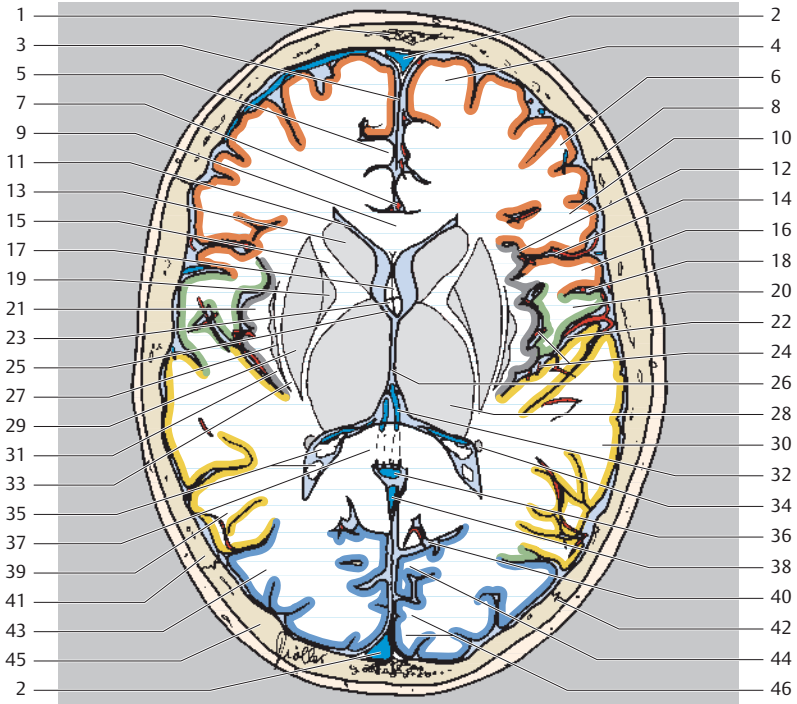


- | | |
|--|---|
| 13 Coronal suture | 30 Insula |
| 14 Fornix (column) | 31 Third ventricle (suprapineal recess) |
| 15 Internal capsule (anterior limb) | 32 Transverse temporal gyrus |
| 16 Precentral gyrus | 33 Choroid plexus in trigone of posterior horn of lateral ventricle |
| 17 Cave of septum pellucidum | 34 Superior temporal gyrus |
| 18 Central sulcus | 35 Great cerebral vein |
| 19 Internal capsule (genu) | 36 Tail of caudate nucleus |
| 20 Postcentral gyrus | 37 Angular gyrus |
| 21 Interventricular foramen (foramen of Monro) | 38 Corpus callosum, splenium |
| 22 Putamen | 39 Parietal bone |
| 23 Internal cerebral vein | 40 Major forceps (occipital forceps) |
| 24 External capsule | 41 Lambdoid suture |
| 25 Claustrum | 42 Parieto-occipital sulcus |
| 26 Extreme capsule | 43 Occipital gyri |
| 27 Internal capsule (posterior limb) | 44 Cuneus |
| 28 Lateral sulcus | 45 Precuneus |
| 29 Thalamus | 46 Occipital bone |

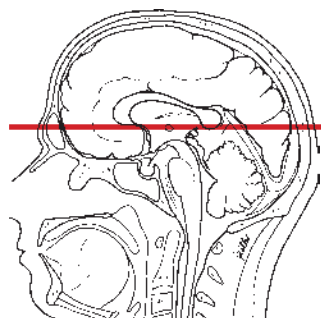
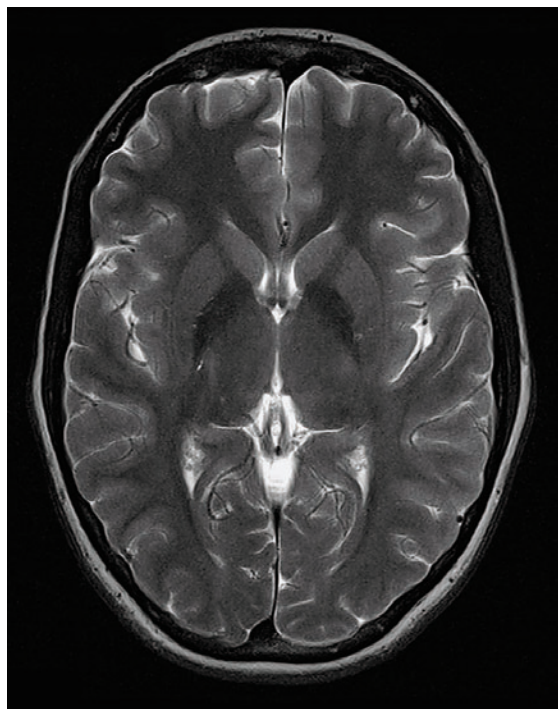


- Frontal lobe
- Temporal lobe
- Parietal lobe
- Occipital lobe

- | | |
|--|--|
| <ul style="list-style-type: none"> 1 Frontal bone 2 Superior sagittal sinus 3 Falx cerebri 4 Superior frontal gyrus 5 Cingulate gyrus | <ul style="list-style-type: none"> 6 Middle frontal gyrus 7 Pericallosal artery 8 Coronal suture 9 Corpus callosum (genu) 10 Inferior frontal gyrus |
|--|--|



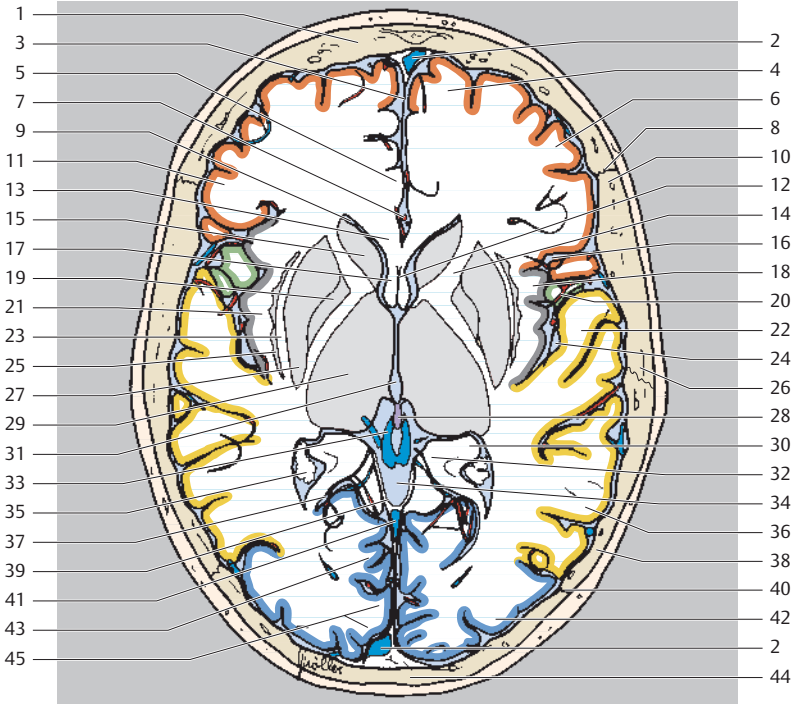
- | | |
|--|---|
| 11 Lateral ventricle (frontal horn) | 29 Putamen |
| 12 Circular sulcus of insula | 30 Superior temporal gyrus |
| 13 Head of caudate nucleus | 31 Extreme capsule |
| 14 Lateral sulcus | 32 Internal cerebral vein |
| 15 Internal capsule (anterior limb) | 33 External capsule |
| 16 Precentral gyrus | 34 Tail of caudate nucleus |
| 17 Cave of septum pellucidum | 35 Choroid plexus in trigone of posterior horn of lateral ventricle |
| 18 Central sulcus | 36 Great cerebral vein |
| 19 Globus pallidus | 37 Corpus callosum, splenium |
| 20 Postcentral gyrus | 38 Straight sinus |
| 21 Insula | 39 Middle temporal gyrus |
| 22 Cistern of lateral cerebral fossa (insular cistern) | 40 Parieto-occipital sulcus |
| 23 Fornix (column) | 41 Parietal bone |
| 24 Insular arteries | 42 Lambdoid suture |
| 25 Interventricular foramen (foramen of Monro) | 43 Occipital gyri |
| 26 Third ventricle | 44 Cuneus |
| 27 Claustrum | 45 Occipital bone |
| 28 Thalamus | 46 Striate cortex |



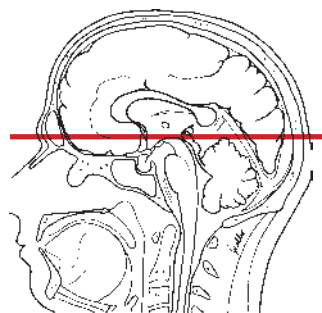
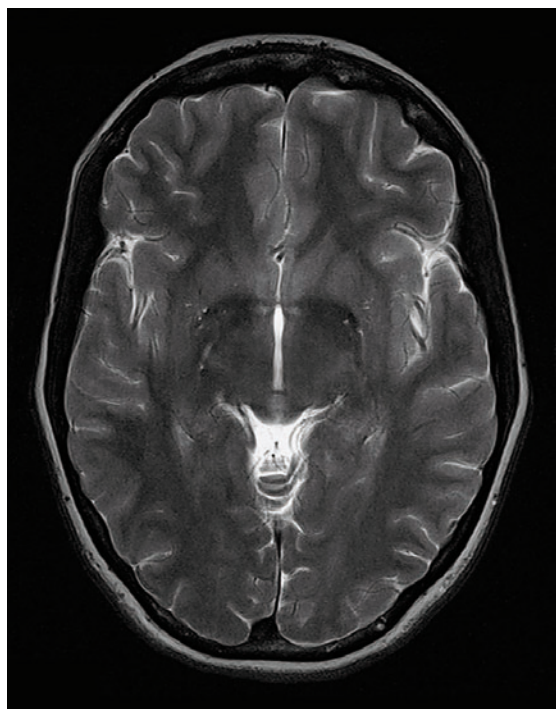
- Frontal lobe
- Temporal lobe
- Parietal lobe
- Occipital lobe

- 1 Frontal bone
- 2 Superior sagittal sinus
- 3 Falx cerebri
- 4 Superior frontal gyrus
- 5 Cingulate gyrus

- 6 Middle frontal gyrus
- 7 Anterior cerebral artery
- 8 Coronal suture
- 9 Lateral ventricle (frontal horn)



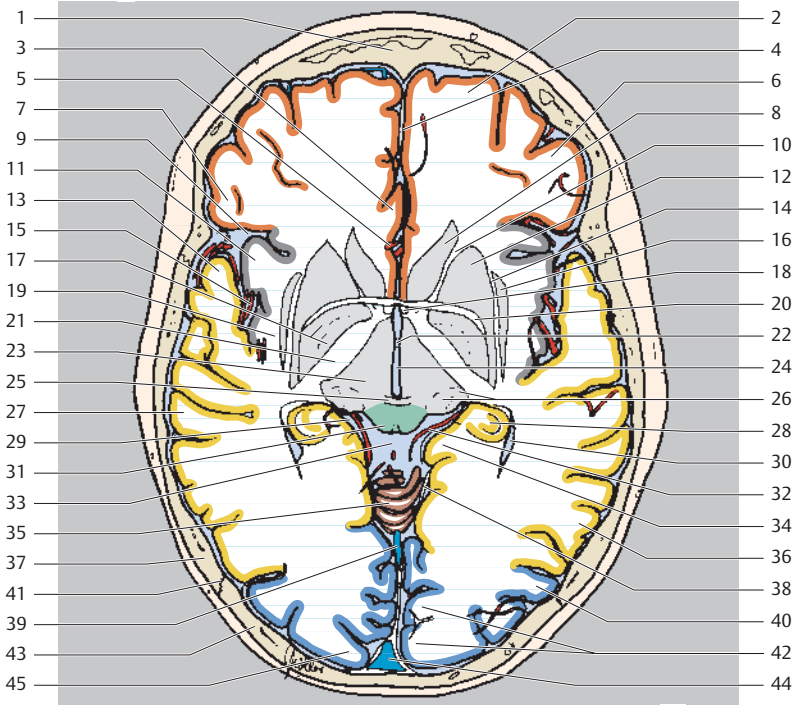
- | | |
|-------------------------------------|---|
| 10 Parietal bone | 29 Thalamus |
| 11 Inferior frontal gyrus | 30 Hippocampus |
| 12 Cave of septum pellucidum | 31 Third ventricle |
| 13 Corpus callosum | 32 Uncus of parahippocampal gyrus |
| 14 Internal capsule (anterior limb) | 33 Internal cerebral vein and great cerebral vein |
| 15 Head of caudate nucleus | 34 Superior cerebellar cistern |
| 16 Lateral sulcus | 35 Choroid plexus in trigone of posterior horn of lateral ventricle |
| 17 Fornix | 36 Middle temporal gyrus |
| 18 Insula | 37 Parieto-occipital artery |
| 19 Pallidum | 38 Parietal bone |
| 20 Insular arteries | 39 Tentorium cerebelli |
| 21 Extreme capsule | 40 Lambdoid suture |
| 22 Superior temporal gyrus | 41 Straight sinus |
| 23 External capsule | 42 Occipital gyri |
| 24 Insular cistern | 43 Cuneus |
| 25 Claustrum | 44 Occipital bone |
| 26 Temporal bone | 45 Striate cortex |
| 27 Putamen | |
| 28 Epiphysis of cerebrum | |



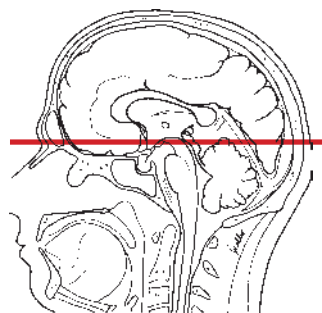
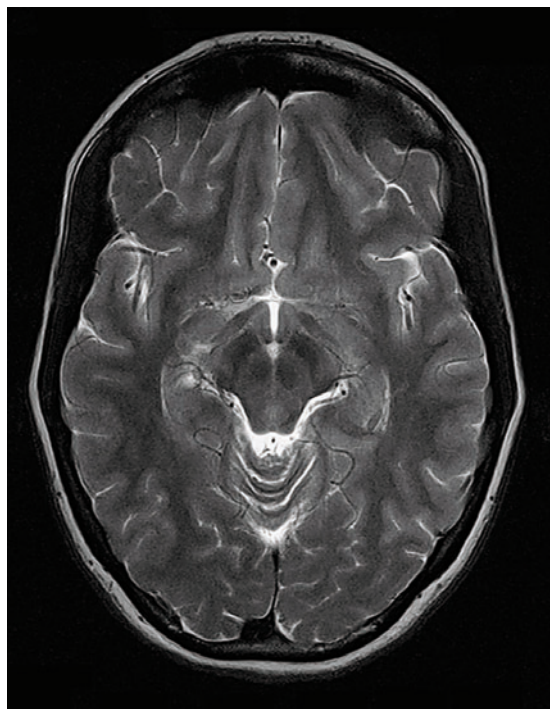
- Frontal lobe
- Temporal lobe
- Occipital lobe
- Cerebellum
- Mesencephalon

- 1 Frontal bone
- 2 Superior frontal gyrus
- 3 Cingulate gyrus
- 4 Falx cerebri
- 5 Anterior cerebral artery

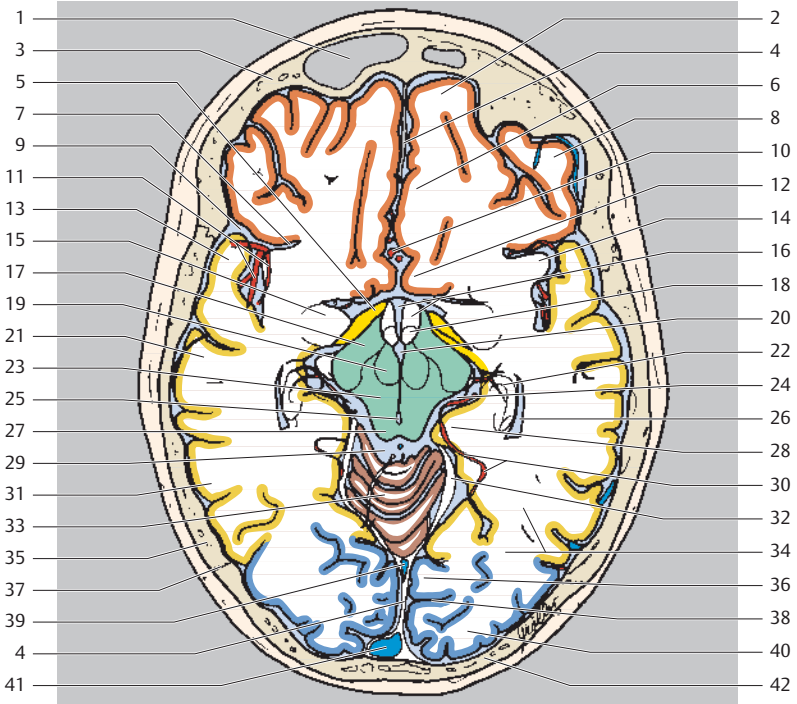
- 6 Middle frontal gyrus
- 7 Inferior frontal gyrus
- 8 Head of caudate nucleus
- 9 Lateral sulcus
- 10 Internal capsule (anterior limb)



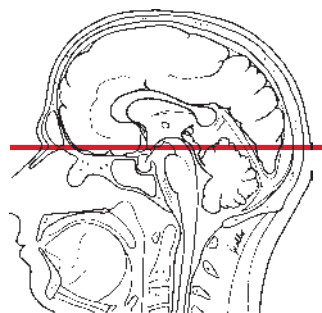
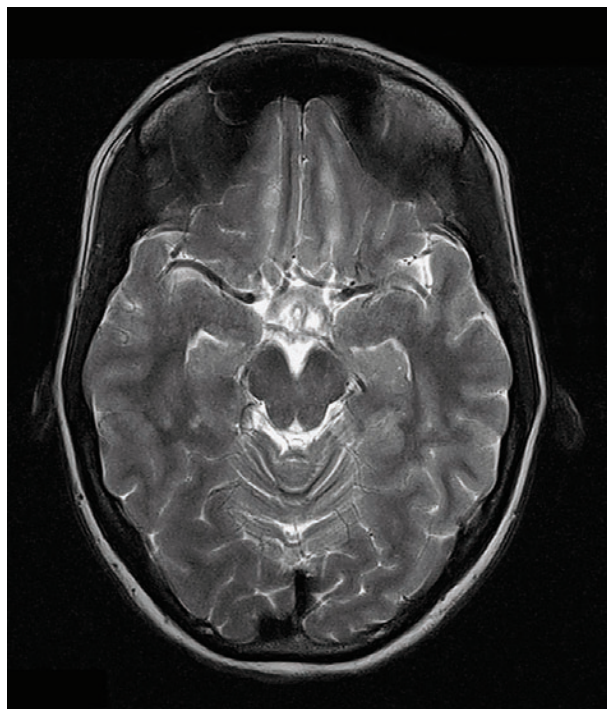
- | | |
|--|---------------------------------------|
| 11 Insula | 27 Middle temporal gyrus |
| 12 Putamen | 28 Hippocampus |
| 13 Superior temporal gyrus | 29 Ambient cistern |
| 14 External capsule | 30 Lateral ventricle (temporal horn) |
| 15 Insular arteries | 31 inferior colliculus |
| 16 Claustrum | 32 Basal vein |
| 17 Globus pallidus (lateral and medial segments) | 33 Quadrigeminal cistern |
| 18 Fornix | 34 Uncus of parahippocampal gyrus |
| 19 Extreme capsule | 35 Vermis of superior cerebellar lobe |
| 20 Anterior commissure | 36 Inferior temporal gyrus |
| 21 Internal capsule (posterior limb) | 37 Temporal bone |
| 22 Interthalamic adhesion | 38 Tentorium cerebelli |
| 23 Thalamus | 39 Straight sinus |
| 24 Third ventricle | 40 Occipital gyri |
| 25 Posterior commissure | 41 Lambdoid suture |
| 26 Medial and lateral geniculate body | 42 Striate cortex |
| | 43 Occipital bone |
| | 44 Superior sagittal sinus |
| | 45 Occipital pole |







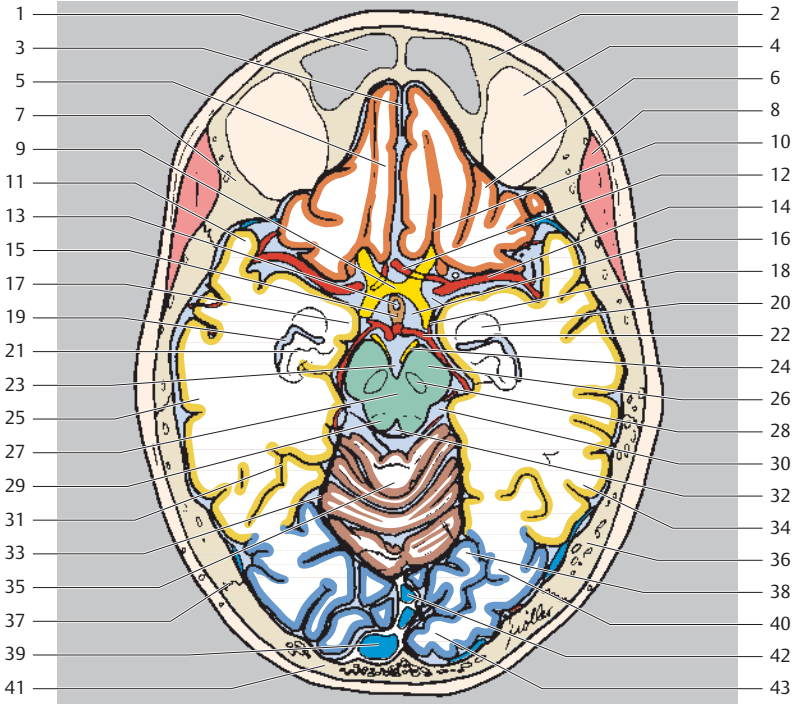
- Frontal lobe
- Temporal lobe
- Occipital lobe
- Cerebellum
- Mesencephalon



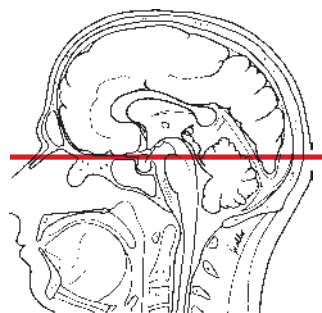
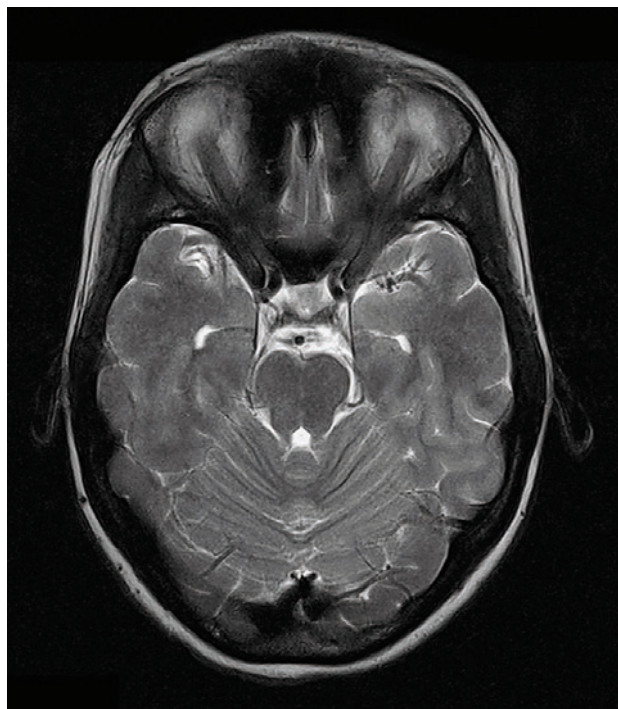
- | | |
|--|--|
| 1 Frontal sinus | 21 Middle temporal gyrus |
| 2 Superior frontal gyrus | 22 Hippocampus |
| 3 Frontal bone | 23 Tegmentum of midbrain |
| 4 Falx cerebri | 24 Ambient cistern |
| 5 Optic tract | 25 Aqueduct of mesencephalon |
| 6 Cingulate gyrus | 26 Lateral ventricle (temporal horn) |
| 7 Circular sulcus of insula | 27 Inferior colliculus |
| 8 Middle frontal gyrus | 28 Uncus of parahippocampal gyrus |
| 9 Lateral sulcus | 29 Quadrigeminal cistern |
| 10 Anterior cerebral artery | 30 Posterior cerebral artery |
| 11 Insular arteries | 31 Inferior temporal gyrus |
| 12 Subcallosal cortex | 32 Tentorium cerebelli |
| 13 Superior temporal gyrus | 33 Anterior cerebellar lobule (Vermis) |
| 14 Insula | 34 Optic radiation |
| 15 Amygdaloid body | 35 Temporal bone |
| 16 Third ventricle (optic recess) and hypothalamus | 36 Striate cortex |
| 17 Cerebral peduncle | 37 Lambdoid suture |
| 18 Mammillary body | 38 Calcarine sulcus |
| 19 Red nucleus | 39 Straight sinus |
| 20 Interpeduncular fossa | 40 Occipital pole |
| | 41 Superior sagittal sinus |
| | 42 Occipital bone |



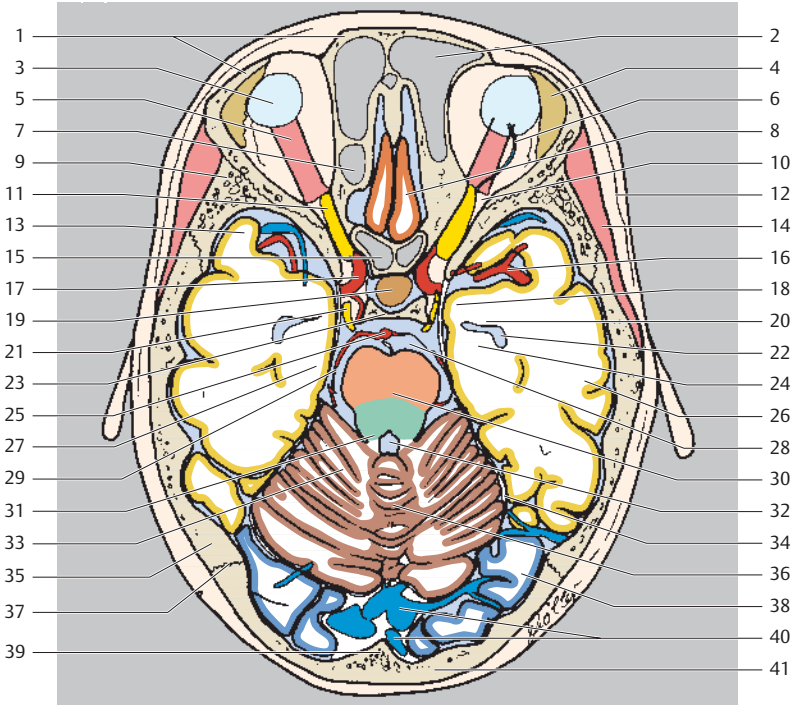
-  Frontal lobe
-  Temporal lobe
-  Cerebellum
-  Mesencephalon



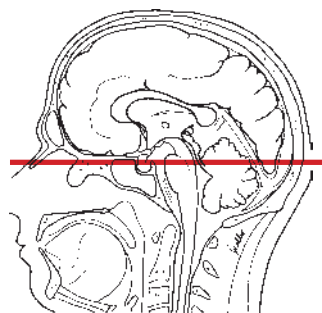
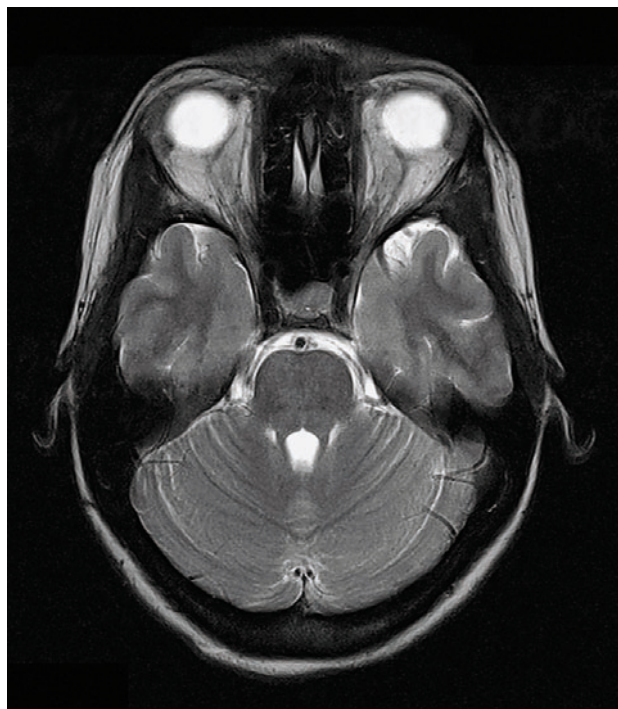
- | | |
|--------------------------------------|-----------------------------------|
| 1 Frontal sinus | 21 Hippocampus |
| 2 Frontal bone | 22 Posterior cerebral artery |
| 3 Falx cerebri | 23 Interpeduncular cistern |
| 4 Orbital roof | 24 Oculomotor nerve (III) |
| 5 Straight gyrus | 25 Middle temporal gyrus |
| 6 Orbital gyrus | 26 Cerebral peduncle |
| 7 Sphenoidal bone | 27 Tegmentum of midbrain |
| 8 Temporal muscle | 28 Substantia nigra |
| 9 Optic chiasm | 29 Inferior colliculus |
| 10 Olfactory sulcus | 30 Ambient cistern |
| 11 Superior temporal gyrus | 31 Collateral sulcus |
| 12 Anterior cerebral artery | 32 Aqueduct of midbrain |
| 13 Infundibular recess | 33 Tentorium cerebelli |
| 14 Middle cerebral artery | 34 Inferior temporal gyrus |
| 15 Hypothalamus | 35 Anterior cerebellar lobulus |
| 16 Chiasmatic cistern | 36 Temporal bone |
| 17 Uncus of parahippocampal gyrus | 37 Lambdoid suture |
| 18 Posterior communicating artery | 38 Medial occipitotemporal gyrus |
| 19 Lateral ventricle (temporal horn) | 39 Superior sagittal sinus |
| 20 Amygdaloid body | 40 Lateral occipitotemporal gyrus |
| | 41 Occipital bone |
| | 42 Straight sinus |
| | 43 Occipital gyri |







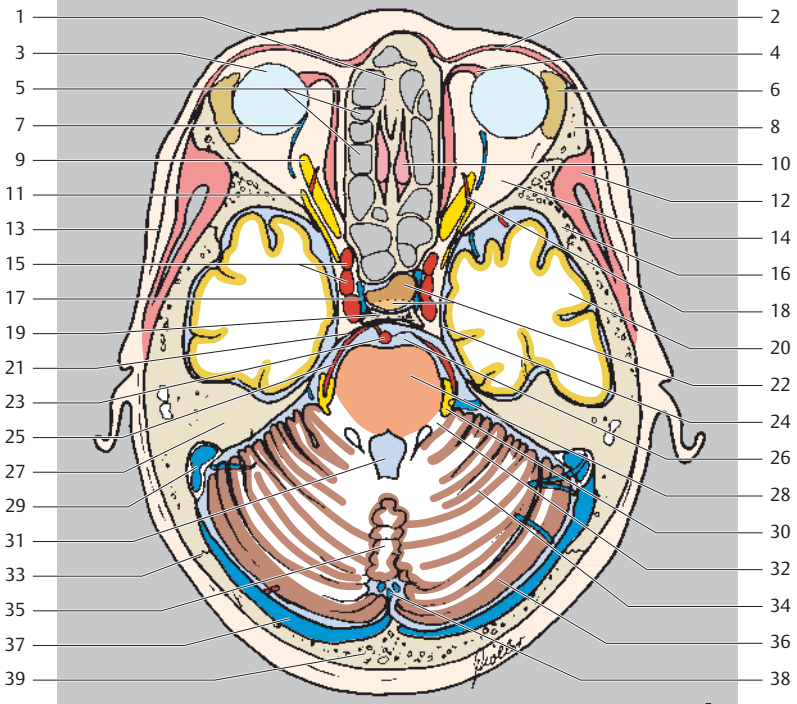
- Temporal lobe
- Occipital lobe
- Cerebellum
- Mesencephalon
- Pons



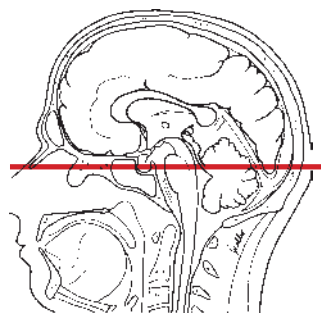
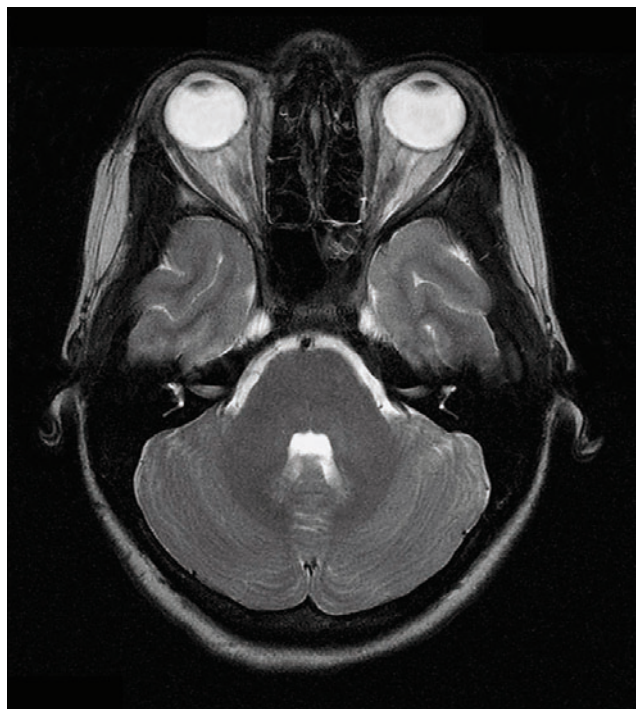
- | | |
|-----------------------------------|--------------------------------------|
| 1 Frontal bone | 21 Abducent nerve |
| 2 Frontal sinus | 22 Lateral ventricle (temporal horn) |
| 3 Eyeball | 23 Dorsum sellae |
| 4 Lacrimal gland | 24 Hippocampus |
| 5 Superior rectus muscle | 25 Basilar artery |
| 6 Ophthalmic vein | 26 Middle temporal gyrus |
| 7 Ethmoidal cells | 27 Parahippocampal gyrus |
| 8 Straight gyrus | 28 Prepontine cistern |
| 9 Sphenoidal bone | 29 Posterior cerebral artery |
| 10 Superior orbital fissure | 30 Pons |
| 11 Optic nerve | 31 Superior cerebellar peduncle |
| 12 Temporoparietal muscle | 32 Fourth ventricle |
| 13 Superior temporal gyrus | 33 Anterior lobe of cerebellum |
| 14 Temporal muscle | 34 Tentorium cerebelli |
| 15 Sphenoidal sinus | 35 Temporal bone |
| 16 Middle cerebral artery | 36 Vermis of cerebellum |
| 17 Internal carotid artery | 37 Lambdoid suture |
| 18 Uncus of parahippocampal gyrus | 38 Occipital gyri |
| 19 Pituitary gland | 39 Internal occipital protuberance |
| 20 Amygdaloid body | 40 Confluence of sinuses |
| | 41 Occipital bone |



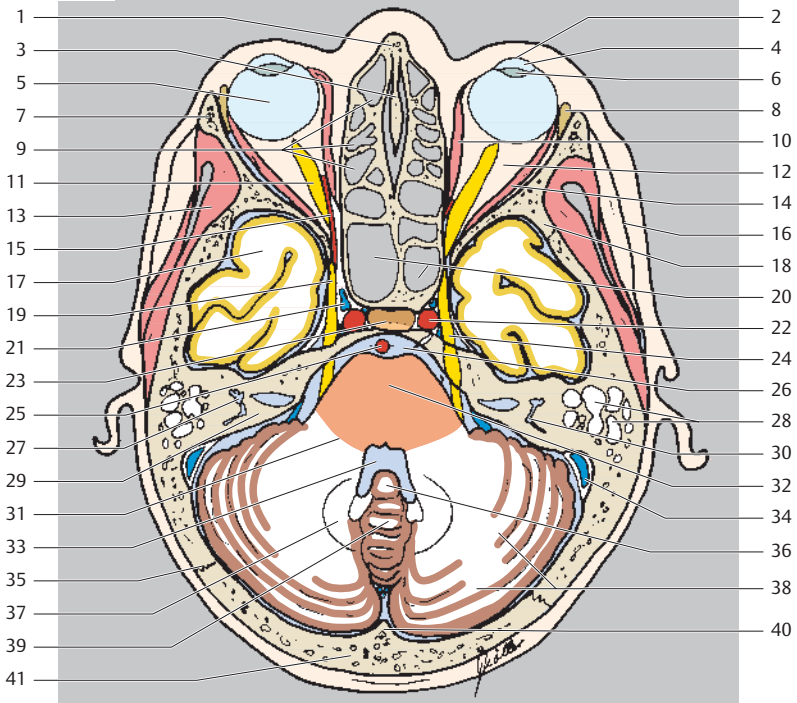
-  Temporal lobe
-  Occipital lobe
-  Cerebellum
-  Pons



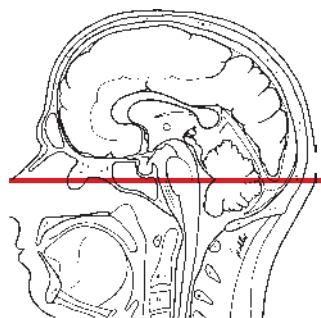
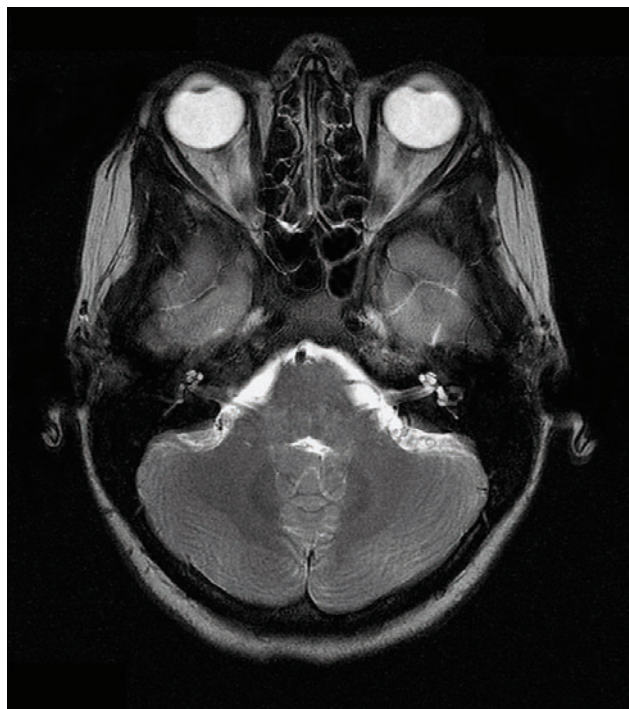
- | | |
|--|--|
| 1 Ethmoidal bone | 20 Inferior temporal gyrus |
| 2 Orbicularis oris muscle and occipitofrontal muscle | 21 Posterior petroclinoid ligament |
| 3 Eyeball | 22 Pituitary gland (neurohypophysis and adenohypophysis) |
| 4 Medial rectus muscle | 23 Basilar artery |
| 5 Ethmoidal cells | 24 Anterior petroclinoid ligament |
| 6 Lacrimal gland | 25 Posterior cerebral artery |
| 7 Superior ophthalmic vein | 26 Prepontine cistern |
| 8 Zygomatic bone | 27 Petrous part of temporal bone |
| 9 Optic nerve | 28 Pons |
| 10 Olfactory bulb | 29 Sigmoid sinus |
| 11 Oculomotor (III) and abducent (VI) nerves | 30 Trigeminal nerve (V) |
| 12 Temporal muscle | 31 Fourth ventricle |
| 13 Temporoparietal muscle | 32 Middle cerebellar peduncle |
| 14 Retro-orbital fatty tissue | 33 Lambdoid suture |
| 15 Internal carotid artery | 34 Anterior lobe of cerebellum |
| 16 Sphenoidal bone | 35 Vermis of cerebellum |
| 17 Cavernous sinus | 36 Posterior lobe of cerebellum |
| 18 Ophthalmic artery | 37 Transverse sinus |
| 19 Dorsum sellae | 38 Occipital sinus |
| | 39 Occipital bone |



-  Temporal lobe
-  Cerebellum
-  Pons



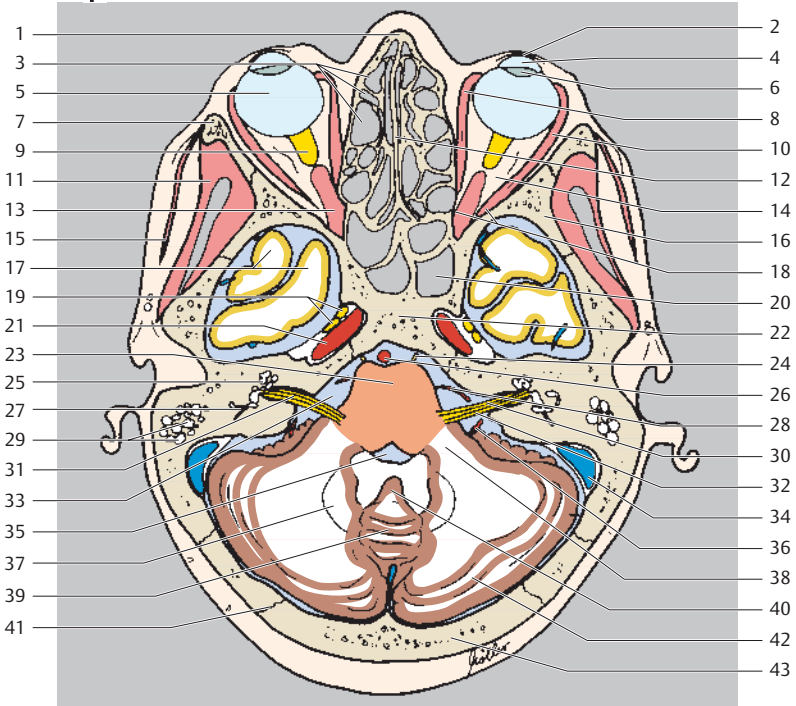
- | | |
|----------------------------------|------------------------------------|
| 1 Nasal bone | 22 Internal carotid artery |
| 2 Cornea | 23 Pituitary gland |
| 3 Nasal septum | 24 Trigeminal ganglion |
| 4 Anterior chamber of eyeball | 25 Basilar artery |
| 5 Eyeball | 26 Prepontine cistern |
| 6 Lens | 27 Cochlea |
| 7 Zygomatic bone | 28 Mastoid cells |
| 8 Lacrimal gland | 29 Petrous part of temporal bone |
| 9 Ethmoidal cells | 30 Semicircular canal |
| 10 Medial rectus muscle | 31 Middle cerebellar peduncle |
| 11 Optic nerve | 32 Pons |
| 12 Retro-orbital fatty tissue | 33 Fourth ventricle |
| 13 Temporal muscle | 34 Sigmoid sinus |
| 14 Lateral rectus muscle | 35 Lambdoid suture |
| 15 Ophthalmic artery | 36 Uvula of vermis |
| 16 Temporoparietal muscle | 37 Dentate nucleus |
| 17 Temporal lobe (temporal pole) | 38 Posterior lobe of cerebellum |
| 18 Sphenoidal bone | 39 Vermis of cerebellum |
| 19 Oculomotor nerve | 40 Internal occipital protuberance |
| 20 Sphenoidal sinus | 41 Occipital bone |
| 21 Cavernous sinus | |



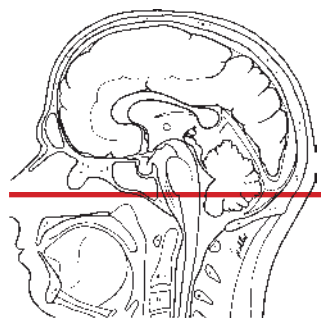
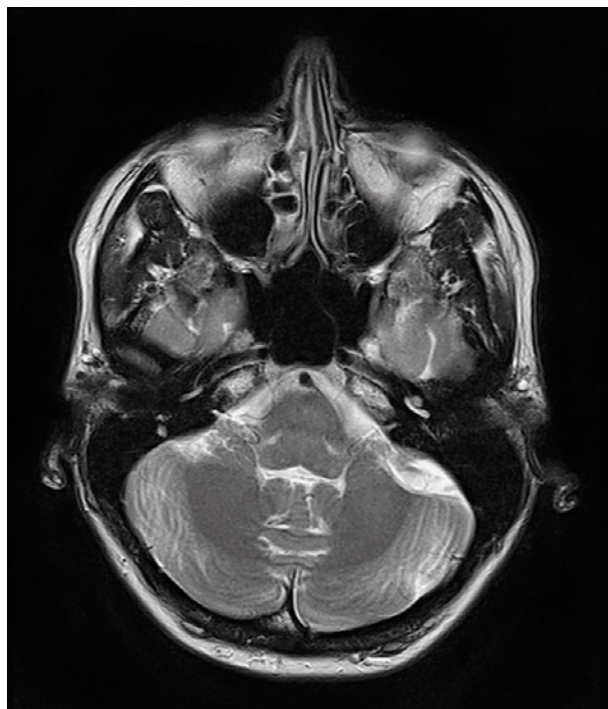
- Temporal lobe
- Cerebellum
- Pons




- 1 Nasal bone
- 2 Cornea
- 3 Ethmoidal cells
- 4 Anterior chamber of eyeball
- 5 Eyeball

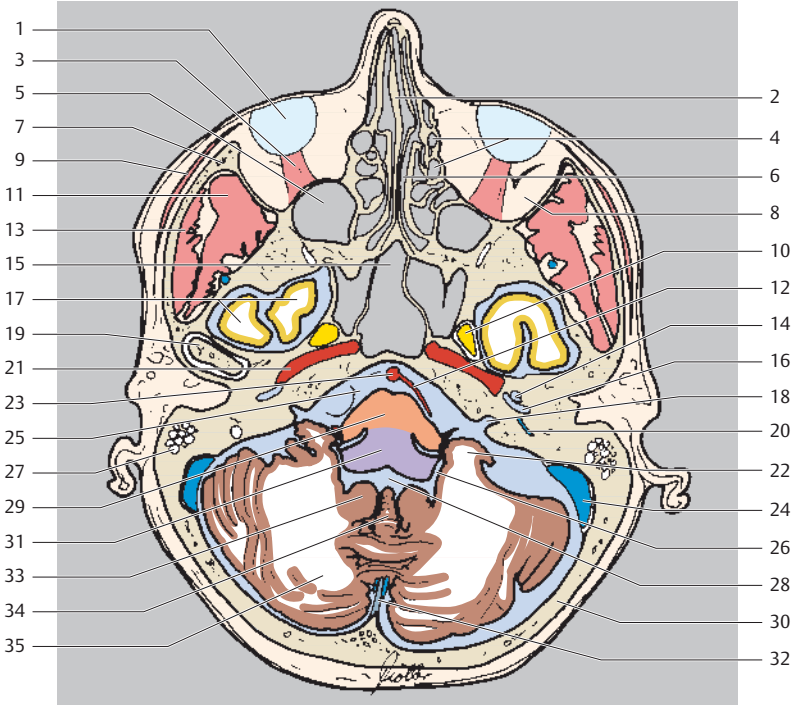
- 6 Lens
- 7 Zygomatic bone
- 8 Medial rectus muscle
- 9 Optic nerve
- 10 Lateral rectus muscle



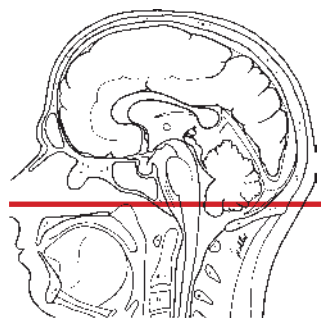
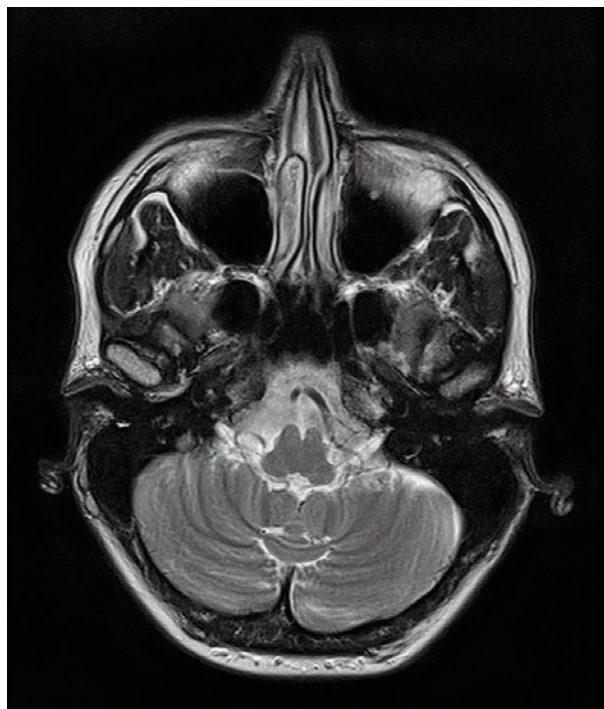
- | | |
|---|--|
| 11 Temporal muscle | 27 Posterior semicircular canal |
| 12 Nasal septum | 28 Superior cerebellar artery |
| 13 Superior rectus muscle and levator palpebrae superioris muscle | 29 Mastoid cells |
| 14 Retro-orbital fatty tissue | 30 Facial nerve (VII) and intermediate nerve |
| 15 Temporoparietal muscle | 31 Internal acoustic meatus |
| 16 Sphenoidal bone | 32 Vestibulocochlear (auditory) nerve (VIII) |
| 17 Temporal pole | 33 Pontocerebellar cistern |
| 18 Superior orbital fissure | 34 Sigmoid sinus |
| 19 Maxillary and mandibular nerves | 35 Fourth ventricle |
| 20 Sphenoidal sinus | 36 Anterior inferior cerebellar artery |
| 21 Internal carotid artery | 37 Dentate nucleus |
| 22 Clivus | 38 Middle cerebellar peduncle |
| 23 Pons | 39 Vermis of cerebellum |
| 24 Abducent nerve (VI) | 40 Uvula of vermis |
| 25 Cochlea | 41 Lambdoid suture |
| 26 Basilar artery | 42 Caudal lobule of cerebellum |
| | 43 Occipital bone |





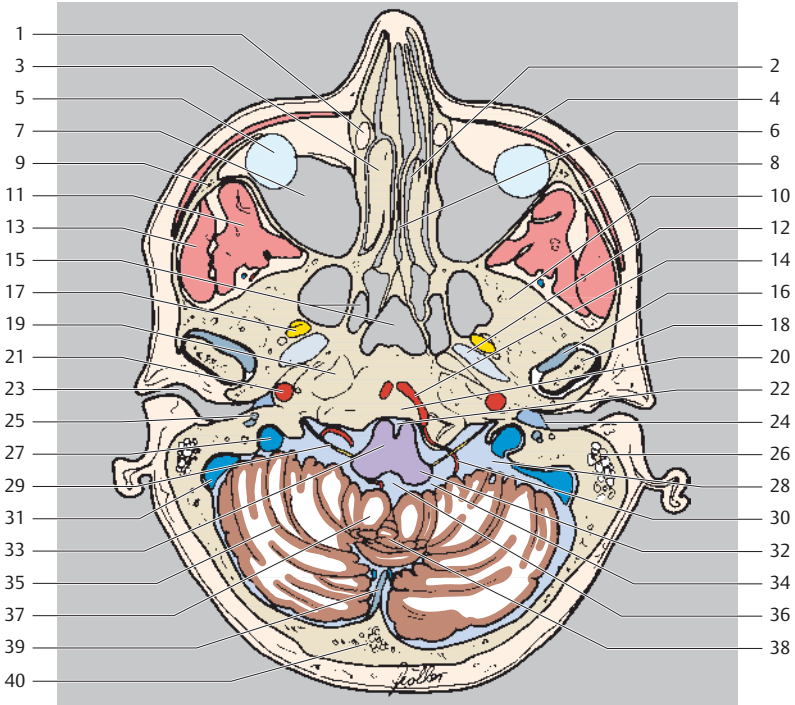
-  Cerebellum
-  Pons
-  Medulla oblongata



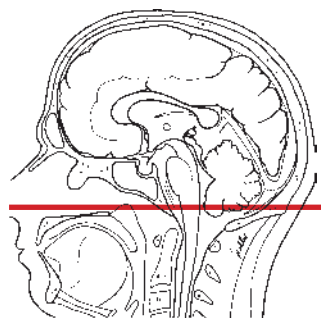
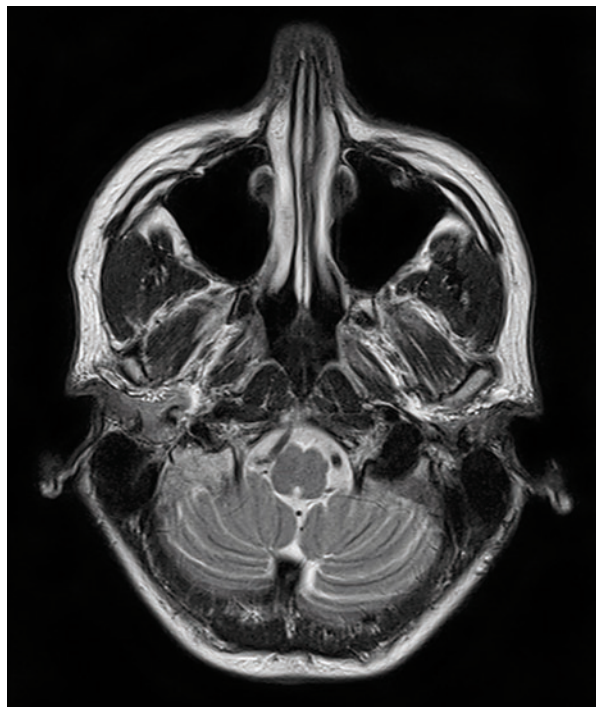- | | |
|--|--|
| 1 Eyeball | 19 Head of mandible |
| 2 Nasal septum | 20 Posterior semicircular canal |
| 3 Inferior rectus muscle | 21 Internal carotid artery |
| 4 Ethmoidal cells | 22 Flocculus |
| 5 Maxillary sinus | 23 Basilar artery |
| 6 Nasal sinus | 24 Transverse sinus |
| 7 Zygomatic bone | 25 Pontocerebellar cistern |
| 8 Retrobulbar fat | 26 Lateral aperture of fourth ventricle (foramen of Luschka) |
| 9 Orbicularis oris muscle | 27 Mastoid cells |
| 10 Trigeminal nerve (V) | 28 Fourth ventricle |
| 11 Temporal muscle | 29 Pons |
| 12 Anterior inferior cerebellar artery | 30 Occipital bone |
| 13 Masseter muscle | 31 Medulla oblongata |
| 14 Cochlea | 32 Falx cerebelli |
| 15 Sphenoidal sinus | 33 Tonsil of cerebellum |
| 16 Vestibule | 34 Vermis of cerebellum |
| 17 Inferior temporal gyrus | 35 Cerebellum |
| 18 Internal acoustic meatus | |



-  Cerebellum
-  Medulla oblongata

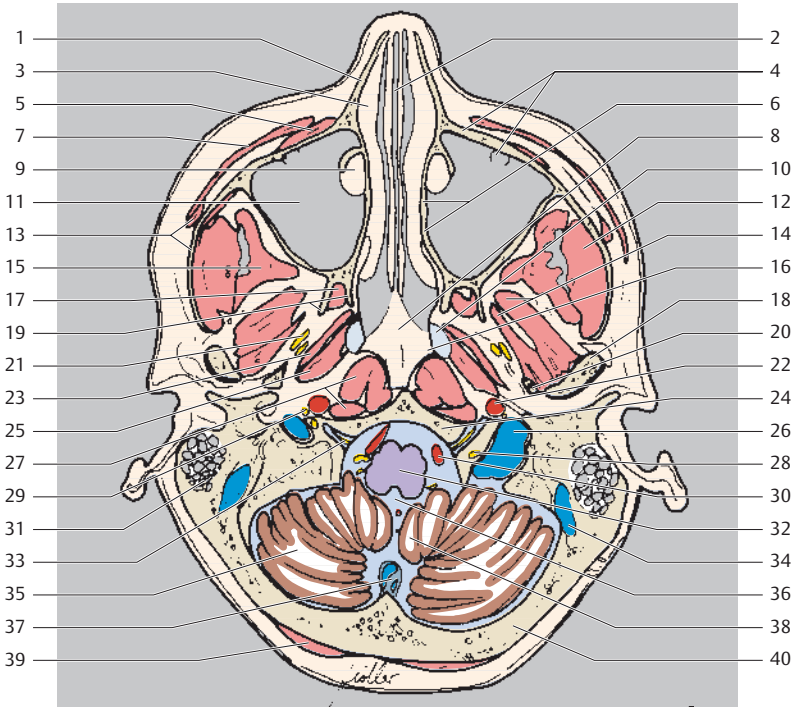


- | | |
|--|--|
| 1 Nasolacrimal duct | 22 Ventral median fissure |
| 2 Nasal cavity | 23 External acoustic meatus |
| 3 Nasal concha | 24 Tympanic membrane |
| 4 Orbicularis oris muscle | 25 Cochlea |
| 5 Eyeball | 26 Mastoid cells |
| 6 Nasal septum | 27 Internal jugular vein |
| 7 Maxillary sinus | 28 Pontocerebellar cistern |
| 8 Sphenoidal bone | 29 Glossopharyngeal nerve (IX) and vagus nerve (X) |
| 9 Zygomatic bone | 30 Anterior inferior cerebellar artery |
| 10 Temporal bone | 31 Sigmoid sinus |
| 11 Temporal muscle | 32 Medulla oblongata (caudal cerebellar peduncle) |
| 12 Pharyngotympanic tube (auditory tube) | 33 Medulla oblongata (olivary nucleus) |
| 13 Masseter muscle | 34 Lateral aperture of fourth ventricle (foramen of Luschka) |
| 14 Vertebral artery | 35 Cerebellum (posterior lobe) |
| 15 Sphenoidal bone | 36 Fourth ventricle |
| 16 Articular disc | 37 Tonsil of cerebellum |
| 17 Trigeminal nerve (V) | 38 Vermis of cerebellum |
| 18 Head of mandible | 39 Falx cerebelli |
| 19 Foramen lacerum | 40 Occipital bone |
| 20 Clivus | |
| 21 Internal carotid artery | |

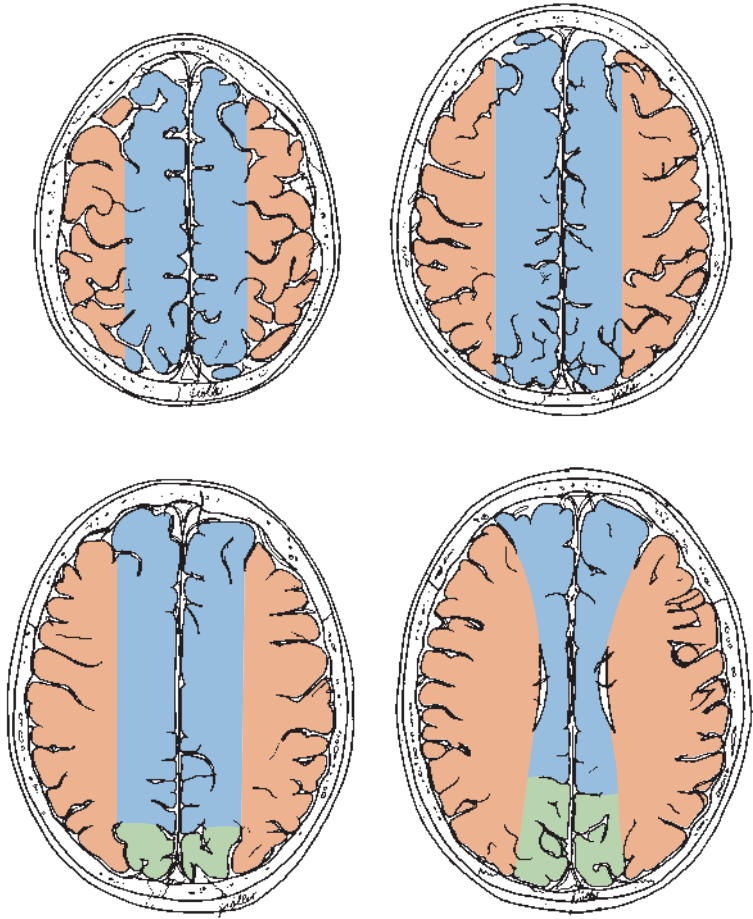





- Cerebellum
- Medulla oblongata

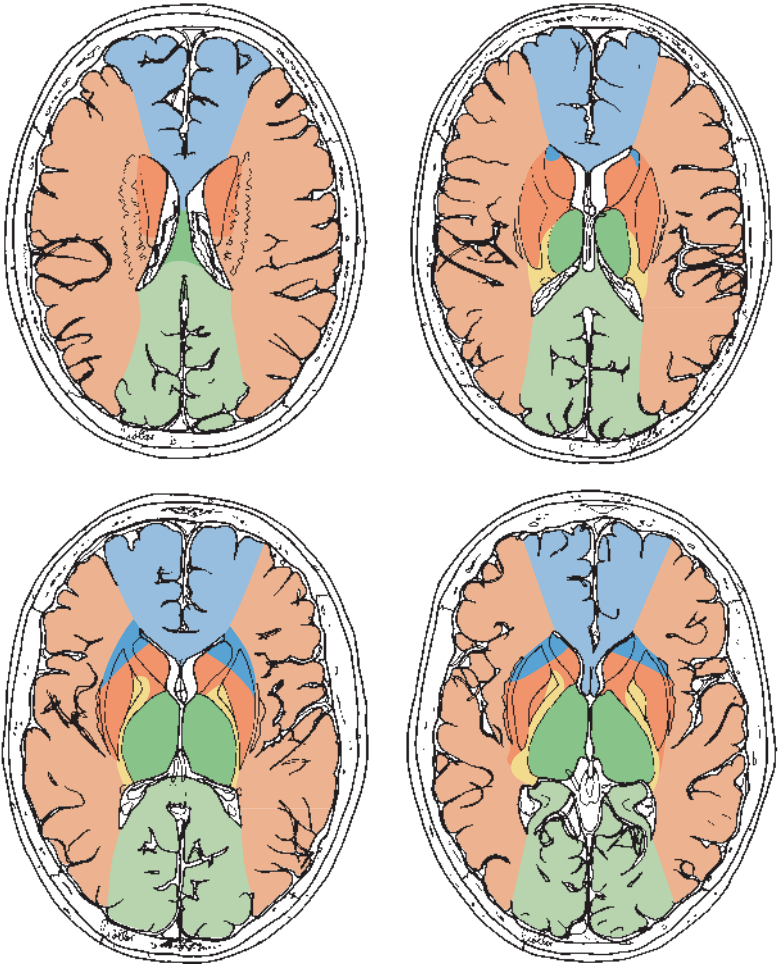
- | | |
|---|---|
| <ul style="list-style-type: none"> 1 Nasal bone 2 Nasal septum 3 Superior nasal concha 4 Maxilla (with infra-orbital canal) | <ul style="list-style-type: none"> 5 Levator labii superioris muscle 6 Medial wall of maxillary sinus (with maxillary hiatus) 7 Orbicularis oris muscle 8 Vomer (sphenoidal bone) |
|---|---|



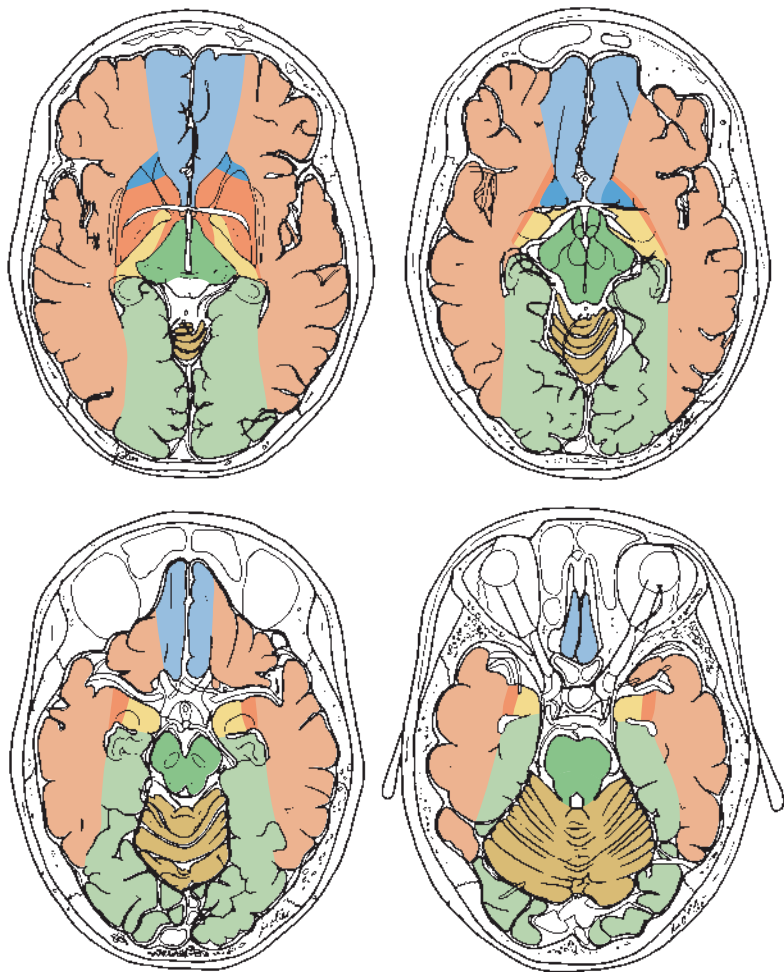
- | | | | |
|----|--|----|---|
| 9 | Nasolacrimal duct | 23 | Tensor veli palatini muscle |
| 10 | Pharyngotympanic tube (auditory tube) | 24 | Clivus |
| 11 | Maxillary sinus | 25 | Levator veli palatini muscle |
| 12 | Masseter muscle | 26 | Internal jugular vein (bulb) |
| 13 | Zygomatic bone and zygomaticus muscles | 27 | Longus capitis muscle |
| 14 | Lateral pterygoid muscle (superior and inferior heads) | 28 | Vagus (X) and accessory (XI) nerves |
| 15 | Temporal muscles | 29 | Glossopharyngeal nerve (IX) |
| 16 | Pharyngeal recess | 30 | Vertebral artery |
| 17 | Medial pterygoid muscle | 31 | Mastoid cells |
| 18 | Head of mandible | 32 | Medulla oblongata |
| 19 | Pterygoid process (medial and lateral plates) | 33 | Hypoglossal nerve (XII) |
| 20 | Sphenoidal bone (tip) | 34 | Sigmoid sinus |
| 21 | Mandibular nerve and auriculotemporal nerve | 35 | Hemisphere of cerebellum (posterior lobe) |
| 22 | Internal carotid artery | 36 | Fourth ventricle (medial aperture) |
| | | 37 | Falx cerebelli with occipital sinus |
| | | 38 | Tonsil of cerebellum |
| | | 39 | Semispinalis capitis muscle |
| | | 40 | Occipital bone |



-  **Anterior cerebral artery**
Terminal branches
-  **Middle cerebral artery**
Terminal branches
-  **Posterior cerebral artery**
Terminal branches



- | | |
|---|---|
| <p>Anterior cerebral artery</p> <ul style="list-style-type: none"> Terminal branches Central branches (striated branches Central branches and Huebner's recurrent including distal medial striate artery) <p>Middle cerebral artery</p> <ul style="list-style-type: none"> Terminal branches Central branches (striated branches) | <p>Posterior cerebral artery</p> <ul style="list-style-type: none"> Terminal branches Central branches (including the posterior communicating artery) <p>Anterior choroidal artery</p> <ul style="list-style-type: none"> Anterior choroidal artery |
|---|---|

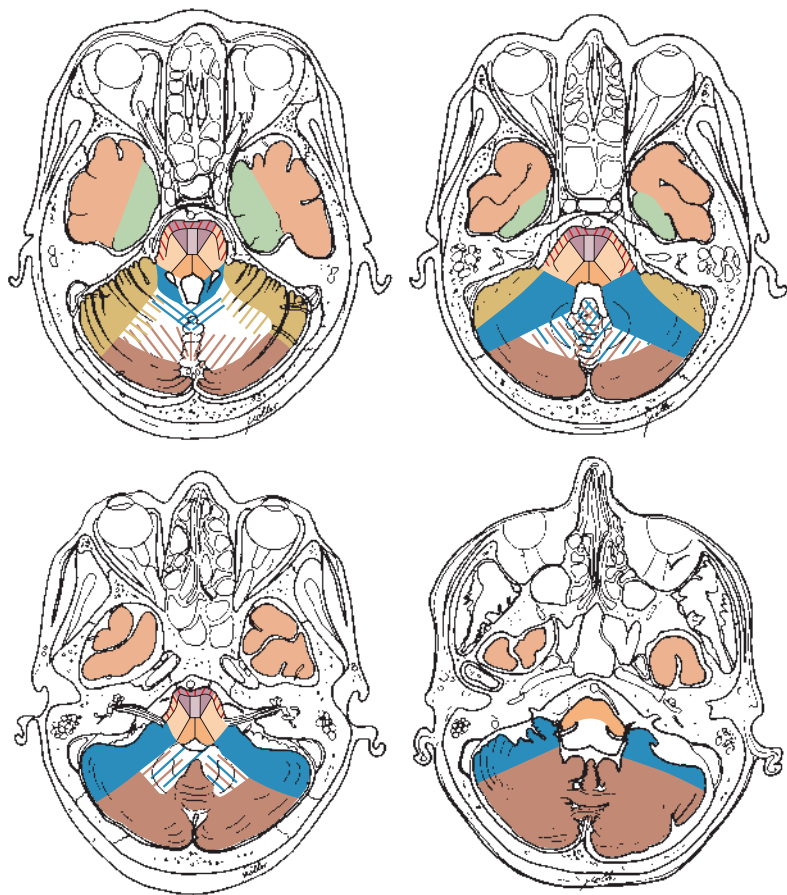















- Anterior cerebral artery**
- Terminal branches
 - Central branches (striated branches)

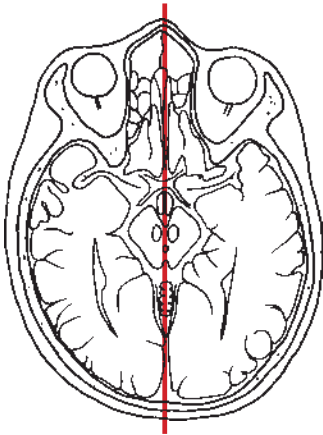
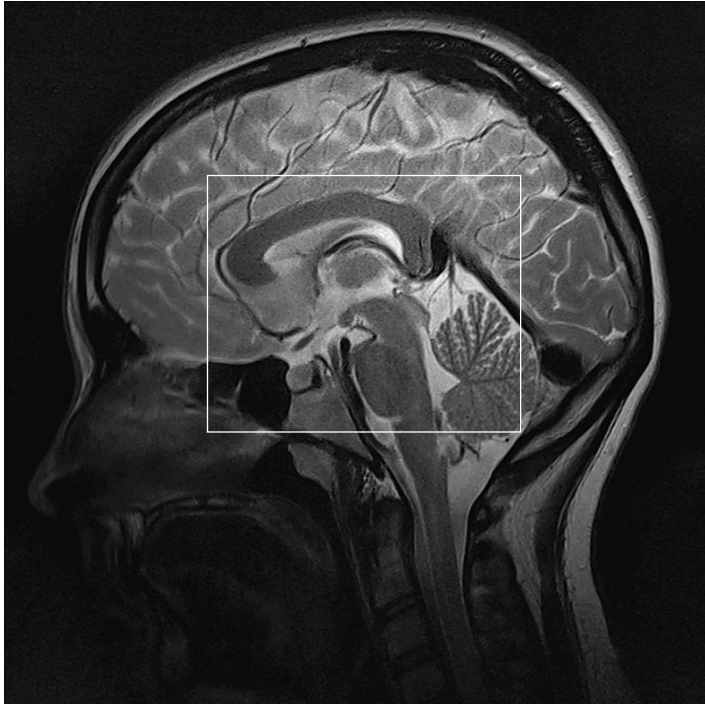
- Middle cerebral artery**
- Terminal branches
 - Central branches (striated branches)








- Posterior cerebral artery**
- Terminal branches
 - Central branches (including the posterior communicating artery)

- Anterior choroidal artery
- Superior cerebellar artery

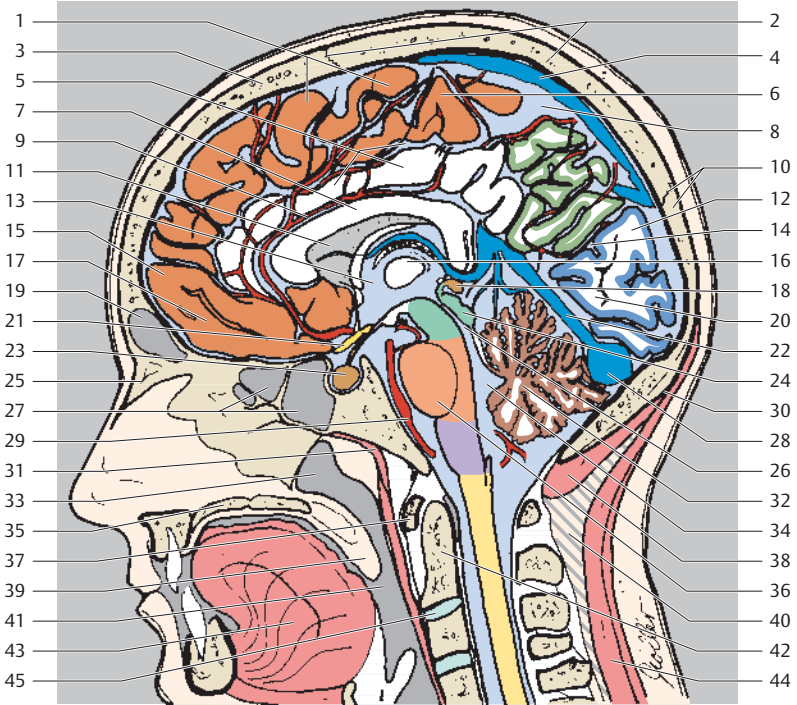


- | | |
|---|--|
| <p>Middle cerebral artery</p> <p> Terminal branches</p> <p>Posterior cerebral artery</p> <p> Terminal branches</p> <p>Basilar artery: superficial arteries</p> <p> Median brain-stem arteries</p> <p> Short circumferential artery</p> <p> Long circumferential artery</p> | <p>Basilar artery: central arteries</p> <p> Anteromedial</p> <p> Anterolateral</p> <p> Lateral</p> <p> Dorsal</p> <p> Superior cerebellar artery</p> <p> Anterior inferior cerebellar artery</p> <p> Border region</p> <p> Posterior inferior cerebellar artery</p> |
|---|--|

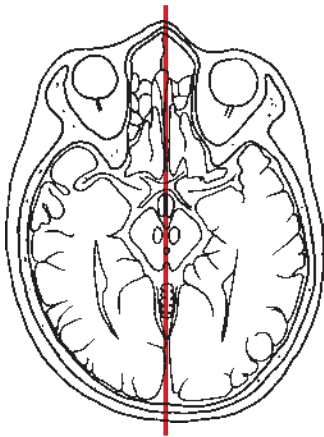
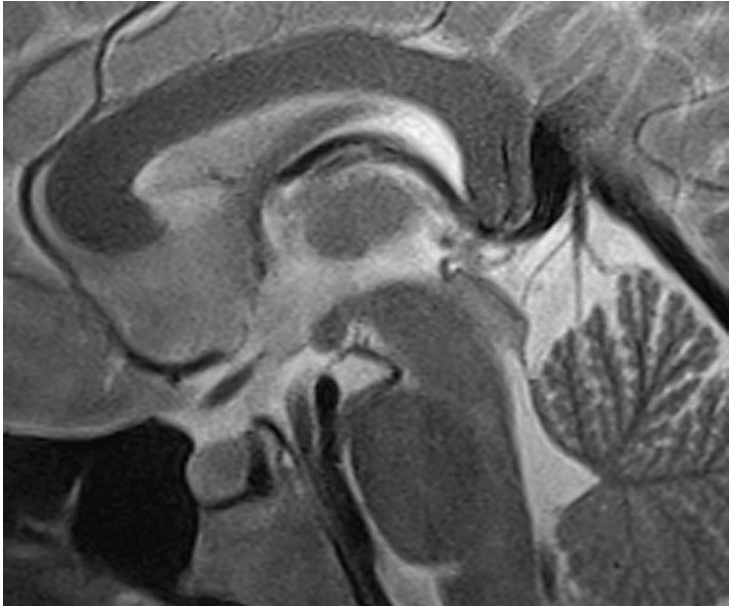









-  Frontal lobe
-  Parietal lobe
-  Occipital lobe
-  Cerebellum
-  Mesencephalon
-  Pons
-  Medulla oblongata

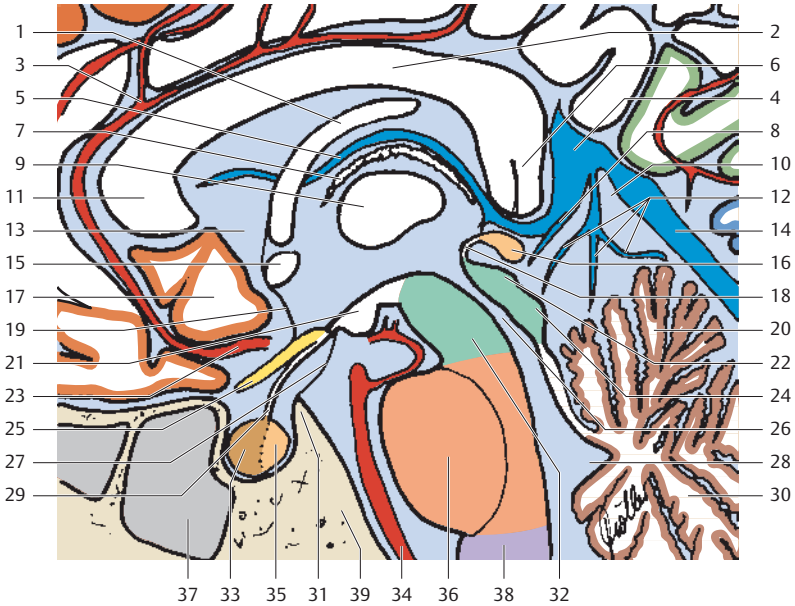
- 1 Superior frontal gyrus
- 2 Parietal bone and coronal suture
- 3 Frontal bone
- 4 Superior sagittal sinus
- 5 Cingulate gyrus and sulcus
- 6 Precentral gyrus
- 7 Corpus callosum (genu)



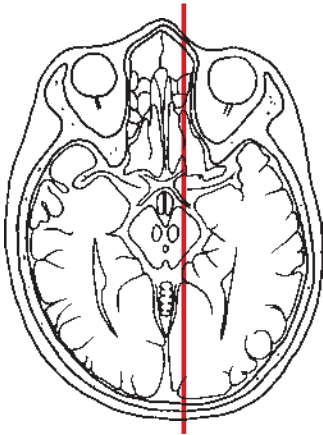
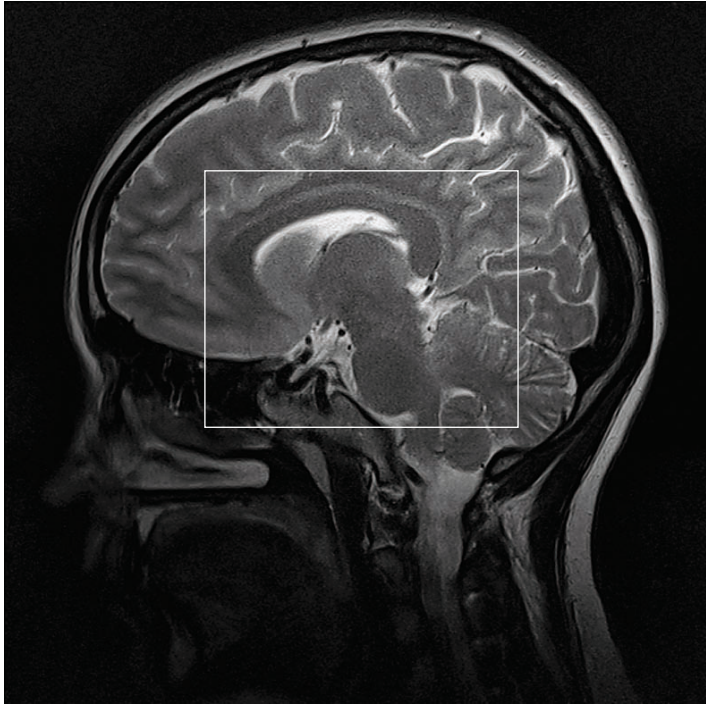
- | | |
|---|---|
| 8 Falx cerebri in Longitudinal cerebral fissure | 27 Ethmoid sinus and sphenoidal sinus |
| 9 Pericallosal artery | 28 Confluence of sinuses |
| 10 Occipital bone and lambdoid suture | 29 Basilar artery |
| 11 Septum pellucidum | 30 External occipital protuberance |
| 12 Cuneus | 31 Superior constrictor muscle of pharynx |
| 13 Third ventricle | 32 Cerebellum |
| 14 Parieto-occipital sulcus | 33 Nasopharynx |
| 15 Frontal pole | 34 Fourth ventricle |
| 16 Interthalamic adhesion | 35 Hard palate |
| 17 Straight gyrus | 36 Pons |
| 18 Cerebral epiphysis | 37 Atlas, anterior arch |
| 19 Frontal sinus | 38 Rectus capitis posterior minor muscle |
| 20 Lingual gyrus | 39 Uvula |
| 21 Optic nerve (II) | 40 Ligamentum nuchae (nuchal ligament) |
| 22 Straight sinus | 41 Oropharynx |
| 23 Pituitary gland | 42 Dens of axis |
| 24 Quadrigeminal plate | 43 Tongue |
| 25 Nasal bone | 44 Semispinalis capitis muscle |
| 26 Aqueduct | 45 Intervertebral disc (C2/C3) |










-  Frontal lobe
-  Parietal lobe
-  Occipital lobe
-  Cerebellum
-  Mesencephalon
-  Pons
-  Medulla oblongata

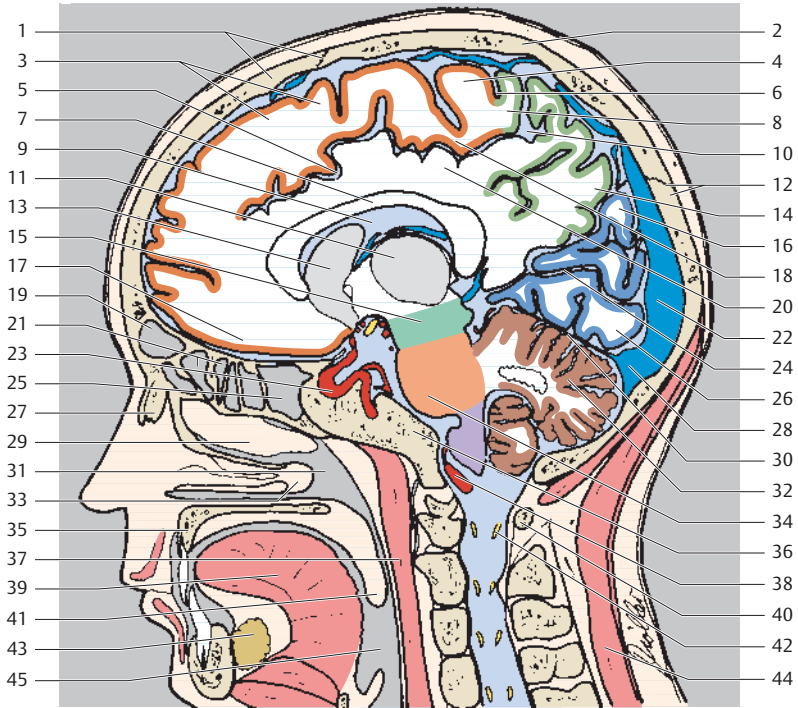


- | | |
|---|--|
| 1 Fornix (body) | 22 Tectal (quadrigeminal) plate (superior colliculus) |
| 2 Corpus callosum (trunk) | 23 Anterior cerebral artery |
| 3 Pericallosal artery | 24 Tectal (quadrigeminal) plate (posterior colliculus) |
| 4 Great cerebral vein | 25 Optic nerve (II) |
| 5 Internal cerebral vein | 26 Aqueduct |
| 6 Corpus callosum (splenium) | 27 Lilliequist's membrane |
| 7 Choroid plexus | 28 Fourth ventricle (roof) |
| 8 Basal vein | 29 Infundibulum of pituitary gland |
| 9 Interthalamic adhesion | 30 Hemisphere of cerebellum (posterior lobe) |
| 10 Cistern of great cerebral vein | 31 Dorsum sellae |
| 11 Corpus callosum (genu) | 32 Mesencephalon (midbrain) |
| 12 Cerebellar veins | 33 Anterior lobe of pituitary gland (adenohypophysis) |
| 13 Third ventricle | 34 Basilar artery |
| 14 Straight sinus | 35 Posterior lobe of pituitary gland (neurohypophysis) |
| 15 Anterior commissure | 36 Pons |
| 16 Pineal body | 37 Sphenoidal sinus |
| 17 Paraterminal gyrus | 38 Medulla oblongata |
| 18 Posterior commissure | 39 Clivus |
| 19 Lamina terminalis | |
| 20 Hemisphere of cerebellum (anterior lobe) | |
| 21 Mammillary body | |

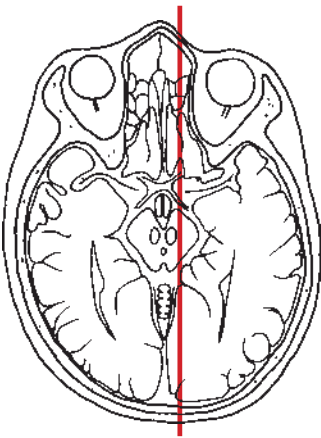
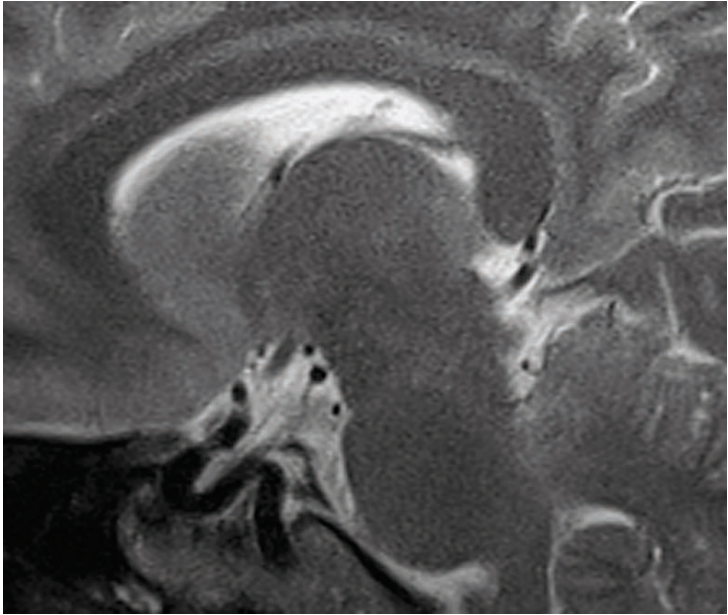









-  Frontal lobe
-  Parietal lobe
-  Occipital lobe
-  Cerebellum
-  Mesencephalon
-  Pons
-  Medulla oblongata

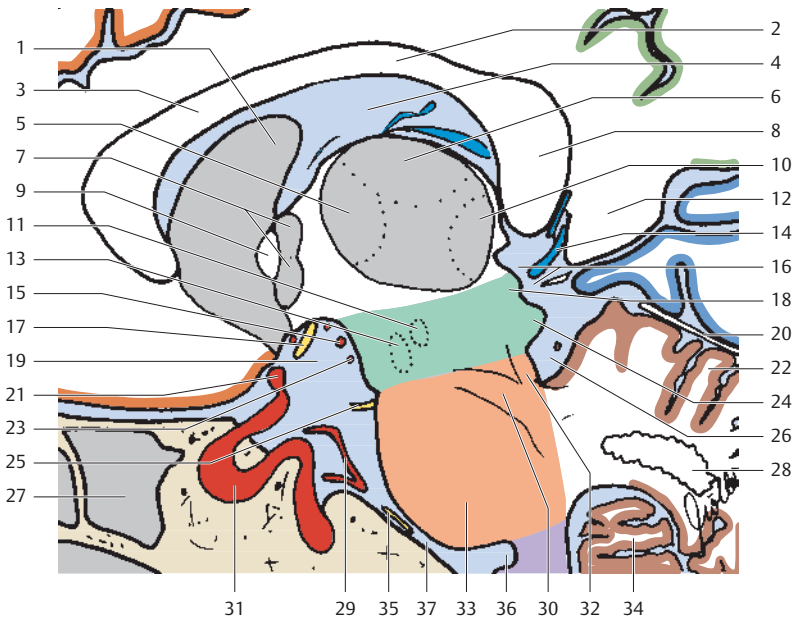
- 1 Frontal bone and coronal suture
- 2 Parietal bone
- 3 Superior frontal gyrus
- 4 Precentral gyrus
- 5 Cingulate gyrus
- 6 Central sulcus
- 7 Corpus callosum
- 8 Postcentral gyrus



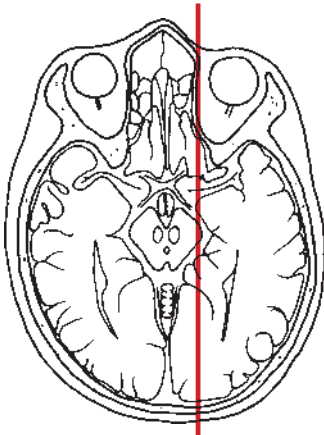
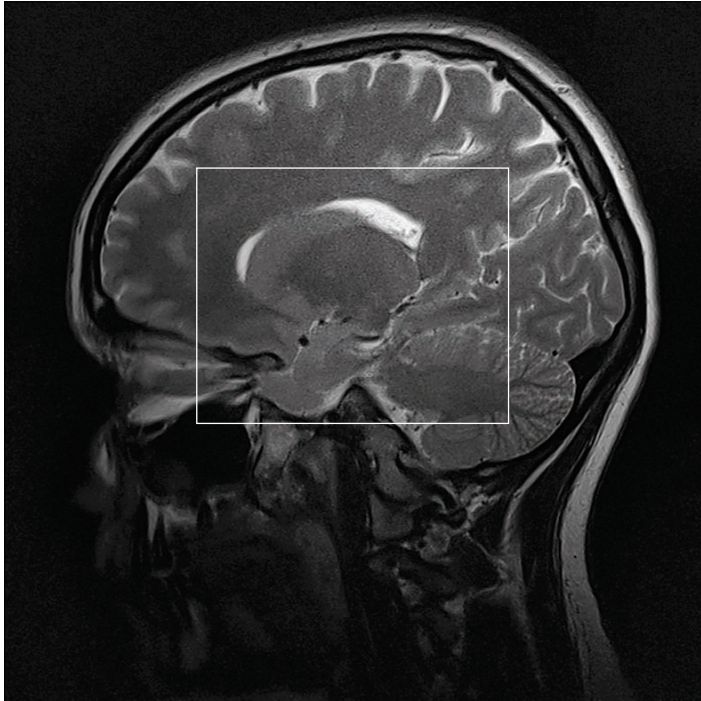
- | | |
|---------------------------------------|--------------------------------|
| 9 Lateral ventricle (central part) | 27 Nasal bone |
| 10 Postcentral sulcus | 28 Confluence of sinuses |
| 11 Thalamus | 29 Middle nasal concha |
| 12 Occipital bone and lambdoid suture | 30 Tentorium cerebelli |
| 13 Caudate nucleus (head) | 31 Nasopharynx |
| 14 Precuneus | 32 Cerebellum |
| 15 Cerebral peduncle | 33 Inferior nasal concha |
| 16 Cuneus | 34 Pons |
| 17 Straight gyrus | 35 Hard palate |
| 18 Precentral lobule | 36 Clivus |
| 19 Frontal sinus | 37 Longus capitis muscle |
| 20 Cingulate gyrus | 38 Vertebral artery |
| 21 Ethmoidal sinus | 39 Tongue |
| 22 Superior sagittal sinus | 40 Atlas, posterior arch |
| 23 Internal carotid artery (syphon) | 41 Uvula |
| 24 Calcarine sulcus | 42 Nerve roots |
| 25 Sphenoidal sinus | 43 Sublingual gland |
| 26 Medial occipitotemporal gyrus | 44 Semispinalis capitis muscle |
| | 45 Oropharynx |









-  Frontal lobe
-  Parietal lobe
-  Occipital lobe
-  Cerebellum
-  Mesencephalon
-  Pons
-  Medulla oblongata

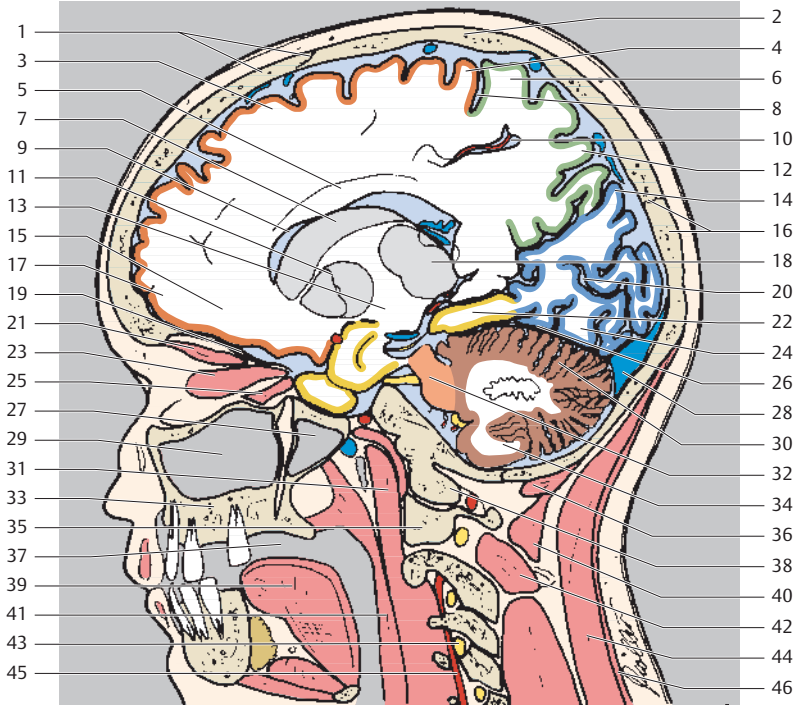


- | | |
|---|--|
| 1 Head of caudate nucleus | 19 Interpeduncular cistern |
| 2 Corpus callosum (trunk) | 20 Tentorium cerebelli |
| 3 Corpus callosum (genu) | 21 Anterior cerebral artery |
| 4 Lateral ventricle | 22 Hemisphere of cerebellum (anterior lobe) |
| 5 Thalamus (ventral lateral complex) | 23 Superior cerebellar artery |
| 6 Thalamus (posterior lateral complex) | 24 Tectal (quadrigeminal) plate (posterior colliculus) |
| 7 Globus pallidus (lateral and medial segments) | 25 Trigeminal nerve (V) |
| 8 Corpus callosum (splenium) | 26 Ambient cistern |
| 9 Anterior commissure | 27 Sphenoidal sinus |
| 10 Thalamus (pulvinar) | 28 Dentate nucleus |
| 11 Red nucleus | 29 Posterior communicating artery |
| 12 Parahippocampal gyrus | 30 Cerebellar peduncle |
| 13 Substantia nigra | 31 Internal carotid artery |
| 14 Great cerebral vein | 32 Lateral lemniscus |
| 15 Posterior cerebral artery | 33 Pons |
| 16 Quadrigeminal cistern | 34 Tonsil of cerebellum |
| 17 Optic tract | 35 Abducent nerve (VI) |
| 18 Tectal (quadrigeminal) plate (superior colliculus) | 36 Fourth ventricle (lateral aperture) |
| | 37 Pontocerebellar cistern |

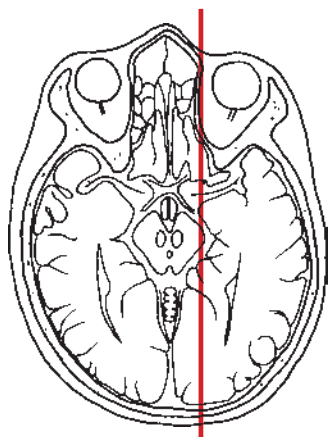
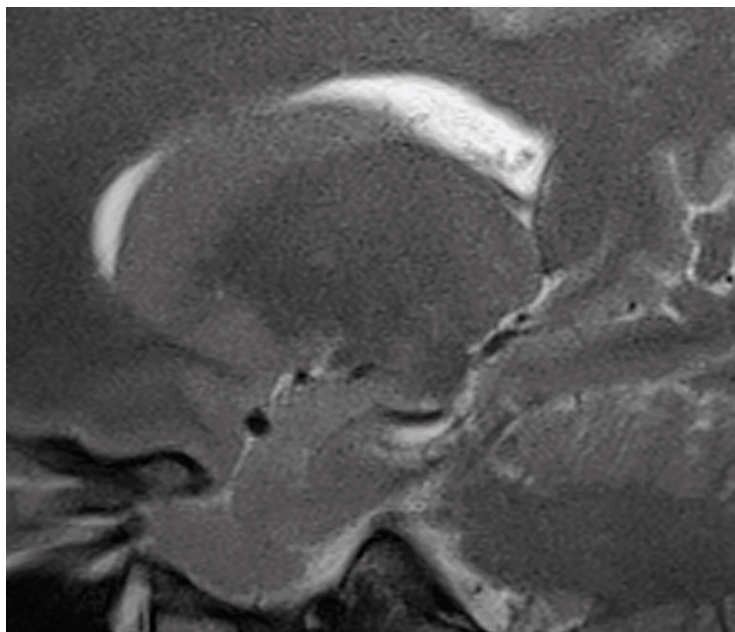







-  Frontal lobe
-  Temporal lobe
-  Parietal lobe
-  Occipital lobe
-  Cerebellum
-  Pons

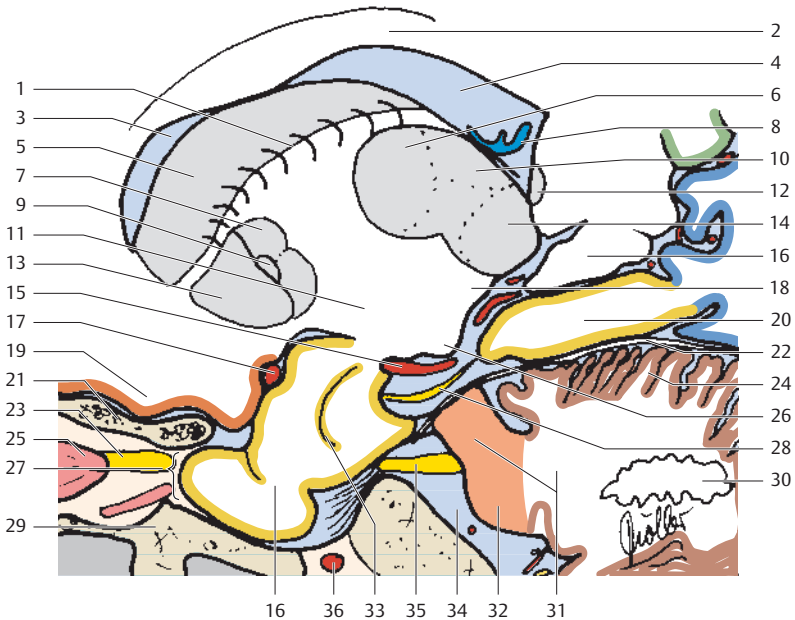
- 1 bone
- 2 Frontal bone and coronal suture
- 3 Parietal Superior frontal gyrus
- 4 Precentral gyrus
- 5 Corpus callosum
- 6 Postcentral gyrus
- 7 Caudate nucleus (body)
- 8 Central sulcus



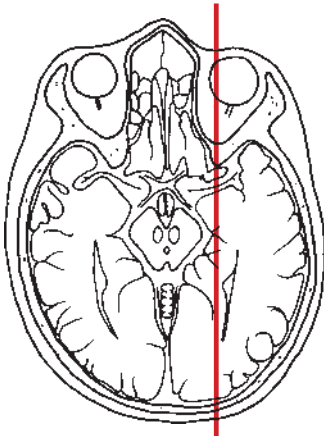
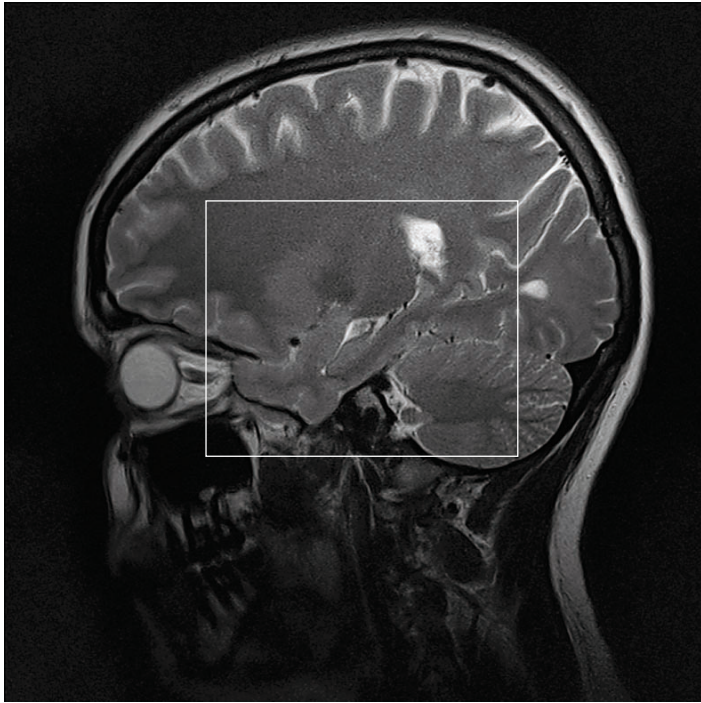
- | | |
|---------------------------------------|--|
| 9 Lateral ventricle (frontal horn) | 28 Transverse sinus |
| 10 Postcentral sulcus | 29 Maxillary sinus |
| 11 Basal nuclei | 30 Superior cerebellar lobe |
| 12 Precuneus | 31 Longus capitis muscle |
| 13 Cerebral peduncle | 32 Middle cerebral peduncle |
| 14 Cuneus | 33 Maxilla |
| 15 Orbital gyrus | 34 Inferior cerebellar lobe |
| 16 Occipital bone and lambdoid suture | 35 Atlas, lateral mass |
| 17 Inferior frontal gyrus | 36 Rectus capitis posterior minor muscle |
| 18 Thalamus | 37 Oropharynx |
| 19 Roof of orbit | 38 Occipital condyle |
| 20 Calcarine sulcus | 39 Tongue |
| 21 Superior rectus muscle | 40 Rectus capitis posterior major muscle |
| 22 Parahippocampal gyrus | 41 Middle constrictor muscle of pharynx |
| 23 Medial rectus muscle | 42 Obliquus capitis inferior muscle |
| 24 Medial occipitotemporal gyrus | 43 Spinal nerve root C4 |
| 25 Inferior rectus muscle | 44 Splenius capitis muscle |
| 26 Tentorium cerebelli | 45 Vertebral artery |
| 27 Sphenoidal sinus | 46 Trapezius muscle |



-  Frontal lobe
-  Temporal lobe
-  Parietal lobe
-  Occipital lobe
-  Cerebellum
-  Pons

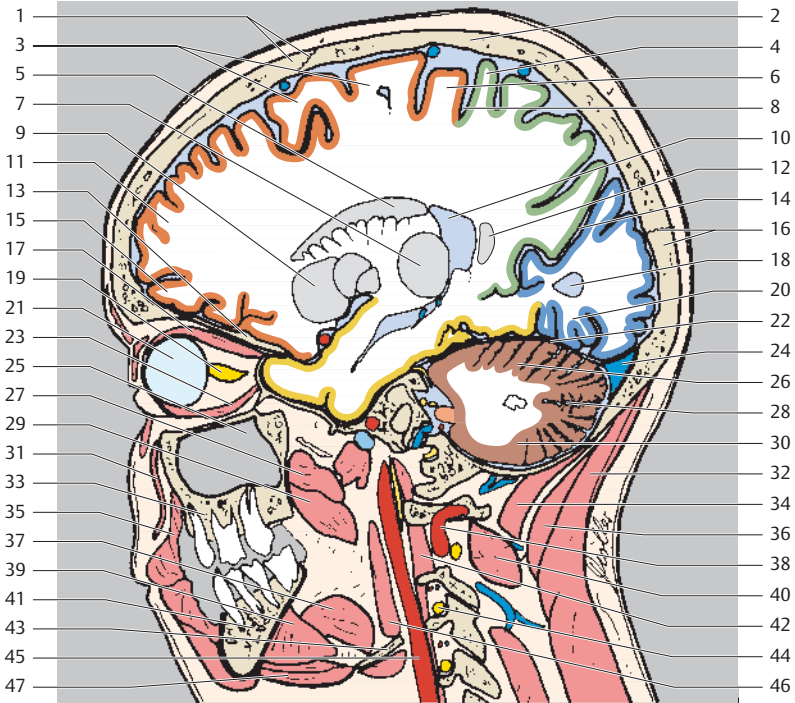


- | | |
|---|---|
| 1 Corpus striatum | 19 Orbital gyrus |
| 2 Corpus callosum (trunk) | 20 Lingual gyrus |
| 3 Lateral ventricle (frontal horn) | 21 Sphenoidal bone (lesser wing) |
| 4 Lateral ventricle | 22 Tentorium cerebelli |
| 5 Caudate nucleus (head) | 23 Optic nerve (II) |
| 6 Thalamus (ventral lateral complex) | 24 Hemisphere of cerebellum (anterior lobe) |
| 7 Globus pallidus | 25 Medial rectus muscle |
| 8 Choroid plexus | 26 Lateral geniculate body |
| 9 Anterior commissure | 27 Superior orbital fissure |
| 10 Thalamus (posterior lateral complex) | 28 Trochlear nerve (IV) |
| 11 Internal capsule | 29 Oculomotor nerve (III) |
| 12 Fornix (crus) | 30 Dentate nucleus |
| 13 Putamen | 31 Middle cerebellar peduncle |
| 14 Thalamus (pulvinar) | 32 Pons |
| 15 Posterior cerebral artery | 33 Lateral ventricle (temporal horn) |
| 16 Parahippocampal gyrus | 34 Pontocerebellar cistern |
| 17 Middle cerebral artery | 35 Trigeminal nerve (V) |
| 18 Medial geniculate body | 36 Internal carotid artery |

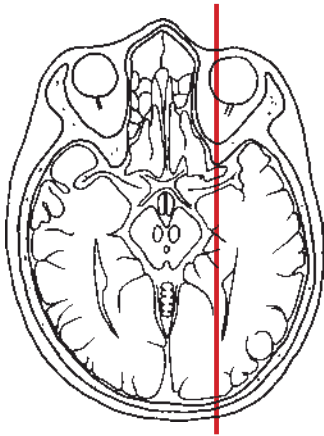
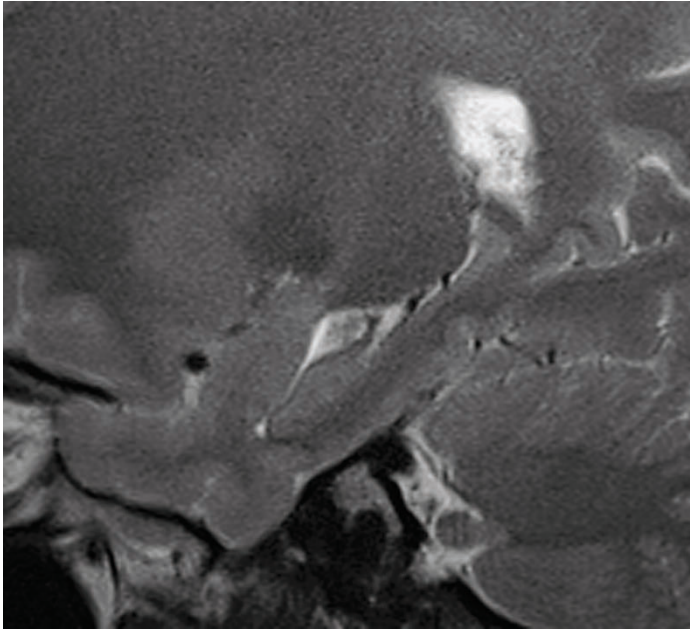


- Frontal lobe
- Temporal lobe
- Parietal lobe
- Occipital lobe
- Cerebellum

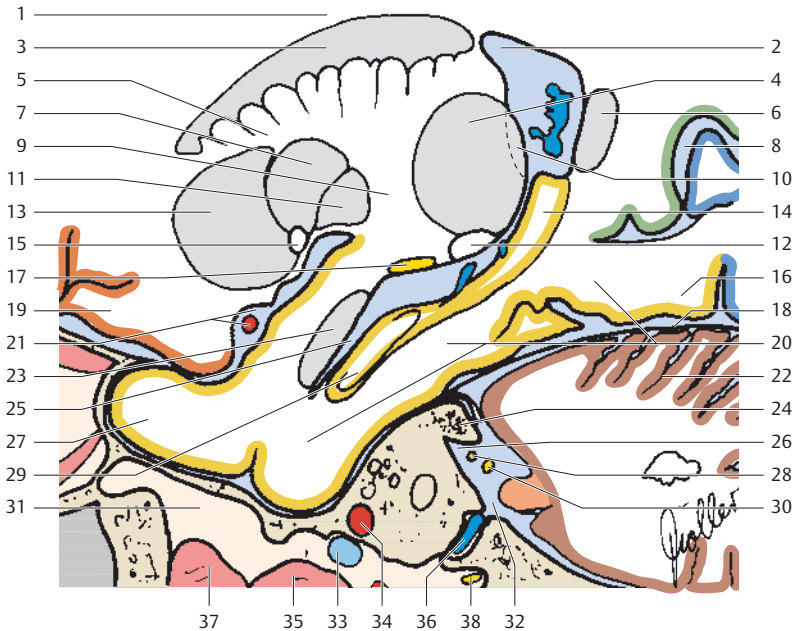
- 1 Frontal bone and coronal suture
- 2 Parietal bone
- 3 Superior frontal gyrus
- 4 Postcentral gyrus
- 5 Caudate nucleus (body)
- 6 Precentral gyrus
- 7 Thalamus
- 8 Central sulcus



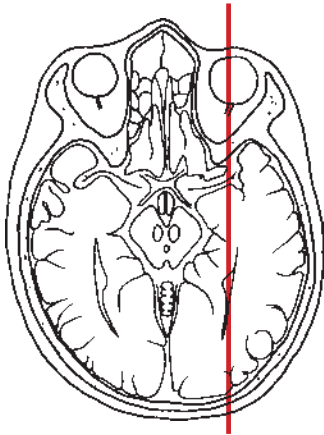
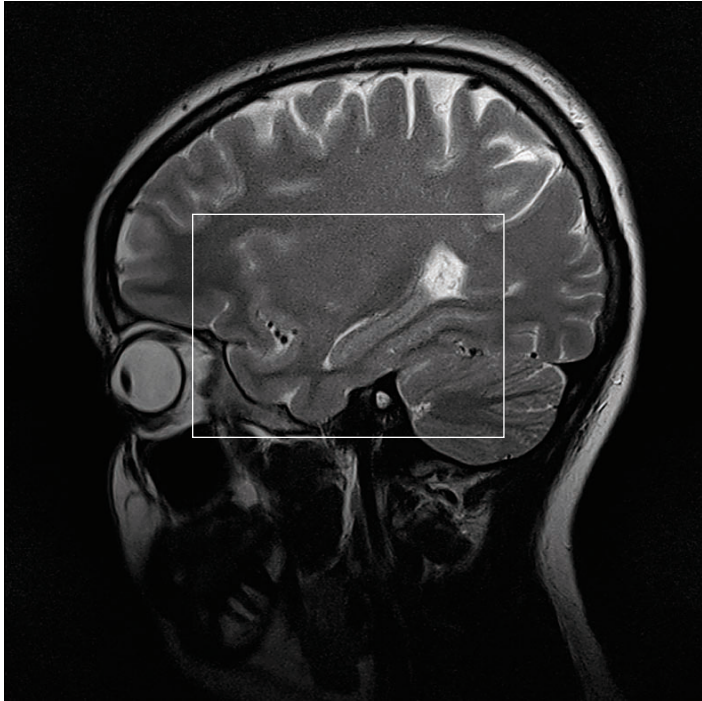
- | | |
|--|--|
| 9 Basal nuclei | 27 Levator veli palatini muscle |
| 10 Lateral ventricle | 28 Horizontal fissure |
| 11 Middle frontal gyrus | 29 Medial pterygoid muscle |
| 12 Corpus callosum
(major forceps) | 30 Posterior lobe of cerebellum |
| 13 Roof of orbit | 31 Levator labii superioris muscle |
| 14 Parieto-occipital sulcus | 32 Splenius capitis muscle |
| 15 Orbital gyrus | 33 Maxilla |
| 16 Occipital bone and lambdoid
suture | 34 Rectus capitis posterior major muscle |
| 17 Superior rectus muscle | 35 Orbicularis oris muscle |
| 18 Lateral ventricle (occipital
horn) | 36 Semispinalis capitis muscle |
| 19 Optic nerve (II) | 37 Hypoglossus muscle |
| 20 Medial occipitotemporal gyrus | 38 Vertebral artery |
| 21 Eyeball | 39 Mylohyoid muscle |
| 22 Tentorium cerebelli | 40 Obliquus capitis inferior muscle |
| 23 Inferior rectus muscle | 41 Mandible |
| 24 Transverse sinus | 42 Longus capitis muscle |
| 25 Maxillary sinus | 43 Hyoid bone |
| 26 Anterior lobe of cerebellum | 44 Spinal nerve root C3 |
| | 45 Internal carotid artery |
| | 46 Middle constrictor muscle of pharynx |
| | 47 Digastric muscle |








- Frontal lobe
- Temporal lobe
- Parietal lobe
- Occipital lobe
- Cerebellum

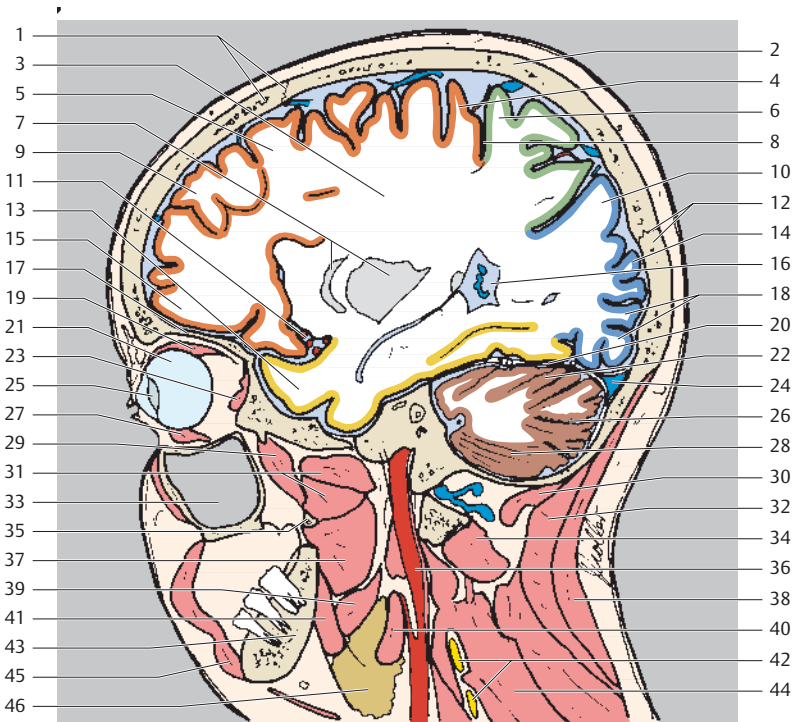


- | | |
|-------------------------------------|--|
| 1 Corpus callosum (trunk) | 21 Middle cerebral artery in cistern of lateral cerebral fossa |
| 2 Lateral ventricle (central part) | 22 Hemisphere of cerebellum (anterior lobe) |
| 3 Caudate nucleus (body) | 23 Amygdaloid nucleus |
| 4 Thalamus (pulvinar) | 24 Petrous pyramid |
| 5 Internal capsule (anterior limb) | 25 Lateral ventricle (temporal horn) |
| 6 Corpus callosum (major forceps) | 26 Internal acoustic meatus |
| 7 Globus pallidus (lateral segment) | 27 Temporal pole |
| 8 Parieto-occipital sulcus | 28 Facial nerve (VII) |
| 9 Internal capsule (posterior limb) | 29 Dentate gyrus |
| 10 Fornix (crus) | 30 Vestibulocochlear (acoustic) nerve (VIII) |
| 11 Globus pallidus (medial segment) | 31 Infratemporal fossa |
| 12 Lateral geniculate body | 32 Pontocerebellar cistern |
| 13 Putamen | 33 Pharyngotympanic tube (auditory tube) |
| 14 Subiculum of hippocampus | 34 Internal carotid artery (petrous part) |
| 15 Anterior commissure | 35 Elevator muscle of the soft palate |
| 16 Medial occipitotemporal gyrus | 36 Internal jugular vein in the jugular foramen |
| 17 Optic tract | 37 Medial pterygoid muscle |
| 18 Tentorium cerebelli | 38 Hypoglossal nerve (XII) in hypoglossal canal |
| 19 Orbital gyrus | |
| 20 Parahippocampal gyrus | |

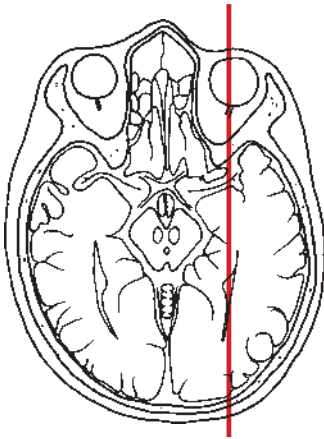
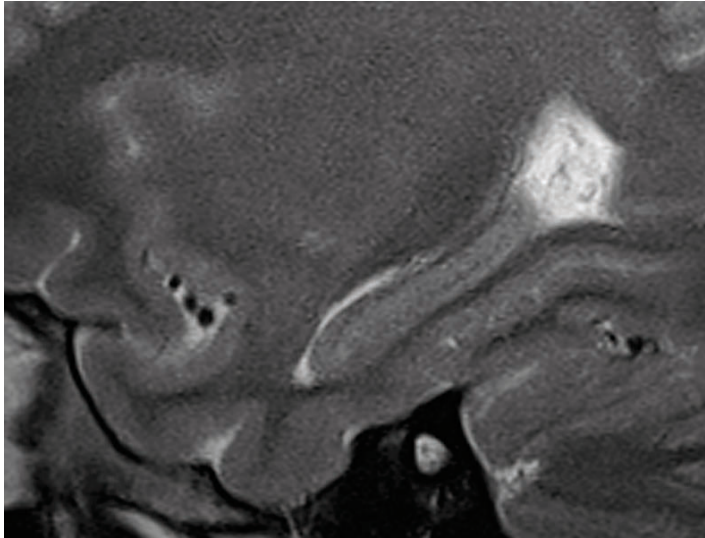


-  Frontal lobe
-  Temporal lobe
-  Parietal lobe
-  Occipital lobe
-  Cerebellum

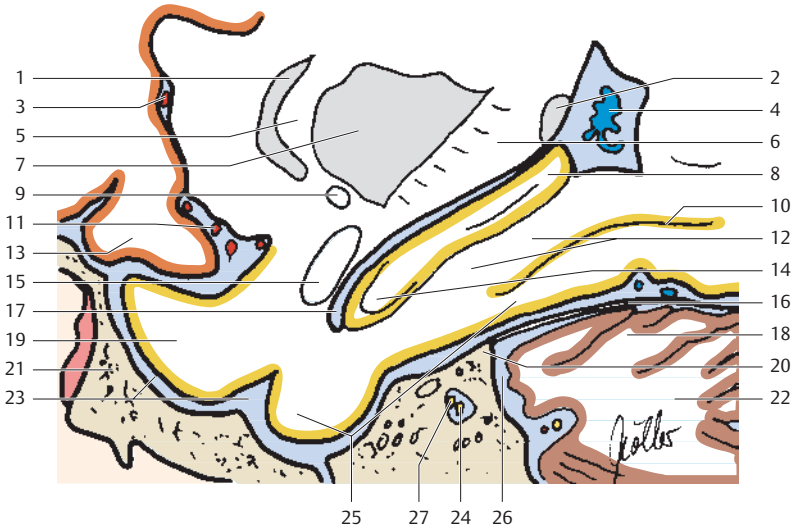
- 1 Frontal bone and coronal suture
- 2 Parietal bone
- 3 Cerebral white matter (semioval center)
- 4 Precentral gyrus
- 5 Superior frontal gyrus
- 6 Postcentral gyrus
- 7 Basal ganglia



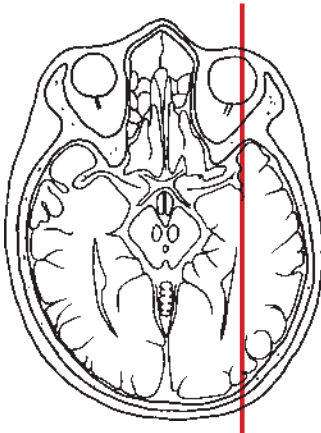
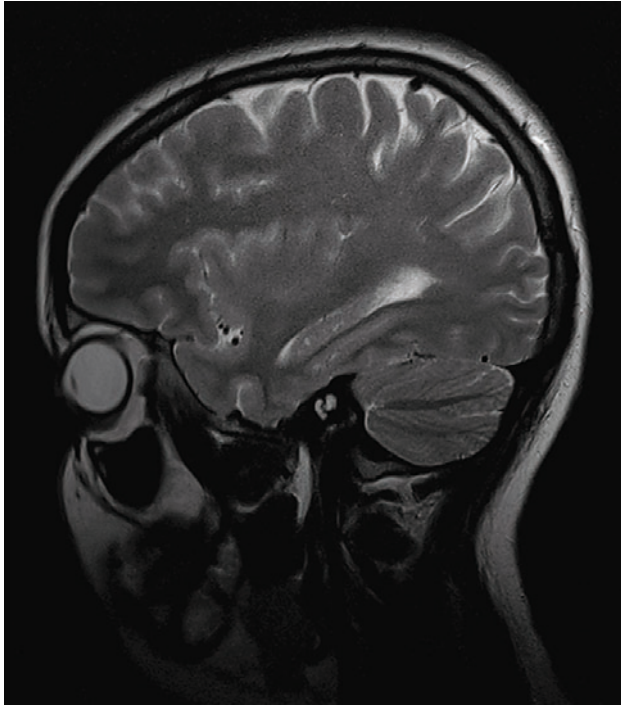
- | | | | |
|----|------------------------------------|----|---------------------------------------|
| 8 | Central sulcus | 27 | Inferior rectus muscle |
| 9 | Middle frontal gyrus | 28 | Posterior lobe of cerebellum |
| 10 | Precuneus | 29 | Temporal muscle |
| 11 | Insular arteries | 30 | rectus capitis posterior major muscle |
| 12 | Occipital bone and lambdoid suture | 31 | Lateral pterygoid muscle |
| 13 | Temporal pole | 32 | Semispinalis capitis muscle |
| 14 | Cuneus | 33 | Maxillary sinus |
| 15 | Orbital gyrus | 34 | Obliquus capitis inferior muscle |
| 16 | Lateral ventricle (occipital horn) | 35 | Pterygoid process, lateral plate |
| 17 | Roof of orbit | 36 | Internal carotid artery |
| 18 | Occipital gyri | 37 | Medial pterygoid muscle |
| 19 | Superior rectus muscle | 38 | Trapezius muscle |
| 20 | Tentorium cerebelli | 39 | Styloglossus muscle |
| 21 | Eyeball | 40 | Digastric muscle |
| 22 | Anterior lobe of cerebellum | 41 | Mylohyoid muscle |
| 23 | Lateral rectus muscle | 42 | Spinal nerve roots (cervical plexus) |
| 24 | Transverse sinus | 43 | Mandible |
| 25 | Lens | 44 | Levator scapulae muscle |
| 26 | Horizontal fissure | 45 | Orbicularis oris muscle |
| | | 46 | Submandibular gland |



- Frontal lobe
- Temporal lobe
- Parietal lobe
- Occipital lobe
- Cerebellum

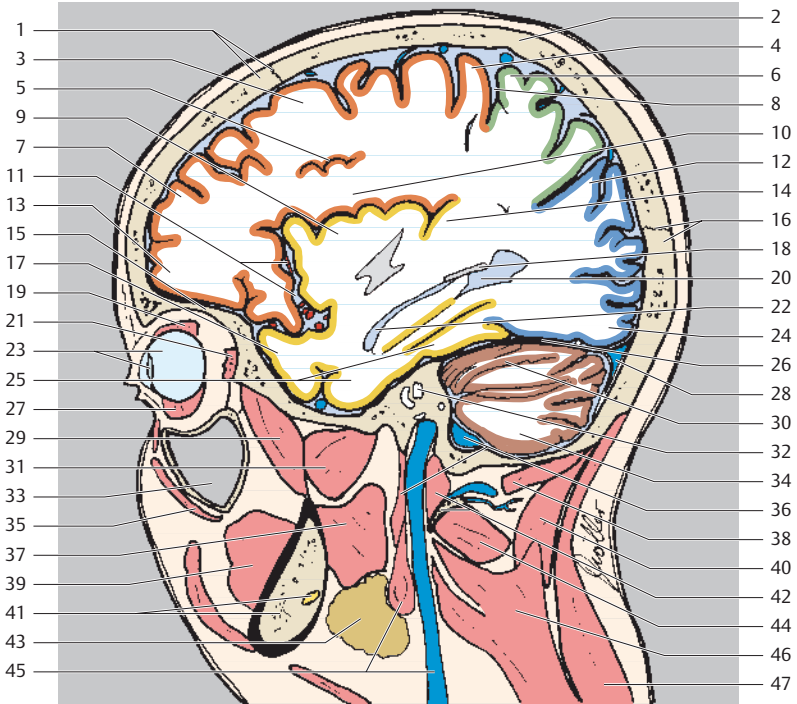


- | | | | |
|----|--|----|---|
| 1 | Clastrum | 16 | Tentorium cerebelli |
| 2 | Caudate nucleus (tail) | 17 | Lateral ventricle (temporal horn) |
| 3 | Insular arteries | 18 | Anterior lobe of cerebellum |
| 4 | Lateral ventricle (central part) with choroid plexus | 19 | Temporal lobe (temporal pole) |
| 5 | External capsule | 20 | Petrous part of temporal bone (superior margin) |
| 6 | Internal capsule | 21 | Sphenoidal bone (greater wing) |
| 7 | Putamen | 22 | Cerebellum (cerebellar white matter) |
| 8 | Subiculum of hippocampus | 23 | Middle cranial fossa |
| 9 | Anterior commissure | 24 | Vestibulocochlear (acoustic) nerve (VIII) in Internal auditory meatus |
| 10 | Collateral sulcus | 25 | Medial occipitotemporal gyrus |
| 11 | Middle cerebral artery | 26 | Pontocerebellar cistern |
| 12 | Parahippocampal gyrus | 27 | Facial nerve (VII) in Internal auditory meatus |
| 13 | Orbital gyrus | | |
| 14 | Dentate gyrus | | |
| 15 | Amygdaloid nucleus | | |

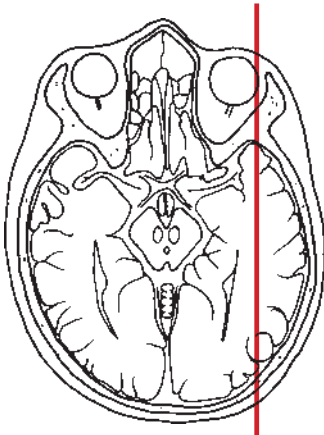
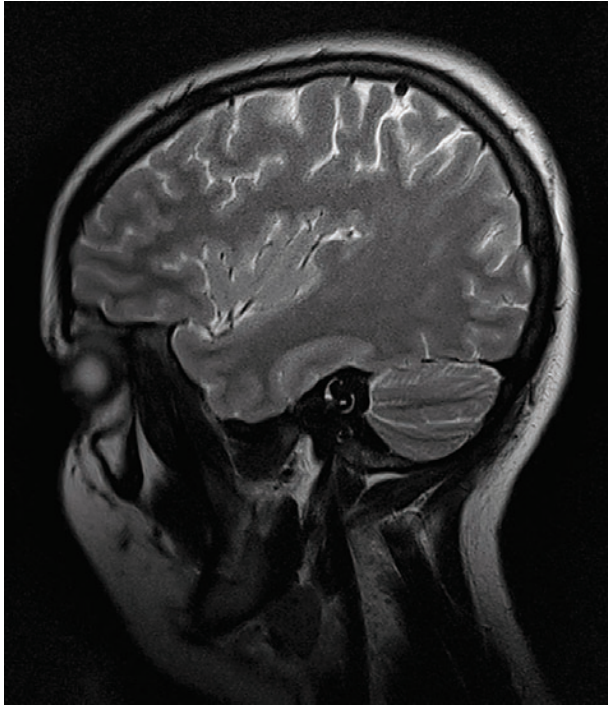







- Frontal lobe
- Temporal lobe
- Parietal lobe
- Occipital lobe
- Cerebellum

- 1 Frontal bone and coronal suture
- 2 Parietal bone
- 3 Middle frontal gyrus
- 4 Precentral gyrus
- 5 Inferior frontal sulcus
- 6 Postcentral gyrus
- 7 Inferior frontal gyrus
- 8 Central sulcus
- 9 Insular gyri
- 10 Frontal operculum
- 11 Cistern of lateral cerebral fossa (insular cistern) and insular arteries

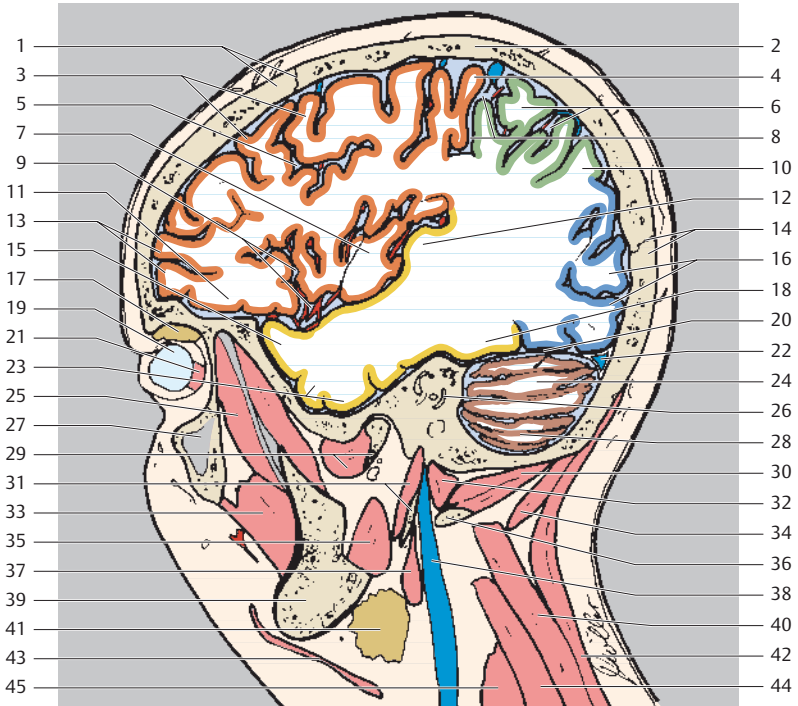


- | | | | |
|----|-------------------------------------|----|--|
| 12 | Precuneus | 30 | Anterior lobe of cerebellum |
| 13 | Orbital gyrus | 31 | Lateral pterygoid muscle |
| 14 | Transverse temporal gyrus | 32 | Internal acoustic meatus |
| 15 | Roof of orbit | 33 | Maxillary sinus |
| 16 | Occipital bone and lambdoid suture | 34 | Posterior lobe of cerebellum |
| 17 | Temporal pole | 35 | Orbicularis oculi muscle |
| 18 | Caudate nucleus (tail) | 36 | Sigmoid sinus and stylopharyngeus muscle |
| 19 | Levator palpebrae superioris muscle | 37 | Medial pterygoid muscle |
| 20 | Lateral ventricle (occipital horn) | 38 | Rectus capitis posterior major muscle |
| 21 | Lateral rectus muscle | 39 | Buccinator muscle |
| 22 | Lateral ventricle (temporal horn) | 40 | Semispinalis capitis muscle |
| 23 | Eyeball and lens | 41 | Mandible and mandibular canal (inferior alveolar nerve) |
| 24 | Occipital gyri | 42 | Atlas (transverse process) and rectus capitis lateralis muscle |
| 25 | Medial occipitotemporal gyrus | 43 | Submandibular gland |
| 26 | Tentorium cerebelli | 44 | Obliquus capitis inferior muscle |
| 27 | Inferior oblique muscle | 45 | Internal jugular vein and digastric muscle |
| 28 | Transverse sinus | 46 | Levator scapulae muscle |
| 29 | Temporal muscle | 47 | Splenius capitis muscle |

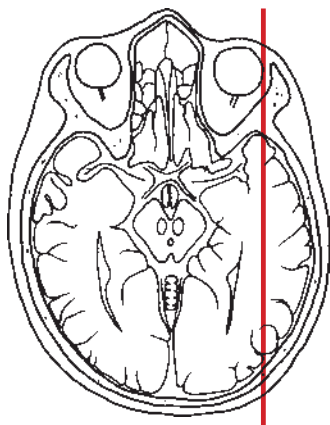
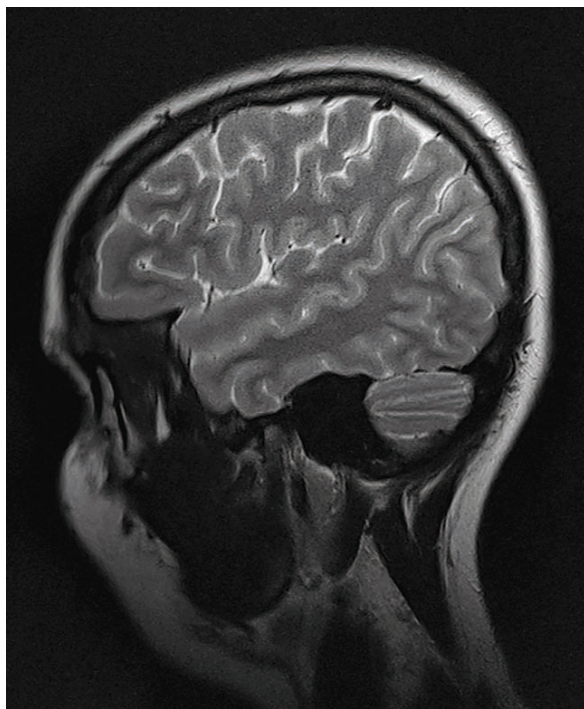


-  Frontal lobe
-  Temporal lobe
-  Parietal lobe
-  Occipital lobe
-  Cerebellum

- 1 Frontal bone and coronal suture
- 2 Parietal bone
- 3 Middle frontal gyrus
- 4 Precentral gyrus
- 5 Inferior frontal sulcus
- 6 Postcentral gyrus and postcentral sulcus
- 7 Insular gyri
- 8 Central sulcus

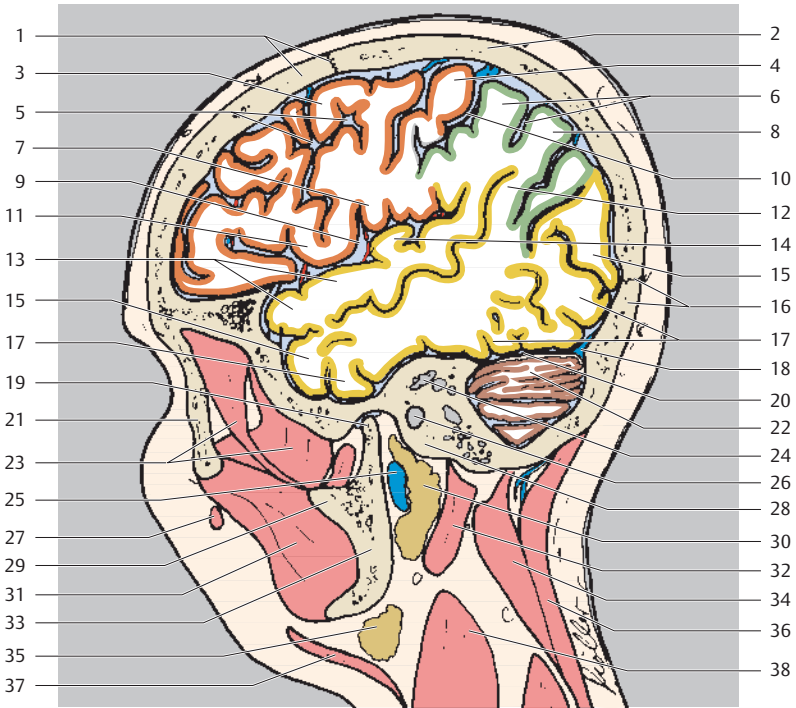


- | | | | |
|----|--|----|---|
| 9 | Cistern of lateral cerebral fossa (insular cistern) and insular arteries | 26 | Posterior semicircular canal |
| 10 | Angular gyrus | 27 | Maxillary sinus |
| 11 | Orbital gyrus | 28 | Posterior lobe of cerebellum |
| 12 | Transverse temporal gyrus | 29 | Lateral pterygoid muscle and head of mandible |
| 13 | Inferior frontal gyrus | 30 | Obliquus capitis superior muscle |
| 14 | Occipital bone and lambdoid suture | 31 | Styloid muscle and styloid process |
| 15 | Superior temporal gyrus | 32 | Rectus capitis lateralis muscle |
| 16 | Occipital gyri | 33 | Buccinator muscle |
| 17 | Lacrimal gland | 34 | Semispinalis capitis muscle |
| 18 | Inferior temporal gyrus | 35 | Medial pterygoid muscle |
| 19 | Eyeball | 36 | Atlas, transverse process |
| 20 | Tentorium cerebelli | 37 | Digastric muscle, posterior belly |
| 21 | Lateral rectus muscle | 38 | Internal jugular vein |
| 22 | Transverse sinus | 39 | Mandible |
| 23 | Temporal pole and middle temporal gyrus | 40 | Levator scapulae muscle |
| 24 | Anterior lobe of cerebellum | 41 | Submandibular gland |
| 25 | Temporal muscle | 42 | Splenius capitis muscle |
| | | 43 | Platysma |
| | | 44 | Splenius cervicis muscle |
| | | 45 | Scalenus posterior muscle |

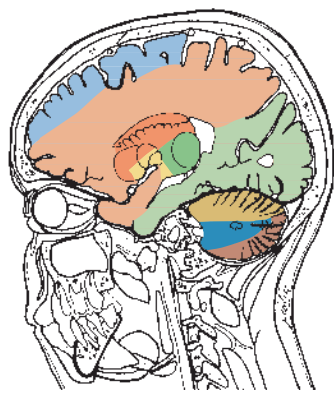
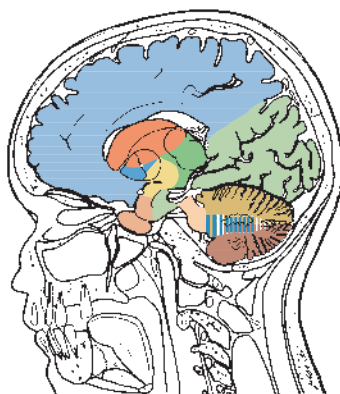
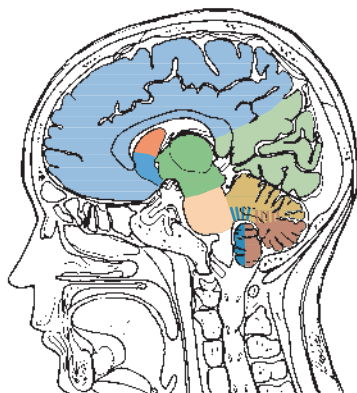
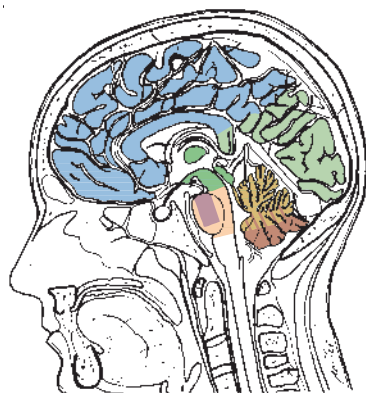


- Frontal lobe
- Temporal lobe
- Parietal lobe
- Cerebellum

- 1 Frontal bone and coronal suture
- 2 Parietal bone
- 3 Middle frontal gyrus
- 4 Precentral gyrus
- 5 Inferior frontal sulcus
- 6 Postcentral gyrus and postcentral sulcus

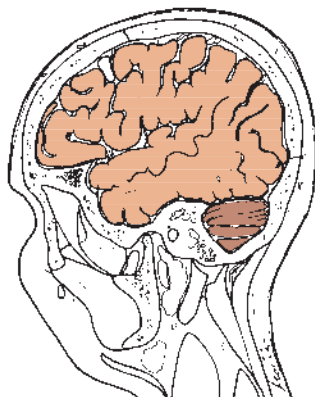
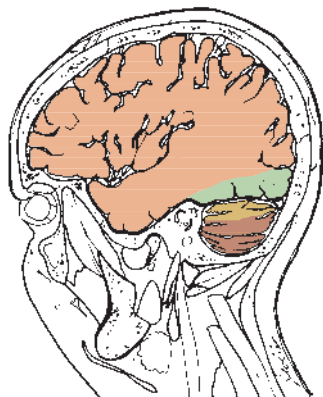
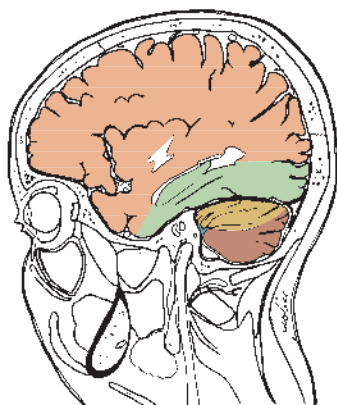
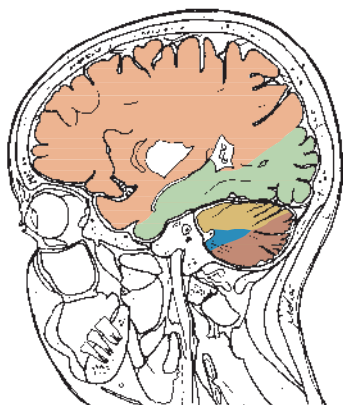


- | | |
|---|--------------------------------------|
| 7 Inferior frontal gyrus, insular cortex | 22 Posterior lobe of cerebellum |
| 8 Supramarginal gyrus | 23 Temporal muscle |
| 9 Lateral sulcus | 24 Mastoid antrum |
| 10 Central sulcus | 25 Retromandibular vein |
| 11 Inferior frontal gyrus, opercular part | 26 External acoustic meatus |
| 12 Angular gyrus | 27 Zygomatic muscle |
| 13 Superior temporal gyrus | 28 Mastoid process |
| 14 Transverse temporal gyrus | 29 Coronoid process |
| 15 Middle temporal gyrus | 30 Parotid gland |
| 16 Occipital bone and lambdoid suture | 31 Masseter muscle |
| 17 Inferior temporal gyrus | 32 Digastric muscle, posterior belly |
| 18 Transverse sinus | 33 Mandible (ramus) |
| 19 Head of mandible | 34 Semispinalis capitis muscle |
| 20 Tentorium cerebelli | 35 Submandibular gland |
| 21 Zygomatic bone | 36 Splenius capitis muscle |
| | 37 Platysma |
| | 38 Sternocleidomastoid muscle |



- Anterior cerebral artery**
- Terminal branches
 - Central branches (striate arteries including distal medial striate artery)
- Middle cerebral artery**
- Terminal branches
 - Central branches (striate branches)
- Posterior cerebral artery**
- Terminal branches
 - Central branches (including the posterior communicating artery)

- Basilar artery**
- Anteromedial and anterolateral paramedian branches
 - Circumferential arteries and lateral and dorsal paramedian branches
 - Superior cerebellar artery
 - Anterior superior cerebellar artery
 - Boundary region
 - Posterior inferior cerebellar artery



Middle cerebral artery

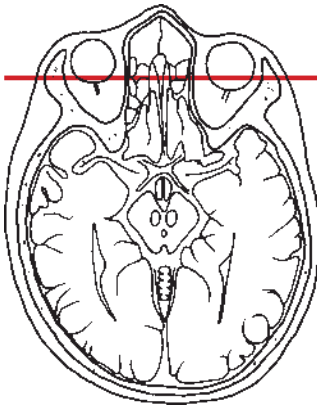
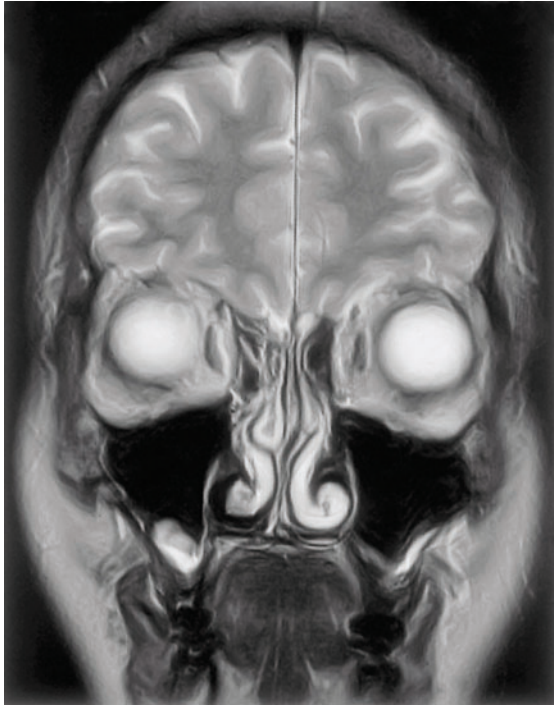
- Terminal branches
- Central branches (striate branches)

Posterior cerebral artery

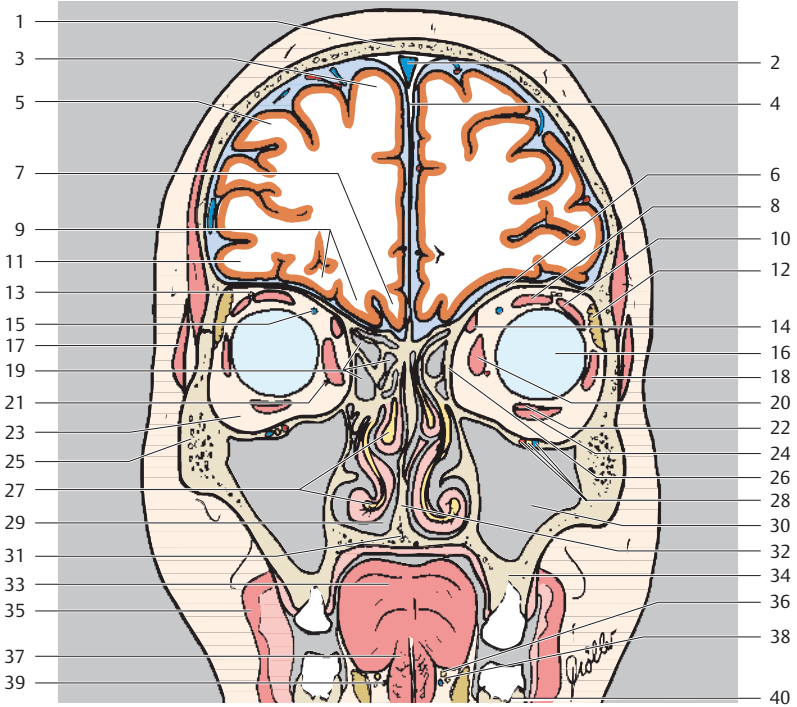
- Terminal branches

- Anterior choroidal artery

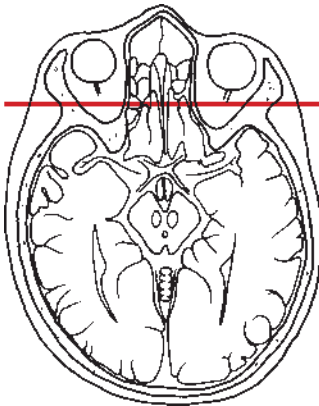
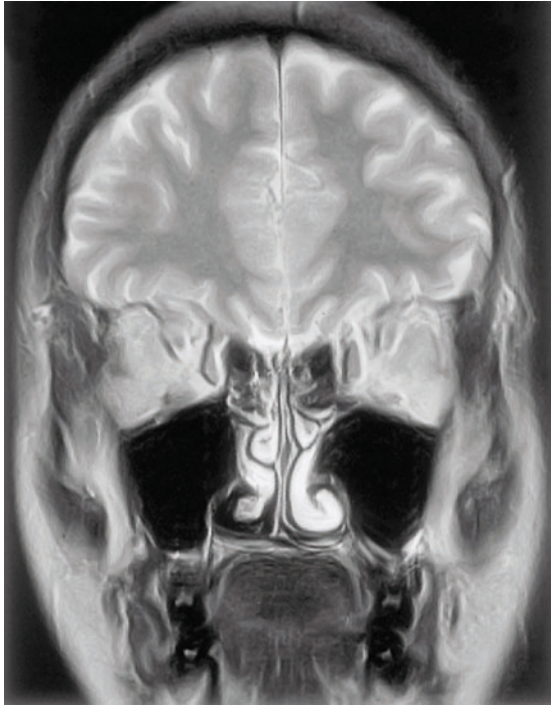
- Superior cerebellar artery
- Anterior superior cerebellar artery
- Posterior inferior cerebellar artery



Frontal lobe

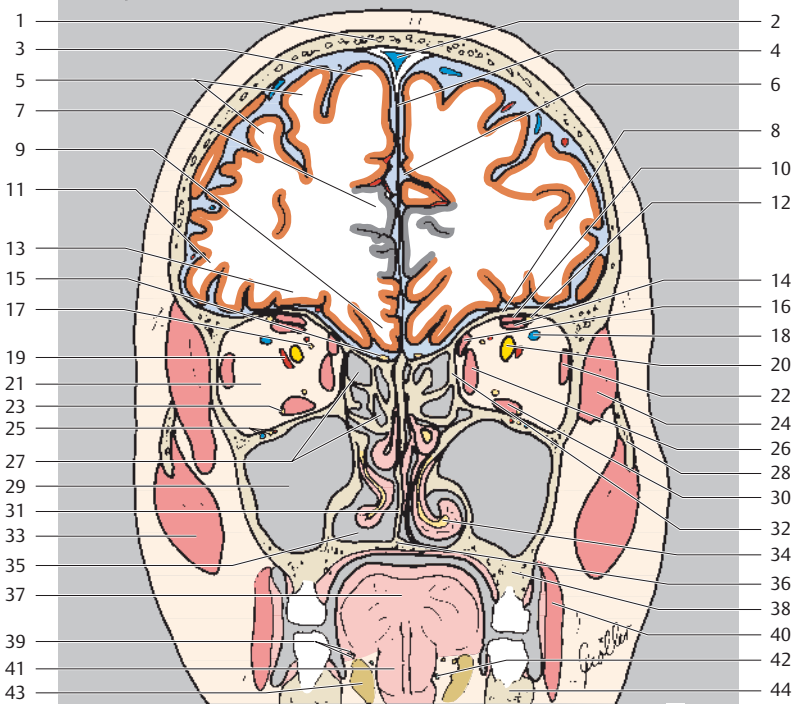


- | | |
|---------------------------------------|---|
| 1 Frontal bone | 21 Ophthalmic artery |
| 2 Superior sagittal sinus | 22 Inferior rectus muscle |
| 3 Superior frontal gyrus | 23 Orbit (retrobulbar fat) |
| 4 Falx cerebri | 24 Inferior oblique muscle |
| 5 Middle frontal gyrus | 25 Zygomatic bone |
| 6 Roof of orbit | 26 Orbital plate |
| 7 Straight gyrus | 27 Middle and inferior nasal conchas |
| 8 Levator palpebrae superioris muscle | 28 Infraorbital artery, vein, and nerve |
| 9 Orbital gyri | 29 Nasal sinus |
| 10 Superior rectus muscle | 30 Maxillary sinus |
| 11 Inferior frontal gyrus | 31 Hard palate |
| 12 Lacrimal gland | 32 Nasal septum |
| 13 Supraorbital nerve | 33 Tongue |
| 14 Superior oblique muscle | 34 Maxilla (alveolar process) |
| 15 Superior ophthalmic vein | 35 Depressor anguli oris muscle |
| 16 Eyeball | 36 Lingual nerve |
| 17 Orbicularis oculi muscle | 37 Genioglossus muscle |
| 18 Lateral rectus muscle | 38 Hypoglossal nerve (XII) |
| 19 Ethmoidal cells | 39 Submandibular duct |
| 20 Medial rectus muscle | 40 Body of mandible |

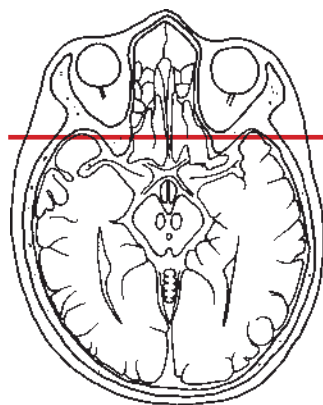
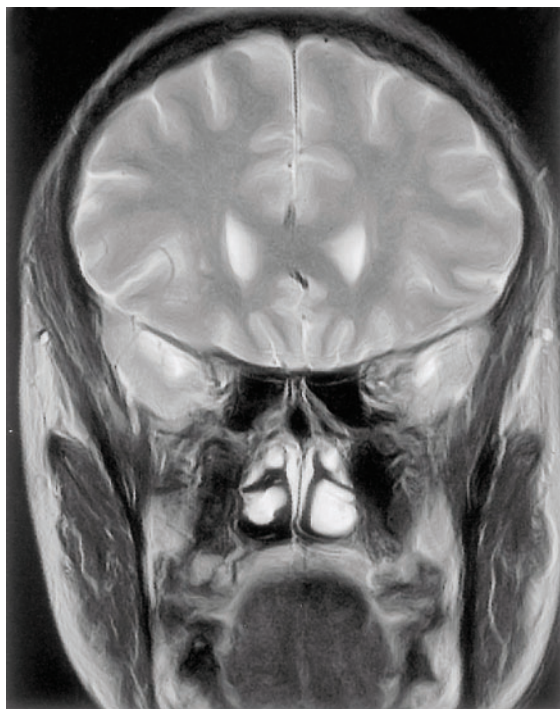

Frontal lobe

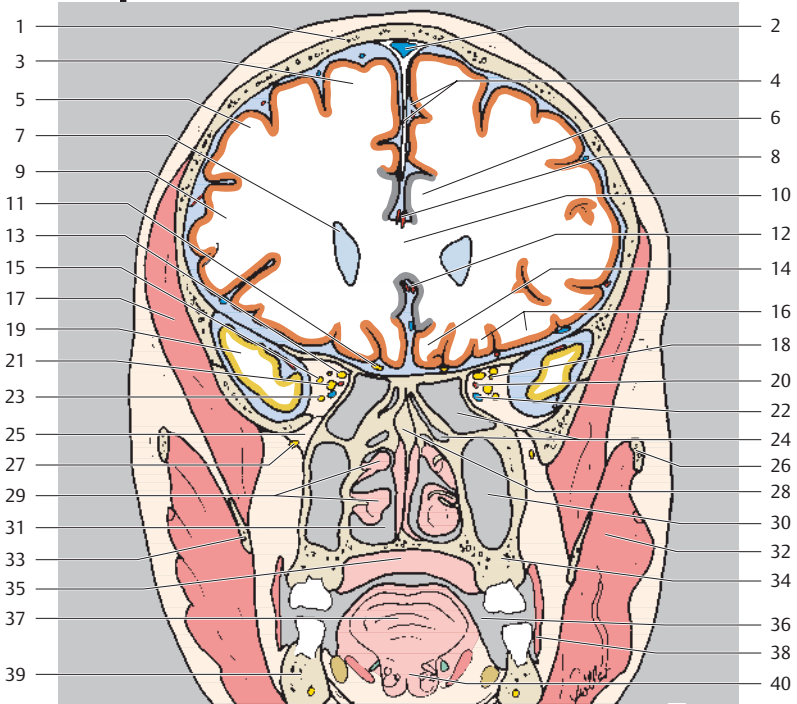
- 1 Frontal bone
- 2 Superior sagittal sinus
- 3 Superior frontal gyrus
- 4 Falx cerebri
- 5 Middle frontal gyrus
- 6 Longitudinal cerebral
- 7 Cingulate gyrus



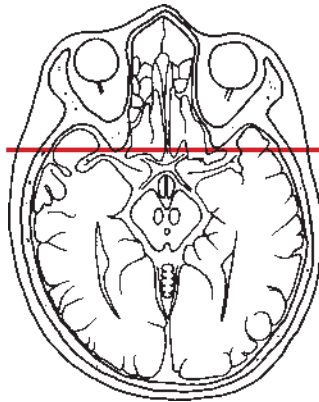
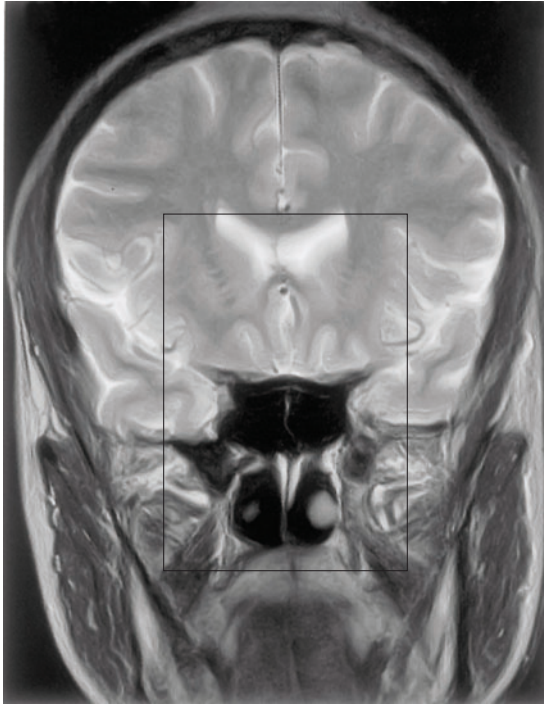
- | | | | |
|----|---------------------------------------|----|---|
| 8 | Roof of orbit | 26 | Medial rectus muscle |
| 9 | Straight gyrus | 27 | Ethmoidal cells |
| 10 | Levator palpebrae superioris muscle | 28 | Zygomatic bone |
| 11 | Inferior frontal gyrus | 29 | Maxillary sinus |
| 12 | Supraorbital nerve | 30 | Inferior rectus muscle |
| 13 | Orbital gyri | 31 | Nasal septum |
| 14 | Superior rectus muscle | 32 | Orbital plate |
| 15 | Olfactory bulb | 33 | Masseter muscle |
| 16 | Superior oblique muscle | 34 | Inferior nasal concha |
| 17 | Nasolacrimal duct | 35 | Nasal cavity |
| 18 | Superior ophthalmic vein | 36 | Hard palate |
| 19 | Ophthalmic artery | 37 | Tongue |
| 20 | Optic nerve (II) | 38 | Maxilla (alveolar process) |
| 21 | Orbit (retrobulbar fat) | 39 | Lingual nerve and hypoglossal nerve (XII) |
| 22 | Lateral rectus muscle | 40 | Depressor anguli oris muscle |
| 23 | Oculomotor nerve (III), inferior part | 41 | Genioglossus muscle |
| 24 | Temporal muscle | 42 | Submandibular duct |
| 25 | Infraorbital nerve, artery, and vein | 43 | Submandibular gland |
| | | 44 | Body of mandible |





- Frontal lobe
- Temporal lobe

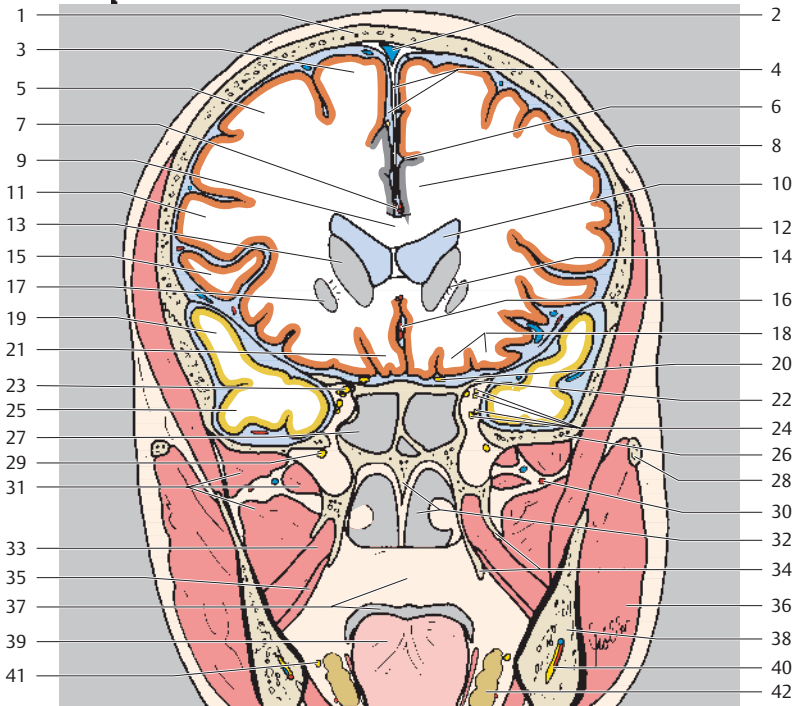


- | | |
|--|--|
| 1 Frontal bone | 21 Ophthalmic nerve (first division of trigeminal nerve) |
| 2 Superior sagittal sinus | 22 Superior ophthalmic vein |
| 3 Superior frontal gyrus | 23 Abducent nerve (VI) |
| 4 Falx cerebri in interhemispheric fissure | 24 Ethmoidal cells |
| 5 Middle frontal gyrus | 25 Pterygopalatine fossa |
| 6 Cingulate gyrus | 26 Zygomatic arch |
| 7 Lateral ventricle (frontal horn) | 27 Maxillary nerve (second division of trigeminal nerve) |
| 8 Pericallosal artery | 28 Nasal septum |
| 9 Inferior frontal gyrus | 29 Middle and inferior nasal conchas |
| 10 Corpus callosum (genu) | 30 Maxillary sinus |
| 11 Olfactory tract | 31 Nasal sinus |
| 12 Anterior cerebral artery | 32 Masseter muscle |
| 13 Optic nerve (II) | 33 Ramus of mandible |
| 14 Straight gyrus | 34 Maxilla (alveolar process) |
| 15 Oculomotor nerve (III) | 35 Soft palate |
| 16 Orbital gyri | 36 Oral cavity |
| 17 Temporal muscle | 37 Tongue |
| 18 Trochlear nerve (IV) | 38 Buccinator muscle |
| 19 Temporal lobe (temporal pole) | 39 Body of mandible |
| 20 Ophthalmic artery | 40 Genioglossus muscle |

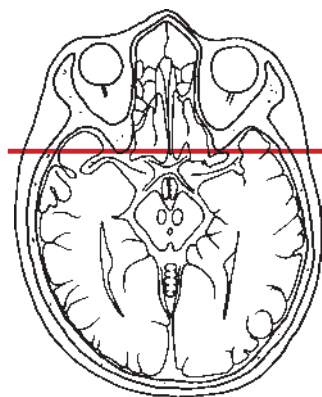
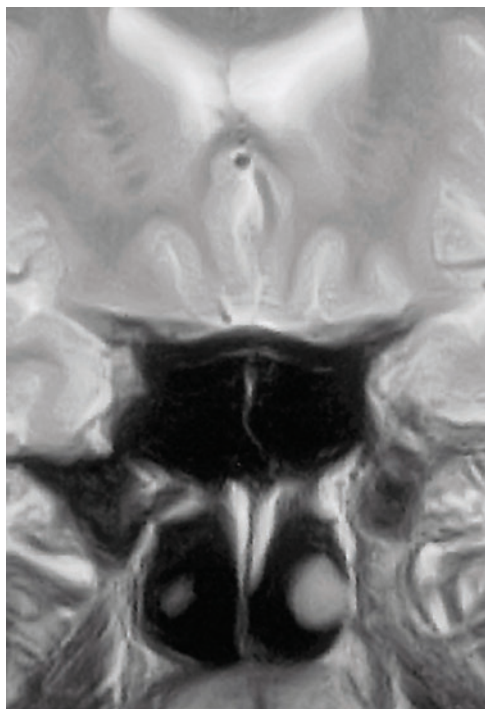


-  Frontal lobe
-  Temporal lobe

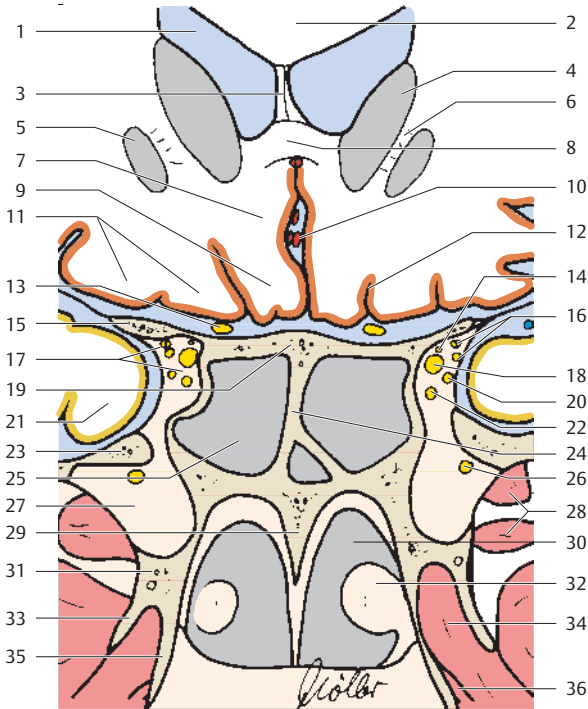
- 1 Frontal bone
- 2 Superior sagittal sinus
- 3 Superior frontal gyrus
- 4 Falx cerebri in Longitudinal cerebral
- 5 Middle frontal gyrus
- 6 Cingulate sulcus
- 7 Pericallosal artery



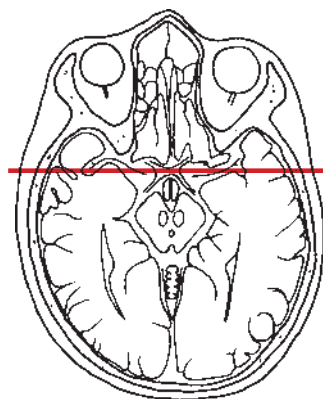
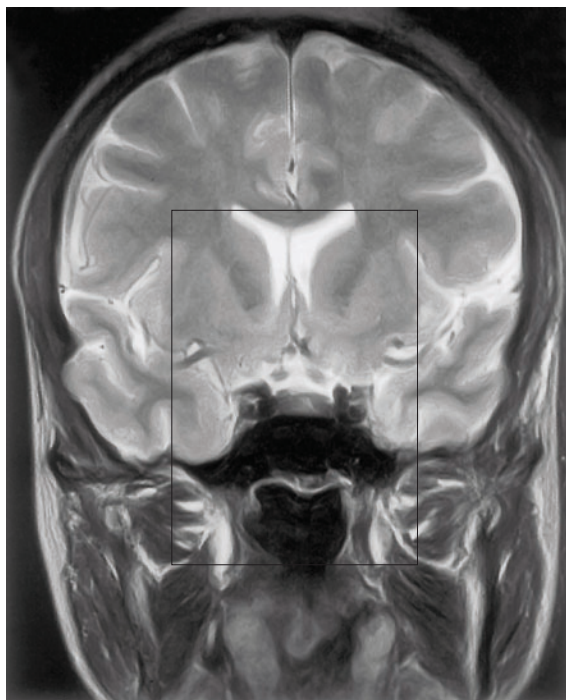
- | | |
|--|--|
| 8 Cingulate gyrus | 26 Temporal bone |
| 9 Corpus callosum (trunk) | 27 Sphenoidal sinus |
| 10 Lateral ventricle (frontal horn) | 28 Zygomatic arch |
| 11 Inferior frontal gyrus | 29 Maxillary nerve in pterygopalatine fossa |
| 12 Temporal muscle | 30 Maxillary artery |
| 13 Head of caudate nucleus | 31 Lateral pterygoid muscle in infratemporal fossa |
| 14 Internal capsule (anterior limb) | 32 Nasal septum and sinus |
| 15 Frontal operculum | 33 Medial pterygoid muscle |
| 16 Anterior cerebral artery | 34 Pterygoid process (medial and lateral plates) |
| 17 Putamen | 35 Tensor veli palatini muscle |
| 18 Orbital gyri | 36 Masseter muscle |
| 19 Superior temporal gyrus | 37 Soft palate and oral cavity |
| 20 Olfactory tract | 38 Ramus of mandible |
| 21 Straight gyrus | 39 Tongue |
| 22 Sphenoidal bone (lesser wing) | 40 Inferior alveolar artery, vein, and nerve in mandibular canal |
| 23 Optic nerve (II) | 41 Lingual nerve |
| 24 Trochlear (IV), oculomotor (III), ophthalmic (first division of trigeminal), and abducent (VI) nerves | 42 Submandibular gland |
| 25 Middle temporal gyrus | |



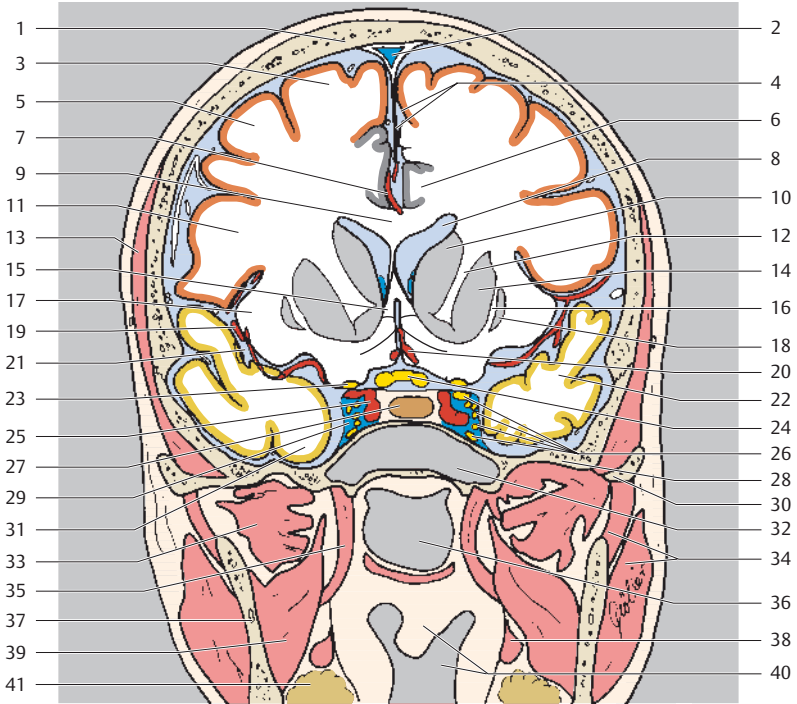
- Frontal lobe
- Temporal lobe



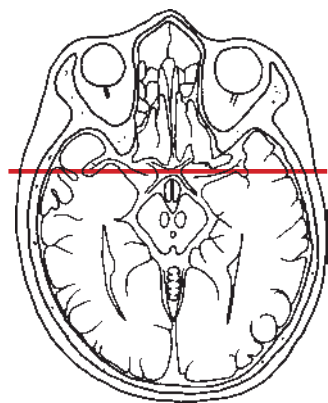
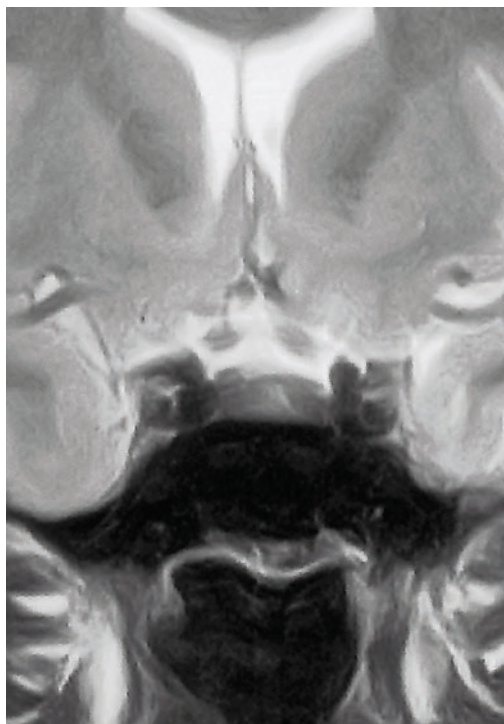
- | | |
|---|---|
| 1 Lateral ventricle (frontal horn) | 18 Optic nerve (II) |
| 2 Corpus callosum (trunk) | 19 Sphenoid plane |
| 3 Septum pellucidum | 20 Abducent nerve (VI) |
| 4 Head of caudate nucleus | 21 Temporal pole |
| 5 Putamen | 22 Oculomotor nerve (III), inferior branch |
| 6 Internal capsule (anterior limb) | 23 Sphenoidal bone, lesser wing |
| 7 Subcallosal gyrus | 24 Septum of sphenoidal sinus |
| 8 Corpus callosum (genu) | 25 Sphenoidal sinus |
| 9 Straight gyrus | 26 Maxillary nerve in pterygopalatine fossa |
| 10 Pericallosal artery | 27 Pterygopalatine fossa |
| 11 Orbital gyri | 28 Lateral pterygoid muscle |
| 12 Olfactory sulcus | 29 Vomer |
| 13 Olfactory tract | 30 Nasal sinus |
| 14 Oculomotor nerve (III, superior branch) | 31 Pterygoid process (sphenoidal bone) |
| 15 Anterior clinoid process (sphenoidal bone, lesser wing) | 32 Middle nasal concha |
| 16 Ophthalmic nerve (frontal, lacrimal, and nasociliary nerves) = superior branch of trigeminal nerve (V) | 33 Pterygoid process (lateral plate) |
| 17 Superior orbital fissure | 34 Medial pterygoid muscle |
| | 35 Pterygoid process (medial plate) |
| | 36 Tensor veli palatini muscle |



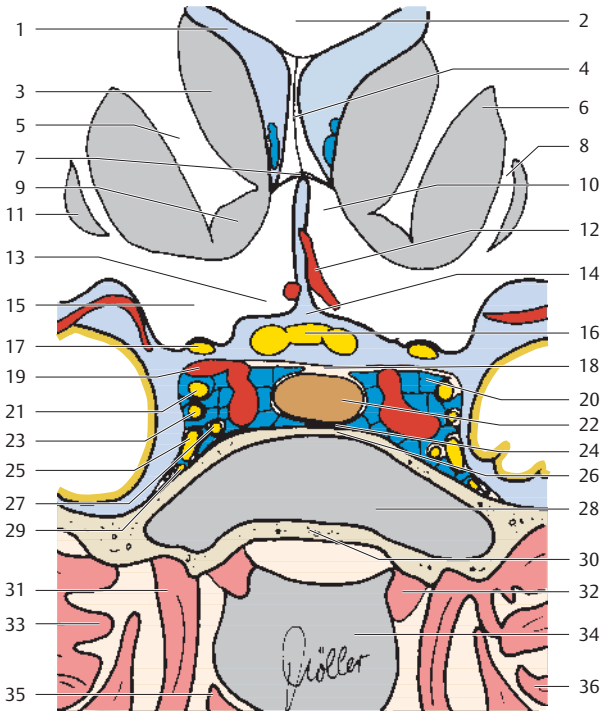
- Frontal lobe
- Temporal lobe



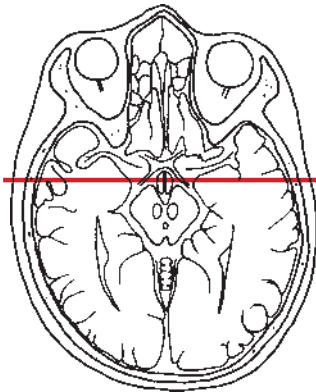
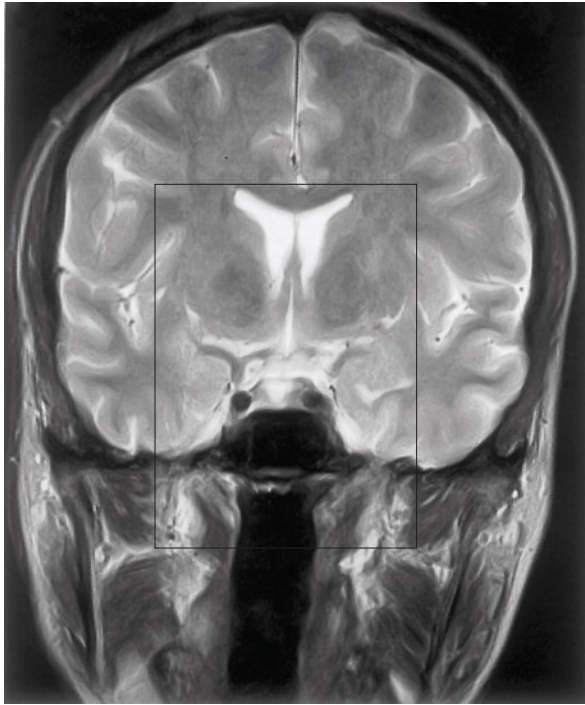
- | | |
|--|---|
| 1 Frontal bone | 22 Superior temporal gyrus |
| 2 Superior sagittal sinus | 23 Olfactory tract |
| 3 Superior frontal gyrus | 24 Optic chiasm |
| 4 Falx cerebri in
Longitudinal cerebral | 25 Internal carotid artery (syphon) |
| 5 Middle frontal gyrus | 26 Trochlear (IV), oculomotor (III),
ophthalmic, and abducent (V) nerves |
| 6 Cingulate gyrus | 27 Pituitary gland |
| 7 Pericallosal artery | 28 Temporal bone |
| 8 Lateral ventricle (frontal horn) | 29 Cavernous sinus |
| 9 Corpus callosum (genu) | 30 Zygomatic bone |
| 10 Head of caudate nucleus | 31 Middle temporal gyrus |
| 11 Inferior frontal gyrus | 32 Sphenoidal sinus |
| 12 Internal capsule (anterior limb) | 33 Lateral pterygoid muscle |
| 13 Temporal muscle | 34 Masseter muscle |
| 14 Putamen | 35 Tensor veli palatini muscle |
| 15 Subcallosal gyrus | 36 Nasopharynx |
| 16 External capsule | 37 Ramus of mandible |
| 17 Insula | 38 Styloglossus muscle |
| 18 Claustrium | 39 Medial pterygoid muscle |
| 19 Insular arteries | 40 Uvula and oropharynx |
| 20 Anterior cerebral artery | 41 Submandibular gland |
| 21 Lateral sulcus | |



■ Temporal lobe

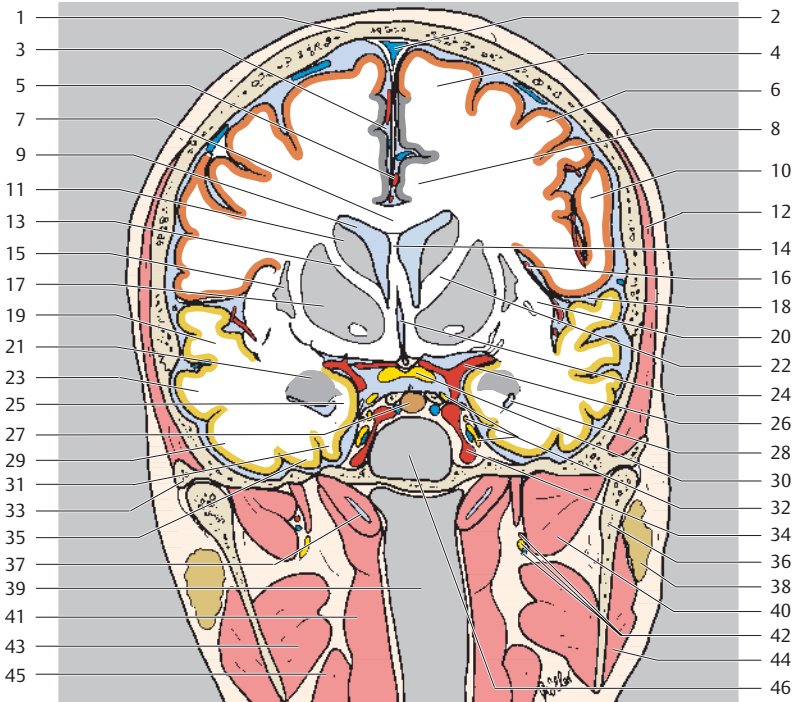


- | | |
|-------------------------------------|--|
| 1 Lateral ventricle (frontal horn) | 20 Cavernous sinus |
| 2 Corpus callosum (trunk) | 21 Oculomotor nerve (III) |
| 3 Head of caudate nucleus | 22 Pituitary gland |
| 4 Septum pellucidum | 23 Trochlear nerve (IV) |
| 5 Internal capsule (anterior limb) | 24 Inferior intercavernous sinus |
| 6 Putamen | 25 Ophthalmic nerve (V ₁) |
| 7 Corpus callosum (rostrum) | 26 Floor of sella |
| 8 External capsule | 27 Abducent nerve (VI) |
| 9 Nucleus acumbens | 28 Sphenoidal sinus |
| 10 Subcallosal gyrus | 29 Maxillary nerve (V ₂) |
| 11 Claustrum | 30 Sphenoidal bone (body) |
| 12 Anterior cerebral artery | 31 Tensor veli palatini muscle |
| 13 Straight gyrus | 32 Pharyngotympanic tube (auditory tube) |
| 14 Chiasmatic cistern | 33 Lateral pterygoid muscle |
| 15 Orbital gyri | 34 Nasopharynx |
| 16 Optic chiasm | 35 Levator veli palatini muscle |
| 17 Olfactory tract | 36 Medial pterygoid muscle |
| 18 Sellar diaphragm | |
| 19 Internal carotid artery (syphon) | |

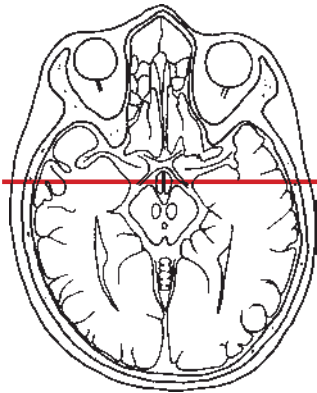
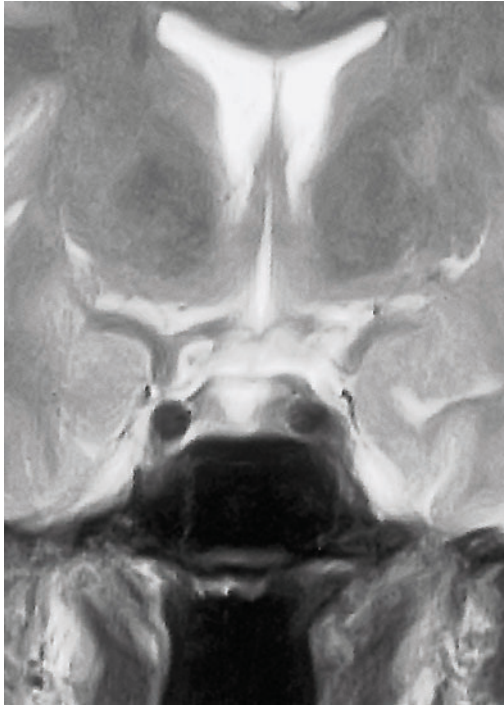


- Frontal lobe
- Temporal lobe

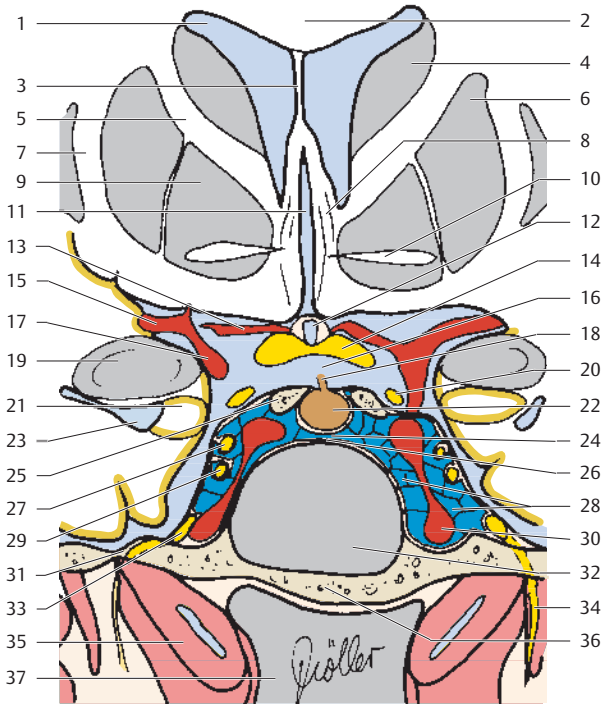
- 1 Frontal bone
- 2 Superior sagittal sinus
- 3 Falx cerebri in Longitudinal cerebral
- 4 Superior frontal gyrus
- 5 Pericallosal artery
- 6 Middle frontal gyrus
- 7 Corpus callosum (genu)



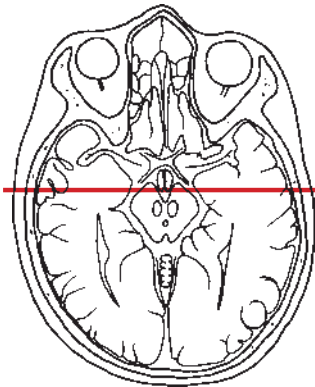
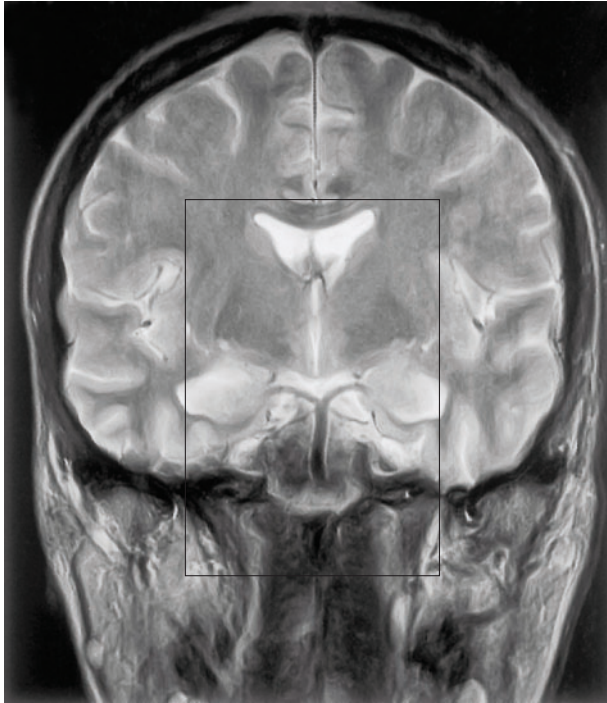
- | | |
|--------------------------------------|---|
| 8 Cingulate gyrus | 29 Inferior temporal gyrus |
| 9 Lateral ventricle (frontal horn) | 30 Optic chiasm |
| 10 Inferior frontal gyrus | 31 Parahippocampal gyrus |
| 11 Head of caudate nucleus | 32 Trochlear (IV), oculomotor (III) and abducent (VI) nerves, trigeminal ganglion |
| 12 Temporal muscle | 33 Temporal bone (zygomatic process) |
| 13 External capsule | 34 Internal carotid artery (syphon) |
| 14 Septum pellucidum | 35 Lateral occipitotemporal gyrus |
| 15 Claustrum | 36 Head of mandible |
| 16 Insular arteries | 37 Pharyngotympanic tube (auditory tube) |
| 17 Putamen | 38 Parotid gland |
| 18 Lateral sulcus | 39 Pharynx |
| 19 Superior temporal gyrus | 40 Lateral pterygoid muscle |
| 20 Insula | 41 Superior constrictor muscle of pharynx |
| 21 Amygdaloid body | 42 Mandibular artery, vein, and nerve |
| 22 Internal capsule (anterior limb) | 43 Medial pterygoid muscle |
| 23 Middle temporal gyrus | 44 Masseter muscle |
| 24 Longitudinal cerebral | 45 Styloglossus muscle |
| 25 Hippocampus | 46 Sphenoidal sinus |
| 26 Middle cerebral artery | |
| 27 Pituitary gland | |
| 28 Lateral ventricle (temporal horn) | |



■ Temporal lobe

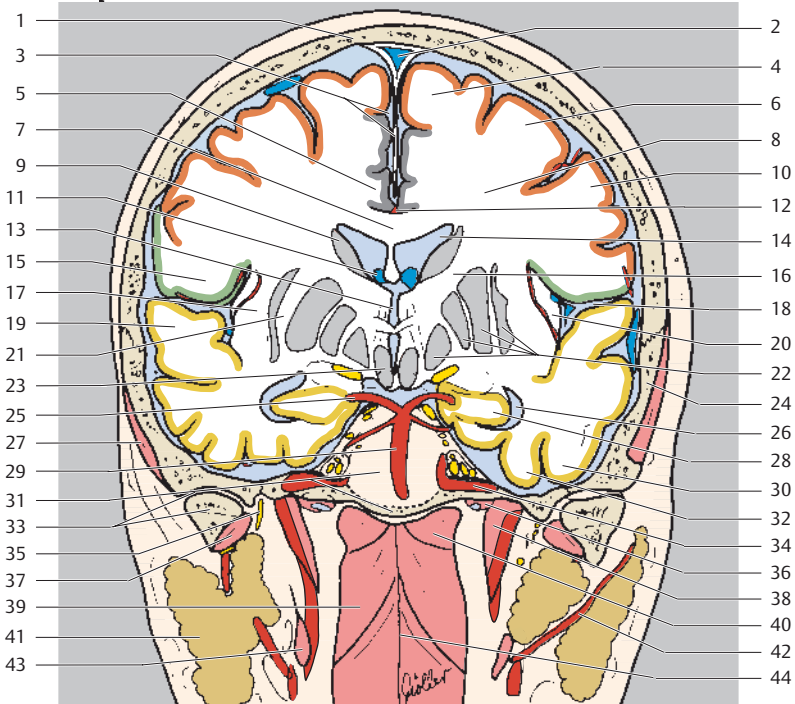


- | | |
|--|---|
| 1 Lateral ventricle (frontal horn) | 20 Oculomotor nerve (III) |
| 2 Corpus callosum (trunk) | 21 Hippocampus |
| 3 Septum pellucidum | 22 Pituitary gland |
| 4 Head of caudate nucleus | 23 Lateral ventricle (temporal horn) |
| 5 Internal capsule (anterior limb) | 24 Inferior intercavernous sinus |
| 6 Putamen | 25 Posterior clinoid process |
| 7 External capsule | 26 Floor of sella |
| 8 Precommissural fornix | 27 Trochlear nerve (IV) |
| 9 Globus pallidus | 28 Cavernous sinus |
| 10 Anterior commissure | 29 Abducent nerve (VI), trigeminal ganglion |
| 11 Longitudinal cerebral | 30 Internal carotid artery (syphon) |
| 12 Supraoptic recess | 31 Foramen ovale |
| 13 Anterior cerebral artery (A1 segment) | 32 Sphenoidal sinus |
| 14 Optic chiasm | 33 Trigeminal (V) ganglion |
| 15 Middle cerebral artery | 34 Mandibular nerve (V ₃) |
| 16 Suprasellar cistern | 35 Pharyngotympanic (auditory) tube |
| 17 Internal carotid artery | 36 Sphenoidal bone (body) |
| 18 Infundibulum | 37 Nasopharynx |
| 19 Amygdaloid body | |

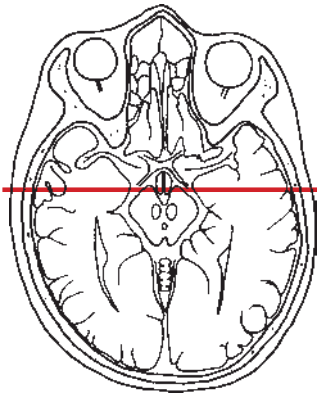
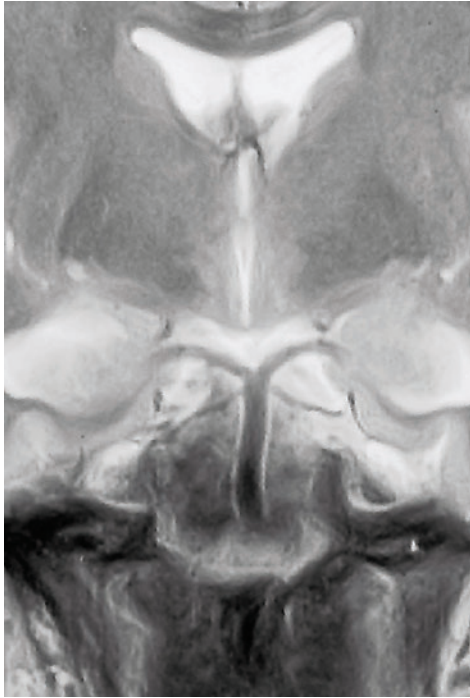


- Frontal lobe
- Temporal lobe
- Parietal lobe

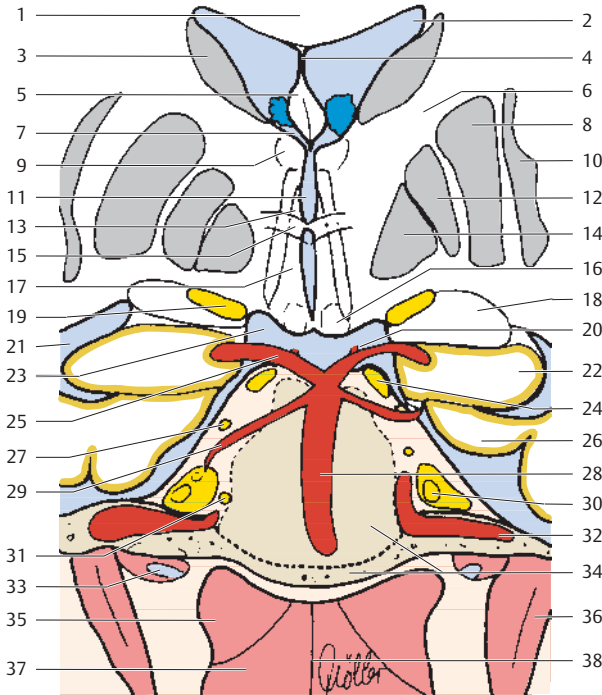
- 1 Frontal bone
- 2 Superior sagittal sinus
- 3 Falx cerebri in Longitudinal cerebral
- 4 Superior frontal gyrus
- 5 Cingulate gyrus
- 6 Middle frontal gyrus
- 7 Corpus callosum (trunk)
- 8 Cerebral white matter (semioval center)



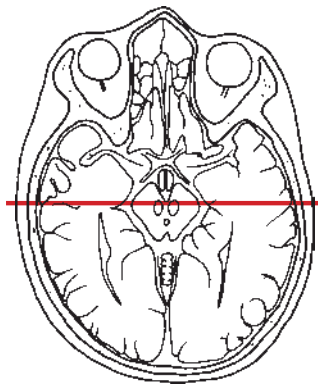
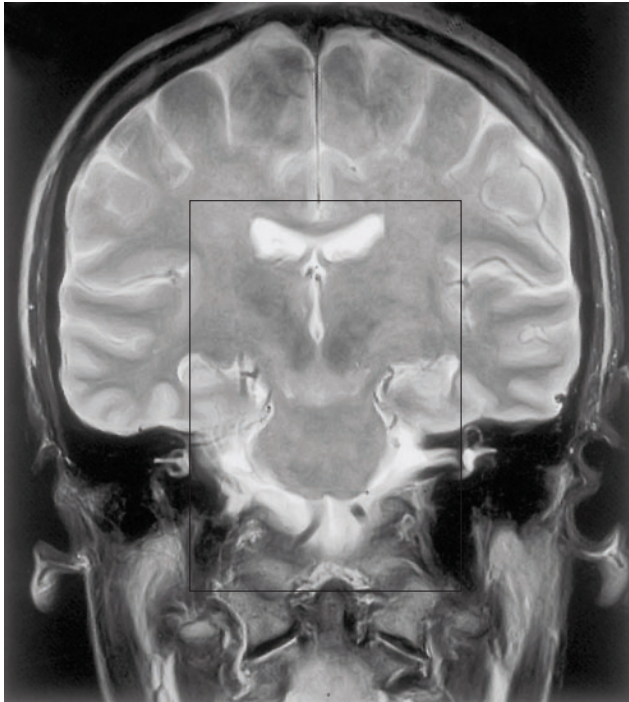
- | | | | |
|----|-----------------------------------|----|--|
| 9 | Caudate nucleus (body) | 27 | Temporal muscle |
| 10 | Inferior frontal gyrus | 28 | Hippocampus |
| 11 | Interventricular foramen | 29 | Basilar artery |
| 12 | Pericallosal artery | 30 | Middle temporal gyrus |
| 13 | Third ventricle | 31 | Occipital bone (clivus) |
| 14 | Lateral ventricle (frontal horn) | 32 | Lateral occipitotemporal gyrus |
| 15 | Frontal operculum | 33 | Head of mandible and temporomandibular joint |
| 16 | Internal capsule (genu) | 34 | Internal carotid artery (syphon) |
| 17 | Extreme capsule | 35 | Mandibular nerve |
| 18 | Lateral sulcus | 36 | Pharyngotympanic (auditory) tube |
| 19 | Superior temporal gyrus | 37 | Lateral pterygoid muscle |
| 20 | Insula | 38 | Levator veli palatini muscle |
| 21 | External capsule | 39 | Constrictor muscle of pharynx (superior, middle, and inferior) |
| 22 | Basal nuclei (lentiform nucleus) | 40 | Pharyngobasilar fascia |
| 23 | Mammillary body and hypothalamus | 41 | Parotid gland |
| 24 | Temporal bone | 42 | External carotid artery |
| 25 | Posterior cerebral artery | 43 | Stylopharyngeus muscle |
| 26 | Lateral ventricle (temporal horn) | 44 | Pharyngeal raphe |



■ Temporal lobe

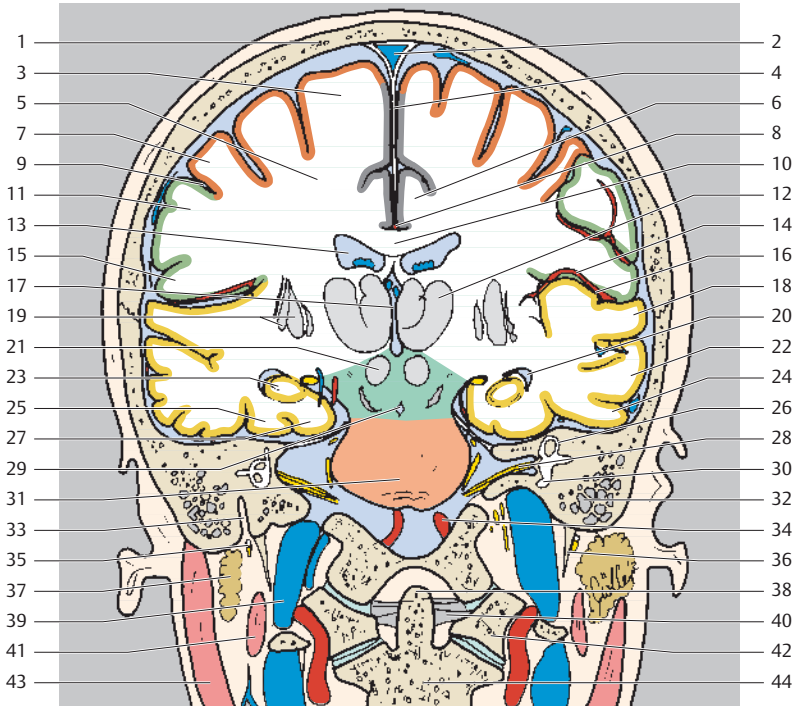


- | | | | |
|----|-------------------------------------|----|--|
| 1 | Corpus callosum (trunk) | 20 | Posterior communicating artery |
| 2 | Lateral ventricle (frontal horn) | 21 | Lateral ventricle (temporal horn) |
| 3 | Body of caudate nucleus | 22 | Hippocampus |
| 4 | Septum pellucidum | 23 | Ambient cistern |
| 5 | Fornix (body) | 24 | Oculomotor nerve (III) |
| 6 | Internal capsule (genu) | 25 | Posterior cerebral artery |
| 7 | Interventricular foramen | 26 | Parahippocampal gyrus |
| 8 | Putamen | 27 | Trochlear nerve (IV) |
| 9 | Thalamus (anterior ventral nucleus) | 28 | Basilar artery |
| 10 | Clastrum | 29 | Superior cerebellar artery |
| 11 | Third ventricle | 30 | Trigeminal nerve (ganglion, V) |
| 12 | Globus pallidus lateral segment | 31 | Abducent nerve (VI) |
| 13 | Fornix (column) | 32 | Internal carotid artery (syphon) |
| 14 | Globus pallidus medial segment | 33 | Pharyngotympanic (auditory) tube |
| 15 | Anterior commissure | 34 | Occipital bone (basilar part), clivus |
| 16 | Mammillary body | 35 | Pharyngobasilar fascia |
| 17 | Hypothalamus | 36 | Levator veli palatini muscle |
| 18 | Amygdaloid body | 37 | Superior constrictor muscle of pharynx |
| 19 | Optic tract | 38 | Pharyngeal raphe |

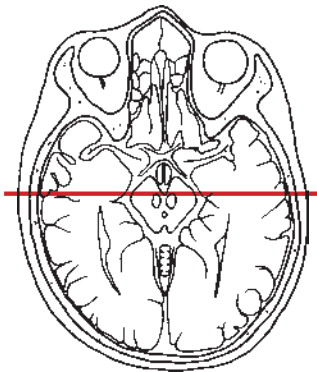
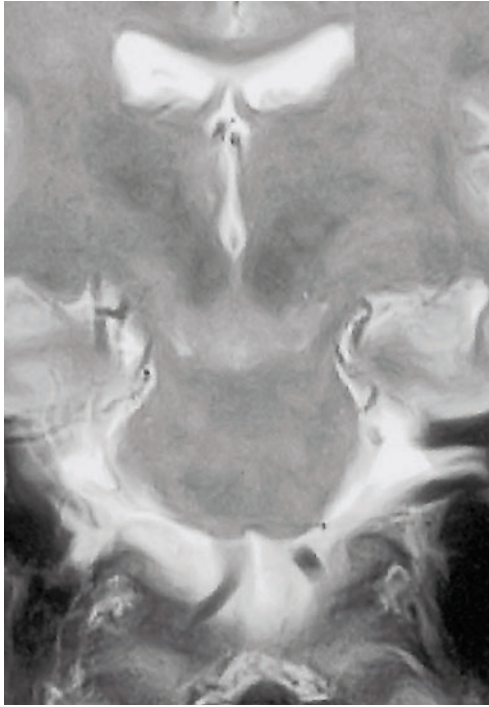







- Frontal lobe
- Temporal lobe
- Parietal lobe
- Mesencephalon
- Pons

- 1 Parietal bone
- 2 Superior sagittal sinus
- 3 Superior frontal gyrus
- 4 Falx cerebri
- 5 Central white matter (semioval center)
- 6 Cingulate gyrus
- 7 Precentral gyrus
- 8 Pericallosal artery
- 9 Central sulcus

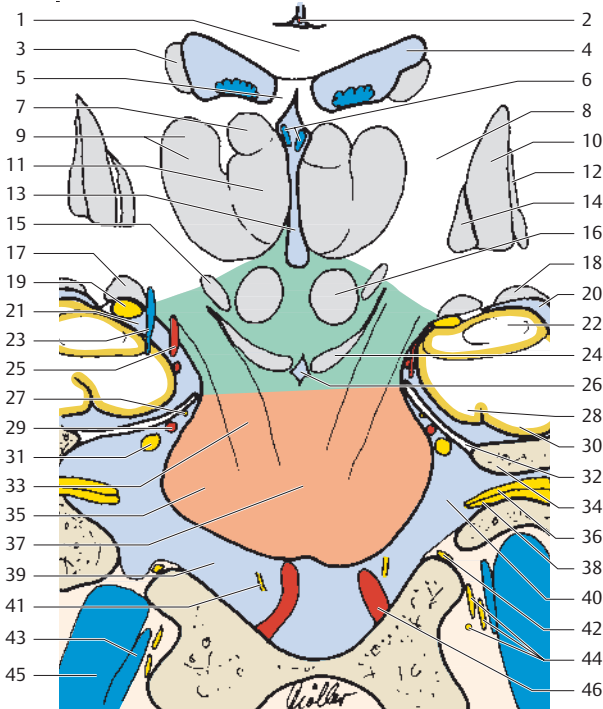


- | | |
|--|---|
| 10 Corpus callosum (trunk) | 28 Vestibulocochlear (VIII) and facial (VII) nerves in internal acoustic meatus |
| 11 Postcentral gyrus | 29 Interpeduncular cistern |
| 12 Thalamus | 30 Cochlea |
| 13 Lateral ventricle | 31 Pons |
| 14 Insular arteries | 32 Mastoid process with mastoid cells |
| 15 Parietal operculum | 33 Stylomastoid foramen |
| 16 Lateral sulcus | 34 Vertebral artery |
| 17 Third ventricle | 35 Facial nerve (VII) |
| 18 Superior temporal gyrus | 36 Styloid process |
| 19 Basal nuclei (lentiform nucleus) | 37 Parotid gland |
| 20 Lateral ventricle (temporal horn) | 38 Dens |
| 21 Red nucleus | 39 Internal jugular vein |
| 22 Middle temporal gyrus | 40 Transverse ligament of atlas |
| 23 Hippocampus | 41 Digastric muscle (posterior belly) |
| 24 Inferior temporal gyrus | 42 Atlas (lateral mass) |
| 25 Lateral occipitotemporal gyrus | 43 Sternocleidomastoid muscle |
| 26 Membranous semicircular canal (superior part) | 44 Axis |
| 27 Parahippocampal gyrus | |

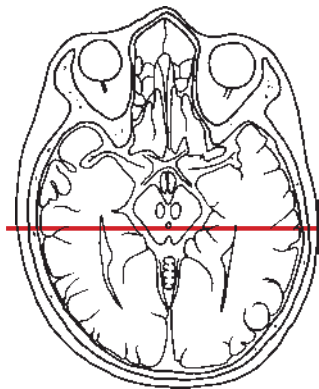
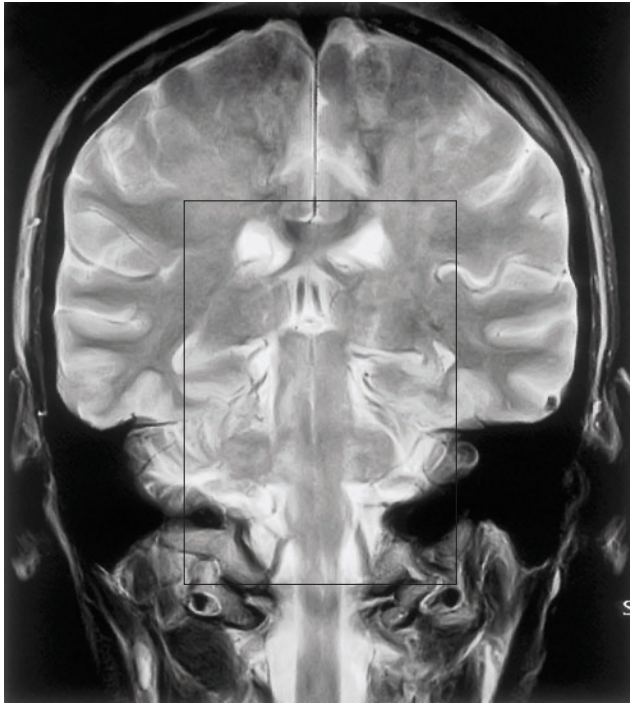


-  Frontal lobe
-  Temporal lobe
-  Parietal lobe
-  Mesencephalon
-  Pons
-  Medulla oblongata

- 1 Corpus callosum (trunk)
- 2 Pericallosal artery
- 3 Caudate nucleus (body)
- 4 Lateral ventricle
- 5 Fornix (crus)
- 6 Internal cerebral vein
- 7 Thalamus (lateral dorsal nucleus)
- 8 Internal capsule (posterior limb)

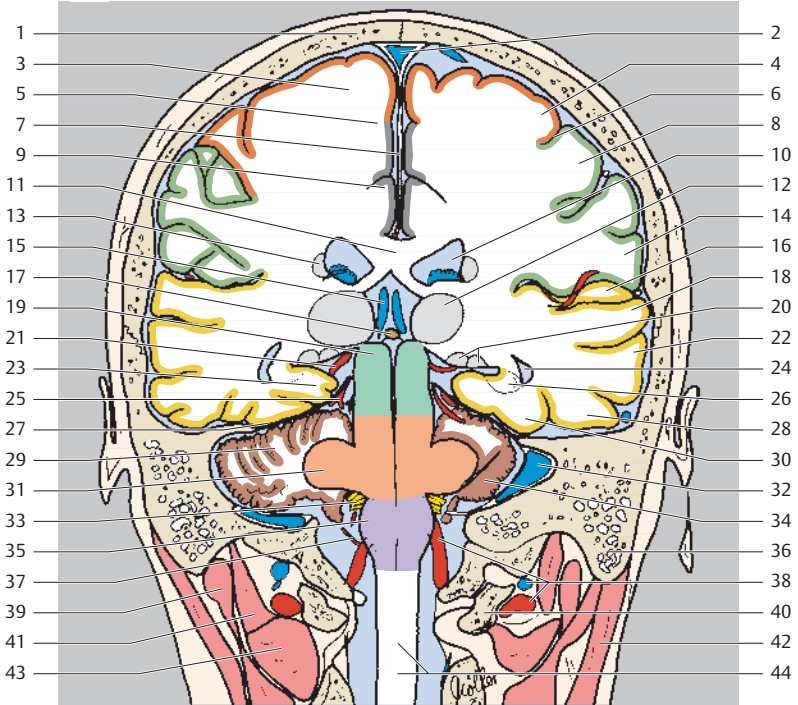


- | | |
|--------------------------------------|---|
| 9 Thalamus (ventral lateral complex) | 29 Superior cerebellar artery |
| 10 Putamen | 30 Lateral occipitotemporal gyrus |
| 11 Thalamus (medial nuclei) | 31 Trigeminal nerve (V) |
| 12 Claustrum | 32 Tentorium cerebelli |
| 13 Third ventricle | 33 Corticospinal tract |
| 14 Globus pallidus | 34 Petrous part of temporal bone |
| 15 Subthalamic nucleus | 35 Middle cerebellar peduncle |
| 16 Red nucleus | 36 Facial nerve (VII) in internal acoustic meatus |
| 17 Lateral geniculate body | 37 Pons |
| 18 Caudate nucleus (tail) | 38 Vestibulocochlear nerve (VIII) in internal acoustic meatus |
| 19 Optic tract | 39 Prepontine cistern |
| 20 Lateral ventricle (temporal horn) | 40 Pontocerebellar cistern |
| 21 Ambient cistern | 41 Abducent nerve (VI) |
| 22 Hippocampus | 42 Glossopharyngeal nerve (IX) |
| 23 Basal vein | 43 Vertebral vein |
| 24 Substantia nigra | 44 Vagus nerve (X), accessory nerve (XI), hypoglossal nerve (XII) |
| 25 Posterior cerebral artery | 45 Internal jugular vein |
| 26 Interpeduncular cistern | 46 Vertebral artery |
| 27 Trochlear nerve (IV) | |
| 28 Parahippocampal gyrus | |

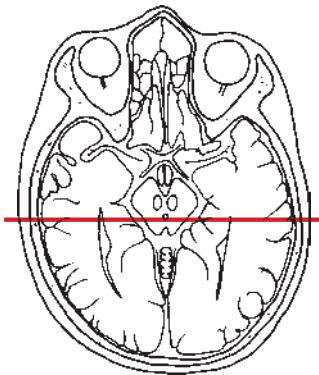
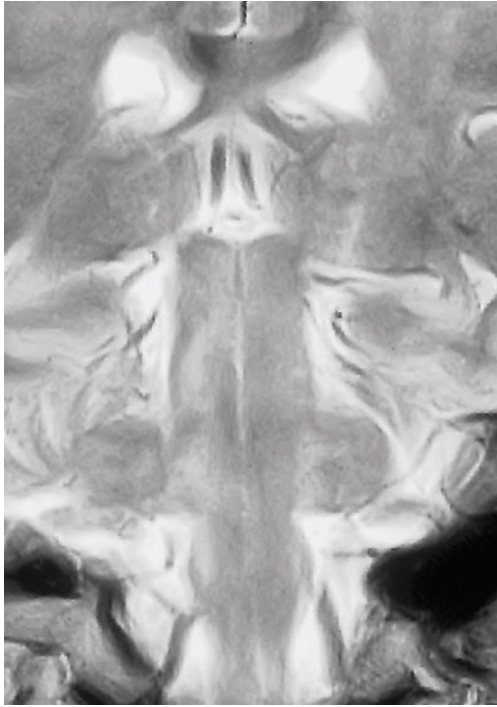







- Frontal lobe
- Temporal lobe
- Parietal lobe
- Cerebellum
- Mesencephalon
- Pons
- Medulla oblongata

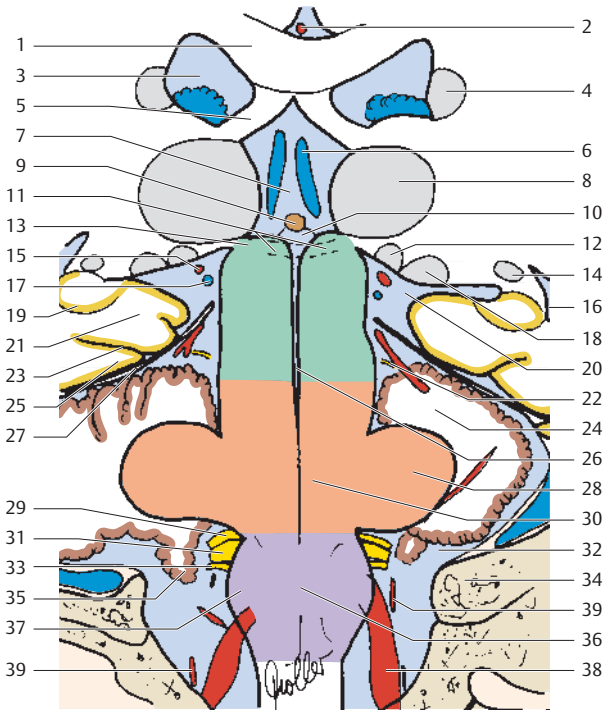
- 1 Parietal bone
- 2 Superior sagittal sinus
- 3 Superior frontal gyrus
- 4 Precentral gyrus
- 5 Paracentral lobe
- 6 Central sulcus
- 7 Falx cerebri
- 8 Postcentral gyrus
- 9 Cingulate gyrus



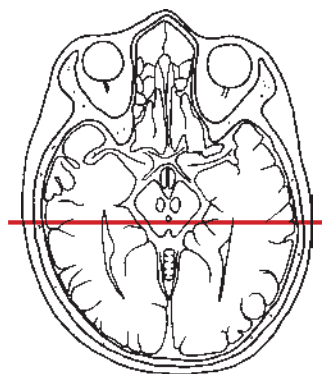
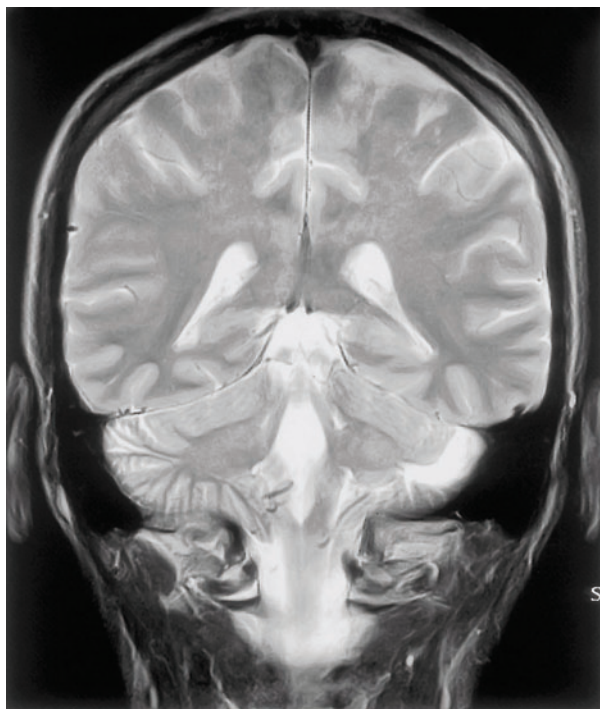
- | | |
|---|--|
| 10 Lateral ventricle | 28 Inferior temporal gyrus |
| 11 Corpus callosum | 29 Anterior lobe of cerebellum |
| 12 Thalamus | 30 Lateral occipitotemporal gyrus |
| 13 Caudate nucleus | 31 Middle cerebellar peduncle |
| 14 Supramarginal gyrus | 32 Sigmoid sinus |
| 15 Internal cerebral vein | 33 Facial nerve (VII), vestibulocochlear nerve (VIII), glossopharyngeal nerve (IX) |
| 16 Transverse temporal gyrus | 34 Flocculus |
| 17 Pineal body | 35 Inferior olivary complex |
| 18 Superior temporal gyrus | 36 Mastoid process with mastoid cells |
| 19 Cranial colliculus | 37 Posterior inferior cerebellar artery |
| 20 Medial geniculate body and lateral geniculate body | 38 Vertebral artery and vein |
| 21 Occipital artery | 39 Digastric muscle (posterior belly) |
| 22 Middle temporal gyrus | 40 Atlas (lateral mass) |
| 23 Parahippocampal gyrus | 41 Obliquus capitis superior muscle |
| 24 Lateral ventricle (temporal horn) | 42 Sternocleidomastoid muscle |
| 25 Superior cerebellar artery | 43 Obliquus capitis inferior muscle |
| 26 Hippocampus | 44 Spinal cord with median fissure |
| 27 Tentorium cerebelli | |



-  Temporal lobe
-  Cerebellum
-  Mesencephalon
-  Pons
-  Medulla oblongata

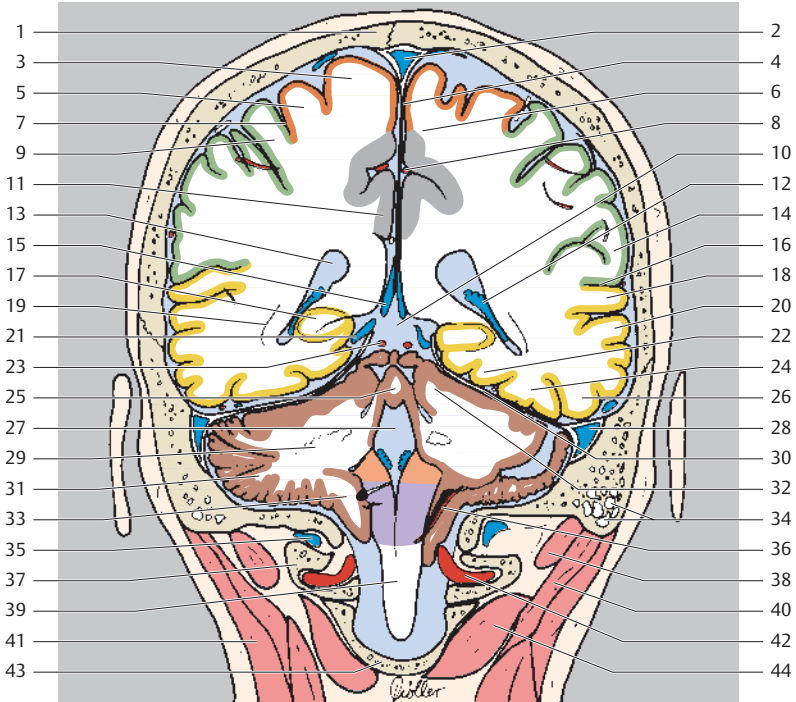


- | | |
|--------------------------------------|---|
| 1 Corpus callosum (trunk) | 20 Ambient cistern |
| 2 Pericallosal artery | 21 Parahippocampal gyrus |
| 3 Lateral ventricle | 22 Trochlear nerve (IV) |
| 4 Body of caudate nucleus | 23 Collateral sulcus |
| 5 Fornix (crus) | 24 Anterior lobe of cerebellum |
| 6 Internal cerebral vein | 25 Lateral occipitotemporal gyrus |
| 7 Suprapineal recess | 26 Aqueduct |
| 8 Thalamus (pulvinar) | 27 Tentorium cerebelli |
| 9 Pineal body | 28 Middle cerebellar peduncle |
| 10 Aqueduct of midbrain | 29 Glossopharyngeal nerve (XI) |
| 11 Posterior commissure | 30 Pons |
| 12 Medial geniculate body | 31 Vagus nerve (X) |
| 13 Cranial colliculus | 32 Pontocerebellar cistern |
| 14 Lateral geniculate body | 33 Accessory nerve (XI) |
| 15 Posterior cerebral artery | 34 Occipital bone |
| 16 Caudate nucleus (tail) | 35 Flocculus |
| 17 Basal vein | 36 Medulla oblongata |
| 18 Lateral ventricle (temporal horn) | 37 Inferior olivary complex |
| 19 Hippocampus | 38 Vertebral artery |
| | 39 Posterior inferior cerebellar artery |

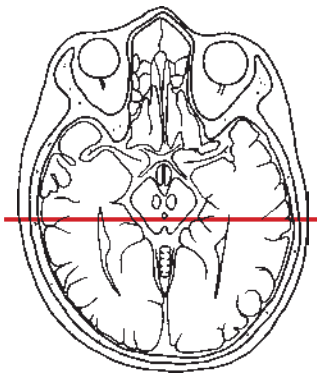
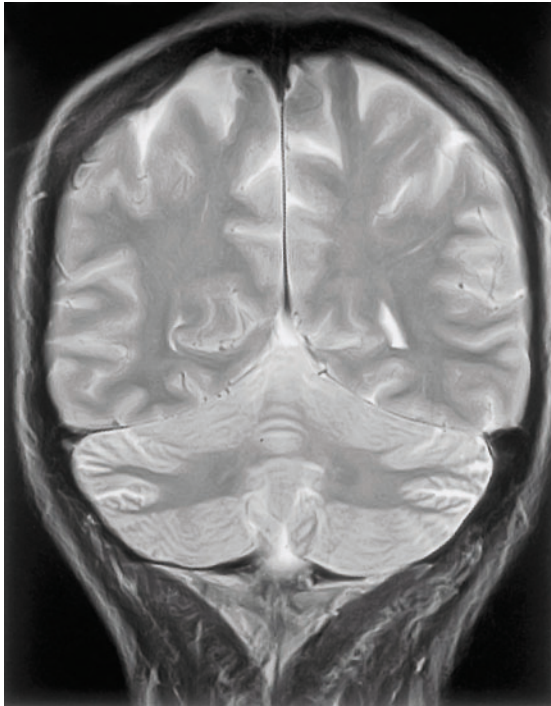






- Frontal lobe
- Temporal lobe
- Parietal lobe
- Cerebellum

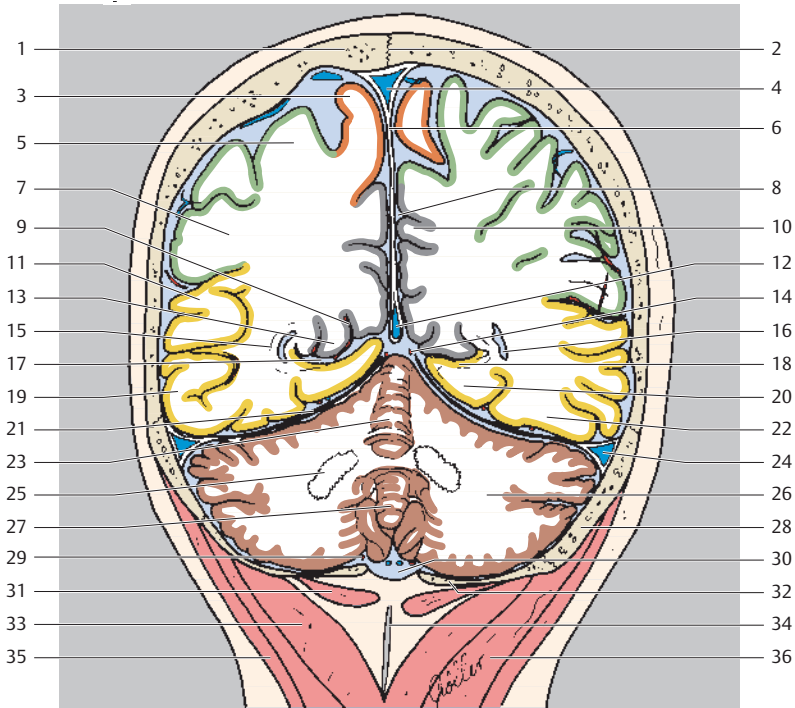
- 1 Parietal bone
- 2 Superior sagittal sinus
- 3 Superior frontal gyrus
- 4 Falx cerebri
- 5 Precentral gyrus
- 6 Paracentral lobule
- 7 Central sulcus



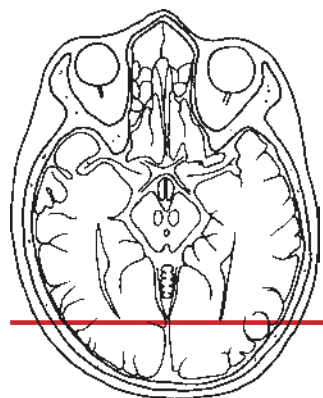
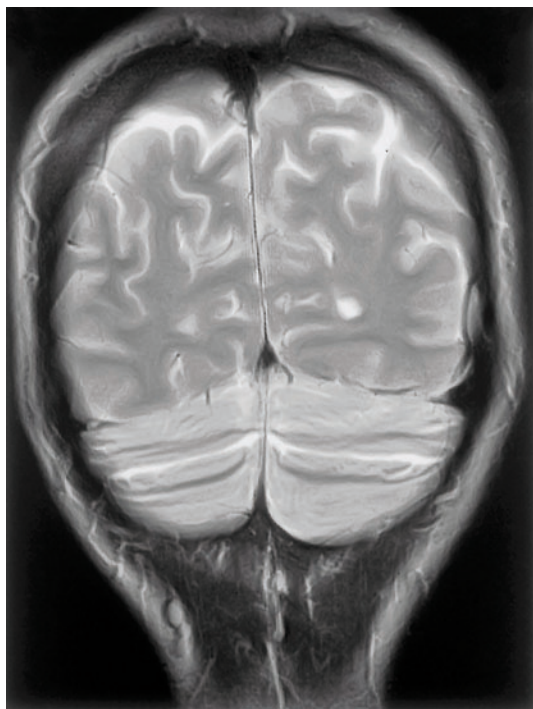
- | | | | |
|----|--|----|--------------------------------------|
| 8 | Precuneal artery | 26 | Inferior temporal gyrus |
| 9 | Postcentral gyrus | 27 | Fourth ventricle |
| 10 | Quadrigeminal cistern | 28 | Transverse sinus |
| 11 | Precuneus | 29 | Dentate nucleus |
| 12 | Choroid plexus | 30 | Tentorium cerebelli |
| 13 | Lateral ventricle (collateral trigone) | 31 | Posterior lobe of cerebellum |
| 14 | Supramarginal gyrus | 32 | Anterior lobe of cerebellum |
| 15 | Internal cerebral vein | 33 | Tonsil of cerebellum |
| 16 | Lateral sulcus | 34 | Mastoid cells in mastoid process |
| 17 | Hippocampus | 35 | Vertebral vein |
| 18 | Superior temporal gyrus | 36 | Posterior inferior cerebellar artery |
| 19 | Optic radiation | 37 | Atlas (lateral mass) |
| 20 | Middle temporal gyrus | 38 | Obliquus capitis superior muscle |
| 21 | Basal vein | 39 | Spinal cord |
| 22 | Medial occipitotemporal gyrus | 40 | Longus capitis muscle |
| 23 | Superior cerebellar artery | 41 | Sternocleidomastoid muscle |
| 24 | Lateral occipitotemporal gyrus | 42 | Vertebral artery |
| 25 | Vermis of cerebellum | 43 | Third cervical vertebra (arch) |
| | | 44 | Obliquus capitis inferior muscle |



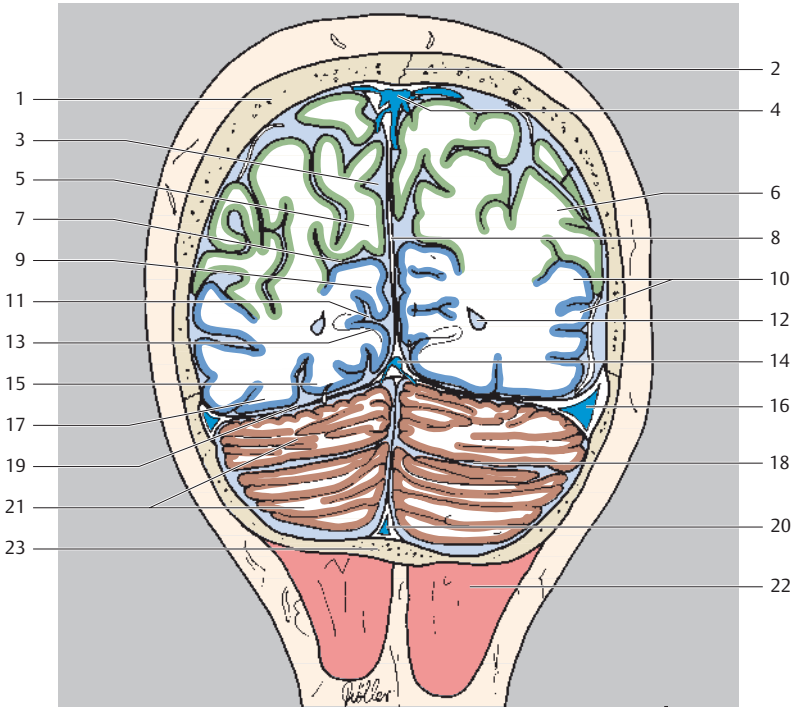
-  Frontal lobe
-  Temporal lobe
-  Parietal lobe
-  Cerebellum



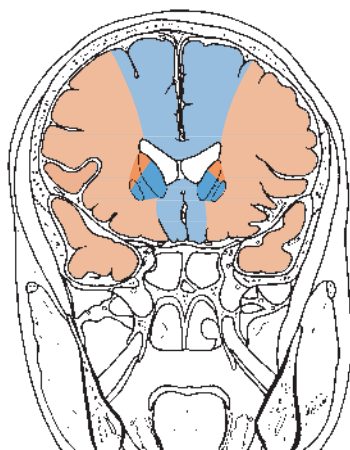
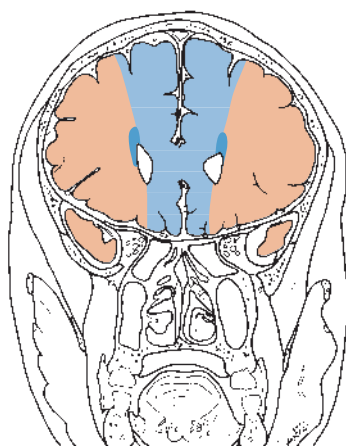
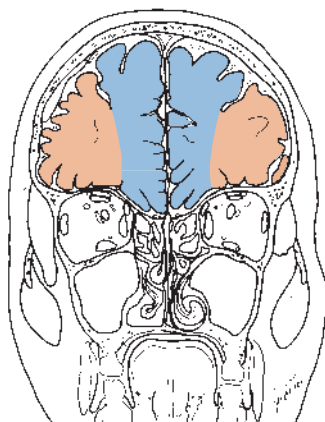
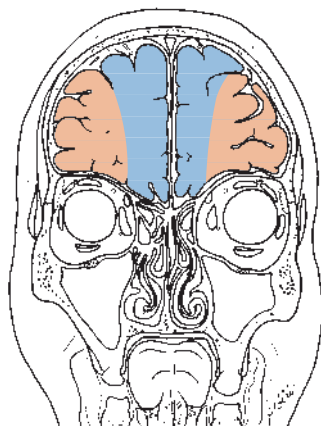
- | | |
|---------------------------------------|--|
| 1 Parietal bone | 19 Inferior temporal gyrus |
| 2 Sagittal suture | 20 Medial occipitotemporal gyrus |
| 3 Precentral gyrus | 21 Tentorium cerebelli |
| 4 Superior sagittal sinus | 22 Lateral occipitotemporal gyrus |
| 5 Postcentral gyrus | 23 Vermis of cerebellum |
| 6 Falx cerebri | 24 Transverse sinus |
| 7 Supramarginal gyrus | 25 Dentate nucleus |
| 8 Longitudinal cerebral | 26 Posterior lobe of cerebellum |
| 9 Parieto-occipital sulcus | 27 Uvula of vermis |
| 10 Precuneus | 28 Temporal bone |
| 11 Middle temporal gyrus | 29 Posterior inferior cerebellar artery |
| 12 Straight sinus | 30 Cisterna magna |
| 13 Cuneus | 31 Rectus capitis posterior minor muscle |
| 14 Superior cerebellar artery | 32 Occipital bone |
| 15 Optic radiation | 33 Rectus capitis posterior major muscle |
| 16 Lateral ventricle (occipital horn) | 34 Nuchal ligament |
| 17 Calcarine sulcus | 35 Splenius capitis muscle |
| 18 Striate cortex | 36 Semispinalis capitis muscle |



- Parietal lobe
- Occipital lobe
- Cerebellum

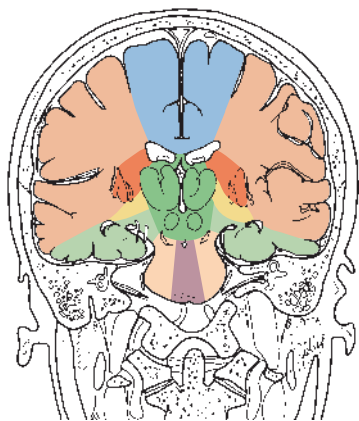
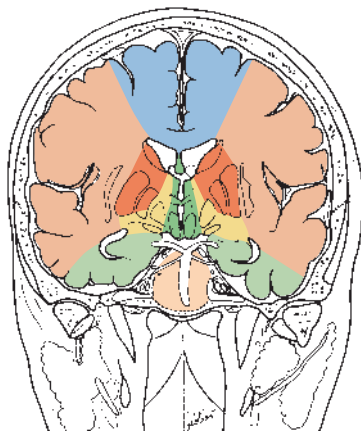
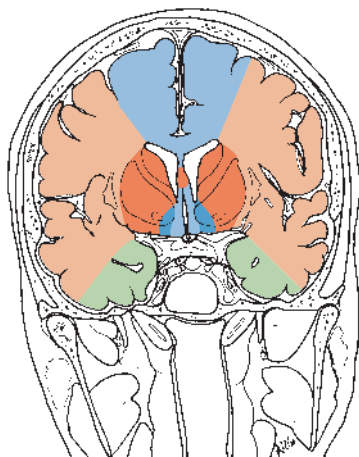
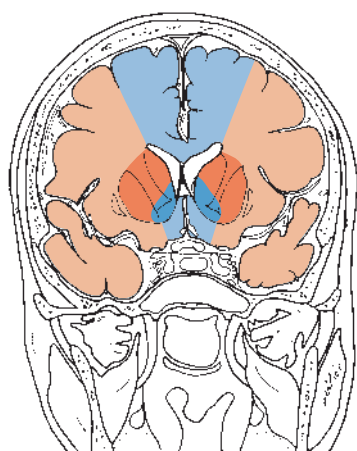


- | | |
|----------------------------|---------------------------------------|
| 1 Parietal bone | 12 Lateral ventricle (occipital horn) |
| 2 Sagittal suture | 13 Striate cortex |
| 3 Longitudinal cerebral | 14 Straight sinus |
| 4 Superior sagittal sinus | 15 Medial occipitotemporal gyrus |
| 5 Precuneus | 16 Transverse sinus |
| 6 Angular gyrus | 17 Lateral occipitotemporal gyrus |
| 7 Parieto-occipital sulcus | 18 Horizontal fissure |
| 8 Falx cerebri | 19 Tentorium cerebelli |
| 9 Cuneus | 20 Occipital sinus |
| 10 Occipital gyri | 21 Posterior lobe of cerebellum |
| 11 Calcarine sulcus | 22 Semispinalis capitis muscle |
| | 23 Occipital bone |



Anterior cerebral artery
 Light blue: Terminal branches
 Dark blue: Central branches

Middle cerebral artery
 Light orange: Terminal branches
 Dark orange: Central branches


Anterior cerebral artery

- Terminal branches
- Central branches (striate arteries including distal medial striate artery)

Middle cerebral artery

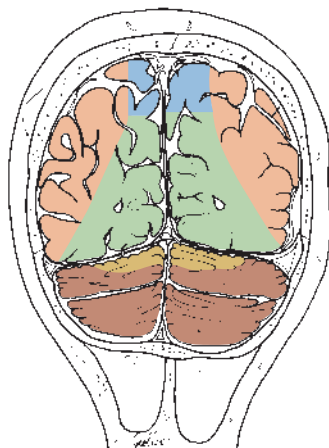
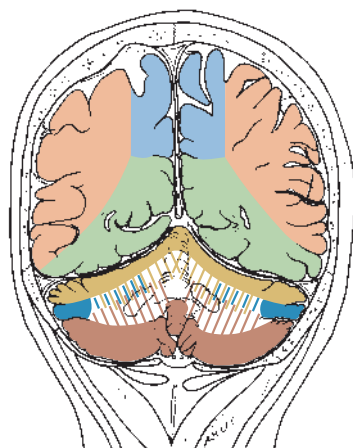
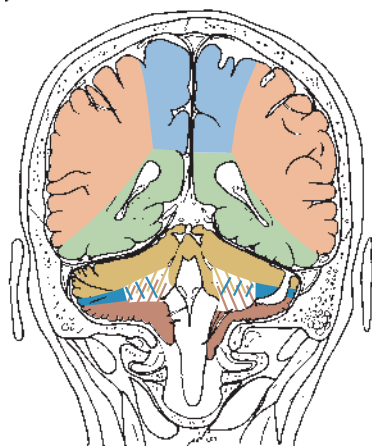
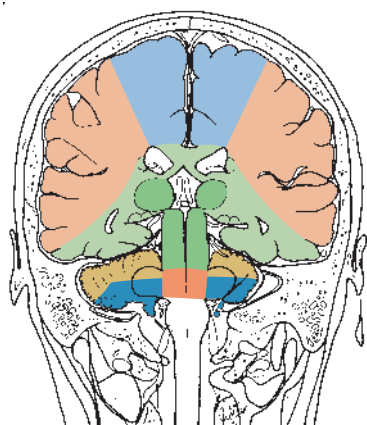
- Terminal branches
- Central branches (striate branches)

Posterior cerebral artery

- Terminal branches
- Central branches (including posterior communicating artery)

Anterior choroidal artery
Basilar artery

- Anteromedial and anterolateral paramedian branches
- Circumferential arteries and lateral and dorsal paramedian branches



Anterior cerebral artery
Terminal branches

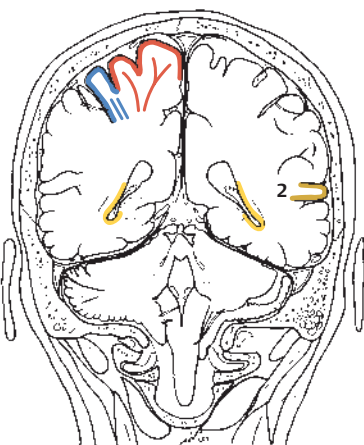
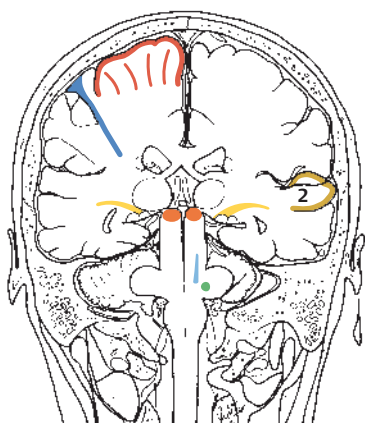
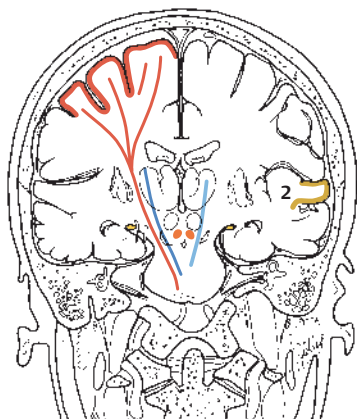
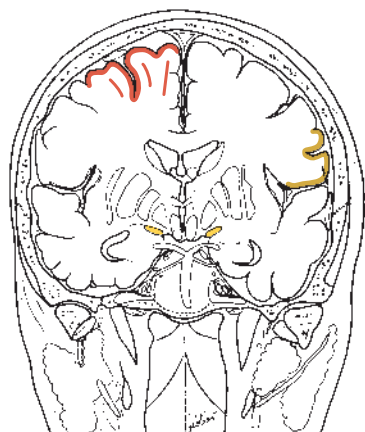
Middle cerebral artery
Terminal branches

Posterior cerebral artery
Terminal branches
Central branches (including posterior communicating artery)

Anterior choroidal artery

Basilar artery
Circumferential arteries and lateral and dorsal paramedian branches

Superior cerebellar artery
Anterior inferior cerebellar artery
Border area
Posterior inferior cerebellar artery





 Motor system

Sensory system


 Medial lemniscus

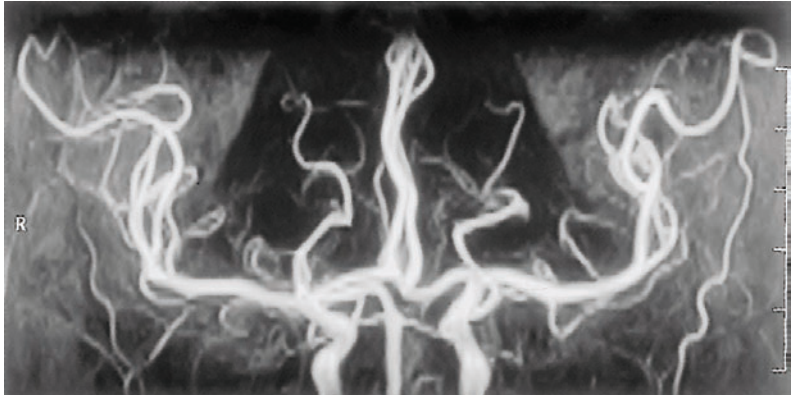
 Spinothalamic tract

 Mesencephalic nucleus of trigeminal nerve

 Oculomotor nucleus and pathways

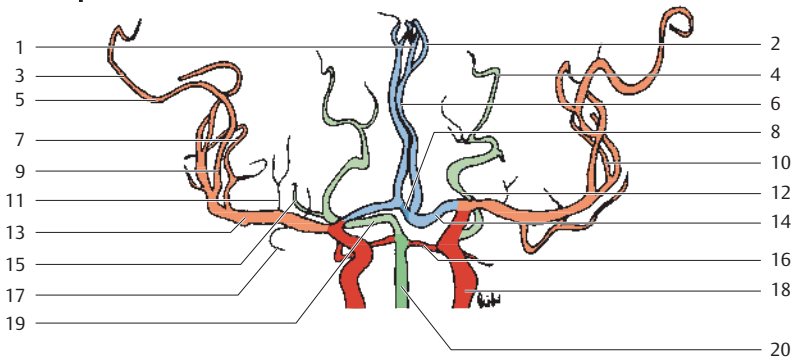
 Optic tract

 Speech center
(1 = motor, 2 = sensory)

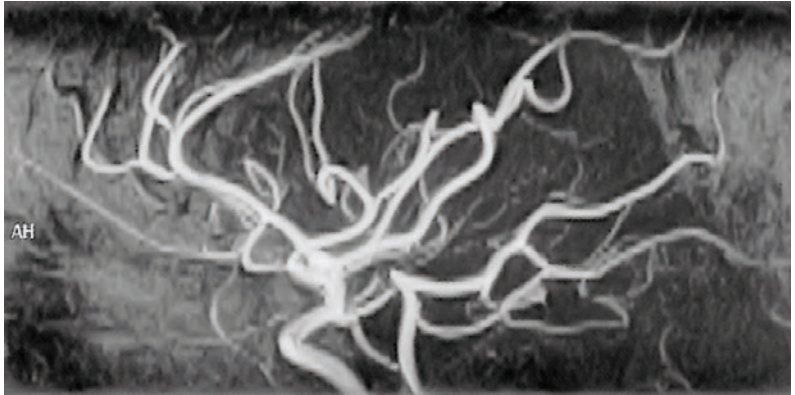


Frontal view




- Anterior cerebral artery
- Middle cerebral artery
- Posterior cerebral artery

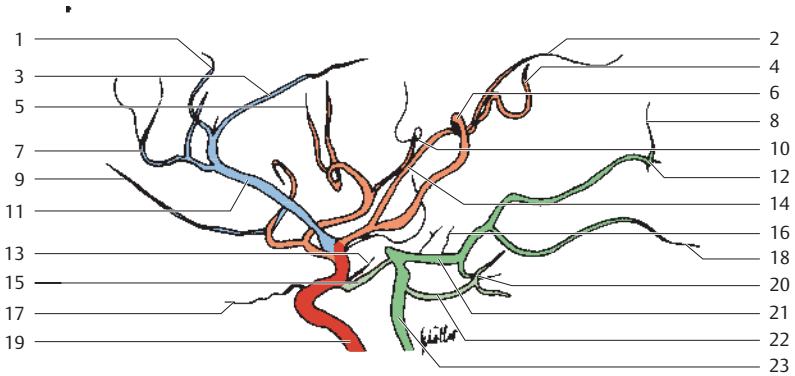


- | | | | |
|----|---|----|--|
| 1 | Callosomarginal artery | 11 | Striate artery |
| 2 | Pericallosal artery | 12 | Left posterior cerebral artery (from internal carotid artery, variant) |
| 3 | Superior parietal artery | 13 | Middle cerebral artery (sphenoid part, M1 segment) |
| 4 | Posterior cerebral artery (parieto-occipital ramus) | 14 | Anterior cerebral artery (precommunicating part) |
| 5 | Middle cerebral artery (opercular part, M3 segment) | 15 | Posterior cerebral artery (temporal and occipitotemporal branches) |
| 6 | Anterior cerebral artery (postcommunicating part) | 16 | Superior cerebellar artery |
| 7 | Insular arteries | 17 | Polar temporal artery |
| 8 | Anterior communicating artery | 18 | Internal carotid artery |
| 9 | Middle cerebral artery (insular part, M2 segment) | 19 | Right posterior cerebral artery |
| 10 | Anterior temporal artery and middle temporal artery | 20 | Basilar artery |

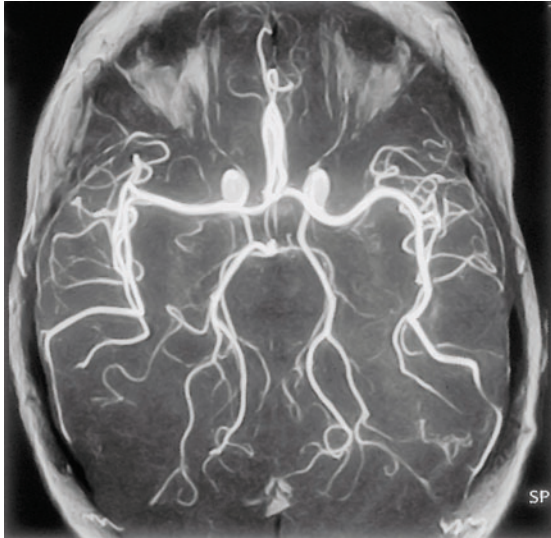

Lateral view

-  Anterior cerebral artery
-  Middle cerebral artery
-  Posterior cerebral artery

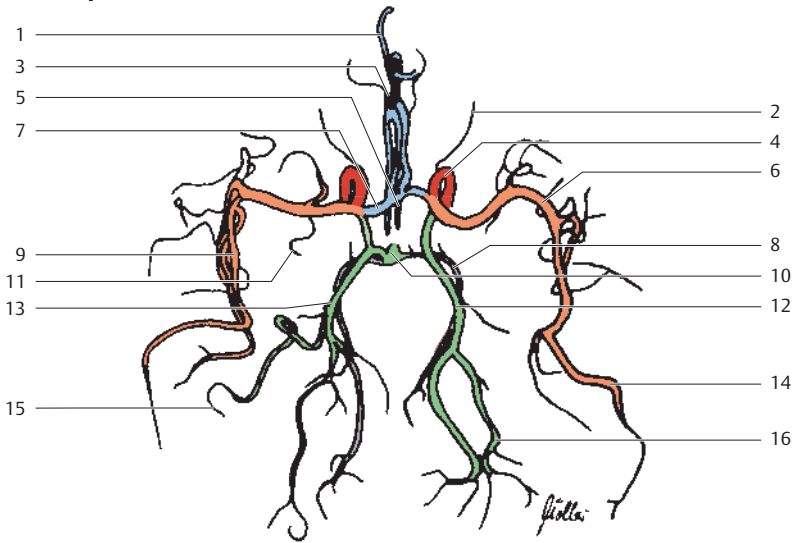


- | | | | |
|----|--|----|-------------------------------------|
| 1 | Callosomarginal artery | 12 | Medial occipital artery |
| 2 | Parietal artery | 13 | Anterior choroidal artery |
| 3 | Pericallosal artery | 14 | Middle cerebral artery (M2 segment) |
| 4 | Artery of angular gyrus | 15 | Posterior communicating artery |
| 5 | Artery of precentral sulcus | 16 | Posteromedial central arteries |
| 6 | Middle cerebral artery (opercular part) | 17 | Ophthalmic artery |
| 7 | Polar frontal artery | 18 | Occipitotemporal branch |
| 8 | Parieto-occipital artery | 19 | Internal carotid artery |
| 9 | Medial frontobasal artery | 20 | Posterior temporal artery |
| 10 | Artery of central sulcus | 21 | Posterior cerebral artery |
| 11 | Anterior cerebral artery (postcommunicating segment, A2 segment) | 22 | Superior cerebellar artery |
| | | 23 | Basilar artery |

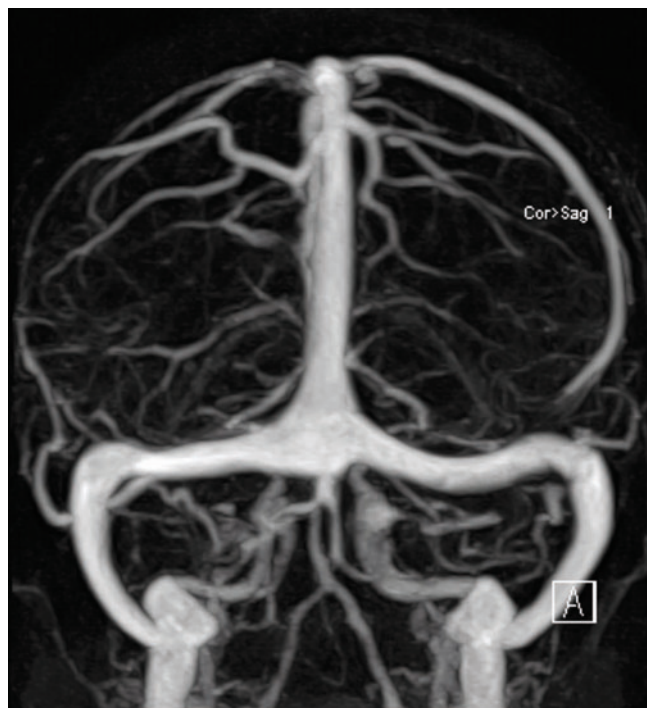


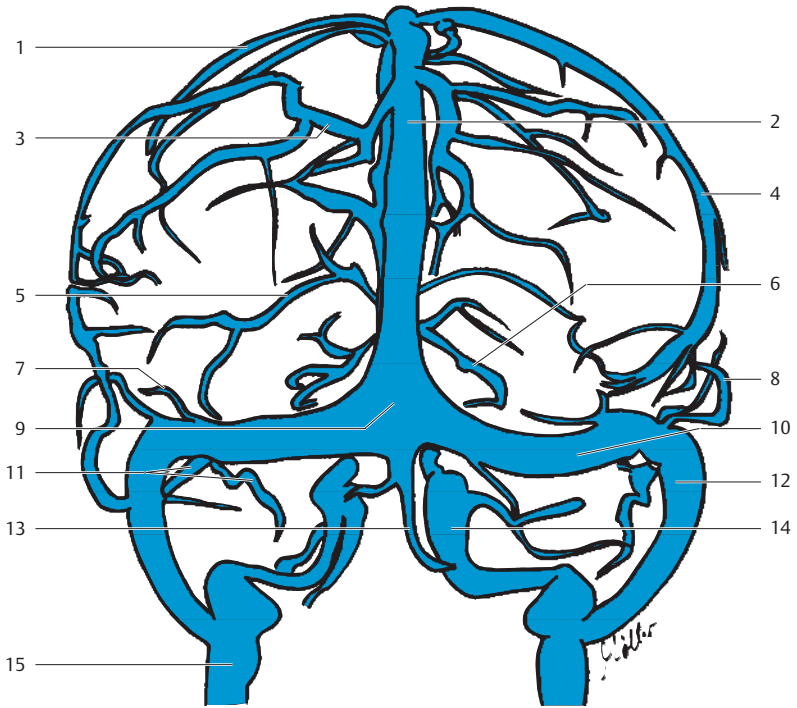
Cranial view

- Anterior cerebral artery
- Middle cerebral artery
- Posterior cerebral artery

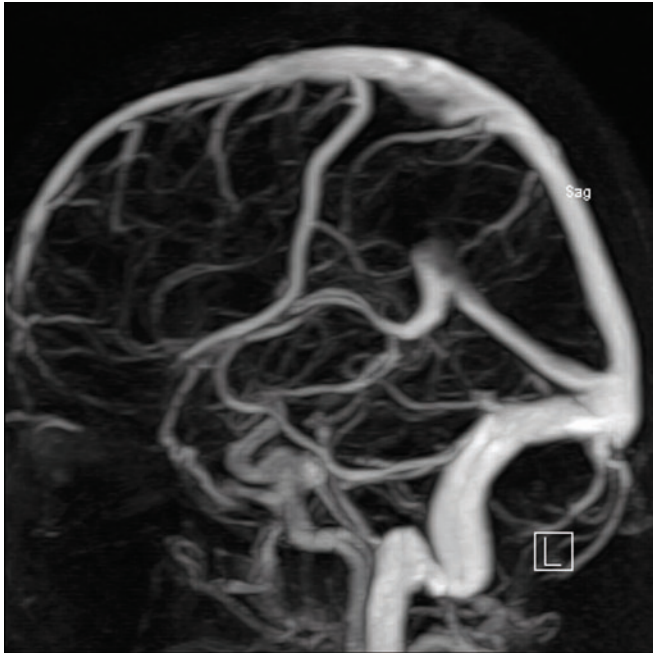


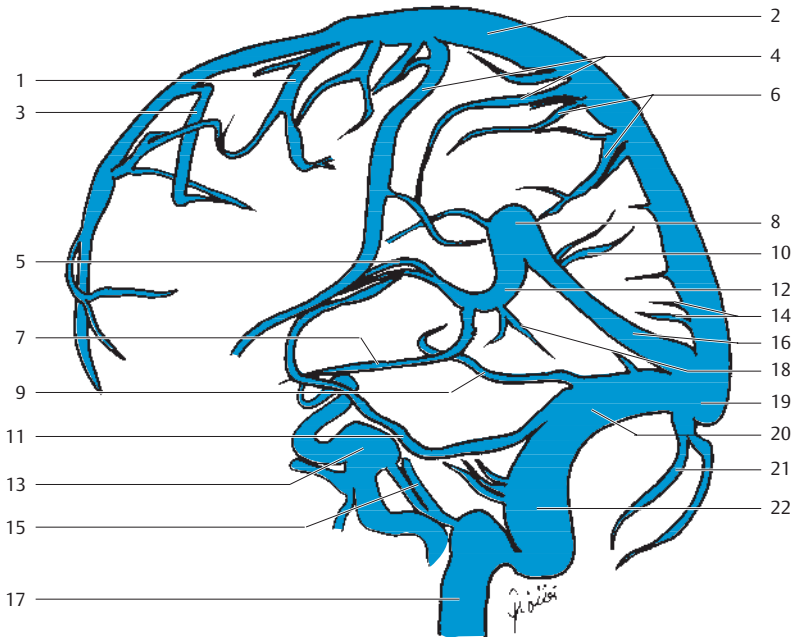
- | | |
|---|---|
| 1 Anteromedial frontal branch of anterior cerebral artery | 8 Superior cerebellar artery |
| 2 Ophthalmic artery | 9 Middle cerebral artery (insular part) |
| 3 Anterior cerebral artery (postcommunicating part) | 10 Basilar artery |
| 4 Internal carotid artery | 11 Anterior choroidal artery |
| 5 Anterior communicating artery | 12 Left posterior cerebral artery (from internal carotid artery, variant) |
| 6 Middle cerebral artery (sphenoid part) | 13 Right posterior cerebral artery |
| 7 Anterior cerebral artery (precommunicating part) | 14 Middle cerebral artery (opercular part) |
| | 15 Temporal artery |
| | 16 Parieto-occipital artery |



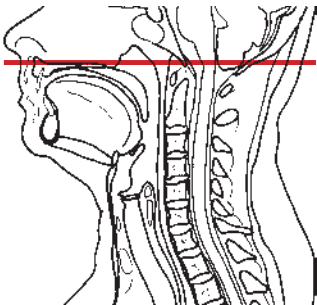
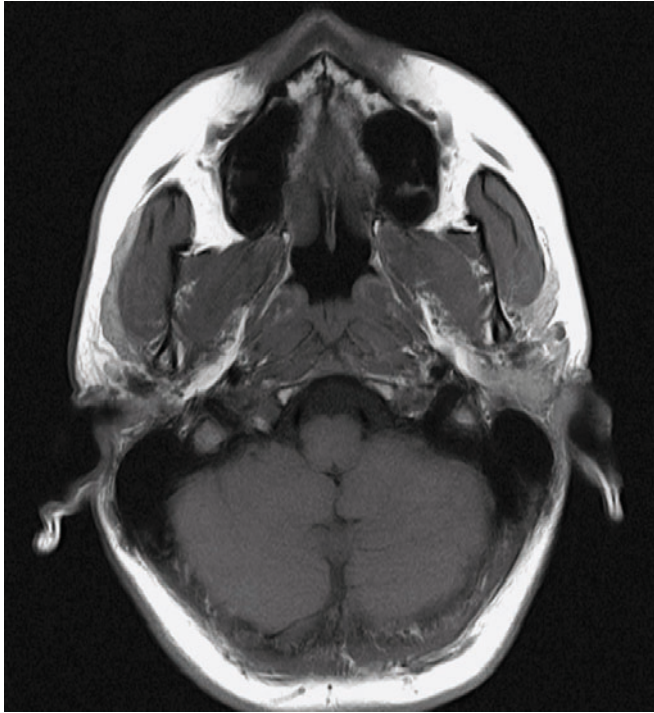


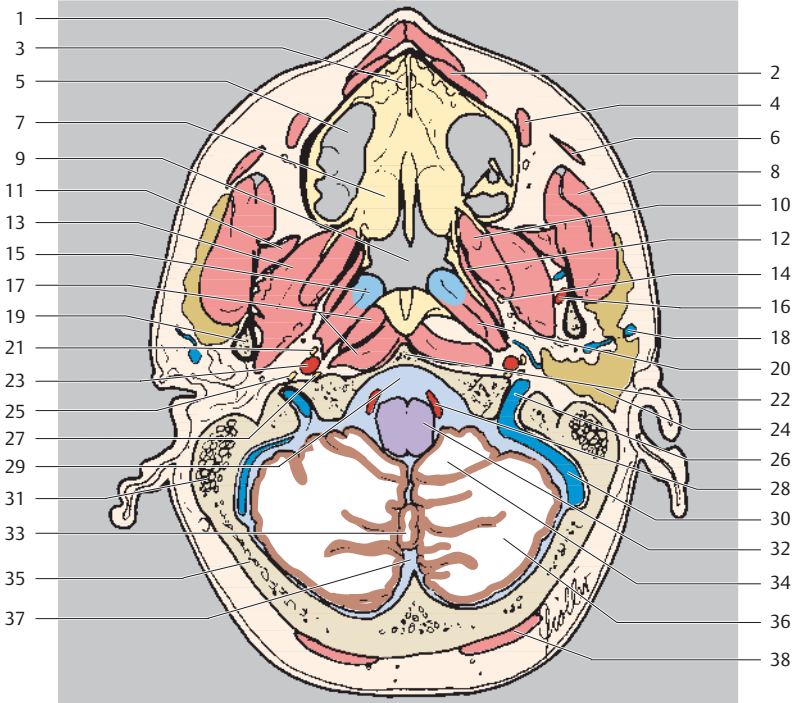
- | | |
|--|--|
| 1 Superior cerebral veins | 8 Sphenoparietal sinus |
| 2 Superior sagittal sinus | 9 Confluence of sinuses |
| 3 Parietal veins | 10 Transverse sinus |
| 4 Superior anastomotic vein (Trolard) | 11 Superior veins of cerebellar hemisphere |
| 5 Frontal veins | 12 Sigmoid sinus |
| 6 Basal vein | 13 Inferior of cerebellar hemisphere |
| 7 Middle cerebral veins (deep and superficial) | 14 Cavernous sinus |
| | 15 Internal jugular vein |



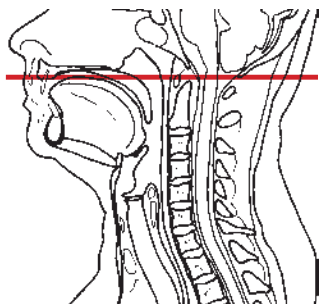
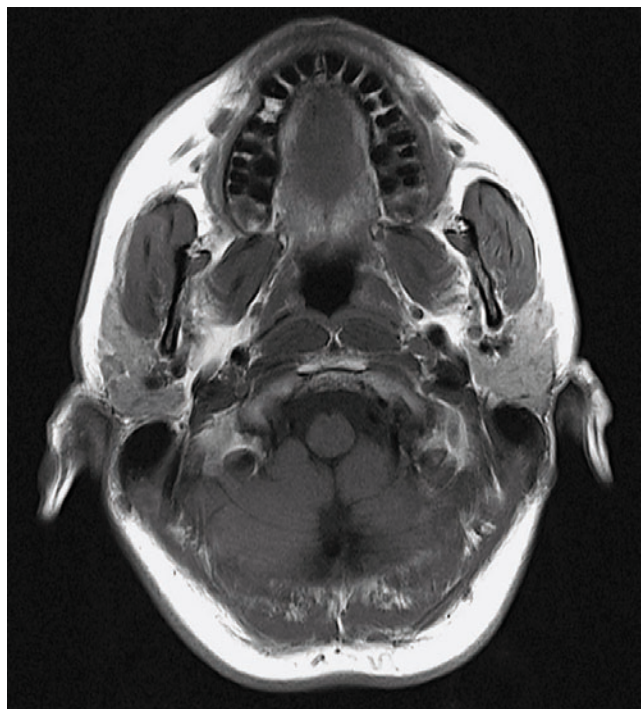


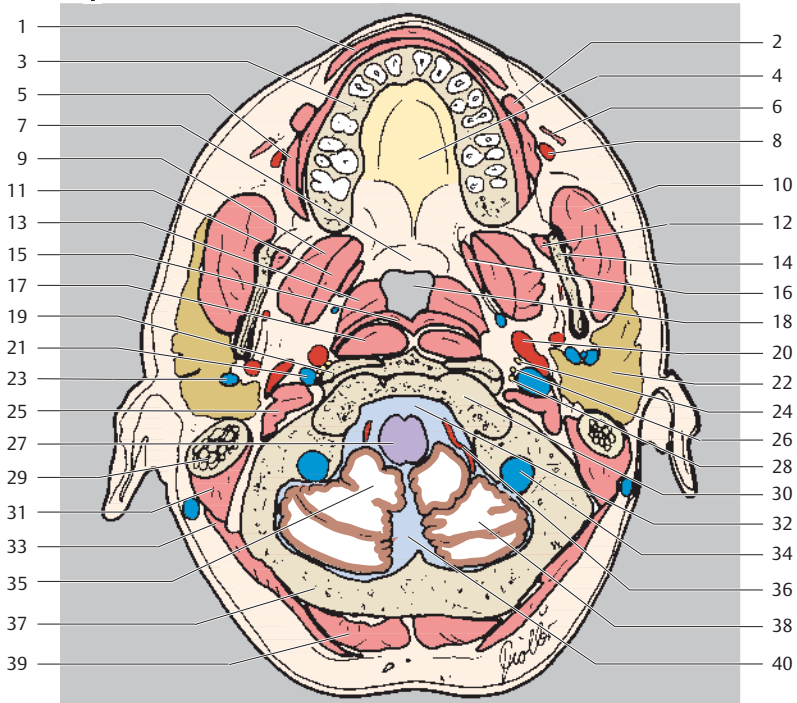
- | | | | |
|----|--------------------------------------|----|---|
| 1 | Precentral cerebellar veins | 12 | Great cerebral vein |
| 2 | Superior sagittal sinus | 13 | Cavernous sinus |
| 3 | Frontal veins | 14 | Posterior cerebral veins |
| 4 | Superior cerebral veins | 15 | Inferior petrosal sinus |
| 5 | Internal cerebral veins | 16 | Straight sinus |
| 6 | Parietal veins | 17 | Internal jugular vein |
| 7 | Basal vein | 18 | Superior veins of cerebellar hemisphere |
| 8 | Falcotentorial confluence of sinuses | 19 | Confluence of sinuses |
| 9 | Inferior anastomotic vein (Labbé) | 20 | Transverse sinus |
| 10 | Internal occipital vein | 21 | Inferior veins of cerebellar hemisphere |
| 11 | Superior petrosal sinus | 22 | Sigmoid sinus |



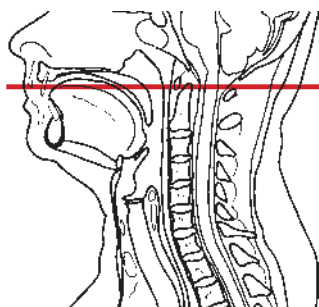
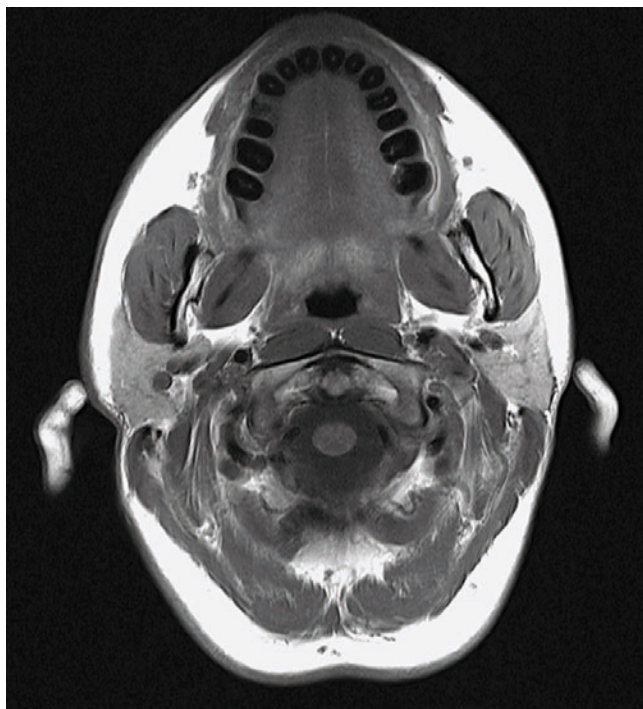


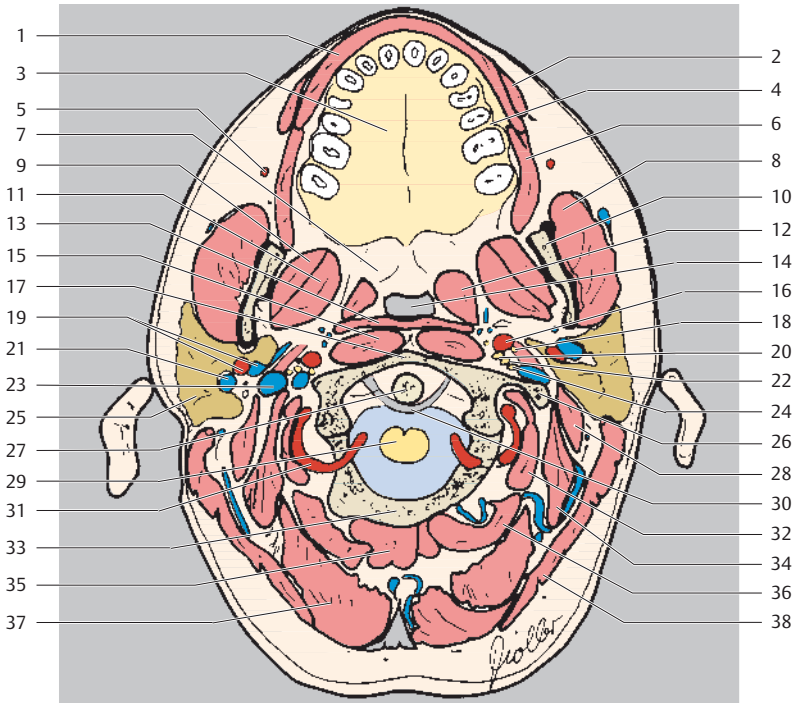
- | | |
|---|--|
| 1 Orbicularis oris muscle | 21 Glossopharyngeal nerve (IX) |
| 2 Levator labii superioris muscle | 22 Occipital bone, basilar part (basion) |
| 3 Maxilla (palatine process) and incisive canal | 23 Internal carotid artery |
| 4 Levator anguli oris muscle | 24 Parotid gland |
| 5 Maxillary sinus | 25 Vagus nerve (X) |
| 6 Major zygomaticus muscle | 26 Internal jugular vein (superior bulb) |
| 7 Soft palate | 27 Hypoglossal nerve (XII) |
| 8 Masseter muscle | 28 Vertebral artery |
| 9 Nasopharynx | 29 Interpeduncular cistern |
| 10 Medial pterygoid muscle | 30 Sigmoid sinus |
| 11 Temporal muscle | 31 Mastoid cells |
| 12 Tensor veli palatini muscle | 32 Medulla oblongata |
| 13 Lateral pterygoid muscle | 33 Vermis |
| 14 Mandibular nerve (V ₃) | 34 Tonsil of cerebellum |
| 15 Pharyngotympanic tube (auditory tube) (torus levatorius) | 35 Occipital bone |
| 16 Maxillary artery | 36 Cerebellar hemisphere (posterior lobe) |
| 17 Longus capitis muscle | 37 Cisterna magna (posterior cerebellomedullary cistern) |
| 18 Retromandibular vein | 38 Semispinalis capitis muscle |
| 19 Ramus of mandible | |
| 20 Levator veli palatini muscle | |



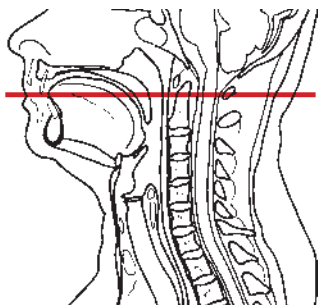
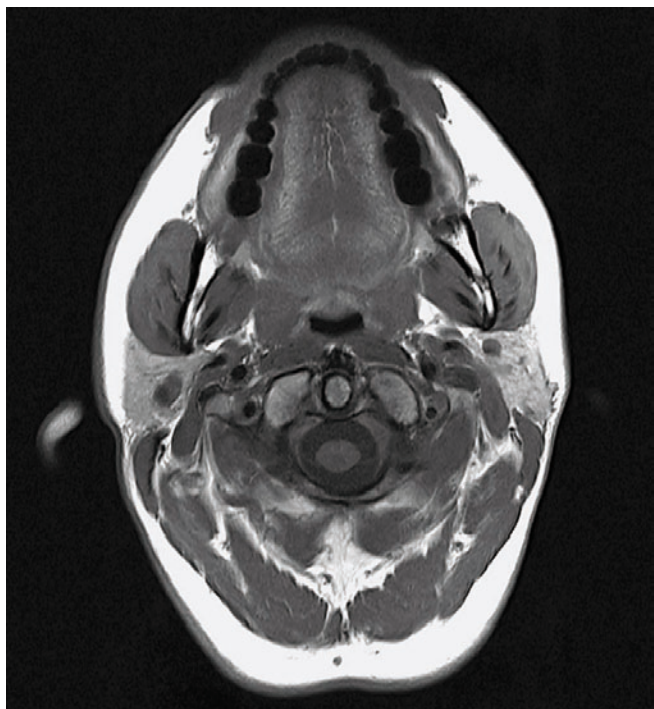


- | | |
|---------------------------------|--|
| 1 Orbicularis oris muscle | 23 Retromandibular vein |
| 2 Levator anguli oris muscle | 24 Vagus nerve (X) |
| 3 Maxilla (alveolar process) | 25 Rectus capitis lateralis muscle |
| 4 Hard palate | 26 Hypoglossal nerve (XII) |
| 5 Buccinator muscle | 27 Medulla oblongata |
| 6 Zygomaticus muscle | 28 Accessory nerve (XI) |
| 7 Soft palate | 29 Mastoid cells (mastoid process) |
| 8 Facial artery | 30 Occipital bone, basilar part (basion) |
| 9 Lateral pterygoid muscle | 31 Digastric muscle (posterior belly) |
| 10 Masseter muscle | 32 Interpeduncular cistern |
| 11 Medial pterygoid muscle | 33 Splenius capitis muscle |
| 12 Temporal muscle | 34 Condylar canal with emissary veins |
| 13 Levator veli palatini muscle | 35 Tonsil of cerebellum |
| 14 Ramus of mandible | 36 Vertebral artery |
| 15 Splenius capitis muscle | 37 Occipital bone |
| 16 Tensor veli palatini muscle | 38 Cerebellar hemisphere (posterior lobe) |
| 17 Longus capitis muscle | 39 Semispinalis capitis muscle |
| 18 Nasopharynx | 40 Cisterna magna (posterior cerebellomedullary cistern) |
| 19 Anterior arch of atlas | |
| 20 Internal carotid artery | |
| 21 Internal jugular vein | |
| 22 Parotid gland | |



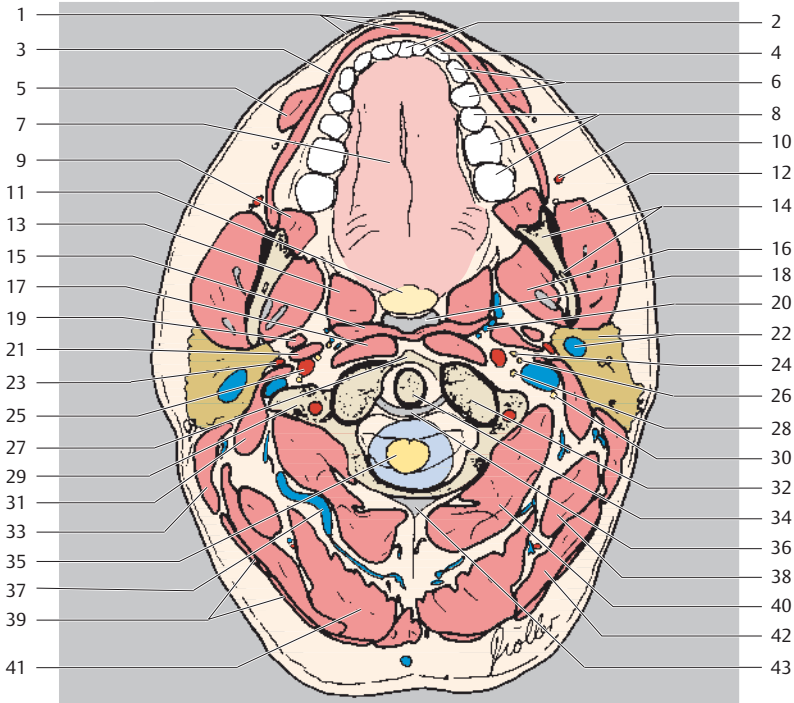


- | | |
|---|--|
| 1 Orbicularis oris muscle | 20 Vagus nerve (X) |
| 2 Levator anguli oris muscle | 21 Retromandibular vein |
| 3 Hard palate | 22 Hypoglossal nerve (XII) |
| 4 Maxilla (alveolar process) | 23 Stylopharyngeus muscle |
| 5 Facial artery | 24 Accessory nerve (XI) |
| 6 Buccinator muscle | 25 Parotid gland |
| 7 Soft palate | 26 Atlas, transverse process |
| 8 Masseter muscle | 27 Dens of axis |
| 9 Lateral pterygoid muscle | 28 Digastric muscle (posterior belly) |
| 10 Ramus of mandible | 29 Medulla oblongata |
| 11 Medial pterygoid muscle | 30 Transverse ligament of atlas |
| 12 Tensor veli palatini muscle | 31 Vertebral artery |
| 13 Superior constrictor muscle of pharynx | 32 Rectus capitis lateralis muscle |
| 14 Pharynx | 33 Atlas, posterior arch |
| 15 Longus capitis muscle | 34 Obliquus capitis superior muscle |
| 16 Internal carotid artery | 35 Rectus capitis posterior minor muscle |
| 17 Atlas (anterior arch) | 36 Obliquus capitis inferior muscle |
| 18 Glossopharyngeal nerve (IX) | 37 Semispinalis capitis muscle |
| 19 Maxillary artery and vein | 38 Splenius capitis muscle |

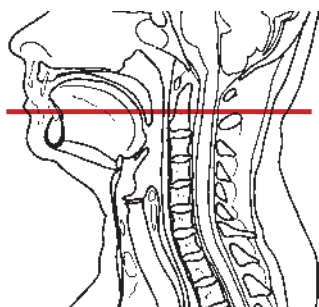
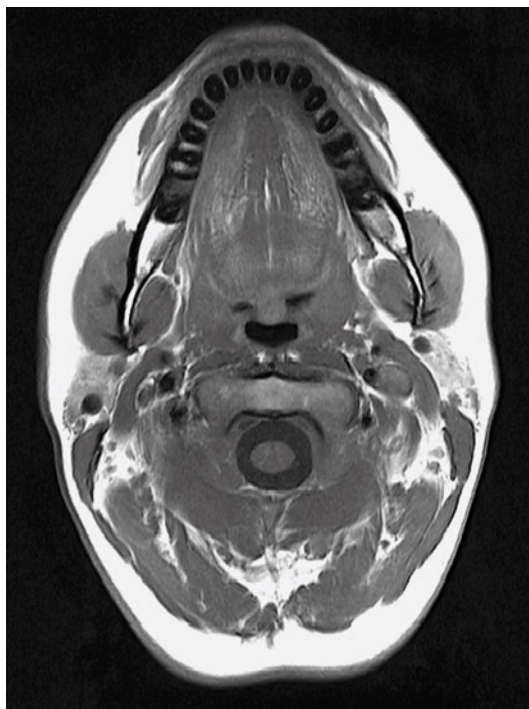


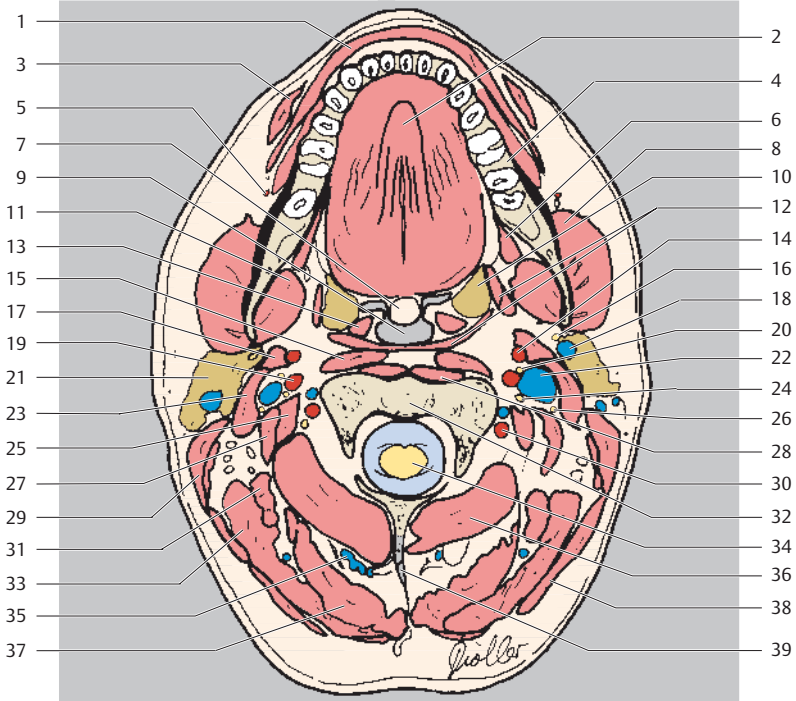
- 1 Upper lip
- 2 Incisors (1 and 2 left)
- 3 Orbicularis oris muscle

- 4 Canine tooth (3 left)
- 5 Levator anguli oris muscle
- 6 Premolar teeth (4 and 5 left)

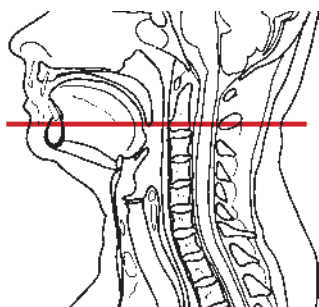
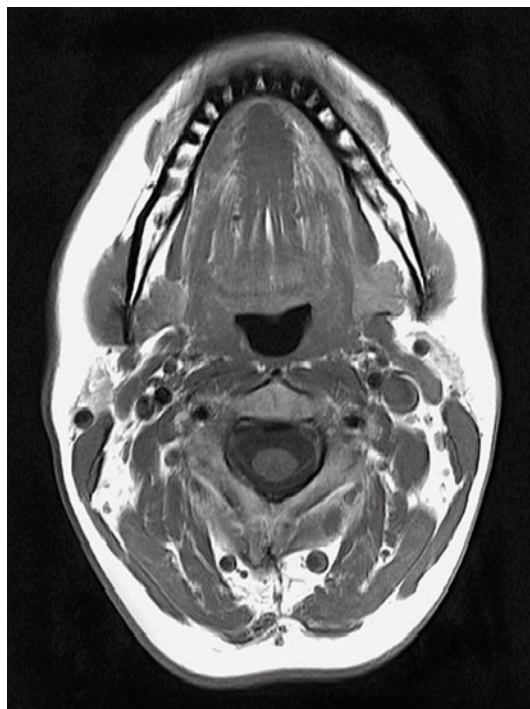

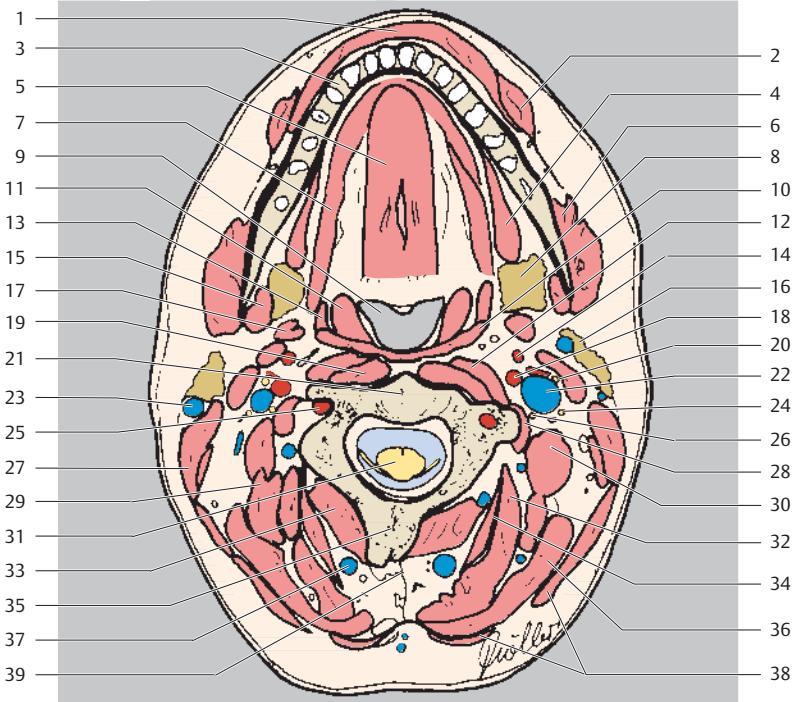
- | | | | |
|----|--|----|---|
| 7 | Tongue | 25 | Internal carotid artery |
| 8 | Molar teeth (6,7 and 8) | 26 | Hypoglossus nerve (XII) |
| 9 | Buccinator muscle | 27 | Atlas (anterior arch) |
| 10 | Facial artery | 28 | Vagus nerve (X) |
| 11 | Uvula | 29 | Transverse process and foramen transversarium |
| 12 | Masseter muscle | 30 | Accessory nerve (XI) |
| 13 | Tensor veli palatini muscle | 31 | Digastric muscle (posterior belly) |
| 14 | Ramus of mandible with alveolar canal | 32 | Atlas, lateral mass |
| 15 | Superior constrictor muscle of pharynx | 33 | Sternocleidomastoid muscle |
| 16 | Medial pterygoid muscle | 34 | Dens of axis |
| 17 | Longus capitis muscle | 35 | Spinal cord |
| 18 | Oropharynx | 36 | Transverse ligament of atlas |
| 19 | Styloglossus muscle | 37 | Deep cervical veins |
| 20 | Pharyngeal venous plexus | 38 | Longissimus capitis muscle |
| 21 | Stylopharyngeus muscle | 39 | Trapezius muscle |
| 22 | Parotid gland and retromandibular vein | 40 | Obliquus capitis inferior muscle |
| 23 | Maxillary artery | 41 | Semispinalis capitis muscle |
| 24 | Glossopharyngeal nerve (IX) | 42 | Splenius capitis muscle |
| | | 43 | Nuchal ligament |



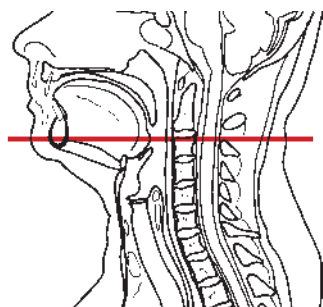
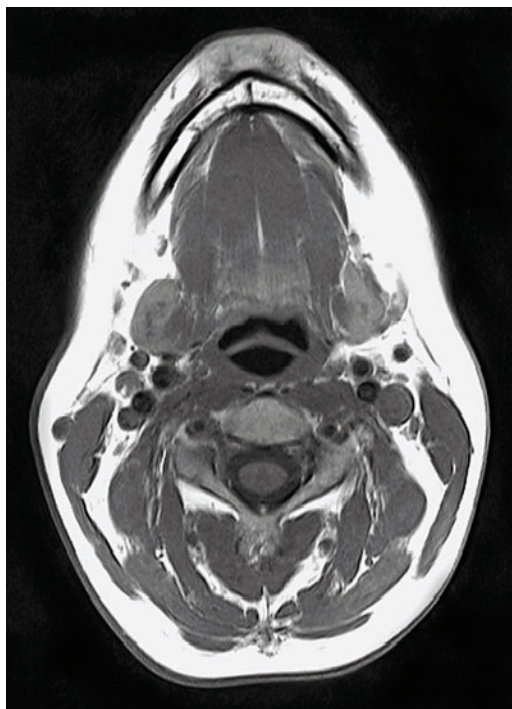

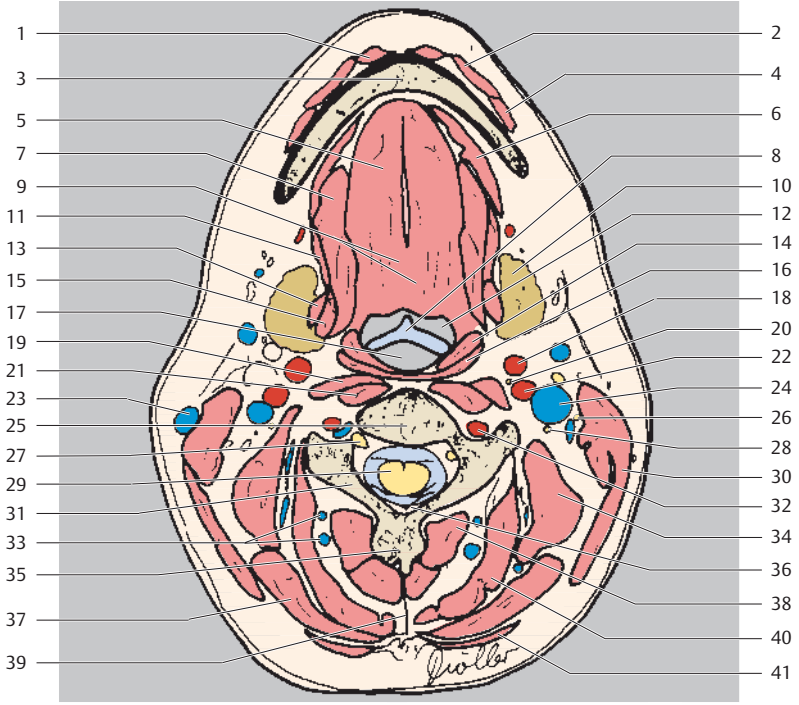
- | | |
|---|---------------------------------------|
| 1 Orbicularis oris muscle | 20 Hypoglossus nerve (XII) |
| 2 Tongue (genioglossus muscle) | 21 Parotid gland |
| 3 Levator anguli oris muscle | 22 Internal jugular vein |
| 4 Mandible | 23 Digastric muscle (posterior belly) |
| 5 Facial artery | 24 Vagus nerve (X) |
| 6 Hypoglossus muscle | 25 Longissimus cervicis muscle |
| 7 Uvula | 26 Accessory nerve (XI) |
| 8 Masseter muscle | 27 Levator scapulae muscle |
| 9 Oropharynx | 28 Longus colli muscle |
| 10 Palatine tonsil | 29 Sternocleidomastoid muscle |
| 11 Medial pterygoid muscle | 30 Vertebral artery |
| 12 Superior constrictor muscle of pharynx | 31 Longissimus capitis muscle |
| 13 Palatopharyngeus muscle | 32 Axis, body |
| 14 External carotid artery | 33 Splenius capitis muscle |
| 15 Longus capitis muscle | 34 Spinal cord |
| 16 Facial nerve (VII) | 35 Deep cervical veins |
| 17 Stylohyoid muscle, styloglossus muscle | 36 Obliquus capitis inferior muscle |
| 18 Retromandibular vein | 37 Semispinalis capitis muscle |
| 19 Internal carotid artery | 38 Trapezius muscle |
| | 39 Nuchal ligament |



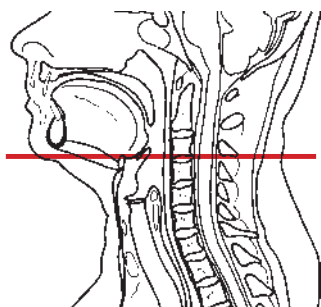
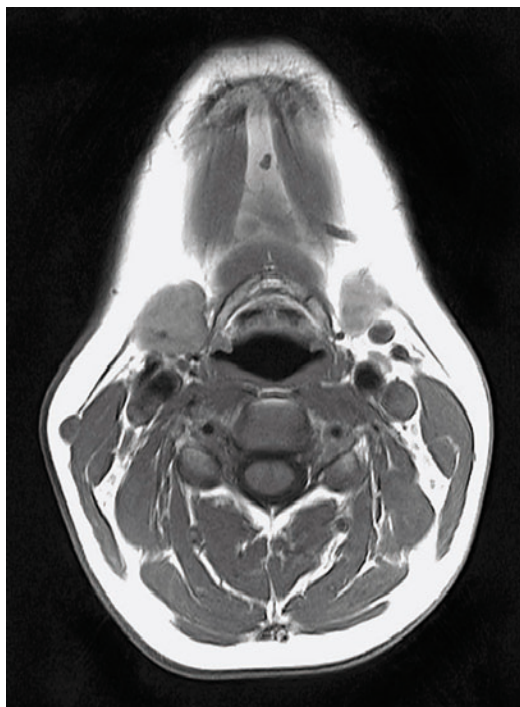

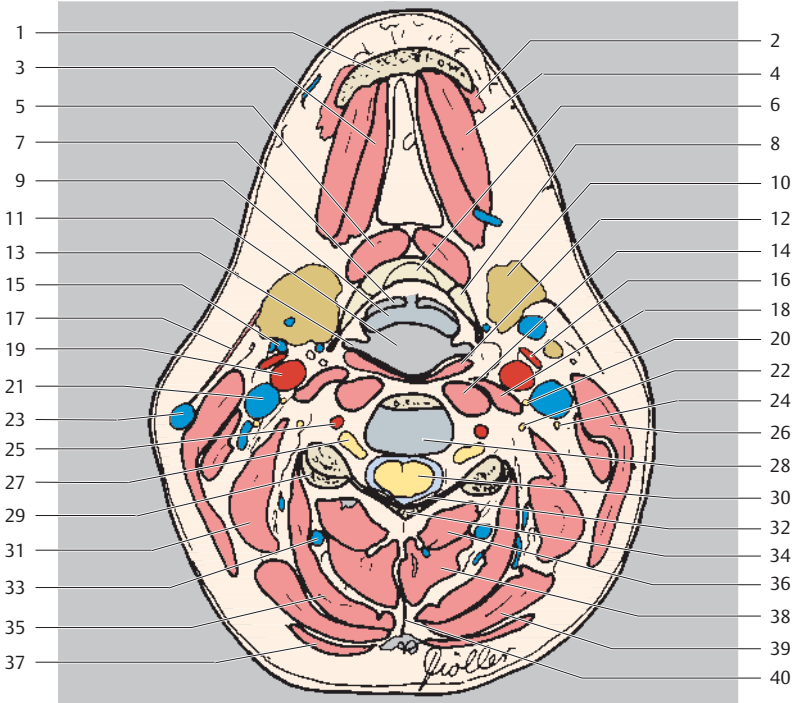
- | | |
|--|--|
| 1 Orbicularis oris muscle | 20 Hypoglossal nerve (XII) |
| 2 Depressor anguli oris muscle | 21 Axis, body |
| 3 Mandible | 22 Internal jugular vein |
| 4 Mylohyoid muscle | 23 Retromandibular vein |
| 5 Genioglossus muscle | 24 Accessory nerve (XI) |
| 6 Masseter muscle | 25 Vertebral artery |
| 7 Hyoglossus muscle | 26 Vagus nerve (X) |
| 8 Submandibular gland | 27 Sternocleidomastoid muscle |
| 9 Oropharynx | 28 Longissimus cervicis muscle |
| 10 Superior constrictor muscle of pharynx | 29 Longissimus capitis muscle |
| 11 Palatopharyngeus muscle | 30 Levator scapulae muscle |
| 12 Longus capitis muscle | 31 Spinal cord |
| 13 Middle constrictor muscle of pharynx | 32 Semispinalis capitis muscle |
| 14 External carotid artery | 33 Spinalis capitis muscle and multifidus muscle |
| 15 Medial pterygoid muscle | 34 Semispinalis cervicis muscle |
| 16 Parotid gland | 35 Spinous process of vertebra |
| 17 Styloglossus muscle and stylohyoid muscle | 36 Splenius capitis muscle |
| 18 Internal carotid artery | 37 Deep cervical veins |
| 19 Longus colli muscle | 38 Trapezius muscle |
| | 39 Nuchal ligament |



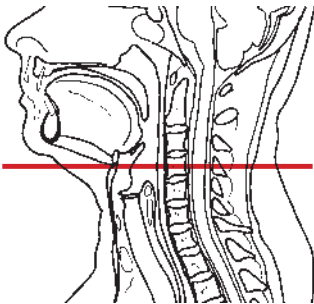
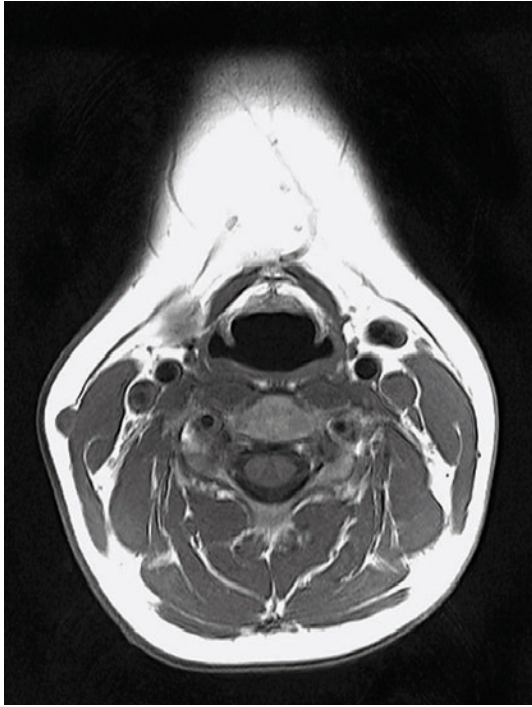

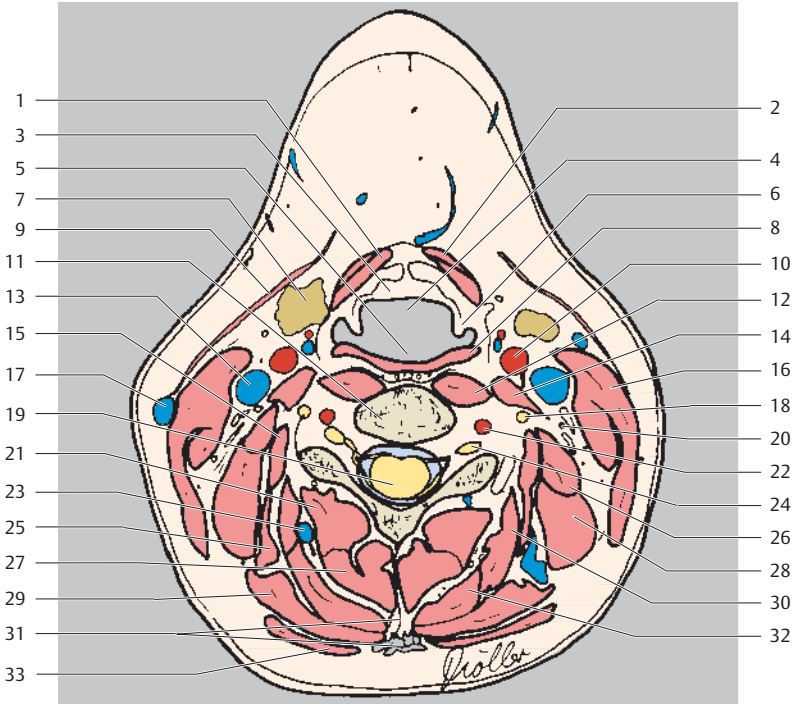
- | | |
|---|--------------------------------|
| 1 Mentalis muscle | 21 Longus colli muscle |
| 2 Depressor anguli oris muscle | 22 Internal carotid artery |
| 3 Mandible | 23 External jugular vein |
| 4 Platysma | 24 Internal jugular vein |
| 5 Genioglossus muscle | 25 Cervical vertebra C3 (body) |
| 6 Mylohyoid muscle | 26 Accessory nerve (XI) |
| 7 Hyoglossus muscle | 27 Spinal nerve root C4 |
| 8 Epiglottis | 28 Vagus nerve (X) |
| 9 Root of tongue | 29 Spinal cord |
| 10 Submandibular gland | 30 Sternocleidomastoid muscle |
| 11 Styloglossus muscle | 31 Posterior arch of C3 |
| 12 Oropharynx | 32 Vertebral artery |
| 13 Stylohyoid muscle | 33 Deep cervical veins |
| 14 Palatopharyngeus muscle | 34 Levator scapulae muscle |
| 15 Digastric muscle (posterior belly) | 35 Spinous process |
| 16 Middle constrictor muscle of pharynx | 36 Ligamentum flavum |
| 17 Hypopharynx | 37 Splenius capitis muscle |
| 18 External carotid artery | 38 Spinalis cervicis muscle |
| 19 Longus capitis muscle | 39 Nuchal ligament |
| 20 Superior laryngeal nerve (vagus nerve) | 40 Semispinalis capitis muscle |
| | 41 Trapezius muscle |



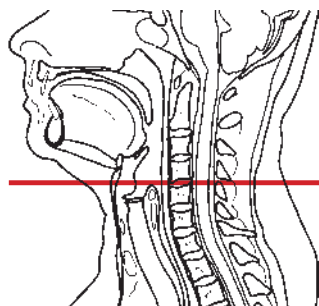
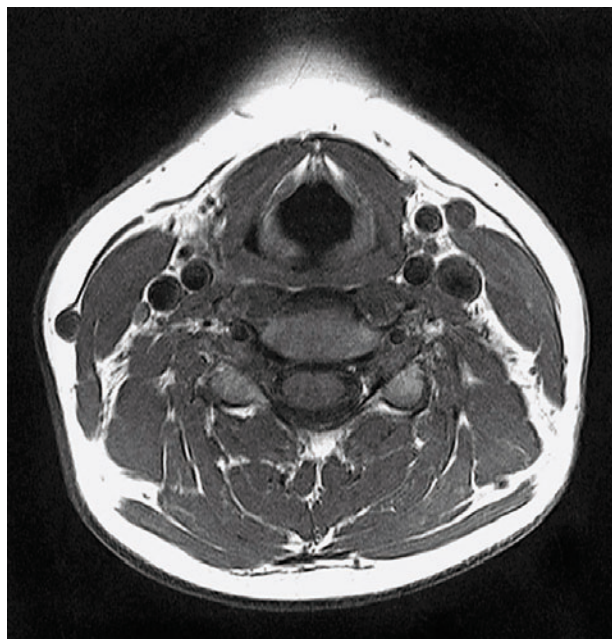


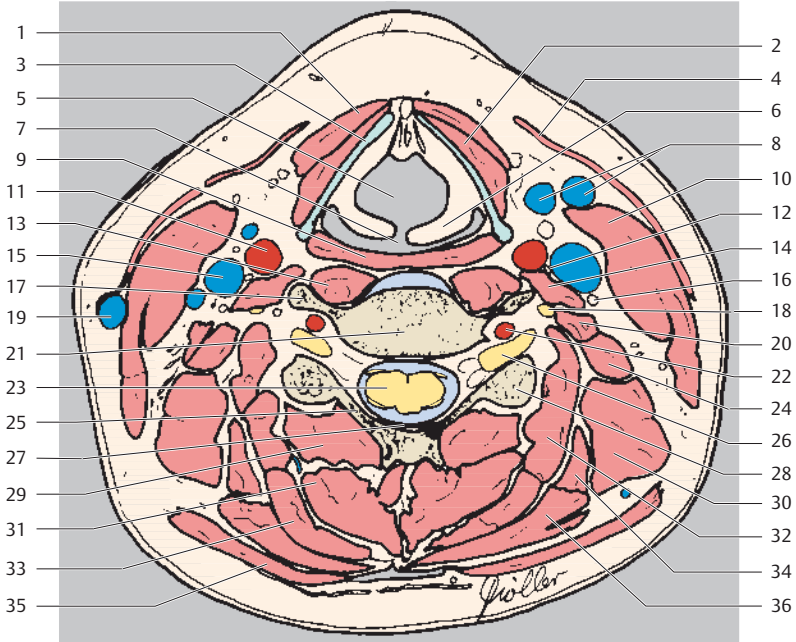
- | | |
|---|----------------------------------|
| 1 Mandible | 20 Vagus nerve (X) |
| 2 Depressor anguli oris muscle | 21 Internal jugular vein |
| 3 Mylohyoid muscle | 22 Spinal nerve (C3) |
| 4 Digastric muscle (anterior belly) | 23 External jugular vein |
| 5 Geniohyoid muscle | 24 Spinal nerve (C2) |
| 6 Hyoid bone (body) | 25 Vertebral artery |
| 7 Epiglottic vallecula | 26 Sternocleidomastoid muscle |
| 8 Hyoid bone (greater horn) | 27 Spinal nerve root (C4) |
| 9 Epiglottis | 28 Intervertebral space (C3/C4) |
| 10 Submandibular gland | 29 Zygapophysial joint |
| 11 Hypopharynx | 30 Spinal cord |
| 12 Inferior constrictor muscle of pharynx | 31 Levator scapulae muscle |
| 13 Piriform recess | 32 Ligamentum flavum |
| 14 Longus colli muscle | 33 Deep cervical veins |
| 15 Retromandibular vein | 34 Posterior arch of C3 vertebra |
| 16 Superior thyroid artery | 35 Semispinalis capitis muscle |
| 17 Platysma | 36 Spinalis cervicis muscle |
| 18 Longus capitis muscle | 37 Trapezius muscle |
| 19 Common carotid artery (bifurcation) | 38 Semispinalis cervicis muscle |
| | 39 Splenius capitis muscle |
| | 40 Nuchal ligament |



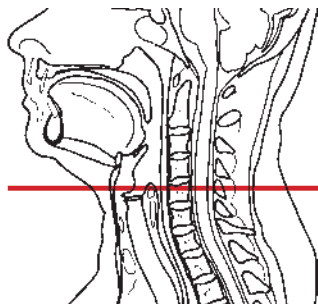
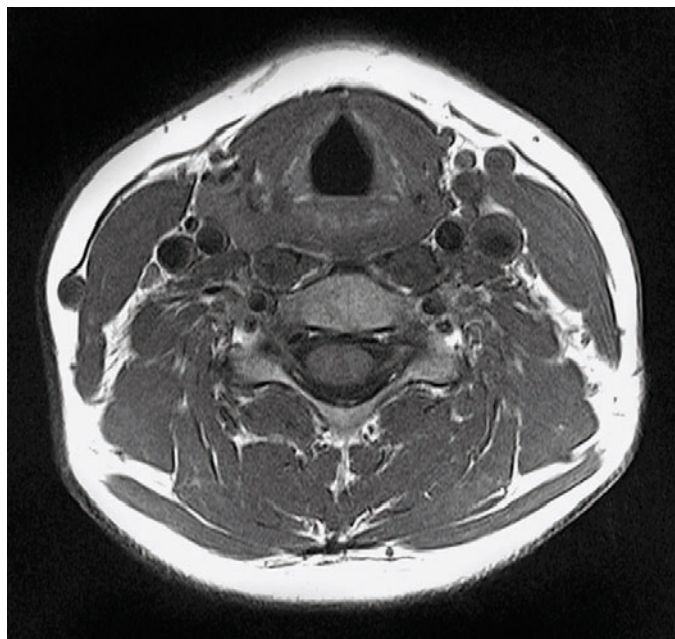


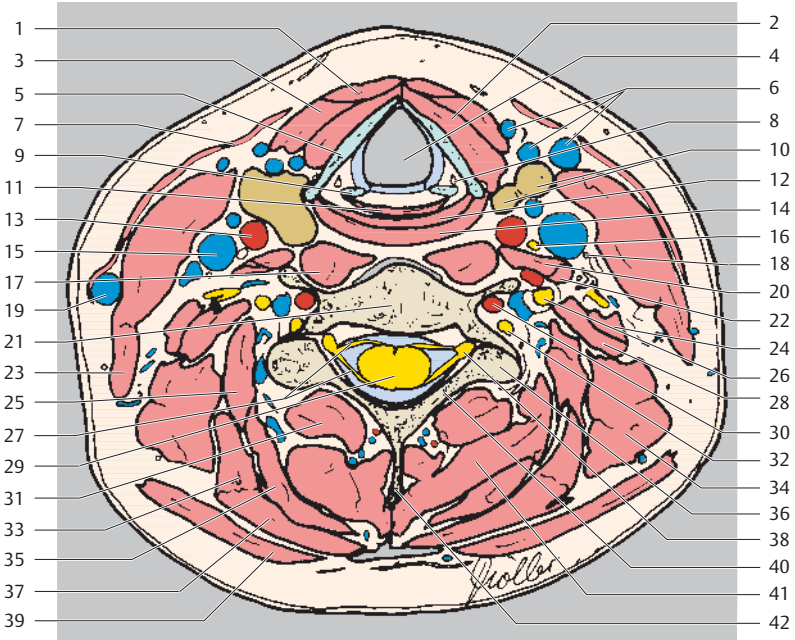
- | | |
|--|---------------------------------|
| 1 Thyrohyoid muscle | 17 External jugular vein |
| 2 Sternohyoid muscle | 18 Spinal nerve (C4) |
| 3 Epiglottis (cartilage) | 19 Spinal cord |
| 4 Laryngeal vestibule | 20 Spinal nerve (C3) |
| 5 Hypopharynx | 21 Spinalis cervicis muscle |
| 6 Aryepiglottic fold | 22 Vertebral artery |
| 7 Submandibular gland | 23 Deep cervical veins |
| 8 Inferior constrictor muscle of pharynx | 24 Spinal nerve root (C5) |
| 9 Platysma | 25 Longissimus cervicis muscle |
| 10 Common carotid artery | 26 Middle scalene muscle |
| 11 Cervical vertebra C4 (body) | 27 Semispinalis cervicis muscle |
| 12 Longus colli muscle | 28 Levator scapulae muscle |
| 13 Internal jugular vein | 29 Splenius capitis muscle |
| 14 Longus capitis muscle | 30 Splenius cervicis muscle |
| 15 Longissimus capitis muscle | 31 Nuchal ligament |
| 16 Sternocleidomastoid muscle | 32 Semispinalis capitis muscle |
| | 33 Trapezius muscle |



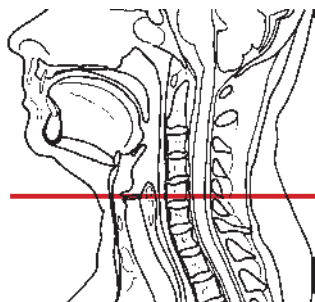
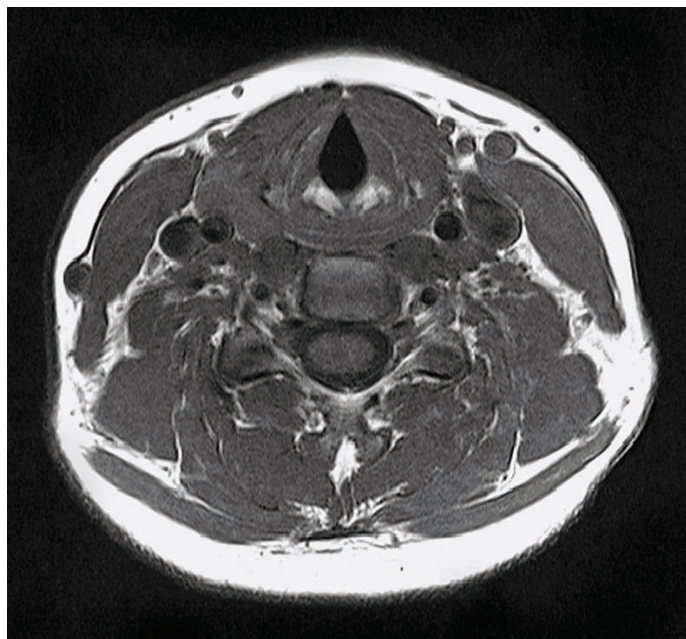


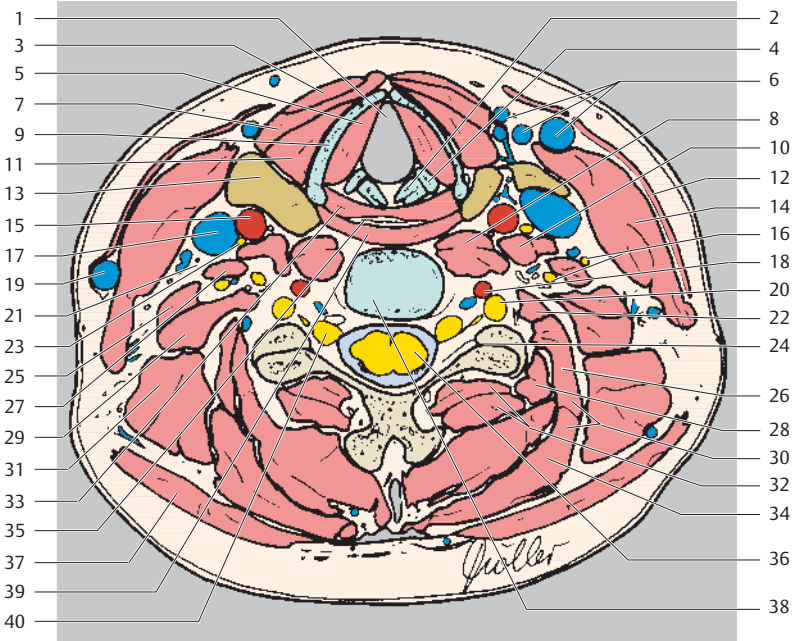
- | | |
|--|---|
| 1 Sternohyoid muscle | 19 External jugular vein |
| 2 Thyrohyoid muscle | 20 Middle scalene muscle |
| 3 Thyroid cartilage (lamina) | 21 Cervical vertebra C5 (body) |
| 4 Platysma | 22 Vertebral artery |
| 5 Laryngeal vestibule | 23 Spinal cord |
| 6 Aryepiglottic fold | 24 Posterior scalene muscle |
| 7 Hypopharynx | 25 Posterior arch of C6 vertebra |
| 8 Anterior jugular vein | 26 Spinal nerve root (C6) |
| 9 Inferior constrictor muscle of pharynx | 27 Ligamentum flavum |
| 10 Sternocleidomastoid muscle | 28 Inferior articular process of vertebra |
| 11 Common carotid artery | 29 Spinalis cervicis muscle and multifidus muscle |
| 12 Vagus nerve (X) | 30 Levator scapulae muscle |
| 13 Longus colli muscle | 31 Semispinalis cervicis muscle |
| 14 Longus capitis muscle | 32 Longissimus cervicis muscle |
| 15 Internal jugular vein | 33 Semispinalis capitis muscle |
| 16 Spinal nerve (C4) | 34 Splenius cervicis muscle |
| 17 Transverse process of C5 vertebra | 35 Trapezius muscle |
| 18 Spinal nerve (C5) | 36 Splenius capitis muscle |



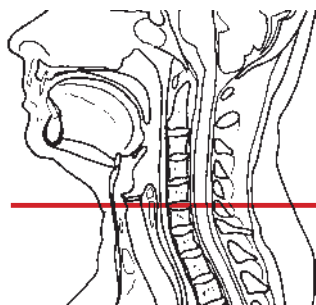
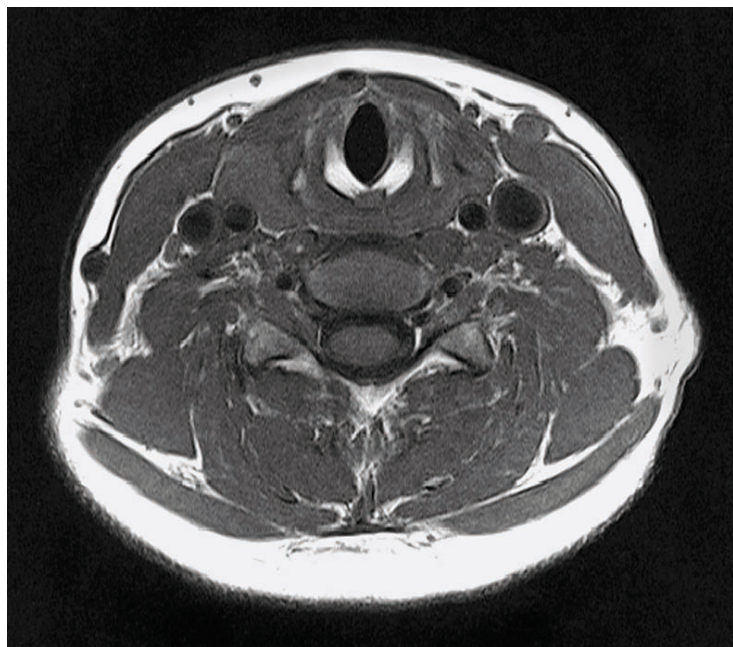


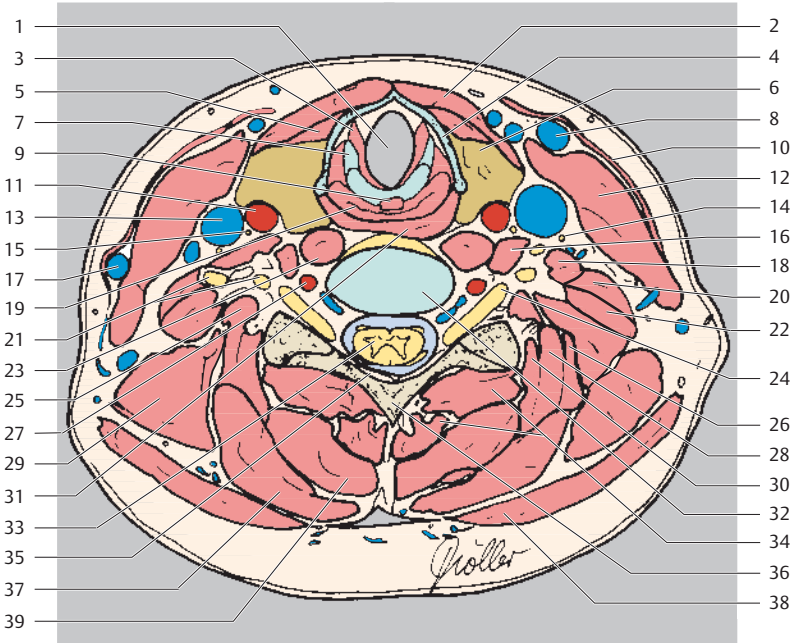
- | | |
|---|---|
| 1 Sternohyoid muscle | 22 Anterior scalene muscle |
| 2 Thyrohyoid muscle | 23 Sternocleidomastoid muscle |
| 3 Omohyoid muscle | 24 Posterior scalene muscle |
| 4 Larynx | 25 Longissimus cervicis muscle |
| 5 Thyroid cartilage (lamina) | 26 Spinal nerve (C4) |
| 6 Anterior jugular vein | 27 Anterior and posterior nerve roots |
| 7 Platysma | 28 Middle scalene muscle |
| 8 Piriform recess | 29 Spinal cord |
| 9 Arytenoid cartilage | 30 Vertebral artery |
| 10 Thyroid gland | 31 Spinalis cervicis muscle and multifidus muscle |
| 11 Cricoid cartilage | 32 Spinal nerve (C5) |
| 12 Hypopharynx | 33 Splenius cervicis muscle |
| 13 Common carotid artery | 34 Levator scapulae muscle |
| 14 Inferior constrictor muscle of pharynx | 35 Semispinalis capitis muscle |
| 15 Internal jugular vein | 36 Inferior articular process of vertebra |
| 16 Vagus nerve (X) | 37 Splenius capitis nerve |
| 17 Longus colli muscle | 38 Spinal nerve root (C6) |
| 18 Phrenic nerve | 39 Trapezius muscle |
| 19 External jugular vein | 40 Posterior arch of C6 vertebra |
| 20 Longus capitis muscle | 41 Semispinalis cervicis muscle |
| 21 Cervical vertebra C5 (body) | 42 Spinous process of C6 vertebra |



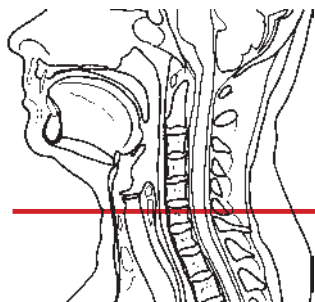
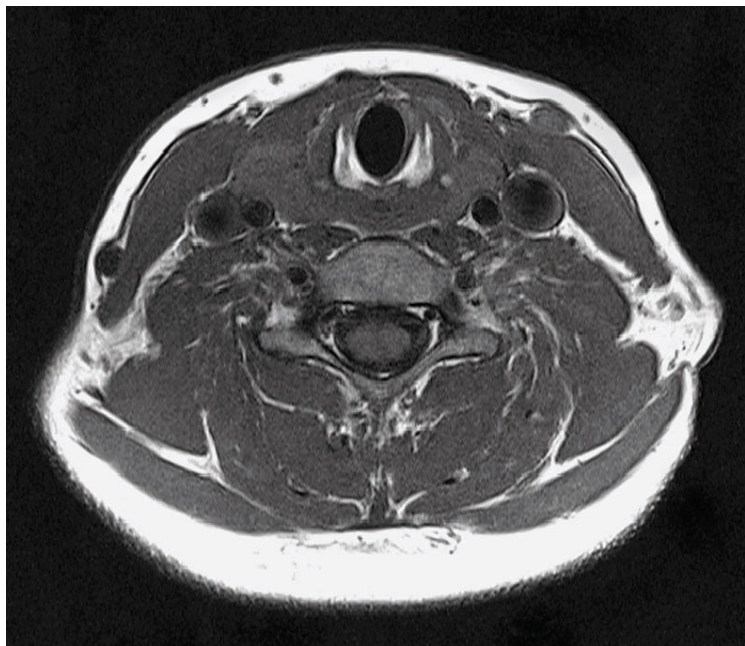


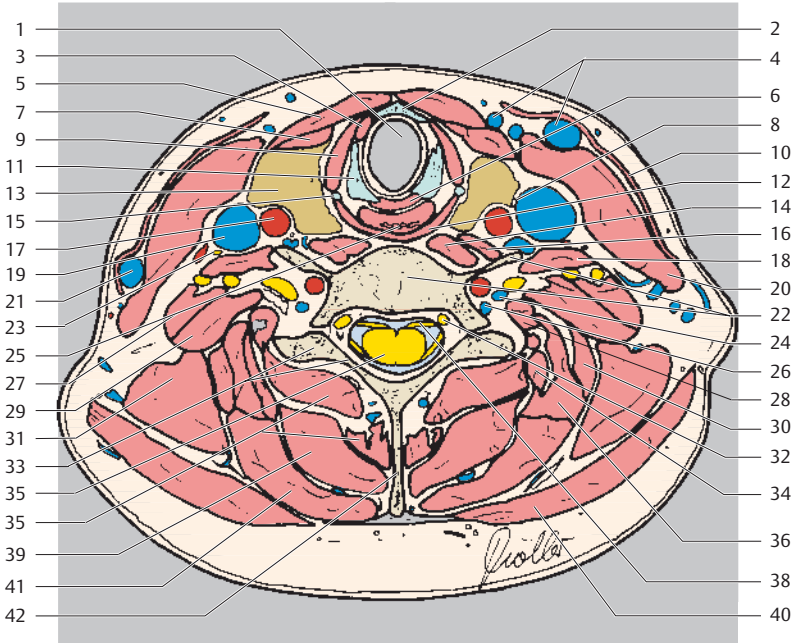
- | | |
|-------------------------------|---|
| 1 Glottis | 22 Longissimus capitis muscle |
| 2 Cricoid cartilage | 23 Vagus nerve (X) |
| 3 Sternohyoid muscle | 24 Zygapophysial joint |
| 4 Arytenoid cartilage | 25 Middle scalene muscle |
| 5 Vocalis muscle | 26 Longissimus cervicis muscle |
| 6 Anterior jugular vein | 27 Anterior scalene muscle |
| 7 Omohyoid muscle | 28 Semispinalis capitis muscle |
| 8 Longus colli muscle | 29 Posterior scalene muscle |
| 9 Thyroid cartilage (lamina) | 30 Splenius cervicis muscle and splenius capitis muscle |
| 10 Longus capitis muscle | 31 Levator scapulae muscle |
| 11 Thyrohyoid muscle | 32 Spinalis cervicis muscle and multifidus muscle |
| 12 Platysma | 33 Posterior cricoarytenoid muscle |
| 13 Thyroid gland | 34 Semispinalis cervicis muscle |
| 14 Sternocleidomastoid muscle | 35 Hypopharynx/esophagus |
| 15 Common carotid artery | 36 Spinal cord |
| 16 Spinal nerves (C4 and C5) | 37 Trapezius muscle |
| 17 Internal jugular vein | 38 Cervical vertebra C5 |
| 18 Vertebral artery | 39 Inferior constrictor muscle of pharynx |
| 19 External jugular vein | 40 Nerve root (C7) |
| 20 Spinal nerve (C6) | |
| 21 Phrenic nerve | |



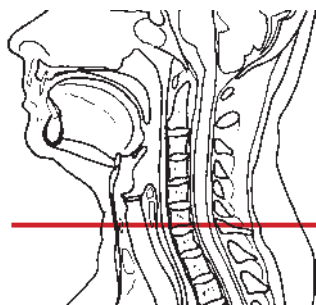
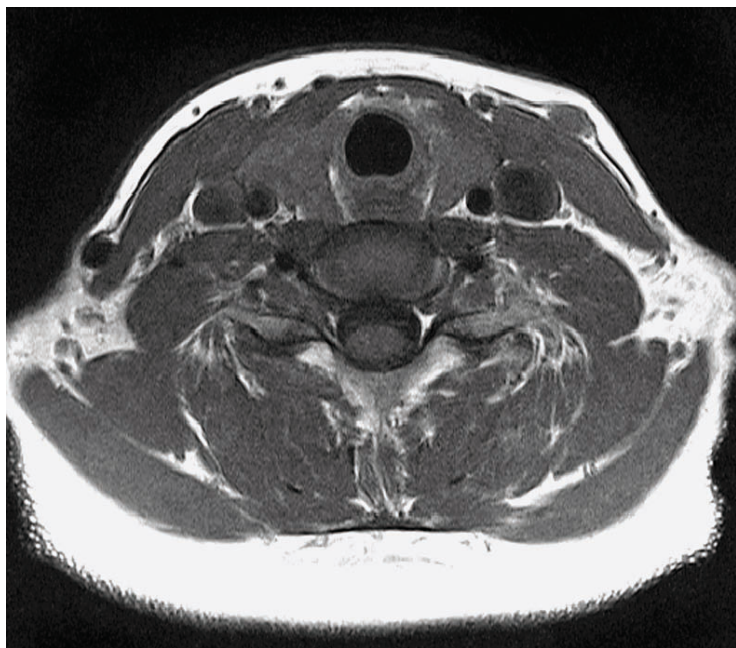


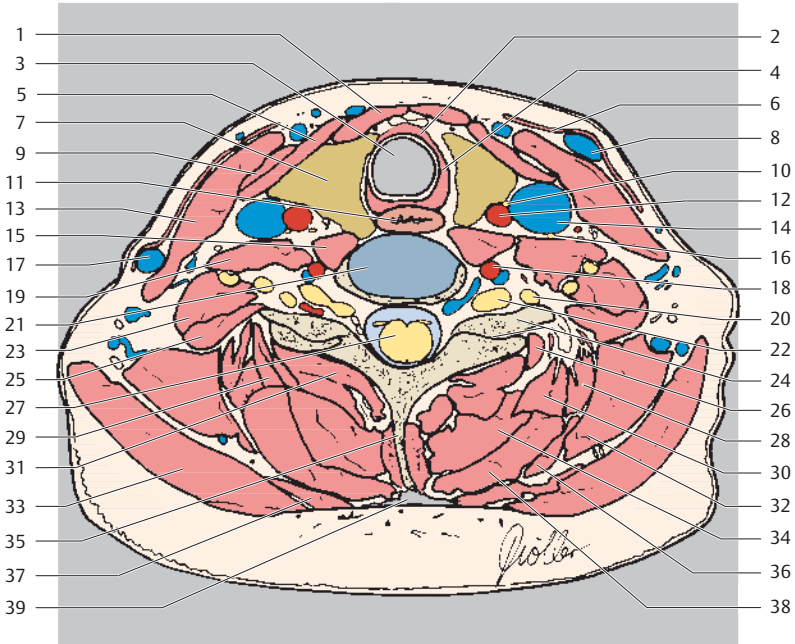
- | | |
|-------------------------------|---|
| 1 Larynx | 21 Spinal nerves (C4 and C5) |
| 2 Sternohyoid muscle | 22 Posterior scalene muscle |
| 3 Vocalis muscle (vocal cord) | 23 Longus colli muscle |
| 4 Thyroid cartilage (lamina) | 24 Spinal nerve root (C6) |
| 5 Thyrohyoid muscle | 25 Longissimus capitis muscle |
| 6 Thyroid gland | 26 Longissimus cervicis muscle |
| 7 Arytenoid cartilage | 27 Vertebral artery |
| 8 Anterior jugular vein | 28 Splenius cervicis muscle |
| 9 Transverse arytenoid muscle | 29 Levator scapulae muscle |
| 10 Platysma | 30 Semispinalis capitis muscle |
| 11 Common carotid artery | 31 Inferior constrictor muscle of pharynx |
| 12 Sternocleidomastoid muscle | 32 Intervertebral space (C5/C6) |
| 13 Internal jugular vein | 33 Spinal cord |
| 14 Phrenic muscle | 34 Spinalis cervicis muscle and multifidus muscle |
| 15 Vagus nerve (X) | 35 Ligamentum flavum |
| 16 Longus capitis muscle | 36 Posterior vertebral arch |
| 17 External jugular vein | 37 Splenius capitis muscle |
| 18 Anterior scalene muscle | 38 Trapezius muscle |
| 19 Hypopharynx/esophagus | 39 Semispinalis cervicis muscle |
| 20 Middle scalene muscle | |



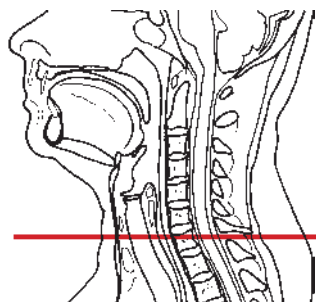
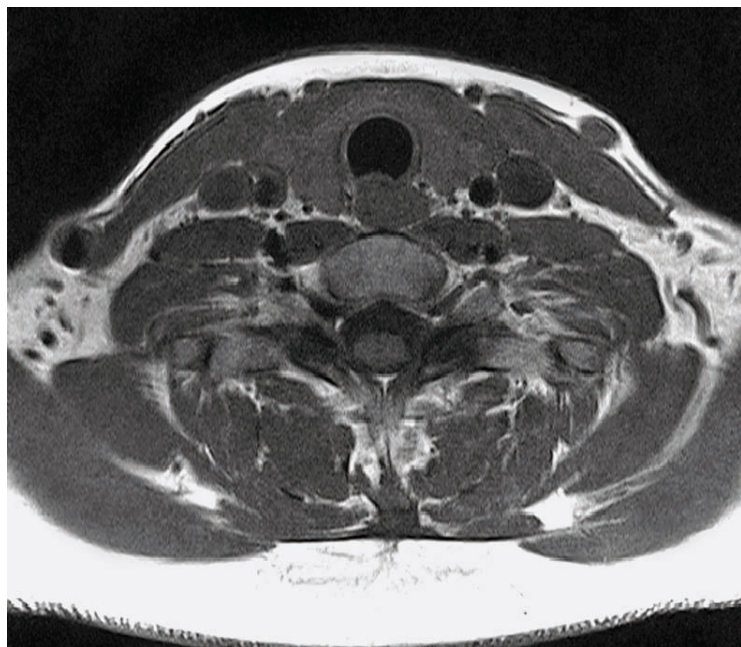


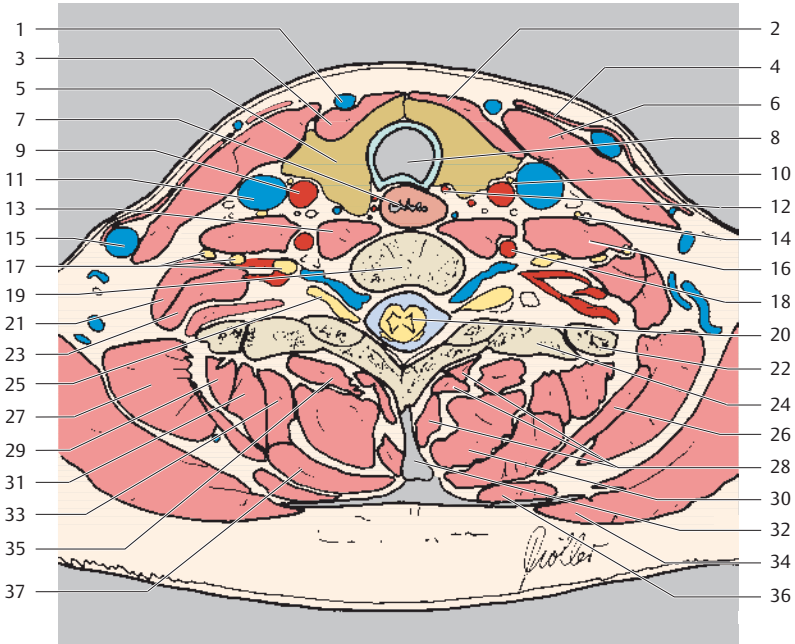
- | | |
|---|--|
| 1 Larynx | 23 Phrenic nerve |
| 2 Thyroid cartilage | 24 Spinal nerves (C4, C5, and C6) |
| 3 Thyro-arytenoid muscle | 25 Esophagus |
| 4 Anterior jugular vein | 26 Vertebral artery |
| 5 Sternohyoid muscle | 27 Middle scalene muscle |
| 6 Transverse arytenoid muscle | 28 Longissimus capitis muscle |
| 7 Thyrohyoid muscle | 29 Posterior scalene muscle |
| 8 Vagus nerve (X) | 30 Longissimus cervicis muscle |
| 9 Sternothyroid muscle | 31 Levator scapulae muscle |
| 10 Platysma | 32 Spinal nerve root (C7) |
| 11 Cricoid cartilage (lamina) | 33 Articular process and posterior arch of C7 vertebra |
| 12 Inferior constrictor muscle of pharynx | 34 Semispinalis capitis muscle |
| 13 Thyroid gland | 35 Spinal cord |
| 14 Longus colli muscle | 36 Splenius cervicis muscle |
| 15 Thyroid cartilage (inferior horn) | 37 Spinalis cervicis muscle and multifidus muscle |
| 16 Longus capitis muscle | 38 Anterior and posterior spinal nerve roots (C8) |
| 17 Common carotid artery | 39 Semispinalis cervicis muscle |
| 18 Anterior scalene muscle | 40 Trapezius muscle |
| 19 Internal jugular vein | 41 Splenius capitis muscle |
| 20 Sternocleidomastoid muscle | 42 Spinous process of vertebra |
| 21 External jugular vein | |
| 22 Cervical vertebra (C6) | |



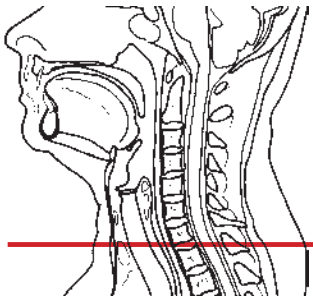
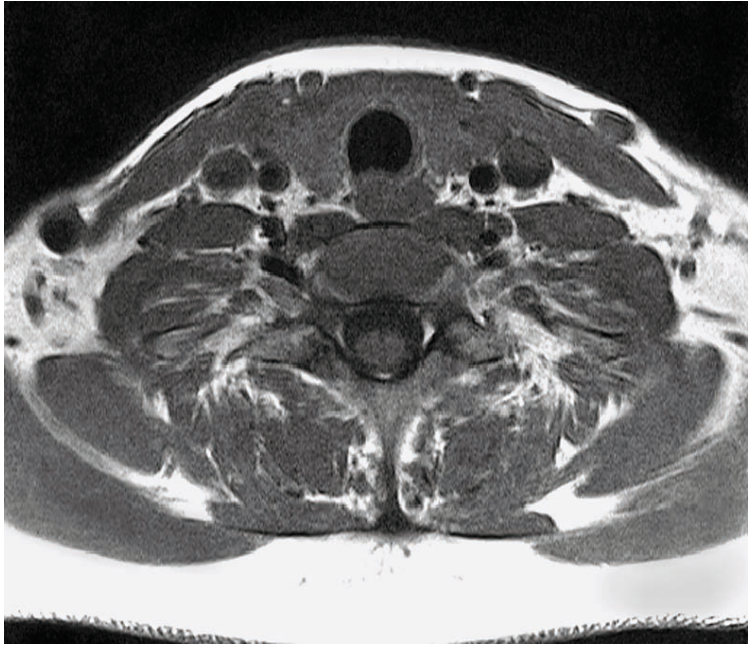

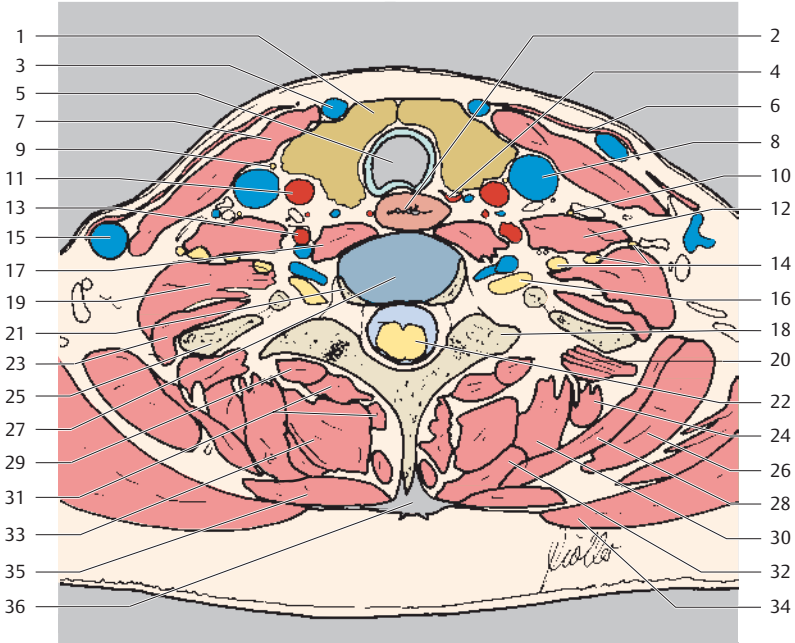
- | | |
|-----------------------------------|---|
| 1 Sternohyoid muscle | 21 Intervertebral space (C6/C7) |
| 2 Cricoid cartilage (arch) | 22 Spinal nerve root (C7) |
| 3 Trachea | 23 Middle scalene muscle |
| 4 Cricothyroid muscle | 24 Zygapophysial joint (C6/C7) |
| 5 Sternothyroid muscle | 25 Posterior scalene muscle |
| 6 Platysma | 26 Longissimus capitis muscle |
| 7 Thyroid gland | 27 Spinal cord |
| 8 Anterior jugular vein | 28 Longissimus cervicis muscle |
| 9 Omohyoid muscle | 29 Semispinalis capitis muscle |
| 10 Vagus nerve (X) | 30 Splenius cervicis muscle |
| 11 Esophagus | 31 Spinalis cervicis muscle and multifidus muscle |
| 12 Common carotid artery | 32 Levator scapulae muscle |
| 13 Sternocleidomastoid muscle | 33 Trapezius muscle |
| 14 Internal jugular vein | 34 Semispinalis cervicis muscle |
| 15 Longus colli muscle | 35 Spinous process of vertebra |
| 16 Phrenic muscle | 36 Serratus posterior superior muscle |
| 17 External jugular vein | 37 Rhomboid minor muscle |
| 18 Vertebral artery | 38 Splenius capitis muscle |
| 19 Anterior scalene muscle | 39 Nuchal ligament |
| 20 Spinal nerves (C4, C5, and C6) | |



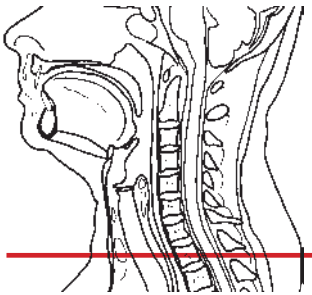
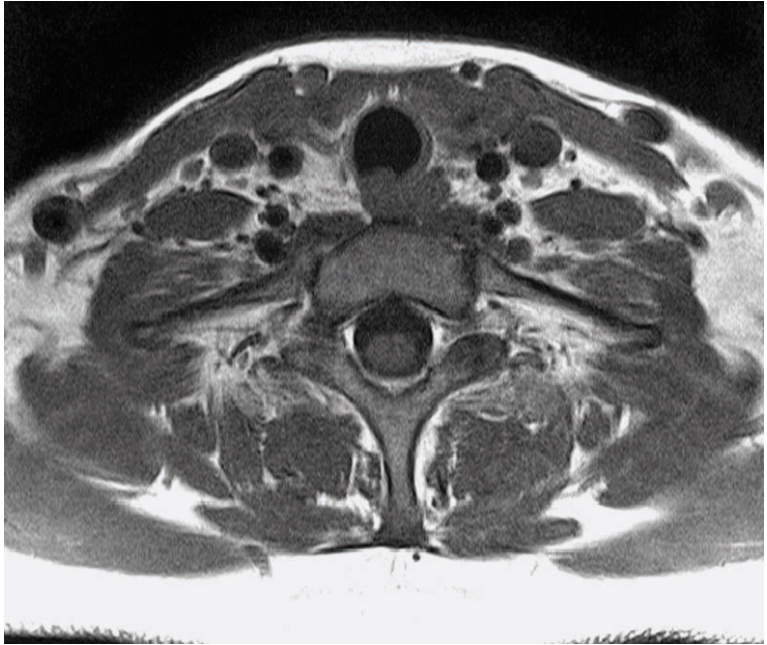


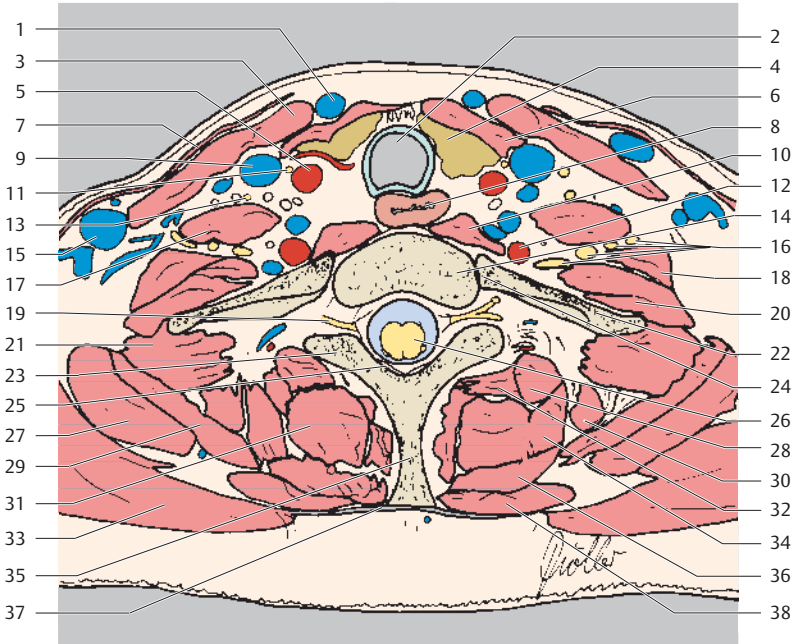
- | | |
|-----------------------------------|---|
| 1 Anterior jugular vein | 20 Spinal cord |
| 2 Sternohyoid muscle | 21 Middle scalene muscle |
| 3 Sternothyroid muscle | 22 First rib |
| 4 Platysma | 23 Posterior scalene muscle |
| 5 Thyroid gland | 24 Transverse process of vertebra |
| 6 Sternocleidomastoid muscle | 25 Spinal nerve root (C8) |
| 7 Esophagus | 26 Serratus posterior superior muscle |
| 8 Trachea | 27 Levator scapulae muscle |
| 9 Common carotid artery | 28 Spinalis cervicis muscle and multifidus muscle |
| 10 Vagus nerve (X) | 29 Iliocostalis cervicis muscle |
| 11 Internal jugular vein | 30 Semispinalis cervicis muscle |
| 12 Inferior thyroid artery | 31 Longissimus cervicis muscle |
| 13 Longus colli muscle | 32 Interspinous ligament |
| 14 Phrenic nerve | 33 Splenius cervicis muscle |
| 15 External jugular vein | 34 Trapezius muscle |
| 16 Anterior scalene muscle | 35 Semispinalis capitis muscle |
| 17 Spinal nerves (C5, C6, and C7) | 36 Rhomboid minor muscle |
| 18 Vertebral artery | 37 Splenius capitis muscle |
| 19 Cervical vertebra (C7) | |



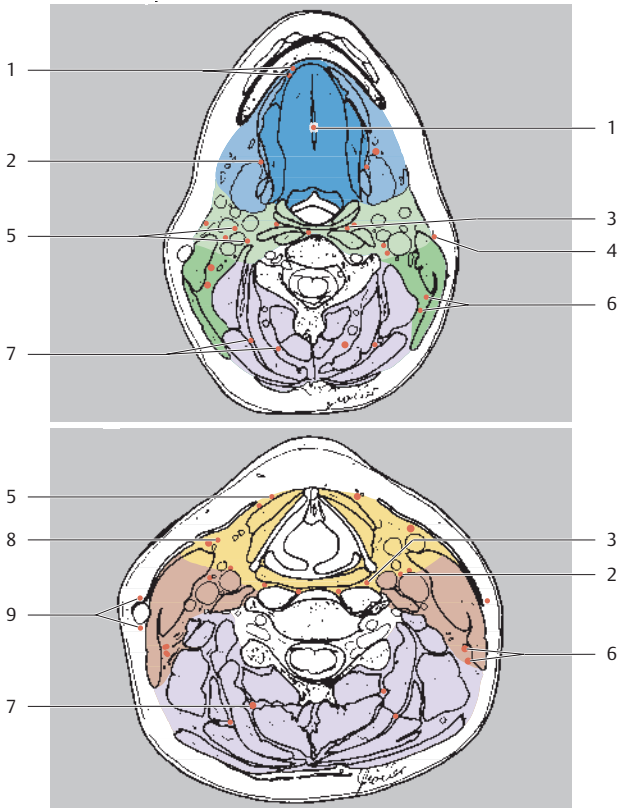


- | | |
|--------------------------------------|---|
| 1 Thyroid gland | 20 Intercostal muscles |
| 2 Esophagus | 21 Superior posterior margin of T1 vertebra |
| 3 Anterior jugular vein | 22 Spinal cord |
| 4 Inferior thyroid vein | 23 Posterior scalene muscle |
| 5 Trachea | 24 Iliocostalis cervicis muscle |
| 6 Platysma | 25 First rib |
| 7 Sternocleidomastoid muscle | 26 Levator scapulae muscle |
| 8 Internal jugular vein | 27 Intervertebral space (C7/T1) |
| 9 Vagus nerve (X) | 28 Serratus posterior superior muscle |
| 10 Phrenic nerve | 29 Semispinalis capitis muscle |
| 11 Common carotid artery | 30 Splenius cervicis muscle |
| 12 Anterior scalene muscle | 31 Spinalis cervicis muscle and multifidus muscle |
| 13 Vertebral artery | 32 Splenius capitis muscle |
| 14 Spinal nerves (C5, C6, and C7) | 33 Semispinalis cervicis muscle |
| 15 External jugular vein | 34 Trapezius muscle |
| 16 Spinal nerve root (C8) | 35 Rhomboid minor muscle |
| 17 Longus colli muscle | 36 Interspinous ligament |
| 18 Transverse process of T1 vertebra | |
| 19 Middle scalene muscle | |





- | | |
|-------------------------------|---|
| 1 Anterior jugular vein | 21 Intercostal muscles |
| 2 Trachea | 22 First rib |
| 3 Sternocleidomastoid muscle | 23 Transverse process of T1 vertebra |
| 4 Thyroid gland | 24 Costovertebral joint |
| 5 Common carotid artery | 25 Ligamentum flavum |
| 6 Sternohyoid muscle | 26 Spinal cord |
| 7 Platysma | 27 Levator scapulae muscle |
| 8 Esophagus | 28 Semispinalis capitis muscle |
| 9 Internal jugular vein | 29 Serratus posterior superior muscle |
| 10 Longus colli muscle | 30 Iliocostalis cervicis muscle |
| 11 Vagus nerve (X) | 31 Semispinalis cervicis muscle |
| 12 Vertebral artery | 32 Spinalis cervicis muscle and multifidus muscle |
| 13 Phrenic nerve | 33 Trapezius muscle |
| 14 Vertebra (T1) | 34 Splenius cervicis muscle |
| 15 External jugular vein | 35 Spinous process of vertebra |
| 16 Cervical plexus (C5 to C8) | 36 Splenius capitis muscle |
| 17 Anterior scalene muscle | 37 Interspinous ligament |
| 18 Middle scalene muscle | 38 Rhomboid minor muscle |
| 19 Spinal nerve root (T1) | |
| 20 Posterior scalene muscle | |

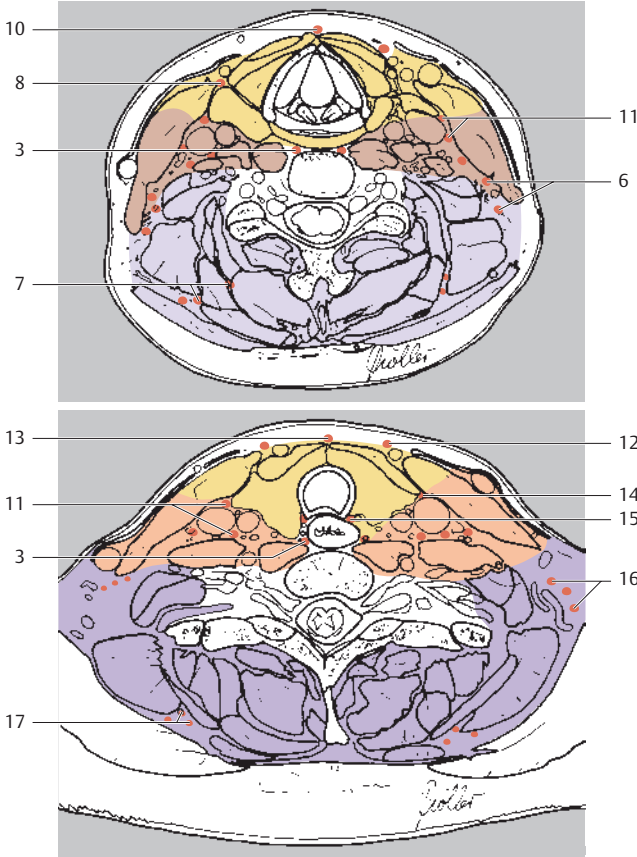


Cervical lymph nodes

- 1 Submental lymph nodes
- 2 Submandibular lymph nodes
- 3 Retropharyngeal lymph nodes
- 4 Preauricular lymph nodes
- 5 Superior jugular group of lymph nodes
- 6 Deep cervical lymph nodes
- 7 Nuchal lymph nodes
- 8 Anterior jugular lymph nodes
- 9 Superficial cervical lymph nodes

Lymph nodes (classified according to levels)

- Level 1a (submental lymph nodes between digastric muscles)
- Level 1b (submandibular lymph nodes)
- Level 2a (lymph nodes anterior, medial, or lateral to the internal jugular vein)
- Level 2b (Lymph nodes dorsal to the internal jugular vein and separated from the vein by a lamella of fat)
- Level 3 (lymph nodes along the jugular vein)
- Level 5a (lymph nodes in the posterior triangle, upper level = above arch of cricoid cartilage)
- Level 6 (upper visceral lymph nodes: ventral between the carotid arteries)

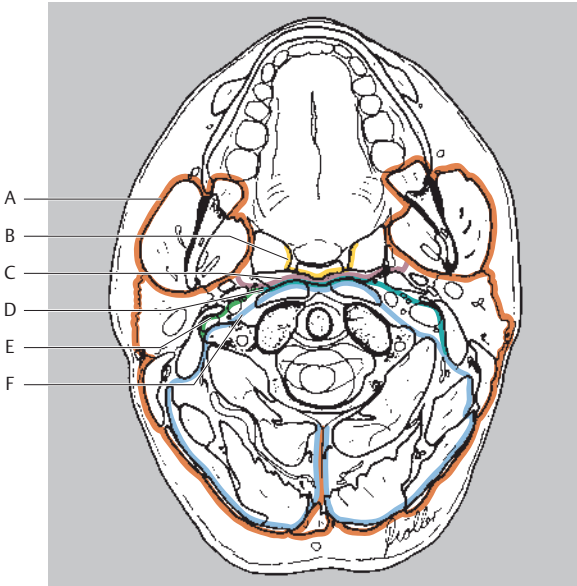
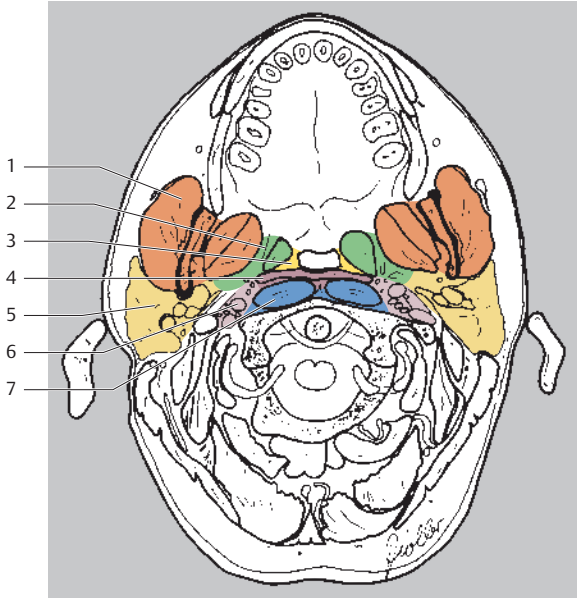


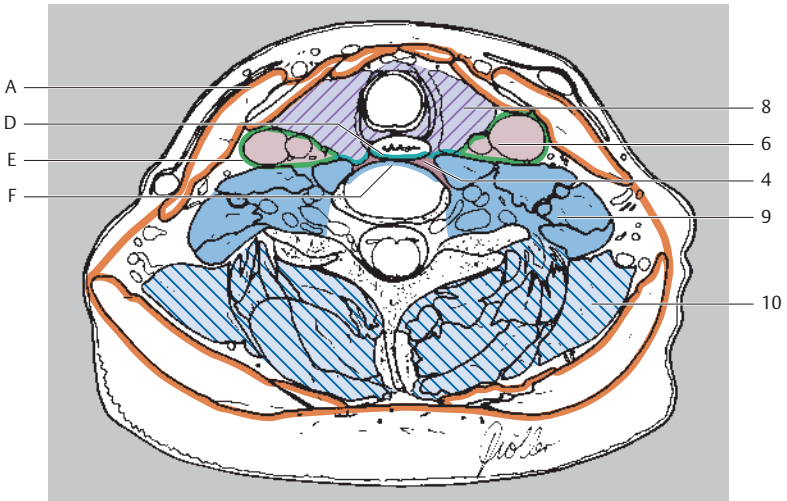
Cervical lymph nodes

- 3 Retropharyngeal lymph nodes
- 6 Deep cervical lymph nodes
- 7 Nuchal lymph nodes
- 8 Anterior jugular lymph nodes
- 10 Prelaryngeal lymph nodes
- 11 Inferior jugular group of lymph nodes
- 12 Anterior cervical lymph nodes
- 13 Pretracheal lymph nodes
- 14 Thyroid lymph nodes
- 15 Paratracheal lymph nodes
- 16 Supraclavicular lymph nodes
- 17 Superficial cervical lymph nodes

Lymph nodes (classified according to levels)

- Level 3 (lymph nodes along the jugular vein)
- Level 4 (lymph nodes of the lower jugular vein)
- Level 5a (lymph nodes of the posterior triangle, upper level = above arch of cricoid cartilage)
- Level 5b (lymph nodes of the posterior triangle, lower level = below arch of cricoid cartilage)
- Level 6 (upper visceral lymph nodes: ventral between the carotid arteries)



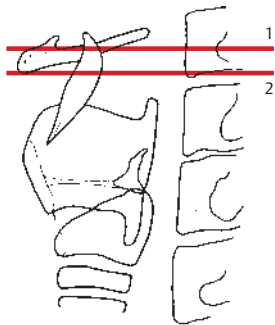
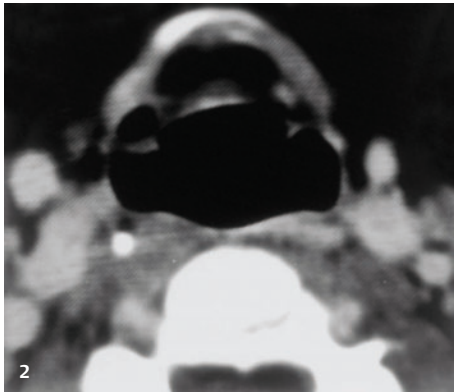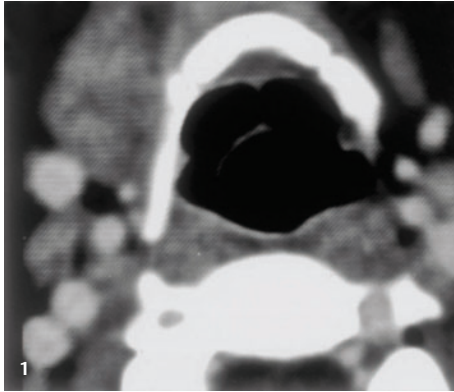


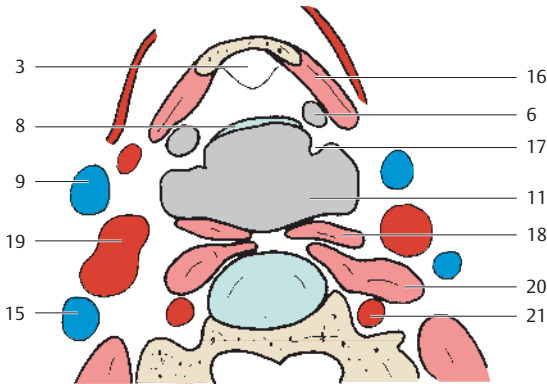
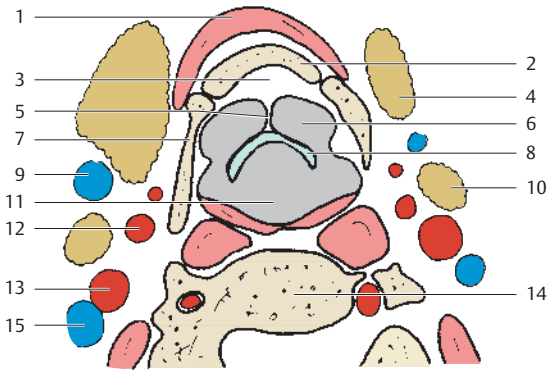
Cervical spaces

- 1 Masticatory space (chewing muscles, ramus and body of mandible, inferior alveolar artery, maxillary artery, pterygoid plexus, lingual nerve)
- 2 Parapharyngeal space (trigeminal nerve, pharyngeal artery)
- 3 Superficial mucosal space (submucosal salivary glands, lymphatic tissue)
- 4 Retropharyngeal space
- 5 Parotid space (parotid gland, facial nerve, external carotid artery, retromandibular vein)
- 6 Carotid space (carotid artery, jugular vein, cranial nerves IX–XII, sympathetic trunk)
- 7 Prevertebral space (prevertebral and paraspinous muscles, phrenic nerve)
- 8 Visceral space (thyroid gland, paratracheal space)
- 9 Perivertebral space (prevertebral part)
- 10 Perivertebral space (paraspinal part)

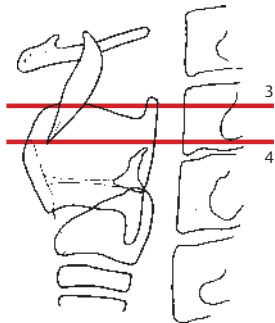
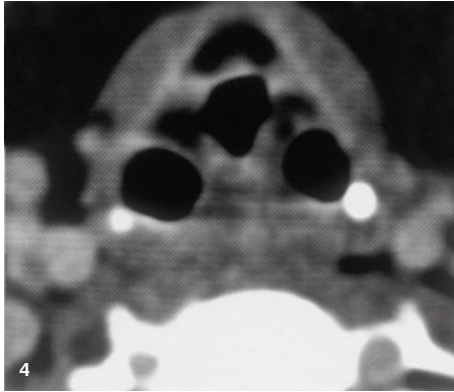
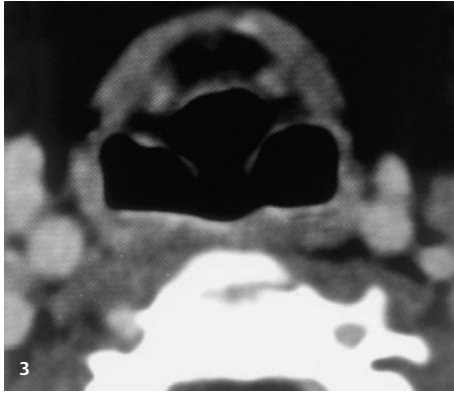
Cervical fasciae

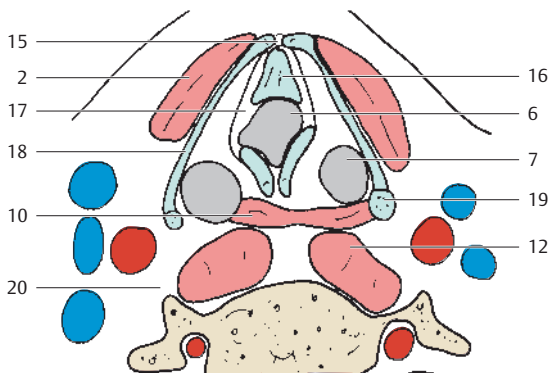
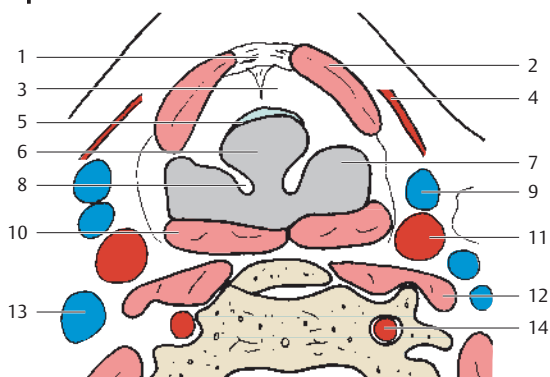
- A Superficial cervical fascia (fascia colli superficialis)
- B Pharyngobasilar fascia
- C Middle layer of deep cervical fascia (pretracheal layer)
- D Intercarotid fascia
- E Carotid sheath
- F Deep layer of deep cervical fascia (prevertebral layer)



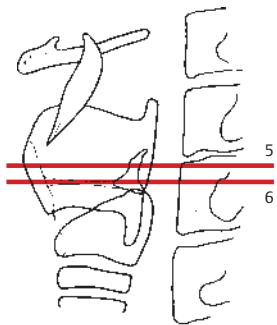
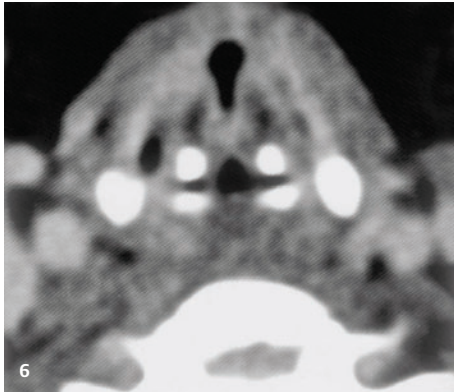
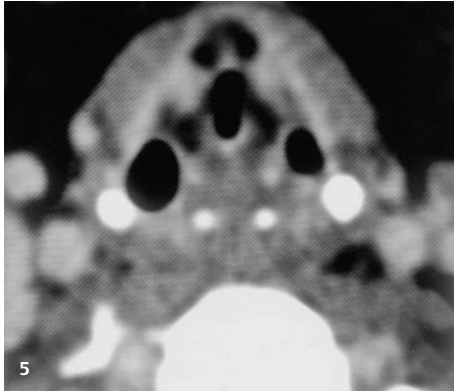


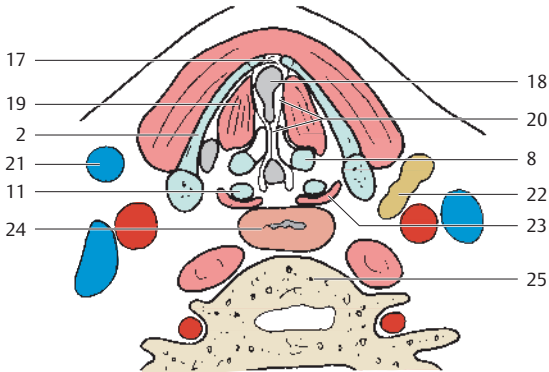
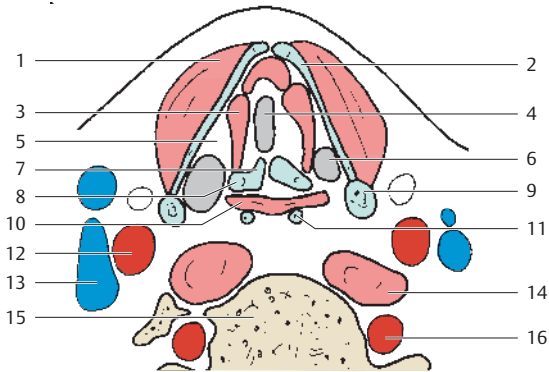
- | | |
|---|---|
| 1 Suprahyoid muscles (mylo- and geniohyoid muscles, hypoglossus muscle) | 12 External carotid artery |
| 2 Hyoid bone (body) | 13 Internal carotid artery |
| 3 Pre-epiglottic space | 14 Cervical vertebra (C3) |
| 4 Submandibular gland | 15 Internal jugular vein |
| 5 Glossoepiglottic fold | 16 Infrahyoid muscles (sternohyoid and sternothyroid muscles) |
| 6 Epiglottic vallecula | 17 Pharyngoepiglottic fold |
| 7 Hyoid bone (greater horn) | 18 Inferior constrictor muscle of pharynx |
| 8 Epiglottis | 19 Carotid bifurcation |
| 9 Anterior jugular vein | 20 Longus colli muscle |
| 10 Parotid gland | 21 Vertebral artery |
| 11 Hypopharynx | |



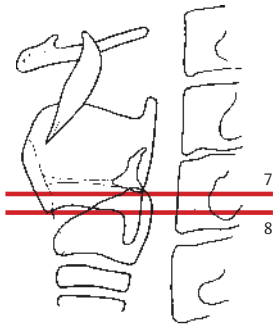
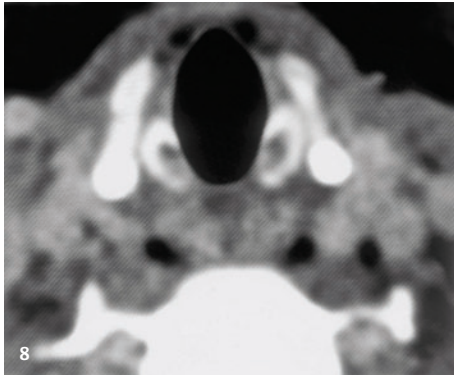
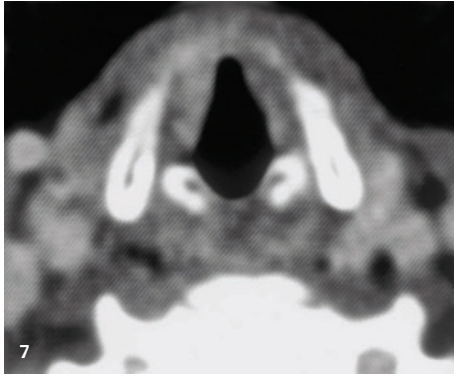


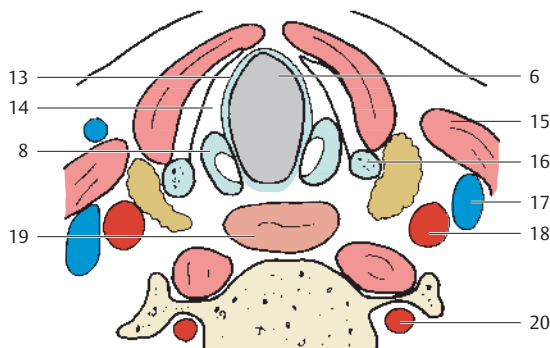
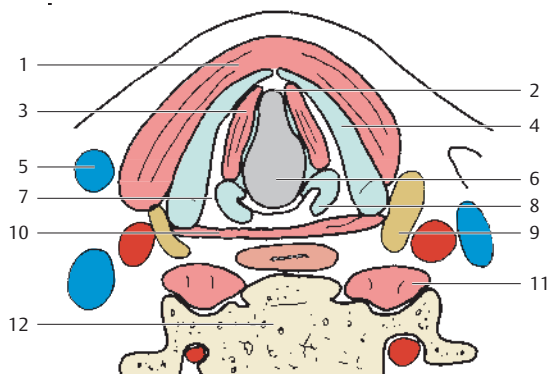
- | | |
|--|---|
| 1 Thyrohyoid membrane | 10 Inferior constrictor muscle of pharynx |
| 2 Infrahyoid muscles
(sternothyroid, omohyoid,
thyrohyoid) | 11 Common carotid artery |
| 3 Pre-epiglottic space | 12 Longus colli muscle |
| 4 Platysma | 13 Internal jugular vein |
| 5 Epiglottis | 14 Vertebral artery |
| 6 Larynx | 15 Superior thyroid notch |
| 7 Piriform recess | 16 Stalk of epiglottis |
| 8 Aryepiglottic fold | 17 Vestibular folds |
| 9 Anterior jugular vein | 18 Thyroid cartilage (lamina) |
| | 19 Thyroid cartilage (superior horn) |
| | 20 Body of cervical vertebra (C4) |



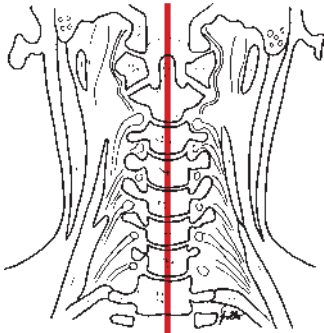
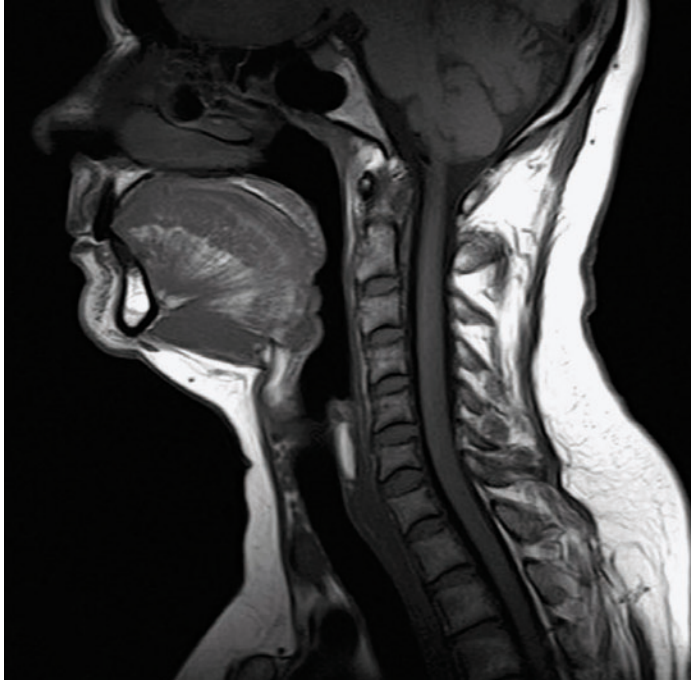


- | | | | |
|----|---|----|------------------------------|
| 1 | Infrahyoid muscles (sternothyroid, omohyoid and thyrohyoid muscles) | 12 | Common carotid artery |
| 2 | Thyroid cartilage | 13 | Internal jugular vein |
| 3 | Thyro-arytenoid muscle | 14 | Longus colli muscle |
| 4 | Larynx (vestibule) | 15 | Body of cervical vertebra C4 |
| 5 | Paralaryngeal space | 16 | Vertebral artery |
| 6 | Piriform recess | 17 | Laryngeal prominence |
| 7 | Arytenoid cartilage (vocal process) | 18 | Rima glottidis |
| 8 | Arytenoid cartilage (body) | 19 | Vocalis muscle |
| 9 | Thyroid cartilage (superior horn) | 20 | True vocal cord |
| 10 | Transverse arytenoid muscle | 21 | Anterior jugular vein |
| 11 | Cricoid cartilage | 22 | Thyroid gland |
| | | 23 | Oblique arytenoid muscle |
| | | 24 | Esophagus |
| | | 25 | Body of cervical vertebra C5 |

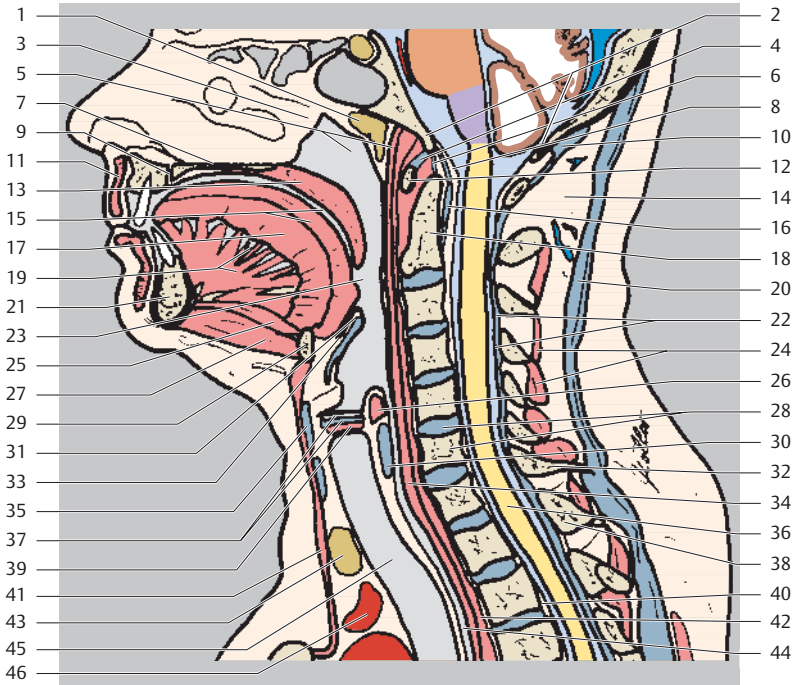




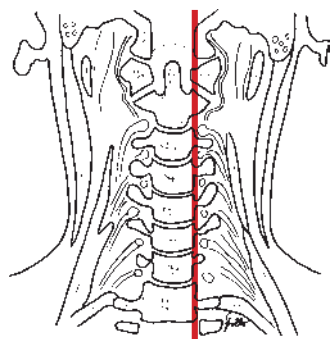
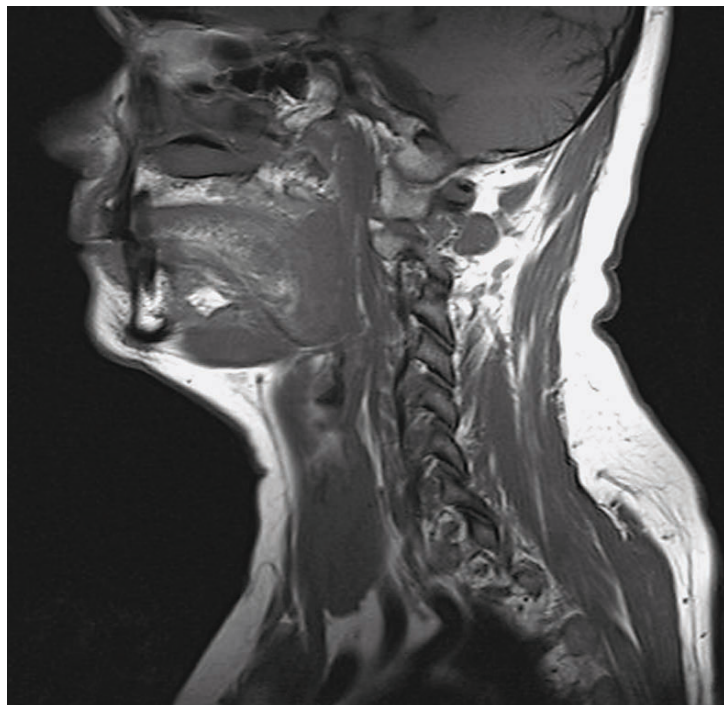
- | | | | |
|----|--|----|--|
| 1 | Infrahyoid muscles
(sternohyoid, omohyoid and
sternothyroid muscles) | 11 | Longus colli muscle |
| 2 | Anterior laryngeal commissure | 12 | Body of cervical vertebra (C6) |
| 3 | Vocalis muscle | 13 | Conus elasticus (cricovocal
membrane) |
| 4 | Thyroid cartilage | 14 | Paralaryngeal space |
| 5 | Anterior jugular vein | 15 | Sternocleidomastoid muscle |
| 6 | Infraglottic cavity | 16 | Thyroid cartilage (inferior horn) |
| 7 | Cricothyroid joint | 17 | Internal jugular vein |
| 8 | Cricoid cartilage (lamina) | 18 | Common carotid artery |
| 9 | Thyroid gland | 19 | Esophagus |
| 10 | Inferior constrictor muscle of
pharynx | 20 | Vertebral artery |



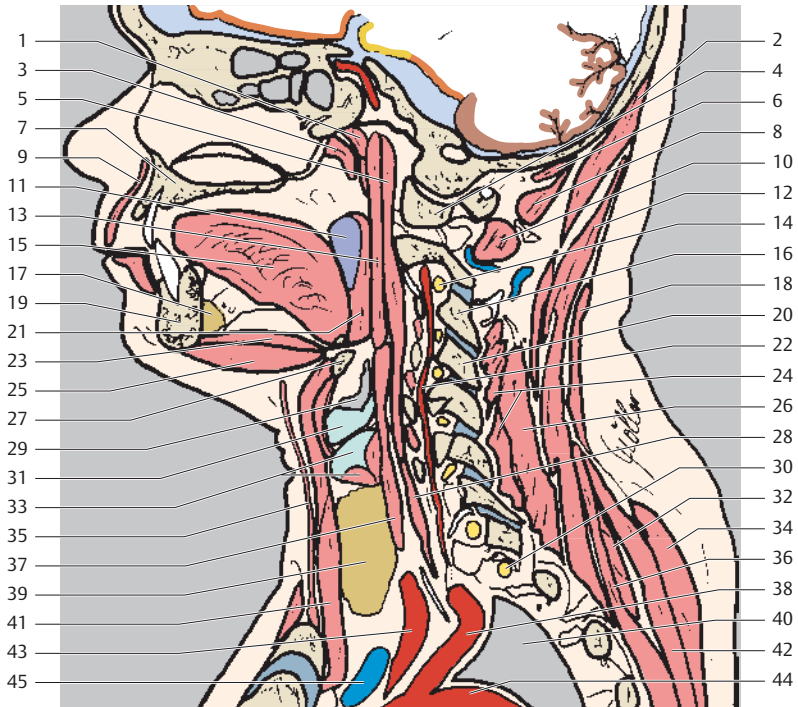
- | | |
|---------------------------------------|---|
| 1 Palatine tonsil | 6 Apical ligament of dens |
| 2 Foramen magnum | 7 Hard palate |
| 3 Vomer | 8 Tectorial membrane |
| 4 Anterior longitudinal ligament | 9 Incisive canal |
| 5 Nasopharynx and longus colli muscle | 10 Posterior atlanto-occipital membrane |
| | 11 Orbicularis oris muscle |



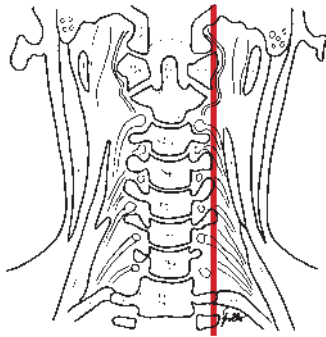
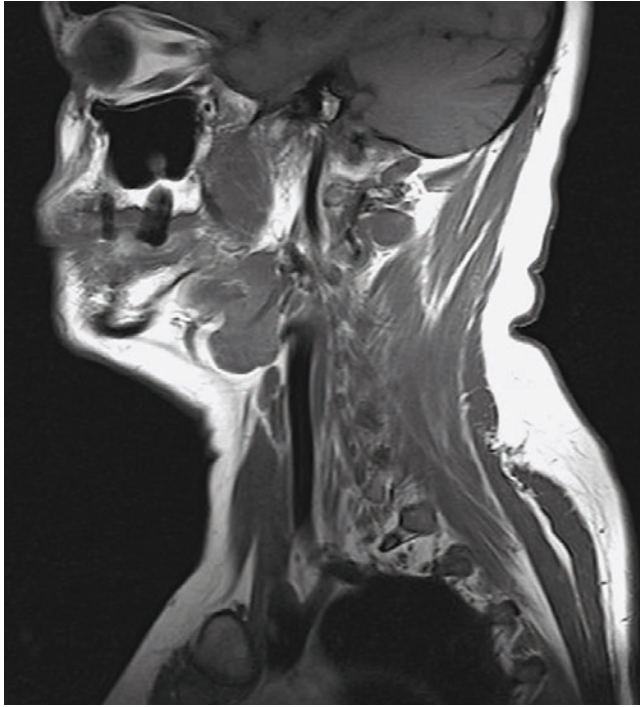
- | | | | |
|----|---|----|---|
| 12 | Anterior arch of atlas | 28 | Vertebra C6 and intervertebral disc |
| 13 | Soft palate | 29 | Hyoid bone |
| 14 | Suboccipital fatty tissue | 30 | Larynx (lamina) |
| 15 | Superior longitudinal muscle of tongue and oral cavity | 31 | Epiglottis |
| 16 | Transverse ligament of atlas (of cruciform ligament of atlas) | 32 | Spinous process of C7 |
| 17 | Transverse muscle of tongue | 33 | Epiglottic vallecula |
| 18 | Dens of axis (C2) | 34 | Inferior constrictor muscle of pharynx |
| 19 | Genioglossus muscle and lingual septum | 35 | Thyroid cartilage |
| 20 | Nuchal ligament | 36 | Spinal cord |
| 21 | Mandible | 37 | Vestibular ligament and laryngeal ventricle (ventricle of Morgagni) |
| 22 | Ligamentum flavum | 38 | Spinous process |
| 23 | Oropharynx | 39 | Vocal ligament (false vocal cord) |
| 24 | Interspinalis muscles | 40 | Posterior longitudinal ligament |
| 25 | Geniohyoid muscle | 41 | Sternothyroid muscle |
| 26 | Transverse and oblique arytenoid muscles | 42 | Anterior longitudinal ligament |
| 27 | Mylohyoid muscle | 43 | Thyroid gland |
| | | 44 | Esophagus |
| | | 45 | Trachea |
| | | 46 | Brachiocephalic artery |



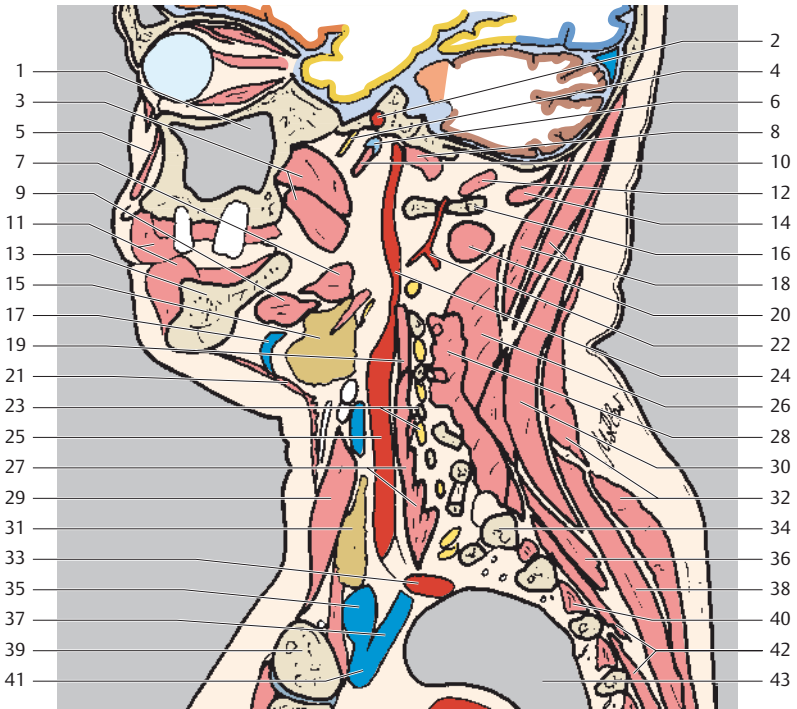
- | | |
|--------------------------------|---|
| 1 Levator veli palatini muscle | 5 Longus capitis muscle |
| 2 Semispinalis capitis muscle | 6 Rectus capitis posterior minor muscle |
| 3 Medial pterygoid muscle | 7 Maxilla |
| 4 Atlas (lateral mass) | 8 Rectus capitis posterior major muscle |



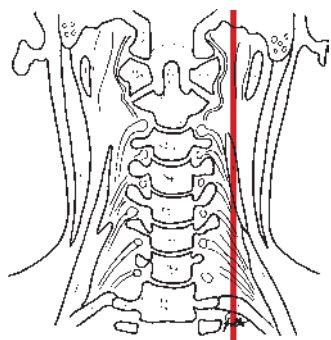
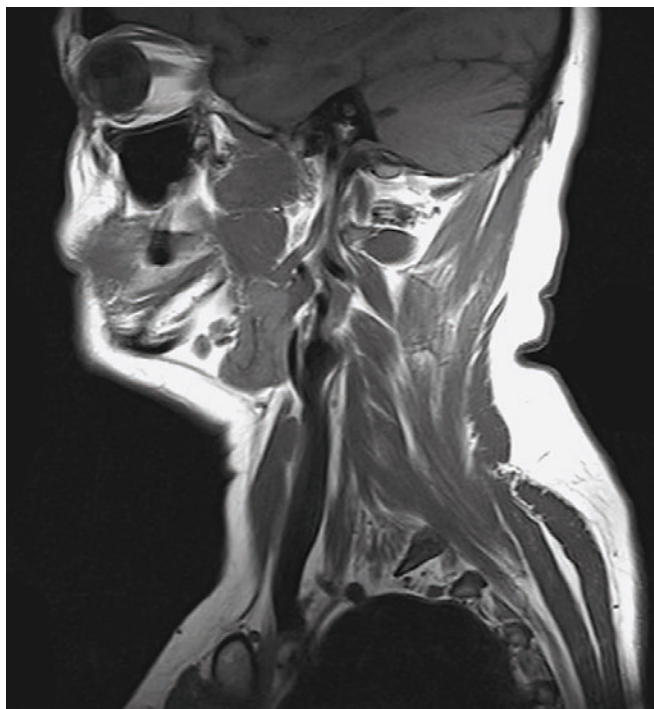
- | | | | |
|----|--|----|--|
| 9 | Orbicularis oris muscle | 26 | Semispinalis cervicis muscle |
| 10 | Inferior oblique muscle | 27 | Hyoid bone |
| 11 | Palatine tonsil | 28 | Longus colli muscle |
| 12 | Splenius capitis muscle | 29 | Pharynx and epiglottic vallecula |
| 13 | Superior constrictor muscle of pharynx | 30 | Spinal nerve root (T1) |
| 14 | Spinal nerve root (C3) | 31 | Thyroid cartilage |
| 15 | Tongue | 32 | Serratus posterior superior muscle |
| 16 | Inferior articular process | 33 | Cricoid cartilage |
| 17 | Sublingual gland | 34 | Trapezius muscle |
| 18 | Trapezius muscle (descending part) | 35 | Platysma |
| 19 | Mandible | 36 | Splenius cervicis muscle |
| 20 | Superior articular process | 37 | Inferior constrictor muscle of pharynx |
| 21 | Palatopharyngeus muscle | 38 | Left subclavian artery |
| 22 | Vertebral artery | 39 | Thyroid gland |
| 23 | Mylohyoid muscle | 40 | Left lung |
| 24 | Multifidus muscle | 41 | Sternohyoid muscle |
| 25 | Digastric muscle (anterior belly) | 42 | Rhomboid (major and minor) muscle |
| | | 43 | Common carotid artery |
| | | 44 | Aortic arch |
| | | 45 | Left brachiocephalic vein |

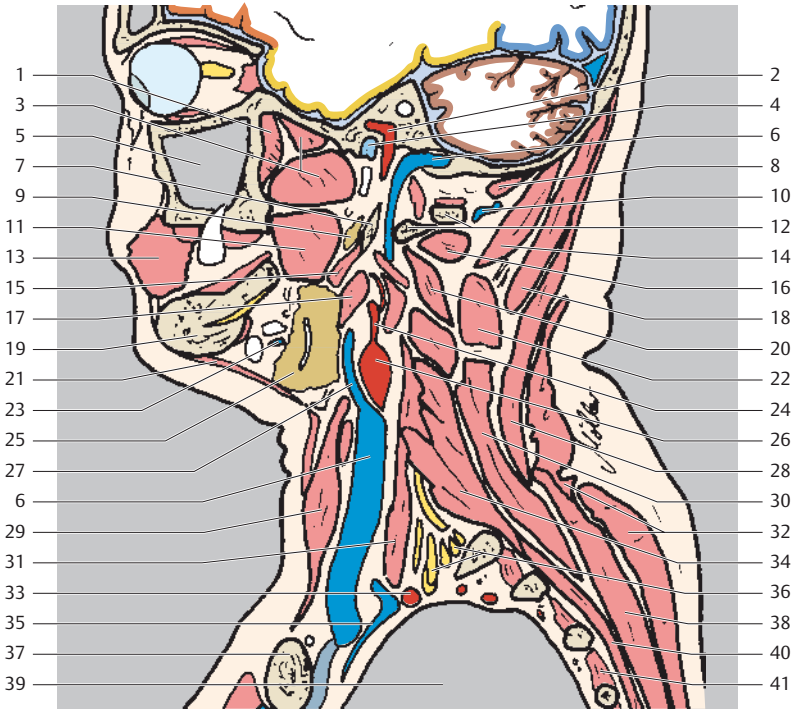


- | | |
|--|---|
| 1 Maxillary sinus | 4 Mandibular nerve |
| 2 Internal carotid artery (carotid syphon) | 5 Levator labii superioris muscle |
| 3 Medial pterygoid muscle | 6 Pharyngotympanic tube (auditory tube) |
| | 7 Digastric muscle |

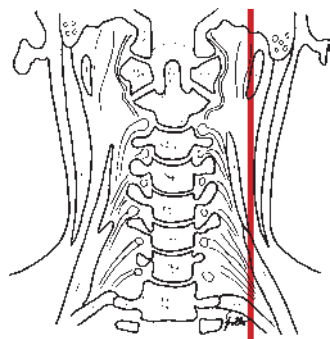
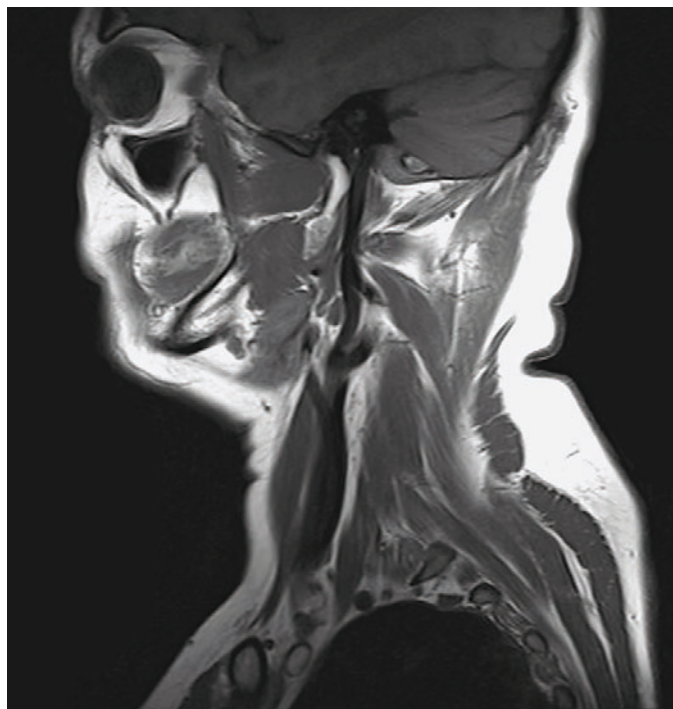

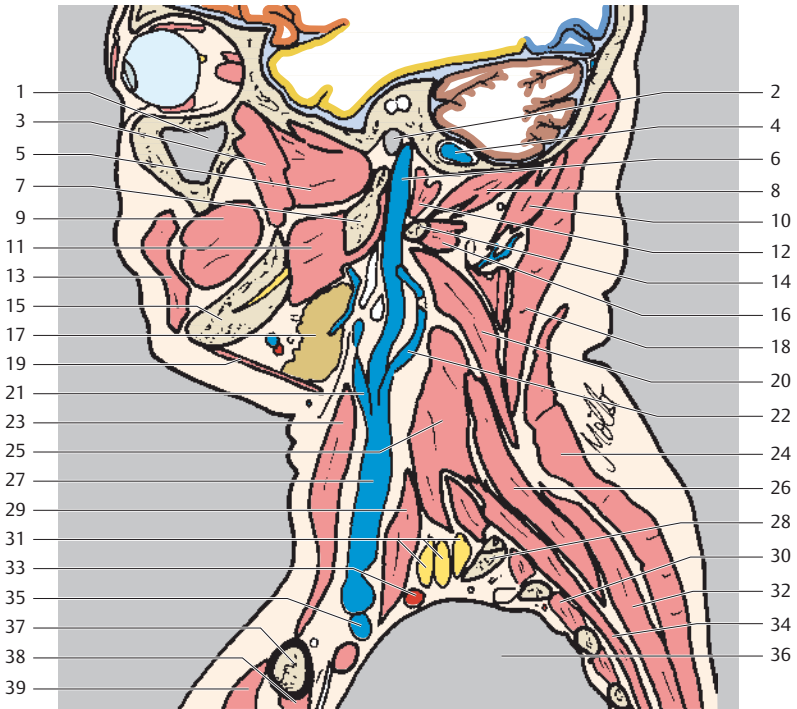
- | | |
|--|--------------------------------------|
| 8 Rectus capitis lateralis muscle | 25 Common carotid artery |
| 9 Mylohyoid muscle | 26 Semispinalis cervicis muscle |
| 10 Tensor veli palatini muscle | 27 Scalenus anterior muscle |
| 11 Orbicularis oris muscle | 28 Scalenus posterior muscle |
| 12 Obliquus capitis superior muscle | 29 Sternocleidomastoid muscle |
| 13 Mandible | 30 Splenius capitis muscle |
| 14 Rectus capitis posterior major muscle | 31 Thyroid gland |
| 15 Submandibular gland | 32 Trapezius muscle |
| 16 Atlas (transverse process) | 33 Subclavian artery |
| 17 Facial vein | 34 First rib |
| 18 Semispinalis capitis muscle | 35 Internal jugular vein |
| 19 Longus colli muscle | 36 Semispinalis cervicis muscle |
| 20 Obliquus capitis inferior muscle | 37 Subclavian vein (left) |
| 21 Platysma | 38 Rhomboid (major and minor) muscle |
| 22 Vertebral artery | 39 Clavicle |
| 23 Transverse processes and spinal nerve roots | 40 Interspinalis muscle |
| 24 Internal carotid artery | 41 Brachiocephalic vein (left) |
| | 42 Serratus anterior muscle |
| | 43 Lung (left) |



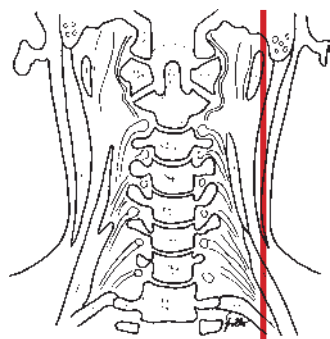
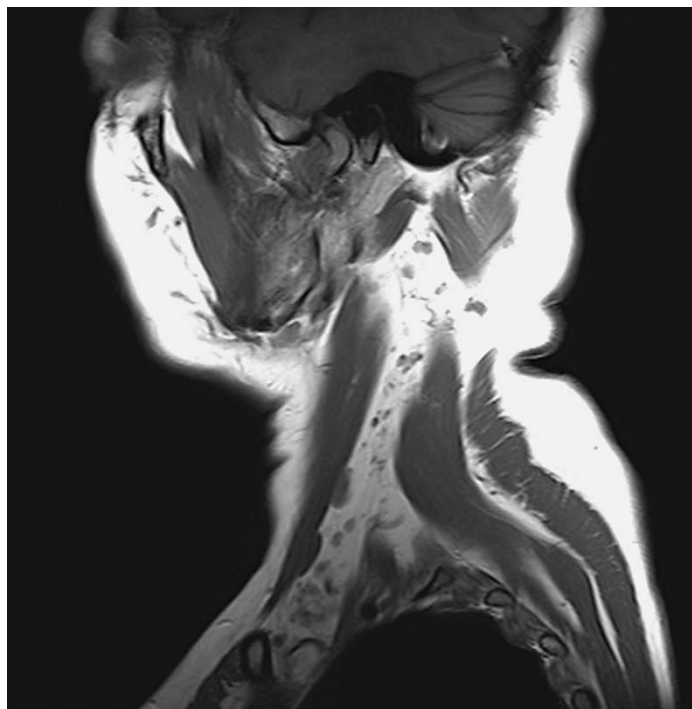


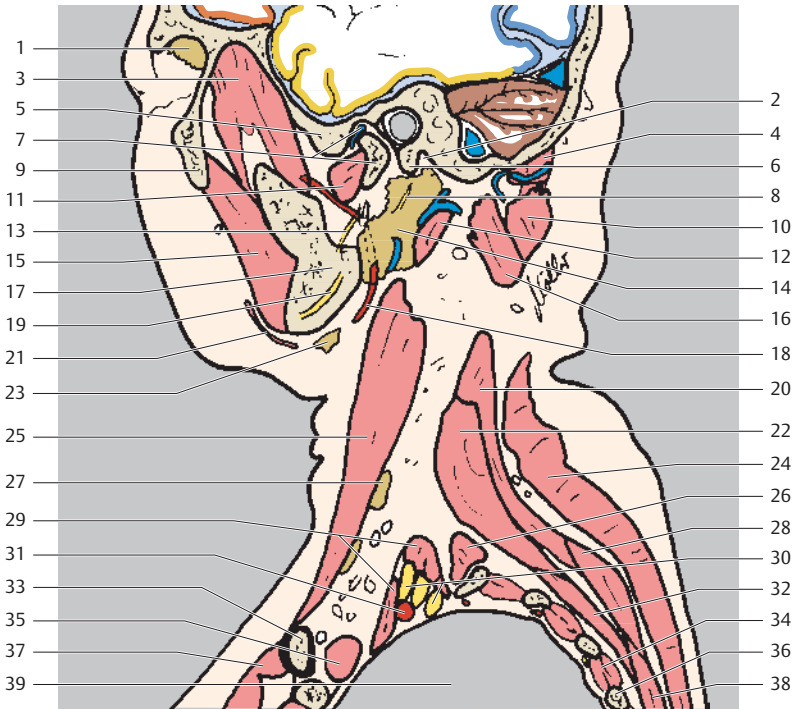
- | | | | |
|----|---------------------------------------|----|-----------------------------------|
| 1 | Temporal muscle | 20 | Levator scapulae muscle |
| 2 | Internal carotid artery (syphon) | 21 | Platysma |
| 3 | Lateral pterygoid muscle | 22 | Semispinalis cervicis muscle |
| 4 | Pharyngotympanic tube (auditory tube) | 23 | Facial vein |
| 5 | Maxillary sinus | 24 | External carotid artery |
| 6 | Internal jugular vein | 25 | Submandibular gland |
| 7 | Styloid process | 26 | Common carotid artery |
| 8 | Rectus capitis posterior minor muscle | 27 | External jugular vein |
| 9 | Parotid gland | 28 | Splenius capitis muscle |
| 10 | Deep cervical veins | 29 | Sternocleidomastoid muscle |
| 11 | Medial pterygoid muscle | 30 | Semispinalis cervicis muscle |
| 12 | Atlas (transverse process) | 31 | Scalenus medius muscle |
| 13 | Buccinator muscle | 32 | Trapezius muscle |
| 14 | Rectus capitis posterior major muscle | 33 | Subclavian artery (left) |
| 15 | Stylohyoid muscle | 34 | Scalenus posterior muscle |
| 16 | Obliquus capitis muscle | 35 | Subclavian vein (left) |
| 17 | Digastric muscle | 36 | Brachial plexus |
| 18 | Semispinalis capitis muscle | 37 | Clavicle |
| 19 | Mandible | 38 | Rhomboid (major and minor) muscle |
| | | 39 | Lung (left) |
| | | 40 | Multifidus muscle |
| | | 41 | Interspinalis muscle |
















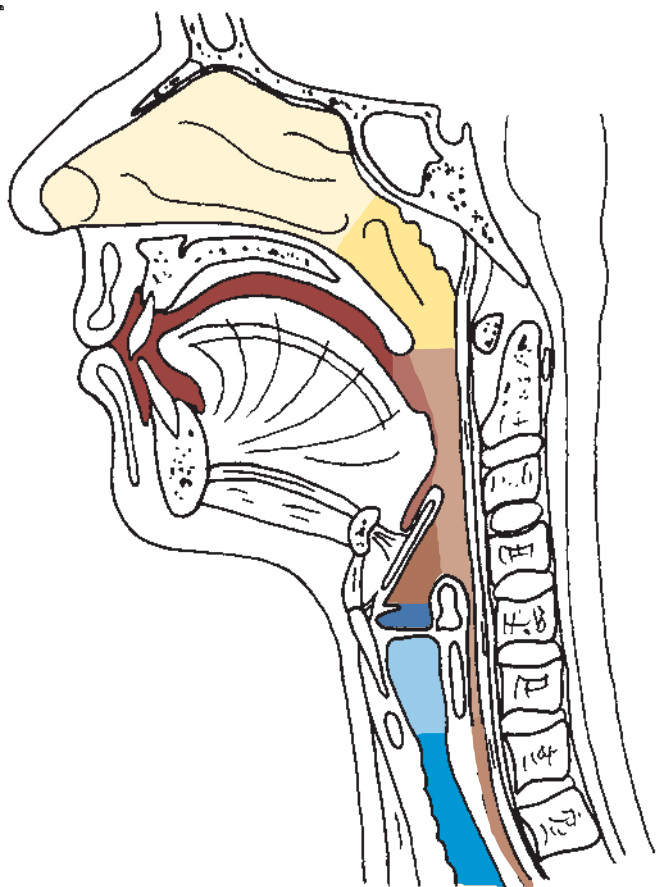
- | | |
|--|--------------------------------------|
| 1 Maxillary sinus | 19 Platysma |
| 2 External acoustic meatus | 20 Levator scapulae muscle |
| 3 Temporal muscle | 21 Common facial vein |
| 4 Sigmoid sinus | 22 Cervical veins |
| 5 Lateral pterygoid muscle | 23 Sternocleidomastoid muscle |
| 6 Internal jugular vein | 24 Trapezius muscle |
| 7 Ramus of the mandible | 25 Scalenus medius muscle |
| 8 Obliquus capitis posterior major and minor muscles | 26 Semispinalis cervicis muscle |
| 9 Buccinator muscle | 27 Internal jugular vein |
| 10 Semispinalis capitis muscle | 28 First rib |
| 11 Medial pterygoid muscle | 29 Scalenus anterior muscle |
| 12 Rectus capitis lateralis muscle | 30 Interspinalis muscle |
| 13 Orbicularis oris muscle | 31 Brachial plexus |
| 14 Transverse process of cervical vertebra C1 | 32 Rhomboid (major and minor) muscle |
| 15 Mandible | 33 Subclavian artery (left) |
| 16 Obliquus capitis superior muscle | 34 Serratus anterior muscle |
| 17 Submandibular gland | 35 Subclavian vein (left) |
| 18 Splenius capitis muscle | 36 Lung |
| | 37 Clavicle |
| | 38 Subclavian muscle |
| | 39 Pectoralis major muscle |

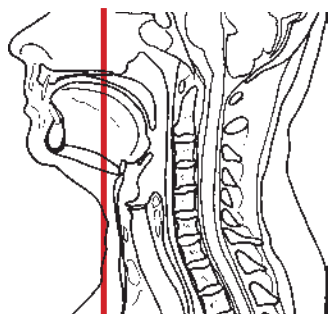
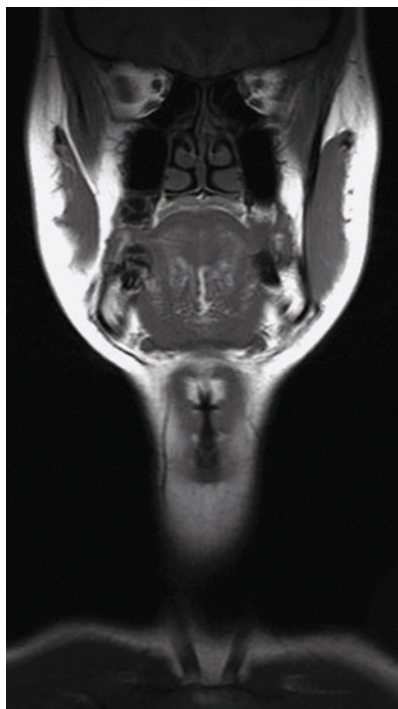


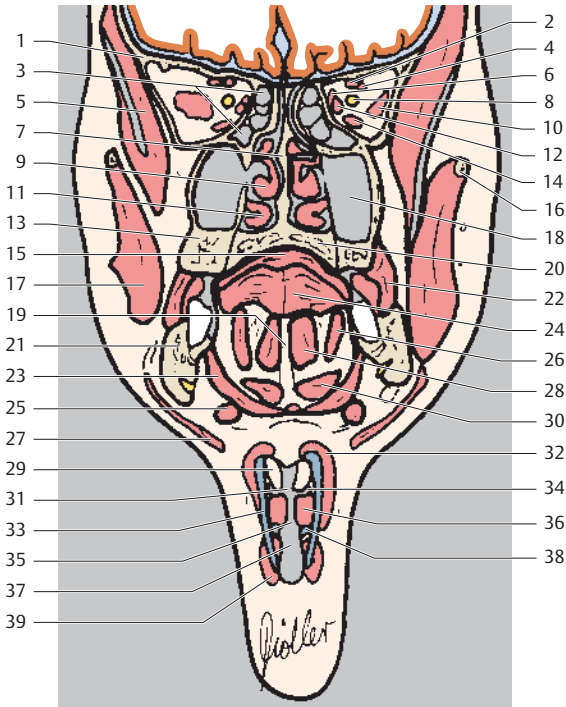


- | | |
|---------------------------------------|-------------------------------|
| 1 Lacrimal gland | 19 Mandibular canal |
| 2 Stylo mastoid foramen | 20 Levator scapulae muscle |
| 3 Temporal muscle | 21 Platysma |
| 4 Obliquus capitis superior muscle | 22 Scalenus posterior muscle |
| 5 Articular tubercle | 23 Submandibular gland |
| 6 Styloid process | 24 Trapezius muscle |
| 7 Head of mandible and articular disc | 25 Sternocleidomastoid muscle |
| 8 Facial nerve | 26 Scalenus medius muscle |
| 9 Zygomatic bone | 27 Lymph nodes |
| 10 Splenius capitis muscle | 28 Rhomboid minor muscle |
| 11 Lateral pterygoid muscle | 29 Scalenus anterior muscle |
| 12 Digastric muscle (posterior belly) | 30 Brachial plexus |
| 13 Inferior alveolar nerve | 31 Subclavian artery (left) |
| 14 Parotid gland | 32 Serratus anterior muscle |
| 15 Masseter muscle | 33 Clavicle |
| 16 Semispinalis capitis muscle | 34 Interspinalis muscle |
| 17 Mandible | 35 Subclavian muscle |
| 18 External carotid artery | 36 Fourth rib |
| | 37 Pectoralis major muscle |
| | 38 Rhomboid major muscle |
| | 39 Lung (left) |

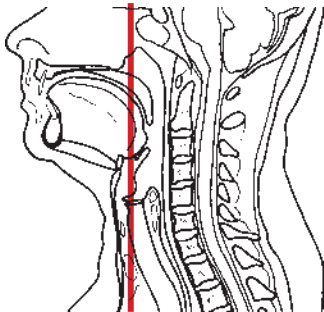
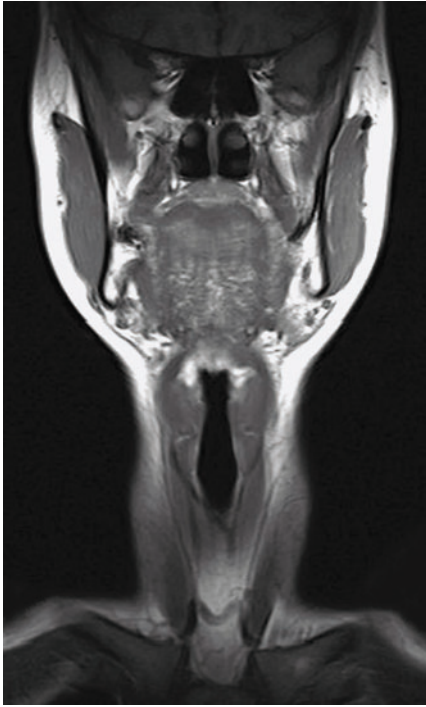
- | | |
|---|---|
|  Nasal vestibule (nasal cavity) |  Laryngeal part of pharynx |
|  Nasopharynx |  Esophagus |
|  Oral cavity proper |  Laryngeal vestibule |
|  Isthmus of fauces (oropharyngeal isthmus) |  Laryngeal ventricle |
|  Oropharynx |  Infraglottic cavity |
| |  Trachea |



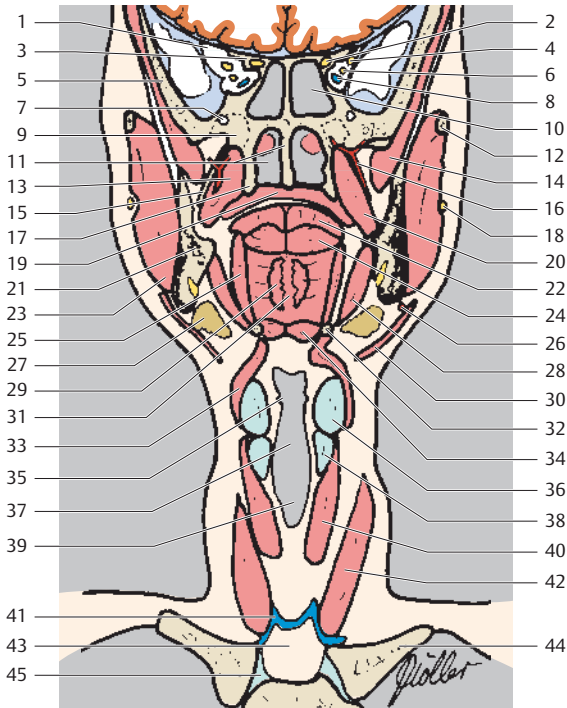




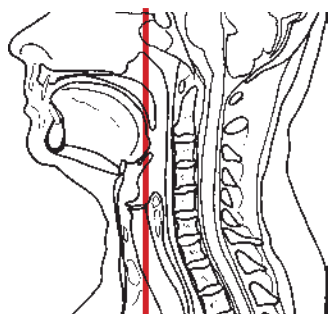
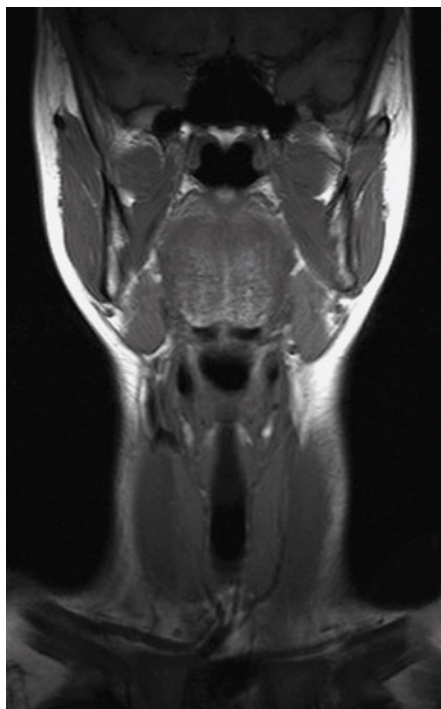
- | | |
|---------------------------------------|--------------------------------------|
| 1 Sphenoidal bone (lesser wing) | 20 Hard palate |
| 2 Levator palpebrae superioris muscle | 21 Mandible |
| 3 Ethmoidal cells (anterior) | 22 Buccinator muscle |
| 4 Superior rectus muscle | 23 Mylohyoid muscle |
| 5 Temporal muscle | 24 Transverse muscle of tongue |
| 6 Superior oblique muscle | 25 Digastric muscle (anterior belly) |
| 7 Nasal septum | 26 Hypoglossus muscle |
| 8 Optic nerve (II) | 27 Platysma |
| 9 Middle nasal concha | 28 Genioglossus muscle |
| 10 Lateral rectus muscle | 29 Vestibular fold |
| 11 Inferior nasal concha | 30 Geniohyoid muscle |
| 12 Medial rectus muscle | 31 Glottis |
| 13 Mandible | 32 Thyrohyoid muscle |
| 14 Inferior rectus muscle | 33 Thyroid cartilage |
| 15 Longitudinal muscle of tongue | 34 Laryngeal ventricle |
| 16 Zygomatic bone (temporal process) | 35 Infraglottic cavity |
| 17 Masseter muscle | 36 Vocalis muscle |
| 18 Maxillary sinus | 37 Trachea |
| 19 Lingual septum | 38 Cricoid cartilage |
| | 39 Sternohyoid muscle |

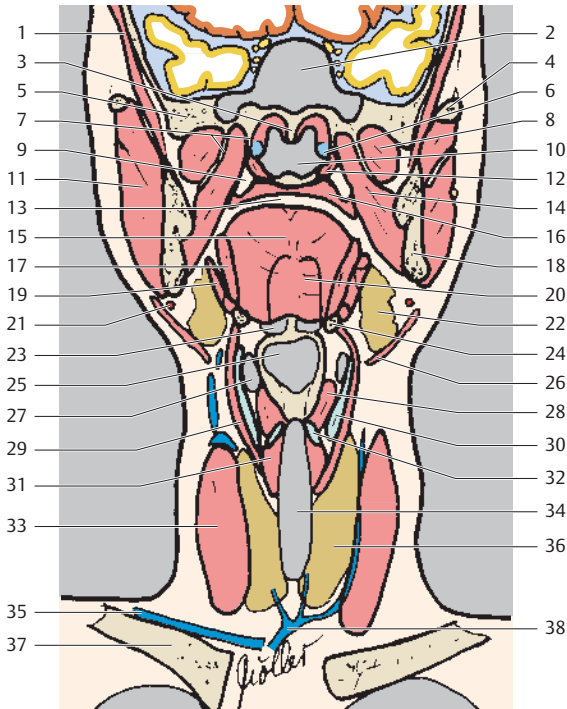


- | | |
|---------------------------------|--|
| 1 Superior orbital fissure | 5 Temporal bone |
| 2 Optic nerve (II) | 6 Frontal nerve |
| 3 Sphenoidal bone (lesser wing) | 7 Foramen rotundum with maxillary nerve (V2) |
| 4 Trochlear nerve (IV) | |

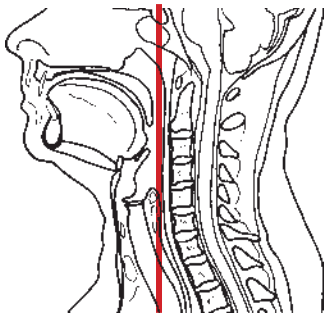
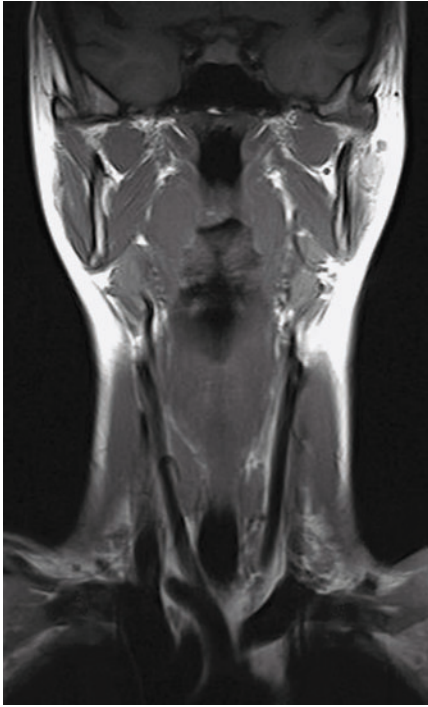


- | | |
|---|------------------------------|
| 8 Superior ophthalmic vein | 26 Facial artery |
| 9 Pterygopalatine fossa | 27 Submandibular gland |
| 10 Sphenoidal sinus | 28 Mylohyoid muscle |
| 11 Dorsal nasal cavity and nasal septum | 29 Vertical muscle of tongue |
| 12 Zygomatic bone (temporal process) | 30 Platysma |
| 13 Pterygoid fossa | 31 Lingual septum |
| 14 Temporal muscle | 32 Hyoid bone |
| 15 Lateral pterygoid process | 33 Thyrohyoid muscle |
| 16 Maxillary artery | 34 Geniohyoid muscle |
| 17 Medial pterygoid process | 35 Laryngeal ventricle |
| 18 Facial nerve (VII) | 36 Thyroid cartilage |
| 19 Soft palate | 37 Infraglottic cavity |
| 20 Medial pterygoid muscle | 38 Cricoid cartilage |
| 21 Mandible (ramus) | 39 Larynx |
| 22 Longitudinal muscle of tongue | 40 Cricothyroid muscle |
| 23 Masseter muscle | 41 Anterior jugular vein |
| 24 Transverse muscle of tongue | 42 Sternohyoid muscle |
| 25 Hypoglossus muscle | 43 Suprasternal space |
| | 44 Clavicle |
| | 45 Sternoclavicular joint |

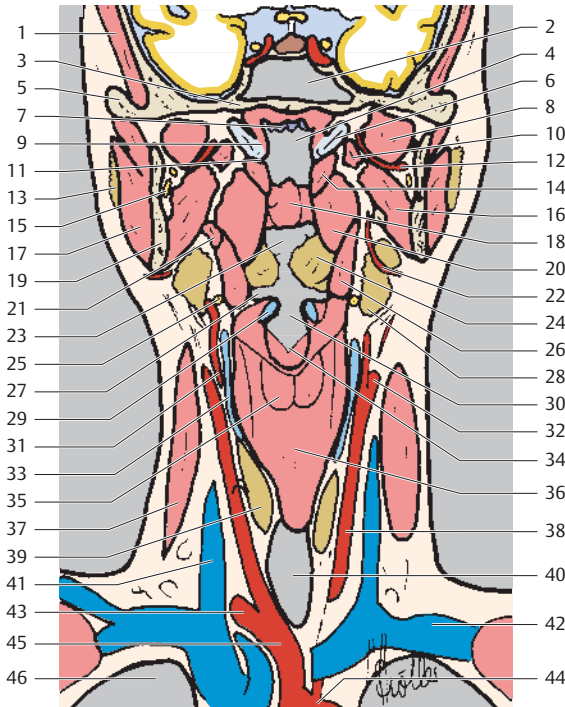




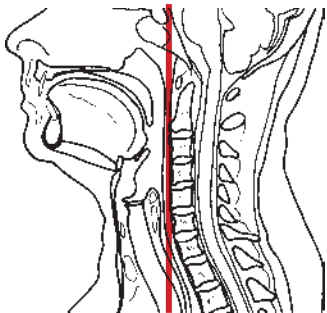
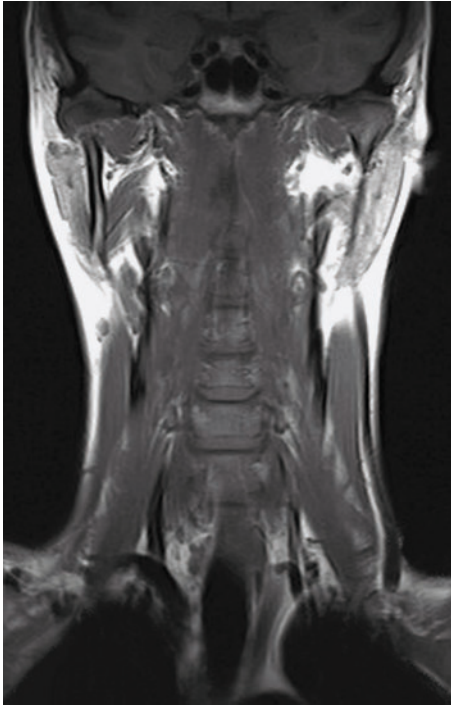
- | | |
|---|---|
| 1 Temporal muscle | 19 Digastric muscle |
| 2 Sphenoidal sinus | 20 Genioglossus muscle |
| 3 Vomer | 21 Facial artery |
| 4 Zygomatic bone (temporal process) | 22 Submandibular gland |
| 5 Sphenoidal bone (greater wing) | 23 Epiglottic vallecula |
| 6 Pharyngotympanic tube (auditory tube) (cartilage) | 24 Hyoid bone (greater horn) |
| 7 Lateral and medial plates of pterygoid process | 25 Laryngeal vestibule |
| 8 Lateral pterygoid muscle | 26 Platysma |
| 9 Peripharyngeal space | 27 Piriform recess |
| 10 Nasopharynx | 28 Aryepiglottic muscle with aryepiglottic fold |
| 11 Masseter muscle | 29 Omohyoid muscle |
| 12 Levator veli palatini muscle | 30 Thyroid cartilage |
| 13 Oropharynx | 31 Thyroarytenoid muscle |
| 14 Medial pterygoid muscle | 32 Arytenoid cartilage |
| 15 Transverse muscle of tongue | 33 Sternocleidomastoid muscle |
| 16 Soft palate | 34 Trachea |
| 17 Hypoglossus muscle | 35 Anterior jugular vein |
| 18 Mandible | 36 Thyroid gland |
| | 37 Clavicle |
| | 38 Inferior thyroid veins |

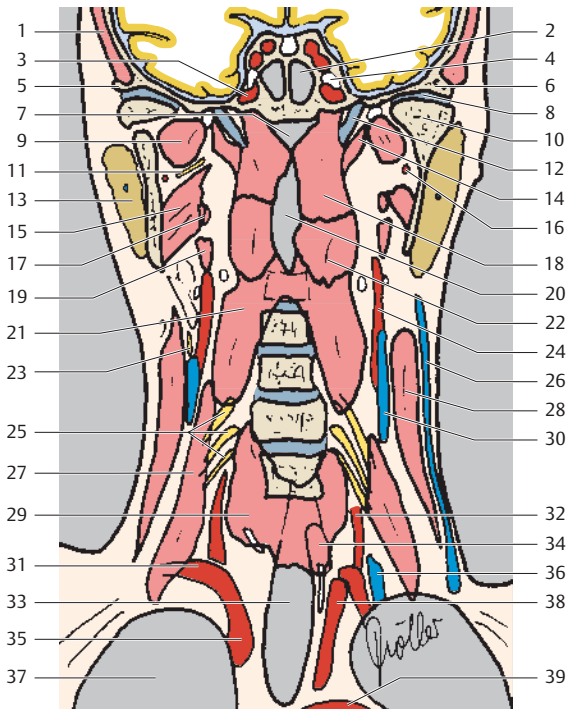


- | | |
|----------------------------------|--|
| 1 Temporal muscle | 5 Zygomatic bone |
| 2 Sphenoidal sinus | 6 Pharyngotympanic tube (auditory tube)
(cartilage) |
| 3 Sphenoidal bone (greater wing) | 7 Pharyngeal tonsil |
| 4 Oropharynx | |

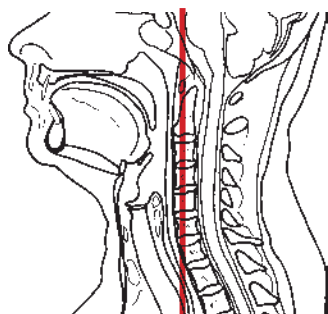
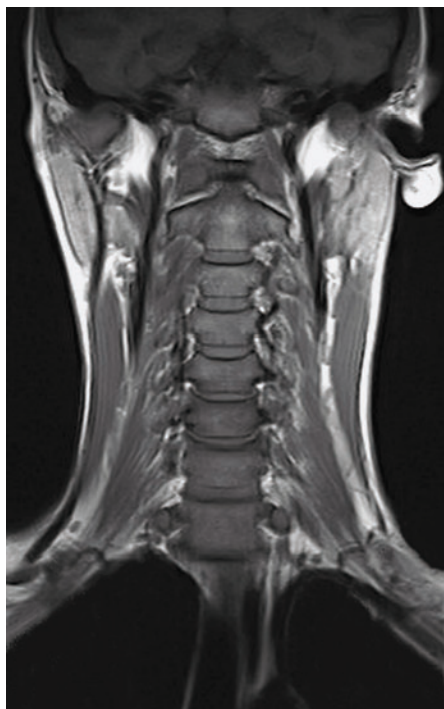


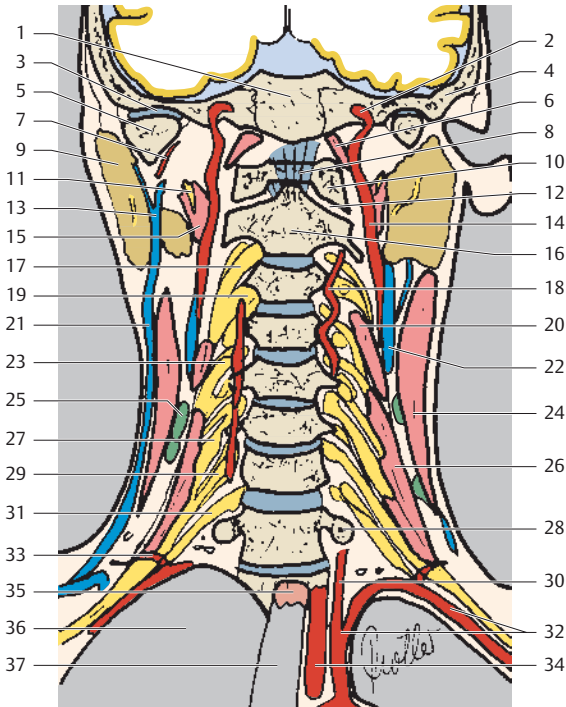
- | | |
|--|---|
| 8 Lateral pterygoid muscle | 27 Epiglottic vallecula |
| 9 Torus tubarius | 28 Submandibular gland |
| 10 Tensor veli palatini muscle | 29 Epiglottis |
| 11 Pharyngeal opening of auditory tube | 30 Laryngeal inlet |
| 12 Maxillary artery | 31 External carotid artery |
| 13 Parotid gland | 32 Internal carotid artery |
| 14 Levator veli palatini muscle | 33 Thyroid cartilage |
| 15 Inferior alveolar nerve | 34 Interarytenoid notch |
| 16 Medial pterygoid muscle | 35 Posterior cricoarytenoid muscle |
| 17 Masseter muscle | 36 Middle constrictor muscle of pharynx |
| 18 Soft palate and uvula | 37 Sternocleidomastoid muscle |
| 19 Ramus of mandible | 38 Common carotid artery |
| 20 Palatopharyngeus muscle | 39 Thyroid gland |
| 21 Styloglossus muscle | 40 Trachea |
| 22 Facial artery | 41 Internal jugular vein |
| 23 Oropharynx | 42 Subclavian vein |
| 24 Palatine tonsil | 43 Subclavian artery (right) |
| 25 Hyoid bone | 44 Aorta |
| 26 Digastric muscle | 45 Brachiocephalic trunk |
| | 46 Lung (right) |



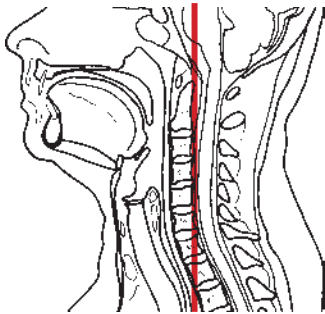
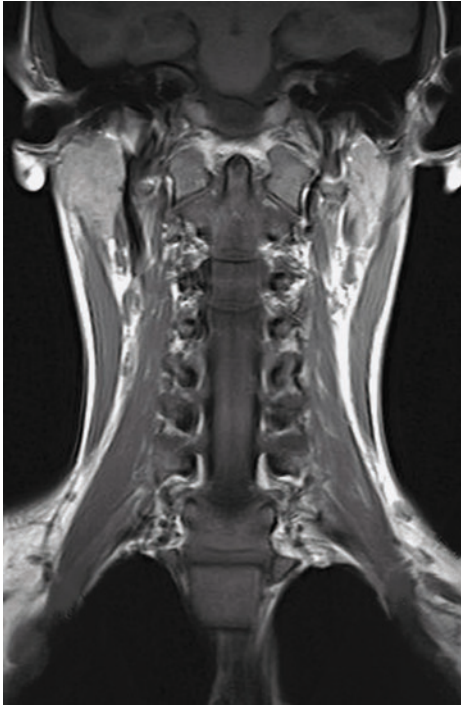


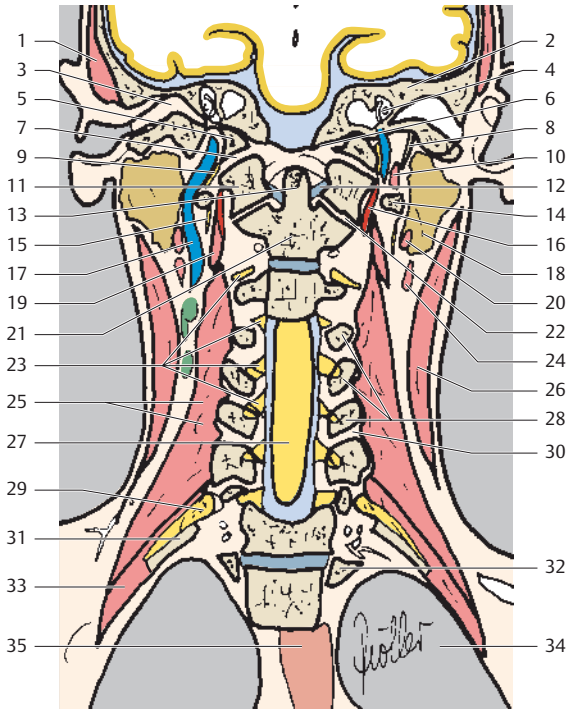
- | | |
|---|---|
| 1 Temporal muscle | 20 Oropharynx |
| 2 Sphenoidal sinus | 21 Longus colli muscle |
| 3 Internal carotid artery (syphon) | 22 Longus capitis muscle |
| 4 Trigeminal cavity | 23 Vagus nerve (X) |
| 5 Zygomatic process | 24 Internal carotid artery |
| 6 Socket of temporomandibular joint (temporal bone) | 25 Spinal nerve roots (cervical plexus) |
| 7 Nasopharynx | 26 External jugular vein |
| 8 Articular disc | 27 Anterior scalene muscle |
| 9 Lateral pterygoid muscle | 28 Sternocleidomastoid muscle |
| 10 Head of mandible | 29 Inferior constrictor muscle of pharynx |
| 11 Lingual nerve | 30 Internal jugular vein |
| 12 Pharyngotympanic tube (auditory tube) | 31 Subclavian vein |
| 13 Parotid gland | 32 Vertebral artery |
| 14 Levator veli palatini muscle | 33 Trachea |
| 15 Medial pterygoid muscle | 34 Esophagus |
| 16 Maxillary artery | 35 Brachiocephalic trunk |
| 17 Stylopharyngeus muscle | 36 Vertebral vein |
| 18 Longus capitis muscle | 37 Lung (right) |
| 19 Digastric muscle | 38 Common carotid artery |
| | 39 Aortic arch |



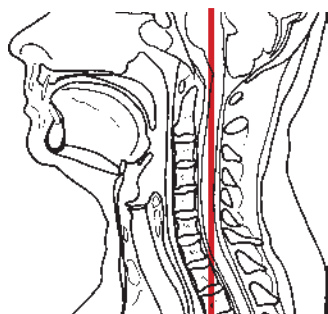
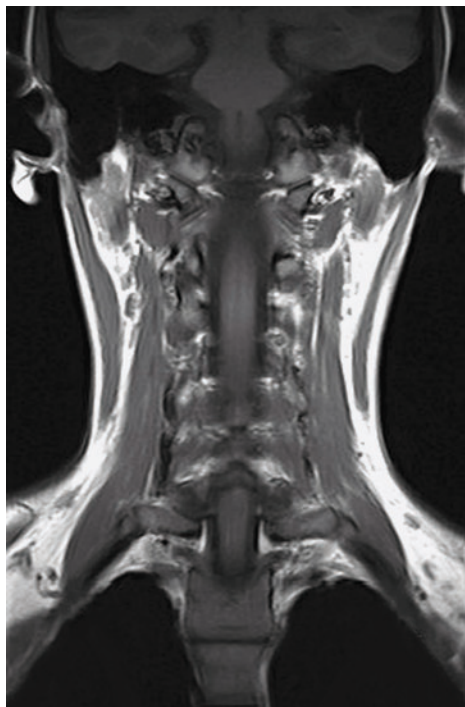


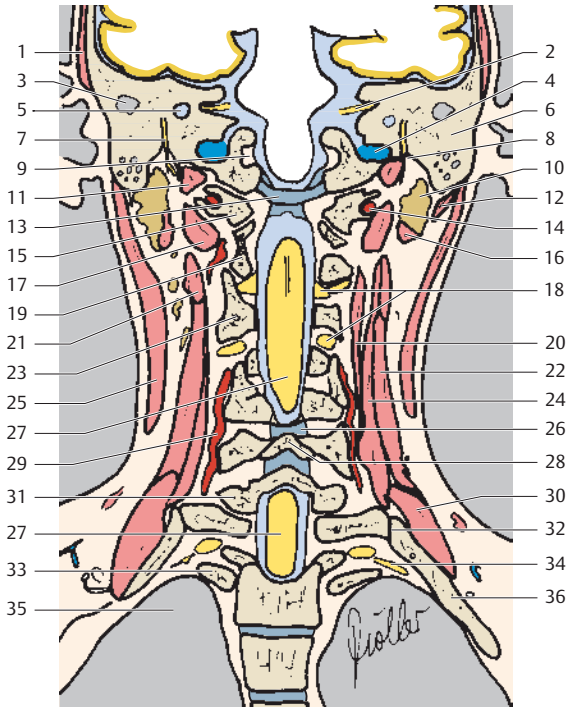
- | | |
|---------------------------------------|-------------------------------|
| 1 Clivus | 19 Spinal nerve root C4 |
| 2 Internal carotid artery (syphon) | 20 Longus colli muscle |
| 3 Articular disc | 21 External jugular vein |
| 4 Petrous part of temporal bone | 22 Internal jugular vein |
| 5 Head of mandible | 23 Spinal nerve root C5 |
| 6 Rectus capitis anterior muscle | 24 Sternocleidomastoid muscle |
| 7 Maxillary artery | 25 Lymph nodes |
| 8 Anterior atlanto-occipital membrane | 26 Anterior scalene muscle |
| 9 Parotid gland | 27 Spinal nerve root C6 |
| 10 Atlas (lateral mass) | 28 Costal process |
| 11 Styloid process | 29 Spinal nerve root C7 |
| 12 Atlanto-axial joint | 30 Vertebral artery (left) |
| 13 Retromandibular vein | 31 Spinal nerve root C8 |
| 14 Internal carotid artery | 32 Subclavian artery |
| 15 Digastric muscle | 33 Suprascapular artery |
| 16 Axis | 34 Internal carotid artery |
| 17 Spinal nerve root C3 | 35 Esophagus |
| 18 Vertebral artery | 36 Lung (right) |
| | 37 Trachea |



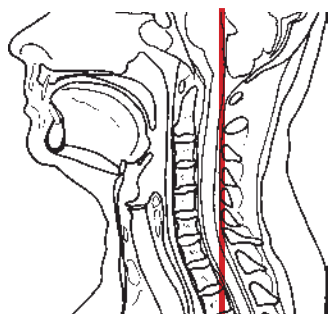
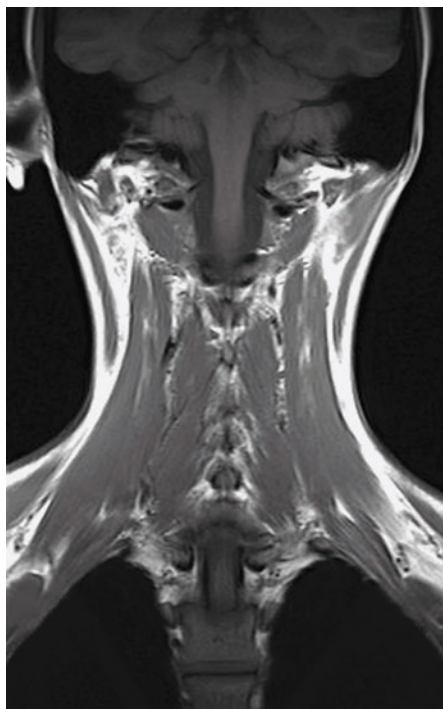


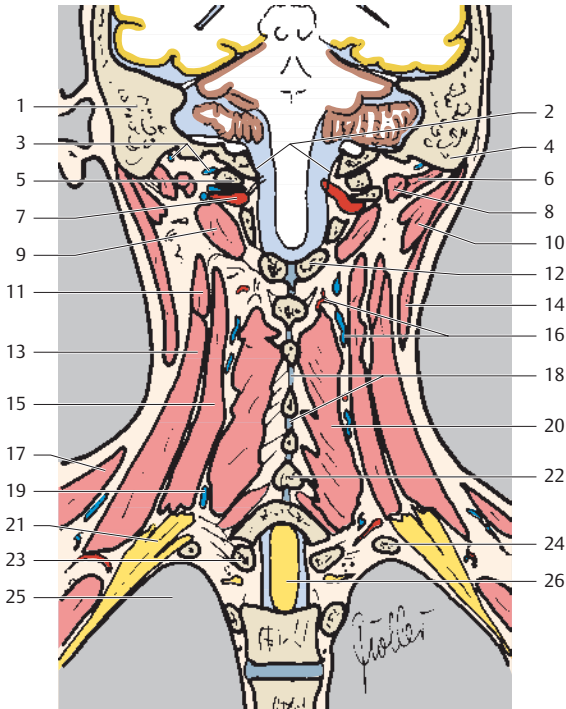
- | | |
|--|-------------------------------------|
| 1 Temporal muscle | 18 Parotid gland |
| 2 Petrous part of temporal bone | 19 Obliquus capitis inferior muscle |
| 3 External acoustic meatus | 20 Stylohyoid muscle |
| 4 Tympanic cavity | 21 Axis (body) |
| 5 Occipital condyle | 22 Atlanto-axial joint |
| 6 Clivus | 23 Spinal nerve roots C3–C6 |
| 7 Atlanto-occipital joint | 24 Digastric muscle |
| 8 Styloid process | 25 Middle scalene muscle |
| 9 Accessory nerve (XI) and hypoglossus nerve (XII) | 26 Sternocleidomastoid muscle |
| 10 Stylopharyngeus muscle | 27 Spinal cord |
| 11 Atlas (lateral mass) | 28 Articular processes C4–C6 |
| 12 Alar ligaments | 29 Spinal nerve root C8 |
| 13 Dens of axis | 30 Zygapophysial joint |
| 14 Atlas (transverse process) | 31 First rib |
| 15 Vagus nerve (X) | 32 Second rib |
| 16 Vertebral artery | 33 Posterior scalene muscle |
| 17 Internal jugular vein | 34 Lung (left) |
| | 35 Esophagus |



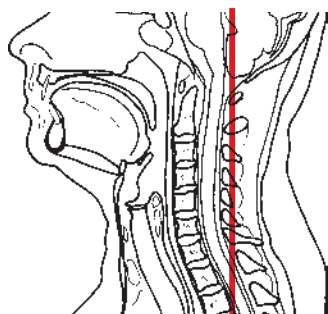
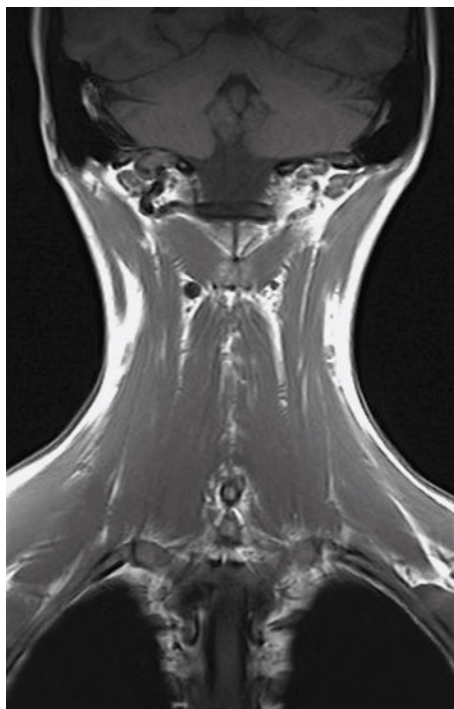


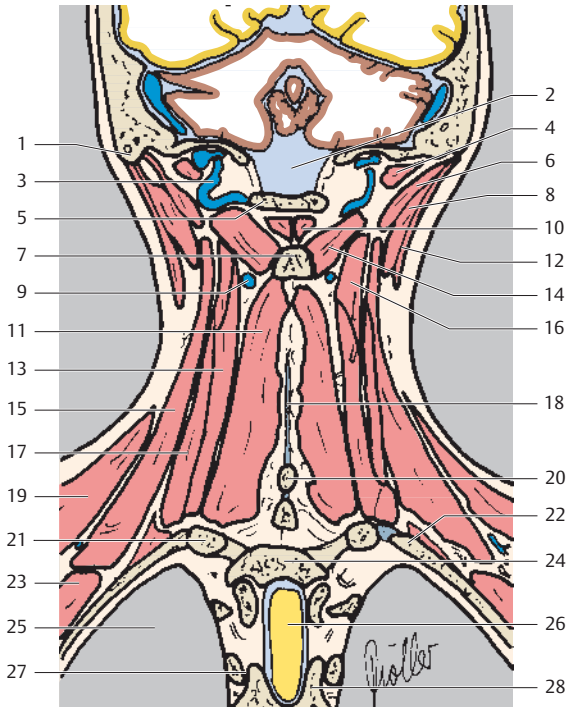
- | | |
|---------------------------------------|------------------------------------|
| 1 Temporal muscle | 18 Spinal nerve roots |
| 2 Internal acoustic meatus | 19 Inferior articular process (C2) |
| 3 Mastoid antrum | 20 Spinalis cervicis muscle |
| 4 Jugular foramen | 21 Longissimus capitis muscle |
| 5 Vestibule | 22 Anterior scalene muscle |
| 6 Mastoid process | 23 Superior articular process (C3) |
| 7 Facial canal | 24 Levator scapulae muscle |
| 8 Stylomastoid foramen | 25 Sternocleidomastoid muscle |
| 9 Hypoglossus canal | 26 Ligamentum flavum |
| 10 Parotid gland | 27 Spinal cord |
| 11 Rectus capitis lateralis muscle | 28 Arch of C6 vertebra |
| 12 Splenius capitis muscle | 29 Vertebral artery |
| 13 Transverse ligament | 30 Scalenus medius muscle |
| 14 Vertebral artery | 31 Transverse process (C7) |
| 15 Atlas (posterior arch) | 32 Costotransverse joint (T1) |
| 16 Digastric muscle (posterior belly) | 33 Second rib (head) |
| 17 Obliquus capitis inferior muscle | 34 Thoracic nerve (T1) |
| | 35 Lung (right) |
| | 36 First rib |



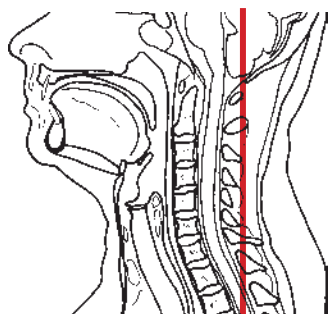
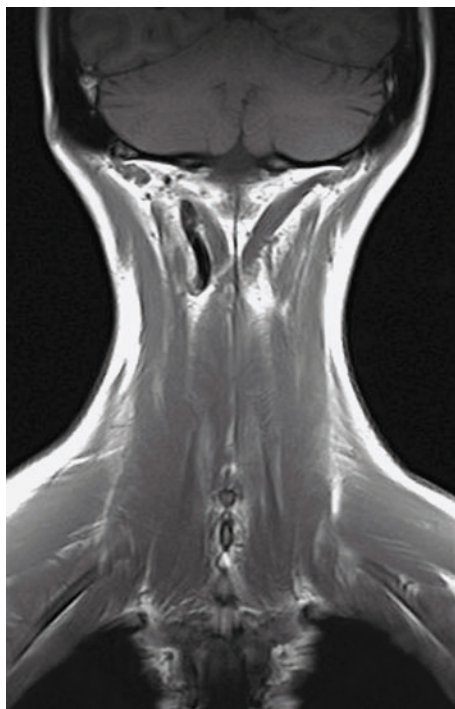


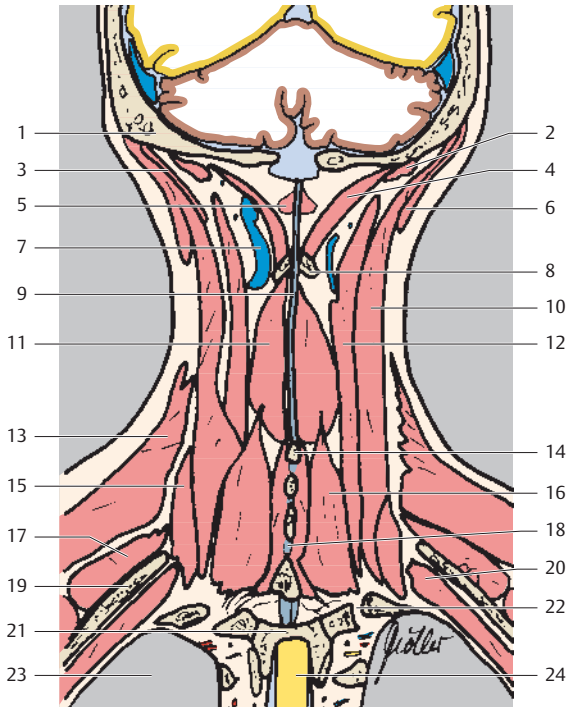
- | | |
|---|----------------------------------|
| 1 Mastoid process (Petrous part of temporal bone) | 12 Spinous process (C2) |
| 2 Foramen magnum | 13 Levator scapulae muscle |
| 3 Suboccipital venous plexus | 14 Sternocleidomastoid muscle |
| 4 Mastoid process | 15 Splenius cervicis muscle |
| 5 Atlas (posterior arch) | 16 Deep cervical artery and vein |
| 6 Digastric muscle (posterior belly) | 17 Trapezius muscle |
| 7 Vertebral artery | 18 Interspinous ligaments |
| 8 Obliquus capitis superior muscle | 19 Deep cervical vein |
| 9 Obliquus capitis inferior muscle | 20 Multifidus muscle |
| 10 Splenius capitis muscle | 21 Brachial plexus |
| 11 Longissimus capitis muscle | 22 Spinous process (C7) |
| | 23 Costal process |
| | 24 First rib |
| | 25 Lung (right) |
| | 26 Spinal cord |



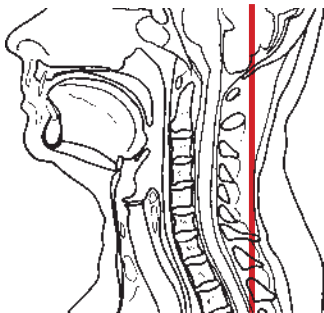
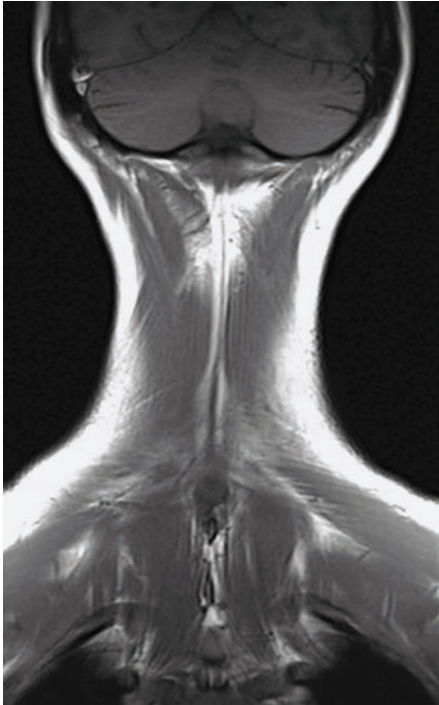


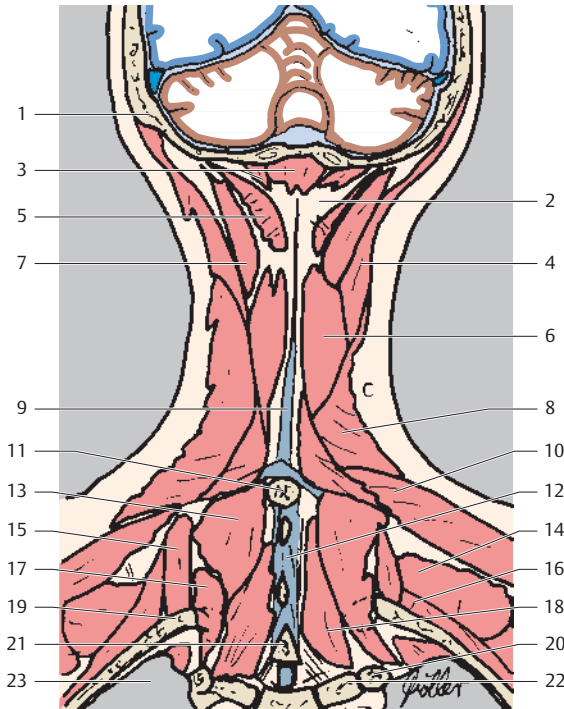
- | | |
|--|--|
| 1 Mastoid process | 15 Levator scapulae muscle |
| 2 Cisterna magna | 16 Semispinalis capitis muscle |
| 3 Deep cervical vein | 17 Splenius cervicis muscle |
| 4 Obliquus capitis superior muscle | 18 Supraspinous and interspinous ligaments |
| 5 Atlas (posterior arch) | 19 Trapezius muscle |
| 6 Longissimus capitis muscle | 20 Spinous process (C7) |
| 7 Spinous process of axis (C2) | 21 Transverse process (T2) |
| 8 Splenius capitis muscle | 22 Second rib |
| 9 Deep cervical vein | 23 Supraspinatus muscle |
| 10 Rectus capitis posterior major muscle | 24 Vertebra (T2) |
| 11 Semispinalis cervicis muscle | 25 Lung (right) |
| 12 Sternocleidomastoid muscle | 26 Spinal cord |
| 13 Longissimus cervicis muscle | 27 Transverse process (T4) |
| 14 Obliquus capitis inferior muscle | 28 Vertebra (T4) |





- | | |
|---|--------------------------------|
| 1 Occipital bone | 12 Semispinalis capitis muscle |
| 2 Obliquus capitis superior muscle | 13 Trapezius muscle |
| 3 Longissimus capitis muscle | 14 Spinous process |
| 4 Rectus capitis posterior major muscle | 15 Rhomboid muscle |
| 5 Rectus capitis posterior minor muscle | 16 Multifidus muscle |
| 6 Sternocleidomastoid muscle | 17 Levator scapulae muscle |
| 7 Deep cervical vein | 18 Interspinous ligament |
| 8 Spinous process of axis (C2) | 19 Second rib |
| 9 Nuchal ligament | 20 Intercostal muscle |
| 10 Splenius capitis muscle | 21 Arch of T3 vertebra |
| 11 Semispinalis cervicis muscle | 22 Costovertebral joint (T3) |
| | 23 Lung (right) |
| | 24 Spinal cord |





- | | |
|---|---------------------------------------|
| 1 Occipital bone | 11 Spinous process (C7) |
| 2 Suboccipital fatty tissue | 12 Interspinous ligament |
| 3 Rectus capitis posterior minor muscle | 13 Splenius cervicis muscle |
| 4 M. splenius capitis | 14 Levator scapulae muscle |
| 5 Rectus capitis posterior major muscle | 15 Rhomboid muscle |
| 6 Semispinalis cervicis muscle | 16 Intercostal muscle |
| 7 Semispinalis capitis muscle | 17 Serratus posterior superior muscle |
| 8 Trapezius muscle, descending part (superior part) | 18 Multifidus muscle |
| 9 Nuchal ligament | 19 Third rib |
| 10 Trapezius muscle, transverse part (middle part) | 20 Costotransverse joint (T4) |
| | 21 Spinous process (T3) |
| | 22 Costal process (T4) |
| | 23 Lung (right) |

Bibliography

- Beyer-Enke, S. A., K. Tiedemann, J. Görich, A. Gamroth: Dünnschichtcomputertomographie der Schädelbasis, *Radiologie* 27 1987: 438–488
- Cahill, D. R., M. J. Orland, C. C. Reading: Atlas of Human Cross-Sectional Anatomy. Wiley-Liss, New York 1995
- Chacko, A. K., R. W. Katzberg, A. Mac Kay: MRI Atlas of Normal Anatomy. Mc Graw-Hill Inc., New York 1991
- Dauber, W.: Pocket Atlas of Human Anatomy, 5th ed. Thieme, Stuttgart 2007 (in print)
- El-Khoury, G. Y., R. A. Bergman, E. J. Montgomery: Sectional Anatomy by MRI/CT. Churchill Livingstone, New York 1990
- El-Khoury, G. Y., et al.: Essentials in Musculoskeletal Imaging. Churchill Livingstone 2003
- Fushimi, Y. et al.: Lilliequist Membrane: Three-Dimensional Constructive Interference in Steady State MR Imaging. *Radiology* 2003: 360–365
- Grumme, T., W. Kluge, K. Kretzmar, A. Roesler: Zerebrale und spinale CT. Blackwell, Berlin 1998
- Hosten, N., T. Liebig: CT of the Head and Spine. Thieme, Stuttgart 2002
- Huk, W. J., G. Gademann, G. Freidmann: MRI of Central Nervous System Diseases. Springer, Berlin 1990
- Kahle, W., M. Frotscher: Color Atlas and Textbook of Human Anatomy, Vol. 3. Thieme, Stuttgart 2003
- Kang, M. S., D. Resnick: MRI of the Extremities: An Anatomic Atlas. Saunders, Philadelphia 2002
- Koritke, J. G., H. Sick: Atlas of Sectional Human Anatomy. Urban & Schwarzenberg, Baltimore and Munich 1988
- Kretschmann, H.-J., W. Weinrich: Cranial Neuroimaging and Clinical Neuroanatomy. Thieme, Stuttgart 2003
- Leblanc, A.: Encephalo-Peripheral Nervous System, Springer, Berlin 2001
- Meschan, I.: Synopsis of Radiologic Anatomy. Saunders, Philadelphia 1978
- Moeller, T. B., E. Reif: MR Atlas of the Musculoskeletal System. Blackwell Science, Boston 1994
- Moeller, T. B., E. Reif: Neuroradiologische Schnittbilddiagnostik. Schnetztor, Konstanz 2002
- Moeller, T. B., E. Reif: Pocket Atlas of Radiographic Anatomy, Thieme, Stuttgart 2000
- Netter, F. H.: Atlas of Human Anatomy. 4th ed., Saunders, Philadelphia 2006
- Rauber, A., Kopsch F.: Anatomie des Menschen. Lehrbuch und Atlas. (eds. H. Leonhardt, Tillmann, G. Töndury, K. Zilles). Vol. I: Bewegungsapparat. Thieme, Stuttgart 2003
- Richter, E., T. Feyerabend: Normal Lymph Node Topographie. Springer, Berlin 1991
- Rummeny, E. J.: Ganzkörper-MR-Tomographie, 2nd edn. Thieme, Stuttgart 2006
- Schnitzlein, H. N., F. Reed Murtagh: Imaging Atlas of the Head and Spine. Urban and Schwarzenberg, Baltimore 1990
- Schünke, M. E. Schulte, L. M. Ross, E. D. Lamberti: Thieme Atlas of Anatomy. General Anatomy and Musculoskeletal System. Thieme, Stuttgart 2006
- Stark, D. D., W. G. Bradley: Magnetic Resonance Imaging. Mosby, St. Louis 1999
- Stoller, D. W., MRI, Arthroscopy, and Surgical Anatomy of the Joints. Lippincott Williams & Wilkins, Philadelphia 1999
- Stoller, D. W., Tirman, Ph. F. J., Bredella, M. A.: Diagnostic Imaging: Orthopaedics. Amirsys, Salt Lake City, Utah 2004
- Uhlenbrock, D.: MR Imaging of the Spine and Spinal Cord. Thieme Stuttgart 2004
- Witzig, H.: Punkt-Punkt-Komma-Strich. Falken, Niedernhausen 2000

Index

A

- adhesion, interthalamic 60–61, 84–87
- antrum, mastoid 18–21, 32–35, 108–109, 238–239
- aorta 230–231
- aqueduct 14–15, 84–87, 140–141
vestibular 30–31
- arch
aortic 212–213, 232–233
vertebral, posterior 174–175, 186–187
zygomatic 24–25, 40–41, 116–119
- artery
alveolar, inferior 118–119
angular gyrus 154–155
basilar 16–23, 66–75, 84–87, 130–133, 152–157
anterolateral 82–83
anterolateral paramedian 28, 110, 149
anteromedial 82–83
anteromedial paramedian 28, 110, 149
border 82–83
central branch 82–83
cerebellar posterior inferior 28
cerebellar superior 28
circumferential 28
dorsal 82–83
dorsal paramedian 28, 149–150
lateral 83
lateral paramedian 28, 149–150
superficial 82–83
- brachiocephalic 210–211
- brain-stem, median 82–83
- callosomarginal 46–51, 152–155
paracentral 46–47
- carotid
bifurcation 202–203
common 160–161, 176–197, 204–209, 212–217, 230–233
external 130–131, 170–175, 202–203, 216–217, 220–221, 230–231
internal 16–25, 30–33, 66–79, 90–91, 94–101, 128–129, 152–157, 162–163, 165–171, 173–175, 202–203, 214–215, 230–235
internal syphon 88–89, 122–133, 216–217, 232–235
- cerebellar
anterior inferior 22–23, 72–77, 82–83, 150
anterior superior 110–111
posterior 132–133
posterior inferior 82–83, 110–111, 138–145, 150
see also artery, vertebral
superior 72–73, 82–83, 90–91, 110–111, 132–133, 136–139, 142–145, 150, 152–157
- cerebral
anteromedial frontal 156–157
anterior 14–17, 58–65, 86–87, 116–119, 122–125, 128–129, 152–156
anterior central branch 27, 80–83, 110, 148–149
anterior postcommunicating 152–157
anterior precommunicating 152–153, 156–157
anterior striate 27, 80–83
anterior terminal branch 26–28, 80–83, 110, 148–150
Huebner's recurrent 80–81
insular part 156–157
middle 16–17, 64–67, 94–95, 98–99, 102–103, 126–129, 152–157
middle central branch 26, 80–83, 110–111, 148–149
middle insular part 152–153
middle opercular part 152–157
middle sphenoid part 152–153, 156–157
middle striate 26, 80–83, 111
middle terminal branch 26, 28, 80–83, 110–111, 148–150

- artery
- cerebellar
 - posterior 16–17, 62–69, 90–91, 94–95, 130–133, 136–137, 140–141, 152–157
 - posterior central branch 26–27, 80–83, 110, 149–150
 - posterior cerebellar 27
 - posterior choroidal 26–28
 - posterior communicating 26–27
 - posterior left 152–153, 156–157
 - posterior occipital branch 152–153
 - posterior right 152–153, 156–157
 - posterior temporal 152–153
 - posterior terminal branch 26–28, 80–83, 110–111, 149–150
 - cervical, deep 240–241
 - choroidal, anterior 80–83, 111, 149, 154–159
 - circumferential 149–150
 - dorsal paramedian 110
 - lateral paramedian 110
 - long 82–83
 - short 82–83
 - communicating
 - anterior 16–17, 152–153, 156–157
 - posterior 16–17, 64–65, 80–83, 90–91, 110, 132–133, 149–150, 154–155
 - facial 164–171, 226–231
 - frontal polar 154–155
 - frontobasal 154–155
 - infraorbital 112–115
 - insular 10–13, 56–63, 100–107, 122–123, 126–127, 134–135, 152–153
 - mandibular 126–127
 - maxillary 118–119, 162–163, 166–169, 226–227, 230–235
 - occipital 138–139
 - medial 154–155
 - occipitotemporal 154–155
 - ophthalmic 68–71, 112–117, 154–157
 - parietal 154–155
 - superior 152–153
 - parieto-occipital 52–53, 58–59, 154–157
 - pericallosal 50–56, 84–87, 116–123, 126–127, 130–131, 134–137, 140–141, 152–155
 - posteromedial, central branch 154–155
 - precuneal 142–143
 - striate 110, 152–153
 - distal medial 80–81, 110, 149
 - subclavian 214–215, 234–235
 - left 212–213, 216–221
 - right 230–231
 - sulcus
 - central 154–155
 - precentral 154–155
 - suprascapular 234–235
 - supratrochlear
 - mediomedial 46–49
 - posteromedial 44–45
 - temporal 156–157
 - anterior 152–153
 - middle 152–153
 - polar 152–153
 - posterior 154–155
 - thyroid
 - inferior 192–193
 - superior 176–177
 - vertebral 24–25, 76–79, 88–89, 92–93, 96–97, 134–143, 162–167, 170–183, 186–197, 202–209, 212–215, 232–239
 - left 234–235
 - see also* artery, cerebellar, posterior inferior
- atlas (C1) 218–219
- arch
 - anterior 84–85, 164–169, 210–211
 - posterior 88–89, 166–167, 238–241
 - lateral mass 92–93, 134–135, 138–139, 142–143, 168–169, 212–213, 234–237
 - ligament 134–135, 166–169
 - process 104–107, 166–167, 214–217, 236–237
 - see also* vertebra, cervical
- axis (C2) 134–135, 234–235
- body 170–173, 236–237
 - dens 84–85, 134–135, 166–169, 210–211, 236–237
 - spinous part 240–241, 244–245
 - see also* vertebra, cervical

- B**
- body
- amygdaloid 16–17, 62–67, 126–129, 132–133
 - geniculate 12–13
 - lateral 60–61, 94–95, 98–99, 136–141
 - medial 60–61, 94–95, 138–141
 - mammillary 62–63, 86–87, 130–133
 - pineal 86–87, 138–141
- bone 92–93
- clivus *see* clivus
 - condyle *see* condyle
 - ear *see* ear
 - ethmoidal 68–69
 - cribriform plate 36–37
 - nasal septum 38–39
 - frontal 2–21, 36–39, 44–67, 88–89, 92–93, 96–97, 100–101, 104–109, 112–119, 122–123, 126–127, 130–131
 - hyoid 96–97, 210–213, 226–227, 230–231
 - body 176–177, 202–203
 - greater horn 176–177, 202–203, 228–229
 - nasal 24–25, 70–73, 78–79, 84–85, 88–89
 - occipital 4–25, 50–79, 84–85, 88–89, 92–93, 96–97, 100–101, 104–109, 140–141, 144–147, 162–165, 244–247
 - basilar 50–78, 130–133, 162–165
 - orbital 48–49
 - palatine 38–39
 - parietal 2–15, 38–41, 44–59, 84–85, 88–89, 100–101, 104–107, 134–135, 138–139, 142–147
 - sphenoidal 20–23, 40–41, 64–73, 76–79
 - body 124–125
 - foramen rotundum of 38–39
 - greater wing 38–39, 102–103, 228–231
 - lesser wing 38–39, 94–95, 118–121, 224–227
 - tip 78–79
 - temporal 12–13, 16–19, 22–25, 58–63, 65–67, 76–77, 118–119, 122–123, 130–131, 144–145, 226–227
 - articular tubercle 40–41
 - mastoid 32–33
 - petrous part 34–35, 68–71, 102–103, 136–137, 234–237
 - squamous part 38–41
 - zygomatic process 126–127
 - zygomatic 22–25, 38–39, 68–79, 108–109, 112–115, 122–123, 220–221, 230–231
 - temporal process 224–229
- bulb, olfactory 20–21, 68–69, 114–115
- C**
- canal
- alveolar 168–169
 - carotid 30–31
 - condylar 164–165
 - facial 30–31, 239
 - hypoglossal 98–99, 238–239
 - incisive 162–163, 210–211
 - mandibular 104–105, 118–119, 220–221
 - optic 38–39
 - pterygoid 38–39
 - semicircular 70–71
 - anterior 34–35
 - lateral 32–35
 - posterior 32–35, 72–75, 106–107
 - superior 134–135
- capsule
- external 12–13, 54–61, 102–103, 122–131
 - see also* white matter
 - extreme 12–13, 54–57, 60–61, 130–131
 - internal 10–13, 94–95, 102–103
 - anterior limb 54–60, 98–99, 118–129
 - genu 54–55, 130–133
 - posterior limb 54–55, 60–61, 98–99, 136–137
- cartilage
- arytenoid 182–187, 228–229
 - body 206–207
 - vocal process 206–207
 - cricoid 182–185, 206–207, 212–213, 224–227
 - arch 190–191
 - lamina 188–189, 208–209

- cartilage
 - thyroid 188–189, 206–213, 224–231
 - inferior horn 188–189, 208–209
 - lamina 180–187, 204–205
 - superior horn 204–207
- cavity
 - infraglottic 208–209, 222–227
 - nasal 36–37, 40–42, 76–77, 114–115, 222–223
 - common meatus 38–39
 - dorsal 226–227
 - oral 116–119, 210–211
 - proper 222–223
 - orbital 40–42
 - trigeminal 232–233
 - tympanic 22–23, 34–35, 236–237
- cells
 - ethmoidal 22–25, 66–75, 112–117
 - anterior 36–37, 224–225
 - middle 36–37
 - posterior 38–39
 - mastoid 20–23, 34–35, 70–79, 134–135, 138–139, 142–143, 162–165
- center
 - semioval 4–5
 - speech 29, 151
- cerebellum 10–24, 60–77, 84–109, 138–139, 142–146
 - caudal lobule 72–73
 - hemisphere 16–25, 164–165
 - tonsil 74–79, 90–91, 142–143, 162–165
 - vermis 10–21, 60–63, 66–77, 142–145
 - white matter 4–5, 102–103
 - see also* flocculus; lobe, cerebellar
- cerebrum 92–93
 - epiphysis 58–59
- chiasm, optic 16–17, 64–65, 122–129
- cingulum 8–9, 46–51
- cistern
 - ambient 12–15, 60–63, 90–91, 132–133, 136–137, 140–141
 - basal 16–17
 - cerebellar, superior 58–59
 - cerebellomedullary 162–165
 - chiasmatic 64–65, 124–125
 - cisterna magna 24–25, 144–145, 242–243
 - posterior 162–165
 - insular 10–13, 58–59, 106–107
 - lateral cerebral fossa 98–99, 104–105
 - interpeduncular 14–15, 34–35, 64–65, 90–91, 135–137, 162–165
 - pontine 18–21
 - pontocerebellar 20–21, 72–77, 90–91, 94–95, 98–99, 102–103, 136–137, 140–141
 - prepontine 66–71, 136–137
 - quadrigeminal 12–15, 60–63, 90–91, 142–143
 - suprasellar 128–129
- claustrum 8–13, 54–61, 102–103, 122–127, 132–133, 136–137
- clavicle 214–221, 226–229
- clivus 22–23, 72–73, 76–79, 86–89, 234–237
- cochlea 32–33, 70–77, 134–135
 - basal turn 30–31
- colliculus
 - cranial 138–141
 - inferior 60–65
- commissure
 - anterior 60–61, 86–87, 90–91, 94–95, 98–99, 102–103, 128–129, 132–133
 - laryngeal, anterior 208–209
 - posterior 60–61, 86–87, 140–141
 - see also* corpus callosum
- complex, olivary, inferior 138–141
- concha, nasal 76–77
 - inferior 36–39, 88–89, 112–117
 - middle 36–39, 88–89, 112–113, 116–117, 120–121, 224–225
 - superior 36–39, 78–79
- condyle, occipital 92–93, 236–237
- conus elasticus 208–209
- cord
 - spinal 138–139, 142–143, 168–197, 210–211, 236–245
 - vocal 186–187
 - false 210–211
 - true 206–207
- cornea 70–73
- corona radiata 8–9, 50–53
- corpus callosum 6–13, 58–59, 88–89, 92–93, 138–139
 - genu 52–57, 84–87, 90–91, 116–117, 120–127

major forceps 96–99
 rostrum 124–125
 splenium 52–57, 86–87, 90–91
 trunk 86–87, 90–91, 94–95, 98–99,
 118–121, 124–125, 128–137, 140–141
see also commissure
 corpus striatum 14–15, 94–95
 cortex, cerebral
 striate 8–11, 56–63, 144–147
 subcallosal 62–63
 cranium 38–39
 crista galli 36–37
 cuneus 6–9, 52–59, 84–85, 88–89, 92–93,
 100–101, 144–147

D

diaphragm, sellar 124–125
 disc
 articular 76–77, 220–221, 232–235
 intervertebral 210–211
 C2/C3 84–85
 dorsum sellae 16–19, 66–69, 86–87
 duct
 nasolacrimal 76–79
 submandibular 112–115

E

ear
 incus 30–33
 malleus 30–33
 middle 30–31
 stapes 32–33
 eardrum 22–23
 epiglottis 174–177, 202–205, 210–211,
 230–231
 cartilage 178–179
 stalk of 204–205
 vallecula 176–177
 epiphysis, cerebral 84–85
 esophagus 184–197, 206–211, 222–223,
 232–237
 eyeball 20–25, 66–77, 96–97, 100–101,
 104–107, 112–113
 anterior chamber 70–73

F

falx cerebelli 74–79
 falx cerebri 2–17, 44–65, 112–117,
 134–135, 138–139, 142–147
 interhemispheric fissure 84–85,
 118–119, 122–123, 126–127, 130–131
 fascia, cervical
 carotid sheath 200–201
 deep pretracheal 200–201
 deep prevertebral 200–201
 intercarotid 200–201
 pharyngobasilar 130–133, 200–201
 superficial 200–201
 fat
 retro-orbital 20–21
 retrobulbar 74–75, 112–115
 fauces, isthmus of 222–223
 fissure
 cerebral, longitudinal 4–5, 44–53,
 114–117, 126–129, 144–147
 horizontal 96–97, 100–101, 146–147
 median 138–139
 orbital
 inferior 38–39
 superior 2–3, 20–21, 38–39, 66–67,
 73, 94–95, 120–121, 226–227
 petro-occipital 24–25
 ventral median 76–77
 flocculus 22–25, 74–75, 138–141
see also cerebellum
 fold
 aryepiglottic 178–181, 204–205,
 228–229
 glossoepiglottic 202–203
 pharyngoepiglottic 202–203
 vestibular 204–205, 224–225
 foramen
 infraorbital 36–37
 interventricular 10–11, 130–133
 of Monro 10–11, 54–57
 jugular 98–99, 238–239
 lacerum 24–25, 76–77
 Luschka 74–77
 magnum 210–211, 240–241
 ovale 24–25, 128–129
 rotundum 226–227
 stylomastoid 134–135, 220–221,
 238–239

- foramen
transversarium 168–169
- forceps, occipital 52–55
- fornix 8–11, 52–53, 58–61
body 86–87, 132–133
column 54–57, 132–133
crus 94–95, 98–99, 136–137, 140–141
precommissural 128–129
- fossa
cerebral, lateral cistern 12–13, 56–57, 106–107
cranial
anterior 40–42
middle 43, 102–103
infratemporal 43, 98–99
interpeduncular 62–63
pterygoid 40–41, 43, 226–227
pterygopalatine 24–25, 38–39, 43, 116–117, 120–121, 226–227
- G**
- Galen, vein of 8–9
- ganglion
basal 100–101
geniculate 34–35
trigeminal (V) 70–71, 126–129
- gland
lacrimal 22–23, 66–71, 106–107, 112–113, 220–221
lymph *see* lymph node
parotid 108–109, 126–127, 130–131, 134–135, 162–173, 202–203, 216–217, 220–221, 230–239
pineal 10–13
pituitary 18–19, 66–67, 70–71, 84–85, 122–129
adenohypophysis 68–69, 86–87
infundibulum of 86–87
neurohypophysis 68–69, 86–87
stalk 16–17
sublingual 88–89, 212–213
submandibular 100–101, 104–109, 114–115, 118–119, 122–123, 172–179, 202–203, 214–221, 226–231
thyroid 182–197, 206–215, 228–231
- globus pallidus 10–13, 56–59, 94–95, 128–129, 136–137
- lateral 60–61, 90–91, 98–99, 132–133
medial 60–61, 90–91, 98–99, 132–133
- glottis 184–185, 224–225
- grey matter *see* claustrum; thalamus
- gyrus
angular 6–7, 46–55, 106–109, 146–147
artery of 154–155
cingulate 8–15, 46–63, 84–85, 88–89, 114–119, 122–123, 126–127, 130–131, 134–135, 138–139
dentate 98–99, 102–103
frontal
inferior 8–15, 46–61, 92–93, 104–109, 112–119, 122–123, 126–127, 130–131
middle 4–15, 44–63, 96–97, 100–108, 112–119, 122–123, 126–127, 130–131
superior 2–15, 44–63, 84–85, 88–89, 92–93, 96–97, 100–101, 112–119, 122–123, 126–127, 130–131, 142–143
insular 104–107
lingual 84–85, 94–95
occipital 6–15, 48–61, 64–67, 100–101, 104–107, 146–147
medial 92–93
occipitotemporal
lateral 14–15, 64–65, 126–127, 130–131, 134–147
medial 64–65, 88–89, 96–99, 102–105, 142–147
orbital 16–19, 64–65, 92–107, 112–121, 124–125
parahippocampal 12–19, 66–67, 90–95, 98–99, 102–103, 126–127, 132–141
uncus of 58–67
postcentral 4–11, 44–45, 48–57, 88–89, 92–93, 96–97, 100–101, 104–109, 134–135, 138–139, 142–145
precentral 2–3, 8–11, 44–49, 52–57, 84–85, 88–89, 96–97, 100–101, 104–106, 108–109, 134–135, 138–139, 142–145
straight 16–21, 64–67, 84–85, 88–89, 112–121, 124–125
subcallosal 120–125

- supramarginal 4–7, 46–53, 108–109, 138–139, 142–145
- temporal 130–131
- inferior 14–21, 60–65, 68–69, 74–75, 106–109, 126–127, 134–135, 138–139, 142–145
 - middle 10–19, 56–67, 106–109, 118–119, 122–123, 126–127, 130–131, 134–135, 138–139, 142–145
 - superior 8–9, 12–19, 54–57, 60–67, 106–109, 118–119, 122–123, 126–127, 130–131, 134–135, 138–139, 142–143
 - transverse 54–55, 104–109, 138–139
 - terminal 86–87
- H**
- hiatus, maxillary 36–37, 78–79
- hippocampus 10–13, 16–17, 58–67, 126–143, 154–155
- subiculum of 98–99, 102–103
- Huebner's recurrent, cerebral artery 80–81
- hypopharynx 174–187, 202–203
- hypothalamus 12–15, 62–65, 130–133
- I**
- incus
- long limb 30–33
 - short limb 32–33
- infundibulum 128–129
- inlet, laryngeal 230–231
- insula 8–11, 14–15, 54–63, 122–123, 126–127, 130–131
- circular sulcus of 56–57
- isthmus, oropharyngeal 222–223
- J**
- joint
- atlanto-axial 234–237
 - atlanto-occipital 236–237
 - costotransverse 238–239
 - T3 244–245
 - T4 246–247
 - costovertebral 196–197
 - cricothyroid 208–209
 - sternoclavicular 226–227
 - temporomandibular 22–23, 130–131
 - articular disc 30–31
 - glenoid roof 30–31
 - socket (temporal bone) 232–233
 - zygapophysial 176–177, 184–185, 236–237
 - C6/C7 190–191
- L**
- Labbé, inferior anastomotic vein of 160–161
- labyrinth, ethmoidal 36–37
- lamina terminalis 86–87
- see also* ventricle, third
- larynx 182–183, 186–189, 204–205, 226–227
- lamina 210–211
 - vestibule 206–207
- lemniscus
- lateral 90–91
 - medial 151
- lens 70–73, 100–101, 104–105
- ligament
- alar 236–237
 - apical, of dens 210–211
 - interspinous 192–197, 240–241, 244–247
 - intraspinous 242–243
 - ligamentum flavum 174–177, 180–181, 186–187, 196–197, 210–211, 238–239
 - longitudinal
 - anterior 210–211
 - posterior 210–211
 - nuchal 84–85, 144–145, 168–179, 190–191, 210–211, 244–247
 - petroclinoid
 - anterior 68–69
 - posterior 68–69
 - supraspinous 242–243
 - transverse 238–239
 - atlas 210–211
 - vestibular 210–211
 - vocal 210–211
- Liliequist's membrane 86–87

- lip, upper 168–169
- lobe
- cerebellar 140–141
 - anterior 62–69, 86–87, 90–91, 96–107, 138–143
 - caudal 72–73
 - posterior 70–71, 76–79, 86–87, 96–97, 100–101, 104–109, 142–147, 162–165
 - superior 60–61, 92–93
 - see also* cerebellum
 - cerebral, inferior 92–93
 - frontal 2–23, 44–53, 56–64, 84–108, 112–123, 126–127, 130–131, 134–139, 142–145
 - occipital 6–15, 46–53, 56–63, 66–69, 84–107, 146–147
 - paracentral 2–5, 44–45, 138–139, 142–143
 - parietal 2–10, 44–53, 56–59, 84–109, 130–131, 134–139, 142–147
 - inferior 4–5
 - superior 44–45
 - precentral 88–89
 - temporal 8–23, 56–73, 92–109, 116–145
- lobule *see* lobe
- lung 218–219
 - left 212–217, 220–221, 236–237
 - right 230–235, 238–245
- Luschka, foramen of 74–77
- lymph node 198–199, 220–221, 234–235
 - cervical
 - anterior 199
 - deep 198–199
 - jugular 198–199
 - nuchal 198–199
 - paratracheal 199
 - preauricular 199
 - prelaryngeal 199
 - pretracheal 199
 - retropharyngeal 198–199
 - submandibular 198
 - submental 198
 - superficial 198
 - supraclavicular 199
 - suprafacial 199
 - thyroid 199
- M**
- malleus
 - handle 30–33
 - head 32–33
- mandible 96–97, 100–101, 104–105, 170–177, 210–221, 224–225, 228–229
 - body 38–39, 112–117
 - head 22–25, 74–79, 106–109, 126–127, 130–131, 220–221, 232–235
 - ramus 38–39, 108–109, 116–119, 122–123, 162–169, 218–219, 226–227, 230–231
- mastoid 32–33
 - antrum 32–33
- maxilla 92–93, 96–97, 212–213
 - alveolar process 36–39, 112–117, 164–167
 - infra-orbital canal 78–79
 - palatine process 162–163
- meatus
 - acoustic
 - external 30–31, 76–77, 108–109, 218–219, 236–237
 - internal 32–35, 72–75, 98–99, 134–137, 238–239
 - auditory
 - external 22–25
 - internal 20–21, 102–103
 - nasal
 - inferior 36–39
 - middle 36–37
- medulla oblongata 22–25, 74–79, 84–91, 136–141, 162–167
- membrane
 - atlanto-occipital
 - anterior 234–235
 - posterior 210–211
 - cricovocal 208–209
 - tectorial 210–211
 - thyrohyoid 204–205
 - tympanic 22–23, 76–77
- mesencephalon (midbrain) 12–15, 60–67, 84–91, 134–141
 - aqueduct of 62–65, 140–141
 - tegmentum of 62–65
- Monro, foramen 10–11, 54–57
- motor system 28–29

- muscle
- acoustic, internal 104–105
 - aryepiglottic 228–229
 - arytenoid
 - oblique 206–207, 210–211
 - transverse 186–189, 206–207, 210–211
 - buccinator 104–107, 116–117, 164–169, 216–219, 224–225
 - cricoarytenoid, posterior 184–185, 230–231
 - cricothyroid 190–191, 226–227
 - depressor anguli oris 112–115, 172–177
 - digastric 24–25, 96–97, 100–101, 104–105, 214–217, 228–237
 - anterior belly 176–177, 212–213, 224–225
 - posterior belly 106–109, 134–135, 138–139, 166–171, 174–175, 220–221, 238–239
 - elevator, soft palate 98–99
 - genioglossus 112–117, 170–175, 210–211, 224–225, 228–229
 - geniohyoid 176–177, 202–203, 210–211, 224–227
 - hyperglossus 96–97
 - hypoglossus 170–175, 224–229
 - iliocostalis cervicis 192–197
 - infrahyoid 202–209
 - intercostal 194–197, 244–247
 - interspinalis 210–211, 214–221
 - levator
 - anguli oris 162–171
 - labii superioris 78–79, 96–97, 162–163, 214–215
 - palpebrae superioris 72–73, 104–105, 112–115, 224–225
 - scapulae 100–101, 104–107, 170–197, 216–221, 238–247
 - veli palatini 78–79, 96–97, 124–125, 130–133, 162–165, 212–213, 228–233
 - longissimus capitis 168–173, 178–179, 184–191, 238–241, 244–245
 - longissimus cervicis 170–173, 178–193, 240–241
 - longitudinal
 - superior 210–211
 - of tongue 224–227
 - longus capitis 10, 78–79, 88–89, 92–93, 96–97, 142–143, 162–189, 212–213, 232–233
 - longus colli 170–189, 192–197, 202–215, 232–235
 - masseter 24–25, 40–41, 74–79, 108–109, 114–119, 122–123, 126–127, 162–173, 220–221, 224–231
 - mentalis 174–175
 - multifidus 172–173, 180–197, 212–213, 216–217, 240–241, 244–247
 - mylohyoid 96–97, 100–101, 172–177, 202–203, 210–215, 224–227
 - oblique
 - inferior 104–105, 112–113, 212–213
 - superior 22–23, 112–115
 - obliquus capitis 216–217
 - inferior 92–93, 96–97, 100–101, 104–105, 138–139, 142–143, 166–171, 214–215, 236–241
 - posterior major 218–219
 - posterior minor 218–219
 - superior 106–107, 138–139, 142–143, 166–167, 214–215, 218–221, 238–241, 244–245
 - occipitofrontal 68–69
 - omohyoid 182–185, 190–191, 204–209, 228–229
 - orbicularis oculi 104–105, 112–113
 - orbicularis oris 68–69, 74–79, 96–97, 100–101, 162–173, 210–215, 218–219
 - palatopharyngeus 170–175, 212–213, 230–231
 - pectoralis major 218–221
 - pharyngeal constrictor 84–85, 126–127
 - inferior 131–132, 176–189, 202–205, 208–213, 232–233
 - middle 92–93, 96–97, 130–131, 172–175, 230–231
 - superior 130–133, 166–173, 182–183, 212–213
 - phrenic 186–187
 - pterygoid 78–79
 - lateral 24–25, 40–41, 78–79, 100–101, 104–107, 118–127, 130–131, 162–167, 216–221, 228–233

- muscle
 - pterygoid
 - medial 40–41, 96–101, 104–107, 118–127, 162–173, 212–219, 226–233
 - rectus
 - inferior 24–25, 74–75, 92–93, 96–97, 100–101, 112–115, 224–225
 - lateral 20–23, 70–73, 100–101, 104–107, 112–115
 - medial 22–25, 68–73, 92–95, 112–115, 224–225
 - superior 20–23, 66–67, 72–73, 92–93, 96–97, 100–101, 112–115, 224–225
 - rectus capitis
 - anterior 234–235
 - lateralis 104–107, 164–167, 214–215, 218–219, 238–239
 - posterior major 24–25, 92–93, 96–97, 100–101, 104–105, 144–145, 212–215, 240–241, 244–247
 - posterior minor 22–25, 84–85, 92–93, 144–145, 166–167, 212–213, 216–217, 244–247
 - rhomboideus 244–247
 - major 212–221
 - minor 190–197, 212–221
 - scalenus (scalenus)
 - anterior 182–197, 214–215, 218–221, 232–235, 238–239
 - medius 218–221, 238–239
 - middle 178–197, 236–237
 - posterior 106–107, 180–197, 214–217, 220–221, 236–237
 - semispinalis
 - capitis 18–25, 78–79, 84–85, 88–89, 96–97, 100–101, 104–109, 144–147, 162–197, 212–221, 242–247
 - cervicis 172–173, 176–197, 212–219, 240–241, 244–247
 - serratus
 - anterior 214–215, 220–221
 - posterior superior 190–197, 212–213, 246–247
 - spinalis
 - capitis 172–173
 - cervicis 174–197, 238–239
 - splenius
 - capitis 22–25, 92–93, 96–97, 105–109, 144–145, 164–181, 184–197, 212–221, 238–241, 244–247
 - cervicis 106–107, 178–197, 212–213, 240–243, 246–247
 - sternocleidomastoideus 2, 108–109, 134–135, 138–139, 142–143, 168–197, 208–209, 214–221, 228–241, 244–245
 - sternohyoideus 178–193, 196–197, 202–203, 208–209, 212–213, 224–227
 - sternothyroideus 188–193, 202–211
 - styloglossus 100–101, 122–123, 126–127, 168–175, 230–231
 - stylohyoideus 170–175, 216–217, 236–237
 - styloideus 106–107
 - stylopharyngeus 104–105, 130–131, 166–169, 232–233, 236–237
 - subclavius 218–221
 - suprahyoideus 202–203
 - supraspinatus 242–243
 - temporalis 2, 18–21, 23–25, 40–41, 64–79, 100–101, 104–109, 114–119, 122–123, 126–127, 130–131, 162–165, 216–221, 226–233, 236–239
 - temporoparietalis 66–73
 - tensor
 - tympani, canal 30–31
 - veli palatini 78–79, 118–125, 162–169, 214–215, 230–231
 - thyroarytenoideus 188–189, 206–207, 228–229
 - thyrohyoideus 178–189, 204–207, 224–227
 - transversus 210–211
 - of tongue 224–229
 - trapezius 24–25, 92–93, 100–101, 168–197, 212–221, 240–245
 - descending 212–213
 - descending (superior) 246–247
 - transversus (middle) 246–247

- muscle
 vocalis 184–187, 206–209, 224–225
 zygomaticus 78–79, 108–109, 164–165
 major 162–163
 myelencephalon 22–23
- N**
- nasopharynx 40–41, 84–85, 88–89,
 122–125, 128–129, 162–165, 210–211,
 222–223, 228–229, 232–233
- nerve
 alveolar, inferior 104–105, 118–119,
 220–221, 230–231
 auricotemporal 78–79
 cranial
 abducent (VI) 22–23, 66–69, 72–73,
 90–91, 116–129, 132–133, 136–137
 accessory (XI) 78–79, 136–137,
 140–141, 164–175, 236–237
 acoustic (VIII) 20–21, 98–99,
 102–103
 facial (VII) 20–21, 34–35, 72–73,
 98–99, 102–103, 134–139,
 170–171, 220–221, 226–227
 glossopharyngeal (IX) 22–23, 76–79,
 136–141, 162–163, 166–169
 hypoglossal (XII) 78–79, 98–99,
 112–115, 136–137, 162–173,
 236–237
 oculomotor (III) 64–65, 68–71,
 94–95, 112–113, 116–129, 132–133
 optic (II) 18–19, 22–23, 66–72,
 84–87, 92–95, 114–121, 224–227
 trigeminal (V) 18–21, 28–29, 68–69,
 74–77, 90–91, 132–133, 136–137,
 150–151
 trochlear (IV) 18–19, 94–95, 116–119,
 122–129, 132–133, 136–137,
 140–141, 226–227
 vagus (X) 22–23, 76–79, 136–137,
 140–141, 162–177, 180–197,
 232–233, 236–237
 vestibulocochlear (VIII) (auditory)
 20–21, 72–73, 98–99, 102–103,
 134–139
 frontal 120–121, 226–227
 infraorbital 112–115
 intermediate 72–73
 lacrimal 120–121
 laryngeal, superior 174–175
 lingual 112–115, 118–119, 232–233
 mandibular 24–25, 72–73, 78–79,
 126–131, 162–163, 214–215
 maxillary 72–73, 116–121, 124–125,
 226–227
 nasociliary 114–115, 120–121
 ophthalmic 116–125
 phrenic 182–185, 188–189, 192–197
 root *see* root, nerve
 spinal
 C2 176–177
 C3 176–179
 C4 178–191
 C5 180–195
 C6 184–185, 188–195
 C7 192–195
 splenius capitis 182–183
 supraorbital 112–115
 thoracic (T1) 238–239
- nose, base of 40–42
- notch
 ethmoidal 36–37
 interarytenoid 230–231
 superior thyroid 204–205
 supraorbital 36–37
- nucleus
 accumbens 124–125
 amygdaloid 98–99, 102–103
 basal 92–93, 96–97
 lentiform 130–131, 134–135
 caudate 8–13, 130–131, 138–139
 body 92–93, 96–99, 130–133,
 136–137, 140–141
 head 52–61, 88–91, 94–95, 118–129
 tail 54–57, 102–105, 136–137,
 140–141
 dentate 16–19, 70–73, 90–91, 94–95,
 142–145
 mesencephalic 29, 151
 oculomotor 29, 151
 red 62–63, 90–91, 134–137
 subthalamic 136–137

O

operculum

- frontal 104–105, 118–119, 130–131
- parietal 134–135
- temporal 8–9

orbit 112–115

- infundibulum 38–39
- roof 18–19, 36–37, 92–93, 96–97, 100–101, 104–105, 112–115
- oropharynx 84–85, 88–89, 92–93, 122–123, 168–175, 210–211, 228–233
- isthmus of fauces 40–41

P

palate

- hard 36–37, 84–85, 88–89, 112–115, 164–167, 210–211, 224–225
- soft 38–41, 116–119, 162–167, 210–211, 226–231

see also uvula

pathway, oculomotor 29, 151

peduncle

- cerebellar 16–19, 90–91
- inferior 20–21
- middle 20–21, 68–73, 94–95, 136–141
- superior 66–67
- cerebral 14–15, 62–65, 88–89, 92–93
- middle 92–93

pharynx 126–127, 166–167, 212–213

laryngeal part 222–223

plane, sphenoid 120–121

plate

- cribriform 36–37
- orbital 36–37, 112–115
- quadrigeminal 12–13, 84–85
- anterior colliculus 90–91
- posterior colliculus 86–87
- superior colliculus 86–87, 90–91
- tectal
- anterior colliculus 90–91
- posterior colliculus 86–87
- superior colliculus 86–87, 90–91

platysma 106–109, 174–197, 204–205, 212–221, 224–229

plexus

brachial 216–221, 240–241

cervical

- C5 196–197
- C6 196–197
- C7 196–197
- C8 196–197

choroid 6–7, 52–59, 86–87, 94–95, 102–103, 142–143

venous

- pharyngeal 168–169
- suboccipital 238–239

pole

- frontal 84–85
- occipital 10–11, 60–63
- temporal 72–73, 98–101, 104–107, 120–121

pons 16–23, 66–75, 84–95, 134–141

precuneus 2–7, 44–55, 88–89, 92–93, 100–101, 104–105, 142–147

process

- articular 212–213
- C2 238–239
- C3 238–239
- C4–C6 236–237

clinoid

- anterior 40–41, 120–121
- posterior 128–129

coronoid 108–109

costal 234–235, 240–241, 246–247

mastoid 20–25, 30–31, 108–109, 134–135, 138–139, 142–143, 164–165, 238–243

pterygoid 38–39, 120–121

- lateral plate 40–41, 78–79, 100–101, 118–121, 226–229
- medial plate 40–41, 78–79, 118–121, 226–229

spinous 174–175, 210–211, 244–247

- C2 240–241
- C7 240–243
- T3 246–247

styloid 106–107, 134–135, 216–217, 220–221, 234–237

transverse 168–169, 214–215

- C7 238–239
- T2 242–243
- T4 242–243

uncinate 36–37
 zygomatic 36–37, 232–233
 prominence, laryngeal 206–207
 protuberance, occipital
 external 84–85
 internal 66–67, 70–71
 putamen 10–13, 54–61, 94–95, 98–99,
 102–103, 118–129, 132–133, 136–137
 pyramid, petrous 98–99

R

radiation, optic 62–63, 142–145
 raphe, pharyngeal 130–133
 recess
 epitympanic 32–33
 infundibular 64–65
 pharyngeal 78–79
 piriform 176–177, 182–183, 204–207,
 228–229
 supraoptic 128–129
 suprapineal 140–141
 rib
 first 192–197, 214–215, 218–219,
 236–241
 second 236–237, 242–245
 head 238–239
 third 246–247
 fourth 220–221
 rima glottidis 206–207
 roof, orbital 64–65
 root
 nerve 88–89
 anterior 182–183
 plexus 100–101, 232–233
 posterior 182–183
 spinal 92–93, 214–215, 238–239
 C3 96–97, 212–213, 234–235
 C3–C6 236–237
 C4 174–177, 234–235
 C5 16–17, 234–235
 C6 180–183, 186–187, 234–235
 C7 188–191, 234–235
 C8 188–189, 192–195, 234–237
 T1 196–197, 212–213

S

sella turcica 40–41
 floor 124–125, 128–129
 septum 70–71
 lingual 210–211, 224–227
 nasal 24–25, 36–37, 72–79, 112–119,
 224–227
 perpendicular plate 38–39
 pellucidum 84–85, 120–121, 124–129,
 132–133
 cave of 54–59
 precommissural 12–13
 verum 12–13
 sinus
 cavernous 20–21, 68–71, 122–125,
 128–129, 158–161
 confluence 16–17, 66–67, 84–85,
 88–89, 158–161
 falcatentorial 160–161
 ethmoidal 84–85, 88–89
 frontal 10–21, 28–29, 36–37, 62–67,
 84–85, 88–89
 superior 134–135, 138–139
 intercavernous, inferior 124–125,
 128–129
 maxillary 36–42, 74–79, 92–93, 96–97,
 100–101, 104–107, 112–117, 162–163,
 214–219, 224–225
 medial wall 78–79
 nasal 74–75, 112–113, 116–121
 occipital 18–23, 68–69, 78–79, 146–147
 petrosal 160–161
 sagittal
 inferior 52–53
 superior 4–15, 44–65, 88–89,
 112–119, 122–123, 126–127,
 130–131, 134–135, 138–139,
 142–147, 158–161
 sigmoid 16–25, 30–31, 34–35, 68–73,
 76–79, 104–105, 138–139, 158–163,
 218–219
 sphenoidal 20–25, 38–41, 66–67,
 70–75, 84–93, 118–129, 226–233
 sphenoparietal 158–159
 straight 9, 11, 13, 15, 57, 59, 61, 63, 65,
 85, 87, 145, 147, 161

- sinus
 - transverse 16–17, 68–69, 74–75, 92–93, 96–97, 100–101, 104–109, 142–147, 158–161
 - tympani 32–33
 - space
 - buccal 42–43
 - cervical
 - carotid 200–201
 - masticatory 43, 200–201
 - parapharyngeal 200–201
 - parotid 200–201
 - perivertebral paraspinal 200–201
 - perivertebral prevertebral 200–201
 - prevertebral 200–201
 - retropharyngeal 200–201
 - superficial mucosal 200–201
 - visceral 200–201
 - intervertebral
 - C3/C4 176–177
 - C5 186–187
 - C6 186–187
 - C6/C7 190–191
 - C7/T1 194–195
 - masticatory 42–43
 - peripharyngeal 228–229
 - pharyngeal 206–209
 - pre-epiglottic 202–205
 - suprasternal 226–227
 - stapes 32–33
 - substantia nigra 64–65, 90–91, 136–137
 - sulcus 84–85
 - basal 16–17
 - calcarine 62–63, 88–89, 92–93, 144–147
 - central 2–5, 8–11, 44–45, 48–57, 88–89, 92–93, 96–97, 100–101, 104–109, 134–135, 138–139, 142–143
 - artery 154–155
 - fissure of Rolando 46–47
 - cingulate 6–7, 46–47, 52–55, 118–119
 - circular 62–63
 - collateral 102–103, 140–141
 - frontal
 - inferior 104–109
 - superior 44–45
 - lateral 8–11, 14–15, 52–63, 108–109, 122–123, 126–127, 130–131, 134–135, 142–143
 - olfactory 64–65, 120–121
 - parieto-occipital 4–11, 14–15, 46–57, 84–85, 96–99, 144–147
 - postcentral 6–7, 46–51, 88–89, 92–93, 106–109
 - precentral 2–5, 44–47, 50–51, 154–155
 - suture
 - coronal 2–7, 44–59, 84–85, 88–89, 92–93, 96–97, 100–101, 104–109
 - frontozygomatic 36–37
 - lambdoid 49–73, 84–85, 88–89, 92–93, 96–97, 100–101, 104–109
 - sagittal 2–3, 44–47, 144–147
 - sphenosquamous 38–41
 - squamous 38–41
 - syphon, carotid 214–215
 - system
 - motor 29, 151
 - sensory 29, 151
- T**
- tentorium cerebelli 12–19, 58–67, 88–109, 136–147
 - thalamus 8–13, 54–61, 88–89, 92–93, 96–97, 134–135, 138–139
 - complex
 - lateral posterior 90–91, 94–95
 - lateral ventral 90–91, 94–95, 136–137
 - nucleus
 - anterior ventral 132–133
 - lateral dorsal 136–137
 - medial 136–137
 - pulvinar 90–91, 94–95, 98–99, 140–141
 - tissue, fatty
 - retro-orbital 68–73
 - suboccipital 210–211, 246–247
 - tongue 84–85, 88–89, 92–93, 112–119, 168–171, 210–213
 - muscle 224–229
 - root 174–175
 - tonsil
 - cerebellar 24–25
 - palatine 170–171, 210–213, 230–231
 - pharyngeal 40–41, 230–231
 - tooth
 - canine 168–169
 - incisor 168–169

- molar 168–169
- premolar 168–169
- torus
 - levatorius 162–163
 - tubaris 230–231
- trachea 190–197, 210–211, 222–225, 228–235
- tract
 - corticospinal 136–137
 - lemniscal medial 29
 - olfactory 116–125
 - optic 14–15, 29, 62–63, 90–91, 98–99, 132–133, 136–137, 151
 - spinothalamic 29, 151
- Troland, superior anastomotic vein of 158–159
- trunk, brachiocephalic 230–233
- tube, auditory 24–25, 30–31, 76–79, 98–99, 128–129, 214–217, 232–233
 - cartilage 228–231
 - pharyngeal opening 230–231
 - pharyngotympanic 30–31, 76–79, 98–99, 124–133, 162–163, 214–217, 228–233
 - torus levatorius 162–163
- tubercle, articular 220–221

- U**
- uvula 84–85, 88–89, 123, 168–171, 230–231
 - vermis 70–73, 144–145
 - see also* palate, soft

- V**
- vallcula, epiglottic 176–177, 202–203, 210–213, 228–231
- vein
 - alveolar, inferior, mandibular canal 118–119
 - anastomotic
 - inferior (Labbé) 160–161
 - superior (Troland) 158–159
 - basal 60–61, 86–87, 136–137, 140–143, 158–161
 - brachiocephalic 212–215
 - cerebellar 86–87
 - inferior 158–161
 - precentral 160–161
 - superior 158–161
- cerebral
 - great 8–9, 54–59, 86–87, 90–91, 160–161
 - internal 10–11, 54–59, 86–87, 136–143, 160–161
 - middle 158–159
 - posterior 160–161
 - superior 48–51, 158–161
- cervical 218–219
 - deep 168–179, 216–217, 240–245
- emissary 164–165
- facial 214–217
 - common 218–219
- frontal 158–161
- infraorbital 112–115
- jugular 24–25
 - anterior 180–197, 202–209, 226–229
 - external 174–197, 216–217, 232–235
 - internal 30–33, 76–79, 98–99, 104–107, 134–137, 158–165, 170–183, 186–197, 202–209, 214–219, 230–237
- mandibular 126–127
- maxillary 166–167
- occipital, internal 160–161
- ophthalmic 20–21, 66–67
 - superior 68–69, 112–117, 226–227
- parietal 158–161
- retromandibular 108–109, 162–173, 176–177, 234–235
- subclavian 230–233
 - left 214–217
- thyroid, inferior 194–195, 228–229
- vertebral 136–139, 142–143, 232–233
- ventricle 12–13
 - fourth 16–21, 66–79, 84–87, 90–91, 142–143
 - laryngeal 210–211, 222–227
 - lateral 90–91, 94–95, 134–139
 - anterior horn 8–13
 - aperture 74–79, 90–91
 - central part 50–51, 88–89, 98–99, 102–103
 - choroid plexus 6–7
 - collateral trigone 142–143

- ventricle
 - lateral
 - frontal horn 52–59, 92–95, 116–133
 - occipital horn 96–97, 100–101, 104–105, 144–147
 - temporal horn 14–19, 60–67, 94–95, 98–99, 102–105, 126–141
 - of Morgagni 210–211
 - third 10–11, 14–15, 54–63, 84–87, 130–137
 - see also* lamina terminalis
- vermis 162–163
 - uvula of 70–73, 144–145
- vertebra
 - cervical
 - C1 *see* atlas (C1)
 - C2 *see* axis (C2)
 - C3 142–143, 202–203
 - body 174–175
 - posterior arch 176–177
 - spinous process 172–173
 - C4, body 178–179, 204–207
 - C5 184–185
 - body 180–183, 206–207
 - inferior articular process 180–183
 - transverse process 180–181
 - C6 188–189, 210–211
 - arch of 238–239
 - body of 208–209
 - posterior arch 180–183
 - spinous process 182–183
 - C7 192–193
 - articular process 188–189
 - posterior arch 188–189
 - spinous process of 188–191, 210–211
 - transverse process 192–193
 - thoracic
 - T1 194–197
 - T2 242–243
 - T3 244–245
 - T4 242–243
 - vestibule 32–35, 74–75, 238–239
 - laryngeal 178–181, 222–223, 228–229
 - nasal 222–223
 - vomer 36–37, 78–79, 120–121, 210–211, 228–229
- W**
 - white matter
 - central 134–135
 - cerebellum 4–5, 102–103
 - cerebral 44–49, 100–101, 130–131
 - see also* capsule, external
 - window
 - oval 32–33
 - round 30–31
- Z**
 - zone, temporal 30–33