

JIMMY D. BARTLETT  
SIRET D. JAANUS

# R CLINICAL OCULAR PHARMACOLOGY

SECTION EDITORS:  
RICHARD G. FISCELLA  
NICKY R. HOLDEMAN  
C. LISA PROKOPICH

FIFTH  
EDITION

ELSEVIER  
S.A. MURRAY, N.J.

BUTTERWORTH  
HEINEMANN  
ELSEVIER

11830 Westline Industrial Drive  
St. Louis, Missouri 63146

CLINICAL OCULAR PHARMACOLOGY, FIFTH EDITION ISBN: 978-0-7506-7576-5  
Copyright © 2008 by Butterworth-Heinemann, an imprint of Elsevier Inc.

**All rights reserved.** No part of this publication may be reproduced or transmitted in any form or by any means, electronic or mechanical, including photocopying, recording, or any information storage and retrieval system, without permission in writing from the publisher. Permissions may be sought directly from Elsevier's Rights Department: phone: (+1) 215 239 3804 (US) or (+44) 1865 843830 (UK); fax (+44) 1865 853333; e-mail: [healthpermissions@elsevier.com](mailto:healthpermissions@elsevier.com). You may also complete your request on-line via the Elsevier website at <http://www.elsevier.com/permissions>.

**Notice**

Knowledge and best practice in this field are constantly changing. As new research and experience broaden our knowledge, changes in practice, treatment and drug therapy may become necessary or appropriate. Readers are advised to check the most current information provided (i) on procedures featured or (ii) by the manufacturer of each product to be administered, to verify the recommended dose or formula, the method and duration of administration, and contraindications. It is the responsibility of the practitioner, relying on their own experience and knowledge of the patient, to make diagnoses, to determine dosages and the best treatment for each individual patient, and to take all appropriate safety precautions. To the fullest extent of the law, neither the Publisher nor the Editors assume any liability for any injury and/or damage to persons or property arising out of or related to any use of the material contained in this book.

The Publisher

**Library of Congress Control Number: 2007932736**

*Vice President and Publisher:* Linda Duncan  
*Senior Editor:* Kathy Falk  
*Senior Developmental Editor:* Christie M. Hart  
*Publishing Services Manager:* Melissa Lastarria  
*Senior Project Manager:* Joy Moore  
*Design Direction:* Julia Dummitt

Printed in the United States of America

Last digit is the print number: 9 8 7 6 5 4 3 2 1

Working together to grow  
libraries in developing countries

[www.elsevier.com](http://www.elsevier.com) | [www.bookaid.org](http://www.bookaid.org) | [www.sabre.org](http://www.sabre.org)

ELSEVIER

BOOK AID  
International

Sabre Foundation

*To Cindy, Andrew, Kenton, and Harrison,  
who have taught me about love and family,  
and to my parents,  
who taught me about the value of hard work.*

**J.D.B.**

*To Jaak, Maire, and Ilomai and her family  
with more love and thanks than life and time can hold.*

**S.D.J.**

# *Contributors*

**Diane T. Adamczyk, OD**

Director of Residency Education and Externships  
State University of New York  
State College of Optometry  
New York, New York

**John F. Amos, OD**

Dean  
School of Optometry  
University of Alabama at Birmingham  
Birmingham, Alabama

**Howard Barnebey, MD**

Specialty Eyecare Centre  
Bellevue, Washington  
Former Clinical Associate Professor  
Department of Ophthalmology  
University of Washington  
Seattle, Washington

**Jimmy D. Bartlett, OD, DOS, ScD**

Professor of Optometry  
School of Optometry  
University of Alabama at Birmingham  
Professor of Pharmacology  
University of Alabama School of Medicine  
Birmingham, Alabama

**David C. Bright, OD**

Professor  
Southern California College of Optometry  
Fullerton, California  
Chief, Optometry Section  
Greater Los Angeles Healthcare System (VHA)  
Los Angeles, California

**Linda Casser, OD, FAAO**

Director of Clinical Examinations  
National Board of Examiners in Optometry  
Charlotte, North Carolina

**David D. Castells, OD**

Associate Professor  
Illinois College of Optometry  
Chicago, Illinois

**John G. Classé, OD, JD**

Professor  
School of Optometry  
University of Alabama at Birmingham  
Member of the Alabama Bar  
Birmingham, Alabama

**Rachel A. Coulter, OD**

Associate Professor  
College of Optometry  
Nova Southeastern University  
Fort Lauderdale, Florida

**Timothy R. Covington, MS, PharmD**

President and CEO  
Covington Healthcare Associates, LLC  
Birmingham, Alabama  
Professor of Pharmacy Practice  
Harrison School of Pharmacy  
Auburn University  
Auburn, Alabama

**Mitchell W. Dul, OD, MS**

Associate Professor  
Chairman, Department of Clinical Sciences  
Director, Glaucoma Institute of the University  
Optometric Center  
State University of New York  
State College of Optometry  
New York, New York  
Private Practice  
Peekskill, New York



**Arthur B. Epstein, OD, FAAO**  
Clinical Adjunct Assistant Professor  
Northeastern State University College of Optometry  
Tahlequah, Oklahoma  
Private Practice  
North Shore Contact Lens & Vision Consultants, PC  
Roslyn Heights, New York

**Richard G. Fiscella, RPh MPH**  
Clinical Professor  
Department of Pharmacy Practice  
Adjunct Assistant Professor  
Department of Ophthalmology  
University of Illinois at Chicago  
Chicago, Illinois

**Marcela Frazier, OD, MPH**  
Assistant Professor  
School of Optometry  
University of Alabama at Birmingham  
Birmingham, Alabama

**Denise Goodwin, OD, FAAO**  
Associate Professor  
Pacific University College of Optometry  
Forest Grove, Oregon

**Susan P. Haesaert, OD**  
Attending Optometrist  
Boston Veterans Administration Healthcare System  
Associate Professor of Optometry  
New England College of Optometry  
Boston, Massachusetts

**Nicky R. Holdeman, OD, MD**  
Professor and Associate Dean for Clinical Education  
Executive Director, University Eye Institute  
Chief of Medical Services  
University Eye Institute  
University of Houston  
Houston, Texas

**Siret D. Jaanus, PhD, LHD**  
Professor  
Southern California College of Optometry  
Fullerton, California

**Alan G. Kabat, OD, FAAO**  
Associate Professor  
Nova Southeastern University, College of Optometry  
Fort Lauderdale, Florida

**David M. Krumholz, OD, FAAO**  
Associate Professor  
State University of New York  
State College of Optometry  
New York, New York

**Kimberly A. Lambrechts, RN, OD**  
Associate Clinical Professor  
University of Houston  
College of Optometry  
Houston, Texas

**Nada Lingel, OD, MS**  
Distinguished Professor of Optometry  
Pacific University College of Optometry  
Forest Grove, Oregon

**Robert W. Lingua, MD**  
Lingua Vision Surgical Group  
Fullerton, California

**Blair B. Lonsberry, MS, OD, MEd, FAAO**  
Associate Professor  
Clinic Director, Portland Vision Center  
Pacific University College of Optometry  
Portland, Oregon

**Gerald G. Melore, OD, MPH**  
Assistant Clinical Professor  
Pacific University  
College of Optometry  
Forest Grove, Oregon

**Cynthia Ann Murrill, OD, MPH**  
Adjunct Faculty  
Pacific University College of Optometry  
Forest Grove, Oregon  
Pacific Cataract and Laser Institute  
Tacoma, Washington

**Jerry R. Paugh, OD, PhD**  
Associate Professor and Associate Dean for Research  
Southern California College of Optometry  
Fullerton, California

**C. Denise Pensyl, OD, MS, FAAO**  
Chief, Optometry  
Bakersfield VA Outpatient Clinic  
Greater Los Angeles VA Healthcare System  
Bakersfield, California

**Joan K. Portello, OD, MPH, FAAO**  
Associate Professor  
State University of New York  
State College of Optometry  
New York, New York

**C. Lisa Prokopich, OD, BSc**  
Lecturer  
Head, Ocular Health Clinic, Optometry  
School of Optometry  
University of Waterloo  
Waterloo, Ontario, Canada  
Head, Freeport Hospital Vision Centre  
Kitchener, Ontario, Canada

**Christopher J. Quinn, OD, FAAO**

President  
Omni Eye Services  
Iselin, New Jersey

**Kimberly K. Reed, OD, FAAO**

Associate Professor  
Nova Southeastern University  
College of Optometry  
Fort Lauderdale, Florida

**Leo Paul Semes, OD**

Professor  
School of Optometry  
University of Alabama at Birmingham  
University Optometric Group  
Birmingham, Alabama

**David P. Sendrowski, OD, FAAO**

Professor  
Southern California College of Optometry  
Fullerton, California

**Leonid Skorin, Jr., OD, DO, FAAO, FAOCO**

Senior Staff Ophthalmologist  
Albert Lea Eye Clinic–Mayo Health System  
Albert Lea, Minnesota  
Clinical Assistant Professor of Ophthalmology  
Department of Surgery  
Chicago College of Osteopathic Medicine  
Midwestern University  
Downers Grove, Illinois  
Clinical Assistant Professor  
Department of Neurology and Ophthalmology  
College of Osteopathic Medicine  
Michigan State University  
East Lansing, Michigan  
Clinical Assistant Professor of Ophthalmology and Visual  
Sciences  
University of Illinois Eye & Ear Infirmary  
Chicago, Illinois  
Adjunct Professor  
College of Optometry  
Pacific University  
Forest Grove, Oregon

**David L. Standfield, OD**

Adjunct Faculty  
Pacific University College of Optometry  
Forest Grove, Oregon  
Pacific Cataract and Laser Institute  
Chehalis, Washington

**Condit F. Steil, PharmD, FAPhA, CDE**

Associate Professor of Pharmacy Practice  
McWhorter School of Pharmacy  
Samford University  
Birmingham, Alabama

**Michael E. Stern, PhD**

Vice President, Inflammation Research Program  
Allergan, Inc.  
Irvine, California

**Tammy Pifer Than, MS, OD, FAAO**

Adjunct Associate Professor  
School of Optometry  
University of Alabama at Birmingham  
Birmingham, Alabama  
Adjunct Faculty  
Mercer University School of Medicine  
Macon, Georgia  
Staff Optometrist  
Carl Vinson VAMC  
Dublin, Georgia

**Michael D. VanBrocklin, OD**

Adjunct Faculty  
Pacific University College of Optometry  
Forest Grove, Oregon  
Pacific Cataract and Laser Institute  
Tacoma, Washington

**Erik Weissberg, OD**

Associate Professor  
New England College of Optometry  
Boston, Massachusetts

**Suzanne M. Wickum, OD**

Clinical Associate Professor  
University of Houston  
College of Optometry  
Houston, Texas

**Elizabeth Wyles, OD**

Assistant Professor  
Illinois College of Optometry  
Chicago, Illinois

**Kathy Yang-Williams, OD, FAAO**

Northwest Eye Surgeons, PC  
Seattle, Washington

**Diane P. Yolton, PhD, OD**

Professor Emeritus  
Pacific University  
College of Optometry  
Forest Grove, Oregon

# Preface

There continues to be an explosion of research on issues of pharmacologic relevance to primary eye care delivery. New ophthalmic formulations are being developed, new diagnostic methods introduced, and new medications and delivery systems are available that were unheard of a decade ago. It is important that these new concepts be introduced to students and practitioners alike. This new fifth edition of *Clinical Ocular Pharmacology* addresses these new concepts and provides “one-stop shopping” for students, residents, and practicing clinicians who need a ready source of information regarding both the basic pharmacology of ophthalmic drugs, as well as their utilization in clinical practice. In this edition, readers will find that every chapter has been substantially updated from our previous work, and several chapters have been completely rewritten.

New topics not previously discussed include several novel drug delivery systems; the pharmacologic treatment of retinal diseases, including age-related macular degeneration and diabetic retinopathy; and nutritional agents relevant to ocular therapy. We have expanded coverage of medications used to treat infections, allergies, and dry eyes. New information on ocular hypotensive drugs and an entirely new chapter on the contemporary medical management of glaucoma offer new insights on treatment of these extremely important diseases.

One of the most challenging tasks facing authors of contemporary medical and scientific books is to ensure

that chapter content is “evidence based.” In this edition, each contributing author has been carefully instructed to ensure that evidence-based material is the cornerstone of every chapter. This is consistent with past editions of this book. However, because reference sources are so easily retrieved today through the internet and other electronic sources, we have elected in this edition to simply provide selected bibliographies rather than detailed annotated references. The bibliographies are current and concise, direct the reader to the most relevant source material, and consist of salient major review articles, as well as important classic literature. Our intent, as in previous editions, is to recognize the work of those individuals who have contributed to the knowledge base in ocular pharmacology and to ensure that our readers receive the most contemporary thought regarding pharmacologic concepts for both the diagnosis and therapeutic intervention in primary eye care.

The updated book design elements you see in these pages, together with the concise writing of our contributing authors and their streamlined reference formatting, have resulted in a book that, although visibly smaller and more portable, retains its goal of providing the most clinically relevant material and guidance to optometrists and ophthalmologists who care for primary eye care patients.

**Jimmy D. Bartlett, OD, DOS, ScD**  
**Siret D. Jaanus, PhD, LHD**

# *Acknowledgments*

We are deeply grateful for our contributing authors, both those who are new to this edition and those who have contributed to previous editions. Without their enthusiasm, commitment, and expert contributions, the preparation of this book would have been impossible. The helpful suggestions from our colleagues and the expert advice from peer referees, who offered insightful and useful comments regarding each revised chapter, have clearly improved the presentation and accuracy of the text. We are most appreciative of our administrative associates, Debi Honeycutt, Donna Scott, and Karen Beeching, for their expert technical skills in preparing the voluminous manuscript. We are extremely grateful for our section editors—Richard Fiscella, Nicky Holdeman, and Lisa Prokopich—who spent enumerable hours reviewing draft manuscript and corresponding with authors and reviewers to achieve the desired end result. As in the

fourth edition, these editors skillfully guided the development, organization, and presentation of their respective chapters. Their work has clearly improved the readability, accuracy, and conciseness of virtually all the material represented in this edition.

Our editor, Christie Hart, Senior Developmental Editor at Elsevier, was steadfast in her commitment to this project and in her efforts to coordinate and to ensure timely contributions from all the authors and section editors. We are extremely grateful to her for her tireless efforts on behalf of this edition.

Most of all, we must also thank our readers, who have continually given us positive feedback regarding the usefulness of this book. Our students, residents, and clinicians from many countries have offered insightful comments and positive encouragement that have led to the development of this new edition.

SECTION

I

---

# Fundamental Concepts in Ocular Pharmacology

---

There is no great danger in our mistaking the height of the sun, or the fraction of some astronomical computation; but here where our whole being is concerned, 'tis not wisdom to abandon ourselves to the mercy of the agitation of so many contrary winds.

*Hippocrates*

# *Pharmacotherapy of the Ophthalmic Patient*

*Rachel A. Coulter, Jimmy D. Bartlett, and Richard G. Fiscella*

*Pharmacotherapy* of the ophthalmic patient refers to the use of diagnostic drugs to facilitate the examination and diagnosis of patients undergoing comprehensive assessment and to the use of therapeutic drugs for the treatment of patients with eye or vision problems. Patients requiring ophthalmic pharmacotherapy are individuals. Individuals with eye problems may have unique medical histories that can include any range or combination of systemic conditions from the common cold or asthma to rheumatoid arthritis or diabetes. Individuals may take medications that can interact with administered or prescribed ocular drugs. Individuals vary in their desire or need to overcome health problems. Some individuals may have socioeconomic disadvantages that make prescribed medications unaffordable. This chapter discusses fundamental issues that must be addressed if each ophthalmic patient is to benefit fully from pharmacotherapy.

## **INITIATING AND MONITORING OCULAR PHARMACOTHERAPY**

The decision to use or refrain from using drugs for diagnosis or treatment is often straightforward. Topical anesthetics must be used for applanation tonometry. Mydriatics are required for stereoscopic ophthalmoscopic examinations. Pharmacologic intervention is needed for patients who have glaucoma. Other situations are less clear. Patients with mild blepharitis may not need antibiotics. Patients with dry eye syndrome who have intermittent symptoms but lack ocular surface abnormalities may not require pharmacotherapeutic intervention. Simple reassurance can be sufficient for some patients, the disease process may be left to run its natural course. The decision to use diagnostic or therapeutic pharmaceutical agents should be based on several factors: symptoms, signs, knowledge of the natural history of the disease process, potential for morbidity, and identification of any underlying ocular or general medical contraindications.

A frequently overlooked factor in prescribing drugs for ophthalmic patients is affordability. Managed health care coverage has limitations. For patients at lower

socioeconomic levels not covered by health insurance, obtaining prescribed medications may not be feasible. This can result in the progression of chronic eye conditions such as glaucoma. To control medication costs and to increase compliance with drug usage, patients should be encouraged to comparison shop among pharmacies, especially for medications used for prolonged periods of time. Several studies have documented that prescription drug prices vary considerably among pharmacies. Patients may need guidance in choosing community pharmacies that combine reasonable prices with necessary services. Prescribing generic drugs when feasible may help to control the costs of therapy, especially for chronic diseases such as glaucoma.

Studies have investigated the pharmacoeconomics of drug therapy. The drug price may reflect only part of the medication "cost." Other costs, such as those associated with adverse drug effects, additional laboratory tests, and office visits, may more realistically reflect the pharmacoeconomics of therapy. For ophthalmic medications, the daily cost of medications also depends on the volume of the medication, the drop size, dosing regimen, compliance, and other factors. Publications have reviewed glaucoma and topical corticosteroid therapy and described more cost-effective treatment options not based solely on the actual medication cost.

Long-term management of chronic eye conditions depends on patient adherence to therapy. This involves an understanding of the ocular condition and a budgeted medical care plan. Clinicians' best intentions and efforts toward therapy are unsuccessful if the medical and pharmacotherapeutic plan is not practical and reasonable to that particular patient.

Patient education can impact the ability or willingness of patients to use prescribed medications. Studies of patient preferences for eyedrop characteristics have determined that patients differ in how they value various drop characteristics and are willing to pay or undergo inconvenience for some attributes but not for others. A frank discussion should include possible side effects, dosage, and cost to determine patient preference and achieve

better compliance. Patients need to be educated and counseled in the simplest, most direct manner possible. If not, they may misunderstand instructions and fail to use medications correctly.

Practitioners should supplement verbal instructions with written and visual aids in counseling patients on proper medication use. Caution should be taken in relying on patients to read and understand the medication inserts required by the U.S. Food and Drug Administration (FDA). Studies of medication inserts used for glaucoma medications have found most to be written on a higher reading grade level than the average glaucoma patient comprehends. Written dosage schedules should be tailored for each patient as a reminder of when and how to use eyedrops or ointments. This is especially important for patients who require chronic therapy for conditions such as glaucoma. Studies of noncompliance in glaucoma patients have determined that patients desire their physicians to teach them how to instill their eyedrops, tell them about new or alternate medications as they become available, and offer new ways to make their drug regimen easier.

The route of drug administration is one of the most important decisions to make when instituting ocular pharmacotherapy. In most cases this is straightforward. Eyedrops, formulated for topical ophthalmic use only, are used as diagnostic agents for patients undergoing tonometry or pupillary dilation. Patients with infectious or inflammatory disease, however, can be given therapeutic agents in a variety of forms. Most ocular surface infections, such as blepharitis or conjunctivitis, are best treated with topical antimicrobial eyedrops or ointments. Some infections of the adnexa such as hordeolum and preseptal cellulitis are treated more effectively with orally administered antimicrobials. Less commonly, patients need injections into or around the eye. Such periocular, intracameral, and intravitreal injections are discussed in Chapter 3. These methods of drug administration are used more often in surgery or for the treatment of complicated inflammatory or infectious diseases that respond poorly to topical therapy alone.

## **DETERMINING CONTRAINDICATIONS TO DRUG USE**

Successful diagnosis and management of ocular disease require rational drug selection and administration. Poorly chosen or contraindicated drug regimens can contribute to iatrogenic ocular or systemic disease with potentially adverse medicolegal consequences. To avoid the use of drugs that may be contraindicated in certain patients, pharmacotherapy should follow guidelines recommended by the FDA. Pharmacists or other qualified drug experts should be consulted when necessary.

### **Patient History**

A careful history alerts practitioners to possible adverse drug reactions and enables practitioners to select the

most appropriate pharmacotherapy for the patient (Box 1-1).

### **Ocular History**

Clinicians should ask about past and current eye disease as well as past ocular trauma. Practitioners should inquire about a history of contact lens wear. Many topically applied medications can cause corneal complications when used in the presence of soft contact lenses. Obtaining a history of current ocular medications is essential. If their continued use is necessary, the old and

#### **Box 1-1 Essential Elements of the Patient History**

##### **Ocular history**

- Past or current eye disease
- Trauma
- Strabismus or amblyopia
- Contact lens wear
- Current ocular medications
- Eye surgery

##### **Medical history**

- Renal and hepatic disease
- Cardiovascular disease
- Pulmonary disorders
- Thyroid disease
- Diabetes
- Seizure disorders
- Affective and mental disorders
- Pregnancy
- Myasthenia gravis
- Erythema multiforme
- Blood dyscrasias
- Immune status

##### **Medication history**

- Antihypertensives
- Dopamine or dobutamine
- Bronchodilators, steroid inhalers, other asthma medication
- Tricyclic antidepressants, monoamine oxidase inhibitors
- Over-the-counter antihistamines, decongestants
- Allergies (preservatives, penicillins, sulfonamides, neomycin, opioids)

##### **Family history**

- Open-angle glaucoma

##### **Social/cognitive history**

- Drug abuse
- Mental abuse

##### **Occupational history**

new medications must be spaced properly to avoid dilution and to achieve maximum benefit. A history of ocular surgery is also important. Topically applied prostaglandin analogues for treatment of glaucoma may increase the risk of cystoid macular edema in pseudophakic patients.

### Medical History

A careful medical history, including a review of systems, is essential. Practitioners can then identify drugs that may be contraindicated on the basis of systemic disease. Topically applied ocular medications, such as  $\beta$ -blockers, readily enter the systemic circulation and have high bioavailability throughout the body. However, one would typically avoid prescribing a topical  $\beta$ -blocker in patients already taking systemic  $\beta$ -blockers.

**Renal and Hepatic Disease.** Systemic anti-inflammatory drugs must be used with caution in patients with renal impairment. These drugs can cause kidney damage. Patients with hepatic disease may not be able to properly metabolize systemically administered medication.

**Cardiovascular Disease.** Patients with systemic hypertension, arteriosclerosis, and other cardiovascular diseases may be at risk when high concentrations of topically administered adrenergic agonists such as phenylephrine are used. Repeated topical doses or soaked cotton pledgets placed in the conjunctival sac have been associated with adverse cardiovascular effects. Likewise,  $\beta$ -blockers should be avoided or used cautiously in patients with congestive heart disease, severe bradycardia, and high-grade atrioventricular block. Topical  $\beta$ -blockers, however, may be used safely in patients with cardiac pacemakers.

**Respiratory Disorders.** Topically applied  $\beta$ -blockers can induce asthma or dyspnea in patients with preexisting chronic obstructive pulmonary disease. Clinicians should inquire about a history of pulmonary disorders before initiating glaucoma treatment with  $\beta$ -blockers. A history of restrictive airway disease also contraindicates the use of opioids for treatment of ocular pain.

**Thyroid Disease.** Elevated blood pressure or other adverse cardiovascular effects can result when patients with Graves' disease receive adrenergic agonists with vasopressor activity. This is due to the increased catecholamine activity associated with hyperthyroidism. The primary agent to be avoided or used cautiously is topically applied phenylephrine for pupillary dilation.

**Diabetes Mellitus.** Systemic administration of some hyperosmotic agents can cause clinically significant hyperglycemia in patients with diabetes. This is particularly important when oral glycerin is given for treatment of acute angle-closure glaucoma. Systemic corticosteroid therapy may represent a significant risk in patients with

diabetes because of drug-induced hyperglycemia. Adequate pupil dilation in patients with diabetes can be difficult to achieve when topically administered mydriatics are used. Topical  $\beta$ -blockers may mask signs associated with hypoglycemia in diabetes.

**Central Nervous System Disorders.** Clinicians should be cautious when using topically applied central nervous system stimulants such as cyclopentolate. High concentrations of these drugs in normal children, and occasionally in adults, have resulted in transient central nervous system effects. The use of topical  $\beta$ -blockers for treatment of glaucoma has been associated with central nervous system side effects, including depression, fatigue, weakness, confusion, memory loss, headaches, and anxiety.

**Affective and Mental Disorders.** Anxiety and emotional instability can be associated with psychogenic reactions, such as vasovagal syncope, that may appear to be drug related. Medications used to treat these disorders may potentiate the activity of ophthalmic medications. The use of monoamine oxidase inhibitors or tricyclic antidepressants can enhance the systemic effects of topically applied phenylephrine and  $\alpha_2$ -adrenergic agonists.

**Pregnancy.** Systemic drugs should not be administered during pregnancy unless absolutely essential for the well-being of either the expectant mother or the fetus. Most topically administered medications, however, are permissible if given in relatively low concentrations for brief periods. Ophthalmic pharmacotherapy for pregnant patients is discussed later in this chapter under Managing Special Patient Populations.

**Other Medical Conditions.** Other systemic disorders can be affected by or contraindicate the use of topically applied medications. Examples include myasthenia gravis, which can be worsened with topical timolol, and erythema multiforme (Stevens-Johnson syndrome), which can be caused or exacerbated by topical ocular sulfonamides and related antiglaucoma drugs such as carbonic anhydrase inhibitors.

### Medication History

A thorough medication history should be taken. Patients may be taking systemic drugs that have a high potential for adverse interactions with ocular pharmacotherapeutic agents. Such interactions can play a significant role in enhancing drug effects and may exacerbate adverse reactions. Several drug-drug interactions between ocular antiglaucoma and systemic medications have been well documented (Table 1-1). Patients with cardiac disease who are treated with potent inotropic agents such as dopamine or dobutamine should not be given topical ocular  $\beta$ -blockers. Likewise,  $\beta$ -blockers may block exogenous stimulation of  $\beta_2$  receptors by medications such as isoproterenol, metaproterenol, and albuterol.



**Table 1-1**  
Adverse Interactions Between Antiglaucoma and Systemic Medications

Systemic Drug	Ocular Drug	Adverse Effect
Cardiac glycosides	$\beta$ -blockers	Cardiac depression
Quinidine	$\beta$ -blockers	Cardiac depression
Xanthines	$\beta$ -blockers	Bronchospasm
$\beta$ -Adrenergic agonists	$\beta$ -blockers	Cardiac depression Bronchospasm
Succinylcholine	Cholinesterase inhibitors	Prolonged respiratory paralysis (apnea)

Practitioners should be aware of over-the-counter (OTC) medications and folk or home remedies that patients may be using. Many patients may not consider OTC agents, especially antihistamines and decongestants for hay fever and colds, as “drugs.” These can affect the autonomic nervous system. OTC preparations can potentially interact with ocular drugs, such as homatropine and phenylephrine, that also influence autonomic functions.

Although the risk of anaphylactic reactions associated with topically administered drugs is extremely remote, inquiry regarding drug allergies is essential. Hypersensitivity to thimerosal or benzalkonium chloride is not uncommon among patients wearing contact lenses. Knowledge of allergy to topically and systemically administered medications is helpful when initiating therapy. For example, those patients with penicillin allergies should not be given either penicillins or cephalosporins, and those allergic to sulfonamides should not be given topical ocular sodium sulfacetamide or carbonic anhydrase inhibitors. Narcotic analgesics should be avoided in patients allergic to opioids. Cross-sensitivity of proparacaine with other local anesthetics is rare and usually not an important clinical consideration (see Chapter 6). A history of hypersensitivity to specific local anesthetics should nevertheless be noted.

### Family History

A history of familial eye disease can be helpful in identifying contraindications to drug use. Studies have demonstrated that approximately 70% of the first-degree offspring of individuals with primary open-angle glaucoma have clinically significant elevations of intraocular pressure (IOP) when given topical steroids long term. When topical steroid therapy is contemplated in close relatives of individuals with glaucoma, steroids less likely to elevate IOP should be chosen and IOP should be monitored carefully.

### Social/Cognitive History

Questions regarding the social history may uncover important patient attributes. These can either enhance or

preclude successful pharmacotherapy. A history of drug abuse may indicate personal instability. This may suggest noncompliance with the intended drug therapy. Observation of the patient’s mental status is helpful in designing a pharmacotherapeutic program with which the patient is likely to comply. Simple drug regimens should be stressed, especially for patients who may have difficulty understanding more complicated treatments.

## Clinical Examination

### Physical Limitations Affecting Compliance

Unlike oral drug therapy in which the dosage unit is usually a tablet or capsule that is swallowed, ocular pharmacotherapy requires a measure of manual dexterity if topical solutions or ointments are to be instilled successfully. When patients cannot successfully instill their ocular medications independently, alternative approaches may need to be considered. Solutions include consideration of altered routes of administration of similar drugs and aid in the administration of the drug by family members or attendants.

### Comprehensive Eye Examination

A complete eye examination is essential to make the definitive diagnosis and to identify contraindications to the intended pharmacotherapy. Some portions of this evaluation should be performed before drug use. Some clinical procedures can be influenced by previously administered drugs.

**Visual Acuity.** Measurement of corrected visual acuity should be the initial clinical test performed at every patient visit. This “entrance” acuity measurement legally protects clinicians and provides baseline information when patients are monitored on successive visits. Topically applied gels and ointments and even some drops may have a detrimental effect on visual acuity, although usually this is transient.

**Pupil Examination.** A meaningful evaluation of pupils after drug-induced mydriasis or miosis is impossible. Pupillary examination, including pupil size and responsiveness, should be undertaken *before* instilling mydriatics or miotics. The presence and nature of direct reflexes as well as the presence or absence of a relative afferent pupillary defect should be recorded.

**Manifest Refraction.** Topically applied cycloplegics may affect the manifest (subjective) refractive error. When indicated, cycloplegic refraction may be performed after the initial manifest refraction or as the initial refractive procedure in children (see Chapter 21).

**Amplitude of Accommodation.** Because of the cycloplegic and mydriatic effects of anticholinergic drugs, amplitude

of accommodation should be measured before administering these agents.

**Tests of Binocularity.** Binocular vision, including accommodation–convergence relationships, should be evaluated before administering cycloplegics. These drugs can produce alterations in the observed heterophoria or heterotropia measurements.

**Biomicroscopy.** The cornea and other anterior segment structures should be evaluated before instilling any agent. Any topically applied drugs, especially anesthetics, or procedures such as applanation tonometry and gonioscopy may compromise the corneal epithelium. The indiscreet application of a sodium fluorescein- or lissamine green-impregnated filter paper strip may result in corneal staining patterns associated with the iatrogenic foreign body abrasion. Certain mydriatics, such as phenylephrine, can liberate pigmented cells in the anterior chamber. It can be important in determining the diagnosis to know whether such cells are iatrogenic. Careful evaluation of the aqueous is essential before pupillary dilation. Evaluation of the anterior chamber angle depth is necessary before administering mydriatics to dilate the pupil (see Chapter 20). In other instances certain drugs should precede others so that the corneal epithelium and precorneal tear film are not adversely affected.

**Tonometry.** In eyes with narrow anterior chamber angles, it is important to record the IOP before dilating the pupil with mydriatics. Cycloplegics can cause slight IOP increases in eyes with open angles, but acute and dangerous IOP elevation occurs in eyes undergoing angle-closure glaucoma attack induced by mydriatics. Thus, baseline tonometry needs to be taken immediately before dilating pupils in eyes with narrow angles.

**Tests of Cardiovascular Status.** Pulse strength, regularity, heart rate, and blood pressure measurements should be evaluated. Some topically administered ocular drugs, such as atropine and  $\beta$ -blockers, can affect systemic blood pressure and cardiac activity. This is especially important before and during long-term treatment with  $\beta$ -blockers in those patients with glaucoma.

## MINIMIZING DRUG TOXICITY AND OTHER ADVERSE REACTIONS

Adverse effects associated with ocular drugs are not uncommon, but serious reactions are extremely rare. These adverse reactions are usually manifestations of drug hypersensitivity (allergy) or toxicity. The allergic or toxic reaction usually occurs locally in the ocular tissues. Occasionally, as in erythema multiforme potentiated by sulfonamide agents, adverse reactions can manifest as a systemic response.

## Ocular Effects of Locally Administered Drugs

Numerous adverse ocular effects from topically administered drugs have been observed (Box 1-2). These occur through a variety of mechanisms. Ocular tissues respond by manifesting cutaneous changes, conjunctivitis,

### Box 1-2 Adverse Ocular Effects From Topically Administered Drugs

#### Eyelids

- Urticaria and angioedema
- Allergic contact dermatitis
- Allergic contact dermatitis
- Photoallergic contact dermatitis
- Irritative or toxic contact dermatitis
- Phototoxic dermatitis
- Cumulative deposition
- Melanotic hyperpigmentation or hypopigmentation
- Microbial imbalance

#### Conjunctiva

- Anaphylactoid conjunctivitis
- Allergic contact (dermato-) conjunctivitis
- Cicatrizing allergic conjunctivitis
- Nonspecific (papillary) irritative or toxic conjunctivitis
- Follicular irritative or toxic conjunctivitis
- Cicatrizing and keratinizing irritative or toxic conjunctivitis (including pseudotrachoma)
- Cumulative deposition
- Microbial imbalance

#### Cornea

- Anaphylactoid keratitis
- Allergic contact keratitis
- Irritative or toxic keratitis
- Phototoxic keratitis
- Toxic calcific band keratopathy
- Pseudotrachoma
- Cumulative deposition
- Microbial imbalance

#### Intraocular pressure

- Elevation (glaucoma)
- Reduction (hypotony)

#### Uvea

- Hypertrophy of pupillary frill (iris "cyst")
- Iridocyclitis
- Iris sphincter atrophy

#### Crystalline lens

- Anterior subcapsular opacification
- Posterior subcapsular opacification

#### Retina

- Detachment
- Cystoid macular edema

Modified from Wilson FM. Adverse external ocular effects of topical ophthalmic medications. *Surv Ophthalmol* 1979;24(2):57–88.

keratitis, hyperpigmentation or hypopigmentation, or infectious complications. Clinicians who administer or prescribe ocular drugs must be aware of these potential complications.

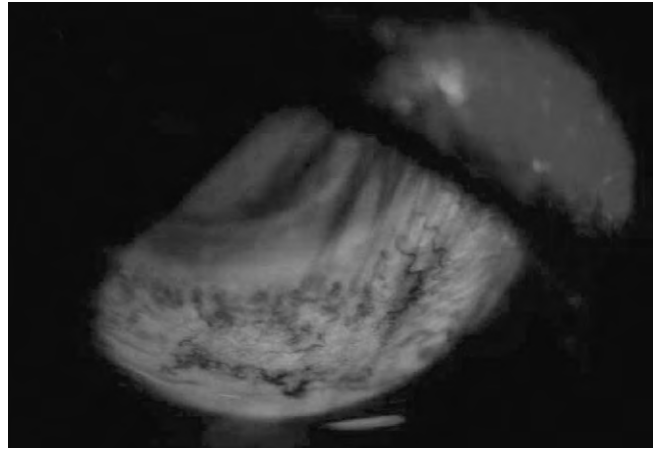
Any topically applied drug or its inactive ingredients can elicit a hypersensitivity response. Such local allergic reactions are especially common with neomycin and with the preservatives thimerosal or chlorhexidine. Practitioners should carefully question patients about any previous drug reactions. If an allergic profile is identified by history or examination, this fact should be recorded on the chart. Alternative drug regimens should be selected. Patients should be informed about expected side effects of drugs as well as allergic and other adverse drug reactions. Patients may incorrectly identify transient burning and stinging of certain eyedrops as an allergic response. Most topical ophthalmic preparations are preserved with benzalkonium chloride. Management of mild hypersensitivity reactions that occasionally occur from topical application of ocular drugs is considered in later chapters.

Iatrogenic infection is possible but can be avoided by careful handling of medications. Airborne contamination is of little significance. The main source of pathogens is the dropper tip that has come into contact with the practitioner's fingers or with the nonsterile surface of the patient's lids, lashes, or face. Cases of inadvertent conjunctival trauma related to contact with drug container tips also have been documented. Self-induced injury diagnoses should be considered in cases of poorly explained delayed healing of the ocular surface, especially if localized in the inferior or nasal bulbar conjunctiva (Figure 1-1). Expired or contaminated solutions should be discarded.

Since 1990 considerable attention has been devoted to developing artificial tears and lubricants without preservatives. Long-term use of agents with preservatives can damage the ocular surface. This toxicity manifests as superficial punctate keratitis accompanied by irritation, burning, or stinging. Preservative-free artificial tear preparations can be used at frequent dosage intervals for long periods without compromising the ocular surface.

Long-term use of topical antiglaucoma medications can induce local metaplastic changes in the conjunctiva. These are related to the active medications themselves, to their preservatives, or to the duration of topical treatment. Conjunctival shrinkage with foreshortening of the inferior conjunctival fornix is a possible consequence. Subsequent glaucoma surgery may be less successful.

Topically administered ophthalmic preparations can affect visual acuity. Examples are lubricating gels and ointments for dry eye, antimicrobial ointments for ocular infections, and gel-forming solutions for glaucoma. Although acuity is only slightly reduced and is only temporary, this effect can be annoying to patients and may lead to noncompliance.



**Figure 1-1** Self-induced injury. Fluorescein staining of the inferior bulbar conjunctiva shows a typical epithelial defect caused by contact with an ointment tube tip. (From Solomon A. Inadvertent conjunctival trauma related to contact with drug container tips. *Ophthalmology* 2003;110:798.)

Abuse of topically administered drugs by practitioners or patients can cause significant ocular toxicity. Infiltrative keratitis has occurred from long-term use of anesthetic eyedrops for relief of pain associated with corneal abrasions. Bilateral posterior subcapsular cataracts have developed after the topical administration of prednisolone acetate 0.12% twice daily over long durations. Practitioners should closely monitor patients treated with drugs known to have potentially significant ocular or systemic side effects.

### **Systemic Effects of Topically Administered Drugs**

Topically applied ocular drugs can have systemic effects. Drugs are absorbed from the conjunctival sac into the systemic circulation through the conjunctival capillaries, from the nasal mucosa after passage through the lacrimal drainage system, or, after swallowing, from the pharynx or the gastrointestinal tract. Topically applied drugs avoid the first-pass metabolic inactivation that normally occurs in the liver. These drugs, then, can exert the same substantial pharmacologic effect as a similar parenteral dose. Each 50-mcl drop of a 1.0% solution contains 0.5 mg of drug. Solutions applied topically to the eye in excessive amounts may exceed the minimum toxic systemic dose. Table 1-2 summarizes some of the clinically important systemic effects caused by topical ocular medications.

Adherence to the following guidelines can reduce systemic drug absorption and reduce the risk of adverse reactions:

- Advise patients to store all medications out of children's reach. Twenty drops of 1% atropine can be fatal if swallowed by a child.

**Table 1-2**  
Clinically Significant Systemic Effects Caused by Ocular Medications

Ocular Drug	Clinical Circumstance Under Which Adverse Effect Occurs	Systemic Effect
$\beta$ -Blockers	Treatment of open-angle glaucoma	Decreased cardiac rate, syncope, exercise intolerance, bronchospasm, emotional or psychiatric disorders
Brimonidine	Treatment of open-angle glaucoma	Dry mouth, central nervous system effects including fatigue, lethargy
Echothiophate	Treatment of open-angle glaucoma when succinylcholine is used as skeletal muscle relaxant during surgery requiring general anesthesia	Prolonged apnea
Pilocarpine	Overdosage in treatment of acute angle-closure glaucoma	Nausea, vomiting, sweating, tremor, bradycardia
Cyclopentolate	Overdosage for cycloplegic refraction	Hallucinatory behavior
Chloramphenicol	Treatment of ocular infections	Bone marrow depression, fatal aplastic anemia

- Instruct patients to wipe excess solution or ointment from the lids and lashes after instillation.
- Use the lowest concentration and minimal dosage frequency consistent with a drug's clinical purpose. Avoid overdosing.
- Confirm the dosage of infrequently used drugs before prescribing or administering them.
- Consider the potential adverse effects of a drug relative to its potential diagnostic or therapeutic benefit. Warn patients so they can give informed consent.
- Consult with each patient's primary physician before prescribing  $\beta$ -blockers for patients with suspected cardiac or pulmonary contraindications.
- Recognize adverse drug reactions. Practitioners often fail to recognize the clinical signs of drug toxicity or allergy, which can occur only a few seconds or minutes after drug administration or months or years later.

Consider the use of manual nasolacrimal occlusion (see Chapter 3) or gentle eyelid closure, particularly for patients who are at high risk for systemic complications associated with certain topically applied drugs (e.g., use of  $\beta$ -blockers in patients with chronic obstructive pulmonary disease).

### Ocular Effects of Systemically Administered Drugs

Practitioners must be aware of the effects of systemic medications on vision and ocular health. Many drug-induced changes are common but benign, such as mild symptoms of dry eye associated with anticholinergic drugs. Some instances, however, can be vision threatening, such as ethambutol-induced optic neuropathy. Knowledge of systemic medications taken by individual

patients can reduce ocular morbidity associated with drug use.

### MANAGING SPECIAL PATIENT POPULATIONS

Practitioners who use ophthalmic medications must be knowledgeable about the unique needs of certain patients to enhance the effectiveness of drugs and to avoid or minimize side effects. Practitioners seeking information regarding special patient populations should review the package inserts available for all prescription medications. Package inserts are printed in hard copy forms in drug packaging and also can be accessed on-line. Information provided is approved by the FDA and is based on clinical trials. The package inserts for thousands of prescription medicines are compiled into reference books such as *The Physicians' Desk Reference* (United States), the *Compendium of Pharmacy Specialties* (Canada), and the *British National Formulary* (United Kingdom). These books and on-line resources compile thousands of prescription medicine monographs into reference sources. The information in a package insert or in these resources follows a standard format for every medication. Box 1-3 shows an example of the information provided by the package insert.

#### Women Who Are Pregnant or Lactating

Mothers are the principal targets for drugs administered during pregnancy. In reality, however, their fetuses become inadvertent drug recipients. Some effects on fetuses can be expected throughout pregnancy, the intrapartum period, and even into early neonatal life because drugs are delivered to infants through breast milk.

**Box 1-3** Information Provided by the Package Insert**Brand Name**

(generic name)

**Description**

Provides the chemical name of the drug and a structural diagram. States whether the drug is in tablet form, capsules, liquid, etc., and how it should be given (topically, orally, by injection, or by parenteral administration). Lists inactive ingredients.

**Clinical Pharmacology**

States how drug works in the body, how it is absorbed and eliminated, and what its effects are likely to be at different concentrations.

*Pharmacokinetics**Microbiology**Indications and Use*

Lists the uses for which the drug has been FDA approved.

*Contraindications*

Lists situations in which the drug should *not* be used.

*Warnings*

Discusses serious side effects that may occur.

**Precautions**

Advises how to use the drug most effectively. May list activities (such as driving) that require special caution while the drug is being taken. Also may include sections explaining what is known about the use of the drug in special patient populations.

*General*

Provides general guidelines for safe use of drug.

*Drug Interactions*

Provides information regarding the effects that the drug may have on other prescription or over-the-counter drugs or the effects other drugs may have on this drug.

**Special Precautions**

Practitioners should pay special attention to the phase of pregnancy when making decisions about medication use and dose. The highest risk of fetal dysmorphism is generally during early pregnancy, usually in the first 6 weeks postconception or the first 8 weeks after the start of the last menstrual period.

Medications should be avoided during pregnancy and lactation. Chronic diseases, however, such as diabetes,

thyroid conditions, rheumatoid arthritis, seizure disorders, and psychological conditions, warrant the continuation of medications with close monitoring to ensure maternal well-being while minimizing potential hazards to the fetus. Drugs may be used carefully and with informed consent in conditions where the benefits of the diagnostic or therapeutic drug outweigh the possible consequences. That is, if needed in a life-threatening situation or a serious disease, the drug may be acceptable if safer drugs cannot be used or are ineffective.

**Dosage Considerations**

Medications used in pregnancy must be given with extreme caution and responsibility. Most drugs administered to mothers pass to fetuses to at least some degree and may have in utero or postpartum effects. Whenever possible, nonpharmacologic intervention should be used. If drugs are used, doses should be low yet effective, and the duration of treatment should be as short as possible. Teratogenic and neonatal effects of drugs used during pregnancy and lactation are minimal, and most of the applicable information comes from isolated case reports. Animal studies are performed extensively in the drug development and approval process, although the degree of cross-species relevance is variable.

When topical ophthalmic drugs must be administered to patients who are pregnant, the medications should be administered at minimally effective doses and for as short a time as possible. The use of nasolacrimal occlusion (see Chapter 3) after the instillation of eye medications minimizes systemic drug absorption and should always be recommended. Patients who take medications should also be advised about the potential risks to newborns during breast-feeding (Figure 1-2). Timolol, for example, has been shown to be concentrated in breast milk.



**Figure 1-2** Counseling a pregnant patient on ophthalmic drug use includes discussing potential risks during the pregnancy as well as risks to newborns during breast-feeding.

### Practical Considerations

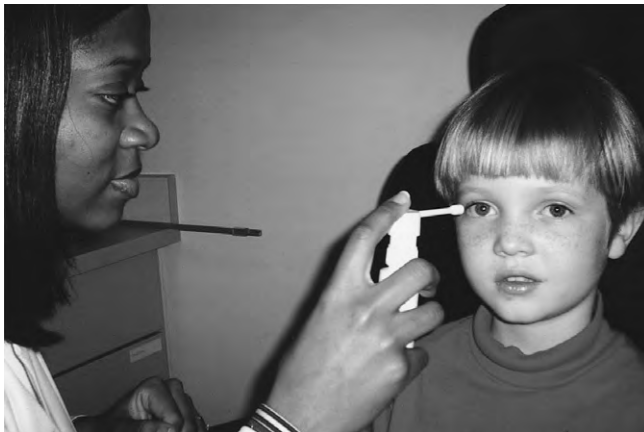The FDA, on approval of medications for commercial use, assigns to each drug a category of risk (A, B, C, D, or X) to suggest the potential safety of the medication during pregnancy. Risk categories range from A (Adequate well-controlled studies in pregnant women have not shown increased risk) to X (Contraindicated; adequate well-controlled or observational studies in animals or pregnant women have demonstrated positive evidence of fetal abnormalities or risks). The FDA pregnancy category is found in standard drug information sources, including the drug package insert. When medications need to be prescribed to pregnant patients, the practitioner should consult with the patient's primary care physician or obstetrician.

### Pediatric Patients

Examination of pediatric patients requires use of diagnostic agents. Investigation and clinical use of spray instillation have grown in the last decade (Figure 1-3). A wide variety of ocular conditions found in the pediatric population are treated through pharmacotherapeutic intervention using both topical and systemic routes. These include eye injuries and acute infections such as hordeolum, blepharitis, conjunctivitis, and dacryocystitis as well as amblyopia and progressive myopia. Special considerations for drug therapy in pediatric patients are discussed in Chapters 20, 21, and 34.

### Special Precautions

Pediatric patients are not just smaller adult patients. Dosage calculations are not just fractions of recommended adult dosages. Dosage determinations based on age and weight solely may actually underestimate the required dose. Pediatric dosing requires knowledge of the individual patient, the disease group, the age group, the drugs to be administered, pharmacokinetic data for children, and an understanding of the dose-response



**Figure 1-3** Spray instillation of diagnostic agents in a child.

relationship of specific drug receptors in growth and development.

Challenges of pediatric dosage determination include the need for precise drug measurement and drug-delivery systems and the lack of commercially available dosage forms and concentrations appropriate for children. There is also a need for more published research on the pharmacokinetics and clinical use of new drugs in children. Further, individual dosages need to be calculated either based on the age of the patient (Young's rule), the weight of the patient (Clark's rule), or on the child's body surface area. This may lead to a high frequency of errors in dosage calculations and associated serious medication errors.

The calculation for Young's rule is as follows:

$$\text{Pediatric dose} = \text{adult dose} \times \frac{\text{age (years)}}{\text{age} + 12}$$

The calculation for Clark's rule is as follows:

$$\text{Pediatric dose} = \text{adult dose} \times \frac{\text{weight (kg)}}{70}$$

or

$$\text{Pediatric dose} = \text{adult dose} \times \frac{\text{weight (lb)}}{150}$$

### Dosage Considerations

Use of dosage determinations based on body surface area may be the most sensitive approach to approximating age-dependent variations in drug disposition. Several body surface area dosing nomograms are available, including some that are condition specific (e.g., Marfan's disease).

Labeling regarding pediatric use, which is based on study in clinical trials, is the most accurate determinant of dosage. Before 1994 few drugs prescribed to children provided information by the manufacturer regarding pediatric use, instead stating "Safety and effectiveness in children have not been established." Changes in FDA policy have increased the number of clinical trials to investigate drug usage in this population, and more drugs now provide information regarding pediatric use. Clinicians should refer to this section of the package insert in making prescribing decisions.

Adjusting the dosage of ophthalmic topical agents in the pediatric population is infrequently done. Researchers have investigated drop size reduction as a mechanism to further reduce risk of systemic toxicity. For the youngest pediatric patients, an approximation may be to use half the adult dose for children from birth to age 2 years and two-thirds the dose for children 2 to 3 years old.

### Practical Considerations

For young children, ophthalmic medications in ointment form are often preferred because they are less likely to be diluted and washed out by tears, and the drop

administrator can more readily determine whether instillation has been successful. Administering ophthalmic medications during nap time or regular bedtime may also facilitate the process.

The oral route of drug administration may be indicated for some conditions in pediatric patients, such as in dacryocystitis and orbital or preseptal cellulitis. Young patients are able to swallow liquid suspensions and solutions more easily than oral solids (e.g., tablets or capsules). Oral medications are the most reliable form of dosing and delivery and continue to be the mainstay in pediatric drug therapy.

Children and their parents or caregivers should be present for drug counseling and should be given the opportunity to ask questions. Family members and children's teachers are the best resources to assist with compliance. These individuals should be encouraged to inform the prescribing optometrist or ophthalmologist of any apparent or suspected problems with the drug therapy.

## Geriatric Patients

### Special Precautions

Because of systemic disease and multiple drug therapy, geriatric patients may experience more adverse drug reactions. Systemic absorption of topically applied drugs may cause adverse effects. Eyelid laxity, as occurs in age-related ectropion, may increase the retention time of ophthalmic drugs in the conjunctival sac, exacerbating the local drug effect or causing ocular toxicity.

Poor compliance with eyedrop dosage schedules is common in the geriatric population. Cognitive difficulties in following directions for drug administration must be evaluated. Not only can preexisting conditions such as stroke and Alzheimer's disease impair cognitive function, but the use of ophthalmic medications such as  $\beta$ -blockers and oral carbonic anhydrase inhibitors may also contribute to patient confusion and cognitive impairment.

Arthritis, tremors, and other conditions such as rheumatoid arthritis may impair fine motor skills and preclude proper self-administration of topical ophthalmic drops or ointments. Some elderly patients find that ophthalmic bottles are too rigid to enable drops to be easily squeezed out. Clinicians must be aware of systemic conditions that may affect ocular pharmacotherapy. Special attention should be given to the combined ophthalmic and systemic use of  $\beta$ -blockers and steroids. Certain cardiac agents, psychotropic drugs, antidepressants, and antiarthritic agents may have adverse ocular effects. Although some adverse effects are transient or disappear on drug discontinuation, others are vision threatening and can be irreversible. Practitioners must detect evidence of ocular toxicity before significant damage occurs (see Chapter 35).

In the general primary eye care population, 75% to 90% of the elderly use at least one prescription or

nonprescription drug. *Polypharmacy* is the prescription or use of more medications than is clinically necessary. Patients may have contraindicated drug combinations, redundant medications prescribed by several clinicians, erroneous duplications of drugs or categories of drugs, interactions from prescription and OTC medications, and outdated drugs or dosage schedules. Inappropriate drug prescribing for elderly patients is a growing problem requiring greater community-based educational and perhaps regulatory efforts.

### Dosage Considerations

Therapeutic dosages for systemic medications in geriatric patients are generally lower than the "normal adult dosage" cited in the drug manufacturer's product information. It is not uncommon for the appropriate dose to be 25% to 50% of the average adult dose. Systemic drug therapy should be started with doses at the lower end of the recommended adult dosage range. Doses can then be slowly titrated upward. Topical dosages of ophthalmic medications, however, are not generally adjusted in the treatment of the elderly.

Renal function is the most important factor in determining systemic dosage regimens in elderly patients. Geriatric dosing usually makes allowances for reduced renal clearance. An age-related decline in creatinine clearance occurs in approximately two-thirds of the population as a function of renal elimination. Because the kidney serves as the principal organ for drug elimination, elderly patients are prone to potentially toxic accumulations of drugs and their metabolites.

Independent of the dosing guidelines, clinical judgment and common sense must remain sovereign over simple dosage calculations. Because elderly patients are more sensitive to the therapeutic and nontherapeutic effects of drugs, the best individualized drug regimen must be determined to preserve the vitality and independence of geriatric living. The long-term use of topical medications by elderly patients with glaucoma is an example of balancing the risk-to-benefit considerations, especially with respect to the individual person's quality of life measures.

### Practical Considerations

Elderly patients appreciate handwritten dosing charts, large numerals written on bottles to signify dosage frequency, and color codes for drug identification. Dosage schedules should be established to fit the patient's lifestyle (e.g., four-times-a-day dosing is usually best facilitated on arising and at lunch, dinner, and bedtime). Patients should be asked to repeat the identification of prescribed medications and the dosing schedules. In addition, they should be able to find telephone numbers of their prescribing practitioner and dispensing pharmacy.

Attention should also be directed toward both the ophthalmic and systemic medication schedules of the geriatric patient. Patients who receive ophthalmic

medications may stop or become confused about continuing their systemic medications.

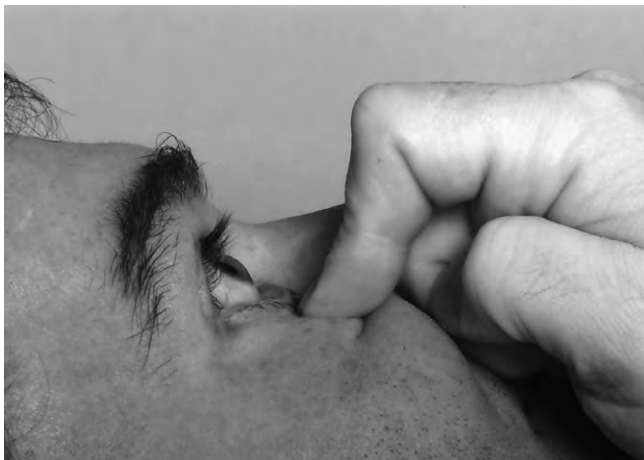Practitioners should develop provisions for additional health care needs and continuity of care for elderly patients. Family members or close friends may accept responsibility for assisting or overseeing drug scheduling and administration. These individuals should be included in the drug counseling process. Community geriatric assistance is available through third-party insurance carriers, skilled nursing facilities, and independent agencies.

### Patients with Visual Impairments

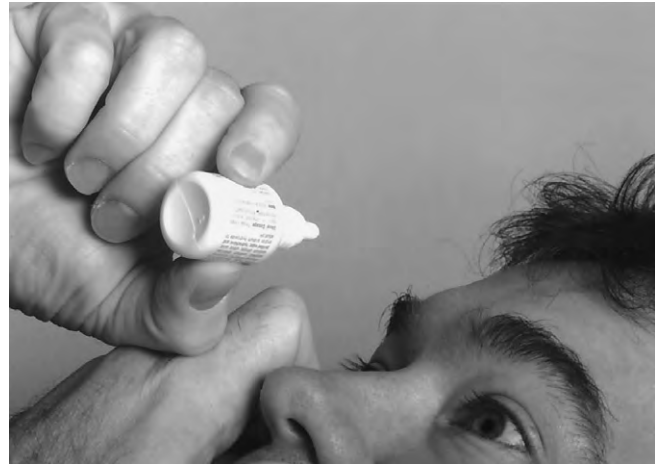Blindness or low vision affects over 3 million Americans or approximately 1 in 28 of those older than 40 years. Persons with visual impairments may find complying with prescribed drug regimens inherently difficult, and their problems can extend beyond the scope of visual compromise.

#### Special Precautions and Practical Considerations

Vision loss can limit the proper use of topical or systemic medications, especially when multiple drug therapies require differentiation of one medication from another. Many patients with visual impairments are capable of recognizing their topical ophthalmic medications but find it difficult to be sure that an administered drop has reached the intended eye. Storage of solutions or suspensions in the refrigerator can provide enough cold temperature sensation for patients to feel the drop when instilled into the eye. Alternative techniques using a variety of aids and utilizing proprioception to compensate for decreased vision have been documented (Figures 1-4 to 1-7).



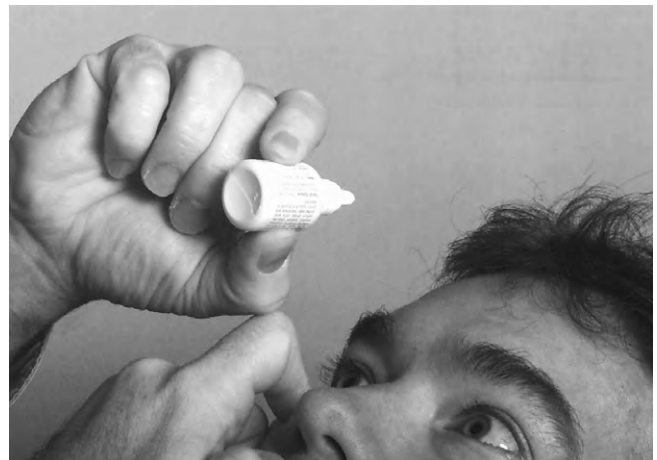**Figure 1-4** The patient grasps the center of the lower lid using the index finger of the nondominant hand and pulls the lid down. The index finger is bent at a right angle at the second knuckle (proximal interphalangeal). (From Ritch R, et al. An improved technique of eyedrop self-administration for patients with limited vision. *Am J Ophthalmol* 2003;135:531-532.)



**Figure 1-5** While holding the bottle, the second knuckle of the thumb (interphalangeal joint) of the dominant hand is placed against the first knuckle of the index finger (metacarpophalangeal joint). (From Ritch R, et al. An improved technique of eyedrop self-administration for patients with limited vision. *Am J Ophthalmol* 2003;135:531-532.)

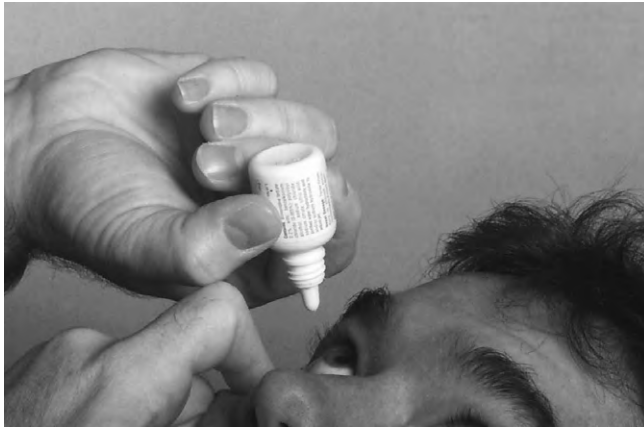Studies of visual acuity and the ability of the visually impaired to read medication instructions have documented the inability of patients to read instructions on their bottle of eyedrops. Subjects with best corrected distance visual acuity of 6/24 or worse benefit from larger font size such as Arial 22. Like geriatric patients, individuals with low vision appreciate handwritten dosing charts using large print, large numerals displayed on bottles to signify dosage frequency (Figure 1-8), and color codings for drug identification.

Patients with visual impairments must be able to identify their medications and the dosing schedules for each



**Figure 1-6** After sliding the second knuckle of the thumb slowly toward the eye along the index finger, the thumb rests upon the second knuckle of the index finger. (From Ritch R, et al. An improved technique of eyedrop self-administration for patients with limited vision. *Am J Ophthalmol* 2003;135:531-532.)



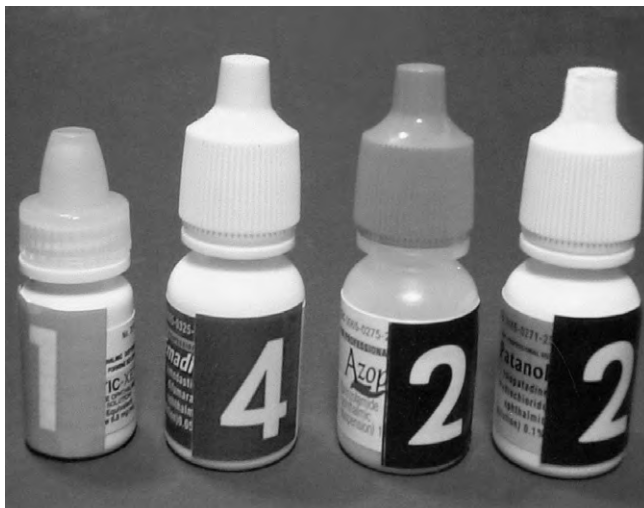

**Figure 1-7** The patient's head is tilted back, the dropper tip is aimed downward, and the bottle tip is directly above the eye. At this point the patient is ready to squeeze the bottle. (From Ritch R, et al. An improved technique of eyedrop self-administration for patients with limited vision. *Am J Ophthalmol* 2003;135:531-532.)

drug. These patients should also be able to use the telephone to contact their prescribing practitioner and dispensing pharmacy. Magnifiers, large-print telephone numerals, or other visual or nonoptical aids may be required and should be recommended when needed.

### Patients Who Cannot Swallow Pills

Some adults, as well as most young children, have difficulty swallowing medications formulated as standard pills (tablets and capsules). When oral medications are needed, drug therapy can be more efficient, and patient compliance improved, by prescribing medications formulated as chewable tablets, solutions, or suspensions, which are usually flavored to improve taste and are easily swallowed.



**Figure 1-8** Large stick-on numerals, such as those used on office charts, can indicate dosage frequency for medications used by visually impaired patients.

Most therapeutic categories of medications used for ophthalmic purposes contain such drug formulations, and these are easily administered by mouth using a teaspoon or various modifications designed for pediatric use.

Though patients vary greatly in their particular history and clinical presentation, the clinician will find that successful pharmacotherapy requires certain constant attributes: knowledge of pharmacologic mechanisms and the disease process, mastery of the art of tailored patient education and effective communication, and attention to economics and resources within the health care system. As the body of evidence-based medicine expands and new drugs are continually introduced, the clinician should anticipate applying lifelong research skills to maintain contemporary standards of patient management.

### SELECTED BIBLIOGRAPHY

- Abelson MB, Paradis A, Grant KK. How to prescribe for the smallest sufferers. *Rev Ophthalmol* 1999;6(2):101-103.
- Akman A, Aydin P. Comparison of mydriatic efficacy of spray instillation and drop instillation of tropicamide 1%. *Eye* 199;13:653-655.
- Bartlett JD. Medications and contact lens wear. In: Silbert J, ed. *Anterior segment complications of contact lens wear*, ed. 2. Boston: Butterworth-Heinemann, 2000.
- Bartlett JD. Ophthalmic toxicity by systemic drugs. In: Chiou GCY, ed. *Ophthalmic toxicology*, ed. 2. Philadelphia: Taylor & Francis, 1999.
- Bartlett JD, Bennett ES, Fiscella RG, et al., eds. *Ophthalmic drug facts*. St. Louis, MO: Wolters Kluwer Health, 2006.
- Congdon N, O'Colmain B, Klaver, CC. Eye Diseases Prevalence Research Group: causes and prevalence of visual impairment among adults in the United States. *Arch Ophthalmol* 2004;122:477-485.
- Coulter RA. Pediatric use of topical ophthalmic drugs. *Optometry* 2004;75:419-429.
- Drummond SR, Drummond RS, Dutton GN. Visual acuity and the ability of the visually impaired to read medication instructions. *Br J Ophthalmol* 2004;88:1541-1542.
- Fiscella R. When generic drugs are not the right Rx. *Rev Optom* 2002;139:1-5.
- Fiscella R, Bloch D, Labib S, Jensen M. Compounding in ophthalmology: know the risks. *Rev Ophthalmol* 2005; October:55-61.
- Fiscella R, Wilensky J, et al. Medical therapy cost considerations for glaucoma. *Am J Ophthalmol* 2003;136:18-25.
- Fiscella R, Wilensky JT, Chiang TH, Walt J. Efficiency of instillation methods for prostaglandin medications. *J Ocul Pharmacol Ther* 2006;22:477-482.
- Fraunfelder FT, Fraunfelder FW. *Drug-induced ocular side effects*, ed. 5. Boston: Butterworth-Heinemann, 2001.
- Jaanus SD. Pharmacologic aspects of aging. In: Rosenbloom A, Morgan M, eds. *Vision and aging*, ed. 2. Boston: Butterworth-Heinemann, 1993.
- Jampel HD, Schwartz GF, Robin AL, et al. Patient preferences for eye drop characteristics: a willingness-to-pay analysis. *Arch Ophthalmol* 2003;121:540-546.
- Johnson SM, Martinez M, Freedman S. Management of glaucoma in pregnancy and lactation. *Surv Ophthalmol* 2001;45:449-454.

- Kaplan S. The importance of the therapeutic alliance. *J Am Optom Assoc* 1998;69:637-642.
- Khurana RN, Lee PP, Challa P. Readability of ocular medication inserts. *J Glaucoma* 2003;12:50-53.
- Mauger TF, Craig EL. *Havener's ocular pharmacology*, ed. 6. St. Louis, MO: Mosby, 1994.
- McPhillips R. Can the elderly afford eye care? Can we afford eye care for the elderly? *Ophthalmology* 1987;94:1199-1204.
- Metry DW, Hebert AA. Topical therapies and medications in the pediatric patient. *Pediatr Clin North Am* 2000;47:867-876.
- Nordenberg T. Pediatric drug studies. *FDA Consum* 1999;33:23-28.
- Platt R, Reardon G, Mozaffari E. Observed time between prescription refills for newer ocular hypotensive agents: the effect of bottle size. *Am J Ophthalmol* 2004;137:S17-S23.
- Repka MX, et al. Two-year follow-up of a 6-month randomized trial of atropine vs patching for treatment of moderate amblyopia in children. *Arch Ophthalmol* 2005;123:149-157.
- Ritch R, et al. An improved technique of eye drop self-administration for patients with limited vision. *Am J Ophthalmol* 2003;135:530-533.
- Solomon A, et al. Inadvertent conjunctival trauma related to contact with drug container tips: a masquerade syndrome. *Ophthalmology* 2003;110:796-800.
- Stewart WC, Garrison PM.  $\beta$ -blocker induced complications in the patient with glaucoma. *Arch Intern Med* 1998;158:221-226.
- Taylor SA, Galbraith SM, Mills RP. Causes of non-compliance with drug regimens in glaucoma patients: a qualitative study. *J Ocul Pharmacol Ther* 2002;18:401-409.
- Urtti A, Salminen L. Minimizing systemic absorption of topically administered ophthalmic drugs. *Surv Ophthalmol* 1993;37:435-456.
- Watson PD, Getschman S, Koren G. Principles of drug prescribing in infants and children, a practical guide. *Drugs* 1993;46:281-288.
- Wilensky J, Fiscella R, Carlson AM, et al. Measurement of persistence and adherence to regimens of IOP-lowering glaucoma medications using pharmacy claims data. *Am J Ophthalmol* 2006;141:S28-S33.
- Willcox SM, Himmelstein DU, Woolhandler S. Inappropriate drug prescribing for the community-dwelling elderly. *JAMA* 1994;272:292-296.
- Yuen J, Fiscella R, Gaynes B. Ophthalmic agents and managed care. *JMCP* 2002;8:217-223.
- Zimmerman TJ, et al. Therapeutic index of pilocarpine, carbachol, and timolol with nasolacrimal occlusion. *Am J Ophthalmol* 1992;114:1-7.

# *Ophthalmic Drug Formulations*

*Richard G. Fiscella*

Drugs affect ocular tissues on the basis of special pharmacokinetic properties of the eye. Pharmacokinetics is the study of the time course of absorption, distribution, metabolism, and elimination of an administered drug. Drug absorption depends on the molecular properties of the drug, the viscosity of its vehicle, and the functional status of the tissue forming the barrier to penetration. Drug distribution over time and bioavailability at the desired site of action can usually be predicted by the interrelationships of the compartments and barriers of the eye. Metabolism plays an important part in eliminating drugs and their sometimes toxic byproducts from the eye and from the body. Metabolic enzymes have recently been studied to assist in the design of prodrugs, which are molecules that are converted to an active form after tissue penetration has occurred. The other end of the spectrum includes the use of compounds that, in the eye, predictably undergo transformation by enzymes to an inactive form associated with fewer side effects than those associated with the parent form.

## **OCULAR TISSUE STRUCTURE AND PHARMACOKINETICS**

The eye is composed of numerous tissues, each of distinct developmental origin and each with a specific role in the functioning visual system. These tissues include the smooth and striate musculature, a variety of simple and mucoid epithelia, connective tissues, sympathetic and parasympathetic nerves, and the retina.

The organization of the eye must provide a path for light through the clear tissues that form the optical imaging system while providing for the nutrition of those same tissues in the absence of a blood supply. This avascularity allows a direct route for ocular drug penetration without absorption by the systemic circulation.

### **Tear Structure and Chemical Properties**

The tear film covering the cornea and defining the major optical surface of the eye is composed of three layers

(Figure 2-1). The outermost, oily layer is usually considered to be a lipid monolayer and is produced primarily by the meibomian glands located in the eyelids. The primary function of the oily layer is to stabilize the surface of the underlying aqueous fluid layer and to retard evaporation. Tear surface lipids are readily washed away if the eye is flushed with saline or medication, resulting in a more than 10-fold tear evaporation increase. Minor infections of the meibomian glands, particularly with staphylococci, can also decrease tear film stability due to an alteration of the chemical nature of meibum, the secretion product of the gland.

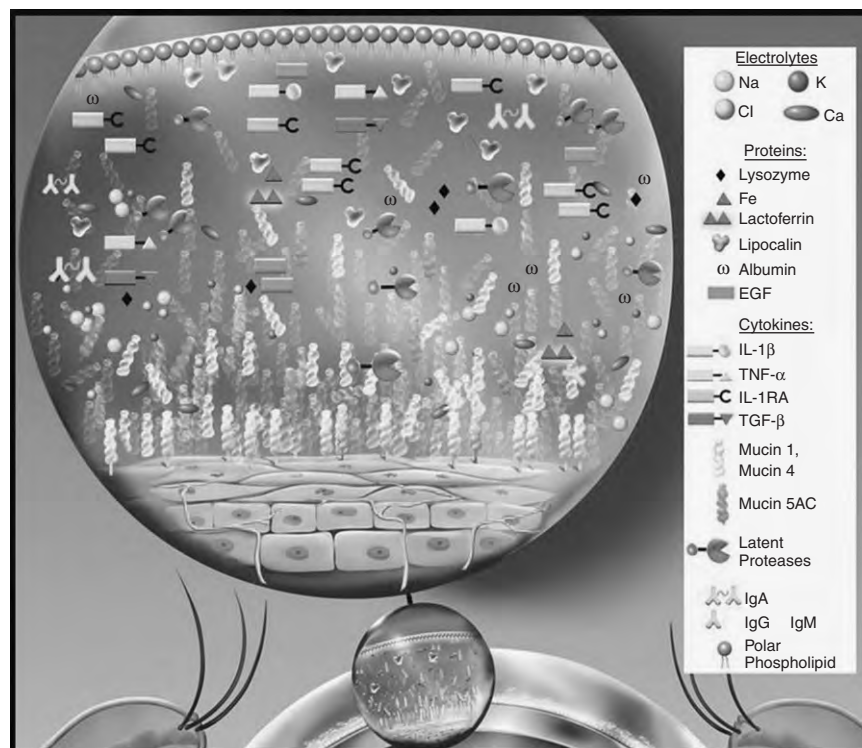
The aqueous phase of the tears comprises more than 95% of the total volume and covers the cornea with a layer that averages approximately 7 mm thick. This layer is inherently unstable, however, and begins to thin centrally at the end of each blink. The tear film in healthy subjects has a breakup time that averages between 25 and 30 seconds.

The inner, or basal, layer of the tears is composed of glycoproteins and is secreted by goblet cells in the conjunctiva. This mucinous layer is a thin hydrophilic coating (Figure 2-2A) covering the cornea and conjunctiva and, at higher magnification, is seen as thick rolls and strands (Figure 2-2B) that cleanse the tears of particulate debris at each blink.

The pH of the tears is approximately 7.4, and the tear layer contains small amounts of protein, including lysozymes, lactoferrins, gamma globulins, and other immune factors. The tears are primarily responsible for supplying the oxygen requirements of the corneal epithelium.

### **Tear Volume**

The normal volume of the tear layer is 8 to 10 mcl, including the fluid trapped in the folds of the conjunctiva. A total volume of perhaps 30 mcl can be held for a brief time if the eyelids are not squeezed after dosing. When a single drop of medication of 50 mcl (0.05 ml) is applied, the nasolacrimal duct rapidly drains the excess, although some may be blinked out of the eye onto the lid.



**Figure 2-1** Tear film components. (Image from *Dry Eye and Ocular Surface Disorders*, 2004.)

Increasing drop size, therefore, does not result in penetration of more medication into the cornea. However, the systemic load is increased linearly with drop size, because after drainage through the nasolacrimal duct, the drug is usually absorbed through the nasal mucosa or is swallowed. For drugs with major systemic side effects, such as  $\beta$ -blockers, efforts have been made to limit drop size. Careful supervision during initial dosing and monitoring of patient compliance is important.

It is difficult to limit the volume of a drop dispensed by gravity from a dropper tip below approximately 25  $\mu$ l, three times the normal tear reservoir. The proposed theoretic optimum volume of drug solution to deliver is zero volume, because increasing the instilled volume increases the volume lost and the percentage of drug lost. Although achieving this theoretic extreme is impossible, it is practical to dispense accurately measured drops as small as 2 to 5  $\mu$ l by reducing the bore size of commercial dropper dispensers. Small drop volumes can also be dispensed from a micrometer syringe by touching a flexible polyethylene tip to the conjunctiva. For investigational purposes, this allows instillation of drugs without greatly affecting size of the tear reservoir.

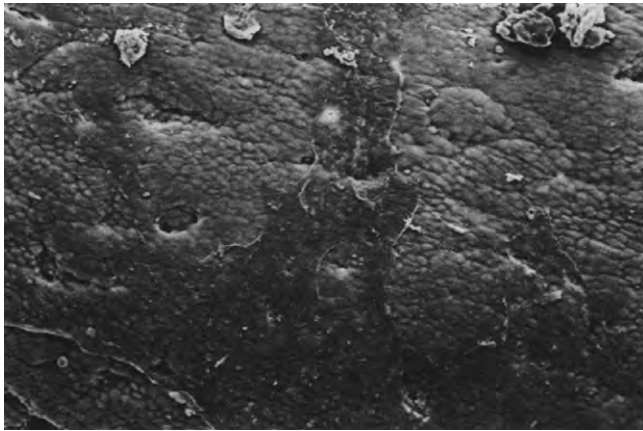
### Tear Flow

The normal rate of basal (unstimulated) tear flow in humans is approximately 0.5 to 2.2  $\mu$ l/min and decreases with age. Tear flow rate is stimulated by the ocular irritation resulting from many topical medications. The concentration of drug available in the tears for

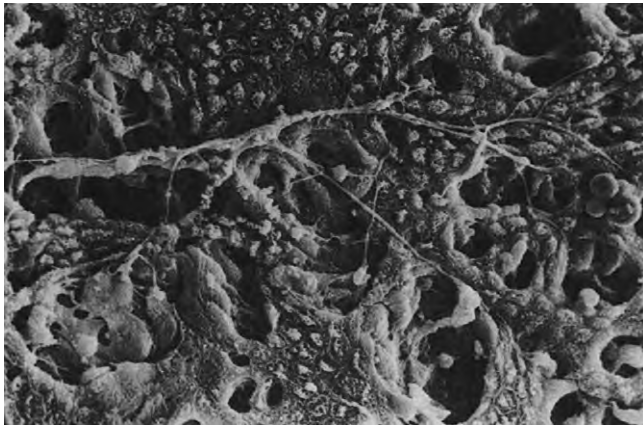transcorneal absorption is inversely proportional to the tear flow, due to the drug's dilution and removal by the nasolacrimal duct and by eyelid spillover. Therefore both the flow rate and the tear volume influence drug absorption by the anterior segment of the eye.

To enhance corneal drug absorption, the tear film concentration can be prolonged by manually blocking the nasolacrimal ducts or by tilting the head back to reduce drainage (see Chapter 3). Another effective technique to increase corneal penetration is to administer a series of ophthalmic solutions at intervals of approximately 10 minutes. It has been determined, however, that when different drug formulations are given as drops in rapid succession, the medications first applied are diluted and do not achieve full therapeutic potential.

Patients with a flow rate near the lower limit of 0.5  $\mu$ l/min, often due to aging or atrophy of the lacrimal ducts and glands, are usually considered to have dry eye (keratoconjunctivitis sicca). This patient group includes many elderly patients, individuals with rheumatoid arthritis, some peri- and postmenopausal women, and persons with exposure keratitis associated with dry climate or dusty work conditions. Several factors contribute to greatly increased drug absorption in these individuals. Their total tear volume is less than normal, so that a drop of medication is not diluted as much as usual. Because lacrimation is reduced, the drug is not rapidly diluted by tears and has a prolonged residence time next to the corneal surface, where the bulk of absorption occurs. Because epithelial surface damage is usually present in



A



B

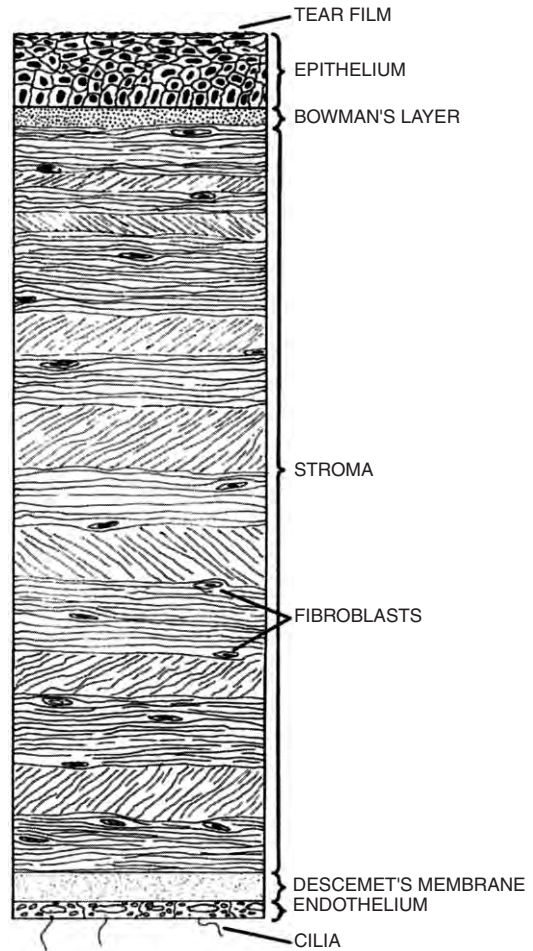
**Figure 2-2** The conjunctiva shown by scanning electron microscopy with surface mucins intact (A). On higher magnification, note the strands (B) that allow the mucins to entrap particles and remove them from the tears. The tears form a reservoir for drug compounds, including those that are delivered as particulate suspensions. (Reprinted with permission from Burstein NL. The effects of topical drugs and preservatives on the tears and corneal epithelium in dry eye. *Trans Ophthalmol Soc U K* 1985;104:402-409.)

patients with dry eye, the final result is greatly increased ocular absorption.

Drugs (e.g., pilocarpine) that cause rapid lacrimation by stinging or by stimulation of lacrimal glands in normal individuals are formulated at high concentration to offset the dilution and washout that occur from tear flow. Patients with dry eyes that do not tear readily can absorb greatly exaggerated doses of topically applied medications. In children, who cry and lacrimate more easily than do adults, rapid drug washout can prevent adequate absorption of topically applied medications.

### Cornea and Sclera

The cornea is a five-layered avascular structure (Figure 2-3). It constitutes the major functional barrier to ocular penetration, and it is also the major site of absorption for topically



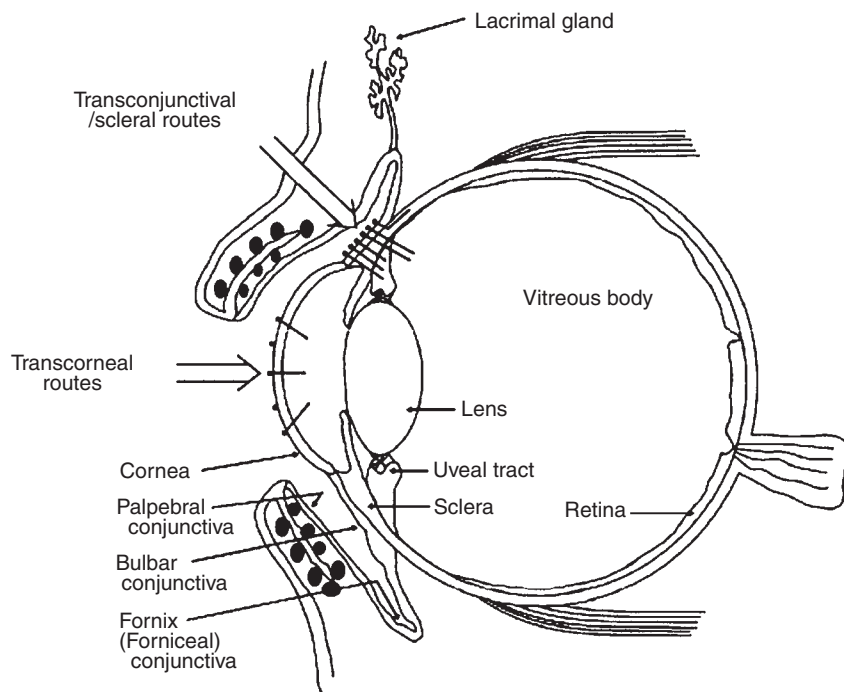
**Figure 2-3** Cross-sectional diagram of the cornea. Note that the epithelium is only approximately one-tenth the total corneal mass. Nevertheless, it can be considered a separate storage depot for certain lipophilic drugs.

applied drugs. The epithelium and stroma have a major influence on pharmacodynamics, because they constitute depots or reservoirs for lipophilic and hydrophilic drugs, respectively.

The sclera is an opaque vascular structure continuous with the cornea at the limbus. The loose connective tissue overlying the sclera—the conjunctiva—is also vascularized. The conjunctiva and sclera, as routes of drug penetration, are responsible for less than one-fifth of all drug absorption to the iris and ciliary body. This limited absorption is due to the extensive vascularization of these tissues, which results in removal of most drugs. However, in recent years, the conjunctiva has been studied as a route of possible drug delivery because it contains a larger surface area than the cornea and possesses key transport processes that may allow for penetration into intraocular tissues (Figure 2-4).

Subconjunctival injections of sustained-release matrix materials or microparticles have produced significant levels in the vitreous cavity. Although the kinetics of transscleral drug delivery to the retina and choroid are





**Figure 2-4** Cross-section of the eye and various drug absorption routes. (From Hosoya K, Lee VHL, Kim KJ. Roles of the conjunctiva in ocular drug delivery: a review of conjunctival transport mechanisms and their regulation. *Eur J Pharm Biopharm* 2005;60:227-240.)

not well known, various simulation models are currently being actively developed and studied to allow for future drug delivery via this route (Table 2-1).

An elegant visualization of the route of scleral penetration was achieved by applying a piece of filter paper moistened with epinephrine to the white of the eye in a human subject. Mydriasis was obtained in an isolated sector of iris adjacent to the site of scleral application.

Studies have determined that certain compounds, including several sulfonamides, various molecular weight compounds, and many prostaglandins, exhibit good scleral penetration. Noncorneal routes of absorption may be an important consideration in some instances.

The conjunctival surface functions as a major depot for some drugs that are superficially absorbed and then re-released to the tears. Trapped particles from a suspension may allow active drug to dissolve slowly from the conjunctival sac and to saturate tear drug levels.

### Corneal Epithelium

The corneal epithelium is 5 to 6 cell layers thick centrally and 8 to 10 cell layers thick at the periphery. It is composed of a basal germinative layer, intermediate wing cells, and a surface squamous layer that possesses structures that are known as zonula occludens, or tight junctions. These junctions constitute a continuing border between epithelial cells formed by the fusion of the outer plasma membrane. Mucopolysaccharides bound to the outer plasma membrane stabilize the tears. The cornea

relies on diffusion of nutrients from the aqueous humor to supply its metabolic needs.

More than one-half of the total corneal electrical resistance is contained in the uppermost squamous cell layer. Because the healthy epithelium presents a continuous layer of plasma membrane to the tear film, it largely resists the penetration of hydrophilic drugs. The anionic diagnostic agent sodium fluorescein is a good example of such a hydrophilic agent. The amount of fluorescein penetrating the intact epithelium is small. If a slight break in the outer cellular layer occurs, fluorescein can penetrate easily and is visible as a green stain for several minutes in the beam of a blue excitation filter. Epithelial erosion or the action of cationic preservatives can greatly increase the penetration of hydrophilic drugs in the same manner.

The interstices between the epithelial cell layers communicate directly by an aqueous pathway with the stroma and aqueous humor. Lipophilic drugs can readily enter the epithelium, because its barrier is composed of phospholipid membranes. Because the epithelium contains more than two-thirds of the plasma membrane mass of the cornea, it is the most significant storage depot for agents that readily partition into lipid media. The release rate of drugs from the epithelium depends on their tendency to reenter an aqueous phase. Thus, agents that are very lipophilic have a very long half-life once in the epithelium.

To penetrate the cornea effectively, a drug must possess a balance of hydrophilic and lipophilic properties

**Table 2-1**

Factors Affecting Transscleral Drug Delivery and the Related Experimental Data

Tissue and Factor	Experimental Data
<b>Conjunctiva and Tenon's capsule</b>	
1) Diffusion across these tissues	1) In vitro permeability of rabbit conjunctiva and Tenon's capsule
2) Clearance via conjunctival blood and lymphatic flow	2) Limited data on blood and lymphatic flow and on capillary permeability
<b>Sclera</b>	
3) Diffusion across sclera	3) In vitro permeability of human and rabbit sclera
4) Clearance via episcleral veins	4) Limited data on blood flow and capillary permeability
<b>Ciliary body</b>	
5) Diffusion across the ciliary body	5) In vitro permeability of rabbit ciliary body
6) Clearance via circulation	6) Blood flow and capillary permeability in rabbits
<b>Choroid-Bruch's membrane-RPE</b>	
7) Passive diffusion across these tissues	7) In vitro permeability of human and bovine tissues; in vivo permeability of rabbit RPE
8) Active transport and efflux in RPE	8) In vitro permeability in rabbit and porcine RPE; in vivo permeability of rabbit RPE
9) Clearance via choroidal circulation	9) Choroidal blood flow in humans and several animal species; in vivo permeability of rabbit and cat choriocapillaris
10) Binding to melanin	10) Melanin amount in human choroid-RPE and binding parameters of drugs to melanin
<b>Neural retina</b>	
11) Diffusion across neural retina	11) In vitro permeability of human and animal retina; in vivo permeability of rabbit retina
<b>Vitreous</b>	
12) Distribution and elimination in vitreous	12) Kinetics of drugs in rabbit vitreous and clinical data

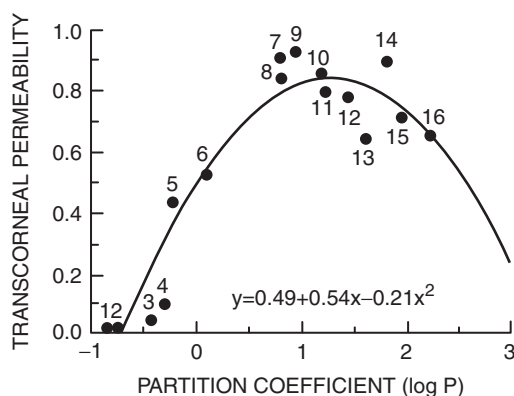
From Ranta V-P, Urtti A. Transscleral drug delivery to the posterior eye: prospects of pharmacokinetic modeling. *Adv Drug Deliv Rev* 2006.

and must be able to partition between both media. This phenomenon is well known through the study of series of compounds of similar properties, such as  $\beta$ -blockers. A plot of partition coefficient versus corneal permeability usually results in the formation of a parabola, an example of which is shown in Figure 2-5. Molecular species with the appropriate partition coefficient at or near the peak are thus readily transferred through the cornea. Those with too low a coefficient do not penetrate well through the outer epithelial barrier. Those with too high a partition coefficient tend to remain in the epithelium and partition into the anterior chamber slowly, resulting in low but prolonged aqueous humor levels.

### Corneal Stroma

Bowman's layer is the modified anterior border of stroma in humans. This layer is 8 to 14  $\mu$ m thick and is composed of clear randomly oriented collagen fibrils surrounded by mucoprotein ground substance. Numerous pores in the inner structure allow the passage of terminal branches of corneal nerves from the stroma into epithelium. The surface of Bowman's layer adjoins the structurally distinct epithelial

basal lamina. The drug penetration characteristics of Bowman's layer are probably similar to those of the stroma.



**Figure 2-5** Parabolic curve of corneal penetration versus octanol-water partition diminished. Numbers refer to reagents. (Adapted from Kishida K, Otori T. Quantitative study on the relationship between transcorneal permeability of drugs and their hydrophobicity. *Jpn J Ophthalmol* 1980;24:251-259.)

The stroma occupies 90% of the corneal thickness and contains approximately one-third of the cells of the cornea in the form of keratocytes. The connective tissue of the stroma is composed of multiple layers of closely knit collagen bundles, or lamellae, arranged to distribute the stress of the intraocular pressure (IOP) evenly to the limbus, the thickened zone that joins the cornea and sclera. The collagen bundles are hexagonally packed and more ordered in the cornea than in the sclera. Their organization, together with the interspersed proteoglycans, is largely responsible for the clarity of the cornea.

The collagen fibrils occupy considerable space and thereby increase the path of diffusion. The net effect of impeding diffusion is to increase by several times the equivalent fluid layer thickness of the actual stroma. Nevertheless, the stroma is transparent to molecular species below approximately 500,000 Da. The stroma serves as the major ocular depot for topically applied hydrophilic drugs, and the keratocytes presumably provide a reservoir for lipophilic compounds as well.

The posterior border of the stroma is the endothelial basal lamina, termed *Descemet's layer*. Descemet's layer appears to pass molecular species as readily as does the stroma and is not known to act as a separate drug depot.

### Corneal Endothelium

The corneal endothelium, a monolayer of polygonal cells approximately 3 mm thick, has a structure and properties unique in the body. It should not be confused with the blood vessel endothelium, which is of different developmental origin and has different characteristics. The nonregenerative property of the corneal endothelium requires that existing cells stretch to cover the space of any neighbors that are destroyed by physical damage or senescence. The endothelial cell layer has the remarkable ability to pump its own weight in fluid from the stromal side into the anterior chamber in 5 minutes. The intercellular borders form a junction that is open along its full length and allows a rapid leakage of water and solutes in the reverse direction to the fluid pump.

The fluid pump is probably a bicarbonate-based ion transport that may be coupled to  $\text{Na}^+\text{-K}^+$  adenosine triphosphatase by an unknown mechanism. The leak is composed of a channel that is 12 nm long and 20 nm wide, narrowing to 5.0 nm at the edge facing the anterior chamber. This space is of a size sufficient to conduct large molecules, such as 3.5-nm diameter colloidal gold and colloidal lanthanum particles. The ultrastructure and ability to pass large molecules render the endothelial border a special type of leaky junction, rather than a tight junction (zonula occludens), as sometimes stated. Globular proteins exceeding 1 million daltons cannot pass readily, but smaller molecules are not hindered. Pinocytosis does occur in the endothelium and allows the transport of high-molecular-weight proteins. Because of the thinness

and small volume of the endothelial layer, it is not considered a major reservoir for drugs.

The cornea can concentrate certain substances from the aqueous, allowing the corneal stroma to hold more drug than would be expected from its fluid mass. This may result from the constant inward leakage of whole aqueous from the anterior chamber to the stroma, offset by the return of osmotic water by the fluid pump. Fluorescein given by mouth or vein thus accumulates rapidly in the corneal stroma from the aqueous. An alternative explanation for this accumulation is the ionic binding of substances by negative charges in stroma, reducing the diffusible pool of solute. Because fluorescein is itself an anion, however, this explanation is not fully satisfactory.

### Iris

The iris functions primarily to adjust the amount of light reaching the retina, simultaneously altering the visual depth of focus without changing the field of vision. It does this by controlling the total area of the visual pathway between the two major refractive components of the eye: the cornea and the lens. Therefore, it contains pigment to absorb light. To accomplish this function, two groups of muscles—the sphincter and the dilator—work in opposition. These are supplied by cholinergic and adrenergic innervation, respectively. Miosis can be accomplished by endogenous or exogenous acetylcholine or by cholinergic stimulation. Mydriasis can be accomplished by an adrenergic stimulant, such as epinephrine (which acts on the dilator musculature), or by an antagonist to acetylcholine (which allows relaxation of the sphincter). The readily observed behavior of the iris has made its action an excellent model for the study of drug penetration in the human eye.

The pigment granules of the iris epithelium absorb light and also can absorb lipophilic drugs. This type of binding is characteristically reversible, allowing release of drug over time. It is usually termed nonspecific or low-affinity binding, indicating that a specific high-affinity drug receptor is not involved. As a result, the iris can serve as a depot or reservoir for some drugs, concentrating and then releasing them for longer than otherwise expected.

An effective level within the eye of a single dose of a lipophilic drug can be prevented or delayed by nonspecific binding. On multiple dosing, however, a saturation equilibrium is reached when the amount of drug being bound is the same as that being released from the reservoir. Once this occurs effective dosing is achieved. Individual iris pigmentation varies widely, and some drugs show a far greater response after the first dose in blue-eyed individuals than in patients with dark irides. Constriction of the pupil (miosis) was demonstrated after a single dose of pilocarpine continuing for 4.7 hours in darkly pigmented subjects as compared with only 2 hours in subjects with blue eyes.



## Aqueous Humor

Aqueous humor is formed by the ciliary body and occupies the posterior and anterior chambers, a compartment measuring approximately 0.2 ml, although the total volume decreases with age as the lens grows. The fluid is constantly generated by the pigmented and nonpigmented epithelium of the ciliary body, which is supplied by a rich bed of capillaries. It flows from the posterior chamber through the pupil and then slowly circles in the anterior chamber, circulated by the thermal differential between the cornea and the deeper ocular tissues. The aqueous exits at the angle between the cornea and iris through the sieve-like trabecular meshwork or conventional outflow. It then enters the canal of Schlemm, which leads directly into low-pressure episcleral veins and finally into the general circulation. Aqueous humor may also exit through the walls of the iris or other tissues forming the margins of the anterior chamber, the uveoscleral route, or nonconventional routes of aqueous humor outflow. The uveoscleral route is believed to account for approximately 20% of aqueous humor outflow.

## Ciliary Body

The major function of the ciliary body is aqueous humor production. Aqueous is composed of a clear ultrafiltrate of blood plasma devoid of large proteins, together with some substances actively transported across the blood-aqueous barrier.

The numerous capillaries of the ciliary body possess no tight junctions to limit the diffusion of drugs or proteins. However, drugs are usually limited by the apically tight junctions of the nonpigmented cells at the paired layers making up the ciliary epithelium. Systemic drugs enter the anterior and posterior chambers largely by passing through the ciliary body vasculature and then diffusing into the iris, where they can enter the aqueous humor.

The ciliary body is the major ocular source of drug-metabolizing enzymes responsible for the two major phases of reactions that begin the process of drug detoxification and removal from the eye. The localization of these enzymes together in a single tissue is important, because the oxidative and reductive products from phase I reactions of the cytochrome P-450 system are highly reactive and potentially more toxic than are the parent compounds. Conjugation by glucuronidation, sulfonation, acetylation, and methylation or with amino acids or glutathione in phase II reactions can then be accomplished by detoxifying enzymes. The uveal circulation provides up to 88% of the total blood flow and can rapidly remove these conjugated products from the eye. Melanin granules of the pigmented ciliary epithelium adsorb polycyclic compounds, such as chloroquine, storing them for metabolism and removal.

## Crystalline Lens

The normal human lens originates from a double layer of epithelium. Its thickened outer basal lamina (the capsule) is analogous to Descemet's layer. The lens grows to become a thick flexible tissue composed of cells densely packed with clear proteins known as crystallins. By the age of 50 years flexibility is reduced, thus diminishing accommodation. The capsule reaches a thickness of several microns anteriorly and is 10 times thinner posteriorly. The anterior lens epithelium is the most active region metabolically, conducting cation transport and cell division. This region is also the most prone to damage from drugs or toxic substances.

Hydrophilic drugs of high molecular weight cannot be absorbed by the lens from the aqueous humor, because the lens epithelium is a major barrier to entry. The capsule prevents the entry of large proteins. Lipid-soluble drugs, however, can pass slowly into and through the lens cortex. Fluorescein, a hydrophilic molecule, can penetrate the capsule and reach the nucleus in a few weeks. The lens can be viewed primarily as a barrier to rapid penetration of drugs from aqueous to vitreous humor.

The lens grows with age, and colorations or opacities may develop and interfere with vision. Cataract formation may be enhanced by some miotics, steroids, and phenothiazines. Aldose reductase inhibitors, which prevent the conversion of sugars to polyols, appear to prevent or delay diabetic cataract. Levels of glutathione and other compounds drop during the formation of some types of cataracts. The pharmacokinetics of delivery and penetration of such compounds into the crystalline lens is currently of great interest.

When cataracts necessitate lens removal to restore vision, the kinetics between aqueous and vitreous humor change. A major barrier to molecular transport is removed, and more rapid exchange can occur between aqueous and vitreous contents and various ocular components. In one experimental study the concentration of a topically applied anti-inflammatory agent, flurbiprofen, was increased in retinal tissues, vitreous humor, and choroid after lens removal.

## Vitreous Humor

The vitreous humor is a viscoelastic connective tissue composed of small amounts of glycosaminoglycans, including hyaluronic acid, and of such proteins as collagen. The collagen fibrils are anchored directly to the basal lamina, which forms the boundaries of the lens, the ciliary body epithelium, and the neuroglial cells of the retina. Although the anterior vitreous is cell free, the posterior vitreous contains a few phagocytic cells, called hyalocytes, and is sometimes termed the *cortical tissue layer*.

At birth, the material of the vitreous is gel-like in humans and primates. A central remnant of the hyaloid artery, Cloquet's canal (which is free of collagen fibrils),

runs from the posterior lens capsule to the optic disc. Because the total volume of the vitreous expands with age while the amount of hyaluronate remains constant, the gel-like material develops a central viscous fluid lake completely surrounded by the gel vitreous. These events can cause condensation and tearing of the sheath of Cloquet's canal, forming structures termed *floaters*, which can interfere with vision.

The vitreous constitutes approximately 80% of the ocular mass. It may be considered an unstirred fluid with free diffusion for small molecules. Some molecular species can diffuse between the posterior chamber and the vitreous. However, very high-molecular-weight substances, such as hyaluronate, are held in place by the zonules and lens capsule and diffuse out of the vitreous only after intracapsular lens extraction. From this discussion, it is apparent that the vitreous can serve both as a major reservoir for drugs and as a temporary storage depot for metabolites. For low-molecular-weight substances, a free path of diffusion exists from the ciliary body through the posterior aqueous humor.

Hydrophilic drugs, such as gentamicin, do not cross the blood-retinal barrier readily after systemic administration. After intravitreal administration they have a prolonged half-life of 24 hours or more in the vitreous humor. Their major route of exit is across the lens zonules and into the aqueous humor and then through the aqueous outflow pathways. For the vitreous to act as a depot for these drugs, the agents must be injected, introduced by iontophoresis, or slowly released by a surgically implanted intraocular device.

## Retina and Optic Nerve

Tight junctional complexes (*zonula occludens*) in the retinal pigment epithelium prevent the ready movement of antibiotics and other drugs from the blood to the retina and vitreous. The retina is a developmental derivative of the neural tube wall and can be viewed as a direct extension of the brain; it is not surprising that the blood-retinal barrier somewhat resembles the blood-brain barrier in form and function. Experimental evidence has shown that histamine does not alter the vascular permeability of the retina but does affect that of all other ocular tissues. The retina closely resembles the brain with respect to this trait.

The capillaries of the retina are lined by continuous, close-walled, endothelial cells, which are the primary determinant of the molecular selectivity that is the major function of the blood-retinal barrier. Bruch's membrane is a prominent structure associated with the retinal-vitreous barrier, yet it contributes relatively little to the barrier's filtration properties.

The barrier protects against the entry of a wide variety of metabolites and toxins and is effective against most hydrophilic drugs, which do not cross the plasma membrane. Glucose, however, can cross much more

easily than would be expected from its molecular structure. This diffusion is probably facilitated by an active transport system involving a transmembrane carrier molecule. There is more evidence of retina and retinal epithelial membrane transporters in recent years (Table 2-2).

**Table 2-2**  
Summary of Molecular and/or Functional Evidence of Known Conjunctival and Retina/Retinal Pigmented Epithelial Membrane Transporters

Transporter	Species	Tissue
Aquaporins (AQPs)	Human, rat	Retina
Amino acid transporters	Mouse Rabbit Rat	Retina Conjunctiva BRB
Dicarboxylate transporters	Mouse	Retina, RPE
Peptide transporter (PepT)	Rabbit	Conjunctiva, RPE
PEPT2	Bovine, human, rat	Retina
Folate transporter	Human, rat	RPE
GABA transporters (GAT)	Bullfrog Mouse, rabbit, rat	Retina, RPE Retina
Glucose transporters (GLU)	Bovine Human Rabbit Rat	Retina, RPE Conjunctiva, retina, RPE Conjunctiva Retina, RPE
Glutamate transporters EAAC	Rat, bullfrog	Retina
GLAST/GLT/EAAC/EAAT	Human, bovine	Retina
Monocarboxylic acid (MCT)	Rabbit Human Bovine, porcine Rat	Conjunctiva Retina, RPE RPE Retina, RPE, inner BRB
MRP efflux	Human, pig	RPE
Nucleoside transporter	Rabbit Human	Conjunctiva, retina Retina, RPE
Organic anion transporters		
Oatp-2	Rat	Retina, RPE
Oatp-3	Mouse, rat	Retina, RPE
Oatp-E	Rat	Retina, RPE
Organic cation transporters		
Non-OCT type	Human	RPE
OCT-type	Mouse	Retina, RPE
OCT-type	Rabbit	Conjunctiva
P-glycoprotein efflux	Human, pig Rabbit Rat	RPE Conjunctiva Retinal endothelium

BRB = blood-retinal barrier; RPE = retinal pigmented epithelium.  
From Hughes PM, et al. *Adv Drug Deliv Rev* 2005;57:2017.

Lipophilic drugs cross the barrier easily in either direction because of their membrane fluidity. Topical epinephrine (often in aphakic eyes) has been associated with cystoid macular edema. Topical brimonidine 0.2% has been demonstrated to provide vitreous concentrations of 185 nM, which is believed to be a significant enough posterior segment concentration to provide neuroprotection. Topical dorzolamide in rabbits achieved significant levels in the retina and choroid to provide inhibition of carbonic anhydrase. Clinically, topical dorzolamide has also demonstrated some beneficial effect in retinitis pigmentosa patients. Topical memantine HCl achieved high retinal bioavailability in rabbits similar to oral dosing.

Systemic agents such as digitalis, phenothiazines, quinine, methyl alcohol, and quinoline derivatives can cause retinal toxicity. Some drugs, such as sildenafil, may cause a temporary toxic effect (color vision disturbance) on the retina. Numerous studies of intraocular penetration after systemic administration of antibiotics such as the fluoroquinolones and linezolid have demonstrated inhibitory concentrations in the vitreous fluid. Some oral antifungal medications such as fluconazole and voriconazole have also produced significant levels in the posterior segment after systemic administration. A growing number of substances have been shown to be transported from the vitreous and retina into the blood plasma, including ions, drugs, and the prostaglandins associated with ocular inflammation.

The optic nerve is of interest here because some drugs are toxic to this tissue. The antibiotics chloramphenicol, ethambutol, streptomycin, and sulfonamides can cause optic neuritis. Vitamin A, especially in large doses, can result in papilledema. Digitalis can cause retrobulbar neuritis (see Chapter 35).

### **Blood Supply and Removal of Drugs and Metabolites**

The parenteral route of administration is effective only for drugs of low systemic toxicity that can be introduced into the eye at therapeutic concentrations. An important example of systemic dosing is the case of internal ocular infections, such as endophthalmitis, where a high concentration of antibiotic must be maintained. The systemic dose can also be augmented by topical drug applications to the eye.

Drugs that are unacceptable as systemic medications due to toxicity to certain organs, such as liver or kidney, can be especially useful for topical ocular dosing. Certain drugs are also well suited for topical use in the eye or for injection, because they are rapidly diluted by the bloodstream to levels that are nontoxic.

The bloodstream is responsible for removing drugs and drug metabolites from ocular tissues. The two circulatory pathways in the eye—the retinal vessels and the uveal vessels—are fairly different. The retinal vessels can remove many drugs, metabolites, and such agents as

prostaglandins from the vitreous humor and retina, apparently by active transport. Organic ions, such as the penicillins and cephalosporins, exhibit short half-lives in the vitreous fluid because they are removed by active transport through the retinal transport system and via the anterior route. On the other hand, drugs such as the aminoglycosides, which exit only through the anterior route, often exhibit longer vitreous half-lives.

The uveal vessels remove drugs by bulk transport from the iris and ciliary body. The direct outflow pathway from aqueous humor through trabecular meshwork and canal of Schlemm into the episcleral vessels is another major source of drug removal from the eye.

### **COMPARTMENT THEORY AND DRUG KINETICS**

The eye is a unique structure, because several of its fluids and tissues—tear film, cornea, aqueous humor, lens, and vitreous humor—are almost completely transparent. These components of the ocular system have no direct blood supply in the healthy state. Each can be considered a separate chamber or compartment. A compartment is defined here as a region of tissue or fluid through which a drug can diffuse and equilibrate with relative freedom. Each compartment is generally separated by a barrier from other compartments, so that flow between adjacent compartments requires more time than does diffusion within each compartment.

The tears are an example of a compartment with constant turnover, because the inflow of lacrimal fluid is constant and equal to the outflow through the puncta. Consider the fate of sodium fluorescein, a diagnostic tracer representative of a highly hydrophilic drug: Once instilled it mixes rapidly with the tears, and the tear flow carries away a portion per unit time, dependent on the drug concentration present.

Approximately 99% of fluorescein or of a hydrophilic drug exits the tears by lacrimal drainage, yet a very small amount penetrates the corneal epithelial barrier and enters the stroma. A barrier is a region of lower permeability or restricted diffusion that exists between compartments. If the epithelium is considered to be a barrier to drug penetration from the tears and the bulk of the cornea forms a compartment, a two-compartment model can be described. In the absence of an active transport mechanism, drugs diffuse across barriers according to the laws of thermodynamics, from a region of higher to one of lower concentration. Fick's first law of diffusion states that the rate of diffusion across a barrier is proportional to the concentration gradient between the compartments on either side of the barrier.

From Fick's law the rate of diffusion of a drug across a barrier is linearly dependent on the concentration difference between the compartments on either side of the barrier. As soon as the concentration of drug in the cornea equals that of the tears, drug no longer inwardly penetrates.

Therefore, corneal absorption depends on the integral tear film concentration (also known as the area under the curve) during the first 10 to 20 minutes after instillation of drug. Absorption is subject to modification by many factors, including other drugs, preservatives, infection, inflammation, or neuronal control, which can greatly affect drug bioavailability at the desired site of action.

The diffusion of drug from the cornea to the aqueous humor is similar to that from tears to cornea, except that for the corneal depot the aqueous humor receives the major proportion of drug. Both lateral diffusion across the limbus and diffusion back across the epithelium contribute relatively little to the total diffusion.

The bulk of the corneal drug depot eventually enters the aqueous humor, and the aqueous level rises to a maximum over approximately 3 hours. After this time the concentration of drug in the cornea and in the aqueous humor drops in parallel as the aqueous humor level decays logarithmically.

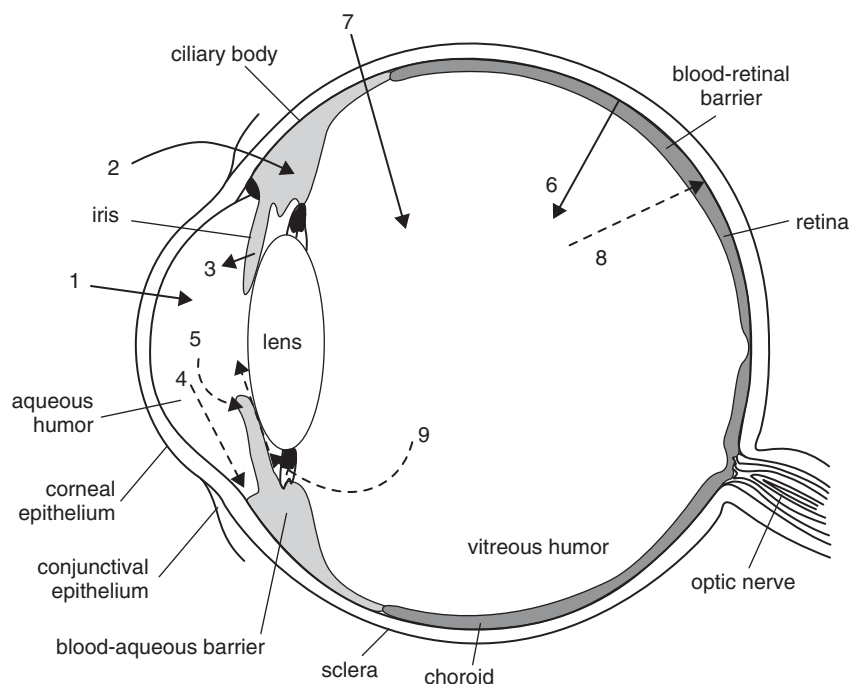
The compartment model just described can estimate the concentrations of drugs within various ocular tissues. A more complex compartment model that includes drug movement through the posterior aqueous, vitreous, and retina is shown in Figure 2-6. This model becomes useful when a drug is introduced directly into the vitreous or

systemic circulation or when the very slight amount of a topically applied drug reaching the lens, vitreous, or retina must be considered.

The molecular properties of drugs influence which tissues act as reservoirs for them and which act as barriers. Modeling parameters vary considerably for drugs with different penetration and partitioning properties. A lipophilic drug that is also water soluble penetrates the corneal epithelium more readily than does fluorescein, a more hydrophilic drug.

### Active Transport and Diffusion Kinetics

Drug distribution usually depends on the rate of passive diffusion within and between compartments. It is governed by the barrier resistance between any two compartments where the distribution is unequal at a given time. In some cases, however, molecules accumulate against a concentration gradient on one side of a barrier. Either of two phenomena is responsible for such an observation: one, coupled pumping mechanisms in the cell may provide the energy necessary for active transport, or two, nonspecific binding due to ionic or other forces may cause an apparent accumulation of molecules against a concentration gradient.



**Figure 2-6** Schematic presentation of the ocular structure with the routes of drug kinetics illustrated. The numbers refer to following processes: 1) transcorneal permeation from the lacrimal fluid into the anterior chamber, 2) noncorneal drug permeation across the conjunctiva and sclera into the anterior uvea, 3) drug distribution from the bloodstream via blood-*aqueous* barrier into the anterior chamber, 4) elimination of drug from the anterior chamber by the aqueous humor turnover to the trabecular meshwork and Schlemm's canal, 5) drug elimination from the aqueous humor into the systemic circulation across the blood-*aqueous* barrier, 6) drug distribution from the blood into the posterior eye across the blood-*retina* barrier, 7) intra-vitreous drug administration, 8) drug elimination from the vitreous via posterior route across the blood-*retina* barrier, and 9) drug elimination from the vitreous via anterior route to the posterior chamber. (From Urtti A. Challenges and obstacles of ocular pharmacokinetics and drug delivery. *Adv Drug Deliv Rev* 2006.)

The properties of passive drug release from a tissue or from an artificial device can vary under certain circumstances. One example is zero-order kinetics, a term used when the release of a drug is constant over time. Zero-order kinetic conditions are satisfied when the concentration of a drug released over time is independent of concentration. Drugs usually obey zero-order kinetics when there is a rate-limiting barrier, as when a carrier system is saturated by an excess of drug. The Vitrasert, implanted into the vitreous cavity, is an example of drug dosing by zero-order kinetics. A reservoir of ganciclovir is released at a nearly constant rate from the device for several months for treatment of cytomegalovirus retinitis.

First-order kinetics is most commonly encountered in ocular drug movement. Here, the rate of movement is directly proportional to the concentration difference across the barrier, and the rate changes with time as the concentration differential across the barrier changes. The passive diffusion of molecules across a nonsaturated barrier generally adheres to first-order kinetics.

### Prodrugs

When the metabolite of a drug is more active at the receptor site than is the parent form, the drug is often termed a prodrug. To be therapeutically useful a prodrug must metabolize predictably to the effective drug form before it reaches the receptor site. The greatest advantage of prodrugs is the potential to add groups that mask features of the drug molecule that prevent penetration or have other undesirable effects. Prodrug design can be a useful way of increasing penetration of a therapeutic agent through corneal or other barriers.

Dipivalyl epinephrine is the first successful example of the ophthalmic prodrug concept. A pair of pivalyl groups is attached to the two charged groups on epinephrine. The epithelial penetration is increased 10-fold by this diesterification because of the lipophilic nature of the modified prodrug. The pivalyl groups are removed by esterases in the cornea, leaving epinephrine to act at the receptor site. Thus, a topically applied dipivalyl derivative need only be one-tenth the concentration of epinephrine to achieve bioavailability equivalent to epinephrine. Systemic absorption of the drug is thereby greatly reduced. Dipivalyl epinephrine was widely used for IOP control in the treatment of glaucoma during the 1980s and early 1990s. Latanoprost and travoprost are also considered prodrugs in that the ester-linked group is cleaved off after penetrating the cornea with the free acid remaining in the aqueous humor.

The future design and use of prodrugs hold much promise in ocular drug delivery, particularly where lipophilic prodrugs can be induced to penetrate the blood-vitreous barrier readily and then are metabolized to a form that is trapped in the vitreous compartment. Because of their selective permeability, drugs could reach an effective concentration in the eye by entrapment

within the vitreous compartment. A major problem with this approach is that the brain may sequester drug in the same manner as that evinced by the vitreous humor. This could be avoided by identifying a suitable enzyme that is present in vitreous humor and not in the brain.

### Active Metabolites

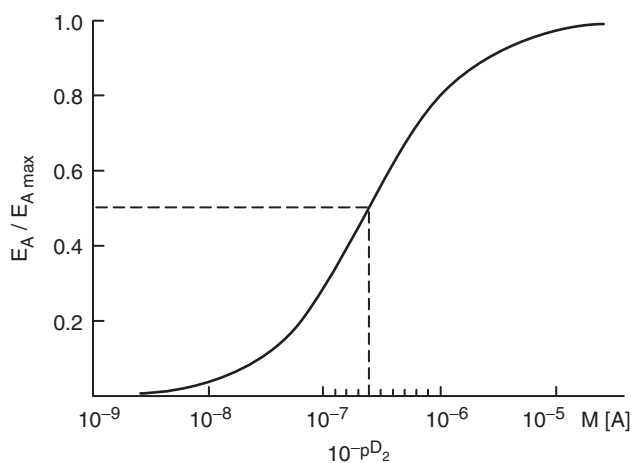
Loteprednol etabonate is an active metabolite of a prednisolone-related compound that predictably and rapidly undergoes transformation by enzymes in the eye to an inactive form associated with fewer side effects. Loteprednol is a potent corticosteroid with less tendency to raise IOP than that of prednisolone.

## PROPERTIES OF DRUG FORMULATIONS AFFECTING BIOAVAILABILITY

Biopharmaceuticals involves the development of optimum dosage forms for the delivery of a given drug. For example, preservatives that compromise the health of corneal epithelial cells have been eliminated from unit-dose medications intended for patients with dry eye and for other sensitive individuals. Major advances are also taking place in the development of vehicles and specific formulations to enhance ocular bioavailability and to decrease systemic absorption of drugs.

### Bioavailability

Bioavailability describes the amount of drug present at the desired receptor site. The dose level producing a response that is 50% of maximum is termed the  $ED_{50}$  (Figure 2-7). An effective dose level must be present for



**Figure 2-7** Classic dose-response curve for a drug agonist A. The sigmoid curve defines the theoretic effect on a specific receptor for varying concentrations of the agonist. ( $pD_2$  = negative log of the molar concentration of agonist producing 50% of maximum receptor effect, the  $ED_{50}$ .) (Reprinted with permission from Van Rossem JM, ed. Kinetics of drug action. Handbook of experimental pharmacology. Berlin: Springer, 1977: 47.)

a time sufficient to produce the desired action. The requirements for concentration and time to achieve  $ED_{50}$  differ widely, depending on the mechanism of action of the drug and the desired response.

### Active Ingredients

Therapeutic and diagnostic drugs given topically or systemically can have major effects on uptake of other drugs as a result of their own actions on tissue permeability, blood flow, and fluid secretion. Preservatives, buffers, and vehicles also can have significant effects on drug absorption. Table 2-3 categorizes some topical medications and preservatives and their effects on the corneal epithelium, as evaluated by scanning electron microscopy.

Many drugs used to treat glaucoma decrease aqueous humor formation and thereby slow their own kinetics of removal and removal of other drugs by the aqueous route. In like manner, anti-inflammatory agents compensate for the increased permeability of the blood–aqueous barrier and help to bring it back within normal limits, thus altering the kinetics of drugs within the eye. Many similar examples of drug modification of pharmacokinetics can be found (e.g., the inhibition of tear flow by systemically administered anticholinergic agents).

### Stability

No complex drug molecule is indefinitely stable in solution. The determination of drug stability is of major concern to the pharmaceutical industry. In the United States a manufacturer must demonstrate that at least 90% of the labeled concentration of a drug is present in the active form after storage at room temperature for the shelf life requested. In many cases a manufactured drug may contain 110% of the labeled amount of medication, so that 18% of the drug can degrade before the minimum acceptable level is reached. A shelf life of less than 18 months usually renders warehousing and distribution of a drug economically impractical, unless the drug is in very high demand. Once a sealed bottle is opened, the contents are subject to the risk of excessive oxidation from light exposure or heat and microbial contamination.

Drugs formulated in an acid solution are sometimes more stable than those at neutral or alkaline pH, particularly when the drug is a weak base. Often, such a drug must be stored at an acid pH to increase protonation and to prevent rapid degradation. Polypeptides, such as growth factors, which are now of interest in ophthalmic formulations, may require alkaline storage. In the eye the normal pH is approximately 7.4. Tear pH can remain altered for more than 30 minutes after addition of a strongly buffered solution. A change of tear pH can cause such irritation and stimulation of lacrimation that drug penetration is decreased. The use of a low concentration of buffer in the drug vehicle can allow the natural ocular

buffering system to reestablish normal tear film pH rapidly after drug instillation.

Certain drug formulations are not stable in solution. An extreme stability problem is posed by acetylcholine, a drug very useful in rapidly and reversibly constricting the pupil in some surgical procedures, such as cataract extraction. This agent degrades within minutes in solution. Therefore, a system for packaging has been developed using a sterile aqueous solution in one compartment and lyophilized (freeze-dried) drug in the other. A plunger displaces a stopper between chambers, allowing mixing just before use.

### Osmolarity

The combination of active drug, preservative, and vehicle usually results in a hypotonic formulation ( $< 290$  mOsm). Simple or complex salts, buffering agents, or certain sugars are often added to adjust osmolarity of the solution to the desired value. An osmolarity of 290 mOsm is equivalent to 0.9% saline, and this is the value sought for most ophthalmic and intravenous medications. The ocular tear film has a wide tolerance for variation in osmotic pressure. However, increasing tonicity above that of the tears causes immediate dilution by osmotic water movement from the eyelids and eye. Hypotonic solutions are sometimes used to treat dry eye conditions and to reduce tear osmolarity from abnormally high values.

### Preservatives

The formulation of ocular medications has included antimicrobial preservatives since the historic problem of fluorescein contamination in the 1940s. *Pseudomonas*, a soil bacterium that can cause corneal ulceration, uses the fluorescein molecule as an energy source for metabolism. Many years ago this bacterium caused serious consequences for practitioners who kept unpreserved solutions of fluorescein in the office to assist in the diagnosis of corneal abrasions. As a result of several tragic infections, two actions have been taken by manufacturers. First, fluorescein is now most commonly supplied as a dried preparation on filter paper, which prevents the growth of pathogens. Second, as a precautionary measure, most ophthalmic solutions designed for nonsurgical, multiple use after opening now contain preservatives. One example, moxifloxacin 0.5%, is considered “self-preserving” and contains no preservative, although it is in a multidose container. However, preservatives used at high concentrations can irritate and damage the ocular surface.

Various types of preservatives are currently available for commercial use. One group, the surfactants, is ionically charged molecules that disrupt the plasma membrane and is usually bactericidal. Another group of chemical toxins includes mercury and iodine and their derivatives, as well as alcohols. These compounds block

**Table 2-3**

Effects of Topical Ocular Drugs, Vehicles, and Preservatives on the Corneal Epithelium of the Rabbit Eye

Topical Preparation	Percentage	SEM Evaluation of Effects on Corneal Epithelium
<b>Preparations causing no epithelial damage</b>		
<i>Drugs</i>		
		Surface epithelial microvilli normal in size, shape, and distribution; no denuded cells; cell junctions intact; plasma membranes not wrinkled; usual number of epithelial "holes"
Atropine	1	
Chloromycetin	0.5	
Epinephryl borate	1	
Gentamicin	0.3	
Proparacaine	0.5	
Tetracaine	0.5	
<i>Vehicles</i>		
Boric acid in petrolatum-mineral oil	5	
Methylcellulose	0.5	
Polyvinyl alcohol	1.6	
Saline	0.9	
<i>Preservatives</i>		
Chlorobutanol	0.5	
Disodium edetate	0.1	
Thimerosal	0.01	
<b>Preparations causing moderate epithelial damage</b>		
<i>Drugs</i>		
Echothiophate iodide	0.25	Most cells normal; some cells showed loss of microvilli and wrinkling of plasma membranes; a small number of cells showed disruption of plasma membrane with premature cellular desquamation
Pilocarpine	2	
Fluorescein	2	
Fluor-I-Strip (wet with one drop 0.9% saline)		
<b>Preparations causing significant epithelial damage</b>		
<i>Drugs</i>		
Cocaine	4	Complete loss of microvilli; wrinkling of plasma membranes; premature desquamation of top layer of cells; severe epithelial microvillus loss
Neopolycin	(no BAC)	
<i>Preservatives</i>		
BAC	0.01	
<i>Drug + preservative</i>		
Pilocarpine	2	Severe membrane disruption; death and desquamation of two superficial layers of cells over 3-hr period
Gentamicin	0.3	
BAC	0.01	

BAC = benzalkonium chloride; SEM = scanning electron microscope.

Adapted from Pfister RR, Burstein NL. The effects of ophthalmic drugs, vehicles, and preservatives on corneal epithelium: a scanning electron microscope study. *Invest Ophthalmol* 1976;15:246-259.

the normal metabolic processes of the cell. They are considered bacteriostatic if they only inhibit growth or bactericidal if they destroy the ability of bacteria to reproduce. In contrast to antibiotics, which selectively destroy or immobilize a specific group of organisms, the preservatives act nonselectively against all cells. Another group, the oxidative preservatives, can penetrate cell membranes or walls and interfere with essential cellular function. Hydrogen peroxide and a stabilized oxychloro-complex (Purite) are examples of these newer preservative systems.

### Benzalkonium Chloride and Other Surfactants

The quaternary surfactants benzalkonium chloride (BAC) and benzethonium chloride are preferred by many manufacturers because of their stability, excellent antimicrobial properties in acid formulation, and long shelf life. They exhibit toxic effects on both the tear film and the corneal epithelium and have long been known to increase drug penetration. The toxicity of these compounds may be increased by the degree of acidity of the formulation.

A single drop of 0.01% BAC can break the superficial lipid layer of the tear film into numerous oil droplets because it can interface with the lipid monolayer of the tear surface and disrupt it by detergent action. BAC reduces the breakup time of the tear film by one-half. Repeated blinking does not restore the lipid layer for some time. The inclusion of BAC in artificial tear formulations is questionable. It neither protects the corneal epithelium nor promotes a stable oily tear surface.

Patients who receive anti-inflammatory agents are at particularly high risk of experiencing tear film breakup and corneal erosion because of the presence of BAC as a preservative. The repeated application of these drops can further compromise an eye in which the tear film or cornea may already be damaged. It may be necessary in superficial inflammation or corneal erosion to eliminate all medications; this alone may allow healing. In many cases of superficial inflammation, a lubricating eyedrop without preservatives may be the best course of treatment.

Histopathologic effects on both the conjunctiva and trabecular meshwork have been demonstrated with BAC-containing antiglaucoma medications. Long-term treatment of patients with antiglaucoma drugs is at least partially responsible for toxic inflammatory effects (or both) on the ocular surface. BAC is reported to produce a dose-dependent arrest of cell growth and death, causing necrosis at higher concentrations and apoptosis at concentrations as low as 0.0001%.

### Chlorhexidine

Chlorhexidine is a diguanide that is useful as an antimicrobial agent in the same range of concentrations occupied by BAC, yet it is used at lower concentrations in marketed formulations. It does not alter corneal permeability to the same degree as does BAC for perhaps two

major reasons. First, the structure of chlorhexidine is such that it has two positive charges separated by a long carbon backbone, and it cannot intercalate into a lipid layer in the same manner as does BAC. Second, proteins neutralize the toxicity of chlorhexidine, and this may occur in the tear film.

### Mercurials

Of the mercurial preservatives, thimerosal is less subject to degradation into toxic mercury than either phenylmercuric acetate or phenylmercuric nitrate. Thimerosal is most effective in weakly acidic solutions. Some patients, however, develop a contact sensitivity and must discontinue use after several weeks or months of exposure. Because thimerosal affects internal cell respiration and must be present at high continuous concentrations to have biologic effects, its dilution by the tear film prevents short-term epithelial toxicity on single application. It has no known effects on tear film stability. A concentration of 1% thimerosal is required to equal the effects on corneal oxygen consumption of 0.025% BAC.

### Chlorobutanol

Chlorobutanol is less effective than BAC as an antimicrobial and tends to disappear from bottles during prolonged storage. No allergic reactions are apparently associated with prolonged use. Scanning electron microscopy of rabbit corneal epithelial cells also indicates that twice-daily administration of a chlorobutanol-preserved artificial tear results in only modest exfoliation of corneal epithelial cells. Chlorobutanol is not a highly effective preservative when used alone and therefore is often combined with ethylenediaminetetraacetic acid (EDTA) in ophthalmic drug formulations.

**Stabilized Oxychloro-Complex and Sodium Perborate**  
Stabilized oxychloro-complex (Purite, Allergan, Irvine, CA) and sodium perborate (CIBA Vision) are relatively new oxidative preservative systems. Both Purite (present in Refresh Tears) and sodium perborate (in GenTeal) are found in artificial tear products. Purite dissipates into water and sodium chloride on exposure to light. Sodium perborate is converted to hydrogen peroxide and then oxygen and water once in the eye. Hydrogen peroxide itself is used as an effective contact lens disinfectant.

The oxidative preservatives, in contrast to the chemical preservatives, can be neutralized by mammalian cells and do not accumulate. These preservative systems thus provide effective activity against microorganisms while producing very low toxicity. Both compounds offer significant advantages over traditional preservatives and may produce less cellular toxicity.

### Miscellaneous Preservatives

The preservatives methylparaben and propylparaben are used in artificial tears and nonmedicated ointments. They can cause allergic reactions and are unstable at high pH.



Disodium EDTA is a special type of molecule known as a chelating agent. EDTA can preferentially bind and sequester divalent cations in the increasing order:  $\text{Ca}^{2+}$ ,  $\text{Mg}^{2+}$ ,  $\text{Zn}^{2+}$ ,  $\text{Pb}^{2+}$ . Its role in preservation is to assist the action of thimerosal, BAC, and other agents. By itself, EDTA does not have a highly toxic effect on cells, even in culture. Contact dermatitis is known to occur from EDTA.

When instilled topically in the eye, mercurial and alcoholic preservatives are rapidly diluted below the toxic threshold by tears. However, surfactant preservatives rapidly bind by intercalating into the plasma membrane and can increase corneal permeability before dilution can occur. The changed barrier property of the cornea can allow large hydrophilic molecules to penetrate the cornea far more readily.

SofZia is a new preservative system composed of boric acid, propylene glycol, sorbitol, and zinc chloride. Incorporated into Travatan Z, a prostaglandin for treatment of glaucoma, it is considered an extension of the manufacturer's borate/polyol preservative systems. SofZia has successfully met challenges from many ocular pathogens including *Pseudomonas aeruginosa*, *Escherichia coli*, *Candida albicans*, and *Aspergillus niger*.

## Vehicles

An ophthalmic vehicle is an agent other than the active drug or preservative added to a formulation to provide proper tonicity, buffering, and viscosity to complement drug action (Box 2-1). The use of one or more high-molecular-weight polymers increases the viscosity of the formulation, delaying washout from the tear film and increasing bioavailability of drugs. Polyionic molecules can bind at the corneal surface and increase drug retention and can stabilize the tear film. Petrolatum or oil-based ointments provide even longer retention of drugs at the corneal surface and provide a temporary lipid depot. In artificial tears the vehicles themselves may be the therapeutically active ingredients that moisturize and lubricate the cornea and conjunctiva and augment the tear film, preventing desiccation of epithelial cells.

The therapeutic index of drugs, particularly those that are systemically absorbed, can be maximized in many ways, including modifying the vehicle used for drug delivery. The  $\beta$ -blockers are an example of such a group. Increased viscosity and controlled-depot drug release are vehicular strategies that can contribute to increased specificity of these drugs. Increasing the pH to a more neutral pH has also allowed for increased bioavailability. Brimonidine Purite 0.15% and 0.1% are formulated at a more neutral pH, thereby providing increased bioavailability inside the aqueous fluid compared with brimonidine 0.2% while maintaining equivalent ability to lower IOP. Timolol maleate 0.5% formulated in potassium sorbate 0.47% provides for a more lipophilic or less polarized form of timolol. The less polarized form produces

better corneal penetration with increased aqueous humor concentrations, allowing for once daily dosing.

The monomer unit structure of the vehicle and its molecular weight and viscosity control the behavior of the vehicle. In the manufacture and purification of polymers, a range of molecular sizes is usually present in the final product.

### Box 2-1 Examples of Excipients Used in Ophthalmic Formulations

#### Viscous agents

Methylcellulose  
Polyvinyl alcohol  
Polyvinylpyrrolidone (povidone)  
Propylene glycol  
Polyethylene glycol  
Polysorbate  
Dextran  
Gelatin  
Carbomers (various; e.g., 934P, 940)

#### Antioxidants

Sodium sulfites  
Ethylenediaminetetraacetic acid

#### Wetting agents and solubilizing agents

Benzalkonium chloride  
Benzethonium chloride  
Cetylpyridinium chloride  
Docusate sodium  
Octoxynol and Nonoxynol  
Polysorbate  
Poloxamer  
Sodium lauryl sulfate  
Sorbitan  
Tyloxapol

#### Buffers

Acetic, boric, and hydrochloric acids  
Potassium and sodium bicarbonate  
Potassium and sodium borate  
Potassium and sodium phosphate  
Potassium and sodium citrate

#### Tonicity agents

Buffers  
Dextrans  
Dextrose  
Glycerin  
Propylene glycol  
Potassium and sodium chloride

Adapted from Bartlett JD, et al., eds. *Ophthalmic drug facts*. St. Louis, MO: Wolters Kluwer Health, 2007; and Ali Y, et al. *Adv Drug Deliv Rev* 2006.

Molecular viscosity, which is measured in centistokes, is a nonlinear function of molecular weight and of concentration. Thus, a 2% solution of polymer in water usually does not have twice the viscosity of a 1% solution. Each batch of a commercial polymer therefore must be measured for viscosity at the appropriate concentration. The addition of salts can affect the final viscosity of some polymers. Divalent anions and cations can have a major effect on the conformation of polymers in solution, occasionally causing incompatibilities when formulations are mixed together in the eye.

### Polyvinylpyrrolidone

Polyvinylpyrrolidone (PVP, U.S. Pharmacopeia [USP] name, povidone) is the homopolymer of *N*-vinyl-2-pyrrolidone, which was used as a blood plasma substitute during World War II. Although PVP is considered to be a non-ionic polymer, it has specific binding and detoxification properties that are of great interest in health care. For example, it complexes iodine, reducing its toxicity 10-fold while still allowing bactericidal action to occur. This occurs through the formation of iodide ions by reducing agents in the polymer, which then complex with molecular iodine to give tri-iodide ions. PVP can also complex with mercury, nicotine, cyanide, and other toxic materials to reduce their damaging effects.

The pharmacokinetics of PVP is well understood as a result of this agent's experimental use to determine the properties of pores in biological membranes. PVP molecules can readily penetrate hydrophilic pores in membranes if they are small enough, and they are also taken up by pinocytotic vesicles. Apparently, PVP is not detectably bound to membrane surfaces and hence does not provide long-lasting viscosity enhancement beyond the normal residence time in the tears.

PVP has very low systemic toxicity, shows no immune rejection characteristics, and is easily excreted by the kidneys at molecular weights up to 100,000 Da. The  $pK_a$  of the conjugate acid ( $PVP \cdot H^+$ ) is between 0 and 1, and the viscosity of PVP does not change until near pH 1, when it doubles. Therefore the ionic character of the PVP chain should not be appreciable at pharmaceutical or physiological pH values. However, with ionic cosolutes, anions are bound much more readily than are cations by PVP.

### Polyvinyl Alcohol

Introduced into ophthalmic practice in 1942, polyvinyl alcohol (PVA) is a water-soluble viscosity enhancer with both hydrophilic and hydrophobic sites. A common concentration used in ophthalmic preparations is 1.4%. PVA is useful in the treatment of corneal epithelial erosion and dry eye syndromes because it is nonirritating to the eye and actually appears to facilitate healing of abraded epithelium. It is used also to increase the residence time of drugs in the tears, aiding ocular absorption.

### Hydroxypropyl Methylcellulose

Like PVA, the viscosity enhancer hydroxypropyl methylcellulose is available in a variety of molecular weights and in formulations with different group substitutions. It has been shown to prolong tear film wetting time and to increase the ability of fluorescein and dexamethasone to penetrate the cornea. Hydroxypropyl methylcellulose 0.5% has been shown to exhibit twice the ocular retention time of 1.4% PVA.

### Carboxymethylcellulose

Carboxymethylcellulose is a vehicle whose properties in solution resemble another cellulose ether, hydroxymethylcellulose. However, the carboxylic and hydroxylic groups provide anionic charge, which may be valuable in promoting mucoadhesion and increasing tear retention time. Tensiometric testing has shown that carboxymethylcellulose has a greater adhesion to mucins than do other viscous vehicles currently used in ocular formulations (Table 2-4). Greater efficacy was demonstrated of unpreserved artificial tears containing carboxymethylcellulose over a preserved formulation of hydroxypropyl methylcellulose. Direct comparison of the two agents is similar, whereas the unpreserved formulation has yet to be demonstrated.

**Table 2-4**  
Mucoadhesive Performance of Several Polymers

Substance	Adhesive Performance
Carboxymethylcellulose	Excellent
Carbopol	Excellent
Carbopol and hydroxypropyl cellulose	Good
Carbopol base with white petrolatum/hydrophilic petrolatum	Fair
Carbopol 934 and EX 55	Good
Poly(methyl methacrylate)	Excellent
Polyacrylamide	Good
Poly(acrylic acid)	Excellent
Polycarbophil	Excellent
Homopolymers and copolymers of acrylic acid and butyl acrylate	Good
Gelatin	Fair
Sodium alginate	Excellent
Dextran	Good
Pectin	Poor
Acacia	Poor
Povidone	Poor
Poly(acrylic acid) cross-linked with sucrose	Fair

From Ali Y, Lehmussaari K. Industrial perspective in ocular drug delivery. *Adv Drug Deliv Rev* 2006.

### Sodium Hyaluronate

High-molecular-weight polymers, including mucin, collagen, and sodium hyaluronate (SH), have a viscosity that rises more rapidly than would be expected from increased concentration alone. When these substances are exposed to shear (e.g., with the motion of blinking), the viscosity decreases as the molecules orient themselves along the shear forces. This non-Newtonian property is termed shear thinning. An advantage of shear-thinning polymers is that they have a high viscosity in the open eye, stabilizing the tear film. When blinking occurs, such polymers thin, preventing the feeling of irritation that would occur with a high-viscosity newtonian fluid.

Several studies have demonstrated that SH remains in contact with the cornea for a longer time than does isotonic saline. Gamma scintigraphy has also shown that a solution of 0.25% has a longer residence time in the precorneal area of humans than does phosphate buffer solution. In addition, when 0.25% SH is combined with certain agents, it can enhance their ocular bioavailability. Compared with phosphate buffer solution, 0.25% SH significantly increases tear concentrations of topically applied gentamicin sulfate at 5 and 10 minutes after instillation. More studies are necessary to establish the safety of SH and its ability to maintain efficient drug levels in the precorneal area.

### Gel-Forming Systems

A newer development in ocular drug delivery systems is the use of large molecules that exhibit reversible phase transitions whereby an aqueous drop delivered to the eye reversibly gels on contact with the precorneal tear film. Such changes in viscous properties can be induced by alterations in temperature, pH, and electrolyte composition. Gelrite, a polysaccharide low-acetyl gellan gum, forms clear gels in the presence of mono- or divalent

cations typically found in tear fluid. Gelrite enhances corneal penetration and prolongs the action of topically applied ocular drugs (Figure 2-8). Comparison of timolol in the gel formulation (Timoptic-XE) to a standard solution has shown that a single daily dose of the gel is as effective in lowering IOP in patients with open-angle glaucoma as is twice-daily instillation of the solution.

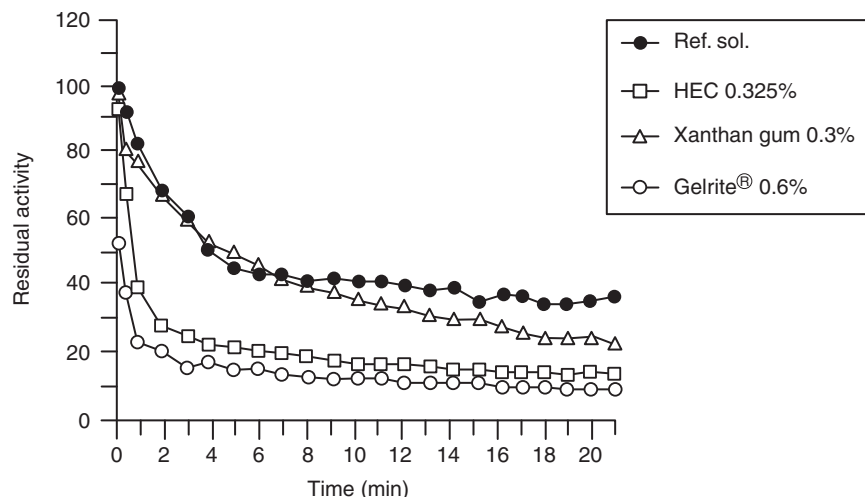
A heteropolysaccharide (xanthan gum) vehicle also produces longer ocular surface contact time and has been incorporated into a once-daily timolol gel formulation (Falcon gel-forming). Twenty-one minutes after instillation, 12% of a reference solution, 25% of the xanthan gum solution, and 39% of Gelrite solution remain on the ocular surface (see Figure 2-8).

### Polyionic Vehicles

Advances in chemical synthesis and in an understanding of the tear film of the eye have resulted in the development of compounds with two or more regions that vary in both their lipophilic nature and binding. The first of these to be tested in the eye was poloxamer 407, a block polymer vehicle with a hydrophobic nucleus of polyoxypropylene, and hydrophilic end groups of polyoxyethylene. One advantage of poloxamers is their ability to produce an artificial microenvironment in the tear film, which can greatly enhance the bioavailability of lipophilic drugs such as steroids.

### Polyacrylic Acids

Several of the polyacrylic acids are used as vehicles for various ophthalmic products. The polyacrylic acids, such as the carbopol gels, display pseudoplastic properties, demonstrating a decrease in viscosity with increasing shear rate, blinking, and ocular movement. These properties allow for greater patient acceptance. The carbopol gels also demonstrate good mucoadhesive and wetting



**Figure 2-8** The mean residual activity on the ocular surface after instillation of 25  $\mu$ l of various ophthalmic solutions containing 0.5% pilocarpine salts. (Modified from Meseguer G, Buri P, Plazonnet B, et al. Gamma scintigraphic comparison of eyedrops containing pilocarpine in healthy volunteers. *J Ocul Pharmacol Ther* 1996;12:483.)

properties on the surface of the eye. Ophthalmic products containing carbopol gels include Pilopine gel (carbopol 940), Vexol (carbomer 934P), Betoptic S (carbomer 934P), and Azopt (carbomer 974P).

#### Cation Exchange Resin (Amberlite)

Emulsions are biphasic lipid-water or water-lipid combinations that can dissolve and deliver both hydrophilic and lipophilic compounds. A binding agent, such as the polyacrylic acid polymer carbopol 934P, is added to the mixture to enhance physical stability and ease of resuspendability of the product. This system has been used with the topical antiglaucoma drug betaxolol. Betaxolol is first combined with a cation exchange resin to which it binds. This binding reduces the amount of free drug in solution and enhances ocular comfort after topical application. The drug-resin particles are then incorporated into a vehicle containing the carbopol 934P, which increases viscosity of the formulation and prolongs ocular contact time of the drug. The ocular bioavailability of 0.25% betaxolol suspension (Betoptic-S) is equivalent to that of 0.5% betaxolol solution.

#### Ointments

Ointments are commonly used for topical application of drugs to the eye. These vehicles are primarily mixtures of white petrolatum and liquid mineral oil with or without a water-miscible agent, such as lanolin. The mineral oil is added to the petrolatum to allow the vehicle to melt at body temperature, and the lanolin is added to the nonemulsive ointment base to absorb water. This allows for water and water-soluble drugs to be retained in the delivery system. Commercial ophthalmic ointments are derivatives of a hydrocarbon mixture of 60% petrolatum USP and 40% mineral oil USP, forming a molecular complex that is semisolid but melts at body temperature. In general, ointments are well tolerated by the ocular tissues, and when antibiotics are incorporated they are usually more stable in ointment than in solution.

The primary clinical purpose for an ointment vehicle is to increase the ocular contact time of the applied drugs. The ocular contact time is approximately twice as long in the blinking eye and four times longer in the nonblinking (patched) eye as compared with a saline vehicle. Ointments are retained longer in the conjunctival sac because the large molecules of the ointment are not easily removed into the lacrimal drainage system by blinking. A nonpolar oil is a component of tears, and this is another factor in the prolonged retention. Because ointments are nonpolar oil bases, they are readily absorbed by the precorneal and conjunctival tear films. Ointments are used to increase drug absorption for nighttime therapy or for conditions in which antibiotics are delivered to a patched eye, such as corneal abrasions, because they markedly increase contact time. They are also useful in treating children because they do not wash out readily with tearing. Ointments have several disadvantages,

however, including transient blurred vision, difficult administration, and potential for minor corneal trauma.

#### Colloidal Systems

Various colloidal systems have been studied for use as potential ophthalmic delivery systems, including liposomes and nanoparticles. Liposomes are bioerodible and biocompatible systems consisting of microscopic vesicles composed of lipid bilayers surrounding aqueous compartments. Liposomes have demonstrated prolonged drug effect at the site of action but with reduced toxicity. Ophthalmic studies have included topical, subconjunctival, and intravitreal administration, but no commercial preparations are currently available for ophthalmic use.

Nanoparticles are polymeric colloidal particles that consist of drug-entrapped macromolecular materials. Nanoparticles represent a comfortable, extended-duration, drug delivery system that has the potential to preferentially adhere to inflamed eyes.

#### Cyclodextrins

Cyclodextrins are a group of cyclic oligosaccharides consisting of a hydrophilic outer surface of six to eight glucose units incorporating lipid-soluble drugs in their center. They are soluble in water and are often used to improve solubility, stability, or irritability of various compounds. They have demonstrated increased ocular bioavailability and have been studied for potential ophthalmic administration.

#### Drug Release Systems

Soft contact lenses and collagen shields absorb drugs from solution and then slowly release them when placed on the eye. This form of drug therapy can be valuable when continuous treatment is desired (see Chapter 3).

Two major types of advanced drug release systems have been designed on the basis of insertion of a solid device in the eye. The first is a device of low permeability filled with drug (Ocuser), which has been discontinued. The second is a polymer that is completely soluble in lacrimal fluid, formulated with drug in its matrix (Lacrisert). Both systems can be made to approach zero-order kinetics. However, patient acceptance has been poor.

In recent years intraocular delivery of medication, including anti-vascular endothelial growth factor, corticosteroids and related compounds, and antiviral agents, has either been approved or is under study for treatment of macular degeneration, uveitis, cytomegalovirus, or diabetic macular edema (Table 2-5). This area of research and development is growing rapidly.

A ganciclovir intravitreal implant (Vitrasert, Chiron Vision, Claremont, CA) that has been developed provides release of 4.5 mg ganciclovir from a PVA and ethyl-vinyl-acetone polymer pellet at approximately

**Table 2-5**  
Marketed Drugs or Drugs Under Development for Intravitreal Delivery

Brand Name	Chemical Name	Manufacturer	Stage of Development	Proposed Indication	Route of Administration
Posurdex®	Dexamethasone implant	Allergan	Phase III	Diabetic macular edema	Biodegradable intravitreal rod-shaped implants
Kenalog®	Triamcinolone acetonide	Bristol-Myers Squibb	Off-label use	Wet AMD, DME, Uveitis	Intravitreal injection
Vitravene®	Fomivirsen	Isis	Past marketed product; withdrawn	Cytomegalovirus	Intravitreal injection
Vitraser®	Ganciclovir	Bausch & Lomb	Marketed product	Cytomegalovirus	Intravitreal implant
Vitrase®	Ovine sodium hyaluronidase	Ista Pharmaceuticals	Off-label use	Vitreous hemorrhage	Intravitreal injection
Retisert®	Fluocinolone acetonide	Bausch & Lomb	Marketed product	Uveitis	Intravitreal implant
Macugen®	Pegaptanib sodium	Eyetech Pharmaceuticals/Pfizer	Marketed product	Exudative AMD	Intravitreal injection
Lucentis	Ranibizumab	Genentech/Novartis	Marketed product	Exudative AMD	Intravitreal injection
Retane	Anecortave acetate	Alcon	Phase III	Exudative AMD	Juxtafoveal sub-Tenon's injection
VEGF Trap	Fusion protein, of extracellular domains of VEGFR-1 and -2 fused to the Fc portion of IgG1	Regeneron Pharmaceuticals	Phase I/II	Exudative AMD	Intravitreal injection

AMD = age-related macular degeneration; DME = diabetic macular edema; VEGF = vascular endothelial growth factor; VEGFR = VEGF receptor. From Duvvuri S, et al. *Advanced Drug Delivery Reviews* 57 (2005) 2080–2091; Table 1, p 2082.

1 mcg/hr. Therapeutic levels may be obtained for 5 to 8 months after surgical implantation into the vitreous cavity. Fluocinolone acetonide intravitreal implant 0.59 mg (Retisert) has been approved for treatment of chronic noninfectious uveitis affecting the posterior segment of the eye. It is surgically implanted into the posterior segment of eye and delivers initially 0.6 mcg/day, decreasing to 0.3 to 0.4 mcg/day over about 30 months.

An intraocular drug delivery system that has been developed consists of a biodegradable polymer matrix and may be able to incorporate various medications. A dexamethasone drug delivery system (Surodex) is under investigation for use in preventing postoperative inflammation after cataract surgery. Inserts may also increase the noncorneal route of drug absorption across the sclera. To date, the expense of the slow-release inserts compared with the economy of eyedrops has hindered their acceptance. However, both theory and clinical experience support the rationality of this approach to ocular dosing. Future improvements in technology and reduced cost would allow increased use of these dosage forms. A posterior segment delivery system (Posurdex) may also allow for similar intraocular administration of a biodegradable matrix for corticosteroid and potentially other medications. Intraocular implants that provide for an extended period of drug delivery are being studied to allow for the treatment of many posterior segment diseases such as cytomegalovirus retinitis, macular degeneration, and macular edema.

## OCULAR DRUG DEVELOPMENT AND THE PATIENT

Many steps are involved in the successful design of an ocular drug formulation. The first is selection of an appropriate drug molecule that maximizes therapeutic benefit and bioavailability while minimizing toxicity. A formulation must then be developed to include a vehicle, a preservative, and a buffer.

Combinations of the aforementioned delivery systems may offer the potential for increased ocular bioavailability and reduced toxicity. Stability, toxicity, and efficacy must then be evaluated for the complete formulation. An effective dosing regimen must also be developed before beginning clinical trials on a wide scale. The U.S. Food and Drug Administration is involved in evaluating these steps to provide formulations that are efficacious and safe.

Of the numerous factors that influence ocular drug efficacy and safety, one of the most important remains that of patient compliance. Determining the proper dosage regimen and getting patients to administer the medication is a primary responsibility of the practitioner. These factors are considered in Chapters 1 and 4.

## SELECTED BIBLIOGRAPHY

- Adams J, Wilcox MJ, Trousdale MD, et al. Morphologic and physiologic effects of artificial tear formulations on corneal epithelium derived cells. *Cornea* 1992;11:234-241.
- Ahmed I, Patton TE. Importance of the noncorneal absorption route in topical ophthalmic drug delivery. *Invest Ophthalmol Vis Sci* 1992;33:581-595.
- Ali Y, Lehmussaari K. Industrial perspective in ocular drug delivery. *Adv Drug Deliv Rev* 2006; July 31.
- Balazs EA, Denlinger JL. The vitreous. In: Davson H, ed. *The eye*, ed. 3. New York: Academic Press, 1984:533-589.
- Bartlett JD, Bennett ES, Fiscella R, et al., eds. *Ophthalmic drug facts*. St. Louis, MO: J.B. Lippincott, 2007.
- Baudouin C, Pisella P, Fillacier K, et al. Ocular surface inflammatory changes induced by topical antiglaucoma drugs. *Ophthalmology* 1999;106:556-563.
- Bito LZ, DeRousseau CJ. Transport functions of the blood-retinal barrier system of the micro environment of the retina. In: Cunha-Vaz J, ed. *The blood-retinal barriers*. New York: Plenum Press, 1980:133-163.
- Bourges JL, Bloquel C, Thomas A, et al. Intraocular implants for extended drug delivery: therapeutic applications. *Adv Drug Deliv Rev* 2006; July 31.
- Burstein NL. Corneal cytotoxicity of topically applied drugs, vehicles, and preservatives. *Surv Ophthalmol* 1980;25:15-30.
- Burstein NL. Preservative alteration of corneal permeability in humans and rabbits. *Invest Ophthalmol Vis Sci* 1984;25:1453-1457.
- Burstein NL. Preservative cytotoxic threshold for benzalkonium chloride and chlorhexidine digluconate in cat and rabbit corneas. *Invest Ophthalmol Vis Sci* 1980;19:308-313.
- Burstein NL. The effects of topical drugs and preservatives on the tears and corneal epithelium in dry eye. *Trans Ophthalmol Soc U K* 1985;104:402-409.
- Burstein NL, Anderson JA. Review: corneal penetration and ocular bioavailability of drugs. *J Ocular Pharmacol* 1985;1:309-326.
- Burstein NL, Bernacchi D, Leopold IH. Gentamicin iontophoresis into vitreous humor. *J Ocular Pharmacol* 1985;1:63-368.
- Canon J, Fiscella R, Pattharachayakul S, et al. Comparative toxicity and concentrations of intravitreal amphotericin B formulations in a rabbit model. *Invest Ophthalmol Vis Sci* 2003;44:2112-2117.
- Chang DF, Garcia IH, Hinkeler JD, Minas T. Phase II results of an intraocular steroid delivery system for cataract surgery. *Ophthalmology* 1999;106:1172-1177.
- Cunha-Vaz J. The blood-ocular barriers. *Surv Ophthalmol* 1979;23:279-296.
- Desaint JM, Brignole F, Bringuier A, et al. Effects of benzalkonium chloride on growth and survival of Chang conjunctival cells. *Invest Ophthalmol Vis Sci* 1999;40:619-630.
- Duvvuri S, Rittenhouse KD, Mitra AK. Micodialysis assessment of drug delivery systems for vitreoretinal targets. *Adv Drug Deliv Rev* 2005;57:2080-2091.
- Fiscella R, Burstein NL. Ophthalmic drug formulations. In: Bartlett JD, Jaanus SD, eds. *Clinical ocular pharmacology*, ed. 4. Boston: Butterworth Heinemann, 2001.
- Fiscella R, Lai WW, Buerk B, et al. Aqueous and vitreous penetration of linezolid (Zyvox) after oral administration. *Ophthalmology* 2004;111:1191-1195.

- Fiscella R, Nguyen T, Cwik MJ, et al. Aqueous and vitreous penetration of levofloxacin after oral administration. *Ophthalmology* 1999;106:2286-2290.
- Fisher RF, Hayes BP. Thickness and volume constants and ultrastructural organization of basement membrane (lens capsule). *J Physiol* 1979;293:229-245.
- Fraunfelder FT, Fraunfelder FW. Drug-induced ocular side effects, ed. 5. Boston: Butterworth Heinemann, 2001.
- Friedlaender M. External disease and allergy. In: Ellis PP, ed. *Current topics in ocular inflammation*. Littleton, CO: Postgraduate Institute for Medicine, 1993:29-34.
- Gaynes B, Fiscella R. Topical non-steroidal anti-inflammatory drugs (NSAIDs) for ophthalmic use: a safety review. *Drug Saf* 2002;25:233-250.
- Ghate D, Edelhauser HF. Ocular drug delivery. *Expert Opin Drug Deliv* 2006;3:275-287.
- Gray RH, Franklin SJ, Reeves BC. Visual recovery using small dilating drops. *J Pharm Pharmacol* 1992;44:682-684.
- Greaves JL, Wilson CG, Rozier A, et al. Scintigraphic assessment of an ophthalmic gelling vehicle in man and rabbit. *Curr Eye Res* 1990;9:415-420.
- Green K, Livingston V, Bowman K. Chlorhexidine effects on corneal epithelium and endothelium. *Arch Ophthalmol* 1980;98:1273-1278.
- Gunning FB, Greve EL, Bron AM, et al. Two topical carbonic anhydrase inhibitors sezolamide and dorzolamide in Gelrite vehicle: a multiple-dose efficacy study. *Graefes Arch Clin Exp Ophthalmol* 1993;31:384-388.
- Hardberger R, Hanna C, Boyd CM. Effects of drug vehicles on ocular contact time. *Arch Ophthalmol* 1975;93:42-45.
- Hosoya K, Lee VHL, Kim KJ. Roles of the conjunctiva in ocular drug delivery: a review of conjunctival transport mechanisms and their regulation. *Eur J Pharm Biopharm* 2005;60:227-240.
- Hughes PM, Olejnik O, Chang-Lin JE, Wilson CG. Topical and systemic drug delivery to the posterior segments. *Adv Drug Deliv Rev* 2005;57:2010-2032.
- Jadhav KR, Shaikh IM, Ambade KW, Kadam VJ. Applications of microemulsion based drug delivery system. *Curr Drug Deliv* 2006;3:267-273.
- Kaila T, Salminen L, Huupponen R. Systemic absorption of topically applied ocular timolol. *J Ocular Pharmacol* 1985;1:79-83.
- Koevary SB. Pharmacokinetics of topical ocular drug delivery: potential uses for the treatment of diseases of the posterior segment and beyond. *Curr Drug Metab* 2003;4:213-222.
- Madhu C, Rix P, Nguyen T, et al. Penetration of natural prostaglandins and their ester prodrugs and analogs across human ocular tissues in vitro. *J Ocul Pharmacol Ther* 1998;14:389-399.
- Marmor MF. Sildenafil (Viagra) and ophthalmology. *Arch Ophthalmol* 1999;117:518-519.
- Maurice DM. Injection of drugs into the vitreous body. In: Leopold IH, Burns RP, eds. *Symposium on ocular therapy*. New York: John Wiley & Sons, 1976:59-71.
- Maurice DM, Mishima S. Ocular pharmacokinetics. In: Sears ML, ed. *Pharmacology of the eye: handbook of experimental pharmacology*, vol. 69. Berlin: Springer-Verlag, 1984:19-116.
- Moshfeghi AA, Peyman GA. Micro and nanoparticulates. *Adv Drug Deliv Rev* 2005;57:2047-2052.
- Nelson JD, Helms H, Fiscella R, et al. A new look at dry eye disease and its treatment. *Adv Ther* 2000;17(2):84-92.
- Ranta VP, Urtti A. Transscleral drug delivery to the posterior eye: prospects of pharmacokinetic modeling. *Adv Drug Deliv Rev* 2006; Sep 15.
- Rozier A, Mazuel C, Grove J, et al. Gelrite: a novel ion-activated, in-situ gelling polymer for ophthalmic vehicles. Effect on bioavailability of timolol. *Int J Pharmacol* 1989;57:163-168.
- Sultana Y, Jain R, Aqil M, Ali A. Review of ocular drug delivery. *Curr Drug Deliv* 2006;3:207-217.
- Szejtli L. Medicinal applications of cyclodextrins. *Med Res Rev* 1994;14:353-386.
- Tan DT, Chee S, Lim L, Lim A. Randomized clinical trial of a new dexamethasone delivery system (Surodex) for treatment of post-cataract surgery inflammation. *Ophthalmology* 1999; 106:223-231.
- Urtti A. Challenges and obstacles of ocular pharmacokinetics and drug delivery. *Adv Drug Deliv Rev* 2006; July 31.
- Urtti A, Salminen L. Minimizing systemic absorption of topically administered ophthalmic drugs. *Surv Ophthalmol* 1993;37: 435-456.
- Van Santvliet L, Ludwig A. Determinants of eye drop size. *Surv Ophthalmol* 2004;49:197-213.
- Yasukawa T, Ogura Y, Kumura H, et al. Drug delivery from ocular implants. *Expert Opin Drug Deliv* 2006;3:261-273.

## *Ophthalmic Drug Delivery*

*Jimmy D. Bartlett*

The pharmacotherapy of eye disease generally requires high local concentrations of drug at the ocular tissues. Treatment of ocular surface infections or inflammations necessitates effective drug delivery to the eyelids, conjunctiva, or cornea. In contrast, treatment of uveitis, glaucoma, or retinitis involves therapeutic drug levels at appropriate target sites deep within the globe. Although many systems have been developed specifically for drug delivery to the eye, most of them suffer from lack of precision, and those associated with intraocular drug delivery can lead to toxicity. This chapter discusses the most clinically useful drug delivery systems developed for ocular pharmacotherapy, with emphasis on those used in primary eye care.

### **TOPICAL ADMINISTRATION**

Topical application, the most common route of administration for ophthalmic drugs, is convenient, simple, and noninvasive, and patients can self-administer the medication. Topically applied anesthetics are even used as the primary anesthetic for contemporary cataract surgery. The primary source of drug loss in topical administration is diffusion into the circulating blood. Diffusion into the blood takes place through blood vessels of the conjunctiva, episclera, intraocular vessels, and vessels of the nasal mucosa and oral pharynx after drainage through the nasolacrimal system. Because of these losses of drug through the systemic circulation, topically administered medications do not typically penetrate in useful concentrations to the posterior ocular structures and therefore are often of no therapeutic benefit for diseases of the posterior segment.

### **Solutions and Suspensions**

Solutions are the most commonly used mode of delivery for topical ocular medications. Solutions or suspensions are usually preferred over ointments, because the former are more easily instilled, interfere less with vision, and have fewer potential complications. Disadvantages of topically applied solutions include short ocular contact

time, imprecise and inconsistent delivery of drug, frequent contamination, and the possibility of ocular injury with the dropper tip.

Suspensions must be resuspended by shaking to provide an accurate dosage of drug, and the degree of resuspension varies considerably among preparations and among patients. Corticosteroid formulations, for example, are not always adequately resuspended even by the most compliant and carefully instructed patients. Some generic steroid suspensions, moreover, have been found to suspend poorly, and some generic products may develop a clogged dropper tip. These problems have been described primarily in association with 1% prednisolone acetate suspension.

### **Packaging**

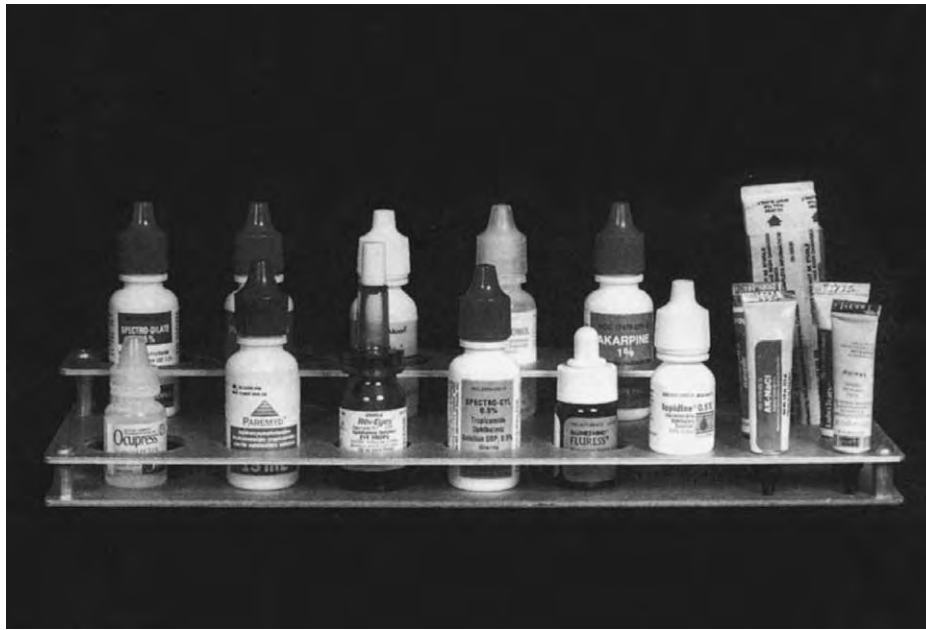Most eyedrop containers consist of two parts, an eyedropper tip and a bottle containing the solution or suspension. Because it is advantageous to administer small volumes of medication to minimize systemic absorption of topically applied solutions or suspensions, some manufacturers have attempted to reduce eyedrop volume by modifying or redesigning dropper tips. Traditionally, commercial eyedrops have ranged in size from 50 to 70 mcL. The typical volumes now delivered by commercial glaucoma medications are in the range of 25 to 56 mcL.

To help reduce confusion in labeling and identification among various topical ocular medications, drug packaging standards are in use. The standard colors for drug labeling and bottle caps are yellow, blue, or both for beta blockers; red for mydriatics and cycloplegics; green for miotics; orange for carbonic anhydrase inhibitors; gray for nonsteroidal anti-inflammatory drugs; pink for steroids; brown or tan for anti-infective agents; and teal for prostaglandin analogues.

### **Storage**

Solutions of drugs should be stored in the examination room in a manner allowing easy identification of labels (Figure 3-1). Containers of solutions often differ little in size, shape, or labeling. The drug name should be





**Figure 3-1** Drug storage tray allows easy identification of packaging labels.

confirmed by inspection each and every time a medication is used.

Although refrigeration of solutions may help to prolong shelf life, there appears to be little difference in local ocular irritation caused by eyedrops stored in the refrigerator or at room temperature. Cold drops, however, often can serve to reinforce proper eyedrop self-administration technique for patients who have difficulty ascertaining when the drops have been properly instilled.

Expiration dates of solutions should be respected. Office staff should periodically survey ophthalmic preparations in the office and discard solutions that have reached the expiration date. The use of old solutions can increase liability as well as introduce the risk of potential drug toxicity or iatrogenic infection. Some commonly used ophthalmic solutions, such as proparacaine, may change color, which indicates oxidation (Figure 3-2), whereas others show no visible signs of deterioration.

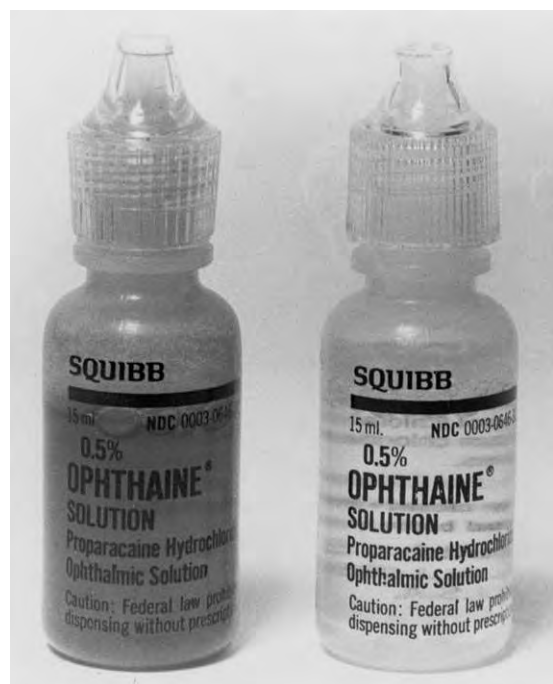### Techniques of Instillation

Two methods are commonly used to instill topical ocular solutions:

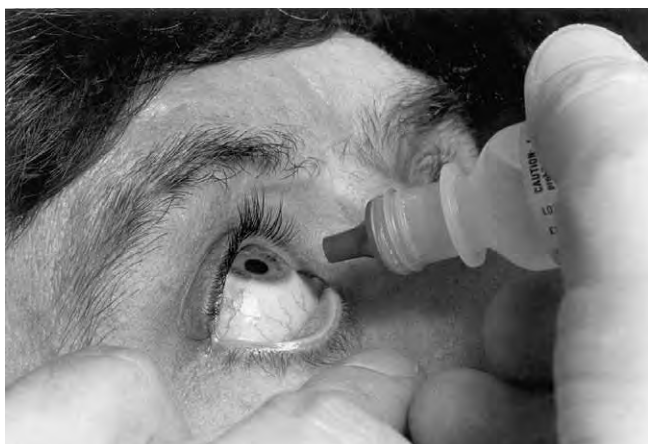1. With the patient looking down and the upper lid retracted, a drop of solution is applied to the superiorly exposed bulbar conjunctiva.
2. With the patient's head inclined backward so that the optical axis is as nearly vertical as possible, the lower lid is retracted and the upper lid stabilized. The patient should be instructed to elevate the globe to move the cornea away from the instillation site to minimize the blink reflex. The solution is instilled, and the dropper tip is kept at least 2 cm from the globe to avoid contact contamination (Figure 3-3). After the lids are gently closed, the patient should be cautioned to avoid lid

squeezing. Pressure should be applied with the fingertips over the puncta and canaliculi to minimize nasolacrimal drainage (Figure 3-4). This position, known as nasolacrimal occlusion, should be maintained for 2 to 3 minutes.

Several investigators have shown that simple eyelid closure alone significantly retards medication drainage and thereby minimizes potential side effects associated



**Figure 3-2** Change in color of proparacaine solution (*left*) indicates deterioration of the formulation.



**Figure 3-3** Traditional technique for instillation of topical ocular solutions. The patient's head is inclined backward, the lower lid is retracted, the globe is elevated, and the dropper tip is kept at least 2 cm from the globe.

with systemic drug absorption. However, when nasolacrimal occlusion is used in conjunction with eyelid closure, intraocular drug absorption may be enhanced. The same maximal drug effect can be achieved with many ocular hypotensive drugs at lower concentrations and with lower dosage frequencies than those generally recommended. This is true at least for use of pilocarpine and timolol. In the long-term treatment of glaucoma with topical drugs, silicone punctal plugs may be used as a



**Figure 3-4** Nasolacrimal drainage of solutions may be minimized by applying pressure with fingertips over the puncta and canaliculi.

### **Box 3-1** Recommended Procedure for Instilling Topical Ocular Solutions

1. Tilt patient's head backward.
2. Instruct patient to direct gaze toward ceiling.
3. Gently grasp lower outer eyelid below lashes and pull eyelid away from globe.
4. Without touching lashes or eyelids, instill one drop of solution into conjunctival sac.
5. Continue to hold eyelid in this position for a few seconds to allow solution to gravitate into deepest portion of lower fornix.
6. Instruct patient to gaze downward while lifting the eyelid upward until it contacts the globe.
7. Instruct patient to gently close eyes.
8. Patient should keep eyes closed for 2 to 3 minutes.

substitute for manual nasolacrimal occlusion. It is unclear, however, whether these devices actually achieve better intraocular pressure control compared with no occlusion. Boxes 3-1 and 3-2 summarize the recommended procedures for drop instillation.

Administering topical solutions to uncooperative children is often difficult. Several techniques may be used to facilitate drug administration to these patients. The child's hand can be placed on the forehead, which proprioceptively reinforces upward gaze. In addition, the palpebral aperture can be widened for drop instillation by telling the child to open his or her mouth. A spread of the neural impulse from the mesencephalic root of the fifth cranial nerve to the nucleus of the levator may explain the effectiveness of this maneuver. Another useful method of administering drops to uncooperative pediatric patients is to instruct them to close their eyes. They usually do not resist and are unable to see the approach of the dropper bottle. Through gentle retraction of the lower lid, a small opening through the lashes into the conjunctival sac is

### **Box 3-2** Instructions to Patients for Self-Administration of Solutions or Suspensions

1. Tilt head backward.
2. With clean hands, gently grasp lower outer eyelid below lashes and pull eyelid away from the eye.
3. Place dropper over eye by looking directly at it.
4. Just before applying a drop, look upward.
5. After applying the drop, look downward for a few seconds.
6. Lift eyelid upward until it contacts the eye.
7. Gently close eyes for 2 to 3 minutes.

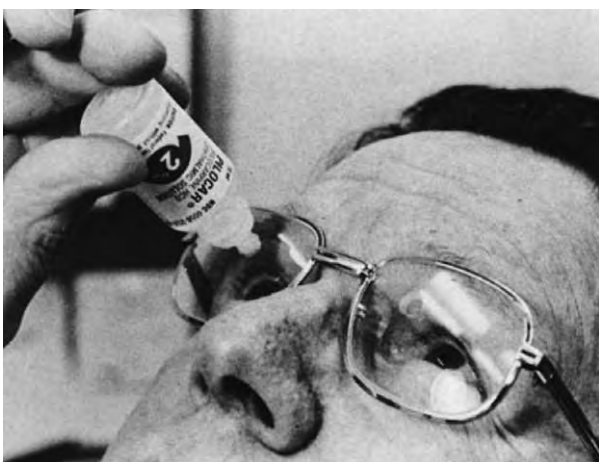created, and the drop can be instilled. The simple placement of the drop on the eyelashes of the closed eyelids has also been shown to achieve effective mydriasis and cycloplegia in the pediatric population.

The self-administration of topical solutions by elderly patients can sometimes be difficult because of arthritis, tremors, or other physically debilitating diseases. It has been shown that most patients older than age 75 have difficulty applying their eyedrops. Although some patients recognize the problem, many are observed to have difficulty but to not acknowledge their inadequacies at eyedrop instillation. Thus, simply asking patients about their eyedrop technique is not likely to reveal which patients are in need of instruction. A better approach is to actually observe the eyedrop instillation technique and to make sure that it is taught to all patients or their caregivers before patients leave the office. The instillation of ocular drugs may be facilitated in these patients by using a pair of spectacle lenses into which a hole has been drilled through the center of each lens. The patient inserts the dropper tip into the hole, gazes superiorly, and squeezes the bottle (Figure 3-5). Only polycarbonate lenses should be used because of the risk associated with drilling into a conventional glass or plastic lens. Various commercial devices are also available (Figure 3-6).

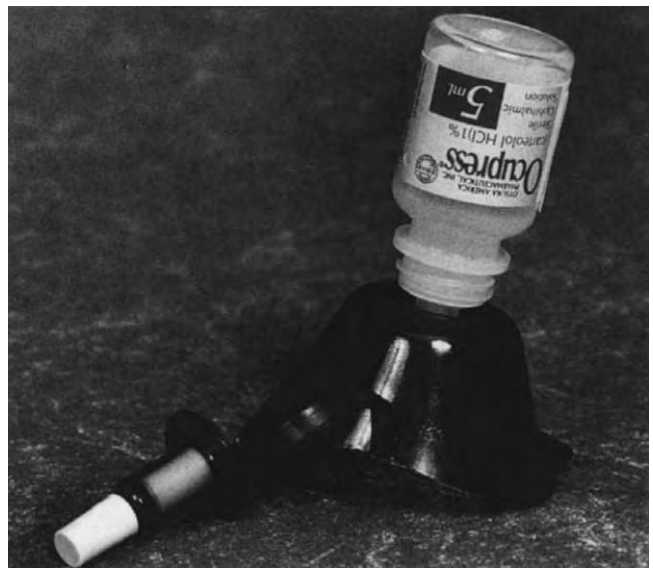Solutions characterized by significant local toxicity or staining potential (e.g., silver nitrate) can be instilled using a cotton swab as an applicator. This technique minimizes drop size and subsequent overflow onto the patient's cheek or clothing.

### Unit-Dose Dispensers

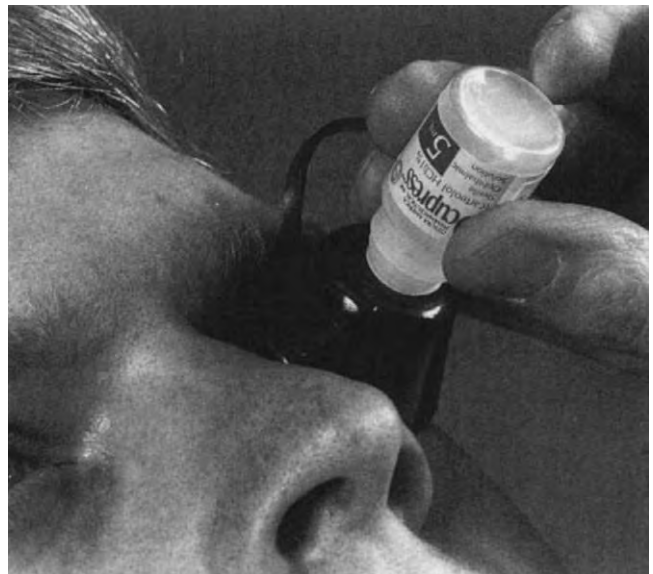
Recognizing that long-term therapy with frequently applied preserved solutions can be toxic to the ocular surface, manufacturers have formulated some ophthalmic solutions in unit-dose dispensers without preservatives (Figure 3-7).



**Figure 3-5** Modification of polycarbonate spectacle lenses to facilitate drop instillation. After a hole is drilled through the center of each lens, the patient inserts the dropper tip into the hole, gazes superiorly, and squeezes the bottle.



A



B

**Figure 3-6** Commercial eyedrop assistance device. (A) Insertion of dropper bottle into device. (B) Device in use.

Unpreserved artificial tears are available in this form, as are timolol, cyclosporine, and ketorolac.

Most unit-dose dispensers accommodate solution volumes ranging from 0.1 to 0.6 ml. Because these solutions are unpreserved, they are designed for short-term use (not exceeding 12 hours), after which the unit is discarded.

### Sprays

The topical administration of solutions to the eye is often an unpleasant procedure associated with significant burning, stinging, lacrimation, and emotional trepidation,

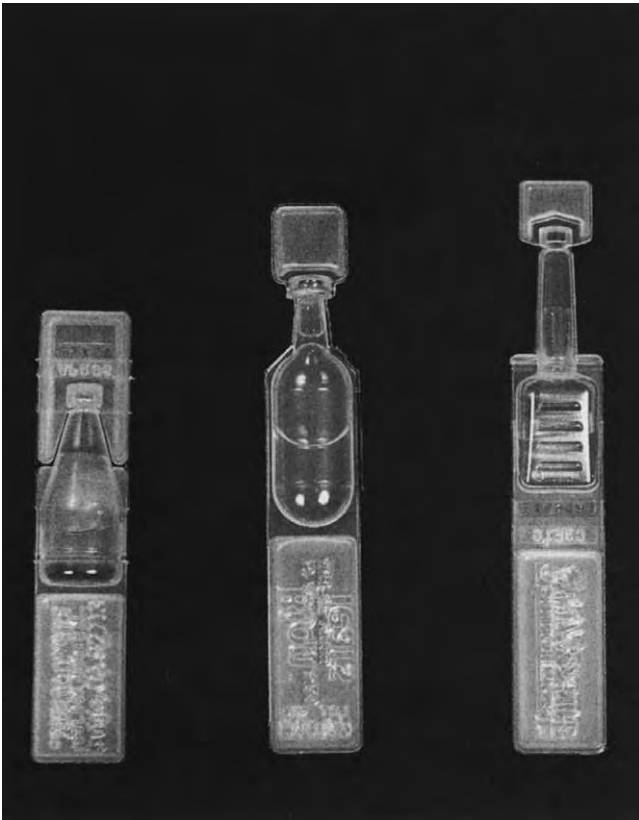

Figure 3-7 Unit-dose dispensers.

especially in children. Topical sprays represent an alternative method of administering ophthalmic solutions that may be less irritating and less objectionable. Combinations of mydriatics and cycloplegics, such as phenylephrine-tropicamide or phenylephrine-tropicamide-cyclopentolate, can be used as sprays for routine mydriasis in adults or for cycloplegia in children. Ophthalmic sprays can be prepared by a compounding pharmacy (Figure 3-8) for application of appropriate mydriatic or cycloplegic combinations (see Chapter 21). The unit is held 5 to 10 cm from the eye before activating the spray. Several artificial tears are commercially available as sprays.

One advantage of a mydriatic or cycloplegic spray is that the drug can be applied to closed eyelids. After drug application, patients should be instructed to blink. If the medication reaches the precorneal tear film, mild stinging is expected. After blinking several times (for 10 to 15 seconds), patients should wipe off the excess solution. If no mild burning or stinging occurs after the eye has been sprayed, it is likely that none of the drug reached the precorneal tear film from the lid margin, and another application is necessary. This may occur in patients who have tightly closed lids in which redundancy of the skin shields the lid margins from the spray.

When the efficacy of sprays is compared with that of topically applied eyedrops, sprays provide both mydriasis

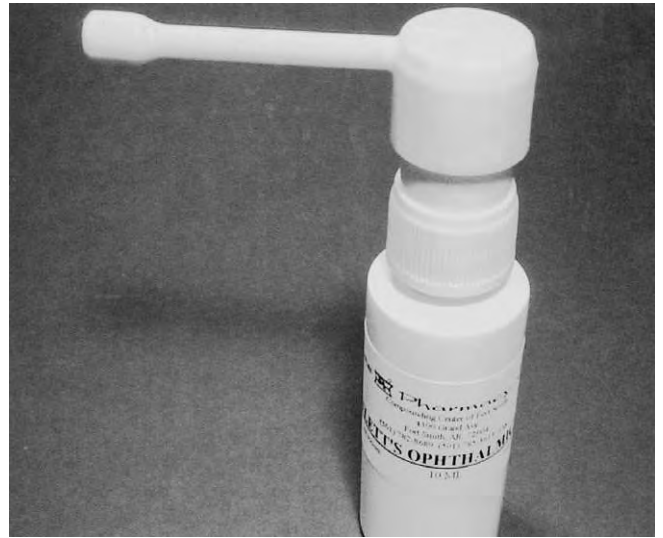

Figure 3-8 Ophthalmic sprays can be extemporaneously prepared for delivery of suitable mydriatics or cycloplegics. (Available from Lee Pharmacy, Inc., Fort Smith, Arkansas.)

and cycloplegia comparable with those obtained with eyedrops (Figure 3-9). This occurs even when the spray is applied to the closed eyelid.

### Ointments

Although solutions are the most commonly used vehicles for topical ocular medications, ointments are also frequently used for application to the eye. When applied to the inferior conjunctival sac, ophthalmic ointments melt quickly, and the excess spreads out onto the lid margins, lashes, and skin of the lids, depending on the amount instilled and on the extent of lacrimation induced by any irritation. The ointment at the lid margins acts as a reservoir and enhances drug contact time.

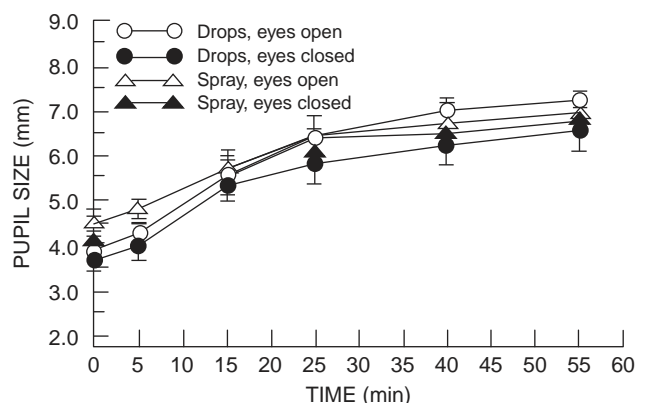


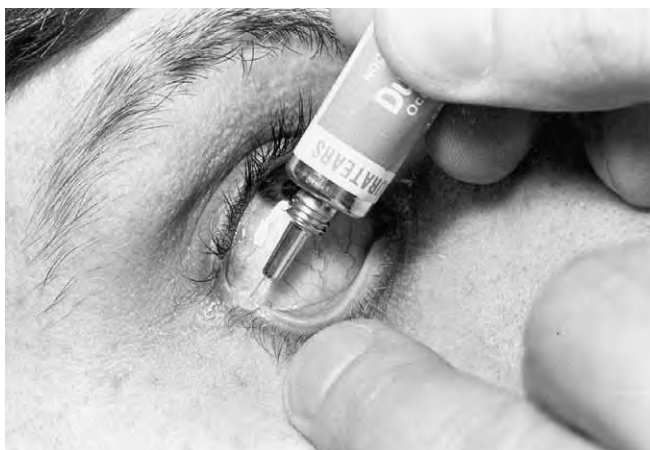Figure 3-9 Mydriatic effect of ophthalmic spray applied to closed eyes is comparable with that of eyedrops applied to open eyes. (Reprinted with permission from Wesson MD, Bartlett JD, Swiatocha J, et al. Mydriatic efficacy of a cycloplegic spray in the pediatric population. *J Am Optom Assoc* 1993;64:637-640.)



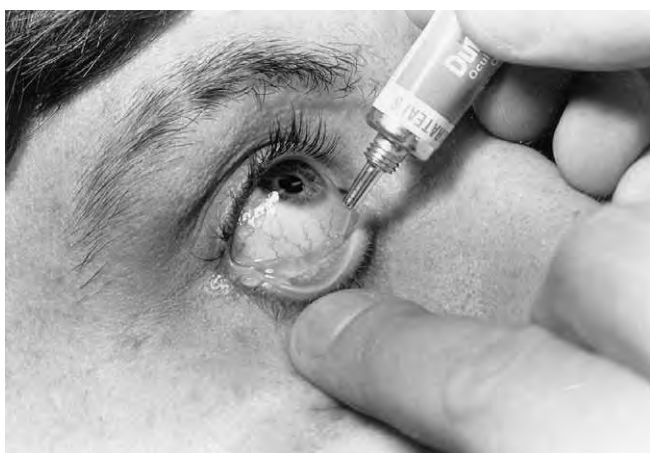### Techniques of Application

Patients are instructed to elevate the gaze, and with the lower lid retracted, the ointment is instilled into the inferior conjunctival sac (Figure 3-10). A pressure patch can then be applied. The daytime use of ointments frequently leads to complaints of blurred vision. For bedtime use, at least 1 cm of ointment is generally applied. If the ointment is not to be applied at bedtime or used under a pressure patch, smaller volumes of ointment should be instilled.

An alternative method of application involves placing the ointment on a cotton-tipped applicator and applying it to the upper lid margin and lashes as well as the medial and lateral canthi. In this way blurring of vision and drug irritation are minimized. In addition, the ointment acts as a drug reservoir and has a therapeutic effect for approximately 6 hours. This method of application may be of practical value in the treatment of ocular infections in all patients, but especially those in the pediatric and geriatric age groups.



A



B

**Figure 3-10** Technique of ointment instillation. With the globe elevated and the lower lid retracted, ointment is instilled into the inferior conjunctival sac in a sweeping fashion from lateral canthus (A) to medial canthus (B).

Once the ointment has been instilled, the bioavailability of subsequently instilled solutions may be altered because the solution is blocked from contact with the ocular surface. Whenever both solution and ointment formulations are used in therapy, the solution should be instilled before the ointment is applied.

### Complications

Contact dermatitis of the lids sometimes occurs during use of ointments containing sensitizing agents such as atropine or neomycin, because ointments are characterized by prolonged ocular contact time. Hypersensitivity to the incorporated preservatives may also occur.

Blurred vision is one of the most frequent adverse effects from ophthalmic ointments. This problem can often be alleviated or minimized by simply reducing the volume of ointment instilled during the daytime. Another option involves instructing patients to apply the ointment to each eye on an alternating schedule. This allows patients to have acceptable vision with at least one eye at all times during the waking hours.

The effect of ophthalmic ointments on the healing of corneal wounds has been studied. Early formulations of ophthalmic ointments contained waxy grades of petrolatum or unwashed lanolin, which interfered with corneal wound healing. Contemporary ophthalmic ointments, however, are nonemulsive and do not contain the coarse grade of white petrolatum. These ointments cause no significant inhibition of corneal wound healing.

The following guidelines are suggested for the clinical use of ophthalmic ointments:

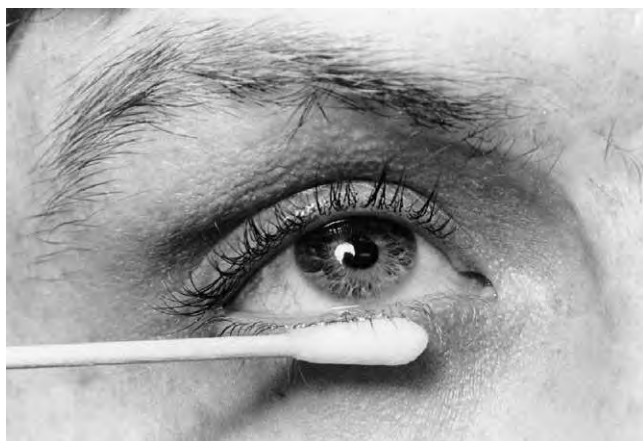- Ointments may be used immediately after intraocular surgery under a conjunctival flap or in corneal incisions with excellent wound approximation, because the risk of entrapment of ointment is minimal. Ointments should not be used, however, in any surgical wound in which there is a question of wound integrity, such as when difficulty is experienced maintaining the anterior chamber at surgery. In such cases ointment application should be delayed for several days.
- Ointments should be used with caution in jagged or flap-like corneal lacerations, in eyes with impending corneal perforation, and in open conjunctival lacerations.
- Ointments can be used routinely for superficial corneal abrasions. However, any abrasion involving corneal tissues deeper than the epithelium should be managed on an individual basis depending on the configuration of the wound edges.
- Ointments may be applied to corneal ulcers with little risk of entrapment or inhibition of wound healing. However, they should be used with caution in ulcers with an impending perforation or large overhanging margins because there is a risk of ointment entrapment under a flap.
- Ointments may be preferred in patients undergoing macular hole surgery with postoperative face-down positioning. Ointment administration

permits less frequent dosing of antibiotics and steroids, reducing the number of times patients must look upward during instillation.

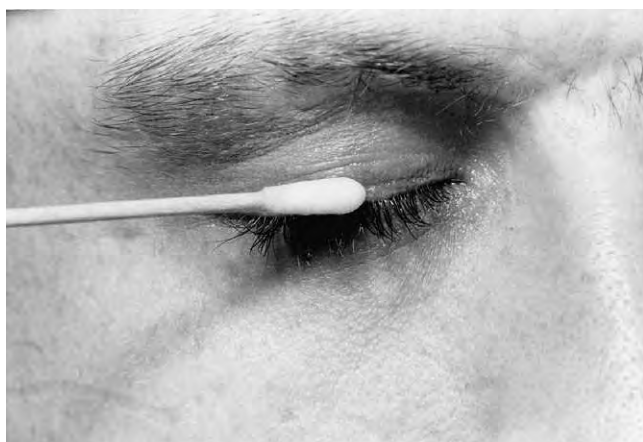### Lid Scrubs

Application of solutions or ointments directly to the lid margin is especially helpful in treating seborrheic or infectious blepharitis. After several drops of the antibiotic solution or detergent, such as baby shampoo, are placed on the end of a cotton-tipped applicator, the solution is applied to the lid margin with the eyelids either opened or closed (Figure 3-11). Antibiotic ointments are applied in the same way.

Although baby shampoo is frequently used for cleaning the eyelid margin, commercially available eyelid cleansers are effective, with potentially less ocular stinging, burning, or toxicity. Commercial lid scrub products are designed to aid in removal of oils, debris, or desquamated skin from the inflamed eyelid. The lid scrubs can



A



B

**Figure 3-11** Technique of lid scrub. Drug application to the lid margin is accomplished with a cotton-tipped applicator applied to the opened (A) or closed (B) eyelids.

also be used for hygienic eyelid cleansing in contact lens wearers. Although these solutions are designed to be used full strength on eyelid tissues, they must not be instilled directly into the eyes. Some of the products (Table 3-1) are packaged with presoaked gauze or cotton pads, which provide an abrasive action to augment the cleansing properties of the detergent. Patients generally express a preference for the commercially available lid scrub products because they are convenient and easy to use.

### Gels

Pilocarpine is commercially available in a carbomer gel vehicle. The 4% pilocarpine gel is packaged in a 3.5-g tube similar to ophthalmic ointments. A practical advantage of this sustained delivery system is the once-daily dosage regimen, with the drug usually administered at bedtime. Minor side effects include superficial corneal haze, which may occur after long-term use (>8 weeks), and superficial punctate keratitis, which can affect almost one-half the treated patients but usually resolves spontaneously.

Several artificial tear preparations are formulated as ophthalmic gels. Tears Again (Cynacon OCuSoft, Richmond, TX) is a sterile lubricant gel consisting of carboxymethylcellulose sodium 2% and povidone 0.1%. GenTeal Lubricant Eye Gel (Novartis Ophthalmics, East Hanover, NJ) contains carbopol 980, a gelling agent with high water-binding affinity that transforms from gel to liquid on contact with ocular tissue. These gel systems tend to minimize the blurred vision that can accompany daytime instillation of ophthalmic ointments.

In situ-activated gel-forming systems are delivered to the ocular surface as eyedrops. These are then converted by temperature changes and ionic movement into a gel-like viscosity that permits prolonged contact with the eye. Gellan gum (Gelrite) and a heteropolysaccharide (xanthan gum) are currently used to deliver timolol in the treatment of glaucoma. Studies have confirmed that treatment with 0.5% timolol in gel-forming solution once daily in the morning achieves intraocular pressure levels equal to twice-daily application of 0.5% timolol solution. The gel-forming solution is well tolerated and does not cause blurred vision or ocular discomfort.

### Solid Delivery Devices

One of the significant problems with the delivery of drugs in solution is that drug administration is pulsed, with an initial period of overdosage followed by a period of relative underdosage. The development of solid drug delivery devices has been an attempt to overcome this disadvantage.

#### Soft Contact Lenses

Drugs penetrate soft contact lenses at a rate that depends on the pore size between the cross-linkages of the three-dimensional lattice structure of the lens, the concentration

**Table 3-1**

Representative Eyelid Scrub Products

Trade Name (Manufacturer)	Ingredients	Formulation
Eye Scrub (CIBA Vision, Atlanta, GA)	PEG-200 glyceryl monotallowate, disodium laureth sulfosuccinate, cocoamido propyl amine oxide, PEG-78 glyceryl monococoate, benzyl alcohol, EDTA	Premoistened pads
SteriLid (Advanced Vision Research, Woburn, MA)	Linalool	Solution
OCuSOFT (Cynacon/OCuSOFT, Richmond, TX)	PEG-80 sorbitan laurate, sodium trideceth sulfate, PEG-150 distearate, cocamido propyl hydroxysultaine, lauroamphocarboxyglycinate, sodium laureth-13 carboxylate, PEG-15 tallow polyamine, quaternium-15	Foam and premoistened pads

EDTA = ethylenediaminetetraacetic acid; PEG = polyethylene glycol.

Adapted from Bartlett JD, Fiscella R, Ghormley NJ, et al., eds. *Ophthalmic drug facts*. St. Louis, MO: Lippincott Williams & Wilkins, 2005.

of drug in the soaking solution, the soaking time, the water content of the lens, and the molecular size of the drug. Lenses with higher water content absorb more water-soluble drug for later release into the precorneal tear film. Maximum drug delivery is obtained by presoaking the lens. This produces a more sustained high yield of drug.

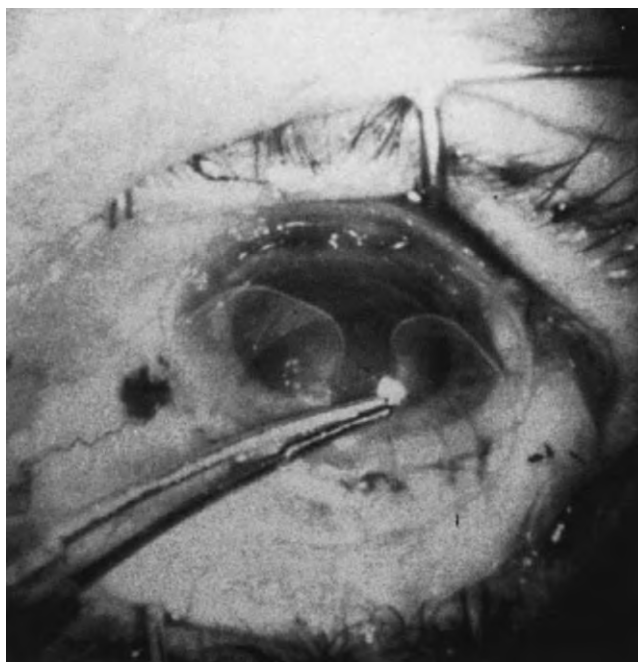
Currently, disposable soft contact lenses can be used for drug delivery and appear to be of greatest clinical value in the treatment of bullous keratopathy, dry eye syndromes, and corneal conditions requiring protection, such as traumatic corneal abrasions or erosions. The most significant disadvantage of this mode of therapy, however, is the rapid loss of most drugs from the lens. Drug-impregnated hydrogel lenses are characterized by first-order kinetics, so they only occasionally offer any significant advantage over topically applied solutions or ointments.

### Collagen Shields

Shaped like contact lenses, collagen shields are thin membranes of porcine or bovine scleral collagen that conform to the cornea when placed on the eye. They are packaged in a dehydrated state and require rehydration before application (Figure 3-12). When a shield is rehydrated in a solution containing a water-soluble drug, the drug becomes trapped in the collagen matrix. Collagen shields have been studied extensively for their potential usefulness as drug delivery devices because the drug is released as the shield dissolves. They have been evaluated for the delivery of antibacterial, antifungal, antiviral, anti-inflammatory, and immunosuppressive drugs, as well as anticoagulants.

Currently available collagen shields have variable dissolution rates of 12, 24, or 72 hours depending on the

amount of collagen cross-linking induced by ultraviolet radiation during the manufacturing process. Shields dissolve as a result of proteolytic degradation by the tear film. Their oxygen permeability is comparable with that of a hydroxyethyl methacrylate lens of similar water content. Before insertion, the shields must be rehydrated for at least 3 minutes in saline, lubricating solution, antibiotic, or steroid. Because the shields can be uncomfortable



**Figure 3-12** Rehydrated collagen shield on eye. (Courtesy Bausch & Lomb, Inc.)

when first placed on the cornea, use of a topical anesthetic may be required.


### Filter Paper Strips

Three staining agents—sodium fluorescein, lissamine green, and rose bengal—are commercially available as drug-impregnated filter paper strips (Figure 3-13). This form of drug delivery allows these agents to be more easily administered to the eye in dosage amounts adequate for their intended clinical purpose. Administration of excessive drug is eliminated, so that unintentional staining of lid tissues or patients' clothing is avoided. Note, however, that the concentration of rose bengal delivered to the ocular surface can be relatively low and depends on the strip soak time and technique. The availability of fluorescein-impregnated paper strips eliminates the risk of solution contamination with *Pseudomonas aeruginosa*.

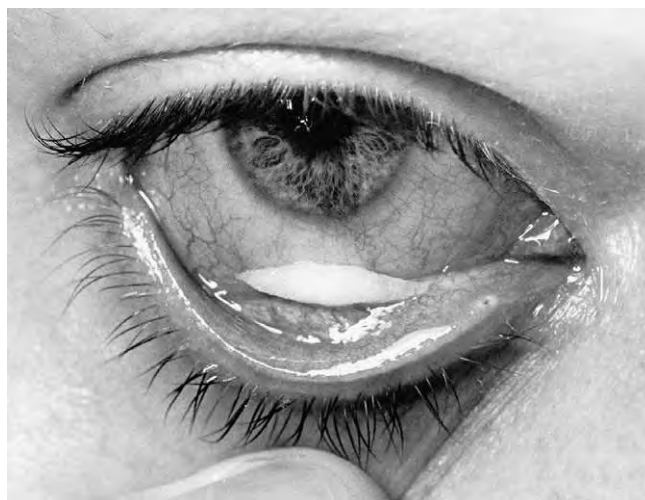For administration, the drug-impregnated paper strip is moistened with a drop of normal saline or extraocular irrigating solution, and the applicator is gently touched to the superior or inferior bulbar conjunctiva or to the inferior conjunctival sac. To avoid the risk of cross-contamination between eyes, practitioners should use separate applicators for dye delivery to eyes with suspected infection.

### Cotton Pledgets

Cotton pledgets saturated with ophthalmic solutions can be of value in several clinical situations. These devices allow prolonged ocular contact time with solutions that are normally topically instilled into the eye. A pledget is constructed by simply teasing the cotton tip of an applicator to form a small (approximately 5 mm) elongated body of cotton. After placing one or two drops of the ophthalmic solution on the pledget, the device is placed into the inferior conjunctival fornix (Figure 3-14).



**Figure 3-13** Drug-impregnated filter paper strips. Rose bengal (*top*), lissamine green (*center*), and sodium fluorescein (*bottom*).



**Figure 3-14** Cotton pledget positioned in the inferior conjunctival fornix.

The clinical use of pledgets is usually reserved for administration of mydriatic solutions such as phenylephrine. This method of drug delivery allows maximum mydriasis in attempts to break posterior synechiae or dilate sluggish pupils. Mydriasis of the inferior pupillary quadrant for intentional sector dilation of the pupil can also be achieved (see Chapter 20).

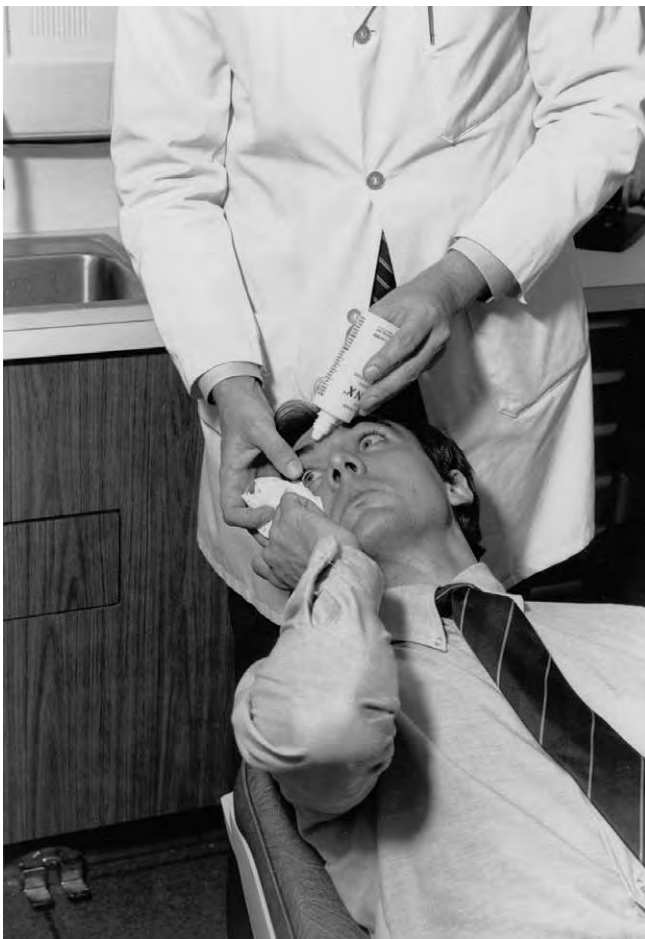### Continuous Flow Devices

When relatively small amounts of drug are required for delivery to the eye, the use of solutions, ointments, or gels is usually satisfactory. However, when large volumes of fluids are required, such as in the treatment of acute chemical burns, other drug delivery systems are necessary. Various methods for delivering large volumes of fluids continuously to the eye have been developed.

### Conventional Irrigating Systems

Extraocular irrigation is often used in the initial treatment of ocular foreign bodies or chemical burns in an effort to dislodge foreign material. It is also used to remove excessive drug from the eye after fluorescein or rose bengal staining or after gonioscopic procedures in which viscous lens-bonding solutions have been used. The conventional delivery system for irrigation fluids consists simply of the container of irrigating solution and a means, usually a tissue, towel, or emesis basin, with which to collect the fluid after bathing the eye. Patients should be in a supine position with head tilted toward the side to be irrigated (Figure 3-15). The irrigating solution should be at room temperature to minimize patient discomfort during the procedure. With the upper and lower lids retracted, the clinician gently bathes the extraocular surfaces with the solution, taking care to collect the fluid in the tissue, towel, or emesis basin and to avoid staining the patient's clothing. In most cases no topical anesthesia is required,






**Figure 3-15** Conventional irrigation system. The head is tilted toward the side to be irrigated, and the irrigation solution is collected in a tissue or towel after it has bathed the extraocular tissues.

unless patients, because of severe pain or ocular involvement, are unable to open the eye.

The obvious limitation of the conventional irrigating system is the need to have an attendant administer the fluid. However, this method represents the most cost-effective means of administering fluids continuously to the eye.

### Continuous Irrigating Systems

To circumvent the need for an attendant to administer the irrigating fluid or drug, various methods have been developed that enable the continuous delivery of fluid on a long-term basis. Most methods that have been devised for continuous ocular irrigation are suitable for use for relatively short periods in nonambulatory patients. The Morgan lens (Figure 3-16) is the most convenient commercially available system. This system is capable of delivering a continuous flow of saline to every surface of the eye and conjunctival sac. Fluid flow acts as a cushion and allows the lens to float above the cornea and below the eyelid, avoiding contact with damaged ocular tissues.



**Figure 3-16** Morgan lens and tubing are attached to an intravenous line for continuous delivery of saline irrigation to the external eye.

## PERIOCCULAR ADMINISTRATION

When higher concentrations of drugs, particularly corticosteroids and antibiotics, are required in the eye than can be delivered by topical administration, local injections into the periocular tissues can be considered. Periocular drug delivery includes subconjunctival, sub-Tenon's, retrobulbar, and peribulbar administration.

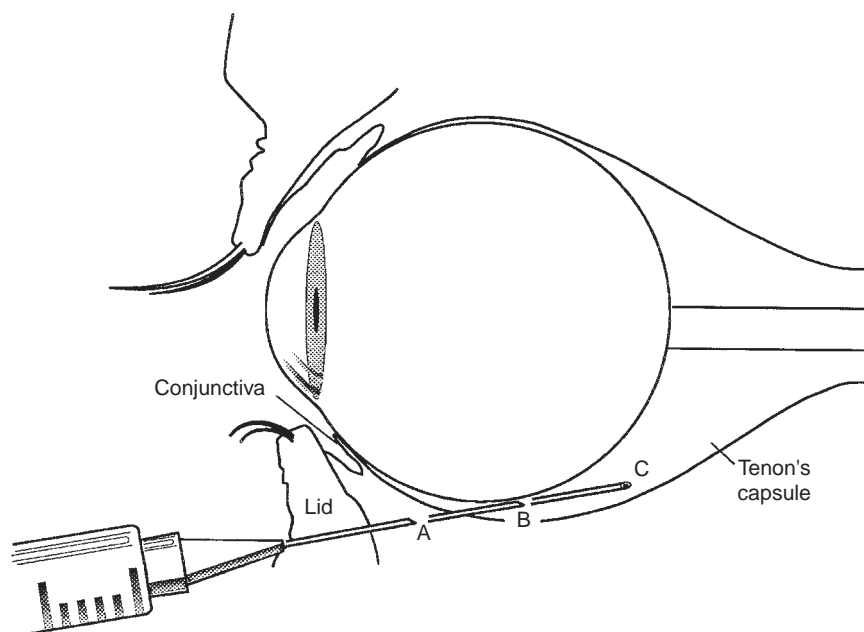
### Subconjunctival Injection

Although repeated topical applications of most ocular drugs result in intraocular drug levels comparable with those achieved with subconjunctival injections, subconjunctival injections offer an advantage in the administration of drugs, such as antibiotics, with poor intraocular penetration. This mode of drug delivery offers the following advantages:

- High local concentrations of drug can be obtained with the use of small quantities of medication, so that adverse systemic effects are avoided.
- High tissue concentrations can be obtained with drugs that poorly penetrate the epithelial layer of the cornea or conjunctiva. This method is useful in patients who do not reliably use topical medication.
- Drugs can be injected at the conclusion of surgery to avoid the necessity of topical or systemic drug therapy.

Subconjunctival injection involves passing the needle between the anterior conjunctiva and Tenon's capsule (Figure 3-17). This can be performed through the eyelid or directly into the subconjunctival space. Tenon's capsule lies between the injected drug and the globe, so the amount of drug absorbed across the sclera is minimized. However, at least for corticosteroids, a subconjunctivally administered drug may penetrate the underlying sclera, which suggests a rationale for placing the drug directly adjacent to the site of inflammation rather than injecting it randomly.

Probably the greatest clinical benefit associated with the subconjunctival route of drug administration is in the treatment of severe corneal disease, such as bacterial ulcers. Much higher concentrations of antibiotics can be achieved in the affected corneal tissues with subconjunctival



**Figure 3-17** Relative positions of periocular injections. A, Subconjunctival; B, sub-Tenon's; C, retrobulbar.

injection than can be obtained by systemic drug administration. Subconjunctival antibiotic administration is also useful as an initial supplement to the systemic or intravitreal antibiotic treatment of bacterial endophthalmitis. A variety of ocular diseases are treated with subconjunctival corticosteroids. Subconjunctival injection of 5-fluorouracil, an antifibroblast agent, is sometimes used after high-risk trabeculectomy surgeries for glaucoma. Subconjunctival anesthesia is now used as an alternative to peribulbar or retrobulbar anesthesia for trabeculectomy or cataract surgery.

### Sub-Tenon's Injection

Anterior sub-Tenon's injection offers no significant advantages over subconjunctival drug administration. In fact, sub-Tenon's injection delivers lower quantities of drug to the eye and is associated with a greater risk of perforating the globe. Despite these disadvantages, however, anterior sub-Tenon's injections of corticosteroids are occasionally used in the treatment of severe uveitis.

Posterior sub-Tenon's injection of corticosteroids is most often used in the treatment of chronic equatorial and mid-zone posterior uveitis, including inflammation of the macular region. Cystoid macular edema after cataract extraction and diabetic macular edema are treated occasionally with sub-Tenon's repository steroids.

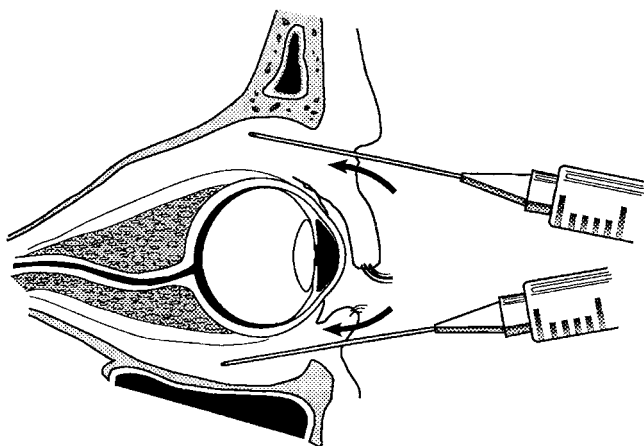
Anecortave acetate (Retaane), a synthetic derivative of cortisol, has been delivered as a posterior juxtasceral depot to exert an angiostatic effect in patients with exudative age-related macular degeneration. The drug is administered with a specially designed curved cannula at 6-month intervals.

### Retrobulbar Injection

Drugs have been administered by retrobulbar injection since the 1920s. The procedure was originally developed to anesthetize the globe for cataract extraction and other intraocular surgeries, and this remains its principal clinical use. However, antibiotics, vasodilators, corticosteroids, and alcohol have also been administered through this route. Currently, retrobulbar anesthetics are frequently used, retrobulbar corticosteroids are used occasionally (although their clinical value remains controversial and unproved), and retrobulbar alcohol or phenol is rarely administered for intractable ocular pain in blind eyes. Although retrobulbar anesthesia has been used routinely for cataract surgery, many surgeons are now using topical anesthetics for most contemporary cataract extractions.

### Peribulbar Injection

Because of the risks associated with retrobulbar injections, the peribulbar technique was introduced during the mid-1980s. The procedure consists of placing one or two injections of local anesthetic around the globe but not directly into the muscle cone (Figure 3-18). Because the fascial connections of the extraocular muscles are incomplete, the anesthetic injected around the globe eventually infiltrates the muscle cone to provide anesthesia and akinesia. Although neither the retrobulbar nor the peribulbar procedure allows visualization of the injection site, the retrobulbar technique intentionally aims for the muscle cone, which contains vital structures. This can be accomplished only by placing the needle extremely close to the globe. In contrast, the peribulbar procedure



**Figure 3-18** Peribulbar injection technique, in which the needle avoids the intraconal space. (Adapted from Fry RA, Henderson J. Local anaesthesia for eye surgery. *The periocular technique*. *Anaesthesia* 1989;45:14–17.)

intentionally avoids the globe and the muscle cone, which makes it safer.

Compared with the retrobulbar technique, peribulbar anesthesia provides similar anesthesia and akinesia for both anterior segment and vitreoretinal surgical procedures, but some patients may have inadequate akinesia and require additional injections. In addition, the onset time of blockade is not as rapid as with retrobulbar injection. Nevertheless, peribulbar anesthesia reduces the potential for inadvertent globe penetration, retrobulbar hemorrhage, and direct optic nerve injury. Although serious problems with retrobulbar and peribulbar injections are uncommon, numerous complications have been reported (Box 3-3).

### INTRACAMERAL ADMINISTRATION

Intracameral administration involves delivering a drug directly into the anterior chamber of the eye. The most common clinical application is the injection of viscoelastic substances into the anterior chamber during cataract extraction and glaucoma filtering surgeries to protect against corneal endothelial cell loss and flat anterior chamber. Ethacrynic acid and tissue plasminogen activator have also been administered intracamerally. More recently, a 1-mm pellet incorporating 60 mcg dexamethasone consists of a biodegradable polymer that is inserted into the eye at the conclusion of cataract or other intraocular surgery. This sustained-release pellet (Surodex) provides high intraocular steroid levels for 7 to 10 days.

Use of intracameral lidocaine has been introduced as a method of supplementing topical anesthesia during cataract surgery. Unpreserved 1% lidocaine is injected into the anterior chamber immediately after the paracentesis incision before injection of viscoelastic agent.

### Box 3-3 Complications of Retrobulbar or Peribulbar Injections

- Retrobulbar hemorrhage
- Conjunctival and eyelid ecchymosis
- Proptosis
- Exposure keratopathy
- Elevated intraocular pressure
- Contralateral amaurosis
- Respiratory arrest
- Bradycardia
- Central retinal artery/vein occlusion
- Optic atrophy
- Transient reduction in visual acuity
- Extraocular muscle palsies
- Ptosis
- Pupillary abnormalities
- Chemosis
- Eyelid swelling
- Pain
- Cardiovascular or central nervous system drug toxicity
- Accidental perforation or explosion of the globe
- Retained intraorbital needle fragment

The lidocaine anesthetizes the iris and ciliary body and can reduce patient discomfort during the surgical procedure.

### INTRAVITREAL ADMINISTRATION

Many drugs have been injected directly into the vitreous. These include antibacterial and antifungal agents for treatment of bacterial and fungal endophthalmitis, respectively, and antivirals for treatment of viral retinitis. The treatment of many intraocular diseases using systemically administered drugs is hampered because of poor drug penetration into the eye. The tight junctional complexes of the retinal pigment epithelium and retinal capillaries serve as the blood–ocular barrier, which inhibits penetration of antibiotics into the vitreous. Patients with endophthalmitis can be successfully treated using intravitreal and subconjunctival rather than systemically administered antibiotics. Although systemic antibiotics are often used to treat bacterial endophthalmitis, the systemic route of administration has limited efficacy as well as potential side effects that limit therapeutic success.

Intravitreal triamcinolone has been used to treat diffuse diabetic macular edema. Also, an intravitreal implant delivering fluocinolone acetonide (Retisert) is effective in the treatment of patients with noninfectious posterior uveitis who have failed to respond to conventional treatment.

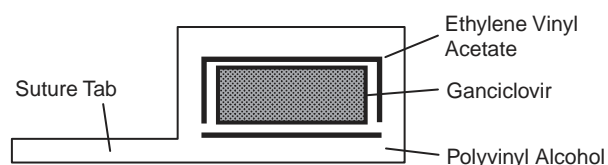
Antiviral agents are sometimes injected intravitreally for treatment of cytomegalovirus (CMV) retinitis in patients

with acquired immunodeficiency syndrome. High doses of intravitreal foscarnet, cidofovir, or ganciclovir can effectively suppress CMV retinitis and preserve vision without adverse systemic effects. To circumvent the need for repeated intravitreal injections, an intraocular sustained-release ganciclovir implant (Vitrasert) was developed. The device is intended only for the treatment of CMV retinitis in patients with acquired immunodeficiency syndrome.

The implant is a nonerodible drug delivery system consisting of a pellet containing a minimum of 4.5 mg of ganciclovir compressed into a 2.5-mm disc. The disc is coated with a thin film of polyvinyl alcohol and a discontinuous film of ethylene vinyl acetate. The device is then coated again with polyvinyl alcohol, and a suture tab made from polyvinyl alcohol is attached (Figure 3-19). The ethylene vinyl acetate and polyvinyl alcohol coatings provide a barrier for drug diffusion and therefore control the rate of drug delivery inside the eye. The Vitrasert is designed to release ganciclovir at the rate of 1 mcg/hr for 5 to 8 months. The device is surgically implanted into the vitreous cavity through the pars plana, and after the implant is depleted of ganciclovir, as evidenced by progression of the CMV retinitis, the device can be removed and replaced with a fresh implant. The average time before a second implant is needed is approximately 6 months.

The Vitrasert has proved to be safe and effective for treatment of CMV retinitis as an adjunct to continued systemic therapy. Although use of the Vitrasert is relatively safe, it is not free of complications. Adverse events can occur in 10% to 20% of patients and can result in significant loss of vision. Acute and long-term complications associated with the Vitrasert or its surgical procedure include retinal detachment, vitreous hemorrhage, and endophthalmitis.

Age-related macular degeneration is the leading cause of legal blindness in the United States. Choroidal vessels invade Bruch's membrane for unknown reasons, possibly stimulated by vasoproliferative substances such as vascular endothelial growth factor (VEGF). New blood vessels penetrate the inner collagenase layer of Bruch's membrane, spreading laterally underneath and within the plane of the drusen. This leads to an increased risk of discrete leakage of blood and serous fluid, detaching both the retinal pigment epithelium and overlying retina. Anti-VEGF compounds represent the newest approach to treatment of exudative age-related macular degeneration, and several such agents are now commercially available.



**Figure 3-19** Cross-section of ganciclovir implant. (Modified from Charles NC, Steiner GC. Ganciclovir intraocular implant. A clinicopathologic study. *Ophthalmology* 1996;103:416-421.)

These include pegaptanib sodium (Macugen) and ranibizumab (Lucentis). These drugs are injected intravitreally at specified intervals (see Chapter 31).

## PHOTODYNAMIC THERAPY

Choroidal neovascularization associated with age-related macular degeneration is difficult to treat with conventional laser procedures because normal retinal tissues can be destroyed, which results in loss of central vision. Photodynamic therapy offers the opportunity to selectively eradicate neovascular membranes while producing minimal damage to normal retinal and choroidal tissues.

The procedure involves intravenous administration of verteporfin (Visudyne) for 10 minutes. Verteporfin is a potent photosensitizing dye. Five minutes after the conclusion of dye administration, during which time the drug selectively accumulates in the neovascular tissue, nonthermal light at 689 nm is applied to the abnormal tissues for 83 seconds. When activated by light, verteporfin causes the production of singlet oxygen and free radicals that produce cell death and occlusion of abnormal vessels.

Photodynamic therapy appears to be a safe procedure. Infrequent complications include reactions at the injection site, transient reduction in vision, and photosensitivity lasting less than 24 hours. No interactions between verteporfin and other medications have been reported.

The use of verteporfin in the photodynamic therapy of neovascular age-related macular degeneration has been shown to be effective in stabilizing the disease. Although retreatments are usually needed for recurring vessel leakage, this therapeutic modality has proved to be an important treatment for patients with the neovascular form of age-related macular degeneration. It has also proved beneficial in treating choroidal neovascularization not associated with age-related macular degeneration, such as pathologic myopia, ocular histoplasmosis, angioid streaks, and that due to idiopathic causes.

## SELECTED BIBLIOGRAPHY

- Ariturk N, Oge I, Erkan D, et al. The effects of nasolacrimal canal blockage on topical medications for glaucoma. *Acta Ophthalmol Scand* 1996;74:411-413.
- Augustin AJ, D'Amico DJ, Mieler WF, et al. Safety of posterior juxtasclear depot administration of the angiostatic cortisone anecortave acetate for treatment of subfoveal choroidal neovascularization in patients with age-related macular degeneration. *Graefes Arch Clin Exp Ophthalmol* 2005;243:9-12.
- Barak A, Alhalel A, Kotas R, et al. The protective effect of early intraoperative injection of viscoelastic material in trabeculectomy. *Ophthalmic Surg* 1992;23:206-209.
- Bartlett JD, Wesson MD, Swiatocha J, Woolley T. Efficacy of a pediatric cycloplegic administered as a spray. *J Am Optom Assoc* 1993;64:617-621.
- Benavides JO, Satchell ER, Frantz KA. Efficacy of a mydriatic spray in the pediatric population. *Optom Vis Sci* 1997;74:160-163.

- Bourlais CL, Acar L, Zia H, et al. Ophthalmic drug delivery systems—recent advances. *Prog Retin Eye Res* 1998;17:33–58.
- Bressler NM, Bressler SB. Photodynamic therapy with verteporfin (Visudyne): impact on ophthalmology and visual sciences. *Invest Ophthalmol Vis Sci* 2000;41:624–628.
- Cardillo JA, Melo LA, Costa RA, et al. Comparison of intravitreal versus posterior sub-Tenon's capsule injection of triamcinolone acetonide for diffuse diabetic macular edema. *Ophthalmology* 2005;112:1557–1563.
- Chang DF, Garcia IH, Hunkeler JD, et al. Phase II results of an intraocular steroid delivery system for cataract surgery. *Ophthalmology* 1999;106:1172–1177.
- Chang M, Dunn JP. Ganciclovir implant in the treatment of cytomegalovirus retinitis. *Expert Rev Med Devices* 2005;2:421–427.
- Crandall AS, Zabriskie NA, Patel BCK, et al. A comparison of patient comfort during cataract surgery with topical anesthesia versus topical anesthesia and intracameral lidocaine. *Ophthalmology* 1999;106:60–66.
- Demediuk OM, Dhaliwal RS, Papworth DP, et al. A comparison of peribulbar and retrobulbar anesthesia for vitreoretinal surgical procedures. *Arch Ophthalmol* 1995;113:908–913.
- Dillon B, Kamal A, Leen C. Intravitreal sustained-released ganciclovir implantation to control cytomegalovirus retinitis in AIDS. *Int J STD AIDS* 1998;9:227–230.
- Feibel RM. Current concepts in retrobulbar anesthesia. *Surv Ophthalmol* 1985;30:102–110.
- Fraunfelder FT. Extraocular fluid dynamics: how best to apply topical ocular medications. *Trans Am Ophthalmol Soc* 1976;74:457–487.
- Fraunfelder FT, Hanna C. Ophthalmic drug delivery systems. *Surv Ophthalmol* 1974;18:292–298.
- Friedberg ML, Pleyer U, Mondino J. Device drug delivery to the eye: collagen shields, iontophoresis and pumps. *Ophthalmology* 1991;98:725–732.
- Fry RA, Henderson J. Local anaesthesia for eye surgery: the periorbital technique. *Anaesthesia* 1989;45:14–17.
- Gilad E, Bahar I, Rotberg B, et al. Therapeutic contact lens as the primary treatment for traumatic corneal erosions. *Isr Med Assoc J* 2004;6:28–29.
- Gillow T, Scotcher SM, Deutsch J, et al. Efficacy of supplementary intracameral lidocaine in routine phacoemulsification under topical anesthesia. *Ophthalmology* 1999;106:2173–2177.
- Huang TC, Lee DA. Punctal occlusion and topical medications for glaucoma. *Am J Ophthalmol* 1989;107:151–155.
- Jaffe GJ, McCallum RM, Branchaud B, et al. Long-term follow up results of a pilot trial of a fluocinolone acetonide implant to treat posterior uveitis. *Ophthalmology* 2005;112:1192–1198.
- Jain MR. Drug delivery through soft contact lenses. *Br J Ophthalmol* 1988;72:150–154.
- Johnston RL, Whitefield LA, Giralt J, et al. Topical vs. peribulbar anesthesia, without sedation, for clear corneal phacoemulsification. *J Cataract Refract Surg* 1998;24:407–410.
- Key JE. A comparative study of eyelid cleaning regimens in chronic blepharitis. *CLAO J* 1996;22:209–212.
- Kim GE, Fern KD, Perrigin JA. Sterility of ophthalmic drugs dispensed from spray bottles. *Optom Vis Sci* 1997;74:865–867.
- Krohn J. Topical medication interferes with face-down positioning after macular hole surgery. *Acta Ophthalmol Scand* 2003;81:226–229.
- Lim JJ, Wolitz RA, Dowling AH, et al. Visual and anatomic outcomes associated with posterior segment complications after ganciclovir implant procedures in patients with AIDS and cytomegalovirus retinitis. *Am J Ophthalmol* 1999;127:288–293.
- Maclean H, Burton T, Murray A. Patient comfort during cataract surgery with modified topical and peribulbar anesthesia. *J Cataract Refract Surg* 1997;23:277–283.
- Martin DF, Dunn JP, Davis JL, et al. Use of the ganciclovir implant for the treatment of cytomegalovirus retinitis in the era of potent antiretroviral therapy: recommendations of the international AIDS society—USA panel. *Am J Ophthalmol* 1999;127:329–339.
- Marx JL, Kapusta MA, Patel SS, et al. Use of the ganciclovir implant in the treatment of recurrent cytomegalovirus retinitis. *Arch Ophthalmol* 1996;114:815–820.
- Miller JW, Schmidt-Erfurth U, Sickenberg M, et al. Photodynamic therapy with verteporfin for choroidal neovascularization caused by age-related macular degeneration. *Arch Ophthalmol* 1999;117:1161–1173.
- Mondino BJ. Collagen shields. *Am J Ophthalmol* 1991;112:587–590.
- Montero MC, Pastor M, Buenestado C, et al. Intravitreal ganciclovir for cytomegalovirus retinitis in patients with AIDS. *Ann Pharmacother* 1996;30:717–723.
- Peyman GA, Schulman JA. Intravitreal drug therapy. *Jpn J Ophthalmol* 1989;33:392–404.
- Putterman AM. Instilling ocular ointments without blurred vision. *Arch Ophthalmol* 1985;103:1276.
- Robin JS, Ellis PP. Ophthalmic ointments. *Surv Ophthalmol* 1978;22:335–340.
- Seah SK, Husain R, Gazzard G, et al. Use of Surodex in phacotribelectomy surgery. *Am J Ophthalmol* 2005;139:927–928.
- Shammas HJ, Milkie M, Yeo R. Topical and subconjunctival anesthesia for phacoemulsification: prospective study. *J Cataract Refract Surg* 1997;23:1577–1580.
- Snyder C, Paugh JR. Rose bengal dye concentration and volume delivered via dye-impregnated paper strips. *Optom Vis Sci* 1998;75:339–341.
- Snyder RW, Sherman MD, Allinson RW. Intracameral tissue plasminogen activator for treatment of excessive fibrin response after penetrating keratoplasty. *Am J Ophthalmol* 1990;109:483–484.
- Steinemann TL, Brown ME. Inadvertent instillation of nonophthalmic antiseptic drops due to packaging similarity. *Arch Ophthalmol* 1998;116:1246.
- Sulewski ME, Kracher GP, Gottsch JD, Stark WJ. Use of the disposable contact lens as a bandage contact lens. *Arch Ophthalmol* 1991;109:318.
- Taravella M, Stepp P, Young D. Collagen shield delivery of tobramycin to the human eye. *CLAO J* 1998;24:166–168.
- Treatment of Age-related Macular Degeneration with Photodynamic Therapy (TAP) Study Group. Photodynamic therapy of subfoveal choroidal neovascularization in age-related macular degeneration with verteporfin. *Arch Ophthalmol* 1999;117:1329–1345.
- Urtti A, Salminen L. Minimizing systemic absorption of topically administered ophthalmic drugs. *Surv Ophthalmol* 1993;37:435–456.
- Weijtens O, Vandersluijs FA, Schoemaker RC, et al. Peribulbar corticosteroid injection: vitreal and serum concentrations after dexamethasone disodium phosphate injection. *Am J Ophthalmol* 1997;123:358–363.
- Whitson JT, Love R, Brown RH, et al. The effect of reduced eyedrop size and eyelid closure on the therapeutic index of phenylephrine. *Am J Ophthalmol* 1993;115:357–359.

# *Pharmaceutical and Regulatory Aspects of Ophthalmic Drug Administration*

*Condit F. Steil and Timothy R. Covington*

Drugs in general and the drug-benefit component of managed health care plans remain among the “best buys” in American health care. Clinicians, health care economists, and fiscal managers are beginning to realize that 85% to 90% of all acute and chronic illnesses can be cured or symptomatically relieved by appropriate drug therapy. All health care providers should work more deliberately to (1) promote the safe, appropriate, effective, and economical use of both prescription and nonprescription drugs; (2) assist in producing optimal therapeutic outcomes by fostering precision in drug therapy management; and (3) encourage the evolution of highly cognitive, outcome-oriented, pharmaceutical care by maximizing the benefits of drug therapy and identifying, resolving, and preventing drug-related problems and therapeutic misadventures. Continual efforts that lead to proper drug and dosage selection, fewer adverse drug reactions, fewer drug-drug interactions, and better patient compliance will produce significant dividends in quality and cost of care.

## **QUALITY-OF-CARE CONSIDERATIONS**

All payers of health care bills are focused on issues of quality and value. Accrediting agencies are following a similar strategy as they look for positive health outcome indicators. The ultimate payer is moving health care providers into an era of assessment and accountability, because too little objective evidence exists that supports a positive correlation between rising costs, quality of care, and optimal health outcomes.

The United States leads the world in health care costs. Despite these large and increasing expenditures, abundant evidence demonstrates that drug therapy management is far less than optimal. A study dealing with drug-related morbidity and mortality estimated the cost of ambulatory drug-related illness at \$167 billion. This figure is shocking when it is known that this cost may be higher than the total cost of purchasing the medications being prescribed to solve patients’ problems. Other evidence of improper drug selection and use and of

“therapeutic misadventuring” is manifest in the following facts listed below:

- Approximately 30% to 50% of the 4 billion prescriptions dispensed annually are taken or used incorrectly by patients.
- Approximately 9% to 11% of patients never get their original prescription filled.
- Approximately 15% of patients do not take the full course of their prescribed medication.
- Approximately 32% of patients do not have their prescriptions refilled, even though they need to do so.
- Approximately 8% to 11% of all hospital admissions are related to failure to take drugs properly.
- Approximately 3% to 5% of all hospital admissions are directly attributable to drug-induced toxicity, much of which is preventable.
- Approximately 16% of all hospital admissions of patients older than 70 years result from adverse drug reactions.
- Noncompliance with drug therapy results in the loss of more than 20 million workdays per year.
- Approximately 125,000 Americans die annually from failure to take drugs properly.

## **COST-OF-CARE CONSIDERATIONS**

The share of the gross domestic product (GDP) for health care is now approximately 15% and is projected to grow to 18% in 2012. The \$1.66 trillion U.S. health care expenditure in 2003 is projected to grow to \$3.1 trillion in the year 2012. Annual health care costs have risen significantly: from \$204 per person in 1965 to \$3,160 per person in 1992, with projections to be nearly \$9,500 per person by the year 2008. Costs of glaucoma medications as a subset of ocular medications were recently reviewed. Though wide cost variance was present, other factors, such as adverse effects, effectiveness, and ease of compliance, should be considered.

The current health care paradigm is shifting toward the reduction of health care expenditures without adversely impacting quality of care. Cost and quality



issues suggest that great emphasis must be placed on optimal drug use. This chapter presents some of the most fundamental yet vital components of ophthalmic drug use. The focus is placed on the components of prescribing that foster positive health outcomes.

## GUIDELINES FOR PRESCRIPTION WRITING

A prescription is defined as a verbal, written, or electronic order for a drug issued by a properly licensed and authorized health care practitioner. The prescription generally completes the initial prescriber-patient encounter but initiates a series of actions on the part of pharmacists that are designed to ensure that the health outcome of patients is optimal.

In most jurisdictions, including the United States and Canada, drugs are legally classified into two groups: drugs regulated to be obtained only with valid prescriptions and drugs that can be obtained without a prescription, or over the counter. Prescription drugs are known as *legend drugs* because they are required to have a message on the manufacturer's label: "Caution: Federal Law Prohibits Dispensing Without Prescription." There are also guidelines for dispensing these medications to patients, termed *detailed instructions*. This is because these drugs tend to have a somewhat lower safety profile than over-the-counter drugs.

The process of pharmacists dispensing prescriptions is designed to ensure that patients receive the proper drug in the correct dosage and with correct directions for use. This pharmaceutical care requires the pharmacist to perform an assessment of the patient's medications, to monitor their use and effects, and to communicate with the prescriber and patient to correct or prevent drug-related problems. This drug therapy review service is codified in the term *medication therapy management*.

Before patients receive a particular drug, pharmacists typically screen for potential drug-related complications through a drug-use evaluation process, which is designed to optimize drug therapy management by attempting to identify and resolve problems or prevent potential drug-related problems. This process does much to create a positive impact on the quality of drug use and clinical outcomes.

Pharmacists then deliver the prescribed drugs to patients or to patients' designees and provide counseling about proper drug use. Cooperation between pharmacists and prescribers is vital to patients' best health interests and often results in positive refinements in the drug use process. The spirit of trust and commitment to high ethical and professional standards with regard to confidentiality of patient information is, of course, essential in the prescriber-pharmacist relationship.

### Anatomy of the Prescription

Prescriptions are usually written on preprinted blank forms provided as a pad. Examples of the format are

shown in Figure 4-1. The prescriber's name, office address, telephone number, and other pertinent information (e.g., facsimile [fax] number) can be printed at the top. Prescribers may write a routine prescription on any paper or writing material. However, prescriptions for certain controlled substances may require special prescription blanks. Specific regulations on the requirements for prescriptions vary from state to state.

The fundamental elements of a prescription include the following:

- Patient's name and current address
- Date on which the prescription was written
- Rx symbol (superscription)
- Medication prescribed (inscription)
- Dispensing directions to pharmacist (subscription)
- Directions for patient use (signa or signatura)
- Refill, special labeling, or other instructions
- Prescriber's signature, address, and other appropriate information (e.g., telephone, fax, and pager numbers)

As with any part of the prescription, legibility is essential. Sloppy, unclear, or barely legible prescription

JOHN A. SMITH, O.D.  
Optometry

1234 Hospital Drive  
Anytown, U.S.A. 12345  
Telephone (100) 555- 2020

---

NAME Frank Q Smith AGE 65  
ADDRESS 123 Main Street DATE 2/14/07

**Rx** *TobraDex ophthalmic susp.*  
*# 5 ml*  
*sig.: 1 gt OD q 2 h while awake*  
*x 24 h, then QID for eye inflammation*

No Refill \_\_\_\_\_, O.D. John A. Smith, O.D.  
 Refill X \_\_\_\_\_ Dispense as Written Product Selection Permitted

A

JOHN A. SMITH, O.D.  
Optometry

1234 Hospital Drive  
Anytown, U.S.A. 12345  
Telephone (100) 555- 2020

---

NAME Donald Doc AGE 13  
ADDRESS 456 Peach Ave. DATE 2/14/07

**Rx** *Erythromycin ophthalmic ung.*  
*# 3.5 g*  
*sig.: apply to cotton-tipped applicator*  
*and scrub eyelids BID*

No Refill \_\_\_\_\_, O.D. John A. Smith, O.D.  
 Refill X 2 Dispense as Written Product Selection Permitted

B

**Figure 4-1** Typical prescription format. (A) Ophthalmic suspension. (B) Ophthalmic ointment.

information substantially increases the risk of medication error. Some prescribers provide more information on the prescription than merely the patient's name and address, including height, weight, age, and even laboratory data. This may be especially helpful for pediatric patients. Practitioners may also include the reason for the drug prescription in the instructions, as in "for inflammation" or "for bacterial conjunctivitis." This helps tremendously in the drug-use evaluation process, particularly if a drug has multiple indications for use as approved by the U.S. Food and Drug Administration (FDA).

The date on which the prescription was written is critical. A delay in presenting the prescription to a pharmacy may warrant communication between the pharmacist and the clinician to determine whether the intent of the prescriber and needs of the patient can still be met. This matter is more crucial in the management of acute rather than chronic illnesses and in the dispensing of controlled substances.

The "Rx" symbol, or superscription, is an ancient symbol associated with healing. The current Rx symbol is actually a distortion or contraction of the Latin verb *recipe*, meaning "take thou" or "you take."

The medication prescribed is the primary portion of a prescription and is termed the inscription. This portion of the prescription contains the name of the drug to be dispensed (brand and/or generic), its concentration or dosage units, and its formulation (e.g., solution, ointment, capsule). Most prescriptions are dispensed in premanufactured dosage forms. Compounded prescriptions are those in which various ordered ingredients are formulated by pharmacists.

The dispensing directions written to the pharmacist, termed the *subscription*, are usually brief. If the product is premanufactured, the subscription usually consists of the number of dosage units or volume or weight amount preceded by a number sign (#). If the subscription is for a compounded prescription, dispensing directions are much more complex. The system of measurement used in prescription writing is continuing to shift from the avoirdupois and apothecary systems to the metric system. The metric system is preferred, and its use is encouraged, although the apothecary system is still occasionally used.

The specific directions to patients about how to use the prescription properly comprise the *signatura* (Sig.) of the prescription. The directions for use are commonly written using abbreviated forms of either English or Latin terms. The translations of commonly used prescription abbreviations are listed in Table 4-1. These directions are interpreted by pharmacists and placed on the label of the prescription container. Written patient information leaflets designed to foster safe and appropriate drug use may also be dispensed with the prescription. Federal law dictates that manufacturers provide FDA-approved patient package inserts for selected products (e.g., estrogens). Clear and specific patient instructions are aimed at improving patient outcomes.

**Table 4-1**  
Selected Prescription Abbreviations and Their Meaning

Abbreviation	English Meaning
a.c.	Before meals
B.I.D.	Twice a day
c̄	With
d.	Day
gtt(s)	Drop(s)
h.	Hour
H.S.	At bedtime
O.D.	Right eye
o.h.	Every hour
O.S.	Left eye
o.u.	Each eye
p.c.	After meals
p.o.	By mouth
p.r.n.	As needed
q.	Each, every
q.h.	Every hour
Q.I.D.	Four times a day
q.o.d.	Every other day
ᄀ	Without
sig.	Label
sol.	Solution
susp.	Suspension
tbsp.	Tablespoonful
T.I.D.	Three times a day
tsp.	Teaspoonful
ung.	Ointment
ut dict.	As directed

Additional instructions to patients may be included on the prescription label. Checking the "label" line on a prescription instructs the pharmacist to list the name and strength of the prescription drug on the patient's drug bottle. Many states require that the product name is included on the label. The benefits of this labeling are that it fosters communication between the patient and his or her pharmacist and prescriber and allows rapid identification in emergencies and cases of accidental or intentional overdose. The manufacturer's expiration date may also be requested, though this date may not be valid once the product's package is opened. Also essential to every prescription is the specific designation of the number of authorized refills. Generally, no refills are given unless the condition being treated is chronic in nature, such as open-angle glaucoma.

Practitioners are encouraged to recommend auxiliary labeling on prescriptions whenever appropriate. Such additional information can be effective in fostering compliance and therefore ensuring the safe, appropriate, and judicious use of the prescription. Common auxiliary labels include phrases listed in Box 4-1. Some prescribers tend to use colloquial shorthand abbreviations for drugs and conditions. Caution should be exercised in using abbreviations, however, because potential for error exists in interpretation.



**Box 4-1** Common Auxiliary Information Used on Prescription Labels or Containers

Shake well before using.  
 For external use only.  
 For the eye.  
 Keep in refrigerator. Do not freeze.  
 Keep out of the reach of children.  
 No refills.  
 \_\_\_ refills available.  
 Take medication until gone.  
 Store in a cool, dry place.  
 Take with food.  
 Avoid alcohol.  
 May cause drowsiness.  
 Take on an empty stomach.  
 Take 30 to 60 minutes before bedtime.  
 Take every \_\_\_ hours around the clock.

Pharmacists often make notations on the written prescription usually via the pharmacy computer. These data may include the dispensing pharmacist's initials, price of the drug, the brand name or generic product dispensed, and other appropriate notations. Prescriptions then are part of a master prescription file for each patient, which is generally kept for many years.

**Types of Prescriptions**

Errors can occur in all steps of prescription communications, from written to oral to fax transmissions. Patients ultimately suffer the consequences of inappropriate prescription communications, and care must be taken by both the prescribing practitioner and the pharmacist to minimize these concerns.

Most prescriptions continue to be presented to the pharmacist in a written or printed form. However, they can also be relayed over the telephone, by fax, or electronically. When telephoning a prescription to the pharmacist, the practitioner should clearly identify him- or herself initially and should verify that the prescription was received and transcribed accurately at the end of the conversation. Prescribers should not be oversensitive to pharmacists who telephone them to verify prescriptions apparently called in by office personnel or nurses. Because prescription drug fraud is common, it is recommended that prescribers not delegate the function of calling in prescriptions to pharmacies; however, this, too, is common practice.

Fax transmission of prescriptions may also lend itself to prescription fraud and drug diversion. Ascertaining the origin of the fax is difficult, so fax prescriptions could be forgeries. Although some states have ruled fax transmission of prescriptions to be invalid, others have developed guidelines for the use of fax transmission.

Similarly, although some states restrict electronic transmission of prescriptions, it is clear that this type of communication of prescriptions is increasing. Medication dispensing errors can be reduced with electronic prescription transmission. Several states have developed or are in the process of developing guidelines to ensure proper handling of electronic prescriptions.

**Steps for Effective Prescription Writing**

Legibility is fundamental to good prescription writing. Illegibility increases the risk of harmful medication errors. The use of potentially confusing abbreviations, such as "q.d.," "Q.I.D.," or "q.o.d.," should be avoided. Use of bold periods and sloppy lettering have resulted in "q.o.d." (every other day) being translated to "Q.I.D." (four times daily). This results in an eightfold (800%) increase in the intended dosage. Several malpractice cases involved a misinterpretation of abbreviations such as "q.d." and "Q.I.D."

Abbreviations of drug names are discouraged. For example, zidovudine is often expressed as AZT, but this abbreviation has also been interpreted to be azathioprine or aztreonam. Decimals should be avoided whenever possible. A "500-mg" designation is preferable to a "0.5-g" designation. "Naked" decimals should also be avoided: For example, "0.25 ml" is preferable to ".25 ml." If a decimal point is not seen, tremendously large multiples of the intended dose can be prescribed and given. The consequence of such errors is the potential to produce profound morbidity and even mortality.

Practitioners should specify the appropriate times during the day at which the prescribed drug should be administered. For example, rather than prescribing a drug four times daily, the exact times may be stated (e.g., 9:00 AM, 1:00 PM, 5:00 PM, and 9:00 PM). If a drug must be administered around the clock, this should be stated clearly, because patients generally take medications only during the waking hours unless advised to do otherwise.

Prescribers are encouraged to include the purpose for the drug treatment on the prescription, as in the following examples: "instill one drop in each eye at 7:00 AM and 7:00 PM for glaucoma"; "take one capsule before bedtime for eye infection"; "take one teaspoonful at 8:00 AM, 2:00 PM, 8:00 PM, and 2:00 AM for eye infection"; or "instill one drop in each eye at 9:00 AM, 3:00 PM, and 9:00 PM to treat eye inflammation" (see *Anatomy of the Prescription*, above).

Vague instructions such as "p.r.n." (take as necessary, take as needed) or "ut. dict." (use as directed or take as directed) are strongly discouraged. "Take as needed" gives patients license to self-assess and self-treat. This introduces subjectivity into the drug use process and invites overuse or underuse, both of which have the potential to produce adverse health consequences. "Take or use as directed" also invites patient subjectivity. Furthermore, it presumes that patients will remember in full the verbal

directions provided by prescribers or pharmacists. It is a dangerous practice to assume that each patient will remember what was intended by the prescriber.

Prescribers should request that the name and strength (or concentration) of the prescribed medication be placed on the prescription label. This can be ensured by indicating the prescription should be “labeled.” Because this information is in the public health interest, most pharmacists routinely provide this information.

The prescription should indicate the number of authorized refills. Although multiple refills may be appropriate for managing chronic diseases, such as open-angle glaucoma, medication prescribed for acute ocular diseases should have few, if any, refills. This is particularly important when prescribing corticosteroids due to the potential for serious adverse effects with prolonged use. If a course of therapy for an acute infection or inflammation does not produce the desired clinical result, prescribers will likely need to see the patient again, to reevaluate his or her condition, and to alter the drug therapy. Refill instructions such as refill “prn” or refill “ad lib” are generally inappropriate.

### Controlled Substances

The Comprehensive Drug Abuse Prevention and Control Act of 1970, most commonly known by the Title II section called the Controlled Substances Act, is enforced by the U.S. Department of Justice. This consolidation of laws regulates the manufacture and distribution of narcotics, stimulants, depressants, hallucinogens, anabolic steroids, and chemicals used in the illicit production of controlled

substances. Controlled substances are categorized into five classes or “schedules” on the basis of their medicinal value, harmfulness, and potential for abuse or addiction. Practitioners who are registered with the Drug Enforcement Administration (DEA) have been given the authorization to prescribe a drug regulated by the DEA. Their assigned DEA number should be handwritten in ink on prescriptions for drugs covered under the Controlled Substances Act. Widespread dissemination of a DEA number on routine prescriptions containing this number fosters fraud, forgeries, drug diversion, and illegal drug use. Because some third-party programs are now requiring a prescriber’s DEA number for third-party billing, the misuse of this number may increase. Some states require use of specialty prescription forms for controlled substance prescriptions. For similar reasons, prescribers should never presign prescriptions; such prescriptions represent “blank checks” for illegal acquisition of prescription drugs of all types. Table 4-2 summarizes the categories of controlled substances with examples commonly used in optometry.

U.S. federal regulations concerning controlled substances may be superseded by more stringent state regulations, resulting in state-to-state variance. Prescribers must recognize that if scheduled medication is inventoried in the office practice, an additional registration must be filed with the DEA, accurate records must be kept regarding receipt and disbursement of scheduled drugs, and practitioners must submit to DEA inspections. The clinical uses of cocaine are described in Chapters 19 and 22, and the uses of opioid narcotic analgesics are discussed in Chapter 7.

**Table 4-2**

Controlled Substance Formulations Commonly Used in Outpatient Ophthalmic Practice

Schedule	Description	Drug
I	<i>Not commercially available</i> , no approved indication, could be investigational use.	None commonly used
II	<i>Accepted for medical use</i> , strict limitations due to recognized high abuse and dependency potential. Prescriptions must be signed by practitioners and cannot be refilled.	Cocaine, oxycodone with acetaminophen
III	<i>Significant but less abuse and dependency potential</i> than that of schedule I and II agents. They may contain limited quantities of certain narcotics.	Aspirin with codeine Acetaminophen with codeine
IV	<i>Relatively low abuse potential and limited</i> dependency potential. Whereas schedule II prescriptions must be written, prescriptions for schedule III and IV drugs may be verbal and may be refilled up to five times in 6 months if authorized by the prescriber.	Propoxyphene with acetaminophen
V	<i>These agents have a lower abuse potential.</i> Many of the products are used to suppress cough and to treat diarrhea. None of these agents is commonly used for ophthalmic purposes.	None commonly used

## Guarding Against Prescription Forgery

Ophthalmic practitioners and pharmacists are encouraged to collaborate in the prescription verification process to attempt to minimize the problem of prescription forgeries. Figure 4-2 illustrates a prescription for a controlled substance in which the number of dosage units to be dispensed is specified parenthetically to prevent alteration of the dosage units.

## GENERIC VERSUS BRAND-NAME DRUGS

The generic drug industry is a vigorous and dynamic component of the health care system. When a drug innovator loses its patent exclusivity on a drug, companies may elect to develop a generic formulation of that drug. Generic drug use has increased dramatically since 1975, when 9.5% of all prescriptions were generic versions. Currently, more than 50% of all prescribed drugs are generic versions of an innovator's brand-name product that has lost its patent exclusivity. Interestingly, several large brand-name pharmaceutical companies have purchased generic drug companies, formed their own generic drug divisions, or begun to distribute products manufactured for them by generic drug firms under a subsequent brand-name label.

Passage of the 1984 Drug Price Competition and Patent Term Restoration Act (Waxman-Hatch Act) permits the FDA to use an expedited review process for approval of generic versions of brand-name drugs that have been found to be safe and effective but are no longer protected by a patent. The expedited review process is known as an abbreviated new drug application (ANDA).

The Waxman-Hatch Act of 1984 was motivated, to a significant degree, by cost considerations, but quality issues concerning bioequivalency and therapeutic equivalency were addressed as well. All FDA-approved drugs (pioneer brand-name and generic versions) are required to meet the same FDA standards of quality.

Generic versions must be bioequivalent to the innovator's product, within predetermined limits, to ensure therapeutic equivalency and no greater risk for drug-induced toxicity. The term *bioequivalency* refers to those pharmaceutically equivalent products that not only contain the same active ingredient in the same concentration and dosage form and are administered by the same route of administration, but also display comparable bioavailability. Bioavailability connotes the rate and extent to which the active or therapeutic ingredient is absorbed from a drug product and becomes available at the site of action.

A generic manufacturer does not have to repeat clinical trials and to redemonstrate drug safety and efficacy. Under the ANDA process, generic manufacturers must provide evidence that the generic version fulfills the following criteria:

- Contains the same active ingredient as the brand-name drug
- Demonstrates similar bioequivalency and bioavailability
- Produces the same pharmacologic and therapeutic activity in the body (in vivo) as does the brand-name product
- Is manufactured according to stringent and universally applied FDA requirements
- Meets FDA requirements for stability, purity, strength, and quality
- Is labeled with the same claims, warnings, and other information as the innovator's product

The graphic representation of bioavailability for systemic medications is generally represented by a serum concentration-time curve that plots serum drug concentration on the abscissa against time on the ordinate. Total drug absorption is reflected by area under the curve.  $C_{max}$  (maximum serum concentration) and  $T_{max}$  (time to reach maximum concentration) are also important because the pharmacologic effect of several drugs depends on their rate of absorption. In comparing generic formulations with the innovator's product, the more superimposable the concentration-time curves, the more likely the two products are bioequivalent and therapeutically equivalent.

Although different standards are set for different classes or types of drugs, the general bioavailability standard is an upward or downward variation of no more than 20%. Most generic versions tested to date have demonstrated plasma levels within 3% to 5% of the innovator drug. Sentiment is growing for an achievable  $\pm 10\%$  bioavailability criterion.

The FDA "Orange Book," officially titled *Approved Drug Products with Therapeutic Equivalency Evaluations*, provides a list of all drugs that have been fully reviewed by the FDA for safety and efficacy and for which new drug applications and ANDAs have been approved. Equivalence evaluations are provided for generic drugs that are pharmaceutical and therapeutic equivalents of brand-name drugs when administered according to the labeling. Products not included are

JOHN A. SMITH, O.D.  
Optometry

1234 Hospital Drive  
Anytown, U.S.A. 12345  
Telephone (100) 555-2020

DEA 150 665169

---

NAME Jane R. Jones AGE 42  
ADDRESS 123 Oak St, Anytown, USA DATE 2/14/07

**R** Tylenol w/ codeine no. 3  
# 16 (sixteen)  
sig:  $\dot{\bar{i}}$  or  $\bar{ii}$  tab. p.o. q 4 h  
prn eye pain

No Refill  Refill X \_\_\_\_\_, O.D. John A. Smith, O.D.  
 Dispense as Written  Product Selection Permitted

**Figure 4-2** Prescription for a controlled substance.

generally those marketed before 1938 or those that were brought to market between 1938 and 1962 that the FDA has certified as safe but has not yet approved as effective.

Of the more than 10,000 drugs in the Orange Book, approximately 80% are generic versions. Of the approximately 8,000 multisource generic drugs, more than 90% are considered therapeutically equivalent to the innovator's product.

Ophthalmic practitioners are encouraged to collaborate with pharmacists in selecting generic versions of drugs. Pharmacists are particularly knowledgeable regarding bioequivalency, product quality, and manufacturer reliability of generic drugs. Prescribers are encouraged to adhere to the following guidelines in prescribing generic drugs:

- Seek bioequivalency information. Only A-rated multi-source products should be prescribed.
- Realize that several companies with large generic drug lines are distributors only. They repackage drugs manufactured by other companies. The manufacturer's reputation and history of producing high-quality generics are paramount. Prescribers may want to specify on the prescription and prescription label the manufacturer of generic versions.
- Do not assume that different dosage forms of the same drug and strength are equivalent.
- Discourage a change in source of supply if a bioequivalent generic product is selected. Patients become confused when, on refill, they receive generically equivalent drugs that differ in color or shape from the medication originally dispensed.
- Assess patient status. Medically fragile patients should avoid changing source of supply.
- Prescribe with great care drugs or drug classes with known bioavailability problems or a narrow therapeutic range.
- Reassure patients that high-quality generic drugs exist in abundance, and teach patients, when using generic medications, to stay with the same "source of supply" or generic product.

Generic drugs represent a low-cost alternative to more expensive brand-name products. The difference in cost between the average generic prescription and average brand name prescription now exceeds \$90.00. Prescribers should take appropriate steps to ensure the prudent use of generic drugs.

## **COMPLIANCE WITH PRESCRIBED DRUG REGIMEN**

The fundamental ubiquitous problem of patient noncompliance (therapeutic nonadherence) continues to be significant in the management of ocular disease in ambulatory outpatients. Much time, effort, and expense are directed at diagnosis and the subsequent selection of drug therapy, but what transpires beyond that point in the patient's care depends on many factors.

Therapeutic noncompliance is one of the most significant dilemmas in health care today. The financial burden of noncompliance is very high. Attention to instructing patients to take medication correctly and providing follow-up to assess the therapy is essential. Only approximately 50% to 75% of patients for whom appropriate therapy is prescribed achieve full benefit from that therapy through strict adherence.

Clinicians tend to blame patients for failure to comply with a prescribed drug regimen. Though such criticism is appropriate in some instances, prescribers and dispensers of medication also have a significant responsibility for ensuring that patients use their drugs properly. Greater appreciation of the incidence, causes, and clinical implications of therapeutic noncompliance allows a higher degree of role clarification, proper perspective, and, it is hoped, more vigorous and meaningful efforts to optimize therapeutic compliance and ocular health outcomes.

## **Incidence of Noncompliance**

In an ambulatory population at large, the range of noncompliance is typically 25% to 50%.

Common errors of compliance are overuse, underuse, and administration of medications at inappropriate time intervals. Medications can also be administered improperly, taken though expiration dates have passed, or can be taken for the wrong purpose. The ultimate error in noncompliance, however, is failing to have the prescription filled. Approximately 7% (280 million) of the 4 billion prescriptions written each year are never purchased.

## **Clinical Implications of Noncompliance**

Noncompliance with a prescribed regimen frequently produces adverse sequelae. The nature of the consequences depends on the type of error. Underuse can lead to therapeutic failure. In some cases of insufficiently administered therapy, noncompliant patients are assumed to be refractory to the prescribed treatment, and a compensatory aggressive approach to treatment with a higher degree of side effect potential may be instituted.

Noncompliance resulting in overuse predisposes to drug-induced adverse effects. Overzealous patients may believe that if one dose is good, an extra one or two doses per day will hasten a cure or relief of symptoms. Others may not remember taking a dose and may follow with another dose.

Other compliance errors, including improper technique or route of administration, using medication for the wrong purpose, or using outdated medication, also have clinical implications. To optimize absorption, an essential factor is appropriate administration of routine ophthalmic solutions, suspensions, and ointments. In addition, patients may self-diagnose and use stored "leftover" prescription medication to treat symptoms perceived to be similar to

those for which the prescription was originally issued. If a drug is used to treat similar symptoms at a later date, the drug could have aged or otherwise deteriorated to subpotent, inactive, or toxic constituents.

### Reasons for Noncompliance

The correlation between noncompliance and several variables has been tested. Significant relationships appear to exist between noncompliance and the factors listed in Box 4-2. The most important reasons for the aforementioned therapeutic noncompliance appear to relate most often to (1) complexity of the drug regimen, (2) lack of understanding of the nature of the illness and the importance of drug therapy, (3) failure to understand thoroughly the instructions for proper use, and (4) a lack of patient instruction. Frequency of interpretive errors of prescription labels ranges between 9% and 64%. For example, a label instructing patients taking the diuretic furosemide to “take one tablet as needed for fluid retention” led one patient to believe that the drug would cause fluid retention. The instruction to “force fluids” on a prescription for a sulfonamide-containing prescription was interpreted to mean “strain during urination.”

It is clearly short-sighted for ophthalmic practitioners to assume that the drug-consuming public is universally knowledgeable and understanding in matters related to prescription instructions. The public’s knowledge level and ability to comprehend medical matters are highly stratified. Health professionals tend to overestimate the intellectual sophistication of patients, who generally make no request for clarification or additional information. Practitioners should ensure that patients truly comprehend the essence of the message by asking them questions or by encouraging them to ask questions. Verification of patient understanding of the regimen by asking them to restate

or demonstrate the instructions can be very helpful. This validation is frequently missing in practitioner–patient encounters. When asked to demonstrate how they instill their topical ophthalmic drops, patients have been known to use their eyedrops in their nose or under their tongue. This reveals why in-office demonstration of technique of administration is often valuable.

Maximizing compliance must be an individualized process. Good communication skills are essential. Warm, empathetic, sincere prescribers generate confidence and trust. Patients cannot be frightened, coerced, or threatened into compliance. Instead, they should be educated, advised, and encouraged to participate in their therapy. Various types of devices have been developed to enhance compliance with administration of medications.

### PATIENT EDUCATION AND COUNSELING CONSIDERATIONS

Recognition by both health care providers and patients that medication can be of maximum benefit only if used properly is still not sufficiently reflected in patient education, compliance, and drug use patterns. Medications have the potential not only to do great good but also to produce morbidity, and even mortality, especially if not used properly. Many factors contribute to effective patient education and counseling, including the verbal communication skills of prescribers and pharmacists, the counseling atmosphere and environment, and the receptivity of patients. The education and counseling of patients about their ocular disease and drug therapy involve the following fundamentals:

1. *Name of the person for whom the medication is intended.* Make patients aware that prescription medication is to be used only by the individual whose name appears on the label.
2. *Purpose of the medication.* With few exceptions, patients should know what the prescribed medication is intended to treat. General terms understood by lay people are preferred (e.g., “pink eye,” glaucoma, granulated eyelids, stye).
3. *Name of the medication.* A prescription label should contain the generic name of the drug (and brand name if applicable). Exceptions to this routine practice rarely exist. This information can be valuable for discussions of drug therapy with other health care providers and dispensing pharmacists. This practice also allows easier and more positive identification of the drug if overdose occurs.
4. *Directions for using the medication.* That most patients use all medication properly is a dangerous assumption. Understanding prescription labels and any instructional “how-to-use” information contained in the package may be difficult or such data may be subject to multiple interpretations. Furthermore, the various precautions and warnings that exist for all drugs must be observed if therapy is to be optimal.

#### Box 4-2 Factors Associated with Noncompliance

Advancing age/dementia  
 Duration of therapy  
 Number of drugs in the regimen  
 Frequency of administration  
 Drug-induced adverse effects  
 Asymptomatic disease or relief of symptoms  
 Fear of drug dependence or addiction  
 Interference with daily routine  
 Poor palatability of drug  
 Absence of a viable patient–prescriber relationship  
 Excessive waiting to see the prescriber or pharmacist  
 Distrust of the health care system  
 Lack of continuity of care  
 Nature of the illness  
 Cost of the medication

Patients themselves bear considerable responsibility for the achievement of the best possible therapeutic outcome, but they can fulfill their responsibility only if health care providers supply effective instructions on use.

5. *Schedule for medication administration.* Patients must be made aware of appropriate intervals between drug doses. Timing of administration may affect absorption and blood or ocular levels of the drug. Clinicians should provide verbal definition of label instructions (e.g., before meals, after meals, at bedtime; two, three, or four times daily; every 4, 6, or 12 hours; on an empty stomach). "As directed" is considered an inappropriate form of patient instruction.
6. *Duration of treatment.* Patients should be encouraged to take a full course of therapy for an acute condition *or* to continue with prompt refill of chronic medications unless untoward events occur. This is particularly critical with antibiotics and other anti-infectives, where failure to take the full course of therapy may lead to a therapeutic failure and reinfection. Patients on chronic maintenance therapy should be counseled about the importance of acquiring refills on time, of the need for continuous therapy, and of potential risk associated with abrupt discontinuation of certain drugs, such as corticosteroids.
7. *Maximum daily dose.* The dose recommended on the prescription label is considered the maximum daily dose and should not be exceeded unless authorized. This limitation is particularly critical with drugs having a narrow therapeutic index or high abuse potential. Clinicians should note that almost all drug-induced adverse events are dose related. Increasing doses beyond those prescribed seldom results in additional therapeutic benefits but may markedly increase the risk of experiencing one or more serious adverse drug effects.
8. *Adverse effects.* All drugs have the potential to produce side effects. Patients should be warned about those most likely to occur and should be told when and how urgently they should report these untoward events. If other steps are required in response to the adverse effect, these should also be communicated.
9. *Drug interactions.* Prescription and nonprescription drugs may interact adversely with one another, and certain drugs may also interact with components of some foods. Drugs may also alter the results of some laboratory tests. Many drug interactions are of little or no clinical significance, and some drugs or foods may be given together if the potential value of the drug combination outweighs the potential risk. Some interactions lead to such significant problems, however, that some drug combinations are absolutely contraindicated.
10. *Storage.* Special requirements for storage of certain drugs may be frequently underappreciated or

overlooked. Proper storage is required for maintenance of drug stability and potency. Patients should appreciate the importance of proper storage (e.g., refrigeration, protection from sunlight, protection from moisture, avoidance of extreme heat). All medication should be kept out of the reach of children.

11. *Miscellaneous considerations.* A variety of specific instructions unique to a particular drug regimen or a specific patient may be required. Patients may require special directions for preparation or administration of drugs, reviews of precautions to be observed during therapy, techniques for self-monitoring response to therapy, prescription refill information, or action to take in the event of a missed dose. Providing this information requires professional judgment and communication skills and is a shared responsibility with prescribers and pharmacists.

Professional practice standards for patient education and counseling are rapidly becoming legal and regulatory mandates. Over-reliance on prescription labels to communicate the essential message is not in the public interest, primarily because of the size limitations of prescription labels. The synergistic combination of a complete prescription label and appropriate verbal counseling appears to be effective in enhancing patients' ability to recall critical information. Supplemental instructional leaflets, brochures, or information sheets render an optimal therapeutic outcome even more probable. Practitioners, however, must recognize the great difference between providing information and educating patients. Validation of patient understanding of instructions is critical.

## SELECTED BIBLIOGRAPHY

- American Society of Hospital Pharmacists. Practice standards of ASHP. Bethesda: Author, 1991-1992:24.
- Ansel HC. The Prescription. In: Remington's practice of pharmacy. Philadelphia: Mack Publishing, 1990:1828-1841.
- Bluml BM. Definition of medication therapy management: development of professionwide consensus. JAPhA 2005;45:566-572.
- Bond W, Hussar D. Detection methods and strategies for improving medication compliance. Am J Hosp Pharm 1991; 48:1978-1988.
- Bond WS. Medication noncompliance. Facts Compar Drug Newsl 1990;9:33-35.
- Bootman JL. Drug-related morbidity and mortality: an economic and clinical perspective. Manag Care 2002;11(suppl 2): 12-15.
- Covington TR. Generic drug utilization: overview and guidelines for prudent use. Am Drug 1991;(suppl).
- Covington TR. Patient education and compliance. In: Brown TR, Smith MC, eds. Handbook of institutional pharmacy practice, ed. 2. Baltimore: Williams & Wilkins, 1986.
- Covington TR. Talk about prescriptions. Facts Compar Drug Newsl 1990;9:76-77.
- Ernst FR, Grizzle AJ. Drug-related morbidity and mortality: updating the cost of illness model. JAPhA 2001;41:192-199.

- Felkey BG, Fox BJ, Thrower MR. Health care informatics: a skills-based resource. Washington, DC: American Pharmacists Association, 2006.
- Fraizer C. E-prescribing in clinical practice. *J Med Pract Manage* 2004;20:148-151.
- Heffler S, Smith S, Keehan S, et al. Health spending projections for 2002-2012. *Health Affairs* 2004;23(W3):54-65.
- Hoffman JM, Shah ND, Vermeulen LC, et al. Projecting future drug expenditures—2004. *Am J Health Syst Pharm* 2004;61:145-158.
- Holt GA, Parker R. Introduction to pharmacy practice. Birmingham, AL: Holt Publishing, 1993: 65, 100.
- Kass MA, Gordon M, Meltzer DW. Can ophthalmologists correctly identify patients defaulting from pilocarpine therapy? *Am J Ophthalmol* 1986;101:524-530.
- Kass MA, Meltzer DW, Gordon M, et al. Compliance with topical pilocarpine treatment. *Am J Ophthalmol* 1986;101:515-523.
- Knowles MR. Improving patient compliance. Proceedings of a symposium. Washington, DC: National Pharmaceutical Council, 1985.
- Lasagna L. Noncompliance data and clinical outcomes: impact on health care. *Drug Topics* 1992;136(suppl):33-35.
- Laster SF, Martin JL, Fleming JB. The effect of a medication alarm device on patient compliance with topical pilocarpine. *J Am Optom Assoc* 1996;67:654-658.
- McClellan M. Medicare part D: opportunities and challenges for pharmacists. *JAPhA* 2005;45:328-335.
- Olin BR, ed. The professional's guide to patient drug facts. St. Louis, MO: J. B. Lippincott, 1994:ix-x.
- Rantucci MJ. Pharmacists talking with patients. A guide to patient counseling. Baltimore: Williams & Wilkins, 1997.
- Strand L, Cipolle RJ, Morley PC. Pharmaceutical care: an introduction. In: *Current concepts*, 1992. Kalamazoo, MI: The Upjohn Co., 1992: 15.

## Legal Aspects of Drug Utilization

*John G. Classé*

Numerous legal issues are involved in the use or prescription of pharmaceutical agents by optometrists. Legislation permitting ophthalmic drug use is the most significant legal event affecting optometry since the 1960s. Issues such as certification, registration, and comanagement are contemporary offshoots of the regulatory process. Responsibility for care is another important legal issue, requiring optometrists to understand and comply with the demands of informed consent, negligence law, and product liability law. Each of these legal principles has a unique influence on the clinical practice of optometry and the use of ophthalmic drugs. In this chapter these issues and their relevance are described, beginning with the most fundamental consideration of all, the legal authority by which optometrists are permitted to use pharmaceutical agents.

### LEGAL BASIS FOR DRUG USE IN OPTOMETRY

The practice of optometry is regulated by state law.\* The original optometry practice acts, which were enacted during the period 1901 to 1924, did not provide for the use of drugs or surgery. Beginning in 1971, however, amendments to optometry laws began to permit the use of drugs, first for diagnosis and then for treatment, and by 1998 all jurisdictions had enacted such laws. Legal challenges to these amendments were uniformly rejected by the courts. Subsequent amendments of state optometry laws permitting an expanded scope of practice (i.e., laser procedures) have met with a similar judicial response.† In fact, no power granted to optometrists by the legislatures has been ruled unconstitutional.

\*The 10th Amendment limits federal regulation to matters specifically described in the U.S. Constitution and grants to the states authority over all other matters. Because health care is not mentioned in the Constitution, it must be regulated on a state basis, which is why licensure of optometrists and other health care providers is determined by state law. See Classé JG. Legal aspects of optometry. Boston: Butterworth, 1989:133-156.

Although the right to use ophthalmic drugs may be authorized by a jurisdiction's optometry statutes, various legal requirements must be satisfied to exercise this right. Two common requirements are certification and registration.

### Certification

To use pharmaceutical agents optometrists must have been granted this right at licensure‡ or must be certified by the board of optometry as qualified to exercise it. Certification—a process of education and examination—is necessary to ensure that ophthalmic drugs are used only by qualified practitioners. Optometrists who have satisfied the educational requirements and have passed the examination are given a certificate, which usually must be displayed with the optometrist's license. Certification confers legal standing on practitioners to use the permitted pharmaceutical agents within the bounds of state law. If optometrists act outside the scope of certification, however, such actions may subject them to discipline by the state board of optometry. Similarly, if optometrists use drugs in the course of patient care without first obtaining the necessary certification, they may be disciplined by the

†A law permitting the use of lasers by optometrists has been enacted in Oklahoma, but there has been no legal challenge to the authority of the legislature to confer this authority on optometrists; however, a legal challenge before this legislation that questioned the state board of optometry's authority to recognize laser use as part of the practice of optometry was upheld. See *Oklahoma Board of Medical Licensure and Supervision v. Oklahoma Board of Examiners in Optometry*, 893 P2d 498 (1995).

‡A license confers upon the licensee all rights that may be exercised in the jurisdiction. Therefore optometrists who qualify for licensure within a state receive a license that enables them to use all the techniques and methods available to optometrists within that state. For example, if a state law describes the therapeutic pharmaceutical agents that may be used by optometrists, successful passage of the licensing examination confers on optometrists the right to use these agents. Optometrists who are already licensed at the time the definition of optometry is changed must be certified before they can use this new right. Thus, certification inevitably occurs after licensure.



board, even though state law authorizes use of the drug by optometrists. Certification is a legal prerequisite to drug use in these circumstances, and failure to satisfy certification requirements violates the optometry practice act.

### Registration

Even if optometrists have complied with licensure and certification requirements, certain federal regulations must be observed if they wish to use controlled substances. The dispensing of central nervous system drugs with significant potential for abuse is regulated by federal law, and enforcement is the responsibility of the Drug Enforcement Administration (DEA). If a state optometry practice act (or board ruling) authorizes the use of controlled substances, optometrists must register with the DEA and obtain a registration number before using these drugs clinically. The DEA number must also be written on every prescription for controlled substances given to patients. Failure to observe these requirements violates federal law (see Chapter 4).

An additional administrative matter concerns the dispensing of drugs to patients by optometrists. Although state pharmacy acts regulate the sale of pharmaceutical products to consumers, direct sale by licensed health care practitioners to patients is usually excluded from the provisions of these laws. Therefore, unless prohibited by the optometry practice act, optometrists usually can dispense pharmaceutical agents to patients directly. If controlled substances are among the drugs provided to patients, optometrists must be certain to comply with all record-keeping requirements.

### Comanagement

Optometrists may provide therapeutic care to patients in conjunction with physicians—referred to as *comanagement*—under certain circumstances. These circumstances most commonly arise in multidisciplinary settings and in practices in which optometrists and physicians work together. Practitioners in separate offices may also find cooperation necessary under certain types of circumstances, such as postoperative care or long-term management of disease. The physician and optometrist comanage patients' care through a delegation of responsibility to the optometrist, who acts in place of the physician to examine patients and monitor treatment. The optometrist's role may be described in a comanagement protocol that is specifically written for the individual optometrist and that carefully delineates the manner in which cooperative care may be undertaken. The mode of treatment (tests to be performed, drug dosages, scheduled patient follow-up) may also be specified in the document (Box 5-1). While following the comanagement protocol, the optometrist is acting as the agent of the physician, who remains primarily responsible for the patient's well-being. Communication between practitioners

#### Box 5-1 Example Protocol for Postoperative Comanagement of Cataract Patients

1. **ZYMAR**  
Begin day of surgery. Use 1 drop four (4) times a day for one (1) week, then stop Zymar.
2. **PRED FORTE (Shake Well)**  
Begin day of surgery. Start 1 drop four (4) times a day for one (1) week, then 1 drop two (2) times a day for one (1) week, then stop.
3. **ACULAR LS**  
Start using this drop on first day after surgery. Use 1 drop in the operated eye four (4) times a day until bottle is empty.
4. Allow 5 minutes between each of the above medications and any other eyedrops patient is using (e.g., for glaucoma).
5. Blurred vision should be expected and begins to clear in a few weeks. Final prescription for glasses can be offered at 4–6 weeks.
6. Minor discomfort is normal after surgery and should improve within a few days. Light sensitivity, scratchy sensation, and redness may be noticed. Tylenol may be taken as needed for pain. If this does not control the pain, please contact the office at (123) 123-4567.
7. Eye shield should be worn during sleep during the first week.
8. Patient may wear habitual glasses if vision is better with them on. For outdoors, sunglasses should be worn.
9. Patient can resume regular diet and routine medications.
10. Patient can resume physical activities. Avoid strenuous activities and lifting anything over 10 pounds for at least two (2) weeks.
11. Patient can bathe the day after surgery. May shampoo hair being careful not to get soap or water in eye for two (2) weeks.
12. If patient has excessive pain that is unrelieved with Tylenol, flashes of light that persist, experiences a veil coming over the vision, or vision gets gray or blackens, CALL OUR OFFICE.

is an essential feature of this type of care. The optometrist should communicate with the physician within a reasonable period after examination concerning patient findings, and the physician should receive a written copy of the optometrist's records (by mail or facsimile transmission) after the examination. These formalities are necessary to ensure that the comanagement protocol is being properly followed.

Should the optometrist be negligent while acting within the scope of the comanagement protocol, both

the physician and optometrist share legal responsibility for any injury suffered by patients. If the optometrist acts outside the limits of delegated authority or in contravention to them, the optometrist is solely liable for any negligence. For this reason the physician must place great confidence in the optometrist's knowledge and skill before entering into a comanagement arrangement. To limit the potential for liability problems, legal and insurance counsel should be consulted before initiating a comanagement relationship. Under a comanagement protocol, the prescribing of drugs for treatment remains the responsibility of the physician. An optometrist who uses a pharmaceutical agent that is outside the scope of practice commits an act for which discipline may be imposed by the appropriate state regulatory agency.<sup>5</sup> Even averring that the circumstances constituted an "emergency" cannot provide legal justification for such an act, for Good Samaritan statutes do not provide legal immunity for in-office procedures even if the condition threatens vision.<sup>6</sup> Optometrists must understand the proscriptions of state optometry laws with regard to the use of ophthalmic drugs and must observe these limitations. Although comanagement allows an optometrist to participate in the medical management of certain types of patients (e.g., patients with glaucoma, individuals needing postoperative care for cataract), the role of the optometrist is to monitor care under the physician-initiated treatment plan. It does not provide legal justification for acts outside the scope of licensure.

The right to use drugs entails certain legal obligations, which are intended to protect patients from the risk of injury. These obligations include the doctrine of informed consent, which in some circumstances requires optometrists to inform patients of the side effects and risks of drug use; the duty to conform to the standard of care, the breach of which may subject optometrists to an action for negligence; and product liability law, under which optometrists can be drawn into the legal dispute created by a drug that is unreasonably dangerous and injures patients. Legal issues involving drugs arise regularly in primary eye care.

---

<sup>5</sup>Optometrists who commit an act that is outside the scope of licensure are subject to discipline by the state board of optometry. Disciplinary measures that the board may use include reprimand, suspension of licensure, and revocation of licensure. Boards may also seek injunctions against continuation of the prohibited activity or may enter into consent agreements in which the defendant optometrist agrees not to continue the proscribed conduct. See Classé JG. *Legal aspects of optometry*. Boston: Butterworth, 1989:152-180.

<sup>6</sup>Good Samaritan statutes in most states do not include optometrists as a covered party. Furthermore, these statutes do not provide legal protection for in-office treatment of ocular urgencies or emergencies. See Classé JG. *Legal aspects of optometry*. Boston: Butterworth, 1989:201-206.

## **INFORMED CONSENT**

An important legal duty that must be observed by doctors is the obligation to provide affirmative disclosure, which requires practitioners to communicate warnings, findings, and other pertinent information to patients. The reason for this duty lies in the legal status that doctors occupy as fiduciaries, persons who occupy a special position of trust and confidence with those they serve. The function of this duty of disclosure is to enable the less knowledgeable patient to understand the treatment recommended by the doctor. It has long been a precept of American law that no treatment may be undertaken without the consent of the patient, a philosophy succinctly stated by Judge Benjamin Cardozo: "Any human being of adult years and sound mind has a right to determine what shall be done with his own body; and a surgeon who performs an operation without his patient's consent commits an assault, for which he is liable for damages."

Cardozo's opinion concerned a case in which surgery was performed without the patient's consent, but the principle he expressed can be applied to any procedure that contains some risk of patient harm. Treatment may not be instituted without the patient's consent, and this consent cannot be legally secured without the patients being informed of the hazards, the possible complications, and both the expected and the unexpected results of treatment. In addition, practitioners must not make any misrepresentations, either by misstating known facts or by withholding pertinent information. This obligation to communicate forms the basis for the doctrine of informed consent.

Requirements for informed consent can arise in many areas of optometry: in the diagnosis of disease, in contact lens practice, in the recommendation of binocular vision therapy, or in the use of ophthalmic drugs. The latter category is one that has grown in importance as optometric drug utilization has increased. Optometrists must understand their legal obligation to discuss the risks of pharmaceutical use and must comply with the doctrine of informed consent when doing so. This legal duty has two aspects: (1) recognizing when the duty arises and (2) determining the amount of information that must be divulged.

### **Disclosure Requirements**

Although optometrists must disclose information sufficient to engender an informed consent, the legal test of how much information must be divulged to satisfy this duty varies among the states. In fact, conflicting opinions have been expressed by the courts and have proved to be a source of consternation for health care practitioners. Even so, these opinions must be understood and complied with, because informed consent issues routinely arise in clinical practice.

Two rival standards have been applied to determine whether practitioners satisfy disclosure requirements: a “professional community” standard and a “reasonable patient” standard.

### “Professional Community” Standard

The first court decisions applied the same legal test to informed consent cases that was applied to negligence cases: The practitioner was held to the standard of the reasonable person. Liability was imposed if the practitioner was found to have breached the duty to act as a reasonable practitioner would have acted under the same or similar circumstances. In determining the standard of care expected of the practitioner, the courts allowed other practitioners to testify concerning the warnings or disclosures that were necessary. Hence, the standard was a profession-set one, based on expert testimony and determined by the conduct of other practitioners. If the defendant practitioner provided that amount of information deemed to be reasonable by other practitioners, then a breach of duty did not occur.

A sample case may be used to illustrate the application of the “professional community” rule. A patient with a corneal foreign body was examined by an ophthalmologist, who removed the metallic foreign body and attempted to debride the rust ring that had formed around it. The procedure resulted in permanent corneal scarring. The patient sued the ophthalmologist, alleging that the risk of scarring had not been described and that the attempt to remove the rust ring had been undertaken without the patient’s consent. In determining that the ophthalmologist was not liable, the court held that the scope of the physician’s disclosure should be measured by the disclosures that would be made by an ophthalmologist in the community acting under the same or similar circumstances. The defendant was found to have met this requirement.

The “professional community” rule was adopted in a number of states (Box 5-2). However, it was soon challenged by another rule, which is found today in a majority of jurisdictions.

### “Reasonable Patient” Standard

The “reasonable patient” standard is based on what a reasonable patient must know rather than on what a reasonable practitioner must divulge. Evidence is offered to establish what a prudent person in the patient’s position would have done if adequately informed of all significant risks. Patients no longer must obtain expert testimony, because the issue concerns what they need to know rather than what practitioners are reasonably expected to divulge.

The standard may be illustrated by a sample case. A patient with an eye laceration was treated by an ophthalmologist, who repaired the laceration but did not attempt to remove a metallic corneal foreign body. By the next day an infection developed, and the patient was referred by the ophthalmologist to another physician. Although treatment

#### Box 5-2 Jurisdictions Applying the “Professional Community” Standard

Arizona	Michigan	North Carolina
Colorado	Minnesota	North Dakota
Delaware	Missouri	Ohio
Florida	Montana	Oregon
Idaho	Nebraska	South Carolina
Illinois	Nevada	Tennessee
Indiana	New Hampshire	Texas
Kansas	New Jersey	Virginia
Kentucky	New Mexico	Washington
Maine	New York	Wyoming

Adapted from *Ketchup v. Howard*, 247 Ga. App. 54, 543 S.E.2d 371, 2000.

was instituted and the foreign body removed, the infection ultimately resulted in enucleation. The patient sued the ophthalmologist, arguing that the doctrine of informed consent required the ophthalmologist to inform the patient of the risk of delay in removing the foreign body. The court held that the ophthalmologist had a duty to disclose the risks or hazards that a reasonable person would need to know to make an informed decision concerning a medical or surgical procedure. Failure to make this disclosure, if it would have caused the patient to proceed differently, constituted a breach of the doctrine of informed consent.

The “reasonable patient” standard has become the subject of much discussion in the medical profession, although studies of professional liability cases have shown that physicians are rarely subjected to informed consent claims. Jurisdictions that have adopted this objective standard are listed in Box 5-3.

#### Box 5-3 Jurisdictions Applying the “Reasonable Patient” Standard

Alabama	Massachusetts
Alaska	Mississippi
Arkansas	Oklahoma
California	Pennsylvania
Connecticut	Rhode Island
District of Columbia	South Dakota
Hawaii	Utah
Iowa	Vermont
Louisiana	West Virginia
Maryland	Wisconsin

Adapted from *Ketchup v. Howard*, 247 Ga. App. 54, 543 S.E.2d 371, 2000.

## **Duty to Disclose Risks of Proposed Treatment**

Practitioners may incur a duty to warn patients of the risks of ophthalmic drug use, both for drugs used diagnostically and for those used therapeutically. Of the two classes, the greater obligation arises when therapeutic agents are used. Patients may also need to be warned of the potential risks of refusing to allow a drug to be administered.

### **Diagnostic Agents**

The common diagnostic drugs used by optometrists are anesthetics, mydriatics, cycloplegics, and dyes. Routine use of these drugs creates a risk of injury only in very unusual circumstances. Therefore informed consent is rarely a legal issue when they are used.

The use of topical anesthetics creates a small risk that patients will experience a toxic response resulting in the disruption or desquamation of the corneal epithelium. Because this is an idiosyncratic response and cannot be predicted, it does not create the kind of risk for which informed consent is necessary. Even if a toxic reaction does occur, the effect is transient and limited. Thus, informed consent should not prevent prudent practitioners from administering these drugs when clinically appropriate.

Dilation of the pupil is a diagnostic procedure with potentially serious side effects (i.e., angle-closure or pupillary-block glaucoma), but the risk of injury must be communicated only to patients for whom it is significant. Studies have determined that only 2% to 6% of the general population have angles anatomically narrow enough to close and that for the patient population most at risk—those older than 30 years—the chance of precipitating an angle-closure glaucoma is 1 in 45,000. These statistics indicate that for the great majority of patients the risk is minimal or nonexistent. Thus, when performing routine dilation, clinicians have no duty to discuss the potential complications of mydriasis.

For that small percentage of the population with anterior chamber angles narrow enough to be closed by pupillary dilation, however, the decision to dilate should be made jointly with patients after they have been informed of the benefits of dilation and of the risks and implications of angle closure. The determination of whether to use dilation should be made in light of the need for it (e.g., if ophthalmoscopy of the retinal periphery is deemed necessary) and after the risk of angle closure has been reasonably determined (e.g., through the use of gonioscopy). Patients' decisions should be documented and retained in the record. Figure 5-1 shows a form suited for this purpose.

Cycloplegia is reserved for a limited number of conditions (e.g., suspected latent hyperopia, accommodative esotropia, amblyopia treatment). Hyperopic patients may have shallow anterior chamber angles that require

assessment before instillation of the cycloplegic. Because cycloplegia is most often needed for young patients, careful attention must be given to the concentration and dosage of the agent used, so that the risk of toxic effects can be minimized. Assuming that the angle is open and that the appropriate drug is selected for use, the risk of angle closure is no different from patients undergoing routine mydriasis. Consequently, clinicians do not have to obtain informed consent. If risk factors are present and clinical complications are a consideration, practitioners should discuss these factors with patients (or, for children, with parents or guardians) and obtain the necessary consent to administer the drug. The administration of atropine to infants to undertake a cycloplegic examination may also necessitate communication. Atropine can also be utilized for the diagnosis of patients 4 years of age or younger who are suspected of having accommodative esotropia, but it should be used conservatively in terms of concentration and dosage. In addition, atropine may be applied on a long-term basis to children undergoing treatment for amblyopia.\* The signs and symptoms of atropine toxicity should be explained to parents in these cases to minimize the risk of an overlooked toxic drug reaction during drug therapy.

Dyes are used for diagnostic purposes; the most important is sodium fluorescein, which is used for the detection of retinal disease (e.g., diabetic retinopathy). Because of the risk of allergic response to the administration of dye (whether by injection or orally), patients must be advised of this potential adverse effect before consenting to the procedure. Forms are often used to document communication of risk and patients' agreement to testing (Figure 5-2).

The preceding circumstances are not the only ones in which risks may have to be communicated to patients. Occasionally, patients refuse to allow a drug to be administered for diagnostic purposes. The usual circumstances involve mydriatics for dilation and topical anesthetics for tonometry. Patients have the right to refuse any test, and clinicians cannot obtain a lawful consent by coercion. Clinicians, however, are obliged to ensure that patients understand the potential ramifications of refusal. For example, elderly patients with visual field loss and optic disc cupping should be warned of the need for tonometry, and patients with reduced visual acuity who complain of floaters and flashes have an obvious need for funduscopy through a dilated pupil. Practitioners must weigh the need for the test in light of the clinical situation and must advise patients accordingly. Refusals should always be documented in the

---

\*A study investigating the use of atropine for treatment of amblyopia indicated it was as successful as patching therapy. Subjects were less than 7 years old and tolerated 1% atropine daily for 2 years without adverse effects. See Pediatric Eye Disease Investigator Group. A randomized trial of atropine vs patching for treatment of moderate amblyopia in children. *Arch Ophthalmol* 2002;120:268-278.

## What You Need to Know About Dilation of the Pupil

Dilation of the pupil is a common diagnostic procedure used by optometrists to better examine the interior of the eye. It allows a more thorough examination by making the field of view wider and by permitting the doctor to see more of the inside of the eye. Being able to examine the inside of the eye is essential to determining that your eye is healthy.

To dilate the pupil, eye drops must be administered. They require roughly half an hour to take effect. Once your pupils are dilated, it is common to be sensitive to light, a symptom that is usually alleviated by sunglasses. If you do not have any sunglasses, a disposable pair will be provided for you. Another common symptom is blurred vision, especially at near. It will require about 4 to 6 hours for your vision to return to normal. During this time you must exercise caution when walking down steps, driving a vehicle, operating dangerous machinery, or performing other tasks that may present a risk of injury. If you have any special transportation needs, please let us know so that they can be arranged prior to dilation.

In about 2% of people there is a possible complication of dilation of the pupil; it has been determined that you fall into this category. You must understand this complication before you give your consent to have this procedure performed.

The doctor's examination has revealed that there is a possibility of elevating the pressure inside your eye when dilation is performed. The medical term for this eventuality is "angle closure glaucoma". Because of this possibility, once your pupil is dilated and the interior of the eye has been examined, the pressure will be checked again. Should it become elevated, it will be necessary to lower the pressure by administering eyedrops and oral medication. Afterwards, it may be necessary to refer you to an eye surgeon for treatment with a laser to prevent further occurrences of this kind.

Because of the structure of your eyes, it is possible for an angle closure to occur at some other time, when the symptoms may not be recognized and treatment may not be immediately provided. Such an eventuality could seriously affect your vision. Therefore, there is a benefit to you in having dilation performed today and in allowing this complication, if it occurs, to be diagnosed and treated immediately.

The decision to undergo dilation is yours. You may choose not to have dilation performed, but because of your history, symptoms, or examination findings, the doctor recommends that dilation of the pupil be used today to examine your eye for disease. If you have any questions concerning the procedure, please ask them so that we may answer them. Then please sign your name in the appropriate place below to signify your decision.

- I understand the risks and benefits of pupillary dilation and I consent to have the procedure performed.
- The risks and benefits of pupillary dilation have been adequately explained to me and I understand them, but I do not wish to undergo the procedure.

\_\_\_\_\_

Date

\_\_\_\_\_

Signature of Patient

\_\_\_\_\_

Attest (initials)

© 1991 John G. Classé

**Figure 5-1** Example of informed consent document for dilation of the pupil when the patient has a narrow anterior chamber angle.

patient record (Figure 5-3). Some practitioners use forms that are signed by patients and retained in the patient record, and these forms are a satisfactory means of documenting patients' decisions. If patients refuse to undergo a procedure, the potential adverse consequences of that decision also must be explained (e.g., the symptoms of retinal detachment for patients reporting the acute onset of flashes and floaters).

### Therapeutic Agents

The duty to inform patients of the potential toxic effects of drug therapy is greatest when therapeutic agents

are prescribed. The reason for this is due, in part, to clinicians' lack of control over drug administration. Whereas the use of drugs for diagnostic purposes is carefully controlled by practitioners and is usually an in-office procedure, the prescribing of therapeutic agents results in extended drug use that is entirely within patients' control. Abuse of therapeutic agents has been documented in the ophthalmologic patient population, and optometrists should be aware of this potential problem, especially when prescribing therapeutic agents such as steroids and antiglaucoma medications.

Patients should be warned of the adverse effects of extended use of therapeutic agents and should be required

### Informed Consent for Oral Fluorography

I, \_\_\_\_\_, hereby consent to photography of my eyes or associated areas for the documentation and/or diagnosis of certain retinal conditions or diseases that may be present.

I also understand that the photography may be used to document my ocular status as well as for future use in publications, videotapes, or other educational presentations that may or may not benefit me.

I understand that the medication, sodium fluorescein, is not yet approved by the Food and Drug Administration for oral use, although it has been documented to be effective in revealing certain abnormalities of the retina when taken orally. I also understand that no side effects have been reported from the use of oral fluorescein with the occasional exception of slight discoloration of the skin or urine lasting up to 24 hours. Possible side effects include nausea, vomiting, and allergic reactions such as hives or anaphylactic shock (breathing, heart, and blood pressure problems).

Signed: \_\_\_\_\_

Witness: \_\_\_\_\_

Dated: \_\_\_\_\_

**Figure 5-2** Informed consent for oral fluorography. (Reprinted with permission from the School of Optometry, University of Alabama at Birmingham.)

to consult the prescribing clinician if additional prescription renewals are needed. As with diagnostic agents, the need to communicate with patients depends on the clinician's assessment of risk. If a drug is used for only a brief time, the risk is far less than if an extended period of treatment is anticipated. Likewise, greater dosages create larger risks and greater necessity for disclosure. Optometrists must be familiar with the allergic and toxic effects of the therapeutic drugs they prescribe and should inform patients of potential risks under the appropriate circumstances (e.g., long-term use of topical steroids).

Of the commonly used therapeutic drugs, the greatest risks are encountered when clinicians prescribe topical steroids (for extended periods), systemic steroids,  $\beta$ -blockers, miotic antiglaucoma agents, and oral carbonic anhydrase inhibitors (CAIs). Optometrists should be aware of the adverse effects that attend the use of these drugs and should warn patients accordingly. Disclosures should be documented in the patient record.

*The patient was warned of the need for dilation due to her symptoms of acute onset symptomatic PNB. She was advised that the only risks of a dilated fundus examination were photophobia and blurred vision of 4-6 hours duration. Despite my recommendation that a DFE be performed, she declined the procedure. The symptoms of retinal detachment were described to her and she was advised to RTC immediately if they occurred.*

**Figure 5-3** Example of handwritten record entry to document informed consent when a patient refuses pupillary dilation. (DFE = dilated fundus examination; PVD = posterior vitreous detachment; RTC = return to clinic.)

### Alternatives to Drug Therapy

The doctrine of informed consent may also be applied to situations in which optometrists fail to disclose alternatives to drug therapy. Disclosure requirements obligate clinicians not only to warn of the risks of treatment but also to describe alternatives to therapy. This duty may arise in various ways when drug use is contemplated. For example, if atropine therapy is recommended for the treatment of amblyopia in a young child, alternative treatment—such as patching—should be discussed as well. Another example involves patients suspected of having glaucoma. Patients with elevated intraocular pressure (IOP) and no optic disc damage or visual field loss should be apprised of the clinical alternatives: receive medical therapy or be monitored by the optometrist until disc damage or measurable field loss occurs. In these and analogous situations, clinicians should avoid dictating the mode of treatment and should ensure that the course of therapy is obtained with patient consent.

In clinical situations for which alternative treatments exist, optometrists should note in the patient record that the alternatives were discussed and that the treatment chosen was obtained with the patient's consent.

### Disclosure of Abnormalities

Not infrequently, diagnostic drug use discloses an ambiguous or suspicious finding. Clinicians must explain these findings so that patients can determine whether they wish to undergo further testing or treatment. A sample case illustrates how informed consent can be applied to such a situation.

A 58-year-old woman complaining of poor focus and gaps in her vision was examined by an ophthalmologist. These complaints were attributed to her contact lenses; however, during the course of the examination Schiøtz tonometry was performed, and readings of 23.8 mm Hg were obtained in each eye. Despite this result no dilated fundus examination or visual field assessment was

performed, and the potential significance of the IOP findings was not discussed with the patient. During the next 2 years the patient was seen a dozen times, but it was not until the end of this period that she was diagnosed as having open-angle glaucoma. Despite medical and surgical therapy, her visual acuity decreased to 20/200 and she suffered profound visual field loss. She sued the ophthalmologist, alleging that he was negligent for failing to diagnose the disease and to warn of the elevated IOPs. Although a judgment in favor of the physician was rendered after trial, the woman filed an appeal. The state supreme court reversed the trial court's decision, ruling that under the doctrine of informed consent the ophthalmologist was obligated to inform the woman of any abnormal findings and to advise her of any diagnostic procedures that could be undertaken to determine the significance of the findings.

Optometrists have a similar duty to discuss the results of diagnostic tests with patients and to advise patients of the availability of further testing to rule out the presence of disease. Ambiguous or suspicious findings should be resolved, and if patients do not return for recall appointments or do not wish to undergo further evaluation, these facts should be documented in the patient record.

### **Documentation of Warnings**

Communications with patients required by the doctrine of informed consent should be documented in the patient record. Either a handwritten entry or a form signed by the patient is adequate for legal purposes. Failure to record communications or inadequate entries concerning such communications may result in a successful legal claim against the practitioner.

In a case involving a military optometrist, a middle-aged military retiree complained of the acute onset of "black spots" in one eye. The optometrist found that the patient's best-corrected acuity was 20/30 in the right eye and 20/40 in the left eye, which was due to cataracts. The optometrist performed a dilated fundus examination with a binocular indirect ophthalmoscope and diagnosed the patient's condition as posterior vitreous detachment. The patient returned home, but 4 weeks later while climbing a ladder he experienced a bright flash of light in the affected eye. The man called the eye clinic and obtained an appointment for 6 days later. At that examination, his visual acuity was 20/200 because of a large retinal detachment that involved the macula. Despite surgery, vision in the eye remained greatly reduced. He sued the optometrist, alleging that the practitioner was negligent in failing to detect the retinal detachment and that he had breached the doctrine of informed consent by failing to warn the patient of the symptoms of retinal detachment.

At the trial the surgeon who repaired the eye testified that the retinal detachment could not have been present

at the time of the optometrist's examination, which thereby exonerated the optometrist of the negligence claim. The key evidence concerning the informed consent claim came from the optometrist's record. Although the optometrist testified that he had warned the patient of the symptoms of detachment, his record stated the following: "PVD. Reassure. RTC PRN." The court found this terse entry to be inadequate to support the optometrist's contention that a warning had been given and awarded a judgment in favor of the patient.

### **NEGLIGENCE**

Although the doctrine of informed consent is an important legal consideration when ophthalmic drugs are used, the most likely source of a professional liability claim against an optometrist is negligence. As various reports have demonstrated, large liability claims against optometrists typically allege misdiagnosis. In most instances the misdiagnosis is due to failure to use the appropriate pharmaceutical agent, usually for anesthesia or pupillary dilation, rather than toxic or allergic drug reactions. Consequently, it may be argued that the likelihood of a negligence claim is highest when optometrists fail to use an ophthalmic drug that, when used appropriately, would permit a proper diagnosis. Claims most commonly allege failure to diagnose open-angle glaucoma, tumors affecting the visual system, or retinal detachment.

Misdiagnosis is also an important aspect of claims involving the use of therapeutic ophthalmic agents. Although the toxic effects of these drugs have been a common cause of liability claims against ophthalmologists, failure to make the correct diagnosis, followed by institution of an inappropriate therapeutic regimen, has become the major concern of optometrists. Because of the restricted nature of most optometry practice acts, which usually limit therapy to the anterior segment of the eye, claims against optometrists most frequently allege mismanagement of corneal problems.

Although negligence represents the most important legal complication of clinical practice, the exposure of optometrists to malpractice claims remains at a relatively low level, far below that of physicians. Within optometry there is no difference between diagnostic and therapeutic drug use with regard to the risk of malpractice, because professional liability insurance premium costs do not vary on this basis.\*\* However, as optometry laws continue to be amended to enable optometrists to serve as primary providers of eye care, this increased clinical responsibility inevitably will result in increased litigation.

---

\*\*The nation's largest carrier of malpractice coverage for optometrists has monitored drug-related claims over the past two decades and has reported no significant liability risk associated with therapeutic drug use by optometrists. For a discussion, see *Classé JG. Liability for the treatment of anterior segment eye disease. Optom Clin 1991;1:1-16.*

Because the use of pharmaceutical agents is an integral part of these responsibilities, optometrists must be familiar with the concept of negligence and must understand how negligence may arise in clinical practice.

## Proof of Negligence

The law holds every individual to a reasonable standard of conduct, and failure to exercise reasonable care creates liability if it results in harm to others. Accordingly, negligence may be defined as “the omission to do something which a reasonable person, guided by those ordinary considerations which ordinarily regulate human affairs, would do, or the doing of something which a reasonable and prudent person would not do.”

Optometrists have an obligation to adhere to a reasonable standard of care when rendering services to patients. This standard may be summarized by the question, “What would a reasonable optometrist do under the same or similar circumstances?” From this question it is apparent that the defendant optometrist’s conduct is to be compared with the conduct expected of a hypothetical “reasonable optometrist.” If the defendant optometrist’s conduct fails to measure up to the conduct expected of this reasonable practitioner, a breach of the standard of care occurs. Proof of negligence, however, entails more than a demonstration that the defendant optometrist has violated the standard of care. There are, in fact, four elements to this tort,<sup>††</sup> and to state a cause of action in a court of law the plaintiff-patient must offer evidence in support of each. These four elements are as follows:

1. A duty on the part of the practitioner to adhere to a reasonable standard of care, which is intended to minimize the risk of injury to the patient.
2. Breach of this standard of care by the practitioner.
3. Actual physical injury suffered by the patient.
4. A proximate relationship between the patient’s injury and the practitioner’s actions (or failure to act).

## Duty

The duty to adhere to a reasonable standard of care is established by the doctor-patient relationship. Proof of the duty is rarely a problem for plaintiff-patients, because in the great majority of cases patients are examined by optometrists in an office or under circumstances that make the relationship apparent. The lack of formal surroundings, or even failure of the optometrist to charge

for services, does not defeat the duty if a doctor-patient relationship has been formed. Once an optometrist has created the relationship, the optometrist is legally obligated to adhere to the standard of care expected of a reasonable practitioner acting under the same or similar circumstances. Because proof of this standard can be offered only by individuals actually familiar with it, expert testimony is required.

## Breach of the Standard of Care

Expert witnesses, unlike other witnesses, are not limited to reporting the perceptions of their senses but may offer opinions. Such witnesses first must be “qualified,” which is a process intended to convince the trial judge that the individual being offered as an expert is competent to testify about the matter at issue. Traditionally, only practitioners of the same “school” have been considered competent to testify about the standard of care expected of defendant practitioners. However, the growing liberality of rules of evidence and the lessening distinction clinically between optometrists and ophthalmologists have combined to change this traditional pattern, and ophthalmologists are frequently deemed competent to testify concerning the standard of care expected of optometrists. This development has led to the imposition of a medical standard of care for optometrists in cases involving misdiagnosis or mismanagement of ocular disease.

The likelihood of testimony by physicians—and the imposition of a medical standard of care—is greatest in cases involving ophthalmic drugs because of the use of these agents to diagnose or treat disease. Of course, expert testimony on behalf of a defendant optometrist may allege that the optometrist acted in conformity with the standard of care. It is then left to the jury to determine liability. This element of proof is usually the most difficult for plaintiffs to establish and is frequently the most contentious aspect of a malpractice trial.

## Injury

Assessment of patients’ injuries is also a matter requiring an expert’s opinion, and either optometrists or ophthalmologists may provide this testimony. Visual impairment is usually evaluated as loss of visual acuity, reduction of visual field, or diminished reading capacity. Other ocular impairments that result in loss of functions, such as defective color vision, diminished accommodation, and loss of binocular vision, may also be evaluated, as may deformities or disfigurements of the orbit or face. Optometrists who testify concerning the degree of injury suffered by patients should be familiar with the accepted standards used in legal proceedings.

## Proximate Cause

The fourth element of negligence is proximate cause, sometimes referred to as legal cause, which serves to tie together the negligent act (or failure to act) and the resulting injury.

<sup>††</sup>A tort is a “breach of duty (other than a contractual or quasicontractual duty) which gives rise to an action for damages.” (Prosser WL. *Law of torts*, ed. 4. St. Paul, MN: West, 1971: 1.) This rather unsatisfactory definition leaves one with more of an indication of what a tort is not; it is not a crime, it is not based on contract, and it does not result in loss of liberty. It is a civil action, brought for the purpose of receiving monetary compensation for damages, and is based on a breach of duty.



For example, failure to use a mydriatic drug for a fundus examination may be the proximate cause of a clinician's failure to detect an intraocular disease. Expert testimony is necessary to link together what the practitioner did (or did not do) and the injury.

Plaintiff-patients must prove each of these four elements by a preponderance of the evidence. As the preceding discussion has demonstrated, expert testimony is crucial to the presentation of this evidence, and it is equally important to defendant optometrists as they seek to refute plaintiffs' allegations. The focus of a malpractice case is usually the standard of care, which has particular requirements when applied to the use of ophthalmic drugs.

## STANDARD OF CARE

Optometrists are expected to display that degree of skill and learning that is commonly possessed by members of the profession who are in good standing and to exercise what is referred to as "due care."<sup>##</sup> This obligation has broad implications whenever optometrists use ophthalmic drugs, because the standard of care requires that optometrists

1. Understand the allergic and toxic side effects of all drugs administered or prescribed.
2. Take an adequate history to determine whether there has been any previous allergic or toxic response to a drug, especially an ophthalmic agent.
3. Select the appropriate drug for patients' needs or conditions.
4. Warn patients of side effects of drug use that may create a risk of injury.
5. Monitor patients while they are under the influence of the diagnostic or therapeutic agent so that complications can be managed in a timely manner.

To conform to these due care requirements, an optometrist is expected to act in the same manner as a reasonable practitioner by observing the following clinical and legal guidelines.

## Knowledge

Practitioners are under a legal duty to keep abreast of new developments, especially information that affects patient care, such as reports of drug toxicity. Therefore practitioners not only must understand the properties of any drugs that are used for patient care, but also must remain knowledgeable concerning more efficacious drugs or reports of adverse events. Failure to stay abreast of these developments has resulted in successful claims

against physicians and could also serve as a cause of action against optometrists.

## History

The standard of care requires that an adequate drug history be taken, including

- The patient's history of past drug use
- Drugs currently being taken
- Any allergic or toxic reactions to drugs, past or present
- History of ophthalmic drug use, including a determination of whether anesthesia and mydriasis have been used at previous examinations

Failure to take an adequate history that results in an allergic or toxic response to a drug may render practitioners liable for this otherwise preventable injury.

## Use of the Appropriate Agent

Adherence to the standard of care is necessary to minimize the risk of injury to patients. An optometrist is obligated to choose the pharmaceutical agent that fulfills this requirement and, in so doing, is expected to exercise the degree of skill and learning that is commonly possessed by like practitioners. The drug that is most appropriate for the patient's condition and its most appropriate route of administration must be determined to minimize the risk of adverse effects. If an optometrist uses an inappropriate agent—such as a topical beta-blocker for a glaucoma patient who has chronic obstructive pulmonary disease, thereby precipitating an otherwise preventable injury—the optometrist has failed to meet this duty and is legally responsible for both transient and permanent effects of the drug's use. The same would be true if an optometrist attempted to treat an anterior uveitis with a systemic steroid without first establishing that a topical route of administration was inadequate or inappropriate. In each instance the optometrist's conduct must measure up to that of a reasonable optometrist; otherwise, liability may result.

## Warnings

Because of the doctrine of informed consent, there are clinical circumstances under which optometrists must discuss the risks and possible side effects of drug use with patients. For example, if patients are to undergo prolonged treatment with topical steroids, the optometrist would be obligated to warn them of potential side effects, including glaucoma, ocular infection, and cataract. Although the amount of information that must be communicated to patients varies among states due to different evidentiary requirements, the circumstances under which warnings are necessary generally do not vary. For example, all patients receiving a dilated fundus examination should be warned of the potential photophobia and blur caused by pupillary dilation.

<sup>##</sup>Due care may be defined as "that care which an ordinarily prudent person would have exercised under the circumstances." (Black's law dictionary, rev. ed. 4. St. Paul, MN: West, 1968.)

Warnings are an essential aspect of drug use and should not be overlooked or ignored.

### Management of Side Effects

If patients experience a drug-related allergic or toxic effect, clinicians must meet reasonable standards of detection and management. For example, a telephone call from a patient complaining of severe headache and blurred vision after undergoing dilation requires an examination instead of the proverbial “Take an aspirin and call me in the morning.” Likewise, patients who are being treated with topical steroids must be recalled with sufficient regularity to detect adverse events before they have significantly affected vision or ocular health.

For each of these due care requirements, optometrists must satisfy reasonable standards of conduct. Also, because the use of ophthalmic drugs is essentially a medical act, ophthalmologists may be competent to state the standard of care expected of optometrists under these circumstances.

Failure to use drugs when clinically indicated, particularly mydriatic agents for diagnosis, is a significant source of liability claims. A hypothetical example illustrates how the standard of care can be applied if drugs are not used appropriately for diagnostic purposes. If a patient has received a blow to the eye from a fist, ball, or other blunt object, the optometrist must rule out the possibility of a retinal break. To perform a reasonable examination, one that conforms to the expected standard of care, dilation of the pupil is necessary. In fact, it may be argued that examination of the retinal periphery with a binocular indirect ophthalmoscope is required under these circumstances. Therefore failure to dilate the pupil and view the retinal periphery falls below the standard of care. If for some reason the optometrist cannot perform a dilated examination, the patient must be referred to another clinician so that the appropriate evaluation can be performed.

### MISDIAGNOSIS

Misdiagnosis of open-angle glaucoma, tumors affecting the visual system, and retinal detachment are the leading causes of large malpractice claims against optometrists. In the great majority of cases, failure to make the appropriate diagnosis is linked to failure to perform a key diagnostic test (e.g., tonometry or funduscopy through a dilated pupil). Therefore the legal problem most likely to be encountered by a clinician is failure to use an ophthalmic agent. Because of the significant role that pupillary dilation plays in the diagnosis of these conditions, clinicians should be familiar with standards for assessment of the interior of the eye (Table 5-1). Example cases may be used to illustrate how claims of misdiagnosis can arise when these three important disorders are encountered.

#### Open-Angle Glaucoma

The standard of care for the detection of open-angle glaucoma has been established by a series of cases involving ophthalmologists. The leading case involved a 22-year-old woman who was fitted for contact lenses and examined intermittently over the course of 10 years before the ophthalmologists discovered that she had open-angle glaucoma and that her visual field was reduced to less than 10 degrees. She sued the ophthalmologists for negligence, and at trial tonometry became the key issue. She alleged that the physicians had a duty to perform the test while she was a contact lens patient; they defended the claim on the basis that tonometry was not a routine test for patients younger than 40 years of age.

Although the ophthalmologists won the trial, the case was reversed on appeal, a decision that evoked a storm of commentary. Ironically, the court’s opinion proved to be a legal dead end, but the intense publicity surrounding the case succeeded in changing the standard of care in both ophthalmology and optometry.

**Table 5-1**  
Recommended Examination Frequency for Adult and Pediatric Patients

Age	Asymptomatic/Risk Free	At Risk
<b>Adult patients</b>		
18–40 yr	Every 2–3 yr	Every 1–2 yr or as recommended
41–60 yr	Every 2 yr	Every 1–2 yr or as recommended
61 yr and older	Annually	Annually or as recommended
<b>Pediatric patients</b>		
Birth to 24 mo	By 6 mo of age	By 6 mo of age or as recommended
2–5 yr	At 3 yr of age	At 3 yr of age or as recommended
6–18 yr	Before first grade and every 2 yr thereafter	Annually or as recommended

Reprinted with permission from American Optometric Association. Comprehensive adult eye and vision examination. St. Louis, MO: American Optometric Association, 1994; and American Optometric Association. Comprehensive pediatric eye and vision examination. St. Louis, MO: American Optometric Association, 1994.

Precedent-setting cases brought against optometrists for failure to diagnose open-angle glaucoma almost uniformly allege failure to perform tonometry. Just as uniformly, defendant optometrists resort to procedural defenses that seek to avoid this issue. The result has been a standard of care that requires routine use of tonometry regardless of patient age. Evaluation of the optic nerve head, visual field assessment, and other appropriate tests for glaucoma (e.g., gonioscopy) are also necessary for diagnosis.

### **Tumors Affecting the Visual System**

Tumors may be external, such as squamous cell carcinomas; intraocular, such as malignant melanomas; or intracranial, such as pituitary adenomas. All three types of tumors may be considered “ocular,” and all pose unique clinical challenges. The detection of intraocular tumors presents one of the most difficult diagnostic dilemmas encountered by optometrists. To make the diagnosis, a dilated fundus examination is needed, but patients with “silent” tumors may not evince symptoms that would lead a reasonable practitioner to determine that dilation is required. Practitioners are not legally obligated to discover all that may be wrong with patients but rather to perform an examination that is reasonable under the circumstances. Therefore failure to detect a silent tumor because dilation is not demanded by a patient’s complaints or history may not be construed as negligence. A precedent-setting case challenges this assumption, however, and imposes a medical standard of care for the use of pupillary dilation.

A 4½-year-old child with accommodative esotropia was examined by a military optometrist, who found 20/30 acuity in each eye and good eye alignment with spectacles. Direct ophthalmoscopy performed through an undilated pupil revealed no evidence of posterior pole disease. The optometrist saw the patient on two other occasions over the next 7 months, but no pathology was observed. Approximately 13 months after the initial examination, the child was found to have leukocoria in the deviating eye. A dilated fundus examination by a base ophthalmologist revealed a 15-disc diameter retinoblastoma located at the equator of the eye and spreading anteriorly. The child was referred to a specialist for treatment, and irradiation was used successfully to destroy the tumor. The irradiation caused a cataract, however, and the tumor caused retinal detachment, which resulted in a best-corrected acuity in the eye of 20/300. A suit was brought against the optometrist, alleging that he was negligent for failing to perform a dilated fundus examination with a binocular indirect ophthalmoscope at the initial examination and periodically thereafter. After a trial found in favor of the optometrist, the case was appealed to a federal appellate court, which ruled that the optometrist had breached the standard of care in failing to perform a dilated fundus examination. The court relied exclusively on medical testimony in reaching its decision, and although the optometrist was

ultimately found not liable, the court’s opinion established a precedent for the use of pupillary dilation in patients with silent tumors.

The use of pupillary dilation is required for symptomatic patients, as illustrated by the following case. An optometrist employed by a multidisciplinary clinic examined a middle-aged woman who complained of reduced vision and found her best-corrected visual acuity to be 20/25 and 20/40. The optometrist attributed this to cataracts. Although refraction, tonometry, and ophthalmoscopy were performed, the optometrist did not dilate the patient’s pupils. After discussing his findings with the patient, he dismissed her. Two months later she realized that the vision in one eye was markedly reduced, and she returned to the clinic, where the diagnosis of retinal detachment secondary to a von Hippel-Lindau tumor was made. Despite surgery the patient was left with a permanent loss of acuity. She sued the optometrist, alleging that he was negligent for failing to make the diagnosis in a timely manner. Although the optometrist prevailed at the trial, the patient was awarded damages on appeal, with the court stating that “the evidence is overwhelming that the (plaintiff’s) eye should have been dilated” and that the optometrist should be held to “the same rules relating to the duty of care and liability as ophthalmologists.”

The rationale for the court’s opinion was that the diagnosis of cataract (a “disease”) required dilation of the pupil and that had dilation been performed at the time of the optometrist’s examination, the possibility of a retinal detachment could have been ruled out. In finding the optometrist liable, the court imposed a medical standard of care. Therefore a dilated fundus examination should be used whenever best-corrected visual acuity is reduced, and coexisting disease should be considered a possibility until an examination determines otherwise. Optometrists may be held responsible for the diagnosis of intraocular tumors—even those as rare as malignant melanoma—in symptomatic patients.

### **Retinal Detachment**

The necessity for dilation of the pupil is probably most evident in cases in which retinal detachment is, or should be, suspected. Many patients are at risk for retinal detachment, and it can be argued that pupillary dilation is necessary whenever patients are found to have any of the following:

- Significant myopia
- Aphakia or pseudophakia
- Recent yttrium-aluminum-garnet capsulotomy
- Glaucoma therapy with strong miotic agents in myopic eyes
- Lattice degeneration
- Blunt trauma to the eye
- History of retinal detachment in the fellow eye
- Proliferative retinopathy (e.g., proliferative stage of sickle cell, diabetes, retinal vein occlusion)

Another important precursor of retinal detachment is acute-onset, symptomatic, posterior vitreous detachment. It has been reported that 7% to 15% of patients with acute symptomatic posterior vitreous detachment have a retinal tear. Approximately one-third of these tears progress to retinal detachment. If patients complain of spots, specks, floaters, or other entoptic phenomena that indicate the possibility of posterior vitreous detachment, optometrists must conduct a dilated fundus examination to rule out the presence of a tear. Although failure to detect the detachment may not be below the standard of care for an optometrist (due to the break's size or location), failure to detect a detachment because pupillary dilation was not used for the retinal examination will be construed as negligent.

Symptoms of reduced visual acuity also require careful assessment of the interior of the eye. In a case involving a diabetic patient who complained of blurred vision, the defendant optometrist performed refraction and prescribed spectacles that he assured the patient would relieve her symptoms. Because of the patient's history of diabetes and the complaint of reduced acuity, the standard of care required a dilated fundus examination. The optometrist did not dilate the pupil, however, and after dispensing spectacles to the patient did not undertake any further treatment. Six months later the patient consulted an ophthalmologist, who found that the patient had proliferative retinopathy due to diabetes and had suffered a retinal detachment in one eye and unmanageable complications in the other. A lawsuit was instituted against the optometrist for negligence in failing to make the diagnosis and to refer the patient for treatment. It is important to note that diabetic patients constitute an important and challenging clinical problem for optometrists because of the number of affected individuals, the frequency of ocular complications, and the long-term management required.

Although other causes of misdiagnosis have been alleged against optometrists, these three types of claims are the most frequent and represent the most significant clinical and legal challenges to diagnostic skill. Failure to diagnose these conditions poses the greatest risk of litigation for optometrists.

## **COMPLICATIONS OF DIAGNOSTIC DRUG USE**

---

Optometrists must be familiar with the adverse effects of any ophthalmic drugs used for diagnostic purposes and must be prepared to manage these complications when they occur. This obligation is frequently encountered when using the common diagnostic agents: anesthetics, mydriatics, and cycloplegics.

### **Anesthetics**

Topical anesthesia is necessary for applanation tonometry and gonioscopy. Proparacaine and benoxinate are most

commonly used. Because these agents may cause an allergic or toxic response, optometrists should determine whether patients have experienced a previous adverse reaction before using the drug. If optometrists observe such a reaction, this fact should be noted conspicuously in the patient record to prevent a second episode at a subsequent examination. Of course, optometrists may choose an alternative drug in this event, because proparacaine and benoxinate are structurally dissimilar and an allergic reaction to one drug does not mean that patients will be allergic to the other (see Chapter 6). If patients experience an adverse reaction, the worst result—desquamation of the corneal epithelium—is transient and the discomfort is not severe. Most episodes resolve within 24 to 48 hours, with no permanent effect on vision. There is little opportunity for negligence or for substantial damages.

Injury may be permanent, however, if a topical anesthetic is applied copiously to a compromised cornea. Anesthetics should never be dispensed to patients for use at home, and if other practitioners have dispensed anesthetics to patients for use on an "as needed" basis, these patients should be counseled concerning this potentially injurious use of topical anesthesia.

### **Mydriatics**

These drugs constitute the most important class of diagnostic agents because of their widespread use for dilating the pupil for funduscopy. A history must be taken to ensure that patients have not experienced symptoms suggestive of angle closure after pupillary dilation by previous examiners, and the anterior chamber angle should be examined to determine the risk of precipitating an angle-closure attack. Because 94% to 98% of the U.S. population has angles incapable of closure by pupillary dilation, there is no requirement under the doctrine of informed consent to warn the great majority of patients of this risk. Only those rare individuals whose histories or anterior chamber angles indicate a risk must be informed of the possibility of angle closure, so that their consent can be obtained before performing the procedure. Clinicians should document that the warning was given and that consent was received (see Figure 5-1). The use of prophylactic laser peripheral iridotomy in lieu of pupillary dilation should also be considered and discussed with patients if management of angle closure would be inappropriate.

A clinical and legal issue of some importance is posed by the necessity for pupillary dilation. If there is litigation, the use of expert testimony is required to determine whether dilation was needed to conform to the standard of care in a specific instance. If a reasonable practitioner would maintain that a dilated fundus examination was necessary under the circumstances, then the patient must receive that evaluation or be referred to another practitioner so that it can be performed. There are numerous

circumstances under which the obligation to use pupillary dilation seems to arise (see Chapter 20).

Because patients who have undergone mydriasis typically experience photophobia and loss of accommodation (if an anticholinergic agent is used), optometrists should be certain to safeguard them from injury while they are in the office and on the premises. Elderly and handicapped patients are particularly susceptible to injury from falls or similar mishaps and may successfully claim damages if it can be shown that optometrists did not take reasonable steps to protect them. Clinical and office staff should be prepared to assist patients who are on the premises.

Because patients whose pupils have been dilated may leave the premises with their vision impaired, the optometrist's obligation is extended to include a warning of the effects of mydriasis on such tasks as driving a motor vehicle, operating machinery, or other foreseeable activities for which there is a risk of injury. In some cases it may be appropriate to administer an  $\alpha$ -adrenergic blocking agent (e.g., dapiprazole) to speed the return of acuity. If it is known in advance that patients will undergo a dilated fundus examination, they should be advised when making the appointment so that appropriate arrangements for transportation can be made. If the risk of injury to patients is deemed significant, examination may be rescheduled (e.g., at the same time ophthalmic materials are to be dispensed) so that patients can make provisions for transportation. In all cases it is wise either to ensure that patients have sunglasses to protect against glare or to provide disposable mydriatic sunglasses designed for this purpose (see Chapter 20).

Failure to warn patients not only subjects optometrists to claims for injuries suffered by patients, it can also widen liability to include third parties who may be injured by patients (e.g., in an automobile accident). Optometrists should routinely document the warnings given to patients rather than relying on patients' memory after the fact.<sup>55</sup>

Another important matter that should be documented is patients' refusal to undergo dilation of the pupil. Optometrists are obligated to explain the importance of a dilated fundus examination to patients in terms that engender understanding. If, despite the warning, patients refuse to undergo the procedure, an entry should be made in the patient record (see Figure 5-3), or they can be asked to sign a form explaining that they have rejected the optometrist's advice and understand the significance of the refusal.

In rare cases the matter may be of such importance that a certified letter, return receipt requested, should be sent to the patient, with a copy retained in the patient record. By whatever means selected, optometrists should not overlook the necessity for documentation in these cases.

## Cycloplegics

Among the cycloplegics most frequently used are cyclopentolate and atropine. Because of their potential side effects, a careful history and assessment of the anterior chamber angle are necessary before use. Selection of the appropriate agent is also important (see Chapter 21). If there is a risk of angle closure, this risk must be communicated to patients, and informed consent should be obtained before the drug is administered.

If atropine is used, clinicians must be aware of the signs and symptoms of atropine toxicity. A similar concern exists when 2% cyclopentolate is used in infants or children. If side effects occur, optometrists should be prepared to manage them either through direct intervention or referral to other practitioners.

Patients may be affected by photophobia and loss of accommodation, as they are with mydriatics. Therefore patients must be monitored while in the office and on the premises and must be warned of the drug's effects while operating a vehicle or performing other tasks that pose a risk of injury to patients or others. Documentation of this warning should be included in the patient record.

Interestingly, failure to use cycloplegia for the purpose of prescribing spectacles for a young patient with latent hyperopia has resulted in a claim of negligence against an optometrist. However, the opportunity for a "slip and fall" injury or an automobile accident poses the greatest legal risks if no warning is given or no protection against glare is provided.

Although the side effects of diagnostic pharmaceutical agents can be the cause of a malpractice claim, the adverse effects of therapeutic drugs are potentially a more likely source of litigation.

## COMPLICATIONS OF THERAPEUTIC DRUG USE

The complications of therapeutic drug use are a leading cause of malpractice claims against ophthalmologists and potentially pose a significant malpractice risk for optometrists. Because drug use occurs outside practitioners' offices and may involve use for an extended period of time, the opportunity for complications, particularly those related to drug toxicity, is greater. If patient follow-up is not timely, the complications may go undetected, so that the injury is compounded. Worst of all, if practitioners fail to make the correct diagnosis, the treatment not only fails to remedy patients' problems but also delays institution of the correct therapy. For these reasons optometrists using

<sup>55</sup>The ability of patients to recall warnings is highly suspect. Several studies have revealed that patients in fact remember very little. See Robinson G, Merav A. Informed consent: recall by patients tested postoperatively. *Ann Thorac Surg* 1976;22:209-212; Priluck IA, Robertson DM, Buettner H. What patients recall of the preoperative discussion after retinal detachment surgery. *Am J Ophthalmol* 1979;87:620-623; and Morgan LW, Schwab IR. Informed consent in senile cataract extraction. *Arch Ophthalmol* 1986;104:42-45.

therapeutic agents face malpractice risks that differ from those encountered with diagnostic agents.

Negligence claims against ophthalmologists involving the use of therapeutic agents may be grouped into three categories:

1. Misuse of steroids
2. Complications of antiglaucoma agents
3. Misdiagnosis, followed by institution of an inappropriate therapeutic regimen

Each of these problems has important legal implications for optometrists.

### **Steroids**

The leading cause of drug-related claims against ophthalmologists is misuse of steroids, particularly topically applied agents. The usual situation is one in which patients use the drug for prolonged therapy, which results in cataracts, open-angle glaucoma, or both. Two legal issues are present in these cases. The first involves practitioners' obligation to warn patients of side effects as required by the doctrine of informed consent. Failure to satisfy this duty can result in successful liability claims against practitioners. Prudent practitioners also ensure that this warning is documented in the patient record. The second issue concerns patients' ability to obtain prescription refills and often involves a complex web of entanglements among the prescribing practitioner, the practitioner's staff, the patient, and the pharmacist who fills the prescription. To reduce the opportunity for misunderstanding or mistake, the prescription should specify the drug quantity and the number of refills and should include a statement that these orders may not be changed. Practitioners should always retain a copy of the prescription given to patients (see Chapter 4).

Systemic steroids are also the cause of numerous negligence claims. These drugs have side effects that can result in serious injury, even death, and consequently must be used conservatively. Systemically administered drugs, with their risk of systemic complications, should not be used if a topical route of administration suffices, and practitioners must be prepared to justify the selection of a systemic route of administration when complications result and a topical route of administration initially was not used. Whenever systemic steroids are prescribed, practitioners must warn patients of side effects, monitor patients adequately so that preventable injuries can be detected, and document the care rendered.

### **Antiglaucoma Agents**

Legal claims arising from glaucoma therapy may be divided into three categories: adverse effects of beta-blockers, retinal detachments after initiation of miotic therapy, and complications resulting from use of CAIs.

A beta-blocker may be used in the treatment of primary open-angle glaucoma, but these drugs are contraindicated for use in persons with chronic obstructive pulmonary disease and heart block (see Chapter 10). A careful history should be taken before initiating therapy to avoid potentially fatal ramifications. It is advisable to monitor patients who are taking beta-blockers (e.g., pulse, blood pressure) and to inquire about side effects at periodic follow-up examinations.

In a sample case, a 68-year-old woman with cataracts underwent uneventful extracapsular cataract extraction. On the first postsurgical day the ophthalmologist dispensed timolol to control elevated IOP. The patient had a long history of asthma and was taking medications for the condition, including prednisone, but the physician had not taken note of them. After the first administration of the timolol, the woman experienced severe bronchospasm, collapsed, and died.

The use of strong miotics in myopic patients has been the cause of negligence claims when therapy has resulted in retinal detachment. Patients who are at risk for detachment should not be treated with miotic agents initially. To comply with the doctrine of informed consent, the use of miotics should be preceded by a discussion with patients of the risks and benefits of the drug chosen. When miotics are used for treatment, patients should be examined carefully to rule out the presence of risk factors (e.g., lattice degeneration) that may increase the likelihood of a retinal detachment.

Oral CAIs such as acetazolamide have well-known side effects (e.g., renal calculi) that require an assessment of the benefits and risks of the use of these drugs before initiating therapy. If a practitioner cannot demonstrate that topically applied drugs are inadequate to control a patient's glaucoma, the choice of an oral CAI may be difficult to justify. The risks of a systemic route of administration obligate practitioners to discuss potential complications and to obtain informed consent from patients. Because of the prolonged nature of glaucoma therapy, patients must be examined periodically both to assess the effectiveness of treatment and to rule out the presence of drug-related complications. An extremely rare complication, aplastic anemia, has been the subject of unsuccessful legal claims alleging that the treating practitioner had a legal duty to warn of this side effect and to monitor patients for signs of its occurrence.

### **Misdiagnosis Related to Therapeutic Drug Use**

Unlike claims of misdiagnosis involving diagnostic agents, which usually concern intraocular disorders, allegations involving therapeutic agents usually concern the cornea and the anterior segment. Optometrists who undertake to treat diseases of the cornea and the external adnexa may be held to a medical standard of care and must be

prepared to justify the treatment rendered accordingly. This area of therapeutic drug use is probably the one in which optometrists are most vulnerable to legal claims.

Litigation has arisen out of misdiagnosis of corneal complications associated with herpes simplex, *Pseudomonas* ulcers, fungal infections, and corneal abrasions occurring in the contact lens population, particularly among patients fitted with extended-wear lenses. Optometrists must be certain to conform to the standard of care in making diagnoses, scheduling patient follow-up visits, and arranging consultations and referrals. Because complications can rapidly lead to permanent injuries and loss of visual acuity, optometrists must be vigilant when diagnosing and managing corneal and external disease. The treatment rendered should be documented with the same meticulous concern.

### Product Liability

Drug-related product liability claims involving optometrists are rare. Because drugs are customarily sold to patients by pharmacists on the prescription of a duly licensed practitioner, it is the manufacturer or seller of the drug who is held liable if patients suffer an injury because the drug is “defective.”<sup>11</sup> However, optometrists may become involved if the drug was negligently prescribed or if there was negligent follow-up while patients were taking the drug. Clinicians may also be charged with failing to comply with the doctrine of informed consent by inadequately warning patients of drug-related side effects.

It should be noted that the manufacturer’s duty to warn extends to the prescriber of the drug and not to the patient. It is the duty of the clinician to communicate the warning to the patient, as required by the doctrine of informed consent, and thus optometrists are legally obligated to understand the side effects of any drugs that are prescribed. Optometrists must stay abreast of reports in the literature and warnings from drug manufacturers and must explain these risks to patients before initiating treatment.

A common source of information concerning the risks of drug use is the package insert that accompanies the drug. The package insert also describes the recommended dosage and treatment regimen for the drug. Optometrists should be familiar with this information and should be prepared to justify any deviation from these recommendations. The risk of adverse effects and the expected benefit

must be discussed with patients before a consent that meets legal requirements can be secured. Because the treatment of eye disease raises the possibility that a court will impose a medical standard of care on a defendant optometrist, deviation from a recommended treatment regimen described in the package insert should be undertaken only with clear clinical justification (see Chapter 4).

The ophthalmic drugs that have been the most frequent causes of product liability and negligence claims are antiglaucoma drugs (i.e., acetazolamide, echthiophate iodide) and steroids (i.e., hydrocortisone, dexamethasone sodium phosphate, and prednisolone acetate).

### DOCUMENTATION

The patient record is a vital part of any litigation in which optometrists are charged with negligence. A properly maintained record may offer an irrefutable defense, and an inadequate record may make the optometrist’s position indefensible. Record keeping is an important task that must not be neglected. Although there are no legally established requirements for organizing records, because of the episodic nature of much of the care rendered by optometrists (particularly when using therapeutic pharmaceutical agents), the problem-oriented record-keeping system is preferable.

Optometrists should record each patient’s drug history, the drugs used for diagnosis or treatment, any appropriate warnings, and the outcome of care if there are complications (Box 5-4). For clinical and legal reasons, optometrists should be certain to document recalls and referrals.

#### Box 5-4 Documentation of Drug Use

Documentation should include the following:

1. All drugs the patient is taking, including any drugs taken for prolonged periods that may have adverse effects on the eyes or vision.
2. Previous allergic or toxic responses to any drugs, including ophthalmic drugs.
3. Drugs used by the optometrist for diagnostic or therapeutic purposes, including concentration and dosage; if therapeutic drugs are prescribed, a copy of the prescription should be retained in the patient’s record.
4. Allergic or toxic responses to any drugs administered, which should be conspicuously noted.
5. Warnings concerning the risks of drug use that are communicated to the patient.
6. Treatment or disposition of the patient if an adverse event is experienced.
7. Recalls and referrals or consultations.

<sup>11</sup>To establish a product liability claim, it must be shown that the product is “defective.” This term was redefined (in 1998) as follows: “A product is defective because of inadequate instructions or warnings when the foreseeable risks of harm posed by the product could have been reduced or avoided by the provision of reasonable instructions or warnings by the seller or other distributor, or a predecessor in the commercial chain of distribution, and the omission of the instructions or warnings renders the product not reasonably safe.” See the Restatement (Third) of Torts, Products Liability, issued by the American Law Institute.

## Recalls

If patients require follow-up care, a recall appointment is necessary. Recalls should be scheduled for a specific date and time before patients leave the office, even if the date of the appointment is weeks or months away. Optometrists should note the reason for the recall on patients' records and should be certain that the recall examination addresses the problem for which patients are required to return. To minimize "no show" appointments, it is best to contact patients before the scheduled date to confirm the day and time of the appointment. In some instances, "no show" patients may need to be contacted to determine why they failed to keep the appointment.\*\*

## Referrals

The preferable means of making a referral is to choose the practitioner and arrange the appointment before patients have left the office. This information, along with any other pertinent data relative to the referral, should be noted in the patient record. If a referral letter is written, a copy of the letter should also be retained in the record. Because of the importance of documenting referrals, clinicians should establish a "fail-safe" system of review to ensure that appropriate entries have been made. The omission of this information, if litigation should ensue, unalterably weakens the optometrist's defense.

## Consultations

Consultations with other practitioners should be scheduled and documented in the same manner as referrals. Consultation creates a joint venture in which liability for negligence may be shared. For this reason consultants should be selected with due care. Patients' records should contain any correspondence to consultants, the consultants' written recommendations, and accounts of the action taken based on consultants' findings.

## Record of Patient Care

Documentation of patient care is essential to the defense of legal claims. If pharmaceutical agents are used, clinicians should ensure that the patient record includes an adequate history, a description of drugs used, any warnings communicated to the patient, required recall appointments (including "no show" appointments), and

an explanation of the treatment rendered if patients experience adverse effects.

If this information is recorded, clinicians are able to substantiate the treatment rendered, and as long as that treatment has been in compliance with the standard of care, clinicians will defeat an action for damages. Inadequate documentation, however, may produce the opposite result. Clinicians should take the time to maintain accurate, thorough, contemporaneous records that reflect the care and attention given to each patient.

## SELECTED BIBLIOGRAPHY

- Adams CM, Alexander LJ, Bartlett JD, Classé JG. Comanagement of patients with glaucoma. *Optom Clin* 1992;2:143-156.
- Alexander LJ. Vision care for the patient with diabetes [editorial]. *J Am Optom Assoc* 1987;58:872-873.
- Alexander LJ, Scholles J. Clinical and legal aspects of pupillary dilation. *J Am Optom Assoc* 1987;58:432-437.
- Andersson GBJ, Cocchiarella L, eds. *Guides to the evaluation of permanent impairment*, ed. 5. Chicago: American Medical Association, 2000.
- Bartlett JD, Classé JG. Dapiprazole: will it affect the standard of care for pupillary dilation? *Optom Clin* 1992;2:113-120.
- Bartlett JD, Wood JW. Optometry and the Drug Enforcement Administration. *J Am Optom Assoc* 1981;52:495-498.
- Beaman v. Schwartz*, 738 S.W. 2d 632 (Tenn. App. 1986).
- Bettman JW. A review of 412 claims in ophthalmology. *Int Ophthalmol Clin* 1980;20:131-142.
- Bettman JW. Seven hundred medicolegal cases in ophthalmology. *Ophthalmology* 1990;97:1379-1384.
- Black's law dictionary, rev. ed. 4. St. Paul, MN: West, 1968.
- Burns RP, Forster RK, Laibson P, Gibson IK. Chronic toxicity of local anesthetics on the cornea. In: Leopold IH, Burns RP, eds. *Symposium on ocular therapy*. New York: John Wiley & Sons, 1977: 31-44.
- Byer NE. Natural history of posterior vitreous detachment with early management as the premier line of defense against retinal detachment. *Ophthalmology* 1994;101:1503-1514.
- Canterbury v. Spence*, 464 F. 2d 772 (D.C. Cir. 1972).
- Classé J. Liability and ophthalmic drug use. *Optom Clin* 1992;2:121-134.
- Classé J. Liability and the primary care optometrist. *J Am Optom Assoc* 1986;57:926-929.
- Classé J. Pupillary dilation: an eye-opening problem. *J Am Optom Assoc* 1992;63:733-740.
- Classé JG. A dark victory. *Optom Econ* 1991;1:44-45.
- Classé JG. A review of 50 malpractice claims. *J Am Optom Assoc* 1989;60:694-706.
- Classé JG. Clinicolegal aspects of vitreous and retinal detachment. *Optom Clin* 1992;2:113-125.
- Classé JG. Glaucoma—a clinicolegal review. *J Am Optom Assoc* 1997;68:389-394.
- Classé JG. Helling revisited: how the "tale" wagged the dog. *J Am Optom Assoc* 1987;58:343-345.
- Classé JG. *Legal aspects of optometry*. Boston: Butterworth, 1989: 133-143.
- Classé JG. Liability for the treatment of anterior segment eye disease. *Optom Clin* 1991;1:1-16.
- Classé JG. Optometrist's duty to detect ocular tumors. *South J Optom* 1985;3:26-32.

\*\*Although practitioners are under no legal duty to contact patients who fail to keep appointments, there are circumstances under which follow-up may be wise. For example, a patient who is undergoing treatment with therapeutic agents and who is in need of further evaluation faces a much higher risk of complication than a daily wear contact lens patient who fails to keep a 6-month recall appointment. Follow-up in the former case may prevent an injury—and a lawsuit.



- Classé JG. Optometrist's duty to detect retinal detachment. *South J Optom* 1985;3:7-13.
- Classé JG. Optometrist's duty to test for glaucoma. *South J Optom* 1984;2:6-10.
- Classé JG. Optometrist's duty to warn of vision impairment. *South J Optom* 1986;4:66-69.
- Classé JG. Optometrist's liability for contact lenses. *South J Optom* 1986;4:52-57.
- Classé JG. Record-keeping and documentation in clinical practice. *South J Optom* 1987;5:11-25.
- Classé JG. Standards of practice for primary eye care. Columbus, OH: Anadem, 1998.
- Classé JG. The eye opening case of *Keir v. United States*. *J Am Optom Assoc* 1989;60:471-476.
- Classé JG, Harris MG. Liability and extended wear contact lenses. *J Am Optom Assoc* 1987;58:848-854.
- Cockburn DM. Prevalence and significance of narrow anterior chamber angles in optometric practice. *Am J Optom Physiol Opt* 1981;58:171-175.
- Collins v. American Optometric Association*, 693 F. 2d 636 (7th Cir. 1982).
- Comprehensive Drug Abuse Prevention and Control Act of 1970. In: *Physician's manual: an information outline of the Controlled Substances Act of 1970*. Washington, DC: U.S. Department of Justice, 1978.
- Cox MS, Schepens CL, Freeman HM. Retinal detachment due to ocular contusion. *Arch Ophthalmol* 1966;76:678-685.
- Curran WJ. Malpractice claims: new data and new trends. *N Engl J Med* 1979;300:26.
- Davis MD. Natural history of retinal breaks without detachment. *Arch Ophthalmol* 1974;92:183-194.
- Dixon MG. Drug product liability. New York: Matthew Bender, 1974: 9.01-9.09.
- Dixon MG. Drug product liability. New York: Matthew Bender, 1974: 7.01-7.26.
- Elmstrom G. Malpractice: what can ODs expect? *Opt J Rev Optom* 1977;114:42-45.
- Esposito v. Shapero*, Civil Action 76-1214, West Virginia Circuit Court, Cabell County, December 16, 1976 (cert. denied June 6, 1977).
- Evans v. Griswold*, 935 P.2d 165 (Ida. 1997).
- Fairchild v. Brian*, 354 So. 2d 675 (La. App. 1977).
- Febarne v. Dunlap*, 565 N.Y.S. 2d 664 (1991).
- Ford v. Ireland*, 699 S.W. 2d 587 (Tex. App. 1985).
- Fykes v. Chatow*, docket no. 976896, Superior Court, Los Angeles County, Cal., 1974. Reported in *The Citation*, 1975;30:120.
- Gates v. Jensen*, 92 Wash. 2d 246, 595 P.2d 919 (1979).
- Gerber P. How to blow your own malpractice defense. *Optom Man* 1981;17:19-25.
- Gold AR. Failure to warn. *J Am Optom Assoc* 1986;57:317-319.
- Gold JA. Informed consent. *Arch Ophthalmol* 1993;111:321-323.
- Graham v. Whitaker*, 321 S.E. 2d 40 (S.C. 1984).
- Gray LG. Avoiding adverse effects of cycloplegics in infants and children. *J Am Optom Assoc* 1979;50:465-470.
- Harris MG, Dister RE. Informed consent in contact lens practice. *J Am Optom Assoc* 1987;58:230-236.
- Harris v. Groth*, 90 Wash. 2d 438, 663 P.2d 113 (Wash. 1983).
- Helling v. Carey*, 83 Wash. 2d 514, 519 P.2d 981 (Wash. 1974).
- Holder A. Medical malpractice law. New York: John Wiley & Sons, 1975: 200-204.
- Holmes v. Iwasa*, 104 Ida. 179, 657 P.2d 476 (1983).
- Kabn v. Shaw*, 65 Ga. App. 563, 16 S.E. 2d 99 (Ga. App. 1941).
- Keir v. United States*, 853 F.2d 398 (6th Cir. 1988).
- Keller JT. The risk of angle closure from the use of mydriatics. *J Am Optom Assoc* 1975;46:19-21.
- Kime v. Aetna*, 66 Ohio App. 277, 33 N.E. 2d 1008 (Ohio App. 1940).
- Koenig v. United States*, case 86-CV-10269-BC, U.S. District Court, Eastern District of Michigan (Jan. 20, 1989).
- Kraushar MF, Steinberg JA. Informed consent: surrender or salvation? *Arch Ophthalmol* 1986;104:352-355.
- Lee v. Gawne et al*, case no. 91L-1441, DuPage County Circuit Court, Ill. Reported in *Medical Malpractice: Verdicts, Settlements, and Experts* 1993;9:17.
- Lipson LG, ed. Diabetes mellitus in the elderly. *Am J Med* 1986;80:1-56.
- Lorentzon v. Rowell*, 321 S.E. 2d 341 (Ga. App. 1984).
- Luttjohann L. Informed consent and release of patient records. *Kansas Optom J* 1984;51:6-7.
- McMahon v. Glixman*, 393 N.E. 2d 875 (Mass. 1979).
- McMickens v. Callaban*, 533 So. 2d 589 (Ala. 1988).
- Miller PJ. Documentation as a defense to legal claims. *J Am Optom Assoc* 1986;57:144-145.
- Modern status of views as to general measure of physician's duty to inform patient of risks of proposed treatment, 88 ALR 3d 1008.
- Molina v. McQuinn*, 758 P.2d 798 (New Mex. 1988).
- Natanson v. Cline*, 187 Kan. 186, 354 P.2d 670 (1960).
- National Association of Insurance Commissioners. *Malpractice Claims*, vol. 2, no. 2. Madison, WI: National Association of Insurance Commissioners, 1980.
- Norden LC. Adverse reactions to topical ocular anesthetics. *J Am Optom Assoc* 1976;47:730-733.
- Ortiz v. Allergan Pharmaceuticals*, 489 S.W. 2d 135 (Tex. Civ. App. 1972).
- Prosser WL. *Law of torts*, ed. 4. St. Paul, MN: West, 1971: 139-235.
- Reed v. Church*, 8 S.E. 2d 285 (Va. 1940).
- Rhode Island Ophthalmological Society v. Cannon*, 317 A. 2d 124 (1974).
- Russell v. Scales*, case no. 92-5254-CA-F, Broward County Circuit Court, Fla. Reported in *Medical Malpractice: Verdicts, Settlements, and Experts* 1994;10:9.
- Schloendorff v. Society of New York Hospital*, 211 N.Y. 125, 105 N.E. 92 (1914).
- Scholles JA. A review of professional liability claims in optometry. *J Am Optom Assoc* 1986;57:764-766.
- Scholles J. Documentation and record-keeping in clinical practice. *J Am Optom Assoc* 1986;57:141-143.
- Scope of practice: Patient care and management manual. St. Louis: American Optometric Association, 1986.
- Semes L, Gold A. Clinical and legal considerations in the diagnosis and management of ocular tumors. *J Am Optom Assoc* 1987;58:134-139.
- Steele v. United States*, 463 F. Supp. 321 (D.C. Alaska 1978).
- Tasman WS. Posterior vitreous detachment and peripheral breaks. *Trans Am Acad Ophthalmol Otolaryngol* 1968; 72:217-224.
- Tempchin v. Sampson*, 262 Md. 156, 277 A. 2d 67 (Md. 1971).
- Thal LS. *Gates v. Jensen*: another precedent for glaucoma testing. *J Am Optom Assoc* 1981;52:349-353.
- Trogun v. Fruchtman*, 209 N.W. 2d 297 (Wis. 1973).
- Truxillo v. Gentilly Medical Building, Inc.*, 225 So. 2d 488 (La. 1969).

Wechsler S, Classé JG. *Helling v. Carey*: Caveat medicus (let the doctor beware). *J Am Optom Assoc* 1977;48:1526-1529.

*Welch v. Whitaker*, 317 S.E. 2d 758 (S.C.App. 1984).

*Welke v. Kuzilla*, 144 Mich. App. 245, 375 N.W. 2d 403 (Mich. App. 1985).

*Westmoreland v. Doe*, case no. CL92- 423, City of Petersburg Circuit Court, Petersburg, Va. Reported in *Medical Malpractice: Verdicts, Settlements, and Experts* 1992;9:11.

*Whitley v. Heston*, 954 S.W. 2d 119 (Tex. Ct.App. 1997).

*Whitt v. Columbus Cooperative Enterprises*, 64 Ohio St. 355, 415 N.E. 2d 985 (1980).

*Wills v. Klingenbeck*, 455 So. 2d 806 (Ala. 1984).

*Wu v. Nelson*, case no. 89-016571, Hennepin County District Court, Minn. Reported in *Medical Malpractice: Verdicts, Settlements, and Experts* 1992;8:20.

*Yorston v. Pennell*, 153 A. 2d 255 (Pa. 1959).

SECTION

II

---

# Pharmacology of Ocular Drugs

---

Drug therapy must be based on correlation of effects of drugs with physiologic, biochemical and microbiologic kinetic aspects of disease. Only through basic knowledge can we understand toxicology and limitations of drugs and how these can be overcome.

*I. H. Leopold*

## Local Anesthetics

Tammy Pifer Than and Jimmy D. Bartlett

Local anesthetics are drugs that produce reversible conduction blockage of nerve impulses. Autonomic system blockade followed by sensory anesthesia and skeletal muscle paralysis occur when local anesthetic concentration is increased. The effects of local anesthetics are completely reversible, with no evidence of structural damage to the nerve fibers. Another prominent clinical feature of local anesthesia is that loss of sensation occurs without loss of consciousness. This property makes local anesthetics highly useful for many office procedures and for eye surgery. This chapter considers the pharmacologic properties of anesthetics currently used for ophthalmic procedures.

### PHARMACOLOGIC PROPERTIES

#### Structural Features

With the exception of cocaine, all local anesthetics in current clinical use are synthetic and are poorly water-soluble, weakly basic, aromatic amines (Figure 6-1). The structural components consist of an aromatic hydrophobic portion, an intermediate linkage site, and a hydrophilic amine. Each of these three components confers different properties to the molecule. The hydrophobic portion must be an aromatic ring and is essential for anesthetic activity. As the hydrophobicity of the molecule increases, potency and duration of action increase. This is because increasing lipid solubility leads to greater access to the site of anesthetic action and to a decreased rate of metabolism. Increasing hydrophobicity also increases toxicity, therefore decreasing the therapeutic index. The intermediate chain, usually of two to three carbons, is linked to the aromatic ring by either an ester ( $-C-O-$ ) or amide ( $-N-C-$ ) linkage (see Figure 6-1), the nature of which determines certain pharmacologic properties of the molecule, including its metabolism. Esters are unstable compounds that are rapidly hydrolyzed by plasma pseudocholinesterase, whereas the amides are very stable and must be metabolized in the liver. All commonly used topical ocular anesthetics are of

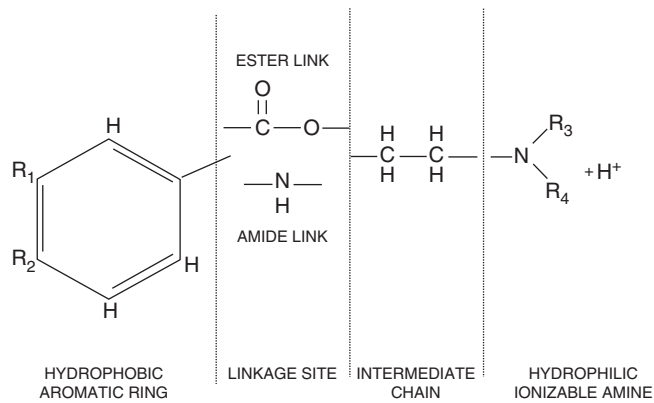
the ester type, whereas most injectable anesthetics have an amide linkage (Box 6-1).

#### Physiochemical Characteristics

All local anesthetics exist in solution either as the uncharged amine or as the positively charged substituted ammonium cation. Because amines are only slightly soluble in water, they are formulated in solution as hydrochloride salts. This enhances water solubility and stability in solution and prolongs their shelf life. The degree of ionization is also important in the distribution of the anesthetic to its site of action, because only the nonionized form readily crosses cell membranes. Because the local anesthetics are weak bases, with a  $pK_a$  between 8 and 9, they tend to ionize in acidic solutions. However, on contact with neutral or alkaline environments, such as tears, the uncharged fraction of the drug molecule increases, which allows more anesthetic to enter the nerve cell membrane. If a local anesthetic is applied or injected into an acidic environment, such as in the presence of infection, the ionized fraction of the drug increases. Thus, the pH of the medium may alter how much anesthetic reaches the site of action.

#### Mechanism of Action

Local anesthetics prevent both generation and conduction of nerve impulses. Their main site of action appears to be the cell membrane, where they block the transient increase in membrane permeability to sodium ions that normally occurs with depolarization of the membrane. Blockade of sodium transport is thought to occur through binding of the local anesthetic to a specific binding site located within a voltage-gated sodium channel present in the cell membrane. A large (300 kDa) heterotrimeric protein containing numerous transmembrane segments forms this sodium channel. Several hydrophobic amino acid residues on a small portion of one of the transmembrane segments serve as the binding site. The greater the hydrophobicity of the local anesthetic,



**Figure 6-1** Generalized molecular structure of a local anesthetic, consisting of a hydrophobic aromatic residue, the linkage site, an intermediate alkyl chain, and a hydrophilic amino group. (Adapted from Leshner GA. General principles of local anesthetics. In: Onofrey BE, ed. *Clinical optometric pharmacology and therapeutics*. Philadelphia: JB Lippincott, 1991; Chapter 53.)

the greater the affinity for binding. After application, anesthetics diffuse across the cell membrane in the uncharged (lipid-soluble) amine form, but at the site of action the charged substituted ammonium cation preferentially interacts with the receptor that is only accessible from the inner membrane surface.

The duration of action of local anesthetics is proportional to the time they are in contact with the nerve tissue. Consequently, any agent or procedure that keeps anesthetics at their site of action prolongs the period of anesthesia. In clinical practice formulation of injectable local anesthetics with vasoconstrictors helps to localize the anesthetic at the desired site. Local vasoconstriction may also offer the advantage of slowing absorption into the systemic circulation, which reduces the potential for

systemic anesthetic toxicity. However, use of vasoconstrictors can cause tissue hypoxia and subsequent cell damage.

In addition, the intrinsic vasodilator activity and degree of plasma protein binding of anesthetics can influence their clinical potency and duration of action. Compared with mepivacaine, lidocaine exhibits enhanced vasodilator action, which results in a clinically shorter duration of action. Although protein binding generally reduces the amount of free drug available for receptor interaction, it can provide a drug depot for maintenance of anesthetic effect. This may partly explain the prolonged duration of action of highly protein-bound anesthetics, such as bupivacaine and etidocaine.

When applied topically to the eye, the anesthetics in current clinical use have relatively low systemic and ocular toxicity. Their sufficiently long duration of action, low cost, stability in solution, and general lack of interference with actions of other drugs make them useful agents for such ocular procedures as tonometry, corneal pachymetry, foreign body and suture removal, gonioscopy, nasolacrimal duct irrigation and probing, and even cataract surgery. When injected to provide local anesthesia, these agents present greater risks of toxicity. However, compared with general anesthesia, the local anesthetics offer many advantages.

## Injectable Anesthetics

When more extensive ophthalmic procedures are to be undertaken, such as incision and curettage of chalazion, administration of anesthetics by injection is necessary (Table 6-1). Xylocaine, a common trade name of lidocaine, is no longer available in the United States, although lidocaine is readily available and widely used. Although lidocaine is most frequently administered via an injectable route, it is also used intracamerally during cataract surgery. Preservative-free 1% lidocaine is often injected into the anterior chamber during cataract surgery to supplement topical anesthesia to minimize perioperative pain and light sensitivity. Most studies have indicated that intracameral lidocaine does not cause morphologic or functional changes in the corneal endothelium.

The duration of the anesthetic effect is determined by the length of time the drug stays bound to the nerve protein. This is dictated by the chemical structure of the drug, the concentration, the amount administered, and the rate of removal by diffusion and circulation.

The addition of epinephrine, a vasoconstrictor, to an injectable anesthetic prolongs the duration of anesthesia and decreases the rate of systemic absorption, thereby decreasing the risk of systemic toxicity. The duration of some anesthetics, such as bupivacaine, a long-acting anesthetic, cannot be significantly extended by adding epinephrine. Epinephrine also decreases local bleeding. Effective vasoconstriction is obtained with a concentration of 1 to 100,000 or even 1 to 200,000. The usual

### Box 6-1 Classification of Local Anesthetics

- Ester linkage
  - Esters of benzoic acid
    - Cocaine
  - Esters of meta-aminobenzoic acid
    - Proparacaine
  - Esters of para-aminobenzoic acid
    - Procaine
    - Chlorprocaine
    - Tetracaine
    - Benoxinate
- Amide linkage (amides of benzoic acid)
  - Lidocaine
  - Mepivacaine
  - Bupivacaine
  - Etidocaine

**Table 6-1**  
Local Anesthetics for Regional Infiltration and Peripheral Nerve Block

Anesthetic (Trade Name)	Formulation (% Solution) <sup>a</sup>	Onset of Action (min)	Duration of Action (hr)	Maximum Dose (mg) <sup>b</sup>
Procaine (Novocain)	1, 2, 10	7-8	½ - ¾	600 (10.0 mg/kg)
Lidocaine	0.5, 1, 1.5, 2, 4	4-6	¾ - 1 (1-2 with epinephrine)	300 (4.5 mg/kg) 500 (7.0 mg/kg) with epinephrine
Mepivacaine (Carbocaine)	1, 1.5, 2	3-5	2-3	400
Bupivacaine (Marcaine, Sensorcaine)	0.25, 0.50, 0.75	5-10	4-12	175
Etidocaine (Duranest)	1, 1.5	3-5	5-10	400 (8.0 mg/kg)

<sup>a</sup>1% solution = 10 mg/ml. Some concentrations are commercially available with epinephrine.

<sup>b</sup>For healthy adults. Use lowest dosage that provides effective anesthesia.

Adapted from Raj PP. Handbook of regional anesthesia. New York: Churchill Livingstone, 1985; Bartlett JD, Fiscella R, Jaanus SD, et al., eds. Ophthalmic drug facts. St. Louis: Facts and Comparisons, 2005; Crandall DG. Pharmacology of ocular anesthetics. In: Duane TD, Jaeger EA, eds. Biomedical foundations of ophthalmology. Philadelphia: J.B. Lippincott, 1994; and Sobol WM, McCrary JA. Ocular anesthetic properties and adverse reactions. *Int Ophthalmol Clin* 1989;29:195-199.

concentrations of epinephrine used for ophthalmic procedures range from 1:50,000 to 1:200,000. When epinephrine is subjected to heat, its potency is destroyed. Consequently, solutions containing epinephrine should not be subjected to heat sterilization. Use of epinephrine as an adjunctive agent can result in undesirable effects on local tissue, such as delayed wound healing and occasional necrosis and intense vasoconstriction. It may also produce adverse systemic reactions, such as apprehension, anxiety, restlessness, tremor, pallor, tachycardia, dyspnea, hypertension, palpitation, headaches, and precordial distress. When subjective palpitation occurs with or without a throbbing headache, tachycardia, and hypertension, a diagnosis of reaction to epinephrine rather than to the local anesthetic is indicated. Although these reactions are temporary, patients with cardiovascular disease may suffer cardiac arrhythmias, angina attacks, or cerebral ischemia.

## Topical Anesthetics

The efficacy of topical ocular anesthetics is usually determined by their ability to suppress corneal sensitivity. When a dose-response relationship is determined for various anesthetics, a concentration for each drug is obtained beyond which no further increase in activity occurs. The concentration at which this maximum efficacy occurs is termed the *maximum effective concentration*. Thus, increasing the concentration of the anesthetic beyond the maximum effective concentration serves no useful purpose but increases the risk of local and systemic toxicity.

The maximum effective concentrations of proparacaine, tetracaine, and cocaine are 0.5%, 1%, and 20%, respectively. In clinical practice, however, the optimum effective concentration of the drug may be less than the

maximum effective concentration. For instance, 0.5% tetracaine is less irritating to the eye than the maximum effective concentration of 1% and thus is better suited for clinical use. The topical application of a combination of two or more local anesthetics does not produce an additive effect, but it does increase the risk of side effects and so is contraindicated. The commonly used topical anesthetics are listed in Table 6-2.

## Cocaine

Cocaine is unique among local anesthetics because it exhibits both anesthetic and adrenergic agonist activity. It is not commercially available in an ophthalmic solution. For clinical use the salt form of cocaine, cocaine hydrochloride, must be specially formulated in aqueous solution. Although not approved by the U.S. Food and Drug Administration for ophthalmic use, solutions of cocaine intended for otolaryngologic purposes are commercially available. Clinical experience indicates an apparent effective and safe for ocular use. The usual concentration for topical ocular use is 1% to 4%, but the 10% solution is often used, due to its adrenergic stimulatory effects, for the diagnosis of Horner's syndrome (see Chapter 22). One drop of a 2% solution produces excellent corneal anesthesia within 5 to 10 minutes. Complete anesthesia lasts approximately 20 minutes, with incomplete surface anesthesia lasting for approximately 1 to 2 hours. Cocaine is used as a nasal spray or in a nasal pack during dacryocystorhinostomy. When applied to the nasal mucosa in a gauze pack, cocaine anesthetizes the contact area for an hour or longer. Cocaine, due to its adrenergic effects, causes vasoconstriction, thus retarding its own absorption. Hence, cocaine constricts the conjunctival and nasal vasculatures when applied topically to these mucous membranes. Because of this vasoconstrictor action, use of epinephrine

**Table 6-2**  
Topical Anesthetics

Anesthetic	Trade Name	Formulation	Preservative
Cocaine hydrochloride	Schedule II controlled substance	1-10% solution prepared from bulk powder	
Tetracaine hydrochloride	Opticaine Tetcaine	0.5% solution	0.4% chlorobutanol
Benoxinate hydrochloride with fluorescein sodium	Fluress	0.4% solution combined with 0.25% fluorescein sodium	1% chlorobutanol
Benoxinate hydrochloride with fluorexon disodium	Flurasafe	0.4% solution combined with 0.35% fluorexon disodium	0.5% chlorobutanol
Proparacaine hydrochloride	AK-Taine Alcaine Ophthetic Parcaine	0.5% solution	0.01% benzalkonium chloride
Proparacaine hydrochloride with fluorescein sodium	Fluoracaine Flucaine	0.5% solution combined with 0.25% fluorescein sodium	0.1% thimerosal

with cocaine is not only unnecessary but may be harmful, because cocaine causes sensitization to exogenous epinephrine. Cocaine may loosen the corneal epithelium to a greater extent than other topically applied anesthetics, thus facilitating debridement of the corneal epithelium.

Because cocaine blocks reuptake of norepinephrine and has an adrenergic potentiating effect, its use is contraindicated in patients with systemic hypertension or patients taking adrenergic agonists. The interaction between cocaine and catecholamines contraindicates the use of cocaine in patients taking drugs that modify adrenergic neuronal activity, such as guanethidine, reserpine, tricyclic antidepressants, methyl dopa, or monoamine oxidase inhibitors. Additionally, drugs that act directly on adrenergic receptors, such as phenylephrine, are contraindicated with use of cocaine. Because cocaine has a mydriatic effect, it is contraindicated in patients predisposed to angle-closure glaucoma.

The major ocular side effect of cocaine is significant corneal epithelial toxicity. Grossly visible grayish pits and irregularities are readily produced by this drug. These are followed by loosening of the corneal epithelium, which may result in large erosions. Although this characteristic is generally considered to be an adverse effect, it is clinically useful in cases requiring corneal epithelial debridement. However, the corneal epithelial effects of cocaine contraindicate its use in any procedure requiring good visualization through the cornea, such as in retinal detachment surgery or in routine ophthalmoscopy or gonioscopy.

Acute systemic cocaine toxicity may result from as little as 20 mg (10 drops of a 4% solution) of drug. The total dose of cocaine should not exceed 3 mg/kg of

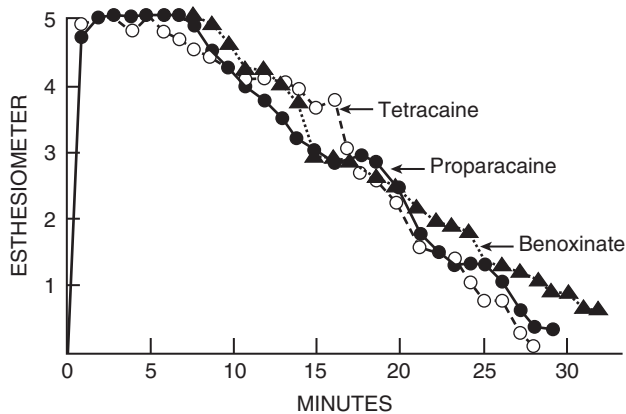
body weight. Typical manifestations of systemic toxicity include excitement, restlessness, headache, rapid and irregular pulse, dilated pupils, nausea, vomiting, abdominal pain, delirium, and convulsions.

Because of the strong abuse potential of cocaine, its distribution and clinical use are subject to federal and state controlled substance regulations under supervision of the Drug Enforcement Administration. Because of its potential ocular and systemic toxicity, cocaine has generally been replaced by the safer synthetic local anesthetics.

#### Tetracaine

Tetracaine, an ester of para-aminobenzoic acid (PABA), has been widely used for topical anesthesia of the eye. It is currently available in a 0.5% solution. Its onset, intensity, and duration of anesthesia are comparable with those of proparacaine and benoxinate (Figure 6-2). Onset of anesthesia sufficient to permit tonometry or other minor procedures involving the superficial cornea and conjunctiva is 10 to 20 seconds, and duration of anesthesia is 10 to 20 minutes. It has been reported, however, that the 1% solution produces anesthesia lasting nearly an hour. Tetracaine 1% has also been used successfully to provide anesthesia during phacoemulsification cataract surgery and intraocular lens implantation.

Tetracaine causes rapid surface anesthesia, but even repeated applications to the conjunctival surface may fail to achieve effective scleral anesthesia. Preparations of local anesthetics for topical use that include tetracaine should never be injected. Practitioners are cautioned to consider tetracaine a potent and potentially toxic local anesthetic. Dangerous overdoses may occur if it is administered in doses higher than 1.5 mg/kg of body weight.



**Figure 6-2** Comparison of onset, intensity, and duration of anesthesia obtained with tetracaine 0.5%, proparacaine 0.5%, and benoxinate 0.4%. (Reprinted with permission from *Am J Ophthalmol* 1955;40:697-704. Copyright, The Ophthalmic Publishing Company.)

A variety of side effects often accompany the use of topical tetracaine. Tetracaine appears to produce greater corneal compromise than proparacaine, including ultrastructural damage to the cell membrane, loss of microvilli, and desquamation of superficial epithelial cells. Perhaps the greatest objection to the use of tetracaine, however, is the moderate stinging or burning sensation that almost always occurs immediately after its topical instillation. This typically lasts 20 to 30 seconds after drug application. Another problem associated with use of tetracaine is allergic reactions. Local allergy to tetracaine may develop because of repeated use (e.g., in tonometry of glaucoma patients), but this is uncommon. Rarely, tetracaine can exhibit cross-sensitivity with proparacaine.

### Benoxinate

Benoxinate is commercially available only in combination with a vital dye solution. It is most commonly combined with sodium fluorescein 0.25%, but recently it was combined with 0.35% disodium fluorexon (Flurasafe by Accutome). Fluorexon is a high-molecular-weight fluorescein that does not stain hydrogel contact lenses; therefore the use of Flurasafe is intended to allow contact lens patients to resume wear sooner without concern of contact lens staining. Benoxinate 0.4%, an ester of PABA, has an onset, intensity, and duration of anesthesia similar to those of tetracaine 0.5% and proparacaine 0.5% (see Figure 6-2). Because benoxinate is available only in combination with a vital dye, its primary clinical use is for applanation tonometry. Although solutions of fluorescein serve as good culture media for *Pseudomonas aeruginosa*, the benoxinate-sodium fluorescein combination has been shown to have substantial bactericidal properties. Thus, the benoxinate-sodium fluorescein combination is ideal for use in applanation tonometry, because it does not have the same risk for *Pseudomonas* contamination characteristic of sodium fluorescein solutions.

Relatively few side effects are associated with the clinical use of benoxinate as an ocular anesthetic. Topical instillation typically produces a sensation of stinging or burning that is greater than that produced by the instillation of proparacaine but less than that produced by tetracaine. In addition, benoxinate appears to cause less corneal epithelial desquamation than proparacaine, but this has not been substantiated by controlled clinical studies. Local allergic reactions to benoxinate are rare. Benoxinate may be safely administered to some patients who are allergic to tetracaine, another ester of PABA, without causing allergic reactions, which suggests that the allergenic potential of benoxinate is extremely low. There is no apparent cross-sensitivity between this agent and proparacaine.

Some individuals demonstrate significant increases or decreases ( $\pm 10$  mcm) in corneal thickness after the instillation of topical benoxinate. This effect must be considered when performing preoperative pachymetry before corneal refractive surgery.

### Proparacaine

Proparacaine is commercially available in a 0.5% solution, both with and without sodium fluorescein 0.25% (see Table 6-2). The onset, intensity, and duration of anesthesia from these preparations are similar to those of tetracaine 0.5% and benoxinate 0.4% (see Figure 6-2). Proparacaine, however, does not appear to penetrate into the cornea or conjunctiva as well as tetracaine.

When used without sodium fluorescein, proparacaine is widely used as a general-purpose topical anesthetic. It produces little or no discomfort or irritation on instillation and is therefore readily accepted by most patients. When compared directly with tetracaine, 86% of patients reported that proparacaine caused less pain on administration. Unopened bottles may be stored at room temperature, but once opened the bottles should be tightly capped and, ideally, refrigerated to retard discoloration. Discolored solutions of proparacaine should be discarded.

Proparacaine has few side effects. Although localized allergic hypersensitivity reactions may develop, these are rare and occur less frequently with proparacaine than with tetracaine. Allergic reactions may be characterized by conjunctival hyperemia and edema, edematous eyelids, and lacrimation. After topical ocular instillation in recommended doses, allergic systemic manifestations are extremely rare. Topically instilled proparacaine was reported to have a possible role in the development of a hypersensitivity reaction that resulted in exacerbation of an existing case of Stevens-Johnson syndrome. Proparacaine was also reported to cause allergic contact dermatitis on the fingertips. This rare work-related hazard was confirmed by skin-patch testing. Rarely, proparacaine can exhibit cross-sensitivity with tetracaine.

As with benoxinate, corneal thickness instability can occur for about 5 minutes after proparacaine administration.



These changes in corneal thickness should be considered when obtaining measurements for refractive surgery or when performing pachymetry in glaucoma patients.

## SIDE EFFECTS

When used in recommended dosages, severe local reactions to topically applied anesthetics are exceedingly rare, and systemic reactions are even more uncommon. Although side effects can occur after use of topical anesthetics, adverse reactions are much more likely to occur with use of local anesthetics injected for infiltration or regional nerve block. Any use of local anesthetics, including topically applied anesthetics, can cause systemic toxicity, but the majority of such systemic reactions occur as a result of overdosage of the drug. Topical ocular use of local anesthetics leading to systemic manifestations of a true allergic hypersensitivity reaction is exceedingly rare. In general, patients who are particularly susceptible to the development of adverse reactions include those with known drug allergies, asthma, cardiovascular disease, liver disease, or hyperthyroidism and patients taking acetylcholinesterase inhibitors. Elderly patients, debilitated patients, and infants are also more vulnerable.

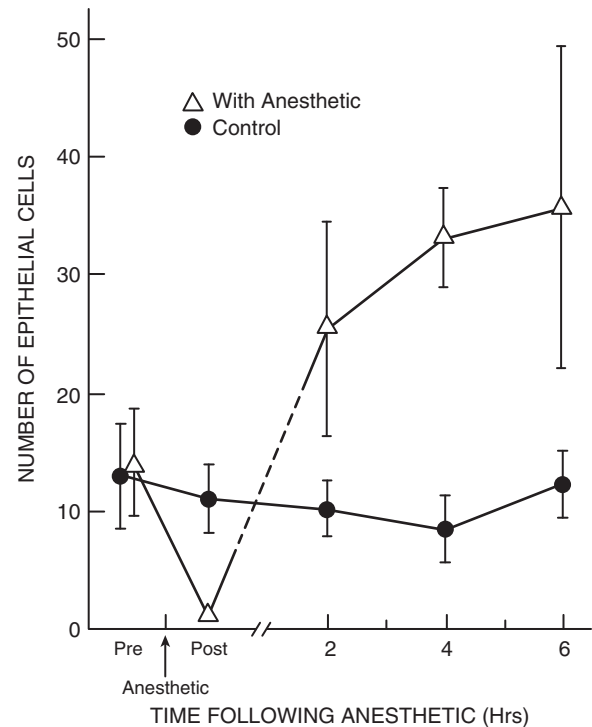
Local reactions include relatively minor allergic or toxic involvement of the cornea, conjunctiva, or lids. Although the small amounts of anesthetic normally used in topical ocular applications are usually insufficient to cause toxic systemic effects, systemic toxicity can potentially occur in any patient if the topical anesthetic is applied in dosages exceeding those normally recommended. There was one report of a systemic reaction after topical proparacaine described as a dermatologic allergic reaction in a patient with preexisting Stevens-Johnson syndrome. In general, serious ocular or systemic side effects from local anesthetics have been associated with the use of cocaine or anesthetics for infiltration and regional nerve block or as a result of prolonged use by self-administration.

## Toxicity

### Ocular

It is not uncommon for topically applied anesthetics, especially benoxinate and tetracaine, to cause mild local stinging or burning after instillation. As discussed previously, however, this lasts only momentarily and requires no specific treatment other than patient reassurance.

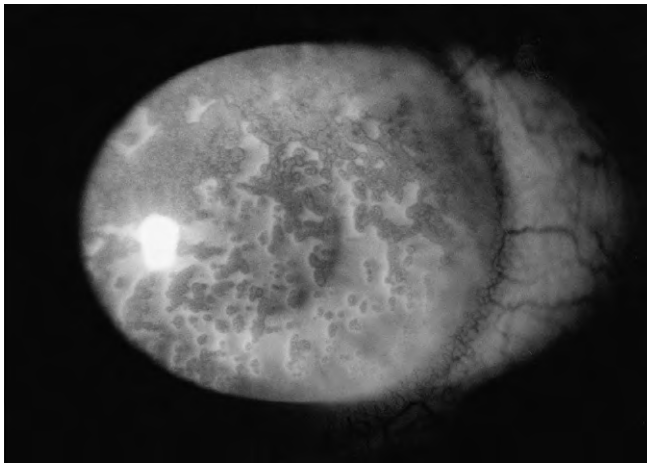
In some patients, especially those over age 50 years, a localized or diffuse desquamation of corneal epithelium becomes evident (Figure 6-3). This epithelial reaction usually consists of superficial punctate keratitis and probably results from exposure and tear film instability associated with decreased reflex tearing, infrequent blinking, and increased tear evaporation. The punctate keratopathy is frequently absent immediately after anesthetic instillation but may appear 5 to 30 minutes later (Figure 6-4).



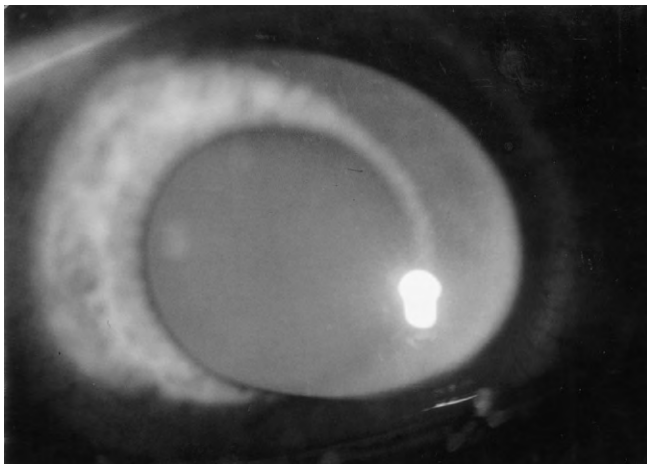
**Figure 6-3** Number of epithelial cells (mean  $\pm$  standard error) irrigated from precorneal tear film at different times. In the 2- to 6-hour period after instillation of 0.5% proparacaine, the number of cells was significantly greater with the anesthetic than with the control ( $p < .001$ , paired  $t$ -test). (Reprinted with permission from Wilson GS, Fullard RJ. Proparacaine sloughs cells. *J Am Optom Assoc* 1988;59:701-702.)

Although it is usually mild and of no clinical significance, occasionally it can be extensive enough to reduce vision to from 20/80 (6/24) to 20/200 (6/60). In its most severe form, it may be characterized by a diffuse, necrotizing, epithelial keratitis with filament formation and corneal edema, but this has been reported to occur in less than 1 of every 1,000 patients receiving a topical ocular anesthetic. The cornea can appear gray because of the epithelial and stromal edema, and folds may develop in Descemet's membrane. The conjunctiva can be hyperemic, and the patient may complain of blurred vision or photophobia. There may be lacrimation and mild to intense ocular pain, which may occur later because of the initial corneal anesthesia. Because the corneal epithelium begins to regenerate almost immediately, treatment other than reassurance or instillation of ocular lubricating agents is usually not required (see Figure 6-4). In moderate to severe cases the episode should be treated as a superficial corneal abrasion. Toxic reactions should be recorded in the patient's chart. Particularly severe epitheliopathies may be mediated by an allergic hypersensitivity; therefore a different topical anesthetic should be used on subsequent patient visits.

The repeated administration of topical ocular anesthetics should be avoided because it may significantly retard



A



B

**Figure 6-4** (A) Severe toxic corneal epithelial desquamation after instillation of proparacaine 0.5%. (B) Same cornea 24 hours later, demonstrating the rapidity with which healing occurs.

healing of corneal epithelium. Topical anesthetics can be particularly dangerous when given to patients for self-administration. The diagnosis and treatment of severe corneal toxicity associated with the long-term high-frequency administration of topical anesthetics are discussed later in this chapter.

### Systemic

With the exception of one case of grand mal seizure possibly associated with the topical application of benoxinate, no cases of serious systemic reactions caused by topically instilled ocular anesthetics have occurred. However, because 98% or more of systemic reactions to local injectable anesthetics are due to drug overdose, such systemic toxic reactions can potentially occur with the excessive administration of topical anesthetics to the eye. Topically applied anesthetics are rapidly absorbed into the systemic circulation, and their blood levels rise almost as rapidly as after intravenous injection.

Systemic absorption of topical anesthetics can result in high blood levels by any of the following mechanisms: (1) too large a dosage of the local anesthetic; (2) unusually rapid absorption of the drug, as in patients with marked conjunctival hyperemia; (3) unusually slow drug detoxification; and (4) slow elimination of the drug.

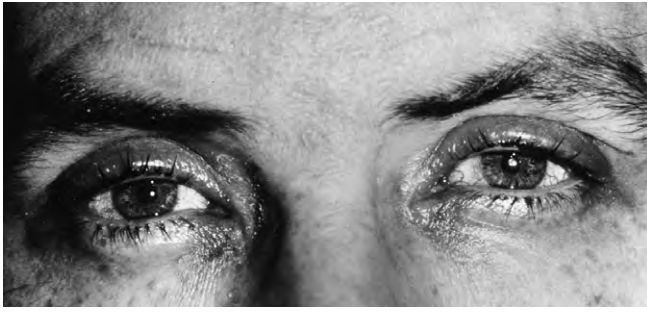High blood levels after topical application or injection of anesthetics may potentially cause systemic reactions. Toxic effects may appear in the central nervous system (CNS), cardiovascular system, or respiratory system. CNS toxicity appears initially as stimulation and may manifest itself clinically as nervousness, tremors, or convulsions. CNS depression, observed clinically as loss of consciousness and depression of respiration, usually follows. The earliest signs of cardiovascular involvement are hypertension, tachycardia, and, occasionally, cardiac arrhythmias. Late cardiovascular signs are hypotension, absent pulse, and weak or absent heartbeat. The effects on the cardiovascular system can develop either simultaneously with CNS depression or alone. If allowed to continue, such cardiac depression and resultant peripheral vasodilation are followed by secondary respiratory failure.

The liver, for the amide-type anesthetics, or plasma esterases, for the ester-type, can eliminate large amounts of local anesthetics. Within 30 to 60 minutes sufficient elimination of the overdose usually occurs to make the CNS stimulation or depression short-lived. Management objectives should therefore center on temporary respiratory and cardiovascular support. Administration of supplemental oxygen usually rapidly restores normal CNS function. In patients in whom cardiovascular collapse is evident, vasopressor therapy may take the form of metaraminol bitartrate 1% (Aramine) given intramuscularly or intravenously. The effect of this potent short-acting vasopressor lasts 20 to 60 minutes, depending on route of administration.

## Hypersensitivity

### Ocular

Although local allergy to topical anesthetics can develop in some patients because of routine diagnostic use over many months or years (e.g., for tonometry), these reactions are extremely uncommon. Allergic episodes occur mainly with use of the ester groups of anesthetics—that is, the commonly used anesthetics for topical ocular use. Although allergic reactions are also possible with the use of the amide group of anesthetics for local injection, such as lidocaine, mepivacaine, and bupivacaine, they occur much less frequently than with the ester group. The usual clinical presentation after topical anesthesia is that of a mild transient blepharoconjunctivitis characterized by conjunctival hyperemia and chemosis, swelling of the eyelids, lacrimation, and itching (Figure 6-5). These signs and symptoms usually appear 5 to 10 minutes after instillation of the anesthetic. Such reactions may be treated with topical decongestants and cold compresses.



**Figure 6-5** Allergic blepharoconjunctivitis after instillation of proparacaine 0.5%. Conjunctival hyperemia, swelling of the eyelids, lacrimation, and itching occur.

Practitioners should record the event in the patient's chart and avoid using the same anesthetic on subsequent patient visits. Because there is apparently little cross-sensitivity between classes of local anesthetics, practitioners can usually change from proparacaine to an ester of PABA, or vice versa, with little risk of local allergy. Unfortunately, no topical anesthetics approved for ocular use have an amide linkage. Such anesthetics, because of their extremely low allergenic potential, would serve as ideal topical ocular anesthetics.

### Systemic

Type I allergic reactions are estimated to account for less than 1% of all adverse reactions to local anesthetics. Moreover, no life-threatening allergic responses to anesthetics applied topically to the eye have been reported. The small amounts of anesthetic absorbed systemically after topical instillation are usually not sufficient to cause systemic reactions. However, topical anesthetics can cause systemic reactions if enough drug is absorbed into the systemic circulation. Most minor drug-induced systemic allergies are characterized by angioneurotic edema, urticaria (hives), bronchospasm, and hypotension. Joint pain and pruritus occur less commonly. Treatment should be directed toward symptomatic relief by the use of systemically administered antihistamines, bronchodilators, or epinephrine. A history of extensive drug allergies should alert practitioners to such a possible consequence of anesthetic administration, but no evidence of immediate hypersensitivity reactions was found when patients with a history of anesthetic allergy were rechallenged, which suggests the relative safety of anesthetic use in such individuals.

Anaphylactoid reactions to local injectable anesthetics are extremely rare. Although these reactions are usually immediate, they may be delayed as long as 15 to 30 minutes. Anaphylactoid reactions are characterized by a sudden circulatory collapse after drug administration. Urticaria, respiratory distress, cyanosis, and hypotension usually occur. Treatment directed at correcting the circulatory collapse and respiratory failure must be initiated promptly, because even a short delay can be fatal.

**Table 6-3**

Suggested Maximum Dosages of Topical Anesthetics

Anesthetic	Dosage (mg)
Cocaine 4%	20 (approximately 5 drops to each eye)
Tetracaine 0.5%	5 (approximately 7 drops to each eye)
Proparacaine 0.5%	10 (approximately 14 drops to each eye)

Modified from Lyle WM, Page C. Possible adverse effects from local anesthetics and the treatment of these reactions. *Am J Optom Physiol Opt* 1975;52:736-744.

### Psychomotor Reactions

Psychomotor reactions such as vasovagal syncope (fainting) may be readily mistaken for an adverse drug-related systemic reaction. However, such responses are not drug related and usually occur from anxiety related to the office visit. Accordingly, they may occur before, during, or after drug administration. If fainting occurs, patients should be reclined with their head in a low position, tight clothing around the neck loosened, and protected from falling or otherwise injuring themselves. Recovery is usually spontaneous within a few seconds. Respiration and cardiovascular status should be monitored to eliminate drug-induced anaphylaxis as a possible cause of the collapse.

### Prevention of Adverse Systemic Reactions

Although it is unlikely that serious systemic reactions will occur from topical ocular application of local anesthetics, practitioners must limit the dosages of the drugs to those compatible with effective anesthesia without substantial risk of systemic toxicity. The determination of exact dosage limits of local anesthetics is impossible, but it has been suggested that the total dose applied topically to mucous membranes such as the conjunctiva should not exceed one-fourth of the maximum allowed for injection. Table 6-3 shows suggested maximum dosages of topical anesthetics based on this formula. It has been reported that the toxicity of local anesthetics increases geometrically rather than arithmetically with increases in concentration. Thus, whereas a given dose of a 1% solution would be four times as toxic as an equal amount of 0.5% solution, a 2% solution would be approximately 16 times as toxic as an equal dose of 0.5% solution.

### CONTRAINDICATIONS

Generally, local anesthetics can be used with little risk of significant adverse local or systemic effects. The following specific contraindications should help to ensure the safe and effective ocular use of these anesthetics.

## Hypersensitivity

As previously stated, allergic reactions to local anesthetics are rare and are virtually limited to the ester-linked anesthetics (see Box 6-1). Allergy to the amide-linked anesthetics such as lidocaine is extremely rare. Unfortunately, intradermal skin tests and conjunctival and patch tests are not reliable for predicting the possibility of allergic reactions. When administering a topical anesthetic, it is advisable to use a drug from a different chemical family if a patient reports a history of hypersensitivity to a specific anesthetic. For example, an allergic reaction to a para-aminobenzoate derivative, such as procaine, should alert the practitioner to avoid using a similar drug such as tetracaine or benoxinate. In such cases proparacaine can usually be administered safely without causing an allergic reaction. Lidocaine, an amide-linked drug, may be used topically on the eye, but it is not currently approved by the U.S. Food and Drug Administration for such use.

Hypersensitivity to benzalkonium chloride has been reported in association with the use of ophthalmic medications. Because several of the commonly used topical ocular anesthetics contain benzalkonium as a preservative (see Table 6-2), it is reasonable to assume that some of the local allergic reactions to anesthetics may be due to this preservative.

## Liver Disease

Local anesthetics containing an amide linkage are metabolized principally by the liver. Thus, patients with hepatic disease may be more likely to exhibit toxic effects from the injectable anesthetics. Local tissue infiltration or nerve blocks should be avoided or performed using minimally effective anesthetic doses in patients with hepatitis, cirrhosis, extrahepatic obstruction (e.g., lithiasis), or other clinically significant hepatic dysfunction.

## Concomitant Medications

Local anesthetics containing an ester linkage are metabolized in plasma by pseudocholinesterases. Thus, patients using anticholinesterase medications may be predisposed to exhibit toxic effects from high doses of topical anesthetics. Multiple applications of topical anesthetics are not usually necessary and should be avoided in patients taking systemic anticholinesterase agents such as neostigmine (Prostigmin) and pyridostigmine (Mestinon).

## Dry Eye Testing

Topical anesthetics can cause instability of the tear film and diminish reflex aqueous tear production. Because they disrupt the surface microvilli of the corneal epithelium, anesthetics decrease mucous adherence and can contribute to a reduced tear breakup time. Preservatives present in topical anesthetics, such as benzalkonium

chloride, can also shorten the tear breakup time. These anesthetic-induced changes may affect the examination by masking or otherwise confusing the corneal or conjunctival signs of dry eye. Thus, when the use of sodium fluorescein or lissamine green is anticipated for staining of ocular tissues, the practitioner must avoid instilling an anesthetic until after the vital staining and associated evaluation procedures have been performed.

## Perforating Ocular Injury

Topically applied anesthetics may cause corneal endothelial toxicity when used after perforating ocular trauma or when used topically for cataract extraction. When injected intracamerally, benzalkonium chloride, the primary preservative used in topical ocular anesthetics, can cause irreversible corneal edema in rabbits.

## Cultures

Whenever possible, culture specimens from the lid margins or conjunctiva should be obtained without the prior instillation of an anesthetic. Preservatives in topical anesthetics exhibit varying degrees of antibacterial and antifungal activity. Moreover, the anesthetic agent itself is often toxic to microorganisms. Proparacaine, when used without preservative, fails to inhibit the growth of *Staphylococcus aureus*, *Pseudomonas aeruginosa*, and *Candida albicans*. Accordingly, it has been suggested that proparacaine, in single-dose containers without preservative, should be used when topical anesthesia is desired before obtaining material for culture.

## Self-Administration of Topical Anesthetics

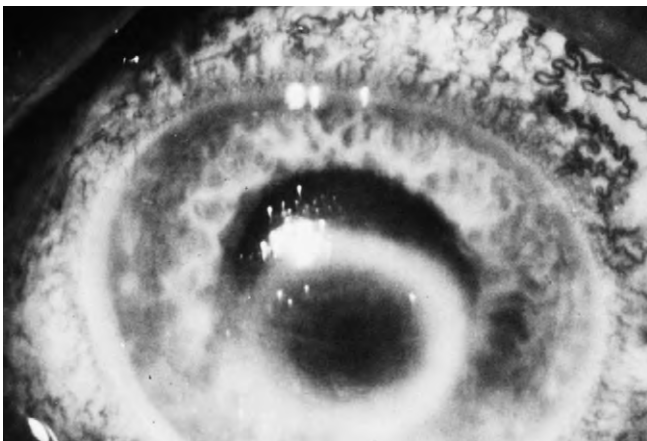
When evaluating an acute injury of the cornea, the practitioner is sometimes tempted to prescribe a topical anesthetic for administration at home by the patient for relief of ocular pain. This practice is extremely dangerous, however, and in numerous instances has led to severe infiltrative keratitis and even loss of the eye from anesthetic misuse or abuse by the patient. Topical anesthetics must be used only for the purpose of obtaining initial relief of ocular pain and never as part of a prolonged therapeutic regimen. The potential corneal toxicity of topical anesthetics precludes their use as self-administered drugs.

A syndrome has been described resulting from the frequent use of topical anesthetics over prolonged periods ranging from 6 days to 6 weeks. Severe corneal lesions and permanent reduction of visual acuity can occur in any eye that has been subjected to prolonged application of topical anesthetics as a means of relieving the pain of minor injuries. Patients using topical anesthetics on their own and those who have received prescriptions for anesthetics as part of their initial treatment may continue to instill the drugs despite warnings from

practitioners to discontinue their use. Furthermore, many of the patients in whom the syndrome has occurred have a medical or paramedical background and thus have easy access to the offending anesthetic.

The numerous signs and symptoms characterizing the syndrome develop over days or weeks. The continuous use of anesthetics, even for only a few days, may cause loss of the corneal epithelium and inhibit the healing of existing epithelial defects. Loss of the epithelial microvilli results in instability and rapid breakup of the tear film, which compounds the drying effect from the decreased blinking secondary to the anesthetic-induced corneal hypoesthesia. Clinically, these changes result in a chronic nonhealing epithelial defect. As the condition progresses, deeper manifestations can include stromal edema with folds in Descemet's membrane, disciform cellular infiltrations into the corneal stroma, keratic precipitates, anterior uveitis, hypopyon, and hyphema. Additional findings may include eyelid edema, conjunctival hyperemia and papillary hypertrophy, mucopurulent discharge, and corneal vascularization. The primary sign allowing objective diagnosis of this disease appears to be a yellowish white, dense, stromal ring surrounding the primary disease process (Figure 6-6). A history of topical anesthetic abuse, if obtainable, also serves to confirm the diagnosis.

Although the syndrome is easily treated once the cause is known, its recognition may be delayed by deceit on the part of patients. The most important requirement in the management of these patients is discontinuation of the topical anesthetic. Treatment consists of cycloplegic agents, broad-spectrum antibiotics, and possibly a bandage contact lens. Pain must be controlled with systemic analgesics (see Chapter 7). Once the topical anesthetic has been discontinued, remarkable corneal clearing can occur for as long as 6 months.



**Figure 6-6** Dense corneal stromal ring associated with abuse of topical anesthetics. (Reprinted with permission from Burns RP, Forster RK, Laibson P, Gipson IK. Chronic toxicity of local anesthetics on the cornea. In: Leopold IH, Burns RP, eds. *Symposium on ocular therapy*. New York: John Wiley & Sons, 1977;10:31-44.)

## ANESTHESIA OF THE SKIN

Patients with a reported history of allergic responses to ester and amide anesthetics pose a challenge, especially when regional anesthesia is necessary. Two alternatives may be considered when minor ophthalmic surgical procedures are performed. A 1% solution of diphenhydramine may be prepared by diluting the 5% solution (Benadryl Steri-Vials) with sterile saline. Additionally, injecting preserved sterile saline alone has been shown to be effective for superficial surgical procedures such as papilloma removal and shave biopsies.

If injectable anesthesia is not possible, several different delivery routes are available that provide sufficient local anesthesia for most minor ophthalmic procedures. Keratinized skin usually provides a barrier preventing diffusion of topical pharmaceutical agents, which makes achieving anesthesia of the skin difficult by topical application. However, a combination of 2.5% lidocaine and 2.5% prilocaine allows high concentrations of the anesthetic bases to be applied to the skin without local irritation. This combination is classified as a eutectic mixture of local anesthetics (EMLA), meaning the melting point of the combination is lower than that of either lidocaine or prilocaine alone. EMLA should be applied in a thick layer (1 to 2 g/10 cm<sup>2</sup>) to intact skin and covered with a patch of Tegaderm or clear plastic wrap to aid penetration through the epidermis. Anesthesia is achieved by blocking transmission of the dermal neuronal receptors. The preparation should be left on for 1 to 2 hours before the minor surgical procedure. It has been shown to be 87% effective in patients undergoing excisional surgery. EMLA should not be used on mucous membranes because of its increased rate of absorption and risk of greater side effects.

Iontophoresis is a means of penetrating the skin with a topical anesthetic using mild electric current. Lidocaine-soaked sponges are applied to the skin, and electrodes are placed on top of the anesthetic pads. Anesthesia can be obtained within 15 to 30 minutes, achieving an anesthetic depth of 1 to 2 cm. This route is infrequently used due to the expense and inconvenience of the apparatus.

Finally, various anesthetic patches are available, such as Lidoderm, although their efficacy in achieving anesthesia before procedures has not been studied. Lidoderm patches contain 5% lidocaine and are approved for treatment of postherpetic neuralgia. Up to three patches can be used at one time for a maximum of 12 hours per day.

## SELECTED BIBLIOGRAPHY

- Ansari H, Garibaldi DC, Jun AS. Anaesthetic abuse keratopathy as a manifestation of ocular Munchausen's syndrome. *Clin Exp Ophthalmol* 2006;34:81-83.
- Asensio I, Rahhal SM, Alonso L, et al. Corneal thickness values before and after oxybuprocaine 0.4% eye drops. *Cornea* 2003; 22:527-532.

- Bartfield JM, Holmes TJ, Raccio-Robak N. A comparison of proparacaine and tetracaine eye anesthetics. *Acad Emerg Med* 1994;1:364-367.
- Bartlett JD, ed. *Ophthalmic drug facts*. St. Louis: Wolters Kluwer Health, 2007.
- Boljka M, Kolar G, Videnšek J. Toxic side effects of local anaesthetics on the human cornea. *Br J Ophthalmol* 1994;78:386-389.
- Calvey TN, Williams NE. *Principles and practice of pharmacology for anaesthetists*. St. Louis: Blackwell Scientific Publications, 1982.
- Dannaker CJ, Maibach HI, Austin E. Allergic contact dermatitis to proparacaine with subsequent cross-sensitization to tetracaine from ophthalmic preparations. *Am J Contact Dermat* 2001;12:177-179.
- Fraunfelder FW, Rich LF. Possible adverse effects of drugs used in refractive surgery. *J Cataract Refract Surg* 2003;29:170-175.
- Gail H, Kaufman R, Kalveram CM. Adverse reactions to local anesthetics: analysis of 197 cases. *J Allergy Clin Immunol* 1996;97:933-937.
- Grant RL, Acosta D. Comparative toxicity of tetracaine, proparacaine and cocaine evaluated with primary cultures of rabbit corneal epithelial cells. *Exp Eye Res* 1994;58:469-478.
- Hom M. *Mosby's ocular drug consult*. St. Louis: Mosby, 2005.
- Kundu S, Achar S. Principles of office anesthesia. Part II. Topical anesthesia. *Am Fam Physician* 2002;66:99-102.
- Liu JC, Steinemann TL, McDonald MB, et al. Topical bupivacaine and proparacaine: a comparison of toxicity, onset of action, and duration of action. *Cornea* 1993;12:228-232.
- McCaughey W, et al. *Anaesthetic physiology and pharmacology*. New York: Churchill Livingstone, 1997.
- Nam SM, Lee HK, Kim EK, et al. Comparison of corneal thickness after the instillation of topical anesthetics: proparacaine versus oxybuprocaine. *Cornea* 2006;25:51-54.
- Onofrey BE, Skorin L, Holdeman N. *Ocular therapeutics handbook: a clinic manual*, ed. 2. Philadelphia: Lippincott Williams & Wilkins, 2005.
- Ruetsch YA, Boni T, Borgeat A. From cocaine to ropivacaine: the history of local anesthetic drugs. *Curr Top Med Chem* 2001;1:175-182.
- Soliman MM, Macky TA, Samir MK. Comparative clinical trial of topical anesthetic agents in cataract surgery. *J Cataract Refract Surg* 2004;30:1716-1720.
- Stoelting RK, Hillier SC. *Pharmacology & physiology in anesthetic practice*, ed. 4. Philadelphia: Lippincott Williams & Wilkins, 2006.
- Wood M, Wood A. *Drugs and anesthesia: pharmacology for anesthesiologists*, ed. 2. Baltimore: Williams & Wilkins, 1990.



## *Analgesics for Treatment of Acute Ocular Pain*

*Jimmy D. Bartlett and Nicky R. Holdeman*

Primary eye care practitioners often encounter patients who are experiencing substantial pain from an underlying ocular disease. For example, patients with corneal or conjunctival foreign bodies, abrasions, or traumatic hyphema usually complain of pain as their primary symptom. This chapter considers the basic mechanisms of pain and its pharmacologic relief. In addition, it offers guidelines for the selection and use of oral analgesics in various situations as well as the management of side effects associated with nonnarcotic and narcotic agents.

### **MECHANISMS OF PAIN AND ANALGESIA**

Pain is an unpleasant sensory and emotional experience associated with actual or potential damage to tissues. Although pain is a subjective phenomenon, it has both biologic and psychological components that must be addressed if a satisfactory response to pain is to be achieved. Pain can be acute or chronic, and each is a very different clinical entity that requires different approaches to therapy. This chapter discusses only acute ocular pain, which generally has a specific and obvious cause, such as recent trauma or surgery. Such pain is predictable, of limited duration, and resolves when the source of the pain is detected and treated. Fortunately, many ophthalmic patients can be effectively managed with topical agents and local measures (see Chapter 26), which generally have fewer side effects and complications than systemic medications. However, some patients may require additional analgesics, in which case oral agents can be very useful.

The pain signal is initiated at specialized pain endings in peripheral tissues known as nociceptors. These nerve endings are found in the viscera, musculoskeletal system, skin, blood vessels, fascia, subcutaneous tissue, and periosteum, including those structures constituting the eye and orbit. Nociceptors can be activated not only by strong mechanical stimulation, such as trauma, but also by chemical compounds released in response to injury. These chemical mediators involve substances such as serotonin,

bradykinin, and histamine. Arachidonic acid metabolites, including prostaglandins and leukotrienes, do not directly stimulate these nerve endings but rather sensitize the nociceptors to mediators such as bradykinin or histamine, which then interact with substance P to stimulate the nerve endings. Figure 7-1 illustrates the sensitization of nociceptors by prostaglandins and other chemical mediators to produce pain and inflammation in ocular tissues.

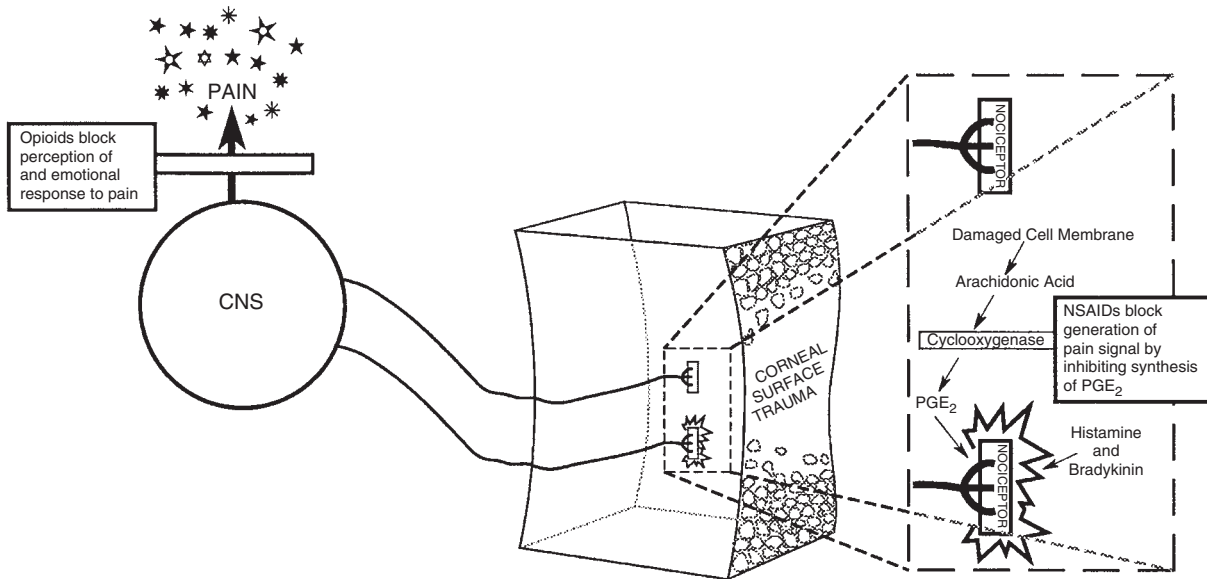
Once the pain signals are initiated at the nociceptive nerve endings in ocular tissue, they are conveyed through the trigeminal nerve to the brainstem. There they impinge on cells of the sensory and spinal nuclei of the trigeminal nerve. The trigeminal nucleus in turn sends the pain message ultimately to the somatosensory cortical areas of the brain, where the degree and location of the pain are perceived.

Although much attention is given to the emotional effects of the pain process, the physiologic effects of pain can be quite significant and can lead to harmful cardiorespiratory responses, including tachycardia, systemic hypertension, and tachypnea. Increases in peripheral vasoconstriction, blood pressure, and workload of the heart can create a dangerous situation for patients with preexisting cardiovascular disease. These physiologic changes mandate that in certain patients the pain be rapidly terminated, not only to make the patient more comfortable, but also to moderate the increased cardiovascular risks. If not appropriately relieved, pain can also lead to emotional distress manifested by poor sleep patterns, anxiety, and even uncooperativeness, all of which may result in slow and unsatisfactory resolution of the ocular condition that is initiating the pain.

Acute ocular pain almost always responds to pharmacologic intervention. Analgesic drugs act in three principal ways:

1. *Peripherally acting agents.* These drugs act on the peripheral pain receptors and prevent sensitization and discharge of the nociceptors. Nonsteroidal anti-inflammatory drugs (NSAIDs), including aspirin, block the formation of inflammatory and pain mediators, such as prostaglandins, at the cyclooxygenase pathway.





**Figure 7-1** Sensitization of nociceptors by prostaglandins and other inflammatory mediators to produce pain and inflammation in ocular tissues. Clinically useful analgesics act either in peripheral tissues by inhibiting prostaglandin production or centrally by interrupting the pain signal and its emotional consequences. (CNS = central nervous system; NSAIDs = nonsteroidal anti-inflammatory drugs; PGE<sub>2</sub> = prostaglandin E<sub>2</sub>.)

2. *Anesthetic agents.* The nociceptive signal can be interrupted between its peripheral source and its central target in the brain or spinal cord. However, the long-term use of topical anesthetics for treatment of acute ocular pain can lead to serious complications and is thus discouraged.
3. *Centrally acting agents.* These drugs interact with specific receptors in the central nervous system (CNS), interrupting both the pain message and its emotional responses. Patients who take centrally acting analgesics are usually indifferent to perceived pain. The opioid (narcotic) analgesics act in this manner.

The peripherally acting and centrally acting analgesics are the mainstay of pain management in outpatient practice. The most useful agents in each class are discussed in the following sections.

## NONOPIOID (NONNARCOTIC) ANALGESICS

The nonopioid analgesics are the drugs of choice for treating mild to moderate pain. Among these, the NSAIDs are typically the most effective and are usually safe for short-term use. Although some clinicians regard the NSAIDs as generally less effective but safer than narcotic analgesics, this presumption is misleading, because both types of analgesics have a significant side-effect potential. The NSAIDs are effective for many types of acute ocular pain, especially when the pain is associated with inflammation. Acetaminophen is also useful as an analgesic for mild to moderate pain but has no effect on inflammation.

## Salicylates

### Pharmacology

The salicylate aspirin (acetylsalicylic acid) is the oldest nonopioid analgesic. In addition to analgesic effects, the salicylates have important anti-inflammatory and antipyretic properties. Acting primarily in peripheral tissues, aspirin reduces pain by inhibiting synthesis of the prostaglandin E<sub>2</sub> by irreversible acetylation and inactivation of cyclooxygenase (see Figure 7-1). The pharmacologic properties of aspirin are predominantly analgesic at lower doses but assume anti-inflammatory effects at higher doses. Full anti-inflammatory effects, however, generally require doses of at least 3 to 4 g daily.

Although aspirin relieves pain primarily through its activity in peripheral tissues (e.g., cornea or conjunctiva), it is also believed to have some central activity by influencing the perception of pain in the hypothalamus. The central mechanisms of action have not been elucidated, but it is clear that when used in therapeutic doses, the salicylates generally produce no clinically significant changes in sensorium or mood. This central activity probably accounts for the analgesic efficacy of aspirin in pain states not associated with inflammation.

All nonnarcotic analgesics, including the salicylates, have a "ceiling effect," that is, a dosage beyond which no further analgesia occurs. Because the salicylates and other nonnarcotic analgesics do not produce tolerance or physical or psychological dependence, they are relatively safe and nonaddicting.

### Clinical Uses

The salicylates are beneficial for pain associated with inflammation, but their use has now been generally supplanted by other NSAIDs, largely because of gastrointestinal (GI) distress. Nevertheless, the salicylates are effective for treatment of mild to moderate pain and may produce analgesic effects comparable with those of weak narcotics such as propoxyphene hydrochloride. When used in combination with narcotics, the salicylates can be effective for severe pain accompanying acute ocular trauma or inflammation.

Aspirin is commercially available in numerous formulations (Table 7-1). It is compounded as a tablet, an enteric-coated tablet, a controlled-release tablet, and as a suppository. Enteric-coated aspirin, which decreases GI tract irritation, is recommended for chronic use but is rarely required for the treatment of acute ocular pain, which usually resolves over several days. Likewise, controlled-release aspirin, because of its relatively long onset of action, is not recommended for treatment of acute ocular pain.

Aspirin is often given in a buffered form. The addition of small amounts of antacids decreases GI irritation and increases the dissolution and absorption rate of the aspirin. Nonacetylated salicylates, including salsalate, sodium salicylate, choline salicylate, magnesium salicylate, and various salicylate combinations, are usually more expensive but can be effective. Although these aspirin substitutes provide less anti-inflammatory effects than aspirin, they exhibit minimal antiplatelet properties and have fewer GI side effects. They can therefore be useful for patients who cannot tolerate aspirin or other NSAIDs.

The adult dosage of aspirin is 325 to 650 mg every 4 hours (not to exceed 4 g/day) as required for treatment of mild to moderate pain. Patients should be advised to take aspirin with food or shortly after meals to decrease GI upset. It should be taken with a full glass of water to reduce the risk of the medication lodging in the esophagus. Aspirin products that have a strong vinegar-like odor should be avoided.

### Side Effects

GI disturbances are the most common adverse effects observed with therapeutic doses of salicylates. However, the short-term (less than 1 week) use of these agents does not usually cause any significant consequences.

Prostaglandins inhibit gastric acid secretion and have a protective effect on the mucosal lining. Aspirin-induced inhibition of prostaglandin synthesis results in increased gastric acid secretion and a more vulnerable gastric mucosa. As a result dyspepsia, gastric irritation, and GI bleeding can occur. Uncoated aspirin can also injure the stomach through a direct effect on the gastric mucosa. Enteric-coated aspirin or buffered preparations may help to minimize this problem. In addition, misoprostol, a prostaglandin analogue, can help to suppress the GI toxicity associated with NSAIDs and should be considered for patients who require anti-inflammatory medication but have a history of duodenal ulcer or gastritis. Combination products are frequently less expensive and can often enhance patient compliance when compared with two separate drugs. Arthrotec incorporates misoprostol and diclofenac in one tablet.

All NSAIDs interfere with platelet aggregation, and because aspirin inactivates cyclooxygenase irreversibly, its effect is to prolong bleeding time (12 to 15 days). The formation of a gastric ulcer or erosion with profuse bleeding is a potentially serious problem with aspirin and other NSAIDs. Evidence indicates that choline-magnesium salicylate (Trilisate) does not inhibit platelet function and may therefore be indicated in some patients.

Aspirin hypersensitivity is also a potential concern and can occur in two ways: (1) a respiratory reaction, which is more profound in patients with rhinitis, asthma, or nasal polyps, or (2) a typical type I hypersensitivity reaction, including urticaria, wheals, angioedema, itching, rash, bronchospasm, laryngeal edema, hypotension, shock, or syncope. This latter response generally occurs within 1 hour of aspirin ingestion. Such aspirin intolerance may manifest itself in 4% to 19% of patients with asthma and may approach 40% of steroid-dependent asthmatics.

**Table 7-1**  
Commonly Used Aspirin Products

Trade Name	Formulation	Dosage Unit (mg)
Aspirin (generic)	Tablet	325
Genuine Bayer	Tablet	325
Empirin	Tablet	325
Bayer Extra Strength	Tablet	500
Ecotrin	Enteric-coated tablet	325
Ecotrin Maximum Strength	Enteric-coated tablet	500
Aspirin (generic)	Suppository	120, 200, 300, 600
Buffered aspirin (generic)	Buffered tablet	325
Ascriptin A/D	Coated, buffered tablet	325
Bufferin	Coated, buffered tablet	325
Ascriptin Extra Strength	Coated, buffered tablet	500

Patients who are sensitive to aspirin should not be given any other NSAID because of possible cross-sensitivity reactions. Aspirin cross-sensitivity, however, does not appear to occur with the nonacetylated salicylates such as sodium salicylate or choline salicylate. As mentioned previously, aspirin hypersensitivity is more prevalent in patients with asthma, rhinitis, or nasal polyposis. This syndrome has been termed the “aspirin triad.”

CNS effects are infrequent yet possible, including confusion in some elderly patients, especially those over age 70 years. Headache, tinnitus, dizziness, and deafness may occur. In addition, aspirin can cause the retention of sodium and water and may reduce renal function, thus inducing acute systemic hypertension or exacerbating congestive heart failure. The effects of aspirin and other NSAIDs on blood pressure seem to be more evident among susceptible patients, such as those with preexisting hypertension. Aspirin also binds tightly to plasma proteins, which can displace other drugs from protein-binding sites, thereby increasing the pharmacologic effects related to the unbound drug. Patients on anticoagulant or oral hypoglycemic therapy, for example, must be monitored closely.

Use of aspirin during an antecedent viral infection, such as influenza or chickenpox, has been associated with Reye’s syndrome in a small but significant number of children and teenagers. Reye’s syndrome is a potentially fatal disease of unknown etiology characterized by vomiting, lethargy, fatty liver degeneration, encephalopathy, and variable hypoglycemia. Given effective alternatives such as acetaminophen, use of aspirin as an antipyretic and analgesic in children should be avoided.

### Contraindications

The most important contraindications to salicylate therapy are listed in Box 7-1. As a general rule, when aspirin is contraindicated or is not well tolerated, acetaminophen

or a nonacetylated salicylate may be effective as an alternative analgesic while minimizing the risk of side effects.

Salicylates are contraindicated in patients with upper GI disease or a history of adult-onset asthma. They should also be avoided in patients with bleeding disorders such as hemophilia, those taking anticoagulants such as warfarin or heparin, and in individuals who consume more than three alcoholic beverages per day. Because aspirin or aspirin-containing products may lead to prolonged bleeding, it is prudent to limit or to avoid their use in patients who have had recent intraocular surgery or surgery of the eyelids. Likewise, aspirin should be avoided for treatment of pain associated with hyphema, because the incidence of rebleeding can be considerably increased. Aspirin is also contraindicated in patients who are sensitive to aspirin, nonsalicylate NSAIDs, or tartrazine (FDC yellow dye no. 5).

Aspirin ingestion during pregnancy can produce adverse effects in the mother, including anemia, prolonged gestation, and prolonged labor. During the later stages of pregnancy, aspirin can produce adverse effects in the fetus, including low birth weight, increased incidence of intracranial hemorrhage in premature infants, and even neonatal death. Because salicylates may be teratogenic, they should be avoided during pregnancy, especially in the third trimester. Salicylate use during breast-feeding may be safe; however, the drug is excreted into breast milk in low concentrations.

### Nonsalicylate Nonsteroidal Anti-Inflammatory Drugs

The analgesic efficacy and safety profiles of the nonsalicylate NSAIDs make them appropriate alternatives to aspirin for treatment of mild to moderate pain. Most NSAIDs are used primarily for their anti-inflammatory effects, but they are also effective analgesics that relieve pain associated with a variety of ocular conditions. The nonsalicylate NSAIDs consist of the propionic acid derivatives, cyclooxygenase-2 (COX-2) inhibitors, and several other less commonly used agents (Table 7-2).

### Pharmacology

Like the salicylates, the nonsalicylate NSAIDs produce analgesic effects primarily by inhibiting cyclooxygenase in injured or inflamed tissues and thus reduce or eliminate production of the sensitizers for peripheral nociceptors (see Figure 7-1). In the CNS a less well-understood effect occurs whereby the recognition of pain is diminished. The analgesic activity of the nonsalicylate NSAIDs, like the salicylates, is characterized by a ceiling effect, and repeated or chronic use causes neither drug tolerance nor addiction.

The largest class of NSAIDs with both anti-inflammatory and analgesic uses is the propionic acid derivatives (see Table 7-2). These drugs are metabolized in the liver and excreted in the urine. The analgesic effects among

#### Box 7-1 Contraindications to Aspirin and Nonsalicylate NSAIDs

- Active upper gastrointestinal disease (peptic ulcers, hiatal hernia, dyspepsia, esophagitis)
- History of heavy alcohol use (>3 alcoholic beverages daily)
- History of bronchial asthma, nasal polyps, or aspirin hypersensitivity
- Bleeding disorders, anticoagulant therapy, or vitamin K deficiency
- Pre-/postop cataract or other invasive surgery
- Chronic renal or hepatic disease
- Hypertension or congestive heart failure
- Pregnancy, especially third trimester/lactation
- Children or teenagers with flu-like (viral) symptoms

**Table 7-2**  
Commonly Used Nonsalicylate NSAIDs

Classification	Trade Name	Generic Name	Formulation	Adult Analgesic Dosage (mg)
Propionic acids	Motrin, Advil, Nuprin	Ibuprofen	50-, 100-, 200-300- to 400-, 600-, 800-mg tablets; 100-mg/5-ml suspension	200-400 q4 h
	Naprosyn	Naproxen	250-, 375-, 500-mg tablets; 125-mg/5-ml suspension	500 initial dose followed by 250 q6-8 h or 500 q12 h
	Anaprox Aleve	Naproxen sodium	220-, 275-, 500-mg tablets	550 initial dose followed by 220-275 q6-8 h or 550 q12 h
	Nalfon	Fenoprofen	200-mg capsules	200 q4-6 h
	Orudis	Ketoprofen	50-, 75-mg capsules	25-50 q6-8 h
COX-2 inhibitors	Daypro	Oxaprozin	600-mg tablet	600-1,200 q.d.
	Celebrex	Celecoxib	100-, 200-mg capsules	100-200 mg once or twice daily

these drugs are approximately equivalent, but systemic absorption to achieve peak plasma levels varies with each agent. Naproxen (Anaprox) was developed specifically to facilitate absorption to reach a peak plasma level rapidly.

Although studies that evaluate analgesic efficacy in painful ocular conditions are lacking, the results of other studies may be helpful to indicate the relative usefulness of various NSAIDs for treatment of ophthalmic pain. Table 7-3 summarizes the comparative analgesic efficacy of the commonly used NSAIDs relative to aspirin. The propionic acid derivatives are superior to aspirin in analgesic efficacy and appear to have a lower incidence and severity of side effects. In dental surgery patients, both ibuprofen and ketoprofen are more effective than 650 mg aspirin, and 100 mg ketoprofen is significantly more effective than 400 mg ibuprofen.

### Clinical Uses

Variability in patient response to the NSAIDs in terms of efficacy and toxicity may be related to differences in binding affinity with cyclooxygenase in various tissues. Consequently, no definitive guidelines can be given in selecting the most appropriate NSAID for a given patient. The choice should be based on clinical experience, patient convenience or preference, history of favorable analgesic use, side effects, and cost. The primary indications include painful conditions associated with inflammation, including postoperative and posttraumatic pain. The most effective analgesics tend to be those with a rapid onset of action, so that analgesia is achieved for the time corresponding to the acute phase of pain.

Although the NSAIDs are most useful for relief of mild to moderate pain, their analgesic effects are

**Table 7-3**  
Comparative Analgesic Efficacy of Commonly Used NSAIDs

NSAID	Analgesic Efficacy Compared With Aspirin (650 mg)
Diflunisal	500 mg superior to aspirin, but has slower onset and longer duration; initial 1,000-mg dose shortens time to onset
Choline-magnesium salicylate	Longer duration of action
Ibuprofen	Superior
Naproxen sodium	275 mg comparable with aspirin, but has slower onset and longer duration; 550 mg superior to aspirin
Fenoprofen	Comparable
Ketoprofen	Superior
Indomethacin	Comparable
Ketorolac tromethamine	Superior

Data adapted from American Pain Society. Principles of analgesic use in the treatment of acute pain and chronic cancer pain, ed. 2. Clin Pharm 1990;9:601-611; and Forbes JA, Butterworth GA, Burchfield WH, et al. Evaluation of ketorolac, aspirin, and an acetaminophen-codeine combination in postoperative oral surgery pain. Pharmacotherapy 1990;10:775-935.

often underestimated. Use of nonsalicylate NSAIDs can be effective for intensely painful conditions, including postoperative pain, and can often avoid or delay the use of narcotic analgesics. Clinicians should note, however, that patients vary in their responses to individual analgesics. Thus, if patients do not respond to a particular drug at the maximum therapeutic dosage, an alternative analgesic should be used.

When instituting NSAID therapy, patients should be advised of the following: (1) the side effects of therapy, which can include GI discomfort and, rarely, more serious events such as GI bleeding; (2) to avoid aspirin and alcoholic beverages; and (3) to take the medication with food, milk, or antacids if GI upset occurs. The commercially available formulations and adult dosage recommendations are summarized in Table 7-2.

### Side Effects

Side effects associated with the nonsalicylate NSAIDs are essentially those caused by salicylate therapy. NSAIDs occasionally cause CNS dysfunction, including decreased attention span, loss of short-term memory, confusion in elderly patients, and headache.

The adverse GI effects seen with aspirin can also occur with nonsalicylate NSAIDs. Although nonsalicylate NSAIDs may be tolerated in some patients who experience GI side effects with aspirin, these patients should be monitored carefully for signs and symptoms of ulceration and bleeding. Patients with antecedent gastric ulcers, debilitating diseases, and advanced age appear to be most susceptible. It is not uncommon for patients to experience minor GI complaints, such as dyspepsia, even after several days of therapy. Serious events such as ulceration, bleeding, or perforation can occur at any time with or without warning symptoms. Susceptible patients who require NSAID therapy should be given the lowest possible therapeutic doses and those agents with the lowest side-effect profile to avoid aggravating or precipitating an adverse GI event. Several of the NSAIDs, including ibuprofen, fenoprofen, diclofenac, nabumetone, and sulindac, appear to cause fewer GI effects than do other nonsalicylate NSAIDs. On the other hand, piroxicam, ketoprofen, and especially azapropazone appear to have a relatively higher risk of serious GI complications. The differing gastric complications associated with various NSAIDs may be due to their varying relative selectivity for the two isoenzymes of cyclooxygenase: cyclooxygenase-1 (COX-1) versus COX-2. The products of COX-1 are cytoprotective in the kidney and in the gastric mucosa, whereas the COX-2 isoform appears responsible for the production of prostaglandins in inflammatory reactions. Antacid therapy with proton pump inhibitors may be useful to prevent or reduce NSAID-related dyspepsia and upper GI complications.

All nonsalicylate NSAIDs can inhibit platelet function. However, in contrast to aspirin, which has an irreversible effect on platelets, the nonsalicylate NSAIDs inhibit

platelet aggregation only as long as an effective serum drug concentration exists. Platelet function returns when most of the drug has been eliminated.

The nonsalicylate NSAIDs can also affect renal function. Risk factors for NSAID-induced acute renal failure include congestive heart failure, glomerulonephritis, chronic renal insufficiency, cirrhosis, systemic lupus erythematosus, diabetes mellitus, significant atherosclerotic disease in the elderly, and use of diuretics. NSAIDs can adversely affect cardiovascular homeostasis and can be a risk factor for the onset or exacerbation of heart failure.

### Contraindications

Contraindications for nonsalicylate NSAID therapy are the same as those for aspirin (see Box 7-1). The formation of a gastric ulcer or erosion that may bleed profusely is a serious potential problem with NSAIDs. Consequently, the nonsalicylate NSAIDs should be avoided or used with great caution in patients with active peptic ulcer disease. NSAIDs may increase the risk of GI complications even when used in conjunction with low-dose aspirin for cardioprotection. In addition, because of potential cross-sensitivity to other NSAIDs, the nonsalicylate NSAIDs should not be given to patients in whom aspirin or other NSAIDs have caused symptoms of asthma, rhinitis, urticaria, angioedema, hypotension, bronchospasm, or of symptoms of hypersensitivity reactions. Opioids, tramadol, or acetaminophen may be suitable alternatives for patients with known or suspected susceptibility.

NSAIDs should be avoided in patients with chronic renal insufficiency due to the risk of inducing further kidney damage. In patients at risk, acute renal failure can occur after a single dose of drug. Risk factors include dehydration, hypertension, congestive heart failure, concomitant use of angiotensin-converting enzyme inhibitors, and advanced age.

Because the safe use of NSAIDs during pregnancy has not been well established, these agents should typically be avoided during pregnancy, especially in the third trimester. Likewise, these drugs should generally be avoided in nursing mothers, because most NSAIDs are excreted in breast milk and may have adverse effects on the cardiovascular system of nursing infants.

### Acetaminophen

Acetaminophen is among the most commonly used analgesics in the United States. It is often the first drug used for management of mild to moderate pain, but it can also be of benefit in more severe pain when used as an adjunct to narcotic analgesics. It differs substantially from the NSAIDs in its pharmacologic action and side-effect profile.

### Pharmacology

The site and mechanism of the analgesic action of acetaminophen are unclear, but activity in the CNS has

been postulated. The drug also appears to be a weak inhibitor of prostaglandin synthesis. The analgesic effects of acetaminophen and aspirin are comparable, but aspirin is superior to acetaminophen for treating pain associated with inflammatory conditions because acetaminophen has little or no anti-inflammatory properties. Acetaminophen, however, does not inhibit platelet aggregation, affect prothrombin time, or produce GI irritation, as does aspirin.

### Clinical Uses

The superior safety profile of acetaminophen provides the opportunity to use this analgesic when aspirin or a nonsteroidal anti-inflammatory drug (NSAID) is contraindicated. The use of acetaminophen is indicated for patients who are allergic to aspirin, because there is no cross-sensitivity between the NSAIDs and acetaminophen. In addition, acetaminophen is generally devoid of GI effects, which means it can be used in patients with upper GI disease (e.g., ulcers, gastritis, hiatal hernia). Because acetaminophen does not inhibit platelet function, it is suitable for patients with bleeding disorders (including hemophilia) or for use after cataract extraction or other surgical procedures. Unlike aspirin, acetaminophen has not been associated with Reye's syndrome and can thus be used more safely in children and adolescents.

The safety of acetaminophen during pregnancy or breast-feeding is especially noteworthy. When used on a short-term basis in therapeutic doses, it appears to be safe during all stages of pregnancy. Although acetaminophen is excreted in breast milk in low concentrations, it has no known adverse effects in nursing infants. Thus acetaminophen is the analgesic of choice for mild to moderate pain during pregnancy or lactation.

Table 7-4 lists commercially available acetaminophen formulations commonly used in clinical practice. A wide

range of products, all nonprescription, is available, including suppositories, chewable tablets, regular tablets, capsules, elixirs, liquids, and pediatric solutions. The vast array of products facilitates drug selection in individual patients who may prefer or require a specific formulation. The typical adult dosage is 325 to 1,000 mg every 4 to 6 hours. The daily dosage for short-term therapy should not exceed 4 g.

### Side Effects

When used as recommended, acetaminophen rarely causes significant side effects. Although 13 to 25 g is considered a lethal dose, overdose (>7.5 g) can lead to serious liver toxicity and ultimately death. More important, liver damage may occur even at recommended doses in chronic alcoholics and others with preexisting liver impairment. In the usual therapeutic doses acetaminophen is generally well tolerated, does not influence platelet aggregation, does not affect the gastric mucosa, and does not induce nephropathy.

### Contraindications

Acetaminophen should be used with caution in patients with chronic alcoholism or with preexisting liver impairment, because liver toxicity and even severe liver failure can occur after therapeutic doses. The U.S. Food and Drug Administration requires that all pain relievers containing acetaminophen (as well as aspirin and other NSAIDs) carry a warning that individuals who consume more than three alcoholic beverages daily consult their doctors before taking these over-the-counter products because of the increased risk of liver damage (or gastric bleeding in the case of NSAIDs). Patients taking microsomal-inducing agents such as barbiturates, phenytoin, or rifampicin may also be at increased risk for acetaminophen hepatotoxicity.

### Nonnarcotic Combinations

Many commercial products have been developed that combine various nonnarcotic analgesics with other agents. Although data are lacking to support the efficacy of most of these formulations, many have proved popular among patients who use them for self-treatment of minor painful conditions such as headache.

Nonnarcotic analgesic combinations usually consist of one or more of the following agents: acetaminophen, salicylates, salsalate, and salicylamide. Some of the products contain barbiturates, meprobamate, or antihistamines to produce a sedative effect, and antacids may be included to minimize gastric upset associated with the salicylates. Caffeine, a traditional adjuvant in many analgesic combinations, may be beneficial in the treatment of certain vascular headache syndromes. Some belladonna alkaloids may be incorporated for their antispasmodic properties. Pamabrom, a diuretic, and cinnamedrine, a sympathomimetic amine, are sometimes included in products for premenstrual syndrome.

**Table 7-4**  
Commonly Used Acetaminophen Products

Trade Name	Formulation	Dosage Unit (mg)
Acetaminophen Unisert	Suppository	120, 325, 650
Children's Tylenol Soft Chews	Chewable tablet	80
Children's Tylenol	Elixir	160/5 ml
Panadol Junior Strength	Caplet	160
Tylenol Regular Strength	Tablet	325
Tylenol Extended Relief	Dual-layer caplet	650
Genapap	Tablet	325
Acetaminophen (generic)	Tablet	325, 500, 650
Tempra 2 Syrup	Liquid	160/5 ml
Acetaminophen Drops (generic)	Solution	100 mg/ml
Aspirin-Free Anacin Maximum Strength	Tablet	500

**Table 7-5**  
Commonly Used Nonnarcotic Combinations

Trade Name	Analgesic Components (mg)
Excedrin Migraine tablets	Acetaminophen (250) Aspirin (250) Caffeine (65)
Vanquish caplets	Acetaminophen (194) Aspirin (227) Caffeine (33) Buffers
Excedrin Aspirin-Free caplets and gels	Acetaminophen (500) Caffeine (65)
Excedrin P.M. tablets	Acetaminophen (500) Diphenhydramine (25)
Anacin caplets and tablets	Aspirin (400) Caffeine (32)
Anacin Maximum Strength tablets	Aspirin (500) Caffeine (32)
BC Powder	Aspirin (650) Salicylamide (195) Caffeine (33.3)

Some of the more commonly used combination products are listed in Table 7-5. The typical adult dose is one or two capsules or tablets or one powder packet every 2 to 6 hours as needed for pain.

## OPIOID (NARCOTIC) ANALGESICS

The narcotic analgesics are also known as opiates (any agent derived from opium) or opioids (compounds that possess morphine-like analgesic properties). These drugs encompass generally all compounds with morphine-like effects, whether synthetic or naturally occurring. The terms *opiate* and *opioid* refer specifically to the phenanthrene alkaloids such as morphine and codeine, but the definition has broadened to include drugs with both agonist and antagonist activity at opioid receptors. The term *narcotic* is commonly used to refer to the opioid analgesics, but this term should generally be avoided because of its negative social, cultural, and legal connotations. The preferred term for this class of drugs is *opioid*. These agents are generally recognized as the drugs of first choice for the treatment of severe acute pain.

**Table 7-6**  
Pharmacologic Properties of Commonly Used Opioids

Drug	Analgesia	Sedation	Nausea or Vomiting	Constipation	Euphoria
Codeine	+	++	++	++	+
Oxycodone	+++	++	+	+	+++
Hydrocodone	+	+	+	+	++
Propoxyphene	±	++	+	++	+
Pentazocine	++	+	+	+	+

Adapted from Turturro MA, Paris PM. Oral narcotic analgesics. Choosing the most appropriate agent for acute pain. *Postgrad Med* 1991;90:89-95.

## Pharmacology

The opioids produce analgesia by binding to various opioid receptors in the brain, brainstem, and spinal cord, thus mimicking the effects of endogenous opioid peptides (endorphins). Opioids appear to affect both the sensation of noxious stimulation (pain) and the emotional component of subjective distress (suffering).

The narcotic analgesics are classified as agonists, partial agonists, or mixed agonist-antagonists based on their activity at various opioid receptors. The action of opioids at receptor sites in the CNS is highly complex, and the precise role of different receptor subtypes in the modulation of pain remains unclear. Although numerous opioid receptors have been identified, five major receptor groups are recognized and are designated as mu, kappa, sigma, delta, and epsilon. Most of the clinically useful opioid analgesics are agonists acting primarily at the mu and kappa receptors, and they exhibit similar clinical effects. Unlike the nonnarcotic analgesics, most opioids generally do not have a ceiling effect. Increasing doses produce additional analgesia; the primary factor that limits dosage is typically the occurrence of adverse reactions. However, some patients can develop tolerance to the analgesic effects of a given opioid. If this occurs, another opioid can often be substituted to provide better analgesia, because opioids exhibit incomplete cross-tolerance.

Morphine is the standard opioid against which other narcotic analgesics are compared. Its potential side effects, however, along with potential for abuse and addiction, usually make it unsuitable for use in outpatients. Other opioids are preferred for the treatment of moderate to severe pain in most patients. Pharmacologic properties of the commonly used opioids are summarized in Table 7-6.

Codeine is usually administered in combination with acetaminophen or aspirin (Table 7-7). A prodrug, codeine depends on the cytochrome P-450 system for metabolism to the active compound, morphine. Patients deficient in cytochrome P-450 (up to 10% of whites) receive less analgesic efficacy. Analgesic effects of codeine occur as early as 20 minutes after oral ingestion and reach a maximum after 60 to 120 minutes. Because the potential for addiction is extremely low when used in recommended doses for treatment of acute ocular pain, codeine has gained



**Table 7-7**  
Commonly Used Opioid Analgesics

Opioid	Trade Name	Formulation (mg)	Federal Controlled Substance Schedule	Adult Oral Dosage
Codeine	Tylenol w/codeine no. 3 tablets	Codeine (30) Acetaminophen (300)	C-III C-V	1-2 q4 hr 3 tsp q4 hr
	Acetaminophen w/codeine elixir (generic)	Codeine (12) Acetaminophen (120)*		
Oxycodone	Percocet tablets	Oxycodone (5) Acetaminophen (325)	C-II	1 q6 hr
	Tylox capsules	Oxycodone (5) Acetaminophen (500)	C-II	1 q6 hr
	Percodan tablets	Oxycodone HCl (4.5) Oxycodone terephthalate (0.38) Aspirin (325)	C-II	1 q6 hr
	Combunox	Oxycodone (5) Ibuprofen (400)	C-II	1 qd to qid
Hydrocodone	Lortab elixir	Hydrocodone (2.5) Acetaminophen (167)*	C-III	3 tsp q4-6 hr
	Lortab 7.5/500 tablets	Hydrocodone (7.5) Acetaminophen (500)	C-III	1 q4-6 hr
	Vicodin HP	Hydrocodone (10) Acetaminophen (660)	C-III	1 q4-6 hr
	Vicoprofen	Hydrocodone (7.5) Ibuprofen (200)	C-III	1 q4-6 hr
Propoxyphene	Darvon capsules	Propoxyphene HCl (65)	C-IV	1 q4 hr
	Darvon-N tablets	Propoxyphene napsylate (100)	C-IV	1 q4 hr
	Darvocet-N 100 tablets	Propoxyphene napsylate (100) Acetaminophen (650)	C-IV	1 q4 hr
Hydromorphone	Dilaudid	Tablet 2, 4, 8	C-II	2-4 mg q4 hr
		Oral liquid 5*		1 q6-8 hr
Tramadol	Ultram tablets	Rectal suppository 3 Tramadol (50)		1-2 tabs q4-6 hr Not to exceed 400 mg/day
	Ultracet	Tramadol (37.5) Acetaminophen (325)		2 q4-6 hr

\*Content given per 5 ml.

widespread acceptance as an oral analgesic agent. However, it produces a relatively high degree of sedation and results in a high incidence of GI side effects. Codeine also appears to have a ceiling effect, whereby increasing the dosage provides little additional analgesia but markedly increases the incidence of adverse reactions.

Oxycodone is a codeine congener that appears to be 10 to 12 times more potent than codeine. When taken orally, oxycodone is as potent as parenteral morphine, and, like codeine, oxycodone retains most of its parenteral potency when given orally. When compared with codeine, morphine, or pentazocine, oxycodone may also have a lower incidence of side effects, but it produces euphoria and thus has potential for abuse. Oxycodone is commercially available in combination with acetaminophen, aspirin, or ibuprofen (see Table 7-7)

and is an effective oral narcotic analgesic for treatment of moderate to severe pain.

Hydrocodone, another codeine congener, is approximately six times more potent than codeine. This agent appears to cause less constipation and less sedation than codeine. It has been suggested that hydrocodone may produce more euphoria than codeine, but this effect has not been substantiated in clinical studies. Hydrocodone is also available in combination with aspirin, acetaminophen, or ibuprofen.

Propoxyphene is an analogue of methadone that is widely used as an analgesic. However, single-dose studies have shown that the analgesic properties of propoxyphene are no better than those of placebo. When propoxyphene is used alone in usual analgesic doses (32 to 65 mg of the hydrochloride salt or 50 to 100 mg of the napsylate salt),

it is no more effective and possibly less effective than 30 to 60 mg codeine or 600 mg aspirin. When combined with other analgesics (acetaminophen or aspirin), however, propoxyphene appears to be more effective than propoxyphene used alone. The marked sedative properties of the drug may account for much of its therapeutic benefit. Propoxyphene is a relatively weak opioid, and it is best reserved for treatment of mild to moderate rather than severe pain. Propoxyphene is commercially available in two salt forms, hydrochloride or napsylate. Although the napsylate form (Darvon N) is more easily absorbed from the GI tract, its tolerance-producing and addicting effects are similar to those of the hydrochloride salt.

Tramadol is a centrally acting synthetic analogue of codeine that binds to mu opioid receptors and inhibits norepinephrine and serotonin reuptake. This agent is indicated for the treatment of moderate to moderately severe pain, with analgesia beginning within 1 hour after oral administration. Common adverse effects of tramadol include dizziness, nausea, dry mouth, and sedation; however, the potential for abuse or addiction appears to be low, and serious complications have not been reported. Because tramadol prevents the reuptake of norepinephrine and serotonin, it should be used with extreme caution in patients receiving monoamine oxidase inhibitors. Likewise, tramadol is contraindicated in patients who are acutely intoxicated with any CNS depressant and in patients with significant renal or hepatic impairment. Because of its inferior efficacy compared with opioid analgesics and no clear benefit regarding safety, tramadol may not be an analgesic of first choice.

Table 7-6 summarizes the comparative analgesic efficacy of the commonly used narcotic agonists. Clinicians should note that the indicated analgesic effects for each drug are only an approximation and can vary widely among patients because of individual differences in both the sensitivity of opioid receptors and the efficiency of drug metabolism and elimination. Bioavailability of the analgesic can vary after oral administration, and the analgesic effects of the centrally acting agents can be clinically unpredictable. Moreover, some of the opioid analgesics have metabolites that in turn have additional analgesic activity. It must be expected that individual patients respond differently or even uniquely to narcotic agents.

Although few studies have directly compared the analgesic efficacy of the various opioids, clinical experience and extrapolation from controlled studies have led to a better understanding of the comparative analgesic efficacy of some of the commonly used agents, both opioid and nonnarcotic. Ketoprofen in doses of 50 and 150 mg has been compared with the analgesia provided by 650 mg acetaminophen combined with 60 mg codeine for the management of moderate to severe postoperative pain. The results suggest that ketoprofen may have a

superior analgesic effect and longer duration of analgesia compared with the acetaminophen-codeine combination.

### Clinical Uses

Many clinicians are reluctant to prescribe narcotic analgesics because of the perceived risk of iatrogenic addiction. However, short-term use of opioids for management of acute pain in patients without a previous history of addiction rarely results in drug abuse. The opioid analgesics are generally safe for short-term treatment of acute ocular pain as long as the use is appropriate and a rational approach is taken to drug selection. Potential opioid side effects can be more problematic compared with those of nonnarcotic analgesics, but opioids may actually be safer for some patients with contraindications to NSAIDs (e.g., patients with renal compromise or peptic ulcer disease).

In the outpatient setting the oral route of administration is preferred because of convenience and relatively steady drug plasma levels. For treatment of severe acute pain the peak drug effect of an opioid usually occurs after 1.5 to 2.0 hours. Evidence indicates that the addition of a peripherally acting agent, such as an NSAID, to the opioid regimen provides an additive or synergistic analgesic effect. Increasing the dose of the narcotic may improve analgesia, but only at the expense of substantially increasing the incidence of side effects. Thus most oral opioid analgesics are commonly used only in combination with a nonnarcotic analgesic (see Table 7-7).

When opioid analgesic therapy is instituted, patients should be advised of the following:

1. Drowsiness, dizziness, blurred vision, or diplopia can occur. Patients should be cautious when driving or performing other tasks that require alertness.
2. Alcohol, muscle relaxants, or other CNS depressants should be avoided because they can exacerbate opioid-induced sedation.
3. Drug-induced anorexia, nausea, vomiting, and constipation are common side effects.
4. If GI upset occurs, the medication may be taken with food to decrease GI irritation.
5. Breathing difficulty or shortness of breath can occur.
6. Palpitations, changes in pulse rate and blood pressure, and syncope may be experienced.

Commonly used commercial formulations and dosage recommendations are listed in Table 7-7. A rational approach to the dosing of opioids requires recognition that patients vary considerably in their response to therapy. In general, doses should be titrated to the needs of particular patients and should not necessarily be taken at fixed intervals. Opioid analgesics are commonly prescribed in doses that are too small and at intervals that are too long for adequate relief of pain. They should instead be administered regularly as needed for pain control, especially if pain is present continually. The opioid analgesics must be given with constant reassessment of efficacy, and dosages should be altered

when required. Because patients are the best judges of the efficacy and duration of action of an analgesic, practitioners should maintain flexibility in dosing requirements for individual patients.

### Side Effects

Because the pharmacologic action of the opioids is complex and can result in either CNS depression or stimulation, it is difficult to predict side effects in given patients. Clinicians should note that at equipotent analgesic doses, all commonly used opioids produce similar degrees of side effects. However, these side effects are usually mild and do not necessitate discontinuing opioid therapy. The most commonly encountered adverse effects include lightheadedness, dizziness, sedation, nausea, vomiting, constipation, and respiratory depression (Box 7-2). These symptoms occur more often in ambulatory patients, in patients without severe pain, and in patients with kidney or liver dysfunction.

Although the opioid analgesics can produce mood elevation (euphoria) in some patients and sedation in others, the more common side effect is CNS depression manifested as drowsiness. A strategy to reduce sedation or drowsiness is to decrease the analgesic dose and shorten the interval between doses. Clinicians should note that the sedative effect of opioid analgesics is additive with the sedative effects of hypnotics such as alcohol and barbiturates. These depressive agents must be avoided when opioids are prescribed.

The incidence of opioid-induced nausea and vomiting is markedly increased in ambulatory patients. If narcotic analgesic therapy must be continued, nausea and vomiting can be treated with hydroxyzine or a phenothiazine antiemetic.

The opioids inhibit intestinal tract motility, which may cause constipation. This is one of the most common side effects encountered with the narcotic analgesics. If constipation becomes problematic, it can often be relieved by a regimen consisting of docusate sodium (Colace), 50 to 300 mg/day, and senna, two tablets twice daily.

The most serious side effect of the opioids is respiratory depression. The narcotic agonists suppress the brainstem respiratory centers and thus alter tidal volume, respiratory rate, rhythmicity, and responsiveness to CO<sub>2</sub>. When used in equianalgesic doses, the opioids, with the exception of pentazocine, produce similar degrees of respiratory depression. Therapeutic doses of opioid analgesics are unlikely to produce significant respiratory depression in most healthy patients. The opioids must be used with caution, however, in patients with preexisting pulmonary disease, especially patients with airway compromise such as chronic obstructive pulmonary disease.

### Contraindications

Opioid analgesics are contraindicated in patients with a history of hypersensitivity to narcotics, because there is a

### Box 7-2 Side Effects of Opioid Analgesics

Central nervous system  
 Sedation  
 Lightheadedness  
 Confusion  
 Dizziness  
 Drowsiness  
 Disorientation  
 Euphoria  
 Headache  
 Gastrointestinal system  
 Anorexia  
 Nausea  
 Vomiting  
 Constipation  
 Dry mouth  
 Respiratory system  
 Bronchospasm  
 Cough suppression  
 Respiratory depression  
 Cardiovascular system  
 Palpitations  
 Changes in pulse rate  
 Changes in blood pressure  
 Orthostatic hypotension  
 Circulatory depression  
 Genitourinary system  
 Reduced libido  
 Urinary retention or hesitancy  
 Oliguria  
 Integumentary system  
 Diaphoresis  
 Rash  
 Urticaria  
 Flushing  
 Pruritus  
 Eye, ear, nose  
 Tinnitus  
 Blurred vision  
 Miosis  
 Diplopia

Data adapted from Ellsworth AJ, Witt DM, Dugdale DC, et al., eds. *Mosby's medical drug reference*. St. Louis: Mosby, 1998.

risk of cross-sensitivity among the various opioids. True allergic reactions to opioids are rare and present clinically as urticaria, skin rashes, and contact dermatitis. Opioids can be categorized as shown in Table 7-8, which suggests that patients allergic to codeine have a risk of cross-sensitivity to other morphine-like drugs. Alternative therapy could consist of a structurally dissimilar drug such as tramadol or ketoprofen.

Opioids are also contraindicated in patients with acute bronchial asthma and in patients with chronic obstructive

**Table 7-8**

Potential Cross-Sensitivity Among Opioids

Opioid	Source	Chemically Related to	Presence of 6-Hydroxyl Group*
Codeine	Natural	Morphine	Yes
Hydrocodone	Semisynthetic	Morphine	No
Hydromorphone	Semisynthetic	Morphine	No
Morphine	Natural	Morphine	Yes
Oxycodone	Semisynthetic	Morphine	No
Oxymorphone	Semisynthetic	Morphine	No
Propoxyphene	Synthetic	Methadone	

\*For opioids that are synthetically derived from morphine.

Adapted from Golembiewski JA. *J Perianesth Nurs* 2002;17:393-398.

pulmonary disease. They should be used cautiously in patients with kidney or liver dysfunction, because these conditions increase the risk of drug accumulation and subsequent toxicity.

When used in excessive doses, propoxyphene can be a major cause of drug-related death. Toxic long-lived metabolites can cause delirium, seizures, and cardiotoxicity. These effects can occur when the drug is used alone but especially when it is used in combination with other CNS depressants such as alcohol. It is prudent to avoid propoxyphene or other opioid analgesics in depressed or suicidal patients and instead use nonnarcotic analgesics as tolerated for pain relief.

The absolute safety of narcotic analgesics during pregnancy has not been established in humans, but some association between congenital birth defects and exposure to codeine during the first trimester has been reported. However, some authors recommend codeine and acetaminophen as drugs of choice for the treatment of migraine headaches during pregnancy. When taken in late pregnancy, opioids can cause withdrawal and respiratory depression in neonates. Most of the opioid analgesics appear in small quantities in breast milk, but drug effects in nursing infants appear to be insignificant. If possible, breast-feeding should be deferred for at least 4 to 6 hours after opioid analgesics are taken.

## GENERAL STRATEGIES FOR PAIN MANAGEMENT

The following guidelines serve as a general basis for a rational approach to analgesic therapy for most patients with acute ocular pain:

- A definitive diagnosis should be made and specific treatment of the underlying disease initiated.
- The experience of pain, and thus the ability to tolerate it, varies considerably among individuals. Thus, analgesic therapy should be adjusted according to the severity of the pain rather than to the extent of objective findings.
- A comprehensive medical and drug history is essential to disclose any contraindications to various analgesics, such as preexisting systemic diseases, medication

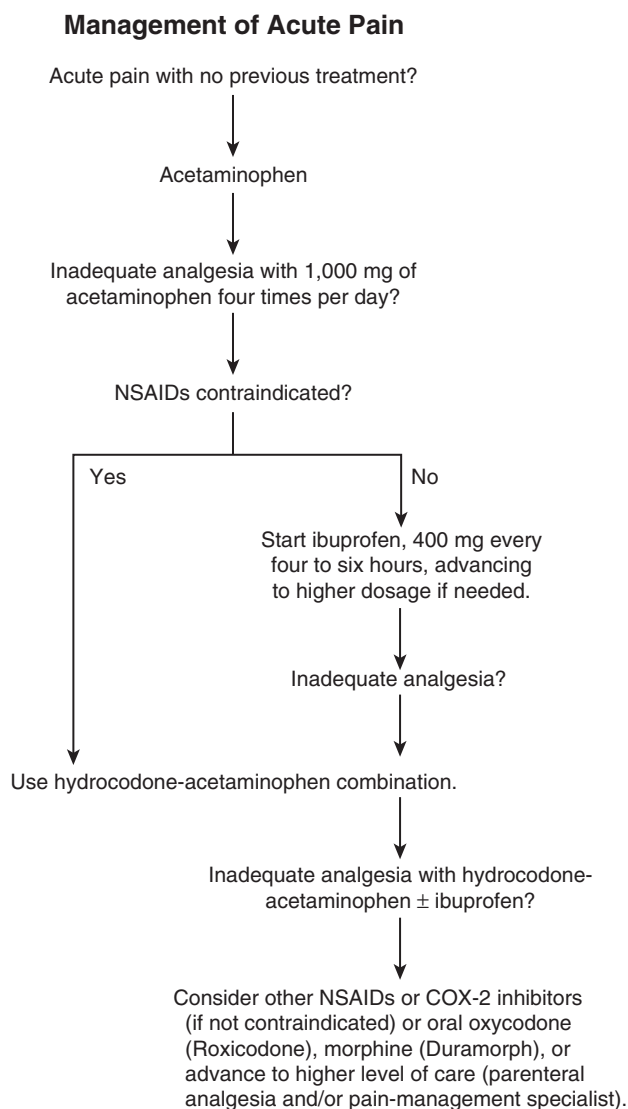
allergies, potential drug interactions, or pregnancy.

- Pain should be treated by the simplest and safest means to achieve patient comfort.
- Analgesic therapy should be provided on a 24-hour schedule to help prevent the return of pain.
- When patients can swallow, the oral route of administration is preferred because of its simplicity, analgesic efficacy, and convenience.
- The use of nonprescription analgesics, such as acetaminophen or ibuprofen, typically reduces the cost of therapy.
- Opioid analgesics should be used with discrimination but should not be withheld if nonopioid agents prove ineffective.

It is prudent to consider analgesic therapy in a stepwise fashion. NSAIDs, usually ibuprofen, or acetaminophen should be used initially for treatment of mild to moderate pain, and opioids should be reserved for treatment of moderate to severe pain (Figure 7-2). This approach is clinically effective, reduces the incidence and severity of side effects, and is generally accepted and well tolerated by most patients. For example, a nonopioid analgesic such as 400 mg ibuprofen or 1,000 mg acetaminophen can be given. The analgesic ceiling effect for aspirin and acetaminophen is approximately 1,300 mg per dose. Although the duration of analgesia can be increased by exceeding this amount, it does not increase the peak analgesic effect. Thus if patients do not respond satisfactorily to a particular NSAID at the maximum therapeutic dose, an alternative NSAID in the same or separate chemical class should be selected. NSAIDs that often provide greater analgesia than aspirin or acetaminophen include ibuprofen and ketoprofen. All NSAIDs except the nonacetylated salicylates should be avoided in a thrombocytopenic or surgical patient because of their antiplatelet effects.

If additional analgesia is required beyond that afforded by the nonnarcotic analgesics, an opioid such as oxycodone, hydrocodone, or codeine should be used. If opioid side effects are unacceptable or become problematic, the narcotic dose is reduced or an alternative opioid is selected.

Various adjuvants and/or procedures can be used to enhance the analgesic effect of the nonopioid and



**Figure 7-2** Algorithm for the treatment of most patients with acute pain. (NSAIDs = nonsteroidal anti-inflammatory drugs; COX = cyclooxygenase) (Adapted from Sacks CJ. Oral analgesics for acute nonspecific pain. *Am Fam Physician* 2005;71:913-918.)

opioid agents. In ophthalmic practice the treatment of acute trauma may involve pressure patching, bandage (or disposable) contact lenses, cold compresses, cycloplegics, or various combinations of these modalities as required for treatment of large corneal abrasions, external ocular foreign bodies, or anterior uveitis. These ancillary strategies can have analgesic-like qualities and may be extremely useful in enhancing the pain-relieving effects of the analgesics. Furthermore, orally administered caffeine can be effective not only in enhancing analgesia but also in overcoming the drowsiness and sedation associated with the opioid analgesics. Continuous or long-term topical anesthetics should never be used to augment orally administered analgesics. The risks of local complications far outweigh the benefits from the unsupervised administration of topical anesthetics (see Chapter 6).

## ANALGESIC USE IN CHILDREN

Although many analgesics are available for clinical use, few opioid and nonopioid analgesics have widely accepted pediatric dosage guidelines. The drugs listed in Table 7-9 are the most commonly prescribed for children, and it is recommended that those dosage schedules approved by the U.S. Food and Drug Administration be used.

### Treatment of Mild to Moderate Pain

As in adults, mild pain in children is initially treated with nonopioids. Because of its association with Reye's syndrome, aspirin has been abandoned in pediatric practice in favor of safer agents, such as acetaminophen and the nonsalicylate NSAIDs. Acetaminophen is as effective as aspirin for treatment of pain in children and produces very few serious side effects when given in therapeutic doses. The recommended dosage is approximately 10 mg/kg orally every 4 hours or 10 to 15 mg/kg rectally every 4 hours, with a maximum of five doses in a 24-hour period. Rectal absorption may be inconsistent, and a larger dose of acetaminophen is sometimes required to achieve effective plasma levels. Because of its favorable safety profile, acetaminophen is often the first agent used for most children with mild to moderate pain, but it can also be of benefit in more severe pain as an adjunct to opioid analgesia.

The nonsalicylate NSAIDs are especially useful for pain of inflammatory origin. These analgesics are relatively safe, are well tolerated, have few serious side effects, can decrease or even eliminate the need for opioids, and are nonaddictive. NSAIDs that have been used effectively and are approved for use in children include ibuprofen, naproxen, and tolmetin. Because all these drugs can cause gastritis, they should be taken with meals. If GI side effects persist with one NSAID, an alternative agent should be selected.

### Treatment of Moderate to Severe Pain

Treatment of moderate to severe pain requires use of opioid analgesics combined with nonopioids such as acetaminophen. An elixir containing 120 mg acetaminophen and 12 mg codeine per 5 ml is generally effective.

**Table 7-9**  
Analgesics Commonly Used in Children

Class	Drug	Dosage
Nonopioids	Acetaminophen	10-15 mg/kg PO q4 hr 15-20 mg/kg PR q4 hr
	Ibuprofen	4-10 mg/kg PO q6-8 hr
	Naproxen	5-7 mg/kg PO q8-12 hr
	Tolmetin	5-7 mg/kg PO q6-8 hr
Opioids	Codeine	0.5-1.0 mg/kg PO q4 hr

PO = oral; PR = rectal.

The oral route of administration should be used whenever possible.

Codeine is the most commonly prescribed opioid analgesic for treatment of moderate to severe pain in ambulatory children older than 3 years of age. Several preparations are available (i.e., liquids or tablets), and use is determined by the patient's age and preference. The recommended initial pediatric dosage for codeine is 0.5 to 1.0 mg/kg orally along with 10 mg/kg acetaminophen, every 4 to 6 hours, administered concurrently. Although dosing is based on the codeine component, the amount of acetaminophen should not exceed the recommended dosage of 15 mg/kg every 4 hours.

### Management of Side Effects

Stool softeners and cathartics can be used in children, as in adults, to relieve symptoms of constipation. Nausea and vomiting generally diminish as opioid therapy is continued, but antihistamines with antiemetic effects, such as hydroxyzine or promethazine, may be helpful as adjuncts to diminish unpleasant GI symptoms. Reducing the opioid dose to minimal analgesic levels may help to limit sedation or drowsiness. Mild respiratory depression, an uncommon side effect in children, may require only that the opioid dose be reduced.

### ANALGESIC USE IN ELDERLY PATIENTS

Prescribing analgesics for elderly patients can be difficult. Older patients are much more likely than younger ones to experience GI and other side effects of drug use. In addition, they are generally taking more medications that may interact with the prescribed analgesic. Other factors, such as reduced renal and hepatic function, can also affect the efficacy and accumulation of the analgesic, thus increasing the risk of drug toxicity.

Practitioners must therefore take a careful medical and drug history to determine potential contraindications to analgesics. Prior analgesic use should be reviewed to determine, if possible, what analgesics were effective and what side effects, if any, occurred. This review is a very practical process in selecting the proper analgesic for all patients, especially the elderly. Acute renal failure induced by the NSAIDs is more common in older patients, especially in those who are taking diuretics or who have congestive heart failure, liver disease, or kidney disease. Safer analgesics for these patients include sulindac (Clinoril) or a nonacetylated salicylate. Ibuprofen and diclofenac are potential alternatives because they do not tend to accumulate in patients with renal impairment. Acetaminophen is another option, because it rarely causes acute renal failure when used on a short-term basis.

One of the major problems with use of NSAIDs in elderly patients, especially women, is the increased incidence of gastric mucosal damage (NSAID gastropathy). This condition can lead to significant GI bleeding and

even death. Options for preventing or treating this problem include the following: (1) use of drugs that may produce less gastric irritation, such as ibuprofen, fenoprofen, diclofenac, COX-2 inhibitors, choline-magnesium salicylate, enteric-coated aspirin, or acetaminophen; (2) use of an H<sub>2</sub> blocker, such as ranitidine or famotidine prophylactically; (3) use of misoprostol (Cytotec), a synthetic prostaglandin E<sub>1</sub> analogue, which inhibits gastric acid secretion while possessing mucosal protective properties; and (4) use of omeprazole (Prilosec), a proton pump inhibitor, which significantly reduces gastric acid secretion and may have fewer side effects than misoprostol.

Most patients having cataract extraction are elderly, and some may have bleeding disorders. Because acetaminophen and the nonacetylated salicylates affect platelet aggregation only minimally, these analgesics are preferred for preoperative or postoperative use.

### Treatment of Mild to Moderate Pain

The most useful nonopioid analgesics for treatment of pain in the elderly are listed in Box 7-3. For treatment of mild to moderate acute pain, a practical approach is to initiate therapy with acetaminophen, 650 to 1,000 mg to a maximum of 4,000 mg/day. If pain continues, an NSAID should be substituted. If pain still persists, an alternative NSAID, preferably from a different therapeutic class, should be selected. If the alternative NSAID is ineffective, full-dose acetaminophen combined with an NSAID should be considered. Combinations of several NSAIDs, however, should not be used. This approach is often effective without resorting to the use of opioid analgesics.

### Treatment of Moderate to Severe Pain

Elderly patients in moderate to severe pain may require narcotic analgesics, but the use of opioids can be associated with significant toxicity because of the unique metabolic and physiologic alterations in aging patients.

#### Box 7-3 Preferred Analgesics for Use in Elderly Patients

Nonopioids
Acetaminophen
Ibuprofen
Diclofenac
Diflunisal
Fenoprofen
Naproxen sodium
COX-2 inhibitors
Opioids
Codeine with acetaminophen
Oxycodone with acetaminophen

Opioids are detoxified in the liver. The metabolic capacity of the liver declines with age, thus reducing drug clearance and enhancing the cumulative effects of narcotics. This is of special concern in elderly patients with heart failure or liver disease. In addition, the degree of analgesia and CNS depression produced by opioids is enhanced by normal aging, especially in patients with preexisting CNS dysfunction such as stroke or dementia. Furthermore, opioid-induced respiratory depression is enhanced in the elderly and in persons with depressed CO<sub>2</sub> drives associated with obesity or chronic obstructive pulmonary disease. Urinary retention can also be a problem in elderly men with benign prostatic hypertrophy.

The opioid analgesics of choice for use in the elderly are listed in Box 7-3. For treatment of moderate to severe pain, an effective opioid regimen consists of a combination of acetaminophen with 15 to 60 mg codeine or acetaminophen with 5 to 30 mg oxycodone. Acetaminophen combinations with hydrocodone are also frequently used. If pain persists, an alternative opioid analgesic should be selected. Adjuvants such as caffeine may enhance the analgesic activity of the opioid.

### Management of Side Effects

Opioid-induced constipation is more troublesome in older patients, and it should be anticipated by instituting laxative therapy along with the narcotic. A typical laxative regimen consists of psyllium and a stool softener. A mild stimulant laxative such as bisacodyl (Dulcolax) can be added if constipation becomes problematic.

Nausea and vomiting are other opioid-induced effects that are more significant in elderly patients. Nausea can result from vestibular stimulation, so limiting physical activity may be useful to reduce symptoms. If drug therapy is needed, hydroxyzine is preferable to a phenothiazine. Because the antihistamines have significant anticholinergic effects that can be troublesome in elderly individuals, these drugs should not be routinely given with the opioid unless absolutely needed.

### SELECTED BIBLIOGRAPHY

Barrett BJ. Acetaminophen and adverse chronic renal outcomes: an appraisal of the epidemiologic evidence. *Am J Kidney Dis* 1996;28(1 suppl 1):S14-S19.

Benson GD, Koff RS, Tolman KG. The therapeutic use of acetaminophen in patients with liver disease. *Am J Ther* 2005;12:133-141.

D'Agati V. Does aspirin cause acute or chronic renal failure in experimental animals and in humans? *Am J Kidney Dis* 1996;28(1 suppl 1):S24-S29.

Feenstra J, Grobbee DE, Mosterd A, Stricker BH. Adverse cardiovascular effects of NSAIDs in patients with congestive heart failure. *Drug Safety* 1997;17:166-180.

Forman JP, Stampfer MJ, Curhan GC. Non-narcotic analgesic dose and risk of incident hypertension in US women. *Hypertension* 2005;46:500-507.

Garcia Rodriguez LA, Jick H. Risk of upper gastrointestinal bleeding and perforation associated with individual non-steroidal anti-inflammatory drugs. *Lancet* 1994;343:769-772.

Gaziano JM. Nonnarcotic analgesics and hypertension. *Am J Cardiol* 2006;97:10-16.

Gaziano JM, Gibson CM. Potential for drug-drug interactions in patients taking analgesics for mild-to-moderate pain and low-dose aspirin for cardioprotection. *Am J Cardiol* 2006;97:23-29.

Glass NL. Pediatric postoperative pain management. *Anesth Analg* 1998;(suppl):28-31.

Goldstein NE, Morrison RS. Treatment of pain in older patients. *Crit Rev Oncol Hematol* 2005;54:157-164.

Golembiewski JA. Allergic reactions to drugs: implications for perioperative care. *J Perianesth Nurs* 2002;17:393-398.

Graham GG, Scott KE. Mechanism of action of paracetamol. *Am J Ther* 2005;12:46-55.

Grond S, Sablotzki A. Clinical pharmacology of tramadol. *Clin Pharmacokinet* 2004;43:879-923.

Henry D, Lim LL, Garcia, Rodrigues LA. Variability in risk of gastrointestinal complications with individual non-steroidal anti-inflammatory drugs: results of a collaborative meta-analysis. *BMJ* 1996;312:1563-1566.

Koren G, Pastuszak A, Ito S. Drugs in pregnancy. *N Engl J Med* 1998;338:1128-1137.

Kowalski ML. Aspirin sensitive rhinosinusitis and asthma. *Allergy Proc* 1995;16:77-80.

Launay-Vacher V, Karie S, Fau JB, et al. Treatment of pain in patients with renal insufficiency: the World Health Organization three-step ladder adapted. *J Pain* 2005;6:137-148.

Lewis KS, Han NH. Tramadol: a new centrally acting analgesic. *Am J Health Syst Pharm* 1997;54:643-652.

Lipton RB. Efficacy and safety of acetaminophen, aspirin, and caffeine in alleviating migraine headache pain. *Arch Neurol* 1998;55:210-217.

Murphy EJ. Acute pain management pharmacology for the patient with concurrent renal or hepatic disease. *Anaesth Intensive Care* 2005;33:311-322.

Palmer GM. A teenager with severe asthma exacerbation following ibuprofen. *Anaesth Intensive Care* 2005;33:261-265.

Perrott DA, Piira T, Goodenough B, et al. Efficacy and safety of acetaminophen vs ibuprofen for treating children's pain or fever: a meta-analysis. *Arch Pediatr Adolesc Med* 2004;158:521-526.

Rodriguez A, Barranco R, Latasa M, et al. Generalized dermatitis due to codeine. Cross-sensitization among opium alkaloids. *Contact Dermatitis* 2005;53:240.

Sachs CJ. Oral analgesics for acute nonspecific pain. *Am Fam Physician* 2005;71:913-918.

Seeff LB, Cuccherini BA, Zimmerman HJ, et al. Acetaminophen hepatotoxicity in alcoholics. *Ann Intern Med* 1986;104:399-404.

Theis JGW. Acetylsalicylic acid (ASA) and nonsteroidal anti-inflammatory drugs (NSAIDs) during pregnancy: are they safe? *Can Fam Physician* 1996;42:2347-2349.

Turturro MA, Paris PM. Oral narcotic analgesics. Choosing the most appropriate agent for acute pain. *Postgrad Med* 1991;90:89-95.

Waters L. Pharmacologic strategies for managing pain in children. *Orthop Nurs* 1992;11:34-40.

Yaster M, Deshpande J. Management of pediatric pain with opioid analgesics. *J Pediatr* 1988;113:421-427.



## *Mydriatics and Mydriolytics*

*Joan K. Portello*

Drugs that stimulate the adrenergic division of the autonomic nervous system, referred to as “sympathomimetics” or “adrenergic agonists,” can affect various ocular functions, including pupil size, width of the palpebral fissure, diameter of ocular blood vessels, and aqueous flow and accommodation. In clinical practice these agents are used for pupillary dilation (see Chapter 20), pharmacologic testing for oculosympathetic lesions (Horner’s syndrome) (see Chapter 22), vasoconstriction of conjunctival vessels and relief of minor allergic reactions (see Chapters 13 and 27), and, on occasion, treatment of ptosis (see Chapter 23). When used for dilating the pupil they are usually referred to clinically as *mydriatics*.

Drugs that block action of the sympathetic nervous system are known as *adrenergic receptor antagonists*, *antiadrenergics*, or *adrenergic-blocking agents*. Drugs that block  $\beta$  receptors are used clinically to control intraocular pressure (IOP) (see Chapters 10 and 34). The  $\alpha$ -receptor-blocking agents, referred to clinically as *mydriolytics*, can be useful to reverse the effects of mydriatic drugs. This chapter presents an overview of the adrenergic innervation to the eye and considers the pharmacologic actions, uses, side effects, and contraindications of mydriatics and mydriolytics in current clinical use.

### **ADRENERGIC INNERVATION TO THE EYE**

The sympathetic innervation to the eye, as previously described, originates from the posterior and lateral nuclei of the hypothalamus. Fibers descend through the lateral aspects of the brainstem to the intermediolateral columns in the cervical cord. Myelinated preganglionic neurons emerge from the thoracic section (C8-T2) of the spinal cord through the anterior roots. They then ascend over the apex of the lung through the stellate ganglion and the cervical sympathetic chain to synapse in the superior cervical ganglion (Figure 8-1). This part of the pathway comprises the preganglionic portion.

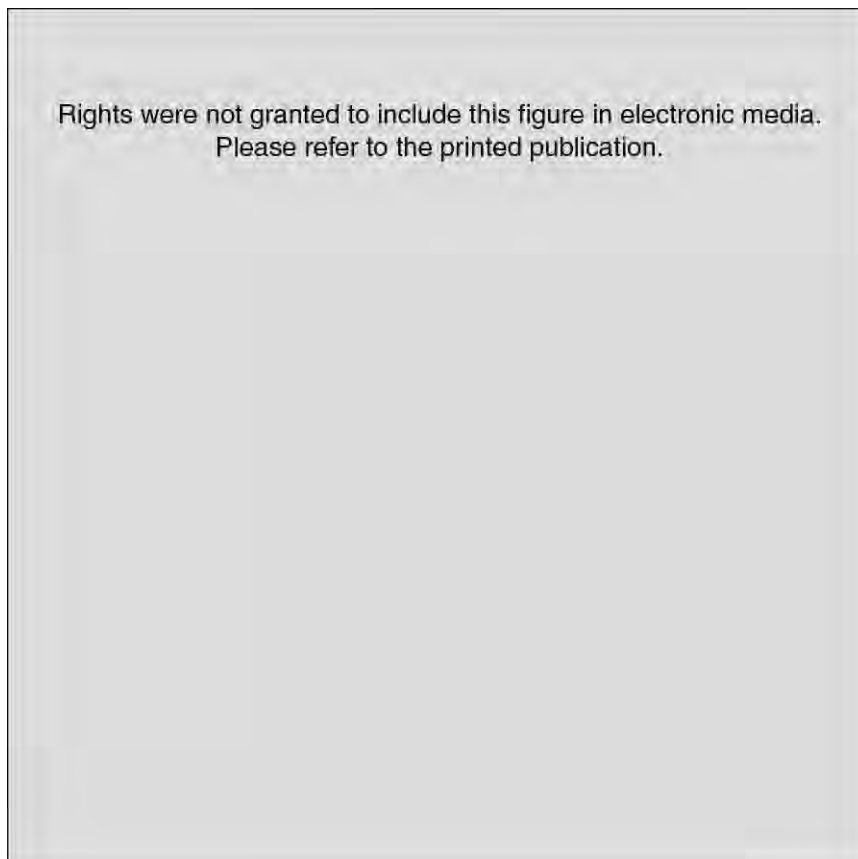Unmyelinated fibers emerge from the superior cervical ganglion and course toward the cavernous sinus by

following the carotid plexus adjacent to the carotid artery. There, the fibers cross over the sixth cranial nerve and join the ophthalmic division of the fifth nerve. The fibers then bypass the ciliary ganglion and accompany the long ciliary nerves to the iris dilator muscle and Müller’s muscle of the eyelid, thus completing the postganglionic portion of the oculosympathetic pathway (see Figure 8-1).

Previous studies have shown that accommodation mediated via ciliary smooth muscle activity also receives sympathetic innervation. Sympathetic nerves reach the ciliary muscle through the uveal blood vessels in close association with arteries and terminal arterioles. The distribution of the adrenergic fibers in the ciliary muscle appears to vary across species. In primates sympathetic nerve terminals, mainly  $\beta$  receptors, can generally be found in the anterior portion of the ciliary muscle. The accommodative amplitude significantly decreased in human subjects after instillation of phenylephrine (an  $\alpha$  agonist) or hydroxyamphetamine (an  $\alpha$  and  $\beta$  agonist). Such observations provide evidence that both sympathetic and parasympathetic divisions of the autonomic nervous system can affect accommodation but not equally. Furthermore, the nature of sympathetic innervation can be summarized as follows:

1. The sympathetic input is inhibitory in nature and mediated via  $\beta$ -adrenergic receptors, predominantly of the  $\beta_2$  subgroup.
2. The input is relatively small with respect to the prominent parasympathetic output and has a maximum dioptric value of around  $-1.50$  D.
3. The time course of sympathetic activity is significantly slower than that of parasympathetic activity, taking 10 to 40 seconds to reach its maximum effect. In contrast, parasympathetically mediated responses are completed in approximately 1 to 2 seconds for normal visual environments.
4. Sympathetic activity appears to be augmented by concurrent parasympathetic activity.

The posterior half of the trabecular meshwork and the inner wall of Schlemm’s canal also contain adrenergic



**Figure 8-1** The oculosympathetic pathway. Note its origin in the hypothalamus and its course through the brainstem and cervical spinal cord (central or first-order neuron), the upper thorax and lower neck (preganglionic or second-order neuron), and upper neck, middle cranial fossa, cavernous sinus, and orbit as it finally reaches Müller's muscle of the lid and the iris dilator muscle (postganglionic or third-order neuron). (a. = artery; n. = nerve.) (Reprinted with permission from Glaser JS. *The pupils and accommodation*. In: Duane TD, Jaeger EA, eds. *Clinical ophthalmology*. Hagerstown, MD: Harper & Row, 1987.)

nerve terminals. Certain orbital muscles also receive adrenergic innervation. The tonic contraction of the tarsal smooth muscle of the upper lid (Müller's muscle) is under adrenergic control. The convergence mechanism through the lateral rectus muscle is also at least partially controlled by adrenergic innervation. In addition, there is adrenergic control of intraocular and orbital muscles, cornea, lens, and retina.

## MYDRIATICS

### Phenylephrine

#### Pharmacology

Phenylephrine is a synthetic sympathomimetic amine structurally similar to epinephrine. It acts primarily on  $\alpha_1$  receptors and has little or no effect on  $\beta$  receptors. A minor part of its pharmacologic effects may be attributed to release of norepinephrine from adrenergic nerve terminals.

After topical application phenylephrine contracts the iris dilator muscle and smooth muscle of the conjunctival arterioles, causing pupillary dilation and blanching of the

conjunctiva, respectively. Müller's muscle of the upper lid is stimulated, which widens the palpebral fissure. IOP may decrease in normal eyes and in eyes with open-angle glaucoma.

Preparations of phenylephrine used for mydriasis are available in 2.5% and 10% solutions (Table 8-1). The designated Pregnancy Category for phenylephrine hydrochloride is C. In solution, phenylephrine is clear and is colorless to slightly yellow. Like all adrenergic agonists, it is subject to oxidation on exposure to air, light, or heat. To prolong its shelf life, an antioxidant, sodium bisulfite, is frequently added to the vehicle.

#### Clinical Uses

For mydriasis, instillation of 2.5% or 10% solution results in maximum dilation within 45 to 60 minutes depending on the concentration instilled (Figure 8-2). Recovery from mydriasis occurs in 6 to 7 hours.

Accommodative amplitude measurements after instillation of 2.5% or 10% phenylephrine generally indicate that the effect is far less than the decrease observed with cycloplegic agents such as tropicamide (see Chapter 9). A loss of approximately 2.00 D (7.93 D from 9.95 D) at

**Table 8-1**  
Mydriatic and Mydriolytic Agents

Generic Name	Trade Name	Manufacturer	Concentration (%)
<b>Mydriatics</b>			
Phenylephrine HCl	AK-Dilate <sup>a</sup>	Akorn	2.5, 10
	Mydrin <sup>b</sup>	Alcon	2.5
	Neofrin	OCuSOFT	2.5, <sup>b</sup> 10 <sup>a</sup>
	NeoSynephrine	Sanofi Winthrop	2.5, <sup>c</sup> 10 <sup>d</sup>
	NeoSynephrine Viscous <sup>c</sup>	Sanofi Winthrop	10
	Paremyd <sup>f</sup>	Akorn	1
<b>Mydriolytics</b>			
Dapiprazole HCl	Rēv-Eyes	Bausch & Lomb	0.5

Contains inactive ingredients of the following:

<sup>a</sup>Benzalkonium chloride.

<sup>b</sup>Benzalkonium chloride 0.01%, EDTA, sodium bisulfite.

<sup>c</sup>Benzalkonium chloride 1:7,500.

<sup>d</sup>Benzalkonium chloride 1:10,000.

<sup>e</sup>Benzalkonium chloride 1:10,000, methylcellulose.

<sup>f</sup>Also contains 0.25% tropicamide.

1 hour with 2.5% phenylephrine was reported. Before drug instillation the average accommodation was 9.31 D, and with 10% phenylephrine residual accommodation was 7.64 D. Two hours after instillation, an average loss of 1.52 D was reported for both concentrations of drug.

Dilation of the pupil with 2.5% and 10% commercial preparations has been studied in patients selected at random and not controlled for age or iris color. The results indicate that the higher concentration does not necessarily produce a significantly greater mydriasis. The data also appear to indicate that the 10% concentration may be a more effective mydriatic in blue irides than is the 2.5% concentration, although no statistically significant

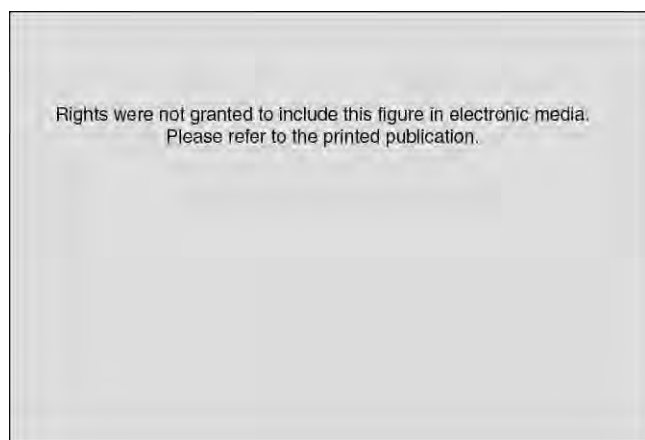
difference was observed. In general, dark irides have a greater frequency of poorer dilation than do light irides with adrenergic mydriatics.

Dose-response curves for phenylephrine indicate, as previously shown, an increasing mydriatic effect with concentrations up to 5%. Between 5% and 10% the curve begins to plateau, and little additional effect is observed by increasing the concentration to 10%.

In certain instances phenylephrine may also dilate the pupil at concentrations much lower than 2.5%. The mydriatic effect of 0.125% phenylephrine has been compared in unabraded and posttonography eyes. Three of 10 patients with unabraded corneas showed significant pupillary dilation of 1.0 to 1.5 mm after instillation of two drops of 0.125% phenylephrine compared with the control eye receiving saline. In posttonography patients, however, the test eye was dilated in all instances compared with the control eye.

Mechanical procedures that alter corneal epithelial integrity, thereby enhancing corneal drug penetration, can affect the response to certain ophthalmic drugs, including phenylephrine. Corneal trauma from procedures such as tonometry or gonioscopy can compromise corneal epithelial integrity and facilitate the pharmacologic effects. The mydriatic response of phenylephrine can also be enhanced by the prior instillation of a topical anesthetic.

Phenylephrine and tropicamide have been mixed together into a single combination solution for routine pupillary dilation. In one study commercially available preparations of 1% tropicamide and 2.5% phenylephrine were mixed together in equal amounts, thus producing a combination solution containing 0.5% tropicamide and 1.25% phenylephrine. This combination solution



**Figure 8-2** Mydriasis induced by 2.5% and 10% phenylephrine ( $n = 112$  eyes). (Reprinted with permission from Paggiarino DA, Brancato LJ, Newton RE. The effect on pupil size and accommodation of sympathetic and parasympatholytic agents. *Ann Ophthalmol* 1993;25:244-253.)

was shown to have the same mydriatic effect as the standard commercially available preparations administered separately. This combination solution allows the patient's pupil to be dilated with only one single drop and is said to be more convenient for the practitioner and better accepted by the patient. Furthermore, the single-drop combination may be better tolerated by young children.

In addition to its usual mydriatic effect for diagnostic purposes, phenylephrine has several other clinical uses. The drug can be a valuable aid in breaking posterior synechiae. Application of the 10% solution to the cornea preceded by a topical anesthetic is usually recommended to help break the adhesion. Furthermore, the effectiveness of topical 10% phenylephrine solution is used for peripheral corneal vessel vasoconstriction during LASIK refractive surgery.

The drug can also be used concomitantly with echothiophate to prevent the formation of miotic cysts during treatment of open-angle glaucoma or accommodative esotropia. Addition of the 2.5% concentration to the echothiophate regimen is recommended. The mechanism whereby phenylephrine prevents cyst formation is not known. However, inhibition of the intense miosis may account, at least in part, for the beneficial effect.

Ptosis resulting from sympathetic denervation, as in Horner's syndrome, may respond to topical phenylephrine. Dramatic effects on the uneven palpebral apertures are sometimes observed (see Figure 23-15).

Phenylephrine can also be used as a diagnostic test for Horner's syndrome (see Chapter 22). Phenylephrine in the 1% concentration can markedly dilate the pupil with postganglionic sympathetic denervation. It causes minimal or no dilation in the normal eye. If the lesion is central or preganglionic, the affected pupil responds in a manner similar to the normal eye because denervation hypersensitivity is minimal or absent.

### Side Effects

Unintended local and systemic consequences can be caused by the topical instillation of phenylephrine (Table 8-2).

**Table 8-2**  
Side Effects of Topical Phenylephrine

Ocular Effects	Systemic Effects
Transient pain	Systemic hypertension
Lacrimation	Occipital headache
Keratitis	Subarachnoid hemorrhage
Pigmented aqueous floaters	Ventricular arrhythmia
Rebound miosis	Tachycardia
Rebound conjunctival congestion	Reflex bradycardia
Conjunctival hypoxia	Blanching of skin

**Ocular Effects.** Local adverse events can include transient pain, lacrimation, and keratitis (see Table 8-2). Phenylephrine eyedrops have also been reported to cause allergic dermatconjunctivitis, resulting in a "scalded" appearance around the eye.

Studies have demonstrated that phenylephrine can cause the release of pigmented granules from the iris. The pigment appears in the aqueous (aqueous floaters) 30 to 40 minutes after instillation of the 2.5% or 10% concentration. These floaters usually disappear within 12 to 24 hours. The release of pigment appears to be related to age and iris color, occurring more frequently in older individuals with brown irides. The pigmented granules have the same characteristics as melanin derived from the pigmented epithelium of the iris. It has therefore been suggested that phenylephrine may cause rupture of the pigmented epithelial cells of the iris. Because this phenomenon has been observed primarily in older patients, it may be due to aging changes in the neuroepithelium.

In patients over age 50 years phenylephrine has been observed to cause a rebound miosis the day after drug administration. Moreover, the instillation of phenylephrine at that time causes a diminished mydriatic response. Similarly, with long-term use of the drug reduced dilation can occur, which makes long-term frequent use clinically unsatisfactory. In addition, long-term use of phenylephrine at low concentrations for ocular vasoconstriction can result in rebound congestion of the conjunctiva.

**Systemic Effects.** Ocular administration of phenylephrine has been reported to induce acute hypertension (see Table 8-2). Sixty patients were studied after three applications of the 10% solution in each eye at 10-minute intervals. Thirty minutes after the last drop, systolic elevations of 10 to 40 mm Hg and diastolic elevations of 10 to 30 mm Hg occurred in all subjects. In each case pulse rate decreased 10 to 20 beats per minute. In contrast to these observations, however, other investigators reported a lack of systemic vasopressor response with the 10% concentration.

Data collected by the National Registry of Drug-Induced Ocular Side Effects suggest that, in the general population, a group of patients may have certain risk factors for side effects from topical ocular 10% phenylephrine. Of 15 patients with myocardial infarcts, 11 died after topical application of 10% phenylephrine. The average age of these patients was 71 years, and nine individuals had a history of cardiovascular disease.

The effects of 2.5% phenylephrine on systemic blood pressure and pulse have also been investigated. No significant change was observed in systolic and diastolic blood pressures in 252 patients ranging in age from 3 to 92 years. In another study, two cases of acute systemic hypertension were reported after instillation of 2.5% phenylephrine. Both patients, who were 69 and 71 years of age, were scheduled for surgery, and each received multiple

drops of the phenylephrine. The medical history of one patient included diabetes and cardiac disease.

It is likely that age and physical status determine patients' responses to topical ocular phenylephrine. Neonates respond to 10% phenylephrine with significant increases in blood pressure. Patients with insulin-dependent diabetes may demonstrate increased systolic and diastolic blood pressure in response to topical 10% phenylephrine. Similarly, individuals with idiopathic orthostatic hypotension respond to low concentrations of phenylephrine with marked blood pressure elevations. Other systemic reactions reported with topical ocular 10% phenylephrine include severe occipital headache, subarachnoid hemorrhage, ventricular arrhythmias, tachycardia, reflex bradycardia, ruptured aneurysm, and blanching of the skin.

Patients taking certain systemic medications are also more sensitive to the pressor effects of phenylephrine. In individuals taking atropine, the pressor effect of phenylephrine is augmented, and tachycardia can occur. Tricyclic antidepressants and monoamine oxidase (MAO) inhibitors also potentiate the cardiovascular effects of topical phenylephrine. The concomitant use of phenylephrine is contraindicated with these agents, even up to 21 days after cessation of MAO inhibitor therapy. Similarly, patients taking reserpine, guanethidine, or methyl dopa are at increased risk for adverse pressor effects from topical phenylephrine because of denervation hypersensitivity accompanying the chemical sympathectomy.

Systemic reactions to 2.5% phenylephrine after topical ocular application to an intact eye have rarely been reported in adults. However, an acute rise in systolic blood pressure occurred in a 1-year-old child after the instillation of 0.5 ml of 2.5% phenylephrine during nasolacrimal duct probing.

The threshold dosage of phenylephrine in the average adult has been estimated to be 0.4 mg intravenously, 2 mg subcutaneously, and 50 mg orally. The upper limit for safe dosage in normal adults is approximately 1.5 mg intravenously and 300 mg subcutaneously. Because a 50-ml drop of 10% phenylephrine contains 5 mg of drug, multiple applications can result in overdosage, especially if absorption from the site of administration is enhanced or if the patient is compromised by age, body size, use of concomitant medications, or trauma. Furthermore, the extent of the absorption into the systemic circulation of topically applied phenylephrine is unknown because absorption has been shown to be possibly diminished due to local vasoconstriction.

### Contraindications

Based on data submitted to the National Registry of Drug-Induced Ocular Side Effects and those acquired by other investigators, the following guidelines for the clinical use of 10% phenylephrine are suggested:

- Use phenylephrine 10% with caution in patients with cardiac disease, idiopathic orthostatic hypotension, hypertension, aneurysms, insulin-dependent diabetes, and advanced arteriosclerosis.

- Give only one application of the 10% concentration per hour to each eye.
- The drug is contraindicated in patients taking MAO inhibitors, tricyclic antidepressants, reserpine, guanethidine, or methyl dopa.
- Concomitant use of topical phenylephrine is discouraged in atropinized patients, because tachycardia and hypertension can occur.
- Prolonged irrigation, application with a conjunctival pledget, or subconjunctival injection of the 10% solution is not recommended.
- Only the 2.5% solution is recommended for infants and the elderly.

Phenylephrine 10% concentration appears to be associated with an increased risk of significant adverse ocular and systemic events; therefore the 2.5% solution, with appropriate precautions, is recommended for routine use. Phenylephrine in solution can lose its pharmacologic activity over time or with improper use or storage; consequently, the manufacturer's instructions should be followed concerning expiration date and proper handling of the drug. Loss of drug effect can occur even without visible color change.

## Hydroxyamphetamine

### Pharmacology

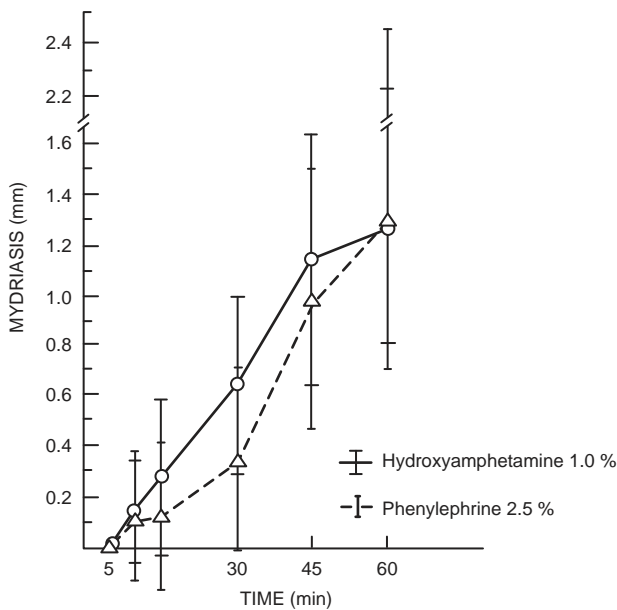
Hydroxyamphetamine ( $\beta$ -4-hydroxyphenylisopropylamine) is similar in chemical structure to norepinephrine. It is classified as an indirect-acting adrenergic agonist, its primary pharmacologic action is believed to be due to release of norepinephrine from adrenergic nerve terminals. It may also directly stimulate  $\alpha$ -receptor and possibly  $\beta$ -receptor sites, although this effect has been considered minimal and probably clinically insignificant.

Hydroxyamphetamine has little if any effect on accommodation or on the refractive state. It also does not raise IOP in eyes with open anterior chamber angles.

### Clinical Uses

Topical instillation of a 1% solution in eyes with normal adrenergic innervation causes mydriasis and also some vasoconstriction. However, hydroxyamphetamine is used only as a mydriatic agent. After topical application onset occurs within 15 minutes, maximum dilation occurs within 60 minutes, and the duration of mydriasis is approximately 6 hours. The U.S. Food and Drug Administration has labeled this drug as a Pregnancy Category C.

Studies have compared the mydriatic effects of phenylephrine and hydroxyamphetamine. One study compared 10% phenylephrine with several drugs, including 1% hydroxyamphetamine. The time to maximum dilation was similar (70.2 minutes for phenylephrine and 64.8 minutes for hydroxyamphetamine). The amount of mydriasis produced was somewhat greater with 10% phenylephrine: 2.42 mm compared with 1.93 mm with 1% hydroxyamphetamine.

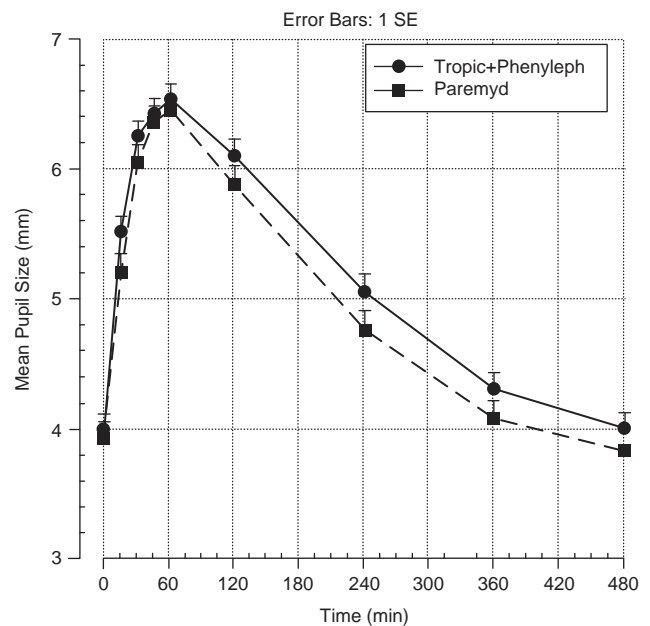


**Figure 8-3** Comparison of mydriatic effect of 2.5% phenylephrine and 1% hydroxyamphetamine in young adult subjects. (Reprinted with permission from Semes LP, Bartlett JD. Mydriatic effectiveness of hydroxyamphetamine. *J Am Optom Assoc* 1982;53:899-904.)

Another study compared the mydriatic effect of 2.5% phenylephrine to 1% hydroxyamphetamine in a group of 28 young adult subjects without ocular disease. The two agents produced a nearly equal pupillary dilation (Figure 8-3). The maximum effect with both drugs occurred at approximately 45 minutes.

To achieve greater pupillary dilation and overcome the constrictor effect of cholinergic stimulation, particularly on exposure to bright illumination, both phenylephrine and hydroxyamphetamine can be used in conjunction with a cholinergic antagonist, such as tropicamide or cyclopentolate. Additionally, phenylephrine 1% combined with a low concentration of 0.2% cyclopentolate (Cyclomydril) is recommended for neonates for fundoscopic examinations.

Hydroxyamphetamine 1% is combined with tropicamide 0.25% as a combination formulation commercially available as Paremyd. A single drop of Paremyd produces a mydriatic effect significantly greater than that of a single drop of either an adrenergic agonist alone or tropicamide 0.5% or 1%. Furthermore, Paremyd has a mydriatic efficacy equivalent to that of phenylephrine 2.5% followed by tropicamide 0.5%, instilled separately, for the first 45 minutes to an hour (Figure 8-4). In addition, statistically significant differences were demonstrated in the cycloplegic effect within the first hour after drug instillation of Paremyd and after instillation of 2.5% phenylephrine followed by 0.5% tropicamide.



**Figure 8-4** Mean pupil size changes as a function of time after the instillation of either Paremyd or a combined dose of phenylephrine 2.5% and tropicamide 0.5%. (SE = standard error.) (Reprinted with permission from Zeise MM, McDougall BWJ, Bartlett JD, et al. *J Am Optom Assoc* 1996;67:681.)

The use of Paremyd results in pupil size sufficient for binocular indirect ophthalmoscopy and, as with 0.5% or 1.0% tropicamide, the effect is independent of age, iris color, or skin color. No significant differences were observed in overall pupil diameter after instillation of either Paremyd alone or separate instillations of phenylephrine (2.5%) and tropicamide (0.5%). A difference in the recovery phase was observed. Pupil size decreased more rapidly as a function of time after instillation of Paremyd than after the use of 2.5% phenylephrine combined with 0.5% tropicamide when the two were administered separately.

Some investigators also showed that two drops of Paremyd instilled 5 minutes apart in contrast to the use of one drop only produced no additional mydriatic effect, irrespective of iris color or skin pigmentation. Furthermore, the use of a topical anesthetic does not appear to increase the efficacy of Paremyd.

Hydroxyamphetamine is clinically useful for differentiating between central or preganglionic and postganglionic sympathetic denervation. Because the drug stimulates release of endogenous norepinephrine from its stores in adrenergic nerve terminals, it fails to dilate a pupil with postganglionic sympathetic denervation, depending on the extent of damage. If the lesion causing Horner's syndrome is central or preganglionic, however, hydroxyamphetamine should cause normal mydriasis, because the nerve endings of the postganglionic fibers should contain normal amounts of norepinephrine and thus respond normally.

### Side Effects

When used for routine mydriasis, hydroxyamphetamine appears to be effective while causing little, if any, ocular irritation. It has been suggested that, due to the indirect action of this drug, it may be a safe mydriatic to use in eyes with shallow anterior chambers, and it may be more readily counteracted with miotics. In patients with open-angle glaucoma, hydroxyamphetamine elevates IOP minimally, if at all. Reductions of IOP have also been reported.

The actions of hydroxyamphetamine on the cardiovascular system differ in certain respects from those of phenylephrine. The drug can raise blood pressure, but unlike with phenylephrine the pressor response is characterized by tachyphylaxis. The drug can also produce sinoauricular tachycardia and ventricular arrhythmia after systemic administration.

### Contraindications

Contraindications to the topical use of hydroxyamphetamine for routine mydriasis are similar to those of phenylephrine. Because of its tachyphylaxis and ineffectiveness in postganglionic denervation, however, hydroxyamphetamine may be a safer mydriatic for use in patients with insulin-dependent diabetes, idiopathic orthostatic hypotension, or chemical sympathectomy produced by therapy with systemic guanethidine, reserpine, or methyl-dopa. Thus hydroxyamphetamine seems to be less strongly contraindicated than phenylephrine for certain high-risk patients.

## Cocaine

### Pharmacology

Cocaine is a naturally occurring alkaloid present in the leaves of the shrub *Erythroxylon coca* and other species of trees indigenous to Peru and Bolivia. Chemically it is an ester of benzoic acid with a nitrogen-containing base.

Cocaine exhibits several pharmacologic effects. After local application it acts as an anesthetic by blocking the initiation and conduction of nerve impulses. In addition, it has been shown to block neuronal reuptake of norepinephrine, thus potentiating adrenergic activity. Moderate doses increase heart rate and cause vasoconstriction. The most striking systemic effect of cocaine is central nervous system stimulation.

The ocular effects of cocaine include anesthesia (see Chapter 6), mydriasis, and vasoconstriction. The mydriatic effect of cocaine depends on the presence of a functioning adrenergic innervation. After topical application to the eye, the pupil begins to dilate within 15 to 20 minutes. The maximum effect, which is typically less than 2 mm of dilation, occurs within 40 to 60 minutes, and the pupil may remain dilated for 6 or more hours. The mydriasis is accompanied by vasoconstriction that causes blanching of the conjunctiva. Cocaine is also readily absorbed through the mucous membranes into the systemic circulation.

### Clinical Uses

Topical ocular application of cocaine can result in serious corneal epithelial damage; therefore clinical uses of this drug are limited. Although it is no longer used for such routine ophthalmic procedures as tonometry, the drug is useful in the diagnosis of Horner's syndrome (see Chapter 22). However, when administering hydroxyamphetamine, 48 hours must elapse before the subsequent test because cocaine inhibits the uptake of hydroxyamphetamine into the presynaptic vesicles. In addition, due to its ability to loosen the corneal epithelium, it can be helpful in the debridement of herpetic corneal ulcers.

### Side Effects

The most striking effect of systemic absorption of cocaine is central nervous system stimulation. Signs and symptoms can include excitement, restlessness, rapid and irregular pulse, dilated pupils, headache, gastrointestinal upset, delirium, and convulsions. Death usually results from respiratory failure. Moderate doses of cocaine can also raise body temperature. Systemic absorption through mucous membranes is rapid and has been compared in speed with that of intravenous administration.

The most significant effect of topical ocular cocaine administration is damage to the ocular tissue. Grossly visible grayish pits and corneal epithelial irregularities can occur, especially with repeated application. The corneal epithelium may loosen, leading to large areas of erosion. Single applications, however, as in the diagnosis of Horner's syndrome, rarely lead to corneal abnormalities. Although cocaine hydrochloride is designated as Pregnancy Category C, it should be administered to a pregnant woman only if needed. Also, after topical use of cocaine for Horner's testing, patients should be cautioned that urine tests may be positive for up to 2 days.

### Contraindications

Because of its peripheral adrenergic and central nervous system stimulatory effects, cocaine should be used with caution in patients with cardiac disease or hyperthyroidism.

## MYDRIOLYTICS

Attention has focused on developing noncholinergic miotic agents that safely and effectively reverse the effects of mydriatics. Theoretical evidence was presented that the use of a cholinergic antagonist, such as pilocarpine, to induce miosis after the use of an adrenergic mydriatic, such as phenylephrine, produced spasm of accommodation and increased the risk of angle-closure glaucoma and pupillary block. In addition, stimulation of the dilator and sphincter muscles simultaneously is most likely to produce shallowing of the anterior chamber and to result in pupillary block. Therefore two agents, thymoxamine and dapiprazole, were developed. Thymoxamine is not commercially available in the United States, and dapiprazole is in clinical use to reverse diagnostic mydriasis.

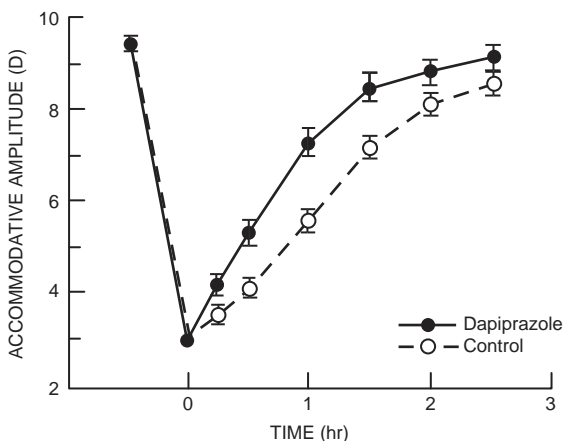
### Dapiprazole

#### Pharmacology

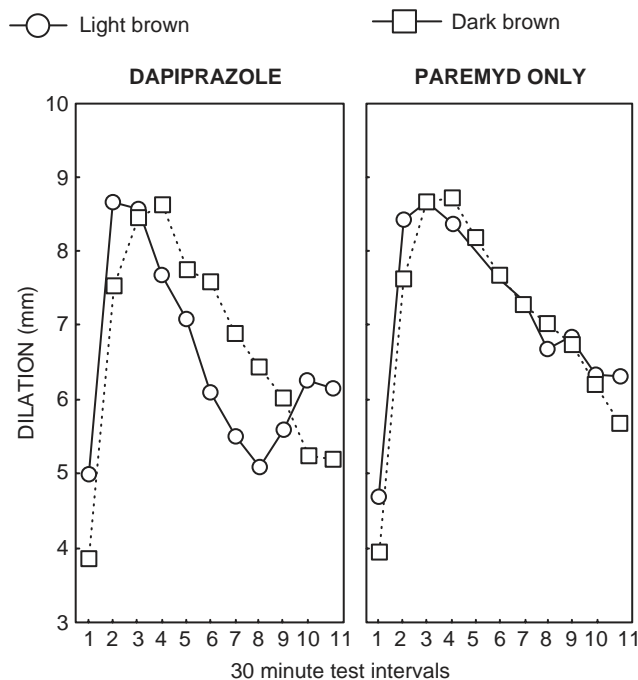
Dapiprazole was specifically developed for ocular use. After topical instillation it produces miosis and a reduction in IOP. Like thymoxamine, dapiprazole reverses mydriasis by blocking  $\alpha$  receptors in the iris dilator muscle. Concentrations ranging from 0.12% to 1.5% significantly reduce pupil size in both normal and glaucomatous eyes. The miotic effect is concentration dependent and can last up to 6 hours after instillation. IOP can be reduced for up to 6 hours. In patients with decreased amplitude of accommodation associated with tropicamide-induced cycloplegia, dapiprazole may partially increase the accommodative amplitude (Figure 8-5). This restoration of near vision seems to come from a combination of increasing depth of field due to pupillary recovery and an actual increase in accommodative amplitude independent of pupillary size.

#### Clinical Uses

Unlike pilocarpine, dapiprazole appears to be a safe miotic for reversing phenylephrine-induced mydriasis. Moreover, the miosis is maintained long after the phenylephrine effect has dissipated. When instilled according to the manufacturer's recommendation of two drops followed 5 minutes later by two drops, dapiprazole can produce nearly complete reversal of phenylephrine-induced pupillary dilation. Studies reported that a single drop of dapiprazole has a clinical effect equivalent to the multiple-drop regimen. Dapiprazole was shown to increase the recovery rate of adequate pupillary dilation and accommodative function with the use of Paremyd more rapidly in mainly white subjects with light brown irides than in mainly black subjects with dark brown



**Figure 8-5** Amplitude of accommodation after instillation of 0.5% dapiprazole (0 hour) in eyes dilated with 0.5% tropicamide. (Reprinted with permission from Nyman N, Reich L. The effect of dapiprazole on accommodative amplitude in eyes dilated with 0.5% tropicamide. *J Am Optom Assoc* 1993;64:625-628.)



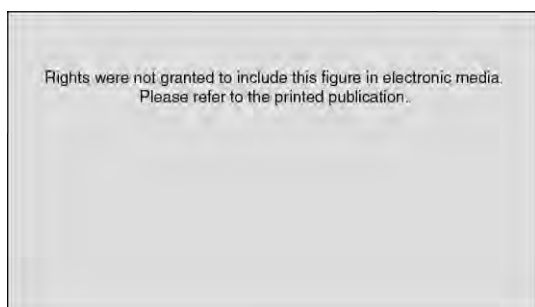
**Figure 8-6** Mean pupil diameter after dilation in subjects with either light or dark irides. Subjects were treated with either Paremyd and dapiprazole or Paremyd only. (Reprinted with permission from Anicho UM, Cooper J, Feldman J, et al. *Optom vis Sci* 1999;76:94-101.)

irides (Figure 8-6). However, the observed difference in pupillary diameters was probably too small to produce any clinically significant change in the patient's visual perception. This was verified by the observation that no significant difference was seen in visual acuity with and without the use of dapiprazole after dilation. Partial reversal of pupillary dilation induced with tropicamide has been reported as well. A tropicamide-dilated pupil returns to within 0.5 mm to 1.0 mm of its premydriatic diameter in less than 2 hours. Pupillary dilation with combinations of phenylephrine and tropicamide or hydroxyamphetamine and tropicamide was studied, and partial reversal of pupillary dilation occurred within 2 hours, with a significant reduction in pupil size after 1 hour (Figure 8-7). In addition, one drop of 0.5% dapiprazole is as effective in reversing mydriasis induced by 2.5% phenylephrine followed by tropicamide 0.5% or by Paremyd than is the recommended dosage of two drops followed 5 minutes later by an additional two drops.

Despite the reduction in pupil size, however, dapiprazole may have only limited usefulness in the pre-presbyopic population, because the drug may induce little improvement in functional vision as measured by changes in accommodation and near visual acuity. The effect seems to depend on the type of agent used for pupillary dilation.

The miosis produced by 0.5% dapiprazole begins 10 minutes after instillation and results in a significant reduction in pupil size, compared with that in the contralateral eye treated with 1% tropicamide alone.





**Figure 8-7** Reversal of mydriasis with two drops followed 5 minutes later with an additional two drops of 0.5% dapiprazole after pupillary dilation induced by a combination of 2.5% phenylephrine and 1% tropicamide. (Reprinted with permission from Allinson RW, Gerber DS, Bieber S, Hodes BL. Reversal of mydriasis by dapiprazole. *Ann Ophthalmol* 1990;22:131-138.)

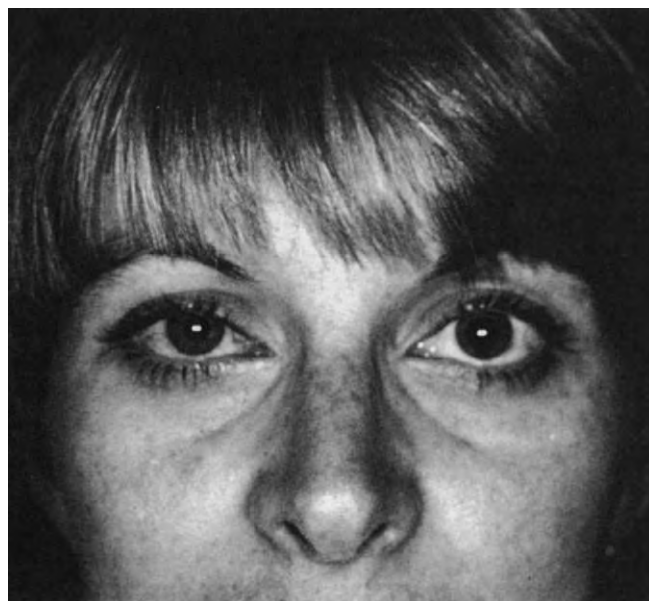Because the miosis is due to  $\alpha$ -receptor blockade in the iris dilator muscle, no shifting of the iris-lens diaphragm occurs with subsequent shallowing of the anterior chamber. As with thymoxamine, eye color can affect the rate of pupillary constriction. The rate of pupillary constriction may be slower in patients with brown irides than in individuals with blue or green irides.

The only U.S. Food and Drug Administration–approved use for dapiprazole at present is the reversal of iatrogenically induced mydriasis produced by adrenergic agents (phenylephrine or hydroxyamphetamine) or anticholinergic agents (tropicamide). An alternative use for dapiprazole is as a weak miotic agent to reduce peripheral distortion after refractive surgery. Another interesting, although theoretical, use for dapiprazole is in the treatment of pigment dispersion glaucoma. Since this  $\alpha$ -adrenergic blocking agent causes miosis and iridoplegia, a decrease in the shedding of pigment from the posterior iris may occur, causing less obstruction of aqueous outflow.

Dapiprazole in 0.25% and 0.5% solutions is effective in cases of angle-closure glaucoma. In patients with gonioscopically narrow angles, the drug has been effective in preventing angle-closure glaucoma.

Intraocular dapiprazole has been shown to be clinically effective for reversing mydriasis during extracapsular cataract extraction with IOL implantation. A study compared intraocular dapiprazole 0.25% with acetylcholine 1% and found that after extracapsular cataract extraction with posterior chamber intraocular lens implantation, 0.25% dapiprazole was effective in producing a more persistent miosis without side effects. The drug also reduced the transient postoperative IOP increase.

Dapiprazole is commercially available as Rēv-Eyes in a kit consisting of one vial of the drug (25 mg), one vial of diluent (5 ml), and a dropper for dispensing. Once the solution has been mixed, the eyedrops are clear, colorless, and slightly viscous and can be stored at room temperature



**Figure 8-8** Right ptosis, miosis, and conjunctival hyperemia induced by 0.5% dapiprazole instilled into right eye after bilateral pupillary dilation with 2.5% phenylephrine.

for 21 days. The recommended dosage per eye is two drops followed 5 minutes later by an additional two drops.

### Side Effects

Transient burning and conjunctival hyperemia after topical ocular application of dapiprazole are common. Other mild to moderate ocular side effects include superficial punctate keratitis, corneal edema, chemosis, ptosis, lid erythema and edema, itching, dry eye, and browache. Many of these are the result of the dilation of conjunctival blood vessels, which is a pharmacologic action of  $\alpha$ -receptor antagonists. Ptosis (Figure 8-8) can also be attributed to  $\alpha$ -receptor blockade in Müller's muscle. Blood pressure and pulse rate are not significantly affected by topical use of dapiprazole. One study concluded that topical application of dapiprazole produces no corneal endothelial toxicity, but intracameral use postsurgically may result in adverse corneal endothelial effects.

### Contraindications

Dapiprazole is contraindicated in circumstances in which pupillary constriction is undesirable, such as acute anterior uveitis, and for patients having hypersensitivity to any component of the preparation.

## SELECTED BIBLIOGRAPHY

- Allinson RW, Gerber DS, Bieber S, Hodes BL. Reversal of mydriasis by dapiprazole. *Ann Ophthalmol* 1990;22:131-138.
- Alster Y, Loewenstein A, Baumwald T, et al. Dapiprazole for patients with night halos after excimer keratectomy. *Graefes Arch Clin Exp Ophthalmol* 1996;234(suppl 1):S139-S141.

- Altman AJ, Albert DM, Fournier GA. Cocaine's use in ophthalmology: our 100-year heritage. *Surv Ophthalmol* 1985;29:300-306.
- Anicho UM, Cooper J, Feldman J, et al. The clinical efficacy of Paremyd with and without dapiprazole in subjects with light and dark brown irides. *Optom Vis Sci* 1999;76:94-101.
- Bartlett JD, Classé JG. Dapiprazole: will it affect the standard of care for pupillary dilation? *Optom Clin* 1992;2:113-120.
- Borromeo-McGrail V, Borduik J, Keitel H. Systemic hypertension following ocular administration of 10% phenylephrine in the neonate. *J Pediatr* 1973;51:1032-1036.
- Brown MM, Brown GC, Spaeth GL. Lack of side effects from topically administered 10% phenylephrine eyedrops. *Arch Ophthalmol* 1980;98:487-488.
- Bucci MG, D'andrea D, Bettini A, De Gregorio M. Dapiprazole for the reversal of mydriasis due to tropicamide. *Glaucoma* 1987;9:94-98.
- Cheeks L, Chapman JM, Green K. Corneal endothelial toxicity of dapiprazole hydrochloride. *Lens Eye Toxicity Res* 1992;9(2):79-84.
- Connor CG, Campbell JB, Tiley WW. The clinical efficacy of Rev-Eyes in reversing the effects of papillary dilation. *J Am Optom Assoc* 1993;64:634-636.
- Cooper J, Feldman JM, Jaanus SD, et al. Pupillary dilation and funduscopy with 1.0% hydroxyamphetamine plus 0.25% tropicamide (Paremyd) versus tropicamide (0.5% or 1.0%) as a function of iris and skin pigmentation, and age. *J Am Optom Assoc* 1996;67:669-675.
- Cremer SA, Thompson HS, Digre KB, et al. Hydroxyamphetamine mydriasis in Horner's syndrome. *Am J Ophthalmol* 1990;110:71-76.
- Doughty MJ, Lyle WM. A review of the clinical pharmacokinetics of pilocarpine, moxisylyte (thymoxamine), and dapiprazole in the reversal of diagnostic pupillary dilation. *Optom Vis Sci* 1992;69:358-368.
- Doughty MJ, Lyle W, Trevino R, et al. A study of mydriasis produced by topical phenylephrine 2.5% in young adults. *Can J Optom* 1988;50:40-60.
- Ehinger B. A comparative study of the adrenergic nerves to the anterior eye segment of some primates. *Z Zellforsch* 1971;116:157-177.
- Fraunfelder FT, Meyer SM, eds. Drug-induced ocular side effects and drug interactions. Philadelphia: Lea & Febiger, 1989; Chapter 6.
- Fraunfelder FT, Meyer SM. Possible cardiovascular effects secondary to topical ophthalmic 2.5% phenylephrine. *Am J Ophthalmol* 1985;99:362-363.
- Friedman JR, Whiting DW, Kosmorsky GS, et al. The cocaine test in normal patients. *Am J Ophthalmol* 1984;98:808-810.
- Gambill HD, Olge KN, Kearns TP. Mydriatic effect of four drugs determined by pupillograph. *Arch Ophthalmol* 1967;77:740-746.
- Geyer O, Lazar M. Allergic blepharoconjunctivitis due to phenylephrine. *J Ocular Pharmacol* 1988;4:123-126.
- Hanna C. Tachyphylaxis. Some cardiovascular actions of hydroxyamphetamine and related compounds. *Arch Int Pharmacodyn* 1960;128:469-480.
- Hanna C, Brainard J, Augsburg KD, et al. Allergic dermatconjunctivitis caused by phenylephrine. *Am J Ophthalmol* 1983;95:703-704.
- Hoffman BB, Lefkowitz RJ. Adrenergic receptor antagonists. In: Gilman AG, Rall TW, Nies AS, et al., eds. Goodman and Gilman's the pharmacological basis of therapeutics. New York: McGraw-Hill 1993; Chapter 11.
- Hoffman BB, Lefkowitz RJ. Catecholamines and sympathomimetic drugs. In: Gilman AG, Rall TW, Nies AS, et al., eds. Goodman and Gilman's the pharmacological basis of therapeutics. New York: McGraw-Hill, 1993; Chapter 10.
- Hogan TS, McDaniel DD, Bartlett JD, et al. Dose-response study of dapiprazole HCl in the reversal of mydriasis induced by 2.5% phenylephrine. *J Ocular Pharmacol Ther* 1997;13:297-302.
- Jennings BJ, Sullivan DE. The effect of topical 2.5% phenylephrine and 1% tropicamide on systemic blood pressure and pulse. *J Am Optom Assoc* 1986;57:382-389.
- Johnson ME, Molinari JF, Carter J. Efficacy of dapiprazole with hydroxyamphetamine hydrobromide and tropicamide. *J Am Optom Assoc* 1993;64:629-633.
- Kamar V, Packer AJ, Choi WW. Hypertension following 2.5% phenylephrine ophthalmic drops. *Glaucoma* 1985;7:131-132.
- Krumholz DM, Portello JK, Rosenfield M, Rosenbaum JD. Reduced concentrations of tropicamide and phenylephrine in a single solution is effective for pupillary dilation. *Optom Vis Sci* 1999;76(suppl):115.
- Lanche R. Systemic reactions to topical epinephrine and phenylephrine. *Am J Ophthalmol* 1966;61:95-98.
- Laties AM, Veleria P, Catanese B, et al. Pharmacokinetics and biochemistry of dapiprazole. In: Dapiprazole: a new alpha blocking agent in ophthalmology. Amsterdam: Kugler Publications, 1987:7.
- Lyle WM, Bobier WR. Effects of topical anesthetics on phenylephrine-induced mydriasis. *Am J Optom Physiol Opt* 1977;54:276-281.
- Mallen EAH, Gilmartin B, Wolffsohn JS. Sympathetic innervation of ciliary muscle and oculomotor function in emmetropic and myopic young adults. *Vision Res* 2004;45:1641-1651.
- Mapstone R. Mechanics of pupil block. *Br J Ophthalmol* 1968;52:19-25.
- Mastropasqua L, Carpineto P, Ciancaglini M, et al. Effect of dapiprazole, an alpha-adrenergic blocking agent, on aqueous humor dynamics in pigmentary glaucoma. *Ophthalmic Res* 1996;28:312-318.
- Meyer SM, Fraunfelder FT. Phenylephrine hydrochloride. *Ophthalmology* 1980;87:1177-1180.
- Mitsui Y, Takagi Y. Nature of aqueous floaters due to sympathomimetic mydriatics. *Arch Ophthalmol* 1961;65:626-631.
- Molinari JF, Carter JH, Johnson ME. Dapiprazole's effect upon accommodative recovery: is it due entirely to changes in depth of field? *Optom Vis Sci* 1995;72:552-556.
- Molinari JF, Johnson ME, Carter J. Dapiprazole. Clinical efficacy for counteracting tropicamide 1%. *Optom Vis Sci* 1994;71:319-322.
- Motameni M, Jaanus SD. Pediatric Horner's syndrome. Case report and review. *Clin Eye Vis Care* 1992;4:103-107.
- Munden PM, Kardon RH, Denison CE, et al. Palpebral fissure responses to topical adrenergic drugs. *Am J Ophthalmol* 1991;111:706-710.
- Neufeld AH, Zawistowski KA, Page ED, Bromberg BB. Influences on the density of beta adrenergic receptors in the cornea and iris-ciliary body of the rabbit. *Invest Ophthalmol* 1978;17:1069-1075.
- Neuhau RW, Hepler RS. Mydriatic effect of phenylephrine 10% vs. phenylephrine 2.5% (aq). *Ann Ophthalmol* 1980;12:1159-1160.
- Nyman N, Keates EU. Effects of dapiprazole on the reversal of pharmacologically induced mydriasis. *Optom Vis Sci* 1990;67:705-709.

- Nyman N, Reich L. The effect of dapiprazole on accommodative amplitude in eyes dilated with 0.5% tropicamide. *J Am Optom Assoc* 1993;64:625-628.
- Ophthalmic drug facts. St. Louis: Facts and Comparisons Division, Wolters Kluwer Health, 2006; Chapter 4.
- Paggiarino DA, Brancato LJ, Newton RE. The effect on pupil size and accommodation of sympathetic and parasympatholytic agents. *Ann Ophthalmol* 1993;25:244-253.
- Ponte F, Cillino S, Faranda F, et al. Intraocular dapiprazole for the reversal of mydriasis after cataract extraction with intraocular lens implantation. *J Cataract Refract Surg* 1991;17:785-789.
- Prosdocimo G, De Marco D. Intraocular dapiprazole to reverse mydriasis during extracapsular cataract extraction. *Am J Ophthalmol* 1988;105:321-322.
- Ritchie JM, Greene NM. Local anesthetics. In: Gilman AG, Rall TW, Nies AS, et al., eds. *Goodman and Gilman's the pharmacological basis of therapeutics*. New York: McGraw-Hill, 1993; Chapter 15.
- Rosenfield, M. Accommodation. In: Zadnik K, ed. *The ocular examination. Measurement and findings*. Philadelphia: W.B. Saunders 1997: 87-121.
- Samantary S, Thomas A. Systemic effects of topical phenylephrine. *Ind J Ophthalmol* 1975;23:16-17.
- Semes LP, Bartlett JD. Mydriatic effectiveness of hydroxyamphetamine. *J Am Optom Assoc* 1982;53:899-904.
- Smith RB, Everett WG. Physiology and pharmacology of local anesthetic agents. *Int Ophthalmol Clin* 1973;13:35-43.
- Solosko D, Smith R. Hypertension following 10% phenylephrine ophthalmic. *Anesthesiol* 1972;36:187-189.
- Stephens KG. Effect of the sympathetic nervous system on accommodation. *Am J Optom Physiol Opt* 1985;62:402-406.
- The National Registry of Drug-Induced Ocular Side Effects. Accessed May 23, 2006 from <http://piodr.sterling.net>
- Thompson HS, Menscher JH. Adrenergic mydriasis in Horner's syndrome; hydroxyamphetamine test for diagnosis of post-ganglionic defects. *Am J Ophthalmol* 1971;72:472-480.
- Van Buskirk EM, Bacon DR, Fahrenbach WH. Ciliary vasoconstriction after topical adrenergic drugs. *Am J Ophthalmol* 1990;109:511-517.
- Weiss DI, Shaffer RN. Mydriatic effects of one-eighth percent phenylephrine. *Arch Ophthalmol* 1962;68:727-729.
- Wellwood M, Goresky GV. Systemic hypertension associated with topical administration of 2.5% phenylephrine HCl. *Am J Ophthalmol* 1982;93:369-374.
- Wicox CS, Heiser JF, Crowder AM, et al. Comparison of the effects on pupil size and accommodation of three regimens of topical dapiprazole. *Br J Ophthalmol* 1995;79:544-548.
- Wilensky J, Woodward H. Acute systemic hypertension after conjunctival instillation of phenylephrine hydrochloride. *Am J Ophthalmol* 1973;76:156-157.
- Zeise MM, McDougall BWJ, Bartlett JD, et al. Comparison of efficacy and tolerance between 1% hydroxyamphetamine plus 0.25% tropicamide (Paremyd) and 0.5% tropicamide combined with 2.5% phenylephrine. *J Am Optom Assoc* 1996;67:681-689.
- Zinn KM. *The pupil*. Springfield, IL: Charles C Thomas, 1972; Chapter 2.

## Cycloplegics

Marcela Frazier and Siret D. Jaanus

Cycloplegic agents are useful for diagnosis and management in eye care because of their effect on pupil size and accommodation. Cycloplegics inhibit the actions of acetylcholine on muscarinic sites innervated by autonomic fibers and on smooth muscle cells that lack cholinergic autonomic innervation. These drugs are also called *anticholinergics*, *antimuscarinics*, and *cholinergic antagonists*.

### CHOLINERGIC INNERVATION TO THE EYE

In the eye the ciliary body, the iris sphincter muscle, and the lacrimal gland receive cholinergic innervation. The innervation for the ciliary body and the iris sphincter muscle originates in the Edinger-Westphal nucleus. From the Edinger-Westphal nucleus preganglionic parasympathetic fibers travel through the third cranial nerve (oculomotor) and proceed to the ciliary ganglion. There they synapse with postganglionic fibers, enter the globe through the short ciliary nerves, and pass to and terminate on the muscarinic receptors in the iris sphincter muscle and ciliary body (Figure 9-1).

Pupil size is determined by varying degrees of parasympathetic innervation to the sphincter muscle, which contracts accordingly and produces a corresponding degree of pupillary constriction. Sympathetic innervation, which is secondary, maintains a persistent tone in the dilator muscle, aiding relaxation of the sphincter and resulting in dilation.

Innervation to the lacrimal gland originates near the superior salivary nucleus in the pons where preganglionic fibers become part of the seventh nerve until they join and synapse with the sphenopalatine ganglion. The postganglionic fibers become part of the fifth nerve and pass to the lacrimal gland through the lacrimal nerve (see Figure 9-1).

Other potential targets of cholinergic stimulation or blockade by drugs include the cornea, lens, and retina. The corneal epithelium contains the neurotransmitter acetylcholine and the enzymes choline acetylase

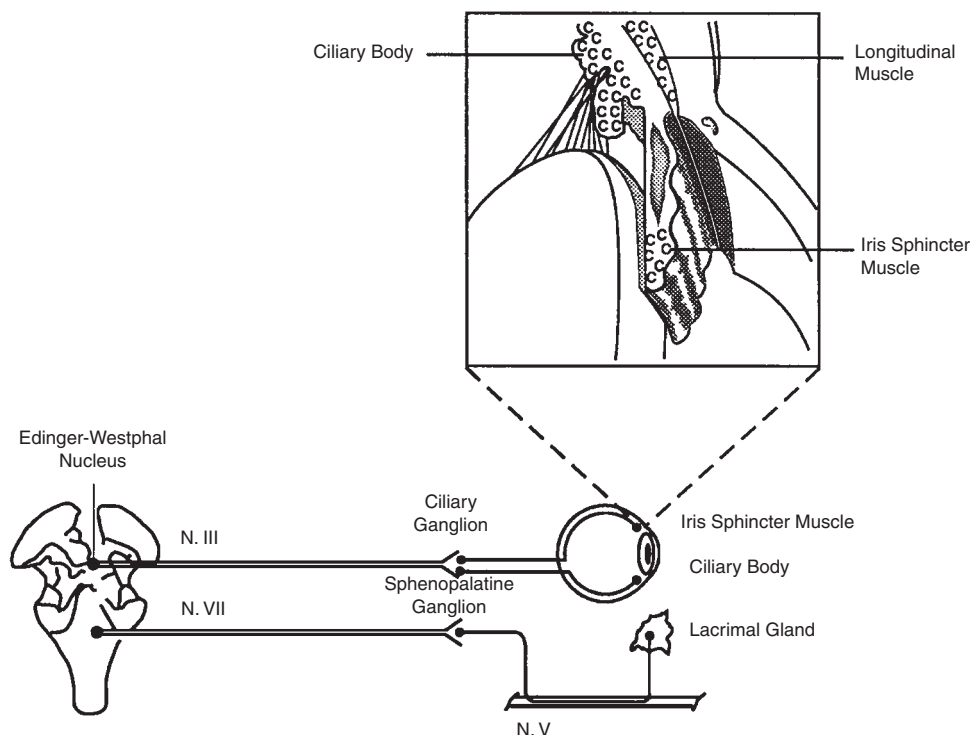
and acetylcholinesterase. Experimental evidence indicates that the cholinergic system may play a role in the transmission of tactile perception and corneal hydration involving epithelial ionic transport. The lens capsule exhibits cholinesterase activity. Cholinergic neurons have also been demonstrated in the human retina. Muscarinic receptors in the retina are believed to be involved in the control of refractive development in humans and other mammals.

### Cholinergic Receptors

Cholinergic receptors in iris sphincter tissue and ciliary body have been shown to be of the muscarinic type. Five muscarinic receptor subtypes (M1–M5) have been identified. Sixty percent to 75% of the muscarinic receptors in the human iris sphincter and ciliary body are M3, and 5% to 10% are M2 and M4. Approximately 7% of receptors in the ciliary processes and iris sphincter are of the M1 subtype. Approximately 5% of receptors present in the iris sphincter are M5. Inhibition of these receptors by cholinergic antagonists induces pupillary dilation (mydriasis) and paralysis of accommodation (cycloplegia) and may elevate intraocular pressure (IOP), particularly in patients with predisposing risk factors.

### CHOLINERGIC ANTAGONISTS

Five mydriatic-cycloplegic cholinergic antagonists are currently available for topical use in the eye: atropine sulfate, homatropine hydrobromide, scopolamine hydrobromide, cyclopentolate hydrochloride, and tropicamide. Atropine and scopolamine are believed to be nonspecific in their binding to the various muscarinic receptors, whereas tropicamide may have a moderate selectivity for M4 receptors. Several subtypes of neuronal nicotinic acetylcholine receptors have been shown to be sensitive to atropine, which suggests that atropine may exert its effects through several different mechanisms. The efficacy of all these agents is influenced by the amount of iris pigmentation.



**Figure 9-1** Cholinergic innervation to the eye (iris sphincter muscle and ciliary body) and lacrimal gland. (C = populations of muscarinic receptor sites, N = nerve.)

The heterogeneity of the muscarinic receptor subtypes in the iris and ciliary body suggests that subtype-selective antagonist drugs could be developed that might have a different action from the currently available muscarinic antagonists. There is investigative work being done to develop other anticholinergic agents with more specific selectivity for the types of muscarinic receptors and with less systemic toxicity. More selective muscarinic antagonists could be useful not only for cycloplegia, but also for the effect they may have in other ocular tissues. For example, ophthalmic pirenzepine hydrochloride, a muscarinic receptor antagonist with M1 selectivity, has been evaluated for slowing of myopia progression.

The reported cycloplegic effect of these drugs is also influenced by the methods used to assess the loss of accommodative function. Most early studies used subjective clinical measures of accommodation (push-up or minus lens blur), which require the subject to report when letters appeared blurred. Recently, objective methods (autorefractors, optometers) have been used to revisit the effectiveness of some of the shorter acting agents. Because selection of the most appropriate agent requires consideration of the risks and benefits associated with each drug on a case-by-case basis, patient characteristics and the ability of the agent to produce the desired outcome are fundamental to the selection process.

## Atropine

### Pharmacology

Atropine, a naturally occurring alkaloid, was first isolated from the belladonna plant, *Atropa belladonna*, in its pure form in 1831. Atropine is a nonselective muscarinic antagonist. The stability of atropine is both pH and temperature dependent. At 20° C, the half-life of atropine is 2.7 years in a pH 7 solution and 27 years at pH 6. At 30° C its stability is reduced to 0.61 years at pH 7 and 6.1 years at pH 6. At the physiologic pH, atropine with a  $pK_a$  of 9.8 is primarily ionized. The ionized state makes corneal penetration difficult, and thus small concentrations of the drug are available at the muscarinic receptor sites. However, atropine is the most potent mydriatic and cycloplegic agent presently available. Depending on the concentration used, mydriasis may last up to 10 days and cycloplegia, 7 to 12 days (Table 9-1). Atropine is available commercially as a sulfate derivative in a 1% solution and in a 1% ointment formulation (Table 9-2).

Feddersen is credited with the first extended study of the ocular effects of atropine sulfate after topical application of a 1% solution. After the instillation of one drop, the mydriatic effect began at 12 minutes and reached maximum in 26 minutes. The pupil began to return to normal in 2 days and reached preinstillation size by the tenth day. Cycloplegia began within 12 to 18 minutes, reaching maximum by 106 minutes. Accommodation began to

**Table 9-1**  
Mydriatic and Cycloplegic Properties of Anticholinergic Agents

Drug	Strength of Sol <sup>a</sup> (%)	Mydriasis		Paralysis of Accommodation	
		Maximal (min)	Recovery <sup>b</sup> (days)	Maximal (min)	Recovery <sup>c</sup> (days)
Atropine sulfate	1	30-40	7-10	60-180	7-12
Homatropine hydrobromide	1 <sup>d</sup>	40-60	1-3	30-60	1-6
Scopolamine hydrobromide	0.5	20-30	3-7	30-60	3-7
Cyclopentolate hydrochloride	0.5-1.0	20-45	1	20-45	0.25-1.00
Tropicamide	0.5-1.0	20-35	0.25	20-45	0.25

<sup>a</sup>One instillation of 1 drop of solution.

<sup>b</sup>To within 1 mm of original pupillary diameter.

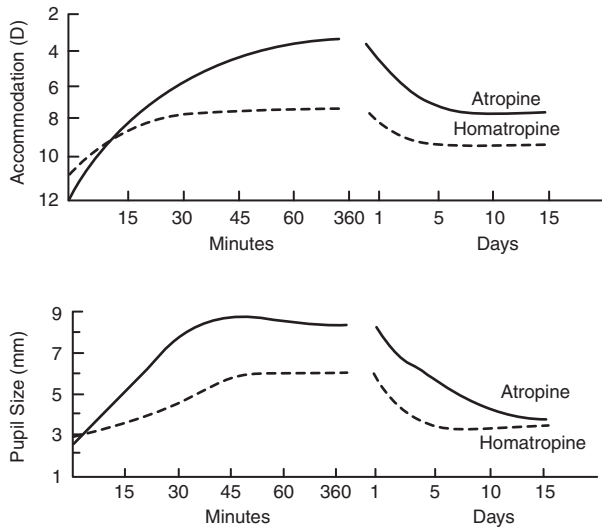
<sup>c</sup>To within 2 D of original amplitude of accommodation; ability to read fine print is possible by the third day after atropine and scopolamine instillation and by 6 hours after homatropine instillation.

<sup>d</sup>Full mydriasis and loss of accommodation require instillation of a 5% solution.

Adapted from Brown JH. Atropine, scopolamine, and related antimuscarinic drugs. In: Gilman AG, Rall TW, Nies AS, et al., eds. Goodman and Gilman's the pharmacological basis of therapeutics. New York, 1993, McGraw-Hill, Chapter 8.

**Table 9-2**  
Mydriatic-Cycloplegic Preparations

Generic Name	Trade Name	Manufacturer	Formulation and Concentration (%)
Atropine sulfate	Atropine Sulfate Ophthalmic	(Various)	Ointment 1
	Isopto Atropine Ophthalmic	Alcon	Solution 0.5, 1
	Atropisol Ophthalmic	CIBA Vision	Solution 1
	Atropine-Care Ophthalmic	Akorn	Solution 1
Homatropine HBr	Homatropine Ophthalmic	(Various)	Solution 5
	AK-Homatropine	Akorn	Solution 5
	Isopto Homatropine HBr	Alcon	Solution 2, 5
Scopolamine HBr	Isopto Hyoscine	CIBA Vision	Solution 5
	Cyclopentolate HCl	Alcon	Solution 0.25
Cyclopentolate	Cyclopentolate HCl	(Various)	Solution 1
	Cyclogyl	Alcon	Solution 0.5, 1, 2
	AK-Pentolate	Akorn	Solution 1
	Pentolair	Bausch & Lomb	Solution 1
Tropicamide	Tropicamide	Bausch & Lomb	Solution 0.5, 1
	Mydriacyl Ophthalmic	Alcon	Solution 0.5, 1
Combinations	Tropicacyl	Akorn	Solution 0.5, 1
	Cyclomydril	Alcon	Solution 0.2% cyclopentolate HCl, 1% phenylephrine HCl
	Murocoll-2	Bausch & Lomb	Solution 0.3% scopolamine HBr, 10% phenylephrine HCl



**Figure 9-2** Changes of accommodation and pupil size after administration of 1% solution of atropine sulfate and 1% solution of homatropine hydrobromide. (Modified from Wolf AV, Hodge HC. Effects of atropine sulfate, methylatropine nitrate [Metropine], and homatropine hydrobromide on adult human eyes. *Arch Ophthalmol* 1946;36:293-301.)

return in 42 hours, with full accommodative ability usually attained within 8 days.

A similar time course of action was observed for 1% atropine sulfate in a series of 16 eyes (Figure 9-2). In addition, wide variations were reported in individual responses to topical ocular atropine.

### Clinical Uses

**Refraction.** Since publication of Risley's essay on cycloplegics in 1881, atropine has become the standard to which all other cycloplegic agents have been compared. Because atropine is the most potent cycloplegic agent currently available, it is often used for cycloplegic refractions in young actively accommodating children with suspected latent hyperopia or accommodative esotropia.

Because of prolonged paralysis of accommodation that renders patients visually handicapped in near vision, atropine is not typically used for routine cycloplegic refractions in school-aged children or adults. Other shorter acting agents are becoming more widely used for refraction in almost all patients when a cycloplegic refraction is deemed necessary, so that the inconvenience of a prolonged accommodative loss is avoided. Use of atropine often reveals more hyperopia, however, and thus may be warranted in cases of esotropia with a suspected accommodative component.

**Treatment of Uveitis.** Atropine is extremely useful in the treatment of anterior uveal inflammation. Atropine relieves the pain associated with the inflammatory process by relaxing the ciliary muscle spasm and helps prevent posterior synechiae by dilating the pupil.

With the pupil dilated, the area of posterior iris surface in contact with the anterior lens capsule decreases. Moreover, the cycloplegia produced by atropine is of additional value in reducing both the thickness and convexity of the lens. If posterior synechiae should develop even when the pupil is dilated, there is less chance of iris bombé. Atropine may also help decrease the excessive permeability of the inflamed vessels and thereby reduce cells and protein in the anterior chamber (aqueous flare).

**Treatment of Myopia.** It has been suggested that topical ocular use of atropine may prevent or slow the progression of myopia. By placing the ciliary muscle at rest accommodation is relaxed, and the tension that produces elongation of the eye may be reduced. With administration of 1% atropine for 1 to 8 years, the decrease in myopia in treated eyes of children has usually been less than 0.5 D; the nontreated eye showed an increase in myopia that averaged approximately 0.91 D per year.

A study showed significant reduction in myopia progression with atropine in patients who presented good compliance. Another uncontrolled study reported that topical instillation of 1% atropine for 6 to 12 months in children 7 to 14 years of age seemed to prevent the progression of myopia, but on discontinuation of the drops only 12% of children maintained improvement for more than 6 months. In a more recent study, 20 children with 6.00 D or more of myopia were treated with 0.5% atropine once at bedtime and followed for up to 5 years. The myopic progression that occurred under atropine treatment was significantly slower than the progression observed before atropine treatment was initiated or under treatment with tropicamide. Although the results from these and other studies appear to be encouraging, dropout rates can be high, and side effects such as glare, photophobia, and increased exposure to ultraviolet radiation appear troublesome. Clearly, a controlled clinical trial is needed to determine the efficacy of atropine in myopia control.

**Treatment of Amblyopia.** Atropine can be used as an alternative to direct occlusion in the treatment of amblyopia. This form of amblyopia therapy is referred to as "penalization" and is often combined with optical overcorrection or undercorrection to blur the better eye for distance or near vision or both. The resultant cycloplegic blur in the eye with normal vision often forces the patient to use the amblyopic eye when the vision in the good eye is rendered poorer than that of the amblyopic eye. Thus this treatment is often reserved for moderate and mild amblyopia (acuity better than 20/100 in the amblyopic eye). Renewed interest in this form of therapy has been expressed because of its potential for improved compliance and stimulation of binocular function. Although pharmacologic occlusion can improve visual acuity in amblyopic eyes, care is needed because penalization can result in amblyopia in eyes with normal acuity.

## Side Effects

**Ocular Effects.** Ocular reactions include direct irritation from the drug preparation itself, allergic contact dermatitis, risk of angle-closure glaucoma, and elevation of IOP in patients with open angles. The allergic reaction to atropine generally involves the eyelids and manifests itself as an erythema, with pruritus and edema. Allergic papillary conjunctivitis and keratitis have also been reported.

In general, topical atropine, as well as other cholinergic antagonists, increases patients' risk for angle-closure glaucoma. However, the risk of inducing angle closure in eyes without a previous history of attack is remote. Patients with open-angle glaucoma may experience an elevation of IOP with topical application. The effect is unpredictable, because not all patients respond to cholinergic antagonists with IOP elevations. The mechanisms involved in the pressure rise are not completely understood. The pressure elevation appears to be related not to the degree of mydriasis attained but rather to a decrease in facility of aqueous outflow.

Systemically administered atropine may also cause mydriasis and raise IOP in patients with open-angle glaucoma. After intramuscular injection of 0.6 mg atropine, three of eight patients developed 0.5- to 1.5-mm mydriasis. A mean increase of 0.8 cm in the near point of accommodation after atropine administration was also reported.

**Systemic Effects.** A large portion of topically applied atropine rapidly enters the systemic circulation, primarily from the conjunctival vessels and the nasal mucosa. Plasma concentrations peak at approximately 10 minutes after application of the drug. Therefore it is not surprising that systemic reactions from the topical administration of atropine have been reported (Box 9-1). Adverse systemic reactions appear to be dose dependent, although patients vary in susceptibility. Systemic peripheral effects occur with low doses, which generally do not produce central symptomatology. Depression of salivation and drying of the mouth are usually the first signs of toxicity.

### Box 9-1 Systemic Reactions to Atropine in Children

- Diffuse cutaneous flush
- Depressed salivation/thirst
- Fever
- Urinary retention
- Tachycardia
- Somnolence
- Excitement/restlessness and hallucinations
- Speech disturbances
- Ataxia
- Convulsions

Slightly higher dosages produce facial flushing and inhibit sweating. Adverse systemic symptoms and central nervous system (CNS) manifestations generally occur at 20 times the minimum dose. Convulsions have been associated with topical ocular atropine instillation, particularly in children. The elderly are more susceptible to anticholinergic toxicity, including cognitive impairments and delirium.

Deaths have been attributed to topical ocular atropine. Six reported cases in the literature have occurred in children 3 years of age and younger. The dosages applied ranged from 1.6 to 18 mg, but the cases are rather poorly documented. Most of the children either were ill or had motor and mental retardation. What these cases imply, however, is that care must be taken not to overdose small children. Two drops of a 1% solution contain 1 mg of the drug or approximately twice the usual preoperative injectable dose. Caution must be exercised particularly with children who are lightly pigmented and individuals who have spastic paralysis or brain damage. White males with Down's syndrome have been shown to have an enhanced cardioacceleratory response to intravenous administration of atropine sulfate. Although the mechanism for this presumed increase in sensitivity to the vagolytic action of atropine is not clear, the rapid systemic absorption of topically applied agents in general warrants caution in this population.

The treatment of atropine overdosage is largely supportive, with prevention of hyperpyrexia and dehydration. Only in cases of severe or life-threatening toxicity should physostigmine be considered. Two milligrams given intramuscularly or a single intravenous dose of 1 to 2 mg, administered very slowly over 5 to 10 minutes, is recommended for adults. However, the short duration of action of physostigmine may require repeated doses of 1 to 2 mg every 30 minutes if life-threatening signs persist. Children are given 0.02 mg/kg intramuscularly or by slow intravenous injection up to a maximum of 0.5 mg per minute. The dosage may be repeated every 5 to 10 minutes up to a maximum dose of 2 mg or until the therapeutic effect is achieved.

## Contraindications

Atropine is contraindicated for patients who are hypersensitive to the belladonna alkaloids, have open-angle or angle-closure glaucoma, or have a tendency toward IOP elevations. Manufacturers' recommended dosages should not be exceeded, particularly in infants, small children, and the elderly. Children with Down's syndrome demonstrate a hyperreactive pupillary response to topical atropine.

## Homatropine

### Pharmacology

Homatropine is approximately one-tenth as potent as atropine and has a shorter duration of mydriatic and



cycloplegic action (see Table 9-1). Homatropine is partly synthetic and partly derived, like atropine, from the plants of the Solanaceae family. It is quite stable in solution. At physiologic pH, homatropine with a  $pK_a$  of 9.88 is approximately 0.32% un-ionized. Homatropine is commercially available as the hydrobromide salt in concentrations of 2% and 5% (see Table 9-2).

After topical instillation of a 1% solution, maximum mydriasis occurs by 40 minutes. The pupil requires 1 to 3 days to recover. The amount of cycloplegia produced by homatropine is significantly less than that produced by comparable doses of atropine (see Figure 9-2) and cyclopentolate. The duration of cycloplegia obtained is longer with homatropine than with cyclopentolate.

### Clinical Uses

Because of its prolonged mydriatic and cycloplegic effect and relatively weak cycloplegic action, particularly in darkly pigmented irides, homatropine is not a drug of choice for fundus examination or cycloplegic refraction. Homatropine is primarily used in the treatment of anterior uveitis, in which its effects are similar to those of atropine.

### Side Effects

The toxic effects of homatropine are indistinguishable from those of atropine, and the treatment is the same.

### Contraindications

Contraindications for homatropine are essentially the same as for atropine. As with atropine, very small amounts of homatropine have been detected in breast milk. According to the American Academy of Pediatrics, however, homatropine use is compatible with breast-feeding, but caution should be exercised when administering homatropine to nursing women. As with topical administration of atropine, homatropine can also induce CNS toxicity in the elderly.

## Scopolamine (Hyoscine)

### Pharmacology

Scopolamine is a nonselective antagonist. The alkaloid scopolamine (hyoscine) is found chiefly in the shrub *Hyoscyamus niger* (henbane) and *Scopolia carniolica*. The antimuscarinic potency of scopolamine on a weight basis is greater than that of atropine. Except for a shorter duration of mydriatic and cycloplegic action at the dosage levels used clinically, its effects are similar to those of atropine (see Table 9-1). Although previously available in both ointment and solution, scopolamine is currently available as the hydrobromide salt in solution at a 0.25% concentration (see Table 9-2). The mydriatic and cycloplegic effects of 0.5% solution of scopolamine were studied in subjects ranging from 15 to 37 years of age. The maximum cycloplegic effect occurred at 40 minutes, with residual amplitude of accommodation of 1.6 D

measured subjectively. This effect lasted for at least 90 minutes, and by the third day accommodation gradually returned to a level at which the average patient could read.

### Clinical Uses

In low dosages scopolamine can produce effects on the CNS, presumably due to its ability to penetrate the blood-brain barrier. Drowsiness and confusion are frequently reported. Patients also tend to exhibit a higher incidence of idiosyncratic reactions to scopolamine than to other anticholinergic agents, and, hence, it is not the drug of first choice for cycloplegic refraction or treatment of anterior uveal inflammations. Its use is reserved primarily for patients who exhibit sensitivity to atropine.

### Side Effects

Systemic reactions from the topical administration of scopolamine are quite similar to those of atropine. However, CNS toxicity appears to be more common with scopolamine than with atropine. In a series of several hundred patients whose pupils were dilated with 1% scopolamine, seven cases of confusional psychosis were observed. The reactions included restlessness, confusion, hallucinations, incoherence, violence, amnesia, unconsciousness, spastic extremities, vomiting, and urinary incontinence. Others have reported similar acute psychotic reactions in children receiving from 0.6 to 1.8 mg of topically administered scopolamine. However, no deaths have been reported from topical ocular use of scopolamine. Treatment of toxic reactions is the same as that for atropine toxicity.

Scopolamine is available as a transdermal drug delivery system for prevention of motion sickness. When placed behind the ear the system delivers 0.5 mg of scopolamine for 3 days. Mydriasis and blurred vision can occur if scopolamine from the patch comes in contact with the eyes.

### Contraindications

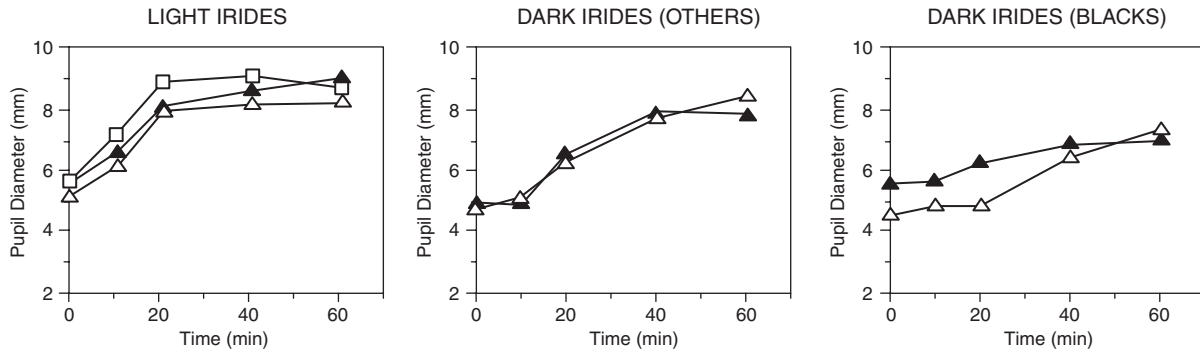
The contraindications for scopolamine are the same as for atropine.

## Cyclopentolate

### Pharmacology

Cyclopentolate was introduced into clinical practice in 1951. A stable water-soluble ester with a  $pK_a$  of 8.4, cyclopentolate is primarily in an ionized state at physiologic pH. It is commercially available in 0.5%, 1%, and 2% solutions (see Table 9-2).

In whites one drop of 0.5% cyclopentolate or two drops of 0.5% cyclopentolate instilled 5 minutes apart or one drop of 1% solution produces maximum mydriasis within 20 to 30 minutes. The average pupil size is usually 6.5 to 7.5 mm. In blacks two instillations of 0.5% cyclopentolate produce a 6.0-mm pupil at 30 minutes and a 7.0-mm pupil at 60 minutes after instillation of the

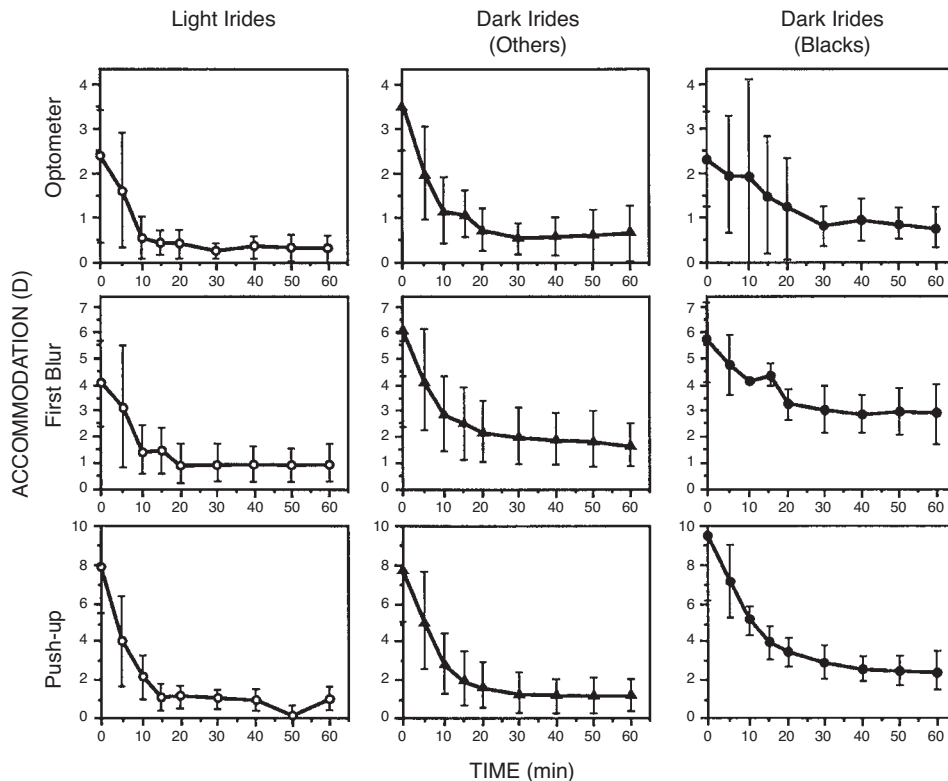


**Figure 9-3** Time course of mydriasis induced by 1% cyclopentolate hydrochloride. Solid symbols represent measurements when stimuli to the parasympathetic system were minimized; open symbols represent results when accommodation, convergence, and proximal cues were present. Open squares in left panel represent results from one child. (Modified from Manny RE, Fern KD, Zervas HJ, et al. 1% Cyclopentolate hydrochloride: another look at the time course of cycloplegia using an objective measure of the accommodative response. *Optom Vis Sci* 1993;70:651-665.)

first drop. Cyclopentolate is also a less effective mydriatic in whites with dark irides (Figure 9-3).

In whites maximum cycloplegia occurs 30 to 60 minutes after instillation of two drops of 0.5% solution or one drop of 1% solution. The residual accommodation measured subjectively ranges between 0.50 D and 1.75 D, with an average of 1.25 D. However, it was reported that in patients with light irides, clinically acceptable cycloplegia may occur as early as 10 minutes after instillation of one

drop of 1% cyclopentolate when cycloplegia is indexed by objective measures of residual accommodation. In a group of adults with light irides, residual accommodation measured 0.57 D at 10 minutes and 0.35 D at 40 minutes after instillation. In a small group of children with light irides, the residual accommodation measured 0.59 D at 10 minutes. In contrast, in individuals with dark irides, 30 to 40 minutes may be required before accommodation is at an acceptable level for cycloplegic refraction (Figure 9-4). Ten minutes



**Figure 9-4** Time course of cycloplegia induced by 1% cyclopentolate hydrochloride. Values represent means  $\pm$  1 standard deviation for subjects with light irides, subjects with dark irides, and blacks with dark irides for each measurement technique (objective optometer, subjective first blur, and subjective push-up). (Reprinted with permission from Manny RE, Fern KD, Zervas HJ, et al. 1% Cyclopentolate hydrochloride: another look at the time course of cycloplegia using an objective measure of the accommodative response. *Optom Vis Sci* 1993;70:651-665.)

after instillation of one drop of 1% cyclopentolate, 1.11 D of residual accommodation was present in individuals with dark irides, whereas 1.84 D of accommodation remained in blacks. Forty minutes after instillation, there was 0.52 D of residual accommodation in individuals with dark irides and 0.83 D in a small group of blacks. It was also shown that eyes with blue irides lose accommodation at a faster rate and also recover in less time than brown eyes. For all eyes the cycloplegic effect usually dissipates within 24 hours.

Among black patients ranging in age from 9 to 40 years, 1% cyclopentolate has been reported to produce satisfactory cycloplegia in 98% of patients. The 0.5% concentration was effective in only 66% of a group of 100 black patients aged 20 to 40 tested using subjective measures of accommodation. In those subjects who achieved less than 2.5 D of residual accommodation after the use of 0.5% cyclopentolate, the average residual accommodation was 1 D. However, 24% of the subjects showed no cycloplegia.

### Clinical Uses

Cyclopentolate is the cycloplegic agent of choice for routine cycloplegic refractive procedures in nearly all age groups, especially infants and young children. Its cycloplegic effect is superior to that of homatropine and closely parallels that of atropine in older children and adults, but with a relatively faster onset and shorter duration (see Table 9-1). Pupils dilated with cyclopentolate do not constrict when exposed to intense light, such as that of the binocular indirect ophthalmoscope, or during fundus photography. Although full recovery from mydriasis and cycloplegia generally occurs within 24 hours, most patients have sufficient recovery of accommodative amplitude to permit reading in 6 to 12 hours. Unlike with atropine and homatropine, onset of maximum cycloplegia generally approximates the onset of maximum mydriasis. Thus, when the pupil is fully dilated, the cycloplegia is adequate for refraction. However, the time course of mydriasis and the time course of cycloplegia are not the same. Pupil dilation typically lags behind the loss of accommodation. Hence, if pupillary dilation is used to determine whether cycloplegia is at a level acceptable for refraction, the refraction may be unnecessarily delayed or additional drugs may be used unnecessarily.

Cyclopentolate is also useful in the treatment of anterior uveitis, particularly in patients sensitive to atropine. If the inflammation is severe, more frequent instillations may be necessary, because its duration of action is less than that of atropine.

### Side Effects

**Ocular Effects.** The most common ocular side effect is transient stinging on initial instillation. The degree of irritation appears to be concentration dependent, with the 0.5% solution causing the least amount of burning and tearing.

Allergic reactions to cyclopentolate are quite rare and may go unrecognized by the practitioner. However, several cases of redness and discomfort in eyes of patients after in-office use of cyclopentolate have been reported. Symptoms consist of irritation and diffuse redness of the eyes and a facial rash that develops within minutes to hours of drug instillation. Lacrimation, a stringy white mucous discharge, and blurred vision are prominent.

Toxic keratitis has also been reported after abuse of cyclopentolate. Instillation of 100 to 400 drops of the 1% solution over several months caused a diffuse epithelial punctate keratitis with marked conjunctival hyperemia. As expected, the pupils were widely dilated and unresponsive to light.

Topically applied cyclopentolate can increase IOP in patients with primary open-angle glaucoma, and it may precipitate an attack of acute glaucoma in patients with narrow angles. It was reported that approximately 1 of 4 eyes with open-angle glaucoma responded to topical 1% cyclopentolate with a significant elevation of IOP (6 mm Hg or more increase compared with the baseline IOP), whereas only 2 of 100 normal eyes responded in a similar manner. These two apparently normal eyes also responded with an IOP increase of 6 mm Hg or more with the application of 5% homatropine or an application of 1% atropine.

**Systemic Effects.** Systemic cyclopentolate toxicity is dose related and evolves in a manner similar to atropine toxicity. Compared with atropine, however, cyclopentolate causes more CNS effects.

The CNS disturbances are characterized by signs and symptoms of cerebellar dysfunction and visual and tactile hallucinations. These can include drowsiness, ataxia, disorientation, incoherent speech, restlessness, and emotional disturbances (Box 9-2). The CNS effects are particularly common in children with use of the 2% concentration, but multiple instillations of the 1% solution may also cause the same symptoms. Forty children were evaluated before and after use of the 2% solution. Of these children, five exhibited transient psychotic reactions within 30 to 45 minutes after instillation of the drops. The symptoms included restlessness with aimless

#### Box 9-2 Side Effects of Cyclopentolate

Ocular Effects	Systemic Effects
Irritation and lacrimation	Drowsiness
Conjunctival hyperemia	Ataxia
Allergic blepharconjunctivitis	Disorientation
Elevated intraocular pressure	Incoherent speech
	Restlessness
	Visual hallucinations

wandering, irrelevant talking, visual hallucinations, memory loss, and faulty orientation of time and place. Psychotic reactions have been reported with the 1% concentration after instillation of two drops in each eye in children and adults. In addition, adults have also complained of drowsiness, nausea, or weakness. All reactions usually subside within 2 hours in adults and within 4 to 6 hours in children without permanent sequelae. Cyclopentolate is not without possible serious toxic effects, however. Grand mal seizures were reported in isolated case reports of three children with use of both 1% and 2% solution. Two of the three children who experienced seizures were neurologically impaired. However, one child, an 11-month-old boy who received one drop of 2% cyclopentolate in each eye, had no neurologic impairments and was reported to be normal. Also, a grand mal seizure was reported in a child after receiving a drop of 1% cyclopentolate and a drop of 10% phenylephrine. The child had abnormally low serum sodium levels, which may have predisposed him for the seizure.

Peripheral effects typical of atropine, such as flushing or dryness of the skin or mucous membranes, have not been observed with cyclopentolate in children or adults. Moreover, temperature, pulse, blood pressure, and respiration are generally not affected. Treatment of cyclopentolate toxicity is the same as that for atropine toxicity. Because toxic reactions occur more commonly with the 2% solution or with multiple instillations of the 1% solution, the smallest possible dose should be used.

### Contraindications

Because increased susceptibility to the side effects of cyclopentolate has been reported in infants, young children, and children with spastic paralysis or brain damage, use of concentrations higher than 0.5% is not recommended in these patients. The potential for systemic absorption of cyclopentolate, as of other topically applied ocular drugs, may be reduced with nasolacrimal occlusion.

## Tropicamide

### Pharmacology

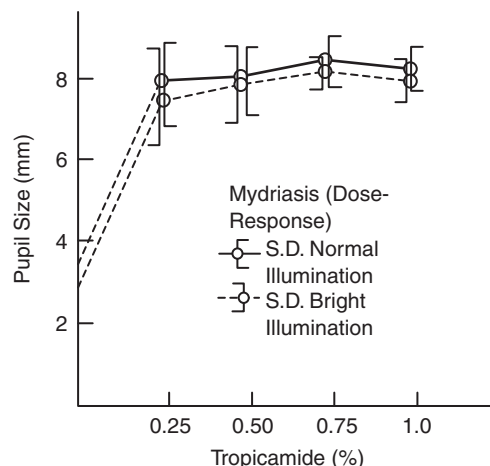
A synthetic derivative of tropic acid, tropicamide became available for ocular use in 1959. Although tropicamide has been reported to be a nonselective muscarinic antagonist, tropicamide may have a moderate selectivity for M4 receptors. With a  $pK_a$  of 5.37, it is only approximately 2.3% ionized at physiologic pH. The un-ionized molecules can readily penetrate the corneal epithelium, and thus a greater concentration of drug can reach the muscarinic receptor sites than is the case with atropine, homatropine, and cyclopentolate, which have  $pK_a$  values of 9.8, 9.9, and 8.4, respectively. The relatively greater diffusibility of tropicamide may also account for its faster onset and shorter duration of action compared with other anticholinergic agents. Tropicamide is

commercially available as 0.5% and 1% solutions (see Table 9-2).

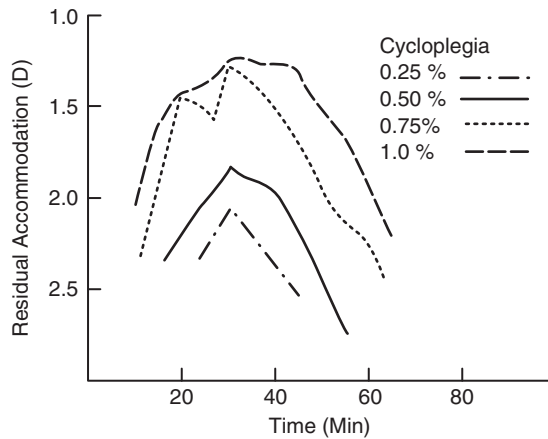
The first English-language report of the effects of the 0.5% and 1% solutions of tropicamide in human eyes showed maximum mydriasis occurred in 20 to 40 minutes after instillation of either the 0.5% or the 1% solution. The 1% concentration produced an average increase of approximately 4.0 mm in pupil size at 30 minutes. Thereafter, the pupil diameter began to decrease, reaching preinstillation size in 6 hours. The effect of the 0.5% solution on mydriasis was only slightly less than that of the 1% concentration.

Tropicamide has been reported to provide sufficient mydriasis for routine ophthalmoscopy at concentrations as low as 0.25% in some individuals. One drop of 0.25% tropicamide was reported to provide a 5-mm or greater dilation in most subjects.

The maximum cycloplegic effect also occurs at 30 minutes after instillation. Unlike the mydriatic effects, which appear less dependent on the concentration of tropicamide in white individuals, the inhibition of accommodation is dose related. The cycloplegic effects of 0.25%, 0.5%, 0.75%, and 1% tropicamide were studied (Figure 9-5). Some inhibition of accommodation occurred with each concentration, and the effects were dose related. The maximum residual accommodation ranged from 3.17 D for the 0.25% concentration to 1.3 D for the 1% concentration when assessed by the subjective push-up method. For all subjects maximum cycloplegia occurred 30 to 35 minutes after instillation. Significant differences in cycloplegic effects were found between the 0.25% and 1% solutions but not among the 0.5%, 0.75%, or 1% concentrations. Figure 9-6 illustrates the residual accommodation (measured subjectively using



**Figure 9-5** Mean mydriatic dose-response curves for tropicamide 0.25%, 0.5%, 0.75%, and 1% under normal and bright illuminance. (SD = standard deviation.) (Reprinted with permission from Pollack SL, Hunt JS, Polse KA. Dose-response effects of tropicamide HCl. *Am J Optom Physiol Opt* 1981;58:361-366.)

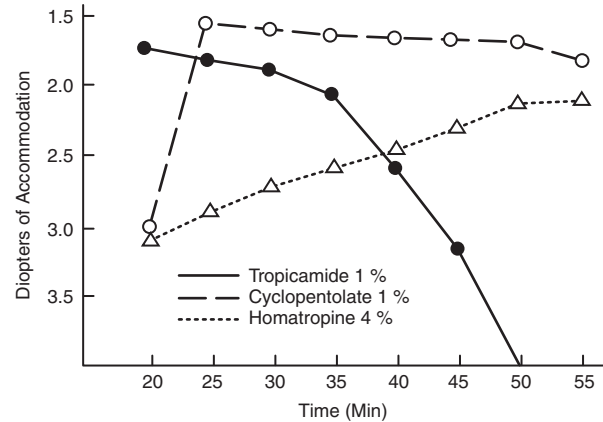


**Figure 9-6** Mean residual accommodation after tropicamide instillation over the period of maximum cycloplegia. (Reprinted with permission from Pollack SL, Hunt JS, Polse KA. Dose-response effects of tropicamide HCl. *Am J Optom Physiol Opt* 1981;58:361-366.)

the push-up method) during the period of maximum cycloplegia for all concentrations of tropicamide tested. Two diopters or less of residual accommodation were present for at least 40 minutes with the 0.75% and 1% concentrations and for approximately 15 minutes with the 0.5% concentration. A mean residual accommodation of 2.2 D was present after the application of 0.25% tropicamide. This effect was sufficient to incapacitate the subjects for most near vision tasks for 40 to 60 minutes.

The cycloplegic effect of 1% tropicamide was studied and found to be clinically effective (less than 2.5 D with the subjective minus-to-blur technique) in 90% of the eyes tested, provided that a second drop was instilled 5 to 25 minutes after the first and provided that the examination was performed 20 to 35 minutes after instillation. Accommodation returned to preinstillation values within 6 hours.

In myopic children two drops of 1% tropicamide instilled 5 minutes apart was demonstrated to be a very effective cycloplegic agent. The effectiveness of tropicamide as a cycloplegic had previously been compared with that of cyclopentolate and homatropine. The maximum cycloplegic effect of 1% tropicamide at 30 minutes was observed to be greater than that obtained from 1% cyclopentolate or 5% homatropine. However, the clinically effective cycloplegia produced by tropicamide was only maintained for approximately 35 minutes after instillation of a single drop. The effects of 1% tropicamide, 1% cyclopentolate, and 4% homatropine combined with 1% hydroxyamphetamine were compared. In one eye, two drops of tropicamide were given 5 minutes apart. The other eye received either one drop of 1% cyclopentolate or two instillations of 4% homatropine combined with hydroxyamphetamine. Subjective measurements of accommodation were performed 20 to 40 minutes after



**Figure 9-7** Average residual accommodation (measured subjectively) after instillation of 1% tropicamide, 1% cyclopentolate, or 4% homatropine in adult patients. (Reprinted with permission from Gettes BC, Belmont O. Tropicamide: comparative cycloplegic effects. *Arch Ophthalmol* 1961;66:336-340. Copyright 1961, American Medical Association.)

the second drop. Figure 9-7 summarizes these subjective measures of accommodation. Although the initial intensity of the cycloplegic effect of tropicamide was nearly equal to that of cyclopentolate, accommodation rapidly returned after approximately 35 minutes. Cyclopentolate remained effective 35 minutes after instillation and for the duration of the measurements (55 minutes after instillation). The homatropine-hydroxyamphetamine combination exhibited a slower onset, reaching clinically effective levels of cycloplegia for refraction at 45 to 55 minutes. Similar studies using 1% tropicamide, 1% cyclopentolate, or 5% homatropine, two drops to each eye, found that cyclopentolate was superior to tropicamide in 92% of patients and homatropine was superior to tropicamide in 80% of patients. Moreover, the magnitude of residual accommodation (assessed subjectively) was inversely related to age and was greater than 2.5 D with tropicamide in patients under 40 years of age (Table 9-3).

The time course of cycloplegia for tropicamide and cyclopentolate in adult subjects aged 20 to 30 years was studied. The data indicated that one drop of 0.5% or 1.0% tropicamide leaves as much as 28% to 40% of baseline accommodation active at 20 minutes after drug instillation when residual accommodation is determined by subjective methods. In contrast, cyclopentolate 0.5% or 1.0% induced a deeper and more stable level of cycloplegia within the same period when the same measurement methods were used.

Prior application of a topical anesthetic appears to prolong the mydriatic and cycloplegic actions of tropicamide. It was reported that prior instillation of proparacaine 0.5% in blue-green eyes prolonged both the time required for 50% recovery to normal pupil size and the time during which mydriasis was maintained within

**Table 9-3**

Residual Accommodation (in Diopters) by the Subjective Push-Up Method After Instillation of Two Drops of 1% Tropicamide in One Eye and 1% Cyclopentolate or 5% Homatropine in the Fellow Eye

Age (yr)	Tropicamide at 30 Min (No. of Subjects)	Cyclopentolate at 60 Min (No. of Subjects)	Homatropine at 60 Min (No. of Subjects)
0-9	6.25 (6)	— (0)	2.5 (6)
10-14	3.65 (20)	1.6 (5)	2.6 (15)
15-19	3.2 (7)	1 (3)	1.6 (4)
20-29	3.1 (7)	1.4 (7)	— (0)
30-39	2.6 (7)	2 (7)	— (0)
40+	1.7 (3)	1.1 (3)	— (0)

Modified from Milder B. Tropicamide as a cycloplegic agent. Arch Ophthalmol 1961;66:60. Copyright 1961, American Medical Association.

90% of maximum. In brown-hazel eyes the time for recovery to 50% was lengthened by 30 minutes, but the time during which mydriasis remained 90% of maximum was not lengthened by prior application of the anesthetic. The time during which cycloplegia was maintained within 90% of maximum was extended by 3 to 4 minutes in all eyes, regardless of degree of pigmentation. The effect of the prior instillation of 0.5% proparacaine on pupil dilation obtained with 0.5% tropicamide was investigated. In persons with light irides, when the instillation of 0.5% tropicamide was preceded by the instillation of 0.5% proparacaine, a statistically significant difference in pupil diameter was obtained compared with the fellow eye, in which tropicamide instillation was preceded by the instillation of saline; however, the effect was small (0.6 mm) and not clinically significant. Proparacaine preinstillation had no effect in the dark iris group. In addition, the rate of pupillary dilation over the first 20 minutes after drug application was not significantly different in the test and control eyes for either iris group. Therefore, the application of proparacaine before the application of tropicamide is not recommended in routine clinical practice. The depth of cycloplegia as assessed by subjective techniques 20 minutes after instillation of 0.5% or 1.0% tropicamide is greater in eyes pretreated with 0.5% proparacaine than in eyes receiving tropicamide alone. However, the difference did not reach statistical significance at the 5% level.

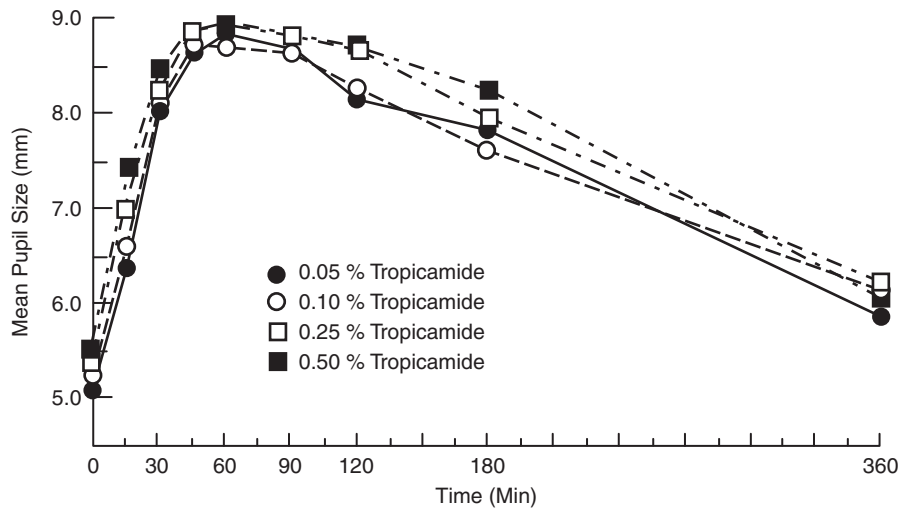
### Clinical Uses

Because of its relatively fast onset, short duration, and sufficient intensity of action, tropicamide is considered the drug of choice for ophthalmoscopy and other procedures in which mydriasis is desirable. Moreover, unlike with atropine, homatropine, or cyclopentolate, pupillary dilation with tropicamide appears to be less dependent on iris pigmentation.

In clinical situations in which only mydriasis is necessary, a pupillary dilation with minimum paralysis of accommodation is desirable so as not to interfere with

near vision tasks. To achieve clinically useful mydriasis with minimal accommodative paralysis, various combinations of drugs have been investigated.

Other investigators have tested various concentrations of tropicamide with adrenergic agonists. A combination of 0.1% tropicamide and 1% hydroxyamphetamine was effective for routine ophthalmoscopic examinations. Various concentrations of tropicamide combined with 1% hydroxyamphetamine were evaluated to find a clinically useful mydriatic with minimal accommodative effects. When combined with 1% hydroxyamphetamine, 0.05%, 0.1%, 0.25%, or 0.5% tropicamide produced mean pupillary diameters 3.5 to 3.8 mm greater than baseline values (Figure 9-8). The differences in pupillary diameter among the concentrations tested were not statistically significant in this group of 16 predominately light iris subjects. However, inhibition of the pupillary response to light was directly related to the concentration of tropicamide. The effect on accommodation was also directly related to the concentration of tropicamide (Figure 9-9). The mean loss of accommodation was 3.8 D for 0.05% tropicamide and 5.5 D for the 0.5% concentration. Most eyes returned to baseline values at 6 hours. By 24 hours both pupil size and accommodation were at predrug levels. The ideal combination was recommended as 0.25% tropicamide combined with 1% hydroxyamphetamine for dilation and inhibition of the light response without reducing accommodation to the point of interfering with near vision. A study compared the mydriatic and cycloplegic effect of 0.25% tropicamide combined with 1% hydroxyamphetamine (Paremyd) to one drop of 0.5% tropicamide combined with 2.5% phenylephrine. Results found that both Paremyd and the 0.5% tropicamide and 2.5% phenylephrine combination produced adequate pupil dilation and that the mydriasis was not affected by iris color. However, the dilation was not challenged with a bright light stimulus such as that needed for a dilated fundus examination. It was observed that dilation with Paremyd was faster in mainly white subjects with light brown irides than in black subjects with dark brown irides.



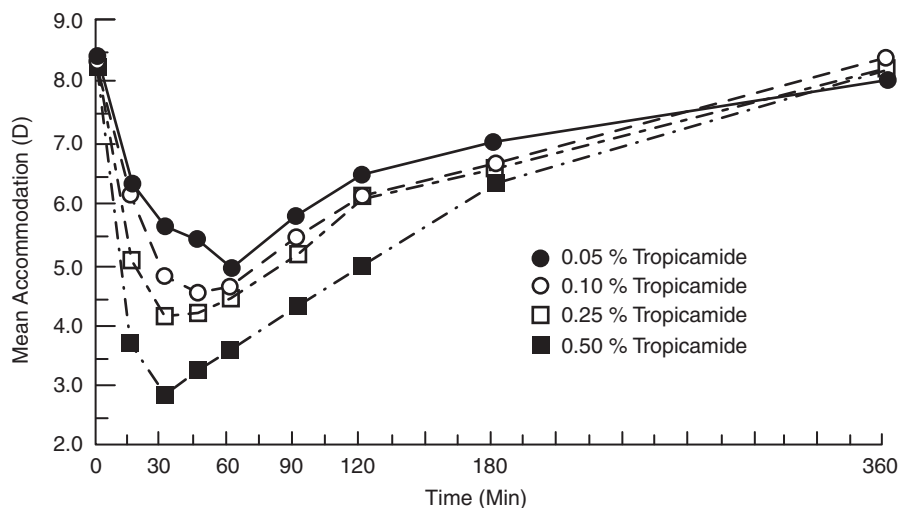
**Figure 9-8** Mydriatic dose-response curve for hydroxyamphetamine 1% combined with one of four concentrations of tropicamide. (Modified from Larkin KM, Charap A, Cheetham JK, Frank J. Ideal concentration of tropicamide with hydroxyamphetamine 1% for routine pupillary dilation. *Ann Ophthalmol* 1989;21:340-344.)

Similarly, subjects with light irides recovered accommodative function more rapidly. Overall, Paremyd provided adequate dilation for the intense illumination of the binocular indirect ophthalmoscope in all study subjects, irrespective of iris pigmentation. Subjects also reported that Paremyd was more comfortable on initial instillation than the 0.5% tropicamide and 2.5% phenylephrine combination. Paremyd is currently only available through compounding pharmacies.

The advantage of tropicamide compared with other mydriatic-cycloplegic agents is its fast onset and relatively short duration of action. Practitioners should note that, clinically, tropicamide has a greater mydriatic than cycloplegic effect. Although tropicamide is not the drug

of choice for cycloplegic refractions in patients with suspected latent hyperopia, tropicamide can stabilize fluctuations in accommodation and thus aid in the refraction of children. One percent tropicamide compared favorably with 1% cyclopentolate as a useful agent for measuring distance refractive error in school-aged children with low to moderate hyperopia. Tropicamide 1% also produces a significant decrease in accommodation when measured both objectively and subjectively and has proved useful in the measurement of ocular components.

Pupil dilation with tropicamide 0.01% is being evaluated as a diagnostic tool for Alzheimer's and Parkinson's disease. However, the dependability of this test is still very controversial.



**Figure 9-9** Cycloplegic dose-response curve for hydroxyamphetamine 1% combined with one of four concentrations of tropicamide. (Modified from Larkin KM, Charap A, Cheetham JK, Frank J. Ideal concentration of tropicamide with hydroxyamphetamine 1% for routine pupillary dilation. *Ann Ophthalmol* 1989;21:340-344.)



### Side Effects

Tropicamide, particularly the 1% concentration, may produce transient stinging on instillation. As with the other mydriatic-cycloplegics, it can raise IOP in eyes with open-angle glaucoma. In most patients the increase in IOP is small and may be related to a decrease in aqueous outflow. In some patients, however, dilation can result in a significant increase in IOP. Dilation with 1.0% tropicamide and 2.5% phenylephrine has resulted in pressure elevations of 5 mm Hg or more in 32% and of 10 mm Hg or more in 12% of patients with open-angle glaucoma. The incidence of pressure elevations appears to be highest in eyes receiving miotic therapy. Thus to reduce the risk associated with iatrogenic pressure elevations, it seems prudent to recheck IOP after dilation with tropicamide in glaucoma patients.

Tropicamide, like atropine, cyclopentolate, and scopolamine, enters the systemic circulation rapidly. After applying two 40-ml drops of 0.5% tropicamide to one eye in eight patients, peak plasma concentrations were reached in 5 to 30 minutes but were variable (1.3 to 5.2 ng/ml). A mean peak concentration of 2.8 ng/ml was measured at 5 minutes. Despite the rapid systemic absorption, tropicamide has a low affinity for systemic muscarinic receptors. Thus adverse systemic reactions to tropicamide are quite rare. Two studies observed no significant adverse reactions associated with the use of tropicamide in 3,851 drug applications in patients undergoing ophthalmoscopy with either 0.5% or 1% tropicamide. The only reported effects were mild and transient; transient changes in IOP on the order of 4 to 12 mm occurred in seven patients, and one individual experienced a transient intermittent esotropia.

One reaction was reported in a 10-year-old white boy. Immediately after instillation of one drop of 0.5% tropicamide into each eye, the patient fell from the chair to the floor unconscious. Generalized muscular rigidity, pallor, and cyanosis followed. Within a few minutes the patient became flaccid and regained consciousness, but he remained in a state of generalized weakness and drowsiness. Approximately 1 hour after the onset of the episode, his vital signs were normal but he remained drowsy. This reaction was classified as acute hypersensitivity manifested by anaphylactic shock. The spontaneous recovery, however, argues against an anaphylactic mechanism. Others suggested that psychomotor factors may have played a role in this reaction or that the child fainted.

Because tropicamide is reported to be devoid of vasopressor effects in adults, it is one of the safest mydriatic agents for use in patients with systemic hypertension, angina, or other cardiovascular disease. Tropicamide has also been shown to be the safest agent (as indexed by changes in blood pressure and heart rate) for dilated retinal examinations in neonates. Additional information on pupil dilation in infants may be found in Chapter 8.

### Contraindications

Patients with hypersensitivity to belladonna alkaloids may also exhibit cross-sensitivity to topical ocular tropicamide. Tropicamide is also contraindicated in patients with narrow anterior chamber angles in whom angle-closure glaucoma may be iatrogenically induced, but the reported risk is small. The eyes of 6,679 nonselected white adults aged 55 years or older were dilated with 0.5% tropicamide and 5% phenylephrine. Although the prevalence of narrow anterior chamber angles was 2.2% (Van Herick method), only two participants (0.03%) developed an acute angle-closure glaucoma. Theoretically, tropicamide is not very likely to cause angle closure because it is moderately selective for M4 receptors, and it was demonstrated that the muscarinic receptors in the trabecular meshwork are primarily of the M2 and M3 kind. In a multiracial population of adults over age 40 years, a 0.8% prevalence of narrow angles by penlight examination was reported. The risk of inducing an acute angle-closure glaucoma with 1% tropicamide and 2.5% phenylephrine was estimated to be approximately 0.3% if patients who have shallow anterior chamber angles via penlight examination or who have a history of glaucoma are excluded from dilation because of these risk factors.

### SELECTED BIBLIOGRAPHY

- Anicho UM, Cooper J, Feldman J, et al. A study of the clinical efficacy of Paremyd with and without dapiprazole in subjects with light and dark brown irides. *Optom Vis Sci* 1999; 76:94-101.
- Applebaum MA, Jaanus SD. Use of diagnostic pharmaceutical agents and incidence of adverse effects. *Am J Optom Physiol Opt* 1983;60:384-388.
- Binkhorst RD, Weinstein GW, Baretz RM, Clahane MS. Psychotic reaction induced by cyclopentolate. *Am J Ophthalmol* 1963; 56:1243-1245.
- Brown C, Hanna C. Use of dilute drug solutions for routine cycloplegia and mydriasis. *Am J Ophthalmol* 1978;86: 820-824.
- Brown JH. Atropine, scopolamine and related antimuscarinic drugs. In: Gilman AG, Rall TW, Nies AS, et al., eds. *Goodman and Gilman's the pharmacological basis of therapeutics*. New York: McGraw-Hill, 1990; Chapter 8.
- Brown MM, Brown GC, Spaeth GL. Lack of side effects from topically administered 10% phenylephrine eyedrops. *Arch Ophthalmol* 1980;98:487-489.
- Chou A-C, Shih Y-F, Ho T-C, Lin L L-K. The effectiveness of 0.5% atropine in controlling high myopia in children. *J Ocul Pharmacol Ther* 1997;13:61-67.
- Dillon JR, Tyhurst CW, Yolton RL. The mydriatic effect of tropicamide on light and dark irides. *J Am Optom Assoc* 1977; 48:653-658.
- Egashira AM, Kish LL, Twelker JD, et al. Comparison of cyclopentolate versus tropicamide cycloplegia in children. *Optom Vis Sci* 1993;70:1019-1026.
- Eggers HM. Toxicity of drugs used in diagnosis and treatment of strabismus. In: Srinivasan DB, ed. *Ocular therapeutics*. New York: Masson, 1980: 115-122; Chapter 15.
- Fedderson IM. Beitrag zur Atropinvergiftung. *Inaug Dissert Berlin*; Francke O. 1884, as cited by Marron J. Cycloplegia and



- mydriasis by use of atropine, scopolamine and homatropine-*paredrine*. *Arch Ophthalmol* 1940;23:340-350.
- Fitzgerald DA, Hanson RM, West C, et al. Seizures associated with 1% cyclopentolate eyedrops. *J Paediatr Child Health* 1990;26:106-107.
- Gambill HD, Ogle KN, Kearns TP. Mydriatic effect of four drugs determined with pupillograph. *Arch Ophthalmol* 1967;77:740-746.
- Gettes BC. Tropicamide: comparative mydriatic effects. *Am J Ophthalmol* 1963;55:84-87.
- Gettes BD, Leopold IH. Evaluation of five new cycloplegic drugs. *Arch Ophthalmol* 1953;49:24-27.
- Gil DW, Krauss HA, Bogardus AM, Wolde-Mussie E. Muscarinic receptor subtypes in human iris-ciliary body measured by immunoprecipitation. *Invest Ophthalmol Vis Sci* 1997;38:1434-1442.
- Huang F, Wu WM, Ji F, et al. Design, pharmacokinetic, and pharmacodynamic evaluation of soft anticholinergics based on tropyl alpha-phenylcyclopentylacetate. *Pharmazie* 2002;57:115-121.
- Iijima A, Haida M, Ishikawa N, et al. Re-evaluation of tropicamide in the pupillary response test for Alzheimer's disease. *Neurobiol Aging* 2003;24:789-796.
- Jaanus SD. Pharmacologic aspects of aging. In: Rosenbloom AA, Morgan MW, eds. *Vision and aging*. Boston: Butterworth-Heinemann, 1993; Chapter 5.
- Lahdes K, Huupponen R, Kaila T, et al. Systemic absorption of ocular scopolamine in patients. *J Ocular Pharm* 1990;6:61-66.
- Lahdes K, Kaila T, Huupponen R, et al. Systemic absorption of topically applied ocular atropine. *Clin Pharmacol Ther* 1988;44:310-314.
- Larkin KM, Charap A, Cheetham JK, Frank J. Ideal concentration of tropicamide with hydroxyamphetamine 1% for routine pupillary dilation. *Ann Ophthalmol* 1989;21:340-344.
- Lovasik JV. Pharmacokinetics of topically applied cyclopentolate HCl and tropicamide. *Am J Optom Physiol Opt* 1986;63:787-803.
- Lovasik JV, Kergoat H. Time course of cycloplegia induced by a new phenylephrine-tropicamide combination drug. *Optom Vis Sci* 1990;67:352-358.
- Luft WA, Ming Y, Stell WK. Variable effects of previously untested muscarinic receptor antagonists on experimental myopia. *Invest Ophthalmol Vis Sci* 2003;44:1330-1338.
- Luu CD, Lau Am, Koh AH, Tan D. Multifocal electroretinogram in children on atropine treatment for myopia. *Br J Ophthalmol* 2005;89:151-153.
- Manny RE, Fern KD, Zervas HJ, et al. 1% Cyclopentolate hydrochloride: another look at the time course of cycloplegia using an objective measure of the accommodative response. *Optom Vis Sci* 1993;70:651-665.
- Manny RE, Hussein M, Scheiman M, et al. Tropicamide (1%): an effective cycloplegic agent for myopic children. *Invest Ophthalmol Vis Sci* 2001;42:1728-1735.
- Merrill DL, Goldberg B, Zavell S. bis-Tropicamide, a new parasympatholytic. *Curr Ther Res* 1960;2:43-50.
- Milder B, Riffenburgh RS. An evaluation of Cyclogyl (compound 75 GT). *Am J Ophthalmol* 1953;36:1724-1726.
- Mutti DO, Zadnik K, Egashira S, et al. The effect of cycloplegia on measurement of the ocular components. *Invest Ophthalmol Vis Sci* 1994;35:515-527.
- Patel KH, Javitt JC, Tielsch JM, et al. Incidence of acute angle-closure glaucoma after pharmacologic mydriasis. *Am J Ophthalmol* 1995;120:709-717.
- Pollack SL, Hunt JS, Polse KA. Dose-response effects of tropicamide HCl. *Am J Optom Physiol Opt* 1981;58:361-366.
- Priestly BS, Medine MM, Phillips CC. Cyclomydril: a new mydriatic agent. *Am J Ophthalmol* 1960;49:1033-1034.
- Repka MX, Ray JM. The efficacy of optical and pharmacological penalization. *Ophthalmology* 1993;100:769-774.
- Sampson WG. Role of cycloplegia in the management of functional myopia. *Ophthalmology* 1979;86:695-697.
- Siatkowski RM, Cotter S, Miller JM, et al. Safety and efficacy of 2% pirenzepine ophthalmic gel in children with myopia: a 1-year, multicenter, double-masked, placebo-controlled parallel study. *Arch Ophthalmol* 2004;122:1667-1674.
- Siderov J, Chuang S M-L, Ian K, et al. Effect of proparacaine on tropicamide-induced mydriasis. *Optom Vis Sci* 1997;74:1039-1043.
- Tan DT, Lam DS, Chua WH, et al. One-year multicenter, double-masked, placebo-controlled, parallel safety and efficacy study of 2% pirenzepine ophthalmic gel in children with myopia. *Ophthalmology* 2005;112:84-91.
- Van Herick WV, Shaffer RN, Schwartz A. Estimation of the width of the angle of the anterior chamber. Incidence and significance of the narrow angle. *Am J Ophthalmol* 1969;68:626-629.
- Von Noorden GK, Milam JB. Penalization in the treatment of amblyopia. *Am J Ophthalmol* 1979;88:511-518.
- Wolf AV, Hodge HC. Effects of atropine sulfate, methylatropine nitrate (Metropine) and homatropine hydrobromide on adult human eyes. *Arch Ophthalmol* 1946;36:293-301.
- Wolfs RCW, Grobbee DE, Hofman A, deJong PTVM. Risk of acute angle-closure glaucoma after diagnostic mydriasis in nonselected subjects: the Rotterdam Study. *Invest Ophthalmol Vis Sci* 1997;38:2683-2687.
- Yolton DP, Kandel JS, Yolton RL. Diagnostic pharmaceutical agents: side effects encountered in a study of 15,000 applications. *J Am Optom Assoc* 1980;51:113-117.
- Zinn KM. *The pupil*. Springfield, IL: Charles C Thomas, 1972; Chapters 1 and 2.

## Ocular Hypotensive Drugs

*Jimmy D. Bartlett, Richard G. Fiscella, Siret D. Jaanus, and Howard Barnebey*

Glaucoma can often lead to visual impairment and even blindness. Although great progress has been made in defining the spectrum of diseases known collectively as *glaucoma*, their etiopathogenesis is still poorly understood. Management of these disorders is almost always directed at lowering the existing intraocular pressure (IOP). This can be accomplished either pharmacologically or surgically by decreasing aqueous production or by increasing aqueous outflow.

Many pharmacologic agents are available to decrease IOP through distinctly different mechanisms. Because of their unique mechanisms of action, these drugs are used either alone or in combination in attempts to reduce IOP to acceptable levels that forestall further damage to retinal ganglion cells. This chapter considers the most clinically useful ocular hypotensive agents (Box 10-1). Chapter 34 addresses how these drugs are used in the context of specific glaucomatous conditions.

### PROSTAGLANDIN ANALOGUES

Because of their convenient use (once daily) in the treatment of glaucoma, their superior efficacy as ocular hypotensive agents, and good safety profile, the prostaglandin analogues are the first-line treatment for most patients with ocular hypertension and open-angle glaucoma. These agents represent a novel class of topically active drug with demonstrated long-term clinical usefulness. Latanoprost was the first commercially successful prostaglandin for clinical use in the treatment of glaucoma.

#### Latanoprost (Xalatan)

##### Pharmacology

Prostaglandins were originally discovered in the eye as mediators of the ocular inflammatory response, and most of the preliminary research focused on their potential role in uveitis and other inflammatory diseases. More recent studies, however, have demonstrated additional roles for prostaglandins in several physiologic processes.

When delivered in adequate doses, prostaglandins can either mediate inflammation or lower IOP. The therapeutic index of various prostaglandin analogues has been explored, and latanoprost demonstrates sufficient ocular hypotensive activity with minimal side effects. Latanoprost is an analogue of the prodrug prostaglandin  $F_{2a}$  (PGF<sub>2a</sub>)-isopropyl ester. When instilled topically into the human eye, latanoprost is converted by corneal esterases into latanoprost acid, which exerts its biologic activity at the FP receptor on the ciliary muscle. The primary ocular hypotensive effect appears to be mediated by activation of FP receptors (receptors for PGF<sub>2a</sub>). Although the prostanoid FP receptors are known to be present in the eye, their specific localization and cellular functions are not well defined. These FP receptors are found in the ciliary muscle and iris sphincter muscle of the human eye. In the late 1990s, these receptors were also discovered in human trabecular meshwork cells, which may play a role in mediating some of the ocular hypotensive effects of PGF<sub>2a</sub> in the eye.

As a selective FP receptor agonist, latanoprost appears to exert its ocular hypotensive effects exclusively by increasing uveoscleral outflow. This effect is mediated by a substantial remodeling of extracellular matrix adjacent to the ciliary muscle cells. Topically applied prostaglandins have been demonstrated to reduce collagen levels in the ciliary muscle and adjacent sclera, and these changes may explain, at least in part, reduced hydraulic resistance to aqueous flow through these tissues. Although the specific mechanisms underlying reduction of collagen are obscure, exposure to PGF<sub>2a</sub> has been shown to increase production of matrix metalloproteinases, which are capable of degrading ciliary muscle extracellular matrix, which could in turn lead to the reduction of hydraulic resistance to uveoscleral flow.

In long-term clinical trials, latanoprost has been shown to be at least as effective as timolol maleate, a  $\beta$ -blocker, in reducing IOP. The ocular hypotensive effect of latanoprost is approximately 27% to 30%, whereas timolol reduces IOP approximately 20% (Figure 10-1). These results are of clinical significance because they reflect

**Box 10-1** Ocular Hypotensive Drugs Used to Treat Glaucoma**Prostaglandin analogues**

Latanoprost  
Travoprost  
Bimatoprost

 **$\beta$ -Adrenergic antagonists ( $\beta$ -blockers)**

Timolol  
Levobunolol  
Betaxolol  
Metipranolol  
Carteolol

**Adrenergic agonists**

Apraclonidine  
Brimonidine

**Carbonic anhydrase inhibitors**

Acetazolamide  
Methazolamide  
Dorzolamide  
Brinzolamide

**Cholinergic agonist (miotic)**

Pilocarpine

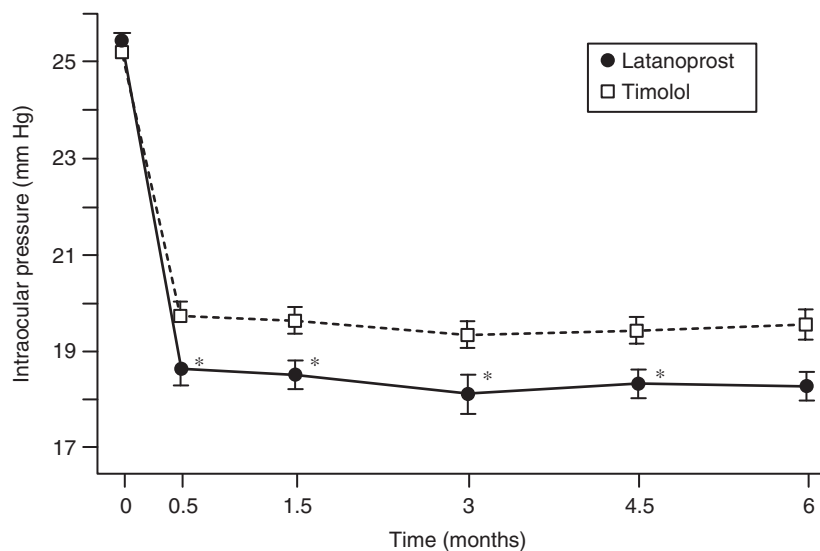
once-daily dosing of latanoprost 0.005% compared with twice-daily dosing of timolol 0.5% in patients with ocular hypertension or early primary open-angle glaucoma. Moreover, in patients with pigmentary and other forms of secondary glaucoma, latanoprost 0.005% dosed once daily has been shown to have a greater hypotensive effect than does timolol 0.5%.

The exact peak ocular hypotensive effect of latanoprost is unknown, but it is probably at least 8 hours after drug administration. Although administration of latanoprost once daily provides relatively uniform circadian (around-the-clock) reduction of IOP by itself or in combination with timolol, latanoprost seems to be most effective in the 12- to 24-hour period after administration. As a result, IOP readings are generally lower during the daytime after drug administration during the preceding evening or at bedtime. Compared with the ocular hypotensive effect of twice-daily timolol, latanoprost applied once daily in the evening seems to provide better diurnal IOP control. In addition to increasing the peak IOP effect during the daytime, evening dosing of latanoprost also reduces the range of diurnal curve compared with morning administration.

The ocular hypotensive effect of latanoprost appears to be independent of race, gender, age, iris color, type of glaucoma, or previous glaucoma therapy.

**Clinical Uses**

Latanoprost and other prostaglandin analogues have supplanted the  $\beta$ -blockers as the drugs of first choice



**Figure 10-1** Effect of latanoprost 0.005% applied once daily at 8:00 PM and timolol 0.5% applied twice daily at 8:00 AM and 8:00 PM on intraocular pressure (IOP) as determined at 8:00 AM (12 hours after last dose) in patients with ocular hypertension or glaucoma. Asterisks signify a significant further reduction of IOP by latanoprost compared with timolol. (Adapted from Camras CB. Comparison of latanoprost and timolol in patients with ocular hypertension and glaucoma. *Ophthalmology* 1996;103:138-147.)

in the management of glaucoma and ocular hypertension because the former are the most effective ocular hypotensive agents available. Moreover, latanoprost has other advantages over  $\beta$ -blockers, including the lack of systemic side effects. Unlike  $\beta$ -blockers, latanoprost reduces IOP as effectively during the night as during the day. The efficacy, convenience of once-daily dosing, rare allergic reactions, ocular tolerability, and systemic safety of latanoprost have permitted this drug to take its place as first- or second-line therapy for many types of glaucoma.

Latanoprost should be dosed only once daily in the evening or at bedtime because twice-daily instillation offers less satisfactory control of IOP. Once-daily dosing offers patient convenience and improves compliance. The drug is well tolerated and provides adequate control of IOP for at least several years in patients with open-angle glaucoma or ocular hypertension. There is no evidence that long-term treatment leads to drug tolerance, with subsequent loss of IOP control. In addition to its efficacy in the treatment of primary open-angle glaucoma and ocular hypertension, latanoprost may significantly reduce IOP in patients with glaucoma associated with Sturge-Weber syndrome. Latanoprost can be more effective than  $\beta$ -blockers in reducing IOP in patients with pigmentary glaucoma. Perhaps because of its effect on uveoscleral outflow, latanoprost can often produce a significant IOP reduction in patients with normal-tension glaucoma, but most eyes on latanoprost monotherapy may not achieve a 30% reduction of IOP. In patients with normal-tension glaucoma, latanoprost seems to be more effective at higher IOP levels. Most patients with pediatric glaucomas have little IOP reductions with latanoprost therapy, but some children, particularly older children and those with juvenile-onset open-angle glaucoma, can have a significant ocular hypertensive effect from the drug.

In addition to its efficacy when used alone as monotherapy, latanoprost can have additive effects when used in conjunction with most other ocular hypotensive medications. This additivity can be explained on the basis of the unique mechanism of action of latanoprost. Because latanoprost reduces IOP by increasing uveoscleral outflow, the drug is useful in combination with both aqueous suppressants and drugs that enhance aqueous outflow through the conventional trabecular meshwork pathway. The additive ocular hypotensive effects achieved with the combination of latanoprost and timolol are greater than when brimonidine, dorzolamide, or pilocarpine is used with timolol. The ocular hypotensive effect of latanoprost is also additive to that achieved with miotics, and pilocarpine seems to be most effective when the bedtime dose is administered 1 hour after administration of latanoprost. In addition to its effects when added to individual ocular hypotensive agents, latanoprost may provide a significant further reduction of IOP in patients already receiving maximal tolerated medical therapy and thus may be capable of delaying surgery in some patients.

Many clinicians tend to add additional medications in the management of patients who are inadequately controlled with ocular hypotensive monotherapy. Recent studies, however, have suggested that patients can be switched from timolol monotherapy to latanoprost monotherapy, which often further reduces IOP by 8% to 25%. The additional ocular hypotensive effect of switching from timolol to latanoprost can be equivalent to that of adding dorzolamide to timolol. Thus, to facilitate patient compliance and reduce medication cost, clinicians should consider switching to latanoprost monotherapy, or another prostaglandin analogue, before attempting combination drug treatment in patients whose IOP is inadequately controlled by  $\beta$ -blockers.

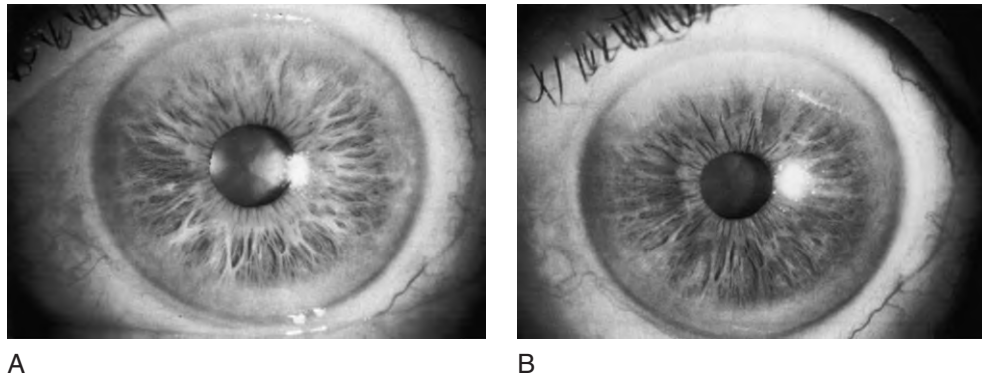
Latanoprost (Xalatan) is commercially formulated as an aqueous solution in a concentration of 0.005% preserved with 0.02% benzalkonium chloride (BAC). The recommended dosage of latanoprost is one drop daily in the evening, which permits better diurnal IOP control than does morning instillation. Refrigeration of the bottle is suggested for patients who use the medication in only one eye. Refrigeration is unnecessary for treatment of both eyes, because the bottle should be depleted within the medication's 6-week shelf-life.

### Side Effects

Reported side effects of latanoprost are listed in Box 10-2. Perhaps the most unique of these is darkening of iris color, which occurs in approximately 5% to 20% of patients and can develop as early as 4 weeks, but usually several months, after initiation of latanoprost therapy. Only mixed-colored irides have the tendency to demonstrate the increased pigmentation, in which the iris becomes uniformly darker (Figure 10-2). These irides are typically green-brown or blue/gray-brown, where the brown is distributed around the pupil. Over time, the brown pigmentation spreads peripherally, giving the iris a more uniformly darker coloration. Irises with a uniform blue, gray, green, or brown color do not appear to be susceptible. Moreover, preexisting iris freckles or nevi do not change shape or color during treatment. The change in eye color appears to be permanent after

#### Box 10-2 Side Effects of Latanoprost

- Iris color darkening
- Increased eyelid pigmentation
- Hypertrichosis
- Conjunctival hyperemia
- Allergy
- Cystoid macular edema
- Anterior uveitis
- Punctate corneal erosions
- Corneal pseudodendrites



**Figure 10-2** Left eye of patient treated with latanoprost before (A) and after (B) 6 months of treatment. (Adapted from Alm A, Stjernschantz J. Effects on intraocular pressure and side effects of 0.005% latanoprost applied once daily, evening or morning. A comparison with timolol. *Ophthalmology* 1995;102:1743-1752.)

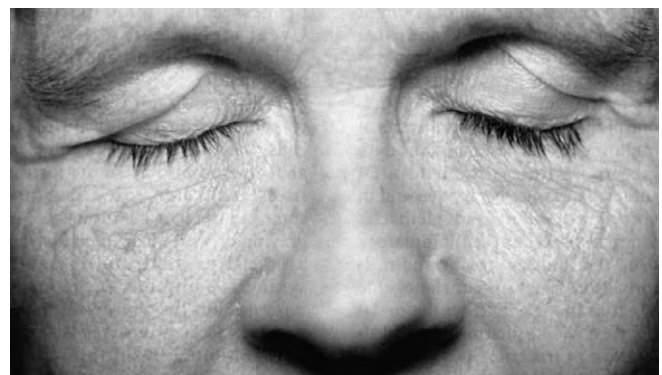latanoprost treatment is discontinued. Both in vivo studies in monkeys and in vitro studies on cultured human iridial melanocytes have shown that the increased pigmentation is caused by an increase of melanin within the iridial melanocytes and is not caused by proliferation of melanocytes. In some eyes that have latanoprost-induced darkening of iris color, a relative ocular sympathetic insufficiency has been demonstrated. It may be possible that the sympathetic nervous system acts through prostaglandins to maintain iris color, and the administration of latanoprost may thus substitute for deficient sympathetic innervation to stimulate melanogenesis.

An increase in pigmentation of eyelid skin is also possible. This increased skin pigmentation can occur several months after latanoprost therapy is begun. Once the drug is discontinued, the drug-induced pigmentary changes usually subside.

PGF<sub>2a</sub> analogues, including latanoprost, bind to cell surface receptors that activate phospholipase C, initiating a variety of cellular responses, including stimulation of cell division and growth. Altered growth patterns can be induced by latanoprost and are manifested as abnormal growth of hair follicles. This phenomenon is known as hypertrichosis. The condition is evident clinically by observation of an increased number, length, thickness, curvature, or darkening of the eyelashes (Figure 10-3). Because the condition can be subtle, it is most evident in patients who receive unilateral latanoprost therapy. Evidence of hypertrichosis can be seen within several weeks after initiation of latanoprost treatment, and the condition can occur in whites, blacks, Asians, and Hispanics. It is most obvious, however, in patients who have brown or black hair. In addition to the presence of elongated or thickened eyelashes, some patients have a striking curling of the lashes, and other patients demonstrate growth of lash-like hair in areas adjacent to the normal eyelash distribution. Although hypertrichosis is benign, it can represent a cosmetic concern for some patients, especially in cases induced by unilateral latanoprost treatment.

Latanoprost can produce a mild, usually clinically insignificant, conjunctival hyperemia in approximately one-third of treated patients. This may represent a cosmetic problem for some patients, thereby leading to noncompliance with therapy. Although relatively rare, some patients develop an allergic reaction or irritation to latanoprost, necessitating discontinuation of the drug. Allergic reactions are probably more common in patients who have had previous allergic reactions and are treated with multiple glaucoma medications.

Numerous cases have been reported in which latanoprost therapy has been associated with the development of cystoid macular edema (CME). Considering the role that prostaglandins play in the pathogenesis of CME, it may be reasonable to assume that topically applied latanoprost can increase the risk of CME. However, latanoprost itself is not known to be vasoactive or to affect vascular permeability. Furthermore, pharmacokinetic studies have failed to demonstrate significant levels of latanoprost in the posterior segment of the eye after topical application. Indeed, controlled clinical studies



**Figure 10-3** Eyelashes of left eye are darker and denser than those of right eye 28 weeks after latanoprost treatment was begun. (Adapted from Wand M. Latanoprost and hyperpigmentation of eyelashes. *Arch Ophthalmol* 1997;115:1206-1208.)

have shown that latanoprost may enhance disruption of the blood-retinal barrier, but the increased incidence of angiographically documented CME formation in early postoperative pseudophakias is low and most likely clinically insignificant. Other studies have suggested that the BAC preservative rather than the active prostaglandin may be causative factors.

Similar to CME, a number of cases have been reported alleging an association between latanoprost therapy and the development of anterior uveitis. Although prostaglandins play an important role in the development of vascular permeability associated with uveitis, disruption of the blood-aqueous barrier associated with latanoprost can be small, transient, and sometimes reversible despite continued latanoprost therapy.

Punctate epithelial corneal erosions have occurred in patients using latanoprost. This epithelial keratopathy is sporadic and mild, and the condition may be associated more with the BAC preservative than with the latanoprost itself.

The development of latanoprost-induced corneal dendritiform epitheliopathy has been reported. These lesions resemble those of herpes simplex virus epithelial keratitis, but, in contrast to herpes simplex virus disease, the pseudodendrites associated with latanoprost promptly disappear on discontinuation of drug therapy. Coincident with discontinuation of latanoprost, patients can be treated with preservative-free artificial tears with or without topical antibiotics.

Several cases have been reported in which herpes simplex virus keratitis developed after initiation of latanoprost therapy. Although these cases are anecdotal, it is known that prostaglandins may play a crucial role in mediating inflammatory events that could incite herpetic infection.

Latanoprost appears to be devoid of any systemic side effects. In contrast to  $\beta$ -blockers, latanoprost has no significant effects on the cardiovascular system or pulmonary system.

### Contraindications

Latanoprost may be relatively contraindicated in patients with a history of uveitis or prior incisional ocular surgery. Likewise, the drug may be contraindicated in patients who have had previous episodes of herpes simplex virus keratitis. Latanoprost should be used cautiously after cataract surgery in patients who have risk factors favoring the development of CME. These include a history of CME, epiretinal membrane formation, vitreous loss during cataract surgery, history of macular edema associated with branch retinal vein occlusion, history of anterior uveitis, and diabetes mellitus. It is also wise to advise patients that unilateral treatment can result in heterochromia or hypertrichosis that may become cosmetically objectionable. Unlike  $\beta$ -blockers, latanoprost is not contraindicated in patients with concomitant bronchial asthma because the drug is not

associated with bronchoconstriction or deterioration of asthma.

## Travoprost (Travatan)

### Pharmacology

Travoprost is a  $\text{PGF}_{2a}$  analogue used for treatment of patients with open-angle glaucoma or ocular hypertension. Its mechanism of action is similar to that of latanoprost. When instilled topically into the human eye, travoprost, a prodrug, is converted by corneal esterases into travoprost acid, which exerts its biologic activity at the FP receptor on the ciliary muscle. The result is enhanced uveoscleral outflow. Clinical studies indicate that the 0.004% solution provides the maximum ocular hypotensive effect with an acceptable safety profile. Travoprost 0.004% provides excellent diurnal IOP control throughout a 24-hour period, reducing IOP from 6.8 to 8.3 mm Hg over the diurnal IOP cycle. Both morning and evening dosing regimens produce significant IOP reductions 24 hours after dosing, and morning and evening dosing schedules appear to be equally effective. As has been shown with latanoprost, twice-daily dosing of travoprost does not appear to have greater ocular hypotensive efficacy compared with once-daily dosing.

### Clinical Uses

Travoprost is indicated for the treatment of elevated IOP in patients with open-angle glaucoma and ocular hypertension. The drug is formulated as an aqueous solution in a concentration of 0.004% preserved with 0.015% BAC. The recommended dosage is one drop daily in the evening.

Both in vitro and in vivo studies of corneal epithelial cells have demonstrated the potential for toxicity to BAC. The implication is that chronic use of BAC-containing glaucoma medications has the potential to cause or exacerbate ocular surface disease. This research has led to the development of a BAC-free prostaglandin analogue for the treatment of glaucoma. Travoprost (Travatan Z) is formulated with a unique ionic buffered compound consisting of zinc, sorbitol, and borate (sofZia), which has the preservative and antimicrobial properties of BAC but without its associated toxic effects.

A 3-month study demonstrated identical IOP lowering efficacy between travoprost 0.004% with and without BAC in patients with open-angle glaucoma or ocular hypertension. In a double-masked multicenter study, patients were randomized to either travoprost 0.004% with BAC or travoprost 0.004% without BAC dosed once-daily in the evening. Mean IOP reductions ranged from 7.3 to 8.5 mm Hg for travoprost 0.004% without BAC and from 7.4 to 8.4 mm Hg for travoprost 0.004% with BAC. Adverse events were comparable between the two treatment groups. In one study conjunctival hyperemia occurred in slightly fewer patients treated with travoprost 0.004% without BAC than in patients treated with

travoprost 0.004% with BAC. The difference in hyperemia might suggest that in some patients BAC may be contributing to the hyperemic response.

### Side Effects

Safety assessments in travoprost studies have included evaluation of visual acuity, pupil diameter, iris color, anterior chamber flare, conjunctival hyperemia, pulse, blood pressure, blood chemistry profiles, and urinalysis values. The observed adverse events have generally been mild to moderate and have resolved without treatment. Most of the side effects seen with latanoprost can occur with travoprost treatment. Conjunctival hyperemia induced by travoprost is clinically insignificant but generally more than that observed with latanoprost.

### Contraindications

The contraindications to travoprost are the same as for latanoprost.

## Bimatoprost (Lumigan)

### Pharmacology

Bimatoprost is generally considered to be part of the prostaglandin family of ocular hypotensive analogues. Studies sponsored by the manufacturer, however, imply that bimatoprost differs sufficiently in both structure and function from other prostaglandin compounds to warrant a new class of ocular hypotensive agents, called prostamides. Prostamides are members of the fatty acid amide family. Bimatoprost is a synthetic analogue that mimics the actions of prostamides, effectively reducing IOP. Controversy exists over this drug's mechanism of action. Early studies suggested that bimatoprost works at novel prostamide-sensitive receptors. Pharmacokinetic studies indicated that bimatoprost does not act through any known prostanoid receptor, including the FP receptor. More recent studies, however, indicate that bimatoprost, like latanoprost and travoprost, does exhibit properties of a prodrug and has weak activity at the FP receptor.

Tonographic facility of outflow has been shown to increase by 35% in bimatoprost-treated eyes relative to placebo-treated eyes. This result suggests that bimatoprost increases outflow through the trabecular-meshwork outflow pathway. From the changes in the measured parameters (IOP, aqueous inflow, and facility of outflow), the drug was calculated to cause a 50% increase in uveoscleral outflow. Thus, the ocular hypotensive action of bimatoprost is believed to be due to a dual mechanism of increasing aqueous outflow through both the pressure-sensitive (trabecular) and pressure-insensitive (uveoscleral) pathways.

### Clinical Uses

Bimatoprost is formulated as a 0.03% solution in citrate/phosphate buffer, pH range 6.8 to 7.8. The concentration of preservative (BAC) is low (0.005%) and thus

may be tolerated by some BAC-sensitive patients. The drug is indicated as primary therapy for the reduction of elevated IOP in patients with open-angle glaucoma or ocular hypertension. Recommended dosage is one drop once daily in the evening.

Bimatoprost dosed once daily provides lower mean IOP than does timolol used twice daily. The mean IOP is consistently 2 to 3 mm Hg lower in patients receiving bimatoprost compared with timolol. During the 6-month pivotal clinical studies, the mean IOP reduction from baseline at 10 AM was 8.1 mm Hg (33%) with bimatoprost used once daily versus 5.6 mm Hg (23%) with timolol 0.5% twice daily. Of the bimatoprost-treated patients, 45% achieved IOP reductions of at least 35% from baseline compared with 21% of timolol-treated patients.

A 12-week, randomized, multicenter study was conducted to compare the ocular hypotensive efficacy and safety of latanoprost 0.005%, travoprost 0.004%, and bimatoprost 0.03% in patients with open-angle glaucoma or ocular hypertension. Medication was dosed once daily in the evening. At the end of 12 weeks each prostaglandin analogue was comparable in its ability to reduce IOP (Figure 10-4). However, fewer patients treated with latanoprost reported ocular adverse events, and those treated with bimatoprost encountered greater conjunctival hyperemia. In other head-to-head comparison studies bimatoprost has been shown to have a slightly greater ocular hypotensive effects that either latanoprost or travoprost.

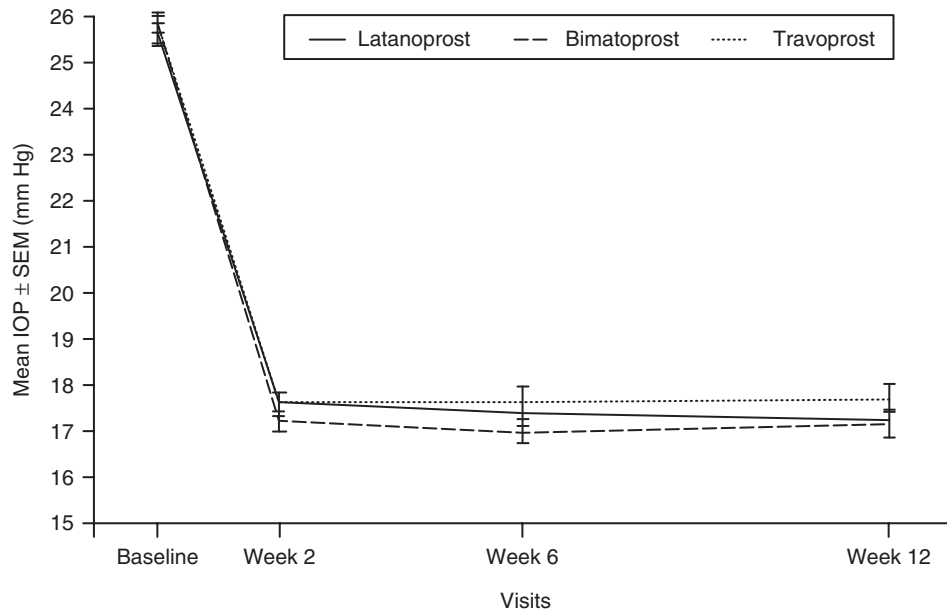
### Side Effects

Similar to latanoprost and travoprost, bimatoprost has been reported to cause changes to pigmented tissues. These reports include pigmentation of the iris and periorbital tissue (eyelid). These changes may be permanent. The long-term effects on the melanocytes and the consequences of potential injury to the melanocytes and/or deposition of pigment granules to other areas of the eye are unknown.

Conjunctival hyperemia is the most frequent side effect associated with bimatoprost therapy and generally occurs more often than in patients treated with travoprost or latanoprost. Most occurrences, however, are mild. For most patients the hyperemia occurs within 6 weeks of initiating treatment. However, hyperemia can be seen as early as within 24 hours for some patients. The severity of hyperemia often diminishes over time and is not associated with ocular surface or intraocular inflammation. The only other frequent side effect (reported in more than 10% of patients) is eye pruritus.

Systemic adverse events reported in approximately 10% of patients are infections (primarily colds and upper respiratory tract infections). Systemic adverse events reported in approximately 1% to 5% of patients include headaches, asthenia, and hirsutism.





**Figure 10-4** Unadjusted 8:00 AM mean intraocular pressure (IOP) levels by treatment and visit. (Adapted with permission from Parrish RK, Palmberg P, Sheu W-P. A comparison of latanoprost, bimatoprost, and travoprost in patients with elevated intraocular pressure: a 12 week, randomized, masked evaluator multicenter study. *Am J Ophthalmol* 2003;135:688-703.)

### Contraindications

The contraindications to bimatoprost are the same as for latanoprost.

## PROSTAGLANDIN COMBINATION COMPOUNDS

It is recognized that many patients treated for glaucoma require a second concomitant medication to lower IOP. The appeal of a combination product stems from the belief that adherence to complex multiple medical regimens is improved with simplified dosing schedules. The two most common ocular hypotensive medications are in the prostaglandin and  $\beta$ -blocker classes. Several combination products are presently available worldwide that combine various prostaglandin analogues with a non-selective  $\beta$ -blocker. These products include a combination of latanoprost or travoprost with timolol. Studies have demonstrated comparable efficacy and in the case of the travoprost-timolol combination, a favorable IOP reduction between the combination product and the separate compounds administered concomitantly. At the present time, neither combination product is available in the United States.

## $\beta$ -ADRENERGIC ANTAGONISTS

The potential ocular hypotensive effects of  $\beta$ -adrenoceptor antagonists ( $\beta$ -blockers) were first evaluated in the 1970s. This section highlights five agents currently marketed in the United States: timolol, levobunolol, betaxolol, metipranolol, and carteolol (Table 10-1).

## Timolol

### Pharmacology

Timolol is a noncardioselective  $\beta$ -blocker without intrinsic sympathomimetic activity (ISA). Antagonism of the  $\beta_2$ -adrenoceptor at the ciliary body is primarily responsible for the ocular hypotensive efficacy of timolol.

Given topically to individuals with elevated IOP, timolol induces a significant and long-lasting ocular hypotension. Mean decreases in IOP are approximately 25%, and the maximal efficacy of 0.25% and 0.5% timolol is similar. The ocular hypotensive activity of timolol is greater than that of pilocarpine and topical carbonic anhydrase inhibitors (CAIs).

Early in the development of timolol, some reports indicated the relatively rapid development of tolerance to the drug's ocular hypotensive effects, referred to as "escape." The IOP is lower early in the course of therapy than with chronic treatment. The IOP results, however, are similar with chronic use of either 0.5% timolol or 0.25% timolol. In addition, the fellow untreated eye may show a decrease in IOP, which most likely results from a consensual (contralateral) effect. Contralateral effects resulting from systemic drug absorption can be significant.

A long-term "drift" or drug tolerance has also been described. This observation may also result from changes in disease state or noncompliance in certain patients rather than as tolerance to timolol per se. Nevertheless, less than half the eyes initially treated with timolol or other  $\beta$ -blockers can be expected to be treated with the original medication after 5 years. The remainder of eyes generally requires either additional medication



**Table 10-1**  
Ophthalmic  $\beta$ -Adrenoceptor Antagonists

Generic Name	Trade Name(s)	Concentrations (%)	Predominant Receptor Blockade		
			$\beta 1$	$\beta 2$	ISA
Timolol	Timoptic	0.25, 0.5	+	+	-
	Timoptic in Ocudose				
	Timoptic-XE				
	Betimol				
	Istalol				
Levobunolol	Betagan	0.25, 0.5	+	+	-
	Levobunolol HCl				
Betaxolol	Betoptic-S	0.25 (suspension)	+	-	-
Metipranolol	OptiPranolol	0.3	+	+	-
Carteolol	Ocupress	1.0	+	+	+

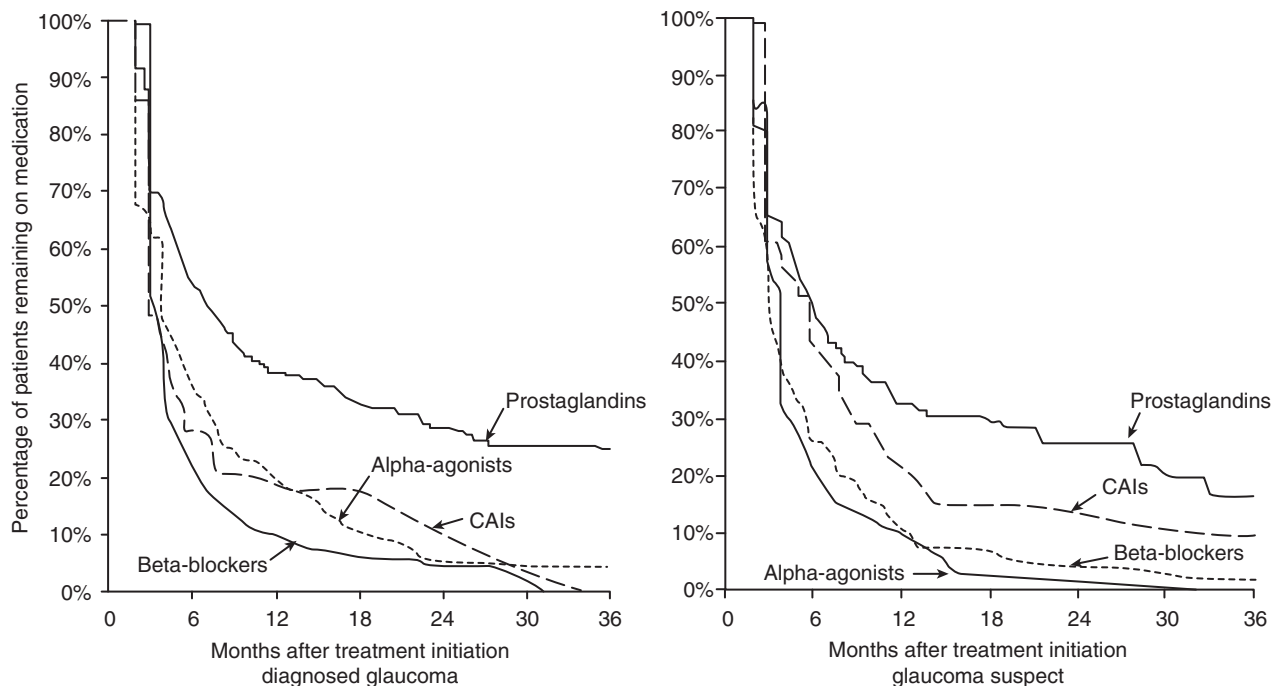
ISA = intrinsic sympathomimetic activity.

or surgery. As a class, prostaglandin analogues are associated with better long-term efficacy and compliance (treatment adherence) than are  $\beta$ -blockers (Figure 10-5).

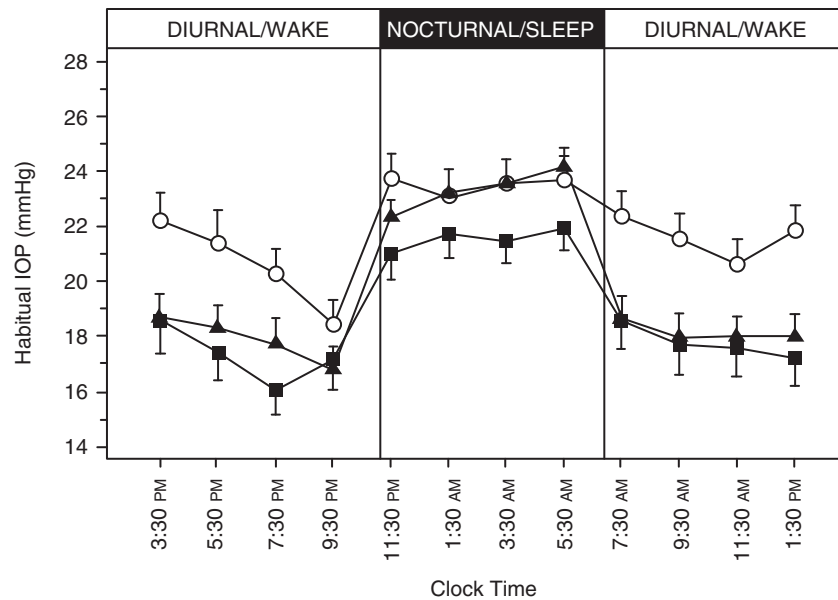
In patients with open-angle glaucoma or ocular hypertension, the ocular hypotensive efficacy of timolol is approximately 7 mm Hg, or a 26% reduction. Timolol used twice daily provides a consistent ocular hypotensive effect throughout the day. Because the IOP is reduced for at least 12 hours during chronic therapy, the instillation of

a second drop provides little additional lowering of IOP. Timolol continues to exert significant ocular hypotensive effects for up to 2 weeks once therapy is discontinued. Longer “washout” periods may be needed in patients with dark irides.

Once-daily therapy with timolol appears to be an effective treatment regimen. The ocular hypotensive effect of once-daily 0.25% or 0.5% timolol ranges from 17% to 28%, which overlaps with that of twice-daily timolol.



**Figure 10-5** Percentage of patients who remained continuously on the initially dispensed topical ocular hypotensive. Kaplan-Meier curves are shown separately by diagnostic status at treatment initiation (diagnosed vs. suspect glaucoma) and class of initial glaucoma medication. (Adapted from Nordstrom BL, Friedman DS, Mazaffari E, et al. *Am J Ophthalmol* 2005;140:598-606.)



**Figure 10-6** Twenty-four-hour patterns of intraocular pressure (IOP) in habitual body positions. Open circles represent no treatment, solid triangles the timolol treatment, and solid squares the latanoprost treatment. Measurements were taken in the sitting position (diurnal period) and in the supine position (nocturnal period) from the same 18 subjects. Error bars represent standard error of the mean. (Adapted from Liu JH, Kripke DE, Weinreb RN. *Am J Ophthalmol* 2004;138:389–395.)

Aqueous flow shows a diurnal variation, and the ability of timolol to reduce IOP is greatest during the day (Figure 10-6).

Serendipitously, most of the chronic studies of once-daily instillation of timolol selected a morning instillation. Because timolol decreases aqueous flow with daytime but not with nighttime instillation and compliance may be greater with a morning rather than evening dose, morning instillation is probably the better time for once-daily use. However, the precise timing of the daytime dose may not be critical in achieving maximal efficacy.

Little evidence exists for a greater ocular hypotensive effect of 0.5% timolol than for 0.25% timolol with chronic use. Although the response of individual patients may vary, long-term controlled clinical trials suggest that 0.25% and 0.5% timolol are equally effective.

As demonstrated with fluorophotometry, timolol acts predominantly by decreasing the production of aqueous humor and does not significantly alter facility of outflow. Most studies support the view that both short-term and long-term administration of timolol do not alter optic nerve head circulation or produce retrobulbar hemodynamic changes. The ocular hypotensive effect of timolol is additive to most other therapies, including outflow agents (e.g., pilocarpine) and inflow agents (e.g., dorzolamide, brinzolamide, apraclonidine, and brimonidine). When added to latanoprost, timolol and most other  $\beta$ -blockers further reduce IOP approximately 2 mm Hg. This reduction is less than that attained by topical CAIs such as dorzolamide (Table 10-2).

**Table 10-2**  
Intraocular Pressure Reduction at 1 Year by Various Agents Added to Latanoprost

Medication	Mean Baseline IOP (mm Hg)	Mean IOP at 1 year (mm Hg)	Mean IOP Change (mm Hg)	<i>p</i> Value <sup>a</sup>
Dorzolamide ALL	19.8	16.0	-3.9 (19.7%)	<.001
Dorzolamide BID	20.5	16.6	-3.9 (19.4%)	<.001
Dorzolamide TID	19.4	15.5	-3.9 (19.9%)	<.001
$\beta$ -blockers	19.9	17.4	-2.5 (12.3%)	<.01
Brimonidine	21.0	19.0	-2.0 (9.3%)	.0011

<sup>a</sup>*p* values are for change from latanoprost baseline.

BID = twice a day; IOP = intraocular pressure; TID = three times a day; ALL = BID and TID patients combined.

Adapted from O'Connor DJ, Martone JF, Mead A. *Am J Ophthalmol* 2002;133:836–837.

### Clinical Uses

Along with prostaglandin analogues, timolol is among the most effective ocular hypotensive agents in patients with primary open-angle glaucoma and ocular hypertension. In clinical practice timolol has been widely accepted, largely as a result of its significant ocular hypotensive efficacy, a duration of action that requires only once- or twice-daily instillation, and a relative lack of untoward ocular symptoms. In addition to its utility in the treatment of primary open-angle glaucoma and ocular hypertension, timolol is effective in the treatment of many secondary glaucomas. Timolol is also effective for the prophylactic treatment of elevations in IOP after laser iridotomy, posterior capsulotomy, and cataract surgery.

When topical timolol is administered to patients already receiving oral  $\beta$ -blocking agents for the treatment of systemic hypertension, a further reduction of IOP may occur. Ocular hypotensive efficacy, however, is generally reduced in patients treated with systemic  $\beta$ -blockers, and systemic safety can be adversely impacted. Ocular hypotensive agents other than  $\beta$ -blockers may be a more appropriate first-line therapy for patients who concurrently take a systemic  $\beta$ -blocker.

Timolol is supplied as a 0.25% and 0.5% sterile ophthalmic solution of the maleate salt (see Table 10-1). The drug is also available as a 0.25% and 0.5% hemihydrate salt (Betimol), which has an ocular hypotensive efficacy and safety profile clinically equivalent to that of the maleate salt. A formulation of timolol in a Gelrite vehicle (Timoptic XE) is also available. A single daily instillation of this formulation in the morning has an ocular hypotensive effect comparable with that of timolol solution used every 12 hours. Timolol (Istalol) is also formulated in potassium sorbate (0.47%), which increases the lipophilicity and allows for higher anterior chamber concentrations. Istalol solution is dosed once daily and is reported to have 45% less systemic levels compared to other timolol solutions dosed twice daily and therefore may exhibit reduced cardiovascular effects. Burning and stinging was 38% in the Istalol group versus 23% in the timolol control group. Multiuse containers of timolol solution are preserved with BAC 0.01% or benzododecinium bromide 0.012% (Timoptic XE), and a unit-of-use nonpreserved product is available (Ocupose). The ocular hypotensive effect of the nonpreserved formulation is the same as that of the preserved formulation. Timolol is approved for either once- or twice-daily use.

### Side Effects

**Ocular Effects.** Timolol may cause some adverse ocular effects (Box 10-3). A local allergic reaction can occur. This allergic reaction manifests as a blepharoconjunctivitis, with erythema and edema of the lids. The reaction can occur as early as the first month of therapy. Management may include changing to another  $\beta$ -blocker or other class of drug.

### Box 10-3 Adverse Events Possibly Associated With Topical Ophthalmic $\beta$ -Blockers

#### Cardiovascular

Bradycardia  
Conduction arrhythmias  
Hypotension  
Raynaud's phenomenon  
Fluid retention

#### Pulmonary

Bronchoconstriction/bronchospasm  
Asthma  
Dyspnea

#### Central nervous system

Amnesia  
Depression  
Confusion  
Headache  
Migraine prophylaxis  
Impotence  
Insomnia  
Myasthenia gravis

#### Gastrointestinal

Diarrhea  
Nausea

#### Dermatologic

Alopecia  
Nail pigmentation  
Urticaria  
Lichen planus

#### Other systemic effects

Hypoglycemia

#### Ocular effects

Allergic blepharoconjunctivitis  
Dry eye/decreased tear breakup time  
Corneal anesthesia  
Macular edema (aphakics)  
Macular hemorrhage/retinal detachment  
Uveitis  
Cataract progression

Adapted from Novack GD, Leopold IH. The toxicity of topical ophthalmic  $\beta$ -blockers. *J Toxicol Cut Ocular Toxicol* 1987; 6:283-297.

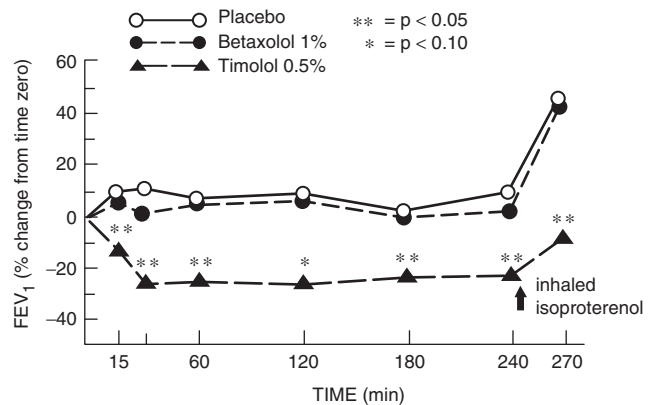
The ability of  $\beta$ -blockers to stabilize membrane excitability has been exploited therapeutically in the treatment of selected cardiac arrhythmias. However, when these agents are given topically, such a property can induce corneal anesthesia. Significant decreases in corneal sensitivity

have been reported in some patients. Timolol, however, ranks low among  $\beta$ -blockers in its corneal anesthetic effects, and corneal sensitivity is not a major clinical problem with timolol. In some patients, timolol can induce superficial punctate keratitis. If this condition becomes chronic and is not treated, it could lead to additional epitheliopathy and possible corneal epithelial erosions. Topical timolol may reduce tear breakup time, elicit some dry eye symptoms, or decrease tear flow. None of the commonly used  $\beta$ -blockers, including timolol, appears to inhibit corneal epithelial wound healing. When timolol is administered in a gel-forming vehicle, it may induce a momentary visual disturbance, but the visual dysfunction does not preclude use during the patient's waking hours.

**Systemic Effects.** When timolol is given by the topical route, the possibility of systemic  $\beta$ -blockade must be considered (see Box 10-3). Within the first few hours after topical instillation of 0.5% timolol solution, the mean drug plasma level is approximately 1 ng/ml. This level can be as high as 20 ng/ml in newborns and can be reduced in adults with nasolacrimal occlusion or simple eyelid closure. Use of timolol in gel-forming solution can substantially lower plasma drug levels. Because the administration of topical timolol results in mean drug plasma levels less than 5 ng/ml, it is somewhat puzzling that bradycardia is a frequently associated side effect of topical timolol. However, it appears that even with systemic administration, plasma levels of beta-blocking agents are not always indicative of systemic beta-blockade. Ocularly instilled medications also may reach the heart directly, via nasolacrimal and pharyngeal absorption, without the potential for inactivation by hepatic metabolism or dilution in total body plasma.

The presence of pharmacologically effective plasma levels of timolol after topical instillation dictates that the clinician considers the risk of systemic beta-blockade when administering any  $\beta$ -blocker for glaucoma. Antagonism of  $\beta$ -adrenoceptors can result in bradycardia, systemic hypotension, congestive heart failure, heart block, bronchospasm, diarrhea, and amnesia.  $\beta$ -Adrenergic antagonists of both subtypes may adversely affect memory. All these adverse effects have occurred with topical timolol therapy. In some cases these adverse events have been serious, life threatening, and even fatal. Systemic adverse events may be more frequent in elderly persons, because these patients have a greater propensity for coexisting systemic conditions and, as a result of flaccid lids, have the propensity for greater storage of instilled drug volumes in the lower cul-de-sac.

Mean resting heart rate may decrease 3 to 10 beats per minute (bpm) during use of timolol. Other cardiovascular effects include palpitations, systemic hypotension, and syncope. Similar to oral  $\beta$ -blockers, topical timolol may reduce exercise-induced tachycardia. This decrease may be a problem not only in patients with compromised cardiovascular status, but also in patients who normally



**Figure 10-7** Mean change in forced expiratory volume in 1 second ( $FEV_{1}$ ) after instillation of timolol, betaxolol, or placebo (vehicle). Timolol induced a significant decrease in airflow, whereas betaxolol produced values no different from those for the placebo. (Reprinted with permission from *Am J Ophthalmol* 1984;97:86-92. Copyright by the Ophthalmic Publishing Company.)

engage in strenuous exercise. Timolol in Gelrite vehicle, however, and timolol hemihydrate, dosed once daily, may have less effect on heart rate, probably because of reduced systemic absorption.

Timolol use can bring on wheezing, dyspnea, bronchospasm, and other signs and symptoms of decreased respiratory function. Acute bronchospasm can occur in previously asymptomatic asthmatic patients after the topical use of timolol. Timolol elicits an average decrease of 25% in forced expiratory volume ( $FEV_{1}$ ) in patients with chronic obstructive pulmonary disease (COPD) (Figure 10-7).

Topical  $\beta$ -blockers have been associated with adverse central nervous system (CNS) effects, including depression, emotional lability, and sexual dysfunction. Complaints of lethargy, lightheadedness, weakness, fatigue, mental depression, dissociative behavior, and memory loss are most common. The onset of symptoms varies from a few days to months after initiation of therapy. In most cases these symptoms are mild and transient. In certain patients, however, timolol must be discontinued.

Timolol may also elicit dermatologic signs and symptoms that include rashes, alopecia, urticaria, and discoloration of nails. Other systemic effects reported after topical timolol treatment include myasthenia gravis and retroperitoneal fibrosis. When treating a nursing mother, clinicians should also be aware that topically applied timolol may be excreted in breast milk.

Topical timolol may alter the plasma lipid profile. Timolol maleate adversely affects the high-density lipoprotein cholesterol levels in older white, black, and Japanese patients. There is no evidence, however, that chronic use of topical timolol increases the risk of coronary artery disease.

### Contraindications

Timolol is contraindicated in patients with bronchial asthma, a history of bronchial asthma, or severe COPD.

### Box 10-4 Contraindications to Topical Ophthalmic $\beta$ -Blockers

Bronchial asthma  
 History of bronchial asthma  
 Severe chronic obstructive pulmonary disease  
 Bradycardia  
 Severe heart block  
 Overt cardiac failure  
 Children and infants

It is also contraindicated in patients with bradycardia (pulse rate less than 60 bpm), severe heart block, overt cardiac failure, and hypersensitivity to any of its components (Box 10-4).

More broadly, timolol therapy should be considered with caution in patients with any significant sign, symptom, or history for which systemic beta-blockade would be medically unwise. This includes disorders of cardiovascular or respiratory origin (e.g., asthma, chronic bronchitis, and emphysema) as well as many other conditions. Spirometric evaluation after institution of timolol therapy may help to identify patients in whom bronchospasm develops after commencement of therapy. In general, however, patients with asthma and other obstructive pulmonary diseases should avoid this drug. Sympathetic stimulation may be essential to support the circulation in individuals with diminished myocardial contractility, and its inhibition by  $\beta$ -adrenoceptor antagonists may precipitate more severe cardiac failure.

As may occur with topical timolol,  $\beta$ -adrenoceptor blockade may mask the signs and symptoms of thyrotoxicosis or acute hypoglycemia. Thus, timolol should be used with caution in patients prone to such disorders, including diabetes.

Using two topical  $\beta$ -blockers simultaneously has no potential for added ocular hypotensive efficacy, and such a combination can only increase the possibility of an untoward event. Because timolol in children and infants may result in a relative systemic overdose, its use in these patients should be avoided.

Careful patient histories and examinations are critical before using this drug. For many patients, the eye care specialist should contact the patient's internist or primary care physician regarding the use of topical timolol or any other topical  $\beta$ -blocker. Although this warning is most important for chronic use, some of the reports of serious adverse reactions to timolol involve a single drop of medication.

## Levobunolol

### Pharmacology

Similar to timolol, levobunolol is a noncardioselective  $\beta$ -blocker without significant local anesthetic activity or ISA.

Its metabolic fate, however, differs from that of timolol. Levobunolol is metabolized to dihydrobunolol, a compound with equipotent beta-blocking effects both systemically and ocularly. The potency of levobunolol at the ocular  $\beta_2$ -adrenoceptor is similar to that of timolol.

When given topically to individuals with elevated IOP, levobunolol induces a long-lasting ocular hypotension. The mean reduction in IOP with twice-daily 0.5% and 1% levobunolol is equivalent to that of timolol. As with timolol, the predominant mechanism of levobunolol's ocular hypotensive action is a decrease in the production of aqueous humor, with no significant effect on facility of outflow.

### Clinical Uses

Levobunolol is used for the chronic treatment of elevated IOP in ocular hypertension and open-angle glaucoma. Also like timolol, levobunolol is effective for prophylactic treatment of elevations in IOP after cataract surgery and anterior segment laser procedures.

Levobunolol is supplied as a 0.25% and 0.5% sterile ophthalmic solution of the levo-isomer of the hydrochloride salt. The formulation contains a viscosity agent, 1.4% polyvinyl alcohol, and is preserved with BAC 0.004% (see Table 10-1).

Once-daily therapy with levobunolol can be an effective ocular hypotensive regimen. The hypotensive effect of once-daily 0.25% or 0.5% levobunolol is similar to that for twice-daily dosing. The 0.25% and 0.5% concentrations used twice daily are also equally effective. Thus, as with timolol, consideration may be given to using the lower concentration once daily.

### Side Effects

**Ocular Effects.** Because levobunolol has the same pharmacologic activity as timolol, it has the propensity for the same untoward ocular effects as timolol. The ocular comfort of levobunolol is similar to that of timolol. Corneal anesthesia is not a significant problem with levobunolol, nor does it seem to elicit dry eye symptoms or mydriasis. Although allergic blepharoconjunctivitis can occur with levobunolol, it may also be tolerated in patients in whom timolol elicits an allergic reaction.

**Systemic Effects.** Because levobunolol is a potent and effective  $\beta_1$  and  $\beta_2$  blocker, it shares with timolol the same potential for systemic beta-blockade. Mean resting heart rate may decrease 3 to 10 bpm during use of levobunolol, and some reduction in blood pressure may occur. Topical ocular dosing with levobunolol results in plasma levels of approximately 1 ng/ml. As with timolol, 0.5% levobunolol reduces maximal exercise-induced heart rate by approximately 9 bpm.

### Contraindications

The contraindications for levobunolol are the same as those for timolol. Levobunolol is contraindicated in

patients with bronchial asthma, a history of bronchial asthma, or severe COPD. It is contraindicated in patients with bradycardia or severe heart block and overt cardiac failure and in patients with hypersensitivity to any of its components. As with timolol, caution should be used when considering levobunolol therapy in patients with any significant sign, symptom, or history for which systemic beta-blockade would be medically unwise.

## Betaxolol

### Pharmacology

Betaxolol exhibits relative specificity for the  $\beta_1$ -adrenoceptor. At the ocular  $\beta_2$ -adrenoceptor, betaxolol is nearly two orders of magnitude less potent than timolol.  $\beta_1$ -Adrenoceptors are involved in cardiac rate, rhythm, and force;  $\beta_2$ -adrenoceptors are involved in pulmonary function. However,  $\beta$  receptors are also present in the vascular system. Approximately 10% to 30% of the  $\beta$ -adrenoceptors in the mammalian cardiac ventricles are of the  $\beta_2$  subtype, but most of the  $\beta$ -adrenoceptors in the heart are of the  $\beta_1$  subtype. In human lung tissue, the ratio of  $\beta_2$ -adrenoceptors to  $\beta_1$ -adrenoceptors is 3 to 1. This distribution suggests that the role of the various adrenoceptor subtypes is probably more complex than generally thought. In addition, this means that agents that exhibit a wide separation of selectivity in preclinical experiments may be less tissue or organ selective in actual clinical use.

Clinical doses of oral betaxolol result in plasma levels of 10 to 40 ng/ml. Given topically, 0.5% betaxolol solution results in plasma levels of approximately 0.5 ng/ml, or half that of timolol 0.25%.

As with other  $\beta$ -blockers, the ocular hypotensive mechanism of betaxolol is a reduction in aqueous production. Although effective in reducing aqueous humor production, betaxolol is less effective than levobunolol or timolol. Both timolol and levobunolol are more effective ocular hypotensive agents than betaxolol by approximately 2 mm Hg in IOP control.

In the late 1990s several investigators demonstrated that, in addition to its ocular hypotensive effects, betaxolol has the ability to block sodium and calcium channels in both vascular tissue and retinal ganglion cells. Animal models have shown that betaxolol may protect critical nerve tissues against retinal ischemic insults. Vasodilatation of retinal and other ocular vascular beds appears to be mediated by betaxolol's calcium channel blocking properties. Moreover, betaxolol inhibits glutamate-induced increases in intracellular calcium in rat retinal ganglion cells. These pharmacologic actions suggest that betaxolol may have potential as a neuroprotective agent in glaucoma patients by promoting ganglion cell survival after ischemic damage or elevated glutamate levels.

### Clinical Uses

Topical betaxolol is indicated in the chronic treatment of ocular hypertension and open-angle glaucoma. Given its

relative cardioselectivity, it may be used successfully in patients with coexistent glaucoma and pulmonary disease. Note, however, that topical betaxolol may still elicit adverse cardiovascular and pulmonary effects.

Overall, the selection of betaxolol is a relative benefit-to-risk decision. In head-to-head studies against the noncardioselective agents, betaxolol is generally a less effective ocular hypotensive agent. From a safety perspective, however, betaxolol induces less systemic beta-blockade than these other agents. Although some evidence indicates that betaxolol may differ from timolol in its effects on visual field progression, no significant clinical advantage to betaxolol use has been demonstrated.

Betaxolol is less effective than timolol or levobunolol in preventing elevations in IOP after cataract surgery, especially when a viscoelastic agent is used. Thus, it is probably not the agent of choice for this indication.

Betaxolol is supplied as a sterile suspension of 0.25% betaxolol HCl (Betoptic-S). The suspension is a unique formulation containing a polyacrylic acid polymer (carbomer 934P) and a cationic exchange resin, which is believed to increase the drug residence time in the eye (see Chapter 2). This product is the racemic compound, preserved with 0.01% BAC, and approved for twice-daily use.

### Side Effects

**Ocular Effects.** Ocular discomfort on topical instillation is the primary local effect associated with the 0.25% betaxolol suspension.

**Systemic Effects.** Systemic betaxolol has, on average, less effect in attenuating pulmonary function than do the noncardioselective agents. A significant clinical advantage of topical betaxolol in the treatment of elevated IOP is its much reduced potential for inhibiting pulmonary function (see Figure 10-7). This finding has been replicated in many studies and substantiates the relative safety of betaxolol in patients with coexistent pulmonary disease and glaucoma.

Thus, a key clinical advantage of betaxolol is in the treatment of patients with coexistent open-angle glaucoma and pulmonary disease. However, some pulmonary physicians strongly caution against the use of any  $\beta$ -blocker, irrespective of cardioselectivity or route of administration, in patients with existing respiratory disease.

The potential of betaxolol to elicit systemic  $\beta_1$ -adrenoceptor blockade has been investigated. In a study on resting cardiovascular function in older patients, topical instillation of timolol (0.25% and 0.5%), carteolol (1% and 2%), and metipranolol (0.3% and 0.6%) decreased mean heart rate 14% to 17%. However, topical betaxolol 0.5% did not have any significant effect. Some patients in all groups did exhibit a 15% to 20% reduction in systolic blood pressure. In a study of exercise-induced tachycardia in normal

volunteers, the maximal heart rate obtained on exercise decreased 9 bpm with topical timolol and 4 bpm with betaxolol. Other studies have shown that compared with a placebo, all  $\beta$ -blockers result in some degree of systemic beta-blockade, and the increasing order of potency is betaxolol (0.5%), metipranolol (0.6%), and timolol (0.5%). Patients who have various adverse experiences, such as dyspnea and bradycardia, with timolol may often successfully switch to betaxolol. Betaxolol therapy, however, may result in poorer control of IOP.

Although betaxolol generally elicits less systemic beta-blockade than do noncardioselective agents, it does cause undesirable systemic effects in some patients. Reported adverse experiences include congestive heart failure, myocardial infarction, respiratory difficulties strongly suggestive of obstructive airway disease, weakness with severe sinus bradycardia, and wheezing with objective reduction in pulmonary function.

The incidence of insomnia, depression, and diarrhea is less with betaxolol than with timolol.

### Contraindications

Betaxolol is contraindicated in patients with sinus bradycardia, greater than first-degree atrioventricular block, cardiogenic shock, or overt cardiac failure. It is also contraindicated in patients with hypersensitivity to any of its components. As noted above, severe respiratory reactions have occurred, and the drug must therefore be used with caution in patients with asthma or COPD. Also, because minor changes in heart rate and blood pressure can occur, this agent must be used with caution, or avoided, in patients with a history of cardiac failure or heart block.

## Metipranolol

### Pharmacology

Like timolol and levobunolol, metipranolol is a noncardioselective  $\beta$ -blocker without significant local anesthetic activity or ISA. Metipranolol has been used worldwide, both orally in the treatment of systemic hypertension and topically for the treatment of elevated IOP.

Like levobunolol, metipranolol has an active metabolite, des-acetyl-metipranolol, which is an effective  $\beta$ -blocker. Metipranolol has been used in concentrations ranging from 0.1% to 0.6% and has ocular hypotensive efficacy within the range of other noncardioselective agents. As with other  $\beta$ -adrenoceptor antagonists, metipranolol decreases aqueous humor production. Retinal perfusion pressure and blood flow appear to increase during treatment with topical metipranolol.

### Clinical Uses

Metipranolol is used for the chronic treatment of elevated IOP in ocular hypertension and open-angle glaucoma. Its utility in IOP elevations after laser or cataract surgery and its additivity with other ocular hypotensive agents have not yet been fully evaluated.

Metipranolol is available in the United States as OptiPranolol, a sterile ophthalmic solution of 0.3% racemic metipranolol HCl preserved with 0.004% BAC and approved for twice-daily use.

### Side Effects

**Ocular Effects.** When given twice daily at the 0.6% strength to ocular hypertensive patients, metipranolol elicits greater discomfort than does levobunolol 0.5%. Metipranolol therapy has also been associated with allergic blepharoconjunctivitis or periorbital dermatitis similar to that reported for other ophthalmic  $\beta$ -blockers.

In 1990 approximately 50 cases of anterior uveitis were reported in the United Kingdom, where metipranolol had been available since 1986. At one hospital the incidence of uveitis in patients using 0.6% metipranolol was 14% (15 of 109). All cases resolved with appropriate management. Drug-induced anterior uveitis has also been reported as a rare event in the United States, but a true causal relationship has not been definitely established.

**Systemic Effects.** Based on its pharmacologic activity, metipranolol theoretically shares with timolol and levobunolol the same potential for systemic beta-blockade. However, several studies show that the  $\beta$ -adrenoceptor blockade elicited by topical metipranolol may be less than that observed with timolol but more than that observed with betaxolol.

### Contraindications

The contraindications for metipranolol are the same as those for the other nonselective  $\beta$ -blockers.

## Carteolol

### Pharmacology

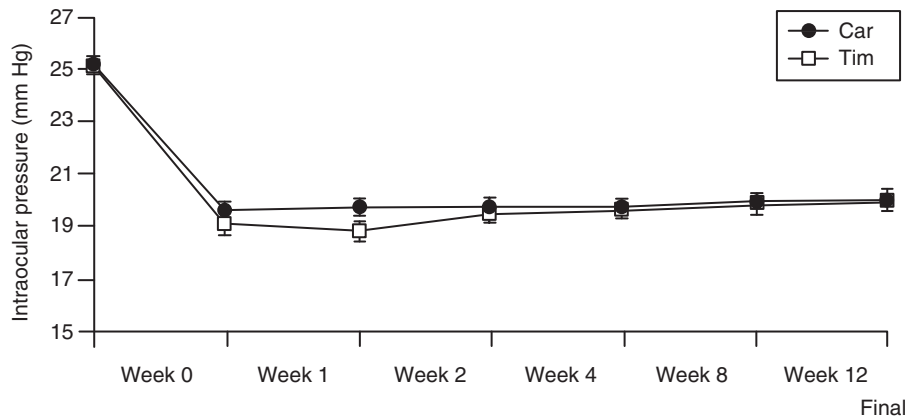
Carteolol is a noncardioselective  $\beta$ -blocker similar to timolol, levobunolol, and metipranolol. As with levobunolol and metipranolol, a primary metabolite of carteolol, 8-hydroxycarteolol, is also an ocular  $\beta$ -blocker. In contrast to other topical  $\beta$ -adrenoceptor antagonists, carteolol possesses intrinsic sympathomimetic ISA. The mechanism of carteolol's ocular hypotensive effect is a reduction in aqueous humor production, without any apparent effect on outflow.

Several studies compared the ocular hypotensive efficacy of carteolol and timolol. In general, carteolol 1% demonstrates an ocular hypotensive effect similar to that of timolol maleate 0.5% solution (Figure 10-8). Carteolol is usually well tolerated, effective, and safe in patients who have been switched from other  $\beta$ -blockers.

### Clinical Uses

Carteolol is used for the chronic treatment of elevated IOP in patients with ocular hypertension and open-angle glaucoma. Its ocular hypotensive effects are additive to





**Figure 10-8** Mean intraocular pressure at trough of dosing cycle at each visit. (Car = carteolol 1%; Tim = timolol maleate 0.5%.) (Adapted from Stewart WC, Cohen JS, Netland PA, et al. Efficacy of carteolol hydrochloride 1% vs timolol maleate 0.5% in patients with increased intraocular pressure. *Am J Ophthalmol* 1997;124:498-505.)

those of latanoprost, but its utility in IOP elevations after laser or cataract surgery and its additivity with other ocular hypotensive agents have not been fully evaluated.

Carteolol is supplied in the United States as Ocupress, a sterile ophthalmic solution of 1.0% racemic carteolol HCl, preserved with 0.005% BAC, and approved for twice-daily use.

#### Side Effects

**Ocular Effects.** Carteolol 1% is less irritating than 0.5% timolol. However, unlike other topical  $\beta$ -blockers, use of carteolol 1% can cause a moderate corneal anesthesia.

**Systemic Effects.** Although the ISA of carteolol might provide some reduced potential for systemic effects, carteolol theoretically shares with other noncardioselective  $\beta$ -blockers the same potential for systemic beta-blockade. When compared with timolol and levobunolol, carteolol appears to be similar in its reduction of mean heart rate. In asthmatics, carteolol has slightly less effect on mean forced expiratory volume in 1 second than does metipranolol. In elderly patients, carteolol has an effect on resting heart rate similar to that of timolol and metipranolol but greater than that of betaxolol. Carteolol causes significantly less nocturnal bradycardia than does timolol in patients with ocular hypertension or primary open-angle glaucoma. In contrast to topical timolol, changes in serum lipid levels, including high-density lipoprotein cholesterol, appear to be negligible with carteolol.

#### Contraindications

The contraindications for carteolol are the same as for other nonselective  $\beta$ -blockers.

#### Choice of $\beta$ -Blocker

Many factors must be considered in choosing an appropriate treatment regimen for glaucoma patients.

Although many  $\beta$ -blockers can be used interchangeably, some may be favored in selected patients. These choices are summarized in Table 10-3.

### ADRENERGIC AGONISTS

Since the early 1920s, when epinephrine was applied topically to the eye to reduce IOP, several adrenergic agonists have proved useful as ocular hypotensive agents. Because of their relatively high potential for both ocular and systemic side effects, the nonselective  $\alpha$  and  $\beta$  receptor agonists epinephrine and dipivefrin have been supplanted by the  $\alpha_2$  receptor agonists apraclonidine and brimonidine. These agents are currently the adrenergic agonists of choice for glaucoma management.

#### $\alpha_2$ Receptor Agonists

$\alpha_2$  Receptors have been identified on presynaptic adrenergic nerve terminals and postjunctionally in the ciliary body. Activation of the presynaptic  $\alpha_2$  receptors inhibits

**Table 10-3**  
Selection of  $\beta$ -Blockers

Clinical Issues	Preferred Drug
Best intraocular pressure control	Avoid betaxolol
Cost	Generic timolol Metipranolol Timolol hemihydrate
Comfort	Carteolol
Hypercholesterolemia	Carteolol
Preservative (BAC) allergy	Timoptic-XE or Timoptic in Ocudose; consider Alphagan P; Travatan Z
Chronic obstructive pulmonary disease	Betaxolol
Pregnancy	Avoid all



**Table 10-4**  
Adrenergic Agonists

Generic Name	Trade Name	Manufacturer	Concentration (%)
Apraclonidine	Iopidine	Alcon	0.5, 1.0
Brimonidine	(Generic) <sup>a</sup>	Various	0.2
	Alphagan P <sup>b</sup>	Allergan	0.1, 0.15

<sup>a</sup>Preserved with benzalkonium chloride.<sup>b</sup>Preserved with Purite 0.005%.

Adapted from Bartlett JD, Fiscella R, Jaanus SD, et al., eds. Ophthalmic drug facts. St. Louis, MO: Facts and Comparisons, 2007.

neurotransmitter release. The amount of norepinephrine available for receptor activation, including postsynaptic  $\beta$  receptors on the ciliary epithelium, is decreased. Administration of  $\alpha_2$  agonists lowers IOP in normal and glaucomatous eyes. At the cellular level, activation of the postsynaptic ciliary body  $\alpha_2$  receptor reduces intracellular levels of cyclic adenosine monophosphate and may also affect other cellular pathways. Therefore aqueous production may be mediated via  $\alpha_2$  receptor activity. The search for suitable  $\alpha_2$  agonists for topical ocular use has resulted in the development of apraclonidine and brimonidine (Table 10-4).

## Apraclonidine

### Pharmacology

Apraclonidine, a relatively selective  $\alpha_2$ -adrenoceptor agonist, was developed as a derivative of the antihypertensive agent clonidine. Apraclonidine lowers IOP by decreasing aqueous production and enhancing uveoscleral outflow. It does not appear to enhance conventional trabecular outflow as measured by tonography. Apraclonidine may also have additional ocular hypotensive effects by influencing ocular blood flow. It can affect vascular tone because it also stimulates  $\alpha_1$  receptors in vascular smooth muscle, causing vasoconstriction.

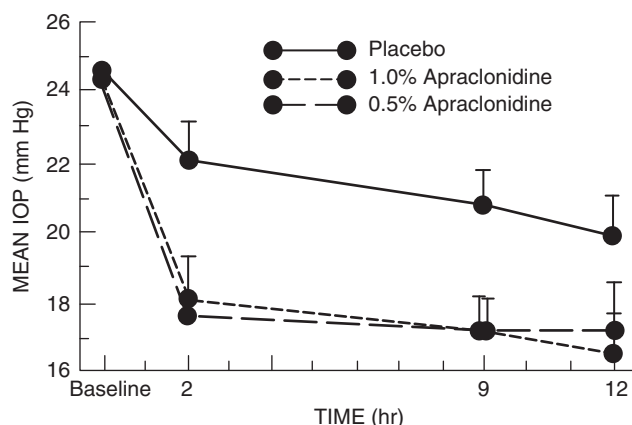
Apraclonidine lowers IOP in both normal volunteers and patients with elevated IOP. Within 1 hour of instillation, there is a significant drop in pressure that lasts about 12 hours. This initial effect has been attributed primarily to a decrease in aqueous flow. The peak effect occurs between 3 and 5 hours, lowering IOP by 30% to 40% at peak with a trough level of IOP reduction of 20% to 30%. Within 8 days of continuous apraclonidine treatment, the magnitude of aqueous flow reduction is diminished, whereas outflow facility appears to be significantly increased. When compared at 0.5% and 1.0% concentrations, apraclonidine produces the same percentage decrease in IOP regardless of the initial level of pressure (Figure 10-9). Most patients treated with apraclonidine show at least a 20% reduction from baseline pressures with the 0.5% or 1.0% solution. However, with chronic treatment tachyphylaxis often occurs, which manifests as a diminished ocular hypotensive effect. Moreover, patients often develop an ocular allergy that may warrant discontinuation of the drug.

### Clinical Uses

When administered three times daily for 3 months, apraclonidine 0.5% has an ocular hypotensive effect comparable with that of timolol 0.5% administered twice daily. Age, race, and iris color do not seem to affect the ocular hypotensive response to apraclonidine.

Apraclonidine is commercially available as apraclonidine hydrochloride 0.5% and 1.0% (Iopidine), preserved with BAC 0.01%. The current labeled indications for the 1.0% concentration are control or prevention of postsurgical elevations in IOP after anterior segment laser surgery and for short-term IOP control in open-angle glaucoma before filtering procedures. Apraclonidine can also lower IOP in the initial treatment of acute angle-closure glaucoma (see Chapter 34).

Apraclonidine 0.5% can be used for short-term therapy of patients on maximally tolerated medical therapy who require additional reductions in IOP. Patients with primary or secondary glaucoma do not appear to differ in either the magnitude or duration of ocular hypotensive response, but patients with developmental or congenital glaucomas tend to respond less satisfactorily.



**Figure 10-9** Mean intraocular pressure (IOP) for subjects with increased baseline IOP. Both 0.5% and 1.0% apraclonidine lowered IOP significantly more than did the placebo. There was no significant difference between 0.5% and 1.0% apraclonidine. Bars represent one standard error. (Reprinted with permission from Am J Ophthalmol 1989;108:230-237. Copyright by the Ophthalmic Publishing Company.)

Moreover, because of the development of tachyphylaxis, the benefit for most patients does not last more than several months.

An acute rise in IOP is a risk factor in laser iridotomy, trabeculoplasty, and posterior capsulotomy. Topical apraclonidine can significantly reduce both the incidence and magnitude of increases in IOP after anterior segment laser surgery. Apraclonidine 1.0% has also been used for prophylaxis of postcycloplegic spikes in IOP. In eyes with open-angle glaucoma dilated with tropicamide 1.0% and phenylephrine 2.5%, apraclonidine can both minimize the incidence of spiking and reduce the spike height.

To control or prevent postsurgical IOP elevations, one drop of the 1% concentration is instilled 1 hour before and a second drop immediately on completion of the laser procedure. As adjunctive therapy for patients with glaucoma inadequately controlled with otherwise maximal therapy, the 0.5% concentration is administered up to three times per day.

### Side Effects

Common ocular side effects associated with topical apraclonidine include conjunctival blanching, eyelid retraction, and mydriasis. These effects are mediated via  $\alpha_1$  receptor stimulation. Although it may be difficult to detect in bilaterally treated patients, conjunctival blanching is the most common side effect, occurring in approximately 85% of patients. However, rebound conjunctival hyperemia associated with other  $\alpha_1$  receptor agonists does not appear to occur with topical administration. Pupillary dilation of less than 1 mm occurs in approximately 45% of eyes treated with 0.5% apraclonidine. The mydriasis has limited clinical significance. Patients sometimes report discomfort, burning, itching, dryness of the eyes, and blurred vision.

Ocular intolerance or allergy is a rare occurrence with short-term use but can be the most serious side effect in chronic therapy. The prevalence of symptoms of itching and conjunctival inflammation can average 20%, and increase to 50% with long-term use. Decreasing the concentration to 0.5% and the frequency of administration lowers the incidence of side effects. The symptoms usually resolve within 3 to 5 days after the medication is discontinued. It has been proposed that the mechanism underlying apraclonidine's allergic response is drug oxidation and conjugation with thiols to form an apraclonidine-protein hapten that elicits the immune response.

The most common nonocular side effect associated with apraclonidine is a sensation of dry mouth or dry nose. These symptoms are dose related. Although the increased polarity of apraclonidine compared with clonidine reduces the drug's potential for systemic absorption, cardiovascular, respiratory, and CNS effects can occur with topical application. However, in both normal volunteers and patients with elevated IOP, topical administration appears to cause only minimal effects on resting heart rate, arterial blood pressure, and respiration.

Fatigue or lethargy is the most frequently reported CNS effect. The incidence ranges between 5% and 15% in studies of 1-week duration. Other possible side effects include headache, sensation of head cold, chest heaviness, shortness of breath, sweaty palms, and taste abnormalities.

### Contraindications

Apraclonidine is contraindicated in patients sensitive to clonidine and those taking monoamine oxidase inhibitors. Caution should be exercised in patients with severe cardiovascular disease, including hypertension. The possibility of vasovagal episodes exists during laser surgery, particularly in patients with a history of such events.

### Brimonidine

#### Pharmacology

Brimonidine tartrate is a relatively potent and highly selective  $\alpha_2$ -adrenoceptor agonist. Radioligand binding studies indicate that brimonidine is about 30 times more selective for  $\alpha_2$  receptors than is apraclonidine. Specific binding sites for brimonidine have been identified on human iris and ciliary epithelium, with a smaller number located on tissues of the retina, retinal pigment epithelium, and choroid. Studies in albino and pigmented rabbit eyes indicate that brimonidine binds to ocular melanin. Half-life calculations further suggest that the pigment acts as a drug reservoir, slowly releasing drug to the adjacent ocular sites.

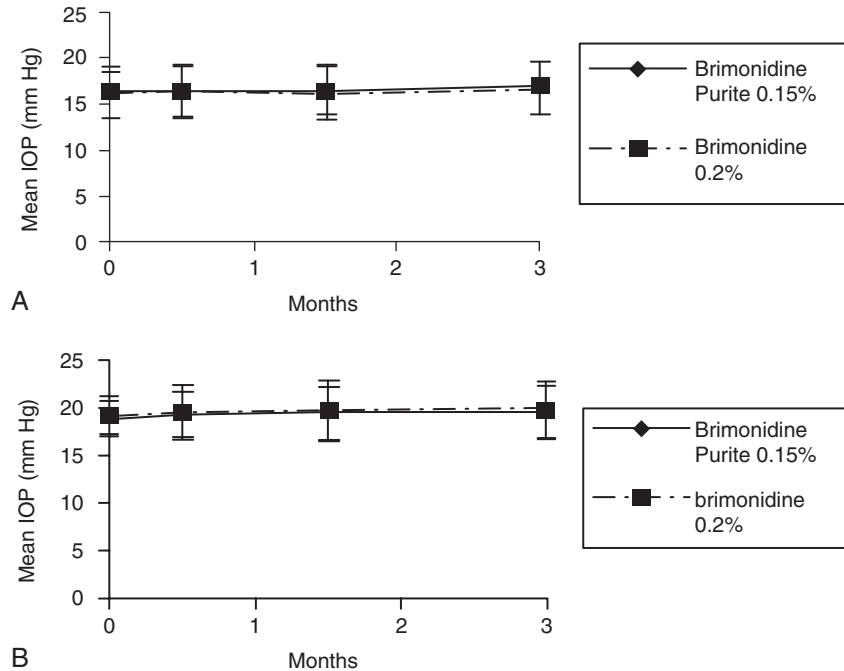
After topical instillation, brimonidine penetrates into the aqueous humor and produces a dose-dependent reduction in IOP in both normal and glaucomatous eyes. Fluorophotometric studies suggest that brimonidine lowers IOP by a dual mechanism, involving a reduction of aqueous production and an increase in aqueous outflow via the uveoscleral pathway. The initial effect of brimonidine on IOP can be attributed to a decrease in aqueous flow. After 8 days, similar to apraclonidine, the initial effect is attenuated, and uveoscleral flow increases.

There is also evidence from animal models that brimonidine may provide neuroprotective properties that could spare retinal ganglion cells and the optic nerve. Using different models to achieve neuronal insult, including mechanical and acute retinal ischemic/reperfusion injury, brimonidine appears to protect the optic nerve and retinal ganglion cells from further degeneration.

Brimonidine also does not appear to alter retinal capillary blood flow or vasomotor activity of the anterior optic nerve. Measurements of blood flow velocities in central retinal, ophthalmic, nasal, and temporal posterior ciliary arteries do not change when 0.2% brimonidine is administered twice daily. When applied to human eyes, brimonidine appears to have little or no contralateral lowering effect on IOP.

### Clinical Uses

For topical application to the eye, brimonidine is commercially available as a 0.2% formulation preserved



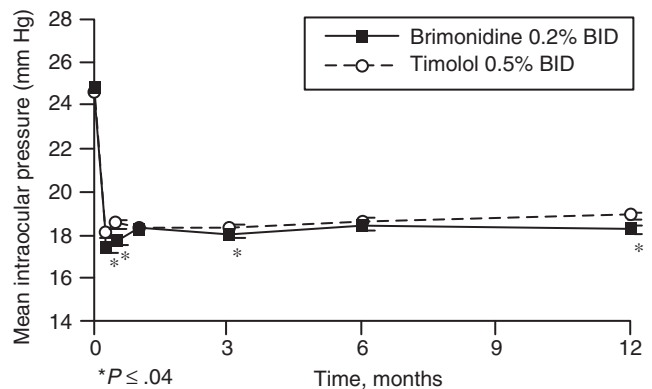
**Figure 10-10** (A) Efficacy at peak (2 hours after morning dose) showing mean intraocular pressure in patients administered brimonidine Purite 0.15% or brimonidine 0.2% at baseline and follow-up visits. The difference in mean IOP between the two groups was less than 0.2 mm Hg at all visits. (B) Efficacy at trough (before morning dose) showing mean intraocular pressure in patients administered brimonidine Purite 0.15% or brimonidine 0.2% at baseline and follow-up visits. The difference in mean IOP between the two groups was less than 0.3 mm Hg at all visits. (Adapted from Mundorf T, Williams R, Whitcup S, et al. *J Ocul Pharmacol Ther* 2003;19:37-44.)

with 0.001% BAC and a 0.10% and 0.15% solution preserved with Purite (see Table 10-4). In patients with either open-angle glaucoma or ocular hypertension, an overall mean peak IOP reduction of 6.5 mm Hg from baseline values has been achieved with brimonidine 0.2%. The peak hypotensive effect occurs approximately 2 hours postdose and lasts up to 12 hours. Twice-daily dosing of brimonidine 0.15% with Purite has an ocular hypotensive effect equal to that of brimonidine 0.2% administered twice daily (Figure 10-10).

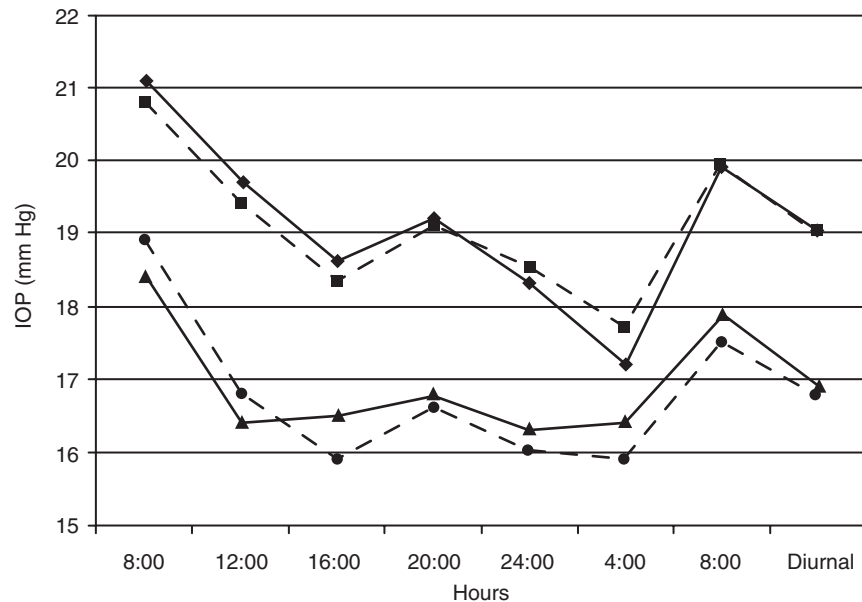
Brimonidine's efficacy has been compared with that of prostaglandin analogues, topical CALs, and  $\beta$ -blockers. Results in patients with glaucoma and ocular hypertension indicate that the peak ocular hypotensive effect of 0.2% brimonidine is comparable with that of 0.5% timolol (Figure 10-11). When dosed twice daily, 0.2% brimonidine is less effective than latanoprost 0.005% administered once daily. Brimonidine 0.15% with Purite is similar to dorzolamide 2% when used twice daily for treatment of primary open-angle glaucoma or ocular hypertension.

Brimonidine, like apraclonidine, is additive to other glaucoma medications. When used either as additive or replacement therapy, it can further lower IOP in patients inadequately controlled on one or more ocular hypotensive drugs. Brimonidine and latanoprost have an additive ocular hypotensive effect, further decreasing IOP approximately 3 mm Hg compared with that of latanoprost alone.

Studies have suggested that brimonidine 0.15% with Purite and dorzolamide 2%, each added to latanoprost, have similar ocular hypotensive efficacy in patients with primary open-angle glaucoma or ocular hypertension (Figure 10-12). Moreover, the combination of brimonidine 0.2% and latanoprost 0.005% provides IOP control superior to that of the fixed combination of



**Figure 10-11** Effect of brimonidine 0.2% and timolol 0.5% at peak 2 hours after morning drug instillation. Asterisks indicate statistically lower intraocular pressure with brimonidine at week 1, week 2, month 3, and month 12. (Adapted from Katz LJ. Brimonidine tartrate 0.2% twice daily versus timolol 0.5% twice daily: 1-year results in glaucoma patients. *Am J Ophthalmol* 1999;127:20-26.)



**Figure 10-12** Diurnal mean intraocular pressure (IOP) for brimonidine Purite at baseline (◆) and at week 6 (▲) and for dorzolamide at baseline (■) and at week 6 (●). (Adapted from Konstas AGP, Karabatsas CH, Lalos N. *Ophthalmology* 2005;112:603–608.)

timolol/dorzolamide (Cosopt). A fixed combination of brimonidine 0.2% and timolol 0.5% provides significantly better IOP control compared with either brimonidine or timolol used alone.

Brimonidine is as effective as apraclonidine in preventing or attenuating IOP spiking after argon laser trabeculoplasty, YAG laser posterior capsulotomy, and laser peripheral iridotomy procedures. Apraclonidine tends to dilate the pupil, whereas brimonidine tends to constrict the pupil.

In addition to its ocular hypotensive effect, brimonidine can be used to improve vision function under scotopic conditions in patients who have had refractive surgery. Brimonidine causes a significant miosis, greater under scotopic than photopic conditions, beginning 30 to 60 minutes after drug instillation and lasting about 6 hours. For postrefractive surgery patients who have difficulty with glare, halos, star bursts, or other night-vision symptoms associated with a large pupil, brimonidine can be instilled about 30 minutes before engaging in night vision activities such as driving. Repeated daily use should be avoided, however, because of the possibility of tachyphylaxis and rebound mydriasis.

The clinician should note that brimonidine may not consistently decrease IOP from untreated levels at 10 to 12 hours after dosing. Thus, the recommended dosage of brimonidine for patients with open-angle glaucoma or ocular hypertension is three times per day when used as monotherapy. However, twice-daily administration appears to be effective for many patients when brimonidine is used in combination with other ocular hypotensive agents.

### Side Effects

Both local and systemic dose-related adverse events can occur with topical brimonidine. The effects are generally

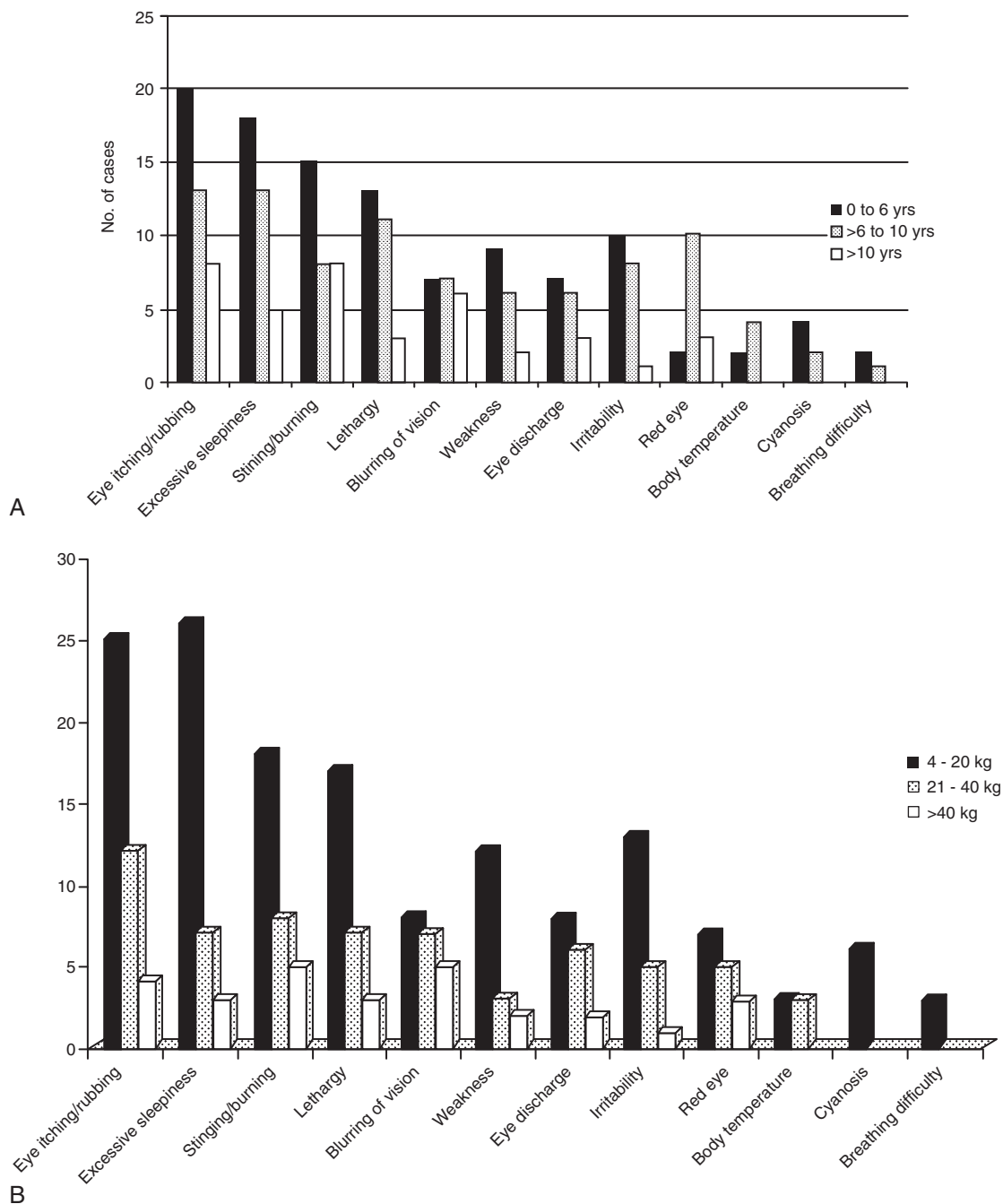
mild to moderate and are similar with twice-daily and three-times-daily administration. The most frequent ocular adverse events are hyperemia, burning, stinging, blurred vision, and foreign body sensation. A slight miotic effect has also been observed, which does not appear to be accompanied by refractive changes nor by changes in anterior chamber depth or angle.

As with apraclonidine ocular allergic reactions, including blepharitis, blepharoconjunctivitis, and conjunctival follicles, have occurred with brimonidine. The incidence of allergy with brimonidine 0.2% ranges from 4.8% during 3 months of therapy to 9% over 12 months but is much lower than the range of 20% to 50% reported for apraclonidine 0.5% or 1.0% for similar time periods. Brimonidine, unlike apraclonidine, lacks the hydroquinone subunit and does not undergo thiol conjugation reactions. Brimonidine 0.15% with Purite has a significantly reduced incidence of allergic reactions compared with the 0.2% concentration.

Systemic effects associated with topical ocular brimonidine include dry mouth, headache, and fatigue or drowsiness. Dry mouth is generally the most common complaint, occurring in 16% to 30% of patients treated with brimonidine 0.2% twice daily. Other observed effects include decreases in systolic and diastolic blood pressure and heart rate, but these effects generally are clinically insignificant. Compared with  $\beta$ -blockers, brimonidine has excellent systemic tolerability and may be useful in elderly patients to improve quality of life and enhance patient satisfaction with glaucoma therapy.

### Contraindications

Brimonidine is contraindicated in patients receiving monoamine oxidase inhibitors. It is not contraindicated



**Figure 10-13** (A) Bar graph showing an overview of brimonidine side effects by age. Note that most side effects were reported in patients younger than 10 years of age. (B) Bar graph showing an overview of brimonidine side effects by weight. Note that most side effects were reported in patients less than 20 kg. (Adapted from Al-Shahwan S, Al-Torbak AA, Turkmani S, et al. *Ophthalmology* 2005;112:2143–2148.)

in patients with cardiopulmonary disease but should be used with caution in patients with severe cardiovascular disease. Although brimonidine is effective in lowering IOP in children, its use has been associated with excessive sleepiness, lethargy, and fatigue (Figure 10-13). This drug should be used with caution or avoided in young children, especially those weighing less than 20 kg and those younger than 6 years of age.

## CARBONIC ANHYDRASE INHIBITORS

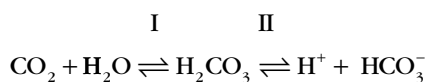
### Mechanism of Action

Bicarbonate formation is an essential component of aqueous production. A relatively high concentration of bicarbonate can be found in the aqueous humor. The presence of carbonic anhydrase in the ciliary processes can also be

demonstrated in both animals and humans. The earliest reported ocular hypotensive properties of acetazolamide, a carbonic anhydrase inhibitor (CAI) demonstrated a decrease in IOP induced from inhibition of aqueous humor production. Other studies have confirmed these results with various CAIs commercially available for use in the treatment of all types of glaucoma.

All commercially available CAIs are unsubstituted aromatic sulfonamides (ARYL-SO<sub>2</sub>NH<sub>2</sub>). The resonating heterocyclic side group confers a high inhibitory activity to these agents. These compounds produce their primary pharmacologic effects through reversible noncompetitive binding with the enzyme carbonic anhydrase.

Carbonic anhydrase catalyzes the first step (I) in the following reaction:



Reaction II is an ionic dissociation reaction that occurs very rapidly and is not under enzymatic control. Therefore carbonic anhydrase catalyzes the cellular production of H<sub>2</sub>CO<sub>3</sub> and thus the formation of H<sup>+</sup> and HCO<sub>3</sub><sup>-</sup>. Although body tissues contain several isoenzymes of carbonic anhydrase, the C-type, sulfonamide-sensitive carbonic anhydrase (also known as type II), is the predominant isoenzyme in the human ciliary processes.

Inhibition of carbonic anhydrase activity in the ciliary processes is probably the mechanism responsible for decreased aqueous formation produced by CAIs. The production of bicarbonate in the ciliary epithelium appears to play a key role in the formation of aqueous humor. Bicarbonate is the key anion associated with the decrease in aqueous formation produced by inhibition of carbonic anhydrase.

Inhibition of carbonic anhydrase also decreases sodium entry into the posterior chamber. Sodium, transported by Na<sup>+</sup>-K<sup>+</sup>-adenosine triphosphatase, probably acts as the counter-ion for newly formed bicarbonate. These two ions are linked such that inhibition of either carbonic anhydrase or Na<sup>+</sup>-K<sup>+</sup>-adenosine triphosphatase reduces sodium movement into the posterior chamber.

Fluid movement from the stroma of the ciliary processes into the posterior chamber requires the transepithelial movement of several ions. Assuming that Na<sup>+</sup>, HCO<sub>3</sub><sup>-</sup>, and Cl<sup>-</sup> are the major ions involved in secretion, Figure 10-14 illustrates how these ions may function in fluid movement across the nonpigmented ciliary epithelium and into the posterior chamber. Inhibition of carbonic anhydrase in the ciliary processes decreases bicarbonate, sodium, and fluid movement into the posterior chamber, with the net result being decreased aqueous humor formation.

It was initially believed that the reduction of IOP produced by the systemic CAIs was attributed in part to the accompanying metabolic acidosis that occurs secondary to

the renal effects of these agents. However, since those initial reports, it does not appear that the metabolic acidosis from CAIs influences IOP.

Most tissues contain carbonic anhydrase in quantities that exceed physiologic requirements. Because of this excess, at least 99% of carbonic anhydrase activity must be inhibited to depress aqueous production significantly. Drug levels sufficient to reduce aqueous humor formation are readily achieved after systemic and topical administration of CAIs. However, systemic use has the disadvantage of significantly inhibiting the activity of carbonic anhydrase throughout the body.

Of the currently available CAIs (Table 10-5), acetazolamide is the prototype drug and has been studied extensively. Other agents within this class include methazolamide and dichlorphenamide. Systemic administration of any of these agents produces a 45% to 55% inhibition of aqueous formation in humans.

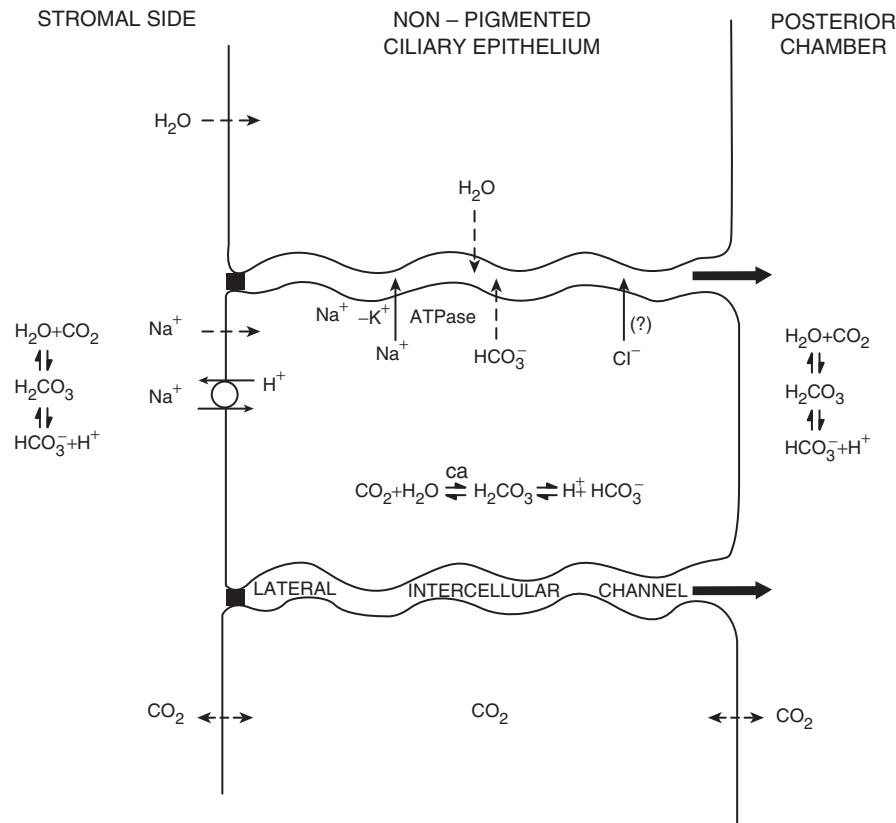
## Acetazolamide

### Pharmacology

In the treatment of all types of glaucoma, acetazolamide is the most widely used orally administered CAI. Acetazolamide is commercially available as 125- and 250-mg tablets, 500-mg sustained-release capsules (Diamox Sequels), and a 500-mg vial formulated for parenteral administration. In glaucoma therapy in adults, acetazolamide is usually administered in doses of 250 mg every 6 hours or a single 500-mg sustained-release capsule twice daily. The recommended acetazolamide dose for children is 5 to 10 mg/kg body weight, administered every 4 to 6 hours.

Acetazolamide is readily absorbed from the gastrointestinal tract after oral administration. After ingestion of acetazolamide tablets, the drug attains peak plasma levels within 2 to 4 hours. Peak levels are maintained for 4 to 6 hours. Drug levels are higher after acetazolamide tablets are ingested than after an equivalent dose of the sustained-release formulation. The time-release capsules produce maximum drug levels in 3 to 4 hours, and levels of 10 mg/ml are maintained for approximately 10 hours.

The time course of acetazolamide's ocular hypotensive effect parallels its plasma concentration. Oral acetazolamide tablets, in dosages greater than 63 mg, produce a significant ocular hypotensive response within 2 hours, and the effects last beyond 6 hours (Table 10-6). The ocular hypotensive effect of the sustained-release capsules begins within 2 hours, and the maximum reduction in IOP occurs 6 to 18 hours after oral administration. Although a 500-mg capsule administered once daily produces a substantial decrease in IOP lasting at least 24 hours, the magnitude of the pressure drop is greater when the drug is administered twice daily. The sustained-release capsules, administered in dosages of 500 mg twice daily, are as effective in reducing IOP as are 250-mg acetazolamide tablets administered every 6 hours.



**Figure 10-14** Ion and fluid movement in the nonpigmented ciliary epithelium.  $\text{Na}^+$  enters the nonpigmented ciliary epithelium from the stromal side either by diffusion or by  $\text{Na}^+/\text{H}^+$  exchange.  $\text{Na}^+$ , the main cation involved in aqueous formation, is transported extracellularly into the lateral intercellular channel by a  $\text{Na}^+/\text{K}^+$ -adenosine triphosphatase-dependent transport system.  $\text{HCO}_3^-$  forms from the hydration of  $\text{CO}_2$ , a reaction catalyzed by carbonic anhydrase.  $\text{HCO}_3^-$ , the major anion involved in aqueous formation, balances a portion of the  $\text{Na}^+$  being transported into the lateral intercellular channel.  $\text{Cl}^-$  enters the intercellular space by a mechanism that is not understood. This movement of ions into the lateral intercellular space creates a hypertonic fluid, and water enters by osmosis. Because of the restriction on the stromal side of the channel, the newly formed fluid moves toward the posterior chamber. A rapid diffusional exchange of  $\text{CO}_2$  allows for its movement into the posterior chamber. (Adapted from Cole DE. Secretion of aqueous humor. *Exp Eye Res* 1977;25(suppl):161-176.)

Plasma levels sufficient to decrease IOP occur only minutes after intravenous administration of acetazolamide, but this route of administration is generally reserved for situations, such as in acute angle-closure glaucoma, when vomiting precludes the oral route. The duration of action of acetazolamide after intravenous administration is approximately 4 hours.

In humans, 90% to 95% of acetazolamide in the blood binds to plasma proteins. Therefore relatively large dosages of acetazolamide are required to produce a significant plasma level of the unbound drug. At plasma pH (7.4), half the unbound acetazolamide ( $\text{pK}_a = 7.4$ ) exists in the un-ionized form, which is the form that penetrates tissues and inhibits carbonic anhydrase.

Acetazolamide is not metabolized; it is excreted, primarily by tubular secretion, into the urine. Because of its action on the kidney, acetazolamide increases urinary excretion of  $\text{HCO}_3^-$  and produces an alkaline urine. This alteration of urinary pH favors excretion of acetazolamide, because more drug exists in the water-soluble, ionized form.

### Clinical Uses

In the treatment of elevated IOP, oral acetazolamide is often reserved for short-term IOP reduction only. The development of topical dosage forms of CAIs and the availability of safer ocular hypotensive agents provide a more attractive therapeutic alternative for long-term administration. Acetazolamide produces an additional decrease in IOP when added to drug regimens including miotics,  $\beta$ -blockers, and prostaglandins.

Although both timolol and acetazolamide inhibit aqueous formation, concurrent administration of these agents produces a nearly additive effect on IOP. In contrast to timolol, which has no significant effect on aqueous flow in sleeping humans, acetazolamide reduces aqueous flow during sleep. In humans, the aqueous flow rate normally decreases approximately 60% during sleep. Acetazolamide suppresses aqueous flow an additional 24% below the nocturnal flow rate.

In acute angle-closure glaucoma, acetazolamide is often administered soon after the diagnosis is made. Use of acetazolamide in the management of acute angle-closure



**Table 10-5**  
Carbonic Anhydrase Inhibitors

Drug	Trade Name (Manufacturer)	Formulation
Acetazolamide (Generic)	Diamox (Bausch & Lomb)	125- and 250-mg tablets; 500-mg sustained-release capsules (Sequels); 500-mg vials for injection
Methazolamide (Generic)	Neptazane (Bausch & Lomb) MZM (CIBA vision)	25- and 50-mg tablets
Dorzolamide	Trusopt (Merck)	2% ophthalmic solution
Brinzolamide	Azopt (Alcon)	1% ophthalmic suspension
Dorzolamide + timolol	Cosopt (Merck)	2% dorzolamide + 0.5% timolol solution

glaucoma is frequently limited to the preoperative period, because many patients require no further medication or can be managed with topical agents after surgery.

Acetazolamide has been given during surgery to prevent IOP elevations after pars plana vitrectomy with fluid-gas exchange. No protective effect was demonstrated on IOP 4 to 8 hours after surgery or on the first postoperative day.

An additional clinical use of acetazolamide is unrelated to its ocular hypotensive properties. The 500-mg acetazolamide capsule administered daily for 2 weeks may produce either a partial or a complete resolution of macular edema in patients with cystoid macular edema (CME), retinitis pigmentosa, and chronic intermediate uveitis (pars planitis). Macular edema produced by primary retinal vascular diseases (branch and central retinal vein occlusion and macular telangiectasia) did not respond to acetazolamide therapy. It is believed that acetazolamide may improve visual function if the macular edema stems from retinal pigment epithelial dysfunction. Improved macular edema in these conditions may be associated with fluid movement from the retina to the choroid. However, acetazolamide does not appear to alter macular blood flow.

### Side Effects

**Systemic Effects.** Although acetazolamide is effective as an ocular hypotensive agent, a significant number of side effects limit its clinical usefulness (Box 10-5). Maximal doses of CAIs produce intolerable effects in 30% to 80% of patients. The incidence of side effects varies with the dose and the formulation; however, when all side effects are considered, the incidence probably approaches 100% in patients taking either acetazolamide tablets or the 500-mg sustained-release capsules. One study demonstrated that only 26% of patients could tolerate acetazolamide tablets beyond 6 weeks, whereas 58% of patients could tolerate prolonged use of the sustained-release formulation.

Numbness and tingling of the fingers, toes, and perioral region are among the most common adverse events resulting from the use of oral CAIs. Another common but tolerable side effect is an alteration in gustation, resulting in a metallic taste.

A symptom complex has also been described consisting of malaise, fatigue, weight loss, depression, anorexia, and often decreased libido as the side effects most likely to require discontinuation of oral CAIs. In addition, impotence has been reported in some patients taking acetazolamide. These symptoms may take several months to

**Table 10-6**  
Pharmacokinetic Properties of Systemic Carbonic Anhydrase Inhibitors

Drug	Dose	Onset of Ocular Hypotensive Action	Maximum IOP Reduction	Duration of Ocular Hypotensive Action (hr)
Acetazolamide tablet	65-250 mg QID	30 min-1 hr	2-4 hr	4-6
Acetazolamide capsule	500 mg BID	1-2 hr	8-12 hr	10-18
Acetazolamide IV	500 mg IV	1 min	20-30 min	4
Methazolamide	25-100 mg BID,TID	1 hr	7-8 hr	10-14
Dichlorphenamide	25-50 mg BID,TID, QID	30 min	2-4 hr	6-12

BID = twice daily; IOP = intraocular pressure; QID = four times daily; TID = three times daily.

(Adapted from Flach AJ. Topical acetazolamide and other carbonic anhydrase inhibitors in the current medical therapy of the glaucomas. *Glaucoma* 1986;8:20-27.)



**Box 10-5** Side Effects of Acetazolamide**Systemic**

Numbness and tingling of extremities and perioral region<sup>a</sup>  
 Metallic taste<sup>a</sup>  
 Symptom complex<sup>a</sup>  
 Decreased libido  
 Depression  
 Fatigue  
 Malaise  
 Weight loss  
 Gastrointestinal irritation<sup>a</sup>  
 Metabolic acidosis<sup>a</sup>  
 Hypokalemia  
 Renal calculi  
 Blood dyscrasias  
 Dermatitis

**Ocular**

Transient myopia

<sup>a</sup>Common.

develop and appear to be related at least partially to serum drug levels. The symptom complex also appears to occur more commonly in patients exhibiting marked acidosis.

Symptoms of gastrointestinal irritation, including abdominal cramps, nausea, and diarrhea, have been reported after the use of acetazolamide. Ingesting the tablets with food or changing from acetazolamide tablets to the sustained-release capsules may improve these symptoms for some patients. These symptoms, if persistent, can become intolerable and may require an alternative means of IOP control.

CAIs alter renal function primarily by inhibiting carbonic anhydrase in the proximal tubule, which results in decreased bicarbonate reabsorption. The net effect of the renal actions of acetazolamide therapy is alkalization of the urine and metabolic acidosis. Metabolic acidosis results from the initial bicarbonate loss and persists with continued acetazolamide use. Moderate metabolic acidosis develops in most patients. Reabsorption of bicarbonate independent of carbonic anhydrase prevents severe acidosis. Initially, acetazolamide produces diuresis, but urinary output decreases with the development of metabolic acidosis. In addition, decreased urinary citrate excretion follows acetazolamide therapy and has been attributed to the metabolic acidosis it produces. A high urinary pH and low urinary citrate concentration are conducive to precipitation of calcium phosphate in both the renal papillae and the urinary tract.

Although acetazolamide therapy increases urinary excretion of potassium, problems associated with

hypokalemia rarely occur. However, this potassium-depleting action may become significant if the patient is also taking a thiazide diuretic or digitalis derivative. Concomitant use of acetazolamide and a thiazide diuretic can lead to drug-induced hypokalemia, and these patients may require potassium supplementation. Because decreased potassium levels also increase the possibility of digitalis toxicity, potassium levels should be monitored closely in patients taking acetazolamide with digitalis derivatives or thiazide diuretics.

The most serious side effects associated with acetazolamide are blood dyscrasias. Thrombocytopenia, agranulocytosis, and aplastic anemia have all occurred in patients taking acetazolamide; however, drug-induced blood dyscrasias are extremely rare.

**Ocular Effects.** Drug-induced transient myopia has been reported with several sulfonamides. Acetazolamide, an unsubstituted heterocyclic sulfonamide, has also been associated with myopic shifts in refractive error. Shallowing of the anterior chamber is the only variable documented to change in eyes exhibiting this increase in myopia after sulfonamide therapy. Myopia probably results from ciliary body edema that produces a forward displacement of the lens-iris diaphragm. The myopia subsides on reduction or discontinuation of acetazolamide therapy (see Chapter 35).

**Contraindications**

Because long-term use of acetazolamide usually brings on a significant number of side effects, patients who are particularly susceptible to these side effects should avoid acetazolamide (Box 10-6). Because of the significant structural differences between the antibacterial and the carbonic anhydrase-inhibiting sulfonamides, there is little evidence to suggest overlapping sensitivities between the two classes of drugs. However, hypersensitivity reactions including exfoliative dermatitis, nonthrombocytopenic purpura, hepatitis, nephropathy, and transient myopia are linked with sulfonamide compounds and their derivatives. There has been at least one reported case of anaphylactic shock and death after a single dose of oral acetazolamide. Thus, patients with known hypersensitivity reactions to sulfonamides should not take CAIs.

**Box 10-6** Contraindications to Acetazolamide

Clinically significant liver disease  
 Severe chronic obstructive pulmonary disease  
 Certain secondary glaucomas<sup>a</sup>  
 Renal disease, including kidney stones<sup>a</sup>  
 Pregnancy  
 Known hypersensitivity to sulfonamides

<sup>a</sup>See text for discussion.

Because acetazolamide is excreted unchanged in the urine, patients with impaired renal function may require substantially lower doses and should be monitored closely for side effects. Patients taking potassium-depleting diuretics must use acetazolamide with caution because of the possibility of drug-induced hypokalemia. Because patients taking digitalis are at greater risk of developing digitalis toxicity secondary to hypokalemia, acetazolamide must be used with caution or avoided in these individuals. Patients with cirrhosis of the liver are particularly sensitive to toxicity associated with acetazolamide use. Alkalinization of the urine decreases urinary trapping of  $\text{NH}_4^+$  and may result in increased levels of ammonia in the systemic circulation. An increased level of ammonia in circulation may contribute to the development of hepatic encephalopathy. Therefore acetazolamide is contraindicated in patients with clinically significant liver disease.

Acetazolamide should be avoided in patients with severe COPD. These patients may be unable to increase their alveolar ventilation enough to compensate for the acid-base alterations induced by acetazolamide. In some patients, especially those with severe pulmonary disease, increased  $\text{CO}_2$  gradients or acidosis may lead to acute respiratory failure. Acetazolamide should be used cautiously in such patients, and the practitioner should use the lowest effective dose to reduce IOP.

Because medical therapy is often ineffective in the management of the closed-angle stage of neovascular glaucoma and other secondary glaucomas characterized by severe impairment of aqueous outflow, acetazolamide should not be used routinely because of the systemic side effects it produces. In addition, it is important to remember that CAIs reduce aqueous formation by only 45% to 55%. In glaucomas arising from severe impairment of outflow, as in chronic angle-closure glaucoma, aqueous production is not inhibited enough to allow long-term control of IOP. Therefore the clinician may derive a false sense of security from the decrease in IOP initially produced by CAIs, while the underlying ocular condition progresses.

Black patients with sickle cell hemoglobinopathies and hyphema-induced secondary glaucomas should be administered acetazolamide with caution. Acetazolamide increases the ascorbate concentration in aqueous humor and reduces plasma pH. Both actions can promote sickling of red blood cells in the anterior chamber and within small blood vessels perfusing intraocular structures. Hyphemas containing sickled red blood cells resolve more slowly and elevate IOP more than do hyphemas containing nonsickled red blood cells. Therefore all black patients with hyphemas should be screened for sickle cell hemoglobinopathies before acetazolamide treatment, as should any black patient requiring long-term acetazolamide therapy.

Acetazolamide may precipitate renal calculi formation in predisposed individuals. Therefore patients with bacteriuria, previous bladder surgery, or a history suggestive of previous calculus formation should not

receive acetazolamide. Furthermore, because high urinary pH and low urinary citrate concentration are conducive to calculus formation, concurrent use of acetazolamide and sodium bicarbonate may increase the risk of calculus formation. In addition, other forms of renal disease should be excluded if long-term acetazolamide therapy is contemplated. If standard doses of acetazolamide are given to patients with diabetic nephropathy, severe acidosis may result; therefore these patients should have serum electrolytes monitored closely to prevent this complication.

In experimental animals acetazolamide can be teratogenic. Acetazolamide use should generally be avoided during pregnancy.

## **Methazolamide**

### **Pharmacology**

In the past orally administered acetazolamide was considered the CAI of choice in the treatment of glaucoma. However, certain properties of methazolamide indicate possible advantages to its use as an oral hypotensive agent. Methazolamide is structurally similar to acetazolamide. The structure of methazolamide was designed to decrease ionization and thereby improve intraocular penetration. After oral administration methazolamide is well absorbed from the gastrointestinal tract. Average serum levels peak in 2 to 3 hours after an oral 100-mg dose and remain nearly constant for at least 8 hours. Methazolamide has higher lipid and water solubilities than does acetazolamide. These properties favor renal tubular reabsorption and increase both its half-life and plasma concentration. Methazolamide has a plasma half-life of approximately 14 hours, compared with 5 hours for acetazolamide. Because only 25% of methazolamide is excreted unchanged in the urine, the remaining 75% is probably metabolized to an inactive form. However, its precise fate is unknown.

Only 55% of methazolamide binds to plasma proteins, compared with 90% to 95% of acetazolamide. Because only the unbound portion of the drug dose is pharmacologically active, methazolamide can be given at lower doses than acetazolamide to achieve comparable effects.

Dose-response studies of the ocular hypotensive effect of methazolamide have shown that IOP decreases in a dose-dependent manner for doses of 25, 50, and 100 mg given every 8 hours; the mean decreases in IOP at these doses are 3.3, 4.3, and 5.6 mm Hg, respectively.

### **Clinical Uses**

Methazolamide, like other CAIs, may be added to the treatment regimen of patients with primary open-angle glaucoma and secondary glaucomas when topical ocular hypotensive agents alone provide inadequate pressure control. However, as with acetazolamide, long-term usage has been supplanted by the use of topical CAIs. Methazolamide produces less alteration of acid-base balance than acetazolamide and may be more reasonable for use in patients with severe obstructive pulmonary disease.

Methazolamide also alters urinary citrate excretion less than does acetazolamide and therefore is safer in patients predisposed to renal calculus formation.

The advantages of methazolamide are numerous enough that many authorities believe it should be the first CAI used for systemic glaucoma therapy. Methazolamide is commercially available in 25- and 50-mg tablets. The adult dosage is 25 to 100 mg three times daily.

### Side Effects

Methazolamide is one of the best-tolerated oral CAIs, especially at low doses. However, administration of this drug poses the same general risk as administration of acetazolamide, and the side effects associated with methazolamide use are essentially the same as those associated with acetazolamide. Compared with acetazolamide, methazolamide generally produces less acidosis and has less effect on urinary citrate levels. Thus, patients who are intolerant of acetazolamide may tolerate methazolamide therapy without difficulty.

Methazolamide is particularly useful in patients predisposed to develop renal calculi. Methazolamide interferes less with excretion of urinary citrate, which may explain why kidney stones have only rarely been associated with its use.

Compared with acetazolamide, methazolamide generally causes less paresthesia but often causes more drowsiness. Although extremely rare, aplastic anemia and agranulocytosis have been reported as complications of methazolamide therapy.

Skin eruptions can also occur. Methazolamide should be used cautiously in patients of Japanese or Korean descent. Reports of severe Stevens-Johnson syndrome have been documented, with one case occurring after a single dose. Although Stevens-Johnson syndrome has been reported after use of acetazolamide in patients with various ethnic backgrounds, methazolamide-induced Stevens-Johnson syndrome has been encountered only in the Japanese.

### Contraindications

Contraindications to the use of methazolamide are the same as those associated with the use of acetazolamide. Methazolamide, however, can be used more safely in patients with a history of kidney stones or renal impairment. Patients with COPD may tolerate methazolamide better than acetazolamide, because the metabolic acidosis is less pronounced.

## TOPICAL CARBONIC ANHYDRASE INHIBITORS

After the introduction of oral acetazolamide, the search began for a topically active CAI that would reduce IOP without the adverse effects associated with the oral CAIs. One group of topical CAIs to be developed that demonstrated good clinical potential was the thienothioipran-2-sulfonamides, such as dorzolamide. Initially,

topical CAIs were thought to gain access to the ciliary body through both local ocular penetration and systemic absorption. Many studies have shown, however, that local penetration is the major route. Topical CAIs alter aqueous humor composition; this includes lowering pH, decreasing bicarbonate levels, and increasing posterior chamber ascorbate levels limited to the eye receiving the dose.

### Dorzolamide (Trusopt)

#### Pharmacology

Dorzolamide was the first commercially available topical CAI to show significant ocular hypotensive activity in humans. The addition of an alkyl amino side group allows this compound to alternate between an acidic and basic form. This property enhances both lipid and water solubility, thereby allowing increased corneal and scleral penetration.

When used as monotherapy, the usual dose is one drop of dorzolamide 2% (approximately 30  $\mu$ L) every 8 hours. The plasma concentration of free drug is approximately 1/200th of the amount required for systemic pharmacologic effects. However, the concentration in the ciliary processes (2 to 10  $\mu$ mol/L) is equivalent to that produced by systemic CAIs.

Inhibition of isoenzyme II in the ciliary processes by dorzolamide is thought to be responsible for decreasing aqueous humor secretion. Dorzolamide also inhibits membrane-bound isoenzyme IV, which is currently being investigated for its role in the production of aqueous humor.

Although effective, topical dorzolamide 2% does not appear to inhibit aqueous humor formation to the same extent as systemic acetazolamide. This may, in part, be a result of incomplete inhibition of one or two carbonic anhydrase isoenzymes responsible for aqueous humor production. In normal humans, dorzolamide 2% reduces aqueous humor flow during the day and at night during sleep 13% and 9%, respectively, although not as effectively as does systemic acetazolamide (24% suppression). The additive effect of dorzolamide on aqueous humor flow in glaucoma patients was studied in patients who had been receiving long-term timolol. Dorzolamide further reduced aqueous flow by  $24\% \pm 11\%$ . There appears to be no additive effect of dorzolamide with latanoprost on the rate of aqueous humor flow in normal subjects.

Topical dorzolamide does not appear to cause a change in retinal circulatory variables, including venous diameter and volumetric blood flow rate, after a single dose in normal subjects. The drug also does not have any apparent effect on retrobulbar hemodynamics as determined by color Doppler imaging. In some studies, however, improvements in retinal, choroidal, and retrobulbar blood flow as determined by various assessment methods and hemodynamic markers demonstrate that dorzolamide alone or in combination therapy may improve ocular blood flow in patients with glaucoma and ocular

hypertension. The clinical significance of this has not been elucidated.

### Clinical Uses

Dorzolamide is indicated for the treatment of elevated IOP in patients with ocular hypertension and open-angle glaucoma. The drug is commercially available as a 2.0% solution (Trusopt). It is supplied as a sterile, isotonic, buffered, slightly viscous solution with a pH of approximately 5.6. BAC 0.0075% is added as a preservative.

When administered twice daily and three times daily, 2.0% dorzolamide reduces IOP 21.8% to 24.4% and 22.2% to 26.2%, respectively. The maximal ocular hypotensive effect occurs 2 hours after administration. Although twice-daily administration reduces IOP, dosing three times daily produces better overall ocular hypotensive effect.

Monotherapy with three-times-daily 2% dorzolamide and twice-daily timolol 0.5% or betaxolol 0.5% demonstrated peak IOP changes of 23%, 25%, and 21%, respectively. Additive effects on IOP occur when dorzolamide is added to timolol gel solution.

Dorzolamide was also evaluated in open-angle glaucoma or ocular hypertension patients as monotherapy and when used with timolol and/or pilocarpine for up to 2 years. At 2 years the mean decrease in IOP was approximately 23% for monotherapy patients and 31% to 36% for adjunctive therapy patients. Although dorzolamide was reasonably well tolerated, most patients required adjunctive therapy within 6 months.

Topical dorzolamide and oral acetazolamide do not produce additive effects, and their concomitant use is not indicated for glaucoma therapy.

Dorzolamide has been compared with acetazolamide for the prevention of IOP spikes after YAG laser capsulotomy. One drop of topical dorzolamide 2% and one 125-mg dose of acetazolamide 1 hour before capsulotomy are comparable in preventing elevations of IOP. Dorzolamide is also effective in preventing IOP spikes after argon laser trabeculoplasty or laser iridotomy.

Because dorzolamide inhibits carbonic anhydrase II in the corneal endothelium, the long-term effects of dorzolamide on corneal endothelial cell density and thickness have been of interest. Patients with glaucoma or ocular hypertension have been evaluated for 1 year by corneal specular microscopy and ultrasonic pachymetry, and dorzolamide has demonstrated good long-term tolerability.

### Side Effects

Dorzolamide is generally well tolerated. Ocular side effects include local irritation, possibly related to pH and tonicity. Stinging (7%), burning or foreign body sensation (12%), and blurring of vision (9%) are among the most common. Others include superficial punctate keratitis and headache. A severe sterile purulent conjunctivitis developing over weeks to months was described in seven patients and resolved on discontinuation of dorzolamide. Because all CAIs are sulfonamides, local sensitization has

been reported in approximately 4% of patients as lid or conjunctival allergies.

Because dorzolamide may inhibit corneal endothelial carbonic anhydrase, it may potentially cause some corneal edema or decompensation. There is generally little or no change in corneal thickness and endothelial cell count. However, nine patients with corneal endothelial compromise developed irreversible corneal edema within 3 to 20 weeks (mean, 8 weeks) after treatment began. All patients had undergone previous intraocular surgery, including four patients who had undergone corneal transplantation. A hypersensitivity reaction causing a marginal keratitis was reported with topical dorzolamide, which resolved upon drug discontinuation.

Systemic side effects reported with oral CAIs have generally not been seen with topical CAIs. Paresthesias, electrolyte imbalance, and CNS side effects, including malaise and fatigue, have not been reported with dorzolamide. Bitter taste is experienced in approximately 25% of patients taking topical dorzolamide. Three cases of nephrolithiasis have been attributed to topical dorzolamide. Onset was from 21 days to 8 months after treatment began. Two patients, however, had previously received systemic CAIs. Because there may be an increased risk of developing nephrolithiasis, a careful history of renal calculi should be obtained.

Because a potential exists for an additive systemic effect with other CAIs, the concomitant use of topical dorzolamide with an oral CAI is not recommended. The safety of dorzolamide use has not been established in pregnancy, lactation, or in children. However, the drug has been studied in children with glaucoma who were previously on oral acetazolamide. Dorzolamide was effective and did not cause any adverse reactions or intolerance.

### Contraindications

Dorzolamide is administered topically but can be absorbed systemically. Although there is risk of systemic hypersensitivity reactions to dorzolamide, a nonantibiotic sulfonamide, in patients allergic to sulfonamide antibiotics, the risk appears to be low.

The use of dorzolamide has not been studied in patients with severe renal impairment ( $\text{CrCl} < 30$  ml/min). The drug, therefore, should be used cautiously in such patients. Likewise, dorzolamide should be used with caution in patients with hepatic impairment. Because of potential additive systemic effects, dorzolamide should be avoided in patients taking an oral CAI.

## Brinzolamide (Azopt)

### Pharmacology

Brinzolamide, a heterocyclic sulfonamide, is a topical CAI suspension that has a high affinity for the carbonic anhydrase II isoenzyme. Because the ocular hypotensive effect of the drug is equivalent whether dosed twice or three times daily, brinzolamide 1% may be administered twice daily.

### Clinical Uses

Brinzolamide is indicated for the treatment of elevated IOP in patients with ocular hypertension or open-angle glaucoma. The drug is commercially available as a sterile 1.0% aqueous suspension with a pH of approximately 7.5. BAC 0.01% is added as a preservative.

The efficacy and safety of brinzolamide 1%, either two or three times daily, were evaluated in 572 patients with open-angle glaucoma or ocular hypertension against timolol 0.5% twice daily and dorzolamide 2.0% three times daily. Mean IOP changes were  $-3.8$  to  $-5.7$  mm Hg,  $-4.2$  to  $-5.6$  mm Hg, and  $-4.3$  to  $-5.9$  mm Hg for two- and three-times-daily brinzolamide and dorzolamide dosing, respectively. The mean IOP changes for timolol 0.5% ranged from  $-5.6$  to  $-6.3$  mm Hg (Figure 10-15). Brinzolamide was well tolerated, with 1.8% (twice daily) and 3% (three times daily) of patients reporting ocular discomfort versus 16.4% with dorzolamide. Complaints of blurred vision were higher with brinzolamide (5–6%) than dorzolamide (1%) or timolol (0%).

A meta-analysis of randomized clinical trials reported peak ocular hypotensive effect on IOP of 17% (19% to 15%) and trough effect of 17% (19% to 15%).

### Side Effects

Both brinzolamide and dorzolamide exhibit similar taste abnormalities. A single case report of the development of metabolic acidosis from topical brinzolamide has been described after twice-daily dosing. Other adverse events are negligible for brinzolamide except for some blurring of vision, attributable to its suspension vehicle.

### Contraindications

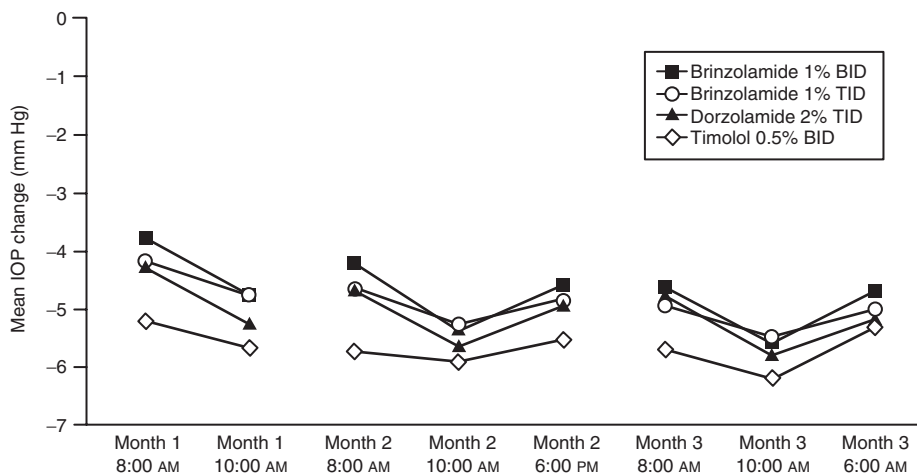
Brinzolamide has the same contraindications and precautions as dorzolamide.

### Timolol 0.5% and Dorzolamide 2% (Cosopt)

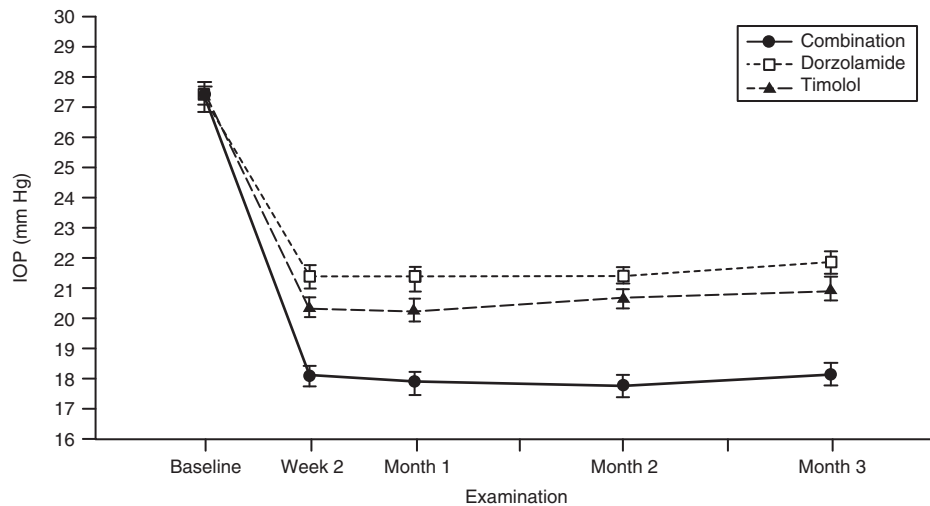
A combination product of timolol 0.5% and dorzolamide 2% is available (Cosopt). This fixed-combination dosed twice daily is equivalent to dorzolamide 2% three times daily and timolol 0.5% twice daily dosed separately. Moreover, the combination product is more convenient, requiring one bottle and fewer drops per day than separate bottles. The combination product used twice daily has been compared with monotherapy with either dorzolamide 2% three times daily or timolol 0.5% twice daily. The mean reduction in IOP was 27.4% ( $-7.7$  mm Hg), 15.5% ( $-4.6$  mm Hg), and 22.2% ( $-6.4$  mm Hg) for the combination product, dorzolamide, and timolol, respectively (Figure 10-16). The dorzolamide–timolol combination was compared with either individual component in patients not controlled on timolol twice daily alone. The combination product was more effective than either timolol 0.5% twice daily or dorzolamide 2% three times daily for up to 3 months. The most frequently reported ocular side effect was ocular burning or stinging, with the overall adverse effects being similar for the combination product and dorzolamide, but less for timolol.

The ocular hypotensive effect of Cosopt has been compared with that of latanoprost. Mean diurnal IOP changes of  $-7.1 \pm 3.8$  mm Hg and  $-7.1 \pm 3.3$  mm Hg for Cosopt and latanoprost, respectively, were found. Both agents are equally effective in lowering IOP, although latanoprost is better tolerated than is Cosopt. Both treatments also show similar efficacy in regards to percentage of patients achieving target pressures.

The substitution of brinzolamide for dorzolamide in addition to concomitant administration of timolol demonstrates equivalent IOP reduction but less ocular burning



**Figure 10-15** Mean intraocular pressure (IOP) change (mm Hg) for the various treatment groups by visit and time of day for a 3-month treatment period. Each value represents the least-squares mean of the change from baseline diurnal IOP, and all were significant. (Adapted from Silver LH, Brinzolamide Primary Therapy Study Group. Clinical efficacy and safety of brinzolamide [Azopt], a new topical carbonic anhydrase inhibitor for primary open-angle glaucoma and ocular hypertension. *Am J Ophthalmol* 1998;126:400–408.)



**Figure 10-16** Mean intraocular pressure (IOP) at hour 2 (morning peak) for dorzolamide, timolol, and the combination product (Cosopt). The combination provided a greater decrease in IOP at all time points than did either single product. (Adapted from Boyle JE, Ghosh K, Gieser DK, et al. A randomized trial comparing the dorzolamide-timolol combination given twice daily to monotherapy with timolol and dorzolamide. *Ophthalmology* 1998;105:1945-1951.)

and stinging. Additional studies have also shown that brinzolamide and dorzolamide are both safe and effective when added as adjunctive therapy to the combination of latanoprost and a  $\beta$ -blocker.

### Clinical Advantages of Topical Carbonic Anhydrase Inhibitors

Topical CAIs offer distinct advantages over other inhibitors of aqueous humor formation. Compared with  $\beta$ -blockers, CAIs reduce the nocturnal aqueous flow rate by 25%.  $\beta$ -Blockers lack the ability to suppress aqueous formation below the already reduced flow rate that occurs during sleep. In contrast to systemic CAIs, topical CAIs lack most of the systemic side effects while producing a comparable ocular hypotensive effect. None of the topical CAIs, however, has the ability to reduce IOP to the level achieved by 500 mg of oral acetazolamide. Topical agents are used in place of systemic CAIs for chronic treatment of primary and secondary open-angle glaucomas. Other recently developed medications have probably relegated the position of topical CAIs to second- or third-line therapy. Cosopt may simplify therapy and improve compliance for patients who require treatment with both timolol and dorzolamide.

### CHOLINERGIC AGONISTS (MIOTICS)

Cholinergic agonists are drugs that produce biologic responses similar to those of acetylcholine. These drugs are also known as parasympathomimetics or cholinomimetics and in clinical practice are usually referred to as miotics. Cholinergic agonists are classified according to their mechanism of action as direct acting or indirect acting (Box 10-7). The direct-acting drugs activate cholinergic

receptors directly at the neuroeffector junctions of the iris sphincter muscle and ciliary body. The indirect-acting agents exert their cholinergic effects primarily by inhibiting cholinesterase, thereby making increased amounts of acetylcholine available at cholinergic receptors. Pilocarpine, carbachol, and echothiophate are formulated for topical use to treat elevated IOP in patients with ocular hypertension and glaucoma (Table 10-7). Of these agents, only pilocarpine is used today in most clinical practices.

#### Box 10-7 Classification of Cholinergic Agonists

##### Direct-acting

Acetylcholine  
Methacholine  
Pilocarpine<sup>a</sup>  
Carbachol<sup>a</sup>

##### Indirect-acting (cholinesterase inhibitors)

Reversible  
Physostigmine  
Neostigmine  
Edrophonium  
Demecarium

Irreversible  
Echothiophate<sup>a</sup>  
Diisopropyl fluorophosphate

<sup>a</sup>Formulated for topical ocular use.

**Table 10-7**

Miotics Used for Treatment of Glaucoma

Generic Name	Trade Name	Manufacturer	Concentration (%)
Pilocarpine HCl solution	(Generic)	(Various)	0.5, 1, 2, 4, 6
Pilocarpine gel	Pilopine H.S. gel	Alcon	4
Carbachol	Isopto Carbachol	Alcon	1.5, 3
Echothiophate iodide	Phospholine iodide	Ayerst	0.125

## Pilocarpine

### Pharmacology

An alkaloid of natural plant origin, pilocarpine is a direct-acting cholinergic agonist with a dominant action at both peripheral and central muscarinic sites. The cholinomimetic action of pilocarpine on smooth muscle muscarinic receptors generally results in contraction. The response of intraocular smooth muscle to pilocarpine is pupillary constriction, spasm of accommodation, and reduction of IOP.

Although the precise mechanism by which pilocarpine reduces IOP has not been established, the most widely accepted explanation involves direct stimulation of the longitudinal muscle of the ciliary body, which in turn causes the scleral spur to widen the trabecular spaces and increase aqueous outflow. Muscarinic agonists such as pilocarpine also increase outflow facility in humans by directly stimulating the outflow tissues, even in the absence of an intact ciliary muscle. In humans there is no loss of IOP or outflow facility response with increasing age. Pilocarpine appears to reduce IOP to the same degree in both healthy and glaucomatous eyes, including those with ocular hypertension. In each case pilocarpine reduces IOP approximately 15%. On long-term administration, pilocarpine has increasing hypotensive effects in concentrations up to 4%, but when used in higher concentrations it appears to have little additional benefit. Ocular pigmentation influences this ocular hypotensive response. Blue eyes show maximal ocular hypotensive responses, whereas darkly pigmented eyes demonstrate a relative resistance to IOP reduction. This dose-response effect should be considered when treating darkly pigmented patients with glaucoma. These patients may require pilocarpine solutions in concentrations exceeding 4%.

Because of its activity at muscarinic receptor sites on the iris sphincter and ciliary muscles, pilocarpine causes pupillary constriction and varying degrees of accommodative spasm, depending on the patient's age. Long-term therapy with pilocarpine or other miotics alters iris muscle activity and may cause permanent miosis resulting from loss of iris radial muscle tone and from fibrosis of the sphincter muscle.

In addition, most eyes with primary open-angle glaucoma treated with pilocarpine demonstrate narrowing of the anterior chamber angle and thickening of the crystalline lens after each instillation of the drug.

These effects are measurable within 15 minutes, reach their maximum in 30 to 60 minutes, and usually dissipate after 2 hours.

### Clinical Uses

Since its introduction into clinical practice in 1876, pilocarpine has remained the most useful miotic for management of primary open-angle glaucoma, acute angle-closure glaucoma, and many secondary glaucomas. Pilocarpine is commercially available as an ophthalmic solution in concentrations from 0.25% to 10% (see Table 10-7). Pilocarpine is also commercially available as a 4% ophthalmic gel that is supplied in 3.5-g tubes.

The dosage frequency for pilocarpine solutions is usually four times daily. Twice-daily dosage without nasolacrimal occlusion usually results in inadequate control of IOP. If nasolacrimal occlusion is performed, however, twice-daily dosing may achieve adequate IOP control. Although pilocarpine is available in concentrations exceeding 4%, there is usually no advantage in using these except in patients with very darkly pigmented irides. Pilocarpine can be used in combination with most other ocular hypotensive medications. A partial or complete additivity can be obtained in combination with the prostaglandin analogue latanoprost, but not with bimatoprost.

The usual dosage of pilocarpine gel is a ½-inch ribbon applied in the lower conjunctival sac of the affected eye or eyes once a day at bedtime. Adverse events associated with the once-daily dosage of the 4% gel are not significantly different from those associated with four-times-daily instillation of the 4% drops.

Pilocarpine is also indicated, along with other agents, to treat acute angle-closure glaucoma. During an acute angle-closure attack, the IOP is often in excess of 60 mm Hg. At those high pressures the ischemic iris sphincter is unresponsive to pilocarpine. Topical  $\beta$ -blockers, apraclonidine, or systemic agents are indicated initially to bring the pressure below 50 mm Hg before pilocarpine is administered. Pilocarpine is also useful during laser iridotomy to facilitate stretching of the iris.

### Side Effects

**Ocular Effects.** Pilocarpine and other miotics are used far less frequently than other classes of ocular hypotensive drugs. Adverse ocular events (Box 10-8) are relatively common and necessitate discontinuing the drug in a



**Box 10-8** Ocular Effects of Miotics

Accommodative spasm  
 Miosis  
 Follicular conjunctivitis  
 Pupillary block with secondary angle-closure glaucoma  
 Band keratopathy<sup>a</sup>  
 Allergic blepharoconjunctivitis  
 Retinal detachment  
 Conjunctival injection<sup>b</sup>  
 Lid myokymia<sup>b</sup>  
 Anterior subcapsular cataract<sup>c</sup>  
 Iris cyst formation<sup>c</sup>

<sup>a</sup>Associated with pilocarpine solutions containing phenylmercuric nitrate as preservative.

<sup>b</sup>Usually subsides within several days or weeks as treatment continues.

<sup>c</sup>Associated with anticholinesterase agents.

substantial number of patients. One of the most annoying adverse effects is accommodative spasm, which can last for 2 to 3 hours after instillation of the topical solution. For this reason patients younger than 40 years of age generally find pilocarpine intolerable. Fortunately, these visual disturbances are less frequent and less pronounced in older patients because the ciliary muscle contractile responses to pilocarpine diminish with age.

In addition to accommodative spasm, a significant ocular problem associated with the use of pilocarpine is miosis. The drug-induced pupillary constriction can visually incapacitate patients with nuclear sclerotic and posterior subcapsular cataracts. Moreover, with long-term use, pilocarpine has been implicated in hastening the development of cataracts. Pilocarpine should be regularly discontinued for several days at least once a year so that the pupils may be pharmacologically dilated for careful stereoscopic examination of the optic disc and retina. Not only does this examination facilitate evaluation of the glaucomatous damage to the optic nerve, but it also prevents permanent miosis, which can result from loss of tone in the iris dilator muscle and fibrosis of the iris sphincter muscle.

Pilocarpine therapy can also induce pupillary block with subsequent angle closure, which almost always occurs in patients with narrow angles who have advancing cataracts. With the forward displacement of the crystalline lens-iris diaphragm associated with the advancing cataract and the physiologic action of the pilocarpine, angle closure becomes progressively superimposed on the underlying component of open-angle glaucoma but often in a subacute or chronic manner.

The relationship between miotic therapy and disorders associated with vitreoretinal traction has been a subject of controversy. Although no factual evidence links miotic therapy with retinal detachment, there is circumstantial evidence—the time interval between institution

of miotic therapy and retinal detachment and the type of detachment—that pilocarpine and other miotics may cause retinal detachment. The proposed mechanism is anterior displacement of the lens-iris diaphragm, leading to vitreoretinal traction or tractional tears, with or without posterior vitreous detachment. It is believed, but not confirmed, that miotics may increase the risk of retinal detachment in patients with myopia, aphakia, or pseudophakia. Where horseshoe-shaped breaks or dialyses are preexisting lesions, these should be treated prophylactically before miotic therapy. Patients who have no predisposing retinal conditions or who have lattice degeneration or operculated holes should be warned of possible retinal detachment before starting miotics. Optimal care entails careful peripheral retinal examination before and periodically during miotic therapy. Other ocular side effects include ciliary and conjunctival hyperemia, lid myokymia, frontal headache, and ocular or periorbital pain. Most of these signs and symptoms tend to disappear within several days or weeks as treatment continues.

**Systemic Effects.** Adverse systemic reactions associated with the cholinergic activity of pilocarpine are rare but do occasionally occur in patients who are given frequent instillations of the drug during treatment of acute angle-closure glaucoma. The systemic toxicity of high-dose pilocarpine can be significant (Box 10-9). Although the symptoms of nausea, diaphoresis, and weakness frequently experienced by patients undergoing attacks of acute angle closure are often attributed to the glaucoma attack itself, high doses of pilocarpine often cause these symptoms. Other systemic manifestations may include salivation, lacrimation, vomiting, and diarrhea. Bronchiolar spasm and pulmonary edema can occur, possibly initiating an asthmatic attack in patients with preexisting asthma.

**Box 10-9** Systemic Effects of Miotics

Headache  
 Browache  
 Marked salivation  
 Profuse perspiration  
 Nausea  
 Vomiting  
 Bronchospasm  
 Pulmonary edema  
 Systemic hypotension  
 Bradycardia  
 Generalized muscular weakness  
 Increased tone and motility of gastrointestinal tract  
 (abdominal pain, diarrhea)  
 Respiratory paralysis<sup>a</sup>

<sup>a</sup>May occur when anticholinesterase agents are not discontinued before use of succinylcholine during elective surgery.

**Box 10-10** Contraindications to Miotics

Presence of cataract  
 Patients younger than 40 years of age  
 Neovascular and uveitic glaucoma  
 History of retinal detachment  
 Asthma or history of asthma  
 Phakic eyes<sup>a</sup>  
 Surgical procedures using succinylcholine<sup>a</sup>

<sup>a</sup>Applies only to anticholinesterase agents.

**Contraindications**

Pilocarpine therapy should be avoided in certain patients (Box 10-10). This drug is contraindicated in patients with cataract, especially nuclear sclerotic and posterior subcapsular cataract, because the drug can affect vision and may accelerate the formation of lens opacities. Pilocarpine is generally contraindicated in patients younger than 40 years of age because of the intolerable accommodative spasm and refractive changes. Because breakdown of the blood-aqueous barrier occurs with the use of pilocarpine and other miotics, particularly in the presence of neovascular and uveitic glaucoma, pilocarpine should be avoided in these patients.

To prevent retinal detachment, miotic therapy should be instituted gradually in patients with myopia, with peripheral retinal disease that predisposes the eye to retinal detachment, and with aphakic or pseudophakic eyes. This gradual approach to miotic therapy can be accomplished by using low concentrations of pilocarpine and increasing the dosage as necessary. Likewise, pilocarpine should be avoided in patients with a history of retinal detachment. Ideally, before initiating pilocarpine therapy, every patient should have a thorough peripheral retinal examination with a binocular indirect ophthalmoscope through dilated pupils. During the course of treatment patients should be instructed to report any light flashes, spots, or floaters. Such incidents necessitate prompt reexamination of the peripheral retina with the pupil dilated.

Pilocarpine should generally be avoided in patients with asthma or a history of asthma. In concentrations exceeding 2%, pilocarpine is contraindicated in acute angle-closure glaucoma because these concentrations can lead to further shallowing of the anterior chamber and to permanent peripheral anterior synechiae and angle closure. Furthermore, pilocarpine in concentrations of 4% or more should be used with caution in patients with narrow angles, because these concentrations may lead to attacks of acute angle closure.

The necessity of administering pilocarpine solutions four times daily without nasolacrimal occlusion makes this form of therapy a poor choice in patients who are likely to demonstrate poor compliance with this medication schedule. In these instances, the practitioner should

use a twice-daily dosage regimen with nasolacrimal occlusion or select an alternative medication requiring less frequent instillation.

**Carbachol and Echothiophate**

Due to their side effects, these drugs are rarely used for treatment of glaucoma. They were discussed in previous editions of this book.

**SELECTED BIBLIOGRAPHY**

- Adamsons I, Clineschmidt C, Polis A, et al. The efficacy and safety of dorzolamide as adjunctive therapy to timolol maleate gellan solution in patients with elevated intraocular pressure. *J Glaucoma* 1998;7:253-260.
- Adamsons IA, Polis A, Ostrov CS, et al. Two-year safety study of dorzolamide as monotherapy and with timolol and pilocarpine. *J Glaucoma* 1998;7:395-401.
- Akingbehin T, Sunder Raj P. Ophthalmic topical  $\beta$ -blockers: review of ocular and systemic adverse effects. *J Toxicol Cut Ocul Toxicol* 1990;9:131-147.
- Allen RC, Hertzmark E, Walker AM, Epstein DL. A double-masked comparison of betaxolol vs. timolol in the treatment of open-angle glaucoma. *Am J Ophthalmol* 1986;101:535-541.
- Alm A, Berggren L, Hartvig P, Roosdorp M. Monitoring acetazolamide treatment. *Acta Ophthalmol* 1982;60:24-34.
- Al-Shahwan S, Al-Torbak AA, Turkmani S, et al. Side-effect profile of brimonidine tartrate in children. *Ophthalmology* 2005;112:2143-2148.
- Ang A, Reddy MA, Shepstone L, et al. Long term effect of latanoprost on intraocular pressure in normal tension glaucoma. *Br J Ophthalmol* 2004;88:630-634.
- Atkins JC, Balfour JA. Brimonidine. A review of its pharmacological properties and clinical potential in the management of open-angle glaucoma and ocular hypertension. *Drugs Aging* 1998;12:225-241.
- Barnebey HS, Orenge-Nania S, Flowers BE, et al. The safety and efficacy of travoprost 0.004%/timolol 0.5% fixed combination ophthalmic solution. *Am J Ophthalmol* 2005;140:1-7.
- Bartlett JD, Olivier M, Richardson T, et al. Central nervous system and plasma lipid profiles associated with carteolol and timolol in postmenopausal black women. *J Glaucoma* 1999;8:388-395.
- Becker B. Use of methazolamide (Neptazane) in the therapy of glaucoma: comparison with acetazolamide (Diamox). *Am J Ophthalmol* 1960;49:1307-1311.
- Berson FG, Epstein DL. Separate and combined effects of timolol maleate and acetazolamide in open-angle glaucoma. *Am J Ophthalmol* 1981;92:788-791.
- Berson FG, Epstein DL, Grant WM, et al. Acetazolamide dosage forms in the treatment of glaucoma. *Arch Ophthalmol* 1980;98:1051-1054.
- Bietti G, Virno M, Pecori-Giraldi J, Pellegrino N. Acetazolamide, metabolic acidosis, and intraocular pressure. *Am J Ophthalmol* 1975;80:360-369.
- Boger WP. Timolol: short term "escape" and long term "drift." *Ann Ophthalmol* 1979;11:1239-1242.
- Boyle JE, Ghosh K, Gieser DK, et al. A randomized trial comparing the dorzolamide-timolol combination given twice daily to monotherapy with timolol and dorzolamide. *Ophthalmology* 1998;105:1945-1951.

- Brubaker RE. Mechanism of action of bimatoprost (Lumigan). *Surv Ophthalmol* 2001;45(suppl 4):S347-S351.
- Butler P, Mannschreck M, Li S, et al. Clinical experience with 1% apraclonidine. Incidence of allergic reactions. *Arch Ophthalmol* 1995;113:293-296.
- Cantor LB. Clinical pharmacology of bimatoprost. *Expert Opin Drug Metab* 2005;1:151-157.
- Chacko DM, Camras CB. The potential of alpha-2 agonists in the medical treatment of glaucoma. *Curr Opin Ophthalmol* 1994;5:76-84.
- Chen J, Dinh T, Woodward DE, et al. Bimatoprost: mechanism of ocular surface hyperemia associated with topical therapy. *Cardiovasc Drug Rev* 2005;23:231-246.
- Clineschmidt CM, Williams RD, Snyder E, et al. A randomized trial in patients inadequately controlled with timolol alone comparing the dorzolamide-timolol combination to monotherapy with timolol or dorzolamide. *Ophthalmology* 1998;105:1952-1959.
- Coakes RL, Brubaker RE. The mechanism of timolol in lowering intraocular pressure. *Arch Ophthalmol* 1978;96:2045-2048.
- Conroy CW, Maren TH. Effect of pH on the ocular distribution of a topical carbonic anhydrase inhibitor. *Exp Eye Res* 1995;61:213-222.
- Croft MA, Oyen MJ, Gange SJ, et al. Aging effects on accommodation and outflow facility responses to pilocarpine in humans. *Arch Ophthalmol* 1996;114:586-592.
- Cyertkovic RS, Perry CM. Brinzolamids: a review of its use in the management of primary open-angle glaucoma and ocular hypertension. *Drug Aging* 2003;20:919-947.
- Dailey RA, Brubaker RE, Bourne WM. The effects of timolol maleate and acetazolamide on the rate of aqueous formation in normal human subjects. *Am J Ophthalmol* 1982;93:232-237.
- Denis P, Lafuma A, Khoshnood B, et al. A meta-analysis of topical prostaglandin analogues intraocular pressure lowering in glaucoma therapy. *Curr Med Res Opin* 2007;23:601-608.
- Dickstein K, Hapnes R, Aarsland T. Comparison of aqueous and gellan ophthalmic timolol with placebo on the 24-hour heart rate response in patients on treatment for glaucoma. *Am J Ophthalmol* 2001;132:626-632.
- Dobbs PC, Epstein DL, Anderson PJ. Identification of isoenzyme C as the principal carbonic anhydrase in human ciliary processes. *Invest Ophthalmol Vis Sci* 1979;18:867-870.
- Dubiner HB, Sircy MD, Landry T, et al. Comparison of the diurnal ocular hypotensive efficacy of travoprost and latanoprost over a 44-hour period in patients with elevated intraocular pressure. *Clin Ther* 2004;26:84-91.
- Enyedi LB, Freedman SF. Latanoprost for the treatment of pediatric glaucoma. *Surv Ophthalmol* 2002;47 (suppl):S129-S132.
- Epstein DL, Grant WM. Carbonic anhydrase inhibitor side effects. Serum chemical analysis. *Arch Ophthalmol* 1977;95:1378-1382.
- Erickson KA, Schroeder A. Direct effects of muscarinic agents on the outflow pathways in human eyes. *Invest Ophthalmol Vis Sci* 2000;41:1743-1748.
- Fanous MM, Maren T. Does metabolic acidosis contribute to the IOP effect of acetazolamide? *Invest Ophthalmol Vis Sci* 1992;33(suppl):1246.
- Fechtner R, McCarroll KA, Lines CR, Adamsons IA. Efficacy of the dorzolamide/timolol fixed combination versus latanoprost in the treatment of ocular hypertension or glaucoma: combined analysis of pooled data from two large randomized observer and patient-masked studies. *J Ocular Pharmacol Ther* 2005;21:242-249.
- Feldman RM. Conjunctival hyperemia and the use of topical prostaglandins in glaucoma and ocular hypertension. *J Ocul Pharmacol Ther* 2003;19:23-35.
- Fishman GA, Gilbert LD, Fiscella RG, et al. Acetazolamide for treatment of chronic macular edema in retinitis pigmentosa. *Arch Ophthalmol* 1989;107:1445-1452.
- Flach A, Smith RE, Fraunfelder FT. Stevens-Johnson syndrome associated with methazolamide treatment reported in two Japanese-American women. *Ophthalmology* 1995;102:1677-1680.
- Fraunfelder FT, Meyer SM, Bagby GC, Dreis MW. Hematologic reactions to carbonic anhydrase inhibitors. *Am J Ophthalmol* 1985;100:79-81.
- Gandham SB, Spaeth GL, DiLeonardo M, Costa VP. Methazolamide-induced skin eruptions. *Arch Ophthalmol* 1993;111:370-372.
- Gharagozloo NZ, Relf SJ, Brubaker RE. Aqueous flow is reduced by the alpha-adrenergic agonist apraclonidine hydrochloride (ALO 2145). *Ophthalmology* 1988;95:1217-1220.
- Goldberg MF. The diagnosis and treatment of secondary glaucoma after hyphema in sickle cell patients. *Am J Ophthalmol* 1979;87:43-49.
- Gross RL, Hensley SH, Gao F, Wu SM. Retinal ganglion cell dysfunction induced by hypoxia and glutamate: potential neuroprotective effects of  $\beta$ -blockers. *Surv Ophthalmol* 1999;43(suppl 1):S162-S170.
- Gross RL, Pinyero A, Orengo-Nania S. Clinical experience with apraclonidine 0.5%. *J Glaucoma* 1997;6:298-302.
- Grover S, Apushkin MA, Fishman GA. Topical dorzolamide for the treatment of cystoid macular edema in patients with retinitis pigmentosa. *Am J Ophthalmol* 2006;141:850-858.
- Grunwald JE, Mathur S, DuPont J. Effects of dorzolamide hydrochloride 2% on the retinal circulation. *Acta Ophthalmol Scand* 1997;75:236-238.
- Halpern DL, Pasquale LR. Cystoid macular edema in aphakia and pseudophakia after use of prostaglandin analogs. *Semin Ophthalmol* 2002;17:181-186.
- Harris A, Jonescu-cuypers CP, Kagemann L, et al. Effect of dorzolamide timolol combination versus timolol 0.5% on ocular blood flow in patients with primary open-angle glaucoma. *Am J Ophthalmol* 2001;132:490-495.
- Higginbotham EJ, Diestelhorst M, Pfeiffer N, et al. The efficacy and safety of unfixed and fixed combinations of latanoprost and other antiglaucoma medications. *Surv Ophthalmol* 2002;47(suppl 1):S133-S140.
- Higginbotham EJ, Schuman JS, Goldberg I, et al. Bimatoprost Study Groups 1 and 2. One-year, randomized study comparing bimatoprost and timolol in glaucoma and ocular hypertension. *Arch Ophthalmol* 2002;120:1286-1293.
- Hollo G. The side effects of the prostaglandin analogues. *Expert Opin Drug Saf* 2007;6:45-52.
- Holstrom S, Buchholz P, Walz J, et al. Analytic review of bimatoprost latanoprost and travoprost in primary open angle glaucoma. *Curr Med Res Opin* 2005;21:1875-1883.
- Hong YJ, Shin DH, Ahn BH, et al. Intraocular pressure after a 2-week washout following long-term timolol or levobunolol. *J Ocul Pharmacol Ther* 1995;11:107-112.
- Hook SR, Holladay JT, Prager TC, Goosey JD. Transient myopia induced by sulfonamides. *Am J Ophthalmol* 1986;101:495-496.

- Johnstone MA, Albert DM. Prostaglandin-induced hair growth. *Surv Ophthalmol* 2002;47(suppl):S185-202.
- Juzych MS, Zimmerman TJ, Robin AL. Update on adrenergic agents in glaucoma. *Ophthalmol Clin North Am* 1997;10:309-325.
- Kaminski S, Hommer A, Koyuncu D, et al. Influence of dorzolamide on corneal thickness, endothelial cell count and corneal sensibility. *Acta Ophthalmol Scand* 1998;76:78-79.
- Kass MA, Korey M, Gordon M, Becker B. Timolol and acetazolamide: a study of concurrent administration. *Arch Ophthalmol* 1982;100:941-942.
- Katz LJ. Brimonidine tartrate 0.2% twice daily vs. timolol 0.5% twice daily: 1-year results in glaucoma patients. Brimonidine Study Group. *Am J Ophthalmol* 1999;127:20-26.
- Kaufman PL. Prostaglandins and cholinomimetics. *Arch Ophthalmol* 1997;115:911-913.
- Konowal A, Morrison JC, Brown SVL, et al. Irreversible corneal decompensation in patients treated with topical dorzolamide. *Am J Ophthalmol* 1999;127:403-406.
- Konstas AG, Karabatsas CH, Lalloo N, et al. 24-hour intraocular pressures with brimonidine purite versus dorzolamide added to latanoprost in primary open-angle subjects. *Ophthalmology* 2005;112:603-608.
- Koskela T, Brubaker RE. Apraclonidine and timolol combined effects in previously untreated normal subjects. *Arch Ophthalmol* 1991;109:604-806.
- Kraushar MF, Steinberg JA. Miotics and retinal detachment: upgrading the community standard. *Surv Ophthalmol* 1991;35:311-316.
- Krauss AH, Woodward DE. Update on the mechanism of action of bimatoprost: a review and discussion of the new evidence. *Surv Ophthalmol* 2004;49(suppl):S5-S11.
- Larsson L, Alm A. Aqueous humor flow in human eyes treated with dorzolamide and different doses of acetazolamide. *Arch Ophthalmol* 1998;116:19-24.
- Lass JH, Khosrof SA, Laurence JK, et al. A double-masked, randomized, 1-year study comparing the corneal effects of dorzolamide, timolol and betaxolol. *Arch Ophthalmol* 1998;116:1003-1010.
- Lee DA. Efficacy of brimonidine as replacement therapy in patients with open-angle glaucoma or ocular hypertension. *Clin Ther* 2000;22:53-65.
- Letchinger SL, Frochlichstein D, Gliesser DK, et al. Can the concentration of timolol or the frequency of its administration be reduced? *Ophthalmology* 1993;100:1259-1262.
- Levobunolol Study Group. Levobunolol: a four-year study of efficacy and safety in glaucoma treatment. *Ophthalmology* 1989;96:642-645.
- Lewis RA, Katz GJ, Weiss MJ, et al. Travoprost BAC-free Study Group. Travoprost 0.004% with and without benzalkonium chloride: a comparison of safety and efficacy. *J Glaucoma* 2007;16:98-103.
- Lichter PR, Musch DC, Medzihirndsky F, et al. Intraocular pressure effects of carbonic anhydrase inhibitors in primary open-angle glaucoma. *Am J Ophthalmol* 1989;107:11-17.
- Liu JH, Kripke DE, Weinreb RN. Comparison of the nocturnal effects of once-daily timolol and latanoprost on intraocular pressure. *Am J Ophthalmol* 2004;138:389-395.
- March WF, Ochsner KI, Brinzolamide Long-Term Therapy Study Group. The long-term safety and efficacy of brinzolamide 1.0% (Azopt) in patients with primary open-angle glaucoma or ocular hypertension. *Am J Ophthalmol* 2000;129:136-143.
- Maren TH. Relations between structure and biological activity of sulfonamides. *Annu Rev Pharmacol Toxicol* 1976;16:309-327.
- Maren TH. The rates of movement of Na<sup>+</sup>, Cl<sup>-</sup>, and HCO<sub>3</sub><sup>-</sup> from plasma to posterior chamber: effect of acetazolamide and relation to treatment of glaucoma. *Invest Ophthalmol* 1976;15:356-364.
- Maren TH, Conroy CW, Wynns GC, Levy NS. Ocular absorption, blood levels, and excretion of dorzolamide, a topically active carbonic anhydrase inhibitor. *J Ocul Pharmacol Ther* 1997;13:23-30.
- Maren TH, Haywood JR, Chapman SK, Zimmerman TJ. The pharmacology of methazolamide in relation to the treatment of glaucoma. *Invest Ophthalmol Vis Sci* 1977;16:730-742.
- Marx-Gross S, Krummenauer F, Dick HB, et al. Brimonidine versus dapiprazole: influence on pupil size at various illumination levels. *J Cataract Refract Surg* 2005;31:1372-1376.
- Mauger TE, Craig EL. Havener's ocular pharmacology, ed. 6. St. Louis, MO: CV Mosby, 1994.
- Maus TL, Larsson L, McLaren JW, Brubaker RE. Comparison of dorzolamide and acetazolamide as suppressors of aqueous humor flow in humans. *Arch Ophthalmol* 1997;115:45-49.
- McCannel CA, Heinrich SR, Brubaker RE. Acetazolamide but not timolol lowers aqueous humor flow in sleeping humans. *Graefes Arch Clin Exp Ophthalmol* 1992;30:518-520.
- Mirza GE, Karakucuk S, Temel E. Comparison of the effects of 0.5% timolol maleate, 2% carteolol hydrochloride, and 0.3% metipranolol on intraocular pressure and perimetry findings and evaluation of their ocular and systemic effects. *J Glaucoma* 2000;9:45-50.
- Miyake K, Ibaraki N. Prostaglandins and cystoid macular edema. *Surv Ophthalmol* 2002;47(suppl):S203-S218.
- Mudge GH. Diuretics and other agents employed in the mobilization of edema fluid. In: Gilman AG, Goodman LS, Gilman A, et al., eds. *The pharmacological basis of therapeutics*. New York: Macmillan, 1980: 896-899.
- Mundorf T, Williams R, Whitcup S, et al. A 3-month comparison of efficacy and safety of brimonidine-purite 0.15% and brimonidine 0.2% in patients with glaucoma or ocular hypertension. *J Ocul Pharmacol Ther* 2003;19:37-44.
- Mundorf TK, Cate EA, Sine CS, et al. The safety and efficacy of switching timolol maleate 0.5% solution to timolol hemihydrate 0.5% solution given twice daily. *J Ocul Pharmacol Ther* 1998;14:129-135.
- Nelson MD, Bartlett JD, Corliss D, et al. Ocular tolerability of timolol in Gelrite in young glaucoma patients. *J Am Optom Assoc* 1996;67:659-663.
- Nordstrom BL, Friedman DS, Mozaffari E, et al. Persistence and adherence with topical glaucoma therapy. *Am J Ophthalmol* 2005;140:598-606.
- Novack GD. Ophthalmic  $\beta$ -blockers since timolol. *Surv Ophthalmol* 1987;31:307-327.
- Novack GD, Leopold IH. The toxicity of topical ophthalmic  $\beta$ -blockers. *J Toxicol Cut Ocul Toxicol* 1987;6:283-297.
- O'Connor DJ, Martone JF, Mead A. Additive intraocular pressure lowering effect of various medications with latanoprost. *Am J Ophthalmol* 2002;133:836-837.
- Osborne NN, Wood JP, Chidlow G. Neuroprotective properties of certain beta-adrenoceptor antagonists used for the treatment of glaucoma. *J Ocul Pharmacol Ther* 2005;21:175-181.
- Parrish RK, Palmberg P, Sheu W-P. A comparison of latanoprost, bimatoprost, and travoprost in patients with elevated

- intraocular pressure: a 12-week, randomized, masked-evaluator multicenter study. *Am J Ophthalmol* 2003;135:688-703.
- Patel NP, Patel KH, Moster MR, Spaeth GL. Metipranolol-associated nongranulomatous anterior uveitis. *Am J Ophthalmol* 1997;123:843-844.
- Peralta J, Abelairas J, Fernandez-Guardiola J. Anaphylactic shock and death after oral intake of acetazolamide. *Am J Ophthalmol* 1992;114:367.
- Pfeiffer N. Dorzolamide: development and clinical application of a topical carbonic anhydrase inhibitor. *Surv Ophthalmol* 1997;42:137-151.
- Podos SM, Serle JB. Topically active carbonic anhydrase inhibitors for glaucoma. *Arch Ophthalmol* 1991;109:38-40.
- Rakofsky S, Melamed S, Cohen JS, et al. A comparison of the ocular hypotensive efficacy of once-daily and twice-daily levobunolol treatment. *Ophthalmology* 1989;96:8-11.
- Robin AL. Effect of topical apraclonidine on the frequency of intraocular pressure elevations after combined extracapsular cataract extraction and trabeculectomy. *Ophthalmology* 1993;100:628-633.
- Rosenberg LF, Krupin T, Tang L, et al. Combination of systemic acetazolamide and topical dorzolamide in reducing intraocular pressure and aqueous humor formation. *Ophthalmology* 1998;105:88-93.
- Rulo AH, Greve EL, Hoyng PFJ. Additive ocular hypotensive effect of latanoprost and acetazolamide. *Ophthalmology* 1997;104:1503-1507.
- Schmitz K, Banditt P, Motschmann M, et al. Population pharmacokinetics of 2% dorzolamide in the aqueous humor of humans. *Invest Ophthalmol Vis Sci* 1999;40:1621-1624.
- Schuman JS, for the Brimonidine Study Groups 1 and 2. Effects of systemic  $\beta$ -blocker therapy on the efficacy and safety of topical brimonidine and timolol. *Ophthalmology* 2000;107:1171-1177.
- Shapiro S, Fraunfelder FT. Acetazolamide and aplastic anemia. *Am J Ophthalmol* 1992;113:328-330.
- Shirato S, Kagaya F, Suzuki Y, Joukou S. Stevens-Johnson syndrome induced by methazolamide treatment. *Arch Ophthalmol* 1997;115:550-553.
- Silver LH, Brinzolamide Primary Therapy Study Group. Clinical efficacy and safety of brinzolamide (Azopt), a new topical carbonic anhydrase inhibitor for primary open-angle glaucoma and ocular hypertension. *Am J Ophthalmol* 1998;126:400-408.
- Steinert RE, Thomas JV, Boger WPI. Long-term drift and continued efficacy after multiyear timolol therapy. *Arch Ophthalmol* 1981;99:100-103.
- Stewart WC, Castelli WP. Systemic side effects of topical  $\beta$ -adrenergic blockers. *Clin Cardiol* 1996;19:691-697.
- Stewart WC, Dubiner HB, Mundorf TK, et al. Effects of carteolol and timolol on plasma lipid profiles in older women with ocular hypertension or primary open-angle glaucoma. *Am J Ophthalmol* 1999;127:142-147.
- Stewart WC, Laibovitz R, Horowitz B, et al. A 90-day study of the efficacy and side effects of 0.25% and 0.5% apraclonidine vs 0.5% timolol. *Arch Ophthalmol* 1996;114:938-942.
- Stierschantz JW, Albert DM, Hu DN, et al. Mechanism and clinical significance of prostaglandin-induced iris pigmentation. *Surv Ophthalmol* 2002;47(suppl):S162-S175.
- Strahlman ER, Tipping R, Vogel R, et al. A double-masked, randomized 1-year study comparing dorzolamide (Trusopt), timolol, and betaxolol. *Arch Ophthalmol* 1995;113:1009-1016.
- Strahlman ER, Vogel R, Tipping R, et al. The use of dorzolamide and pilocarpine as adjunctive therapy to timolol in patients with elevated intraocular pressure. *Ophthalmology* 1996;103:1283-1293.
- Strohmaier K, Snyder E, DuBiner H, et al. The efficacy and safety of the dorzolamide-timolol combination versus the concomitant administration of its components. *Ophthalmology* 1998;105:1936-1944.
- Talluto DM, Wyse TB, Krupin T. Topical carbonic anhydrase inhibitors. *Curr Opin Ophthalmol* 1997;8:2-6.
- Thompson CD, Macdonald TL, Garst ME, et al. Mechanism of adrenergic agonist induced allergy bioactivation and antigen formation. *Exp Eye Res* 1997;64:767-773.
- Thorsden JE, Bower KS, Warren BB, et al. Miotic effect of brimonidine tartrate 0.15% ophthalmic solution in normal eyes. *J Cataract Refract Surg* 2004;30:1702-1706.
- Toor A, Chanis RA, Polikoff LA, et al. Additivity of pilocarpine to bimatoprost in ocular hypertension and early glaucoma. *J Glaucoma* 2005;14:243-248.
- Toris CB, Camras CB, Yablonski ME. Acute versus chronic effects of brimonidine on aqueous humor dynamics in ocular hypertensive patients. *Am J Ophthalmol* 1999;128:8-14.
- Toris CB, Tafoya ME, Camras CB, et al. Effect of apraclonidine on aqueous humor dynamics in human eyes. *Ophthalmology* 1995;102:456-461.
- van der Valk R, Webers CA, Schouten JS, et al. Intraocular pressure-lowering effects of all commonly used glaucoma drugs: a meta-analysis of randomized clinical trials. *Ophthalmology* 2005;112:1177-1185.
- Vanlandingham BD, Brubaker RE. Combined effect of dorzolamide and latanoprost on the rate of aqueous humor flow. *Am J Ophthalmol* 1998;126:191-196.
- Vanlandingham BD, Maus TL, Brubaker RE. The effect of dorzolamide on aqueous humor dynamics in normal human subjects during sleep. *Ophthalmology* 1998;105:1537-1540.
- Walters TR. Development and use of brimonidine in treating acute and chronic elevations of intraocular pressure: a review of safety, efficacy, dose response and dosing studies. *Surv Ophthalmol* 1996;41:S19-S26.
- Watson PG, Barnett MF, Parker V, Haybittle J. A 7 year prospective comparative study of three topical  $\beta$ -blockers in the management of primary open angle glaucoma. *Br J Ophthalmol* 2001;85:962-968.
- Wayman L, Larsson L-I, Maus T, et al. Comparison of dorzolamide and timolol as suppressors of aqueous humor flow in humans. *Arch Ophthalmol* 1997;115:1368-1371.
- Wayman LL, Larsson L-I, Maus TL, Brubaker RE. Additive effect of dorzolamide on aqueous humor flow in patients receiving long-term treatment with timolol. *Arch Ophthalmol* 1998;116:1438-1440.
- Werblin TP, Pollack IP, Liss RA. Blood dyscrasias in patients using methazolamide (Neptazane) for glaucoma. *Ophthalmology* 1980;87:350-353.
- Wheeler L, WoldeMussie E, Lai R. Role of alpha-2 agonists in neuroprotection. *Surv Ophthalmol* 2003;1:S47-S51.
- Wheeler LA, Lai R, Woldemusie E. From the lab to the clinic: activation of an alpha-2 agonist pathway is neuroprotective in models of retinal and optic nerve injury. *Eur J Ophthalmol* 1999;9:S17-S21.
- Whitson JT. Travoprost—a new prostaglandin analogue for the treatment of glaucoma. *Expert Opin Pharmacother* 2002;3:965-977.

Woodward DE, Phelps RL, Krauss AH, et al. Bimatoprost: a novel antiglaucoma agent. *Cardiovasc Drug Rev* 2004;22:103-120.

Woodward DE, Krauss AH, Chen J, et al. The pharmacology of bimatoprost (Lumigan). *Surv Ophthalmol* 2001;45(suppl 4):S337-S345.

Zimmerman TJ. Pilocarpine. *Ophthalmology* 1981;88:85-88.

Zimmerman TJ, Kaufman HE. Timolol: dose response and duration of action. *Arch Ophthalmol* 1977;95:605-607.

Zimmerman TJ, Kooner KS, Kandarakis AS, Ziegler LP. Improving the therapeutic index of topically applied ocular drugs. *Arch Ophthalmol* 1984;102:551-553.

## *Anti-Infective Drugs*

*Diane P. Yolton and Susan P. Haesaert*

Humans are constantly exposed to a variety of microorganisms, including bacteria, viruses, and fungi. In most cases these microorganisms do not produce infection because the skin and mucous membrane surfaces provide effective barriers against invasion. A few microorganisms, however, can invade directly through these barriers, and others can cause infection if introduced into the body through lesions from surgery or trauma. If microorganisms penetrate the body's outer barriers, the immune system usually deals with them quite effectively. However, some microorganisms possess special properties that allow them to overcome this system. In addition, patients' immune systems do not always function optimally, allowing microorganisms that would normally not pose a problem to cause an infectious disease. When the immune system is depressed, the term *immunocompromised* is used. Two of the many situations that can cause immunocompromise are the use of drugs, such as corticosteroids that depress the immune response, and infection with human immunodeficiency virus (HIV), which causes acquired immunodeficiency syndrome (AIDS).

Many different compounds have been used to assist the body's immune system in killing microorganisms. An especially important property of an anti-infective drug is selective toxicity. The drug must be more toxic for the microorganism than for the host. An ideal anti-infective drug kills microorganisms while causing minimal or no adverse reaction in the host.

Each of the major categories of microorganisms that cause disease (bacteria, viruses, and fungi) has a unique physical structure and metabolism. The differences between the categories are so broad that drugs that are toxic for organisms in one category are usually not active against members of the other two categories. Thus anti-infective drugs are classified as being antibacterial, antiviral, or antifungal.

An anti-infective drug is usually not active against all species of microorganisms within a category. The species against which a drug shows intrinsic activity is referred to as the drug's *spectrum of activity*. A narrow-spectrum anti-infective drug is active against only a few species,

whereas a broad-spectrum drug is active against a wide variety of species. Knowledge of a drug's spectrum of activity is useful in determining clinical applications for the drug.

As anti-infective drugs are used to treat diseases, microorganisms evolve various strategies to resist them. Resistance occurs when a microorganism that was originally in an anti-infective drug's spectrum of activity is no longer susceptible to the drug. Resistance limits the usefulness of an anti-infective drug. Knowledge of the resistance patterns in the geographic area where the patient resides can help to determine an initial drug to treat an infection. Using this type of information, the drug choice is considered empiric. When information on the specific resistance pattern of the microorganism that is causing the infection is available, this determines whether the microorganism is susceptible to the initial drug or whether another drug would be better for treatment of the infection.

This chapter describes the mechanisms of action, spectra of activity, resistances, indications, and potential side effects for each of the major antibacterial, antiviral, and antifungal drugs. Antiprotozoal drugs of interest in ocular pharmacotherapy are also discussed.

### **GUIDELINES FOR EFFECTIVE ANTIMICROBIAL THERAPY**

The clinical process of selecting an anti-infective drug for the treatment of disease can be complex, and many factors must be considered (Box 11-1). First, the patient's history, symptoms, and signs need to be evaluated to establish a tentative infectious diagnosis, and then a "best guess" regarding the causative microorganism(s) is made. An anti-infective agent (or combination of agents) can then be selected and empiric therapy planned.

Samples of tissue or body fluids may be obtained for laboratory culture and identification so that the clinician's "guess" can be confirmed and susceptibility of the isolated microorganisms(s) to anti-infective drugs can be assessed. Because laboratory identification and susceptibility



**Box 11-1** Guidelines for Effective Antimicrobial Therapy

Establish accurate clinical and laboratory diagnosis  
 Select anti-infective drug to which the microorganism is sensitive  
 Select least toxic anti-infective drug  
 Establish adequate drug levels at site of infection  
 Select optimum route(s) of administration  
 Use appropriate dosage regimen  
 Prescribe drug for appropriate length of time  
 Augment drug therapy with physical procedures  
 Educate patient

testing requires several days, the clinician often must initiate empiric anti-infective therapy before this process is complete.

After the clinician has selected a drug for use, he or she needs to determine which route(s) of administration will best ensure a therapeutic concentration at the site of infection. For different types of ocular infection, topical application, oral administration, intramuscular injection, intravenous injection, intravitreal injection, or a combination of routes may be appropriate (Table 11-1).

Topical instillation of anti-infective drugs is usually the preferred mode for local therapy of ocular infections. Solution formulations are typically chosen over ointments for adults, particularly for use during waking hours, because ointments tend to blur vision after application. Ointments, on the other hand, are often preferred for infants and young children because of prolonged contact

**Table 11-1**  
 Antibacterial Drugs of Choice for Initial Treatment of Ocular Infections

Ocular Infection	Antibacterial Drugs	Route of Administration
Blepharitis		
Staphylococcal	Bacitracin or erythromycin	Topical
Angular	Bacitracin, erythromycin, or zinc sulfate	Topical
Seborrheic	Bacitracin or erythromycin	Topical (prophylactic)
Acne rosacea	Doxycycline or erythromycin	Oral
Meibomianitis	Doxycycline or tetracycline	Oral
Hordeolum		
External	Bacitracin or erythromycin	Topical (prophylactic)
Internal (nonresolving)	Dicloxacillin or cephalexin	Oral
Conjunctivitis		
Acute mucopurulent	Gentamicin, tobramycin, trimethoprim/polymyxin B, ciprofloxacin, norfloxacin, ofloxacin, levofloxacin, gatifloxacin, or moxifloxacin	Topical
Gonococcal	Ceftriaxone	Parenteral
Chlamydial (adult)	Doxycycline or azithromycin	Oral
Dacryocystitis		
Acute	Amoxicillin/clavulanate or cefaclor or cefuroxime or cefazolin and erythromycin	Oral Parenteral
Neonatal	Trimethoprim/polymyxin B	Topical (prophylactic) Topical (prophylactic)
Preseptal cellulitis		
Mild	Amoxicillin/clavulanate or dicloxacillin or cephalexin or cefaclor	Oral
Moderate to severe	Ceftriaxone and vancomycin or cefuroxime and ampicillin/sulbactam	Parenteral
Orbital cellulitis	Nafcillin and ceftazidime or ampicillin/sulbactam	Parenteral
Keratitis		
Small	Ciprofloxacin or ofloxacin	Topical
Large	Fortified cefazolin and gentamicin or tobramycin	Topical
Endophthalmitis		
	Vancomycin and amikacin or vancomycin and ceftazidime	Intravitreal
	Vancomycin and amikacin or vancomycin and ceftazidime	Topical
Syphilitic eye disease (neurosyphilis)	Penicillin G or procaine penicillin and probenecid	Parenteral

time between the drug and eye and the resistance to tear washout.

When planning antibiotic therapy, the clinician should also estimate the length of time of drug administration. An appropriate period eradicates the microorganisms while minimizing adverse events. Excessive use of anti-infective drugs can cause hypersensitivity or toxicity reactions. In addition, using an antibacterial drug longer than necessary to eradicate the microorganism or using it inappropriately facilitates the development of resistant strains of bacteria. The risk of superinfection, which is an overgrowth of microorganisms that are usually held in check by the body's normal flora, also exists with the use of any antibacterial drug, especially with excessive use of multiple antibacterial drugs.

Another factor to consider in developing a treatment plan is to determine which physical procedures might augment the drug therapy. Such procedures can be especially useful when appreciable quantities of purulent exudate or necrotic tissue are present and must be removed from the site of infection. As an example, the application of hot compresses and lid scrubs to improve circulation and to remove crusting deposits on the lids and lashes is especially useful in the treatment of lid infections with staphylococci.

Educating the patient about his or her disease and the use of the anti-infective drug that is being prescribed is essential for effective therapy. The right drug with the right route of administration cannot be effective unless the patient uses or takes the medication appropriately.

When a patient with an ocular disease fails to respond to anti-infective therapy even though an appropriate treatment plan was developed and followed, a variety of explanations are possible. Box 11-2 outlines these explanations.

## ANTIBACTERIAL DRUGS

### Bacteria That Cause Ocular Infections

Bacteria are a diverse group of single-celled microorganisms that, in most cases, can produce their own energy and cellular components. The largest division of bacteria can be subdivided using microscopic morphology: Gram stain

reaction, shape of the cells, and arrangement of the cells. Of the many bacterial species, only a few are pathogenic in humans. Table 11-2 shows the most common pathogenic bacteria and the infections they cause.

Gram-positive spherical bacteria (cocci) arranged in clusters are staphylococci. *Staphylococcus epidermidis* is found normally on the skin and mucous membranes in high numbers. However, it can cause an infection if an opportunity such as a skin abrasion occurs. *Staphylococcus aureus* is also found on the skin and mucous membranes but in lower numbers than *S. epidermidis*. It is a much more virulent pathogen and usually causes more serious disease. About half the ocular infections that occur are caused by staphylococci.

The streptococci are the other group of gram-positive cocci that cause ocular infections; morphologically, they are arranged in chains. This group includes *Streptococcus pneumoniae* (morphologically seen as diplococci), which causes corneal ulcers and pediatric conjunctivitis.

Gram-negative cocci that cause infections include *Neisseria gonorrhoeae*, which causes gonorrhea. *Neisseria gonorrhoeae* initially causes hyperpurulent conjunctivitis but can quickly invade the cornea and the rest of the eye.

Two types of gram-negative rods cause eye infections. *Haemophilus influenzae* causes infections in early childhood, with otitis media and conjunctivitis often seen concurrently. The enteric gram-negative rods include *Escherichia coli*, *Serratia marcescens*, *Proteus*, and *Pseudomonas aeruginosa*. These bacteria are typically found in the intestinal tract and commonly cause urinary tract infections. In the eye they can cause corneal ulcers.

In addition, several groups of bacteria with unique structural morphology or metabolism can cause ocular disease. *Chlamydia* lacks the ability to produce sufficient energy to grow independently and mimics viruses in that it must grow and multiply inside other living cells. *Chlamydia trachomatis* is transmitted by finger-to-eye or fomite-to-eye in the case of trachoma or by self-contamination from a genital infection in the case of inclusion conjunctivitis.

The spirochetes, which have a special morphology consisting of flexible spirals, include *Treponema pallidum*, which can cause syphilis. Possible syphilitic eye disease findings include interstitial keratitis, uveitis, pigmentary retinopathy, vitritis, retinal vascular sheathing, and papillitis.

### Bacterial Resistance

As antibiotics are used to treat infections, bacteria evolve various strategies to resist them. Resistance occurs when bacteria that were initially susceptible to an antibiotic become resistant to the action of the drug. Bacteria become resistant through one or more of the following mechanisms: (1) producing an enzyme capable of destroying or inactivating the antibiotic, (2) altering the

#### Box 11-2 Reasons for Antimicrobial Failure

- Inaccurate diagnosis
- Resistant microorganism
- Inadequate drug dosage (amount, frequency, or duration)
- Inadequate supplemental physical procedures
- Inadequate patient immune system response
- Patient noncompliance

**Table 11-2**  
Pathogenic Bacteria and the Diseases They Cause

Bacteria	Systemic Infection	Ocular Infection
Gram-positive cocci		
<i>Staphylococcus aureus</i>	Skin abscesses, impetigo, cellulitis, pneumonia, septic arthritis, osteomyelitis, toxic-shock syndrome, enterotoxin food poisoning, surgical infections	Blepharitis, hordeolum, conjunctivitis, dacryocystitis, corneal ulcer, preseptal and orbital cellulitis, endophthalmitis
<i>Staphylococcus epidermidis</i>	Trauma and surgical infections	Blepharitis, hordeolum, conjunctivitis, dacryocystitis, corneal ulcer, endophthalmitis
<i>Streptococcus pyogenes</i>	Pharyngitis, impetigo, erysipelas, scarlet fever, puerperal fever, cellulitis, glomerulonephritis, wound and burn infections, rheumatic fever	Rare: conjunctivitis, dacryocystitis, central corneal ulcer, preseptal and orbital cellulitis, endophthalmitis
<i>Streptococcus pneumoniae</i>	Pneumonia, meningitis, otitis media, sinusitis, upper respiratory infections	Conjunctivitis, corneal ulcer, dacryocystitis, preseptal and orbital cellulitis, endophthalmitis
Viridans group of streptococci	Endocarditis, dental caries	Conjunctivitis, corneal ulcer
Gram-negative cocci		
<i>Neisseria gonorrhoeae</i>	Gonorrhea	Hyperacute purulent conjunctivitis
Gram-negative rods		
<i>Haemophilus influenzae</i>	Upper respiratory tract infections, otitis media, sinusitis, pneumonia, meningitis	Conjunctivitis, dacryocystitis, preseptal and orbital cellulitis, endophthalmitis
<i>Pseudomonas aeruginosa</i>	Burn, wound, and systemic infections	Corneal ulcer, endophthalmitis
<i>Escherichia</i> species	Gastrointestinal, urinary tract, wound, and respiratory tract infections	Conjunctivitis, corneal ulcer, endophthalmitis
<i>Enterobacter</i> species		
<i>Acinetobacter</i> species		
<i>Salmonella</i> species		
<i>Proteus</i> species		
<i>Klebsiella</i> species		
<i>Serratia marcescens</i>		

target site receptor for the antibiotic so as to reduce or block its binding, and/or (3) preventing the entry of the antibiotic into the bacterial cell and/or actively transporting the antibiotic out of the bacterial cell.

Exposure to antibiotics does not, in itself, cause bacteria to become drug resistant. Changes in bacteria that facilitate resistance occur naturally as a result of mutation (i.e., change in the chromosomal DNA) or as a result of the bacteria receiving extrachromosomal DNA in the form of a plasmid from other bacteria. Exposure to an antibiotic simply selects for strains of the organism that have become resistant through these natural processes. Misuse of antibiotics (e.g., prescribing them for nonbacterial infections) increases the rate at which this selection occurs.

Resistant mutants are more likely to arise after exposure of a bacterial subpopulation to repeated sublethal doses of an antibiotic. Thus antibiotics should not be used intermittently. Patients should be educated about using or taking antibiotics according to the dosage schedule and should use or take the entire amount of antibiotic prescribed. Sublethal exposure can also occur during

tapering of an antibiotic. Thus antibiotics are not tapered but are discontinued abruptly while at the therapeutic level.

As bacteria become drug resistant, new drugs must be isolated or developed in the laboratory. Unfortunately, bacterial resistance is developing faster than the development of new antibiotics; thus choosing an effective antibiotic for treating a serious bacterial infection is becoming more difficult.

Because of bacterial drug resistance, information about a pathogen's pattern of resistance/susceptibility is essential when choosing an antibacterial agent. Several laboratory tests are used to determine resistance/susceptibility of a bacterial pathogen. In these *in vitro* tests, an organism is generally considered susceptible if the concentration of antibiotic necessary to inhibit its growth is lower than the concentration potentially attainable in body fluids, particularly blood.

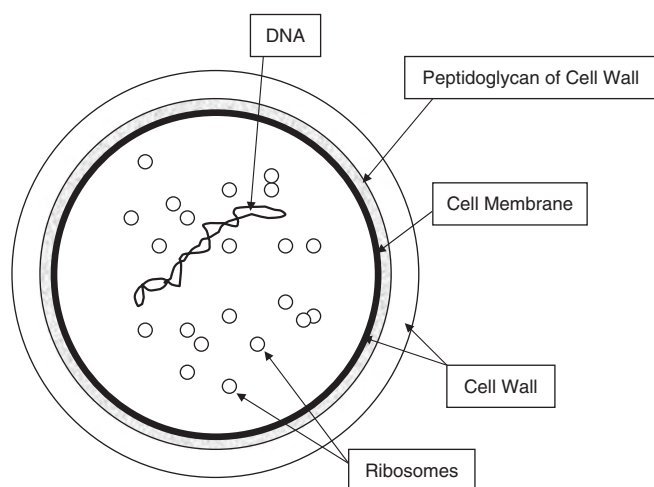
In a common type of susceptibility testing, serial dilutions of the antibacterial drug are inoculated with the bacteria to determine a minimal inhibitory concentration (MIC), which is the lowest concentration of the drug that

produces no apparent bacterial growth. The MIC is then compared with the concentration of the antibacterial drug typically attainable in the blood. If the MIC of the bacteria is higher than the attainable blood level, the bacteria are resistant to the drug. If the MIC is lower than the blood level, the bacteria are susceptible to the drug. Because the results of *in vitro* tests correlate closely with *in vivo* results, culture and susceptibility testing should be requested when a systemic antibiotic is needed to treat the infection.

To evaluate the clinical significance of resistance to an antibiotic that is to be used topically, it is helpful to quantify the level of resistance as low level or high level. Low-level *in vitro* resistance seen when the MIC is just slightly above the level attainable in the blood may not necessarily translate into clinical treatment failure because the tissue levels that can be achieved with topical dosing may be much higher than those typically achieved after systemic dosing. By contrast, high-level resistance seen when the MIC is significantly higher than the levels achievable with systemic dosing is more likely to be associated with treatment failure because the MIC of the isolate may not be achievable even with a topical route of delivery.

### Relationship Between Bacterial Structure and Antibacterial Drug Action

Several differences exist between bacterial and human cells, and these differences form the basis for selective toxicity of the antibacterial drugs (Figure 11-1). First, bacteria have a unique outermost layer, a cell wall that is not found in any human cell. A specific layer within the cell wall, called the peptidoglycan, is necessary for the bacterium's structural integrity; without it the bacterium lyses and dies. Several antibacterial drugs act by inhibiting synthesis of the cell wall, specifically the peptidoglycan.



**Figure 11-1** Morphology of a bacterial cell.

A second way in which bacterial and human cells may differ involves their cell membranes. However, because membranes of both cells are so similar, only a few compounds have been found that can selectively disrupt bacterial cell membranes while leaving those of the human cells intact.

A third difference between bacterial and human cells involves their ribosomes. Bacterial ribosomes are neither the same size nor have the same composition as human ribosomes. Thus drugs that bind more to bacterial than to human ribosomes can inhibit bacterial protein synthesis and have a selective toxicity for these cells.

A fourth difference between bacterial and human cells involves specific biosynthetic pathways. Bacterial cells usually synthesize their own folic acid, whereas humans receive folic acid preformed in their food. Thus drugs that can inhibit folic acid synthesis are selectively toxic for bacteria.

A fifth difference between bacterial and human cells involves the enzymes DNA gyrase and topoisomerase IV. These enzymes are involved in bacterial DNA synthesis and are responsible for cutting and resealing DNA strands to prevent excessive supercoiling. Because human cells lack these enzymes, drugs that inhibit the enzymes are specifically active against bacteria.

### Drugs Affecting Cell Wall Synthesis

Antibacterial drugs that affect cell wall synthesis include two large families, the penicillins and cephalosporins, and two individual drugs, bacitracin and vancomycin.

#### Penicillins

##### *Pharmacology*

All penicillins contain a common nucleus composed of a thiazolidine ring and a  $\beta$ -lactam ring connected to a side chain. An intact  $\beta$ -lactam ring is necessary for biologic activity, but the side chain primarily determines the antibacterial spectrum, susceptibility to destruction by gastric acid and  $\beta$ -lactamase enzymes, and pharmacokinetic properties.

The penicillins act by inhibiting synthesis of the bacterial cell wall. The rigid cell wall structure is due to peptidoglycan, which is a mucopolysaccharide made up of linear polysaccharide chains cross-linked by peptide bonds. Penicillins inhibit the enzymes called transpeptidases that create the peptide cross-linkage, and this leads to an incomplete cell wall structure. The enzymes are located beneath the cell wall and are also known as "penicillin-binding proteins." Penicillins exert their bactericidal effect most strongly on actively dividing cells that are synthesizing new cell walls.

The basic penicillin nucleus has been and continues to be chemically modified to produce penicillins with unique advantages. Based on their spectra of antibacterial activity and their clinical applications, the penicillins can be divided into four categories (Table 11-3).

**Table 11-3**  
Commonly Used Penicillins

Drug/Additive	Trade Name	Route Of Administration	Clinically Useful Spectra of Activity
<b>Penicillins Effective Against Gram-Positive Bacteria</b>			
Penicillin G	Wycillin Bicillin Permapen Pfizerpen	IV, IM	<i>Streptococcus pyogenes</i> , susceptible <i>Streptococcus pneumoniae</i> and viridans streptococci, gram-positive rods, anaerobes except <i>Bacteroides fragilis</i> , spirochetes including <i>Treponema</i> and <i>Borrelia</i> , <i>Neisseria meningitidis</i> , <i>Escherichia coli</i> , <i>Enterobacter</i> , <i>Salmonella</i> , <i>Shigella</i> , <i>Proteus</i>
Penicillin V	Beepen VK Lederacillin Betapen VK Pen Vee K V-Cillin K Veetids Penicillin VK	PO	<i>Streptococcus pyogenes</i> , susceptible <i>Streptococcus pneumoniae</i> and viridans streptococci, gram-positive rods, anaerobes except <i>Bacteroides</i> , spirochetes including <i>Treponema</i> and <i>Borrelia</i>
<b>Penicillins Resistant to Penicillinase</b>			
Methicillin	Staphcillin	IV, IM	<i>Staphylococcus aureus</i> , <i>Staphylococcus epidermidis</i>
Oxacillin	Prostaphin Bactocill	PO, IV, IM	
Cloxacillin	Cloxapen	PO	
Dicloxacillin	Pathocil Dycill	PO	
Nafcillin	Dynapen Nallpen Nafcil Unipen	PO, IV, IM	
<b>Penicillins with Extended Spectra of Activity</b>			
Ampicillin	Totacillin Ampicil Omnipen Principen	PO, IV, IM	<i>Streptococcus pyogenes</i> , susceptible <i>Streptococcus pneumoniae</i> and viridans streptococci, gram-positive rods, certain gram-negative rods such as <i>Haemophilus influenzae</i> , <i>Escherichia coli</i> , <i>Proteus mirabilis</i> , <i>Salmonella</i> , <i>Shigella</i>
Ampicillin and Sulbactam	Unasyn	IV, IM	
Amoxicillin	Wymox Amoxil Biomox Polymox Trimox	PO	
Amoxicillin and Clavulanate	Augmentin	PO	
<b>Penicillins with Antipseudomonal Activity</b>			
Carbenicillin	Geocillin	PO	<i>E. coli</i> , <i>H. influenzae</i> , <i>Proteus</i> , <i>Salmonella</i> , <i>Morganella</i> , <i>Providencia</i> , <i>Enterobacter</i> , <i>Citrobacter</i> , <i>Pseudomonas aeruginosa</i> , <i>Serratia</i> , anaerobes including <i>Bacteroides</i>
Ticarcillin	Ticar	IV, IM	
Ticarcillin and Clavulanate	Timentin	IV	
Piperacillin	Pipracil	IV, IM	
Piperacillin and Tazobactam	Zosyn	IV	
Mezlocillin	Mezlin	IV, IM	

IV, intravenous; IM, intramuscular; PO, oral.

### *Clinical Uses*

**Penicillins Effective Against Gram-Positive Bacteria.** The two most important drugs in this category are penicillin G and penicillin V. Penicillin G is not stable in gastric acid and is administered parenterally. Penicillin V, which is not inactivated by gastric acid, can be given orally.

A major mechanism of acquired resistance to the penicillins is bacterial production of enzymes called  $\beta$ -lactamases. These enzymes hydrolyze the penicillin  $\beta$ -lactam ring that is necessary for its activity.  $\beta$ -Lactamases with a strong proclivity for penicillins are called penicillinases. Because most strains of *Staphylococcus aureus* and many strains of *Staphylococcus epidermidis* produce penicillinase, penicillins G and V are not effective against these gram-positive bacteria.

Some streptococci have developed a different mechanism of acquired resistance to penicillin drugs. These bacteria have altered transpeptidases (also known as penicillin-binding proteins) that no longer bind penicillin, and thus peptidoglycan synthesis is not disrupted. This mechanism of resistance is found in *Streptococcus pneumoniae*. Estimates of penicillin-resistant *S. pneumoniae* in the United States range from 25% to 66%, including strains recovered from ocular and periocular infections. Many isolates of penicillin-resistant *S. pneumoniae* also are resistant to the cephalosporins, macrolides, and the older fluoroquinolones. Use of alternative antibiotics such as vancomycin is necessary for infections caused by penicillin-resistant isolates.

In addition to *S. pneumoniae*, the viridans group of streptococci is also developing resistance to penicillin through the same mechanism, altered penicillin-binding proteins. In contrast, resistance has not developed in *Streptococcus pyogenes*, and both penicillins G and V are antibiotics of choice for systemic infections caused by this organism.

Gram-negative *Neisseria gonorrhoeae* is within the spectrum of activity for penicillin G, but many strains of this organism produce penicillinase. Because antibiotic therapy is typically taken before bacterial susceptibilities are known, recommended drugs for treatment of gonococcal infections include the cephalosporins, ceftriaxone and cefixime, which are not inactivated by gonococcal penicillinase.

Because *Treponema pallidum* is sensitive to penicillin G, this antibiotic is the drug of choice for treatment of syphilis and syphilitic eye disease (see Table 11-1). Syphilitic eye disease can include interstitial keratitis (stromal inflammation and vascularization), episcleritis, scleritis, nongranulomatous or granulomatous iritis, iris papules (collections of dilated capillaries in the iris), chorioretinitis, papillitis, retinal vasculitis, and exudative retinal detachment. Probenecid can be added to procaine penicillin to decrease excretion of the penicillin by the kidneys, thus causing an increase in penicillin plasma levels. Penicillins are not used for the treatment of minor ocular infections such as blepharitis and conjunctivitis

because of the high incidence of allergic reactions when the drug is administered topically.

**Penicillins Resistant to Penicillinase.** Modification of the penicillin structure produced a group of drugs including methicillin, oxacillin, cloxacillin, dicloxacillin, and nafcillin that are not susceptible to staphylococcal penicillinase. Their appropriate use is in the treatment of infections caused by strains of *Staphylococcus aureus* and *Staphylococcus epidermidis* that produce penicillinase. These include most strains isolated from hospital settings and the general community.

As this category of penicillins was used for treatment, *S. aureus* and *S. epidermidis* became resistant to them through the production of altered penicillin-binding proteins. These strains of staphylococci are called “methicillin resistant,” which denotes resistance not only to all penicillinase-resistant penicillins but to all penicillin drugs. Methicillin-resistant staphylococci have become a major problem in treatment because they are also resistant to the cephalosporins, aminoglycosides, and macrolides. For this reason vancomycin, a more toxic antibiotic, is the drug of choice for these organisms.

Penicillins resistant to penicillinase can be used to treat ocular infections. An internal hordeolum, which is an infection of a meibomian gland typically with staphylococci, can be treated with oral dicloxacillin when the hordeolum is severe or not resolving with more conservative treatment.

Orbital cellulitis is an infection of the orbital contents posterior to the orbital septum. Streptococci and staphylococci are common bacterial isolates. Many regimens exist for empiric treatment of this disease, but no regimen has been tested in clinical trials. Intravenous nafcillin can be used as initial therapy for orbital cellulitis, especially when a staphylococcal infection is suspected or known (see Table 11-1).

**Penicillins With Extended Spectra of Activity.** Further modification of the basic penicillin structure produced ampicillin and amoxicillin with broader spectra of activity than the original penicillins. One important organism included in the spectra of these antibiotics is *Haemophilus influenzae*. These antibiotics are used to treat otitis media and respiratory infections in children.

A disadvantage of ampicillin and amoxicillin is that they are inactivated by penicillinase, and more strains of *H. influenzae* are becoming resistant through penicillinase ( $\beta$ -lactamase) production. The addition of a  $\beta$ -lactamase inhibitor such as clavulanate (clavulanic acid) or sulbactam to a penicillin preparation can protect the penicillin component because these chemicals irreversibly inactivate bacterial  $\beta$ -lactamases.

Amoxicillin/clavulanate and ampicillin/sulbactam are useful for treating lower respiratory infections, otitis media, and sinusitis caused by  $\beta$ -lactamase-producing strains of *H. influenzae* (see Table 11-3). They are also

useful for treating skin infections caused by penicillinase-producing strains of *Staphylococcus aureus* and for urinary tract infections caused by  $\beta$ -lactamase-producing strains of *Escherichia coli*, *Klebsiella* sp., and *Enterobacter* sp. Penicillin-susceptible *Streptococcus pneumoniae* responds to this drug combination, but penicillin-resistant *S. pneumoniae* does not because its resistance is not due to production of a penicillinase.

Amoxicillin/clavulanate given orally and ampicillin/sulbactam given intravenously are useful for treating ocular infections suspected or caused by penicillinase-producing strains of *Staphylococcus aureus* and *Staphylococcus epidermidis*, penicillin-susceptible strains of *Streptococcus pneumoniae*, and  $\beta$ -lactamase-producing strains of *H. influenzae*. These infections include orbital cellulitis, preseptal cellulitis, and dacryocystitis (see Table 11-1).

Preseptal cellulitis is an infection anterior to the orbital septum in the connective tissue of the lid and anterior periorbital tissues. *Staphylococcus aureus*, *Streptococcus pyogenes*, and, in children less than 5 years of age, *H. influenzae* are often isolated. In mild preseptal cellulitis oral amoxicillin/clavulanate can be prescribed, whereas in a more serious infection of the lids, ampicillin/sulbactam can be used intravenously (see Table 11-1).

Dacryocystitis occurs when the lacrimal drainage system is blocked and bacteria from the tears infect the lacrimal sac. Bacterial etiology includes staphylococci, *Streptococcus pneumoniae*, and *H. influenzae* in children, all of which are susceptible to oral amoxicillin/clavulanate. More serious infections require intravenous administration of ampicillin/sulbactam. This bacterial infection needs to be treated before nasolacrimal duct irrigation, probing, or surgery is performed.

In about 2% to 4% of full-term newborns, the membrane over the valve of Hasner at the nasal end of the duct has not perforated. This causes a recurrent conjunctivitis and sometimes a dacryocystitis. Because spontaneous opening frequently occurs 1 to 2 months after birth, management is typically not aggressive. Warm compresses, massage from the canaliculi down over the lacrimal sac, and a topical antibiotic, if mucopurulent discharge is present, are usually prescribed for initial treatment (see Table 11-1).

**Penicillins With Antipseudomonal Activity.** The chief advantage of the antipseudomonal penicillins, carbenicillin, mezlocillin, piperacillin, and ticarcillin, is that they act against *Pseudomonas aeruginosa* and certain *Proteus* and *Enterobacter* species not susceptible to most other penicillins. Patients with septicemia, burn infections, pneumonia, severe urinary tract disease, and meningitis caused by these organisms have often dramatically improved after use of these drugs, often in combination with an aminoglycoside. The drugs are also useful for serious ocular infections caused by gram-negative bacteria, especially *P. aeruginosa*. Ticarcillin or piperacillin have

been used along with an aminoglycoside for the topical treatment of bacterial corneal ulcers caused by gram-negative rods, including *P. aeruginosa*.

### Side Effects

The major adverse reactions to the penicillins are hypersensitivity responses. Manifestations of hypersensitivity include urticaria, angioedema, and anaphylaxis (type I reaction); hemolytic anemia (type II reaction); interstitial nephritis, vasculitis, and serum sickness (type III reaction); and contact dermatitis or Stevens-Johnson syndrome (type IV reaction). A maculopapular rash occurs late in the treatment course of 2% to 3% of patients receiving a penicillin drug. Once a patient has had a hypersensitivity response to a penicillin, it is probable, but not certain, that a reaction will occur with exposure to the same penicillin or to any other penicillin. Intradermal skin tests can predict whether a patient is at risk for developing a hypersensitivity reaction to the penicillins. If the results are positive, penicillins should generally be avoided.

Penicillins can cause local effects such as pain, induration, and tenderness at the site of an intramuscular injection. Administration of penicillin intravenously can also cause burning or phlebitis. Hematologic toxicity produced by penicillins is rare, but various types of dyscrasias such as leukopenia, granulocytopenia, abnormal platelet aggregation, and anemia have been reported.

Adverse effects of the penicillins on the central nervous system include headache, dizziness, somnolence, confusion, tremor, and seizures. The penicillins can also adversely affect the liver, as evidenced by elevated liver enzymes and bilirubin, and the kidney, as evidenced by elevated blood urea nitrogen and creatinine.

Penicillins alter the normal bacterial flora in areas of the body, including the respiratory and intestinal tracts. Patients taking oral penicillins may experience nausea, vomiting, or diarrhea. This is usually of little clinical significance because the normal microflora reestablishes itself quickly after cessation of therapy. However, serious superinfection with resistant organisms such as *Pseudomonas*, *Proteus*, or *Candida* can follow long-term therapy with any penicillin. Superinfection with *Clostridium difficile* can lead to potentially fatal pseudomembranous colitis.

Very infrequently and unpredictably, penicillins can cause oral contraceptives to fail. For maximal protection, a barrier contraceptive method should be used routinely while taking a short course of a penicillin and for at least 7 days afterward.

Penicillin use may be related to breast cancer development. However, more research is needed to determine whether the relationship is causal.

### Contraindications

Because penicillins and cephalosporins have a common chemical structure, cross-allergies occur with these drugs. Thus before initiating therapy with a penicillin,

careful inquiry should be made concerning previous hypersensitivity reactions to any penicillin or cephalosporin.

## Cephalosporins

### Pharmacology

Like the penicillins, cephalosporins contain a  $\beta$ -lactam ring that is necessary for antimicrobial activity. However, a six-member dihydrothiazine ring replaces the five-member thiazolidine ring characteristic of the penicillins.

Penicillins and cephalosporins have similar mechanisms of action. They both interfere with the terminal step in bacterial cell wall formation by preventing proper cross-linking of the peptidoglycan.

An important mechanism of acquired resistance to cephalosporins is drug inactivation by  $\beta$ -lactamases to which the cephalosporins have variable susceptibility. For example, the  $\beta$ -lactamases produced by *S. aureus* are considered true penicillinases and do not affect the cephalosporins. Thus the cephalosporins are usually active against penicillinase-producing *S. aureus*. In contrast, gram-negative bacteria produce  $\beta$ -lactamases that inactivate many of the cephalosporins.

Adding different side chains extensively modified the parent cephalosporin compound and created a whole family of cephalosporin antibiotics. For the sake of convenience, these drugs are considered as first-, second-, third-, or fourth-generation compounds based on their spectra of bacterial activity and their clinical uses (Table 11-4).

### Clinical Uses

**First-Generation Cephalosporins.** First-generation cephalosporins include cephadrine, cephalixin, cefadroxil, and cefazolin (see Table 11-4). All act effectively against gram-positive bacteria (e.g., methicillin-sensitive *Staphylococcus aureus*, *Streptococcus pyogenes*, penicillin-sensitive *Streptococcus pneumoniae*) but have relatively modest activity against gram-negative bacteria.

Cefazolin is used in combination with gentamicin or tobramycin to treat bacterial corneal ulcers as part of a broad-spectrum approach (see Table 11-1). Cefazolin is used because its spectrum of activity encompasses the gram-positive cocci, including penicillinase-producing staphylococci. However, there is increasing concern about treating corneal ulcers with cefazolin because more penicillin-resistant *Streptococcus pneumoniae* and viridans streptococci are being isolated from corneal infections. Cefazolin is administered topically as fortified eyedrops that are prepared by diluting high concentration products intended for parenteral use.

**Second-Generation Cephalosporins.** Second-generation cephalosporins include cefaclor, cefprozil, cefuroxime, cefoxitin, and cefotetan (see Table 11-4). Drugs in this group have increased activity against certain gram-negative pathogens (e.g., *H. influenzae*), and cefoxitin and cefotetan are effective against bowel anaerobes.

Cefaclor is used to treat bacterial infections of the middle ear, lung, and urinary tract. Oral cefaclor can also be used to treat mild preseptal cellulitis. Parenteral administration of cefuroxime along with ampicillin/sulbactam is a recommended treatment for severe or unresponsive preseptal cellulitis (see Table 11-1). However, with the increase of penicillin-resistant isolates of *Streptococcus pneumoniae*, the effectiveness of empirically treating this condition with  $\beta$ -lactam drugs needs to be carefully considered.

**Third-Generation Cephalosporins.** Third-generation cephalosporins include cefixime, cefdinir, cefotaxime, ceftriaxone, and ceftazidime (see Table 11-4). These drugs are somewhat less active against gram-positive cocci but are much more active against enteric gram-negative bacteria. The primary advantage of ceftazidime when compared with the other currently available third-generation cephalosporins is its excellent activity against gram-negative bacteria, including *P. aeruginosa*. Ceftazidime is used as an alternative for topical and intravitreal amikacin, an aminoglycoside, to cover gram-negative organisms, including *P. aeruginosa*, in the treatment of endophthalmitis (see Table 11-1). Ceftazidime or ceftriaxone combined with nafcillin can be used to treat orbital cellulitis. Ceftriaxone combined with vancomycin can be used to treat moderate to severe preseptal cellulitis.

With a nationwide distribution of penicillinase-producing *N. gonorrhoeae*, a recommended regimen for treating gonococcal infections, including gonococcal conjunctivitis, is intramuscular ceftriaxone, a third-generation cephalosporin (see Table 11-1). Intramuscular or intravenous ceftriaxone is also the recommended treatment for gonococcal ophthalmia neonatorum. Cefixime, another third-generation cephalosporin, has been recommended for treatment of gonorrhea and is advantageous because it can be administered orally.

**Fourth-Generation Cephalosporins.** The fourth-generation cephalosporin, cefepime, has an extended spectrum of activity against both gram-positive (e.g., methicillin-sensitive *S. aureus*) and gram-negative organisms (e.g., *Pseudomonas*).

### Side Effects

As with the penicillins, hypersensitivity reactions are the most common systemic adverse events caused by cephalosporins. Maculopapular rash, urticaria, fever, bronchospasm, and anaphylaxis have been associated with the use of cephalosporins. Because the molecular structure of the penicillins and the first-generation cephalosporins are similar, there is a risk in patients who are allergic to penicillin to manifest allergic cross-reactions when prescribed any of this group of cephalosporins. In contrast, the risk of cross-reactivity between the penicillins and the second-, third-, and fourth-generation cephalosporins has been overestimated, and patients with a previous allergic



**Table 11-4**  
Commonly Used Cephalosporins

Drug	Trade Name	Route Of Administration	Indications
First generation			
Cephadrine	Velosef	PO	Skin and soft tissue infections; urinary tract infections
Cephalexin	Keflex, Others		
Cefadroxil	Ultracef, Duricef		
Cefazolin	Ancef, Kefzol	IV, IM	
Second generation			
Cefaclor	Ceclor	PO	Skin infections
Cefprozil	Cefzil	PO	Upper and lower respiratory tract infections, otitis media, sinusitis
Cefuroxime axetil	Ceftin	PO	Pharyngitis, otitis media, sinusitis, bacterial infections associated with acute bronchitis, urinary tract infections, skin infections, Lyme disease
Cefuroxime	Kefurox, Zinacef	IV, IM	
Cefoxitin	Mefoxin	IV, IM	Perioperative prophylaxis in abdominal surgery, treatment of intra-abdominal infections, urinary tract infections, gynecological infections, septicemia, bone and joint infections, skin infections, lower respiratory infections
Cefotetan	Cefotan		
Third generation			
Cefixime	Suprax	PO	Urinary tract infections, gonorrhea
Cefdinir	Omnicef	PO	Community-acquired pneumonia, otitis media, sinusitis, skin and soft tissue infections, uncomplicated urinary tract infections
Cefotaxime	Claforan	IV, IM	Pneumonia, genitourinary tract infections, gynecological infections, bacterial septicemia, bone and joint infections, meningitis, prophylaxis of surgical infections, intra-abdominal infections
Ceftriaxone	Rocephin	IV, IM	Pneumonia, skin infections, urinary tract infections, gonorrhea, bacterial septicemia, bone and joint infections, intra-abdominal infections, meningitis, prophylaxis of surgical infections, Lyme disease
Ceftazidime	Ceptaz, Fortaz, Tazidime, Tazicef	IV, IM	<i>Pseudomonas</i> infections including pneumonia, skin infections, urinary tract infections, bacterial septicemia, bone and joint infections, intra-abdominal infections, meningitis, prophylaxis of surgical infections
Fourth generation			
Cefepime	Maxipime	IV, IM	Nosocomial infections, septicemia, urinary tract infections, pneumonia

All cephalosporins lack activity against enterococci, methicillin-resistant *S. aureus* and *S. epidermidis*, and *Acinetobacter* species. IV, intravenous; IM, intramuscular; PO, oral.

reaction to penicillin may be able to safely take these cephalosporins.

Like penicillins, cephalosporins alter the normal microflora of the intestinal tract and can cause anorexia, nausea, vomiting, and diarrhea. In some cases the diarrhea can become severe enough to warrant discontinuation of the drug. Antibiotic-associated pseudomembranous colitis due to *C. difficile* can also occur with the cephalosporins. This condition should be considered in the differential diagnosis of diarrhea associated with cephalosporin use.

Overgrowth of resistant organisms such as *Acinetobacter*, *Candida*, and enterococci can occur after

long-term use of the cephalosporins. If therapy is prolonged, the patient should be closely monitored for signs of superinfection, especially if he or she is severely ill or if invasive devices such as catheters have been used.

Cephalosporins can also destroy certain components of the intestinal microflora, and a vitamin K deficiency leading to bleeding episodes can result. Administration of vitamin K can reverse this bleeding.

Administration of cephalosporins can lead to reversible renal impairment. When a cephalosporin and an aminoglycoside are administered concomitantly, an additive nephrotoxicity can occur. This reaction is most

likely to occur in the elderly and in patients with decreased renal function.

Cefaclor has been associated with a high incidence of adverse joint and skin reactions. This unusual serum sickness-like reaction appears to be due to an inherited defect in the body's handling of cefaclor metabolic products.

Cephalosporin use may be related to breast cancer. However, more research is needed to determine whether the relationship is causal.

### *Contraindications*

The cephalosporins are contraindicated in patients with known allergies or intolerances to any of the cephalosporins. Because the penicillins and cephalosporins have a common chemical structure, cross-allergies occur with these drugs. Thus before initiating therapy with a cephalosporin, careful inquiry should be made concerning previous hypersensitivity reactions to the other drugs. Because a secondary vitamin K deficiency can develop with cephalosporin use, the cephalosporins are contraindicated in patients with hemophilia. Cefaclor is also contraindicated in any patient with previous drug-related joint and skin reactions.

## **Bacitracin**

### *Pharmacology*

Bacitracin inhibits bacterial cell wall synthesis by inhibiting the movement of a precursor of peptidoglycan through the cell membrane from the cytoplasm to the cell wall. Most gram-positive bacteria such as staphylococci and streptococci are susceptible to bacitracin. Although this drug is active against *Neisseria*, most other gram-negative bacteria are resistant.

### *Clinical Uses*

Bacitracin is seldom used parenterally because renal necrosis has been reported after systemic use. Bacitracin is primarily used topically to treat skin and mucous membrane infections caused by gram-positive bacteria because only a few of these bacteria have become resistant to it.

Bacitracin is available in topical preparations either as a single-entity product or as a component of fixed-combination products. Because bacitracin is unstable in solution, it is available only in ointment form. The rationale for combining drugs containing bacitracin along with other antibacterial agents, such as neomycin and polymyxin B, is that by judicious selection, combinations can be produced with complementary antibacterial spectra covering most of the common pathogens. The antibacterial spectrum of bacitracin is mostly gram positive and the spectrum of polymyxin B is gram negative. The spectrum of neomycin includes many gram-negative organisms. Thus bacitracin complements either of the other two drugs. Topical fixed-combination ointments containing

bacitracin are effective for a variety of dermatologic infections such as ulcers and impetigo. Topical combination products are also available as over-the-counter preparations to treat minor skin cuts and abrasions.

Topical ophthalmic preparations containing bacitracin (Tables 11-5, 11-6, and 11-7) are effective for treatment of superficial eye infections. Bacitracin is especially useful for treating staphylococcal blepharitis, because most staphylococci remain sensitive to this antibiotic (see Table 11-1).

### *Side Effects*

Hypersensitivity reactions, usually presenting as contact dermatitis, are rare but can occur with topically applied bacitracin.

### *Contraindications*

Bacitracin is contraindicated in patients with known hypersensitivity or intolerance to the drug.

## **Vancomycin**

### *Pharmacology*

Like the other drugs discussed in this section, vancomycin acts by inhibiting biosynthesis of the bacterial cell wall, specifically the mucopeptide portion of the peptidoglycan. It is highly active against the gram-positive cocci, staphylococci and streptococci, and *C. difficile*.

### *Clinical Uses*

Because of its potential toxicity, vancomycin is reserved for serious infections in which less toxic antibiotics are ineffective or not tolerated. Generally, vancomycin is administered intravenously because of poor intestinal absorption. It is the drug of choice for treating infections caused by methicillin-resistant staphylococci and penicillin-resistant *Streptococcus pneumoniae*. Vancomycin has been used to treat enterococcal infections because of their resistance to the  $\beta$ -lactam antibiotics, but most enterococci are now also resistant to vancomycin. Oral administration of vancomycin is important for treatment of some gastrointestinal infections such as pseudomembranous colitis caused by *C. difficile*.

Methicillin-resistant strains of *Staphylococcus aureus* and *S. epidermidis* and penicillin-resistant *Streptococcus pneumoniae* have been isolated from ocular infections. Therefore treatment of ocular infections caused by these organisms might require use of vancomycin for resolution. Vancomycin is also recommended for empiric intravitreal and topical therapy in bacterial endophthalmitis and for parenteral therapy in moderate to severe preseptal cellulitis (see Table 11-1).

### *Side Effects*

The use of intravenous vancomycin in prolonged therapy, in concomitant or sequential use with other ototoxic or nephrotoxic drugs, or in patients with impaired renal function has caused permanent deafness and

**Table 11-5**  
Antibacterial Drugs for Topical Ocular Therapy

Generic Name	Formulation	Concentration	Trade Name (Manufacturer)	
Bacitracin	Ointment	500 U/g	Bacitracin (Various) AK-Tracin (Akorn)	
Chloramphenicol	Solution	0.5%	Chloramphenicol (Ivax) Chloromycetin (Monarch)	
Ciprofloxacin	Ointment	0.5%	Chloromycetin (Monarch)	
	Solution	0.3%	Generic (Various) Ciloxan (Alcon)	
Erythromycin	Ointment	0.3%	Ciloxan (Alcon)	
	Ointment	0.5%	Erythromycin (Various) Ilotycin (Dista) Romycin (OCuSoft)	
Gatifloxacin	Solution	0.3%	Zymar (Allergan)	
Gentamicin	Solution	0.3%	Gentamicin (Various) Genoptic (Allergan) Gentacidin (Novartis) Garamycin (Schering) Gentak (Akorn) Gentasol (OCuSoft)	
			Ointment	0.3%
	Levofloxacin	Solution	0.5%	Quixin (Santen/J&J Vistakon)
			1.5%	Iquix (Santen)
	Moxifloxacin	Solution	0.5%	Vigamox (Alcon)
	Norfloxacin	Solution	0.3%	Chibroxin (Merck)
	Ofloxacin	Solution	0.3%	Ofloxacin (Various) Ocuflox (Allergan)
	Tobramycin	Solution	0.3%	Tobramycin (Various) Tobrex (Alcon) AK-Tob (Akorn)
				Ointment

fatal uremia. Thus hearing and renal function should be monitored frequently when administering systemic vancomycin.

If vancomycin is needed in a topical form to treat an eye infection, a highly concentrated solution intended for intravenous injection can be diluted. Because this concentrated solution is acidic, dilution with artificial tears or a buffer increases patient comfort.

#### *Contraindications*

Vancomycin is contraindicated in patients with known hypersensitivity or intolerance to the drug.

### **Drugs Affecting the Cell Membrane**

Antibacterial drugs that affect the bacterial cell membrane include polymyxin B and gramicidin.

#### **Polymyxin B** *Pharmacology*

Of the large number of compounds that affect the bacterial cell membrane, only a few have sufficient selective toxicity to be therapeutically useful. Polymyxin B is a cationic detergent or surfactant that interacts with the phospholipids of the cell membrane, thus disrupting the osmotic integrity of the cell. This increases the bacterial cell's permeability and causes cell death. Polymyxin B acts selectively on gram-negative bacteria, including *P. aeruginosa*.

#### *Clinical Uses*

Polymyxin B is not used systemically because of its neurotoxicity and nephrotoxicity. Topically, it is used in combination with other antibacterial drugs or steroids to prevent and treat skin infections and external otitis.

**Table 11-6**  
Combination Antibacterial Drugs for Topical Ocular Therapy

Generic Name	Concentration	Trade Name (Manufacturer)
<b>Solutions</b>		
Polymyxin B	10,000 U/ml	Generic (Various)
Neomycin	0.175%	Neosporin (GlaxoSmithKline)
Gramicidin	0.0025%	AK-Spore (Akorn)
Polymyxin B	10,000 U/ml	Generic (Bausch & Lomb)
Trimethoprim	0.1%	Polytrim (Allergan)
<b>Ointments</b>		
Polymyxin B	10,000 U/g	Generic (Bausch & Lomb)
Bacitracin	500 U/g	AK-Poly-Bac (Akorn) Polysporin (Monarch) Polycin-B (OCuSoft)
Polymyxin B	10,000 U/g	Terramycin w/Polymyxin B (Pfizer)
Oxytetracycline	0.5%	Terak (Akorn)
Polymyxin B	10,000 U/g	Generic (Various)
Neomycin	0.35%	Triple Antibiotic Ophthalmic Ointment (Various)
Bacitracin	400 U/g	Neosporin (GlaxoSmithKline) AK-Spore (Akorn)

Ocular polymyxin B is commercially available in combination with other antibiotics (see Table 11-6) or with steroids (see Table 11-7) to treat infections of the lids and conjunctiva. It is also used to prevent infection when the conjunctiva or cornea is compromised or when a steroid is used.

#### Side Effects

Adverse reactions to topical application of polymyxin B include irritation and allergic reactions of the eyelids and conjunctiva but are infrequent and typically mild. However, when administered by subconjunctival injection, polymyxin B can cause pain, chemosis, and tissue necrosis.

#### Contraindications

Polymyxin B is contraindicated in patients with known hypersensitivity or intolerance to the drug.

#### Gramicidin

Like polymyxin B, gramicidin changes permeability characteristics of the cell membrane, thus killing the cell. However, in contrast to polymyxin B, gramicidin is effective against gram-positive bacteria. It replaces bacitracin in some fixed-combination antibacterial solutions used topically for ocular infections (see Table 11-6).

### Drugs Affecting Protein Synthesis

Antibacterial drugs that affect bacterial protein synthesis include the aminoglycosides, tetracyclines, macrolides, and the single drug chloramphenicol.

#### Aminoglycosides

Aminoglycosides include gentamicin, tobramycin, neomycin, and amikacin.

#### Pharmacology

Aminoglycosides inhibit bacterial protein synthesis by binding to the 30S subunit of the bacterial ribosome. Consequences of this interaction include inhibition of bacterial protein synthesis and incorrectly reading the genetic code.

Aminoglycosides are bactericidal against a broad spectrum of bacteria, including *Staphylococcus aureus*, and many strains of gram-negative bacteria, including *P. aeruginosa*, *Proteus*, *Klebsiella*, *E. coli*, *Enterobacter*, and *Serratia*. They are inactive against anaerobes and poorly active against streptococci, enterococci, and methicillin-resistant *S. aureus*. In contrast to gentamicin, tobramycin, and amikacin, neomycin is not effective against *P. aeruginosa*. An important attribute of the aminoglycosides is their ability to achieve an additive or synergistic effect against most aerobic gram-negative bacilli and gram-positive cocci when combined with  $\beta$ -lactam antibiotics. There is a similar effect against gram-positive cocci when aminoglycosides are combined with vancomycin.

Gram-negative bacilli show widespread resistance to the aminoglycosides because the bacilli produce enzymes that inactivate the drugs. Gram-negative bacilli produce many different aminoglycoside-inactivating enzymes, with some enzymes inactivating certain drugs but not others. Thus knowledge of general resistance patterns is helpful only in the initial selection of an

**Table 11-7**  
Antibiotic-Steroid Combinations for Topical Ocular Therapy

Antibiotic	Steroid	Trade Name (Manufacturer)
<b>Solutions and Suspensions</b>		
Neomycin 0.35%	Dexamethasone 0.1%	Generic (Various) NeoDecadron (Merck) Neo-Dexameth (Major)
Neomycin 0.35% Polymyxin B 10,000 U/ml	Dexamethasone 0.1%	Generic (Various) Maxitrol (Alcon) Methadex (Major) AK-Trol (Akorn) Poly-Dex (OCuSOFT)
Neomycin 0.35% Polymyxin B 10,000 U/ml	Hydrocortisone 1%	Generic (Various) AK-Spore HC (Akorn) Cortisporin (Monarch)
Neomycin 0.35% Polymyxin B 10,000 U/ml	Prednisolone 0.5%	Poly-Pred (Allergan)
Neomycin 0.35% Polymyxin B 10,000 U/ml Gentamicin 0.3% Tobramycin 0.3% Tobramycin 0.3%	Prednisolone 1% Dexamethasone 0.1% Loteprednol 0.5%	Pred-G (Allergan) TobraDex (Alcon) Zylet (Bausch & Lomb)
<b>Ointments</b>		
Neomycin 0.35% Neomycin 0.35% Polymyxin B 10,000 U/g	Dexamethasone 0.05% Dexamethasone 0.1%	NeoDecadron (Merck) Generic (Akorn) Maxitrol (Alcon) AK-Trol (Akorn)
Neomycin 0.35% Bacitracin 400 U/g Polymyxin B 10,000 U/g	Hydrocortisone 1%	Generic (Various) Cortomycin (Major) Cortisporin (Monarch) AK-Spore HC (Akorn)
Gentamicin 0.3% Tobramycin 0.3%	Prednisolone 0.6% Dexamethasone 0.1%	Pred-G (Allergan) TobraDex (Alcon)

aminoglycoside. The specific sensitivity to each drug must be determined for the individual pathogen.

Aminoglycosides are poorly absorbed from the gastrointestinal tract, so when used systemically they must be given parenterally. Note that penicillins or cephalosporins can inactivate aminoglycosides if mixed together in the same solution for injection or for topical application; each drug must be administered separately. If topical fortified cefazolin and fortified tobramycin are used to treat a corneal ulcer, each should be prepared and administered in a separate bottle.

### *Clinical Uses*

**Neomycin.** Neomycin is the oldest aminoglycoside. It is available for oral, topical, and parenteral administration, but there are almost no indications for oral and parenteral use.

The most common form of neomycin administration is topical. The drug is available in combination with other antibiotics and steroids in numerous ophthalmic, otic, and dermatologic preparations designed to treat a variety of skin and mucous membrane infections (see Tables 11-6 and 11-7). Topical ocular application of neomycin can result in

sensitization to the drug, which leads to contact dermatitis in approximately 4% of patients. Therefore routine use of topical preparations containing neomycin is not recommended, and other drugs or combinations (e.g., bacitracin-polymyxin B) should generally be substituted.

**Gentamicin.** Gentamicin is widely used in the treatment of severe infections. Uses include septicemia, neonatal sepsis, neonatal meningitis, biliary tract infection, pyelonephritis, prostatitis, and endocarditis. Gentamicin is frequently used for empiric therapy in presumed gram-negative bacillary infections before the identification and susceptibility of the causative organism are known. Patients with cystic fibrosis and those in intensive care units often have *Pseudomonas* infections and are typically treated with gentamicin.

Topical dermatologic preparations of gentamicin are commonly used for the treatment of infected burns. Topical ophthalmic gentamicin (see Table 11-5) is used to treat a variety of bacterial infections of the external eye and adnexa (e.g., conjunctivitis, blepharitis, and keratoconjunctivitis).

Gentamicin is used for the initial treatment of bacterial corneal ulcers, but the commercially available strength of ophthalmic gentamicin solution is considered inadequate. Consequently, solutions containing fortified concentrations are prepared from sterile products intended for parenteral use. Empiric therapy with fortified gentamicin drops along with a penicillinase-resistant cephalosporin (e.g., cefazolin) is useful until the causative organism and susceptibility are known. An initial loading dose (one drop every minute for 5 minutes) rapidly increases the antibiotic concentrations in the cornea. Drops can then be applied every hour, with the first antibacterial applied on the hour and the second on the half hour. Gentamicin, sometimes in combination with a penicillin having antipseudomonal activity (e.g., ticarcillin), is a specific treatment for *P. aeruginosa* corneal ulcers.

**Tobramycin.** The antibacterial activity and pharmacokinetic properties of tobramycin resemble those of gentamicin, and the therapeutic uses of tobramycin are essentially identical to those for gentamicin. Although some bacteria are resistant to both gentamicin and tobramycin, it is unpredictable in individual strains. Amikacin is usually effective for infections caused by organisms resistant to both gentamicin and tobramycin.

Tobramycin is available as a topical ophthalmic solution and an ointment (see Table 11-5). Tobramycin is also prepared as a topical fortified solution for the treatment of corneal ulcers and is used in place of fortified gentamicin using the same dosage schedule (see Table 11-1).

**Amikacin.** Amikacin was the first semisynthetic aminoglycoside to be marketed. Because a chemical modification present in amikacin protects the molecule from many aminoglycoside-inactivating enzymes, it has become the preferred drug for treatment of gram-negative bacillary infections in which resistance to both gentamicin and tobramycin is encountered. At the clinical level, however, evidence is lacking that amikacin is more efficacious than gentamicin or tobramycin for infections caused by susceptible organisms. Because amikacin is active in vitro against many gram-negative bacilli that are resistant to other aminoglycosides and because amikacin is less toxic when injected intravitreally, it has become a primary antibiotic, along with vancomycin, for treatment of bacterial endophthalmitis (see Table 11-1).

#### Side Effects

Neurotoxicity manifested as auditory and vestibular ototoxicity can occur in patients treated systemically with any of the aminoglycosides. High concentrations of aminoglycosides that can accumulate in the kidney and urine correlate with the potential for these drugs to cause nephrotoxicity. Usually, discontinuing the drug can reverse early changes. Because the incidence and severity of nephrotoxicity and ototoxicity relate directly to aminoglycoside concentration in the body and to the

length of drug exposure, these antibiotics should be used only when less toxic antibiotics are not effective. Systemic gentamicin can also cause a rare visually related side effect: pseudotumor cerebri with secondary papilledema.

Side effects produced by topical gentamicin or tobramycin are uncommon but can include corneal and conjunctival toxicity. Punctate epithelial erosions, delayed reepithelialization, and corneal ulceration characterize this corneal toxicity, whereas chemosis, hyperemia, and necrosis characterize conjunctival toxicity. Allergic reactions to topical gentamicin occur infrequently, but approximately 50% of patients who are allergic to neomycin are also allergic to gentamicin.

Retinal damage in the form of macular infarction has occurred after intravitreal administration of gentamicin. Because amikacin is less toxic when injected intravitreally, the current recommendation for treatment of postoperative endophthalmitis is intravitreal amikacin (or ceftazidime) for gram-negative coverage.

#### Contraindications

The aminoglycosides are contraindicated in patients with hypersensitivity or intolerance to any drug within the family.

#### Tetracyclines

The tetracyclines are a family of drugs that can be divided into three groups based on differences in pharmacokinetics: short acting, intermediate acting, and long acting (Table 11-8).

Doxycycline is the preferred tetracycline because it is better absorbed and distributed than the others.

**Table 11-8**  
Tetracyclines: Classes and Oral Doses

Generic Name	Trade Name	Usual Adult Dosage	
Short acting Tetracycline	Sumycin	500 mg q6h	
	Achromycin		
	Panmycin		
Oxytetracycline	Terramycin	500 mg q6h	
Intermediate acting	Demeclocycline	300 mg q12h	
	Declomycin		
Long acting	Doxycycline	100 mg q12h	
			Monodox
			Vibramycin
			Doryx
			Vibra-Tabs
			Adoxa
			Atridox
Minocycline	Myrac	100 mg q12h	
	Minocin		
	Dynacin		

Doxycycline also requires only twice-a-day dosing and can be taken with foods, both of which encourage patient compliance.

### *Pharmacology*

Tetracyclines inhibit bacterial protein synthesis by binding to the 30S subunit of the ribosome, thus blocking the attachment of aminoacyl-tRNA to the receptor site on the messenger RNA-ribosome complex.

Although tetracyclines have been widely used antibiotics, their clinical usefulness has declined because of increased bacterial resistance. The resistance is due to a decrease in the bacterial drug concentration caused by an active drug efflux mechanism developed by the bacterial cells.

### *Clinical Uses*

Although the clinical usefulness of tetracyclines is limited for most of the common microbial pathogens, they remain drugs of choice (or very effective alternative therapy) for a wide variety of infections caused by less common pathogens. These include brucellosis; rickettsial infections such as Rocky Mountain spotted fever, typhus, and Q fever; *Mycoplasma pneumoniae*; cholera; plague; *Ureaplasma urethritidis*; *Chlamydia* infections; and Lyme disease. Oral doxycycline, 100 mg orally twice a day for 7 days, is a recommended treatment for chlamydial sexually transmitted disease.

In adults with chlamydial ocular infections such as inclusion conjunctivitis or trachoma, treatment with oral doxycycline or tetracycline is a recommended strategy (see Table 11-1). In community-based programs to control trachoma, topical tetracycline ointment administered twice daily on an intermittent schedule (5 consecutive days each month for 6 months) can be useful. However, incomplete cure and subsequent disease transmission can result. In contrast, oral treatment with tetracycline or doxycycline cures trachoma.

A fixed-combination ointment containing oxytetracycline and polymyxin B is available for topical ocular use (see Table 11-6). The Centers for Disease Control and Prevention recommends ophthalmic ointments containing a tetracycline or erythromycin as an effective alternative to silver nitrate for prophylaxis of gonococcal ophthalmia neonatorum. A major advantage of using an antibiotic ointment such as oxytetracycline-polymyxin B is that it does not cause the chemical conjunctivitis typically produced by silver nitrate.

Oral tetracycline or doxycycline can be an effective therapy for noninfectious conditions involving the eye such as acne rosacea and meibomianitis. When patients with acne rosacea or meibomianitis receive oral tetracycline, two changes occur: amelioration of the symptoms and reduction of free fatty acids in the surface sebum. Free fatty acids are released from sebum by bacterial lipases and are irritating as well as inflammatory. Tetracycline causes a significant decrease in lipase

production in sensitive or resistant *S. epidermidis* without necessarily affecting bacterial growth. Although some patients can discontinue medication without recurrence of symptoms, others must continue on low-dose maintenance for extended periods.

Oral tetracycline has been effective for recalcitrant (i.e., resistant to corticosteroid therapy) cases of nontuberculous phlyctenular keratoconjunctivitis. The manner in which systemic tetracycline affects the ocular flora or alters the immune response remains unclear.

Tetracycline and doxycycline are metalloproteinase inhibitors and when given orally can block the action of corneal collagenases. Either may be effective for resolving noninfected corneal ulcers or "corneal melting" in which progressive necrosis of stromal tissue occurs despite the absence of a positive culture. Similarly, the anticollagenolytic activity of tetracycline or doxycycline can prove clinically useful in treating persistent corneal epithelial defects.

### *Side Effects*

A photosensitivity reaction, which manifests as an exaggerated sunburn, is common in patients receiving any tetracycline drug. Hypersensitivity reactions to tetracyclines including anaphylaxis, urticaria, periorbital edema, and morbilliform rashes can occur but are uncommon.

At the usual dosage levels, all tetracyclines have relatively low toxicity, but oral administration can produce varying degrees of gastrointestinal irritation. Anorexia, heartburn, nausea, vomiting, flatulence, and diarrhea commonly occur. Although not usually disabling, these reactions can become severe enough to require discontinuation or interruption of therapy. When diarrhea persists or becomes severe, pseudomembranous colitis caused by *C. difficile* must be considered.

The administration of tetracycline with food can ameliorate its irritative effects, but food can adversely affect the drug's absorption. In contrast, the absorption of doxycycline is only slightly affected by the presence of food, including dairy products. Because all tetracyclines can form complexes with divalent cations, the absorption of any tetracycline is markedly decreased when administered with iron-containing tonics or antacids containing calcium, magnesium, or aluminum. Sodium bicarbonate also adversely affects tetracycline absorption.

Most tetracyclines can cause azotemia in patients with impaired renal function. The only tetracycline recommended for use in such patients is doxycycline because it exits the body mainly via the intestinal tract rather than through the kidneys.

Tetracyclines are attracted to embryonic and growing bone tissues. A tetracycline-calcium orthophosphate complex is formed that temporarily depresses bone growth. Tetracyclines can also cause changes in both deciduous and permanent teeth during the time of tooth development; these changes include dysgenesis, staining, and an increased tendency to caries. Discoloration may be progressive and can vary from yellowish brown to dark gray. Because of

bone growth depression and tooth discoloration, women in the last half of pregnancy, nursing mothers, and children under 8 years of age should avoid tetracyclines.

Intracranial hypertension (pseudotumor cerebri) secondary to the use of many tetracycline analogues can occur in infants and adults. When the antibiotic is discontinued, cerebral fluid pressure and any accompanying visual and ophthalmoscopic changes usually return to normal over days or weeks. Rarely, tetracycline causes blood dyscrasias such as hemolytic anemia, thrombocytopenia, neutropenia, and eosinophilia.

Vestibular toxicity appears to be unique to minocycline. Lightheadedness, loss of balance, dizziness, nausea, and tinnitus beginning 2 to 3 days after starting therapy can occur in up to 70% of patients. Although these side effects are usually reversible after discontinuing the drug, they have severely limited the use of minocycline.

Tetracyclines can interact significantly with other drugs, and these interactions should be considered when patients are taking concomitant medications. Tetracyclines can potentiate the effects of Coumadin-type anticoagulants and seriously interfere with blood clotting. They may also interfere with the bactericidal action of the penicillins after concomitant parenteral administration, and such use should be avoided. By increasing hepatic drug metabolism, carbamazepine, diphenylhydantoin, and barbiturates decrease the half-life of doxycycline by approximately 50%. Doxycycline dosages must therefore be increased to compensate for this factor or a different antibiotic selected.

Tetracycline use may be related to breast cancer. However, more research is needed to determine whether the relationship is causal.

### *Contraindications*

Tetracyclines are contraindicated in patients with known hypersensitivity or intolerance to any member of the tetracycline family. The use of tetracyclines during tooth development can cause permanent discoloration of teeth and is thus contraindicated in pregnant or breast-feeding women and in children 8 years of age or younger.

### *Macrolides*

The macrolide antibiotics include erythromycin, clarithromycin, and azithromycin.

### *Pharmacology*

Macrolides inhibit bacterial protein synthesis by binding to the 50S ribosomal subunit and preventing elongation of the peptide chain. These drugs have low toxicity because they do not bind to mammalian ribosomes.

Erythromycin is active against gram-positive cocci with the exception of enterococci. Erythromycin is also active against *Mycoplasma pneumoniae*, *Chlamydia trachomatis*, *Chlamydia pneumoniae*, and *Borrelia burgdorferi*. Clarithromycin and azithromycin have antibacterial spectra similar to that of erythromycin except that they have enhanced activity against *H. influenzae*.

A common mechanism of resistance to the macrolides is due to a change in the bacterial ribosomal RNA that results in poor binding of the drug to the ribosome. Resistance is developing to the macrolides among the gram-positive cocci including *Staphylococcus aureus*, coagulase-negative staphylococci, *Streptococcus pyogenes* and *Streptococcus pneumoniae*, and also *H. influenzae*.

***Erythromycin.*** Erythromycin is available in topical, oral, and intravenous preparations. Only the free base has biologic activity in vivo. When given orally, however, gastric acid inactivates the erythromycin base, resulting in decreased absorption. Thus a large number of formulations and derivatives have been prepared to optimize stability and absorption. When oral erythromycin preparations are administered in the correct dose and with proper timing in relation to food intake, no one type of preparation appears to offer a significant therapeutic advantage in treating mild to moderate infections.

Erythromycin estolate is usually not recommended for adults because of the increased risk of cholestatic hepatitis. In children, however, this derivative rarely causes hepatitis, and some pediatric specialists prefer this formulation because of better availability.

Erythromycin has been a widely used macrolide antibiotic because of its relative lack of toxicity and good activity against susceptible organisms. However, because resistance to erythromycin by *Streptococcus pneumoniae* is developing, this drug is less often used as a first-line drug for the treatment of respiratory infections such as acute sinusitis, otitis media, bacterial bronchitis, and pneumonia. However, erythromycin or another macrolide remains the substitute of choice for *Streptococcus pyogenes* pharyngitis and tonsillitis, for prophylaxis of endocarditis, and for recurrences of rheumatic fever when the patient is allergic to penicillin.

Staphylococcal infections of the eyelid are commonly treated with erythromycin ointment applied to the lid margins (see Table 11-1). Warm moist compresses should be applied to the lid, and then the lid margins should be gently cleaned with diluted baby shampoo or a commercial lid cleanser before applying the drug. Erythromycin ointment can be applied only at bedtime or more often as required by infection severity. For the prophylaxis of ophthalmia neonatorum, a 0.5- to 1-cm ribbon of erythromycin ointment is instilled into each conjunctival sac and not flushed from the eyes after application.

*Chlamydia trachomatis* infections in infants and children are primary indications for the use of oral erythromycin. This antibiotic is as effective as the tetracyclines for chlamydial infections and is safer for pregnant women, nursing mothers, and children under 8 years of age.

Erythromycin is also an effective alternative to tetracycline for the treatment of adult chlamydial sexually transmitted disease. Adults should receive 2 g of erythromycin daily in four divided doses for at least 7 days. Trachoma and inclusion conjunctivitis in older children or adults



can also be effectively treated with oral erythromycin by using a 3-week course of 2 g daily in four divided doses. Patients receiving full oral therapeutic doses of antibiotic do not need topical antimicrobial treatment with ophthalmic erythromycin ointment.

**Clarithromycin.** Clarithromycin, a more recently developed macrolide antibiotic, is a 6-O-methyl derivative of erythromycin. It is stable in gastric acid and is well absorbed. Because the half-life of clarithromycin is approximately twice that of erythromycin, patients take clarithromycin only twice daily compared with four times a day for erythromycin.

Clarithromycin is indicated for the treatment of mild to moderate upper and lower respiratory tract infections as well as skin infections caused by susceptible strains of *Staphylococcus aureus*, *Streptococcus pyogenes*, *Streptococcus pneumoniae*, *H. influenzae*, *Legionella pneumophila*, and *Mycoplasma pneumoniae*. The usual dosage is 250 to 500 mg twice a day for 7 to 14 days.

**Azithromycin.** Azithromycin is another recently developed macrolide antibiotic. After oral administration on an empty stomach, azithromycin is rapidly absorbed and widely distributed throughout the body. Because azithromycin has an extended half-life, once-daily dosing is effective and encourages patient compliance.

Azithromycin is indicated for mild to moderate infections of the respiratory tract and skin caused by susceptible strains of *Staphylococcus aureus*, *Streptococcus pyogenes*, *Streptococcus pneumoniae*, *H. influenzae*, and *Moraxella catarrhalis*. Treatment of pneumonia, tonsillitis, and skin infections is two 250-mg tablets as a single dose on the first day followed by 250 mg once daily on days 2 through 5 (a “Z-Pak” is five 250-mg tablets packaged to encourage compliance with this treatment regimen). Treatment of bacterial exacerbation of chronic obstructive pulmonary disease and sinusitis is 500 mg once daily for 3 days. These infections can also be treated with a single 2-g dose of Zmax (azithromycin extended release).

A single 1-g dose of azithromycin is a recommended treatment for chlamydial urethritis and cervicitis. Similarly, a single 1-g dose is effective for the treatment of chlamydial conjunctivitis and trachoma in adolescents and adults, whereas a single oral dose of 20 mg/kg can be used for treatment in children.

### Side Effects

Gastrointestinal irritation, including abdominal cramps, nausea, vomiting, and diarrhea, is the most common adverse event produced by erythromycin and is usually associated with oral administration. Irritation is dose related and more common with daily doses of 2 g or more. Some brands of enteric-coated tablets and the ester derivatives (e.g., ethylsuccinate) can be taken with food to minimize these adverse effects.

Like erythromycin, the most common side effects of azithromycin and clarithromycin are gastrointestinal, with diarrhea, nausea, and abdominal pain being the most frequently reported. Clarithromycin can also cause headache and dyspepsia. Other side effects of azithromycin include palpitations, vaginitis, headache, dizziness, fatigue, and hypersensitivity reactions.

The most serious toxicity of erythromycin involves cholestatic hepatitis, which occurs mainly in adults and only when the estolate preparation of erythromycin is used. Mild allergic reactions such as urticaria and other rashes, fever, and eosinophilia have occurred occasionally after erythromycin use. Sensorineural hearing loss, although extremely rare, has been reported after the use of large doses of erythromycin or the use of erythromycin in the presence of renal failure. The hearing loss usually improves gradually on discontinuation of the drug. Concurrent use of macrolides and theophylline has been associated with increases in the serum concentrations of theophylline.

Macrolide use may be related to breast cancer. However, more research is needed to determine whether the relationship is causal.

### Contraindications

Macrolide antibiotics are contraindicated in patients with known hypersensitivity or intolerance to any macrolide. Because clarithromycin can have adverse effects on embryo-fetal development in animals, this drug should be avoided in pregnant women unless no other therapy is appropriate. Concurrent administration of the macrolides and astemizole or terfenadine can cause elevated antihistamine levels, resulting in life-threatening cardiac arrhythmias, and should be avoided.

### Chloramphenicol Pharmacology

Chloramphenicol inhibits protein synthesis by binding to the 50S subunit of the bacterial ribosome and blocking aminoacyl-tRNA binding.

### Clinical Uses

Chloramphenicol is active against most gram-positive and gram-negative bacteria, *Rickettsia*, *Chlamydia*, spirochetes, and *Mycoplasma*; however *P. aeruginosa* is resistant to this drug. Despite its broad antibacterial spectrum, generally good tolerance by patients, and desirable pharmacokinetic characteristics, chloramphenicol's ability to cause fatal aplastic anemia limits its usefulness. Indications for chloramphenicol include severe or life-threatening infections caused by susceptible organisms that are not responsive to less toxic drugs.

Topical application of chloramphenicol solution or ointment is effective against most bacterial infections of the external eye. However, because aplastic anemia has also occurred after topical ocular use of chloramphenicol, its use must be limited to infections for which less toxic antibiotics prove ineffective.

### Side Effects

Chloramphenicol causes two types of hematopoietic abnormality. The first is a dose-related toxic effect causing a bone marrow depression associated with inhibition of mitochondrial protein synthesis. Usually, discontinuing the antibiotic reverses this toxicity.

A second, more serious, type of bone marrow depression consists of aplastic anemia. Considered an idiosyncratic reaction rather than a toxic reaction, aplastic anemia occurs most commonly weeks to months after completion of therapy and is not dose related. In the most severe form of aplastic anemia, pancytopenia with an aplastic marrow is present. Prognosis is very poor because the anemia is usually irreversible.

### Contraindications

Because serious and fatal blood dyscrasias can occur after the administration of chloramphenicol, it should be used only in serious infections for which less potentially dangerous drugs are ineffective or contraindicated. Chloramphenicol is contraindicated in patients with known hypersensitivity or intolerance to this drug, who have blood cell or bone marrow disorders, or who are undergoing dialysis and have other complications such as cirrhosis.

## Drugs Affecting Folate Metabolism

Antibacterial drugs that affect the folate (folic acid) metabolism of bacteria include sulfonamides, pyrimethamine, and trimethoprim.

### Sulfonamides, Pyrimethamine, and Trimethoprim *Pharmacology*

Sulfonamides were the first group of chemotherapeutic agents used for the prevention or treatment of bacterial infections in humans. Sulfonamides (e.g., sulfisoxazole) act by inhibiting bacterial synthesis of folic acid, a chemical required for synthesis of nucleic acid and protein. These drugs competitively inhibit the first step in the synthesis of folic acid—the conversion of para-aminobenzoic acid into dihydrofolic acid. Because humans absorb preformed folic acid from food, sulfonamide inhibition has only a minimal effect on human cells.

Pyrimethamine and trimethoprim reversibly inhibit the second step in the synthesis of folic acid by inhibiting the enzyme dihydrofolate reductase, which catalyzes the reduction of dihydrofolic acid to tetrahydrofolic acid. The trimethoprim-binding affinity is much stronger for the bacterial enzyme than the corresponding mammalian enzyme, which produces selective toxicity. A powerful synergism exists between either pyrimethamine or trimethoprim and sulfonamides (e.g., sulfamethoxazole and trimethoprim) because of sequential blockage of the same biosynthetic pathway.

Acquired resistance to sulfonamides is widespread. Mechanisms of resistance include overproduction of

para-aminobenzoic acid by the bacteria, decreased enzyme affinity for the sulfonamide, decreased bacterial permeability to the drug, and increased inactivation of the drug by bacteria. Bacteria resistant to one sulfonamide are commonly resistant to all of them.

### Clinical Uses

Sulfamethoxazole in combination with trimethoprim is an effective and inexpensive treatment for acute uncomplicated urinary tract infection. This combination is also useful for treatment of *Pneumocystis carinii* pneumonitis in immunologically impaired patients.

Pyrimethamine is used for prophylaxis and treatment of malaria. An ocular use of pyrimethamine is in the treatment of the protozoan disease toxoplasmic retinochoroiditis. In this disease recurrent necrotizing lesions in the retina/choroid result from the active multiplication of previously encysted *Toxoplasma gondii*. The classic use of pyrimethamine along with sulfadiazine appears to be effective for the treatment of the active form of this disease. The synergism of the combined drugs greatly enhances the therapeutic effect. Topical ophthalmic preparations of sulfonamides include sulfacetamide and sulfisoxazole and sulfacetamide in combination with the steroids prednisolone acetate, prednisolone phosphate, and fluorometholone alcohol.

These antibacterial drugs have been used extensively in the past for the treatment of blepharitis and conjunctivitis. However, they are rarely used today because of widespread bacterial resistance and the availability of more effective antibacterial drugs.

A combination of trimethoprim and polymyxin B is available as a topical ophthalmic solution and ointment (see Table 11-6). Trimethoprim has significant in vitro activity against gram-positive and gram-negative organisms, including staphylococci, streptococci, *Haemophilus*, and gram-negative enterics. However, because it is not active against *Pseudomonas*, polymyxin B is included in the combination to cover gram-negative bacteria, including *Pseudomonas*.

Trimethoprim-polymyxin B is effective for the treatment of blepharitis, conjunctivitis, and blepharoconjunctivitis. Side effects are very rare. Because it is clinically effective against *H. influenzae* and *Streptococcus pneumoniae*, which are the most common causes of bacterial pediatric eye infections, it is a drug of choice for treating eye infections in children.

### Side Effects

The sulfonamides can produce a wide variety of side effects, and an adverse reaction to one sulfonamide frequently precludes the use of other sulfonamide derivatives. The most common adverse effects are gastrointestinal disturbances, including anorexia, nausea, vomiting, and diarrhea.

Allergic skin reactions such as rash and urticaria and the more severe Stevens-Johnson syndrome can occur. Skin reactions have an increased incidence when the

sulfamethoxazole–trimethoprim combination is used as compared with use of a sulfonamide alone.

Oral use of sulfonamides, pyrimethamine, and trimethoprim can cause blood dyscrasias such as hemolytic anemia, aplastic anemia, leukopenia, and agranulocytosis. Because these blood changes are due to a drug-induced folic acid deficiency, administering folinic (not folic) acid can counteract the toxicity. Use of folinic acid bypasses the need for dihydrofolate reductase by supplying the fully reduced folate.

Myopia, with or without induced astigmatism, has been reported in patients taking systemic sulfonamides. The refractive state usually returns to normal when the serum drug level decreases.

The most frequently reported reactions to topically applied sulfonamides are local irritation, stinging, and burning. Contact dermatitis is common with topical application of these drugs, and they can cause more serious dermatologic problems such as erythema nodosum, erythema multiforme (Stevens-Johnson syndrome), and exfoliative dermatitis. In addition to hypersensitivity reactions, topical administration of sulfonamides can lead to local photosensitization, which can result in sunburn on the lid margins or skin of the face.

Trimethoprim–polymyxin B is well tolerated with few reported serious adverse reactions after topical ophthalmic use. The most frequent adverse event (about 4%) is local irritation, including transient burning or stinging, itching, or redness. Less than 2% of patients experience a hypersensitivity reaction consisting of lid edema, itching, increased redness, tearing, or periocular rash. Because no cross-allergic reactions occur between the sulfonamides and trimethoprim, trimethoprim–polymyxin B can be used in patients allergic to the sulfonamides.

### Contraindications

Sulfonamides are contraindicated in patients with known hypersensitivity or intolerance to any member of this drug family. Sulfonamides are also contraindicated in pregnancy at term, for nursing mothers, and for infants less than 2 months old because they can promote kernicterus in the newborn by displacing bilirubin from plasma proteins. The sulfonamides, pyrimethamine, and trimethoprim are contraindicated in patients with documented blood dyscrasias.

Caution should be used in prescribing sulfonamides for patients taking oral hypoglycemic drugs such as tolbutamide or chlorpropamide, because the sulfonamides can potentiate the hypoglycemic effect of these drugs. Sulfonamides can enhance the action of Coumadin-type anticoagulants and should be used with caution in patients taking these drugs.

### Drugs Affecting Bacterial DNA Synthesis

Drugs that inhibit bacterial DNA synthesis include fluorinated quinolones (fluoroquinolones), which are structurally

related to nalidixic acid: lomefloxacin, norfloxacin, enoxacin, ciprofloxacin, ofloxacin, sparfloxacin, gemifloxacin, levofloxacin, gatifloxacin, and moxifloxacin.

### Fluoroquinolones

#### Pharmacology

Fluoroquinolones act by rapidly inhibiting bacterial DNA synthesis, which leads to cell death. The primary targets are DNA gyrase (topoisomerase II) and topoisomerase IV, which are involved in maintaining the superhelical structure of DNA during synthesis. Human cells lack these enzymes so they are not affected by fluoroquinolones.

Bacteria have developed resistance to the fluoroquinolones by two main mechanisms. The first involves modifying the enzyme(s) targeted by the drug: either DNA gyrase or topoisomerase IV or both. The second involves reduction of fluoroquinolone access to its target enzyme either by efflux pumps that remove the fluoroquinolone from the cell or by the cell's membrane acquiring reduced permeability to the fluoroquinolone.

**Table 11-9**  
Fluoroquinolones for Oral Therapy

Drug	Trade Name	Clinical Indications
First generation		
Nalidixic acid	NegGram	Uncomplicated urinary tract infections
Second generation		
Group 1		
Lomefloxacin	Maxaquin	Uncomplicated urinary tract infections
Norfloxacin	Noroxin	
Enoxacin	Penetrex	
Group 2		
Ciprofloxacin	Cipro	Complicated urinary tract infections, pyelonephritis, chlamydial sexually transmitted disease, prostatitis, skin and soft tissue infections
Ofloxacin	Floxin	
Third generation		
Sparfloxacin	Zagam	Acute exacerbations of chronic bronchitis, community-acquired pneumonia As above plus urinary tract infections, skin infections
Gemifloxacin	Factive	
Levofloxacin	Levaquin	
Fourth generation		
Moxifloxacin	Avelox	Acute exacerbations of chronic bronchitis, community-acquired pneumonia, acute sinusitis, skin infections

### *Clinical Uses*

The classification of the fluoroquinolones into generations is somewhat informal and unstandardized. However, it does serve a clinical purpose by helping to classify them on the basis of their spectra of action and indications (Table 11-9).

Some second-generation fluoroquinolones (e.g., lomefloxacin, norfloxacin, and enoxacin) have, compared with nalidixic acid, improved activity against gram-negative bacteria, including *Pseudomonas*, and are used almost exclusively for urinary tract infections.

Ciprofloxacin and ofloxacin have broader spectra of activity that includes some gram-positive organisms so they have been used for a broad range of infections. Oral ciprofloxacin or ofloxacin is indicated for the treatment of complicated urinary tract infections and prostatitis. Ofloxacin is an effective therapy for chlamydial urethritis/cervicitis and acute pelvic inflammatory disease. Oral ciprofloxacin or ofloxacin is effective in the treatment of acute diarrhea caused by enterotoxigenic *E. coli* (e.g., travelers' diarrhea), *Salmonella*, *Shigella*, and *Campylobacter*.

Ciprofloxacin and ofloxacin have been used extensively to treat upper and lower respiratory tract infections. However, there are concerns about the increasing resistance of *S. pneumoniae* to these drugs.

Newer fourth-generation fluoroquinolones such as gatifloxacin, gemifloxacin, and moxifloxacin have improved activity against pneumococci, including macrolide- and penicillin-resistant strains, and are often termed the "respiratory quinolones." They are indicated for acute exacerbations of chronic bronchitis, community-acquired pneumonia, and sinusitis.

Ciprofloxacin, ofloxacin, norfloxacin, levofloxacin, gatifloxacin, and moxifloxacin are available as topical ophthalmic solutions, and ciprofloxacin is available as an ophthalmic ointment (see Table 11-5). These drugs are broad spectrum and effective against both gram-positive and gram-negative bacteria. However, the clinical utility and effectiveness of the older fluoroquinolones (ciprofloxacin, norfloxacin, and ofloxacin) have been eroded due to growing rate of resistance, particularly among gram-positive bacteria. Moxifloxacin and gatifloxacin have enhanced activity against gram-positive bacteria while maintaining potency against gram-negative bacteria. These fourth-generation quinolones are active not only against fluoroquinolone-resistant staphylococci and streptococci, but also against penicillin- and macrolide-resistant isolates as well.

All the available ophthalmic fluoroquinolones are indicated for bacterial conjunctivitis with a treatment regimen of usually one to two drops four times a day. However, because the newer gatifloxacin and moxifloxacin have wider spectra and less resistance, they should probably be reserved for treatment of the more serious infection, bacterial keratitis.

Ciprofloxacin and ofloxacin are also indicated for bacterial keratitis caused by a variety of pathogens. These

two antibiotics offer the convenience of "off-the-shelf" treatment for bacterial corneal ulcers. The suggested regimen for ciprofloxacin therapy is one to two drops applied to the affected eye every 15 minutes for the first 6 hours and then every 30 minutes for the rest of the day. The dosage on day 2 is one to two drops every hour. Monotherapy with ciprofloxacin or ofloxacin, although usually successful, is becoming more controversial as resistance develops to these antibiotics. Some suggest that fluoroquinolone monotherapy be used only for small off-visual axis corneal ulcers and that larger more visual-threatening ulcers should be treated with fortified antibiotics.

Although the fourth-generation drugs, moxifloxacin and gatifloxacin, are not approved for treatment of bacterial keratitis, they are now the preferred fluoroquinolones for this disease. They have wide spectra of activity and lesser resistance by the common corneal pathogens, especially the gram-positive cocci.

### *Side Effects*

As a group the fluoroquinolones are generally well tolerated with a low incidence of adverse reactions. When adverse effects are reported after systemic administration, they are usually gastrointestinal, dermatologic, and central nervous system reactions, which rarely necessitate withdrawal of therapy. The typically reported gastrointestinal symptoms include nausea, anorexia, and dyspepsia; diarrhea, abdominal pain, and vomiting are less frequently reported. Liver enzyme abnormalities occur in 2% to 3% of patients and are usually mild and reversible. Although nonspecific skin rashes, pruritus, and urticaria have been reported, it is phototoxicity that manifests as a severe sunburn that has received the most attention. Sparfloxacin has caused a high rate of phototoxicity, but phototoxic reactions to ciprofloxacin, ofloxacin, and levofloxacin are rare. The central nervous system reactions produced by fluoroquinolones include headache, dizziness, mild tremor, or drowsiness. Because it can cause hypoglycemia or hyperglycemia in diabetics, oral gatifloxacin is no longer available.

Fluoroquinolones as a group produce destructive arthropathy in weight-bearing diarthrodial joints of juvenile animals after prolonged administration of high dosages. This effect has never been observed in children. However, these drugs are not recommended for systemic administration in children, adolescents below the age of 18 years, or pregnant women.

An association between fluoroquinolones and tendonitis, especially involving the Achilles tendon, has been reported. Magnetic resonance imaging can be useful for early detection of damage, and discontinuation is recommended at the first sign of tendon pain or inflammation.

The frequency of adverse reactions to the topical ophthalmic fluoroquinolones is low. The most frequently reported adverse reactions to ciprofloxacin are local burning or discomfort after instillation, bitter taste after

instillation, white precipitates, foreign body sensation, itching, and conjunctival hyperemia, chemosis, and photophobia. Frequent instillation of ciprofloxacin for treatment of corneal ulceration can result in white precipitates forming on the surface of the eye, but the precipitates typically do not require discontinuation of therapy. Opaque deposits can also form on “bandage” soft contact lenses when ciprofloxacin and prednisolone are used concurrently. Corneal epithelial cytotoxicity of the fluoroquinolones has been evaluated in animal models, and each drug was found to have only minimal toxicity at therapeutic concentrations.

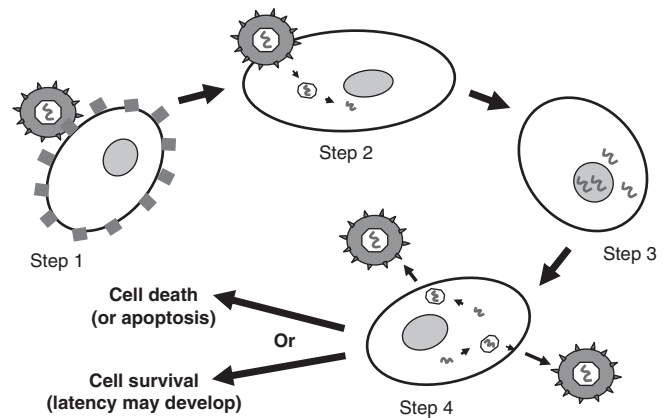
Topical administration of the fluoroquinolones to immature animals does not cause arthropathy, and the ophthalmic dosage form does not appear to affect the weight-bearing joints in humans. All the topical ophthalmic fluoroquinolones, except levofloxacin, are approved for use in patients 1 year of age and older.

### *Contraindications*

The quinolones are contraindicated in patients with a history of hypersensitivity to any drug in this family. Absorption of the fluoroquinolones is reduced by antacids, iron, and zinc salts, and thus they should not be taken concurrently. Oral ciprofloxacin and enoxacin inhibit the metabolism of theophylline, and toxicity can occur when these two drugs are administered concurrently. Oral administration of the fluoroquinolones can cause convulsions and should therefore be done with caution in patients with central nervous system disorders. These drugs are not recommended for systemic administration in children, adolescents younger than age 18 years, or pregnant women. Topical administration is contraindicated for use in patients younger than 1 year of age.

## **ANTIVIRAL DRUGS**

Ranging in size from about 20 to 300 nm, viruses are the smallest of the infectious organisms. Electron micrograph studies show viruses to vary not only in size, but also in shape, symmetry, and surface characteristics. The basic structure of a virus particle (virion) consists of an outer protein coat, or capsid, that protects and delivers the inner viral genetic material, or genome, within a host cell (Figure 11-2). The genome material is either single- or double-stranded DNA or RNA. Most viruses contain or encode enzymes that orchestrate viral replication inside the host cell. Newly synthesized viral genetic material and capsids assemble to form multiple viral progeny that are released from the infected cell to infect other cells. The replication process generally results in host cell death, or apoptosis. However, viruses like herpesviruses can cause latent infections by incorporating the viral genome into host DNA, thereby escaping detection by the host’s immune system and allowing the host cell to survive. Recurrent disease results from activation of the



**Figure 11-2** Steps in viral replication. Step 1: Attachment of virus to host cell using specialized receptors on the virus and host cell. Step 2: Penetration of virus into host cell and uncoating of virus. Step 3: Duplication of viral DNA or RNA using host DNA/RNA. Step 4: Assembly of viral genome and capsid within host cell and then release of progeny. (The host cell can then either die or survive, depending on the virus and host cell type.)

viral genetic material, by various triggers or stressors, to produce progeny.

Effective antiviral agents must interfere with viral replication to stop virus multiplication. Ideally, the antiviral demonstrates selective toxicity by preferentially inhibiting viral replication while sparing host cell-directed nucleic acid or protein synthesis. Most of the currently available antiviral drugs are antimetabolites that inhibit nucleic acid synthesis (refer to step 3 in Figure 11-2). Currently approved antiviral drugs target viral enzymes, such as thymidine kinase, to inhibit viral replication. Thymidine kinase helps cells incorporate the nucleoside thymidine into DNA. Because thymidine is an integral building block of DNA, inhibiting the action of thymidine kinase blocks DNA duplication. The more selective the antiviral agent is for viral enzymes, the less likely are host side effects.

Herpesviruses range in size from 120 to 300 nm and have DNA genomes and outer lipid membranes (envelopes). As enveloped viruses, herpesviruses are sensitive to drying and adverse conditions. Herpesviruses are spread by inoculation of susceptible mucous membranes or direct cell-to-cell contact. Over 100 herpesviruses have been identified, but only 5 cause human eye infections with any frequency: herpes simplex virus-1 (HSV-1), herpes simplex virus-2 (HSV-2), varicella zoster virus (VZV), cytomegalovirus (CMV), and Epstein-Barr virus. Herpesviruses can cause blepharitis, conjunctivitis, epithelial and stromal keratitis, uveitis, retinitis, and ARN. HSV-1 is the most frequent cause of primary and recurrent eye disease. The host immune system influences the rates of reactivation. Immunocompromised patients tend to have more frequent reactivations and more severe disease manifestations. The strain of virus also affects the

disease severity, presumably because of the presence of virulence genes. In addition to neuronal or ganglionic latency, there is evidence of persistent HSV DNA in the cornea between episodes. Studies have also suggested that donor-to-host transmission of HSV-1 through corneal grafts may occur. Furthermore, genotypic analysis of HSV isolates has shown that subsequent infection by different HSV strains is possible.

Adenoviruses also have DNA as their genetic material and are smaller than herpesviruses, with diameters of 70 to 100 nm. Adenoviruses do not have lipid envelopes and can survive on inanimate objects. Adenoviral serotypes 3, 7, 8, 19, and 37 cause conjunctivitis and epidemic keratoconjunctivitis. Currently, no antivirals are approved for ocular adenoviral infections. Studies have shown that topical cidofovir may be effective in lowering the frequency of severe corneal opacities, but additional studies are needed to address corneal toxicity.

This section contains information primarily about the antiviral activity, pharmacology, and treatment of herpesvirus infections. There is limited information on the antiviral treatment of adenovirus infections. The anti-retroviral agents used to treat RNA viruses responsible for AIDS are listed and their functions reviewed. However, there is no information on clinical trials pertaining to antiretroviral agents.

## **Drugs for the Treatment of Herpes Simplex and Herpes Zoster Viral Infections**

### **Idoxuridine**

Due to corneal toxicity and the availability of more effective drugs, idoxuridine is infrequently used. Idoxuridine has poor ocular bioavailability and is not effective for deep stromal disease. Resistance to idoxuridine can develop during treatment. Idoxuridine is too toxic for systemic use.

### **Vidarabine**

Vidarabine, once marketed under the trade name Vira-A™, has been discontinued by the manufacturer and is only available through compounding pharmacies.\* Vidarabine may be effective in cases that fail to respond to idoxuridine or in rare cases of hypersensitivity to trifluridine.

---

\*Compounding pharmacies provide a valuable patient service by supplying drugs that are not commercially available or are not available in a formulation a patient can use (i.e., due to preservative allergies, etc.). Not all compounding pharmacies formulate ophthalmic medications. Pharmacies that compound products for ophthalmic use must be able to formulate sterile accurately prepared products. It is best to use a pharmacy that specializes in compounding ophthalmic drugs. Also, keep in mind that when using compounded medications, there can be no assurance of quality and safety that the FDA demands of commercial manufacturers.

### **Trifluridine**

#### *Pharmacology*

Trifluridine has a mechanism of action similar to idoxuridine and vidarabine. Trifluridine is an effective inhibitor of thymidine synthetase and inhibits DNA synthesis in both virus-infected and normal host cells.

#### *Clinical Uses*

Trifluridine is the current drug of choice in the United States for topical treatment of primary and recurrent HSV keratitis, types 1 and 2. The average healing time is 6 to 7 days. Treatment of dendritic and geographic corneal ulcers with trifluridine is generally superior to idoxuridine and vidarabine. A randomized double-blind trial demonstrated that trifluridine and topical acyclovir had similar efficacy for treating HSV keratitis in both time of healing and frequency of healing (Table 11-10). A report of four patients with Thygeson's superficial punctate keratitis suggested trifluridine may be an effective treatment.

#### *Side Effects*

Compared with idoxuridine and vidarabine, trifluridine is less toxic. Side effects include transient burning and stinging, contact dermatitis, corneal punctate keratopathy and edema, conjunctival hyperemia and chemosis, impaired stromal wound healing, keratitis sicca, punctal narrowing, and increased intraocular pressure. The toxic side effects may mimic infection and may be assumed to be a worsening of the disease. A report indicated that long-term use of trifluridine, as well as idoxuridine and vidarabine, could cause conjunctival scarring and cicatrization.

#### *Contraindications*

Trifluridine is contraindicated in patients who are allergic to or intolerant of the drug or any of its components.

### **Acyclovir**

#### *Pharmacology*

Acyclovir is a purine analogue to guanine that is specific for virus-infected cells of HSV-1, HSV-2, VZV, and some CMVs. The highly selective antiviral action of acyclovir inhibits viral DNA polymerases significantly more than host DNA polymerases, significantly reducing host toxicity, and enables oral and intravenous administration. Acyclovir causes termination of the DNA chain and leads to irreversible inactivation of viral DNA polymerase. The prevalence of resistance to acyclovir is small. A recent study showed a resistance prevalence of 0.3% in immunocompetent patients and 3.6% in immunocompromised patients. Viral strains resistant to acyclovir are frequently resistant in vitro to other viral drugs, especially ganciclovir. This pattern supports the theory that thymidine kinase mutations are most often responsible for acyclovir resistance. Because absorption from the gastrointestinal tract is variable and incomplete, oral bioavailability is poor, with 10% to 30% absorbed. Acyclovir has a relatively short half-life in plasma.

**Table 11-10**  
Antiviral Drug Evidence-Based Guidelines

Study Conclusion(s)	Study Findings
<b>Trifluridine: Viroptic (1% ophthalmic solution)</b>	
See topical acyclovir studies detailed below	
<b>Acyclovir:</b> Topical available outside of the United States. <b>Zovirax:</b> Tablets, oral—400 mg, 800 mg; capsule, oral—200 mg; suspension, oral—200 mg/5 ml; injectable—50 mg/ml; generic also available	
Topical acyclovir is similar in efficacy to idoxuridine, vidarabine, and trifluridine but less toxic to the eye.	A small, multicenter, double-blind, randomized trial comparing the efficacy of 0.5% idoxuridine ointment and 3% acyclovir ointment showed no significant difference in overall healing patterns, duration of symptoms, or frequency of development of deeper involvement (McCulley et al.).
When treating HSV epithelial keratitis, there is no benefit achieved by adding oral acyclovir to treatment with trifluridine to prevent the development of herpes stromal keratitis or iritis.	A small, randomized, double-blind trial showed similar efficacy of topical acyclovir and trifluridine in the treatment of epithelial dendritic keratitis in both mean duration of treatment to healing and frequency of healing (Hovding).
When treating HSV stromal keratitis, there is no clinical benefit to adding oral acyclovir to concomitant treatment with topical steroids and trifluridine.	Topical acyclovir and vidarabine showed equivalent efficacy in frequency and mean duration of treatment to healing (Jackson et al.).
Prophylactic oral acyclovir reduces the recurrence rate of HSV eye disease.	Acyclovir is less toxic to the ocular surface than idoxuridine, vidarabine, and trifluridine (Tabery, Grant). A large, randomized, controlled study showed that adding oral acyclovir to trifluridine treatment was not effective in preventing stromal keratitis or iritis in patients with HSV keratitis (HEDS).
Adding oral acyclovir to HSV iridocyclitis treatment with topical corticosteroids and trifluridine may be beneficial.	A placebo-controlled study of patients with stromal keratitis receiving topical prednisolone and trifluridine showed no benefit to adding oral acyclovir in terms of time to healing or treatment failure, likelihood of resolution, or 6-month best corrected acuity (HEDS).
Long-term oral acyclovir treatment remains effective in decreasing the number of HSV recurrences beyond 12 months.	A large, randomized, controlled study showed oral acyclovir prophylaxis effective in reducing the recurrence rate of ocular HSV disease and orofacial HSV disease in immunocompetent participants (HEDS).
Prophylactic oral acyclovir reduces the likelihood of HSV recurrence after penetrating keratoplasty for herpetic eye disease.	A small, randomized, controlled study showed a possible benefit to adding oral acyclovir to the treatment of HSV iridocyclitis in patients receiving topical corticosteroids and trifluridine, but the patient numbers were too small to be statistically significant (HEDS).
Oral acyclovir 800 mg, five times daily, is the most effective dose for treating HZO. Treatment is most effective when started within 72 hours of rash onset.	A small retrospective study showed that long-term oral acyclovir appeared effective in reducing the recurrence rate of ocular HSV recurrences when used longer than 12 months (Uchoa et al.).
Oral acyclovir may be as effective as topical acyclovir in the treatment of HSV epithelial keratitis.	A randomized, double-blind, placebo-controlled, multicenter trial showed a significant reduction in HSV recurrences in participants status post PK for herpetic eye disease who were treated with oral acyclovir (van Rooij et al.).
Oral acyclovir 800 mg, five times daily, is the most effective dose for treating HZO. Treatment is most effective when started within 72 hours of rash onset.	A small retrospective study showed a significantly lower HSV keratitis recurrence rate in patients undergoing PK for HSV keratitis who received oral acyclovir for at least 1 year (Tambasco et al.).
Oral acyclovir 800 mg, five times daily, is the most effective dose for treating HZO. Treatment is most effective when started within 72 hours of rash onset.	A small, randomly assigned, double-blind, placebo-controlled study of patients with dendritic HSV keratitis treated with oral acyclovir or topical acyclovir ointment showed no significant difference between treatment groups in the number of patients healed or the median healing time (Collum et al.).
Oral acyclovir 800 mg, five times daily, is the most effective dose for treating HZO. Treatment is most effective when started within 72 hours of rash onset.	A double-blind placebo-controlled trial showed 800 mg more effective than 400 mg of oral acyclovir for significantly accelerated time to 50% scabbing, accelerated time to 50% healing, less frequent formation of new lesions, and reduced duration and severity of pain. All participants had localized zoster rashes present for 72 hours or less (Huff et al.).

Seven days of oral acyclovir may be adequate for treating HZO.	<p>A large study showed oral acyclovir treatment to be most effective when 800 mg, five times daily, for at least 7 days is started within 72 hours of the onset of skin lesions (Borrat et al.).</p> <p>A randomized double-blind study of immunocompetent patients with acute HZO showed no significant difference between 7 or 14 days of oral acyclovir treatment in regard to subjective symptoms, skin lesions, and ocular complications (Hoang-Xuan et al.).</p>
There is contradictory evidence regarding the role of oral acyclovir in lessening postherpetic neuralgia associated with HZO.	<p>A large, double-blind, controlled trial showed no long-term benefit from a longer 21-day course of oral acyclovir treatment or the use of prednisolone in reducing the frequency of postherpetic neuralgia (Wood et al.).</p> <p>A randomized, double-blind, placebo-controlled study of immunocompetent participants showed no treatment effect from oral acyclovir 600 mg, five times daily, for 10 days on the incidence, severity, or duration of postherpetic neuralgia (Cobo et al.).</p> <p>A small, randomized, double-blind, placebo-controlled study showed that oral acyclovir significantly reduced pain from postherpetic neuralgia between 2 and 6 months (Harding and Porter). The previously mentioned study by Hoang-Xuan et al. indicated that only 13% of the participants experienced postherpetic neuralgia (see above).</p>
Topical acyclovir alone is not effective in treating herpes zoster ocular inflammation.	<p>A small, multicenter, open-label, randomized study showed that patients with early HZO who received topical acyclovir ointment had a higher rate of significant ocular complications after one month than patients receiving oral acyclovir (Neoh et al.).</p> <p>A small, controlled, double-blind trial showed topical acyclovir is insufficient for severe ocular inflammation. Topical steroids alone were effective but needed prolonged treatment times. Combined topical acyclovir and steroids were better than steroids alone and resulted in fewer rebound inflammations (Marsh and Cooper).</p>
<b>Valacyclovir:</b> Valtrex: Tablet, oral—1,000 mg, 500 mg Oral valacyclovir appears effective in treating HSV keratitis.	<p>A small randomized clinical trial demonstrated significantly faster healing of HSV keratitis with oral valacyclovir than topical acyclovir ointment (Sozen, Avunduk, Akyo).</p>
Valacyclovir is similar to oral acyclovir in efficacy and safety for treating genital HSV infections. No large trials have evaluated treatment for HSV keratitis.	<p>A multicenter, randomized, double-blind clinical trial showed no significant difference in duration of viral shedding, duration of pain, or time to loss of all symptoms in immunocompetent adults with an initial episode of genital HSV treated with oral valacyclovir or oral acyclovir (Valaciclovir International Study Group).</p> <p>A large, multicenter, double-blind, randomized, placebo-controlled, parallel-design study showed oral valacyclovir and oral acyclovir equally effective in the self-initiated treatment of recurrent genital herpes infection (Valaciclovir International Study Group).</p>
Valacyclovir is safe and effective in suppressing recurrent genital HSV infection in HIV-infected patients.	<p>A multicenter, randomized, placebo-controlled study showed oral valacyclovir (500 mg, twice daily) effective for the suppression of recurrent genital HSV infections in HIV-infected participants (DeJesus et al.).</p>
Oral acyclovir and oral valacyclovir are similar in efficacy and safety for the treatment of HZO. Oral valacyclovir may be more effective in reducing pain from postherpetic neuralgia.	<p>A multicenter, randomized, double-masked study of immunocompetent patients with HZO showed that oral valacyclovir and oral acyclovir were equally effective in preventing the ocular complications of HZO (Colin et al.).</p> <p>A large, randomized, double-blind, multicenter trial compared the safety and efficacy of oral valacyclovir and oral acyclovir for treating herpes zoster in immunocompetent adults and concluded that treatment with valacyclovir was convenient, equivalent in safety to acyclovir, accelerated the resolution of zoster-associated pain and postherpetic neuralgia, and reduced the number of patients with pain lasting <math>\geq 6</math> months (Beutner et al.).</p>

*Continued*



**Table 11-10**  
Antiviral Drug Evidence-Based Guidelines—cont'd

Study Conclusion(s)	Study Findings
<p><b>Famciclovir:</b> Famvir: Tablet, oral—125 mg, 250 mg, 500 mg</p> <p>Oral famciclovir is an effective and well-tolerated treatment for suppressing recurrent genital HSV infection. No studies have been done for HSV ocular infections.</p>	<p>Two randomized, double-blind, placebo-controlled studies determined oral famciclovir safe and effective in reducing the recurrence rate of HSV in patients with a history of recurrent genital HSV infection (Tyring et al.).</p> <p>A multicenter, randomized, double-blind, double-placebo, parallel-design study of immunocompetent patients with recurrent HSV genital infections showed no significant difference between oral famciclovir and oral acyclovir in time to complete healing, resolution of symptoms, or frequency, type, and severity of adverse events (Chosidow et al.).</p>
<p>Oral famciclovir is similar to oral acyclovir in oral efficacy, safety, and side effects in the treatment of HZO.</p>	<p>A large, international, multicenter, randomized, double-blind study compared the efficacy and safety of famciclovir and oral acyclovir in adult immunocompetent participants with HZO and found no significant difference in ocular complications or vision loss (Tyring et al.).</p>
<p>Oral famciclovir and oral valacyclovir are comparable in efficacy and safety for treating herpes zoster in immunocompetent patients and treating zoster-associated pain.</p> <p>There is evidence that famciclovir therapy may decrease the duration of postherpetic neuralgia.</p>	<p>A large, multicenter, randomized, double-blind, placebo controlled study compared the efficacy and safety of oral valacyclovir and oral famciclovir for treating acute HZ in immunocompetent outpatients, aged 50 years and older, and found no significant difference between the treatment groups in resolution of zoster-associated pain or safety profile (Tyring et al.).</p>
<p>There is evidence that famciclovir therapy may decrease the duration of postherpetic neuralgia.</p>	<p>A large, multicenter, randomized, double-blind, placebo-controlled study evaluated the treatment effect of famciclovir on herpes zoster and post-herpetic neuralgia in immunocompetent participants and found faster resolution of post-herpetic neuralgia, faster lesion healing, and a safety profile similar to the placebo group (Tyring et al.).</p>
<p>Oral famciclovir appears comparable with oral acyclovir in efficacy and safety profile for treating HZO in immunocompromised patients.</p>	<p>A multicenter, randomized, double-blind, controlled study evaluated the efficacy and safety of famciclovir and oral acyclovir in immunocompromised patients with HZO and found no significant difference in the number of patients reporting new lesions while on therapy, in time to complete healing, or time to resolution of acute phase pain (Tyring et al.).</p>

### *Clinical Uses*

**Topical for HSV.** Acyclovir is available in Europe and Canada as a 3% ophthalmic ointment but is not commercially manufactured as a topical formulation in the United States. The most common side effects of acyclovir 3% ointment are punctate superficial keratitis, occurring in about 10% of patients, and burning or stinging on application (4%) (Table 11-11; see also Table 11-10).

**Oral for HSV.** The use of oral acyclovir has been extensively studied in several National Eye Institute multicenter randomized trials called the Herpetic Eye Disease Study (see Table 11-10). Prolonged oral antiviral prophylaxis is most important in patients with a history of HSV stromal disease to lessen the likelihood of recurrent episodes and progressive corneal opacification. Recurrent HSV keratitis has been reported after penetrating keratoplasty, laser in situ keratomileusis, photorefractive keratectomy, and YAG laser peripheral iridotomy. Clinical researchers suggested that prophylactic oral antiviral therapy should be considered after refractive surgery, after YAG peripheral iridotomy, and after penetrating keratoplasty in high-risk patients.

The treatment of HSV epithelial keratitis with oral acyclovir has not been studied by the Herpetic Eye Disease Study, but there is some evidence to suggest that oral acyclovir may be as effective as topical acyclovir. The clinical management of HSV in immunocompromised patients differs from that of immunocompetent patients because the immunocompromised experience more frequent and more severe infections.

**Oral for Herpes Zoster Ophthalmicus (HZO).** The MIC for VZV is higher than that of HSV types 1 and 2. Because higher plasma concentrations are needed to be effective against zoster, higher dosages of acyclovir are needed to effectively treat active zoster infections. Therapy for ocular zoster is similar to therapy for zoster elsewhere in the body.

Several randomized double-blind trials provided evidence that oral acyclovir 800 mg, five times daily, is the most effective dosage for treating HZO. Studies also stressed the importance of initiating treatment within the first 72 hours to prevent severe complications of HZO (i.e., keratitis, uveitis, secondary glaucoma, scleritis, optic neuritis, and acute retinal necrosis [ARN]). When there is ophthalmic involvement, it is recommended to treat even if the rash has been present for more than 72 hours. In addition, there is evidence that 7 days of treatment may be adequate. Studies have been shown that oral acyclovir may lessen the incidence and duration of postherpetic neuralgia associated with HZO, as shown in Table 11-10.

Herpes zoster is a common opportunistic infection in people with depressed immune systems. For example, zoster affects 8% to 11% of people with HIV. A retrospective cohort study of 239 HIV patients suggested that zoster infection rates have not changed in the current highly active antiretroviral therapy (HAART) era. A number

of complications can develop in the immunocompromised patient, such as persistent skin lesions, disseminated VZV, encephalitis, and ARN. ARN, which may also occur in healthy adults, is most often caused by VZV but can be caused by HSV (see Chapter 32 for the treatment of ARN). Two studies suggest that acyclovir ointment does not have a role in the treatment of herpes zoster ocular inflammation. Refer to Table 11-11 for dosage information and to Table 11-10 for study conclusions and details. Zostavax, a recently approved live attenuated vaccine, has been reported to significantly reduce the morbidity, incidence of postherpetic neuralgia, and incidence of herpes zoster in adults over 60 years of age.

### *Side Effects*

Oral acyclovir is a remarkably safe drug. Common side effects include nausea, vomiting, diarrhea, and abdominal pains. Additional side effects include skin rash, photosensitivity, headaches, dizziness, hallucinations, lethargy, confusion, seizures, and coma. Side effects are most frequent in patients with renal impairment. Rarer complications include anemia, leukopenia, thrombocytopenia, increases in blood urea and creatinine, acute renal failure, reversible increases in bilirubin and liver enzymes, hepatitis, and jaundice. Cautious dosing and monitoring are recommended in elderly and immunocompromised patients and in patients with renal or liver disease.

### *Contraindications*

Acyclovir is contraindicated in patients with a history of hypersensitivity or intolerance to acyclovir, valacyclovir, or any component of the formulation.

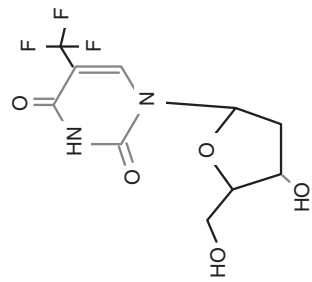
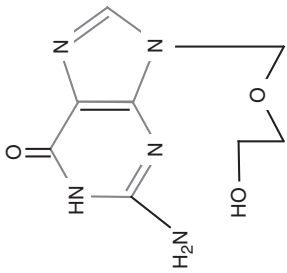
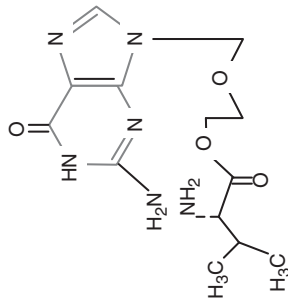
### *Valacyclovir Pharmacology*

Valacyclovir, a prodrug of acyclovir, is available only in oral formulation. Valacyclovir is hydrolyzed by esterases in the gastrointestinal tract and liver, converting more than 95% to acyclovir, to provide significantly greater bioavailability than oral acyclovir.

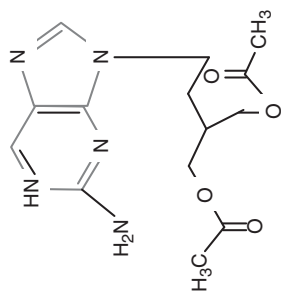
### *Clinical Uses*

Oral valacyclovir may be an effective treatment for HSV keratitis, as shown in a small randomized trial. No large clinical trials have been done to date to study the efficacy and safety of valacyclovir in HSV keratitis. Two large prospective clinical trials of immunocompetent participants provided evidence that valacyclovir is similar to acyclovir in efficacy and safety for the treatment of genital HSV infections. There is also evidence that valacyclovir is safe and effective in suppressing recurrent genital HSV infection in HIV-infected patients. Multicenter trials evaluating oral acyclovir and oral valacyclovir for the treatment of HZO found both treatments to be similar in efficacy and safety. Valacyclovir may be effective in resolving or lessening postherpetic neuralgia and has a convenient dosing schedule.

**Table 11-11**  
Most Commonly Used Herpes Simplex and Zoster Antiviral Drugs<sup>a</sup>

Drug	Structure	Clinical Indications	Dosage	Comments
Trifluridine		HSV epithelial keratitis	Nine times daily for 10-14 days Consider decreasing to 5 times daily after 7 days if ulcer is healed or almost healed	Good topical penetration 2+ corneal toxicity Use for >21 continuous days increases potential for ocular toxicity Pregnancy category C; lactation safety unknown
Acyclovir Topical Systemic		HSV epithelial keratitis HZO Recurrent HSV keratitis, prophylaxis <sup>b</sup> HSV epithelial keratitis <sup>b</sup>	Five times daily for 10-14 days Consider decreasing to 3 times daily after 7 days if ulcer is healed or almost healed 800 mg five times daily for 7-10 days 400 mg two times daily for 12-18 months 400 mg five times daily for 7-10 days	1+ corneal toxicity Good topical penetration Not commercially available in the United States <sup>b</sup>  Doses given are for immunocompetent adult patients Reduce dose if impaired renal function Use caution with impaired liver function Pregnancy category B; lactation safe
Valacyclovir		HZO Recurrent HSV keratitis, prophylaxis <sup>b</sup> HSV epithelial keratitis <sup>b</sup>	1,000 mg three times daily for 7 days 500 mg twice daily for 12-18 months 1,000 mg twice daily for 7-10 days	Bioavailability over 3 times greater than acyclovir Doses given are for immunocompetent adult patients Reduce dose if impaired renal function Use caution with impaired liver function Pregnancy category B; lactation safe

Famciclovir



HZO  
 Recurrent HSV keratitis,  
 prophylaxis<sup>b</sup>  
 HSV epithelial keratitis<sup>b</sup>

500 mg three times daily for  
 7 days  
 250 mg twice daily for  
 12–18 months  
 500 mg twice daily for  
 7–10 days

Doses given are for immunocompetent adult  
 patients  
 Reduce dose if impaired renal function  
 Use caution with impaired liver function  
 Pregnancy category B; lactation safety unknown

<sup>a</sup>Adult doses.<sup>b</sup>Not FDA approved for this specific purpose.

### *Side Effects*

The side effects of valacyclovir are similar to acyclovir. Cautious dosing and monitoring are recommended in elderly and immunocompromised patients and in patients with renal or liver disease.

### *Contraindications*

Valacyclovir is contraindicated in patients with a history of hypersensitivity or intolerance to acyclovir, valacyclovir, or any component of the formulation.

### **Famciclovir**

#### *Pharmacology*

Famciclovir, an oral prodrug of penciclovir, is well absorbed orally and is rapidly converted to active penciclovir with a bioavailability of 65% to 77%. Penciclovir is active against HSV-1, HSV-2, and VZV with potency and spectrum of activity similar to acyclovir, in that penciclovir selectively affects viral DNA synthesis and inhibits replication. The plasma half-life of the active drug, penciclovir phosphate, is very long, which permits infrequent dosing.

#### *Clinical Uses*

No randomized controlled trials have evaluated the efficacy of famciclovir for the treatment of recurrent HSV keratitis. Randomized controlled trials have studied the efficacy and safety of famciclovir in the suppression of recurrent genital HSV infection, indicating that famciclovir is an effective and well-tolerated treatment for the suppression of genital HSV infection.

There is evidence that famciclovir is similar to acyclovir in efficacy, safety, and side effects for the treatment of HZO. In addition, famciclovir and valacyclovir are comparable in efficacy and safety when treating herpes zoster in immunocompetent patients. A large prospective study provided evidence that famciclovir therapy significantly decreases (twofold) the duration of postherpetic neuralgia when compared with a placebo. When famciclovir was compared with acyclovir in treating immunocompromised patients, the treatments showed a similar efficacy and safety profile.

#### *Side Effects*

The most common side effects are headache, nausea, and gastrointestinal disturbances. A small number of patients experienced fatigue, pruritus, paresthesia, migraine, and dysmenorrhea.

#### *Contraindications*

Famciclovir is contraindicated in patients with known hypersensitivity to the product, or its components, or penciclovir cream (Denavir®).

#### **Topical Ganciclovir**

Topical ganciclovir has also been shown to be active against HSV keratitis. Ganciclovir gel is commercially available outside of the United States as a 0.15% ophthalmic gel. Two small trials indicated that topical ganciclovir and

topical acyclovir are similar in efficacy and safety. Ganciclovir gel was reported to be more comfortable than the acyclovir ointment, with less stinging, burning, and blurred vision. Similar findings were reported by a multicenter randomized trial comparing 0.15% ganciclovir gel and 3% acyclovir ointment.

### **Drugs for the Treatment of CMV Infections**

CMV retinitis is the most common opportunistic eye infection in patients with AIDS and immunocompromised transplant patients. Antiviral medications used in the treatment of CMV are generally administered in two stages: induction therapy, to achieve disease regression, followed by maintenance therapy. The incidence of CMV retinitis has decreased significantly with the advent of HAART for AIDS, and antiviral therapy for CMV may often be discontinued in patients who respond favorably to HAART and achieve an elevation in CD4 cell levels above 100/ $\mu$ l. Refer to Chapter 32 for the drug treatment of ocular CMV infections.

### **Drugs for the Treatment of AIDS**

HIV is an RNA retrovirus that infects CD4 lymphocytes, macrophages, and dendritic cells. Untreated HIV infection causes the progressive loss of CD4 T cells, the immune system white blood cells that protect against infection and malignancy. AIDS is diagnosed based on a low CD4 count, a high viral load, and the increased susceptibility to various infections or malignancies.

Currently, four categories of antiretroviral drugs are used in HIV therapy: nucleoside reverse transcriptase inhibitors, non-nucleoside reverse transcriptase inhibitors, protease inhibitors, and fusion inhibitors. HAART is a treatment strategy combining several antiretroviral drugs (two or more nucleoside reverse transcriptase inhibitors with either a protease inhibitor or non-nucleoside reverse transcriptase inhibitor) to more effectively suppress HIV replication. HAART lowers the likelihood of viral resistance developing, which is an increasingly common problem. In patients who respond to HAART achieving immune recovery status, CD4 counts may increase up to normal levels and viral loads may fall below detectable levels (below 200,000 Eq/ml). Over 85% of patients treated with HAART achieve CD4 counts equal to 350 cells/mcl, which will likely protect them against developing opportunistic infections. HAART has significantly decreased the incidence of opportunistic eye diseases, such as CMV retinitis, HZO, ARN, and toxoplasmosis retinochoroiditis, infections which are most likely to occur with CD4 counts less than 50 cells/mcl.

The current limiting factors for long-term success of HAART are adverse effects and patient compliance, suggesting that improving the safety profile may be an effective strategy to improve outcome. These medications have potential serious side effects such as

hepatomegaly, hepatotoxicity, nephrotoxicity, renal failure, lactic acidosis, pancreatitis, and more. The most frequent side effects for these drugs include nausea, vomiting, diarrhea, rash, anorexia, fever, arthralgias, myalgias, abdominal pains, headache, peripheral neuropathy, and elevated liver enzymes. Table 11-12 lists the current antiretroviral drugs, modes of action, dosing, and non-antiretroviral drug interactions.

## ANTIFUNGAL DRUGS

There are more than 70,000 species in the diverse group of fungal organisms, but only two basic types of fungi, yeasts and molds. Yeasts are single cells, usually round or oval in shape, with diameters varying from 3 to 15  $\mu\text{m}$ . Yeasts usually reproduce by budding. Molds have branching cylindrical tubules called hyphae, varying in diameter from 2 to 10  $\mu\text{m}$ . The hyphae may be divided into compartments by cross-walls, called septae. Molds grow by branching and apical extension. The growth of hyphae produces a multicellular filamentous mass on culture media called a mycelium. Dimorphic fungi exist in two distinct morphologic forms: a yeast phase in host tissues and a mycelial phase on culture media. It is sometimes possible to identify a specific fungus in tissue sections or in smears based on characteristic structural features.

Fungi are more complex than bacteria and viruses and are classified as eukaryotic cells, with an internal membrane system dividing the cell into different regions, membrane-enclosed organelles, and DNA contained in a membrane bound nucleus. In addition, fungi have a rigid cell wall containing polysaccharides and chitin that determines the organism's shape. The complexity of fungal organisms, and a closer similarity to mammalian cells than to bacteria or viruses, makes it more challenging to develop antimicrobials with selective toxicity.

As with bacteria, fungal virulence factors can be divided into two main categories: virulence factors that facilitate infection and virulence factors that affect the host. Virulence factors that promote adherence to host cells and facilitate fungal invasion include capsule production to inhibit phagocytosis and cytokines to depress the host immune system. Multiple virulence factors target the host, such as cell wall polysaccharides that activate the complement cascade and provoke an inflammatory reaction or the secretion of cytokines and mycotoxins that directly damage host tissues.

Surprisingly, only a small number of fungi cause eye infections. The most common ocular fungal pathogens are the yeast *Candida* and the molds *Aspergillus*, *Fusarium*, and *Curvularia*. Fungi can infect virtually every eye structure, including the cornea, conjunctiva, lens, ciliary body, vitreous, and the entire uveal tract. Predisposing factors include contact lenses, topical steroids, trauma, and a compromised immune system. There is an increasing number of fungal infections and an

increasing diversity of infecting fungal species in immunosuppressed and immunocompromised patients. Fungal infections may be localized or disseminated, and the eye can become infected by direct inoculation or endogenous spread.

Clinical treatment should not be started without laboratory evidence of a fungal infection, because prolonged toxic therapy is often required. As with bacterial infections, patient history and clinical appearance are not diagnostic. Laboratory identification of fungi includes microscopic examination of smears or scrapings and cultures. Fungi can be identified using Gram, Giemsa, Gomori's methenamine silver, periodic acid-Schiff, and calcofluor stains (in order of increasing sensitivity). More advanced testing is now available, including DNA sequencing for yeast and molds and polymerase chain reaction to identify molds, such as *Aspergillus*. Recently, the National Committee for Clinical Laboratory Standards began adapting, standardizing, and validating susceptibility testing for antifungal agents against yeasts and molds. This testing is similar to antibacterial susceptibility testing, and fungi are classified as susceptible, susceptible dose dependent, intermediate, or resistant to specific antifungals. Therefore reliable MICs are now available for some fungi and antifungal drugs. However, MICs can vary depending on the testing methods used. Clinical trials are now needed to better demonstrate the relationship between in vitro susceptibility data and the clinical response to topical antifungal medications. Case reports documented positive clinical responses despite resistance in vitro, illustrating the difficulty in choosing antifungal agents based on susceptibility results.

Antifungal treatment options usually have one or more limitations, such as significant side effects, a narrow antifungal spectrum of activity, poor tissue penetration, or fungal resistance. During the past few years, the echinocandin antifungals became available (anidulafungin, micafungin, and caspofungin). There are now four main classes of antifungals: polyenes, pyrimidines, azoles, and echinocandins. The antifungals listed for each group are only those mentioned in the chapter and are not all-inclusive.

### General Pharmacology of Antifungal Drugs

- Polyenes** (amphotericin B and lipid formulations of amphotericin B, natamycin): Polyenes work by binding to ergosterol present in the cell membranes of sensitive fungi to increase permeability. Polyenes bind human cell membranes to a lesser extent. Polyenes are concentration dependent in action, tending to be fungistatic at low concentration and fungicidal at higher concentration. Resistance is relatively rare.
- Pyrimidines**, or antimetabolites (Flucytosine): Pyrimidines block thymidine synthesis in susceptible fungi, impairing DNA synthesis. Pyrimidines are fungistatic, and resistance can develop during treatment.

**Table 11-12**  
Antiretrovirals for HIV

Generic Name	Trade Name	Formulations	Interactions With Drugs Prescribed for Ocular Conditions <sup>a</sup>
<i>Nucleoside reverse transcriptase inhibitors:</i> NRTIs are substrates for reverse transcriptase, which converts viral RNA into proviral DNA for incorporation into the host cell DNA. NRSIs are phosphorylated by host cell enzymes to resemble normal nucleotides. When reverse transcriptase uses NRTI triphosphate instead of a nucleoside to form proviral DNA, the necessary chemical bonds cannot form and the DNA chain formed is left incomplete.			
Abacavir (ABC)	Ziagen	300 mg tablet; 20 mg/ml solution	
ABC + 3TC	Epzicom	300 mg and 600 mg tablets	
ABC + AZT + 3TC	Trizivir	150 mg and 300 mg tablets	Trimethoprim/sulfamethoxazole, trimethoprim, ganciclovir, fluconazole
AZT + 3TC	Combivir	150 mg and 300 mg tablets	Trimethoprim/sulfamethoxazole, trimethoprim, ganciclovir, fluconazole
Darunavir (TMC114)	Prezista	300 mg tablet	Dexamethasone, erythromycins, voriconazole, itraconazole, ketoconazole, aspirin, fluconazole, NSAIDs, diclofenac topical
Didanosine (ddI)	Videx, Videx-EC	Videx: 100 mg; 150 mg; 200 mg; 25 mg; 50 mg tablets, chewable; solution: oral: 10 mg/ml Videx EC: 125 mg; 200 mg; 250 mg; 400 mg capsules	Cefpodoxime, cefuroxime, ketoconazole, itraconazole, tetracyclines, oral quinolones, ganciclovir Adverse reaction: optic neuritis
Emtricitabine (FTC)	Emtriva	200 mg capsule; 10 mg/ml solution	
Lamivudine (3TC)	Epivir	150 mg and 300 mg tablets; 10 mg/ml solution	Trimethoprim/sulfamethoxazole, posaconazole
Stavudine (d4T)	Zerit Zerit XR	Zerit: 15 mg, 20 mg, 30 mg, 40 mg capsules; 1 mg/ml solution Solution Zerit XR: 100 mg; 37.5 mg; 50 mg; 75 mg capsules, extended release	
Tenofovir (TDF)	Viread	300 mg tablet	IV aminoglycosides, acyclovir, famciclovir, ganciclovir, valacyclovir, cidofovir
TDF + FTC	Truvada	200 mg and 300 mg tablet	IV aminoglycosides, acyclovir, famciclovir, ganciclovir, valacyclovir, amphotericins, vancomycin
Zalcitabine (ddC)	Hivid	0.375 mg and 0.75 mg tablets	
Zidovudine (AZT)	Retrovir	100 mg capsule, 300 mg tablets; 10 mg/ml injectable; 50 mg/5 ml syrup	Trimethoprim/sulfamethoxazole, trimethoprim, cidofovir
Nonnucleoside reverse transcriptase inhibitors: NNRTIs are a distinct class of synthetic compounds that interfere with reverse transcriptase activity by binding next to the enzyme's active site, altering the configuration. NNRTIs are not phosphorylated and are only active against HIV-1, not HIV-2.			
Delavirdine (DLV)	Rescriptor	100 mg and 200 mg tablets	Dexamethasone, erythromycins, ketoconazole, voriconazole, H <sub>2</sub> blockers
Efavirenz (EFV)	Sustiva	50 mg, 100 mg, and 200 mg capsules; 600 mg tablets	Caspofungin, itraconazole, ketoconazole, posaconazole
Nevirapine (NVP)	Viramune	200 mg tablet; 50 mg/5 ml suspension	Systemic corticosteroids, caspofungin, itraconazole, voriconazole, ketoconazole, fluconazole, erythromycins
Protease inhibitors: HIV protease is essential for virus infectivity because protease is needed for viral replication. Protease inhibitors bind reversibly to the active site of HIV protease preventing protease from cleaving the viral precursor polypeptide and blocking viral maturation. Immature viral particles are noninfectious.			
Amprenavir (APV)	Agenerase	50 mg capsule; 15 mg/ml solutions	Itraconazole, fluconazole, ketoconazole, voriconazole, erythromycins

Atazanavir (ATV)	Reyataz	100 mg, 150 mg, and 200 mg capsules	Erythromycins, H <sub>2</sub> blockers, itraconazole, ketoconazole, voriconazole, fluconazole, aminoglycosides, erythromycins
Fosamprenavir (FPV)	Lexiva	700 mg tablet	
Indinavir (IDV)	Crixivan	100 mg, 200 mg, 333 mg, and 400 mg capsules	Erythromycins, itraconazole, ketoconazole, fluconazole, tetracycline, dexamethasone
Lopinavir/ritonavir (LPV/r)	Kaletra	33.3 mg and 133.3 mg capsules; 20 mg/ml and 80 mg/ml solutions	Acetaminophen/propoxyphene or tramadol, codeines, aspirin/caffeine/propoxyphene, erythromycins, itraconazole, ketoconazole, fluconazole, voriconazole
Nelfinavir (NFV)	Viracept	250 mg and 625 mg tablets; 50 mg/scoopful suspension	Itraconazole, ketoconazole, fluconazole, voriconazole, erythromycins
Ritonavir (RTV)	Norvir	100 mg capsule; 100 mg/ml solution	Acetaminophen/propoxyphene or tramadol, codeines, aspirin/caffeine/propoxyphene, erythromycins, itraconazole, ketoconazole, fluconazole, tetracycline
Saquinavir (SQV)	Invirase Fortovase	Invirase: 200 mg capsule, 500 mg tablet Fortovase: 200 mg capsule	Itraconazole, ketoconazole, fluconazole, voriconazole, erythromycins,
Tipranavir (TPV)	Aptivus	250 mg capsule	All azole antifungals, tetracycline, aspirin, erythromycins
Fusion Inhibitors: Novel drugs from a new class with different resistance features than the other three classes. Fusion inhibitors bind to a region of the HIV-1 virus that inhibits fusion of the virus with CD4 cells. This inhibition reduces viral replication slowing progression from HIV infection to AIDS.			
Enfuvirtide (T-20)	Fuzeon	Glass vial containing 108 mg, for delivery of approximately 90 mg/ml when reconstituted with 1.1 ml of sterile water for injection	No significant interactions known

<sup>a</sup>May not be all inclusive.



3. **Azoles** (voriconazole, posaconazole, ketoconazole, itraconazole, fluconazole, miconazole): At concentrations obtainable with oral use, the azoles impair the biosynthesis of ergosterol in the fungal cell membrane, increasing membrane permeability and inhibiting fungal growth. Azole antifungals are not selective and can also inhibit many mammalian cytochrome P450-dependent enzymes. Therefore, *drug interactions can occur between azole antifungals and medications metabolized through the P450 pathway*. Azoles are fungistatic, and resistance has been increasing among immunocompromised patients.

4. **Echinocandins** (caspofungin, micafungin, anidulafungin): Echinocandins target the fungal cell wall by inhibiting glucan synthesis, thus depleting glucan polymers in the fungal cell wall and causing an abnormally weak cell wall. Echinocandins are selective in action, because there is no counterpart to a cell wall in the mammalian cell. Oral bioavailability is poor for these new fungicidal drugs.

Few randomized controlled studies have been performed for antifungal drugs because of the difficulty in recruiting a sufficient number of cases within a given time frame. Evidence-based information is scant, as many of the reports have been in the form of single case reports, studies of small numbers of patients, or retrospective reviews of patient records (Table 11-13).

## Polyene Antifungal Drugs

### Amphotericin B

#### Pharmacology

Amphotericin B is produced by a strain of bacteria, *Streptomyces nodosus*. Please refer to the general pharmacology section for antifungal drugs.

#### Clinical Uses

Amphotericin B, a broad-spectrum antifungal, has been used as a topical formulation (ointment and solution) to treat fungal keratitis and as an injectable to treat intraocular infections. In a recent case report intrastromal injections were combined with intravitreal amphotericin B in one patient to successfully treat recurrent *Candida* keratitis and endophthalmitis. Topical amphotericin B is not commercially available but can be obtained through a compounding pharmacy. It is the first line of treatment for *Candida* infections in many countries. Amphotericin B is not effective in oral formulation due to poor bioavailability. Three lipid formulations are now commercially available (Table 11-14), providing the advantage of the same in vitro spectrum of activity with less nephrotoxicity and better therapeutic indices than amphotericin B deoxycholate. Until recently, amphotericin B was the treatment of choice for invasive fungal infections of the orbit and endophthalmitis due to dimorphic fungi. Evidence has been based primarily on single case reports

because there have been no randomized controlled trials to evaluate the efficacy and safety of intravenous amphotericin B by itself (Table 11-15; see also Table 11-14).

#### Side Effects

Adverse reactions, particularly renal toxicity, are limiting factors in achieving an effective dose with conventional amphotericin B (see Table 11-14).

#### Contraindications

Amphotericin B is contraindicated if there is a known sensitivity to any formulation component.

### Natamycin (Pimaricin)

#### Pharmacology

Please refer to the general pharmacology section for antifungal drugs.

#### Clinical Uses

It is currently the only U.S. Food and Drug Administration- (FDA) approved topical ophthalmic for fungal infections. Natamycin is the broad spectrum well-tolerated drug of choice for filamentous fungi. Natamycin is generally effective against *Fusarium*, *Aspergillus*, *Curvularia*, and *Acremonium*, but the response is variable for some fungi.

#### Side Effects

Please refer to Table 11-14.

#### Contraindications

Natamycin is contraindicated in individuals with a history of hypersensitivity to any of its components.

## Pyrimidine Antifungal Drugs

### Flucytosine

Flucytosine, a fungistatic antifungal, is rarely used because resistance is a major problem among many types of fungi. Monotherapy is not effective, and flucytosine must be used in combination with another antifungal. Flucytosine shows selective activity against yeast fungi and only moderate activity against *Aspergillus*. It has been used successfully in oral combination with amphotericin B. Flucytosine is generally well tolerated systemically, but bone marrow and liver toxicity can occur with plasma levels above 100 mcg/ml. Dosing must be adjusted in patients with liver toxicity. It is not available as a commercially prepared topical. Topical penetration of a 1% solution is generally good. It has been used in combination with miconazole and natamycin.

## Azole Antifungal Drugs

### Ketoconazole

Ketoconazole was the first successful, oral, broad-spectrum azole antifungal. Ketoconazole is in the imidazole

**Table 11-13**  
Antifungal Drug Evidence-Based Guidelines

Study Conclusion(s)	Study Findings
<b>Polyene antifungals</b>	<b>Amphotericin B:</b> Abelcet (ABLC) [injectable: 5 mg/ml, lipid complex], Ambisome (L-AMB) [injectable: 50 mg/vial, liposomal], Amphocin (injectable: 50 mg/vial, nonlipid), Amphotec (ABCD) [injectable: 50 mg/vial, 100 mg/vial, colloidal dispersion], Fungizone [injectable: 50 mg/vial, nonlipid], generic also available.
Intracameral injection of amphotericin B may have a role in management of severe fungal keratitis not responding to topical treatment.	Three of 4 patients who failed to respond to initial treatment with 5% topical natamycin, followed by 2% topical the ketoconazole and systemic ketoconazole underwent repeated amphotericin B intracameral injections and had complete resolution of the ulcer (Kuriakose et al.).
Topical amphotericin B appears to be very effective against <i>Candida</i> keratitis.	Three patients with culture proven <i>Aspergillus flavus</i> corneal ulcers and hypopyon who did not respond to 5% topical natamycin, 0.15% amphotericin B solution, or oral itraconazole, received intracameral amphotericin B injections and had complete resolution of the ulcer and hypopyon (Kaushik et al.).
Ocular penetration of IV amphotericin B is inflammation dependent and the liposomal formulation (L-AMB). May reach the highest aqueous and vitreous concentrations.	A rabbit model for <i>Candida albicans</i> compared the efficacy of topical amphotericin B with four other antifungal agents. Amphotericin B and 5% natamycin were the most effective, 1% miconazole and 1% flucytosine were effective but inferior to the polyenes, and 1% ketoconazole was not effective (O'Day et al.).
Lipid-complex formulations of amphotericin B are as efficacious and of lower risk for renal toxicity than conventional amphotericin B.	Goldblum et al. studied the ocular penetration of IV amphotericin B and its lipid formulations in a rabbit model and determined L-AMB achieved at least eightfold higher amphotericin B concentrations in the aqueous of inflamed eyes when compared with ABLC or amphotericin B. The Collaborative Exchange of Antifungal Research (CLEAR) retrospectively reviewed the efficacy and renal safety in patients with <i>Candida</i> infections treated with lipid-complex amphotericin B (ABLC) and showed comparable response rates compared with conventional amphotericin B and evidence that ABLC may be used safely to treat patients at increased risk for renal impairment (Alexander and Wingard).
<b>Natamycin (pimaricin):</b> Natacyn-5% ophthalmic suspension 5% natamycin is the treatment of choice for treating filamentous fungal keratitis. Natamycin is more effective than itraconazole for treating <i>Fusarium</i> keratitis but is not effective in treating deep stromal infections.	A prospective nonrandomized study compared the efficacy of 1% itraconazole drops with 5% natamycin for monotherapy of fungal keratitis. In patients with <i>Fusarium</i> keratitis, 79% responded favorably to natamycin compared with 44% to itraconazole ( $p < .02$ ). Both treatments were well tolerated with no obvious adverse effects reported (Kalavathy et al.).
<b>Azole antifungals</b>	<b>Itraconazole:</b> Sporanox capsule, oral: 100 mg; solution, oral: 10 mg/ml; injectable: 10 mg/ml (generic also available)
Topical itraconazole appears effective in treating superficial, less severe fungal ulcers. Itraconazole may be less effective than natamycin for treating <i>Fusarium</i> keratitis.	A small, randomized prospective study compared the efficacy of topical 1% and systemic itraconazole in the treatment of superficial fungal corneal ulcers (44 culture proven). 42 of 54 participants (77.78%) responded; 29.63% in the 1% topical itraconazole group, and 48.15% in the combined treatment group. Of the 12 eyes not responding well, 4 had <i>Fusarium</i> infections (Agarwal et al.).
Fluconazole: Difucan Suspension, oral: 200 mg/5 ml, 50 mg/5 ml; tablet, oral: 100 mg; 150 mg; 200 mg; 50 mg	

*Continued*

**Table 11-13**  
Antifungal Drug Evidence-Based Guidelines—cont'd

Study Conclusion(s)	Study Findings
Topical fluconazole has good corneal penetration, achieving therapeutic aqueous levels after single dose and loading dose administrations for most strains of <i>Candida</i> .	Aqueous levels of fluconazole measured in patients prior to cataract surgery demonstrated fluconazole concentrations higher than the MICs of <i>Candida albicans</i> and <i>C. parapsilosis</i> after a single dose and levels higher than the MICs of <i>C. albicans</i> , <i>C. parapsilosis</i> , and <i>C. tropicalis</i> after loading doses (Abbasoglu et al.).
There is conflicting evidence regarding the efficacy of topical 0.2% fluconazole for treating filamentous fungal keratitis.	A rabbit model study suggested that topical 0.2% fluconazole has pharmacokinetic properties, low toxicity, and selective MICs that merit further studies as an ophthalmic agent (Yee et al.). A retrospective chart review of patients treated with topical 0.2% fluconazole for filamentous fungal keratitis showed 16 of 23 patients had resolution of the keratitis. Less severe cases responded better and adding oral ketoconazole to topical treatment did not improve the treatment outcome (Sonego-Krone et al.).
Topical fluconazole may be safe and effective in managing <i>Candida</i> keratitis with abscess formation.	A study was discontinued because an interim analysis of data revealed 4 patients with filamentary keratitis treated with 0.2% topical fluconazole (and concurrent oral fluconazole) had failed to respond to treatment (Rao et al.).
Topical fluconazole may be safe and effective in managing <i>Candida</i> keratitis with abscess formation.	A small prospective clinical study of 6 patients with laboratory diagnosed <i>Candida</i> infections reported that all 6 patients responded to topical fluconazole therapy, with no local or systemic side effects, in an average of 22.6 days (Panda et al.).
Subconjunctival fluconazole may be effective for the treatment of severe fungal keratitis.	A small prospective study reported that 13 of 14 patients with severe fungal keratitis ( <i>Aspergillus</i> , <i>Fusarium</i> , and <i>Candida</i> ) had resolution with subconjunctival fluconazole after failing to respond to topical and systemic fluconazole and itraconazole therapy. No local or systemic toxic side effects were reported (Yilmaz and Maden).
<b>Voriconazole:</b> Vfend tablets, oral: 50 mg and 200 mg; injection: 200 mg/vial	
Oral voriconazole appears to reach therapeutic aqueous and vitreous levels in the noninflamed human eye.	A prospective nonrandomized study that evaluated aqueous and vitreous voriconazole concentrations after oral administration in 14 patients scheduled for elective pars plana vitrectomy showed therapeutic MIC <sub>90</sub> concentrations in the vitreous and aqueous against a wide range of organisms, including <i>Aspergillus</i> and <i>Candida</i> (Hariprasad et al.).
Voriconazole has demonstrated high susceptibilities for <i>Aspergillus</i> , <i>Candida</i> , and <i>Fusarium</i> .	A retrospective record review of fungal isolates associated with fungal keratitis and endophthalmitis evaluated the MICs of common fungal pathogens against amphotericin B, fluconazole, ketoconazole, flucytosine, itraconazole, and voriconazole. Voriconazole showed the highest susceptibilities for <i>Aspergillus</i> , <i>Candida</i> , and <i>Fusarium</i> (Marangon et al.).
<b>Echinocandin antifungals</b>	
<b>Caspofungin:</b> Cancidas injection: 50 mg/vial, 70 mg/vial	
Oral, IV and intravitreal voriconazole, and voriconazole in combination with caspofungin, may be efficacious in treating both endogenous and exogenous endophthalmitis.	Case report of 2 patients with exogenous <i>Fusarium</i> and <i>Aspergillus</i> endophthalmitis successfully treated using voriconazole, and voriconazole and caspofungin in combination (Durand et al.).
<b>Micafungin:</b> Mycamine injectable: 50 mg; IV infusion: 50 mg/vial	A retrospective review of 5 patients with <i>Candida</i> endophthalmitis showed that 4 of 5 patients had resolution with IV and oral voriconazole.
Topical micafungin shows potential as a treatment for fungal keratitis.	A case report of 3 patients originally treated with topical corticosteroids, who did not respond to initial treatment with topical azoles and polyenes, reported resolution of <i>Candida</i> ulcers with topical 0.1% micafungin (Matsumoto et al.).

**Table 11-14**  
Antifungal Drugs: Clinical Application, Side Effects, and Comments

Drug	Clinical Regimens <sup>a</sup>	Side Effects, Contraindications, and Comments
Natamycin	Topical: Commercially available 5% suspension One drop 6–8 times per day	Well tolerated, less irritating than amphotericin B Not effective for deep stromal infection
Amphotericin B	Topical: 0.15–0.3% solution 1 drop q1h Intracamerai use: 5–10 mcg/0.1 ml Intravitreal use: 5–10 mcg/0.1 ml Intravenous: 0.3–1 mg/kg qd	Pregnancy category C; lactation safety unknown Not commercially available as a topical formulation Good corneal penetration with topical use Corneal toxicity increases with topical concentrations over 0.15% Marked tissue necrosis at injection site <i>Oral use not effective: poor ocular bioavailability</i> Side effects include nephrotoxicity, agranulocytosis, liver dysfunction, thrombocytopenia, leukopenia, electrolyte imbalance, anemia, headache, nausea, vomiting, malaise, weight loss, phlebitis, fever, chills; lipid formulations associated with less nephrotoxicity; antagonism with miconazole Pregnancy category B; lactation safety unknown
Ketoconazole	Topical: 1–5% suspension, depending on vehicle Oral: 200–400 mg PO qd	Topical formulation not commercially available, must compound Fungistatic activity, therapy response generally slow; inappropriate for severe or progressive fungal disease Side effects include adrenal insufficiency, hepatotoxicity, anaphylaxis, leukopenia, thrombocytopenia, hepatic failure, nausea, dizziness, diarrhea, headache, lethargy, somnolence, gynecomastia, <i>papilledema</i> Many drug interactions exist including CYP3A4 substrates Pregnancy category C; lactation safety unknown
Miconazole	Topical: 1% ophthalmic suspension 1 drop q1h Subconjunctival: 10 mg/0.5 ml	Topical side effects of burning, itching, tearing Not commercially available; both topical and subconjunctival formulations must be compounded; IV brand discontinued in United States Good ocular penetration with topical and subconjunctival use Toxic conjunctival necrosis may occur with subconjunctival use Pregnancy category C; lactation safety unknown
Itraconazole	Topical: 1% suspension 1 drop q1h Oral: 200 mg PO qd–bid	Topical not effective for severe infections; penetrates cornea poorly; not commercially available; must be compounded Penetrates all eye tissues poorly with oral administration Side effects include hepatotoxicity, gastrointestinal problems, hypokalemia, elevated liver enzymes, rash, vasculitis, headache, fever, HTN, hypertriglyceridemia Many drug interactions exist including CYP3A4 substrates Coadministration of itraconazole is contraindicated with multiple antiretrovirals (refer to Table 11-12)
Fluconazole	Topical: 2 mg/ml solution 1 drop q2h Oral: 100–400 mg PO qd–bid (adjust dose for renal impairment)	Pregnancy category C; lactation safety unknown Very good bioavailability, low toxicity Topical not commercially available; must be compounded

*Continued*

**Table 11-14**  
Antifungal Drugs: Clinical Application, Side Effects, and Comments—cont'd

Drug	Clinical Regimens <sup>a</sup>	Side Effects, Contraindications, and Comments
Voriconazole	Oral: 200 mg bid IV: 4 mg/kg q12h; may use 6 mg/kg q12 loading dose	One of the best tolerated drugs. Side effects include gastrointestinal problems, hepatotoxicity (rare), allergic rash, Stevens-Johnson syndrome, thrombocytopenia, angioedema, agranulocytosis, headache, elevated liver enzymes Increases concentrations of cyclosporine, warfarin, sulfonyleureas, phenytoin, metformin (risk of hypoglycemia), and others Many drug interactions exist including CYP3A4 substrates. Coadministration of terfenadine, and cisapride with multiple antiretrovirals (refer to Table 11-2) Pregnancy category C; lactation probably safe Excellent bioavailability Can increase concentrations of digoxin, warfarin, cyclosporine, and others Side effects include <i>visual disturbances (blurred vision, photophobia, altered visual perception)</i> , hepatitis, renal failure, liver failure, Stevens-Johnson syndrome, angioedema, blood dyscrasias, fever, chills, headache, gastrointestinal symptoms, liver function test elevations Many drugs interactions exist including CYP3A4 substrates Coadministration of voriconazole with sirolimus, rifampin, rifabutin, ergot alkaloids, carbamazepine, and long-acting barbiturates is contraindicated Coadministration of voriconazole is contraindicated with multiple antiretrovirals (refer to Table 11-12)
Caspofungin	IV 50 mg q24h; loading dose 70 mg × 1 on day 1	Pregnancy category D; lactation safety unknown Scant ocular treatment information Side effects include pulmonary edema, blood dyscrasias, hypercalcemia, hepatotoxicity (rare), gastrointestinal symptoms, headache, fever, chills, anemia, eosinophilia, hypokalemia, liver function test elevations, infusion site reactions. Drug interaction with cyclosporine and additional voriconazole. Pregnancy category C; lactation safety unknown. Coadministration of caspofungin is contraindicated with multiple antiretrovirals (refer to Table 11-3) Topical not commercially available Report of 3 cases of yeast keratitis treated successfully with topical micafungin Side effects include anaphylaxis, thrombophlebitis, hepatic failure, renal failure, hemolytic anemia, phlebitis, injection site reaction, headache, leukopenia, nausea, hyperbilirubinemia, hypokalemia, vasodilation, liver function test elevations, pruritus, facial swelling. Concurrent use with nifedipine and sirolimus may increase the levels of these drugs. Pregnancy category C; lactation safety unknown
Micafungin	Topical: 0.1% solution 1 drop q1 h while awake; reduce to 5 times a day after epithelialization IV: 50–150 mg qd	

<sup>a</sup>Varies with site of infection, severity of infection, and fungal organism; adult doses.

**Table 11-15**  
Clinical and In Vitro Spectra of Activity for Antifungal Drugs<sup>a</sup>

	<i>Candida</i> sp.	<i>Aspergillus</i> sp.	<i>Fusarium</i> sp.	<i>Scedosporium</i> sp.	<i>Curvularia</i> sp.
Amphotericin B <sup>1</sup>	+,+ <sup>2</sup>	± <sup>2</sup>	- <sup>2</sup>	-	+ <sup>2,3</sup>
Natamycin	±	±	+ <sup>4,5</sup>	±	+,+ <sup>5</sup>
Flucytosine <sup>6</sup>	+	Resistant in vitro	-	Resistant in vitro	Resistant in vitro
	(use with amphotericin B)				
Miconazole	Insufficient data	Insufficient data	-	±	+ <sup>3</sup>
Ketoconazole	+ <sup>7</sup>	± <sup>8</sup>	± <sup>8</sup>	-	+ <sup>8</sup>
Itraconazole	+ <sup>3,7</sup>	+	±	- <sup>3</sup>	+ <sup>8</sup>
Fluconazole	+,+ <sup>8</sup>	- <sup>3</sup>	- <sup>3</sup>	± <sup>3</sup>	Resistant in vitro
Voriconazole	+	Susceptible in vitro	Susceptible in vitro	+	Susceptible in vitro
Caspofungin	Strong response in rabbit model	Susceptible in vitro	Resistant in vitro	Susceptible in vitro	Susceptible in vitro
Micafungin	+ <sup>3</sup>	Susceptible in vitro	Resistant in vitro	Insufficient data	Insufficient data

+, + strong response; + good response; ± variable response; - poor response.

<sup>a</sup>Usual clinical response, based on small numbers of published cases. Interpret with caution because there are exceptions. Clinical responses do not always agree with in vitro sensitivity results.

<sup>1</sup>Includes lipid formulations.

<sup>2</sup>Topical use.

<sup>3</sup>Limited data.

<sup>4</sup>Use in combination with oral ketoconazole, for deep lesions.

<sup>5</sup>Preferred therapy.

<sup>6</sup>Combination therapy indicated. Resistance develops with monotherapy.

<sup>7</sup>In combination with topical amphotericin B.

<sup>8</sup>Topical and/or oral administration.

subgroup of azole antifungals that were developed to provide an effective group of drugs with lower toxicity issues than amphotericin B. Ketoconazole, fungistatic in activity, has been largely replaced by itraconazole and other triazoles that have good broad-spectrum activity for many ocular fungi and less liver toxicity. Ketoconazole has very good activity against *Candida albicans* but spotty species dependent *Aspergillus* coverage. The response to therapy is generally slow, making this drug inappropriate for severe or progressing fungal disease. It has been used as a topical suspension in concentrations from 1% to 5% depending on the formulation. However, it is not commercially available.

### Miconazole

Miconazole comes in topical (1% ophthalmic suspension), subconjunctival depot (10 mg/0.5 ml), and oral (200–400 mg/day) formulations but is not commercially available now in any of these formulations. Miconazole is relatively broad spectrum and active against most yeast but has variable coverage of *Aspergillus* and *Fusarium*. Miconazole is generally well tolerated with topical and subconjunctival administration, but cases of corneal toxicity have been reported.

### Itraconazole

#### Pharmacology

Please refer to the general pharmacology section for antifungal drugs.

#### Clinical Uses

Itraconazole is a broad-spectrum synthetic triazole that has good oral bioavailability and is less toxic than amphotericin B and ketoconazole. The solution has better bioavailability than the capsule and provides higher plasma concentration levels. Compared with fluconazole and ketoconazole, itraconazole penetrates all ocular tissues poorly when orally administered. Itraconazole can be used as a 1% ophthalmic suspension but is not very effective in treating severe fungal keratitis.

#### Side Effects

Itraconazole is generally well tolerated with oral administration with gastrointestinal symptoms as the most common reaction.

#### Contraindications

Itraconazole is contraindicated in patients who have shown hypersensitivity to the drug or its components.

There is no information regarding cross-hypersensitivity between itraconazole and other azole antifungal agents. Caution should be used in prescribing itraconazole to patients with hypersensitivity to other azoles. Refer to Table 11-14 for drug interactions.

### Fluconazole

#### *Pharmacology*

Please refer to the general pharmacology section for antifungal drugs.

#### *Clinical Uses*

Fluconazole has been used topically and in subconjunctival injection. Fluconazole, fungistatic in action, is mainly effective against yeast, including *Candida* and *Cryptococcus*, but has no clinically significant activity against molds, such as *Aspergillus*. Resistance has been developing, especially in immunocompromised patients. Fluconazole has a bioavailability of about 90% with oral or intravenous administration and appears to penetrate well into the ocular fluids. Fluconazole has a relatively long half-life of approximately 30 hours. Fluconazole lacks the broad-spectrum coverage necessary to be effective against many of the most commonly encountered fungal organisms that cause endophthalmitis.

#### *Side Effects*

Fluconazole is one of the best tolerated antifungal drugs, with the most common complaint being gastrointestinal. Hepatotoxicity occurs only in a small number of patients.

#### *Contraindications*

Fluconazole is contraindicated in patients who have shown hypersensitivity to fluconazole or to any of its components. There is no information regarding cross-hypersensitivity between fluconazole and other azole antifungal agents. Caution should be used in prescribing fluconazole to patients with *hypersensitivity* to other azoles. Refer to Table 11-14 for drug interactions.

### Voriconazole

#### *Pharmacology*

Voriconazole exhibits dose-dependent pharmacokinetics. Voriconazole has 96% oral bioavailability and reaches peak plasma concentrations in 2 to 3 hours after oral administration. Please refer to the general pharmacology section for antifungal drugs.

#### *Clinical Uses*

Voriconazole is the first of the second-generation broad-spectrum triazoles approved by the FDA and the first antifungal agent since amphotericin B to be approved for first-line treatment of invasive aspergillosis. Voriconazole has now replaced amphotericin B as the treatment of choice for systemic *Aspergillus* infections. Voriconazole also has activity against *Fusarium*. It is a derivative of

fluconazole that shows activity to some fungi resistant to fluconazole.

#### *Side Effects*

Voriconazole is well tolerated after oral or intravenous administration.

#### *Contraindications*

Voriconazole is contraindicated in patients with known hypersensitivity to voriconazole or its components. There is no information regarding cross-sensitivity between voriconazole and other azole antifungal agents. Caution should be used when prescribing voriconazole to patients with hypersensitivity to other azoles. Refer to Table 11-14 for drug interactions.

## Echinocandin Antifungal Drugs

### Caspofungin

#### *Pharmacology*

Caspofungin has linear pharmacokinetics and a half-life of 9 to 11 hours, permitting once a day usage. Please refer to the general pharmacology section for antifungal drugs.

#### *Clinical Uses*

Caspofungin, the first FDA-approved echinocandin antifungal, is fungicidal in activity. Caspofungin has activity against a wide range of fungi, including all *Candida* species. Caspofungin shows activity against some azole-resistant organisms. An investigation showed that caspofungin and amphotericin B were synergistic or synergistic to additive for a least half of the *Aspergillus* and *Fusarium* isolates evaluated in vitro. Topical formulations are not available.

#### *Side Effects*

Very few drug interactions occur with the echinocandins, compared with the azoles. This is because echinocandins are not acted on by the major liver enzymes.

#### *Contraindications*

Caspofungin is contraindicated in patients with hypersensitivity to any component of this product.

### Micafungin

#### *Pharmacology*

Please refer to the general pharmacology section for antifungal drugs.

#### *Clinical Uses*

Micafungin has activity against *Candida*, including azole-resistant *C. albicans*. It has some activity against molds such as *Aspergillus* but no activity against *Fusarium*.

#### *Side Effects*

Refer to Table 11-14 for side effects.

### Contraindications

Micafungin is contraindicated in patients with hypersensitivity to any *component* of this product.

### Anidulafungin

Anidulafungin is available as an intravenous infusion. It is fungicidal and effective against azole- and amphotericin B-resistant strains of *Candida*. Anidulafungin has a half-life of 24 hours and is the least protein bound of the echinocandins, at 84%. Anidulafungin does not need to be dose adjusted for hepatic or renal insufficiency and appears to not have any significant drug interactions.

## ANTIPROTOZOAL DRUGS

### Drugs Used to Treat *Acanthamoeba* Keratitis

*Acanthamoeba* keratitis is known to be difficult to diagnosis and to treat. Most patients are initially treated for viral, fungal, or bacterial keratitis before the diagnosis of *Acanthamoeba*. Most *Acanthamoeba* infections are associated with contact lens wear (85% to 92%), but a smaller number are secondary to trauma. The incidence of *Acanthamoeba* keratitis may be greater than 1 per 30,000 contact lens wearers per year as indicated by cohort studies and questionnaires. The frequency of *Acanthamoeba* keratitis in contact lens wearer may be 1 per 10,000/year or higher.

*Acanthamoeba* are amoeba that can exist in two forms, as trophozoites or as cysts. *Acanthamoeba* are found in fresh water and soil, and the cystic form can be airborne. Not all strains of *Acanthamoeba* are pathogenic. Fifty percent of the apparently healthy adults tested had *Acanthamoeba* cultured from their nasal passages. Both trophozoites and cysts can adhere to the surface of unworn soft contact lenses. A break in the corneal epithelium can then allow an organism present on a contact lens to invade the eye tissues.

A retrospective review indicated that an early diagnosis (less than 18 days) results in a better final visual acuity and lessens the likelihood of needing penetrating keratoplasty. In the early stages of an infection, the trophozoite form predominates and is confined to the epithelium. As the infection progresses, the organism enters the stroma and encysts. The cystic form protects the organism from adverse conditions and is more resistant to treatment. Thus treatment failures are more frequent in advanced infections because the organism is deeper in the cornea and encysted. A biocidal agent must destroy both the trophozoite and cystic stages to be clinically effective. Although most agents are effective against trophozoites, not all agents are consistently effective against cysts.

A clinical suspicion of an *Acanthamoeba* infection is the critical first therapeutic step. *Acanthamoeba* can be diagnosed by eye smears, culture, tissue biopsy, polymerase chain reaction, and confocal microscopy.

Unfortunately, no reliable readily available methods test the sensitivity of *Acanthamoeba* organisms to various antimicrobials. A significant study determined a poor correlation between the clinical outcomes of individual cases and the in vitro sensitivity results. This study concluded that there was no value in a technique that gives only minimum cidal values for 90% of the organisms, when it is essential to achieve a 100% pharmaceutical kill for successful treatment. There is also no method for definitively testing whether the organism has been eradicated from the cornea, except for stopping treatment and waiting for a recurrence.

There are no drugs specifically approved by the FDA to treat *Acanthamoeba*, necessitating the compounding of all medications. Antimicrobial agents are generally used in combination to increase the likelihood of a successful response. Treatment is often prolonged as the mean time to healing is about 100 days. A small number of patients develop *Acanthamoeba* sclerokeratitis. It is not known whether this severe scleral inflammation is infective or immune mediated.

Randomized controlled studies have not been performed for *Acanthamoeba* treatments because of the difficulty in recruiting a sufficient number of cases within a given time frame. Evidence-based information is scant, because many of the reports have been in the form of single case reports, studies of small numbers of patients, or retrospective reviews of patient records.

Two classes of antimicrobial agents are currently used to treat most *Acanthamoeba* infections, biguanides and diamidines. The biguanides include polyhexamethylene biguanide (PHMB) and chlorhexidine (bis-biguanide), and the diamidines include propamidine (Brolene), hexamidine (Desomedine), and pentamidine. Published reports of the amoebicidal activities of the different agents vary, which may be due to different degrees of pathogenicity and virulence among different *Acanthamoeba* species or strains.

PHMB<sup>†</sup> is generally the preferred agent, either in combination or as a monotherapy. Chlorhexidine has also been used as a monotherapy, but it does not appear to be as effective as when used in combination. Propamidine is used in combination with a biguanide, PHMB, or chlorhexidine, because biguanides have the lowest minimum cysticidal concentrations in vitro and are generally more effective against *Acanthamoeba* cysts. PHMB is also used in combination with hexamidine, because some clinicians believe hexamidine is more efficacious and less toxic than propamidine. The use of neomycin should be avoided because cysts are almost always resistant (Table 11-16).

The greatest frequency of ocular toxicity has been reported with propamidine. Superficial punctate

<sup>†</sup>PHMB has been used as a disinfectant in swimming pools and contact lens solutions.



**Table 11-16**  
Agents used to treat *Acanthamoeba*

Agent(s)	Study Conclusions
PHMB	Five of 6 patients who failed to respond to other antiameobic agents had complete resolution with 0.02% PHMB. Only PHMB was cysticidal at low concentrations (Larkin et al.).
PHMB, chlorhexidine	Chlorhexidine showed greater anti-acanthamoeba activity with a mean minimum cysticidal concentration (MCC) <sup>a</sup> of 32.81 ug/ml compared with 55.26 µg/ml for PHMB (Narasimhan et al.). Both agents are generally time-dependent in action. Trophozoites were killed more rapidly than cysts and both agents had similar levels of activity (Tirado-Angel et al.). Chlorhexidine was more effective than PHMB in eradicating both trophozoites and cysts (Borazjani et al., Wysesbeck et al.). Seal et al. demonstrated a lower MCC for chlorhexidine than PHMB. PHMB and chlorhexidine cause structural and membrane damage to trophozoites and cysts, and both agents appear to target the <i>Acanthamoeba</i> plasma membrane (Khunkitti et al.).
PHMB, chlorhexidine, neomycin, propamidine	PHMB and chlorhexidine were found to be the most successful cysticidal agents. Neomycin was reported to be ineffective against <i>Acanthamoeba</i> cysts in vivo. The cysticidal effectiveness of propamidine was more variable than its trophozoite amoebicidal activity (Elder et al.).
PHMB, propamidine, chlorhexidine	PHMB and propamidine were found to be the most active agents against corneal <i>Acanthamoeba</i> isolates with MIC values < 10 mcg/mL. Chlorhexidine had intermediate activity (Lim et al.). Chlorhexidine as a monotherapy does not appear to be as effective as when used in combination with propamidine or PHMB (Kosirukvongs et al.).
Hexamidine, propamidine	Hexamidine demonstrated greater amoebicidal activity than propamidine. Perrine et al. recommended replacing propamidine with hexamidine in <i>Acanthamoeba</i> treatment. Twelve patients were successfully treated with the combination of topical chlorhexidine and propamidine (Seal et al.).
Chlorhexidine, propamidine	Kitagawa and Oikawa successfully treated two patients with 0.02% chlorhexidine, natamycin, and debridement. No toxic effects were reported.
Chlorhexidine, natamycin	Ishibashi et al. reported successful treatment of 3 <i>Acanthamoeba</i> keratitis patients with oral itraconazole, topical miconazole, and topical miconazole debridement.

<sup>a</sup>MCC is the lowest concentration of a test solution that results in no cyst formation or growth of *Acanthamoeba* trophozoites after 7 days of incubation.

keratopathy is common. Propamidine keratopathy was reported in two patients who presented with corneal microcysts in a pattern that followed the lacrimal lake contour.

Rarely, non-*Acanthamoeba* amebic keratitis may present. There is limited clinical evidence that nonacanthamoeba infections may respond to *Acanthamoeba* treatment. Two cases were reported of presumed non-*Acanthamoeba* keratitis in contact lens wearers in which the clinical presentation resembled *Acanthamoeba* keratitis. Nonacanthamoeba cysts (*Vahlkampfia jugosa* and *Naegleria*) were cultured from the contact lenses. One patient responded to treatment with PHMB 0.2% and propamidine 0.1% and the other patient was lost to follow-up.

### Drugs Used to Treat Ocular Toxoplasmosis

Toxoplasmosis is a recurrent, potentially blinding, disease caused by the obligate intracellular parasite *Toxoplasma gondii*. Toxoplasmosis affects millions of people worldwide. Cats are the definitive host for the parasite but not the primary source of human infection. Environmental contamination of the soil, water, fruits and vegetables, and infection in other animals cause most human infections. Human infection may be either congenital or acquired, and acquired disease appears to be the most prevalent.

Once ingested, *Toxoplasma* invades the retina where it transforms into the cyst form. Primary and recurrent toxoplasmic retinitis is believed to occur when cysts rupture, releasing trophozoites that multiply in surrounding cells to cause retinal and choroidal inflammation. Ocular toxoplasmosis is self-limiting and usually resolves in 6 to 8 weeks without treatment. However, vision may be threatened if the macula or optic nerve is involved. Antimicrobial drugs are thought to limit proliferation of trophozoites during the active phase, thereby limiting the inflammatory response and resultant retinal damage. None of the currently available drugs destroys cysts in the eye tissues, so recurrent disease is not prevented. Please refer to Chapter 31 for the treatment of toxoplasmosis.

### SELECTED BIBLIOGRAPHY

Abbasoglu OE, Hosal BM, Sener B, et al. Penetration of topical fluconazole in human aqueous humor. *Exp Eye Res* 2001;72:147-151.

Agarwal PK, Roy P, Das A, et al. Efficacy of topical and systemic itraconazole as a broad-spectrum antifungal agent in mycotic corneal ulcer. A preliminary study. *Indian J Ophthalmol* 2001; 49(3):173-176.

Al-Nammari S, Robertson B, Ferguson C. Towards evidence based emergency medicine: best BETs from the Manchester Royal Infirmary. Should a child with preseptal periorbital cellulitis be treated with intravenous or oral antibiotics? *Emerg Med J* 2007;24:128-129.

Alexander BD, Wingard JR. Study of renal safety in amphotericin B lip complex-treated patients. *Clin Infect Dis* 2005;40(suppl 6): S414-S421.

American Academy of Ophthalmology. Preferred practice pattern. Bacterial keratitis. Retrieved 2006 from <http://www.AAO.org>

Arikan S, Loranzo-Chin M, Paetznick V, et al. In vitro synergy of caspofungin and amphotericin B against *Aspergillus* and *Fusarium* spp. *Antimicrob Agents Chemother* 2002;46(1): 245-247.

Barron BA, Gee I, Hanuck WW, et al. Herpetic eye disease study. A controlled trial of oral acyclovir for herpes simplex stromal keratitis. *Ophthalmology* 1994;101:1871-1882.

Beutner KR, Friedman DJ, Forszpaniak C, et al. Valaciclovir compared with acyclovir for improved therapy for herpes zoster in immunocompetent adults. *Antimicrob Agents Chemother* 1995;39(7):1546-1553.

Borazjani RN, May LL, Noble JA, et al. Flow cytometry for determination of the efficacy of contact lens disinfecting solutions against *Acanthamoeba* spp. *Appl Environ Microbiol* 2000; 66(3):1057-1061.

Borderie VM, Meritet J, Chaumeil C, et al. Culture-proven herpetic keratitis after penetrating keratoplasty in patient with no previous history of herpes disease. *Cornea* 2004; 23(2):118-124.

Borruat FX, Buechi ER, Piguet B, et al. Prevention of ocular complications of herpes zoster ophthalmicus by adequate treatment with acyclovir. *Klin Monatsbl Augenheilkd* 1991; 198(5):358-360.

Brandt CR. Virulence genes in herpes simplex virus type 1 corneal infection. *Curr Eye Res* 2004;29(2-3):103-117.

Breit SM, Hariprasad SM, Mieler WF, et al. Management of endogenous fungal endophthalmitis with voriconazole and caspofungin. *Am J Ophthalmol* 2005;139(1):135-140.

Buznach N, Dagan R, Greenberg D. Clinical and bacterial characteristics of acute bacterial conjunctivitis in children in the antibiotic resistance era. *Pediatr Infect Dis J* 2005;24: 823-828.

Centers for Disease Control and Prevention. Sexually transmitted diseases treatment guidelines 2002. *MMWR* 2002; 51(No. RR-6):1-80.

Chosidow O, Drouault Y, Leconte-Vavriac F, et al. Famciclovir vs. aciclovir in immunocompetent patients with recurrent genital herpes infections: a parallel-groups, randomized, double-blind clinical trial. *Br J Dermatol* 2001;144(4):818-824.

Claerhout I, Goegebuer A, Van Den Broecke, et al. Delay in diagnosis and outcome of *Acanthamoeba* keratitis. *Graef Arch Clin Exp Ophthalmol* 2004;242:648-653.

Colin J, Prisant O, Cochener B, et al. Comparison of the efficacy and safety of valaciclovir and acyclovir for the treatment of herpes zoster ophthalmicus. *Ophthalmology* 2000;107: 1507-1511.

Colin J, Hoh HB, Easty DL, et al. Ganciclovir ophthalmic gel (Virgan; 0.15%) in the treatment of herpes simplex keratitis. *Cornea* 1997;16(4):393-399.

Collum LM, McGettrick P, Akhtar J, et al. Oral acyclovir (Zovirax) in herpes simplex dendritic corneal ulceration. *Br J Ophthalmol* 1986;70(6):435-438.

Danve-Szatanek C, Avmard M, Thouvenot D, et al. Surveillance network for herpes simplex virus resistance to antiviral drugs: 3-year follow up. *J Clin Microbiol* 2004;42(1): 242-249.

- Dau HS, AzuarapBlanco A, Hossain M, et al. Non-*Acanthamoeba* amebic keratitis. *Cornea* 1998;17(6):675-677.
- Degreef H, Andrejevic L, Aoki F, et al. Famciclovir, a new oral antiherpes drug: results of the first controlled clinical study demonstrating its efficacy and safety in the treatment of uncomplicated herpes zoster in immunocompetent patients. *Int J Antimicrob Agents* 1994;p4(4):241-246.
- DeJesus E, Wald A, Warren T, et al. Valacyclovir for the suppression of recurrent genital herpes in human immunodeficiency virus-infected subjects. *J Infect Dis* 2003;188(7):1009-1016.
- Donley TG, Smith RE, Roy B. Reduced oral contraceptive effectiveness with concurrent antibiotic use: a protocol for prescribing antibiotics to women of childbearing age. *Compendium* 1990;11:392-396.
- Duggirala A, Sharma JJ, Nutheti R, et al. Activity of newer fluoroquinolones against gram-positive and gram-negative bacteria isolated from ocular infections: an in vitro comparison. *Indian J Ophthalmol* 2007;55:15-19.
- Duguid IGM, Dart JKG, Morlet N, et al. Outcome of *Acanthamoeba* keratitis treated with polyhexamethyl biguanide and propamidine. *Ophthalmology* 1997;104(10):1587-1592.
- Dupont B. Overview of the lipid formulations of amphotericin B. *J Antimicrob Chemother* 2002;49(suppl S1):31-36.
- Durand ML, Kim IK, D'Amico DJ, et al. Successful treatment of *Fusarium* endophthalmitis with voriconazole and *Aspergillus* endophthalmitis with voriconazole plus caspofungin. *Am J Ophthalmol* 2005;140(3):552-554.
- Elder MJ, Kilvington S, Dart JKG. A clinicopathologic study of in vitro sensitivity testing and *Acanthamoeba* keratitis. *Invest Ophthalmol* 1994;35(3):1059-1064.
- Fife KH, et al. Valaciclovir versus acyclovir in the treatment of first-episode genital herpes infection. Results of an international, multicenter, double-blind, randomized clinical trial. The Valaciclovir International Herpes Simplex Virus Study Group. *Sex Transm Dis* 1997;24(8):481-486.
- Frøbert E, Ooka T, Cortay JC, et al. Herpes simplex virus thymidine kinase mutations associated with resistance to acyclovir: a site-directed mutagenesis study. *Antimicrob Agent Chemother* 2005;49(3):1055-1059.
- Garcia-Valenzuela E, Song CD. Intracorneal injection of amphotericin B for recurrent fungal keratitis and endophthalmitis. *Arch Ophthalmol* 2005;123:1721-1723.
- Gaynor BD, Chidambaram JD, Cevallos V, et al. Topical ocular antibiotics induce bacterial resistance at extraocular sites. *Br J Ophthalmol* 2005;89:1097-1099.
- Gebo KA, Kalvani R, Moore RD, et al. The incidence of, risk factors for, and sequelae of herpes zoster among HIV patients in the highly active antiretroviral therapy era. *J Acquir Immune Defic Syndr* 2005;40(2):169-174.
- Givner LB. Periorbital versus orbital cellulitis. *Pediatr Infect Dis J* 2002;21:1157-1158.
- Goldblum D, Rohrer K, Frueh BE, et al. Ocular distribution of intravenously administered lipid formulation of amphotericin B in a rabbit model. *Antimicrob Chemother* 2002;46(12):3719-3723.
- Grant DM. Acyclovir (Zovirax) ophthalmic ointment: a review of clinical tolerance. *Curr Eye Res* 1987;6(1):231-235.
- Harding SP, Porter SM. Oral acyclovir in herpes zoster ophthalmicus. *Curr Eye Res* 1991;10(suppl):177-182.
- Hariprasad SM, Mieler WF, Holz ER, et al. Determination of vitreous, aqueous, and plasma concentration of orally administered voriconazole in humans. *Arch Ophthalmol* 2004;122:42-47.
- Herpetic Eye Disease Study Group 1. A controlled trial of oral acyclovir for the prevention of stromal keratitis or iritis in patients with herpes simplex virus epithelial keratitis. *Arch Ophthalmol* 1997;115:703-712.
- Herpetic Eye Disease Study Group 3. A controlled trial of oral acyclovir for iridocyclitis caused by herpes simplex virus. *Arch Ophthalmol* 1996;114(9):1065-1072.
- Herpetic Eye Disease Study. Acyclovir for the prevention of recurrent herpes simplex virus eye disease. *N Engl J Med* 1998;339:300-306.
- Hillenkamp J, Reinhard T, Ross RS, et al. The effects of cidofovir 1% with and without cyclosporine A 1% as a topical treatment of acute adenoviral keratoconjunctivitis: a controlled clinical pilot study. *Ophthalmology* 2002;109(5):845-850.
- Hoang-Xuan T, Buchi ER, Herbort CP, et al. Oral acyclovir for herpes zoster ophthalmicus. *Ophthalmology* 1992;99(7):1062-1070.
- Hoh HB, Hurley C, Claoue C, et al. Randomized trial of ganciclovir and acyclovir in the treatment of herpes simplex dendritic keratitis: a multicenter study. *Br J Ophthalmol* 1996;80(2):140-143.
- Hou Y, Chen C, Wang I, et al. Recurrent herpetic keratouveitis following YAG laser peripheral iridotomy cornea 2004; 23:641-642.
- Hovding G. A comparison between acyclovir and trifluorothymidine ophthalmic ointment in the treatment of epithelial dendritic keratitis. *Acta Ophthalmol* 1989;67(1):51-54.
- Huff JC, Bean B, Balfour HH, et al. Therapy of herpes zoster with oral acyclovir. *Am J Med* 1988;29:84-89.
- Hwang DG. Fluoroquinolone resistance in ophthalmology and the potential role for newer ophthalmic fluoroquinolones. *Surv Ophthalmol* 2004;49(suppl 2):S79-S83.
- Ishibashi Y, Matsumoto Y, Kabata T, et al. Oral itraconazole and topical miconazole with debridement for *Acanthamoeba* keratitis. *Am J Ophthalmol* 1990;109(2):121-126.
- Ito JJ, Hooshmand-Rad R. Treatment of *Candida* infections with amphotericin B lipid complex. *Clin Infect Dis* 2005; 40(suppl 6):S384-S391.
- Jackson Breslin CW, Lorenzetti DW, et al. Treatment of herpes simplex keratitis: comparison of acyclovir and vidarabine. *Can J Ophthalmol* 1984;19(3):107-111.
- Jain A, Rubin PAD. Orbital cellulitis in children. *Int Ophthalmol Clin* 2001;41:71-86.
- Johns KJ, Head WS, O'Day DM. Corneal toxicity of propamidine. *Arch Ophthalmol* 1988;106(1):68-69.
- Kalavathy CM, Parmar P, Kaliyamurthy J, et al. Comparison of topical itraconazole 1% with topical natamycin 5% for the treatment of filamentous fungal keratitis. *Cornea* 2005;24(4):449-452.
- Kana JS. Delayed trifluridine treatment of subepithelial corneal infiltrates. *Am J Ophthalmol* 1992;113(2):212-214.
- Katusic D, Petricek I, Mandic Z, et al. Azithromycin vs doxycycline in the treatment of inclusion conjunctivitis. *Am J Ophthalmol* 2003;135:447-451.
- Kaushik S, Ram J, Brar GS, et al. Intracameral amphotericin B. Initial experience in severe keratomycosis. *Cornea* 2001; 20(7):715-719.
- Khunkitti W, Hann AC, Lloyd D, et al. Biguanide-induced changes in *Acanthamoeba castellanii*: an electron microscopic study. *J Appl Microbiol* 1998;84(1):53-62.
- King BA, Geelhoed GC. Adverse skin and joint reactions associated with oral antibiotics in children: the role of cefaclor in

- serum sickness-like reactions. *J Paediatr Child Health* 2003; 39:677-681.
- Kitagawa K, Oikawa Y, Nakamura T, et al. A novel combination treatment of chlorhexidine gluconate, natamycin (primarin) and debridement for *Acanthamoeba* keratitis. *Jpn J Ophthalmol* 2003;47:616-617.
- Kosirukvongs P, Wanachiwanawin D, Visvesvara GS, et al. Treating *Acanthamoeba* keratitis with chlorhexidine. *Ophthalmology* 1999;106(4):798-802.
- Kuriakose T, Kuriakose T, Kothari M, et al. Intracameral amphotericin B injection in the management of deep keratomycosis. *Cornea* 2002;21(7):653-656.
- Larkin DE, Kilvington S, Dart JK. Treatment of *Acanthamoeba* keratitis with polyhexamethylene biguanide. *Ophthalmology* 1992;99(2):185-191.
- Lee GA, Gray TB, Dart JKG, et al. *Acanthamoeba* sclerokeratitis. Treatment with systemic immunosuppression. *Ophthalmology* 2002;109(6):1178-1182.
- Leibovitch I, Lai TF, Senarath L, et al. Infectious keratitis in South Australia: emerging resistance to cephazolin. *Eur J Ophthalmol* 2005;15:23-26.
- Leibowitz HM. Clinical evaluation of ciprofloxacin 0.3% ophthalmic solution for treatment of bacterial keratitis. *Am J Ophthalmol* 1991;112(suppl):S34-S47.
- Levy J, Lapid-Gortzak R, Klemperer I, et al. Herpes simplex virus keratitis after laser in situ keratomileusis. *J Refract Surg* 2005;21(4):400-402.
- Lim L, Coster DJ, Badenoch PR, et al. Antimicrobial susceptibility of 19 Australian corneal isolates of *Acanthamoeba*. *Clin Exp Ophthalmol* 2000;28:119-124.
- Mah FS. Fourth-generation fluoroquinolones: new topical agents in the war on ocular bacterial infections. *Curr Opin Ophthalmol* 2004;15:316-320.
- Malvy D, Treilhaud M, Boues S, et al. A retrospective, case-control study of acyclovir resistance in herpes simplex virus. *Clin Infect Dis* 2005;41(3):320-326.
- Marangon FB, Miller D, Giaconi JA, et al. In vitro investigation of voriconazole susceptibility for keratitis and fungal pathogens. *Am J Ophthalmol* 2004;137(5):820-825.
- Marsh RJ, Cooper M. Double-masked trial of topical acyclovir and steroids in the treatment of herpes zoster ocular inflammation. *Br J Ophthalmol* 1991;75(9):542-546.
- Mathers WD. *Acanthamoeba*. A difficult pathogen to evaluate and treat. *Cornea* 2004;23(4):325.
- Mathers WD, Nelson SE, Lane JL, et al. Confirmation of confocal microscopy diagnosis of *Acanthamoeba* keratitis using polymerase chain reaction analysis. *Arch Ophthalmol* 2000;118:178-183.
- Matsumoto Y, Dogru M, Goto E, et al. Successful topical application of a new antifungal agent, micafungin, in the treatment of refractory fungal corneal ulcers. *Cornea* 2005;24(6):748-753.
- McCulley JP, Binder PS, Kaufman HE, et al. A double-blind, multicenter clinical trial of acyclovir vs. idoxuridine for treatment of epithelial herpes simplex keratitis. *Ophthalmology* 1982;89(10):1195-1200.
- McCulley JP, Shine WE. Changing concepts in the diagnosis and management of blepharitis. *Cornea* 2000;19:650-658.
- Mills R. Controversies in ophthalmology. View 1: corneal scraping and combination antibiotic therapy is indicated. *Br J Ophthalmol* 2003;87:1167-1169.
- Morlet N, Daniell M. View 2: empirical fluoroquinolone therapy is sufficient initial treatment. *Br J Ophthalmol* 2003; 87:1169-1172.
- Narasimhan S, Madhavan HN, Therese KL. Development and application of an in vitro susceptibility test for *Acanthamoeba* species isolated from keratitis to polyhexamethylene biguanide and chlorhexidine. *Cornea* 2002;21(2): 203-205.
- Neoh C, Harding SP, Saunders D, et al. Comparison of topical and oral acyclovir in early herpes zoster ophthalmicus. *Eye* 1994;8(6):688-691.
- Nesburn AB, Lowe GH, Lapoff NJ, et al. Effect of topical trifluridine on Thygeson's superficial punctate keratitis. *Ophthalmology* 1984;91(10):1188-1192.
- O'Day DM, Robinson R, Head WS. Efficacy of antifungal agents in the cornea. *Invest Ophthalmol Vis Sci* 1983; 24:1098-1102.
- Panda A, Sharma N, Angra SK, et al. Topical fluconazole therapy of *Candida* keratitis. *Cornea* 1996;5(4):373-375.
- Parmar P, Salman A, Kalavathy CM, et al. Comparison of topical gatifloxacin 0.3% and ciprofloxacin 0.3% for the treatment of bacterial keratitis. *Am J Ophthalmol* 2006;141:282-286.
- Perrine D, Chenu JP, Georges P, et al. Amoebicidal efficiencies of various diamidines against two stains of *Acanthamoeba polyphaga*. *Antimicrob Agents Chemother* 1995;39(2): 339-342.
- Pharmakakis NM, Andrikopoulos GK, Papdadopoulos GE, et al. Does identification of the causal organism of corneal ulcers influence the outcome. *Eur J Ophthalmol* 2003; 13:11-17.
- Pichichero ME. A review of evidence supporting the American Academy of Pediatrics recommendation for prescribing cephalosporin antibiotics for penicillin-allergic patients. *Pediatrics* 2005;115:1048-1057.
- Polcicova K. Herpes keratitis in the absence of anterograde transport of virus for sensory ganglia to the cornea. *Proc Natl Acad Sci USA* 2005;102(32):11462-11467.
- Rao SK, Madhavan HN, Rao G, et al. Fluconazole in filamentous fungal keratitis. *Cornea* 1997;16(6):700.
- Remeijer L, Maertzdorf J, Buitenwerf J, et al. Corneal herpes simplex virus type 1 superinfection in patients with recrudescing herpetic keratitis. *Invest Ophthalmol Vis Sci* 2002; 43(2):358-363.
- Roth DB, Flynn HW. Antibiotic selection in the treatment of endophthalmitis: the significance of drug combinations and synergy. *Surv Ophthalmol* 1997;41:395-401.
- Ruter T, Cockerham KP. A single case report of successful treatment of periorbital zygomycosis (mucormycoses) with posaconazole. *Am J Ophthalmol* 2006;142(D):187-188.
- Seal D, Hay J, Kirkness C, et al. Successful medical therapy of *Acanthamoeba* keratitis with topical chlorhexidine and propanamide. *Eye* 1996;10(4):413-421.
- Seal DV. *Acanthamoeba* keratitis update—incidence, molecular epidemiology and new drugs for treatment. *Eye* 2003; 17:893-905.
- Shama S, Garg P, Rao GN. Patient characteristic, diagnosis, and treatment of non-contact lens related *Acanthamoeba* keratitis. *Br J Ophthalmol* 2000;84:1103-1108.
- Shen M, Lin H, Lee SS, et al. Double-blind, randomized, acyclovir-controlled, parallel-group trial comparing the safety and efficacy of famciclovir and acyclovir in patients with uncomplicated herpes zoster. *J Microbiol Immunol Infect* 2004; 37:75-81.
- Shin YK, Cai G, Weinberg A, et al. Frequency of acyclovir-resistant herpes simplex virus in clinical specimens and laboratory isolates. *J Clin Microbiol* 2001;39(3):913-917.

- Solomon AW, Holland MJ, Alexander ND, et al. Mass treatment with single-dose azithromycin for trachoma. *N Engl J Med* 2004;351:1962-1971.
- Sonego-Krone S, Sanchez-DiMartino D, Ayala-Lugo R, et al. Clinical results of topical fluconazole for the treatment of filamentous fungal keratitis. *Graefes Arch Clin Exp Ophthalmol* 2005.
- Sotozono C, Inagaki K, Fujita A, et al. Methicillin-resistant *Staphylococcus aureus* and methicillin-resistant *Staphylococcus epidermidis* infections in the cornea. *Cornea* 2002; 21:S94-S101.
- Sozen E, Avunduck AM, Akyol N. Comparison of efficacy of oral valaciclovir and topical acyclovir in the treatment of herpes simplex keratitis: a randomized clinical trial. *Chemotherapy* 2006;52(1):29-31.
- Steingrimsdottir H. Bioavailability of aciclovir after oral administration of aciclovir and its prodrug valaciclovir to patient with leukopenia after chemotherapy. *Antimicrob Agents Chemother* 2000;44(1):207-209.
- Tabery HM. Healing of recurrent herpes simplex corneal epithelial lesions treated with topical acyclovir. *Acta Ophthalmol Scand* 2001;79(3):256-261.
- The Ofloxacin Study Group. Ofloxacin monotherapy for the primary treatment of microbial keratitis. A double-masked, randomized, controlled trial with conventional dual therapy. *Ophthalmology* 1997;104:1902-1909.
- Tirado-Angel J, Gabriel MM, Wilson LA, et al. Effects of polyhexamethylene biguanide and chlorhexidine on four species of *Acanthamoeba* in vitro. *Curr Eye Res* 1996;15(2):225-228.
- Tu EY, McCartney DL, Beaty RF, et al. Successful treatment of resistant ocular fusariosis with posaconazole (SCH-56592). *Am J Ophthalmol* 2007;143:222-227.
- Tyring S, Belanger R, Bezwoda W, et al. A randomized, double-blind trial of famciclovir versus acyclovir for the treatment of localized dermatomal herpes zoster in immunocompromised patients. *Cancer Invest* 2001;19(1):13-22.
- Tyring S, Engst R, Corriveau C, et al. Famciclovir for ophthalmic zoster: a randomized aciclovir controlled study. *Br J Ophthalmol* 2001;85(5):576-581.
- Tyring S, Barbarash Ra, Nahlik JE, et al. Famciclovir for the treatment of acute herpes zoster. Effects on acute disease and postherpetic neuralgia: a randomized, double-blind, placebo-controlled trial. *Ann Intern Med* 1995;123(2):89-96.
- Tyring SK, Douglas JM, Corey L, et al. A randomized, placebo-controlled comparison of oral valaciclovir and acyclovir in immunocompetent patients with recurrent genital herpes infections. The Valaciclovir International Study Group. *Arch Dermatol* 1998;134(2):185-191.
- Tyring SK, Beutner KR, Tucker BA, et al. Antiviral therapy for herpes zoster. Randomized, controlled clinical trial of valaciclovir and famciclovir therapy in immunocompetent patients 50 years and older. *Arch Fam Med* 2000;9: 863-869.
- Tyring SK, Diaz-Mitoma F, Shafran SD, et al. Oral famciclovir for the suppression of recurrent genital herpes: the combined data from two randomized controlled trials. *J Cutan Med Surg* 2003;7(6):449-454.
- Uchoa UBC, Rezende RA, Carrasco MA, et al. Long-term acyclovir use to prevent recurrent ocular herpes simplex infection. *Arch Ophthalmol* 2003;121(12):1702-1704.
- Udell IJ. Trifluridine-associated conjunctival cicatrization. *Am J Ophthalmol* 1985;99(3):363-364.
- Van Rooij J, Rijneveld WJ, Remeijer L, et al. Effect of oral acyclovir after penetrating keratoplasty for herpetic keratitis: a placebo-controlled multicenter trial. *Ophthalmology* 2003; 110(10):1916-1919.
- Velicer CM, Heckbert SR, Lampe JW, et al. Antibiotic use in relation to the risk of breast cancer. *JAMA* 2004;291(7):827-835.
- Wood MJ, Johnson RW, McKendrick MW, et al. A randomized trial of acyclovir for 7 days or 21 days with and without prednisolone for treatment of acute herpes zoster. *N Engl J Med* 1994;330(13):896-900.
- Wood MJ, Shukla S, Fiddian AP, et al. Treatment of acute herpes zoster: affect of early (<48 h) versus late (48-72 h) therapy with acyclovir and valaciclovir on prolonged pain. *J Infect Dis* 1998;178(suppl 1):S81-S84.
- Wroblewski KJ, Pasternak JE, Bower KS, et al. Infectious keratitis after photorefractive keratectomy in the United States army and navy. *Ophthalmology* 2006;113:520-525.
- Wu Z, Yiu H, Yiu S, et al. Fungal keratitis caused by *Scedosporium apiospermum*. Report of two cases and review of treatment. *Cornea* 2002;21(5):519-523.
- Wysenbeek YS, et al. The reculture technique. Individualizing the treatment of *Acanthamoeba* keratitis. *Cornea* 2000; 19(4):464-467.
- Yee RW, Cheng CJ, Meenakshi S, et al. Ocular penetration and pharmacokinetics of topical fluconazole. *Cornea* 1997; 16(1):64-71.
- Yilmaz S, Maden A. Severe fungal keratitis treated with subconjunctival fluconazole. *Am J Ophthalmol* 2005;140(3):454-458.

## *Anti-Inflammatory Drugs*

*David P. Sendrowski, Siret D. Jaanus, Leo Paul Semes, and Michael E. Stern*

Since the recognition of the anti-inflammatory activity of adrenocortical extracts in the early 1940s, hydrocortisone (cortisol), the main glucocorticoid secreted by the human adrenal cortex, and various synthetic derivatives have proven useful in ocular inflammatory and autoimmune disease states. The human glucocorticoid receptor gene is one locus on chromosome 5q31-32. There is a variation in both the structure and expression of the gene that generates diversity in glucocorticoid signaling. Although corticosteroids can bring about dramatic clinical results, chronic high-dose therapy is often accompanied by undesirable side effects. Attempts have therefore been made to develop both steroidal and nonsteroidal compounds with effective anti-inflammatory activity but reduced tendency for toxicity. In addition to corticosteroids, two other classes of pharmacologic agents, the nonsteroidal anti-inflammatory drugs (NSAIDs) and cyclosporine A medications, can modulate ocular inflammatory processes.

### **CORTICOSTEROIDS**

Since their introduction into ocular therapy, corticosteroids are still the commonly used agents for control of both posterior and severe anterior segment inflammatory disease. They can be effective in protecting the ocular structures from many of the deleterious effects accompanying the inflammatory response, particularly scarring and neovascularization. They are generally more effective in acute than in chronic inflammatory states, and degenerative diseases usually are completely refractory to steroid therapy. The anti-inflammatory effects of steroids appear to be nonspecific, occurring whether the etiology is allergic, traumatic, or infectious. In most clinical applications steroids do not act directly to correct a specific disorder but appear to modify a preexisting or ongoing response to a foreign or endogenous substance.

### **PHARMACOLOGIC PRINCIPLES**

Present evidence indicates that specific receptor proteins mediate the effects of steroids. The glucocorticoid receptor

inhibits inflammation via three distinct mechanisms. These mechanisms work through both direct and indirect genomic and nongenomic actions. Virtually every tissue has receptors for steroids, a condition that most likely contributes to the many physiologic and pharmacologic effects that occur after steroid administration. This fact has made it difficult to determine which of the many cellular events that occur after steroid administration relate directly to the observed clinical effects. Experimental observations indicate that at least some of the effects at the cellular level result from altered protein production in immunologically competent cells.

Steroids appear to have an effect on nearly every aspect of the immune system. They inhibit both migration of neutrophils into the extracellular space and their adherence to the vascular endothelium at the site of tissue injury. In therapeutic dosages steroids also inhibit macrophage access to the site of inflammation, interfere with lymphocyte activity, and decrease the number of B and T lymphocytes.

Evidence indicates that steroids affect other cells and substances that modulate inflammation. Exposure of human basophils to steroid in culture inhibits histamine release induced by an IgE-dependent stimulus. Steroids inhibit phospholipase A<sub>2</sub>, which prevents biosynthesis of arachidonic acid and subsequent formation of prostacyclin, thromboxane A, prostaglandins, and leukotrienes. Steroids also decrease capillary permeability and fibroblast proliferation and the quantity of collagen deposition, thereby influencing tissue regeneration and repair.

### **BIOAVAILABILITY OF TOPICAL OPHTHALMIC STEROIDS**

Ophthalmic steroids vary in their ability to penetrate the cornea and in their subsequent distribution and metabolism in structures. This variability has been attributed to properties of the cornea and physicochemical differences among the individual steroidal compounds. To penetrate the cornea, which consists of both hydrophobic and

hydrophilic layers, the ideal steroid should be biphasic in its polarity. This property allows for solubility in both the lipid (hydrophobic) layers of the epithelium and endothelium and the aqueous (hydrophilic) media of the stroma. Deepithelialization of the cornea by removal or inflammation alters the hydrophobic properties of the corneal surface and allows water-soluble preparations to penetrate to a greater extent.

Although each steroid has an inherent water or lipid solubility, this characteristic can be altered by chemical modification of the steroid base into various derivatives. Acetate and alcohol derivatives of the base compound render the steroid molecule more lipophilic or fat soluble. Salts, such as sodium phosphate and hydrochloride, are relatively more hydrophilic or water soluble. The alcohol derivative has intermediate lipophilicity between acetates and salts such as the phosphates.

Modification of a steroid base influences not only ocular penetration and metabolism but also the formulation of the particular steroid product. The water-soluble salts generally are formulated as solutions, and the more lipid-soluble derivatives are available as suspensions and ointments. Because the acetate and, to a lesser extent, the alcohol preparations are more lipophilic, in theory they should be able to penetrate the intact cornea better than the water-soluble phosphates. Experimental data in both animal models and human subjects appear to support this hypothesis. Topical administration of an acetate or alcohol derivative to an uninfamed eye with an intact epithelium produces significantly higher corneal and aqueous steroid levels than does administration of a phosphate derivative of the same steroid base. In the absence of the corneal epithelium in an uninfamed eye, comparison of bioavailability of topically applied acetate and phosphate derivatives shows that the drug level of the phosphate derivative is several times higher than that of the acetate (Table 12-1). In the presence of intraocular inflammation in an eye with an intact epithelium, the acetate derivative again produces the highest corneal concentration. However, some decrease in the hydrophobic epithelial barrier occurs, as the phosphate derivative attains somewhat higher levels in the anterior chamber of the inflamed eye with an intact epithelium as compared with the uninfamed eye with an intact epithelium.

In addition to variables in clinical signs and symptoms and the ability to penetrate the ocular structures, the derivative of a steroid base also seems to influence its anti-inflammatory efficacy. Using a rabbit corneal model, it was demonstrated that acetate and alcohol derivatives are more effective than the phosphate derivative in suppressing corneal inflammation both in the presence and absence of corneal epithelium (see Table 12-1). The mechanism by which a derivative affects the anti-inflammatory activity of a steroid base applied topically to the eye is not known, but some data seem to indicate that receptor binding or metabolism plays a role in the observed anti-inflammatory and ocular hypertensive effects.

**Table 12-1**

Relationship of the Derivative of an Ophthalmic Corticosteroid Base to Its Corneal Concentration

Corticosteroid	Bioavailability (mcg/min/g)	Anti-Inflammatory Efficacy (%)
Epithelium intact		
Prednisolone acetate 1.0%	2,395	51
Prednisolone phosphate 1.0%	1,075	28
Epithelium absent		
Prednisolone acetate 1.0%	4,574	53
Prednisolone phosphate 1.0%	16,338	47
Epithelium intact		
Fluorometholone alcohol 0.1%		31
Fluorometholone alcohol 0.25%		35
Fluorometholone acetate 0.1%		48
Epithelium absent		
Fluorometholone alcohol 0.1%		37
Epithelium intact		
Dexamethasone acetate 0.1%	111	55
Dexamethasone alcohol 0.1%	543	40
Dexamethasone phosphate 0.1%	1,068	19
Epithelium absent		
Dexamethasone acetate 0.1%	118	60
Dexamethasone alcohol 0.1%	1,316	42
Dexamethasone phosphate 0.1%	4,642	22

Adapted from Leibowitz HM, Kupferman A. Use of corticosteroids in the treatment of corneal inflammation. In: Leibowitz HM, ed. *Corneal disorders: clinical diagnosis and management*. Philadelphia: Saunders, 1984.

## THERAPEUTIC PRINCIPLES

After five decades of clinical experience with ocular corticosteroid therapy, the use of these drugs remains largely empirical. However, some general therapeutic principles have been suggested:

- The specific type and location of the inflammation determine whether topical, systemic, periocular, or multiple routes of administration are appropriate.
- Treatment should be instituted as soon as possible when indicated, and the dose should be high enough and administration frequent enough to suppress the inflammatory activity.

- The appropriate dose for a specific condition is largely determined by clinical experience and must be reevaluated at frequent intervals during the course of treatment.
- Long-term high-dosage therapy should not be discontinued abruptly. The dose should be tapered over time.
- Short-term low-dosage topical ocular therapy generally does not produce significant side effects.

Ideally, the effective dose should be used for the shortest time necessary to secure the desired clinical response. The dosage should be individualized as much as possible to the patient and the severity of the condition. The patient's general health must be considered and close supervision maintained to assess the effects of steroid therapy on the course of the disease and possible adverse effects. With ocular disease the route of steroid administration is an important determinant of the pharmacologic and therapeutic effects observed. Topical ocular therapy is usually satisfactory for inflammatory disorders of the eyelids, conjunctiva, cornea, iris, and ciliary body. In severe forms of anterior uveitis, topical therapy may require supplementation with systemic or periocular (local injection) steroids. Chorioretinitis and optic neuritis are most often treated with systemic steroids.

### Topical Ocular Administration

Shortly after the introduction of corticosteroids to ocular therapeutics, clinical use indicated that local treatment was equal to or superior to systemic administration, provided that the diseased tissue could be brought in contact with sufficient concentration of steroid. In general, when possible topical administration is indicated for anterior segment disease. Ease of application, comparatively low cost, and relative absence of systemic complications make it the preferred route of steroid therapy. Selection of a particular topical steroid and the dosage

administered varies with the location and severity of the inflammation.

Topical therapy usually should continue at a reduced dosage for several days to several weeks after inflammatory signs and symptoms have disappeared, because prematurely discontinuing treatment can lead to relapse, particularly with high-dosage therapy. Corticosteroids reduce the leukocyte elements of the blood. Consequently, white cells proliferate when therapy stops. The immature cells can produce large quantities of antibodies to residual antigen in the ocular tissue. A massive polymorphonuclear leukocytic reaction follows the resultant antigen-antibody reaction. This sequence of events, unless interrupted immediately, can lead to a recurring, serious, necrotizing inflammatory reaction. Thus, depending on the response obtained and the dosage used, topical therapy should generally be tapered over several days to weeks.

### Systemic Treatment

Inflammations of the posterior segment, optic nerve, or orbit usually require systemic administration of steroids. Selection of the particular steroid preparation and the dosage remains largely an individual choice, but the tendency is to use compounds with minimal mineralocorticoid activity. Table 12-2 compares various systemic steroids to hydrocortisone in terms of equivalent dose (20 mg) and relative anti-inflammatory and sodium-retaining activities when giving a value of 1.0 for hydrocortisone. Prednisone is a popular agent of choice for oral administration. For intravenous administration, methylprednisolone sodium succinate has proven useful.

Because adverse effects are more likely to occur with systemic therapy (Box 12-1), dosage should be individualized as much as possible for each patient. With long-term therapy the lowest possible dose to control the disease is advocated.

**Table 12-2**

Relative Anti-Inflammatory Activity, Sodium-Retaining Activity, and Equivalent Doses of Representative Systemic Corticosteroids

Generic Name	Trade Name	Relative Anti-Inflammatory Activity	Relative Sodium-Retaining Activity	Equivalent Dose (mg)
Hydrocortisone (cortisol)	Coref, Hydrocortone	1.0	1.0	20.00
Cortisone acetate	Cortisone, Cortone	0.8	0.8	25.00
Prednisone	Prednicen-M, Orasone, Deltasone, Meticorten	4.0	0.8	5.00
Prednisolone	Prednicen-M, Delta-Cortef, Sterane	4.0	0.8	5.00
Triamcinolone	Aristocort, Kenacort	5.0	0.0	4.00
Methylprednisolone	Medrol	5.0	0.0	4.00
Paramethasone acetate	Haldrone	10.0	0.0	2.00
Fludrocortisone acetate	Florinef	20.0	125.0	0.10
Dexamethasone	Decadron, Hexadrol	25.0	0.0	0.75
Betamethasone	Celestone	25.0	0.0	0.75



**Box 12-1** Systemic Effects of Corticosteroid Therapy

Adrenal insufficiency  
 Cushing's syndrome  
 Peptic ulceration  
 Osteoporosis  
 Hypertension  
 Muscle weakness or atrophy  
 Inhibition of growth  
 Diabetes  
 Activation of infection  
 Mood changes  
 Delay in wound healing

Some general therapeutic guidelines for systemic steroids have been suggested. For most mild to moderate ocular inflammatory disorders, an initial daily dose of 20 to 40 mg of prednisone or its equivalent is recommended. For patients with severe inflammation, initial daily doses of 40 to 60 mg of prednisone or its equivalent should be used. If no improvement occurs within 48 to 72 hours, an increase of 80 to 100 mg or more may be necessary. As soon as the clinical response occurs the dose should be decreased over days or weeks, depending on the length of treatment. Reduction should be in graduated decrements, guided strictly by the clinical course of the disease, usually reducing the daily dosage by 10 mg for larger doses and 2 to 5 mg for smaller doses at intervals of 3 to 4 days. Once a dose level of 15 to 20 mg is reached, the patient should remain at that level for 1 to 2 weeks to prevent recurrent flare-up of inflammation. If exacerbation of the inflammation follows a given dose reduction, the dose of steroid must be immediately raised to the prereduction level. As long as evidence of active disease persists, therapy must continue at a level that permits control of signs or symptoms.

The available steroids vary in their ability to suppress the inflammatory response. Table 12-2 shows the approximate equivalent doses of systemic steroids in current use. Methylprednisolone is commercially available in a package for programmed delivery of oral steroid tapered over 6 days of therapy. This formulation (Medrol DosePak) is highly convenient for short-term treatment and helps to ensure patient compliance in the tapering schedule.

**Local Injection**

Periocular steroids can be administered by subconjunctival, sub-Tenon's capsule, or retrobulbar injection. A topical anesthetic often is instilled before the steroid is injected. This route of administration can be effective during surgical procedures, as a supplement to topical and systemic steroids in cases of severe inflammation, and in patients not compliant with the prescribed regimen.

One study compared vitreous and serum concentrations after 7.5-mg oral doses of dexamethasone with peribulbar injections of 5 mg dexamethasone phosphate. Peribulbar administration of the agent resulted in 3.9% higher intravitreal than vitreous concentrations, but serum dexamethasone levels were approximately equal with both routes of administration.

Experiments using labeled methylprednisolone acetate (Depo-Medrol) indicate that retrobulbar injection can deliver high concentrations of medication to sclera, choroid, retina, and vitreous for a week or longer. Long-term repository vehicles containing triamcinolone acetonide injected beneath Tenon's capsule have proven valuable in several chronic inflammatory conditions, including anterior uveitis. Locally injected methylprednisolone acetate and triamcinolone acetate have been shown to be effective in the treatment of chalazia. Combined excision and drainage with intralesional steroid injection is another option associated with a high success rate.

The use of periocular steroids has several limitations and complications. The injections are usually somewhat uncomfortable, and thus patients prefer to avoid them. Adverse ocular effects have included retinal detachment, optic nerve atrophy, and preretinal membrane formation. Intraocular pressure (IOP) can rise, particularly because the drug may remain in the eye for several days to weeks. Some of the observed effects may result from the vehicle rather than from the steroid itself.

Periocular injection of steroids should be reserved for those situations requiring an anti-inflammatory effect greater than that obtainable with topical or systemic administration. Concurrent administration of steroid by both topical and subconjunctival routes does appear to produce an additive therapeutic effect in severe inflammations, but periocular injection alone does not necessarily result in greater anti-inflammatory effects. These facts suggest that topical administration should be the primary route of steroid therapy for anterior segment inflammations. Table 12-3 compares the advantages and disadvantages of the three routes of steroid administration.

**Intravitreal Corticosteroid Use**

Corticosteroids administered intravitreally bypass the blood-ocular barrier to achieve therapeutic levels in the eye while minimizing systemic side effects. Initial studies of intravitreal corticosteroids combined dexamethasone and gentamicin in the treatment of inflammation associated with experimentally reduced endophthalmitis. As of late, interest has shifted to triamcinolone acetonide because of the longer half-life in the vitreous and its use in treatment of proliferative vitreoretinopathies.

The use of intravitreal corticosteroids is presently being explored in the treatment options of exudative macular degeneration and proliferative diabetic retinopathy. The rationale for their use stems from the fact that corticosteroids as a drug class represent one of the most

**Table 12-3**

Advantages and Disadvantages of the Three Routes of Corticosteroid Administration

Topical	Periocular	Systemic
<b>Advantages</b>		
Placed near where it is needed	Placed near where it is needed	Easy administration of tablets
Simple to apply	Can treat one eye and use the other as a control	May be better at reaching all parts of the eye
Can treat unioocular disease	Can treat the worse of two eyes	
Avoids most systemic effects	Can treat unioocular diseases	
	Avoids most systemic effects	
	Of value if patient cannot be trusted to take medication	
	Valuable at time of surgery to help prevent flare-up	
<b>Disadvantages</b>		
Occasional development of adrenal suppression	Probable development of some adrenal suppression	Adrenal suppression
Aggravation of a dendritic ulcer	Discomfort with injection	Occurrence of systemic side effects more likely
White residue possible	Occasional white material, which is cosmetically objectionable	
Epithelial keratopathy from frequent applications	Subconjunctival adhesions	
Occasional conjunctival infections	Allergy to diluent	
	Occasional orbital infection	
	Occasional intraocular injection of steroid	
	Ulceration of conjunctiva after repeated injections if not given behind the eye	
	Exophthalmos and rugae in fundus	
	Papilledema	

Adapted from Schlaegel TF Depot corticosteroid by the cul-de-sac route. In: Kaufman HE, ed. Ocular anti-inflammatory therapy, vol. 3. Springfield, IL: Charles C Thomas, 1970: 117.

potent antiangiogenic agents known. In fact, the ability of corticosteroids to reduce vascular permeability has resulted in a wide array of intravitreal treatments for macular edema associated with many ocular diseases.

One of the most common adverse events associated with the type of treatment is ocular hypertension. In one study intravitreal injections of 25 mg triamcinolone acetonide resulted in ocular hypertension in approximately 50% of treated eyes, commencing 1 to 2 months after the injection. IOP was responsive to topical therapy and normalized after approximately 6 months after the injection. Other studies reported that patients who failed medical therapy required surgical intervention to reduce iatrogenic pressure elevations.

Inflammation is another serious side effect of intravitreal injections of corticosteroids. Pseudoendophthalmitis, sterile endophthalmitis, and infectious endophthalmitis have all been reported after injection. True infectious endophthalmitis tends to present later than pseudoendophthalmitis, usually occurring 1 to 2 weeks after injection. This might be caused by the masking effect of the presence of corticosteroid injected into the eye. Steroid endophthalmitis tends to be self-limiting, and some

investigators believe the use of topical steroids may actually hasten the recovery.

### **Novel Delivery Devices for Intraocular Steroids**

The success of intravitreal implants, such as achieved with ganciclovir, has renewed interest in developing an intravitreal corticosteroid implant to further enhance the intravitreal route of administration, thus reducing the need for multiple injections. Bausch and Lomb and Control Delivery Systems have developed an intravitreal implant that can deliver the corticosteroid fluocinolone acetonide (Retisert) to posterior eye tissue for up to 3 years. The implant, which was approved in 2005 by the U.S. Food and Drug Administration (FDA), delivers 0.59 or 2.1 mg of fluocinolone acetonide. The long-term ocular side effects of this device are unknown at this time.

A biodegradable implant is being developed that consists of a steroid combined with a degradable polymer that gradually releases the corticosteroid as a polymer that undergoes hydrolysis. The breakdown byproducts of this implant are glycolic acid and lactic acid, which are then

further metabolized to water and carbon dioxide. With this delivery system no permanent devices remain in the eye after treatment. At this writing, the Posurdex (Allergan Inc., Irvine, CA) implant, which contains dexamethasone, was under phase II clinical trials for posterior segment use.

Finally, conjugate drugs that are covalently linked with corticosteroids decrease drug solubility and consequently increase its half-life. This allows a limited amount of active drug to be present at any given time. Studies covalently linked 5-fluorouracil with dexamethasone and covalently linked 5-fluorouracil with triamcinolone administered by intravitreal injection. More recently, a fluocinolone with 5-fluorouracil conjugate has been investigated for possible use against proliferative vitreoretinopathies.

### Alternate-Day Therapy

In 1963, it was reported that single-dose, alternate-day, systemic administration of corticosteroid can be as effective as divided-dose daily treatment. With the alternate-day regimen, a patient receives the entire total dose that would be given over a 2-day period as a single dose every other morning. This regimen permits metabolic recovery and prevents toxic effects from accumulating. The concept of alternate-day systemic therapy applies only to shorter acting systemic steroids, such as prednisone. Compounds with longer half-lives, such as triamcinolone and dexamethasone, continue their activity on the off-treatment day. Because the normal physiologic release of adrenocorticotropic hormone and cortisol is characterized by episodic secretion, with highest levels occurring at 8:00 AM, administration of single-dose therapy or the first dose of the day in divided-dose therapy should occur in the early morning.

Alternate-day therapy can prove useful for such conditions as chronic uveitis that require long-term systemic administration. This approach has also been advocated for treatment of chronic conditions in children because it minimizes growth suppression. The alternate-day regimen has not been widely accepted, and modifications have been suggested. Clinical experience also indicates that this treatment method is not as effective as divided daily doses, particularly in severe ocular inflammatory conditions. Adrenal gland suppression and other side effects associated with systemic therapy can still occur with the alternate-day regimen.

### CLINICAL USES

Box 12-2 lists the primary ocular inflammatory disorders in which steroids may provide a therapeutic benefit. Steroids are generally contraindicated in most ocular infections because they are not bactericidal and because they reduce resistance to many types of invading microorganisms, including bacteria, viruses, and fungi. In particular, because of the difficulty in controlling replication of fungi in ocular infection, steroid use can enhance microbial replication in this and other types of infections

#### Box 12-2 Indications for Use of Corticosteroids in Ocular Disease

- Eyelids
  - Allergic blepharitis
  - Contact dermatitis
  - Herpes zoster dermatoblepharitis
  - Chemical burns
  - Neonatal hemangioma
- Conjunctiva
  - Allergic conjunctivitis
  - Vernal conjunctivitis
  - Herpes zoster conjunctivitis
  - Chemical burns
  - Mucocutaneous conjunctival lesions
- Cornea
  - Immune reaction after keratoplasty
  - Herpes zoster keratitis
  - Disciform keratitis
  - Marginal corneal infiltrates
  - Superficial punctate keratitis
  - Chemical burns
  - Acne rosacea keratitis
  - Interstitial keratitis
- Uvea
  - Anterior uveitis
  - Posterior uveitis
  - Sympathetic ophthalmia
- Sclera
  - Scleritis
  - Episcleritis
- Retina
  - Retinal vasculitis
- Optic nerve
  - Optic neuritis
  - Temporal arteritis
- Globe
  - Endophthalmitis
  - Hemorrhagic glaucoma
- Orbit
  - Pseudotumor
  - Graves' ophthalmopathy
- Extraocular muscles
  - Ocular myasthenia gravis

and also can mask evidence of progression of an infection. In severe infections marked by considerable ocular involvement and a threat to vision, steroids may be used within 48 hours of starting the appropriate anti-infective therapy.

### OPHTHALMIC CORTICOSTEROIDS

#### Prednisolone

A synthetic analogue of the major glucocorticoid hydrocortisone (cortisol), prednisolone has proven an effective

**Table 12-4**  
Topical Ophthalmic Corticosteroids

Corticosteroid Base	Derivative	Formulation	Concentration (%)	Trade Name (Manufacturer)
Prednisolone	Acetate	Suspension	0.125	Econopred (Alcon) Pred Mild (Allergan)
		Suspension	1.0	Econopred Plus (Alcon) Pred Forte (Allergan)
Prednisolone	Sodium phosphate	Solution	0.125	Inflamase Mild (Bausch & Lomb) AK-Pred (Akorn)
		Solution	1.0	Inflamase Forte (Novartis) AK-Pred (Akorn)
Dexamethasone	Alcohol	Suspension	0.1	Maxidex (Alcon)
Dexamethasone	Sodium phosphate	Solution	0.1	Decadron Phosphate (Falcon)
		Ointment	0.05	Decadron Phosphate (Bausch & Lomb) Maxidex (Alcon) AK-Dex (Akorn)
		Suspension	0.5	Lotemax (Bausch & Lomb)
Loteprednol	Etabonate	Suspension	0.2	Alrex (Bausch & Lomb)
Loteprednol	Etabonate	Suspension	1.0	Vexol (Alcon)
Rimexolone	—	Suspension	0.1	FML (Allergan)
Fluorometholone	Alcohol	Ointment	0.1	FML (Allergan)
		Suspension	0.1	Fluor-Op (Novartis)
		Suspension	0.25	FML Forte (Allergan)
Fluorometholone	Acetate	Suspension	0.1	Flarex (Alcon)
		Suspension	0.1	Eflone (Alcon)
Medrysone	Alcohol	Suspension	1.0	HMS (Allergan)

anti-inflammatory agent in patients with external and intraocular inflammations. It is commercially formulated as an acetate and a phosphate (Table 12-4). Experimental models using inflamed rabbit corneas indicate that the mean decrease in corneal inflammation is greater for the prednisolone acetate derivative than for the phosphate, regardless of whether the corneal epithelium is intact or absent (see Table 12-1). The acetate substitution in the 21 position of the steroid molecule may increase the affinity of the steroid for its receptor, possibly explaining part of the enhanced effect. This increased affinity could enhance its pharmacologic response and also, in some way, alter its metabolism in ocular tissue.

Prednisolone acetate is available in 0.125% and 1.0% concentrations. Kinetic studies have shown that raising the concentration of prednisolone acetate from 1.0% to 1.5% or 3.0% does not enhance its anti-inflammatory effects. In severe inflammatory reactions, topical dosing of prednisolone acetate 1% at 1-minute intervals for 5 minutes each hour may provide the best clinical suppression of inflammation (Table 12-5). As compared with other topical ocular steroids, 1% prednisolone acetate is generally considered the most effective anti-inflammatory agent for anterior segment ocular inflammation.

### Dexamethasone

Dexamethasone is available as an alcohol or phosphate derivative in the form of a 0.1% ophthalmic suspension or

solution. It is also formulated as dexamethasone sodium phosphate ointment, 0.05% (see Table 12-4). Experimental studies indicate that dexamethasone alcohol is superior in anti-inflammatory activity to dexamethasone sodium phosphate, whether in the presence or absence of the corneal epithelium (see Table 12-1).

The human aqueous humor contains detectable levels of both dexamethasone alcohol and dexamethasone phosphate within 30 minutes of topical application.

**Table 12-5**  
Anti-Inflammatory Effect of Different Dosage Schedules for Topical Administration of Prednisolone Acetate 1%

Treatment Regimen	Total No. of Doses Delivered	Decrease of Corneal Inflammation (%)
One drop every 4 hr	6	11
One drop every 2 hr	10	30
One drop every hr	18	51
One drop every 30 min	34	61
One drop every 15 min	66	68
One drop each min for 5 min every hr	90	72

Reprinted with permission from Leibowitz HM, Kupferman A. Anti-inflammatory medications. *Int Ophthalmol Clin* 1980;20: 117-134.

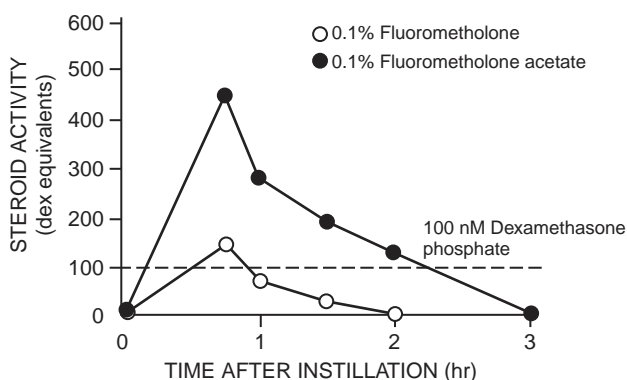
Peak levels occur between 90 and 120 minutes. Thereafter drug levels diminish, but detectable amounts remain 12 hours after administration. Observations such as this suggest that dexamethasone is resistant to metabolism after penetration into the aqueous humor.

### Fluorometholone

Unlike prednisolone and dexamethasone, which are structurally related to cortisol, fluorometholone is a fluorinated structural analogue of progesterone. Formulated both as an alcohol and acetate derivative, fluorometholone has proven to be an effective agent in external ocular inflammations, with relatively low potential for elevating IOP.

After topical application to the eye, fluorometholone alcohol penetrates and is rapidly metabolized within the aqueous humor. Comparative anti-inflammatory studies indicate that the efficacy of fluorometholone alcohol is somewhat less than dexamethasone alcohol and prednisolone acetate (see Table 12-1). Increasing the concentration of fluorometholone alcohol from 0.1% to 0.25% does not significantly increase its anti-inflammatory activity but does enhance its tendency to raise IOP. The 17-acetate derivative of fluorometholone has demonstrated greater anti-inflammatory activity in the experimental rabbit keratitis model than has fluorometholone alcohol. However, studies with fluorometholone acetate show that it is metabolized slowly as compared with the alcohol derivative (Figure 12-1). Thus it is possible that the 17-acetate substitution to the fluorometholone base not only enhances its anti-inflammatory effects, but also impedes its metabolism.

Clinical evaluation of patients with conjunctivitis, episcleritis, and scleritis indicates that fluorometholone acetate improves clinical signs and symptoms of inflammation significantly more than fluorometholone alcohol. Furthermore, when fluorometholone acetate 0.1% was compared with prednisolone acetate 1.0% in patients



**Figure 12-1** Aqueous humor steroid activity using the glucocorticoid receptor assay after administration of topical unlabeled fluorometholone 0.1% and fluorometholone acetate 0.1% in rabbits. (Adapted from Polansky JR. Basic pharmacology of corticosteroids. *Curr Top Ocul Inflam* 1993;1:19.)

with moderate inflammation, no difference in the anti-inflammatory effects of the two steroids was observed.

### Medrysone

Like fluorometholone, medrysone is a synthetic derivative of progesterone. As compared with prednisolone, dexamethasone, and fluorometholone, medrysone exhibits limited corneal penetration and a lower affinity for glucocorticoid receptors. In clinical use it appears to be the weakest of the available ophthalmic steroids. Medrysone can be useful for superficial ocular inflammations, including allergic and atopic conjunctivitis, but intraocular inflammatory conditions generally do not respond. Clinical experience with medrysone has also indicated that it is less likely to cause a significant rise in IOP. However, caution needs to be exercised in patients known to respond to steroids with a rise in IOP (so-called steroid responders), because pressure increases can lead to ocular damage.

### Loteprednol Etabonate

Loteprednol etabonate (LE) was designed as an analogue of prednisolone according to the “soft drug” concept. Synthesis of a soft drug is achieved by starting with a known inactive and nontoxic metabolite of an active drug. The inactive metabolite then is structurally modified to an active but metabolically unstable compound that undergoes, *in vivo*, a predictable one-step transformation to the inactive metabolite after its pharmacologic effects have been expressed at or near the site of application. LE and its metabolites are present in the cornea, aqueous humor, iris, and ciliary body after ocular administration.

The clinical efficacy of LE has been assessed in randomized placebo-controlled human studies for such conditions as giant papillary conjunctivitis, seasonal allergic conjunctivitis, postoperative inflammation, and acute anterior uveitis. The potential efficacy of LE 0.5% in patients with contact lens-associated giant papillary conjunctivitis has been studied in three double-masked, placebo-controlled, parallel study groups. Patients on LE showed improvement of papillae of at least one grade at the final 6-week visit. LE was also significantly more effective in relieving itching and lens intolerance. The effects of LE on both signs and symptoms was observed by the end of the first week and maintained throughout the 6-week study period.

The efficacy of LE 0.2% and 0.5% has been compared with a placebo vehicle in patients in whom seasonal allergic conjunctivitis has been diagnosed. Patients on either concentration of LE had fewer signs and symptoms, including severity of itching and bulbar conjunctival injection, than did the placebo groups when treated four times daily for 6 weeks.

LE 0.5% has also been compared with a placebo vehicle in controlling chamber cell and flare reaction in patients

undergoing cataract surgery with intraocular lens implantation. Starting 1 day after surgery in patients with at least moderate postoperative inflammation, use of LE four times daily for 14 days led to a clinically meaningful reduction in signs and symptoms of anterior chamber inflammation when compared with placebo. The safety and efficacy of LE 0.5% has been compared with prednisolone acetate 1.0% in acute anterior uveitis. Clinically meaningful reduction in symptoms and signs, such as anterior chamber cell and flare, was achieved in both treatment groups; however, LE was less effective than prednisolone acetate.

LE is commercially available as a 0.5% suspension (Lotemax) and a 0.2% suspension (Alrex) (see Table 12-4). Class labeling for Lotemax includes any eye inflammation responsive to steroids, whereas Alrex is indicated for seasonal allergic conjunctivitis and other mild non-vision-threatening conditions.

### Rimexolone

Like fluorometholone, rimexolone lacks a hydroxyl group in the 21 position. Available as a 1% ophthalmic suspension (Vexol) (see Table 12-4), it has FDA approval for treatment of uveitis and postoperative inflammation.

Two multicenter studies have compared rimexolone 1% and prednisolone acetate 1% in patients with acute uveitis, recurrent iridocyclitis, or chronic uveitis. Both controlled studies and clinical experience with rimexolone appear to indicate that its efficacy is comparable with prednisolone acetate only if administered in aggressive pulse doses to patients with moderate inflammatory reactions.

The anti-inflammatory effect of rimexolone has been compared with placebo after cataract extraction. Rimexolone was both clinically and statistically more effective in suppressing cells, flare, keratin precipitates, and photophobia, with no between-group differences in IOP. Rimexolone has not been FDA approved for allergies or giant papillary conjunctivitis.

### SIDE EFFECTS OF OPHTHALMIC CORTICOSTEROIDS

Although the effectiveness of these agents in the treatment of ocular inflammation has stood the test of time, the use of corticosteroids can be associated with side effects. Adverse events can occur with all routes of administration and all preparations currently available. Systemic absorption of corticosteroid occurs with topical use on the eyes, skin, and mucosa of the upper respiratory tract. The incidence of side effects appears to rise significantly with long-term high-dose therapy, although short-term high-dose therapy appears to cause fewer side effects than prolonged courses with lower doses. Ocular complications can develop after either local or systemic steroid administration and range from actual physical damage to

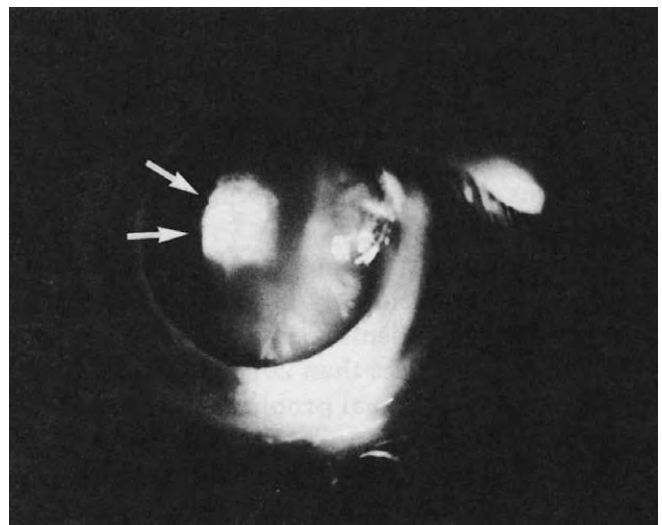
#### Box 12-3 Ocular Effects of Corticosteroid Therapy

- Posterior subcapsular cataracts
- Ocular hypertension or glaucoma
- Secondary ocular infection
- Retardation of corneal epithelial healing
- Keratitis
- Corneal thinning or melting
- Scleral thinning
- Uveitis
- Mydriasis
- Ptosis
- Transient ocular discomfort

the ocular tissue to interference with healing and immune mechanisms (Box 12-3).

### Cataracts

Posterior subcapsular cataracts (PSCs) can occur with all routes of administration (Figure 12-2), including systemic, topical, cutaneous, nasal aerosols, and inhalation corticosteroids. In a study of 44 rheumatoid arthritis patients treated with various steroids, including prednisone and dexamethasone, 17 (39%) developed bilateral PSCs. Dosage and duration of therapy appeared to be correlated with the incidence of cataract development. Patients who received prednisone therapy for 1 to 4 years showed an 11% incidence if the dose range was less than 10 mg/day, a 30% incidence if the dose was



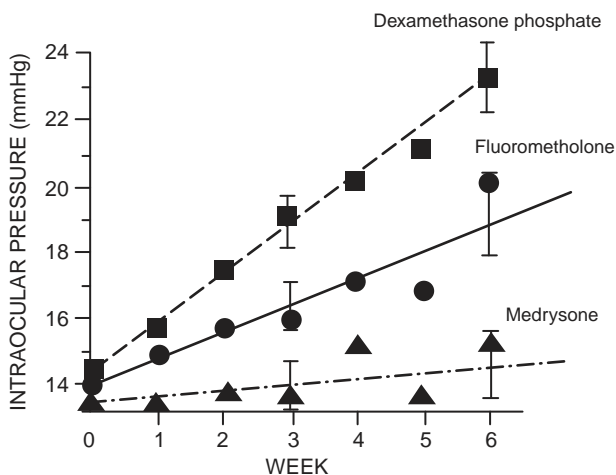
**Figure 12-2** Posterior subcapsular cataract (*arrows*) in a 48-year-old man who had taken oral prednisone, 7.5 mg/day, for 13 years for the treatment of rheumatoid arthritis. Visual acuity was 20/30 (6/9).

10 to 15 mg/day, and an 80% incidence if the dose was greater than 15 mg/day.

Additional evidence became available when several investigators observed an increased incidence of PSCs in children receiving systemic steroid therapy for rheumatoid arthritis, systemic lupus erythematosus, and the nephrotic syndrome. Although steroid-related PSCs do not usually occur in adults within the first year of therapy, regardless of dose, children can manifest lens changes at lower doses and within shorter periods.

Topical ocular steroid administration also may cause the development of cataracts in both children and adults. Use of topical steroids for several years to eliminate redness associated with contact lens wear resulted in PSC formation as well as glaucoma and visual field loss. The opacities associated with steroid administration resemble those produced by ionizing radiation and ocular disease such as uveitis, retinitis pigmentosa, and retinal detachment. They differ from opacities associated with diabetes and trauma but are indistinguishable from lens changes associated with posterior subcapsular age-related cataract.

In most patients lens changes accompanying steroid therapy do not significantly impair visual acuity. In fewer than 10% of patients receiving long-term therapy is vision reduced to less than 20/60 (6/18). Patients seldom complain of visual problems unless the practitioner makes a direct inquiry. Photophobia and glare may be complaints. Once vision is affected, reduction or cessation of steroid therapy seldom resolves the opacity, but it does halt its progression; in some cases the area of opacity decreases.



**Figure 12-3** Weekly intraocular pressure responses of eyes treated with medrysone 1%, fluorometholone 0.1%, and dexamethasone phosphate 0.1%. Each point represents a mean value (mm Hg) of 12 eyes. (Reprinted with permission from Mindel JS, Tovitian HO, Smith H, et al. Comparative ocular pressure elevations of topical corticosteroids. *Arch Ophthalmol* 1980;98:1578. Copyright 1980, American Medical Association.)

Although it now is generally accepted that corticosteroids are cataractogenic, the mechanisms for development of the lens opacities have still not been fully elucidated. The relationship among total dose, dosage schedule, patient age, associated disease, and the steroid administered requires further study. Possibly, glucocorticoids cause cataract formation by gaining entry to the lens fiber cells. After reacting with specific amino groups of lens crystallins, a conformational change occurs within the cells, exposing sulfhydryl groups. These then form disulfide bonds, which subsequently lead to protein aggregation and, finally, to complexes that refract light. Significant causative factors might include the relationship of the lens changes to total dose, duration of therapy, and individual susceptibility. Several studies have suggested that the most important factor in steroid-induced PSC formation may be individual susceptibility to the effects of corticosteroids. An ethnic susceptibility may also exist. Reportedly, Hispanics are more predisposed to PSC development than are whites or blacks. Diabetic patients also appear to be more susceptible with topical steroid administration.

### Ocular Hypertension or Glaucoma

After the introduction of corticosteroids for treating ocular inflammatory disease, reports began to appear in the literature that implicated topical steroid therapy as a cause of elevated IOP. In 1962 after reported observations with topical steroid therapy it became generally accepted that these agents can produce the clinical picture of open-angle glaucoma.

More conclusive evidence of the ability of steroids to raise IOP comes from controlled studies in which patients showed reversible elevations of pressure with repeated use of topical steroids. The hypertensive response can occur in both normal and glaucomatous eyes and usually develops 2 to 8 weeks after initiation of therapy. The effect on pressure and the associated reduction in outflow facility generally are reversible and return to their original levels within 1 to 3 weeks after steroid administration terminates. Pressure elevations are usually greater in eyes with open-angle glaucoma and tend to be higher than normal in children of glaucoma patients.

Topically administered steroids tend to produce ocular hypertension in certain susceptible individuals. Statistical analysis of volunteers given topical dexamethasone 0.1% three times daily indicated three separate groups of responders in the general population. The largest group in the volunteer population responded with an average pressure elevation of 1.6 mm Hg after 4 weeks of topical dexamethasone administration. A second group responded with an average elevation of 10 mm Hg. Pressure elevations of 16 mm Hg or greater occurred in the third group. The groups also differed in the timing of their pressure elevation: The second and third groups showed a continued and steady pressure elevation during the 4 weeks of



observation as compared with the first group. The first group showed a small initial pressure increase that did not continue to rise during subsequent weeks of the study.

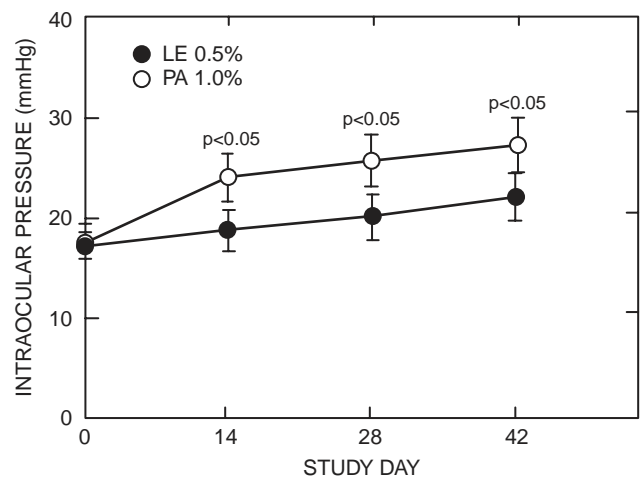
The degree of response to topical corticosteroid thus appears to be genetically determined. Patients with primary open-angle glaucoma and their relatives show a remarkably high prevalence of pressure elevations with topical steroids. Approximately 70% of the first-degree offspring of individuals with glaucoma have IOP elevations of at least 5 mm Hg. Information regarding patient or family history of glaucoma, therefore, becomes important when considering the use of steroids. In addition to genetic tendencies, other factors can contribute to the pressure elevations resulting from topical steroid administration. These can include patient age, myopia of 5D or more, and Krukenberg's spindles.

Long-term systemic steroid therapy can also cause IOP elevations. Patients treated with systemic cortisone, 25 mg or its equivalent, for rheumatoid arthritis and other collagen vascular diseases showed significantly higher mean applanation pressures as compared with untreated individuals. A decreased facility of outflow and changes in ocular rigidity in steroid-treated patients were also observed.

Corticosteroid-induced ocular hypertension appears to relate not only to the individual patient but to the specific steroid used. In general, dexamethasone 0.1%, betamethasone 0.1%, and prednisolone acetate appear more likely to induce significant IOP elevations than do fluorometholone alcohol and medrysone. Clinical studies with rimexolone and LE indicate that they have less potential to elevate IOP than does dexamethasone phosphate or prednisolone acetate.

A masked study using male volunteers compared ocular pressure elevations with dexamethasone phosphate 0.1%, fluorometholone alcohol 0.1%, and medrysone 1% applied four times daily for 6 weeks. Figure 12-3 shows the relative ability of these steroids to raise IOP. At the end of 6 weeks of treatment, the mean pressure increases for dexamethasone, fluorometholone, and medrysone were 63.1%, 33.8%, and 8.3%, respectively. Additional studies have compared the effects of fluorometholone alcohol suspension 0.25% with dexamethasone sodium phosphate solution 0.1% in steroid-responsive patients. Subjects received the medication in one eye four times daily for up to 6 weeks. Although both drugs elevated IOP, mean pressure increases from baseline in eyes treated with fluorometholone were significantly lower than those in eyes treated with dexamethasone at weeks 2, 4, and 6. Further studies are needed to compare the effects of the alcohol and acetate derivatives of fluorometholone on IOP in both nonsteroid and steroid responders.

With a significant elevation of IOP defined as equal to or greater than 10 mm Hg at any visit, analysis of pooled data from 1,442 patients and 206 volunteers treated for 28 days with LE 0.2% or 0.5%, prednisolone acetate 1%, or



**Figure 12-4** Mean intraocular pressure response in known corticosteroid responders to loteprednol etabonate (LE) 0.5% or prednisolone acetate (PA) 1.0%. (Reprinted with permission from Bartlett JD, Horowitz B, Laibovitz R, et al. Intraocular pressure response to loteprednol etabonate in known steroid responders. *J Ocul Pharmacol* 1993;9:161.)

placebo showed a 0.6%, 1.0%, and 6.7% rise in IOP, respectively. The effect of LE 0.5% and prednisolone acetate 1.0% has been compared in known steroid responders. Four-times-daily administration of LE for 6 weeks increased IOP by 24% as compared with baseline pressure (Figure 12-4). In contrast, prednisolone acetate increased IOP by 50% as compared with baseline. The pressure rise was statistically significant for prednisolone but not for LE. The IOP of rimexolone has also been compared with fluorometholone alcohol in known steroid responders. The drugs were instilled four times daily for 4 weeks. Rimexolone was reported to be equivalent to fluorometholone in its IOP-elevating potential.

Factors contributing to the reduced propensity of some steroids to raise IOP could include their intraocular bioavailability, considerably shorter pharmacokinetic half-life, and greater susceptibility to metabolism as compared with dexamethasone and prednisolone. In addition to the individual steroid's effect on IOP, concentration, frequency, and length of administration may play a role in IOP elevation.

The molecular mechanism whereby corticosteroids increase resistance to aqueous humor outflow is not fully understood. Human trabecular cells possess receptors that are responsive to steroids. A direct action on meshwork cells could mediate alterations in outflow facility. Electron microscope studies of steroid-treated trabecular specimens have indicated the presence of extracellular materials (including glycosaminoglycans) in eyes with corticosteroid-induced glaucoma. These materials are different from those seen in eyes with open-angle glaucoma. Experimental studies of cultured human eyes or trabecular cells also indicate that corticosteroids can cause changes in the proteoglycans of the extracellular



matrix, alter protein synthesis, stabilize the actin microfilament network within cells, and decrease phagocytic capacity.

## Infection

Because steroids reduce one's immunologic defense mechanisms, these drugs lower resistance to many types of infection. In addition, inhibiting the inflammatory response may mask symptoms of disease. Evidence indicates that steroid administration can increase susceptibility to viral, fungal, and bacterial infections.

The use of steroids in ocular infections requires caution to avoid interfering with reparative processes. If the appropriate antibiotic is selected and if the course of therapy is relatively short, steroids can help to reduce inflammation and prevent possible scarring. In general, however, steroids should be avoided in cases of routine bacterial infections of the eyelids and conjunctiva when no scarring is anticipated, because steroids provide relatively little benefit in the healing process.

Steroids may prolong the clinical course of dendritic keratitis caused by herpes simplex virus. Experiments with rabbits have confirmed these observations.

There is general agreement that topical use of steroids enhances ocular susceptibility to fungal infection. Treatment of minor ocular injuries with steroids or steroid-antibiotic combinations has resulted in fungal keratitis. Indirect evidence indicates that steroids decrease human resistance to fungal infections. Therefore for patients using topical or systemic steroid therapy in whom discontinuation of the steroid is not feasible, elimination of the infection can be difficult and prolonged. The enhanced risk of superinfection by bacteria, fungi, and viruses emphasizes the need to maintain a balance between the steroid and the chemotherapeutic agent. Although steroids decrease the amount of tissue damage caused by the inflammatory response, preserving the ocular structures requires the use of specific anti-infective therapy to eradicate the replicating organism. It is generally accepted that steroids should never be the sole therapeutic agent in conditions caused by actively replicating microorganisms.

## Retardation of Corneal Epithelial Healing

Both systemic and topical ocular steroid therapy can retard corneal healing. Persistent punctate staining of the cornea can indicate epithelial damage by the corticosteroid if the original disease has been eliminated. Effects on collagen synthesis and fibroblast activity have been proposed as a possible mechanism.

In recent studies topical corticosteroids have shown promising results in treating dry eye and epithelial damage from inflammatory medications. Steroids may help increase goblet cell density and reduce the accumulation of inflammatory cells within the ocular tissues.

Topical LE 0.5% (Lotemax) four times a day may benefit patients with keratoconjunctivitis sicca that has at least a moderate inflammatory component. Currently, however, the use of topical steroids for dry eye treatment is strictly "off label."

## Corticosteroid Uveitis

It seems paradoxical that the topical use of corticosteroids can lead to acute inflammation of the anterior segment. However, since the first association of the development of anterior uveitis during provocative testing with steroids for glaucoma, additional cases have been reported. The incidence is higher in blacks (5.4%) than in whites (0.5%). Symptoms include pain, photophobia, blurred vision, and perilimbal (ciliary) hyperemia; anterior chamber cells and flare can be observed. The corticosteroid itself, rather than its vehicle, appears to cause the condition. Treatment includes discontinuation or reduction of the steroid medication and using steroid-sparing agents such as nonsteroidal anti-inflammatory or immunosuppressive agents to reduce the inflammation. It does not appear to be related to a particular steroid preparation, because it can occur with either the sodium phosphate or alcohol derivatives of dexamethasone and prednisolone acetate.

## Mydriasis and Ptosis

Dilation of the pupil and ptosis can occur with topical steroid administration. Application of dexamethasone 0.1% in human volunteers produced mydriasis as early as 1 week after the drug's initial use. The average increase in pupillary diameter was approximately 1 mm. The effect disappears on cessation of drug therapy.

The mydriatic effect of topically applied corticosteroids was investigated in living monkey eyes. Instillation of dexamethasone 0.1% (Decadron) produced pupillary dilation and ptosis as well as elevation of IOP. When the steroids were tested without their vehicles but in saline solution, the effects on IOP, pupil size, and upper eyelid did not occur. Thus it has been suggested that an excipient in the vehicle mixture causes the effects, possibly by altering cell membrane permeability to the steroid.

## Other Side Effects

Transient ocular discomfort can ensue after topical application of steroids to the eye. Mechanical effects of the steroid particles in suspension, the vehicle itself, and the severity of the inflammatory condition can all be causative factors.

Steroid-induced calcium deposits in the cornea have been reported. Patients with such persistent epithelial defects such as postoperative inflammation, penetrating keratoplasty, and a history of herpetic keratitis and dry eye have developed a calcific band keratopathy after topical use of a steroid phosphate formulation.

## **SYSTEMIC EFFECTS OF LOCALLY ADMINISTERED CORTICOSTEROIDS**

Topical or periocular steroids cause few systemic effects. When topical dexamethasone sodium phosphate was administered four times daily for 6 weeks, subjects showed reduced plasma levels of cortisol. However, elevation of 11-deoxycortisol with the oral metyrapone tartrate test indicated that the pituitary-adrenal axis was intact.

Intralesional injection of steroid can lead to adrenal suppression. Infants and small children are especially susceptible, because a given amount of steroid is distributed in a smaller volume of fluid and tissue compartments. Infants injected with mixtures of triamcinolone acetonide and betamethasone or dexamethasone for periocular hemangiomas exhibited depressed serum cortisol and adrenocorticotropic hormone levels. The adrenal suppression can last up to 5 months and can result in weight loss and growth retardation. It is not known whether other corticosteroid preparations would produce similar effects or which other factors might influence these results. In general, topical and periocular use of steroids produces minimal systemic effects. Withdrawal of topical or periocular steroids does not generally cause adrenal crisis.

## **CONTRAINDICATIONS TO CORTICOSTEROID USE**

Because side effects can complicate the use of corticosteroids, a careful history and certain tests may be advisable, particularly if a patient may require prolonged ocular therapy. Steroids should be used with great caution in patients with diabetes mellitus, infectious disease, chronic renal failure, congestive heart failure, and systemic hypertension. Systemic administration is generally contraindicated in patients with peptic ulcer, osteoporosis, or psychoses. Topical steroids should be used with caution and only when necessary in patients with glaucoma.

Patients receiving prolonged systemic therapy usually lack sufficient adrenal reserve to respond appropriately to such stresses as trauma or surgery. These individuals may need supplementary corticosteroids to cover the period of stress.

Concurrent administration of other drugs may interfere with the metabolism and alter the effects of corticosteroids. Some of the effects appear to result from increased metabolism of administered steroid. Barbiturates, phenylbutazone, and phenytoin may enhance metabolism and reduce the anti-inflammatory and immunosuppressive potential of systemic steroids. Additionally, the response to anticoagulant therapy may be reduced by simultaneous administration of steroids.

Patients receiving topical ocular steroids must be examined periodically for corneal, lens, and IOP changes. Slit-lamp examination for punctate, herpetic, or fungal keratitis

is necessary. Patients receiving systemic therapy should be monitored for systemic hypertension, glaucoma, and cataracts. If prolonged systemic therapy is necessary, blood glucose levels should be evaluated at appropriate intervals.

## **NONSTEROIDAL ANTI-INFLAMMATORY DRUGS**

Topical ophthalmic steroids represent the gold standard for mediating ocular inflammation. Because steroids have the potential for increased incidence of adverse events, judicious application is indicated. The most notable among these is elevation of IOP. NSAIDs offer some advantages over steroids in reducing inflammation. In perspective, there are some disadvantages as well. Topical NSAIDs may be inferior candidates for suppressing anterior-chamber inflammation after ocular surgery. However, no topical NSAID has ever been reported to increase IOP. One strong point of oral NSAIDs is that they can be cost-effective alternatives (rescue medications) to topical forms by offering antipyretic, analgesic, and anti-inflammatory activity without the potential to increase IOP.

To understand the mechanism of action of NSAIDs, it is important to explore pathways of inflammation. The inflammatory response involves production of prostaglandins. These mediators of inflammatory activity are ubiquitous throughout the body. In addition, they mediate other cellular and tissue responses that are crucial to homeostasis, such as platelet aggregation and renin release. Because of these necessities, prostaglandins are produced on demand and consequently have a short half-life.

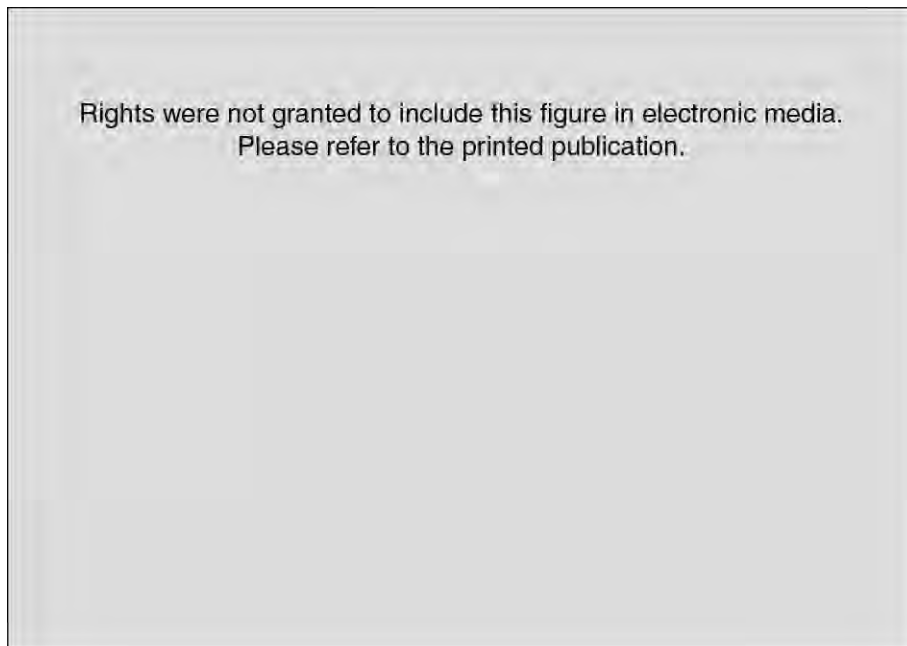
The omega-6 fatty acid pathway is the source for the cascade of inflammatory prostaglandin production. From linolenic acid, the enzyme delta-6-desaturase is responsible for producing gamma-linolenic acid. This then becomes the source of arachidonic acid, which under the influence of cyclooxygenase is converted to the so-called series 2 prostaglandins, which are inflammatory (Figure 12-5).

Under the influence of omega-3 fatty acids, the pathway proceeds to produce series 1 prostaglandins, which are anti-inflammatory, and leukotrienes (less inflammatory). From alpha-linolenic acid, enzymes eventually synthesize eicosapentaenoic acid. Cyclooxygenase, given this substrate, can synthesize series 3 prostaglandins, which are also anti-inflammatory (Figures 12-6 and 12-7).

What this allows is targeting of either the cyclooxygenase or leukotriene arms of the prostaglandin pathways. Although this is a convenient separation of mechanisms, there is often overlap. It is for this reason, for example, that postoperative cataract patients are administered both topical steroids and NSAIDs.

## **Pharmacology of Nsaids**

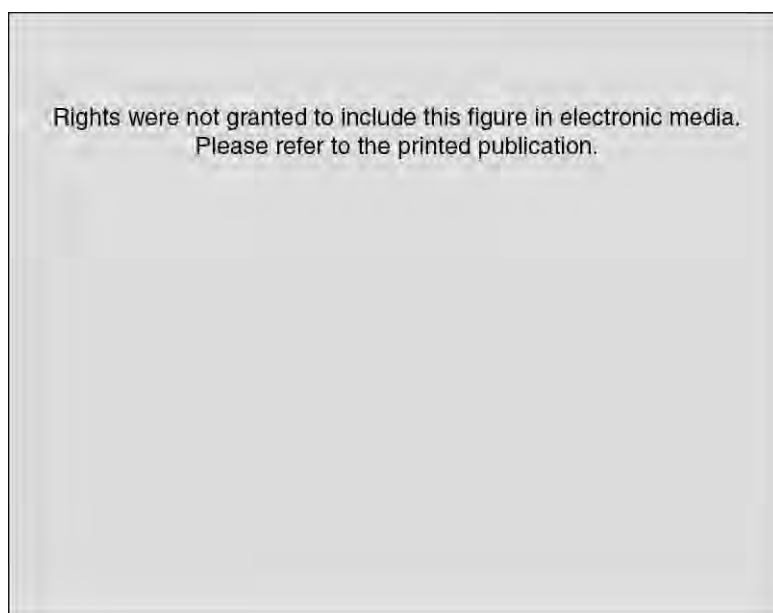
The cyclooxygenase pathway may be interrupted at a number of stages. Two cyclooxygenase enzyme isoforms



**Figure 12-5** Series 1 prostaglandin synthesis pathway. In this scheme delta-5-desaturase plays a key role in producing arachidonic acid, but its preferred substrate is omega-3 fatty acid. Compare with Figure 12-6. (From <http://www.asthmaworld.org/OMEGA3.htm>)

have been identified to date, cyclooxygenase-1 and cyclooxygenase-2. Cyclooxygenase-1 inhibits thromboxane production and thus platelet aggregation. The resultant blood thinning may lead to bleeding ulcers when the gastric mucosa is sufficiently disrupted. An advantage of cyclooxygenase-2 is that it is less disruptive of mucosal surfaces but may adversely affect hemostatic balance and favor thrombosis.

Although oral NSAIDs have application to ophthalmic pain management, topical NSAIDs have the more immediate utility. Some of the earliest indications for topical NSAIDs were prophylaxis and treatment for cystoid macular edema (CME) as well as pain and inflammation management after cataract surgery. This pioneering work was done before the introduction of less traumatic procedures such as clear corneal incisions. The seminal investigations using



**Figure 12-6** Eicosapentaenoic acid synthesis pathway from alpha-linolenic acid. Note that the enzymes necessary to the process are delta-6-desaturase and delta-5-desaturase. (From <http://www.asthmaworld.org/OMEGA3.htm>)

Rights were not granted to include this figure in electronic media.  
Please refer to the printed publication.

**Figure 12-7** Simplified concept of prostaglandin and leukotriene synthesis pathway from eicosapentaenoic acid. Note the enzymes involved in this process (cyclooxygenase and lipoxygenase), which become the target for anti-inflammatory drugs. (From <http://www.asthmaworld.org/OMEGA3.htm>)

topical indomethacin also demonstrated higher intraocular levels than provided by the oral route and showed the efficacy of topical indomethacin for CME. Prophylaxis for CME has been demonstrated in studies worldwide, as well. Topical NSAIDs offer analgesic, anti-inflammatory, and antipyretic effects as their primary application, although other attributes and applications exist.

### Side Effects of and Contraindications to NSAIDs

In general, when administered orally these medications are rapidly absorbed into systemic circulation (30 to 120 min). Because prostaglandins, the mediators of inflammation, are produced extemporaneously, dosing schedules are based on the peak plasma drug levels (i.e., every 4 to 6 hours). For the sake of precaution, it is important to note that oral NSAIDs are metabolized in the kidneys.

Drug interactions with the oral NSAIDs include aspirin, which with concomitant administration increase the unbound circulating fraction of an orally administered NSAID. For patients taking warfarin, there is risk of prolonged clotting times and the potential consequences of decreased platelet aggregation. A similar precaution should be observed for those taking *Ginkgo biloba*. Patients who are dosing with antacids, however, require no increased dosages of oral NSAIDs, because these will not interfere with absorption. These interactions are not applicable to topically applied NSAIDs because significantly lower amounts reach the systemic circulation.

With regard to topical NSAIDs, there are few significant contraindications. One reported interaction is between oral indomethacin and topical brimonidine. Patients taking this oral medication were found to have escape of IOP control when using brimonidine. However, the study failed to demonstrate such loss of IOP-lowering control with latanoprost.

Another potential contraindication to topical NSAIDs is concomitant administration of topical prostaglandin analogues used for lowering IOP. In studies reporting small numbers of normal and glaucoma patients, slight and perhaps clinically insignificant IOP increases

were noted. Clinicians should be aware of this potential, but, perhaps more importantly, the studies may reflect additional mechanisms for IOP reduction by the prostaglandin analogues.

Burning and stinging are the most prevalent side effects of topically administered NSAIDs. The original FDA approval for ketorolac, for example, was modulation of postoperative refractive surgery pain and inflammation. Ketorolac, however, has application in a variety of ocular inflammatory conditions, including seasonal allergic conjunctivitis, giant papillary conjunctivitis, as prophylaxis, postoperatively in ophthalmic surgery, and pain modulation for managing corneal abrasions. It has been demonstrated that although the potential for delayed wound healing exists, this is not a practical impediment to administering topical ketorolac (0.4%) to patients with small corneal abrasions. In addition, the lower concentration (0.5% was the original) is responsible for fewer instances of minor and transient ocular irritation on instillation.

A more significant side effect has been reported with topical diclofenac ophthalmic solution. Keratolysis (corneal melting) was associated with a small number of cases in high-risk patients after ophthalmic surgery. Responsibility for this side effect has been attributed subsequently to the vitamin E-based solubilizer/preservative in the generic formulation, which has been withdrawn from the marketplace.

### Clinical Uses

The most widely prescribed topical NSAID is ketorolac (Acular-LS 0.4%). Its FDA labeling is for the reduction of ocular pain and discomfort after corneal refractive surgery. Among its off-label applications are treatment of acute and chronic postoperative CME, seasonal allergic conjunctivitis, giant papillary conjunctivitis, and inflamed pterygia.

FDA approval of Ocufer (0.03% flurbiprofen, Allergan) in 1986 represented the first approved topical ophthalmic NSAID in the United States. The indication was maintenance of pupil dilation during cataract surgery. Off-label uses were rapidly discovered and reported. These included postoperative pseudophakic CME management. A trial to mitigate the inflammatory component of dry eye syndrome, however, has proven flurbiprofen less useful than either tear supplements alone or in combination with topical ophthalmic steroids. Other adjunctive paradigms such as topical ketorolac with topical cyclosporine A may show a more favorable outcome.

Suprofen 1% (Profenal, Alcon) was approved also for the maintenance of pupil dilation during cataract surgery. It, too, has found many other applications. These include treatment of pseudophakic CME.

Diclofenac sodium 0.1% (Voltaren, Ciba), one of the topical ophthalmic NSAIDs derived from oral formulations,

was also approved initially for the maintenance of pupil dilation during cataract surgery. However, it too has found a host of alternative applications, such as management of post-refractive surgery (photorefractive keratectomy and laser in situ keratomileusis [LASIK]) pain and photophobia. In addition, Voltaren has been reported as an alternative treatment for postoperative cataract surgery inflammation and may have a prophylactic role in contact lens care because it has been shown to inhibit the adherence of *Staphylococcus epidermidis* to soft lens material. Topical diclofenac has also been demonstrated to be superior to dexamethasone or ketorolac for post-strabismus surgery pain management. However, diclofenac has been used in the postoperative period after cataract surgery with mixed results. When combined with gentamicin, it controlled anterior chamber cells and flare at least as well as a topical steroid (dexamethasone), but there was greater superficial punctate staining. Voltaren has also found application in filamentary keratitis. Topical application four times per day for 30 days has been reported to eliminate filaments.

Bromfenac 0.09% (Xibrom, ISTA) has been approved for topical application outside the United States for many years. Bromfenac has compiled an excellent safety record with only 13 reported postmarketing adverse events among 6 million prescriptions written. Perhaps its greatest advantage is reported less initial stinging on instillation (1.5% vs. 20% to 45% for ketorolac 0.4%). The current FDA approval is for the management of postoperative cataract surgery pain.

The first nonsteroidal prodrug for topical ophthalmic application is nepafenac 0.1% (Nevanac, Alcon). It is hydrolyzed to amfenac in the anterior chamber. By this mechanism it reaches higher intraocular concentrations than other topical NSAIDs. In animal models nepafenac has been shown to inhibit prostaglandin synthesis in the retina and choroid after topical administration. For this reason it may have a clinical role in conditions that are caused by prostaglandin-mediated vascular leakage. Nepafenac has been FDA approved for treatment of pain and inflammation associated with cataract surgery.

The topical NSAIDs as a group have demonstrated adjunctive efficacy in several clinical situations. These include synergistic activity with topical cortical steroids after cataract surgery. Amelioration of pain, inflammation, and resolution of CME after cataract surgery has been demonstrated. A similar effect on the mitigation of post-photorefractive keratectomy pain has also been shown. Ketorolac specifically has been suggested for concomitant application with cyclosporine A for the initial treatment of chronic dry eye disease.

In summary, topical NSAIDs currently have application for their analgesic, anti-inflammatory, and antipyretic effects in a variety of ocular inflammatory conditions (Table 12-6). These versatile drugs may be used prophylactically before cataract and other refractive surgical procedures. In addition, suppression of inflammation

**Table 12-6**  
Contemporary Topical NSAIDs

Proprietary Name	Manufacturer	Generic/Concentration	Formulation
Acular-LS	Allergan	Ketorolac/0.4%	Solution
Indocid <sup>a</sup>	MSD	Indomethacin/0.5%	Solution
Nevanac	Alcon	Nepafenac/0.1%	Suspension
Ocufen	Allergan	Flurbiprofen/0.03%	Solution
Profenal <sup>b</sup>	Alcon	Suprofen/1%	Suspension
Voltaren	Ciba	Diclofenac/0.1%	Solution
Xibrom	Ista	Bromfenac/0.09%	Solution

<sup>a</sup>Not commercially available in the United States.

<sup>b</sup>Not commercially available in Canada.

before glaucoma surgery with topical NSAIDs may become routine. Postoperatively, ketorolac has been shown to be useful for treatment of postoperative CME. In the future topical NSAIDs may be combined with antibiotics for other prophylactic and active treatment applications.

### **CYCLOSPORINE A: IMMUNOMODULATOR OF OCULAR SURFACE INFLAMMATION**

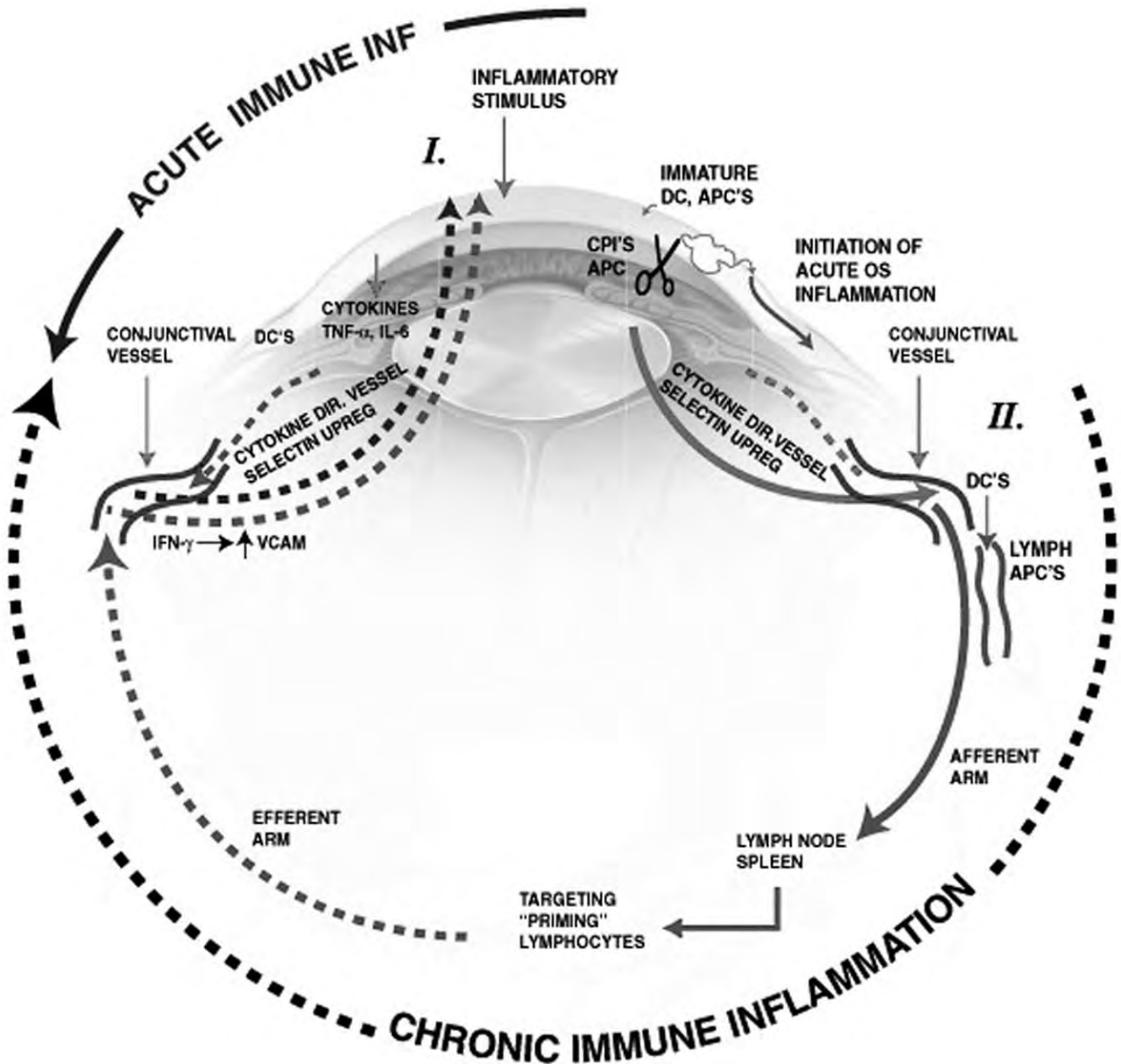
Cyclosporine A (CsA, Restasis 0.05%) was approved in 2002 by the FDA as an ocular therapeutic for patients with keratoconjunctivitis sicca (dry eye). Until 2002 the therapy of choice for the treatment of dry eye was artificial tears and punctal plugs and the occasional use of pulse doses of topical steroids. Artificial tears and punctal plugs brought some temporary relief to patients, but the underlying cause of dry eye, inflammation, was not affected. Steroids carried the threat of a multitude of side effects. With as many as 7.1 million people in the United States alone encountering dry eye symptoms, the development of a therapy that eliminates the inflammatory events associated with the disease has been a significant benefit.

### **Pharmacology**

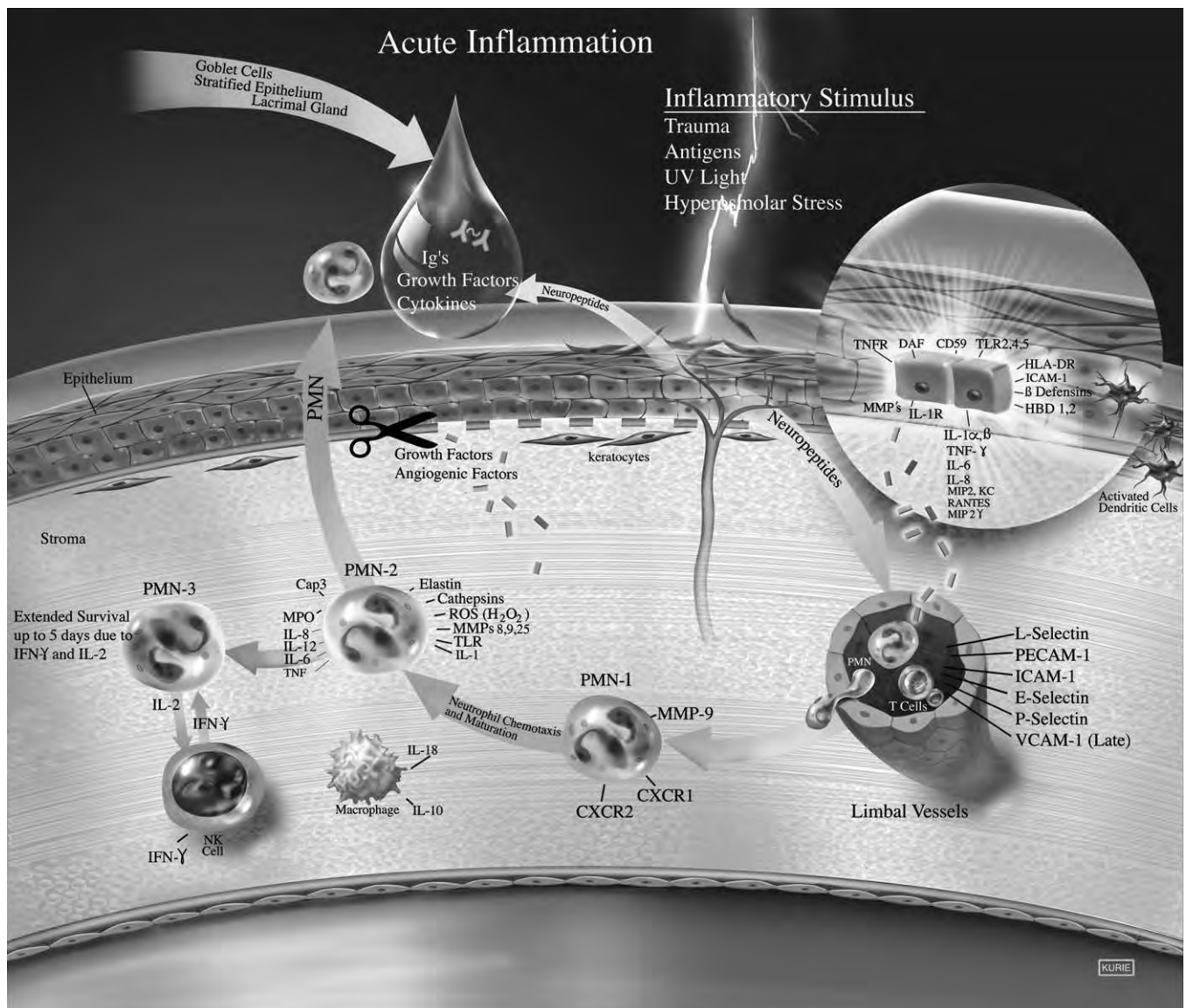
Inflammation of the ocular surface is characterized by acute inflammatory events that occur within 24 hours of being exposed to an offending stimulus and if not controlled can transform into a chronic inflammatory state. In an acute response, in both the cornea and conjunctiva, physical injury to the eye can damage the epithelium, resulting in the release of proinflammatory cytokines from these cells (Figures 12-8 and 12-9). Cytokines are proteins that serve as the main intermediaries of communication among cells of the immune

system and are responsible for many of the functions of immune cells. These inflammatory cytokines upregulate vascular endothelial adhesion molecules such as vascular cell adhesion molecule-1 and platelet endothelial cell adhesion molecule-1, thereby enhancing the movement of immune cells from the limbal vessels into the ocular surface (see Figure 12-9).

In a susceptible individual, a chronic response develops after the acute response, if the irritant cannot be eliminated or is constantly recurring and inflammatory cytokine levels persist. Chronic inflammation can result in tissue damage due to the irritant itself, but also by the constant presence of inflammatory cytokines. Immune-mediated inflammation can be characterized by the types



**Figure 12-8** Ocular acute and chronic inflammation. *I.* Inflammatory insult to the eye induces an acute immune-mediated inflammation due to the production and secretion of inflammatory cytokines. These proinflammatory cytokines activate immature antigen-presenting cells and initiate an increase in adhesion molecule expression and selectins by the conjunctival vascular endothelium. This up-regulation of adhesion molecules enhances recruitment of inflammatory cells to the ocular surface. *II.* Chronic immune inflammation involves antigen processing by ocular antigen-presenting cells that then migrate via the conjunctival lymphatics and veins to the regional lymph nodes and spleen. Within these lymphoid organs, the antigen-presenting cells can prime naïve T cells. Once the CD4+ T cells are primed, they migrate back to the conjunctiva where they produce and release proinflammatory cytokines, including interferon- $\gamma$ , which serve to amplify the immune-mediated inflammatory response. (From McDermott AM, Perez V, Huang AJ, et al. Pathway of corneal and ocular surface inflammation: a perspective from the Cullen Symposium, *Ocul Surf* 2005;Oct;3(4 Suppl):S131-138.)

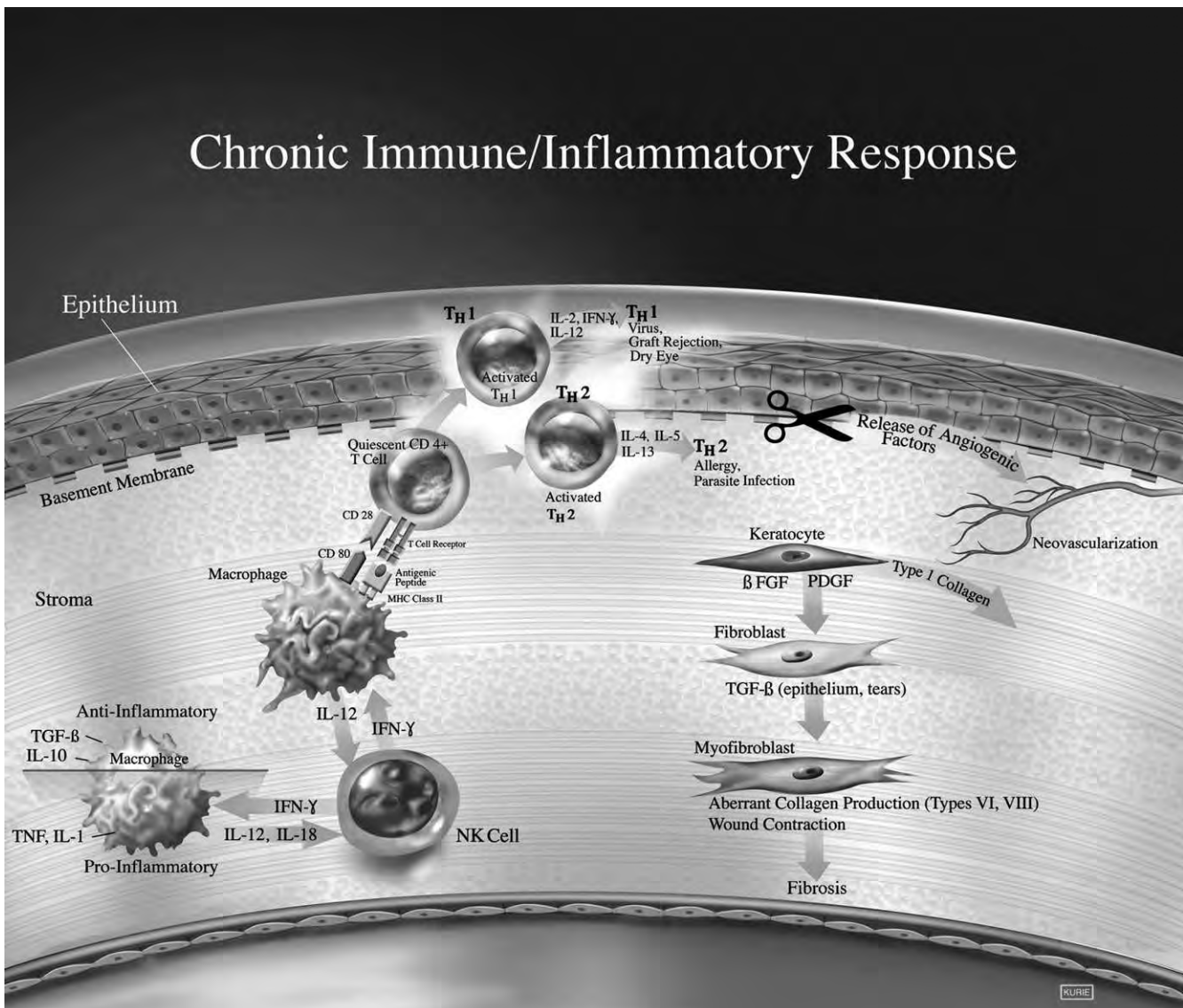


**Figure 12-9** Corneal acute inflammation. *Inset:* Corneal epithelial cells that have been activated by proinflammatory molecules. Activated cytokines disperse through the stroma and in the limbal vessels. Proteases (represented by the *large scissors*) can damage the basement membrane, leading to growth factor and angiogenic factor release. (From McDermott AM, Perez V, Huang AJ, et al. Pathways of corneal and ocular surface inflammation: a perspective from the Cullen Symposium, *Ocul Surf* 2005;Oct;3(4 Suppl):S131-138.)

of phlogistic proteins present at the site of tissue damage. Ocular surface inflammation can be associated with CD4+ T-cell activation. In 1986 the existence of two subsets of T cells were reported, called T helper 1 ( $T_H1$ ) and T helper 2 ( $T_H2$ ) cells. These cells were classified into either  $T_H1$  or  $T_H2$  type T helper cells based on the types of cytokines they produced.  $T_H1$  cells produce interferon- $\gamma$  (IFN- $\gamma$ ) and tumor necrosis factor- $\alpha$ .  $T_H2$  cells produce interleukin (IL)-4, IL-5, and IL-13. T cells are activated by recognizing antigen in the context of MHC class II molecules on antigen-presenting cells such as macrophages. Antigen-presenting cells infiltrate the inflamed tissue toward the end of the acute response. These cells engulf the foreign antigen, process the antigen into peptides, and present these peptides in the context of their MHC class II molecules. T cells with antigen-specific T-cell receptors

recognize the antigen in the MHC class II molecule, and in combination with interaction of costimulatory molecules the T cell becomes activated (Figure 12-10). The differentiation of CD4+ T cells into  $T_H1$  or  $T_H2$  cells is controlled by the cytokine expression at the site of injury. For dry eye the desiccating atmosphere on the ocular surface promotes a  $T_H1$ -inducing environment.

Dry eye results from an unstable tear film or tear evaporation, which results in damage to the ocular surface. The Unified Theory published in 1998 provided the basis for understanding dry eye as an inflammatory disease of the integrated lacrimal functional unit. The lacrimal functional unit consists of the ocular surface (cornea, meibomian glands, and conjunctiva), main and accessory lacrimal glands, and their interconnecting nerves. In the healthy state the lacrimal functional unit maintains a



**Figure 12-10** Chronic immune-mediated inflammatory response. (From McDermott AM, Perez V, Huang AJ, et al. Pathways of corneal and ocular surface inflammation: a perspective from the Cullen Symposium, *Ocul Surf* 2005;Oct;3(4 Suppl): S131-138.)

healthy stable tear film on the ocular surface. A healthy patient secretes a normal tear film when the dense population of free nerve endings of the corneal surface is stimulated. This stimulation induces afferent nerve impulses to the central nervous system. Within the central nervous system these impulses are integrated through cortical and other systems and then result in the efferent secretomotor impulses that are sent to the main and accessory lacrimal glands. If the components of the lacrimal functional unit face an inflammatory environment, the secreted tear film constituents are altered, thereby destabilizing the tear film that is required for maintaining, protecting, and supporting the ocular surface. Inflammatory cytokines can be secreted by epithelial cells of the ocular surface and infiltrating lymphocytes into the lacrimal functional unit. These inflammatory cytokines have the ability to hinder neural transmission both directly and indirectly. The composition of the tear

film changes from “ocular surface supportive” to “proinflammatory.”

Dry eye patients express a number of inflammatory cytokines in the tear fluid, including tumor necrosis factor- $\alpha$  and IFN- $\gamma$ , displaying a classical Th1 response. IL-1, IL-6, and IL-8 have also been detected in the tear fluid of dry eye patients. Patients with allergic conjunctivitis express IL-4, a Th2 type cytokine. For many years this clear-cut classification was applied to diseases such as systemic lupus erythematosus, which was believed to be Th2 in nature due to the high levels of autoantibodies. Recent reports, however, have contradicted this classification, instead showing the absolute requirement of the Th1 cytokine IFN- $\gamma$  in systemic lupus erythematosus. In another example, allergic conjunctivitis has been thought to be a Th2-mediated disease. New research has shown the importance of IFN- $\gamma$  and IL-12 in allergic conjunctivitis in a murine model of allergic conjunctivitis.



Another example is the role of  $T_H2$  in enhancing graft rejection, in which  $T_H2$  cytokines are found to play an important role in corneal graft rejection in atopic individuals. Ocular surface inflammation can be exacerbated when both  $T_H1$  and  $T_H2$  type diseases occur simultaneously. For example, many dry eye patients experience severe ocular allergy.

Cyclosporine binds to cyclophilin within T cells. The CsA-cyclophilin complex then binds to calcineurin and inhibits calcineurin's activity required for the dephosphorylation of regulatory proteins necessary for the transcription and production of proinflammatory cytokines (IL-2, IL-4, IFN- $\gamma$ , and tumor necrosis factor- $\alpha$ ) from T-helper cells. CsA prevents pathologic apoptosis of the tear-secreting epithelia by preventing the ability of the mitochondrial permeability transition pore to open, a required step in the apoptotic process.

### Clinical Uses

CsA is used in transplant patients by oral administration. Although CsA is a positive therapeutic for transplantation patients, complete body immunosuppression is neither required nor desired for treating ocular surface inflammatory events. To avoid potential side effects of systemic immunosuppression, an emulsion was designed to permit a suitable vehicle for drug delivery topically to the ocular surface. Because of the lipid-soluble properties of cyclosporine, it is capable of residing in the epithelium of the cornea after topical administration. Topical treatment with cyclosporine results in accumulations of CsA on the ocular surface at 0.236 mg/kg. Cyclosporine is a hydrophobic cyclic undecapeptide. Because of the hydrophobicity of cyclosporine, the ophthalmic formulation includes a castor oil-water emulsion, glycerin, and polysorbate 80 and the pH is buffered with sodium hydroxide. This formulation permits the maintenance of ocular retention time at about 2 hours. High levels of cyclosporine were detectable in the conjunctiva, cornea, and lacrimal glands (502, 452, and 89.3 ng/ml, respectively) of dogs treated twice daily with 35  $\mu$ l of 0.05% CsA in castor oil-water emulsion at 20 minutes to 1 hour after topical application. Intraocular levels were very low (9 ng/ml or less). Based on the observation that cyclosporine is not metabolized in dog or rabbit eyes, humans are not anticipated to metabolize cyclosporine on the ocular surface.

### Animal Models of Ocular Surface Inflammation

The original beneficial properties of CsA for ocular surface inflammation were first determined in dogs with dry eye. Conjunctival biopsies taken from dogs with spontaneous chronic idiopathic dry eye contained numerous CD3+ T cells. The lacrimal acinar and conjunctiva epithelial cells of dogs with dry eye underwent apoptosis, whereas the infiltrating inflammatory CD4+ T cells

had a much lower rate of apoptosis comparatively. This lack of apoptosis within the lymphocytic population allows for amassing of these inflammatory cells. CsA was shown to enhance the apoptosis of inflammatory lymphocytes on the ocular surface, and lacrimal acinar and conjunctival epithelial cell survival was restored.

Dry eye can result from a single phenomenon or as a secondary event associated with different types of autoimmune diseases. The autoimmune disease that is most closely associated with dry eye is Sjögren's syndrome, with the phenotype of the disease including CD4+ T-cell infiltration into the lacrimal and submandibular glands. The MRL/lpr mouse, which contains a defective Fas receptor, has severe CD4+ T-cell infiltration into the lacrimal gland. Female mice of this strain have more severe lacrimal gland cellular infiltration as compared with male mice. Animal models of dry eye that induce inflammation in the lacrimal functional unit in pathologic ways similar to that seen in humans provide a platform to evaluate the mechanisms of dry eye disease.

### Human Studies

For treatment of dry eye, topical cyclosporine (Restasis) is supplied as a 0.05% ophthalmic emulsion in 32 preservative-free vials per tray. Dosage is one drop twice daily. In an FDA phase II clinical trial, both eyes of 129 patients were treated with CsA (0.05%, 0.1%, 0.2%, and 0.4%) twice daily. Of these, 33 patients received vehicle. A subgroup consisting of 90 patients had moderate to severe dry eye at baseline. Thirty-two percent of the patients in this subgroup had Sjögren's syndrome. At all CsA concentrations tested, a significant improvement in ocular signs and symptoms, including rose bengal staining, superficial punctate keratitis, and a feeling of grittiness, dryness, and itching at the ocular surface, were reported. For objective end points, 0.1% CsA gave the best results. The most improvement seen with patient symptoms was reported at 0.05%. There was no identifiable dose-response in this study.

Two FDA phase III clinical trials evaluated 0.05% CsA, 0.1% CsA, or vehicle in 877 patients with moderate to severe dry eye over a 6-month treatment period. With both 0.05% and 0.1% CsA, there was a significant improvement in categorized Schirmer values and corneal fluorescein staining as compared with the vehicle-treated group. In 15% of the patients receiving CsA, patients had high Schirmer values with anesthesia test scores that were 10 mm or greater than baseline. The vehicle group had only 5% of patients with a Schirmer value that improved more than 10 mm ( $p < .01$ ). Both 0.05% and 0.1% CsA had high safety profiles and no adverse systemic effects, except 17% of patients did experience a burning sensation after CsA treatment. In an extension study of these patients, it was reported that continued use of CsA for 1 to 3 years was safe and well tolerated, with no association with systemic side effects. In dry eye

patients there is an increase in inflammatory markers, including lymphocytic infiltration (CD3+, CD4+, and CD8+ T cells), HLA-DR, HLA-DQ, and intracellular adhesion molecule-1, in both patients with Sjögren's syndrome and patients without Sjögren's syndrome. These inflammatory markers and other inflammatory cytokines decrease in the presence of CsA treatment.

### Other Ocular Uses

Systemic treatment with cyclosporine at concentrations of 2 to 15 mg/kg/day alleviates inflammation associated with Behçet's disease, uveitis, and bird-shot retinochoroiditis. Unfortunately, systemic administration of cyclosporine can lead to severe side effects, including renal dysfunction, hypertension, and high serum creatine. Because of these side effects, topical treatment with cyclosporine significantly reduces these potential risks. Topical cyclosporine administration does not result in sufficient intraocular delivery of this agent. CsA has no inhibitory effect on phagocytic cells, whereas corticosteroids do. This maintenance of the phagocytic system in the presence of CsA permits the body to continue fighting microbial infections. Although CsA has been approved only for dry eye treatment, the drug holds many promising therapeutic alternatives for other ocular inflammatory events.

Sympathetic ophthalmia, once associated primarily with traumatic injury as the most common initiating event, can now also be associated with ocular surgery, especially vitreoretinal surgery. Immune dysregulation is now considered to be the primary etiologic mechanism of sympathetic ophthalmia. Exposure to and recognition of ocular self-antigens expressed by choroidal melanocytes initiates an autoimmune inflammatory response. CD4+ and CD8+ T cells infiltrate and mediate the inflammation in sympathetic ophthalmia. The first treatment for sympathetic ophthalmia is often systemic steroid treatment. If this treatment fails or responds poorly, cyclosporine can be added or used alone starting at 5 mg/kg/day and can be increased during the remaining presence of inflammation. Sympathetic ophthalmia has a good response when cyclosporine is added to already existing systemic steroid treatment and permits a decrease in steroid dose, thereby reducing the potential for toxic effects.

Until the FDA approval of Restasis, many immune-mediated ocular diseases were managed with systemic administration of immunomodulators. For high-risk keratoplasty patients, systemic CsA and steroids remain the treatment of choice. However, the side effects associated with systemic treatment can be threatening. Prolonged use of topical or systemic steroids can lead to cataracts, high IOP, and delayed wound healing. Topical CsA in corneal graft rejection has shown promise in some studies. A number of studies used combined therapy of CsA and steroids. In one study, eyes were evaluated after pediatric keratoplasty and treatment with either CsA (2% topical) or topical corticosteroids. After 22 grafts in

16 pediatric patients, 9 eyes were treated with CsA (88.9% rejection-free grafts) and 13 eyes served as control (38.5% rejection-free grafts;  $p = .0465$ ). In another study the long-term effect of topical 2% CsA after penetrating keratoplasty was evaluated. High-risk patients received either CsA or no CsA treatment. Both groups received corticosteroid eyedrops postoperatively. The CsA-treated eyes (83 patients, 86 eyes) had a rejection-free survival rate of 80.2%, whereas the control group had 68% survival (95 patients, 97 eyes). From this study it was concluded that topical CsA was effective in preventing graft rejection in a safe manner either alone or in combination with corticosteroid topical treatment.

Conventional treatments for atopic keratoconjunctivitis (AKC) and vernal keratoconjunctivitis (VKC) have not been sufficient to fully arrest the disease process.  $T_H2$  cells predominate in these diseases, and IgE is produced by plasma cells. Although AKC is thought to be primarily  $T_H2$  in nature, there have been detectable levels of IFN- $\gamma$ , a  $T_H1$  type cytokine in AKC patients. VKC is a serious ocular inflammatory event that affects primarily adolescent males. VKC can result in visual impairment associated with inflammation-induced corneal damage. Antiallergic compounds such as cromolyn, nedocromil sodium, and topical antihistamines relieve signs and symptoms associated with the disease. However, these treatments do not target the  $T_H2$  mediators of the inflammatory process. Topical steroids are the most effective treatment, but because of the side effects other non-steroidal anti-inflammatory therapies are being evaluated for the treatment of VKC. One alternative to steroid treatment in severe VKC is topical application of CsA (0.5% to 2%) given four times per day. In this disease, CsA is effective at inhibiting  $T_H2$  cell proliferation and IL-2 production. There is a reduced amount of IL-5 in the presence of CsA treatment, resulting in a loss of eosinophil recruitment to the conjunctiva. In another study, 26 AKC patients and 12 VKC patients were treated with 2% CsA topically two or three times per day along with an antiallergic treatment and lubricants. Clinical signs and symptoms were reduced in both AKC and VKC patients taking CsA. Severe cases of VKC can result in the formation of corneal shield ulcers. Treatment of four corticosteroid-resistant VKC patients with shield ulcers with CsA (0.5% to 2%) four times daily for 6 months was analyzed. In all four cases the ulcers were healing in 10 days using the 2% CsA concentration. The only reported side effect was a burning sensation at the time of administration.

Topical CsA (2%) is a beneficial therapy for symptomatic treatment of Thygeson's superficial punctate keratitis. Topical corticosteroids are generally the first line of treatment. Secondary therapy includes extended-wear contact lenses and CsA. CsA, however, has been shown to be beneficial when used as the primary treatment. In one study long-term use of 2% topical CsA in olive oil (four times a day for 3 months followed by twice daily treatment for 1 month) was evaluated in eight Thygeson's'

superficial punctate keratitis patients. Patients were monitored for 12 to 25 months posttreatment. These eight patients had 5 to 15 corneal lesions before treatment. After CsA treatment there were no detectable corneal lesions. The patients' corneas remained clear after cessation of CsA treatment. Although the etiology of Thygeson's keratitis remains unclear, CsA shows promise in treating the disease without the adverse effects associated with corticosteroids.

LASIK induces dry eye symptoms in 15% to 25% of patients. One potential cause could be a loss of corneal sensation and therefore dysregulation of the lacrimal functional unit and loss of neuroregulatory factors produced by corneal nerves and required for maintaining a healthy epithelium. Loss of corneal sensation in these LASIK patients appears to correlate with decreased tear production, tear film stability, tear clearance, and goblet cell density. The efficacy and safety of LASIK in patients with preexisting dry eye before surgery are not affected by the presence of this condition. However, the symptoms associated with dry eye can be much more severe in these patients. Topical treatment with CsA may reduce the discomfort and pathology associated with LASIK-induced dry eye.

Blepharitis is a chronic condition often associated with dry eye. Currently, treatment of blepharitis consists of tetracycline, doxycycline, minocycline, topical erythromycin, and/or topical corticosteroids. In one study 12 patients were treated with topical CsA or preservative-free artificial tears at one drop twice daily in each eye for 3 months. Patients treated with topical CsA had improvement, but not significantly, in ocular symptoms as compared with the placebo-treated group. However, lid margin vascular injection, telangiectasis, and fluorescein staining were significantly better in the group receiving topical CsA. Most importantly, the number of meibomian gland inclusions was significantly decreased in the topical CsA group.

### Side Effects of Cyclosporine

Overall, studies of topical cyclosporine have demonstrated that the drug is safe and well tolerated. The most common adverse finding is burning and stinging upon instillation, occurring in approximately 17% of patients.

### Contraindications to Cyclosporine

Topical cyclosporine is safe and well tolerated in most patients, and there are no absolute contraindications to its use. It has not been approved for use in children, and the FDA pregnancy category is C.

## SELECTED BIBLIOGRAPHY

### CORTICOSTEROIDS

Androudi S, Letko E, Meniconi M, et al. Safety and efficacy of intravitreal triamcinolone acetonide for uveitic macular edema. AAO Annual Meeting 2003. November 15-18, Anaheim, CA.

- Armaly MF. Genetic factors related to glaucoma. *Ann N Y Acad Sci* 1968;151:861-875.
- Avunduk AM, Avunduk MC, Varnell ED, et al. The comparison of efficacies of topical corticosteroids and non-steroidal anti-inflammatory drops on dry eye patients: a clinical and immunocytochemical study. *Am J Ophthalmol* 2003; 136:593-602.
- Beck RW, Cleary PA, Anderson MA, et al. A randomized, controlled trial of corticosteroids in the treatment of acute optic neuritis. *N Engl J Med* 1992;326:581-588.
- Becker B. The genetic problem of chronic simple glaucoma. *Ann Ophthalmol* 1971;3:351-354.
- Cardillo JA, Melo Jr LAS, Costa RA, et al. Comparison of intravitreal versus posterior sub-Tenon's capsule injection of triamcinolone acetonide for diffuse diabetic macular edema. *Ophthalmol* 2005;112:1557-1563.
- Ciulla TA, Walker JD, Fong DS, Criswell MH. Corticosteroids in posterior segment disease: an update on new delivery systems and new indications. *Curr Opin Ophthalmol* 2004; 15:211-220.
- Jonas JB, Kreissig I, Degearing R. Intraocular pressure after intravitreal injection of triamcinolone acetonide. *Br J Ophthalmol* 2003;87:24-27.
- Leibowitz HM, Kupferman A. Periocular injection of corticosteroids. *Arch Ophthalmol* 1977;95:311-314.
- Leibowitz HM, Kupferman A. Topically administered corticosteroids. Effects on antibiotic-related bacterial keratitis. *Arch Ophthalmol* 1986;98:1287-1290.
- Leibowitz HM, Lass JH, Kupferman A. Quantitation of inflammation in the cornea. *Arch Ophthalmol* 1974;92:427-430.
- Leibowitz HM, Ryan WJ, Kupferman A. Comparative anti-inflammatory efficacy of topical corticosteroids with low glaucoma-inducing potential. *Arch Ophthalmol* 1992;110: 118-120.
- Leopold IH. The steroid shield in ophthalmology. *Trans Am Acad Ophthalmol Otolaryngol* 1967;71:273-289.
- Leopold IH, Purnell JE, Camon EJ. Local and systemic cortisone in ocular disease. *Am J Ophthalmol* 1951;34:361-371.
- MacGregor RR, Sheagren HN, Lipsett MD, Wolff SM. Alternate day prednisone therapy. *N Engl J Med* 1969;280:1427-1431.
- Martins JC, Wilensky JT, Asseth CE, et al. Corticosteroid-induced uveitis. *Am J Ophthalmol* 1974;77:433-437.
- Reichle ML. Complications of intravitreal steroid injections. *Optometry* 2005;76:450-460.
- Rhen T, Cidlowski JA. Antiinflammatory action of glucocorticoids—new mechanisms for old drugs. *N Engl J Med* 2005; 353:1711-1723.
- Weinreb RN, Bloom E, Baxter JD, et al. Detection of glucocorticoid receptors in cultured human trabecular cells. *Invest Ophthalmol Vis Sci* 1981;21:403-407.

## NONSTEROIDAL ANTI-INFLAMMATORY DRUGS

- Assouline M, Renard G, Arne JL, David T, et al. A prospective randomized trial of topical soluble 0.1% indomethacin versus 0.1% diclofenac versus placebo for the control of pain following excimer laser photorefractive keratectomy. *Ophthalmic Surg Lasers* 1998;29:365-374.
- Calder LA, Balasubramanian S, Fergusson D. Topical nonsteroidal anti-inflammatory drugs for corneal abrasions: meta-analysis of randomized trials. *Acad Emerg Med* 2005;12:467-473.

- Chiba T, Kashiwagi K, Chiba N, Tsukahara S. Effect of non-steroidal anti-inflammatory ophthalmic solution on intraocular pressure reduction by latanoprost in patients with primary open angle glaucoma or ocular hypertension. *Br J Ophthalmol* 2006;90:314-317.
- Cupples HP, Lefler WH, Pulido JS, et al. Improvement in visual acuity in chronic aphakic and pseudophakic cystoid macular edema after treatment with topical 0.5% ketorolac tromethamine. *Am J Ophthalmol* 1991;112:514-519.
- Donnenfeld ED, Donnenfeld A. Global experience with Xibrom (bromfenac ophthalmic solution) 0.09%: the first twice-daily ophthalmic nonsteroidal anti-inflammatory drug. *Int Ophthalmol Clin* 2006;46:21-40.
- Flach AJ, Jampol LM, Weinberg D, et al. Topical indomethacin solution versus dexamethasone solution for treatment of inflamed pterygium and pinguecula: a prospective randomized clinical study. *Am J Ophthalmol* 1999;127:148-152.
- Hargrave SL, Jung JC, Fini ME, et al. The possible role of the vitamin E solubilizer in topical diclofenac on matrix metalloproteinase expression in corneal melting. An analysis of postoperative keratolysis. *Ophthalmology* 2002;109:343-350.
- Kraff M, et al. Prophylaxis of pseudophakic cystoid macular edema with topical indomethacin. *Ophthalmology* 1982;89:885-890.
- Lane SS, Modi SS, Lehmann RP, Holland EJ. Nepafenac ophthalmic suspension 0.1% for the prevention and treatment of ocular inflammation associated with cataract surgery. *J Cataract Refract Surg* 2007;33:53-58.
- Lindstrom R. The pharmacologic and pathophysiologic rationale for using NSAIDs in ocular inflammatory disease and ocular surgery. *Int Ophthalmol Clin* 2006;46:7-11.
- Lindstrom R, Kim T. Ocular permeation and inhibition of retinal inflammation: an examination of data and expert opinion on the clinical utility of nepafenac. *Curr Med Res Opin* 2006;22:397-404.
- Perry HD, Donnenfeld ED. An update on the use of ophthalmic ketorolac tromethamine 0.4%. *Expert Opin Pharmacother* 2006;7:99-10.
- Sivaprasad S, Bunce C, Patel N. Non-steroidal anti-inflammatory agents for treating cystoid macular oedema following cataract surgery. *Cochrane Database of Systematic Reviews* 2004, Issue 3. Art. No. CD004239.
- Sivaprasad S, Bunce C, Wormald R. Non-steroidal anti-inflammatory agents for cystoid macular oedema following cataract surgery: a systematic review. *Br J Ophthalmol* 2005;89:1420-1422.
- Damico FM, Kiss S, Young LH. Sympathetic ophthalmic. *Semin Ophthalmol* 2005;20:191-197.
- Fox RI, Stern ME. Sjögren's syndrome: mechanisms of pathogenesis involve interaction of immune and neurosecretory systems. *Scand J Rheumatol* 2002;116:3-13.
- Kawson RL. Characteristics of a canine model of KCS: effective treatment of topical cyclosporine. *Adv Exp Med Biol* 1994;350:583-594.
- Kunert KS, Tisdale AS, Stern ME, et al. Analysis of topical cyclosporine treatment of patients with dry eye syndrome. *Arch Ophthalmol* 2000;118:1489-1496.
- Lemp MA. Report of the national eye institute/industry workshop on clinical trials in dry eyes. *CLAO J* 1995;21:222-232.
- Luo L, Li D-Q, Doshi A, et al. Experimental dry eye induced expression of inflammatory cytokines (IL-1a and TNF-a), MMP-9 and activated MAPK by the corneal epithelium [Abstract]. *Invest Ophthalmol Vis Sci* 2003;44:E-Abstract 1026.
- McDermott AM, Perez V, Huang AJW, et al. Pathways of corneal and ocular surface inflammation: a perspective from the Cullen symposium. *Ocul Surf* 2005;3:S-131-S-138.
- Mosmann TR, Cherwinski H, Bond MW, et al. Two types of murine helper T cell clone. I. Definition according to profiles of lymphokine activities and secreted proteins. *J Immunol* 1986;136:2348-2357.
- Nagra PK, Rapuano CJ, Cohen EJ, Laibson PR. Thygeson's superficial punctate keratitis: ten years' experience. *Ophthalmology* 2004;111:34-37.
- Perry HD, Doshi-Carnevale S, Donnenfeld ED, et al. Efficacy of commercially available topical cyclosporine A 0.05% in the treatment of meibomian gland dysfunction. *Cornea* 2006;25:171-175.
- Pflugfelder SC. Antiinflammatory therapy for dry eye. *Am J Ophthalmol* 2004;137:337-342.
- Reinhard T, Sundmacher R. Topical cyclosporine A in Thygeson's superficial punctate keratitis. *Graefes Arch Clin Exp Ophthalmol* 1999;237:109-112.
- Sall K, Stevenson OD, Munford TK, et al. Two multicenter randomized studies of the efficacy and safety of cyclosporine ophthalmic emulsion in moderate to severe dry eye disease. *CsA phase 3 study group. Ophthalmology* 2000;107:631-639.
- Stern ME, Beuerman RW, Fox RI, et al. The pathology of dry eye: the interaction between the ocular surface and lacrimal glands. *Cornea* 1998;17:584-589.
- Stern ME, Gao J, Siemasko KF, et al. The role of the lacrimal functional unit in the pathophysiology of dry eye. *Exp Eye Res* 2004;78:409-416.
- Stern ME, Siemasko KF, Niederkorn JY. The Th1/Th2 paradigm in ocular allergy. *Curr Opin Allergy Clin Immunol* 2005;5:446-450.
- Stevenson D, Tauber J, Reis BL. Efficacy and safety of cyclosporine A ophthalmic emulsion in the treatment of moderate-to-severe dry eye disease: a dose-ranging study, randomized trial. The cyclosporine A phase 2 study group. *Ophthalmology* 2000;107:967-974.
- Stonecipher K, Perry HD, Gross RH, et al. The impact of topical cyclosporine A emulsion 0.05% on the outcomes of patients with keratoconjunctivitis sicca. *Curr Med Res Opin* 2005;21:1057-1063.
- Strong B, Farley W, Stern ME, Pflugfelder SC. Topical cyclosporine inhibits conjunctival epithelial apoptosis in experimental murine keratoconjunctivitis sicca. *Cornea* 2005;24:80-85.

### **CYCLOSPORINE A: IMMUNOMODULATOR OF OCULAR SURFACE INFLAMMATION**

- Barber LD, Pflugfelder SC, Tauber J, et al. Phase III safety evaluation of cyclosporine 0.1% ophthalmic emulsion administered twice daily to dry eye disease patients for up to 3 years. *Ophthalmology* 2005;112:1790-1794.
- Bielory L. Ocular allergy and dry eye syndrome. *Curr Opin Allergy Clin Immunol* 2004;4:421-424.
- Cetinkaya A, Akova YA, Dursun D, Pelit A. Topical cyclosporine in the management of shield ulcers. *Cornea* 2004;23:194-200.
- Cosar CB, Laibson PR, Cohen EJ, Rapuano CJ. Topical cyclosporine in pediatric keratoplasty. *Eye Contact Lens* 2003;29:103-107.

Theofilopoulous AN, Koundouris S, Kono DH, Lawson BR. The role of IFN-gamma in systemic lupus erythematosus: a challenge to the Th1/Th2 paradigm in autoimmunity. *Arthritis Res* 2001;3:136-141.

Vroman DT, Sandoval HP, Fernandez de Dastro LE, et al. Effect of hinge location on corneal sensation and dry eye after laser in situ keratomileusis for myopia. *J Cataract Refract Surg* 2005;31:1881-1887.

## *Antiallergy Drugs and Decongestants*

*Diane T. Adamczyk and Siret D. Jaanus*

The eye is a common site of allergic responses, reflecting immune reactions that have a potential range of clinical manifestations. The conjunctiva is most frequently involved in ocular allergy, but the lids and cornea may also be affected. Pharmacologic management is directed at alleviating the signs and symptoms of ocular allergy and is based on the pathophysiologic mechanisms of allergy.

### **ALLERGIC IMMUNOLOGY: THE PHARMACOLOGIC FOUNDATION**

The immune system provides a defense mechanism against antigens, or substances that are recognized as foreign to the body. Allergens, such as pollen, ragweed, or animal dander, are antigens that initiate an allergic response in a susceptible or atopic individual. When the immune system encounters an antigen for the first time, a memory response is formed, typically without clinical manifestations. As a result of this memory response, subsequent antigen reexposures result in a rapid immune reaction. A normal immune response acts to remove an antigen, with an inflammatory reaction that has a minimum amount of tissue damage. In contrast, hypersensitivity or allergic reactions are inappropriate exaggerated immune responses to antigen that result in tissue damage.

Although there are five types of hypersensitivity responses, two of these, types I and IV, play a significant role in the pathophysiology of allergic eye disease. The ocular manifestations include seasonal allergic conjunctivitis (SAC), giant papillary conjunctivitis (GPC), vernal keratoconjunctivitis (VKC), atopic keratoconjunctivitis, contact dermatitis, and urticaria. These are discussed in Chapter 27.

### **Type I Hypersensitivity Response**

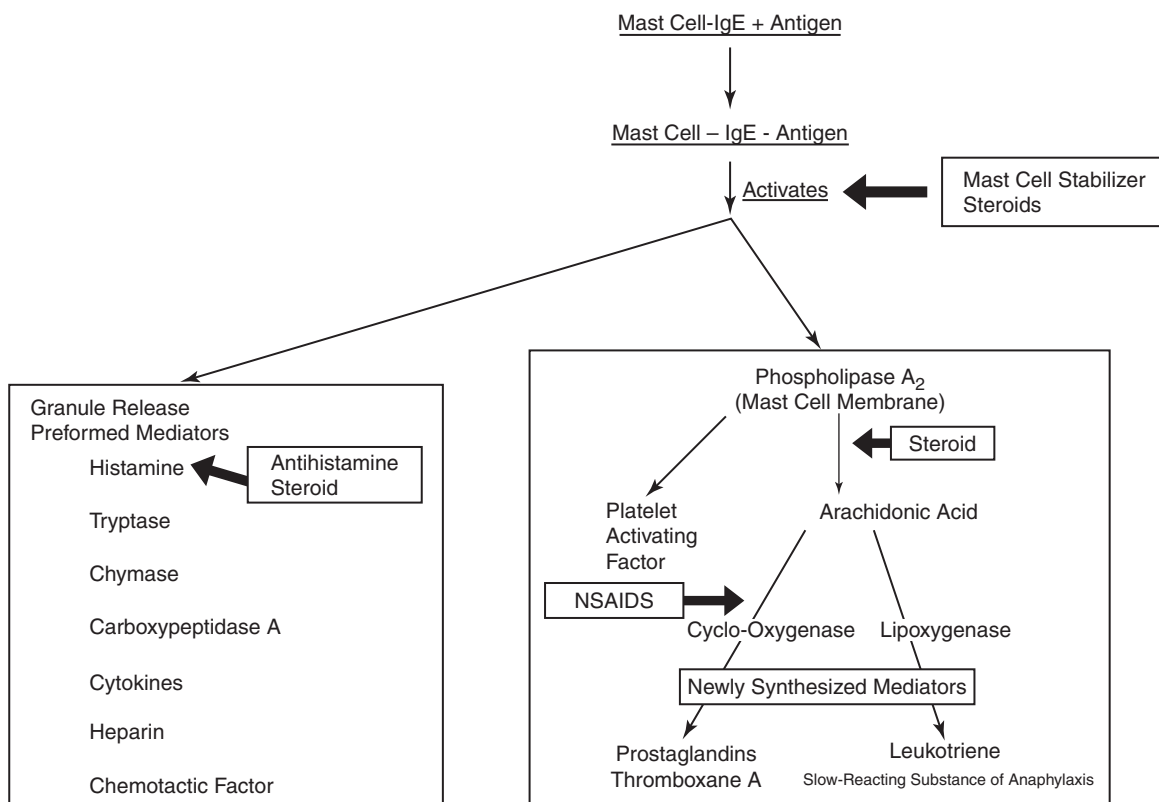
In a type I or humoral hypersensitivity response, the allergen activates the B lymphocyte. Immunoglobulin E (IgE) is produced and binds to the surface of mast cells and basophils, causing them to become sensitized (Figure 13-1).

The cell membrane becomes more permeable to calcium ions, resulting in the entry of calcium into the cell. This then triggers phospholipase A<sub>2</sub> in the mast cell, which results in mast cell degranulation and preformed mediator release. It also triggers the breakdown of membrane phospholipids to arachidonic acid. Arachidonic acid from the plasma membranes is converted via the cyclooxygenase pathway to form prostaglandins, prostacyclin, and thromboxane A and is converted via the lipoxygenase pathway to form leukotrienes. Mediators of type I hypersensitivity responses include histamine, serotonin, eosinophil chemotactic factor, neutrophil chemotactic factor, proteases, leukotriene, prostaglandins, bradykinin, tryptase, and cytokines. Cytokines that are synthesized and released by mast cells include interleukin-4, -5, -6, -8, and -13; platelet activating factor; and tumor necrosis factor. Eosinophils and neutrophils enter the sequence, inflammation occurs, along with secretion of mucus, smooth muscle contraction, vasodilation, increased vascular permeability, and itching.

Type I hypersensitivity reactions usually occur within minutes to hours of exposure to an antigen in sensitized individuals. The immediate allergic response is initiated 5 to 30 minutes after allergen exposure and resolves in 30 to 60 minutes. This may be followed by the late-phase reaction, which is more severe and of greater duration. The late phase develops 4 to 6 hours after the initial response and may last up to 2 days. Neutrophils, eosinophils, macrophages, lymphocytes, basophils, and mast cells are involved in the late-phase inflammatory reaction, resulting in tissue damage.

### **Histamine and Histamine Receptors**

As noted, mast cells and their mediators are integral components of the allergic response. Histamine, the main mediator involved in type I allergic reactions, is released from mast cells and basophils. Histamine is synthesized and stored in nearly all tissues, with especially high concentrations in the lungs, skin, stomach, duodenum, and nasal mucosa. Histamine causes smooth muscle contraction, increased vascular permeability, vasodilation,



**Figure 13-1** Sequence of events involving mast cell activation and the mediators released, along with where pharmacologic intervention takes place.

and sensory nerve stimulation. Histamine release can result in a range of clinical manifestations, from life-threatening anaphylactic shock to the relatively benign presentations of rhinitis, itching, tearing, and conjunctival hyperemia. The result clinically is bronchoconstriction, rhinitis, sneezing, itching, hyperemia, headache, urticaria (hives), angioneurotic edema, and anaphylactic shock. Histamine also causes hypotension, tachycardia, and decreased atrioventricular node conduction time.

Four types of histamine receptors have been identified:  $H_1$ ,  $H_2$ ,  $H_3$ , and  $H_4$ .  $H_1$  and  $H_2$  are best understood and involved in the allergic response.

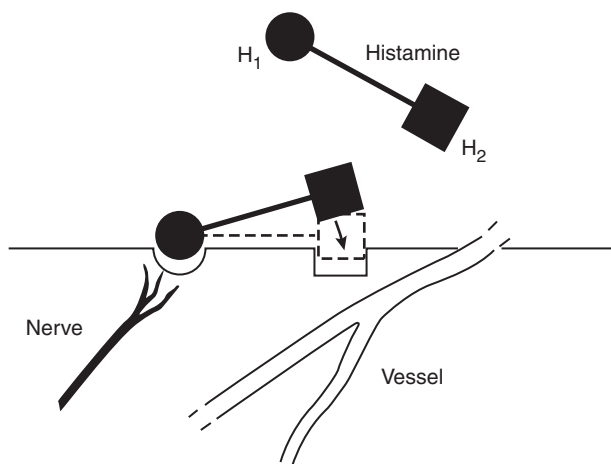
$H_1$  receptors occur in many tissues, including the smooth muscle of bronchi, blood vessels, and intestine.  $H_2$  receptors play a major role in the secretory function of gastric parietal cells and have also been identified in the heart, pulmonary blood vessels, cells of the immune system, and the eye (Table 13-1 and Figure 13-2). Many tissues contain both  $H_1$  and  $H_2$  receptors, and the effects of simultaneously stimulating both may be antagonistic or complementary, depending on the specific tissue. When stimulated,  $H_1$  receptors cause vasodilation, increased vascular permeability, itching, and contraction of smooth muscle in the gastrointestinal tract and bronchi;  $H_2$  receptors cause vasodilation, itching, mucous discharge, and gastric secretion.

In the eye histamine release produces characteristic manifestations of ocular allergy: itching, which results

from conjunctival nerve stimulation; tearing; chemosis; conjunctival and lid edema; dilation of conjunctival blood vessels; and a papillary reaction. In animal studies topically administered or injected histamine produces hyperemia and edema in the uvea and conjunctiva, increased intraocular pressure (IOP), mild pupillary constriction, and in some cases breakdown of the blood-aqueous barrier.

**Table 13-1**  
Distribution of  $H_1$  Receptors

Histamine Receptor	Tissue
$H_1$	Bronchial smooth muscle
	Heart
	Central nervous system
	Mucous membranes
	Eye (blood vessels)
$H_2$	Gastric parietal cells
	Heart
	Blood vessels
	Mast cells
	Eyes (blood vessels)
	Bronchial smooth muscle
Central nervous system	
	White blood cells



**Figure 13-2** Histamine receptor subtype location on neuronal and vascular tissues. Activated  $H_1$  receptors are associated with neuronal tissue and result mainly in itching.  $H_2$  receptors are associated with vascular tissue and result primarily in redness. (Adapted from Abelson MB, Schaefer K. Conjunctivitis of allergic origin: immunologic mechanisms and current approaches to therapy. *Surv Ophthalmol* 1993;38:115-132.)

### Type IV or Cell-Mediated Immune Response

In a type IV or cell-mediated immune response, a delayed hypersensitivity reaction occurs involving the T lymphocyte, with an onset ranging from 12 to 72 hours. In a type IV response antigen-presenting cells, such as Langerhans cells, present antigen to the T cell, resulting in the T-cell activation. Sensitization takes 1 to 2 weeks after first exposure to the antigen. Upon antigen reexposure, cytokines, such as interleukin and interferon, are released. The cytokines activate macrophages, resulting in a cytotoxic response through increased phagocytic activity and lytic enzymes. The delayed hypersensitivity response takes 24 hours, peaking at 48 to 72 hours.

### Treatment Options for Allergic Eye Diseases

In general, treatment of ocular allergic disease is based on symptoms, severity, and characteristics of the allergic reaction. A stepped-care approach to therapy has been advocated, whereby treatment aggressiveness is tailored to the level of disease. When possible, avoidance of environmental allergens such as pollen, dust, and grasses is a key factor in management.

Among the treatment options, topical decongestants, topical and oral antihistamines, mast cell stabilizers, dual-action/multi-action drugs, and certain nonsteroidal anti-inflammatory agents have proven useful for alleviating the signs and symptoms associated with ocular allergic reactions. Homeopathic preparations have also become of interest to the ophthalmic community, and their scientific

merits are being scrutinized. Corticosteroids and immunosuppressive agents, representing the most effective agents for severe ocular inflammatory reactions, are discussed in Chapter 12.

## DECONGESTANTS

The synthetic adrenergic agonists—phenylephrine, naphazoline, oxymetazoline, and tetrahydrozoline—are available as ocular decongestants (Table 13-2). After topical application to the eye, constriction of conjunctival blood vessels occurs at drug concentration levels that generally do not cause pupillary dilation. These agents provide only palliative therapy, because they have no effect on the conjunctival response to antigen.

### Pharmacology

Phenylephrine, the oldest of the currently available agents, is a synthetic adrenergic agonist. It differs chemically from epinephrine by the absence of the hydroxyl group on position 4 of the benzene ring. At the concentrations used for ocular decongestion, phenylephrine causes vasoconstriction by direct stimulation of  $\alpha$ -adrenergic receptors on the conjunctival vasculature. The resultant clinical effect is usually a decrease in conjunctival hyperemia and edema.

At the 0.12% concentration used for ocular decongestion, phenylephrine can occasionally dilate the pupil. This effect is most likely to occur if the corneal epithelium is compromised. Moreover, with long-term use phenylephrine can cause a rebound conjunctival congestion and result in conjunctivitis medicamentosa. For this reason the use of phenylephrine has declined.

Classified chemically as imidazole derivatives, naphazoline, oxymetazoline, and tetrahydrozoline differ structurally from other adrenergic agonists by replacement of the benzene ring with an unsaturated ring. In general, these agents exhibit greater  $\alpha$ - than  $\beta$ -adrenergic receptor activity. After topical application to the eye, they induce a marked vasoconstriction. The imidazole derivatives seem to have a clinical advantage over phenylephrine in that they are less likely to induce rebound congestion and pupillary dilation.

Phenylephrine and the imidazole derivatives are chemically compatible with a variety of compounds. They can be combined in ophthalmic formulations with antihistamines, corticosteroids, and antimicrobial agents.

### Clinical Uses

The various clinical effects of phenylephrine and the imidazole derivatives have been studied. The ability of several ocular decongestant formulations to counteract histamine-induced erythema was compared. Phenylephrine 0.12%, tetrahydrozoline 0.05%, and naphazoline ranging in concentrations from 0.012% to 0.1% were tested in a double-masked fashion in human eyes with no ocular disease. All preparations tested produced



**Table 13-2**  
Ophthalmic Decongestant Preparations

Generic Name	Trade Name (Examples)	Concentration (%)	Duration (hr)	Dosage	Pregnancy Category	Pupil Effect	IOP Effect	Other
Synthetic adrenergic agonist								
Phenylephrine HCl	Relief	0.12	0.5-1.5	QID	C	May dilate	Minimum to none	More likely rebound vs. imidazole
Imidazoles								
Naphazoline HCl	Clear Eyes Naphcon VasoClear All Clear AR AK-Con AlbalonVasocon Regular Visine LR	0.012 0.02 0.03 0.1	3-4 3-4 3-4 3-4	QID QID QID QID	C C C C	None	May increase slightly	
Oxymetazoline HCl	Visine LR	0.025	4-6	Q6H	C	None	None	No affect accommodation
Tetrahydrozoline HCl	Collyrium Fresh Eyesine Visine	0.05	1-4	QID	C	None	May decrease	No affect accommodation

blanching of the conjunctiva. Naphazoline 0.02%, however, produced greater blanching of the conjunctiva than other nonprescription decongestants containing 0.05% tetrahydrozoline or 0.12% phenylephrine. No significant differences were observed between the 0.02% concentration and higher concentrations of naphazoline such as 0.1%.

Higher concentrations of naphazoline, either alone or in combination with an antihistamine, have been compared with placebo in normal eyes and eyes congested from various causes. The effects of 0.1% naphazoline were studied in more than 100 subjects with both normal and congested eyes. Slit-lamp evaluation revealed constriction of the conjunctival vessels, with no effect on the deeper vessels. At this concentration, however, an increase in pupil size occurred in 68 of 120 eyes, and 20 eyes demonstrated an increase in IOP of 3 to 7 mm Hg. No accommodative effects were observed with 0.1% naphazoline. In a study using a double-masked design with placebo, the effects of 0.05% naphazoline alone and in combination with 0.5% antazoline phosphate were compared in patients with allergic conjunctivitis. Naphazoline performed better than the placebo on all parameters tested and, except for producing symptoms of itching, was more effective than antazoline alone. Naphazoline was as effective as the combination formulation for relief of conjunctival inflammation.

Tetrahydrozoline has also been evaluated in patients with allergic or chronic conjunctivitis. Tetrahydrozoline 0.05% produced “good” results in 67% and “fair” results in 30% of the cases. Most eyes blanch within 1 minute after instillation, and the effect of a single application can last up to 4 hours. Tetrahydrozoline 0.05% does not appear to alter pupil size or raise IOP.

Three decongestant formulations containing phenylephrine 0.12%, naphazoline 0.012%, or tetrahydrozoline 0.05% were compared in 40 adult subjects with no apparent ocular disease. No significant changes in pupil size or anterior chamber depth occurred. However, tetrahydrozoline 0.05% significantly lowered IOP at 30 minutes, compared with phenylephrine 0.12%, which had only a minimal or no effect. Naphazoline 0.012% produced a somewhat higher average IOP than the control agent.

Oxymetazoline is available as an ocular decongestant at the 0.025% concentration. Oxymetazoline has been demonstrated to be useful in patients with allergic conjunctivitis and has been demonstrated to improve symptoms of burning, itching, tearing, and foreign body sensation in patients with moderate to severe conjunctival hyperemia. Onset of action can be as early as 5 minutes after instillation, with peak effects at 60 minutes, and the effect can last up to 6 hours. Oxymetazoline 0.025% does not seem to alter IOP or affect pupil size or accommodation.

### Side Effects

Transient stinging can occur with all decongestant preparations after instillation. Because of the relatively low

concentrations required for ocular decongestion, systemic side effects occur infrequently. Dosage frequency is generally two to four times daily but should be as infrequent as possible to minimize possible ocular side effects. Pupillary dilation, blurred vision, epithelial erosions, and rebound congestion can occur with extended use. A case series analysis of 70 patients associated conjunctival hyperemia, follicular conjunctivitis, and blepharoconjunctivitis with use of phenylephrine, naphazoline, or tetrahydrozoline for a median of 3 years (range, 8 hours to 20 years). After discontinuation of use, time to resolution of signs and symptoms averaged 4 weeks (range, 1 to 24 weeks). Upper lid retraction has been associated with use of 0.025% oxymetazoline and other decongestants.

### Contraindications

Because these agents are adrenergic agonists, they can potentially affect all target tissues innervated by the adrenergic division of the autonomic nervous system. Caution should be exercised in patients with cardiovascular disease, hyperthyroidism, and diabetes.

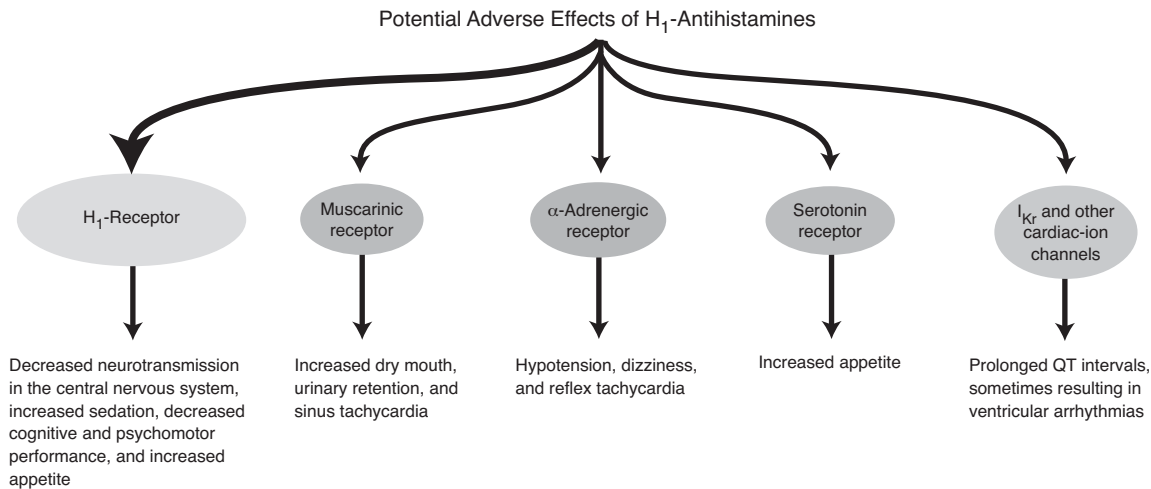
Use of these agents is contraindicated in patients with angle-closure glaucoma or potentially occludable angles. Application to a diseased or traumatized cornea can result in sufficient absorption to cause a systemic vasopressor response.

## ANTIHISTAMINES

### Pharmacologic Actions of H<sub>1</sub> Antihistamines

Antihistamines inhibit the physiologic or pharmacologic actions of histamine and provide relief of signs and symptoms associated with histamine release. These agents block histamine-induced capillary dilation, increase in capillary permeability, and the associated itching and pain and provide relief for urticaria and mucosal congestion. If the dilation and edema have already occurred, administration of these drugs prevents further histamine action but usually does not reverse the clinical manifestations already present. Local anesthetic properties explain some of the antipruritic effects of oral and topical H<sub>1</sub> antihistamines. Although antihistamines may relieve anaphylactic shock and angioedema, the onset of the antihistaminic action is slow. H<sub>1</sub> antihistamines are useful, however, as adjuncts to other agents in preventing development of additional symptoms.

The pharmacologic effect of H<sub>1</sub> antihistamines is to prevent histamine-H<sub>1</sub> receptor interaction. Additionally, other receptors may be affected (Figure 13-3), anti-inflammatory effects may occur, and mast cell and basophil mediator release is prevented. An increased understanding of the pharmacologic mechanism has resulted in H<sub>1</sub> antihistamines being reclassified as inverse agonists.



**Figure 13-3** Potential adverse effects of H<sub>1</sub> antihistamines through central nervous system and effect on various receptors and through ion channels. (I<sub>Kr</sub> = rapid component of the delayed rectifier potassium current.) (Adapted with permission from Simons FER. *Advances in H<sub>1</sub>-antihistamines*. *N Engl J Med* 2004;351:2204.)

## Oral H<sub>1</sub> Antihistamines

### Pharmacology

The first-generation H<sub>1</sub> antihistamines, also referred to as sedating antihistamines, and the second-generation antihistamines, the less or nonsedating antihistamines, are among the most frequently used oral medications for ocular allergies. Table 13-3 lists commonly used oral antihistamines and some of their important pharmacologic properties.

The first-generation antihistamines can depress or stimulate the central nervous system (CNS), with depression more common, especially in adults. Sedation may have an anticholinergic basis, but other central mechanisms are presumed to participate as well.

Penetration of the blood-brain barrier is related to a number of different mechanisms, including drug lipophilicity and low molecular weight. The second-generation antihistamines are less lipid soluble and penetrate the CNS to a lesser extent than the first-generation drugs, with systemic administration resulting in minimal or no sedation. In the brain the first-generation antihistamines have a 50% to 58% H<sub>1</sub> receptor occupancy, in contrast to 20% to 50% for cetirizine and 0% for fexofenadine. Binding to cholinergic and  $\alpha$ -adrenergic receptors is less with second-generation antihistamines. As a result the adverse effects of CNS depression, dry mouth, blurred vision, and tachycardia are less likely to occur. A longer elimination time, for second-generation drugs, allows for a once-a-day dosage. Some of these drugs are metabolites of other drugs. For example, desloratadine is a metabolite of loratadine. These drugs are formulated as syrups, tablets, or capsules, and several are available in sustained- or timed-release form or in combination with the adrenergic agonist pseudoephedrine.

### Clinical Uses

Oral antihistamines provide symptomatic relief of nasal and conjunctival itching, sneezing, congestion, and

watery and red eyes. The oral route of administration helps to ensure drug delivery deep within the affected ocular tissues where topical antihistamines may not penetrate. Oral antihistamines are therefore effectively used in patients with moderate to severe eyelid edema (angioedema) and chemosis. Topical intranasal or ocular administration provides a more direct and rapid route for relief. However, more frequent dosing may be required.

First-generation oral antihistamines are available over the counter or by prescription. Historically, they have been classified by their potential sedative effect as mild, moderate, or strongly sedating. The mildly sedating antihistamines are suitable for daytime use.

The moderately sedating group of antihistamines should not be used when operating hazardous equipment or when good motor and sensory skills are required. Some of these agents, such as clemastine, are moderately potent cholinergic blockers.

Antihistamines that are strongly sedating include diphenhydramine and promethazine. The most widely used, diphenhydramine, is available over the counter. Because these antihistamines are potent cholinergic blocking agents, their most appropriate use is to provide relief of allergic symptoms during sleep. Administration at bedtime and adjustment of dosage can help to eliminate side effects. However, due to central nervous system H<sub>1</sub> receptor blockade, drowsiness can occur the following morning, commonly referred to as “drug hangover.”

Fexofenadine, loratadine, desloratadine, and cetirizine are second-generation antihistamines. These agents are essentially nonsedating or minimally sedating at usual therapeutic doses and are practically devoid of cholinergic-blocking properties (see Table 13-3). In addition to their histamine-blocking properties, they may also inhibit the release of histamine, which may account for some of their therapeutic effectiveness. Second-generation antihistamines have a relatively long half-life, and once- or twice-daily dosing

**Table 13-3**  
Oral H<sub>1</sub> Antihistamines

Drug Generic Name	Trade Name	Anticholinergic Activity	Antiemetic Activity	Adult Dosage (mg)	Pregnancy Category	Onset (hr)	Duration (hr)	Availability/Supplied	Combination
<b>First generation</b>									
<i>Mildly sedating</i>									
Brompheniramine	Generic	Moderate	None	4 mg 4-6x/day	C			OTC	Brompheniramine 2 mg, dextromethorphan 10 mg, and pseudoephedrine 30 mg Brompheniramine 1 mg, dextromethorphan 5 mg, and pseudoephedrine 15 mg
Chlorpheniramine	Chlor-Trimeton	Moderate	None	4 mg QID to q4 hr	B	3	24	OTC	Chlorpheniramine maleate 2 mg, ibuprofen 200 mg, and pseudoephedrine 30 mg Acetaminophen 500 mg, dextromethorphan 15 mg, pseudoephedrine HCl 30 mg, and chlorpheniramine maleate 2 mg Chlorpheniramine 1 mg, dextromethorphan 5 mg, and pseudoephedrine 15 mg Others
<i>Moderately Sedating</i>									
Clemastine	Tavist	Strong	Strong	1.34-2.68 mg BID-TID	B			OTC	
<i>Strongly Sedating</i>									
Diphenhydramine	Benadryl	Strong	Strong	25-50 mg TID-QID	B	2	12	OTC 25 mg	Acetaminophen 500 mg and diphenhydramine HCl 25 mg Acetaminophen 500 mg, diphenhydramine 12.5 mg, and pseudoephedrine 30 mg
Promethazine	Phenergan	Strong	Very strong	6.25-12.5 mg TID	C			12.5, 25, 50 mg	
<b>Second generation</b>									
Fexofenadine	Allegra	None to mild	None	60 mg BID 180 mg QOD	C	2 (1-2)	24	Rx Supplied: 30-, 60-, 180-mg tablets; 60-mg capsule	Also available with pseudoephedrine 120-240 mg

*Continued*

**Table 13-3**  
Oral H<sub>1</sub> Antihistamines—cont'd

Drug Generic Name	Trade Name	Anticholinergic Activity	Antiemetic Activity	Adult Dosage (mg)	Pregnancy Category	Onset (hr)	Duration (hr)	Availability/Supplied	Combination
Loratadine	Claritin	None to mild	None	10 mg QD	B	2 (1.5)	24	OTC Supplied: 5, 10 mg; syrup	Also available with pseudoephedrine 120–240 mg
Desloratadine	Clarinex			5 mg QD	C	2 (0.5–3)	24	Rx Supplied: 5-mg tablet; 2.5-, 5-mg reditab; syrup	Also available with pseudoephedrine 240 mg
Cetirizine	Zyrtec	None to mild	None	5 or 10 QD	B	1 (1–1.5)	24	Rx Supplied: 5-, 10-mg tablet or chewable tablet; syrup	Also available with pseudoephedrine 120 mg

OTC = over the counter; Rx = prescription.

is therefore possible. Because these agents have a minimum sedating effect, they can provide relief while the patient works, operates hazardous equipment, or drives. Several combination formulations are also available with the adrenergic agonist pseudoephedrine (see Table 13-3.)

Fexofenadine has replaced terfenadine, the first non-sedating antihistamine introduced in the United States. Fexofenadine is the active metabolite of terfenadine, and its clinical efficacy is comparable with that of the parent drug. It is well absorbed after oral administration, and serum concentrations peak at 2.5 hours. Fexofenadine is excreted in the bile and urine, and diminished renal function slows its elimination. Because fexofenadine is effective and safe, it is a good first-choice drug for mild to moderate symptomatic patients. When a patient does not respond to one of these antihistamines, a different drug in this category may be tried or switched and still prove to be effective. Fexofenadine offers a good option as a switch drug when another antihistamine is ineffective.

Loratadine is well absorbed after oral administration, with peak plasma concentrations at approximately 1.5 hours. Clinically significant relief of symptoms is usually obtained within 2 to 4 hours of the first dose. Excretion of loratadine occurs almost equally through the urine and feces. This dual mechanism of secretion provides a measure of safety in patients with liver or kidney disease, but caution should be exercised in both groups. Also, torsades de pointes may occur with the concurrent use of loratadine and amiodarone. Desloratadine is a metabolite of loratadine.

Cetirizine is an active metabolite of the first-generation antihistamine hydroxyzine. It is a piperazine derivative. It is rapidly absorbed, reaching peak serum levels after 1 hour. Elimination is primarily through the kidney, with minimal liver metabolism. Cetirizine is the most potent of the second-generation antihistamines; it is a good switch drug in patients who are not responding to other antihistamines and is a good choice in patients whose symptoms are severe. Cetirizine provided the best suppression to antigen-challenged wheal and flare, followed by fexofenadine and then loratadine.

Dosage adjustments may need to be made for the very young and the elderly. Also, those with renal or hepatic impairment need adjusted dosages, because the half-life may be longer in these patients.

### Side Effects and Interactions

Adverse reactions with antihistamines are the result of multiple mechanisms (see Figure 13-3). Muscarinic,  $\alpha$ -adrenergic, and serotonin receptor blockade may result in mydriasis, dry mouth and eyes, urinary retention, constipation, and dizziness in first-generation antihistamines. When the neurotransmitter effect of histamine is interrupted, various CNS adverse reactions may occur. These side effects include increased sedation, decreased cognitive function, decreased psychomotor function, and headache.

Sedation and depression of reflexes and sensory input are the most common side effects of the first-generation oral antihistamines. Alcohol (or other CNS depressants) and antihistamines should not be taken together, because of the synergistic sedative actions of alcohol and  $H_1$  antihistamines. In addition to increasing the actions of CNS depressants, first-generation  $H_1$  antihistamines are additive with the anticholinergics, adrenergic agonists, phenothiazines, and monoamine oxidase inhibitors. Although sedation is much less likely to occur with second-generation antihistamines, cetirizine is 3.5 times more likely to cause sedation than fexofenadine, loratadine, and desloratadine, affecting up to 10% of those treated.

Systemic side effects associated with administration of first-generation antihistamines include palpitations, drying of secretions in the throat and bronchi, and gastrointestinal and urinary tract disturbances such as anorexia, nausea, vomiting, diarrhea or constipation, urinary frequency, and dysuria. Taking the agents with meals can minimize several of these effects. Adjustment of dose or change of drug may also decrease or eliminate these effects.

Ocular side effects relate primarily to the anticholinergic properties of the  $H_1$  antihistamine. Accordingly, one can anticipate decreased secretion of tears and mucus and mydriasis with the potential of acute angle-closure glaucoma. Continued use can bring about decreased accommodation and decreased vision. Usually the therapy can continue, because the effects typically diminish with time.

Allergic reactions to  $H_1$  antihistamines can occur with oral administration but are much more likely after topical use. The ocular allergic signs and symptoms resemble the conditions for which the antihistamine was prescribed. Because of the structural diversity of  $H_1$  antihistamines, an allergic reaction to one agent does not imply hypersensitivity to another  $H_1$  drug. Accordingly, the practitioner can change to another structurally different  $H_1$  antihistamine.

When used in recommended dosages, antihistamines are reasonably safe drugs. Acute toxicity after massive doses is characterized by marked CNS stimulation (convulsions) in children and depression (coma) followed by stimulation (convulsions) in adults. Coma, cardiorespiratory failure, and death follow convulsions in cases of severe toxicity.

Second-generation drugs may be affected by various foods and drugs. Absorption is delayed when cetirizine and loratadine are taken with food. Absorption of fexofenadine is also affected by food. Antacids and grapefruit, orange, and apple juices decrease fexofenadine concentrations and absorption, and erythromycin and ketoconazole increase concentrations. Table 13-4 compares various adverse reactions and interactions of second-generation antihistamines.

### Contraindications

$H_1$  antihistamines are contraindicated in cases of known hypersensitivity reactions to individual agents. Oral preparations are also contraindicated in nursing mothers and in the third trimester of pregnancy. The  $H_1$

**Table 13-4**  
Adverse Reactions and Interactions of Second-Generation Antihistamines

Effect	Cetirizine	Fexofenadine	Desloratadine	Loratadine
Drowsiness, %	13.7	1.3	2.1	8
HA, %	>2	10.6		12
Dry mouth, %	5		3	3
Food effects	Delay	Decreased 25%	No effect	Increased 43%
Drug Interaction	Unlikely	Unlikely Antacid-decrease effect	Unlikely	Unlikely
Protein bind, %	88-90	50-70	73-77	97

Modified in part with Permission from Golightly LK, Greos LS. Second-generation antihistamines. Actions and efficacy in the management of allergic disorders. *Drugs* 2005;65:347-355.

antihistamines are secreted in milk, and infants and neonates appear more susceptible to these drugs' adverse effects. As with all medication, extreme caution should be used in prescribing antihistamines to women in the first 3 months of pregnancy, because risk of fetal malformation is very high. The second-generation antihistamines are generally well tolerated.

Antihistamines that produce sedation should not be used with alcohol or any other sedating drug, such as opioid analgesics. Antihistamines with strong anticholinergic effects should be avoided in patients with peptic ulcer disease, prostatic hypertrophy, or bladder or pyloro-duodenal obstruction and in patients who have the potential for acute angle-closure glaucoma.

### Topical H<sub>1</sub> Antihistamines

Antihistamines currently available for topical ophthalmic use include the first-generation agents pheniramine maleate and antazoline phosphate and the second-generation antihistamines emedastine, azelastine, ketotifen, and olopatadine. The latter three have dual action, which includes a mast cell-stabilizing effect.

### Pharmacology and Clinical Uses

The first-generation antihistamines (Table 13-5) have been used topically since the mid-1940s. Pheniramine is a member of the alkylamine group of antihistaminic drugs, whereas antazoline is classified as an ethylenediamine. Both agents are similar in action and are commercially available only in combination formulations with the adrenergic agonist naphazoline. Using the allergen challenge model, the effects of antazoline phosphate combined with naphazoline (Vasocon-A) were evaluated in patients with known allergic history to cat dander, ragweed, or bluegrass pollen. The combination formulation significantly inhibited signs and symptoms of itching, redness, chemosis, lid swelling, and tearing compared with placebo, antazoline alone, or naphazoline alone. In a conjunctival allergen challenge, the ocular allergy index was compared for pheniramine-naphazoline and olopatadine 0.1%. Both drugs were administered before the challenge. Both drugs were effective in decreasing the ocular allergy index; however, pheniramine-naphazoline had a greater effect compared with olopatadine at 12 and 20 minutes.

The second-generation topical antihistamines (see Table 13-5) exhibit selective affinity for H<sub>1</sub> receptors.

**Table 13-5**  
Topical Ocular Antihistamines

Trade Name	Antihistamine	Decongestant	Dosage/Age	Availability
Vasocon-A	Antazoline phosphate 0.5	Naphazoline HC1 0.05	QID 6-yo	OTC
Naphcon-A	Pheniramine maleate 0.3	Naphazoline HC1 0.025	QID 6-yo	OTC
Visine-A	Pheniramine maleate 0.3	Naphazoline HC1 0.025	QID 6-yo	OTC
Opcon-A	Pheniramine maleate 0.315	Naphazoline HC1 0.027	QID 6-yo	OTC
Livostin	Levocabastine 0.05		QID (shake) 12-yo	No longer available
Emadine	Emedastine 0.05		QID 3-yo	Rx

OTC = over the counter; Rx = prescription; yo = year-old.

In addition, they may also inhibit release of histamine and other mediators from mast cells. Studies indicate that they do not affect  $\alpha$ -adrenergic, dopamine, muscarinic, or serotonin receptors.

Levocabastine, a highly specific H<sub>1</sub> receptor antagonist, was the first ophthalmic antihistamine formulated without a decongestant. Levocabastine, formulated as a 0.05% suspension (Livostin), is no longer available.

Emedastine is a selective H<sub>1</sub> receptor antagonist that also inhibits histamine release from mast cells. Studies in patients with allergic conjunctivitis comparing emedastine with placebo demonstrated more effective relief of ocular signs and symptoms, such as itching and redness, than placebo. Emedastine significantly reduces itching and redness within 10 minutes of instillation, with a duration of action of at least 4 hours. It is formulated as a 0.05% solution (Emadine), and the recommended dosage is four times per day. Emedastine is approved for use in patients 3 years of age and older.

### Side Effects

Topical ocular antihistamines are generally well tolerated. Burning, stinging, and discomfort on instillation are not uncommon. There is some evidence that pheniramine may produce somewhat less stinging on instillation than does antazoline. A combination formulation of 0.3% pheniramine with 0.05% tetrahydrozoline has been reported to cause significant mydriasis from 30 to 120 minutes after topical application to the eye. The effect was more pronounced in patients with light irides. Long-term use of topical antihistamines may induce drug-associated allergy. The antazoline-naphazoline combination has also been implicated as a cause of verticillate-type keratopathy on long-term administration.

### Contraindications

There are no absolute contraindications to topical antihistamine use other than sensitivity to one of the component agents. Because the anticholinergic properties of the antihistamines can produce some degree of mydriasis, these drugs could potentially produce angle-closure glaucoma in patients with narrow angles. The topical antihistamines are thus contraindicated in patients with narrow anterior chamber angles. Because antihistaminic compounds have the potential to produce sedation, caution should be used in combining topical with systemic antihistamines.

## MAST CELL STABILIZERS

Type I immune responses are inhibited by mast cell stabilizers. They play an important role, both historically and currently, in the treatment of various allergic eye diseases. Included in this group are cromolyn sodium, lodoxamide, nedocromil, and pemirolast (Table 13-6).

### Pharmacology

The traditional view has been that these agents inhibit mast cell degranulation and release of mediators of allergic

disease by preventing calcium influx across mast cell membranes. Evidence indicates, however, that mast cell stabilizers may also act via other mechanisms. These include inhibition of the activation of other cell types, including neutrophils, monocytes, and eosinophils.

Cromolyn sodium inhibits mast cell degranulation. As a result its main mode of action is to prevent mediator release and its subsequent clinical manifestations. There is no evidence of antihistamine, anti-inflammatory, or vasoconstrictive activity. Absorption is poor.

Although lodoxamide has a mechanism of action similar to that of cromolyn, this compound is 2,500 times more potent in its ability to inhibit mediator release. In addition to its mast cell stabilization effect, clinical improvement with the drug is also associated with inhibition of eosinophil migration and decrease in levels of leukotrienes (LTB<sub>4</sub> and LTC<sub>4</sub>) and other inflammatory cells after allergen exposure.

Nedocromil was developed as a result of research for compounds to control asthma. Its activity has been studied *in vitro* in a variety of inflammatory cells, including mast cells, eosinophils, and polymorphonuclear leukocytes. Nedocromil appears to be more potent than cromolyn in its ability to inhibit immunologic release of mast cell mediators. It can also modify the actions of eosinophils, neutrophils, monocytes, macrophages, and platelets. Pharmacokinetic studies indicate that ocular penetration of nedocromil is slow, and clearance from the eye is relatively rapid. Nedocromil differs from the other mast cell stabilizers in that it is effective within 15 to 30 minutes.

Pemirolast, as with nedocromil, was developed as a result of research for compounds to control asthma. In addition to interrupting mast cell degranulation, pemirolast inhibits eosinophil chemotaxis.

There is typically a lag period before the clinical effects are evident. A trial period of 7 or more days may be necessary before evaluation of its therapeutic efficacy. Patients need to be advised that effective therapy depends on administering the drug at recommended time intervals and continuing as long as needed to sustain improvement.

### Clinical Uses

Mast cell stabilizers may be used in the treatment of all types of allergic eye diseases, including allergic conjunctivitis, GPC, and VKC. Treatment effectiveness may vary slightly among the different mast cell stabilizers for each of these conditions. When a more rapid response is needed, other agents such as antihistamines may be used concurrently. When the clinical presentation is severe, adjunctive treatment such as steroids should be considered. The typical dosage for mast cell stabilizers is four times a day, with a maintenance dose of twice a day. Nedocromil is the exception, because there is a more rapid response, and dosage is twice a day. See Table 13-6 for a comparison of various aspects of each mast cell stabilizer, with salient points discussed below.



**Table 13-6**  
Topical Ocular Mast Cell Stabilizers

Drug/ Concentration	Trade Name	Preservative	FDA Indication	Pregnancy Category	Age (yr)	Dosage	ADR Ocular	ADR Systemic
Pemirolast 0.1%	Alamast	Lauralkonium chloride 0.005%	Itch, allergic conjunctivitis	C	3	QID	Sting/burn	Nasal congestion Cold or flu symptoms HA
Nedocromil 2.0%	Alocril	Benzalkonium chloride 0.01%	Itch, allergic conjunctivitis	B	3	BID	Sting/burn Hyperemia	HA Nasal congestion Unpleasant taste
Lodoxamide 0.1%	Alomide	Benzalkonium chloride 0.007%	VKC	B	2	QID	Sting/burn Dry eye Hyperemia Watery eyes Itch	Uncommon: Nausea HA
Cromolyn sodium 4.0%	Opticrom Crolom	Benzalkonium chloride 0.01% and ethylenedia- minetetraacetic acid 0.1%	VKC	B	4	4-6×/day	Sting/burn Hyperemia Watery eyes Itch Dryness around eye Puffiness Styes	Uncommon

ADR = adverse reaction; FDA = U.S. Food and Drug Administration; HA = headache.

Cromolyn sodium has been found to be effective in treating the signs and symptoms of allergic conjunctivitis, VKC, and GPC. Patients may obtain relief within 7 days of initiation of therapy. In cases of GPC, clinical evidence of reduction in size of papillae of the upper tarsal conjunctiva may be seen after 3 weeks of treatment.

Lodoxamide has shown efficacy in the treatment or prevention of several types of allergic conjunctivitis, notably VKC. A randomized, double-masked, placebo-controlled clinical trial of 118 patients aged 2 to 71 years evaluated the safety and efficacy of 0.1% lodoxamide in VKC. Lodoxamide or placebo was instilled four times daily for 90 days. Lodoxamide significantly reversed the corneal complications. Discomfort associated with limbal changes and conjunctival discharge was also relieved. Itching decreased to a significantly greater extent in the lodoxamide-treated group. The efficacy of 0.1% lodoxamide was compared with that of 4% cromolyn sodium in a 28-day study of 120 patients with VKC. Patients were instructed to instill one drop of the masked medication four times daily. Lodoxamide gave a significantly greater and earlier improvement in signs and symptoms than did cromolyn. The clinical superiority of lodoxamide over cromolyn may be related to the former drug's greater effect on CD4+ cells, which are known to play a significant role in the pathogenesis of VKC.

Nedocromil sodium has been found to be effective in treating SAC and GPC. In SAC, there was found to be significant improvement in itching, conjunctival injection, and overall disease when compared with placebo. In treatment of contact lens-induced GPC, when compared with placebo, the medication reduces itching and mucous discharge. Nedocromil is available as a clear, yellow, 2% ophthalmic solution, and it differs from other mast cell stabilizers by having a twice-daily dosage.

Pemirolast is used to treat the itch in allergic conjunctivitis. Some symptomatic relief may occur after days of treatment, but typically weeks may be needed.

### Side Effects

Mast cell stabilizers are relatively safe drugs to use. This is likely the result of minimal ocular or systemic absorption after topical application to the eye. Adverse reactions for mast cell stabilizers are rare but may include stinging or burning most commonly, with less common presentations that include conjunctival injection and itchy and watery eyes. Systemically, there is a low potential for adverse reactions because of the low plasma levels of the drug. Headache, however, is a common adverse effect, particularly for nedocromil and pemirolast. Other adverse reactions, along with a delineation of specific drug and side effects, are listed in Table 13-6.

### Contraindications

Contraindications for all mast cell stabilizers include patients sensitive to the ophthalmic solution or any of its components.

## Mast Cell–Antihistamine Combinations

Mast cell stabilizers prevent the mast cell from degranulating and therefore the subsequent release of mediators. However, once the mast cells have already degranulated, mast cell stabilizers are ineffective against the released mediators. Combination drugs with both mast cell-stabilizing and antihistamine effects provide both long-term treatment and a more rapid relief of symptoms. Drugs with this dual-action or multiaction mechanism include azelastine, epinastine, ketotifen, and olopatadine (Table 13-7).

### Pharmacology

The mechanism of action of this group of drugs includes selective H<sub>1</sub> receptor antagonism and inhibition of mast cell mediator release. To variable degrees basophil degranulation is affected, as is eosinophil chemotaxis. In studies using the allergen conjunctival challenge model, they are effective in reducing allergic response.

Olopatadine, in addition to its high affinity for the H<sub>1</sub> receptor, has a lesser affinity for the H<sub>2</sub> and H<sub>3</sub> receptors. In *in vitro* studies the drug inhibits mast cell and basophil degranulation by greater than 90%. The mast cell-stabilizing properties olopatadine are less than those of cromolyn, nedocromil, or pemirolast. Olopatadine also inhibits the production of inflammatory cytokines.

Ketotifen fumarate, in addition to its dual action, decreases chemotaxis and activation of eosinophils. Ketotifen binds to multiple histamine receptors, including H<sub>1</sub>, H<sub>2</sub>, and H<sub>3</sub>, with the strongest affinity to the H<sub>1</sub> and H<sub>2</sub> receptors. Ketotifen is available over the counter.

Azelastine is a selective H<sub>1</sub> antagonist mast cell inhibitor. Azelastine also decreases eosinophil chemotaxis and activation.

Epinastine was first approved over two decades ago for the treatment of rhinitis. It is a mast cell stabilizer and an H<sub>1</sub> receptor antagonist. There is weak affinity to other receptors, including H<sub>2</sub> and H<sub>3</sub> and  $\alpha_1$ - and  $\alpha_2$ -adrenergic, and an inhibitory effect against eosinophil chemotaxis. In a conjunctival antigen challenge, epinastine decreased ocular itch, lid swelling, hyperemia, and chemosis. It has been found to be effective in treating ocular itching when compared with placebo, and it is in general equivalent in efficacy when compared with other dual-acting agents for ocular itch and hyperemia. Onset is rapid, in 3 minutes.

### Clinical Uses

The clinical indication for the dual-acting drugs is ocular itching and allergic conjunctivitis. Dosage is twice a day, with the exception of olopatadine 0.2%, which is once a day. Onset is rapid, usually within minutes. In both clinical trials and the conjunctival allergen model, these drugs have been found to be effective when compared with placebo. Efficacy and preference may differ in clinical use.

**Table 13-7**  
Antihistamine–Mast Cell Stabilizers

Drug/ Concentration	Trade Name	FDA Indication	Pregnancy Category	Age (yr)	Dosage	ADR Ocular	ADR Systemic	Availability
Azelastine hydrochloride 0.05%	Optivar	Itch, allergic conjunctivitis	C	3	BID	Burn/sting Itch	Headache Bitter taste Rhinitis Flu syndrome	Rx
Epinastine hydrochloride 0.05%	Elestat	Itch, allergic conjunctivitis	C	3	BID	Burn/sting Hyperemia Itch Folliculosis	Headache Rhinitis Flu syndrome	Rx
Ketotifen fumarate 0.25%	Zaditor	Itch, allergic conjunctivitis	C	3	BID	Burn/sting Hyperemia Dry eyes Itch	Headache Rhinitis Flu syndrome	OTC
Olopatadine hydrochloride 0.1%	Patanol	Itch, allergic conjunctivitis	C	3	BID	Burn/sting Foreign body Sensation Dry eye Itch	Headache Rhinitis Cold syndrome Taste perversion	Rx
Olopatadine hydrochloride 0.2%	Pataday	Itch, allergic conjunctivitis	C	3	QD	Similar to olopatadine 0.1%	Similar to olopatadine 0.1%	Rx

ADR = adverse reaction; FDA = U.S. Food and Drug Administration; OTC = over the counter; Rx = prescription.

Olopatadine has been found to be more effective in decreasing itching than epinastine, azelastine, and ketotifen. Although some studies may vary, olopatadine has been found to be preferred over ketotifen in regards to efficacy and comfort.

Olopatadine 0.2% is similar to olopatadine 0.1%. The 0.2% concentration is effective in treating the itch, redness, and chemosis. It differs from olopatadine 0.1% in its duration, which is over a 24-hour period, allowing for a once a day dosage.

Onset of action is rapid for this group of drugs. It is usually within minutes of administration.

### Side Effects

Adverse reactions for these multi-action drugs include burning, foreign body sensation, dry eye, and pruritus. Systemic side effects may include headache, flu-like syndrome, and rhinitis. Most common to all these drugs is headache and burning and stinging. Table 13-7 delineates the various adverse reactions.

### Contraindications

The antihistamine-mast cell stabilizer drugs should not be administered to patients sensitive to any components of the product.

## NONSTEROIDAL ANTI-INFLAMMATORY DRUGS

Various nonsteroidal anti-inflammatory drugs (NSAIDs) have been studied for potential clinical use in allergic conjunctivitis. Specifically, ketorolac tromethamine 0.5% has been found to be beneficial in treating SAC and is currently the only NSAID approved for topical treatment of SAC.

### Pharmacology

Ketorolac tromethamine is a member of the pyrrolopyrrole group of NSAIDs. Its primary action in ocular inflammatory disease may result from its ability to affect prostaglandin synthesis by inhibiting the activity of cyclooxygenase, one of the enzymes responsible for the conversion of arachidonic acid to prostaglandins (see Chapter 12). Prostaglandins have been shown to be potent itch-producing substances in the conjunctiva, and the antipruritic efficacy of ketorolac appears to involve inhibition of conjunctival prostaglandins.

Pharmacokinetic data indicate that ketorolac penetrates the cornea after topical ocular administration and reaches concentrations that reduce prostaglandin E levels in the aqueous humor. Plasma levels of ketorolac after topical ocular application are usually below detectable limits compared with oral administration. Ketorolac does not affect IOP, pupillary response, or visual acuity.

### Clinical Uses

Ketorolac has been approved for management of SAC. It has been found to be effective in relieving itching associated

with allergic conjunctivitis when compared with placebo, as well as showing improvement in clinical signs that include erythema, edema, and mucous discharge.

Ketorolac tromethamine (Acular) is formulated as a 0.5% solution with benzalkonium chloride 0.01% and edetate sodium 0.1%. The pH of the solution is 7.4. It is also formulated as a 0.4% solution, but this is not approved by the U.S. Food and Drug Administration for allergies.

### Side Effects

The most frequent adverse event reported with ketorolac use is transient stinging and burning after instillation of the ophthalmic solution. Rarely, allergic reactions and superficial keratitis have occurred. Although inconsistent cases of corneal toxicity have been reported with NSAIDs, prolonged use of NSAIDs in a select group of patients showed the potential for corneal melt. Because other treatment options exist for allergic eye disease, NSAIDs do not need to be used in patients with compromised corneas or those at risk for potentially serious adverse corneal reactions.

### Contraindications

Ketorolac tromethamine is contraindicated in patients while wearing soft contact lenses. Caution should be used with patients who have previously exhibited sensitivity to acetylsalicylic acid, phenylacetic acid derivatives, and other NSAIDs because a potential exists for cross-sensitivity.

## OTHER AGENTS SPECIFIC TO ALLERGIC EYE DISEASE TREATMENT

Steroids can be effective agents for severe allergic disease. Multiple mechanisms of action account for steroid's efficacy in allergic disease. These include decreasing histamine; preventing degranulation of mast cells, basophils, and neutrophils; and preventing the formation of various mediators (see Chapter 12). Site-specific drugs such as loteprednol have been found to be effective in treating allergic conjunctivitis while providing less potential of adverse reactions that are found in traditional steroids. Loteprednol 0.2%, used continuously for more than 1 year for seasonal and perennial allergic conjunctivitis, showed a safety profile that includes lack of cataract formation or worsening of preexisting cataracts as well as no clinically significant rise in IOP.

## SELECTED BIBLIOGRAPHY

- Abelson MB, Butrus SI, Kliman GH, et al. Topical arachidonic acid: a model for screening anti-inflammatory agents. *J Ocul Pharmacol* 1987;3:63-75.
- Abelson MB, Butrus SI, Weston JH, Rosner B. Tolerance and absence of rebound vasodilation following topical ocular decongestant usage. *Ophthalmology* 1984;91:1364-1367.
- Abelson MB, George M, Garofalo C, et al. An effective treatment for allergy sufferers. *Contact Lens Spectrum* 1995;10:28-32.

- Abelson MB, Gomes P, Crampton HJ, et al. Efficacy and tolerability of ophthalmic epinastine assessed using the conjunctival antigen challenge model in patients with a history of allergic conjunctivitis. *Clin Ther* 2004;26:35-47.
- Abelson MB, Paradis A, George MA, et al. Effects of Vasocon-A in the allergen challenge model of acute allergic conjunctivitis. *Arch Ophthalmol* 1990;108:520-524.
- Abelson MB, Schaefer K. Conjunctivitis of allergic origin: immunologic mechanisms and current approaches to therapy. *Surv Ophthalmol* 1993;38:115-132.
- Abelson MB, Udell IJ. H2 receptors in the human ocular surface. *Arch Ophthalmol* 1981;99:302-304.
- Abelson MB, Yamamoto GK, Allansmith MR. Effects of ocular decongestants. *Arch Ophthalmol* 1980;98:856-858.
- Ahmet A, Irkek M, Orhan M, et al. Effect of Iodoxamide on tear leukotriene levels in giant papillary conjunctivitis associated with ocular prosthesis. *Ocul Immunol Inflamm* 1998; 6:179-184.
- Allansmith MR, Ross RN. Ocular allergy and contact lenses. *Ophthalmol Clin North Am* 1989;2:235-242.
- Asai T, Nakagami T, Mochizuki M, et al. Three cases of corneal melting after instillation of a new nonsteroidal anti-inflammatory drug. *Cornea* 2006;25:224-227.
- Avunduk AM, Avunduk MC, Kapioglu Z, et al. Mechanisms and comparison of anti-allergic efficacy of topical Iodoxamide and cromolyn sodium treatment in vernal keratoconjunctivitis. *Ophthalmology* 2000;107:1333-1337.
- Babe KS, Serafin WE. Histamine, bradykinin and antagonists. In: Goodman and Gilman's the pharmacological basis of therapeutics, ed. 9. New York: McGraw-Hill, 1996.
- Banfield C, Gupta S, Marino M, et al. Grapefruit juice reduces the oral bioavailability of fexofenadine but not desloratadine. *Clin Pharmacokinet* 2002;41:311-318.
- Bartlett JD, ed. *Ophthalmic drug facts*, ed. 18. St. Louis, MO: Wolters Kluwer Health, 2007.
- Berdy GJ, Abelson MB, George MA, et al. Allergic conjunctivitis—a survey of new antihistamines. *J Ocul Pharmacol* 1991; 7:313-324.
- Bielory L, Lien KW, Bigelsen S. Efficacy and tolerability of newer antihistamines in the treatment of allergic conjunctivitis. *Drugs* 2005;65:215-228.
- Bonini S, Schiavone M, Bonini S, et al. Efficacy of Iodoxamide eye drops on mast cells and eosinophils after allergen challenge in allergic patients. *Ophthalmology* 1997;104: 849-853.
- Breaky AS, Cinotti AA, Hirshman M, et al. A double-blind, multicenter controlled trial of 0.25% oxymetazoline ophthalmic solution in patients with allergic and non-infectious conjunctivitis. *Pharmatherapeutica* 1980;2:353-356.
- Butler K, Thompson JP, Yolton DP. Effects of non-prescription ocular decongestants. *Rev Optom* 1978;115:49-52.
- Butrus S, Portela R. Ocular allergy: diagnosis and treatment. *Ophthalmol Clin North Am* 2005;18:485-492.
- Caldwell DR, Verin P, Hartwich-Young R, et al. Efficacy and safety of Iodoxamide 0.1% vs. cromolyn sodium 4% in patients with vernal keratoconjunctivitis. *Am J Ophthalmol* 1992;113: 632-637.
- Capron M, Loiseau S, Papin JP, et al. Inhibitory effect of Iodoxamide on eosinophil activation. *Int Arch Allergy Immunol* 1998;116:140-146.
- Church MK, McGill JI. Human ocular mast cells. *Curr Opin Allergy Clin Immunol* 2002;2:419-422.
- Ciprandi G, Buscaglia S, Cerqueti PM. Drug treatment of allergic conjunctivitis. *Drugs* 1992;43:154-176.
- Clissold SP, Sorkin EM, Goa KI. Loratadine: a preliminary review of its pharmacodynamic properties and therapeutic efficacy. *Drugs* 1989;1:42-57.
- Cromolyn sodium. Clinical considerations. *Excerpta Medica Monograph*, 1987.
- Dahlen SE, Bjorck T, Kumlin M, et al. Dual inhibitory action of nedocromil sodium on antigen-induced inflammation. *Drugs* 1989;37:63-68.
- Desager JP, Horsmans Y. Pharmacokinetic-pharmacodynamic relationships of H<sub>1</sub> antihistamines. *Clin Pharmacokinet* 1995;5:419-432.
- Drug facts and comparisons. St. Louis, MO: J.B. Lippincott, 2000.
- Duzman E, Anderson J, Vita JB, et al. Topically applied oxymetazoline. *Arch Ophthalmol* 1983;101:1122-1126.
- Duzman E, Warman A, Warman R. Efficacy and safety of topical oxymetazoline in treating allergic and environmental conjunctivitis. *Ann Ophthalmol* 1986;18:28-31.
- Easty DL, Rice NSA, Jones BR. Clinical trials of topical sodium cromoglycate in allergic conjunctivitis. *Clin Allergy* 1972;2: 99-107.
- Elena PP, Amar T, Fetz A, et al. Comparison of efficacy between ketotifen and olopatadine eye drops in allergic conjunctivitis. *Invest Ophthalmol Vis Sci* 1998;39:S949.
- Foster CS. Evaluation of topical cromolyn sodium in the treatment of vernal keratoconjunctivitis. *Ophthalmology* 1988;95: 194-201.
- Friedlaender MH. Update on allergic conjunctivitis. *Rev Ophthalmol March*, 1997;25(1):92-98.
- Galindez OA, Kaufman HE. Coping with the itchy-burnies: the management of allergic conjunctivitis. *Ophthalmology* 1996;103:1335-1336.
- Ganz M, Koll E, Gausche J, Detjen, et al. Ketotifen fumarate and olopatadine hydrochloride in the treatment of allergic conjunctivitis: a real-world comparison of efficacy and ocular comfort. *Adv Ther* 2003;20:79-91.
- Gelmi C, Occuzzi R. Mydriatic effect of ocular decongestants studied by pupillography. *Ophthalmologica* 1994;208: 243-246.
- Golightly LK, Greos LS. Second-generation antihistamines. Actions and efficacy in the management of allergic disorders. *Drugs* 2005;65:341-384.
- Gonzalez JP, Brogden RN. Nedocromil sodium: a preliminary review of its pharmacodynamic and pharmacokinetic properties and therapeutic efficacy in the treatment of reversible obstructive airway disease. *Drugs* 1987;34:560-567.
- Gonzalez MA, Estes KS. Pharmacokinetic overview of oral second generation H<sub>1</sub> antihistamines. *J Clin Pharmacol Ther* 1998;36:292-300.
- Greiner JV, Udell IJ. A comparison of the clinical efficacy of pheniramine maleate/naphazoline hydrochloride ophthalmic solution and olopatadine hydrochloride ophthalmic solution in the conjunctival allergen challenge model. *Clin Therap* 2005;27:568-577.
- Herman DC, Bartley GB. Corneal opacities secondary to topical naphazoline and antazoline (Albalon-A). *Am J Ophthalmol* 1987;103:110-111.
- Hill SJ. Distribution and functional characteristics of the three classes of histamine receptors. *Pharmacol Rev* 1990;42:45-83.
- Hingorani M, Lightman S. Therapeutic options in ocular allergic disease. *Drugs* 1995;50:208-221.

- Hurwitz P, Thompson JM. Use of naphazoline (Privine) in ophthalmology. *Arch Ophthalmol* 1950;43:712-717.
- Ilyas H, Slonim CB, Braswell GR, et al. Long-term safety of loteprednol etabonate 0.2% in the treatment of seasonal and perennial allergic conjunctivitis. *Eye Contact Lens* 2004;30:10-13.
- Kidd M, McKenzie SH, Steven I, et al. Efficacy and safety of ketotifen eye drops in the treatment of seasonal allergic conjunctivitis. *Br J Ophthalmol* 2003;87:1206-1211.
- Koay P. The emerging roles of topical non-steroidal anti-inflammatory agents in ophthalmology. *Br J Ophthalmol* 1996;80:480-485.
- Kuby J. *Immunology*, ed. 2. New York: WH Freeman, 1996;1-20, 47-84, 417-442.
- Lanier BQ, Finegold I, D'Arienzo P, et al. Clinical efficacy of olopatadine vs. epinastine ophthalmic solution in the conjunctival allergen challenge model. *Curr Med Res Opin* 2004;20:1227-1233.
- Leino M, Jaanio E, Koivunen T, et al. A multicenter double-blind group comparative study of 2% nedocromil sodium eye drops (Tilavist) with placebo eye drops in the treatment of seasonal allergic conjunctivitis. *Ann Allergy* 1990;64:398-402.
- Leino M, Montan P, Njå F A double-blind group comparative study of ophthalmic sodium cromoglycate, 2% four times daily and 4% twice daily in the treatment of seasonal allergic conjunctivitis. *Allergy* 1994;49:147-151.
- Leonardi A. Role of histamine in allergic conjunctivitis. *Acta Ophthalmol Scand* 2000;78:18-21.
- Leonardi A, Zafirakis P. Efficacy and comfort of olopatadine versus ketotifen ophthalmic solutions: a double-masked, environmental study of patient preference. *Curr Med Res Opin* 2004;20:1167-1173.
- Markham A, Wagstaff AJ. Fexofenadine. *Drugs* 1998;55:269-274.
- Matsukura M, Yajima A, Yamazaki F, et al. Epinastine inhibits eosinophil chemotaxis and adhesion molecules in atopic dermatitis. *Skin Pharmacol App Skin Physiol* 2003;16:405-410.
- McGill JI. A review of the use of olopatadine in allergic conjunctivitis. *Int Ophthalmol* 2004;25:171-179.
- Melamed J, Schwartz RH, Hirsh SR, et al. Evaluation of nedocromil sodium 2% ophthalmic solution for treatment of seasonal allergic conjunctivitis. *Ann Allergy* 1994;73:57-64.
- Menger HC. New ophthalmic decongestant tetrahydrozoline hydrochloride. *JAMA* 1958;170:178-179.
- Miller J, Wolf EM. Antazoline phosphate and naphazoline hydrochloride, singly and in combination for the treatment of allergic conjunctivitis. A controlled double-blind clinical trial. *Ann Allergy* 1975;35:81-86.
- Mogbel R, Walsh GM, MacDonald AJ, et al. The effect of nedocromil sodium on the activation of human eosinophils, neutrophils and histamine release from mast cells. *Allergy* 1988;43:268-276.
- Montan P, Zetterström O, Eliasson E, et al. Topical sodium cromoglycate (Opticrom) relieves ongoing symptoms of allergic conjunctivitis within 2 minutes. *Allergy* 1994;49:637-640.
- Motterle L, Diebold Y, Enriques de Salamanca A, et al. Altered expression of neurotransmitter receptors and neuromediators in vernal keratoconjunctivitis. *Arch Ophthalmol* 2006;124:462-468.
- Nightingale CH. Treating allergic rhinitis with second generation antihistamines. *Pharmacotherapy* 1996;16:905-914.
- Ophthalmic drug facts. St. Louis, MO: Wolters Kluwer Health, 2006.
- PDR electronic library 2006. New Jersey: Thomson PDR, 2006.
- Rooks WH. Pharmacologic activity of ketorolac tromethamine. *Pharmacotherapy* 1990;10:308-311.
- Samson CR, Danzig MR, Sasovetz D, Thompson HS. Safety and toleration of oxymetazoline ophthalmic solution. *Pharmatherapeutica* 1980;2:347-352.
- Santos CI, Huang AJ, Abelson MB, et al. Efficacy of lodoxamide 0.1% ophthalmic solution in resolving corneal epitheliopathy associated with vernal keratoconjunctivitis. *Am J Ophthalmol* 1994;117:488-497.
- Simons FER. Advances in H1-antihistamines. *N Engl J Med* 2004;351:2203-2217.
- Slater JW, Zechnick AD, Haxby DG. Second generation antihistamines. A comparative review. *Drugs* 1999;1:31-47.
- Soparkar CNS, Wilhelmus KR, Koch DD, et al. Acute and chronic conjunctivitis due to over-the-counter ophthalmic decongestants. *Arch Ophthalmol* 1997;115:34-38.
- Stjernschantz J. Autocoids and neuropeptides. In: Sears ML, ed. *Pharmacology of the eye. Handbook of experimental pharmacology*, vol. 69. Berlin: Springer-Verlag, 1984: 311-332.
- Tinkelman DG, Rupp G, Kaufman H, et al. Double-masked, paired-comparison clinical study of ketorolac tromethamine 0.5% ophthalmic solution compared with placebo eyedrops in the treatment of seasonal allergic conjunctivitis. *Surv Ophthalmol* 1993;38:133-140.
- Van Arsdell PP Jr, Beall GN. The metabolism and functions of histamine. *Arch Intern Med* 1960;106:714-733.
- Vogelson CT, Abelson MB, Pasquine T, et al. Preclinical and clinical antiallergic effect of olopatadine 0.2% solution 24 hours after topical ocular administration. *Allergy Asthma Proc* 2004;69-75.
- Weiss DI, Shaffer RN. Mydriatic effects of one-eighth percent phenylephrine. *Arch Ophthalmol* 1962;68:727-729.
- Whitcup SM, Bradford R, Lue J, et al. Efficacy and tolerability of ophthalmic epinastine: a randomized, double-masked, parallel-group, active- and vehicle-controlled environmental trial in patients with seasonal allergic conjunctivitis. *Clin Ther* 2004;26:29-34.
- Xuan B, Chiou GCY. Efficacy of oxymetazoline eye drops in infectious conjunctivitis, the most common cause of acute red eyes. *J Ocul Pharmacol Ther* 1997;13:363-367.
- Yanni JM, Stephens DJ, Miller ST, et al. The in vitro and in vivo ocular pharmacology of olopatadine (AL-4943A), an effective anti-allergic/antihistaminic agent. *J Ocul Pharmacol Ther* 1996;12:389-400.
- Yanni JM, Stephens DJ, Parnell DW, et al. Preclinical efficacy of emedastine, a potent, selective histamine H1 antagonist for topical ocular use. *J Ocul Pharmacol* 1994;10:665-675.
- Yanni JM, Weimer LK, Glaser RL, et al. Effect of lodoxamide on in vitro and in vivo conjunctival hypersensitivity response of rats. *Int Arch Allergy Immunol* 1993;101:102-126.

## *Preparations for Dry Eye and Ocular Surface Disease*

*C. Denise Pensyl*

In its mild form ocular surface disease (OSD) may cause intermittent patient discomfort with symptoms of burning, itching, and blurring of vision. At its most severe the condition may precipitate secondary keratitis and conjunctivitis, corneal ulceration and scarring, and permanent vision loss. Up to one-fourth of all adults in the United States are affected by OSD. Fortunately, in most the condition is mild to moderate, and with proper diagnosis and treatment these patients can maintain comfortable clear vision and good ocular health.

Any disorder affecting the integrated functional structures of the ocular surface may result in OSD; the most common etiologies are dry eye, blepharitis, and meibomianitis. The diagnosis and treatment of blepharitis and meibomianitis are discussed in Chapter 23. This chapter focuses on dry eye, giving due consideration to the fact that this specific condition may occur as a single entity or in conjunction with other diseases or anomalies in the formation of OSD.

In a dry eye workshop sponsored by the National Eye Institute, the following definition was proposed: "Dry eye is a disorder of the tear film due to tear deficiency or excessive tear evaporation which causes damage to the interpalpebral ocular surface and is associated with symptoms of ocular discomfort." Evidence has also emerged that dry eye is associated with varying degrees of ocular surface inflammation.

Ten percent to 15% of Americans older than age 65 years are reported to have symptoms of this disease. Other studies put the prevalence of dry eye between 5% and 28% of the population. Over 14 million Americans are believed to experience some form of dry eye, and with an estimated 20% to 25% of eye care practitioner visits related to dry eye symptoms, the need for proper diagnosis and treatment of this condition is enormous.

### **TEAR FILM PHYSIOLOGY**

In addition to moistening the corneal and conjunctival surfaces and providing lubrication for the eyelids, the tear film provides nutrients and oxygen to the ocular surface


epithelial cells, removes foreign material, inhibits microorganism growth, and fills in epithelial surface irregularities to maintain a smooth optical surface. The ocular tear film is described as a three-layer structure: the outermost lipid layer, the middle aqueous layer, and the innermost mucin layer. A fourth layer should also be considered: The microvilli on the corneal epithelium must be intact for the tear film to adhere properly to the ocular surface (Figure 14-1). The eyelids also play an important role in tear film maintenance, secreting meibomian oil and spreading the mucin, aqueous, and lipids over the surface. The qualitative and quantitative composition of each layer is crucial to the maintenance of a stable tear film. Although tear volume is believed to average 6 to 7  $\mu\text{cl}$  in non-dry eye patients, the thickness of the tear layer is debated. A thicker tear film and mucin layer than proposed by previous researchers has been measured (Figure 14-2).

### **Lipid Layer**

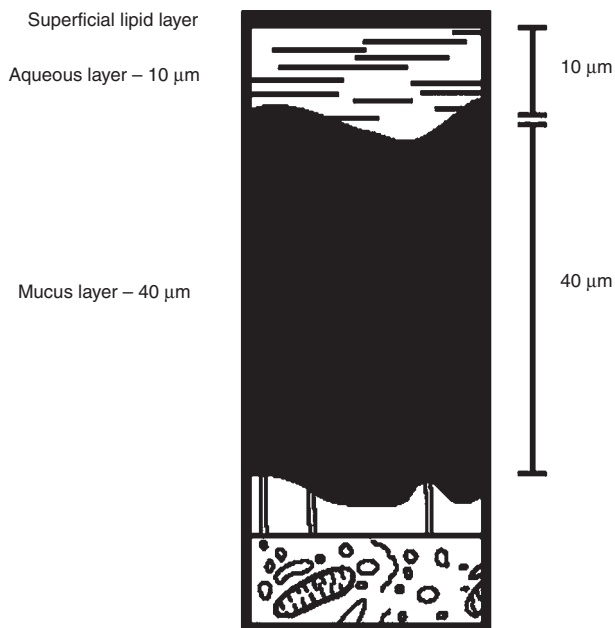
Positioned at the interface between the air and tear film, the lipid layer is produced by the meibomian glands with contributions from the glands of Zeis and Moll. Most of this layer consists of low-polarity lipids, such as wax and cholesterol esters, with traces of triglycerides. A thin polar portion, adjacent to the tear-aqueous layer, may contain surfactant phospholipids needed to spread lipid film over aqueous layers. The main purpose of the lipid layer appears to be to reduce evaporation of the tear film.

### **Aqueous Layer**

The aqueous layer is 98% to 99% water combined with electrolytes, glucose, urea, trace elements, and soluble proteins and mucins. It contains immunoglobulins (primarily IgA), lactate dehydrogenase, epidermal growth factor, and inhibitors of proteolytic activity. Protective substances in tears include lactoferrin, lysozyme, nonlysozyme antibacterial factor, complement and anti-complement factor and interferon, and immunoglobulins



**Figure 14-1** Structure and composition of tear film as previously proposed. (Modified from Holly FJ, Lemp MA. Tear physiology and dry eyes. *Surv Ophthalmol* 1977;22:70.)



**Figure 14-2** Structure of tear film as proposed by Prydal et al. (Adapted with permission from Prydal JI, Actal P, Woon H, et al. *Invest Ophthalmol Vis Sci* 1992;33:2006-2101. Illustration by James J. Hays.)

and lymphocytes. Proteins and bicarbonate ions add buffering capacity to tears. Aqueous is produced by the major orbital lacrimal gland and the minor conjunctival accessory lacrimal tissue (glands of Krause and Wolfring).

### Mucin Layer and Surface Epithelium

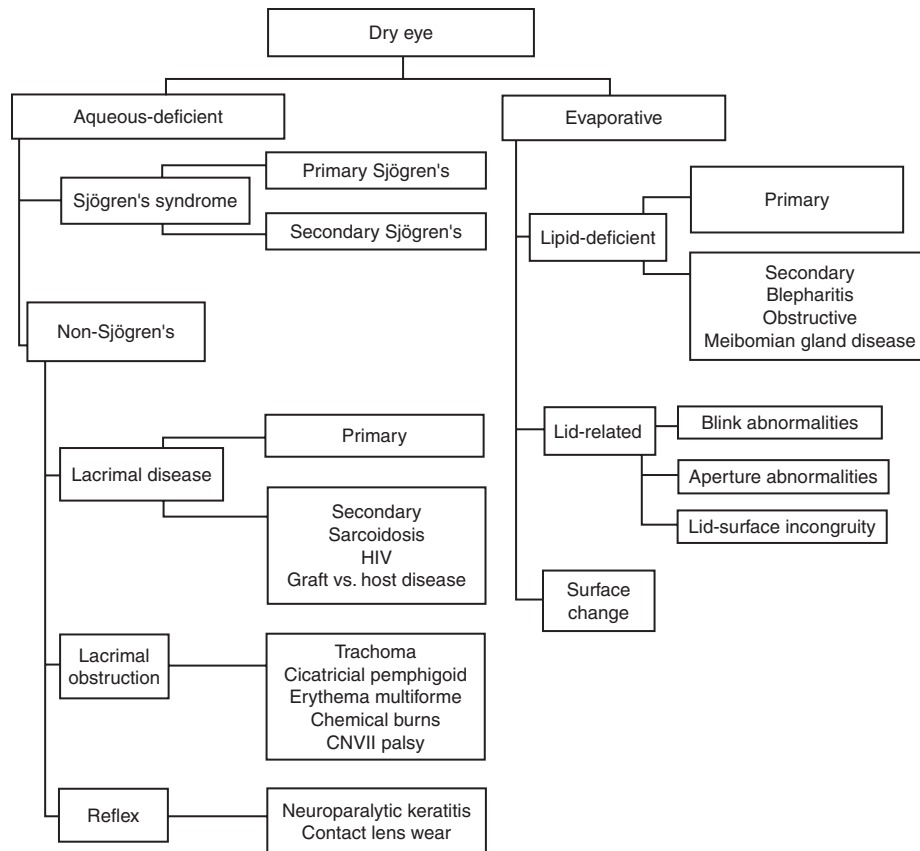
The mucin layer consists of a sponge-like meshwork of fluid and glycoprotein molecules produced by the conjunctival goblet cells, the crypts of Henle, and the glands of Manz. The layer is spread from the goblet cells across the corneal surface by the eyelids. The surface epithelial cell membranes are composed of hydrophobic lipoproteins and are covered with a dense layer of microvilli. Mucin anchors to the microvilli and is adsorbed partly onto the epithelium, providing a hydrophilic surface over the cornea and inhibiting bacterial adhesion to the ocular surface. If the mucus layer is disrupted or contaminated (by lipid), local instability triggers breakup of the tear film.

### TEAR FILM ABNORMALITIES

The etiology of dry eye is generally differentiated into two main categories: aqueous deficient and evaporative (Figure 14-3). The largest category, aqueous deficient, occurs from decreased tear volume secondary to a disorder of lacrimal gland function or a failure of lacrimal fluid transfer. Dry eye secondary to aqueous deficiency is often referred to as keratoconjunctivitis sicca (KCS). Evaporative dry eye exhibits normal lacrimal function, but meibomian gland dysfunction or increased palpebral fissure width leads to increased evaporation or an anomaly of tear distribution. Multiple subgroups exist in each category, and disorders in both categories may be present simultaneously. Clinical diagnostic tests and evaluation of the various dry eye states are discussed in Chapter 24.

The lacrimal glands produce tears based on information received via a neural loop with the ocular surface. Sensory nerves in the ocular surface synapse with the efferent nerves in the brainstem that stimulate tear secretion by the lacrimal glands. A relatively new theory has emerged that dry eye is the result of an underlying cytokine and receptor-mediated inflammatory process affecting both the ocular surface and the lacrimal gland. Decreased tear production and clearance lead to ocular surface inflammation with inflammatory cell infiltration and activation of the ocular surface epithelium, releasing adhesion molecules and cytokines. Cytokines are hormone-like proteins that regulate the immune response of T-cell proliferation and differentiation; they can damage tissue when overabundant. The inflammation creates a cyclical problem because the exposure of inflammatory mediators on the surface leads to a decrease of ocular surface sensitivity, disrupting sensory signals from the eye surface. This affects the stimulus for tear secretion, leading to decreased aqueous tear production and clearance.





**Figure 14-3** Classification of dry eye. (cnVII = cranial nerve VII; HIV = human immunodeficiency virus.) (Adapted from Lemp MA. Report of the National Eye Institute Industry Workshop on Clinical Trials in Dry Eyes. *CLAO J* 1995;21:221-232.)

The main and accessory lacrimal glands also may be destroyed or damaged by neurogenic inflammation and T-cell infiltration activation. The infiltrated glands secrete inflammatory mediators (interleukins and interferons) and cytokines into the tears, leading to activation of more T cells and production of more inflammatory substances, further inflaming the ocular surface and causing more tissue damage.

A significant positive correlation has been observed between the levels of inflammatory cytokines in the conjunctival epithelium and the severity of ocular irritation symptoms and corneal fluorescein staining. The inflammatory cytokines and other inflammatory mediators also correlate positively to severity of conjunctival squamous metaplasia in Sjögren patients. These proinflammatory cytokines also have been implicated in regulation of epithelial mucin expression, with several studies suggesting inflammation is central to the pathogenesis of meibomian gland dysfunction as well.

### Refractive Surgery

Several studies show that photorefractive keratectomy and laser in situ keratomileusis (LASIK) can induce or exacerbate dry eye. Refractive surgery is believed to cause aqueous-deficient dry eye by a neural-based mechanism.

By destroying sensory innervation, refractive surgery reduces corneal sensitivity and causes a decrease in feedback to the lacrimal gland and subsequent reduction in aqueous production. In LASIK the microkeratome severs the nerves of the corneal surface. In photorefractive keratectomy the corneal epithelium along with its nerve endings are removed, and then the exposed stromal bed is ablated by laser, further obliterating the central corneal nerves. The dry eye is generally transient, lasting for approximately 6 months to 1 year and generally resolves without permanent complications. Other causes of post-operative dry eye may include increased evaporation, inflammation, or toxicity of medications.

### TREATMENT OF TEAR FILM ABNORMALITIES

The goals of OSD treatment are to relieve symptoms, heal the ocular surface, and prevent serious complications. Treatment of dry eye generally falls into one of three categories—tear supplementation, tear conservation, or tear stimulation—in an attempt to reestablish the tear film quantitatively and qualitatively (Box 14-1). When possible, it is important to diagnose and treat coexistent or ancillary conditions that provoke or aggravate dry eye (e.g., blepharitis, meibomian gland disease, eyelid abnormalities).

**Box 14-1** Treatment Options for Dry Eye

Tear supplementation: artificial tears, Lacrisert  
 Tear conservation: ointment, punctal occlusion  
 Tear stimulation: secretagogues, anti-inflammatories/  
 immunomodulators

**Tear Supplementation**

Polymer-based artificial tears are the most common tear supplementation product used in dry eye treatment. In addition to dry eye, ocular lubricants are used in the treatment of corneal abrasions, ultraviolet keratitis, herpes simplex and zoster keratitis, phlyctenular disease, giant papillary conjunctivitis, superior limbic keratoconjunctivitis, vernal disease, adenoviral infections, and other ocular surface conditions.

The ideal artificial tear would reproduce the metabolic, optical, and physical characteristics of natural tears. Additionally, it would have a long ocular residence time and would contain therapeutic additives to treat primary and secondary damage to the eye. Supplementation of natural tears with a substance that prolongs residence time generally improves tear film breakup time (TBUT) and is superior to tear replacement fluids of low retention time.

Most artificial tear formulations are water based, with polymers added to enhance viscosity, lubrication, and retention time, to promote tear film stability. Commonly used polymers include methylcellulose (MC) and derivatives, polyvinyl alcohol (PVA), povidone (polyvinylpyrrolidone [PVP]), dextran, and propylene glycol. Other viscosity increasing agents include gelatin, glycerin, polyethylene glycol, poloxamer 407, and polysorbate 80. Sodium chloride, potassium chloride, various other ions, and boric acid help to maintain tonicity and pH similar to normal tear film. Multidose bottles have preservatives (including benzalkonium chloride [BAK], chlorobutanol, sodium perborate, ethylenediaminetetraacetic acid [EDTA], polyquaternium, methylparaben, and propylparaben) to retard the growth of microorganisms. Additional constituents may include nutrients, buffers, and mucolytic agents.

**Polysaccharides and Vinyl Derivatives**

Because they are not produced constantly, as are natural tears, tear substitutes should have properties to enhance their retention time in the tear film. The addition of various types of polymers to artificial tears not only improves retention of added fluid but also increases corneal surface wettability, decreases blink friction, and minimizes surface tension. Natural tears contain glycoproteins and other surfactant macromolecules to decrease surface tension. Although polymers may enhance tear film stability without enhancing viscosity, there appears to be no correlation between retention time and viscosity. Polysaccharides, including mucilages, dextrans, and

viscoelastic substances, and vinyl derivatives are the most common polymers used in tear substitutes (Table 14-1).

Mucilages are true colloidal solutions, having viscous and adhesive properties, and are made of cellulose or vegetable gums. Cellulose mucilages, such as MC and other substituted cellulose ethers, are the most widely used in dry eye treatment increasing the viscosity of tears (even at low concentrations) and providing moderate absorptive properties to the corneal epithelium. They have little effect on surface tension and osmotic pressure. Dextran, a branched glucose polymer, also is used frequently, whereas viscoelastic agents such as hyaluronic acid and chondroitin sulfate have additionally been evaluated for various dry eye states.

Over the years other synthetic polymers have been used to enhance the viscosity of artificial tear solutions, increasing ocular retention time but not necessarily relieving dry eye on its own. Thus other less viscous hydrophilic substances such as PVA and PVP have been included as the polymeric ingredients of many artificial tear formulations. Mild and moderate viscosity agents are best for artificial tear solutions. Highly viscous substances have good retention time but make blinking difficult, form lumps that disturb vision, and may mechanically remove the natural tear film and cause epithelial damage.

**Substituted Cellulose Ethers.** Since their introduction for ophthalmic use, MC and other substituted cellulose ethers such as hydroxyethylcellulose, hydroxypropylcellulose, hydroxypropyl methylcellulose (HPMC), and carboxymethylcellulose (CMC) have been used in artificial tear formulations. These colloids dissolve in water to produce colorless solutions of varying viscosity. They have the proper optical clarity, a refractive index similar to the cornea, and are nearly inert chemically. Their relative lack of toxicity, their viscous properties, and their beneficial effects on tear film stability have made cellulose ethers useful components of artificial tear preparations. Historically, the most frequently used representative of this group was MC.

MC is a synthetic granular white substance that forms a viscous solution when added to water. A stable compound at the pH range tolerated by the eye, MC is unaffected by light or aging in solution. High temperatures ( $\geq 100^\circ\text{C}$ ) produce coagulation, but on cooling MC redissolves, making heat sterilization possible. Solutions containing only pure MC do not support growth of microorganisms. MC is available in varying degrees of viscosity, and at concentrations in excess of 2% it becomes sufficiently viscous to be classified as an ointment. For ocular use a concentration range of 0.25% to 1.0% is preferred.

Over the years the other substituted cellulose ethers, particularly hydroxyethylcellulose and HPMC, have been more frequently used. They are somewhat less viscous than MC but possess cohesive and emollient properties equal or superior to those of MC. Like MC, these ethers also mix well with other polymers and substances present in artificial tear formulations and are compatible with

**Table 14-1**  
Selected Artificial Tear Solutions

Solution	Ingredients	Preservatives
<b>Advanced Vision Research</b>		
TheraTears	0.25% sodium CMC; borate buffers; CaCl; MgCl; KCl; sodium bicarbonate; NaCl; sodium phosphate (Sodium perborate) TheraTears Liquigel: 1.0% sodium CMC, borate buffers, CaCl, MgCl, KCl, sodium bicarbonate, NaCl, sodium phosphate	None
<b>Alcon</b>		
Bion Tears	0.1% dextran 70; 0.3% HPMC 2910; NaCl; KCl; MgCl; ZnCl; CaCl; sodium bicarbonate	None
Tears Naturale II	0.1% dextran 70; 0.3% HPMC 2910; KCl; NaCl; sodium borate	0.001% Polyquaternium
Tear Naturale Free	0.1% dextran 70; 0.3% HPMC 2910; KCl; NaCl; sodium borate	None
Tear Naturale Forte	0.1% dextran 70; 0.2% glycerin; 0.3% HPMC; boric acid, CaCl; glycine; MgCl; polysorbate 80; KCl; NaCl; ZnCl	Polyquaternium
Systane	0.4% PEG-400; 0.3% propylene glycol; boric acid; CaCl; HP-guar; MgCl; KCl; NaCl, ZnCl	Polyquaternium
<b>Allergan</b>		
Optive	0.5% CMC; 0.9% glycerin	Purite
Refresh Celluvisc	1% CMC; CaCl; KCl; NaCl; sodium lactate	None
Refresh	1.4% PVA; 0.6% povidone; NaCl	None
Refresh Endura	1.0% glycerin; 1% polysorbate 80; carbomer; castor oil; mannitol	None
Refresh Liquigel	1.0% CMC; boric acid; CaCl; MgCl; KCl; NaCl; sodium borate	Purite
Refresh Plus	0.5% CMC; boric acid; CaCl; MgCl; KCl; NaCl; sodium borate	None
Refresh Tears	0.5% CMC; boric acid; CaCl; MgCl; KCl; NaCl; sodium borate	Purite
<b>Aqueous Pharma</b>		
NutraTear	0.6% PVA; cyanocobalamine (vitamin B <sub>12</sub> ); KCl; sodium borate; NaCl	EDTA and Polyquaternium-42
<b>Bausch &amp; Lomb</b>		
Moisture Eye	1.0% propylene glycol; 0.3% glycerin; boric acid; EDTA; KCl; sodium borate; NaCl	BAK
Moisture Liquigel	1.0% dextran 70; 0.8% HPMC 2910; dextrose; dibasis sodium phosphate; KCl; NaCl	BAK
<b>Novartis (CIBA Vision)</b>		
GenTeal Mild	0.2% HPMC; boric acid; KCl; CaCl dihydrate; phosphonic acid; NaCl	Sodium perborate
GenTeal	0.3% HPMC; boric acid; KCl; phosphonic acid; NaCl	Sodium perborate
<b>Vision Pharm</b>		
Viva-Drops	Polysorbate 80; NaCl; citric acid; EDTA; retinyl palmitate; mannitol; sodium citrate; pyruvate	None

BAK = benzalkonium chloride; CMC = carboxymethylcellulose; EDTA = ethylenediaminetetraacetic acid (edetate); HP-guar = hydroxypropyl guar; HPMC = hydroxypropyl methylcellulose; PEG = polyethylene glycol; PVA = polyvinyl alcohol.

many drugs and chemicals used on the eye. Anionic polymers such as CMC are more bioadhesive than are neutral polymers such as HPMC. The former may provide electrolytes that help to maintain ocular surface health, but it also may form a complex with metabolites or debris in tears and create insoluble precipitates. Neutral polymers such as HPMC are highly water soluble and less likely to form insoluble precipitates.

In addition to their use in tear substitutes, cellulose ethers are used to moisten contact lenses and, as

discussed in Chapter 2, are added to ophthalmic drug formulations to prolong contact time of the active drug with the eye. More viscous solutions (goniogels) are used for application of gonioscopic lenses to the eye. The viscous properties of the colloid aid in maintaining contact between the lens and the cornea and also prevent damage to the corneal epithelium.

Although the cellulose ethers enhance viscosity and prolong the ocular retention time of solutions, they may also exert other effects that are less well understood.

For example, cellulose ethers and other water-soluble polymers may adsorb at the cornea–aqueous tear layer interface, thereby stabilizing a thicker layer of fluid adjacent to the adsorbing surface. The observation that these compounds can prolong TBUT supports such assumptions. The cellulose ethers are generally nonirritating and nontoxic to the ocular tissues.

**Viscoelastic Agents.** Sodium hyaluronate and sodium chondroitin sulfate are mucopolysaccharides found in the extracellular matrix of connective tissues, including the vitreous, cornea, and aqueous humor. Both are used for intraocular surgery, but their tolerance, lubricating qualities, and strong adhesion to the epithelium make these viscoelastic agents good candidates for off-label usage in the treatment of severe dry eye disorders.

**Sodium Hyaluronate.** Sodium hyaluronate is a hydrophilic high-molecular-weight polysaccharide polymer (glycosaminoglycan). At physiologic pH it is a viscoelastic solution, with a viscosity more than 500,000 times that of physiologic saline. Because hyaluronate is a natural polymer and its concentration increases in response to ocular damage and during corneal wound healing, it may play a part in controlling the localized inflammation present in KCS patients. Diluted, it has been shown to reduce subjective symptoms and objective signs in dry eye patients, but reports on its efficacy on ocular surface damage vary.

Using solutions from 0.1% to 0.5%, studies have found a variety of dry eye syndromes show subjective as well as objective improvement, including decreased itching and burning, reduced foreign body sensation, and reduction of mucous strands. Staining of cornea and conjunctiva decreases, whereas tear film stability and corneal wettability may improve. Schirmer test values may also increase, probably due to water retentive properties. Hyaluronic acid use has been reported to incite significant improvement of corneal epithelial disruption and impression cytology compared with that provided by artificial tear treatment alone.

The beneficial effects of sodium hyaluronate follow from its viscoelastic properties, which lubricate as well as protect the ocular surface. A study found a 0.2% solution of sodium hyaluronate had a significantly longer ocular residence time than did 0.3% HPMC or 1.4% PVA. Most patients achieve control of symptoms with topical instillation up to four times daily. Subjective relief of symptoms such as burning and grittiness usually occurs immediately after drug instillation, and these effects can last 60 minutes or longer.

Positive effects on the tear film and ocular surface have not been reported by all researchers, however. Two studies showed no significant advantage of sodium hyaluronate over chondroitin sulfate or PVA, respectively. In a clinical study involving 104 dry eye patients, no statistical

difference in subjective symptoms, rose bengal staining, or TBUT with sodium hyaluronic application was found, although fluorescein staining did decrease. These results suggest that hyaluronic acid may not stabilize the precorneal tear film (as no improvement in rose bengal staining occurred) but may improve cell-to-cell adhesions between corneal epithelial cells, as exemplified by decreased fluorescein staining.

Sodium hyaluronate appears to be free of adverse ocular or systemic effects when used topically on the eye at the 0.1% concentration. Current limitations to its use as an artificial tear are the absence of a commercial preparation for the dry eye and its cost; this agent is considerably more expensive than other dry eye preparations for long-term use. It is available in disposable syringes and can be prepared as a 0.1% topical solution in saline.

**Chondroitin Sulfate.** Chondroitin sulfate is 350,000 times as viscous as saline. Solutions of hyaluronic acid 0.1%, chondroitin sulfate 1%, and a mixture of chondroitin sulfate 0.38% and hyaluronic acid 0.3% were compared with an artificial tear solution containing PVA and polyethylene glycol. All four solutions appeared equally effective in alleviating symptoms of itching, burning, and foreign body sensation in patients with KCS. Patients with low Schirmer's test scores, however, uniformly preferred a solution containing chondroitin sulfate, but because only 20 patients took part in this study, it may be premature to conclude that patients derive greater benefit from chondroitin sulfate as compared with other viscous agents present in artificial tear products. Chondroitin sulfate is available as Viscoat, a mixture of sodium chondroitin sulfate (40%) and sodium hyaluronate (30%). A study comparing Viscoat with 0.25% sodium hyaluronate and 0.4% sodium hyaluronate solutions noted all three solutions appeared to protect the ocular surface and increase TBUT, but no specific formula was preferred over the others or showed significant differences in the clinical and subjective parameters.

**Vinyl Derivatives.** Vinyl derivatives are water-soluble polymers and include PVA, PVP, polyvinyl (or polyacrylic) acid, and polyvinyl chloride.

**Polyvinyl Alcohol.** PVA enhances the ocular contact time of ophthalmic medications and is also a wetting agent for contact lenses. Most frequently used in a 1.4% concentration, it is much less viscous than is MC but has good retention time due to its adsorptive properties. Like MC, PVA is transparent and colorless in solution. Solutions of PVA can be easily sterilized, because they can withstand high temperatures. They can also be autoclaved or filter sterilized through a Millipore filtering system. At the concentration used in ophthalmic preparations, PVA is nonirritating to the eye. Moreover, it does not appear to interfere with normal plasma membrane integrity or corneal epithelial regeneration.

Like MC and HPMC, PVA may also enhance stability of the precorneal tear film. A study reported that 1.4% PVA increased TBUT by a factor of 1.89. Higher concentrations of PVA further prolonged TBUT with a maximum increase in TBUT (prolonged by a factor of 7.16) occurring with 10.0% PVA.

Although PVA is compatible with many commonly used drugs and preservatives, certain agents can thicken or gel solutions containing PVA. These include sodium bicarbonate, sodium borate, and the sulfates of sodium, potassium, and zinc. The reasons for these reactions are not well understood. The clinical use of solutions containing any of these agents concomitantly with solutions containing PVA requires caution to avoid incompatibility. For example, some extraocular irrigating solutions containing sodium borate can cause such a reaction when used to irrigate contact lens wetting solutions containing PVA from the eye.

**Other Vinyl Derivatives.** PVP is a nonionic surfactant used in 3% to 5% concentrations to increase viscosity of solutions. Although it exhibits surface-active properties similar to the cellulose ethers, PVP appears to have less ability to lower the interfacial tension at a water-oil interface. Nevertheless, in contrast to the cellulose ethers, PVP appears capable of forming hydrophilic coatings in the form of adsorbed layers. Because conjunctival mucin is believed to interact with the ocular surface to form an adsorbing surface for aqueous tears, the formation by artificial means of a hydrophilic layer that would mimic conjunctival mucin (mucomimetic) appears to be clinically desirable. Both mucin- and aqueous-deficient dry eyes would benefit, because the wetting ability of the corneal surface would be enhanced.

Other parameters of surface chemistry that have been evaluated—surface tension, contact angle of solutions on clean cornea, or polymethyl methacrylate—are similar among cellulose ethers, PVA, and the polymeric systems. Surface tension measurements indicate that all are less surface active than is mucin. Moreover, the action of artificial tear preparations exhibiting surface activity resulted from the presence of other ingredients, particularly the preservative BAK. These observations indicate that subtle interactions may occur between the various ingredients present in artificial tear formulations. The effects could further extend to interactions among synthetic polymers, preservatives, tear film constituents, and the epithelial surface. Questions remaining are numerous and can be answered only as better and less ambiguous testing procedures, both in vitro and in vivo, are developed. Clinical results and patient acceptance remain the final criteria of in vivo efficacy of specific artificial tear solutions. No single formulation has yet been identified that universally provides improvement in clinical signs and symptoms while allowing patient comfort and acceptance.

### Other Viscosity-Enhancing Agents

Hydroxypropyl guar (HP-Guar) is a high-molecular-weight branched polymer of mannose and galactose contained in Systane eye drops (Alcon). It is a gellable lubricant designed to mimic the mucin layer of tears, to prolong contact time and promote the retention of two viscosity-enhancing agents, polyethylene glycol 400 and polypropylene glycol. HP-Guar is a liquid with a pH of 7.0 but forms a soft gel when exposed to the pH (about 7.5 in normal subjects) of the tear film by forming reversible cross-links of the borate ions with the HP-Guar. This creates a matrix that reduces tear clearance and allows the polyethylene glycol and polypropylene glycol to adhere to the ocular surface. The matrix protects the ocular surface by creating an ocular shield, allowing for epithelial repair and retaining aqueous. Studies have found Systane significantly improved ocular symptoms and significantly reduced ocular surface staining in dry eye patients.

### Other Ingredients

**Electrolytes.** The addition of electrolytes is designed to maintain or lower the osmolarity of artificial tears as compared with natural tears. Some electrolytes are important for corneal epithelial metabolism and as part of a buffer system. Sodium chloride contains the most important electrolytes in tears, but potassium is another necessary nutrient for corneal epithelial metabolism.

Most tear substitutes are isotonic with natural tears. Hyperosmolar tears attract water from the corneal epithelial cells and interfere with metabolism, decrease cell vitality, reduce microvilli, and disrupt the mucin layer. Osmolarity may be an etiologic factor in pathophysiologic abnormalities of the ocular surface seen in dry eye, because KCS patients tend to have elevated tear tonicity as compared with normal individuals. Therefore some artificial tears are hypotonic in an attempt to dilute and decrease osmolarity of the tear film. The use of hypotonic saline was found to be superior to isotonic solutions in diluting the tear osmolarity of KCS patients to tonicity levels often associated with non-dry eye patients. However, both the isotonic and hypotonic solutions improved rose bengal staining to a statistically similar level. The first hypotonic artificial tear formulation was HypoTears (IOLAB, Claremont, CA) with a 214-mOsm/kg tonicity. However, clinical studies did not find a prolonged significant effect on tear osmolarity with its use. TheraTears (Advanced Vision Research), an electrolyte-based solution with an osmolarity of 175 mOsm/L, was found to increase corneal collagen and conjunctival goblet cell density in rabbits with KCS. In a clinical study involving 11 dry eye patients, TheraTears was found to decrease significantly the tear osmolarity measured after 4 and 8 weeks of formulation use.

**Buffers.** The normal tear pH of 7.5 depends on bicarbonates and, to a lesser degree, proteins, phosphates,

ammonium, and other substances. In ophthalmic solutions slightly alkaline environments are more compatible with the epithelium than are neutral or acid compositions. Artificial tears with a pH approaching 8.5 are most comfortable for dry eye patients. Some of the most common buffer systems used in tear substitutes include phosphate, phosphate-acetate, phosphate-citrate, phosphate-citrate-bicarbonate, borate, and sodium hydroxide. An artificial tear solution with bicarbonate ions was reported to significantly enhance the maintenance of corneal epithelial barrier function in dry eye patients.

**Preservatives.** Preservatives are added to ophthalmic solutions to kill or inhibit growth of microorganisms. Because the cornea and conjunctiva are compromised in OSD, contaminated ophthalmic solutions have a greater chance of causing infection. Contamination can occur when the bottle tip touches any surface, including the eye. Current preservatives in artificial tears have a bacteriostatic effect on microorganisms. They include quaternary ammonium compounds (BAK, polyquaternium, cetylpyridinium chloride), mercurials (thimerosal), alcohols (chlorobutanol), and esters of parahydroxybenzoic acid (methylparaben and propylparaben). EDTA, which does not have sufficient antimicrobial strength on its own but enhances the activity of the quaternary ammonium base, and sorbic acid (sorbate), which has limited antimicrobial activity by itself as well, may also be added to tear solutions. Few studies have been conducted of the contamination of artificial tears with microorganisms. Tears preserved with BAK, chlorobutanol, and polyquaternium were compared with an unpreserved tear substitute. *Pseudomonas aeruginosa* and *Staphylococcus aureus* were eliminated by all three preservatives within 6 hours but were still present in the nonpreserved solution after 15 hours.

Of primary concern with frequent or prolonged use of tear substitutes is the potential for epithelial toxicity, disruption of tear film stability, and hypersensitivity reactions induced by preservatives present in the formulation. BAK is a cationic surfactant that is preferred for many ophthalmic solutions because of its long shelf life and ability to increase corneal drug penetration. However, overuse of 0.004% and 0.02% concentrations of BAK may be toxic to the tear film and cornea. In concentrations of more than 0.01% it damages the lipid layer, reducing TBUT. Chlorobutanol is less effective as a preservative than is BAK but is associated with fewer allergic reactions. Polyquaternium (Polyquad) has few toxic effects. Thimerosal causes little epithelial damage but produces allergic reactions. EDTA chelates calcium required for cell junction formation and may be cytotoxic during prolonged use. Sorbate is rarely associated with adverse reactions, although punctate keratitis has been reported.

Computerized subjective fluorophotometry was used to compare the effect of artificial tears containing 2% PVP

with and without the preservative BAK in dry eye patients. The epithelial permeability decreased significantly in patients treated with unpreserved tears, whereas patients treated with preserved tears showed an increase in permeability. Other studies have also compared the effects of preserved and unpreserved artificial tears on symptoms and signs in dry eyes. These observations indicate that KCS patients using unpreserved artificial tear products can achieve both subjective and clinical improvement. Generally, any patient using artificial tears more than four times daily should use nonpreserved formulas.

Use of preserved tear substitutes with contact lenses is a concern because the preservatives may bind to the lens polymer, prolonging ocular retention and exposure, which may result in toxic or hypersensitivity reactions. BAK is more readily absorbed than are thimerosal and chlorhexidine in most hydrogel lenses.

Unpreserved artificial tear formulations are available as unit-dose packages of artificial tear solutions. Though less convenient and more expensive than multidose bottles, they are generally recommended for patients with dosing regimens that exceed three or four times a day. However, they can be easily contaminated during use, and strict hygienic procedures must be followed. The tips of containers should not come in contact with the ocular or any other surface, and any excess solution must be discarded 12 hours after first use. Refrigeration has been reported to lower the rate of microorganism replication in unpreserved aqueous eye drops.

A more recent development in ophthalmic solution preservation is the advent of formulations that are preserved in the container (bottle) but break down to nontoxic substances when exposed to light or the ocular surface. One such compound, sodium perborate, generates very low yet bactericidal levels of hydrogen peroxide. After contact with the tear film, this substance breaks down first to low-concentration hydrogen peroxide and then to water and oxygen. Purite, a stabilized oxychloro-complex, degrades to sodium chloride, oxygen, and water on light exposure. Stabilized oxychloro-complex has a wide spectrum of antimicrobial activity and has been shown to destroy the fungus *Aspergillus niger*, one of the most difficult organisms to kill. These preservatives provide the convenience of a multidose formulation without the adverse effects associated with chronic use of preservatives.

**Nutrients.** In natural tears nutrients are necessary for corneal and conjunctival epithelial metabolism as well as for the synthesis of mucin and the glycocalyx. Water is the most important nutrient contained in tear substitutes, but other nutrients include dextrose, sodium lactate, sodium citrate, and vitamins A, B<sub>12</sub>, and C.

Vitamin A deficiency can affect a variety of epithelial-lined organs, including the eye. This nutrient is essential for the differentiation and maintenance of mucosal

epithelium, and its absence causes loss of goblet cells and keratinizing metaplasia of the epithelium. Cytologic characteristics of the conjunctival squamous metaplasia that occurs with KCS and mucin deficiency diseases are similar to those that occur with hypovitaminosis A. Cellular differentiation results in poor adhesion and insufficient spreading of tear film, with corneal complications such as poor epithelium healing. Tear fluid is the main vehicle carrying vitamin A to the corneal and conjunctival epithelium. Conventional dry eye therapies do not reverse keratinization.

Epidermal keratinization and mucous membrane squamous metaplasia respond to both oral and topical vitamin A therapy. Vitamin A exists in three forms: retinol, retinal, and retinoic acid. Vitamin A increases the mucous production of goblet cells and perhaps the aqueous and lipid components of the tears as well. Tretinoin is a normal metabolite and the carboxylic form of retinol. Retinol is present in tears and the lacrimal gland appears to be its major provider. Retinoic acid has been shown to be effective in ocular surface disorders such as squamous metaplasia by reversing the corneal and conjunctival keratinization and improving epithelium wound healing rate.

A controlled study evaluated the efficacy and safety of topical tretinoin ointment 0.01% in patients with noncicatricial dry eyes and found it ineffective in improving either symptoms or clinical signs. However, the drug was able to reverse conjunctival keratinization in patients with conjunctival cicatricial diseases, although in these patients clinical symptoms and signs showed no significant improvement with tretinoin therapy as compared with placebo. Another study also found that 0.01% tretinoin did not improve clinical symptoms better than placebo in dry eye patients. Schirmer test values and TBUT were significantly improved but not more so with retinoic acid. Retinoic acid did improve rose bengal staining significantly, suggesting it reduces keratinized and devitalized cells in the cornea and conjunctiva. An additional study also noted were improvement and reversal of keratinization in severe dry eye patients. Others, however, found vitamin A ointment to be of no benefit in KCS. Some studies using vitamin A (retinol) in solution with polysorbate 80 (Viva-Drops) reported some relief of signs and symptoms in patients with various dry eye disorders.

Side effects associated with use of topical tretinoin ointment include transient hyperemia, irritation, or burning. Ocular pharmacokinetic studies in rabbits show low levels of drug in the aqueous humor after topical application of [ $^3$ H]-tretinoin, with major tissue uptake in the surface epithelium and the iris. Because retinoic acid has poor stability in the presence of light and oxygen and is insoluble in water, its formulations and clinical use are limited. Although it is capable of reversing squamous metaplasia and keratinization, these ocular surface changes are seen only in severe, not mild to moderate, cases of dry eye.

Other vitamins, including B<sub>12</sub>, have also been included in artificial tear formulations. NutraTear (Aqueous Pharma) contains vitamin B<sub>12</sub>, but the effects of this nutrient have not been well documented. B<sub>12</sub>, which is needed for normal cell growth, cannot be synthesized by the body. It may protect the eye from oxidative free radicals and has been found to increase the healing rate of denuded epithelium in rabbit cornea. Controlled clinical studies regarding the clinical efficacy of this and other nutrient products in patients with OSD are presently lacking.

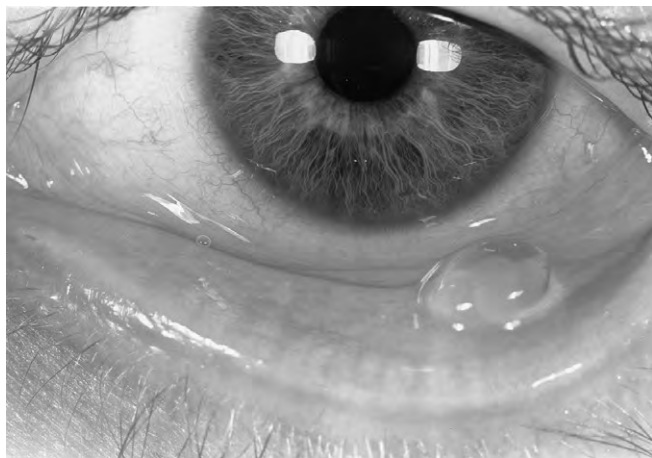**Mucolytic Agents (Acetylcysteine).** Mucolytics soften mucus and make it more fluid. They also have an intracellular effect on goblet cells during mucin formation, facilitating production and improving quality. Therefore they may be considered mucin hypersecretors. Bromhexine, tyloxapol, *N*-acetylcysteine, and methyleysteine are examples of mucolytic agents.

Acetylcysteine has been clinically useful as a mucolytic agent in acute and chronic bronchopulmonary conditions. Available as Mucomyst in a 10% or 20% solution of the sodium salt of acetylcysteine, it usually is administered by nebulization for its local effect on the bronchopulmonary tree. Unlabeled uses for Mucomyst include the treatment of vernal and giant papillary conjunctivitis and filamentary keratitis; aqueous-deficient dry eye is the most common ocular condition associated with filamentary keratitis. A commercial ophthalmic formulation containing acetylcysteine is not currently available, but it can be prepared for topical ocular use by diluting the commercial preparation to 2% to 5% with artificial tears or physiologic saline. When applied topically to the eye, Mucomyst can dissolve mucous threads and decrease tear viscosity. A 20% solution of acetylcysteine, when compared with artificial tears, was reported to exhibit greater improvement in conjunctival and corneal staining and dissolution of mucous threads and filaments. However, no subjective differences were observed between the groups. Acetylcysteine solutions produce a stinging sensation on instillation, which may in part explain the subjective results.

#### Artificial Tear Inserts

Lacrisert (Merck) is a solid, water-soluble, cylindrical rod approximately 1.25 mm wide and 3.50 mm long containing 5 mg of hydroxypropylcellulose without preservative. When placed in the inferior cul-de-sac, it imbibes fluid and swells to several times its original volume (Figure 14-4). After the initial swelling the insert dissolves over 6 to 8 hours. It is designed to be replaced every 24 hours, although some patients require more frequent replacement.

Clinical studies indicate that the insert can be beneficial in the treatment of certain dry eye syndromes. Some patients may experience relief of symptoms of burning, photophobia, and foreign body sensation. Corneal abnormalities and rose bengal staining of cornea and conjunctiva



**Figure 14-4** Artificial tear insert (Lacrisert).

may decrease. Measurements in human subjects indicate that the insert prolongs TBUT. It is uncertain, however, whether this effect lasts longer than with tear substitutes applied as drops. The insert produces a tear film that is clinically thicker than normal and that appears to retain fluid within it.

The device is generally comfortable and well accepted by many patients, but its use does have certain disadvantages. Some patients have problems with discomfort (foreign body sensation) or expulsion of the Lacrisert. The insert can be wetted with saline before insertion to improve comfort, but this can make even more difficult the insert's placement into the lower cul-de-sac, which requires a moderate amount of dexterity. Supplementation with artificial tears after insertion may improve comfort. The most common patient complaint is blurred vision associated with the intense release of polymer during the first 4 to 6 hours after instillation, from a thickened tear film. Adding such fluid as drops of NaCl 0.9% or artificial tear solution can reduce the tear film viscosity and minimize the visual complaints. As the insert dissolves it releases debris that can blur vision and cause irritation. Most patients with mild signs and symptoms of dry eye do not experience improvement with use of the insert, as compared with the use of conventional tear solutions. Because some tear secretion is necessary to dissolve the Lacrisert, KCS patients with low basal tear secretion may not benefit from or tolerate its use.

#### Autologous Serum

Serum has been proposed as a source of tear replacement in severe dry eye. Autologous serum application to dry eye was reported as early as 1984. Tears contain several essential growth factors important in regulating the proliferation and maturation process of the epithelium; these same growth factors are present in serum. Improved ocular surface staining has been reported in patients using serum diluted in saline. Tsubota et al. demonstrated the use of serum eyedrops in Sjögren

patients resulted in significant increase in mucin expression and a beneficial effect on rose bengal staining. The main drawbacks of serum solutions are time-consuming preparation, short storage (refrigerated) time, and handling difficulties in patients with transmissible diseases.

#### Tear Conservation

Tear conservation may be achieved through techniques that reduce evaporation or obstruct tear outflow. Evaporation can be minimized by use of nonmedicated ophthalmic ointment and control of environmental factors. Shielded goggles, moisture chambers, and room humidifiers are helpful for some patients. Drafts, wind, smoke, air conditioning and heating systems, and fans can aggravate dry eye conditions by increasing evaporation. Obstruction of the lacrimal drainage system can be achieved through surgical methods, cautery or laser procedures, or punctal plugs. In severe cases tarsorrhaphy may be indicated. Tear conservation techniques are indicated with aqueous-deficient dry eye but may help other forms of dry eye as well. For such techniques to be effective, at least some aqueous secretion must be present unless tear supplementation also occurs.

#### Ointments

Nonmedicated ointments are indicated for moderate to severe dry eye, especially with lagophthalmos, persistent inferior corneal stippling, or severe epithelial compromise. Esters of fatty acids with long-chain alcohols, such as petrolatum, mineral oil, lanolin, and lanolin alcohols, serve as lubricants and create a lipid layer, retarding evaporation. Although these preparations (Table 14-2) melt at the temperature of the ocular tissue and disperse with the tear fluid, they appear to be retained longer than other ophthalmic vehicles. Because of their molecular

**Table 14-2**

Selected Nonmedicated Ophthalmic Ointments

Ointment	Ingredients	Preservatives
<b>Allergan</b>		
Lacri-Lube NP	55.5% White petrolatum; 32% mineral oil; 2% petrolatum/lanolin alcohol	None
Lacri-Lube S.O.P.	56.8% White petrolatum; 42.5% mineral oil; lanolin alcohols	Chlorobutanol
Refresh PM	57.3% White petrolatum; 42.5% mineral oil	None
<b>Bausch &amp; Lomb</b>		
Moisture Eyes PM	20% Mineral oil; 80% white petrolatum	None



size, petrolatum and mineral oil are not as easily removed by the lacrimal drainage system by blinking. Another significant factor appears to be the physiochemical relationship between the components of the ointment and the cornea. The precorneal tear film and the ointment bases both have nonpolar components, allowing adsorption of the oil bases to the cornea.

Patient acceptance of ointment preparations is highly variable. Because ointments are insoluble in water and do not mix readily with the tear film, they can reduce TBUT and blur vision. They are not generally recommended for daytime use in patients with aqueous-deficient dry eyes. Limiting the use of ointments to the evening or at bedtime avoids the visual effects. Ointment preparations generally are nonirritating to ocular tissue. In addition, ointment vehicles currently used do not appear to interfere with corneal or conjunctival wound healing. Ointment use, however, should be avoided in eyes with impending corneal perforations, deep or flap-like corneal abrasions, or severe corneal lacerations because of the possibility of ointment entrapment.

#### Lacrimal Occlusive Devices

Occlusion of the lacrimal drainage system has been used to preserve existing tears since electrocautery of the canaliculi was first advocated in 1936. Punctal plugs were introduced in 1974 to block tear drainage and thereby prolong the action of natural tears as well as artificial tear preparations. Absorbable inserts made with hydroxypropyl cellulose, polydioxanone, collagen, or gelatin and permanent ones made with silicone, thermodynamic acrylic polymer, or hydrogel material are available. Permanent punctal occlusion can also be achieved through thermal methods (cautery, diathermy, or laser) that destroy or shrink canaliculi walls.

The two most common types of plugs currently in use are collagen and silicone (Table 14-3). The water-soluble collagen rods are temporary, dissolving 4 to 7 days after insertion. Silicone plugs are more permanent but can be removed when necessary.


Temporary collagen implants come in a variety of sizes (diameters) to ensure as close a fit as possible. The plug is grasped with a jeweler's forceps and, with the aid of magnification, placed halfway into the punctal opening (Figure 14-5). It then is nudged until flush with the punctum and is further advanced into the horizontal canaliculus. Topical anesthetics may be used to minimize eyelid reaction, but the procedure can be performed without anesthesia. The aqueous environment of the canaliculus causes the collagen implant to swell, impeding tear flow by as much as 60% to 80%. Degradation time of implants is unpredictable, because they have been reported to block tear drainage from 3 days to 2 weeks. Plugs made from synthetic materials such as polydioxane and PCL are also promoted as absorbable, but last considerably longer—up to 5 or 6 months. These provide a possible treatment option for temporary dry eye

**Table 14-3**  
Selected Punctal Plugs

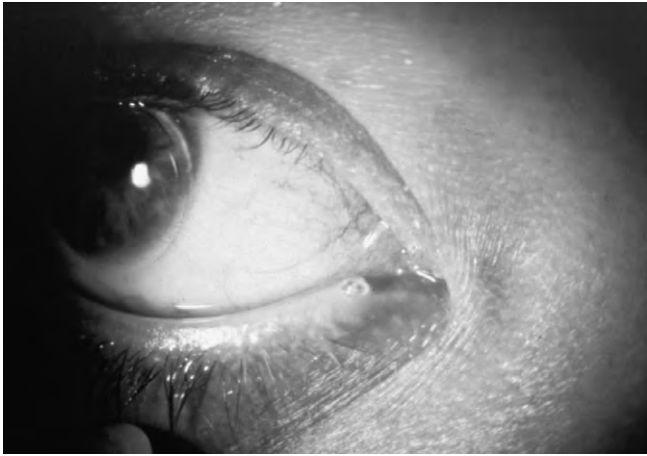
Plug	Material
<b>Lacrimedics</b>	
Herrick OPAQUE Lacrimal Plug	Silicone
Herrick Dissolvable OPAQUE Lacrimal Plug	Polydioxanone
Herrick Dissolvable Collagen Plug	Collagen
<b>Medennium</b>	
SmartPLUG	Thermodynamic acrylic polymer
<b>Eagle Vision</b>	
EagleFlex	Silicone
EaglePlug	Silicone
Duraplug	PCL (E-Caprolactone-L-Lactide copolymer)
<b>FCI Ophthalmics</b>	
“Ready-Set” Punctum Plug	Silicone
PVP Perforated Plug	Silicone coated with PVP
Collagen Plug	Collagen
<b>OASIS</b>	
Form-fit intracanalicular long-term plug	Hydrogel material
Silicone punctal plugs	Silicone
Collagen intracanalicular plug	Collagen

conditions, such as frequently experienced after refractive surgery.

Silicone plugs are inserted into either the punctum or the canaliculus, depending on the plug design. They are also available in a range of sizes (diameters) and shapes (designs). Some come with their own applicator (insertion device). The inferior drainage system is plugged most often, because it has a greater responsibility for tear drainage and is more accessible than the superior branch. The procedure by which silicone plugs are placed may require topical anesthesia and dilation of the punctal opening.



**Figure 14-5** Insertion of collagen plug. (Courtesy Leo Semes.)



**Figure 14-6** Inserted punctal plug. (Courtesy Leo Semes.)

In some cases insertion can be difficult or the plug can be expelled, especially if the patient rubs the eyelid. Spontaneous extrusion of plug appears to be the most common complication, with replacement plugs having an even lower retention rate than the initial plugs. Some studies show no significant difference in retention between upper and lower plugs, but others found plugs placed in the upper puncta were more prone to be lost than those in the lower lid. If reversal of occlusion is desired, lacrimal (intra-canalicular) plugs, inserted into the horizontal canaliculus, can be removed through saline irrigation. Punctal plugs have heads that sit outside the punctum to impede migration and aid in removal (Figure 14-6).

Other materials are also available for patients deemed suitable for more permanent occlusion. “Form Fit” intra-canalicular plugs (OASIS) are made of hydrogel material that once inserted into the vertical canaliculus and exposed to tears expands to form a gelatinous plug. The SmartPLUG (Medennium) also expands into a gelatinous plug after insertion into the canaliculus. Instead of hydration, body temperature conforms the thermodynamic acrylic polymer to the puncta.

Lacrimal occlusion can benefit patients who have symptoms of dryness or other ocular abnormalities that topical therapy alone does not resolve. The procedures are indicated in moderately severe to severe dry eye patients to prevent drainage and thereby conserve natural tears as well as instilled tear substitutes, reducing the frequency of application. Lacrimal occlusion also can improve contact lens tolerance in mild dry eye cases. Various studies have demonstrated that plugs may increase the aqueous tear component of the tear film, decrease corneal and conjunctival staining, and improve patient symptoms. Tear osmolarity decreases, probably due to increased tear volume.

Although rare, punctal occlusion can lead to epiphora, rupture of the punctal ring, pruritus, or canaliculitis. Pyogenic granulomas, in response to the presence of silicone plugs, have also been reported in a few patients.

Tearing with mucopurulent discharge, secondary to chronic dacryocystitis, is a contraindication to the use of lacrimal plugs.

Although punctal occlusion decreases dry eye symptoms in many patients, others may actually experience increased irritation. After occlusion, ocular surface sensation may diminish and reduced tear turnover can result from a decline in tear production and/or tear drainage.

As tear clearance decreases, the concentration of proinflammatory cytokines increases in the tear film, exacerbating ocular surface desensitization. This affects the neural feedback loop between the ocular surface and lacrimal gland, leading to decreased tear production and, consequently, further inflammation and irritation.

## Tear Stimulation

If some secretory parts of the lacrimal gland remain functional, stimulation to enhance tear production may be possible. Secretagogues or lacrimomimetics, such as cholinergic agents (carbachol, bethanecol, pilocarpine) and mucolytics (bromhexine and ambroxol), have been used to stimulate lacrimal glands, but none of these agents is in general use in the United States for the treatment of dry eye. P2Y2 nucleotide receptor agonists are also being investigated as topical secretagogues. Reducing ocular surface inflammation, through anti-inflammatories, immunomodulation or other means, may also stimulate tear production.

### Pilocarpine

Pilocarpine is a parasympathomimetic agent with a muscarinic secretagogue effect. Pilocarpine HCl (Salagen) has been used orally in the treatment of xerostomia secondary to radiation for head and neck cancer and in Sjögren’s syndrome. It decreases symptoms of dry mouth and may also improve eye, skin, nose, and vaginal dryness. Subjective improvement in dry eye symptoms has been reported in investigations of oral pilocarpine for the treatment of KCS in Sjögren’s syndrome. Objectively, oral pilocarpine increases tear volume and flow, although nausea and sweating can be present. Topically applied pilocarpine shows no effect on stimulation of accessory lacrimal glands in rabbits.

### Bromhexine

Bromhexine hydrochloride (Bisolvan) is a bronchial mucolytic agent and secretagogue that may have a stimulating effect on tear secretion. Oral bromhexine and its derivative ambroxol have equivocal results in clinical trials and are associated with side effects of nausea, sweating, and rashes.

### Diquafosol

P2Y2 receptors are present in the epithelial cells of the ocular surface and stimulation of them by ATP increases mucin-like glycoprotein secretions in conjunctival

goblet cells. Activation of the receptors also stimulates the fluid pump mechanism of the accessory lacrimal glands, increasing water flow through cells and tear production. Some studies also suggest that receptor is present in meibomian glands and could control lipid composition. Therefore P2Y2 receptor agonists potentially have an effect on all three layers of the tear film.

Diquafosol tetrasodium 2% (diuridine tetraphosphate) is a potent and selective P2Y2 purinergic receptor agonist. In several clinical trials it was efficacious in improving corneal and conjunctival staining and Schirmer test values as well as providing some symptomatic benefit for dry eye patients. Phase II and III studies are completed, and a New Drug Application was submitted by Inspire Pharmaceuticals to the U.S. Food and Drug Administration in 2003. An amendment to the New Drug Application was filed in 2005, after the completion of two additional phase III trials.

Diquafosol is highly water-soluble dinucleotide, stable at room temperature. It does not appear to be systemically absorbed and is rapidly metabolized on the surface of the eye to naturally occurring compounds. It is well tolerated with localized side effects (burning/stinging). It is administered four times a day as an unpreserved, sterile, aqueous drop.

### Inflammation Control

Chronic dry eye is the result of an underlying cytokine and receptor-mediated inflammatory process that affects the ocular surface and lacrimal gland, leading to decreased tear production or altered tear film contents. Hormonal, anti-inflammatory, or immunomodulatory agents may be able to suppress the inflammation and normalize the neural reflex between the ocular surface and lacrimal glands.

**Hormone Therapy.** When androgen levels decrease with age, certain autoimmune diseases (i.e., Sjögren's syndrome) or menopause, a stimulus such as an infection or dry environment can activate T cells, causing an inflammatory immune response on the ocular surface and/or lacrimal gland. Two studies showed that hormones are important contributors to the lacrimal gland's maintenance of function and resistance of immune insult. Others have reported androgens regulate meibomian gland function and promote the formation of tear film's lipid layer. Therefore hormone insufficiency may contribute to meibomian gland dysfunction, tear film instability, and evaporative dry eye. Systemic androgen therapy suppresses the inflammation and stimulates the function of the lacrimal gland in mice, further suggesting topical androgen might be an effective therapy for dry eye. Topical androgen drops for the treatment of dry eye are currently being studied.

**Corticosteroids.** Studies have shown unpreserved topical corticosteroids (i.e., methylprednisone or loteprednol

etabonate) can improve the severity of KCS symptoms and decrease levels of ocular surface inflammation and cytokines. However, they can have potential unwanted side effects such as ocular hypertension, glaucoma, cataracts, and secondary infections. Therefore topical corticosteroid use in dry eye should be limited to short periods (less than 2 weeks) and for symptoms that are severe and refractory to other treatments.

**Cyclosporine.** Cyclosporine (cyclosporin A) is used principally in autoimmune disease and to prevent rejection after organ/tissue transplantation, but it has also been used systemically to treat the ocular manifestations of autoimmune disease and endogenous uveitis. Topical cyclosporine was approved by the U.S. Food and Drug Administration in December 2002 and released in 2003 as Restasis (Allergan) to reduce the inflammatory response on the ocular surface and in the lacrimal gland in patients with dry eye. A decrease in inflammation contributes to an improvement in the ocular surface epithelial integrity and sensitivity. The neural signals to the lacrimal gland are increased by enhanced ocular surface sensitivity.

Cyclosporin is an immunomodulator that inhibits activation of T cells by cytokines and other agents of inflammation. Studies show conjunctival levels of activated lymphocytes, immune activation markers, and the inflammatory cytokine interleukin-6 significantly decreased after 6 months of treatment with topical 0.05% cyclosporin. The density of conjunctival goblet cells was significantly greater after the same treatment in Sjögren's and non-Sjögren's KCS patients. There have also been reports of successful treatment of meibomian gland dysfunction with cyclosporin.

A 6-week crossover study compared cyclosporine 1% ophthalmic ointment with a placebo and reported improvement in ocular surface staining, patient symptoms, and Schirmer's test results with cyclosporine. Cyclosporin A ophthalmic emulsions in 0.05%, 0.1%, 0.2%, and 0.4% concentrations were studied by another group. Used twice a day for 12 weeks in moderate to severe dry eye, all concentrations showed significant improvement in rose bengal staining, superficial punctate keratitis, and subjective symptoms. Although no clear dose-response relationship was noted, the 0.1% solution produced the most consistent objective and subjective endpoints and the 0.05% solution produced the most consistent improvements in patient symptoms. Another study compared 0.05% and 0.1% cyclosporin with the vehicle alone in moderate to severe dry eye in patients with and without Sjögren's. After 6 months of twice daily use, both cyclosporin emulsions resulted in significantly greater improvements than the vehicle in corneal staining and Schirmer's test values, whereas the 0.05% emulsion showed significantly more improvement than the vehicle in subjective parameters of blurred vision and use of lubricating eyedrops. This study found improvement only

in Schirmer's tests obtained with anesthesia. The lack of improvement in tests obtained without anesthesia suggests cyclosporin affects baseline tearing and not reflexive tearing.

Restasis is a 0.05% emulsion of cyclosporin with a vehicle of glycerin, castor oil, polysorbate 80, carmoner 1342, purified water, and sodium hydroxide. (The vehicle is marketed separately as Refresh Endura.) It is preservative free and white opaque to slightly translucent in color. The most common adverse effects are mild burning and stinging; topical cyclosporin appears to have minimal systemic absorption. It is used twice daily, and patients can expect results after 3 to 6 months of treatment.

**Fatty Acids.** Some essential fatty acids, which cannot be produced by the body, are natural modulators of inflammatory activity. Omega-3 fatty acids are present in oily fish, such as tuna, mackerel, salmon, sardines, and herring; they are also found in flaxseed oil. Sources for omega-6 fatty acids include beef, dairy products, and vegetable cooking oils and shortenings.

N-3 fatty acids contain eicosapentaenoic acid and docosahexaenoic acid and are metabolized to eicosanoids, hormone-like lipids involved in inflammation control. Oral omega-3 fatty acids can enhance meibomian gland function, resulting in a more stable tear film and reduction in evaporative tear loss. Some suggest n-3 fatty acids may also affect tear production by reducing inflammation of the lacrimal gland and ocular surface. N-6 fatty acids are converted to arachidonic acid, which promotes inflammation; eicosapentaenoic acid and docosahexaenoic acid may inhibit this conversion. TheraTears Nutrition (Advanced Vision Research), a capsule-form supplement containing flaxseed oil (1,000 mg), eicosapentaenoic acid (400 mg), and docosahexaenoic acid (300 mg), is promoted to treat OSD by decreasing inflammation and enhancing lipid and aqueous production.

It was recently reported that women with a higher intake of n-3 fatty acids tend to have a lower risk of dry eye, based on information gathered from a questionnaire on dietary habits. A completed questionnaire was received from over 32,000 subjects in the Women's Health Study. A high dietary intake ratio of n-6 to n-3 fatty acids was associated with a greater prevalence in dry eye. Although the questionnaire results suggest intake of n-3 fatty acids and the ratio of their consumption to n-6 fatty acids can affect the amount of inflammatory activity in the body, there has been no systematic study to establish the role of fatty acids in the treatment of dry eye.

## SELECTED BIBLIOGRAPHY

- Absolon MJ, Brown CA. Acetylcysteine in keratoconjunctivitis sicca. *Br J Ophthalmol* 1968;52:310-316.
- Ang RT, Dartt DA, Tsubota K. Dry eye after refractive surgery. *Curr Opin in Ophthalmol* 2001;12:318-322.
- Aragona P, Di Stefano G, Ferreri F, et al. Sodium hyaluronate eye drops of different osmolarity for the treatment of dry eye in Sjogren's syndrome patients. *Br J Ophthalmol* 2002; 86: 879-884.
- Aragona P, Papa V, Micali A, et al. Long term treatment with sodium-hyaluronate-containing artificial tears reduces ocular surface damage in patients with dry eye. *Br J Ophthalmol* 2002;86:181-184.
- Balaram M, Schaumberg DA, Dana MR. Efficacy and tolerability outcomes after punctual occlusion with silicone plugs in dry eye syndrome. *Am J Ophthalmol* 2001;131:30-36.
- Beetham WP. Filamentary keratitis. *Trans Am Ophthalmol Soc* 1936;33:413-435.
- Bernal DL, Ubels JL. Artificial tear composition and promotion of recovery of the damaged corneal epithelium. *Cornea* 1993; 12:115-120.
- Blaug SM, Canada AT. Relationship of viscosity, contact time, and prolongation of action of methyl-cellulose-containing ophthalmic solutions. *Am J Hosp Pharm* 1965;22:662-666.
- Brown NAP, Bron AJ, Harding JJ, Dewar HM. Nutritional supplements and the eye. *Eye* 1998;12:127-133.
- Caffery BE, Richter D, Simpson T, et al. The Canadian dry eye epidemiology study. *Adv Exp Med Biol*. 1998;438:805.
- Calonge M. The treatment of dry eye. *Surv Ophthalmol* 2001; 45(suppl 2):S227-S239.
- Cermak JM, Krenzer KL, Sullivan RM, et al. Is complete androgen insensitivity syndrome associated with alterations in the meibomian gland and ocular surface? *Cornea* 2003;22: 516-521.
- Condon PI, McEwen CG, Wright M, et al. Double blind, randomized, placebo controlled, crossover, multicentre study to determine the efficacy of 0.1% (w/v) sodium hyaluronate solution (Fermavisc) in the treatment of dry eye syndrome. *Br J Ophthalmol* 1999;83:1121-1124.
- Dana MR, Hamrah P. Role of immunity and inflammation in corneal and ocular surface disease associated with dry eye. *Adv Exp Med Biol* 2002;506:729-738.
- Dilly PN. Structure and function of the tear film. In: Sullivan DA, ed. *Lacrimal gland, tear film and dry eye syndrome*. New York: Plenum Press, 1994: 239-247.
- Doughty MJ, Fonn D, Richter D, et al. A patient questionnaire approach to estimating the prevalence of dry eye symptoms in patients presenting to optometric practices across Canada. *Optom Vis Sci* 1997;74:624-631.
- Fischbar J. Diquafosol tetrasodium Inspire/Allergan/Santen. *Curr Opin Invest Drugs* 2003;4:1377-1383.
- Fox RI, Chan R, Michelson JB, et al. Beneficial effect of artificial tears made with autologous serum in patients with keratoconjunctivitis sicca. *Arthritis Rheum* 1984;27:459-461.
- Freeman JM. Punctal plug: evaluation of a new treatment for dry eyes. *Trans Am Acad Ophthalmol Otolaryngol* 1975;79: 874-879.
- Friedlaender MH, Fox RI. Punctal occlusion for the treatment of dry eye. In: Sullivan DA, Dartt DA, Meneray MA, eds. *Lacrimal gland, tear film and dry eye syndromes 2: basic science and clinical relevance*. New York: Plenum Press, 1998: 1017-1020.
- Gilbard J. Tear film osmolarity in keratoconjunctivitis sicca. *CLAO J* 1985;11:243-250.
- Gilbard JP, Kenyon KR. Tear diluents in the treatment of keratoconjunctivitis sicca. *Ophthalmology* 1985;92:646-650.
- Gilbard JP, Rossi SR. An electrolyte-based solution that increases corneal glycogen and conjunctival goblet-cell density in a

- rabbit model for keratoconjunctivitis sicca. *Ophthalmology* 1992;99:600-604.
- Gilbard JP, Rossi SR, Heyda KG. Ophthalmic solutions, the ocular surface, and a unique therapeutic artificial tear formulation. *Am J Ophthalmol* 1989;107:348-355.
- Gobbels M, Spitznas M. Corneal epithelial permeability of dry eyes before and after treatment with artificial tears. *Ophthalmology* 1992;99:873-878.
- Hardberger R, Hanna C, Boyd CM. Effect of drug vehicles on ocular contact time. *Arch Ophthalmol* 1975;93:42-45.
- Harris MG, Gee A, Kusumoto R, Lee H. Survival of contaminating bacteria in over-the-counter artificial tears. *J Am Optom Assoc* 1996;67:676-680.
- Hartstein I, Khwarg S, Przydryga J. An open-label evaluation of HP-guar gellable lubricant eye drops for the improvement of dry eye signs and symptoms in a moderate dry eye adult population. *Curr Med Res Opin* 2005;21:255-260.
- Holly FJ, Lamberts DW. Effect of nonisotonic solutions on tear film osmolality. *Invest Ophthalmol Vis Sci* 1981;20:236-245.
- Kobayashi TK, Tsubota K, Takamura E, et al. Effect of retinol palmitate as a treatment for dry eye: a cytological evaluation. *Ophthalmologica* 1997;211:358-361.
- Krishna N, Brow F. Polyvinyl alcohol as an ophthalmic vehicle: effect on regeneration of corneal epithelium. *Am J Ophthalmol* 1964;57:99-106.
- Krishna N, Mitchell B. Polyvinyl alcohol as an ophthalmic vehicle: effect on ocular structures. *Am J Ophthalmol* 1965;59:860-864.
- Kunert KS, Tisdale AS, Stern ME. Effect of cyclosporine ophthalmic emulsion on the number of inflammatory cells and goblet cells in conjunctival biopsies with dry eye. *Invest Ophthalmol Vis Sci* 1999;44(suppl):S771.
- Kunert KS, Tisdale AS, Stern ME, et al. Analysis of topical cyclosporine treatment of patients with dry eye syndrome: effect on conjunctival lymphocytes. *Arch Ophthalmol* 2000;118:1489-1496.
- Laibovitz RA, Solch S, Andriano K, et al. Pilot trial of cyclosporine 1% ophthalmic ointment in the treatment of keratoconjunctivitis sicca. *Cornea* 1993;12:315-323.
- Lee JB, Ryu CH, Kim JH, et al. Comparison of tear secretion and tear film instability after photorefractive keratectomy and laser *in situ* keratomileusis. *J Cataract Refract Surg* 2000;26:1326-1331.
- Lemp MA. Report of the National Eye Institute/Industry workshop on Clinical Trials in Dry Eyes. *CLAO J* 1995;21:221-232.
- Lemp MA, Goldberg M, Roddy MR. Effect of tear substitutes on tear film breakup time. *Invest Ophthalmol* 1975;14:225-258.
- Lemp MA, Holly FJ. Ophthalmic polymers as ocular wetting agents. *Ann Ophthalmol* 1972;4:15-20.
- Limberg MB, McCaa C, Kissling GE, Kaufman HE. Topical application of hyaluronic acid and chondroitin sulfate in treatment of dry eyes. *Am J Ophthalmol* 1987;103:194-197.
- Miljanovic B, Trivedi KA, Dana MR, et al. Relation between dietary n-3 and n-6 fatty acids and clinically diagnosed dry eye syndrome in women. *Am J Clin Nutr* 2005;82:887-893.
- Mishima S, Gasset A, Klyce SD Jr, Baum JL. Determination of tear volume and tear flow. *Invest Ophthalmol* 1966;5:264-276.
- Murube J, Murube A, Zhuo C. Classification of artificial tears. II. Additive and commercial formulas. In: Sullivan DA, Dartt DA, Meneray MA, eds. *Lacrimal gland, tear film, and dry eye syndromes 2: basic science and clinical relevance*. New York: Plenum Press, 1998: 705-715.
- Murube J, Paterson A, Murube E. Classification of artificial tears. I. Composition and properties. In: Sullivan DA, Dartt DA, Meneray MA, eds. *Lacrimal gland, tear film, and dry eye syndromes 2: basic science and clinical relevance*. New York: Plenum Press, 1998: 693-704.
- Nelson JD, Farris RL. Sodium hyaluronate and polyvinyl alcohol artificial tear preparations. *Arch Ophthalmol* 1988;106:484-487.
- Nelson JD, Friedlainer M, Yeatts RP, et al. Oral pilocarpine for symptomatic relief of keratoconjunctivitis sicca in patients with Sjögren's syndrome. In: Sullivan DA, Dartt DA, Meneray MA, eds. *Lacrimal gland, tear film, and dry eye syndromes 2: basic science and clinical relevance*. New York: Plenum Press, 1998: 979-983.
- Nepp J, Schauersberger J, Schild G, et al. The clinical use of viscoelastic artificial tears and sodium chloride in dry-eye syndrome. *Biomaterials* 2001;22:3305-3310.
- Norn MS, Opauzki A. Effects of ophthalmic vehicles on the stability of the precorneal film. *Acta Ophthalmol* 1977;55:23-34.
- O'Brien PD, Collum LM. Dry eye: diagnosis and current treatment strategies. *Curr Allergy Asthma Rep* 2004;4:314-319.
- Oldham GB, Andrews V. Control of microbial contamination in unpreserved eyedrops. *Br J Ophthalmol* 1996;80:588-591.
- Papas AS, Fernandez MM, Castano RA, et al. Oral pilocarpine for symptomatic relief of dry mouth and dry eyes in patients with Sjögren's syndrome. In: Sullivan DA, Dartt DA, Meneray MA, eds. *Lacrimal gland, tear film, and dry eye syndromes 2: basic science and clinical relevance*. New York: Plenum Press, 1998: 973-978.
- Perry H, Donnenfeld E. Medications for dry eye syndrome: a drug-therapy. *Manag Care* 2003;12(12 suppl):S26-S32.
- Perry HD, Donnenfeld ED. Dry eye diagnosis and management in 2004. *Curr Opin Ophthalmol* 2004;15:299-304.
- Perry HD, Donnenfeld ED. Topical 0.05% cyclosporin in the treatment of dry eye. *Expert Opin Pharmacother* 2004;5:2099-2107.
- Pflugfelder SC. Antiinflammatory therapy for dry eye. *Am J Ophthalmol* 2004;137:337-342.
- Power WJ, Mullaney P, Farrell M, Collum LM. Effect of topical cyclosporine A on conjunctival T-cells in patients with secondary Sjögren's syndrome. *Cornea* 1993;12:507-511.
- Prause JU. Treatment of keratoconjunctivitis sicca with Lacrisert. *Scand J Rheum* 1986;61(suppl):S261-S263.
- Prydal JI, Artal P, Woon H, Campbell FW. Study of human precorneal tear film thickness and structure using laser interferometry. *Invest Ophthalmol Vis Sci* 1992;33:2006-2011.
- Sall K, Stevenson OD, Mundorf TK, Reis BL. Two multicenter, randomized studies of the efficacy and safety of cyclosporine ophthalmic emulsion in moderate to severe dry eye disease. CsA Phase 3 Study Group. *Ophthalmology* 2000;107:631-639.
- Selek H, Unlu N, Orhan M, Irkec M. Evaluation of retinoic acid ophthalmic emulsion in dry eye. *Eur J Ophthalmol* 2000;10:121-127.
- Shimmura S, Masafumi O, Shinozaki K, et al. Sodium hyaluronate eyedrops in the treatment of dry eyes. *Br J Ophthalmol* 1995;79:1007-1011.
- Small DS, Acheampong A, Reis B, et al. Blood concentrations of cyclosporin A during long-term treatment with cyclosporin A ophthalmic emulsions in patients with moderate to severe dry eye disease. *J Ocul Pharmacol Ther* 2002;18:411-418.
- Smith RE. The tear film complex. Pathogenesis and emerging therapies for dry eyes. *Cornea* 2005;24:1-7.

- Snibson A, Greaves JL, Soper NDW, et al. Ocular surface residence times of artificial tear solutions. *Cornea* 1992; 11:288-293.
- Soong HK, Martin NE, Wagoner MD, et al. Topical retinoid therapy for squamous metaplasia of various ocular surface disorders. A multicenter, placebo-controlled double-masked study. *Ophthalmology* 1988;95:1442-1446.
- Stenbeck A, Ostholm I. Ointments for ophthalmic use. *Acta Ophthalmol* 1954;43:405-423.
- Stevenson D, Tauber J, Reis B. Efficacy and safety of cyclosporin A ophthalmic emulsion in the treatment of moderate-to-severe dry eye disease. *Ophthalmology* 2000;107:967-974.
- Swan KC. Use of methylcellulose in ophthalmology. *Arch Ophthalmol* 1945;33:378-380.
- Tauber J, Davitt WF, Bokosky JE, et al. Double-masked, placebo-controlled safety and efficacy trial of diquafosol tetrasodium (INS365) ophthalmic solution for the treatment of dry eye. *Cornea* 2004;23:784-792.
- Tauber JT. A dose-ranging clinical trial to assess the safety and efficacy of cyclosporine ophthalmic emulsion in patients with keratoconjunctivitis sicca. In: Sullivan DA, Dartt DA, Meneray MA, eds. *Lacrimal gland, tear film, and dry eye syndromes 2: basic science and clinical relevance*. New York: Plenum Press, 1998: 693-704.
- Tsubota K. New approaches to dry-eye therapy. *Int Ophthalmol Clin* 1994;34:115-128.
- Turner K, Pflugfelder SC, Ji Z, et al. Interleukin-6 levels in the conjunctival epithelium of patients with dry eye disease treated with cyclosporin ophthalmic emulsion. *Cornea* 2000;19:492-496.
- Ubels J, Clousing D, Van Haitsman T, et al. Pre-clinical investigation of the efficacy of an artificial tear solution containing hydroxypropyl-guar gelling agent. *Curr Eye Res* 2004;28:437-444.
- Ubels JL, Dennis MH, Mitchell JH, et al. Biological activity of N-(4-hydroxyphenyl) retinamide-O-glucuronide in corneal and conjunctival cells of rabbits and humans. *Curr Eye Res* 1995;14:1115-1124.
- Wen Q, Kuang K, Yerxa B, et al. Effects of P2Y2 agonists on lipid secretion by cultured rabbit meibocytes. *Invest Ophthalmol Vis Sci* 2002;43(suppl):Abstr 3146.
- Werblin TP, Rheinstrom SD, Kaufman HE. The use of slow-release artificial tears in the long-term management of keratitis sicca. *Ophthalmology* 1981;88:78-81.
- Westerhout DI. Treatment of dry eyes with aqueous antioxidant eye drops. *CLAO J* 1991;19:165-173.
- Wolback S, Howe P. Tissue changes following deprivation of fat-soluble A vitamin. *J Exp Med* 1925;42:753-777.
- Wolff E. The muco-cutaneous junction of the lid-margin and the distribution of the tear fluid. *Trans Ophthalmol Soc UK* 1946; 66:291-308.
- Yen MT, Pflugfelder SC, Feuer WJ. The effect of punctal occlusion of tear production, tear clearance, and ocular surface sensation in normal subjects. *Am J Ophthalmol* 2001;131:314-323.
- Yokoi N, Komuro A, Nishida K, Kinoshita S. Effectiveness of hyaluronan on corneal epithelial barrier function in dry eye. *Br J Ophthalmol* 1997;81:533-536.

## *Antiedema Drugs*

*Siret D. Jaanus*

Osmotherapy was introduced to ocular therapeutics in 1904 with the use of oral hypertonic saline to reduce elevated intraocular pressure. Topical ocular use of hyperosmotic agents has been proven clinically useful in the treatment of corneal edema, particularly when the cause is endothelial dysfunction.

The following discussion considers the pharmacologic properties of hyperosmotic agents available for topical use. Chapter 26 discusses the clinical uses of topical osmotherapy in the management of conditions characterized by corneal edema.

### **CORNEAL EDEMA**

A variety of clinical situations can give rise to corneal edema (Box 15-1). Because the endothelium is the main structure involved in maintaining normal corneal deturgescence, it plays a role in stromal hydration and compensates for the driving force of intraocular pressure. Also, the active transport system involved in the movement of water and electrolytes from the cornea to the aqueous humor must be maintained to prevent fluid retention. Endothelial failure, a frequent cause of corneal edema, can occur due to defects in the transport system or stromal compression resulting from elevation of intraocular pressure, which can induce water movement toward the epithelium.

Whenever swelling takes place, transparency is lost in the region where the edema occurs. Because the corneal epithelium and tear film constitute the most anterior optical surface of the eye, epithelial edema can exert a major detrimental influence on vision because it induces anterior irregular astigmatism.

It is clinically useful to consider corneal edema as epithelial, stromal, or a combination of both. In general, epithelial edema is more responsive to topical hyperosmotic therapy.

### **TOPICAL HYPEROSMOTIC AGENTS**

Topical hyperosmotic agents can be useful in dehydrating edematous corneas. The clinical objective of topical

osmotherapy is to increase the tonicity of the tear film and thereby enhance the rate of movement of fluid from the cornea. All the currently available hyperosmotic preparations are hyperosmolar to the ocular tissue fluid. When applied to the ocular surface, water is drawn from the cornea to the more highly osmotic tear film and is eliminated through the usual tear flow mechanisms. Patients with minimal to moderate epithelial edema often achieve subjective comfort and improved vision with use of these agents.

Various agents can reduce corneal edema, including corn syrup, glucose, gum cellulose, sodium chloride, and glycerin. Only a few of these have proved clinically useful and acceptable to most patients. Sodium chloride and glycerin (Table 15-1) are the preferred agents in clinical practice.

### **Sodium Chloride**

#### **Pharmacology**

Sodium chloride is a component of all body fluids, including tears. A solution of 0.9% is approximately isotonic with tears. Of the various concentrations tested, 2% to 5% formulations have proven effective, with an irritation level acceptable to most patients. Studies comparing various hyperosmotic agents in human subjects have confirmed the usefulness of hypertonic sodium chloride in the treatment of corneal edema. Use of 5% sodium chloride in ointment form can be effective in reducing corneal thickness and in improving vision. The maximum reduction in corneal thickness occurs 3 to 4 hours after instillation of the ointment (Figure 15-1).

Despite their apparent efficacy, the usefulness of sodium chloride solutions in the treatment of edematous corneas with a traumatized epithelium appears to be limited. The intact corneal epithelium exhibits limited permeability to inorganic ions. In the absence of an intact epithelium the cornea imbibes salt solutions, which reduces the osmotic effect. In the management of corneal edema associated with traumatized epithelium, hypertonic saline solutions may be of limited value due to their increased ability to penetrate the epithelial barrier.

**Box 15-1** Causes of Corneal Edema

Endothelial  
 Birth trauma  
 Congenital hereditary corneal dystrophy  
 Fuchs' dystrophy  
 Keratoconus and hydrops  
 Mechanical trauma  
 Surgical trauma  
 Inflammation  
 Increased intraocular pressure  
 Acute angle-closure glaucoma  
 Chronic glaucoma

Adapted from Boruchoff SA. Clinical causes of corneal edema. *Int Ophthalmol Clin* 1968;8:581-600.

**Clinical Uses**

Sodium chloride is useful for reducing corneal edema of various etiologies, including bullous keratopathy. Generally, one to two drops are instilled in the eye every 3 to 4 hours. Sodium chloride ointment requires less frequent instillation and is generally reserved for nighttime use.

Sodium chloride is commercially available in 2% and 5% solutions and as 5% ointment (see Table 15-1). In clinical practice, the 5% concentration appears to be somewhat more effective.

The way in which hyperosmotic preparations are administered may affect the clinical results. Because vision is usually worse on arising, several instillations during the first waking hours can prove helpful. On hot dry days, eyes may require less medication, because tear film evaporation is enhanced.

**Side Effects**

Whereas isotonic saline (0.9% sodium chloride) is nontoxic to the cornea and conjunctiva, sodium chloride, especially at the 5% concentration, can cause discomfort on instillation. Stinging, burning, and irritation are common complaints, but patients generally tolerate the therapy, especially if vision is improved. Epistaxis has been associated with use of 2% sodium chloride solution. The solution formulation should not be used if it changes color or becomes cloudy.

**Glycerin (Glycerol)****Pharmacology**

Glycerin is a clear, colorless, syrupy liquid with a sweet taste. It is miscible with both water and alcohol. In contact with water, glycerin absorbs water and thereby exerts an osmotic effect. When placed on the eye, its hygroscopic action clears the haze of corneal epithelial edema. Because the molecules mix readily with water, the osmolality of the applied solution decreases rapidly as water is imbibed from the cornea, and the clinical effect is transient.

**Clinical Uses**

Topical application of glycerin in concentrations from 50% to 100% results in a significant reduction of corneal edema within 1 to 2 minutes. Because application to the eye is painful, a topical anesthetic must be instilled before use. It is useful in ophthalmoscopic and gonioscopic examination of the eye in acute angle-closure glaucoma, bullous keratopathy, and Fuchs' endothelial dystrophy.

Because its action is transient and application to the eye painful, glycerin is used primarily for diagnostic purposes.

**Table 15-1**

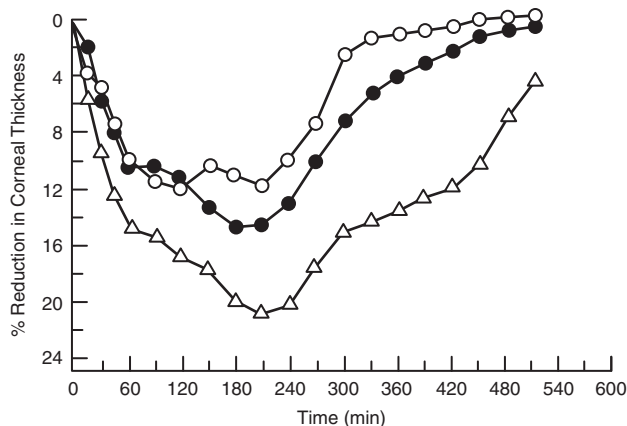
Topical Hyperosmotic Preparations

Trade Name (Manufacturer)	Composition
<b>Sodium chloride</b>	
Adisorbonac Solution, 2% and 5% (Alcon)	NaCl, povidone and other water-soluble polymer, thimerosal 0.0004%, EDTA 0.1%
Muro-128 Solution, 2% and 5% (Bausch & Lomb)	NaCl, hydroxypropylethylcellulose, methylparaben, propylparaben, boric acid
Muro-128 Ointment, 5% (Bausch & Lomb)	NaCl, anhydrous lanolin, mineral oil, white petrolatum
AK-NaCl 5% Ointment (Akorn)	NaCl, anhydrous lanolin, mineral oil, white petrolatum
Sochlor, 5% solution (OCuSoft)	NaCl
Sochlor, 5% ointment (OCuSoft)	NaCl
<b>Glycerin (Glycerol)</b>	
Ophthalgan* (compounded product)	Anhydrous glycerin
<b>Glucose</b>	
Glucose-40* (compounded product)	Glucose 40%, usually white petrolatum, anhydrous lanolin

\*Available only by prescription.

EDTA = ethylenediaminetetraacetic acid.





**Figure 15-1** Percent reduction in corneal thickness after application of 5% sodium chloride ointment (triangles = central; unfilled circles = nasal; filled circles = temporal). (Modified from the American Journal of Ophthalmology 1971;71:847-853. Copyright The Ophthalmic Publishing Company.)

In acute angle-closure glaucoma, additional glycerin may be used as the gonioscopic bonding solution to prolong the hyperosmotic effect during gonioscopy.

### Side Effects

When applied topically to the eye without prior instillation of an anesthetic, glycerin causes significant stinging and burning. Reflex tearing follows, and dilation of conjunctival vessels may occur. These effects are transient, and no significant toxic effects occur with short-term use.

Glycerin is classified as Pregnancy Category C, and it is unknown whether it is excreted in breast milk. Safety for use in children has not been established.

## Glucose

### Pharmacology

Glucose solutions ranging from 30% to 50% have been used topically on the eye to treat corneal edema. The dehydrating action of a 30-minute glucose bath eliminates corneal epithelial edema and reduces corneal thickness. The effect lasts 3 to 4 hours.

### Clinical Uses

The clinical effectiveness of 40% glucose is comparable with that of 5% sodium chloride. Because it is difficult to maintain sterility of the solution unless a preservative is added, a commercial preparation containing 40% glucose may often contain preservatives and is available in ointment formulation (see Table 15-1).

### Side Effects

After topical application glucose exhibits a low degree of irritation and in the 30% to 50% concentrations is nontoxic to the eye. However, some transient stinging and irritation of the conjunctiva may occur after instillation.

## SELECTED BIBLIOGRAPHY

- Bartlett JD, Fiscella RG, Jaanus SD, et al. Hyperosmotic agents. *Ophthalmic drug facts*. St. Louis, MO: J.B. Lippincott, 2006: 249-258.
- Boruchoff SA. Clinical causes of corneal edema. *Int Ophthalmol Clin* 1968;8:581-600.
- Bietti GB, Pecori J. Topical osmotherapy of corneal edema. *Ann Ophthalmol* 1969;1:40-49.
- Cantonnet A. Essai de traitement du glaucome par les substances osmotiques. *Arch D'Ophtalmol* 1904;24:1-25.
- Cogan DG. Clearing of edematous corneas by glycerine. *Am J Ophthalmol* 1943;26:551.
- Hine CH, Anderson HH, Moon HD, et al. Comparative toxicity of synthetic and natural glycerin. *Arch Ind Hyg* 1953;7: 282-291.
- Kushner FH. Sodium chloride eye drops as a cause of epistaxis. *Arch Ophthalmol* 1987;105:1634.
- Lamberts DW. Topical hyperosmotic agents and secretory stimulants. *Int Ophthalmol Clin* 1980;20:163-169.
- Levenson JE. Corneal edema: cause and treatment. *Surv Ophthalmol* 1975;20:190-204.
- Luxenberg MN, Green K. Reduction of corneal edema with topical hypertonic agents. *Am J Ophthalmol* 1971;71:847-853.
- Mishima S, Hedbys BO. Physiology of the cornea. *Int Ophthalmol Clin* 1968;8:527-560.
- Payrau P, Dohlman CH. Medical treatment of corneal edema. *Int Ophthalmol Clin* 1968;8:601-610.

# Dyes

Jerry R. Paugh

Dyes for ophthalmic care came into use in the late 1800s, following Baeyer's synthesis of sodium fluorescein in 1871 and Ehrlich's use of it to study aqueous dynamics. Since then, several dyes have been used for ophthalmic diagnosis, including fluorescein sodium (e.g., to examine corneal damage, tear stability, intraocular pressure [IOP], and retinal vascular characteristics), fluorexon (a larger molecular weight fluorescein to facilitate examination in hydrogel contact lens wearers), rose bengal, and (more recently) lissamine green (for conjunctival staining). In addition, other dyes such as indocyanine green and methylene blue are developing acceptance in ocular vasculature observation and intraocular surgery, respectively.

## FLUORESCHEIN SODIUM

Fluorescein is probably one of the most widely used dyes for ophthalmic use. Several factors contribute to its utility, including its hydrophilicity, low toxicity, and excellent fluorescent properties in the visible spectrum, even in very dilute concentration. Early ocular applications were used in detection of corneal ulcers and aqueous flow, followed shortly thereafter by retinal diagnostic application.

### Pharmacology

Fluorescein sodium, 3',6'-dihydroxyspiro[isobenzofuran-1(3H),9'-[9H]xanthen],  $C_{20}H_{10}Na_2O_5$ , CAS number 518-47-8, is a yellow acid dye of the xanthene series. Its molecular weight is 376 Da, and its solubility in water at 15°C is 50% (i.e., it is freely soluble). It is generally formulated as its sodium salt (Figure 16-1). When exposed to light, fluorescein maximally absorbs light at approximately 493 nm and emits (fluoresces) at approximately 520 nm. Figure 16-2 illustrates the excitation and emission spectra of dilute fluorescein in phosphate buffer.

Because fluorescein is a weak acid, depending on the pH of the solution, it can exist in various ionic states. Below pH 2, the cationic form predominates, and a weak blue-green fluorescence occurs. Between pH 2 and 4 the cations dissociate to neutral molecules. At pH 7

negative ions prevail and are associated with a brilliant yellow-green fluorescence. The pH sensitivity has been used to noninvasively examine human stromal pH.

Several factors can alter the fluorescence of fluorescein in solution: its concentration, the pH of the solution, the presence of other substances, and the intensity and wavelength of the absorbed light. In the eye the thickness of the media being measured becomes important in quantitative measurements due to fluorescein self-absorption (or "quenching"). One clinical effect can be to obscure corneal staining if the tear concentration is too great. The intensity of fluorescence increases with increasing pH, reaching a plateau at approximately pH 8. Thus at physiologic pH the fluorescence is nearly maximum. Further increases in pH above 8 reduce the intensity of fluorescence.

### Clinical Uses

Fluorescein may be applied topically to the eye in the form of a solution or by fluorescein-impregnated filter paper strips (Table 16-1). It is also available in injection form for intravenous use (Table 16-2).

Fluorescein in solution is highly susceptible to bacterial contamination, especially by *Pseudomonas aeruginosa*, which grows easily in the presence of fluorescein. Major methods of reducing the possibility of bacterial growth include sterile formulation and air-tight seal of solutions (e.g., injection fluorescein), use of effective

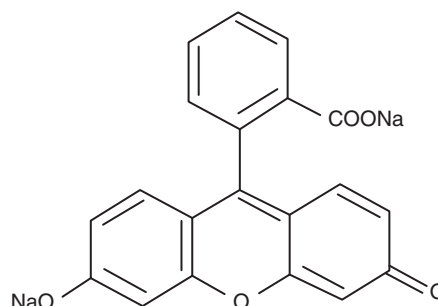
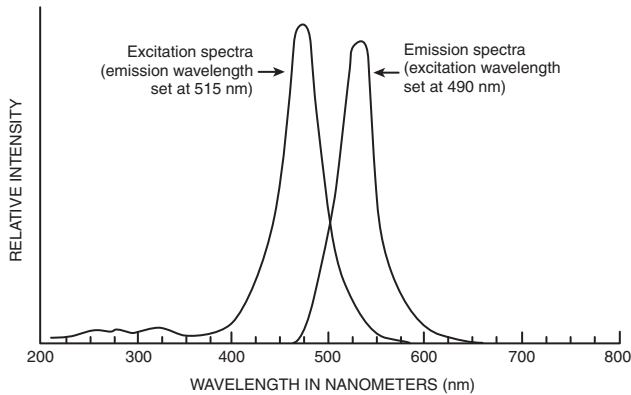


Figure 16-1 Molecular structure of fluorescein sodium.



**Figure 16-2** Excitation and emission spectra of a 0.00005% solution of sodium fluorescein in  $\text{KH}_2\text{PO}_4$ - $\text{K}_2\text{HPO}_4$  buffer at pH 8. (Reprinted with permission from Romanchuk KG. Fluorescein. *Physiochemical factors affecting its fluorescence*. *Surv Ophthalmol* 1982;26:269-283.)

preservatives in fluorescein solution (e.g., Fluress<sup>®</sup>), and the development of sterile fluorescein impregnated strips.

Although both injection fluorescein and that used clinically from sterile strips are used once and discarded, fluorescein-anesthetic combination solutions are used repeatedly on sequential patients. Thus the problem of maintaining sterility, particularly when accidental contamination from patient contact can easily occur, becomes a major issue.

Many studies have examined the issue of microbial contamination of fluorescein-anesthetic solutions designed for clinical use. Although most have directly inoculated the liquid solution, it seems more useful to consider the evidence of contamination from products retrieved from clinical use and from direct contamination

**Table 16-1**  
Fluorescein Preparations for Topical Ocular Use

Product (Manufacturer)	Composition
<b>Fluorescein sodium solutions</b>	
Fluress (Akorn)	0.25% with 0.4% benoxinate HCl; chlorobutanol 1%, povidone, boric acid; 5 ml
Fluoracaine (Akorn)	0.25% with 0.5% proparacaine HCl; thimerosal 0.01%; 5 ml
Fluorescein sodium and benoxinate (Bausch & Lomb)	0.25% with 0.4% benoxinate HCl; 5 ml
<b>Fluorescein strips</b>	
Ful-Glo (Akorn)	0.6 and 1.0 mg; sterile
Fluor-I-Strip (Bausch & Lomb)	9 mg, 0.5% chlorobutanol, polysorbate 80, with buffers
Fluor-I-Strip A.T. (Bausch & Lomb)	1 mg, 0.5% chlorobutanol, polysorbate 80, with buffers

**Table 16-2**  
Fluorescein Preparations for Intravenous Use

Product (Manufacturer)	How Supplied
Fluorescite (Alcon Laboratories)	10%, 5-ml ampule
AK-Fluor (Akorn)	10%, 5-ml ampule and 5-ml vial
AK-Fluor (Akorn)	25%, 2-ml ampule and 5-ml vial
Fluorescite (Alcon Laboratories)	25%, 2-ml ampule

of the bottle tip (if attached, as for some generic products) and dropper tips (for separate droppers), as would occur clinically.

Both dropper tip or bottle tip contamination was examined using *Staphylococcus* and *Pseudomonas* species, and Fluress<sup>®</sup> was found to prevent colonization after 1 minute but the generic fluorescein-anesthetic combinations all allowed growth up to 2 hours. It was suggested that the preservative used in Fluress<sup>®</sup>, chlorobutanol, worked more rapidly than the thimerosal used in the competing formulations and also that the benoxinate and weak boric acid in Fluress<sup>®</sup> may confer additional antibacterial properties.

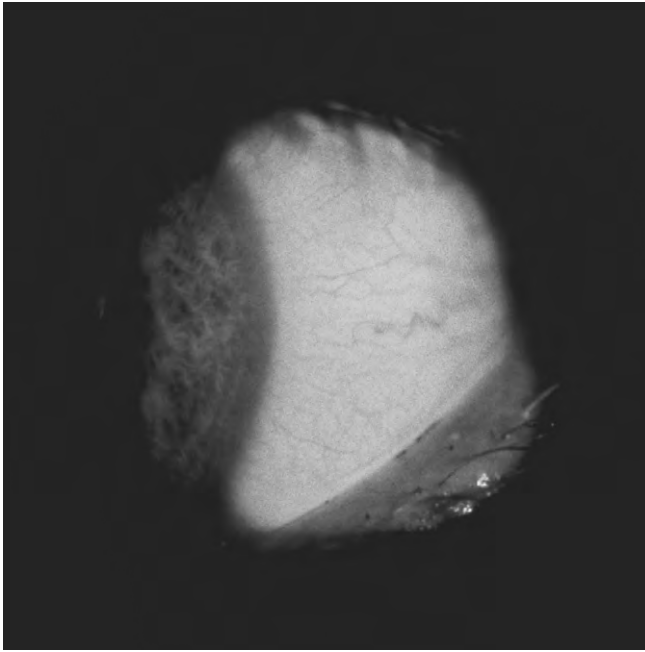
Bottles of Fluress<sup>®</sup> sourced from the clinic, which might be expected to demonstrate contamination, were examined and found to be largely free of either *Staphylococcus* or *Pseudomonas* species. Although it appears that resistance to bacterial contamination is quite good for Fluress<sup>®</sup>, the potential for viral contamination appears more serious.

The resistance to adenoviruses types 8 and 19, both common causes of epidemic keratoconjunctivitis, in Fluress<sup>®</sup> was studied and survival was found for 3 to 4 weeks for types 19 and 8, respectively. Extreme care should be taken when examining suspect patients. Conversely, resistance to contamination for Fluress<sup>®</sup> from herpes simplex virus type 1 was examined and found to be quite good. Overall, it appears that Fluress<sup>®</sup>, with its unique formulation, is generally the most effective of the combination fluorescein-anesthetic solutions for clinical use but that care must be taken when using generic versions.

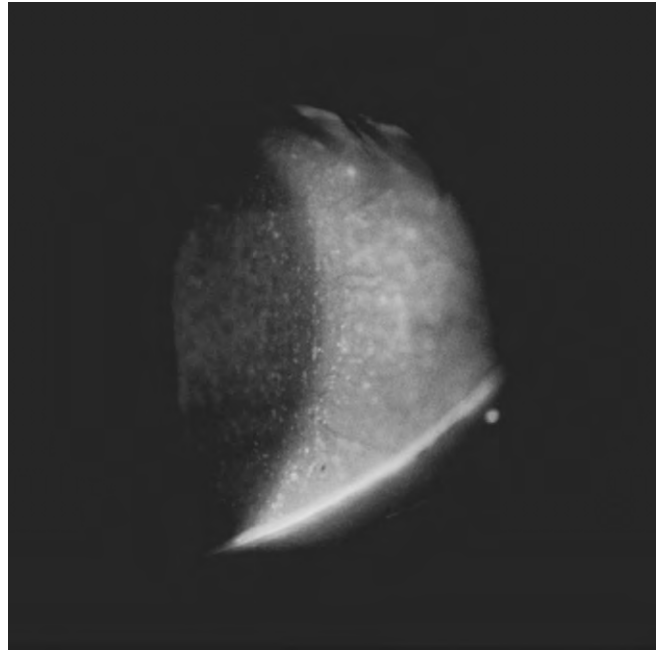
## Topical Ocular Applications

### Assessment of Ocular Surface Integrity

Instillation of the dye in the cul-de-sac allows detection of corneal and conjunctival lesions, such as abrasions, ulcers, and edema, and aids in the detection of foreign bodies. When the cobalt blue filter of the slit lamp is used to excite the dye, the epithelial defect usually appears outlined in vivid green fluorescence. The dye turns green in the tear film, in spite of being introduced as a yellow-orange liquid, due to dilution with tear fluid.



**Figure 16-3** Fluorescein photograph of conjunctival staining taken without barrier filter. (From Courtney RC, Lee JM. Predicting ocular intolerance of a contact lens solution by use of a filter system enhancing fluorescein staining detection. *Int Contact Lens Clin* 1982;9:302-310.)



**Figure 16-4** Fluorescein photograph of conjunctival staining taken with a Wratten No. 12 yellow barrier filter in place. (From Courtney RC, Lee JM. Predicting ocular intolerance of a contact lens solution by use of a filter system enhancing fluorescein staining detection. *Int Contact Lens Clin* 1982;9:302-310.)

Although the use of the cobalt blue excitation illumination is adequate for some observations, the addition of a yellow barrier filter over the observation system of the slit lamp, Burton lamp, or camera greatly enhances visibility of the stained areas, especially on the conjunctiva. Kodak Wratten No. 12 or No. 15 photographic filters or Tiffen No. 2 photographic filters are relatively inexpensive and serve well in this capacity (Figures 16-3 and 16-4). The yellow barrier filter must be placed over the optics of the instrument, not in the path of the blue excitation light. It is highly recommended that the yellow barrier filter be used for staining assessment and for other tests such as fluorescein breakup time.

The mechanism of fluorescein staining of ocular epithelia has been subject to some conjecture. In earlier work it was suggested that staining occurred due to accumulation in intraepithelial spaces rather than direct staining of the cells. However, it has become clear that fluorescein can directly stain diseased human corneal cells and rabbit epithelial cells. Moreover, the hyperfluorescence that probably represents micropunctate clinical staining is likely due to optimum dye concentration and fluorescence within the cell rather than simple pooling. Cellular hyperfluorescence occurred from both mechanical abrasion and chemically induced toxicity, conditions that presumably promote an intracellular concentration that allows definitive clinical visualization. An issue that has received some attention is whether repeated

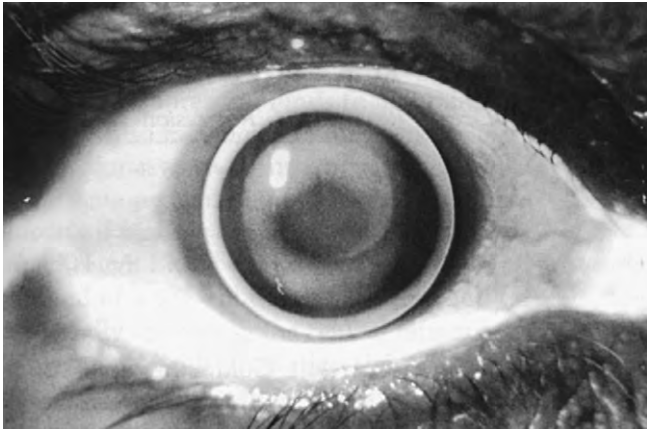
instillations of fluorescein might serve as a predictive test for corneal compromise.

Sequential instillations of fluorescein (up to six times, 5 minutes apart) may have value as a mildly provocative test of corneal integrity. Although only 19% of patients showed fluorescein staining after a single instillation of fluorescein, an additional 23% exhibited staining after repeated instillations. It was also noted that the severe degrees of staining appeared to be correlated with contact lens intolerance. However, it was demonstrated that the fluorescein itself was inducing the staining, apart from physicochemical formulation properties or preservatives. Additional work related to the predictive value of sequential staining, using nonpreserved and physiologically compatible formulations, may be warranted.

#### Contact Lens Fitting and Management

Fluorescein staining of the tear film is a major aid in the fitting of rigid gas-permeable contact lenses. After topical application of fluorescein to the eye the tear layer becomes visible, with a characteristic pattern of green fluorescence. Observation of the fluorescein-stained tear film with an ultraviolet light or the cobalt blue filter of the slit lamp allows determination of the fit of the lens.

However, it should be understood that many recently developed contact lens materials contain polymers that block the transmission of light in the ultraviolet region. Therefore when an ultraviolet light source, such as a



**Figure 16-5** Contact lens fluorescein pattern in eye with keratoconus. Central dark area reflects the absence of fluorescein, indicating central contact lens bearing (touch). There is also bearing in the intermediate area, surrounded by peripheral clearance indicated by the pooling of fluorescein. (Courtesy A. Christopher Snyder, O.D.)

Burton lamp, is used, the fluorescein behind the lens may not be visible. Visualizing the fluorescein necessitates changing to a blue light source in the visible region. This may be accomplished by fitting the Burton lamp or other ultraviolet light with a white light source covered with a deep blue excitation filter, such as a Kodak Wratten No. 47, 47A, or 47B photographic filter. Areas where the lens makes corneal contact show minimal fluorescence or absence of the fluorescein dye (Figure 16-5).

In addition to its usefulness during contact lens fitting procedures, fluorescein is essential for assessing the integrity of the cornea in contact lens wearers. Common contact lens complications that stain with sodium fluorescein include those thought to be due to mechanical etiologies (e.g., foreign body abrasions, 3- to 9-o'clock staining, edge desiccation, vascularized limbal keratitis, superior epithelial arcuate lesions, conjunctival flaps, etc.) and those related to other causes such as solution incompatibilities (e.g., superficial punctate keratopathy) and lack of lens tear exchange (e.g., inferior "smile face" or arcuate staining).

The practitioner should be cautious in interpreting apparent fluorescein staining in a contact lens wearer, as areas of indentation, which do not represent cellular damage, also demonstrate increased fluorescence. Indentation may result from the accumulation of bubbles (known as dimple veiling) or from compression by a lens edge or poorly finished junction, which often results in an arcuate pattern of fluorescein pooling.

### Lacrimal System Evaluation

Topical ocular fluorescein can be used to evaluate two key aspects of the lacrimal system. These are the stability of the precorneal tear film and the patency of the lacrimal drainage system.

Tear breakup time (TBUT) is used clinically as a diagnostic aid in dry eye syndromes and for testing the efficacy of therapeutic approaches. Assessment of TBUT, typically defined as the interval between the last complete blink and the development of the first randomly distributed dark spot in the tear film, is commonly used to estimate tear film stability. Fluorescein can be instilled into the eye with either a pipette or wetted fluorescein strip and observed with cobalt blue excitation and with or without a yellow barrier filter for observation.\* Unfortunately, there is still no global standard as to how TBUT should be determined and no consensus as to appropriate cut-off values.

Historically, TBUTs of less than 10 seconds were thought to indicate an unstable tear film. However, TBUTs in normal asymptomatic Hong Kong and Singapore Chinese were found ranging from approximately 8 seconds to 6 seconds, which suggests that a cut-off value for instability less than perhaps 7 seconds may be sensible.

Fluorescein is also useful clinically in evaluating epiphora. Fluorescein testing for lacrimal obstruction usually involves instilling the dye into the conjunctival cul-de-sac and then observing for the presence of fluorescein in the nose. Appearance of the dye in the nose or posterior oropharynx indicates that the lacrimal drainage system of that eye is functional. Generally, a 2% fluorescein solution is used, and this test can be used in conjunction with other procedures for diagnosis of lacrimal obstruction (see Chapter 24).

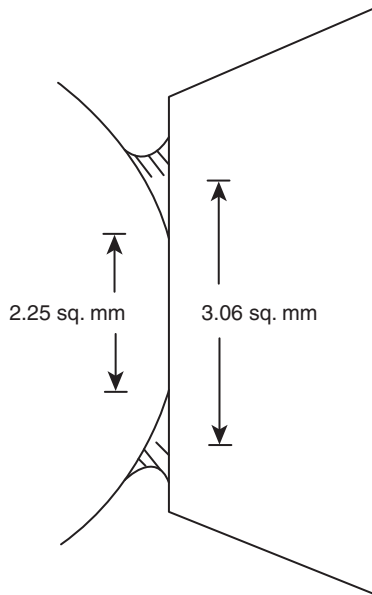
### Applanation Tonometry

The use of topical fluorescein is an important component in the measurement of IOP with the Goldmann applanation tonometer. The dye permits visualization of the applanated area, which is 3.06 mm<sup>2</sup> for accurate IOP measurement.

Measurement of IOP with the Goldmann applanation tonometer requires the meniscus of tear fluid surrounding the flattened corneal surface to be sufficiently stained with fluorescein so that the apex of the wedge-shaped meniscus is visible. If the fluid apex is not visible, IOP will be underestimated due to inadequate applanation (Figure 16-6).

The mire visualization problem is likely the reason why IOP measurement without fluorescein has been discredited. For example, it was found that readings without fluorescein were lower by an average of 7.01 mm Hg (Table 16-3). The mean reading with Fluress was 18.03 mm Hg compared with 11.02 mm Hg with the anesthetic Ophthalmic in the absence of fluorescein. By performing a regression analysis, it was further suggested that the difference in IOP readings with and without fluorescein becomes even greater as the pressure rises.

\*NB: The author recommends the yellow filter for use in TBUT because it seems to provide more definitive TBUT end points.



**Figure 16-6** Cornea partially flattened by applanation tonometer. The apices of the fluorescein-stained wedges above and below the flattened area are too dilute to be visible. The 3.06-mm<sup>2</sup> end point of applanation appears to have been reached but in reality consists of a smaller flattened area. (Modified and reprinted with permission from Moses RA. Fluorescein in applanation tonometry. *Am J Ophthalmol* 1960;49:1149-1155.)

### Intravenous Applications

The introduction of fluorescein angiography in the early 1960s provided a useful method for studying various parameters of ocular function. Intravenous fluorescein is used extensively to delineate vascular abnormalities of the fundus and occasionally to evaluate anterior segment blood and aqueous flow.

### Fluorescein Angiography

In the bloodstream fluorescein is excited by a wavelength of 465 nm and emits a wavelength of 525 nm. Circulating fluorescein binds to albumin and red blood cells. It is also metabolized to a weakly fluorescent conjugate, fluorescein monoglucuronide, which exhibits less plasma protein binding than fluorescein. The amount of binding

can affect the penetration of fluorescein through blood-ocular barriers. After injection of 5 ml of a 10% or 3 ml of a 25% fluorescein solution in the antecubital vein, the dye usually appears in the central retinal artery in 10 to 15 seconds. Both circulation time and integrity of the retina and choroid may be examined. Injection of the 25% concentration is well visualized and may cause fewer side effects.

Fluorescein angiography shows retinal blood vessels in high contrast. Nonvascularized pigmented retinal and subretinal lesions appear as dark areas against the green fluorescing background. The abnormal fluorescence of various retinal and choroidal lesions is explained by several mechanisms, including (1) some abnormalities in the retina, allowing for greater visibility of choroidal fluorescence; (2) neovascularization, producing enhanced fluorescence due to new vascular channels; and (3) pathologic processes resulting in enhanced capillary permeability, allowing for leakage of fluorescein into the lesion. These types of abnormalities may often be differentiated by time at onset of fluorescence.

Choroidal fluorescence appears early and usually precedes the arterial phase by about 1 second. Depending on the origin of the new vessels, neovascular fluorescence coincides with the arteriolar or venous phase of fluorescence. Enhanced capillary permeability (leakage) delays fluorescence, followed by a slow increase in fluorescence as the dye recirculates and stains the affected tissues.

Fluorescein angiography has proven helpful in the diagnosis of a variety of pathologic conditions of the fundus. Various macular lesions, central serous choroidopathy, diabetic retinopathy, and disciform macular degeneration show typical fluorescein patterns. Moreover, tumors such as malignant melanoma, those arising from metastasis, and hemangiomas of the choroid demonstrate fluorescence. Fluorescein angiography does not illustrate well the choroidal vasculature, which can be complemented by indocyanine green angiography (see below).

Chapter 31 discusses the clinical procedure and interpretation of fluorescein angiography.

**Iris Angiography.** Intravenous injection of fluorescein can be useful for visualization of iris tumors and vessel abnormalities such as rubeosis irides. After injection into

**Table 16-3**

Results of Intraocular Pressure Readings for Ophthalmic and Fluorescein in 100 Eyes

	Mean Tonometric Readings (mm Hg)	Standard Deviation	Standard Error	R	Regression
Fluorescein	18.03	4.27	0.427	0.552	$y = 0.45 + 0.59x$
Ophthalmic	11.02	4.53	0.453		

Reprinted with permission from Bright DC, Potter JW, Allen DC, et al. Goldmann applanation tonometry without fluorescein. *Am J Optom Physiol Optics* 1981;58:1120-1126.



the antecubital vein, the dye first appears in the radial vessels of the iris, which are demonstrated as linear spokes with slow leakage. The amount of iris pigmentation and the pattern of its distribution affect the amount of detail observed in a normal iris angiogram. Blue irides generally show the vessels in greater detail than do brown irides. An adapter mounted in front of a fundus camera lens has rendered possible more complete visualization of the vascular structure in heavily pigmented irides.

**Aqueous Flow.** Changes in the concentration of fluorescein in the anterior chamber after intravenous injection were measured as early as 1950. Using a slit lamp or objective fluorophotometer, the time course of the fluorescence in the circulating blood and the anterior chamber can be determined in humans. The rate of aqueous flow is approximately 1.5% to 2.0% of the volume of the anterior chamber per minute. Following the early work other methods were devised to measure aqueous turnover, and all have given comparable results. Anterior chamber fluorometry is also useful in monitoring inflammation after oral or injected fluorescein.

#### Vitreous Fluorophotometry

Vitreous fluorophotometry is a noninvasive quantitative method for measuring small amounts of fluorescein in various ocular compartments, including assessment of the blood-retinal barrier. Both slit-lamp-based and objective scanning fluorimeters have been used to characterize the fluorescence of the vitreous in health and disease.

Because the normal blood-retinal barrier resists various substances, including fluorescein, the presence of fluorescein in the vitreous humor indicates a functional breakdown of this barrier. Although physiologic factors and instrument artifacts can influence vitreous fluorescence, this technique has been used to detect retinal vascular disease, especially in diabetes. The procedure has also been used to study the integrity of the blood-retinal barrier in various other diseases, including retinitis pigmentosa, optic neuritis, and essential hypertension.

#### Oral Fluorescein Angioscopy

Because the integrity of the normal ocular physiologic barriers to fluorescein depends less on dye administration velocity than on certain other parameters, such as retinal circulation time, fluorescein has also been administered by mouth to study posterior pole lesions. The oral procedure in adults usually involves administering 1 to 2 g of fluorescein powder or three vials of 10% injectable fluorescein mixed in a citrus drink over ice. In children, fruit juice containing 1 ml of a 10% fluorescein solution per 20 ml juice per 5 kg body weight has been used to determine macular leakage after removal of congenital cataracts. The dye begins to appear in the fundus in approximately 15 minutes, but maximal fluorescence is not obtained until 45 to 60 minutes after ingestion.

The oral route of administration yields adequate clinical angiograms in approximately 97% of cases and has the advantage that side effects are rare.

#### Adverse Reactions

Studies of humans undergoing fluorescein angiograms indicate an incidence range of adverse effects ranging from 1.1% to 10%. The most common mild adverse reaction is nausea, accompanied less frequently by vomiting. The nausea usually occurs 15 to 30 seconds after injection and subsides within several minutes. Moderate adverse reactions include fainting, localized reactions, and urticaria (hives), although no severe adverse reactions were reported. Interestingly, in patients with a history of adverse reaction to injected fluorescein, the incidence of adverse reactions becomes nearly 50%, suggesting that careful history and medical monitoring of these patients are imperative. A significant adverse effect that can occur with intravenous fluorescein injection includes pain at the site of injection, especially if the dye becomes extravasated. Patients should be advised that intravenous fluorescein temporarily discolors both skin and urine and can appear in breast milk for up to 76 hours after administration. Itching, discomfort, or nausea was found in 1.7% of 1,787 patients taking oral fluorescein for fundus angiography, approximately the same percentage as for injected fluorescein.

Adverse effects associated with topical fluorescein and anesthetic-fluorescein combinations are usually limited to transient irritation of the cornea or conjunctiva.

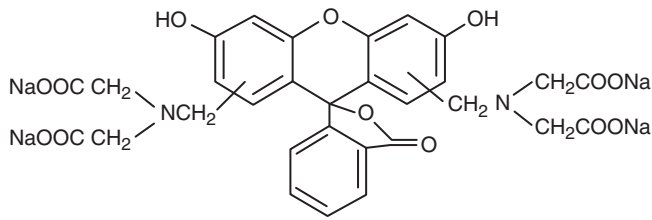
#### Contraindications

Because of the possibility of adverse reactions a family and personal history of allergies, and especially prior angiographic procedures, should be obtained from every patient undergoing fluorescein angiography. Appropriate emergency kits need to be available that range from a minimum of oxygen, cardiopulmonary resuscitation equipment, antihistamine, and smelling salts to a full crash cart.

Because topically administered fluorescein discolors soft contact lenses, the eye should be thoroughly irrigated with sterile saline until the tears show no discoloration or a less absorbent dye such as fluorexon (see below) should be used.

#### FLUOREXON

Because fluorescein sodium can penetrate into many hydrogel contact lenses, the lenses become discolored, which raises bacterial growth issues and renders the lenses cosmetically objectionable. In addition, the boundary between lens and tears becomes obscured, which precludes the use of fluorescein in soft contact lens fitting. Fluorexon, a molecule similar in fluorescent characteristics to that of fluorescein, is less readily absorbed by the soft lens material, which renders it useful in fitting and evaluating soft and hybrid design lenses.



**Figure 16-7** Molecular structure of fluorexon.

## Pharmacology

Fluorexon, *N,N*-bis((carboxymethyl)-amino)ethylfluorescein tetrasodium salt (Chemical Abstract Registry no. 1461-15-0), has a molecular weight of approximately 710 Da, about twice that of sodium fluorescein (Figure 16-7). It is a hydrophilic dye due to its multiple polar moieties. Compared with sodium fluorescein, fluorexon has a paler yellow-brown color. Its staining properties are similar to those of fluorescein, although the fluorescence is much less (due to a lower quantum yield) and thus it must be used at greater concentration.

Like sodium fluorescein, fluorexon is vulnerable to bacterial contamination, but it appears to support bacterial growth longer than does a comparable solution of fluorescein sodium. For clinical use, therefore, it is dispensed as single-dose sterile pipettes (see Table 16-1), a preserved solution with benoxinate (Flura-Safe™, Rose Stone Enterprises, Rancho Cucamonga, CA, USA), or recently as fluorexon-impregnated sterile strips.

## Clinical Uses

Fluorexon can aid in the fitting of soft contact lenses and is particularly useful in evaluating hybrid designs, such as the SoftPerm lens (Ciba Vision, Duluth, GA, USA), which consists of a rigid gas-permeable center with a hydrogel surround. The use of fluorexon allows visualization of the tear film under the rigid portion of the lens without discoloring the hydrogel portion. Similarly, in a piggy-back lens system, wherein a rigid lens is placed on a hydrogel lens for fitting special cases (e.g., advanced keratoconus), the use of fluorexon can be a valuable adjunct to the fitting process. It can be applied to the eye with the lens in place, but it is more effective when placed in the posterior bowl of the lens before insertion.

Recently, fluorexon was examined relative to TBUT in contact lens wearers and nonwearers and the stability time was found to be not statistically different. Moreover, a fluorexon-benoxinate combination (Flura-Safe™, Rose Stone Enterprises) was compared with a Fluress® analogue (AccuFluoro, Altaire Pharmaceuticals Inc., Aquebogue, NY, USA) in Goldmann applanation tonometry in normal individuals. They found that IOP readings were comparable and that the Flura-Safe formulation induced greater comfort and less stinging and burning compared with the gold standard preparation. Flura Safe® may become the diagnostic aid of choice in practices with large soft lens populations.

## Side Effects

Fluorexon stains the soft lens if it remains in contact with the lens for more than a few minutes. However, repeated rinsing with saline usually removes the dye from the lens. Occasional conjunctival injection may occur. Topical application to the eye of a fluorexon-benoxinate combination solution for tonometry has been suggested to produce less stinging and burning compared with a standard fluorescein-benoxinate solution. In clinical use fluorexon has proven nontoxic to ocular tissue.

## Contraindications

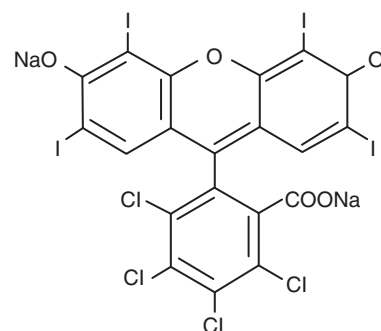
Fluorexon is not recommended for use with highly hydrated soft lenses having a water content of 60% or higher. In such cases the lens can absorb significant amounts of dye, resulting in unwanted lens discoloration.

## ROSE BENGAL

Widely used in the diagnosis of ocular surface disease, the understanding of the staining characteristics of rose bengal has evolved. Relatively recent evidence suggests that it is not a vital dye but one that may actually cause toxicity and cell death under certain circumstances.

## Pharmacology

Rose bengal is the 4,5,6,7-tetra-chloro-2',4',5',7'-tetraiodo derivative of fluorescein (Figure 16-8; CAS no. 632-69-9, MW 1017.6) and is a dye commonly used in ophthalmic diagnosis. Tissues stained with rose bengal display a vivid pink or magenta color when viewed with white light. It has been formulated as a 1% solution and in the form of sterile impregnated paper strips that require moistening with sterile saline or extraocular irrigation solution. When using a rose bengal-impregnated strip a variable volume of dye is delivered to the eye based on differing strip soak times (e.g., 15, 30, or 45 seconds). Moreover, the estimated volume applied to the eye using an *in vitro* eye model was approximately 17  $\mu$ l, possibly explaining the discomfort commonly reported with the strip application method.



**Figure 16-8** Molecular structure of rose bengal.



Rose bengal is a photoreactive compound. With excitation light it generates singlet oxygen, which may be responsible for its ability to kill microorganisms such as bacteria and viruses.

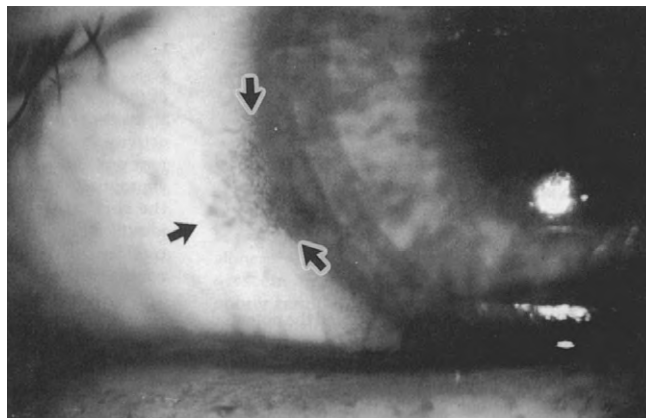Relatively recent studies demonstrated that cells do not need to be devitalized or necrotic to display rose bengal staining. In fact, rose bengal will stain numerous types of healthy cultured cells, including rabbit and human corneal epithelial cells, in a dose-dependent manner. These studies have confirmed earlier observations that the nucleus of the cell retains the dye. A toxic response to rose bengal has been observed. Cells exposed to the dye demonstrated instantaneous morphologic changes, loss of cellular motility, cell detachment, and cell death. Exposure to light further augmented this effect, indicating that photosensitivity may be an additional factor in the dye's intrinsic toxicity on unprotected epithelial cells. However, this staining could be blocked by the addition of albumin and mucin to the culture medium. This strongly suggests that rose bengal staining results not from a lack of cell vitality, but rather from the lack of the protective precorneal tear film. This theory appears consistent with the clinical disorders traditionally associated with rose bengal staining, such as dry eye wherein the mucous layer is compromised.

### Clinical Uses

Traditionally, the most frequent use of rose bengal is in the differential diagnosis of dry eye syndromes. However, rose bengal also has other uses in clinical practice. Rose bengal is helpful in the evaluation of most types of corneal and conjunctival lesions, including abrasions, ulcerations, and foreign bodies, and conjunctival dysplasia or metaplasia. A clinical conundrum exists for the use of rose bengal in diagnosing corneal viral disease. Although it is helpful in differentiating herpes simplex from herpes zoster, it is toxic to herpes simplex virus type 1 and thus may prevent accurate identification if used before culturing.

The use of rose bengal in dry eye evaluation is by far the most common use of the dye. Use of liquid volumes of 1% has been reported in dry eye diagnosis ranging from 1 to 20  $\mu$ l. The use of 3.0  $\mu$ l of nonpreserved 1% rose bengal, instilled with a laboratory pipette, seems to be comfortable for a majority of dry eye subjects.

The use of rose bengal for dry eye diagnosis remains controversial, with numerous workers continuing to value the test and others championing lissamine green. Interestingly, the several worldwide criteria (i.e., the Japanese, American, and European) suggested for the diagnosis of Sjögren's syndrome include use of rose bengal to assist the diagnosis (Figure 16-9). Although it could be argued that Sjögren's syndrome is perhaps the most morbid dry eye condition and thus easily visualized using rose bengal, the working group endorsements are powerful statements. Greater comfort in dry eye patients using lissamine green was demonstrated compared with rose bengal, and the conjunctival staining was found to be



**Figure 16-9** Rose bengal staining in patient with keratoconjunctivitis sicca (arrows). Note the typical triangular shape and location in the area of eyelid gap of the cornea and conjunctiva. (Courtesy Mark Williams, O.D.)

helpful in diagnosis. A new concept in dry eye diagnosis is the concept of rose bengal staining on the upper eyelid junctional epithelium, demonstrating greater upper lid staining in patients symptomatic for dryness compared with asymptomatic patients.

### Contraindications

Because rose bengal also stains skin, clothing, and contact lenses, contact with these entities should be avoided. Wearers of soft contact lenses should perform a thorough irrigation of the ocular surface and fornices before resuming contact lens wear. Irrigation after dry eye evaluation may be helpful to some patients.

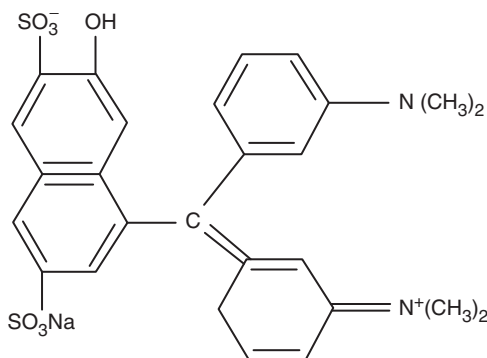
A dilemma exists with the use of rose bengal in the differential diagnosis of dendritic lesions of the cornea. Rose bengal is particularly useful in identifying epithelial herpetic corneal ulcers, by virtue of the characteristic staining of the edges of the dendritic lesion, whereas fluorescein stains the center. However, because of its potent antiviral activity, rose bengal used on a suspected herpetic ulcer may preclude a positive culture result, thus delaying the appropriate course of therapy. Therefore the severity of the corneal lesion and the importance of positive identification of the causative organism must be carefully considered in deciding whether to use rose bengal. A false-negative culture result can lead to inappropriate treatment.

### LISSAMINE GREEN

Lissamine green is a vital stain that stains degenerate cells, dead cells, and mucus in much the same way as rose bengal. It is also widely used in the food industry as a colorant.

### Pharmacology

Lissamine green has a chemical formula of  $C_{27}H_{25}N_2NaO_7S_2$ , CAS number 3087-16-9, and a molecular



**Figure 16-10** Molecular structure of lissamine green B.

weight of 576.6 Da. Figure 16-10 shows the molecular structure of lissamine green B.

### Clinical Uses

Lissamine green 1% stains in a fashion identical to that of 1% rose bengal. It is currently available in sterile strips, which when wetted with saline solution probably deliver variable concentrations and volumes to the eye similar to that for rose bengal. It may be useful when a patient is known to be sensitive to rose bengal. Lissamine green stains membrane-damaged epithelial cells as well as corneal stroma in a manner similar to that of fluorescein and, like rose bengal, also binds to the nuclei of severely damaged cells. An antiviral effect *in vitro* was also reported with lissamine green B concentrations as low as 0.06%.

In contact lens wear it has become apparent that conjunctival staining in general is related to symptoms of irritation and that lissamine green in particular may be more specific compared with fluorescein for those with symptoms.

### Side Effects

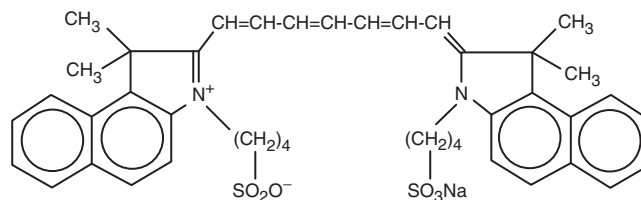
Instillation of lissamine green B into the conjunctival sac appears to cause no ocular irritation, and no other adverse effects have been reported. Clinical experience suggests the staining effect of lissamine green to be longer lasting than that of rose bengal.

## INDOCYANINE GREEN

Although the possibility of using indocyanine green (ICG) to observe vasculature of the human choroid was first introduced in the early 1970s, not until years later did it gain widespread recognition as a clinical diagnostic tool. Modifications to the original technique and the development of commercial ICG angiographic instrumentation were primary factors leading to its emergence into clinical practice.

### Pharmacology

ICG is a water-soluble tricyanin dye, chemical formula  $C_{43}H_{47}N_2NaO_6S_2$  (molecular weight, 774.96 Da;



**Figure 16-11** Molecular structure of indocyanine green.

CAS number 3599-32-4). It has a peak absorption in the near-infrared spectrum at 805 nm and maximal emission at 835 nm (Figure 16-11). This feature constitutes an important difference between ICG and fluorescein angiography. In the 800-nm region of ICG absorption, the pigment epithelium and choroid absorb only 21% to 38% of the light, as compared with 59% to 75% in the 500-nm region with fluorescein. Photography in the near-infrared region also enhances angiogram viewing in the presence of media opacities and subretinal exudation of fluid or blood. Moreover, unlike fluorescein, ICG is rapidly and completely bound to plasma proteins after intravenous injection in blood (especially albumin), so that it does not leak through the fenestrated capillaries of the choriocapillaris to obscure underlying details.

### Clinical Uses

ICG's primary use is as a fluorescent dye for retinal and choroidal angiography. Its low fluorescence property initially limited its use in angiography studies. Improvements in video technology, the introduction of appropriate excitation and barrier filters, and the development of the scanning laser ophthalmoscope with a modification to permit infrared recording ultimately allowed choroidal angiograms with high temporal and spatial resolution.

ICG videoangiography (ICGV) is useful in studying a variety of choroidal abnormalities, including congenital anomalies and ischemic, inflammatory, and degenerative disorders. It is used most frequently to identify and characterize choroidal neovascularization (CNV) in age-related macular degeneration. The collaborative work of the Macular Photocoagulation Study Group has shown that laser photocoagulation is of value in treating CNV. However, fewer than one-half of patients with newly diagnosed age-related macular degeneration are eligible for laser therapy on the basis of results of fluorescein angiography alone. Cases of ill-defined (or occult) CNV on the fluorescein angiogram are generally associated with poorer results with laser photocoagulation. The efficacy of angiography could be improved with the ability of the ICGV technique to locate and image more accurately the vessels targeted for photocoagulation.

ICG is available commercially from Akorn, Inc., as a two-part system; the dry dye powder (25 mg) is dissolved into a volume of aqueous diluent and should be used within 10 hours. Amounts up to 40 mg of dye dissolved in 2 ml

of diluent yield acceptable angiograms, depending on the imaging equipment used (package insert). Images can be obtained at 1- or 2-second intervals until the retinal and choroidal circulations are at maximum brightness and at increasing intervals over 30 to 40 minutes until fluorescence subsides. An ICG concentration of 50 mg/ml and injected 3.0 mg/kg followed by a 5.0-ml flush of sterile saline was found to be well tolerated.

ICGV studies are better able to visualize the choroid than is fluorescein angiography, and they allow imaging of rapid choroidal filling not captured by fluorescein angiography. Moreover, the ICG remains in the area of the CNV long after the dye has cleared from the surrounding retinal and choroidal circulation. Thus the ICGV technique appears to be particularly beneficial for visualizing poorly defined membranes, especially those with overlying hemorrhage and those near the edge of previously treated areas. Use of the infrared scanning laser ophthalmoscope can provide the high resolution required to render the ICGV technique even more successful.

### Adverse Reactions

Intravenous ICG has proven essentially as safe as sodium fluorescein. Few toxic effects have occurred, but severe allergic reactions have been reported. In one study ICG was generally well tolerated and caused fewer reactions than did fluorescein. However, two patients developed hives, and one experienced transient nausea and vomiting. In another series it was found that the near-infrared illumination of the technique was more comfortable than that used in fluorescein angiography. Patients did not experience nausea or other adverse effects from ICG. Because ICG remains bound to proteins in the blood and is rapidly metabolized by the liver, discoloration of the urine, skin, or mucous membranes does not occur.

### Contraindications

Because ICG contains a small amount of sodium iodide, it should not be used in patients with sensitivities to iodine or shellfish or in patients at high risk for anaphylactic reaction. The safety of this agent in pregnancy has not been established.

## METHYLENE BLUE

Methylene blue, a vital stain (Urolene blue), has properties similar to those of rose bengal. It can stain both devitalized cells and mucus and corneal nerves. It is not a specific stain when applied to the eye because the blue areas may be either cells or mucus. Clinically, methylene blue is useful for staining the lacrimal sac before dacryocystorhinostomy and outlining glaucoma filtering blebs, and it may prove useful in gonioscopic laser sclerostomy. More recently it has been used *in vitro* (tissue extraction and absorbance at 660 nm) to examine the effects of

artificial tear preparations on corneal integrity in dry eye models.

### Pharmacology

Methylene blue, 3,7-bis (dimethylamino)-phenazathionium chloride tetramethylthionine chloride (C<sub>16</sub>H<sub>18</sub>N<sub>3</sub>C<sub>1</sub>S; CAS no. 61-73-4) has a molecular weight of 373.91 Da. It is an aniline dye with an absorption peak of 660 nm. The dye is usually used as a 5% solution, and benzalkonium chloride may be added to the dye solution to enhance sterility. Methylene blue precipitates in alkaline solutions.

### Clinical Uses

Vital staining of corneal nerves requires up to three instillations at 5-minute intervals. The bluish ocular discoloration may remain for 24 hours.

For staining of the lacrimal sac before surgery, the sac is irrigated with methylene blue. The dye should remain in the sac for several minutes. Before the beginning of surgery the dye should be washed out of the sac, because it can spill out on incision and stain the surrounding tissues.

Methylene blue can also be administered intracamerally to stain the crystalline lens capsule to aid in visualization during cataract surgery.

### Adverse Reactions

When topically applied methylene blue can be fairly irritating to ocular tissue. A topical anesthetic may be used, because it enhances penetration of the drug at the same time as it relieves the discomfort.

### Contraindications

Methylene blue is contraindicated in patients allergic to the dye.

## SELECTED BIBLIOGRAPHY

- Baeyer A. Uber eine neue klasse von farbstoffen. *Ber Deutsch Chem Ges* 1871;4:555-558.
- Berkow JW, Flower RW, Orth DH, Kelley JS. Fluorescein and indocyanine green angiography: technique and interpretation. *Am Acad Ophthalmol* 1997;5-6.
- Bonnano J, Polse K. Measurement of *in vivo* human corneal stromal pH: open and closed eyes. *Invest Ophthalmol Vis Sci* 1987; 28:522-530.
- Bright DC, Potter JW, Allen DC, Spruance RD. Goldmann applanation tonometry without fluorescein. *Am J Optom Physiol Opt* 1981;58:1120-1126.
- Brubaker RF. Flow of aqueous humor in humans. *Invest Ophthalmol Vis Sci* 1991;32:3145-3166.
- Brubaker RF, Maurice DM, McLaren JW. Fluorometry of the anterior segment. In: Masters BR, ed. *Noninvasive diagnostic techniques in ophthalmology*. New York: Springer-Verlag, 1990: 248-280.

- Cherrick GR, Stein SW, Leery CM. Indocyanine green: observation on its physical properties, plasma decay, and hepatic function. *J Clin Invest* 1960;39:592-601.
- Cho PBB. Review of the tear break-up time and a closer look at the tear break-up time of Hong Kong Chinese. *Optom Vis Sci* 1993;70:30-38.
- Chodosh J, Dix RD, Howell RC, et al. Staining characteristics and antiviral activity of sulforhodamine B and lissamine green B. *Invest Ophthalmol Vis Sci* 1994;35:1046-1058.
- Courtney RC, Lee JM. Predicting ocular intolerance of a contact lens solution by use of a filter system enhancing fluorescein staining detection. *Intern Contact Lens Clinic* 1982; 9:302-310.
- Craig EL. Fluorescein and other dyes. In: Mauer TF, Craig EL, eds. *Havener's ocular pharmacology*. St. Louis, MO: Mosby, 1994: 451.
- Cunha-Vas J, De Abreu JRF, Campos AJ. Early breakdown of the blood-retinal barrier in diabetes. *Br J Ophthalmol* 1975;59:649-656.
- D'Anna SA, Hochheimer BF, Joondeph HC, Graebner KE. Fluorescein angiography in the heavily pigmented iris and new dyes for iris angiography. *Arch Ophthalmol* 1983; 101:289-293.
- Destro M, Puliafito CA. Indocyanine green videoangiography of choroidal neovascularization. *Ophthalmology* 1989; 96:846-853.
- Doughty MJ, Jalota V, Bennett E, et al. Use of high molecular weight fluorescein (fluorexon) ophthalmic strip in assessments of tear film break-up time in contact lens wearers and non-contact lens wearers. *Ophthalm Phys Opt* 2005; 25:119-127.
- Duffner L, Pflugfelder SC, Mandelbaum S, Childress LL. Potential bacterial contamination in fluorescein-anesthetic solutions. *Am J Ophthalmol* 1990;110:199-202.
- Ehrlich P. Über provocirte fluorescenzerscheinungen am Auge. *Deutsch Med Wehnschr* 1882;2:21.
- Feenstra R, Tseng SCG. Comparison of fluorescein and rose bengal staining. *Ophthalmology* 1992;99:605-617.
- Feenstra RP, Tseng SCG. What is actually stained by rose bengal? *Arch Ophthalmol* 1992;110:984-993.
- Flower RW, Hochheimer BF. A clinical technique and apparatus for simultaneous angiography of the separate retinal and choroidal circulation. *Invest Ophthalmol* 1973;12:248-261.
- Geeraets WJ, Berry ER. Ocular spectral characteristics as related to hazards from lasers and other light sources. *Am J Ophthalmol* 1968;66:15-20.
- Geyer O. Management of large, leaking, and inadvertent filtering blebs with the neodymium:YAG laser. *Ophthalmology* 1998; 105:983-987.
- Goldmann H. Über fluorescein in der menschlichen vorderkammer. *Das kammer-wasser-minutevolumen des menschen*. *Ophthalmologica* 1950;120:65-79.
- Goldmann H. Applanation tonometry. In: Newell FW, ed. *Glaucoma*. New York: Josiah Mach, Jr. Foundation, 1956: 167-220.
- Guillon M, Maissa C. Bulbar conjunctival staining in contact lens wearers and non-lens wearers and its association with symptomatology. *Contact Lens Anterior Eye* 2005;28: 67-73.
- Guyer DR, Yannuzzi LA, Slakter JS, et al. Digital indocyanine green videoangiography of central serous chorioretinopathy. *Arch Ophthalmol* 1994;112:1057-1062.
- Hara T, Inami M, Hara T. Efficacy and safety of fluorescein angiography with orally administered sodium fluorescein. *Am J Ophthalmol* 1998;126:560-564.
- Hope-Ross M, Yannuzzi LA, Gragoudas ES, et al. Adverse reactions due to indocyanine green. *Ophthalmology* 1994;101:529-533.
- Kelley JS, Kincaid M. Retinal fluorography using oral fluorescein. *Arch Ophthalmol* 1979;97:2331-2332.
- Korb DR, Herman JP. Corneal staining subsequent to sequential fluorescein instillations. *J Am Optom Assoc* 1979;50: 361-367.
- Korb DR, Herman JP, Greiner JV, et al. Lid wiper epitheliopathy and dry eye symptoms. *Eye Contact Lens* 2005;31:2-8.
- Kowalski R, Romanowski EG, Waikhom B, Gordon YJ. The survival of adenovirus in multidose bottles of topical fluorescein. *Am J Ophthalmol* 1998;126:835-836.
- Kwan ASL, Barry C, McAllister IL, Constable I. Fluorescein angiography and adverse drug reactions revisited: the Lions Eye Experience. *Clin Exp Ophthalmol* 2006;34:33-38.
- Kwiterovich K, Maguire MG, Murphy RP, et al. Frequency of adverse systemic reactions after fluorescein angiography: results of a prospective study. *Ophthalmology* 1991;98:1139-1142.
- Lakkis C, Brennan NA. Bulbar conjunctival fluorescein staining in hydrogel contact lens wearers. *CLAO J* 1996;22:189-193.
- Latina MA, Melamed S, March WF, et al. Gonioscopic ab interno laser sclerostomy. *Ophthalmology* 1992;99:1736-1744.
- Manning F, Wehrly SR, Foulks GN. Patient tolerance and ocular surface staining characteristics of lissamine green versus rose bengal. *Ophthalmology* 1995;102:1953-1957.
- Marsh RJ, Fraunfelder FT, McGill JI. Herpetic corneal epithelial disease. *Arch Ophthalmol* 1976;94:1899-1902.
- Maurice DM. The use of fluorescein in ophthalmological research. *Invest Ophthalmol* 1967;6:464-477.
- Meyer PAR, Watson PG. Low dose fluorescein angiography of the conjunctiva and episclera. *Br J Ophthalmol* 1987;72:2-10.
- Morgan KS, Franklin RM. Oral fluorescein angiography in aphakic children. *J Pediatr Ophthalmol Strabis* 1984;21:33-36.
- Morris PF. Fluorescein sodium and indocyanine green: uses and side effects. In: Saine PJ, Tyler ME, eds. *Ophthalmic photography*. Boston: Butterworth-Heinemann, 2002:137-165.
- Nagataki S, Matsunaga I. Binding of fluorescein monoglucuronide to human serum albumin. *Invest Ophthalmol Vis Sci* 1985;26:1175-1178.
- Ng LT, Tong JW, DeLand PN. The validity of fluorexon disodium versus sodium fluorescein for use in Goldmann tonometry. *Cornea* (in press).
- Norn M. Fluorexon vital staining of cornea and conjunctiva. *Acta Ophthalmol* 1973;51:670-678.
- Norn MS. Vital staining of the cornea and conjunctiva. *Acta Ophthalmol* 1962;40:389-401.
- Norn MS. Rose bengal vital staining. Staining of cornea and conjunctiva by 10 percent rose bengal, compared with 1 percent. *Acta Ophthalmol* 1970;48:546-559.
- Norn MS. Lissamine green. Vital staining of cornea and conjunctiva. *Acta Ophthalmol* 1973;51:483-491.
- Novotny HR, Alvis DL. A method of photographing fluorescence in circulating blood in human retina. *Circulation* 1961;24:82-86.
- Obana A, Mike T, Hayashi K, et al. Survey of complications of indocyanine green videoangiography in Japan. *Am J Ophthalmol* 1994;118:749-753.
- Palmberg R, Gutierrez YS, Miller D, et al. Potential bacterial contamination of eyedrops used for tonometry. *Am J Ophthalmol* 1994;117:578-582.

- Pflugfelder SC, Tseng SCG, Sanabria O, et al. Evaluation of subjective assessments and objective diagnostic tests for diagnosing tear-film disorders known to cause ocular irritation. *Cornea* 1998;17:38-56.
- Potter JW, Bartlett JD, Alexander LJ. Oral fluorography. *J Am Optom Assoc* 1985;56:784-792.
- Quaranta M, Cohen SY, Krott R, et al. Indocyanine green videoangiography of angoid streaks. *Am J Ophthalmol* 1995;119:136-142.
- Refojo MF, Korb DR, Silverman HI. Clinical evaluation of a new fluorescent dye for hydrogel lenses. *J Am Optom Assoc* 1972;43:321-326.
- Refojo MF, Miller D, Fiore AS. A new fluorescent stain for soft hydrophilic lens fitting. *Arch Ophthalmol* 1972;87:275-277.
- Romanchuk K. Fluorescein: physiochemical factors affecting its fluorescence. *Surv Ophthalmol* 1982;26:269-283.
- Scheider A, Kaboth A, Neuhauser L. Detection of subretinal neovascular membranes with indocyanine green and an infrared scanning ophthalmoscope. *Am J Ophthalmol* 1992;113:45-51.
- Schein OD, Tielsch JM, Munoz MS, et al. Relation between signs and symptoms of dry eye in the elderly. *Cornea* 1997;104:1395-1401.
- Slatker JS, Yannuzzi LA, Sorenson AJ, et al. A pilot study of indocyanine green videoangiography-guided laser photocoagulation of occult choroidal neovascularization in age-related macular degeneration. *Arch Ophthalmol* 1994;112:465-472.
- Snyder C, Paugh JR. Rose bengal dye concentration and volume delivered via dye-impregnated paper strips. *Optom Vis Sci* 1998;75:339-341.
- Tabery HM. Dual appearance of fluorescein staining in vivo of diseased human corneal epithelium. A non-contact photomicrographic study. *Br J Ophthalmol* 1992;76:43-44.
- Thomas ML, Szeto VR, Gan CM, Polse KA. Sequential staining: the effects of sodium fluorescein, osmolarity, and pH on human corneal epithelium. *Optom Vis Sci* 1997;74:207-210.
- Ubels JL, Clousing DP, van Haitsma TA, et al. Pre-clinical investigation of the efficacy of an artificial tear solution containing hydroxypropyl-guar as a gelling agent. *Curr Eye Res* 2004;28:437-444.
- Wilson FM. Rose bengal staining of epibulbar squamous neoplasms. *Ophthalmic Surg* 1976;7:21-23.
- Wilson G, Ren H, Laurent J. Corneal epithelial fluorescein staining. *J Am Optom Assoc* 1995;66:435-441.
- Yannuzzi LA, Rohrer KT, Tindel LJ, et al. Fluorescein angiography complications survey. *Ophthalmol* 1986;93:611-617.
- Yannuzzi LA, Slakter JS, Sorenson JA, et al. Digital indocyanine green videoangiography and choroidal neovascularization. *Retina* 1992;12:191-221.
- Zeimer RC. Assessment of posterior segment transport by vitreous fluorophotometry. In: Masters BR, ed. *Noninvasive diagnostic techniques in ophthalmology*. New York: Springer-Verlag, 1990: 366-389.

## *Nutritional Agents*

*Leo Paul Semes*

Dietary supplements (vitamins and inorganic essentials) fall under Title 21 of the Federal Register and must comply with regulations for labeling and health claims. The U.S. Food and Drug Administration (FDA) does not require supplement (or drug) companies to submit documentation that each batch of product contains the labeled ingredients. Rather, manufacturers are responsible for following Good Manufacturing Practices, including product validation. Furthermore, dietary supplement manufacturers may be subject to product liability claims if impurities are found, they cause harm, or they are improperly labeled. Advertising for dietary supplements is regulated by the Federal Trade Commission and also falls under The 1994 Dietary Supplement Health and Education Act. Only "Structure-Function" claims are allowed; that is, manufacturers are prohibited from making claims that products prevent or treat diseases.

Vitamins are organic compounds necessary for growth and health and cannot be synthesized in sufficient quantities for physiologic health by the body. Therefore they must be obtained from food sources or supplementation. Inorganic essentials (minerals are trace elements) are required in much smaller quantities than vitamins. In general, minerals and trace elements aid and support physiologic functions and, like vitamins, must be obtained from dietary sources.

The quantity of vitamins and minerals necessary for normal physiologic functioning is the dietary reference intake (DRI), which replaces the recommended dietary allowance. The DRI is a set of dietary recommendations and appears as "DV" (daily values). FDA regulations went into effect in March 1999 that requires such labeling. The DRI designation was formerly the FDA's reference daily intake. DRIs are reviewed by the Dietary Allowances Committee of the Food and Nutrition Board of the Institute of Medicine of the National Academy of Sciences. Based on age and sex, these amounts are estimated to provide for the physiologic needs of healthy individuals. Vitamins are generally divided into two main categories, fat soluble and water soluble.

A primer of the physiologic effects of the vitamins and inorganic essentials can be found in Tables 17-1 and 17-2. Vitamins are named alphabetically in the order in which they were discovered or first reported. Therefore the listing intersperses fat- and water-soluble members. Food sources and deficiency states of vitamins are listed in Tables 17-3 and 17-4.

It is important to remember that healthy individuals can obtain sufficient vitamins and inorganic essentials from food sources in the normal diet. Unfortunately, many individuals fail to observe healthy eating patterns. A food pyramid has been suggested recently by the U.S. Department of Agriculture (<http://www.mypyramid.gov/>) as a template. Other factors, such as lack of exercise, may result in nutritional deficiencies as well as diseases such as obesity, diabetes, and other chronic disorders.

Although absolute vitamin deficiency (e.g., beriberi, pellagra, scurvy) may be relatively rare in developed countries, malabsorption, poor nutritional habits, or other factors may lead to such situations. In fact, many Americans may be vitamin deficient based on recommended daily allowance or recommended daily intake. The interested reader is referred to the U.S. Department of Agriculture food and nutrition information center for recommended daily allowance and recommended daily intake (<http://fnic.nal.usda.gov/>). These are also summarized in Table 17-1 as DRI values.

Supplementation intervention, therefore, must be considered in specific deficiencies or recommended for clinically proven efficacy. Vitamin A deficiency can be treated readily, for example. The latter becomes difficult to define in the face of studies that offer inconsistent, incomplete, or even conflicting results.

Inorganic essentials and trace elements serve as cofactors in a variety of physiologic functions. These are summarized in Table 17-2.

The most significant vitamins from an ophthalmic standpoint include the antioxidant vitamins (A, C, and E) and are discussed with respect to function and deficiency as well as potential clinical benefits. The B vitamin group has been added because of their widespread representation in foods and supplements.

**Table 17-1**  
Vitamins and Selected Examples of Physiologic Effects

Vitamin	Solubility	Adult <sup>a</sup> DRI	Physiological Effect(s)
A (retinol, vitamin A alcohol)	Fat	5,000 IU	Vision, cell differentiation
B <sub>1</sub> (thiamin)	Water	1.5 mg	Cofactor in enzyme reactions
B <sub>2</sub> (riboflavin)	Water	1.7 mg	Cofactor for tissue oxidation and respiration
B <sub>3/4</sub> complex (niacin, niacinamide)	Water	20 mg	ATP synthesis; nicotinic acid may lower serum cholesterol
B <sub>6</sub> (pyridoxine)	Water	2.2 mg	Amino acid metabolism, nucleic acid synthesis
B <sub>9</sub> (folic acid/folate)	Water	400 mcg	Amino acid metabolism
B <sub>12</sub> (hydroxy/cyanocobalamin)	Water	2.6 mcg	Cell mitosis; detoxifies cyanide
C	Water	120 mg	Antioxidant
D (calciferol/cholecalciferol)	Fat	400 IU	Retinal function, Ca <sup>2+</sup> metabolism
E (CVD)	Fat	30 IU	Free radical scavenger, protective against tocopherol family
K (phytonadione)	Fat	80 mg	Blood clotting

<sup>a</sup>DRI may vary for infants and pregnant women, for example.

ATP = adenosine triphosphate; DRI = dietary reference intake; IU = International Units.

Vitamins B<sub>5</sub> (pantothenic acid), B<sub>6</sub> (pyridoxine), B<sub>7</sub> (biotin), B<sub>8</sub> (inositol), B<sub>10</sub> (para-aminobenzoic acid), B<sub>11</sub> (choline), lecithin, and B<sub>15</sub> (pangamic acid) are listed here for sake of completeness but not shown in the table. The reader is referred to <http://www.acu-cell.com> for examples.

Zinc is present in a variety of dietary sources, including seafood, liver, and eggs, and is an integral part of superoxide dismutase and catalase, two antioxidant enzymes. In populations at risk for developing age-related macular degeneration (AMD), dietary zinc levels have been shown to be decreased, and other researchers have shown that those with zinc intake from dietary sources had a lower risk for some types of AMD. An early uncontrolled pilot study of zinc supplementation demonstrated reduced visual deterioration in AMD. This probably represented the beginning of the era of clinical trials on the effects of nutrition on visual function and ocular health status. Zinc deficiency leads to a syndrome similar to vitamin A deficiency because the conversion of retinol to retinal requires zinc. Deficiency may result in night blindness, decreased color perception, hyperkeratinization of lid margins with lacrimal punctal stenosis, blepharitis,

conjunctivitis, and photophobia. Therefore zinc is thought to be protective of vitamin A in the retina.

Copper stores are decreased by excessive zinc ingestion, so copper supplementation is essential with concomitant zinc administration. Wilson's disease is a genetic abnormality that leads to progressive accumulation of copper that may manifest in the cornea (Kayser-Fleischer ring). In addition, sunflower cataracts and renal dysfunction may accompany the corneal sign. Copper toxicity results when greater than 15 mg is administered. It is characterized by abdominal pain, nausea, vomiting, diarrhea, myalgia, metabolic acidosis, coma, and death.

Contemporary scientific evidence lacks sufficient consistency to suggest that any single or multiple vitamin and mineral supplementation has specific beneficial effect on ocular diseases such as AMD, cataract development, or glaucoma. For example, lowering the intraocular pressure in patients with ocular hypertension or glaucoma has been demonstrated to slow progression. Multivitamin and mineral supplementation has been shown to be of value in some cases of advanced stages of AMD. No clear evidence exists to suggest that cataract or glaucoma treatment may benefit from supplementation at this time. Vitamin and mineral supplementation, therefore, may benefit selected at-risk patients. Current clinical data on the benefit of nutritional supplements are unclear and, in some cases, contradictory. When confounders of patient age, sample size, supplement use versus intake from foods, supplementation with a single or multivitamin, presence of undisclosed or undiscovered underlying disease processes, gauging disease progression, inconsistent outcomes measures, genetic and ethnic influences, environmental factors such as smoking, and the unavoidable imprecision of data collection from retrospective

**Table 17-2**  
Selected Inorganic Essentials and Their Physiologic Function

Inorganic Essential	Adult DRI Range	Physiologic Function
Copper	0.4–3.0 mg	Monoamine oxidase formation
Zinc	5–19 mg	Carbonic anhydrase activity
Selenium	10–75 mcg	Protects against oxidative damage to hemoglobin

DRI = dietary reference intake.

**Table 17-3**

Common Food Sources and Selected Deficiency and Overdose Manifestations for Selected Vitamins of Potential Interest to Ophthalmic Practitioners

Vitamin	Food Sources	Deficiency	Overdose
A	Eggs, liver, butter, cheese, whole milk, fish, and green leafy or yellow vegetables	Nyctalopia, xerophthalmia	Papilledema
D	Conversion in skin by exposure to ultraviolet radiation		Hypercalcemia
E	Vegetable oils, wheat germ, leafy vegetables, egg yolks, and legumes	Neurologic abnormalities (including ophthalmoplegia)	Vitamin K deficiency
K	Green vegetables and synthesized by intestinal bacteria	Reduced blood clotting ability	None known
B <sub>1</sub>	Fortified breads, cereals, pasta, whole grains (especially wheat germ), lean meats (especially pork), fish, dried beans, peas, soybeans, nuts, and seeds	Toxic optic neuropathy	Beriberi
B <sub>2</sub>	Unrefined whole grains, liver, all meats, eggs, green leafy vegetables, nuts, seeds	Light sensitivity, keratoconjunctivitis sicca	Nausea, vomiting, fatigue, anemia, low blood pressure
B <sub>3/4</sub> complex	Same as B <sub>2</sub>	Pellagra	Flushing (vitamin B <sub>3</sub> ), nausea, vomiting, headache
B <sub>5</sub>	Same as B <sub>2</sub>	Insomnia, joint pains, edema	Edema, severe fatigue, joint pains
B <sub>6</sub>	Same as B <sub>2</sub>	Seborrheic dermatitis, dizziness, migraine	Low blood sugar, migraine, muscle spasms
B <sub>7</sub>	Same as B <sub>2</sub>	Skin disorders, hair loss, brittle nails	Skin eruptions, increased blood sugar
B <sub>9</sub> (folic acid/folate)	Same as B <sub>2</sub>	Hemolytic and megaloblastic anemia	Headache
B <sub>12</sub>	Meat, dairy, eggs, seafood	Toxic optic neuropathy	Optic nerve atrophy (in Leber's disease)
C	Citrus fruits, potatoes, tomatoes, strawberries, cabbage	Scurvy	

Vitamins B<sub>8</sub> (inositol), B<sub>10</sub> (para-aminobenzoic acid), B<sub>11</sub> (choline), lecithin, and B<sub>15</sub> (pangamic acid) are not shown. The reader is referred to <http://www.acu-cell.com> for additional details.

analysis are considered, interpretation of even the most promising results may be clouded. Interpretation of any single, large, well-designed and conducted clinical trial is complex and has limitations. Caution is therefore warranted when making generalized recommendations for supplement use. The prudent clinician should recognize that potential benefits are limited but that multivitamin administration is comparatively safe versus certain prescription and over-the-counter preparations.

The following discussion is intended as a guide for those recommendations based on contemporary knowledge of risks and benefits of vitamin and mineral supplementation and considers the potential impact on three ophthalmic disease states: glaucoma, cataract, and AMD. These were selected for reasons of significance as well as the body of literature available. In addition, specific treatment recommendations for disorders resulting from nutritional deficits are discussed. Finally, the role of

complementary and alternative medicine in ophthalmic disorders is outlined.

## CLINICAL USES OF VITAMIN AND MINERAL SUPPLEMENTATION

### Primary Open-Angle Glaucoma

Antioxidant intake for primary open-angle glaucoma was reported in a prospective study. As part of the Health Professionals Follow-up Study and Nurses' Health Study, a selected group of patients was evaluated using a food frequency questionnaire to assess antioxidant intake from foods and supplements. The glaucoma diagnosis was confirmed by record review, and the authors found no protective associations with antioxidant intake and reduced risk of primary angle glaucoma progression. The theory of antioxidant protection arises from



**Table 17-4**

## Components of Ideal Ocular Nutritional Supplements

General Supplementation	Recommended Daily Dose <sup>a</sup>
Vitamin C	40 mg
Vitamin E	40 mg
Lutein/ Zeaxanthine	12 mg
Macular Degeneration	Recommended Daily Dose <sup>b</sup>
Vitamin C	500 mg
Vitamin E	400 IU
Beta-carotene	15 mg (equivalent to 25,000 IU vitamin A)
Zinc (as Zn oxide)	80 mg
Copper (as cupric oxide)	2 mg
Cataract	Recommended Daily Dose <sup>c</sup>
Vitamin C	up to 1,000 mg
Ocular Surface Disorders	Recommended Daily Dose <sup>d</sup>
Vitamin A (retinyl palmitate)	1,040 IU (range: 200–5,000 IU)
Vitamin C (calcium ascorbate)	90 mg (at least 50 mg)
Vitamin B <sub>6</sub> (pyridoxal 5-phosphate)	6.3 mg (range: 2.0–20 mg)
Magnesium (magnesium sulfate)	20 mg (range: 10–50 mg)
Gamma linolenic acid (GLA)	750 mg (at least 300 mg)
Mucin	150 mg (range: 100–300 mg)
Cod liver oil	1.6 mg (range: 0.5–3.0 mg)
OR	
Vitamin E	187 IU
Mixed tocopherol concentrate	20 mg
Marine lipid oil	1,541 mg
EPA	450 mg
DHA	300 mg
Flaxseed oil	1,000 mg

<sup>a</sup>These doses are within the safe limits but may be below DRI values. (See Table 1 and Bartlett H, Eperjesi F. *Ophthalmic Physiol Opt.* 2004; 24: 339-49.)

<sup>b</sup>These doses are consistent with the AREDS formulation (see text).

<sup>c</sup>For its antioxidant properties, this recommendation represents an upper limit.

<sup>d</sup>United States Patent: 6,506,412, Issued: January 14, 2003; and TheraTears Nutrition®.

Investigations have supported as well as refuted various nutritional supplement components for the prevention of cataract formation, macular health supplementation (inner and outer layers), stabilization of visual field damage in glaucoma, and for maintaining ocular surface integrity. A formulation that supports general ocular health would contain anti-oxidants in moderate amounts. Supplements that target specific diseases would necessarily differ in composition. This table lists components of a general formulation as well as components of specific formulations. In addition, selected products containing these ingredients are listed for reference. The reader is also referred to Tables 17-1 and 17-3.

Commercial products containing these ingredients are available from a variety of sources. Selected commercial brands are listed below.

B&L OcuVite PreserVision (tablet) (Bausch and Lomb, Rochester, NY; [www.bausch.com](http://www.bausch.com))

B&L (softgel) PreserVision (Bausch and Lomb, Rochester, NY; [www.bausch.com](http://www.bausch.com))

EyePromise Restore (Zeavision, Saint Louis, MO; [www.zeavision.com](http://www.zeavision.com))

HydroEye, Macular Protect (Science Based Health, Carson City, NV; [www.sciencebasedhealth.com](http://www.sciencebasedhealth.com))

iCaps (Alcon Laboratories, Ft. Worth, TX; [www.alcon.com](http://www.alcon.com))

MaxiVision, MaxiTears (MedOp, Oldsmar, FL; [www.medop.com](http://www.medop.com))

TheraTears Nutrition (Advanced Vision Research, Woburn, MA; [www.theratears.com](http://www.theratears.com))

oxidation-reduction agents being protective against glutamate-induced toxicity.

Several characteristics of complementary and alternative medicine have been suggested to be favorable to glaucoma treatment. Neuroprotective agents may offer

such properties as oxidative alterations of low-density lipoproteins, scavenging of oxygen free radicals, and inhibition of glutamate toxicity. The lack of persuasive evidence from placebo-controlled clinical trials limits recommendation of such potentially promising agents as

Ginkgo biloba, which improves cerebral blood flow. Anecdotal reports of ginkgo and other potentially neuroprotective agents may be of value in the future for adjunctive glaucoma treatment. Lowering intraocular pressure in patients with glaucoma continues to be the primary modifiable risk factor worthy of intervention.

## Cataract

Because the lens is avascular it might be expected that vitamin or mineral augmentation would not protect against cataract formation. The exception is vitamin C, which is actively transported from the circulation to ocular tissues and the aqueous and therefore is present in greater concentrations than in blood. Selected epidemiologic studies regarding antioxidants and cataract have suggested that single vitamins (vitamin C and E) may have salutary effects on specific types of cataract formation (nuclear, cortical, or posterior subcapsular) or their progression. A more beneficial strategy may include multivitamin and mineral supplementation begun early in life and taken over long periods.

Although some individual trials present persuasive evidence supporting efficacy or benefit from single or multivitamin supplementation, universal guidance remains obscure. The confounding factors associated with clinical or epidemiologic studies are myriad. Not every study investigates the same population. In some studies benefit was associated with elderly populations whose nutritional habits may be lacking. In other studies efficacy was demonstrated among selected cases such as among cancer patients. Some study populations are assayed by “snapshot” serum samples. Other studies assess single nutrients, whereas some include supplement classes such as antioxidants or carotenoids. Many researchers measure dietary intake using validated food frequency questionnaires that harbor the limitation of depending on patient recall. Studies are inconsistent in whether any lens opacity, specific (nuclear, cortical, or posterior subcapsular) cataract type, or cataract extraction is the endpoint. Finally, some studies use observational approaches, whereas others are prospective and interventional.

Currently, retrospective analysis of auxiliary multivitamin and mineral supplementation in the Age-Related Eye Disease Study (AREDS) is under way. This will assess whether concomitant Centrum<sup>®</sup> (Wyeth Consumer Healthcare) use will delay the progression of lens opacities, as has been suggested by a statistical appraisal of AREDS data. In fact, AREDS Report No. 9 did not find any protective effect from the AREDS formulations\* against cataract formation. Risk factors other than nutritional status/intake or in combination with supplement use may influence development, progression, or visual impairment from cataract. Current evidence offers only weak support at best for a recommendation of multivitamin or other nutritional interventions as protective against cataract formation or progression.

## Age-Related Macular Degeneration

Necessarily, this term encompasses a variety of clinical presentations. Drusen and pigment changes are recognized as clinically observable risk factors for macular degeneration, but indices in clinical studies include stages of outer retinal changes (examiner specification) as well as visual acuity (patient performance). For these and other reasons mentioned above, making sense of even carefully conducted studies makes deriving consistent clinical recommendations a conundrum.

Fewer than 20 years ago high-dose zinc supplementation was reported to reduce significantly the risk of vision loss in a short-term study that lacked a control arm. Since then, nutritional interventions have become popular with researchers as well as the general public. Unfortunately, subsequent trials have failed to substantiate this initial result.

Nevertheless, at least six randomized, double-blind, placebo-controlled, intervention trials have assessed the effect of vitamin or micronutrient supplements on AMD risk. The consensus from these and other trials seems to suggest a positive response of the retina as well as improved visual performance from vitamin and mineral supplementation such as the AREDS formulation (see above). Specifically, the AREDS results should be interpreted as understanding that the formulation was effective in slowing the risk of progression of AMD in persons 55 years of age and older who had some macular changes consistent with early age-related maculopathy. More recently, substantiation of these results was reported on a primarily white population as part of the Rotterdam Study. An above-median intake of beta-carotene, vitamin C, vitamin E, and zinc was associated with a 35% reduced risk of AMD. Still other clinical research has demonstrated short-term beneficial effects in small populations for lutein and a combination of lutein and antioxidants in AMD.

Although these studies are promising as a basis for specific clinical guidance, the application to general populations is limited. The interaction of specific nutrients, for example, remains unknown. In AREDS, only patients in intermediate AMD, categories 3 and 4, showed a treatment benefit. And, high-dose beta-carotene supplementation may have adverse effects among smokers.

Because the treatment options are limited for patients suffering from AMD and vision loss is rarely recovered, this information should be portrayed to patients with cautious optimism. Generally, well-nourished patients with AMD may experience some reduced progression

---

\*The specific daily amounts of antioxidants and zinc used by the AREDS researchers were 500 mg vitamin C, 400 IU vitamin E, 15 mg beta-carotene (often labeled as equivalent to 25,000 IU vitamin A), 80 mg zinc as zinc oxide, and 2 mg copper as cupric oxide. Copper was added to the AREDS formulations containing zinc to prevent copper deficiency anemia, a condition associated with high levels of zinc intake. (Retrieved March 28, 2007, from <http://www.nei.nih.gov/amd/summary.asp#2>)

with antioxidant and mineral supplementation. Recommendations should be based on evidence that many Americans may not, in fact, enjoy optimal nutrition. Because supplements are available without prescription (nor FDA scrutiny) in the United States, a balance needs to be struck between probable benefits and potential risks.

Using the example of AMD, it appears that many patients may benefit from the AREDS formulation as well as a diet high in green leafy vegetables. The potential for adverse effects (increased incidence of lung cancer) among smokers, in particular, from ingestion of high doses of beta-carotene has been suggested. Long-term effects in healthy populations have not been reported. Further characterization of an ideal formulation awaits future research. One such study is currently under way. AREDS II is evaluating the potential benefits of the antioxidants lutein/zeaxanthin as well as omega-3 long-chain polyunsaturated fatty acids in delaying progression of vision loss in AMD.

## **SPECIFIC VITAMIN AND MINERAL SUPPLEMENTATION FOR NUTRITIONAL DEFICIENCIES**

---

### **Vitamin A Deficiency**

Although rarely encountered in developed countries, vitamin A deficiency remains a global public health problem. The current World Health Organization recommendation for vitamin A treatment in children 1 year of age and older who are at risk (see Table 17-3) is one 200,000 IU oral dose every 3 to 6 months for prophylaxis, and three such doses for treatment and prevention of xerophthalmia. Animal studies (rat model) have shown some improvement in corneal epithelial function with topical vitamin A supplementation. In human trials, evidence is contradictory regarding the beneficial role of topical vitamin A application. The apparent mechanism is reduction of inflammatory components.

### **Folic Acid Deficiency**

Folic acid deficiency may result in neural tube defects in newborns. Folic acid is one of the few nutritional supplements shown in clinical trials to be effective in preventing disease. Maternal prenatal supplementation with 400 mg/day folic acid reduced significantly the incidence of neural tube defects in newborns, which indicates that low maternal folate concentrations were associated with these defects.

### **Toxic Optic Neuropathy (Cyanocobalamin)**

Deficiency of cyanocobalamin, or vitamin B<sub>12</sub>, can result in reduced visual acuity secondary to optic nerve dysfunction. Causes range from malabsorption to alcohol abuse. Treatment is with oral (1,000 to 2,000 mcg daily)

or intramuscular injections (1,000 mcg daily for 2 weeks or 1,000 mcg twice weekly for 2 weeks followed by weekly injections of 1,000 mcg for 2 months) of cyanocobalamin. In chronic deficiency, lifelong treatment is required.

### **Vitamin A in Retinitis Pigmentosa**

The initial clinical trial examining the effects of vitamins A and E on retinitis pigmentosa showed a modest decline in progression of the disease based on electrophysiologic findings. Recommendations from this and subsequent trials have given rise to a treatment algorithm for retinitis pigmentosa patients. Adults with early or middle stages of retinitis pigmentosa should take 15,000 IU of oral vitamin A palmitate every day and avoid high-dose vitamin E supplements. Beta-carotene is not a suitable substitute for vitamin A because it is not reliably converted to vitamin A. People on this regimen should have annual measurements of fasting vitamin A concentrations in serum and liver function tests, although no cases of toxic effects have been reported.

### **Omega-3 Fatty Acids in Dry Eye**

Oral supplementation with omega-3 fatty acids may play a role in relief of dry eye. Postmenopausal women are most susceptible to the signs and suffer the symptoms to a greater extent than other segments of the population. Intervention may have a positive effect. Recent studies also have demonstrated potential benefits on AMD, as well.

## **SIDE EFFECTS AND CONTRAINDICATIONS**

---

Contraindications and adverse reactions associated with the use of nutritional supplements, although rare, should be considered. The risk of side effects from nutrients is reduced compared with that from over-the-counter or prescription drugs. On the other hand, interactions with over-the-counter or prescription drugs may potentiate these reactions. Perhaps the best known interactions are those that interfere with clotting mechanisms. Because nonsteroidal anti-inflammatory drugs and warfarin have the therapeutic effect of blood thinning, caution is advised in recommending vitamin C (doses > 1 g/day), vitamin E, or Ginkgo biloba in these cases. Vitamin C may interfere with normal metabolism of acetaminophen, resulting in liver-damaging accumulation.

Clinicians should be aware that specific recommendations, such as the AREDS formulation, may not be recognized as compounding doses of other over-the-counter supplements. An example would be accumulating a toxic dose of beta-carotene from using the AREDS formulation along with additional sources of beta-carotene. Other examples exist, and a complete enumeration of

supplements that the patient may be taking should be evaluated to ensure that dosing remains within published guidelines.

Other associations have been reported anecdotally. These include competitive absorption among antioxidants such as vitamin A and lutein/zeaxanthin. In general, adhering to the DRI recommendations is safe for patients. The DRIs as well as side effects of overdose of vitamins are listed in Table 17-3.

The ocular side effects from herbal medications and nutritional supplements have been reviewed recently. The Dietary Supplement and Health Education Act of 1994 govern their manufacture and distribution. No efficacy or safety standards are required to be met for marketing some 700 available botanicals and 1,000 nutritional products. There may be significant variation in purity, potency, and even content. Ocular side effects may range from accommodative impairment, secondary to anticholinergic effects (kava kava), to visual disturbances (licorice). The World Health Organization has developed a classification scheme to categorize such side effects. In the United States a registry is available at [www.eyedrugregistry.com](http://www.eyedrugregistry.com).

One danger is that because herbal medications are not regulated, few if any clinical trials are performed even for safety or efficacy. One example is bilberry. Bilberry fruit is used to treat diabetes and diabetic retinopathy. Although animal models support the antioxidant role in vasoprotection, no well-designed and conducted clinical trials exist. The antioxidant effect may have benefit in AMD, as well. The antioxidant efficacy in bilberry is likely due to the tannin content, which is also found in grapes.

Another danger of herbal medication supplementation is that anecdotal information rises to a level of truth or even dogma. Various estimates suggest that not only are large sums of money (\$60 billion worldwide) spent on complementary and alternative medicine strategies, but a large portion of the population (42% by some estimates) uses them without proof and in many cases without sanction or knowledge of the attending and treating physician.

In summary, nutrients play a vital role in physiologic functioning. The eye is no exception. Consequently, there are potentially useful as well as harmful effects of supplementing vitamins and inorganic essentials. The least studied category, herbal medications, may hold great promise for application in ophthalmic disorders but currently pose too great a risk for wholesale recommendation. Even though many of these compounds were discovered centuries ago, current research has neglected an opportunity to investigate their potential systematically. What does appear to emerge is some benefit from antioxidant supplementation against progression of AMD in selected older individuals. The influence against cataract progression seems to be limited to vitamin C. Primary open-angle glaucoma patients should be offered traditional intraocular pressure-lowering medications at the present time.

## SELECTED BIBLIOGRAPHY

- Age-Related Eye Disease Study Research Group. A randomized, placebo-controlled, clinical trial of high-dose supplementation with vitamins C and E and beta-carotene for age-related cataract and vision loss: AREDS Report No. 9. *Arch Ophthalmol* 2001;119:1439-1452.
- Age-Related Eye Disease Study Research Group. Risk factors associated with age-related nuclear and cortical cataract: a case-control study in the Age-Related Eye Disease Study, AREDS Report No. 5. *Ophthalmology* 2001;108:1400-1408.
- Bartlett H, Eperjesi F. Age-related macular degeneration and nutritional supplementation: a review of randomised controlled trials. *Ophthalmic Physiol Opt* 2003;23:383-399.
- Bartlett H, Eperjesi F. Possible contraindications and adverse reactions associated with the use of ocular nutritional supplements. *Ophthalmic Physiol Opt* 2005;25:179-194.
- Chiu CJ, Taylor A. Nutritional antioxidants and age-related cataract and maculopathy. *Exp Eye Res* 2007;84:229-245.
- Clemons TE, Milton RC, Klein R, et al. Age-Related Eye Disease Study Research Group. Risk factors for the incidence of advanced age-related macular degeneration in the Age-Related Eye Disease Study (AREDS) AREDS Report No. 19. *Ophthalmology* 2005;112:533-539.
- Evans JR. Antioxidant vitamin and mineral supplements for slowing the progression of age-related macular degeneration. *Cochrane Database Syst Rev* 2006 Apr 19;(2):CD000254.
- Hartong DT, Berson EL, Dryja TP. Retinitis pigmentosa. *Lancet* 2006;368:1795-1809.
- Kang JH, Pasquale LR, Willett W, et al. Antioxidant intake and primary open-angle glaucoma: a prospective study. *Am J Epidemiol* 2003;158:337-346.
- Katz J, West KP Jr, Khatry SK, et al. Impact of vitamin A supplementation on prevalence and incidence of xerophthalmia in Nepal. *Invest Ophthalmol Vis Sci* 1995;36:2577-2583.
- Kaushansky K, Kipps TJ. Hematopoietic agents: growth factors, minerals, and vitamins. In: Brunton LL, Lazo JS, Parker KL, eds. Goodman and Gilman's the pharmacological basis of therapeutics, ed. 11. New York: McGraw-Hill, 2006.
- Kumar N. Nutritional neuropathies. *Neurol Clin* 2007; 25:209-255.
- Miljanovic B, Trivedi KA, Dana MR, et al. Relation between dietary n-3 and n-6 fatty acids and clinically diagnosed dry eye syndrome in women. *Am J Clin Nutr* 2005;82: 887-893.
- Milton RC, Sperduto RD, Clemons TE, et al. Age-Related Eye Disease Study Research Group. Centrum use and progression of age-related cataract in the Age-Related Eye Disease Study: a propensity score approach. AREDS Report No. 21. *Ophthalmology* 2006;113:1264-1270.
- Newsome DA, Swartz M, Leone NC, et al. Oral zinc in macular degeneration. *Arch Ophthalmol* 1988;106:192-198.
- Ritch R. Complementary therapy for the treatment of glaucoma: a perspective. *Ophthalmol Clin North Am* 2005;18:597-609.
- Sadun AA. Metabolic optic neuropathies. *Semin Ophthalmol* 2002;17:29-32.
- van Leeuwen R, Boekhoorn S, Vingerling JR, et al. Dietary intake of antioxidants and risk of age-related macular degeneration. *JAMA* 2005;294:3101-3107.
- West AL, Oren GA, Moroi SE. Evidence for the use of nutritional supplements and herbal medicines in common eye diseases. *Am J Ophthalmol* 2006;141:157-166.

## *Drugs for Retinal Diseases*

*David C. Bright*

The rapid development of an ever-increasing variety of drugs for retinal disease has been a boon to individuals living with the vision loss associated with retinal disease, including two conditions for which few treatment options existed: recalcitrant macular edema and age-related macular degeneration (AMD). Just 10 years ago the only treatment modality for patients with these retinal diseases was laser photocoagulation. Although none of these new medications is perfect, none provides a definitive resolution for conditions that wax and wane, and all require repeated use to maintain the gains in visual acuity and improved retinal status, their appearance in patient care is most welcome.

### **PHOTODYNAMIC THERAPY**

Hematoporphyrin, with its ability to fluoresce red-orange upon exposure to near-ultraviolet light, was the first photosensitizing substance used in clinical care. It was initially used for localizing tumors, but a hematoporphyrin derivative was subsequently used in detection and management of cancer beginning in the 1960s. Because photosensitizing drugs accumulate preferentially in rapidly dividing cells, particularly in the proliferating neovascular tissue of cancers, they offered a potentially more focused and less destructive treatment modality. That principle of focused destruction of neovascularization was borrowed for management of choroidal neovascularization.

Photodynamic therapy (PDT) requires the combination of photosensitizer with both specially selected light and oxygen. A photosensitizer absorbs specifically selected light energy, after which its electrons are increased from the ground state to the excited state. Most sensitizers in the ground state are in the electron singlet state, in which all electron spins in the atom are paired (numbers of electrons spinning to the right equal numbers of electrons spinning to the left). When the photosensitizer absorbs the light energy, that absorbed energy may cause the spin of one electron to reverse direction. When the electron reverses direction, it moves out of the singlet state into the triplet state (in which two

electrons spin in the same direction without the counterbalancing effect of two electrons spinning oppositely). Oxygen molecules play an essential part in PDT, because oxygen is already in the triplet state ( $^3\text{O}_2$ ) when in its normal ground state. When ground state oxygen plus the newly excited photosensitizer in its triplet state join, the unstable photosensitizer transfers its energy to the stable triplet oxygen. Oxygen now has one of its unpaired electrons reverse its spin, so there are now no unpaired electron spins and oxygen is now in its atypical singlet excited state. Singlet oxygen must transfer its energy to regain stability, and it does so in the form of peroxides and free radicals, which are presumed to promote most of the desired cascade of destructive tissue changes. After the photosensitizer has released its excess energy, it returns to its ground (singlet) state and can then absorb more light.

### **Verteporfin (Visudyne)**

Verteporfin (Visudyne, Novartis Pharmaceuticals USA and Novartis Ophthalmics International) is a second-generation photosensitizer, synthesized from protoporphyrin. Verteporfin is described as a “benzoporphyrin derivative monoacid ring A,” where ring A refers to the conjugation position of the chlorine structure. Most PDT agents are of the porphyrin class, with four pyrrole rings. If one of the rings is reduced and yields a chlorine molecule, this alters the absorption properties into the far-red end (between 630 and 690 nm). When molecular oxygen is present, verteporfin, upon activation by low-intensity nonthermal laser light at 689 nm, becomes an efficient generator of singlet oxygen ( $^1\text{O}_2$ ). The light selected is in the far-red spectrum, corresponding to the chemical’s absorbance profile, with greater transmission through both blood and tissue compared with lower wavelengths. As with other photosensitizing substances, verteporfin accumulates preferentially in target tissue after intravenous administration. The drug has a mean serum half-life of 5 hours. There is little metabolism by the liver, and most of the drug is excreted unchanged in the feces.

Verteporfin's delivery and activity are governed by principles of light energy. The *fluence* is the amount of light delivered, measured as joules per square centimeter. The *power density* is the rate at which the light is delivered, measured as milliwatts per square centimeter. To deliver a fluence of 50 J/cm<sup>2</sup> at a power density of 600 mW/cm<sup>2</sup>, an illumination time of 83 seconds is needed (because the energy of light delivered is a product of the time of illumination and the rate at which the power is delivered).

Verteporfin is a hydrophobic substance administered in a lipid-based formulation that promotes rapid transfer to plasma lipoproteins. Because the drug has affinity for lipoproteins, particularly plasma low-density lipoproteins, it is taken up by cells with high levels of low-density lipoprotein receptors. This is the basis for its effects on choroidal neovascularization, which include vasoconstriction, blood cell aggregation, and endothelial cell damage. PDT is potentially superior to conventional retinal laser, because the inner and outer retinal layers overlying the CNVM (choroidal neovascular membrane) are relatively spared, given the correct light dose and fluence. In contrast, laser's transmitted energy results in severe and immediate necrosis of all retinal layers.

Phase I and II trials of verteporfin demonstrated that CNVMs were occluded for 1 to 4 weeks after a single PDT session, with fluorescein leakage noted 4 to 12 weeks later. Because CNVM reperfusion occurred after a single PDT session, researchers evaluated the safety and efficacy of repeated treatments on CNVM stability. They discovered that retreatment at 2 or 4 weeks after the initial PDT still allowed for leakage to recur in most subjects at 4 to 12 weeks but to a lesser extent after multiple treatments.

Large clinical phase III trials of verteporfin were undertaken in carefully defined patient populations. The Treatment of Age-Related Macular Degeneration with Photodynamic Therapy (TAP) study demonstrated that patients with CNVM treated with verteporfin had better visual acuity and fluorescein angiography outcomes than placebo-treated patients at both 12 months and 2 years. Follow-up evaluations were conducted every 3 months to detect reperfusion of CNVM, and many patients were retreated with PDT. Twelve months after the first treatment, 61% of patients receiving PDT compared with 46% of patients receiving placebo lost less than 15 letters on an ETDRS (Early Treatment of Diabetic Retinopathy Study) chart. One critical point was that patients with predominantly classic CNVM (occupying 50% or more of the lesion) had less vision loss. The benefits seen at 12 months persisted at 24 months, with 53% (PDT) versus 38% (placebo) losing less than 15 letters of visual acuity.

A subsequent trial, the Verteporfin in Photodynamic Therapy (VIP), used the same treatment and follow-up protocol as did the TAP study, but it evaluated AMD in subjects with CNVM that was either occult only (with evidence of recent progression or hemorrhage) or

presumed early onset classic CNV (choroidal neovascularization); individuals with CNV from pathologic myopia were also evaluated. Among the AMD patients, the risk of moderate vision loss (15 or more letters) was similar between the two groups at 12 months but was reduced in verteporfin-treated individuals at 24 months (54% verteporfin-treated vs. 67% controls). For those individuals with pathologic myopia, 72% of verteporfin-treated patients and 44% of control patients lost less than eight letters of visual acuity at 12 months.

Side effects of verteporfin therapy have been extensively studied. The TAP study provided the largest amount of data on adverse effects, which included the following incidences in treated versus control patients: visual disturbance (abnormal or decreased vision) in 22.1% versus 15.5%, injection-site adverse events in 15.9% versus 5.8%, photosensitivity reactions in 3.5% versus 0%, back pain in 2.5% versus 0%, and allergy reactions in 2.0% versus 3.9%. Further data on adverse events were provided by the VIP study, determining that many of the resulting adverse events were similar in incidence to those reported in the TAP study but fewer photosensitivity or injection site reactions were observed. This latter difference was attributed to better compliance with overall protocols of the study design.

The procedure for PDT occurs in two steps: intravenous drug administration followed by activation of the drug by nonthermal red light in the presence of oxygen. The recommended dose is 6 mg/m<sup>2</sup>, diluted with 5% dextrose to a total volume of 30 ml, administered over 10 minutes. After 15 minutes from the time of starting the infusion, the light dose is given at 50 J/cm<sup>2</sup> with an intensity of 600 mW/cm<sup>2</sup> delivered over 83 seconds, using 689 nm wavelength nonthermal laser light. The treatment spot size is 1,000 mcm larger than the lesion size (i.e., 500 mcm larger on each side), and the nasal edge of the treatment spot is more than 200 mcm from the temporal edge of the optic nerve head. PDT can be done on both eyes at the same visit, with the light source illuminating the second area within 20 minutes of the start of the infusion. An inexperienced patient with two-eye involvement can have the eye with more aggressive disease treated first and then the fellow eye 1 week later.

Contraindications for use of verteporfin include breastfeeding women, patients younger than 18 years of age, pregnant women, and patients with porphyria. However, the dosage does not require reduction in patients who are elderly or in individuals with renal impairment. All treated individuals must avoid sun exposure or bright interior light exposure, with avoidance of 5 days (U.S. standard) or 48 hours (European Union, Canada, and Australia).

PDT has become a widely used treatment modality for choroidal neovascularization in AMD and has been extensively studied in the TAP and VIP trials. There is less extensive study of PDT in other conditions, but clinicians have reported its use in a variety of entities, including

choroidal neovascularization associated with ocular histoplasmosis, pathologic myopia, multifocal choroiditis, angioid streaks, traumatic choroidal rupture, and central serous choroidopathy; retinal angiomatous proliferation; idiopathic choroidal neovascularization; and symptomatic choroidal hemangioma.

### **Rostaporfin (Photrex)**

A second photosensitizing chemical with potential ocular indications is tin ethyl etiopurpurin (SnET2), which was evaluated in the late 1990s for its effects on induced neovascularization in animal models. The substance has since received the generic name rostaporfin (Photrex, Miravant Medical Technologies) and has undergone phase I, II, and III trials in human subjects with AMD.

Although it has not been compared directly with verteporfin, rostaporfin appears to have the same potential for management of choroidal neovascularization. Fifteen minutes after intravenous infusion, a red nonthermal diode laser source (664 nm) is used to activate the drug. The phase III trial compared rostaporfin with placebo in over 900 patients with vision between 20/500 and 20/40 and determined that patients treated with rostaporfin 0.5 mg/kg had stable vision compared with placebo recipients (65.6% vs. 39.3%). Patients with vision better than 20/200 and study-compliant lesion size likewise had significantly higher rates of stable vision compared with placebo (63.2% vs. 25%). A smaller subset of patients with predominantly occult CNV derived a treatment benefit relative to placebo for patients losing less than 15 letters of acuity (63.6% vs. 29.4%).

One significant difference between verteporfin and rostaporfin is the duration of photosensitivity after drug administration. Dermal photosensitive responses were maximal at 2 days after rostaporfin administration and declined thereafter. Precautions (protective clothing and eyewear) for 5 to 6 days after rostaporfin administration have been proposed.

### **ANGIOGENESIS AND VASCULAR ENDOTHELIAL GROWTH FACTOR**

There has been considerable interest in the study and isolation of putative factors that influence blood vessel growth in eye disease. Interest in new vessel growth in tumor development has been increasingly intense since 1971, when it was proposed that tumor growth is dependent on angiogenesis. Vascular permeability factor, later known as vascular endothelial growth factor (VEGF), was first described in 1983 as a factor secreted by tumor cells possessing the ability to promote vascular permeability. Further isolation and analysis of this factor noted its ability to induce angiogenesis *in vivo* as an endothelial specific mitogen.

VEGF is not a single chemical substance but is a group of growth factors that comprise seven secreted glycoproteins,

referred to as VEGF-A, VEGF-B, VEGF-C, VEGF-D, VEGF-E, and placenta growth factors 1 and 2. VEGF-A is a critical factor for several normal postnatal angiogenic processes that include wound healing, ovulation, maintenance of blood pressure, pregnancy, and skeletal growth. However, VEGF-A has also been linked to intraocular neovascularization in diabetic retinopathy, retinal vein occlusion, and neovascular AMD. VEGF-A itself is a 45-kDa homodimeric glycoprotein that has a diverse range of angiogenic activities. There are four different isoforms of VEGF-A, each named for the number of amino acids: VEGF<sub>121</sub>, VEGF<sub>165</sub>, VEGF<sub>189</sub>, and VEGF<sub>206</sub>. VEGF<sub>165</sub> is the predominant isoform of VEGF-A and appears to be the major participant in abnormal angiogenesis.

Angiogenesis itself is an extremely complex process, and VEGF-A, although a central mediator in the process, is not the only substance involved in the process, because multiple enzymes participate in blood vessel growth. However, VEGF has been studied extensively and has become an attractive target for therapeutic intervention. Pegaptanib has high affinity for the VEGF<sub>165</sub> isoform and binds directly to it, whereas both ranibizumab and bevacizumab, with specificity for *all* isoforms of human VEGF, exert their neutralizing influence by inhibiting the binding of VEGF to its receptor.

### **ANTIANGIOGENESIS DRUGS**

#### **Pegaptanib (Macugen)**

Pegaptanib (Macugen, Eyetech/Pfizer) was the first of the specific anti-VEGF therapies to be used for management of choroidal neovascularization in wet AMD. Pegaptanib is an oligonucleotide (a polymer made of a small number of nucleotides). Certain oligonucleotides are known as aptamers (from the Latin word *aptus*, to fit, and from the Greek word *meros*, part or region). Aptamers are designed to bind to specific molecular targets and are constructed using the Selex technology (systematic evolution of ligands by exponential enrichment; Gilead Sciences, Inc). Pegaptanib is an aptamer consisting of 28 nucleotide bases, which is covalently linked to two branched polyethylene-glycol moieties (pegylation). It was developed specifically to bind to and block the activity of VEGF. Aptamers typically bind with high specificity and affinity to their targeted molecules; pegaptanib was structurally modified to prevent destruction by endogenous enzymes, and the polyethylene-glycol moieties were added to increase the half-life of the drug in the vitreous.

Pegaptanib was evaluated for its antiangiogenesis effects in several animal studies. The Miles Assay in guinea pigs demonstrated almost complete inhibition of VEGF-induced dye leakage from superficial vessels after administration of the study drug. Significant inhibition (65%) of corneal angiogenesis in a rat model and reduction of retinal neovascularity in a retinopathy of prematurity study in mice were noted, as was suppression of tumor

growth in mice with xenografts of human tumor A673 rhabdomyosarcoma. Pegaptanib's pharmacokinetic profile was evaluated in rabbit eyes, and its terminal half-life was determined to be 83 hours. At 4 weeks after administration of the drug, levels in the vitreous remained well above the  $K_D$  for VEGF, suggesting that once-monthly dosing in humans was appropriate, assuming that pharmacokinetic parameters are comparable in rabbit and human vitreous humor.

Pegaptanib has been evaluated in phase I, II, and III clinical trials. Phase I was a dose-ranging study in 15 patients, with doses varying from 0.25 to 3.0 mg per eye administered via intravitreal injection. Eleven of 15 patients experienced 17 mild or moderate adverse events; 6 events were considered to be probably or possibly related to the study drug, including mild intraocular inflammation, visual distortion, and eye pain. The phase II study used 3 mg per injection on three occasions at 28-day intervals; pegaptanib injections were given in addition to PDT with verteporfin in patients with predominantly classic CNV (greater than 50%). No serious drug-related adverse events were noted for the 21 patients enrolled in the phase II study. Ocular adverse events included vitreous floaters, mild anterior chamber inflammation, and ocular irritation. Of the eight patients who completed the 3-month treatment regimen without PDT, 87.5% had stabilized or improved vision. In the VEGF Inhibition Study in Ocular Neovascularization (V.I.S.I.O.N.) phase III trial of 1,190 patients, all angiographic subtypes of CNV lesions were permitted. Patients received either sham injection or three different doses of pegaptanib (0.3, 1.0, or 3.0 mg) delivered at 6-week intervals. At week 54, 70% of patients receiving 0.3 mg, 71% of patients receiving 1.0 mg, and 65% of patients receiving 3.0 mg experienced a loss of fewer than 15 letters (three lines) of visual acuity. There was no evidence that any angiographic subtype of lesion (predominantly classic, minimally classic, or occult), size of lesion, or baseline visual acuity precluded a treatment benefit. Most adverse events were attributed to the injection procedure rather than the study drug. Adverse events associated with pegaptanib were eye pain, vitreous floaters, punctate keratitis, vitreous opacities, anterior chamber inflammation, and visual disturbances. Only 1.3% of the 890 patients receiving pegaptanib developed endophthalmitis.

An exploratory analysis of results from the phase III study was undertaken in patients with specifically defined early disease who received injections of 0.3 mg. Group 1 was characterized by four criteria: lesion size less than two disk areas, baseline visual acuity of equal to or better than 54 EDTRS letters, no prior PDT or thermal laser photocoagulation to the lesion, and absence of scarring or atrophy within the lesion. Group 2 was characterized by three criteria: occult with no classic CNV, absence of lipid, and better baseline acuity in the fellow eye (or worse acuity at baseline in the study eye). Patients receiving pegaptanib treatment had response rates of

76% (group 1) and 80% (group 2) at week 54. The investigators concluded that treatment of patients early in the course of disease may provide greater gain in vision in AMD. Analysis of the original phase III cohort extended to 102 weeks determined that a sustained treatment, with mean visual acuity of patients on treatment remaining stable. Ten percent of patients on treatment gained three or more lines of acuity, while 7% on treatment lost over 15 letters, a two-fold reduction compared to patients who either discontinued pegaptanib or remained on usual care. The safety profile of the treatment remained favorable through the extensive study. Pegaptanib intravitreal injections were not associated with VEGF inhibition-related adverse events, including hypertension, thromboembolic events, or serious hemorrhagic events, which have been observed with systemic administration of nonselective VEGF inhibitors. Pegaptanib is presently FDA approved for management of wet AMD, utilizing an intravitreal injection of 0.3 mg every 6 weeks.

## Monoclonal Antibodies

Humanized monoclonal antibodies are drugs that target specific molecular sites. They have been engineered from murine (mouse) antibodies, and most of the mouse genetic sequences have been replaced by equivalent human gene sequences, thus "humanizing" them and reducing immunogenicity. Ranibizumab is an antigen-binding fragment of a recombinant humanized monoclonal antibody that binds specifically to VEGF and prevents binding of VEGF to its receptors. This drug, initially known as rhuFAB VEGF and rhuFab V2, is the Fab portion (the antigen-binding portion) of an anti-VEGF monoclonal antibody (bevacizumab). This smaller molecule has a nonbinding human sequence, which makes it less antigenic in primates, plus a high-affinity binding epitope derived from the mouse, which serves to bind VEGF. The molecular weight of ranibizumab is 48,000, making it a much smaller molecule than the parent full-length monoclonal antibody, with a molecular weight of 148,000. Early studies suggested that the parent molecule was unable to penetrate the ILM (internal limiting membrane) of the retina as opposed to the Fab antibody fragment, which demonstrated good penetration to the RPE and long duration in that location.

### Ranibizumab (Lucentis)

Ranibizumab (Lucentis, Genentech, Inc.) was initially studied in a laser-injury model of choroidal neovascularization in monkey eyes. Intravitreal administration of the drug at 2-week intervals prevented formation of CNV and showed no significant toxic effects. Transient anterior chamber inflammation was observed in all eyes treated. A phase I dose-ranging trial of ranibizumab in human subjects found that 500 mcg per injection was the maximally tolerated dose; the first two patients given doses of 1,000 mcg experienced dose-limiting toxicity of



2–3+ anterior chamber and vitreal inflammation. No systemic antibodies to ranibizumab were detected, and no systemic adverse events were linked to an anti-VEGF effect. Two additional trials determined that sterile, painless, reversible inflammation was very common following repeated administration of ranibizumab, with 85% of subjects manifesting at least trace inflammation, and 26% manifesting a 2+ to 4+ inflammatory response in the aqueous or vitreous. The more pronounced inflammatory responses were most severe on the day after injection, and usually resolved without treatment within 14 days. There was also a tendency to observe less inflammation after each subsequent injection.

A phase I/II randomized clinical trial compared ranibizumab injections, given at 4-week intervals, with “usual care” (control arm) in 64 subjects with predominantly classic or minimally classic AMD. The drug appeared to be effective for both types of AMD as evidenced by improvements in visual acuity at 3 and 6 months and was found to have an acceptable tolerability profile. Subjects with less than 15 letters of acuity at the end of the phase I/II study were followed for over 1 year, but the fixed dosing interval of every 4 weeks was relaxed to a more flexible strategy of holding a dose if acuity was stable (with a change of less than 5 letters) and lesion characteristics were stable on two consecutive visits. Acuity and lesion characteristics continued to be stable in subjects, and the median dosing rate of 1.0 injection every 4 weeks decreased to 0.22 injections every 4 weeks.

Ranibizumab has been evaluated in several large trials. The MARINA trial (minimally Classic/Occluded Trial of the Anti-VEGF Antibody Ranibizumab in the Treatment of Neovascular Age-Related Macular Degeneration) was a 2-year, double-blind, sham-controlled study comparing monthly 0.3 mg or intravitreal injections to no injection, in patients with minimally classic or occult CNV. Of over 700 patients enrolled with minimally classic or occult CNV, at 1 year, almost 95% of patients treated with either dose lost fewer than 15 letters, with 24.8% of the 0.3-mg group and 33.8% of the 0.5-mg group having gains of 15 or more letters; those gains were maintained at 24 months. Mean increases in acuity were 6.5 letters in 0.3-mg group and 7.2 letters in the 0.5-mg group. The ANCHOR Trial (Anti-VEGF Antibody for the Treatment of Predominantly Classic Neovascularization in Age-Related Macular Degeneration) is a 2-year double-blind study of over 400 patients randomized to either monthly ranibizumab intravitreal injection (either 0.3-mg or 0.5-mg) plus sham PDT or monthly sham injections plus active PDT. At the end of the first year, approximately 95% of the patients receiving active ranibizumab injections lost less than 15 letters, as compared to 64% of those and 40.3% of the 0.5-mg group, with mean acuity increase of 8.5 letters and 11.3 letters, respectively. The smaller PrONTO study (Prospective OCT Imaging of Patients with Neovascular AMD Treatment with Intra-Ocular

Lucentis) is evaluating a less frequent, variable dosing schedule for AMD patients. Subjects are given 3 consecutive monthly ranibizumab injections, with frequent ocular coherence tomography (OCT) and acuity measurement. They are retreated after the third injection only if one of the following instances occurred: an increase on the central OCT thickness of at least 100  $\mu\text{m}$ , a loss of 5 letters in conjunction with recurrent fluid measured by OCT, new onset classic neovascularization, or a new macular hemorrhage. At 12 months, 95% of the patients had less than 15 letters of acuity lost, and 35% gained 15 or more letters. Ranibizumab is presently approved by the U.S. Federal Drug Administration for management of wet AMD, utilizing a 0.5 mg intravitreal injection once a month.

### **Bevacizumab (Avastin)**

Bevacizumab (Avastin, Genentech, Inc.) has become an established drug for the treatment of advanced colorectal cancer, when used in combination with fluorouracil. The drug is a monoclonal antibody that has been humanized from the murine antihuman VEGF monoclonal antibody. Bevacizumab is the “parent” molecule of ranibizumab but is considerably larger because it is a full-length monoclonal antibody. Early studies of bevacizumab in animal models did not detect any penetration through the retina, but fluorescein-conjugated bevacizumab was noted to leak from laser-induced CNV in a cynomolgus monkey after systemic administration. This observation combined with the promising results from phase I/II trials of ranibizumab stimulated investigators to evaluate the off-label use of the parent compound in patients with neovascular AMD. The commercially available form of bevacizumab (Avastin) was administered every 2 weeks as a systemic infusion in a salvage trial of nine patients with subfoveal CNV in the SANA study (Systemic Avastin for Neovascular AMD). By 6 weeks the only adverse event noted was a mild elevation of systolic blood pressure, which is commonly observed with systemic bevacizumab therapy. At 12 weeks the median and mean acuity letter scores had increased by 8 letters and 12 letters, respectively. Angiographic outcomes and OCT evaluation noted improvements in all eyes under study.

The beneficial outcomes of systemic bevacizumab therapy for CNV stimulated investigators to administer the drug intravitreally, using a dose that would be therapeutically equivalent to the systemic dose used in the SANA study but approximately 400-fold less overall (about 1.25 mg total dose vs. 5 mg/kg). Although initial studies had not suggested any benefit from bevacizumab, a 1.0-mg intravitreal injection of bevacizumab was administered to a patient with wet AMD poorly responsive to pegaptanib therapy and to another patient with macular edema after central retinal vein occlusion (CRVO). Both patients demonstrated complete resolution of edema by OCT at 1 week; acuity improved from 20/200

to 20/50 in the patient with the central retinal vein occlusion.

The off-label use of intravitreal bevacizumab (1.25 mg/0.05 mL) was described in subsequent reports, all of which were consecutive, retrospective studies. One factor driving the utilization of this off-label strategy was a one-year lag until the U.S. Food and Drug Administration approved ranibizumab. These off-label studies suggested that, at least in the short term, intravitreal bevacizumab could be as effective as intravitreal ranibizumab without its considerably higher cost. The short-term improvements in vision of subjects in the largest study were similar to those demonstrated in the MARINA trial, albeit evaluated for just 3 months: 30.3%, 31.3%, and 38.3% of patients had acuity improvement defined as halving of the visual angle, at 1 month, 2 months, and 3 months, respectively. There are several critical differences between the published studies of intravitreal bevacizumab and ranibizumab. None of the bevacizumab studies has enrolled as many patients, all the studies were retrospective (neither randomized or placebo-controlled), none has run for 1 to 2 years, none has used ETDRS acuity measures, and many patients studied had already failed other AMD treatments, including PDT or pegaptanib. Nonetheless, this off-label strategy is being utilized with great frequency, although a direct head-to-head comparison trial of ranibizumab and bevacizumab is sorely needed to elucidate any differences in drug activity, patient characteristics, responsiveness of CNV lesion subtypes, impact of previous therapy, and dosing frequency. The National Eye Institute has announced that it will fund a comparative multicenter clinical trial to assess the relative safety and effectiveness of intravitreal bevacizumab and ranibizumab.

Concerns exist about the long-term safety of intravitreal injections with both ranibizumab and bevacizumab, since the inhibition of VEGF can lead to hypertension and arterial thromboembolic events (including stroke). Although the amount of medication injected is extremely small, the molecules themselves have extremely high binding affinity for all isoforms of VEGF. The Antiplatelet Trialists' Collaboration devised a classification system for adverse events, which includes nonfatal myocardial infarction, nonfatal stroke, and death from a vascular or unknown cause. This classification system has been the basis for evaluation of systemic adverse events in the ranibizumab trials. Rates of the events were slightly but were not statistically significant. However, Genentech issued a warning early in 2007 of an increased risk of stroke among elderly patients treated with 0.5-mg doses of ranibizumab although the risk was specifically higher in patients with a previous stroke. Since the patient population treated with these anti-VEGF drugs is typically elderly, the risks are measurable and must be taken into account by the provider. Additional data from ongoing trials will hopefully further clarify these risks.

## **CORTICOSTEROIDS AND DERIVATIVES**

### **Intravitreal Triamcinolone Acetonide**

Triamcinolone is a familiar corticosteroid with many uses (asthma, allergy, topical dermatologic, depot injection, etc.). Although it is not specifically engineered or designed for intraocular use and has the potential to raise intraocular pressure in many patients, intravitreal injections of crystalline triamcinolone acetonide (IVTA) have been used widely in a variety of retinal diseases. The conditions that appear to be most responsive to IVTA are several forms of macular edema resulting from a variety of conditions, including cystoid macular edema after cataract extraction or posterior uveitis, diffuse diabetic macular edema that cannot be managed with laser photocoagulation, and macular edema after central retinal vein occlusion. Triamcinolone acetonide is quite hydrophobic, a characteristic that confers a lengthy duration of action, although the benefits of IVTA tend to wane 5 to 6 months after the initial injection. IVTA is under intense study as an adjunctive therapy to other AMD therapies, including PDT and the injected anti-VEGF agents, in an attempt to prolong the therapeutic effect and lengthen the interval between administrations of costly drugs, whether verteporfin or the anti-VEGF injectable drugs.

The beneficial action of triamcinolone appears to be related to its inhibition of synthesis of inflammatory mediators (prostaglandins and interleukins), inhibition of the VEGF gene, and improved stability of the blood-retinal barrier. The rise in intraocular pressure typically occurs in 40% to 50% of patients but is controllable with one or two topical antiglaucoma agents. Other complications of IVTA include ptosis, endophthalmitis, accelerated development of cataract, and retinal detachment. The most worrisome complication is infectious endophthalmitis, but the incidence of cases is quite low.

With proper precautions, the risk of infectious sequelae after IVTA can be significantly minimized. (These precautions apply broadly to intravitreal injection of any drug and are not limited to triamcinolone.) Preparation of the patient with pre- and postoperative antibiotic prophylaxis, careful maintenance of a sterile operating area, use of eyelid specula, and rigorous utilization of 5% povidone-iodine for control of eyelid and conjunctival bacterial microflora have been urged. IVTA is performed in the outpatient setting. Topical proparacaine solution is administered, followed by povidone-iodine solution. With lid specula in place, the area to be injected (typically the inferior-temporal region 4 mm posterior to the limbus, selected for causing fewer floaters) is anesthetized with proparacaine on a cotton-tipped applicator. Either a 27- or 30-gauge needle is used; the 27-gauge is preferred by some for avoidance of clogging by suspended corticosteroid particles. The suspension is injected slowly, and then indirect ophthalmoscopy is used to observe the

characteristic cloudy wisps of triamcinolone and to view perfusion of the optic nerve head.

The risk of endophthalmitis can be minimized, but any presentation must be promptly recognized and appropriately managed by the practitioner. Endophthalmitis can be roughly separated into infectious and sterile presentations. The onsets may differ, as do the degrees of pain and the clinical presentations. Infectious endophthalmitis commonly presents with clinical findings of iritis, vitritis, hypopyon, red eyes, and decreased vision. Sterile or noninfectious endophthalmitis is proposed to result from an inflammatory reaction to some constituent in the drug formulation. Its features in common with infectious endophthalmitis are blurred vision, hypopyon, anterior chamber reaction, and vitritis. However, the sterile form causes no pain, only mild to moderate conjunctival hyperemia, and appears to have an onset earlier than the infectious form (with hypopyon occurring on the first day postinjection).

### **Intravitreal Corticosteroid Implants**

Several extended-release devices able to deliver a consistent level of corticosteroid to the retina have been devised. Two will be presented in this chapter, although other devices are under evaluation or in the development pipeline at the time of writing. The primary indications for these devices are persistent macular edema associated with several conditions, including diabetic retinopathy, retinal vascular occlusive disease, cataract surgery, and posterior uveitis.

The Retisert implant (Bausch and Lomb Incorporated, Tampa, FL, USA) has undergone several clinical trials in patients with diabetic macular edema and recurrent posterior uveitis. In the largest trial thus far, 278 patients with noninfectious posterior uveitis were treated with implant, with stabilization or improvement of vision occurring in 87% of subjects. The implant device (either 0.59-mg or 2.1-mg) reduced the rate of uveitis recurrences from 51.4% in the 34 weeks preceding implantation to 6.1% post-implantation. Efficacies of the two devices did not differ, suggesting that effective therapeutic level were achievable with the lower-dose implant. At week 34, 51.1% of implant eyes required topical medication for elevated intraocular pressure. The Retisert was approved by the U.S. Food and Drug Administration in 2005 for management of chronic noninfectious posterior uveitis. The Retisert consists of 0.59 mg of fluocinolone acetonide in a sustained release device and is implanted surgically in a similar fashion to the ganciclovir implant (Vitrasert, Bausch & Lomb Incorporated, Tampa, FL, USA). The device is intended to release the medication over a period of 2.5 years. Cataract progression and elevated intraocular pressure were the most commonly reported adverse events reported in patients evaluated. Within an average period of 2 years after device implantation, many patients are expected to develop cataracts and require

surgery, with over 90% of patients requiring cataract extraction at 3 years. Within 34 weeks after implantation, approximately 60% of patients need topical medications to lower intraocular pressure.

The Posurdex implant (Allergan, Irvine, CA, USA) is a bioerodable copolymer consisting of 70% dexamethasone (either 350 or 700 mcg) mixed with 30% polylactic-glycolic acid. As the body breaks down the implant, dexamethasone is released over approximately 6 weeks, after which the implant dissolves completely. The polylactic-glycolic acid component initially hydrolyzes into lactic and glycolic acids. Lactic acid is metabolized to water and carbon dioxide, whereas glycolic acid is either excreted or enzymatically converted to other metabolized chemicals. The Posurdex has been found to improve vision in patients with macular edema. The device is delivered via an applicator with a 22-gauge needle as an in-office procedure. Phase III clinical trials are under way, evaluating the device in persistent macular edema due to either venous occlusions or diabetic retinopathy. The Posurdex differs from the Retisert in several critical areas: dexamethasone is about 7-fold more potent than triamcinolone, and the amount contained in the device is either 350 or 700 micrograms. The intended duration of the device is just under 40 days, with a quicker release of drug, less exposure, and potentially fewer side effects.

### **Anecortave Acetate**

Anecortave acetate is described as an antiangiogenesis or angiostatic steroid. Because of its specificity, it is essentially free of the typical corticosteroid-induced adverse reactions familiar to eye care providers with use of steroids as anti-inflammatory therapeutic agents. Effects on intraocular pressure increase, cataract formation, suppression of infection, and other unwanted characteristics are not seen with this unique formulation. This drug also does not exhibit the classic anti-inflammatory activity of corticosteroids. The critical structural modification of a specific double bond that replaces a hydroxyl group would otherwise confer upon the molecule its familiar steroid features of glucocorticoid and mineralocorticoid activities. With this structural alteration to the cortisol backbone, the original cortisol structure now becomes a cortisene.

Neovascularization is an extremely complex series of events that are initially mediated by proteases. It is proposed that plasminogen activators, a group of protease enzymes, are responsible for initiating critical vessel changes in neovascularization. The urokinase-type plasminogen activator (u-PA) is specific to endothelial cells in new vessel growth; its activity appears to be related to breakdown or remodeling of the extracellular matrix during migration of endothelial cells. Activity of u-PA is counterbalanced by an inhibitory substance, plasminogen activator inhibitor (PAI)-1. After the migration of endothelial cells and development of vessel sprouts,

abnormal new vessels demonstrate increased permeability, fragility, and hypoxia because they cannot recruit sufficient numbers of mural cells for stability. It is suspected that hypoxia provides the signaling to up-regulate activity of VEGF, which further aggravates these already permeable new vessels.

Anecortave was initially described in a report from 1985, demonstrating its angiostatic effects in the chicken embryo chorioallantoic membrane model of neovascularization. Angiostatic steroids were initially believed to suppress activity of PA and later were determined to specifically exert inhibitory effects by increasing the synthesis of PAI-1, which then inhibits normal PA function. After numerous studies evaluating different aspects of function, it is now believed that anecortave both inhibits the expression of u-PA and up-regulates the expression of PAI-1. This results in blockade of the proteolytic cascade that is needed for degradation of the extracellular matrix and subsequent migration of vascular endothelial cells, which is a cornerstone of angiogenesis. Anecortave has also been linked to inhibition of matrix metalloproteinases, which would otherwise degrade and remodel the extracellular matrix.

Anecortave for ocular use must be administered by a unique delivery system, consisting of a curved, 56-degree, blunt-tipped cannula that is placed as a periocular juxtasceral depot on the outer surface of the sclera. The cannula tip itself releases anecortave near the macular region. Placement of the cannula requires careful preparation of the area, because proper placement is essential to the success of the therapy. After anesthesia and instillation of ophthalmic 5% povidone-iodine, a 1- to 1.5-mm incision is made in the superotemporal quadrant of the orbit between superior and lateral rectus muscle insertions, about 8 mm posterior to the limbus. The overlying tissues (conjunctiva and Tenon's capsule) must be carefully dissected to provide the visualization of bare white sclera, which itself is not incised. After visualization of the sclera, the curved portion of the cannula tip is inserted, keeping it in direct contact with the outer scleral surface at all times. Full insertion of the cannula shaft results in tip positioning near the macula. After location of the cannula tip, with pressure applied to prevent medication reflux, the medication is administered. Administration of anecortave is performed at 6-month intervals.

Safety of posterior juxtasceral anecortave acetate was found to be quite good. Changes in intraocular pressure were seen in 9 of 98 patients receiving anecortave: There were four instances of both intraocular pressure elevation and decrease and one instance of both increase and decrease in the same patient. Cataractous changes were seen after administration of both anecortave and placebo (32% after anecortave vs. 43% after placebo) as were vision decreases (26% after anecortave vs. 43% after placebo). Serious adverse events (not specified) were experienced by both study patients and placebo patients, but none of these events was attributed to treatment with anecortave.

The initial study of anecortave was done in a group of 128 patients (30 given placebo, the remainder assigned to varying doses). All patients had exudative AMD, choroidal neovascularization (size equal to or less than 12 disk areas as defined by the Macular Photocoagulation Study), CNV occupying at least 50% of the lesion area, and the area of CNV either composed of at least 50% classic CNV or the area of classic CNV being at least 0.75 disk areas in size. The study eye was to have an ETDRS chart acuity of 0.3 to 1.2 (ranging from 20/40 to 20/320 Snellen equivalents). Results at 12 months and 2 years determined that anecortave therapy was statistically superior to placebo for stabilization of vision (less than 3 log MAR line change from baseline) and inhibition of lesion growth. A later trial compared a 15-mg dose of anecortave to PDT in 535 patients with AMD with a predominantly classic CNVM. The trial failed to demonstrate non-inferiority of the anecortave therapy, because 45% of anecortave-treated eyes lost fewer than 3 lines of vision compared with 49% of PDT-treated eyes. Approximately 1.5 times more patients in the anecortave study arm dropped out prematurely due to adverse events. The investigation proposed that reflux of study medications through the conjunctival incision site may have adversely affected the study outcome, and the drug administration procedure has since been modified with a counterpressure device to minimize reflux. Further studies with anecortave are under way at this time: study C-01-99 is evaluating over 500 patients with predominantly classic CNVM, and the Anecortave Acetate Risk Reduction Trial is evaluating the potential of anecortave to reduce the risk of progression of dry AMD (drusen and RPE changes only) to wet AMD.

## MISCELLANEOUS AGENTS

---

### VEGF Trap

The VEGF trap is different from the antibodies that neutralize VEGF, among them bevacizumab and ranibizumab, because it acts essentially as a decoy receptor for VEGF. VEGF-A, the principal VEGF subtype involved in angiogenesis and particularly in neovascularization, binds to two separate receptors, VEGFR-1 and VEGFR-2, both of which are transmembrane protein tyrosine kinases. Both of these receptors are expressed on the vascular endothelium of both small and large blood vessels. VEGF trap is a human IgG1 molecule, with its Fc portion (the constant region) being fused to fragments of two different VEGF receptors. The second Ig domain of VEGFR-1 and the third Ig domain of VEGFR-2 bind endogenous VEGF and thus neutralize its effects in the process of angiogenesis.

Most of the work with VEGF trap has been in cancer therapy, using various animal models to demonstrate the effect of VEGF neutralization in reducing the angiogenic process in tumor growth. The drug appears to have potent binding affinities with VEGF and has provided

impressive results in suppression of tumor growth and vascularization. VEGF trap has been evaluated in two studies of prevention of hemangiogenesis (angiogenesis) and lymphangiogenesis in mouse models of corneal transplant rejection. The drug completely inhibited both processes and thus provided the potential for improved graft survival after transplantation. VEGF trap was additionally studied in experimental models of choroidal neovascularization in mice and monkeys. The drug was demonstrated to reduce breakdown of the blood-retinal barrier, prevent neovascularization, and cause regression of neovascularization, with either intravitreal or intravenous administration. It is interesting that VEGF trap was demonstrated to have a binding affinity that was potentially 100-fold tighter for VEGF than bevacizumab in a phase I study of the drug administered to patients with advanced solid tissue malignancies.

The VEGF trap (VEGF Trap-Eye, Regeneron, Tarrytown, NY, USA) was administered intravenously in a phase I, placebo-controlled trial of 3 different concentrations (0.3-, 1.0-, or 3.0-mg/kg) in patients with neovascular AMD. Significant reductions in retinal thickness were noted after single or multiple infusions, but no significant change in acuity was detected. Two of 5 patients in the highest dose group (3.0-mg/kg) experienced either grade 4 hypertension or grade 2 proteinuria. The elevation in blood pressure is not unexpected since VEGF inhibition results in reduced nitric oxide release, with less vasodilation and resultant increase in blood pressure. The mechanism of proteinuria due to VEGF inhibition is not well understood at this time.

The VEGF trap was later evaluated as an intravitreal injection in a phase I trial, structured without a placebo study arm. Three patients at each of 4 dose levels (0.05-, 0.15-, 0.5-, and 1.0-mg) have received the study medication. Preliminary results note that excess foveal thickness was reduced by at least 70% in 75% of patients, and acuity was stable or improved in 75% of subjects. Although this drug is in preliminary clinical trials, it offers an approach to VEGF inhibition that is different from aptamer or monoclonal antibody strategies.

### **Squalamine (Evizon)**

Squalamine was initially isolated in 1993 during a search for antibiotic substances in the gastrointestinal tracts of diverse animals. Stomach extracts of the dogfish shark *Squalus acanthias* were found to possess bactericidal activity against both gram-positive and gram-negative bacteria while structurally consisting of a steroid backbone with a spermidine side chain. This substance formed the basis for a group of chemically synthesized aminosterols, which have been studied for their anticancer and antiangiogenesis properties. The antimicrobial action of squalamine is not known, but the compound has several modes of activity on endothelial cells. Squalamine blocks mitogen-induced proliferation and migration of

endothelial cells and inhibits NHE-3, the endosomal isoform of the sodium-exchange pump, which influences cell volume and shape and thus cellular proliferation. It appears to affect these endothelial cellular processes after the stimulation of endothelial cells by VEGF. Further, squalamine has been demonstrated to disrupt the integrity of endothelial cell-cell attachments, which negatively impacts the ability of endothelial cells to move, grow, and form new blood vessels. Interestingly, squalamine appears to have greatest affinity for endothelial cells that are part of newly developing or embryonic microvessels. Squalamine has been evaluated in numerous animal models of human cancer (using xenografts) and in some human cancers. Because it has no affinity for tumor cells and acts indirectly against tumor vasculature, the drug has no direct antitumor activity but must be combined with classic cytotoxic agents in treating advanced cancers. Toxicities of squalamine infusion include liver toxicity (hyperbilirubinemia and elevations in hepatic transaminases) and mild to moderate fatigue.

Squalamine was initially evaluated in animal models of neovascularization, specifically oxygen-induced retinopathy, iris neovascularization, and laser trauma-induced choroidal neovascularization. The drug has also been evaluated in human subjects with wet AMD. It was found to allow 74% of subjects in a small trial to maintain their initial acuity or to lose no more than three lines of acuity at a 4-month follow-up. Squalamine therapy only inhibited new vessel growth without causing significant regression of existing neovascularization. Safety evaluations of intravenous administration of squalamine in AMD patients found no serious adverse events related to the drug and no adverse drug-drug interactions. Results of a phase II clinical study indicate that intravenous squalamine lactate (Evizon, Genaera Corporation, Plymouth Meeting, PA, USA), when used with PDT (verteporfin, Visudyne), allowed about 90% of study participants to maintain their initial acuity at 29 weeks of follow-up. Also, only 10% of subjects treated with both squalamine lactate and PDT needed additional PDT, whereas 47% of patients treated with PDT only required additional laser treatment. In January 2007 Genaera Corporation announced that it would terminate the clinical development program of squalamine lactate, because the drug, despite a good safety profile, could not match the efficacy of ranibizumab or bevacizumab.

### **Ruboxistaurin**

Protein kinase C plays a critical part in the vascular changes associated with diabetes mellitus. It has been proposed that chronic hyperglycemic states begin a cascade of reactions, initially involving the increased tyrosine phosphorylation of phospholipase C $\gamma$ , which results in elevated levels of diacylglycerol, which then activates protein kinase C. The beta isoform (PKC $\beta$ ) is the predominant isozyme that is activated in vascular tissue

during hyperglycemia. This activation of protein kinase C subsequently results in synthesis of VEGF. VEGF itself, after binding to its receptor VEGF-R2, similarly activates phospholipase C $\gamma$ , which can then initiate the same cascade. VEGF activity is also driven by hypoxia, and it is uncertain whether hyperglycemia alone can drive VEGF formation in diabetes mellitus or whether the hyperglycemic state has additional influences on reducing blood flow, which in turn causes retinal hypoxia that would stimulate further VEGF formation. Protein kinase C activation has been determined to be partly responsible for up-regulation of expression of endothelin-1, which is an important vasoconstrictor responsible for decreased retinal blood flow and possibly also for hypoxia.

A therapeutic strategy could encompass the suppression of protein kinase C activity, thus short-circuiting at least part of the pathway driving VEGF activity in the retina. The initial chemical studied as a protein kinase C inhibitor was known as LY333531 and was found to have very selective inhibition of both  $\beta$ I and  $\beta$ II isoforms of protein kinase C. This drug was studied in animal models and was found to reduce VEGF-mediated retinal vascular permeability, increase retinal blood flow, and inhibit retinal neovascularization.

Ruboxistaurin (Axxant, Eli Lilly and Company, Indianapolis, IN, USA) has been evaluated in a randomized clinical trial of 252 patients, called the Protein Kinase C  $\beta$  Inhibitor Diabetic Retinopathy Study. Three orally administered doses were evaluated for their potential in preventing the progression of nonproliferative diabetic retinopathy to proliferative diabetic retinopathy or in preventing progression of diabetic macular edema. Endpoints in the initial published results were progression of diabetic retinopathy on the ETDRS retinopathy severity scale or occurrence of moderate vision loss (doubling or more of the visual angle). Ruboxistaurin was not found to have any significant effects on preventing progression to proliferative diabetic retinopathy at any of the three oral doses (8, 16, and 32 mg/day) after a minimum 3 years of follow-up. It is possible that pathologic retinal changes due to protein kinase C may have occurred very early in diabetes, before clinically apparent retinopathy, and those changes may not have been amenable to inhibition of PKC $\beta$ . Ruboxistaurin is not primarily an inhibitor of VEGF, and protein kinase C activation may not be critical for the progression of diabetic retinopathy into the proliferative stage. However, treatment with 32 mg/day of oral ruboxistaurin was associated with a 40% reduction of the rate of sustained moderate visual loss (15 or more letter decrease in the ETDRS acuity score). 9.1% of placebo-treated patients versus 5.5% of ruboxistaurin-treated patients experienced sustained moderate visual loss ( $p = .034$ ). When clinically significant macular edema was greater than 100 microns from the center of the macula, ruboxistaurin therapy was associated with less frequent progression of edema to within 100 microns (68% versus 50%,  $p = .003$ ). There were no

serious adverse effects associated with treatment, and diarrhea and flatulence were the most frequently encountered nonserious adverse events associated with therapy. In September 2006, the U.S. Food and Drug Administration requested that the manufacturer conduct an additional, three-year, phase 3 clinical trial before considering approval of the drug for the treatment of moderate to severe non-proliferative diabetic retinopathy. Clearly, more studies are needed with this therapeutic modality to determine whether it has benefit in earlier forms of diabetic retinopathy.

## CONCLUSION

---

It is clear that a dramatic surge in the development of agents for retinal diseases has occurred in the past 5 to 10 years. A decade ago there were no agents for utilization in patients with AMD. Just over 5 years ago verteporfin was determined to provide stabilization of CNVM in certain groups of patients with hemorrhagic AMD. In the intervening 5 years we have witnessed the development of drugs that interfere with the deleterious effects of the angiogenesis process, whether directly interacting with VEGF itself or acting at different stages in angiogenesis. We expect even further advances in the future that will provide benefit to patients with retinal disease that includes, but is not limited to, choroidal neovascular AMD macular degeneration. With the benefits of newer medications, we also look forward to the judicious study of these medications used in combination, with the ultimate goal of preserving vision and improving quality of life.

## SELECTED BIBLIOGRAPHY

---

### Verteporfin

- Anonymous. Photodynamic therapy of subfoveal choroidal neovascularization in age-related macular degeneration with verteporfin: one-year results of 2 randomized clinical trials—TAP Report. Treatment of Age-Related Macular Degeneration with Photodynamic Therapy (TAP) Study Group. *Arch Ophthalmol* 1999;117:1329. [Erratum appears in *Arch Ophthalmol* 2000;118:488.]
- Bressler NM. Treatment of Age-Related Macular Degeneration with Photodynamic Therapy (TAP) Study Group: photodynamic therapy of subfoveal choroidal neovascularization in age-related macular degeneration with verteporfin: two-year results of 2 randomized clinical trials—TAP Report 2. *Arch Ophthalmol* 2001;119:198.
- Keam SJ, Scott LJ, Curran MP. Verteporfin: a review of its use in the management of subfoveal choroidal neovascularization. *Drugs* 2003;63:2521.
- McCaughan JS Jr. Photodynamic therapy: a review. *Drugs Aging* 1999;15:49.
- Miller JW, Schmidt-Effurth U, Sickenberg M, et al. Photodynamic therapy with verteporfin for choroidal neovascularization caused by age-related macular degeneration: results of a single treatment in a phase 1 and 2 study. *Arch Ophthalmol* 1999;117:1161.

- Schmidt-Erfurth U, Miller JW, Sickenberg M, et al. Photodynamic therapy with verteporfin for choroidal neovascularization caused by age-related macular degeneration: results of retreatments in a phase 1 and 2 study. *Arch Ophthalmol* 1999;117:1177. [Erratum appears in *Arch Ophthalmol* 2000;118:488.]
- Verteporfin in Photodynamic Therapy Study Group. Verteporfin therapy of subfoveal choroidal neovascularization in age-related macular degeneration: two-year results of a randomized clinical trial including lesions with occult with no classic choroidal neovascularization—Verteporfin in Photodynamic Therapy Report 2. *Am J Ophthalmol* 2001;131:541.
- Verteporfin Roundtable Participants. Guidelines for using verteporfin (Visudyne) in photodynamic therapy for choroidal neovascularization due to age-related macular degeneration and other causes: update. *Retina* 2005;25:119.
- Woodburn KW, Engelman CJ, Blumenkranz MS. Photodynamic therapy for choroidal neovascularization: a review. *Retina* 2002;22:391.

## Rostaporfin

- Anonymous. Rostaporfin: PhotoPoint SnET2, Purlytin, Sn(IV) etiopurpurin, SnET2, tin ethyl etiopurpurin. *Drugs R&D* 2004;5:58.
- Anonymous. The Macular Degeneration Partnership: photodynamic therapy (PDT). Retrieved April 10, 2006 from [www.amd.org/site/PageServer?pagename=pdt](http://www.amd.org/site/PageServer?pagename=pdt)
- Hill J, Cusimano P, Snyder WJ, et al. Intensity and duration of dermal photosensitization with rostaporfin (SnET2, or Photrex) photodynamic therapy (PDT): results of two solar simulation studies. *ARVO abstract* 2005;310/B284.
- Thomas EL, Danis RP, SnET2 Study Group. Lesion progression and visual acuity outcomes for occult choroidal neovascularization treated with rostaporfin (SnET2) photodynamic therapy. *ARVO abstract* 2005;3571.

## Angiogenesis and VEGF

- Aiello LP, Avery RL, Arrigg PG, et al. Vascular endothelial growth factor in ocular fluid of patients with diabetic retinopathy and other retinal disorders. *N Engl J Med* 1994;331:1480.
- Carmeliet P. Angiogenesis in health and disease. *Nat Med* 2003;9:653.
- Ferrara N. Vascular endothelial growth factor: basic science and clinical progress. *Endocrine Rev* 2004;25:581.
- Folkman J. Tumor angiogenesis: therapeutic implications. *N Engl J Med* 1971;285:1182.
- Van Wijngaarden P, Coster DJ, Williams KA. Inhibitors of ocular neovascularization: promises and potential problems. *JAMA* 2005;293:1509.

## Pegaptanib

- Eyetech Study Group. Anti-vascular endothelial growth factor therapy for subfoveal choroidal neovascularization secondary to age-related macular degeneration: phase II study results. *Ophthalmology* 2003;110:979.
- Eyetech Study Group. Preclinical and phase Ia clinical evaluation of an anti-VEGF pegylated aptamer (EYE001) for the treatment

of exudative age-related macular degeneration. *Retina* 2002;22:143.

- Gonzales CR, VEGF Inhibition Study in Ocular Neovascularization (V.I.S.I.O.N.) Clinical Trial Group. Enhanced efficacy associated with early treatment of neovascular age-related macular degeneration with pegaptanib sodium: an exploratory analysis. *Retina* 2005;25:815.
- Gragoudas ES, et al. Pegaptanib for neovascular age-related macular degeneration. *N Engl J Med* 2004;351:2805.
- Siddiqui MA, Keating GM. Pegaptanib: in exudative age-related macular degeneration. *Drugs* 2005;65:1571.
- VEGF Inhibition Study in Ocular Neovascularization (V.I.S.I.O.N.) Clinical Trial Group. Pegaptanib sodium for neovascular age-related macular degeneration. Two-year safety results of the two prospective, multicenter, controlled clinical trials. *Ophthalmology* 2006;113:992.
- VEGF Inhibition Study in Ocular Neovascularization (V.I.S.I.O.N.) Clinical Trial Group. Year 2 efficacy results of 2-randomized controlled clinical trials of pegaptanib for neovascular age-related macular degeneration. *Ophthalmology* 2006;113:1508.

## Ranibizumab and Bevacizumab

- Anonymous. Collaborative overview of randomized trials of antiplatelet therapy I: Prevention of death, myocardial infarction, and stroke by prolonged antiplatelet therapy in various categories. *Antiplatelet Trialists' Collaboration. BMJ* 1994;308:81. [Erratum, *BMJ* 1994;308:1540.]
- Avery RL, Pieramici DJ, Rabena MD, et al. Intravitreal bevacizumab (Avastin) for neovascular age-related macular degeneration. *Ophthalmology* 2006;113:363.
- Brown DM, Kaiser PK, Michels M, et al. Ranibizumab versus verteporfin for neovascular age-related macular degeneration. The ANCHOR Study Group. *N Engl J Med* 2006;355:1432.
- Freeman WR, Falkenstein I. Avastin and new treatments for AMD: where are we? *Retina* 2006;26:853.
- Fung AE, Lalwani GA, Rosenfeld PJ, et al. An optical coherence tomography-guided, variable dosing regimen with intravitreal ranibizumab (Lucentis) for neovascular age-related macular degeneration. *Am J Ophthalmol* 2007;143:566.
- Gillies Mc. What we don't know about Avastin might hurt us. *Arch Ophthalmol* 2006;124:1478.
- Groner B, Hartmann C, Wels W. Therapeutic antibodies. *Curr Mol Med* 2004;4:539.
- Heier JS, Antoszyk AN, Pavan PR, et al. Ranibizumab for treatment of neovascular age-related macular degeneration. A phase I/II multicenter, controlled, multidose study. *Ophthalmology* 2006;113:633.
- Heier JS. Review of Lucentis™ (ranibizumab rhuFAB V2) phase I/II trial results: 6-month treatments of exudative AMD, *ARVO abstract* 2004;1109.
- Krzystolik MG, Afshari MA, Adamis AP, et al. Prevention of experimental choroidal neovascularization with intravitreal anti-vascular endothelial growth factor antibody fragment. *Arch Ophthalmol* 2002;120:338.
- Meyerhardt JA, Mayer RJ. Systemic therapy for colorectal cancer. *N Engl J Med* 2005;352:476.
- Michels S, Rosenfeld PJ, Puliafito CA, et al. Systemic bevacizumab (Avastin) therapy for neovascular age-related macular degeneration: twelve-week results of an uncontrolled open-label clinical study. *Ophthalmology* 2005;112:1035.

- Mordenti J, Cuthbertson RA, Ferrara N, et al. Comparisons of the intraocular tissue distribution, pharmacokinetics, and safety of 125I-labeled full-length and Fab antibodies in rhesus monkeys following intravitreal administration. *Toxicol Pathol* 1999;27:536.
- Rich RM, Rosenfeld PJ, Puliafito CA, et al. Short-term safety and efficacy of intravitreal bevacizumab (Avastin) for neovascular age related macular degeneration. *Retina* 2006;26:495.
- Rosenfeld PJ. An OCT-guided variable dosing regimen with Lucentis™ (ranibizumab) in neovascular AMD: one year results from the PrONTO Study. Program and Abstracts of the 24th Annual American Society of Retina Specialists and 6th Annual European Vitreoretinal Society Meeting. September 9-13, 2006; Cannes, France.
- Rosenfeld PJ. Intravitreal Avastin: the low cost alternative to Lucentis? *Am J Ophthalmol* 2006;142:141.
- Rosenfeld PJ, Brown DM, Heier JS, et al. Ranibizumab for neovascular age-related macular degeneration. The MARINA Study Guide. *N Engl J Med* 2006;355:1419.
- Rosenfeld PJ, Heier JS, Hantsbarger G, et al. Tolerability and efficacy of multiple escalating doses of ranibizumab (Lucentis) for neovascular age-related macular degeneration. *Ophthalmology* 2006;113:623.
- Rosenfeld PJ, Fung AE, Puliafito CA. Optical coherence tomography findings after an intravitreal injection of bevacizumab (Avastin) for macular edema from central retinal vein occlusion. *Ophthalmic Surg Lasers Imaging* 2005;36:336.
- Rosenfeld PJ, Moshfeghi AA, Puliafito CA. Optical coherence tomography findings after an intravitreal injection of bevacizumab (Avastin) for neovascular age-related macular degeneration. *Ophthalmic Surg Lasers Imaging* 2005;36:331.
- Spaide RF, Laud K, Fine HF, et al. Intravitreal bevacizumab treatment of choroidal neovascularization secondary to age-related macular degeneration. *Retina* 2006;26:383.
- Tolentino MJ, Husain D, Theodosiadis P, et al. Angiography of fluoresceinated anti-vascular endothelial growth factor antibody and dextrans in experimental choroidal neovascularization. *Arch Ophthalmol* 2000;118:78.

### **Intravitreal Triamcinolone Acetonide**

- Bakri SJ, Beer PM. The effect of intravitreal triamcinolone acetonide on intraocular pressure. *Ophthalmic Surg Lasers Imaging* 2003;34:386.
- Ip MS, Gottlieb JL, Kahana A, et al. Intravitreal triamcinolone for the treatment of macular edema associated with central retinal vein occlusion. *Arch Ophthalmol* 2004;122:1131.
- Jager RD, Aiello LP, Patel SC, et al. Risks of intravitreal injection: a comprehensive review. *Retina* 2004;24:676.
- Nelson ML, Teeceant MT, Sivalingam, et al. Infectious and presumed noninfectious endophthalmitis after intravitreal triamcinolone acetonide injection. *Retina* 2003;23:686.
- Reichle ML. Complications of intravitreal steroid injections. *Optometry* 2005;76:450.
- Ta CN. Minimizing the risk of endophthalmitis following intravitreal injections. *Retina* 2004;24:699.

### **Intravitreal Corticosteroid Implants**

- Anonymous. Fluocinolone acetonide ophthalmic—Bausch & Lomb: fluocinolone acetonide Envision TD Implant. *Drugs R&D* 2005;6:116.

- Anonymous. Retisert. Retrieved April 10, 2006 from [www.bausch.com/retisert\\_pi.pdf](http://www.bausch.com/retisert_pi.pdf)
- Bakri SJ, Beer PM. Intravitreal triamcinolone for the treatment of macular disease. *Compr Ophthalmol* 2005;6:143.
- Bethke W. Present and future retinal implants. *Rev Ophthalmol* 2006;13(8):39.
- Jaffe GJ, Martin D, Callanan D, et al. Fluocinolone acetonide implant (Retisert) for noninfectious posterior uveitis. Fluocinolone acetonide implant (Resisert) for noninfectious posterior uveitis. Fluocinolone Acetonide Uveitis Study Group. *Ophthalmology* 2006;113:1020.
- Tranos PG, Wickremasinghe SS, Stangos NT, et al. Macular edema. *Surv Ophthalmol* 2004;49:470.

### **Anecortave Acetate**

- Augustin AJ, D'Amico DJ, Meier WF, et al. Safety of posterior juxtasclear depot administration of the angiostatic corticosteroid anecortave acetate for treatment of subfoveal choroidal neovascularization in patients with age-related macular degeneration. *Graefes Arch Clin Exp Ophthalmol* 2005;243:9.
- Chakravarthy U, Soubrane G, Bandello F, et al. Evolving European guidance on the medical management of neovascular age related macular degeneration. *Br J Ophthalmol* 2006;90:1188.
- D'Amico DJ, Goldberg MF, Hudson H, et al. Anecortave acetate as monotherapy for the treatment of subfoveal lesions in patients with exudative age-related macular degeneration (AMD): interim (month 6) analysis of clinical safety and efficacy. Anecortave Acetate Clinical Study Group. *Retina* 2003;23:14.
- D'Amico DJ, Goldberg MF, Hudson H, et al. Anecortave acetate as monotherapy for treatment of subfoveal neovascularization in age-related macular degeneration: twelve-month clinical outcomes. *Ophthalmology* 2003;110:2372, discussion 2384-2385.
- Penn JS, Rajaratnam VS, Collier RS, et al. The effect of an angiostatic steroid on neovascularization in a rat model of retinopathy of prematurity. *Invest Ophthalmol Vis Sci* 2001;42:283.
- Schmidt-Erfurth U, Michels S, Michels R, et al. Anecortave acetate for the treatment of subfoveal choroidal neovascularization secondary to age-related macular degeneration. *Eur J Ophthalmol* 2005;15:482.
- Slakter JS, Bochow T, D'Amico DJ, et al. Anecortave acetate (15 milligrams) versus photodynamic therapy for treatment of subfoveal neovascularization in age-related macular degeneration. *Ophthalmology* 2006;113:3.

### **VEGF Trap**

- Bergsland EK. Update on clinical trials targeting vascular endothelial growth factor in cancer. *Am J Health-Syst Pharm* 2004;61(Suppl 5):S12.
- Cursiefen C, Cao J, Chen L, et al. Inhibition of hemangiogenesis and lymphangiogenesis after normal-risk corneal transplantation by neutralizing VEGF promotes graft survival. *Invest Ophthalmol Vis Sci* 2004;45:2666.
- NGUYEN QD. C.L.E.A.R.-IT 1: a phase I safety tolerability, and bioactivity study of intravitreal VEGF Trap in patients with neovascular AMD. Program and Abstracts of the 24th Annual American Society of Retina Specialists and 6th Annual



European Vitreoretinal Society Meeting. September 9-13, 2006; Cannes, France.

Ngyuen QD, Shah SM, Hafiz G, et al. A phase I trial of a IV-administered vascular endothelial growth factor trap for treatment in patients with choroidal nonvascularization due to age-related macular degeneration. CLEAR-AMD 1 Study Group. *Ophthalmology* 2006;113:1522.

Saishin Y, Saishin Y, Takahashi K, et al. VEGF-TRAP (R1R2) suppresses choroidal neovascularization and VEGF-induced breakdown of the blood-retinal barrier. *J Cell Physiol* 2003;195:241.

Weigand SJ, Zimmer E, Nork TM, et al. VEGF trap both prevents experimental choroidal neovascularization and causes regression of established lesions in non-human primates. ARVO abstract 2005;1411/B180.

Zhao L, Liu T, Li Y, et al. Complete inhibition of neovascularization by VEGF trap in a Matrigel CNV model. ARVO abstract 2005;5300/B503.

## Squalamine

Akhter S, Nath SK, Tse CM, et al. Squalamine, a novel cationic steroid, specifically inhibits the brush-border Na<sup>+</sup>/H<sup>+</sup> exchanger isoform NHE3. *Am J Physiol* 1999;276(1 Pt 1):C136.

Anonymous. Evizon shows promise as treatment for macular degeneration. Many macular degeneration patients maintained or improved vision with Evizon [press release 2005]. Retrieved April 3, 2006 from <http://vision.about.com/od/maculardegeneration/a/evizon.htm>

Ciulla TA, Criswell MH, Danis, RP, et al. Squalamine lactate reduces choroidal neovascularization in a laser-injury model in the rat. *Retina* 2003;23:808.

Garcia CA, Quiroz-Mercado H, Uwaydat S, et al. A phase I/II trial of intravenous squalamine lactate for treatment of choroidal neovascularization in age related macular degeneration (ARMD). ARVO Abstract 2004;2362.

Garcia CA, Connelly B, Thomas E, et al. A phase 2 multi-dose pharmacokinetic study of MSI-1256F (squalamine lactate) for

the treatment of subfoveal choroidal neovascularization associated with age-related macular degeneration (AMD). ARVO Abstract 2005;206/B180.

Higgins RD, Yan Y, Geng Y, et al. Regression of retinopathy by squalamine in a mouse model. *Pediatr Res* 2004;56:144.

Sills AK Jr, Williams JI, Tyler BM, et al. Squalamine inhibits angiogenesis and solid tumor growth in vivo and perturbs embryonic vasculature. *Cancer Res* 1998;58:2784.

## Ruboxistaurin

Aiello LP. The potential role of PKC  $\beta$  in diabetic retinopathy and macular edema. *Surv Ophthalmol* 2002;47(Suppl 2):S263.

Aiello LP, Bursell SE, Clemont A, et al. Vascular endothelial growth factor-induced retinal permeability is mediated by protein kinase C in vivo and suppressed by an orally effective beta-isoform-selective inhibitor. *Diabetes* 1997;46:1473.

Aiello LP, Cahill MT, Cavallerano JD. Growth factors and protein kinase C inhibitors as novel therapies for the medical management diabetic retinopathy. *Eye* 2004;18:117.

Duh E, Aiello LP. Vascular endothelial growth factor and diabetes: the agonist versus antagonist paradox. *Diabetes* 1999;48:1899.

Frank RN. Potential new medical therapies for diabetic retinopathy: protein kinase C inhibitors. *Am J Ophthalmol* 2002;133:693.

Gardner TW, Antonetti DA. Ruboxistaurin for diabetic retinopathy. *Ophthalmology* 2006;113:2135.

The PKC-DRS Study Group. The effect of ruboxistaurin on visual loss in patients with moderately severe to very severe nonproliferative diabetic retinopathy: initial results of the Protein Kinase C  $\beta$  Inhibitor Diabetic Retinopathy Study (PKC-DRS) multicenter randomized clinical trial. *Diabetes* 2005;54:2188.

The PKC-DRS2 Group. Effect of ruboxistaurin on visual loss in patients with diabetic retinopathy. *Ophthalmology* 2006;113:2221.

SECTION

III

---

# Ocular Drugs in Clinical Practice

---

Experience is the best teacher.  
*Anonymous*

## *Topical and Regional Anesthesia*

*Tammy Pifer Than and Kathy Yang-Williams*

Synthetic local anesthetics enable the practitioner to perform numerous diagnostic or surgical procedures in the office while keeping the patient comfortable and avoiding the relative risk and inconvenience of general anesthesia. Because most procedures involving the eye and its adnexa are of short duration and can be accomplished with local anesthesia, they present almost no risk to the patient's general health.

### **TOPICAL ANESTHESIA**

Topical application represents the most common route of administration of local anesthetics for procedures involving the eye. Topically applied anesthetics are surface-acting drugs that produce a reversible inhibition of the sensory nerve endings within the corneal and conjunctival epithelium, producing transient local anesthesia of the corneal and conjunctival surfaces.

Although most commonly used topical anesthetics are similar in onset, duration, and depth of anesthesia (see Chapter 6), several important differences exist. For diagnostic and treatment procedures requiring topical anesthesia, the clinician essentially has two choices: tetracaine or proparacaine. Both provide rapid onset of anesthesia within 10 to 20 seconds and last approximately 10 to 20 minutes. If prolonged anesthesia is required, it may be accomplished by repeated application. Tetracaine may cause more discomfort upon instillation than proparacaine and typically results in more corneal compromise. In general, proparacaine 0.5% has a low incidence of hypersensitivity reactions and is the anesthetic of choice for topical anesthesia in ophthalmic applications. Other anesthetics that have occasional topical application are cocaine (4% to 10%) and lidocaine (4%).

After the instillation of most topical anesthetics, many patients report a heaviness of the eyelids that frequently lasts for several minutes after the return of corneal sensation. Conjunctival hyperemia and mild lacrimation sometimes occur after the application of most topical anesthetics. Rarely, the reflex action associated with discomfort may cause the fellow eye to become hyperemic

when the anesthetic is placed in only one eye. In addition to these direct effects, many topically applied anesthetics produce various indirect effects, such as increasing corneal permeability to subsequently applied drugs, occasionally desquamating corneal epithelium, and retarding the mitosis and migration processes associated with corneal epithelial regeneration.

### **Clinical Use**

The following general guidelines should be observed to facilitate the safe and effective use of topical anesthetics:

1. For routine diagnostic procedures, such as applanation tonometry and gonioscopy, topical anesthetics render the eye vulnerable to accidental damage during the period of anesthesia. The protective blink reflex is inhibited, and abnormal drying of the cornea can occur. Because minute foreign bodies can cause corneal damage if brushed across the hypoesthetic cornea, the patient should be advised against rubbing the eye during the period of anesthesia, usually lasting 20 to 30 minutes after the diagnostic procedure.
2. It is beneficial to instill the topical anesthetic into both eyes before routine diagnostic procedures, such as gonioscopy, applanation tonometry, and fundus contact lens biomicroscopy. Bilateral usage of anesthetic inhibits the blink reflex of the fellow eye, facilitating the diagnostic procedure on the eye under examination. This practice also reduces examination time, because drug instillation into both eyes occurs before beginning the procedure.
3. The mild local stinging or burning sensation after instillation of the anesthetic is transient, and treatment requires only patient reassurance.
4. Because topically applied anesthetics may cause transient irregularity of the corneal epithelium, corneal disruption can interfere with subsequent procedures requiring critical visualization inside the eye, such as fundus photography. Ideally, photographic procedures should be performed without application of a topical anesthetic.

5. Corneal integrity should be assessed before instillation of a topical anesthetic because of the epithelial disruption that may occur. For this same reason, tear breakup time should be measured before topical anesthesia.
6. Topical anesthetics are ineffective on skin surfaces and are, therefore, ineffective for dermatologic procedures, such as removal of verrucae.
7. Ideally, resumption of contact lens wear should be delayed for at least 60 minutes after application of the anesthetic.
8. Epinephrine or other vasoconstrictors have no significant effect on the duration of topical anesthesia and should never be combined with commercially available topical anesthetics.

Topical ocular anesthetics have many uses in clinical practice. Most commonly, they are used to improve patient tolerance of various diagnostic procedures. In addition, these drugs often provide sufficient anesthesia for minor operations on the cornea, conjunctiva, and nasolacrimal system.

### Diagnostic Procedures

One or two drops of 0.5% proparacaine are sufficient for most ophthalmic diagnostic procedures requiring topical anesthesia. Most often, procedures are performed bilaterally, and it is most efficient if the anesthetic is instilled in both eyes before beginning the procedure. Because the duration of action is 10 to 20 minutes, it is not necessary to reapply anesthetic before beginning the procedure on the second eye. If a procedure is to be performed on one eye only, it is still recommended that anesthetic be instilled in both eyes to inhibit the blink reflex in the fellow eye. Examples of diagnostic procedures that require topical anesthesia on all or some occasions are listed in Box 19-1.

#### Box 19-1 Diagnostic Procedures Associated With Topical Anesthesia

Applanation tonometry  
 A-scan ultrasonography  
 B-scan ultrasonography  
 Contact lens fitting  
 Cultures  
 Cytology  
 Dilution and irrigation of nasolacrimal system  
 Forced duction test  
 Fundus contact lens biomicroscopy  
 Gonioscopy  
 Pachymetry  
 Pre-drug instillation  
 Schirmer I tear flow test (basal secretion measurement)

### Applanation Tonometry

Use of a solution of benoxinate-sodium fluorescein (Fluress) or proparacaine-sodium fluorescein allows simultaneous application of the required anesthetic and sodium fluorescein dye. This method increases the efficiency of the procedure by eliminating the need for separate applications of the anesthetic and dye, but it has the disadvantages of irritation from the benoxinate and excessive instillation of dye. On occasion, a few seconds must elapse to allow tears and excess dye to dissipate before accurate tonometry can be performed. Notably, the differences in the results of tonometry using either benoxinate or proparacaine are not clinically significant.

### Cultures

Microbiologic culture studies are useful for bacterial identification, especially when an ocular infection fails to respond to treatment. Cultures are often obtained from the eyelids, the conjunctiva, expressed material from the lacrimal sac, and the cornea. Because preserved ophthalmic anesthetics have a bacteriostatic effect, cultures should be obtained if possible before anesthetic instillation. In the case of corneal sampling, it is necessary to provide topical anesthesia for patient comfort. The anesthetic of choice is 0.5% proparacaine because it causes the least bacterial growth inhibition. To enhance the bacterial yield, sterile preservative-free anesthetic may be used. Samples obtained may be inoculated directly onto solid media plates (e.g., blood agar). Amies without charcoal transport medium (e.g., BBL CultureSwab Plus) appears to be an acceptable alternative to direct plating and has the added benefit of convenience.

### Evaluation of Superficial Abrasions

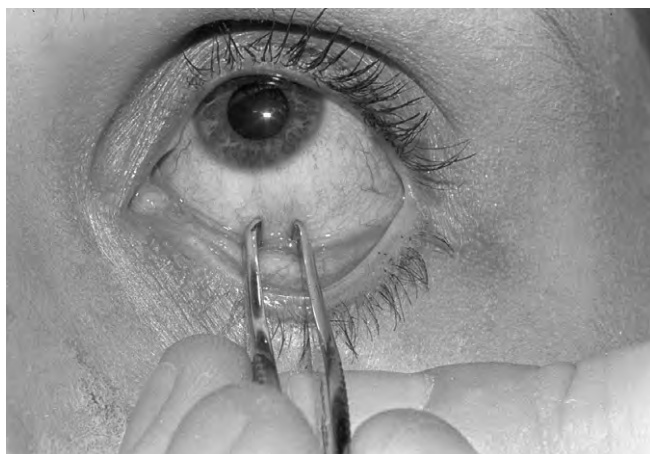Because repeated applications of a topical anesthetic to an injured cornea may seriously delay or prevent regeneration of the epithelium, the practitioner should refrain from the liberal instillation of topical anesthetics in cases of corneal abrasions, foreign bodies, or other superficial injuries. Often, however, the blepharospasm, lacrimation, and pain accompanying the corneal injury prevent adequate examination of the eye. In such cases one or two drops of 0.5% proparacaine frequently relieve the pain enough to allow slit-lamp evaluation of the injury. The patient, however, should never be given a topical anesthetic for self-administration at home. Very serious corneal damage may result (see Chapter 6). Instead, any pain associated with the injury should be treated with cycloplegics, a bandage contact lens, topical nonsteroidal anti-inflammatory agents, and/or systemic analgesics (see Chapter 7).

### Forced Duction Test

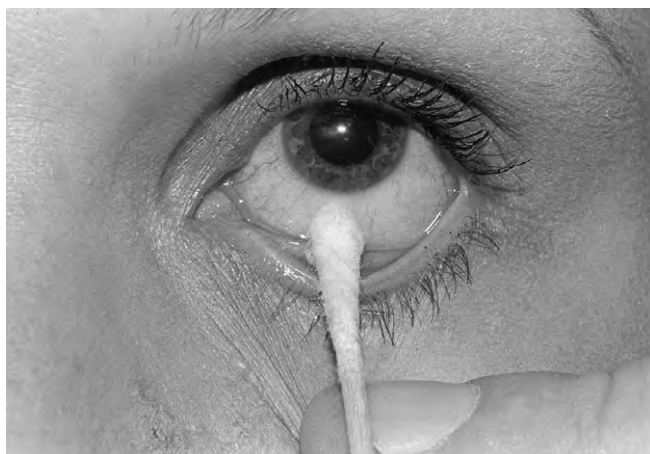The forced duction test is used to investigate anomalous ocular movements to differentiate between deficiencies due to neurogenic or myogenic weakness from those caused

by muscle restrictions, such as in Graves' ophthalmopathy. The practitioner can detect a mechanical limitation (restrictive myopathy) if in the attempt to move the globe actively considerable resistance prevents movement of the eye. On the other hand, a neurogenic cause is suspected if the globe moves freely on forced duction testing. Two methods of performing this test are commonly used: the traditional technique, involving attempted movement of the globe with toothed forceps, or a less traumatic technique, involving attempted movement of the globe with a cotton-tipped applicator positioned at the limbus.

In the forceps technique the practitioner uses the forceps to grasp the insertion of the rectus muscle to be investigated and attempts to move the globe in a direction opposite the field of action of that muscle (Figure 19-1A). Most commercially available topical anesthetics fail to



A



B

**Figure 19-1** Forced duction test. (A) Traditional technique involving attempted movement of the globe with toothed forceps. (B) Technique involving attempted movement of the globe with cotton-tipped applicator positioned at limbus.

eliminate completely the patient's awareness of the forceps. Although this awareness is not particularly painful, the sensation of the eye being touched often increases patient apprehension, provokes blepharospasm, and prevents adequate investigation of the muscle being tested. Using a 4% solution of topical lidocaine as the anesthetic can greatly reduce or eliminate this problem. A cotton-tipped applicator, moistened with this solution, should be applied to the surface of the conjunctiva at the site overlying the rectus muscle insertion to be investigated. The applicator should be applied for 1 to 2 minutes. The depth of topical anesthesia achieved using this method has been found to be far more satisfactory than the more routinely used anesthetics, such as tetracaine or proparacaine. Alternatively, after topical anesthesia with 0.5% proparacaine, movement of the globe is attempted by placing a cotton-tipped applicator at the limbus (Figure 19-1B). This latter technique allows the practitioner to detect a mechanical limitation of the globe without subjecting the patient to the discomfort associated with toothed forceps.

### Pachymetry

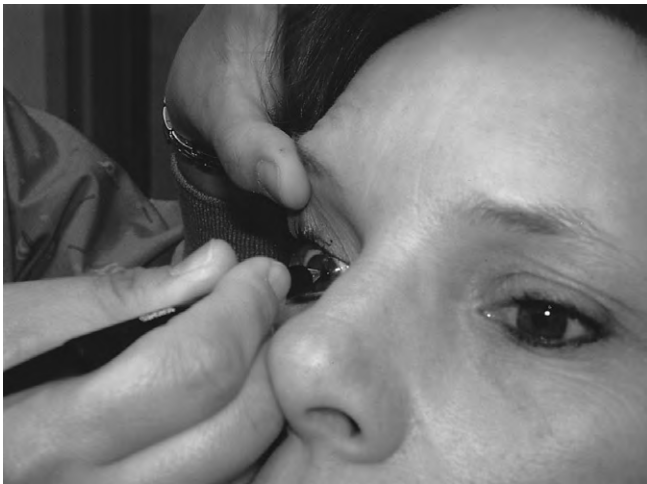Using ultrasound technology, a corneal pachymeter determines the central corneal thickness. The procedure is accomplished by first instilling one or two drops of 0.5% proparacaine into both eyes. The pachymeter probe is then placed perpendicular to the central cornea (Figure 19-2). The Goldmann applanation tonometer is calibrated for a central corneal thickness of approximately 530  $\mu\text{m}$ . Any deviation from 530  $\mu\text{m}$  produces an artifact in the intraocular pressure measurement. A thicker cornea results in a measured intraocular pressure reading that is too high, whereas a thinner cornea measures lower than actuality. Pachymetry is also a standard procedure in determining whether a patient is a suitable candidate for laser refractive surgery. The residual thickness of the stromal bed must be sufficient to prevent corneal ectasia. Calculation of this value is dependent on the flap thickness, the patient's refractive error, and the ablation size. Pachymetry is also useful in measuring the degree of corneal edema that may result from contact lens wear or other corneal conditions, such as corneal dystrophies.

### Ultrasonography

A-scan ultrasonography determines the axial length of the globe, which is an important consideration in selecting the correct power of an intraocular implant for patients undergoing cataract surgery. The A-scan probe is applied perpendicularly to the apex of the cornea after topical anesthesia. B-scan ultrasonography may be performed by applying the probe directly to the conjunctiva and cornea. Topical anesthesia should be instilled in both eyes before performing the procedure. B-scan ultrasound should not be performed on an eye that may have sustained an open globe.



A



B

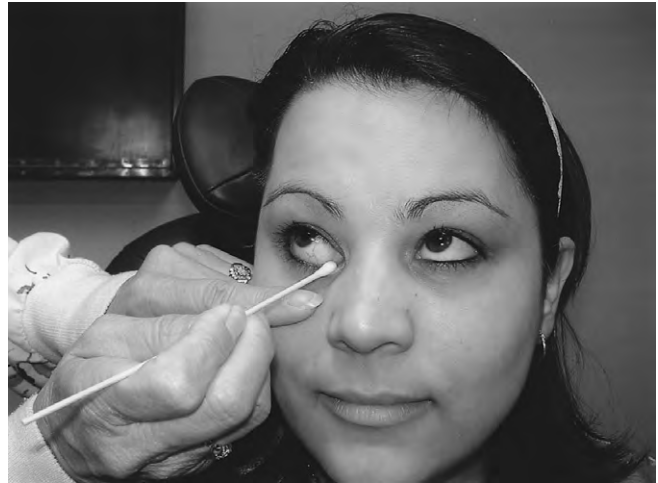**Figure 19-2** After topical anesthesia, corneal pachymetry is performed by placing the probe perpendicular to the central cornea.

### Schirmer No. 1 Test

Schirmer No. 1 test is used as a quantitative test of aqueous tear production. To eliminate the neurogenic component of tear secretion, Schirmer's test can be performed after the application of a topical anesthetic, thus allowing a more accurate assessment of basal aqueous secretion. The conjunctival sac should be dried with a cotton-tipped applicator after administration of the anesthetic. This maneuver absorbs any reflex tearing that may result from irritation by the anesthetic and also prevents false-negative findings from strip wetting by the anesthetic itself. The average Schirmer's test result, after topical anesthesia in a patient with a normal lacrimal system, is approximately 15 mm of strip wetting at 5 minutes.

### Lacrimal Drainage Procedures

Increasing patient comfort during lacrimal dilation and irrigation (see Chapter 24) requires the application of a



**Figure 19-3** Anesthetic-soaked cotton pledget may be applied to the punctum for 1 to 2 minutes before procedures involving the nasolacrimal system.

topical anesthetic, such as 0.5% proparacaine. One or two drops are instilled topically. To enhance patient comfort, an anesthetic-soaked cotton-tipped applicator is placed over the punctum for 1 to 2 minutes (Figure 19-3). The dilation and irrigation procedures can begin 1 or 2 minutes after instillation of the anesthetic.

### Contact Lens Fitting

To evaluate the eye's normal physiologic responses to contact lens wear, contact lenses should be fitted without topical anesthesia. However, certain limited circumstances may justify the use of topical anesthetics in contact lens evaluations. Topical anesthesia allows a rigid lens to be easily placed on the cornea and readily tolerated by the patient during the initial diagnostic evaluation. Topical anesthesia may also be used in fitting infants and very young children with rigid contact lenses.

### Pre-Drug Instillation

Because topical anesthetics increase permeability of the corneal epithelium to subsequently applied drugs, the clinical effectiveness of mydriatics and cycloplegics may be enhanced.

### Miscellaneous Treatments Requiring Topical Anesthesia

Box 19-2 lists other treatments that require topical anesthesia, elucidated below.

#### Superficial Foreign Body Removal

As with the evaluation of corneal abrasions, the application of one or two drops of 0.5% proparacaine is often necessary to allow adequate examination of the eye with a corneal or conjunctival foreign body. It is advisable to obtain informed consent, preferably written, before proceeding with any minor surgical procedure.



### Box 19-2 Miscellaneous Procedures That May Require Topical Anesthesia

Anterior stromal puncture  
 Continuous ocular irrigation systems (e.g., Morgan lens)  
 Corneal debridement  
 Punctal plug insertion  
 Subconjunctival injection  
 Superficial foreign body removal  
 Suture barb removal

Acquiring consent is especially prudent when the foreign body overlies the visual axis or in cases where Bowman's membrane has been penetrated. Before removing superficial foreign bodies, an additional one to two drops of topical anesthetic loosen the epithelium. The additional topical anesthetic also allows somewhat deeper anesthesia for removal of corneal foreign bodies in the deep epithelium or superficial stroma. The limbal area, however, is often difficult to anesthetize, and a solution of 4% lidocaine applied with a cotton-tipped applicator may achieve adequate anesthesia. Topical anesthetics must never be prescribed for self-administration by the patient at home. If topical anesthesia is needed to examine an eye suspected of having a penetrating or perforating injury, a nonpreserved anesthetic should be used to decrease the risk of corneal endothelial damage. Nonpreserved agents include tetracaine, 0.5%, in a 1-ml unit-dose formulation.

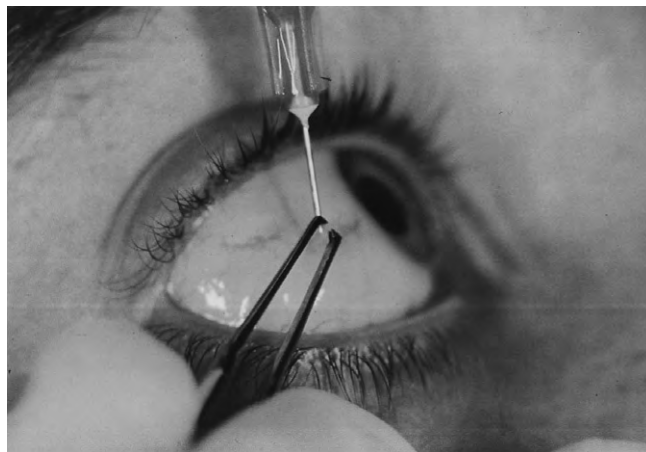
#### Subconjunctival Injection

Various ocular conditions may benefit from medication delivered via a subconjunctival injection. Applications include recalcitrant uveitis, cystoid macular edema, failing trabeculectomy, and severe corneal ulcer in a noncompliant patient. One to two drops of topical anesthesia should be instilled. Additionally, an anesthetic-soaked pledget of 4% lidocaine applied to the area of injection may enhance comfort, particularly if the conjunctiva is to be lifted with forceps before introducing the needle into the subconjunctival space (Figure 19-4).

#### Minor Surgery of the Conjunctiva

The excision of small superficial conjunctival lesions, such as concretions, can usually be achieved with topical anesthesia alone. Two or three drops instilled at 1-minute intervals allow sufficient anesthesia for this purpose. Alternatively, a cotton pledget or cotton-tipped applicator soaked in anesthetic solution may be applied for 1 to 2 minutes before surgery. This local application allows anesthesia of deeper portions of the conjunctiva.

Before infiltration anesthesia for chalazion resection, 4% lidocaine solution can be applied to the tarsal conjunctiva using a cotton-tipped applicator. This procedure



**Figure 19-4** Lifting the conjunctiva with tissue forceps exposing the subconjunctival space before injection is better tolerated if an anesthetic-soaked cotton pledget is applied to the area first.

effectively reduces the pain of chalazion surgery without additional side effects.

#### Punctal Plug Insertion

Although not always required, one or two drops of topically applied 0.5% proparacaine and an anesthetic-soaked cotton-tipped applicator placed over the punctum for 1 to 2 minutes improve patient comfort for the insertion of collagen implants and other forms of punctal and canalicular occlusion (see Chapter 24).

#### Corneal Epithelial Debridement

Topical anesthesia not only provides adequate surface anesthesia before debridement, it also has the beneficial effect of loosening the corneal epithelium. If both tetracaine and proparacaine are on hand, tetracaine is the preferred agent due to its greater effect on the corneal epithelium. Debridement may be accomplished with either a moistened cotton-tipped applicator or an Algerbrush. Both techniques effectively remove loose and damaged epithelial tissue. Debridement should be followed by irrigation and management of the corneal defect as an abrasion (see Chapter 26).

## REGIONAL ANESTHESIA

Some minor surgical procedures involving the eye and adnexa, including papilloma and eyelid lesion removal, chalazion incision and drainage, electrohyfreacation for trichiasis, and repair of eyelid lacerations, require a deeper and more prolonged anesthesia than can be achieved with topically applied anesthetics. Such cases require injectable anesthetics, such as lidocaine or bupivacaine, for increased duration of anesthesia. Preparations may include epinephrine, in a concentration of 1:100,000 or less, to produce a longer acting block, to decrease systemic side effects of the anesthetic, and to provide for local hemostasis.

## Local Infiltrative Injection

Infiltrative anesthesia is the major type of local anesthesia used in eyelid surgery. It can be subdivided into two forms: a pretarsal subcutaneous block and a retrotarsal block. A pretarsal subcutaneous block provides excellent anesthesia to the anterior lamella, including skin, orbicularis muscle, orbital septum, and the anterior tarsal surface. When anesthesia is needed for surgery on the palpebral conjunctiva or posterior tarsal surface, a retrotarsal block is indicated.

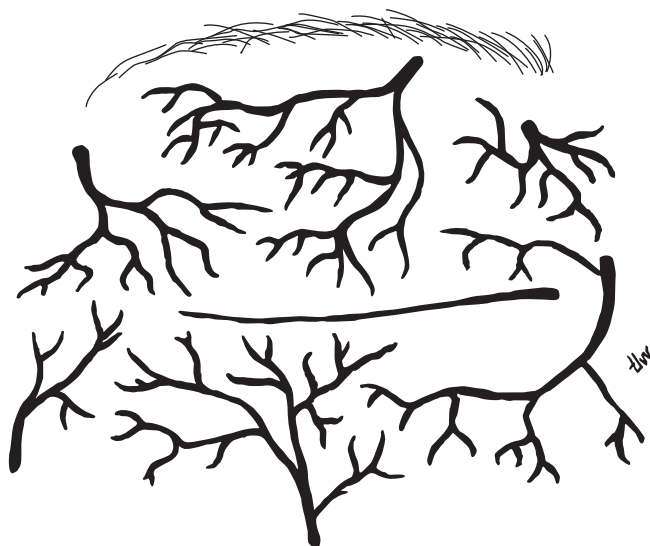
## Regional Nerve Block Anesthesia

In most minor surgical procedures of the eye, local infiltrative anesthesia is adequate. However, patients having multiple lesion removal or those exceptionally sensitive to pain may require a more complete regional anesthesia using an orbital nerve block. Nerve blocks provide excellent regional anesthesia without distortion of tissues but do not allow local epinephrine-induced hemostasis.

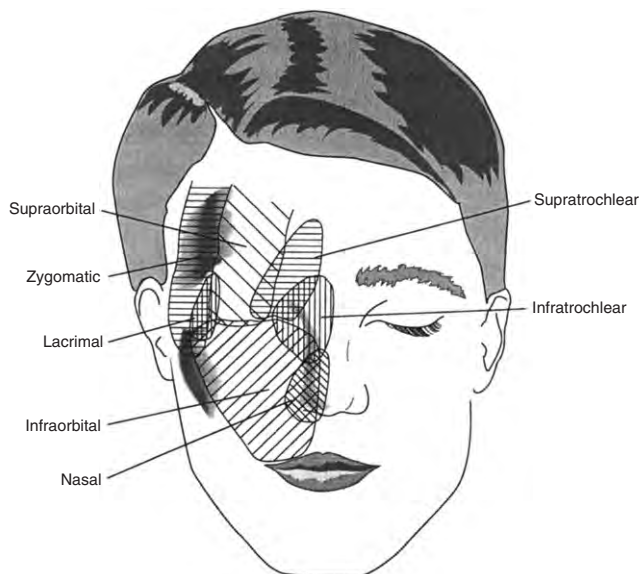
Administration of an orbital nerve block requires intimate familiarity with both the anatomic locations of the sensory nerve fibers of the orbit (Figure 19-5) and the sensory distribution of these nerve branches (Figure 19-6). A description of orbital nerve blocks and distribution of regional anesthesia associated with these injections is included in Table 19-1. Care must be taken to avoid nerve laceration that may manifest as severe pain or paresthesias during needle insertion.

## PRESURGICAL EVALUATION

Preparing the patient for minor eye surgery is an important aspect of care. Areas of concern that may affect anesthesia



**Figure 19-5** Sensory nerves of the eyelids. (From Remington LA. *Clinical anatomy of the visual system*, 2e, Butterworth Heinemann, 2005.)



**Figure 19-6** Distribution of area for regional anesthesia blocks. (Adapted from Wilson RP. *Anesthesia*. In: Spaeth GL, ed. *Ophthalmic surgery: principles and practice*. Philadelphia: Saunders, 1990: 81.)

are the patient's age, systemic health history, current medications, allergies, and level of apprehension.

Local anesthesia of the eye may be used in cooperative children as young as 6 years of age. Younger or uncooperative patients require general anesthesia.

The patient's systemic health should be reviewed to determine physical status and ability to tolerate local anesthetic procedures. A careful history should include possible bleeding diatheses (e.g., easy bruising, hemorrhaging during previous surgical procedures or dental extractions) and unstable systemic disease (e.g., hypertension, diabetes, and cardiac arrhythmia). For example, elevation of blood pressure may result in excessive bleeding. The presence of significant liver dysfunction may increase the risk of anesthesia by limiting drug metabolism. The patient should also be asked about and examined for keloid formation. Answers to questions regarding prior anesthesia and any family history of problems with anesthesia aid in assessing the patient's suitability for local anesthesia.

Patients should also be questioned about the use of any medications that might impair clotting. These might include prescription medications such as warfarin or over-the-counter medications such as aspirin. Even dietary supplements such as ginkgo biloba may have potential impact on bleeding. Consultation with the patient's physician is necessary to approve discontinuation of any prescribed anticoagulation agent.

Allergic reactions to commonly used amide anesthetics are rare. To identify patients with true allergic reactions, a careful history should be recorded regarding prior anesthesia. Attention should be placed on the offending drug, route of administration, concurrent medications,



**Table 19-1**  
Orbital Nerve Block and Distribution of Regional Anesthesia

Nerve Block	Nerve(s) Involved	Sensory Distribution	Site of Injection <sup>a</sup>
<b>Ophthalmic Division of Trigeminal Nerve (V<sub>1</sub>)</b>			
Frontal	Supratrochlear, supraorbital	Supratrochlear: medial upper eyelid Supraorbital: Central upper eyelid, superior conjunctiva, supraorbital area of forehead	Lateral to the supraorbital notch to a depth of 1.25 inches along the roof of the orbit (avoids orbital hemorrhage from vessel damage in supraorbital notch)
Nasociliary	Anterior and posterior ethmoidal, infratrochlear	Inner canthus, the lacrimal sac, and adjacent nasal skin	Just above the medial canthal ligament to a depth of 1 inch
Lacrimal	Lacrimal	Lateral upper eyelid and lacrimal gland	Along the upper outer wall of the orbit to a depth of 1 inch
<b>Maxillary Division of Trigeminal Nerve (V<sub>2</sub>)</b>			
Infraorbital	Infraorbital	Lower eyelid, medial aspect of cheek, part of the inner canthus and lacrimal sac, upper lip and lateral portion of nose	2 ml of anesthetic at the mouth of the infraorbital foramen located as a palpable, small depression in the maxilla, two-thirds of an inch inferior to the midpoint of the lower eyelid

<sup>a</sup>Most orbital nerve blocks require approximately 1 ml of anesthetic (without epinephrine) injected with a 25- to 27-gauge needle of varying lengths as described above.

vasoconstrictors, and preservatives. Patients with a proven history of an allergic reaction can often be given a preservative-free anesthetic of unrelated structure. More commonly, adverse reactions related to systemic toxicity are usually secondary to overdosage, rapid systemic absorption, or inadvertent intravascular injection.

Most patients experience some apprehension regarding surgery. Preoperative counseling regarding the anticipated sequence of events can minimize this apprehension. Some patients may require a mild sedative, such as 5 to 10 mg of diazepam by mouth 60 minutes before surgery.

## CLINICAL APPLICATIONS: MINOR SURGICAL PROCEDURES

### Technique of Local Infiltrative Injection

Written informed consent must be obtained before any minor surgical procedure. Patient safety and comfort during the procedure must be maximized. Controlling the patient's movement and continually reassuring the patient can accomplish this objective.

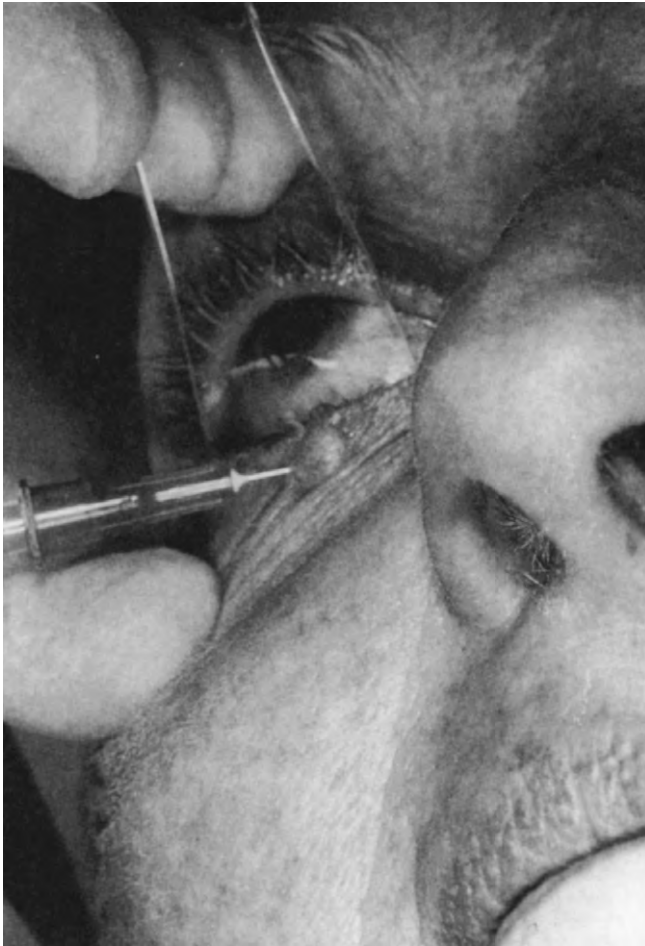
The surgical area should be cleaned with either 70% isopropyl alcohol or povidone-iodine solution. The skin is then allowed to dry. Marking the affected area with a skin marker to aid in identification of the site can be useful because infiltration of the anesthetic may distort the appearance of the site.

A Jaeger plate may be used to decrease the likelihood of penetrating the globe while the injection is performed (Figure 19-7). A drop of topical anesthetic should be

instilled before inserting the Jaeger plate. Typically, a 25- to 27-gauge needle on a tuberculin syringe is used for a local infiltrative injection. The needle should be positioned with the bevel up and the skin pulled taut to reduce resistance. The needle is inserted using a gentle stabbing motion, angled about 15 degrees to the skin surface (Figure 19-8). The plunger of the syringe should be withdrawn slightly to ensure no intravascular penetration, which would be seen as a "flash" of blood as it enters the base of the needle. The patient should be asked to move the eye to ensure the needle has not impaled or penetrated the globe before the injection.

Approximately 0.2 to 0.6 ml of anesthetic should be injected by simultaneously expressing the plunger and slowly withdrawing needle. Slow and steady infiltration can minimize the pain of the injection. Care should be taken to check if anesthetic is following a line instead of diffuse filling. A linear infiltration is an indication that the needle may have penetrated a small vessel. Continued injection of the anesthetic could cause a cardiac arrhythmia. The procedure should be halted and the patient monitored for 5 to 10 minutes while checking the heart rate and heart rhythm.

Two to three injection sites may be needed to provide adequate anesthesia. For minor surgical procedures of the eyelid, the volume of anesthetic required would be far less than the maximum dose of most local anesthetics (e.g., procaine, lidocaine, and mepivacaine)—approximately 500 mg as a 1% or 2% solution. A ring block or field block may be used to anesthetize around the area of the surgical site in a circumferential manner without injecting



**Figure 19-7** Use of a Jaeger eyelid plate protects the globe from accidental perforation in performing anesthetic injections into the eyelid.

the area to be excised. This allows a decreased volume of anesthetic to be used in a larger surgical area. Moderate pressure should be applied with sterile gauze to allow diffusion of local anesthesia. Gently massaging the area after injection disperses the bolus of anesthetic, helps to restore normal anatomy, and reduces the chance of hematoma.

Approximately 5 minutes after injection, the patient should be evaluated by pinching the lesion or anesthetized



**Figure 19-8** Schematic representation of subcutaneous injection. (From Hockenberry. *Wong's clinical manual of pediatric nursing*, 6/e, St. Louis: Mosby, An imprint of Elsevier.)

area with tissue forceps. The patient should be able to detect the forceps but not experience any discomfort. Alternatively, the anesthetized area could be tested by pinching it with the original needle; if additional anesthetic is needed, it can be injected from the same syringe. The needle and syringe should be discarded in an appropriate sharps container.

### **Papilloma and Eyelid Lesion Removal**

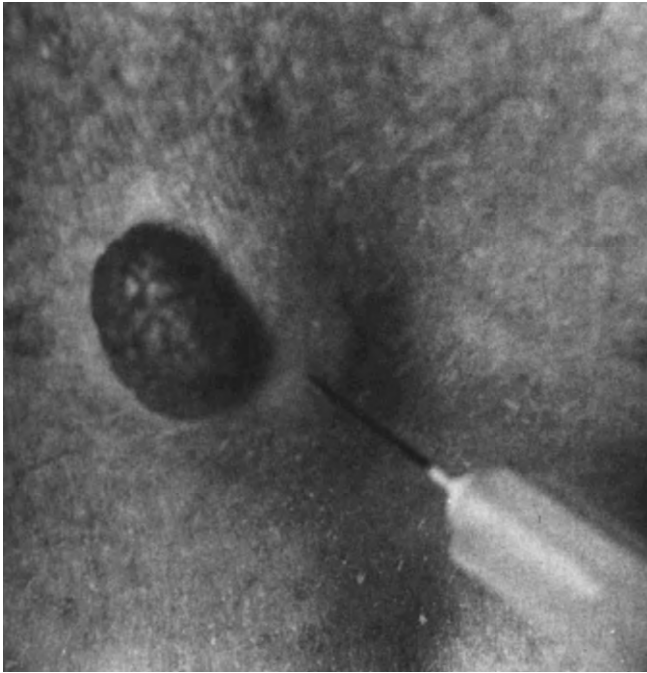Eyelid lesions are common and often benign. In most cases the patient desires removal for cosmetic reasons, but occasionally the lesion may interfere with the patient's spectacle placement or present with a suspicious history that warrants removal for pathologic analysis (Table 19-2). Anesthesia for the surgical removal of most eyelid lesions is accomplished using a pretarsal subcutaneous block. A typical anesthetic agent such as 1% lidocaine with 1:100,000 epinephrine is injected subcutaneously at the base of the lesion with a 27-gauge 0.5-inch needle using the technique described previously (Figure 19-9).

Once local anesthesia has been verified, the lesion should be grasped with tissue forceps and removed at the base using a scalpel, iris scissors, or Westcott scissors. The excised lesion should be placed in a vial of fixative and sent to the laboratory for pathologic evaluation. Hemostasis should be maintained with direct pressure using a cotton swab, or bleeding vessels should be cauterized with a disposable cautery. An antibiotic ointment

**Table 19-2**

Assessment of an Eyelid Lesion (H-ABCs)

H	History? Presence of hair?	History of skin cancer or previous malignant growths? Is there hair growing out of the lesion? Hair growing out of lesion is more likely a benign lesion.
A	Avascularity? Asymmetry?	Malignant growths tend to have feeder vessels. Benign lesions tend to be symmetric.
B	Borders? Bleeding?	Blurred and irregular vs. well-defined? Benign lesions tend to have regular well-defined borders. Is the lesion ulcerated or bleeding? Malignant lesions tend to bleed and form ulcerations.
C	Color? Changes?	Is the lesion a consistent color or is it variable? Benign lesions are usually a consistent color throughout. Have there been any changes in characteristics? Malignant growths tend to have more significant and rapid changes than benign growths.
S	Size?	What is the size? Benign growths are generally smaller.



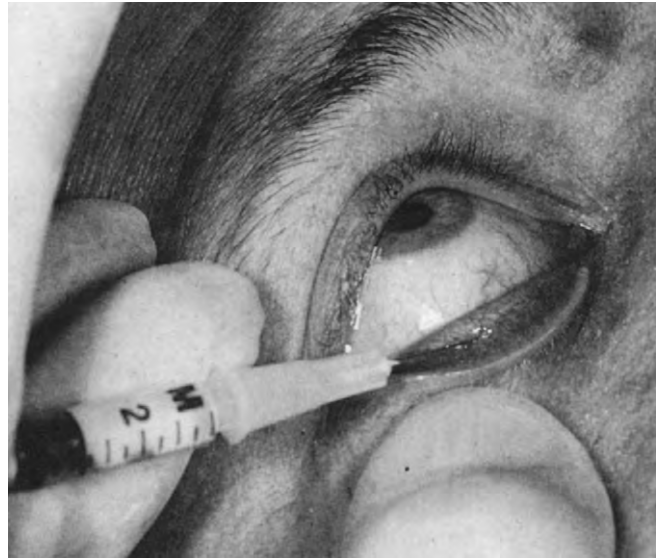
**Figure 19-9** Subcutaneous injection of 1% lidocaine with epinephrine at base of papilloma provides adequate anesthesia for excision.

should be applied to the area, and the patient should be educated on appropriate postoperative medications and follow-up appointments. Potential complications to removal of an eyelid lesion may include bruising, bleeding, scarring, lid notching, pitting, recurrence, or infection.

### **Chalazion Incision and Drainage**

Anesthesia for chalazion incision and drainage depends on the extent of lipid material and its location. Small to medium-size chalazia anterior to the tarsus require a transcutaneous approach warranting a pretarsal subcutaneous block. If the chalazion is located posterior to the tarsus, however, surgery occurs through the palpebral conjunctiva. After instillation of one drop of 0.5% proparacaine to each eye, the palpebral conjunctiva and eyelid margin should be anesthetized using a sterile cotton-tipped applicator soaked in 4% lidocaine before injection of 1% lidocaine with epinephrine. Large chalazia (>8 mm) and hypersensitive patients may require a regional nerve block at the appropriate branches of the trigeminal nerve (Figure 19-10).

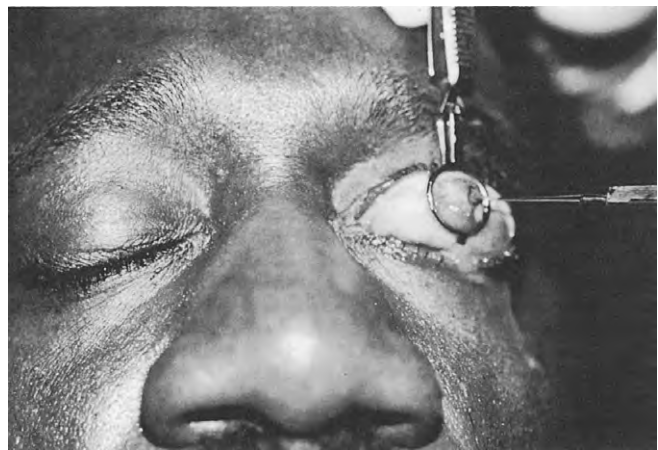The eyelid may be stabilized with a chalazion clamp before the initial incision. A horizontal incision is typically used for a transcutaneous approach, whereas a vertical incision is used in a transconjunctival approach. The contents of the chalazion are removed with a curette or cotton swab (Figure 19-11), and special care is taken to ensure that the capsule wall is excised with scissors. A disposable cautery can be used to hyfrecate the base of



**Figure 19-10** A retrotarsal block is performed by injecting anesthetic subconjunctivally along the proximal tarsal border.

the capsule to control bleeding. Sutures (e.g., 6-0 or 7-0 nylon) may be required to close the eyelid skin for chalazia anterior to the tarsus. A topical antibiotic ointment is applied postoperatively, and the eye may be pressure patched for up to 6 hours if needed.

Complications of chalazion incision and drainage include risks for infection, bleeding (normally minimal and controlled by direct compression or cautery), pain, loss of cilia, scarring, notching of the eyelid, and recurrence in cases of incomplete excision as well as chronic obstruction of meibomian glands. Alternatives to surgical excision include conservative therapy such as monitoring, lid hygiene, or other procedures such as intralesional steroid injection.



**Figure 19-11** Curettage of large chalazion involving the central upper eyelid, transconjunctival approach. Anesthesia was delivered using both retrotarsal infiltration and a supraorbital nerve block.

**SELECTED BIBLIOGRAPHY**

---

- Bergin DJ. Anatomy of the eyelids, lacrimal system and orbit. In: McCord CD, Tanenbaum M, eds. *Oculoplastic surgery*, ed. 2. New York: Raven Press, 1987.
- Casser L, Fingeret M, Woodcome HT. *Atlas of primary eyecare procedures*, ed. 2. Stamford, CT: Appleton & Lange, 1997.
- Dutton JJ. *Atlas of ophthalmic surgery*, vol. 2. Oculoplastic, lacrimal and orbital surgery. St. Louis: Mosby-Year Book, 1992.
- Dzubow LM, Halpern AC, Layden JJ, et al. Comparison of preoperative skin preparations for the face. *J Am Acad Dermatol* 1988;19:737-741.
- Eggleston St, Lush LW. Understanding allergic reactions to local anesthetics. *Ann Pharmacother* 1996;30:851-857.
- Naguib M, Magboul MM, Jaroudi R, et al. Adverse effects and drug interactions associated with local and regional anaesthesia. *Drug Saf* 1998;18:221-250.
- Stoelting R, Hillier S. *Pharmacology & physiology I: anesthetic practice*, ed. 2, Philadelphia: Lippincott Williams & Wilkins: 2006.
- Tetzlaff JE. The pharmacology of local anesthetics. *Anesthesiol Clin North Am* 2000;18:217-233.
- Wilson RP. Anesthesia. In: Spaeth GL, ed. *Ophthalmic surgery: principles and practice*. Philadelphia: WB Saunders, 1990: 77-88.

## *Dilation of the Pupil*

*Joan K. Portello and David M. Krumbolz*

Since the development of the direct ophthalmoscope in the 19th century, practitioners have used mydriatic drugs to facilitate examination of the crystalline lens, vitreous, retina, and optic nerve. With the advent of the binocular indirect ophthalmoscope, three-mirror fundus contact lenses, and other diagnostic instrumentation, a panoramic and stereoscopic view of the fundus from ciliary body to optic nerve has become available to the ophthalmic practitioner. Much of this view, however, is accessible only with the use of mydriatics. The proper use of mydriatics enables the practitioner to identify and diagnose more accurately various abnormalities of the eye. This chapter considers the incorporation of routine pupillary dilation into office practice, anterior chamber angle evaluation before dilation, dilation drug regimens, postdilation procedures, and complications of pupillary dilation.

### **EXAMINATION ROUTINE**

For routine examinations most clinicians dilate patients' pupils only after most other examination procedures have been performed. Complete ocular and medical histories, visual acuities, external examination, pupillary examination, refraction, biomicroscopy, tonometry, and other routine evaluations precede instilling the mydriatic (Figure 20-1). This approach ensures that dilation does not interfere with the refraction, assessment of accommodation or binocularity, or any other refractive finding. In addition, the predilation examination procedures allow the clinician to identify any cautions or contraindications to dilation. In most routine cases ophthalmoscopy or fundus biomicroscopy is the only procedure remaining after dilation. After drops have been instilled for dilation, the patient may proceed to the reception area, the "dilation room," or the dispensary for spectacle frame selection while the pupils dilate. While the patient's pupils dilate, the practitioner can examine the next scheduled patient. In 20 to 30 minutes, after all procedures except dilation have been performed on the second patient and the mydriatic drops instilled, the first

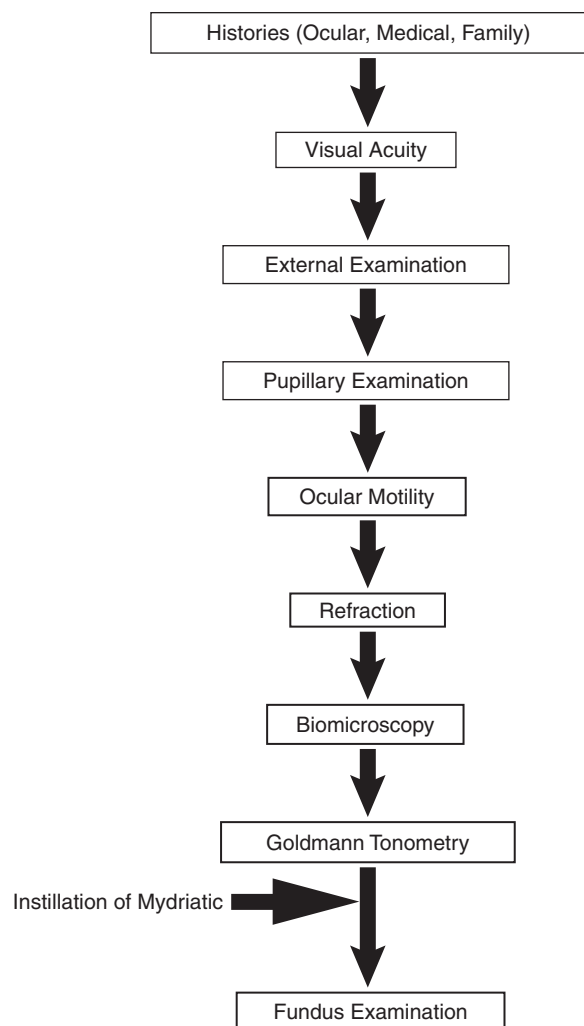
patient can return for ophthalmoscopy and any other indicated procedures.

The placement of dilation procedures toward the conclusion of the routine examination enables the practitioner to perform all of the mydriatic preinstillation examination as a standard routine. All procedures that should be accomplished before instilling the mydriatic (e.g., gross assessment, visual acuity, tonometry, pupil testing, anterior angle evaluation, and drug sensitivity history) occur in a natural and logical sequence. Thus the patient may immediately undergo pupillary dilation if warranted. If the practitioner does not wish to dilate the pupils at this time, an undilated fundus examination can be performed in the usual manner.

### **INDICATIONS AND CONTRAINDICATIONS**

When the various clinical and legal factors governing patient care are considered, a standard of care (see Chapter 5) emerges that provides for dilated fundus evaluation for virtually all "new" patients presenting for a comprehensive eye examination. Pupillary dilation allows a substantially more thorough evaluation of the ocular media, the fundus (including peripheral retina), and the posterior pole than is possible without dilation. Although it is possible to merely detect the presence of many abnormal conditions through an undilated pupil, a careful internal ocular examination needs to be performed through a dilated pupil to definitively rule out subtle internal ocular conditions.

In rare clinical situations dilation of the pupil may be contraindicated (Box 20-1), but if the patient's history, signs, or symptoms indicate that dilation is necessary, the practitioner should proceed by following the guidelines given later in this chapter. Legal issues of negligence (failure to dilate) and patient informed consent are extremely important and can play a pivotal role in the selection of patients whose pupils should be dilated or when dilation should be deferred (see Chapter 5).



**Figure 20-1** Example of routine examination in which the mydriatic is instilled near the conclusion of the examination.

## ANTERIOR ANGLE EVALUATION

Acute angle-closure glaucoma is a rare but well-recognized complication of mydriatic use. Because the risk of such a complication is greatest in eyes with shallow anterior chambers, the practitioner should evaluate the anterior chamber angle before instilling any mydriatic.

### Box 20-1 Contraindications to Pupillary Dilation

Iris-supported intraocular lens  
 Subluxated crystalline lens  
 Subluxated intraocular lens  
 Extremely narrow or closed anterior chamber angles<sup>a</sup>  
 History suggesting angle-closure glaucoma, without surgical or laser intervention<sup>a</sup>

<sup>a</sup>Dilate with caution.

Adapted from Alexander IJ, Scholles J. Clinical and legal aspects of pupillary dilation. *J Am Optom Assoc* 1987;58:432-437.

The angle can be assessed by using the shadow test, the slit-lamp method, or most accurately by gonioscopy.

### Shadow Test

The easiest and fastest method of evaluating the anterior angle entails using a penlight to illuminate the iris from the side (Figure 20-2). This method is less accurate than the slit-lamp or gonioscopic procedures; nevertheless, it is reliable for identifying critically narrow angles that might be predisposed to angle closure. Furthermore, it is useful in the pediatric age group, when slit-lamp examination or gonioscopy may not be possible. It may easily be integrated into the examination routine while performing pupillary light reflex testing.

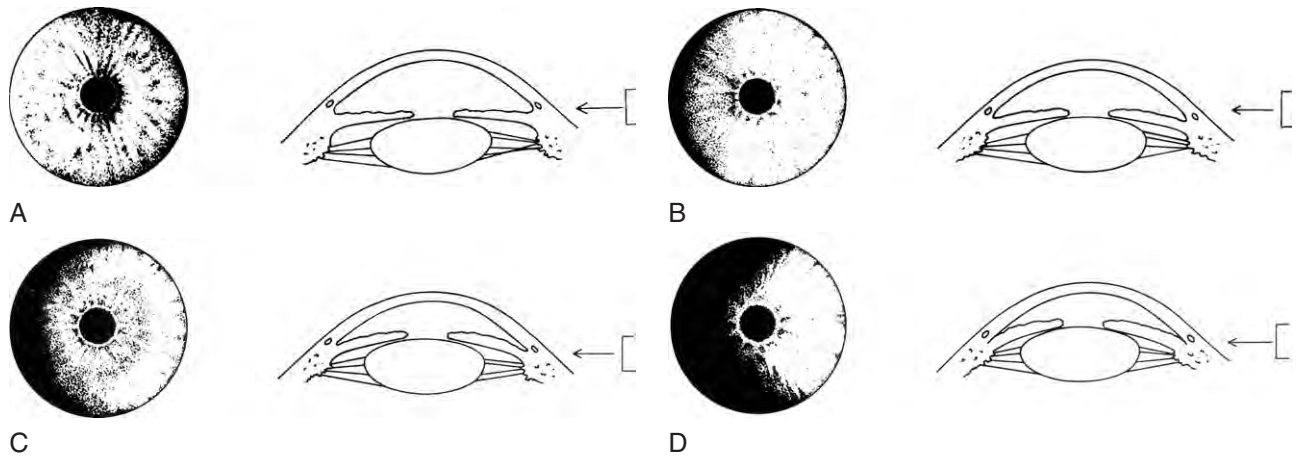
The penlight beam is directed across the eye from the temporal side at the level of the iris perpendicular to the line of sight. The entire iris is illuminated if the iris lies in a flat plane (see Figure 20-2A). This is characteristically observed in eyes with deep anterior chambers, such as those in myopia and aphakia, in which the open angle (grade 4) makes a 45-degree angle between the iris and cornea. When the iris is bowed forward or the lens-iris diaphragm is displaced anteriorly, the penlight beam illuminates the temporal iris but a shadow falls on the nasal aspect of the iris in proportion to the convexity of the iris or the displacement of the lens-iris diaphragm.

Although this method of evaluating the anterior angle is reliable in most patients, the practitioner must avoid misinterpretation. It is possible to estimate the angle as being narrower than it actually is because of central shallowing of the anterior chamber. This is especially common in older patients with enlarged lenses. In such eyes the peripheral iris often recedes from the trabecular meshwork, leaving the angle incapable of closure. Properly positioning the penlight exactly perpendicular to the visual axis enhances the accuracy of this method. If the penlight is positioned too far anteriorly or if the eye is deviated temporally, the penlight may illuminate the nasal aspect of the iris directly, thus giving a false-negative result by indicating a wider angle than is actually present.

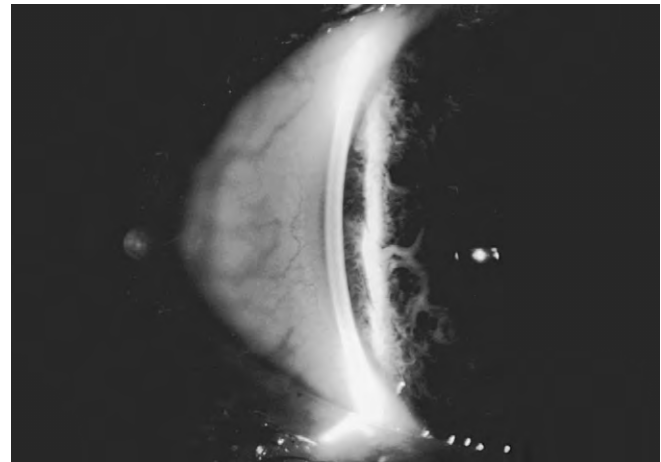
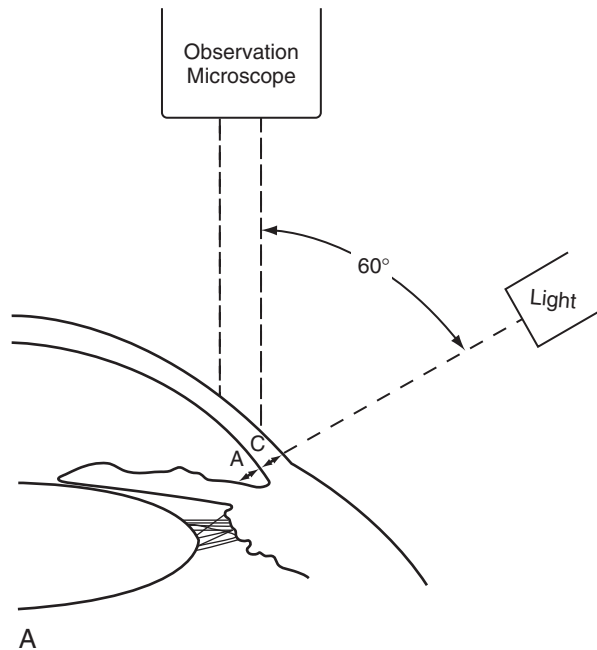
### Slit-Lamp Method

A more accurate method for anterior angle evaluation is the van Herick slit-lamp technique. With the patient at the slit lamp, a vertical slit-lamp beam is placed at the temporal limbus just inside the corneoscleral junction. The slit-lamp beam should be as narrow as possible and should be directed toward the eye at an angle of approximately 60 degrees from the direction of the observation microscope (Figure 20-3). The depth of the anterior chamber at the temporal limbus is compared with the thickness of the cornea through which the beam travels and is graded on a scale of 1 to 4. If the depth of the anterior chamber is equal to or greater than approximately one-half the thickness of the cornea, the angle is judged anatomically

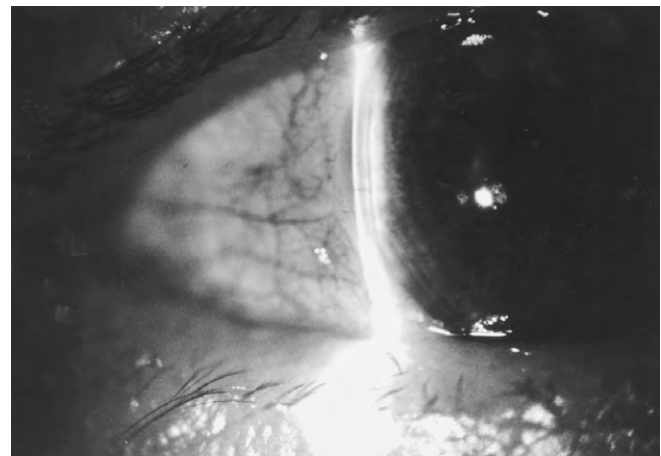




**Figure 20-2** Shadow test. The light source illuminates the nasal aspect of the iris to varying degrees, depending on the depth of the anterior chamber. (A) Wide open angle (grade 4). (B) Open angle (grade 3). (C) Moderately narrow angle (grade 2). (D) Extremely narrow angle (grade 1).



B



C

**Figure 20-3** Slit-lamp method for anterior angle evaluation. (A) The slit-lamp beam should be as narrow as possible and should be directed toward the eye at an angle of approximately 60 degrees from the direction of the observation microscope. The depth of the anterior chamber (A) is compared with the thickness of the cornea (C) through which the beam travels. (B) Slit-lamp view of a wide open (grade 4) angle in which the depth of the anterior chamber is greater than the thickness of the cornea. (C) Slit-lamp view of a grade 2 angle in which the depth of the anterior chamber is one-fourth the thickness of the cornea.

**Table 20-1**

Classification and Implications of Slit-Lamp Assessment of Anterior Angle

Ratio of Anterior Chamber Depth to Corneal Thickness	Grade (van Herick)	Implication
1	4	Angle incapable of closure
0.5	3	Angle incapable of closure
0.25	2	Narrow angle; gonioscopy required
<0.25	1	Dangerously narrow angle; gonioscopy required

incapable of closure, and the patient can be safely dilated. An anterior chamber depth of less than one-half the corneal thickness indicates a narrow angle, and gonioscopy should be performed to directly view the angle structures and verify that the eye is safe to dilate. This technique is extremely rapid (requiring only seconds) and accurate for estimating the depth of the anterior chamber angle. Also, it tends to correlate well with gonioscopic findings. Table 20-1 shows the classification and implications of the slit-lamp assessment in terms of the risk for angle closure.

Using this technique, grade 1 narrow angles have a prevalence of only 0.64% and grade 2 angles have a prevalence of 1%. The prevalence of grade 1 and grade 2 angles increases with age, but this finding is expected, considering the normal increase of lens thickness with age. The practical implication of the slit-lamp method is that angles graded at 2 or less indicate a risk of angle closure and merit gonioscopic confirmation before dilation of the pupil.

Another quick and useful technique performed at the slit lamp is to place a narrow slit beam entering at a 60-degree angle at the inferior limbus. This beam is observed as it passes from the limbus onto the cornea and iris. A gap between the corneal and iris beams indicates that the two structures are physically separated in space and that the angle is open. If the two beams appear to meet at the angle, then gonioscopy should be performed to directly view the angle structures before dilating.

## Gonioscopy

Gonioscopy provides the most definitive assessment of the anterior angle. This procedure allows visualization of the anterior chamber angle structures and thus indicates with greater accuracy the risk of angle closure associated with pupillary dilation. The techniques most commonly used involve use of the Goldmann, Zeiss (Posner), or Sussman gonioprisms (Figure 20-4). Each of these



**Figure 20-4** Sussman (*top left*), Goldmann (*top right*), and Posner gonioprisms.

gonioprisms allows an indirect view of the anterior chamber angle by reflection through a mirror. Although gonioscopy yields a great deal more information than whether or not an angle is safe to dilate, we only address this one concern here.

When viewed gonioscopically, the normal anterior angle most often appears narrower superiorly and widest inferiorly and has a depth intermediate between these two extremes at the temporal and nasal aspects. The risk of angle closure is inversely proportional to the extent to which the angle structures are visualized during gonioscopy. A conservative estimate of the risk of angle closure is when the posterior trabecular meshwork is obscured. Table 20-2 summarizes the classification and implications of the gonioscopic observations. While observing the angle, the iris configuration should be recorded (i.e., bowed, flat, or concave) (Figure 20-5). In addition, any abnormalities such as synechiae, recession, dense pigmentation, exfoliative debris, neovascularization, or angle dysgenesis should be noted and documented.

In most instances the slit-lamp method of evaluating the anterior chamber depth correlates well with gonioscopy, except when the angle is extremely narrow. The slit-lamp method may be used to screen and select patients in need of gonioscopy; patients having an anterior chamber depth of 0.25 of the corneal thickness or less should generally undergo gonioscopy. If, during gonioscopy, one-half or less of the trabecular meshwork depth is visible in all quadrants, the eye should be considered at risk of angle closure during pupillary dilation. Notably, however, partial angle closure can occur without



**Table 20-2**

Classification and Implication of Gonioscopic Assessment of Anterior Angle

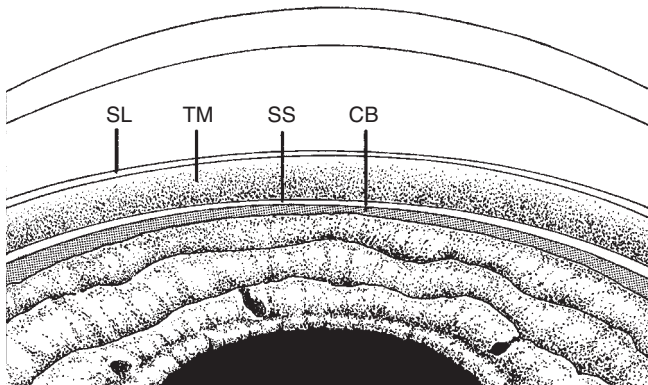
Visible Angle Anatomy	Grade (Shaffer)	Implication
All ciliary body	4	Angle incapable of closure
Some ciliary body	3	Angle incapable of closure
Most trabecular meshwork depth	2	Narrow angle
Only narrow section of the trabecular meshwork depth	1	Dangerously narrow angle
No angle anatomy visible	0	Closed angle

significant elevation of intraocular pressure (IOP) or ocular damage. Thus the widest quadrant of the anterior chamber angle is generally the most critical for evaluation. Despite careful indirect method of gonioscopy, predicting precisely which eyes sustain angle closure on pupillary dilation is still not possible. However, with high-resolution ultrasound biomicroscopy the risk of angle closure during pupil dilation can be determined with higher probability. This instrument can also be useful where evaluating atypical angle configurations, such as a plateau iris.

### GENERAL GUIDELINES FOR MYDRIATIC USE

The following general guidelines for the clinical use of mydriatics should enhance the clinical effectiveness of pupillary dilation:

1. Instilling topical anesthesia before the mydriatic enhances patient comfort and reduces tearing from the stinging caused by the mydriatic drops. In addition, if applanation tonometry has been performed immediately before dilation, then the patient is already anesthetized, and any corneal epithelial disruption caused by the tonometer can enhance the dilation.
2. The goal of dilation should be wide and rapid mydriasis. The use of a combination of adrenergic and anticholinergic agents achieves this goal. The single instillation of tropicamide or phenylephrine alone may allow some



**Figure 20-5** Major anatomic landmarks in gonioscopy. Schwalbe's line (SL), trabecular meshwork (TM), scleral spur (SS), and ciliary body (CB).

pupillary constriction on intense light stimulation, such as that received during funduscopy. Furthermore, tropicamide alone may prove less effective in the elderly because of decreased sympathetic pupillary tone. Thus topically administered adrenergic and anticholinergic drugs used in combination produce faster and more complete mydriasis. In most cases pupils obtain maximum mydriasis within 15 to 30 minutes. The combination of phenylephrine and tropicamide is suitable for routine dilation purposes because the drugs have a similar duration of action and because tropicamide is less likely to produce cycloplegia than are most other anticholinergic drugs.

3. Various combinations of mydriatics have been investigated for their efficacy in pupillary dilation while minimizing side effects. The individual agents (usually tropicamide and phenylephrine or tropicamide and hydroxyamphetamine) can be instilled in any order, and instilling the second drug immediately after the first does not seem to adversely influence the drugs' additive effects for this diagnostic purpose. One commercially available mydriatic combination, 0.2% cyclopentolate with 1% phenylephrine (Cyclomydril), has far too prolonged mydriatic and cycloplegic durations for routine pupillary dilation. Use of this combination requires nearly 8 hours for sufficient accommodation to return to allow reading. In contrast, a combination of 0.25% tropicamide with 1% hydroxyamphetamine (Paremyd) provides satisfactory mydriasis and inhibition of the pupillary light response in young adults, with only minimal paralysis of accommodation. We have had success in combining equal amounts of commercially available 1% tropicamide with 2.5% phenylephrine to produce a solution containing final concentrations of 0.5% tropicamide and 1.25% phenylephrine. One drop of this combination solution is enough to produce adequate pupillary dilation in virtually all patients on whom this combination has been used (see Chapter 8).
4. Although mydriatic combinations give faster and wider dilation, phenylephrine may be used alone for dilation when the patient or practitioner has concerns about the possibility of drug-induced blurred near vision. These adrenergic drugs spare accommodation but usually require more than one instillation and more time for adequate dilation to occur. Also, some

small amount of pupillary constriction inevitably occurs during examination due to the bright light and lack of sphincter paralysis.

5. Multiple instillations of anticholinergic mydriatics are rarely required to achieve a wide pupillary dilation. The single instillation of a suitable combination of mydriatics usually achieves rapid and complete mydriasis while minimizing the risk of side effects associated with drug overdoses. However, in patients whose pupils may be anticipated to dilate poorly, such as those with poorly controlled diabetes mellitus, surgical pupils, posterior synechia, or darkly pigmented irides, multiple applications may be used.
6. A pupillary diameter of 7 mm is usually adequate to permit most examination procedures to be performed, including peripheral retinal examination using the standard indirect biomicroscope or three-mirror fundus contact lens. However, the desired pupil size depends on what one wants to achieve. For example, the optical coherence tomographer, the Heidelberg retinal tomographer, and GDx instruments can all be used with an undilated pupil; however, some dilation results in improved image quality and ease of use.
7. The goal of dilation should be a maximally dilated pupil. Minimally dilated or pupils that remain in a mid-dilated state pose a risk of pupillary-block glaucoma in eyes with narrow angles that is not present with maximally dilated pupils.
8. Unless specifically contraindicated the pupils of both eyes should be dilated rather than dilating only one eye for initial examinations. Failure to dilate the pupil of the contralateral eye can cause diagnostic errors because lesions considered to be normal variants frequently occur bilaterally. In addition, the contralateral eye can serve as a control, or normal eye, for that individual. Once a lesion has been documented, on subsequent visits the affected eye can be dilated alone, with the unaffected eye being dilated on a routine periodic basis. However, dilating one eye only could be determined by patient preference due to the Pulfrich effect.
9. In patients at risk for systemic side effects from topically administered pharmacologic agents, eyelid closure and manual nasolacrimal occlusion (see Figure 3-6) are reasonable procedures to minimize nasolacrimal drainage of drug and subsequent absorption into the systemic circulation.

## **DILATION DRUG REGIMENS**

### **Routine Dilation**

#### **Adults**

For routine use, rapid and effective mydriasis may be obtained in adults by using one drop each of 2.5% phenylephrine and 1.0% tropicamide. As stated previously, this combination is effective in dilating pupils with age-related miosis in which there is decreased sympathetic

pupillary tone, where the use of tropicamide alone would be less effective. To facilitate drop administration, the two commercially available drugs may be mixed together to form a single solution with final concentrations of 1.25% phenylephrine and 0.5% tropicamide. Drops may be applied to the medial canthus with the lids closed and head tilted back in uncooperative patients. The drug flows into the eye when the patient opens his or her lids.

### **Children**

Effective dilation for patients in the pediatric age group may be obtained by using 0.5% to 1.0% tropicamide and 2.5% phenylephrine, instilled separately or as a combination solution as outlined above. This regimen produces wide mydriasis for fundus examination. Adding 0.5% or 1.0% cyclopentolate produces effective cycloplegia for retinoscopy or subjective refraction. Administration of these eyedrops to the medial canthus with the head tilted back and the eyes closed can be an effective means of ophthalmic drug delivery in uncooperative children. Alternatively, these agents can also be administered together as a spray solution containing 0.5% cyclopentolate, 0.5% tropicamide, and 2.5% phenylephrine. The spray is applied to the closed eyelids and produces mydriasis and cycloplegia comparable with that provided by the same combination of mydriatics administered as eyedrops to the open eye. Moreover, children usually have less avoidance reaction with the spray than with traditional eyedrop instillation.

### **Neonates and Infants**

Ophthalmoscopic examination of premature infants requires wide pupillary dilation and binocular indirect ophthalmoscopy. Because premature infants treated with oxygen concentrations exceeding room air are at increased risk of developing retinopathy of prematurity, binocular indirect ophthalmoscopy of the peripheral retina is required to detect early signs of this disease. Other neonates or infants may require dilation to evaluate congenital cataracts or to search for ocular signs of toxoplasmosis, cytomegalovirus, or herpes. Thus the mydriatics chosen must be effective and safe.

Because of the premature infant's small body mass and less mature cardiovascular and cerebrovascular status, prudence dictates using the lowest concentration yet the most effective combination of mydriatics for pupillary dilation. A combination of 2.5% phenylephrine and 0.5% to 1.0% tropicamide provides sufficient mydriasis without adverse cardiovascular effects in preterm infants. The use of tropicamide alone, however, does not generally produce a sufficient mydriasis in premature infants. Adding cyclopentolate to the tropicamide regimen improves mydriasis but may contribute to elevated blood pressure and heart rate. Moreover, because of possible gastric secretory inhibition in preterm infants, the concentration of cyclopentolate should be limited to 0.25%. A commercially available combination of 1% phenylephrine and

0.2% cyclopentolate (Cyclomydril) has proven effective and has minimal risk of cardiovascular or gastrointestinal effects in these patients.

To facilitate the application of mydriatics in neonates and infants, a single-instillation solution may be prepared by combining 3.75 ml cyclopentolate 2% with 7.5 ml tropicamide 1% and 3.75 ml phenylephrine 10%. The final solution contains 0.5% cyclopentolate, 0.5% tropicamide, and 2.5% phenylephrine. This combination produces no major side effects and provides an effective pupillary dilation. Alternatively, equal amounts of 1% tropicamide and 2.5% phenylephrine may be mixed together to yield a single combination solution with final concentrations of 0.5% tropicamide and 1.25% phenylephrine. This too should produce adequate pupillary dilation with no major side effects. Again, these solutions can also be applied as a spray. Cyclopentolate, tropicamide, and phenylephrine administered in microdrops (mean drop volume, 5.6 microliters, as opposed to commercially available standard drops) have the same efficacy with a decreased risk for systemic side effects.

### **Dilation in Patients with Systemic Disease**

Because of its risk of adverse pressor effects, the 10% concentration of topical phenylephrine should be avoided for pupillary dilation, especially in patients with cardiac disease, systemic hypertension, aneurysms, and advanced arteriosclerosis. However, mild hypertension is not necessarily a contraindication to the use of the 2.5% concentration phenylephrine.

Patients with Down syndrome are hypersensitive to topically applied anticholinergic agents. The pupils often dilate widely in response to tropicamide, reflecting an imbalance between cholinergic and adrenergic autonomic activity in the iris. Cyclopentolate, scopolamine, homatropine, and atropine should therefore be avoided in these patients if at all possible.

Ectopia lentis may occur as part of the syndrome of homocystinuria and Marfan's syndrome. Dilate these patients with caution with a weak mydriatic due to the risk of angle closure. Place the patient in a supine position during the fundus assessment. After the examination, confirm that the crystalline lens remains behind the iris and then mydriasis can be reversed by using a miotic, such as 0.5% dapiprazole.

### **Dilation in Pregnant and Nursing Women**

Although the drugs used for routine pupil dilation are not known to have teratogenic effects, common sense dictates that practitioners must use caution in pregnant women because topically administered drugs may be absorbed systemically. In many cases the dilated fundus examination can be postponed until after delivery. However, if the patient must be dilated, tropicamide is the drug of choice. The risk-to-benefit ratio must be carefully

weighed in each individual case. A consult with the patient's obstetrician/gynecologist may be indicated.

### **Open-Angle Glaucoma**

The management of open-angle glaucoma requires periodic dilation of the pupil for fundus, optic nerve, and visual field examination. Pupillary dilation is essential for the following reasons:

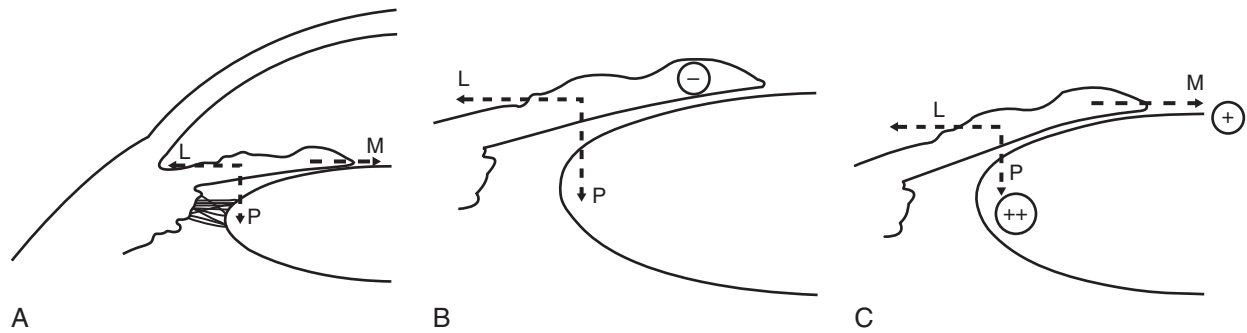
1. Stereoscopic examination of the optic nerve head is essential for the proper long-term management of glaucoma. Critical judgments are often necessary in establishing the initial diagnosis of glaucomatous disc damage, and monocular viewing can easily overlook subtle changes of the nerve head.
2. Accurate evaluation of glaucomatous visual fields requires at least a 3- to 4-mm pupillary aperture so that cataractous changes or miosis do not cause artifactual field loss.
3. Imaging instruments yield higher quality images with larger pupils (e.g., photos, Heidelberg retinal tomographer, GDx, optical coherence tomographer).
4. Miotics may cause peripheral retinal tears with subsequent rhegmatogenous retinal detachment. Periodic dilation for peripheral retinal examination can identify these patients.

Dilation of eyes with exfoliation or pigmentary glaucoma may liberate pigment into the anterior chamber. Profuse pigment liberation during dilation of such eyes may cause blocking of the trabecular meshwork, with obstruction of aqueous outflow and subsequent elevation of IOP. This elevation of pressure is transient, and pigment can be liberated during pupillary dilation without a concurrent elevation of pressure. The pupils of eyes with exfoliation syndrome generally dilate more poorly than do those in healthy eyes. This situation may result from bonding of the posterior surface of the iris to the preequatorial lens capsule and anterior zonules by exfoliation material or from iris infiltration and fibrosis.

In summary, the combination of phenylephrine and tropicamide generally permits wide mydriasis while minimizing potential elevation of IOP and is recommended for routine clinical use. They may be administered as two separate drops or as a combination solution. Cyclopentolate may be used in addition to provide cycloplegia, if necessary.

### **Narrow Angle With Intact Iris**

Mydriatic-induced angle-closure glaucoma most commonly occurs in elderly patients with narrow angles. It can, however, occur in young patients, and the previous use of mydriatics without adverse sequelae does not necessarily indicate that angle closure will not develop on subsequent dilation. Thus the practitioner should approach the dilation of eyes with narrow anterior angles with the knowledge that some risk exists for angle closure.



**Figure 20-6** Mechanics of pupillary dilation. (A) Components of iris muscle activity. Medial component of iris sphincter activity (M), lateral component of iris dilator activity (L), and posterior component of iris dilator activity (P). (B) Pupillary dilation with anticholinergic mydriatic. The iris sphincter is inactivated, and the posterior component of the iris dilator acts peripherally. (C) Pupillary dilation with adrenergic mydriatic. The iris dilator is stimulated, and its posterior component is augmented while the medial component of the iris sphincter persists.

An understanding of the mechanics of pupillary dilation lends support to the various philosophies governing the dilation of eyes with narrow angles.

#### Mechanics of Pupillary Dilation and Angle Closure

Eyes with deep anterior chambers are essentially free of the risk of pupillary block and iris bombé. However, in eyes predisposed to angle-closure glaucoma, the lens is generally displaced anteriorly, which increases the pressure of the iris against the lens. This situation favors pupillary block and iris bombé with subsequent secondary angle closure.

When the iris rests on an anteriorly positioned lens, the forces of pupillary dilation (iris dilator muscle activity) can be resolved into two components: posterior and lateral. Likewise, the force of pupillary constriction (iris sphincter muscle activity) can be resolved into two components: medial and posterior (Figure 20-6A). The total sphincter pupillary blocking force varies according to size and position of the pupil. A miotic pupil is generally associated with a taut iris and small pupillary blocking force, a mid-dilated pupil is associated with a lax iris and large pupillary blocking force, and wide dilation is associated with a compressed iris and small pupillary blocking force. Thus, the position of greatest risk with respect to potential angle closure is mid-dilation. With a mid-dilated pupil, regardless of how it is obtained pharmacologically, the pupillary blocking force is maximum, and if predisposed to angle closure, some eyes undergo acute angle closure because the pupillary block has increased the pressure in the posterior chamber. The increased pressure in the posterior chamber produces iris bombé, which presses the iris against the cornea, blocking aqueous access to the drainage angle, and leads to secondary angle closure (Figure 20-7).

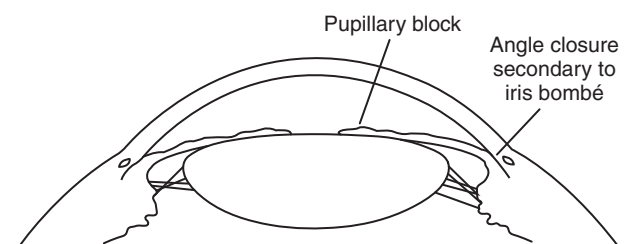
#### Narrow Angle After Surgical Iridectomy or Laser Iridotomy

Peripheral iridectomy or iridotomy removes the risk of pupillary block by creating a channel between the

posterior and anterior chambers, reducing pressure in the posterior chamber and thus preventing iris bombé. Thus precipitation of angle closure must be primary rather than secondary to pupillary block and iris bombé, providing the peripheral iridectomy or iridotomy is patent. Eyes with plateau iris undergo angle closure by a mechanism involving crowding of the iris against the trabecular meshwork rather than by a mechanism involving pupillary block. Although it is possible to induce angle closure with mydriatics despite a patent iridotomy in a patient with plateau iris syndrome, it is extremely rare. Therefore once it is established that the peripheral iridectomy or iridotomy is indeed patent, the routine drug regimen may be used to dilate the patient's pupils.

#### Routine Dilation of Narrow Angle Patients

A valid approach to the dilation of eyes with extremely narrow angles is to refer the patient for a peripheral iridotomy before dilation. However, if dilation must be performed, then use of routine drug regimens, such as a combination of tropicamide and phenylephrine, is recommended to avoid a mid-dilated state. If drug-induced angle closure occurs and is promptly recognized and treated, the patient ultimately benefits from the experience, because the angle-closure attack occurs under controlled conditions in which proper treatment is readily available.

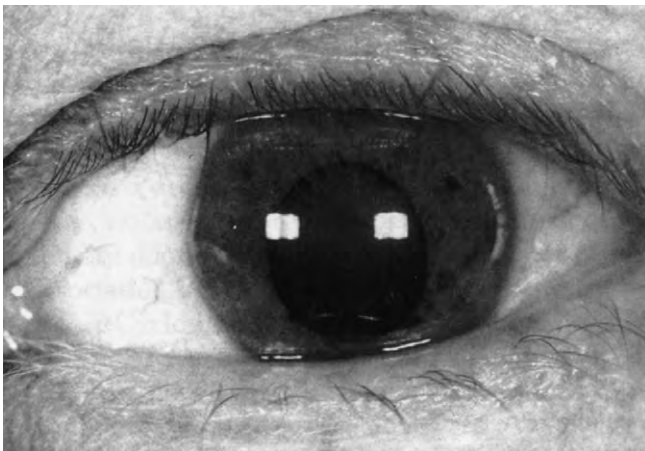


**Figure 20-7** Pupillary block causes increased pressure in the posterior chamber relative to the anterior chamber. This produces iris bombé, which obstructs aqueous outflow and causes secondary angle closure.

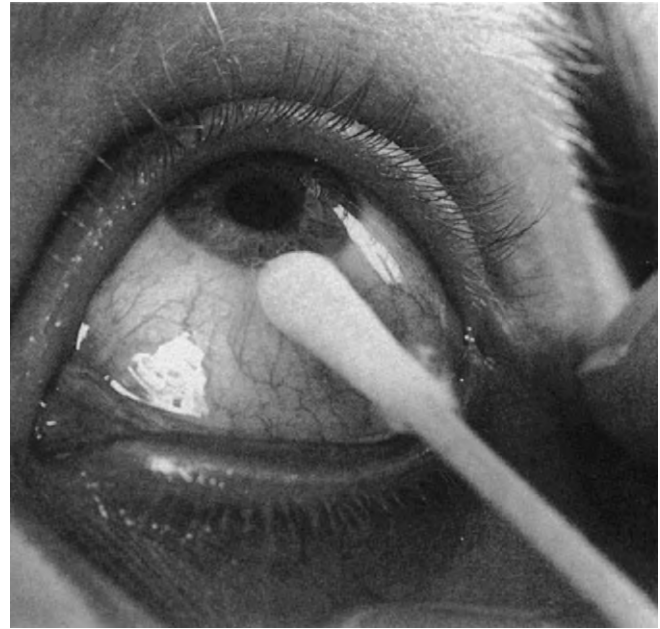However, before proceeding with such an approach, the practitioner should obtain the patient's informed consent (see Chapter 5), dilate only one eye at the initial visit, and postpone dilation of the fellow eye until the response of the initial dilation has been ascertained. Because most angle-closure attacks occur 4 to 8 hours after instillation of the mydriatics, the dilation should be performed earlier in the day, when appropriate emergency care is more readily available. If angle closure occurs, the IOP usually is brought readily to normal levels because angle closure after dilation is rarely complete. Before the patient is dismissed the angle should be evaluated, the IOP should be determined, and the patient should be informed of the symptoms of acute angle-closure glaucoma and be given specific instructions for emergency treatment should it become necessary. The use of cholinergic miotics after dilation is discouraged, because it is both unnecessary and may actually induce angle closure by increasing pupil block.

### Sector Dilation

An alternative to full dilation of the pupil is sector dilation, first described in 1967. This procedure primarily dilates the inferior aspect of the pupil. A small, pear-shaped, partially dilated pupil can be obtained by placing a cotton pledget moistened with 2.5% phenylephrine in the inferior conjunctival sac. The pledget should remain for only 2 to 3 minutes, because too much drug delivery can cause complete dilation of the pupil. Tropicamide cannot be used for sector dilation because it paralyzes the iris sphincter muscle, allowing the entire pupil to dilate, whereas phenylephrine causes the dilator to contract, pulling open just a sector of the pupil. A vertically oval pupil results (Figure 20-8). Alternatively, the tip of a thin strip of filter paper (Schirmer's strip) can be moistened with 2.5% phenylephrine and placed in the inferior conjunctival sac. The paper should remain for only 1 minute, because longer contact may dilate the entire pupil. Another technique is applying a sterile cotton-tipped



**Figure 20-8** Vertically oval pupil produced by sector dilation.



**Figure 20-9** Sector dilation technique using cotton-tipped applicator held at inferior limbus. Phenylephrine-moistened swab is applied for approximately 20 seconds.

applicator moistened with 2.5% phenylephrine for approximately 20 seconds to the inferior limbus of the anesthetized eye (Figure 20-9).

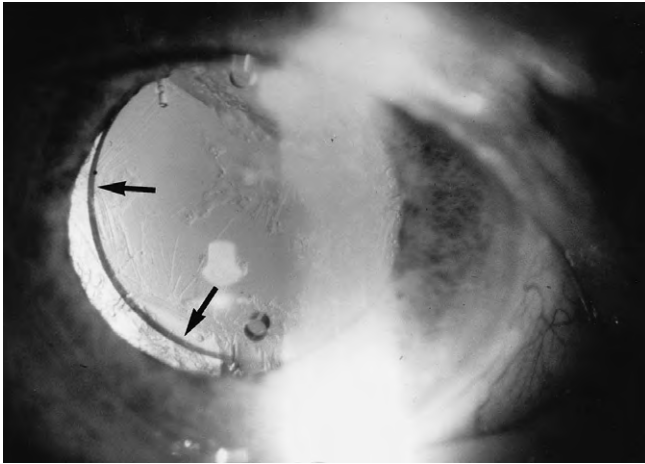
Before sector dilation the eye should be anesthetized topically to reduce subsequent lacrimation, which might dilute and spread the mydriatic. The sectorially enlarged pupil, obtained from sector dilation, usually allows easy access to the posterior pole of the eye by enabling satisfactory binocular indirect ophthalmoscopy or other procedures requiring stereopsis. Although this technique may not necessarily prevent angle closure, it does seem to reduce the risk of angle closure because of the minimal and brief focal dilation.

### Dilation After Cataract Surgery

Patients who have had cataract extraction with implantation of an intraocular lens (IOL) often have pupils that dilate less well than they did preoperatively. The poorer pupillary response probably relates to the amount of iris trauma occurring at surgery. The difference in mydriatic response may affect evaluating and treating peripheral retinal abnormalities in aphakic and pseudophakic eyes. However, even with maximally dilated pupils often the capsulotomy is the limiting factor.

Wide dilation is possible in pseudophakic eyes in which an anterior or posterior chamber lens has been implanted (Figure 20-10). Dilation can be safely accomplished even if the IOL appears to be slightly malpositioned. Dilation of the pupil does not change the position of these IOLs, unlike that of an iris-fixated IOL, which cannot be dilated without dislodging the IOL.

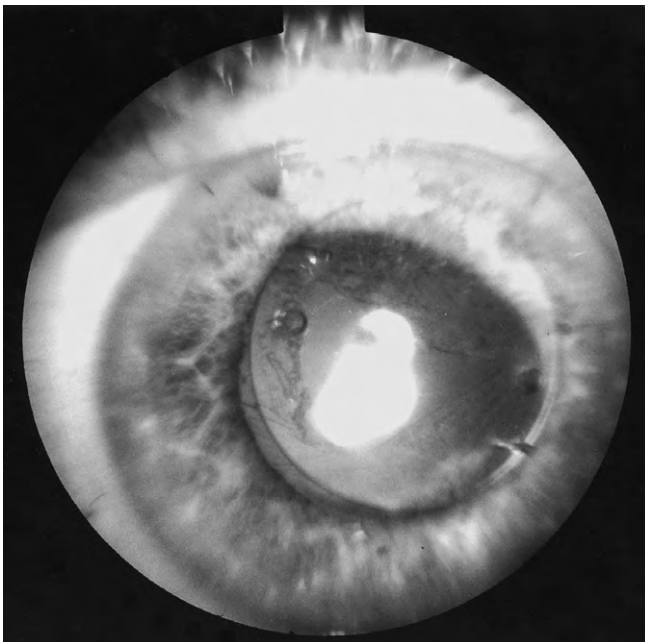




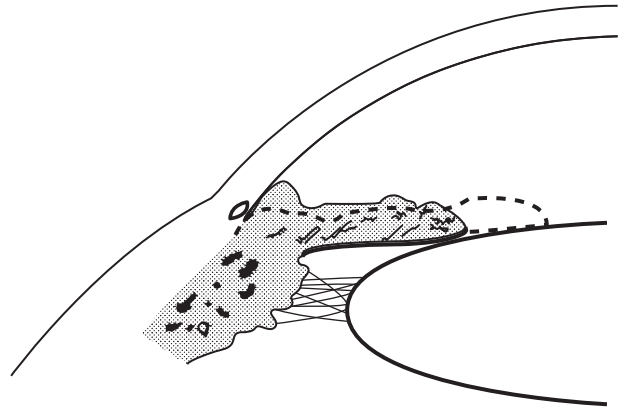
**Figure 20-10** Wide pupillary dilation of eye with posterior chamber intraocular lens. Arrows denote edge of lens.

Although rare, an important complication of mydriasis in pseudophakia is pupillary capture. Here, the IOL becomes entrapped within the pupillary aperture and the pupil cannot return to its normal size after dilation (Figure 20-11). Several conditions can predispose the eye to pupillary capture, including damage to the crystalline lens zonules or to the capsular bag during surgery, IOL fixation into the ciliary sulcus, and the presence of nonangulated IOL haptics.

If pupillary capture persists, secondary complications can occur, including pupillary block glaucoma, iris chafing, iris sphincter erosion, and disruption of the blood-aqueous barrier with secondary inflammation



**Figure 20-11** Posterior chamber intraocular lens entrapped within the pupillary aperture after dilation. (Courtesy Hernan Benavides, O.D.)



**Figure 20-12** Plateau iris. Dilation of the pupil causes the iris to obstruct aqueous outflow, thus causing acute angle-closure glaucoma.

leading to corneal decompensation, cystoid macular edema, or hemorrhage. Because pupillary capture rarely leads to vision loss, noninvasive corrective procedures should be used initially to reposition the IOL; pupillary dilation and patient positioning alone may correct the problem. New IOL designs minimize these risks.

### Plateau Iris

In 1960 the concept of plateau iris was first proposed and described. Although the prevalence of plateau iris configuration is unknown, it is believed to be quite rare.

Plateau iris configuration can result in angle closure by a mechanism independent of pupillary block. Because the anterior chamber has normal depth and the iris plane is flat, little or no pupillary block occurs. Instead, dilation of the pupil causes a peripheral iris roll to approximate and close the angle, thus precipitating an attack of acute angle-closure glaucoma (Figure 20-12). In eyes with plateau iris syndrome, ultrasonographic biomicroscopy demonstrates anteriorly positioned ciliary processes. These processes provide structural support beneath the peripheral iris, thus preventing the iris root from falling away from the trabecular meshwork after iridectomy or iridotomy. In most cases the diagnosis is made only after an apparently open angle has sustained angle closure after pupillary dilation. Once the diagnosis is established, the practitioner should exercise caution with future dilation. These eyes can sometimes be managed with peripheral laser iridoplasty.

### POSTDILATION PROCEDURES

The routine measurement of IOP after dilation of the pupil is probably unnecessary. In nonglaucomatous patients with open angles, dilation with adrenergic mydriatics, such as phenylephrine, would not be expected to elevate the IOP, whereas dilation with relatively weak anticholinergic agents, such as tropicamide, would be

expected to slightly elevate the IOP in approximately 2% of patients. Thus patients with open angles can be dismissed after dilation, without regard to the IOP.

In contrast, monitoring the IOP after dilation of eyes with narrow angles is reasonable and prudent. The patient should be advised of the symptoms of angle closure and instructed to return to or telephone the practitioner's office in the event of such an attack.

### **Use of Miotics**

The instillation of pilocarpine to counteract the effects of the mydriatic is contraindicated. When pilocarpine is used after dilation with a regimen that includes phenylephrine, the relative pupillary block is likely to increase due to stimulation of the iris sphincter. In addition, pilocarpine increases aqueous outflow through the trabecular meshwork, which, in the presence of pupillary block, might create a greater differential pressure between the anterior and posterior chambers and lead to iris bombe with secondary angle closure. Pilocarpine can also reduce the depth of the anterior chamber, which exacerbates the factors causing angle closure. These changes may predispose the eye to angle closure, even in eyes in which closure seems unlikely.

The use of  $\alpha$ -adrenergic antagonists is an effective and safe alternative to cholinergic miotics. Dapiprazole 0.5% (Rev-Eyes) can reverse mydriasis induced by 2.5% phenylephrine or 0.5% to 1.0% tropicamide. Unlike miosis induced by pilocarpine, the  $\alpha$ -receptor blockade produced by dapiprazole does not shift the lens-iris diaphragm forward; the anterior chamber depth remains constant, and accommodation is not stimulated. The most significant side effects of dapiprazole are transient stinging or burning on instillation and conjunctival hyperemia lasting several hours in many patients.

## **COMPLICATIONS**

### **Blurred Vision**

Patients generally encounter some degree of blurred vision after dilation because of glare induced by light, spherical aberration associated with the large pupillary aperture, and accommodative paresis after use of an anticholinergic agent. In the latter instance, patients likely to encounter blurred distance vision are limited to those with uncorrected hyperopia. In addition, patients who have had photorefractive keratectomy may have greater coma-like and spherical aberration after pupillary dilation. Most other patients should not encounter significant difficulty with distance vision associated with pupillary dilation. However, it is prudent to caution all patients who will be driving that poorer performance could ensue until the pupils return to normal size.

For reading and other near visual activities after dilation, myopic patients can remove their spectacles and

presbyopic patients can wear their reading lenses. Thus, with proper instructions to the patient, debilitating blurred vision after dilation is relatively uncommon. When tropicamide has been used for dilation, most patients recover reading ability within 1 to 3 hours, and virtually all patients completely recover accommodation within 4 to 6 hours. In many instances patients never lose the ability to read. Patients can therefore be reassured that any postdilation blurred vision will be transient and relatively mild.

### **Light Sensitivity**

Mydriatic-induced light sensitivity can be problematic for many patients, especially those with cataracts or other opacities of the ocular media. Troublesome glare and reduced contrast sensitivity can limit visual activities after pupillary dilation. To help reduce sensitivity to light, the patient should have some form of protection from bright sunlight and other brightly illuminated environments. Commercially available mydriatic spectacles are designed specifically for this purpose.

### **Acute Angle-Closure Glaucoma**

Although the prevalence of significantly narrow angles in the general population ranges from 2% to 6%, the risks of angle-closure glaucoma from the use of mydriatics have been estimated at only 1 in 183,000 for the general population and only 1 in 45,000 for the population older than 30 years. In the Baltimore Eye Survey none of the 4,870 subjects, aged 40 and older, whose eyes were dilated with 2.5% phenylephrine and 0.5% tropicamide developed acute angle closure.

When the benefit-to-risk ratio approach is applied to potential angle closure after pupillary dilation, the low risk of angle closure should not prevent the practitioner from using mydriatics when indicated. It was suggested that the greater danger derives from overlooking significant retinal disease by failure to dilate rather than from inducing angle closure by dilating. The discovery of peripheral retinal breaks in 6% of 250 patients without symptoms supports this statement. Also, dilation is especially important in the pediatric population. A study indicated that 25% of a group of pediatric patients had one or more posterior pole anomalies not detected by nondilated examination. By evaluating the anterior angle with slit lamp or gonioscopy, eyes predisposed to angle closure are readily identified, and appropriate precautions taken according to the guidelines were discussed previously. Chapter 34 discusses the signs and symptoms and the definitive management of acute angle-closure glaucoma.

### **Systemic Complications**

Although adverse systemic reactions to topically administered mydriatics can occur, dilation of the pupil is safe

and without adverse sequelae in the vast majority of patients. The risk of adverse reactions is greater in patients with certain systemic illnesses or in those using certain systemic medications. There have been few reports of adverse systemic reactions associated with the use of 2.5% phenylephrine in recommended dosages. The potential for adverse reactions associated with the use of 10% phenylephrine increases in patients with cardiac disease, systemic hypertension, type 1 diabetes mellitus, and idiopathic orthostatic hypotension and should be avoided (see Chapter 8).

In patients who are predisposed to adverse cardiovascular events, the use of tropicamide either alone or in combination with 2.5% phenylephrine provides satisfactory mydriasis while minimizing the risks of systemic complications. In addition, the use of low concentrations of drug, single applications, eyelid closure, and nasolacrimal occlusion minimizes adverse reactions in susceptible patients. Thus the combination solution made by mixing equal amounts of 1% tropicamide and 2.5% phenylephrine as previously described may have the added benefit of reducing the chances of an adverse reaction even further.

## CONCLUSION

Pupil dilation is a safe and effective means of examining the internal health of the eye. Even instruments that are capable of being used with an undilated pupil often perform better when the pupil is dilated, especially in the presence of media opacities. Contraindications and serious complications are rare and, in the case of phobophobia and blurred vision, transient. The standard of care is such that a funduscopy examination, through a dilated pupil, should be advised for each patient at least once, or more frequently depending on their individual condition.

## SELECTED BIBLIOGRAPHY

- Amos JE, Semes LP, Swanson MW, et al. Pupillary dilation for aphakic patients, pseudophakic patients, and patients with cataract. *Optom Clin* 1991;1:188-194.
- Anderson DR, Jin JC, Wright MM. The physiologic characteristics of relative papillary block. *Am J Ophthalmol* 1991; 111:344-350.
- Benavides JO, Satchell ER, Frantz KA. Efficacy of a mydriatic spray in the pediatric population. *Optom Vis Sci* 1997; 74:160-163.
- Bolt B, Benz B, Korner F, et al. A mydriatic eyedrop combination without systemic effects for premature infants: a prospective double-blind study. *J Pediatr Ophthalmol Strabismus* 1992; 29:157-162.
- Classé JG. Pupillary dilation: an eye opening problem. *J Am Optom Assoc* 1992;63:733-741.
- Gilmartin B, Amer AC, Ingleby S. Reversal of tropicamide mydriasis with single instillations of pilocarpine can induce substantial pseudo-myopia in young adults. *Ophthalmol Physiol Opt* 1995;15:475-479.
- Halpern JL. Routine screening of the retinal periphery. *Am J Ophthalmol* 1966;62:99-102.
- Hatch SW. Clinicolegal aspects of practice guidelines for pediatric eye and vision examination. *J Am Optom Assoc* 1995; 66:501-509.
- Hogan TS, McDaniel DD, Bartlett JD, et al. Dose-response study of dapiprazole HCl in the reversal of mydriasis induced by 2.5% phenylephrine. *J Ocul Pharmacol Ther* 1997;13:297-302.
- Ismail EE, Rouse MW, DeLand PN. A comparison of drop instillation and spray application of 1% cyclopentolate hydrochloride. *Optom Vis Sci* 1994;71:235-241.
- Keller JT. The risk of angle closure from the use of mydriatics. *J Am Optom Assoc* 1975;46:19-21.
- Kudrna GR, Stanley MA, Remington LA. Pupillary dilation and its effects on automated perimetry results. *J Am Optom Assoc* 1995;66:675-680.
- Locke LC, Meetz R. Sector pupillary dilation: an alternative technique. *Optom Vis Sci* 1990;67:291-296.
- Loewenstein A, Bolocinic S, Goldstein M, et al. Application of eye drops to the medial canthus. *Graefes Arch Clin Exp Ophthalmol* 1994;32:680-682.
- Martinez CE, Applegate RA, Klyce SD, et al. Effect of pupillary dilation on corneal optical aberrations after photorefractive keratectomy. *Arch Ophthalmol* 1998;116:1053-1062.
- Newell FW, Ernest JT. *Ophthalmology: principles and concepts*. St. Louis: CV Mosby, 1974;3:150.
- Nyman N, Keats EU. Effects of dapiprazole on the reversal of pharmacologically induced mydriasis. *Optom Vis Sci* 1990; 67:705-709.
- Olsen CL, Gerber TM, Kassoff A. Care of diabetic patients by optometrists in New York state. *Diabetes Care* 1991;14:34-41.
- Panton RW, Sulewski ME, Parker JS, et al. Surgical management of subluxated posterior-chamber intraocular lenses. *Arch Ophthalmol* 1993;111:919-926.
- Parisi ML, Scheiman M, Coulter RS. Comparison of the effectiveness of a nondilated versus dilated fundus examination in the pediatric population. *J Am Optom Assoc* 1996; 67:266-272.
- Patel KH, Javitt JC, Tielsch JM, et al. Incidence of acute angle-closure glaucoma after pharmacologic mydriasis. *Am J Ophthalmol* 1995;120:709-717.
- Pavlin CJ, Ritch R, Foster FS. Ultrasound biomicroscopy in plateau iris syndrome. *Am J Ophthalmol* 1992;113: 390-395.
- Pollack AL, Brodie SE. Diagnostic yield of the routine dilated fundus examination. *Ophthalmology* 1998;105:382-386.
- Rebolleda G, Munoz FJ, Fernandez Victorio JM, et al. Effects of pupillary dilation on automated perimetry in glaucoma patients receiving pilocarpine. *Ophthalmology* 1992;99:418-423.
- Ritch R, Lowe RF. Angle-closure glaucoma: therapeutic overview. In: Ritch R, Shields MB, Krupin T, eds. *The glaucomas*, ed. 2. St. Louis: CV Mosby, 1996: 1521-1531.
- Rollins L. Repositioning of subluxated intraocular lenses. *South J Optom* 1993;11:19-20.
- Sebag J. Seeing the invisible: the challenge of imaging vitreous. *J Biomed Opt* 2004;9:38-46.
- Shaffer RN. Gonioscopy, ophthalmoscopy, and perimetry. *Trans Am Acad Ophthalmol Otol* 1960;64:113-127.



- Shaffer RN. Problems in the use of autonomic drugs in ophthalmology. In: Leopold IH, ed. *Ocular therapy: complications and management*. St. Louis: CV Mosby, 1967;2:18-23.
- Straub RH, Jeron A, Kerp L. The pupillary light reflex. 2. Prevalence of pupillary autonomic neuropathy in diabetics using age-dependent and age-independent pupillary parameters. *Ophthalmology* 1992;204:143-148.
- van Herick W, Shaffer RN, Schwartz A. Estimation of width of angle of anterior chamber. Incidence and significance of the narrow angle. *Am J Ophthalmol* 1969;68:626-629.
- Wesson MD, Bartlett JD, Swiatocha J, et al. Mydriatic efficacy of a cycloplegic spray in the pediatric population. *J Am Optom Assoc* 1993;64:637-640.
- Wolfs RC, Hofman A, de Jong PT. Risk of acute angle-closure glaucoma after diagnostic mydriasis in nonselected subjects: the Rotterdam Study. *Invest Ophthalmol Vis Sci* 1997;38:2683-2687.
- Zangwill LM, Berry CC, Weinreb RN. Optic disc topographic measurements after pupil dilation. *Ophthalmology* 1999;106:1751-1755.

## *Cycloplegic Refraction*

*Suzanne M. Wickum and John F. Amos*

Cycloplegic refraction remains a time-tested, reliable, and valid procedure for obtaining an accurate refraction. Without cycloplegic drugs, determining the true refractive status of some patients would be fraught with error. Cycloplegia is essential for the proper diagnosis of refractive error in patients with refractive or accommodative esotropia, pseudomyopia, latent hyperopia, anisometropia, and amblyopia. Additionally, cycloplegic refraction is important in determining the refractive error in patients who are uncooperative, noncommunicative, inconsistent, or those presenting with functional visual deficits.

This chapter considers the indications, precautions, and contraindications associated with the use of cycloplegics in refraction. The chapter also discusses such clinical topics as selecting the appropriate cycloplegic agent, administration techniques, procedures for refraction, and general considerations for spectacle prescribing.

### **INDICATIONS AND ADVANTAGES**

Cycloplegia plays a very important role in the refractive evaluation of young patients and thus should be performed during all first-time pediatric comprehensive eye examinations. In numerous clinical situations, cycloplegia can supply the practitioner with information that could not otherwise be obtained.

It is wise to perform a cycloplegic examination in infants, toddlers, and preschoolers because these children often have variable fixation with accommodative fluctuations. Clearly, as an objective method for determining refractive error in infants and young children, cycloplegic techniques are superior to those that are noncycloplegic. Not only is cycloplegic retinoscopy of infants and young children more accurate, it is also more easily performed because the examination does not depend on the patient's fixation distance.

Cycloplegic examination is recommended for patients who are mentally impaired and for patients who are unresponsive or inconsistent in their responses to subjective refraction. Indeed, this may be the only way the clinician can determine the degree of refractive error, if any. In a

similar category are patients suspected of ocular malingering or hysteria. The clinician can avoid the unreliable patient's subjective responses and arrive at objective refractive data through the use of cycloplegics.

In young patients with esotropia, determining the full amount of hyperopia is vital to prescribe plus-power lenses to relieve the effort placed on the accommodative-convergence system and, in turn, bring the eyes into alignment. Although the full correction may or may not be prescribed, the value derived from the cycloplegic examination serves as a starting point that is then modified based on clinical judgment and experience.

In a more general sense, cycloplegic refraction is also indicated in young patients who demonstrate any type of strabismus. Not only does cycloplegia allow the clinician to diagnose correctly any accompanying refractive error, it also prepares the patient for a dilated fundus examination. All strabismic patients should have a thorough ocular health evaluation, especially when initially examined. This evaluation can exclude a pathologic etiology of the strabismus and can conveniently be incorporated into the examination after the cycloplegic refraction.

Nonstrabismic children with latent hyperopia are perhaps less obvious in their presentation, but this is another instance in which information gained by cycloplegic examination is essential to the ultimate management plan. In considering the amount of total hyperopia in conjunction with the patient's signs and symptoms, a successful spectacle prescription can be determined more accurately.

The clinician may consider using cycloplegics in children who exhibit myopia for the first time. This approach allows the practitioner to rule out accommodative spasm (pseudomyopia) as the etiology. With the diagnosis of myopia established, future cycloplegic examinations need not be performed for a cooperative child. Similarly, prepresbyopic patients who have suffered a traumatic brain injury may manifest traumatic myopia, a form of pseudomyopia. Cycloplegic refraction aids the clinician in both the diagnosis and management of such patients.

**Box 21-1** Indications for Cycloplegic Refraction

Infants, toddlers, preschoolers  
 Noncommunicative patients  
 Uncooperative patients  
 Suspected malingering or hysterical amblyopia  
 Patients with variable and inconsistent subjective responses during manifest refraction  
 Strabismic patients (particularly esotropes)  
 Suspected latent hyperopia  
 Suspected pseudomyopia/traumatic myopia  
 Amblyopia  
 Visual acuity not corrected to a predicted level  
 Patients whose symptoms seem unrelated to the nature or degree of the manifest refractive error

Cycloplegic refraction is also indicated for patients with active accommodative systems whose best corrected visual acuity in each eye is less than 20/20 and for whom there is no apparent reason for the decreased vision. It allows the clinician to determine whether uncorrected refractive error is responsible for the reduced acuity. This data may be particularly helpful in young patients with uncorrected antimetropia, latent hyperopia, or hyperopic anisometropia.

Amblyopic patients tend to have inaccurate responses during subjective refraction, thus necessitating cycloplegic evaluation. Cycloplegic retinoscopy reveals the true refractive error from which the clinician can base the patient's refractive correction.

Finally, patients whose visual signs or symptoms do not correlate with the nature and degree of their manifest refraction may benefit from cycloplegic evaluation. A cycloplegic refraction aids in the differential diagnosis by helping to ensure that the patient's problem is not refractive in nature. The clinician can then concentrate on other aspects of the visual system. Box 21-1 summarizes the indications for cycloplegic refraction.

**DISADVANTAGES**

Despite the previously mentioned advantages of cycloplegic refraction, it does have some disadvantages. Wide dilation of the pupil can create excessive spherical aberration in the ocular media, resulting in difficult retinoscopy and refraction. This situation is especially true when synergistic agents, such as phenylephrine, are used to permit fundus examination after retinoscopy. In addition, an allowance for ciliary tonus is usually necessary, and the clinician must consider this allowance when determining the appropriate refractive correction. Furthermore, because all cycloplegic drugs have potential side effects, caution must be exercised in their use. Cycloplegics may blur vision for several days, and sunlight

or any bright light can be annoying, even with the use of sunglasses.

**PRECAUTIONS AND CONTRAINDICATIONS**

Before administering a cycloplegic agent, the clinician should perform a preinstillation ocular evaluation. This evaluation not only protects the clinician legally but also provides valuable information regarding contraindications to the drug. Moreover, it furnishes certain baseline clinical information that may be unobtainable after cycloplegia. The following information and procedures, usually obtained as part of the comprehensive eye examination, constitute the minimum examination recommended before instilling a cycloplegic drug:

- Medical and ocular history, with particular emphasis on present medications, allergies, drug reactions, and previous eye examinations
- Visual acuity at distance and near
- Pupillary examination
- Evaluation of eye alignment
- Manifest ("dry") retinoscopy/refraction
- Accommodative function, if desired
- Sensory-motor fusion, if desired
- Slit-lamp evaluation, with particular attention to the cornea, anterior chamber depth, and an estimation of the anterior chamber angle by shadow test or van Herick's classification
- Tonometry, if possible
- Gonioscopy, if a shallow anterior chamber is observed or suspected

Often, some of these tests are not practical or possible with infants or uncooperative children. Penlight estimation (shadow test) of the anterior chamber depth (see Chapter 20) can give the practitioner a reasonable idea regarding the safety of pupillary dilation without the necessity of a comprehensive slit-lamp evaluation.

Caution must be exercised when using cycloplegic agents in infants, because they are more susceptible to systemic complications due to their immature metabolism and excretion systems and their low body weight. The clinician should use the lowest concentration of drug that yields the desired cycloplegia.

Cycloplegia is contraindicated in patients with a history of angle-closure glaucoma. Atropine, in particular, should be used judiciously in patients with Down syndrome and in patients receiving systemic anticholinergic drugs because of potential adverse central nervous system side effects. Any known sensitivity to a specific cycloplegic agent can often be avoided by substituting another cycloplegic. In addition, obtaining patient or parental consent before administering cycloplegic agents is recommended. Finally, the patient and/or parent should be advised regarding the expected duration of dilated pupils, increased sensitivity to light, and blurred vision.

## SELECTION AND USE OF CYCLOPLEGIC AGENTS

All cycloplegics exhibit anticholinergic properties by blocking the response to acetylcholine at muscarinic receptor sites on the iris sphincter muscle and ciliary body. Clinically, this anticholinergic response manifests as some degree of pupillary dilation and cycloplegia.

To be clinically useful, cycloplegics should ideally possess the following properties:

- Rapid onset of cycloplegia
- Complete paralysis of accommodation
- Adequate duration of maximum cycloplegia
- Rapid recovery of accommodation
- Absence of side effects

Although no cycloplegic agent meets all these criteria, some agents satisfactorily achieve the desired clinical purpose with a minimum of disadvantages. Table 21-1 lists the clinical characteristics of common cycloplegic agents in current use. The pharmacologic properties of cycloplegic agents are discussed in greater detail in Chapter 9.

Generally, when selecting cycloplegic agents for use in infants (12 months of age and younger), in patients with Down syndrome, and in patients with other central nervous system disorders, the lowest concentration of the appropriate drug is recommended. More specifically, when using tropicamide and/or cyclopentolate, the 0.5% concentration should be used rather than the 1% concentration for these patient populations.

## COMPARISON OF CYCLOPLEGICS

The residual accommodation of various cycloplegics relative to 1% atropine was compared. The cycloplegic drugs were considered to be efficacious if the residual accommodation was less than 2.50D at the time of cycloplegic retinoscopy. It was found that two drops of 1% tropicamide was effective in 79% of whites and in 69% of African-Americans, as long as retinoscopy was performed within 20 to 35 minutes after instillation. If retinoscopy was performed after 35 minutes, the effectiveness of cycloplegia quickly became inadequate. One drop of 1% cyclopentolate was effective in 83% of cases with

examination between 20 and 40 minutes; however, when the examination time was extended to 60 minutes, the efficacy increased to 91%. When two drops of 4% homatropine and 1% hydroxyamphetamine were used, the cycloplegic efficacy was 40% within 40 minutes of instillation and increased to 59% if examination was performed 40 to 60 minutes after drug instillation. It was concluded that tropicamide was an effective cycloplegic agent as long as refractive error was assessed within 20 to 35 minutes of drug instillation. Cyclopentolate was found to be more effective than tropicamide and yielded a longer examination period before the cycloplegia becomes ineffective. The 4% homatropine was the least effective cycloplegic agent.

In another report, no statistically significant difference was found in refractive error between 1% cyclopentolate instilled three times within 15 minutes as compared with the traditional instillation of 1% atropine three times per day for 3 days. On the contrary, several other studies found significant differences in the mean cycloplegic refractive error when comparing 1% cyclopentolate to 1% atropine. One study found on average 0.66D more hyperopia in children younger than 6 years and 0.77D more hyperopia in children older than 7 years when using atropine versus cyclopentolate. Similarly, another study compared the cycloplegic effectiveness of 1% atropine versus a combination of 1% cyclopentolate and 1% tropicamide and found approximately 0.66D more hyperopia in the atropine group. Yet another study found that 1% atropine yielded on average 0.40D more hyperopia than 1% cyclopentolate in a population-based comparison of 1-year-old children.

The mean refractive difference in esotropic children between 3 months and 6 years of age was 0.34D more hyperopia when 1% atropine was used versus 1% cyclopentolate. This study implies that, clinically, cyclopentolate is sufficient for cycloplegic retinoscopy. However, in a subgroup of 22% of children, atropine uncovered an additional +1.00D or more of hyperopia. Almost all children in this subgroup demonstrated +2.00D or more on their initial cyclopentolate retinoscopy. Therefore the use of atropine may prove more important in children who have moderate hyperopia and esotropia.

**Table 21-1**

Clinical Characteristics of Common Cycloplegic Agents

Cycloplegic Agent	Commonly Used Concentration (%)	Onset of Maximum Cycloplegic Effect	Duration of Cycloplegic Effect	Relative Residual Accommodation
Atropine	1.0	60–180 min	7–12 days	Negligible
Scopolamine	0.25	30–60 min	3–7 days	Negligible
Cyclopentolate	0.5, 1.0	20–45 min	6–24 hr	Minimal
Tropicamide	0.5, 1.0	20–35 min	≤ 6 hr	Moderate in hyperopes

Adapted from Drug Facts and Comparisons. St. Louis, MO: Wolters Kluwer Health, 2006.

In recent years several studies investigated the effectiveness of cyclopentolate versus tropicamide in determining the refractive error of children and adults. One study found no statistically or clinically significant difference in refractive error measurements between 1% tropicamide and 1% cyclopentolate in healthy nonstrabismic infants between 4 and 7 months of age. Another study compared cyclopentolate versus tropicamide cycloplegia in children 6 to 12 years of age who were nonamblyopic and nonstrabismic and had low to moderate hyperopia (+0.25D up to +4.50D). There was no statistically significant difference between cyclopentolate and tropicamide refractive error values. The residual accommodation was also evaluated in these patients comparing subjective amplitude of accommodation to objective autorefractor measurements. Although accommodation was more effectively inhibited with cyclopentolate, the difference in residual accommodation was less than previous literature implied. Residual accommodation with tropicamide was 0.39 to 0.56D more than with cyclopentolate. These findings are in agreement with others that found objective measurement of residual accommodation after cycloplegia with cyclopentolate to be 0.57D in adults and 0.59D in children. The effects of cyclopentolate and tropicamide were evaluated on myopic children and found that the drugs revealed clinically equivalent refractive error results. Similarly, it was demonstrated that cyclopentolate and tropicamide showed no statistical difference in the cycloplegic refractive error of myopic adult refractive surgery patients. Thus tropicamide is clinically useful and effective for cycloplegic refraction of nonamblyopic, nonstrabismic, myopic, or low hyperopic children and adults.

## CLINICAL PROCEDURE

---

### Administration of Cycloplegic Agents

Many clinicians prefer to use a topical anesthetic before instilling a cycloplegic. The anesthetic diminishes the local stinging, irritation, and lacrimation that often accompany cycloplegic drops. Several authors have reported increased corneal drug penetration and therefore increased effectiveness of phenylephrine after topical anesthesia. Increased duration and effectiveness of cycloplegics may also occur after topical anesthesia.

The cycloplegic can be administered alone or as a combination cycloplegic-mydriatic solution to permit adequate binocular indirect ophthalmoscopy in neonates, infants, and young children after cycloplegic retinoscopy. The combination drugs can be administered individually or as a combination solution.

The most widely accepted cycloplegic refraction regimen includes instillation of one drop of topical anesthetic followed by one drop of 1% cyclopentolate and one drop of either 2.5% phenylephrine or 1% tropicamide to facilitate dilation. After waiting 5 minutes, instillation of one

more drop of 1% cyclopentolate is recommended. If the patient is under 12 months of age the concentration of cyclopentolate and tropicamide should be reduced to 0.5%. Based on research, cycloplegic refraction may be performed after as little as 10 to 15 minutes in individuals with light irides and after 30 to 40 minutes in individuals with dark irides.

The cycloplegic, or combination cycloplegic-mydriatic solution, can be administered to the eye as a drop, spray, or ointment (atropine). As a drop, the chosen solution can be instilled in the traditional manner into the lower cul-de-sac with the eyelids open. However, in patients resistant to eyedrop instillation, the drop(s) can be applied to the medial canthus of closed eyes after which the patient is asked to open the eyes, allowing the solution to diffuse into the eyes. Using the medial canthus drop instillation method, one study evaluated the mydriatic effect of tropicamide in adults, whereas another study evaluated the mydriatic and cycloplegic effects of cyclopentolate in children. Both studies found that mydriasis and/or cycloplegia was equal using the traditional open-eyedrop instillation versus the medial canthus instillation. When children were asked to evaluate the comfort between these two drop-instillation techniques, 92% of the children surveyed reported better comfort with the medial canthus drop instillation.

Similar to the medial canthus technique, some clinicians found that sprays are particularly effective in treating children who are resistant to drop instillation in the usual manner. Several studies compared the efficacy of administering cycloplegic agents in a spray compared with the conventional eyedrop. Cycloplegic agents were instilled in four matched groups of children between 6 months and 12 years of age. Sixty-eight percent of the eyes were brown, 24% of the eyes were blue, and 8% were classified as "other." Eyedrops were instilled in eyes that were opened or closed and a cycloplegic spray was administered to opened or closed eyes. Residual accommodation was measured using dynamic retinoscopy or the push-up method at various times after administration of the medications. No statistical differences were reported in cycloplegic effect among the four groups. Another study found no statistically significant difference between a cycloplegic eyedrop instilled in opened eyes and spray administered to closed eyes based on objective refractive measurements in children between 18 months and 6 years of age, with 62% of the subjects having light eyes and 38% having dark eyes. This study also compared ease of administration of the two formulations and found the spray significantly better.

The practitioner must observe the recommended dosages for cycloplegic refraction. To overmedicate when maximum cycloplegia has been reached increases the probability of systemic drug absorption and the risk of side effects. The clinician using the spray method of instillation also needs to be diligent in preventing extraneous drug spray from getting into the patient's mouth and/or

nose because this increases systemic drug absorption and leads to increased risk of side effects.

## Refractive Techniques

After the cycloplegic agent has been instilled and the time limit for maximum cycloplegia has been reached, the clinician must decide whether the degree of cycloplegia is adequate to permit reliable refraction. Several methods have been described for measuring residual accommodation. One procedure involves the patient viewing a near visual acuity card through +2.50D lenses at 40 cm. The acuity card is then slowly moved toward the patient until blur is reported. The distance from the card to the patient's eyes is measured and converted to a dioptric value. Residual accommodation is then calculated by subtracting 2.50D from the dioptric equivalent of the measured distance.

Of course, performing tests of residual accommodation is often impossible in the very patients who require cycloplegia, and the experienced clinician quickly learns to use the retinoscope to judge accommodative activity. Completeness of cycloplegia can be ascertained clinically by asking the patient to fixate the light of the retinoscope. If cycloplegia in the emmetropic patient is complete, a nonfluctuating "with" motion of approximately 2.00D is observed. If accommodation in the emmetropic patient is active, however, fluctuation of the retinoscopic reflex is observed. If residual accommodation exceeds 2.00D, cycloplegic refraction may be unreliable and inaccurate. Of special note, the clinician must be careful not to use pupillary reaction as an indication of depth of cycloplegia because it has been found that it takes longer to reach maximum pupillary dilation than to reach maximum cycloplegia.

After the cycloplegia has been determined to be clinically satisfactory, retinoscopy should be performed. The best guideline for retinoscopy is to neutralize the central 4 mm of the pupil, ignoring the movement in the periphery, which may be confusing and distracting because of spherical aberration associated with the dilated pupil. The patient should fixate a distant target if the cycloplegia is not completely adequate. However, if the cycloplegia is complete, the patient may fixate directly at the retinoscope light without jeopardizing the retinoscopic result. In addition, the retinoscope should be as close to the visual axis as possible to avoid errors. It is often difficult to perform retinoscopy on young children through a phoropter. Instead, loose handheld trial lenses or lens bars can be used to facilitate retinoscopy of the young child or infant.

After retinoscopy, subjective refraction may be attempted, although practitioners often cannot perform this procedure on young patients because of their lack of maturity and cooperation. The practitioner should note that spherical aberration can cause errors in the subjective cycloplegic refraction just as it does in retinoscopy.

## Spectacle Prescribing

Prescribing spectacle lenses from cycloplegic findings is truly an art rather than an exact science, thus placing great demands on the clinician's judgment, skill, and experience. In many cases determination of the final spectacle prescription is straightforward, but in other cases it requires considerable thought and judgment. Because the ultimate criterion for a satisfactory and successful prescription is prevention or relief of patient symptoms, guidelines for spectacle prescribing are necessarily somewhat broad and imprecise.

A complete discussion of prescribing philosophies is outside the scope of this text. Numerous excellent resources discussing these topics are available elsewhere; however, the following questions should be considered when making spectacle prescription decisions:

- What are the patient's unaided visual acuities at distance and near? If visual acuity is reduced secondary to uncorrected refractive error, a spectacle prescription is indicated.
- Is the refractive error outside of normal limits for the patient's age? If so, refractive correction is likely indicated.
- Is the refractive error equal between the eyes? If significant anisometropia is present the patient not only has an imbalance in accommodation but may also be at risk for anisometropic amblyopia.
- Is the refractive error potentially amblyogenic? If the answer is yes, then prescribing a refractive correction is a must.
- If astigmatism is present, what is the spherical equivalent? If the spherical equivalent is not significant and the acuities are not reduced, a spectacle correction is not indicated; however, if the spherical equivalent is significant or the magnitude of the astigmatism could be amblyogenic, refractive correction is necessary.
- Are there any binocular or accommodative disorders that the refractive correction would improve? For example, in the case of refractive/accommodative esotropia, the prescription for hyperopic correction is critical in reducing or eliminating the esotropia.
- Would refractive correction prevent future problems from developing? For example, if a preschool-aged child is found to have moderate hyperopia, by prescribing spectacles the clinician may prevent the child from developing refractive/accommodative esotropia.
- If the patient is a child, is the child having any school difficulties? An uncorrected refractive error may contribute to academic problems.
- The practitioner must also consider the intrinsic ciliary muscle tonus and consider accounting for this in the refractive correction prescribed.

In summary, cycloplegic refraction is a valuable and perhaps underused refractive procedure that the clinician should consider when applicable. In contemporary

practice, cyclopentolate is the cycloplegic of choice for almost all patients. In children and adults, 1% cyclopentolate is the preferred dosage. For neonates and infants, 0.5% cyclopentolate, alone or in combination with 2.5% phenylephrine, and/or 0.5% tropicamide is preferred.

## SELECTED BIBLIOGRAPHY

- Bartlett JD, Wesson MD, Swiatocha J, et al. Efficacy of a pediatric cycloplegic administered as a spray. *J Am Optom Assoc* 1993; 64:617-621.
- Celebi S, Aykan U. The comparison of cyclopentolate and atropine in patients with refractive accommodative esotropia by means of retinoscopy, autorefractometry and biometric lens thickness. *Acta Ophthalmol Scand* 1999;77:426-429.
- Drug facts and comparisons. St. Louis, MO: Wolters Kluwer Health, 2006.
- Egashira SM, Kish LL, Twelker JD, et al. Comparison of cyclopentolate versus tropicamide cycloplegia in children. *Optom Vis Sci* 1993;70:1019-1026.
- Gettes BC, Belmont O. Tropicamide: comparative cycloplegic effects. *Arch Ophthalmol* 1961;66:336-340.
- Goldstein JH, Schneekloth BB. Atropine versus cyclopentolate plus tropicamide in esodeviations. *Ophthalmic Surg Lasers* 1996;27:1030-1034.
- Hofmeister EM, Kaupp SE, Schallhorn SC. Comparison of tropicamide and cyclopentolate for cycloplegic refractions in myopic adult refractive surgery patients. *J Cataract Refract Surg* 2005;31:694-700.
- Ingram RM, Barr A. Refraction of 1-year-old children after cycloplegia with 1% cyclopentolate: comparison with findings after atropinization. *Br J Ophthalmol* 1979; 63:348-352.
- Ismail EE, Rouse MW, De Land PN. A comparison of drop instillation and spray application of 1% cyclopentolate hydrochloride. *Optom Vis Sci* 1994;71:235-241.
- Kawamoto K, Hayasaka S. Cycloplegic refractions in Japanese children: a comparison of atropine and cyclopentolate. *Ophthalmologica* 1997;211:57-60.
- Lin LL, Shih YF, Hsiao CH, et al. The cycloplegic effects of cyclopentolate and tropicamide on myopic children. *J Ocul Pharmacol Ther* 1998;14:331-335.
- Loewenstein A, Bolocinic S, Goldstein M, et al. Application of eye drops to the medial canthus. *Graefes Arch Clin Exp Ophthalmol* 1994;32:680-682.
- Maino JH, Cibis GW, Cress P, et al. Noncycloplegic vs cycloplegic retinoscopy in pre-school children. *Ann Ophthalmol* 1984;16:880-882.
- Manny RE, Fern KD, Zervas HJ, et al. 1% Cyclopentolate hydrochloride: another look at the time course of cycloplegia using an objective measure of the accommodative response. *Optom Vis Sci* 1993;70:651-665.
- Manny RE, Hussein M, Scheiman M, et al. Tropicamide (1%): an effective cycloplegic agent for myopic children. *Invest Ophthalmol Vis Sci* 2001;42:1728-1735.
- Mordi JA, Lyle WM, Mousa GY. Does prior instillation of a topical anesthetic enhance the effect of tropicamide? *Am J Optom Physiol Opt* 1986;63:290-293.
- Rosenbaum AL, Bateman JB, Bremer DL, et al. Cycloplegic refraction in esotropic children. Cyclopentolate versus atropine. *Ophthalmology* 1981;88:1031-1034.
- Stolovitch C, Alster Y, Golsstein M, et al. Application of cyclopentolate 1% to the medial canthus in children. *J Pediatr Ophthalmol Strabismus* 1998;35:182-184.
- Twelker JD, Mutti DO. Retinoscopy in infants using a near noncycloplegic technique, cycloplegia with tropicamide 1%, and cycloplegia with cyclopentolate 1%. *Optom Vis Sci* 2001;78:215-222.

## *Neuro-Ophthalmic Disorders*

*Leonid Skorin, Jr.*

Clinicians often encounter patients with ophthalmic manifestations of neurologic impairment. Patients with anisocoria, neuromuscular abnormalities, and optic neuropathies can be challenging. This chapter describes the diagnostic and therapeutic uses of various pharmacologic agents in the management of these conditions.

### **ANISOCORIA**

Many clinical conditions can exhibit anisocoria as a primary or secondary feature. Box 22-1 lists the most common disorders for which unequal pupils are a primary diagnostic sign. Some of these conditions, such as physiologic (essential) anisocoria, are benign and carry an excellent prognosis. Others, such as third-nerve palsy, can indicate significant intracranial disease and may have a grave prognosis. Although a discussion of all conditions associated with anisocoria is beyond the scope of this chapter, those disorders that most easily lend themselves to evaluation by clinical and pharmacologic methods are emphasized. These conditions have in common that only one pupil is involved and that the basic underlying abnormality manifests itself as an inability of the affected pupil either to dilate or to constrict. Consequently, either the sympathetic or the parasympathetic nervous system can be implicated, and various drugs affecting the autonomic nervous system may pharmacologically differentiate the site of impairment. Box 22-1 identifies the disorders that are most easily evaluated pharmacologically and in which only one pupil is abnormal.

Lesions of the retina, optic nerve, chiasm, and optic tract do not cause anisocoria. A lesion in the midbrain produces a subtle and transient anisocoria. However, most neurologic causes of anisocoria involve lesions in the efferent pupillary pathway. These defects arise due to asymmetric disruptions of the parasympathetic or sympathetic nervous systems that innervate the iris. The presence of anisocoria may help to limit a lesion to this pathway but does not localize the lesion's location within that pathway.

When anisocoria is greater in bright illumination, the dilated pupil is considered abnormal until proven otherwise. The differential diagnosis of this dilation includes

pharmacologic blockade, a tonic pupil, or damage to the efferent fibers of the third cranial nerve.

### **Pupil Size**

In addition to the customary evaluation of pupillary function (direct reflexes and evaluation for Gunn's pupillary phenomenon), pupil size must be measured accurately. This measurement can be obtained by flash photography, or it can be accurately estimated using the area of the pupil rather than its diameter. The easiest method is to use a Haab scale with a printed gradient of increasingly larger semicircles, which is held just temporal to the eye. Measurement is made first in dim and then in bright illumination. The patient is instructed to fixate at a distant point slightly above the horizon, thereby avoiding the miosis attributable to the near reflex.

### **Light Reaction**

In tests of the response to direct light, a pupil that responds poorly clearly indicates the abnormal pupil. The differential diagnosis includes third-nerve palsy, anticholinergic mydriasis, Adie's pupil, or local iris disease. If each eye exhibits a good pupillary light reaction, differential diagnosis includes Horner's syndrome and physiologic anisocoria (Table 22-1).

### **Nature of Anisocoria in Light Versus Dark**

A comparison of the anisocoria in bright and dim ambient illuminations may help one to reach a diagnosis by clinical means alone. Although use of a semidarkened room facilitates the clinical evaluation of unequal pupils, this method often is self-defeating if the patient has dark irides, because of poor contrast between the iris and the pupil. Use of an ultraviolet light in a completely darkened room can overcome this problem. The technique uses the principle of lenticular fluorescence from ultraviolet stimulation. The ultraviolet light source (such as a Burton lamp) should be held 8 to 12 inches from the patient so



**Box 22-1 Disorders Characterized by Anisocoria**

Physiologic (essential) anisocoria  
 Alternating contraction anisocoria  
 Bernard's syndrome  
 Horner's syndrome<sup>a</sup>  
 Benign episodic unilateral mydriasis  
 Tadpole-shaped pupil  
 Adie's syndrome<sup>a</sup>  
 Third-nerve palsy<sup>a</sup>  
 Adrenergic mydriasis  
 Anticholinergic mydriasis<sup>a</sup>  
 Argyll Robertson pupils  
 Local iris disease (e.g., sphincter atrophy,  
 sphincter tear, posterior synechiae)  
 Hutchinson's pupil  
 Angle-closure glaucoma

<sup>a</sup>Disorders that are most easily evaluated pharmacologically, in which usually only one pupil is abnormal.

that the visible emission does not stimulate pupillary activity. If the anisocoria increases in darkness, the differential diagnosis includes Horner's syndrome and physiologic anisocoria (Figure 22-1). In Horner's syndrome the oculosympathetic paresis does not allow the iris dilator to function properly in darkness; consequently, the anisocoria increases as the normal pupil dilates in response to darkness. Although no autonomic nervous system abnormalities exist in physiologic anisocoria, this benign condition also exhibits increased anisocoria in darkness. The physiologic anisocoria decreases in bright light as the smaller pupil reaches the zone of mechanical resistance first, allowing the larger pupil a chance to make up the size difference.

An anisocoria that is greater in the light than in the dark generally indicates an abnormal parasympathetic innervation to the iris sphincter (see Figure 22-1). Differential diagnosis includes Adie's pupil, iris sphincter atrophy (possibly associated with previous anterior segment trauma), and any of the disorders implicated as a unilateral fixed and dilated pupil (i.e., third-nerve palsy, anticholinergic mydriasis, Adie's pupil). Because the underlying abnormality is generally associated with the parasympathetic innervation to the iris sphincter, the abnormal (larger) pupil does not appropriately constrict to light stimulation. The anisocoria is therefore greater in bright light than in dim illumination.

**Slit-Lamp Examination**

The clinician should carefully examine with the biomicroscope the physical characteristics of the iris for evidence of mechanical restrictions of the pupils. Some patients have iris damage due to previous ocular inflammation

or trauma. Careful evaluation may uncover subtle areas of posterior synechiae that immobilize the pupil. Careful biomicroscopic examination can also detect iris sphincter atrophy. Meticulous examination of the iris, moreover, may reveal sector palsies with associated vermiform movements, indicating Adie's pupil.

**Inspection of Photographs**

Frequently, the question arises whether the anisocoria is recent or long-standing. Patients often insist that their newly found condition is of recent onset. In such cases examination of personal photographs (both recent and old) may indicate with some certainty the onset and duration of the condition. However, different conditions of lighting and accommodation in old photographs could result in differences between present and past observations of anisocoria. Old photographs are of most value when they agree with current observations of anisocoria.

**Associated Ocular or Systemic Findings**

Diagnostic physical findings often are associated with the observed anisocoria. For example, ipsilateral ptosis and facial anhidrosis are highly suggestive of Horner's syndrome. On the other hand, the patient with a unilateral sluggish pupil, associated accommodative insufficiency, and diminished deep tendon reflexes may be strongly suspected of having Adie's syndrome, especially if these signs and symptoms are of recent onset in a healthy, young, adult woman.

Hence, careful pupillary examination, with special attention to the patient's history, as well as to other ocular or systemic physical findings, may allow the practitioner to establish the diagnosis without resorting to pharmacologic or other more sophisticated methods of examination. When the findings are ambiguous, however, or if insufficient clinical information is available to establish the diagnosis with certainty, pharmacologic evaluations should be performed as discussed in the following sections.

**Guidelines for the Pharmacologic Evaluation of Anisocoria**

Pharmacologic evaluation of unequal pupils is easily and quickly accomplished in the office and frequently obviates the need for further neuroradiologic or laboratory investigations (Table 22-2).


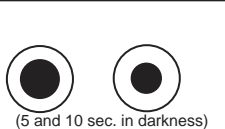





Adherence to the following general guidelines facilitates pharmacologic evaluation and improves the accuracy with which the drugs allow a definitive diagnosis:

- One drop of the indicated drug should be instilled into each eye and repeated after several minutes. This ensures adequate drug application if the first drop is removed by tearing. No other drops (anesthetic) should be instilled or procedures (tonometry) done

**Table 22-1**  
Differential Diagnosis Based on Location

Lesion Location	Pupil Responses	Anisocoria	Field Defects	Nerve Head	Near Reflex	Oculomotor Involvement	Accommodation	Disease or Syndrome
Retina	+RAPD	No	Yes	Normal	Intact	No	Reduced if VA is reduced	Varied
Optic nerve	+RAPD	No	Yes	Normal or pale	Intact	No	Intact	Varied
Optic chiasm	Usually no discernible RAPD	No	Yes	Normal	Intact	No	Intact	Varied
Optic tract	Usually no discernible RAPD	No	Yes	Normal	Intact	No	Intact	Varied
Dorsal midbrain	Lost light reaction, dilated pupils	Yes	No	Normal	Intact	Yes	Reduced	Parinaud's syndrome or dorsal midbrain syndrome
Rostral midbrain	Miosis, distorted with no light responses	Yes	No	Normal	Intact	No	Intact	Argyll Robertson's syndrome
Third-nerve nucleus	Dilated ipsilateral pupil unresponsive	Yes	No	Normal	Absent	Yes	Absent	Total ophthalmoplegia
Afferent Arc	Dilated ipsilateral pupil unresponsive	Yes	No	Normal	Absent	No	Absent	Internal ophthalmoplegia
Ciliary ganglion	Sluggish ipsilateral pupil, -RAPD	Yes	No	Normal	Reduced	No	Reduced	Tonic pupil
Sympathetic efferent system	Miosis ipsilateral, -RAPD	Yes	No	Normal	Increased	No	Increased	Horner's syndrome

+ indicates positive; - indicates negative; RAPD = relative afferent pupillary defect; VA = visual acuity.

	LIGHT	DARK
Physiologic anisocoria (Larger right pupil)		 (5 and 10 sec. in darkness)
Left Horner's pupil (Anisocoria greater in darkness, but less at 10 seconds than at 5)		 (5 sec. in darkness)  (10 sec. in darkness)
Right third nerve palsy (Anisocoria greater in light than in dark)		

**Figure 22-1** Use of light and dark illumination in differentiating the various causes of anisocoria.

before the application of the drops being used for the pharmacologic evaluation.

- The drops should always be instilled into both eyes so that the reaction of the affected pupil can be compared with that of the normal pupil. If the condition is bilateral, as in anticholinergic mydriasis caused by systemic agents, the drop should be placed in only one eye so that the response of each pupil can be compared.
- The patient's general status can influence the size of the pupils. A change in alertness, either toward arousal or somnolence, can affect the "before" and "after" comparisons. If the patient becomes uncomfortable or anxious while waiting for the drug to act, both pupils may dilate. If the patient becomes drowsy, both pupils may constrict. In the case of Adie's pupil, drowsiness may constrict the normal pupil more than the

**Table 22-2**  
Pharmacologic Features of Agents Used for Diagnosis of Pupillary Disease

Agent	Classification	Action	Use
Cocaine 4-10%	Adrenergic agonist	Mydriatic	Fails to dilate pupil in Horner's syndrome
Apraclonidine 1%	$\alpha_2$ Adrenergic agonist	Mydriatic	Dilates Horner's pupil but fails to dilate normal pupil
Hydroxyamphetamine 1%	Adrenergic agonist	Mydriatic	Dilates preganglionic but not postganglionic pupil in Horner's syndrome
Pilocarpine $\frac{1}{6}$ - $\frac{1}{8}$ %	Cholinergic agonist	No constriction	Constricts an Adie's tonic pupil owing to hypersensitivity
Pilocarpine 1%	Cholinergic agonist	Miosis	Fails to constrict a pharmacologically dilated pupil

Adie's pupil. This fact emphasizes the importance of instilling the drug into both eyes so that one pupil always serves as a control when only a single pupil is affected.

- The amount of ambient illumination before and after drug instillation must be constant.
- Accommodation should be carefully controlled during the "before" and "after" evaluations so that it can be eliminated as a factor producing the change in pupil size.
- Photography can enable a more accurate evaluation of pupil size both before and after instillation of the indicated drug. An accuracy of 0.1 mm can be obtained using flash photography. Because appropriate patient management depends on accurate diagnosis, the practitioner should not simply estimate the differences in pupil size, because this estimate may lead to an incorrect diagnosis.

### Physiologic Anisocoria

The most common condition characterized by unequal pupils is physiologic (essential) anisocoria. Depending on how it is defined, this condition is found in from 1% to more than 50% of the general population. It is seldom greater than 1 mm and can be variable, changing from day to day or even from hour to hour. The clinical and pharmacologic features of physiologic anisocoria can be summarized as follows:

- Pupil constricts briskly to light.
- There is no dilation lag in darkness.
- There is no disturbed psychosensory dilation.
- Pupil dilates normally with cocaine.
- Pupil exhibits greater anisocoria in darkness than in bright light. In bright light, the smaller pupil reaches the zone of mechanical resistance first, giving the larger pupil a chance to make up the size difference.

### HORNER'S SYNDROME

The term *Horner's syndrome* is used to refer to any oculosympathetic palsy or paresis.

### Etiology

The fibers composing the oculosympathetic pathway have a long and tortuous course from the hypothalamus to the eye. Because a variety of vascular, traumatic, or neoplastic lesions can interrupt this pathway and produce the signs characteristic of Horner's syndrome, the clinician must understand the clinical anatomy to evaluate and manage appropriately patients with lesions of the oculosympathetic pathway. This pathway can be divided into three portions:

1. The central (first-order) neuron originates in the hypothalamus, courses through the brainstem and cervical cord, and terminates at the ciliospinal center of Budge at C8-T2.
2. The preganglionic (second-order) neuron is located in the chest and neck extending from the cervical cord (C8-T2) through the stellate ganglion at the pulmonary apex to the superior cervical ganglion at the bifurcation of the internal and external carotid arteries.
3. The postganglionic (third-order) neuron originates at the superior cervical ganglion (located at the level of the angle of the jaw) and travels through the internal carotid plexus until it penetrates the base of the skull, passes through the cavernous sinus, and accompanies the long ciliary nerves to the dilator muscle of the iris. Postganglionic sympathetic fibers also innervate Müller's muscle of the upper and lower eyelids.

The sympathetic fibers for sweating that innervate the face leave the superior cervical ganglion, follow the external carotid artery, and therefore are not involved in lesions of the carotid plexus. In some patients, however, a portion of the sympathetic fibers to the sweat glands in the ipsilateral forehead may follow branches of the internal carotid artery, allowing a lesion of the postganglionic oculosympathetic pathway to produce a small area of anhidrosis above the brow.

The most common acquired causes of Horner's syndrome are listed in Box 22-2. Congenital Horner's syndrome can be inherited by autosomal dominant transmission.

**Box 22-2** Etiologies of Horner's Syndrome

Central
Basal meningitis
Pituitary tumor
Tumor of third ventricle
Syphilis of midbrain
Tumor of pons
Syringobulbia
Syringomyelia
Cervical cord trauma and tumors
Spinal tabes
Poliomyelitis
Stroke
Multiple sclerosis
Preganglionic
Spinal birth injury
Tuberculosis
Pancoast tumor
Aortic aneurysm
Enlarged mediastinal glands
Enlargement of thyroid
Lymphadenopathy
Thoracic neuroblastoma
Pulmonary mucormycosis
Trauma
Cervical arthritis
Thoracostomy tube
Swan-Ganz catheter
Postganglionic
Abnormalities of the internal carotid artery
Unilateral vascular headache syndromes
Direct or indirect trauma
Spontaneous or traumatic occlusion
Aneurysms
Atherosclerosis
Spontaneous dissection
Lesions involving the middle cranial fossa and cavernous sinus
Basal skull fractures
Locally invasive neoplasms (meningiomas, etc.)
Metastatic neoplasms
Inflammation of adjacent structures
Tolosa-Hunt syndrome
Otitis media
Trigeminal herpes zoster
Sinusitis

Most lesions causing Horner's syndrome involve the preganglionic neuron. Patients with such lesions may have an apical lung tumor (Pancoast tumor) or breast malignancy that has spread to the thoracic outlet. The patient may also have a history of surgery or trauma to the neck, chest, or cervical spine. Nonoperative injuries to

the brachial plexus due to delivery or to motor vehicle accidents are common trauma related causes.

Although most lesions producing postganglionic Horner's syndrome are benign, a variety of potentially serious conditions may interrupt the postganglionic sympathetic pathway (see Box 22-2). Neoplasia as a cause of postganglionic Horner's syndrome is relatively rare. Causative lesions include nasopharyngeal tumors, meningiomas of the middle cranial fossa, and carcinomas invading from the sphenoid sinus. Patients with cluster headache may develop Horner's syndrome probably as a result of compromise of the postganglionic oculosympathetic fibers as they course with the sheaths surrounding a swollen internal carotid artery in the bony petrous canal.

The patient's age at the time of onset is an important aid to the clinician investigating Horner's syndrome of unknown etiology. Trauma is the leading cause in patients from birth to age 20 years. Almost one-half of the cases occurring in 21- to 50-year-olds result from tumors (most often benign). In the older age group ( $\geq 51$  years), neoplasia (more often malignant than benign) is the most important cause.

**Diagnosis**

**Clinical Evaluation.** Box 22-3 lists the primary clinical signs diagnostic of Horner's syndrome. Although the complete syndrome is dramatic, it is encountered only rarely. Consequently, diagnosis based on the patient's clinical signs alone can be difficult.

Because Müller's muscle, which is innervated by oculosympathetic fibers, assists in elevating the upper eyelid, interruption of the sympathetic innervation to this muscle results in variable degrees of ptosis. In some patients ptosis may be completely absent, in others it may be substantial, and in some it can worsen with fatigue. If the lesion is located centrally (i.e., in the first-order neuron), the only sign clinically observable may be pupillary constriction, without ptosis. In contrast, if the lesion is in the cervical sympathetic region, all the signs comprising the syndrome, including ptosis, may be present. The clinician should not misinterpret the partial ptosis of Horner's syndrome for retraction of the contralateral eyelid, because the patient can use the levator or frontalis muscles to elevate the ptotic lid. The practitioner should simply cover the eye that does not appear to display eyelid retraction. If the patient has Horner's syndrome, the covered eye manifests a ptosis.

Because sympathetically innervated smooth muscle fibers also exist in the lower eyelid, oculosympathetic paresis can produce elevation of the lower lid (so-called upside-down ptosis). This condition is often subtle. However, this sign, along with ptosis of the upper lid, contributes to a narrowing of the palpebral fissure, giving the appearance of enophthalmos.

Disruption of the sympathetic innervation to the iris dilator enables the parasympathetically innervated iris

**Box 22-3** Diagnostic Signs in Horner's Syndrome

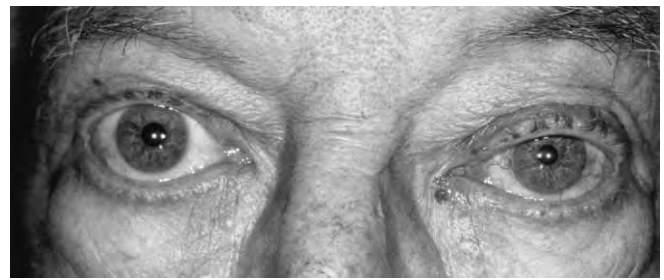Unilateral ptosis  
 Elevation of the lower eyelid ("upside-down ptosis")  
 Narrowed palpebral fissure (apparent enophthalmos)  
 Ipsilateral miosis  
 Dilation lag  
 Absence of dilation to psychosensory stimuli  
 Conjunctival hyperemia  
 Facial or body anhidrosis  
 Heterochromia iridis, if congenital

sphincter to exert the predominant action on the iris, thus producing miosis. The degree of anisocoria, however, may not remain constant in any given patient, because the pupil size can vary with completeness of the syndrome, location of the lesion, patient alertness, ambient illumination, degree of denervation hypersensitivity, patient fixation, and the concentration of neurotransmitter substances.

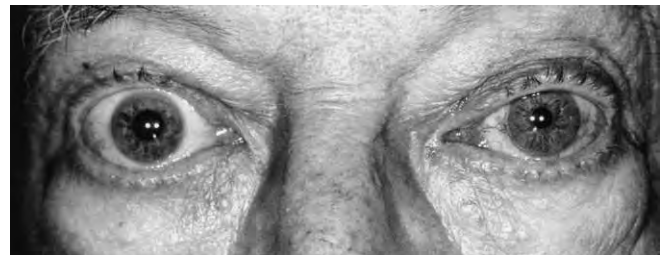An extremely helpful sign in the clinical diagnosis of Horner's syndrome is dilation lag, in which the pupil fails to redilate quickly to its original size when light is extinguished. This phenomenon can be easily evaluated by comparing the dilation time in each eye. After exposure to a bright stimulus, the normal pupil returns to its original darkness diameter in approximately 12 to 15 seconds, with approximately 90% of the dilation occurring during the first 5 to 6 seconds. This includes pupils manifesting physiologic anisocoria. In Horner's syndrome, however, the pupil requires approximately 25 seconds to return to its original darkness diameter, reaching nearly 90% of its final diameter within the first 10 to 15 seconds. The maximum difference between the normal pupil and Horner's pupil on dark dilation occurs after 4 to 5 seconds of darkness. This difference is an expression of the dilation lag that is pathognomonic of Horner's syndrome. Flash Polaroid photographs should be taken first after the patient has been in bright light for a few minutes, then in darkness 4 to 5 seconds after the light has been extinguished, and finally in darkness 10 to 12 seconds after the light has been extinguished (Figure 22-2). The criteria for recognizing dilation lag are poor dilation of the more miotic pupil at 4 to 5 seconds, as compared with the dilation achieved after 10 to 12 seconds of darkness, and increased anisocoria in darkness, more marked at 4 to 5 seconds than at 10 to 12 seconds.

Conjunctival hyperemia is generally a transient clinical sign and occurs only in the acute phase of Horner's syndrome. It usually disappears after the first few weeks.

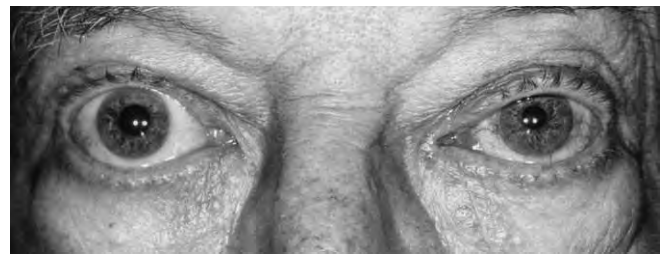Because sweating is mediated by sympathetic innervation, interruption of these fibers results in facial or body anhidrosis or hypohidrosis. However, lesions involving the postganglionic sympathetic pathway generally cause Horner's syndrome without anhidrosis. The presence of



A



B



C

**Figure 22-2** Dilation lag in 72-year-old man with left-sided Horner's syndrome. (A) Obvious anisocoria in bright illumination. Note greater anisocoria at 4 to 5 seconds in darkness (B) as compared with the anisocoria at 10 to 12 seconds in darkness (C).

asymmetric sweating between opposite sides of the forehead can be easily assessed by performing the friction sweat test. This test assesses sweating by evaluating resistance to the movement of a standard office prism bar across the forehead. After cleaning both the forehead and prism bar with an alcohol pad, the face and bar are allowed to dry. Holding the bar against the forehead and perpendicular to the floor, the bar is drawn downward while exerting mild pressure against the forehead. The amount of resistance to movement of the bar is compared for each side of the forehead. The anhidrotic side will be almost frictionless, whereas the normal side will display marked resistance to movement of the bar.

The finding of heterochromia iridis indicates congenital or neonatal Horner's syndrome. Normal pigmentation of the iris is associated with integrity of the cervical sympathetic nervous system. Pigmentation of the iris is not complete until age 2 years. Hypopigmentation of the iris on the side of the lesion is characteristic of spinal birth injury involving the preganglionic (second-order) neuron. Oculosympathetic paresis occurring after 2 years

of age generally does not result in heterochromia, but several cases have been reported in adults.

The term Raeder's syndrome designates any painful postganglionic Horner's syndrome. The pain may consist of a unilateral headache or facial pain in the distribution of the trigeminal nerve. Patients with Raeder's syndrome fall into three major groups: (1) those with either multiple parasellar cranial nerve involvement (III, IV, V, VI) or involvement of the second, third, or all three divisions of the trigeminal nerve; (2) those with a typical history of cluster headache; and (3) those with a pain history atypical of cluster headache, in whom the first (ophthalmic) division of the trigeminal nerve only may be involved. Common to all three groups is the association of unilateral headache with interruption of the postganglionic oculosympathetic fibers along the course of the internal carotid artery. Recently it was suggested that group 3 Raeder's syndrome cases be named strictly for their anatomic description, paratrigeminal oculosympathetic syndrome, to help clarify their benign nature.

**Pharmacologic Evaluation.** The decision to proceed with pharmacologic testing is based solely on the clinical findings. If there is unequivocally no ptosis and no dilation lag, the anisocoria can be considered to be physiologic, and the patient does not need to undergo pharmacologic evaluation. The patient who has minimal anisocoria with minimal ptosis but without dilation lag likewise can be considered to have physiologic anisocoria. If enough clinical findings, however, strongly suggest the possibility of Horner's syndrome, such as definite ptosis but equivocal dilation lag, then the cocaine test is indicated to confirm the diagnosis. If definite miosis exists in association with definite ptosis and if an unequivocal dilation lag also exists, the diagnosis of Horner's syndrome can be made on clinical grounds, and the practitioner may proceed directly to the hydroxyamphetamine test. Table 22-3 summarizes the indications for pharmacologic testing in patients with suspected Horner's syndrome.

**Cocaine Test.** When topically applied, cocaine produces dilation of the pupil by preventing the reuptake of norepinephrine that has been released into the synaptic junctions of the iris dilator muscle in response to a nerve impulse. If the sympathetic innervation to the eye

is interrupted at any level (central, preganglionic, or postganglionic), cocaine should theoretically have no mydriatic effect because in each case the flow of nerve impulses has been impeded and no endogenous norepinephrine is released. However, when the lesion is in the brainstem or spinal cord (first-order neuron), mydriasis with cocaine may be impaired but not entirely abolished. This impairment results from incomplete interruption of the descending sympathetic pathway. Thus, as a rule, dilation with cocaine is reduced or absent in any Horner's pupil, regardless of the site of impairment. Consequently, the cocaine test is useful as a screening procedure to confirm the presence or absence of oculosympathetic paresis; however, this test does not indicate the location of the lesion.

The cocaine test is valid only if the cornea is intact, so it is important that the clinician not perform applanation tonometry before the test. In addition, the test is not as effective on darkly pigmented irides as it is on lighter irides. The patient should be informed that he or she may have a positive urine test for cocaine for 24 hours after the test.

To perform the test one drop of cocaine solution should be instilled into each eye once and again after several minutes, and the pupils should be evaluated after 50 to 60 minutes (Figure 22-3). Cocaine 10% is preferred over a weaker concentration because it may require several hours before significant dilation is recognized in the normal pupil. This situation is especially true for patients with dark irides, which may dilate very slowly and poorly. In general, a postcocaine anisocoria of at least 1 mm is required to confirm the diagnosis.

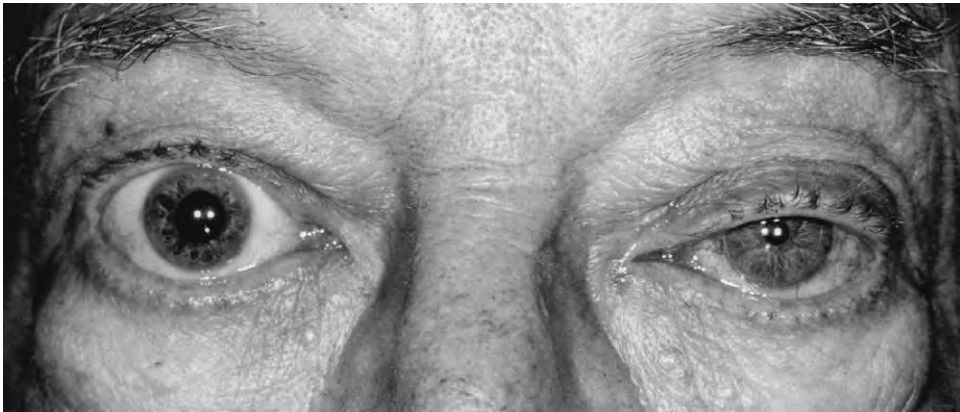**Apraclonidine Test.** Apraclonidine 1% has shown promise in testing for Horner's syndrome. The drug should be instilled in both eyes. Significant pupillary dilation occurs in the eye with Horner's syndrome, whereas little or no dilation occurs in the normal eye. The up-regulation of  $\alpha$ -receptors that occurs with sympathetic denervation in Horner's syndrome appears to unmask apraclonidine's  $\alpha_1$  effect in the eye with Horner's syndrome.

**Hydroxyamphetamine Test.** The failure of hydroxyamphetamine to dilate the postganglionic Horner's pupil can distinguish patients with postganglionic lesions from

**Table 22-3**  
Indications for Pharmacologic Testing in Suspected Horner's Syndrome

Signs <sup>a</sup>	Presumptive Clinical Diagnosis	Indicated Pharmacologic Testing
No ptosis, no dilation lag	Physiologic anisocoria	None
Minimal ptosis, no dilation lag	Physiologic anisocoria	None
Definite ptosis, equivocal dilation lag	Horner's syndrome	Cocaine or apraclonidine test followed by hydroxyamphetamine test
Definite ptosis, unequivocal dilation lag	Horner's syndrome	Hydroxyamphetamine test

<sup>a</sup>Documented by photography.



**Figure 22-3** Cocaine test for Horner's syndrome (same patient as in Figure 22-2A). After instillation of 10% cocaine into each eye, dilation occurs in the normal right pupil but not in the left Horner's pupil.

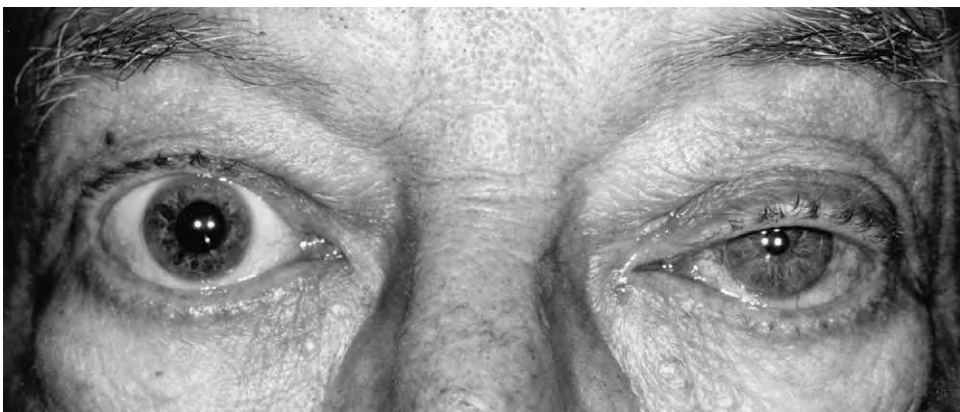patients with central or preganglionic lesions. The localizing value of hydroxyamphetamine lies in its indirect pharmacologic action. The drug is an indirectly acting  $\alpha$ -adrenergic agonist that dilates the pupil only in the presence of endogenous norepinephrine. In the case of postganglionic Horner's syndrome, the postganglionic sympathetic pathway is compromised enough to diminish the normal concentration of norepinephrine contained within the presynaptic vesicle. Consequently, hydroxyamphetamine cannot produce mydriasis or produces only incomplete mydriasis (Figure 22-4). In the case of central or preganglionic lesions, the postganglionic sympathetic pathway is left undisturbed so that the norepinephrine contained within the presynaptic vesicles may be released by the topically instilled hydroxyamphetamine, thus producing normal mydriasis.

Hydroxyamphetamine has a mydriatic effect only when the postganglionic sympathetic pathway to the eye is intact. However, one source of error in hydroxyamphetamine testing is its use in infants with acquired preganglionic lesions: In such cases, due to transsynaptic

degeneration, the pupil may behave pharmacologically as if a postganglionic lesion were present.

Hydroxyamphetamine provides a clearer distinction between preganglionic and postganglionic defects than does any other mydriatic test. Although the hydroxyamphetamine test is not subject to error because of factors that tend to enhance corneal penetration, the results of this test may be somewhat ambiguous when the Horner's syndrome is incomplete. Because pretreatment with cocaine interferes with the action of hydroxyamphetamine, at least 2 days should elapse after cocaine administration before proceeding with the hydroxyamphetamine test. The pupils should be observed at 45 to 60 minutes after the medication is instilled.

**Phenylephrine Test.** If hydroxyamphetamine is not readily available, an alternative is to use a weak 1% solution of phenylephrine to demonstrate that the pupil in postganglionic Horner's syndrome has denervation sensitivity. Solutions of 1% phenylephrine do not dilate the normal pupil, but in the presence of sympathetic denervation may



**Figure 22-4** Hydroxyamphetamine test in Horner's syndrome (same patient as in Figure 22-2A). After instillation of 1% hydroxyamphetamine into each eye, dilation occurs in the normal right pupil but not in the left Horner's pupil, indicating a postganglionic lesion.



**Table 22-4**  
Response to Mydriatic Drug Tests in Horner's Syndrome

Drug	Normal Pupil	Central Lesion	Preganglionic Lesion	Postganglionic Lesion
Cocaine 10% (2 drops)	Mydriasis	Impaired dilation	No dilation	No dilation
Hydroxyamphetamine 1% (2 drops)	Mydriasis	Normal dilation	Normal dilation	No dilation

Modified from Thompson HS. Diagnostic pupillary drug tests. In Blodi FC, ed. *Current concepts in ophthalmology*, vol 3. St. Louis: Mosby, 1972:76-90. With permission.

produce mydriasis and the Horner's pupil dilates larger than the normal pupil. In a study of patients with Horner's syndrome, it was found that 71% of the patients were sensitive to 1% phenylephrine. A 1% phenylephrine dilution is obtained by mixing one drop of 10% commercially available phenylephrine with nine drops of irrigating solution or normal saline.

**Application of Pharmacologic Test Results.** Table 22-4 summarizes the expected responses of the Horner's pupil to cocaine and hydroxyamphetamine. This current schema for drug testing in Horner's syndrome applies only to complete lesions of the oculosympathetic pathway and should not be relied on in patients with incomplete lesions. Cocaine is used initially to confirm the presence of Horner's syndrome, whereas hydroxyamphetamine is used several days later to localize the lesion to the central, preganglionic, or postganglionic sympathetic pathway. Note that presently no pupillary drug test clearly distinguishes central from preganglionic lesions.

### Management

It is crucial to differentiate central or preganglionic lesions from postganglionic lesions, because appropriate patient management depends on accurate localization of the lesion. When the detailed history, clinical examination, and pharmacologic testing indicate a central or preganglionic lesion of unknown etiology, the patient should be referred to a thoracic surgeon or internist because of the risk of malignancy. Because of the risk of neuroblastoma, pediatric patients with early onset Horner's syndrome should also be investigated. Neurologic consultation should be considered when central lesions are suspected.

Postganglionic lesions are most likely associated with a benign vascular headache syndrome. Such patients with unilateral headache and isolated postganglionic Horner's syndrome usually follow a benign course and need no further evaluation. However, if the headaches do not spontaneously resolve within several months or if objective involvement of the trigeminal nerve or other parasellar cranial nerves is documented, then further neurologic investigation should be considered. Figure 22-5 summarizes the management of the patient with Horner's syndrome of unknown etiology.

## ADIE'S SYNDROME

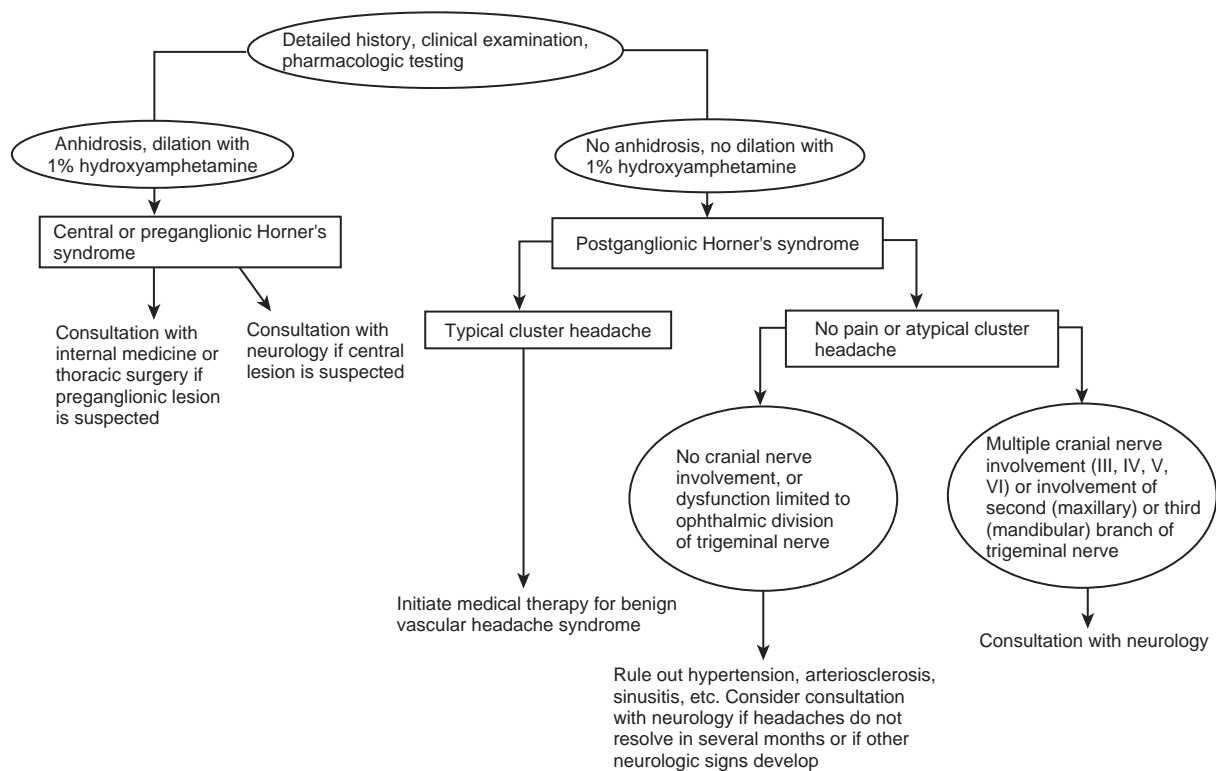
An association between tonic pupils and hyporeflexia is known as Adie's syndrome. A tonic pupil alone without associated hyporeflexia is termed Adie's pupil.

### Etiology

The etiology of Adie's pupil is usually unknown. It is generally accepted, however, that the lesion is in the ciliary ganglion, with damage to the postganglionic neurons serving the ciliary muscle and iris sphincter. Adie's pupil frequently follows a mild upper respiratory infection, and thus in some cases it may be associated with a nonspecific viral illness. In other instances orbital trauma can produce the syndrome. Surgical repair of orbital floor fractures can also cause Adie's pupil due to damage to the ciliary ganglion or postganglionic neurons. Adie's-like pupils with accommodative paresis have occurred as complications after peripheral retinal laser treatment. They result from laser damage to cholinergic nerve fibers, beneath the treated area, that innervate the ciliary body and iris sphincter. An Adie's-like sector palsy, without accommodative insufficiency, can follow argon laser trabeculoplasty for treatment of certain glaucomas. When Adie's pupil occurs bilaterally, it may be associated with orthostatic hypotension, Riley-Day syndrome, or neurosyphilis.

The most widely accepted interpretation of Adie's pupil involves the concept of aberrant regeneration of nerve fibers. The parasympathetic accommodative fibers in the ciliary ganglion are believed to be far more numerous than those that supply the iris sphincter. After destructive ciliary ganglion disease, nerve fiber regeneration may occur, with some accommodative fibers becoming misdirected and supplying the iris sphincter. This aberrant regeneration results in attenuation or loss of the pupillary light response, with preservation of constriction of the pupil in accommodation—so-called light-near dissociation. Although this hypothesis does not explain the hyporeflexia that often accompanies the ocular findings in Adie's syndrome, the syndrome may represent a form of mild polyneuropathy, accounting for the diminished deep tendon reflexes. In rare cases Adie's syndrome and a severe polyneuropathy can be associated with underlying malignant disease. Perhaps the most noteworthy difference between the clinical signs of Adie's pupil





**Figure 22-5** Flow chart for management of the patient with Horner's syndrome of unknown etiology. (Modified from Grimson BS, Thompson HS. Raeder's syndrome. A clinical review. *Surv Ophthalmol* 1980;24:199-210.)

and those of isolated third-nerve pupillary palsy is the presence of light-near dissociation in the former and its absence in the latter.

### Diagnosis

**Clinical Evaluation.** Adie's pupil is a benign disorder. A diagnosis of Adie's pupil eliminates the need for elaborate and expensive neuroradiologic investigations. Box 22-4 lists the primary clinical characteristics diagnostic of Adie's syndrome.

Adie's pupil is unilateral in 80% to 90% of cases. Approximately 4% become bilateral each year. In the

acute stage, the pupil is usually dilated and reacts very poorly to light. The tonic pupil often changes size in a random manner, possibly being larger in the morning and smaller in the afternoon. Adie's pupils tend to become smaller over time. Some patients who have been monitored for several years have shown a strikingly progressive miosis of the affected pupil. The gradual constriction is more marked than the normal miosis of aging. The dilated pupil usually returns to its original size within a few months; after approximately 2 years a very slowly progressive additional miosis occurs.

In a patient with an Adie's pupil that is larger than the normal pupil in darkness, the condition is most likely of very recent onset. The tendency of Adie's pupils to become progressively miotic and bilateral with age suggests that many Adie's pupils eventually become disguised as Argyll Robertson-like pupils or simply become inconspicuous among the smaller pupils of the elderly.

The reaction of an Adie's pupil to an accommodative stimulus is very sluggish and poor. The typical slow and tonic near response serves as the mechanism for the most distinguishing clinical feature of this syndrome—namely, tonic and sluggish redilation as the patient changes fixation from near to distance.

Of patients with Adie's pupil, 50% to 90% demonstrate significantly impaired or absent deep tendon reflexes, and this sign serves as a helpful clinical confirmation of the diagnosis. Most patients have tendon reflexes that are abnormal throughout the body, but the ankles and triceps

#### Box 22-4 Diagnostic Signs in Adie's Syndrome

- Relative mydriasis in bright illumination
- Absent or poor light reaction
- Slow (tonic) contraction to prolonged near effort
- Slow redilation after near effort
- Vermiform movements of pupillary margin (i.e., sector palsies of iris sphincter)
- Accommodative paresis
- Diminished deep tendon reflexes
- Onset in third to fifth decade<sup>a</sup>
- Women affected in 70% of cases

<sup>a</sup>Can rarely occur in children.

often demonstrate greater impairment than the knees and biceps. Approximately one-third of patients with Adie's syndrome have entirely normal knee jerks, but approximately one-half of patients have completely absent ankle jerks.

When observed with the slit lamp, the iris may demonstrate subtle and irregular (vermiform) movements of its sphincter. Segmental palsies of portions of the iris sphincter occur in almost every patient with Adie's pupil. Vermiform movements of the sphincter are nothing more than physiologic pupillary unrest (hippus) of those segments of the sphincter that are intact and still functioning in response to light. Although the affected pupil shows some residual light reaction in most patients, approximately 10% of patients have a total palsy of the iris sphincter. Segmental palsies of the iris sphincter characterize Adie's pupil, but they are not pathognomonic.

Most patients with Adie's pupil have an accommodative paresis in the involved eye at the onset of the condition, and this paresis is often the primary source of symptoms. A relative accommodative paresis in the affected eye of 0.50 D or more at initial examination occurs in two-thirds of the patients. Accommodation tends to recover during the first 2 years.

In summary, the typical patient with acute Adie's syndrome is a young (aged 20–40 years) otherwise healthy woman presenting with a unilateral fixed and dilated pupil, blurred near vision in the affected eye, and impaired deep tendon reflexes. Clinical evaluation reveals tonic redilation of the pupil from near to distance. Such a patient can usually be given the diagnosis of Adie's syndrome on clinical grounds, without the need for pharmacologic, laboratory, or neuroradiologic investigations. However, in those instances in which the clinical signs are ambiguous or incomplete, pharmacologic testing is indicated.

**Pharmacologic Evaluation.** The denervated iris sphincter in Adie's pupil shows cholinergic hypersensitivity. This response is expected according to the principle of denervation hypersensitivity. The hypersensitivity does not seem to correlate with either the amount of sphincter denervation, the duration of the Adie's pupil, or the amount of light-near dissociation. Occasionally, an acute Adie's pupil shows very little hypersensitivity during the first few weeks after onset but gradually becomes increasingly hypersensitive several months after the initial episode.

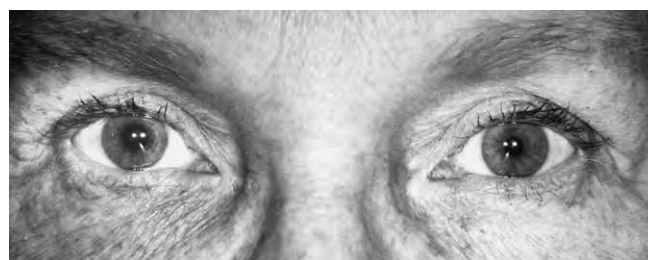Cholinergic hypersensitivity can be tested by using pilocarpine in 0.0625%, 0.1%, 0.125%, or 0.25% solution (Table 22-5). The usefulness of the pilocarpine test in eliciting cholinergic hypersensitivity depends on the presence of a standardized concentration of drug at the iris. Thus any clinical procedure that compromises the corneal epithelium, the use of wetting agents, or other factors that enhance corneal penetration may result in false-positive findings.

**Table 22-5**  
Dilution of Commercially Available Pilocarpine

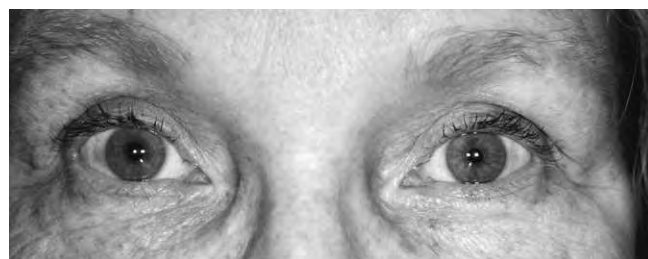Concentration (%) of Commercially Available Pilocarpine	Desired Final Concentration (%)	
	0.1	0.125
1	1/9	1/7
2	1/19	1/15

*Note:* Dilutions are prepared by mixing the indicated number of drops of commercially available drug (numerator of fraction) with the indicated number of drops of extraocular irrigating solution or normal saline (denominator of fraction). Equal drop sizes should be used.

A concentration of 0.125% solution slightly constricts most normal pupils, with the degree of miosis differing among individuals from just noticeable to several millimeters. Using a concentration that slightly constricts the normal pupil allows the clinician to ascertain whether each eye has received an adequate amount of drug. In the typical patient with Adie's pupil, 0.125% pilocarpine causes a slight constriction of the normal pupil, whereas the affected pupil becomes even more miotic (Figure 22-6). A 0.1% concentration of pilocarpine usually does not constrict a normal pupil but does constrict a tonic pupil. The 0.25% concentration has been found to produce too many false-positive responses, whereas the 0.0625% concentration produces too many false-negative responses.



A



B

**Figure 22-6** Pilocarpine test in a 57-year-old woman with right Adie's pupil. (A) Before drug instillation. (B) After instillation of 0.125% pilocarpine into each eye, the normal left pupil constricts slightly, whereas the right Adie's pupil constricts significantly.

When cholinergic hypersensitivity is being evaluated, it is important that the lowest ambient illumination possible be used to reduce the additional miotic influence of light. This approach enhances judgment of pupil size and response to the dilute pilocarpine. If the patient's larger pupil becomes the smaller pupil in dim illumination after dilute pilocarpine is instilled into both eyes, the reaction of the larger pupil most likely represents a hypersensitive response and thus indicates a diagnosis of Adie's pupil. This endpoint does not apply, however, to suspected bilateral tonic pupils, tonic pupils that are smaller than their normal fellow pupils in dim illumination, or long-standing Adie's pupils that are small in both darkness and normal ambient light.

### Management

Because Adie's syndrome is a benign disorder, the most important aspect in patient management is reassurance. The associated accommodative paresis tends to recover during the first several years, and any visual impairment thus improves. The patient should be advised that the second eye may become involved but that the other changes associated with the syndrome (decreased light reaction and diminished deep tendon reflexes) do not represent significant functional impairments. For many patients the chief concern is the cosmetic appearance of the unequal pupils. Most patients can be reassured that, with time, this should become less noticeable.

Blood tests should be ordered to rule out syphilis in cases of a tonic pupil. If there is associated pain, the patient should receive a workup for an intracranial lesion or orbital mass.

Symptomatic patients may benefit from the instillation of 0.1% to 0.125% pilocarpine into the affected eye three or four times daily. Because of individual variability, various low concentrations of pilocarpine should be attempted to determine the optimum concentration of miotic that alleviates symptoms as periocular discomfort, headache, photophobia, or blurred vision. If a miotic is used in this fashion, the patient should be carefully monitored in anticipation of modifying the drug regimen if the degree of cholinergic hypersensitivity changes over time.

The practitioner can also prescribe tinted lenses, which not only shield the cosmetic appearance of the unequal pupils but also alleviate perception of the Pulfrich phenomenon produced by the anisocoria. Moreover, when affected patients are presbyopic, unequal bifocal powers can be used and frequently serve to alleviate the asthenopia associated with near vision. Reading lenses may be indicated for patients who are prepresbyopic.

## UNILATERAL FIXED AND DILATED PUPIL

A unilateral fixed and dilated pupil in an ambulatory and otherwise healthy patient is seldom associated with a significant neurologic disorder. Yet, historically, the practitioner

has been cautioned to consider this a sign of potentially grave intracranial disease. Although the possible causes of a fixed and dilated pupil are numerous and include potentially destructive vascular and neoplastic processes, the clinician can usually, by comprehensive history and physical examination, narrow the possible diagnoses to (1) involvement of the intracranial third nerve, (2) Adie's pupil, or (3) anticholinergic mydriasis.

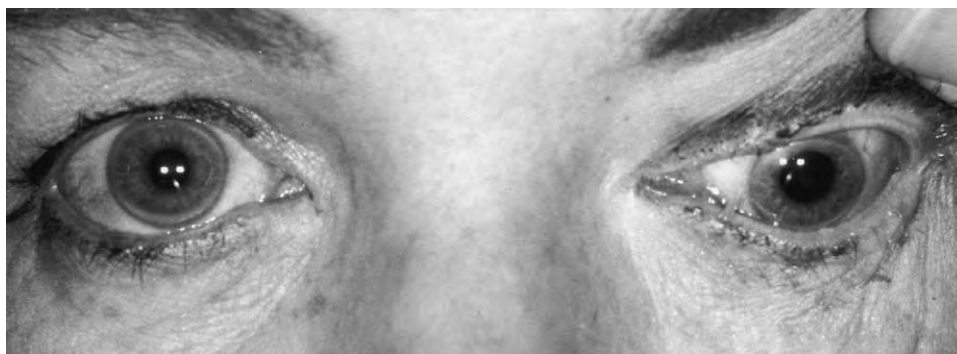Because the fixed and dilated pupil is clearly the abnormal pupil, the pharmacologic evaluation involves instillation of a miotic, usually pilocarpine, to assess the degree of impairment of the iris sphincter or its parasympathetic innervation. In most cases only one pupil is dilated and fixed, and instilling the drug into both eyes can avoid false-positive or false-negative drug tests. Constriction of the normal pupil thus indicates that enough pilocarpine was instilled. When both pupils are dilated and fixed, the drops should be placed in only one eye so that any constriction can be attributed solely to the drug.

The following sections consider the most common disorders associated with a unilateral fixed and dilated pupil, including third-nerve palsy, anticholinergic mydriasis, iris sphincter atrophy, and adrenergic mydriasis. Because a dilated pupil does not always characterize Adie's syndrome, this disorder has been discussed separately.

### Third-Nerve Palsy

The patient presenting with the classic signs of a complete third-nerve palsy does not need to undergo pharmacologic testing; the diagnosis can be made on clinical findings alone (Figure 22-7). The most common cause of sudden unilateral third-nerve palsy in an adult with a dilated and fixed pupil and with headache is an aneurysm at the junction of the ipsilateral internal carotid artery and the posterior communicating arteries. The most common cause of sudden unilateral third-nerve palsy in an adult with headache in whom the pupil is spared is diabetes mellitus. The pupillary findings, therefore, are extremely important in the evaluation and management of acute third-nerve palsy.

If, however, the patient exhibits only a unilateral fixed and dilated pupil without evidence of ptosis or extraocular muscle involvement, the clinician should perform the pilocarpine test, first using a 0.125% solution to reveal any cholinergic hypersensitivity as evidence for Adie's pupil. If there is no local iris damage by slit-lamp examination, no sector palsy of the iris sphincter, and no cholinergic hypersensitivity demonstrated by the 0.125% pilocarpine test, then the condition might be associated with interruption of the preganglionic innervation to the iris sphincter (i.e., third-nerve palsy). If the patient has third-nerve palsy, topically instilled pilocarpine in moderate concentrations activates the muscarinic receptor sites on the iris sphincter. Therefore if 0.125% pilocarpine reveals no cholinergic hypersensitivity, the practitioner



**Figure 22-7** Complete third-nerve palsy. Note the left ptosis, exotropia, hypotropia, and dilated pupil.

should subsequently instill pilocarpine in a concentration of 0.5% or 1.0%. This should promptly constrict the affected pupil (Figure 22-8). Some patients with intracranial third-nerve palsy may appear to manifest hypersensitivity to low concentrations of pilocarpine. This finding occurs because of the greater mechanical reactivity of the larger pupil; in long-standing cases it also may be caused by actual denervation hypersensitivity of the iris sphincter from transsynaptic degeneration of postganglionic neurons. Thus the clinician should evaluate carefully all clinical signs and symptoms before reaching a final diagnosis.

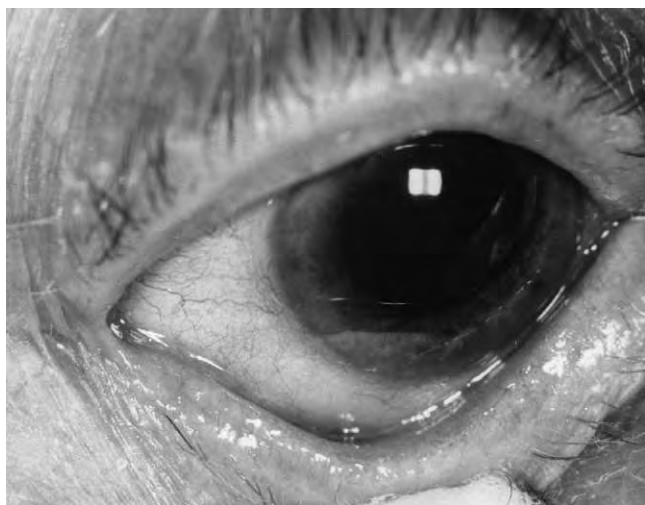
### Anticholinergic Mydriasis

#### Etiology

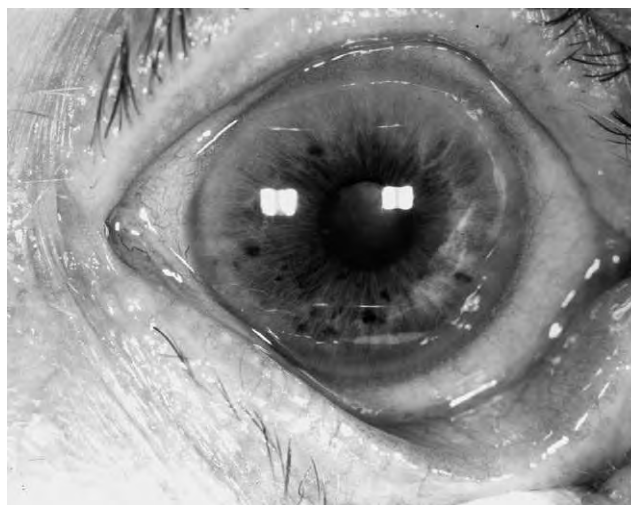
Anticholinergic mydriasis, also known as pharmacologic blockade or atropinic mydriasis, refers to a fixed and dilated pupil resulting from the instillation or inoculation into the eye of drugs or substances with anticholinergic properties. Medical personnel such as doctors, nurses,

and pharmacists are particularly susceptible to this condition, because they frequently handle such agents. Commonly, some medication spills over the side of its bottle, and the practitioner or nurse who next handles the bottle comes into contact with the dried medication, which then is easily transferred to the eye by simple rubbing. On occasion, the patient admits to having placed some drops into the affected eye but often cannot recall the name of the medication. In these cases the practitioner should inquire about the color of the medication's cap, because cycloplegics are commercially packaged with red caps. Patients often have instilled into their mildly irritated eye atropine drops previously prescribed for an episode of anterior uveitis.

Cyclopentolate, homatropine, scopolamine, and atropine are among the most frequently implicated drugs, but many other drugs or substances with anticholinergic properties have also been implicated in anticholinergic mydriasis. Jimson weed (*Datura stramonium*) grass is found in many parts of the United States, and the entire plant, from root to flower, contains significant concentrations of belladonna



A



B

**Figure 22-8** Pilocarpine test in third-nerve palsy. (A) Before drug instillation. (B) After instillation of 1.0% pilocarpine, the pupil promptly constricts.

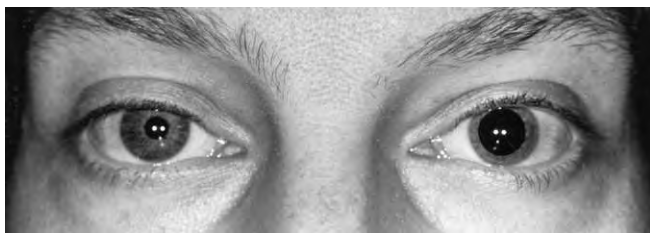

alkaloids, including atropine, scopolamine, and hyoscyamine. One should suspect jimson weed mydriasis in farmers or in children who have been “picking flowers” if these patients present with an acute-onset unilateral mydriasis. Moreover, the dried pods of the plant often are used in floral arrangements for indoor decoration during the winter. This use may contribute to an increased risk of systemic toxicity in the pediatric age group, because children have been known to consume such “berries.” Fatal cases of systemic toxicity have been reported in children whose stomachs contained the seeds at autopsy. In addition to bilaterally dilated pupils, when the weed is consumed orally the early symptoms of toxicity are those typical of anticholinergic drugs: blurred vision, dryness of the mouth, extreme thirst, constipation, urinary retention, convulsions, dry and flushed skin, diffuse erythematous rash, tachycardia, and fever.

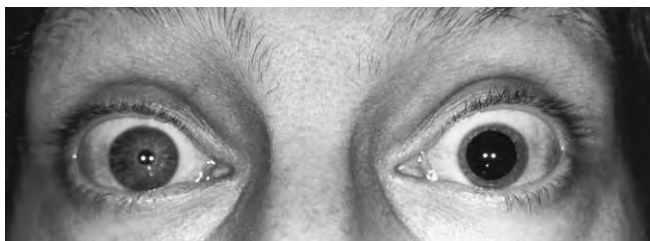The practitioner should be alert to the possible inoculation into the eye of any drug or substance with anticholinergic properties, including plants, cosmetics, perfumes, or medicines. Unilateral fixed and dilated pupils have been reported after the use of antiperspirants, transdermal scopolamine (Transderm Scōp) for the prophylaxis of motion sickness, and from direct droplet contamination associated with the use of anticholinergic aerosols for treatment of acute asthma and other airflow obstructions.

### Diagnosis

The diagnostic procedure of choice in distinguishing between neurogenic and anticholinergic pupillary paralysis is one or two drops of 0.5% or 1.0% pilocarpine instilled into each eye (Figure 22-9). If the muscarinic



A



B

**Figure 22-9** Pilocarpine test in anticholinergic mydriasis. (A) A 27-year-old man with fixed and dilated left pupil. (B) After instillation of 1.0% pilocarpine into each eye, the right pupil constricts, whereas the left pupil does not.

receptor sites on the affected iris sphincter have been occupied by an anticholinergic drug, the pilocarpine fails to activate the receptors and constrict the pupil. This simple test quickly and easily differentiates between anticholinergic mydriasis and pupillary paralysis associated with third-nerve palsy; in the former condition the pupil does not react to the pilocarpine, whereas in the latter it constricts.

### Management

Once the diagnosis of anticholinergic mydriasis has been confirmed, the patient should be reassured that with time—usually a few days to a few weeks—the pupil will spontaneously return to its original size and vision (accommodation) will improve as the effects of the substance subside.

### Damage to the Iris

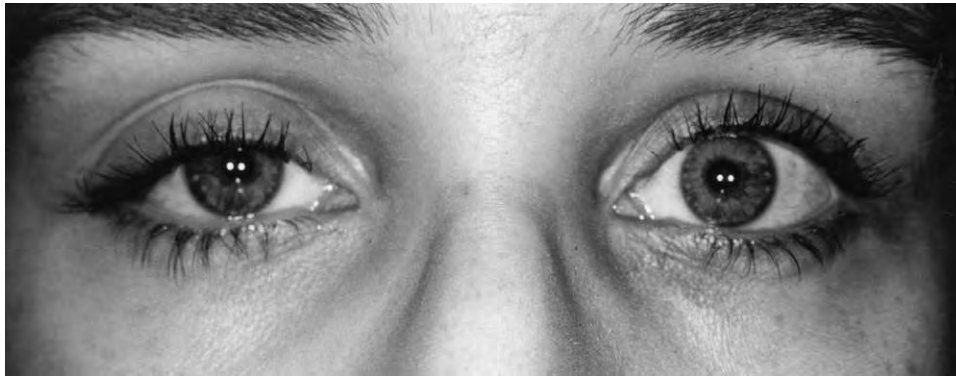Damage to the iris sphincter muscle by high intraocular pressure, trauma, or inflammation may impair pilocarpine's ability to constrict the pupil. Clinically, these conditions can usually be excluded by a careful history taking and biomicroscopic examination. Mechanical factors associated with malpositioned intraocular lenses or posterior synechiae may also limit movement of the iris. Depending on the extent of iris damage, the pupil may demonstrate complete to nonexistent constriction.

### Adrenergic Mydriasis

The pupil that has become dilated in response to topically instilled adrenergic drugs may not be completely immobile. A patient who is unusually sensitive to adrenergic agonists may sustain a dilated pupil as a consequence of the accidental inoculation into the eye of nose drops, nasal sprays, or other substances with adrenergic properties. In addition, some patients with minor corneal epithelial compromise may sustain a dilated pupil after the instillation of decongestant eyedrops. In these instances, however, the adrenergic mydriasis can usually be distinguished from the dilated pupil of third-nerve palsy or anticholinergic mydriasis by the blanched conjunctiva, the residual pupillary light reaction, and the occasional retracted upper eyelid (Figure 22-10). Although dilation associated with adrenergic agonists usually is incomplete and short-lived, the concomitant use of topical epinephrine and timolol for the treatment of glaucoma may occasionally result in the development of long-standing fixed and dilated pupils. A careful history and clinical evaluation of the patient usually eliminate the need for pharmacologic testing. Figure 22-11 summarizes the clinical and pharmacologic evaluations of the patient with anisocoria in which only one pupil is affected.

## OPTIC NERVE DISEASE

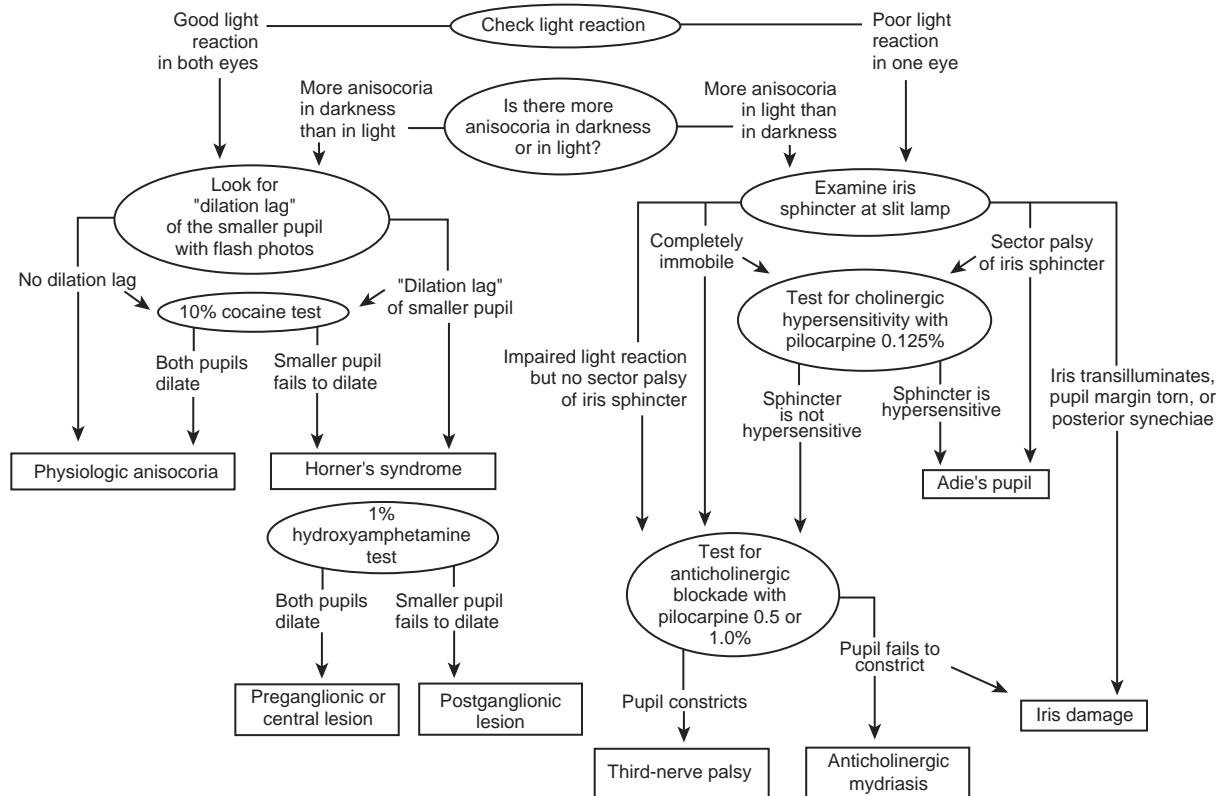
The diseases that affect the optic nerve can be broadly classified into congenital disc anomalies and acquired



**Figure 22-10** Retracted left upper eyelid after instillation of 0.012% naphazoline (Degest 2) as a decongestant.

optic neuropathies. This section considers those optic nerve diseases, or optic neuropathies, that are acquired in origin. Optic neuropathies may be due to abnormal accumulation of substances in the nerve or nerve sheath (infiltrative neuropathy), invasion of microorganisms (infectious optic neuropathy), localized responses (inflammatory optic neuropathy), demyelinating processes (optic neuritis), toxic reactions, trauma, and nutritional deficiencies. The term *optic neuritis* has traditionally referred to an inflammatory optic neuropathy of unknown etiology or one associated with multiple sclerosis

(MS), which is a demyelinating disorder. When optic neuritis occurs without disc swelling, the condition is called retrobulbar neuritis. When disc swelling is associated with optic neuritis, the condition is called papillitis. Papilledema is bilateral disc edema associated with increased intracranial pressure (ICP). Optic atrophy, the end stage of many optic neuropathies, is characterized by a pale disc and associated with a relative afferent pupillary defect (RAPD) and possible loss of visual acuity, color vision, and visual field. One example of disc atrophy occurs in cases of Leber's hereditary optic neuropathy



**Figure 22-11** Flow chart for the clinical and pharmacologic evaluation of a patient with anisocoria in which only one pupil is affected. (Modified from Thompson HS, Pilley SFJ. Unequal pupils. A flow chart for sorting out the anisocoria. *Surv Ophthalmol* 1976;21:45-48.)

(LHON), in which the pallor begins 2 to 4 weeks after vision loss.

### Optic Neuropathy Due to Long-Standing Papilledema

The ophthalmoscopic picture of papilledema, comprising the classic blurred disc margins, nerve fiber layer (NFL) swelling, disc hyperemia, and splinter hemorrhages, is caused by an increase in ICP. This elevated pressure may be due to an increase in cerebrospinal fluid (CSF) level or a space-occupying lesion compressing brain tissue. There are four stages of papilledema, and the clinical appearance of the swollen nerve head varies depending on the stage at which it is being viewed.

The earliest stage, or incipient papilledema, reveals a mild segmental blurring of the NFL bundles. The disc margin is commonly blurred at the upper and lower poles. The disc itself is hyperemic with small splinter hemorrhages in the NFL at the disc margin.

The second stage, acute papilledema, produces increased swelling such that the disc protrudes into the vitreous. The retinal veins often become engorged and tortuous, and NFL infarcts, or cotton-wool spots, may occur close to the disc margin. During the fully developed acute stage, thin retinal folds, known as Paton's lines, may develop concentric with the disc. Acute papilledema should be considered a medical emergency, whether or not it is fully developed.

If papilledema is present for a prolonged period, then it becomes chronic, the third stage. The disc protrudes forward, and the cup is obliterated. The final stage, chronic atrophic papilledema, is characterized by a flattened grayish white disc with reabsorption of the hemorrhages, exudates, and cotton-wool spots.

Patients with papilledema may have no symptomatology, and visual acuities and fields may remain fairly normal. Most often, however, there is enlargement of the blind spot. Over time, the chronic papilledema may slowly progress toward optic atrophy. Additionally, symptoms related to the underlying pathology may coexist with the papilledema and include headache, nausea, vomiting, and focal neurologic signs if there is a mass lesion.

#### Etiology

Increased ICP and, thus, papilledema have many causes. Any intracranial space-occupying lesion may create increased ICP. Superior sagittal sinus thrombosis, spinal cord tumors with associated elevated CSF protein, spinal cord injuries, and traumatic brain injury may all cause papilledema.

#### Diagnosis

The diagnosis of papilledema in its early stages often presents a significant clinical challenge. It involves a combination of stereoscopic observation of the optic disc, visual

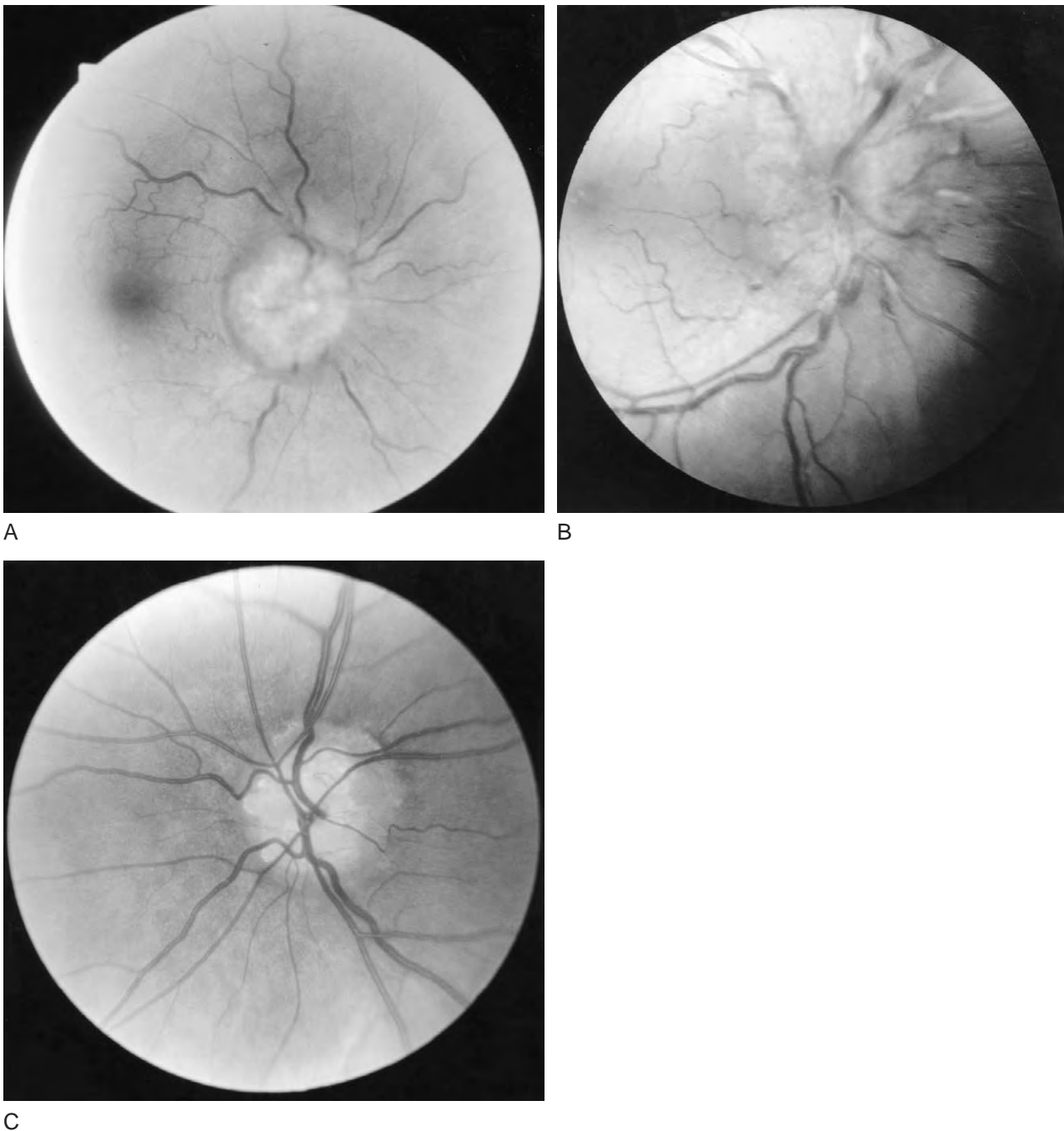
field analysis, evaluation of focal neurologic signs, and the patient's history of transient visual obscurations (5 to 30 seconds of blurring or loss of vision usually associated with postural changes). How quickly papilledema develops depends on the etiology of the increased ICP. Papilledema may develop within 2 to 8 hours if there is an intracranial hemorrhage. The absence of a venous pulsation may be a sign of increased ICP, although as many as 20% of normal patients may not have venous pulsations.

Proper patient management requires a successful differential diagnosis between papilledema and pseudopapilledema (Table 22-6, Figure 22-12). Pseudopapilledema is a congenital anomalous elevation of the optic nerve head that may occur in conjunction with high hyperopia, myelinated nerve fibers, and optic disc drusen. Preinjection fluorescein angiography may show autofluorescence of drusen, but standard fluorescein angiography will not show dye leakage as would be seen in true disc edema. Other useful tests include stereoscopic fundus photography, observation of the peripapillary reflex with a red-free filter, B-scan ultrasonography, and high-resolution orbital computed tomography (CT).

Optic disc edema is the first observable sign of increased ICP. The swelling of the nerve fibers and subsequent transudation of the debris first appear in the inferior

**Table 22-6**  
Distinguishing between Papilledema and Pseudopapilledema

Characteristic	Papilledema	Pseudopapilledema
Abnormal vasculature	Venous congestion	Yes
Familial patterns	No	Yes
Hemorrhages	Yes	Only when drusen shear vessels
Nerve fiber layer swelling	Yes, into retina	No
Exudates and cotton-wool spots	Yes	No
Enlarged blind spot	Yes	No
Transient obscurations of vision	Yes	No
Spontaneous venous pulsation	Usually, no	No
Maintenance of central cup	Yes, until late	No
Buried drusen	No	Yes, at times
Headache	Postural and severe	No
Other neurologic signs or symptoms	Yes	No
Fluorescein leakage	Yes	No



**Figure 22-12** (A) Compensated edema in a case of pseudotumor cerebri. (B) Noncompensated papilledema in a case of acute aqueductal stenosis. (C) Pseudopapilledema secondary to buried drusen of the optic nerve head.

aspect of the disc, followed by the superior and then the nasal aspects. The temporal part of the disc is last to show swelling. This swelling eventually spreads into the surrounding retina. The disc margins then blur, with obscuration of the small vessels of the disc. As the process progresses, hemorrhage on or near the disc may occur at any retinal level but rarely beyond the radius of the macula. As the papilledema progresses, vision is maintained. Later, visual field defects result that progress to involve fixation and mimic glaucoma as chronic atrophic papilledema sets in.

Other rare complications that may lead to reduced visual acuity are subretinal pigment epithelial neovascularization, choroidal folds, preretinal macular hemorrhage, choroidal and subretinal hemorrhages, macular star formation, and retinal pigment epithelial disease.

In the evaluation of papilledema, magnetic resonance imaging (MRI) or CT is an invaluable and necessary adjunct to determine whether there is a mass in the head or signs of meningeal involvement, which can occur with infection, tumor, or infiltration. MRI is especially sensitive in imaging the enlargement of the subarachnoid space



around the optic nerves. Magnetic resonance venography should be done if obstruction of cerebral venous drainage is suspected.

### Management

If left untreated papilledema can progress to intractable optic atrophy. A diagnosis of true papilledema should always initiate an emergent workup. Medical treatment depends on the cause of the increased ICP, and management should focus on identifying the correct etiology using imaging and lumbar puncture.

## Pseudotumor Cerebri

Pseudotumor cerebri (PTC) is a syndrome characterized by papilledema consequent to increased ICP that is not due to a space-occupying intracranial lesion or other cause. PTC, a diagnosis of exclusion, is seen most frequently in young to middle-aged (10- to 50-year-old) obese women, with a peak incidence in the third decade.

### Etiology

PTC rarely may occur secondary to middle-ear disease, minor head injury, childhood systemic lupus erythematosus (SLE), or toxic conditions such as hypervitaminosis A, tetracycline, amiodarone, and oral contraceptive use.

The condition appears to result from poor resorption of the CSF. Other less likely mechanisms to explain increased ICP include increased blood volume, increased CSF production, and parenchymal brain edema. In more than 50% of cases the underlying etiology is unknown.

### Diagnosis

Patients with PTC often present with a generalized headache that is worse in the morning and is exacerbated by Valsalva's maneuver. Nausea and vomiting may frequently accompany the headache. The patient may also describe transient visual obscurations that last just a few seconds. Although the transient visual obscurations are temporary, a definite potential for permanent blindness exists. This permanent loss of vision is due to optic atrophy or, rarely, to a choroidal neovascular net. Occasionally, diplopia may be reported due to sixth-nerve palsy. Visual field testing is mandatory in all cases of papilledema. In PTC there usually is an enlarged blind spot, arcuate nerve fiber bundle loss, and constricted fields. MRI is effective in establishing the absence of an intracranial lesion and aqueductal stenosis. A lumbar puncture demonstrates a high opening pressure (>200 mm H<sub>2</sub>O) and a normal CSF profile.

### Management

Depending on the visual acuity and visual fields, one determines how quickly intervention is needed. If the patient has no afferent system loss, the first step in the treatment of PTC is to remove any agent that caused it (e.g., tetracycline). If the patient is obese, as is usually the case, then loss of excess weight may reverse

the condition. Some patients have shown a dramatic improvement with as little as a 6% reduction in body mass. Gastric bypass surgery may be indicated in severely obese individuals. If weight loss does not mitigate the PTC, then medical therapy may be tried. Oral carbonic anhydrase inhibitors, such as acetazolamide, may act to reduce the ICP. Acetazolamide may be used as 250 to 1,000 mg in one to four divided daily doses or a 500-mg sustained-release capsule twice daily; larger doses may be necessary in some patients. Acetazolamide may worsen venous sinus thrombosis by exacerbating volume depletion and worsening the clot.

Oral corticosteroids have no role in the chronic treatment of PTC, because there are significant side effects of high-dose oral steroid use, and patients may eventually gain weight. However, in the short term, steroid treatment may be effective in patients with severe or rapid visual deterioration. Corticosteroids must be used with caution because coming off the steroids can cause PTC exacerbation.

If the patient fails to respond to weight loss and medical intervention and if there is a loss of visual function, then surgical maneuvers may be attempted. A shunt between the lumbar spinal cord and the peritoneal cavity (lumboperitoneal shunt) may be tried. As an alternative, fenestration of the optic nerve sheath allows for decompression, which relieves symptoms, reduces papilledema, and improves visual acuity. Mitomycin-C has been shown to increase the success rate of the decompression surgery.

## Infiltrative Optic Neuropathy

In infiltrative optic neuropathy, substances that are not normal to the optic nerve or nerve sheath accumulate within the optic nerve. This diffusion of material results in optic nerve dysfunction. Clinically, the loss of optic nerve function may result in loss of visual acuity, visual field defects, color vision defects, and RAPD. In some cases the optic disc is swollen because of infiltration of the prelaminar or immediate retrolaminar region. An absence of disc swelling, with visual acuity loss, may occur secondary to infiltration of the retrolaminar portion of the nerve, which causes a retrobulbar optic neuropathy.

### Etiology

Infiltration of the optic nerve most often occurs from autoimmune inflammatory processes or tumor. Common infiltrative sources include sarcoidosis, SLE, leukemia, lymphoma, and primary tumors of the optic nerve.

Sarcoidosis is a multisystem granulomatous disease of unknown etiology characterized by the deposition of noncaseating granulomas surrounded by lymphocytes. The infiltrative optic neuropathy in sarcoidosis may be the first and only ocular sign or may occur in conjunction with other ocular manifestations of sarcoidosis such as uveitis, candle-wax drippings (exudates around the retinal vessels), and choroidal granulomas. Optic disc edema

may occur due to intraocular inflammation or primary infiltration of the optic nerve by granulomas. True papilledema may also occur in sarcoidosis due to a granulomatous mass lesion or meningitis, which may block CSF resorption, thus leading to elevated ICP. Retrobulbar neuropathy may also occur in sarcoid involvement.

SLE is a multisystem, idiopathic, autoimmune disease characterized by infiltration of capillaries of collagen-vascular tissue by antibody-antigen complexes. The optic disc in SLE can be elevated, and there may be a painless reduction in visual acuity. SLE optic neuropathy may present as either a retrobulbar optic neuropathy or as an anterior ischemic optic neuropathy (AION).

Leukemia, a malignant disease of the blood-forming organs, may cause optic nerve dysfunction manifested as papilledema with or without optic nerve infiltration. These patients present with a variable clinical picture that may include white elevated lesions of the optic nerve from leukemic cell infiltration but with preservation of vision.

Lymphoma, a neoplastic malignant disorder of the lymphoid tissue, is the most common malignancy that infiltrates the optic nerve. Lymphomatous cells infiltrate the retrolaminar portion of the nerve, leading to a progressive painless loss of visual acuity, color and visual field defects, and RAPD. The disc is often swollen.

The primary optic nerve tumor that originates within the optic nerve is glioma. Affected patients often present with reduced visual acuity, visual field defects, transient visual obscurations, and disc edema.

### Diagnosis

The differential diagnosis of infiltrative optic neuropathy requires an extensive medical history with particular attention to any concurrent systemic symptoms, a physical examination, ancillary testing, and neuroimaging. Sarcoidosis commonly causes pulmonary infiltration and may lead to a complaint of coughing. Laboratory testing for sarcoid includes angiotensin-converting enzyme, alkaline phosphatase, and serum calcium levels. Imaging tests include a chest roentgenogram or chest CT and a gallium scan.

SLE is most commonly diagnosed by the clinical constellation of signs and antinuclear antibody testing, anti-double-stranded DNA, the Smith and RNP antibodies, and antibodies to RO and LA (SS-A and SS-B). The suspicion of leukemia requires a hematology and oncology workup that includes a complete blood count. Primary tumors of the optic nerve are diagnosed based on appearance, growth, and, occasionally, biopsy.

### Management

Sarcoidosis therapy is aimed at improving visual field defects, eliminating the optic neuropathy, and clearing any granulomas. Systemic steroids (60 to 100 mg/day) should be instituted immediately on the finding of optic neuropathy and completion of the diagnostic evaluation. Delaying the institution of therapy has been shown to

cause permanent optic nerve damage. Internal medicine referral is also advised.

SLE appears to be steroid responsive only in the early course of the disease. Optic atrophy occurs in untreated cases, with the development of permanent visual field defects. Therapy includes high-dose intravenous methylprednisolone, oral prednisone, or steroid-sparing medications such as mycophenolate mofetil (CellCept). A rheumatology referral is also advised.

The treatment of choice for leukemia is chemotherapy, but because of the blood-brain barrier cytotoxic drugs are ineffective in treating leukemic optic neuropathy. Radiotherapy is the preferred treatment for the optic neuropathy, because the optic nerve is relatively insensitive to radiotherapy but the leukemic cells are very radiosensitive. Chemotherapy and local irradiation have not shown promise in the treatment of lymphomatous optic neuropathy. Meningiomas, likewise, are insensitive to chemotherapy and irradiation and require surgical excision.

### Infectious Optic Neuropathy

Ocular infection may be due to bacterial, viral, fungal, or parasitic organisms. Any tissue is vulnerable to infection, and the optic nerve is no exception.

#### Human Immunodeficiency Virus (HIV) Infection

Acquired immunodeficiency renders a host much more susceptible to secondary infections, including cytomegalovirus, syphilis, herpes zoster, fungi, hepatitis B, tuberculosis, and toxoplasmosis. HIV invades the tissues of the optic nerve and initiates an immune complex-mediated response that results in an optic neuropathy. The primary HIV infection may be responsible for color vision defects, loss of contrast sensitivity, and visual field defects. HIV infection itself may also cause direct degeneration of retinal ganglion cell axons in the optic nerve without a secondary opportunistic infection.

#### Lyme Optic Neuropathy

The causative agent in Lyme disease is a spirochetal bacterium (*Borrelia burgdorferi*) that is transmitted directly through the bite of a deer tick. Optic neuropathy can occur due to Lyme disease and manifests as papillitis, retrobulbar neuropathy, or ischemic optic neuropathy. Serologic testing may help to identify Lyme infection by use of indirect immunofluorescent assay and enzyme-linked immunosorbent assay. The treatment of Lyme disease includes oral or intravenous penicillin, doxycycline, erythromycin, or ceftriaxone.

#### Toxoplasmic Optic Neuropathy

The parasite *Toxoplasma gondii* may be transmitted through the placenta after contact of the mother with cat feces or may be acquired as an adult. The optic neuropathy may manifest as a neuroretinitis, papillitis, disc edema,

or retrobulbar optic neuropathy. Serologic tests (enzyme-linked immunosorbent assay) help to confirm the diagnosis. Antiparasitic drugs for the treatment of toxoplasmosis include pyrimethamine, sulfadiazine, tetracycline, trimethoprim/sulfamethoxazole, and clindamycin.

### Cat-Scratch Disease

Cat-scratch disease is caused by *Bartonella henselae* or *B. quintana*, which are gram-negative bacteria. It is transmitted through a cat scratch, bite, or lick and may cause a neuroretinitis with variable effect on visual acuity. The *Bartonella* species organisms are susceptible to a number of antibiotics. Systemic steroids can be used as an adjunctive treatment.

### Anterior Ischemic Optic Neuropathy

AION is the most common cause of unilateral optic nerve head swelling in patients older than 50 years. In AION there is acute compromise of the optic nerve due to an infarction of the prelaminar portion of the nerve. This occurs in the absence of demyelination, compression by cranial mass lesions, or systemic inflammatory disease (e.g., sarcoidosis). Two forms of AION exist: temporal arteritis or arteritic AION and nonarteritic AION (NAION). NAION is characterized by a sudden, painless, monocular loss of vision. This loss of vision is often greatest at the onset of the disease and is most commonly noticed on awakening. There is optic nerve head swelling segmentally or encompassing the entire disc. The optic nerve heads in these patients typically have a small cup-to-disc ratio and are known as the disc-at-risk. The fellow eye should be evaluated for this finding because the involved eye exhibits disc edema. Splinter hemorrhages of the nerve head may be present. Visual field examination often reveals altitudinal field defects, but arcuate, nasal step, and cecocentral defects also can exist. Eventually, optic atrophy and permanent vision and field loss develop.

### Etiology

NAION occurs in the short posterior ciliary arteries that supply the choroid and distal optic nerve. Regardless of the pathogenesis, however, sudden systemic hypotension and a high prevalence of associated systemic hypertension and diabetes mellitus lend credence to the claim that this condition is simply an acute alteration of the pressure-perfusion ratio at the nerve head. The underlying causes of the altered pressure perfusion include Lyme disease, complications of general surgery, radiotherapy, relapsing polychondritis, beta-blockers, and tamoxifen therapy. The erectile dysfunction drugs, sildenafil (Viagra), tadalafil (Cialis), and vardenafil (Levitra), have also been implicated in causing NAION. Maintaining nerve head tissue perfusion entails precisely balancing intraocular pressure, blood pressure, and CSF pressure. Altering this balance compromises optic nerve tissue.

### Diagnosis

Temporal arteritis (TA) often presents with headache, scalp tenderness, pain on jaw movement (jaw claudication), polymyalgia rheumatica, weight loss, fever, and malaise. NAION usually has no associated systemic symptoms. TA occurs primarily in older individuals from ages 65 to 80 years, whereas the peak incidence for NAION is 60 to 70 years of age. Although there is no race or gender predilection for NAION, TA occurs more commonly in women and whites, especially of Scandinavian descent. Visual acuity loss is usually more severe in TA than in NAION. Inferior altitudinal defects are the most common visual field defect in both types. The disc in TA typically exhibits chalky white swelling (pallid edema), which is not as common in NAION, and the optic disc edema in NAION is usually sectorial.

The erythrocyte sedimentation rate is normal to mildly elevated in NAION (up to 40 mm/hr) but is normal to very high in TA (50 to 120 mm/hr). To calculate the high end of normal for the sedimentation rate based on the patient's age and sex, the following formulas should be used: male = age/2, female = (age + 10)/2. If a suspected TA patient has a near-normal sedimentation rate, then an elevated C-reactive protein may help to confirm presence of the arteritic form. Patients with arteritic AION may also have larger cup-to-disc ratios and a delay in fluorescein dye appearance in the choroid and retinal vessels when compared with patients with NAION and normal subjects. TA biopsy remains the most sensitive and specific test for TA.

### Management

Differentiation of NAION and TA is important for proper management. Despite the fact that 80% of all AION cases are of the nonarteritic variety, all AION cases should be considered ocular emergencies until proven otherwise.

The underlying inflammatory vasculitis of TA makes high-dose steroids necessary in the treatment of arteritic AION. Steroids decrease capillary permeability so that the anoxic and toxic destruction by edema of the NFL is reduced to a minimum. The goal of steroid therapy in cases of TA is to prevent blindness in the fellow eye and to impede further vision loss in the involved eye. If TA occurs with no visual symptoms, then the recommended initial dose of oral prednisolone is 80 to 100 mg/day.

Arteritic AION is a true medical emergency. If vision is affected in a case of TA, then 1 g intravenous methylprednisolone every 6 to 8 hours should be initiated. This is followed by a maintenance dose of 100 to 120 mg oral prednisone daily for 11 days. The sedimentation rate and C-reactive protein results dictate the eventual steroid taper. In general, the dosage is reduced by 10 mg every 4 days until it is discontinued. Steroid therapy may be required for years to prevent recurrence of TA. Because of the potential of long-term steroid treatment, it is imperative that the diagnosis is confirmed with a TA biopsy.

The prognosis in arteritic AION is poor. Though in very rare cases vision returns to normal after steroid therapy, most patients either retain permanent vision loss or experience further deterioration despite treatment. The fellow eye usually becomes involved within the first 10 days of the initial vision loss, though such involvement may occur months later. The fellow eye is affected in approximately 65% of untreated cases, and even in the event of treatment, permanent bilateral blindness occurs in 15% to 25% of all TA cases.

No medical or surgical treatment is effective for NAION. Optic nerve sheath decompression surgery has been shown to be ineffective and may be harmful in the treatment of NAION. Up to 43% of NAION patients experience spontaneous recovery of vision by three or more lines of Snellen acuity at 6 months.

### **Demyelinating Optic Neuropathy**

The process of demyelination occurs as a result of an immunologic inflammation that produces loss of the insulating myelin sheath that surrounds a nerve's axons. When the myelin sheath is disrupted, saltatory conduction is disturbed, resulting in a reduced, deranged, or absent nerve impulse. This process ultimately causes motor or sensory impairment. When demyelination of the optic nerve occurs, the resulting optic neuropathy may produce loss of visual acuity and color vision, central scotomas, and pain on eye movement. Classically, demyelinating optic neuropathy has been referred to as optic neuritis, because it was assumed that the underlying pathology was inflammatory in nature. Because the underlying primary pathology appears to be immunologic in nature, the term *optic neuritis* may be a misnomer when applied to demyelinating optic nerve disease.

#### **Etiology**

The most common cause of primary demyelination is MS, so demyelinating optic neuropathy is often associated with MS. Other conditions have been implicated in demyelinating optic neuropathy, including acute transverse myelitis, acute disseminated encephalomyelitis, herpes zoster, Guillain-Barré syndrome, Devic's neuromyelitis optica, Epstein-Barr virus, Charcot-Marie-Tooth syndrome, and chronic multifocal demyelinating neuropathy.

MS is defined as an acquired, multifactorial, demyelinating disease affecting the white matter located in the central nervous system. Demyelinating optic neuropathy is the initial presenting sign in 20% to 25% of MS patients. If a patient presents with demyelinating optic neuropathy, he or she has a 35% to 75% chance of developing MS, and the risk of developing MS increases steadily for the first 15 years after the initial presentation. Women have a two- to threefold higher chance of developing MS after demyelinating optic neuropathy than do men. However, the Optic Neuritis Treatment Trial (ONTT) did not confirm a differential risk by gender. According to the

ONTT, 13.3% of women and 11.2% of men developed MS within 2 years of first developing demyelinating optic neuropathy, and 49% of the women and 47% of men developed MS within 5 years of the optic neuropathy. According to geographic location, the distribution of cases of demyelinating optic neuropathy that have converted to MS is most common in Finland, England, and tropical and subtropical areas; it is most rare in Japan and Africa. The prognosis for a patient with MS is most favorable for a female patient younger than 40 years with sensory symptoms at the time of onset, a disease course characterized by exacerbations and remissions, and a low frequency of attacks. The worse prognosis is for a male patient older than 40 years with initial motor symptoms, a progressive course, and a high number of attacks.

Although the exact cause of MS remains unknown, the most significant theories involve an immune process as the mechanism that initiates demyelination. The loss of myelin is variously believed to be due to either a cellular (macrophage and T cell) response or a humoral (antibody and B cell) response.

#### **Diagnosis**

Characteristics of the vision loss can aid in the diagnosis of demyelinating optic neuropathy. The vision loss is progressive, is maximal in 1 week, and achieves variable recovery within 4 to 6 weeks. The reduction in vision frequently is accompanied or preceded by periocular pain on movement of the eye. Color vision often is severely impaired, and visual fields most commonly reveal a relative central scotoma. The ophthalmoscopic picture is usually one of a normal optic nerve head, because most commonly the optic neuropathy is behind the globe and thus is called retrobulbar optic neuritis. When there is optic disc swelling, it is known as papillitis.

During an acute unilateral attack, pupil testing reveals RAPD, because demyelinating disease can disrupt the impulses traveling within the pupillary fibers of the light reflex pathway. Color vision is reduced in most cases. Contrast sensitivity is reduced in cases of MS and may remain reduced after visual recovery occurs. The ONTT reported that diffuse visual field loss occurred in 48.2% of eyes and that altitudinal field defects or other nerve fiber bundle-type defects were present in 20.1% of eyes. Significantly, there was asymptomatic visual field involvement in the fellow eye in 68.8% of patients.

Electrodiagnostic testing may be useful in the diagnosis of demyelinating optic neuropathy. The visual evoked potential shows a delayed peak latency amplitude in MS patients.

After a rise in the core body temperature by as little as 0.1°C, there may be an exacerbation of demyelinating-type symptoms, including visual blur, dimming of vision, diplopia, and nystagmus. This is known as Uhthoff's symptom and may occur from hot showers, exercise, and sunbathing.

In patients suspected of having demyelinating disease, laboratory testing may be beneficial. Testing of the CSF may reveal oligoclonal IgG bands consistent with MS. Minor pleocytosis may occur. In addition, an increase in the IgG index and oligoclonal bands is of value in the differential diagnosis. Elevated titers of antimyelin basic protein are also correlated with acute idiopathic optic neuropathy and relapses of MS.

On MRI multiple periventricular and discrete cerebral hemisphere white-matter lesions (plaques measuring at least 3 mm in diameter) are seen as bright areas. The 10-year ONTT results showed that an MRI obtained at baseline (new optic neuritis attack) can predict the risk of a patient developing MS. Patients with at least one brain lesion on MRI at the time of the optic neuritis episode have a 56% risk of developing MS within 10 years, whereas those with no brain lesions have only a 22% risk. There appears to be no increased risk of developing MS with a higher number of baseline lesions.

### Management

Prognosis for return of vision is good. Vision characteristically begins to improve within 2 to 3 weeks, with stabilization at near normal by the fourth to fifth week. Some patients improve rapidly to a moderate acuity level, stabilize, and then experience a return of vision to near normal over a prolonged period. Recurrences characterize the disease, and with each recurrence acuity and visual fields become further compromised. If visual acuity drops to no light perception in the first attack, approximately two-thirds of patients recover vision to 20/400 or better, whereas one-third maintain dense central scotomas with visual acuity of less than 20/400. Each attack of retrobulbar optic neuritis can produce optic atrophy, although the incidence is as low as 36%.

A condition known as neuromyelitis optica (Devic's disease), which may be a variant of MS in children and young adults, is characterized by a rapid bilateral loss of vision. This disease has a poorer prognosis for visual recovery than does optic neuritis. There is a transient myelitis before, during, and after the vision loss.

The ONTT provided important information regarding steroid intervention in demyelinating optic neuropathy. This randomized clinical trial assessed the effects of oral prednisone (1 mg/kg body weight/day for 14 days), intravenous methylprednisolone (250 mg every 6 hours for 3 days) followed by oral prednisone (1 mg/kg body weight/day for 11 days), or an oral placebo. The oral prednisone group and the oral placebo group had essentially the same outcome at 6 months, except that the oral prednisone group actually experienced more recurrences than did either the intravenous drug or placebo group. The intravenous methylprednisolone group had slightly better visual fields, contrast sensitivity, and color vision than did the oral prednisone or placebo groups but did not demonstrate significantly better visual acuity at

6 months. The intravenous drug group also recovered vision function faster and had fewer recurrences than did the placebo or oral prednisone groups. Thus the treatment of choice for optic neuropathy appears to be intravenous methylprednisolone followed by oral prednisone. Oral prednisone alone is not effective. Side effects associated with intravenous methylprednisolone include psychotic depression, acute pancreatitis, sleep disturbances, mood changes, gastrointestinal distress, facial flushing, and weight gain.

A 1-year follow-up on the trial demonstrated that visual acuity was 20/40 or better in 95% of the placebo group, 94% of the intravenous methylprednisolone group, and 91% of the oral prednisone group. The recurrence rate at the 1-year visit was significantly higher for the oral prednisone group. The use of intravenous methylprednisolone, therefore, has only a short-term benefit, but oral prednisone should not be used.

A 3-year follow-up of the patients in the ONTT demonstrated that treatment with intravenous methylprednisolone followed by oral corticosteroid regimens reduced the 2-year rate of MS development. The 10-year follow-up of the ONTT found that 92% of affected eyes had 20/40 or better vision. There was a 35% recurrence of optic neuritis, which was greatest in those patients who developed MS. Patients who were at the lowest risk category were those with a normal MRI, male gender, painless vision loss, profound disc edema, optic disc or retinal hemorrhages, and retinal exudates on presentation.

The most important goal of MS therapy is to prevent permanent neurologic disability. Corticosteroids are still the mainstay of therapy to accelerate recovery, but they have no long-term functional benefit. Patients may obtain long-term functional benefits from various immunomodulatory and immunosuppressive medications. Immunomodulators include interferon beta-1a (Avonex, 30 mcg intramuscular injection once a week, and Rebif, 44 mcg subcutaneous injection used three times per week), interferon beta-1b (Betaseron, 0.25 mg subcutaneous injection every other day), and glatiramer acetate (Copaxone, 20 mg subcutaneous injection every day). Mitoxantrone (Novantrone) is an immunosuppressive agent administered as an intravenous infusion every 3 months. It comes as a dark purple fluid that can cause a bluish tint to the sclera and a blue cast to the patient's urine. It also has potential cardiotoxic side effects.

## Nutritional and Toxic Optic Neuropathy

### Etiology

Nutritional and toxic optic neuropathy refers to vision loss secondary to degenerative changes of the optic nerve fibers in response to exogenous metabolic stimuli. There are four primary causes of toxic optic neuropathy: (1) exposure to substances within the work environment, (2) ingestion of foods containing toxic substances, (3) elevated systemic drug levels, and (4) deficiencies of

essential nutrients or the presence of a metabolic disorder that causes toxic effects to the nerve.

Vision loss may occur in deficiency states (thiamine or vitamin B<sub>12</sub>) or as a toxic response to certain drugs or substances (Box 22-5). In most cases one can establish that the patient has been exposed to toxins or has had some dietary deficiency. The precise pathogenesis of the atrophic process is somewhat obscure, although adenosine triphosphate formation appears to undergo a change. This change leads to a stasis of axoplasmic flow with subsequent optic disc edema, eventually resulting in axonal death.

### Diagnosis

A gradual, bilateral, painless reduction of visual acuity with eventual centrocecal scotomas characterizes the atrophies. The scotomas have variable margins that are better defined and appear much larger with the use of red targets. There are no specific nerve fiber bundle defects, but often a dense scotoma is located in the area corresponding to the papillomacular bundle. The defects characteristically do not cross the vertical meridian, although ethambutol toxicity may demonstrate a bitemporal hemianopsia, because the chiasm may be implicated in the process. The visual field changes usually are progressive. Dyschromatopsia occurs, but the patient may remain unaware of the color vision loss. Even though this condition can cause reduced vision, visual acuity generally is not reduced below hand motion. Ophthalmoscopically, the optic disc may initially appear normal. Some agents cause a slight disc edema with rare hemorrhages

in the early stages, but the nerve head eventually becomes atrophic.

The clinician should suspect toxic optic neuropathy in any case of bilateral painless and symmetric loss of vision with normal or sluggish pupils. Because of the symmetric nature of the accumulation of toxins in the optic nerve head, pupillary fibers of either eye are equally affected and thus no RAPD is produced.

Once characteristics of the neuropathy are determined, the clinician should carefully record the history and make note of any possible exposure to toxins. Review of the current medications and diet of the patient is essential. The offending toxin may affect the optic nerve anywhere along the visual pathway. Therefore visual field loss is variable but usually somewhat symmetric. Color vision testing should also be performed.

Systemic evaluation of the patient includes a complete blood count, blood chemistry, thiamine level, urinalysis, serum vitamin B<sub>12</sub> and folate levels, heavy metal screening (lead, mercury, arsenic), and tests for megaloblastic anemia. The hair may also be tested for indications of toxicity.

A review of certain chemicals is essential. Ethylene glycol is an antifreeze used for gasoline engines and may produce somnolence, unreactive pupils, disc swelling, and kidney failure. Systemic lead poisoning produces headaches, coma, cranial nerve palsies, and papilledema. Wood alcohol, or methanol, may produce severe toxic neuropathy and disc edema. Drugs known to produce toxic optic neuropathy include amiodarone (an antiarrhythmic), quinine, aminoquinolines, ibuprofen, ethambutol, isoniazid, and chloramphenicol.

### Management

The condition is reversible and has a favorable prognosis if the toxic agent or nutritional deficiency is detected and removed. Occasionally, vision function may improve even without treatment. Patients treated with ethambutol can develop atrophy because of the chelation of zinc and other metals necessary for optic nerve function. Therefore serum zinc levels should be evaluated in these patients. Zinc sulfate, 100 to 250 mg three times daily, may promote reversal of the neuropathy. The dosage of oral zinc sulfate depends on the individual's ability to absorb the drug as well as the possible side effects such as nausea, vomiting, diarrhea, and bleeding secondary to gastric erosion. Zinc therapy is not yet approved by the U.S. Food and Drug Administration.

If isoniazid is implicated in optic neuropathy or other neurologic signs, then pyridoxine (vitamin B<sub>6</sub>), 25 to 100 mg/day, may be used. Prophylactic administration of this agent can be combined with isoniazid and monoamine oxidase inhibitor therapy.

The patient with tobacco or alcohol amblyopia usually has either low serum levels of vitamin B<sub>12</sub> or cannot absorb this vitamin in sufficient amounts. Thus the treatment for this condition involves supplemental vitamin therapy.

#### **Box 22-5** Drugs or Other Substances Associated With the Development of Retinal Changes or Optic Neuropathy

Alcohol	Iodide compounds
Amiodarone	Isoniazid
Barbiturates	Hexamethonium
Carbon monoxide	Lead
Chlorambucil	Lithium
Chloramphenicol	Methotrexate
Chloroquine	Placidyl
Ciprofloxacin	Phenothiazines
Cocaine	Sildenafil
Corticosteroids	Steroid compounds
Cyanide	Streptomycin
Cyclosporine	Tamoxifen
Cyproterone	Tobacco
Digitalis	Tryparsamide
Diiodohydroxyquin	Vitamin A and
Disulfiram	retinoids
Ethambutol	Vitamin D
Ethylene glycol	

After documenting a serum vitamin B<sub>12</sub> deficiency, the patient should receive 300 mg oral thiamine each week and 1,000 g intramuscular hydroxocobalamin each week for 10 weeks. The sooner this therapy begins, the better the prognosis. The hydroxocobalamin form of vitamin B<sub>12</sub> appears to be more effective than cyanocobalamin. In terms of recovery from the amblyopia, cessation of smoking or drinking does not appear to produce remission unless the patient concurrently improves their diet. Thus it is unnecessary and, in practice, difficult to persuade patients who are habitual abusers of tobacco and alcohol to stop the use of such agents. Improvement of dietary status seems to be the most important factor in recovery.

Vitamin B<sub>12</sub> deficiency can also cause megaloblastic anemia. White-centered hemorrhages can occur in the posterior pole, and disc pallor also may be seen. If the anemia is severe, cotton-wool spots may appear. A complete blood count can confirm that megaloblastic anemia exists. Serum folate and vitamin B<sub>12</sub> levels should be determined and appropriate therapy (intramuscular injections of hydroxocobalamin) should be instituted at the earliest sign of megaloblastic anemia.

The crucial feature of all optic neuropathies that must never be ignored is the possibility of an underlying neoplasm. Visual field analysis at regular intervals aids in excluding the possibility of an optic nerve or chiasmal neoplasm.

### **Leber's Hereditary Optic Neuropathy**

#### **Etiology**

LHON is a distinct form of optic atrophy. LHON is a point mutation in the mitochondrial genome. These mutations occur at nucleotide sites 3,460, 11,778, and 14,484. These DNA mitochondrial mutations are transmitted with the cytoplasm, making this disease maternally inherited. Environmental epigenetic triggers (smoking, alcohol) have been identified.

Men are affected four to five times as often as women. The average age at onset is within the third decade of life. Later onset is possible. The following characteristics summarize the disease's inheritance patterns:

- Men are predominantly affected.
- Affected men cannot transmit the disease.
- The sister of an affected man is a carrier.
- Affected women all have normal fathers.
- All women born into families in which only female members are affected are carriers.
- The heterozygous woman can transmit the trait to her sons and the carrier state to her daughters.

#### **Diagnosis**

LHON is characterized by a sudden painless and bilateral loss of vision. An interval of 1 to 6 months may occur between involvement of the two eyes, though the second eye may not become involved for up to 8 years. The duration of visual dysfunction varies and may take months to stabilize.

Preacute signs and symptoms do occur. In some patients atrophy of retinal nerve fibers, an altered Farnsworth-Munsell 100-hue test, and altered visual evoked potentials occur before the actual attack.

Early ophthalmoscopic findings include blurred disc margins, peripapillary telangiectatic microangiopathy (which is transient), optic disc pseudoedema, and vascular tortuosity. Disc atrophy begins 2 to 4 weeks after the initial symptoms. The disease has a predilection for the nerve fibers of the macula, thereby causing an early vision loss and a central scotoma that can break out to the periphery. This vision loss is to the 20/200 (6/60) to 20/400 (6/120) level, and the condition eventually settles into a permanent optic atrophy that most often affects the temporal sector of the disc. During the active condition the patient may have headaches associated with meningitis or cerebral edema.

The visual evoked potential recordings in LHON become desynchronized early in the disease. This is accompanied by a prolonged latency and reduction in peak amplitude. In the later stages of the disease, visual evoked potentials may diminish entirely. Nerve fiber analysis shows severe and progressive loss of the NFL.

#### **Management**

No treatment is known to be effective. Any suspected epigenetic triggers should be avoided in those at risk. The condition most often becomes stationary, though there are rare reports of excellent unilateral and bilateral recovery of central vision. The younger the patient is at onset of LHON, the better the prognosis for vision recovery.

### **MYASTHENIA GRAVIS**

Myasthenia gravis is an autoimmune disease that affects the neuromuscular junction. A decrease in the number of available acetylcholine receptors due to circulating antibodies results in impaired neuromuscular transmission. This impairment manifests clinically as weakness and fatigability of voluntary musculature. Ocular and other muscles innervated by cranial nerves are most often involved. Although different treatment modalities are available, anticholinesterase drugs remain the mainstay of therapy.

#### **Etiology**

Although the originating event in myasthenia gravis is unknown, the presence of antibodies to the acetylcholine receptor reduces the availability of functioning acetylcholine receptors at the neuromuscular junction, resulting in defective neuromuscular transmission. The antibodies not only block the binding site but also accelerate receptor degradation and cause primary damage to the receptors themselves. There is widening of the synaptic cleft, allowing more time for acetylcholinesterase molecules to degrade the acetylcholine as it passively diffuses across the cleft, and the folding pattern of the



postsynaptic membrane in which acetylcholine receptor antibodies reside is simplified. The acetylcholine receptor antibodies operative in myasthenia include blocking antibodies (which block the binding site), binding antibodies (which bind to sites other than the binding site), and modulating antibodies (which cross-link neighboring acetylcholine receptors, rendering them inactive). These circulating antibodies can be found in up to 90% of patients with generalized myasthenia gravis and in almost 70% of individuals with only ocular symptoms.

Pathologic changes in myasthenia gravis are limited to voluntary (skeletal) muscle and the thymus gland. The most common abnormality in muscle is single-fiber atrophy, although lymphocytic infiltration is also prevalent. A normal single-fiber examination in a clinically weak muscle effectively rules out the diagnosis of myasthenia gravis.

Approximately 75% of myasthenic patients have thymus gland abnormalities. Of these, 85% show germinal center formation or hyperplasia, and encapsulated tumors or thymomas occur in the remaining 10% to 30%. The overall risk of thymoma in patients with ocular myasthenia is lower, at approximately 4%. The mean age at which the thymoma is diagnosed is 37 years. The complex relationship between the thymus gland and myasthenia gravis suggests that this organ may play a critical role in both the origin and maintenance of the autoimmune process. Anywhere from 3% to 15% of patients with myasthenia gravis also have thyroid disease (hypothyroidism or hyperthyroidism), 5% have rheumatoid arthritis, and another 2% have SLE.

### Epidemiology

The prevalence of myasthenia gravis is estimated to be from 43 to 83 per million population in the United States. The disease may begin at any age, but onset in the first decade is relatively rare. The peak age at onset in women is between 20 and 30 years, whereas the male incidence peaks in the sixth or seventh decade. In those younger than age 40, women are affected two or three times as often as men, whereas in later life the incidence in men is higher.

Infants born to myasthenic mothers exhibit generalized weakness for several days or weeks, but resolution is usually complete. Congenital myasthenia occurs in children of nonmyasthenic mothers, and these children exhibit ophthalmoplegia from birth. This type of myasthenia is not autoimmune in nature, because these patients have no measurable serum acetylcholine receptor antibodies.

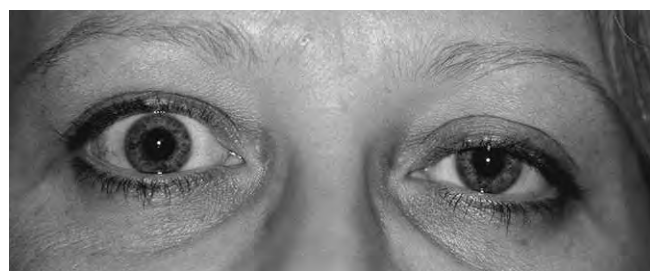### Diagnosis

The diagnostic evaluation of myasthenia gravis includes a complete history and physical examination, objective evidence of circulating acetylcholine receptor antibodies, electrophysiologic evidence of abnormal neuromuscular transmission, and pharmacologic evaluation with anticholinesterase drugs.

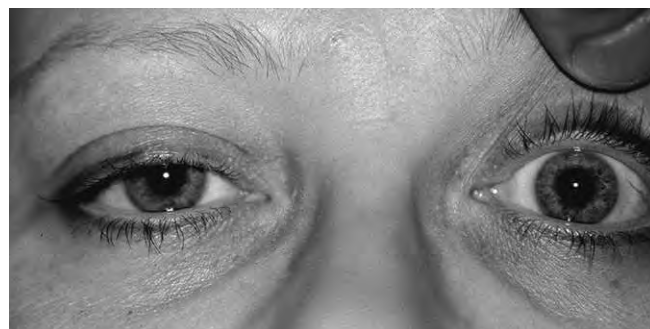**Clinical Features.** The voluntary or skeletal musculature exhibits variable weakness, which can fluctuate during the day or from day to day. Usually, the weakness is greater after muscle use and diminishes with rest.

In 20% to 30% of patients, the condition remains confined to the eye region, whereas 90% of patients with generalized myasthenia also have ocular involvement. Unilateral or bilateral ptosis is often the first presenting sign. Levator weakness can be tested by instructing the patient to blink several times in rapid succession to determine whether the ptosis worsens. The patient should also stare upward at a fixed point so that the practitioner can observe the upper eyelids for gradual lowering. In testing for Cogan's eyelid twitch sign, the patient is directed to look down for 10 to 15 seconds and then to refixate quickly in the primary position. Observation of an upward overshoot of the eyelid with several twitches, followed by repositioning of the eyelids to the original ptotic state, identifies the easy fatigability and rapid recovery of the myasthenic levator muscle. The phenomenon of "enhanced" ptosis can be demonstrated in patients with bilateral ptosis by elevating and maintaining the more ptotic eyelid in a fixed position. The opposite eyelid slowly falls and may close completely (Figure 22-13).

Diplopia secondary to extraocular muscle involvement may occur separately or may accompany eyelid ptosis and can be variable. Variability in measuring phorias and tropias during the same examination or on different examination days is highly suggestive of myasthenia. Extraocular muscle weakness can also mimic internuclear ophthalmoplegia,



A



B

**Figure 22-13** (A) Left upper eyelid ptosis. (B) After manual elevation of left upper eyelid, the contralateral eyelid shows ptosis.



horizontal or vertical gaze palsies, or oculomotor nerve palsies. Fatigue of the extraocular muscle is a clinical sign that may develop with eccentric gaze.

Strength of the orbicularis oculi muscle can be easily tested by instructing the patient to close the eyes forcefully while the examiner attempts to open the eyelids manually. Because the orbicularis oculi muscle is often affected in myasthenics, the eyelids may offer little resistance and open easily.

Nonocular muscle involvement is also prevalent, ranging from fluctuating dysarthria to dysphagia. Because of involvement of muscles that control breathing and swallowing, myasthenia is a potentially fatal condition. No specific pattern of limb weakness occurs, although the proximal muscles are most often affected.

**Pharmacologic Evaluation.** The most commonly used pharmacologic test for the diagnosis of myasthenia gravis is the edrophonium (Tensilon, Enlon) test. This anticholinesterase agent acts by inactivating the enzyme acetylcholinesterase, which leads to accumulation of excessive amounts of acetylcholine, which in turn results in prolonged neurotransmitter activity on the muscle fiber's specialized motor end plate. Edrophonium is a reversible agent of rapid onset (30 to 60 seconds after intravenous injection) and short duration of action (approximately 10 minutes).

The edrophonium test can be performed in the clinician's office if appropriate resuscitation equipment is available. Patients with a history of cardiac disease, asthma, or other significant medical health problems should have this test performed in a hospital setting. The ideal testing protocol involves two examiners, one giving the injection and the other recording the results. Photographing or videotaping the objective findings is also helpful. Although any muscle or muscle groups can be observed for clinical improvement, ptosis appears to respond better than diplopia to edrophonium testing.

Edrophonium is available in multiple-dose or single-dose 10-mg/ml ampules. An accessible vein is found on one of the patient's arms, and a butterfly infusion set with a 27-gauge needle is attached to a 1-ml tuberculin syringe containing 10 mg edrophonium solution. Initially, 2 mg (0.2 ml) edrophonium is injected intravenously. A saline flush may follow this injection to confirm appropriate dose administration. If after 1 or 2 minutes definite improvement in ptosis or ocular misalignment occurs, the test is considered positive and no further edrophonium injection is necessary. If no definite improvement occurs, however, another 3 mg (0.3 ml) edrophonium is injected and the patient is again observed.

If no improvement occurs, the remaining 5 mg (0.5 ml) edrophonium can be given and the patient evaluated for several more minutes. Doses higher than 10 mg do not produce any improvement of symptoms if lower doses fail to elicit improvement. In ocular myasthenia without

systemic manifestations, up to 95% of patients have a positive edrophonium test.

Cholinergic side effects associated with edrophonium include increased salivation, nausea, vomiting, sweating, perioral fasciculations, and diarrhea. These side effects resolve quickly after the testing has stopped. More serious side effects include systemic hypotension, bradycardia, or increased muscle weakness resulting in respiratory distress. These adverse effects may require treatment with atropine sulfate. Atropine can be administered prophylactically by giving 0.3 to 0.4 mg intramuscularly 15 minutes before edrophonium testing. Alternatively, 0.3 to 0.5 mg atropine should be available in a tuberculin syringe for intravenous injection in case edrophonium testing brings on a severe life-threatening reaction.

The neostigmine test is used more often to help evaluate limb strength in suspected myasthenics. Neostigmine, a reversible cholinesterase inhibitor with a duration of action longer than that of edrophonium, can be administered either intravenously or intramuscularly. The usual adult dose is 1.5 mg intramuscularly in combination with 0.5 mg atropine to prevent cholinergic-induced side effects.

**Other Diagnostic Tests.** Electromyographic response to nerve stimulation is also used to diagnose myasthenia gravis. The characteristic electrodiagnostic abnormality is progressive decrement in the amplitude of muscle action potentials evoked by repetitive nerve stimulation at 3 or 5 Hz. In generalized myasthenia, this decremental response occurs in approximately 90% of patients if multiple muscles are tested and from 50% of patients with ocular myasthenia. Unlike neurogenic pareses, myasthenics show rapid saccades on electromyography.

Serum testing reveals circulating antibodies to acetylcholine receptors in approximately 90% of individuals with generalized myasthenia and in almost 70% of those with ocular symptoms only. False-positive results are rare, and the antibody titer does not correlate with the severity of symptoms. In those patients who are seronegative for antiacetylcholine receptor antibodies, which is about 6% of myasthenia gravis patients overall, anti-MuSK antibodies may be present. MuSK is a muscle-specific transmembrane protein with intrinsic tyrosine kinase activity. Anti-MuSK antibodies are almost never seen in patients who have antiacetylcholine receptor antibodies, and vice versa.

An office test shown to be of value for supporting a diagnosis of ocular myasthenia gravis, particularly if ptosis is present, is the ice-pack test. The test is based on the premise that neuromuscular transmission improves at lower temperatures. An ice pack is applied to the affected eye for 1 to 2 minutes, and the eye is observed to see whether the ptosis improves.

The sleep test exploits the frequently cited observation that patients' symptoms are much less noticeable immediately after awakening. Patients are asked to take a

short nap or at least rest with their eyes closed for 30 minutes. They then are observed immediately on awakening and are evaluated for improvement of symptoms. The sleep test often is done in conjunction with the ice-pack test.

In patients with unioocular myasthenia, MRI or CT of the brain should be considered to rule out a compressive parasellar lesion. Rarely, patients with pupil-sparing third-nerve palsies from intracranial lesions may have clinical pseudomyasthenic features, including fatigable weakness, Cogan's eyelid twitch sign, and positive edrophonium or neostigmine tests. Therefore a positive edrophonium test is not 100% diagnostic of myasthenia.

### Management

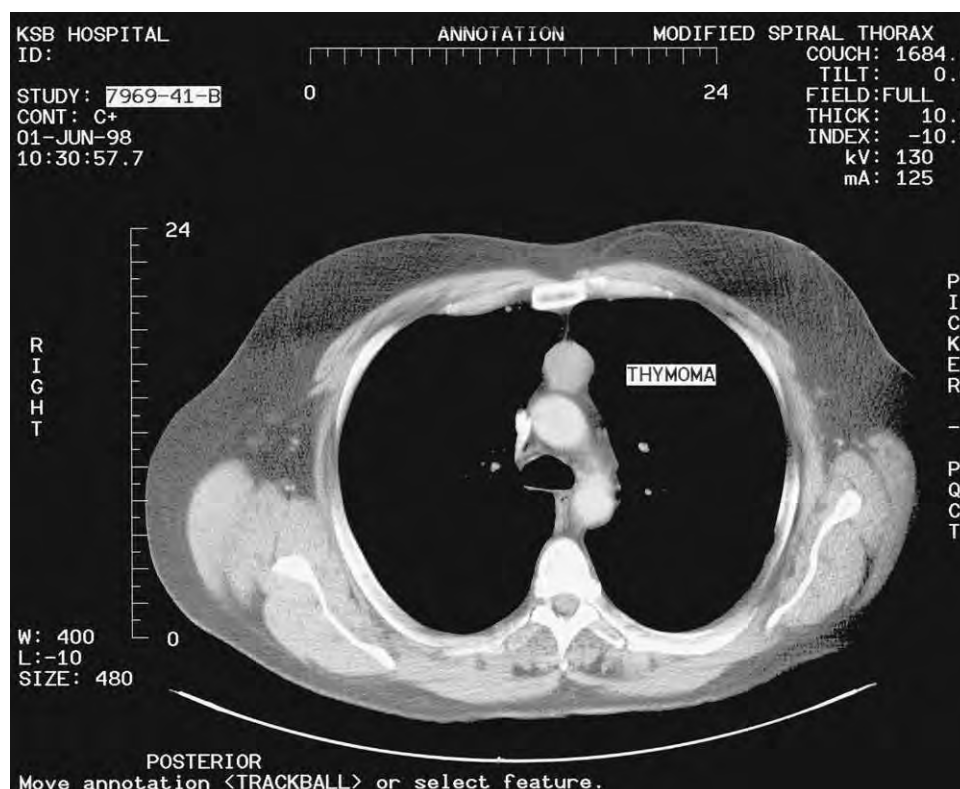
Before initiating treatment, the clinician should rule out the presence of myasthenia-like syndromes such as Eaton-Lambert syndrome, which has clinical features similar to those of myasthenia but typically spares the eyes. Definitive diagnosis is important, because approximately 70% of Eaton-Lambert patients harbor malignant neoplasms, usually bronchogenic carcinoma.

The pharmacologic treatment of myasthenia gravis is based on increasing the amount of available acetylcholine by use of oral cholinesterase inhibitors such as neostigmine or pyridostigmine. Pyridostigmine bromide (Mestinon) is used most often and effectively relieves myasthenic symptoms in small muscles innervated by cranial nerves, particularly those involved in ptosis,

diplopia, and dysarthria. An analogue of neostigmine, pyridostigmine has a longer duration of action and fewer gastrointestinal side effects than neostigmine. In adults the usual starting dose of pyridostigmine is 60 mg orally every 4 hours. This dose may be increased, but additional clinical benefit is not expected in doses exceeding 120 mg every 2 hours. The drug is also available in a slow-release tablet (Timespan) of 180 mg and as a syrup for children.

Thymectomy, corticosteroids, and other immunosuppressive drugs such as azathioprine and cyclosporine have been used to suppress the disease itself. Thymectomy is beneficial for patients with thymoma and usually is recommended in patients with generalized myasthenia gravis (Figure 22-14). Clinical improvement or complete remission of myasthenia can be achieved in up to 75% of all patients after thymectomy and in up to 95% in young patients with early disease.

Most patients show improvement with corticosteroids. Steroids may be of optimum benefit when added to another therapeutic regimen such as anticholinesterase therapy or immunosuppressants such as azathioprine. Moderate-dose daily prednisone for 4 to 6 weeks, followed by low-dose alternate-day therapy as needed, has been found to improve ocular motility and decrease the development of generalized myasthenia. Steroid therapy must be used cautiously in these patients because of the worrisome character and incidence of unwanted effects of these drugs. It is possible for patients to develop immunosuppression such that tapering of



**Figure 22-14** Computed tomographic scan of the chest showing thymoma.

patients' drug regimens is difficult, the result being that many myasthenic patients are unable ever to discontinue steroid use fully. Other immunosuppressive agents used in the treatment of myasthenia include azathioprine (Imuran), cyclophosphamide (Cytoxan), mycophenolate mofetil (CellCept), and cyclosporine (Sandimmune).

Short-term immunotherapy is used when patients develop significant dangerous or intolerable symptoms from their myasthenia. Intravenous immunoglobulin from pooled human gamma globulin can be administered for a rapid result (24 to 72 hours).

Plasmapheresis is an intermediate form of therapy for myasthenia gravis, having effects that last longer than those of cholinesterase inhibitors but shorter than those of thymectomy. Improvement in myasthenic symptoms often occurs, but its duration is unpredictable. Plasmapheresis usually is reserved for patients who have severe symptoms resistant to other therapeutic approaches or for patients preparing for thymectomy.

In addition to these medical and surgical therapies, optical management of ptosis using dark lenses or a ptosis crutch may also be indicated. For smaller constant ocular muscle misalignments, Fresnel press-on prisms may be used. An opaque (occluder) lens may be needed for larger fluctuating deviations.

Patients should be advised to rest and to avoid extreme heat. They should be warned that symptoms may be aggravated by illness, stress, malnutrition, pain, or surgery. Various drugs have been shown to worsen symptoms of myasthenia gravis. These include the aminoglycoside antibiotics such as tobramycin, gentamicin, and neomycin; tetracyclines such as doxycycline and minocycline; class I antiarrhythmics such as lidocaine, quinidine, and procainamide; magnesium in calcium and multivitamin supplements; beta-blockers such as timolol and propranolol; calcium channel blockers such as verapamil; and penicillamine.

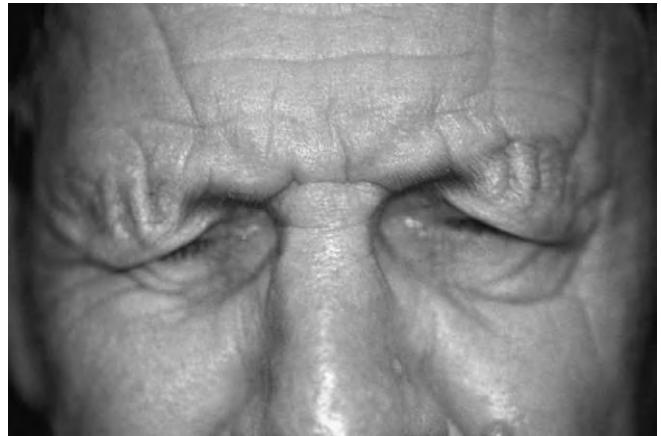Patients may be referred for additional support to the Myasthenia Gravis Foundation of America, 1821 University Ave. W., Suite S256, St. Paul, MN 55104. There is also a website ([www.myasthenia.org](http://www.myasthenia.org)).

## **BENIGN ESSENTIAL BLEPHAROSPASM AND HEMIFACIAL SPASM**

Benign essential blepharospasm (BEB) is a dystonia characterized by involuntary sustained (tonic) and spasmodic (rapid or clonic) repetitive contractions involving the orbicularis oculi, procerus, and corrugator musculature (Figure 22-15). When the muscles of facial expression that are innervated by the facial nerve are similarly involved on only one side of the face, a hemifacial spastic dystonia occurs.

### **Etiology**

The exact neuroanatomic and neurophysiologic origins of blepharospasm and its related cranial-cervical



**Figure 22-15** A patient with benign essential blepharospasm. Note deep furrows, indicating chronicity of disease.

dystonias are still unknown. Radiologic evidence indicates possible lesions located in the brain. Specific sites identified include the thalamus, basal ganglia, cerebellum, and mesencephalon. Occasionally, blepharospasm can occur secondary to ischemic, degenerative, and other basal ganglionic or thalamic disorders.

Adrenergic variability may be a neurochemical cause of blepharospasm. Decreased norepinephrine levels have been identified in the hypothalamus, mamillary bodies, and locus ceruleus, whereas increased norepinephrine levels have been identified in the dorsal raphe nucleus, red nucleus, substantia nigra, and thalamus. A neurochemical abnormality, if it exists, appears to result from a loss of inhibitory adrenergic input to the locus ceruleus, which supplies information to the cortex, brainstem, and spinal cord, resulting in adrenergic excess at the distal sites. This neurochemical abnormality may be genetically identifiable in 33% of patients.

Unlike blepharospasm, the origins of hemifacial spasm are much better understood. Hemifacial spasm may occasionally be familial. In most instances, however, the spasm results from microvascular compression or irritation of the facial nerve by an aberrant artery of abnormal vasculature in the posterior fossa or from a cerebellopontine tumor.

### **Diagnosis**

A careful history and examination are critical for the definitive diagnosis of blepharospasm. Up to 78% of patients who eventually develop BEB first show variable episodes of increased blinking lasting from seconds to minutes. These episodes eventually progress to involuntary spasms of eyelid closure. Up to 57% of patients with blepharospasm have symptoms of dryness of the eyes, grittiness, irritation, or photophobia at the onset of their illness, and examination at the time of presentation may reveal demonstrable ocular surface or eyelid pathology in approximately 40% of patients.

Remissions and exacerbations are common during the early stages of the disease. Even when symptoms initially affect only one side, bilateral involvement becomes the rule. BEB usually begins in individuals aged 50 to 70 years, with a mean age at onset of 56 years. Almost two-thirds of these patients are female.

Functional incapacitation can be significant, with visual disability as the most incapacitating functional defect in more than 10% of patients. In most patients symptoms become stable within 5 years.

External events can initiate or aggravate the episodes of spasm. These events include stress, driving (especially night driving when faced with oncoming headlights), and bright sunlight. Sleep and other stress-relieving forms of relaxation can alleviate the blepharospasm.

All patients with blepharospasm should receive dry eye testing, because dry eye can exacerbate the spasms. Appropriate dry eye therapy with ocular lubricants or lacrimal occlusion should accompany any other treatment for blepharospasm. The clinician should search for and correct other treatable problems that may exacerbate the disease, such as corneal erosion, foreign bodies, acute glaucoma, uveitis, entropion, eyelash abnormalities, and blepharitis. Emotional problems and neurosis usually are not a significant precipitating cause of blepharospasm in adults but may play a prominent role in affected younger individuals.

The term *essential blepharospasm* applies specifically to spasms localized to the orbicularis oculi, procerus, and corrugator musculature. Similar dyskinesias can occur in the entire distribution of the facial nerve and in muscles other than those innervated by the facial nerve. These dyskinesias can occur in the lower face, mouth, jaw, neck, and soft palate. Localized self-limited spasm of the orbicularis oculi muscle is termed *eyelid myokymia* (benign fasciculations). This condition differs from blepharospasm in that it causes a twitch of the lower or upper eyelid muscles and does not cause eye blinking. It is benign and does not progress to eye closure. However, if this eyelid twitching is associated with twitching of the ipsilateral facial muscles with or without eyelid involvement, this could be a potentially serious disorder called facial myokymia. Facial myokymia has been associated with brainstem tumors and demyelinating disease.

When blepharospasm is accompanied by periodic lower facial movement, the disorder is referred to as Meige's syndrome or idiopathic orofacial dystonia. If the mandible also becomes involved, the disorder is referred to as Breughel's syndrome or oromandibular dystonia. When several cranial nerves are involved, the disorder is called segmental cranial dystonia. Although often discussed as separate entities, these dystonic syndromes may be the same disease process with variable clinical manifestations.

Hemifacial spasm differs from blepharospasm in that the former is unilateral when fully developed. Hemifacial spasm may begin in the orbicularis oculi

muscle and then slowly spread to other ipsilateral facial muscles. Unlike blepharospasm, which sleep may relieve, hemifacial spasm continues during sleep. As with blepharospasm, hemifacial spasm occurs in middle-aged individuals and is more common in women. Hemifacial spasm rarely may be associated with a posterior fossa tumor and therefore necessitates appropriate neuroimaging.

### Management

Before appropriate treatment for blepharospasm can be administered, a correct diagnosis must be made. In the early stages of the disease a patient's condition often is misdiagnosed, and he or she is assigned a diagnosis of a psychogenic disorder such as neurosis and is referred to a psychiatrist or psychologist. Ophthalmic therapy includes treating any underlying ocular condition and using spectacle-mounted ptosis crutches. Adjunctive pharmacotherapy may include such medications as antiparkinsonism drugs (e.g., levodopa with carbidopa [Sinemet], bromocriptine [Parlodel], orphenadrine [Norflex]), anticholinergic drugs (e.g., trihexyphenidyl [Artane] or benzotropine [Cogentin]), muscle relaxants (e.g., baclofen [Lioresal]), benzodiazepines (diazepam [Valium] and clonazepam [Klonopin]), antidepressants (e.g., lithium [Lithobid]), anticonvulsants (e.g., carbamazepine [Tegretol] or valproic acid [Depakene]), antihistamines, the antiserotonin cyproheptadine, tranquilizers (e.g., haloperidol [Haldol]), and beta-blockers (e.g., propranolol [Inderal]). Only one-third of patients may be satisfied with one or more of the listed medications. In addition to these measures, emotional or psychological counseling may prove effective for patients having difficulty adjusting to or accepting their condition or its treatment.

Information on emotional and psychological support can be obtained from the Benign Essential Blepharospasm Research Foundation, Inc., P.O. Box 12468, Beaumont, TX 77726-2468 or at its website ([www.blepharospasm.org](http://www.blepharospasm.org)).

**Botulinum Toxin.** The most effective nonsurgical treatment for both BEB and hemifacial spasm is botulinum toxin. Botulinum toxin works by inhibiting calcium-dependent release of acetylcholine at the neuromuscular junction, causing muscle paralysis. Of patients receiving botulinum toxin injection, 69% to 100% demonstrate clinically significant improvement. Currently, there are two U.S. Food and Drug Administration–approved botulinum toxins: botulinum toxin type A (Botox, Botox Cosmetic) and botulinum toxin type B (Myobloc).

Each vial of Botox contains 100 units botulinum toxin. In its nonreconstituted form, the toxin can remain stable for up to 4 years. The recommended diluent for reconstitution is sterile nonpreserved 0.9% sodium chloride. The reconstituted toxin deteriorates within a few hours and, if not used immediately, should be refrigerated (2 to 8°C).

**Table 22-7**

Dilution of Botulinum Toxin

Diluent Added <sup>a</sup> (ml)	Resulting Dose (units/0.1 ml)
1	10
2	5
4	2.5
8	1.25

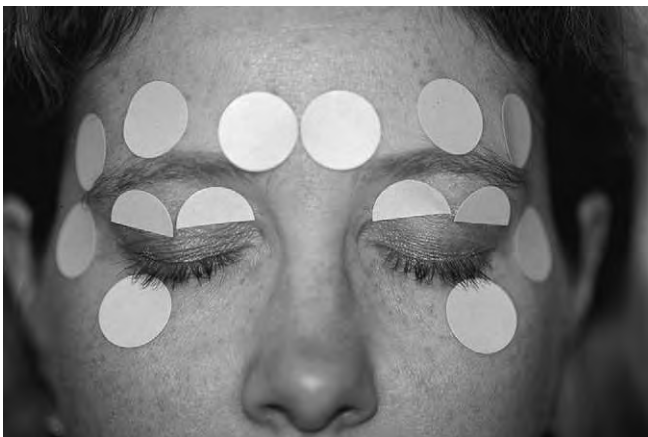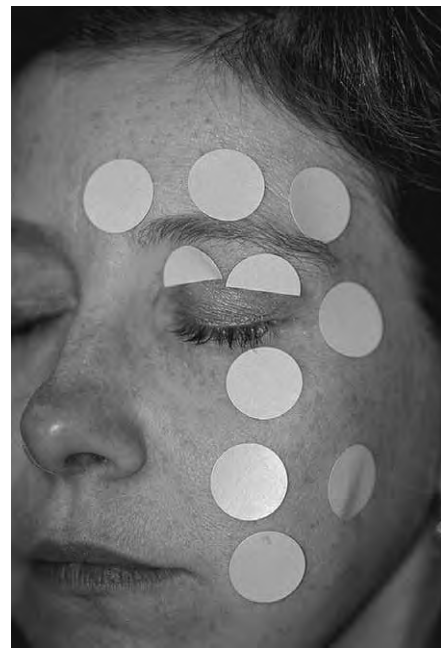<sup>a</sup>Diluent = 0.9% NaCl injection.

Modified from Physicians' Desk Reference, ed. 59. Montvale, NJ:Thompson PDR, 2005:562-565.

The diluent of sterile normal saline is drawn up in a syringe and gently injected into the vial containing the Botox. Rapid forceful injection that causes frothing or other mechanical stress is discouraged because this can inactivate the toxin. Table 22-7 gives the recommended dilutions calculated for an injection volume of 0.1 ml.

Without previous anesthesia and avoiding penetration of the orbital septum, the diluted Botox typically is injected subcutaneously or intramuscularly, using a 27- or 30-gauge needle. The most commonly used dilution is 2.5 units per 0.1 ml of volume at each injection site. In patients with blepharospasm, the initial injection sites should include the medial and lateral pretarsal orbicularis oculi of the upper eyelid and the lateral pretarsal orbicularis oculi of the lower eyelid (Figure 22-16). Patients with hemifacial spasm should receive similar injections to any affected muscles of the lower face (Figure 22-17). The cumulative dose of Botox in a 30-day period should not exceed 200 units.

Muscle mass affects the toxin's response. More toxin is needed locally to produce a desired effect in areas of increased muscle mass. Histologic examination of orbicularis oculi musculature after treatment with botulinum toxin shows no evidence of alteration of muscle fiber diameter, disruption of internal muscle architecture, or pathologic changes in the motor end plates.

**Figure 22-16** Sites of botulinum toxin injections in patient with blepharospasm.**Figure 22-17** Sites of botulinum toxin injection in patient with hemifacial spasm.

In addition to titrating the injection dose for desired effect, the practitioner can also modify the injection sites. If the corrugator and procerus muscles are affected, the toxin may be injected in the glabellar region.

The initial effect of the injections usually occurs within 3 days and is maximal 1 to 2 weeks after treatment. The therapeutic effectiveness of Botox in patients with blepharospasm lasts 6 to 28 weeks, with most patients becoming symptomatic again in approximately 3 months. The average interval between injections is longer in patients with hemifacial spasm, sometimes up to 6 months. With repeated injections the therapeutic interval decreases in some patients but appears to stabilize in most after the fourth or fifth injection. This reduction in efficacy may result from the toxin's binding to the nonactive large protein chain, a resprouting of motor end plates, or the development of an antitoxin.

Unfortunately, there is no simple and readily available assay for botulinum antibodies. The frequency of detectable botulinum antibodies has been found to range from 3% to 5%, with evidence that increased dose and reduced interval between injections are related to the presence of antibodies. Often, the clinician must increase the botulinum toxin dose to maintain the same effect with subsequent treatments. A mean 50% increase in dose may be required for patients with BEB over the first six injections, with no further increase required with later treatments. If a treatment produces an unexpected shorter interval of relief after several good responses from earlier injections, it is likely that the former duration of effect will be reestablished with subsequent treatments. It is possible that the total cumulative toxin dose

might be a factor in the development of antibodies. The incidence of antibodies has been found to increase in a cumulative dose-dependent manner from 4% with a 1-year cumulative dose of less than 500 units to 100% at a dose of greater than 2,000 units. This suggests that even small doses of toxin given over very long periods might induce the development of antibodies. Repeat injections should be delayed as much as possible to avoid cumulative effects.

Myobloc is available premixed in a clear colorless to light yellow sterile solution. It is available in three dosing volumes: 2,500 units/0.5 ml, 5,000 units/1 ml, and 10,000 units/2 ml. It can remain stable under refrigeration for up to 21 months. Myobloc exists at pH 5.6 when in aqueous solution. This relatively acidic pH can cause increased discomfort in patients during injection. Myobloc has been found to have a less complete or shorter duration of muscle paralysis compared with Botox.

Botulinum toxin is contraindicated in patients with a known allergy to the drug or with infection or inflammation at the proposed injection sites. Safety for use during pregnancy or lactation has not been established. Other contraindications include poor patient cooperation, coagulopathy (including pharmacologic anticoagulation), and other neuromuscular diseases such as myasthenia gravis or amyotrophic lateral sclerosis (Lou Gehrig's disease). Both Botox and Myobloc contain pooled human albumin to stabilize the active ingredient. Therefore individuals with allergy to eggs should not receive botulinum toxin.

The most frequently encountered local side effect, occurring in up to 40% of patients, is exposure keratitis resulting from decreased blinking and lagophthalmos. Ptosis is the second most common side effect and results from the toxin's direct effect on the levator palpebrae superioris muscle. Avoiding injection of the middle of the upper eyelid and adjacent eyebrow region can reduce or eliminate this outcome. Effective treatment for the induced ptosis includes topical 0.5% apraclonidine (Iopidine), which is administered four times daily for approximately 1 month. Apraclonidine stimulates Müller's muscle by activating the  $\alpha_1$ -adrenergic receptors. If allergy to apraclonidine develops, the patient may use naphazoline until the major effect of the botulinum toxin subsides and the ptosis resolves.

Other side effects include pain at the injection site, ecchymosis, increased tearing, ectropion, entropion, dry eye symptoms, and diplopia. Avoiding injection of the middle or the entire lower eyelid may alleviate some of these side effects.

Adverse events in patients who receive botulinum toxin injections for hemifacial spasm are virtually identical to those that occur in treatment of BEB. However, diplopia and lower facial weakness are more common in patients with hemifacial spasm.

**Surgery.** Surgical treatment is a viable option for patients who cannot tolerate repeated botulinum toxin injections or for those who have an inadequate response. Effective procedures for blepharospasm include selective facial myectomy involving removal of the muscles that close the eyelids and strengthening of the muscles that open the eyelids. In some individuals, modified upper eyelid surgery, such as blepharoplasty and limited myectomy or blepharoplasty with levator advancement, may prolong botulinum toxin's duration of effect.

Surgery for hemifacial spasm involves microvascular decompression of the facial nerve by placement of a sponge under posterior fossa vessels (Jannetta procedure). Surgery for hemifacial spasm is associated with cure rates exceeding 80%, and beyond 2 years there appears to be little risk of relapse. However, surgical intervention can have serious complications such as permanent facial paralysis, deafness, stroke, and even death.

## SELECTED BIBLIOGRAPHY

- Burde RM, Savino PJ, Trobe JD. *Clinical decisions in neuro-ophthalmology*, ed. 3. St. Louis, MO: Mosby, 2002.
- Engel AG, ed. *Myasthenia gravis and myasthenic disorders*. New York: Oxford University Press, 1999.
- The Ischemic Optic Neuropathy Decompression Trial Research Group. Optic nerve decompression surgery for non-arteritic arteriole ischemic optic neuropathy (AION) is not effective and may be harmful. *JAMA* 1995;273:625-632.
- Kline LB, Bajandas FJ, eds. *Neuro-ophthalmology review manual*, ed. 5. Thorofare, NJ: SLACK Incorporated, 2004.
- Lipham WJ. *Cosmetic and clinical applications of botulinum toxin*. Thorofare, NJ: SLACK Incorporated, 2004.
- Loewenfeld IE. *The pupil: anatomy, physiology, and clinical applications*, vols. 1-2. Boston: Butterworth-Heinemann, 1999.
- Miller NR, Newman JB, eds. *Walsh & Hoyt's clinical neuro-ophthalmology*, ed. 6, vols. 1-3. Philadelphia: Lippincott Williams and Wilkins, 2005.
- Optic Neuritis Study Group. High- and low-risk profiles for the development of multiple sclerosis within 10 years after optic neuritis. *Arch Ophthalmol* 2003;121:944-949.
- Optic Neuritis Study Group. The clinical profile of optic neuritis. Experience of the optic neuritis treatment trial. *Arch Ophthalmol* 1991;109:1673-1678.
- Skorin L, Larsen K, Eggers D. Temporal arteritis. *Contemp Optom* 2006;4:1-8.

## *Diseases of the Eyelids*

*Kimberly A. Lambreghts and Gerald G. Melore*

Eyelid disorders are among the most common abnormalities encountered by primary eye care practitioners. Because of their high prevalence and the fact that eyelid diseases are often associated with significant symptoms, adjacent tissue involvement, or even systemic manifestations, the practitioner must be able to recognize and treat these disorders. This chapter considers the etiology, diagnosis, and management of the more clinically significant eyelid conditions.

### **CLINICAL ANATOMY AND PHYSIOLOGY OF THE EYELIDS**

An understanding of eyelid anatomy and function aids in the diagnosis and management of lid pathology. Figure 23-1 shows the major anatomic features of the eyelid. The lids are mobile structures comprising three separate tissue layers; epithelium/conjunctiva, muscle, and connective tissue. They are lined anteriorly by the dermis and posteriorly by conjunctiva. Deep to the dermis is the muscular layer which comprises the orbicularis oculi, the levator palpebrae superioris, and Müller's muscle. Cranial nerve VII innervates the orbicularis muscle, which is primarily responsible for normal involuntary blinking and tight eyelid closure. Cranial nerve III innervates the levator, which elevates the upper eyelid. Müller's muscle is innervated by sympathetics carried on cranial nerve III; its function is to augment the action of the levator.

The eyelids play an important role in the production, excretion, and spreading of tears. Goblet cells within the palpebral conjunctiva are responsible for the mucin component of the tear film. The superior and inferior tarsal plates are composed of dense connective tissue. They are responsible for giving the lids their convex shape, which is necessary for adequate tear movement during each blink, and for protecting the orbital cavity from penetration by bacteria or other foreign material. Contained within the tarsal plates are the meibomian glands, sebaceous glands that secrete oil. They may be seen in a single row, which marks the mucocutaneous junction, termed the *gray line*, just posterior to the

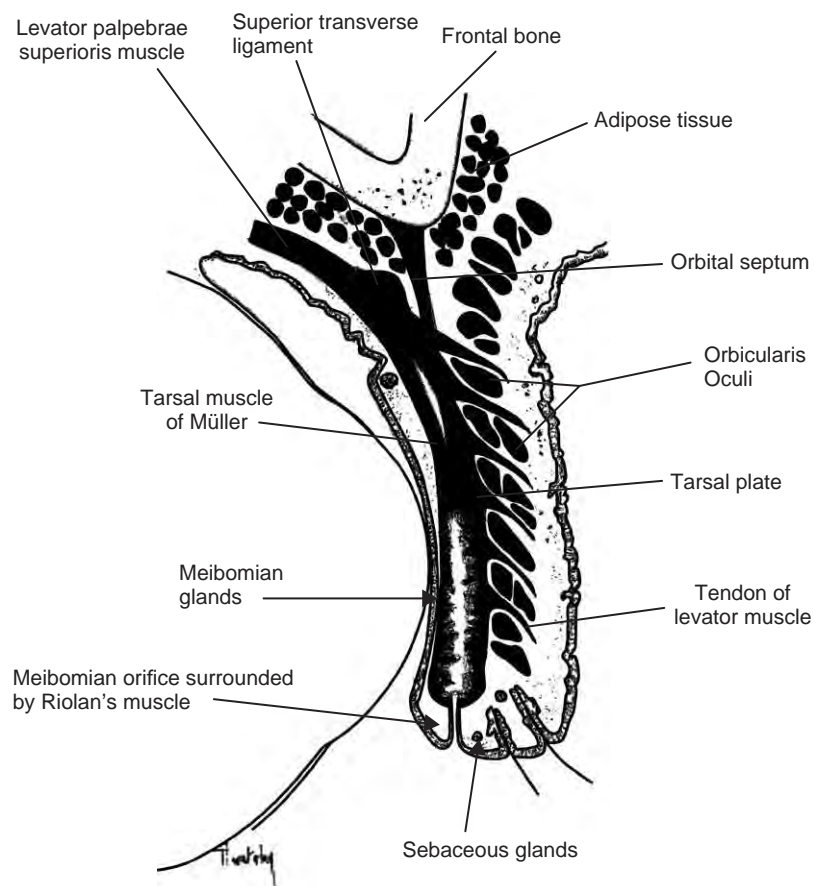
eyelashes, and are responsible for the lipid component of the tear film. Riolan's muscle, a smooth muscle that surrounds each gland orifice, is thought to play a role in secretion. The gray line delineates the lid into anterior and posterior lamella, which is an important landmark in defining eyelid margin disease. The eyelashes (cilia) emerge from individual follicles, surrounded by the glands of Zeis (sebaceous) and Moll (modified sweat glands).

### **Anterior Lid Margin**

#### **Blepharitis**

Blepharitis is a broad term that refers to a collection of lid margin inflammatory disorders that cause changes in adjacent or surrounding structures and often includes, or is associated with, dermatologic conditions such as seborrhea and rosacea. The etiology remains poorly understood despite a strikingly high prevalence in the population; it has been reported that approximately 590,000 patients per year seek care due to blepharitis, and it is estimated that 20 million people suffer from this disorder worldwide.

Classifying blepharitis is a challenge. Many patients present on a continuum rather than in a specific disease category, and they tend to have varied and sometimes overlapping clinical signs and symptoms. There have been many proposed classification schemes over the years, yet none has gained widespread popularity. Currently, blepharitis in all its forms is usually defined by anatomic location: anterior/posterior to the gray line or lateral/medial canthus. Secondary descriptors are usually attached that define potential etiology. Box 23-1 displays the descriptive scheme used in this chapter. Anterior blepharitis, also referred to as "marginal," may be infectious and/or "seborrheic" in nature. Posterior blepharitis consists of two forms of meibomian gland dysfunction (MGD), meibomitis or meibomianitis, which is inflammatory, and meibomian seborrhea, which is not. Angular blepharitis is the term used when the inflammation is located in the lateral or medial canthal areas. It is most often infectious; however, it may also be associated with atopy.



**Figure 23-1** Major anatomic features of the eyelid. (From Remington LA. Clinical anatomy of the visual system, 2e, Butterworth Heinemann, 2005.)

### Box 23-1 Eyelid Margin Disease

Anterior lid margin
Infectious, bacterial, staphylococcal blepharitis
Angular
Medial
Lateral
Seborrheic blepharitis
Mixed seborrheic–staphylococcal blepharitis
Posterior lid margin
Meibomian gland dysfunction
Meibomian seborrhea
Meibomitis
Primary
Secondary

Modified from Smith RE, Flowers CW Jr. Chronic blepharitis: a review. *CLAO J* 1995;21:200–207; McCulley JP, Dougherty JM, Deneau DG. Classification of chronic blepharitis. *Ophthalmology* 1982;89:1173–1180; and Wilhelmus KR. Inflammatory disorders of the eyelid margins and eyelashes. *Ophthalmol Clin North Am* 1992;5:187–194.

Care must be taken when diagnosing a patient with blepharitis, especially in the elderly. There are some striking morphologic changes that occur to the lids with aging that do not necessarily signify pathology. The lid margins become slightly thicker with advancing age, the lids become more vascularized, the upper lid may become more rounded, telangiectasia and hyperkeratinization are often more evident, and gland orifices may narrow and pout.

The exact etiology of eyelid margin disease remains poorly understood, making the diagnosis and treatment a frustrating endeavor for both the patient and the eye care professional. Blepharitis in most forms has no cure, and treatment is meant to quell the acute phase only.

#### Infectious, Bacterial, Staphylococcal Blepharitis

**Etiology.** Microbiologic studies of lid flora in control and blepharitis patients determined that the most common bacteria isolated from both groups were staphylococcal epidermidis (*S. epidermidis*), *Propionibacterium acnes*, and *Corynebacterium* sp. *S. aureus* was cultured more often in the infectious and mixed varieties of

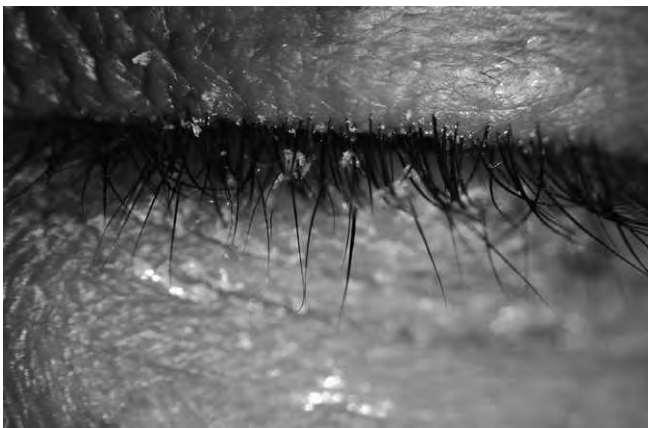

blepharitis, thus suggesting its potential role as a causative agent in at least these patients.

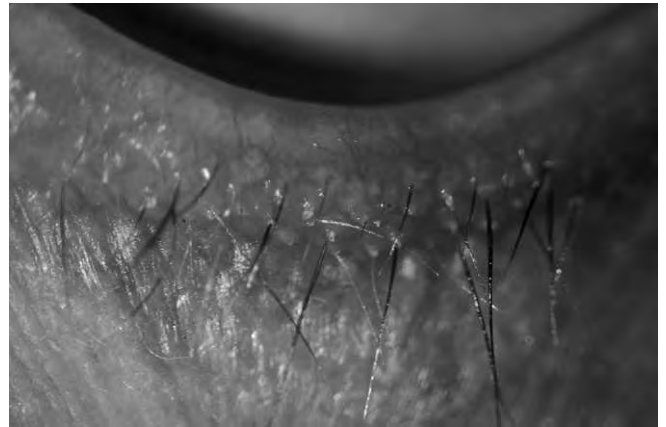Infectious blepharitis is thought to be caused by a direct infection from bacteria that are either found in greater quantity, are more virulent in nature, or are pathogenic in certain individuals. It has also been postulated that patients with atopy or other dermatologic conditions (e.g., rosacea) are more likely to have blepharitis and are more prone to staphylococcal infections. Currently, *S. aureus* remains the primary suspect in bacterial and mixed variety blepharitis, although the exact mechanism remains a mystery.

For many years *S. aureus* exotoxins have been considered the cause of associated conditions such as blepharokeratoconjunctivitis. It has been determined that all *Staphylococcus* species produce exotoxins, and because these species are found on the lids of both normal and blepharitis patients, they are most likely not primarily responsible for the findings. More recent evidence suggests that an abnormal blink mechanism or destabilization of the tear film due to bacterial lipolytic enzyme pathways and increased hydrolysis of phospholipids may be the cause. It has also been shown that a delayed hypersensitivity to these toxins can produce the marginal keratitis seen in many patients.

**Diagnosis.** Hard, “dry,” brittle, fibrinous scales, often called *collarettes*, found surrounding the lashes and on the lid margin, characterize staphylococcal blepharitis (Figure 23-2). These scales resemble a “collar” surrounding the lash at its base. This finding is not to be confused with the tubular “sleeves” found at the base of the eyelash typical of a *Demodex* infestation. *Scurf* is another commonly used term for flaking on the lashes and by definition is typically used to describe dandruff seen on the scalp or the greasy scales on the lids of seborrhea blepharitis patients. Typically, patients with infectious blepharitis



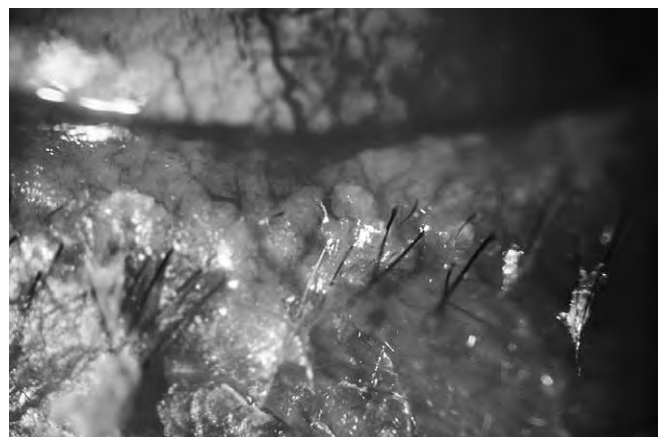
**Figure 23-2** Collarettes and flaking seen in staphylococcal blepharitis.



**Figure 23-3** Telangiectasia or “rosettes” seen on the lower lid in infectious blepharitis.

show significant hyperemia of the lid margin, caused by the dilation of fine vessels, termed telangiectasia or “rosettes” (Figure 23-3), which appears much greater than that found in noninfectious blepharitis varieties. Symptoms include foreign body sensation, matting of the lids upon awakening, itching, burning, and tearing. Hard crusts surrounding the individual lashes at their base characterize the less common ulcerative type of staphylococcal blepharitis. Removing these crusts often exposes small ulcers, and bleeding may occur. In chronic staphylococcal blepharitis associated findings may include loss of lashes (madarosis), misdirection of lashes (trichiasis), irregular or thickened lid margins (tylosis ciliaris) (Figure 23-4), and poliosis (whitening of the cilia).

Associated conditions may include papillary conjunctivitis; keratoconjunctivitis sicca (KCS), present in as many as 50% of patients; superficial punctate keratitis (SPK), affecting predominantly the inferior quadrant of the cornea;



**Figure 23-4** Inflammation, madarosis, and tylosis ciliaris in long-standing staphylococcal blepharitis. (From Kanski JJ. *Eyelids*. In: *Clinical ophthalmology: a systematic approach*, ed. 5. Philadelphia: Butterworth-Heinemann, 2003:10.)

marginal infiltrates or ulcers; and phlyctenular keratitis. Patients with staphylococcal blepharitis are also more prone to develop an acute infection in the glands of Zeiss (external hordeola or sty) or meibomian glands (internal hordeola).

**Management.** The most important step in successful management is comprehensive patient education and lid hygiene. Staphylococcal blepharitis can become chronic; thus it should be treated aggressively. The patient needs to understand that treatment is meant to control the condition rather than cure it. There are two phases of treatment: the initial acute phase and the long-term management phase. The first phase of therapy may be expected to last at least 2 to 8 weeks and consists of vigorous treatment to bring the condition under control. The long-term phase aims at keeping the signs and symptoms in check and should last indefinitely.

Lid hygiene consists of hot compresses, lasting 5 to 10 minutes and performed two to four times daily, followed by lid scrubs using a mild detergent cleanser such as baby shampoo and a washcloth or prepackaged commercially available lid scrubs (Box 23-2). Dilution of the shampoo is not necessary unless the patient has an unfavorable reaction to full strength. The hot compresses serve to loosen lid debris and dilate blood vessels to allow increased blood flow to the area. The scrubs not only facilitate removal of debris but also serve to lyse bacterial membranes and to reduce the bacterial load. Antibiotic ointment should then be applied directly to the lid margin two to four times daily. Antibiotic drops are used when a secondary conjunctivitis is also present.

Sulfonamides, though previously popular, are not recommended because only 30% of *S. aureus* strains cultured from the lids are sensitive. Bacitracin and erythromycin ointment are each effective against both *S. aureus* and *S. epidermidis*; therefore they have become the treatment of choice. Aminoglycosides, such as gentamicin and tobramycin, have also been used; however, many *Staphylococcus* isolates are now resistant to aminoglycosides and long-term treatment can lead to medicamentosa. The combination of trimethoprim and polymyxin B, as well as the fluoroquinolone ciprofloxacin 0.3%, has also been reported to be an effective treatment option. When writing the prescription it is important to specify that the drug should be applied to the lid margins two to four times daily and not simply placed into the cul-de-sac.

Treatment must be intense for 2 to 8 weeks and then tapered to the lowest effective dosage for maintenance. Whichever antibacterial agent is chosen as initial therapy, it is important to alternate treatment using a different antibiotic on consecutive weeks or months to avoid or minimize the development of resistant organisms. Prescribing below the recommended dosages can also

### Box 23-2 Instructions for Lid Hygiene

#### Warm compresses

1. Dip a cloth washcloth in hot tap water, being careful to test the heat against your wrist to prevent a burn.
2. Place this compress against your closed eyelid for 45–60 seconds.
3. Repeat steps 1 and 2 for a total of ~10 minutes.

#### Lid massage

1. Immediately after the warm compresses and with the eyes closed, place a finger on top of the closed upper eyelid just below the brow.
2. With a rolling motion, roll the finger in a downward direction toward the eyelashes. Continue this across the entire lid to be sure all glands are “milked” in a downward motion.
3. Follow the same procedure for the lower lid except roll the finger in an upward motion.

#### Lid scrubs

1. Immediately after applying the warm compresses and/or lid massage, wrap a finger or two in the washcloth.
2. Using a no-tears baby shampoo (dilute the solution if irritation occurs) form lather on the washcloth.
3. With the eyes closed, gently scrub the lids and eyelashes, in a horizontal motion from left to right, for approximately 20 passes across each lid.
4. Rinse the eye area with clean water.

Modified from McCulley JP. Blepharconjunctivitis. *Int Ophthalmol Clin* 1984;24:65–77.

lead to resistance. In treatment-resistant cases a culture of the lids and conjunctiva should be performed.

Associated toxic epithelial keratitis should respond to blepharitis treatment. Topical steroids are generally not required unless the cornea is significantly involved or a phlyctenule is present. In this case prednisolone 0.12% used two or three times a day for a few days may be used. Combination steroid-antibiotic ointments, such as tobramycin-dexamethasone or the topical combination drop tobramycin-loteprednol, may prove to be useful for those patients complaining of excessive itching and burning. Steroids control the hypersensitivity component that is often present and reduce the congestion and irritation that often provoke the patient to rub the eye and aggravate the blepharitis.

Patients need to understand the importance of complying with the recommended therapy. Because of complications associated with chronic staphylococcal

blepharitis, the importance of early and effective treatment cannot be overemphasized.

### Angular Blepharitis

**Etiology.** Angular blepharitis is caused by infection with *Staphylococcus*, *Moraxella*, *Candida*, or, rarely, herpes simplex virus.

**Diagnosis.** The characteristic signs of angular blepharitis include chronic hyperemia, desquamation, and ulceration of the lateral, and sometimes medial, canthal regions (Figure 23-5). Simultaneous involvement of the conjunctiva often occurs. Symptoms include irritation and tenderness of the involved area.

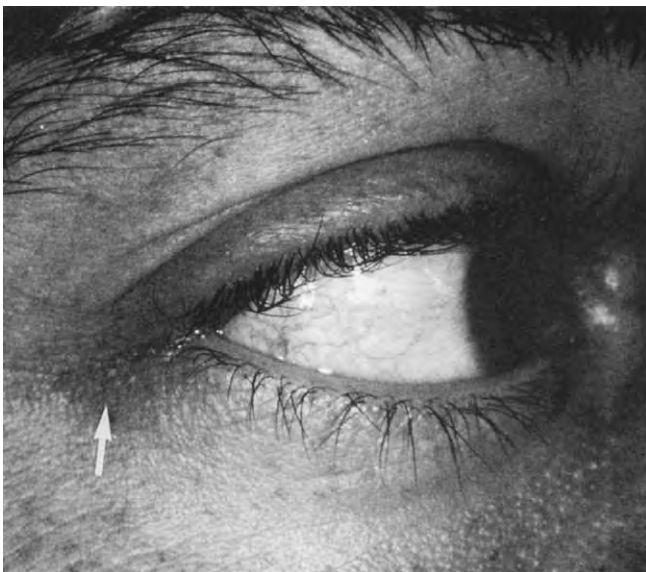**Management.** Angular blepharitis usually responds to classic blepharitis treatment; however, if this fails a suspected *Moraxella* infection must be considered. Topical fluoroquinolone ointments such as ciprofloxacin may be useful.

### Seborrheic Blepharitis

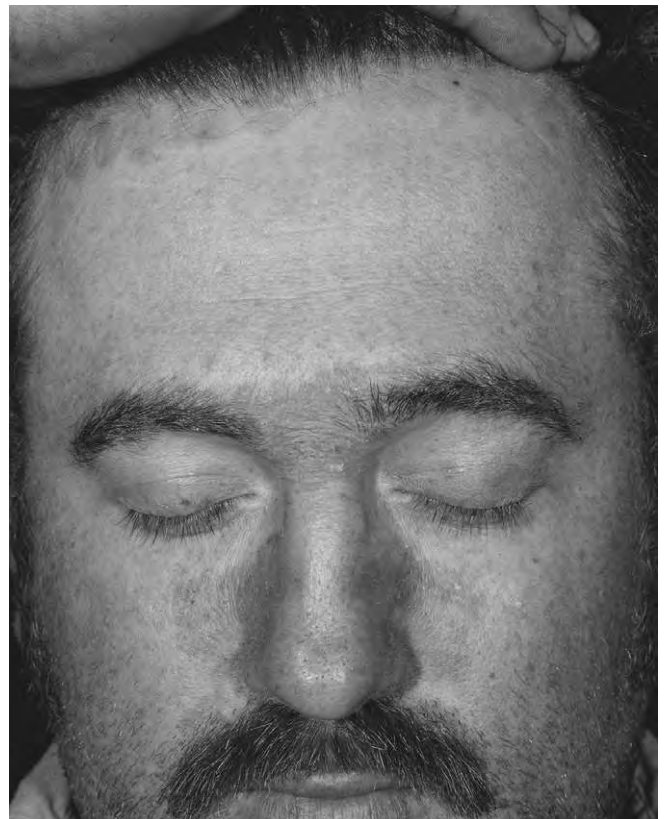
**Etiology.** Seborrheic dermatitis is often associated with seborrheic blepharitis, which is typically low grade and chronic. Seborrheic dermatitis is a very common skin condition that involves sebaceous glands of the head (Figure 23-6), ears, and flexural creases. It is marked by a change in the quantity or quality of gland secretions, termed *sebum* on the body and *meibum* on the lids. *Pityrosporum ovale* (*P. ovale*), hormones, infection, nutrition, and/or stress may all be causative factors. Treatment that eradicates *P. ovale* improves seborrhea, but whether

the yeast is causative is still unclear and how eradication relates to blepharitis treatment is unknown. Previously, it was postulated that *Demodex folliculorum* played a large role in the lid disease process; however, there is no statistically significant difference in the isolation rates of *D. folliculorum* between seborrheic blepharitis patients and unaffected patients.


**Diagnosis.** Seborrheic blepharitis may be so minimal that the clinician must examine the face for further evidence of seborrhea or look for signs of dandruff, the most common presentation of seborrhea. History may also be helpful, because patients may recall episodes of erythema and tenderness, particularly in the areas of the forehead and the sides of the nose. Seborrheic blepharitis tends to have a long course with less obvious exacerbations and remissions than one sees when microbes are involved. The lid margins may or may not be particularly hyperemic. Greasy scales, called *scurf*, are noted on the lid margin (Figure 23-7) and often on the skin of the lid above. Patients report symptoms of a foreign body sensation, mattering, and burning that persists for a longer duration than reported in staphylococcal blepharitis.



**Figure 23-5** Inflammation of temporal bulbar conjunctiva and excoriation of outer canthus (arrow), characteristic of angular blepharoconjunctivitis.



**Figure 23-6** Seborrheic dermatitis in a classic distribution at hairline and between eyebrows and nasolabial folds. (From Habib TP. Psoriasis and other papulosquamous diseases. In: Clinical dermatology, a color guide to diagnosis and therapy, ed. 4. Philadelphia: Mosby, 2004:244.)



**Figure 23-7** Greasy lashes and scurf in seborrheic blepharitis. Note the external hordeolum (stye) on the lower lid margin (*black arrow*). (From Kanski JJ. *Eyelids*. In: *Clinical ophthalmology: a systematic approach*. Philadelphia: Butterworth-Heinemann, 2003:10.)

Seborrheic blepharitis may be found in isolation, in conjunction with staphylococcal infection, or with posterior blepharitis with or without inflammation of the glands.

Associated conditions may include KCS, SPK (typically over the lower one-third of the cornea), and/or marginal corneal infiltrates or ulcers.

**Management.** As with infectious blepharitis the first step in successful management is explaining the long-term nature of the condition and the importance of lid hygiene (refer to the treatment for staphylococcal blepharitis above). After improvement, the patient should continue daily warm water washcloth scrubs, preferably in the morning, to maintain control.

Seborrheic dermatitis on the scalp (dandruff) usually responds to frequent shampooing with over-the-counter products containing 3% to 5% sulfur and 2% to 3% salicylic acid. For the face and body topical cream preparations containing 3% sulfur and 3% salicylic acid or 1% topical glucocorticoids are effective. In addition, a topical preparation containing antifungal agents has also been used. A dermatologic consultation should be obtained if these are not effective or if seborrhea is reported elsewhere on the body. Follow-up is necessary, especially when topical medications are used around the eyes. In a reported case, the use of fluocinonide cream to the scalp and forehead along with ketoconazole shampoo caused a transient band-like keratopathy in a patient being treated for seborrheic dermatitis. Care should also be taken when using topical steroid cream on the face because prolonged contact with the skin can cause atrophy and telangiectasia formation.

In resistant cases of seborrheic blepharitis, bacterial superinfection must be considered and an antibiotic ointment may be added to the regimen if indicated.

Associated KCS should be treated using artificial tears and lubricants.

### Mixed Seborrheic–Staphylococcal Blepharitis

Most cases of blepharitis involve a combination of staphylococcal and seborrheic changes. The patient should be instructed carefully in appropriate lid hygiene techniques and the application of antibiotics as previously described. In addition, the patient should be referred for treatment of the dermatitis. An over-the-counter dandruff shampoo should be recommended.

## Posterior Lid Margin

### Meibomian Gland Dysfunction

The meibomian glands are modified sebaceous glands that are imbedded in a single row within the tarsal plate. There are approximately 20 to 25 glands in the lower lid and 30 to 40 in the upper lid. Each meibomian gland orifice is surrounded by a muscle of Riolan that acts as a sphincter for the retention and release of meibum. Gland function is governed in part by neuronal control, vascular regulation, and hormones; blinking is also thought to contribute to the release of meibum.

**Etiology.** Meibomian gland secretions are responsible for the lipid component of the precorneal tear film. The chemical composition of meibum and/or the lipase action of the normal lid bacteria is thought to contribute to or cause blepharitis and in many cases the dry eye that accompanies it. The composition of meibum has been found to be different in normal and blepharitis patients, and there is a distinct difference between the types of MGD as well. Most studies of lid flora in bacterial blepharitis cases did not find any appreciable isolates from meibum that were not found as normal flora on the lids, therefore disproving the theory that the meibomian glands act as a bacterial reservoir.

There are two forms of clinically relevant MGD: meibomian seborrhea and meibomitis/meibomianitis. Meibomian seborrhea has been defined as either excessive secretion of or easily expressed meibum. The composition of the meibum makes the secretions in this group of patients very fluid and toxic to the cornea. In contrast, meibomitis is divided into two distinct clinical forms: secondary and primary. Secondary meibomitis is glandular dysfunction occurring in a random fashion, and primary meibomitis refers to MGD that affects all the meibomian glands. Either condition may be associated with staphylococcal blepharitis and with seborrhea or rosacea. Both entities are thought to be forms of obstructive MGD. This obstruction may be due to a blockage in the meibomian gland orifices by keratinized epithelial cells or due to an alteration in the meibum, leading to stagnation and perhaps infection. All forms of MGD cause multiple symptoms of varying degrees and should be considered carefully in all cases of dry eye syndrome.

**Diagnosis.** In meibomian seborrhea the symptoms frequently outweigh the clinical signs. Symptoms are described as being worse upon awakening. The glands and the easily expressed meibum appear normal; however, the clinical sign of bulbar injection and foam in the tear film support the likelihood that the chemical composition of the meibum has changed. Biomicroscopy may disclose a thickened oily layer of the precorneal tear film. Although meibum is released at a basal rate, further production occurs with blinking. It is theorized that nonblinking during sleep causes retention of secretions; upon first awakening the initial blinks release the stored secretions containing elevated levels of oleic acid, which causes the ocular irritation.

As mentioned previously, meibomitis is infectious in nature and may be primary or secondary. Either type may be associated with staphylococcal blepharitis and with seborrhea or rosacea. Meibomian gland changes are not always accompanied by significant inflammatory signs, and the condition may be easily overlooked. Although the clinical findings can vary considerably, symptoms usually consist of irritation, chronic burning, stinging, foreign body sensation, or mild conjunctival injection.

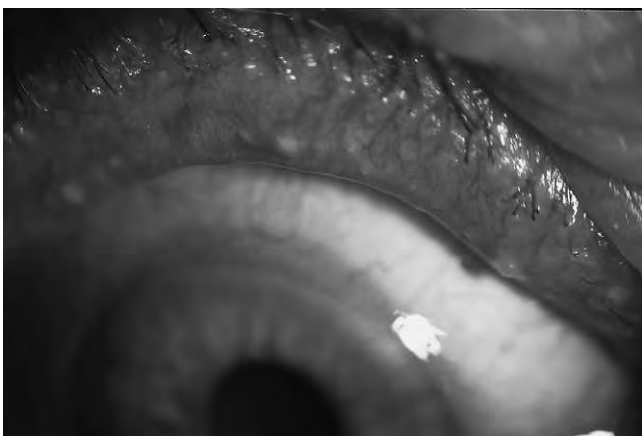Signs of meibomitis include inspissated orifices of the meibomian glands (Figure 23-8A), cloudy or thickened yellow-white meibomian secretions on gland expression, “frothy” tear film (Figure 23-8B), hyperemia, mild papillary conjunctivitis, and thickened rounded eyelid margins. SPK of the cornea and conjunctiva in the interpalpebral space is associated with an unstable tear film evidenced by a markedly reduced tear breakup time.

**Management.** The most effective treatment for MGD involves relieving any obstruction of the meibomian ducts and orifices by digital massage and gland expression two


to four times daily. The practitioner can perform this treatment in the office and instruct the patient in the proper technique for meibomian expression at home. Digital massage involves manually “massaging” the glands by rolling a finger placed over the glands, in a downward motion for the upper lid and upward motion for the lower lid. The application of hot compresses before gland expression is usually more effective in promoting normal gland flow. In moderately severe cases, lid hygiene and meibomian gland expression bring immediate, albeit temporary, relief of symptoms.

Oral tetracycline has become adjunctive therapy for moderate to severe cases of MGD. The drug is prescribed at a dosage of 250 mg four times a day initially and then tapered over the course of 3 to 4 months. Once the condition is controlled, low maintenance dosages of 250 mg daily may be required to ensure long-term control. Tetracycline appears to reduce the quantity of enzymes produced by bacteria residing on the lid margin, which reduces free fatty acids in the sebum and thus stabilizes the tear film. This alteration of free fatty acids can be accomplished without dosages high enough to kill the organisms. Minocycline and doxycycline have also been shown to be effective. Pregnant women and children under 12 years of age should be given erythromycin rather than tetracycline due to its detrimental effect on bone formation and tooth discoloration. In a recent study, *N*-acetylcysteine was given orally at a dosage of 100 mg three times a day for 8 weeks and was found to improve tear film stability by altering lipid metabolism. More research is needed to support this claim but results look promising, and it may one day become a viable treatment option.

Recently, a commercially available all-in-one therapy became available that packages a foaming lid cleanser



A



B

**Figure 23-8** (A) Meibomitis with inspissated orifices and scarring of the posterior lid margin. (B) Frothy tear film in meibomitis. (From Kanski JJ. *Eyelids*. In: *Clinical ophthalmology: a systematic approach*. Philadelphia: Butterworth-Heinemann, 2003:11-12.)

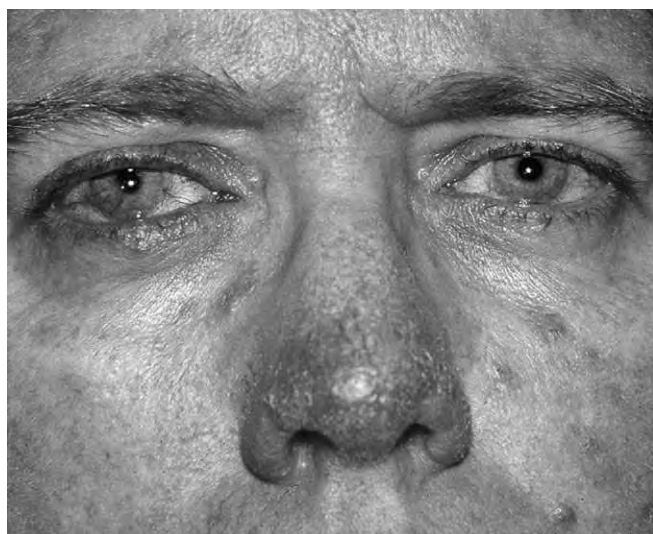with an oral antibiotic for the treatment of blepharitis. This kit is available by prescription only.

Topical antibiotic use in MGD is controversial. Some authors recommend against topical applications to avoid further disruption of the tear film and also because efficacy is questionable. Topical steroids are unlikely to have any benefit. During the course of therapy, attention should be given to the KCS that occurs in nearly every case. Artificial tears or lubricating ointments are indicated to ensure improvement in symptoms. More recent treatment options include topical cyclosporine A 0.05% as well as “soft steroids” such as loteprednol or rimexolone.

### Blepharitis in Rosacea

**Etiology.** Acne rosacea, better described as rosacea, may be associated with acne but is not caused by it. Rosacea is a chronic, facial, inflammatory skin disorder frequently related to infectious blepharitis. Rosacea affects the face, nose, chin, and forehead. It has been reported to occur in up to 10% of the population and roughly 14 million Americans. It affects mostly fair-skinned individuals with an onset of between 20 and 50 years. It is characterized by periods of exacerbation that may be mild to very severe. One of the many forms of rosacea is ocular rosacea.

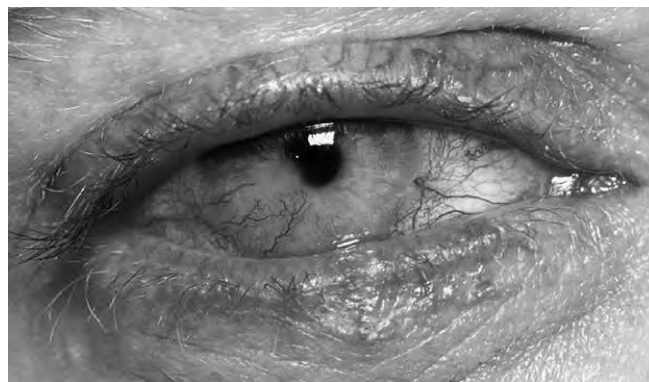**Diagnosis.** The diagnosis of rosacea depends on the presence of one or more of the following signs found on the face: transient or persistent flushing, papules, pustules, and telangiectasia (Figure 23-9). Up to 58% of patients with rosacea develop eye signs or ocular rosacea. The exact etiology of ocular rosacea is unknown; however, the possible causative factors may be *D. folliculorum* infestation, staphylococcal infection, chronic meibomitis, or blood vessel dysfunction. In its severe form rosacea often



**Figure 23-9** Rosacea of the face with flushing, papules, pustules, and telangiectasia of the nose. (From Palay DA, Krachmer JH. Conjunctival abnormalities. In: Primary care ophthalmology, ed. 2. Philadelphia: Mosby, 2005:99.)

affects the cornea, leading to significant symptoms and visual impairment. Facial erythema and telangiectasia with MGD suggests the need for dermatologic consultation, even without the more obvious signs of papules and pustules. The most common eye findings are conjunctivitis and meibomitis. Corneal signs include neovascularization, scarring or thinning, and/or SPK (Figure 23-10). The patient may have a history of recurrent hordeola or chalazia. Other less common ocular signs include episcleritis/scleritis and iritis. Ocular rosacea may precede cutaneous signs, and in 20% of patients it is the only clinical sign. However, in most cases the presentation is concurrent or the skin findings occur first. Ocular rosacea is under-diagnosed in the population, partly because facial signs may be subtle, but also because eye care practitioners often fail to look for facial signs in patients with nonspecific complaints.

**Management.** Recently, a few randomized clinical trials have evaluated the efficacy of various ocular rosacea treatments. Oral therapy is the mainstay because there is better follicular penetration than with topical treatments. Oral tetracycline, minocycline, or doxycycline remains the treatment of choice, along with erythromycin, azithromycin, and clindamycin. Oral tetracycline is prescribed at 250 mg four times a day for at least 3 weeks and then tapered when the condition begins to respond. It may also be cycled with a pattern of 3 weeks on and 1 week off the medication. Although slower acting, doxycycline is often better tolerated and has better gastrointestinal tract absorption. Doxycycline is effective at 100 mg once a day for 6 to 12 weeks, tapered to 50 mg once a day for 4 weeks and then 50 mg every other day and gradually discontinued. Many patients require a maintenance dosage to prevent relapse. Currently, low-dose or submicrobial-dose doxycycline at 20 mg twice daily used for its anti-inflammatory property is under investigation. A formulation of controlled-release, 40 mg doxycycline



**Figure 23-10** Rosacea with severe blepharitis. Note the thickened lid margins and the corneal neovascularization. This is the same patient as seen in Figure 23-9. (From Palay DA, Krachmer JH. Conjunctival abnormalities. In: Primary care ophthalmology, ed. 2. Philadelphia: Mosby, 2005:98.)



monohydrate, taken once daily, is available. Warm compresses, lid expression, and lid hygiene are also important.

KCS is more prevalent in rosacea, so attention to this aspect of management is crucial. The use of artificial tears, lubricating ointments, or topical cyclosporin is often required to ensure improvement in symptoms.

Topical preparations for the treatment of rosacea include metronidazole 0.75% or 1% cream, 0.75% gel, or lotion. None of these preparations is FDA-approved for ophthalmic use, but they have been beneficial for some patients.

## INFLAMMATORY DISEASES

Hordeola are extremely common typically self-limiting infections of the meibomian glands or the glands of Zeis and Moll. There are two distinct clinical types of hordeola defined by the glands involved, either external or internal.

### External Hordeolum

External hordeolum, also called a *stye*, is often self-treated by the patient. However, the optometrist or other primary care clinician may be consulted because of its painful and cosmetically displeasing course.

#### Etiology

An external hordeolum is an acute focal inflammation with abscess formation, most often caused by a *S. aureus* infection of the glands of Zeis and Moll. It may occasionally be associated with staphylococcus blepharitis and can be recurrent.

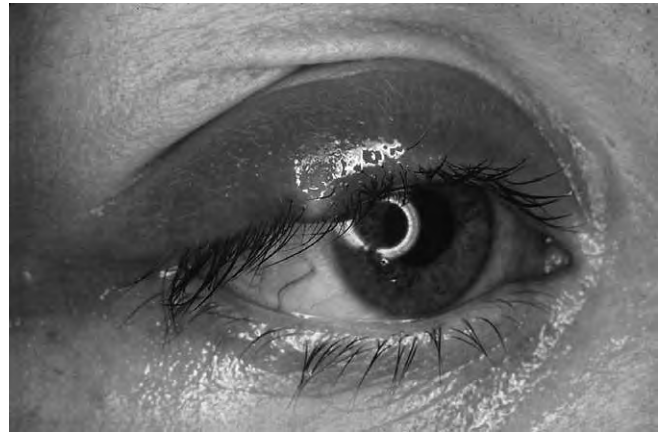
#### Diagnosis

The lesion usually appears as a localized area of redness, tenderness, and swelling adjacent to or surrounding an eyelash (Figure 23-11). The primary symptom is localized pain of recent onset. Within a few days the lesion develops a yellow point on the surface of the lid margin. In most cases the abscess spontaneously drains within 3 or 4 days after pointing. Rarely do external hordeola cause any other tissue damage.

#### Management

The application of hot compresses several times daily serves to hasten pointing and drainage. Generally, this is all that is necessary for resolution. Topical application of antibiotic solutions or ointments may prevent infection of surrounding lash follicles but does not affect the course of the external hordeolum itself. One of the best methods to hasten drainage is to epilate the involved lash, which creates an effective drainage channel.

For lesions resistant to the usual therapy, a stab incision can be made with a sterile needle or blade into the area of pointing, allowing the abscess to drain. The area



**Figure 23-11** External hordeolum (stye). Presents as a localized area of redness, pain, and swelling adjacent to an eyelash. (From Kanski JJ. *Eyelids*. In: *Clinical ophthalmology: a systematic approach*. Philadelphia: Butterworth-Heinemann, 2003:14.)

should then be treated with a topical antibiotic ointment, such as tobramycin or polymyxin B/bacitracin. If the external hordeolum is recurrent despite topical antibiotic therapy, a lid culture should be obtained to identify the organism so that specific antibiotic therapy can be instituted.

### Internal Hordeolum

#### Etiology

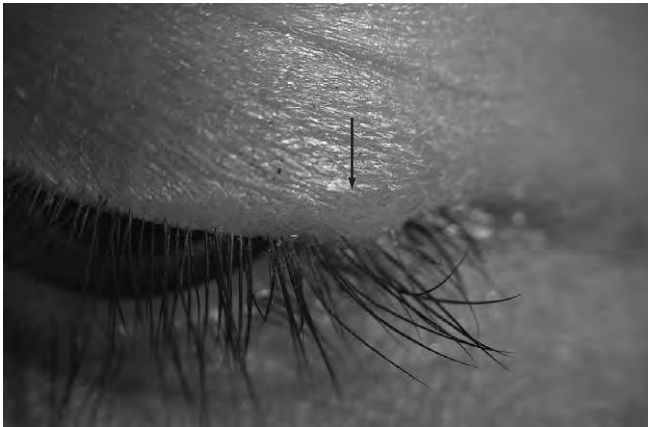An internal hordeolum is a localized staphylococcal infection of the meibomian glands. The infection may result from blockage of the gland and is found more frequently in the upper lid. A specific change in meibomian gland secretion has been linked to internal hordeolum formation.

#### Diagnosis

Inspection and palpation of the affected lid reveal a localized area of infectious inflammation with swelling, warmth, redness, and tenderness within the tarsus (Figure 23-12). The lesion may point toward the surface of the lid or toward the palpebral conjunctiva. The onset and course of an internal hordeolum are usually more prolonged than that of an external hordeolum. Internal hordeola may represent an extension of infection from a primary site and are often associated with a preexisting condition such as blepharitis. If not treated adequately, an internal hordeolum may extend into surrounding tissues, causing preseptal or orbital cellulitis.

#### Management

Because the infection is deep within the lid tissue, topical antibiotics are usually ineffective. If the lesions are small and without significant pain and tenderness, the application of hot compresses several times daily is usually sufficient for resolution. If the lesion is causing moderate to



**Figure 23-12** Small internal hordeolum of the upper eyelid (arrow). (Courtesy Dr. Katrina Parker, University of Houston, College of Optometry.)

severe symptoms and is large in size, oral antibiotics are indicated. Because most internal hordeola are caused by *Staphylococcus* species, primary therapy should consist of a penicillinase-resistant synthetic penicillin such as dicloxacillin. Dosages of 125 to 250 mg every 6 hours for 1 to 2 weeks usually results in prompt resolution of the infection. Second-line oral therapies include erythromycin, azithromycin, or cephalosporins if the patient is not allergic to PCN (penicillin). In cases resistant to such oral therapy, incision and drainage may be necessary. Topically applied antibiotic solution or ointment after drainage serves to prevent secondary infection. One should carefully inspect the surrounding lid tissue for edema and hyperemia because of the high incidence of preseptal cellulitis, which requires an oral antibiotic.

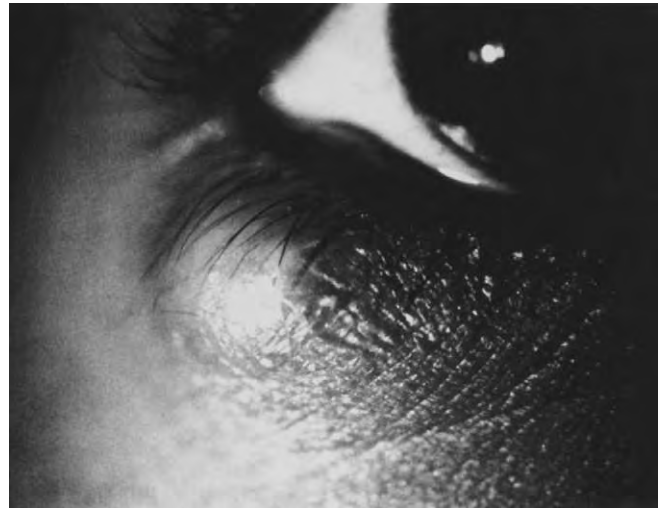## Chalazion

### Etiology

A chalazion is a chronic, sterile, lipogranulomatous inflammation of the meibomian gland due to retention of normal secretions. Such duct obstruction and granuloma formation may occur during *Demodex brevis* invasion of the meibomian glands, but the precise role of this organism in the formation of chalazia has not been established. Chalazia occur spontaneously or may follow an acute internal hordeolum.

### Diagnosis

The lesion usually develops over several weeks and is more common in the upper lid, appearing as a hard, painless, immobile mass (Figure 23-13). Examination of the lesion reveals noninfectious inflammation. Palpation discloses a hard, mobile, painless growth without redness, an important feature differentiating it from an internal hordeolum. If the chalazion enlarges it may produce mild discomfort, be cosmetically displeasing, or induce corneal astigmatism. Twenty-five percent of chalazia resolve spontaneously within 6 months of onset, but most require treatment.



**Figure 23-13** A large chalazion located at the lateral aspect of the lower eyelid.

### Management

In most cases chalazia can be treated successfully by the application of hot compresses, followed by vigorous digital massage several times daily for 2 to 4 weeks. Topical and systemic antibiotics are not necessary because the lesion is sterile. The longer a chalazion is present the more resistant it will be to conservative treatment; however, even lesions present for over 6 months may respond to warm compresses and digital massage. Consequently, local measures should be implemented before seeking more aggressive therapy.

Chalazia that fail to respond to conservative management may be treated with an intralesional injection of steroids; 0.1 to 0.2 ml of triamcinolone acetonide is injected into the center of the lesion, using a 1-ml tuberculin syringe fitted with a 27- or 30-gauge 5/8-inch needle. If the chalazion points anteriorly, the injection is given through the skin of the lid. If the chalazion points posteriorly, a topical anesthetic is applied and the injection is given through the conjunctiva. The patient is seen in 1 week; if the chalazion persists, a second injection is indicated. Chalazia typically resolve within 1 or 2 weeks after a single injection of steroid, but larger lesions (>6 mm in diameter) often require a second injection. The overall success rate is 77% to 93% after one or two injections. If the chalazion persists after the second injection, surgical excision and curettage is indicated (see Surgical Treatment of the Lids, below).

Complications after steroid injection are minimal but can occur. The patient can expect slight discomfort at the injection site and occasionally subcutaneous white (steroid) deposits in the treated area. Depigmentation of the eyelid at the injection site, especially in dark-skinned individuals, and temporary skin atrophy can also occur. Skin depigmentation can be minimized by using a transconjunctival rather than a transepidermal injection in persons of color. When depigmentation occurs, it is



usually reversible. Very rarely, retinal and choroidal vascular occlusions immediately after a steroid injection have been reported. These occlusions are due to embolization and may be reduced by aspirating for blood before injecting, injecting slowly, and avoiding heavy digital pressure during and after injection. Other rare cases of globe penetration have been reported; however, this can be avoided by using a chalazion clamp that has a solid footplate.

If after 1 or 2 months of conservative therapy or 2 to 4 weeks of intralesional steroid injection the chalazion has not resolved, surgical resection can be recommended. In atypical cases or lesions that recur after surgical removal, the chalazion should be submitted for pathologic examination to exclude the possibility of sebaceous gland carcinoma or Merkel cell tumor. Chalazia presenting in the elderly are more likely to be associated with malignancy. Coexisting blepharoconjunctivitis that is resistant to therapy and has associated lymphadenopathy, especially involving the preauricular and submandibular nodes, also suggests the possibility of malignancy and warrants histologic examination of excised tissues.

## Preseptal (Periorbital) Cellulitis

### Etiology

Preseptal or periorbital cellulitis is an infectious process involving lid structures anterior to the orbital septum. The condition generally occurs due to one of three clinical scenarios: (1) secondary to a localized infection or an inflammation of the eyelids or adjacent structures (i.e., sinusitis, conjunctivitis, blepharitis, and/or internal hordeolum), (2) secondary to eyelid or facial trauma, and (3) after an upper respiratory tract infection.

Profound inflammation and edema of the eyelid may accompany infection of the skin of the face (i.e., impetigo), eyelids, or conjunctiva. Infection occurs by invasion of the organism into the subcutaneous tissue through an abrasion or ulceration. In most patients, *S. aureus*, group A *Streptococcus pyogenes*, or  $\beta$ -hemolytic streptococci cause the infection. These organisms can also accompany infected lacerations and abrasions, insect stings or bites, foreign bodies, or bacterial infection of viral lesions caused by herpes simplex or varicella-zoster virus (VZV). There has been an increase in preseptal cellulitis caused by uncommon bacteria such as *Acinetobacter*, a gram-negative coccobacilli, and at least one reported case caused by *Trichophyton* (ringworm). Erysipelas, a rare form of preseptal cellulitis, is caused by *S. pyogenes* group A and is mainly found in children. Anaerobic organisms such as *Peptostreptococcus* and *Bacteroides* species, which are part of the normal oral flora, can be the causative organisms in patients with preseptal cellulitis associated with human or animal bites. Foul-smelling discharge, necrotic tissue, gas in the tissue, or severe toxemia suggests an anaerobic infection.

In patients without evidence of local infection or trauma, preseptal cellulitis is often secondary to a respiratory tract

infection and/or sinusitis or ethmoiditis in most cases; the causative pathogen is usually *S. aureus*, *Streptococcus pneumoniae*, or *Haemophilus influenzae*. Cellulitis may result from a direct extension of infection from the sinus cavity. Although the most likely primary focus of infection is the nasopharynx and sinuses, cellulitis may also develop by spread of organisms from the middle ear to the preseptal space via the vascular or lymphatic systems. Young children with a sinusitis and secondary cellulitis pose a very serious health risk, because the infection can cause severe orbital or intracranial complications.

Before the introduction of the *H. influenzae* type B vaccine in 1985, nearly all children under 6 years of age with preseptal cellulitis were found to have *H. influenzae* type B or a *S. pneumoniae* infection. This condition was of great concern due to the mortality from secondary meningitis. Because *H. influenzae* is no longer of primary concern in children, the most common causative bacteria are the group A streptococci. An important component in the history of young children with cellulitis should be to confirm or exclude *H. influenzae* type B vaccination.

### Diagnosis

Cellulitis can pose a significant risk for morbidity and mortality if undiagnosed. For this reason the practitioner needs to differentiate preseptal cellulitis from the more serious orbital cellulitis (Table 23-1). Chemosis, conjunctival injection, and pain on eye movement occur more often in orbital cellulitis; both conditions present with redness and swelling of the eyelid. When a swollen lid

**Table 23-1**  
Differential Diagnosis: Preseptal and Orbital Cellulitis

Clinical Finding	Preseptal	Orbital
Visual acuity	Normal	Reduced
Proptosis	Absent	Marked
Chemosis	Rare/mild	Common
Hyperemia	Rare/mild	Marked
Pupils	Normal	RAPD <sup>a</sup>
Motility	Normal	Restricted
Pain (motility)	Absent	Present
IOP	Normal	May be increased
Temperature	Normal/mildly elevated	102–104°F
Headache	Absent/mild	Common
Associated symptoms (nausea, vomiting)	Absent	Common

IOP, intraocular pressure,

<sup>a</sup>Relative afferent pupillary defect.

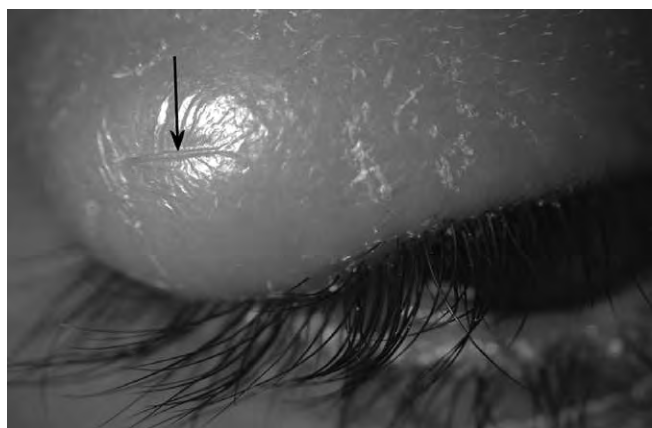Modified from Jones DB, Steinkuller PG. Microbial preseptal and orbital cellulitis. In: Tasman W, Jaeger EA, eds. Duane's clinical ophthalmology, vol. 4. Philadelphia: JB Lippincott, 1993:1–24; and Holdeman NR. Preseptal cellulitis/orbital cellulitis. In: Onofrey BE, Skorin Jr L, Holdeman NR, eds. Ocular therapeutics handbook; a clinical manual, ed. 2. Philadelphia: Lippincott Williams and Wilkins, 2005:189–193.)

occurs without evidence of proptosis, the diagnosis is invariably preseptal cellulitis (Figure 23-14). In addition to proptosis, other signs of orbital cellulitis include limited extraocular motility, reduced visual acuity, an afferent pupillary defect, and systemic involvement. Occasionally, fever and headache occur in patients with preseptal infection; however, when these occur in conjunction with proptosis, decreased visual acuity, and restrictions on eye movement, orbital cellulitis is typically the cause.

The eyelid and adnexal tissues should be carefully examined for the presence of puncture wounds, trauma, or infectious lesions of the skin. Facial tenderness, nasal discharge, and malodorous breath are signs of paranasal sinusitis. Focal medial canthal tenderness and tearing may indicate acute dacryocystitis.

In distinguishing preseptal from orbital cellulitis, if the eyelids cannot be separated to look for proptosis, limited ocular motility, afferent pupillary defect, or vision loss, computed tomography of the orbit should be considered to exclude the presence of orbital involvement. Moreover, computed tomography helps to detect the presence of orbital foreign bodies and sinusitis. A computed tomography is recommended if orbital involvement cannot be excluded on the basis of the clinical examination; if there is progression of disease despite antibacterial treatment; if there is ophthalmoplegia, deteriorating visual acuity, or color vision; or if the infection is bilateral.

In cases that do not resolve or become worse, in the absence of overt signs of orbital involvement, laboratory evaluation should include a complete blood count with differential as well as blood cultures. Cultures often show positive growth in children under the age of 4 years (usually streptococci) but are rarely positive in older children or adults. In patients with skin lesions, specimens should be obtained for culture onto blood, chocolate, and



**Figure 23-14** Preseptal cellulitis of the upper eyelid secondary to an internal hordeolum. Note the shallow skin fissure (*arrow*) secondary to the significant swelling. (Courtesy Dr. Anastas Pass, University of Houston, College of Optometry.)

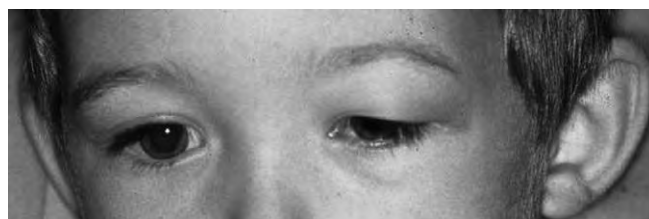Sabouraud's agar plates. Although cultures of draining wounds may be useful in cases of preseptal cellulitis related to trauma or local infection, cultures of the conjunctiva, eyelids, and nasal mucosa are generally misleading.

As previously stated, *H. influenzae* is no longer a major cause of cellulitis in children. However, when present, the condition is characterized by significant fever, leukocytosis, and unilateral hyperemia and edema of the eyelids. There is a sharply demarcated dark purple discoloration of the eyelid skin and adnexal area. Mild conjunctival hyperemia and chemosis may also occur. Unless the patient has received antibiotics, blood cultures are the most effective means of establishing the diagnosis. If meningeal signs are present, a lumbar puncture should be performed, because 12% to 25% of patients with *Haemophilus* preseptal or orbital cellulitis have concomitant meningitis.

In cases where there is sudden onset, with swelling and pruritus, an allergic reaction should be considered and is often the result of an insect bite (Figure 23-15). These patients respond well to oral antihistamines, and the condition usually resolves within 24 to 48 hours without further intervention.

### Management

The initial choice of antibiotic for treatment of preseptal cellulitis is largely empiric, as the causative pathogen is not identified. Thus appropriate therapy must take into consideration the most plausible etiologic organisms. Because preseptal cellulitis associated with local trauma or infections is not usually serious, treatment often consists of oral antibiotics. Mild to moderate infections usually respond to oral penicillinase-resistant synthetic penicillins, such as dicloxacillin (250 mg orally every 6 hours) or amoxicillin-clavulanic acid (250 to 500 mg orally three times a day or 875 mg orally twice daily), or to a first-generation cephalosporin, such as cephalexin (250 to 500 mg orally three times a day). If the patient is allergic to penicillin, trimethoprim-sulfamethoxazole (one double-strength tablet orally twice daily), azithromycin "Z-Pak," or levofloxacin (500 mg orally every day) is recommended. Therapy should continue for at least 7 to 10 days. Topical antibiotic therapy is indicated



**Figure 23-15** Sudden onset of preseptal cellulitis of left eye in a 3-year-old child secondary to an insect bite.

when there is external lid involvement or a secondary conjunctivitis. In severe cases, when the patient is under 5 years of age, or if the patient is immunocompromised, hospitalization and intravenous antibiotics are warranted.

## VIRAL EYELID DISORDERS

### Herpetic Ocular Disease

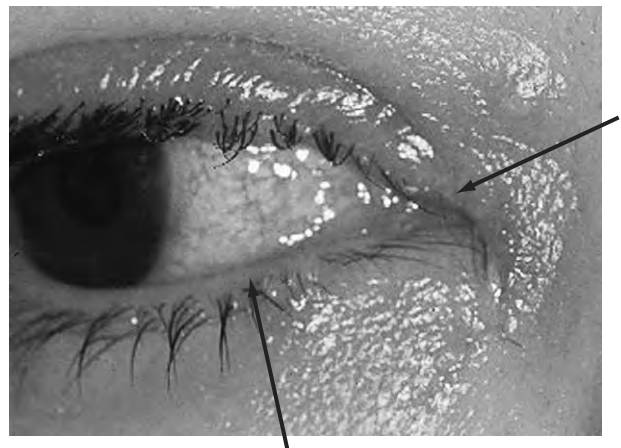
Herpes simplex virus (HSV), the most common virus found in humans, and VZV have both been known to cause serious ocular complications. Generally speaking, primary disease occurs as a blepharoconjunctivitis in HSV and as chickenpox in VZV but may recur in older children and adults. Both viruses typically manifest as a unilateral ocular disease.

#### Herpes Simplex Blepharoconjunctivitis

**Etiology.** HSV type 1 causes most of the ocular simplex infections. Type 2 HSV is predominantly a genital pathogen, although there has been an increase in the number of ocular cases caused by this strain of HSV. Blepharoconjunctivitis, caused by type 1 HSV, usually occurs as a primary infection in children, between the ages of 6 months and 5 years, without significant systemic signs or symptoms. The infection is usually spread via contact with cold sores, saliva, or other fomites; it may also be passed onto the neonate during vaginal delivery. Once the primary infection is quelled, the virus lies dormant in the trigeminal ganglion, cornea, or sclera until reactivation occurs. Reactivation may be triggered by stressors such as illness, fatigue, trauma, and ultraviolet sun exposure, although none of these factors has specifically been proven. There have been several reported cases of recurrent HSV blepharitis; however, recurrence typically presents as a dendritic keratitis, not as an eyelid manifestation. Approximately one-fifth of patients with ocular herpes simplex have lid involvement as the only sign of infection. Recurrence rates for HSV are approximately 20% within 2 years, 40% within 5 years, and 67% within 7 years.

**Diagnosis.** In the classic form, vesicles form along the eyelid margin and/or periocular skin (Figure 23-16). The lesions are clear, pinhead in size, and have an inflamed erythematous base. Typically, within 1 week of presentation the vesicles break and ulcerate, resulting in a painful edematous blepharitis or dermatitis. The involved portion of the lid usually demonstrates mild swelling and tenderness. Pronounced conjunctival injection, a secondary follicular conjunctivitis, a “weepy” wet eye, and a regional lymphadenopathy may all be present.

**Management.** Because topically administered antiviral agents have little or no effect on skin lesions, treatment of HSV infection of the eyelid is nonspecific. In the



**Figure 23-16** Herpes simplex blepharoconjunctivitis. Note the open vesicles in the medial canthus and the lower lid margin with secondary viral conjunctivitis. (Courtesy Dr. Ralph Herring, University of Houston, College of Optometry.)

immunocompetent host, the vesicular lesions from a primary herpetic infection of the lids remain localized, are generally self-limited, and resolve without scarring, usually within 10 to 14 days. If the lesions are near the lid margins, topical trifluridine can be administered prophylactically several times daily to prevent corneal infection. If corneal involvement occurs, vigorous antiviral therapy should be instituted (see Chapter 26).

Palliative treatment of lid lesions includes lid hygiene with warm compresses. Drying agents can be applied to periocular skin lesions, carefully avoiding those on the lid margins. These agents include calamine lotion, spirits of camphor, or 70% alcohol. Another reported treatment for viral skin lesions is the application of topical povidone-iodine, thought to have an antibacterial and a drying effect, though not yet clinically proven. If the lesions become secondarily infected, a topical antibiotic ointment should be applied. Steroids are contraindicated because they may predispose the patient to serious corneal involvement.

Herpes simplex infection in the immunocompromised host, especially the patient infected with the human immunodeficiency virus (HIV), requires careful comanagement with the patients' physician.

#### Herpes Zoster Ophthalmicus

**Etiology.** VZV is a DNA virus that causes two separate but distinct clinical entities: varicella (chickenpox) and zoster (shingles). It is estimated that over 90% of all adults in the United States are seropositive for VZV and almost all carry latent virus.

Primary disease, termed chickenpox (varicella), is benign and usually occurs before the age of 10 years. It is estimated that 3 million new cases of chickenpox occur in the United States each year, with a peak incidence in the spring. Once infected, the virus lays dormant in the

dorsal root ganglion or trigeminal ganglion until reactivation occurs, typically in otherwise healthy adults between the ages of 50 and 70 years.

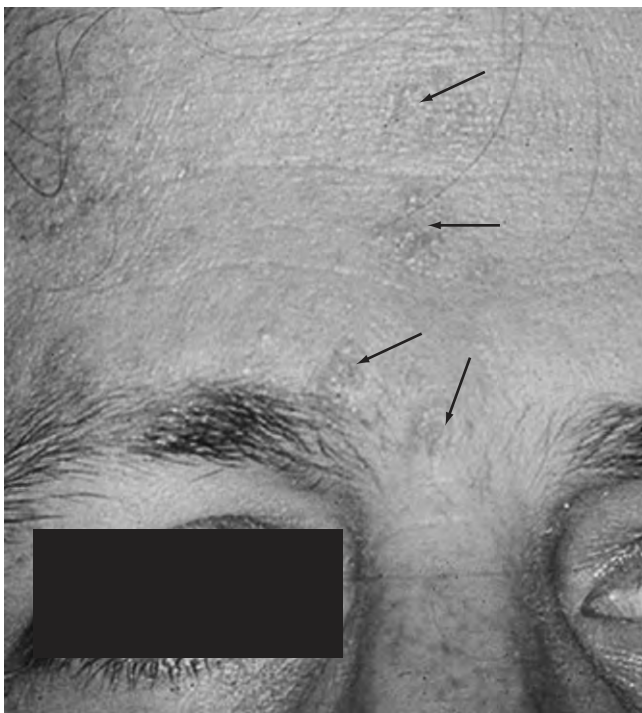Recurrent disease is termed zoster or shingles and spreads via a spinal nerve or cranial nerve to the affected dermatome. Zoster affects one-fifth of the population with an incidence of 2.2 to 3.4/1,000 per year. The incidence of zoster in the elderly is reported to be as high as 10/1,000 per year in those over 80 years; however, recurrent zoster in younger immunocompetent patients is low and is estimated to be about 4%. The total lifetime risk for developing shingles is estimated to be 10% to 20%. In recent years the incidence and severity of varicella-zoster infection has increased because of the growing number of immunosuppressed patients, including transplant patients and those with Hodgkin's disease, chronic lymphocytic leukemia, and acquired immunodeficiency syndrome. The diagnosis of herpes zoster in patients younger than 45 years warrants testing for HIV, because herpes zoster ophthalmicus (HZO) can be the initial manifestation. The relative risk of VZV is 15 times greater in patients infected with HIV than in those who are not. Identification of HIV status is extremely important because ocular involvement can be rapidly progressive and potentially blinding, thus requiring aggressive treatment.

Reactivation of VZV is thought to be related to an inciting or predisposing event or condition. These factors include trauma, surgery, advanced age, stress, corticosteroids,

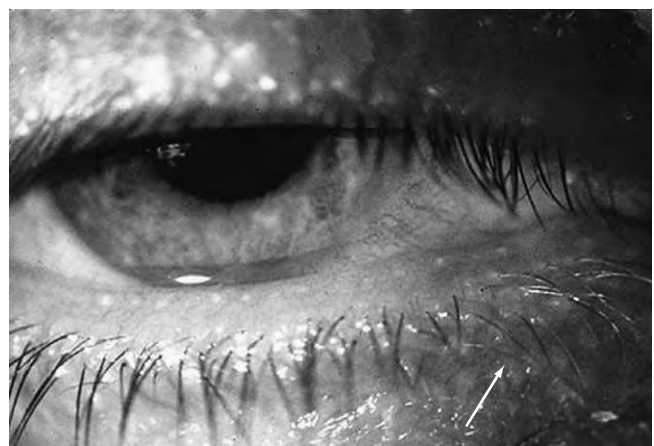infection, underlying neoplasm, ultraviolet light or irradiation, and heavy metal or chemical exposure or toxicity.

Frequently, HZV affects the cranial nerves. When the first (ophthalmic) division of the fifth cranial nerve is affected, the resultant disease is considered to be HZO; eye involvement occurs in 10% to 20% of all cases of zoster. One or all of the branches of cranial nerve V<sub>1</sub> may become involved. The frontal nerve is the most frequently affected, involving the upper lid, forehead, and superior conjunctiva. The virus may also involve the nasociliary branch of cranial nerve V<sub>1</sub>, which innervates the sclera, cornea, iris, ciliary body, and choroids as well as the side and tip of the nose. Lesions affecting the tip of the nose are termed Hutchinson's sign and signify a greater risk of ocular involvement. It is estimated that if Hutchinson's sign is present, there is a 50% to 80% greater risk for developing HZO.

**Diagnosis.** The prodromal phase is characterized by headache, malaise, fever, and chills, followed in 1 or 2 days by neuralgic pain and 2 or 3 days later by hot, flushed, hyperesthesia and edema of the involved dermatome(s). The skin overlying the affected area then erupts with a single crop of clear vesicles. The vesicles are distributed on only one side of the face and almost never cross more than 1 to 2 mm beyond the midline (Figure 23-17). These vesicles then become yellow and turbid and by day 7 to 10 form deep scab-like eschars,



A



B

**Figure 23-17** (A) Herpes zoster ophthalmicus. Note the rash is very subtle and does not cross the midline (*arrows*). (B) Close-up of the patient in A. Arrow points to a subtle crop of vesicles near the medial canthus. (Courtesy Dr. Nancy George, University of Houston, College of Optometry.)

which may leave permanent pitted scars. Viable viruses can be cultured from the vesicles for up to 14 days after appearance of the rash. Health care workers are advised to know their immune status with regard to varicella and, if necessary, to seek immunization. It is advisable to caution families and/or partners of patients regarding the contagion.

Some patients experience only relatively minor tingling and numbness, but often excruciating neuralgic pain accompanies the disease. In most cases the severe pain subsides during the first several weeks, but many patients develop postherpetic neuralgia (PHN), a chronic condition caused by scarring of the nerves. Although the cause of PHN is not well understood, the prevalence is important in management decisions. More than 50% of patients over the age of 60 develop PHN after an episode of herpes zoster. Once established, the pain often becomes intractable and management is, at best, difficult. PHN is one of the most common causes for presentation at pain clinics. Involvement of the trigeminal nerve is a predictive factor for PHN as well as advanced age, the presence of prodromal pain, and unusually severe pain at the onset of the dermatitis. Such patients experience persistent aching and burning, which can interrupt daily activities and in some instances can lead to severe depression or even suicide. Thus one of the most important aspects of therapy is to prevent scarring and subsequent neuralgia. Although the acute inflammatory stage lasts only 2 to 3 weeks, the skin ulceration may require many weeks to heal and can result in the equivalent of third-degree burns. As a result serious complications can arise, including total lid retraction, ptosis, madarosis, entropion, or cicatricial ectropion.

### **Management**

**Dermatitis.** In most cases the skin and lid lesions of varicella-zoster are self-limited and benign. The primary concern should be coincident keratitis, and thus the swollen lids must be carefully separated so that the cornea can be examined. The treatment of corneal lesions is discussed in Chapter 26.

Optimal antiviral treatment is begun within 48 to 72 hours of the first skin eruption to reduce further ocular involvement and perhaps decrease the duration of associated pain; it has not been proven to prevent PHN. This optimal time course, however, should not detract from the value of antiviral therapy begun late, which may still be beneficial when initiated 3 to 7 days after eruption. Oral antivirals effectively hasten resolution of signs and symptoms, reduce viral shedding and formation of new skin lesions, and decrease both the incidence and severity of ocular complications. Controversy remains as to the best choice of oral therapy. Acyclovir 800 mg five times a day for 7 to 14 days has been the standard. Alternatively, valacyclovir, a prodrug of acyclovir, is administered at 1,000 mg three times a day and is considerably less expensive than acyclovir. Famciclovir, a prodrug of penciclovir,

is administered at 500 mg three times a day for 7 days. Dosing compliance is easier with valacyclovir or famciclovir than with acyclovir; therefore they may be considered as first-line treatment options.

The main side effect associated with oral acyclovir, valacyclovir, and famciclovir is intestinal disturbance such as nausea and vomiting. Acyclovir is available in an 800-mg tablet that does not contain lactose; therefore it is less likely to cause lactose-related diarrhea. Lower dosages are recommended for treatment of elderly patients with impaired creatinine clearance. Perhaps the most significant factor in favor of antivirals is that they minimize the common complications of the disease, including dendriform keratopathy, stromal keratitis, and anterior uveitis.

Drying lotions should not be used on skin lesions because they may increase scarring. In the child or adult for whom the skin lesions itch or are irritating, an oral antihistamine may help to prevent scratching, which can lead to secondary infection and thereby scarring. Recommended agents include oral chlorpheniramine or diphenhydramine. The use of cimetidine is controversial; as an H<sub>2</sub> blocker, oral cimetidine has an immunosuppressive action. The effects are not always consistent, however, and use of cimetidine is risky in autoimmune disorders and organ transplant patients.

In patients with severe lid involvement, lubricating ointments should be instilled into the cul-de-sac to prevent complications arising from exposure or trichiasis. An oculoplastic surgeon should manage scarring and contraction of lid tissue that creates cicatricial ectropion, lid retraction, lid margin deformity, or severe corneal complications.

It is important to note that the acute lid edema occurring soon after the onset of viral invasion does not result from bacterial cellulitis and typically resolves within a few days without antibiotic therapy.

**Acute and Postherpetic Neuralgia.** In addition to antivirals, oral analgesics are recommended for pain. If the pain is severe, an opioid analgesic may be prescribed. A stellate ganglion block, administered by an anesthesiologist within 14 days of the rash, may also be helpful.

Although oral corticosteroids have had an established use in herpes zoster treatment, their value has become controversial. They are clearly contraindicated in HIV and while the virus is still present in immunocompetent patients. Some authors report increased quality of life and decreased acute pain with oral steroid use in the elderly, but this value is offset by potential risk. Significant relief may be obtained with early antiviral therapy so that oral steroids are an unnecessary risk. Oral steroids are of no value in preventing PHN as was previously believed. The duration of PHN, however, is significantly shortened by early and aggressive use of oral antiviral agents in the acute phase of herpes zoster. Tricyclic antidepressants may also be useful when prescribed at the time of acute



onset of herpes zoster for treatment of PHN that develops later; however, due to their anticholinergic, sedation, and postural hypotensive effects, they have limitations. It has also been reported that preemptive treatment with an anticonvulsant (i.e., gabapentin) may reduce the incidence of PHN. Only one-third of patients with PHN of 6 months duration find adequate pain relief. For this reason PHN is best managed by an ophthalmologist and/or pain specialist. Oral H<sub>2</sub> blockers have been suggested as treatment for PHN and for the dermatologic sequela of HZO; however, this has yet to be conclusively proven.

Topical therapy may be of some benefit to the PHN patient. They are used after the skin lesions have healed but cannot be used on periocular tissue. Topical lidocaine patches for analgesia is one such treatment. Capsaicin cream has also been used and may provide pain relief within 2 to 4 weeks of treatment. The cream is applied three to four times daily to the area of painful skin. Approximately 30% of treated patients experience burning, stinging, or redness of the skin on initial application, but with repeated use these reactions usually diminish or subside.

**Immunocompromised Patients and HZO.** In the immunosuppressed patient, especially the HIV patient, the risk of virus dissemination is higher, postherpetic pain can be greater, and ocular/systemic complications can be more severe. Hospitalization for intravenous acyclovir ensures higher drug concentrations than with oral agents. Outpatient therapy with oral antivirals may be considered for mild localized herpes zoster in some immunosuppressed patients, home intravenous acyclovir therapy may be considered for slightly more immunosuppressed patients, and hospitalization with isolation and intravenous ganciclovir is the treatment of choice for HIV patients who are already receiving acyclovir. HIV patients develop retinitis, which can advance to progressive outer retinal necrosis or endogenous endophthalmitis. Periodic fundus examinations are necessary in these patients, and prophylaxis treatment is often maintained for life. Although triple drug therapies including antiretrovirals and protease inhibitors have thus far resulted in fewer cases of herpes zoster in the HIV population, this trend is not expected to endure because triple therapy also allows patients to live longer, and zoster cases may merely be postponed.

**Varicella-Zoster Immunization.** Immunization against varicella was approved in the United States in 1995 and is administered to children 12 to 18 months of age or older if they have not had chickenpox. It has been shown to be most effective in the year after vaccination; however, breakthrough disease was noted but found to be mild. Varicella vaccination reduces the number of related deaths, especially in children aged 1 to 4 years,

and reduces the overall hospitalization and ambulatory visit rates in children and adolescents. It does not affect the age-specific rate of developing shingles.

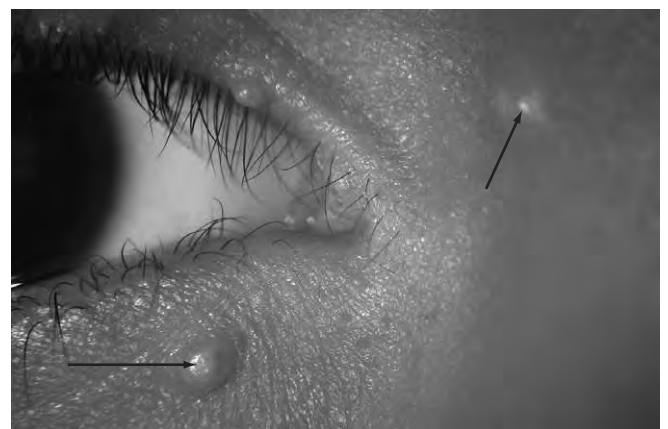
In May 2006 the U.S. Food and Drug Administration approved a live attenuated VZV vaccine. It is indicated for patients 60 years of age and older who have had a history of chickenpox but not shingles. It has been shown to reduce the incidence of VZV, PHN, and the duration and severity of illness.

### Molluscum Contagiosum

Molluscum contagiosum is a relatively common viral infection of the skin that may be problematic when located near or around the eyes. It is seen most often in children but may be found in adults, especially if immunocompromised.

**Etiology.** Molluscum contagiosum is a localized self-limiting skin infection caused by a human-specific pox virus. Infection is most often due to autoinoculation or by direct contact; it is rarely sexually transmitted.

**Diagnosis.** Diagnosis is typically made based on the clinical appearance of the skin and eyelid lesions; however, occasionally it is made after excision and histology is performed. The lesions, called mollusca, are multiple, dome-shaped, pearly, or flesh-colored papules with a central depression or umbilication (Figure 23-18). Lesions range between 1 and 10 mm in size with an average of 2 to 3 mm. Mollusca typically occur over the trunk or flexural areas of the body but may also be found on the skin of the face, eyebrows, and eyelids. Incubation, on average, takes 2 weeks but may be as long as 6 months, with a mean duration of 6 to 8 weeks. Lid lesions frequently go unnoticed unless they shed virus into the cul-de-sac, causing a follicular conjunctivitis (see Chapter 25). Patients



**Figure 23-18** Molluscum contagiosum showing the typical dome-shaped lesions with central depression (*arrows*). (Courtesy Dr. Mona Younes, University of Houston, College of Optometry.)

often complain of a red watery eye and occasionally blurry vision.

**Management.** Treating molluscum is controversial. The condition is typically benign and self-limiting with little or no residual sequela. However, to speed the process some recommend piercing the lesion with a sterile needle and expressing the umbilicated core and cautery, excision, or destruction of the lesion with phenol. Some of the more invasive treatment options can cause scarring, and unless the condition is causing extensive patient discomfort these are not recommended. Antivirals have little effect and are therefore not recommended.

## LID INFESTATIONS

### Demodex

The *Demodex* mite is an ectoparasite that is found on many different hosts. Of all the many different species of *Demodex*, only two infest humans: *D. folliculorum* and *D. brevis*. *D. folliculorum* is 0.35 to 0.40 mm long and is found in small hair follicles such as the eyelashes. *D. brevis* is 0.15 to 0.20 mm long and is found deep within sebaceous glands of the eyelashes and in the meibomian glands. Both organisms are extremely prevalent on the skin of the face, especially the forehead, cheeks, nasolabial folds, and the nose. Each parasite has eight small stumpy legs and an elongated body. They typically are found head down toward the lash root or gland. Infestation is much more common in adults than in children and can be quite severe in an immunocompromised individual. Controversy exists as to the prevalence and pathogenicity of *Demodex*, especially in patients with rosacea and blepharitis. Studies have shown that *D. folliculorum* is not more prevalent in blepharitis than in normal control patients, thus suggesting it is not an etiologic factor in the disease process. Other research seems to refute this theory. *D. brevis* has not been as extensively studied; therefore its pathogenicity remains relatively unknown. Current theory holds that in certain adult populations, *Demodex* can cause granulomatous or suppurative reactions and inflammation.

### Etiology

Demodicosis is thought to be caused by an over-infestation of the mite in the follicles and pilosebaceous glands of the eyelids. These parasites cause destruction of the epithelial and glandular tissue, producing follicular distension, hyperplasia, increased keratinization, and acute inflammation. Dead mites and keratinization may play a role in the stagnation of secretions, which adds to the overall disease process. No current studies adequately prove the minimum number of mites necessary to produce symptoms; therefore their role in pathogenesis remains unclear. It has been postulated that *Demodex*

may play a role in chalazion formation, blepharitis, and rosacea.

### Diagnosis

Clinically, demodicosis of the lids manifests as a form of blepharitis with patients complaining of itching and burning, although many patients remain asymptomatic. In one recent study it was determined that although *Demodex* is found in all age groups and subpopulations, there is a higher prevalence of recoverable mites (*D. folliculorum*) in eyelashes with “cylindrical dandruff” than in eyelashes without. This finding correlates to that seen clinically as the typical “sleeve” or “cylinder” that covers the base and lower one-third of the lash and rests on the surface of the lid margin (Figure 23-19). In severe or persistent cases it is recommended that a few of the involved lashes be epilated and viewed with a light microscope to confirm the diagnosis. Saline is generally used as the fixing fluid for microscopy; however, in cases where the sleeve is compacted, it is recommended that 100% alcohol be added to facilitate migration of the organism out of the casing.

### Management

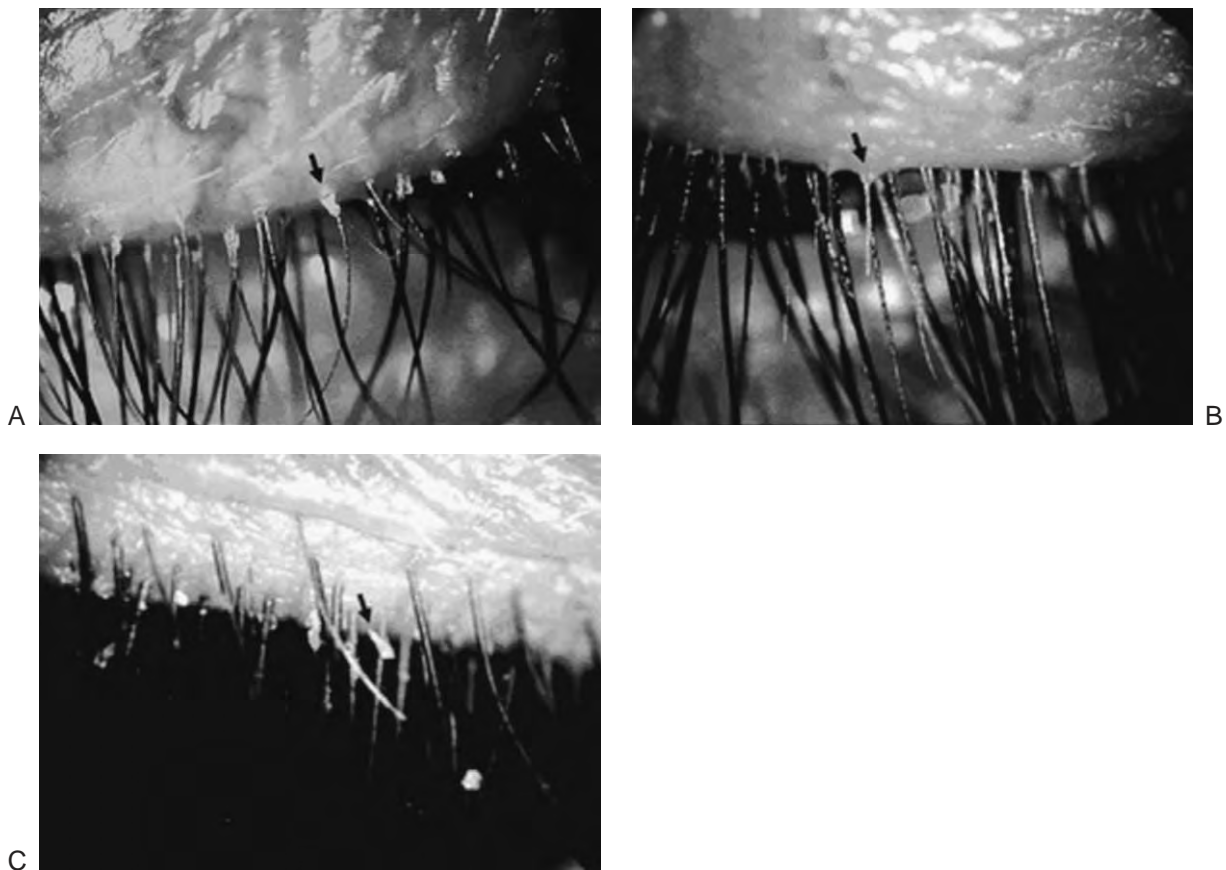
Many studies have determined that lid hygiene appears to be quite beneficial, and less toxic, in treating superficial *Demodex* infestations. However, the mites buried deep within the glands are not eradicated to any great extent, and therefore more research must be conducted to find an alternative treatment. Others suggested therapies include cleansing the lid and lid margins with diethylene ether, applying pilocarpine gel, or 1% ophthalmic mercury ointment. None of these methods has proven to be totally effective.

## Phthiriasis Palpebrarum

Phthiriasis palpebrarum is an uncommon eyelid infestation by *Phthirus pubis* (crab louse) and, less commonly, by the *Pediculus humanus* species, *P. humanus* var. *capitis* (head louse) and *P. humanus* var. *corporis* (body louse). The term *pediculosis* refers to infestation by the two *P. humanus* species and should not generally be used when referring to eyelid manifestations.

### Etiology

Phthiriasis palpebrarum results from lid infestation by *P. pubis*, the pubic louse. In postpubescent individuals infestation typically occurs in the pubic area, and in children the eyelashes and eyebrows are most commonly involved. In adults phthiriasis is usually transmitted by sexual contact, but in children infestation usually occurs from contact with an infested parent, usually the mother. The lice may also be transferred by fomites such as bedding and towels. The parasite is well equipped for the pubic area or eye region because of its wide body and



**Figure 23-19** (A-C) Cylindrical “sleeves” (*arrows*) that rest on the lid margin as seen in *Demodex* blepharitis. (Gao Y, Pascuale MA, Li W, et al. High prevalence of *Demodex* in eyelashes with cylindrical dandruff, *Invest Ophthalmol Vis Sci* 2005;46:3089-3094).

claw-like appendages, which allow it to easily grasp the widely spaced hair located in those regions; for this reason it is also referred to as the “crab” louse. Body or head lice are much less likely to inhabit these regions because their bodies are much narrower, which prevents them from easily grasping the hair. The parasites survive by sucking the blood of their host, which has not been shown to transfer disease. However, the fecal material and saliva excreted by the parasites can be both toxic and antigenic, resulting in an inflammatory response manifested by conjunctivitis, marginal keratitis, and preauricular lymphadenopathy.

### Diagnosis


Diagnosis is made based on careful slit-lamp examination, which readily detects the eggs (nits) attached to the eyelashes or eyebrows (Figure 23-20). The adult lice vary in size from 1.0 to 1.5 mm and have a translucent body, which makes them more difficult to visualize. After they have fed, reddish brown fecal material in the lower abdomen can be easily seen (Figure 23-21), and occasionally they may be seen moving on the eyelash margin.

Severe itching and irritation characterize phthiriasis palpebrarum. Blepharoconjunctivitis, blood-stained thickened discharge from fecal matter on the lid margins, nits, and adult parasites on the eyelashes may all be visible.

Faint bluish-gray spots, known as maculae caeruleae, may be seen which are caused by a salivary enzyme conversion of bilirubin to biliverdin. A preauricular lymphadenopathy may also be present.


### Management

The scalp and body, including the pubic areas, should be treated as well as the eyelids. In addition, for treatment to



**Figure 23-20** Heavy infestation of nits seen on the upper eyelashes. (Courtesy Dr. Laura Kenyon, University of Houston, College of Optometry.)





**Figure 23-21** Phthiriasis palpebrarum attached to lid. Head (*large black arrow*); claws grasping eyelashes (*small white arrows*). Fecal matter may be viewed as a dark spot located in the lower end of the louse abdomen (*large white arrow*). (Courtesy Dr. Laura Kenyon, University of Houston, College of Optometry.)

be effective thorough investigation and treatment of all contacts should be performed, including family members and sexual partners.

In cooperative patients the nits, which are strongly attached to the eyelashes, can be mechanically removed. This procedure is most easily performed using three-prong forceps and attempting to slide the egg case toward the tip of the eyelash. When removal is not possible, lashes bearing eggs should be epilated. Typically, there are so many nits that not all the lashes can be epilated; consequently, this may be accomplished over several visits. The practitioner can remove the adult parasites with forceps using the slit lamp, but again this procedure is somewhat uncomfortable, especially for children. Other reported treatments include cutting the eyelashes at their base, cryotherapy, and pharmacologic eradication. Most notably, bland petrolatum ointment can be thickly applied twice daily for 2 weeks to smother the parasites. However, this particular treatment has little effect on the nits, and therapy should be continued twice daily for 10 to 14 days to ensure that all the eggs have hatched and that the emerging parasites have been adequately treated. Care must be taken to examine the lids for live organisms, and treatment must continue until no lice or viable nits are present.

Anticholinesterase agents, such as 0.25% physostigmine ointment, are also a viable treatment option and may be applied to the lid margins. Side effects, such as miosis and browache, may limit their use. Gamma benzene hexachloride should be avoided on treating the lid condition because of potential ocular irritation and

chemical conjunctivitis. Similarly, pyrethrin gel and other pediculicides should not be used near the eye. One reported study cited the efficacy of a one-time application of sodium fluorescein (NaFl) 10% to 20% swabbed onto the lid margins as an in-office procedure. It was reported to eradicate all live louse and nits; however, no further studies have been done to support this claim. An oral antihelminthic agent, Ivermectin, given in two doses of 200 mcg/kg one week apart, has also surfaced as a louse eradicator. It has been reported that within 2 days all lice were killed with this method; however, it cannot be used in those weighing less than 15 kg and only with caution in pregnant or breast-feeding women.

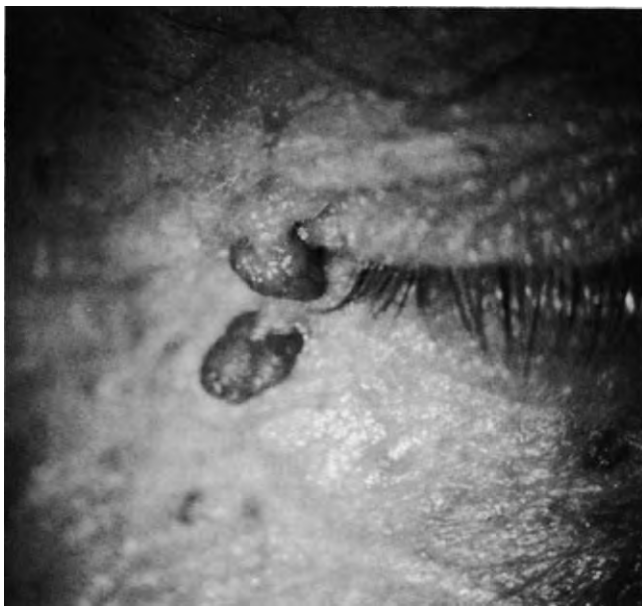Scalp, body, and pubic hair must be treated with an appropriate pediculicidal agent in combination with careful nit removal via fine-tooth comb. Although lindane (gamma benzene hexachloride), an insecticide, is generally considered the drug of choice for the treatment of head and pubic lice, a pyrethrin-based pediculicide (RID) is equally effective and is available over the counter. A single application to the affected body areas is usually adequate to eradicate the lice. The application should be repeated in 1 week if viable nits persist or if new nits appear. A few all natural products containing essence of fruit oils have been developed. These agents are reported to eradicate infestation in a two-step process that uses a one-time shampoo application and a follow-up rinse for prevention of reinfestation. There is no comb-out necessary, and lice are reported to be killed within 40 minutes of a single application. Translucent empty nits are signs of inactive infestation and require no further treatment. Because lindane may lead to central nervous system toxicity, it must be used cautiously in infants, children, and pregnant women, and excessive application or exposure should be avoided. None of the above-mentioned treatment options is approved for use around the eye or on the eyelids.

It is necessary to examine and treat family members or sexual contacts due to the high risk of reinfestation. Clothing, linens, and grooming instruments should be laundered or sterilized by exposing to dry heat at 140°F (50°C) for 20 to 30 minutes. This heat sterilization can usually be accomplished at the highest temperature settings of most household dryers. Contaminated cosmetics should be discarded.

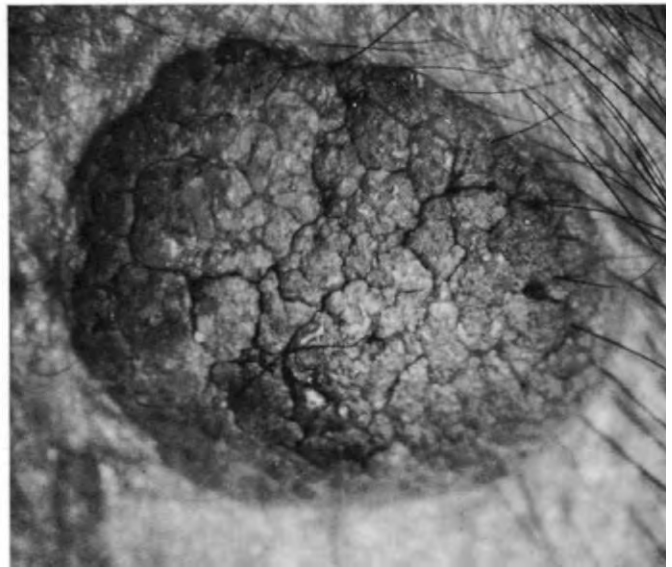
## BENIGN TUMORS OR PAPILLOMAS

### Verrucae

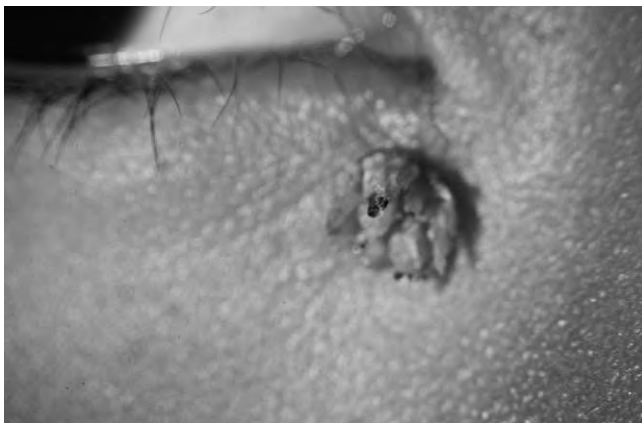
Verrucae, commonly known as *warts*, are benign skin tumors that can affect any part of the body, including the eyelids. The morphology of these benign lesions is quite characteristic. A verruca vulgaris is a raised, multilobulated, grape-like mass of tissue that is attached to the body by a stalk (pedunculated) of varying thickness (Figure 23-22A). A verruca plana is a round, slightly raised, flat wart (sessile)



A



B



C

**Figure 23-22** Types of verruca: (A) verruca vulgaris, (B) verruca plana, and (C) cutaneous horn. (Courtesy Lloyd Pate, O.D.)

varying in size from a few millimeters to several centimeters in diameter. It is cauliflower-like and pitted in appearance and may be darkly pigmented (Figure 23-22B). A cutaneous horn is a cornified verruca vulgaris (Figure 23-22C). Because cutaneous horns are keratinized and firm, they do not have the fleshy-soft consistency of verruca vulgaris.

### Etiology

Verruca vulgaris, verruca plana, and cutaneous horn are forms of viral warts produced by the human papilloma virus (HPV). They are caused by an overgrowth of normal epithelium that may become keratinized and pigmented. Because they occur only in the superficial tissue layer, the body does not recognize them as foreign and therefore does not mount an immune reaction. They are most commonly found in children and young adults and may

be spread by direct contact; thus the eyelid or face is usually a secondary site of infection. Because these lesions are viral in nature, they tend to shed viral toxins and desquamated epithelium onto the conjunctiva, which sometimes results in a secondary mild chronic conjunctivitis. Verrucae on the eyelids or in close proximity to the globe are most symptomatic. Of particular importance are warts that occur on the lid margin among the lashes.

### Diagnosis

The most common type of wart to occur on the face and lid area is the flat wart (verruca plana). These are round, slightly raised, 2 to 6 mm in diameter, tan to yellow-pink, and with a granular surface. They may be quite numerous and even confluent. A small black center is not uncommon and represents thrombosed blood vessels.

### Management

Verrucae are self-limiting but can be very serious in the immunosuppressed. Treatment is primarily cosmetic but also prevents further dissemination. Most verrucae lesions resolve spontaneously after several months to years; therefore therapy should be conservative. Because the lesions are localized to the epidermis, most treatments are limited to this level and should not result in scarring. Benign treatments include topical applications of irritants; salicylic acid and lactic acid, applied under an occlusive barrier, can be purchased over the counter. More advanced treatment modalities include cryotherapy, surgical removal, or electro- or chemical cautery. Neither of these cautery methods is suitable for lesions on the lid margin because of the risk to the ocular surface.

### Sudoriferous (Mucoid/Moll) Cysts

#### Etiology/Diagnosis

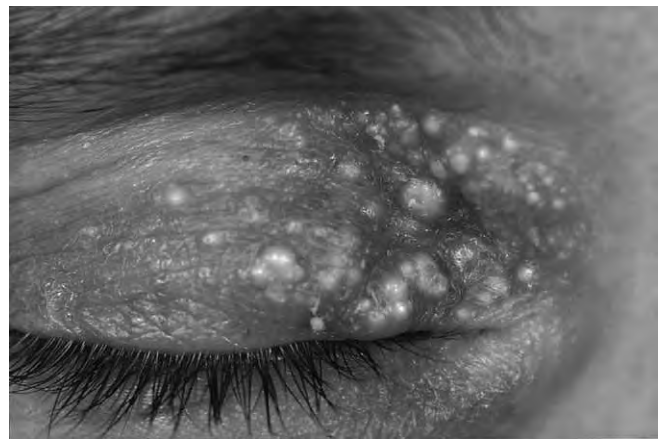
Sudoriferous cysts are small, round, translucent, elevated masses caused by blockage of the ducts of Moll's glands. One or more lesions, ranging from 2 to 4 mm in diameter, may be observed on the anterior eyelid margin. The cysts are painless but can occasionally cause irritation or interfere with successful contact lens wear. They are filled with clear watery fluid (Figure 23-23).

#### Management

Most cysts do not require treatment; however, excessively large lesions or ones that cause ocular irritation can be managed surgically. The most common treatment involves puncturing the center of the lesion to allow for drainage; however, they tend to reform after this type of treatment. The lesions rarely reappear if the dome of the cyst is excised.



**Figure 23-23** Sudoriferous (mucoid/moll) cyst that is translucent and fluid filled. (From Kanski JJ. *Eyelids*. In: *Clinical ophthalmology: a systematic approach*. Philadelphia: Butterworth-Heinemann, 2003:15.)



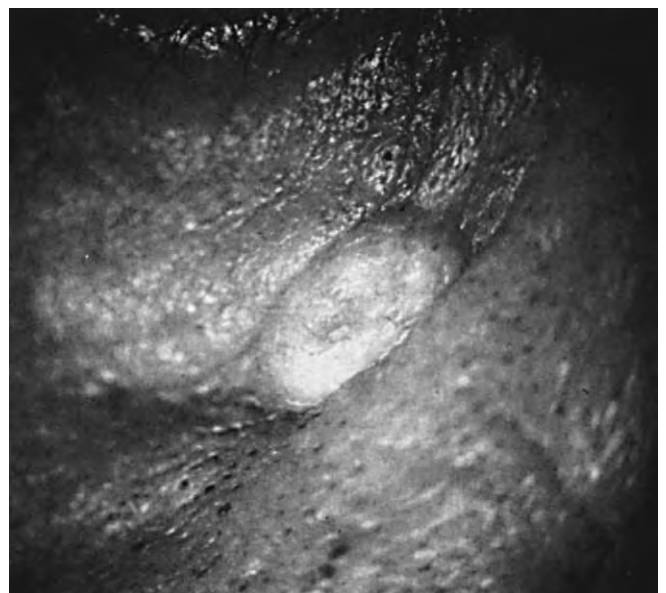**Figure 23-24** Milia located on the medial aspect of the right upper eyelid. (From Kanski JJ. *Eyelids*. In: *Clinical ophthalmology: a systematic approach*. Philadelphia: Butterworth-Heinemann, 2003:15.)

### Sebaceous Cysts

#### Etiology/Diagnosis

Sebaceous cysts are benign retention cysts of sebum. They often appear in the geriatric population due to aging. Milia are small (0.5 mm), round, sebaceous cysts that tend to remain intracutaneous (Figure 23-24). They are common on the eyelids, are whitish in color, are found away from the lid margin, and cause little irritation. They are important only from a cosmetic standpoint.

Subcutaneous sebaceous cysts are yellowish in color, may be larger than milia (up to 10 to 12 mm), are asymptomatic, and are firm to the touch (Figure 23-25). The capsule and its contents are moveable under the overlying skin. Often the plugged orifice of the gland duct is visible.



**Figure 23-25** Subcutaneous sebaceous cyst.

These cysts can occur singly or in groups and are bothersome only from a cosmetic perspective.

### Management

Milia are easily removed without the use of anesthesia. A small stab incision is carefully made through the surface of the lesion using the point of a no. 11 disposable scalpel or of a 25- or 27-gauge hypodermic needle. The sebum contained in the cyst is expressed with cotton-tipped applicators or smooth forceps. The interior of the cyst is then cauterized with dichloroacetic acid applied with a sharpened wooden applicator. The removal site is usually invisible in 2 weeks.

Subcutaneous sebaceous cysts must be removed by total excision, because simple incision usually results in recurrence.

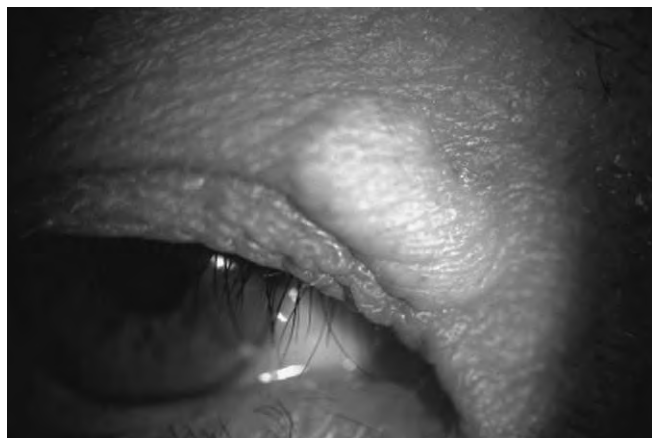### Xanthoma Palpebrarum (Xanthelasma)

Xanthoma palpebrarum is an elevated yellowish discoloration that occurs most commonly in women during the fourth and fifth decades of life. The lesions usually occur bilaterally on the medial aspect of the upper eyelids (Figure 23-26). There is no race predilection.

### Etiology

Xanthelasma is caused by an infiltration of the dermis by xanthoma cells, which are benign histiocytes that imbibe lipids. The condition may occur independently, without associated systemic disease, or may be a manifestation of hypercholesterolemia or other associated disturbance of lipid metabolism.

Patients with xanthelasma, particularly younger individuals, should be evaluated for elevated serum lipid levels, because 30% to 50% will have hyperlipoproteinemia. Among the remaining 50% to 70%, some have subtle changes in lipid composition that may indicate a tendency toward atherosclerotic changes. Thus, in addition to



**Figure 23-26** Xanthelasma of the medial right upper eyelid.

cosmesis, the major concern is the potential for atherosclerotic cardiovascular disease, as well as possible systemic disorders such as diabetes mellitus and cirrhosis.

### Diagnosis

The diagnosis of xanthelasma is made based on the clinical presentation of the cutaneous lesions. They are oval or elongated yellowish plaques occurring just beneath the skin. There is no concomitant inflammation or pain, but they may be of cosmetic concern.

### Management

Removal is only considered when cosmesis is of primary concern. Treatment modalities include chemical cautery, electrodesiccation, cryotherapy, laser ablation, or surgical excision. Complications of laser and cryotherapy include scar formation and pigmentary changes. Chemical cautery and surgical excision tend to produce better results with less scarring. Recurrence is extremely high and must be considered before initiating any of the aforementioned treatment options.

## MALIGNANT PERIOCCULAR LESIONS

The periocular area is a common site for malignant cutaneous lesions. Five percent to 10% of all skin cancer affects the lid and surrounding areas. Basal cell carcinomas (BCCs) are by far the most common lesions, followed by squamous cell carcinoma (SCC) and sebaceous cell carcinoma. Any of these malignancies can be fatal if there is orbital invasion with intracranial spread; for this reason it is prudent to discuss the etiology, diagnosis, and management options. Risk factors for development include, most notably, ultraviolet radiation exposure. Another potential etiologic factor implicated in BCC, SCC, and actinic keratosis (AK) is HPV. It has been shown that HPV-DNA can be detected in up to 50% of patients with BCC, in up to 60% of patients with SCC, and in over 90% of AK patients. Careful observation and documentation of all suspicious lid lesions are paramount to accurate and timely diagnosis. The clinician is urged to use a simple list of notable characteristics, termed the “ABCs” (Box 23-3).

### Box 23-3 ABCs of Suspicious Skin Lesions

- A—Asymmetric shape
- B—Border irregularity
- C—Color mottling of variability
- D—Diameter > 6 mm
- E—Elevation

Data from Myers M, Gurwood AS. Periocular malignancies and primary eye care. *Optometry* 2001;72:706.

## Basal Cell Carcinoma

BCCs represent the most common form of human malignancy. Roughly 80% to 90% of all BCCs occur on the head and neck and 20% of those occur on the lid or lid margin. BCCs account for 90% of all eyelid tumors; thus extreme care must be taken when evaluating any suspicious eyelid lesion. The incidence is 500/100,000 people in the United States, with 60 years the average age at diagnosis.

There are three forms of BCC: nodular, sclerosing, and ulcerative. Not all malignancies exhibit the typical pearly rounded borders that have come to denote the diagnosis of a BCC. BCCs tend to occur on the lower lid and in the medial canthus, are slow growing, locally invasive, and are only rarely metastatic. Because of their destructive nature, it is imperative that they be diagnosed early to prevent the mutilation that is inherent with some of the more invasive treatment options.

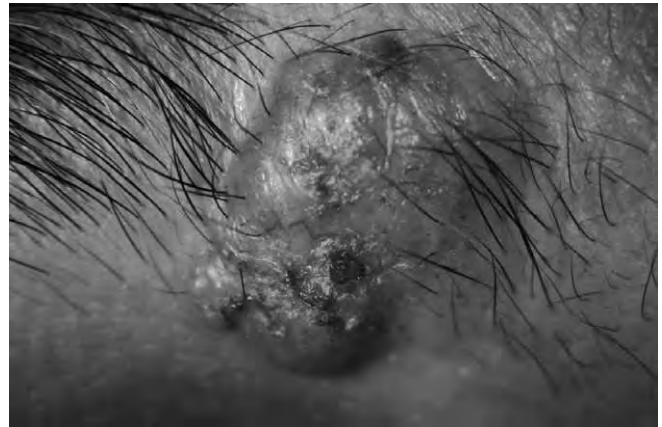### Etiology

BCCs arise in the basal cell layer of the epidermis and are insidious in nature. They then invade the tarsus and, if left unchecked, break through the orbital septum into the orbit. Most are thought to be caused by an overexposure to sunlight, which is why they are often found on exposed areas of the body such as the face, ears, neck, scalp, shoulders, and back. There have been reports of BCC on unexposed areas of the skin, but this is atypical. Other reported risks include exposure to arsenic, radiation, or after tattooing. These factors have not been adequately proven and are anecdotal. Patients most at risk are fair-skinned individuals with blond or red hair and blue or green eyes; BCC is seen much less often in dark-skinned people. Other risks include sun exposure early in childhood, sun exposure due to job or leisure activity, or living in extremely sunny climates. In at least one study cigarette smoking was implicated as being a risk factor for development of BCC in women.

### Diagnosis

The most common warning signs of a BCC are a lesion that is present for months to years, is changing in size or shape, tends to bleed, or has remained open for at least 3 weeks. Other hallmark signs are the pearly borders and telangiectatic vessels present across the lesion surface (Figure 23-27), just under the epithelium. Most BCCs are painless, unless secondarily infected, and are firm to the touch.

Nodular BCCs are typically shiny or translucent elevated lesions, of any color, that resemble a mole. They may occur anywhere on the lid or lid margin and might be confused with a papilloma. It is important to remember that papillomas do not grow over time, do not bleed, and have a "normal" overlying skin appearance. The nodule may ulcerate, forming the most easily recognized BCC,

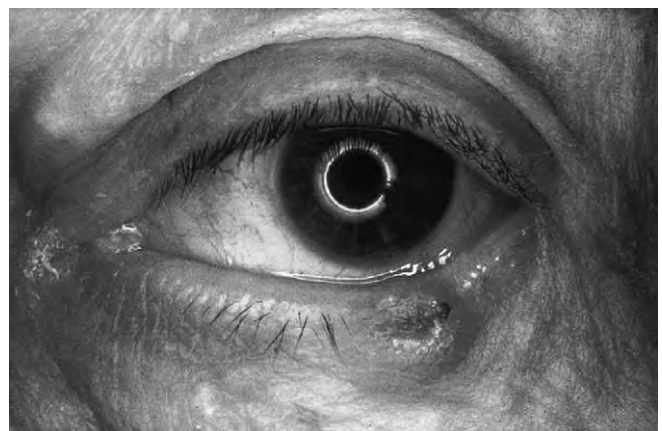


**Figure 23-27** Basal cell carcinoma of the right upper eyelid. Note the telangiectatic vessels right below the skin surface and the loss of cilia over much of the lesion's surface. (Courtesy Dr. Justina Taube, University of Houston, College of Optometry.)

with the typical shiny rolled border and ulcerated center (Figure 23-28).

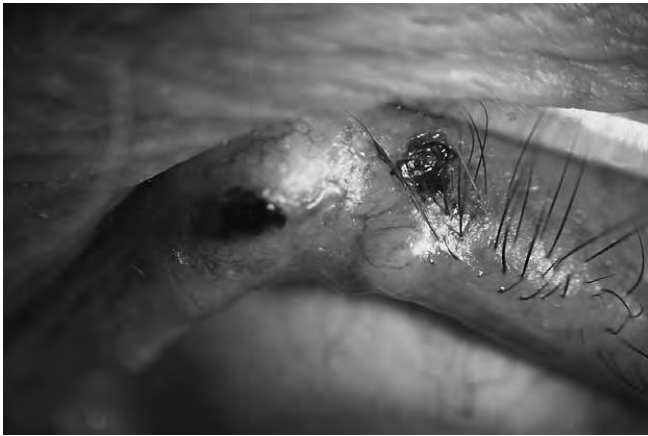Sclerosing, infiltrating, or morpheaform BCCs are flat indurated plaques that have very ill-defined margins, which make the skin appear shiny and taut. These lesions may easily be confused with chronic blepharitis, which may present with tylosis ciliaris and irregular lid margins (Figure 23-29) but does not cause a significant alteration in the position or the destruction of the marginal tissue and cilia.

Any suspicious lesion that appears to alter the surrounding skin, causing loss of eyelashes or irregular lid margins, which cannot be determined as benign, must be referred for biopsy; this is the only true method to diagnosis a malignancy. It is not uncommon to confuse a BCC



**Figure 23-28** Basal cell carcinoma with typical shiny rolled borders and an ulcerated center. (From Kanski JJ. *Eyelids*. In: *Clinical ophthalmology: a systematic approach*. Philadelphia: Butterworth-Heinemann, 2003:21.)





**Figure 23-29** Sclerosing basal cell carcinoma mimicking chronic blepharitis. (From Kanski JJ. *Eyelids*. In: *Clinical ophthalmology: a systematic approach*. Philadelphia: Butterworth-Heinemann, 2003:21.)

for sebaceous cell carcinoma or SCC because they share common cutaneous characteristics. One distinguishing factor is that BCCs have a much slower growth rate than most other lid malignancies.

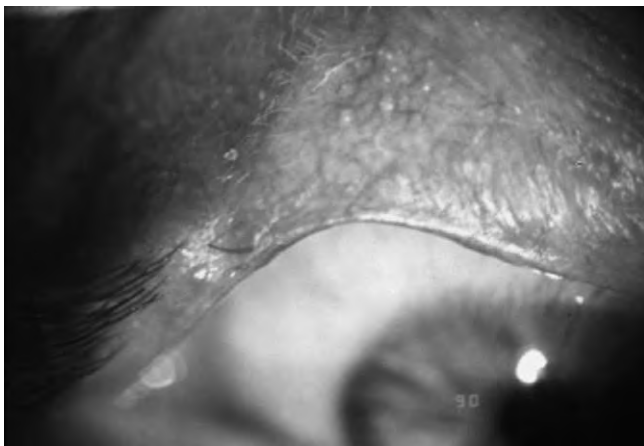
#### Management

Management always includes referral to a dermatologist or oculoplastic surgeon for confirmatory biopsy and treatment. Treatment options include immune system modulators, 5-fluorouracil, chemotherapy, curettage and electrodesiccation, surgical excision, radiation, Mohs' micrographic surgery, cryo- or laser surgery, and photodynamic therapy. The cure rate is 95% posttreatment, which depends on the size, location, and histopathology of the malignancy.

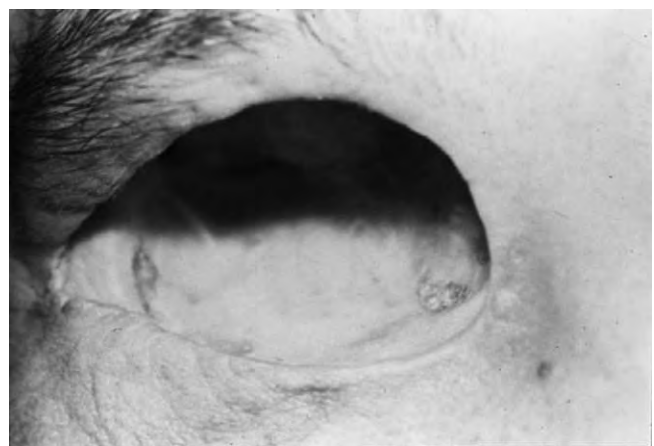
### Sebaceous and Squamous Cell Carcinomas

Sebaceous cell carcinomas are relatively rare, but when they do occur it is usually in the sebaceous glands of the eyelids, namely the meibomian glands. They may resemble benign conditions, such as chalazion or unilateral blepharoconjunctivitis, which may cause a delay in the diagnosis and lead to local invasion and the potential for metastasis to lymph nodes and other organs. It is for this reason that they have a higher morbidity and mortality rate than a BCC. The mean age at diagnosis is similar to BCC, being more common in older (>60 years) adults, but a greater frequency is seen in females. Lesions are more common in the upper lid followed by the lower. Sebaceous cell carcinomas are difficult to discern (Figure 23-30) unless they have well-defined borders; a high degree of suspicion should exist when a patient presents with a recurrent chalazion in the same area. Hallmark signs of any malignant lid lesion are destruction of the overlying skin features and eyelash loss. When these lesions occur on the upper lid, they tend to have a yellow appearance. Management includes prompt referral to an oculoplastics specialist for biopsy and treatment (see Management, above, for BCC).

SCCs are epithelial malignancies that are extremely invasive, fast growing, with the potential to be fatal. They are rare, accounting for only 5% to 10% of all eyelid tumors with an incidence of 0.09 to 2.42/100,000. SCCs are often associated with actinic (solar) keratosis (see below) and are found most often on the lower eyelid or lid margin of elderly men but may be found on the upper eyelid as well (Figure 23-31). Because of their suspected actinic origin, they often occur after radiation treatment for other lesions. SCCs can metastasize but do so more often if they are large, if they deeply penetrate underlying tissue, if they have an undifferentiated histologic subtype,

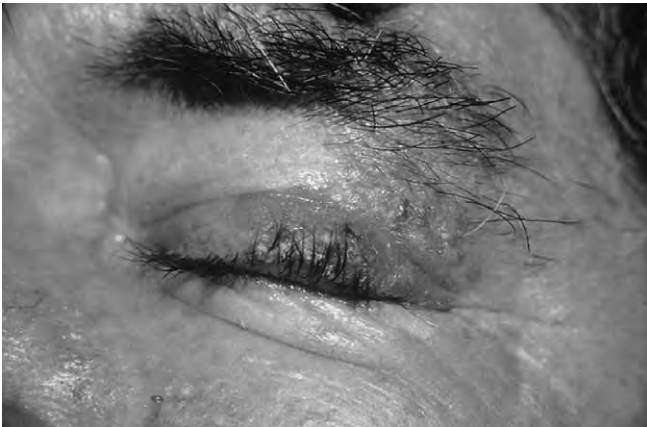

A



B

**Figure 23-30** (A) Recurrent sebaceous gland carcinoma of the right upper eyelid with ill-defined borders. (B) Postoperative right orbital exenteration and nasolacrimal duct resection of the patient in A. (Courtesy Dr. Nick Holdeman, University of Houston, College of Optometry.)



**Figure 23-31** Squamous cell carcinoma of the left upper eyelid margin. (From Kanski JJ. *Eyelids*. In: *Clinical ophthalmology: a systematic approach*. Philadelphia: Butterworth-Heinemann, 2003:22.)

or if the patient is immunocompromised. Diagnosis and treatment options are similar to BCC and sebaceous cell carcinoma (see above).

## PREMALIGNANT OR KERATINOCYTIC INTRAEPIDERMAL NEOPLASIA

### Actinic Keratosis

#### Etiology

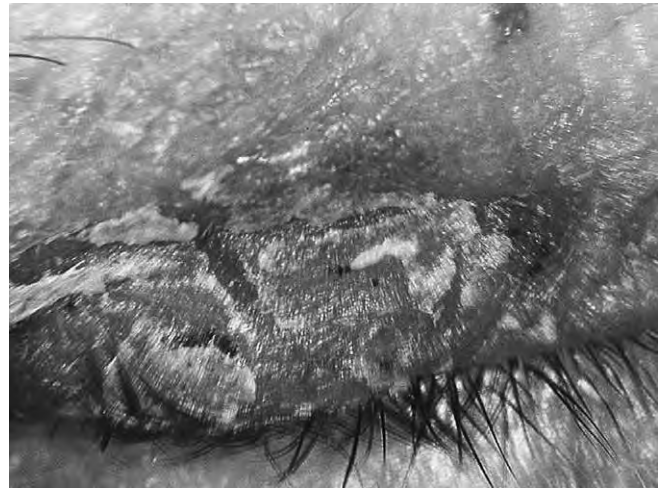AKs are common, sun-induced, inflammatory skin lesions traditionally defined as being “pre-malignant.” Recently, it was suggested they be reclassified as a malignancy “in situ” because they do possess the capability of converting to a neoplasm, usually SCC. The incidence of an AK converting to an SCC is 0.075% to 0.096% per lesion per year. AKs that are large or found on the lips are more likely to convert to an SCC. Pathogenesis begins with ultraviolet exposure, causing a morphologic change in keratinocytes and leading to the classic AK lesions seen clinically. As stated previously, HPV is also a possible etiologic factor in development.

#### Diagnosis

Clinically, AKs present as a broad, rough, pink or red lesion with an overlying thick yellow scale (Figure 23-32). Management is controversial because many lesions have been reported to spontaneously resolve. Proponents of treatment point out that because there is a possibility of conversion to an SCC and because many treatment options are noninvasive and well tolerated, most lesions, even if they are small, should be treated.

#### Management

Treatment options include destructive therapy (i.e., cryotherapy, curettage, or shave excision), field destruction (i.e., ablative laser resurfacing, dermabrasion, and



**Figure 23-32** Actinic keratosis of the upper eyelid showing roughened surface with overlying scale. (From Kanski JJ. *Eyelids*. In: *Clinical ophthalmology: a systematic approach*. Philadelphia: Butterworth-Heinemann, 2003:16.)

chemical peel), or topical chemotherapy (i.e., 5-fluorouracil, diclofenac, topical amino levulinic acid and blue light exposure, tretinoin, or Imiquimod). The treatment is selected based on the size, number, and location of the lesions.

## LID AND LASH ANOMALIES

### Trichiasis and Distichiasis

#### Etiology

Trichiasis is an acquired condition in which some or all of the eyelashes are directed inward toward the globe. It is most often the result of aging; however, it may also be caused by an inflammatory process or trauma that causes scarring and fibrosis around the eyelash follicles at the lid margin. Potential etiologies include cicatricial conjunctivitis, trachoma, herpes simplex and herpes zoster, chronic blepharitis, lacerations, burns, and postsurgical procedures.

Distichiasis can be an acquired or, rarely, a congenital condition in which there is an accessory row of eyelashes emanating from the meibomian gland orifices. When congenital, it may occur sporadically or may be autosomal dominant.

Both conditions can cause a wide range of symptoms, the most common a foreign body sensation and a red irritated eye. Severe or debilitating symptomatology is a result of corneal surface damage, including corneal abrasion and superficial punctate keratitis. Corneal hypoesthesia with subsequent neurotrophic ulceration is also possible.

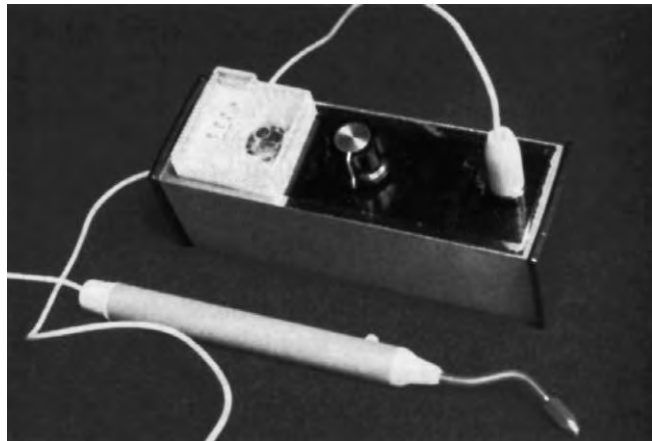
#### Diagnosis

Occasionally, the involved lashes are without pigment, making them very difficult to see; therefore diagnosis is

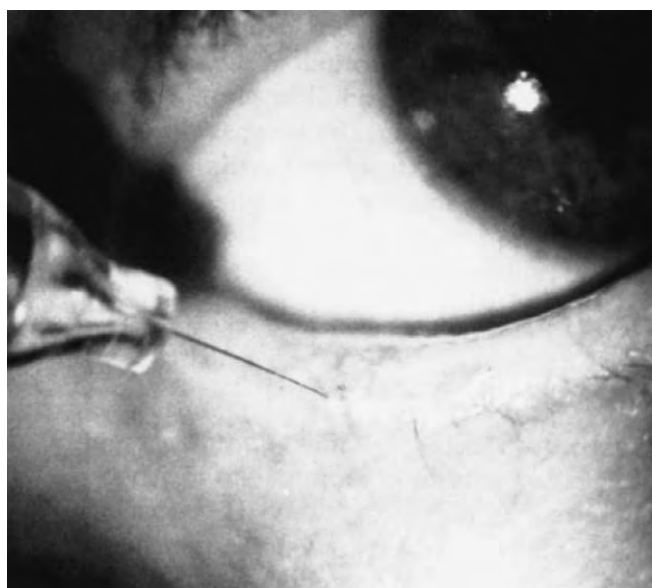based on a careful slit-lamp examination. Whenever the lid margin is altered or if entropion is present, meticulous external assessment is necessary to rule out the possibility of a malignancy.

### Management

Treatment depends on the severity of the condition and patient symptoms. In mild cases, with only a few lashes involved, epilation is easiest to perform and has no side effects except for mild discomfort during the procedure. Electrolysis may also be preformed using the Pro-Lectro ophthalmic epilator (Figure 23-33). With this handheld instrument, a mild current is generated and directed into the lash follicle. Once destruction has occurred, the lash may be easily removed with forceps. Cryoablation and diathermy may also be used for mild cases. When severe, surgical correction is needed. Surgery poses more serious



A



B

**Figure 23-33** (A) Pro-Lectro ophthalmic epilator. (B) Stylus being inserted into empty eyelash follicle for electrolysis.

postoperative complications and is therefore reserved for the most severe cases.

## Lagophthalmos

Lagophthalmos is a common condition in which the eyelids do not fully close, either with a blink or during sleep.

### Etiology

The etiology depends on the type of lagophthalmos present. Physiologic or nocturnal lagophthalmos occurs when the eyelids do not fully close during sleep. Orbital lagophthalmos is due to severe proptosis, as in Graves' thyroidopathy (see Chapter 32). Mechanical lagophthalmos is secondary to scarring of the lid muscle or other lid tissue. Paralytic, the most common form of lagophthalmos, occurs secondary to Bell's palsy (see Chapter 22) and incomplete blink of unknown etiology.

### Diagnosis

The diagnosis of lagophthalmos or incomplete blink is usually made based on the patient's symptoms, slit-lamp examination, and gross observation during a blink. Patients usually complain of ocular irritation, which is worse upon awakening. Biomicroscopy reveals SPK over the inferior portion of the cornea or over the area of exposure. The patient should be asked to blink while at the slit lamp; they should be closely examined outside of the slit lamp, which will often reveal the exposure; or occasionally a family member will confirm that the patient sleeps with his or her eyes open.

### Management

Management in most cases is aimed at relieving symptoms unless the lagophthalmos is orbital or paralytic; in these cases the underlying cause must be addressed. If the exposure is mild and nocturnal, lubricating ointment at bedtime is indicated. If this does not resolve the signs and symptoms, taping the lids at bedtime or having the patient wear a sleep mask may be helpful. In more severe cases a moisture chamber, made from a pair of swim goggles, may be used at night. If the lagophthalmos is mechanical, artificial tears used every few hours during the day may be necessary. If there is evidence of a secondary bacterial infection, appropriate antibiotic ointment and/or drops should be initiated. Bandage contact lens wear may also be indicated. In very severe or long-standing cases, oculoplastic surgery may be necessary.

## EYELID HYPERLAXITY

### Floppy Eyelid Syndrome and Lax Eyelid Syndrome

Eyelid hyperlaxity has been reported to include two separate syndromes, floppy eyelid syndrome (FES) and lax eyelid syndrome (LES). FES was first reported in 1981 and



was described by the clinical triad of obesity, easily everted “floppy” upper eyelids, and an associated chronic papillary conjunctivitis. Patients are usually middle-aged obese men who have nonspecific symptoms, either monocular or binocular, which include a thick mucoid discharge and a nonspecific ocular irritation that is worse upon awakening. There have been reported cases in women, children, and the nonobese; however, this is the exception, not the rule. The condition is usually bilateral but tends to be worse on the side on which the patient sleeps.

LES was reported in 1994 and is thought to be much more prevalent. It is described as having similar characteristics as FES, such as lid hyperlaxity and ocular irritation, but it does not include the other classic findings of obesity, easily inverted tarsus, and/or papillary conjunctivitis.

Both syndromes are thought to be associated with obstructive sleep apnea (OSA) and normal tension glaucoma; however, this correlation remains questionable.

### Etiology

FES has been associated with keratoconus, hyperglycemia, obesity, and OSA, which suggests mechanical abnormalities, metabolic dysfunction, degenerative processes, and connective tissue disorders as possible etiologies. The exact mechanism for both the eyelid hyperlaxity syndromes remains unknown. FES maybe related to a decrease in the elastin fiber content of the tarsus and thus a loss of integrity, causing eyelid eversion during sleep, which creates mechanical irritation of the lids, cornea, and conjunctiva. In addition, poor contact between the loose upper eyelid and the globe, found in both syndromes, may interfere with distribution of the tear film over the cornea and conjunctiva, creating ocular surface drying and irritation.

In FES it is thought that sleeping with an everted eyelid causes the pretarsal orbicularis oculi and skin to override the lid margins, which causes the eyelashes to point downward (eyelash ptosis). Because some patients with FES also have keratoconus, an underlying connective tissue disorder may be implicated.

Although the reason remains unclear, patients with FES and LES are frequently found to have some degree of sleep disorder of breathing. The most likely relationship is an elastic tissue abnormality.

### Diagnosis

A “rubbery,” hyperlax, easily everted upper tarsus that “rolls” outward when the lid is mechanically elevated (Figure 23-34) and eyelashes that point downward and curl either toward the cornea or in various directions are reliable indicators of FES. Upper eyelid vertical hyperlaxity is determined by mechanically elevating the upper lid to its maximum position and measuring the distance between the lid margin and the center of the pupil; hyperlaxity of the lid is considered to be a measurement



**Figure 23-34** Floppy eyelid syndrome. (From Kanski JJ. *Eyelids*. In: *Clinical ophthalmology: a systematic approach*. Philadelphia: Butterworth-Heinemann, 2003:39.)

equal to 15 mm. The upper eyelid may also hyperextend when the lid is pulled downward. A mucoid discharge with papillary conjunctivitis is also seen. The conjunctival inflammation is thought to be caused by rubbing of the palpebral tarsal conjunctiva on the bedding during sleep. Another factor is the poor contact between the lax upper eyelid and the globe (seen in both FES and LES). In addition, the patient may be observed by a family member sleeping with one or both of the upper eyelids everted.

LES is diagnosed in much the same way; however, the patient may not be obese or may not have an easily everted upper tarsus. A careful history, including sleeping patterns, is very useful information.

### Management

Treatment consists of ocular lubrication for symptoms or signs of dry eye and treating any secondary bacterial infection with an appropriate topical antibiotic. Topical lubricants alone usually cannot control the symptoms of FES or LES. Preventing lid eversion generally requires lid taping or use of nocturnal eye shields. The definitive treatment, however, is surgical tightening of the eyelid and therefore requires an oculoplastics consult.

Because OSA is a cause of considerable morbidity and mortality, the clinician is advised to recommend sleep studies if the patient reports heavy snoring or other symptoms of OSA. A few cases of resolved hyperlaxity eyelid syndromes with treatment for OSA have been reported.

## EYELID MYOKYMIA OR BENIGN EYELID TWITCHING

Eyelid myokymia or benign eyelid twitching is a common localized form of facial myokymia. It is a transient condition in which mild to moderate fine undulating contractions of the orbicularis muscle occurs, causing an annoying

twitching sensation, often with no observable eyelid signs. The condition tends to be unilateral and affects the lower lid most often.

### **Etiology**

The etiology remains unknown; however, various psychosocial factors may play a role: fatigue, stress, tension, anxiety, lack of sleep, smoking, and alcohol or caffeine consumption. In the past topical instillation of anticholinesterase agents or the use of oral fluphenazine and haloperidol has been reported to cause isolated lid myokymia; no firm data exist to confirm these claims. Isolated lid myokymia has not been related to any serious underlying neurologic conditions; however, in at least one reported case there were abnormal electrophysiologic results suggesting perhaps an underlying stable neurologic disease.

Eyelid myokymia does not progress to other parts of the face. When myokymia involves the other facial muscles, it is a sign of an underlying neurologic problem that needs further evaluation and referral.

### **Diagnosis**

The diagnosis of isolated eyelid myokymia can usually be made after the case history. Affected patients often complain that the eyelid “jumps” or “quivers”; however, gross external examination and slit-lamp assessment may fail to uncover any abnormality. Neuroimaging studies are generally not warranted in the absence of any other clinical signs, symptoms, or neurologic findings unless the condition persists for months to years.

### **Management**

Most cases of isolated eyelid myokymia can be managed conservatively with patient reassurance, rest, and elimination or reduction of alcohol, cigarette, and caffeine use. Most cases of eyelid myokymia spontaneously resolve in a few days to weeks, with an occasional case lasting many months. When eyelid fasciculations are isolated and severe or chronic (>3 months duration), further intervention may be necessary. Topically administered antihistamines, such as antazoline or pheniramine, are often effective and may give significant relief within 15 to 20 minutes. Antihistaminic therapy relaxes the spasming orbicularis muscle by prolonging its refractory time. The topical medication should be used every 4 hours as needed to abolish symptoms. If this is ineffective, 12.5 to 25.0 mg of promethazine can be administered orally one to three times daily, or 25 to 75 mg of tripeleminamine can be administered orally four times daily. For recalcitrant cases oral quinine, 200 to 300 mg, may be administered one to two times daily either alone or in combination with oral antihistamine therapy. Quinine relaxes the orbicularis muscle by a curari-like action, but it must be avoided in pregnant women. Quinine should be discontinued if the

patient experiences tinnitus or visual disturbances. When these measures do not relieve the symptoms, a botulinum toxin injection into the affected muscle may be used or, for very severe cases, a referral for a surgical myectomy is warranted.

## **CYANOACRYLATE TARSORRHAPHY**

Cyanoacrylate adhesives (Krazy glue, Super glue) are common household products. They are packaged similar to topical ocular preparations and therefore have accidentally been instilled into the eye. Although these adhesives typically do not cause serious harm, they can and are the cause of significant anxiety when accidents occur.

### **Etiology**

Once the glue is instilled into the eye, it causes an instantaneous tarsorrhaphy, total or partial, due to the apposition of the upper and lower eyelashes or, less commonly, a total ankyloblepharon. Corneal abrasion, SPK, eyelash loss, skin excoriation, and conjunctivitis can also occur, and immediate irrigation is indicated if possible.

### **Management**

Initial conservative management includes the application of water- or mineral oil-soaked eye pads to the lids and/or the copious application of a broad-spectrum antibiotic ointment over the area along with a light pressure dressing. Within 24 hours the glue should soften enough to be easily removed with forceps. Careful application of acetone to the lid margins, using a cotton-tipped swab, may also prove useful in breaking the tarsorrhaphy; care must be taken not to use this preparation if a penetrating injury is suspected. Other means of manual separation of the lids include forceps, a Jameson muscle hook, or scissors. Any retained glue fragments must be removed from the eye to prevent further complications such as infection, inflammation, keratitis, or cataracts. In the event the patient is uncooperative, sedation may be required. Oral analgesics may be helpful and patient education and reassurance is always warranted. Continued topical antibiotics may be necessary to treat corneal abrasions or keratitis. In the event the corneal abrasion is large, bandage contact lenses may also be indicated. The use of topical steroids is contraindicated, because fungal and viral contamination cannot be excluded and because they can mask the symptoms of infection.

## **SURGICAL TREATMENT OF THE LIDS**

### **Neuroanatomy of the Eyelids**

To perform a surgical procedure on or around the eyelids, it is most often necessary to give an injection of local anesthetic to ensure the patient's comfort during the procedure and to lessen the likelihood of surgical

bleeding and/or weeping. Keep in mind that the entire upper eyelid is innervated from above (the lacrimal nerve in the outer canthus, the supraorbital nerve centrally, and the supratrochlear and infratrochlear nerves in the inner canthal area), whereas the entire lower eyelid is innervated from below (infraorbital nerve for the entire lower eyelid). Hence, to ensure local anesthesia of the area of a lesion on the eyelid, the injection site is proximal to the origin of the nerve (inject between the nerve origin and the lesion). Therefore if the lesion is on the upper eyelid the injection of anesthetic is placed superior to the lesion, and if the lesion is on the lower eyelid the injection is placed inferior to the lesion.

### **Rhytids (Eyelid and Facial Wrinkles and Folds)**

It is extremely important to respect the natural folds and wrinkles of the face and eyelids when making an incision in the surrounding tissue so as not to create an undesirable healing outcome. When making an incision through the skin, always make the incision parallel to, or within, the rhytid (fold) of the skin. When this is done correctly, the incision will close in upon itself at the conclusion of the procedure and no closure (suturing) will be necessary. A small butterfly bandage or Steri-Strip may be all that is needed for the closure of surgical wounds that require it. Also, if a thin lineate scar results from the incision, it will be hidden in the rhytid and will not be perceivable. Study the area of the lesion and first determine the orientation of the incision before starting the procedure. If an incision is made contrary to the folds of the skin, the surgical wound probably will require suturing at the completion of the procedure, and the healing will result in an undesirable bunching of tissue.

### **Procedures**

There are a number of surgical techniques and procedures used to treat eyelid and periocular lesions and anomalies. These techniques include chemical and thermal cautery, used to destroy tissue; incision, used to cut into and/or separate tissue; and excision, used to remove tissue.

#### **Chemical Cautery**

Chemical cautery uses dichloroacetic acid to treat verrucae, xanthelasma, dermatosa papulosa nigra, keratoacanthoma, and solar keratosis. The area of the lesion is swabbed with alcohol and a thin layer of petrolatum jelly is spread in the area surrounding the lesion to protect the adjacent normal skin. The cauterant (dichloroacetic acid) is then judiciously and carefully applied to the lesion in small amounts with a sharpened wooden applicator. The patient is forewarned regarding a stinging sensation that will seem to escalate, then level off, and finally subside. During and immediately after the application of the cauterant, the lesion turns a milky white. After a few

hours the lesion darkens to a blackish coloration. In a day or 2 an eschar (scab) forms. On small lesions the eschar falls off in 7 to 10 days. Larger lesions may require a second application of cauterant 2 weeks after the initial application. When the eschar eventually falls off, the underlying skin is pinkish or lighter than the surrounding normal skin. With time this skin area assumes normal skin coloration as melanin migrates to the area. Care should be taken with darkly pigmented individuals, especially African-Americans, who may have a tendency to form keloids. A keloid is formed when healing is achieved by secondary intention and results in excessive scar formation. Simply questioning the patient about previous trauma to the skin will determine if the individual is a keloid former. Alternatively, a single small lesion in an inconspicuous area can be treated and followed for untoward effects. If the healing results are desirable, then other lesions can be safely treated.

#### **Thermal Cautery**

Thermal cautery uses heat to destroy tissue. A similar technique, called fulguration, uses electric current to destroy tissue. Heat cautery is performed using a disposable heat cautery unit and is used to stop bleeding during surgical procedures and to remove skin tags, cutaneous horns, and pedunculated verrucae. It can also be used to occlude a punctum, reposition an ectopic punctum with resultant epiphora, and alleviate trichiasis as a result of spastic entropion.

To remove a pedunculated lesion, swab the area with alcohol, anesthetize the area of the lesion with a  $\frac{1}{4}$  to  $\frac{1}{2}$  cc shallow subcutaneous injection of 2% lidocaine with epinephrine, and grasp the tip of the lesion with a mouse-tooth forceps. Pull the lesion away from the skin and sever the base of the lesion with the hot tip of the cautery unit. The tip removes the lesion and cauterizes the blood vessels at the same time. An eschar forms and falls off in 7 to 10 days.

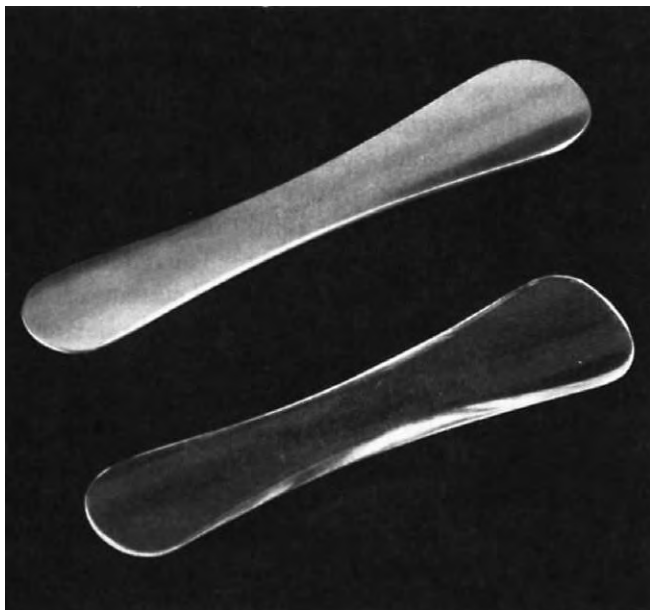
To occlude a punctum with heat cautery, a  $\frac{1}{4}$  to  $\frac{1}{2}$  cc subconjunctival injection of 2% lidocaine with epinephrine is given below the punctum and the vertical arm of the canaliculus in the everted lid. After the patient compresses the in situ lid to compress the bullous of lidocaine, the punctum is dilated. The lid is then put on stretch by pulling on the lid at the outer canthus. This stabilizes the lid and makes it easier to insert the tip of the heat cautery unit. Before the tip is inserted, the unit is turned on to sanitize and clean the tip. The unit is then turned off and allowed to cool before inserting it into the punctum. It is inserted cold then turned on when it is in the punctum. A blanching of the tissue surrounding the punctum is noted. The tip is removed with the unit still turned on. It will be retrieved easily, and a darkened charred area of the punctum is noted in the center of the blanched area. Prophylactic antibiotic ointment is applied four times a day for 3 days.

**Warning:** If one tries to remove the cautery tip from the punctum after the area is cauterized and the unit is

turned off the tissue will adhere to the tip and a tug of war will ensue. Always remove the tip before the unit is turned off.

To treat an ectopic punctum of the lower lid with secondary epiphora, first evert the lower lid at the inner canthus and subconjunctivally inject  $\frac{1}{4}$  to  $\frac{1}{2}$  cc of 2% lidocaine with epinephrine below the punctum and vertical arm of the canaliculus. Have the patient compress the in situ lower lid with a folded  $2 \times 2$  gauze sponge for 5 minutes. This flattens the bullous of lidocaine and anesthetizes the area. The lower lid is again everted and, respecting the anatomy of the nasolacrimal drainage system, a double row of three to four cautery burns is placed horizontally 4 mm below the punctum. The spot of each cautery burn blanches out around a central blackened charred area. The destruction of conjunctival tissue causes fibrosis that shrinks and pulls the tissue tight, repositioning the punctum in the lacrimal lake. Antibiotic ointment applied four times a day for 3 days is ordered as a prophylactic measure. This technique works nicely for ectopic puncta but will not correct a frank ectropion.

To correct spastic entropion of the lower lid, one or several shallow subcutaneous injections are given the entire length of the lower lid in the fold at the border of the anatomically inferior tarsal plate. The patient compresses the bullous of lidocaine to expose the area to be cauterized. A drop of  $\frac{1}{2}\%$  proparacaine is inserted onto the eye and a Jaeger plate (Figure 23-35) is inserted between the globe and the lower lid. The Jaeger plate protects the globe and, when pulled toward the clinician, pulls the lid tight and stabilizes it for the procedure. The clinician now proceeds to place a line of cautery burns at the junction of the tarsal orbicularis oculi muscle and the preseptal orbicularis oculi muscle the entire length of the



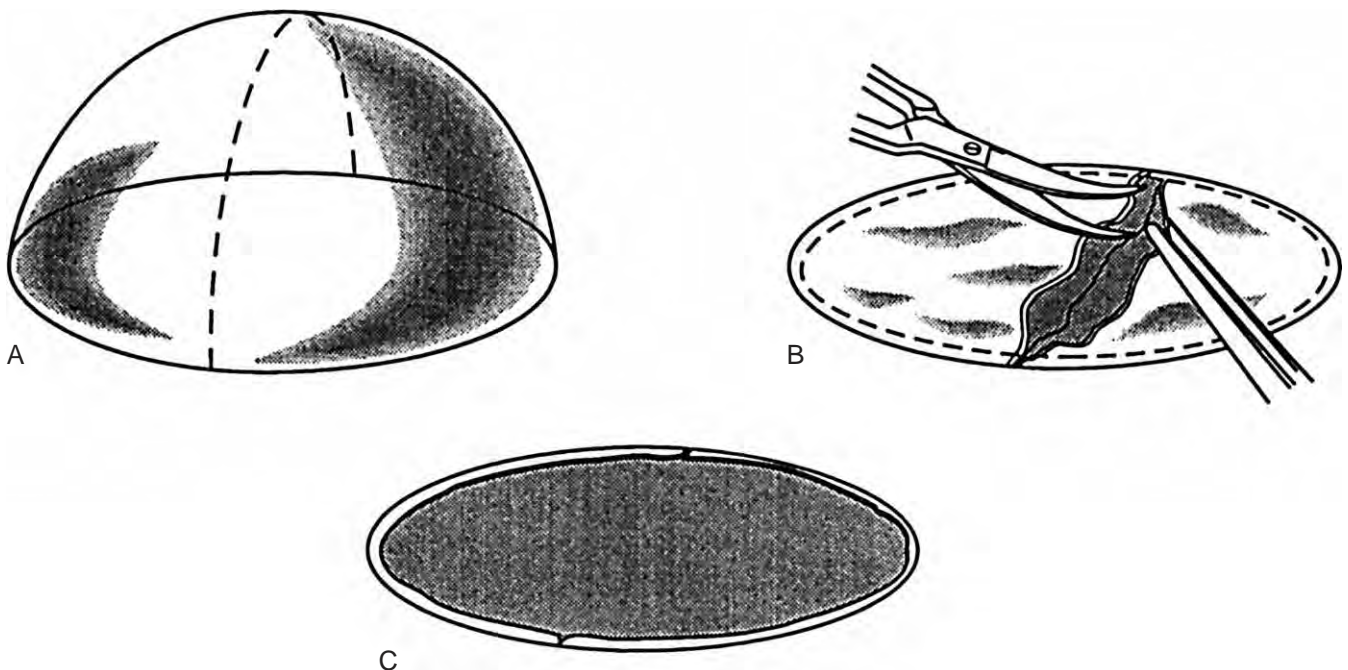
**Figure 23-35** Plastic and metal Jaeger plates.

lower lid. With the cautery tip turned on each cautery burn pierces the skin, the orbicularis oculi muscle, and into the tarsal plate. The burns destroy tissue and cause fibrosis, which pulls the tissue tight and away from the globe, preventing the lower lid folding back onto the globe. The resulting wounds form an elongated eschar that will fall off in a week or two. The area is prophylactically treated with antibiotic ointment four times a day for 3 days.

#### Incisional Surgical Procedures

**Stab Incision.** A stab incision is done with a no. 11 disposable scalpel. It is performed to provide an outlet for pus such as with an external hordeolum or an acute dacryocystitis. Pus, under pressure, needs to be released. The area is first cleansed with an alcohol swab or Betadine. A subcutaneous injection of lidocaine may not be beneficial as the injection itself is painful because the space-occupying bolus of anesthetic creates pressure in an already tender area. Also, the pH of the infection site is acidic, which neutralizes the alkaline anesthetic, rendering it less effective. A quick stab of the abscess causes the contents to spill out. Once this occurs the tenderness of the area is immediately relieved as the pressure within the abscess is eliminated. The wound area can be treated with topical antibiotic ointment four times a day for 3 days. In the case of an acute dacryocystitis, the patient ideally should be taking oral antibiotics for several days before the procedure. Topical and oral antibiotics are also prescribed after the procedure. Draining an acute dacryocystitis is necessary to relieve the often severe pain and to prevent a fistula formation in which the body creates its own passageway to drain the pus. Once the stab incision is made through the overlying skin and into the nasolacrimal sac, pressure is created over the sac with cotton-tipped applicators to express the pus through the wound of the stab incision. Copious amounts of pus are usually evacuated from the infected area, and this material should be cultured and sent for identification and sensitivity.

**Lineate Incision.** A lineate incision starts with a stab incision with a no. 11 disposable scalpel and is continued until the desired incision length is achieved. The incision through the skin should always be in or parallel to the rhytids (folds) of the skin. A single lineate incision parallel to the lid margin through the skin and into the tarsal plate is used when an anteriorly pointing chalazion is to be treated by incision and curettage. The lineate incision is also the basis for the removal of hydrocystomas (sudoriferous cysts, cyst of an eccrine sweat gland) when combined with snip excisions. The combination of the two techniques is referred to as an exenteration procedure (Figure 23-36). A lineate incision is also used to cut through the skin immediately overlying a cyst to be excised (such as a subcutaneous sebaceous cyst). The technique of excising a subcutaneous cyst by creating an incision into but without removing skin is known as a marsupialization technique. A double lineate incision,



**Figure 23-36** Surgical dissection of sudoriferous cyst. (A) Incision through dome of mucoid cyst. (B) Removing anterior half of cyst with forceps and curved-tipped scissors. (C) Floor of cyst will epithelialize to form new skin.

made at right angles to and crossing each other, is known as a cruxiate (cross) incision. A cruxiate incision is made through a posteriorly pointing chalazion on the conjunctival side of the lid. The incisions are made through the conjunctiva and into the tarsal plate. One incision is parallel to the lid margin and the other crosses the first perpendicular to the lid margin. Once the two lineate incisions are made, the corners of the cuts unfurl like the opening of the petals of a flower bud. After curettage, these four corners are then removed with snip excisions.

**Incision and Curettage.** This procedure is used to treat anterior pointing chalazia (the chalazion is pushing out or has erupted through the tarsal plate on the skin side of the lid). Usually, two lidocaine injections are given before this procedure is done. The first is a ring block technique injection proximal to the origin of the enervating nerve. Therefore if the chalazion is on the upper lid the first injection of  $\frac{1}{2}$  to 1 cc of 2% lidocaine with epinephrine is given subcutaneously superior and around the sides of the chalazion. Then, a second deep peribulbar injection is given above the chalazion site. The patient compresses the injection site for 5 to 10 minutes. When the clinician is ready to proceed, the area to be operated on is tested for sensitivity by pricking the area with a sharp object (e.g., the end of the needle used to inject the lidocaine). Be sure to also test an area of the eyelid and face that is not anesthetized so the patient can differentiate between a sensitive (unanesthetized) area with a nonsensitive (anesthetized) area. When the clinician is convinced that

the area in question is numb, a drop of  $\frac{1}{2}\%$  proparacaine is introduced onto the globe, and a chalazion clamp of the appropriate size is placed with the slightly concave flat solid jaw of the clamp between the globe and the posterior surface of the eyelid. The ring side of the clamp is positioned centrally over the lump on the skin side of the eyelid so that the chalazion is centered in the ring. The clamp is tightened significantly on the lid and a 3- to 4-mm lineate incision is made parallel to the lid margin through the skin, into the orbicularis oculi muscle, and into the tarsal plate in the area of the chalazion. The incision through the orbicularis oculi merely separates the fibers and does not sever them, ensuring no functional impairment after the procedure. Pressure on either side of the incision with a cotton-tipped applicator causes the typical grayish gelatinous inflammatory material of a chalazion to ooze out of the wound. Vigorous curettage with a curette follows, making sure that all recesses of the chalazion capsule are probed. After each curettage, the scoop of the curette is wiped clean with a gauze sponge and curettage is repeated until no more material is extracted. The tip of a sterile cotton-tipped applicator is introduced into the wound to remove any tenacious material. Finally, the wound is irrigated with sterile saline to rinse out any loose material. After drying the eyelid of excessive saline, the clamp is loosened but not removed. A drop of blood will appear in the wound at which point the clamp is retightened. After several minutes the blood droplet coagulates and the clamp can be removed. An alternative method is to simply remove the clamp at the end of the

procedure and have the patient compress the area with his or her hand using a folded  $4 \times 4$  gauze pad or an eye pad.

The eyelids are very vascular and are very forgiving, and secondary infection after an eyelid procedure is rare. However, an application of antibiotic ointment is gently applied to the area and is prescribed four times a day for 3 days. It is important to inform the patient that the eyelid is going to look worse immediately after the procedure than it did before the procedure. The trauma created by the injections, the clamp tightening, and the incision and curettage make the lid appear swollen. By the next day the lid will be markedly improved in appearance. There should be total resolution of the lesion within 2 to 3 weeks with no evidence of the procedure. Pain after the procedure and after the anesthetic wears off is virtually nonexistent. If there is discomfort, ibuprofen is prescribed for pain control.

### Excision

Excision is the removal of tissue utilizing a number of different techniques. A snip excision using a pair of Wescott surgical scissors can be used to remove or excise any pedunculated lesions such as skin tags or stalked verrucae. A shave excision, using a no. 15 scalpel, is used to remove a lesion or a section of a lesion. It is often used to take a tissue sample for a biopsy.

### Excision and Curettage

For posterior pointing chalazia (on the conjunctival side) a somewhat different approach is needed. The lid is everted and a  $\frac{1}{4}$  to  $\frac{1}{2}$  cc subconjunctival injection of lidocaine is given proximal to the enervating nerve origin. The lid is returned to its normal position and a deep peribulbar injection is given below the chalazion. The patient applies pressure with a folded gauze sponge over the closed eye after which the conjunctival area of the chalazion is probed to determine sensitivity. Once the area is anesthetized a chalazion clamp is applied, with the ring of the clamp centering the chalazion on the conjunctival side of the lid. Once the clamp is tightened and the eyelid everted, a lineate incision is made through the chalazion perpendicular to the lid margin. If any inflammatory material oozes out, the chalazion capsule should be curetted. A second lineate incision is made parallel to the lid margin bisecting the first incision. When both incisions are made, the four edges of the incised tissue will bulge up. After curetting the chalazion capsule each of these flaps needs to be excised by grasping the tip of the flap with a mouse-toothed forceps and the base of the flap is cut with Wescott scissors. When all four flaps are removed, a divot remains. Again, the clamp is loosened, a drop of blood is permitted to enter the wound, and then the clamp is retightened. After the blood droplet coagulates, the clamp is removed and antibiotic ointment is prescribed four times a day for 3 days. If needed, ibuprofen is used for pain control. The wound will fill in by secondary intention and will appear milky white as

fibrosis results. The wound will be fully healed in 2 to 3 weeks.

### Patient Management

Many patients present to eye care practitioners with any number of eyelid and/or periocular lesions. Most of these lesions are benign and are of no consequence except for their unsightly appearance. A large, long-standing, centrally located chalazion of the upper lid can induce mechanical with-the-rule astigmatism. Its removal can be considered a therapeutic intervention because it eliminates the induced astigmatism. Similarly, a viral lesion on the lid margin or close to the globe, such as a verruca or molluscum contagiosum, can create eye symptoms of irritation, epiphora, and/or burning. Removal of the offending lesion relieves the symptoms and can also be considered a therapeutic intervention. However, for the most part, the only reason to remove many lesions of the eyelid and periocular area is for cosmetic considerations. Even after informing the patient that a lesion is benign and is of no cause for concern, she or he may still want to have it removed. These patients are extremely grateful and appreciative of a successful outcome. In fact, often these patients have consulted their family practitioner about these lesions and are told not to worry about them because they pose no threat to the health or well-being of the patient. However, the patient is still conscious of and often embarrassed by the appearance of these lesions. Many of these lesions are a result of aging skin and are unavoidable in the susceptible individual. As the general population continues to gray, more and more aging patients will present with these lesions.

If a patient is interested in treatment of an eyelid lesion, it is very important to first explain to the patient what the lesion is and then to explain in lay terms exactly what procedure will be performed to treat or remove the lesion. Once the patient understands the procedure and the sensations experienced during the procedure, what course the healing process will take, and what the desired outcome is as well as any possible untoward side effects, let the patient make his or her own decision as to whether to have the procedure done. If the patient decides to have it done, have him or her sign an informed consent form which explains all of the above in lay terms. It is also important to have a witness to the patient's agreement to the procedure, and the witness's signature should also appear on the informed consent form.

Before starting any procedure needing local anesthesia, ask the patient if he or she has any allergies to anesthetics. Also inquire if the patient is on any anticoagulant medications (e.g., aspirin, Coumadin, and heparin) that could create bleeding problems.

During the procedure the clinician should keep a constant ongoing communication with the patient. Occasionally ask the patient if he or she is alright. Above all, speak in a calm, confident, and reassuring manner.

**SELECTED BIBLIOGRAPHY**

- Arici MK, Sumer Z, Toker MI, et al. The prevalence of *Demodex folliculorum* in blepharitis patients and the normal population. *Ophthalmic Epidemiol* 2005;12:287-290.
- Banik R, Miller NR. Chronic myokymia limited to the eyelid is a benign condition. *J Neuro Ophthalmol* 2004;24:290-292.
- Buechner SA. Rosacea: an update. *Dermatology* 2005;210:100-108.
- Crawford GH, Pelle MT, James WD, et al. Rosacea. I. Etiology, pathogenesis, and subtype classification. *J Am Acad Dermatol* 2004;51:327-344.
- Culbertson WW, Ostler HB. The floppy eyelid syndrome. *Am J Ophthalmol* 1981;92:568-575.
- Dawson CR. Herpetic eye disease study, you can help. *Arch Ophthalmol* 1996;114:89-90.
- Donaldson MJ, Sullivan Tj, Whitehead KJ, et al. Squamous cell carcinoma of the eyelids. *Br J Ophthalmol* 2002;86:1161-1165.
- Driver PJ, Lemp MA. Meibomian gland dysfunction: major review. *Surv Ophthalmol* April-March 1996;40:343-366.
- Forton F, Germaux MA, Brasseur T, et al. Demodicosis and rosacea: epidemiology and significance in daily dermatologic practice. *J Am Acad Dermatol* 2005;52:87.
- Herpetic Eye Disease Study Group. Oral acyclovir for herpes simplex virus eye disease: effect on prevention of epithelial keratitis and stromal keratitis. *Arch Ophthalmol* 2000;118:1030-1036.
- Hosal BM, Zilelioglu G. Ocular complications of intralesional corticosteroid injection of a chalazion. *Eur J Ophthalmol* 2003;13:798-799.
- Huber-Spitz V, Baumgartner I, Bohler-Sommeregger K, et al. Blepharitis—a diagnostic and therapeutic challenge, A report on 407 consecutive cases. *Graefe's Arch Clin Exp Ophthalmol* 1991;229:224-227.
- Johnson RW. Pain following herpes zoster: implications for management. *Herpes* 2004;11:63-65.
- Landow K. Rosacea: the battle goes on. *Comp Ther* 2005;31:145-158.
- Lee PK, Harwell WB, Leven KH, et al. Long-term clinical outcomes following treatment of actinic keratosis with imiquimod 5% cream. *Dermatol Surg* 2005;31:559-663.
- Liesegang TJ. Herpes simplex virus epidemiology and ocular importance. *Cornea* 2001;20:1-13.
- Liesegang TJ. Herpes zoster virus infection. *Curr Opin Ophthalmol* 2004;15:531-536.
- Liesegang TJ. Varicella-zoster virus eye disease. *Cornea* 1999;18:511-531.
- McCulley, Dougherty BS, Deneau DG. Classification of chronic blepharitis. *Ophthalmology* 1982;89:1173-1180.
- McNab AA. Reversal of floppy eyelid syndrome with treatment of obstructive sleep apnoea. *Clin Exp Ophthalmol* 2000;28:125-126.
- McNab AA. Floppy eyelid syndrome and obstructive sleep apnea. *Ophthal Plast Reconstr Surg* 1997;13:98-144.
- Olson MC, Korb DR, Greiner JV. Increase in tear film lipid layer thickness following treatment with warm compresses in patients with meibomian gland dysfunction. *Eye Contact Lens* 2003;29:96-99.
- Onofrey BE, Skorin Jr L, Holdeman NR, eds. *Ocular therapeutics handbook: a clinical manual*, ed. 2. Philadelphia: Lippincott Williams and Wilkins, 2005.
- Opstelten W, Zaal MJW. Managing ophthalmic herpes zoster in primary care. *BJM* 2005;331:147-151.
- Özdal PC, Corera F, Caissie AL, et al. Accuracy of the clinical diagnosis of chalazion. *Eye* 2004;18:135-138.
- Scheinfield NS. Seborrheic dermatitis. *Skin Med* 2005;4:49-50.
- Shine WE, McCulley JP, Pandya AG. Minocycline effect on meibomian gland lipids in meibomianitis patients. *Exp Eye Res* 2003;76:417-420.
- Shingles Prevention Group. A vaccine to prevent herpes zoster and postherpetic neuralgia in older adults. *N Engl J Med* 2005;352:2271-2284.
- Simon GJB, Huang L, Nakra T, et al. Intralesional triamcinolone acetonide injection for primary and recurrent chalazia: is it really effective? *Ophthalmology* 2005;112:913-917.
- Smolinski KN, Yan AC. How and when to treat molluscum contagiosum and warts in children. *Pediatr Ann* 2005;34:211-221.
- Spencer JM, Hazan C, Hsiung SH, et al. Therapeutic decision making in the therapy of actinic keratoses. *J Drugs Dermatol* 2005;4:296-301.
- Stone DU, Chodosh J. Ocular rosacea: an update on pathogenesis and therapy. *Curr Opin Ophthalmol* 2004;15:499-502.
- Stoncipher K, Perry HD, Gross RH, et al. The impact of topical cyclosporine A emulsion 0.05% on the outcomes of patients with keratoconjunctivitis sicca. *Curr Med Res Opin* 2005;21:1057-1063.
- Uchoa UBC, Rezende RH, Carrasco MA, et al. Long-term acyclovir use to prevent recurrent ocular herpes simplex virus infection. *Arch Ophthalmol* 2003;121:1702-1704.
- Vafai A, Berger M. Zoster in patients infected with HIV: a review. *Am J Med Sci* 2001;321:372-380.
- Vazquez M, LaRussz PS, Gershon AA, et al. Effectiveness over time of varicella vaccine. *JAMA* 2004;291:851-855.
- Weissenborn SJ, Nindl I, Purdie K, et al. Human papillomavirus-DNA loads in actinic keratoses exceed those in non-melanoma skin cancers. *J Invest Dermatol* 2005;125:93-97.
- Wolf JE. Present and future rosacea therapy. *Cutis* 2005;75(suppl 3):4-7.



## *Diseases of the Lacrimal System*

*Kimberly K. Reed*

Diseases and disorders involving the lacrimal system are among the more common conditions experienced by ophthalmic patients, with as many as 25% complaining of dry eye symptoms alone. The lacrimal system is most easily considered as having three components—the secretory system, the distribution system, and the excretory or drainage system. These components must work in harmony to support a healthy, moist, and comfortable ocular surface.

Although the components are anatomically separate, if a disruption in any subcomponent of the lacrimal system occurs, patients report strikingly similar symptoms. For example, tearing is a common complaint and can be caused by disorders within the secretory, distribution, or excretory system. An increase in tear secretion as a result of ocular surface irritation (pseudoeiphora), poor lid apposition interfering with the distribution system, and obstruction of the lacrimal excretory system (true eiphora) may all cause tearing. Other common lacrimal system-based symptoms include general irritation, discomfort, burning, foreign body sensation, redness, or dryness. To further complicate matters, some complaints reported by patients with lacrimal disease can mimic symptoms associated with infectious and inflammatory diseases not directly involving the lacrimal system. As an example, a red irritated eye with mucopurulent discharge may initially appear as a bacterial conjunctival infection but may in fact be an infection associated with a blockage within the lacrimal drainage system.

A healthy lacrimal system is necessary for ocular comfort, resistance to disease and exposure, corneal oxygenation, and optimal visual function. A careful patient history and examination is necessary to arrive at an accurate diagnosis, which directs appropriate management.

### **CLINICAL ANATOMY AND PHYSIOLOGY OF THE LACRIMAL SYSTEM**

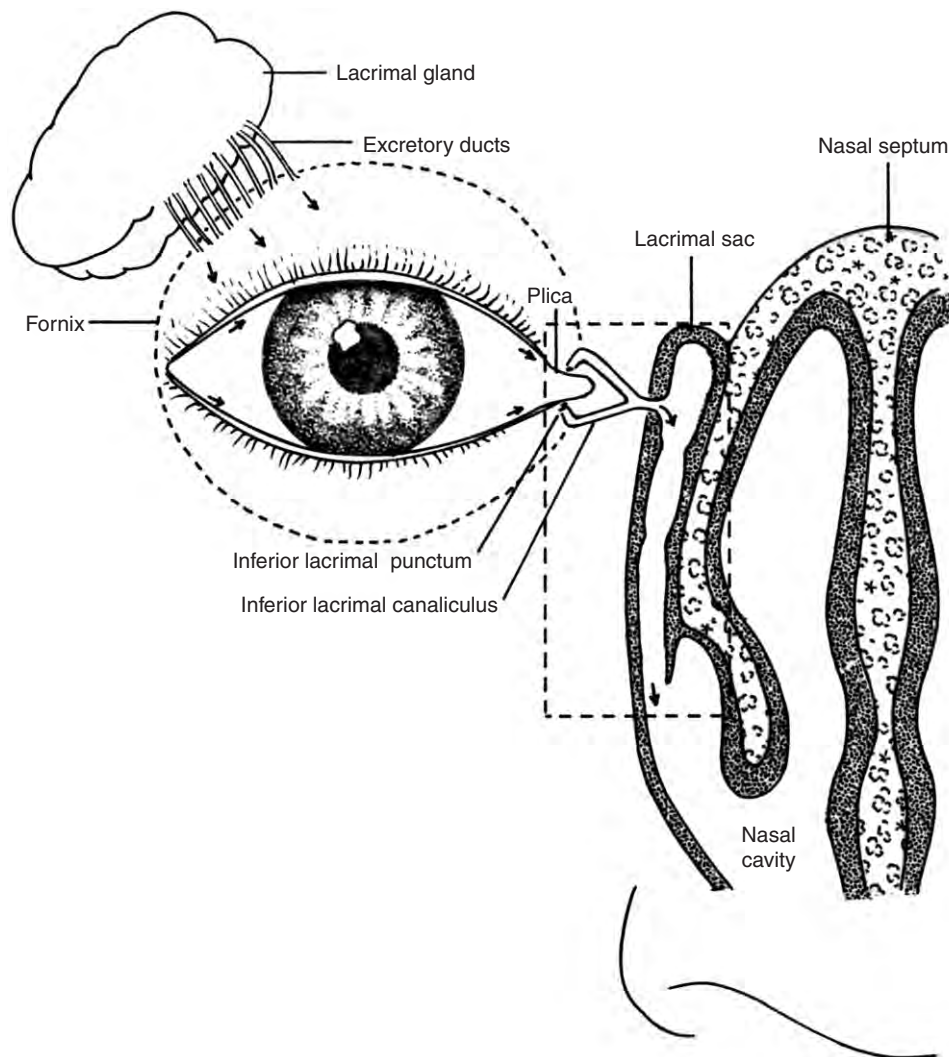
#### **Secretory System**

Recently, clinicians have begun to better appreciate the importance of the interrelationship among the various

components within the lacrimal secretory and distribution systems. The concept of a lacrimal “functional unit,” comprising the lacrimal gland, the ocular surface, and the sensory/autonomic neural reflex loop that is the communication network between the ocular surface and the lacrimal gland, provides a useful model to examine the etiology of dry eye disease (Figure 24-1).

The lacrimal gland is approximately the size and shape of a shelled almond and consists of main and accessory portions separated by the aponeurosis of the levator muscle into the orbital and palpebral portions. The lacrimal gland is primarily responsible for reflex secretion, which is caused by irritation of the trigeminal nerve endings in the cornea, conjunctiva, and proximal structures or by bright light stimulation of the retina. Emotional impulses from the frontal cortex, basal ganglion, thalamus, and hypothalamus also contribute to reflex secretion. Primary neuronal control of the lacrimal gland is through parasympathetic nerve fibers traveling in the seventh cranial nerve. Androgens (male hormones) have been shown to help regulate the normal functioning of the lacrimal gland. Disease or inflammation of the lacrimal gland has an adverse effect on its output, thereby reducing the secretion to the ocular surface. As tear secretion decreases, ocular surface sensitivity also decreases, providing an impaired feedback loop from the ocular surface to the lacrimal gland.

The ocular surface, including the cornea, conjunctiva, accessory lacrimal glands, and meibomian glands, is the second critical component of the functional unit. Irritation of the cornea or conjunctiva, whether from infection, contact lens overwear, allergic reaction, mechanical or environmental irritation, or from dry eye itself, causes trigeminal stimulation and abnormal neural feedback to the lacrimal gland. This in turn causes a modification of lacrimal gland output. The accessory lacrimal glands of Krause (embedded in the conjunctival fornices) and Wolfring (located along the upper border of the tarsal plate) are thought to be the main contributors to the aqueous component of the tear film under normal conditions. The meibomian glands, within the tarsal plates,



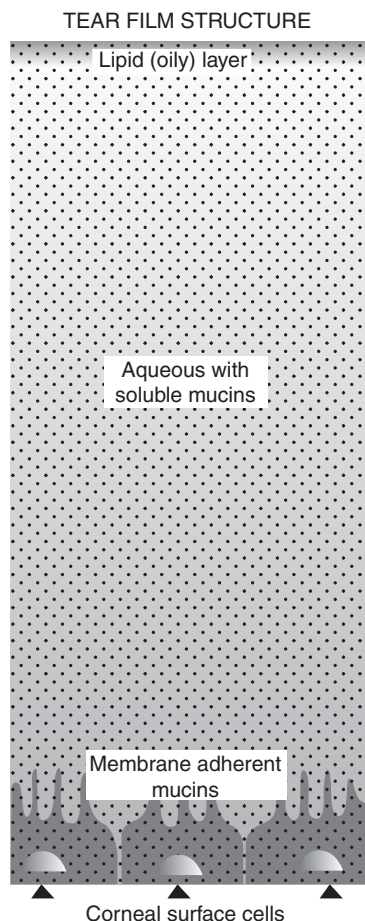
**Figure 24-1** Schematic view of the lacrimal system. The lacrimal gland supplies aqueous (reflex) secretions. Arrows indicate the pathway that tears follow to drainage, beginning at the punctum. The area enclosed by dashed lines represents the drainage apparatus. (Adapted from Botelho SY. Tears and the lacrimal gland. *Sci Am* 1964;211:78-85. Copyright 1964 by Scientific American, Inc. All rights reserved.)

secrete an oily substance that helps limit evaporative loss of the aqueous component of the tear film. Although the mechanism is not completely understood, androgens likely play a role in the maintenance of the structure and function of these glands, with a reduction in androgens having a deleterious effect on the functional unit.

Disruption in either the lacrimal gland or any part of the ocular surface results in abnormal neural activity. This disruption initiates and perpetuates an inflammatory-based cyclic feedback loop including reduced lacrimal output, reduced sensitivity at the ocular surface, further ocular surface inflammation, and a reduced ability of the ocular surface to respond to environmental challenges. This inflammatory loop results in chronic neurosensory fatigue and is the currently accepted model for most dry eye syndrome diagnoses.

The tear film is a dynamic fluid layer with lipid, aqueous, and mucin components that interact with each other

and with the ocular surface. The bulk of the tear film layer is aqueous, secreted by the glands of Wolfring and Krause. Historically, the tear film has been described as a trilayered structure, with mucin at the ocular surface, aqueous in the “middle,” and a lipid layer superficially. It may be more accurate to conceptualize these three layers as being somewhat integrated, in that the tear film’s “resting state” assumes the configuration of a bilayer (Figure 24-2). According to this model, there is a lipid layer superficially and a mucin–aqueous layer comprising the rest of the tear film. Regardless of whether the three components are fully stratified or somewhat “blended,” the origins and functions of the various components are well established. The lipid layer serves to thicken, stabilize, and prevent premature evaporation of the aqueous component of the tears and is the product of secretions of the meibomian glands with additional contributions from the glands of Zeis (sebaceous) and Moll (apocrine), both of which are



**Figure 24-2** The tear film layer. (From [http://www.systeme.com/consumer/What\\_are\\_Tears.asp](http://www.systeme.com/consumer/What_are_Tears.asp); Copyright 2006, Alcon, Inc.)

located at the eyelid margin in close proximity to the cilia follicles. A layer of mucin, made up of large highly glycosylated glycoproteins, serves to make the normally hydrophobic ocular surface more favorable for the aqueous-based tears to inhabit. The mucin layer is secreted primarily by the goblet cells within the conjunctiva. Soluble mucin is secreted by the lacrimal gland epithelial cells and is thought to be mixed within the aqueous layer. These mucins in the tear film are more active than previously thought; inadequate mucins may significantly contribute to ocular surface disease (Figure 24-3).

Tears also contain a number of proteins, enzymes, metabolites, and electrolytes (Table 24-1). These components, although present in very small quantities, serve critical functions, including maintaining tear film structural integrity, contributing to immunoprotection, providing trace nutrients to the ocular surface, maintaining tear osmolarity, and maintaining the pH level of tears at approximately 7.45.

### Distribution System

The lacrimal distribution system incorporates the opening and closing of the eyelids and the fluid dynamics of

the tear film. Eyelid closure is under the muscular control of the orbicularis oculi muscle, which is innervated by cranial nerve VII. Eyelid opening is achieved through contraction of the levator palpebrae superioris muscle, innervated by cranial nerve III, with secondary elevation activity provided by Müller's muscle, which receives sympathetic innervation.

Under normal conditions the various components of the tear film are continually produced in sufficient quantity, not only to cover the ocular surface but also to supply a reservoir of tears that is stored at the margin of the upper and lower eyelids. The movement of the upper eyelid distributes this reservoir, called the tear river or tear meniscus, during blinking or voluntary lid closure. As the tear film thins and "breaks up," the blink reflex is stimulated. The down-phase of each blink compresses the superficial lipid layer, and the up-phase redistributes the lipid layer, which remains in a fairly dynamic state well after the completion of the blink. Each time the eyelid reopens, a new tear film layer is spread across the ocular surface. The blink itself may also augment meibomian gland expression.

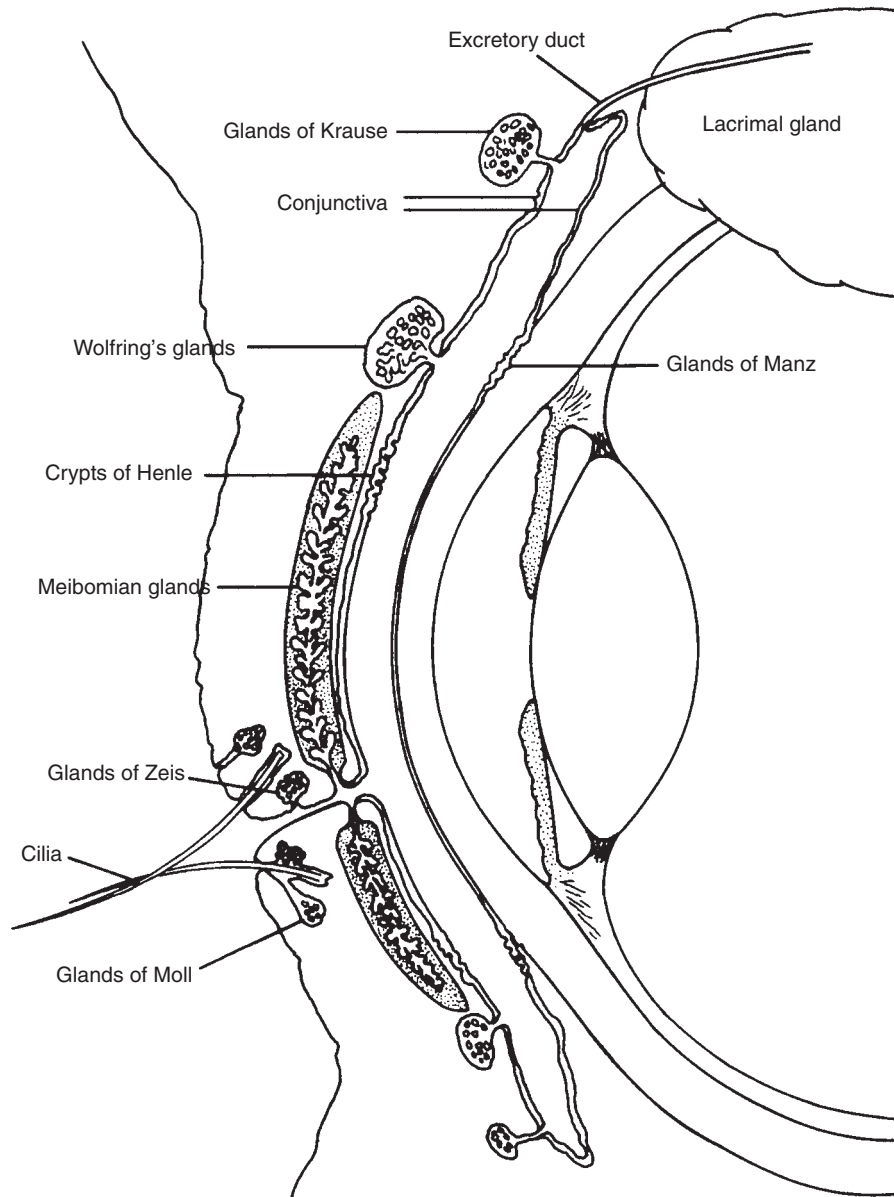
### Excretory System

The action of the blink also facilitates tear drainage (see Figure 24-1). The eyelids direct the lacrimal fluid along a channel formed by the globe and the plica semilunaris toward the inner canthi for drainage into the puncta.

The puncta are located on the posterior margins of the upper and lower eyelids, at the nasal end of the tarsus, approximately 6 mm from the nasal canthus. Each punctal opening measures 0.2 to 0.3 mm in diameter and is surrounded by a connective tissue ring. The four puncta point toward the globe, so that under normal conditions they are not directly visible without lid manipulation. Normally, when the eyelids are closed, the upper and lower puncta are directly opposed to one another.

Except for the punctum, the remainder of the lacrimal drainage system is hidden from direct observation. After tears enter the punctum, they flow through a 2-mm vertical segment of each canaliculus. The upper and lower canaliculi then turn toward the nose, run a horizontal course of approximately 8 mm, and join together as the common canaliculus at the entrance to the lacrimal sac. This structure is approximately 10 to 12 mm in vertical dimension, the top one-third of which balloons above the common canaliculus (Figures 24-4 and 24-5). The lacrimal sac is housed within the bony lacrimal fossa.

The lacrimal sac is normally collapsed when the eyelids are open. As the eyelids close, tears are squeezed into the sac, aided by the negative pressure within the sac (see Figure 24-5). A valve-like structure at the opening to the lacrimal sac helps to retain tears within the sac and prevent their backflow into the canaliculus. The nasolacrimal duct (NLD) is continuous with the lacrimal sac inferiorly. The NLD extends 15 to 20 mm caudally,



**Figure 24-3** Cross-section of the lacrimal secretory system. See text for products of the labeled basal secretors. (Adapted from Botelho SY. Tears and the lacrimal gland. *Sci Am* 1964;211:78-85. Copyright 1964 by Scientific American, Inc. All rights reserved.)

narrows, and finally opens into the inferior meatus, which is a space located under the inferior turbinate bone in the outer wall of the nasopharynx. Tears are then drained toward the back of the throat to be swallowed. Regurgitation of tears from the nasopharynx into the nasolacrimal system is prevented by the negative pressure within the drainage apparatus and by a membranous valve at the end of the NLD, termed the valve of Hasner.

Approximately 90% of the tears are drained in this manner, with the remainder being lost to evaporation. To facilitate normal drainage of tears, the entire nasolacrimal drainage system must be properly positioned and patent. Blockages anywhere along the way generally result in epiphora and may create an environment that is conducive to infection and inflammation.

## DIAGNOSIS AND MANAGEMENT OF DISORDERS OF THE SECRETORY AND DISTRIBUTION SYSTEMS

### History

As in most ocular conditions, a well-conducted patient interview assists greatly in the diagnosis of disorders of any subcomponent of the lacrimal system, even before any clinical tests are performed (Box 24-1). Social and demographic factors such as the patient's gender, age, occupation, and environment may influence differential diagnostic considerations between secretory and excretory abnormalities. For example, infants who present with tearing are more likely to suffer from a drainage

**Table 24-1**

Composition of Tear Fluid

Component	Concentration in Tears	Component	Concentration in Tears
Protein	6-20 g/l	Lipids	
Prealbumin	Small fraction	Cholesterol	200 mg% (same as blood)
Lysozyme	1-2 g/l	Meibomian lipids:	—
Lactoferrin	—	hydrocarbons, wax esters,	
Transferrin	—	cholesterol esters, triglycerides,	
Ceruloplasmin	—	diglycerides, monoglycerides,	
Immunoglobulin A (IgA)	10-100 mg%	free fatty acids, free cholesterol,	
Immunoglobulin G (IgG)	Very low concentration	and phospholipid	
Immunoglobulin E (IgE)	26-144 ng/ml	Metabolites	
Complement	1:4	Glucose	0.2 mmol/l
Glycoproteins	0.05-3 g/l (hexosamine concentration)	Lactate	1-5 mmol/l
Antiproteinasases	Much lower than in serum	Pyruvate	0.05-0.35 mmol/l
$\alpha_1$ -antitrypsin ( $\alpha_1$ -at)	0.1-3 mg%	Urea	Equivalent to amounts in plasma
$\alpha_1$ -antichymotrypsin ( $\alpha_1$ -ach)	1.4 mg%	Catecholamines	0-1.5 $\mu$ g/ml
inter- $\alpha$ -trypsin inhibitor	0.5 mg%	Dopamine	to 280 $\mu$ g/ml
$\alpha_2$ -macroglobulin ( $\alpha_2$ -M)	3-6 mg%	Epinephrine	—
Enzymes		Norepinephrine	—
Glycolytic and tricarboxylic cycle enzymes	Very low levels	Dopa	—
Lactate dehydrogenase	Highest in tears	Histamine	10 mg/ml
Lysosomal enzymes	2-10 times levels in serum	Prostaglandin F	75 pg/ml
Amylase	Similar to level in urine	Electrolytes	
Peroxidase	10 <sup>3</sup> U/l	Na <sup>+</sup>	80-170 mmol/l
Plasminogen activator	—	K <sup>+</sup>	6-42 mmol/l
Collagenase	Only with corneal ulceration	Ca <sup>2+</sup>	0.3-2.0 mmol/l
		Mg <sup>2+</sup>	0.3-1.1 mmol/l
		Cl <sup>-</sup>	106-138 mmol/l
		HCO <sub>3</sub> <sup>-</sup>	26 mmol/l
		Osmotic pressure	305 mOsm/l
		pH	7.45 (7.14-7.82)

From Van Haeringen NH. Clinical biochemistry of tears. *Surv Ophthalmol* 26:84-96. Reprinted in Farris. Abnormalities of the tears and treatment of dry eyes. In: Kaufman, Barron, McDonald, et al., eds. *The cornea*. New York: Churchill Livingstone, 1988: 140.

problem, whereas tearing in an adult whose occupation involves exposure to noxious fumes is likely to be the result of ocular surface irritation and subsequent reflex tearing. Postmenopausal women are relatively deficient in both estrogens and androgens, which adversely affects the lacrimal functional unit, making this demographic group significantly more predisposed to dry eye disease. Infrequent blinking and palpebral fissure widening, with a resultant increase in ocular surface evaporation, have been linked to use of video display terminals. Certain medications like anticholinergic agents, anti-anxiety drugs, and antihistamines can decrease aqueous production and cause dry eye (see Chapter 35). Patients with obstructed drainage systems may have adapted to carrying a handkerchief or tissue to address the epiphora. A suggested protocol for obtaining a history from patients complaining of tearing is outlined in Box 24-2.

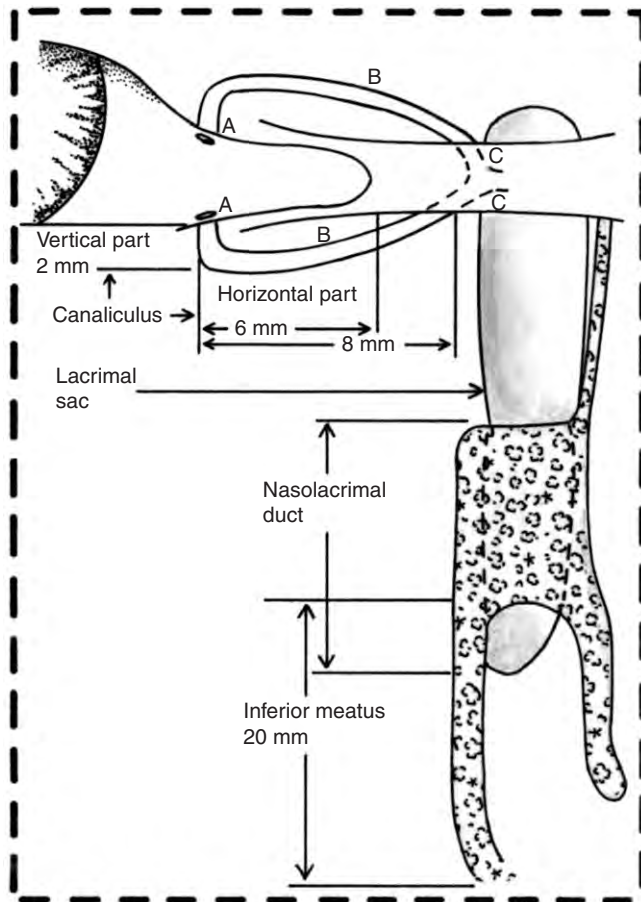
A sensitive and specific dry eye questionnaire is now widely used, either in its original or in a modified form, in

research and clinical settings (Box 24-2). A thorough interview for patients complaining of dry eye symptoms should include all elements addressed in the questionnaire.

### Evaluation of the Secretory System

A wide array of testing procedures is available to assess lacrimal secretory function. There is significant controversy in the literature as to the reliability and repeatability of these tests. This dissension is reflected in the wide variability in practitioner opinion as to which tests are most clinically useful in the diagnosis of dry eye disease and related conditions. The standard of care currently stipulates that at least one objective measure of the lacrimal secretory system be used in addition to a comprehensive case history before a diagnosis is reached. The test selected is largely left to individual preference, but most practitioners frequently use ocular surface staining (sodium fluorescein [NaFl], lissamine green, and/or rose bengal).





**Figure 24-4** Cut-away view showing the lacrimal excretory system. Tears drain through the punctum (A) and eventually under the inferior turbinate bone of the nose. Dimensions of the canaliculi serve as references for probing and irrigation. B, canaliculus; C, common canaliculus. (Redrawn with permission from Jones LT. *Ophthalmic anatomy: a manual with some clinical applications*. I. The orbital adnexa. *Am Acad Ophthalmol* 1970:70.)

### Examination of the Tear Film

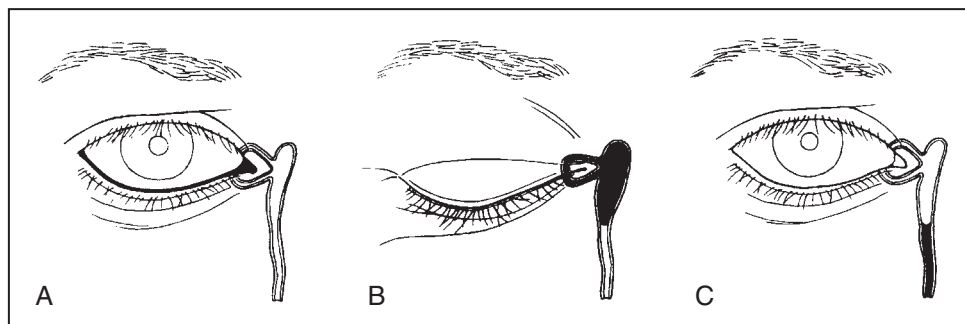
It is often useful to grossly observe the patient before conducting a slit-lamp examination. A patient who is complaining of “constant watering” of the eyes but who

does not display any tearing during the case history or preliminary testing might require a different evaluation and management strategy than does the patient who presents with a box of tissues and frequently dabs excess tears while seated in the examination chair.

Biomicroscopy should include a quick inspection of the tear film and tear meniscus before the instillation of diagnostic drops or dyes. The test should look for appropriate quantity (the tear meniscus should occupy a height of at least  $\frac{1}{2}$  mm above the lower lid margin) and quality (the tear film should be free of mucous strands, which often indicate an inadequate aqueous component; “frothing” and “oil slick” color fringes strongly suggest oil overproduction). There are two other common clinical tests available for measuring tear quantity: the Schirmer test, which has three subcomponents, and the phenol red thread test.

The Schirmer I, also called the standard Schirmer test or the Basal plus Basic Schirmer, involves the use of a paper filter strip that is bent and placed over the lower eyelid margin approximately one-third of the distance from the outer canthus. During the test the patient should be seated comfortably, away from direct drafts, in a moderately dim room. The patient should be instructed to blink normally but to keep his or her eyes open and in slight up-gaze during the test. Both eyes can be measured simultaneously. After 5 minutes the strips are gently removed, and the amount of tearing is assessed by measuring the linear distance of moistness on the strip. This zone of wetting may be more readily viewed by using filter paper strips that have been impregnated with a dye (Figure 24-6). There is some variation for interpreting this test, but it is generally agreed that less than 10 mm of wetting in 5 minutes is highly suggestive of aqueous deficiency, with less than 5 mm of wetting virtually confirming inadequate aqueous production. More than 15 mm of wetting is not diagnostic of a “normal” eye, however. No conclusions regarding lacrimal secretion can be drawn from a “normal” Schirmer I test, because both the reflex and the basic secretions are included, which is not representative of the patient’s natural state. In almost all cases further testing is pursued.

The Basic Secretion Schirmer test is performed in essentially the same way as the Schirmer I, with the



**Figure 24-5** Dynamics of tear flow. (From Kanski JJ. *Clinical ophthalmology*. Reprinted in Melroe. *Evaluation of the lacrimal system*. In: Roberts and Terry, eds. *Ocular disease: diagnosis and treatment*, ed 2. Edinburgh: Butterworth-Heinemann, 1996.)

**Box 24-1** Outline of Clinical Procedures for the Tearing Patient

History  
 Physical observation of excess tearing pattern, if present  
 Medial: obstruction  
 Lateral: tear overproduction  
 Slit-lamp evaluation  
 White light  
 Vital dye staining  
 Dye disappearance (clearance) test  
 Fluorescein should begin to clear the inferior cul-de-sac within 1 minute  
 Fluorescein should begin to appear in nasopharynx at this time  
 Drainage testing (Jones testing series)  
 Fluorescein present: patent system  
 Fluorescein absent: obstructed drainage pathway (lacrimal lavage indicated)

important addition of a topical anesthetic to reduce or eliminate basal tear secretion to evaluate basic secretion alone. It is essential to carefully swab the cul-de-sac after anesthetic instillation to remove artificial “wetness” from the eye before conducting the test. Again, interpretation of results is variable, but less than 5 mm of wetting in 5 minutes is generally considered to be a relatively dependable indicator of aqueous deficiency.

The Schirmer II test can be performed in extremely dry eyes with very low results on Schirmer I. Before removing the paper strips at the conclusion of the Schirmer I test, a cotton swab is inserted into the nose to mechanically irritate the nasal mucosa. In normal subjects this stimulates an impressive basal tear secretion. If this response is present, ocular surface disease that has interfered with the normal neurologic feedback mechanism is suspected of contributing to the dry eye state. If the response is absent, lacrimal gland dysfunction is the likely cause.

The phenol red thread test is also a method to quantitatively evaluate aqueous tear production. This test is similar to the Schirmer test, but instead of a paper filter strip a thin thread is inserted into the lower cul-de-sac about one-third of the distance from the outer canthus. The small caliber of the thread diminishes basal tear contribution as compared with the Schirmer I test. A color change in the thread from yellow to red makes the visibility of the wet versus dry portions of the thread readily visible. Interpretation of this test is also the subject of some debate, but it is generally agreed that after 15 seconds less than 10 mm of wetting is abnormal, whereas 20 mm or greater indicates normal tear production. This test is done one eye at a time, because measurement is made in seconds versus minutes.

**Box 24-2** Elements of the Case History for the Dry Eye Patient

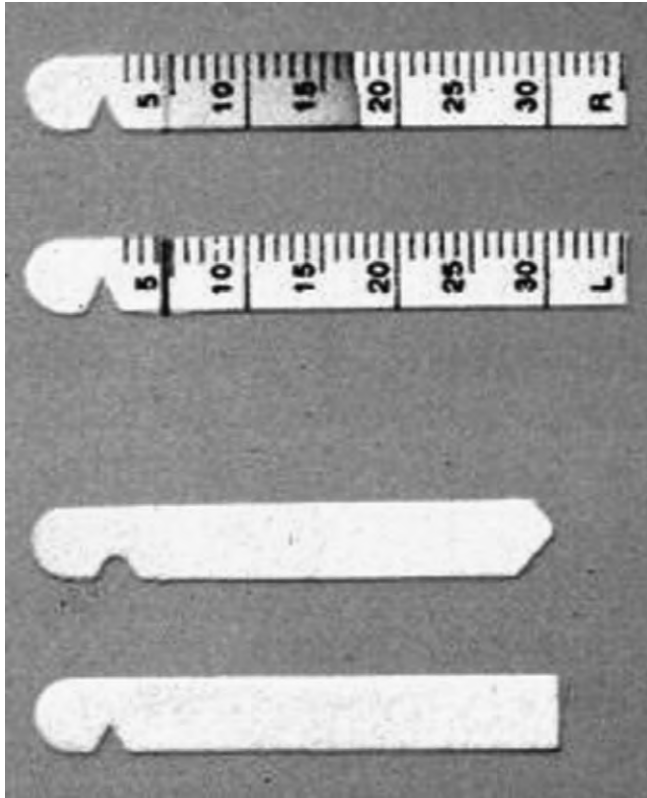
Laterality (one eye or both?)  
 Onset (gradual or acute?)  
 Course and frequency (progressive, intermittent, or stable? Seasonal?)  
 Duration  
 Severity  
 Factors relieving or exacerbating the symptoms  
 Ocular and visual history  
 Contact lens use and history, including wearing schedule and solutions used  
 Prescription or over-the-counter remedies used for ocular or visual disorders  
 Prior ocular surgery (including refractive surgery and eyelid surgery) and trauma history  
 Chronic ocular surface disease (allergies, chemical burns, pemphigoid, trachoma, Stevens-Johnson syndrome)  
 Systemic health history  
 Full systems review including dry mouth, joint pain, atopy, skin rashes, etc.  
 Prior systemic surgery  
 Prior radiation in or around face/orbit  
 Neurologic conditions  
 Menopause  
 Endocrine disorders (e.g., Graves' disease)  
 Chronic viral infections  
 Medication history  
 Allergy history  
 Occupational or environmental exposures (social history)  
 Smoking  
 Lifestyle (outdoor activities, driving with windows down, etc.)  
 Family history—ocular or systemic disease

It should be noted that both the Schirmer and phenol red thread tests should be performed before the instillation of ophthalmic dyes. A summary of these tests and interpretation of the results is provided in Table 24-2.

Evaluation of the lipid layer has recently received much attention. There have been many methods and types of instrumentation proposed in the literature, including the use of videokeratography to detect lipid-induced reversible changes in corneal contour and a continuous functional visual acuity test to measure the effect of the lipid layer on functional vision. However, there is not as yet an easily accessible uniform method to assess the lipid layer of the tear film.

Measurement of the tear breakup time (TBUT) is one of the more common tests to evaluate the tear film (Figure 24-7). This test is most frequently done using NaFl and the cobalt filter on the slit lamp. Instability of the tear





**Figure 24-6** Schirmer tear volume test strips. Strips are available with or without markings; some strips are impregnated with dye to allow easy visualization of wetting distance (*top*).

film is seen as a dark spot or “break” in the fluorescein tear fluid. Normally, patients have a TBUT of 10 seconds or longer with this technique; a TBUT of less than 5 seconds is highly suggestive of dry eye disease, with measurements between 5 and 10 seconds indicating an unstable tear film. This test can also be done noninvasively using the keratometer mires or other instrument requiring a smooth reflecting ocular surface. Noninvasive TBUT

times should be longer than TBUT using NaFl, with normal patients often having a noninvasive TBUT time of 30 seconds or longer. If this method is used, it should be done before the topical instillation of drugs or dyes.

## THE FUNCTIONAL UNIT

### Evaluation of the Ocular Surface

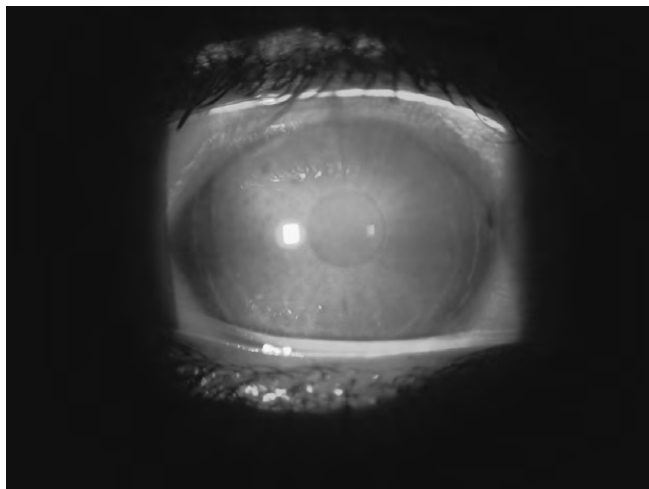
If NaFl stain is instilled for a TBUT measurement, it is a natural extension to then look for corneal and/or conjunctival staining. The presence of NaFl “staining,” rather than representing a true stain, indicates epithelial disruption, because the NaFl pools in areas of intercellular defects. Typically, the distribution of dry eye-related punctate epithelial keratopathy is in the lower third of the cornea and/or conjunctiva.

Adding rose bengal or lissamine green dye further enhances the diagnostic picture. Rose bengal stains dead and devitalized cells. The distribution pattern of rose bengal staining in dry eye is the same as that seen with NaFl but is observed with white light rather than the cobalt filter. Rose bengal also vividly stains mucous strands and filaments, which are prevalent in aqueous deficient dry eyes due to a lack of aqueous volume within which the mucus would ordinarily be dissolved. Rose bengal is available in liquid form, which is associated with significant ocular stinging upon instillation, and impregnated paper strips. Lissamine green, available on impregnated paper strips only, is offered as an alternative to rose bengal, because it appears to have similar staining properties but with less ocular stinging upon instillation. Both rose bengal and lissamine green staining properties are dose dependent, so it is important to instill a sufficient amount of these dyes for accurate ocular surface evaluation.

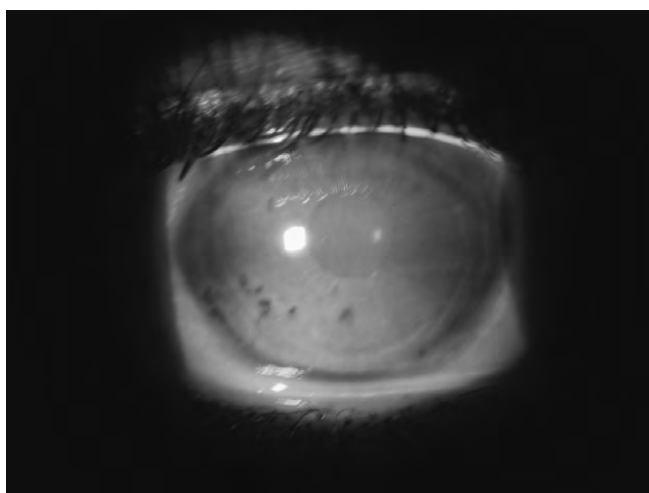
NaFl and rose bengal stains can be instilled simultaneously. Several grading scales for quantifying ocular staining with NaFl, rose bengal, and lissamine green have been

**Table 24-2**  
Clinical Interpretation of Tear Volume Tests

Test Type	Extent of Wetting	Interpretation
Schirmer I (without anesthetic, Basal plus Basic tearing)	<5 mm wetting in 5 minutes	Hyosecretion disorder
Basic secretion test (with anesthetic)	<10 mm wetting in 10 minutes	Strongly suggestive of hyosecretion disorder
	>15 mm wetting in 5 minutes	No conclusions; need further evaluation
Schirmer II (with manual stimulation of nasal mucosa)	<5 mm wetting in 5 minutes	Basal tear secretion deficit
	>5 mm wetting in 5 minutes	Normal basal secretion
Phenol red thread test (without anesthetic)	Increased wetting	Lacrimal gland intact; suspect neural pathway or chronic ocular surface neurosensory fatigue
	No increased wetting	Suspect lacrimal gland disease
Phenol red thread test (without anesthetic)	<10 mm wetting in 15 seconds	Hyosecretion
	>20 mm wetting in 15 seconds	Normal basal secretion



A



B

**Figure 24-7** Tear breakup time test. (A) Immediately after several complete blinks, there is homogeneous tear film stained with sodium fluorescein. (B) Randomly formed dry spot signals conclusion of the test and indicates instability of the tear film.

proposed; use of such a scale in clinical research is critical to uniformly quantify clinical findings.

Another diagnostic strategy for evaluating the ocular surface in suspected dry eye syndrome is conjunctival impression cytology. With this method a strip of cellulose acetate filter paper is gently pressed against the bulbar or palpebral conjunctiva. After staining and preparation, the specimen is evaluated using a microscope. Conjunctival impression cytology is performed to detect morphologic alterations in the ocular surface, such as goblet cell density, structural changes within the epithelial cells, and the expression of inflammatory markers. These changes have been highly correlated with dry eye disease and are frequently used in clinical research as an objective measure of ocular surface changes. It is possible that conjunctival impression cytology will become more practical for routine clinical use in the future.

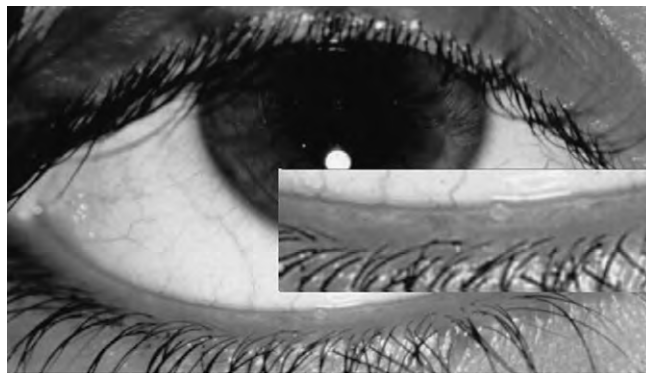
Clinical analysis of the tear film has become increasingly more developed. Examples include tear osmolarity, tear function index, and tear protein analysis, including lactoferrin, lysozyme, albumin, and immunoglobulin. Tear osmolarity and lactoferrin concentration measurements, in particular, appear to have a reliable positive predictive value among dry eye patients. At this time these techniques have more application in research than in clinical practice.

Evaluation of the ocular surface should also include inspection of the meibomian glands. The upper lid contains 30 to 40 glands, and the lower lid contains 20 to 30 glands. These glands are oriented perpendicularly to the lid margins, with their openings at the posterior edge of the margin, closest to the ocular surface. Normally, these orifices are visible as small depressions; when “expressed,” or gently manipulated, a small quantity of clear oily fluid should be liberated. In meibomian gland dysfunction (MGD) the openings are often “capped,” with the secretions taking on a more solidified state (Figure 24-8). MGD is covered in Chapter 23.

It is important to recognize that other diseases affecting the ocular surface may cause or exacerbate preexisting dry eye, often to a significant degree. Disorders such as ocular cicatricial pemphigoid, Stevens-Johnson syndrome, chemical burns, trachoma, and hypovitaminosis A all cause damage to the conjunctival goblet cells with a subsequent reduction or elimination of mucin production. These conditions can produce severe consequences for the ocular surface. A suggested strategy for evaluating patients with dry eye symptoms is provided in Box 24-3.

### Evaluation of the Lacrimal Gland

The Schirmer II test can offer a preliminary functional assessment of lacrimal gland function. Gross inspection of the superior-lateral portion of the orbit may reveal prolapse of the gland, which may or may not adversely



**Figure 24-8** Meibomian gland disease. Note “caps” or domes over meibomian orifices. These can be translucent, as in this case, or opaque, indicating a more severe solidification of meibomian secretions.

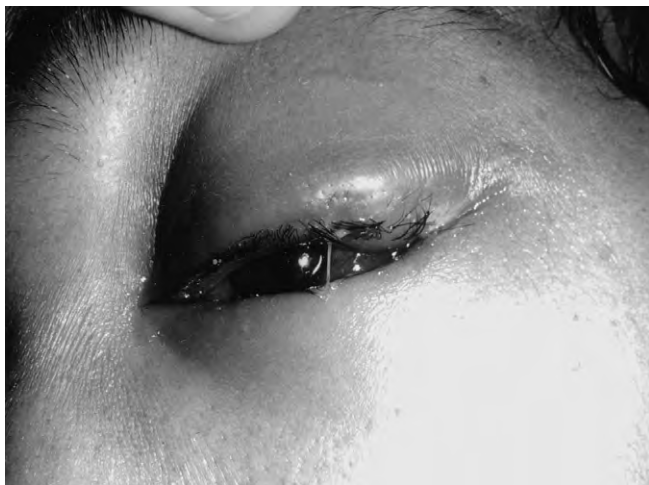**Box 24-3** Evaluation of the Dry Eye Patient

Complete case history (see Box 24-2)  
 Observe patient outside of slit lamp (blink rate, tearing, lid abnormalities, level of discomfort displayed, etc.)  
 Noninvasive TBUT (keratometer)  
 Slit-lamp examination: without dyes or anesthetic  
 Observe tear meniscus height  
 Observe quality of tear film  
 Evaluate integrity of ocular surface  
 Evaluate lids, lashes  
 Observe and palpate lacrimal gland region  
 Perform Schirmer test, if desired (note: instillation of topical anesthetic will interfere with interpretation of TBUT)  
 Slit-lamp examination: instill NaFl  
 Evaluate for ocular surface staining  
 Measure TBUT  
 Slit-lamp examination: Instill rose bengal or lissamine green  
 Evaluate for ocular surface staining, mucous strands, etc.

affect lacrimal gland function or disclose swelling and/or masses within the lacrimal gland. Enlargement of the lacrimal gland causes a characteristic “S”-shaped deformity of the upper eyelid, regardless of the underlying cause of the enlargement (Figure 24-9). Imaging studies may be required in cases involving lacrimal gland abnormalities.

**Evaluation of the Distribution System**

Because the eyelids represent the distribution system for lacrimal fluids, their neural, muscular, and structural



**Figure 24-9** Dacryoadenitis. Inflammation of the lacrimal gland is characterized by swelling of the superolateral eyelid and adnexal tissue and the diagnostic S curve of the upper eyelid. (Courtesy Michael A. Callahan, M.D.)

components must remain intact for proper maintenance of the tear film. The examination should note lid position, blink properties, and include a full evaluation of the lid margins and eyelashes.

**DISORDERS OF THE SECRETORY AND DISTRIBUTION SYSTEMS****Disorders of the Lacrimal Gland**

Dacryoadenitis is an inflammatory process of the lacrimal gland. Clinical characteristics include unilateral local tenderness, redness, eyelid swelling, conjunctival chemosis, discharge or suppuration, and enlarged preauricular nodes. Common causes include viral and bacterial infections, which generally produce an acute onset of symptoms, and systemic disorders such as sarcoidosis, tuberculosis, Graves' ophthalmopathy, Mikulicz's syndrome (dacryoadenitis combined with parotid gland swelling), “sclerosing pseudotumors,” or Wegener's granulomatosis, all of which more commonly present with a chronic disease course.

Persistent enlargement of the lacrimal gland requires differentiation between chronic dacryoadenitis and a lacrimal gland tumor (benign or malignant). Biopsy may be necessary when the episode does not follow the pattern for common causes of chronic dacryoadenitis. Neoplastic disease may present with or without pain or other inflammatory signs, so caution should be exercised in these cases. The presence of blood in the tears should heighten suspicion for lacrimal gland tumor formation.

**Management**

Acute dacryoadenitis usually responds rapidly to systemic corticosteroids. Patients with viral dacryoadenitis associated with acute epidemic parotitis (mumps), infectious mononucleosis, or herpes zoster infection should receive supportive therapy, such as rest, local application of ice, and use of oral analgesics, such as acetaminophen. Supportive therapy for mumps should be continued for its typical 2- to 4-week self-limiting course.

Bacterial dacryoadenitis should be treated with specific antibiotics after culture and sensitivity testing. Until results are obtained, many practitioners recommend an oral first-generation cephalosporin, such as cephalexin (Keflex, 500 mg four times a day for adults) or amoxicillin (250 to 500 mg three times a day for adults). This regimen should be followed for 7 days. Gonorrheal dacryoadenitis is treated with penicillin administered intramuscularly or with tetracycline taken orally.

**Disorders of the Ocular Surface**

Underlying ocular disease, such as allergic conjunctivitis, chronic infectious or inflammatory disease, or contact lens-related disorders, should be properly managed either before or as an adjunct to treatment of lacrimal

system disorders. Discussion of these diseases is covered elsewhere in Chapters 23, 25, 26, and 27.

### Disorders of the Distribution System

The seventh cranial nerve is responsible for eyelid closure during the blink reflex. Partial or complete disturbance of cranial nerve VII can interrupt these impulses, resulting in incomplete lid closure. Loss of muscular tone can also lead to ectropion, disruption of the “lacrimal pump,” and ultimately impaired tear drainage.

The eyelid margins normally are smooth and regular. Inflammatory conditions and trauma can distort the lid margins, potentially disrupting the flow of the tear film. An inward-turning lid margin, with or without misdirected lashes (trichiasis), can disrupt the tear film dynamics or irritate the ocular surface causing punctate epithelial keratopathy and reflex tearing. Blepharitis and MGD are frequently associated with ocular surface disease and tear film abnormalities; these disorders are covered in Chapter 23.

### Dry Eye Syndrome

Dry eye syndrome, or keratoconjunctivitis sicca (KCS), was defined in 1993 and 1994 by the National Eye Institute Industry Workshop on Clinical Trials in Dry Eyes as “a disorder of the tear film because of tear deficiency or excessive tear evaporation which causes damage to the interpalpebral ocular surface and is associated with symptoms of ocular discomfort.” Based on this definition, the same workshop yielded a classification system for dry eye that includes two broad categories: evaporative dysfunction and aqueous deficiency. Each category has subgroups. This system is probably the most widely accepted paradigm. However, since this classification system was adopted, a much broader understanding of the inflammatory basis of most forms of dry eye disease has been achieved; further, new associations with dry eye have been recognized, such as refractive surgery. Despite these limitations the strategy continues to provide a reasonable means for classifying the disease and establishing a treatment plan.

#### Evaporative Dysfunction

Evaporative dysfunction is caused by a reduction in the lipid layer of the tear film. Most often, this condition is caused by MGD or blepharitis. MGD is traditionally conceptualized as a triad of meibomianitis (stagnated secretions within the meibomian glands), meibomian seborrhea (overabundance of meibomian secretions into the tear film), and seborrheic blepharitis (oily debris visible on the eyelashes and ocular adnexal surfaces). Additionally, we have become increasingly aware of the influence of male hormones, or androgens, on the health of the meibomian glands. Clinically significant androgen deficiency, which naturally occurs in women of menopausal age and men in

their seventh decade and beyond, may lead to MGD, tear film instability, and ultimately in evaporative dry eye.

Several forms of blepharitis may cause evaporative dysfunction as well. Increased bacterial colonization of the eyelids causes breakdown of the lipids present on the surface of the tear film into free fatty acids; this in turn causes instability of the lipid layer.

Evaporative loss can also occur from abnormal ocular surface exposure, due to incomplete blink, nocturnal lagophthalmos, exophthalmos, proptosis, cranial nerve VII palsy, lid retraction, or other eyelid position and apposition disorders. Contact lenses may also contribute to an increased tear evaporation rate.

#### Management

To augment the dry eye therapies discussed below, MGD of the “standard” type is often managed using warm compresses, lid massage, and lid cleansing, with or without oral antiseborrheic agents (e.g., doxycycline 50 to 100 mg/day). In fact, warm compresses alone have been shown to have an immediate effect in thickening the lipid layer of the tear film. Blepharitis, both staphylococcal and seborrheic varieties, can be satisfactorily managed in many cases using lid hygiene with or without topical antibiotic ointment. Punctal occlusion, discussed below, serves to preserve the aqueous and the lipid layers of the tears. Androgen supplementation may prove to be a viable treatment for evaporative dry eye in the future.

#### Aqueous Deficiency

Aqueous-deficient dry eyes are subdivided into Sjögren’s syndrome (SS) and non-Sjögren’s syndrome (non-SS).

**Sjögren’s Syndrome.** SS is an autoimmune disorder characterized by the triad of dry eye, dry mouth (xerostomia), and a connective tissue disease. At least two components of the triad need to be present for the diagnosis of SS to be made. Primary SS, an exocrinopathy, is characterized by a lymphocytic infiltration and subsequent destruction of salivary and lacrimal glandular tissues. Symptoms include both dry eyes and dry mouth. Secondary SS includes dry eyes or xerostomia, plus a connective tissue disease, most frequently rheumatoid arthritis but also lupus, scleroderma, polyarteritis, or other related diseases. Unfortunately, there is no cure for SS at this time. Clinical trials using oral immunomodulatory agents have produced mixed results.

**Non-Sjögren’s Syndrome.** Non-SS KCS can be congenital or acquired. This category encompasses all other aqueous deficiency dry eye syndrome subtypes, including the “mucin-deficiency” dry eye, caused by damage to the goblet cells from disease, injury, or avitaminosis A.

Acquired non-SS KCS disorders are far more common than congenital forms. Although in the past it was believed that a significant difference between SS and non-SS KCS was the presence or absence of inflammation, it is

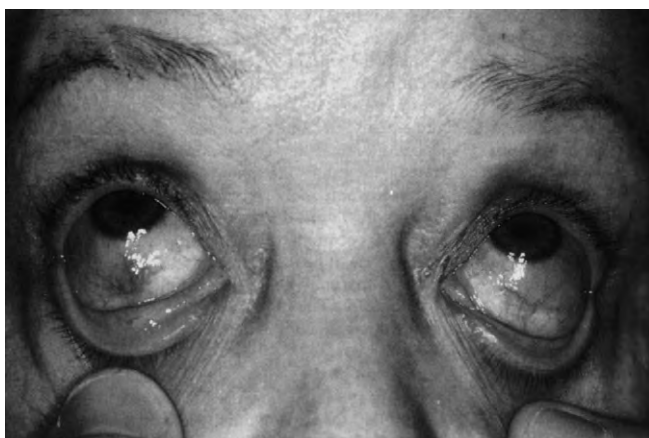now widely held that both SS and non-SS patients display inflammatory changes at the ocular surface and within the lacrimal gland, with associated alterations in the neural-sensory feedback communication system between these two structures. The main diagnostic distinction, it seems, is the presence of nonocular complaints resulting from the systemic autoimmune disease process in SS.

Lack of aqueous production at birth is a disorder termed congenital alacrima. This rare condition may result from hypoplasia of lacrimal gland tissue or congenital paralysis of cranial nerves. Another congenital and equally rare cause of aqueous deficiency is familial dysautonomia (Riley-Day syndrome), a disorder associated with a short life span.

### Diagnosis

In addition to the evaluation protocols discussed previously to diagnose dry eye, it is important to probe for symptoms related to connective tissue disease. Simply inspecting the patient's hands may yield a presumptive diagnosis of rheumatoid arthritis. A useful technique to screen for xerostomia is to listen for a "clicking" sound as the patient speaks, caused by inadequate saliva and poor oral lubrication. Alternatively, a tongue depressor may be placed on the patient's tongue; the depressor often adheres to the surface of the tongue in patients with xerostomia.

Because of the thinned aqueous in SS and non-SS, lipid-contaminated mucous strands collect in the fornices. Patients may also complain of increased "mattering" associated with the presence of dried mucus at the nasal canthus on arising. The irritation accompanying the disorder, combined with excess mucus, may prompt the patient to manually attempt to remove the strands. The resulting mechanical irritation can cause further irritation and tearing. This vicious cycle, termed the mucous fishing syndrome, is characterized by rose bengal staining of mucous strands and the affected bulbar conjunctiva and cornea (Figure 24-10).



**Figure 24-10** Mucous fishing syndrome. Rose bengal staining on the inferior bulbar conjunctiva instead of the expected interpalpebral location. (Courtesy Jimmy D. Bartlett, O.D.)

### Management

Before directly treating dry eye, any comorbid conditions should be treated to the best extent possible. As previously mentioned, any associated ocular disease, such as blepharitis, MGD, ocular allergy, infections, and contact lens-related problems, should be appropriately addressed. Local or systemic disease, such as thyroid orbitopathy and orbital inflammatory pseudotumor, can cause exophthalmos and proptosis and should be comanaged with the patient's primary care physician or appropriate specialist. Neuroimaging is often required to exclude orbital tumors in these cases.

Maximizing environmental conditions can have a significant impact in ameliorating symptoms. Some patients with an incomplete blink can be trained to make a full blink excursion. Redirecting air vents and fans, particularly ceiling fans, often brings symptoms to a manageable level. The use of humidifiers, particularly in dry climates, can be beneficial. Reminding patients to optimize their individual situations (e.g., drive with the car windows up, wear protective eyewear in dusty environments) is an important component of patient management.

**Tear Supplementation.** Tear substitutes, or artificial tears, have traditionally been the mainstay of treatment for dry eye syndrome. Artificial tears are often classified as low, medium, or high viscosity. Some artificial tears are supplied in single-dose units without preservation; other formulations offer a "disappearing" preservative that is neutralized before contacting the ocular surface. The elimination of potential effects from preservatives is desirable, particularly in highly sensitive patients. With a better understanding of the dynamics of the lipid layer of the tear film, artificial tear preparations have been developed that more closely approximate the bilayer of natural human tears.

For overnight use artificial tears are available in gel or ointment formulations. These products are much thicker than the high viscosity artificial tears and offer a prolonged ocular surface contact time. These formulations have the disadvantage of transiently blurring vision on instillation; patients should be informed of this effect and be advised to perform any visual tasks before instilling the gel or ointment. Gel formulations have the benefit of being water soluble, so removing any residue off the eyelids is more easily accomplished.

Tear supplements continue to be a rapidly evolving market. As many as 50 different over-the-counter artificial tears are available. These formulations are available either in unit-dose vials or in multidose bottle delivery systems and vary by consistency, active ingredients, and preservatives. Table 24-3 lists many of these preparations.

**Tear Preservation.** Occlusion of the lacrimal puncta, either temporarily or permanently, is one method of preserving tears that are available. Lacrimal plugs are available in diagnostic (dissolvable collagen) or reversible

**Table 24-3**

Examples of Tear Supplements

Brand Name	Ingredients	Features
Refresh products (Allergan)	Carboxymethylcellulose; preserved products contain Purite, which breaks down into sodium chloride and water after contact with the eye	Offers preservative-free formulation (Refresh Plus) as well as special formulation for use with contact lenses; Refresh Tears is low viscosity; Celluvisc is high viscosity; Liquigel formulation is even thicker for longer lasting lubrication; Refresh PM is an ointment formulated for overnight use.
Genteal products (Novartis)	Hydroxypropyl methylcellulose	GenAqua is a disappearing preservative (sodium perborate); available in 0.2% drops (mild), 0.3% drops (moderate), and 0.3% gel (severe) formulations as well as 0.3% single-use preservative-free vials; contacts may be inserted 15 minutes after drop instillation.
Tears Naturale products (Alcon)	0.1% Dextran 70 and hydroxypropyl methylcellulose 0.3% 0.2% glycerin added in "Forte" formulation; preserved products contain Polyquad	Available as Tears Naturale Free (without preservative), Tears Naturale Polyquad II (low viscosity), Tears Naturale Forte (medium viscosity), and Tears Naturale PM (ointment).
Bion Tears (Alcon)	0.3% Hydroxypropyl methylcellulose with 0.1% dextran	Moderate viscosity; preservative-free single-use vials; contains zinc and bicarbonate to more closely match natural tears.
TheraTears (Advanced Vision Research)	0.25% Sodium carboxymethylcellulose	Low viscosity; formulated to match electrolytes found in human tears. Hypotonic. Drops and liquigel available in preservative-free vials; drops also available with disappearing preservative in 0.5 ml bottle size.
Systane (Alcon)	Polyethylene glycol 400, propylene glycol, HP-Guar	Balances pH; forms a lubricating gel on contact with ocular surface and reported to reduce ocular inflammatory changes. Longer lasting formulation as compared with traditional formulations and can be dosed every 8 hours.
Soothe (Bausch & Lomb)	Restoryl (highly refined mineral oil products)	Restoryl augments lipid layer; milky white in appearance; patients should wait 10 minutes after drop instillation before inserting contact lenses. Dosed every 8 hours (more often if desired). Patient should "blink forcibly three times" after instillation to spread the drop.
Refresh Endura (Allergan)		Lipids within formulation cause drop to appear slightly milky; formulated to augment all three layers of tear film. Dosed two to four times a day.

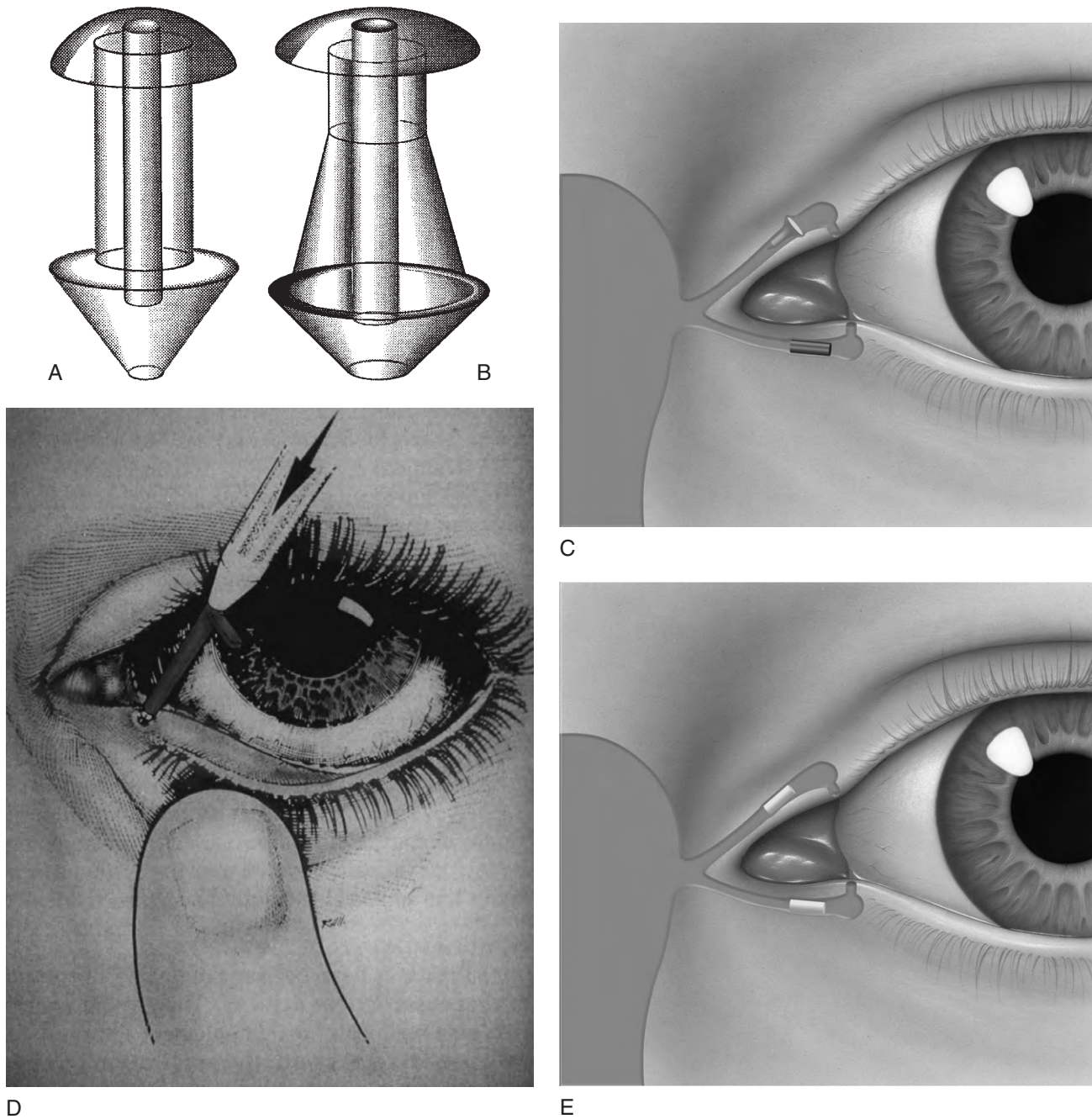
(silicone) modalities (Figure 24-11). The collagen implants are useful as a trial for more permanent punctal occlusion. These plugs are inserted into the lacrimal puncta (either the lower puncta or both the upper and the lower puncta) and remain in place until they dissolve, which typically takes between 3 and 7 days but can be formulated to last approximately 1 month. If the patient experiences an improvement in symptoms during this time, with a subsequent exacerbation of symptoms after the implants dissolve and without experiencing epiphora during the trial period, it is fairly safe to assume that permanent (yet reversible) punctal occlusion is a reasonable option for that patient. Ocular surface

inflammation has been shown to improve with the use of punctal occlusion. Adverse effects of punctal plugs include potential infection within the canaliculus (canalculitis) and spontaneous punctal plug extrusion (loss). Several varieties of reversible punctal plug devices are available. A summary of these devices is presented in Table 24-4.

Some practitioners prefer to occlude the puncta using laser or cautery. Although these methods do not present the same risk of infection, they are much more likely to result in spontaneous reopening of the puncta.

A more dramatic treatment to preserve the tears is lateral tarsorrhaphy, which is a joining of the lateral aspects





**Figure 24-11** Silicone punctal plugs and intracanalicular insert. (A) Original Freeman punctal plug. (B) Tapered-shaft punctal plug (Eagle Vision). (C) Schematic illustration of lacrimal plugs: Upper canaliculus with silicone plug, lower canaliculus with dissolvable medium-term plug. (D) Schematic insertion of punctal plug. (E) Schematic illustration of collagen lacrimal plugs. (D Courtesy Eagle Vision, Inc.; C and E courtesy Lacrimedics, Inc.)

of the upper and lower eyelids. This procedure can be done with laser or by suturing and results in a smaller ocular surface area for the tears to cover. This treatment is considered a last resort, after other modalities have failed.

**Tear Augmentation.** Oral pilocarpine (Salagen) is available in 5- and 7.5-mg tablets taken three or four times daily to treat the dry mouth associated with SS. This drug

has the beneficial side effect of increasing lacrimation, making it especially useful for SS patients.

Flax seed oil has recently received much attention for its health benefits, primarily attributed to the high omega-3 fatty acid content. Omega-3 fatty acids have been shown to dampen the effects of omega-6 fatty acids through competitive inhibition; omega-6 fatty acids are linked to increased inflammation. It is believed that the overall effect of



**Table 24-4**  
Devices for Punctal Occlusion

Manufacturer	Name	Type	Parameters	Unique Features
SmartPlug	Medennium	Long term/ reversible	“One size fits all” – before insertion, is approximately 9 mm at room temperature; once placed or exposed to body temperature, shrinks in length and expands in width, forming a soft gel-like plug	Made of a thermosensitive hydrophobic acrylic polymer; conforms to punctum; has no protruding cap, which prevents “rubbing out” of plug
Form Fit	Oasis	Long term/ reversible	“One size fits all”	Made of a hydrogel that forms a gelatinous material when in contact with tears; gel fills vertical portion of canaliculus
Various (Lacrimedics, Oasis, Odyssey, Alcon, Eagle Vision)	Nondissolvable punctal plugs (usually silicone)	Permanent/ reversible	Available in 0.4- to 0.8-mm diameter; may be “preloaded” into insertion device or may be inserted with forceps	These plugs have a “cap” that protrudes from the punctum, which is uncomfortable and/or cosmetically displeasing to some patients
	Dissolvable punctal plugs	Short term (2-7 days) or medium term (up to 6 months)	Available in multiple sizes	Short-term plugs are often used diagnostically before longer lasting plug insertion

omega-3 fatty acids is in reducing inflammatory events, particularly involving the ocular surface and specifically the meibomian glands. Omega-3 fatty acids are also naturally found in salmon, mackerel, herring, sardines, and walnuts.

**Mucolytic Agents.** Acetylcysteine, which is frequently used as a bronchial mucolytic agent in patients with cystic fibrosis, can be used topically in a weakened concentration for ophthalmic use. It is malodorous and may sting on instillation; however, this drug is fairly effective in disrupting mucous strands that are often present in patients with aqueous deficiency dry eye. It is not commercially available in an ophthalmic formulation; it must be compounded by a pharmacist.

**Immunomodulatory Agents.** For many years some practitioners treated severe dry eye with topical steroids; although anecdotal evidence was plentiful as to the benefit of this therapeutic strategy, it was not universally accepted because of a lack of understanding of the inflammatory nature of dry eye disease. Now, steroids and nonsteroidal anti-inflammatory agents are much more frequently used in the treatment of dry eye, particularly at initial diagnosis.

Cyclosporine A 0.05% (Restasis) is another immunomodulatory agent that has an excellent safety profile, even when used over a period of months or years. This treatment has been in widespread use in veterinary care since the 1970s. It has been shown to significantly improve the ocular signs and symptoms of dry eye disease, with a very

low incidence of adverse effects. This drug does not provide full therapeutic benefit when initially instilled; patients may have to wait up to a full month, or sometimes even longer, before noticing the full benefit. It is strongly recommended that during the first month of use an additional treatment modality be prescribed, such as a mild steroid plus copious artificial tears.

## EVALUATION AND MANAGEMENT OF THE LACRIMAL DRAINAGE SYSTEM

### Epiphora

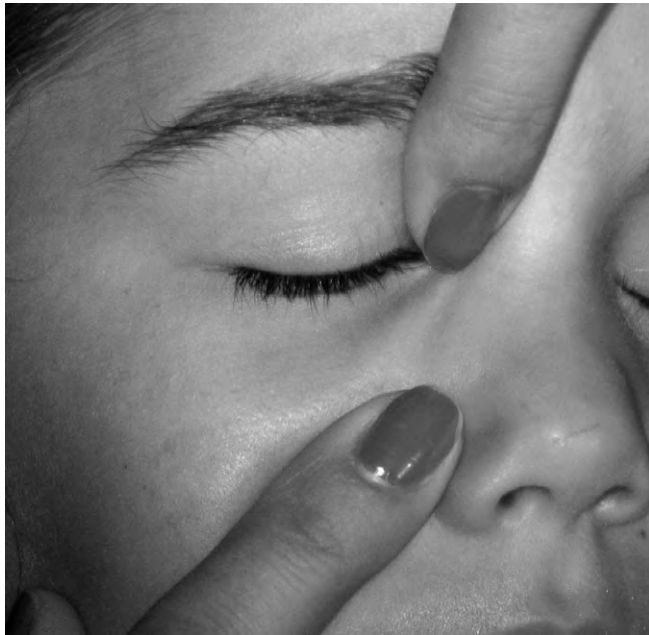Epiphora (spilling of tears over the lid margin) can be congenital or acquired and is one of the most common symptoms in lacrimal system disorders. If a patient complains of epiphora, dry eye syndrome should be excluded before a formal evaluation of the lacrimal drainage system, including Schirmer testing, because dry eyes can prompt reflex tearing, and a true hypersecretion disorder, although rare, also results in epiphora. If the lacrimal secretory system is intact, then testing of the drainage system should be pursued.

Congenital epiphora usually results from a failure of the valve of Hasner to completely open by the time of birth. This defect is often termed congenital NLD obstruction and may be present in up to 6% of infants. Infants with NLD obstruction display epiphora, and many may have a concurrent secondary dacryocystitis (see below) as a result of the stagnated tears in the lacrimal sac.

In these cases it may be difficult to distinguish NLD obstruction from neonatal conjunctivitis. A large percentage of infants have a spontaneous resolution of incomplete canalization of the lacrimal drainage system within the first weeks to months of life. Others may require intervention. Typically, the hydrostatic technique, or “massage,” is attempted before more invasive procedures. This massage technique relies on the hydrostatic pressure of the tears present within the drainage system to help rupture Hasner’s membrane.

It is important to understand that the volume of tears within the lacrimal sac and NLD is quite small; to maximize the effect of the massage technique it is imperative that both the upper and lower puncta be gently held closed with one finger while the other hand is used to gently trace the area of the lacrimal sac and NLD in a downward motion (Figure 24-12). If the puncta are not occluded during this technique, any external pressure applied to the drainage apparatus is released in the path of least resistance. Because in these cases there is a known obstruction distally, the effects of the pressure would be directed proximally or back in the direction of the puncta.

When properly performed this method can be very effective in rupturing Hasner’s membrane. In cases resistant to the massage technique, the clinician may attempt forceful lacrimal irrigation, probing with a flexible lacrimal probe, balloon catheter dilation, or silicone intubation. These procedures, especially the latter two, are done under general anesthesia and are typically considered only after the child reaches at least 3 to 4 months of



**Figure 24-12** Hydrostatic massage technique for congenital nasolacrimal duct obstruction. The puncta are held gently closed with one finger while the area over the lacrimal drainage apparatus is gently massaged downward.


age; many practitioners delay surgery until 21 months due to the high likelihood of spontaneous resolution within this period.

In adults, complaints of “excessive tearing” or watering should prompt the clinician to note the blink rate and amplitude, without the patient’s knowledge that he or she is being observed for these characteristics. For the tear pump to function effectively, a full blink excursion must be made at an appropriate rate. As mentioned previously, neither the upper nor the lower puncta should be visible without lid manipulation; if the puncta are visible, it is likely that the epiphora is caused, at least in part, by poor punctal positioning. When the lids are moved so that the puncta can be evaluated, the puncta should be patent (open) and free of debris and purulent material. The lid margins should be even and regular, with no obstructions to the normal flow of tears along the tear lake. Next, gentle digital pressure should be applied at the area of the canaliculi and lacrimal sac. The presence of mucopurulent material from the puncta is indicative of canaliculitis and/or dacrycystitis, which is discussed in the next section.


If no cause for epiphora is evident, an evaluation of the remainder of the lacrimal drainage system should be performed. This sequence of analysis is collectively known as Jones testing. To perform these tests, the minimum equipment required is a lacrimal punctal dilator (Figure 24-13) and a lacrimal irrigation apparatus, consisting of a 2- to 5-ml syringe fitted with a 23-gauge cannula (Figure 24-14). Depending on the patient’s needs, a fine Bowman’s probe and a nasal speculum may also be needed (Figure 24-15).

The Jones No. 1 and Jones No. 2 test is an evaluation of the ability of the tears to pass through the lacrimal drainage apparatus under normal physiologic conditions. It is conducted as follows:

1. NaFl is instilled into the eye (NaFl strips may be used, but many practitioners recommend that one drop of 2% liquid NaFl be used instead).



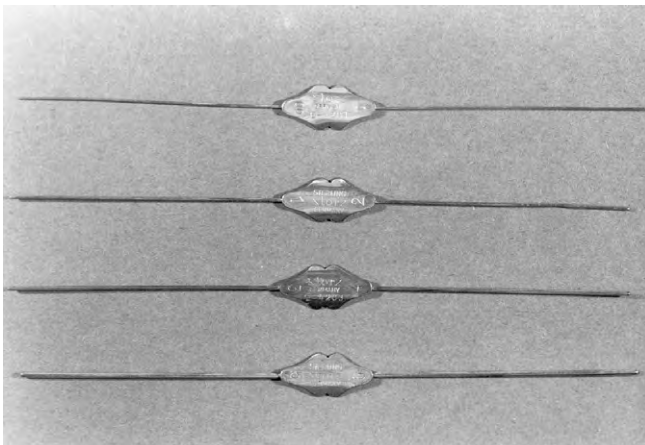
**Figure 24-13** Lacrimal dilators (Storz, Inc., St. Louis, MO, USA). Top dilator is the Muldoon instrument; note the medium tip and rapid expansion. The next two are different sizes of the Wilder dilator. The bottom dilator is the Reudemann. It has a very fine tip and narrow taper, rendering it perhaps the most useful of the group.



**Figure 24-14** Lacrimal cannulae. (Top) The 23-gauge West cannula. The shaft is straight and approximately 25 mm long. The tip is blunt, with a needle hole in the side. (Bottom) Reinforced 23-gauge cannula and syringe.

2. The patient is instructed to sit quietly without forcefully blinking.
3. After 5 minutes the clinician notes the amount of NaFl dye that remains in and around the ocular surface and adnexa.

If there is a significant amount of dye still present, it is assumed that the lacrimal drainage system is not properly functioning. If very little or no fluorescein is present in and around the eye, it may be assumed that the fluorescein drained with the tears in the normal fashion (i.e., through the lacrimal drainage system). To confirm this finding, the patient can be asked to open his or her mouth and the clinician can look in the back of the throat for fluorescein. The use of a Burton lamp or other blue filter light source may enhance visibility of the fluorescein, but it is not mandatory. Alternatively, the patient can clear his or her nose onto a white tissue by



**Figure 24-15** Bowman probes.

holding the opposite nasal opening closed and forcefully blowing onto the tissue. In either method the presence of fluorescein confirms a patent lacrimal drainage system. The absence of fluorescein with either of these two tests prompts further evaluation.

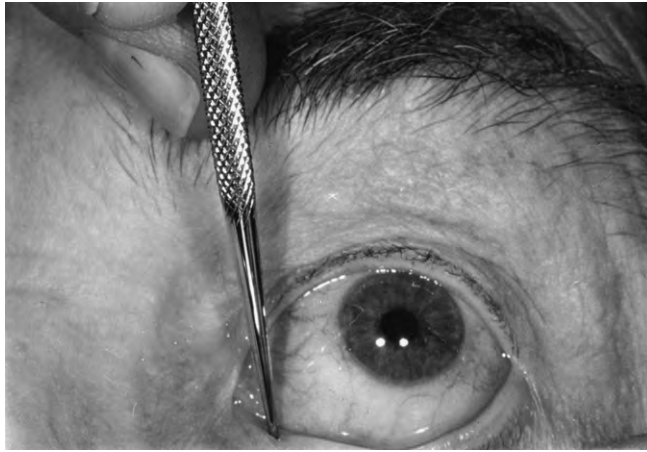
Many practitioners at this stage proceed directly to Jones II testing, with the assumption that there is an obstruction in the lacrimal drainage system beyond (i.e., more distal to) the punctal opening. However, before attempting Jones II, some practitioners require further efforts to demonstrate evidence of fluorescein within the nasolacrimal drainage system. To accomplish this, the patient may be asked to forcefully gather mucus from the nose and nasopharynx and then expel the mucus onto a white tissue. If no fluorescein is seen, the practitioner can then anesthetize the area under the inferior meatus with topical Xylocaine, and then swab this area using a thin wire probe tipped with cotton or calcium alginate. If negative results are found with these two tests, Jones II testing is performed.

The procedure for the Jones II test is as follows:

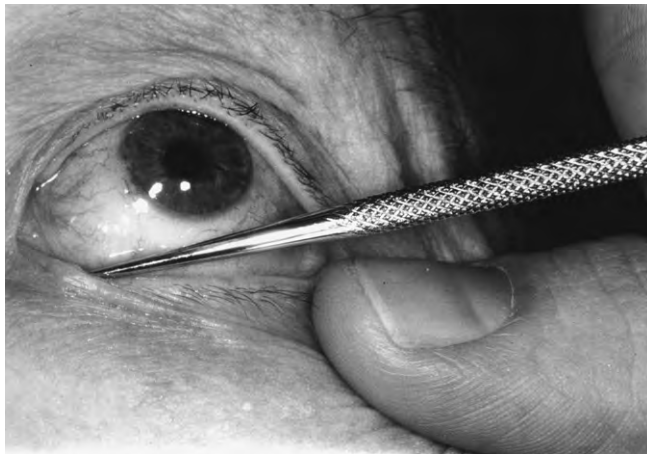
1. Residual fluorescein is rinsed from the eye. The punctal area is anesthetized using a cotton swab soaked in a topical anesthetic, such as proparacaine. The swab is left in place for 30 to 60 seconds, during which time the patient remains sitting upright.
2. The syringe of the lacrimal irrigation apparatus is filled with sterile saline.
3. The lower punctum is dilated using a punctal dilator. The insertion of the dilator or probe is facilitated by pulling the lid slightly down and away from the nose and twisting the probe clockwise and counterclockwise. Once past the punctal opening, the probe is inserted approximately 2 mm in a vertical direction, and then it is turned nasally for a few more millimeters until whitening or “blanching” is seen at the punctal opening (Figure 24-16).
4. The dilator is then removed and the lacrimal irrigation apparatus is inserted, again respecting the anatomic configuration of the canaliculus.
5. The patient is asked to place his or head forward, with chin on or near chest, with a collection basin (white in color or lined with a white tissue) underneath the nose and mouth (Figure 24-17).
6. The clinician then attempts to inject a small amount (1 to 2 ml) of saline into the punctum by depressing the plunger on the syringe.

There are three possible outcomes to Jones No. 1 and Jones No. 2 testing:

1. No fluid exits the system; a complete obstruction exists within the drainage apparatus. Usually, it is impossible to inject any fluid into the system at the time of testing due to the complete blockage (i.e., no fluid goes in, no fluid comes out).
2. Fluid is injected into the lower punctum but regurgitates through the upper punctum. The fluid may be mixed with mucopurulent material and/or



A




B

**Figure 24-16** Procedure for lower punctal dilation. (A) The dilator is inserted vertically approximately 2 mm. (B) It is then brought near the horizontal plane of the lower eyelid. The lower lid can be gently pulled laterally to straighten the canaliculus. (Courtesy Richard J. Clompus, O.D.)

blood, indicating infection or a possible neoplasm, respectively.

- Fluorescein-stained fluid exits the nose; this indicates a partial distal (farther away from the punctum) obstruction. Occasionally, the obstruction is composed of a bolus of mucopurulent material that is dislodged by the force of the irrigation. In these cases the irrigation procedure itself is therapeutic, and often the epiphora disappears immediately. Other cases may require surgical intervention to maintain the patency of the lower lacrimal drainage system (dacryocystorhinostomy).

If clear fluid is expelled from the nose without any fluorescein present, it is likely that rather than a true obstruction of the lacrimal drainage system a punctal stenosis or ectropion is the culprit. This diagnosis can be assumed by the fact that no fluorescein ever entered the drainage system during the Jones I test, in contrast to the situation where fluorescein enters the system but gets lodged deep within the drainage apparatus (scenario 3 above).



**Figure 24-17** Secondary dye test (Jones No. 2 test). Lacrimal lavage. Patient is seated and inclined forward for irrigation. Note basin to catch effluent. (Reprinted with permission from Semes L, Melore GG. Dilation and diagnostic irrigation of the lacrimal drainage system. *J Am Optom Assoc* 1986; 57:518-525.)

## DIAGNOSIS AND MANAGEMENT OF LACRIMAL DRAINAGE DISORDERS

### Punctal Disorders

#### Etiology

Occlusion of the lacrimal puncta is called atresia when congenital and stenosis when it is acquired. Each produces true epiphora, although congenital cases tend to produce fewer clinical signs and symptoms than do acquired cases.

Stenosis of the punctum can be secondary to allergy, infection, trauma, or simply the result of aging-associated loss of collagen and elastin tone. The latter is the most frequent cause of acquired epiphora.

Punctal ectropion is the result of eyelid ectropion. Causes include mechanical (e.g., excess weight on the lid as the result of a lid growth), cicatricial (resulting from scar tissue formation), congenital, age-related, and allergic.

### Management

In some cases of punctal occlusion, the dilation and irrigation procedures are at least temporarily therapeutic; redilation of the lacrimal punctum may need to be performed on a semiregular basis to ensure continued comfort. Often, patients with mild degrees of punctal ectropion can be satisfactorily managed by instructing the patient to manually reposition the eyelid at regular intervals throughout the day.

If these methods are ineffective, surgery may be required. Procedures to repair the punctum are referred to as punctoplasty.

If the punctum is involuted such that it cannot be identified or opened, dacryocystorhinostomy may be required. This surgical procedure shunts the tears around lacrimal drainage obstructions into the nasal cavity.

## Canalicular Disorders

### Etiology

Canalculitis, or infection and inflammation within the canaliculus, is a relatively rare disorder. Obstruction of the canaliculi may also result from surgery, trauma, and neoplastic disorders.

### Diagnosis

Typical patient complaints with canalculitis include a smoldering usually unilateral red eye that has been resistant to antibiotic therapy. Epiphora may or may not be a primary symptom. An important clinical sign in the diagnosis of canalicular obstruction has been termed the wrinkle sign. When a “soft stop” is encountered during lacrimal probing or irrigation, the clinician can observe compression of the medial canthal skin (wrinkling) in the presence of canalicular obstruction. This is in contrast to the presentation in normal patients, where the visualization of smooth skin and unobstructed advancement of the instrument to the lacrimal bone are present (i.e., “hard stop”), indicating a patent proximal drainage system. The “soft stop” can be caused by bacterial colonization or more frequently by stones, or dacryoliths, forming within the canaliculus.

Common causative organisms in adults with canalculitis include *Staphylococcus aureus* and *Actinomyces* species. Primary herpetic infections (herpes simplex, varicella, and vaccinia) have a higher prevalence among patients younger than age 20 years and often present with cutaneous manifestations of the infectious disease. Chronic allergies may also be associated with canalicular obstruction. Occasionally, patients may suffer from canalicular obstruction as a result of topical antimetabolite treatment such as 5-fluorouracil or mitomycin C.

### Management

Some mild cases of canalicular obstruction can be temporarily or permanently “cured” with the dilation and irrigation procedure. However, this is the exception rather than the rule.

Because of the antibiotic resistance of many subspecies of *Staphylococcus*, it is recommended that culture and sensitivity studies of any purulent material be undertaken to maximize the chance for successful treatment of canalculitis. Antibiosis should be directed at the specific causative organism isolated. Systemic penicillin is usually recommended in treating actinomyces, in addition to topical penicillin.

Success in eradicating the infection also depends on removal of concretions and purulent material from the involved canaliculi. *Actinomyces* species are especially problematic in this regard, often forming casts within the canaliculus. These particles make it exceedingly difficult to treat cases of bacterial canalculitis with topical medications alone; in general, these dacryoliths must be removed before successful antibiotic treatment. In a few cases manual expression of the stones or casts is possible; in others, canaliculotomy is required. In very resistant cases dacryocystorhinostomy may be necessary.

Herpetic canalculitis should be treated using standard treatment protocols, including oral antiviral agents. Periodic dilation and irrigation of the lacrimal drainage system may enhance the chance for successful recanalization, though there is a risk of scar tissue formation with repeated dilation and irrigation procedures.

Relief of allergic canalicular obstruction may be managed with topical medications, but these cases, as well as drug-induced canalicular obstruction, may require dacryocystorhinostomy procedures.

## Acquired Dacryocystitis

### Etiology

When a patient older than 1 year has swelling over the lacrimal sac, the swelling most often results from acquired dacryocystitis. Culture studies usually identify *Staphylococcus aureus*, *Staphylococcus epidermidis*, and *Pseudomonas* species as the offending organisms in adults. Cases of methicillin-resistant *S. aureus* have been detected, along with a trend toward a relatively higher prevalence of gram-negative organisms as compared with gram-positive bacteria, with *Haemophilus influenzae* a potential pathogen in children. As with canalculitis, culture studies of any purulent material present are highly recommended, because many other uncommon pathogens have been reported in this disorder. It should be noted, however, that results from culture studies may take several days and in some cases yield no growth.

Faced with a chronic dacryocystitis, the clinician needs to be aware of masquerade syndromes. Epithelial carcinomas and malignant lymphoma have been reported from histologic and immunohistochemical analysis, respectively, of biopsies of the lacrimal sac taken at dacryocystorhinostomy. Rhabdomyosarcoma has also been identified. Displaced silicone plugs have been found as potential vectors for infection not only in the lacrimal sac but also in other areas of the lacrimal drainage route.

## Diagnosis

The swelling characteristic of dacryocystitis is limited in its upward extent by the medial canthal tendon. Mucocoeles and solid tumor masses may extend above the tendon and masquerade as dacryocystitis. Pain and hyperemia are consistent features of infectious dacryocystitis, whereas mucocoeles and tumors are often painless.

## Management

Daily massage over the area of the lacrimal sac, with or without the application of hot compresses, is critical to empty the infected contents of the sac. If the patient is afebrile, broad-spectrum antibiotics, such as Augmentin or a second-generation cephalosporin, should be prescribed for 10 to 14 days. Antimicrobial therapy should be directed at the causative organism identified in culture studies, if available. Some practitioners recommend daily irrigation of the lacrimal drainage apparatus with topical antibiotics, because this has been reported to help focus the drug in the area of highest bacterial colonization. After resolution of the infection, diagnostic dilation and irrigation should be carried out to determine the necessity for surgical repair.

## SELECTED BIBLIOGRAPHY

- Albietz J, Bruce A. The conjunctival epithelium in dry eye subtypes: effect of preserved and non-preserved topical treatments. *Curr Eye Res* 2001;22:8-18.
- Albietz J, Sanfilippo P, Troutbeck R, et al. Management of filamentary keratitis associated with aqueous-deficient. *Optom Vis Sci* 2003;80:420-430.
- Altan-Yaycioglu R, Gencoglu E, Akova Y, et al. Silicone versus collagen plugs for treating dry eye: results of a prospective randomized trial including lacrimal scintigraphy. *Am J Ophthalmol* 2005;140:88-93.
- Barber L, Pflugfelder S, Tauber J, et al. Phase III safety evaluation of cyclosporin 0.1% ophthalmic emulsion administered twice daily to dry eye disease patients for up to 3 years. *Ophthalmology* 2005;112:1790-1794.
- Billing K, Karagiannis A, Selva D. Punctal-canalicular stenosis associated with mitomycin-C for corneal epithelial dysplasia. *Am J Ophthalmol* 2003;136:746-747.
- Bourcier T, Acosta M, Borderie V, et al. Decreased corneal sensitivity in patients with dry eye. *Invest Ophthalmol Vis Sci* 2005;46:2341-2345.
- Briscoe D, Rubowitz A, Assia E. Changing bacterial isolates and antibiotic sensitivities of purulent dacryocystitis. *Orbit* 2005; 24:95-98.
- Bron, A, Evans V, Smith, J. Grading of corneal and conjunctival staining in the context of other dry eye tests. *Cornea* 2003; 22:640-650.
- Bron A, Tiffany J, Gouveia S. Functional aspects of the tear film lipid layer. *Exp Eye Res* 2004;78:347-360.
- Craig J, Tomlinson A. Importance of the lipid layer in human tear film stability and evaporation. *Optom Vis Sci*. 1997; 74:8-13.
- Darsun D, Ertan A, Bilezikci B, et al. Ocular surface changes in keratoconjunctivitis sicca with silicone punctum plug occlusion. *Curr Eye Res* 2003;26:263-269.
- Di Pascuale M, Goto E, Tseng S. Sequential changes of lipid tear film after the instillation of a single drop of a new emulsion eye drop in dry eye patients. *Ophthalmology* 2004;111:783-791.
- Dogru M, Stern M, Smith J, et al. Changing trends in the definition and diagnosis of dry eyes. *Am J Ophthalmol* 2005; 140(3):507-508.
- Erdol H, Akyol N, Imamogly H, et al. Long-term follow-up of external dacryocystorhinostomy and the factors affecting its success. *Orbit* 2005;24:99-102.
- Esmaeli B, Harvey J, Hewlett B. Immunohistochemical evidence for estrogen receptors in meibomian glands. *Ophthalmology* 2000;107:180-184.
- Fox P, Datiles M, Atkinson J, et al. Prednisone and piroxicam for treatment of primary Sjögren's syndrome. *Clin Exp Rheumatol* 1993;11:149-156.
- Gipson I, Argueso P. Role of mucins in the function of the corneal and conjunctival epithelia. *Int Rev Cytol* 2003;231:1-49.
- Goto E, Tseng S. Kinetic analysis of tear interference images in aqueous tear deficiency dry eye before and after punctal occlusion. *Invest Ophthalmol Vis Sci* 2003; 44:1987-1905.
- Haller-Schober E, Schwantzer G, Berghold A, et al. Evaluating an impression cytology grading system (IC Score) in patients with dry eye syndrome. *Eye* 2006 Aug;20(8):927-933.
- Hartstein I, Khwarg S, Przydryga J. An open-label evaluation of HP-Guar gellable lubricant eyedrops for the improvement of dry eye signs and symptoms in a moderate dry eye adult population. *Curr Med Res Opin* 2005;21:255-260.
- Ishida R, Kojima T, Dogru M, et al. The application of a new continuous functional visual acuity measurement system in dry eye syndromes. *Am J Ophthalmol* 2005;139:253-258.
- Isreb M, Greiner J, Korb D, et al. Correlation of lipid layer thickness measurements with fluorescein tear film break-up time and Schirmer's test. *Eye* 2003;17:79-83.
- Jones M, Please C, McElwain D, et al. Dynamics of tear film deposition and draining. *Math Med Biol* 2005;22:265-288.
- Korb D, Baron D, Herman J, et al. Tear film lipid layer thickness as a function of blinking. *Cornea* 1994;13:354-359.
- Korb D, Scaffidi R, Greiner J, et al. The effect of two novel lubricant eye drops on tear film lipid layer thickness in subjects with dry eye symptoms. *Optom Vis Sci* 2005;82:594-601.
- Lee J, Flanagan J. Complications associated with silicone intracanalicular plugs. *Ophthalm Plast Reconstr Surg* 2001; 17:465-469.
- Mainstone J, Bruce A, Golding T. Tear meniscus measurement in the diagnosis of dry eye. *Curr Eye Res* 1996;15:653-661.
- Nichols K, Mitchell G, Zadnik K. The repeatability of clinical measurements of dry eye. *Cornea* 2004;23:272-285.
- Nichols K, Nichols J, Zadnik K. Frequency of dry eye diagnostic test procedures used in various modes of ophthalmic practice. *Cornea* 2000;19:477-482.
- Olson M, Korb D, Greiner J. Increase in tear film lipid layer thickness following treatment with warm compresses in patients with meibomian gland dysfunction. *Eye Contact Lens* 2003; 29:96-99.
- Park A, Morganstern K, Kahwash S, et al. Pediatric canaliculitis and stone formation. *Ophthalm Plast Reconstr Surg* 2004; 20:243-246.
- Perry H, Donnenfeld E. Dry eye diagnosis and management in 2004. *Curr Opin Ophthalmol* 2004;15:299-304.
- Pijpe J, van Imhoff G, Spijkervet F, et al. Rituximad treatment in patients with primary Sjögren's syndrome: an open label phase II study. *Arthritis Rheum* 2005;52:2740-2750.

- Ridder W 3rd, Tomlinson A, Paugh J. Effect of artificial tears on visual performance in subjects with dry eye. *Optom Vis Sci* 2005;82:835-842.
- Saleh T, McDermott B, Bates A, et al. Phenol red thread test vs Schirmer's test: a comparative study. *Eye* 2005; ePub ahead of print.
- Sall K, Stevenson O, Mundorf T, et al. Two multicenter, randomized studies of the efficacy and safety of cyclosporine ophthalmic emulsion in moderate to severe dry eye disease. CsA Phase 3 Study Group. *Ophthalmology* 2000;107:631-639.
- Schirra F, Suzuki T, Richards S, et al. Androgen control of gene expression in the mouse meibomian gland. *Invest Ophthalmol Vis Sci* 2005;46:3666-3675.
- Stern M, Beuerman R, Fox R, et al. The pathology of dry eye: the interaction between the ocular surface and lacrimal glands. *Cornea* 1998;17:584-589.
- Stern M, Gao J, Siemasko K, et al. The role of the lacrimal functional unit in the pathophysiology of dry eye. *Exp Eye Res* 2004;78:409-416.
- Stevenson D, Tauber J, Reis B. Efficacy and safety of cyclosporin A ophthalmic emulsion in the treatment of moderate-to-severe dry eye disease: a dose-ranging, randomized trial. The Cyclosporin A Phase 2 Study Group. *Ophthalmology* 2000; 107:967-974.
- Sullivan D, Belanger A, Cermak J, et al. Are women with Sjögren's syndrome androgen-deficient? *J Rheumatol* 2003;30:2413-2419.
- Sullivan D, Sullivan B, Evans J, et al. Androgen deficiency, meibomian gland dysfunction, and evaporative dry eye. *Ann N Y Acad Sci* 2002;966:211-222.
- Sullivan D, Yamagami H, Liu M, et al. Sex steroids, the meibomian gland and evaporative dry eye. *Adv Exp Med Biol* 2002; 506(Pt A):389-399.
- Sun S, Liang Q, Luo S, et al. Microbiological analysis of chronic dacryocystitis. *Ophthalmic Physiol Opt* 2005; 25:261-263.
- Varma D, Chang B, Msaad S. A case series on chronic canaliculitis. *Orbit* 2005;24:11-14.
- Versura P, Campos E. Menopause and dry eye. A possible relationship. *Gynecol Endocrinol* 2005;20:289-298.
- Wang J, Fukuda M, Shimomura Y. Diagnosis of dry eye. *Semin Ophthalmol* 2005;20:53-62.
- Yokoi N, Komuro A, Maruyama K, et al. New instruments for dry eye diagnosis. *Semin Ophthalmol* 2005;20:63-70.
- Zhu H, Chauhan A. A mathematical model for tear drainage through the canaliculi. *Curr Eye Res* 2005;30:621-630.



## *Diseases of the Conjunctiva*

*Arthur B. Epstein and Christopher J. Quinn*

Disorders of the conjunctiva are one of the leading causes of unscheduled visits to eye care practitioners. A wide range of etiologies for conjunctival disease exists, including infection, inflammation, trauma, degeneration, and neoplasm. Dermatologic conditions and systemic diseases may also affect the conjunctiva. Despite this broad variety of possible etiologies, the clinical response of the conjunctiva is relatively limited. This narrow range of possible presentations can sometimes make diagnosis of conjunctival disorders challenging for the clinician.

Advances have been made in the diagnosis and management of conjunctival disease. These advances include new medications, new diagnostic techniques, and better understanding of the management of what is often a deceptively simple disorder. These new developments ease the diagnostic burden and improve treatment efficacy for the clinician.

### **ANATOMY OF THE CONJUNCTIVA**

The conjunctiva is a mucous membrane that lines the inner portions of the eyelids and is reflected onto the globe, overlying the episclera and anterior sclera to the limbus. The membrane consists of normally nonkeratinized epithelium overlying a substantia propria or stroma containing connective tissue and a vascular network. Anatomically and clinically, the conjunctiva consists of three distinct sections: palpebral or tarsal conjunctiva, fornix conjunctiva, and bulbar conjunctiva (Figure 25-1). The conjunctiva develops embryologically from surface ectoderm, along with the epidermis of the eyelid, corneal epithelium, and lens epithelium. This common derivation provides an anatomic basis for the clinical association of conjunctivitis with dermatologic conditions of the eyelids as well as certain systemic diseases.

#### **Palpebral Conjunctiva**

The palpebral conjunctiva begins at the posterior eyelid margin and extends posteriorly toward the fornix.

The keratinized epithelium of the eyelids gradually transforms into the moist mucous membrane of the conjunctiva. The palpebral conjunctiva adheres tightly to the tarsus over the entire superior eyelid, as compared with the loosely adherent inferior palpebral conjunctiva. Clinically, this anatomic variation contributes to the different appearance of papillary hypertrophy occurring in the superior versus inferior palpebral conjunctiva.

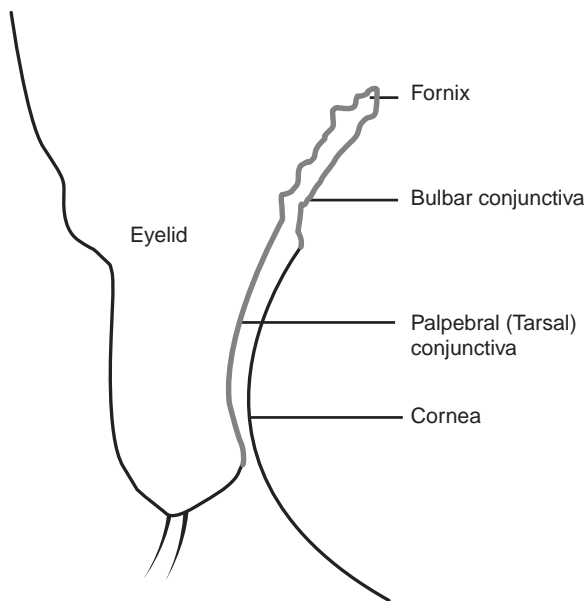
The palpebral conjunctiva is composed of nonkeratinized stratified epithelium that decreases in thickness as it proceeds from the eyelid margin. Many mucin-secreting goblet cells are located near the fornix. The epithelium overlies the substantia propria, which consists of delicate connective tissue and blood vessels. Most of the immune system cellular components reside in the substantia propria. The stroma contains lymphocytes, lymphoid follicles, neutrophils, plasma cells, and mast cells, all of which proliferate extensively in conjunctival inflammatory disease. This proliferation leads to the formation of papillae and follicles.

#### **Fornix Conjunctiva**

The conjunctival fornix extends over the globe, beginning and ending at the medially located plica semilunaris and caruncle. The fornix adheres loosely to the underlying stroma. A small fold or folds in the fornix conjunctiva permit free motion during eye movements. The lower fornix contains an abundance of lymphoid follicles and inflammatory cells. The accessory lacrimal glands of Krause are located in the superior fornix, with few accessory lacrimal glands situated in the lower fornix.

#### **Bulbar Conjunctiva**

The conjunctiva proceeds onto the globe from the fornix to form the bulbar conjunctiva, which overlies Tenon's capsule and merges with the limbal cornea. Loosely attached to the capsule over the entire globe, the bulbar conjunctiva forms a homogeneous layer of stratified squamous epithelium at the limbus and contains many goblet



**Figure 25-1** Anatomic division of the conjunctiva.

cells near the fornix. Stratified squamous epithelium is notable for its ability to bear friction and shearing forces that might occur from lid action during the blink. The goblet cells secrete mucopolysaccharides that form the mucin layer of the tear film. Loss of goblet cells may result in various forms of ocular surface disease, ranging from dry eye syndrome to cicatricial disorders. There is evidence that the conjunctival epithelium also produces mucin. The limbal conjunctival substantia propria contains many sensitive unmyelinated nerve fibers and free nerve endings as well as a complex network of perilimbal vessels and vascular arcades. Medially, the bulbar conjunctiva is bordered by the caruncle, which forms a mucocutaneous junction between the bulbar conjunctiva and the epidermis of the skin. Accessory lacrimal glands may occasionally be located in the caruncle.

A substantial concentration of Langerhans cells exists at the limbus. These cells, also known as monocytes within the blood and macrophages when deposited in tissues, derive from bone marrow and have a dendritic morphologic shape. They occur within all epithelial surfaces and mucous membranes. Langerhans cells initiate the ocular immune response by functioning as antigen-presenting cells. Foreign antigens displayed on their surfaces are recognized by T lymphocytes in a complex interaction.

## MICROBIOLOGIC FEATURES OF THE CONJUNCTIVA

### Normal Flora

At birth, infants emerge from a sterile environment to be almost immediately exposed to an environment filled with a wide variety of microbes. The conjunctiva, as with

other mucous membranes, normally sustains permanent flora of indigenous bacteria. These organisms constitute a protective host defense that helps prevent pathogens from multiplying efficiently by competing with them for resources. Normal flora shifts with age, physical state of the host, and local environmental factors. Adults normally harbor a greater number of species than do children. Children typically have significantly higher numbers of *Streptococcus* species, whereas adults have higher numbers of anaerobic species, predominantly *Propionibacterium*. Long-term contact lens wearers show higher numbers of bacterial species, whereas short-term contact lens wear appears to cause no significant alteration in microbial flora.

Normal flora may become pathogenic in immunocompromised or debilitated patients and in cases where epithelial barrier disturbances and immune compromise retardation exposes the conjunctiva or cornea to infection. Compromised host defenses, such as reductions in tear lactoferrin levels, may be a factor. Viruses and parasites, although often present in asymptomatic individuals, are not considered part of the normal flora. Several studies have documented the similarity between the normal flora of the conjunctiva and that of the upper respiratory tract and eyelid skin. The primary microbial organisms retrieved from normal uninfected eyes are *Staphylococcus epidermidis*, *Staphylococcus aureus*, and *Corynebacterium* species (diphtheroids). At least one of these organisms could be isolated from 61% of the specimens from 92 healthy eyes during repetitive cultures of the conjunctiva. *S. epidermidis* was most commonly found. Other organisms found on a transient basis include *Streptococcus pneumoniae*, the viridans group of streptococci, *Haemophilus influenzae*, and *Pseudomonas aeruginosa*. Occasionally, even enteric gram-negative rods such as *Escherichia coli* are detected. Obligate gram-positive rod anaerobes are isolated in 50% of the eyes cultured.

*Propionibacterium acnes*, commonly isolated from the skin, is the most frequently found anaerobe. Factors and conditions such as blepharitis, dry eye syndrome, meibomian gland dysfunction, and contact lens use may influence the composition of the normal flora or cause disruption to normal epithelial microbial barriers, either of which can lead to disease in susceptible patients. Although immunocompromised individuals may harbor *Candida albicans*, fungi are considered opportunistic pathogens. Little evidence supports the existence of any indigenous fungi in the normal conjunctival flora.

### Common Microbial Pathogens

Almost any microbial organism can cause infectious conjunctivitis. The infectious organisms include bacteria, chlamydia, fungi, and viruses. In immunocompetent persons the primary causes of conjunctivitis are bacteria and viruses in children younger than 12 years and viruses

**Box 25-1** Causes of Infectious Conjunctivitis**Bacterial****Gram positive**

*Staphylococcus aureus*  
*Staphylococcus epidermidis*  
*Streptococcus pneumoniae*  
*Streptococcus pyogenes*  
*Corynebacterium diphtheriae*

**Gram negative**

*Haemophilus influenzae*  
*Neisseria gonorrhoeae*  
*Escherichia coli*  
*Pseudomonas aeruginosa*  
*Proteus mirabilis*  
*Moraxella lacunata*  
*Moraxella catarrhalis*

**Viral**

Adenovirus  
 Herpes simplex  
 Varicella-zoster  
 Molluscum contagiosum  
 Enterovirus 70  
 Epstein-Barr

**Chlamydial**

*Chlamydia trachomatis*

**Fungal**

*Candida albicans*  
*Aspergillus* species

in adults and children older than 12 years of age. The primary bacterial pathogens are *S. aureus*, *H. influenzae*, and *S. pneumoniae*.

Adenovirus and herpes simplex virus (HSV) are the most common causes of viral conjunctivitis. The frequency of infection by one of these organisms varies depending on the particular region's climate and other environmental factors. Box 25-1 summarizes the most significant ocular infectious agents.

**INFLAMMATION OF THE CONJUNCTIVA**

Several distinct clinical signs herald conjunctival inflammation. However, the actual presentation depends on the nature of the causative agent, the time course, and any preexisting disease. Conjunctival tissue may be exposed to antigens, pathogens, toxins, or irritants through airborne transmission; direct contact (hand to eye, person to person, or from contaminated instruments or surfaces); and inadvertent sexual transmission.

Systemic disorders may also manifest with conjunctival inflammation. Acute or chronic conjunctivitis may present with any of five signs of conjunctival inflammation: chemosis, hyperemia, discharge or exudate, follicles, and papillae (Table 25-1). Specific patterns of inflammation may be helpful in diagnosis of the underlying cause.

All immune system inflammatory cells may be elicited in extraordinary numbers in conjunctival tissues. Lymphocytes, neutrophils, mast cells, and plasma cells are present from birth and increase in quantity with age and antigenic exposure. Lymphoid tissue, however, is not present at birth but develops within the first few months of life. Increased vascular permeability, resulting from the ocular immune response to antigens, infectious agents, toxins, or other environmental stimuli (e.g., smoke or wind), often results in hyperemia, chemosis, or exudative discharge. The severity of the clinical presentation depends on both the causative agent and type of immune response. When present, conjunctival discharge may be serous, mucoid, purulent, fibrinous, or hemorrhagic.

Conjunctival membranes and pseudomembranes consist of fibrin and cellular debris. True membranes are attached firmly to the underlying conjunctival epithelium such that when removed, the underlying epithelium is stripped away, leaving an abraded bleeding surface. Pseudomembranes are similar in composition to true membranes but do not adhere to the underlying epithelium, making their removal less traumatic. Clinically, the distinction may be difficult to ascertain. Removal is indicated when the membranes interfere with the healing process or are a source of irritation. True membranes and pseudomembranes are associated with specific causes, and their presence can be helpful in establishing a differential diagnosis.

Papillary hypertrophy represents a nonspecific inflammatory response of the conjunctiva most commonly observed in allergic or bacterial conjunctivitis. It is due to cellular infiltration of the substantia propria by inflammatory cells, including eosinophils, lymphocytes, mast cells, and polymorphonuclear leukocytes. Papillary hypertrophy produces elevations of the conjunctival epithelium and stroma termed papillae, which have a delineating margin and contain a small central vascular tuft. This central vessel is the source of cellular infiltration. Papillae vary in size from less than 1 mm to the giant cobblestone-shaped excrescences seen in contact lens-related giant papillary conjunctivitis or, more notably, in vernal keratoconjunctivitis (VKC). When the papillae are small, the conjunctiva has a grossly smooth velvety appearance.

Follicles result from focal lymphoid hyperplasia most commonly associated with chlamydial, viral, or toxic exposure, including preservatives in eyedrops or high levels of chlorine in pool water. Clinically, conjunctival follicles appear as avascular, translucent to whitish gray, amorphous nodules 0.5 to 1.5 mm in diameter, usually located in the tarsal and fornix conjunctiva. Small external

**Table 25-1**  
Signs of Conjunctival Inflammation

Clinical Entity	Physical Appearance	Etiology
Chemosis	Edematous swollen tissue	Increased vascular permeability
Hyperemia	Pale to bright-red engorged vessels	Pathophysiologic response to injury
Discharge		
Serous	Clear watery discharge	Increased vascular permeability
Mucoid	Clear to yellowish tinged, translucent, sticky or stringy discharge	Increased mucus from goblet-cell irritation
Mucopurulent	Yellowish white, less translucent, sticky discharge	Increased mucus combined with inflammatory cells (e.g., eosinophils and macrophages)
Purulent	Yellowish white to yellow-green tinged, opaque, thick discharge	High concentration of inflammatory cells (e.g., polymorphonuclear leukocytes and macrophages)
Fibrinous	White, opaque, flat-appearing discharge that follows contour of conjunctiva and may be attached to underlying tissue	High degree of fibrin mixed with inflammatory cells (e.g., polymorphonuclear leukocytes and macrophages)
Hemorrhagic	Red-streaked discharge that may also have any of the foregoing characteristics	Red blood cells in discharge from increased vascular permeability or trauma
Papillary hypertrophy	Elevations of conjunctival epithelium and stroma with a delineating margin and small central vascular tuft; when papillae are small, the conjunctiva has a velvety appearance	Cellular infiltration of the substantia propria by inflammatory cellular material (e.g., eosinophils, lymphocytes, mast cells, and polymorphonuclear leukocytes)
Follicles	Elevated, avascular, rounded lesions, translucent to whitish gray, usually located in fornices; small vessel may surround the follicle; no central vascular tuft present	Germinal cells (immature lymphocytes) and macrophages comprise central portion with mature cells forming the periphery

vessels may encircle or envelop the follicle. Germinal cells (immature lymphocytes) and macrophages compose the central portion; mature cells form the periphery. The conjunctival lymphatic system responds to antigen exposure with hyperplasia of the T lymphocytes contained within the lymphoid germinal center of the follicle. This antigenic response can occur in viral, chlamydial, and certain bacterial infections and after exposure to toxic agents. Follicles may also be observed in young asymptomatic children as an incidental finding. Follicles located in the fornices usually are nonspecific; however, follicles located on the superior tarsus or at the limbus frequently represent disease.

## LABORATORY DIAGNOSIS OF CONJUNCTIVITIS

### Indications for Laboratory Analysis

The differential diagnosis of conjunctivitis can sometimes be challenging. Laboratory testing can help both to identify the etiology and to effectively direct treatment. Ideally, in all cases of infectious conjunctivitis, cultures or ocular smears should be obtained to determine the exact etiology. However, in practice this rarely is done. Experienced practitioners typically treat infectious conjunctivitis empirically. In most cases eye care providers can diagnose conjunctivitis accurately and treat it effectively

by assessing the clinical history, signs, and symptoms. With some forms of conjunctivitis the disease severity or increased risk for ocular tissue damage demands ancillary testing as part of the workup and management plan. In other cases laboratory diagnosis is suggested but not mandatory. Conjunctival disorders requiring mandatory laboratory analysis include severe chronic conjunctivitis, hyperacute conjunctivitis, membranous conjunctivitis, ophthalmia neonatorum, Parinaud's oculoglandular syndrome, conjunctivitis in immunocompromised patients, and in postoperative infections. Laboratory diagnosis is recommended for moderate chronic conjunctivitis, conjunctivitis secondary to canaliculitis or dacryocystitis, conjunctivitis secondary to infectious eczematous or ulcerative blepharitis, and conjunctivitis unresponsive to therapy (Box 25-2). The inexperienced clinician may find laboratory evaluation helpful in confirming clinical judgment.

### Cultures

Whenever bacterial or fungal etiologies are suspected, ocular specimens for culture should ideally be plated directly on agar plates containing enriched or selective bacteriologic media. Commercially available transport media may not be sufficient for bacteria or fungi because most ocular specimens may contain diminutive quantities of fastidious microorganisms. However, transport solutions for viruses and chlamydia can effectively maintain

### Box 25-2 Indications for Laboratory Diagnosis of Conjunctivitis

#### Mandatory

Severe chronic conjunctivitis  
Hyperacute conjunctivitis  
Ophthalmia neonatorum  
Membranous conjunctivitis  
Parinaud's oculoglandular syndrome  
Postoperative infections

#### Recommended

Any chronic conjunctivitis  
Conjunctivitis secondary to canaliculitis or dacryocystitis  
Conjunctivitis secondary to infectious eczematous or ulcerative blepharitis  
Conjunctivitis unresponsive to therapy

specimens for laboratory analysis. Inoculating agar plates directly enhances a practitioner's chances of isolating an offending organism. Solid media plates also enable laboratory technicians to identify the organism's morphology more efficiently and thus shorten the waiting time for reports. Three types of solid media and one liquid medium are recommended for routine inoculation: blood agar, chocolate agar, and Sabouraud's agar and thioglycolate broth. The liquid medium provides for transport of any anaerobic microorganisms and permits the laboratory to inoculate additional media plates if necessary. Other selective media may be indicated when isolation of specific microorganisms, such as *Neisseria* species, is being attempted.

The use of Mini-tip Culturette (Becton Dickinson, Cockeysville, MD) has been compared with traditional culture techniques using a rabbit model as well as community-acquired presumed bacterial keratitis. The sensitivity of the Mini-tip Culturette was 83.3% and the specificity 100%. Detected organisms included group A  $\beta$ -hemolytic *Streptococcus*, *S. aureus*, coagulase-negative *Staphylococcus*, *Serratia marcescens*, and *Pseudomonas aeruginosa*.

Blood agar is an all-purpose enriched medium appropriate for isolating most ocular aerobic or anaerobic pathogens except *Haemophilus*, *Neisseria*, and *Moraxella* species. When incubated under anaerobic conditions, blood agar is useful for isolating most anaerobes, including *Actinomyces*. This medium is trypticase-soy agar with 5% to 10% sterile defibrinated sheep blood. Blood agar is the standard bacteriologic medium used for cultivating fastidious microorganisms and determining hemolytic reactions that characterize certain bacteria.

Chocolate agar is a polypeptone or beef infusion agar enriched with 2% hemoglobin released from defibrinated heated rabbit's or sheep's blood. The blood hemolysis creates the chocolate color. Free hemin and nicotinamide

adenine dinucleotide permit cultivation of *Haemophilus*, *Neisseria*, and *Moraxella* species. Because its usefulness is more limited, chocolate agar cannot take the place of blood agar.


Sabouraud's agar is a glucose-peptone agar combination, the pH of which has been adjusted to 6.7 to 7.1 to favor isolation of opportunistic fungi. The addition of antibiotics such as chloramphenicol or gentamicin prevents the growth of bacteria, thus enhancing the growth environment for fungal microorganisms. This medium should not contain cycloheximide, which inhibits saprophytic fungi that may cause ocular infection.

Thioglycolate broth is an enriched trypticase-peptone broth usually containing glucose, hemin, and vitamin K. This medium is favorable for culturing a variety of fastidious aerobic or anaerobic microorganisms. Although it is superior to commercially available bacterial transport media systems for conveying specimens to the laboratory, thioglycolate broth should not be used as the sole medium. Solid media are still superior for isolating and quantifying microorganisms. Extra care must be taken to use an uncontaminated plate because of the relatively low numbers of microorganisms found in most ocular specimens. This contamination increases the risk of overgrowth of unwanted organisms when using a medium that supports multiple microbial species.

Mannitol salt agar is a selective medium for the isolation of *Staphylococcus* species that ferment mannitol from nonmannitol-fermenting species. The peptone-based agar contains mannitol, with 7.5% sodium chloride and a phenol red indicator dye. The salt concentration inhibits most other bacteria. Thayer-Martin medium is a selective agar for isolating *Neisseria gonorrhoeae* or *Neisseria meningitidis* from specimens contaminated with other bacteria and fungi. It consists of an enriched chocolate agar to which vancomycin, colistin, trimethoprim, and nystatin are added to inhibit the growth of other bacteria and fungi. If *Neisseria* infection is suspected, chocolate agar should be inoculated in conjunction with Thayer-Martin medium, because some strains of pathogenic *Neisseria* species are inhibited by the additives.

Several viral transport systems are available commercially or through medical laboratories. These transport solutions contain antibiotics to inhibit the growth of bacteria and are adequate for maintaining all types of viruses until the laboratory can culture them.

A Dacron-tipped or calcium alginate swab is recommended for obtaining all conjunctival specimens for culture. The use of cotton-tipped swabs should be avoided, because the fatty acids in the cotton material may inhibit the growth of some bacteria. Specimens should also be obtained without the use of topical anesthesia. All topical anesthetics have some antimicrobial effects in addition to preservatives that may inhibit the recovery of some microorganisms. The swab should be moistened with either thioglycolate broth or sterile saline and gently rolled through the full length of the conjunctival



**Figure 25-2** Standard convention for streaking agar plates.

fornix, maintaining contact for several seconds. Specimens should be obtained from both eyes, one swab being used for each eye to inoculate all media. Contact with the eyelid margins should be avoided so as not to contaminate the conjunctival specimen. The agar plates are inoculated by streaking (lightly dragging) the swab across the surface of the plate. The swab should be rolled gently during the streaking process. After the conjunctiva has been swabbed, specimens are obtained from the eyelid margins using a second moistened swab. The inoculum from both the conjunctiva and eyelid margins may be placed on the same plate using the standard convention shown in Figure 25-2. After inoculation of the agar plates, the swab should be plunged into the thioglycolate broth and twirled, after which the end that was handled is broken or cut off, allowing the sterile untouched lower portion of the swab to drop into the broth. The same

procedure used with thioglycolate broth is followed for inoculating the viral or chlamydial transport media. However, dry swabs may be used to collect these samples. The practitioner is strongly advised to wear disposable gloves when obtaining ocular specimens with swabs or other ophthalmic instruments.

Until the laboratory reports the results of the cultures, empirical therapy is initiated on the basis of clinical findings. The results of most aerobic bacterial cultures usually are known in 24 to 48 hours, anaerobic cultures in 3 to 7 days, and fungal cultures may take up to 1 to 2 weeks. Antibiotic sensitivity testing should be routinely ordered for all culture specimens. This testing allows for proper management of the conjunctivitis after receipt of the laboratory report. Antibiotic sensitivity testing either confirms the appropriateness of the initial empiric therapy or indicates organism resistance, requiring the selection of another anti-infective agent (Table 25-2).

Sensitivity testing usually is performed by a microbroth dilution method and should encompass all categories of antibiotics. Zones of inhibition around antibiotic-containing drugs indicate relative sensitivity. The agents to be tested may vary based on availability of antibiotic discs, geographic prevalence rates of infection, or practitioner preference (Box 25-3).

### Smears and Scrapings

Conjunctival smears and scrapings are used to investigate exudative discharge or to perform a cytologic analysis of

**Table 25-2**  
Efficacy of Commonly Used Topical Antibacterial Agents

Antimicrobial Agent	Bacterial Species Typically Susceptible
Bacitracin	<i>Staphylococcus</i> , <i>Streptococcus</i> , <i>Actinomyces</i> , <i>Corynebacterium</i> , <i>Neisseria</i>
Ciprofloxacin	<i>Staphylococcus</i> , <i>Streptococcus</i> , <i>Corynebacterium</i> , <i>Neisseria</i> , <i>Escherichia</i> , <i>Haemophilus</i> , <i>Moraxella</i> , <i>Proteus</i> , <i>Pseudomonas</i> , <i>Serratia</i> , <i>Chlamydia</i>
Erythromycin	<i>Staphylococcus</i> , <i>Streptococcus</i> , <i>Corynebacterium</i> , <i>Neisseria</i> , <i>Moraxella</i> , <i>Chlamydia</i>
Gatifloxacin	<i>Corynebacterium</i> , <i>Staphylococcus</i> , <i>Streptococcus</i> , <i>Haemophilus</i> , <i>Listeria</i> , <i>Acinetobacter</i> , <i>Escherichia</i> , <i>Citrobacter</i> , <i>Neisseria</i> , <i>Mycobacterium</i> , <i>Legionella</i> , <i>Moraxella</i> , <i>Proteus</i> , <i>Pseudomonas</i> , <i>Serratia</i>
Gentamicin	<i>Staphylococcus</i> , <i>Escherichia</i> , <i>Haemophilus</i> , <i>Proteus</i> , <i>Pseudomonas</i> , <i>Serratia</i>
Gramicidin	<i>Staphylococcus</i> , <i>Streptococcus</i> , <i>Actinomyces</i> , <i>Corynebacterium</i>
Neomycin	<i>Neisseria</i> , <i>Escherichia</i> , <i>Moraxella</i> , <i>Proteus</i> , <i>Serratia</i>
Ofloxacin	<i>Staphylococcus</i> , <i>Streptococcus</i> , <i>Neisseria</i> , <i>Escherichia</i> , <i>Haemophilus</i> , <i>Moraxella</i> , <i>Pseudomonas</i> , <i>Serratia</i>
Moxifloxacin	<i>Corynebacterium</i> , <i>Staphylococcus</i> , <i>Streptococcus</i> , <i>Citrobacter</i> , <i>Neisseria</i> , <i>Mycobacterium</i> , <i>Legionella</i> , <i>Listeria</i> , <i>Klebsiella</i> , <i>Acinetobacter</i> , <i>Escherichia</i> , <i>Haemophilus</i> , <i>Listeria</i> , <i>Moraxella</i> , <i>Proteus</i> , <i>Pseudomonas</i> , <i>Serratia</i> , <i>Chlamydia</i>
Polymyxin B	<i>Escherichia</i> , <i>Haemophilus</i> , <i>Moraxella</i> , <i>Pseudomonas</i>
Sulfonamides	<i>Haemophilus</i> , <i>Moraxella</i> , <i>Chlamydia</i>
Tetracycline	<i>Actinomyces</i> , <i>Neisseria</i> , <i>Chlamydia</i>
Tobramycin	<i>Staphylococcus</i> , <i>Escherichia</i> , <i>Haemophilus</i> , <i>Proteus</i> , <i>Pseudomonas</i> , <i>Serratia</i>
Trimethoprim	<i>Staphylococcus</i> , <i>Streptococcus</i> , <i>Escherichia</i> , <i>Haemophilus</i> , <i>Moraxella</i> , <i>Proteus</i> , <i>Serratia</i> , <i>Chlamydia</i>

Adapted from Smolin G, Thoft RA. The cornea, ed. 3. Boston: Little, Brown, 1994: 135.

**Box 25-3** Suggested Agents for Antibiotic Sensitivity Testing

Ampicillin  
 Bacitracin  
 Carbenicillin  
 Cefazolin  
 Ciprofloxacin  
 Colistin (polymyxin E)  
 Erythromycin  
 Gatifloxacin  
 Gentamicin  
 Levofloxacin  
 Moxifloxacin  
 Neomycin  
 Ofloxacin  
 Polymyxin B  
 Tetracycline  
 Tobramycin  
 Trimethoprim  
 Vancomycin

Note: If *Neisseria gonorrhoeae* is suspected, test ceftriaxone and penicillin G.

conjunctival tissue. These techniques provide more immediate information regarding the disease process than do cultures. A Kimura platinum spatula is the instrument of choice for obtaining conjunctival scraping specimens. After the conjunctiva has been anesthetized with two drops of 0.5% proparacaine solution, the spatula is used to scrape the inferior palpebral conjunctival epithelial surface. Although some conjunctival blanching may occur, care should be taken to avoid any bleeding. The material is spread in a thin layer onto a clean glass microscope slide; it then is fixed either with a commercial fixative

solution or methyl alcohol or is air-dried. Next, the smear is stained to inspect for the presence of bacteria or inflammatory cells. Gram stain identifies bacteria as gram positive (stains blue or purple) or gram negative (stains pink). This information aids the practitioner in selecting the initial antibiotic for therapy until the culture report has been received. A conjunctival scraping often reveals a definitive inflammatory cell response indicating a particular disease process. Staining with Giemsa solution is the most useful method, because Giemsa stains inflammatory cells, epithelial cells, fungi, and chlamydial inclusion bodies present in the smear (Table 25-3). Wright's solution or the Diff-Quik system stains conjunctival inflammatory cells, but chlamydial inclusion bodies are not stained adequately. Papanicolaou stain is superior for eliciting viral intranuclear inclusion bodies as well as cytologic examinations for premalignant lesions or malignancies. The clinician is advised to consult standard ocular microbiology and cytology texts for additional information on standard stain preparation techniques.

Direct fluorescent antibody smears have become a more efficient method than Giemsa stains or tissue cultures for identifying chlamydia. Commercially prepared kits make specimen collection convenient, and results are available in approximately 24 hours. Good results, however, depend on obtaining an adequate specimen. Fluorescein-labeled monoclonal antibodies in the staining reagent specific for *Chlamydia trachomatis* outer membrane proteins bind to the *C. trachomatis* in the smear. Studies that compare direct fluorescein antibody techniques with tissue culture results have found acceptable sensitivity and specificity values.

Newer techniques have equal sensitivity and greater specificity. Enzyme-linked immunosorbent assay (ELISA) tests can identify *C. trachomatis*, HSV-1 and -2, and adenoviruses through the detection of microbial antigens. In the direct ELISA, an enzyme is covalently linked to an antigen-specific monoclonal or polyclonal antibody.

**Table 25-3**  
 Ocular Smear Interpretation for Gram and Giemsa Stains

Stain	Cells	Appearance
Gram	Gram positive	Violet to blue-black color
	Gram negative	Pinkish red color
Giemsa	Basophil	Dark blue nucleus, blue cytoplasm with dark blue-black granules
	Eosinophil	Blue nucleus, light blue cytoplasm with red to pink granules
	Epithelial	Blue nucleus, light blue cytoplasm
	Lymphocyte	Dark purple nucleus, light blue cytoplasm that may contain reddish granules
	Monocyte (macrophage)	Light purple nucleus, light gray to blue cytoplasm
	Mast	Dark blue-purple nucleus, blue cytoplasm with dark blue-black granules
	Neutrophil	Dark purple nucleus, light pink cytoplasm containing small light pink to blue-black granules
	Plasma cell	Dark purple, eccentric nucleus, light to dark blue cytoplasm, distinct perinuclear halo

Adapted from Haesaert CT. Clinical manual of ocular microbiology and cytology. St. Louis: Mosby, 1993: 80-84.



The antigen then is mixed with serial dilutions of the enzyme-labeled antibody. A chromogenic substrate mixed with the conjugated enzyme yields a water-soluble product, the absorbency of which can be measured by a spectrophotometer. Recent technology has led to the development of rapid tests that do not require intact cells, live organisms, or cell cultures. ELISAs using monoclonal antibody techniques for the rapid detection of HSVs, adenoviruses, and *C. trachomatis* are highly sensitive and specific.

Polymerase chain reaction testing is a nucleic acid amplification test (NAAT) that amplifies the number of copies of a specific region of DNA to produce enough DNA to be adequately tested. It has been used to identify a variety of ocular pathogens, including *C. trachomatis*, adenoviruses, HSV-1 and -2, varicella-zoster virus, Epstein-Barr virus, and cytomegalovirus. Specimen DNA is denatured, specific primers are attached to the strand, and a new DNA strand is synthesized in an elegant expression of applied practical molecular biology. With each round the number of DNA strands is doubled, allowing more than a million-fold amplification. Polymerase chain reaction testing is both sensitive and specific and can be used with clinical samples containing minuscule amounts of the pathogen, such as tears. Combining two or more primers into one multiplex test for detection of several pathogens may replace individual tests and, consequently, decrease costs and erroneous results, especially when the clinical picture is confusing. Ongoing developments in micro- and nanotechnology and electronics will likely lead to diminutive, likely handheld, in-office microbiological diagnostic devices.

## INFECTIOUS CONJUNCTIVITIS

### Mechanisms of Infection

The conjunctiva has several nonimmune defense barriers that protect it from infection. These natural defenses include the intact mucous membrane surface and glycocalyx, rapid epithelial cell turnover, cool temperature due to tear evaporation, mechanical action of the eyelids, and the flushing action of the tears and lacrimal system. The normal bacterial flora and tear film constituents, such as lactoferrin,  $\beta$ -lysine, and lysozyme, have antibacterial action and supplement the anatomic barriers. Additional antibacterial proteins from inflamed blood vessels may play an adjunctive role during dry eye states when normal tear proteins are diminished. The prominently vascularized conjunctiva has highly active immunologic barriers. All cellular components of the immune system, except basophils and eosinophils, typically are found in the conjunctival substantia propria. These barriers work harmoniously to protect against infection. Conjunctivitis may result from a disruption in any of the barriers, leading to invasion by a pathogen or overgrowth of endogenous flora.

Irregular eyelid margins or function, irregular blinking, disturbed ocular surface innervation, or abnormal tear film may compromise the epithelial surface. When an inoculum of sufficient quantity invades the conjunctiva, over-colonization by the infectious organism may result either from overwhelming normal flora or because the antimicrobial capabilities of the tear constituents have been exceeded.

For example, tear lysozyme is not effective against *S. aureus*. Once an infectious conjunctivitis becomes established, the severity of the infection depends on several factors, including the organism's virulence, invasiveness, and level of toxin production; environmental elements such as temperature; pH; and the function and effectiveness of existing active nonimmune barriers and immune defenses.

### Principles of Therapy

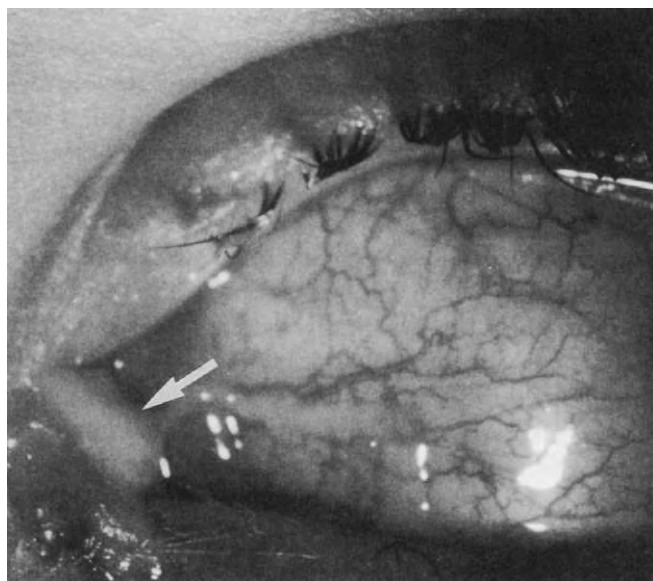
In theory, antimicrobial therapy for infectious conjunctivitis should be specific for the infecting organism; however, in current practice such is rarely the case. Most commonly, treatment is based on the patient's history, signs, and symptoms rather than on laboratory analysis of ocular cultures or smears. The advent of effective broad-spectrum topical antibiotics made empiric treatment of presumed bacterial conjunctivitis commonplace, despite the still accepted belief that pathogen-specific therapy selected on the basis of known antibiotic sensitivity characteristics of the infecting microorganism is preferred (see Table 25-2). The introduction of the fluoroquinolones reinforced empiric treatment, and the even broader spectrum fourth-generation fluoroquinolones have furthered this now well-accepted clinical practice. Nonetheless, clinical experience tempered by appropriate scientific evidence remains the most important guide to selecting an appropriate antibiotic for empiric treatment of conjunctivitis.

Severe infection such as gonococcal conjunctivitis requires systemic therapy, which may be used in conjunction with topical agents. Treatment of viral infections often is directed at relieving patient symptoms, because specific antiviral agents do not currently exist in most cases. Chlamydial disease requires systemic therapy frequently combined with adjunctive topical therapy.

### Acute Bacterial Conjunctivitis

#### Etiology

Acute bacterial conjunctivitis is the most frequently encountered ocular infection in optometric practice, especially among the pediatric population. Both gram-positive and gram-negative organisms can cause acute bacterial conjunctivitis. As is the case with most ocular infections, gram-negative bacterial conjunctivitis is generally more severe than conjunctivitis induced by gram-positive organisms. *S. aureus*, *S. pneumoniae*, and *H. influenzae*

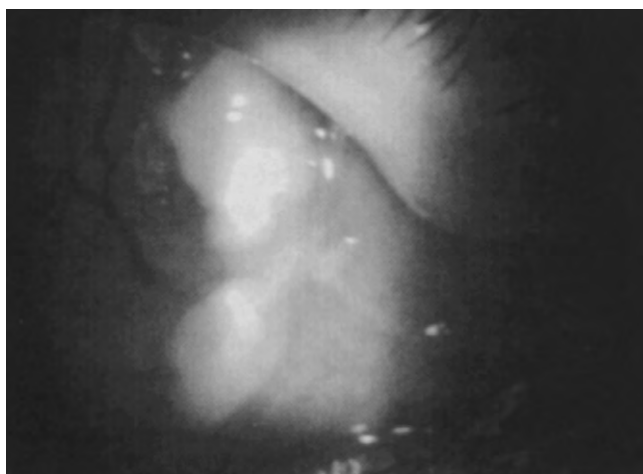

**Figure 25-3** Acute bacterial conjunctivitis with typical mucopurulent discharge (*arrow*).

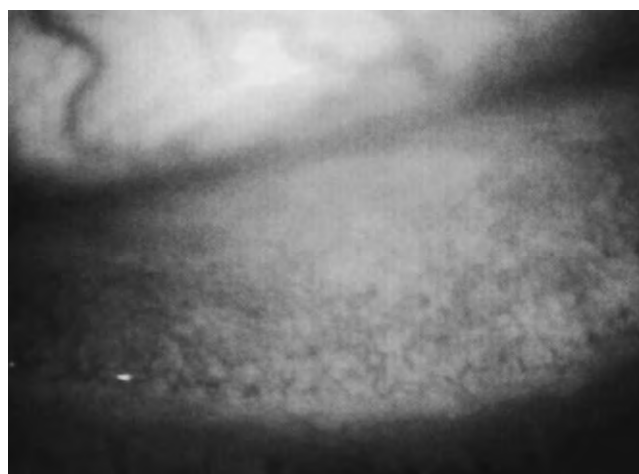
are most frequently associated with acute bacterial conjunctivitis. *S. aureus* is the most common infectious agent in patients of all ages. Less common causative organisms include *S. epidermidis*, *Moraxella lacunata*, *Corynebacterium diphtheriae*, *Serratia marcescens*, and *P. aeruginosa*. *S. pneumoniae* and *H. influenzae* occur more commonly in pediatric patients.

#### Diagnosis

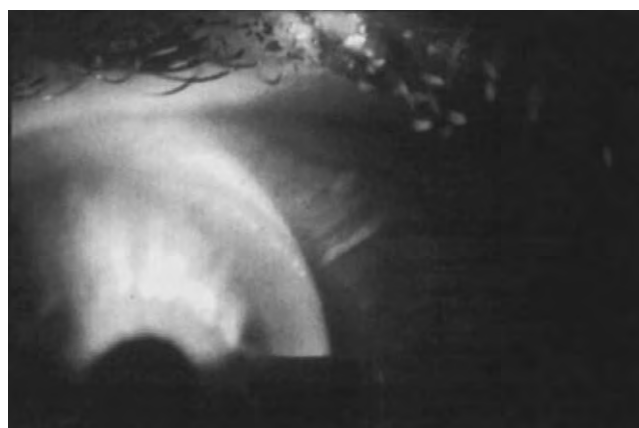
Acute bacterial conjunctivitis usually begins suddenly in one eye with hyperemia and a mild to moderate mucopurulent or purulent discharge (Figure 25-3). The discharge may be trapped beneath the upper eyelid and expelled upon lid eversion or manipulation (Figure 25-4A). Patients initially complain of unilateral tearing and vague irritation. Associated mild to moderate eyelid edema and erythema may give the appearance of pseudoptosis. No preauricular lymph node swelling or tenderness occurs. The hyperemia may be either diffuse or localized to a particular sector—often nasally because of the higher accumulation of organisms and elaborated toxins in this region due to tear drainage. The hyperemia tends to be



A



B



C

**Figure 25-4** (A) Exudate spilling from beneath upper eyelid. (B) Velvety papillary response typical of bacterial conjunctivitis. (C) Marginal corneal infiltrates associated with staphylococcal conjunctivitis.

more intense toward the fornix and diminishes at the limbus. A velvety papillary reaction is frequently seen on the tarsal conjunctiva (Figure 25-4B). Exudative material may accumulate on the eyelashes, prompting complaints that the patient's eyelids stick together on awakening. The fellow eye may become involved 2 to 3 days after the first eye. In some cases, a diffuse superficial punctate keratitis (SPK) may be present, caused by microbial exotoxins. Pseudomembrane or membranes may form, typically when *Streptococcus pyogenes*, *S. aureus*, or *C. diphtheriae* causes the conjunctivitis. Conjunctival cultures and smears assist in the diagnosis and treatment of moderately severe or severe acute bacterial conjunctivitis.

Acute *S. aureus* conjunctivitis occurs less commonly than does chronic staphylococcal conjunctivitis. It is usually characterized by inferior palpebral conjunctival hyperemia with a mucopurulent discharge. In many cases the bulbar conjunctiva beneath the eyelid is more hyperemic than is the exposed bulbar conjunctiva. The presence of staphylococcal exotoxins may cause SPK and marginal corneal infiltrates that frequently accompany the conjunctivitis (Figure 25-4C).

*S. pneumoniae* is a common cause of acute bacterial conjunctivitis in children (Figure 25-5). Concurrent upper respiratory tract infections and otitis media, especially in children younger than 4 years, are common. In moderate climates *S. pneumoniae* is often the cause of acute bacterial conjunctivitis epidemics. This condition commonly presents with diffusely scattered petechial hemorrhages, especially on the superior bulbar conjunctiva, a mucopurulent discharge in the lower fornix, and transient marginal corneal infiltrates. Pseudomembranes may form.

Before the development of an effective vaccine, *H. influenzae* was another frequent cause of acute bacterial conjunctivitis in children that concurrently

caused upper respiratory infections and otitis media. Conjunctivitis caused by *Haemophilus* species tends to occur more frequently in warmer climates and last longer than *S. pneumoniae* infections. The clinical presentation consists of bulbar and palpebral hyperemia with occasional petechial hemorrhages, mucopurulent discharge, and marginal corneal infiltrates. *H. influenzae* biogroup *aegyptius* causes a severe conjunctivitis that may precede the life-threatening pediatric disease, Brazilian purpuric fever. Young children with severe or improperly treated *Haemophilus* infections may present with periorbital bluish discoloration and edema suggestive of preseptal cellulitis or incipient orbital cellulitis.

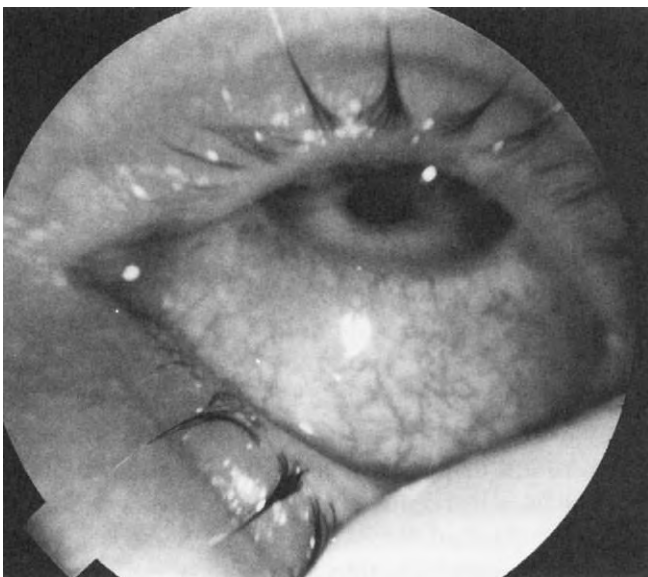
### Management

Many cases of mild bacterial conjunctivitis are self-limiting and resolve without treatment. However, antibiotic therapy often lessens the patient's anxiety and ocular symptoms, shortens the duration of the disease, and prevents recurrence or spread to the fellow eye. Contagion is also a significant risk. Several severe bacterial conjunctivitis outbreaks have been reported. Among the more common requests in ophthalmic practice are releases permitting patients who had conjunctivitis to return to work or school. Epidemiologic data support the clinical and public health benefits of early treatment.

Current initial treatment for bacterial conjunctivitis is application of a broad-spectrum topical antibiotic. With the introduction of the highly effective fourth-generation fluoroquinolones many clinicians have adopted these agents as a first choice for treating bacterial conjunctivitis. Benefits of the fourth-generation fluoroquinolones include enhanced tissue penetration, a generally better dosing profile (moxifloxacin), reduced likelihood for causing resistant strains, and excellent gram-positive, gram-negative, and atypical mycobacterium coverage. The fourth-generation fluoroquinolones are also effective against many organisms resistant to previous generation fluoroquinolones.

Alternatively, antibiotics such as trimethoprim-polymyxin B (Polytrim), gentamicin, or tobramycin solution, instilled as one drop four times daily for 5 to 7 days, or prior generation fluoroquinolones such as ciprofloxacin, ofloxacin, or levofloxacin, dosed four times daily for 5 to 7 days, may be prescribed. Bacitracin-polymyxin B (Polysporin), erythromycin, gentamicin, tobramycin, or ciprofloxacin ointment may be used at bedtime as supplemental therapy or four times daily in children or other patients who are not comfortable with eyedrops.

Moderate conjunctivitis may require a more frequent initial dosage, up to six to eight times daily, tapering to four times daily over 7 to 10 days depending on the antibiotic used. In moderate to severe bacterial conjunctivitis, conjunctivitis with pseudomembrane or membrane formation, or cases of drug resistance, a fourth-generation fluoroquinolone is currently the initial drug of choice. These antibiotics may be applied as often as six to eight times



**Figure 25-5** *Streptococcus pneumoniae* conjunctivitis with petechial hemorrhages.

daily initially and then tapered as the condition responds to therapy.

To minimize the possibility of overgrowth of resistant strains in more severe or recalcitrant conjunctivitis, a bactericidal dose of antibiotic should be maintained until the therapy is discontinued. For most topical ophthalmic antibiotics, this is generally at least four times daily if not more frequently. Moderate to severe conjunctivitis often requires antibiotic therapy for 7 to 14 days to achieve complete resolution.

Severe acute bacterial conjunctivitis with risk of preseptal cellulitis or conjunctivitis associated with otitis media requires concurrent oral antibiotic therapy, especially in children with severe *Haemophilus* infections. Possible systemic agents include amoxicillin or Augmentin, cefdinir, cefpodoxime, cefotaxime, cefuroxime, or cefaclor with dosages appropriate for the patient's age and body weight (see Chapter 23). Azithromycin or clarithromycin are alternatives. Empiric treatment should ideally be based on in vitro activity against locally prevalent organisms. In adults treatment with systemic fluoroquinolone antibiotics may be appropriate for severe infection. Resistance is an ongoing concern in treating conjunctivitis and related diseases with both topical and systemic agents.

Topical steroids are not indicated for most cases of acute bacterial conjunctivitis. The exception is acute conjunctivitis accompanied by severe inflammation or pseudomembranes or true membranes. Concurrent topical antibiotic-steroid therapy hastens resolution of inflammatory response; however, caution is prudent in cases in which the infectious agent has not been definitively identified and until the infection has clearly responded to antibiotic therapy.

Sulfonamide, chloramphenicol, and tetracycline antibiotics generally are no longer used for treating bacterial conjunctivitis. The sulfonamides have a broad spectrum of activity against gram-positive and gram-negative organisms, but they are bacteriostatic agents that require intact immune responses to eliminate infection. Because *S. aureus* often is resistant to these agents, sulfonamides may actually delay resolution of the infection or initiate a low-grade chronic conjunctivitis. The anti-infective activity of the sulfonamides is also inhibited by para-aminobenzoic acid, found in purulent exudate. Although largely obsolete drugs, topical 10% sodium sulfacetamide and 4% sulfisoxazole may be effective in mild cases of acute bacterial conjunctivitis when little or no mucopurulent discharge is present. The sulfonamides also are contraindicated in patients with allergies to these drugs that may lead to erythema multiforme. Although uncommon, erythema multiforme has reportedly followed topical application of 10% sodium sulfacetamide.

Although seldom used in the United States, chloramphenicol has a broad spectrum of activity against *S. pneumoniae* and many gram-negative organisms. Because of the potential for adverse reactions, other readily available

anti-infective agents that are equally or more effective have largely replaced it. Chloramphenicol has been linked to numerous cases of aplastic anemia, although the actual risk is subject to significant debate. The reaction is not dose related and typically occurs weeks or months after completion of therapy.

Topical tetracycline may be used as an adjunctive therapy for chlamydial infections but not for initial treatment of acute bacterial conjunctivitis. Numerous organisms are resistant to tetracycline.

Trimethoprim is a bactericidal agent effective against most gram-positive and gram-negative organisms, except *P. aeruginosa*. When combined with polymyxin B, which is effective against *Pseudomonas* species, it provides broad-spectrum antimicrobial activity for the initial treatment of acute bacterial conjunctivitis. The usual dose of the solution is one drop four times daily. Studies indicate that trimethoprim is a safe and effective agent for treating conjunctivitis caused by a variety of organisms in patients of all ages older than 2 months. Trimethoprim-polymyxin B (Polytrim) has been found to be effective and well tolerated in both adults and children. It is particularly useful in the pediatric population because of its antimicrobial activity against *S. pneumoniae* and *H. influenzae*. However, reports of growing resistance suggest that caution should be used with empiric treatment, especially in children, where fourth-generation fluoroquinolones may be a more effective choice.

In decreasing favor since the emergence of the fluoroquinolones, the aminoglycosides gentamicin and tobramycin are bactericidal against most gram-negative bacteria, especially *P. aeruginosa*, and some gram-positive bacteria, particularly *S. aureus*. *H. influenzae* and *Neisseria* species are variably susceptible to the aminoglycosides. Anaerobes, *S. pneumoniae*, and the  $\alpha$ -hemolytic streptococci are resistant to the aminoglycosides. The usual dose frequency for these agents is four times daily, whether in solution or ointment. Potential adverse effects include a toxic epitheliopathy, SPK, and hypersensitivity reactions. The risk of adverse reactions is greater when the drugs are applied more often than six times daily or are applied as ointments. Other rarely occurring adverse events reported with gentamicin are pupillary mydriasis, conjunctival paresthesia, and neuromuscular blocking activity. Pseudomembranous conjunctivitis has been reported after treatment with topical gentamicin. Aminoglycosides should be used cautiously in patients with myasthenia gravis, because these patients are more susceptible to the potential neuromuscular blocking action of such agents, which may lead to respiratory failure.

Neomycin is a topical aminoglycoside widely used for skin wounds and in otolaryngology. Its antibacterial activity resembles that of gentamicin and tobramycin, except that *P. aeruginosa*, *S. pneumoniae*, and the  $\alpha$ -hemolytic streptococci are generally resistant. Neomycin's usefulness for treating acute bacterial conjunctivitis is limited

by the relatively high rate of hypersensitivity reactions. Allergic reactions occur in nearly 6% to 8% of patients treated and are often more severe than the original infection. For these reasons most clinicians avoid neomycin and combination drugs containing neomycin for routine use in treating acute bacterial conjunctivitis.

Bacitracin is bactericidal for most gram-positive organisms, especially *Staphylococcus* and *Streptococcus* species. It is particularly useful when combined with polymyxin B in an ophthalmic ointment. Bacitracin-polymyxin B ointment (Polysporin) provides broad-spectrum antibacterial activity for patients who require nighttime therapy or who are not comfortable with eyedrops. Bacitracin-polymyxin B ointment is particularly effective in the pediatric population because of the high incidence of *Streptococcus* infection. The usual dose frequency is three to four times daily. Although adverse events are rare, hypersensitivity reactions can occur. Additionally, bacitracin can sometimes be uncomfortable.

Polymyxin B is bactericidal for most gram-negative organisms, especially *Haemophilus* and *Pseudomonas* species. *Neisseria* and *Proteus* species, however, are resistant. Combining polymyxin B with bacitracin or trimethoprim achieves broad-spectrum antibacterial activity for treating acute bacterial conjunctivitis. Because it is not absorbed through mucous membrane or skin tissue, polymyxin B is used primarily for superficial infections. Adverse reactions are rare.

Erythromycin is bacteriostatic for many gram-positive organisms, such as *S. aureus* and *S. pneumoniae*. Erythromycin may have some bacteriostatic activity against *Haemophilus* and *Neisseria*, but it is not a drug of choice for these organisms. Resistant strains of *S. aureus* may be encountered. Because of its low incidence of adverse reactions, erythromycin is extremely well tolerated, particularly by children. It is used primarily as adjunctive therapy at bedtime.

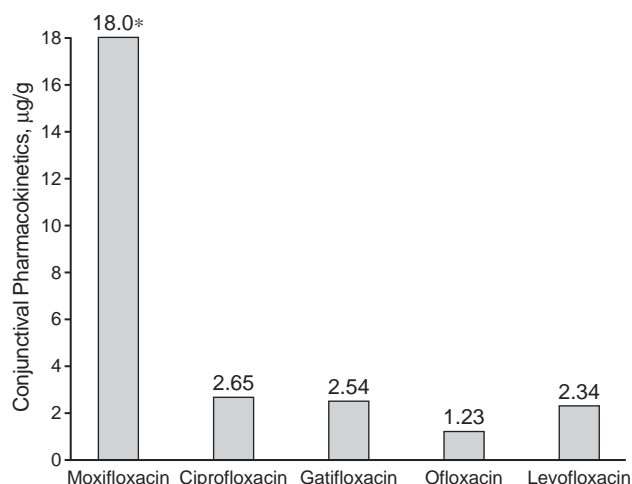
The fluoroquinolone antibiotics are potent agents with strong dose-dependent bactericidal and variable bacteriostatic activity against most gram-negative organisms. They evolved from nalidixic acid, which was approved by the U.S. Food and Drug Administration in 1963. Modern fourth-generation fluoroquinolones have expanded gram-positive activity and enhanced antibiotic characteristics. Several studies have shown the fluoroquinolones to be equally or more effective than earlier generation antibiotics used in ophthalmic practice. Fluoroquinolones usually are prescribed for moderate to severe acute bacterial conjunctivitis, although the broader spectrum of the fourth-generation fluoroquinolones has prompted wider use. The usual initial dose for second- and third-generation fluoroquinolones is six to eight times daily, tapering to four times daily over 5 to 7 days. With the fourth-generation fluoroquinolones, moxifloxacin is prescribed three times daily for 7 days, whereas gatifloxacin requires 2-hour dosing for the first 2 days followed by four times daily for an additional 5 days.

Despite the safety and effectiveness of the fluoroquinolones and their reduced potential for inducing resistance, their use in routine therapy still remains somewhat controversial.

Emergent resistance to the second- and third-generation fluoroquinolones has been of significant concern. Resistance to the prior generation fluoroquinolones is likely due to one or more of the following three possible mechanisms: alterations in bacterial quinolone enzymatic targets (DNA gyrase), decreased outer membrane permeability, and the development of efflux mechanisms. Newer fourth-generation fluoroquinolones target two enzymatic systems responsible for DNA manipulation, DNA gyrase (topoisomerase II) and topoisomerase IV. This dual mechanism of action increases lethality, minimizes survival of resistant organisms, and effectively treats organisms that have already become fluoroquinolone resistant. Five topical fluoroquinolones are currently available: ciprofloxacin, ofloxacin, levofloxacin, gatifloxacin, and moxifloxacin. Norfloxacin is no longer distributed.

Ciprofloxacin is still relatively effective against many gram-negative and some gram-positive organisms, including aminoglycoside-resistant *Pseudomonas*, methicillin-resistant *Staphylococcus*, *Neisseria* species, and *C. trachomatis*. However, *S. pneumoniae* infections are more likely to be resistant. More aggressive dosing achieves higher tissue concentrations and can effect satisfactory resolution of infection in some cases. Reports that indicate increasing resistance to ciprofloxacin among some strains of *Pseudomonas*, *Staphylococcus*, and *Streptococcus* are of growing concern. Ciprofloxacin does not exhibit any significant epithelial toxicity, as is common with aminoglycosides; the white drug precipitate seen in 16% of the patients receiving keratitis therapy may serve as an active drug depot and does not generally occur in the treatment of acute bacterial conjunctivitis. Ciprofloxacin appears to possess more rapid bacterial kill times than does ofloxacin. Although of less significance in treating conjunctivitis, rapid kill rates are important in preoperative and perioperative prophylaxis.

Ofloxacin has a bactericidal potency and spectrum similar to ciprofloxacin. It has relatively strong antibacterial activity against a wide spectrum of gram-negative and gram-positive organisms, including *S. pneumoniae*, but more frequent dosing should be used when infection with *Streptococcus* species is suspected. It is not as effective against *Pseudomonas* as ciprofloxacin. As compared with gentamicin, ofloxacin had a greater clinical (98% vs. 92%) and microbiological (78% vs. 67%) resolution in a study of 198 patients. Only 3.2% reported side effects for ofloxacin, as compared with 7.1% for gentamicin. Ofloxacin achieved better clinical resolution than did tobramycin in a multicenter study on days 3 to 5 after initiation of treatment, but the efficacy of the two agents was relatively equal at day 11. Additionally, when compared with ciprofloxacin and norfloxacin, ofloxacin has a higher level of corneal penetration and attained aqueous levels four times greater than



**Figure 25-6** Conjunctival pharmacokinetics of topical antibiotics. (From Wagner RS, Abelson MB, Shapiro A, Torkildsen G. Evaluation of moxifloxacin, ciprofloxacin, gatifloxacin, ofloxacin, and levofloxacin concentrations in human conjunctival tissue. *Arch Ophthalmol* 2005;123:1282-1283.)

the other agents. More recent data show comparatively lower penetration of ofloxacin compared with other fluoroquinolones (Table 25-6). Twice-daily dosing of ofloxacin has been shown to be as effective as four-times-daily dosing in treating external ocular infection; however, emergent resistance is a concern, with less than four-times-daily dosing not recommended.

Levofloxacin, a third-generation fluoroquinolone, is approved for topical ophthalmic use in treating conjunctivitis. Dosing for adults and children 1 year of age and older is one to two drops every 2 hours for the first 2 days followed by one to two drops every 4 hours for the next 5 days. Levofloxacin shows enhanced activity against gram-positive species, including *S. pneumoniae*, *S. aureus*, and *Enterococcus* species, as well as good activity against *Mycoplasma* and *Chlamydia* species.

Gatifloxacin is a synthetic broad-spectrum 8-methoxy-fluoroquinolone that, like many other ophthalmic anti-infective agents, derives from prior systemic use. Commonly classified as a fourth-generation fluoroquinolone, gatifloxacin interferes with both DNA gyrase and topoisomerase IV activity. The result is broader antibacterial spectrum with clinically similar activity to prior generation fluoroquinolones against gram-negative organisms and significantly improved gram-positive coverage. This dual activity also results in decreased likelihood of creating resistant organisms. Gatifloxacin is approved for the treatment of bacterial conjunctivitis in children over 3 years of age as well as adults.

Moxifloxacin is a broad-spectrum fourth-generation 8-methoxyfluoroquinolone. In ophthalmic use, moxifloxacin is indicated for treatment of conjunctivitis in children over 1 year of age and adults and noted for a

simplified dosing regimen of one or two drops three times a day for 7 days. Moxifloxacin is particularly effective against *S. pneumoniae*, which has been linked to epidemics of conjunctivitis. Isolates of *S. pneumoniae* from three patients were exposed to moxifloxacin 0.5%, tobramycin 0.3%, gentamicin 0.3%, and polymyxin B 10,000 IU-trimethoprim 1.0%. All medications were diluted 1:100 and 1:1,000 to emulate tear concentrations. Moxifloxacin killed actively growing *S. pneumoniae* faster and to a greater extent than did the other three antibiotic products when tested at concentrations corresponding to tear film levels 5 to 10 minutes and 30 to 60 minutes after instillation of the products. Numerous studies report significantly greater penetration of moxifloxacin compared with gatifloxacin into ocular tissues. As a result higher concentrations of moxifloxacin have been reported in the anterior chamber, the cornea, and the conjunctiva (see Figure 25-6).

Preservatives have been a differentiating point for the ophthalmic fourth-generation fluoroquinolones. In the United States gatifloxacin ophthalmic solution is preserved with benzalkonium chloride 0.005%, whereas moxifloxacin drops contain no preservative. Although several studies have attributed advantages or disadvantages related to the preservatives (or lack thereof), clinically no differences have been found.

Topical azithromycin 1.5% (Astern) is currently undergoing testing for bacterial conjunctivitis with good results reported. Introduction to the United States is expected by the fourth quarter of 2007.

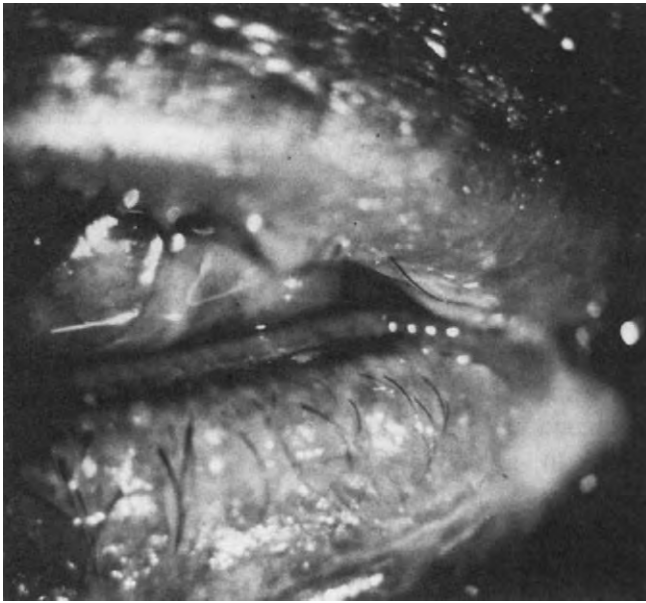Since the 1980s, when methicillin-resistant *S. aureus* emerged in the United States, vancomycin has been the last uniformly effective antimicrobial agent available for treatment of serious and, in some cases, life-threatening *S. aureus* infections. Sporadic cases of vancomycin-resistant *S. aureus* have been reported. Despite concerns expressed by the Centers for Disease Control and Prevention (CDC) in Atlanta and recommendations regarding the prevention of the spread of vancomycin resistance, vancomycin is being used with increasing frequency for ocular therapy and prophylaxis. Use of topical vancomycin at a concentration of 31 mg/ml has been successful in treating patients with chronic *S. epidermidis* and methicillin-resistant *S. aureus* infection. However, because of the possibility of fostering resistance to this last-line antibiotic, vancomycin should be considered for use only after commercially formulated agents have failed and sensitivity testing indicates likely effectiveness. The fourth-generation fluoroquinolones are generally effective against methicillin-resistant *S. aureus*; however increased resistance has been reported.

## Hyperacute Bacterial Conjunctivitis

### Etiology

Hyperacute bacterial conjunctivitis most commonly results from *N. gonorrhoeae* and, less frequently, from





**Figure 25-7** Hyperacute bacterial conjunctivitis with copious purulent discharge.

*N. meningitidis*. Other pathogens that can cause hyperacute conjunctivitis include *S. aureus*, *Streptococcus* species, *H. influenzae*, *Moraxella (Branhamella) catarrhalis*, *E. coli*, and *P. aeruginosa*.

### Diagnosis

Hyperacute bacterial conjunctivitis is characterized by a sudden rapid onset of purulent conjunctivitis with abundant discharge, chemosis, and severe hyperemia (Figure 25-7). Complaints of ocular pain, tenderness of the globe, periorbital discomfort, and eyelid swelling are common. Typically, the purulent discharge is copious and quickly recurs when wiped or washed away. Laboratory assessment, including both conjunctival cultures and smears, is mandatory to confirm the diagnosis of hyperacute conjunctivitis before initiating medical treatment. Smears should be analyzed with Gram stain at the time of the initial visit. Cultures should be performed using blood, chocolate, and Thayer-Martin agar media.

*N. gonorrhoeae* hyperacute conjunctivitis, a disease primarily of the neonate and of sexually active adolescents or young adults, most likely results from direct contact with infected genitals or indirect contact by the hands. Nonsexually transmitted cases have also been reported. Ocular involvement does not occur often; only four cases of hyperacute conjunctivitis were reported among 800,000 cases of gonorrhea. The patient's medical and sexual history must be reviewed, because associated systemic findings such as urethritis or vaginitis frequently occur and must be treated also. Potential sexual abuse should be considered when a child develops gonococcal conjunctivitis.

Gonococcal conjunctivitis usually is unilateral and progresses rapidly, often with periocular involvement.

Ocular pain with preauricular lymphadenopathy is common. The marked conjunctival inflammatory response includes chemosis and hyperemia with eyelid edema and a profuse, thick, yellow-green purulent exudate. If not treated promptly, the conjunctivitis can lead to preseptal cellulitis, bacterial keratitis, dacryoadenitis, and potential septicemia. Depending on the offending pathogen, hyperacute conjunctivitis also can lead to subsequent conjunctival membrane or symblepharon formation. If left untreated, *N. gonorrhoeae* can penetrate an intact cornea in 48 hours.

*N. meningitidis* hyperacute conjunctivitis usually occurs in children. It generally causes a milder conjunctivitis than that caused by *N. gonorrhoeae*, although the two are clinically similar. *N. meningitidis* hyperacute conjunctivitis can lead to devastating ocular and systemic complications if not treated promptly and effectively. Because of the potential danger, prophylaxis should be considered for close contacts. The disease often is bilateral and may occur in conjunction with meningococemia, meningitis, and endogenous endophthalmitis. One report indicates that meningococcal conjunctivitis led to systemic meningococcal infection in 6 of 21 patients. In a study of 21 patients and a literature review of another 63 patients with primary meningococcal conjunctivitis, 9 were neonates, 55 were children, and 20 were adults, with a male-to-female ratio of 1.76:1.00. The most common ocular complication was corneal ulceration. Systemic disease developed in 17.8% of the patients and was significantly more frequent in patients receiving only topical therapy.

### Management

Hyperacute bacterial conjunctivitis must be treated aggressively, because it carries potentially blinding consequences. Administration of topical and systemic antibiotics should begin immediately after specimens have been collected for laboratory analysis. Frequent irrigation of the conjunctiva with normal saline removes the purulent exudate, permitting better antibiotic access to the affected tissues. If gram-negative diplococci are identified on conjunctival smears, the patient should receive full doses of systemic antibiotics. Early diagnosis and aggressive systemic treatment can prevent the development of ocular, neurologic, or systemic complications. Concomitant *C. trachomatis* infection is common and must be treated. A study of 13 patients indicated that a single 1-g dose of intramuscular ceftriaxone is curative for gonococcal conjunctivitis. All patients' cultures were negative 6 hours and 12 hours after treatment. However, the treatment can be repeated for 5 consecutive days if necessary.

Because of their broad potent bactericidal activity, the fluoroquinolone antibiotics are also an appropriate topical therapy for nongonococcal hyperacute conjunctivitis. Topical moxifloxacin or gatifloxacin should be administered initially in a dose of two drops every hour.



Adjunctive systemic therapy includes ampicillin, amoxicillin, Augmentin, or cefaclor, 250 mg four times daily, depending on the patient's body weight and antibiotic sensitivities. Severe or disseminated infection requires hospitalization and treatment with intramuscular or intravenous antibiotics.

## Chronic Bacterial Conjunctivitis

### Etiology

Chronic bacterial conjunctivitis occurs infrequently, and its diagnosis and treatment may be difficult. *S. aureus* and *M. lacunata* are common causes. Other microorganisms that constitute normal flora may be implicated if overgrowth disrupts the normal balance among the organisms. Frequently, *S. epidermidis* is the etiologic agent in chronic blepharitis, which may alter the normal tear film composition. *Proteus mirabilis*, *E. coli*, *Klebsiella pneumoniae*, or *S. marcescens* may also cause chronic conjunctivitis. Environmental factors such as air pollution, allergies, and contact lens wear may influence the nature of the offending bacterial agent and the subsequent immunologic response. Lacrimal system problems are another common cause of chronic bacterial conjunctivitis.

### Diagnosis

Chronic bacterial conjunctivitis may present with various nonspecific symptoms and signs that are difficult to evaluate. Complaints of intermittent irritation, foreign body sensation, burning, tearing, redness, and sticky eyelids are common. Clinically, the conjunctiva may exhibit a mild diffuse hyperemia, a thickened appearance, mucoid or mucopurulent discharge, and a papillary or follicular reaction. The differential diagnosis includes chronic conjunctivitis caused by chlamydia, HSV, acne rosacea, floppy eyelid syndrome, irritants, allergens, and factitious causes. Patients with chronic bacterial conjunctivitis must undergo a thorough evaluation of the eyelids, because of the high correlation of lid disease with chronic bacterial conjunctivitis. In the presence of chronic blepharitis or angular blepharoconjunctivitis, the eyelid margins often appear hyperemic and crusty with markedly reduced tear film quality and breakup time. The clinician also should carefully evaluate the lacrimal drainage system for signs of dacryocystitis or stagnant tear flow. *Actinomyces israelii* is a frequent cause of canaliculitis and chronic conjunctivitis. Other clinical findings include bacterial exotoxin hypersensitivity reactions, marginal corneal infiltrates, and phlyctenules. Conjunctival smears stained with Giemsa and Gram stains are extremely useful for evaluating the infectious versus inflammatory components of chronic bacterial conjunctivitis. Impression cytology may also be helpful in establishing a diagnosis. Because of the chronic nature of this condition, it is prudent to attempt to identify and target the specific causative agent. Cultures on blood and chocolate agar media with drug sensitivities may prove

helpful in isolating the offending organism and determining the appropriate anti-infective agent.

### Management

The causative bacterial pathogen often inhabits the eyelid margins or the base of the eyelashes, even in asymptomatic patients. Successful treatment usually requires good eyelid hygiene by the patient, in conjunction with topical antibiotics. To eliminate any bacterial reservoir, concurrent blepharitis must be treated aggressively. Appropriate eyelid treatment consists of a routine of warm moist compresses applied for 10 to 15 minutes, massage of the eyelid margins, and, ideally, gentle eyelid scrubs two to four times daily. Compresses transfer heat to the eyelids, softening congealed meibomian gland secretions and freeing lid debris. Eyelid hygiene is crucial and must be performed by the patient on a regular ongoing basis. Lid scrubs may be accomplished with a warm washcloth, a cotton-tipped applicator, or a commercially available cleansing agent (see Chapter 3).

Because *S. aureus* often is associated with blepharitis, treatment may also require topical erythromycin or bacitracin ointment applied two or three times daily. If gram-negative bacteria are the offending organisms, bacitracin-polymyxin B or an aminoglycoside ointment is the drug of choice. In cases of primary meibomianitis, adjunctive oral treatment consisting of tetracycline, 250 mg four times daily, doxycycline, or minocycline, 50 mg twice daily, for 10 to 21 days significantly improves the patient's symptoms. The chronic bacterial conjunctivitis is treated with topical antibiotics that have broad antibacterial activity, such as trimethoprim-polymyxin B (Polytrim) or gentamicin solution applied four times daily. In recalcitrant cases, antibiotic treatment should be guided by culture and sensitivity results.

Antibiotic therapy should be limited to periods of disease exacerbation, with the eyelid hygiene providing the daily maintenance regimen. Occasionally, topical erythromycin, bacitracin, or bacitracin-polymyxin B ointment applied at bedtime for several weeks proves beneficial as part of the therapeutic protocol. This type of chronic therapy, however, always carries the risk of fostering overgrowth of resistant organisms.

If a significant inflammatory component or a response to bacterial exotoxin hypersensitivity in the form of marginal corneal infiltrates or phlyctenules is present, treatment may require concurrent topical steroid therapy. When chronic dacryocystitis is involved, treatment should include irrigation of the lacrimal system with trimethoprim-polymyxin B or gentamicin. Adjunctive systemic antibiotic therapy may also be required (see Chapter 24).

## Adenoviral Conjunctivitis

### Etiology

Adenoviral infection is a common cause of acute follicular conjunctivitis. More than 45 immunologically distinct

adenoviral serotypes have been identified, many of which are pathogenic for humans. Most adenoviral infections initially involve the upper respiratory tract or nasal mucosa (or both). Epidemic outbreaks of adenoviral conjunctivitis are recognized as the distinct clinical entities epidemic keratoconjunctivitis (EKC) and pharyngoconjunctival fever (PCF). In clinical practice the exact viral serotype is rarely identified, and different viral serotypes have been implicated as the causative agent of both EKC and PCF. Viral transmission in epidemic outbreaks occurs through direct contact, via droplet transmission, in swimming pools, and, occasionally, through contact with contaminated ophthalmic instruments and solutions.

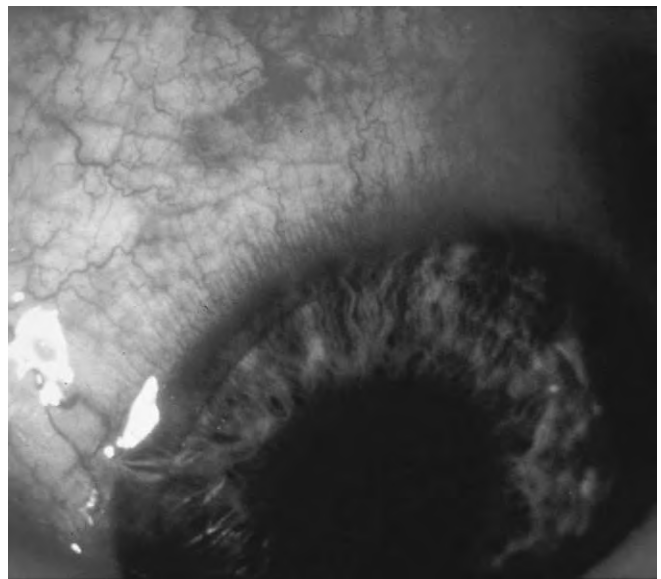
### Diagnosis

Adenoviral conjunctivitis classically presents as an acute follicular conjunctivitis. The infection usually is unilateral at onset but often becomes bilateral after several days. The second eye frequently is less severely involved than the first. Symptoms of adenoviral conjunctivitis include moderate foreign body sensation, tearing, and a watery to mucoid discharge. Patients often experience eyelid crusting, particularly on awakening.

Initially, marked conjunctival injection develops, along with variable degrees of conjunctival chemosis. In addition to conjunctival injection, moderate to marked eyelid and periorbital edema may also occur (Figure 25-8). Occasionally, petechial subconjunctival hemorrhages form and are most easily observed on the bulbar conjunctiva (Figure 25-9). These hemorrhages may coalesce, resulting in diffuse subconjunctival hemorrhage. Ipsilateral preauricular or submandibular lymphadenopathy, with or without tenderness, is a common feature of adenoviral conjunctivitis (Figure 25-10). In severe cases pseudomembranes or true conjunctival membranes may form on the



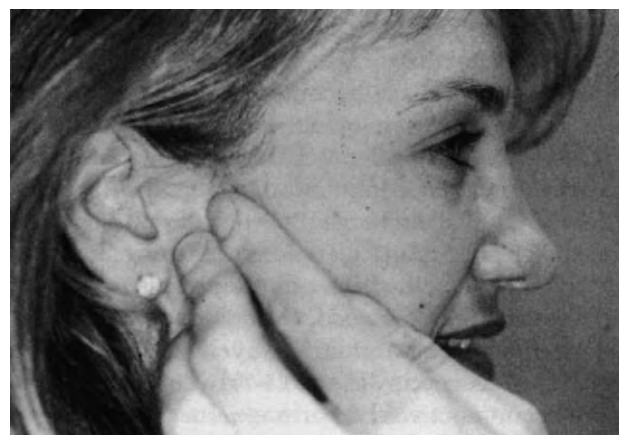**Figure 25-8** Epidemic keratoconjunctivitis affecting right eye first and then left eye. Note more intense involvement of right eye. Marked conjunctival injection and chemosis, subconjunctival hemorrhages, and eyelid edema are present. (Courtesy William Wallace, O.D.)



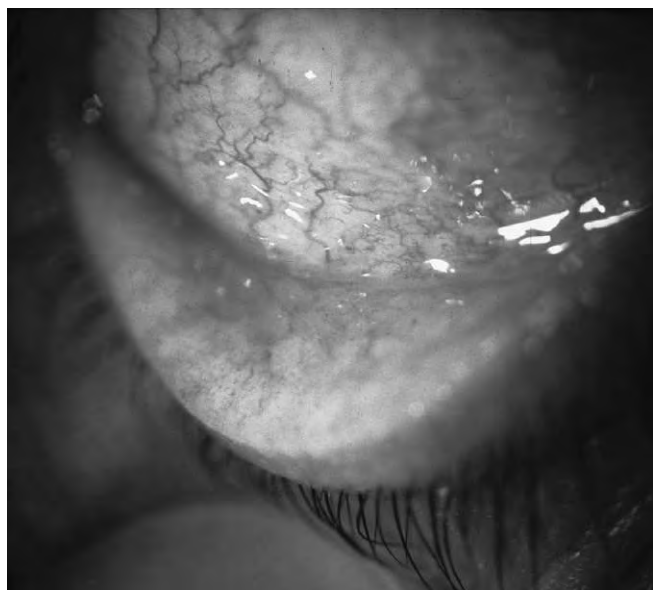
**Figure 25-9** Bulbar conjunctival injection and petechial hemorrhage.

lower or upper tarsal conjunctiva. These membranes result from the accumulation of mucus and inflammatory debris. Membranes and pseudomembranes can cause significant discomfort and foreign body sensation. Inadequately treated conjunctival membranes may lead to conjunctival scarring, symblepharon formation, and secondary cicatricial entropion.

When acute follicular conjunctivitis is accompanied by mild fever and pharyngitis, the clinical triad is recognized as PCF (Figure 25-11). An adenoviral infection seen most commonly in children, PCF is highly contagious and often is spread from contaminated swimming pools. Hence, PCF has been termed “swimming pool conjunctivitis.” Corneal involvement, however, distinguishes EKC from other forms of adenoviral conjunctivitis. The first manifestation of corneal disease in EKC is the appearance of



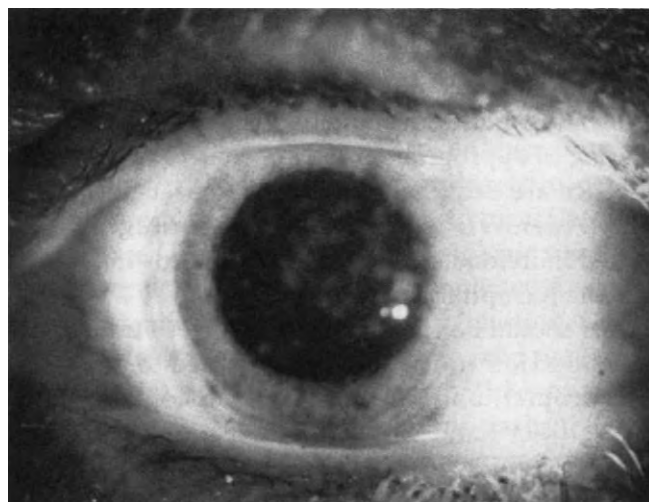
**Figure 25-10** Palpation of preauricular node in patient with adenoviral conjunctivitis.



**Figure 25-11** Follicular conjunctival changes in lower conjunctival fornix.

diffuse punctate epitheliopathy. A multifocal epithelial keratitis (discrete, coarse, epithelial erosions) ensues. Faint subepithelial opacities may begin to form under the epithelial lesions 10 to 14 days after the onset of infection (Figure 25-12). The punctate epithelial lesions resolve, but the subepithelial infiltrates may remain for an extended period, months or even years. When infiltrates or epithelial lesions occur on the visual axis, patients may experience decreased visual acuity. Besides loss of vision, the epithelial lesions and subepithelial opacities can cause bothersome glare, photophobia, and foreign body sensation. Extensive subepithelial infiltrates can cause permanent corneal scarring, resulting in reduction in visual acuity if scars occur on the visual axis or reduced acuity because of induced irregular astigmatism.

Most all cases of adenoviral conjunctivitis are diagnosed on the basis of a patient's signs and symptoms. Microbiologic investigation often is not needed, but adenoviral isolation via tissue culture can be achieved with conjunctival samples. A rapid immunochromatography test (RPS Adeno Detector, Rapid Pathogen Screening, Inc.)



**Figure 25-12** Multiple subepithelial corneal opacities in epidemic keratoconjunctivitis.

for visual qualitative detection of adenoviral antigens in human eye fluid that has good sensitivity for detection of adenovirus compared with cell culture is available. Other conditions that can have a similar clinical appearance include herpetic conjunctivitis, adult inclusion conjunctivitis, and hemorrhagic conjunctivitis. Severe membranous conjunctivitis can also occur in infections from group B streptococci or *C. diphtheriae* or, uncommonly, in Stevens-Johnson syndrome (SJS). The almost 50% occurrence of significant subepithelial infiltrates and their time course best differentiates EKC from these conditions. The conjunctivitis associated with EKC tends to be more severe than that caused by nonspecific adenoviral infection (Table 25-4). Patients can experience a considerable degree of discomfort and reduced visual function when infiltrates are extensive. Therefore they should receive assurance that symptoms may worsen before they begin to abate, typically about 5 days after the onset of symptoms.

#### Management

Adenoviral conjunctivitis is a self-limited infection. Most cases resolve spontaneously over approximately

**Table 25-4**

Differentiation of Epidemic Keratoconjunctivitis From Pharyngoconjunctival Fever

Condition	Age	Conjunctivitis	Cornea	Associated Findings	Etiologic Agent
Epidemic keratoconjunctivitis	Any age	Follicles, hyperemic membranes	Subepithelial infiltrates common	Tender, palpable preauricular node	Adenovirus types 8 and 19
Pharyngoconjunctival fever	Predominantly children	Follicles, hyperemic membranes	Superficial punctate keratitis; subepithelial infiltrates not common	Fever, pharyngitis, nontender node	Adenovirus types 3 and 7

14 to 21 days. In patients who develop keratitis and subepithelial infiltrates, however, corneal infiltrates can last for many months. During the acute phase of adenoviral conjunctivitis, particularly in patients who are mildly or moderately symptomatic, supportive therapy, including cold compresses, decongestants, and lubricants, can help to relieve patients' symptoms.

The use of antiviral agents in the management of adenoviral conjunctivitis has proved uniformly disappointing. Because of the relatively high degree of toxicity of antiviral agents and due to the generally self-limited course of the infection, currently available antiviral agents are not generally indicated.

Use of povidone iodine has been advocated by some for the treatment of adenoviral conjunctivitis. The only controlled study of this treatment option demonstrated no significant effect of 1.25% povidone iodine administered four times daily on either days to resolution or proportion of cases resolved at 1 and 2 weeks.

Topical nonsteroidal anti-inflammatory agents also do not appear to improve symptoms in adenoviral conjunctivitis. Topical ketorolac 0.5% used four times daily was shown to be no better than artificial tears at relieving the symptoms or signs of viral conjunctivitis and produced more stinging than artificial tears.

Topical antibiotics generally are not useful in managing adenoviral infections. Although secondary bacterial infection is possible, the risk of hypersensitivity and toxic reactions to topical antibiotics must be weighed against the potential benefit of preventing secondary bacterial infection. The exception is in patients who develop significant conjunctival membranes or pseudomembranes. After these membranes or pseudomembranes have been removed, patients should be treated with a broad-spectrum antibiotic, because they may be at increased risk for secondary bacterial infection. In these patients consideration should also be given to the use of an antibiotic-steroid combination that may help prevent scarring.

The role of steroids in the management of EKC remains controversial. Subepithelial infiltrates associated with adenoviral infection represent a cell-mediated immune response, most likely to viral protein. Topical steroids enhance viral replication and increase viral shedding. Suppressing the immune response with steroids may interfere with clearing the viral antigen, which ultimately may prolong the course of the corneal disease. Although steroids are highly effective in reducing corneal infiltrates, some patients may develop a steroid dependence in which discontinuation of the steroid results in recurrence of the subepithelial infiltrates. These patients may require prolonged treatment with topical steroids for periods of months to even years and may be subject to the complications associated with chronic steroid use. The existence of an EKC-like variant of HSV keratoconjunctivitis should further discourage the routine use of topical steroids. The early epithelial phase of EKC can be

clinically indistinguishable from this form of diffuse herpetic keratitis, and treatment of herpetic keratitis with topical steroids leads to exacerbation of the herpetic infection. Steroids should be reserved for patients who are highly symptomatic or are visually impaired by subepithelial infiltrates. Clinicians should inform patients about the potential risks and benefits before instituting steroid treatment. As an alternative to topical steroids, the use of topical cyclosporin A in the management of adenoviral corneal subepithelial infiltrates has yet to be defined.

Educating patients about appropriate hygiene and adhering to standard infection control procedures in the office are extremely important aspects of management. Adenoviral infections are contagious, and infected individuals continue to shed virus in tears and from the nasopharynx for approximately 2 weeks. Patients should be educated with regard to transmission of the infection and should be instructed to adopt stringent, droplet, and contact infection control precautions. Direct hand-to-eye contact may result in the transmission of infection.

The practitioner's office should follow proper recommended infection control procedures to prevent transmission of adenoviral conjunctivitis. Staff should carefully disinfect equipment, particularly tonometer tips, used in examining infected patients. Safe practice includes the use of barrier protection, such as gloves, while the practitioner examines patients with adenoviral conjunctivitis. Careful hand washing before and after patient examination is mandatory.

## **Herpes Simplex Conjunctivitis**

### **Etiology**

In the United States 70% of the population has immunologic evidence of prior HSV infection by the age of 15 to 20 years and 97% by the age of 60. The primary HSV infection is subclinical in 85% to 90% of cases. Of the two types of HSV, HSV-1 predominates, accounting for approximately 85% of adult cases and is responsible for infection above the waist. Type 1 and type 2 ocular infections are clinically indistinguishable, although type 2 infections tend to be more severe.

Herpetic conjunctivitis is usually a manifestation of primary HSV infection, which generally occurs in children between the ages of 6 months and 5 years. Most cases of herpetic ocular infection result from the nonvenereal form of the virus (HSV-1). Ocular infection with HSV-2 can occur in both newborns and adults. Infection may result from contact with the virus in the infected birth canal (herpetic neonatal conjunctivitis) or from autoinoculation after sexual contact with an infected partner.

### **Diagnosis**

The acute onset of unilateral bulbar conjunctival injection and tearing in a young child should always bring to mind the possibility of primary herpetic infection. If the



**Figure 25-13** Vesicular herpes simplex lesions of eyelid margin and periocular skin.

conjunctival injection is bilateral, the second eye will most commonly have become inflamed less than 1 week from the onset of infection in the first eye. Careful examination of the eyelids and periorbital skin may reveal the typical vesicular eruptions characteristic of herpes simplex dermatitis (Figure 25-13). These erythematous vesicular eruptions may appear similar to ulcerative staphylococcal blepharitis but tend to be unilateral and isolated (see Chapter 23). The dermatologic signs do not always occur, and acute follicular conjunctivitis may be the only manifestation of the primary infection. Conjunctival follicles are a prominent feature, and pseudomembrane formation is not uncommon. Many patients develop preauricular lymphadenopathy. Corneal involvement may manifest as diffuse punctate epitheliopathy, subepithelial infiltrates, or the appearance of a typical dendritic or geographic corneal ulcer (see Chapter 26). Rarely, dendritic or geographic bulbar conjunctival ulcerations occur.

Care must be taken to diagnose accurately any case of herpetic conjunctivitis. Herpetic conjunctivitis shares many of the clinical features of adenoviral conjunctivitis, and in the absence of recognizable corneal disease the two entities cannot easily be distinguished. Differentiation is particularly important if the practitioner contemplates using steroids as part of the management of adenoviral conjunctivitis, because the use of topical steroids exacerbates HSV infections.

### Management

Herpetic conjunctivitis without corneal involvement usually is benign and self-limited. In patients with primary herpetic blepharoconjunctivitis, prophylactic treatment with antiviral agents to prevent corneal involvement is common practice. Trifluridine (Viroptic) usually is well tolerated and is effective against many strains of HSV. The typical dose is one drop every 2 hours for a maximum

of nine drops daily. One drop five times daily is sufficient when there is no corneal involvement. This dose is reduced to one drop every 4 hours when clinical improvement occurs. Treatment continues for 3 to 5 days after the infection has resolved clinically.

Steroids are specifically contraindicated in the treatment of HSV conjunctivitis, because they can increase virus replication and interfere with the host immune response to the infection. Topical antibiotics are also of limited value in treating HSV. The risk of bacterial superinfection is low, and the potential toxic and hypersensitivity reactions associated with topical antibiotic use may obscure the clinical course of the underlying viral infection.

### Varicella-Zoster Conjunctivitis

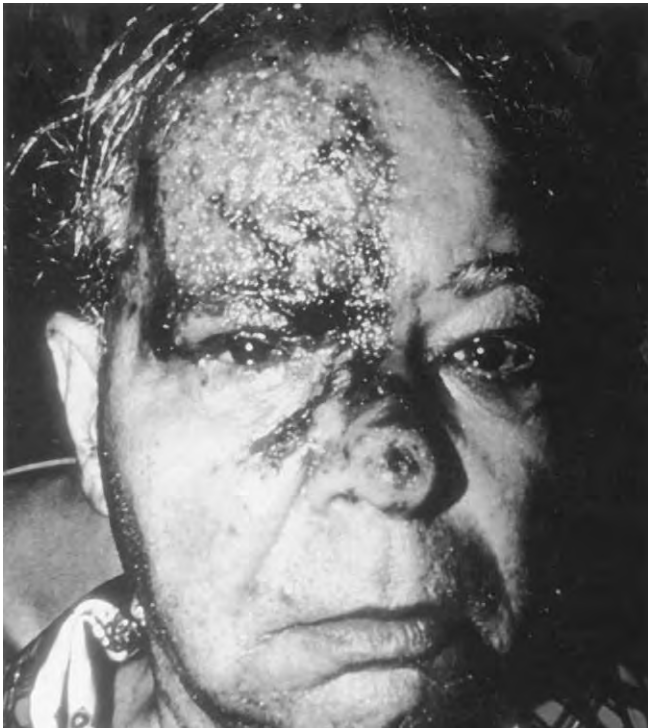#### Etiology

Herpes zoster results from reactivation of the dormant varicella virus, the same virus that generally is acquired during childhood and results in chickenpox. The incidence and severity of herpes zoster infections increase with age. An increased incidence of herpes zoster is also associated with immunocompromise. Peak incidence occurs between the ages of 50 and 75 years. In young patients with no history of malignancy or immunosuppression, herpes zoster infection may be the presenting sign of acquired immunodeficiency syndrome–related complex or frank acquired immunodeficiency syndrome. Ocular lesions occur in approximately 50% to 71% of the patients who develop active herpes zoster infection involving the first (ophthalmic) division of the trigeminal nerve, the most commonly affected division. Ocular involvement is much less common when the infection affects the second or third division of the trigeminal nerve.

#### Diagnosis

Patients with herpes zoster infection typically experience a prodrome of low-grade fever, headache, and pain or paresthesia along the affected dermatome. Subsequently, patients develop erythematous vesicular eruptions localized to the dermatome innervated by the affected nerve ganglia. The vesicular eruptions respect the midline, revealing the neurologic nature of the infection. The vesicles may affect the skin of the eyelids and extend onto the side and tip of the nose (Hutchinson's sign), a result of spread along the nasociliary branch of the ophthalmic division of the trigeminal nerve (Figure 25-14). In the early stages vesicles may be subtle, such that careful examination of the skin and hairline are necessary to appreciate the lesions. After several days the eruptions begin to crust, at which point they usually become obvious.

In addition to eyelid swelling on the affected side, acute conjunctivitis is the most common ocular manifestation of herpes zoster infection. The conjunctivitis is



**Figure 25-14** Hutchinson's sign in herpes zoster ophthalmicus. Note simultaneous involvement of the eye and the side and tip of the nose. (Courtesy William Wallace, O.D.)

predominantly follicular, although there may be a mixed papillary and follicular response. Regional lymphadenopathy on the affected side occasionally may develop. Because the conjunctivitis associated with zoster infection is largely indistinguishable from other types of viral conjunctivitis, recognition of the dermatologic features of the infection is the key to diagnosis. Herpes zoster infection can result in many other ocular manifestations, including keratitis (punctate, dendritic, or disciform), uveitis, and increased intraocular pressure. Cranial nerve palsies, optic neuritis, and retinitis also occur, though rarely.

### Management

Conservative treatment of zoster-associated conjunctivitis, including cold compresses, lubricants, and decongestants, carries the lowest risk of treatment-related complications. Treatment of the acute conjunctivitis with topical broad-spectrum antibiotics may help to prevent secondary bacterial infection. Increased patient comfort by reduction of conjunctival inflammation may be affected by the use of topical steroids. Often, a combination antibiotic-steroid is used to accomplish both of these goals. In contrast to herpes simplex infection in which steroids are specifically contraindicated, topical steroids do not exacerbate herpes zoster infection. If steroids are used, the patient should be carefully monitored for intraocular pressure elevation.

The use of oral antiviral agents to treat the acute herpes zoster infection has been successful. Oral acyclovir, 800 mg five times daily for 7 days, effects a rapid resolution of the signs and symptoms of acute herpes zoster ophthalmicus, particularly if treatment is initiated within 72 hours of the initial skin eruption. Oral antiviral agents also reduce the duration and intensity of postherpetic neuralgia, which occurs in approximately 20% of patients. Although acyclovir has been effective and few complications are associated with its use, the limited bioavailability of acyclovir in oral form requires frequent dosing. Newer antiviral prodrugs include valacyclovir and famciclovir. Both of these agents provide an increase in bioavailability of the active drug, thus requiring less frequent dosing. In addition to the decreased dosing schedule, valacyclovir, 1,000 mg three times daily, and famciclovir, 500 mg three times daily, accelerate lesion healing, reduce the duration of viral shedding, and result in faster resolution of postherpetic neuralgia.

The increased bioavailability and decreased dose frequency, combined with the potential shorter duration of the associated postherpetic neuralgia, argue for careful consideration of these newer agents for the acute treatment of herpes zoster infections.

## Inclusion Conjunctivitis

### Etiology

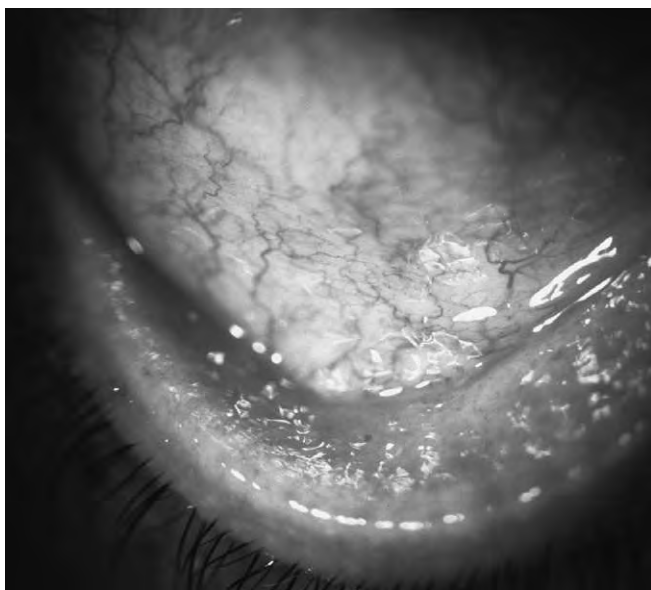
Chlamydiae are obligate intracellular parasites that depend on the host cell to carry out metabolic biosynthesis. The genus includes two major species: *C. trachomatis*, which causes disease in humans, and *Chlamydia psittaci*, which infects primarily nonhumans. The many different serotypes cause a wide spectrum of disease states, including inclusion conjunctivitis, trachoma, lymphogranuloma venereum, and cervicitis or urethritis.

Chlamydial infection is the most common sexually transmitted disease in the United States, with an estimated 2.8 million new cases per year. In 2002 over 800,000 cases of chlamydial infection were reported to the CDC, with many more cases remaining unreported.

Approximately 75% of women and 50% of men have no urogenital symptoms. Chlamydial infections should be suspected in patients who develop nongonococcal urethritis, mucopurulent cervicitis, or pelvic inflammatory disease. Ocular infection commonly occurs by autoinoculation in the infected individual.

### Diagnosis

Inclusion conjunctivitis presents in teenagers and sexually active adults as an acute or chronic follicular conjunctivitis often accompanied by a mucopurulent discharge. Upper respiratory symptoms and fever generally are lacking. The disease often occurs in patients who have acquired a new sexual partner in the last 1 to 2 months. After an incubation period of 5 to 12 days, there is acute onset of conjunctival injection, mixed follicular-papillary



**Figure 25-15** Mixed follicular-papillary hypertrophy in adult inclusion conjunctivitis.

hypertrophy, and foreign body sensation (Figure 25-15). The disease usually is unilateral. A small, nontender, preauricular node on the affected side may develop during the initial stages of the infection. During the second week of the infection keratitis may develop, along with marginal or central infiltrates, superficial pannus, and even EKC-like opacities. The corneal involvement has a predilection for the superior cornea.

Patients often seek treatment during the acute phase of the disease, which practitioners may misdiagnose as a viral or bacterial conjunctivitis. Treatment with a variety of broad-spectrum topical antibiotics or topical steroids may initially help the patient's symptoms, but because such treatment is inadequate to eradicate the systemic infection, the patient invariably returns with complaints of recurrent episodes of conjunctival injection and mucopurulent discharge. As in all cases of chronic conjunctivitis, conjunctival cultures and scrapings should be performed to establish a definitive diagnosis. Specimen culture has been the historical gold standard for laboratory diagnosis of *Chlamydia* infection. In addition, conjunctival scrapings with identification of inclusion bodies by Giemsa staining are considered diagnostic of chlamydial infections. Direct immunofluorescent and immunoenzyme antibody assay of conjunctival scrapings are rapid and easily performed diagnostic tests with fair sensitivity and good specificity. NAAT offer superior sensitivity for the detection of *C. trachomatis* infection but are more expensive and take longer to obtain results.

#### Management

Topical therapy of adult inclusion conjunctivitis by itself cannot effect a cure. Currently, the CDC recommends azithromycin 1 g orally in a single dose or doxycycline

100 mg orally twice a day for 7 days when not otherwise contraindicated. This single dose of azithromycin should be considered particularly for patients in whom compliance may be a problem.

Pregnant and lactating women and children younger than 8 years should avoid oral doxycycline therapy. In these patients erythromycin base, 500 mg four times daily for 7 days, or amoxicillin, 500 mg three times daily for 7 days, is an alternative to doxycycline. Once systemic therapy has been initiated, topical treatment with lubricants, vasoconstrictors, or a combination antibiotic-steroid may help to relieve the patient's ocular symptoms.

All patients with suspected or confirmed chlamydial conjunctivitis should be tested for other sexually transmitted diseases and evaluation and consideration given to comanagement with a gynecologist or urologist. If left untreated, chlamydial vaginitis can result in severe pelvic inflammatory disease, ectopic pregnancy, and infertility. Sexual partners of infected individuals should also receive systemic antibiotics, even if no symptoms are present. In preadolescent children, sexual abuse must be considered in cases of confirmed chlamydial infection.

## Trachoma

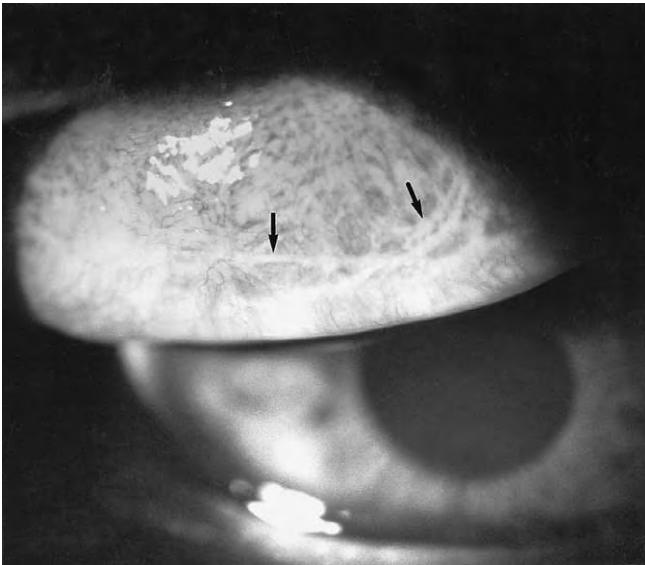
### Etiology

Although *C. trachomatis* is the infectious agent of both trachoma and adult inclusion conjunctivitis, the clinical presentations and the epidemiologic characteristics of the two diseases are very different. Trachoma and its complications still represent a serious world health problem and today remain a major cause of preventable blindness. The incidence of trachoma is highest in unhealthy, dirty, crowded conditions typically associated with a low socioeconomic stratum. Trachoma affects approximately one-seventh of the world's population. In the United States the disease is limited mostly to small pockets of Native American populations living in the Southwest. A global initiative to eliminate trachoma as a blinding disease, entitled GET 2020 (Global Elimination of Trachoma), was launched under the World Health Organization's leadership in 1997.

### Diagnosis

In its early stages trachoma presents as a chronic follicular conjunctivitis with a predilection for the superior tarsal and bulbar conjunctiva. Over time, the conjunctival reaction becomes papillary in nature and, with the inflammatory infiltration that occurs, the follicular character of the infection can become obscured. Patients experience symptoms of photophobia, tearing, and mucoid or mucopurulent discharge. Limbal edema and superior bulbar conjunctival hyperemia also may occur. Conjunctival follicles that form at the limbus are characteristic of severe trachoma. Primary corneal involvement often includes superior epithelial keratitis and superficial superior pannus formation. A wide variety of corneal infiltrates





**Figure 25-16** Conjunctival scarring with Arlt's lines (arrows) in stage IV trachoma.

(superior, diffuse, limbal) may occur, and marginal ulcerations are common.

As the disease progresses conjunctival subepithelial scarring begins to replace the acute inflammatory signs. Fine, linear, horizontal subepithelial scars that form on the upper tarsal conjunctiva are known as Arlt's lines (Figure 25-16). The scarring can result in entropion and trichiasis, which, in turn, can lead to corneal ulceration and scarring; these are the major blinding complications of trachoma. The involution of limbal follicles results in sharply demarcated limbal depressions known as Herbert's pits, which are considered pathognomonic for trachoma. Patients with severe conjunctival scarring often develop secondary complications, including severe dry eye syndrome and punctal stenosis.

In areas endemic for this disease, the presence of two of the typical signs—upper tarsal follicles, pannus, or limbal follicles—is sufficient for the diagnosis of trachoma. In nonendemic populations trachoma must be differentiated from other causes of follicular conjunctivitis, such as *Moraxella*, adenoviral infection, HSV infection, molluscum, and chemical conjunctivitis. The practitioner should obtain a careful history, including travel to any area associated with endemic trachoma. The predilection of trachoma to affect the upper tarsal conjunctiva as well as the superior cornea has great diagnostic value. Laboratory studies may be useful in mild cases, either by isolating *Chlamydia* in tissue culture or by detecting chlamydial antibodies in serum or tears by means of immunofluorescent assay or with the use of NAAT.

### Management

The World Health Organization recommended SAFE strategy (surgery of late-stage disease, antibiotics for acute

infection, and improved facial hygiene and environmental change, i.e., improved access to water and sanitation) forms the basis for treatment for elimination of blindness from trachoma.

Trachoma can be effectively treated with a 4- to 6-week course of topical tetracycline ointment. Additionally, oral tetracycline 250 mg four times a day or doxycycline 100 mg orally twice a day for 14 days is an effective option if not contraindicated. Alternatively, azithromycin in a single oral dose (20 mg/kg) was found to be equally effective in resolving active trachoma and offers the advantage of increased compliance. Reinfection rates are high, especially in endemic areas. In patients with severe conjunctival cicatrization, surgical intervention may be required to correct trichiasis and entropion and to prevent corneal scarring.

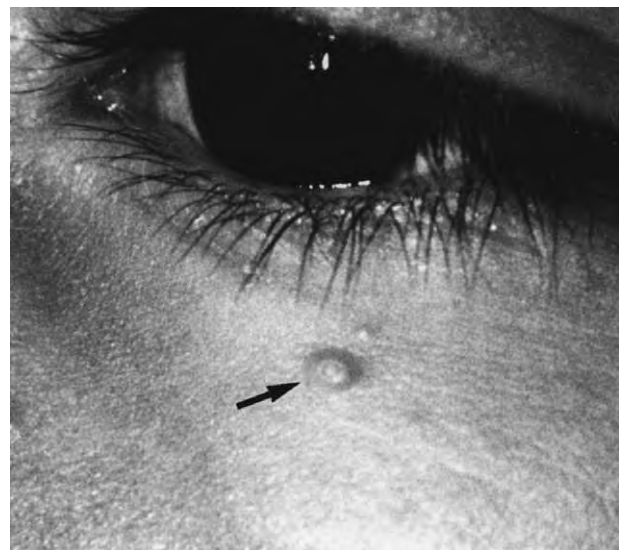
## Molluscum Contagiosum

### Etiology

Molluscum contagiosum is a dermatologic lesion caused by a poxvirus and is responsible for causing chronic or recurrent follicular conjunctivitis in patients who have lesions of the periorbital skin or eyelids.

### Diagnosis

The eyelid lesion is smooth with a central area of umbilication (Figure 25-17). Detection of some lesions may be difficult, because the eyelashes can obscure them. Clinical manifestations of conjunctivitis include the chronic and intermittent occurrence of conjunctival hyperemia, tearing, and follicular hypertrophy of the lower tarsal conjunctiva. Symptoms frequently wax and wane, and patients often use multiple topical antibiotics and steroids without success. The treatment may allow



**Figure 25-17** Molluscum contagiosum lesion (arrow) on lower eyelid of young child.

the condition to improve, but the untreated skin lesion continues to shed virus particles that cause a toxic reaction and chronic inflammation.

### Management

The management of chronic follicular conjunctivitis associated with molluscum contagiosum is removal of the dermatologic lesion to prevent further spread of virus particles into the eye. This treatment is curative, and no further intervention is required. Multiple or recurrent molluscum lesions may be associated with systemic immunosuppression and may be a sentinel lesion in patients with human immunodeficiency virus infection.

## Acute Hemorrhagic Conjunctivitis

### Etiology

Both *Enterovirus* and Cocksackievirus are recognized as causing acute hemorrhagic conjunctivitis (AHC). During the last 25 years, several large epidemic outbreaks of AHC have occurred worldwide.

### Diagnosis

A rapid onset of bulbar conjunctival injection, tearing, and pain characterizes AHC. The incubation period for AHC is often 1 day or less. This rapid onset contrasts with most cases of adenoviral conjunctivitis, which have a longer incubation period and duration. The conjunctiva develops moderate to severe hyperemia. Small petechial hemorrhages may subsequently form on the bulbar conjunctiva. The superior bulbar conjunctival petechial hemorrhages may increase and spread until there is diffuse and extensive subconjunctival hemorrhage. However, extensive subconjunctival hemorrhage is not a universal feature of the infection. Ocular examination or eyelid eversion may incite hemorrhaging. Most patients develop follicles in the lower tarsal conjunctiva and demonstrate regional lymphadenopathy. The cornea may demonstrate a fine punctate epithelial keratitis or subepithelial infiltrates. In addition to the acute conjunctivitis, several reports describe late neurologic complications, including asymmetric flaccid motor paralysis and cranial nerve palsies.

### Management

AHC is self-limited over a period of 5 to 10 days. Because antiviral agents are ineffective, the preferred treatment consists of topical application of cool compresses and astringents. Patients require reassurance, because the appearance of diffuse subconjunctival hemorrhage in the presence of pain and tearing is quite stressful. Patient education should stress the severe communicability of this disorder, and appropriate precautions should be taken to limit the spread of the infection. Topical steroids have not demonstrated any significant effect and may actually prolong the infection.

## Nonspecific Viral Conjunctivitis

Acute conjunctivitis is a common feature of many other viral illnesses. The clinical manifestations are nonspecific, and knowledge of the systemic manifestations of these diseases leads to the appropriate diagnosis. Most cases result in mild, acute, transient, bilateral, follicular conjunctivitis. Treatment of the conjunctivitis in each case is generally supportive, with cold compresses, decongestants, and lubricants used to ease the symptoms of acute conjunctivitis. Table 25-5 summarizes clinical features of the most common viral illnesses with which conjunctivitis is associated.

## Nonviral Infectious Etiologies

Several other infectious agents can cause follicular conjunctivitis and should be included in the differential diagnosis of either acute or chronic follicular conjunctivitis.

### *Moraxella* Conjunctivitis

*M. lacunata* has long been recognized as a cause of conjunctivitis. It may produce at least two types of conjunctival infections: acute angular blepharoconjunctivitis and chronic follicular conjunctivitis. Conjunctival hyperemia, pain, adherent eyelids on awakening, and follicular conjunctivitis characterize *Moraxella* conjunctivitis. Epidemic outbreaks can occur, and sharing eye makeup among school-aged girls has been identified as a risk factor for infection. Conjunctival scrapings demonstrate the characteristically large, square, diplobacillus organism. Traditional treatment of *Moraxella* conjunctivitis has included topical 0.25% zinc sulfate; however, topical 0.5% erythromycin or topical bacitracin ointment two to three times daily is more effective and less toxic.

### Lyme Disease

Lyme disease, caused by the spirochete *Borrelia burgdorferi*, incites a variety of ocular manifestations, the most common being a conjunctivitis that occurs in up to 10% of patients with early disease. Although the characteristics of the conjunctivitis have not been clearly defined, several reports have described follicular conjunctivitis. Increased antibody titers to *B. burgdorferi* indicate the presence of Lyme disease. A history of tick bite or erythema chronicum migrans should alert the clinician to consider Lyme disease in the differential diagnosis in areas of the country where this disease is prevalent. Treatment of Lyme disease conjunctivitis should include topical tetracycline as an adjunct to oral doxycycline, 100 mg twice daily for 2 to 3 weeks, which is used to treat the systemic infection.

### Parinaud's Oculoglandular Syndrome

Parinaud's oculoglandular syndrome constitutes a broad spectrum of conjunctival diseases caused by a variety of

**Table 25-5**  
Systemic Viral Diseases With Associated Conjunctivitis

Disease	Virus	Systemic Findings	Conjunctival Findings	Other
Infectious mononucleosis	Epstein-Barr virus	Malaise, headache, fever, sore throat, lymphadenopathy	Eyelid hyperemia, edema, follicles, membranes	Dacryoadenitis, episcleritis, epithelial and nummular keratitis
Newcastle's disease	Paramyxovirus	Mild upper respiratory symptoms, lymphadenopathy	Unilateral follicular conjunctivitis	Associated with poultry exposure
Measles	Rubeola	Fever, cough, brownish pink maculopapular eruptions of skin	Hyperemia, chemosis commonly associated with prodrome	Koplik's spots
German measles	Rubella	Malaise, fever, rhinitis, fine pinkish macules	Mild hyperemia, follicles	Tender postauricular lymphadenopathy
Mumps	Paramyxovirus	Malaise, headache, anorexia, parotiditis	Hyperemia, follicles	Rare disciform keratitis
Influenza	Influenza	Cough, fever, malaise, headache	Hyperemia, follicles	Epidemic seasonal outbreaks
Avian flu	Avian influenza A	Influenza like symptoms and pneumonia	Nonspecific	

infectious agents. The manifestations of the condition vary and are nonspecific to the etiologic agent. Unilateral follicular conjunctivitis and conjunctival granulomas and ulcerations associated with prominent regional lymphadenopathy are the primary clinical characteristics of the condition. The conjunctivitis and adenopathy usually resolve in 4 to 5 weeks. The specific clinical entity most commonly associated with Parinaud's oculoglandular syndrome is cat-scratch disease, which now is believed to be caused by *Bartonella henselae*, a *Rickettsia*-like organism. Box 25-4 lists the other agents responsible for Parinaud's oculoglandular syndrome.

**Ophthalmia Neonatorum**

Ophthalmia neonatorum, or conjunctivitis of the neonate (within 30 days of birth), warrants special consideration because of its relatively common occurrence; up to 12% of newborns demonstrate this condition. Because of the potentially devastating effects of neonatal infections resulting from *N. gonorrhoeae*, *Pseudomonas*, *Chlamydia*, and HSV, laboratory investigation is essential in establishing the cause. Infants usually acquire infection from an infected birth canal. Premature membrane rupture and prolonged delivery can also cause increased exposure to maternal pathogens and an increased risk of neonatal infection.

***Neisseria gonorrhoeae* Ophthalmia Neonatorum.** Gonococcal neonatal conjunctivitis is characterized by the neonate's development of hyperacute conjunctivitis between 2 and 5 days postpartum. Most cases of neonatal gonococcal conjunctivitis are bilateral; periorbital edema, chemosis, and purulent exudate are prominent (Figure 25-18).

Because of the ability of *N. gonorrhoeae* to penetrate intact epithelium, prompt and accurate diagnosis is imperative to prevent corneal ulceration and perforation. *N. gonorrhoeae* can also be associated with systemic infection. Specific dermatologic manifestations are possible, and careful neurologic monitoring for evidence of central nervous system involvement is imperative.

**Box 25-4** Causes of Parinaud's Oculoglandular Syndrome

**Common**

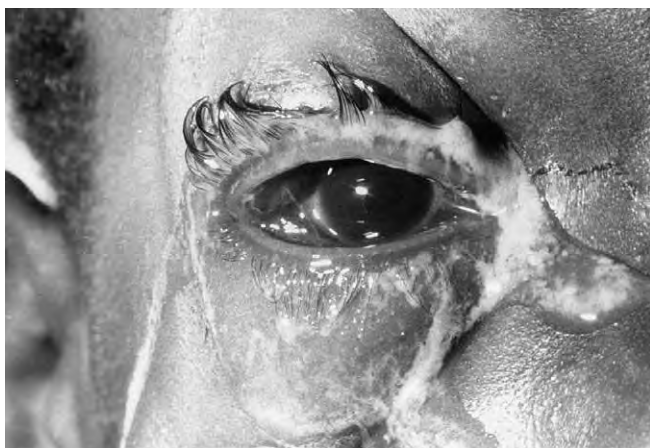- Cat-scratch disease
- Tularemia
- Sporotrichosis

**Occasional**

- Tuberculosis
- Syphilis
- Coccidioidomycosis

**Rare**

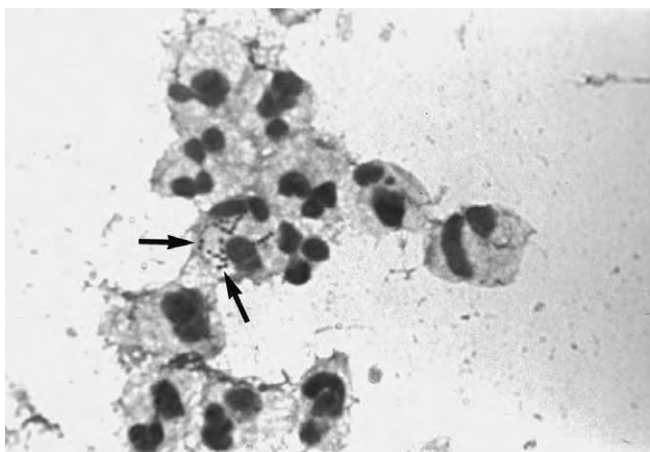
- Pasteurella septica*
- Yersinia pseudotuberculosis*
- Chancroid
- Lymphogranuloma venereum
- Listerellosis
- Actinomycosis
- Blastomycosis
- Mumps



**Figure 25-18** Neonatal conjunctivitis secondary to *Neisseria gonorrhoeae*. Note the copious purulent exudates and pronounced chemosis. (Courtesy William Wallace, O.D.)

Presumptive diagnosis is based on the finding of gram-negative diplococci on Gram staining of conjunctival exudate (Figure 25-19). Conjunctival cultures should be obtained and incubated on Thayer-Martin or chocolate agar at 37°C under 2% to 10% CO<sub>2</sub>. Antibiotic sensitivities are essential for all isolates due to the increasing incidence of penicillin-resistant strains of *N. gonorrhoeae*.

Topical antibiotic agents alone are inadequate and unnecessary when systemic treatment is administered. A single dose of ceftriaxone, 25 to 50 mg/kg intravenously or intramuscularly, not to exceed 125 mg, is the regimen currently recommended by the CDC. Simultaneous infection with *C. trachomatis* should be considered when a patient does not improve after treatment. Both mother and infant should be tested for chlamydial infection at the same time that gonorrhea testing is conducted.



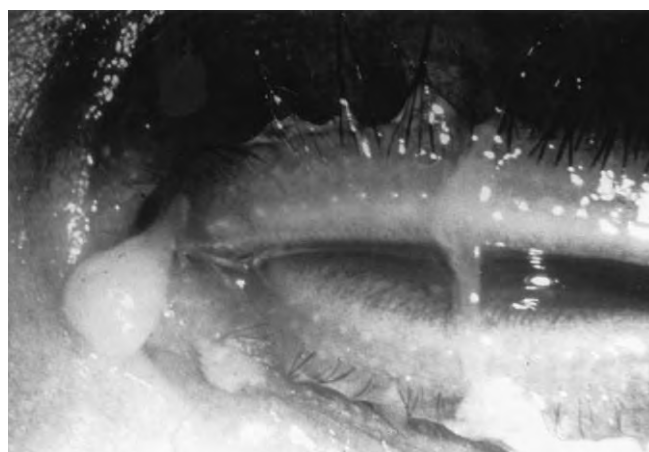
**Figure 25-19** Gram-stained smear from neonate with hyperacute conjunctivitis showing intracellular *Neisseria gonorrhoeae* (arrows). (Courtesy William Wallace, O.D.)

***Chlamydia trachomatis* Ophthalmia Neonatorum.** The leading infectious cause of ophthalmia neonatorum is *C. trachomatis*. This infection has been estimated to occur in 2% to 6% of all newborns. Its high incidence is attributable to the fact that up to 13% of women shed *Chlamydia* from the urogenital tract during the third trimester of pregnancy. The high incidence of infection may also be related to the ineffectiveness of silver nitrate in preventing chlamydial infection.

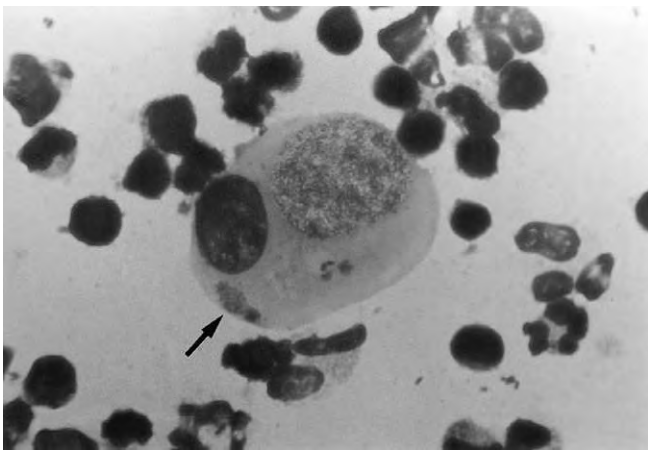
Chlamydial ophthalmia neonatorum is characterized by the onset of a mild to moderate unilateral or bilateral mucopurulent conjunctivitis 5 to 14 days postpartum (Figure 25-20). Eyelid edema, chemosis, and conjunctival membrane or pseudomembrane formation may also accompany this condition. Corneal findings occasionally include punctate opacities and micropannus formation. Ophthalmia neonatorum secondary to *C. trachomatis* was once considered a benign and self-limited condition. However, systemic chlamydial infection, especially pneumonitis, is now well recognized in patients with chlamydial conjunctivitis. More than 50% of infants who develop chlamydial pneumonitis may also have ophthalmia neonatorum.

Diagnosis of chlamydial ophthalmia neonatorum is established by conjunctival smears that reveal typical basophilic intracytoplasmic inclusions with Giemsa stain and by traditional specimen culture (Figure 25-21). Direct immunofluorescent, immunoenzyme antibody, or NAAT testing can also be helpful in confirming the diagnosis.

Optimal treatment of chlamydial ophthalmia neonatorum has not been determined. The CDC recommends erythromycin base or ethylsuccinate syrup 50 mg/kg/day orally divided into four doses daily for 14 days. Topical antibiotic therapy alone is inadequate and unnecessary when systemic treatment is administered. Another important aspect of treatment is concurrent therapy for the mother and her sexual partners.



**Figure 25-20** Neonatal inclusion conjunctivitis with prominent mucopurulent exudates. (Courtesy William Wallace, O.D.)



**Figure 25-21** Intracytoplasmic inclusions (*arrow*) associated with neonatal inclusion conjunctivitis. (Courtesy William Wallace, O.D.)

**Other Bacterial Etiologies in Ophthalmia Neonatorum.** Many cases of ophthalmia neonatorum result from nongonococcal bacterial infections. *S. aureus*, *Haemophilus* species, *Streptococcus viridans*, *E. coli*, and *P. aeruginosa* have been implicated as causative agents in ophthalmia neonatorum. These pathogens are most likely acquired as the newborn travels through the birth canal. All these bacteria are part of the normal bacterial flora of the female genital tract. Infection may arise from other sources as well, because 20% to 79% of the conjunctivae of infants delivered by cesarean section show bacterial growth.

Clinical manifestations of bacterial ophthalmia neonatorum are nonspecific and similar to those caused by other pathogens discussed previously. Infants experience the acute onset of hyperemia, chemosis, eyelid edema, and purulent or mucopurulent exudate 5 to 21 days postpartum. Practitioners should take care to rule out nasolacrimal duct obstruction, a finding that is relatively common in newborns and that can be associated with a secondary bacterial infection.

Because the etiology of ophthalmia neonatorum cannot be distinguished on the basis of clinical examination alone, laboratory investigations (smears and cultures) are mandatory. Differentiation of bacterial infections, particularly *Pseudomonas*, is important, because pseudomonal infections in premature infants can lead to septicemia and death if not aggressively and appropriately treated.

Initial treatment of bacterial ophthalmia neonatorum should be directed by the results of conjunctival smears. Broad-spectrum antibiotics with low toxicity should be used. Topical erythromycin or tetracycline ointment can be used four to six times daily for gram-positive organisms, and gentamicin or tobramycin solution four to six times daily can be started if gram-negative organisms are isolated. Trimethoprim-polymyxin B (Polytrim) has

broad-spectrum activity against a range of both gram-positive and gram-negative organisms, including *Pseudomonas* species.

**Herpes Simplex Virus Ophthalmia Neonatorum.** HSV infection is an uncommon but important cause of neonatal infection and is associated with conjunctivitis in 5% to 10% of cases. The clinical manifestations are nonspecific and include conjunctival hyperemia, chemosis, periorbital edema, and mucous discharge. Corneal involvement is not uncommon and can include dendritic, geographic, or stromal keratitis. Herpetic ophthalmia neonatorum represents a primary herpetic infection. Central nervous system involvement, encephalitis, retinitis, optic neuritis, uveitis, choroiditis, and a fatal viremia can be serious sequelae of primary herpetic infections.

Diagnosis often is difficult, but laboratory testing can aid in establishing a diagnosis. An absence of bacteria in conjunctival smears should alert the clinician to the possibility of viral infection. Papanicolaou stain may reveal intranuclear inclusions and multinucleated giant cells can be seen on Giemsa staining. A maternal history of HSV infection and the characteristic corneal findings can also help to establish the diagnosis. Viral cultures can be obtained, particularly in cases that are refractory to antibiotic treatment.

The prognosis for an infant with neonatal HSV infection is guarded. Treatment of the conjunctivitis should include topical 1% trifluridine every 2 hours until the infection begins to resolve and then tapered according to the clinical response. Systemic therapy with intravenous acyclovir is indicated in the presence of viremia and disseminated disease.

**Chemical Ophthalmia Neonatorum.** Chemical conjunctivitis is the most common cause of ophthalmia neonatorum, occurring in up to 90% of infants to whom silver nitrate was administered. Mild transient conjunctival hyperemia and watery discharge occurring 1 to 2 days postpartum characterize chemical conjunctivitis. The conjunctivitis is self-limited over a course of 1 to 2 days. Most cases are the direct result of toxic reaction to silver nitrate used as prophylaxis for ophthalmia neonatorum. Silver nitrate can damage the corneal and conjunctival epithelium, disrupting the protective epithelial barrier and making the infant more susceptible to secondary bacterial infections. If the history confirms the use of silver nitrate, no treatment is necessary. If the condition does not improve after several days, other etiologic mechanisms must be considered (Table 25-6).

**Prevention.** The best method for preventing neonatal conjunctivitis is the diagnosis and treatment of infections in pregnant women through appropriate prenatal care. In 1881 Credé first described the advantage of silver nitrate prophylaxis for the prevention of gonococcal infection. Since that time the incidence of infection from

**Table 25-6**  
Causes of Ophthalmia Neonatorum

Etiologic Agent	Onset	Conjunctival Features	Cytology
Chemical	24 hours	Diffuse hyperemia, purulent exudate	Polymorphonuclear lymphocytes
<i>Chlamydia</i>	5-10 days	Diffuse hyperemia, purulent exudate	Basophilic cytoplasmic inclusion bodies
Other bacterial	>5 days	Diffuse hyperemia, mucopurulent discharge	Causative agent
<i>Neisseria gonorrhoeae</i>	3-5 days	Hyperacute conjunctivitis with mucopurulent discharge	Intraepithelial gram-negative diplococci
Herpetic	5-15 days	Diffuse hyperemia, watery discharge	Multinucleated giant cells

*N. gonorrhoeae* has decreased from approximately 10% to less than 0.66%. Silver nitrate prophylaxis, however, is not without limitations. This agent is toxic to the epithelium, because it acts by sloughing epithelial cells. Therefore it frequently causes chemical conjunctivitis. In addition, silver nitrate prophylaxis is not completely effective, failing to act against chlamydiae, a major cause of ophthalmia neonatorum. Various alternatives to silver nitrate prophylaxis have been advocated, and currently the CDC recommends a single application of 0.5% erythromycin or 1% tetracycline ointment immediately after birth for the prophylaxis of gonococcal conjunctivitis. The efficacy of these agents in preventing chlamydial conjunctivitis is unclear. In general, though, both erythromycin and tetracycline ointment are effective and less toxic alternatives to silver nitrate. Despite its shortcomings, silver nitrate continues to provide effective prophylaxis for gonococcal ophthalmia neonatorum and is commonly used.

## OCULODERMATOLOGIC DISORDERS THAT AFFECT THE CONJUNCTIVA

Dermatologic disease and its related ocular complications are commonly encountered entities in general ophthalmic practice. The conjunctiva frequently is affected with ocular involvement. Although numerous dermatologic conditions can affect the eye, this section focuses on the three conditions that are most often encountered: acne rosacea, psoriasis, and atopic dermatitis.

### Rosacea

#### Etiology

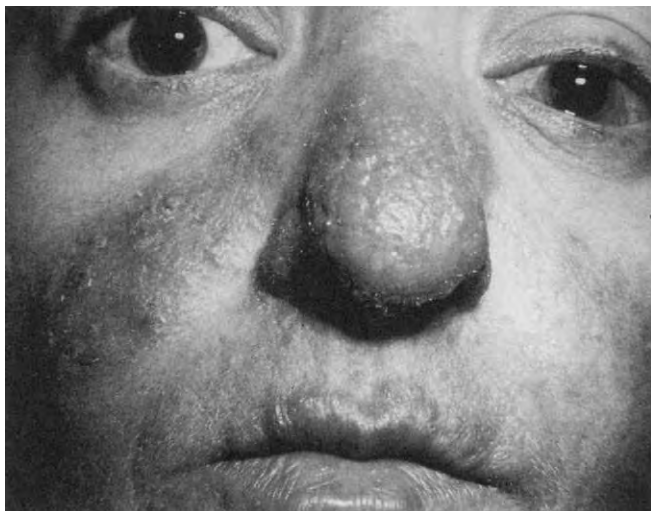The etiology of rosacea, which is a comparatively common dermatologic condition, remains obscure. The disorder typically presents between the third and fifth decades and is more frequently seen in women than in men. However, men are typically more severely affected. Specific trigger factors have been associated with rosacea, including trauma. An ethnic predisposition has been noted. Use of alcohol was once considered a factor, but this is no longer believed to be true.

Rosacea has characteristic clinical findings. These include an acneiform papular-pustular eruption associated with erythema and hypertrophic sebaceous glands. Typically, these changes appear on the cheeks, nose, and forehead, known as the “facial flush” areas. The frontal area of the chest may also be involved. Infestation and possible inflammation caused by the hair follicle mites *Demodex folliculorum* and *Demodex brevis* have been linked to rosacea. Rosacea has no known relationship to previous juvenile acne.

#### Diagnosis

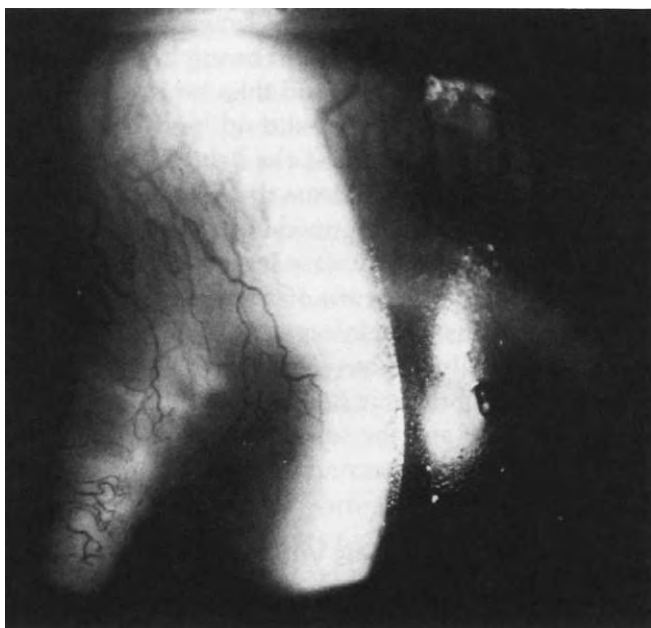
Rosacea manifests with a wide spectrum of clinical presentations ranging from extremely subtle facial erythema to severely disfiguring facial scarring. When mild, rosacea may go unnoticed by the patient and unrecognized by many physicians. Stressful or emotional situations or even laughter often cause facial flushing, with patients’ faces turning “beet red.” Some patients go to extremes to mask the condition, such as using green-tinted makeup to balance their ruddy complexion. As the dermatologic disease progresses, recurrent episodes of livid inflammatory papules and pustules grow more frequent. Scarring causes coarseness of the skin and may eventually produce rhinophyma, a bulbous disfigurement of the nose that is pathognomonic of rosacea (Figure 25-22).

In some patients the eye alone is involved; in others, ocular involvement precedes the dermatologic manifestations. Still other patients manifest dermatologic disease in isolation. Up to 58% of patients with rosacea show ocular involvement. Children may also have ocular rosacea, although this may often go unrecognized. The ocular manifestations of rosacea mirror the dermatologic signs, with involvement of the meibomian glands and sebaceous glands of the eyelashes. This most commonly produces meibomianitis, blepharitis, or both, with resultant tear film instability and evaporative dry eye. Keratoconjunctivitis sicca (KCS) is more common in patients with rosacea. Abnormal lipid production and overcolonization of the eyelids by staphylococci lead to the development of chalazion, hordeolum, and conjunctivitis caused by staphylococcal exotoxin and tear film instability.



**Figure 25-22** Ocular rosacea with conjunctivitis, maculopustular involvement of skin, and rhinophyma. (Courtesy William Wallace, O.D.)

Patients with ocular rosacea often complain of foreign body sensation, irritation, burning, and, most notably, injection, especially toward the end of the day. Corneal involvement occurs later and may be severe and sight threatening. SPK, progressive inflammation, and infiltration starting at the limbus with neovascularization may be seen (Figure 25-23). In severe disease the cornea may actually thin, ulcerate, and ultimately perforate. Because of the chronic nature of this disease, recurrent episodes are common, which should lead the practitioner to consider rosacea as a possible etiology of a noninfectious recurrent or persistent red eye.



**Figure 25-23** Corneal neovascularization in a patient with rosacea.

### Management

The treatment of rosacea has remained relatively constant over the recent past, with newer variations in management favoring longer acting synthetic tetracyclines such as doxycycline. Tetracycline class drugs act multifactorially by decreasing bacterial flora and the expression of matrix metalloproteinases, altering meibum secretion, inhibiting the production of bacterial lipases, and providing an immunomodulatory effect.

Standard dosage for tetracycline is 250 mg four times daily for approximately 4 to 6 weeks. Results of the therapy then are assessed, and the medication is tapered over a more extended period. Doxycycline is as effective as tetracycline when used in a dosage of 100 mg twice daily by mouth over a 3- to 6-week period. As with tetracycline, this dose, if effective, may be tapered to as low as 50 mg/day for approximately 1 month and then to 50 mg every other day for several weeks, as long as effectiveness is sustained. When doxycycline is not effective, the recommended therapy is tetracycline, 250 mg four times daily. Erythromycin may be substituted when treating children with dosing based on the child's age and weight.

In most instances patients demonstrate significant improvement of clinical symptomatology and physical signs in the first 2 to 3 weeks. Many patients, however, require chronic therapy and demonstrate exacerbations of the disease during its course. Metronidazole (MetroGel) is a topical gel developed to treat the skin of the facial area in patients with chronic disease and thus reduce the reliance on oral antimicrobial agents. It is applied twice daily. Although not yet an approved use, metronidazole gel applied to the eyelids was found to be an effective treatment of ocular rosacea.

Although topical antibiotics are used frequently in the management of ocular rosacea, no firm evidence demonstrates their efficacy as a sole therapeutic agent. Topical steroids, however, are effective for treating the inflammatory aspects and frequently are used four times daily in conjunction with antibiotics in combination products such as TobraDex (tobramycin-dexamethasone), Pred-G (gentamicin-prednisone), or Maxitrol (neomycin-polymyxin B-dexamethasone). Because of potential steroid-induced side effects, chronic use of these agents should be avoided.

In addition to management with medications, therapy for ocular rosacea must include eyelid hygiene and warm compresses to manage concurrent blepharitis and meibomianitis. Eyelid scrubs using commercial products or diluted baby shampoo applied with a washcloth or cotton-tipped applicator help to manage blepharitis by removing debris and debulking bacteria. In addition, moist heated compresses should be applied to the eyes several times daily initially and then tapered over several weeks. The compresses should be followed by a brisk massage of the eyelids; the heat melts the saturated oils and the massage clears the glands. Ideally, this treatment should be maintained indefinitely once daily or at least



every other day. It is important to explain to patients the chronic nature of rosacea. The need for continual care must be reinforced to manage this condition successfully. In severe cases of rosacea the primary concern of the ophthalmic practitioner is to prevent corneal involvement and the subsequent scarring and vascularization that occur secondary to inflammation.

## Psoriasis Vulgaris

### Etiology

Psoriasis vulgaris is a relatively chronic skin disease, of unknown etiology, that affects 1% to 4% of the population. Typically, the disease presents with circumscribed, erythematous, plaque-like elevations having a coarse, dry, silvery texture. As with other oculodermatologic conditions, it is typically more common in women, whites, and individuals younger than 40 years. Most patients present with focal outbreaks of the disease, usually on extensor surfaces such as the knee and elbow. It is also sometimes seen on the scalp. Most have a local or limited form of psoriasis, with approximately one in seven progressing to a more severe generalized disease process. The overall incidence of ocular involvement in patients with generalized psoriatic disease may be approximately 1 in 10; however, more recent studies suggest that this number may be as high as 2 of every 3 patients. The degree of clinical symptomatology is highly variable.

### Diagnosis

Ocular involvement commonly is manifest as typical epidermal plaque formations on the conjunctiva or eyelids (Figure 25-24). Chronic blepharoconjunctivitis has also been reported to be a common finding among these patients. Early conjunctival changes in patients with

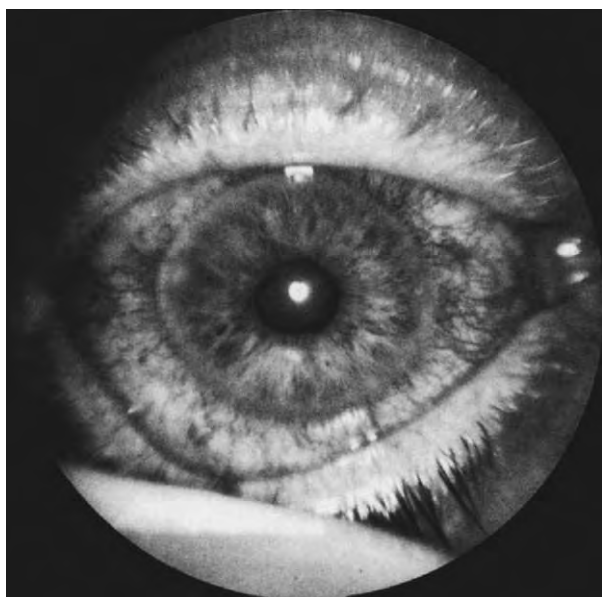
psoriasis have been noted using impression cytology. Keratitis occurs in some individuals but is primarily limbal and is believed to be related to the localized activity in the conjunctiva and eyelid margin area. Sterile corneal abscesses may occur. There is also an increased frequency of uveitis, which differs from typical HLA-B27-associated forms. However, uveitis is not a significant component of this disease. Secondary involvement of the eyelids in the form of ectropion, entropion, and trichiasis usually relates to the eyelid lesions themselves and does not represent a primary component of the disease.

Psoriasis can occur in association with chronic juvenile arthritis as well as Reiter's syndrome. Some investigators have demonstrated a significant increase in prevalence in patients with human immunodeficiency virus infection. The pathogenesis of this relationship is unclear, but an immune recognition event may occur related to the HLA-B27 antigen. A large, retrospective, population-based study found that psoriatic arthritis is mild, uncommon, and not associated with a significant increase in mortality.

### Management

The pharmacotherapeutic management of psoriasis has met with variable success. Therapy focuses primarily on altering the abnormal physiology of the epidermis. Tazarotene (Tazorac), a retinoid gel, has been used in combination with topical steroids and ultraviolet (UV) radiation with good success. Tazarotene is a vitamin A analogue believed to help normalize the rate at which epithelial cells differentiate or divide. Other topical agents include corticosteroids, calcipotriene, a vitamin D<sub>3</sub> analogue (Dovonex), and coal tar products. Topical anthralin, a wood tar derivative (Anthra-Derm), successfully clears psoriatic lesions, but it can cause inflammation and staining of the unaffected surrounding skin. Alterations in anthralin's structure minimize this complication.

Many individuals require systemic therapy to show significant improvement in the more severe psoriatic disease states. Currently, methotrexate is approved for systemic use in severe psoriasis. The standard dosage is 2.5 mg two to four times daily, three times weekly. Other agents such as hydroxyurea, aminopterin, thioguanine, and retinoid etretinate have also been shown to be effective. Cyclosporine may be useful in the treatment of severe recalcitrant disease but has been demonstrated to have significant side effects. Topical tacrolimus, a potent macrolide lactone anti-inflammatory and immunosuppressant, has proven effective in treating psoriasis, but recent warnings about an increased risk of certain cancers may temper its use. A new class of immunomodulators used for treating psoriasis has emerged. Etanercept (Enbrel) is a tumor necrosis factor antagonist approved in the United States, Canada, and Europe for treating adult patients with chronic moderate to severe plaque psoriasis.



**Figure 25-24** Psoriatic blepharoconjunctivitis.

Photochemotherapy in the form of psoralen ultraviolet A irradiation (PUVA) is one of the most effective treatment modalities. PUVA involves the use of an oral agent (psoralen), which sensitizes the epidermis to UV light. The patient is treated intensively over a 2- to 3-week period and subsequently is placed on maintenance UV therapy for an extended time. Studies show that in the acute period this therapy is 90% successful in disease remediation and that in long-term therapy more than 60% of patients have remained in remission at 1 year. Risks associated with PUVA therapy include nonmelanoma skin cancers similar to those changes noted with any chronic solar exposure. Although case reports have suggested cataract formation as a complication of PUVA therapy, large-scale investigation has proven this association to be unfounded.

## Atopic Dermatitis

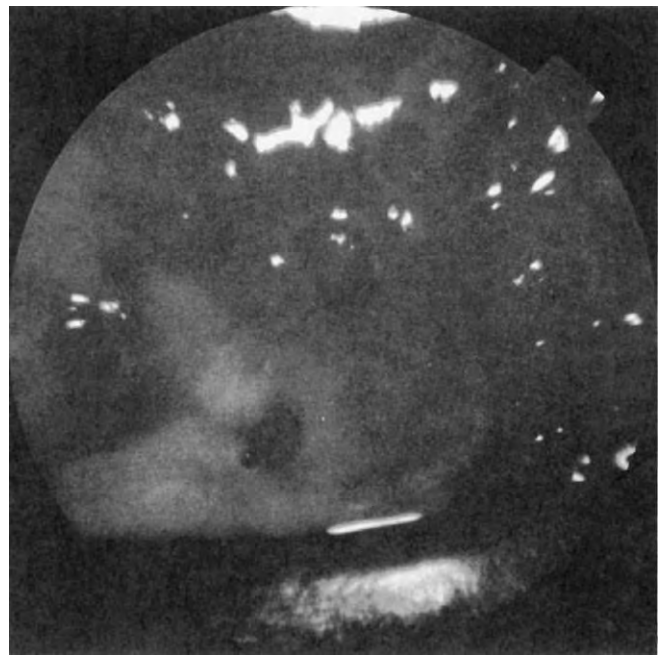
### Etiology

Atopic dermatitis is a unique form of hypersensitivity that presents with eczematous skin eruptions. Primarily, it is a disease typically initiating in childhood or early adolescence, although it can develop in adults. Immunologic factors have been implicated in the onset of this entity. Other etiologic factors suggest genetically mediated defects in metabolism or the biochemical response to exogenous substances. A decrease in cellular immunity and an abnormality in the IgE antibody response system have also been identified. The triggers for atopic keratoconjunctivitis appear to be similar to those of atopic dermatitis. Food allergies, such as eggs, peanuts, milk, soy, wheat, or fish, and airborne allergens, particularly dust mites and dander, should be considered and investigated.

### Diagnosis

Atopic dermatitis is primarily characterized by a patchy excoriation of the skin with lability to heat and pressure stimulus. All aspects of the body surface may be involved. Ocular involvement may include erythema, scaling of the eyelids, and secondary staphylococcal blepharitis. Eyelid eczema (65.7%), atopic keratoconjunctivitis, and SPK (67.5%) appear to be the dominant ocular diseases in these patients. The conjunctiva frequently presents with chemosis and hyperemia as well as a papillary response (Figure 25-25). As the disease progresses, shrinkage of the fornices and subsequent scarring may occur. Corneal involvement can range from SPK to cicatrization and vascularization (Figure 25-26). The association between keratoconus and atopy has been well established, although eye rubbing may be the proximate factor in the genesis of keratoconus.

A significant hereditary component to the ocular disease has been noted among patients with either a personal or a family history of atopic dermatitis. Abnormalities in IgE production, leukocyte cyclic adenosine monophosphate response, and abnormal methacholine

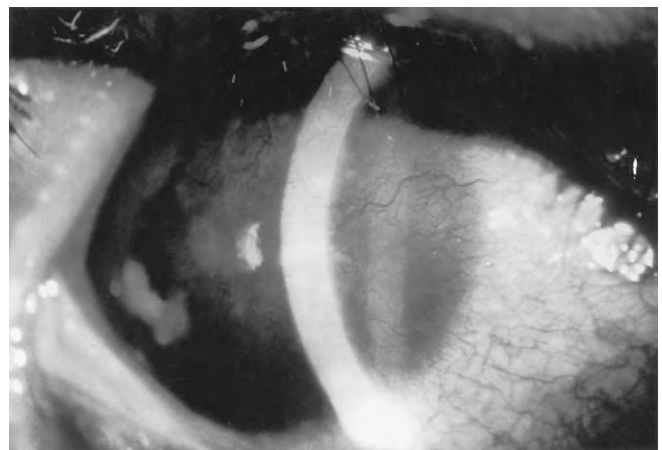


**Figure 25-25** Papillary response of upper tarsal conjunctiva in a patient with atopic keratoconjunctivitis.

inhalation testing have all been noted in association with the disease. Cataract formation and retinal detachments have also been linked to atopic dermatitis. Atopic keratoconjunctivitis is a specific severe ocular disorder associated with atopic dermatitis; it is described in detail in Chapter 27.

### Management

Therapy for the patient with atopic dermatitis can be divided into three distinct categories: topical therapy for the skin, systemic therapy, and ocular therapy. Therapy for the skin includes the use of fluorinated corticosteroids such as triamcinolone or betamethasone or hydrocortisone



**Figure 25-26** Corneal neovascularization in a patient with atopic keratoconjunctivitis. (Courtesy William Wallace, O.D.)

applied by an occlusive dressing or other method to potentiate the drug's effect. In less severe cases the use of topical emollients, lubricants, oils, lotions, and creams can successfully keep the skin moist. As in other severe dermatologic disorders, coal tar derivatives can be used in cases in which steroids are ineffective. Systemic management is oriented primarily toward the use of oral corticosteroids. In the acute phase, high-dose prednisone is the most effective agent, but patients can be managed chronically on low-dose therapy of 5 to 10 mg/day for prolonged periods. In patients with severe pruritus, oral antihistamines can minimize itching and provide symptomatic relief.

Therapy for the eye-related complications of atopic dermatitis focuses on reducing inflammation. Specific management of this ocular disease is discussed in Chapter 27.

Surgical intervention in atopic dermatitis has been associated with a relatively high rate of complication. In particular, the incidence of retinal detachment is relatively high. The etiology is not clear, but one study noted breaks in the pars plicata of the ciliary body in four eyes of three patients with atopic dermatitis.

## MUCOUS MEMBRANE DISORDERS OF THE CONJUNCTIVA

Mucous membrane disorders that involve the conjunctiva include cicatricial pemphigoid, erythema multiforme, and, less commonly, pemphigus vulgaris. Cicatricial pemphigoid and pemphigus vulgaris appear to be primarily type II hypersensitivity reactions, whereas erythema multiforme appears to be primarily a type III immune complex-mediated hypersensitivity reaction. Mucous membrane diseases are an immune-mediated reaction to antigens in the mucosal tissue's basement membrane. Although our understanding of the etiology of these disorders has grown in the recent past, complete understanding remains elusive.

### Ocular Cicatricial Pemphigoid

#### Etiology

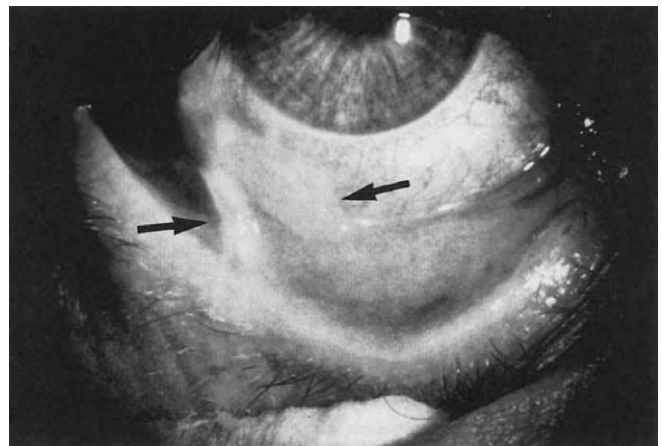
Ocular cicatricial pemphigoid (OCP) is a bilateral cicatricial disease of the conjunctiva that initially presents as a diffuse inflammation with subepithelial vesicles, edema, and hyperemia. OCP is part of a spectrum of disorders termed *mucous membrane pemphigoid*, that affects other parts of the body, including the skin and mucous membranes lining the mouth, nose, trachea, esophagus, vagina, and rectum. The initial phase may be mild and is often mistaken for chronic nonspecific conjunctivitis. As the condition progresses, subepithelial fibrosis, loss of goblet cells, and conjunctival and eyelid keratinization clarify the nature of the disease. In advanced cases symblepharon formation, fornix foreshortening, trichiasis, and entropion occur.

Although the disorder is relatively rare, occurring in 1 in 30,000 people, the incidence of significant visual loss is as high as 25% to 33%. Repair of the damage caused by advanced disease is difficult, making early detection and treatment crucial for visual preservation. OCP affects females more than males and occurs in all races. It is typically diagnosed in a person's sixth or seventh decade but is likely to originate earlier in many patients who present with subtle disease. Two distinct forms have been identified: idiopathic and a drug-induced pseudo-OCP.

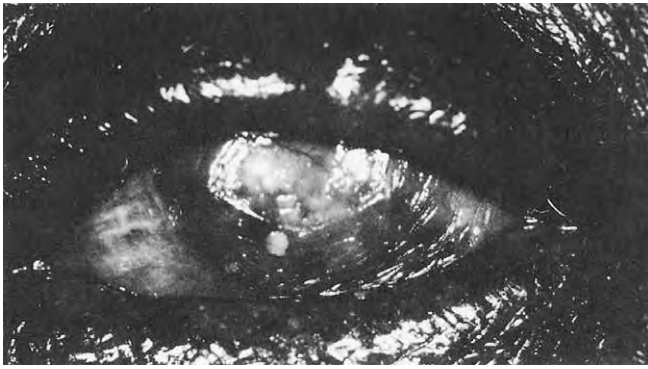Despite evidence that OCP affecting the eye alone is a clinically distinct disorder, involvement of the skin and other mucosal surfaces occurs in a significant percentage of cases with ocular findings. Dermatologic manifestations occur in 21% of patients and lesions of the oral mucosa in 50%. Unlike bullous pemphigoid, which rarely affects the eye, cicatricial pemphigoid invariably produces scarring and morbidity.

#### Diagnosis

The most common initial sign of OCP is a conjunctivitis associated with subepithelial fibrosis, which may be subtle and easily missed. OCP should be considered in any case of chronic conjunctivitis. Chronic inflammation accompanying fibrotic changes produces progressive shrinkage of the ocular tissue with subsequent symblepharon formation (Figure 25-27). In the more advanced stages of the disease, cicatrization begins to occur. The chronic contraction of conjunctival tissue can lead to shortening of the fornices, entropion, and subsequent trichiasis. In more advanced presentations the cornea may demonstrate persistent epithelial defects, limbal inflammation with stem cell destruction, and stromal thinning and ulceration. Keratinization of the conjunctiva and cornea can lead to profound vision loss (Figure 25-28). The resultant ocular surface disruption can lead to severe dry eye. A frequent finding is cicatricial closure of the puncta and lacrimal ducts. Cicatrization takes place in much the same way as the conjunctival adhesions and



**Figure 25-27** Conjunctival shrinkage and symblepharon formation (arrows) in ocular cicatricial pemphigoid.



**Figure 25-28** Keratinization of conjunctiva and cornea in ocular cicatricial pemphigoid.

can produce marked epiphora or contribute to dry eye, depending on the degree of conjunctival scarring.

The differential diagnosis of OCP varies depending on the stage of the disease. It includes conditions that produce cicatricial changes of the ocular surface, such as chemical trauma, radiation injury, and other mucous membrane disorders. Conjunctival biopsy can aid in the diagnosis. Immunofluorescence study of the tissue demonstrates deposition of immunoreactants at the epithelial basement membrane zone in OCP.

### Management

Although the predominant clinical findings in OCP are ocular, topical therapy alone generally proves insufficient. Historically, the most significant success follows the use of oral corticosteroids. Unfortunately, steroids act simply as a mechanism to suppress the response and are not curative. In most instances patients are placed initially on high-dose steroids, show significant remission of symptoms, and can be tapered to a maintenance dosage level. The initial dose generally is 40 to 60 mg prednisone daily. Maintenance therapy can be as little as 5 mg every other day. Approximately 25% of patients cannot continue long-term steroid therapy due to complications, and these patients eventually progress to severe visual impairment or blindness. Only one-third of patients on chronic immunosuppressive therapy can achieve long periods of remission off medication.

Dapsone is effective in treating the acute inflammatory stage of OCP. As with steroids, dapsone does not significantly affect the cicatricial component of the disease, but it does control the inflammatory aspect. In recent studies an initial dose of 100 mg/day was well tolerated with no toxicity. The use of 150 mg/day brought on significant side effects. Once an initial response was obtained (usually in 1 to 4 weeks), a maintenance dose of 50 to 100 mg on alternate days was used. Many patients experienced significant periods of remission, but in all instances therapy had to be reinstated on a regular basis. Sulfapyridine has been suggested as an alternative to dapsone.

In patients with more advanced disease, who show rapid progression, or when either steroids or dapsone fails, immunosuppressive agents such as cyclophosphamide and azathioprine may produce sustained remission. The standard dose for cyclophosphamide is 1 to 2 mg/kg daily combined with an equal amount of prednisone. After a 1-month to 6-week initial treatment period, the effectiveness of therapy is assessed, and cyclophosphamide dosage may increase if the disease is still present or progressive. In most instances steroids can be reduced at this point because of the obvious complications with long-term use. Cyclophosphamide combined with high-dose pulsed steroids has been found to be a successful therapeutic combination. This may reduce some of the risks inherent in long-term steroid use. Cyclophosphamide therapy routinely continues for a period of 12 months or longer. In the treatment of acute severe OCP, cyclophosphamide was successful in 96% of the patients when administered for 10 months or longer. Azathioprine was successful in 85% of the patients over the same period.

Recent therapeutic approaches have been directed to the immunologic aspects of OCP. Intravenous immunoglobulin immunomodulatory therapy has proven a safe and effective therapy for otherwise treatment-resistant OCP. Subconjunctival mitomycin C was recently described as a promising treatment of OCP. Currently, use of tacrolimus and etanercept has been reported to be successful in managing mucous membrane pemphigoid and OCP.

Adjunctive ocular therapy is directed toward management of the dry eye associated with OCP. Dry eye results from damage to the ocular surface and conjunctival goblet cells. Chronic lubricant therapy is beneficial. Ideally, nonpreserved agents should be used. Ointments or gels are effective in providing lubrication either overnight or, in the more advanced forms of the disease, during the daytime hours. The patient's symptoms determine dosage frequencies. Use of adjunctive therapy such as eyelid hygiene and the treatment of secondary infections should be implemented on an individual basis. However, the chronic use of antibiotics is contraindicated because of potential overgrowth of resistant organisms and antibiotic toxicity.

The goal of therapy is the maintenance of corneal integrity and patient comfort. Procedures such as eyelash epilation, eyelid scrubs, and antibiotics can help in the early phases of the disease process. As the disease progresses, surgical procedures may be of benefit. These include procedures for the correction of entropion and trichiasis as well as oculoplastic surgery for the resolution of symblepharon and conjunctival shrinkage. Buccal mucosal grafting shows promise in the rehabilitation of this disease, and investigators have evaluated nasal mucosal grafts as adjunctive therapy. Amniotic membrane transplantation to reconstruct the ocular surface has been successful. Limbal stem cell transplantation and, more recently, transplantation of autologous limbal epithelial cells cultured on amniotic membrane have

been used effectively to reconstruct the corneal surface. Surgical intervention should generally be withheld until the disease progresses unchecked by methods that are more conservative and, ideally, should be performed with the disease under medical control. Surgery itself can induce further inflammation. Unfortunately, penetrating keratoplasty and other corneal procedures are not particularly successful in treating OCP.

### **Stevens-Johnson Syndrome, Erythema Multiforme Major, and Toxic Epidermal Necrolysis**

#### **Etiology**

SJS was for many years considered a severe variant of erythema multiforme major (EMM); however, over the past decade some experts have reclassified SJS as a less severe variant of toxic epidermal necrolysis (TEN) rather than a form of EMM. However, this perspective is not universally accepted. SJS occurs acutely in all ages, with 20% in children and a peak incidence in adults between the second and fourth decades of life. SJS is a potentially fatal disorder with a mortality of approximately 5%. TEN has a mortality rate of approximately 30%. About 50% of cases of these disorders are idiopathic. Identifiable causal factors include microbial infection, particularly with *Mycoplasma pneumoniae* and HSV, and medications, including sulfonamides, tetracycline, penicillin, non-steroidal anti-inflammatory drugs (NSAIDs), psychotropic agents, antiepileptics, and immunizing vaccines. Recent research suggests that HSV infection is a principal factor in the genesis of EMM, whereas medications are a more likely precipitant of SJS and TEN.

Erythema multiforme minor is comparatively benign. SJS or EMM involves the ocular tissues and produces the classic signs of a catarrhal pseudomembranous conjunctivitis. Erythema multiforme occurs more frequently in men than in women.

#### **Diagnosis**

SJS and TEN are systemic disorders typically presenting with constitutional signs, including fever, malaise, headache, loss of appetite, nausea, and vomiting. The skin is involved with inflammatory vesiculobullous lesions, frequently accompanied by hemorrhage and necrosis. In contrast, EMM usually presents with a diffuse erythematous papular and macular eruption that evolves into characteristic target or bull's-eye lesions with an erythematous center surrounded by a zone of normal skin and then by an erythematous ring. The soles of the feet and the palms of the hands often are affected in EMM. Mucous membranes of the nose and mouth are the most commonly affected, and conjunctival involvement is common in both EMM and SJS/TEN. At least two mucous membranes surfaces are involved in SJS and TEN.

EMM has an associated purulent conjunctivitis in approximately 10% of cases. SJS and TEN have a bacteria-like

pseudomembranous conjunctivitis frequently associated with significant discharge. The onset is rapid. As the disorder progresses, bullae formation followed by rapid rupture and subsequent scarring in the area of the epithelial erosions characterize the disease. It is typical for the conjunctiva to show vascular changes with necrosis and subsequent scarring. If the eyelids are involved in the cicatricial process, entropion and trichiasis frequently are noted, and in many individuals an ulcerative bullous-type process develops near or on the eyelid margin. The condition may include a wide spectrum of clinical manifestations not unlike those encountered with OCP. These may range from minimal punctal stenosis to severe corneal opacification and infiltration with scarring. More remarkable ocular involvement typically occurs only in individuals with extremely severe disease.

#### **Management**

Immediate withdrawal of suspected causative agents appears to improve outcome and survival in SJS. The condition is treated similarly to OCP. Although still controversial, the use of systemic steroids and, in some instances of severe disease, immunosuppressive agents has been successful. Tetracycline and fluoroquinolone antibiotics may be used to combat any secondary infections of the bullous regions of the epidermis. Fluid and electrolyte levels must be monitored to assess potential dehydration secondary to the skin lesions, and intravenous fluids should be administered as necessary.

Ocular therapy is directed primarily at the prevention of infectious complications secondary to the colonization of organisms such as *Staphylococcus* species and other skin flora. This can be accomplished with topical fluoroquinolones or other broad-spectrum antibiotics. Dosage frequencies are variable depending on the severity of the disease, but in most instances a dosage regimen of every 3 to 4 hours is recommended. The use of topical steroids has been advocated in managing the inflammatory components of this disease. Prednisolone acetate 1% used every 2 to 3 hours initially and tapered after the inflammatory response begins to subside is a reasonable adjunct to antibiotic therapy. The use of eyelid scrubs, epilation in the case of trichiasis, sweeping of the fornices with a glass rod to prevent adhesions between raw surfaces, and the use of cool compresses to provide symptomatic relief can prove extremely valuable in conjunction with topical pharmacotherapy.

The management of dry eye associated with SJS can be accomplished in an aggressive fashion with the use of nonpreserved lubricant solutions and bland ointments. Unfortunately, patients with SJS or OCP frequently have chronic severe dry eye. The challenge in managing this condition is to provide the best environment and visual performance possible in the face of rather severe compromise of the ocular surface. The best approach may entail using a variety of mechanisms to preserve lacrimal function, such as moisture chambers, lacrimal occlusion,

and bandage lenses. Scleral contact lenses have been used in some cases. These techniques should be considered on an individual basis when topical therapy alone is inadequate.

Although the ocular consequences of SJS and TEN are successfully managed with topical therapy and adjunctive procedures in most patients, some cases require surgical intervention. Tarsorrhaphy, partial or complete, prevents excessive drying of the ocular surface. Other procedures to manage the sequelae of entropion or trichiasis, such as diathermy or cryosurgery, are effective for short-term resolution but frequently regress with time and must be repeated. Ocular surface reconstruction using amniotic membrane and stem cell transplantation has met with good, and in some cases startling, success.

## **CONNECTIVE TISSUE DISORDERS (COLLAGEN VASCULAR DISEASES)**

The connective tissue disorders comprise a unique family of systemic diseases that have distinctive yet nonspecific systemic manifestations associated with organ involvement. Such diseases as rheumatoid arthritis (RA), rheumatic fever, systemic lupus erythematosus (SLE), scleroderma, and periarteritis nodosa all demonstrate the typical histologic and clinical findings characteristic of this category of diseases.

The histologic changes noted in affected patients involve diffuse inflammatory damage to connective tissue and vascular systems. Nonspecific deposition of fibrin material in connective tissue and blood vessels typifies this damage. This grouping of diseases is somewhat arbitrary, relating to the general acceptance of an autoimmune mechanism as an etiologic factor. Though many of the diseases share common clinical findings, each also has unique and differentiating elements. Because Reiter's syndrome is believed to be autoimmune in nature, it too is considered in this discussion.

Most disorders in this group do not present with significant ocular involvement. However, SLE, periarteritis nodosa, Reiter's syndrome (reactive arthritis), juvenile RA, and, in some instances, RA can be clinically identified by their ophthalmic presentation at an early stage in the disease. There is evidence that early treatment can reduce morbidity and have a positive impact on the course of these disorders.

RA is a crippling potentially lethal disease that affects connective tissue and the vascular system throughout the body. It affects the eye in a variety of ways, notably through autoimmune damage to the lacrimal gland and with resultant dry eye syndrome. Indeed, Sjögren's syndrome and KCS are common threads that tie these disorders together.

The term *connective tissue* describes a diverse group of structural elements that include collagen, elastin, proteoglycans, and other typical glycoproteins. The unique distribution of these individual elements within

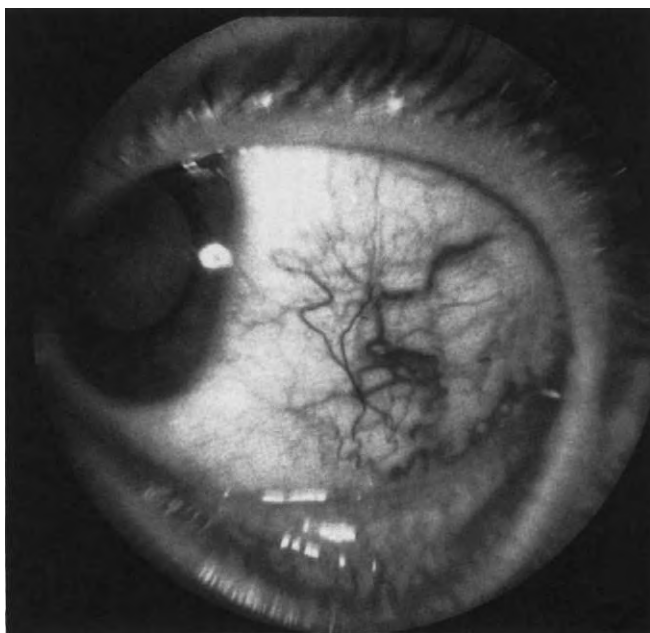
an individual organ defines the specialized roles that connective tissues play within the body. Collagen and glycoproteins make up basement membranes and, as such, occur throughout the body as unique biologic and physical barriers. Little evidence exists that primary disease of these tissues is the precipitating pathologic event. On the contrary, the connective tissue and vascular systems are secondarily involved as sites of inflammation. The traditional term *collagen vascular disease* still is used to describe this broad category of disease, although it is no longer considered an acceptable description. Most of these conditions have widespread and diffuse effects on a variety of organs and tissues. The American College of Rheumatology has developed a series of diagnostic criteria that are used to identify each of these clinical entities.

### **Systemic Lupus Erythematosus**

SLE is a chronic inflammatory disease of unknown etiology and unpredictable course that primarily affects the skin, cardiovascular system, nervous system, mucous membranes, and kidneys. The prevalence of this disease is approximately 1 per 1,000 population. Although the occurrence is slightly greater in blacks than in whites, the most notable epidemiologic factor is the remarkably high incidence among women, particularly of childbearing age. Both juvenile and later onset SLE may occur. Disease activity tends to be lower in patients with late-onset disease; however, they tend to accrue more damage and experience higher mortality than patients with early-onset lupus. These findings probably reflect the contribution exerted by other comorbid conditions in the overall impact of lupus in these patients. SLE may be triggered by exposure to sunlight, infection, and stress. Other factors include endocrine, genetic, and autoimmune mechanisms; medications; and exogenous antigens. Drug-induced SLE resolves on cessation of the causative agent. Pregnancy, use of a variety of medications, and use of contraceptives have all been associated with exacerbations of the disease. Conversely, there have been reports of disease remission during pregnancy, with exacerbation postpartum.

### **Diagnosis**

Systemically, SLE may masquerade as many different conditions, in some cases simultaneously, and thus may present a daunting diagnostic challenge. Differential diagnosis of the disease is based on the presence of 4 of the 11 diagnostic criteria listed by the American College of Rheumatology. Ocular effects can include a variety of clinical manifestations, but KCS is most common. Other ocular findings are chemosis, recurrent episcleritis, scleritis, conjunctival scarring, and symblepharon (Figure 25-29). There is also a relatively high incidence of anterior uveitis and, in a small percentage of patients, the presence of eyelid plaques. Other common findings are infiltrative keratitis and marginal corneal ulcers.



**Figure 25-29** Episcleritis in patient with systemic lupus erythematosus.

Although ocular manifestations may contribute to the diagnosis of SLE, it is important to evaluate the patient for systemic manifestations as well. These include fever, weight loss, arthralgia, nephritis, and the typical malar butterfly rash seen on the face. This cutaneous presentation is evident in less than one-half of patients with SLE. In many instances more subtle signs may include a blush and swelling of the skin on the cheeks after exposure to the sun. These lesions frequently scale and are termed *discoïd* when they present in this fashion. Subsequent episodes can produce either a hyper- or hypopigmented state and atrophy of the epidermal tissue. Raynaud's phenomenon is not uncommon, and many individuals develop ulcerative changes of the extremities in association with this aspect of the disease. Patients can show evidence of purpura and ecchymosis. Antiphospholipid antibodies, or lupus anticoagulant, may play a role in retinal vaso-occlusive disease in the formation of either branch retinal or central retinal vein occlusion.

### Management

Therapy for SLE is both complex and, in many instances, disappointing for both patient and practitioner. Management of the systemic signs and symptoms may not improve the ocular manifestations of the disease. The most common therapy for the arthritic and cardiac complications is NSAID use. Hydroxychloroquine and chloroquine are particularly effective in treating the discoïd rash associated with the disease. In some cases oral steroids are used either alone or in combination with other immunosuppressive agents. Methotrexate can effectively reduce the need for systemic steroids in the treatment of mild to moderate SLE. Cyclophosphamide and

azathioprine have been used for more severe disease for which steroid therapy is inadequate. Hematopoietic stem cell transplantation was used successfully to treat severe life-threatening SLE. Rituximab, previously approved by the U.S. Food and Drug Administration for non-Hodgkin's lymphoma, is a genetically engineered antibody that targets B cells and eliminates them from the blood. Clinical trials for SLE have proved successful; however, the risk of infections of the brain has raised some concerns. Other novel treatments are currently under investigation.

Treatment of the ocular manifestations of SLE primarily involves the management of associated ocular surface disease. Maintenance of the tear film using lubricants is an important therapeutic adjunct. To reduce toxicity nonpreserved lubricants should be used. Management of associated bacterial conjunctivitis should be undertaken with appropriate antibiotic therapy, but long-term antibiotic therapy should be avoided, because it can complicate disease management. In some instances clinicians have used bandage lenses, punctal or intracanalicular occlusion, and other methods to support the ocular surface. However, these are often of limited effectiveness in long-term management.

### Polyarteritis Nodosa

Polyarteritis nodosa (PAN) is an uncommon systemic necrotizing vasculitis that predominantly affects small and medium-size arteries. The lesions generally are distributed diffusely throughout the vascular system and often are asymmetric in presentation. The necrotizing inflammatory component is fairly evident in the acute stage and is accompanied by infiltration of inflammatory cells throughout the vessel walls and surrounding tissue. Vascular damage from the inflammatory process usually causes thrombosis and fibrosis, with subsequent blockage of blood flow and infarction of the affected tissue. Unlike SLE, PAN occurs more frequently in men than in women. Although patients of all ages are affected, the onset most commonly occurs in the third to sixth decade of life. Many etiologies have been postulated, including hypersensitivity reactions and response to such microorganisms as *Streptococcus* species and viral entities.

### Diagnosis

Like SLE, PAN has a wide range of clinical manifestations. These include fever, weight loss, severe abdominal and musculoskeletal pain, tachycardia, acute glomerulonephritis, polyneuritis, myocardial infarction, and such pulmonary manifestations as bronchial asthma. The frequency of this disease is approximately 8 per 1,000 population, but the clinical diagnosis rate is considerably lower than postmortem studies suggest. In the United States incidence is reported to range from 3 to 4.5 cases per 100,000 population per year. Renal involvement is one of the most common and devastating aspects of



the disease. It can be manifested by simple hematuria or, in more severe cases, painful infarction and acute decompensation. Renal disease occurs in approximately 75% of patients, and hypertension occurs in more than 50%.

Typical findings of the ocular anterior segment include KCS, lacrimal gland atrophy, conjunctival hyperemia, subconjunctival hemorrhages, and chemosis. Peripheral ulcerative keratitis may mark the onset of systemic disease. Nongranulomatous uveitis and necrotizing sclerokeratitis may also occur. Retinal vaso-occlusive disease in the form of cotton-wool spots, edema, hypertensive retinopathy, and hemorrhage is typical, and some instances of more extreme disease display nonrhegmatogenous retinal detachments (Figure 25-30). Other less common findings include optic nerve involvement and extraocular muscle palsies. Episcleritis may be a presenting sign of PAN. In severe cases nodular episcleritis or scleritis can progress to a necrotizing state. As is common in connective tissue diseases, anterior uveitis can occur.

Ocular involvement relates primarily to the vascular inflammatory aspect of the disease. In the central nervous system the disease manifests itself as neurologic deficits and in the retina, as typical vaso-occlusive episodes.

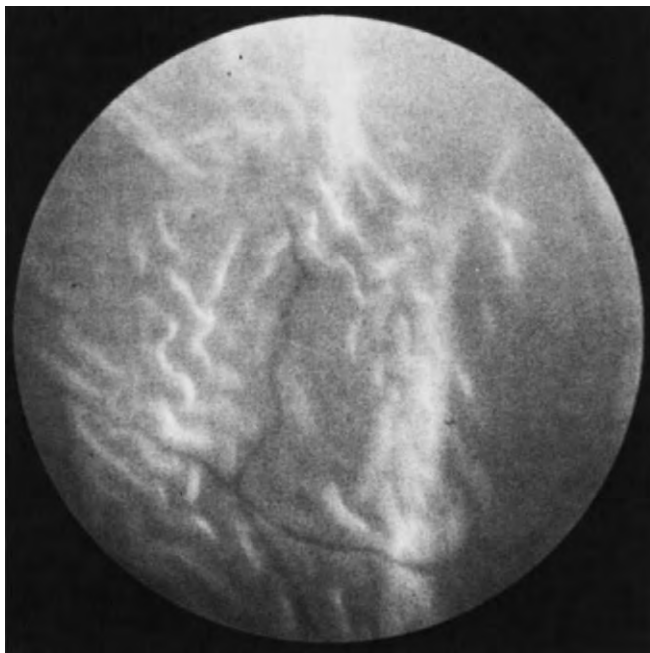
### Management

The underlying etiology of the disease determines the treatment of PAN. The survival rate over 5 years for patients with untreated PAN is approximately 10%. Thus the use of aggressive systemic management is of vital importance. Corticosteroid therapy has demonstrated improvement in the mortality rate and, in some studies,

has increased the 5-year survival to approximately 50%. Regimens for steroid therapy can be as high as 1 to 2 mg/kg daily. This type of management requires following the patient carefully and tapering steroid therapy as rapidly as possible. However, even high-dose steroids are not adequate for some patients.

The addition of immunosuppressive therapy can dramatically increase survival. As with SLE, cyclophosphamide and azathioprine are the two most commonly used agents. Methotrexate has also been used successfully. Immunosuppressants are generally administered with steroids. In many instances they allow significant reduction in steroid dosage while patient symptomatology is stabilized. However, the morbidity associated with this disease is significant, and management of the complications related to systemic hypertension and organ failure can be extremely important in allowing the patient to maintain a more normal lifestyle. Because of the persistent presence of joint and muscle discomfort associated with the disease, analgesic agents can be helpful in minimizing symptoms.

As with other connective tissue diseases, ocular therapy focuses on the management of ocular surface disease. If uveitis is present, the use of topical steroids along with a cycloplegic agent is appropriate. The most effective means of controlling ocular complications generally is aggressive management of systemic components of the disease. In some instances patients are relatively asymptomatic systemically while being treated with steroids and immunosuppressive therapy but still demonstrate active disease. In these individuals determining the status of ocular inflammatory changes can be helpful in assessing the effectiveness of systemic therapy.



**Figure 25-30** Nonrhegmatogenous retinal detachment in polyarteritis nodosa.

### Reiter's Syndrome

Classically, Reiter's syndrome has been defined as a triad of arthritis, urethritis, and conjunctivitis. In 1981 the American Rheumatism Association revised its defining criteria for Reiter's syndrome to describe the disorder as an episode of peripheral arthritis of more than 1 month's duration occurring in association with urethritis or cervicitis (or both). Reiter's syndrome recently was termed reactive arthritis; however, some authors qualify this as an incomplete presentation. It is the most common type of inflammatory polyarthritis seen in young men. Infectious agents appear to play a critical role in the initiation or perpetuation of Reiter's syndrome. The syndrome most frequently follows genitourinary infection with *C. trachomatis*, although a variety of other organisms and mechanisms have also been implicated. It may present as a complication of nonspecific urethritis, postgonococcal urethritis, or gastrointestinal disease involving such organisms as *Salmonella*, *Clostridium*, and *Yersinia*. An HLA-B27 genotype is a predisposing factor in more than two-thirds of patients. A relation to human immunodeficiency virus infection has been reported, although this

remains uncertain. In the United States the frequency of Reiter's syndrome is estimated at 3.5 per 100,000, although the actual incidence is hard to gauge due to difficulty in establishing a definitive diagnosis.

### Diagnosis

Affected patients generally experience genitourinary or gastrointestinal disturbances that precede ocular findings. In some patients the onset of ocular disease can be delayed for several months. A low-grade fever and malaise are frequent findings. Mucocutaneous findings, such as aphthous ulcers and balanitis, may be seen. The polyarthritides commonly associated with the disease is generally asymmetric and shows a predilection for the joints of the lower extremities. In most cases remission occurs within several weeks to months after onset. Only a small number of individuals progress to a chronic or recurrent form of the disease. Heel pain from plantar fasciitis and low back pain caused by sacroiliitis may be helpful diagnostic clues. Less typical complications include cardiac and neurologic involvement, ankylosing spondylitis, amyloid disease, and aortic incompetence.

An unusual but clinically important finding is that of painful deformity of the feet in the form of keratoderma blennorrhagica (Figure 25-31), which is primarily confined to the plantar surfaces. Although it occurs in a

small percentage of patients (5% to 7%), when seen in conjunction with other findings it can be extremely helpful in making the diagnosis.

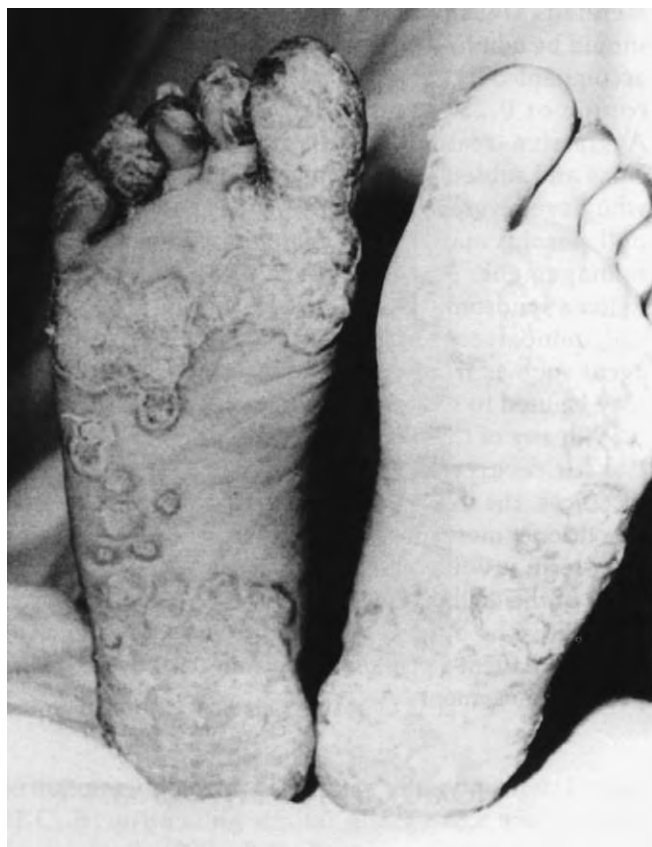
Nonspecific laboratory findings in patients with Reiter's syndrome include an increase in peripheral blood leukocytosis and an elevated sedimentation rate. Radiographic abnormalities are typical of RA.

Conjunctivitis is the most common ocular presentation of Reiter's syndrome, unlike in the aforementioned entities. The conjunctivitis is generally bilateral, with papillary hypertrophy and a mucopurulent discharge. Most cases are transient and mild. Subepithelial corneal opacities, SPK, and edema may occur along with the typical conjunctivitis. An acute-onset unilateral anterior uveitis may occur and recur during the course of Reiter's syndrome. The anterior uveitis is typically severe and of relatively long duration. Up to 50% of patients with lumbar inflammatory disease develop recurrent uveitis, whereas only 10% of those who do not have lumbar involvement develop recurrent episodes. Other less typical ocular findings include the presence of optic nerve inflammation in the form of optic neuritis or papillitis. Patients may also present with macular edema, which is thought to be secondary to the inflammatory process.

### Management

Initial treatment of the systemic manifestations of Reiter's syndrome consists of high doses of NSAIDs. Patients with large joint involvement may also benefit from intra-articular corticosteroid injection. The use of antibiotics in treating Reiter's syndrome is controversial; however, treatment with tetracycline or its analogues sometimes shortens the course or aborts the onset of the arthritis. The current recommended treatment is oral tetracycline, 250 mg four times daily for a minimum of 3 to 4 weeks. The long-acting tetracyclines, such as doxycycline, can also be used. The use of erythromycin is recommended in individuals sensitive to tetracycline, in pregnant women, or in children. The normal adult dosage is 500 mg every 12 hours. A 3-month course of ciprofloxacin did not show any significant benefit. Children can be comanaged in conjunction with their pediatrician. In instances of Reiter's syndrome that have been precipitated by enteric organisms, treatment with trimethoprim-sulfamethoxazole should be instituted.

Management of the ocular aspects of Reiter's syndrome is directed toward control of inflammation. The uveitis can be fairly severe and resistant to therapy. In most instances such topical steroids as 1% prednisolone acetate or 0.1% dexamethasone are recommended. Dosage is variable but in severe cases should be administered initially every 1 to 2 hours and accompanied by such cycloplegic agents as 5% homatropine or 0.25% scopolamine two to three times daily. Aggressive treatment reduces formation of synechiae and subsequent secondary glaucoma. In patients who have severe uveitis, either sub-Tenon's capsule or oral steroids may be used in conjunction with topical management.



**Figure 25-31** Blennorrhagica in Reiter's syndrome. (Courtesy William Wallace, O.D.)

The conjunctivitis associated with Reiter's syndrome is usually mild and transient. A topical aminoglycoside, erythromycin, or a combination agent such as trimethoprim-polymyxin B (Polytrim) may be used to treat more severe conjunctivitis.

With any of the connective tissue diseases the potential for recurrence is relatively high, and in most instances the disease becomes chronic. Therefore the practitioner must educate the patient to the potential for long-term involvement with the disease. Also, treatment of the ocular disease should not be undertaken in isolation. The ophthalmic practitioner should consult with the patient's primary physician to optimize therapeutic management.

## TOXIC CONJUNCTIVITIS

### Etiology

Conjunctivitis caused by toxic agents can occur as either a primary or a secondary finding. Toxicity most commonly results from exposure to medications, contact lens care products, or cosmetics. However, any agent can cause a toxic response. Toxic conjunctivitis may have a wide variety of presentations. When superimposed over infection or allergic reaction, toxicity to a medication may complicate the diagnosis.

### Diagnosis

Affected patients frequently complain of a hot gritty feeling in the eye. Itching is not a common complaint unless allergy is a part of the overall clinical picture. Patients often have a history of use of the suspected agent. Preservatives are a frequent cause of toxic reactions. Thimerosal, benzalkonium chloride, and chlorhexidine are common culprits. Topical antibiotics such as gentamicin and tobramycin can also cause toxic conjunctivitis. Antiviral medications are commonly associated with toxicity. When a specific agent cannot be identified, investigation of the patient's environment often is productive in finding the cause. Environmental agents are often obvious once the nature of the conjunctivitis is identified. The temporal relation of exposure and response can serve as a valuable clue in such cases. Chronic exposure to toxic agents, as occasionally occurs with glaucoma medications, typically produces a follicular reaction.

### Management

Elimination of the toxin is the only totally effective means by which to eliminate toxic conjunctivitis. Often, products that contain different preservatives from those contained in the offending product can be substituted, typically resulting in complete cure. Once the toxin is identified, patients should be advised to avoid agents to which they are sensitive. Dilution of environmental toxins may reduce symptoms; however, this is only palliative.

## LOCALIZED CONJUNCTIVAL INFLAMMATION

A variety of conditions present with localized inflammation or other focal changes of the conjunctiva. These entities have a variety of causes, diagnoses of which range from simple to extremely challenging.

### Phlyctenulosis

#### Etiology

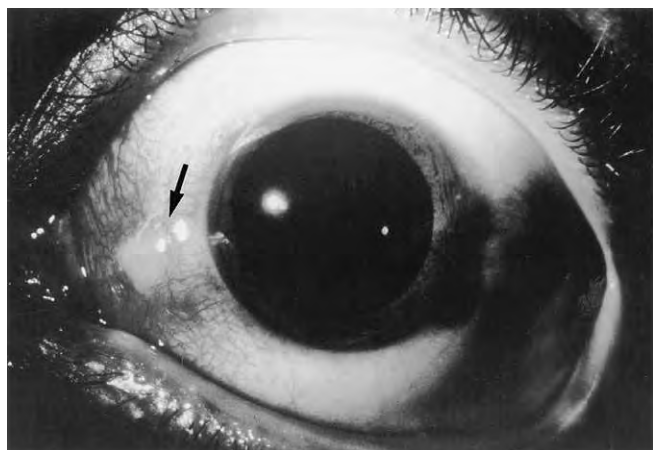
Phlyctenular conjunctivitis is an allergic hypersensitivity response of the conjunctiva and, occasionally, of the cornea. Although the disease is worldwide in distribution, the etiologic factors vary considerably depending on geographic location. In general, phlyctenular conjunctivitis occurs more commonly in areas of poor sanitation and health care. It is typically more common in women (60% to 70%) than in men and occurs with greater frequency in children. This condition can have numerous causes. In populations where poverty is endemic, tuberculosis is a common cause. In patient populations with access to health care and appropriate sanitation, the bacterial protein from the staphylococcal organism may be the causative agent. Other agents, such as intestinal parasites, are also potential sources of phlyctenular disease.

#### Diagnosis

Although phlyctenular conjunctivitis can occur without obvious associated disease, patients with phlyctenules may exhibit concurrent evidence of either dermatologic or systemic disease, such as rosacea and seborrheic blepharoconjunctivitis. The symptoms associated with phlyctenulosis are similar to those of a mild to moderate conjunctivitis. The patient frequently has foreign body sensation as well as ocular discomfort and injection. Although not common, mucopurulent discharge may also occur simultaneously with bacterial infection. In most instances, the patient complains of the stringy mucous-like discharge seen in ocular allergy.

Phlyctenules appear as small, raised, nodular lesions that are usually pinkish white and surrounded by dilated blood vessels. The conjunctival lesions are self-limiting and rarely produce significant symptoms beyond those already mentioned. The more typical response occurs when the lesion develops at the limbal margin and encroaches onto the corneal surface. These junctional lesions are generally more symptomatic, causing photophobia, ciliary spasm, and tearing. Limbal phlyctenules resemble those of the conjunctiva, but they bridge the corneal limbus (see Figure 26-26). Limbal lesions usually occur in the inferior aspect of the eye near the eyelid margin, whereas the conjunctival lesions develop within the interpalpebral aperture (Figure 25-32).

The diagnosis of phlyctenular conjunctivitis is based primarily on the typical appearance of the lesion,



**Figure 25-32** Conjunctival phlyctenule (arrow) in interpalpebral aperture. (Courtesy William Wallace, O.D.)

its location, and a thorough ocular examination and health history. Differential diagnosis includes such entities as chlamydial conjunctivitis, pterygium, pinguecula, nodular episcleritis, and VKC. Phlyctenulosis has a relatively acute presentation; pterygium and pinguecula do not. Chlamydial infection presents with a much more chronic course and a follicular reaction typical of the disease. In its early phases rosacea can appear subtle, but typical dermatologic changes allow easy differentiation. Limbal VKC, by producing similar allergy-like mucous discharge, can be difficult to diagnose in its early phase but has a seasonal component that helps to differentiate it from phlyctenulosis. Trantas' dots, associated with limbal VKC, are also much smaller than phlyctenules.

### Management

Therapy depends on etiology. In individuals who are suspected of having tuberculosis, diagnosis should make use of a purified protein derivative skin test, chest radiograph, and sputum cultures if necessary. These individuals should be referred for comanagement to their primary physician or to an infectious disease specialist. Though antituberculin agents are systemically administered, the ocular lesions are appropriately treated with topical steroids. In most instances, patients respond to 1% prednisolone acetate every 3 to 4 hours for the first day, subsequently tapered rapidly on the basis of the clinical response.

When patients are suspected of having underlying staphylococcal disease, both inflammatory and bacterial components can be managed with a steroid-antibiotic combination. Initial doses should be administered every 2 to 4 hours, depending on severity, for the first 24 to 48 hours. In most instances, patients obtain dramatic relief from symptoms and can diminish use of the drug in 7 to 10 days. Because of the association of *Staphylococcus* with eyelid disease, lid therapy should be instituted. Antibiotic ointments such as erythromycin, bacitracin,

or bacitracin-polymyxin B can be used twice daily in conjunction with warm compresses and eyelid scrubs. Oral tetracycline is effective in treating phlyctenular keratoconjunctivitis. Tetracycline is typically prescribed 250 mg four times daily for approximately 4 to 6 weeks; alternatively, doxycycline, 100 mg twice daily for 4 to 6 weeks, is administered. When other etiologic agents, such as intestinal parasites, *Chlamydia*, gonococci, and HSV are suspected, patients should receive appropriate systemic medications.

### Superior Limbic Keratoconjunctivitis

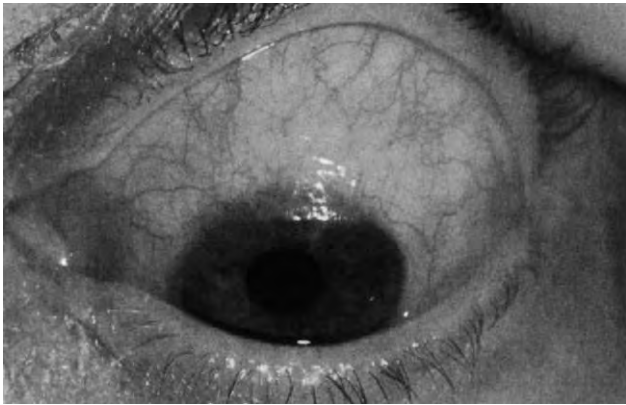
#### Etiology

Superior limbic keratoconjunctivitis (SLK) is a chronic inflammatory disorder involving the superior bulbar conjunctiva and cornea. The superior tarsal conjunctiva is diffusely inflamed, with a pronounced papillary response. It is a disorder primarily of middle age, with women more often and more severely affected than men. SLK is usually bilateral, though significant asymmetry can exist. Patients may be highly symptomatic, complaining of burning, foreign body sensation, irritation, pain, and photophobia. The disease is often episodic; exacerbations may resolve within days or can wax and wane over many years. One of the unusual aspects is varying intensity between eyes without significant remission taking place in either. This course frequently is accompanied by fluctuating ocular discomfort. Although there is no established etiology for this disease, dry eye was a common finding in the original study. Thyroid dysfunction is another common finding. Recently, SLK has been attributed to superior limbal stem cell damage, perhaps related to chronic hypoxia, lid-induced microtrauma, and conjunctivochalasis.

#### Diagnosis

The diagnosis of SLK is aided by several unique factors. Patients tend to be more symptomatic than the clinical examination justifies. The clinical picture is that of a sectional area of inflammation at the limbal margin (at the 10 o'clock to 2 o'clock position; Figure 25-33), demonstrating mild to moderate injection and, in more advanced cases, a gelatinous thickening of the limbal conjunctiva. Some individuals may also have filamentary keratitis and a mild mucous discharge, but these findings may be more related to associated dry eye and increased mucin content of the tears. The classic clinical picture is of intense punctate rose bengal staining of the affected ocular surface. The staining pattern is typically more severe than the conjunctival involvement would suggest and frequently correlates well with the patient's symptoms. The cornea, although it can demonstrate punctate staining, filament development, and, occasionally, pannus, is usually not as severely involved as the conjunctiva.

A variant of the classic form of SLK is that of soft contact lens-induced SLK. Although affected individuals typically show findings very similar to patients with SLK,



**Figure 25-33** Superior limbic keratoconjunctivitis.

they almost universally respond to aggressive use of nonpreserved artificial tears, elimination of preserved care products, or discontinuation of contact lens wear.

### Management

The etiology of SLK remains uncertain, but the most appealing hypothesis suggests a mechanical cause. For many years therapy has consisted of a wide variety of agents, including steroids, antibiotics, and ocular lubricants, followed by other more aggressive forms of treatment. Topical pharmacotherapy has not been particularly successful, but because some patients do respond, it is a prudent course of treatment before initiating more aggressive therapeutic intervention. A recent study found topical cyclosporine emulsion helpful in the management of SLK.

Other topical therapy used with some success includes 10% to 20% acetylcysteine applied four times daily, especially when corneal filaments are present, and 4% cromolyn sodium used every 4 hours. Both these agents have demonstrated modest success and should be considered before more aggressive intervention. If these topical agents give no relief, the current recommended therapy is 0.25% to 0.50% silver nitrate solution followed by irrigation, selectively applied to the tarsal and bulbar conjunctival surfaces. Such therapy may not result in permanent resolution, but most patients achieve reasonably prolonged relief after chemical cautery. Similar treatments include scraping of the tarsal conjunctiva, electrocautery, diathermy, cryotherapy, or laser therapy. Other less invasive forms of therapy include pressure patching of the affected eye and bandage contact lenses. Punctal occlusion has shown promise in managing SLK. Though none of these treatments has been universally successful, all have demonstrated some capacity to relieve symptoms in patients for finite periods.

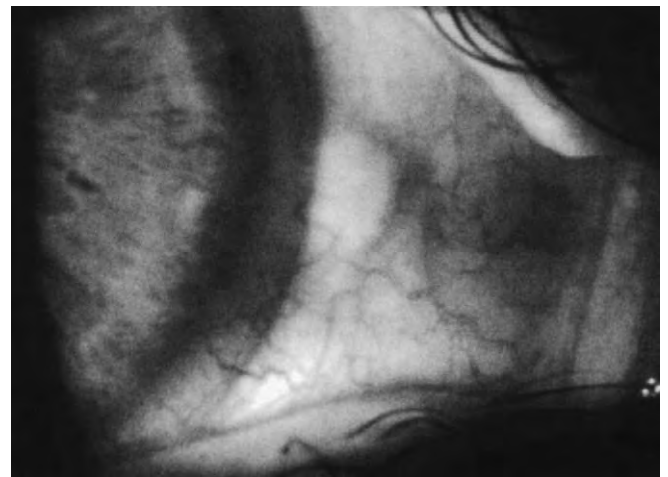
In individuals who do not respond to these therapeutic regimens, resection of the involved conjunctiva should be considered. This surgery involves the removal of a 5- to 6-mm section of conjunctiva in the affected area. However, no single remedy has proved consistently

successful, and the patient frequently demonstrates symptomatic relief followed by exacerbation. For this reason the clinician must provide adequate counseling to the patient regarding the potential chronicity of the disease. Any associated problems (e.g., dry eye, bacterial conjunctivitis) that develop during the course of therapy must also be treated, because they may produce an increase in symptoms.

### Pinguecula

Pingueculae are well-demarcated yellowish to yellow-white elevated lesions that appear within the intra-palpebral bulbar conjunctiva, typically adjacent to the limbus. Pingueculae can present on the nasal or temporal conjunctiva or, less frequently, on both. There is a predilection for the nasal side, which is most likely caused by increased reflectance of UV rays from the nose. Histologically, pingueculae consist of accumulations of an amorphous material that is believed to arise from the degeneration of collagen within the substantia propria of the conjunctiva. Additional degeneration can occur, including calcific inclusions and concretions. The epithelium overlying a pinguecula can vary from atrophic and thinned to hyperplastic and thickened. Pingueculae are unlikely to undergo malignant conversion. However, a lesion that looks atypical should be approached with suspicion. Actinic keratosis, dysplastic changes, and even carcinoma can arise within the epithelium overlying a pinguecula.

Pingueculae may become inflamed, resulting in so-called pingueculitis. The most common causes of such inflammation are mechanical irritation or ocular surface disease. Irritation by the edge of a contact lens is a frequent cause (Figure 25-34). Treatment includes elimination of the causal factor, increased lubrication, and a short course of topical steroids when inflammation is significant.



**Figure 25-34** Irritated pinguecula adjacent to edge of a soft contact lens.

## Pterygia

### Etiology

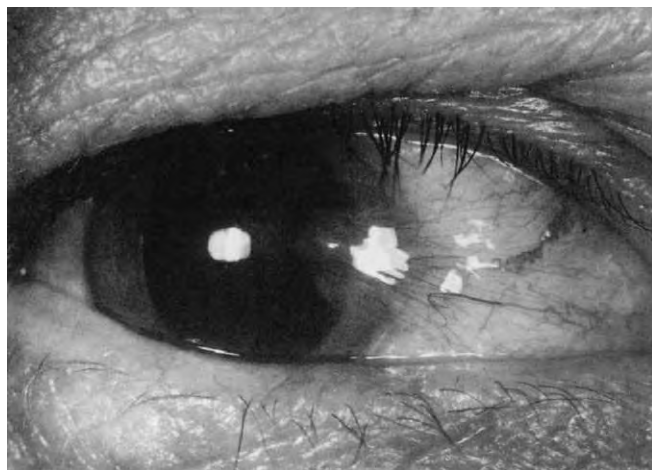
Recent thinking about pterygia suggests that they are an active, invasive, inflammatory process associated with focal limbal failure. In a two-stage process, “conjunctivalization” of the cornea occurs, in which tissue is characterized by extensive chronic inflammation, cellular proliferation, connective tissue remodeling, and angiogenesis. Histologically, pterygia are identical in cellular composition to pingueculae.

The primary etiologic factors may relate to both heredity and environment. UV radiation to the limbal area may contribute to the genesis of these lesions. The incidence of pterygia increases with proximity to the equator. Pterygia also typically occur in individuals who spend significant amounts of time outdoors and therefore are exposed to high levels of UV light. Other agents that may contribute to the development of pterygia include external stimuli, such as allergens, noxious chemicals, and irritants. Because of the marked similarity in cellular composition, a pinguecula may, in many instances, be a precursor to a pterygium.

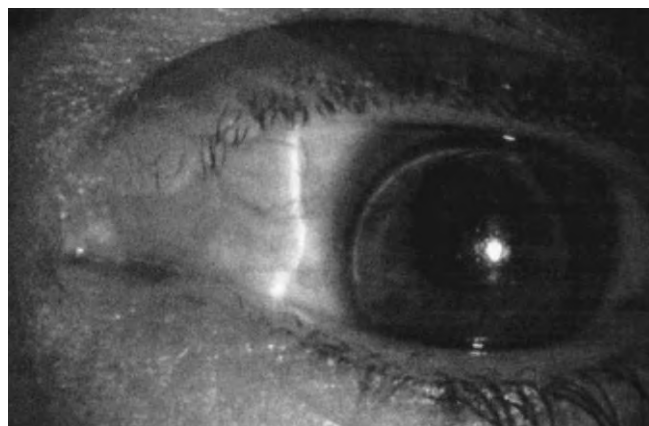
The term *pterygium* means “wing,” which is descriptive of its typical appearance in most patients. Pterygia are primarily located in the interpalpebral area and more frequently occur in the nasal aspect of the bulbar conjunctiva. They appear as a wedge-like structure with its base toward the medial or lateral canthus and its apex toward the corneal surface (Figure 25-35).

### Diagnosis

A thorough history and examination of the anterior segment can readily establish a diagnosis of pterygia. The typical interpalpebral wedge-like elevated mass of a pterygium is not characteristic of other lesions. The only exception is a pseudopterygium (Figure 25-36), which can arise after long-standing chronic peripheral corneal



**Figure 25-35** Pterygium. Note base toward canthus and apex on corneal surface.



**Figure 25-36** Pseudopterygium associated with long-term use of a rigid gas-permeable contact lens.

desiccation associated with rigid contact lens wear. Pseudopterygium has also been described as vascularized limbal keratopathy. A true pterygium firmly adheres to the underlying corneal and conjunctival tissue, whereas the pseudopterygium does not.

The actual clinical presentation of a pterygium depends on the length of time during which the lesion has been present and any inflammatory component. Pterygia are usually quiescent, but patients can present with significant inflammation and marked injection of the conjunctiva and associated tissue overlying the cornea. In advanced cases, pterygia can produce up to 4.00 to 6.00 D of corneal curvature change. Another important and clinically significant finding is a dellen, an area of drying and tissue loss adjacent to the elevated edge of the pterygium. This lesion may result from inadequate eyelid-cornea or eyelid-conjunctiva contact on blinking and a subsequent lack of mucin coverage and wetting of the involved area.

When they encroach on the cornea, pterygia often have visual consequences. Most associated refractive change is generally correctable to normal visual levels unless the pterygium has encroached on the visual axis. In such cases a rather marked reduction in visual acuity can occur. Moreover, once pterygia reach a critical size, they induce visually significant central with-the-rule astigmatic changes that may not be apparent by subjective refraction. Such changes may be more apparent on corneal topography. This finding helps to identify those patients who may benefit from surgical intervention. Significant visual disturbance is a primary reason for surgical intervention. In some instances patients can have pterygia on both the nasal and temporal aspect of each eye and have remarkable injection of the interpalpebral area, with a relatively quiet conjunctiva beneath the upper and lower eyelids.

### Management

In the early stages the management of pterygia usually involves palliative therapy. Patients show significant relief of symptoms with the use of artificial tears and ointments. When these are insufficient, mild steroids, such as

fluorometholone four times daily, can be administered to combat the inflammatory component. Chronic use of steroids, however, is not recommended. Topical indomethacin solution has been proposed as an alternative to topical steroid treatment, because it was found to be as effective as a steroid for treating inflamed pterygia. Pterygia and cataract development have been associated. Patients exposed to excessive sunlight or the elements should be advised to wear protective eyewear and wide-brimmed hats.

Surgical treatment of the disease generally is considered only when cosmesis or visual compromise becomes an issue. Because pterygia often recur after surgical removal, various strategies have been developed to prevent recurrence. Simple resection, rotation and reimplantation of the head of the pterygium, conjunctival autografts, conjunctival rotation autografts, and buccal mucosal grafts have all been applied with varying degrees of success. Currently, primary resection alone has a 40% to 50% recurrence rate. Amniotic membrane transplantation has proved a helpful adjunct in pterygium surgery. Strontium 90 irradiation and thiotepa application have also been used to prevent recurrence.

Mitomycin C has gained favor as a surgical adjunct. By inhibiting fibroblast proliferation, mitomycin C may decrease the rate of pterygium recurrence after surgical excision. The drug has been applied intraoperatively by holding a sponge soaked in 0.02% to 4.00% mitomycin against the sclera for 3 to 5 minutes. The medication has also been administered postoperatively with success. Long-term complications include delayed epithelialization and degenerative calcification of conjunctiva. The recent increase in awareness of the role of localized limbal epithelial stem cell damage in the pathogenesis of pterygia has led to limbal allograft surgery. Success with this method has been comparable with that of conventional surgical approaches.

## **NUTRITIONAL DEFICIENCIES**

Although rare in the United States, malnutrition and nutritional deficiencies may affect the conjunctiva and should be kept in mind in unusual presentations.

### **Etiology**

Generalized malnutrition may produce conjunctival keratinization. Vitamin B deficiency can cause abnormal dilatation of the conjunctival vasculature. Vitamin C deficiency can produce petechial or spontaneous subconjunctival hemorrhages. Avitaminosis A can cause severe drying of the ocular surface and the appearance of Bitot's spots on the temporal conjunctiva.

### **Diagnosis**

Nutritional deficiency is identified after recording a careful social history. Blood work confirms the presence

and extent of any vitamin deficiency. In some settings, malnutrition and nutritional deficiency may be associated with abusive situations; thus, the clinician should be aware of the possible social and legal implications of these findings. Of note, vitamin A deficiency may be associated with Bitot's spots, triangular, paralimbal, foamy, grayish plaques of keratinized conjunctival debris. Loss of conjunctival goblet cells and subsequent squamous metaplasia of conjunctival epithelial cells leads to profound drying and damage to the ocular surface. Impression cytology may be used to diagnose the conjunctival changes associated with vitamin A deficiency. It is important to consider that vitamin A deficiency not in keeping with the patient's social situation may be associated with disorders that interfere with vitamin absorption, such as gastrointestinal or liver disease.

### **Management**

Supplementation with appropriate vitamins and the addition of sufficient protein generally resolve nutritionally based disorders. Severe corneal disease caused by prolonged vitamin A deprivation is typically more resistant to treatment. Topical treatment with lubricants or retinoic acid may be helpful in combating vitamin A deficiency.

## **CONJUNCTIVAL TRAUMA**

Injuries to the conjunctiva may arise from a variety of different household, school, sports, or workplace activities. Children and young adults are particularly at risk. Conjunctival and corneal foreign bodies cause 40% of eye injuries. A disproportionate number of severe injuries occur in children and young adults. Clinical findings may include foreign bodies, chemical or thermal burns, and abrasions, lacerations, and contusions from blunt trauma. Conjunctival trauma should cause concern because of the risk of concurrent corneal injury or the possibility of penetration of the globe by a foreign body involved in a high-speed impact.

### **Foreign Bodies**

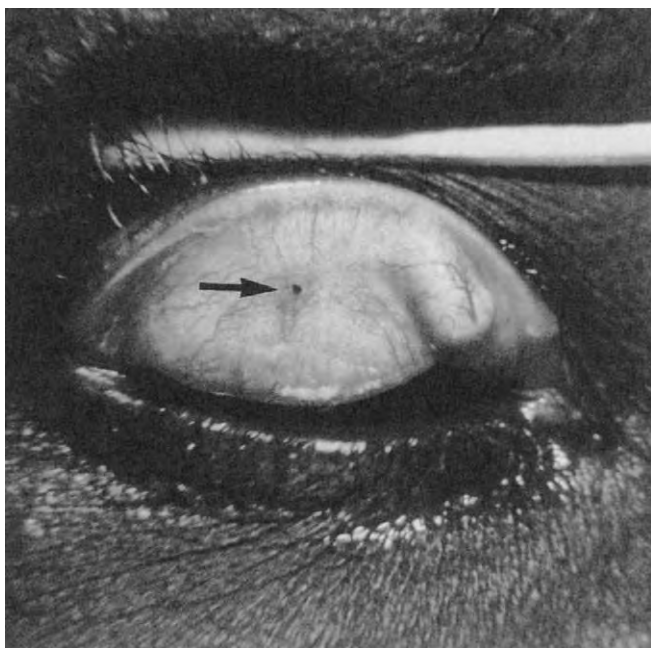
#### **Etiology**

Environmental foreign bodies, such as dirt, dust, glass, metal, or other material, may contact and adhere to the conjunctiva. Often, patients report that something blew into the eye on a windy day. The workplace is also a frequent source of foreign body material, particularly for individuals not wearing protective eyewear.

#### **Diagnosis**

Recording a thorough history and performing a biomicroscopic examination are crucial steps in the diagnosis of all conjunctival injuries, both to assess the degree of conjunctival damage and to determine the extent of any corneal or scleral involvement. The case history should





**Figure 25-37** Foreign body (*arrow*) on upper palpebral conjunctiva. (Courtesy of Larry J. Alexander, O.D.)

determine painstakingly the source, mass, trajectory, and impact speed of the foreign material, because this information guides the clinician's examination and helps to determine the need for adjunctive testing, such as radiologic studies. The eyelids must be everted to assess the palpebral conjunctiva carefully (Figure 25-37). Occasionally, double eyelid eversion may be required. In some cases topical anesthesia may be necessary to evaluate the eye adequately. The evaluation should also include a Seidel test using sodium fluorescein dye to rule out any aqueous leakage from penetration of the globe. The anterior chamber depth should also be evaluated. A flat chamber would indicate a penetrating injury even in the absence of an apparent entry wound. Most conjunctival foreign bodies are superficial and usually are found on the superior palpebral conjunctiva (see Figure 25-37). Depending on the length of time the foreign body has been present, the wound site may have some surrounding hyperemia. When foreign bodies become embedded in the conjunctiva, a subconjunctival hemorrhage or conjunctival granuloma may envelop the impact site, in some cases entrapping the object.

### Management

Copious lavage of the conjunctiva with normal saline or extraocular irrigating solution may loosen and remove some foreign bodies. Swabbing the affected area with a moistened cotton-tipped applicator is often effective when the foreign body is only partially adhered. When visualizing the foreign material is difficult, as with fiberglass particles, swabbing the fornices is often necessary to remove the foreign material. Any swabbing should be

followed by a saline lavage. Embedded foreign bodies may be removed with a sterile needle or spud. A broad-spectrum topical antibiotic, such as trimethoprim-polymyxin B (Polytrim) solution or bacitracin-polymyxin B ointment, should be applied to the eye after removal of the foreign body to prevent secondary infection. The antibiotic may be continued for 24 hours, if necessary, after the removal of embedded foreign bodies. Semipressure patching with cycloplegia and a topical antibiotic may be indicated after removal of deeply embedded foreign bodies.

### Burns

#### Etiology

Chemical burns of the conjunctiva usually result from inadvertent splashes of chemicals into the face or from hydrogen peroxide contact lens solutions. Occasionally, patients may instill a chemical irritant directly into the eye, resulting in severe injury. Cigarettes, curling irons, and overexposure to UV radiation frequently cause thermal burns.

#### Diagnosis

The diagnosis of conjunctival burns requires essentially all the procedures outlined for diagnosing foreign bodies. For chemical burns the clinician must determine whether the offending chemical is acid or alkaline. If the chemical is not familiar to the clinician, the local poison control center can provide information. The conjunctival fornix and tear film can be tested with pH paper to determine whether an acid or base is present. The conjunctiva must then be carefully assessed to determine the depth of the burn. Most acid burns cause superficial epithelial damage, as indicated by punctate staining with sodium fluorescein. In severe cases, however, blanching of the conjunctiva is possible. Alkaline burns from chemicals, such as lye or lime, usually blanch the conjunctiva and cause more severe injury, due to their collagenolytic effects. Thermal burns may cause either superficial or severe injury, depending on contact time of the offending agent. Specific management is discussed in more detail in Chapter 26.

### Abrasions, Contusions, and Lacerations

#### Etiology

Direct trauma is the most frequent cause of conjunctival abrasions, contusions, or lacerations. The nature of the contact usually determines what type of wound the patient suffers. For example, a thrown object may cause only a contusion, whereas a sharp pencil point can lacerate the conjunctiva.

#### Diagnosis

The diagnosis of conjunctival injuries is determined through the history and careful biomicroscopic examination. Symptoms usually consist of mild irritation or foreign body sensation. Clinical findings accompanying

conjunctival abrasions include superficial epithelial cell loss, chemosis, and subconjunctival hemorrhage. Most conjunctival contusions result in subconjunctival hemorrhages. Lacerations are usually associated with hemorrhaging and frequently result in loose conjunctival tissue flaps if they are full-thickness tears. The white sclera may be visible, flanked by clumping of conjunctival tissue, chemosis, and subconjunctival hemorrhages. The sclera must be carefully evaluated to rule out perforation of the globe. A Seidel test should be performed.

### Management

Conjunctival abrasions and lacerations should be irrigated with sterile normal saline or extraocular irrigating solution to remove any foreign material. Abrasions may be treated with topical trimethoprim-polymyxin B (Polytrim) or aminoglycoside solution applied four times daily for several days or until the abrasion is healed. In pediatric cases, bacitracin-polymyxin B ointment may be substituted, if necessary, to improve patient comfort. Many conjunctival abrasions do not require patching. Conjunctival lacerations may be managed with bacitracin-polymyxin B or aminoglycoside ointment applied four times daily for 5 to 7 days or until the wound is sufficiently healed. Conjunctival lacerations frequently require semipressure patching with cycloplegia and topical antibiotic ointment to achieve adequate resolution. Sutures are not needed for small uncomplicated conjunctival lacerations.

Once healing has begun, frequent use of nonpreserved artificial tears or lubricating gels often improves patient comfort. No specific therapy is required for conjunctival contusions, because most involve only subconjunctival hemorrhages that are self-limiting. Warm compresses used for 15 to 20 minutes several times daily may hasten resorption of blood.

## **FACTITIOUS CONJUNCTIVITIS (OCULAR MUNCHAUSEN SYNDROME)**

Although not often reported in the literature, self-abuse—either accidental or intentional—is an important differential diagnosis in otherwise inexplicable cases of conjunctivitis.

### Etiology

A variety of underlying factors can lead to self-abuse. Munchausen syndrome describes the situation wherein patients actively but surreptitiously harm themselves. These patients sometimes go to great extremes to hide this behavior and may shift methods when detection is eminent. Although the specific reasons vary for each patient, such behavior is often an attention-seeking device.

### Diagnosis

Factitious conjunctivitis should be considered whenever an examiner is confronted with a clinical picture that

seemingly makes little sense. Young female patients and those who have such motivations as seeking workers' compensation or sick leave should be examined with suspicion. Because of purposeful deception, a specific diagnosis often remains elusive, and prior consultations with physicians are not uncommon. A confusing clinical picture is the first sign. Inserting foreign objects is a common method, with chalk being among the objects used most frequently. Chalk is readily available to young students and can be broken into pieces small enough to be placed in the eye furtively. The mild alkali causes irritation and eventually dissolves, rendering detection difficult. Solutions and medications are also common tools for these patients. Topical anesthetic, secretly removed from a prior doctor's office, is another frequent source of factitious conjunctivitis, producing confusing corneal and conjunctival findings. Chronic, long-standing, unilateral membranous conjunctivitis may be a sign of factitious causes. Instruments may also be used to create focal conjunctival damage. Because damage to the cornea produces so much pain, the conjunctiva is the area most likely to be involved.

Mucus fishing syndrome is an example of inadvertent damage caused by patient-induced irritation to the ocular surface. Patients use their fingernails to fish out strings of mucus. They often report foreign body sensation, irritation, and excessive mucous production. The behavior exacerbates the problems, causing a worsening spiral. A careful history examination will reveal the actual cause.

### Management

Treatment of self-abusive behavior typically requires medical counseling and psychological or psychiatric intervention. Identification of the inciting events and subsequent confrontation may not be productive, because the actual cause of the problem might not be addressed. When children are involved, parents should be counseled to approach the issue with caution and sensitivity. Because detecting these cases may be difficult, patients often are seen by several clinicians, and parents may be angry and frustrated when they discover that their child is causing the problem.

Mucus fishing syndrome requires treatment of the underlying condition and education about the patient's role in creating the disorder. When present, allergy must be addressed. The newer antihistamine-mast cell stabilizer combination products, such as olopatadine, have been particularly helpful in managing the disorder in these patients.

## **SELECTED BIBLIOGRAPHY**

- Allansmith MR, Greiner JV, Baird BS. Number of inflammatory cells in the normal conjunctiva. *Am J Ophthalmol* 1978; 86:250.
- Barnhorst DA Jr, Foster JA, Chern KC, Meisler DM. The efficacy of topical metronidazole in the treatment of ocular rosacea. *Ophthalmology* 1996;103:1880-1883.

- Baron EJ, Finegold SM. Diagnostic microbiology. St. Louis: CV Mosby, 1990: 84.
- Battle TJ, Golden MR. Evaluation of laboratory testing methods for *Chlamydia trachomatis* infection in the era of nucleic acid amplification. *J Clin Microbiol* 2001;39: 2924-2927.
- Block SL, Hedrick J, Tyler R, et al. Increasing bacterial resistance in pediatric acute conjunctivitis (1997-1998). *Antimicrob Agents Chemother* 2000;44:1650-1654.
- Bowman RJ, Sillah A. Operational comparison of single-dose azithromycin and topical tetracycline for trachoma. *Invest Ophthalmol Vis Sci* 2000;41:4074-4079.
- Brinser JH, Weiss A. Laboratory diagnosis in ocular disease. In: Tasman W, Jaeger EA, eds. *Duane's clinical ophthalmology*. Philadelphia: J.B. Lippincott, 1993:1-14.
- Bron AJ, Mengher LS, Davey CC. The normal conjunctiva and its response to inflammation. *Trans Ophthalmol Soc U K* 1985;104:424-435.
- Centers for Disease Control and Prevention. 2006 guidelines for treatment of sexually transmitted diseases. (<http://www.cdc.gov/std/treatment/2006/clinical.htm>)
- Chatterjee S, Quarcoopome CO, Apenteng A. Unusual type of epidemic conjunctivitis in Ghana. *Br J Ophthalmol* 1970;54: 628-630.
- Cochereau I, Meddeb-Ouertani A, Khairallah M, et al. 3-Day treatment with Azithromycin 1.5% eye-drops (Astern(R)) versus 7-day treatment with Tobramycin 0.3% for purulent bacterial conjunctivitis: multicentre, randomised and controlled trial in adults and children. *Br J Ophthalmol* 2007;91(4):466-69.
- Colin J, Prisant O. Comparison of the efficacy and safety of valacyclovir and acyclovir for the treatment of herpes zoster ophthalmicus. *Ophthalmology* 2000;107:1507-1511.
- Coroneo MT, Di Girolamo N, Wakefield D. The pathogenesis of pterygia. *Curr Opin Ophthalmol* 1999;10:282-288.
- Crede CSF. Die verhaltung der augenentzündung der neugeborenen. *Arch Gynak* 1881;21:179.
- Cruciani F, Santino G, Trudu R, Balacco GC. Ocular Munchausen syndrome characterized by self-introduction of chalk concretions into the conjunctival fornix. *Eye* 1999;13(pt 4): 598-599.
- Cvenkel B, Globocnik M. Conjunctival scrapings and impression cytology in chronic conjunctivitis. Correlation with microbiology. *Eur J Ophthalmol* 1997;7:19-23.
- Division of STD Prevention. Sexually transmitted disease surveillance 2005. U.S. Department of Health and Human Services, Public Health Service. Atlanta: Centers for Disease Control and Prevention, 2005.
- Donnenfeld ED, Perry HD, Wallerstein A. Subconjunctival mitomycin C for the treatment of ocular cicatricial pemphigoid. *Ophthalmology* 1999;106:72-78.
- Emerson PM, Burton M. The SAFE strategy for trachoma control: using operational research for policy, planning and implementation. *Bull World Health Organ* 2006;84: 613-619.
- Everett SL, Kowalski RP, Karenchak LM, et al. An in vitro comparison of the susceptibilities of bacterial isolates from patients with conjunctivitis and blepharitis to newer and established topical antibiotics. *Cornea* 1995;14:382-387.
- Flach AJ, Lavoie MD. Episcleritis, conjunctivitis and keratitis as ocular manifestations of Lyme disease. *Ophthalmology* 1990;97:973-975.
- Fouchier RA, Schneeberger PM. Avian influenza A virus (H7N7) associated with human conjunctivitis and a fatal case of acute respiratory distress syndrome. *Proc Natl Acad Sci USA* 2004;101:1356-1361.
- Friedlaender MH. Allergy and immunology of the eye. New York: Raven Press, 1993: 53-55.
- Friedlander MH. Allergy and immunology of the eye. New York: Raven Press, 1993: 9-10.
- Frucht-Pery J, Chayet AS, Feldman ST, et al. The effect of doxycycline on ocular rosacea. *Am J Ophthalmol* 1989;107: 434-435.
- Garrett DO, Jochimsen E, Murfitt K, et al. The impending apocalypse: the emergence of vancomycin resistance in *Staphylococcus* spp. *Infect Control Hosp Epidemiol* 1997;18:32.
- Genvert GI, Cohen EJ, Donnenfeld ED, et al. Erythema multiforme after use of topical sulfacetamide. *Am J Ophthalmol* 1985;99:465.
- Goldstein MH, Kowalski RP, Gordon YJ. Emerging fluoroquinolone resistance in bacterial keratitis: a 5-year review. *Ophthalmology* 1999;106:1313-1318.
- Herpes simplex: the primary infection. *Br J Ophthalmol* 2000;84:968-972.
- Honavar SG, Bansal AK, Sangwan VS, Rao GN. Amniotic membrane transplantation for ocular surface reconstruction in Stevens-Johnson syndrome. *Ophthalmology* 2000;107: 975-979.
- Isenberg SJ, Apt L. A controlled trial of povidone-iodine to treat infectious conjunctivitis in children. *Am J Ophthalmol* 2002;134:681-688.
- Katusic D, Petricek I. Azithromycin vs doxycycline in the treatment of inclusion conjunctivitis. *Am J Ophthalmol* 2003;135:447-451.
- Khorazo D, Thompson R. The bacterial flora of the normal conjunctiva. *Am J Ophthalmol* 1935;18:1114.
- Kleinfeld J, Ellis PP. Effects of topical anesthetics on the growth of microorganisms. *Arch Ophthalmol* 1966;76:712.
- Lesser RL. Ocular manifestations of Lyme disease. *Am J Med* 1995;98(4A):60S-62S.
- Lichtenstein SJ, Dorfman M, Kennedy R, Stroman D. Controlling contagious bacterial conjunctivitis. *J Pediatr Ophthalmol Strabismus* 2006;43:19-26.
- Liesegang TJ. Conjunctival changes associated with glaucoma therapy: implications for the external disease consultant and the treatment of glaucoma. *Cornea* 1998;17:574-583.
- Limberg MB. A review of bacterial keratitis and bacterial conjunctivitis. *Am J Ophthalmol* 1991;112:2S-9S.
- Locatcher-Khorazo D, Seegal BC. Microbiology of the eye. St. Louis: C.V. Mosby, 1972: 14-15.
- MacCallan A. The epidemiology of trachoma. *Br J Ophthalmol* 1931;15:369.
- Mannis MJ. Bacterial conjunctivitis. In: Tasman W, Jaeger EA, eds. *Duane's clinical ophthalmology*. Philadelphia: J.B. Lippincott, 1993:1-7.
- McGhee CN, Anastas CN. Widespread ocular use of topical chloramphenicol: is there justifiable concern regarding idiosyncratic aplastic anaemia? *Br J Ophthalmol* 1996;80: 182-184.
- McNutt J, Allen SD, Wilson LA, et al. Anaerobic flora of the normal human conjunctival sac. *Arch Ophthalmol* 1978;96:1448.
- Messmer EM, Foster CS. Vasculitic peripheral ulcerative keratitis. *Surv Ophthalmol* 1999;43:379-396.
- Mombaerts IM, Maudgal PC, Knockaert DC. Bilateral follicular conjunctivitis as a manifestation of Lyme disease. *Am J Ophthalmol* 1991;98:96-97.

- Mondino BJ. Use of pressure patching and soft contact lenses in superior limbic keratoconjunctivitis. *Arch Ophthalmol* 1982;100:1932-1934.
- Nguyen QD, Foster CS. Cicatricial pemphigoid: diagnosis and treatment. *Int Ophthalmol Clin* 1996;36:41-60.
- Ostler HB. *Diseases of the external eye and adnexa*. Baltimore: Williams & Wilkins, 1993.
- Ostler HB. Herpes simplex: the primary infection. *Surv Ophthalmol* 1976;21:91-99.
- Patel PB, Diaz MC, Bennett JE, Attia MW. Clinical features of bacterial conjunctivitis in children. *Acad Emerg Med* 2007;14:1-5.
- Pavan-Langston DP, Dunkel EC. A rapid clinical diagnostic test for herpes simplex infectious keratitis. *Am J Ophthalmol* 1989;107:675.
- Perkins RE, Kundsins RB, Pratt MV, et al. Bacteriology of normal and infected conjunctiva. *J Clin Microbiol* 1975;1:145-147.
- Rapoza PA, Quinn TC, Terry AC, et al. A systematic approach to the diagnosis and treatment of chronic conjunctivitis. *Am J Ophthalmol* 1990;109:138-142.
- Read RW, Weiss AH, Sherry DD. Episcleritis in childhood. *Ophthalmology* 1999;106:2377-2379.
- Reporting of chlamydial infection—Massachusetts, January–June 2003. *MMWR* 2005;54:558-560.
- Roblin PM, Hammerschlag MR, Cummings C, et al. Comparison of two rapid microscopic methods and culture for detection of *Chlamydia trachomatis* in ocular and nasopharyngeal specimens from infants. *J Clin Microbiol* 1989;27:968.
- Romanowski EG, Pless P. Topical cyclosporine A inhibits subepithelial immune infiltrates but also promotes viral shedding in experimental adenovirus models. *Cornea* 2005;24:86-91.
- Romanowski EG, Roba LA. The effects of corticosteroids of adenoviral replication. *Arch Ophthalmol* 1996;114:581-585.
- Romanowski EG, Yates KA. Topical corticosteroids of limited potency promote adenovirus replication in the Ad5/NZW rabbit ocular model. *Cornea* 2002;21:289-291.
- Roy FH. The red eye. *Ann Ophthalmol* 2006;38:35-38.
- Rubin RL. Etiology and mechanisms of drug-induced lupus. *Curr Opin Rheumatol* 1999;11:357-363.
- Sambursky R, Tauber S. The RPS adeno detector for diagnosing adenoviral conjunctivitis. *Ophthalmology* 2006;113:1758-1764.
- Sandstorm KI, Bell TA, Chandler JW, et al. Microbial causes of neonatal conjunctivitis. *J Pediatr* 1984;105:706-711.
- Saw SM, Tan D. Pterygium: prevalence, demography and risk factors. *Ophthalmic Epidemiol* 1999;6:219-228.
- Shiuey Y, Ambati BK. A randomized, double-masked trial of topical ketorolac versus artificial tears for treatment of viral conjunctivitis. *Ophthalmology* 2000;107:1512-1517.
- Tabbara KF, Abu-el-Asrar A, al-Omare O, et al. Single dose azithromycin in the treatment of trachoma. A randomized controlled study. *Ophthalmology* 1996;103:842-846.
- Tavares FN, Costa EV. Acute hemorrhagic conjunctivitis and coxsackievirus A24v, Rio de Janeiro, Brazil, 2004. *Emerg Infect Dis* 2006;12:495-497.
- Theodore FH. Further observations on superior limbic conjunctivitis. *Trans Am Acad Ophthalmol Otolaryngol* 1967;71:341-351.
- Tripathi A, Ditto AM, Grammer LC, et al. Corticosteroid therapy in an additional 13 cases of Stevens-Johnson syndrome: a total series of 67 cases. *Allergy Asthma Proc* 2000;21:101-105.
- Tsai RJ, Li LM, Chen JK. Reconstruction of damaged corneas by transplantation of autologous limbal epithelial cells. *N Engl J Med* 2000;343:86-93.
- Tsubota K, Satake Y, Kaido M, et al. Treatment of severe ocular surface disorders with corneal epithelial stem-cell transplantation. *N Engl J Med* 1999;340:1697-1703.
- Uchio E, Takeuchi S. Clinical and epidemiological features of acute follicular conjunctivitis with special reference to that caused by herpes simplex virus type 1. *Br J Ophthalmol* 2000;89(9):968-972.
- Wagner RS. Results of a survey of children with acute bacterial conjunctivitis treated with trimethoprim-polymyxin B ophthalmic solution. *Clin Ther* 1995;17:875-881.
- Washington JA. *Laboratory procedures in clinical microbiology*. New York: Springer-Verlag, 1985: Appendix B.
- Wilson L, Ahearn D, Jones D, Sexton R. Fungi from the normal outer eye. *Am J Ophthalmol* 1969;67:52.
- Wolff E. *Anatomy of the eye and orbit*. Philadelphia: W.B. Saunders, 1976; 206.
- Workowski KA, Berman SM. Sexually transmitted diseases treatment guidelines, 2006. *MMWR Recomm Rep* 2006;55(RR-11):1-94.
- Wormser GP, Dattwyler RJ. The clinical assessment, treatment, and prevention of Lyme disease, human granulocytic anaplasmosis, and babesiosis: clinical practice guidelines by the Infectious Diseases Society of America. *Clin Infect Dis* 2006;43:1089-1134.
- Yanoff M, Fine BS. *Ocular pathology*. Philadelphia: J.B. Lippincott, 1989: 216-219.
- Zagorski Z, Biziorek B. Ophthalmic manifestations in Lyme borreliosis. *Przegl Epidemiol* 2002;56(suppl 1):85-90.

## *Diseases of the Cornea*

*Blair B. Lonsberry, Elizabeth Wyles, Denise Goodwin, Linda Casser, and Nada Lingel*

The cornea is the avascular, transparent, richly innervated anterior-most surface of the globe, which is the eye's primary refracting surface. As a result of these characteristics, diseases and disorders of the cornea can result in symptomatology, such as loss of vision, pain, and photophobia, that generally prompts the patient to seek care. Both the prevalence and potential severity of corneal conditions obligates the eye care provider to be fully versed in the diagnosis, treatment, and management of corneal diseases and disorders.

This chapter provides practical information regarding common corneal conditions that may require treatment. By nature of its anatomic proximity to and integration with other ocular and adnexal structures, corneal abnormalities may result from diseases primary to the eyelids, conjunctiva, lacrimal system, episclera, and other tissues. The details of these conditions are not emphasized in this chapter; thus the reader should refer to other appropriate chapters for this information.

### **CLINICAL ANATOMY AND PHYSIOLOGY**

#### **The Normal Cornea**

Histologic cross-section of the cornea reveals five identifiable layers: epithelium, Bowman's layer, stroma, Descemet's membrane, and endothelium. Fluid surrounds the cornea in the forms of the tear film in front and the aqueous behind. The various corneal layers combine to form a structure that is approximately 633  $\mu\text{m}$  thick at the inferior periphery, 673  $\mu\text{m}$  at the superior periphery, and 515  $\mu\text{m}$  thick centrally. The adult corneal diameter measures 11 to 12 mm horizontally and 9 to 11 mm vertically, creating a horizontally oriented ellipse. The radius of curvature of the central 3-mm optical zone ranges between 7.5 and 8.0 mm.

The epithelium is stratified and composed of five to seven layers of interconnected squamous cells of various types, sizes, and shapes. The deepest layer of epithelial cells,

known as the basal cell layer, adheres to a basement membrane and is the source for new cells that gradually move toward the surface. The outcome of this process is replacement of the entire epithelium every 7 days. An intact corneal epithelium helps to protect the cornea from most potential pathogenic organisms.

Bowman's layer is a thin homogeneous sheet of acellular randomly arranged collagen fibers lying between the epithelial basement membrane and the stroma. Bowman's layer is relatively tough and provides substantial resistance to corneal injury or infection. Because it cannot regenerate, scarring results when it is disrupted.

The stroma constitutes approximately 90% of the total corneal thickness and is primarily composed of collagen fibers, keratocytes, and glycosaminoglycans. The uniform arrangement of the collagen fibers is the major determinant of corneal transparency, in contrast to the opaque and less regularly arranged fibers of the sclera. Disruption of the stromal layer regularity results in loss of corneal transparency and potential scar formation.

Descemet's membrane (posterior limiting lamina) is a strong, homogeneous, and resistant membrane consisting of very fine collagen fibers in a regular array, which thickens throughout life. Descemet's membrane does not regenerate if damaged; however, endothelial cells migrate over the disrupted site and resurface the defect.

The endothelium consists of a single layer of interdigitating cells, which provides a slightly leaky barrier to the aqueous humor. The abundance of cellular organelles within the endothelial cells is consistent with the high level of metabolic activity provided by these cells as they actively transport aqueous out of the cornea. Maintenance of relative corneal dehydration also is achieved by the barrier functions of the epithelium and endothelium against the influx of tears and aqueous, respectively. Endothelial cells do not replicate *in vivo*. Loss of endothelial cells due to injury may disrupt corneal transparency and results in enlargement of the remaining adjacent cells to cover the affected area.

## DEGENERATIONS AND DYSTROPHIES

### Corneal Dystrophies

The corneal dystrophies are a group of corneal disorders genetically determined and traditionally classified with respect to the layer of the cornea they involve. Classification was based on slit-lamp examination and clinical appearance in an attempt to determine an apparent inheritance pattern and to monitor the natural progression. Histopathologic examination was typically performed postmortem or after corneal removal in transplant surgery. With the advent and increased understanding of molecular science, a new picture is emerging with respect to the genetic defects causing corneal disorders. Molecular science not only allows a basic understanding of the disease etiology and manifestation, but also offers potential for therapeutic intervention.

In addition to the explosion in molecular science, there has been a dramatic improvement in the ability to view the intact cornea and other ocular structures. In particular, the use of confocal microscopy has allowed for detailed corneal imaging in vivo and throughout the disease course. Table 26-1 outlines the contemporary inherited corneal disorder classification system, using information gathered from both molecular science and improved structural analysis. Table 26-1 lists the “old” name, the new name if applicable, the defective gene, inheritance pattern, phenotype, and typical complications. Each corneal dystrophy and gene has a unique OMIM (Online Mendelian Inheritance in Man) reference number, which is part of the national database. In addition, each gene has been assigned a symbol by the Human Genome Organization, also known as HUGO, which was established to standardize the gene names according to the family to which they belong.

**Table 26-1**

New Classification System for Corneal Dystrophies Including Current Name, Alternate Name, Gene Affected, and Inheritance Pattern

Current Name	Alternate Name	Gene	Inheritance	Phenotype	Potential Complications
Meesmann's		K <sub>3</sub> K <sub>12</sub>	AD	Multiple intraepithelial vesicles/microcysts.	Generally asymptomatic but susceptible to RCE with associated pain and blurred vision.
Macular	Groenouw type II	CHST <sub>6</sub>	AR	Grayish opacities with indistinct edges in superficial stroma. Later extension into deeper stroma with intervening stroma becoming hazy.	Progressive loss of vision, photophobia, and ocular discomfort. Definitive surgical treatment usually required by second or third decade.
Granular type 1	Groenouw type I	TGFBI	AD	Discrete white granular opacities in central anterior corneal stroma. Increasing number, density, size, and depth with intervening stroma and peripheral cornea remaining clear (unlike macular).	RCE common with associated pain. Decreased vision from subepithelial scarring or dense stromal deposits, requiring surgical intervention.
Corneal dystrophy of Bowman's layer type I	Reis-Bücklers	TGFBI	AD	Corneal surface appears rough and irregular with accumulation of opacities at Bowman's layer in annular, crescent, polygonal, or map-like formations. Opacities are confined to central and mid-peripheral cornea, whereas the extreme periphery remains transparent.	RCE common with surgery often required in second or third decades due to severe vision loss.
Corneal dystrophy of Bowman's layer type II	Thiel-Behnke	TGFBI	AD	Characteristic superficial opacification in a “honeycomb” pattern.	RCE common, though symptoms and opacification not as severe as in Bowman's type I.

**Table 26-1**

New Classification System for Corneal Dystrophies Including Current Name, Alternate Name, Gene Affected, and Inheritance Pattern—cont'd

Current Name	Alternate Name	Gene	Inheritance	Phenotype	Potential Complications
Avellino	Granular type II	TGFBI	AD	Granular and lattice-like, branching deposits within the stroma.	Central visual axis progressively opacifies and scarring results in decreased vision.
Lattice (types I, III/IIIa)		TGFBI	AD	Linear, refractile, branching deposits within the anterior stroma (periphery clear).	Central cornea is progressively opacified by stromal haze, with scarring and deterioration of vision. RCE are also present.
Lattice type II	Finnish type, familial amyloidosis, Meretoja syndrome	GSN	AD	Distinct from type I and characterized by multisystem manifestations due to systemic amyloidosis. Lattice lines are fewer, more radially oriented, and primarily affect the periphery, sparing the central cornea.	RCE and visual loss less common than other lattice dystrophies. There is relative corneal anesthesia, with increased risk of neurotropic ulcer. Glaucoma may be present secondary to amyloid deposition in trabecular meshwork.
Central crystalline dystrophy of Schnyder		?	AD	Central discoid opacification posterior to Bowman's membrane in anterior stroma. Opacities consist of small, needle-shaped, refractile crystals that are white or polychromatic. Opacities may extend into deeper stroma but epithelium remains normal.	Vision typically mildly affected. May be associated systemic complications.
Corneal fleck	Francois-Neetens, Mouchetee	?	AD with variable expression	Multiple tiny white flecks scattered through all corneal layers. May present congenitally or appear in first few years.	Generally asymptomatic, though mild photophobia may be present.
Fish-eye disease		LCAT	AD	Diffuse stromal haze, denser peripherally.	
Fuchs'		COL8A2	AD, sporadic	Generally occurs over the age of 40 with guttata visible in the central cornea. Endothelial polymegathism (reduced numbers and irregular shape) gives a beaten metal appearance.	Resulting functional loss results in corneal edema and corneal decompensation.
Posterior polymorphous		VSX1	AD, highly variable expression	Characterized by endothelial lesions (vesicular, band, and diffuse).	Visual loss is generally not significant though glaucoma and keratoconus have been associated.

*Note:* AD refers to autosomal dominant, AR refers to autosomal recessive.

Adapted from Vincent AL, Patel DV, McGhee NJ. Inherited corneal disease: the evolving molecular, genetic and imaging revolution. *Clin Exp Ophthalmol* 2005;33:303-316.



Treatment of the corneal dystrophies has been limited, for the most part, to the treatment of the associated complications. For example, most dystrophies result in the patient experiencing recurrent corneal erosions (RCEs). Patients are treated for the erosions without treating the underlying disease. Excimer laser phototherapeutic keratectomy (PTK) has been performed on patients with a variety of pathologies in the anterior one-third of the cornea with varying success. Excimer PTK is useful in the treatment of superficial stromal opacification and surface irregularity. PTK can restore and preserve useful function for a significant period of time. Although corneal dystrophies are likely to recur, successful retreatment with PTK is possible.

Traditionally, when a patient's vision had become significantly impaired, penetrating keratoplasty was performed to improve vision and function. However, with genetically determined disorders, the graft tissue has the potential to undergo the same disease process. Because the underlying etiology of these disorders is genetic, the latest therapeutic approach is evolving from the area of gene therapy. Gene therapy is being explored in corneal graft survival, corneal haze treatment, modulation of corneal wound healing, and the treatment of corneal dystrophies.

The following discussion focuses on the specific corneal dystrophies and degenerations that are most commonly encountered clinically.

## **Anterior Basement Membrane Dystrophy**

### **Etiology**

Abnormal corneal epithelial regeneration and maturation, along with an abnormal basement membrane, are the primary features in anterior basement membrane dystrophy (ABMD). The prevalence of ABMD has been reported to be as low as 2% and as high as 42% of all patients. In patients over the age of 70 the estimates are as high as 76%. Although ABMD often is considered the most common corneal dystrophy, it may be an age-related degeneration. The large number of patients with the condition, its increasing prevalence with age, and its late onset support classifying ABMD as a degeneration instead of a dystrophy.

### **Diagnosis**

Not all patients with this condition are symptomatic. The estimates of symptomatic ABMD patients range from lows of 10% to 20% to highs of 69%. The most common symptom is a mild foreign body sensation that usually is worse in dry weather, wind, and air conditioning. Blurred vision from irregular astigmatism or a rapid tear breakup may occur, especially in patients over the age of 45. Pain, when reported, usually is caused by RCE, which is estimated to occur in 10% of patients with ABMD.

It is easy to overlook ABMD during a clinical examination. This lack of detection may be the reason for such

wide variations in reported prevalence. The condition typically is bilateral but is often asymmetric. Females are affected more often than males. It often is first diagnosed between the ages of 40 and 70 years, but it has been reported in patients as young as 5 years.

With careful biomicroscopy examination, the most common findings in ABMD are gray chalky patches, intraepithelial microcysts, and fine lines, or a combination of these seen in the central two-thirds of the cornea. These findings are known as maps, dots, and fingerprints. These corneal changes may vary in appearance at each examination.

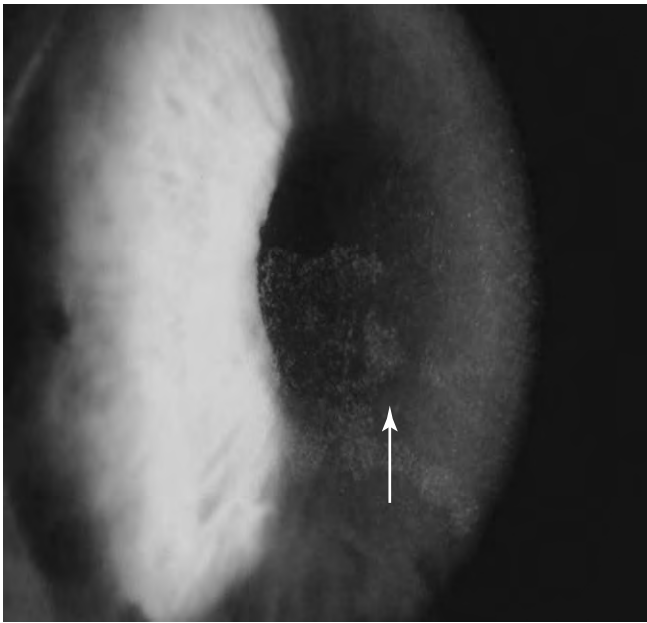
Maps appear as diffuse gray patches with sharp margins and thick irregular lines that may be surrounded by a haze. Maps often are separated by clear zones and may contain lacunae or white microcysts within their borders (Figures 26-1 and 26-2). They are seen most easily with tangential illumination. The tears over map areas break up rapidly and NaFl helps outline areas of mapping due to negative staining (Figure 26-3). Maps are caused by thickening of the basement membrane due to a proliferation of collagen material.

Dots contain degenerated epithelial cells that are trapped in intraepithelial extensions of the basement membrane. This prevents the normal migration of these cells toward the epithelial surface. Dots develop two different appearances. Some appear gray-white and have distinct edges. They often form clusters and vary in size from barely visible to 1 mm. These dots are seen easily on direct illumination and exhibit positive staining with NaFl only when they break through to the corneal surface. If the dots are very prominent, the condition is known as Cogan's microcystic dystrophy. Blebs, the second type of dots, are fine, clear, closely clustered refractile lesions that are seen only on retroillumination. They have no effect on tear breakup time and do not enhance the likelihood of RCEs. Blebs are formed by the accumulation of fibrogranular material between the basement membrane and Bowman's layer.

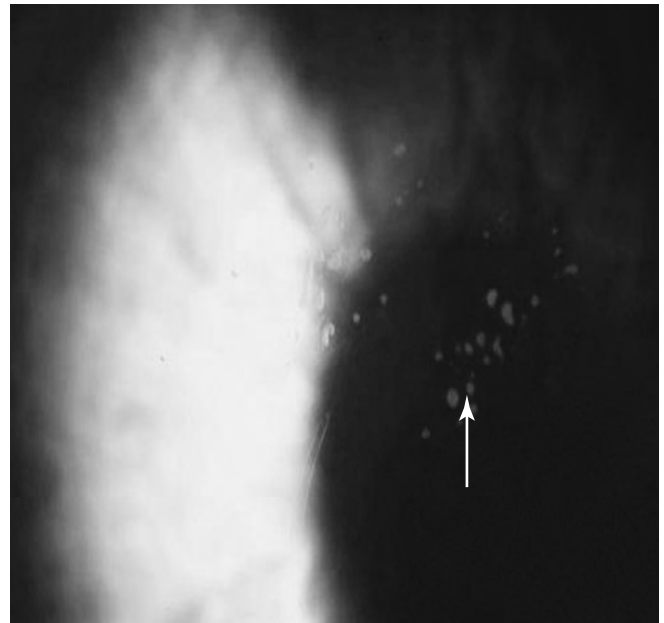
Fingerprint lines are thin, translucent, hair-like lines often arranged parallel to each other, resembling fingerprints (Figure 26-4). They are caused by a thickened and reduplicated basement membrane that extends into the epithelial layers. Retroillumination or indirect illumination are the best methods for seeing these lines, but a rapid tear breakup time over the areas also helps distinguish them. Findings similar to fingerprint lines also can develop in association with herpes simplex keratitis and bullous keratopathy.

### **Management**

Treatment is directed toward preventing RCEs and most commonly consists of the use of 5% sodium chloride ointment instilled into the conjunctival sac at bedtime. This agent is especially indicated for patients who notice blurring of their vision upon awakening due to associated edema. If epithelial edema consistently contributes to a



A

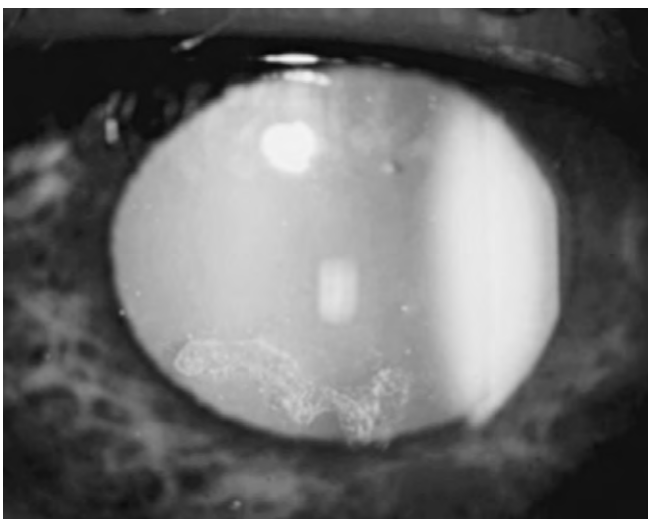


B

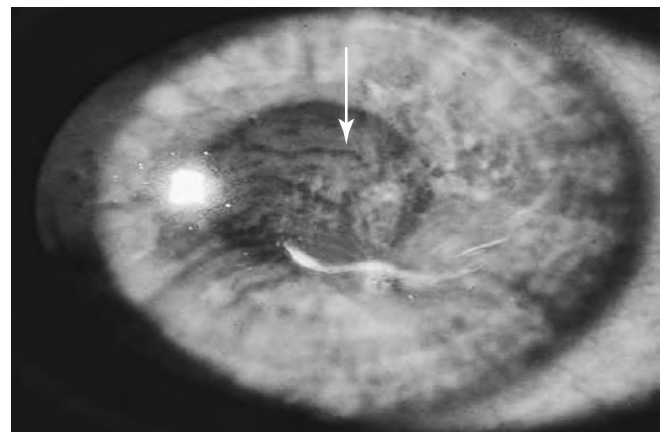
**Figure 26-1** Using diffuse illumination (A) maps (*arrow*) and (B) dots (*arrow*) are noted in a patient with ABMD. (Courtesy of Pat Caroline.)

reduction in visual acuity, then 5% sodium chloride drops may be added during the day. Nonhypertonic lubricating solutions may enhance patient comfort and visual acuity. The use of punctal occlusion may improve ocular lubrication.

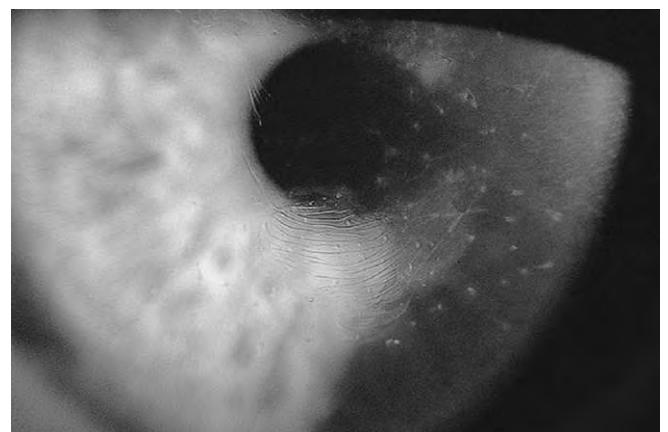
If RCE develops acutely as a result of ABMD, appropriate treatment should be instituted. If ABMD is severe enough to cause significant visual loss, then debridement, superficial keratectomy, or PTK may be considered.



**Figure 26-2** ABMD mapping is seen in retroillumination. The irregular corneal surface caused by this condition may result in reduced visual acuity. (Courtesy of Pat Caroline.)



**Figure 26-3** Negative staining (*arrow*) after instillation of NaFl helps to outline ABMD mapping. (Courtesy of Pat Caroline.)



**Figure 26-4** Subtle fingerprint lines are noted in this diffuse illumination photo. (Courtesy of Pat Caroline.)

Patients with ABMD who have undergone laser in situ keratomileusis (LASIK) may present with visual complaints and/or RCEs. Patients who have signs or symptoms of ABMD may not be ideal candidates for LASIK and should be carefully screened for this condition before pursuing surgery.

## Guttata and Fuchs' Dystrophy

### Etiology

The endothelium functions as both a barrier and “pump” and is responsible for maintaining corneal transparency by regulating stromal hydration. The endothelium undergoes an age-related decrease in cell density due to a reduced proliferation rate that does not keep pace with cell loss. As a result, the endothelium becomes “fragile” and its function can potentially be compromised as a result of trauma or disease.

The development of corneal guttata is a common form of endothelial anomaly. The endothelium produces excessive amounts of an abnormal basement membrane material resulting in the formation of a posterior collagenous layer. Guttata are wart-like prominences on Descemet's membrane and result from excessive accumulations of the abnormal corneal endothelial secretions. Histologic studies indicate that guttata are accompanied by thinning of the overlying endothelial cells along with thickening of Descemet's membrane.

Guttata generally are located in the central cornea, except in the case of Fuchs' endothelial dystrophy, when the peripheral endothelium also becomes involved. When these lesions are noted in the peripheral corneal endothelium only, they are termed *Hassall-Henle bodies*. Guttata usually are first noticed in patients in their thirties and forties or older, although the density of the guttata may vary significantly from patient to patient. Mild guttata commonly appear as occasional scattered lesions in the central cornea. Moderate guttata appear as a relatively dense collection of lesions in the central cornea. Pigment is commonly associated with guttata and may be entrapped in the irregular endothelial surface. Moderate guttata may exhibit a plaque-like appearance in the central cornea, which somewhat obscures the typical guttata detail due to clinically significant thickening of Descemet's membrane. In the presence of mild to moderate guttata, the overlying stroma and epithelium remain clear, and these conditions tend to remain stationary for years. Guttata have also been reported in association with keratoconus.

Fuchs' (endothelial) dystrophy has a component of guttata, but the involvement is such that corneal physiology is affected adversely. Fuchs' dystrophy occurs bilaterally, has been reported to be transmitted dominantly (with incomplete penetrance), and females are three times more likely to develop the condition. Prominent guttata initially occur centrally and then become extensive enough to involve the peripheral cornea. In Fuchs' dystrophy the

endothelial cells become sufficiently compromised to interfere with their metabolic “pump” ability, thus permitting aqueous to enter the cornea. As a result, and over a course lasting several decades, stromal edema, epithelial edema, and bullous keratopathy ensue. Histologic studies suggest an initial increase in the pump site activity in early Fuchs', followed by a gradual deterioration toward end-stage Fuchs'. Secondary abnormalities in the basement membrane and Bowman's layer also develop and may result in conditions such as RCE.

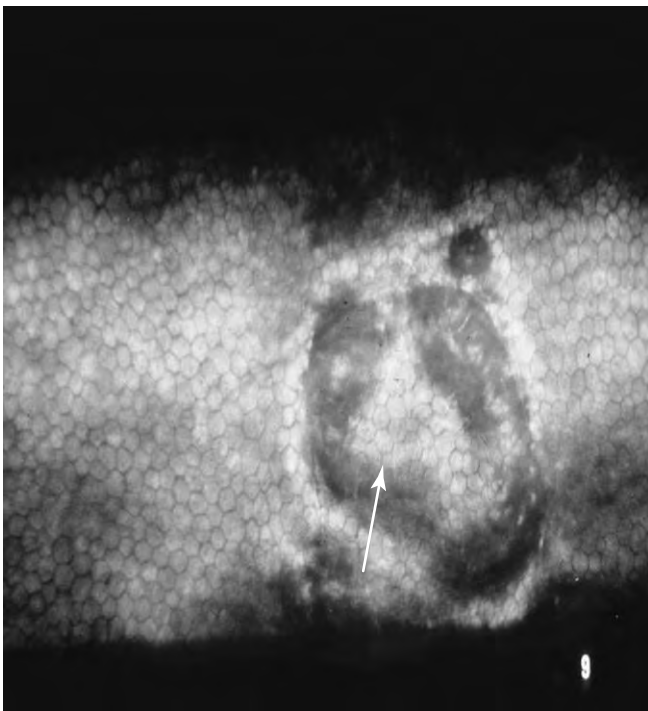
Transient secondary guttata may develop in association with degenerative corneal disease, trauma, or inflammation. Transient guttata associated with corneal edema have been termed pseudoguttata.

### Diagnosis

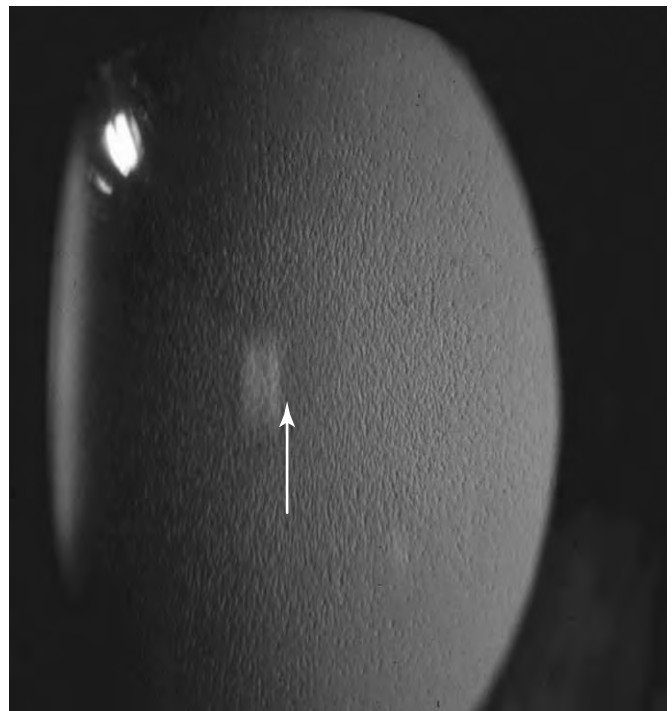
The diagnosis of corneal guttata is made using the biomicroscope. In direct illumination, particularly with a parallelepiped, guttata appear as small refractile “drops” on the corneal endothelium. Closer inspection using specular reflection microscopy reveals orange peel-like “dimpling” of the endothelium caused by the guttata, appearing as dark spots in the reflected light (Figure 26-5). This clinical presentation may be accentuated by evaluating the cornea after pupillary dilation. The pigmentation and plaque-like haze of moderate guttata are quite apparent.

Established Fuchs' dystrophy consists of dense guttata, most pronounced centrally but involving the entire corneal endothelium. The endothelium may acquire a bronzed, beaten, metal-like appearance. Accompanying stromal edema appears as a central whitish haze (Figure 26-6). Epithelial edema may appear as corneal bedewing, best seen in indirect illumination, and frank bullae may be present. Long-standing corneal edema may result in corneal scarring, and advanced cases may exhibit subepithelial fibrosis and vascularization.

Patient symptomatology varies with the extent of the guttata. Mild corneal guttata have no effect on visual function. Moderate corneal guttata, with its central and rather dense distribution, may affect visual function, including light scatter and reduced visual acuity to approximately 20/25 to 20/30. Decreased visual acuity due to corneal edema may be noticed upon awakening, which may improve during the course of the day as the corneal fluid evaporates. The visual impact of moderate guttata will be most noticeable under conditions of pupillary constriction. Overlying corneal edema in association with moderate guttata is not generally visible using a biomicroscope; however, anecdotal evidence suggests that patients with this condition may report blurring of vision upon awakening in the morning, which may represent an exacerbation of corneal edema resulting from closure of the lids overnight. Rupture of associated bullae produces symptoms of foreign body sensation, pain, and redness.



A



B

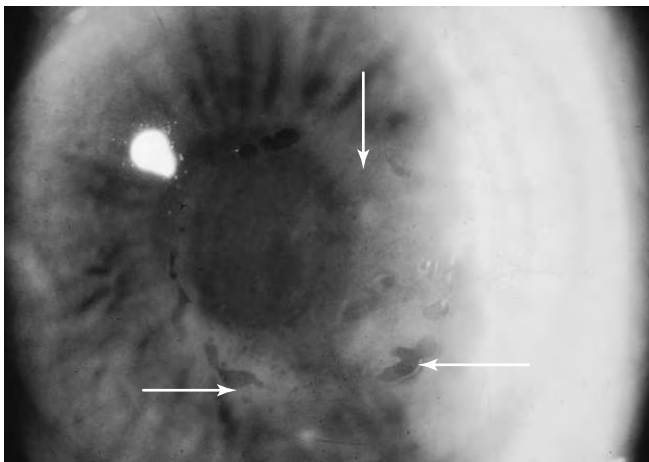
**Figure 26-5** (A) Specular reflection illumination reveals the honeycomb appearance of the normal cornea and the “black” zones in the endothelium caused by guttata (*arrow*). (B) Transillumination revealing orange-peel dimpling characteristic of central corneal guttata (*arrow*). (Courtesy of Pat Caroline.)

### Management

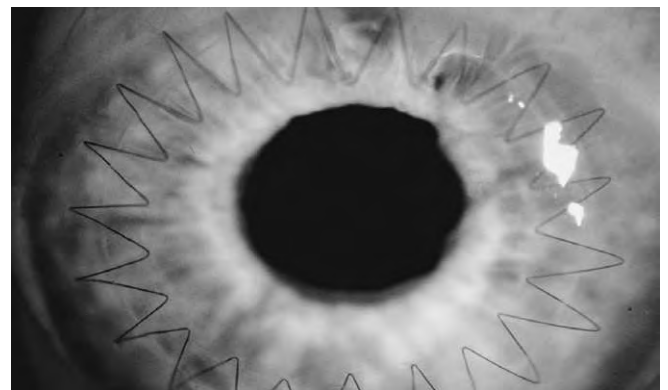
Treatment options are primarily palliative, with the goal of improving patient comfort and function. The use of topical ophthalmic hypertonic agents may reduce epithelial edema related to Fuchs' dystrophy; however, these agents do not reduce stromal edema. The use of topical 5% sodium chloride drops six to eight times daily, along with 5% sodium chloride ointment instilled into the conjunctival sac at bedtime, may be instituted to determine

the effect on symptoms and visual acuity. Although epithelial edema is not an obvious factor in moderate corneal guttata, 5% sodium chloride ointment instilled into the conjunctival sac at bedtime may relieve the symptoms of those patients who experience accentuated blurring of vision upon awakening.


To help relieve patient discomfort due to the rupture of epithelial bullae, a therapeutic soft contact lens may be tried. Effective restoration of patient comfort and visual function for well-established Fuchs' dystrophy, however, may be best achieved through penetrating keratoplasty (Figure 26-7). Fuchs' dystrophy is the primary condition



**Figure 26-6** Stromal haze of Fuchs' dystrophy with bullae (*arrows*). (Courtesy of Pat Caroline.)



**Figure 26-7** Penetrating keratoplasty. (Courtesy of Pat Caroline.)



**Figure 26-8** Diagram of the deep lamellar endothelial keratoplasty procedure for patients with Fuchs' corneal dystrophy and pseudophakic bullous keratopathy. (Diagram courtesy of Dr. Mark Terry of the Devers Eye Institute in Portland, Oregon.)

for which penetrating keratoplasty is performed in the Western world. The current trend is to initiate surgery before the patient reaches the painful end-stage. A contemporary alternative to penetrating keratoplasty is deep lamellar endothelial keratoplasty. In this procedure the recipient cornea is stripped of Descemet's membrane and endothelium, and the posterior stroma and endothelium of a donor cornea are transplanted through a small incision (Figure 26-8). This procedure provides improved endothelial function resulting in corneal clarity and restored useful vision. Additionally, the procedure results in minimal refractive changes, provides rapid visual recovery, and maintains structural integrity of the cornea by preserving the recipient's other corneal structures. A potential alternative with this surgical procedure is the transplantation of bioengineered human corneal endothelium, eliminating the use of a donor cornea.

Recent research has demonstrated that adult human corneal endothelial cells can be grown in culture and transplanted into recipient corneas. Because human endothelial cells retain the capacity to proliferate, growth factors and inhibitors are under study as a potential method for regenerating damaged endothelial cells and increasing cell density to restore endothelial layer function.

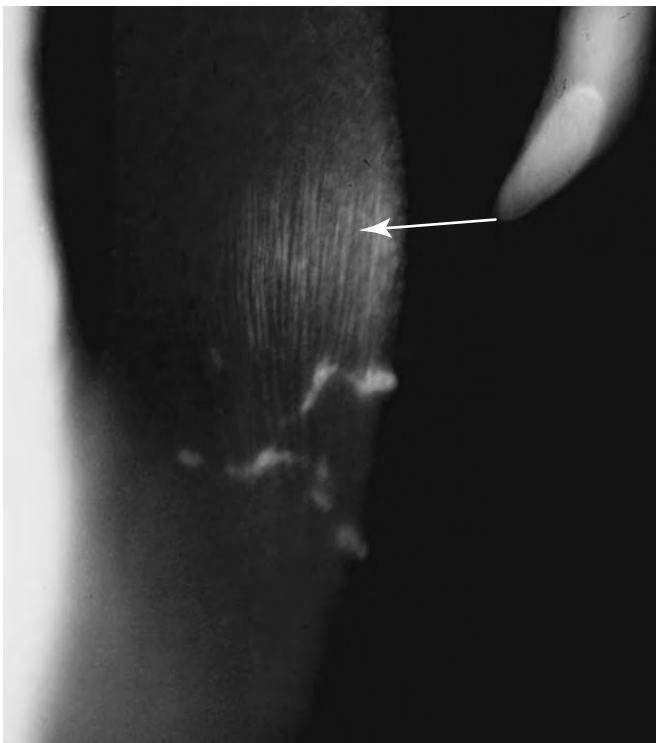### Corneal Hydrops Secondary to Keratoconus

#### Etiology

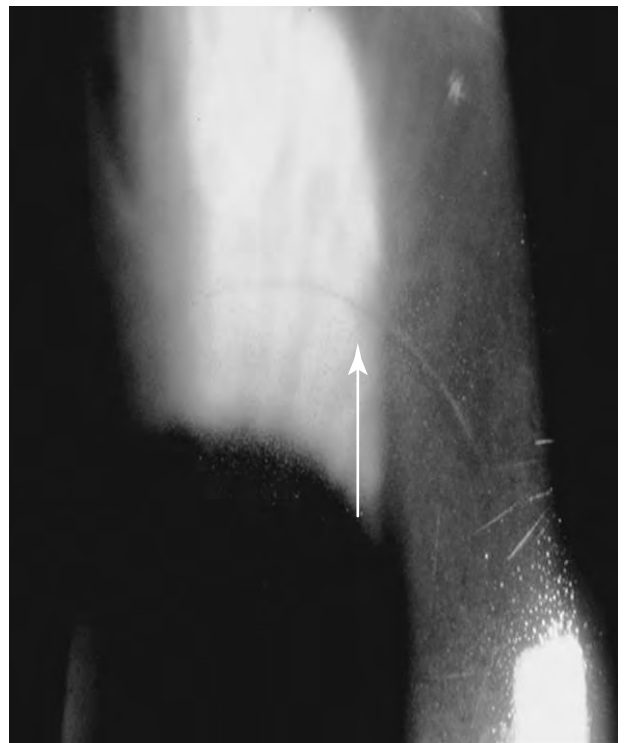
Keratoconus is an ectatic corneal dystrophy that tends to be bilateral but may be asymmetric and generally manifests in the second or third decade of life. There is evidence that keratoconus is a hereditary condition, with a family history reported in 6% to 8% of patients with the disease. The prevalence in first-degree relatives is 15% to 67% higher than in the general population, and the incidence has been reported at approximately 1 in 2,000. The inheritance pattern has been variably reported as sporadic, autosomal recessive, and autosomal dominant. Keratoconus is likely a multigenic disease with a complex mode of inheritance, and its manifestation likely involves environmental factors.

The familiar slit-lamp manifestations include central corneal thinning, Fleischer's ring, scarring at the level of Bowman's layer or anterior stroma, and vertical endothelial striae (Vogt's lines) (Figure 26-9). The advanced keratoconic cornea exhibits an accentuated outward bowing of the lower lid in downgaze, known as Munson's sign. Common refractive or topographic effects include irregular astigmatism and poor best-corrected visual acuity

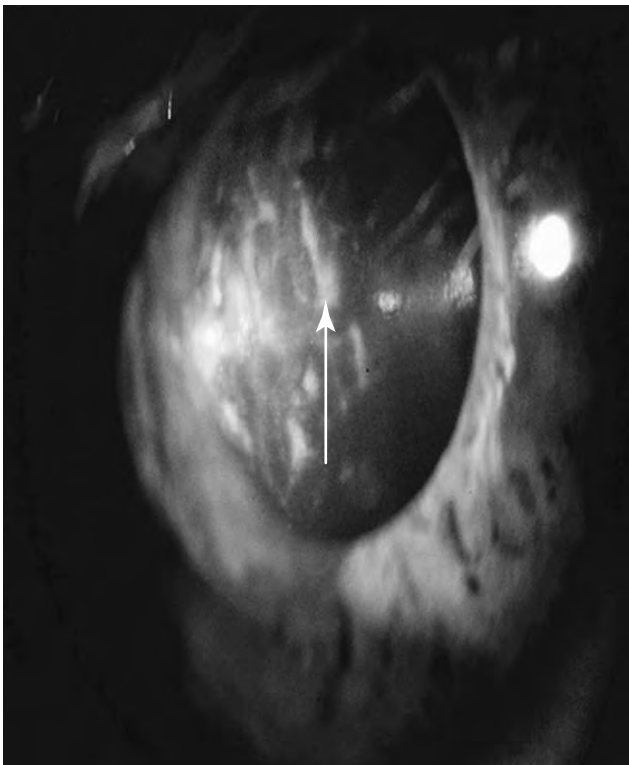




A

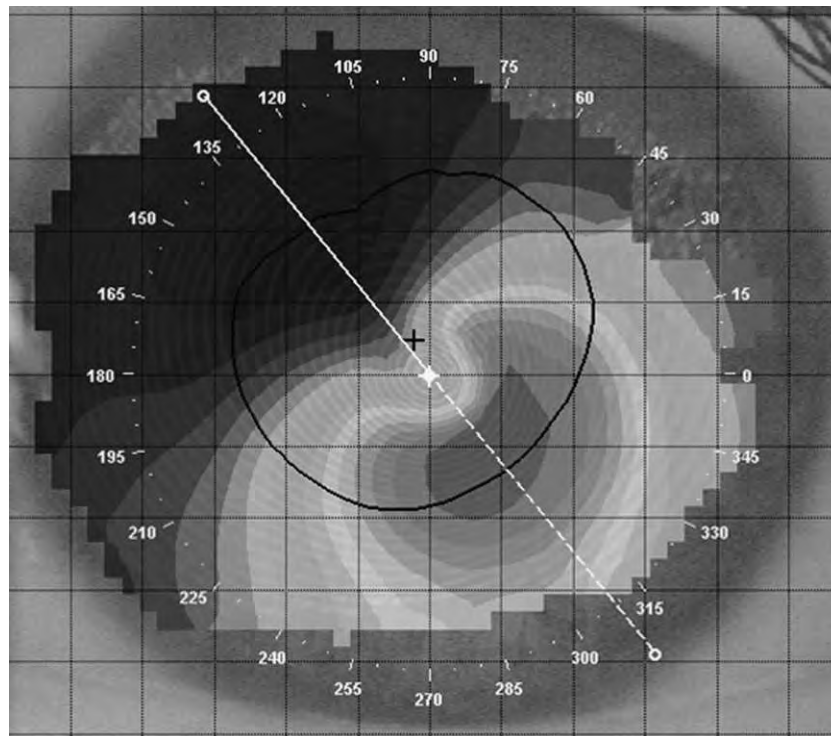


B



C

**Figure 26-9** (A) Vertical striae; (B) Fleischer's ring; (C) scarring at Bowman's layer. (Courtesy of Pat Caroline.)



**Figure 26-10** Corneal topography showing inferior conic steepening. (Courtesy of Randy Kojima, Precision Technology Services.)

with spectacles. Visual acuity typically is maximized after correction with rigid gas-permeable contact lenses. Characteristic conic steepening patterns are noted on corneal topography (Figure 26-10), including computer-assisted videokeratography.

Keratoconus tends to progress over 7 to 8 years and then stabilizes. The severity of keratoconus varies among patients and often is asymmetric when comparing the two eyes. In some keratoconic patients the progressive corneal thinning proceeds to such an extent that Descemet's membrane ruptures. In this event a sudden influx of aqueous into the cornea occurs, known as acute hydrops.

### Diagnosis

Patients presenting with acute corneal hydrops typically are aware of the preexisting diagnosis of keratoconus. Symptoms of hydrops include a sudden decrease in best-corrected visual acuity, redness, and a foreign body sensation or pain in the involved eye.

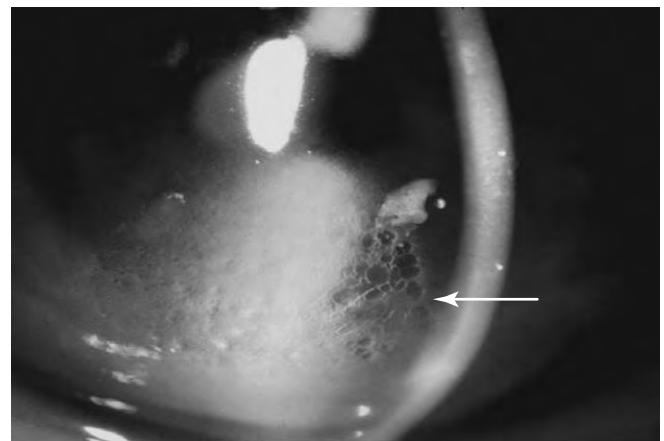
Slit-lamp examination of acute hydrops reveals prominent central or inferior corneal edema and clouding along with conjunctival hyperemia (Figure 26-11). The contralateral eye generally exhibits findings of keratoconus but without hydrops.

### Management

Acute hydrops secondary to keratoconus tends to be self-limiting in approximately 8 to 10 weeks when the corneal endothelial cells regenerate across the rupture in

Descemet's membrane, reestablishing stromal deturgescence. Conservative therapeutic measures may be instituted during this resolution period, including the use of topical 5% sodium chloride drops during the day and 5% sodium chloride ointment instilled into the conjunctival sac at bedtime. Broad-spectrum topical ophthalmic antibiotics may be instituted to protect the compromised cornea from secondary bacterial infection.

It is common for corneal scarring to remain once the edema related to acute hydrops resolves. Topical ophthalmic steroid drops may be used in an effort to minimize resultant scar formation.



**Figure 26-11** Acute corneal hydrops secondary to keratoconus. (Courtesy of Pat Caroline.)



Penetrating keratoplasty currently is the most common surgical management for keratoconus (see Figure 26-7). This intervention is considered when contact lens intolerance occurs or if the visual acuity can no longer be corrected adequately using a rigid contact lens. Acute hydrops may result in chronic corneal edema or central corneal scarring that adversely impacts best-corrected visual acuity. Both of these conditions also may be indications for surgical intervention. It is possible, however, that the corneal edema due to hydrops will leave a sufficiently small scar that contact lens wear can be resumed without the need for surgery.

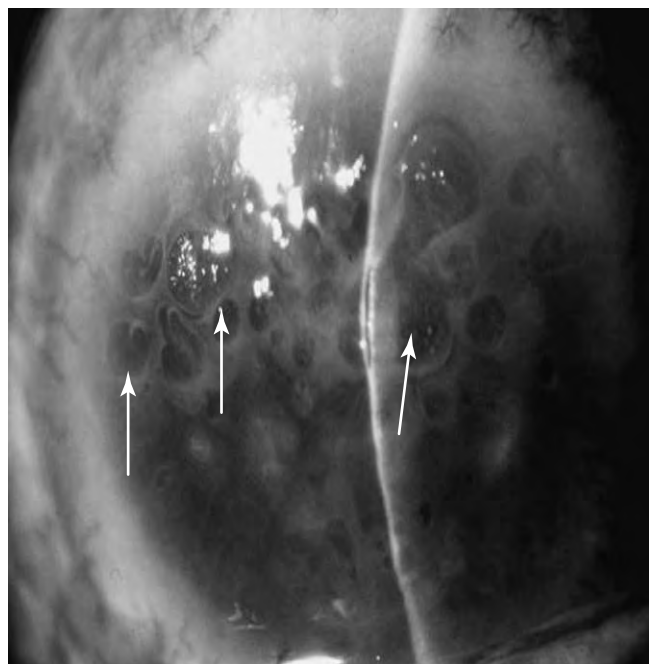
## Bullous Keratopathy

### Etiology

If fluid enters the cornea at a rate faster than it is removed by the endothelial cells, edema results. Fluid accumulates in the epithelium as well as the stroma and causes the epithelium to separate from Bowman's layer. Clinically, these areas of separation between Bowman's layer and the epithelium are called *bullae*, which appear like small blisters on the front surface of the cornea. With time and the normal growth of epithelial cells, these bullae are pushed anteriorly in the cornea and erupt at its surface.

Bullous keratopathy most commonly develops after cataract surgery and intraocular lens implantation. Pseudophakic bullous keratopathy is found more often with intracapsular cataract extraction and anterior chamber intraocular lenses (approximately 4%) when compared with extracapsular cataract extraction and posterior chamber intraocular lenses (<1%). When it occurs, the average length of time from cataract surgery to the development of bullous keratopathy is 18 to 24 months. The occurrence of bullous keratopathy after cataract surgery is thought to be due primarily to trauma to the endothelium from contact with the intraocular lens implant or surgical instruments. Other authors opine that corneal decompensation results from the release of inflammatory mediators due to continuous trauma to the eye by the intraocular lens implant or by shock waves from pseudophakodonesis. The inclusion of dispersive ophthalmic viscosurgical products (Viscoat®, Healon®) has been shown to decrease endothelial cell loss during intraocular procedures.

Although cataract surgery is a potential precursor to bullous keratopathy, there are many other causes. Fuchs' endothelial dystrophy, infection, trauma, retained foreign body, posterior polymorphous dystrophy, chronic uveitis, chronically elevated intraocular pressure (IOP), and vitreous touch are all known causes of bullous keratopathy. Other less common causes of bullous keratopathy include corneal thermal injury secondary to carbon dioxide laser skin resurfacing, air bag trauma, the use of topical dorzolamide hydrochloride in glaucoma patients with endothelial compromise, and use of mitomycin C during trabeculectomy surgery.



**Figure 26-12** Bullous keratopathy bullae (arrows). (Courtesy of Pat Caroline.)

### Diagnosis

Subjectively, the patient with bullous keratopathy reports tearing, foreign body sensation, and pain. The pain is caused by either the exposure of nerves with the eruption of the bullae or the stretching of nerves as they pass through swollen edematous epithelium. Another common symptom is decreased vision due to edema and distortion of the anterior corneal surface.

Evaluation reveals an edematous, thickened, usually hazy cornea with bullae (Figure 26-12). Some areas of the cornea stain with NaFl due to ruptures of the bullae. Focal involvement of the cornea is possible, especially if there has been local disruption such as birth trauma or foreign body injury.

### Management

A thorough examination should be performed to determine the cause of bullous keratopathy. The specific treatment plan depends on both the cause and severity. Examination of the endothelium, internal structures, and fundus can be enhanced by the use of topical hyperosmotics to decrease epithelial edema. Internal examination is essential to determine if there is corneal touch by the intraocular lens or vitreous face and to rule out cystoid macular edema or intraocular inflammation.

If there is a treatable cause, its management is necessary for resolution of the edema. If, however, the corneal edema appears to be due to changes in endothelial function, hyperosmotic therapy with 5% sodium chloride solution four to eight times a day and 5% sodium chloride ointment in the conjunctival sac at bedtime is the most appropriate treatment. Treatment with hypertonic agents

is limited by stinging on instillation and by the difficulty caused by frequent applications. Hair dryers, used on a low setting and directed toward the eyes at arm's length, may occasionally prove useful. The evaporation of tears changes their tonicity, which, in turn, draws fluid from the epithelium and stroma to decrease corneal edema.

If patients are experiencing pain or poor vision, a therapeutic soft contact lens often is applied. The usefulness of therapeutic contact lenses for pain relief and vision improvement is well supported. The relief of pain from soft contact lenses probably is due to protection of the nerves exposed by ruptured bullae. Many patients also experience a significant improvement in visual acuity when wearing therapeutic contact lenses likely secondary to the covering of an irregular cornea with the regular surface of the contact lens. Maximum relief of symptoms is obtained when therapeutic contact lenses are used on an extended-wear basis, but daily-wear use also has been successful. Patients with bullous keratopathy wearing therapeutic contact lenses should be monitored closely because they are more susceptible to other complications from soft contact lens wear, such as ulcerative keratitis, neovascularization, increased edema, and inflammation secondary to corneal breaks and reduced endothelial function. These patients should be monitored closely, with a recommendation of monthly follow-up visits. Although there is concern about the uptake of medications or their preservatives by soft contact lenses, some authors support the concurrent use of therapeutic contact lenses and topical medications such as prophylactic antibiotics, hypertonics, and nonsteroidal anti-inflammatory drugs (NSAIDs). Many of these authors, however, used nonpreserved formulations.

Some practitioners prefer not to recommend the use of therapeutic soft contact lenses during episodes of bullae eruption. When a patient presents with corneal epithelial defects due to ruptured bullae, a prophylactic antibiotic ointment such as 0.3% tobramycin or 0.3% ciprofloxacin four times a day can be administered, along with a cycloplegic agent (e.g., 5% homatropine two times a day).

Long-term use of prophylactic antibiotics has been associated with an increased risk of ulcerative keratitis in patients with bullous keratopathy. This may simply be secondary to a relatively increased use of prophylactic antibiotics in these patients who are more susceptible to developing infectious keratitis, or it is also possible that there is an increased risk of developing colonization with antibiotic-resistant bacteria. To diminish this possibility, prophylactic antibiotics should only be used when epithelial breaks are present. Topical corticosteroid use is also a strong risk factor for the development of ulcerative keratitis and should be avoided.

Because even normal IOP can force fluid into the cornea if the endothelium is not functioning properly, many authors suggest the use of topical or oral medications to decrease the IOP in patients with bullous keratopathy.

Patients with bullous keratopathy should have their IOP measured (even though corneal edema results in underestimated IOP) because angle-closure glaucoma can cause similar corneal edema. In addition, patients with Fuchs' dystrophy have an increased risk of developing open-angle glaucoma in addition to the bullous keratopathy. Topical carbonic anhydrase inhibitors should be avoided in these patients because of the potential of worsening the corneal decompensation.

As bullous keratopathy becomes more severe, surgical intervention may be considered. Pseudophakic bullous keratopathy is one of the leading indications for penetrating keratoplasty in the United States and Canada. Results indicate that grafts remain clear in a large percentage of patients who have penetrating keratoplasty. A contemporary alternative to penetrating keratoplasty is deep lamellar endothelial keratoplasty.

If the patient has limited visual potential because of other factors, pain relief may be provided by surgical intervention, such as a conjunctival flap procedure, anterior stromal puncture with a 20-gauge needle, or PTK. Electrocautery of Bowman's layer and partial trephination of the cornea have also been reported as successful methods of pain control.

Follow-up for patients with bullous keratopathy varies depending on therapeutic contact lens wear and the severity of the disease. Most patients should be monitored every 1 to 6 months.

## **Calcific Band Keratopathy**

### **Etiology**

Band keratopathy was first described in 1848 and is a chronic degenerative condition characterized by the deposition of calcium carbonate salts in the superficial corneal layers, most frequently in the interpalpebral area. Although there are many reported cases of idiopathic band keratopathy, some of which seem to have a hereditary component, the most common causes are associated with chronic ocular inflammation and systemic conditions resulting in altered calcium metabolism. Band keratopathy is typically seen in eyes with chronic uveitis, severe superficial keratitis, corneal ulcers, chemical burns, interstitial keratitis (IK), trachoma, phthisis bulbi, and prolonged glaucoma. The chronic anterior uveitis of juvenile idiopathic arthritis is frequently associated with band keratopathy, with one study reporting its development in 66% of patients with juvenile idiopathic arthritis.

Alterations in systemic calcium-to-phosphorus ratios are another known cause of band keratopathy. This includes hypercalcemia caused by conditions such as hyperparathyroidism, sarcoidosis, and vitamin D intoxication, as well as the elevated serum phosphorus commonly found with kidney failure. Gout can also cause band keratopathy.

Topical and intraocular medications have also been reported as common causes of band keratopathy. The use

of topical steroid–phosphate preparations may contribute to its development, especially in patients with persistent epithelial defects. Exposure to silicone oil used in surgery to treat trauma and retinal detachments can result in the rapid development of band keratopathy, as did the original formulation of sodium chondroitin sulfate (Viscoat®) when used with BSS-Plus during cataract surgery. Chronic exposure to topical medications with phenylmercuric preservatives also has been reported as a cause of band keratopathy.

### Diagnosis

In the early stages the patient with band keratopathy remains asymptomatic. However, once the calcification extends into the visual axis, the patient reports decreased visual acuity, visual halos, or a white spot on the eye. The accumulation of calcium can result in disruption of the normal ocular surface, resulting in irritation, photophobia, or RCEs. A patient who develops band keratopathy in a non-seeing eye may be asymptomatic for this condition.

Examination shows a dusting of gray-white deposits in Bowman's layer or a slight hazing of the cornea early in the course of the disease. It typically starts at 3 and 9 o'clock and progresses slowly toward the center, usually taking several months to years to coalesce and form a complete band across the interpalpebral cornea (Figure 26-13). The deposit is separated from the limbus by a clear zone and develops the characteristic "Swiss cheese" appearance because of the multiple clear areas within the plaque.

Reports show some variation in the characteristics of band keratopathy. There may be two morphologic types, with the first type presenting with an intact and smooth epithelium, little discomfort, and deposition of the calcium at the level of Bowman's layer. The second type presents with unstable epithelium in a painful eye. The deposits in the second type tend to extend into the stroma. Band keratopathy occurs much faster in patients

with severely dry eye, with reports of cases developing in as little as 24 hours though more commonly within 2 to 3 weeks. Band keratopathy due to gout appears more brownish in color instead of the classic gray-white, and band keratopathy due to phenylmercuric nitrate preservatives can start centrally and progress toward the periphery.

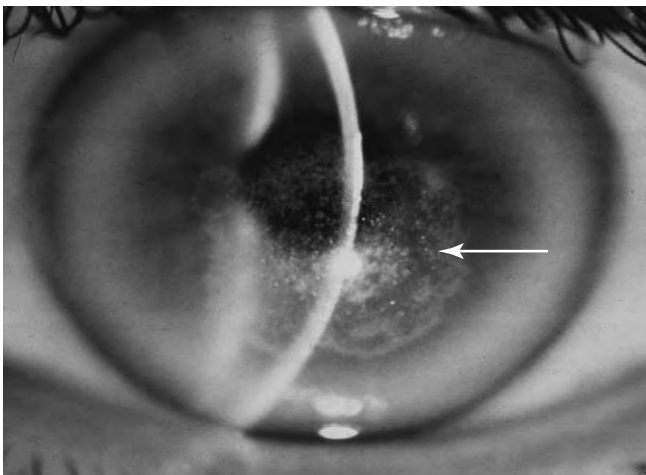
### Management

A careful history along with slit-lamp examination for signs of chronic anterior segment inflammation, end-stage glaucoma, or other underlying conditions should be performed to determine the etiology of band keratopathy. If no cause can be detected, laboratory tests can be performed to evaluate kidney function, including blood urea nitrogen, serum albumin, magnesium, creatinine, and phosphorus levels. Serum calcium should be measured to exclude hyperparathyroidism, and serum uric acid should be assessed if there is a possibility of gout.

Treatment of band keratopathy should be directed toward an underlying cause. If the patient's symptoms are mild, artificial tears four to six times a day with lubricating ointment at bedtime may suffice. Patients with mild symptoms may be monitored every 3 to 12 months.

If the symptoms are severe or vision is poor, the calcium band should be removed to restore a clear and smooth optical surface. Various modalities have been used; the most widely used treatment is sodium ethylenediaminetetraacetic acid (NaEDTA) chelation. This procedure is performed at the slit lamp with a mixture of 2% to 3% NaEDTA. After instillation of a topical anesthetic, the corneal epithelium over the affected area is debrided with a sterile scalpel. The calcium band is wiped with a cotton swab or ophthalmic cellulose sponge saturated with the 3% NaEDTA solution for 5 to 30 minutes until the calcium clears. Scraping of the calcium is discouraged because it can cause damage to Bowman's layer. Because this procedure can cause anterior uveitis, a cycloplegic agent such as 5% homatropine should be administered. Prophylactic antibiotics are prescribed and a therapeutic contact lens is then applied. The patient should return in 24 hours for evaluation, and therapeutic contact lens should be repeated until the epithelium is healed. Oral analgesics (see Chapter 7) enhance patient comfort.

When the calcium plaque is thick, it can be removed by scraping with a scalpel or by performing a superficial keratectomy. Other reported methods include the use of a diamond burr, neodymium-yttrium aluminum garnet (Nd:YAG) laser, lamellar keratoplasty, and PTK. A recent treatment option described the combined use of superficial lamellar keratectomy, NaEDTA chelation, and amniotic membrane transplantation. In this procedure the calcific lesions were treated with NaEDTA and a blunt superficial lamellar keratectomy was performed. Once a smooth ocular surface was achieved, an amniotic membrane was transplanted to replace the excised epithelium and stroma. The procedure resulted in the



**Figure 26-13** Band keratopathy (*arrow*) showing the typical "Swiss cheese" appearance. (Courtesy of Pat Caroline.)

removal of a deep plaque, allowing the recovery of a stable ocular surface.

## TRAUMA AND TRAUMATIC CORNEAL COMPLICATIONS

### Corneal Abrasion

#### Etiology

Corneal abrasions result from traumatic removal of the corneal epithelium. Corneal abrasions are among the most common eye injuries presenting to emergency departments. Abrasions are caused by a wide variety of etiologic agents; any object that may strike the patient's eye or facial area has the potential to cause a corneal abrasion. Some of the common etiologies include injuries from fingernails, tree branches, paper, contact lens overwear or mishandling, and foreign body removal.

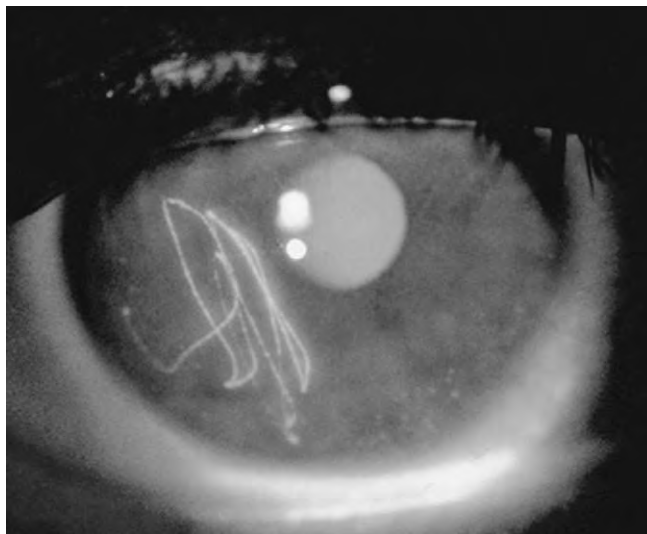
#### Diagnosis

A patient with a corneal abrasion typically reports a history of recent ocular trauma, such as being struck by a flying object or by a finger striking the eye. Patients with intermediate to large corneal abrasions usually seek treatment within 24 hours of the injury because of the significance of their symptoms.

Symptoms of a corneal abrasion include pain, excessive tearing, photophobia, foreign body sensation, blepharospasm, blurred vision, and headache. The degree of pain tends to be proportional to the extent of the abrasion and is also influenced by the pain tolerance of the patient. Because the cornea is so richly innervated, even small corneal abrasions can cause significant pain. Often, symptomatology and pain-induced blepharospasm are severe enough to require instillation of a topical anesthetic to allow adequate examination. In contrast, patients with reduced corneal sensitivity, such as may be associated with preexisting corneal disease, long-term contact lens wear, or prior ocular surgery, may have minimal pain associated with even large abrasions.

During examination with the slit lamp, the size, shape, depth, and location of corneal abrasions vary widely based on the nature of the traumatic event. The use of NaFl staining helps to more fully delineate the area of denuded corneal epithelial. Lesions may range from superficial foreign body tracking to large areas of epithelial loss. Abrasions resulting from paper, fingernail, foreign body tracking, or tree branch injuries are often linear (Figure 26-14). If the injury has been present for 24 hours or longer, the onset of corneal healing may affect the shape of the abrasion.

Moderate to severe corneal abrasions usually are accompanied by other ocular signs. Diffuse or focal conjunctival injection is present depending on the size and location of the abrasion. Eyelid edema is common when profuse reflex lacrimation occurs. If the lesion has been present for at least 12 to 24 hours, a secondary traumatic anterior



**Figure 26-14** Linear corneal abrasion is shown stained with NaFl after removal of a foreign body under a rigid contact lens. (Courtesy of Pat Caroline.)

uveitis may result as indicated by an anterior chamber reaction (cells and flare), ciliary flush, and miosis (see Chapter 29).

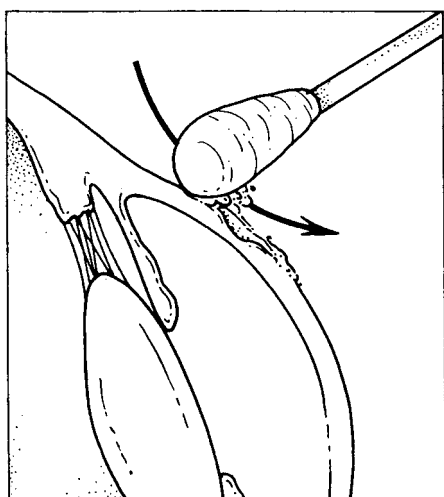
During the examination, and when considering the history of the traumatic episode, it is important to rule out corneal laceration or penetration, retained foreign bodies, or other ocular traumatic sequelae. “Clean” corneal abrasions should not exhibit opaque infiltration suggestive of bacterial or fungal keratitis.

#### Management

If particulate matter was a factor in the cause of the corneal abrasion, it is important to evert the eyelids and remove or irrigate debris from the eye. If a flap of displaced epithelium is present, it is helpful to debride this necrotic tissue to provide a clean leading edge for the start of corneal healing (Figure 26-15).

Small corneal abrasions typically heal quickly (24 to 36 hours). Topical prophylactic antibiotic therapy protects the disrupted corneal epithelium from secondary infection as the tissue heals. Broad-spectrum ophthalmic antibiotic drops, such as 0.3% tobramycin or 0.5% moxifloxacin, may be instilled four times daily, along with a broad-spectrum antibiotic ointment such as 0.3% tobramycin or 0.3% ciprofloxacin instilled at bedtime. Prophylactic topical antibiotic therapy can be discontinued once the corneal epithelium has healed.

Topical NSAIDs such as diclofenac sodium 0.1% solution and ketorolac 0.5% solution have been shown to reduce pain associated with corneal abrasions and shorten the time before patients can resume normal activities. The use of topical NSAIDs also reduces the need for oral analgesics; however, if pain is not adequately controlled by topical medications, patients may benefit from the use of oral analgesics such as aspirin, ibuprofen,



**Figure 26-15** Loosened epithelial cells may be debrided using a cotton-tipped applicator. (Reprinted with permission from Casser L, Fingeret M, Woodcome HT. Corneal debridement. In: Atlas of primary eyecare procedures, ed. 2. Norwalk, CT: Appleton & Lange, 1997: 180-183.)

or tramadol. Topical anesthetics should be avoided after the initial examination because they slow wound healing and can cause severe corneal damage.

The benefit of topical cycloplegic agents in patients with corneal abrasion is unproven. Topical mydriatics are thought to be beneficial in pain management by preventing ciliary spasm. However, one study showed no difference in pain when comparing patients using homatropine to patients using an eye lubricant and no difference in patients using an NSAID alone compared with patients using both an NSAID and homatropine.

If topical cycloplegic agents are necessary, clinical experience suggests that dilating the abraded eye in-office with the traditional diagnostic agents of 0.5% to 1% tropicamide and 2.5% phenylephrine followed by instillation of a long-acting cycloplegic after 15 to 20 minutes results in pupillary dilation of quicker onset. Once the pupil is fully dilated with the short-acting agents, one to two drops 5% homatropine is added for patients with lightly pigmented irides or 0.25% scopolamine for patients with darkly pigmented irides or those who exhibit a significant anterior chamber reaction at the time of presentation. Once the pupil is fully dilated, it is prudent to perform a dilated fundus examination, particularly if contusion accompanied the abrasion or a penetrating wound is suspected. Following in-office instillation, cycloplegics can then be prescribed if indicated. Cycloplegia should be instituted if anterior uveitis is present but can be discontinued once the abrasion has resolved.

Traditionally, patching was thought to reduce pain by decreasing eyelid-induced corneal irritation that occurred while blinking. Studies have shown that patients heal as quickly or quicker, had less pain, and had better visual function without patching. Patching of closed

eyelids results in binocular vision impairment, decreased oxygen supply to the cornea, reduced tear turnover, and increased risk of infection. Therefore patching is no longer recommended for corneal abrasions. Patching is specifically contradicted in corneal abrasions secondary to contact lenses due to the increase risk of *Pseudomonas* infections.

High oxygen-permeable silicone hydrogel contact lenses that are approved for therapeutic use have been shown to be safe and effective in reducing pain by protecting the nerve endings from exposure and constant movement of the eyelid. NSAIDs, used four times a day in conjunction with a therapeutic soft contact lens, provide analgesia. Cycloplegics are instilled as indicated, and antibiotic solutions are instilled four times a day with the lens in place. The patient is reexamined in 24 hours and at appropriate intervals thereafter. The contact lens is removed when the healing is complete. Careful monitoring is needed because of the potential risk of corneal vascularization or bacterial keratitis associated with the therapeutic contact lens wear.

At the 24-hour follow-up examination, the cornea is assessed at the slit lamp to determine the degree of healing. The healing rate of an abrasion has been found to correlate with the initial wound size. However, relative healing rates may vary among patients: Younger patients tend to exhibit faster healing, and older or diabetic patients tend to heal more slowly. Round lesions tend to heal faster than irregular ones, and abrasions at the peripheral cornea heal faster than centrally located lesions. In the case of an intermediate to large abrasion, the signs of corneal healing can be rather pronounced. The formation of epithelial fusion lines may occur as the abrasion heals and the sheets of resurfacing epithelium come together. The fusion lines may have a swirl, pseudodendrite, or vortex-type appearance and exhibit positive and/or negative staining and have been confused with dendritic lesions of herpes simplex virus (HSV) keratitis.

The degree of corneal healing observed at the first follow-up visit determines subsequent management. If the lesion has not healed substantially, the patient should continue the treatment prescribed for the initial abrasion and be reexamined in another 24 hours. If healing has progressed substantially and the patient is comfortable without the therapeutic contact lens, the contact lens and NSAID use can be discontinued. The use of prophylactic topical antibiotics should be continued until the tissue is completely healed. If significant corneal edema is present, the prophylactic antibiotic therapy should be supplemented with hyperosmotic agents, such as 5% sodium chloride drops during the day and 5% sodium chloride ointment at bedtime. Patient compliance may be enhanced by advising the patient that the hyperosmotic agents will cause some burning, particularly if the epithelium is still disrupted. The use of an antibiotic or hyperosmotic ointment instilled in the conjunctival sac at bedtime

is particularly helpful to prevent reirritation of the cornea on awakening when the eyelids are opened. Up to 12% of patients have recurrent symptoms within 3 months of the injury that affect daily activities or cause them to seek further care. Cut-like abrasions (e.g., those caused by a fingernail or paper) that disrupt the epithelial basement membrane have a higher risk of resulting in RCEs. Therefore after resolution of the initial abrasion in these instances, the subtle signs of corneal healing should be monitored and the patient treated for at least 8 weeks with bland ophthalmic lubricating or hyperosmotic ointment instilled into the conjunctival sac at bedtime.

Because most corneal abrasions involve loss of only the superficial epithelial cells, the lesions generally heal in 24 to 72 hours without scar formation. As the cornea is monitored during follow-up care, it is important to determine that the signs and symptoms are consistent with the healing of a clean abrasion and that bacterial or fungal keratitis does not develop, particularly in abrasions caused by vegetative matter. Once the acute care aspects associated with the abrasion are resolved, it is helpful to discuss with the patient the appropriateness of protective eyewear, particularly if the patient is monocular. Protective eyewear may be needed in occupational, domestic, or recreational settings.

## Foreign Bodies

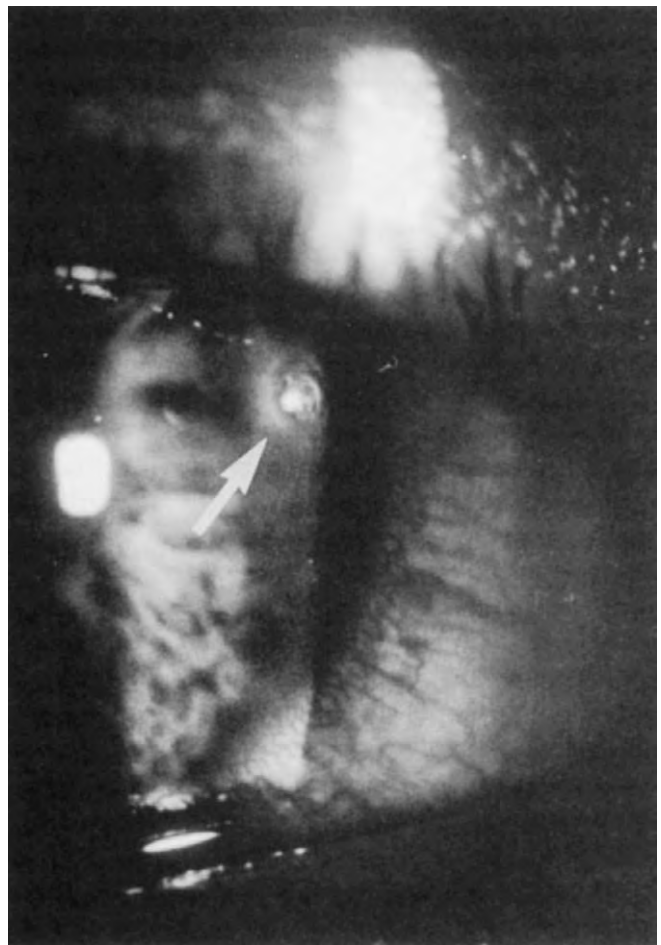### Etiology

Any foreign material that may strike the eye has the potential of becoming a corneal foreign body. Among the most common are metallic foreign bodies, as may result when a patient is doing autobody work on a car and metallic debris flies or drops into the patient's eye (Figure 26-16). Other types of corneal foreign bodies include glass, plastic, insect parts, plant debris, wood splinters, and paint chips (Figure 26-17). A vegetative foreign body may result in secondary fungal keratitis. Most corneal foreign bodies are work related and occur in men. Common occupations of patients presenting with eye injuries are machine tool operators, mechanics, metal workers, construction workers, electricians, and welders.

Although most corneal foreign bodies tend to be superficial and lodge at Bowman's membrane, corneal penetration may occur from a high-speed projectile or sharp object, such as the spines of a plant. A careful history is crucial for patients with corneal foreign bodies. It is crucial to determine, to the extent possible, the etiology, trajectory, mass, and velocity of the resulting foreign body. If an etiology associated with high speed is present or suspected (e.g., a nylon cord weed trimmer, a grinding wheel, or hammer pounding on a nail), the likelihood of corneal penetration is greater.

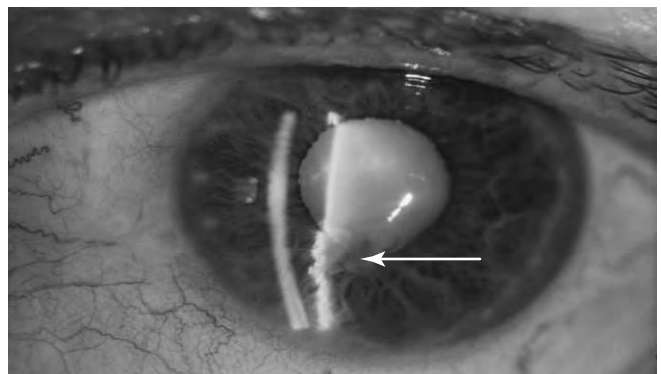
### Diagnosis

Patient symptomatology related to a corneal foreign body may vary widely. Occasionally, an asymptomatic patient



**Figure 26-16** Example of a metallic corneal foreign body (arrow).

who presents for a routine examination may incidentally exhibit a small epithelial foreign body. More commonly, patients with corneal foreign bodies present acutely with symptoms similar to a corneal abrasion, such as pain, photophobia, and reflex tearing. The patient may not be able to identify or recall the inciting event, and symptoms may have been present for a few days before



**Figure 26-17** Example of a wood splinter foreign body (arrow). (Courtesy of Pat Caroline.)

worsening or continued symptoms prompted the patient to seek care.

Slit-lamp examination will discern the presence of the foreign body. The appearance of the foreign body often reveals its etiology; for example, a metallic foreign body may exhibit oxidative rusting. A ring of edema and white blood cell infiltration may surround the foreign body. Other ocular signs that often accompany the corneal findings include conjunctival hyperemia and eyelid edema if profuse tearing is present. If the foreign body and resultant inflammation have been present for 24 hours or longer, an anterior uveitis is often present, manifested as an anterior chamber reaction (cells and flare) and miosis.

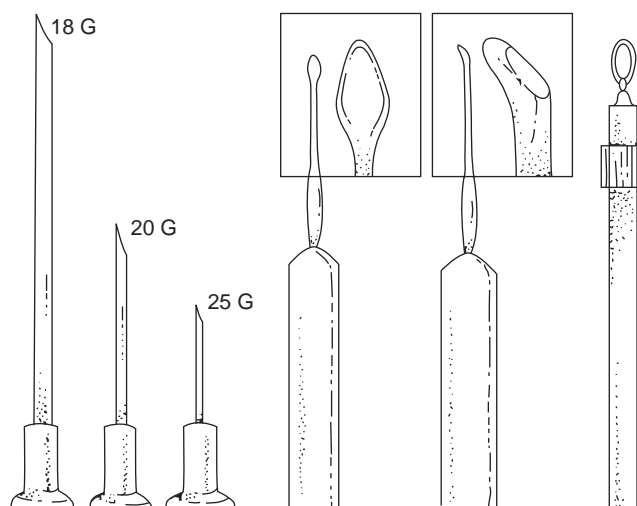
Careful biomicroscope technique is necessary to determine specifically the depth of the corneal foreign body. An optic section is used to determine the degree of corneal penetration. If it is determined that corneal penetration by the foreign body is sufficiently deep so that removal may risk corneal penetration, then a consultation for surgical removal is appropriate. Eyelid eversion is helpful to rule out the presence of an accompanying foreign body on the palpebral conjunctiva. A thorough dilated fundus examination assists in ruling out a concurrent intraocular foreign body. It is especially important to conduct a thorough dilated fundus examination if the mechanism of the foreign body has the potential for corneal penetration.

Some clinicians advocate the use of orbital radiographs to exclude an intraocular foreign body when a metallic corneal foreign body is discovered. Although this practice is not universal, and perhaps is not a practical use of health care resources, if the history or signs suggest the possibility of a metallic intraocular or intraorbital foreign body, then orbital radiographs, B-scan, or preferably computed tomography is indicated to identify and localize the object. Magnetic resonance imaging is contraindicated when an intraocular foreign body is suspected because of potential interaction between the magnetic field and a metallic foreign object, which may exacerbate injury to the globe.

### Management

Of the several effective techniques available for removal of a corneal foreign body, the one chosen often depends on the depth of the foreign body, the cooperation of the patient, and personal preference of the clinician (Figure 26-18). Instillation of a topical anesthetic precedes removal of the foreign body. Instillation of anesthetic drops in both eyes helps to control the patient's blink reflex during removal.

If the foreign body is very superficial, if patient cooperation is poor (e.g., a small child), or if particulate debris in the conjunctival sac accompanies the corneal foreign body, removal can be attempted by irrigation with sterile saline solution. It is helpful to direct the stream of solution from the bottle toward the foreign body in an attempt to dislodge it.

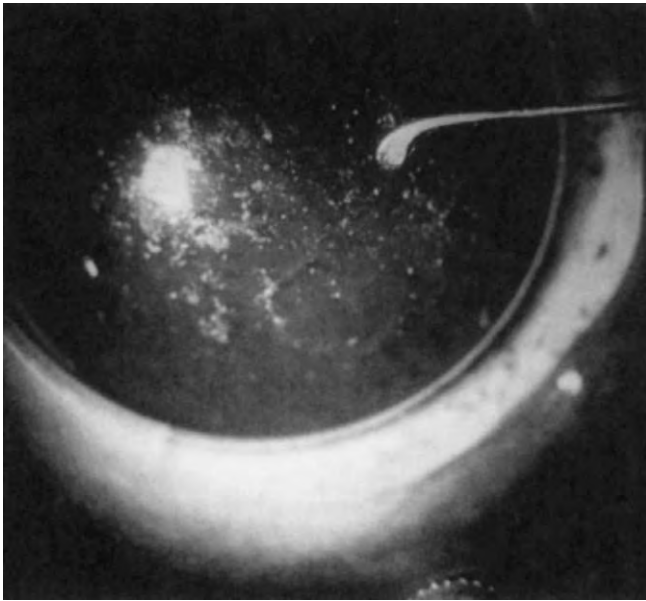


**Figure 26-18** From left to right, sterile needles, spuds, or a loop may be used to remove a corneal foreign body. (Reprinted with permission from Casser L, Fingeret M, Woodcome HT. Corneal foreign body removal. In: Atlas of primary eyecare procedures, ed. 2. Norwalk, CT:Appleton & Lange, 1997: 164-169.)

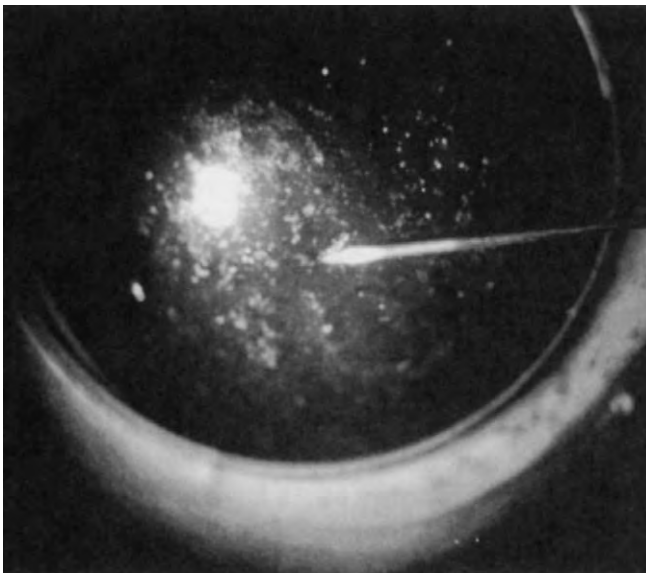
Common techniques for removing more deeply embedded corneal foreign bodies include the use of a sterile 25-gauge needle or spud at the slit lamp. The tip of the needle or edge of the spud is directed tangentially to the corneal surface to lift the edge of the foreign body and dislodge it (Figure 26-19). Once the foreign body is dislodged, it is helpful to irrigate the conjunctival sac to remove residual particulate debris from the surface of the wound. The advantage of the spud over the needle technique is that a broader edge is available with which to contact the foreign body, and small movements of the patient's eye or the examiner's hand may be less likely to induce superficial corneal injury. Other instruments used to remove corneal foreign bodies include an ophthalmic loop and magnetized forceps. Because many corneal foreign bodies are ferromagnetic, a small magnet attached to sterile jeweler's forceps may be used to dislodge the material, after which the foreign body can be magnetically lifted away from the ocular surface. It may be prudent to retain the material removed either for culture and/or to determine whether it is radiodense.

A rust ring is common when a metallic corneal foreign body has been present for 24 hours or longer (Figure 26-20). Although some of this residual rust tends to slough as the cornea heals, removal of the rust ring at the time of foreign body removal is preferable. The rust can be effectively cleared using the edge of a spud or needle to scrape it away or an Alger brush to burr it away (Figure 26-21). A burr is thought to be a quicker method of rust ring removal compared with a needle. Because rust ring removal tends to generate some debris, irrigation after this technique is recommended.





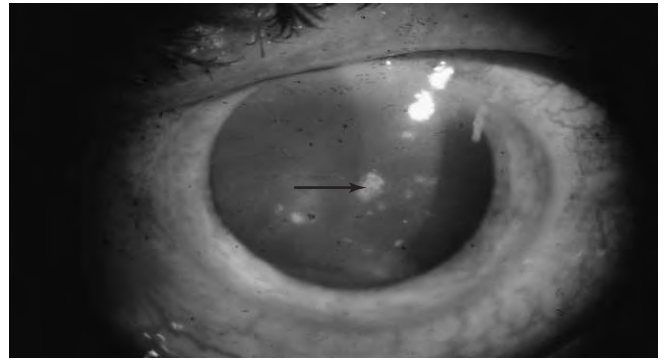
A



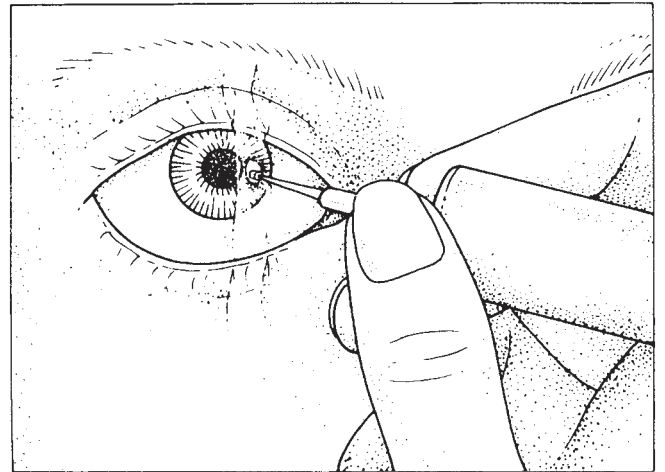
B

**Figure 26-19** Using a mounted bovine eye, the techniques of corneal foreign body removal are illustrated. (A) Spud is directed tangentially to the cornea, and the edge is used to lift the foreign body. (B) The tip of a sterile 25-gauge needle is used to lift the foreign body. Note that the bevel of the needle is positioned away from the cornea.

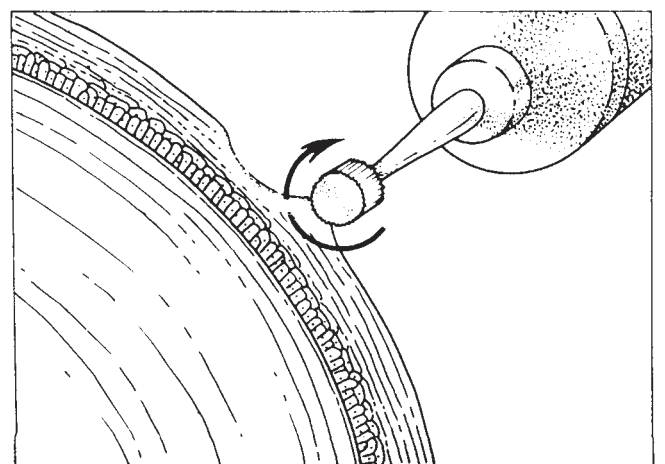
A small crater-like depression results after removal of a corneal foreign body and any accompanying rust ring. Once the foreign body is removed, the management is similar to treating a corneal abrasion. If the corneal disruption is minimal and accompanying symptoms are not significant, then broad-spectrum antibiotics, such as 0.5% moxifloxacin drops during the day and 0.3% ciprofloxacin ointment at bedtime, are used until the corneal tissue heals (Figure 26-22). NSAIDs, such as



**Figure 26-20** Rust ring (arrow) noted following removal of a metallic corneal foreign body. (Courtesy of Pat Caroline.)

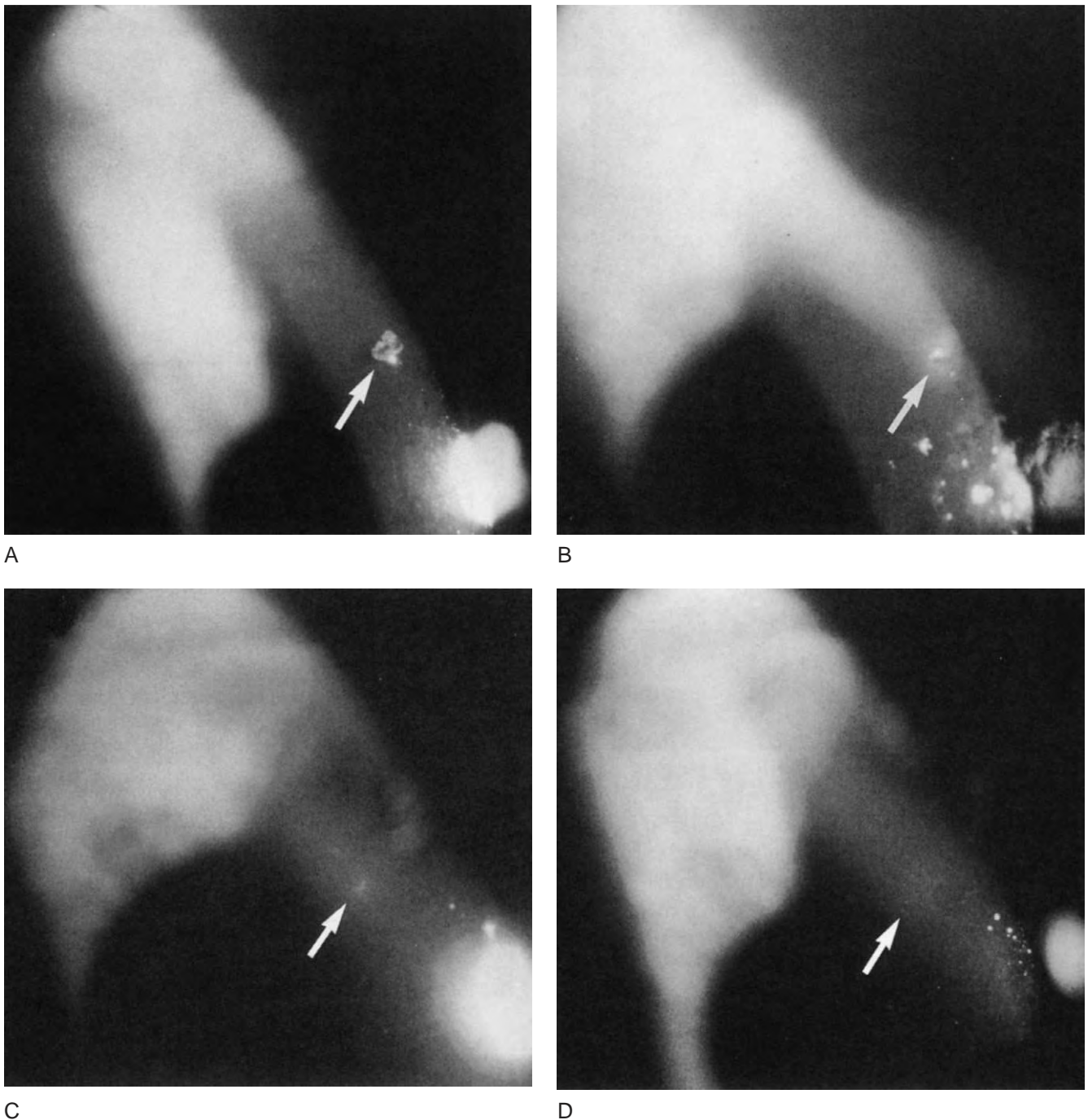


A



B

**Figure 26-21** Corneal rust ring removal. Introduced tangentially to the cornea (A), the Alger brush is used to remove rust-containing epithelial cells gently (B). (From Casser L, Fingeret M, Woodcome HT. Corneal rust ring removal. In: Atlas of primary eyecare procedures, ed. 2. Norwalk, CT:Appleton & Lange, 1997: 170-173.)

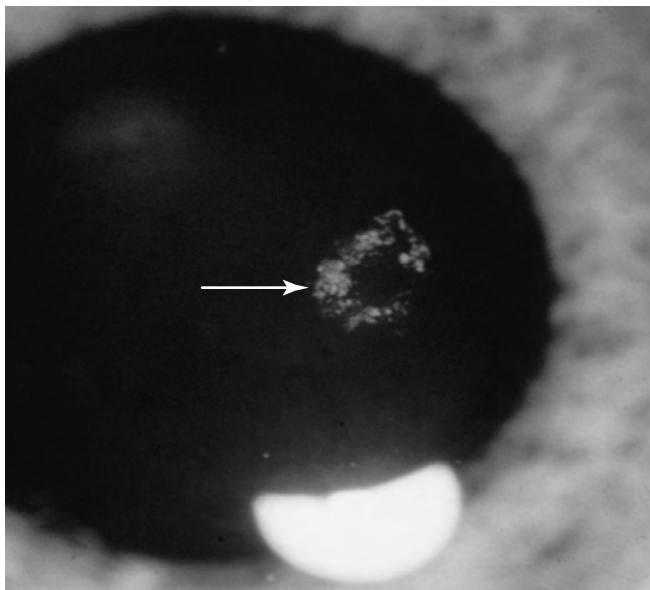


**Figure 26-22** Corneal foreign body removal with subsequent healing. (A) Small metallic corneal foreign body (*arrow*) is noted in superior cornea. (B) After removal with a spud, a small crater-like depression remains that stains with NaFl (*arrow*). (C) The following day, the epithelium is virtually healed, but a small focal area of edema and leukocyte infiltration remains (*arrow*). (D) Five days later, the epithelium has healed completely, and a small diffuse spot of edema is noted (*arrow*), which ultimately resolved.

topical 0.1% diclofenac, provide pain relief, especially after corneal rust ring removal. Therapeutic soft contact lenses can aid in reducing pain by protecting the corneal nerve endings. NSAIDs and prophylactic antibiotics are instilled four times a day with the lens in place. Eye patching provides no benefit in healing time or pain. If an anterior

uveitis is present, cycloplegic agents such as 5% homatropine should be instilled.

A follow-up examination is performed 24 hours later. During follow-up examinations it is important to monitor for signs of secondary bacterial keratitis, secondary fungal keratitis, or an intraocular foreign body that may have



**Figure 26-23** Small Coat's white ring (*arrow*) noted during routine examination of an asymptomatic patient. (Courtesy of Pat Caroline.)

been overlooked initially. Most epithelial defects left after foreign body removal heal within 24 to 48 hours.

If the foreign body disrupted Bowman's membrane and the anterior stroma, a small, usually circular, corneal opacity results after the healing process. Even when located on the visual axis, these small opacities tend not to significantly affect visual acuity and often are noted during routine eye examinations. If a metallic foreign body and rust ring had been present, the resultant opacity often retains a light brown tinge. It also is not uncommon to note a Coat's white ring during routine slit-lamp examination in an asymptomatic patient. This granular white ring opacity is believed to represent residual iron deposits at the site of a prior corneal foreign body (Figure 26-23).

Once the acute episode related to a corneal foreign body has resolved, it is important to provide patient education about the value of protective eyewear to help prevent future corneal foreign bodies. This is especially important if the patient is monocular, exhibits multiple corneal opacities from past foreign bodies, or is engaged in an occupation in which the likelihood of debris striking the eyes is great.

### Lamellar Lacerations and Penetrating Injuries

#### Etiology

Any sharp object that injures the eye with sufficient force can cause a corneal laceration in which the stroma is penetrated to any depth. Corneal penetration occurs if the object or foreign body passes completely through the cornea. Objects that may cause lacerating or penetrating

injuries include glass, knives, thorns, darts, pencils, wire, or high-velocity foreign bodies from striking or grinding metal. Penetrating injuries caused by metal wire can be associated with intraocular cilia (eyelashes), which may be difficult to detect. Severe ocular injuries occur most commonly in young adult males, with an average age of 25 to 34 years.

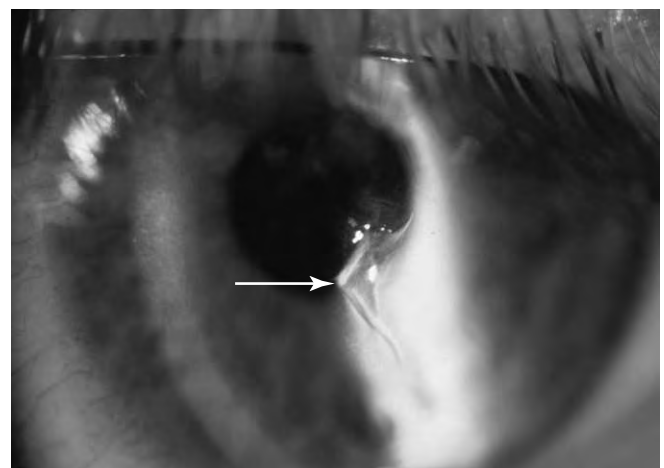
One obvious concern in the event of a lamellar laceration or corneal penetration is the insult to the regularity and clarity of the corneal surface and the potential impact on visual acuity. This issue also affects the method chosen for repair. In the case of corneal penetration, there is also concern about intraocular foreign bodies, damage to intraocular structures, and, most importantly, the risk of polymicrobial endophthalmitis.

#### Diagnosis

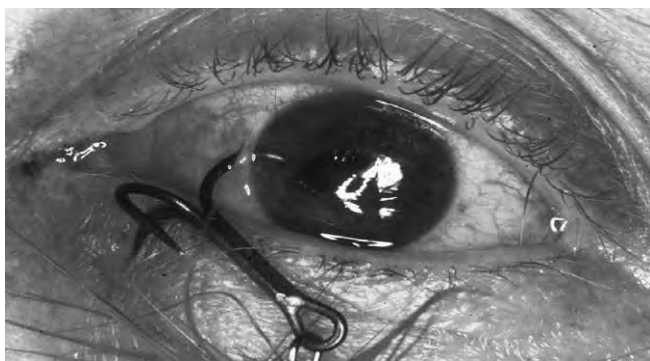
A careful history helps to reveal the etiology of the traumatic event, although the possibility of corneal laceration or penetration may not be determined definitively from the history alone. Patient symptomatology associated with deep corneal injuries may vary widely. In the event of a small corneal penetration that has self-sealed, associated symptomatology may be relatively minor. More extensive involvement may produce symptoms of pain, photophobia, tearing, or blepharospasm.

If the history or examination indicates that deep laceration or penetration is present, care must be taken to avoid undue pressure on the globe (Figure 26-24). The use of topical or regional anesthesia helps to minimize blepharospasm as a cause of pressure on the globe. If this is the case, it is best to apply a Fox shield and refer the patient to a cornea specialist. There is no need for further examination and potentially exacerbate the injury.

In the event of a large object impaled into the eye, such as a nail or fishhook (Figure 26-25), the etiology of the corneal wound is obvious. Otherwise, careful slit-lamp examination is needed to determine the extent of



**Figure 26-24** Corneal laceration (*arrow*). (Courtesy of Pat Caroline.)



**Figure 26-25** Corneal penetration secondary to imbedded fishhook. (Courtesy of Pat Caroline.)

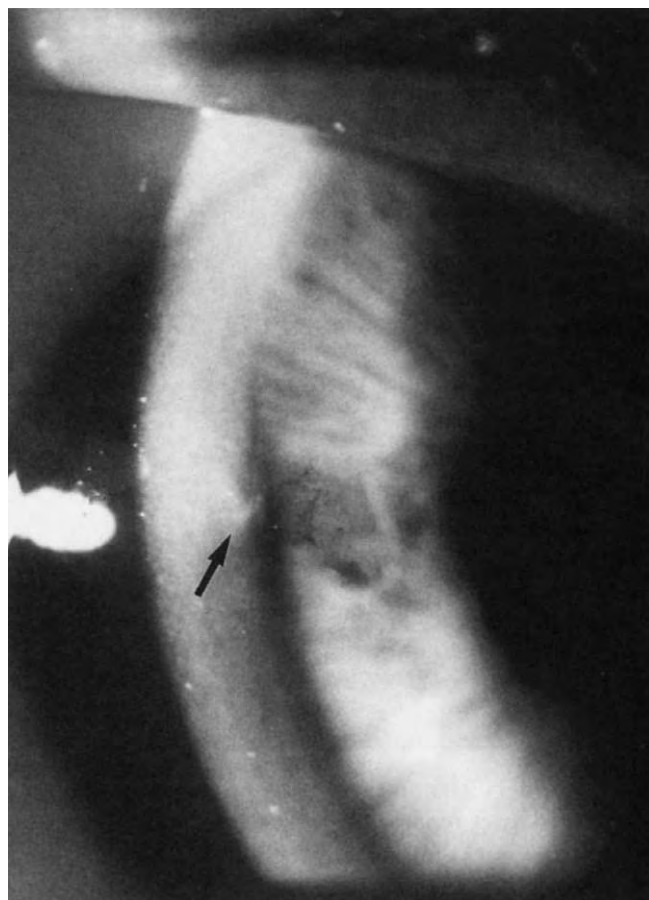the injury. An optic section at the site of the wound should be evaluated under high magnification to determine the depth of the laceration. A full-thickness corneal “track” suggests that penetration has occurred. Evaluating for Seidel’s sign at the site of the wound also helps to determine whether corneal penetration has occurred (see Chapter 30). It is possible, however, that small lacerations or puncture wounds will self-seal so that Seidel’s sign is negative even after penetration. An anterior chamber reaction, abnormally shaped pupil, cataract, prolapsed black uveal tissue, shallowing of the anterior chamber, iris transillumination defects, vitreous hemorrhage, and dramatic lowering of IOP indicate a corneal penetrating injury.

It is important to examine thoroughly for retained foreign material that may have entered the eye. When indicated, orbital radiographs, B-scans, and/or computed tomography should be obtained to aid in identifying and localizing the object. Magnetic resonance imaging is contraindicated when a metallic intraocular foreign body is suspected.

### Management

Small, shallow, nonpenetrating corneal lacerations may be treated the same as corneal abrasions (Figure 26-26). Small self-sealing corneal penetration with no sign of active aqueous loss may be treated conservatively with topical antibiotic prophylaxis, systemic antibiotic prophylaxis to prevent endophthalmitis, and pupillary dilation and cycloplegia. Larger lacerations with tissue loss and obvious corneal penetration require aggressive treatment by a corneal specialist (Figure 26-27). Taping a metal Fox shield over the eye to prevent further injury is appropriate while the patient is transported (Figure 26-28). Corneal suturing, penetrating keratoplasty, tissue adhesives, and conjunctival flaps are among the treatment options that may be used by the corneal specialist.


After surgical repair of a corneal laceration, visual rehabilitation may be obtained with the fitting of a contact lens, even with prominent central scarring and sutures intact. This is especially necessary to help retain binocularity and



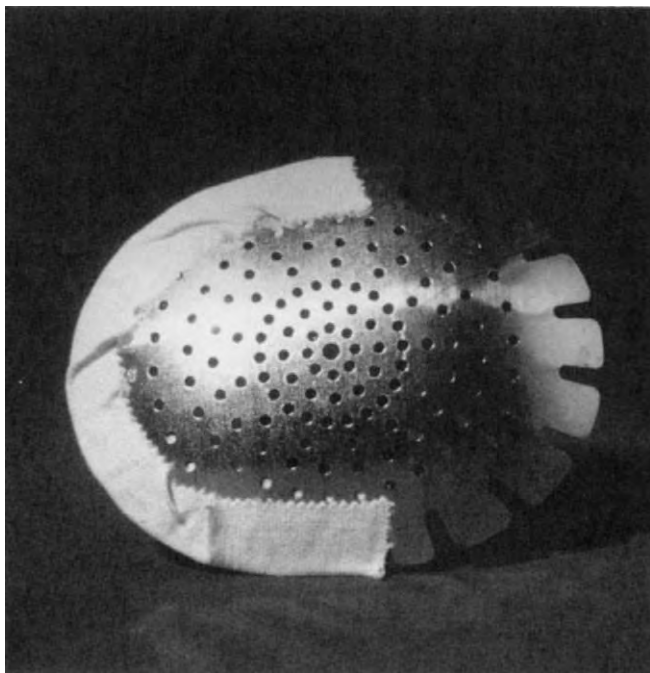
**Figure 26-26** During routine examination, a small full-thickness corneal scar was noted from prior corneal injury (*arrow*). The patient also exhibited an iris sphincter tear and small rosette cataract but denied a prior traumatic ocular event.

prevent amblyopia in pediatric patients who have had corneal laceration repair. A positive visual outcome with a contact lens may preclude the need for penetrating keratoplasty in these patients.

Penetrating keratoplasty may restore functional vision when posttraumatic corneal scars are dense and



**Figure 26-27** Full-thickness corneal scar secondary to a full thickness penetrating injury. (Courtesy of Pat Caroline.)



**Figure 26-28** If a patient is referred for consultation due to a suspected corneal penetrating injury, it is appropriate to tape a metal Fox shield over the eye to protect from further trauma during transportation. Tape is placed over the edge of the Fox shield to enhance patient comfort (here shown partially completed).

centrally located. Although emergency penetrating keratoplasty may be needed in the event of a large traumatic corneal penetration, the chances of obtaining a clear graft after penetrating keratoplasty improve if the procedure is delayed for at least 3 months.

A lacerating or penetrating injury will likely result in a dense corneal scar (see Figure 26-27). Other complications include anterior synechia, cataracts, and irregular astigmatism. Lacerations more than 4 mm in length have a higher incidence of residual astigmatism. Factors that predict the visual outcome are visual acuities at the time of injury; the presence of hyphema, uveal prolapse, cataract, vitreous loss, vitreous hemorrhage, or retinal detachment; length of the laceration; time duration between the injury and surgical care; and an injury located posterior to the rectus muscle insertion.

Patient education in the use of protective eyewear may help prevent corneal injuries and is particularly important in the monocular patient. Tetanus immunization is recommended following significant corneal injuries.

## Recurrent Corneal Erosion

### Etiology

RCEs are reoccurring episodes of spontaneous breakdown or sloughing of the epithelial layer of the cornea. RCEs are caused by poor adhesion complexes between the epithelial basement membrane and Bowman's layer.

Ultrastructural changes include abnormalities in the epithelial basement membrane, defective or absent hemidesmosomes, and decreased anchoring fibrils. The condition may occur after superficial corneal trauma, in conjunction with ABMD, or may be idiopathic.

Approximately 42% to 64% of RCEs occur after superficial trauma to the cornea. Fingernail injuries are reported to be the most common cause of traumatic RCE. Other causes of traumatic RCE include injuries from paper, cardboard, vegetative material, contact lenses, foreign body removal, and trauma to the epithelium during LASIK.

Approximately 16% to 46% of RCEs are associated with ABMD. Other corneal dystrophies associated with RCE include Fuchs', Reis-Bücklers, lattice, and granular. Dystrophic RCEs are typically bilateral and less severe.

There are many other causes of RCE, but they occur much less frequently. Among these causes are chemical or thermal burns, herpes simplex keratitis, neuroparalytic keratitis, bullous keratopathy, severe dry eyes, nocturnal lagophthalmos, diabetes mellitus, meibomian gland dysfunction, ocular rosacea, and Alport syndrome. Approximately 5% to 30% of RCEs occur spontaneously without any known predisposing factor.

After RCE, the epithelial lesion heals rapidly, usually within 5 days with no visible sequelae. At some later time the symptoms suddenly recur. The mean time to recurrence in one study of 80 patients was 18 months. Although the time from initial injury to recurrence was reported to range from 2 days to 16 years, 63% of recurrences were noted within the first 4 months. Although RCEs can start at any age, depending on the underlying corneal etiology, early adulthood to middle age is the common age at onset.

### Diagnosis

The most common symptom of RCE is acute pain on awakening. Other common symptoms include photophobia, tearing, blurred vision, redness, burning, blepharospasm, and foreign body sensation. These symptoms, which can cause great anxiety and lifestyle disruption, tend to recur in cycles of days, weeks, or months.

RCEs can be classified into two main groups. Macroform RCEs may last several days, have large epithelial defects, and involve severe pain. Microform RCEs typically result in milder symptoms that last 30 minutes to several hours, and the epithelium may appear intact at the time of the slit-lamp examination. Most erosions occur in the lower third of the cornea in the approximate location of most Hudson-Stähli lines (Figure 26-29). Investigators believe that RCEs occur in this location because epithelial stem cells derive from the limbus, and healing of central corneal lesions is accomplished by centripetal movement of peripheral epithelial cells.

In addition to a frank epithelial defect that stains with NaFl, epithelial edema, microcysts, and poor epithelial attachment may be seen in acute cases of RCE. If the

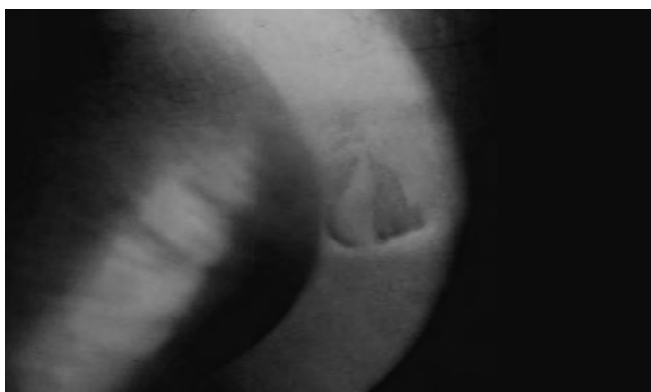




**Figure 26-29** Recurrent corneal erosion in the inferior third of the cornea (*arrow*) exhibits positive NaFl staining centrally. Note the surrounding punctate positive and negative stains.

epithelium is loose but still in position, it may appear as a slightly wavy or irregular area with surrounding edema. Negative NaFl staining will be seen in the area of loose or elevated epithelium (Figure 26-30). Perilimbal injection, upper eyelid edema, and blepharospasm are possible in severe cases.

An ABMD may be evident. Classic findings of ABMD include intraepithelial geographic opacities, microcysts, and concentric refractile lesions that resemble fingerprints. The use of retroillumination is helpful in viewing the epithelial defects with the slit-lamp biomicroscope.



**Figure 26-30** Negative NaFl staining over an area of raised epithelium. (Courtesy of Pat Caroline.)

Negative NaFl staining may be present in areas where the epithelium is elevated and not adhering well.

Rarely, sterile anterior stromal infiltrates may develop late in RCE. These lesions are typically less than 2 mm in diameter and located paracentrally. They are usually culture negative and most likely represent an inflammatory reaction.

Between episodes, the most common signs of RCE are epithelial microcysts, surface irregularities, and subepithelial scarring. A pseudodendrite appearance is possible due to apposition of the loose and well-attached epithelium. Reports indicate corneal topography may also exhibit well-delineated areas that are more than 2 diopters flatter than the surrounding corneal tissue. These areas, called *corneal topographic lagoons*, measure less than 2 mm and are more commonly seen in patients with RCE than in control patients.

### Management

Treatment generally focuses on decreasing symptoms and encouraging regrowth and reanchoring of the epithelium. It is important to warn the patient of the recurrent nature of the condition and to continue treatment for some time after the cornea appears to be healed.

During acute episodes a broad-spectrum topical prophylactic antibiotic ointment, such as 0.3% tobramycin or 0.5% moxifloxacin, protects the cornea from secondary infection while it heals. The use of a therapeutic contact lens and topical NSAIDs, such as diclofenac sodium 0.1% solution or ketorolac 0.5% solution, provide symptomatic relief. The therapeutic soft contact lens also protects the regenerating epithelium and temporarily provides epithelial stability. A cycloplegic agent, such as 5% homatropine, should be instilled to decrease ciliary spasm and pain. Oral analgesics can be prescribed as needed (see Chapter 7). The eye should be examined in 24 hours and the therapy continued until the epithelial defect is healed.

If the epithelium is not healing or if the patient presents with grossly loose and elevated epithelium, the area should be debrided. First, a topical anesthetic is instilled to anesthetize the cornea and loosen the epithelium. A dry cellulose ophthalmic sponge or moistened sterile cotton-tipped applicator can be used to gently remove the epithelium (see Figure 26-15). Debriding too aggressively must be avoided, because this could damage the basement membrane and increase healing time. Debridement should be followed by the use of a broad-spectrum topical prophylactic antibiotic, a topical NSAID, a therapeutic soft contact lens, and a cycloplegic agent. Debridement facilitates the healing process but does not affect the incidence of recurrences.

Once the epithelial defect is healed, artificial tears should be used four to eight times daily, and hypertonic agents, such as 5% sodium chloride ointment, should be administered at bedtime for 3 to 6 months. Patients should continue using hypertonic agents for several months after

symptoms have resolved because there is a tendency for recurrence of the erosion if the hypertonic therapy is withdrawn prematurely. Hypertonic agents decrease eyelid adhesion and also may create an osmotic gradient that draws fluid from the epithelium, keeping it apposed to Bowman's membrane and thereby promoting adherence.

Although some clinicians believe bland ointment may be just as effective, studies have shown that artificial tears and steroids are not as effective as hypertonic ointment for controlling recurrences. It has been reported that 80% to 90% of patients with symptomatic RCEs experience some improvement in symptoms with the use of hypertonic ointment.

Topical ophthalmic corticosteroids and oral tetracyclines have been shown to decrease the frequency of RCEs by inhibiting matrix metalloproteinase enzymes. Metalloproteinase enzymes, which have an increased concentration and activity after RCE, have been shown to degrade the epithelial basement membrane and anchoring fibrils. In seven patients who did not respond to conventional therapy, oral doxycycline 50 mg two times a day for 2 months and topical steroids two or three times a day for 3 weeks resulted in rapid healing and no recurrences over an average follow-up period of 22 months. The therapeutic effect of topical corticosteroids and oral tetracyclines may also be due to decreased inflammation or improved meibomian gland secretion. Because meibomian gland dysfunction is thought to play a role in recalcitrant RCEs, treating the meibomian gland dysfunction may contribute to healing.

Autologous serum, obtained from a blood sample and instilled topically, has been shown to considerably reduce the recurrences of RCE without side effects such as allergic reactions. Autologous serum supplies the eye with substances such as fibronectin, vitamin A, lysozyme, epidermal growth factor, transforming growth factor- $\beta$ , and other cytokines, which are essential for repairing damaged epithelium.

If erosions are occurring more frequently than once monthly and diffuse areas are involved, long-term use of a therapeutic soft contact lens may aid in reforming the adhesion complexes. A large-diameter therapeutic contact lens should be fitted to allow minimal movement. Such lenses are used in an attempt to protect the epithelium from eyelid trauma during blinking and adhering to the tarsal conjunctiva. The lenses tend to increase patient comfort and decrease the severity and frequency of recurrences, but they do not always prevent recurrences. Besides erosions occurring underneath the contact lens, other problems associated with contact lens wear may develop, including contact lens loss, discomfort, deposits, vascularization, stromal infiltrates, and infection. It is suggested that the patient be examined 24 hours after a therapeutic contact lens is dispensed, 1 week later, and each month subsequently to monitor for these complications. If the patient is tolerating the lens well, it should be

left in place for 2 months after the erosion has healed. This regimen typically results in 3 to 6 months of wearing time. When lens wear is discontinued, the patient should be instructed to instill 5% sodium chloride ointment into the conjunctival sac at bedtime for several months.

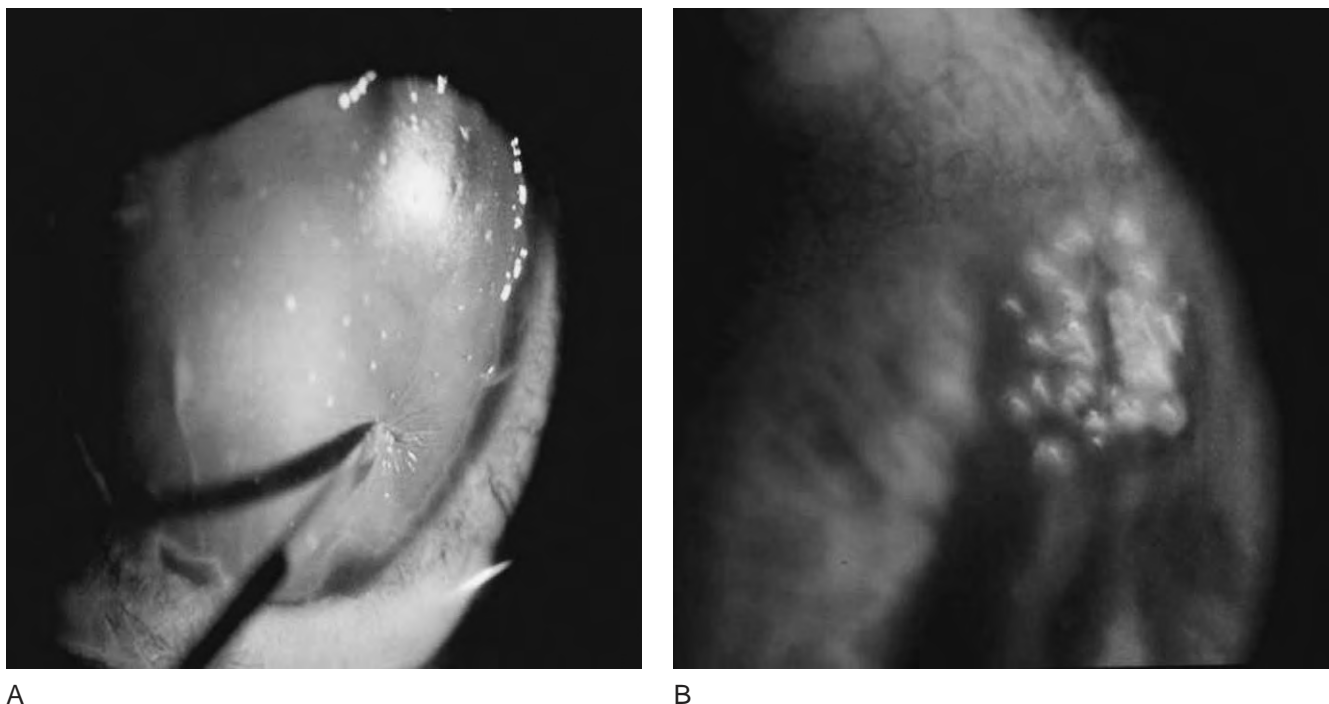
During corneal healing it is important to monitor for any signs of corneal infiltrate or anterior uveitis. Although most corneal infiltrates associated with RCE have been shown to be sterile, the clinical appearance of these infiltrates is not definitive in differentiating infectious from immune causes. For this reason any infiltrates that develop should initially be treated with antibiotic drops as if they were infectious.

Up to 95% of patients with symptomatic RCEs experience some improvement in symptoms with the use of medical therapy. If the patient experiences more than one erosion per month despite medical therapy, invasive treatment is indicated. These treatment options include anterior corneal stromal puncture with a needle or an Nd:YAG laser, PTK, and superficial epithelial keratectomy.

Anterior stromal puncture stimulates the production of collagen and fibronectin, which improve the attachment of the epithelium and basement membrane to the anterior stroma. A bent-tipped 23- to 25-gauge needle is used to puncture through loose epithelium and Bowman's layer into the anterior stroma (Figure 26-31). Enough pressure should be applied to indent the cornea one-fourth to one-third the depth of the anterior chamber, which should cause approximately 50% stromal thickness penetration. The bent tip prevents accidental penetration and controls the penetration depth. These punctures are placed approximately 0.5 mm apart over the entire area of loose epithelium and about 1 mm outside the area delineated by NaFl. Although scarring from anterior stromal puncture with a needle is minimal enough to cause no apparent effect on visual acuity, it is typically avoided in the visual axis due to the risk of decreased vision and glare. Stromal puncture with an Nd:YAG laser is less likely to produce scarring. However, one major disadvantage of the laser procedure is the need, in some cases, to debride the corneal epithelium before the treatment is administered. This makes the procedure more painful for the patient and prolongs the recovery time. The rate of recurrence after anterior stromal puncture is 14% to 40%. Anterior stromal puncture is not the treatment of choice in patients with an ABMD that is not well defined.

Patients with chronic RCE and widespread ABMD benefit from therapeutic modalities that treat larger areas of the cornea. PTK has been shown to be an effective treatment for these patients, resulting in decreased symptoms and increased visual acuity. PTK is useful for corneal erosions that affect the visual axis, and it can be combined with photorefractive keratectomy. One drawback of PTK is the expensive equipment required to perform the procedure. PTK removes superficial tissue of Bowman's layer to allow the formation of a new basement





**Figure 26-31** Anterior stromal puncture procedure. (A) A 25-gauge needle is used to puncture the anterior stroma. (B) NaFl staining after an anterior stromal puncture procedure. (Courtesy of Pat Caroline.)

membrane with stronger adhesion complexes. The rate of recurrence after one PTK procedure is 0 to 27%. Retreatment with PTK has been successful, with a recurrence rate of 0 to 20%. A mild corneal haze that may cause visual symptoms occurs 3 to 7 weeks after the procedure in 36% to 80% of patients. This haze typically requires no treatment. Although there is a trend toward hyperopia, most studies showed no statistically significant refractive error shift as long as the ablation depth was less than 10  $\mu\text{m}$ .

Superficial epithelial keratectomy with a variable-speed diamond burr or Amoils epithelial scrubber has also been shown to be safe and effective in treating larger erosion areas and areas that affect the visual axis. No significant difference was found in corneal haze, recurrence of erosions, or best-corrected visual acuity in patients treated with superficial epithelial keratectomy with diamond burr polishing and patients undergoing PTK. Both treatment options are safe and effective. However, treatment with a diamond burr is simpler and less expensive.

After anterior stromal puncture, PTK, or superficial keratectomy, broad-spectrum topical prophylactic ophthalmic antibiotic drops such as 0.3% tobramycin, 0.3% ciprofloxacin, or one of the newer generation fluoroquinolones, moxifloxacin or gatifloxacin, should be instilled three to four times daily, along with a broad-spectrum antibiotic ointment such as 0.3% tobramycin or 0.3% ciprofloxacin instilled into the conjunctival sac at bedtime. NSAIDs such as diclofenac sodium 0.1% solution

or ketorolac 0.5% solution and a therapeutic soft contact lens should be instituted. A cycloplegic agent and/or oral analgesic may also be helpful in controlling pain. The patient should be examined each day until the epithelium is healed. The antibiotic solution should be continued for 1 week after the procedure. Patients should instill hypertonic ointment into the conjunctival sac at bedtime for several months and should be examined at 1-week and 2-month intervals after the epithelium is healed.

Corneal delamination with 20% alcohol has been described for RCE treatment. After the application of 20% alcohol for 40 seconds, 73% of patients were free of symptoms over an average period of 23 months' follow-up. No patients had decreased visual acuity after the procedure. The successful use of substance P-derived peptide and botulinum toxin injections has also been described to treat RCE, but no controlled studies have been performed. Other interventions, such as microdiathermy and surface cautery or diathermy, are used primarily for symptom relief if there is no visual potential.

## Exposure Keratopathy

### Etiology

Numerous neurologic and mechanical factors may result in chronic corneal drying due to infrequent or incomplete blinking or inadequate eyelid closure (lagophthalmos). The resultant irritation to the corneal tissue is known as exposure keratopathy.

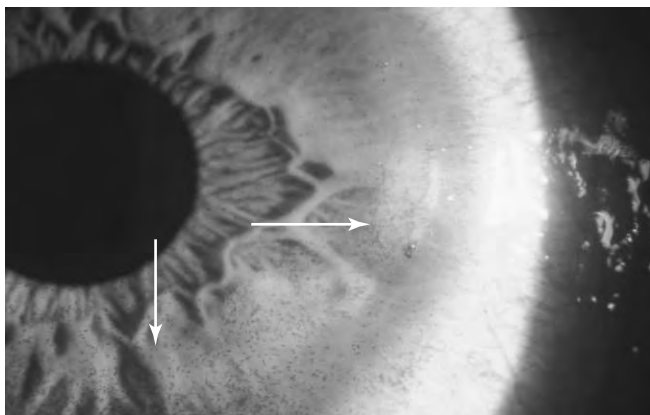
Ectropion is an example of an eyelid abnormality that may result in exposure keratopathy. Bell's palsy involves disrupted innervation to the orbicularis oculi muscle. The resultant retraction of the lower eyelid together with reduced blink capability of the upper lid may result in exposure keratopathy. Graves' disease is an example of a systemic condition that can produce exophthalmos (see Figure 32-5) and accompanying exposure keratopathy. Patients who have had cosmetic lid or facial surgery, such as CO<sub>2</sub> laser cosmetic skin resurfacing or blepharoplasty, and patients under deep sedation are more likely to have lagophthalmos and exposure keratopathy. Nocturnal lagophthalmos, in which the eyelids do not close fully during sleep, is a relatively common cause of exposure keratopathy.

### Diagnosis

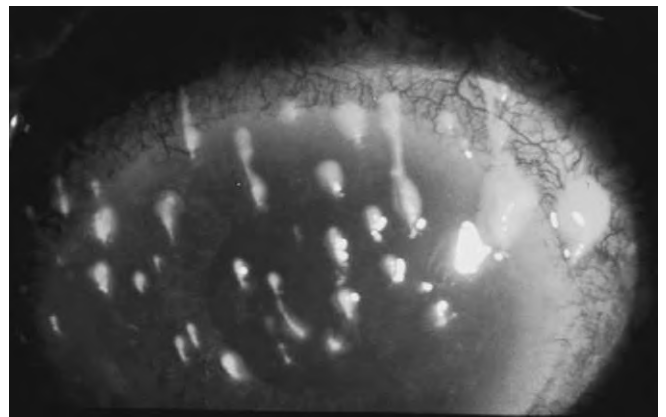
Patients with exposure keratopathy typically present with symptoms of foreign body sensation, burning, stinging, photophobia, tearing, and redness. The symptomatology may be more pronounced in the morning after a night of corneal desiccation, particularly in the case of nocturnal lagophthalmos. In the less frequent event of secondary corneal ulceration or infection, the symptoms are more pronounced and consistent with these conditions.

Depending on the patient's eyelid configuration, slit-lamp examination reveals punctate epithelial erosions in the interpalpebral or inferior areas of the cornea. These lesions stain prominently with NaFl and, often, rose bengal (Figure 26-32). Corresponding conjunctival injection is common. In more severe long-standing cases inferior micropannus, scarring, or corneal thinning may be noted.

Patients with exposure keratopathy may develop filamentary keratitis. The dry eye can cause corneal irregularities and increased mucin, which promotes the formation of fine epithelial and mucous strands that are attached to



**Figure 26-32** Patient with exposure keratopathy exhibits staining inferiorly/intrapalpebrally with rose bengal. (Courtesy of Pat Caroline.)



**Figure 26-33** Corneal filaments with lissamine green staining. (Courtesy of Pat Caroline.)

the cornea. These corneal filaments stain with rose bengal or lissamine green (Figure 26-33).

A thorough history along with other observed ocular, facial, or systemic findings assists in determining the etiology of exposure keratitis. The potential for lagophthalmos can be assessed by asking the patient to gently close his or her eyes and inspecting for incomplete lid closure and exposure of the globe. In patients with lagophthalmos a portion of the globe is visible through the incompletely closed fissure (see Figure 24-17). If the patient has a normal Bell's reflex, the bulbar conjunctival-scleral portion of the globe is visible; if the patient has a poor Bell's reflex, the cornea is visible through the incompletely closed fissure, and exposure keratopathy results. Friends or family members can observe the patient's eyelids during sleep to help determine whether nocturnal lagophthalmos is present. It is essential that eyelid apposition be evaluated carefully in patients under deep sedation to avoid exposure keratopathy.

### Management

If exposure keratopathy is the result of an ocular or systemic abnormality, the underlying condition should be addressed. Patients with exposure keratopathy resulting from Bell's palsy or Graves' disease often are comanaged by a physician caring for the systemic problem together with the eye care practitioner attending to the ocular complications.

Management of exposure keratopathy is directed toward lubrication of the globe and cornea as long as the lagophthalmos is present. These measures typically include ocular lubricating drops during the day and bland ophthalmic lubricating ointment instilled into the conjunctival sac at bedtime. If lubrication is not sufficient, and often as an interim measure, the eyelids may be closed with hypoallergenic tape to prevent corneal exposure during sleep. Moreover, several types of plastic shields are available to reduce tear evaporation and resultant corneal desiccation.

If an underlying lid abnormality such as ectropion is the cause of exposure keratitis, then an oculoplastics consultation is appropriate. In extreme cases of exposure, a tarsorrhaphy may be performed to preserve corneal health. In the event that exposure keratitis has become complicated by secondary infection, appropriate treatment must be initiated.

If filamentary keratitis is present, treatment should include the use of nonpreserved ocular lubricating drops during the day, bland ophthalmic lubricating ointment instilled into the conjunctival sac at bedtime, and punctal occlusion. Topical medications, including hypertonic solution (5% NaCl), mucolytic agents such as acetylcysteine, steroids, NSAIDs, aid in the resolution of the corneal filaments. The filaments typically resolve within 1 to 4 weeks after initiating treatment. NSAIDs such as 0.1% diclofenac instilled four times per day for 3 to 4 weeks have been shown to improve clinical symptoms such as foreign body sensation, itching, and pain in addition to eliminating the filaments. Some advocate the mechanical removal of the filaments with jeweler's forceps; however, this may cause further surface damage and slow the resolution of the filamentary keratitis. Silicone hydrogel contact lenses that are approved for therapeutic use protect the compromised epithelium from sheering effects of the eyelids, allowing the epithelium to reattach to the basement membrane. Maintenance treatment for filamentary keratitis may be necessary, including nonpreserved ocular lubricating drops during the day, bland ophthalmic lubricating ointment at bedtime, punctal occlusion, and NSAIDs for acute flare-ups.

## Chemical and Thermal Burns

### Etiology

Thermal and chemical burns account for 8% to 19% of traumatic eye injuries. Most burns are mild; however, burns can potentially cause severe cosmetic and visual impairment. Most ocular burn victims are males with an average age of 28 to 36 years. Alkali injuries are more frequent than acid or thermal injuries and are typically the most damaging.

Alkali injuries to the eye represent true medical emergencies because the impact on ocular tissue, including the cornea, may be devastating. The chemical composition of alkaline substances promotes rapid penetration through all corneal layers without neutralization of the substance. Calcium hydroxide (in lime, plaster, cement, mortar, and whitewash) is the most common cause of alkali burns. It forms precipitates that can be retained in the fornix. These precipitates can cause severe damage if not recognized and removed. Other common alkali agents that may cause ocular burns include ammonia (a common cleaning agent), sodium hydroxide (in lye, drain cleaners, or caustic soda), potassium hydroxide (in caustic potash), and magnesium hydroxide (a component of flares and fireworks).

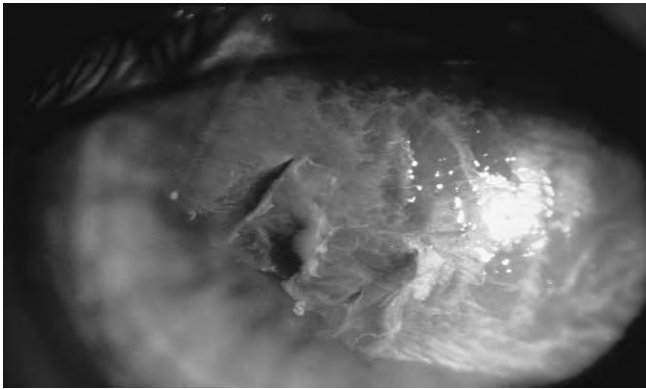
Burns secondary to acid solutions result in coagulation of proteins. This reaction forms a barrier of precipitated tissue, which tends to limit ocular damage to local superficial effects. However, strong acids such as hydrofluoric acid can penetrate as quickly as alkali chemicals. The most common solutions implicated in acid corneal burns include sulfuric acid (used in car batteries and the manufacturing of fertilizer and detergents), sulfurous acid (used as a bleaching agent), acetic acid (a component of vinegar), hydrofluoric acid (used in glass polishing and silicone production), and hydrochloric acid (used in petroleum production and metal cleaning).

Thermal burns are less common than chemical burns. The cornea may be exposed to thermal burns from a variety of sources. The nature of the resultant injury is determined by the form and temperature of the causative agent. Open flame burns are the most common cause of severe thermal burns. Other causes of thermal burns include hot objects or liquid, such as molten metal or glass that continues to radiate heat while in contact with the eye; boiling fluids; firecracker particles; lit match heads; curling irons; and steam from boiling water or after the preparation of microwave popcorn.

### Diagnosis

A patient with a chemical or thermal burn typically reports the source. The patient generally presents soon after the injury or seeks care if ocular irritation persists after a day or two. The degree of symptomatology tends to be consistent with the extent of the ocular burn. Symptoms range from mild irritation and focal redness to severe pain, burning, redness, tearing, and photophobia. Patients with chemical burns report that the offending solution or solid came in contact with one or both eyes or the face. The patient, a friend, or a family member can often identify the offending solution. Resources such as a poison control hot line or *Grant's Toxicology of the Eye* are available to help determine the potential ocular effects of an identified chemical agent.

Because the tissue exposed in the palpebral fissure is most likely to be involved in an ocular burn, the clinical signs tend to be most prominent in that area. Bulbar conjunctival injection is most pronounced within the palpebral fissure. However, diffuse conjunctival injection may be present. In mild chemical burns, punctate epithelial erosions are noted at the areas of chemical contact with the cornea. NaFl staining of the bulbar conjunctiva and corresponding inferior palpebral conjunctiva may also be present. A thermal epithelial corneal burn appears as a focal, milky, gray-white coagulation of tissue that tends to slough (eschar), often within the palpebral fissure (Figure 26-34). Depending on the extent of the injury, the skin of the eyelids and face also may exhibit involvement, including lash and brow singeing or chemical burn, depending on the nature of the injury. A grading system has been described to determine the severity of ocular burns, which also impacts prognosis (Table 26-2).



**Figure 26-34** Corneal eschar in patient who sustained a thermal burn from a curling iron. (Courtesy of Pat Caroline.)

Determination of the degree of tissue involvement is particularly important in evaluating the severity of alkali burns. Corneal haze and limbal or conjunctival ischemia indicate more severe involvement and a poorer visual and ocular prognosis. Areas of limbal or conjunctival ischemia or necrosis, which appear white and devoid of blood vessels, indicate damage to the limbal stem cells responsible for epithelial cell regeneration. Severe alkali burns cause destruction of superficial ocular tissue and consequent corneal scarring, symblepharon, entropion, and keratitis sicca (Figure 26-35). Corneal penetration of an alkaline substance produces uveitis, cataract, and secondary glaucoma.

### Management

The long-term prognosis of a patient with a chemical burn depends on immediate irrigation. When a history of recent chemical injury is reported, copious ocular irrigation must be immediately instituted in an effort to neutralize the offending agent and to wash away any accompanying particulate debris. If a patient telephones with this complaint, the patient, a friend, or a family member must be instructed to perform irrigation before and during transport. Phosphate-buffered solutions and Diphoterine, a non-phosphate-buffered solution, restores the normal ocular pH more quickly than saline or tap water and is recommended for initial irrigation. Sterile saline,

eyewash solution, or on-site irrigation with clean water can also be used for initial irrigation if a buffered solution is unavailable. A phosphate buffer should not be used after the initial first aid because this has been shown to increase corneal calcification. Immediate ocular irrigation is also recommended for thermal burns. Irrigation cools the corneal surface and removes inflammatory substances. The patient should be instructed to present for in-office care after thorough irrigation. A patient with a severe alkali burn to the eyes and face should be transported immediately to an emergency medical facility after ocular irrigation, unless life-threatening issues take precedence.

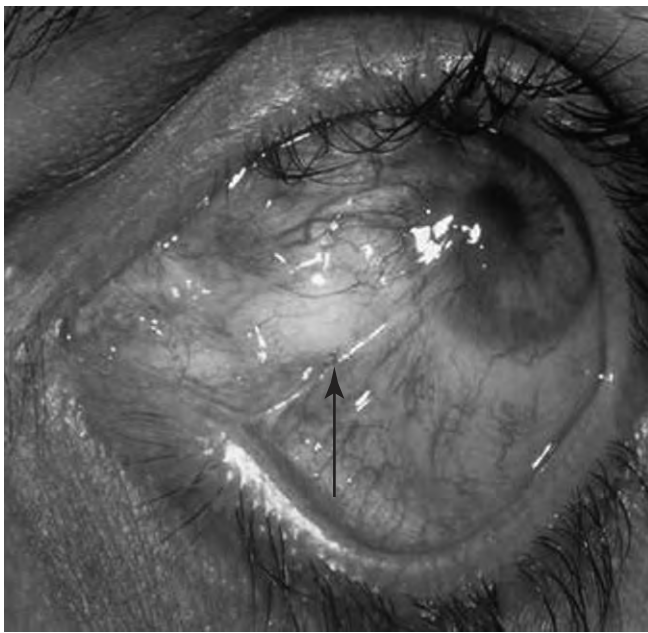
If the patient presents as an office ocular emergency reporting a recent chemical burn injury, ocular irrigation should be instituted immediately, even before implementing other aspects of patient check-in and ocular examination. Instilling a drop of topical anesthetic into each eye will enhance patient cooperation during irrigation. The globe must be thoroughly irrigated using a buffered solution (see Figure 3-22). The solution stream should be directed toward the fornices. A 20- to 30-minute irrigation is needed, and litmus paper may be used to determine the effectiveness of irrigation in neutralizing the agent (end point, 7.3–7.7). If patient cooperation is poor for ocular irrigation, use of an eyelid speculum may be helpful (Figure 26-36). For both chemical and thermal burns, all particulate debris must be removed using appropriate techniques, and necrotic epithelium should be removed with a sterile cotton-tipped applicator (see Figure 26-15).

The main treatment objectives of both thermal and chemical burns are to promote epithelialization, reduce inflammation, and minimize ulceration and scarring. If the cornea shows no signs of opacification or conjunctival blanching after irrigation, lesions can be treated medically. Severe acid and thermal burns involving more than superficial tissue injury and grades II, III, and IV alkali burns should be managed by a corneal specialist. Antibiotic prophylaxis using broad-spectrum agents, such as 0.5% moxifloxacin drops three times daily and 0.3% tobramycin or ciprofloxacin ointment in the conjunctival sac at bedtime, protect the tissue from secondary infection. Concurrent use of a low-potency topical steroid such as 0.12% prednisolone or 0.1% fluorometholone

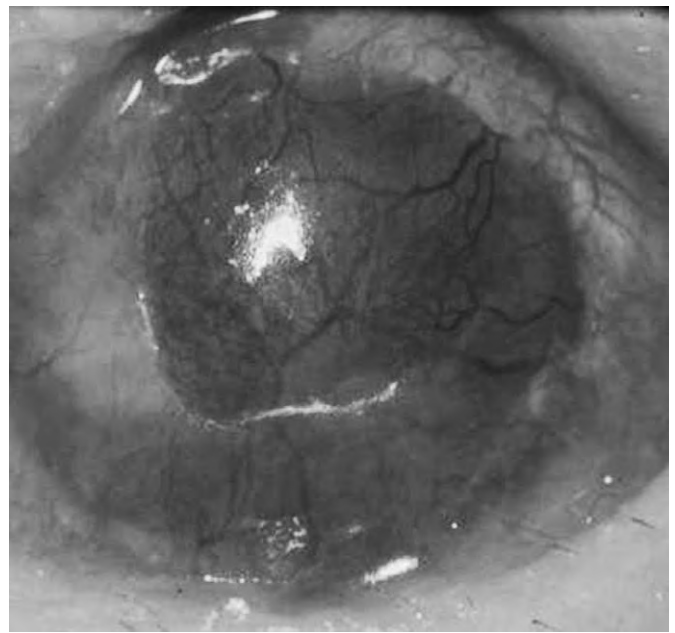
**Table 26-2**  
Classification of Ocular Burns

Grade	Corneal Findings	Limbal Ischemia	Prognosis
I	Epithelial damage	None	Excellent
II	Hazy but iris details visible	<½	Good
III	Total epithelial loss Stromal haze obscures iris details	½–¾	Guarded
IV	Opaque cornea; iris and pupil are not visible	>¾	Poor

Modified from Arffa RC. Corneal trauma. In: Grayson's diseases of the cornea, ed. 4. St. Louis, MO: Mosby, 1997: 685–708.



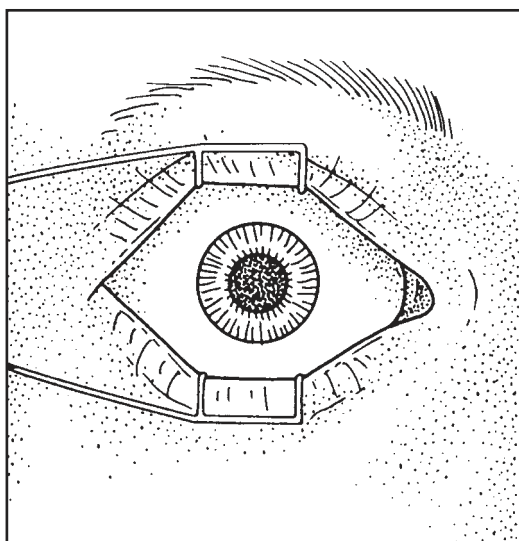
A



B

**Figure 26-35** Alkali chemical burn resulting in (A) symblepharon and (B) corneal opacification. (Courtesy of Pat Caroline.)

alcohol drops four times daily helps to reduce the inflammatory response. However, the use of steroids beyond the first 7 days may increase the risk of corneal ulceration. More extensive burns may require pupillary dilation and cycloplegia with a long-acting agent such as 5% homatropine. If tolerated, a therapeutic soft contact lens can be used to promote epithelial healing and adhesion. After removal of corneal eschar, a mild thermal burn is treated similarly to a corneal abrasion.



**Figure 26-36** Spring-type Barraquer eyelid speculum is shown in place. (Reprinted with permission from Casser L, Fingeret M, Woodcome HT. Speculum insertion. In: Atlas of primary eyecare procedures, ed. 2. Norwalk, CT: Appleton & Lange, 1997: 98-99.)

The patient is followed daily until the corneal injury resolves. Unless an anterior uveitis is present, the cycloplegic, steroid, and antibiotic can be discontinued once the epithelium has healed. If healing of the mild alkali burn does not proceed as expected, it is possible that ischemia is present, necessitating reevaluation of the treatment.

More severe burns typically require extensive medical and surgical treatment. Ascorbate and citrate have been shown to reduce the risk of corneal ulceration and perforation. The use of topical sodium citrate 10% and topical sodium ascorbate 10% every 2 hours and oral vitamin C (500 mg) every 6 hours has been recommended for grades II, III, and IV burns. Oral tetracyclines have also been shown to reduce collagenase activity, decreasing corneal ulceration after chemical burns. Doxycycline 100 mg twice daily is recommended for grades II, III, and IV chemical burns. Surgical options include conjunctival transplantation, amniotic membrane transplantation, limbal stem cell transplantation, and lamellar keratoplasty.

Because of nerve damage and epithelial irregularity, dry eye is common after burn injuries; preservative-free lubricants are crucial in the long-term treatment. Patient education about the use of protective eyewear in circumstances when accidents may occur is very important and may help to prevent future injury.

### Photokeratitis

#### Etiology

The most common type of radiation burn sustained by the cornea is due to excessive exposure to ultraviolet (UV) light. The UV radiation spectrum ranges from 100 to 400 nm.

UVC (100 to 290 nm) is mainly filtered by the ozone layer but can be found in artificial situations such as arc welding lamps. UVB (290 to 320 nm) causes sunburn and is responsible for most of the harmful effects of UV radiation. UVA (320 to 400 nm) produces tanning and the photosensitivity reaction. The cornea absorbs UV radiation up to 295 nm, primarily in the epithelium and Bowman's membrane.

The most common sources of excessive UV light exposure include direct sunlight, reflection of sunlight off snow when protective sunwear is not worn ("snow blindness"), and exposure to an electric welding arc without using appropriate filters. Corneal damage from UV exposure has also been reported in glassblowers. Photokeratitis can occur in tanning booths if protective goggles are defective or even briefly removed. This is more likely to occur with defective lamps or lamps that emit lower UVB radiation levels.

### Diagnosis

The patient with photokeratitis typically reports a recent history of excessive UV light exposure. When the cause is related to excessive sunlight or sunlamp exposure, the patient generally exhibits the dermatologic manifestations of sunburn on the face or other skin areas, including erythema and blistering if severe. Ocular symptoms include pain, photophobia, tearing, and blepharospasm. The onset of symptoms usually occurs within 24 hours after excessive UV light exposure.

External examination reveals erythema and swelling of the affected skin areas. Slit-lamp examination reveals diffuse conjunctival injection and punctate epithelial erosions of the cornea with corresponding NaFl staining. If the epithelial lesions are extensive and if lacrimation is profuse, corneal edema also may be noted.

### Management

As with any superficial keratitis, the corneal lesions related to excessive UV radiation generally resolve within 8 to 24 hours. Supportive therapy for mild cases may include topical lubricating agents only, including drops during the day and ointment at bedtime. As with a sunburn, cold compresses applied to the eyes three to four times daily may also provide some symptomatic relief.

Broad-spectrum antibiotic drops, such as 0.3% tobramycin, 0.3% ciprofloxacin, or the newer generation fluoroquinolones, moxifloxacin or gatifloxacin, may be instilled four times daily to prevent secondary infection as the epithelium heals. A broad-spectrum ophthalmic ointment, such as 0.3% ciprofloxacin, may be instilled into the conjunctival sac at bedtime for prophylaxis. In more pronounced cases, pupillary dilation and cycloplegia with a long-acting agent such as 5% homatropine may help to relieve pain from associated ciliary spasm.

Anecdotal evidence suggests that some burning pain associated with UV radiation keratitis may last for days to weeks, even after complete resolution of the keratitis.

Patients should be advised of the value of protective eyewear to prevent UV radiation keratoconjunctivitis, including appropriate filters for occupational or industrial use and appropriate sunwear for outdoor use that offers UV light-blocking capability.

## Dellen

### Etiology

Dellen are small areas of corneal thinning typically located at the limbus. They are caused by localized drying of the cornea usually due to poor spreading of the tear film. The tear film disruption is often due to a local surface elevation of the conjunctiva in the adjacent perilimbal area. Pterygium, pinguecula, conjunctival chemosis, subconjunctival hemorrhage, scarring from ocular surgery, filtering blebs, nerve palsies, scleritis, and episcleritis commonly result in dellen, but any mass that prevents close apposition of the eyelids to the cornea can be responsible for their formation. The use of systemic medications with anticholinergic side effects, such as antihistamines, may precipitate or exacerbate the clinical signs or symptoms.

### Diagnosis

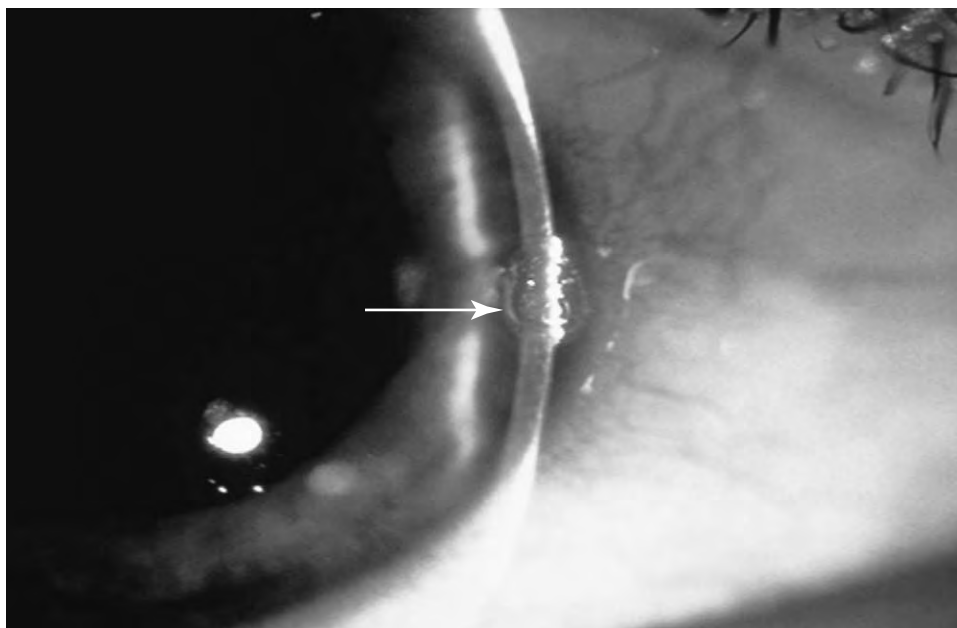
Patients with dellen usually present with a foreign body sensation or slight discomfort. They often have a history of irritated eyes, which have recently become worse. They commonly report redness of their eyes and focal conjunctival injection is usually noted. Slit-lamp examination reveals a small, oval, saucer-like excavation usually less than 2.0 mm in size located on the corneal side of the limbus (Figure 26-37). The oval-shaped dellen has its long axis parallel to the limbus and occurs more frequently on the temporal margin. Although the lesion has clearly defined borders, its base appears hazy and dry. The wall of the excavation is steeper on the corneal side and more sloping on the limbal side. The epithelium is typically intact, and the stroma is not inflamed. NaFl pools in the excavation. Actual staining is variable in the early stages but likely develops in advanced cases.

Early in the development of a dellen, the stroma is intact but thinned due to loss of fluid. Stromal degeneration can occur, and true scarring with or without vascularization develops if the dellen is allowed to persist. The formation of a descemetocele in a long-standing dellen that required a corneoscleral patch graft has been reported.

### Management

Treatment for dellen is directed toward rehydrating the cornea and, if possible, removing the cause. Nonpreserved artificial tears administered every 2 hours and lubricating ointment instilled into the conjunctival sac at bedtime usually allow resolution within 48 hours. If the dellen is diagnosed early in its development and treated aggressively, it can resolve within 24 hours. Very severe dellen may require prophylactic topical antibiotics such





**Figure 26-37** Oval saucer-like appearance of a dellen. (Courtesy of Pat Caroline.)

as polymyxin B-bacitracin or erythromycin ointment. If the dellen has formed secondary to an inflammation such as scleritis or episcleritis, appropriate therapy should be initiated. Patients should be asked to return for evaluation in 1 to 7 days depending on the severity of the lesion.

## Toxic Keratitis

### Etiology

A wide range of substances that are toxic to the cornea may produce epithelial insult known as *toxic keratitis*. This terminology is generally reserved for mild superficial corneal irritation after contact with a harmful substance. Solutions foreign to the eye that commonly cause toxic keratitis include shampoos, lotions, and chlorinated pool water. Toxic corneal reactions have been reported from tonometer tips contaminated with 70% isopropyl alcohol or hydrogen peroxide that was not fully removed after disinfection of the probe. Irreversible corneal scarring has resulted from inadvertent ocular contamination with chlorhexidine gluconate, a skin cleanser used preoperatively. The mistaken use of nonophthalmic products for eyedrops may result in various forms of corneal trauma.

The term *medicamentosa* refers to toxic keratitis related to the use of topical ophthalmic agents. A number of topical ophthalmic preparations are known to cause toxic keratitis, including antivirals, antibiotics, antifungals, anesthetics, antiglaucoma medications, and contact lens solutions. Aminoglycoside antibiotics are reported to cause the most frequent ocular reactions followed by glaucoma medications. The causative agents may be the active ingredients of these preparations or the preservatives

used in formulating them. After routine use of topical anesthetic, mydriatic, or cycloplegic agents, it is common to observe a fairly prominent toxic keratitis characterized by punctate epithelial erosions in the inferior one-third to one-half of the cornea. Prolonged use of topical anesthetics can result in permanent scarring and visual loss.

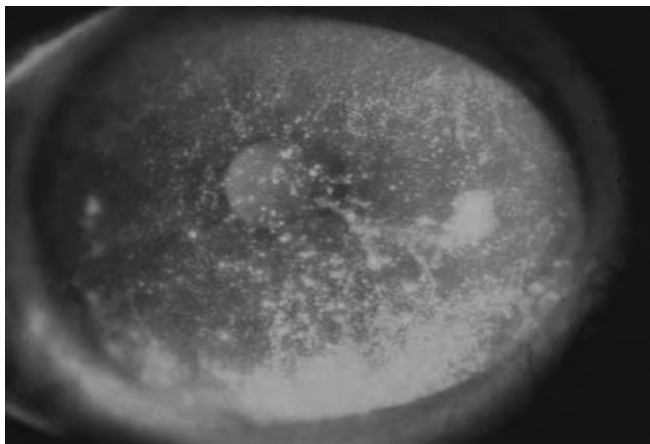
### Diagnosis

The patient with toxic keratitis or medicamentosa generally reports recent exposure to the offending substance or the use of an ophthalmic preparation on a short- or long-term basis. In the case of mild toxic keratitis, the patient may have few or no symptoms. More involved cases may produce very definite symptoms of redness, irritation, burning, tearing, and ocular discomfort upon instillation.

Clinical signs are also of variable severity. Mild medicamentosa may manifest as scattered punctate epithelial erosions in the inferior third of the cornea in a patient who is being treated with topical medications. More pronounced toxic keratitis may present as diffuse punctate epithelial erosions and punctate epithelial keratopathy in the exposed interpalpebral corneal area or over the entire cornea (Figure 26-38). Conjunctival involvement may range from none, to mild inferior bulbar injection, to prominent diffuse injection, chemosis, and follicles. Accompanying dermatitis of the lids suggests an allergic hypersensitivity reaction rather than a toxic keratitis.

Patients abusing topical anesthetics such as tetracaine and proparacaine will likely conceal the use of the anesthetic and will repeatedly deny anesthetic use even after extensive treatment, such as a penetrating keratoplasty. Patients typically have a history of a corneal injury that





**Figure 26-38** Diffuse punctate epithelial erosions in a patient with toxic keratitis. (Courtesy of Pat Caroline.)

prompted anesthetic use such as a corneal abrasion, RCE, or corneal surgery. The anesthetic is often obtained from a physician or is stolen. These patients are commonly health care employees or have friends or family members who are health care workers with access to the anesthetic.

Punctate keratopathy is seen in the early stages of toxic keratitis secondary to anesthetic abuse. In later stages eyelid edema, hyperemia, a large epithelial defect (up to 95% of the cornea), and dense ring-shaped stromal infiltrates are present (Figure 6-6). The appearance of the stromal ring-shaped infiltrates is similar to that of an *Acanthamoeba* infection. Corneal cultures are generally negative, and unless the anesthetic use is discontinued, the corneal appearance will continue to progress despite the use of antibiotic, antifungal, and corticosteroid medications.

### Management

Discontinuation or avoidance of the offending agent usually brings resolution of the toxic keratitis within a few days. The risk-to-benefit ratio of treating toxic keratitis should be assessed, because ceasing topical ophthalmic medications may exacerbate the original condition. In general, mild medicamentosa can be tolerated without treatment, both from the patient and examiner standpoints, until the condition prompting initial treatment is resolved and the medication is discontinued. If toxic keratitis results in intolerance of a certain contact lens solution or a needed therapeutic agent, alternative therapy should be chosen. Preservative-free medications should be prescribed if available.

In the case of mild transient toxic keratitis, patient comfort may be enhanced with the use of topical nonpreserved lubricating agents while the condition resolves. In the case of more pronounced toxic keratitis, particularly with conjunctival injection, topical decongestant agents

may be used, such as 0.1% naphazoline drops instilled four times daily, until resolution occurs.

More severe forms of toxic keratitis may require prophylactic antibiotic therapy to protect the inflamed cornea. The use of topical aminoglycosides should be avoided, however, as they tend to exacerbate the condition. The use of a mild steroid, such as 0.12% prednisolone drops four times a day, aids the resolution of more advanced cases. Any allergic component involving the eyelids or conjunctiva should be treated appropriately.

If topical anesthetic abuse is suspected, discontinuation is critical. A broad-spectrum topical antibiotic such as 0.5% moxifloxacin three times daily is used to protect the disrupted corneal epithelium from secondary infection as the tissue heals. Topical NSAIDs, such as 0.1% diclofenac sodium solution or 0.5% ketorolac solution, and a therapeutic soft contact lens help to reduce pain. Cycloplegic and topical steroids are indicated if an anterior chamber reaction is present. Toxic keratitis can heal without permanent vision loss within days after discontinuing the use of the anesthetic but may result in permanent scarring, vascularization, and visual loss. Surgical treatment, such as a penetrating keratoplasty, may be necessary.


The role of a topical anesthetic is as a surgical and diagnostic agent. In addition to informing the patient, education of eye care employees as well as other medical personnel regarding the devastating effects of long-term anesthetic use is essential. Psychiatric counseling may also be helpful with some.

## BACTERIAL AND BACTERIAL-RELATED KERATITIS

### Superficial Punctate Keratitis

#### Etiology

The term *superficial punctate keratitis* (SPK) is commonly used to describe superficial punctate corneal epithelial disruptions of multiple etiologies. It is important to recognize that SPK often consists of two forms: *punctate epithelial erosions* and *punctate epithelial keratopathy*. Punctate epithelial erosions refer to fine focal corneal epithelial lesions, usually slightly depressed, that may be difficult to view with the slit lamp but stain prominently with NaFl, rose bengal, and lissamine green (Figure 26-39). They are found in many primary and secondary corneal conditions. Punctate epithelial keratopathy describes accumulations of epithelial cells that are surrounded by a focal inflammatory cell infiltrate, as often accompanies staphylococcal blepharokeratoconjunctivitis. These lesions appear as larger grayish white opacities more easily identified with the slit lamp than punctate epithelial erosions. Although punctate epithelial keratopathy lesions stain well with rose bengal and lissamine green, they stain poorly with NaFl.



**Figure 26-39** Mild diffuse inferior punctate epithelial erosions stained prominently with NaFl. (Courtesy of Pat Caroline.)

SPK with a bacterial origin usually is associated with blepharitis, the most common cause of which is infection of the lid margins and glands with *Staphylococcus*. Additionally, conjunctivitis from organisms such as *Streptococcus*, *Moraxella*, and *Haemophilus* may also cause SPK.

#### Diagnosis

Patients with SPK typically report ocular foreign body sensation, photophobia, redness, and tearing. Patients with an associated blepharitis or blepharoconjunctivitis may also complain of debris on the lids and redness of their lid margins as well as previous episodes, characterized by exacerbations and remissions. If there is a concurrent conjunctivitis, the patient may note an ocular discharge and difficulty opening the lids in the morning.

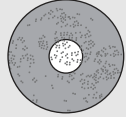





Examination typically reveals diffuse SPK erosions and also may disclose punctate epithelial keratopathy that is visible as small grayish opacities in the epithelium. The location and pattern of this keratitis can be helpful in determining the etiology (Box 26-1) and in distinguishing the condition from bacterial-related causes. SPK from blepharitis usually is more severe in the inferior one-third of the cornea where it contacts the staphylococcal exotoxins from infection of the lower lid. In cases of SPK caused by bacterial conjunctivitis, the entire cornea may be involved.

Associated ocular and periocular findings also help determine the cause. In blepharitis the lid margins usually are thickened, red, and scaly; lashes may be missing (madarosis). With bacterial conjunctivitis, there is infection of the conjunctiva and a mucopurulent discharge.

#### Management

Treatment of SPK is directed toward the underlying cause. Bacterial conjunctivitis should be treated with topical antibiotics (see Chapter 25), and staphylococcal blepharitis should be treated with lid hygiene and antibiotics (see Chapter 23). Additional supportive treatment

#### Box 26-1 SPK Staining Patterns in a Variety of Disease Conditions

Pattern	Potential Etiologies
<b>Diffuse</b> 	Bacterial conjunctivitis Viral conjunctivitis Medicamentosa Allergic conjunctivitis
<b>Superior</b> 	Superior limbic keratoconjunctivitis Vernal keratoconjunctivitis Inclusion keratoconjunctivitis Trachoma
<b>Inferior</b> 	Staphylococcal blepharitis Ectropion Entropion Lagophthalmos Exposure keratopathy
<b>Interpalpebral</b> 	Keratoconjunctivitis sicca Exposure keratopathy UV keratopathy
<b>Sectoral</b> 	Trichiasis Trauma Pinguecula Pterygium
<b>Linear</b> 	Mechanical abrasion Trichiasis Entropion Foreign body

to reduce symptomatology caused by SPK may include the use of artificial tears four to six times daily.

#### Interstitial Keratitis

##### Etiology

IK, also known as nonulcerative keratitis, syphilitic keratitis, and immune stromal keratitis, is a nonulcerative inflammation of the corneal stroma generally with stromal vascularization. The condition is characterized by stromal inflammation without primary epithelial or endothelial involvement. Although corneal thinning is not a feature of the active stage of inflammation, it is a potential sequela.

IK is a manifestation of both infectious and noninfectious disease (Box 26-2). Occasionally, the ocular findings may be the initial sign of an underlying undiagnosed disease.

**Box 26-2** Causes of Interstitial Keratitis**Bacterial infection**

Syphilis (congenital and acquired)  
 Tuberculosis  
 Leprosy  
 Lyme disease  
 Brucellosis  
 Chlamydia

**Viral infection**

Herpes simplex  
 Herpes zoster  
 Epstein-Barr  
 Mumps  
 Rubella

**Parasitic infection**

Leishmaniasis  
 Onchocerciasis  
 Trypanosomiasis  
 Acanthamoeba  
 Microsporidiosis

**Systemic disease**

Cogan's syndrome  
 Sarcoidosis  
 Lymphoma

**Other**

Gold toxicity  
 Arsenic toxicity  
 Contact lens related

Historically, syphilis has been described as the most common cause of IK. However, with the advent of antibiotics, the completion of the genome sequence of *Treponema pallidum*, and improved serodiagnosis, congenital and acquired syphilis has become less common with fewer than 500 new cases of syphilitic IK occurring each year in the United States. Thus the eye care practitioner is more likely to see postsyphilitic sequelae of corneal scarring and ghost vessels rather than active keratitis. Herpetic eye disease has become the leading cause of IK in North America.

**Diagnosis**

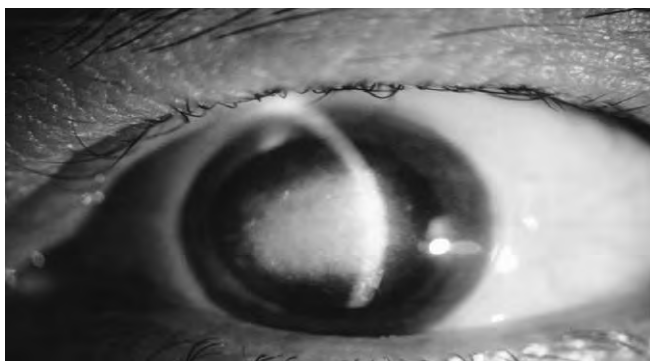
The diagnosis of IK begins with the distinction between active and residual corneal disease. At the time of active corneal inflammation, the most common symptoms include pain, tearing, photophobia, decreased vision, and blepharospasm. The bilateral or unilateral inflammation may be caused by active infection or an immune response to disease.

Slit-lamp examination of active IK often reveals perilimbal injection, stromal infiltration, edema, neovascularization, and potentially an immune ring. The exact appearance of the cornea depends on the specific etiology and stage of the disease (Table 26-3). The epithelium, with or without edema, is generally intact but can erode over superficial infiltrates. The stromal inflammation may be sectoral, diffuse, central, paracentral, or peripheral. An anterior uveitis with fine endothelial keratic precipitates may accompany active corneal disease. Without treatment the inflammation generally resolves in weeks to months. Upon resolution, scarring typically is present and may be accompanied by stromal thinning. Reduplication of Descemet's membrane and endothelial decompensation with stromal edema may remain as

**Table 26-3**  
 Clinical Characteristics of Interstitial Keratitis

Disease	Laterality	Stromal Involvement	Vasculature	Associations
Congenital syphilis	Bilateral	Diffuse	Deep, profound	Iritis, edema; systemic
Acquired syphilis	Unilateral	Sectoral	Mild	
Tuberculosis	Unilateral	Sectoral, inferior	Anterior or mild stromal	Scleritis
Leprosy	Bilateral	Superotemporal	Avascular	Systemic
Lyme disease	Bilateral	Poorly defined, focal	Avascular	Systemic
Herpes simplex virus	Unilateral	Variable	Variable	Sensation, iritis
Epstein-Barr virus	Bilateral	Nummular keratitis	Avascular	Preceding parotiditis
Mumps	Unilateral	Focal, mild	Avascular	Possible iritis
Onchocerciasis	Bilateral	Interpalpebral	Sclerosing	Other ocular inflammation
Cogan's syndrome	Bilateral	Variable	Variable	Otological symptoms

From Knox CM, Holsclaw DS. Interstitial keratitis. *Int Ophthalmol Clin* 1998;38:183-195.



**Figure 26-40** Inactive interstitial keratitis in a patient with congenital syphilis. The presentation was bilateral. (Courtesy of Dr. Tammy Than.)

features of inactive IK (Figure 26-40). The corneal vascularization from the active stage remains as ghost vessels in the stroma once blood flow has subsided. On occasion, lipid exudation occurs in association with the neovascularization that may resolve slowly or remain indefinitely.

### Management

A comprehensive review of systems, physical examination, ocular examination, and laboratory testing with a multidisciplinary approach to determine the etiology of IK is essential. Treatment should be aimed at addressing any underlying systemic disease and may involve the use of systemic steroids or immunosuppressive drug therapy depending on the cause.

Although active IK eventually resolves spontaneously, corneal scarring with decreased vision may result. To shorten the course of the corneal disease and to prevent unnecessary vision loss and the potential need for a penetrating keratoplasty, treatment should include 1% prednisolone acetate or an equivalent, one drop every 1 to 6 hours depending on the degree of inflammation. Additionally, a topical cycloplegic agent, such as 5% homatropine, can be used two to three times per day for a concomitant anterior uveitis. The steroid should be slowly tapered once improvement is noted, but long-term low-dose steroid therapy may be necessary to avoid recrudescence. Follow-up examinations should be scheduled every 3 to 7 days initially and then every 2 to 4 weeks as inflammation subsides. Close monitoring of IOP is mandatory because of steroid use.

## Phlyctenular Keratoconjunctivitis

### Etiology

A phlyctenule is a focal nodule composed of leukocytes, generally the result of a delayed hypersensitivity reaction to microbes or their toxins. For this antigenic response to occur, the patient must have a history of previous exposure and sensitization to the causative organism

or allergen. Reintroduction of the allergen causes development of the phlyctenule approximately 48 hours later.

In the United States the most common cause of phlyctenular keratoconjunctivitis, also known as phlyctenulosis, is *Staphylococcus aureus*. *S. aureus* is a prevalent microbe, and its cell wall antigens have been proven to cause phlyctenulosis in rabbits.

Tuberculosis has reemerged in the United States among recent immigrants and patients with acquired immune deficiency syndrome. It has been suggested that hypersensitivity to tuberculo-protein has a role in the development of phlyctenules. Considering the ease of air travel and the fact that approximately one-third of the world's population has been infected with tuberculosis, the possibility of tuberculosis exists in every patient with phlyctenulosis. Many patients who exhibit phlyctenulosis also have a high rate of positive skin and radiology tests for tuberculosis. It is not uncommon for patients with phlyctenulosis to relate a history of recent exposure to, or family members with, known tuberculosis.

Rarely, phlyctenulosis has been associated with pneumococci, Koch-Weeks, *Candida albicans*, *Chlamydia*, viruses, roundworm nematodes, rosacea dermatitis, and meibomianitis. Malnutrition, vitamin deficiency, and poor public health conditions increase the incidence of phlyctenulosis.

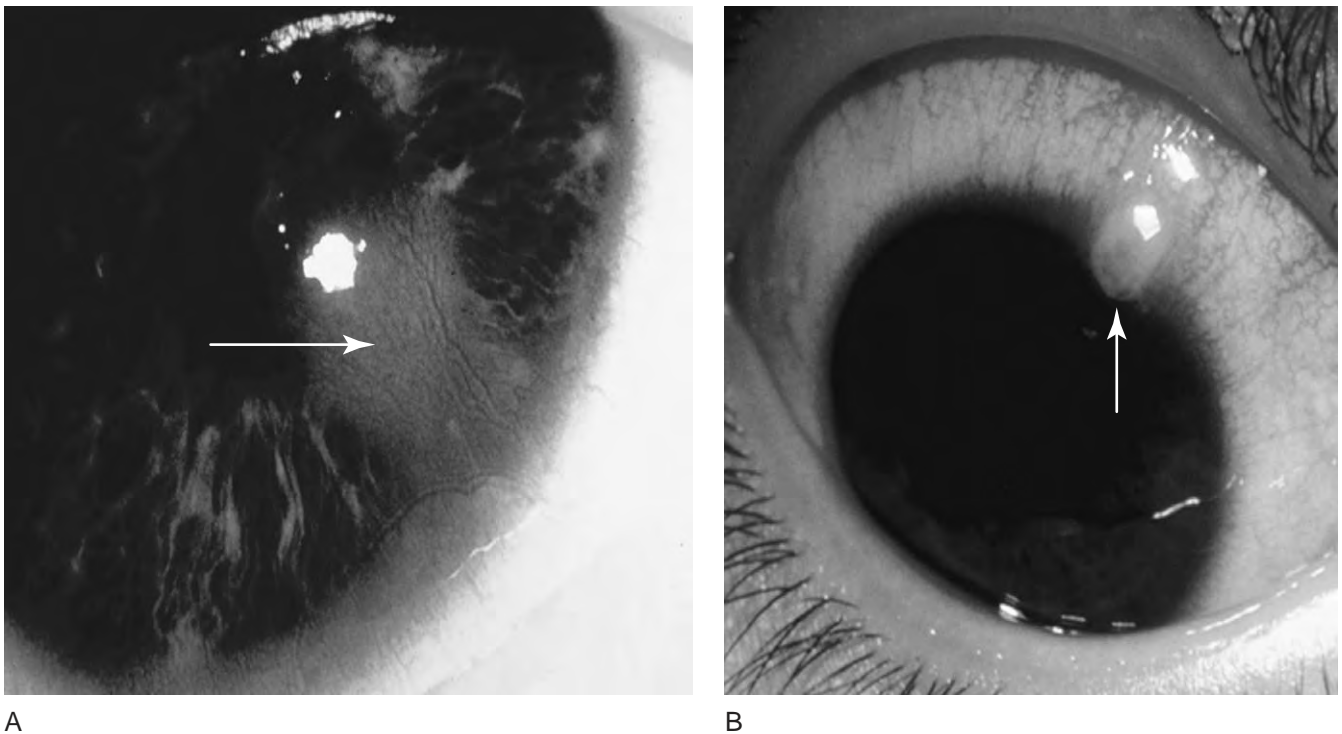
### Diagnosis

The most common symptoms of phlyctenulosis include bilateral tearing, irritation or pain, mild to severe photophobia, and itching. Symptoms are usually more severe if there is corneal involvement and may include blepharospasm. The patient may report previous similar episodes.

Slit-lamp examination reveals single or multiple phlyctenules that appear as pinkish white nodules on the cornea or conjunctiva, ranging in size from just visible to several millimeters in diameter. They typically appear first at the limbus and can easily be mistaken for catarrhal ulcers. Unlike catarrhal ulcers, phlyctenules are adjacent to the limbus, and the long axis of a phlyctenule is perpendicular to the limbus rather than parallel to it.

Along with the phlyctenule, examination often reveals conjunctival hyperemia, a scanty watery discharge, and diffuse corneal staining. If the phlyctenule is caused by *Staphylococcus*, an associated blepharitis is common. Phlyctenules typically last from 10 to 14 days and occur primarily in children, with girls more frequently affected than boys.

Conjunctival phlyctenules appear on the limbus or bulbar conjunctiva. Lesions are usually close to the limbus near the free lid margin but can present anywhere on the bulbar conjunctiva. They rarely affect the palpebral conjunctiva. They often are surrounded by hyperemia. Corneal phlyctenules typically start at the limbus and are accompanied by a leash of conjunctival vessels (Figure 26-41). Initially, the overlying epithelium is intact



**Figure 26-41** (A) Corneal phlyctenule accompanied by a leash of conjunctival vessels. (B) Corneal phlyctenule. (Courtesy of Pat Caroline.)

but often erodes, leading to an epithelial defect that stains with NaFl. These phlyctenules can progress toward the center of the cornea as the more peripheral margin heals and the central area remains active.

The vessels associated with the phlyctenule also migrate toward the center of the cornea and produce focal neovascularization. Triangular corneal scars with their base at the limbus often form as phlyctenules heal. These scars can be vascularized. Scarring in the central cornea can decrease visual acuity if the phlyctenulosis is long-standing. Corneal perforation in phlyctenulosis is rare but has been reported.

### Management

A thorough history and examination is important to determine the cause of phlyctenulosis. Inspect the lid margins for signs of staphylococcal blepharitis and question the patient regarding recent infections or tuberculosis exposure. If there is reason to suspect tuberculosis or if no other cause can be found, a tuberculin skin test may be indicated. If diarrhea or gastrointestinal distress is present, consider a stool examination for nematodes.

Although phlyctenules can resolve spontaneously, they usually ulcerate and scar before resolution. To prevent scarring, treatment should include 1% prednisolone acetate, one drop every 2 to 4 hours for 3 to 4 days. Also, instill prophylactic antibiotic ointment or drops, such as bacitracin, erythromycin, or polymyxin B/trimethoprim, into the conjunctival sac four times a day and continue as

long as the steroid is used. Alternatively, a steroid-antibiotic combination product, such as tobramycin-dexamethasone or tobramycin-loteprednol, may be used to improve patient compliance. The steroid should be tapered rapidly once improvement is noted. Typically, total antibiotic-steroid therapy continues for 10 to 14 days. If *Staphylococcus* blepharitis is suspected, recommend warm compresses and lid scrubs two to three times a day followed by an application of antibiotic ointment, such as bacitracin, to the lid margins. Because many cases of staphylococcal blepharitis are chronic, lid scrubs with baby shampoo or commercial preparations may be necessary each day indefinitely. Artificial tears can be used up to four times a day for comfort.

A course of oral tetracycline or erythromycin may be a reasonable treatment alternative for patients with chronic or recurrent phlyctenular keratoconjunctivitis. Some clinicians recommend 250 mg tetracycline three times daily for 3 weeks followed by 250 mg once daily for 2 months. In children under 8 years of age, erythromycin 25 mg/kg in four divided doses may be used. Additionally, a recent study reported topical cyclosporine 2% as a safe and effective therapy for children with severe phlyctenular keratoconjunctivitis not responding to oral medications.

Patients with phlyctenulosis should be reevaluated in 3 to 4 days. Significant improvement in signs and symptoms should occur within 48 hours. If the tuberculin skin test is positive, chest x-rays and a medical consultation are indicated.

## Corneal Infiltrative Events

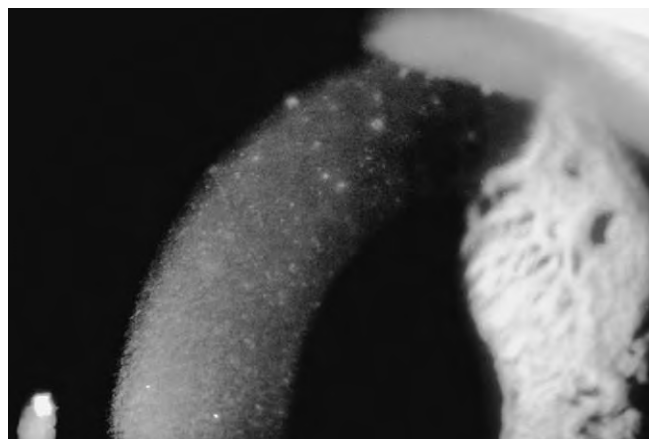
### Etiology

A corneal infiltrative event (CIE) is a broad term used to describe corneal inflammation associated with infiltrates. These infiltrates are usually the result of an antigen-antibody reaction or hypoxia. Typically, cultures are negative, with Gram and Giemsa stains of corneal scrapings from these areas exhibiting neutrophils but no bacteria. The patient's antibody response results in corneal infiltration by polymorphonuclear leukocytes and other cells resulting from antigen interaction. CIEs can be associated with soft contact lens wear, in which case they are further classified (see Contact Lens-Related Corneal Complications, below). Alternatively, CIEs can stem from long-standing staphylococcal blepharconjunctivitis and acute conjunctivitis caused by  $\beta$ -hemolytic *Streptococcus*, *Haemophilus aegyptius*, and *Moraxella lacunata* and have been reported in association with chronic dacryocystitis.

### Diagnosis

Patients with CIE complain of pain, tearing, foreign body sensation, and photophobia. When asked, they often report a history of soft contact lens wear or staphylococcal lid disease. CIE is common in adults but is quite rare in children.

Examination reveals single or multiple intraepithelial infiltrates separated from the limbus by a clear (lucid) interval (Figure 26-42). This lucid area is about 2 mm wide and can be bridged by vessels. The infiltrates are usually between 0.5 mm and 2 mm in size and are most commonly found at the 2, 4, 8, and 10 o'clock positions where the lid margins cross the cornea. Early in the process the infiltrate is elevated due to accumulation of cells and debris. The infiltrate can become ulcerated and exhibit positive staining centrally, ranging from punctate to a full-thickness epithelial break. Edema can develop



**Figure 26-42** Multiple small intraepithelial corneal infiltrates.

around the infiltrates. Although this edema usually is limited to the epithelium, it also can be found in the anterior stroma. The anterior chamber is typically quiet. As the eye becomes more involved, the infiltrates can become more extensive. The spread of lesions is more common in patients with blepharitis and is usually concentric with the limbus. It is possible for individual infiltrates to coalesce and form a ring-like infiltrate around the entire cornea.

### Management

It is important to differentiate between true infection of the corneal tissue and CIE (Table 26-4). The examiner must look for signs of bacterial corneal ulcers such as discharge or anterior chamber reaction and evaluate the patient's history for risk factors known to be associated with bacterial keratitis. These risk factors include extended wear of contact lenses, contaminated ophthalmic solutions, poor personal hygiene, diabetes mellitus, recent

**Table 26-4**

CIE Compared With Bacterial Keratitis

	CIE	Bacterial Keratitis
Symptoms	Minimal	Moderately severe
Conjunctival injection	Minimal, possibly sectoral	Moderate to severe, most likely diffuse
Location	Usually mid-peripheral to peripheral, subepithelial	Random with deeper involvement, tend to be more central
Size	Usually 1-1.5 mm; tends to remain small	>1.5 mm; enlarges over 24-36 hr
NaFl staining	None or minimal	Moderate to extensive
Anterior chamber reaction	None or minimal	Moderate
Stromal edema	None or minimal	Moderate
Number of infiltrates	Tend to be multiple (>1)	1
Clear zone at limbus	Positive	Negative
Shape	Oval	Any
Purulent discharge	Negative	Positive

Adapted from Baum J, Dabezies OH Jr. Pathogenesis and treatment of "sterile" midperipheral corneal infiltrates associated with soft contact lens use. *Cornea* 2000;19:777-781.

or concurrent use of steroids, a compromised immune system, recent ocular surgery, dry eyes, epithelial damage, neuroparalytic keratopathy, Bell's palsy, rheumatoid arthritis, patching, and malnutrition.

If CIE is diagnosed, treatment should be directed at resolving any underlying etiology such as blepharitis and/or conjunctivitis (see Chapters 23 and 25). Topical 1% prednisolone acetate or 0.1% fluorometholone four times a day is the mainstay treatment to reduce inflammation and aid resolution of the infiltrates. Antibiotic drops such as tobramycin are recommended four times a day as prophylaxis, particularly if there is any associated epithelial staining. Alternatively, a steroid-antibiotic combination product may be used to assist patient compliance. The patient should be reexamined in 2 to 3 days and should exhibit definite improvement in both signs and symptoms. The topical steroid should be tapered, with the goal of discontinuing the drug in approximately 2 weeks.

If a definitive diagnosis between CIE and bacterial keratitis cannot be made, corneal cultures should be obtained before starting antibiotic or steroid therapy. If multiple risk factors are present, treat the condition as a bacterial keratitis and reevaluate within 24 hours to assess any changes in corneal health.

## Bacterial Corneal Ulcers

### Etiology

Bacterial corneal ulcers, also known as bacterial keratitis, most often occur in eyes susceptible to infection by preexisting conditions. There are many predisposing risk factors, and their incidence in patients with bacterial ulcers varies over time, with patient characteristics, and from region to region. Studies worldwide continue to show contact lens wear, particularly extended contact lens wear, and trauma to be the leading risk factors for the development of bacterial keratitis. Other reported predisposing factors include a history of HSV, ocular surface disease, dry eye, systemic disease (diabetes mellitus, rheumatoid arthritis), steroid use, smoking, alcoholism, malnutrition, immunocompromised status, and low socioeconomic status. Males are more likely to have corneal ulceration than females. Ultimately, any condition that causes epithelial damage, such as bullous keratopathy, RCE, eyelid abnormalities, and neurotrophic keratitis, may increase the risk of infectious corneal ulcers. Furthermore, prolonged use of prophylactic antibiotics can cause corneal ulcers due to an overgrowth of resistant bacteria.

Corneal ulcers are bimodal in occurrence, with the highest incidence in patients in their twenties and those in their sixties to seventies. This pattern can be attributed to the increased incidence of trauma and contact lens wear in the younger group and to ocular surface disease and eyelid disease in the older group.

The type of bacteria isolated from corneal ulcers is influenced by several factors, including the presence of

predisposing conditions, the examiner's technique, the media used for isolation and culture, the patient's age, and the patient's geographic location. Frequent isolates from bacterial corneal ulcers include *Pseudomonas aeruginosa*, *Staphylococcus aureus*, *Moraxella*, *Streptococcus pneumoniae*,  $\alpha$ -hemolytic *Streptococcus*, *Staphylococcus epidermidis* (coagulase-negative *Staphylococcus*), *Klebsiella*, *Proteus*, and *Serratia*. The main bacterial isolates in children vary somewhat among studies, but most commonly include gram-positive organisms such as *Staphylococcus* and  $\alpha$ -hemolytic streptococci and gram-negative organisms such as *Pseudomonas* in large numbers.

The clinical appearance of bacterial corneal ulcers is similar irrespective of the causative organism, and laboratory studies are needed to make a definitive diagnosis. It can be useful, however, to evaluate the clinical appearance as an aid in choosing the initial antibiotic (Table 26-5). In general, ulcers caused by gram-negative organisms are diffuse and gray-white, have a "wet" or "soupy" appearance, and have abundant mucopurulent discharge. The central cornea often is involved and the ulcer spreads rapidly. Gram-positive organisms cause more discrete round or oval ulcers. These are also gray-white but are "drier" in appearance. Some of the gram-positive organisms can cause a severe anterior chamber reaction.

A rare microbial keratitis known as infectious crystalline keratitis, characterized by branching intrastromal crystalline opacities that appear like cracked glass or needles in the anterior and mid-corneal stroma, has been reported. It presents with minimal inflammation due to the presence of biofilm, which is involved in phagocytosis suppression and interferes with polymorphonuclear chemotaxis. Predisposing factors may include previous corneal surgery; herpetic keratitis; neurotrophic keratopathy; topical, periocular, and intravitreal corticosteroids; and topical anesthetic abuse. Although it progresses slowly, it responds poorly to treatment with antibiotics because of the existence of biofilm produced by the causative organisms. *Streptococcus viridans* is most commonly associated with infectious crystalline keratitis; however, *Staphylococcus epidermidis*, *Pseudomonas*, *Haemophilus*, *Enterococcus*, *Mycobacterium*, *Candida*, and *Alternaria* have also been implicated. No significant clinical features differentiate the different pathogens, so laboratory evaluation is highly suggested to guide antimicrobial or antifungal therapy.

### Diagnosis

Patients with infectious corneal ulcers present with similar symptoms regardless of the causative agent. These symptoms include photophobia, decreased visual acuity, redness, swelling of the lids, discharge, reports of a "white spot" on the eye, and variable degrees of pain. Patients with ulcers caused by *Moraxella* are less likely to report pain, as are patients who have corneal hypoesthesia.

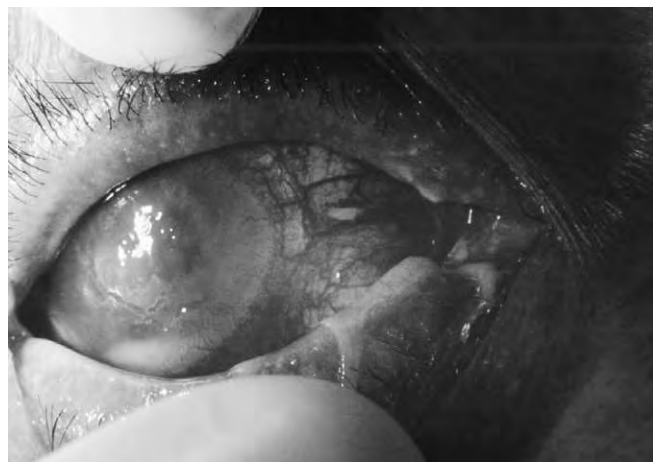


**Table 26-5**

Summary of Subtle Clinical Differences of Bacterial Corneal Ulcers With Different Causative Organisms

	Gram Stain Status	Organism Shape	Ulcer Location	Ulcer Characteristics	Ulcer Color	Anterior Chamber Reaction	Response to Therapy
Staphylococci	Positive	Cocci	Central	Round or oval	Yellow-white	Minimal	<i>S. epidermidis</i> : rapid <i>S. aureus</i> : less rapid
<i>S. pneumoniae</i>	Positive	Lancet shaped	Creeps centrally	Disc-shaped with leading overhanging margin	Gray-yellow	Hypopyon common	Resistant strains common
<i>P. aeruginosa</i>	Negative	Rod	Central	Adjacent area to ulcer appears hazy due to edema	Gray infiltrate with yellow-green discharge (fluoresces in cobalt light)	Hypopyon common	Resistant strains common; often appears worse in first 24 hr
<i>Moraxella</i>	Negative but can appear as gram positive	Diplobacillus	Central or inferior	Oval with a necrotizing edge that may progress deep into the stroma	Gray-white dense anterior stromal abscess	Hypopyon common, hyphema possible	Responds poorly to antibiotics and slow to heal

Slit-lamp examination typically reveals moderate to severe edema and inflammation of the lid and conjunctiva, a purulent discharge, and ulceration of the corneal epithelium (Figure 26-43). As previously described, these ulcerations can take on many appearances, usually accompanied by surrounding corneal edema and stromal infiltration beneath the ulcer. A mild to severe anterior chamber reaction, which can cause hypopyon, cataracts,

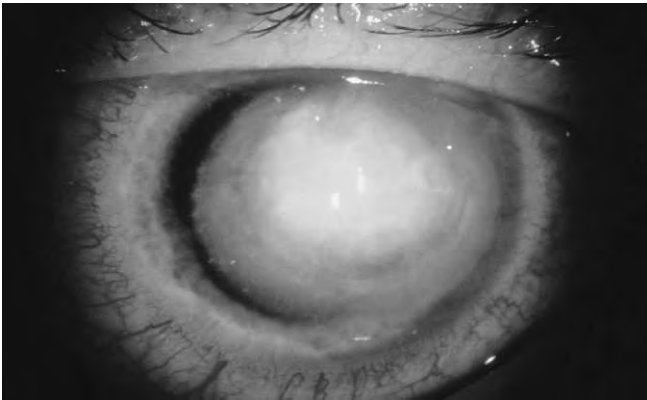


**Figure 26-43** Bacterial corneal ulcer with a hypopyon. (Courtesy of Pat Caroline.)

synechiae, and elevated IOP, also is frequently associated with corneal ulcers. Descemetocelles, perforation, and scarring have been reported.

A thorough history should be performed on all patients with corneal ulcers to determine which risk factors, if any, are present. The severity of the corneal ulcer should be determined by performing a detailed clinical examination, including slit-lamp biomicroscopy. The initial antibiotic regimen should be selected based on patient history and clinical appearance. For instance, a patient who wears extended-wear soft contact lenses and presents with a very large ulcer of short duration is more likely to have a *Pseudomonas* infection and should be treated with agents known to be effective against this organism (Figure 26-44). Photodocumentation or detailed corneal diagramming, including size, location, neovascularization, depth of hypopyon, and depth of the ulcer, should also be performed to allow accurate monitoring of the lesion.

The role of culturing in the management of corneal ulcers is a topic of ongoing debate in the ophthalmic literature. Advantages of performing smears include immediate determination of the presence of bacterium in the ocular tissues and whether the organism is gram-positive or gram-negative. Cultures can help determine the actual pathogen and may be useful in determining an alternative antibiotic if initial therapy is ineffective. Organism sensitivities allow



**Figure 26-44** *Pseudomonas* corneal ulcer. (Courtesy of Pat Caroline.)

selection of the most appropriate antibiotic and prevent overuse of ineffective antibiotics, which can cause corneal toxicity. Studies have shown that appropriate initial therapy is a very important influence on the outcome of severe corneal ulcers. An additional advantage to culturing is that it allows ocular microbiologists to identify varying patterns of responsible microorganisms and to detect emerging resistance. Continual observation of keratitis isolates and their vulnerability provides guidelines for developing treatment recommendations.

Although many authors and corneal specialists advocate microbiologic studies before the treatment of ulcerative keratitis, surveys show that many general ophthalmologic practices are likely to forgo scrapings and cultures for ulcers that appear less severe. Common reasons for not culturing before treatment include the high cost in time, equipment, and financial resources; the poor isolation rate; and the high success rate of treating empirically. Studies have shown that patients treated in general ophthalmology clinics tend to have smaller more peripheral ulcers that did not require culture data for modification of therapy because they typically respond to empiric broad-spectrum antibiotics.

Until controlled studies are undertaken to determine the true costs, risks, and benefits of corneal cultures, consensus about the need for cultures before treating corneal ulcers is unlikely. Conservative management supports the use of corneal cultures before treatment of any infectious corneal ulcer. Other options include reserving microbiologic studies for severe or sight-threatening ulcers or those suspected of being nonbacterial. Looking at the characteristics of patients for which medical therapy is more likely to fail may be helpful in determining which ulcers need to be cultured under this model. These characteristics include older patients, individuals treated with topical steroids, those with a past history of ocular surgery, or those who have very poor visual acuity at presentation. Ulcer characteristics which increase the risk of failure include a central location, a larger size at presentation, limbal involvement,

and hypopyon. Culturing would also be indicated for patients who are monocular, have trauma from vegetable matter, or have ulcers that are not responding to therapy.

Microbiologic evaluation of a corneal ulcer is aimed at determining the causative organism and instituting appropriate treatment. It has been demonstrated that more positive cultures are obtained by using a calcium alginate swab instead of a platinum spatula (better for retrieval of fungi). Culture specimens of the conjunctiva and eyelid margins are acquired with a calcium alginate swab moistened with thioglycolate or trypticase soy broth. The specimens are directly plated onto solid blood and chocolate agar plates using an “R” and “L” pattern for the lids and a horizontal and vertical line for the conjunctiva. A new swab is used for each area cultured. These specimens are collected without anesthesia because the preservative in the anesthetic can inhibit bacterial growth. Rayon, Dacron, and cotton swabs are not recommended because they also may inhibit the growth of some bacteria, although Dacron has been reported to be acceptable. Moistening the swab increases patient comfort and the number of bacteria that are collected and released when plated.

For the second step, a topical nonpreserved anesthetic solution is instilled and a sterile platinum spatula is used to obtain material from the corneal ulcer for Gram and Giemsa staining. This material should be smeared onto clean glass slides, heat fixed with an alcohol lamp for gram staining and air dried for Giemsa staining, and then stained following each stain manufacturer’s suggestions. Gram stains are useful for determining if the most prevalent organism is gram-positive or gram-negative, but it is important to realize that the topical anesthetic can cause damage to the cell walls of gram-positive bacteria, causing them to stain more like gram-negative organisms. Gram stains correlate with culture results in approximately 65% to 77% of cases. Giemsa stains are useful for determining the type of inflammatory cell present and, more importantly, can reveal fungal components.

In the third step a sterile platinum spatula is used to scrape the corneal ulcer and, without cutting into the media, two blood agar plates, one chocolate agar plate, and a Sabouraud’s dextrose agar plate without cycloheximide are inoculated with one row of “C’s” each. One blood agar plate is stored at 37°C. The other blood agar plate and the Sabouraud’s agar are stored at 25°C to improve the chances of fungal growth. Aerobic and facultatively anaerobic bacteria, such as *Neisseria* and *Haemophilus*, are more likely to grow on the chocolate agar plate.

The next step is to gently rub the ulcer with a sterile calcium alginate swab moistened with thioglycolate broth or trypticase soy broth and inoculate three rows of “C” on each of the blood, chocolate, and Sabouraud’s plates. This swab is placed in a tube of thioglycolate broth medium to isolate anaerobes. A freshly moistened swab should then be rubbed across the corneal ulcer and used

to reinoculate the same "C" streaks on the agar plates. This swab should then be placed in trypticase soy broth. If there are any indications that the corneal ulcer may be caused by *Acanthamoeba*, cultures also should be performed on non-nutrient agar with an *Escherichia coli* overgrowth. The use of both the swab and the spatula has been suggested because filamentous bacteria or fungi may be cultured more easily with the spatula.

Twenty-four to 48 hours are needed to obtain information from cultures. From 28% to 93% will be culture positive, with an average around 50%. If a fungal ulcer is suspected, 2 to 6 weeks are necessary before the cultures should be declared negative. Some of the bacteria recently considered pathologic instead of normal flora also take longer to grow on cultures. These include *Diphtheroids*, which require 1 week to grow, and *Mycobacterium*, which may require as long as 8 weeks to grow on routine culture media.

A recent study compared the microbiological yield of cultures established by direct inoculation of media versus indirect inoculation by means of Amies without charcoal transport medium. For bacterial ulcers, all cultures that were positive after direct plating were also positive after passage through transport medium at either 4 to 8 or 24 hours. Additionally, all cultures that were negative after direct plating were also negative after both 4 to 8 and 24 hours in transport medium. Thus it was concluded that cultures obtained by means of Amies medium held for up to 24 hours appear to produce positive cultures at a rate comparable with direct plating for bacterial ulcers. The results of this study provide encouraging data that clinicians can comfortably use an Amies transport medium to culture bacterial corneal ulcers as an alternative to in-office direct plating.

Once an organism has grown on culture, sensitivity testing can be performed to determine which antibiotics are the most effective. The most commonly used method, the Kirby-Bauer diffusion disc system, usually takes 48 hours to perform. Unfortunately, it can be inaccurate because of the lower concentrations of antibiotic on the test discs compared with levels that can be achieved in the cornea through topical application. In addition, some topical ocular preparations are not available on discs for sensitivity testing.

### Management

Treatment of microbial keratitis is started immediately irrespective of whether microbiologic evaluation has been performed. The best antimicrobial agent or agents to use initially is debated in the ophthalmic literature. The two main choices for initial antibiotic treatment are the combination of two fortified antibiotics, such as cefazolin and tobramycin, or monotherapy with topical fluoroquinolones. Just as with the decision to culture, the choice of antibiotic is often influenced by history and clinical presentation. Milder presentations, in low-risk

patients, are often treated successfully with fluoroquinolone monotherapy.

Initial treatment has traditionally included broad-spectrum antibiotics that were chosen based on the Gram stain results, history, and clinical impression. If no organisms or multiple organisms are seen on the Gram stain or if there are risk factors that differ from the Gram stain result, treatment is initiated with cefazolin (50 mg/ml), one drop every 15 to 30 minutes, and gentamicin or tobramycin (13.6 mg/ml), one drop every 15 to 30 minutes. This is the most common fortified antibiotic treatment suggested for sight-threatening infections and is often considered the standard against which other treatments are compared. When initiating treatment, it is important to give a loading dose by instilling five drops of each of the suggested antibiotics, 1 minute apart.

The advantages to using fortified antibiotics include broad-spectrum coverage when the pathogen is not clearly identified and the use of a specific antimicrobial known to be effective against the type of organism identified by staining. The disadvantages to this method include the need to have the fortified drops prepared by the pharmacy (few pharmacies do sterile compounding), expense, the use of multiple drops, corneal toxicity, stinging upon instillation, and the need to keep cefazolin refrigerated to prevent discomfort from a change in pH. Prepared solutions of fortified tobramycin and cefazolin also have a short shelf-life of 4 weeks.

The fluoroquinolones have advantages over combined fortified antibiotic therapy. They are considered by many to be an excellent choice for initial treatment of non-sight-threatening ulcerative keratitis. They are readily available as commercially prepared medications that do not need to be fortified to be effective. As a result, there is less chance of contamination and less epithelial toxicity compared with fortified drops. Their wide spectrum of activity allows the patient to use only one medication, and, when compared with fortified antibiotics, they cause less discomfort upon instillation and are also less expensive. These attributes may increase patient compliance.

The second-generation fluoroquinolones, ciprofloxacin and ofloxacin, are approved by the U.S. Food and Drug Administration (FDA) for the treatment of bacterial corneal ulcers. The use of ciprofloxacin and ofloxacin has provided successful coverage against most of the frequently encountered gram-positive and gram-negative pathogens; however, the increasing number of bacterial strains resistant to these fluoroquinolones is becoming a concern when they are used as monotherapeutic agents. Reports have shown an increased resistance of *Staphylococcus aureus*, coagulase-negative *Staphylococcus* species, *Streptococcus*, and aerobic gram-positive rods. Additionally, several centers have reported emerging resistance of *Pseudomonas aeruginosa*. Moxifloxacin and gatifloxacin are two fourth-generation fluoroquinolones introduced for topical ophthalmic use. In vitro studies have confirmed these medications have enhanced

activity against *S. aureus* isolates, coagulase-negative *Staphylococcus*, and *Streptococcus* and certain strains of atypical mycobacteria. Other potentially beneficial features of these compounds include enhanced drug delivery into the anterior segment and lower likelihood of selecting for resistant bacterial strains.

Despite the aforementioned benefits to the fourth-generation fluoroquinolones, both moxifloxacin and gatifloxacin are only FDA approved for bacterial conjunctivitis. A study conducted in India was among the first to validate the benefits of the fourth-generation fluoroquinolones by clinical trial on human eyes. This study compared the bacteriologic and clinical efficacy of gatifloxacin and ciprofloxacin for the treatment of bacterial keratitis. A significantly higher proportion of ulcers that had been treated with gatifloxacin exhibited complete healing compared with those that had been treated with ciprofloxacin; however, the mean time to healing of the ulcers was similar in both groups. Additionally, gatifloxacin had a significantly better action against gram-positive cocci both in vitro and in vivo when compared with ciprofloxacin. Despite the generally promising results, further clinical trials are indicated on human eyes to definitively establish the role of the newer fourth-generation fluoroquinolones as first-line monotherapy in bacterial keratitis, particularly in infections resulting from *P. aeruginosa*.

Ciprofloxacin, which is available in an aqueous 0.3% ophthalmic solution and an ointment form, has a broad spectrum of action. Ciprofloxacin has been shown to be at least as successful in treating corneal ulceration as fortified antibiotics; however, as mentioned earlier, there appears to be an increasing number of resistant strains since its introduction. The usual dosage of ciprofloxacin solution for the treatment of bacterial ulcers is two drops every 15 minutes for 6 hours, then two drops every 30 minutes for 18 hours, followed by two drops every hour for 24 hours. Ciprofloxacin is then used every 4 hours for the next 12 days. Ciprofloxacin ointment also is effective in the treatment of bacterial keratitis. It is applied every 1 to 2 hours in the first 2 days and then every 4 hours for the next 12 days.

When ciprofloxacin is used in either form, a white corneal precipitate may develop in patients. This deposit, which is actually ciprofloxacin in precipitate, usually occurs at the ulcer site from 1 to 7 days after initiating treatment. Its presence makes it more difficult to evaluate the corneal ulcer and may decrease the patient's visual acuity. Anecdotal information suggests that this decrease in visual acuity may be severe enough for alternative pharmacotherapy to be chosen in a monocular patient. The white precipitate may disappear spontaneously even with continued treatment and resolves without adverse effect once ciprofloxacin therapy is discontinued.

Ofloxacin 0.03% ophthalmic solution has also been shown to be effective in the treatment of corneal ulcers. Studies demonstrate that ofloxacin causes less burning

and stinging and less corneal toxicity than the fortified antibiotics. However, data suggest an increased risk of corneal perforation after fluoroquinolone treatment of bacterial keratitis, particularly ofloxacin, when compared with treatment with fortified antibiotics. Until further studies are conducted, extra care should be exercised in the use of these drugs.

Cycloplegic agents, such as 5% homatropine instilled three times a day or 1% atropine two times a day, may help decrease the iritis associated with infectious keratitis and decrease patient discomfort.

In situations in which patient compliance is questionable, subconjunctival injections of traditional antibiotics such as cefazolin, gentamicin, and penicillin G may be necessary. The risks of subconjunctival injections should be weighed against the benefit of constant and high corneal drug levels achieved by this method. The use of corneal collagen shields as drug delivery devices can often achieve corneal antibiotic levels significantly higher than those obtained by subconjunctival injection. The use of a collagen shield as a method for drug delivery may reduce the frequency of antibiotic instillation by maintaining a more uniform drug concentration. It also has been suggested that collagen shields may compete for the collagen-damaging enzymes released by *Pseudomonas*. When considering the use of corneal collagen shields with combination drug therapy, drug compatibility must be considered. For example, vancomycin and gentamicin have been combined effectively; however, gentamicin and cefazolin precipitate and penicillins inactivate aminoglycosides. Unfortunately, collagen shields are often uncomfortable, and many patients do not tolerate them well.

It is important to determine whether hospitalization is necessary by evaluating the likelihood of corneal perforation as well as the patient's ability to comply with the frequency of drop instillation and the follow-up schedule. The patient must be examined at least daily to evaluate the size and depth of the ulcer, the degree of anterior chamber reaction, the development of satellite lesions, and the amount of pain the patient is experiencing. Ulcers caused by gram-negative organisms often appear worse in the first 24 hours after initiation of therapy, even if treatment is successfully decreasing the bacterial count. In milder ulcers it is possible to see subtle signs of improvement after 18 to 24 hours of appropriate therapy. If the ulcer is no worse, the original antibiotics are continued for at least 36 to 48 hours. If the ulcer appears worse, therapy should be changed based on the culture results, which usually are available after 48 hours. As the cornea is assessed, it is important to consider the potential for toxicity caused by the antibiotics. If performed, the results from sensitivity testing can be used to alter the medication schedule, to discontinue the less effective drug if two are being administered, or to substitute equally effective medications if the patient is experiencing an adverse reaction to the original antibiotic(s).

As the corneal ulcer responds to antibiotics, the frequency of instillation can be tapered slowly. Patients with ulcers caused by gram-negative rods must be tapered very slowly and may be on medications for as long as 2 to 4 weeks. Patients should continue to use antibiotics for 1 week after resolution of the ulcer. If the ulcer is not responding to treatment, the possibility of nonbacterial causes must be considered, and corneal scraping may need to be repeated. If possible, antimicrobial therapy is discontinued for 24 to 48 hours before the scraping and culturing.

The use of topical steroids for the treatment of bacterial corneal ulcers is controversial. Because some of the damage that occurs with bacterial corneal ulcers is inflammatory in nature, some authors believe topical steroids may be used if adequate bacteriocidal drugs are instilled concurrently. However, the efficacy and safety for the use of topical steroids in bacterial keratitis have not been determined. Conservative therapy advocates that steroids should not be used until the infecting organism and the most effective antibiotic have been identified through microbiologic evaluation. Furthermore, steroids should not be used until progressive improvement of the ulcer has been noted for 2 to 3 days. At that time, 1% prednisolone acetate, loteprednol, or 0.1% dexamethasone might be considered if the infiltrate is compromising the visual axis. If topical steroids are used, they are typically administered two to four times a day, and the antibiotic must be instilled more frequently than the steroid. Additionally, it is important to monitor the patient very closely because steroids decrease the host response to bacteria.

The use of steroids is contraindicated in eyes in which there is a threat of perforation, because the steroid negatively affects collagen synthesis. When a penetrating keratoplasty is necessary, steroids may be used up to 24 hours before surgery to lessen postsurgical inflammation and improve the chances of success.

## **VIRAL KERATITIS**

### **Epidemic Keratoconjunctivitis**

#### **Etiology**

As its name implies, epidemic keratoconjunctivitis (EKC) is highly contagious and communicable. It is typically caused by adenoviruses, with types 8, 19, and 37 most commonly reported. Adenoviruses can cause severe epidemics and can be spread by finger-to-eye contact, medical instruments such as tonometers, and possibly chairs, magazines, and other articles found in the practitioner's reception area. The contagious period may last as long as 3 weeks, and the virus is recoverable from all body secretions the first 10 days after ocular involvement occurs.

It has been shown that adenovirus type 8 survives up to 4 days on a metal tonometer; type 19 has been recovered

up to 8 days from paper and 35 days from dry plastic. The incubation period from exposure to onset of symptoms is 4 to 18 days, with a mean of 10 days.

#### **Diagnosis**

Patients usually present with complaints of acute onset of ocular redness, foreign body sensation, burning, profuse tearing, lid swelling, photophobia, and lid matting, especially in the morning. The symptoms typically are unilateral, with the second eye becoming involved over time. Because of systemic immune responses, the second eye usually is affected less severely than the first.

History often elicits an acquaintance, family member, or coworker with similar signs or symptoms. These symptoms are usually more severe in adults. Rarely, the patient reports a low-grade fever and upper respiratory symptoms.

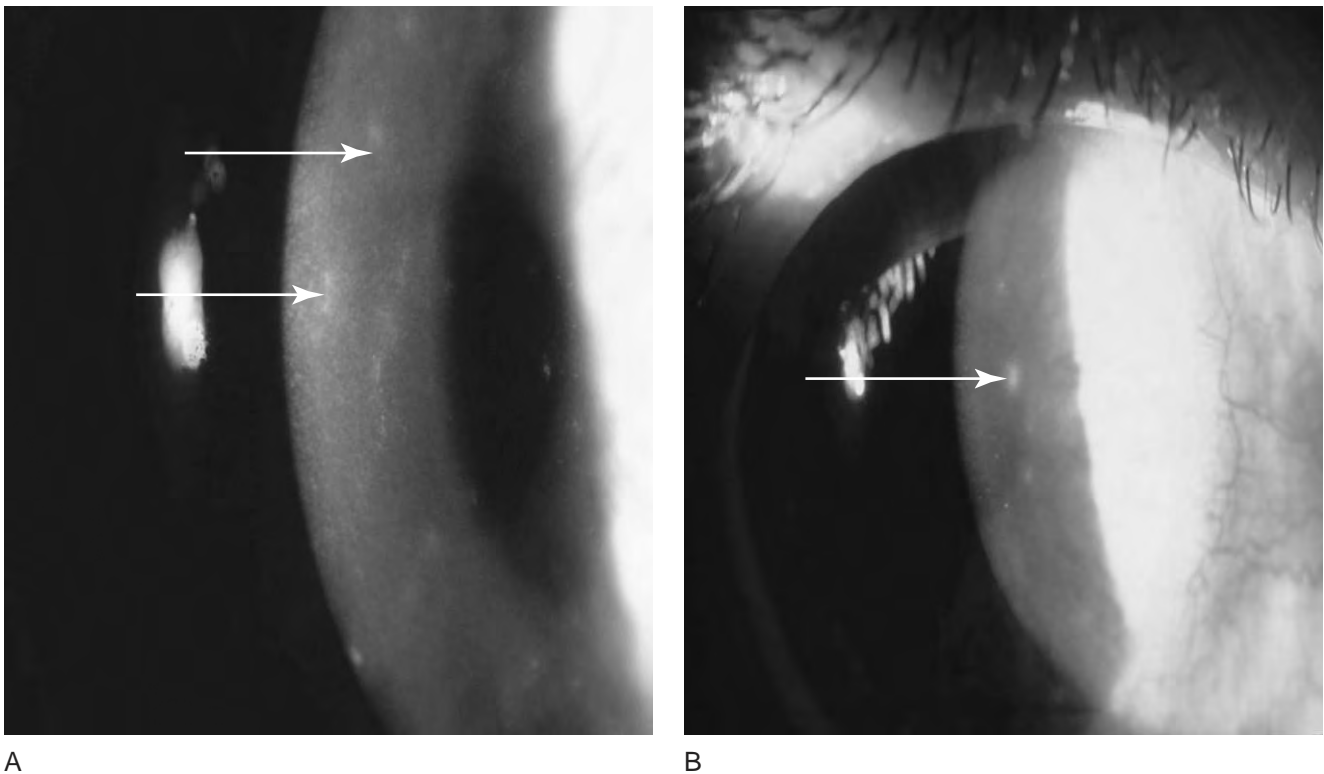
Examination typically reveals a marked conjunctivitis with a primarily follicular and papillary response of the palpebral conjunctiva. The follicles typically are worse in the inferior palpebral conjunctiva, with papillae more common in the superior. Preauricular lymphadenopathy is present in about 64% of patients at presentation and lasts approximately 1 week. Small subconjunctival hemorrhages are not an uncommon characteristic.

The conjunctivitis and symptoms last 7 to 16 days, with a mean between 8.6 and 10 days. A diffuse superficial epithelial keratitis usually develops in the first week and may be caused by proliferation of live virus within the corneal epithelium. In approximately 1 week this fine keratitis progresses to become deeper, positively staining, slightly elevated focal epithelial lesions. These epithelial lesions fade slowly, usually disappearing by 4 weeks.

Granular or fluffy subepithelial opacities typically develop under the focal epithelial lesions 11 to 15 days after the onset of symptoms (Figure 26-45). These lesions likely represent antigen-antibody complexes that form in response to the viral antigen. Subepithelial infiltrates occur in 10% to 90% of cases depending on the serotype of the causative agent. Severe subepithelial infiltrates may decrease the patient's visual acuity to 20/200 or worse. They can last from 3 months to 2 years and may cause permanent focal anterior stromal scars.

Additional findings in EKC can include pseudomembrane formation (Figure 26-46) and corneal epithelial sloughing. Symblepharon, scleritis, and anterior uveitis rarely develop. Nasolacrimal system obstruction due to inflammation or adhesion of opposing surfaces, as occurs in symblepharon formation, also is a rare complication.

Confirmatory laboratory testing has been limited to viral cultures with subsequent immunoassay testing, which has limited its use, making reliance on history and clinical signs for diagnosis. A new in-office test for the adenovirus has been marketed. The RPS Adeno Detector is a 10-minute, in-office, lateral flow immunoassay that detects the presence of adenovirus in suspected



**Figure 26-45** (A-B) Subepithelial infiltrates (*arrows*) secondary to EKC. (Courtesy of Pat Caroline.)

adenoviral conjunctivitis. The test possesses both good sensitivity and specificity for the detection of adenovirus.

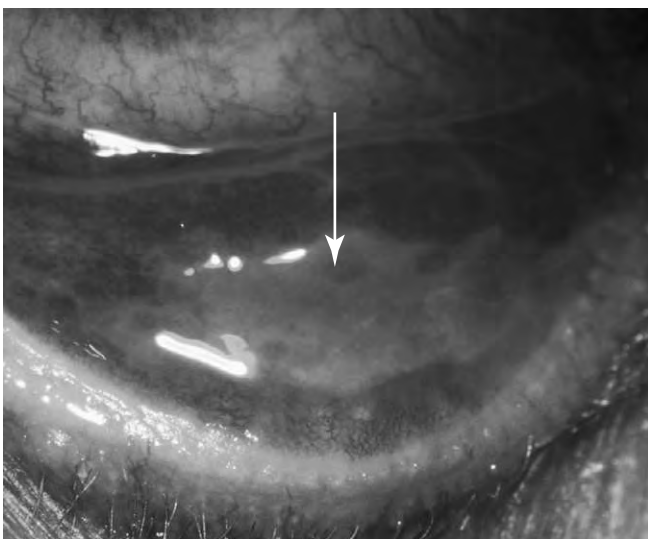#### Management

Treatment of EKC is primarily supportive. It is very important to inform the patient of the expected course of the disease, including the likelihood that the symptoms will increase in severity for several days and then

spontaneously resolve in 2 to 4 weeks. Artificial tears or lubricants, topical ophthalmic decongestants, and cold compresses may be used for symptomatic relief. Cleaning mucus from the lids and lashes and the use of oral analgesics and sunglasses also may increase patient comfort.

It is equally important to warn the patient of the contagious nature of EKC. The patient should be instructed to wash his or her hands frequently, to use separate towels and soap, to dispose of facial tissues, and to avoid direct contact with others. It may be necessary to instruct the patient to remain at home for up to 2 weeks after the onset of symptoms. To avoid spreading EKC to other patients and staff members in the practitioner's office, it is important to minimize the number of return visits, isolate affected patients from others by using a single room for examining these patients when possible, and disinfecting one's hands and instruments carefully between each patient. EKC can be cultured from the hands of approximately 50% of patients with this condition. Conventional hand washing has been shown to be an unreliable method of removing adenovirus from contaminated hands, so gloves should be used whenever examining these patients.

There are promising new drugs, such as *N*-chlorotaurine, in FDA trials as potential treatments for adenoviral infections. *N*-chlorotaurine has demonstrated good efficacy in vitro in treating adenovirus and is now currently being investigated as a potential treatment for patients with adenoviral infections.



**Figure 26-46** Pseudomembrane (*arrow*) located in inferior fornix of an EKC patient. (Courtesy of Pat Caroline.)

The appropriate use of topical anti-inflammatory agents to control patient symptoms poses a clinical challenge in the management of patients with EKC. The use of topical ophthalmic steroids is not recommended by most authors as a general course; however, their use to enhance patient comfort and reduce severe inflammation during the acute phase of EKC is fairly widespread in clinical practice. As a result of their effective anti-inflammatory and anti-immune activity, topical ophthalmic steroids may be necessary if central infiltrates are affecting visual acuity or if signs and symptoms are particularly severe. When necessary, a mild steroid such as 0.5% loteprednol or 0.1% fluorometholone alcohol two to four times a day is usually sufficient. Tapering can be started as soon as the patient becomes more comfortable and is continued for 2 to 4 weeks. When steroids are used, the formation of subepithelial infiltrates may be suppressed, but they usually reappear when the steroids are discontinued.

No controlled studies have been performed to determine whether NSAIDs are helpful in providing symptom relief in EKC. However, in animal studies there is a suggestion that treatment of EKC using topical NSAIDs may be a safer alternative to using potent topical steroids (e.g., 1% prednisolone acetate) to control symptoms during the acute phase.

The use of topical ophthalmic antiviral agents such as idoxuridine and adenine arabinoside generally has been found to be ineffective in the treatment of EKC. However, 1% trifluridine has been shown to decrease replication of adenovirus types 8, 13, and 19 *in vitro*, though no strong evidence exists for its use in EKC patients.

Pharyngoconjunctival fever and acute hemorrhagic conjunctivitis are similar to EKC in presentation except for a recent history of upper respiratory problems and fever in pharyngoconjunctival fever and development of large subconjunctival hemorrhages in acute hemorrhagic conjunctivitis. The cornea typically is less involved in each of these conditions, but they are treated in the same manner as EKC.

## **Herpes Simplex Keratitis**

### **Etiology**

Humans are the only natural host for HSV, and more than 80% of the population carries systemic antibodies to them. However, ocular manifestation afflicts less than 1% of those exposed to the virus. The primary, or initial, HSV infection usually occurs by the age of 5 and often goes unnoticed or is too mild for the parent to seek medical attention for the child. After the primary infection, the virus settles into the central nervous system and localizes in the nerve ganglia. Latency of the virus persists for life in the innervating sensory ganglia.

Typically, but not universally, HSV type 1 infects tissue above the waist, including the oral and ocular areas. It is transmitted by kissing or other close contact with individuals who are shedding the virus in active lesions.

The virus remains latent in the trigeminal nerve, may remain in the cornea, and has been reported in tears. HSV type 2 usually infects the genital area and is transmitted sexually but can cause ocular infection if transmitted to the eye via infected genital secretions. This most commonly occurs in neonates who are exposed to the virus in the birth canal. In neonates, herpes simplex can cause a fatal systemic infection.

Both types of latent HSV are thought to be reactivated by many factors, including UV exposure, trauma, stress, extreme temperatures, immunosuppression, and menstruation. When activated, the virus travels along the sensory nerve to peripheral tissue to cause recurrent HSV infection. An estimated 300,000 cases of primary and recurrent HSV infections develop each year.

Herpes simplex keratitis (HSK) is caused by HSV type 1 in adults and is one of the most common infectious etiologies of blindness. It is second only to trauma as a cause of corneal blindness in the United States, where an estimated 50,000 new or recurrent cases are seen each year. Recurrent HSK can be reactivated by many factors in addition to those listed above. Reactivation has been reported in patients after penetrating keratoplasty, argon laser trabeculoplasty, Nd:YAG laser peripheral iridotomy, or treatment with excimer lasers, including cases in which ocular herpes had not occurred previously. It is important to realize that because most patients have latent HSV it is possible for a reactivation to occur despite a negative history of a primary infection.

The severity of HSK is related to the viral strain as well as host factors. Most published HSK studies show a male prevalence; however, when evaluating keratoplasties due to HSK, a male preponderance is not always seen. This finding suggests that females may be more likely to acquire a more severe form of HSK or more readily seek surgical intervention. Additionally, the status of the immune system plays a key role with regard to HSK severity.

### **Diagnosis**

Although pain, photophobia, and decreased vision are reported by patients with both primary and secondary HSV ocular infection, these symptoms are usually mild during the primary infection and are accompanied by signs and symptoms similar to an upper respiratory infection such as mild rhinitis, pharyngitis, fever, malaise, and a generalized skin rash. An ulcerative or vesicular blepharitis (see Chapter 23) or an acute follicular conjunctivitis often occurs in patients with primary HSV infection. Although the preauricular lymph node often is swollen, the patient frequently reports no node tenderness.

Corneal involvement in the form of epithelial keratitis or dendrites occurs in up to 63% of initial clinical HSV infections. These tend to be small, late in onset, and transitory, lasting only 1 to 3 days. Stromal disciform keratitis, which manifests as a round area of stromal edema with an overlying intact epithelium, is much less frequent in

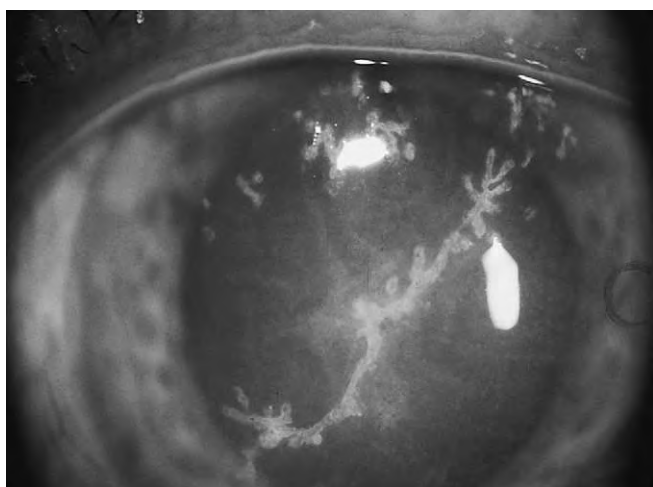


patients with initial clinical HSV infection, occurring in about 6%.

Unrecognized primary HSV keratoconjunctivitis is most commonly misdiagnosed as EKC because of the follicular conjunctivitis, lymphadenopathy, and corneal changes. One clinical feature that is helpful in making the diagnosis is the tendency for primary HSK to be unilateral and EKC to be bilateral.

After the primary infection the predominant form of recurrent ocular HSV infection is epithelial and stromal keratitis. A history of epithelial keratitis is not a significant risk factor for recurrent epithelial keratitis. In contrast, a previous episode of stromal keratitis significantly increases the probability of subsequent stromal keratitis. The Herpetic Eye Disease Study Group (HEDS) showed that a patient with at least one previous episode of stromal keratitis is 10 times more likely to have a subsequent episode of stromal keratitis during the subsequent 18 months. Furthermore, it was found that a progressive increase in the number of previous episodes of stromal keratitis correlated with an increasing risk of recurrent stromal keratitis. Additionally, HEDS found that stromal keratitis may occur in the absence of a history of superficial ocular HSV. The patient is usually most symptomatic during the first episode of recurrent HSK, with symptoms decreasing with each subsequent episode due to reduced corneal sensitivity. This corneal hypoesthesia is a classic but not pathognomonic sign of HSK.

Recurrent HSK has accompanying lid and conjunctival involvement in about 31% of cases. This involvement typically appears as unilateral follicular conjunctivitis with moderate to severe diffuse conjunctival hyperemia. The initial epithelial lesions of HSK are small vesicles that are generally described as punctate epithelial keratopathy. Although dendritic or ameboid keratitis is the most common manifestation of HSK (Figure 26-47), a diffuse



**Figure 26-47** Typical branching pattern of dendritic epithelial herpes simplex keratitis. (Courtesy of Pat Caroline.)

punctate keratitis often develops first. This keratitis is caused by a swelling of the epithelial cells from intracellular replication of HSV and a contiguous cell-to-cell spread of the virus in the corneal epithelium. Initially, this swelling causes NaFl to pool around the cells, but within 24 hours the cells die and a coarse punctate or stellate keratitis develops. As these areas of punctate keratitis coalesce, they develop into the typical branching dendritic or ameboid herpes simplex keratitis.

Dendritic ulcers from herpes simplex stain brightly with NaFl and have dichotomous branching, terminal end bulbs, and a delicate pattern. The edges of these lesions are formed by swollen opaque cells that stain well with rose bengal. Although these lesions are typical of HSK and often suggest the diagnosis, it is important to rule out other causes of dendritiform lesions. These include pseudodendrites caused by contact lens wear, herpes zoster ophthalmicus, healing epithelial defects, Epstein-Barr, medicamentous primarily from antivirals, corneal dystrophy, *Acanthamoeba* keratitis, systemic tyrosinemia type II, and Thygeson's SPK (TSPK). Herpes simplex dendritic lesions can enlarge to form an amoeboid (geographic) shape. Stromal edema and subepithelial infiltrates can develop under the dendrite in just a few days. These infiltrates can leave faint scars in the superficial stroma, which can be useful for diagnosing previous episodes of HSK.

Noninfectious indolent epithelial ulcers also can occur in HSK. These ulcers, formerly referred to as *metaherpetic* lesions, tend to be ovoid, 2 to 8 mm in size, with smooth rolled edges. They may be caused by damage to the epithelial basement membrane due to inflammation, tear film abnormalities, neurotropic cornea, or toxicity from antiviral medications. These ulcers may be recalcitrant, resulting in neovascularization and scarring.

Disciform or stromal keratitis may develop beneath a dendrite in recurrent HSK, can occur months after the initial episode, or may develop without a history of epithelial keratitis or blepharoconjunctivitis. The 5- to 7-mm disc-shaped area of edema in the corneal stroma can cause folds in Descemet's membrane. Disciform keratitis occurs in approximately 20% to 48% of patients with recurrent HSK.

Epithelial bullae can be found in some cases of disciform keratitis, as can a Wessley ring, which is composed of immune cells surrounding the discoid edema. A mild to moderate uveitis with keratic precipitates is usually present, although it may not be visible due to corneal edema. Secondary glaucoma can also develop, primarily the result of intraocular inflammation (trabeculitis).

The diagnosis of herpes simplex disciform keratitis is usually based on clinical appearance. If a history of previous episodes, ghost scars, or decreased corneal sensation is found, herpes simplex is the likely cause, but it is important to rule out other etiologies such as herpes zoster, varicella, vaccinia, mumps, and syphilis.

Necrotizing IK, a chronic form of HSK, may occur after multiple attacks. It is characterized by a white, dense,

cottage cheese-like infiltrate of the stroma with epithelial ulceration. Anterior uveitis, secondary glaucoma, vascularization, scarring, corneal thinning, and perforation can all occur with necrotizing IK.

Although not typically used, laboratory tests are available to help diagnose HSK in equivocal cases. One of the most reliable and fastest tests is the Herpchk®<sup>®</sup>, which is an enzyme immunoassay test that yields results in 1 day. Additional laboratory tests include viral culture microbiologic studies, enzyme-linked virus inducible system, and polymerase chain reaction detection.

### Management

Treatment of HSK is primarily based on whether the corneal condition is caused solely by active virus, as is found in epithelial dendritic keratitis, or has an immune component, as is typical of disciform keratitis. No treatment has been proven to remove the virus from the ganglia, so treatment is designed to stop the replication of the virus, eradicate live virus, reduce the rate of recurrence, and maintain visual acuity.

Treatment for corneal epithelial disease is typically started with 1% trifluridine ophthalmic drops every 2 hours, not to exceed nine times a day. Trifluridine is the drug of choice in the United States because it is the only commercially available topical ophthalmic antiviral.

If the corneal lesions are superficial, the patient is an adult, and no topical steroids have been used, minimal-wipe corneal debridement can be performed as an adjunct to the use of antivirals. Gentle debridement is performed by instilling topical anesthetic drops such as proparacaine and using a sterile cotton-tipped applicator to remove the lesions.

If there is an anterior chamber reaction or if debridement has been performed, a cycloplegic agent such as 5% homatropine or 0.25% scopolamine should be used two to three times a day. Topical steroids should be tapered or discontinued in any patient using them, because they are contraindicated in the presence of active HSV corneal epithelial disease. Antibiotics have no benefit in the treatment of herpes simplex epithelial disease but can be used prophylactically if the epithelial defect is greater than 6 mm in size.

Antivirals are toxic to the corneal epithelium and may delay healing, so their frequency of use should be decreased after the first week to five times a day. Therapy should be continued for several days after healing to allow time for the dormant virus to be shed. Some authors suggest tapering antiviral medications.

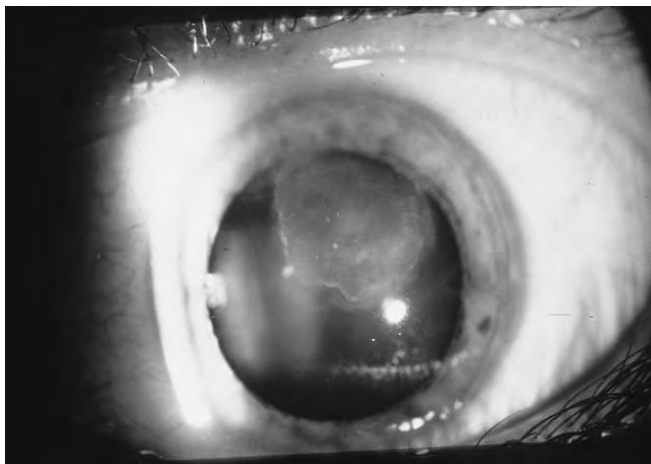
Within 2 weeks of using 1% trifluridine solution, 97% of cases resolve. Although drug-resistant HSV is rare, it is possible and should be considered if there is no improvement within the first few days. If there is no improvement or an adverse reaction occurs, use of a different antiviral is indicated. Acyclovir 3% ointment, although not commercially available for ophthalmic use in the United States, has been shown to be effective and well tolerated

for treatment of HSK when used five times per day. Alternative agents such as cyclosporin A, ganciclovir gel, and cidofovir have also been shown to be useful in the treatment of HSK.

Unlike dendritic keratitis, indolent ulcers are typically very difficult to treat. Instillation of a prophylactic antibiotic, such as polymyxin B-bacitracin ointment two to four times a day, and a cycloplegic agent, such as 5% homatropine two to three times a day, is indicated. Therapeutic soft contact lens use with appropriate antibiotic therapy can also be considered as alternatives. These patients must be monitored carefully to ensure that no secondary infection develops. If the ulcer deepens, a new infiltrate forms, or if there is an increase in the anterior chamber reaction while the patient is being treated, cultures should be performed to rule out bacterial or fungal infection. Cyanoacrylate glue, conjunctival flap surgery, or tarsorrhaphy may be required if healing does not occur.

Although there may be an active viral component in disciform keratitis, treatment is typically directed toward controlling inflammation. If the disciform keratitis is very mild and off the visual axis, control of uveitis with cycloplegics such as 5% homatropine three times a day and lubricating drops for comfort are all that is needed. If the disciform keratitis is affecting vision because of its severity or location, topical steroids are indicated to shorten the duration of the stromal keratitis as shown in the HEDS. Topical antivirals should be administered concurrently any time steroids are used for this condition. Although many clinicians choose to use antivirals at the same frequency as the topical steroid, another report by HEDS suggests that antiviral use four times a day is adequate prophylaxis. Because of the possibility of active virus in disciform keratitis, it is prudent to use the lowest dose of topical steroid that will resolve the inflammation. It is also prudent to postpone the use of steroids to allow antiviral drugs to work, because this delay has been shown to have no effect on visual outcome at 6 months.

Improvement occurs quickly in disciform keratitis with topical corticosteroids, but the steroid must be tapered very slowly. It is common for the patient to instill a drop of 1% prednisolone acetate every day or every other day after 3 months of treatment. It is not uncommon to have the patient use lower concentrations of topical steroids, such as prednisolone 0.12%, every other day for more than a year. Topical antiviral agents can be discontinued when steroids are used no more than once a day. If the steroid is tapered too quickly and the disciform keratitis recurs, the topical steroid and antiviral agent should both be reinstated at a higher frequency of instillation. Disciform keratitis generally leaves a scar after resolution of the acute inflammation (Figure 26-48). Although some success in removing herpetic scarring has been reported with PTK, penetrating keratoplasty may be necessary for the patient to regain useful vision. Unfortunately, recurrence of herpetic disease in corneal grafts can be as high as 44% in 2 years.



**Figure 26-48** Disciform corneal scar secondary to HSK disciform (stromal) keratitis. (Courtesy of Pat Caroline.)

Generally, necrotizing IK should be treated in the same manner as disciform keratitis, but necrotizing keratitis is much less responsive to steroids. As with disciform keratitis, the steroid must be tapered very slowly, often over a period of months or years. Conjunctival flaps may be necessary as may temporary or permanent tarsorrhaphy, and penetrating keratoplasty.

The use of oral antivirals for the treatment of herpetic eye disease has been the subject of many studies. The HEDS group evaluated the use of oral acyclovir when used with topical steroids and trifluridine in patients with stromal keratitis without concomitant epithelial keratitis. Oral acyclovir did not alter the duration or success rates in treating stromal keratitis. In addition, oral acyclovir did not prevent the development of stromal keratitis in patients with epithelial disease. However, the HEDS group reported that 400 mg of oral acyclovir twice daily decreased the recurrence rate of any type of ocular HSV disease to 19% compared with 32% in the placebo group. As would be expected from a medication that prevents duplication of but does not eradicate the virus, this effect continues only as long as the drug is being used. After discontinuing the acyclovir treatment, there was no significant difference between the acyclovir group and the placebo group in the rate of recurrences. Patients who have had recurrences of stromal disease and patients at risk from vision loss from epithelial disease should be considered candidates for long-term oral acyclovir prophylaxis. Although not formally tested in controlled studies, it would be expected that other oral antivirals, such as famciclovir or valacyclovir, would have similar effects on HSK recurrences.

Accumulating evidence suggests the use of oral antivirals for acute as well as prophylactic therapy of HSK. A recent study that compared oral valacyclovir with topical acyclovir found a more rapid reduction in symptoms and faster resolution in those treated with oral valacyclovir. Efforts to improve the treatment of HSK include

the development of additional antiviral medications and an HSV vaccine.

## Herpes Zoster Ophthalmicus

### Etiology

Varicella-zoster virus is a member of the Herpesviridae family. The viral contagion is transmitted via aerosolized water droplets or close physical contact with infected lesions. The primary infection results in varicella or chickenpox. The varicella infection can have potentially devastating ocular sequelae; the most common is anterior uveitis followed by SPK. After the primary infection, latent infection occurs in multiple ganglia throughout the body. Herpes zoster is the resultant reactivation of the latent varicella-zoster virus and most often occurs in elderly and immunocompromised patients. Factors such as physical and emotional trauma, immunosuppressive medications, irradiation, cancer, tuberculosis, malaria, and syphilis are known to reactivate the virus.

Herpes zoster is found worldwide and affects both sexes equally. It is more common in individuals over the age of 40 and rarely occurs in children. Approximately 95% of all adults in the United States have blood antibodies to herpes zoster, and about 20% experience a reactivation of the virus.

When reactivation occurs, the virus passes along the sensory nerve and erupts on the tissue innervated by that nerve (dermatome). The thoracic ganglion ranks first and the trigeminal ganglion second in order of frequency of zoster involvement. The ophthalmic division of the trigeminal ganglion is involved 20 times more frequently than the maxillary and mandibular branches and is known as herpes zoster ophthalmicus (HZO).

The nasociliary branch of the trigeminal nerve supplies the conjunctiva, cornea, iris, ciliary body, anterior choroid, and the skin of the upper lid and the tip of the nose. Herpes zoster involvement of the terminal branch of the nasociliary is indicated by cutaneous vesicles on the tip of the nose and is often referred to as *Hutchinson's sign*. Their presence of this sign increases the chances of serious ocular involvement.

### Diagnosis

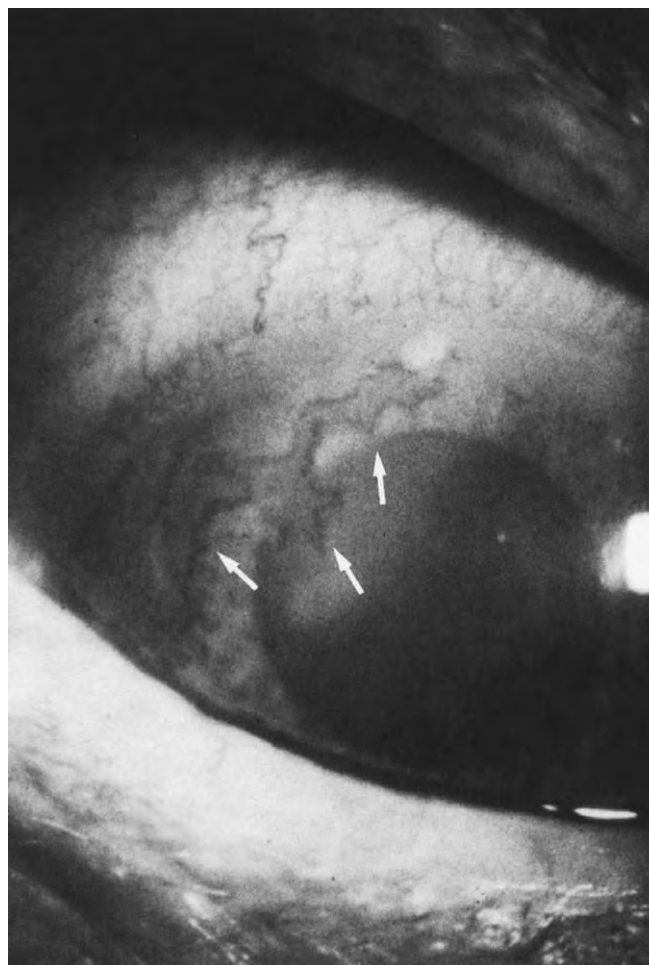Patients with HZO typically report a history of influenza-like illness with headache, malaise, fever, and chills for 2 to 3 days before the appearance of a forehead rash. At the same time they may notice pain, tingling, burning, itching, erythema, and edema of the skin over the affected nerve. Some patients also have ocular symptoms of pain, tearing, and foreign body sensation. A few days later, patients develop flushing of the skin and an eruption of vesicles along the distribution of the nerve. Untreated, these vesicles become pustular and hemorrhagic in 3 to 4 days, developing crusts in 7 to 10 days. Severe pain is common both while the vesicles are present because of inflammation of the neurons and after the vesicles are

healed because of scarring in and around the nerves. Permanent scarring of the skin also is quite common unless aggressive therapeutic measures are taken with systemic antiviral therapy before the vesicles erupt. Involvement of the ophthalmic branch of the trigeminal nerve usually causes lymphadenopathy.

Ocular involvement can develop as soon as several days, to as long as years, after vesicle formation. Ocular involvement may include lid edema, follicular conjunctivitis, corneal changes, anterior uveitis, glaucoma, episcleritis, scleritis, Horner's syndrome, extraocular muscle palsy, chorioretinitis, optic neuritis, and scarring of the lids and lacrimal canalicular system. It is possible, but rare, to have ocular complications, such as uveitis and disciform keratitis, without any skin lesions.

Corneal changes can occur within the first week of the disease or months later and can result in significant vision loss. Corneal involvement may result from direct viral infection, antigen-antibody reactions, delayed cell-mediated hypersensitivity reactions, and neurotropic damage. Patients with corneal involvement report varying symptoms, including decreased vision, pain, and photophobia. The corneal changes include SPK and pseudodendritic keratitis and occur in a significant number of patients with HZO. Punctate epithelial keratitis is the earliest corneal finding and is coarse in appearance, with blotchy swollen epithelial cells. The lesions are numerous and located peripherally in the cornea. They probably contain live virus and may either resolve or progress to dendrite formation.

The dendritic corneal lesions of HZO are more superficial, smaller, and have blunter ends than do the dendrites caused by herpes simplex, which often have terminal bulbs (Table 26-6). They usually occur 4 to 6 days after the skin vesicles erupt and stain moderately well with rose bengal and NaFl (Figure 26-49). In addition to dendritic keratitis, mucous plaque keratitis may also occur almost anytime in the course of the disease but typically occurs



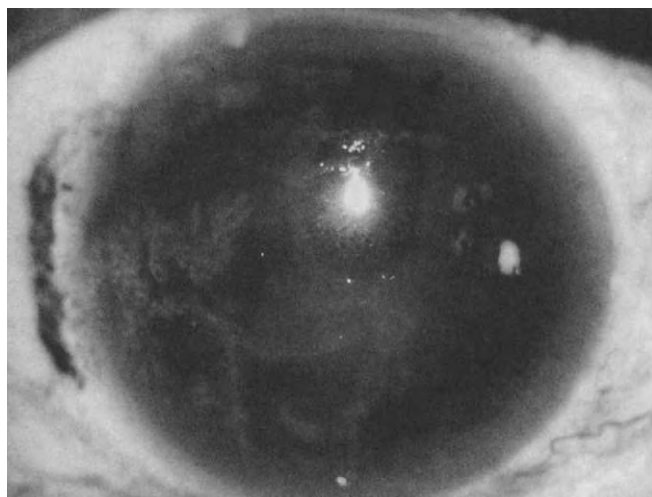
**Figure 26-49** Dendritic corneal lesion (*arrows*) resulting from herpes zoster ophthalmicus, shown stained with rose bengal and NaFl.

**Table 26-6**

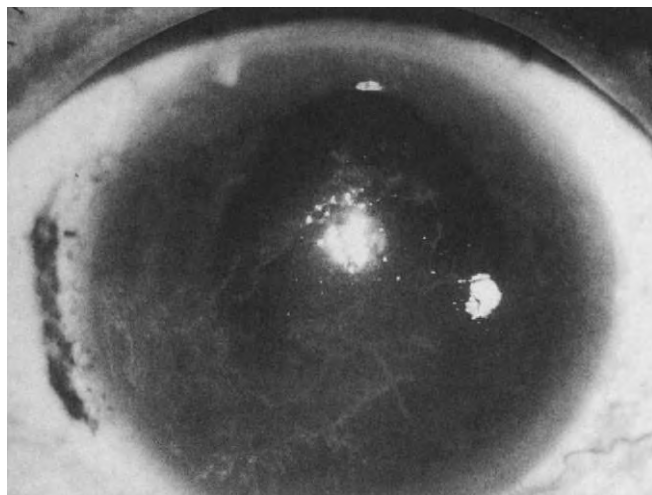
Differential Diagnosis of Herpes Simplex and Herpes Zoster

	<b>Herpes Simplex</b>	<b>Herpes Zoster</b>
Dermatomal distribution	Limited	More complete
Pain	Mild to moderate	Severe
Dendrite appearance	Larger, more branching, discrete, delicate pattern, more central	Smaller, less branching, coarse, blunted pattern, usually peripheral
Epithelium	Ulcerated	Blunted dendrite with slightly raised edges
NaFl staining	Prominent	Dull and irregular
End bulbs	Present	Absent
Scarring of skin	Rare	Common
Postherpetic neuralgia	Rare	Common
Iris atrophy	Rare	Common
Recurrence	Common	Rare

Modified from Nichols B, ed. Basic and clinical science course. External disease and the cornea, section 7. American Academy of Ophthalmology. San Francisco, CA. 1990.



A



B

**Figure 26-50** Mucous plaque keratitis associated with herpes zoster. (A) Initial presentation. (B) Note migratory nature of lesions 3 weeks later. (Courtesy Marc A. Michelson, MD.)

3 to 4 months after the initial infection. These plaques appear as elevated, sharply demarcated, opaque, gray-white lesions that are variable in size and shape. They stain well with rose bengal but poorly with NaFl. A poor tear film and neurotropic corneal changes are common in these cases. Viral cultures are negative, and the lesions appear to be mucous deposits on abnormal epithelial cells, which can migrate or disappear with time (Figure 26-50).

Anterior stromal infiltrates can develop under the dendritic HZO lesions and appear as hazy, granular, nummular, subepithelial opacities. They have been observed in close proximity to enlarged corneal nerves, which possibly represents a perineuritis from viral destruction of the sensory nerves. These lesions are responsive to topical steroids, indicating they are most likely caused by a local immune reaction to the epithelial dendrites.

The lesions can be self-limiting or chronic and rarely result in scarring or vision loss.

Deep corneal edema with folds in Descemet's membrane, in the presence of an intact epithelium, can develop from 3 to 4 months after acute HZO. This disciform keratitis may involve the full thickness of the cornea and may be surrounded by a ring-like cellular infiltrate called a Wesley ring. It is considered to be an immune response to viral antigens and responds quickly to topical steroids, especially when initiated early. Unfortunately, it is common to have recurrences when steroids are tapered or discontinued and can lead to corneal scarring or, more seriously, corneal melt. There is often an associated anterior uveitis with keratic precipitates as well as diffuse corneal edema, endothelial cell loss, and increased IOP secondary to trabeculitis.

A significant number of patients with HZO develop impaired sensation of the cornea, bulbar conjunctiva, and eyelid margins secondary to trigeminal ganglionitis and damage to the sensory nerves innervating the skin and other tissues. The resulting corneal anesthesia produces a decreased blink rate and loss of the normal nasolacrimal reflex with a secondary reduction in aqueous tear production. A neurotropic keratitis can occur as early as 10 days and up to several years after the HZO infection. The characteristic neurotropic ulcer occurs in the inferior cornea or interpalpebral area, similar to exposure keratitis. The ulcers are ovoid in shape and have an opaque appearance with underlying stromal edema. These ulcers are slow to heal, are susceptible to secondary bacterial infections, and may result in scarring with neovascularization and potentially corneal penetration.

### Management

Systemic antiviral therapy promotes resolution of HZO skin lesions and reduces the incidence and severity of dendritiform keratopathy, anterior uveitis, and stromal keratitis by decreasing the rate of virus replication. All patients with acute HZO should receive antiviral therapy with the goal of minimizing ocular complications. Acyclovir, valacyclovir, and famciclovir are FDA approved for management of herpes zoster. Acyclovir usually is administered orally in dosages of 800 mg five times per day for 7 days. Valacyclovir has better bioavailability when taken orally and can be used with a recommended dosage of 1 g three times a day for 7 days. Famciclovir, which has bioavailability similar to valacyclovir, has an increased half-life and also has the advantage of less frequent administration than acyclovir: 500 mg three times a day for 7 days.

For antivirals to have the maximum effect, treatment should be started within 72 hours of the vesicular eruptions. Effectiveness of antiviral therapy started beyond 72 hours has not been established, but reports suggest a benefit. Because HZO is often more chronic in patients who are immunocompromised, they should be treated more aggressively and potentially for a longer duration

than patients with a healthy immune system. The use of intravenous antivirals may be required.

The early corneal changes of SPK and pseudodendrites usually are self-limiting, lasting weeks to months, and require no treatment. Artificial tears and cool compresses may be helpful for symptomatic relief.

Use of topical steroids usually is not necessary if there is only mild inflammation and good vision. Prednisolone acetate 1% can be used four times a day for corneal changes caused by inflammation such as stromal infiltrates and disciform keratitis. Some authors suggest using prophylactic antibiotics along with the steroid. If there is any possibility that herpes simplex is present, a topical ophthalmic antiviral agent should be used concurrently with the steroid. To avoid recurrences of inflammation, steroids must be tapered very slowly. A cycloplegic agent such as homatropine 5% used two to three times a day can decrease pain and help prevent or control anterior uveitis and synechiae.

Mucous plaque keratitis can be treated with 10% acetylcysteine but also resolves without treatment. Keeping the eye moist with artificial tears may be helpful. Exposure keratitis and neurotropic keratitis are best treated with artificial tears, lid taping at bedtime, and, if necessary, tarsorrhaphy. Therapeutic contact lenses should not be used because of the risk of developing infectious ulcers in an eye with decreased sensitivity.

Corneal scarring that affects vision is best treated with penetrating keratoplasty. Penetrating keratoplasty generally is considered to have a poor outcome after HZO because of recurrent or chronic inflammation, vascularization, glaucoma, and poor tear film quality. The chances of success seem to improve, however, if the corneal surface is protected after surgery by lubricants, therapeutic lenses, or tarsorrhaphy or if there has been a long interval since the previous occurrence.

Because chronic pain is a common occurrence with herpes zoster, management should also include consultation with a dermatologist, family practitioner, or pain specialist as needed.

## **Thygeson's Superficial Punctate Keratitis**

### **Etiology**

TSPK is a chronic epithelial keratitis of unknown etiology, suggested to be due to chronic subclinical viral infection in the deep layers of the basal epithelium. Support for this theory includes the protracted course of this condition, its tendency to recur, the lack of effect by antibiotics on its clinical course, and lack of bacterial isolation from eyes affected by the condition. The clinical presentation of corneal mononuclear cell infiltrates, the rapid resolution of these infiltrates with topical steroids, and their rapid reappearance if topical steroids are stopped too quickly support the possibility that the primary presentation is a typical immunologic response.

Additionally, TSPK has been associated with histocompatibility antigen HLA-DR3, suggesting that immune mechanisms play a role.

### **Diagnosis**

When Thygeson described this condition in 1961, he noted that the disease was chronic, bilateral, and had a long duration with exacerbations and remissions. Also noted was the typical punctate epithelial keratitis that showed no response to antibiotics or epithelial debridement, a rapid response to very low doses of steroids, and eventual healing without scars. These features, with few variations, are still characteristic of the disease today. Although the disease is bilateral in most patients, there are reports of unilateral cases and cases with marked asymmetry between the two eyes.

The duration of the disease is quite long, lasting weeks to years. Authors have reported an average duration of 2.5 to 3.5 years. It has been suggested that the use of topical ophthalmic steroids may increase the duration of the disease. Most authors have reported no gender or age predilection; however, there may be a mild female predominance. The age at onset ranges from 2.5 years to 70 years, with a mean in the late twenties.

Patients with TSPK usually report an insidious onset of symptoms such as foreign body sensation or pain, tearing, photophobia, slightly decreased vision, burning, and itching. These symptoms are primarily the result of epithelial disruption, with decreased vision occurring due to infiltrates on the visual axis and irregularity of the corneal surface. However, there have been reported cases without symptoms.

Examination of these patients reveals multiple, gray-white, coarse, granular, intraepithelial lesions (Figure 26-51). Subepithelial opacities, which may be caused by edema, also may be seen. The intraepithelial lesions are of variable size and may number between 12 and 20. They are more numerous in the pupillary zone and appear as stellate, round, or oval areas composed of smaller punctate opacities.

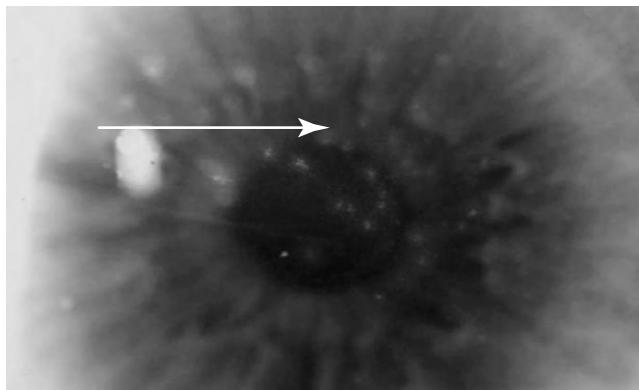
The lesions are often slightly raised and stain variably with NaFl and rose bengal. They come and go and change locations quickly. The eye usually is white with little, if any, accompanying conjunctival reaction. Corneal sensitivity may be reduced or normal.

The differential diagnoses of TSPK include viral, toxic, bacterial, chlamydial, exposure, and dry eye causes of punctate epithelial keratopathy. Most of these conditions resolve in shorter time periods and are found to have a more obvious conjunctival involvement. Considering the lack of laboratory confirmatory tests, the diagnosis of TSPK remains solely clinical.

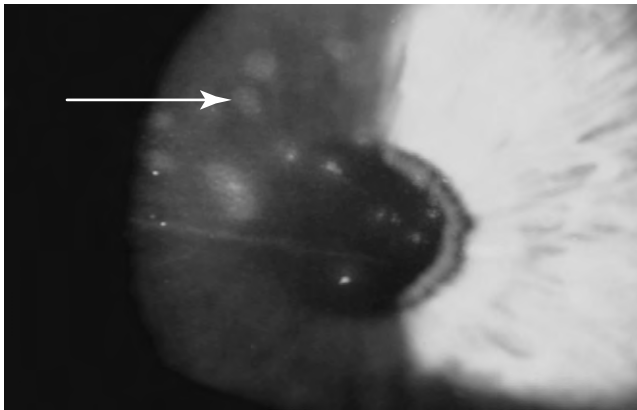
### **Management**

Mild cases of TSPK can be treated with artificial tears four to eight times a day and lubricating ointment at bedtime

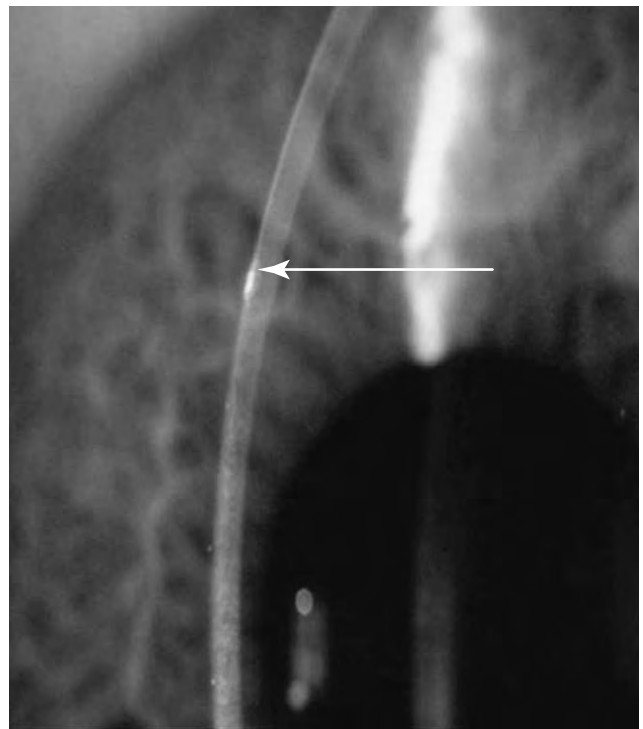




A



B



C

**Figure 26-51** (A-C) A granular intraepithelial lesion of TSPK. (Courtesy of Pat Caroline.)

for symptomatic relief. It is important to counsel the patient regarding the chronic nature of the disease.

Moderate to severe cases may require topical steroids for relief of symptoms. A mild steroid such as 0.12% prednisolone, 0.1% fluorometholone, or 0.2% loteprednol should be used four times a day for 1 week and then tapered slowly on the basis of resolution of symptoms and clinical examination. Some patients may require the tapering over the course of months, with some requiring weekly or biweekly use of steroids to control symptoms. The use of steroids has been found to control exacerbations in about 50% of cases.

Therapeutic soft contact lenses may also be used to increase comfort, but they can be responsible for inducing exacerbations. The lenses need to be worn every day, and patients should be monitored closely for contact lens-induced problems.

Patients experiencing exacerbations of TSPK may be followed weekly while undergoing therapy. Patients in remission may be followed every 3 to 12 months.

## FUNGAL KERATITIS

### Etiology

Although corneal infection can be caused by more than 100 fungal species, classified in 56 genera, the primary

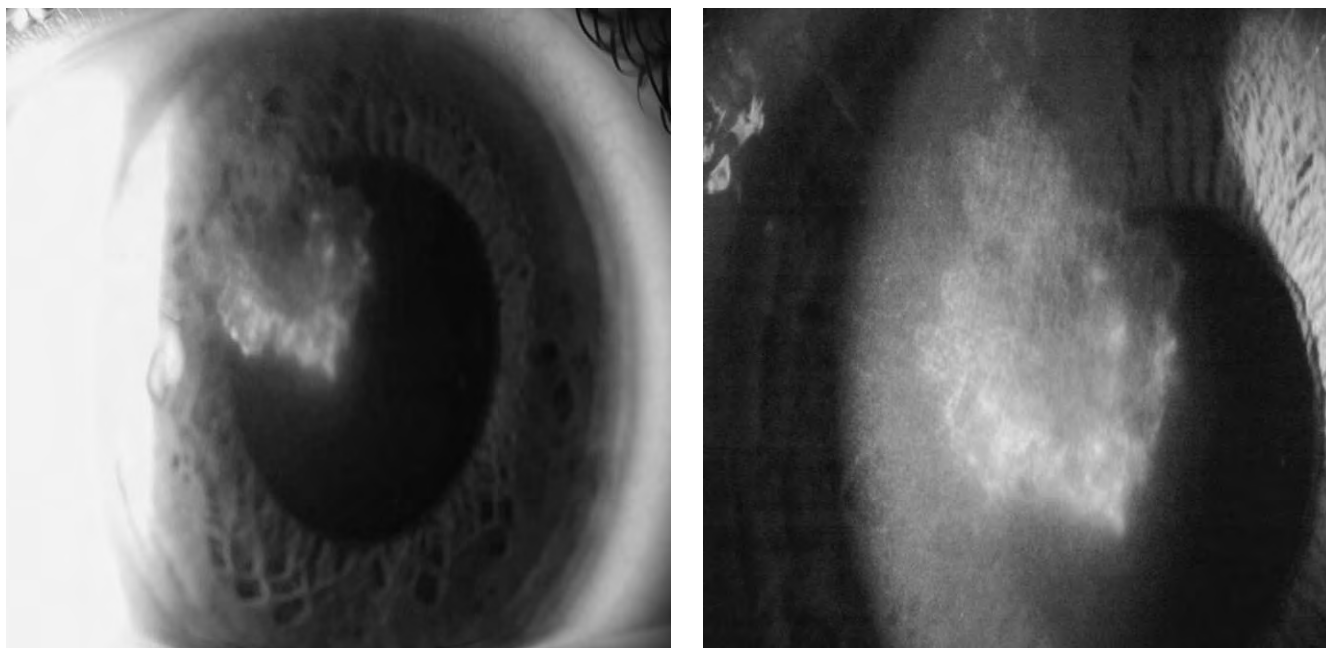
pathogens come from two main groups: filamentous and yeast organisms. Worldwide, septate filamentous organisms most commonly cause corneal ulcers and include *Fusarium*, *Aspergillus*, *Curvularia*, and *Penicillium* species. *Candida* species, another common corneal pathogen, is from the yeast group.

The most common fungal isolates vary by geographic location. In the southern United States the septate filamentous organisms, *Fusarium* species, are the most common cause of fungal corneal ulcers because they thrive in hot and humid environments. *Aspergillus* or *Candida* is the most likely cause of fungal keratitis in northern regions. Several recent studies reported *Candida* as the most common cause of fungal keratitis in the northeastern United States.

The incidence of fungal keratitis also varies by geographic location. The relative prevalence of filamentous fungal keratitis increases toward the tropical latitudes. Overall, the incidence of fungal keratitis has increased over the last 20 years. This may be due to widespread topical steroid or antibiotic use, contact lens use, or improvements in diagnosis.

Patients who develop fungal keratitis frequently have a history of previous corneal trauma with vegetation such as sticks, branches, and soil. Agriculture workers and gardeners are specifically predisposed. However, in metropolitan areas where agricultural





**Figure 26-52** (A) Fungal corneal ulcer. (B) Magnified view of the affected area of the fungal ulcer in A. (Courtesy of Christopher R. Croasdale, MD.)

employment is low, predominant risk factors include chronic ocular surface disease, systemic disease (particularly diseases associated with immunosuppression), contact lens wear, and steroid use. Additionally, there have been several recent case reports of fungal keratitis after LASIK and photorefractive keratectomy. Fungal keratitis can occur at any age, but several studies suggest the age range between 31 and 42 years as most likely to be affected; males are affected more frequently than females.

### Diagnosis

Patients with fungal keratitis present with the same basic symptoms as those with bacterial corneal ulcers. These symptoms include photophobia, decreased visual acuity, redness, swelling of the lids, discharge, and reports of a “white spot” on the eye. Pain may be less than that expected from the clinical picture.

Although there is no pathognomonic clinical picture of fungal ulcers, there are characteristics that aid in the correct diagnosis. Characteristic clinical features of filamentous keratitis include serrated margins, dirty white with a dry rough texture, and satellite lesions. Filamentous fungal ulcers appear as unifocal or multifocal infiltrates with fine feathery edges and relatively mild stromal inflammation. Corneal yeast infections appear as unifocal or multifocal dense infiltrates. The ulcer can be elevated above the corneal surface and can exhibit branching lines that radiate from the ulcer margin into the stroma. Satellite infiltrates often develop subsequent to,

and in the same location as, these distinct branching lines. The formation of a dense, white, endothelial plaque and a white ring of polymorphonuclear cells in the mid-periphery of the cornea are fairly common, and corneal vascularization may be present (Figure 26-52). In general, the eye tends to react severely even if the ulcer is superficial, including folds in Descemet’s layer, ciliary flush, and an anterior chamber reaction possibly with a hypopyon. Although bacterial corneal ulcers are associated with a hypopyon and fibrin in the anterior chamber more frequently than fungal ulcers, no significant differences have been observed between the frequencies of immune rings, keratic precipitates, perineural infiltrates, endothelial plaque, and cells or flare in the anterior chamber. It is generally held that microbiologic investigations should be performed because a definitive diagnosis between fungal and bacterial keratitis cannot be made by clinical appearance alone.

Gram and Giemsa stains assist in the diagnosis of fungal infection by staining the fungal hyphae. Laboratory evaluation of suspected fungal ulcers should be performed in the same way as for suspected bacterial ulcers. Clinicians can comfortably use an Amies transport medium device to culture fungal corneal ulcers as an alternative to in-office direct plating.

Although most fungi grow in Sabouraud’s without cycloheximide medium within 48 hours, others can take as long as 2 to 3 weeks. Thioglycolate broth and blood agar are other useful media for culturing fungi. Additional procedures such as the use of calcofluor white stain and potassium hydroxide wet mount may improve the detection of fungal pathogens. Because rapid diagnosis of

fungal keratitis can often improve the visual outcome, research is being conducted on polymerase chain reaction as a method for early and correct diagnosis. Confocal microscopy is also being investigated for use in fungal keratitis diagnosis and follow-up.

If not done routinely, clinical laboratory diagnostic evaluations should be considered any time fungal keratitis is suspected. More routine methods of laboratory evaluation yield no positive results.

## Management

Treatment of fungal keratitis is a prolonged process, with therapy typically lasting about 6 weeks. Because of this long-term treatment and the known toxicity of antifungal drugs, treatment generally is not started unless there is microbiologic (culture or smear) support for a fungal infection. Because of the difficulty in treatment and the prolonged course, a patient suspected of a fungal keratitis should be referred to a corneal specialist.

If the smear shows a septate hyphal fragment suggestive of filamentous fungi, natamycin 5% is the drug of choice. Natamycin 5% is the only antifungal agent commercially available for ophthalmic use in the United States and is effective against *Fusarium* and *Aspergillus*. If natamycin is not available or there is no positive response to treatment, amphotericin B 0.15% plus flucytosine is the next treatment of choice.

If the smear shows the oval buds or pseudohyphae of yeast, treatment is initiated with amphotericin B 0.15% with or without flucytosine. If the ulcer fails to respond to this treatment, the most common alternative is fluconazole 1% applied topically in conjunction with 200 mg taken orally.

Several topical antifungal agents have been shown to have synergistic activity. Amphotericin B and subconjunctival rifampin are more effective than amphotericin B alone. As mentioned earlier, amphotericin B and flucytosine have synergistic effects. Because antifungal agents penetrate the cornea very poorly, daily mechanical debridement of the corneal epithelium is necessary when treating any fungal keratitis.

Most antifungal agents reach fungistatic, not fungicidal, concentrations in the cornea. Because of this, topical steroids, which allow the fungi to replicate more freely, are generally contraindicated in the treatment of fungal ulcers.

Because fungal ulcers resolve very slowly and antifungal agents are toxic to the cornea, it can be difficult to determine whether the antifungal agent is clinically effective. Lack of progression of the ulcer is generally considered to be the first sign of efficacy. Improvement is suggested when the patient has decreased pain, the infiltrate is smaller, satellite lesions are disappearing, and the feathery margins of the ulcer become more rounded. Therapy is continued for at least 6 weeks and is modified, if needed, primarily based on the culture results.

Other antifungal agents are available and may need to be considered if the current treatment is ineffective.

Topical treatment is often unsuccessful in fungal keratitis with approximately 20% to 25% of cases requiring surgery. The gold standard surgical intervention is penetrating keratoplasty; however, a recent report stated that lamellar corneal surgery was effective in eradicating fungal infection in 92.7% of 55 surgeries. In patients with advanced and nonresponsive fungal keratitis, the use of amniotic patch grafts and cyanoacrylate glue application with the concurrent use of antifungals may help resolve inflammation and promote healing.

## ACANTHAMOEBA KERATITIS

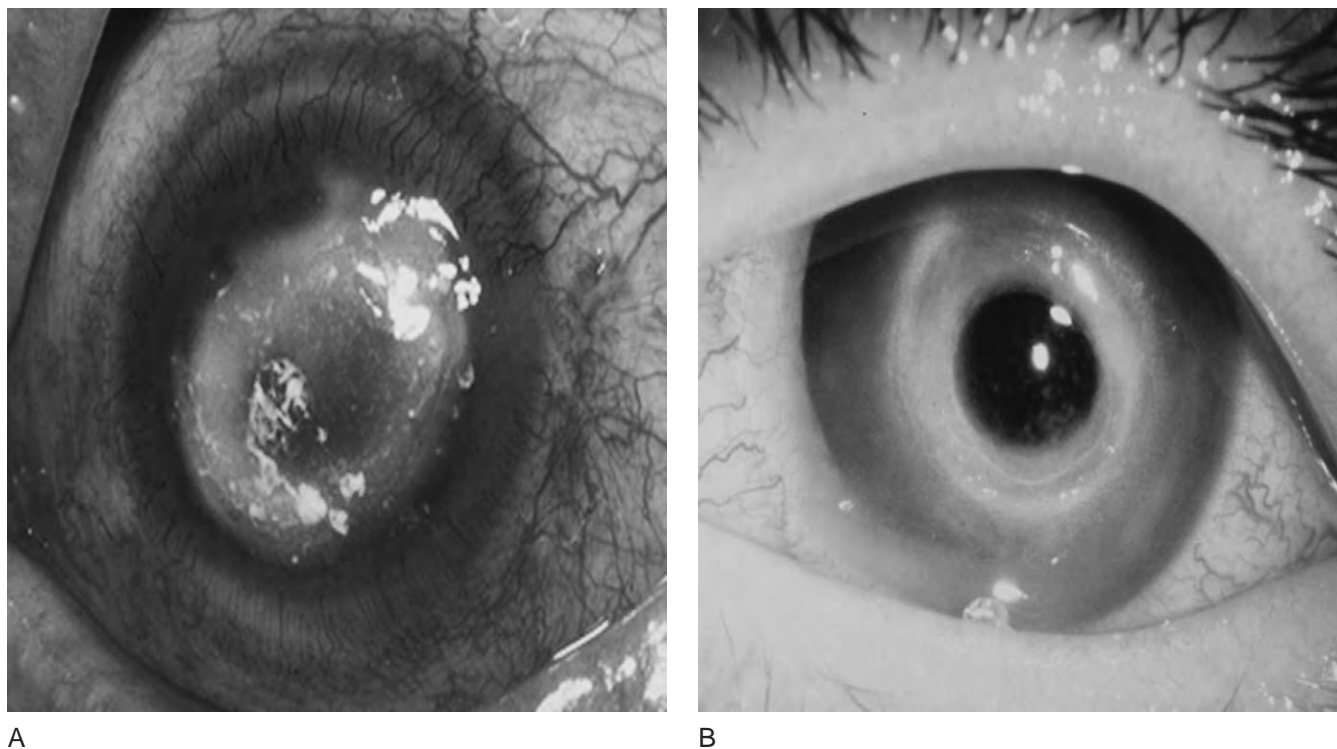
### Etiology

*Acanthamoeba* is a free-living, opportunistic, nonparasitic protozoan found in soil, fresh water, salt water, tap water, distilled water, bottled mineral water, chlorinated swimming pools, sewage, and saliva. There have only been a relatively few reported cases of infection despite the abundance of potential exposure opportunities. It has been reported that more than 80% of immunocompetent individuals contain serum antibodies against *Acanthamoeba* antigens, suggesting common exposure. Pathogenic and nonpathogenic isolates occur with 24 named species of *Acanthamoeba* identified. Isolates from keratitis patients reveals that pathogenicity may be limited to certain genotypes. The exact mechanism of corneal infection by this organism is uncertain but seems to involve many factors, including epithelial trauma, a large inoculum of organism, and compromised host defense mechanisms.

*Acanthamoeba* have adapted to withstand the variety of environmental conditions they experience by switching their phenotype. In harsh environmental conditions, *Acanthamoeba* transforms into its resistant cyst form. The cyst form is resistant to various antimicrobial agents, presenting a significant problem in treatment. In favorable conditions the cysts transform into their vegetative infective trophozoite forms, resulting in a reinfection of the tissue.

*Acanthamoeba* ocular infection was first described in 1973. *Acanthamoeba* keratitis can occur in both healthy and immunocompromised individuals and is initiated by contact with contaminated water. Most *Acanthamoeba* keratitis cases described in the mid-1980s involved daily-wear soft contact lens wearers who were using saline made from distilled water and salt tablets. Cases have also been described in extended-wear soft contact lens wearers and rigid contact lens wearers. In a survey of corneal specialists, it was found that 85% of the reported cases were in contact lens patients using primarily daily-wear or extended-wear soft lenses.

*Acanthamoeba* keratitis can occur in patients other than contact lens wearers. This condition may result after corneal contamination or injury from water or vegetative matter.



**Figure 26-53** *Acanthamoeba* keratitis. (A) Active infection. (B) Ring-infiltrative pattern of late-stage infection.

*Acanthamoeba* keratitis has been reported after penetrating keratoplasty in a patient with no identifiable risk factors for this condition. Fungal, viral, chlamydial, and bacterial infections, including crystalline keratopathy caused by the viridans group of streptococci, have been reported concurrent with *Acanthamoeba* keratitis. It is theorized that these organisms, along with damaged host cells, may potentiate *Acanthamoeba* infection by serving as an initial source of nutrition for the protozoan.

### Diagnosis

The patient with *Acanthamoeba* keratitis typically presents with symptoms of redness, irritation, severe pain due to radial neuritis, photophobia, and reduced visual acuity. History of corneal contamination with water, saliva, or vegetative matter may be elicited with careful questioning. The duration of symptoms may vary from days to weeks, with waxing and waning of signs and symptoms common. Not infrequently, the condition has been present for weeks or months, and treatment with multiple agents for viral or bacterial keratitis had been attempted without result.

Clinical signs of *Acanthamoeba* keratitis include lid edema, conjunctival injection, and usually a fluctuating anterior chamber reaction. Early in the disease course an edematous necrotic dendritiform keratitis, central or paracentral infiltration, or elevated epithelial lines may be evident. Late in the course a prominent complete or partial stromal ring-shaped infiltrate with recurrent epithelial breakdown is highly suggestive of this

condition (Figure 26-53). Subepithelial infiltrates, similar to those seen in viral or chlamydial corneal infections, have been noted late in the disease away from the site of original infection and with minimal to no accompanying inflammatory signs. It has been theorized that an immunologic mechanism may be responsible for these late-onset steroid-responsive infiltrates.

*Acanthamoeba* keratitis should be suspected in at-risk patients who exhibit a deteriorating corneal condition unresponsive to multiple therapy regimens. Early diagnosis is important for a successful outcome. Definitive diagnostic information is obtained through laboratory analysis. Epithelial material can be scraped and placed in a tube containing saline and then agitated, centrifuged, and examined by wet-field microscopy for cysts. Keratoplasty biopsy has been used to identify encysted organisms as well as trophozoites, the stage when the amoebas emerge from dormant cysts to become actively feeding cells. Specular microscopy has been used as a noninvasive “photographic biopsy” to identify *Acanthamoeba* cysts within the corneal stroma. Alternative microbiologic techniques have been evaluated to diagnose *Acanthamoeba* keratitis. More recently, routine microbiologic techniques have been used to identify *Acanthamoeba* keratitis. The cysts may be identified using Gram and Giemsa stains, and *Acanthamoeba* may be isolated from a corneal scraping plated onto a non-nutrient agar enriched with *E. coli* and incubated at 32°C for 4 weeks sealed in a plastic box. Amoebae are usually visible by light microscopy after 1 week.

## Management

*Acanthamoeba* keratitis poses an extremely challenging clinical management problem with the potential for treatment failure. The condition should be treated by a provider experienced in its management. The free-living trophozoite stage of infection is responsive to treatment, while the cysts are highly resistant. Aggressive medical therapy is initiated using multiple antibacterial, antifungal, and antiamebic agents. If diagnosed early, there is the potential for complete recovery of vision.

Prevention of *Acanthamoeba* keratitis is its best treatment. Contact lens-wearing patients must be educated carefully as to the proper use and care of their lenses. Homemade saline is no longer an approved or accepted contact lens solution. It is advisable not to wear contact lenses while swimming or in hot tubs, although swimming goggles may provide some protection from water exposure. Prescription swimming goggles may be preferable for correction of high refractive errors in this setting. Rigid contact lens wearers should be advised not to contaminate their lenses with saliva. Water contamination of contact lenses, including the case, should be avoided. It also is important that eye care providers remain alert to the possibility of this diagnosis so that the signs and symptoms of *Acanthamoeba* keratitis might be recognized as early in the disease course as possible, which may enhance the success of medical treatment.

Table 26-7 summarizes the commonly used treatments. For a more detailed discussion of treatment and management options, the reader is referred to several reviews in the current literature.

Penetrating keratoplasty may be needed after pharmacotherapy if a visually debilitating corneal scar remains. The use of keratoplasty as a therapy for *Acanthamoeba* keratitis that is not responding to medical therapy is a subject of debate. It is preferable to perform the surgery when active inflammation is not present, and recurrence appears to be common if it is

performed too soon; however, the success rate is higher before the organism has disseminated throughout the cornea and caused excessive tissue damage. The success of currently available medical treatment suggests that surgical intervention in the presence of active *Acanthamoeba* keratitis is contraindicated until a medical cure has been achieved.

## CONTACT LENS-RELATED CORNEAL COMPLICATIONS

There are approximately 33 million contact lens wearers in the United States, and each year approximately 6% of those experience some form of contact lens-related problem. Contact lens wear results in significant alterations in corneal function, including changes in corneal epithelium and endothelium function, tear composition, oxygen levels, and carbon dioxide levels. These changes can result in a wide variety of ocular disorders and exacerbate preexisting conditions. Table 26-8 outlines the variety of potential contact lens-related complications including corneal neovascularization (Figure 26-54), giant papillary conjunctivitis (Figure 26-55) and corneal SPK secondary to toxic/sensitivity response to contact lens solution (Figure 26-56). These conditions can be benign in nature, but many have serious, even sight-threatening, complications and are associated with all modalities of contact lens wear.

## Infiltrative Events

Infiltration of the cornea is a common adverse event strongly associated with contact lens wear. The Cornea and Contact Lens Research Unit (Australia) devised a classification system for corneal infiltrates associated with contact lens wear identifying six distinct etiologies. The classification system was designed to aid in diagnosis, management, and treatment of corneal infiltrates and to assist in investigation into the etiology of each. The six categories are microbial keratitis, contact lens-induced

**Table 26-7**

Medications Currently Used in the Treatment of *Acanthamoeba* Keratitis

Medication	Effective Against
Chlorhexidine digluconate 0.02% (mainstay treatment)	Trophozoite and cystic stage
PHMB 0.02% (mainstay treatment)	Trophozoite and cystic stage
Propamidine 0.1% (Brolene®) (additive therapy)	Trophozoite with some cystic activity
Hexamidine isethionate 0.1% (Vivier®) (additive therapy)	Trophozoite with some cystic activity
Flurbiprofen (oral)	Adjunctive therapy providing anti-inflammatory and analgesic properties
Topical steroids	Can be used in late stages after the amoebae have been killed to control inflammation
Imidazoles 1% (e.g., ketoconazole)	Effective against trophozoites but not cysts; never used as primary therapy but may be used concurrently

**Table 26-8**

Contact Lens–Related Potential Complications and the Associated Signs and Symptoms

Complication	Signs	Symptoms
Corneal neovascularization (Figure 26-54)	Extension of limbal blood vessels into clear corneal tissue	None initially, though may lead to blurred vision in late stages
Microcysts	Mild to moderate injection, collection of tiny, clear, epithelial cysts	Burning, foreign body sensation, tearing, photophobia, and possible decreased vision
Corneal abrasion (for detailed discussion see Corneal Abrasion) (see Figure 26-14)	Watering, redness, epithelial defect	Acute pain, photophobia, blurred vision
Giant papillary conjunctivitis (Figure 26-55)	Cobblestone-appearing papillae under upper lid, mucous discharge	Itching, blurred vision, reduced CL wear time
Hypersensitivity to CL care solutions (Figure 26-56)	Chemosis and injection of conjunctiva, SPK	Ocular irritation soon after CL insertion
Bacterial conjunctivitis	Injection, chemosis, tearing, mucopurulent discharge	Blurred vision, photophobia, foreign body sensation
Infiltrative events: includes six subcategories: microbial keratitis, CL-induced peripheral ulcer, CL-induced red eye, infiltrative keratitis, asymptomatic infiltrative keratitis, and asymptomatic infiltration	Severe injection, chemosis, possible ulceration of corneal epithelium and stroma, mucopurulent discharge, stromal infiltrate	Pain, photophobia, blurred vision
<i>Acanthamoeba</i> keratitis	Injection, chemosis, eyelid edema, anterior chamber reaction, necrotic dendritic corneal ulcer, subepithelial infiltrates	Severe pain, photophobia, blurred vision, foreign body sensation

CL = contact lens.

peripheral ulcer, contact lens–induced acute red eye, infiltrative keratitis, asymptomatic infiltrative keratitis, and asymptomatic infiltrates. The details of each category are outlined in Table 26-9.

It is critical to distinguish between the different etiologies of infiltrative events associated with contact lens wear. The classification system separates the different categories into clear clinical differences based on signs and symptoms. As a result the seriousness of the condition can be judged, and appropriate treatment and management options can be made. For instance, microbial keratitis (Figure 26-54 to Figure 26-57) is the most serious of the infiltrative events because of its potential to be sight threatening and requires aggressive treatment and management. This potentially severe entity can be contrasted to relatively benign asymptomatic infiltrates (Figure 26-58), which require contact lens discontinuation until resolution and subsequent refitting of the contact lenses.

It is also important to differentiate a red eye associated with contact lens wear from other potential causes. The definitive diagnosis can pose a clinical challenge with respect to excluding other conditions that cause an acute red eye with corneal infiltration. EKC, chlamydial keratoconjunctivitis, marginal infiltrative keratitis,

*Acanthamoeba* keratitis, and bacterial keratitis are among the most prominent differential diagnoses. To rule out other possible diagnoses, other signs and symptoms need to be assessed thoroughly such as the presence or absence of conjunctival follicles, lymphadenopathy, mucopurulent or purulent discharge, and bilateral involvement. Anecdotal experience suggests that prominent perilimbal injection and chemosis are important features of the infiltrative red eye reaction.

One critical distinction to make is whether a focal corneal infiltrate is infected with bacteria or is a sterile immunologic response. Many clinicians advocate routine scraping for smears and cultures of corneal infiltrates associated with soft contact lens wear to determine definitively whether active bacterial keratitis is present. Investigators have found that sterile infiltrates usually are smaller (less than 1 mm), multiple or arcuate, and lack significant pain, epithelial staining, or anterior chamber reaction. Conversely, infected ulcers are associated with increased pain, a larger size (over 2 mm), more extensive epithelial staining, a discharge, and a more prominent anterior chamber reaction. When in doubt it is best to assume that a lesion is infected and initiate appropriate laboratory analysis and aggressive therapeutic intervention.

**Table 26-9**

Classification of the Six Contact Lens–Related Infiltrative Events Including Symptoms, Signs, and Management and Treatment Options

<b>Infiltrative Category</b>	<b>Symptoms</b>	<b>Signs</b>	<b>Management and Treatment</b>
Microbial keratitis	Severe limbal/bulbar injection, acute onset of severe pain, decreased visual acuity, mucopurulent discharge, tearing, photophobia, and lid swelling	Large (>1 mm) focal infiltrates in para/central cornea with overlying tissue necrosis and excavation	Immediate treatment with topical fluoroquinolone eyedrops every 30–60 min, with cycloplegics two to three times a day for first day. Fluoroquinolone ointment at night. Patient followed on daily basis until epithelium healed, then taper therapy.
CL-induced peripheral ulcer	Limbal/bulbar injection, tearing, severe to moderate pain, foreign body sensation, or potentially asymptomatic	Small (<1 mm), single, circular mid/peripheral infiltrate with overlying tissue necrosis, excavation	Immediate treatment with topical fluoroquinolone eyedrops every hour during waking hours, ointment at night. Cycloplegics depend on patient's pain. Follow daily until epithelial defect healed, then taper therapy.
CL-associated red eye	Moderate/severe circumferential injection, irritation to moderate pain, tearing, and photophobia; patient awakened by symptoms or noticed soon after awakening	Small, multiple, focal infiltrates and diffuse infiltration in mid/periphery of cornea without punctate staining	Discontinuation of CL wear, application of unpreserved AT for comfort. More severe cases, consider use of topical steroid eyedrops four times a day until resolution of infiltrates, then taper.
Infiltrative keratitis	Mild to moderate irritation, injection, and occasional discharge	Anterior stromal infiltrates with/out accompanying epithelial involvement in the mid/periphery	Discontinuation of CL wear and initiate unpreserved AT for comfort. In more severe cases or when epithelial defect, fluoroquinolone eyedrops every 2 hr to four times a day. Consider use of steroid eyedrops to resolve infiltrates if not resolving on own.
Asymptomatic infiltrative keratitis	Mild to moderate limbal and bulbar injection, no patient subjective symptoms of discomfort	Small focal infiltrates with/out mild to moderate diffuse infiltration in the periphery	Discontinue CL wear, unpreserved AT for comfort. May consider use of a steroid to resolve infiltrates.
Asymptomatic infiltrates	No patient symptoms	Very small focal infiltrates and/or mild diffuse infiltration with no overlying epithelial staining	Discontinue CL wear until resolution. May consider use of steroid eyedrops to speed recovery of infiltrates.

AT = artificial tears; CL = contact lens.

Adapted from Sweeney DE, Jalbert I, Convey M, et al. Clinical characterization of corneal infiltrative events observed with soft contact lens wear. *Cornea* 2003;22:435–442.

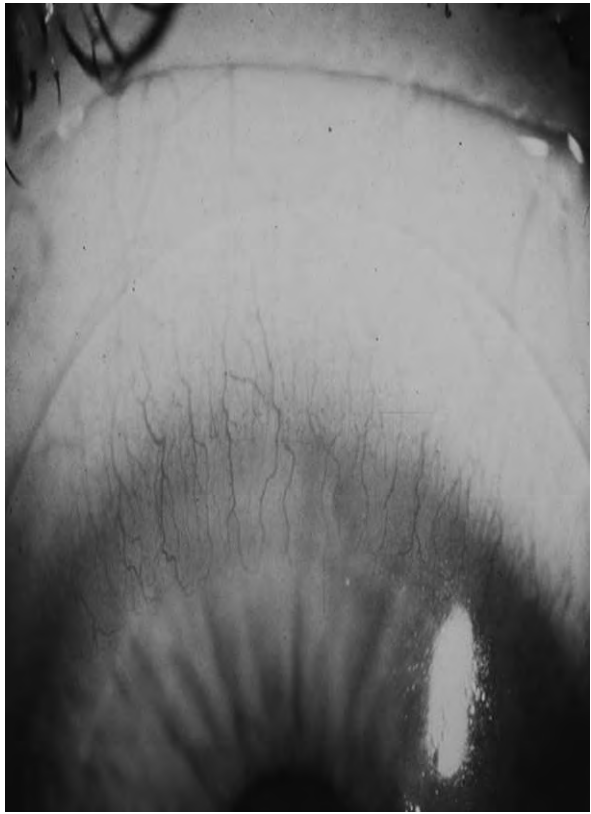### Management

Any infiltrative event necessitates discontinuation of contact lens wear. With significant corneal involvement and an anterior chamber reaction, cycloplegia with a long-acting agent such as 5% homatropine enhances patient comfort and helps to relieve iris congestion.

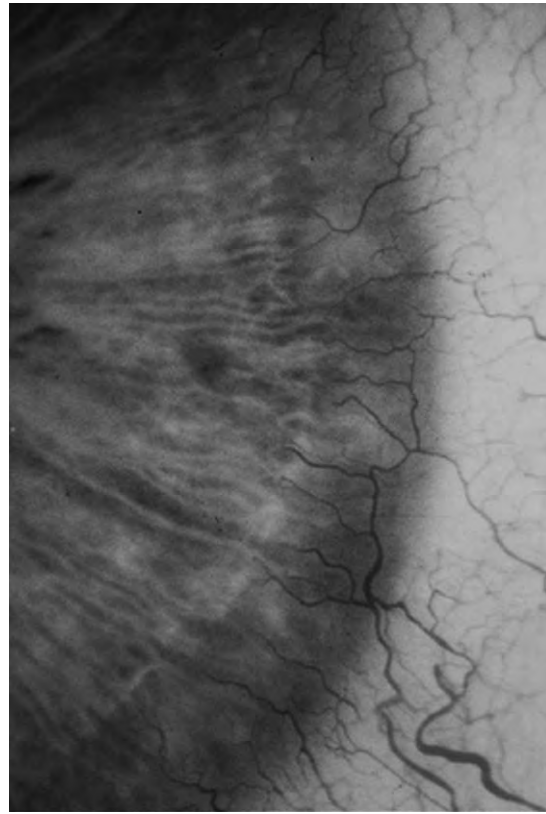
Once contact lens wear is discontinued, mild infiltrative events are self-limiting over a few days to a week. The infiltrates take longer to resolve than the associated

conjunctival hyperemia and injection. Topical prophylactic antibiotic therapy is appropriate to protect the inflamed eye from infection as it heals. With the potential for gram-negative pathogens in a soft contact lens wearer, especially extended wear, broad-spectrum agents should be used, such as 0.3% ciprofloxacin drops, or the newer generation of fluoroquinolones such as 0.5% moxifloxacin or 0.3% gatifloxacin four times a day, and 0.3% ciprofloxacin ointment at bedtime. If bacterial keratitis is

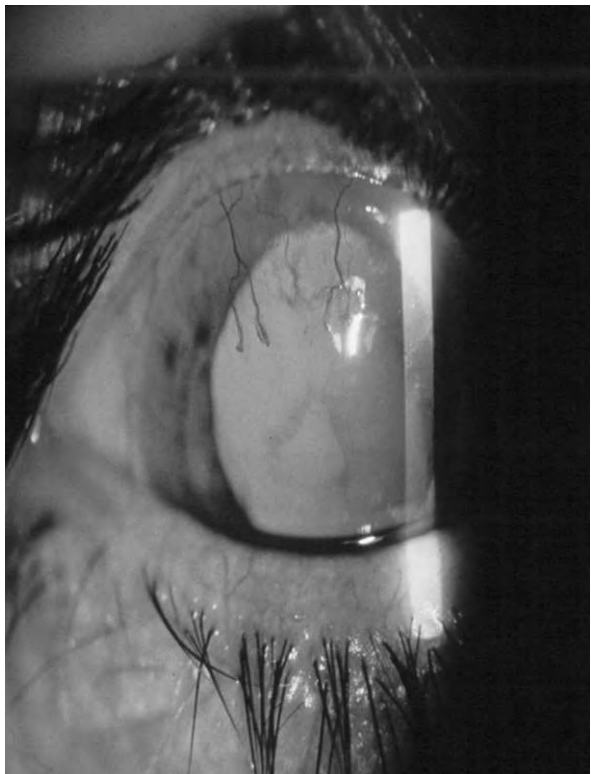




A



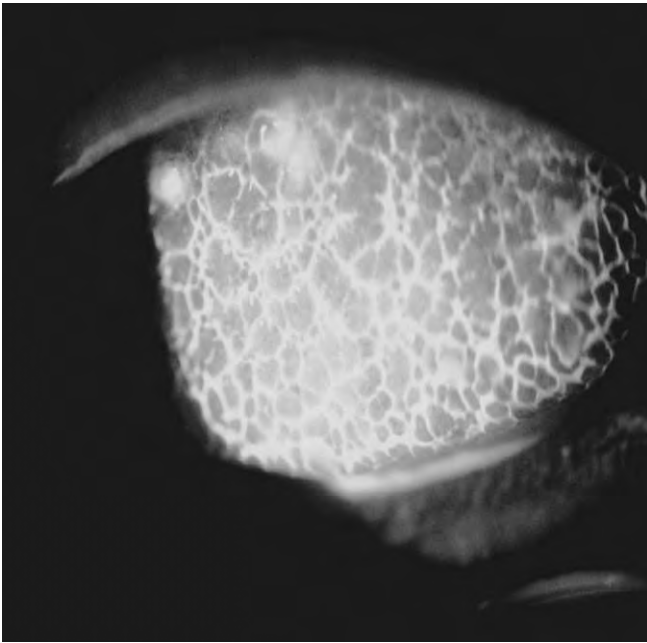
B



C

**Figure 26-54** (A-C) Corneal neovascularization secondary to contact lens wear. (Photos A and B courtesy of Pat Caroline; photo C courtesy of Dr. Tammy Than.)





**Figure 26-55** Giant papillary conjunctivitis secondary to rigid gas-permeable contact lens wear. (Courtesy of Pat Caroline.)

suspected or while waiting for culture results, more aggressive dosage intervals may be initiated.

Some clinicians advise against the use of topical steroid therapy in this condition. However, the addition of a topical steroid, such as 1% prednisolone or newer site-specific steroids such as loteprednol 1% four times a day, accelerates resolution of the stromal infiltrates and the accompanying inflammatory response of the eye. The use of these steroids also treats any anterior chamber reaction that may be present. The addition of topical steroids should be judicious pending the definitive

diagnosis issues discussed previously. Drug therapy usually is needed for 5 to 7 days. The patient should be monitored closely for the development of new signs or symptoms that alter the initial diagnosis of contact lens-associated infiltrative event.

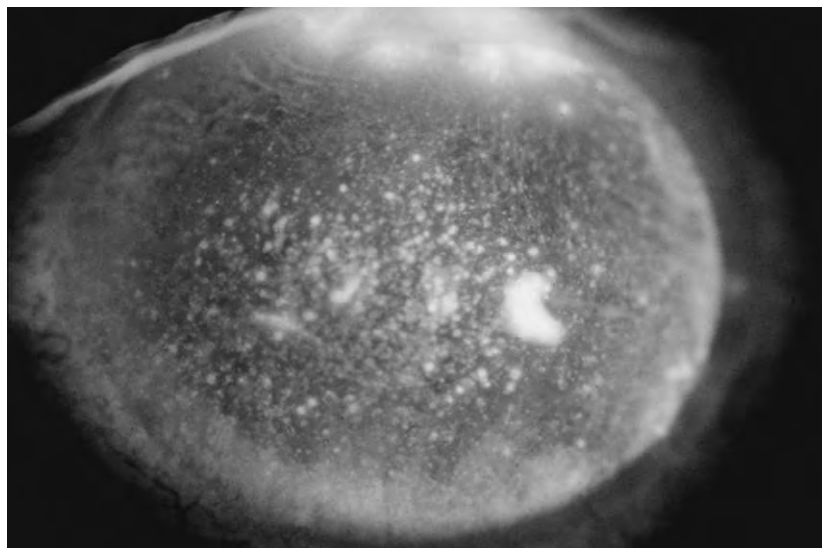
The infiltrative event may recur if contact lens wear is reinstated too soon and the eye has not been given adequate time to heal. Ideally, contact lens wear should not be resumed until all infiltrates, epithelial defects (including microcysts and subtle negative staining), and signs of inflammation have resolved, which may take up to several weeks. It is not uncommon, however, for prominent anterior stromal infiltrates to leave a persistent opacity (Figure 26-59) that does not preclude resumption of contact lens wear after complete resolution of the acute signs and symptoms.

Once contact lens wear is resumed, it is important to evaluate the lens fit, wearing time, and cleaning regimen in an effort to avoid recurrences of the infiltrative event. Contact lens replacement, a temporary or ongoing switch from extended to daily wear, refitting to a flatter lens, changing to disposable lenses, or refitting with rigid gas-permeable lenses may be needed, singly or in combination. It also is important to remind the patient of appropriate contact lens follow-up care intervals in an effort to minimize the development of acute problems.

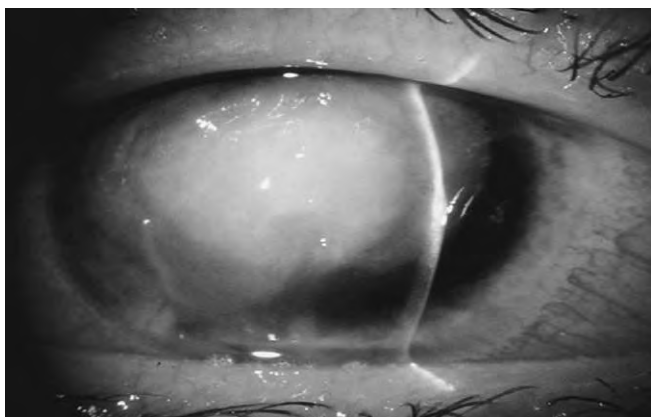
## Epithelial Microcysts

### Etiology

Epithelial microcysts are an abnormal corneal response at the cellular level to chronic hypoxia from contact lens wear. When present, they tend to be observed in soft contact lens wearers, particularly those wearing extended-wear lenses. A hypoxic state can result in the development of microcysts due to such causes as



**Figure 26-56** Corneal SPK secondary to toxic/sensitivity response to contact lens solution. (Courtesy of Pat Caroline.)



**Figure 26-57** Microbial keratitis. (Courtesy of Pat Caroline.)

excessive wearing time, aging lens material, a tight-fitting lens, or excessive coating and depositing on the lenses.

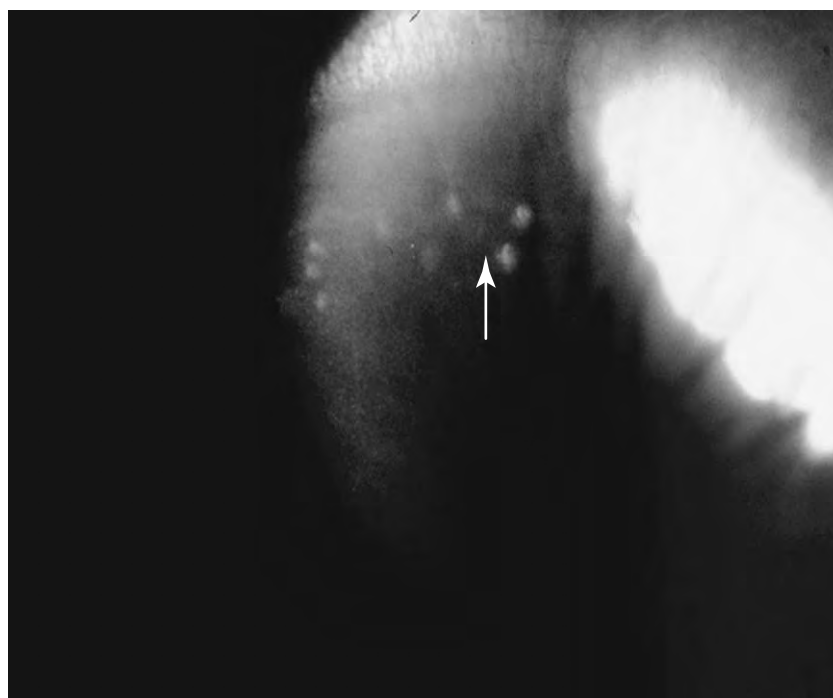Epithelial microcysts likely represent small pockets of cellular debris and disorganized cell growth arising from the basement membrane and basal layers of the cornea. The inciting event to microcyst development may be the accumulation of fluid in the intracellular spaces of the epithelium. Microcysts appear as tiny, refractile, spheroidal dots in the central and paracentral corneal epithelium. Because of normal cell turnover, the microcysts tend to migrate through the corneal epithelium where they may rupture and erode onto the epithelial surface. Although an occasional epithelial microcyst may be noted in an asymptomatic extended-wear soft contact

lens patient, a patient who develops large numbers of densely aggregated microcysts eventually develops symptomatology. It is the latter patient who requires therapeutic intervention.

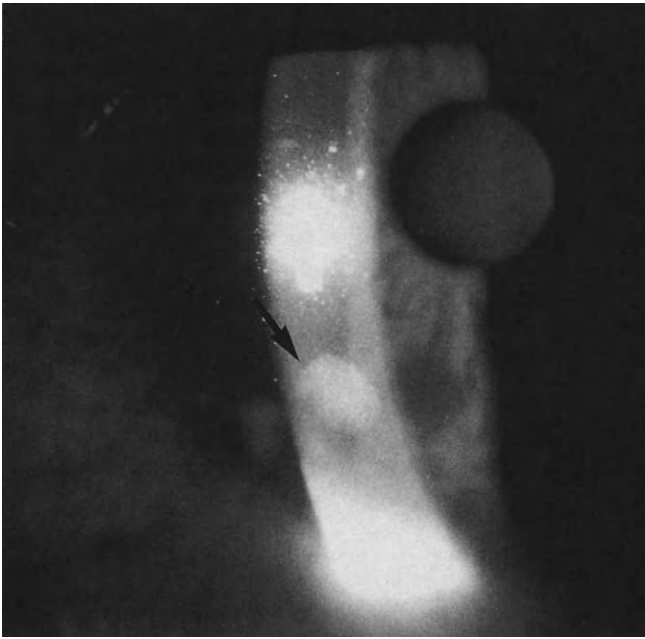
### Diagnosis

The soft contact lens patient who becomes symptomatic from epithelial microcysts tends to develop symptoms rather suddenly after uneventful contact lens wear. It is not uncommon for the patient with microcysts to have been remiss in timely follow-up care, when the formation of microcysts may have been detected before symptoms developed. Symptoms associated with this condition include burning, foreign body sensation, tearing, and photophobia, all likely related to the disrupted epithelium. Decreased visual acuity results, even with the best spectacle correction in place, because of the now irregular corneal surface.

Mild to moderate conjunctival injection occurs and may be enhanced in the perilimbal area. Careful slit-lamp examination reveals a dense collection of tiny, clear, epithelial cysts in the central cornea. This appearance is best viewed using indirect illumination and retroillumination techniques (Figure 26-60). Instillation of NaFl reveals an irregular central epithelial surface with almost a discoid collection of punctate “positive” and “negative” stains. Positive stains occur when the microcysts have emptied onto the epithelial surface and caused microerosions; negative stains occur over the tiny “bumps” in the epithelium where the microcysts have invaded the epithelium but not yet eroded it.



**Figure 26-58** Subepithelial infiltrates secondary to soft contact lens wear. (Courtesy of Pat Caroline.)

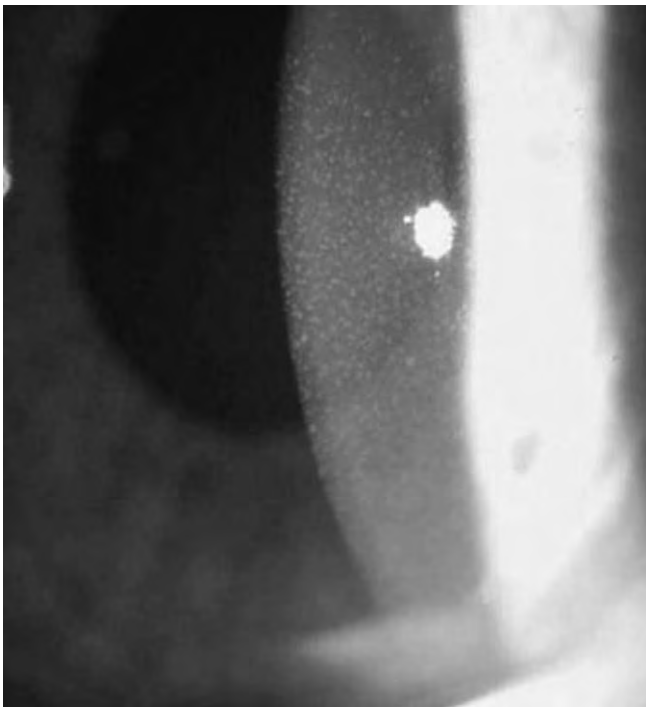


**Figure 26-59** An anterior stromal scar remains (*arrow*) after resolution of infiltrative keratitis and associated corneal infiltrate.

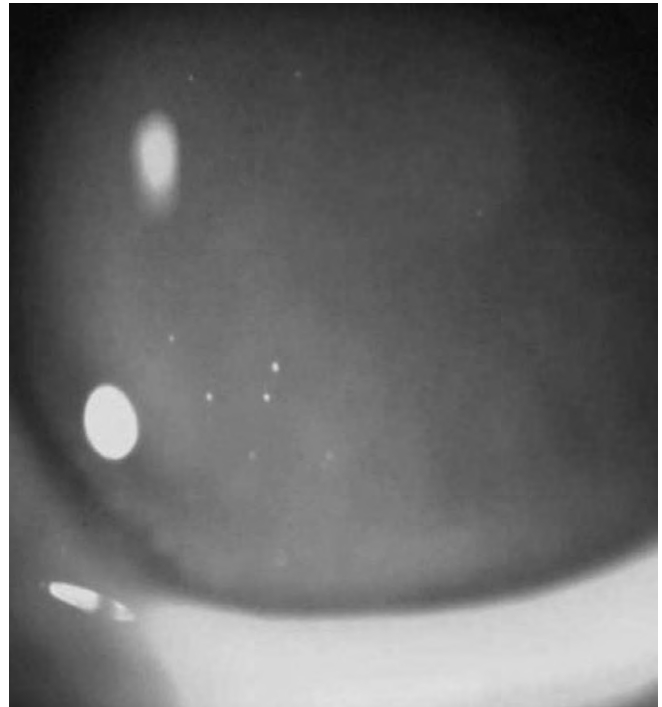
### Management

Treatment requires discontinuation of contact lens wear until the epithelial microcysts resolve. Therapeutic measures are primarily supportive in nature while the tissue heals and returns to a normal state. Patients who are acutely symptomatic may benefit from cycloplegia, using long-acting agents such as 5% homatropine for several days. Prophylactic topical antibiotic therapy, such as 0.3% tobramycin drops or 0.3% ciprofloxacin, or the newer generation fluoroquinolones, moxifloxacin 0.5% and gatifloxacin 0.3%, instilled four times daily, protect the cornea from secondary infection. A topical ophthalmic ointment, such as 0.3% tobramycin or 0.3% ciprofloxacin, instilled at bedtime, provides a cushioning layer between the lid and the irritated epithelium. Additionally, the instillation of a mild topical steroid drop, such as 0.12% prednisolone, 0.1% fluorometholone, or 0.5% loteprednol four times a day, enhances patient comfort. Patient compliance can be increased by prescribing combination products such as tobramycin-dexamethasone or tobramycin-loteprednol four times daily.

Epithelial microcysts may take weeks to months to resolve, although the therapy described above is generally needed only for the first 1 or 2 weeks after acute presentation. Once the patient becomes asymptomatic, it can be a challenging management issue to convince the patient that contact lens wear should be discontinued until the corneal tissue is healed. While corneal healing is being



A



B

**Figure 26-60** Epithelial microcysts observed in diffuse illumination (*A*) and with NaFl staining (*B*) secondary to soft contact lens wear.

monitored, it is important to observe closely for subtle positive and negative staining, which is indicative of persistent epithelial disruption.

Once the microcysts resolve completely, contact lens wear may be reinstated carefully. If age of the lens material, deposited lenses, tight-fitting lenses, or low water content was related to the development of the microcysts, then pursue contact lens refitting. Patient education must be addressed regarding the need for proper lens hygiene, wearing time, and follow-up care. Once contact lens wear is resumed, careful periodic corneal examination is needed to monitor for recurrence of epithelial microcysts.

## SELECTED BIBLIOGRAPHY

- Aasuri MK, Venata N, Kumar VM. Differential diagnosis of microbial keratitis and contact lens-induced peripheral ulcer. *Eye Contact Lens* 2003;29(1 suppl):S60-S62; discussion S83-S84, S192-S194.
- Albietz J, Sanfilippo P, Troutbeck R, Lenton LM. Management of filamentary keratitis associated with aqueous-deficient dry eye. *Optom Vis Sci* 2003;80:420-430.
- Alfonso E, Crider J. Ophthalmic infections and their anti-infective challenges. *Surv Ophthalmol* 2005;50(suppl 1):S1-S6.
- Arffa RC. Corneal trauma. In: Grayson's diseases of the cornea, ed 4. St Louis: Mosby-Year Book, 1997: 685-708.
- Avisar R, Robinson A, Appel I, et al. Diclofenac sodium, 0.1% (Voltaren Ophtha), versus sodium chloride, 5%, in the treatment of filamentary keratitis. *Cornea* 2000;19:145-147.
- Avunduk AM, Beurerman RW, Varnell ED, et al. Confocal microscopy of *Aspergillus fumigatus* keratitis. *Br J Ophthalmol* 2003;87:409-410.
- Baudouin C. Allergic reaction to topical eyedrops. *Curr Opin Allerg Clin Immunol* 2005;5:459-463.
- Baum J, Dabezies OH Jr. Pathogenesis and treatment of "sterile" midperipheral corneal infiltrates associated with soft contact lens use. *Cornea* 2000;19:777-781.
- Bharathi MJ, Ramakrishnan R, Meenakshi R, et al. Epidemiological characteristics and laboratory diagnosis of fungal keratitis. A three year study. *Indian J Ophthalmol* 2003;51:315-321.
- Bourcier T, Thomas F, Fordeur V, et al. Bacterial keratitis: predisposing factors, clinical and microbiological review of 300 cases. *Br J Ophthalmol* 2003;87:834-838.
- Callegan MC, Ramierz R, Kane ST, et al. Antibacterial activity of the fourth-generation fluoroquinolones gatifloxacin and moxifloxacin against ocular pathogens. *Adv Ther* 2003;20: 246-252.
- Charukamnoetkanok P, Pineda R 2nd. Controversies in management of bacterial keratitis. *Int Ophthalmol Clin* 2005;45: 199-210.
- Christakopoulos CE, Prause JU, Heegaard S. Infectious crystalline keratopathy histopathological characteristics. *Acta Ophthalmol Scand* 2003;81:659-661.
- Cosar CB, Rapuano CJ, Cohen EJ. Corneal laceration and intraocular foreign body in a post-LASIK eye. *Cornea* 2002; 21:234-236.
- Dajcs JJ, Thibodeau BA, Marquart ME, et al. Effectiveness of ciprofloxacin, levofloxacin or moxifloxacin for treatment of experimental *Staphylococcus aureus* keratitis. *Antimicrob Agents Chemother* 2004;48:1948-1952.
- Daniell M. Overview: initial antimicrobial therapy for microbial keratitis. *Br J Ophthalmol* 2003;87:1172-1174.
- Daniell M, Mills R, Morlet N. Microbial keratitis: what's the preferred initial therapy? *Br J Ophthalmol* 2003;87:1167.
- Doan S, Gabison E, Gatinel D, et al. Topical cyclosporine A in severe steroid-dependent childhood phlyctenular keratoconjunctivitis. *Am J Ophthalmol* 2006;141:62-66.
- Donnenfeld E, Perry HD, Chruscicki DA, et al. A comparison of the fourth-generation fluoroquinolones gatifloxacin 0.3% and moxifloxacin 0.5% in terms of ocular tolerability. *Curr Med Res Opin* 2004;20:1753-1758.
- Dua HS, King AJ, Joseph A. A new classification of ocular surface burns. *Br J Ophthalmol* 2001; 85:1379-1383.
- Dursun D, Kim MC, Solomon A, Pflugfelder SC. Treatment of recalcitrant recurrent corneal erosions with inhibitors of matrix metalloproteinase-9, doxycycline and corticosteroids. *Am J Ophthalmol* 2001;132:8-13.
- Efron N, Morgan PB, Hill EA, et al. The size, location, and clinical severity of corneal infiltrative events associated with contact lens wear. *Optom Vis Sci* 2005;82:519-527.
- Fite SW, Chodosh J. Photorefractive keratectomy for myopia in the setting of Thygeson's superficial punctate keratitis. *Cornea* 2001;20:425-426. [Comment in: *Cornea* 2001;20: 904; *Cornea* 2002;21:736-737; author reply 737.]
- Galor A, Jeng BH, Singh AD. Current management of traumatic corneal abrasions: an evidence-based update. *Compr Ophthalmol Update* 2005;6:105-111.
- Goegebuer A, Ajay L, Claerhout I, et al. Results of penetrating keratoplasty in syphilitic interstitial keratitis. *Bull Coc Belge Ophthalmol* 2003;290:35-39
- Goldstein MH, Feistmann JA, Bhatti MT. PRK-pTK as a treatment for a patient with Thygeson's superficial punctate keratopathy. *CLAO J* 2002;28:172-173.
- Hariprasad SM, Moon SJ, Allen RC, et al. Keratopathy from congenital syphilis. *Cornea* 2002;21:608-609.
- Herpetic Eye Disease Study Group. Oral acyclovir for herpes simplex virus eye disease. *Arch Ophthalmol* 2000;118: 1030-1036.
- Herpetic Eye Disease Study Group. Predictors of recurrent herpes simplex virus keratitis. *Cornea* 2001;20(2):123-128.
- Isaac DLC, Ghanem VC, Nascimento MA, et al. Prognostic factors in open globe injuries. *Ophthalmologica* 2003;217:431-435.
- Jabbur NS, O'Brien TP. Recurrence of keratitis after excimer laser keratectomy. *J Cataract Refract Surg* 2003;29:198-201.
- Jeng BH, McLeod SD. Microbial keratitis. *Br J Ophthalmol* 2003;87:805-806.
- Joyce NC. Proliferative capacity of the corneal endothelium. *Prog Retin Eye Res* 2003;22:359-389.
- Keay L, Edwards K, Naduvilath T, et al. Microbial keratitis predisposing factors and morbidity. *Ophthalmology* 2006; 113:109-116.
- Khan, NA. Pathogenesis of *Acanthamoeba* infections. *Microb Pathogen* 2003;34:277-285.
- Khaw PT, Shah P, Elkington AR. Injury to the eye. *BMJ* 2004;328:36-38.
- Knox CM, Holsclaw DS. Interstitial keratitis. *Int Ophthalmol Clin* 1998;38:183-195.
- Kim J. The use of vital dyes in corneal disease. *Curr Opin Ophthalmol* 2000;11:241-247.

- Kompa S, Redbrake C, Hilgers C, et al. Effect of different irrigating solutions on aqueous humour pH changes, intraocular pressure and histological findings after induced alkali burns. *Acta Ophthalmol* 2005;83:467-470.
- Kowalski RP, Dhaliwal DK, Karenchak LM, et al. Gatifloxacin and moxifloxacin: an in vitro susceptibility comparison to levofloxacin, ciprofloxacin and ofloxacin using bacterial keratitis isolates. *Am J Ophthalmol* 2003;136:500-505.
- Kuckelkorn R, Schrage N, Keller G, Redbrake C. Emergency treatment of chemical and thermal eye burns. *Acta Ophthalmol* 2002;80:4-10.
- Kumar M, Mishra NK, Shukla PK. Sensitive and rapid polymerase chain reaction based diagnosis of mycotic keratitis through single stranded conformation polymorphism. *Am J Ophthalmol* 2005;140:851-857.
- Kurt E, Öztürk F, Inan ÜÜ, et al. Efficacy of eye patching for corneal healing after removal of corneal foreign body. *Ann Ophthalmol* 2003;35:114-116.
- Kwon, YS, Song YS, Kim JC. New treatment for band keratopathy; superficial lamellar keratectomy, EDTA chelation and amniotic membrane transplantation. *J Korean Med Sci* 2004; 19:611-615.
- Lalitha P, Prajna NV, Kabra A, et al. Risk factors for treatment outcome in fungal keratitis. *Ophthalmology* 2006;113: 526-530.
- Liesegang TJ. Herpes zoster virus infection. *Curr Opin Ophthalmol* 2004;15:531-536.
- Lit ES, Young LH. Anterior and posterior segment intraocular foreign bodies. *Int Ophthalmol Clin* 2002;42:107-120.
- Mah FS. Fourth-generation fluoroquinolones: new topical agents in the war on ocular bacterial infections. *Curr Opin Ophthalmol* 2004;15:316-320.
- Mallari PLT, McCarty DJ, Daniell M, et al. Increased incidence of corneal perforation after topical fluoroquinolones treatment for microbial keratitis. *Am J Ophthalmol* 2001;131:131-133.
- Mather R, Karenchak LM, Romanowski EG, et al. Fourth generation fluoroquinolones: new weapons in the arsenal of ophthalmic antibiotics. *Am J Ophthalmol* 2002;133:463-466.
- McLeod, Kumar A, Cevallos V, et al. Reliability of transport medium in the laboratory evaluation of corneal ulcers. *Am J Ophthalmol* 2005;140:1027-1031.
- Mills R. View 1: corneal scraping and combination antibiotic therapy is indicated. *Br J Ophthalmol* 2003;87:1167-1169.
- Morlet N, Daniell M. View 2: empirical fluoroquinolones therapy in sufficient initial treatment. *Br J Ophthalmol* 2003;87:1169-1172.
- Netto MV, Chalita MR, Krueger RR. Thygeson's superficial punctate keratitis recurrence after laser in situ keratomileusis. *Am J Ophthalmol* 2004;138:507-508.
- Nichols B, ed. Basic and clinical science course. External disease and cornea, section 7. American Academy of Ophthalmology. San Francisco, CA. 1990.
- Oliva MS, Taylor H. Ultraviolet radiation and the eye. *Int Ophthalmol Clin* 2005;45:1-17.
- Orsoni JG, Zavota L, Manzotti F, et al. Syphilitic interstitial keratitis: treatment with immunosuppressive drug combination therapy. *Cornea* 2004;23:530-532.
- Parmar P, Salman A, Kalavathy CM, et al. Comparison of topical gatifloxacin 0.3% and ciprofloxacin 0.3% for the treatment of bacterial keratitis. *Am J Ophthalmol* 2006;141:282-286.
- Pepose JS, Keadle TL, Morrision LA. Ocular herpes simplex: changing epidemiology, emerging disease patterns, and the potential of vaccine prevention and therapy. *Am J Ophthalmol* 2006;141:547-557.
- Rashad KM, Hussein HA, El-Samadouny MA, et al. Phototherapeutic keratectomy in patients with recurrent corneal epithelial erosions. *J Refract Surg* 2001;17:511-518.
- Reidy JJ, Paulus MP, Gona S. Recurrent erosions of the cornea: epidemiology and treatment. *Cornea* 2000;19:767-771.
- Reim M, Redbrake C, Schrage N. Chemical and thermal injuries of the eyes. Surgical and medical treatment based on clinical and pathophysiological findings. *Arch Soc Esp Oftalmol* 2001;76:79-124.
- Reinhard T, Roggendorf M, Fengler I, et al. PCR for varicella zoster virus genome negative in corneal epithelial cells of patients with Thygeson's superficial punctate keratitis. *Eye* 2004;18:304-305.
- Remeijer L, Osterhaus A, Verjans G. Human herpes simplex virus keratitis: the pathogenesis revisited. *Ocul Immunol Inflamm* 2004;12:255-285.
- Ritterband DC, Seedor JA, Shah MK, et al. Fungal keratitis at the New York eye and ear infirmary. *Cornea* 2006;25: 264-267.
- Rohatgi J, Dhaliwal U. Phlyctenular eye disease: a reappraisal. *Jpn J Ophthalmol* 2000;44:146-150.
- Rosenberg ME, Tervo TM, Petroll WM, Vesaluoma MH. In vivo confocal microscopy of patients with corneal recurrent erosion syndrome or epithelial basement membrane dystrophy. *Ophthalmology* 2000;107:565-573.
- Roussel, T, Grutzmacher, R, Coster D. Patterns of superficial keratopathy. *Aust J Ophthalmol* 1984;12:301-316.
- Schaefer F, Bruttin O, Zografos L, et al. Bacterial keratitis: a prospective clinical and microbiological study. *Br J Ophthalmol* 2001;85:842-847.
- Schrage NF, Langefeld S, Zschocke J, et al. Eye burns: an emergency and continuing problem. *Burns* 2000;26:689-699.
- Schuster FL, Visvesvara GS. Opportunistic amoebae: challenges in prophylaxis and treatment. *Drug Resist Updates* 2004;7: 41-51.
- Seal D. Treatment of *Acanthamoeba* keratitis. *Exp Rev Anti-Infect Ther* 2003;1:205-208.
- Shaikh S, Ta CN. Evaluation and management of herpes zoster ophthalmicus. *Am Fam Physician* 2002;66:1723-1730.
- Sharma V, Sharma S, Garg P, et al. Clinical resistance of *Staphylococcus* keratitis to ciprofloxacin monotherapy. *Ind J Ophthalmol* 2004;52:287-292.
- Sridhar MS, Sharma S, Garg P, et al. Epithelial infectious crystalline keratopathy. *Am J Ophthalmol* 2001;131:255-257.
- Sridhar MS, Rapuano CJ, Cosar CB, et al. Phototherapeutic keratectomy versus diamond burr polishing of Bowman's membrane in the treatment of recurrent corneal erosions associated with anterior basement membrane dystrophy. *Ophthalmology* 2002;109:674-679.
- Stapleton F. Contact lens-related microbial keratitis: what can epidemiologic studies tell us? *Eye Contact Lens* 2003; 29(1 suppl):S85-S89; discussion S115-118, S192-S194.
- Starr CE, Pavan-Langston D. Varicella-zoster virus: mechanisms of pathogenicity and corneal disease. *Ophthalmol Clin North Am* 2002;15:7-15.
- Steele C. Contact lens fitting today: therapeutic and prosthetic contact lens fitting. *Optometry Today UK* 2005;45:40-46.
- Stooper ET, Pinto A, DeRossi SS, Sollecito TP. Herpes simplex and varicella-zoster infections: clinical and laboratory diagnosis. *Gen Dent* 2003;513:281-286.

- Suchecki JK, Donshik P, Ehlers WH. Contact lens complications. *Ophthalmol Clin North Am* 2003;16:471-484.
- Sweeney DE, Jalbert I, Convey M, et al. Clinical characterization of corneal infiltrative events observed with soft contact lens wear. *Cornea* 2003;22:435-442.
- Tabbara KE. Treatment of herpetic keratitis. *Ophthalmology* 2005;112:1640.
- Thomas PA. Fungal infections of the cornea. *Eye* 2003;17:852-862.
- Thomas PA, Leck AK, Myatt M. Characteristic clinical features as an aid to the diagnosis of suppurative keratitis caused by filamentous fungi. *Br J Ophthalmol* 2005;89:1554-1558.
- Thompson MJ, Albert DM. Ocular tuberculosis. *Arch Ophthalmol* 2005;123:844-849.
- Tullo A. Pathogenesis and management of herpes simplex virus keratitis. *Eye* 2003;17:919-922.
- Varga JH, Rubinfeld RS, Wolf TC, et al. Topical anesthetic abuse ring keratitis: report of four cases. *Cornea* 1997;16:424-429.
- Vincent AL, Patel DV, McGhee NJ. Inherited corneal disease: the evolving molecular, genetic and imaging revolution. *Clin Exp Ophthalmol* 2005;33:303-316.
- Vincent, AL, Rootman D, Munier FL, Heon E. A molecular perspective on corneal dystrophies. *Dev Ophthalmol* 2003;37:50-66.
- Viswalingam M, Rauz S, Morlet N, Dart JK. Blepharokeratoconjunctivitis in children: diagnosis and treatment. *Br J Ophthalmol* 2005;89:400-403.
- Wasserman BN, Liss RP, Santander SH. Recurrent corneal ulceration as late complication of toxic keratitis. *Br J Ophthalmol* 2002;86:245-246.
- Watson SL, Hollingsworth J, Tullo AB. Confocal microscopy of Thygeson's superficial punctate keratopathy. *Cornea* 2003;22:294-299.
- Wilhelmus KR. Indecision about corticosteroids for bacterial keratitis: an evidence-based update. *Ophthalmology* 2002;109:835-842.
- Willoughby CE, Batterbury M, Kay SB. Collagen corneal shields. *Surv Ophthalmol* 2002;47:174-182.
- Xie L, Shi W, Liu Z, et al. Lamellar keratoplasty for the treatment of fungal keratitis. *Cornea* 2002;21:33-37.
- Yuen HK, Rassier CE, Jardeleza MS, et al. A morphologic study of Fuchs' dystrophy and bullous keratopathy. *Cornea* 2005;24:319-327.

## Allergic Eye Disease

*Diane T. Adamczyk*

Allergic eye disease, with its many varieties and types of presentations, affects people of all ages and has varying degrees of severity and clinical manifestation. These presentations manifest in the conjunctiva as allergic conjunctivitis, giant papillary conjunctivitis (GPC), vernal keratoconjunctivitis (VKC), and atopic keratoconjunctivitis (AKC). Dermatologic manifestations include contact dermatitis and atopic dermatitis. The immunologic basis is undeniable in allergic eye disease, and recognizing it allows one to understand the disease's pathogenesis, clinical presentation, and how best to treat and manage the condition. Chapter 13 provides an overview of the immune component in allergic eye disease, with the pertinent points to the clinical manifestations described below.

### **ALLERGIC IMMUNOLOGY: THE CLINICAL FOUNDATION**

When the immune system has an exaggerated response to the allergen, a hypersensitivity or allergic reaction occurs. Allergens are antigens that initiate this hypersensitivity response and may include pollen, ragweed, mold, dust, trees, and animal dander. Hypersensitivity reactions may also result from food, insect venom, and drugs, including local anesthetics, sulfonamides, and penicillin. The respiratory system, gastrointestinal tract, skin, and eyes may be affected. Local clinical manifestations include hay fever (conjunctivitis), eczema, asthma, and hives. A systemic response may also occur that results in anaphylactic shock and possibly death.

Susceptible or atopic individuals often have a hereditary or familial predisposition to allergic responses. A genetic defect may account for the IgE response. When both parents are atopic, their child has a 50% chance of developing type I allergic reactions, and when only one parent is atopic the likelihood is 30%.

Allergic eye disease may result from a type I or type IV hypersensitivity reaction. Typically, on initial exposure to the allergen, there are no clinical manifestations. In contrast, clinical manifestations occur in sensitized individuals or

individuals who have already been exposed to the antigen. An immediate hypersensitivity reaction or humoral response (type I) occurs within minutes to hours in sensitized individuals. In comparison, cell-mediated immunity (type IV) is a delayed-type hypersensitivity that may take days to occur.

### **Ocular Immunology**

Allergens may dissolve in the tears, thereby providing an avenue of antigen exposure to the ocular structures. Blinking and flushing actions of the precorneal tear film are protective. The conjunctiva provides an environmental barrier characteristic of innate or nonspecific immunity. The conjunctiva contains a variety of cells, including T and B lymphocytes, that are necessary for a specific immunologic response. In the normal state, mast cells and plasma cells are present in the substantia propria, with mast cells numbering 10,000/mm<sup>3</sup>. In response to abnormal conditions, the distribution and number of mast cells change. Evidence of this response is found in GPC, seasonal allergic conjunctivitis, and AKC, in which an increased number of mast cells are found in the substantia propria. Mast cells normally are not found in the epithelium; however, they are found in the epithelium of patients with GPC and VKC. Mast cells have been subclassified into tryptase-containing mast cells and tryptase- and chymase-containing mast cells. Both types have been found in the conjunctival substantia propria, with tryptase- and chymase-containing mast cells predominant in healthy persons. In patients with vernal conjunctivitis, the total concentration of both mast cells and tryptase-containing mast cells is higher than that in healthy individuals. Although patients with GPC and atopic conjunctivitis have slightly increased mast cell concentration in the substantia propria compared with healthy persons, the distribution of mast cell types is similar to that of healthy individuals. These findings provide a basis for a better understanding of the pathogenesis, clinical variation, and potential treatment modalities for different allergic diseases.



Other cells that are not normally found in the conjunctiva are eosinophils and basophils. Both play an important role in allergic disease and its associated inflammatory process. Eosinophilic chemotactic factor, released by the mast cell, attracts eosinophils to the site of inflammation. In addition to this local eosinophilia, blood eosinophil levels may be elevated in those affected by chronic allergic conjunctivitis. Eosinophils may play a greater and more detrimental role in AKC and palpebral VKC than in other ocular allergies. In AKC and VKC, eosinophils are involved in the sight-threatening corneal changes.

Allergic disease also affects the lids and ocular adnexa. Contact dermatitis is an example of a delayed hypersensitivity reaction that affects the ocular adnexa. In contact dermatitis, exposure to antigen results in the infiltration of T cells and macrophages into the dermis within approximately 3 hours. Over a 48- to 72-hour period the peak response occurs, with T cells and macrophages spreading to the epidermis in an attempt to eliminate the antigen. Clinically, eczema or dermatitis develops. Even with the antigen removed, dermatitis may continue for up to 3 weeks.

### Immunologic Considerations in Treating Allergic Eye Disease

Management of allergic eye disease begins with identifying the allergen. Eliminating or avoiding the allergen is the optimal management strategy; however, this is often not possible. Lubricating drops may assist by diluting the allergen, but this alone may not provide adequate treatment, so that drug intervention is required. Various types of drugs interrupt specific stages of the immunologic response brought on by allergens. Table 27-1 lists various drugs used in the treatment of allergic disease.

Different types of drugs affect various stages of the allergic response. Decongestants cause vasoconstriction and alleviate signs of hyperemia. Antihistamines block histamine from binding to the H<sub>1</sub> receptor. Mast cell stabilizers prevent mast cell degranulation. Nonsteroidal anti-inflammatory drugs (NSAIDs) inhibit cyclooxygenase, an enzyme involved in the conversion of arachidonic acid to prostaglandins, prostacyclin, and thromboxane, thereby preventing the inflammatory reaction.

Steroids suppress inflammation by inhibiting phospholipase A<sub>2</sub>, preventing the formation of arachidonic acid and the synthesis of prostaglandins, prostacyclin, thromboxane, and leukotrienes. Steroids also inhibit degranulation of neutrophils, mast cells, and basophils, as well as histamine synthesis. These drugs decrease capillary permeability, decrease B and T lymphocytes, decrease vasodilation, and inhibit neovascularization and leukocyte migration. Side effects of steroids can limit their use. These adverse effects include elevated intraocular pressure, cataracts, delayed wound healing, increased susceptibility to infection, and rebound anterior uveitis. The potential for producing increased intraocular pressure is reduced with steroids

such as fluorometholone, which has less corneal penetration, as well as the “site-specific” steroids, such as rimexolone and loteprednol.

Cyclosporine A is an immunosuppressive agent that quells inflammation by inhibiting T helper cell proliferation and cytokine production. It also inhibits eosinophil and mast cell activation.

## ALLERGIC CONJUNCTIVAL DISEASE

Allergic conjunctivitis affects approximately 15% of the population. The incidence is found to be increasing in developed countries and may be related to genetics, air pollution, pet ownership, and the hygiene hypothesis. This hypothesis proposes that when the immune system is not exposed to allergens early in life, there is a greater likelihood to develop allergies later in life.

The various types of allergic diseases that affect the conjunctiva include allergic conjunctivitis (hay fever conjunctivitis), GPC, VKC (spring catarrh), and AKC (eczematous conjunctivitis). The clinical manifestations of each of these allergic diseases vary in severity and duration, ranging from mild to severe. Loss of vision is a serious complication that may occur in AKC and VKC.

The pathophysiology of allergic disease involves the immune system and its components, which include mast cells, eosinophils, and lymphocytes. Diagnosis is predominantly based on history and clinical findings. Treatment is based on severity. Initial treatment is best achieved by avoiding the allergen and providing supportive therapy, followed by the use of antihistamines, antihistamine/decongestant combinations, NSAIDs, and steroids as needed. The various types of allergic conjunctival inflammatory response and their etiology, diagnosis, treatment, and management are presented in Tables 27-2 and 27-3.

### Allergic Seasonal or Perennial Conjunctivitis

Conjunctival allergy most commonly affects people seasonally and is known as seasonal allergic conjunctivitis or hay fever conjunctivitis. Airborne allergens, such as pollen, are the cause of seasonal allergic conjunctivitis. Less commonly, allergic conjunctivitis may be present year round, and this form is known as perennial allergic conjunctivitis. This variety results from ubiquitous allergens, which include dust mites and animal dander. Frequently, nasal symptoms or rhinitis occur along with the ocular symptoms, and the combination is known as allergic rhinoconjunctivitis. Allergic conjunctivitis affects both genders and all age groups.

#### Etiology

Allergic conjunctivitis results from a type I immediate allergic reaction. The clinical manifestations reflect the immune response, and this response is discussed above and in Chapter 13.

*Text continued on page 560*

**Table 27-1**  
Overview of Drugs for Treatment of Allergic Disease

Drug Name (Generic Name)	Dosage	FDA Approved/ Off-Label Use	Minimum Age/Weight	Action	Adverse Reaction	Comments
Antihistamine/decongestant Vasocon-A (antazoline phosphate 0.5%, naphazoline hydrochloride 0.05%)	1–2 drops QID	Allergic conjunctivitis Off-label: VKC, AKC	6 yr	Antihistamine (antazoline phosphate) Vasoconstrictor (naphazoline hydrochloride)	Rebound congestion	Considerations: angle closure; MAOI use OTC
Naphcon-A (pheniramine maleate 0.3%, naphazoline hydrochloride 0.025%)	1–2 drops QID	Allergic conjunctivitis Off-label: VKC, AKC	Not available	Antihistamine (pheniramine maleate) Vasoconstrictor (naphazoline hydrochloride)	Rebound congestion	Considerations: angle closure; MAOI use OTC
Antihistamine (topical) Livostin (levocabastine hydrochloride)	1–2 drops QID	Allergic conjunctivitis Off-label: VKC	12 yr	H <sub>1</sub> receptor antagonist	Sting/burn Headache	Shake bottle before use No longer available U.S. Caution: contact lens wearers, children
Emadine (emedastine difumarate)	1 drop QID	Allergic conjunctivitis	3 yr	H <sub>1</sub> receptor antagonist Inhibits histamine- stimulates vascular permeability in the conjunctiva	Headache Bad taste	
Antihistamine (oral) Benadryl (diphenhydramine hydrochloride)	Adult: 25–50 mg TID–QID	Allergic reactions Conjunctivitis Urticaria Anaphylactic shock Insect bites Angioedema Allergic rhinitis Allergic conjunctivitis Angiodema	12 yr or as directed	Antihistamine	Somnolence	OTC
Chlor-Trimeton (chlorpheniramine maleate)	Adult: 4 mg QID–Q4H	Allergic conjunctivitis Angiodema	6 yr or as directed	Antihistamine	Somnolence	OTC

*Continued*

**Table 27-1**  
Overview of Drugs for Treatment of Allergic Disease—cont'd

Drug Name (Generic Name)	Dosage	FDA Approved/ Off-Label Use	Minimum Age/Weight	Action	Adverse Reaction	Comments
Zyrtec (cetirizine hydrochloride)	Adult: 5 or 10 mg/day 6–12 yr: 5 or 10 mg/day 6 mo–5 yr: 0.5 teaspoon	Allergic rhinitis Urticaria	2 yr 6 mo–2 yr (syrup)	H <sub>1</sub> receptor antagonist	Somnolence Dry mouth	Also available with pseudoephedrine 120 mg Supplied: 5-, 10-mg tablet or chewable tablet; syrup Also available with pseudoephedrine 120–240 mg Supplied: 30-, 60-, 180-mg tablets; 60-mg capsule
Allegra (fexofenadine hydrochloride)	60 mg BID 180 mg/day	Allergies Rhinitis	6 yr	H <sub>1</sub> receptor antagonist	Headache	Also available with pseudoephedrine 120–240 mg Supplied: 30-, 60-, 180-mg tablets; 60-mg capsule
Claritin (loratadine)	10 mg/day 2–6 yr: 1 teaspoon	Allergic rhinitis Urticaria	6 yr	Long-acting tricyclic antihistamine with selective peripheral H <sub>1</sub> receptor antagonist	Headache Somnolence Dry mouth	Also available with pseudoephedrine 120–240 mg Supplied: 5, 10 mg; syrup OTC
Clarinex (desloratadine)	Adult: 5 mg/day Child: age-dependent liquid	Seasonal allergic rhinitis Perennial allergic rhinitis Chronic urticaria	6 years 6 mo (syrup)	Long-acting tricyclic antihistamine with selective peripheral H <sub>1</sub> receptor antagonist	Pharyngitis Dry mouth	Also available with pseudoephedrine 240 mg Supplied: 5-mg tablet; 2.5-, 5-mg rebitab; syrup Also used for anxiety, as a sedative
Hydroxyzine hydrochloride	Adult: 25 mg TID–QID	Allergies Dermatitis	May use under 6 yr	Selected cortical suppression Antihistamine effects		
Antihistamine/mast cell stabilizer Patanol (olopatadine hydrochloride 0.1%)	1 drop BID	Allergic conjunctivitis	3 yr	Inhibits release of histamine from mast cell Selective H <sub>1</sub> antagonist Inhibits type I hypersensitivity	Headache	10 minute time lag to contact lens insertion

Pataday (olopatadine hydrochloride 0.2%)	1 drop/day	Allergic conjunctivitis	3 yr	Inhibits release of histamine from mast cell Selective H <sub>1</sub> antagonist Inhibits type I hypersensitivity	10 minute time lag to contact lens insertion
Zaditor (ketotifen 0.025%)	1 drop q8-12h	Allergic conjunctivitis	3 yr	Antihistamine Decreases chemotaxis and eosinophil activation	10 minute time lag insertion OTC
Optivar (azelastine hydrochloride 0.05%)	1 drop BID	Allergic conjunctivitis	3 yr	Antihistamine Decreases chemotaxis and eosinophil activation	Burn/sting Bitter taste
Elestat (epinastine hydrochloride 0.05%)	1 drop BID	Allergic conjunctivitis	3 yr	Inhibits release of histamine from mast cell Selective H <sub>1</sub> antagonist Affinity for H <sub>2</sub> , $\alpha_{1,2}$ , and 5HT <sub>2</sub> receptor	Burn Itch Cold symptoms URI
<b>Mast cell stabilizers</b>					
Alomide (lodoxamide 0.1%)	1-2 drops QID	VKC Off-label: allergic conjunctivitis, AKC, GPC	2 yr	Blocks calcium influx across mast cell membrane Inhibits mast cell degranulation	Burn/sting contact lens wearers Loading time: days Maximum use: 3 mo
Alamast (pemirolast 0.1%)	1 drop QID	Allergic conjunctivitis	3 yr	Inhibits mast cell degranulation	Headache Rhinitis Cold symptoms
Crolom (cromolyn sodium 4%)	1-2 drops 4-6 times/day	VKC Off-label: allergic conjunctivitis, AKC/GPC	4 yr	Blocks calcium influx across mast cell membranes Inhibits mast cell degranulation	Burn/sting Cold symptoms
Alocril (nedocromil sodium ophthalmic solution 2%)	BID	Allergic conjunctivitis	3 yr	Inhibits mast cell degranulation Decreases chemotaxis	Caution: contact lens wearers Loading time: days Relief in minutes

Continued

**Table 27-1**  
Overview of Drugs for Treatment of Allergic Disease—cont'd

Drug Name (Generic Name)	Dosage	FDA Approved/ Off-Label Use	Minimum Age/Weight	Action	Adverse Reaction	Comments
Nonsteroidal anti-inflammatory drugs						
Acular (ketorolac tromethamine 0.5%)	1 drop QID	Allergic conjunctivitis Off-label: GPC, VKC	3 yr	Anti-inflammatory Cyclooxygenase inhibitor; inhibits prostaglandin, prostacyclin, thromboxane biosynthesis	Burn/sting	Caution: children Also available: 0.5% preservative free
Aspirin	650 mg TID	Analgesic, anti- inflammatory Off-label: VKC	Not available	Anti-inflammatory Cyclooxygenase inhibitor; inhibits prostaglandin, prostacyclin, thromboxane biosynthesis	GI disturbances GI bleeding	
Steroids						
Prednisolone	0.01–1.00%, q1h–BID (varies)	Nonviral conjunctivitis (allergic, GPC, AKC)	Not available	Anti-inflammatory Inhibits phospholipase A <sub>2</sub> and arachidonic acid, preventing biosynthesis of prostaglandins, prostacyclin, thromboxane, and leukotrienes	Increase IOP Cataract Infection	Caution: children
Alrex (loteprednol 0.2%)	0.2% suspension: QID	Seasonal allergic conjunctivitis	Not established	Anti-inflammatory Site specific Inhibits phospholipase A <sub>2</sub> and arachidonic acid, preventing biosynthesis of prostaglandins, prostacyclin, thromboxane, and leukotrienes	Increase IOP Cataract Infection	Shake bottle before use

Lotemax (loteprednol 0.5%)	0.5% suspension: 1–2 drops QID	Steroid-responsive conditions of the anterior segment	Not established	Anti-inflammatory Site specific Inhibits phospholipase A <sub>2</sub> and arachidonic acid, preventing biosynthesis of prostaglandins, prostacyclin, thromboxane, leukotrienes	Increase IOP Cataract Infection	Shake bottle before use
Fluorometholone (FML)	1 drop BID–QID	Reduces inflammation of conjunctiva	2 yr	Anti-inflammatory Inhibits phospholipase A <sub>2</sub> and arachidonic acid, preventing biosynthesis of prostaglandins, prostacyclin, thromboxane, and leukotrienes	Increase IOP Cataract Infection	
Other						
Mucomyst (acetylcysteine)	QID	Bronchopulmonary conditions Off-label: VKC, GPC	Not available	Mucolytic agent		Formulated by pharmacist
Cyclosporine A	QID	Unlabeled: keratoconjunctivitis (VKC, AKC)	Not available	Immunosuppressive agent, T-cell inhibition	Burning	Oral: mainly used for transplant, rheumatoid arthritis, psoriasis Treatment atopic dermatitis
Protopotic 0.03 or 0.1% ointment (tacrimolus)	BID	Atopic dermatitis (moderate/severe)	0.03% 2–15 yr 0.1% >15 yr	Calcineurin inhibitor (immunosuppressant)	Burning Herpes zoster/ simplex infection	
Elidel (pimecrolimus) cream	BID	Atopic dermatitis (mild/moderate)	2 yr	Calcineurin inhibitor (immunosuppressant)	Burning	Treatment atopic dermatitis

AKC = atopic keratoconjunctivitis; FDA = U.S. Food and Drug Administration; GI = gastrointestinal; GPC = giant papillary conjunctivitis; OTC = over the counter; VKC = vernal keratoconjunctivitis; URI = upper respiratory infection; MAOI = monoamine oxidase inhibitor  
 From PDR electronic library 2006, Thomson PDR; Bartlett JD, ed. Ophthalmic drug facts, ed 18. St. Louis, Wolters Kluwer Health, 2007; Rhee DJ, Rapuano CJ, Papliodis GN, Fraunfelder FW, eds. Physicians desk reference for ophthalmology 2007. Montvale, NJ: Thomas PDR, 2006.

**Table 27-2**  
Conjunctival Allergic Disease: Etiology, Immune Findings, and Clinical Manifestations

Type	Causes/		Signs						
	Hypersensitivity Reactions	Immune Findings	Symptoms	Conjunctiva	Lid	Cornea	Lens	Age/Gender	Miscellaneous
Allergic conjunctivitis (seasonal, perennial)	Airborne allergens Type I	IgE (elevated): tears, serum) IgG (elevated): tears) Mast cell degranulation Mast cells (conjunctival epithelium, increase substantia propria) Eosinophilia (local, possibly blood) Histamine	Itching (mild/moderate) Burning Tearing Pressure behind eyes Stringy watery discharge	Injection Chemosis Small papillary changes (upper/lower lid) Follicles (chronic)	Swelling Dennie's line Allergic shiners	Rare	n/a	M or F Any age	OU May have no signs Vision usually unaffected Rhinitis associated
GPC	Contact lens Mechanical trauma Type I Type IV	Mast cells, lymphocytes (conjunctival epithelium) Basophils, eosinophils (conjunctival epithelium and substantia propria) Increased mast cells (substantia propria) IgG, IgE, IgM (elevated: tears) Tear complement	Itching (varying intensity) Mucus Tearing Burning Contact lens: coating, movement, awareness Blurred vision Foreign body sensation	Hyperemia Erythema Macro/giant papillae (upper lid) Trantas' dots	Mechanical ptosis	SPK Infiltrate	n/a	M or F Any age	OU May affect vision



VKC	Environment Genetic Type I Type IV	C3, C3a (elevated: tears) Mast cells (conjunctival epithelium) Basophils, eosinophils (conjunctival epithelium and substantia propria) Eosinophils (tears, blood) IgG, IgE, IgM (elevated: tears) IgE (elevated: serum) Tear complement C3, C3a (elevated: tears) Mast cell degranulation Histamine IgE (elevated: serum, tears) Mast cell, eosinophil (conjunctival epithelium) T cell (abnormal numbers) Inflammatory cytokines	Intense itching Mucous discharge Tearing Lid matting Foreign body sensation Photophobia	Papillae, macro/giant papillae (upper lid) Limbal nodule/ papillae Trantas' dots Symblepharon	Mechanical ptosis Dennie's line	SPK Epithelial macroerosion Plaques Pannus/ neovascu- larization Keratitis Shield ulcer Scarring High astigmatism Keratoconus	Cataracts	Children M:F = 2:1 (before puberty) M = F >20 yr Peak age: 11-13 yr	OU Vision affected, risk of vision loss Occurs in springtime Warm, dry climates Self-limited (2-10 yr) Positive family/ self history of atopic disease Types: palpebral (conjunctiva/ cornea) limbal, mixed
AKC	Type I Type IV	Hypereimia Erythema Chemosis Diffuse papillae (more on lower lid) Symblepharon Trantas' dots	Moderate/ severe Itching Tearing Burning Mucous discharge Photophobia	Dermatitis Blepharitis Melbomianitis Induration Trichiasis Ectropion Entropion Madarosis Dennie- Morgan line Allergic shiner Staphylococcal blepharitis	SPK Ulcer Pannus/ neovascu- larization Scarring Keratoconus Filamentary keratitis Herpes simplex keratitis	Cortical, Anterior/ posterior subcapsule	Adults (30-50 yr) Males	OU Occurs year round Risk of vision loss Positive self/family History of atopy Associated Atopic dermatitis Goblet cells	

AKC = atopic keratoconjunctivitis; F = female; GPC = giant papillary conjunctivitis; Ig = Immunoglobulin; M = Male; n/a = not applicable; OU = both eyes; SPK = superficial punctate keratopathy; VKC = vernal keratoconjunctivitis.

**Table 27-3**  
Treatment for Conjunctival Allergic Disease

Type	General	Topical Antihistamine	Mast Cell Stabilizer	NSAIDs	Steroids	Oral Antihistamines	Oral Steroids	Miscellaneous
Allergic	Avoid allergen	Moderate Antihistamine	Moderate/severe (e.g., lodoxamide, cromolyn QID)	Severe (e.g., ketorolac QID)	Limited use Severe (e.g., loteprednol 0.2% QID, fluorometholone TID-QID × 1 wk)	May use for itching, rhinitis	—	Another home for cat/dog Replace natural fibers (cotton, wool) with synthetic (nylon, dacron) in bedroom and wardrobe Eliminate down pillows Zipper-sealed pillow covers Hypoallergenic products (makeup)
	Cool compresses	(emedastine QID)	Prophylactic Maintenance (e.g., BID-QID)					
	Nonpreserved artificial tears	Decongestant (e.g., Vasocon-A QID, OTC)						
	Vasoconstrictors	Mast cell stabilizer (e.g., olopatadine/day)						
GPC	Contact lens considerations: Cleaning/disinfecting/enzyme Replacement-Frequent Wearing time Material-Low water/nonionic-Rigid Refit: Switch hydroxyethylmethacrylate to glyceryl methyl methacrylate or RGP Discontinue		Moderate/severe (e.g., cromolyn BID) Prophylactic Maintenance	Moderate/severe (e.g., suprofen QID)	Moderate/severe (e.g., prednisolone 1% QID)			

VKC	Mild: Environmental controls (cool, moist) Cold compresses Artificial tears	Mild: decongestant Moderate/severe	Mild Moderate/severe (e.g., lodoxamide QID, cromolyn sodium 4% 4-6 times/day) Maintenance (e.g., BID-QID) Used with acute treatment (e.g., steroids)	Moderate/severe Moderate/severe (e.g., prednisolone 1% q1h to QID) Maintenance (1-3 times a day) Pulse	Moderate/severe	Moderate/severe Severe	Mucolytic (e.g., acetylcysteine QID) Severe: aspirin Cyclosporine A (topical/systemic) Surgical excision Cryotherapy Supratarsal steroid injection Mucolytic (e.g., acetylcysteine QID) Lid scrubs/hygiene Antibiotic and/or steroid, topical (for blepharitis) Antibiotic, oral for posterior blepharitis (e.g., doxycycline 100 mg × 3 mo) Severe: cyclosporine (topical, QID; oral, 3-5 mg/kg/day)
AKC	Mild: Environmental controls Cold compresses	Mild Moderate/severe	Maintenance Prophylactic Used with steroids (e.g., cromolyn QID)	Moderate/severe Moderate/severe (e.g., prednisolone 1% q1h to QID) Ointment (for skin, e.g., hydrocortisone)	Moderate/severe Severe	Moderate/severe Severe	Mucolytic (e.g., acetylcysteine QID) Lid scrubs/hygiene Antibiotic and/or steroid, topical (for blepharitis) Antibiotic, oral for posterior blepharitis (e.g., doxycycline 100 mg × 3 mo) Severe: cyclosporine (topical, QID; oral, 3-5 mg/kg/day)

AKC = atopic keratoconjunctivitis; GPC = giant papillary conjunctivitis; NSAIDs = nonsteroidal anti-inflammatory drugs; OTC = over the counter; VKC = vernal keratoconjunctivitis.

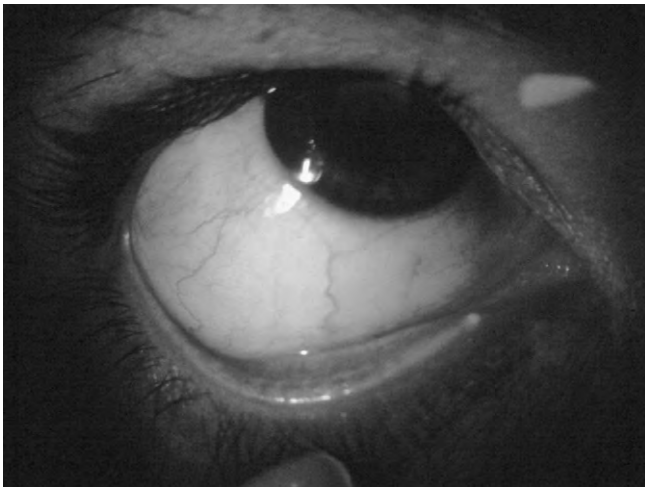
### Diagnosis

The diagnosis of allergic conjunctivitis is largely based on history and clinical presentation. The ocular signs and symptoms may be the only finding, or it may occur as rhinoconjunctivitis. Seasonal signs and symptoms are important diagnostic clues, reflecting allergies to various pollens. Perennial allergic conjunctivitis usually has a less severe clinical presentation than seasonal allergic conjunctivitis but may be exacerbated during certain times of the year.

Allergic conjunctivitis affects both eyes, with symptoms of mild to moderate itching, burning, and a stringy or watery discharge. The bulbar conjunctiva may be hyperemic and chemotic, and small palpebral papillary changes are often present. Follicles may be found in chronic cases. Lid involvement includes swelling, Dennie's line (a horizontal fold in the lower lid), and "allergic shiners." Allergic shiners manifest as a dark pigmentation around the eye. This results from periocular venous congestion or impaired venous return (in the skin and subcutaneous tissue) that is associated with lid swelling. In allergic conjunctivitis the cornea is rarely involved and vision is usually unaffected. Rhinitis may also be present along with the ocular manifestations.

Skin testing is a good adjunctive diagnostic test. Scratch testing may assist in determining the allergen involved.

At times a definitive diagnosis of allergic conjunctivitis may be elusive. Patients may present with symptoms but without obvious clinical signs. Perennial conjunctivitis should be considered when symptoms persist year round. Differential diagnosis is also important to consider, particularly because overlapping clinical presentations occur between allergic conjunctivitis and dry eye or blepharitis (Figure 27-1).



**Figure 27-1** Allergic conjunctivitis (note papillary changes in lower lid). The patient was treated with olopatadine hydrochloride. This patient also presented with a mild blepharitis and dry eye.

### Management

The best treatment for allergic conjunctivitis is avoidance of the causative allergen. Because this is often impossible, the severity of the clinical manifestations determines the management. In addition to the ocular treatment, comanagement with an allergist may be necessary to determine and manage the specific underlying allergens responsible. Educating the patient to avoid rubbing the eyes because it may aggravate clinical presentations is also an important consideration.

In mild cases of allergic conjunctivitis, the use of cold compresses, nonpreserved ocular lubricants, and vasoconstrictors provide symptomatic relief. Nonpreserved lubricants dilute and flush the precorneal tear film and wash away the allergens.

When allergic conjunctivitis is of moderate severity, topical antihistamines, either in combination with decongestants or without decongestants, are the next level of treatment. Because histamine is involved in vasodilation and itching, antihistamine–decongestant combinations, such as Vasocon-A (antazoline phosphate–naphazoline), provide relief from itching, redness and hyperemia, chemosis, lid swelling, and tearing. One or two drops are used four times a day. These drops are approved for children older than 6 years of age. Rebound hyperemia and vasodilation, angle-closure glaucoma, follicular conjunctivitis, and eczematoid blepharoconjunctivitis may occur with long-term use of decongestants and vasoconstrictors such as naphazoline and tetrahydrozoline.

Emedastine difumarate (Emadine) is an H<sub>1</sub> antagonist, approved for treating allergic conjunctivitis in patients aged 3 years and older. It is used four times a day. Levocabastine hydrochloride (Livostin), a suspension, is also a topical H<sub>1</sub> antihistamine that provides rapid relief of ocular symptoms. Emedastine has been found to be more effective in alleviating itching, chemosis, and lid swelling in allergic conjunctivitis than levocabastine. Levocabastine is no longer available in the United States.

In moderate to severe cases of allergic conjunctivitis, treatment considerations also include mast cell stabilizers, antihistamine–mast cell stabilizer combinations, oral antihistamines, NSAIDs, and, in severe cases, topical steroids.

Mast cell stabilizers are an effective and safe treatment modality for allergic conjunctivitis. They are useful in patients who have perennial allergic conjunctivitis and as a prophylaxis for seasonal allergic conjunctivitis. Mast cell stabilizers are effective only when used before the onset of allergic symptoms, because most drugs in this class have a typical therapeutic effect that occurs in 7 days to 14 days. Because there is a delay in noticeable clinical improvement with most mast cell stabilizers, concurrent therapy with other agents may be necessary for immediate relief. Nedocromil is an exception in this category, because it provides a more rapid relief of symptoms, usually within 15 to 30 minutes.

Mast cell stabilizers include cromolyn sodium 4% (Opticrom, Crolom) and lodoxamide tromethamine 0.1% (Alomide), which are currently approved by the U.S. Food and Drug Administration for VKC but offer off-label relief for allergic conjunctivitis. Other mast cell stabilizers include pemirolast (Alamast) and nedocromil sodium 2% (Alocril), with both approved for treatment of itching in allergic conjunctivitis. Perennial allergic conjunctivitis may be treated with mast cell stabilizers year round.

Drugs that have both a mast cell stabilizing effect and act as an antihistamine include olopatadine hydrochloride 0.1% (Patanol), olopatadine hydrochloride 0.2% (Pataday), ketotifen fumarate 0.5% (Zaditor), azelastine hydrochloride 0.05% (Optivar), and epinastine hydrochloride 0.05% (Elestat). These drugs are dual-acting and also multiacting drugs. Ketotifen (Zaditor) and azelastine hydrochloride (Optivar) also decrease chemotaxis and eosinophil activation. Epinastine, in addition to being a selective H<sub>1</sub> receptor inhibitor, has an affinity for other receptors, including the H<sub>2</sub> receptor. This group of drugs provides both long-term management for allergic conjunctivitis and rapid relief of symptoms. Ophthalmic olopatadine 0.2% has also been found to be effective in decreasing nasal symptoms that include sneezing and itchy and runny nose. These drugs may be used in patients 3 years of age and older. Dosage is twice a day, except for olopatadine 0.2%, which is a once a day dosage.

The use of steroids should be reserved for severe cases of allergic conjunctivitis, and long-term use should be limited because of their potential adverse effects. Loteprednol is a site-active steroid with a good safety profile and less potential for steroid side effects. It therefore is a good treatment option for seasonal allergic conjunctivitis. Site-active (or specific) drugs, such as loteprednol, undergo a rapid transformation to an inactive metabolite when they enter the target areas, therefore decreasing the potential for the side effects seen with traditional steroids. Loteprednol is formulated as a 0.2% suspension (Alrex) and a 0.5% suspension (Lotemax). Loteprednol 0.2% has been found to be effective in treating seasonal allergic conjunctivitis and a safe option for long-term treatment of seasonal and perennial allergic conjunctivitis. When steroid treatment is used to alleviate acute symptoms, long-term management includes the use of antihistamines, decongestants, or mast cell stabilizers to ultimately replace the steroid.

Oral antihistamines may be used to alleviate symptoms of allergic rhinoconjunctivitis. These include over-the-counter first-generation antihistamines such as chlorpheniramine maleate (Chlor-Trimeton) and diphenhydramine hydrochloride (Benadryl). Second-generation less sedating antihistamines include fexofenadine hydrochloride (Allegra), loratadine (Claritin), desloratadine (Clarinex), and cetirizine hydrochloride (Zyrtec). Dry eye symptoms may be an adverse reaction to oral antihistamines, including second generation.

Combination therapy of topical and systemic drugs is also an important treatment consideration. When symptoms are isolated to the eye, topical treatment is rapid and most efficient. However, in cases of rhinoconjunctivitis, when nasal symptoms are also present, optimum management includes combining topical ophthalmic medications, olopatadine or ketotifen, for example, with a nasal spray or systemic treatment, such as the oral antihistamine desloratadine. For rhinitis, nasal steroids provide a good treatment option. The above approach targets particular areas of involvement by utilizing the most efficacious route of treatment.

Treatment for allergic rhinitis may also include standard allergen immunotherapy that requires multiple injections. The short-term benefit is limited and the long-term effect is finite. Clinical trials have found promising results for the Amb a 1-immunostimulatory oligodeoxyribonucleotide conjugate (AIC) vaccine in those individuals allergic to ragweed. A series of six injections over 6 weeks has been found to provide improvement in rhinoconjunctivitis, with encouraging results for long-term effect.

Other treatment options include the use of topical NSAIDs, which provide relief of itching. Ketorolac tromethamine (Acular) is the only NSAID approved for the treatment of seasonal allergic conjunctivitis, with symptomatic relief occurring within 30 minutes after administration. Topical NSAIDs are not typically the treatment option chosen, because the other classes of drugs provide better well-established relief.

## Giant Papillary Conjunctivitis

GPC is an inflammatory condition that occurs primarily in contact lens wearers. The clinical manifestations include giant papillae in the upper tarsal conjunctiva, increased mucous secretion, itching, and lens intolerance. When GPC occurs with contact lens wear, it is referred to as contact lens papillary conjunctivitis (CLPC). In addition to contact lens wearers, GPC may also affect patients with ocular prostheses or exposed sutures.

All ages and both genders may be affected. Although study results vary widely, 3% to 15% of rigid lenses wearers and 5% to 10% of soft contact lens wearers are reported to develop GPC. Eighty-five percent of GPC occurs in hydrogel lens wearers. The incidence of GPC is lower in those wearing disposable versus conventional contact lenses and is lower with more frequent versus less frequent lens replacement.

## Etiology

The cause of GPC is multifactorial, with mechanical trauma and hypersensitivity reactions involved. In those genetically predisposed, the antigen-coated contact lens may trigger the hypersensitivity reaction, which includes both an immediate type I reaction and a type IV delayed reaction.

The mechanical and immunologic mechanisms, although distinct, overlap in the pathogenesis of GPC.

With each blink the antigen-coated contact lens mechanically traumatizes the tarsal conjunctiva. This process causes the release of mediators, such as neutrophil chemotactic factor and eosinophil chemotactic factor, which attract inflammatory cells (e.g., neutrophils, eosinophils, mast cells, and basophils). The immunologic sequence of events results in an increase in tear immunoglobulins IgE and IgG and C3 anaphylatoxin. The tear immunoglobulins and C3 anaphylatoxin then interact with the inflammatory cells produced from the mechanical trauma. This interaction causes the release of vasoactive amines, resulting in subsequent clinical manifestations. Papillae formation is related to structural changes in the conjunctival epithelium and stroma associated with increased eosinophils and inflammatory cells.

A variety of factors contributes to the development of GPC: contact lens coating, increased wearing time and

therefore greater antigen exposure, infrequent lens replacement, individual reaction to the lens type, larger lens and therefore a greater area for antigenic deposits, and a genetic predisposition. Any type of contact lens may cause GPC, including high Dk silicone lenses. Meibomian gland dysfunction has been suggested to be a factor in GPC; however, findings are inconsistent. A history of environmental allergies may be a predisposing factor, with GPC found more commonly in patients with these allergies.

### Diagnosis

The diagnosis of GPC is based on the clinical presentation and a history of contact lens wear, ocular prosthesis, or exposed sutures. In 90% of cases both eyes are affected. Symptoms may occur after only weeks of contact lens wear or may manifest after many years of wear. Four clinical stages of GPC have been described. Table 27-4 delineates these various stages.

**Table 27-4**

Giant Papillary Conjunctivitis: Signs, Symptoms, and Treatment Considerations

GPC Stage	Signs	Symptoms	Treatment Considerations
1: Preclinical (minimal symptoms, no signs)	Mucous discharge: mild Conj hyperemia: normal to mild Lens coating: minimum	Itch: slight (especially on lens removal)	Frequent lens replacement Disposable CLs Cleaning, disinfecting regimen
2: Early clinical (mild symptoms, early signs)	Mucous discharge: moderate Conj erythema: mild Lens coating: mild Papillae: variable sized (upper tarsal conjunctiva) Fluorescein assist identify Cornea: SPK rare Lens coating: mild	Itch: with CL wear Blur: s/p hours of CL wear Lens awareness: end of day	Frequent lens replacement CL material change Cleaning, disinfecting regimen
3: Moderate (moderate symptoms, moderate signs)	Mucous discharge: moderate to severe Conj erythema and edema: may be present Lens coating: moderate to severe Papillae: number, size >0.3 mm, elevation Fluorescein stain apices Lens coating: moderate to severe Lens movement: mild increase	Itch: variable Blur: moderate Lens awareness: thru day CL wearing time: decreased	Discontinue CL wear (approximately 4 weeks) Refit (consider RGP refit) Frequent lens replacement (1-2 wk) Therapeutic intervention
4: Severe (severe symptoms, severe signs)	Mucous discharge: significant Conj erythema/edema: variable Lens coating: immediate Papillae: giant Flattened apices stain with fluorescein Cornea: infiltration superior Lens coating: immediate Lens movement: excessive Lids: AM matting, mechanical ptosis	Itch: significant Blur: immediate clouding Lens awareness: marked CL wearing time: complete loss of lens tolerance	D/C CL 4 wks Frequent lens replacement: 2-3 days Daily disposable Refit (consider RGP refit) Cleaning regimen Therapeutic intervention

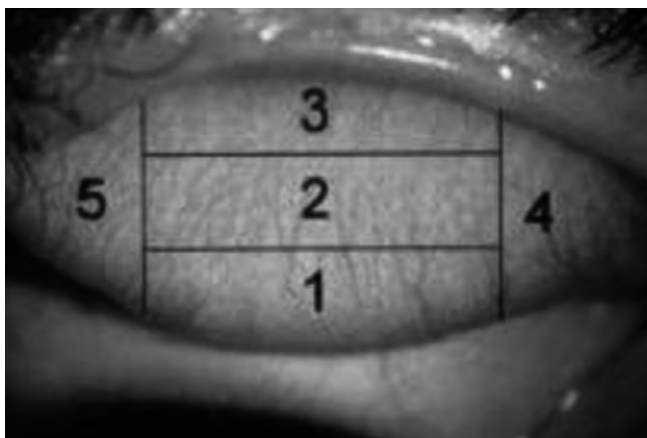AM = morning; CL = contact lens; Conj = conjunctival; D/C = discontinue; RGP = rigid gas permeable; SPK = superficial punctate keratitis. From Allansmith MR, Korb DR, Greiner JV, et al. Giant papillary conjunctivitis in contact lens wearers. *Am J Ophthalmol* 1977;83:700.

Conjunctival papillary changes are an integral component of GPC. Micropapillae, by definition, are smaller than 0.3 mm and are present in 80% of normal eyes. Macropapillae are 0.3 to 1.0 mm in size and are usually not a normal clinical presentation. Giant papillae are at least 1 mm in size and develop, separate from normal papillae, as part of the pathologic process of GPC.

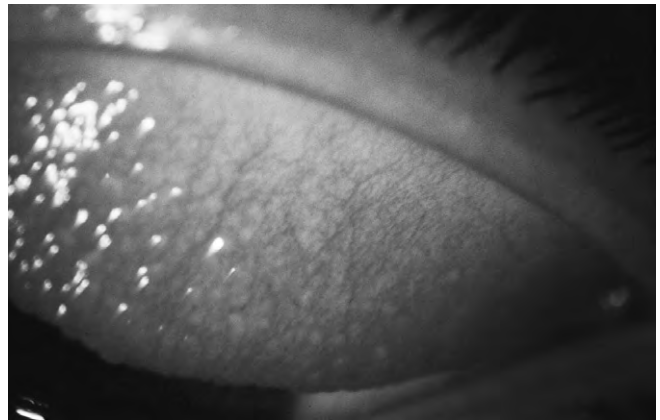Soft contact lens wearers first show papillary changes in the upper or inside edge of the tarsal plate (zone 1), followed by involvement of the middle area of the tarsal plate (zone 2), and finally progression toward the lid margin (zone 3). Rigid contact lens patients have fewer and smaller papillae that appear closer to the lid margin (zone 3) or in the central zone (zone 2) of the upper tarsal area (Figure 27-2).

There are two types of papillary presentations of CLPC: general and local. General CLPC may affect two, more, or all lid zones (Figure 27-3). Localized CLPC affects one or two lid zones, reflecting a mechanical trauma (Figure 27-4). General CLPC is more commonly seen with low Dk hydrogel lenses, and local CLPC is more commonly seen with high Dk silicone lenses. With silicone hydrogel lenses typically zones 2 and 3 are involved. The stiffer lens material of silicone lenses and the lens edge are probable factors. Localized papillary changes are also seen with ocular prosthetics and exposed sutures. Although symptoms are similar between both general and local CLPC, the occurrence of symptoms is greater in the general form. An exception is dryness, which is more common to local type CLPC.

GPC develops earlier in patients wearing soft contact lenses than in those wearing rigid lenses. The reaction has been found to develop as early as 3 weeks after initiation of soft contact lens wear and may begin as early as 14 months after initiation of rigid lens wear. The average time for GPC to develop with soft lens wear is 10 months; however, the interval varies depending on the study.



**Figure 27-2** Delineation of the upper lid zones. (Reprinted with permission Optom Vis Sci 2006;83:30.)



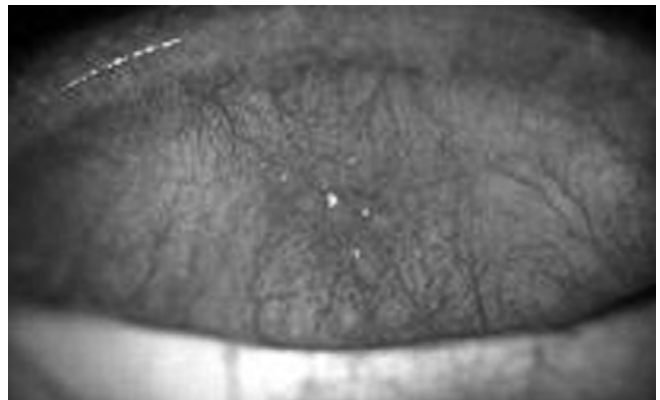
**Figure 27-3** Generalized giant papillary conjunctivitis.

The differential diagnosis of GPC includes VKC, which also presents with giant papillae. In contrast to VKC, GPC has a history of contact lens wear, both genders are affected, all ages are affected, a milder amount of itching is present, and it occurs without seasonal predisposition.

#### Management

The management of GPC depends on the severity of symptoms. Management includes frequent lens replacement or disposable contact lenses, appropriate contact lens cleaning, and vigilant monitoring of contact lens wearing time. Medical management includes use of mast cell stabilizers, topical NSAIDs, and steroids.

Frequent or planned and daily replacement lenses play an important role in the management of GPC. The incidence of GPC is significantly decreased when lenses are replaced in less than 4 weeks (36% incidence with 4 weeks or longer lens replacement vs. 4.5% incidence with daily to every 3 week lens replacement). In those at risk, replacement should be no longer than 2 weeks, and in



**Figure 27-4** Localized giant papillary conjunctivitis. (Reprinted with permission Optom Vis Sci 2006;83:31.)



those with a predisposing history of allergy, more frequent lens replacement is warranted.

In addition, assessment of the patient's contact lens cleaning regimen is also important. Cleaning regimen, once a critical component to lens care, has been eliminated with daily disposable lens replacement and has evolved with frequent lens replacement. Daily cleaning is essential, and when applicable, disinfection with a hydrogen peroxide system may still be an important consideration. The use of enzymatic cleaning has diminished because disposable lenses have replaced the need for it, but it may be a consideration in select cases.

Contact lens wearing time should be decreased, and in some cases contact lens wear should be discontinued. Discontinuing contact lens wear often relieves the symptoms within 2 to 3 days. Lens wear should not be resumed until mucous discharge, redness, and irritation are cleared. Discontinuing contact lens wear for 3 weeks or longer provides the best success in managing GPC patients.

In patients who present with early symptoms of GPC, replacing the old contact lenses with new lenses has a 78% rate of success. When more advanced GPC is present, however, discontinuing contact lens wear and then refitting the patient provides the best results, with success achieved in 93.96%.

Lens material and replacement schedule are important management considerations. When contact lenses are replaced frequently, the antigenic load is decreased, and the subsequent mechanism that leads to GPC is less likely to develop. The suggested treatment plan for the various stages of GPC is delineated in Table 27-4.

Pharmacologic treatment of GPC is used in patients with moderate to severe clinical manifestations. Treatment options include mast cell stabilizers, NSAIDs, and steroids (see Table 27-1).

Mast cell stabilizers are best used for long-term control of clinical manifestations. Although contact lens wear is not suggested with use of mast cell stabilizers, drops may be instilled before lens insertion and after lens removal and as directed according to practitioner's discretion during lens wear. With prolonged use, a maintenance dose of twice a day may be prescribed.

Although not a common treatment option, NSAIDs may be effective for GPC. NSAIDs may improve the signs and symptoms of GPC in 2 to 4 weeks of treatment.

Steroids may also be used in the treatment of GPC, with careful monitoring for adverse effects. Loteprednol 0.5% is an effective and safe treatment option for GPC when used four times a day. Improvement in itching, lens tolerance, and papillae has been noted after 1 week of therapy and continued for 6 weeks after treatment. When intraocular pressure does rise with loteprednol use, it is usually transient, and pressure typically returns to normal within 7 days of drug discontinuation.

With appropriate management patients with GPC may continue contact lens wear. Even with good control of the

inflammation associated with GPC, papillary changes may remain or papillae may decrease slowly in size.

## Vernal Keratoconjunctivitis

VKC is an uncommon, bilateral, ocular allergic disorder. More frequently it affects children. Vernal means "spring," and VKC typically occurs during the months of April to August; however, it may occur anytime during the year. In 23% of patients clinical manifestations occur continuously. In more than 60% recurrences occur. VKC is more likely to affect those living in warm dry climates.

Adolescent boys are affected twice as often as girls. After puberty, however, girls are increasingly afflicted. After the age of 20 years women and men are affected equally, which may reflect a hormonal influence. The age at onset for VKC is usually before puberty and reaches a peak at around 11 to 13 years. Patients as young as 1 month and as old as 75 years may be affected; 80% of VKC patients are younger than 14 years.

VKC is a self-limited disease, with a duration ranging from 1 to 23 years, with a median of about 5 years. VKC usually runs its course by the time patients reach their early twenties, with the severity of the disease decreasing between 16 and 21 years of age. Some VKC patients develop an overlying AKC. Typically, the patient or family has a history of atopic disease, such as asthma, eczema, or allergic rhinitis.

VKC may present as a palpebral disease, limbal disease, or mixed disease that has both limbal and palpebral manifestations. Palpebral or mixed disease has the most serious sequelae, which include corneal scarring and vision loss.

## Etiology

The pathophysiology of VKC is derived from a combination of type I and IV hypersensitivity reactions. This allergic response involves IgE, Th-2 lymphocytes, eosinophils, mast cells, basophils, neutrophils, macrophages, proinflammatory cytokines, interleukins, histamine, and other associated mediators. Also involved in this immune response are hormonal and neuroendocrine influences. This immune response results in the clinical manifestations of photophobia, itching, redness, tearing, papillae, corneal vascularization, mucous discharge, and plaque formation.

Specifically, the giant papillae found in VKC consist of dense fibrous tissue (connective tissue hyperplasia) as well as eosinophils, mast cells, basophils, polymorphonuclear leukocytes, lymphocytes, and macrophages. Mucous discharge contains eosinophils. Trantas' dots, which appear as elevated white opacities at the limbus, contain eosinophils and epithelial cells.

The cause for corneal changes is multifactorial. These include a mechanical component, from the giant palpebral papillae; conjunctival inflammation; inflammatory toxins; and an ocular surface component (i.e., dry eyes).

Mediators released from mast cells and eosinophils also play a role in corneal changes.

There is also evidence of autonomic involvement in VKC. Muscarinic and  $\beta_1$ -adrenergic receptors are altered in the inflamed conjunctiva. Also, muscarinic receptor stimulation activates the goblet cells to produce mucus.

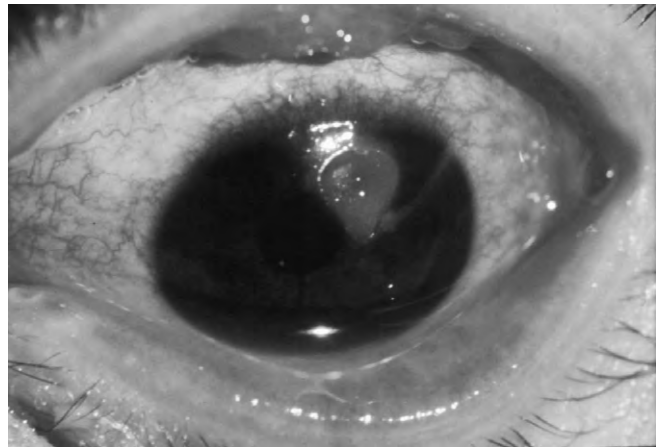
### Diagnosis

Diagnosis of VKC is based on clinical presentation, the young age at onset, and geographic distributions. VKC is typically a bilateral disease, and the patient presents with ocular symptoms that include intense itching, tearing, pain or foreign body sensation, blurred vision, and mucous discharge. Signs include giant papillae on the upper tarsal conjunctiva or limbus, corneal changes that range from superficial keratopathy to shield ulcer, and Trantas' dots.

An early stage of VKC, known as forme fruste, should also be considered when making the diagnosis. Here the patient experiences severe itching, mucous discharge, and matting of the eyelids in the morning. Giant papillae have not yet formed on the upper palpebral conjunctiva, which distinguishes forme fruste from the more advanced stages of VKC.

Palpebral VKC is characterized by conjunctival and corneal changes. Although conjunctival papillae may be found on the lower palpebral conjunctiva, the classic presentation in VKC is giant papillae greater than or equal to 1 mm on the upper tarsal conjunctiva (Figure 27-5). These cobblestone papillae may be flat topped, with the tips eroded, which results in fluorescein staining. The papillae may cause a mechanical ptosis. Larger papillae correlate with a poorer prognosis and potential for chronicity.

The corneal response in VKC occurs with varying levels of severity. The changes initially begin with punctate epithelial keratopathy, which may be serious enough to cause a decrease in vision to 20/200, with associated photophobia. Corneal epithelial macroerosion or areas

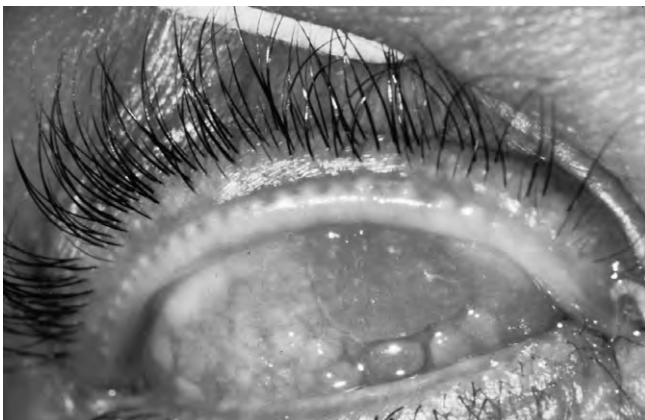

**Figure 27-6** Shield ulcer in vernal conjunctivitis.

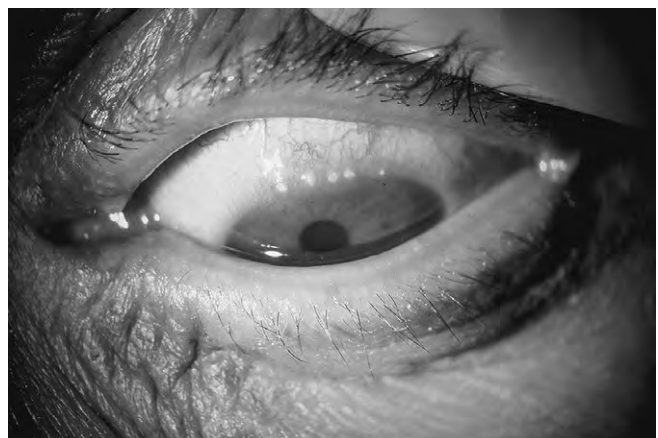without epithelium may develop. Mucus may adhere to the areas of disrupted epithelium. Plaque formation, along with mucous and fibrin deposition, occurs on the area of macroerosion. Other corneal changes include pannus or neovascularization; keratitis, usually of the superior cornea; keratitis with small gray-white intraepithelial opacities (keratitis epithelialis vernalis of Tobgy); shield ulcers (Figure 27-6); and scarring. Decreased vision secondary to corneal scarring affects 6%.

Limbal VKC is characterized by limbal papillae or nodules that are small, semitransparent, gray-white to pink, gelatinous elevations at the limbal-corneal junction. These limbal papillae are analogous to the tarsal papillae found in palpebral VKC. Limbal VKC does not typically have giant papillae or corneal plaque formations. Complications from corneal disease are usually absent in limbal disease, perhaps because there is less inflammatory activity. Limbal VKC has a shorter clinical course than palpebral VKC. Individuals affected by limbal disease are also less likely to suffer from other atopic diseases.

Trantas' dots may be found in any of the types of VKC (Figure 27-7). They are usually found at the upper limbus



**Figure 27-5** Papillary changes in vernal conjunctivitis.



**Figure 27-7** Patient with Trantas' dots in vernal keratoconjunctivitis.

but may also be found on the bulbar conjunctiva, semilunar folds, or less commonly on the tarsal conjunctiva. They occur either singly or in groups, as grayish white to white-yellow dots, and occur in approximately 69% of patients with mixed VKC, 41% of patients with limbal VKC, and 21% of those with palpebral VKC. Trantas' dots last for several days to up to a week.

Other clinical manifestations of VKC include conjunctival scarring, with possible symblepharon formation, and high corneal astigmatism and keratoconus. Dennie's line, an extra lid fold, may be seen. Cataracts may also occur.

VKC is differentiated from GPC and AKC by its clinical presentation. Distinguishing features include age at onset, male predisposition, geographic distribution, lack of relationship to contact lens use, and absence of atopic dermatitis.

### Management

Treatment of VKC depends on the severity of symptoms and the clinical presentation. In mild cases the use of cool compresses, ocular lubricants, decongestant-antihistamine combinations, and mast cell stabilizers may be sufficient. Environmental controls include maintaining a cool moist environment, for example, with air conditioning.

In moderate to severe cases topical and oral antihistamines, mast cell stabilizers, NSAIDs, and topical steroids are treatment options. Acetylcysteine may also be used four times a day for the elimination of mucus. Topical antihistamines such as emedastine are good treatment options. These agents are effective and well tolerated in treating VKC, with improvement in symptoms seen generally within 1 to 2 weeks.

Mast cell stabilizers play an important role in the management of VKC. In addition to its mast cell stabilizing effect, lodoxamide, specifically, has been found to have other actions. These actions include decreasing levels of Th-2 in the tears, inhibiting the release of cytokines from the mast cells and thus affecting papillary formation, and interrupting the recruitment of eosinophils after mast cell degranulation and therefore diminishing the opportunity for corneal changes, mucous secretion, and the formation of Trantas' dots.

Treatment with mast cell stabilizers is most effective when begun before the onset of symptoms, because 14 days may be needed for clinical effects to occur. The dosage may be continued during the peak season. Lodoxamide has been found to be effective in treating serious corneal complications in VKC and in improving papillae, limbal involvement (papillae, hyperemia, and Trantas' dots), and conjunctival discharge. Lodoxamide has been found to be superior to cromolyn sodium 4% in alleviating the signs and symptoms of VKC.

Because clinical improvement may be delayed with mast cell stabilizers, a topical antihistamine or steroid may

be used concomitantly to alleviate symptoms immediately. Dual-acting drugs, with mast cell stabilizing and antihistamine effects, may also be used. Olopatadine 0.1% has been found to be effective in treating the clinical manifestations of VKC, including decreasing mucous discharge by decreasing the number of goblet cells. NSAIDs, such as diclofenac, alleviate symptoms, probably through the decreased production of prostaglandins. In very severe cases oral steroids may be considered.

Topical steroids are a mainstay of treatment, with up to 85% of patients requiring its use. Dosage for topical steroid treatment is adjusted depending on the severity of the clinical presentation. Prednisolone 1% (acetate or phosphate) may be used during the first few days, with the dosage tapered over 1 to 2 weeks. Maintenance therapy includes a reduced dosage of one to three times per day or the use of less potent steroids, such as fluorometholone or loteprednol 0.2%. Pulse therapy is also a treatment option and sometimes alleviates acute symptoms. This approach may be used in conjunction with a mast cell stabilizer for long-term management. In pulse therapy prednisolone 1% may be used every 1 to 2 hours while awake for 4 to 7 days and then four times a day for 4 to 7 days.

Intractable cases of VKC may be effectively treated with a combination of systemic aspirin and topical cromolyn sodium. Aspirin inhibits cyclooxygenase and the production of prostaglandins from mast cells in VKC. Aspirin used in conjunction with the mast cell stabilizers results in improvement of both clinical signs and symptoms.

Topical cyclosporine A is an effective, safe, well-tolerated treatment option for severe or intractable VKC. An immunosuppressant, it affects and inhibits cell-mediated and immediate hypersensitivity reactions. It inhibits the release of interleukins, and it may prevent mediator release from mast cells. Relief is often noted after the first month of cyclosporine treatment, with continued results for up to 2 years. Some, however, have found a return of signs and symptoms 1 to 2 months after discontinuance of treatment.

Shield ulcers may be treated with topical cyclosporine A. Steroids in conjunction with a topical antibiotic and cycloplegic are also used in the treatment of shield ulcer.

In severe refractory cases of VKC, treatment options include surgical excision of the giant papillae and cryotherapy of the upper tarsus. Improvement is limited, however, and scarring may result. Supratarsal steroid injection is another treatment option. Symptomatic relief takes place in 1 to 5 days, giant papillae decrease in 5 to 17 days, and shield ulcers resolve in 12 to 20 days. After injection, patients are maintained on conventional treatment modalities. Mitomycin C, which inhibits inflammatory cells and fibroblast proliferation, has been found to alleviate the signs and symptoms of severe refractory cases. Amniotic membranes are another treatment consideration for severe cases.

## Atopic Keratoconjunctivitis

AKC is one of the most serious of the ocular allergies because of the potential for loss of vision from corneal involvement. Patients with AKC usually have a personal or family history of atopic disease such as asthma, hay fever, and urticaria. Atopic dermatitis has ocular involvement in 25% to 40% of cases.

AKC may occur throughout the year, with no seasonal, geographic, or climatic preference. Men are more commonly affected. With age at onset in late teens or early twenties, AKC is typically an adult disease, affecting those aged 30 to 50 years. A patient may subsequently be afflicted with AKC for decades.

### Etiology

AKC is believed to be a result of both a type I (IgE) and type IV (T cell-mediated) hypersensitivity reaction. Patients with AKC may have a depressed T-cell function. Elevated levels of serum IgE and tear IgE have been found. T lymphocytes and eosinophils are important components of AKC's pathogenesis. See Table 27-2 for immune findings.

### Diagnosis

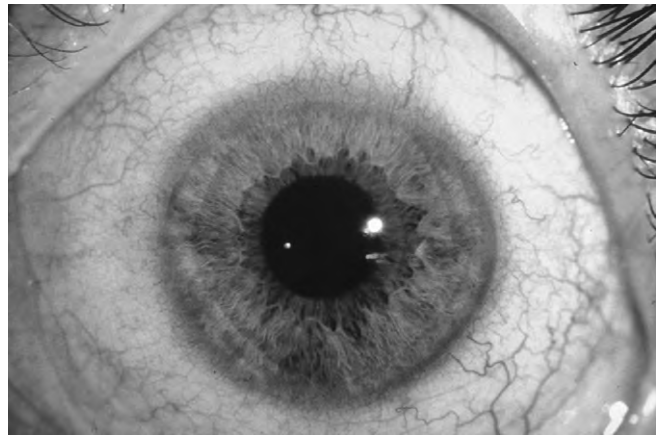
AKC is typically bilateral, with symptoms ranging from moderate to severe ocular and periocular itching, tearing, burning, mucous discharge, and photophobia. Extraocular atopy occurs frequently in patients who have AKC; eczema is found in 100% of cases and allergic rhinitis in approximately 65%. The presence of other atopic findings assists in the diagnosis of AKC. A family history of atopy is found in at least 50% of patients.

Lid involvement in AKC includes dermatitis, found in 62.2% of cases, as well as blepharitis, meibomianitis, trichiasis, ectropion, entropion, and madarosis. The lids may be eczematous and may appear red, indurated, and crusted. Infraorbital lid edema may cause a skin crease known as Dennie-Morgan line.

In patients with AKC there is conjunctival hyperemia, erythema, injection, and chemosis (Figure 27-8). Papillary changes, diffuse in presentation, affect the inferior palpebral conjunctiva more commonly than the superior. Less frequently, giant papillae and follicles may be found. Conjunctival fibrosis and scarring may occur, along with symblepharon formation.

Corneal involvement, in the form of superficial punctate keratopathy of the epithelium, is common and is found in 100% of patients. More serious changes include corneal ulceration, with subsequent loss of vision in 70% of patients, neovascularization, pannus, and scarring. Other corneal findings include Trantas' dots, keratoconus, and filamentary keratitis.

Cataracts of some degree occur in approximately 10% of AKC patients and, in one series, in 25% of patients with severe recurrent disease. Posterior subcapsular cataracts



**Figure 27-8** Atopic conjunctivitis.

are the most common form of cataract, followed by anterior subcapsular cataracts, and then by changes throughout the entire lens. More typically, the lens changes are minimal, with simple fleck opacities observed in the lens. In some cases, however, significant changes may occur, and reduced vision may necessitate cataract removal. Teenagers with AKC are most susceptible to cataracts. Once the cataract develops it progresses quickly, sometimes maturing in weeks. Cataract removal may be required as soon as a year after onset of visual disturbances.

Patients with AKC are prone to staphylococcal blepharitis and herpes simplex keratitis. This may be associated with a depressed T-cell function.

AKC is differentiated from other allergic diseases, most notably by its association with atopic dermatitis. However, other important diagnostic clues include lack of a seasonal association, age at onset, inferior conjunctival involvement, and longevity of the clinical manifestations of the disease.

### Management

Treatment of AKC depends on severity of symptoms and the secondary manifestations. Mild clinical manifestations may be managed with environmental controls, cold compresses, vasoconstrictors, and topical antihistamines. However, treatment often includes oral antihistamines, mast cell stabilizers, steroids, and, in more severe cases, cyclosporine.

Lid eczema may be treated with steroid ointments or creams, such as hydrocortisone 1%, and, in severe cases, with systemic steroids (prednisone). Topical steroids may be required to prevent corneal and conjunctival scarring.

When blepharitis and meibomianitis are present, treatment includes maintenance of good lid hygiene and use of topical antibiotics or antibiotic-steroid combinations. In some cases systemic antibiotics such as tetracycline may be necessary.

In difficult-to-treat sight-threatening cases of AKC, topical cyclosporine A 2% and 0.05% have been found to be

an effective and safe treatment. In the most severe cases oral cyclosporine, 3 to 5 mg/kg/day may be necessary; however, significant side effects include renal or nephrotoxicity and arterial hypertension.

Amniotic membrane patching is a treatment option with difficult-to-manage corneal manifestations, such as ulcers. The amniotic membrane acts like a bandage contact lens, stabilizing the epithelium and limiting cytokine and inflammatory cell access to the cornea.

## ALLERGIC DISORDERS OF THE EYELIDS

Eyelid inflammation is a common result of exposure to allergens. The thin tissue of the eyelids and its highly vascularized nature make it a common site for allergic response. The eyelids share many common features with the conjunctiva, and because the bulbar and palpebral conjunctivas are continuous, there is a predisposition to inflammation from an immunologic hypersensitivity reaction. Consequently, the clinical features of the allergic response of the conjunctiva and lids often overlap. In addition, the eyelid skin is a frequent site for microbial colonization, in particular by *Staphylococcus*, which makes it susceptible to a variety of combination reactions.

Allergic disorders of the eyelid include atopic dermatitis, contact dermatitis, and urticaria. Eczema is a common feature of both atopic and contact dermatitis. Table 27-5 summarizes the clinical manifestations and management of each entity.

### Atopic Dermatitis

Atopic dermatitis is a chronic inflammatory skin disorder that affects the epidermis and is characterized by eczema and itching. Two percent of the adult population is afflicted by atopic dermatitis, often with the earliest manifestation first appearing in childhood. The peak incidence occurs during the fourth or fifth decade. There is a family tendency as well as a predisposition to allergy and asthma. Periorbital inflammation is a common manifestation of atopy. Acute manifestations include exudative lesions, erythema, and edema. Chronic manifestations include dry scaly lesions with lichenification.

### Etiology

The pathogenesis of atopic dermatitis remains unclear, although there appears to be a relation to IgE, along with a genetic influence. Although investigators have focused on a dysfunctional immune system, there is no conclusive evidence to support the assumption that cell-mediated response occurs in atopic dermatitis. Elevated serum IgE levels may be found.

### Diagnosis

The patient often demonstrates a bilateral chronic inflammation of the eyelids, characterized by dryness of the skin of the eyelids, tylosis, punctal scarring, and,

in extreme cases, symblepharon and cicatrization. Typically, lesions occur on the face in infants; in flexural areas in older children; and in flexural areas, hands, wrists, feet, ankles, and face (especially the forehead and around the eyes) in adults. Diagnosis is based on itchy skin, along with a history of asthma or hay fever, dry skin, and dermatitis affecting the typical locations of the forehead, cheeks, or flexural areas.

Pruritic and inflamed periocular skin is a common eyelid manifestation of periorbital dermatoses. The poor ability of involved skin to bind water in atopic disease decreases the resistance to irritants and allergens and promotes inflammation. Red itchy eyes are accompanied by erythema, edema, and fine scaling of the eyelids. Papules and fine fissures are sometimes noted, and if the condition is chronic, normal skin lines become thickened and accentuated. Chronic rubbing leads to exacerbation of the symptoms, and brown discoloration of the upper eyelids can be observed. Referred to as lichen simplex chronicus, the changes appear to be more common in women and Asian individuals and result from a repeated rubbing cycle.

Other specific and nonspecific markers of atopic dermatitis have been recognized and include lid edema, a midline lower eyelid crease that extends to the outer canthus (Dennie-Morgan infraorbital fold), periorbital darkening, madarosis, ectropion, ptosis, and trichiasis. Staphylococcal infestation of the eyelids can cause infectious eczema and can lead to chronic blepharitis, a common accompanying response to the liberated toxins of the staphylococcal microorganism. Chronic anterior blepharitis can result in an array of signs and symptoms, including itching; burning; foreign body sensation; thickening, induration, and pitting of the eyelids; loss of lashes; conjunctival hyperemia; and, in severe cases, marginal corneal involvement. Atopic dermatitis also appears to have an increased association with herpes simplex dermatitis, molluscum contagiosum, and superinfection.

Numerous ocular findings have been reported in atopic dermatitis, including keratoconus and cataracts. In the case of keratoconus, eye rubbing has been proposed as a causative factor, although the typical patient does not develop keratoconus earlier in life. Cataract formation appears to have a genetic predisposition and may be exacerbated by the use of corticosteroids, a mainstay for treating the atopic patient. Marginal punctate keratitis and corneal infiltrates or ulceration often accompany the blepharitic process. Additional cutaneous findings are also seen in atopic patients, typically involving the extensor and flexural surfaces. In the case of the latter manifestation, moisture and scratching and rubbing of the skin due to the severe pruritus are causative factors.

Differential diagnosis includes irritant contact dermatitis and allergic contact dermatitis. History of exposure to an offending substance assists in making the differential diagnosis.

**Table 27-5**  
Allergic Lid Disease: Etiology, Immunology, Clinical Manifestations, and Management

Type	Causes/Immunology	Symptoms	Lid Signs	Ocular Manifestations	Management	Miscellaneous
Atopic dermatitis	Probably cell mediated	Pruritus Foreign body sensation	Erythema Edema Fine scaling Ectropion Ptosis Madarosis Trichiasis Inflammation Lichenification Dennie-Morgan line (infraorbital fold)	Conjunctival hyperemia, papillae Hyperpigmented periorbital area Punctal scarring Symblepharon Cicatrizaton Infectious eczema Marginal SPK Keratoconus Corneal ulcer Cataracts	Avoid rubbing Cool compresses Emollient (e.g., petrolatum) Topical: antihistamine, NSAIDs, mast cell stabilizer, steroid (e.g., hydrocortisone 5-10 days) Oral antihistamine: (e.g., hydroxyzine hydrochloride 10-25 mg) QID Bacitracin, erythromycin Calcineurin inhibitor: (tacrolimus, pimecrolimus BID) Avoid offending agent Cool compresses Topical steroid (5-10 days) Nonpreserved artificial tears Oral antihistamine	Fourth-fifth decades Child/family history of atopy Associated: Eczema Hay fever Rhinitis Asthma HSV Molluscum Superinfection Extensor/flexor skin involvement Dry skin
Contact dermatitis	Allergic type IV Irritant: Exposure	Allergic: pruritus Irritant: burn, sting Watery discharge	Allergic: edema, vesicles, erythema, crusting, oozing Irritant: edema, erythema, local, flat, dry, scaly skin	Conjunctival hyperemia, chemosis SPK Corneal infiltrate		
Urticaria	Type I immunity Nonimmune Exposure Psychogenic causes Stress Idiopathic	Itch, burn	Wheals	Conjunctival injections, chemosis	Avoid allergen Cool compresses Topical steroid Oral antihistamine Subcutaneous epinephrine	Associated: Rhinitis Angioedema Asthma Syncope Hypotension

HSV = herpes simplex virus; NSAIDs = nonsteroidal anti-inflammatory drugs; SPK = superficial punctate keratopathy.

## Management

Treatment should initially be directed toward decreasing xerosis and subsequent pruritus. Avoidance of rubbing breaks the “itch-scratch” cycle that leads to exacerbation of inflammation and of symptoms. Application of cool damp compresses for 15 to 30 minutes decreases itching. Compresses should be followed by the application of a soothing preservative- and fragrance-free emollient, such as white petrolatum. Oral antihistamines such as hydroxyzine hydrochloride or chlorpheniramine maleate are prescribed to relieve itching. Patients should be informed of their sedating effects and should be advised to take one dose 1 hour before bedtime to lessen or relieve pruritus during sleep.

Topical corticosteroids are used in cases of exacerbation and should be applied sparingly to the affected area. Hydrocortisone 1% twice a day or dexamethasone 0.1% applied to the periorbital area helps to relieve symptoms during these periods. Secondary infection manifested as blepharitis or keratoconjunctivitis should be treated with topical ophthalmic antibiotic ointments such as bacitracin or erythromycin. Topical antihistamines, NSAIDs, or mast cell stabilizers can be used to control itching, and topical steroids are sometimes required to treat severe keratoconjunctivitis associated with the atopic response. Because of side effects, steroids are not indicated for long-term use.

Topical calcineurin inhibitors are also used to treat atopic dermatitis and include pimecrolimus (Elidel) and tacrolimus (Protopic). Treatment effects are seen in 1 to 3 weeks. Adverse reactions most commonly include burning. Although a causal relation has not been established, rare skin malignancy and lymphoma have been reported.

## Contact Dermatitis

Contact dermatitis occurs from an environmental “contact” of an offending agent that results in the hallmark clinical manifestation of eczema. Contact dermatitis may be divided into allergic and irritant (nonallergic) varieties. Clinically, the two types may be indistinguishable. Irritant contact dermatitis affects two-thirds of all contact dermatitis sufferers, versus one-third affected by the allergic type. Irritant contact dermatitis results from a single concentration-dependent exposure to the offending agent and occurs within 1 to 24 hours of exposure. In contrast, allergic contact dermatitis requires a sensitizing exposure, with minimal subsequent reexposure necessary to cause a reaction. Contact dermatitis from topical ophthalmic medications is of an irritant or toxic nature in 90% of cases, with an allergic response accounting for only 10%.

## Etiology

The heightened sensitivity of the eyelid skin increases susceptibility to contact dermatitis. Inflammation of the

skin of the lids occurs from hypersensitivity or from exposure to irritants. Exposure to offending agents may result from airborne allergens, inadvertent touching or rubbing of the eyelids, use of ophthalmic medication, or cosmetic use.

The allergic variety of contact dermatitis is a type IV hypersensitivity response involving sensitization of T lymphocytes. Antigen formation after the sensitizing substance (haptens or partial antigens) comes into contact with the dermal protein for the first time, which results in sensitization. Sensitization may take weeks to years to develop. On reexposure to the same or a related substance, a delayed inflammatory response is elicited, usually within 48 to 72 hours. Allergic contact dermatitis is often associated with the eyelids or periorbital area and in some instances may involve the face and the hands.

Irritant contact dermatitis is a less specific inflammation and does not result from prior exposure and sensitization.

Box 27-1 summarizes a variety of offending substances that are involved in contact dermatitis, which include

### Box 27-1 Offending Agents in Contact Dermatitis

Contact lens solutions
Medications
Antibiotics
Aminoglycosides (gentamicin, tobramycin, neomycin)
Chloramphenicol, polymyxin B, sulfacetamide
Antivirals
Idoxuridine, trifluridine, vidarabine
Steroids
Mydriatics/anticholinergics
Phenylephrine, atropine, scopolamine, homatropine, tropicamide
Topical anesthetics
Proparacaine
Glaucoma
Betaxolol, timolol, brimonidine, dorzolamide, carbachol, pilocarpine, echothiophate, epinephrine, dipivefrin, levobunolol
Vehicles
Propylene glycol
Preservatives
Thimerosal, benzalkonium chloride
Metals
Nickel
Rubber (eyelash curlers)
Other
Makeup
Shampoo
Fingernail polish
Perfumes



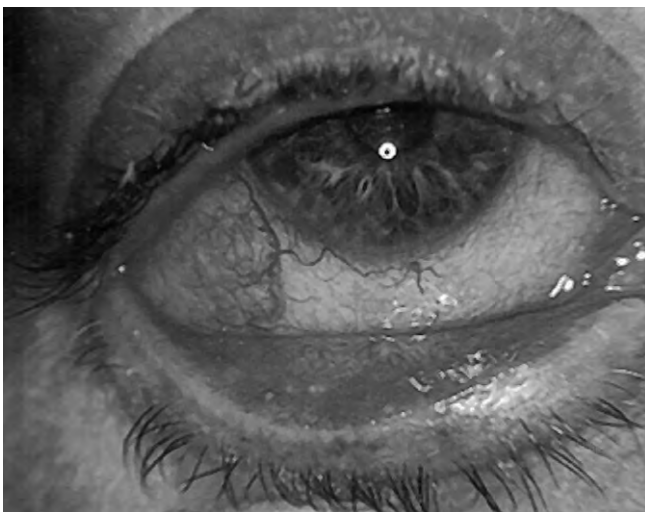preservatives used in ophthalmic agents, medications, cosmetics, and hair and skin care products. Prevalent among offending antigens and a well-documented cause of allergic dermatitis are parabens, a frequent preservative in many facial creams and lotions, as well as nickel, chromates, foam rubber, fragrances, and surfactants. Brimonidine can cause an allergic response in up to 25.7% of patients. Hyperemia and dermatitis may manifest within 2 weeks of treatment initiation (Figure 27-9).

### Diagnosis

The overlap in signs, symptoms, and the offending substances involved in both allergic and irritant contact dermatitis can make the diagnosis difficult. A careful history assists in the diagnosis by providing information about occupational or domestic exposure to relevant allergens. Signs and symptoms include itching, eczema, blepharitis, follicles, or papules and hyperemia.

The primary signs of irritant dermatitis are erythema and edema, which are often localized to the skin of the eyelid, with associated symptoms of burning and stinging more common than itching. The skin usually is flat and dry, with scaling (Figure 27-10).

In contrast, a predominant feature of allergic contact dermatitis is pruritus, rather than burning, and in severe cases marked periorbital edema is present. A papillary conjunctivitis, with hyperemia, chemosis, and serous discharge, can occur. An erythematous blepharitis and, in severe cases, a superficial punctate keratitis can develop. When allergic contact conjunctivitis is present before lid involvement, the likely cause is a topical ophthalmic medication, as opposed to a cosmetic or hair product. Eyelid findings in chronic allergic contact dermatitis are similar to those in atopic dermatitis. Here lichenification, erythema, hyperpigmentation, and scaling are present.



**Figure 27-9** Allergic response secondary to use of brimonidine 0.2%.

Allergic contact dermatitis may occur in the presence of treatment with topical corticosteroids.

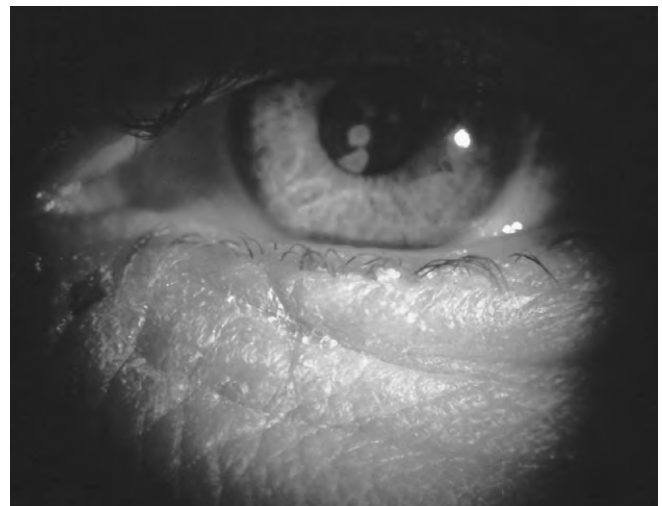
Allergic contact dermatitis may be diagnosed with the assistance of patch testing. Although patch testing is not diagnostic for irritant dermatitis, a negative patch test in combination with clearing of the dermatitis after removal of the offending agent is indicative of an irritant cause. Common agents producing allergic contact dermatitis include nail polish, rubber, nickel, mascara, eye liners and eye shadow, and drugs such as neomycin.

### Management

Contact dermatitis may resolve without treatment within days but may take up to 3 weeks in allergic cases. In contrast, in toxic cases resolution may take 3 to 6 weeks. Avoidance of the offending agent is the first step in the treatment of contact dermatitis, with emphasis given to decreasing rubbing and scratching. Supportive therapy includes cool compresses. In addition, application of topical steroid ointment or cream preceded by cool compresses temporarily relieves symptoms. Steroid use should be limited to 5 to 10 days due to the risk of tachyphylaxis, atrophy of the skin, and increased risk of infection.

### Urticaria

Urticaria, also known as hives, involves the outer dermis and is characterized by wheals and itching. The diagnosis is critical because acute asthma and anaphylaxis can occur. Angioedema is similar to urticaria but differs in that the deeper layers of the skin, the deep dermis or subcutaneous areas, are involved. Angioedema is present with urticaria in 40% of patients and without urticaria in 20%; urticaria presents alone in 40%.



**Figure 27-10** Contact dermatitis.

## Etiology

Urticaria may occur as a result of immune mediation (type I, IgE-mediated), nonimmune mechanisms (involving mast cell mediators), offending physical agents, psychogenic causes, or stress or it may be idiopathic. Precipitating factors may include cold air, water, or objects; high temperatures; heat; sunlight; and pressure to the skin. Urticaria may also be a result of insect bites, drugs, cosmetics, hair products, ophthalmic agents, latex, or formaldehyde.

## Diagnosis

The clinical manifestations of urticaria include itching, papules, and plaques. In contrast, angioedema consists of deeper swelling, without itching.

The diagnosis of urticaria involves taking a thorough history of insect bites, use of medications or cosmetics, specific types of food intake, and use of occupational agents (e.g., latex gloves). Clinical findings indicative of urticaria include the characteristic wheals, edema, burning, stinging, and itching. When urticaria is a result of an allergen, the clinical presentation occurs as early as 30 to 60 minutes after exposure, with a delayed reaction occurring 4 to 6 hours later. Additional clinical findings may include angioedema, rhinitis, conjunctival injection, and chemosis. Severe clinical manifestations may result in syncope, asthma, hypotension, and anaphylaxis.

Diagnostic evaluation using patch testing should be done with caution and only with the ability to manage a severe reaction such as anaphylaxis. Patch testing may be done by a dermatologist or an allergist. An open patch test may be performed in which small amounts of the offending agent are placed on the flexor forearm for only 15 minutes. The area is evaluated every 15 minutes for 1 hour. The presence of follicular erythema or wheal indicates a positive finding. If a negative result is found with the open patch test, a closed patch test may be performed for only 15 minutes. If negative findings persist, prick or scratch testing may be done.

## Management

Application of cool compresses for 10 to 15 minutes four times a day for 1 to 2 days and use of topical steroids and systemic antihistamines may provide relief of acute symptoms of urticaria. In cases of allergen-related urticaria, determination of the cause, followed by its subsequent avoidance, is essential to management. Urticaria, however, carries the risk of serious sequelae, including anaphylaxis.

Oral antihistamines can be effective in alleviating the itch as well as assisting in the resolution of the wheals. When urticaria or angioedema has a severe presentation, diphenhydramine or oral steroids can be effective.

## SELECTED BIBLIOGRAPHY

- Abelson MB, Gomes PJ, Vogelsson CT, et al. Effects of a new formulation of olopatadine ophthalmic solution on nasal symptoms relative to placebo in two studies involving subjects with allergic conjunctivitis or rhinoconjunctivitis. *Curr Med Res Opin* 2005;21:683-691.
- Abramovits W. Atopic dermatitis. *J Am Acad Dermatol* 2005;53:S86-S93.
- Akpek EK, Dart JK, Watson S, et al. A randomized trial of topical cyclosporin 0.05% in topical steroid-resistant atopic keratoconjunctivitis. *Ophthalmol* 2004;111:476-482.
- Akpek EK, Hasiripi H, Christen WG, Kalayci D. A randomized trial of low-dose, topical mitomycin-C in the treatment of severe vernal keratoconjunctivitis. *Ophthalmol* 2000;107:263-269.
- Allansmith MR, Korb DR, Greiner JV, et al. Giant papillary conjunctivitis in contact lens wearers. *Am J Ophthalmol* 1977;83:697-708.
- Allansmith MR, Ross RN. Ocular allergy. *Clin Allergy* 1988;18:1-13.
- Allansmith MR, Ross RN. Ocular allergy and mast cell stabilizers. *Surv Ophthalmol* 1986;30:229-244.
- Amemiya T, Matsuda H, Uehara M. Ocular findings in atopic dermatitis with special reference to the clinical features of atopic cataract. *Ophthalmologica* 1980;180:129-132.
- Avunduk AM, Avunduk MC, Dayanir V, et al. Pharmacological mechanism of topical lodoxamide treatment in vernal keratoconjunctivitis: a flow-cytometric study. *Ophthalmic Res* 1998;30:37-43.
- Baddeley SM, Bacon AS, McGill JI, et al. Mast cell distribution and neutral protease expression in acute and chronic allergic conjunctivitis. *Clin Exp Allergy* 1995;25:41-50.
- Bartlett JD, ed. *Ophthalmic drug facts*, ed 18. St. Louis: Wolters Kluwer Health, 2007.
- Berger W, Abelson MB, Gomex PJ. Effects of adjuvant therapy with 0.1% olopatadine hydrochloride ophthalmic solution on quality of life in patients with allergic rhinitis using systemic or nasal therapy. *Ann Allergy Asthma Immunol* 2005;95:361-371.
- Bonini Stefano, Bonini S, Lambiase A, et al. Vernal keratoconjunctivitis revisited. *Ophthalmol* 2000;107:1157-1163.
- Butrus S, Portela R. Ocular allergy: diagnosis and treatment. *Ophthalmol Clin North Am* 2005;18:485-492.
- Caldwell DR, Verin P, Hartwich-Young R, et al. Efficacy and safety of lodoxamide 0.1% vs. cromolyn sodium 4% in patients with vernal keratoconjunctivitis. *Am J Ophthalmol* 1992;113:632-637.
- Calonge M. Ocular allergies: association with immune dermatitis. *Acta Ophthalmol Scand* 2000;78:69-75.
- Cetinkaya A, Akova YA, Dursun D, Pelit A. Topical cyclosporine in the management of shield ulcers. *Cornea* 2004;23:194-200.
- Corum I, Yeniad B, Bilgin LK, Ilhan R. Efficiency of olopatadine hydrochloride 0.1% in the treatment of vernal keratoconjunctivitis and goblet cell density. *J Ocul Pharmacol Ther* 2005;21:400-405.
- Crampton HJ. Comparison of ketotifen fumarate ophthalmic solution alone, desloratadine alone, and their combination for inhibition of the signs and symptoms of seasonal allergic rhinoconjunctivitis in the conjunctival allergen challenge model: a double-masked, placebo- and active-controlled trial. *Clin Ther* 2003;25:1975-1987.
- Creticos PS, Schroeder JT, Hamilton RG, et al. Immunotherapy with a ragweed-toll-like receptor 9 agonist vaccine for allergic rhinitis. *N Engl J Med* 2006;355:1445-1455.
- D'Angelo G, Lambiase A, Cortes M, et al. Preservative-free diclofenac sodium 0.1% for vernal keratoconjunctivitis. *Graefes Arch Clin Exp Ophthalmol* 2003;241:192-195.

- Dell SJ, Lowry GM, Northcutt JA, et al. A randomized, double-masked, placebo-controlled parallel study of 0.2% loteprednol etabonate in patients with seasonal allergic conjunctivitis. *J Allergy Clin Immunol* 1998;102:251-255.
- Donshik PC. Contact lens chemistry and giant papillary conjunctivitis. *Eye Contact Lens* 2003;29(IS):S37-S39.
- Donshik PC. Giant papillary conjunctivitis. *Trans Am Ophthalmol Soc* 1994;92:687-744.
- Donshik PC, Ehlers WH. The contact lens patient and ocular allergies. *Int Ophthalmol Clin* 1991;31:133-145.
- Ehlers WH, Donshik PC. Allergic ocular disorders: a spectrum of diseases. *CLAO J* 1992;18:117-124.
- Friedlaender MH. Update on allergic conjunctivitis. *Rev Ophthalmol March*:1997;92-98.
- Friedlaender MH, Howes JA. A double-masked, placebo-controlled evaluation of the efficacy and safety of loteprednol etabonate in the treatment of giant papillary conjunctivitis. *Am J Ophthalmol* 1997;123:455-464.
- Goossens A. Contact allergic reactions on the eyes and eyelids. *Bull Soc Belg Ophthalmol* 2004;292:11-17.
- Gurwood AS, Altenderfer DS. Contact dermatitis. *Optometry* 2001;72:36-44.
- Hingorani M, Moodaley L, Calder VL, et al. A randomized, placebo-controlled trial of topical cyclosporine A in steroid-dependent atopic keratoconjunctivitis. *Ophthalmology* 1998;105:1715-1720.
- Hoang-Xuan T, Prisant O, Hannouche D, Robin H. Systemic cyclosporine A in severe atopic keratoconjunctivitis. *Ophthalmology* 1997;104:1300-1305.
- Holsclaw DS, Whitcher JP, Wong IG, Margolis TP. Supratarsal injection of corticosteroid in the treatment of refractory vernal keratoconjunctivitis. *Am J Ophthalmol* 1996;121:243-249.
- Ilyas H, Slonim CB, Braswell GR, et al. Long-term safety of loteprednol etabonate 0.2% in the treatment of seasonal and perennial allergic conjunctivitis. *Eye Contact Lens* 2004;30:10-13.
- Jones L. What other nonoxygen-related design factors affect lens performance. *Eye Contact Lens* 2003;29:S57-S59.
- Joseph MA, Kaufman HE, Insler M. Topical tacrolimus ointment for treatment of refractory anterior segment inflammatory disorders. *Cornea* 2005;24:417-420.
- Kaan G, Ozden O. Therapeutic use of topical cyclosporine. *Ann Ophthalmol* 1993;25:182-186.
- Kaplan AP. Chronic urticaria and angioedema. *N Engl J Med* 2002;346:175-179.
- Koevary SB. *Ocular immunology in health and disease*. Boston: Butterworth-Heinemann, 1999.
- Kuby J. *Immunology*, ed. 2. New York: W.H. Freeman, 1999.
- Maibach HI, Engasser P, Ostler B. Upper eyelid dermatosis syndrome. *Dermatol Clin* 1992;10:549-554.
- Manni GM, Centofanti M, Sacchetti M, et al. Demographic and clinical factors associated with development of brimonidine tartrate 0.2%-induced ocular allergy. *J Glaucoma* 2004;13:163-167.
- Mathers WD, Billborough M. Meibomian gland function and giant papillary conjunctivitis. *Am J Ophthalmol* 1992;114:188-192.
- Mendicute J, Aranzasti C, Eder F, et al. Topical cyclosporine A 2% in the treatment of vernal keratoconjunctivitis. *Eye* 1997;11:75-78.
- Molinari JF, Stanek S. Meibomian gland status and prevalence of giant papillary conjunctivitis in contact lens wearers. *Optometry* 2000;71:459-461.
- Montan PG, van Hage-Hamsten M. Eosinophil cationic protein in tears in allergic conjunctivitis. *Br J Ophthalmol* 1996;80:556-560.
- Moschos MM, Eperon S, Guex-Crosier Y. Increased eotaxin in tears of patients wearing contact lenses. *Cornea* 2004;23:771-775.
- Motterle L, Diebold Y, Enriques deSalamanca A, et al. Altered expression of neurotransmitter receptors and neuromediators in vernal keratoconjunctivitis. *Arch Ophthalmol* 2006;124:462-468.
- Netland PA, Leahy C, Krenzer KL. Emedastine ophthalmic solution 0.05% versus levocabastine ophthalmic suspension 0.05% in the treatment of allergic conjunctivitis using the conjunctival allergen challenge model. *Am J Ophthalmol* 2000;130:717-723.
- PDR electronic library 2006. New Jersey: Thomson PDR, 2006.
- Porazinski AD, Donshik PC. Giant papillary conjunctivitis in frequent replacement contact lens wearers: a retrospective study. *CLAO J* 1999;25:142-147.
- Power WJ, Tugal-Tutkun I, Foster CS. Long-term follow-up of patients with atopic keratoconjunctivitis. *Ophthalmology* 1998;105:637-642.
- Raizman MB, Rothman JS, Maroun F, Rand WM. Effect of eye rubbing on signs and symptoms of allergic conjunctivitis in cat-sensitive individuals. *Ophthalmol* 2000;107:2158-2161.
- Rhee DJ, Rapuano CJ, Papiodis GN, Fraunfelder FW, eds. *Physicians' desk reference for ophthalmology* 2007. Montvale, NJ: Thomas PDR, 2006.
- Rikkers SM, Holland N, Drayton GE, et al. Topical tacrolimus treatment of atopic eyelid disease. *Am J Ophthalmol* 2003;135:297-302.
- Santos CI, Huang AJ, Abelson MB, et al. Efficacy of lodoxamide 0.1% ophthalmic solution in resolving corneal epitheliopathy associated with vernal keratoconjunctivitis. *Am J Ophthalmol* 1994;117:488-497.
- Seamone C, Jackson WB. Immunology of the external eye. In: Tasman W, ed. *Duane's clinical ophthalmology*, vol. 4. Philadelphia: Lippincott Williams & Wilkins, 2006.
- Secchi A, Ciprandi G, Leonardi A, et al. Safety and efficacy comparison of emedastine 0.05% ophthalmic solution compared to levocabastine 0.05% ophthalmic suspension in pediatric subjects with allergic conjunctivitis. *Acta Ophthalmol Scand* 2000;78:42-47.
- Secchi A, Leonardi A, Discepolo M, et al. An efficacy and tolerance comparison of emedastine difumarate 0.05% and levocabastine hydrochloride 0.05%: reducing chemosis and eyelid swelling in subjects with seasonal allergic conjunctivitis. *Acta Ophthalmol Scand* 2000;78:48-51.
- Simons FER. Advances in H<sub>1</sub>-antihistamines. *N Engl J Med* 2004;351:2203-2217.
- Simpson EL, Hanifin JM. Atopic dermatitis. *Med Clin North Am* 2006;90:149-167.
- Skotnitsky CC, Naduvilath TJ, Sweeney DE, Sankaridurg PR. Two presentations of contact lens-induced papillary conjunctivitis (CLPC) in hydrogel lens wear: local and general. *Optom Vis Sci* 2006;83:27-36.
- Smolin G, O'Connor GR. *Ocular immunology*, ed. 2. Boston, Little, Brown, 1986.
- Soparkar CNS, Wilhelmus KR, Koch DD, et al. Acute and chronic conjunctivitis due to over-the-counter ophthalmic decongestants. *Arch Ophthalmol* 1997;115:34-38.
- Spangler DL, Abelson MB, Ober A, Gotnes PJ. Randomized, double-masked comparison of olopatadine ophthalmic

- solution, mometasone furoate monohydrate nasal spray, and fexofenadine hydrochloride tablets using the conjunctival and nasal allergen challenge models. *Clin Ther* 2003;25:2245-2267.
- Takano Y, Fukagawa K, Miyake-Kashima M, et al. Dramatic healing of an allergic corneal ulcer persistent for 6 months by amniotic membrane patching in a patient with atopic keratoconjunctivitis. *Cornea* 2004;23:723-725.
- Tauber J, Raizman MB, Ostrov CS, et al. A multicenter comparison of the ocular efficacy and safety of diclofenac 0.1% solution with that of ketorolac 0.5% solution in patients with acute seasonal allergic conjunctivitis. *J Ocul Pharmacol Ther* 1998;14:137-145.
- Williams HC. Atopic dermatitis. *N Engl J Med* 2005;352:2314-2324.
- Wilson FM II. Allergy to topical medications. *Int Ophthalmol Clin* 2003;43:73-81.
- Zhan H, Smith L, Calder V, et al. Clinical and immunological features of keratoconjunctivitis. *Int Ophthalmol Clin* 2003;43:59-71.
- Zierhut M, Schlote T, Tomida I, Steimer R. Immunology of uveitis and ocular allergy. *Acta Ophthalmol Scand Suppl* 2000;230:22-25.
- Zug KA, Palay DA, Rock B. Dermatologic diagnosis and treatment of itchy red eyelids. *Surv Ophthalmol* 1996;40:293-306.

## *Diseases of the Sclera*

*David D. Castells*

The episclera is a fully vascularized fibroelastic tissue loosely overlying yet tightly attached to the sclera. Disease of the episclera tends to be transient and of minimal impact to the patient. The sclera, along with the cornea, serves as the protective shell of the eye and is composed chiefly of various types of collagen, elastin, and proteoglycans arranged in an extracellular matrix with little vascular supply. Diseases of the sclera tend to be serious, painful and of significant consequence to the patient. This chapter discusses inflammation of these tissues, termed *episcleritis* and *scleritis*. Both are rare, episcleritis less so; therefore limited large-scale studies exist and no true prevalence studies have been done. However, the literature provides significant understanding and management standards.

### **VASCULATURE OF THE EPISCLERA AND SCLERA**

The sclera is considered avascular because it contains no capillary beds. It obtains sufficient nutrition to meet its low metabolic requirements from the episcleral and choroidal blood supplies. The episclera obtains a rich blood supply from the anterior and posterior ciliary arteries. The episclera contains two vascular supplies, a superficial vascular plexus and a deep vascular plexus.

Episcleritis is characterized by a vasculitis of the superficial episcleral vascular plexus and edema of the episcleral tissue. The deep vascular plexus and sclera are not involved and remain flat in episcleritis. This is in contrast to scleritis, in which vasculitis involves the deep episcleral vascular plexus and scleral edema. Although scleritis may potentially occur in the absence of episcleritis, it is usually associated with varying degrees of episcleritis. This associated involvement of the superficial vascular plexus may present a challenge in visualizing and excluding scleritis from the diagnosis.

### **EPISCLERITIS**

Episcleritis is a somewhat uncommon and usually benign self-limiting inflammation of the episcleral tissues. Of new

patient referrals to specialty clinics, the incidence of episcleritis was 0.08% to 1.4%. However, true incidence is probably considerably higher because most occurrences are mild and do not require treatment. Although episcleritis can affect any age group, it is most often found in younger adults, with a smaller grouping in older adults, and it rarely affects children. Episcleritis affects women up to 75% of the time. Involvement is unilateral in approximately two-thirds of cases, and the risk of second eye involvement is approximately 12%. Over 50% of patients have recurrence that often continue up to 6 years, but recurrences can occur as long as 30 years after the initial event.

Episcleritis is clinically classified as either simple or nodular. Simple episcleritis is usually the milder form, being limited to a sector of the eye in approximately two-thirds of cases, but can affect the entire episclera in approximately one-third of cases. Nodular episcleritis is usually more serious and involves the presence of a definitive nodule and mild to moderate discomfort. Approximately 20% to 25% of cases present as nodular. Only 2% to 5% of episcleritis progresses to scleritis. Simple episcleritis usually lasts 1 to 3 weeks, whereas nodular episcleritis has a more variable course, in some cases lasting up to 2 months. Both forms periodically recur but become less frequent with time until the disease no longer remits. Either form may recur as the other.

Episcleritis is idiopathic approximately 70% of the time. Mild, nonrecurring, and resolving presentations do not require further assessment. However, about 30% of patients with episcleritis have an underlying condition. These individuals tend to be older with a history of systemic disease. The episcleritis tends to last longer than usual and may not respond to topical steroid treatment. There are a wide range of reported rates of association with systemic disease most likely representing practice modality bias. Seven percent of patients with episcleritis demonstrate hyperuricemia even in the absence of clinical gout and 15% demonstrate serologic indications of connective tissue disease. The most commonly associated systemic diseases are shown in Box 28-1; however, theoretically,

### Box 28-1 Common Diseases Associated With Episcleritis

#### Inflammatory/immunologic

Inflammatory bowel disease  
Relapsing polychondritis  
Rheumatoid arthritis  
Systemic lupus erythematosus

#### Infectious

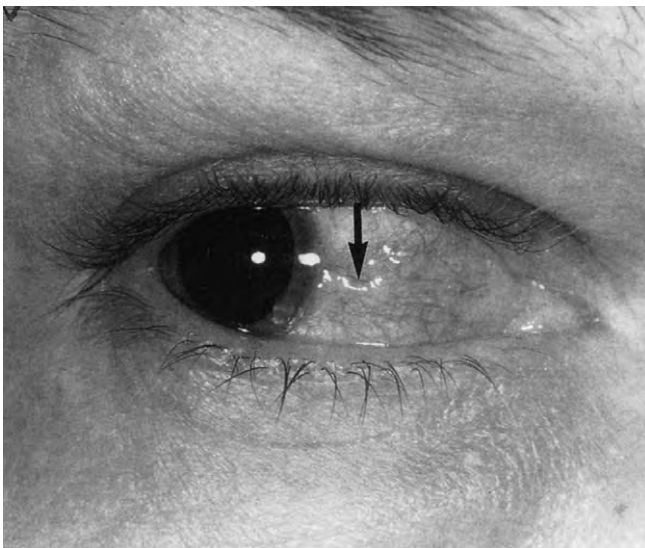Herpes zoster  
Lyme disease  
Syphilis

#### Other

Idiopathic (most common)  
Atopy  
Gout

all the disorders that can cause scleritis (Box 28-2) can also cause episcleritis. Episcleritis can be the initial sign of a systemic vasculitic disease; therefore, a careful review of systems is recommended at initial and yearly evaluations.

The underlying cause of episcleritis often remains elusive but has been associated with stress. Pathologically, the involved area shows a heavy primarily lymphocytic infiltration devoid of polymorphic cells. Because of the loose richly vascularized nature of the episclera, inflammation can spread quickly, leading to vessel dilation, edema, cellular infiltrate, and discomfort (Figure 28-1). In some patients a migrainous etiology has been identified. Episcleritis has shown an association with antigen-antibody reactions, as in those with penicillin sensitivity. There is controversy about whether the rate of atopy for family or patient is greater than in the general population.



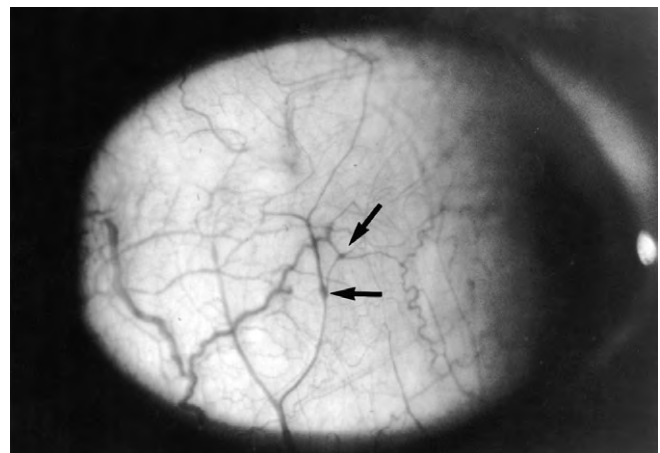
**Figure 28-1** Nodular episcleritis in sectorial configuration. Arrow points to elevated edematous nodule.

It has also been hypothesized that a type I hypersensitivity reaction may be involved in some patients. A definitive pathogenic mechanism for episcleritis has still not been established.

### Diagnosis

The hyperemia of simple episcleritis is often seen in one or more sectors within the interpalpebral fissure (see Figure 28-1), usually developing within 1 hour. The vessels are usually tortuous and often demonstrate saccular dilatations (Figure 28-2). The vessel injection in simple episcleritis can vary from a mild red flush to an intense fiery red. For diagnosis of episcleritis versus scleritis, natural daylight examination is highly recommended over the slit lamp because the former brings out the colors whereas the latter diminishes them. Episcleritis presents a salmon red or bright red color versus the bluish-red or purplish tones of scleritis. If daylight examination is not readily available, then incandescent light is the next best choice. Excluding involvement of the deep episcleral vascular plexus is another way to rule out scleral involvement. This is often accomplished with the red free filter in the slit lamp or after application of 10% phenylephrine to constrict the conjunctival and superficial episcleral vascular plexus, allowing clear visualization of the deep episcleral vascular plexus that is not blanched by phenylephrine.

In nodular episcleritis there is usually only a single distinct, elevated, red, edematous nodule with surrounding congestion (see Figure 28-1). This classification is localized to discrete areas, each of which consists of an elevated nodule that is mobile over the underlying sclera. Because edema is isolated to the episclera, a biomicroscope slit beam does not show any upward deviation of the underlying sclera. Nodules vary in size and elevation,



**Figure 28-2** Diffuse episcleritis demonstrating vessel injection, tortuosity, and saccular dilatations (arrows).

**Box 28-2** Reported Diseases Associated With Scleritis**Immunologic and collagen vascular**

Acne fulminans  
 Ankylosing spondylitis  
 Atopy  
 Behçet's disease  
 Churg-Strauss syndrome<sup>a</sup>  
 Cogan's syndrome  
 Dermatomyositis  
 Erythema nodosum  
 Crohn's disease  
 Goodpasture syndrome  
 Giant cell arteritis  
 Inflammatory bowel disease  
 Juvenile rheumatoid arthritis  
 Polyarteritis  
 Polyarteritis nodosa  
 Relapsing polychondritis  
 Polymyalgia rheumatica  
 Psoriatic arthritis  
 Sarcoidosis  
 Schönlein-Henoch purpura<sup>b</sup>  
 Systemic lupus erythematosus  
 Reiter's syndrome  
 Rheumatoid arthritis  
 Sjögren's syndrome  
 Takayasu disease  
 Ulcerative colitis  
 Waldenström's macroglobulinemia  
 Wegener's granulomatosis

**Infectious****Bacterial infection**

*Chlamydia*  
*Mycobacterium leprae* (leprosy)  
*Nocardia asteroides*  
*Pseudomonas aeruginosa*  
*Staphylococcus aureus*  
*Staphylococcus epidermidis*  
*Streptococcus pneumoniae*  
 Tuberculosis (*Mycobacterium*)

**Viral infections**

Epstein-Barr virus  
 Herpes simplex  
 Herpes zoster  
 Human immunodeficiency virus  
 Mumps

**Fungal infections**

*Acremonium*  
*Aspergillus fumigatus*  
*Aureobasidium pullulans*  
*Proteus mirabilis*  
*Rhinosporidium seeberi*  
*Sporothrix schenckii*

**Parasitic infections**

*Acanthamoeba*  
*Onchocerca volvulus*  
*Toxocara canis*  
*Toxoplasma gondii*

**Spirochetes**

*Borrelia burgdorferi* (Lyme disease)  
*Treponema pallidum* (syphilis)

**Other****Injury**

Chemical burns  
 Foreign bodies  
 Penetrating injuries  
 Radiation  
 Thermal burns  
 Trauma

**Postsurgical**

Cataract  
 Glaucoma  
 Keratoplasty  
 Pterygium surgery  
 Retinal detachment repair  
 Strabismus  
 Vitrectomy

**Metabolic**

Gout  
 Porphyria  
 Thyrotoxicosis

**Miscellaneous**

Acne rosacea  
 Goodpasture's syndrome  
 Influenza vaccine  
 Mucosa-associated lymphoid tissue lymphoma  
 Self-inflicted  
 Vitamin B<sub>12</sub> deficiency

Watson PG, et al. The sclera and systemic disorders, ed. 2. New York: Butterworth-Heinemann, 2004.

Cury D, Breakey AS, Payne BF. Allergic granulomatous angiitis associated with uveoscleritis and papilledema. *Arch Ophthalmol* 1956;55:261-266.

Adapted with permission from Castells DD. Anterior scleritis: three case reports and a review of the literature. *Optometry* 2004;75:437.



potentially causing adjacent dellen formation. Nodular episcleritis may last longer than simple episcleritis. Regression is often within 3 to 4 weeks but can persist up to 2 months, with rare cases requiring anti-inflammatory intervention.

Both types of episcleritis have edema of the episclera and overlying conjunctiva. The edema is distributed diffusely or focally in simple versus nodular episcleritis respectively. There may be grayish infiltrates present that appear yellow in red-free light. In both classifications, the patient may complain of a sensation of heat, pricking, light sensitivity, and/or mild discomfort. Pain is usually absent and rarely significant or radiating. The eye is rarely tender to the touch. Although tearing is common, there is no ocular discharge. In rare instances the eyelids may become edematous, and if photophobia is present an associated keratitis should be suspected. Episcleritis does not affect visual acuity, and intraocular structures are usually not involved.

Nodular episcleritis is similar to diffuse but may have a more insidious onset and longer duration. In severe cases of episcleritis, one may observe rare anterior chamber cells that resolve with the episcleritis and do not represent a true uveitis. In the case of concurrent uveitis and episcleritis, the uveitis treatment may also control the episcleritis, and a systemic evaluation may be indicated to explore the possibility of an underlying etiology.

Episcleritis usually resolves without any permanent effect to the involved tissues, regardless of the severity or number of recurrences. However, multiple attacks of nodular episcleritis in the same location may cause thinning of the superficial scleral lamellae, causing slight transparency. If episcleritis occurs close enough to the cornea, it may cause mild peripheral corneal thinning or vascularization. Neither of these consequences is usually significant.

## Management

Episcleritis is a self-limiting disease with minimal symptoms and risk; therefore it generally does not require treatment, and patients should be encouraged to let the condition run its course. Simple anterior episcleritis, in particular, tends to greatly improve within 1 week and resolve by 3 weeks. Lubricants, particularly cold artificial tears, and cold compress can be used as supportive measures. Often, however, patients desire symptomatic relief from the redness and discomfort. In other cases, particularly nodular episcleritis, there may be some discomfort.

Rarely, a history of sensitization to an external agent can be identified. In these cases removal of the offending agent is the recommended treatment. Possible contributory or causal diseases, such as dry eye syndrome, acne rosacea, ocular allergic disease, or blepharitis, have been noted in up to 50% of episcleritis patients. These concurrent conditions should be treated if present. Full response to treatment in any patient who smokes can be delayed by a month or more. For this reason and because episcleritis

is recurrent, patients who smoke should be counseled to stop smoking and given smoking cessation options when necessary.

Vasoconstrictors, such as phenylephrine, naphazoline, oxymetazoline, and tetrahydrozoline, are available over the counter and may be beneficial in mild cases. However, there is no evidence that they shorten the course of the disease and, when abused, they can cause rebound hyperemia and medicamentosa, which can increase the redness or edema in the episclera. For these reasons, vasoconstrictors should be used sparingly.

Topical nonsteroidal anti-inflammatory drugs (NSAIDs), such as bromfenac, diclofenac, ketorolac, and nepafenac, have been advocated, but there is evidence that commercially available preparations do not appear effective in treating episcleritis. Topical flurbiprofen and ketorolac were found to be no more effective than placebo in treating episcleritis; therefore, treatment modalities other than topical NSAIDs should be used.

When intervention is indicated, topical steroids have often been considered the drug of choice. This is a debated treatment, however, not only due to the possible side effects of repeated or long-term topical steroid use, but because topical steroids have been shown to cause a “rebound effect” upon withdrawal of the drug that includes an increase in both the intensity and frequency of future attacks. Treating episcleritis with supportive measures only has been suggested, using drug therapy only if absolutely necessary, and then using NSAIDs as a first-line treatment.

Topical steroids have been shown effective in treating episcleritis, despite their inherent risks. Prednisolone has been shown effective; however, it may be prudent to use a topical steroid with a lower likelihood to cause an increase in intraocular pressure. These agents include fluorometholone, loteprednol, or rimexolone. Fluorometholone 1% has been shown successful in treating episcleritis and 0.25% can also be used. Loteprednol etabonate (0.2% or 0.5%) shows a minimal risk of raising intraocular pressure and is probably less likely to cause cataract formation than other topical steroids.

Topical steroid dosing is often suggested at four times a day, although more frequent installation may be necessary. Dosing should be tapered over a few days after resolution to avoid rebound. Tapering may not, however, avoid the observed consequences of increasing severity and frequency in future episodes. Another popular dosing approach is to consider a short high-dose steroid pulse over 2 weeks, such as one drop every hour for 2 days, then six drops a day for 2 days, five drops a day for 2 days, and so on until one drop a day for 2 days, and then stop. This strategy is often sufficient to significantly minimize severe episodes. It is prudent to remember that episcleritis is generally self-resolving and that steroid therapy serves only to hasten its resolution.

Oral NSAIDs are useful in the management of episcleritis, either as a first-line treatment or in cases that are

intractable or nonresponsive to topical steroids. Not all oral NSAIDs are effective in treating episcleritis. Patients have variable responsiveness to specific NSAIDs; therefore, if one is not effective another one should be tried. Naproxen, 250 to 500 mg twice daily, or ibuprofen, 200 to 600 mg four times daily, is the recommended NSAID for episcleritis. More potent NSAIDs include flurbiprofen, 100 mg three times daily, and indomethacin, 25 mg four times daily or 75 mg sustained-release capsules twice daily. The side effects and cautions of NSAIDs, which include cardiovascular and gastrointestinal effects, should be carefully considered, explained to the patient, and monitored during therapy.

## SCLERITIS

Unlike the more commonly encountered episcleritis, inflammation of the sclera is relatively rare, painful, and capable of extensive and permanent tissue and visual destruction. Scleritis is characterized by an immune-mediated vasculitis and inflammatory cell infiltration of the sclera and episclera. Scleritis usually occurs in the fourth to sixth decades of life but can be seen at any age. Peak incidence for men is in the fourth decade, whereas there are two peaks for women: the third and sixth decades. Diffuse scleritis shows a 1:1 distribution, whereas the other forms, particularly necrotizing and posterior scleritis, show a female predilection. Scleritis presents bilaterally about 50% of the time, and unilateral presentations usually

involve the fellow eye within 6 years. Bilateral scleritis is more common when there is an underlying systemic etiology, and scleritis may recur in up to 39% of cases.

The classification for scleritis (Figure 28-3) is an established and substantiated system based on clinical appearance and tissue involvement. This classification also correlates to the severity of ocular and systemic disease states. Approximately 8% of patients change classification during the course of their scleritis. Anterior scleritis is subclassified as diffuse, nodular, or necrotizing. Of patients presenting with scleritis, 39% to 45% present with diffuse and 23% to 45% with nodular. Approximately 4% progress from diffuse to nodular, and 3.4% progress from nodular to necrotizing. Necrotizing anterior scleritis is the most severe form because of active tissue destruction and is further classified as with inflammation or without inflammation. The term *necrotizing scleritis without inflammation* is based on the lack of clinically visible inflammation compared with the other classifications and can be considered a misnomer because inflammation is still the underlying etiology. For clarity's sake, some prefer to refer to this classification of scleritis as scleromalacia perforans. Of those with necrotizing scleritis 10% to 23% present with scleromalacia perforans and 3% to 4% present with necrotizing scleritis with inflammation. Two percent to 12% of patients presenting with scleritis manifest the posterior kind, although, due to a high rate of missed diagnosis, it is suggested that up to 20% of presenting scleritis is posterior.

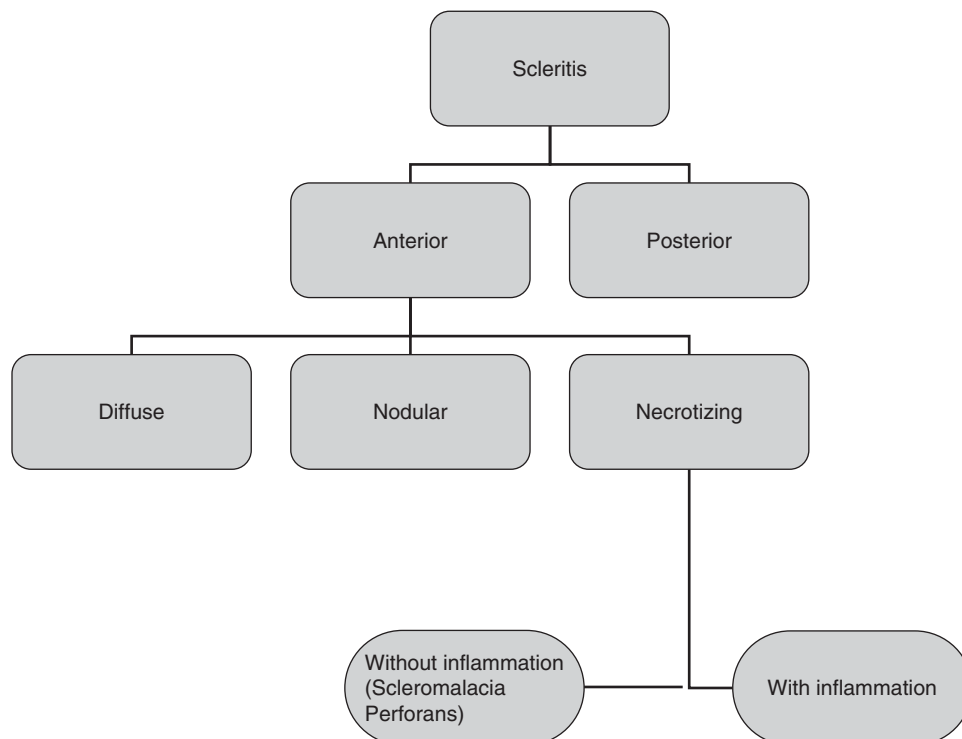


Figure 28-3 Classification of scleritis.

Up to 57% of scleritis cases are associated with an underlying systemic disease (see Box 28-2). Thus, more commonly than with episcleritis, scleritis may be the initial or only indication of a severe and life-threatening systemic disease. These diseases are usually connective tissue and autoimmune disorders with rheumatoid arthritis being the most common, followed by Wegener's granulomatosis. Other less frequent underlying diseases include inflammatory bowel disease, systemic lupus erythematosus, relapsing polychondritis, and herpes zoster infection. Five percent to 10% of anterior scleritis cases are infectious, with bacteria, viruses, fungi, and parasites all potential causes.

Scleritis occurs in 0.3% to 6.3% of rheumatoid arthritis patients, and the incidence of rheumatoid arthritis in scleritis patients is reported as 10% to 33%. In Wegener's granulomatosis scleritis may be the only clinical sign in up to 16% of patients. These statistics reinforce the importance for patients with systemic autoimmune and collagen vascular disorders to receive routine eye care and to be educated about possible ocular involvement of their diseases. For scleritis patients with an identifiable systemic etiology, up to 84% demonstrate a systemic vasculitis that usually produces the more destructive necrotizing forms of scleritis and scleromalacia perforans in particular. Approximately half of patients with necrotizing scleritis die from systemic vascular events. This fact emphasizes the need for timely referral and adequate comanagement with the appropriate medical specialist to minimize patient morbidity and mortality.

The pathophysiology of scleritis is complex and not fully understood. The main dysfunction is thought to be the deposition of immune complexes in the vasculature of the sclera and episclera, creating a vasculitis. This leads to edema and inflammatory cell infiltration of the sclera and episclera, which in turn cause disorganization and destruction of the collagen lamellae. However, not all presentations of scleritis demonstrate the same pathology.

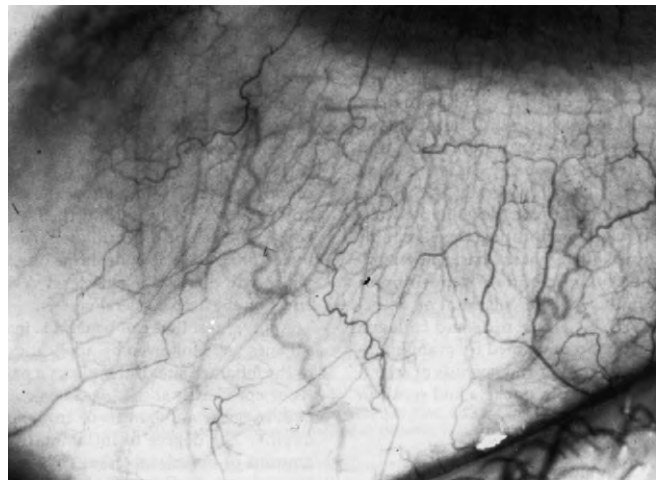
In idiopathic cases the histology often suggests a type IV delayed hypersensitivity reaction, whereas cases associated with rheumatoid arthritis or systemic vasculitis display histology consistent with a type III immune complex-mediated process. In diffuse and nodular scleritis the inflammatory infiltrate is generally nongranulomatous; however, in necrotizing scleritis the infiltrate is usually granulomatous, and deposition of immune complexes can be seen in the walls of the superficial and deep episcleral vascular plexus. Cell necrosis and collagen degeneration appear to be caused by proteolytic enzymes, which stimulate intracellular tissue digestion. The primary site for vascular occlusion, termed *vascular closure*, is the venules, except in scleromalacia perforans where it occurs in the capillaries. Whichever of the various pathogenic mechanisms may be involved in a given presentation the result is inflammation and, in the necrotizing classifications, scleral necrosis and thinning.

## Diagnosis

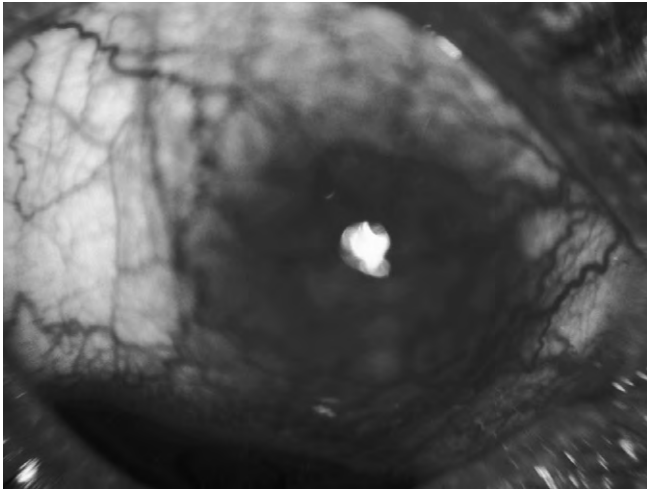
The onset of scleritis is usually slow, with symptomatic increase over many days. Tearing and photophobia are common complaints in scleritis, with or without a concurrent keratitis. There should be no discharge, but vision loss is possible. Scleritis may be one of the most painful eye conditions known and, except in the case of scleromalacia perforans, the hallmark symptom of scleritis is severe pain, often described as boring in nature. The pain often prompts the patient to seek care and may be localized to the eye but often radiates to the jaw, temple, or head. The severity can lead to weight loss, interfere with sleep and be only minimally or temporarily relieved by even prescription analgesics. The eye can become exquisitely tender to the touch, with the slightest digital pressure eliciting patient recoil. The pain may appear greatly disproportionate to clinical findings, particularly in posterior scleritis where there are no readily visible findings. The pain is secondary to inflammation, with distention of the sensory nerve endings as they become edematous and damaged. In some cases intractable pain may be relieved only by the use of retrobulbar alcohol injections.

In diffuse anterior scleritis (Figure 28-4), the pain is often less severe. This form of scleritis is the mildest and most common type, and it manifests as an area of sectorial or diffuse dilation of the deep episcleral vascular plexus with overlying and adjacent episcleritis that can affect the whole eye. There can be mild anomalous changes in the blood vessels that may persist even after successful treatment, which is associated with a 9% incidence of vision loss.

Nodular scleritis consists of one or more focal nonmovable nodules of inflamed scleral tissue (Figure 28-5), usually in the interpalpebral region. These nodules are frequently tender to palpation, and nodular scleritis is more likely to cause severe or radiating pain than diffuse scleritis.



**Figure 28-4** Diffuse scleritis with deep vessel injection and associated episcleritis.



**Figure 28-5** Focal scleral and episcleral inflammation seen in nodular scleritis.

Approximately one-half of affected patients have a bilateral occurrence. Scleral inflammation typically does not extend beyond the nodule, and the sclera usually does not become necrotic. However, rarely, the nodule may become avascular, leading to necrosis that may cause the sclera to become thin and transparent beneath the nodule. In rare worst-case scenarios up to a 26% incidence of vision loss may be seen, but usually only in older patients with associated systemic disease.

In contrast to the non-necrotizing classifications, necrotizing scleritis with inflammation, although rare, is more severe, more likely to cause permanent tissue destruction including vision loss, and carries a 45% to 54% mortality rate over 5 to 10 years. Necrotizing scleritis may indicate a potential lethal underlying systemic vasculitis. The pain from this form of scleritis is the most devastating of all types. More than 60% of patients develop complications other than scleral thinning, and 40% to 74% have loss of visual acuity. The sclera can become transparent with visible choroid and rapid progression over the course of a few weeks. Perforation is a possibility, and the entire anterior segment can become involved without prompt treatment. Even with successful treatment, small areas of uvea may be covered by only a thin layer of conjunctiva or episclera. The actual uvea may be exposed, which if small enough can be covered by new collagen growth; large defects may require a scleral graft.

Unlike other types of scleritis, scleromalacia perforans is minimally symptomatic and insidious in onset. Scleromalacia perforans is bilateral more than 90% of the time and is almost always associated with long-standing rheumatoid arthritis. There is little to no pain or visible inflammation; however, the eye undergoes the same destruction of the sclera as in scleritis with inflammation. Patients may not present until advanced stages of their disease, often not until the characteristic gray or blue-gray of scleral thinning becomes readily evident. Globe perforation can occasionally occur asymptotically.

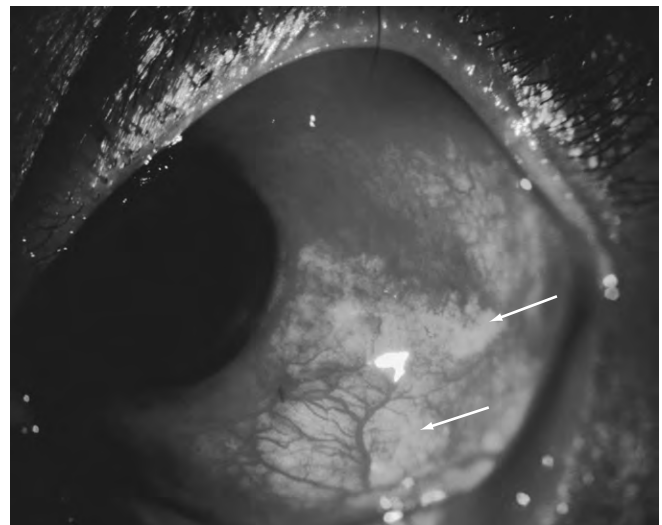
Patients may not be compliant with drug therapy due to side effects, the need for follow-up visits, and a lack of perceived need. Thorough patient education is critical. The 5-year mortality rate associated with scleromalacia perforans is as high as 73%; therefore appropriate and timely referral and comanagement with the appropriate medical specialist is important in minimizing mortality.

### Clinical Evaluation

Scleritis can be an extremely destructive disease; therefore early diagnosis is crucial, yet challenging, as demonstrated by reported misdiagnosis as high as 40%. A thorough and detailed history is necessary, including a comprehensive review of systems, to uncover any likely ocular or systemic etiologies for scleritis. A number of time-honored techniques are useful in diagnosing scleritis.

Topical anesthetic installation followed by applied pressure with a cotton swab to the inflamed site can be useful in diagnosis. If this elicits a pain response, scleritis or episcleritis should be suspected, whereas the absence of pain suggests conjunctivitis or uveitis. If 10% phenylephrine or epinephrine 1:1,000 blanches all episcleral vessels, then a scleritis is not present; however, these drugs do not constrict the deep episcleral vascular plexus that is dilated in scleritis.

Lesion color and examination lighting can play a crucial role in scleritis evaluation. For example, red-free light can be used to enhance blood vessels and may allow the clinician to observe areas of vascular closure (Figure 28-6) within a scleritis lesion. These areas represent vascular occlusion and destruction from progressive infiltrative inflammation. Except in scleromalacia perforans, anterior scleritis creates a characteristic bluish red or purplish (violaceous) color in contrast to the salmon red or bright red injection observed in episcleritis. This violaceous

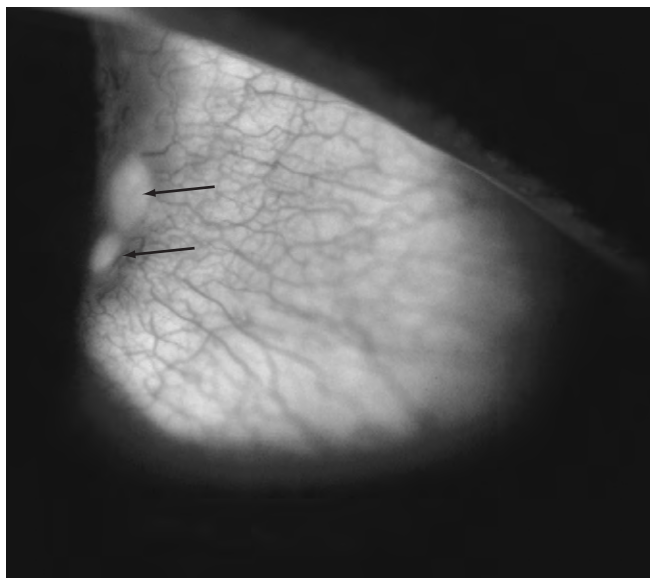


**Figure 28-6** Scleritis with areas of vascular closure (arrows).

color is seen far more easily in daylight and is often overlooked in tungsten or fluorescent light and the light of the slit lamp. As such, examinations should include evaluation in daylight, actually outside or at least next to a window. When scleral thinning occurs, such as in necrotizing forms of anterior scleritis, visible choroid can create a blue-gray or light gray tone to areas of the sclera. Examination with an overly bright slit lamp can obscure these colors, whereas examination outside the slit lamp may make these areas easier to visualize.

Comprehensive assessment of the eye, including the cornea and the uveal tract, is indicated at the initial examination and follow-up visits for scleritis because complications are extensive and can include uveitis, glaucoma, keratitis, corneal ulceration, proptosis, cataract, extraocular muscle paresis, myositis, and orbital cellulitis. Corneal involvement in scleritis is reported to be 29% to 43% and usually indicates a severe and active systemic disease that requires immediate treatment. Scleritis-related corneal involvement can occur as an infiltrative keratitis, termed *sclerokeratitis* (Figure 28-7), or noninflammatory corneal thinning such as peripheral ulcerative keratitis. Patients with rheumatoid arthritis and peripheral ulcerative keratitis require prompt immunosuppressive therapy due to the high association of life-threatening vasculitis. Uveitis is associated with scleritis in up to 42% of patients and in almost all patients with posterior scleritis or scleromalacia perforans. Uveitis is viewed as a negative prognostic indicator.

Traditional examination alone may not always be adequate to diagnose or manage scleritis, to identify areas of early vascular closure (see Figure 28-6), to differentiate benign nondestructive scleritis from necrosis, or to adequately monitor the success of treatment. Although not readily available, high-frequency ultrasound biomicroscopy



**Figure 28-7** Sclerokeratitis adjacent to an area of scleritis (arrows).

is able to image the anterior segment in fine detail. The ultrasound biomicroscopy can be used to detect and monitor scleral inflammatory diseases at the anterior segment, allowing the differentiation of episcleritis and scleritis and measurement of scleral tissue thickness. These properties make it particularly useful for diagnosis and monitoring of anterior scleritis.

Low-dose fluorescein angiography of the anterior segment, alone or in combination with indocyanine green angiography, provides detailed studies of vascular filling and leakage patterns in episcleritis and scleritis. Angiography can identify which vessels, episcleral or scleral, are leaking and if there are areas of vascular closure, making this procedure particularly useful for diagnosing and monitoring anterior scleritis. Fluorescein angiography can assist in confirming necrotizing scleritis and differentiating early necrotizing scleritis from diffuse and nodular forms. Angiography may be particularly useful in challenging cases, including posterior scleritis, and is also helpful in monitoring the effectiveness of treatment.

Laboratory tests are often indicated to exclude an underlying systemic disease. However, tests are expensive and may not be successful in making a definitive diagnosis; therefore they should be ordered in a focused fashion, based on the clinical presentation and a thorough history. The eye care practitioner may prefer to send a scleritis patient to an internist for laboratory testing because a physical examination of the patient is also indicated. Clear communication of the suggested tests and systemic diseases to be considered is recommended if this is the chosen path for further assessment. Table 28-1 lists some of the laboratory tests used in exploring the systemic etiologies of scleritis.

## Posterior Scleritis

Posterior scleritis is defined as scleritis occurring posterior to the ora serrata. The mean age at onset is 49; however, 30% are under the age of 40, and children may present as well. Posterior scleritis is severe and potentially blinding with complications that include uveitis, retinal and choroidal detachments, choroidal thickening, optic disc or macular edema, retinal hemorrhages, proptosis, subretinal mass, and ophthalmoplegia. Misdiagnosis of posterior scleritis is common, and it can mimic a subretinal mass, such as a choroidal melanoma or hemangioma, metastatic carcinoma, or uveal lymphoid hyperplasia. It is not uncommon for an eye to be enucleated because of a suspected intraocular tumor that later was shown to be posterior scleritis. Conversely, intraocular tumors have been misdiagnosed as posterior scleritis. Dilatation and evaluation of the posterior segment at regular intervals are indicated.

Posterior scleritis is more difficult to diagnose than anterior scleritis because it is harder to visualize and can present with few to no clinical signs. The underestimation of posterior scleritis is high, as demonstrated by studies in which 43% to 100% of enucleated eyes with histologic

**Table 28-1**  
Diagnostic Laboratory Testing in Scleritis

Laboratory Test	Identified Condition
CBC with differential	Nonspecific: infection, tumor, other
Chemistry panel: includes BUN, creatine, CO <sub>2</sub>	Nonspecific for vasculitis-induced renal disease
Urinalysis	Kidney or liver dysfunction, metabolic disease
RPR or VDRL	Syphilis, screening
FTA-ABS or MHA-TP	Syphilis, confirming
ESR	Nonspecific for systemic inflammation
ANA	Rheumatoid arthritis, collagen vascular disease
ANCA	Specific for Wegener's granulomatosis, polyarteritis nodosa, and related vasculitis-associated diseases
Cryoglobulins	Rheumatoid arthritis, systemic lupus erythematosus
ACE	Sarcoid
C-reactive protein	Nonspecific for systemic inflammation
PPD	Tuberculosis
Circulating immune complexes	Rheumatoid arthritis, systemic lupus erythematosus, Cogan's syndrome
Rheumatoid factor	Rheumatoid arthritis
Uric acid	Gout
Scleral biopsy	Infectious diseases and rare causes
Chest radiography	Tuberculosis, sarcoidosis, Wegener's granulomatosis
Sacroiliac radiography	Ankylosing spondylitis
Sinus radiography	Detect changes consistent with Wegener's granulomatosis
ELISA	Lyme disease, human immunodeficiency virus
HLA typing	HLA-related inflammatory disease such as ankylosing spondylitis

ACE = angiotensin-converting enzyme; ANA = antinuclear antibody; ANCA = antineutrophil cytoplasmic antibody; BUN = blood urea nitrogen; CBC = complete blood count; ELISA = enzyme-linked immunoassay assay; ESR = erythrocyte sedimentation rate; FTA-ABS = fluorescent treponemal antibody absorption; HLA = human lymphocyte antigen; MHA-TP = microhemagglutination-*Treponema pallidum*; PPD = purified protein derivative; RPR = rapid plasma reagin; VDRL = venereal disease reference laboratory.

Adapted with permission from Castells DD. Anterior scleritis: three case reports and a review of the literature. *Optometry* 2004;75:433.

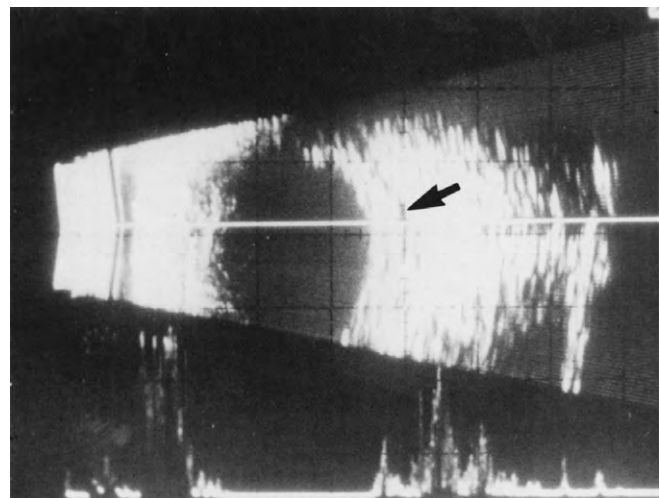
evidence of posterior scleritis did not have a previous diagnosis. Posterior scleritis should be suspected in the above-mentioned complications, all cases of anterior scleritis, unexplained reduction in vision, and when unexplained pain is present. However, it is important to note that only 55% of patients with posterior scleritis report severe pain. When pain is present, it is of the same nature as anterior scleritis.

Posterior scleritis is associated with anterior scleritis 60% of the time. Monitoring for change in visual acuity is important in scleritis because it may indicate new or progressive posterior involvement. Serial refractions can reveal scleritis-induced refractive error changes and scleral depression can identify and localize an area of posterior scleritis by eliciting intense pain when applied to the involved site.

In up to 15% of patients there are no presenting signs of posterior scleritis, and the diagnosis must be made on imaging studies of the orbit such as with B-scan ultrasonography or computed tomography. Magnetic resonance imaging is not useful for detecting soft tissue masses within or next to the sclera. Ultrasonography shows a thickened sclera and a possible clear zone immediately posterior to the globe (Figure 28-8). The normal thickness of the sclera varies from 0.3 to 1.0 mm, but in scleritis it can become as thick as 6 mm. Computed tomography can also reveal the inflammation as a thickening of the sclera and a separation between the sclera and Tenon's capsule. The thickening of the sclera is rendered obvious by comparing it with the fellow globe on computed tomography. Unfortunately, there may be no way to detect posterior scleritis of the painless necrotizing variety.

### Management

Appropriate management of scleritis requires accurate classification and diagnosis plus appropriate identification



**Figure 28-8** B-scan ultrasonogram of posterior scleritis demonstrating the edematous zone (arrow) produced by the posterior scleritis.

of etiology and any associated complications or systemic disease. Aggressive treatment is important to minimize potential complications that contribute to loss of vision or damage to the globe. Decreasing pain is the key indicator of improvement, whereas other parameters of effective treatment include a decrease in episcleral and scleral injection, tenderness, and corneal and intraocular involvement. Smoking has been shown to necessitate higher drug treatments and delay response to treatment by a month or more; therefore any scleritis patient who is an active smoker should be counseled to quit immediately.

Systemic therapy is usually required to control all but the mildest cases of scleritis. These treatments include NSAIDs, corticosteroids, and immunosuppressive agents. Because these agents have significant potential side effects, it is prudent to discuss the risks and benefits with the patient and to monitor closely for toxicity. Appropriate management of any underlying systemic condition may not only treat the scleritis but extend life. Particularly, in the case of underlying active vasculitic disease, delay in diagnosis and treatment may lead to death. As such, appropriate and timely comanagement between the eye care practitioner and the patient's physician is paramount. Although complications and vision loss are common with scleritis, early and intensive systemic treatment is often successful in preserving the eye and vision. Treatment is primarily determined by the etiology and severity of the inflammation.

An infectious etiology has been found in 6% to 18% of patients with scleritis. Many infectious agents have been reported to cause scleritis (see Box 28-2), with varicella zoster being the most common. A known infection should be treated with a targeted therapeutic regimen; however, infectious scleritis is difficult to treat due to the poor antimicrobial penetration into the avascular sclera and to the ability of some microorganisms to persist within the avascular intrascleral lamellae for long periods without inciting an inflammatory response. Often, when the sclera develops an infectious inflammation, medical treatment alone is not effective and surgical intervention is necessary. Cryotherapy may be useful in the treatment of infectious scleritis due to mechanical destruction of the microorganisms by the extracellular ice or enhancement of antibiotic absorption through damage to bacterial cell walls or disrupted scleral tissue. Prognosis is better if the cornea is not involved. Approximately 60% of eyes with infectious sclerokeratitis require evisceration or enucleation or are left blind.

Topical ocular steroids are often not effective alone in treating scleritis; however, up to 47% of patients with diffuse or nodular scleritis may recover with only 1% topical prednisolone acetate. Therefore, topical steroids may be appropriate in treating mild inflammation and pain, to maintain a state of remission between exacerbations, and as adjunctive therapy to oral agents. Topical cyclosporine A may also be effective in treatment of scleritis, either alone or as an adjunctive agent to systemic treatment.

## Oral NSAIDs

Oral NSAIDs are the established first-line treatment for non-necrotizing classifications of scleritis, providing control for up to 90% of cases. The initial drug choice should be one with established efficacy in treating scleritis as not all NSAIDs are equally effective. Individual patient response to NSAIDs is variable; therefore, if the initial drug is not effective, a different classification of NSAID should be tried before progressing to another form of medication. Failure of three different NSAIDs constitutes failure of the drug category. Some NSAIDs are available with an enteric coating (EC) or sustained-released (SR) formulations, such as Naprosyn EC and Indocin SR. Such preparations may reduce gastric side effects. One needs to seriously consider the risks and contraindications associated with NSAIDs, such as gastrointestinal bleeding, myocardial infarction, and stroke, when choosing this drug class.

Flurbiprofen, 100 mg three times daily, is a well-established first-line NSAID providing there is no evidence of vascular closure or scleral destruction on biomicroscopy. Flurbiprofen should provide pain relief within 2 days and improvement in clinical signs within 1 week. Indomethacin SR formulation, 75 mg twice daily, is a well-established second-choice drug when flurbiprofen is not effective but has also been used as first line. NSAIDs that have shown efficacy and are now available in over-the-counter formulations include naproxen, 500 mg twice daily, and ibuprofen, 600 mg four times daily. If a simplified dosing schedule is a consideration, then piroxicam, 20 mg/day, may be considered. Once effective control is established, a lower maintenance dose may suffice until the scleritis enters remission. To reduce the risk of gastrointestinal side effects, patients should be instructed to take NSAIDs with food or antacids.

## Oral Steroids

Systemic corticosteroid therapy is usually considered as the second-line treatment when NSAIDs are not effective, when NSAIDs are contraindicated, in cases of severe or necrotizing scleritis, and when vascular closure is evident. Sufficiently high initial dosage must be given to control the scleritis, and then the drug should be rapidly tapered to the minimal maintenance dose. Oral steroids control scleritis in almost all patients who can tolerate the appropriate dosage and duration of therapy. NSAIDs, even if not effective alone, may be useful when used in combination with steroids; however, this poses an additive risk of gastrointestinal side effects. Injectable steroids have been used effectively including intravenous, intramuscular, subconjunctival and orbital floor. These routes of administration may increase effectiveness but carry unique risks that must be carefully considered.

Although steroid therapy must be individualized, a typical prednisone dosage is 1 mg/kg/day (usually 60 to



100 mg daily in adults), initially tapered to 20 mg over the first week. The dose is then reduced by 5 to 10 mg per week (often 2.5-mg steps every other day) until the drug is discontinued without incident or an acceptable maintenance dose is achieved (typically 10 to 20 mg/day), which is usually required for a few weeks before a final taper. NSAIDs should be used to maintain a patient off steroids when possible. Because of the high rate of gastrointestinal side effects, prophylactic gastric acid suppressors are often given in conjunction with steroids. These drugs include esomeprazole, omeprazole, and ranitidine.

## Immunosuppressants

Immunosuppressive drugs are a third-line therapy in non-necrotizing scleritis, but the first choice in necrotizing forms of scleritis. In patients with necrotizing scleritis, up to 100% and 91% will fail initial treatment with NSAIDs or steroids, respectively, whereas only 26% of patients will fail initial treatment with immunosuppressive drugs. This treatment may also aid in minimizing the mortality rate. For example, in patients with rheumatoid arthritis or peripheral ulcerative keratitis and rheumatoid arthritis it was shown to decrease mortality from 54% for patients receiving NSAID and steroidal therapy to zero for patients who consistently remained on immunosuppressive drugs. The side effects of immunosuppressive agents are unique to the drug and can be severe; thus this therapeutic strategy is best administered and monitored by a specialist familiar with these therapeutic regimens. Drugs in this group include cyclophosphamide, methotrexate, azathioprine, and cyclosporine.

## SELECTED BIBLIOGRAPHY

- Akpek EK, Uv HS, Christen W, et al. Severity of episcleritis and systemic disease association. *Ophthalmology* 1999; 106:729-731.
- Albini TA, Rao NA, Smith RE. The diagnosis and management of anterior scleritis. *Int Ophthalmol Clin* 2005;45:191-204.
- Boonman ZF, De Keizer RJ, Watson PG. Smoking delays the response to treatment in episcleritis and scleritis. *Eye* 2005;19:949-955.
- Castells DD. Anterior scleritis: three case reports and a review of the literature. *Optometry* 2004;75:430-444.
- Fong LP, Sainz de la Maza M, Rice BA, et al. Immunopathology of scleritis. *Ophthalmology* 1991;98:472-479.
- Foster CS, Sainz de la Maza M. *The sclera*. New York: Springer-Verlag, 1994.
- Fraunfelder FT, Roy FH. *Current ocular therapy*, ed. 5. Philadelphia: Saunders, 2000.
- Goldstein DA, Tessler HH. Episcleritis, scleritis, and other scleral disorders. In: Yanoff M, Duker JS, eds. *Ophthalmology*. St. Louis: Mosby, 2004.
- Heiligenhaus A, et al. Ultrasound biomicroscopy in scleritis. *Ophthalmology* 1998;105:527-534.
- Jabs DA, Mudun A, Dunn JP, et al. Episcleritis and scleritis: clinical features and treatment results. *Am J Ophthalmol* 2000;130:469-476.
- Kunimoto DY, Kanitkar KD, Makar MS, eds. *The wills eye manual: office and emergency room diagnosis and treatment of eye disease*, ed. 4. Philadelphia: Lippincott Williams and Wilkins, 2004.
- McClusky P. Scleritis. In: Lightman S, ed. *Fundamentals of clinical ophthalmology*. London: BMJ Books, 2001.
- McCluskey PJ, Watson PG, Lightman S, et al. Posterior scleritis: clinical features, systemic associations, and outcome in a large series of patients. *Ophthalmology* 1999;106:2380-2386.
- McMullen M, Kovarik G, Hodge WG. Use of topical steroid therapy in the management of nonnecrotizing anterior scleritis. *Can J Ophthalmol* 1999;34:217-221.
- Medway DC, Donzis DM, Donzis PB. Ketoprofen in the treatment of scleritis. *Am J Ophthalmol* 1991;111:249-250.
- Nakajima N, Hayasaka S. Clinical features of episcleritis and scleritis in some Japanese patients. *Ophthalmologica* 1995;209:256-259.
- Read RW, Weiss AH, Sherry DD. Episcleritis in childhood. *Ophthalmology* 1999;106:2377-2379.
- Reynolds MG, Alfonso E. Treatment of infectious scleritis and keratoscleritis. *Am J Ophthalmol* 1991;112:543-547.
- Sainz de la Maza M. Scleritis immunopathology and therapy. *Dev Ophthalmol* 1999;30:84-90.
- Sainz de la Maza M, Foster SC. Sclera. In: Tasman W, Jaeger AE, eds. *Duane's ophthalmology on CD-Rom*. Philadelphia: Lippincott Williams and Wilkins, 2006.
- Sainz de la Maza M, Foster CS, Jabbur NS. Scleritis-associated uveitis. *Ophthalmology* 1997;104:58-63.
- Sainz de la Maza M, Foster CS, Jabbur NS. Scleritis associated with rheumatoid arthritis and with other systemic immune-mediated diseases. *Ophthalmology* 1994;101:1281-1286; discussion 1287-1288.
- Sainz de la Maza M, Foster CS, Jabbur NS. Scleritis associated with systemic vasculitic diseases. *Ophthalmology* 1995; 102:687-692.
- Sainz de la Maza M, Foster CS, Jabbur NS, et al. Ocular characteristics and disease associations in scleritis-associated peripheral keratopathy. *Arch Ophthalmol* 2002;120:15-19.
- Sainz de la Maza M, Jabbur NS, Foster CS. An analysis of therapeutic decision for scleritis. *Ophthalmology* 1993;100: 1372-1376.
- Sainz de la Maza M, Jabbur NS, Foster CS. Severity of scleritis and episcleritis. *Ophthalmology* 1994;101:389-396.
- Sarkis HS. Episcleritis and scleritis: diagnosis and therapy. *Semin Ophthalmol* 1996;11:79-92.
- Shimura M, Yasuda K, Fuse N, et al. Effective treatment with topical cyclosporin A of a patient with Cogan syndrome. *Ophthalmologica* 2000;214:429-432.
- Watson P. Diseases of the sclera and episclera. In: Tasman W, Jaeger AE, eds. *Duane's ophthalmology on CD-rom*. Philadelphia: Lippincott Williams and Wilkins, 2006.
- Watson PG. The diagnosis and management of scleritis. *Ophthalmology* 1980;87:716-720.
- Watson PG, Hayreh SS. Scleritis and episcleritis. *Br J Ophthalmol* 1976;60:163-191.
- Watson PG, Hazalman BL, Pavesio CE, et al. *The sclera and systemic disorders*, ed. 2. New York: Butterworth-Heinemann, 2004.
- Williams CP, Browning AC, Sleep TJ, et al. A randomised, double-blind trial of topical ketorolac vs artificial tears for the treatment of episcleritis. *Eye* 2005;19:739-742.
- Woon WH, Stanford MR, Graham EM. Severe idiopathic posterior scleritis in children. *Eye* 1995;9(Pt 5):570-574.

## *Uveitis*

*Alan G. Kabat*

Uveitis, by definition, describes an inflammatory state affecting the uveal tissues of the eye; these include the iris, ciliary body, and choroid. Any or all of these structures may be involved in uveitis, a potentially blinding disorder that has great potential impact from both a medical and socioeconomic standpoint. This chapter reviews the classification, pathophysiology, epidemiology, diagnostic considerations, and medical management of uveitis.

### **PERTINENT ANATOMY**

The uveal tract constitutes the middle tunic of the eye, located between the innermost retina and the outer protective scleral coat. This tissue and its constituent parts are both richly vascularized and highly innervated. The iris defines the anterior-most part of the uvea. It serves primarily as a diaphragm to admit light into the eye. Just posterior to the iris is the ciliary body, responsible for aqueous production and accommodation of the lens. Finally, the choroid defines the posterior-most aspect of the uvea. The choroid, via the *choriocapillaris*, is responsible for blood supply to the outer one-third of the retina. It also serves as a pathway for numerous sensory and autonomic neurons traveling to the anterior eye.

### **DESCRIPTION AND CLASSIFICATION OF UVEITIS**

Uveitis has been historically described in a variety of ways. Duration of the inflammation—essentially, acute versus chronic—is one way of classifying uveitis. Another is the nature of the underlying etiology, that is, traumatic, inflammatory, immune-related, infectious, or idiopathic uveitis. Additionally, when the uveitis is associated with systemic inflammatory conditions such as tuberculosis or sarcoidosis, the condition may be described by pathologic features, such as “granulomatous.” Granulomatous disorders typically are associated with specific clinically detectable signs, such as “mutton-fat” keratic precipitates (KPs) and/or iris nodules. The final way of classifying

uveitis is by location (anterior, intermediate, or posterior) and the involved ocular structures (e.g., iritis, cyclitis, choroiditis, etc.).

Throughout the years this lack of consistency in the classification of uveitis has been a source of confusion to students, clinicians, and researchers alike. Fortunately, today, terms like *nongranulomatous iridocyclitis* are used somewhat sparingly. Uveitis now tends to be classified according to the International Uveitis Study Group recommendations, which describe the condition in terms of symmetry (unilateral or bilateral), course (acute, i.e., <12 weeks, or chronic, i.e., >12 weeks), and most importantly, anatomic location. Recognized International Uveitis Study Group categories of uveitis are as follows:

1. *Anterior uveitis*: Involves the anterior-most portion of the uvea, that is, the iris and/or the anterior aspect of the ciliary body (*pars plicata*). The terms *iritis* and *iridocyclitis*, although more descriptive of the specific tissues involved, are less favorable today in the formal classification scheme. In the United States anterior uveitis is the most common form of uveitis encountered in clinical practice.
2. *Intermediate uveitis*: Describes inflammation confined to the posterior aspect of the ciliary body (*pars plana*) and/or the peripheral choroid. Secondary involvement of the retina and vitreous may also be seen. The most common form of intermediate uveitis in the United States is *pars planitis*.
3. *Posterior uveitis*: Involves the choroid, overlying retina, and vitreous. The terms *choroiditis*, *chorioretinitis*, and *retinochoroiditis* are still used to describe specific conditions, for example, ocular histoplasmosis or acute retinal necrosis, but these conditions both technically constitute a posterior uveitis.
4. *Panuveitis*: Describes the situation in which all aspects and structures of the uvea are inflamed. This form of uveitis, rare in the United States, is most commonly encountered with widespread ocular infection (e.g., infantile toxocariasis) or severe autoimmune disease (e.g., Vogt-Koyanagi-Harada syndrome).

## ETIOLOGY AND PATHOPHYSIOLOGY

Uveitis should not be thought of as a singular ocular disorder but rather as a diverse collection of pathologic conditions with similar clinically observable signs. A vast multitude of etiologies may induce uveitis, ranging from blunt trauma to widespread systemic infection (e.g., tuberculosis) to generalized ischemic disorders (e.g., giant cell arteritis). Some other well-known systemic etiologies include ankylosing spondylitis, rheumatoid arthritis, sarcoidosis, multiple sclerosis, syphilis, Lyme disease, and histoplasmosis. A more thorough compilation of etiologic conditions is listed in Box 29-1. Of course, not all forms of uveitis are associated with systemic illness. Localized inflammations may occur as well, either by iatrogenic or idiopathic means. Some primary uveitic syndromes include Fuchs' heterochromic iridocyclitis and Posner-Schlossman syndrome. In addition, various retinal "white dot syndromes," such as bird-shot choroiditis, acute

posterior multifocal placoid pigment epitheliopathy, multiple evanescent white dot syndrome, and serpiginous choroiditis are also associated with uveitis.

Although the precise pathophysiology of uveitis has not been entirely elucidated, we do have a basic understanding of the cascade of events involved during this inflammatory state. In the normal human eye, the intraocular space remains free of inflammatory cells and plasma proteins by virtue of the blood-aqueous barrier anteriorly and the blood-retina barrier posteriorly. The blood-aqueous barrier is comprised of tight junctions between the endothelial cells of the iris vasculature and between the apicolateral surfaces of the nonpigmented epithelium of the ciliary body. Tight junctions between the retinal pigment epithelial cells and between endothelial cells of the retinal vasculature constitute the blood-retina barrier. In an inflammatory ocular state, cytokines mediate numerous tissue changes, among them vasodilation and increased vasopermeability. When the uveal vessels dilate, exudation of plasma, white blood cells, and proteins into the extravascular spaces (e.g., the anterior chamber) becomes possible. Small-molecular-weight proteins may cloud the ocular media but have little impact otherwise; however, as larger molecular weight proteins like fibrinogen accumulate in the aqueous and/or vitreous, pathologic sequelae follow. Fibrinogen is ultimately converted into fibrin, an insoluble protein involved in the blood-clotting process. In the anterior chamber fibrin acts as a glue, binding with cellular debris to form KPs; more importantly, fibrin facilitates the adhesion of adjacent ocular structures, such as the peripheral iris and cornea (anterior synechia) or the pupillary margin and anterior lens surface (posterior synechia). With synechiae comes the risk of secondary glaucomas, in particular angle closure with or without pupillary block. In the posterior segment, transudation of fluid and cells from the choroid can result in cystoid macular edema (CME) and, in extreme cases, exudative retinal detachment. The accumulation and contraction of fibrin within the vitreous cavity can initiate a tractional retinal detachment. Additionally, chronic uveal inflammation results in an increased concentration of vaso-proliferative mediators, promoting angiogenesis or neovascularization. Neovascular changes in the iris and angle can further predispose an individual to secondary glaucoma, whereas in the posterior segment neovascularization of the retina enhances the risk of hemorrhage and tractional detachment.

Box 29-1 Systemic Disease Associations in Uveitis	
Autoimmune	Infectious
Ankylosing spondylitis	Cat-scratch disease ( <i>Bartonella henselae</i> , <i>B. quintana</i> )
Behçet's disease	Cytomegalovirus
Giant cell arteritis	Herpes simplex virus
Inflammatory bowel disease	Herpes zoster virus
Juvenile idiopathic arthritis	Histoplasmosis ( <i>Histoplasma capsulatum</i> )
Multiple sclerosis	Human immunodeficiency virus
Polyarteritis nodosa	Human T-cell lymphotropic virus type I
Psoriatic arthritis	Leprosy ( <i>Mycobacterium leprae</i> )
Rheumatoid arthritis	Leptospirosis ( <i>Leptospira interrogans</i> , <i>L. biflexa</i> )
Systemic lupus erythematosus	Lyme disease ( <i>Borrelia burgdorferi</i> )
Tubulointerstitial nephritis	Onchocerciasis ( <i>Onchocerca volvulus</i> )
Vogt-Koyanagi-Harada syndrome	Syphilis ( <i>Treponema pallidum</i> )
Wegener's granulomatosis	Toxocariasis ( <i>Toxocara canis</i> )
	Toxoplasmosis ( <i>Toxoplasma gondii</i> )
	Tuberculosis ( <i>Mycobacterium tuberculosis</i> )
	Whipple's disease ( <i>Tropheryma whippelii</i> )

Adapted from Wade NK. Diagnostic testing in patients with ocular inflammation. *Int Ophthalmol Clin* 2000;40:37-54.

## EPIDEMIOLOGY

Because uveitis represents a group of vastly heterogeneous ocular disorders with a multitude of etiologic factors, epidemiologic studies of this entity prove to be somewhat challenging. The incidence and prevalence of uveitis, as well as its clinical presentation, may vary widely with regard to geographic location, age, medical history, and

other factors. Crucial considerations in the epidemiology of uveitis are as follows:

1. **Geography:** The worldwide annual incidence of uveitis is between 14 and 52 per 100,000 population. However, vast differences exist between and within countries. For example, a French study in 1984 revealed a prevalence of 38 per 100,000, whereas a 1962 U.S. study noted 200 cases per 100,000. A study from India in 2000 indicated an overwhelming 730 cases per 100,000 population. Most likely, these discrepancies are due to differences in reporting, access to medical care, and inclusion/exclusion criteria of the different studies. In addition, there are significant variations in the presentation of uveitis based on geographic location. In the United States, Europe, and Australia anterior uveitis is most prevalent, followed by posterior uveitis. In Argentina and Western Africa, however, panuveitis is the most common presentation of uveitis. These differences may be attributable to the high rate of endemic infection by toxoplasmosis and onchocerciasis in these regions, respectively. Similarly, panuveitis and posterior uveitis may be more common in Asian countries such as Japan and Korea because of the high incidence of Vogt-Koyanagi-Harada disease. Regional differences within countries also account for wide variations in uveitis epidemiology. In the United States, for example, uveitis associated with ocular histoplasmosis is more frequently observed in patients from the Ohio–Mississippi River valley.
2. **Age:** Uveitis is most commonly encountered in persons between ages 20 and 59 years. Interestingly, this period corresponds with an individual's peak T-cell activity. It unfortunately also coincides with the greatest potential earning period of a person's life and hence can have significant economic impact in terms of disability. Children and the elderly are rarely affected by uveitis; however, when individuals in these age groups are encountered, specific disorders must be considered. In those under the age of 16, juvenile idiopathic arthritis (JIA) is responsible for nearly 40% of anterior uveitis cases. Posterior uveitis in children is typically associated with toxoplasmosis. In those over age 60 presenting with uveitis, common causes include herpes zoster, Acute Retinal Necrosis (ARN), serpiginous chorioretinopathy, bird-shot retinopathy, and herpes simplex. Giant cell arteritis and other ischemic disorders must be considered as well.
3. **Gender:** Overall, uveitis does not tend to favor either gender; however, certain predisposing conditions may have a predilection for males or females. For example, HLA-B27–associated uveitis (e.g., ankylosing spondylitis, Reiter's syndrome) is encountered more commonly in males (3:1), whereas uveitis of JIA shows a distinct female preponderance (5:1).
4. **Race:** There is no known racial predilection associated with uveitis as a diagnosis. However, in the same way

that gender-specific etiologies may be identified, race-specific disorders are known to occur in uveitis patients. In the white population, for example, both the HLA-B27 conditions and ocular histoplasmosis are encountered more commonly than in other races. Individuals of African descent are at greater risk for sarcoidosis, whereas Asian individuals demonstrate a higher frequency of Vogt-Koyanagi-Harada syndrome and Behçet's disease.

5. **History:** Numerous factors in a patient's history can be contributory to uveitis. The ocular history is paramount, and factors such as trauma, surgery, and infection must be considered. Numerous systemic illnesses associated with uveitis have already been discussed and listed in Box 29-1. It is important for the clinician to probe the history for symptoms or signs that might be pertinent to these disorders, such as joint pain or joint deformities, lower back pain, gastrointestinal disturbances, respiratory problems, oral or genital lesions, rashes, and nail pitting. Any prior hospitalizations should be elucidated, as well as the reason and duration. Sexual history must also be taken into account, because syphilis, herpes simplex, and human immunodeficiency virus (HIV) infection in particular may be associated with uveitis. Reiter's syndrome (or reactive arthritis), with its characteristic findings of conjunctivitis, uveitis, arthritis, and urethritis, often follows a chlamydial or dysentery infection. Likewise, a thorough review of the drug history is important in patients with uveitis, not only to determine prior therapy for systemic illness but also to ascertain clues as to other potential etiologies. Numerous drug therapies have been associated with uveitis, among them topical agents such as latanoprost and metipranolol; systemic drugs purported to cause uveitis include rifabutin, cidofovir, the sulfonamides, and the family of drugs known as the bisphosphonates, used in the treatment of osteoporosis.

## DIAGNOSIS

The diagnosis of uveitis is typically based on the clinical presentation, including symptoms and signs specific to this immune-mediated ocular response. Most, though not all, patients with anterior uveitis present with pain. The pain tends to be a dull ache deep within the eye, which may radiate to the surrounding orbit and face. Typically, this discomfort is exacerbated by bright light (photophobia), which induces miosis and stretches the inflamed uveal tissues. Lacrimation is another common symptom. Visual acuity is variably affected; anterior uveitis usually displays only mild visual impairment; however, in cases of posterior uveitis the deficit may be profound. In most cases a visible inflammatory response involving the conjunctiva and episclera is observable on gross examination. Perhaps the most recognizable signs associated with

uveitis are “cells and flare.” Cells represent leukocytes, liberated from dilated blood vessels in the iris and ciliary body. Flare is the visibly observable accumulation of plasma protein. Both cells and flare may be observed readily in the anterior chamber, because the aqueous is normally optically empty. In the vitreous it may be more difficult to observe cells and flare; however, specific presentations, such as “snow banking” and “strings-of-pearls,” can be pathognomonic for intermediate or posterior uveitis. More distinct findings may be seen with biomicroscopy and/or funduscopy, depending on the tissues involved.

### Anterior Uveitis

Anterior uveitis accounts for approximately 90% of uveitis cases seen in the primary care setting and roughly 50% to 60% of uveitis managed at the tertiary care level. Anterior uveitis may be acute or chronic; acute cases tend to be unilateral and devoid of “granulomatous” changes, whereas chronic uveitis may be bilateral and usually has more significant pathology. Etiologies abound in anterior uveitis, but the most common identifiable cause is HLA-B27-associated disease.

### Visual Acuity

The evaluation of any ocular malady begins with visual acuity assessment, performed in both the involved and uninvolved eye. In the earliest stages of anterior uveitis, visual acuity is minimally compromised. However, as the condition persists over days to weeks, accumulation of cells and flare, as well as photophobia and lacrimation, may result in subjectively blurred vision. Pigment accumulation on the anterior lens capsule and corneal endothelium may further compromise acuity and may serve to disrupt the endothelial pumps, resulting in corneal edema. At this stage visual acuity may be impaired on the order of 20/60 or worse. Over months to years, chronic inflammation and corticosteroids can induce cataract formation, leading to a precipitous drop in visual acuity. Secondary glaucomas, such as those encountered in synechia-induced angle-closure or neovascular glaucoma, can result in profound irreversible vision loss.

### External Examination

The patient with anterior uveitis may display a sluggish, fixed, and/or irregular pupil on the involved side. Typically, the pupil is miotic secondary to ciliary spasm, though it may assume a larger more irregular shape due to synechia formation. Ocular motility is generally intact. Gross observation may reveal a pseudoptosis, secondary to photophobia; there is not typically any notable lid edema. Conjunctival and episcleral vessels are characteristically dilated, often profoundly, so that a unilateral “red eye” presentation is seen. Except in rare cases, there is no ocular discharge or palpable preauricular lymphadenopathy

associated with anterior uveitis. Vesicular lesions near the eyes may signify a herpetic etiology.

### Biomicroscopy

Biomicroscopy is critical in the uveitis assessment. It allows for accurate diagnosis as well as identification of potentially sight-threatening complications. The following structures and areas should be given special attention:

1. *Redness*: Anterior uveitis typically presents with a characteristic circumlimbal hyperemia, or “ciliary flush” as it is sometimes described. This pattern corresponds to the inflammation of the underlying ciliary body. In more profound reactions, however, the redness may be diffuse.
2. *Cornea*: The cornea is often involved in anterior uveitis. KPs, inflammatory cells that accumulate and coalesce, are often seen to deposit on the endothelium. In acute, traumatic, and idiopathic anterior uveitis KPs take the form of a fine powdery-white dusting. In anterior uveitis associated with granulomatous disorders, however, KPs tend to be larger and denser. In newly active cases these “mutton-fat” KPs may appear somewhat three-dimensional and “greasy” in consistency. Over time they become more densely pigmented, ranging from yellow to dark brown in color, and tend to flatten. Mutton-fat KPs suggest a more chronic recalcitrant course of uveitis.
3. *Anterior chamber*: The finding of cells and flare in the anterior chamber is crucial to a diagnosis of anterior uveitis. It is important to assess the anterior chamber before instilling any diagnostic dyes or drugs; dyes such as fluorescein can penetrate the cornea and simulate flare, whereas pharmacologic dilation can release pigment from the iris, which may be mistaken for white cells. Proper technique also requires that the anterior chamber be viewed in a completely dark room under high magnification (25 to 40×) with a small intense beam of white light directed obliquely through the aqueous (45- to 60-degree angle). Because of the Tyndall effect, cells and flare become visible in the anterior chamber and are reminiscent of smoke or dust circulating within a sunbeam. Grading schemes for cells and flare are shown in Tables 29-1 and 29-2, respectively. The grading of cells and flare is useful in determining the severity of the anterior uveitis and for monitoring the response to therapy.
4. *Iris*: In cases of granulomatous disease, inflammatory nodules may be detected in the iris. Nodules seen at the pupillary margin are termed Koeppe nodules, whereas Busacca nodules occur within the iris stroma. Iris nodules have been identified in association with a variety of disorders, including sarcoidosis, tuberculosis, leprosy, syphilis, multiple sclerosis, Vogt-Koyanagi-Harada syndrome, and Fuchs’ heterochromic iridocyclitis. The pupillary margin and iris surface should also be examined for neovascular membranes in cases of chronic uveitis. Additionally, iris

**Table 29-1**  
Grading Scheme for Anterior Chamber Cells

Grade	Cells in Field <sup>a</sup>
0	< 1
0.5+	1-5
1+	6-15
2+	16-25
3+	26-50
4+	> 50

<sup>a</sup>Field size is a 1 mm × 1 mm slit beam.

Adapted from The Standardization of Uveitis Nomenclature (SUN) Working Group.

atrophy may be noted in chronic or recurrent anterior uveitis, particularly Fuchs' heterochromic iridocyclitis, cytomegalovirus, and herpes zoster infections. It is also crucial to evaluate the iris for areas of synechia. Posterior synechia is noted at the pupillary margin, though it may be difficult to detect when the pupil is miotic. Pharmacologic dilation facilitates the diagnosis of posterior synechia and often helps to break areas of adhesion as well. Peripheral anterior synechia may be seen in some cases by direct illumination of the limbus; however, peripheral anterior synechia should always be confirmed by gonioscopic evaluation.

5. **Lens:** Pigment and cellular debris, similar to KPs, are often detected on the anterior lens surface. Faint fibrin membranes at the pupillary margin may precede areas of posterior synechia. Cataracts are an important consideration in chronic recalcitrant uveitis and for those on long-term corticosteroid therapy, because the latter is also linked with the development of posterior subcapsular cataracts.
6. **Vitreous:** In all cases of uveitis it is important to evaluate the vitreous by direct and indirect means. Occasionally, a presumed anterior uveitis may simply represent "spillover" of inflammatory cells from an intermediate or posterior uveitis or a "masquerade syndrome."

**Table 29-2**  
Grading Scheme for Anterior Chamber Flare

Grade	Description
0	None
1+	Faint
2+	Moderate (iris and lens details clear)
3+	Marked (iris and lens details hazy)
4+	Intense (fibrin or plastic aqueous)

Adapted from Jabs DA, Nussenblatt RB, Rosenbaum JT, et al. Standardization of uveitis nomenclature for reporting clinical data. Results of the First International Workshop. Standardization of Uveitis Nomenclature (SUN) Working Group. *Am J Ophthalmol* 2005;140:509-516.

Comparison of the aqueous versus vitreous response is critical. In most cases of truly anterior uveitis, there are minimal to no cells in the vitreous.

### Tonometry

The measurement of intraocular pressure (IOP) is essential in the initial assessment and ongoing management of uveitis. In the early stages of uveitis the IOP is typically low, due to secretory hypotony within the ciliary body. Over time, however, the IOP may normalize or rise to abnormal levels due to numerous mechanisms, including trabecular blockage by inflammatory debris and synechia formation. Elevated IOP usually indicates a more chronic condition.

### Gonioscopy

Gonioscopy is crucial to confirm the presence of peripheral anterior synechia. Even angles that appear deep centrally may have peripheral anterior synechia, because the pathogenesis of these adhesions involves an inflammatory etiology rather than an anatomic anomaly. Gonioscopy may also reveal neovascularization of the angle (NVA) and in cases of posttraumatic uveitis, angle recession.

### Fundus Examination

All patients with anterior uveitis should undergo dilated funduscopy. Such examination should be attempted on the initial visit, although it may be difficult because of patient discomfort and/or posterior synechia. In such cases, ophthalmoscopy on the first follow-up visit may yield more useful information. Without adequate careful examination of the peripheral fundus and posterior pole, one cannot rule out the possibility of posterior involvement or masquerade syndromes. Masquerade syndromes are disorders that present as uveitis but do not have an inflammatory etiology. Such diseases either cause a secondary uveitis or are mistaken for a primary uveitis, because of the presence of white cells, red blood cells, pigment, or tumor cells. Examples of masquerade syndromes may include lymphoma, leukemia, retinoblastoma, malignant choroidal melanoma, retinal detachment, and intraocular foreign body.

### Intermediate Uveitis

Intermediate uveitis tends to affect younger patients, ranging from their teens to early forties. The most common presentation involves vague complaints of blurry vision and persistent floaters, with a slow insidious onset. Pain and photophobia are uncommon symptoms. Whereas the signs of anterior uveitis are primarily seen in the aqueous and iris, the diagnosis of intermediate uveitis typically involves evaluation of the vitreous and peripheral retina. Bilateral involvement at initial presentation is near 80%, and approximately one-third of unilateral cases ultimately become bilateral. Intermediate uveitis has been reported

in association with autoimmune diseases, most notably multiple sclerosis. Pars planitis is the most common recognized form of intermediate uveitis.

### Visual Acuity

Visual acuity is often compromised on presentation in intermediate uveitis. A study in 2001 found a mean entering visual acuity of 6/12 (20/40) in patients with pars planitis; on average, children with this disease were found to have worse visual acuity than adults at the time of initial presentation. CME is the most common cause of reduced acuity in intermediate uveitis. Other complications, including chronic vitritis, cataract, and band keratopathy, may ensue in cases of untreated or undertreated intermediate uveitis, resulting in potentially significant visual compromise.

### External Examination

External evaluation is often fruitless in cases of intermediate uveitis, because there are generally no outward signs of inflammation. The eye appears white, and pupillary reaction is rarely compromised. There is typically no pain or photophobia on pupil or motility testing.

### Biomicroscopy

Biomicroscopy of the anterior segment typically reveals little in cases of intermediate uveitis, although occasionally a few “spillover” cells may be seen in the aqueous. Hallmark findings of anterior uveitis, such as conjunctival hyperemia, KPs, and iris nodules, are characteristically absent. Late-stage findings may include corneal band keratopathy, anterior and/or posterior synechia, and cataract (most commonly of the posterior subcapsular variety).

### Tonometry

Because intermediate uveitis does not involve the ciliary body or trabecular meshwork, IOP is rarely impacted by this disease course. However, should late-stage changes occur in the anterior chamber (e.g., synechiae, iris neovascularization), the clinician is obligated to perform tonometry and monitor for secondary glaucoma. Also, use of topical, injectable, and/or systemic corticosteroids in the treatment of uveitis may induce a precipitous rise in IOP, resulting in steroid-induced glaucoma.

### Gonioscopy

It is important to perform gonioscopy only in recalcitrant cases of intermediate uveitis to rule out complications such as peripheral anterior synechia and neovascularization. Otherwise, this test is superfluous.

### Fundus Examination

The most critical aspect of diagnosing intermediate uveitis involves inspection of the posterior segment through a dilated pupil. Inspection of the anterior vitreous through the biomicroscope may reveal white cells

posterior to the lens. However, the hallmark of intermediate uveitis is the accumulation of inflammatory cells within the vitreous. Typically, clumps of cells aggregate along the peripheral retina, appearing as yellow-to-white vitreal tufts often referred to as “vitreous snowballs.” A more extensive geographic accumulation of exudative inflammatory cells along the ora serrata and extending to the pars plana may also be seen; this phenomenon is referred to as “snow banking” and is the hallmark sign of pars planitis. Snowballs and snow banks are virtually always located inferiorly due to the effects of gravity. Their presence is facilitated by scleral indentation. Other less common fundus findings in intermediate uveitis include perivascular sheathing of the venules or, rarely, the arterioles.

## Posterior Uveitis

Posterior uveitis is rarely a stand-alone diagnosis. Rather, this term is typically used to describe the manifestations of numerous inflammatory conditions involving the choroid and/or retina. The more common etiologies of posterior uveitis include toxoplasmosis, sarcoidosis, syphilis, histoplasmosis, and retinal white-dot syndromes. These conditions may affect a wide range of individuals with regard to age, gender, race, and national origin.

Generally, patients with posterior uveitis present with symptoms of blurred vision and/or floaters, whereas ocular redness and pain are characteristically absent. The condition may present unilaterally or bilaterally depending on the underlying etiology. In fact, posterior uveitis can display a myriad of differing presentations, many of which are specific to the causative element.

### Visual Acuity

The visual acuity in posterior uveitis varies dramatically from case to case. Vitritis, macular edema and/or exudate, subretinal neovascularization and/or hemorrhage, retinal detachment, and necrotic macular scarring may all serve to diminish acuity. In addition, the optic nerve may be involved in some infectious forms of posterior uveitis, such as toxoplasmosis, herpes, syphilis, or tuberculosis. Optic neuritis or neuroretinitis can further serve to compromise vision.

### External Examination

Most often, patients with posterior uveitis display no external signs of inflammation. Ocular motility is rarely compromised. In cases of extensive unilateral involvement of the retina or optic nerve, a relative afferent pupillary defect may be noted; otherwise, the external examination is entirely normal.

### Biomicroscopy

Biomicroscopy of the anterior segment is often unremarkable in posterior uveitis. In cases of severe vitritis, some “spillover” of inflammatory cells may be seen in



the aqueous. KPs may also be noted; however, the iris and cornea are often completely uninvolved. Cataract may be seen as a late-stage complication of chronic inflammation and/or immunosuppressive therapy.

### Tonometry and Gonioscopy

IOP is rarely affected in cases of posterior uveitis; however, patients on chronic systemic corticosteroid therapy must be monitored for changes in the IOP. Gonioscopy is generally not necessary.

### Fundus Examination

A multitude of fundus findings may be seen in patients with posterior uveitis. The accumulation of inflammatory cells in the vitreous is common and may be more pronounced with some etiologies than others. For example, vitritis is an exceedingly common finding in toxoplasmosis but is almost never seen in histoplasmosis. Inflammatory choroidal lesions predominate in many conditions. These anomalies may be seen as solitary elevated granulomas or as a multifocal choroiditis with punched-out yellow-gray or white choroidal lesions. Perivascular exudates (“candle-wax drippings”) and vessel sheathing associated with vasculitis are other notable signs of posterior uveitis.

Inspection of the posterior pole may be hindered by vitreous debris; however, it is vitally important to evaluate for CME, a primary cause of visual deficit. Another notable finding in the posterior pole is papillitis, which may occur in a variety of etiologies such as syphilis, herpetic infection, and sympathetic ophthalmia. Chronic long-term complications involving the fundus may include choroidal neovascularization, chorioretinal scarring, epiretinal membrane formation, neovascularization, and retinal detachment.

### Panuveitis

Panuveitis encompasses aspects of anterior, intermediate, and posterior uveitis. Hence, the diagnosis is made based on a compilation of signs and symptoms consistent with each of the aforementioned categories. A thorough evaluation is imperative whenever panuveitis is suspected.

## OVERVIEW OF UVEITIS MANAGEMENT

Unfortunately, most of the current management strategies for uveitis are borne out of anecdotal and/or empirical approaches. Few if any randomized, controlled, clinical trials exist regarding conventional therapy for uveitis; indeed, only a handful of such trials have been identified in the current literature, and most of those focus on the use of systemic cyclosporine.

Essentially, the four goals for the medical management of uveitis are (1) preservation of vision, (2) relief of ocular pain, (3) amelioration of ocular inflammation, and (4) prevention of pathologic sequelae, including synechia

formation and managing IOP elevation. The pharmaceuticals used to achieve these goals include topical corticosteroids, cycloplegics, oral and periocular steroids, nonsteroidal anti-inflammatory drugs (NSAIDs), and immunosuppressive/immunomodulatory agents.

### Corticosteroids

The mainstay of treatment for anterior uveitis involves, first and foremost, topical corticosteroids. Corticosteroids are useful because they help to stabilize cell membranes, inhibit the release of lysozyme by granulocytes, and suppress the circulation of lymphocytes. Liberal application of steroids in the early phase of the disease is important to achieve successful suppression of the inflammation. When in doubt, it is better to overtreat than to undertreat. Most consider the gold standard for uveitis management to be 1% prednisolone acetate, because it demonstrates maximal efficacy and superior corneal penetration. Common alternatives may include 0.1% dexamethasone, 0.1% fluorometholone acetate, and 0.5% loteprednol etabonate. Boxes 29-2 and 29-3 illustrate commercially available topical corticosteroids and their relative efficacy. It should be noted that many steroid preparations, including prednisolone acetate and fluorometholone acetate, are suspensions; as such, patients should be advised to shake the bottle vigorously before use. Rimexolone and loteprednol etabonate have been shown to be effective in controlling inflammation with less propensity to elevate IOP.

The frequency of corticosteroid administration varies with the intensity of the reaction. For mild anterior uveitis (1+ cells and flare), dosing every 4 hours may be sufficient. Moderately severe anterior uveitis may be managed with 1% prednisolone acetate or similar medication every 2 to 3 hours. In severe cases steroids may be dosed hourly or even more frequently. Corticosteroid ointments may be used at bedtime, though the duration of this drug modality only extends the medication's efficacy for perhaps an additional hour or 2. In the case of severe anterior uveitis, it is probably better to have the patient awakened every 2 to 3 hours and instill another drop.

#### Box 29-2 Topical Corticosteroids

Prednisolone acetate 0.125%, 1%
Prednisolone sodium phosphate 0.125%, 0.5%, 1%
Dexamethasone alcohol 0.1%
Dexamethasone sodium phosphate 0.1% (also available in 0.05% ointment form)
Fluorometholone 0.1%, 0.25% (also available in 0.1% ointment form)
Rimexolone sodium phosphate 1%
Loteprednol etabonate 0.2%, 0.5%

**Box 29-3** Relative Anti-Inflammatory Effectiveness of Topical Steroids With Intact Corneal Epithelium

**Minimal Efficacy**

Dexamethasone sodium phosphate (ointment) 0.05%  
Dexamethasone sodium phosphate 0.1%

**Moderate Efficacy**

Fluorometholone alcohol 0.1%  
Prednisolone sodium phosphate 1.0%

**Maximal Efficacy**

Dexamethasone alcohol 0.1%  
Fluorometholone acetate 0.1%  
Loteprednol etabonate 0.5%  
Prednisolone acetate 1.0%  
Rimexolone 1.0%

Modified from Leibowitz HM, Kupferman A. Anti-inflammatory medications. *Int Ophthalmol Clin* 1980;20:117–134.

Potential complications associated with topical corticosteroids include infectious keratitis, cataract formation, and IOP elevation. The latter two conditions are dose and duration dependent.

### Cycloplegic and Mydriatic Agents

Cycloplegic agents are nonspecific muscarinic (parasympathetic) antagonists that have a paralyzing effect on the ciliary body and iris sphincter muscle. The role of cycloplegic agents in uveitis management is multifaceted. First, cycloplegics help to relieve pain by immobilizing the inflamed iris tissue, much like a cast immobilizes a fractured bone. Second, these drugs impede iris adhesion to the adjacent anterior lens capsule (posterior synechia), a phenomenon that can induce iris bombé and a secondary angle closure. Most importantly, however, cycloplegics stabilize the blood–aqueous barrier and help to prevent further leakage of white cells and protein (i.e., flare). Numerous cycloplegic agents are available, though the two most common—tropicamide and cyclopentolate—are essentially only of value as diagnostic agents. For therapeutic management the most widely used cycloplegic agents include 5% homatropine, 0.25% scopolamine, or 1% atropine. Although 2% homatropine is also available, it usually is not adequate to control more than mild uveitis. Likewise, 2% atropine is available, but this concentration is associated with a higher incidence of adverse reactions and is generally not used.

Like corticosteroids, cycloplegic agents are selected and dosed according to the severity of the inflammation. Five percent homatropine two to three times a day may

be adequate for a mild to moderate anterior uveitis. Typically, 0.25% scopolamine is used two to three times a day for more significant reactions, whereas 1% atropine two to three times a day is appropriate for the most severe inflammatory responses.

Mydriatics work at the level of the iris dilator muscle, directly stimulating  $\alpha$ -adrenergic receptors. The adrenergic agonist phenylephrine (2.5% and 10%) may be used to augment dilation in an attempt to break recalcitrant posterior synechiae. Phenylephrine is not generally recommended as part of the initial therapeutic regimen, however, because it has neither cycloplegic nor anti-inflammatory effects. Additionally, it may cause a release of pigment cells into the anterior chamber, which may render the evaluation for anterior chamber cells more difficult.

Topical cycloplegics have the potential to induce systemic anticholinergic toxicity, though this is rare. Clinicians should be concerned when dosing topical scopolamine or atropine at higher levels, particularly in children or those of smaller stature. Signs of anticholinergic toxicity may include fever, generalized erythema, dry mouth and lack of sweating, altered mental states, tachycardia and systemic hypertension, and gastrointestinal distress.

### Periocular/Intraocular Steroids, Oral Steroids, and NSAIDs

Deeper or more severe forms of uveitis may not respond to topical therapy; hence, injectable and/or oral routes of administration may be required. Periocular corticosteroids may be used occasionally for anterior uveitis; however, this therapy is more often used in cases of intermediate uveitis or, less commonly, unilateral posterior uveitis. A small amount of depot corticosteroid (e.g., 1 ml of 40 mg/ml triamcinolone acetonide injected superiorly or inferiorly in the orbit) is considered acceptable and appropriate treatment in such situations. In cases of chronic posterior uveitis or uveitis associated with CME, intravitreal triamcinolone has also been used with some success. A retrospective study in 2005 demonstrated that intravitreal injection of 4 mg/0.1 ml triamcinolone acetonide can effectively reduce CME and improve visual acuity and, in some eyes, allow for the reduction of immunosuppressive therapy.

Another relatively recent development for the management of intermediate and/or posterior uveitis is the sustained-release intravitreal corticosteroid implant, for example, Retisert™ (fluocinolone acetonide 0.59 mg; Bausch & Lomb, Rochester, NY, USA). Retisert™ is indicated for the treatment of chronic noninfectious uveitis affecting the posterior segment of the eye. An intravitreal dexamethasone implant is also currently under investigation.

Oral corticosteroids represent the treatment of choice for bilateral posterior uveitis and nonresponsive anterior or intermediate uveitis. Prednisone 0.5 to 1.0 mg/kg

(or up to 2 mg/kg in moderate to severe cases) is recommended as initial therapy, followed by a slow taper as resolution occurs. In most cases, an H<sub>2</sub> receptor antagonist such as cimetidine (Tagamet™) 200 mg orally twice a day or ranitidine (Zantac™) 150 mg orally twice a day is prescribed with oral corticosteroids to prevent secondary gastrointestinal complications.

There is limited documentation in the ophthalmic literature to suggest that NSAIDs are of significant value in the management of uveitis. However, topical NSAIDs, such as flurbiprofen (Ocufen™), diclofenac (Voltaren™), and ketorolac (Acular™), have been shown to be effective in reducing CME, a significant complication of intermediate and posterior uveitis. In addition, the use of topical NSAIDs may have a steroid-sparing effect, reducing the extent and/or duration of corticosteroid therapy. Likewise, oral NSAIDs, such as diclofenac (Voltaren™), diflunisal (Dolobid™), indomethacin (Indocin™), and naproxen (Naprosyn™), may be helpful as adjunctive treatment in the management of uveitis, particularly for recalcitrant or protracted cases, or as maintenance therapy.

The potential adverse effects associated with oral corticosteroids are well known. In addition to ocular effects including cataractogenesis and IOP elevation, systemic steroids may induce sodium retention (leading to systemic hypertension and edema), headache, and generalized muscle weakness. Weight gain is also common; redistribution of bodily fat may result in the classic “moon face” and/or “buffalo hump” appearance. Additional complications may include hirsutism, thinning and bruising of the skin, impaired wound healing, gastrointestinal ulceration, osteoporosis, worsening of diabetes, irregular menses, convulsions, and psychiatric disturbances. Because of their immunosuppressive properties, patients taking corticosteroids are also at greater risk for secondary infection. As with topical therapy, complications associated with systemic corticosteroids occur more frequently with higher doses and prolonged treatment.

The use of periocular steroids circumvents many of the side effects associated with systemic steroids; however, complications may still arise. IOP response is a particular concern, because depot medications cannot be removed easily, as compared with tapering or discontinuing an oral preparation. Cataractogenesis may occur with any steroid preparation; with intravitreal corticosteroid implants, the incidence of cataract formation requiring surgery over 2 years is nearly 90%.

## Immunosuppressive Agents

Immunosuppressive therapy may be used in severe sight-threatening uveitis for which steroids are insufficiently effective. These agents work by modifying the specific immune sensitization of lymphoid cells. Four categories of immunosuppressive drugs appear to be effective in the treatment of ocular inflammation: the alkylating agents, antimetabolites, antibiotics, and biologic agents.

The possible systemic complications associated with these agents are varied and potentially severe. These drugs should only be prescribed by clinicians who are well trained in their use and able to manage their side effects.

Alkylating agents interfere with DNA replication and transcription, resulting in depression of T- and/or B-cell populations. The most commonly used alkylating agents in uveitis management include cyclophosphamide (Cytoxan™) and chlorambucil (Leukeran™).

Antimetabolites selectively compete for intermediary metabolites critical to immune cell function, exerting a cytotoxic effect. Methotrexate (Folex™), which inhibits folic acid, is the most widely recognized and used drug in this class. Other antimetabolites that may be used in treating uveitis include azathioprine (Imuran™) and mycophenolate mofetil (CellCept™), both of which interfere with purine metabolism.

Several drugs that fall into the broad category of antibiotics actually have powerful immunosuppressive properties and may be beneficial adjuncts in uveitis therapy. The prototypical agent in this category is cyclosporine (Neoral™), a drug derived from a soil fungus, *Beauveria nivea* (formerly known as *Tolypocladium inflatum*). Cyclosporine acts by inhibiting T-cell proliferation and blocking production of interleukin-2, a powerful proinflammatory mediator. This drug is most commonly prescribed for moderate to severe uveitis, with dosing ranging from 2 to 5 mg/kg/day. Tacrolimus (FK506, Prograf™) works by a similar mechanism to cyclosporine, inhibiting T-cell activation and proliferation. It is a naturally occurring product of the bacterium *Streptomyces tsukubaensis*. For uveitis therapy, tacrolimus is typically given orally at 0.15 to 0.3 mg/kg/day. It is most commonly used in those who are refractory to or have known hypersensitivity to cyclosporine.

Biologic agents represent a relatively new category of immunosuppressive drugs. Probably the most well known of these agents is interferon. Specific types of interferon, particularly interferon- $\alpha$ , can have profound immunomodulatory effects in certain disease processes, most notably hepatitis C and chronic myelogenous leukemia. Although not specifically approved for managing uveitis, interferon- $\alpha$  may have a role in the management of refractory Behçet disease-associated uveitis. Infliximab (Remicade™) represents a monoclonal antibody directed against tumor necrosis factor- $\alpha$ . Several reports suggest that infliximab may be beneficial in cases of severe unresponsive uveitis. Currently, the Remicade European Study for Chronic Uveitis is evaluating the safety and efficacy of infliximab for patients with intermediate and posterior uveitis. Etanercept (Enbrel™) is yet another biologic agent, which is U.S. Food and Drug Administration approved for the treatment of rheumatoid arthritis and JIA as well as psoriasis and psoriatic arthritis. Etanercept specifically binds extracellular tumor necrosis factor- $\alpha$ , truncating the autoimmune cascade. Again, this

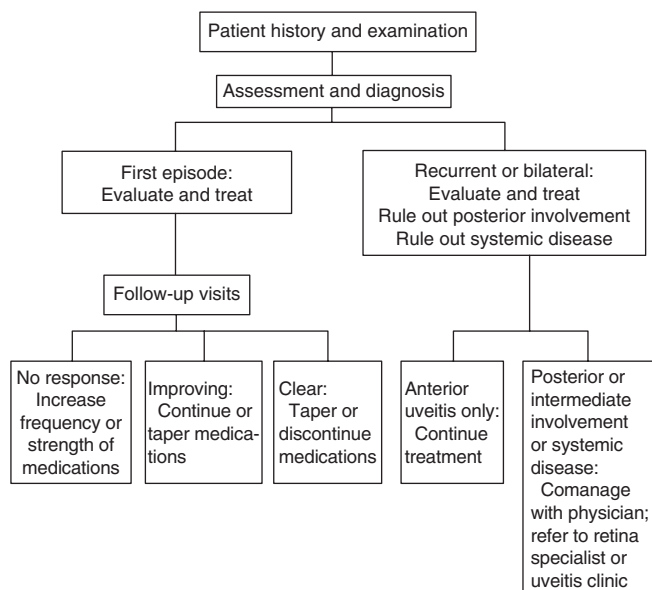
agent may be beneficial in cases of severe uveitis that are unresponsive to conventional treatment, due to its immunomodulatory and steroid sparing anti-inflammatory properties.

## SPECIFIC MANAGEMENT AND POTENTIAL COMPLICATIONS

### Anterior Uveitis

Anterior uveitis represents the most common form of uveitis seen in the primary care setting. In general, it shows a good response to conventional topical therapy with corticosteroids and cycloplegic agents. Oral or periorbital steroids may be used in severe or recalcitrant cases. Additional immunosuppressive agents are not commonly necessary. The clinical management of anterior uveitis is illustrated in Figure 29-1.

Initial follow-up for patients with anterior uveitis varies between 1 and 7 days, depending on the severity. Once a response to therapy is noted, the clinician may begin to reduce the medications, though it is important not to discontinue medications prematurely. Cycloplegics may be discontinued more abruptly than corticosteroids. Most commonly, these agents are continued only until all flare is absent and the cellular reaction is notably subsiding. Topical steroids should be continued until cells are minimal (grade 0.5+) or absent. Tapering of steroids is based on the potency, frequency, and the duration of use as well as the initial severity of the uveitis and its clinical response to treatment. A typical taper involves gradual



**Figure 29-1** Flow chart for management of patient with anterior uveitis. (Reprinted with permission from Alexander KL. Optometric clinical practice guidelines: care of the patient with anterior uveitis. St. Louis, MO: American Optometric Association, 1994.)

reduction of steroids over a 1- to 2-week period. The patient should be observed both during and a few weeks after the tapering process for signs of rebound inflammation.

Complications associated with anterior uveitis may include cataracts, glaucoma, band keratopathy, and CME. Posterior subcapsular cataracts are the most commonly encountered lenticular change associated with chronic uveitis. Additionally, it is well known that long-term topical steroid use can induce or accelerate posterior subcapsular cataract development.

Elevated IOP (secondary glaucoma) is another complication that may arise from a variety of mechanisms: trabeculitis, inflammatory debris blocking aqueous outflow at the trabecula, posterior synechia and resulting pupillary block, the formation of peripheral anterior synechiae with secondary tractional angle closure, IOP response to steroid use, or neovascularization of the iris (*rubeosis irides*) resulting in neovascular glaucoma. Elevated IOP due to topical corticosteroid use may be addressed by changing to one of the “soft” steroids (e.g., loteprednol etabonate 0.5%, rimexolone sodium phosphate 1%), which may have less propensity to increase IOP; however, this is not always a plausible option. Another strategy is to use appropriate ocular hypotensive medications. Topical beta-blockers,  $\alpha$ -adrenergic agonists, and carbonic anhydrase inhibitors may all be of value in steroid-induced inflammatory glaucoma; however, pilocarpine is absolutely contraindicated, because this agent invariably exacerbates the underlying inflammation. Similarly, the various prostaglandin analogues (e.g., latanoprost, bimatoprost, and travoprost) are typically avoided in uveitis therapy. Some believe they may worsen the uveitis, whereas others believe they are simply less potent in an inflamed eye. This continues to be a controversial issue.

Band keratopathy is a relatively infrequent complication associated with long-standing uveitis. CME may result from the sustained release of prostaglandins; however, this complication is far more likely in cases of intermediate or posterior uveitis.

### Intermediate Uveitis

Intermediate uveitis may not warrant any therapeutic intervention in mild cases where the visual acuity is 20/40 or better. However, medical therapy is required for most patients. Macular edema is a frequent complication and requires prompt management to prevent permanent vision loss. In general, topical steroids are minimally effective in intermediate uveitis, except in those patients who are aphakic. Periocular and systemic steroids are substantially more efficacious. Periocular steroid injections are preferable in unilateral presentations and in children, whereas oral or other systemic routes are required for bilateral cases. For steroid-resistant intermediate uveitis, immunosuppressive therapy or surgery (cryotherapy and vitrectomy) may be necessary. Complications associated with intermediate uveitis include persistent CME,

posterior subcapsular cataracts, secondary glaucomas, band keratopathy (particularly in children), and retinal detachment.

## Posterior Uveitis

The most critical aspect of managing posterior uveitis is excluding or identifying an infectious agent. This process must be accomplished before initiating steroid therapy. A variety of local or systemic infections may induce a posterior uveitis, including toxoplasmosis, toxocariasis, herpes simplex, herpes zoster, syphilis, Lyme disease, tuberculosis, leprosy, leptospirosis, onchocerciasis, and HIV infection. Appropriate testing for these disorders is discussed in the section “Laboratory Tests and Ancillary Studies.”

After identifying the etiology, the general goals of therapy in posterior uveitis are to (1) preserve macular function, (2) protect the optic nerve and papillomacular bundle, (3) prevent vitreous opacification, (4) prevent cataract formation, and (5) prevent phthisis bulbi. Treatment options for anterior uveitis differ significantly for posterior uveitis, because in general topical medications penetrate poorly to the posterior ocular structures. Topical steroids are minimally effective, and cycloplegia is often unnecessary. Periocular, intravitreal, or oral steroids are the first-line treatment modalities for noninfectious posterior uveitis; however, some cases may only respond to the immunosuppressive agents mentioned previously.

## LABORATORY TESTS AND ANCILLARY STUDIES

A number of laboratory tests and ancillary studies may aid in the management of uveitis. Such testing is indicated when the patient presents with any of the following conditions: (1) recurrent uveitis or uveitis unresponsive to treatment, (2) bilateral uveitis, (3) uveitis with posterior involvement, or (4) uveitis associated with signs or symptoms suggestive of systemic disease.

### Laboratory Tests

If the history or symptoms associated with an episode of uveitis are suggestive of a definitive etiology, a disease-specific workup of the patient is indicated (Table 29-3). In bilateral cases with no posterior involvement or indication of a systemic cause, a nonspecific workup is suggested (Box 29-4). Laboratory testing is not always productive; in fact, only about 25% of uveitis cases have an underlying systemic disease that can be identified through laboratory evaluation. Still, the results may occasionally be helpful when considered in terms of the complete clinical picture. The clinician should always weigh the potential benefit of ancillary studies before ordering a comprehensive “shotgun” battery of tests.

Although most eye care practitioners are capable of ordering laboratory tests directly, it is often more productive to communicate with the patient’s primary care physician before proceeding, such that all aspects of the systemic history may be taken into account. Should the patient be diagnosed with a contributory systemic disease, comanagement with the primary care physician becomes paramount.

The following clinical laboratory tests are the most common and often the most useful in the management of uveitis:

1. *Angiotensin-converting enzyme*: Because angiotensin-converting enzyme is produced by a variety of cells, including granulomatous cells, serum angiotensin-converting enzyme levels reflect the total amount of granulomatous tissue in the body. Although not disease specific for sarcoidosis, angiotensin-converting enzyme levels are generally elevated in active sarcoidosis and should direct the clinician toward the diagnosis of sarcoidosis in patients with uveitis.
2. *Antinuclear antibody*: In autoimmune diseases plasma cells produce antibodies that are directed against one’s own tissues. These may be detected in patients with a variety of autoimmune diseases. More than 95% of patients with systemic lupus have a positive antinuclear antibody. Other disorders with a positive antinuclear antibody include Sjögren’s disease (70%) and rheumatoid arthritis (40%), both potential causes of uveitis.
3. *Complete blood cell count with differential*: In cases of uveitis a complete blood cell count can help identify an underlying bacterial or viral etiology based on the white cell differential. Additionally, this test may assist in the detection of a white blood cell malignancy, such as leukemia or lymphoma. A complete blood cell count should also accompany an erythrocyte sedimentation rate (ESR) analysis, because the complete blood cell count identifies anemia that may affect the results of the ESR.
4. *Enzyme-linked immunosorbent assay*: A multistage test offering identification of disease-specific antibodies, the enzyme-linked immunosorbent assay may be useful in identifying infectious etiologies of uveitis, such as toxoplasmosis, toxocariasis, HIV, and Lyme disease.
5. *Westergren ESR*: The ESR is a nonspecific test that indicates the presence and intensity of inflammatory activity in the body. This test relies on the premise that certain inflammatory disorders yield abnormal proteins, which bind to red cells and make them “sticky.” This causes the erythrocytes to clump together and settle out of the plasma more rapidly. The ESR measures the rate at which erythrocytes settle in a standard test tube over 1 hour. This test is not conclusive for any specific illness, though when taken together with a positive C-reactive protein, the specificity for giant cell arteritis approaches 97%.

**Table 29-3**  
Suggested Tests to Identify Systemic Causes of Uveitis

Suspected Disorder	Hematologic or Serologic Tests	Radiologic Studies	Consults, Referrals	Other Tests
Ankylosing spondylitis	≠ ESR (+) HLA-B27	Sacroiliac films	Rheumatologist	—
Inflammatory bowel disease	(+) HLA-B27	—	Internist or gastroenterologist	—
Reiter's syndrome (reactive arthritis)	≠ ESR (+) HLA-B27	Sacroiliac and peripheral joints	Internist, urologist, rheumatologist	Cultures (conjunctival, urethral, prostate)
Psoriatic arthritis	≠ ESR (+) HLA-B27	Phalanx	Rheumatologist, dermatologist	—
Herpes simplex, herpes zoster	Diagnosed clinically	—	Dermatologist	—
Behçet's disease	(+) HLA-B5 or (-) BW51	—	Internist, rheumatologist	Behçet's skin puncture test
Lyme disease	ELISA for Lyme immunofluorescent assay	—	Internist, rheumatologist	—
Juvenile idiopathic arthritis	≠ ESR (+) Antinuclear antibody (-) Rheumatoid factor	Joints	Rheumatologist, pediatrician	—
Sarcoidosis	≠ Angiotensin-converting enzyme	Chest	Internist	—
Syphilis	(+) RPR (+) FTA-ABS	—	Internist	—
Tuberculosis	QuantIFERON-TB Gold	Chest	Internist	Purified protein derivative skin test

≠, elevated; (+), positive; (-), negative; ELISA, enzyme-linked immunosorbent assay; FTA-ABS, fluorescent treponemal antibody absorption; RPR, rapid plasma reagin.

Adapted from Rhee DJ, Pyfer MF, eds. *The Wills eye manual*, ed. 3. Philadelphia: Lippincott, 1999:396-397.

6. *Human leukocyte antigen (HLA)*: HLAs are proteins that are present in high concentrations on the surface of white blood cells and serve as the major histocompatibility antigens for tissue recognition. These antigens may be detected via a serologic blood test known as HLA typing, and several have been linked with uveitis. Perhaps the most widely recognized is HLA-B27, which is found in as many as 95% of individuals with ankylosing spondylitis and 70% of those with Reiter's syndrome. About 50% of patients with inflammatory bowel disease (e.g., Crohn's, Whipple's) also test positive for the HLA-B27. HLA type testing carries the highest prognostic value for patients with acute unilateral anterior uveitis.

7. *Purified protein derivative*: The purified protein derivative test for tuberculosis may be recommended in patients with chronic or granulomatous uveitis. Sterile tuberculin protein injected intradermally on the forearm produces induration at the site of inoculation if the patient is seropositive for tuberculosis. Purified protein derivative should be ordered when the physical

examination or family-social history is suggestive of tuberculosis. False positives may be encountered in patients who have been vaccinated against tuberculosis. False negatives may be seen in those who are immunocompromised; for these individuals, an anergy panel (consisting of trichophyton, mumps, and *Candida* proteins) on the fellow arm is strongly indicated.

8. *Tests for syphilis*: A number of laboratory tests help to detect syphilis. The Venereal Disease Research Laboratory and rapid plasma reagin are nonspecific serology tests for syphilis. These tests evaluate serum antibodies that appear and rise after syphilitic infection but are not absolutely specific to *Treponema pallidum*. A positive response on either of these tests correlates with disease activity (i.e., active syphilis). However, numerous other disorders can yield a false positive on these screening tests, including lupus, malaria, mononucleosis, hepatitis, leprosy, atypical pneumonia, tuberculosis, typhus, and pregnancy. Also, the Venereal Disease Research Laboratory and rapid plasma reagin tests eventually revert to negative over time.

**Box 29-4** Suggested Workup for Bilateral, Granulomatous, or Recurrent Anterior Uveitis With No Indication of Systemic Cause

Complete blood count  
 Erythrocyte sedimentation rate  
 Angiotensin-converting enzyme  
 Antinuclear antibody  
 Venereal Disease Research Laboratory or rapid plasma reagin  
 Fluorescent treponemal antibody absorption or microhemagglutination assay for *Treponema pallidum*  
 Purified protein derivative and anergy panel  
 Chest radiograph for sarcoidosis and tuberculosis  
 Lyme enzyme-linked immunosorbent assay  
 HLA-B27 typing (possibly)

Adapted from Rhee DJ, Pyfer MF, eds. The Wills eye manual, ed. 3. Philadelphia: Lippincott, 1999:396.

Tests that are considered to be “trep-specific” (i.e., specifically detect antibodies to *T. pallidum*) include the fluorescent treponemal antibody absorption and the microhemagglutination assay for *T. pallidum*. Trep-specific tests do not correlate with disease activity; they merely indicate whether the patient has had a syphilitic infection at some point in their lives, despite whether appropriate treatment was given or not. Fortunately, there is a lower incidence of false-positive results with trep-specific tests, yet false positives can occur in cases of Lyme disease, genital herpes, mononucleosis, malaria, and leprosy. Typically, in acute situations a nontreponemal-specific test, such as the rapid plasma reagin, is ordered first, because it is inexpensive and because this presentation generally indicates an active disease state. In cases of chronic long-standing inflammation, a trep-specific test is likely sufficient, particularly if the history and physical examination is suggestive of syphilis. Although some clinicians advise consistently ordering both tests simultaneously, the usefulness of such an approach can be debated.

Often, despite the clinician’s best efforts no underlying cause can be identified in cases of uveitis. It is important to realize that laboratory testing may still be of value, if only to rule out infectious etiologies before proceeding with empiric anti-inflammatory therapy.

## Imaging Studies

When symptoms and clinical findings associated with uveitis suggest conditions such as JIA, ankylosing spondylitis, tuberculosis, or sarcoidosis, imaging studies may aid in confirming the diagnosis. Specific studies may be helpful in identifying JIA, for which various joint radiographs may be taken; when there are no symptoms, knee radiographs are recommended. In patients suspected

of having ankylosing spondylitis, x-rays of the sacroiliac joint are typically obtained. A chest radiograph is indicated to rule out tuberculosis and/or sarcoidosis infiltration into the pulmonary system.

## Fluorescein Angiography and Optical Coherence Tomography

Fluorescein angiography may help to reveal CME associated with uveitis, demonstrating a late petaloid hyperfluorescence in the macula. More recently, however, optical coherence tomography (Stratus 3 OCT™, Carl Zeiss Meditec) has emerged as a noninvasive method for the early detection of CME. Optical coherence tomography has the capacity to demonstrate not only retinal thickening associated with CME in uveitis patients, but also can graphically display the intraretinal cystic areas. Optical coherence tomography has been shown to be as effective as fluorescein angiography in detecting CME in patients with uveitis.

## SELECTED BIBLIOGRAPHY

- Bloch-Michel E, Nussenblatt RB. International Uveitis Study Group recommendations for the evaluation of intraocular inflammatory disease. *Am J Ophthalmol* 1987;103:234-235.
- Chang JH, Wakefield D. Uveitis: a global perspective. *Ocul Immunol Inflamm* 2002;10:263-279.
- Guest S, Funkhouser E, Lightman S. Pars planitis: a comparison of childhood onset and adult onset disease. *Clin Exp Ophthalmol* 2001;29:81-84.
- Jabs DA, Akpek EK. Immunosuppression for posterior uveitis. *Retina* 2005;25:1-18.
- Jabs DA, Nussenblatt RB, Rosenbaum JT, et al. Standardization of uveitis nomenclature for reporting clinical data. Results of the First International Workshop. *Am J Ophthalmol* 2005;140:509-516.
- Jaffe GJ, Martin D, Callanan D, et al. Fluocinolone acetonide implant (Retisert) for noninfectious posterior uveitis thirty-four-week results of a multicenter randomized clinical study. Fluocinolone Acetonide Uveitis Study Group. *Ophthalmology* 2006;113:1028-1034.
- Kok H, Lau C, Maycock N, et al. Outcome of intravitreal triamcinolone in uveitis. *Ophthalmology* 2005;112:1916-1921.
- Lustig MJ, Cunningham ET. Use of immunosuppressive agents in uveitis. *Curr Opin Ophthalmol* 2003;14:399-412.
- Okada AA. Noninfectious uveitis: a scarcity of randomized clinical trials. *Arch Ophthalmol* 2005;123:682-683.
- Onofrey BE, Skornin L, Holdeman NR, eds. *Ocular therapeutics handbook: a clinical manual*, ed. 2. Philadelphia: Lippincott Williams & Wilkins, 2005.
- Rathinam SR, Cunningham ET Jr. Infectious causes of uveitis in the developing world. *Int Ophthalmol Clin* 2000;40(2):137-152.
- Rosenbaum JT, Wernick R. Selection and interpretation of laboratory tests for patients with uveitis. *Int Ophthalmol Clin* 1990;30:238-243.
- Smith JR. Management of uveitis. *Clin Exp Med* 2004;3:21-29.
- Wade NK. Diagnostic testing in patients with ocular inflammation. *Int Ophthalmol Clin* 2000;40:37-54.
- Wakefield D, Chang JH. Epidemiology of uveitis. *Int Ophthalmol Clin* 2005;45:1-13.



## *Postoperative Care of the Cataract Patient*

*Cynthia Ann Murrill, David L. Stanfield, and Michael D. VanBrocklin*

Cataract is the leading cause of blindness in developing countries. In the United States approximately 26.6 million people over age 40 have a cataract or have had surgery to remove it. Cataract surgery accounts for 60% of vision-related Medicare costs, rendering it the most common type of surgery performed on Americans aged 65 and older.

Three basic types of cataract extraction are available: intracapsular cataract extraction, extracapsular cataract extraction with nuclear expression, and extracapsular cataract extraction with phacoemulsification-aspiration. Intraocular lens (IOL) implantation typically is performed at the time of cataract extraction to help correct postoperative refractive error. Extracapsular cataract extraction with phacoemulsification-aspiration is the predominant surgery today, whereas the relative numbers of planned extracapsular cataract extraction, and particularly intracapsular cataract extraction, procedures have diminished.

Primary eye care providers may collaborate with ophthalmic surgeons to comanage the cataract patient. This method of eye care delivery provides quality care for the patient in convenient familiar surroundings. In addition, it is efficient and cost-effective. The goals of the comanagement team during postoperative care are those of everyday optometric practice: to educate and reassure the patient, to prevent infection, to control inflammation, to maintain desired intraocular pressure (IOP), to manage complications if they arise, to control pain, and to optimize vision.

### **PATIENT EDUCATION AND REASSURANCE**

The foundation of exemplary patient education and reassurance is communication concerning the expected postoperative course between the ophthalmic surgeon and the optometric physician. In addition, during each postoperative visit patients should be advised of their progress and reassured or counseled about the examination findings. Level of physical activity, use or discontinuance of medications, and any cautions regarding symptoms should be reviewed.

### **PREVENTING POSTOPERATIVE INFECTION**

Many practitioners believe that prevention of postoperative infection begins with preoperative management of the cataract patient. Some advocate the use of eyelid scrubs or a topical broad-spectrum antibiotic for several days before surgery. This is particularly important with patients who have preexisting conditions, such as conjunctivitis, dacryocystitis, or chronic bacterial blepharitis. Ophthalmic surgeons often administer topical antibiotics within 1 to 2 hours preoperatively to prevent wound infection.

There is a preponderance of evidence that the incidence of postoperative endophthalmitis is reduced when antiseptics (povidone iodine) and antibiotics are used preoperatively. The use of balanced salt solution, to which an antibiotic has been added, to irrigate the eye during surgery is advocated by some but tempered by concerns of intraocular toxicity and questions of efficacy. Sub-Tenon's capsule injection of an antibiotic just before surgery or subconjunctival injection of antibiotic at the end of the surgery is also used to prevent infection, but risk of inadvertent intraocular injections resulting in retinal antibiotic toxicity must be considered. In addition, oral antibiotics may be used at the time of surgery and 1 day postoperatively as a prophylactic measure.

Although the rationale is not supported in the ophthalmic literature, the most universal prophylactic treatment calls for topical antibiotics or antibiotic-steroid combinations after surgery. Postoperative antibiotics are especially important with a clear corneal incision or a wound leak. Fluoroquinolones are especially effective in penetrating into the anterior chamber. Topical antibiotics are typically administered using a dosage of one drop four times daily for 1 to 2 weeks after surgery. Antibiotic-steroid combinations are usually administered in a regimen of one drop four times daily for the first 7 to 14 days and tapered over subsequent weeks. The dosage and duration of therapy with antibiotic-steroid combinations may vary, however, depending on the desired anti-inflammatory effect of the steroid component.

## **CONTROLLING INFLAMMATION**

Postoperative inflammation is produced by trauma associated with the surgical procedure and by the antigen response to lens material, viscoelastics, and the like. Surgically induced corneal edema, iritis, or cystoid macular edema (CME) are usually minimal and self-limited and may occur after even the most uneventful cataract extraction. Preoperative factors that predispose some eyes to an exaggerated postoperative inflammatory response include a history of ocular trauma, previous intraocular inflammation (specifically, history of recurrent iritis or macular edema), previous ocular surgery, complicated surgery, nonwhite race, and brown irides. In clinical practice it is standard procedure to suppress the postoperative response with topical steroids and/or topical nonsteroidal anti-inflammatory drops and to monitor the resolution of postoperative inflammation for 4 to 6 weeks after surgery. Slit-lamp biomicroscopy is used to detect and record the inflammatory response of the cornea, conjunctiva, anterior chamber, and macula.

Occasionally, an abnormally intense anterior segment inflammatory reaction occurs within the first 5 days after cataract extraction and can be characterized according to etiology as endophthalmitis, toxic iritis, or aseptic iritis. Endophthalmitis is discussed later in the chapter. Toxic iritis is usually produced by unplanned intraocular introduction of drugs or chemicals; acute aseptic iritis is caused by surgical trauma to the iris or ciliary body or (occasionally) by particulate foreign material inadvertently introduced at the time of surgery.

### **Corticosteroids**

As early as 1951 it was thought that steroids applied topically may suppress the inflammatory response after eye surgery. It was not until the 1970s, however, that published studies began to appear to support this. In addition to topical steroids, periocular steroids may be useful in complicated cases (as listed previously). Patients with recurrent or chronic uveitis often respond to surgical procedures better during extended periods of remission and with prophylactic topical and/or subconjunctival steroids before surgery. Postoperatively, they may require an enhanced anti-inflammatory regimen, as compared with routine cases.

The typical postoperative anti-inflammatory regimen includes the use of a topical steroid separate from or in combination with an antibiotic. Patients who experience an abnormal elevation in IOP due to steroid therapy may experience a delayed or diminished pressure rise with 0.1% fluorometholone acetate, 1% rimexolone, or 0.5% loteprednol versus other agents and still have the desired anti-inflammatory effect.

Steroids are typically administered using a regimen of one drop four times daily for the first 1 to 2 weeks and then tapered on a variety of schedules (e.g., three drops

daily for 1 week, then two drops daily for 1 week, one drop daily for 1 week, then discontinued). The dosage may be more frequent and the tapering more prolonged if there is significantly increased postoperative inflammation.

To enhance convenience and compliance and to reduce cost, antibiotic-steroid combination drops are often used instead of prescribing the individual drugs separately. The primary disadvantage of using a combination is that the practitioner is less able to prescribe in a way that uses the individual components to their maximum effectiveness. The frequency and duration of administration are driven by the desired anti-inflammatory effect of the steroid component rather than by the anti-infective properties of the antibiotic component. In general, the advantages of using antibiotic-steroid combinations usually outweigh the disadvantages. When postoperative inflammation persists after 1 week, it is prudent to treat with a topical steroid only to enhance effectiveness and decrease the risk of toxicity secondary to excessive antibiotic use (especially in the case of aminoglycosides).

### **Nonsteroidal Anti-Inflammatory Drugs**

Corticosteroids are the mainstay for treatment of inflammation after routine cataract extraction. Their usefulness, however, can be limited by side effects. For this reason efforts have been made to develop compounds with fewer adverse reactions. The fact that aspirin inhibits prostaglandin synthesis, along with the well-known observation that aspirin can have prominent anti-inflammatory actions, has resulted in development of other compounds in the same therapeutic class. All are thought to act in some way on the prostaglandin or leukotriene biosynthetic mechanism. The fact that prostaglandin release during cataract surgery can induce miosis and thus contribute to surgical complications has provided a basis for the use of nonsteroidal anti-inflammatory drugs (NSAIDs) prophylactically to inhibit intraoperative miosis. Clinical trials have shown that topically applied NSAIDs have a statistically significant effect on pupil size, compared with placebo, when administered preoperatively with topical mydriatic agents. These data, however, suggest that the pharmacologic effect on the pupil is minimal and that the slight inhibition of intraoperative miosis appears to vary according to the surgical technique. As a result many surgeons remain unconvinced and therefore do not routinely use topical NSAIDs preoperatively.

A variety of studies suggest that several of the currently available NSAIDs are effective in reducing postoperative anterior segment inflammation and early angiographic and clinically significant pseudophakic CME. Therefore topical NSAIDs may be used for this purpose pre- and postoperatively, especially for patients at higher risk for postoperative inflammation.

## **MAINTAINING DESIRED IOP**

---

Before cataract extraction it is desirable to lower the IOP to prevent intraocular hemorrhage, loss of vitreous, and associated complications. Reduction of IOP is especially critical in patients with preexisting glaucoma. Mechanical, medical, and surgical techniques are used to accomplish this objective. Mechanical pressure from digital massage, a Honan balloon, or a "Super Pinkie" rubber ball can be applied either before or after retrobulbar anesthesia to create a "soft eye." Hyperosmotics such as oral 50% glycerin (Osmoglyn), oral or intravenous acetazolamide, or intravenous 20% mannitol are also effective in lowering the IOP. If neither mechanical nor medical techniques are effective, a posterior sclerotomy is used occasionally to reduce IOP before creating the incision for cataract extraction.

Perioperative use of oral and topical ocular hypotensive medications is common. Increased IOP may occur and varies with surgical technique and surgeon experience. Both topical  $\alpha$ -agonists and beta-blockers are reported to decrease IOP 3 to 24 hours postoperatively, respectively.

The careful monitoring of IOP with applanation tonometry at each follow-up visit is an important aspect of postoperative management. IOPs that are either elevated or depressed outside the expected range for a particular patient are considered to be a postoperative complication and should be managed accordingly (see *Managing Complications*, below).

## **CONTROLLING PAIN**

---

Sometimes preanesthesia agents are used before cataract surgery. These agents help to relieve anxiety and to produce sedation and, in some cases, short-term amnesia. Oral or intravenous diazepam (Valium) or midazolam (Versed) or intravenous fentanyl citrate (Sublimaze) are commonly used for preoperative sedation.

The basic methods of controlling intraoperative pain during cataract extraction are general, retrobulbar, periocular (peribulbar), intracameral, or topical anesthesia. General anesthesia was the primary method used before the development of long-acting local and regional anesthetic agents. In addition, improvements in surgical techniques significantly reduced surgical time, thus decreasing the need for general anesthesia. Retrobulbar anesthesia became the mode of choice because systemic complications, such as cardiac or pulmonary arrest, are much less frequent than with general anesthesia. Agents commonly used for retrobulbar anesthesia include 2% lidocaine with epinephrine, 0.75% bupivacaine, and hyaluronidase. Bicarbonate may be added to adjust the pH and decrease the onset time of the anesthesia. With most cataract extractions being performed in outpatient surgical centers, where anesthesiologists or nurse anesthetists are not always available, some surgeons advocate periocular

(peribulbar) anesthesia over retrobulbar anesthesia. The same agents are used in either approach. Although it is less effective in producing extraocular muscle akinesia as compared with retrobulbar techniques, periocular administration is believed to produce fewer complications, such as retrobulbar hemorrhage, central retinal artery occlusion, and perforation of the globe or optic nerve. Moreover, it is often tolerated better by the patient. Most recently, surgeons have performed cataract surgery using only topical anesthesia, usually 4% lidocaine hydrochloride. This procedure can be successful in cooperative patients with uncomplicated cataract extractions.

Cataract patients, in general, have relatively little immediate postoperative pain. This absence of pain is, at least in part, due to the long duration of action (up to 12 hours) of bupivacaine used in retrobulbar anesthesia. Some practitioners recommend the use of oral analgesics, such as acetaminophen or ibuprofen, as needed, if the patient experiences minor discomfort in the immediate postsurgical period. Topical NSAIDs are also reported to decrease immediate postoperative pain. Significant or persistent postoperative pain is considered to be abnormal and may be a symptom of such complications as corneal abrasion, bullous keratopathy, high IOP, or endophthalmitis.

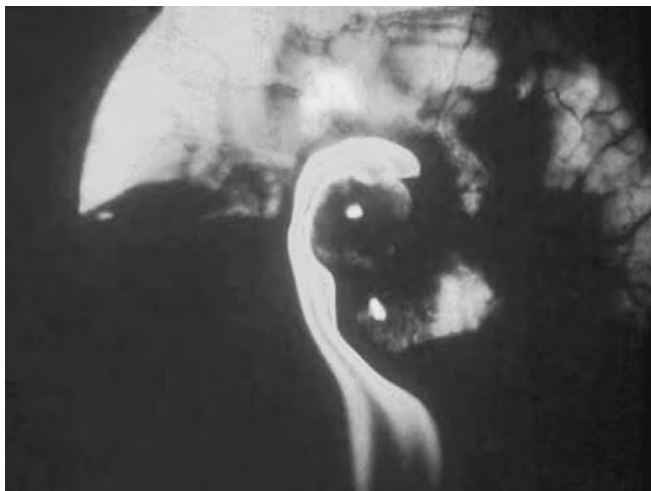## **OPTIMIZING VISION**

---

The three methods of correcting distance vision after cataract extraction are aphakic spectacles, contact lenses, and IOL implantation. The latter method is now used almost exclusively. The power of the IOL is determined by preoperative measurements of axial length and corneal curvature.

Although it is relatively easy to bring the spherical component of the refractive error close to emmetropia with an IOL, a residual astigmatic component may remain. Astigmatism may also be iatrogenically induced by incision and suturing techniques. With limbal incisions, a moderate amount of postoperative astigmatism that decreases as the wound heals is considered to be normal.

Several procedures, including using small incisions, modifying incision placement, and judiciously placing or removing sutures, have been used to control postoperative astigmatism. The appropriate time to remove a suture for astigmatism control depends on the surgeon's technique. Continuous sutures, for example, should not be cut for at least 6 weeks after surgery. Single interrupted sutures placed specifically for astigmatism control, on the other hand, may be removed as early as 1 week after surgery. Advances in surgical techniques have created a new standard of one-stitch and no-stitch procedures. Therefore the need for suture removal to control astigmatism has diminished significantly. Astigmatic keratotomy or limbal relaxing incisions at the time of cataract extraction and postoperative excimer laser astigmatic correction are other alternatives to reduce postoperative astigmatism.



**Figure 30-1** Positive Seidel's test result. Site of wound leak is highlighted by stream of sodium fluorescein. (Courtesy Oli Traustason, M.D.)

To remove a suture the eye must first be anesthetized topically with an agent such as 0.5% proparacaine and may be treated prophylactically with a topical antibiotic, such as an aminoglycoside or fluoroquinolone. A small Beaver blade or 22-gauge needle is slipped under the suture to cut it near the inferior insertion. Forceps are then used to grasp the free end of the suture and pull it downward. Care should be taken to minimize pulling the suture knot and/or exposed contaminated suture through the cornea and anterior chamber. After removal the wound integrity should be evaluated using the Seidel's test (Figure 30-1). A patient with a positive Seidel's sign must be treated with topical fluoroquinolone and, possibly, topical aqueous suppressants until the leak is sealed. If the Seidel's test result is negative, the patient should be prescribed a prophylactic topical antibiotic and followed as necessary. A similar technique may be used to remove symptomatic protruding suture barbs in the late postoperative period.

Topical steroids may control postoperative astigmatism pharmacologically. Increasing the dosage or duration of steroids may delay wound healing, which may reduce astigmatism.

In the absence of other pathology, the patient's vision should be fully correctable within a few weeks after cataract surgery. Vision that is initially clear after cataract extraction but then deteriorates is suggestive of a postoperative complication, such as capsular opacification, bullous keratopathy, CME, or retinal detachment.

## MANAGING COMPLICATIONS

Cataract extraction is considered to be a safe surgical procedure, with relatively few postoperative complications. Use of the small-incision and no-stitch techniques in preference to the larger incision techniques has reduced

the rate of most complications. The most common complications noted in the early postoperative period include eyelid edema, subconjunctival hemorrhage, conjunctival injection, corneal edema, and anterior chamber reaction. Although serious complications are uncommon, the practitioner who is providing postoperative care must be able to diagnose and manage these conditions if they arise. Table 30-1 is a suggested guide to patient care after cataract extraction. Notable, however, is that each surgeon has a preferred postoperative regimen and follow-up schedule, and the comanagement team should communicate with each other concerning those preferences.

## Complications of the Eyelids and Conjunctiva

Both the eyelids and conjunctiva may become red and edematous after surgery. A small amount of redness and edema during the first postoperative week is usually considered to be normal. Severe lid or conjunctival redness may be due to an allergic reaction to one of the topical postoperative medications or may be an indication of endophthalmitis. Allergic reactions can be managed by removing the sensitizing agent, whereas endophthalmitis requires immediate and aggressive treatment. Ecchymosis and ptosis may be caused by trauma from the eyelid speculum or local anesthesia. Bruising resolves spontaneously, as does ptosis typically, but the latter may persist and may require surgical correction. Subconjunctival hemorrhage may be caused by damage to the episcleral and conjunctival vessels due to injections, or at the incision site for limbal or conjunctival approaches, and may appear to move or enlarge as gravity pulls it downward. Subconjunctival hemorrhages typically resolve spontaneously within 2 to 3 weeks.

## Endophthalmitis

### Etiology

Although endophthalmitis is a relatively uncommon sight-threatening complication of cataract surgery, its potentially devastating effect mandates that all practitioners involved in comanagement have a very thorough understanding of its clinical presentation. Infection generally occurs when an overwhelming number of microbes enter the anterior chamber during surgery initiating the destructive process. The main factors that influence whether or not an individual develops endophthalmitis include the number of organisms introduced as well as the patient's immunologic status. A surgical facility can minimize risk of infection by implementing and adhering to strict sterile technique, and the surgeon must ensure appropriate closure of the wound. In some individuals, despite perfect surgical and sterilization technique, endophthalmitis may occur.

**Table 30-1**  
Postoperative Management of the Pseudophakic Patient

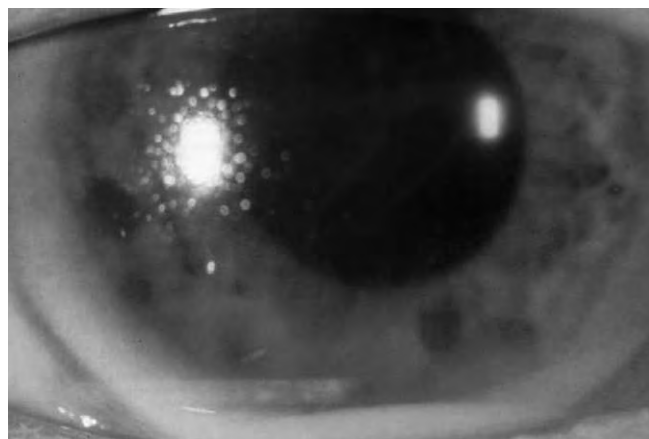
Examination Schedule	Medication	Examination	Patient Instructions
Immediately after surgery	Topical antibiotic ointment or topical antibiotic-steroid ointment		Eye patch or shield, to be removed by patient or practitioner Return in 1 day Acetaminophen or ibuprofen as needed
Day 1	Topical antibiotic and steroid drops four times daily (topical NSAIDs four times daily, optional) If intraocular pressure elevated, topical antiglaucoma therapy; avoid prostaglandin analogue	History Visual acuity (pinhole) Slit-lamp examination Tonometry	Use medications as prescribed Take acetaminophen or ibuprofen as needed Wear eye shield at bedtime (optional) Wear glasses or sunglasses during day (optional) Limit lifting or straining (optional) Avoid rubbing eye Return in 1 week
1 Week	Discontinue or taper antibiotic and may begin taper of steroid drops	History Visual acuity (pinhole) Slit-lamp examination Keratometry (optional) Refraction (optional) Tonometry Dilated fundus examination if vision <20/50	Same as day 1 instructions Return in approximately 1 month
3-5 Weeks	Discontinue medications	History Visual acuity (pinhole) Slit-lamp examination Keratometry Refraction Tonometry Examination of dilated fundus (optional, if performed earlier in follow-up) If high astigmatism, remove suture, if appropriate Check clarity of posterior capsule	Discontinue eye shield, if used Prescribe spectacles or contact lens if refraction stable Resume normal activity if previously restricted Return in approximately 1 month
6-8 Weeks		Similar to 3- to 5-week examination	Return in approximately 4 months
6 Months		History Visual acuity (best corrected) Slit-lamp examination Tonometry Examination of dilated fundus, if not performed previously in postoperative period Check clarity of lens capsule	

The risk of endophthalmitis has been reported in several large studies of phacoemulsification with IOL implantation and varies from 0.12% to 0.015%. The role of incision type as a risk factor for endophthalmitis has been brought into question. A large-scale literature analysis of cataract surgery from 1964 to 2003 showed a declining rate of endophthalmitis from 1964 to 1991 and an increasing rate of endophthalmitis from 1992 to 2003. It has been suggested that this increasing incidence over the last decade could be due to the advent of the clear corneal temporal incision. The clear corneal incision has been shown to have poor appositional closure during a transient reduction in IOP. This suboptimal wound adherence may be a potential cause for endophthalmitis in patients receiving clear corneal incisions. However, a recent study at The Bascom Palmer Eye Institute showed that the incidence of endophthalmitis with clear corneal incision was 0.05% and 0.02% by all other incisions. The difference was not considered statistically significant.

Although a variety of microbial organisms have been shown to cause postoperative infections, the undisputed majority are gram-positive bacteria, particularly *Staphylococcus epidermidis* and *Staphylococcus aureus*. The Endophthalmitis Vitrectomy Study (EVS) reported that 90% of the 410 patients with culture-proven endophthalmitis were gram positive. Although gram-negative bacteria make up only 6% to 11% of these infections, they must always be considered because of their potential for rapid destruction of ocular tissues. Less aggressive later-onset causes of endophthalmitis have been well documented to be associated with less virulent bacteria, such as *Propionibacterium acnes*.

### Diagnosis

The two most important factors that should increase the suspicion of endophthalmitis in a postoperative patient are sudden loss of vision and inflammation out of proportion to what one would expect. The EVS showed that endophthalmitis within 72 hours of surgery is associated with either gram-negative or gram-positive organisms with high virulence, compared with onset of symptoms 3 or more days postoperatively, which are more likely to yield less virulent gram-positive coagulase-negative micrococci. With more virulent forms of endophthalmitis, the signs and symptoms usually occur within 72 hours of surgery. The classic presentation consists of ocular pain, reduced vision, episcleral and conjunctival injection, loss of red reflex, lid edema, and severe anterior as well as posterior chamber reaction, oftentimes with hypopyon (Figure 30-2). However, the EVS found that about 26% of patients were without pain, particularly in diabetics. The same study found that 14% of patients presenting with endophthalmitis had no evidence of hypopyon. In addition, a condition that can result in delayed, rather than early, onset of more virulent forms of endophthalmitis occurs in individuals who have persistent wound leaks that later become infected.



**Figure 30-2** Endophthalmitis with hypopyon. (Courtesy Jeff Miller, O.D.)

With improvements in surgical techniques including wound architecture, more biocompatible lens implant materials, more efficacious antibiotics, and fewer hospital-based cases, less virulent bacteria such as gram-positive infections or *P. acnes* are now more common causes of infection with later onset and more insidious signs and symptoms. Patients may present with a history of postoperative iritis for days, weeks, or months that intensifies when corticosteroids are withdrawn. Despite an initial improvement with topical corticosteroids, the clinical signs and symptoms usually worsen over time. Cases are reported of patients who have developed signs and symptoms of endophthalmitis a year or more after their cataract extraction as the organisms were sequestered between the implant and the capsule and were not dispersed until yttrium aluminum garnet (YAG) capsulotomy was performed. The clinician should therefore keep the diagnosis of endophthalmitis in mind in patients who have had YAG capsulotomy and experience excessive inflammation, particularly if a white fluffy capsular plaque was noted preoperatively.

### Management

Any patient who presents with signs and symptoms of endophthalmitis is presumed to have an infectious etiology until proven otherwise. The operating surgeon should be contacted immediately. After this call the decision may be made to immediately refer to a retinal vitreous surgeon or to be seen in consultation with the operating surgeon to determine the need for emergent management of culturing, either by anterior chamber or vitreous tap, and administration of intravitreal antibiotics. Intravitreal antibiotics are the standard of care for endophthalmitis, because it achieves the highest concentration of drug. The EVS did not show any benefit to adding intravenous antibiotic to the standard intravitreal amikacin, 0.4 mg per 0.1 ml, and vancomycin, 1.0 mg per 0.1 ml. Subconjunctival and topical antibiotics, although increasing anterior chamber levels of drug, did not significantly

increase vitreal concentration of antibiotics. The EVS also showed that immediate vitrectomy may not be as helpful in patients as once thought and recommended initial vitrectomy only in cases in which presenting visual acuity is light perception or worse. Patients with hand motion or better vision showed no benefit with pars plana vitrectomy, compared with immediate vitreous tap/biopsy. Finally, some postcataract surgery patients experience increased inflammatory reaction that is noninfectious, and the surgeon may therefore decide to increase topical steroids and monitor carefully, rather than immediately treat surgically.

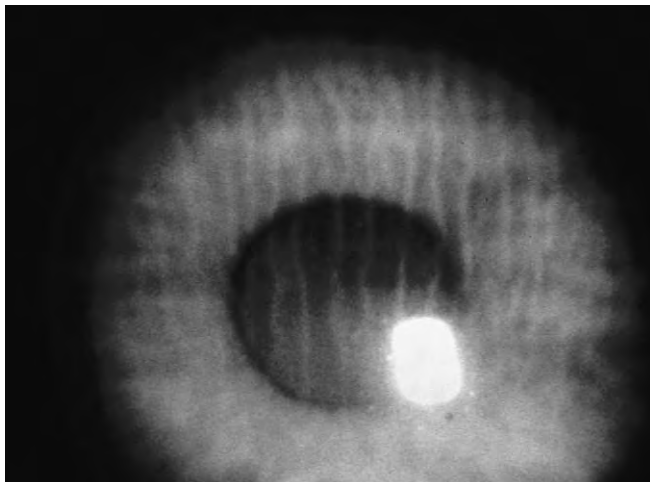
## Ocular Hypotony

### Etiology

Low IOP after cataract surgery can be due to a variety of reasons, including wound leak, ciliochoroidal effusion, cyclodialysis cleft, retinal detachment, or aqueous suppression from ophthalmic medication.

### Diagnosis

The patient may report episodes of watering or tenderness. When reduced IOP is found by applanation tonometry, a careful examination of the wound is necessary. This inspection is achieved by painting sodium fluorescein over the cataract incision to observe for Seidel's sign. Occasionally, the auxiliary incisions can leak, so they should also be examined. The clinician should note the appearance of the cornea, which often shows endothelial folds. After the instillation of sodium fluorescein, a waffled appearance of the cornea is generally apparent if the IOP is markedly reduced (Figure 30-3). In addition, the anterior chamber depth should be assessed as well as the presence of inflammation. The pupils should be dilated and a retinal examination should be performed to rule out serous or hemorrhagic choroidal separations or a retinal break or detachment.



**Figure 30-3** Hypotonic eye with corneal waffling.

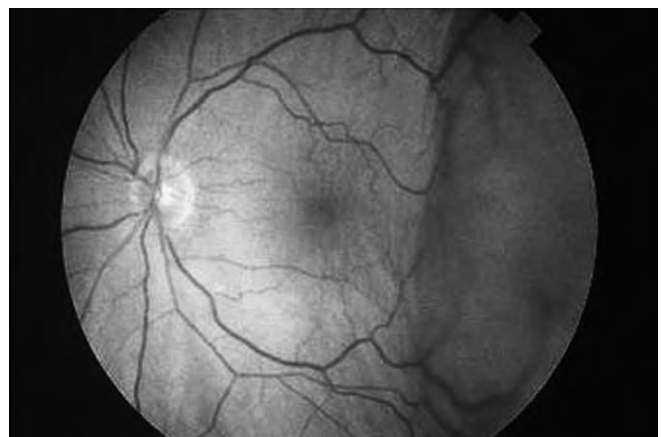Although most people who have an incisional leak have a reduced IOP in the single digits, in some cases patients may have leaks when the IOP is higher. The practitioner should therefore keep in mind that any patient who presents in the early postoperative period with a sudden onset of a watery eye, gaping wound, or a wound that is tender when the eyelid is touched should have a Seidel's test performed.

### Management

A patient with low IOP due to a wound leak, who also has a flat or markedly shallow anterior chamber, should be considered for surgical repair of the wound. The surgeon may elect to re-form the anterior chamber with air, saline, or viscoelastic and suture the wound.

In the case of ocular hypotony and a positive Seidel's sign with a formed anterior chamber in the early postoperative period, the treatment of choice is to discontinue the steroid to encourage wound closure and avoid secondary infection. The patient should be placed on a third- or fourth-generation topical fluoroquinolone. A topical aqueous suppressant may also be used to ensure secure wound closure. The patient is asked to limit activities and is given an eye shield to wear at night. An alternative treatment may include the use of a topical antibiotic and a 24-hour pressure patch with an eye shield while sleeping. If the wound fails to seal after several days to 1 to 2 weeks, surgical repair should be considered.

When a choroidal effusion (Figure 30-4) is detected without a wound leak, the patient can be treated with topical corticosteroids, such as 1% prednisolone acetate, one drop every 2 to 4 hours, with or without cycloplegia, such as homatropine 5% or atropine sulfate 1%, one drop two to four times daily. Routine topical antibiotics should be continued. When medical management fails to resolve the choroidal detachment (effusion) or if anterior synechiae form, consideration should be given to draining the fluid and re-forming the anterior chamber.



**Figure 30-4** Choroidal effusion.



## Ocular Hypertension

### Etiology

Elevated IOP is a common early postoperative occurrence found in cataract surgery regardless of technique. Patients with a history of glaucoma also have a higher incidence of elevated IOP after cataract surgery as compared with nonglaucomatous patients. During cataract surgery liberated lens material, red blood cells, iris pigment, inflammatory cells, and viscoelastic material in the anterior chamber may obstruct the trabecular meshwork or cause a trabeculitis resulting in an elevated IOP. Topical steroids may also cause IOP elevation in steroid-responsive patients.

### Diagnosis

The patient is often asymptomatic or may report a blur due to corneal edema or pain, particularly a browache over the affected eye. Applanation tonometry is the standard method by which elevated IOP is confirmed. At the first postoperative examination, the elevated IOP typically causes epithelial microcystic edema that may occur in the presence of a clear stroma. Less often, stromal edema is present. The examiner should carefully evaluate the anterior chamber to rule out pupillary block or the presence of retained lens material. A patient presenting later in the postoperative period, with or without symptoms, may have steroid-induced increased IOP. A patient with increasing symptoms of discomfort or pain, high IOP, corneal microcystic edema, and persistent anterior chamber inflammation should be evaluated gonioscopically to observe for any signs of retained lens material or angle abnormalities. Angle-closure glaucoma is rarely observed in patients who have properly positioned posterior chamber IOLs in the capsular bag. It is more commonly observed in patients with sulcus-fixated posterior chamber IOLs or anterior chamber IOLs in which iridectomies are not patent. Angle-closure glaucoma secondary to aqueous misdirection is also rarely observed but should be suspected when the anterior chamber is uniformly shallow in a postoperative eye. In these patients the aqueous becomes misdirected behind the vitreous, which is pushed forward, compressing the iris into the angle.

Patients who have elevated IOPs with previous history of wound leak should be carefully examined to rule out epithelial downgrowth. This rare complication can have devastating effects if diagnosis is delayed. Generally, a translucent opacification of the corneal endothelium is observed from the cataract incision. The conjunctival epithelium is responsible, and when this obstructs the angle, elevated IOP results. Treatment requires the drastic approach of surgically removing the affected corneal and iris tissue. Visual results are generally poor.

### Management

Patients with modest elevations of the IOP, in the presence of a healthy nerve and without other risk factors, can be monitored without treatment. If the IOP is

more elevated (30 mm Hg or greater) or if the patient has coexisting glaucoma, then more aggressive treatment is recommended.

The most efficient topical medications to reduce IOP in postoperative patients are those whose mechanism involves aqueous suppression. These agents would include topical carbonic anhydrase inhibitors, apraclonidine, brimonidine, beta-blockers, and oral carbonic anhydrase inhibitors. Prostaglandin analogues and miotics are effective in lowering the IOP postoperatively; however, they may cause increased inflammation and should not be considered a first-line treatment.

At 1-day postoperative visits, if the IOP is elevated to a level of between 30 and 40 mm Hg in patients who have healthy nerve heads, a single drop of an aqueous suppressant can be administered with the IOP checked within 24 hours. In patients with higher IOPs or preexisting glaucoma, multiple aqueous suppressants can be administered either in topical or oral form. In patients who need more immediate control, careful release of fluid from the corneal side port can temporarily lower the IOP. In some cases patients may need to be maintained on topical or oral medication(s) for a few days until the IOP stabilizes. Topical steroids should be continued during this time to reduce inflammation and aid in increasing the outflow of the trabecular meshwork. In pseudophakic angle closure a peripheral iridotomy should promptly be performed. Aqueous suppressants are used before laser iridotomy to reduce IOP and clear the cornea. If an iridotomy cannot be promptly performed, pupillary dilation generally relieves pupillary block.

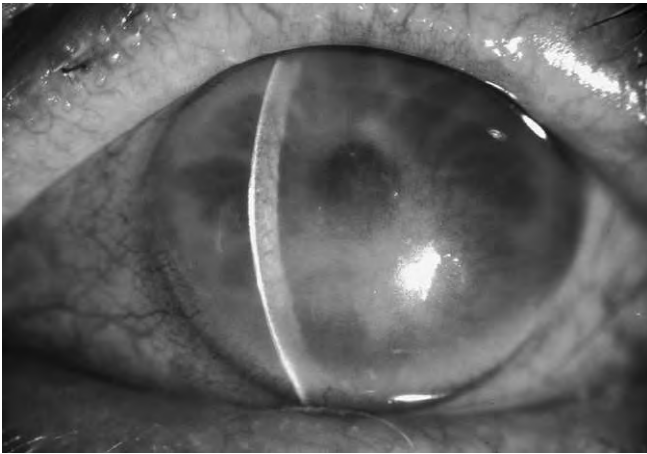
In patients who have malignant glaucoma, aqueous suppressants help lower the IOP and cycloplegics deepen the angle and may help restore normal aqueous flow. If conservative measures fail, an anterior vitrectomy is usually curative.

Patients who have elevated IOP 1 to 4 weeks after cataract surgery may be suspected of having a steroid response. These individuals may benefit from having their steroid discontinued or by substituting a steroid drop less likely to increase the IOP (rimexolone, loteprednol etabonate) or by using an NSAID.

## Corneal Edema

### Etiology

Corneal edema is a common finding postoperatively after uncomplicated, sutureless, scleral tunnel or clear corneal incision cataract surgery. More severe involvement (Figure 30-5) with persistent stromal edema, epithelial microcysts, and bullae may be found in patients with low endothelial cell counts, excessive inflammation from corneal trauma during the surgery, or an increased IOP secondary to retained lens material or inflammatory response. Bullae are typically secondary to increased corneal aqueous absorption due to high IOP or to a breakdown of the corneal endothelial aqueous pump.



**Figure 30-5** Corneal stromal edema.

### Diagnosis

The patient may complain of blur or discomfort. One day after cataract surgery, it is not unusual to see corneal edema around the wound, with or without Descemet's folds and stromal edema, geographic epithelial microcysts, and, occasionally, bullae. These corneal signs typically resolve during the first 3 to 10 days of the normal postoperative course. In addition to evaluating corneal signs, the clinician should look for anterior chamber inflammation, lens remnant in the anterior or posterior chamber, and malpositioning of the IOL. The IOP should be examined by applanation tonometry, if possible.

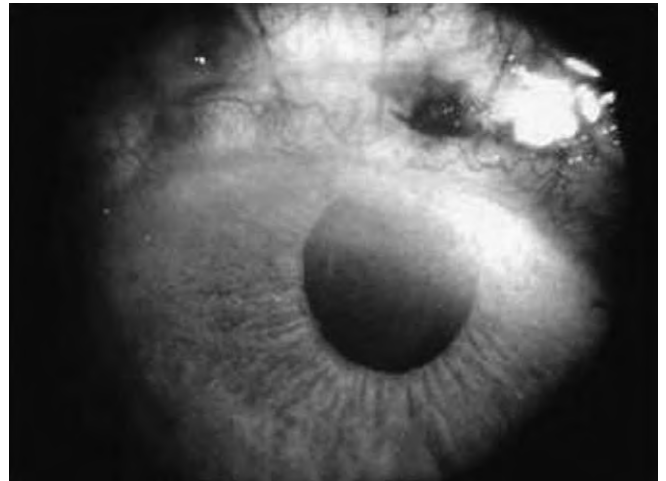
### Management

Mild Descemet's folds, stromal edema, and epithelial microcysts or bullae around the wound are treated with normal postoperative medicines and follow-up. In patients with persistent edema, increased pressure, and anterior chamber inflammation, thorough gonioscopy and dilated fundus examination should be performed to exclude the presence of retained lens material. If none is found, increased IOP should be treated with appropriate hypotensive therapy, and more aggressive topical anti-inflammatory drops may be helpful, including cycloplegia. Topical hyperosmotic agents, such as 5% sodium chloride drops or ointment, may be used to reduce epithelial microcystic edema, which causes blurred vision upon awakening. If significant corneal edema persists at 3 or more months after cataract extraction (corneal decompensation), corneal transplantation may be considered.

## Pupil Distortion

### Etiology

Pupil distortion may be caused by many factors. If a wound leak is present, a wick of vitreous or prolapsed iris may become incarcerated in the wound, causing a distorted or "peaked" pupil. The peak of the pupil often points toward the incarcerated area (Figure 30-6).



**Figure 30-6** Iris incarcerated in wound.

Surgical trauma can also cause an irregularly shaped pupil. In phacoemulsification procedures the iris can be traumatized by accidental touching with the phacoemulsifier tip. The iris can be altered intentionally during cataract extraction: If the pupil dilates poorly, due to pseudoexfoliation, long-term miotic therapy, or use of an oral  $\alpha_1$ -antagonist (Flomax), stretching of the iris with retractor hooks during surgery may result in a surgical sphincterotomy or pupilloplasty. Occasionally, the pupil may become distorted if the iris is captured by the edge of the IOL optic (pupillary capture) or if the lens becomes decentered or dislocated.

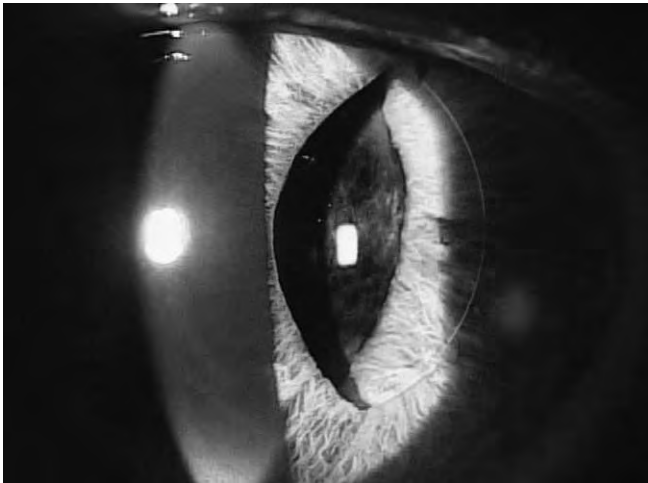
Pupil distortion may be related to the type and location of IOL implants. Some of the early iris-fixated and iris-plane lenses often caused square pupils, and some of the early anterior chamber IOLs, such as the Choyce lens, caused the pupil to be stretched in an oval appearance. The older lenses were also more likely to irritate the iris and anterior chamber angle, causing chronic low-grade iritis. Chronic iritis, in turn, resulted in iris atrophy, synechiae formation, and pupil distortion. These lenses have been replaced by posterior chamber IOLs inserted into the capsular bag. Dislocation of a posterior IOL is rare but possible (Figure 30-7).

### Diagnosis

The patient may or may not have symptoms from pupil distortion. Clinically, the pupil and anterior chamber should be evaluated before dilation. If the pupil is peaked at the first postoperative visit, the examiner may carefully examine with gonioscopy, looking for vitreous or iris extending to the wound. Presence of vitreous prolapse in the anterior chamber necessitates a thorough retinal evaluation early in the postoperative period, looking for secondary retinal breaks. IOL position and capsule integrity should be evaluated to further define the source of pupil distortion.

### Management

In general, the earlier the intervention, the more successful the pupil repair procedure. If no vitreous is found in the



**Figure 30-7** Oval stretching of pupil secondary to posterior chamber intraocular lens.

wound but the iris is up-drawn to the wound, one drop of 1% to 4% pilocarpine may be instilled in an attempt to release the iris. This maneuver usually fails, and surgical repair must be considered. Pupil distortion caused by IOL capture, if detected early, may occasionally be remedied by dilating the pupil with mydriatic or mydriatic-cycloplegic agents, reclining the patient, and applying gentle pressure to the sclera. If synechiae have formed, however, surgical or laser procedures are necessary if signs or symptoms warrant repair.

## Hyphema

### Etiology

Hyphema after cataract surgery is a common occurrence in scleral tunnel sutureless cataract surgery but less common with clear corneal incision surgery. The most common cause of surgical hyphema is laceration or rupture of the vessels of the episclera, with leakage into the anterior chamber through a scleral tunnel incision. A far less common source of bleeding is from a damaged iris vessel during the cataract surgery or a phacoemulsification strike along the pupillary border. Hyphemas are more common and more severe in patients with blood dyscrasias or in those receiving anticoagulants, such as warfarin (Coumadin), aspirin, or clopidogrel (Plavix). They may also be seen more frequently in patients with abnormal iris vasculature from ocular inflammatory disease, Fuchs' heterochromic iridocyclitis, or proliferative diabetic eye disease. In a large-scale study involving 19,283 cataract surgeries at nine centers in the United States and Canada, the ocular risk of continuing patients on anticoagulants versus the systemic risk of discontinuing anticoagulants in patients undergoing cataract surgery was evaluated to determine whether one of those two approaches had a greater safety profile. Ocular and systemic markers included retrobulbar hemorrhage, vitreous or choroidal hemorrhage, hyphema, transient ischemic

attacks, strokes, deep venous thrombosis, myocardial ischemia, and myocardial infarction. The results showed a low occurrence of these complications in each group and no significant difference in outcome in either of the two groups. This study illustrated that practitioners would be justified in either discontinuing anticoagulants before cataract surgery or in continuing anticoagulants before cataract surgery, whichever the clinical situation mandates. Hyphemas that occur in the later postoperative period can be caused by neovascularization, bleeding from the wound in a case of poor scleral wound closure, or by mechanical destruction of iris tissue from a misplaced IOL. In the uveitis-glaucoma-hyphema syndrome a combination of rebleeds and inflammation is associated with increased IOP and glaucoma. This syndrome has been described mostly with iris-fixated and anterior chamber IOLs but may occur in sulcus fixated IOLs.

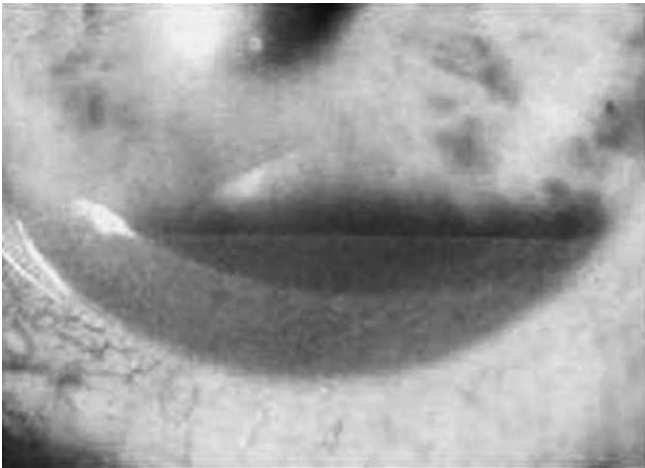### Diagnosis

The patient usually complains of a sudden painless loss of vision within a week of cataract extraction and may report a difference in iris coloration, with the affected eye having a more reddish-brown appearance. The degree that the vision is affected is directly proportional to the amount of red blood cells liberated. Some patients have no visual complaints, whereas patients with dense hyphemas may report bare light perception. The various clinical presentations are as follows:

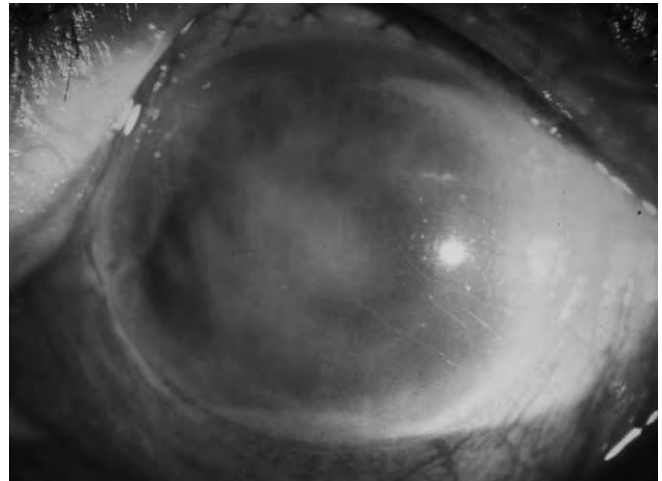
1. Microhyphema, in which a limited number of red blood cells circulate in the aqueous with mild visual acuity reduction;
2. Moderate diffuse hyphema, in which substantial red blood cells are exhibited in the aqueous, often with reduction in the patient's visual acuity;
3. A clot hemorrhage, in which blood coagulates, forming a clot at the site of bleeding or elsewhere in the anterior chamber (Figure 30-8);



**Figure 30-8** Red blood cell coagulum in anterior chamber.



**Figure 30-9** Layered hyphema.



**Figure 30-10** Severe persistent hyphema with layering.

4. A layered hyphema, in which liquefied red blood cells settle at the base of the anterior chamber (Figure 30-9).

On examination the hyphema should be graded and described as diffuse (microhyphema), clot, or layered. The dimensions of the clot hyphema may be measured with the slit lamp. Layered hyphemas should be recorded by the amount of anterior chamber they occupy (percentage volume of the anterior chamber or millimeter depth). Any abnormalities of the IOL should be observed. Because hyphemas are more common with poor appositional closure of the wound, a Seidel's test should be performed to rule out a concomitant wound leak. It is important to note the IOP by applanation. NCT should be avoided because it may precipitate more bleeding.

### Management

Typically, hyphemas cause great distress to the patient because of the marked decrease in visual acuity. The patient should be reassured that most hyphemas clear without any serious sequelae. After uncomplicated scleral tunnel phacoemulsification, affected patients need only stay on their normal postoperative course and be monitored every 2 to 7 days to ensure that the IOP does not increase as the hemorrhage is cleared through the trabecular meshwork. The patient may be advised to limit activities and to sleep with his or her head elevated to increase functional vision while the hyphema clears. If there is a significant clot or layered hyphema with elevated IOP, the IOP should be treated topically with antiglaucoma drops, in addition to the usual postoperative antibiotic and anti-inflammatory medications. This patient should be followed every 1 to 4 days.

Patients with a severe persistent hyphema or "eight-ball" clots that are creating blood staining to the cornea should be returned to the surgeon for consultation and possible aspiration of the hyphema from the anterior chamber (Figure 30-10). Likewise, patients with glaucoma before surgery and significantly elevated IOP from a hyphema

may benefit from more prompt surgical evacuation to maintain the health of the optic nerve.

## Posterior Capsular Opacification

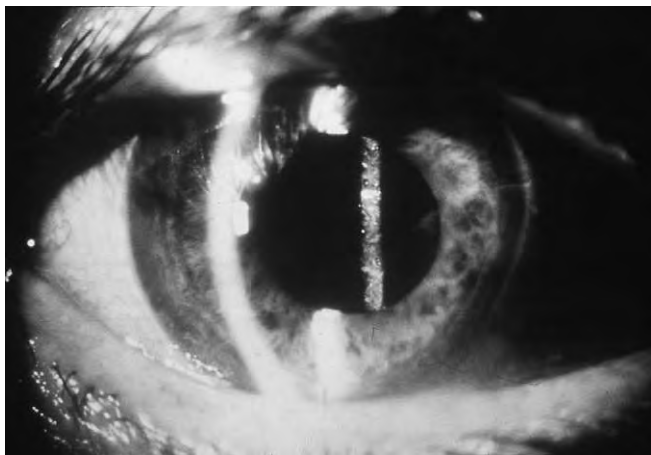### Etiology

Posterior capsular opacification (PCO) is a thickening and opacification of the posterior lens capsule after phacoemulsification or extracapsular cataract extraction. It is caused by proliferation and migration of the equatorial lens epithelial cells onto the posterior capsule. As these cells proliferate, they lay down collagen and other fibers that distort the capsular bag. They may also form organized structures, such as Elschnig's pearls, which further thicken and distort the capsule.

PCO most commonly occurs within 5 years of surgery, with rates as high as 50% as measured in the 1980s and early 1990s. With advanced surgical techniques, including precise capsulorrhexis, careful cortical cleanup, and secure placement of the implant in the capsular bag, the rate of PCO has rapidly diminished. Additionally, with the advent of modern foldable IOLs, particularly those that have square truncated (sharp as opposed to rounded) posterior edges that are biocompatible, the incidence of YAG capsulotomy may soon be less than 10%. Studies have shown that younger patients who have age-related cataract extraction are at greater risk for developing opacification compared with older patients.

### Diagnosis

Patients often report that their visual acuity was fairly good after surgery and then slowly decreased, as though the cataract had returned. Decreased visual acuity and glare are common symptoms. Slit-lamp examination with a dilated pupil shows a thickened capsule with a bubble-like appearance or sheet-like haze (Figure 30-11). The cornea, anterior chamber, vitreous, and fundus should be examined to exclude other sources for the symptoms.

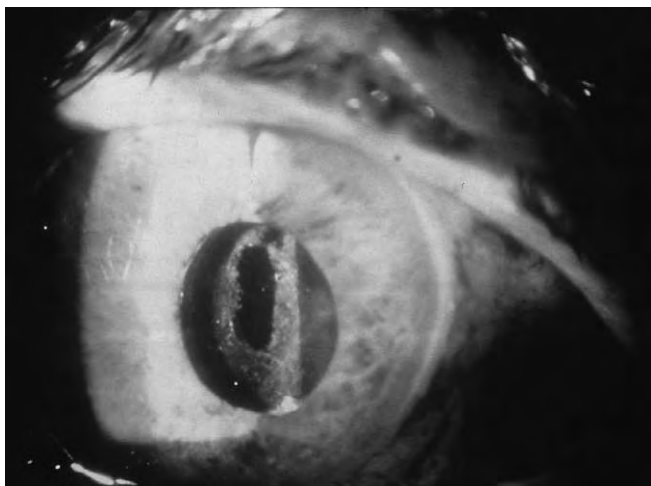


**Figure 30-11** Posterior capsular opacity, viewed at slit lamp with direct illumination.

If PCO is found within the first 3 months of cataract surgery, CME should be specifically ruled out, because the two can occur concurrently. The patient typically shows increased visual acuity on potential acuity testing if the macula is healthy.

### Management

An asymptomatic patient with a mild PCO found on slit-lamp examination does not need to be treated. When the patient becomes symptomatic with decreased vision, glare, or visual distortion such that their daily activities are affected, neodymium (Nd):YAG laser capsulotomy should be considered. Nd:YAG laser photodisrupts the involved tissues (Figure 30-12) and represents a low risk for a retinal break after the procedure. Therefore, before the Nd:YAG treatment, the patient should have a careful dilated examination of the peripheral retina to rule out breaks or degeneration that could lead to retinal detachment after capsulotomy.



**Figure 30-12** YAG capsulotomy of PCO pictured in Figure 30-11.

Common post-Nd:YAG complications include mild anterior chamber reaction and IOP elevation. Studies have also shown an association between Nd:YAG capsulotomy and retinal detachment. Patients who have plate haptic silicone IOLs are at risk of dislocation of the IOL into the posterior chamber after YAG capsulotomy. The risk is probably greater if the integrity of the posterior capsule is compromised during surgery.

In patients with history of ocular inflammation, 1% prednisolone acetate, one drop four times a day for 3 to 7 days, can be prescribed prophylactically after Nd:YAG. Rarely, a patient without history of inflammation may present with flare or mild cells in the anterior chamber or CME after capsulotomy. This also should be treated with topical steroids in the same manner. Post-YAG elevated IOP can often be prevented by treating the eye with apraclonidine (Iopidine) or other aqueous suppressant topical medication. The recommended dosage is one drop applied before the capsulotomy and one drop immediately after the procedure. Because of the potential risk of a retinal break, patients should receive dilated fundus examinations postoperatively as part of the routine follow-up within 1 to 4 weeks of capsulotomy, or sooner if symptoms develop.

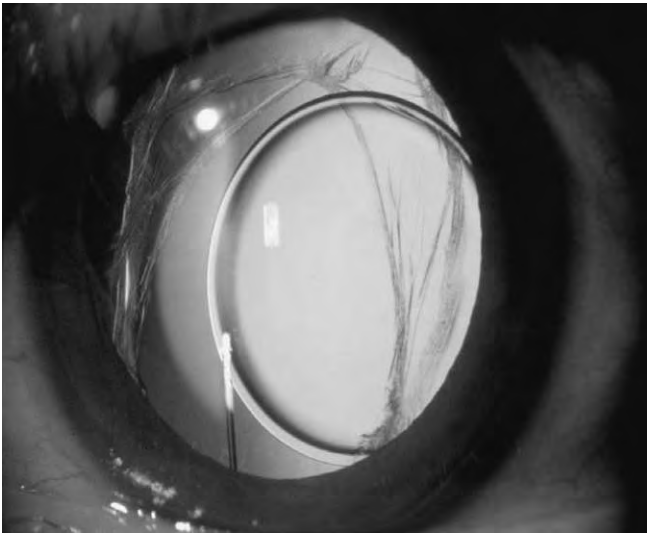
### Intraocular Lens Decentration or Dislocation

#### Etiology

IOL decentration or dislocation, with (see Figure 30-7) or without pupillary capture, is an uncommon finding in cataract surgery, due to the current standard of creating an intact capsulorrhexis and placement of the posterior chamber IOL in the capsular bag. Nevertheless, decentration may occur if an IOL is inserted with one haptic in the bag and one haptic in the ciliary sulcus or if an IOL is inserted into a bag with a tear that allows the lens haptic to enter the sulcus (Figure 30-13). An IOL may decenter late if the capsular bag fibroses around the lens irregularly or if a sulcus-placed IOL is sized too small for the sulcus space. Finally, a lens may dislocate secondary to trauma or, in the case of plate haptic IOLs, when a large Nd:YAG capsulotomy is performed before the IOL has fibrosed into the bag. Pupillary capture occurs when the pupillary margins become posterior to the optic of the posterior chamber IOL.

#### Diagnosis

Some patients with lens decentration or with pupillary capture have no symptoms. However, other patients with IOL decentration or pupillary capture note visual distortion, reflections, and decreased visual acuity. It is common to find increased myopia or induced astigmatism. The pupil may appear distorted, and the IOL optic edge and/or haptic may be visible when the pupil is undilated. When the eye moves, phacodonesis may be observed. Except when contraindicated because of lens type or



**Figure 30-13** Decentered intraocular lens with large posterior capsular tear.

location, pupil dilation further helps to determine haptic positioning, bag support, and stability of the decentration. There may be iritis or ocular irritation secondary to pupillary capture. In the case of lens dislocation, the IOL may move posteriorly and is assessed with slit-lamp examination and dilated fundus examination.

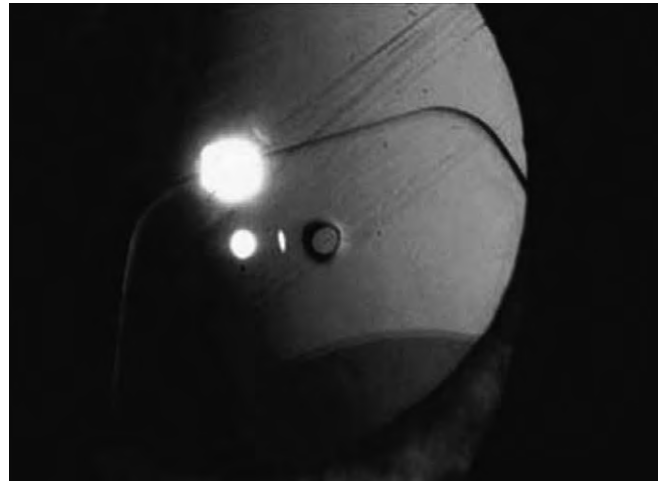### Management

Detection of pupillary capture at the first postoperative visit allows one to attempt repositioning by dilating the pupil, reclining the patient, and applying gentle pressure to the sclera. If the patient is asymptomatic and the lens remains stable but malpositioned, no treatment is necessary beyond advising the patient and the surgeon. If decentration or pupillary capture causes visual symptoms, visual distortion, or halos, the patient may be informed of the risks and benefits of repositioning the IOL. An unstable lens position, or any significant symptom of visual disturbance, necessitates a surgical consultation to consider IOL repositioning or exchange. A lens that dislocates (Figure 30-14) into the posterior segment must be surgically removed and replaced.

### Cystoid Macular Edema

#### Etiology

CME is a well-documented complication of cataract surgery. The pathogenesis includes accumulation of fluid in the macular intracellular and extracellular spaces as a result of increased permeability of perifoveal capillaries. The mechanism is likely mediated by release of prostaglandins and leukotrienes from the injured tissue or as a direct result of traction on the macula by vitreal tissue movement, especially secondary to vitreous entrapment in the wound. Prostaglandin analogue ocular hypotensive agents may play a role in pseudophakic CME.



**Figure 30-14** Dislocated plate haptic IOL.

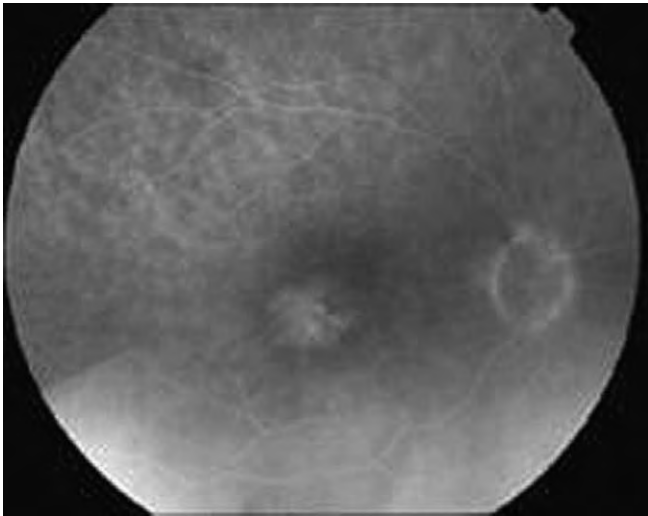
#### Diagnosis

Clinical presentation involves a normal postoperative course for several weeks to 6 months, followed by vision loss that is often the only symptom but may be accompanied by photophobia, injection, anterior chamber reaction, or Amsler grid distortion. There is some evidence of an increased prevalence of early age-related macular degeneration in eyes that have undergone cataract surgery. Also, diabetic retinopathy and clinically significant diabetic macular edema may both be exacerbated by CE. Therefore the differential diagnosis of postoperative vision loss must include these conditions.

The clinical examination should include a careful review of the intra- and postoperative history to disclose any complications, such as capsular rupture, vitreous or iris adhesion to the wound, or chronic uveitis. These complications carry a much higher incidence of CME and increase the possibility of chronic CME. Fundus examination reveals thickening of the macular area, with possible observation of cyst formation. Cysts may be accompanied by small perifoveal hemorrhages, yellowing of the macula, or mild disc edema. Because CME is often diffuse or low grade, biomicroscopic evaluation may be equivocal, and fluorescein angiography or ocular coherence tomography is useful to confirm the diagnosis and to quantify the amount of macular edema (Figure 30-15).

CME can be divided into one of three presentations: angiographic, clinical, and chronic. Macular fluorescein angiogram dye accumulation without reduction of Snellen visual acuity defines angiographic CME. Although definitions vary, clinical CME typically is characterized by a positive fluorescein angiogram and by reduced Snellen acuity of at least two lines. Chronic CME is defined as clinical CME that lasts longer than or is recurrent within 6 months.

The incidence of angiographic CME varies widely, from 2.9% to 78.0% of patients. Clinical CME occurs in approximately 1% to 3% of uncomplicated sutureless cataract extractions but may occur more frequently in



**Figure 30-15** Fluorescein angiogram demonstrating clinical cystoid macular edema.

patients with uncomplicated surgery with history of ocular inflammation, macular edema, or surgery. Chronic CME is found in 0.3% of cases and is often associated with operative complications, such as capsular rupture and vitreous loss.

### Management

Patients with a history of prior macular edema may be considered at greater risk of developing pseudophakic CME and may be pretreated with topical or injected steroids or topical NSAIDs. These patients may be given prophylactic topical NSAIDs postoperatively along with the usual steroid drops. Antiglaucoma prostaglandin analogue drops should be avoided or used judiciously in patients with an increased risk for postoperative CME.

CME spontaneously resolves in all but 25% of cases. Treatment, especially in uncomplicated cases, is therefore unproven. Accordingly, clinicians treat uncomplicated CME in a stepwise approach unless the initial presentation is extremely severe. Initial treatment of uncomplicated CME consists of additional standard postoperative topical corticosteroids, such as 1% prednisolone acetate, 1% prednisolone phosphate, or 0.1% dexamethasone instilled four times daily. An additional NSAID drop, such as 0.1% diclofenac or 0.5% ketorolac, may be added four times daily. The newer nepafenac 0.1% may be instilled three times a day. Topical treatment may be expanded by more frequent use of the steroid drops and by adding cycloplegics, such as 0.25% scopolamine or 5% homatropine, one drop twice daily. If no improvement occurs after the use of topical agents, intravitreal or subconjunctival corticosteroids may be considered and typically would be an injection of triamcinolone acetonide (Kenalog) suspension. Finally, 60 to 80 mg prednisone per day may be given orally for 1 week with tapering. Oral carbonic anhydrase inhibitors, such as acetazolamide or methazolamide, may be effective in a small percentage of patients.

## Retinal Detachment

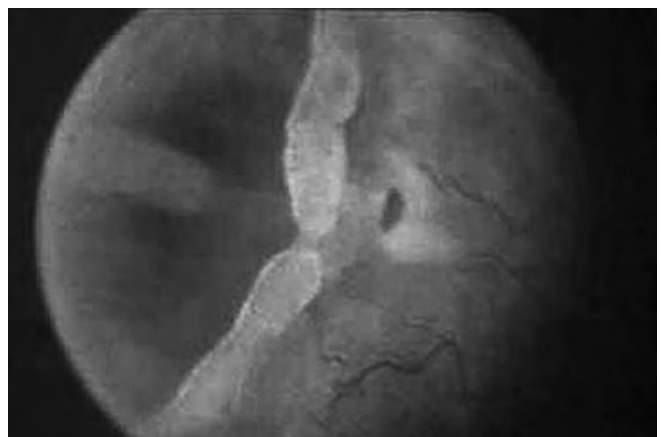
### Etiology

Although asymptomatic operculated holes and atrophic holes are generally not prophylactically treated, treatment is often considered if cataract surgery is planned. Retinal detachment after cataract surgery is a result of vitreous traction-adhesion on such areas of weakly adhered or thin retina. As the vitreous moves forward, the retina is torn and pulled forward as well. These events result in a continuing tear (horseshoe tear) with the apex pointing toward the posterior pole or, if the retina is pulled free, a round tear (operculum). Most tears do not lead to detachment, but if liquefaction of the vitreous occurs over the retinal break, fluid can accumulate and separate the sensory retina from the retinal pigment epithelium, producing a rhegmatogenous detachment.

The incidence of detachment after extracapsular cataract surgery or phacoemulsification is approximately 1%. The incidence may increase in cases in which the capsular bag is broken and vitreous loss occurs during the surgery. Most detachments occur within 6 months after surgery. Ocular conditions that are associated with detachment (e.g., peripheral lattice degeneration, vitreal tufts or tags, meridional folds, history of retinal detachment in the family or in the opposite eye, or axial myopia) place a patient at greater risk for postoperative retinal detachment, and preoperative retinal consult and prophylactic retinal treatment, if appropriate, may be considered.

### Diagnosis

Patients presenting with a retinal detachment typically report an onset of flashing lights (photopsia) and floaters. Patients may also report decreased peripheral or central vision. Any patient presenting with these symptoms requires prompt dilation and a thorough examination of the central and peripheral retina. Slit-lamp biomicroscopy and indirect ophthalmoscopy with scleral depression are



**Figure 30-16** Retinal detachment.



the standard examination modalities. On examination, a rhegmatogenous retinal detachment appears undulating and semitransparent when compared with surrounding attached retina (Figure 30-16). Decreased IOP or pigmented cells on the IOL implant or in the anterior vitreous (Shafer's sign or tobacco dusting) may also be found on examination.

### Management

Postoperative patients who are found to have symptomatic tears or frank retinal detachment should be referred immediately to a vitreoretinal surgeon for treatment. Repair of a rhegmatogenous retinal detachment involves locating retinal breaks, draining subretinal fluid, and sealing the breaks with cryotherapy, endolaser, or diathermy in conjunction with application of a scleral buckle or sponge or pneumatic retinopexy.

### SELECTED BIBLIOGRAPHY

- American Optometric Clinical Practice Guidelines. Care of the adult patient with cataract. 2004.
- Apple DJ, Solomon KD, Tetz MR, et al. Posterior capsule opacification. *Surv Ophthalmol* 1992;37:73-116.
- Assia EI, Legler UFC, Merrill C, et al. Clinicopathologic study of the effect of radial tears and loop fixation on intraocular lens decentration. *Ophthalmology* 1993;100:153-158.
- The Endophthalmitis Vitrectomy Study. Relationship between clinical presentation and microbiologic spectrum. *Ophthalmology* 1997;104:261-272.
- Endophthalmitis Vitrectomy Study Group. Results of the endophthalmitis vitrectomy study: a randomized trial of immediate vitrectomy and of intravenous antibiotics for the treatment of postoperative bacterial endophthalmitis. *Arch Ophthalmol* 1995;13:1479-1496.
- The Eye Diseases Prevalence Research Group. Prevalence of cataract and pseudophakia/aphakia in the United States. *Arch Ophthalmol* 2004;122:487-494.
- Jaffe NS, Jaffe MS, Jaffe GE. *Cataract surgery and its complications*, ed. 5. St. Louis, MO: CV Mosby, 1990: 361-364.
- Javitt JC, Tielsch JM, Canner JK, et al. National outcome of cataract extraction: increased risk of retinal complications associated with Nd:YAG laser capsulotomy. *Ophthalmology* 1992;99:1487-1498.
- Javitt JC, Vitale S, Canner JK, et al. National outcomes of cataract extraction/endophthalmitis following inpatient surgery. *Arch Ophthalmol* 1991;109:1085-1089.
- Javitt JC, Vitale S, Canner JK, et al. National outcomes of cataract extraction. I. *Ophthalmology* 1991;98:895-902.
- Katz J, for the Study of Medical Testing for Cataract Surgery Team (Johns Hopkins Bloomberg School of Public Health, Baltimore, MD). Risk and benefits of anticoagulant and antiplatelet medication use before cataract surgery. *Ophthalmology* 2003;110:1784-1788.
- Kowalski RP, Dhaliwal DK, Karenchak LM, et al. Gatifloxacin and moxifloxacin: an in vitro susceptibility comparison to levofloxacin, ciprofloxacin, and ofloxacin using bacterial keratitis isolates. *Am J Ophthalmol* 2003;136:500-505.
- McDonnell PJ, Taban M, Sarayba M, et al. Dynamic morphology of clear corneal cataract incisions. *Ophthalmology* 2003;110:2342-2348.
- Miller JJ, Scott IU, Flynn HW Jr, et al. Acute-onset endophthalmitis after cataract surgery (2000-2004): incidence, clinical settings, and visual acuity outcomes after treatment. *Am J Ophthalmol* 2005;139:983-987.
- Petersen AM, Bluth LL, Campion M. Delayed posterior dislocation of silicone plate-haptic lenses after neodymium:YAG capsulotomy. *J Cataract Refract Surg* 2000;26:1827-1829.
- Revicki DA, Brown RE, Adler MA. Patient outcomes with co-managed postoperative care after cataract surgery. *J Clin Epidemiol* 1993;46:5-15.
- Roth DB, Flynn HW Jr. Antibiotic selection in the treatment of endophthalmitis: the significance of drug combinations and surgery. *Surv Ophthalmol* 1997;41:395-401.
- Schmitz S, Dick HB, Krummenauer F, Pfeiffer N. Endophthalmitis in cataract surgery: results of a German survey. *Ophthalmology* 1999;106:1869-1877.
- Starr MB, Lally JM. Antimicrobial prophylaxis for ophthalmic surgery. *Surv Ophthalmol* 1995;39:494-496.
- Taban M, Behrens A, Newcomb RL, et al. Acute endophthalmitis following cataract surgery: a systematic review of the literature. *Arch Ophthalmol* 2005;123:613-620.
- Williams DL, Gillis JP. Infectious endophthalmitis following sutureless cataract surgery [letter, discussion]. *Arch Ophthalmol* 1985;110:913-915.

## *Diseases of the Retina*

*David C. Bright*

Retinal diseases pose a serious threat to vision, but many conditions are unresponsive to pharmacologic intervention. This chapter reviews only those conditions in which pharmacologic management plays a significant role in diagnosis, reduction of tissue damage, and preservation of vision.

### **DIAGNOSTIC TESTS FOR RETINAL DISEASE: FLUORESCEIN ANGIOGRAPHY**

Fluorescein angiography reveals subtleties in vasculature not readily apparent with ophthalmoscopy or fundus biomicroscopy. The two diseases most often evaluated angiographically are macular degeneration and diabetic retinopathy.

Sodium fluorescein is a pharmacologically inert component of resorcinolphthalein. Its fluorescent characteristics allow its electrons to be stimulated by blue light (465 to 490 nm) and then to decay, emitting yellow-green light (520 to 530 nm). In the eye fluorescein is confined to the retinal and choroidal vasculature, which is seen in stark contrast to the surrounding nonfluorescent structures.

The fundus camera adapted for fluorescein angiography contains wavelength-matched filters to ensure an image with both high contrast and high resolution. The white light flash passes through a blue excitation filter, exciting circulating fluorescein molecules that then emit yellow-green light. This yellow-green light is focused back onto the film. Blue light is also reflected back from the retinal surface, but a green-yellow barrier filter blocks the image-degrading blue light from the film.

#### **Technique**

For fluorescein angiography a properly equipped fundus camera must have a high-intensity flash system combined with a rapid recycle time, power winding, appropriate excitation filters (the Baird Atomic B2 470 or Kodak Wratten 47), and barrier filters (an Ilford 1109 Delta Chromatic 3 or Kodak Wratten G15). Both excitation and

barrier filters fade with age and must be replaced according to manufacturer's specifications. Appropriate black-and-white film is either ASA 200 or 400 Kodak Tri-X or other type. Either 10% or 25% concentrations of injectable fluorescein solution are well tolerated, with no increased adverse reactions with the higher concentration. Outdated fluorescein solutions may carry the potential for more side effects, particularly nausea.

Before any invasive procedure is performed, informed consent must be obtained from the patient after discussion of risks and benefits. Patients may be anxious about the procedure, concerned that the injection goes directly into the eye, that the dye is harmful or toxic, or that a harmful amount of radiation is involved.

The patient's pupils should be maximally dilated. Poor pupillary dilation, media opacities (cornea, lens, or vitreous), poor patient cooperation, and an insufficient concentration of fluorescein all contribute to suboptimal results. Improper injection technique most often contributes to decreased retinal-choroidal fluorescein concentration. A crash cart (cardiopulmonary resuscitation unit) must be on hand to handle any potential side effects.

A syringe is prepared with heparinized saline and a 21-, 23-, or 25-gauge scalp-vein needle, and the patient is phlebotomized, usually in the antecubital vein. Fluorescein may also be injected into the veins of the back of the hand or wrist. The needle must be monitored, because extravasation of dye results in localized pain. Before injecting fluorescein the photographer takes baseline color photographs and then red-free fundus pictures.

Fluorescein is evenly injected over 4 to 6 seconds to promote adequate patient tolerance. After waiting approximately 15 seconds for the dye to reach the retina, the photographer takes pictures at approximately 1-second intervals, continuing until fluorescein has coursed through the veins (typically 8 to 10 exposures). Photographs are taken in the late phase, typically 2 to 3 minutes after injection, but may be taken up to 20 minutes after injection to document persistent leakage or pooling of fluorescein (from retinal neovascularization,

choroidal neovascular membranes [CNVMs], cystoid macular edema [CME], and uveal tumors).

## Complications

Fluorescein angiography is a safe procedure with few serious side effects reported. Based on the Fluorescein Angiography Complication Survey, complications are classified into three levels of severity. Mild adverse reactions, including nausea and extravasation, are transient, do not require treatment, and resolve rapidly without sequelae. Reassurance for nausea and cold packs for extravasation are appropriate. Moderate reactions such as urticaria and syncope are likewise transient but may require some form of medical treatment; resolution is gradual but without sequelae. Use of systemic antihistamines (diphenhydramine 25 to 50 mg) and management of syncopal episodes (administration of smelling salts, elevation of the legs) are appropriate. Severe adverse reactions involving respiratory, cardiac, or neurologic systems exhibit prolonged effects and require intense treatment because they pose a threat to the patient's safety. Cardiopulmonary resuscitation and other strategies, including systemic epinephrine administration, are critical elements. The Fluorescein Angiography Complication Survey evaluated 221,781 procedures performed in 1984 by 2,434 ophthalmologists and determined a frequency rate of 1 in 63 for a moderate reaction, 1 in 9,000 for a severe reaction, and 1 in 222,000 for death.

A study reported 241 adverse reactions in 5,000 consecutive angiograms, for a rate of 4.82%. The most frequent adverse reactions were nausea (2.24%), vomiting (1.78%), and urticaria or pruritus (0.34%), but no life-threatening reactions were noted. Another study that retrospectively evaluated fluorescein angiography in pregnant women found no higher rate of birth anomalies or complications during pregnancy, but practitioners routinely avoid performing the procedure on pregnant women or nursing mothers.

Most side effects, such as transient yellowing of the skin and conjunctiva, a fluorescent cast to the urine, and the warm flush or early nausea occurring within 30 seconds of injection, can be explained to the patient before the procedure. Some practitioners advocate prophylaxis for nausea and vomiting, including administration of prochlorperazine, promethazine, or trimethobenzamide, although there is no conclusive evidence for their benefit to patients. For patients likely to develop urticaria, premedication with systemic antihistamines is possible. Benzodiazepines, such as diazepam, may also be useful to control anxiety.

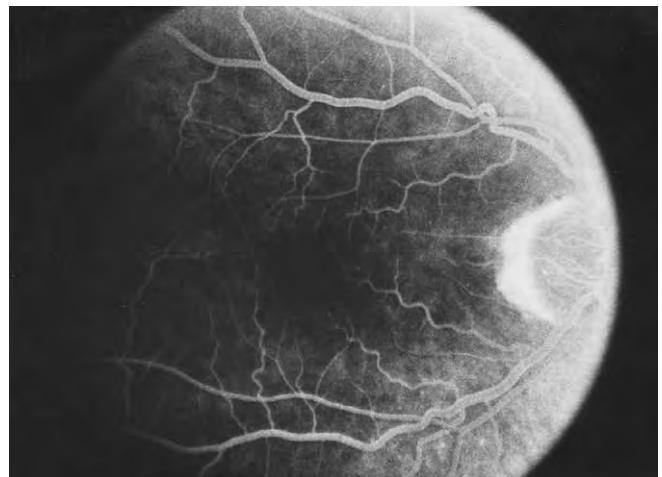
## Interpretation

Interpretation of fluorescein angiograms requires knowledge of both retinal and choroidal blood supply and normal anatomic barriers. Arterial branches derived from

the central retinal artery supply the inner retina, whereas the outer retina is fed by the choriocapillaris. Choroidal circulation derives from the short posterior ciliary arteries. Retinal blood vessels and capillaries are not fenestrated and do not leak, whereas the fenestrated choriocapillaris vessels leak freely. The tight adhesion of Bruch's membrane to the retinal pigment epithelium (RPE) is a barrier to fluid passage from the choriocapillaris to the retina. The RPE allows part of the choroidal glow to show through, but its greatest thickness in the macular area prevents any view of choroidal fluorescence. Loss of RPE cells allows abnormal degrees of choroidal fluorescence to be observed.

Ten to 12 seconds after injection, fluorescein is seen in the choroidal circulation, with free passage of dye into the extracellular spaces. This choroidal "flush" is part of the prearterial phase of angiography. Several seconds after the choroidal flush, retinal arterioles begin to fluoresce, which is known as the arterial phase. The arteriovenous phase is the complete filling of both arteries and capillaries, and fluorescein enters the veins in a laminar fashion as its molecules collect first along venous walls and then fills the entire lumen (Figure 31-1). The venous phase includes further laminar flow and complete venous filling. The late phase usually occurs approximately 10 minutes after injection. Arteries, veins, and choriocapillaris are minimally fluorescent, but the optic nerve remains hyperfluorescent because dye adheres to nerve tissue. Late leakage, if present, occurs at this point.

Hypofluorescence occurs from blockage of fluorescence by barriers such as blood, melanin, fibrous or glial tissue, inflammatory material, and asteroid hyalosis. It may also result from vascular filling defects that impede blood flow to the involved area, which appear dark or black on the angiogram. In contrast, hyperfluorescence produces a whiter or lighter image. Transmitted fluorescence from the choriocapillaris is seen through RPE defects of any size ("window defects"). Retinal or choroidal vascular



**Figure 31-1** Normal fluorescein angiogram, arteriovenous phase. (Photo courtesy Sheila F. Anderson, O.D.)

leakage stains surrounding tissue in cystic or persistent and diffuse patterns. Hyperfluorescence also results from pooling of accumulated fluorescein, usually between two layers, which produces a well-defined and uniform pattern.

## **DIAGNOSTIC TESTS FOR RETINAL DISEASE: INDOCYANINE GREEN ANGIOGRAPHY**

Limitations inherent in fluorescein angiography may prevent evaluation of choroidal circulatory pathology. The most promising alternative dye is indocyanine green (ICG). Advances in high-resolution digital image capture systems and scanning laser ophthalmoscopes have allowed applicability of this angiographic technique to evaluation of choroidal pathology, providing increased image resolution and contrast and providing an adjunct to fluorescein angiography.

### **Angiography Procedure**

For standard ICG angiography (ICGA), 25 mg (12.5 to 50.0 mg) of dye in the manufacturer's diluent is administered in an intravenous bolus fashion, as in fluorescein angiography protocols. The camera system best suited for ICGA is presently a trifunction digital retinal camera (with capabilities for color, black-and-white fluorescein angiography, and black-and-white ICGA image capture). Images are obtained at intervals of several seconds until both retinal and choroidal circulations are maximally hyperfluorescent. Images continue to be captured at 30- to 60-second intervals for the next few minutes, through the early phase of the angiogram. Subsequent images are taken between 8 to 12 minutes for the middle phase and then between 18 to 25 minutes for the late phase. Significant abnormal ICG hyperfluorescence is usually obtainable by 25 minutes, but some images obtained at 30 to 40 minutes are also helpful.

The early phase of ICGA is the first appearance of dye in the choroidal arterial circulation up to the point of maximal choroidal hyperfluorescence, occurring within the first minute after dye injection. During the early phase both medium and large choroidal arteries and veins are seen beneath the hyperfluorescent retinal vasculature. The middle phase demonstrates homogeneous diffuse choroidal fluorescence as individual choroidal veins become less distinct. During the middle phase lesions demonstrating abnormal ICG hyperfluorescence begin to stand out. The middle phase occurs 6 to 15 minutes after injection. In the late phase all details of normal retinal and choroidal vasculature are lost, the optic nerve head is dark, retinal vessels are no longer visible, and the hyperfluorescence has faded even further. Maximal contrast associated with any abnormal hyperfluorescent lesions occurs during the late phase, beyond 18 to 22 minutes after injection.

### **Toxicity**

The most comprehensive analysis of toxic reactions to ICGA evaluated 1,923 ICGA procedures performed in 1,226 patients. Toxic reactions included nausea and vomiting in two cases, urticaria in two cases, vasovagal reactions in two cases, and acute hypotension in one case. These reactions represent a 0.3% adverse reaction rate. Further analysis of the ICGA literature identified 18 severe reactions and 3 deaths. With approximately 1 million doses of ICG sold by that point, a 1 in 333,333 incidence of death was estimated. Given the 1 in 222,000 death rate for fluorescein angiography, ICGA potentially appears to be the safer procedure.

### **Clinical Applications**

ICGA is most valuable for evaluation of choroidal neovascularization. Fluorescein angiography of early choroidal fluorescence is potentially inhibited by media opacities, fundus pigmentation, xanthophyll, RPE, hemorrhage, or serous exudate in the retina. Rapid leakage from the fenestrated choroidal capillaries is sometimes not easily appreciated with fluorescein angiography in attempting to identify subretinal CNVMs.

Up to 50% of CNVMs go undetected with conventional fluorescein angiography. ICGA of CNVMs is theoretically better, because infrared fluorescence penetrates pigment and fluid more readily than the visible-light fluorescence of fluorescein, and late imaging (images obtained after the clearing of the dye from the choroidal circulation) shows persistently hyperfluorescent areas in CNVMs. Additionally, the extremely high protein binding of ICG reduces dye leakage from abnormal vessels compared with fluorescein. Both ill-defined and well-defined CNVMs are more readily observed with ICGA. Up to 59% of CNVMs recur after laser treatment over a 2-year period; ICGA is potentially valuable in detecting persistence of neovascularization. ICGA can potentially detect a recurrent CNVM by the greater visible difference between a photocoagulated CNVM and a recurrent CNVM, and prompt laser treatment of CNVMs detected with ICGA may resolve exudation and improve visual acuity in selected cases.

Although ICGA analysis of CNVMs is perhaps the most common use of this technique, ICGA evaluation of benign and malignant choroidal tumors benefits from limited leakage of dye and relatively good penetration of infrared light through pigment. Additionally, ICGA is now being used for evaluation of various retinal and RPE diseases as well as choroidal pathology. An evidence-based review of the indications for ICGA strongly recommended ICGA for identification of choroidal disease that may be treatable (polypoidal choroidal vasculopathy, occult choroidal neovascularization, recurrent CNVMs, and neovascularization associated with pigment epithelial detachments) and for improved diagnosis in other conditions (including

chronic central serous retinopathy, MEWDS (multiple evanescent white dot syndrome), vasculitis, AMPPE (acute posterior multifocal placoid pigment epitheliopathy), Vogt-Koyanagi-Harada syndrome, angioid streaks, and bird-shot retinopathy).

## NECROTIZING HERPETIC RETINOPATHIES

### Acute Retinal Necrosis

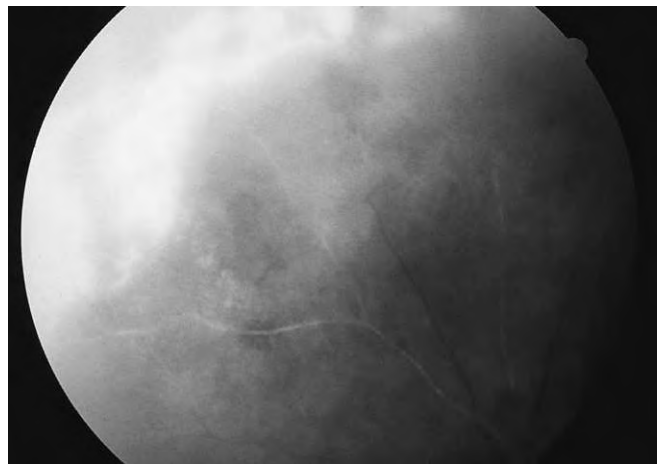
#### Etiology

Acute retinal necrosis (ARN) is an ocular syndrome consisting of vaso-occlusive necrotizing retinitis in one or both eyes. It typically affects patients between 20 and 60 years of age, although individuals as young as 9 and as old as 89 have developed the syndrome. Many ARN patients are immunocompetent, which led to the claim that ARN occurred in “healthy” individuals, but cases have subsequently been reported in patients with varying degrees of immunosuppression, leading to a reassessment of ARN as occurring along a spectrum of immunocompetence, without immune status or other systemic characteristics influencing the diagnosis.

ARN has frequently followed systemic or dermatologic herpesvirus infections, including chickenpox, herpes zoster dermatitis, and herpes simplex dermatitis. There is often no obvious temporal connection, however, between a systemic or dermatologic herpes episode and ARN. Conclusive laboratory evidence has been presented for an etiologic role of the following herpesviruses in ARN: varicella-zoster virus, herpes simplex virus type 1, herpes simplex virus type 2, and cytomegalovirus (CMV). New lines of evidence indicate a bimodal distribution of herpes simplex virus serotypes by age as etiologic agents of ARN: Herpes simplex virus type 1 tends to cause ARN in patients older than 25 years of age, whereas herpes simplex virus type 2 tends to cause ARN in patients younger than 25 years of age. Most cases of ARN are presumably due to secondary reactivation of latent herpesvirus infection.

#### Diagnosis

Clinical features of ARN must include (1) focal well-demarcated areas of retinal necrosis located in the retinal periphery, (2) rapid circumferential progression of necrosis, (3) evidence of occlusive vasculitis, and (4) moderate to severe anterior chamber and vitreal inflammation. Mild presentations may manifest low-grade anterior chamber inflammation with or without blurred vision, whereas severe cases may include episcleritis, scleritis, and pain on eye movement. Early clinical findings include anterior and posterior uveitis, keratic precipitates, and presence of vitreous cells. Within several days to weeks, the patient develops dramatic progressive retinal whitening in multifocal and confluent patches, vasculitis of both retinal arteries and veins, and possible optic nerve head



**Figure 31-2** Acute retinal necrosis syndrome, with confluent retinal whitening, vitreitis, and vasculitis. (Reprinted with permission from Holland GN, Tufail A, Jordan MC. Cytomegalovirus diseases. In: Pepose JS, Holland GN, Wilhelmus KR, ed. *Ocular infection and immunity*. St. Louis, MO: Mosby, 1996.)

swelling (Figure 31-2). Retinitis may be limited to less than 180 degrees of the periphery, but approximately two-thirds of cases involve up to 360 degrees of the periphery within 1 week.

ARN usually does not extend posterior to the vascular arcades and initially spares central vision, unless there is an associated optic neuropathy or vascular occlusion. The syndrome progresses to maximal retinal involvement in 7 to 10 days. As the vasculitis regresses vitreitis becomes increasingly severe, with necrotic retina sloughing into the vitreous cavity. At this point vision typically is reduced. ARN resolves with decreased retinal whitening and mild pigmentary scarring, with a sharp demarcation between normal and involved retina. Rhegmatogenous retinal detachment is very common, due to extreme retinal thinning with preretinal and transvitreal traction, complicated by large posterior and multifocal retinal breaks.

Definitive diagnosis of ARN requires isolation of viral organisms from aqueous humor, vitreous humor, or retina with the appropriate clinical presentation. Diagnostic vitrectomy or endoretinal biopsy during acute infection and immunofluorescent analysis of local antibody production in aqueous humor can confirm viral involvement. Polymerase chain reaction identifies herpesvirus DNA from aqueous samples, even when local antibody production is negative, thus establishing the identity of the causative organism in uncertain diagnoses.

#### Management

Acyclovir treatment of ARN is the current standard of care, with the drug administered intravenously at a recommended adult dosage of 1,500 mg/m<sup>2</sup> in three divided doses for 5 to 10 days. After intravenous therapy, 400 to 600 mg of oral acyclovir five times daily is administered

for up to 6 weeks after onset of infection. Because most fellow eye occurrences begin within 6 weeks of the appearance in the first eye, 6 weeks of acyclovir has become standard therapy. Acyclovir potentially speeds retinitis regression, while delaying or preventing new lesion formation. Unfortunately, acyclovir therapy neither reduces the frequency of subsequent retinal detachment nor completely protects the fellow eye, but it may reduce the frequency of second eye involvement. If acyclovir cannot control active retinitis or prevent new foci, famciclovir may be used at a dosage of 500 mg orally three times a day for 3 months. Oral valganciclovir (1 g orally thrice daily for 3 weeks) or valganciclovir (900 mg orally twice daily) has similarly been used as alternatives to intravenous acyclovir.

Administration of anticoagulants may prevent frequent vascular obstructive complications. Oral anticoagulation with aspirin in small doses, typically 125 to 650 mg, once or twice daily, is a reasonable choice for patients without systemic contraindications.

Use of systemic, periocular, or topical corticosteroids reduces intraocular inflammation, particularly vitreous opacification, but does not affect the severity of retinal necrosis. The usual dosage is 60 to 80 mg of oral prednisone for at least 1 week, followed by tapering over 2 to 6 weeks. Topical corticosteroids should be used to treat anterior segment inflammation.

Long-term visual prognosis for ARN patients varies widely. Many patients retain good central vision if neither the macula nor the optic nerve is involved, but the extent of retinal arterial involvement (sheathing or obliteration) may predict the visual outcome. It was noted that diffuse arteritis or arteritis presenting upon initial examination while retinal necrosis was limited to the periphery was correlated with poor outcomes (<20/600); arteritis only presenting adjacent to peripheral retinal necrosis suggested a good visual outcome (20/30 or better).

## CMV Retinitis

### Etiology

CMV infects many adults worldwide and is transmitted by close contact with an individual excreting the virus in urine, saliva, semen, or other body fluids. Loss of T lymphocyte-mediated immunologic control of CMV results in reactivation of CMV from a latent state into an active infection, which then causes end-organ disease. The progressive loss of CD4+ T lymphocytes in human immunodeficiency virus (HIV) infection results in increasingly severe immunodeficiency, which was responsible for the high incidence of CMV retinitis, as well as a panoply of other opportunistic diseases in late-stage acquired immunodeficiency syndrome (AIDS). Occurrence of CMV retinitis is most likely when the CD4+ count is extremely low, less than 50 cells/mm<sup>3</sup>. Retinitis was the most common form of systemic CMV infection in AIDS, occurring in 71% to 85% of episodes.

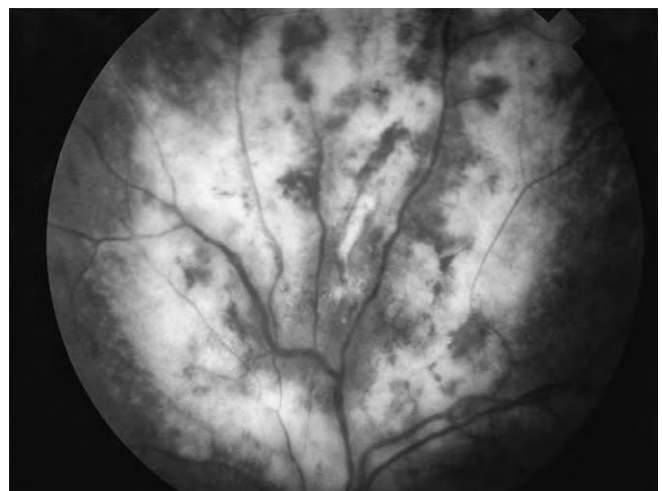
Before the introduction of highly active antiretroviral therapy (HAART) in 1996, CMV retinitis occurred at a frequency of approximately 25% in all patients with AIDS. Presently, new cases of CMV retinitis have dropped by approximately 75% to 85% due to improvements in cell-mediated immunity as a result of optimal viral suppression from HAART.

### Diagnosis

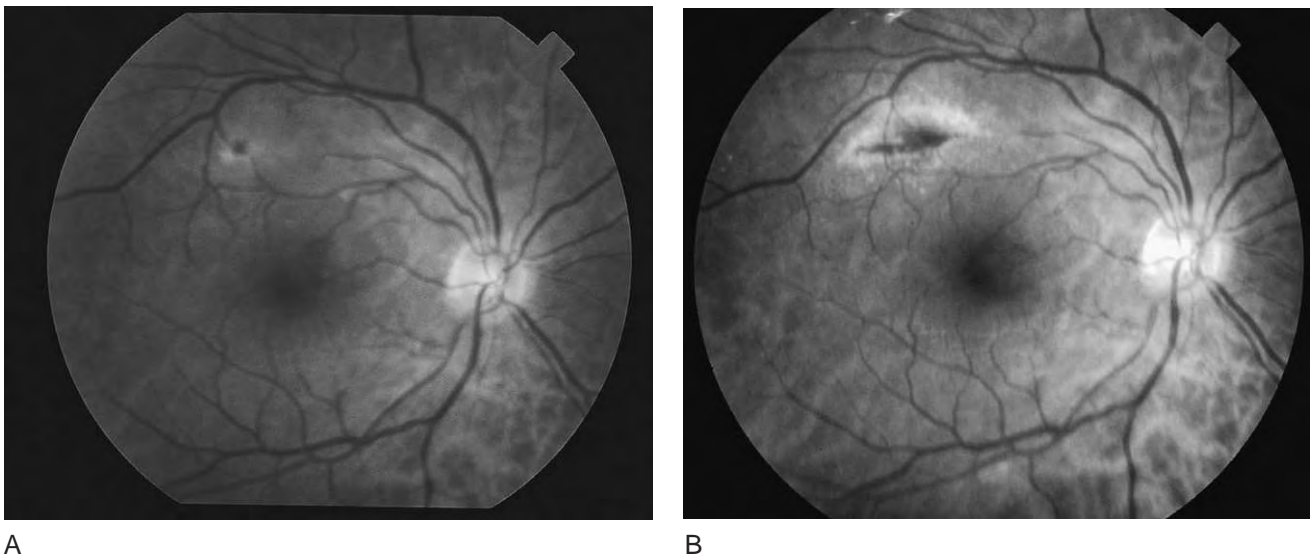
CMV retinitis presumably results from hematogenous spread of CMV-infected monocytes to the retina. Once retinal infection is established, virus diffuses along the nerve fiber layer, spreading outward from cell to cell, which results in full-thickness retinal necrosis. Two types of CMV retinitis occur, differing in both retinal location and clinical characteristics. The hemorrhagic/fulminant type presents with intraretinal hemorrhage, lying above a background of thick, opaque, white necrotizing retinitis, frequently near blood vessels, and most often in the posterior pole (Figure 31-3). The granular/indolent type progresses more slowly, with little or no hemorrhage, located more often in the retinal periphery, with a granular leading edge of retinitis. Without treatment retinal lesions increase in size by 750  $\mu$ m every 3 weeks and ultimately destroy the entire retina in approximately 6 months (Figure 31-4). Retinal necrosis is eventually replaced by a thin gliotic scar, with RPE alterations and fine pigmentary mottling. Anterior and vitreal inflammation is common but insufficiently severe to cause redness, pain, or synechiae. Symptoms are most often blurred or decreased vision with posterior pole involvement and floaters if retinitis is presenting anterior to the posterior pole.

### Management

CMV retinitis is managed with antiviral medications administered systemically (intravenously or orally) or



**Figure 31-3** Hemorrhagic/fulminant form of cytomegalovirus retinitis, with full-thickness retinal necrosis and hemorrhage. The patient's CD4+ count was 2 cells per mm<sup>3</sup>.



**Figure 31-4** (A) New focus of cytomegalovirus retinitis in fellow eye of patient in Figure 31-3. (B) Focus of cytomegalovirus retinitis 1 month later, with expansion, increasing granularity, and multiple satellites. Patient had refused all pharmacologic intervention.

locally (intravitreal injection or implant). Systemic drug therapy causes one or more systemic toxicities, usually hematologic or renal, whereas local delivery is associated with endophthalmitis, retinal detachment, inflammation (iritidocyclitis or vitritis or both), and vitreous hemorrhage (Box 31-1).

**Intravenous Therapy.** There are three drugs administered intravenously for management of CMV retinitis. All are virustatic, able to control viral replication, but unable to definitively eradicate CMV from the retina. Active infection is brought under control using a high-dose induction regimen, followed by a lower dose maintenance regimen. Recurrence of previously stable retinitis while on maintenance doses is often inevitable, presenting with new

lesions, enlargement of preexisting lesions, increasing opacification of lesion borders, or a combination of these features. Recurrence likely results from low intravitreal levels achievable with intravenous administration plus the development of drug-resistant viral strains. Recurrence of retinitis requires reinduction therapy, followed by a second maintenance regimen after reactivated retinitis became quiescent.

Ganciclovir (Cytovene-IV, Roche Pharmaceuticals, Nutley, NJ, USA), the first drug used in management of CMV retinitis, is phosphorylated by CMV-specific enzymes into ganciclovir triphosphate, which inhibits CMV DNA synthesis by competitive inhibition of viral DNA polymerases. Ganciclovir administered intravenously for 2 to 3 weeks resulted in decreased retinal opacification and clearance of vascular changes, but retinitis reactivated in all instances upon discontinuation of the drug, necessitating a reduced maintenance dose after the initial induction. Standard regimens of intravenous ganciclovir require induction of 5 mg/kg twice a day for 2 weeks, followed by maintenance of 5 mg/kg daily or 6 mg/kg 5 of 7 days per week. Ganciclovir is administered through a subclavian indwelling catheter of the Hickman type. Neutropenia, the primary toxicity of ganciclovir therapy, develops in approximately 25% of all patients on an intravenous regimen.

Foscarnet (Foscavir, AstraZeneca LP, Wilmington, DE, USA), the second drug used for CMV retinitis, has a clinical profile very similar to ganciclovir. Foscarnet, an analogue of inorganic pyrophosphate, does not require phosphorylation and exerts its effects by selective inhibition at the pyrophosphate binding site on CMV-specific DNA polymerase. Like ganciclovir, foscarnet is virustatic, requiring maintenance therapy after retinitis is controlled. The current foscarnet regimen is induction

**Box 31-1** Pharmacologic Treatment of Cytomegalovirus Retinitis

Ganciclovir	Intravenous administration Intravitreal injection Intravitreal implant Oral administration (valganciclovir) Primary toxicity = neutropenia
Foscarnet	Intravenous administration Intravitreal injection Primary toxicity = nephrotoxicity
Cidofovir	Intravenous administration Primary toxicity = nephrotoxicity
Fomivirsen	Intravitreal injection Primary toxicity = intraocular inflammation



with either 60 mg/kg three times a day or 90 mg/kg twice daily for 2 weeks, followed by daily maintenance of 120 mg/kg. Foscarnet is poorly water soluble and frequently causes renal toxicity with elevation of serum creatinine, so prehydration of the patient with 1 liter of normal saline is needed, delivered by means of an infusion pump to avoid too rapid an infusion.

The third drug for intravenous administration is cidofovir (Vistide, Gilead Sciences, Foster City, CA, USA). Cidofovir is a nucleotide analogue of cytosine and does not require intracellular activation by virus-specific enzymes; it is converted to the active metabolite by host cellular enzymes independently of viral infection. This drug can be administered at longer intervals between doses as a result of the exceptionally long half-life of active intracellular metabolites trapped inside infected cells. Intravenous cidofovir was initially evaluated in patients with either untreated peripheral retinitis or relapsing retinitis. Induction therapy of 5 mg/kg once weekly for 2 weeks followed by maintenance therapy of 5 mg/kg every other week was found to be the optimal regimen. Saline prehydration and oral probenecid are necessary to reduce frequently encountered renal toxicity. Iridocyclitis is also a frequent complication, typically occurring after several infusions, but is successfully managed with topical corticosteroids and cycloplegics. Other toxic effects of cidofovir include neutropenia, ocular hypotony, and toxicity from probenecid. Many patients have difficulty tolerating intravenous cidofovir therapy for more than 6 months.

**Local Therapy.** Intravitreal ganciclovir injections were first used as maintenance therapy for patients recovering from ganciclovir-induced neutropenia or for supplementation of intravenous therapy in those with relapsing retinitis. Practitioners subsequently discovered that twice weekly induction injections followed by weekly maintenance injections of either ganciclovir or foscarnet were well tolerated and provided the same degree of retinitis control possible with intravenous therapy. The technique also provided the potential for improved management of retinitis that was directly threatening to critical vision. There have been no randomized clinical trials; however, in reported studies, several small series of patients were treated with a variety of regimens for different forms of retinitis. Complications of intravitreal ganciclovir administration, although encountered infrequently, included vitreous hemorrhage, retinal detachment, CME, endophthalmitis, and cataract formation.

An intravitreal implant device (Vitrasert, Bausch & Lomb Surgical, San Dimas, CA, USA) consists of a 6-mg pellet of ganciclovir compressed into a 2.5-mm disk, coated with polyvinyl alcohol on all sides, and then coated with ethylvinyl alcohol on all sides except the top. It releases ganciclovir at a constant rate into the vitreous cavity after implantation through the pars plana under local anesthesia. Perhaps the greatest benefit of intravitreal

implantation was a prolonged interval to retinitis recurrence compared with intravenous therapy: median times to relapse were 46 days (ganciclovir) versus 53 days (foscarnet) versus 221 to 226 days (Vitrasert). Initial reports suggested a higher risk of retinal detachment associated with Vitrasert implantation, but a later analysis found no substantial excess risk of detachment compared with systemic anti-CMV therapy only. Other complications included spontaneously resolving vitreous hemorrhage (10%) and endophthalmitis (2%).

Advantages of the Vitrasert include improved quality of life, no risk of catheter-induced sepsis, and potentially better control of retinitis due to delivery of consistent drug levels. Retinitis presented in the untreated fellow eye in 40% to 50% of cases, prompting subsequent recommendations of combining the implant with 4.5 g of oral ganciclovir three times a week to reduce the risk of contralateral CMV retinitis and extraocular CMV infection. Prophylactic oral ganciclovir combined with the Vitrasert in patients with unilateral CMV retinitis significantly reduced a 6-month incidence of fellow-eye retinitis (37.8% for implant plus placebo versus 22.4% for implant plus oral ganciclovir). For patients with posterior pole retinitis that remain immunosuppressed or have not experienced immune restoration from combination anti-HIV therapy, the Vitrasert plus oral valganciclovir (which now replaces oral ganciclovir) is a good choice for initial therapy.

Fomivirsen (Vitravene, formerly manufactured by Novartis Ophthalmics, Duluth, GA, USA) is an "antisense drug" that inhibits messenger RNA translation, which is critical for protein synthesis necessary for production of infectious human CMV, but does not target CMV DNA polymerase, as do ganciclovir and foscarnet. Fomivirsen, administered as an intravitreal injection of 330 mcg, is given as induction therapy (two doses 2 weeks apart), followed by maintenance injections once monthly. This drug is effective for control of CMV retinitis in patients intolerant of systemic therapy and who are not good candidates for ganciclovir implant surgery. Ocular side effects include mild to moderate intraocular pressure increase, RPE changes, and reversible intraocular inflammation. At this time of writing, fomivirsen is no longer being manufactured and its formula has not been sold to another company.

**Oral Therapy.** Oral ganciclovir therapy was devised to avoid intravenous therapy-related complications. However, the drug (Cytovene, Roche Laboratories) has low oral bioavailability (2.6% to 7.3%) and is not widely used at the present time. It has been replaced by valganciclovir, an oral prodrug of ganciclovir, which has markedly higher oral bioavailability (approximately 60%) after hydrolysis to ganciclovir by esterases in the gut and liver. Oral valganciclovir (Valcyte, Roche Laboratories) provides systemic ganciclovir exposure equivalent to that of intravenous ganciclovir. Valganciclovir induction therapy

is 900 mg twice a day followed by maintenance therapy of 900 mg daily. The single study of valganciclovir induction therapy for CMV retinitis suggested that valganciclovir was not inferior to intravenous ganciclovir. The most common adverse events related to valganciclovir in a trial of maintenance therapy were diarrhea, nausea, fever, anemia, and neutropenia. Because of convenience and efficacy, valganciclovir appears to be a reasonable first choice for systemic therapy of CMV retinitis, unless there are problems with drug absorption.

**Present State of CMV Retinitis.** Replication of HIV can be reduced through judicious combination of one or two HIV protease inhibitors or a single nonnucleoside reverse transcriptase inhibitor with two nucleoside inhibitors of HIV reverse transcriptase. Combination therapy (HAART) results in striking reductions in HIV viral load and significant increases in CD4+ cell counts over pretreatment levels. Additionally, after initiation of HAART patients have experienced dramatically reduced risks of opportunistic infections, which are associated with qualitative improvements in host immune responses. It is assumed that restoration of pathogen-specific immune defenses is responsible for the reduced risk of opportunistic infections, including CMV retinitis. Some patients experiencing CD4+ increases can stop maintenance anti-CMV therapy without progression of retinitis. Restoration of partial immunity takes 3 to 4 months after initiation of combination antiretroviral therapy, and authorities advocate discontinuing CMV therapy only in patients who demonstrate a sustained elevation of CD4+ cell counts over 3 to 6 months (over 100 to 150 cells/mm<sup>3</sup>) with healed retinitis that is stable for greater than 4 months.

Some patients have developed “immune recovery uveitis” in eyes with inactive CMV retinitis after immune restoration from HAART. This was presumably due to some degree of heightened immune response to residual CMV antigens. Immune recovery uveitis ranges widely in incidence (11% to 83%), depending on definitions of the syndrome. Common findings are immediate inflammation (vitritis) and the subsequent complications of inflammation, including CME and epiretinal membranes. Eyes with the smallest area of retinal involvement or those with optimal control of retinitis appear to be at lower risk of immune recovery uveitis than eyes with larger areas of retinitis or suboptimal control (typically with intravenous therapies). Management of immune recovery uveitis consists of topical and periocular corticosteroids, or intravitreal triamcinolone injections.

Not all patients experiencing immune reconstitution may discontinue CMV retinitis therapy due to a lack of restored CMV-specific T lymphocyte defenses, despite increases in the overall CD4+ cell count. Additionally, patients who have experienced CD4+ cell increases but later discontinue HAART run the risk of experiencing recurrence of CMV retinitis, if the CD4+ count drops

below 50 cells/mm<sup>3</sup>. Regular follow-up at 6- to 12-week intervals is critical in these cases.

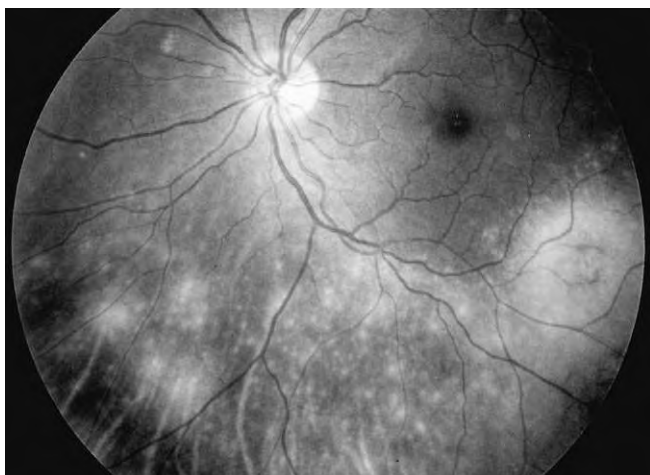Because of widespread use of HAART, there has been a reduction of about 75% to 85% in the number of new cases of CMV retinitis. A number of individuals have been able to discontinue maintenance CMV therapy indefinitely. There are also individuals with CMV retinitis who have not experienced the striking immune reconstitution seen in many AIDS patients but demonstrate lower rates of retinitis progression than were seen in patients with comparable immunologic function in the era before combination antiretroviral therapy. This suggests possible indirect benefits from anti-HIV therapy, despite the patient remaining severely immunodeficient. Finally, CMV retinitis, although less frequently encountered, has not been eradicated and remains a condition with potential for serious visual loss in certain groups, including AIDS patients unresponsive to or noncompliant with HAART, and iatrogenically immunosuppressed individuals (cytotoxic therapy for cancer, transplant recipients).

### **Progressive Outer Retinal Necrosis or Rapidly Progressive Herpetic Retinal Necrosis**

#### **Etiology**

A third necrotizing retinal syndrome was first described in the early 1980s and initially named progressive outer retinal necrosis (PORN). Although originally described as a visually devastating condition involving the outer retinal layers, an alternative name, rapidly progressive herpetic retinal necrosis, was proposed to reflect the consistent presence of herpesvirus, rapid disease progression, and involvement of all retinal layers. This latter name, despite its greater descriptiveness and accuracy, has not superseded the unfortunate older acronym of PORN, which remains in use to this day. Most patients with PORN are in the late stages of AIDS, with a CD4+ count less than 50 per mm<sup>3</sup>. Like ARN, PORN is frequently preceded by episodes of cutaneous varicella-zoster, which suggests that the syndrome may be a localized varicella-zoster virus recurrence with ocular and neural dissemination. Cutaneous infections with herpes simplex types 1 and 2 have been implicated less frequently.

PORN is relatively uncommon in AIDS, compared with the much higher frequency of CMV retinitis. PORN was considered potentially to be the second most common cause of infectious retinitis in AIDS patients, with reported incidences of 2% to 4%. With the widespread benefit of combination antiretroviral therapy, it is very likely that new cases of PORN will be even less frequently encountered than before, similar to the decline in cases of CMV retinitis. It should be noted that PORN has presented in patients without AIDS but with iatrogenic immunosuppression and that this condition should be considered a rare but possible disease among this patient group.



**Figure 31-5** Rapidly progressive herpetic retinal necrosis syndrome, with multiple discrete and confluent foci of necrosis. (Reprinted with permission from Holland GN, Tufail A, Jordan MC. Cytomegalovirus diseases. In: Pepose JS, Holland GN, Wilhelmus KR, eds. *Ocular infection and immunity*. St. Louis, MO: Mosby, 1996.)

### Diagnosis

Classic features of PORN include multifocal retinal necrosis, occurring as discrete foci in early stages, followed by rapid confluence (Figure 31-5). Necrosis occurs in the periphery, mid-periphery, or posterior pole and may spread anteriorly or posteriorly, with peripheral involvement being most common. Presumably due to profound immunosuppression, PORN is characterized by relative infrequency of other inflammatory processes, including iritis, vitreous cells, and vasculopathy (vessel sheathing or occlusion). Patients report a sudden change in visual status, usually a painless loss of either central or peripheral vision.

Features distinguishing PORN from CMV retinitis are its multifocal nature, lack of granular borders, lack of

extensive hemorrhage, and very rapid spread. Visual dysfunction is widespread in PORN, compared with CMV retinitis, in which vision loss is linked to the size and location of retinitis lesions. Features distinguishing ARN from PORN are primary involvement of the peripheral retina in ARN, with marked anterior chamber and vitreous inflammation, and marked vasculitis. PORN is more often bilateral than ARN; up to 71% of PORN cases in a series involved both eyes. PORN is painless, in contrast to ARN, in which visual changes are usually associated with red eyes and pain from iridocyclitis (Table 31-1).

Sequelae of PORN include vision loss and retinal detachment. In early reports vision reduction was typically profound, with up to two-thirds of patients progressing to no light perception within 1 month after diagnosis. Retinal detachment results from full-thickness retinal necrosis and retinal holes, occurring in up to 70% of patients, often within 1 month of disease onset.

### Management

The earliest cases of PORN were treated with intravenous acyclovir for a median of 2 weeks, followed by maintenance oral acyclovir. Most outcomes were dismal despite aggressive treatment, with only 18% of cases responding to therapy in a series. Maintenance oral acyclovir, with relatively low oral bioavailability, was often unable to prevent recurrence of PORN.

Intravenous foscarnet and ganciclovir, routinely used for CMV retinitis, resulted in significantly better preservation of vision when used either in combination or individually, combined with intravenous acyclovir. Many patients retained 20/100 or better vision and retinal detachment was less frequent, although outcomes were not uniformly successful and all patients did not retain functional vision. The regimen most often used was 5 mg/kg ganciclovir twice a day plus 60 mg/kg foscarnet three times a day, followed by maintenance therapy of 5 mg/kg ganciclovir daily plus 120 mg/kg foscarnet daily. Intravitreal ganciclovir

**Table 31-1**

Differential Diagnosis of Necrotizing Herpetic Retinitis

PORN	CMV	ARN
Multifocal	Single focus	Multifocal
No granular borders	Granular borders	Sharp borders
No extensive hemorrhages	Variable hemorrhages	Marked vasculitis
Infrequent AC reaction	Mild AC reaction	Marked AC reaction
Infrequent vitritis	Few vitreous cells	Marked vitritis
Painless	Painless	Pain, redness
Bilateral > unilateral	Unilateral > bilateral	Unilateral > bilateral
Extremely rapid progression	Slow progression	Fast progression
Peripheral > central	Peripheral or central	Peripheral >> central
Widespread vision loss	Loss to retina involved	Central vision usually spared
VZV, HSV-1, HSV-2	CMV	VZV, HSV-1, HSV-2, CMV

AC = anterior chamber; HSV-1 = herpes simplex virus type 1; HSV-2 = herpes simplex virus type 2; VZV = varicella-zoster virus.

and foscarnet have been used in PORN patients with good results. Some authors consider intravitreal plus systemic intravenous therapy to be the most efficacious treatment modality for PORN. Similar to AIDS patients, individuals with iatrogenic immunosuppression presenting with PORN were treated with intravenous two-drug regimens (ganciclovir plus foscarnet) plus intravitreal ganciclovir and foscarnet with good results.

## PARASITIC RETINAL INFECTIONS

### Toxoplasmosis

#### Etiology

*Toxoplasma gondii* is a single-celled, obligate, intracellular parasite existing in varying forms, with a serologic prevalence in the United States ranging from 3% to 70% of healthy adults. Oocysts, products of sexual reproduction, can survive in soil for more than 1 year and are ingested with unwashed produce or inhaled from dust or soil. Tissue cysts persist for the life of the host, most commonly in the central nervous system and skeletal or cardiac muscle; ingestion of tissue cysts in undercooked meat is the most common mode of transmission of toxoplasmosis. Tachyzoites are the obligate intracellular form and can be transmitted transplacentally or through ingestion of contaminated milk.

Transplacental transmission of *T. gondii* occurs most frequently when infection is acquired by women during pregnancy, with a prevalence of 0.2% to 1.0% in the United States. Seventy percent to 80% of women of child-bearing age are at risk for primary or newly acquired infection, and 30% to 50% of infants develop congenital infection if born to mothers with serologic evidence of new infection acquired during pregnancy. The rate of fetal infection relates to the stage of pregnancy during which the mother becomes infected and is highest during the third trimester. Severity of infection is highest during the first trimester, however, and often results in spontaneous abortion. In individuals with congenital toxoplasmosis, toxoplasmic retinochoroiditis is the most common manifestation, with a frequency of 70% to 90%.

*T. gondii* reaches the eye by hematogenous spread, penetrates host cells, and is surrounded by a vacuole resistant to both microbicides and normal digestion. The host's major defense against toxoplasmic infections is cellular immunity. For reasons not clearly understood, retinal toxoplasmosis results from rupture of tissue cysts containing live organisms, with subsequent retinal invasion by actively multiplying *T. gondii*. Retinal tissue destruction is accompanied by inflammatory events involving retinal vessels, choroid, vitreous, iris, and trabecular meshwork.

Ocular toxoplasmosis is a frequent cause of posterior segment infection, probably accounting for at least 25% of cases in the United States. Most cases of ocular toxoplasmosis were earlier believed to result from recurrence of

congenital infections, although acquired toxoplasmosis is now believed to be considerably more frequent, with one study suggesting that at least two-thirds of patients acquired the infection postnatally rather than prenatally. Recurrences of retinal toxoplasmosis are common, occurring with either congenitally or postnatally acquired infections, reaching prevalence as high as 79% in patients followed for more than 5 years.

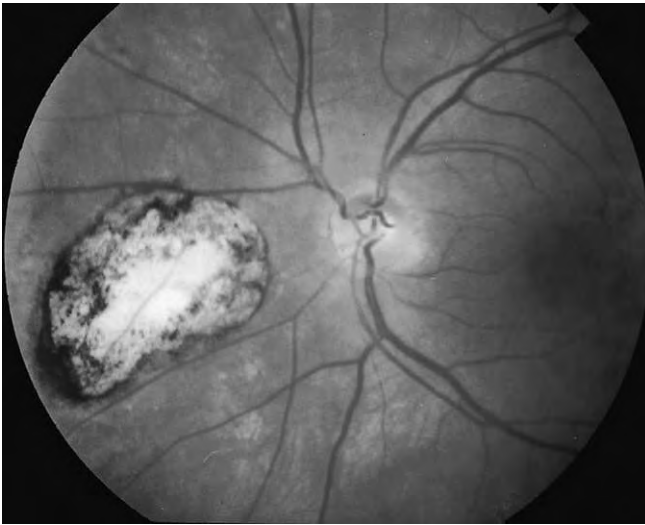
Toxoplasmosis occurs frequently in immunosuppressed patients. Retinal toxoplasmosis was seen commonly at the height of the AIDS epidemic, but was less frequent than CMV retinitis; it occurred more often as a newly acquired infection rather than as reactivation of a congenital infection.

#### Diagnosis

Active lesions of toxoplasmic retinochoroiditis are white, thick, and focal, with overlying vitreous haze often obscuring the retina ("headlight in the fog") and possibly an intense iridocyclitis (Figure 31-6). Active lesions have the same clinical characteristics whether resulting from congenital or acquired disease. Recurrent lesions tend to occur at the borders of quiet chorioretinal scars, implying loss of immune control, but immunosuppression alone does not seem to precipitate recurrence of retinal lesions in patients with inactive scars. Individuals with recurrent disease experience more episodes in previously affected eyes (with old retinal scars) than in the healthy fellow eyes. Although bilateral macular lesions are considered the hallmark of congenital infection, whereas acquired lesions are more often unilateral, congenital toxoplasmosis does not seem to be associated with any unique ocular characteristics.



**Figure 31-6** Recurrent toxoplasmosis. Active satellite lesion at inferior border of a retinochoroidal scar, with significant vitritis. (Reprinted with permission from Holland GN, O'Connor GR, Belfort R Jr, et al. Toxoplasmosis. In: Pepose JS, Holland GN, Wilhelmus KR, eds. Ocular infection and immunity. St. Louis, MO: Mosby, 1996.)



**Figure 31-7** Inactive retinochoroidal scar from toxoplasmosis.

In most cases toxoplasmic retinochoroiditis is self-limited, brought under control by both cellular and humoral immunity. Untreated lesions begin to heal after 1 to 2 months, although larger lesions may take longer to resolve. Healing lesions become gray-white and less ill-defined with time; the borders become more discrete and often hyperpigmented (Figure 31-7).

The diagnosis of active toxoplasmic retinochoroiditis in immunocompetent patients is straightforward, with a recurrent lesion appearing adjacent to a retinochoroidal scar. Immunocompetent patients have only one focus of active disease, even if there are multiple retinal scars. Differential diagnosis of toxoplasmic retinochoroiditis in immunosuppressed patients can be difficult. Vitritis varies from almost nil to moderately severe, and retinal lesions may be single or multifocal or encompass broad areas of necrotic retina. Toxoplasmic lesions may resemble CMV retinitis or the necrotizing herpetic retinal necrosis syndromes but are opaque and thick with smooth borders (compared with dry granular borders in CMV retinitis); vitreous and anterior chamber reactions are more severe than in CMV retinitis or PORN. In most cases of toxoplasmosis retinochoroiditis in AIDS patients, no preexisting scars were noted.

Ocular toxoplasmosis is an important cause of posterior segment infection in older patients, with reports of disease presentation describing many atypical findings, including diffuse disease, multifocal lesions, and areas of involvement greater than three disc diameters in size. These individuals were not immunocompromised, but the disease severity was attributed to the decline in immune function that naturally occurs with aging.

In toxoplasmic retinochoroiditis, serologic tests are used to confirm past exposure to *T. gondii* by demonstration of specific antibodies, although they cannot confirm a diagnosis, because antibodies can persist for years after acute infection. Enzyme-linked immunosorbent assays

detect antibodies against *T. gondii*, but they vary widely in sensitivity and specificity. Toxoplasmic retinochoroiditis is a clinical diagnosis, although confusing presentations may be clarified by serologic testing, analysis of aqueous humor antibodies, or *Toxoplasma* DNA analysis by polymerase chain reaction.

### Management

The primary goal of therapy is to prevent damage to both retina and optic nerve and to reduce complications due to inflammation. Caveats to treatment of toxoplasmic retinochoroiditis are that the condition is self-limiting, medications are frequently toxic, and virtually no drug eliminates tissue cysts and therefore cannot prevent further recurrences. A general rule is that lesions that are peripheral and do not threaten the macula or papillomacular bundle do not warrant treatment. Most uveitis specialists surveyed in 1991 believed that lesions could be observed without treatment if acuity remained 20/20 in the affected eye and lesions were located in the far retinal periphery. Medical therapy was warranted, however, when the following situations occurred: decreased visual acuity, macular or peripapillary lesions, moderate to severe vitritis, lesions larger than one disc diameter in size, persistence of disease for more than 1 month, or lesions associated with recently acquired disease. A 2002 survey of the same group (the American Uveitis Society) indicated that the factors most likely to influence treatment decisions were the location of the lesion and the presence of vitreal inflammation; virtually all respondents were likely to initiate therapy if lesions were in macular or peripapillary locations or if the vitreous inflammatory reaction was severe. Additional factors favoring treatment were poor vision in the fellow eye, proximity of lesions near major retinal vessels, prominent retinal vasculitis, serous retinal detachment, and good response to treatment during past episodes of disease.

It should be noted that a recent, evidence-based, systematic review of published randomized clinical trials of therapy for toxoplasmic retinochoroiditis found only three studies that met the authors' criteria for inclusion, two of which were carried out more than 35 years ago. Based on this evaluation the authors concluded that there was a lack of evidence to support routine antibiotic treatment for ocular toxoplasmosis, finding no evidence for a beneficial effect on the duration and severity of signs of the disease process. However, the preponderance of evidence supports the concept that appropriate antibiotic therapy is a community standard of care, which is bolstered by guidelines for treatment in many published sources, plus the responses of those practitioners recently surveyed about their preferred patterns of management of the condition.

Classic triple therapy for retinal toxoplasmosis consists of pyrimethamine plus sulfadiazine, with steroids to reduce inflammation. Pyrimethamine and the sulfonamides act synergistically on *T. gondii*. Pyrimethamine is

typically administered as a 75- to 100-mg loading dose on the first day, followed by 25 to 50 mg daily for 4 to 6 weeks depending on clinical response. Sulfadiazine is administered as a 2- to 4-g loading dose, followed by 1 g four times daily for 4 to 6 weeks. Because pyrimethamine can cause both leukopenia and thrombocytopenia, some authorities urge that patients be monitored regularly during therapy. Folic acid is usually added to pyrimethamine therapy; it is given as a 5-mg tablet two to three times per week more often than as a 3-mg intravenous preparation. In place of sulfadiazine clinicians use trimethoprim/sulfamethoxazole more often; clinical efficacy appears to be similar to pyrimethamine/sulfadiazine. A recent study suggested that trimethoprim/sulfamethoxazole (160 mg/800 mg) twice daily with corticosteroids seems to be an acceptable alternative to classic therapy. The coformulation is readily available, less expensive, and does not require either folic acid supplementation or hematologic monitoring, unless the patient has renal failure or is elderly. Clindamycin is an effective alternative in cases of sulfonamide allergy. It is also combined with sulfadiazine, pyrimethamine, and a corticosteroid as quadruple therapy for use when lesions threaten the macula or optic nerve or acuity is no better than 20/70 due to vitreous opacification. Clindamycin 300 mg is administered orally four times a day for 4 weeks; side effects include colitis and diarrhea.

Two other agents show promise in treatment of ocular toxoplasmosis. Atovaquone, primarily used for mild to moderate episodes of *Pneumocystis carinii* pneumonia, has been effective in small series of patients with toxoplasmosis. It appears to have activity against both tachyzoites and tissue cysts. More recent studies on atovaquone in toxoplasmosis are limited to murine models, and no further reports on this drug therapy in humans have been published. Azithromycin, a macrolide antibiotic, is efficacious against *T. gondii* and can also kill tissue cysts. A randomized study of 46 patients compared the combinations of azithromycin plus pyrimethamine versus pyrimethamine plus sulfadiazine in treatment of ocular toxoplasmosis; efficacy was similar, but the azithromycin/pyrimethamine regimen caused less adverse effects.

The anti-inflammatory effects of corticosteroids reduce CME, vitreous inflammation, and retinal vasculitis. Use of corticosteroids is especially important if the macular area is threatened. Because they are immunosuppressive, they should never be used without concurrent antimicrobial agents. Oral prednisone 40 to 60 mg is given daily for 2 to 6 weeks depending on clinical response. Topical corticosteroids are used for the secondary anterior chamber reaction but have no impact on retinal inflammation, and periocular injections should be used cautiously, if at all, because of their intense anti-inflammatory activity.

Most clinicians use a combination of oral antimicrobial agents and corticosteroids until there are definite signs of disease resolution. Decreasing inflammation with healing

of retinal lesions typically occurs within 4 to 6 weeks. At that time corticosteroids are tapered, but antimicrobial agents are continued until corticosteroids are stopped completely, and then they are discontinued as well. Drug therapy can be discontinued before all signs of inflammation have resolved. Management of ocular toxoplasmosis is sometimes modified in certain patient groups, including pregnant women, patients anticipating cataract extraction, individuals with HIV/AIDS, and the elderly.

**Pregnant Women.** Suspected acquired ocular toxoplasmosis in a pregnant woman that is severe and sight-threatening should be treated to prevent vision loss. Antimicrobial agents are both toxic and potentially teratogenic, particularly pyrimethamine. Spiramycin, with the lowest risk of toxicity for the fetus, has been advocated for therapy; although not licensed in the United States, it can be obtained from the U.S. Food and Drug Administration on a compassionate basis. Many providers refer pregnant women with ocular toxoplasmosis to either an infectious disease specialist or their obstetrician/gynecologist for treatment.

**Patients Anticipating Cataract Extraction.** A recent study identified an increased risk of reactivation of retinal toxoplasmosis after cataract extraction in 36% of patients, which was significantly higher than the incidence of recurrences in age- and sex-matched control subjects, raising the possibility that the mechanical trauma, psychological stress of surgery, or postoperative use of corticosteroids may have contributed to the development of recurrent disease. The study suggested that antibiotic prophylaxis might be justified during and after surgery in patients with old lesions in the proximity of retinal areas that are crucial for visual function.

**Individuals With HIV/AIDS.** Most clinicians treat all cases of toxoplasmic retinochoroiditis in AIDS patients regardless of visual acuity or retinal location, because untreated disease is continuously progressive. With treatment, retinitis typically heals within 4 to 6 weeks. The antimicrobial agents used for immunocompetent patients are similarly used for AIDS patients, although pyrimethamine can be problematic because of its potential for exacerbating the bone marrow suppression caused by many drugs used for HIV infection or opportunistic infections. Corticosteroids are generally not combined with antimicrobial agents, because they may further impair host defenses.

**The Elderly.** Older patients may be considered to have a degree of immunosuppression due to the waning of immune defenses associated with aging; choices of antibiotic agents are no different from those of younger patients with typical lesions, but corticosteroid therapy may be reduced or eliminated out of consideration for altered host defenses.

Because recurrences of ocular toxoplasmosis are frequent, providers have questioned whether a preventative strategy is worthwhile, particularly in reducing the risk of vision loss resulting from reactivation of infection from scars adjacent to critical retinal areas. An open-label randomized trial evaluated the benefits of intervention with trimethoprim (160 mg)/sulfamethoxazole (800 mg) every 3 days in patients with histories of recurrent toxoplasmic retinochoroiditis. A significant reduction in recurrences was demonstrated with the therapy intervention (6.6% in treated patients versus 23.8% in control patients), suggesting that this strategy may be beneficial for patients with recurrent toxoplasmic retinochoroiditis, particularly with those at risk of further vision loss.

## Toxocariasis

### Etiology

*Toxocara canis*, the common roundworm of dogs, can cause systemic infection in humans as visceral larva migrans (VLM). Ocular manifestations are less common, presenting as a solitary posterior pole retinal granuloma, peripheral granuloma, or chronic endophthalmitis. *T. canis* is a common parasite in puppies (higher than 80% frequency in puppies between 2 and 6 months) but is less frequent in adult animals (20% or less). Dogs, the definitive mammalian host, are infected by ingestion of infective eggs or larvae, by transplacental infection, via transmammary passage in milk to nursing pups, or by ingestion of organisms in vomit or feces of infected pups. Larvae invade multiple organs and lie dormant for many years. Infected puppies shed the eggs in feces, and eggs remain viable for months in humid soil. Transmission to humans occurs by ingestion of eggs in soil or from contaminated hands or other objects. *T. canis* seropositivity in U.S. children is 7% or less, with higher rates of seropositivity occurring in children of lower socioeconomic standing, those living in rural areas, boys, and older children.

When ingested by humans, eggs hatch in the proximal small intestine, enter the systemic circulation, and are impeded when their diameter is larger than that of the surrounding blood vessel. They then bore through the vessel wall and migrate aimlessly in the surrounding tissue, leaving necrosis and immune-mediated inflammatory processes in their wake.

### Diagnosis

VLM is diagnosed in children between 1 and 4 years of age with a history of pica (eating nonnutritive substances) and typical clinical signs, including cough, wheeze, pallor, malaise, irritability, hepatomegaly, and weight loss. Pulmonary involvement is typically mild, presenting as acute bronchitis, asthma, or pneumonitis. Clinical findings result from the human host's immune response to the migrating worm.

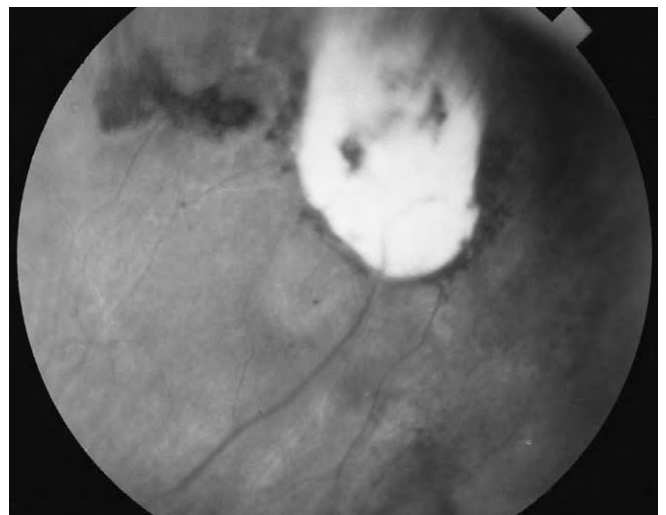
Ocular larva migrans, the other form of this disease, is most often seen in children at an average age of 7.5 years.

Varying retinal manifestations of ocular larva migrans depend on the site of lodgment of the larva, severity of the individual reaction, and the stage at which the eye is examined. Ocular presentations are typically unilateral, with symptoms ranging from none to profound vision loss. It should be noted that ocular larva migrans rarely coexists with VLM.

Localized retinal involvement begins as an acute fluffy lesion with overlying vitritis, which is later replaced by a focal elevated granuloma as inflammation abates. Granulomas may occur more often in the posterior pole than periphery, but data on location frequencies are contradictory. Posterior pole granulomas, which are white, round, and the size of the optic disc or larger, may have fibrous bands extending into the vitreous and pars plana. A dark gray area within the whitish mass may represent the dead larva. Peripheral granulomas have dense connective tissue strands in the vitreous that may connect to the optic disc or macula (Figure 31-8). Cicatrization of fibrous bands produces traction on various retinal structures.

Chronic endophthalmitis presents with severe retinal vessel leakage, frequently causing exudative retinal detachment, and inflammatory vitreal debris, which may organize and cover the posterior lens surface. Complications include posterior subcapsular cataract, secondary glaucoma, leukocoria, and phthisis bulbi. Interestingly, patients with nematode endophthalmitis are usually quite comfortable, although they may have an intense anterior chamber reaction. Endophthalmitis is considerably less frequent than toxocaral granulomas occurring in either the posterior pole or retinal periphery.

Hypereosinophilia is common in VLM, but eosinophilia is usually absent in ocular toxocariasis. Laboratory testing with the enzyme-linked immunosorbent assay is currently the most valuable diagnostic test. Titers of 1:32 or greater are generally considered positive for VLM, but titers of 1:8 are considered positive for ocular toxocariasis. If the



**Figure 31-8** Peripheral granuloma in ocular toxocariasis.



enzyme-linked immunosorbent assay on serum is not definitive, the test can be performed on aqueous samples. Definitive diagnosis, however, results only from histologic demonstration of larvae in ocular tissue.

Differential diagnosis of ocular toxocariasis includes retinoblastoma (frequently confused with toxocariasis), Coats' disease, persistent hyperplastic primary vitreous, retinopathy of prematurity, familial exudative vitreoretinopathy, intermediate uveitis, toxoplasmosis, and idiopathic subretinal neovascular membranes. Because toxocariasis frequently mimics retinoblastoma, differential diagnosis is critical, because their treatments are radically different.

### Management

Most authors agree that treatment of ongoing nematode endophthalmitis is necessary to prevent vision loss. If inflammation is mild and primarily located at the pars plana, topical corticosteroids may be sufficient, although more diffuse inflammation requires subconjunctival or sub-Tenon's injections of longer-acting corticosteroids. With severe or vision-threatening forms of endophthalmitis, systemic steroids are mandatory. Because many patients are younger than 10 years of age, they must be observed for adverse effects on the pubertal growth process. Steroid therapy typically requires weeks to months, so very careful tapering is necessary. Use of steroids may also prevent exacerbation of inflammation resulting from the death of the worm.

The anthelmintic agents thiabendazole, albendazole, mebendazole, and diethylcarbamazine have been used with varying degrees of success. Albendazole resulted in more clinical cures when compared with thiabendazole, although no more than one-third of either treatment group achieved a clinical cure. No report of anthelmintic therapy provided conclusive proof that larvae were killed. It is likewise difficult to evaluate the efficacy of these drugs, because they are frequently used with corticosteroids. Most authors believe that anthelmintic drugs may result in clinical improvement and reduction of antibody levels, although observed changes may represent no more than the natural course of the disease.

A stepwise approach to therapy was proposed for cases of ocular toxocariasis. For eye disease alone, local and periocular or systemic steroids should be used, with surgery (vitrectomy, membrane peel) when appropriate. For eye disease unresponsive to steroids, a specific anthelmintic agent is added and systemic steroids are continued (e.g., thiabendazole 50 mg/kg per day for 7 days plus prednisolone 0.5 to 1.0 mg/kg per day). For eye disease with systemic symptoms (VLM) or high antibody levels, local steroids and mydriatics are used, in addition to oral thiabendazole and oral steroids from the outset.

Prevention should occur through two strategies: worm control in puppies and lactating bitches, and reduction of soil contamination. Additionally, children and

adults should avoid contact with puppy feces. Animal deworming is possible with various agents, including piperazine, thiabendazole, and ivermectin. Avoidance of direct contact with puppies is only partially effective, because ova are found in soil in most communities. Children exhibiting either pica (eating nonnutritive substances) or geophagia (eating dirt) should be removed as much as possible from potentially contaminated environments.

## SARCOIDOSIS

### Etiology

Sarcoidosis is a granulomatous multisystem disease of unknown etiology, affecting virtually every organ system, with lungs, thoracic lymph nodes, skin, and eyes most frequently involved. A helper/inducer T-cell response results in accumulation of large numbers of activated T cells in affected organs, which distort architecture of the affected tissue and cause organ dysfunction. The secondary phenomenon of granuloma formation results from mononuclear phagocytes, with granulomas simply taking up space without causing local dysfunction.

In the United States most patients are between 20 and 40 years of age when sarcoidosis is diagnosed. Black patients outnumber white patients by approximately 15 to 1, with annual adjusted incidences of 8 per 100,000 for whites and 82 per 100,000 for blacks. Outside the United States the incidence peaks bimodally at ages 20 to 30 and 50 to 60. In Europe most affected patients are white, and the disorder is most common in the United Kingdom (20 per 100,000) and Sweden (64 per 100,000).

Systemic sarcoidosis may present either acutely or chronically. Acute or subacute sarcoidosis develops abruptly over several weeks and represents up to 40% of all cases. Patients usually have constitutional symptoms such as fever, malaise, and weight loss. In the United States 40% to 70% of patients develop insidious disease and have respiratory complaints without constitutional symptoms. Up to 50% of patients, however, are asymptomatic at the time of diagnosis, with the disease detected only during a routine examination.

Although sarcoidosis is a systemic disease, it is important clinically because of pulmonary abnormalities and, to a lesser extent, eye, lymph node, and skin involvement. Thoracic manifestations are the hallmark of sarcoidosis, with bilateral hilar adenopathy being the most common finding. Respiratory symptoms typically consist of dyspnea, dry cough, and chest pain. Peripheral lymphadenopathy is also common, involving the cervical, axillary, epitrochlear, and inguinal nodes. Skin involvement is primarily characterized by erythema nodosum (red tender nodules mainly on the anterior surfaces of the legs) or lupus pernio, consisting of blue and purple skin lesions, primarily on the face. Neurologic involvement is uncommon and typically involves cranial nerves, particularly the trigeminal and optic nerves.

### Diagnosis

The primary vision-threatening manifestations of sarcoidosis are uveitis, glaucoma, and optic nerve involvement; dry eye (keratoconjunctivitis sicca) is common but of lower risk. Anterior segment findings (including conjunctival granulomas, iris nodules, iridocyclitis, and keratoconjunctivitis sicca) occur in up to 70% of patients. In contrast, posterior uveitis occurs in up to 30% of patients. If only vasculitis, periphlebitis, or retinal neovascularization is considered, the frequency ranges from 4% to 17% of cases. Optic nerve involvement presents in up to 7% of patients.

Posterior segment involvement may be the only ocular manifestation in some individuals. A recent demographic analysis, evaluating posterior segment involvement in ocular sarcoidosis, found vitreitis to be the most common manifestation (69%), followed by choroidal “punched-out” lesions (56%), “snowball” lesions (46%), CME (31%), and periphlebitis (29%). Retinal hemorrhages and edema may occur with periphlebitis as well as the less common yellow perivenous exudates (*taches de bougie* or “candle-wax drippings”), consisting of perivascular granular tissue with exudation (Figure 31-9). Retinal neovascularization develops as a complication of capillary nonperfusion. Granulomas may be preretinal, intraretinal, or sub-RPE, whereas choroidal granulomas may cause overlying sensory retinal detachments or mimic the appearance of metastatic choroidal carcinoma. Optic nerve involvement in ocular sarcoidosis manifests as edema, swelling, or, less commonly, granulomata, neovascularization, or opticiliary shunts.

Definitive diagnosis of sarcoidosis requires both a consistent clinical or radiologic appearance and biopsy-proven granulomata without bacterial or fungal involvement. The classic pathologic finding in sarcoidosis is the epithelioid granuloma. An abnormal chest film is

common in patients with sarcoidosis and facilitates staging of the patient’s disease, whereas computed tomography, magnetic resonance imaging, and positron emission tomography are also helpful with diagnosis of sarcoidosis in optic nerves, lungs, and other organs.

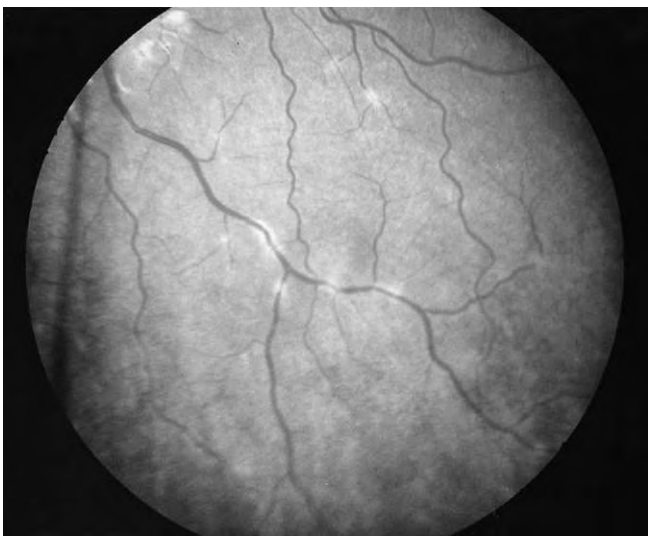Gallium-67 citrate localizes to areas of active inflammation after injection and is increased in lymphoma, carcinoma, tuberculosis, silicosis, and other conditions besides sarcoidosis. Although not specific for sarcoidosis, gallium scanning can identify increased metabolic activity in lacrimal glands. Gallium uptake in lacrimal and parotid glands (“panda sign”) together with pulmonary and mediastinal uptake (“lambda sign”) is very suggestive of sarcoidosis. Diagnostic specificity of a positive gallium scan is improved with elevated levels of serum angiotensin-converting enzyme (ACE).

In disease states serum levels of ACE reflect the total body mass of ACE-producing granulomata. Serum ACE is elevated in most patients with active sarcoidosis. However, ACE is also elevated in other diseases, including tuberculosis, leprosy, asbestosis, silicosis, Gaucher’s disease, hyperthyroidism, and cirrhosis. Elevated ACE in patients with uveitis is largely limited to sarcoidosis, leprosy, histoplasmosis, and tuberculosis and is generally a useful diagnostic test for ocular sarcoidosis. With the increasing use of ACE inhibitors for management of hypertension, there is the potential for interference in testing serum ACE levels. Patients should be questioned about their use of ACE inhibitors before having serum ACE levels tested. A switch to an alternative modality for hypertension treatment for at least 1 month before testing serum ACE should be considered.

### Management

Systemic corticosteroids are the mainstay of treatment for sarcoidosis and are mandatory for manifestations that are life-threatening or cause permanent structural damage. Either moderate doses (0.5 mg/kg per day) or high doses (1 mg/kg per day) of oral prednisone are used in organ-threatening disease. Regimens are continued for 2 to 4 weeks until a clinical response is achieved and then are tapered very carefully and slowly, often over months, until the lowest maintenance dosage that controls the disease is reached. Relapses are common and typically require that the dosage be increased. Oral steroid therapy has multiple side effects, including peptic ulcer disease, systemic hypertension, endocrine irregularities, and impaired wound healing.

Posterior segment disease is unaffected by topical therapy and minimally requires periorbital administration of corticosteroids; systemic therapy is needed if the condition is bilateral or sight threatening. Indications for posterior segment treatment include significant vision loss from macular edema or severe vitreitis, choroidal granulomas, optic nerve involvement, or retinal neovascularization. Conversely, if vision remains at 20/40 or better and there are no complicating factors, systemic



**Figure 31-9** Retinal periphlebitis in ocular sarcoidosis. (Photo courtesy David P. Sendrowski, O.D.)

treatment may not be needed. Active retinal vasculitis and chorioretinitis generally respond to oral prednisone or periocular injections of methylprednisolone or triamcinolone. Laser photocoagulation is useful for retinal neovascularization.

Alternative medications are used to avoid iatrogenic effects of corticosteroids. These include cytotoxic agents (methotrexate, azathioprine), noncytotoxic agents (chloroquine, hydroxychloroquine), and agents that suppress tumor necrosis factor- $\alpha$  release (pentoxifylline, thalidomide, and infliximab). All steroid-sparing treatments have been used only in small numbers of patients, without randomized controlled clinical trials. Methotrexate has emerged as the preferred second-line drug for sarcoidosis treatment and has been effective in management of sarcoid-associated uveitis and panuveitis. Infliximab has been successful in treating cases of chronic sarcoid eye disease refractory to other immunosuppressive treatments but has been associated with cases of tuberculosis in patients taking the drug for treatment of rheumatoid arthritis and Crohn's disease. Increased understanding of the molecular mechanisms of sarcoidosis may allow for development of new drugs that specifically affect macrophage function, including the release of tumor necrosis factor- $\alpha$ ; these drugs may have ocular applications as well.

## ACQUIRED MACULAR DISEASE

### Cystoid Macular Edema

#### Etiology

CME results from many ocular conditions but is not an independent disease entity. Retinal cell processes in Henle's layer run parallel to the surface of the internal limiting membrane, and the laxity of this layer forms a potential reservoir for extravascular fluid resulting from breakdown of the blood-retinal barrier, which forms extracellular cystoid spaces in the perifoveal area. CME accompanies several retinal vascular diseases, including diabetic maculopathy, central retinal venous occlusion, and branch venous occlusion. It may follow surgical procedures, most often cataract extraction and retinal detachment repair, or posterior inflammatory conditions, including pars planitis, chronic uveitis, and miscellaneous conditions such as retinitis pigmentosa.

CME after cataract extraction is classified as *angiographic*, in which most patients have good vision and undergo spontaneous recovery, or *clinical*, with both angiographic findings and reduced acuity, usually within the first 3 months after surgery. Current practices, in which extracapsular cataract extraction is followed by intraocular lens replacement, result in very low incidences of clinical CME, typically 0.2% to 0.4%, in striking contrast to older techniques of intracapsular procedures, with clinical CME occurring with an 8% incidence. Intraoperative complications, such as posterior capsular

rupture and vitreous loss, result in higher incidences of CME, and diabetic patients face a higher risk of CME after cataract extraction, particularly when diabetic retinopathy is present before surgery. CME after cataract surgery is presumably due to prostaglandin release from the iris with diffusion to the retina, altered capillary permeability, and fluid accumulation. Other factors theoretically related to postoperative CME include vitreoretinal traction on the macula and increased vitreal disruption or loss.

Retinal venous occlusive disease is frequently accompanied by CME. In eyes with ischemic central retinal vein occlusion (CRVO) edema is chronic and acuity is quite poor, with 90% of patients having acuity of 20/400 or worse. Branch retinal venous occlusion (BRVO) may also cause varying degrees of CME, with vision reduction correlating with the degree of compromised macular venous drainage. The course of CME complicating a superior-temporal BRVO varies widely: 25% of cases have spontaneous resolution of edema and achieve acuity of 20/20 to 20/40, but 65% of cases have a poorer prognosis, with 90% declining to acuity of 20/50 or worse.

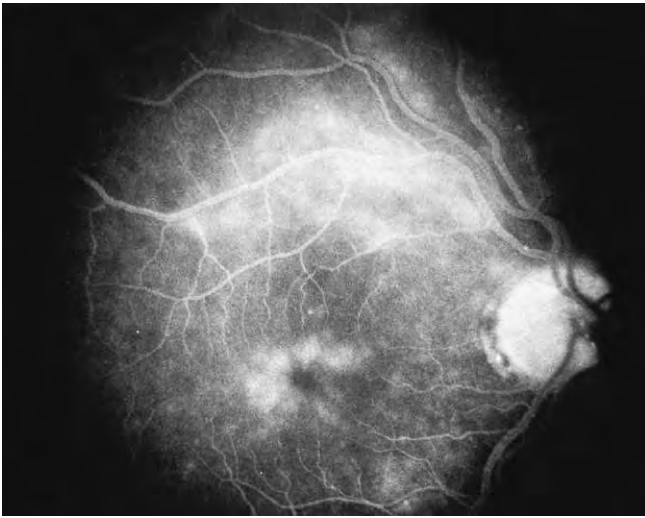Diabetic macular edema (DME) is either focal or diffuse. As the severity of overall retinopathy increases, so does the proportion of eyes with macular edema. In a review, 3% of eyes with mild nonproliferative retinopathy had DME, 38% of eyes with moderate to severe nonproliferative retinopathy had DME, and 71% of eyes with proliferative changes had DME. In patients with diabetic retinopathy, CME usually occurs after long-standing DME.

CME occurs in other somewhat uncommon posterior segment disease states. Pars planitis is associated with CME at a frequency of 28% of cases, and CME is the primary cause of vision loss in chronic severe uveitis.

#### Diagnosis

Visual acuity in clinical CME ranges from 20/25 to 20/400, with metamorphopsia and increased photostress test results. Direct ophthalmoscopy may demonstrate a foveal area appearing more yellow than usual with an absent foveal reflex, but only in the most severe cases are discrete foveal cysts ophthalmoscopically visible. With dilated fundus biomicroscopy, cystic spaces show a ground-glass or honeycomb appearance with retroillumination as the observer looks adjacent to the illuminating beam. Larger cysts may be surrounded by progressively smaller cysts extending away from the fovea.

CME is best diagnosed with fluorescein angiography. During the early phase of angiography there is slight leakage from the perifoveal capillaries, resulting in an irregular circular pattern, followed by the collection of fluorescein in cystic spaces centrally within the pattern and peripheral to it. A central stellate figure appears against the contrast of the surrounding fluorescein of the cystic spaces, and photographs taken later (5 to 15 minutes) reveal the classic petaloid pattern (Figure 31-10).



**Figure 31-10** Cystoid macular edema, late phase of fluorescein angiogram. (Photo courtesy Sheila F. Anderson, O.D.)

### Management

Management of CME depends on the underlying disease. CME after cataract surgery is usually managed with topical nonsteroidal anti-inflammatory drugs (NSAIDs), often in combination with topical corticosteroids. In contrast, pharmacologic management of CME resulting from venous occlusive disease, diabetes, or uveitis was previously disappointing but has been significantly impacted by the rapid increase in use of intravitreal triamcinolone acetonide (IVTA).

**Cataract Surgery.** Success in treating established CME after cataract surgery depends on the use of topical ophthalmic NSAID solutions. Studies have demonstrated the efficacy of topical 1% indomethacin, 0.5% ketorolac tromethamine, and 0.1% diclofenac in improving visual acuity in most patients with pseudophakic (or aphakic) CME. A meta-analysis reviewed randomized clinical trials using topical NSAIDs to treat CME and found a benefit of improved final visual acuity of two or more Snellen lines. Clinical judgment dictates the use of a topical NSAID four times a day for 8 to 12 weeks for treatment of pseudophakic CME. Neither of the newest topical NSAIDs, bromfenac 0.09% solution (Xibrom, ISTA Pharmaceuticals, Irvine, CA, USA) or nepafenac 0.1% suspension (Nevanac, Alcon Laboratories, Fort Worth, TX, USA), has yet been evaluated for treatment of CME. Because of less frequent dosing (bromfenac) and increased potency (nepafenac), these drugs may have the potential to be used off label as topical agents for CME after cataract surgery, but clinical data from patient trials are needed. The role of simultaneous therapy with NSAIDs and 1% prednisolone acetate is not clearly established, although many practitioners empirically combine the corticosteroid with a topical NSAID. There is potential for synergy between the NSAID and the corticosteroid, but it is difficult to conclude

whether the resolution of edema is related to the NSAID alone or that true synergy has resulted in clinical benefit, and studies are contradictory about the added therapeutic benefit of 1% prednisolone acetate.

IVTA has been used in several small series of patients with pseudophakic CME refractory to all therapies. The studies all noted initial benefit in both retinal thickness (monitored by optical coherence tomography) and in visual acuity, but differing amounts of triamcinolone were used (4, 8, and 25 mg) and outcomes varied, with most patients demonstrating recurrence of edema after 3 to 4 months. The most stable duration of benefit was seen with the highest dose (25 mg).

Many studies evaluated the use of topical NSAIDs in preventing CME after cataract extraction. Studies found consistent benefits in prevention of CME with administration of 0.5% ketorolac tromethamine, 0.03% flurbiprofen, and 0.1% diclofenac. A meta-analysis of 16 randomized clinical trials evaluating topical NSAIDs for prevention of CME found that NSAID use was beneficial in reducing the incidence of both angiographically evident and clinically relevant CME.

**Diabetic Macular Edema.** IVTA was initially proposed in 1999 as a potential therapy for diffuse DME in an attempt to control the increase in capillary permeability mediated by vascular endothelial growth factor (VEGF) presumed to cause DME. Diffuse macular edema in diabetic retinopathy responds poorly to laser therapy, in contrast to clinically significant macular edema, for which focal macular laser is the treatment of choice. In eyes with DME, laser therapy cannot be focused on localized leakage spots because the entire macula is involved. Several small clinical series have evaluated the use of IVTA in diffuse DME. Most researchers used injections of 4 mg triamcinolone, noting improvements in retinal thickness (per optical coherence tomography results) and modest improvements in acuity in the short term. However, these benefits had eroded at 6 months, suggesting that clinical improvement lasted as long as triamcinolone deposits were visible in the vitreous cavity. Others used 25 mg in similar types of patients and found that improvements in acuity, usually two Snellen lines, held at 6 months but would erode thereafter. Eyes with larger areas of macular ischemia tended to show less improvement after IVTA. Attempting to avoid complications of intravitreal injections, posterior sub-Tenon's injections of triamcinolone acetonide were evaluated for refractory DME. This technique provided improvements in both retinal anatomy and acuity similar to those seen with IVTA. Clinical benefits were of longer duration with posterior sub-Tenon's injections (about 12 months), but a direct comparison of IVTA and posterior sub-Tenon's injections demonstrated a greater clinical benefit with IVTA. Triamcinolone acetonide therapy for DME has expanded significantly, and this trend is clearly beneficial for both patients and practitioners, who have only been able to depend on

laser photocoagulation for 30 years. More studies with larger enrollments are needed to further clarify the role of IVTA in DME as a new treatment modality.

**Retinal Vein Occlusions.** CRVO, whether nonischemic or ischemic, is frequently accompanied by CME. IVTA has been used in single cases and in several small series of patients with both types of CRVO. Individuals with nonischemic CRVO frequently, but not universally, experienced both anatomic improvements in retinal thickness and marked improvements in acuity (often twofold or better). In patients with longer follow-up, the clinical gains were usually sustained at 6 months but not at 1 year. Individuals with ischemic CRVO tended to demonstrate anatomic improvement only, without a concurrent improvement in acuity. BRVOs are also accompanied by CME, and several studies demonstrated improvements in both retinal anatomy and vision, although the follow-up times were typically no longer than 6 months. Improvements in vision were found to be statistically significant, using the logarithm of the minimal angle of resolution. Because studies of both CRVO- and BRVO-related CME have had follow-up no greater than 12 months at the most (with the majority having 6 months of follow-up), it becomes apparent that clinical trials with larger enrollment and longer duration are critically needed. The National Eye Institute has sponsored a multicenter, randomized, clinical trial (the Standard Care vs. Corticosteroid for Retinal Vein Occlusion study) evaluating the use of 1- and 4-mg IVTA versus the standard of care for the treatment of retinal vein occlusions. This 3-year study will evaluate 630 patients with BRVO and 630 patients with CRVO at 4-month intervals, with additional treatment as required. Patients will be randomized in a 1:1:1 ratio to one of three groups: intravitreal injection of 4 mg of triamcinolone acetonide, intravitreal injection of 1 mg of triamcinolone acetonide, or standard care (observation of macular edema with CRVO, immediate grid laser photocoagulation of macular edema in BRVO without a dense macular hemorrhage, or observation of macular edema in BRVO with subsequent grid laser if the dense macular hemorrhage clears sufficiently).

**Chronic Uveitis.** IVTA has been used in several small series of patients with chronic CME due to chronic uveitis. Despite the long duration of edema, most patients demonstrated improvement in acuity lasting for 3 to 6 months, but others experienced a decline between 6 and 12 months after the initial injection, returning to the pretreatment acuity level. Anatomic improvement, demonstrated as reduced retinal thickening by optical coherence tomography, was likewise achieved by patients with CME that had been persistent for up to 11 years. Few of these patients had subsequent injections, so the ability of IVTA to maintain the initial improvement in acuity is unknown. An intravitreal implant device (Retisert, Bausch & Lomb Incorporated, Tampa, FL, USA)

is able to provide an extended release of fluocinolone acetonide. This device was approved by the United States Food and Drug Administration in 2005 for chronic CME associated with noninfectious posterior uveitis. Almost 90% of treated patients experienced stabilized or improved vision, and the rate of disease recurrence was reduced eightfold.

**Complications.** Endophthalmitis is a well-known complication of intravitreal injections. A comprehensive evaluation of 14,866 injections in 4,382 eyes determined an estimated prevalence of endophthalmitis to be 1.4% per eye and 1.4% per injection. (These prevalences included suspected cases of “noninfectious” endophthalmitis, “sterile” endophthalmitis, and “pseudoendophthalmitis.”) When endophthalmitis was considered to be only infectious, prevalences were 0.6% per eye and 0.6% per injection, which is a small but not negligible risk. Infectious endophthalmitis presents with common clinical findings of iritis, vitritis, hypopyon, pain, conjunctival injection, and decreased vision. The median time to presentation of infectious endophthalmitis was 7.5 days in one study. Sterile or noninfectious endophthalmitis is proposed to be caused by an inflammatory reaction to some constituent in the triamcinolone formulation. It has features in common with infectious endophthalmitis: blurred vision, hypopyon, severe anterior chamber inflammation, and vitritis. However, the sterile form causes no pain, cause mild to moderate conjunctival hyperemia, and appears to occur earlier than the infectious form (with hypopyon occurring on the first day postinjection). Any suspected case of endophthalmitis requires immediate attention; infectious forms are managed with vitreous tap and injection of antibiotics (typically vancomycin plus ceftriaxone or ceftazidime for gram-positive microbes or third-generation cephalosporins for gram-negative microbes).

Risk of endophthalmitis can be minimized by scrupulous preparation and control of the following areas of contamination: microbes from multiuse drug bottles, bacteria from conjunctiva, bacteria from eyelids, and the surgical site. Specific procedures include the following: pre- and posttreatment with topical broad-spectrum antibiotics, rigorous use of 5% povidone-iodine for control of eyelid and conjunctival flora, administration of eyedrops from single-use bottles, use of sterile eyelid specula, and maintenance of sterile operating conditions.

Increases in intraocular pressure and development of posterior subcapsular cataracts are familiar sequelae to corticosteroid therapy. Increased intraocular pressure after IVTA is considerably more common than endophthalmitis and has been established in different studies. Results are not readily comparable, because different amounts of triamcinolone were administered. However, it should be noted that approximately 30% or more of patients had an increase in intraocular pressure, regardless of the dose given, which is consistent with the finding that a significant number of patients are steroid

responders, with intraocular pressure increases secondary to steroid therapy. The intraocular pressure increase may be of longer duration with higher concentrations of steroids than with lower concentrations (about 7 to 9 months versus 3 to 5 months). It should also be noted that virtually all patients with intraocular pressure increases after IVTA were successfully managed with topical glaucoma medications. Posterior subcapsular cataracts became visually significant at 1 year in almost half of 93 eyes after treatment with IVTA for macular edema in a retrospective case series.

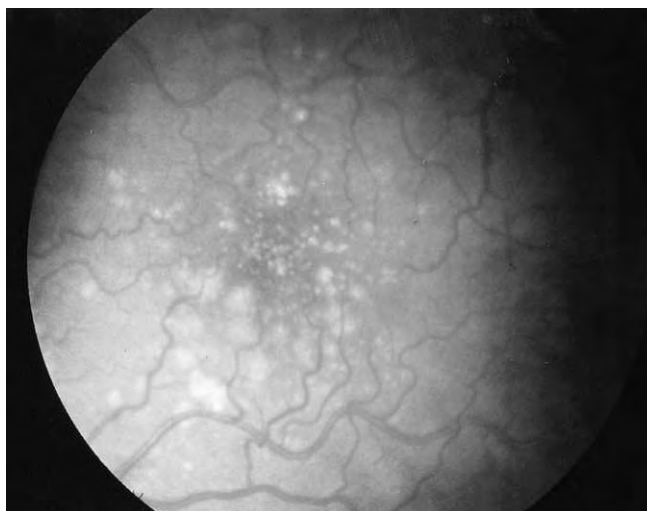
## Age-Related Macular Degeneration

### Etiology

Age-related macular degeneration (AMD) is the leading cause of legal blindness. AMD has classically been divided into “dry” and “wet” forms, separated between nonexudative pigmentary alteration for dry forms and exudative maculopathy due to choroidal neovascularization in the wet forms. The dry or nonexudative forms of this disease constitute about 85% of cases, and many cases of AMD do not result in legal blindness; of those individuals who were legally blind due to AMD in the Framingham study, 90% had neovascular maculopathy. Retinal aging changes, such as large or soft drusen or RPE alterations, are not uncommon in older patients. More individuals face the likelihood of AMD and potential loss of vision because they live longer.

In the late 1980s studies proposed that photooxidative stress underlies the pathogenesis of AMD, with most solar radiation-induced retinal damage resulting from photochemical mechanisms. Excess photon energy remaining unabsorbed by retinal elements produces a cascade of free radicals. These free radicals damage polyunsaturated free fatty acids of photoreceptor membranes, which in turn remain undigested by the RPE. They accumulate as lipofuscin, which subsequently alters normal metabolism to the extent that RPE cellular by-products are extruded as basal laminar deposits. Additional RPE compromise leads to drusen and debris within Bruch's membrane, which further speeds degeneration of the overlying RPE. This process is followed by increasing damage to Bruch's membrane with deposition of abnormal collagen, cellular debris, and development of multiple gaps and cracks (Figure 31-11).

Choroidal vessels invade Bruch's membrane for reasons that are not yet clear, although the role of VEGF is becoming increasingly important, as new information establishes the responsiveness of VEGF to local hypoxia or ischemia, with resultant development of neovascularization. The risk of developing a CNVM is highest when the RPE is at an advanced degenerative stage, with thickened basal laminar deposits and soft drusen. New vessels penetrate the inner collagenous layer of Bruch's membrane, with an increased risk of discrete leakage of blood and serous fluid that detaches both the RPE and

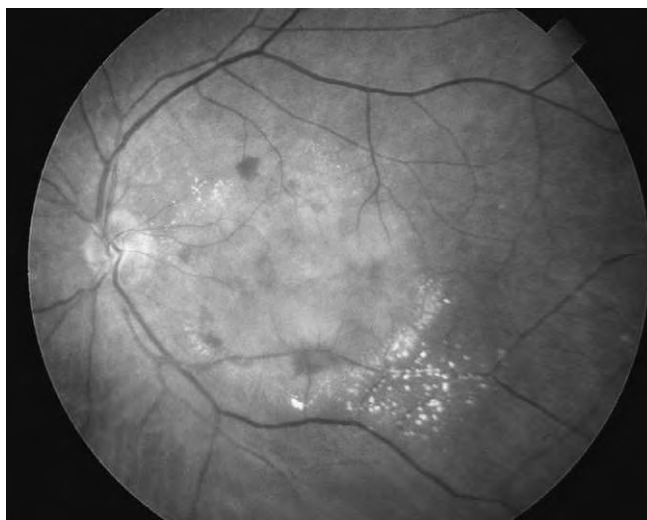


**Figure 31-11** Age-related macular degeneration with multiple soft drusen of varying sizes. Corrected visual acuity is 20/20.

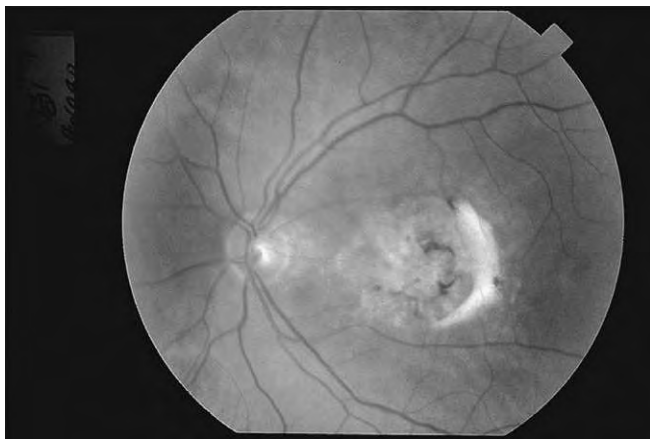overlying retina (Figure 31-12). Hemorrhage under the retina or RPE stimulates proliferation of fibrous tissue, ultimately producing a disciform scar (Figure 31-13).

### Diagnosis

Diagnosis of AMD is based on ophthalmoscopic findings of drusen of all sizes, RPE dropout and stippling, geographic atrophy, discrete hemorrhage and/or exudate (particularly in the absence of coexisting background diabetic retinopathy), and CNVMs. Visual acuity may be quite variable; often the fundusoscopic appearance correlates poorly with visual acuity, and many patients with drusen only have normal acuity. Results of Amsler grid testing often, but not consistently, show metamorphopsia



**Figure 31-12** Wet age-related macular degeneration with disciform serous detachment, discrete hemorrhages, and exudates. Corrected visual acuity is 20/100.



**Figure 31-13** End-stage age-related macular degeneration with a disciform fibrovascular scar. Corrected acuity is worse than 20/400.

but may correlate poorly with the retinal appearance. Fluorescein angiography demonstrates hyperfluorescence from drusen of all sizes as well as from RPE dropout (“window defects”), allowing choroidal fluorescence to be easily seen. CNVMs may be visualized with fluorescein angiography if unobscured by bleeding or turbid serous fluid. In questionable cases ICGA can often better detect CNVM than fluorescein angiography.

### Management

**Nutritional.** Because most cases of AMD are nonexudative, increasing emphasis has been placed on preventative strategies in patients at risk. Protection against oxidative stress using supplemental antioxidant compounds (vitamin C, vitamin E, beta-carotene, lutein, and zeaxanthin) has gained acceptance since the 1990s. Vitamin C is a water-soluble antioxidant capable of quenching superoxide, hydroxyl radicals, and singlet oxygen. Vitamin E is a lipid-soluble antioxidant found in cell membranes, able to quench singlet oxygen, superoxide, and the lipid peroxy radicals. Beta-carotene is a lipid-soluble pigment produced by plants, capable of quenching singlet oxygen and free radicals. It is a proform of vitamin A and is an effective antioxidant, although vitamin A itself does not share this property. Lutein and zeaxanthin are carotenoids that are very efficient filters for blue light, acting in a passive antioxidant fashion by reducing oxidative stress on the retina.

One approach to preventing or managing AMD may involve enhancing the body’s free radical defenses. Because the body does not produce antioxidant vitamins or minerals internally, it must continuously receive them from either diet or supplements. Researchers studied nutritional supplementation in human subjects with AMD. Early research demonstrated less vision loss in patients taking oral zinc, but further studies using zinc have been contradictory. Several reports demonstrated protective aspects to AMD patients with increased levels

of vitamins A and E as well as of carotenoids, particularly lutein and zeaxanthin, which are primarily obtained from dark leafy green vegetables. Studies evaluating an “antioxidant index” or a mixture of vitamins, carotenoids, and other substances (including ascorbic acid and selenium) found benefits from supplements containing mixtures of antioxidants. Results are interesting but often contradictory, which raises the issue that AMD remains a disease of multifactorial causes, many of which are difficult to control or prevent (e.g., smoking).

Only large randomized clinical trials have the potential to provide definitive results regarding the impact of nutritional supplements on AMD. The National Eye Institute designed the Age-Related Eye Disease Study to evaluate the benefit of high-dose nutrients on progression of AMD. The nutrients used were vitamin C, 500 mg; vitamin E, 400 IU; beta-carotene, 15 mg; and zinc, 80 mg as zinc oxide with copper and 2 mg as cupric oxide. Patients were divided into four separate groups based on visible retinal changes of increasing severity. Category 1 subjects had a few small drusen only (smaller than 64  $\mu$ m in diameter).

A second AREDS trial (AREDS-2) will evaluate the benefits of lutein, zeaxanthin and omega-3 fatty acids (docosahexaenoic acid and eicosapentaenoic acid) in addition to the original high-dose mineral components of the first AREDS trial. AREDS-2 has enrolled 4,000 adults with either bilateral large drusen or large drusen in one eye and advanced AMD in the fellow eye (neovascular AMD or geographic atrophy). The trial will run seven years, similar to the initial AREDS trial. Definitive recommendations for these additional constituents are eagerly awaited, although they are already included (sometimes haphazardly) in many over-the-counter “ocular vitamins” at the present time.

Category 2 subjects had multiple small drusen, single or nonextensive intermediate drusen (64–124  $\mu$ m in diameter), pigment abnormalities, or any combination of these features. Category 3 subjects could not have advanced AMD in either eye but required that at least one eye have at least one large drusen (125  $\mu$ m or greater in diameter), extensive intermediate drusen, or geographic atrophy that did not involve the center of the macula. Category 4 subjects had advanced AMD in one eye, with the fellow eye meeting criteria for categories 1, 2, or 3. Advanced AMD was defined as choroidal neovascularization, other exudative maculopathy, or geographic atrophy involving the center of the macula. Groups 1 and 2 were at low risk of progression, whereas groups 3 and 4 were at the highest risk of progression. Risk reductions for progression to advanced AMD were 17%, 21%, and 25% for subjects taking antioxidants alone, zinc alone, and antioxidants plus zinc, respectively. Benefits were seen for groups 3 and 4 only; there were too few advanced AMD events in category 2 participants to determine whether treatment could slow the progression to this stage of disease in individuals with milder drusen and RPE abnormalities.



Recommendations for over-the-counter vitamin or mineral supplements should be made only after discussion with the patient and informed consent. Based on the results of Age-Related Eye Disease Study, it seems reasonable to defer nutritional supplementation until patients present with higher risks of progression, because no benefit was seen in individuals in either category 1 or 2, and additional analysis did not determine efficacy in slowing the progression of AMD from category 2 to either category 3 or 4. Additionally, patients with a prior or present history of smoking should not take beta-carotene because of a greater risk of lung cancer. There is no information yet about benefits of dietary intervention as a “preemptive strike” in patients with normal vision but with a family history of vision loss from AMD. A prudent approach would be for patients to take only those products suggested for possible prevention of macular degeneration, to take only specific “smoker’s formula” products if there is a prior or present history of smoking, and to avoid haphazard ingestion of antioxidants and vitamins. Both practitioners and patients should be aware that few products meet the exact doses advocated by the Age-Related Eye Disease Study and that a normal diet plus routinely used multivitamins do not meet those requirements. The only major concerns regarding overdosing relate to zinc and copper. Patients who should not take these minerals without prior consultation with a physician are individuals with ischemic heart disease (zinc may exacerbate cardiovascular disease) or Wilson’s disease (excess copper may cause hepatic, neurologic, or psychiatric disease). Additional attention should be paid to potential drug–drug reactions between the patient’s habitual medications (whether prescription or over the counter) and zinc.

In the past management of AMD due to choroidal neovascularization depended on laser photocoagulation of the CNVM. The Macular Photocoagulation Study demonstrated that photocoagulation effectively prevented large decreases in visual acuity compared with observation without laser intervention. However, no more than 26% of patients with exudative ARMD had well-demarcated “classic” CNVM eligible for laser treatment according to Macular Photocoagulation Study criteria. Individuals with poorly demarcated or “occult” membranes make up most patients with AMD and were ineligible for laser therapy in the Macular Photocoagulation Study.

**Photodynamic Therapy.** A newer approved treatment for exudative AMD is photodynamic therapy (PDT). This technique derives its benefit from cancer therapy, in which a tissue-targeted photosensitizing agent causes localized damage to tumor tissues. PDT for AMD uses an intravascular compound that causes vascular occlusion after stimulation by a specific wavelength of light at sufficiently low intensity to spare the irradiated tissues from thermal damage. Verteporfin (Visudyne, Novartis AG, Basel, Switzerland) is liposome encapsulated to enhance delivery

to vascular tissue via low-density lipoprotein receptors on proliferating vascular endothelium. Very low laser energies release the dye from the liposomes and stimulate formation of reactive free radical species, which then cause photooxidative damage to the targeted tissue, occlusion of vessels, and damage to neovascular endothelium, whereas retinal areas overlying the occluded CNVM maintained normal function.

Multiple studies of PDT have been undertaken to evaluate its benefit in patients with CNVM. Evaluation of the type of CNVM was a critical part of patient selection for these trials, using the definitions of “classic” and “occult” CNVM from the Macular Photocoagulation Study. Classic CNVM has well-demarcated areas of hyperfluorescence visible in the early phase of the angiogram, whereas occult CNVM has leakage at the level of the RPE in the late phase of the angiogram without visible well-demarcated early hyperfluorescence. The Treatment of Age-Related Macular Degeneration with Photodynamic Therapy (TAP) investigation evaluated patients with evidence of some classic CNVM. The AMD arm of the Verteporfin in Photodynamic Therapy evaluated patients with occult with no classic CNVM with recent disease progression or with presumed early onset of classic CNVM with good visual acuity. Both trials demonstrated a reduction in risk of losing three or more lines of visual acuity or losing six or more lines of visual acuity compared with no treatment. When compared with patients with predominantly classic lesions, individuals with occult CNVM with no classic lesions and minimally classic lesions had a greater reduction in risk of vision loss with lesions of smaller size.

Selection of patients for PDT depends on fluorescein angiography to establish the presence of CNVM, plus evaluation of lesion composition (classic or occult), size, visual acuity, recent disease progression, and location. PDT is recommended for patients with predominantly classic CNVM (in which the area of the classic CNVM occupies 50% or more of the area of the entire lesion at baseline). PDT should be considered for patients with minimally classic lesions no greater than four disc areas in size (in which the area of classic CNVM occupies less than 50% but more than 0% of the area of the entire lesion). PDT is recommended for patients with subfoveal occult CNVM with no classic lesions and recent disease progression, defined as presence of blood from the CNVM and either at least a 10% increase in the greatest linear dimension or deterioration of visual acuity (at least five letters or one line) within the last 12 weeks. Further analysis indicated greater benefit for patients with smaller lesions (no greater than four disc areas) or lower levels of acuity (approximately 20/50 or less). Subfoveal lesions or juxtafoveal lesions that are so close to the fovea that conventional laser photocoagulation would involve the central fovea are appropriate for PDT. Patients are followed at 3-month intervals after the initial PDT session. Treatments are repeated if there is any fluorescein leakage

but are deferred if leakage is absent. Due to verteporfin's potential for photosensitization, patients should scrupulously avoid skin exposure to direct sunlight or bright indoor light for 48 hours after treatment.

PDT is not an inexpensive therapy, and it is hopeful to note, from the TAP Report No. 5, that the frequency of repeat verteporfin treatments decreased over 3 years: 3.6 treatments during the first year of follow-up, to 2.4 during the second year of follow-up, and then to 1.3 during the third year of follow-up. The frequency of retreatment sessions in the first year may be reduced in number by the combination of PDT with intravitreal triamcinolone injections, in which the immediate effect of verteporfin can be combined with the longer lasting and possibly synergistic effects of triamcinolone, but randomized large-scale clinical trials are needed to establish guidelines for combined use of PDT and IVTA.

**Antiangiogenesis Therapy.** It has been clearly demonstrated that PDT is most beneficial in patients with predominantly classic CNVM or in those with occult CNVM with recent progression. Some patients do not fit into either of these groupings. The newest treatments for exudative maculopathy use agents targeting the physiologic processes of angiogenesis, several of which are specific for VEGF, the protein that promotes new vascular proliferation. Theoretically, these agents should work for all types of neovascularization, because it should respond to the blockage of VEGF. These anti-VEGF agents include pegaptanib, a pegylated oligonucleotide aptamer that binds VEGF; bevacizumab, a recombinant humanized monoclonal antibody that binds VEGF; and ranibizumab, a second recombinant humanized monoclonal antibody, derived from bevacizumab, which likewise binds VEGF. Anecortave, an antiangiogenic cortisol derivative without glucocorticoid activity, acts at a variety of sites during the process of angiogenesis.

Pegaptanib (Macugen, Eyetech Pharmaceuticals, Inc., New York, NY, USA) is an aptamer that potently inhibits the binding of VEGF to its receptors, thus inhibiting neovascularization in cancer cells. A phase IA trial of this drug evaluated a small number of patients with subfoveal CNVM, determining that 80% of subjects showed stable or improved vision 3 months after treatment. A subsequent phase II trial in 21 patients revealed similar stabilization of vision 3 months after treatment. The largest, randomized, double-blind trial of pegaptanib (VEGF Inhibition Study on Ocular Neovascularization; V.I.S.I.O.N.) enrolled 1,186 patients with all types of angiographic subtypes of CNVM. It determined that 70% of patients lost fewer than 15 letters of visual acuity, compared with 55% of control patients ("sham injection" or usual care) at 54 weeks. Pegaptanib was beneficial for all lesion subtypes. A reduced risk of loss of visual acuity was noted as early as 6 weeks after treatment was begun, with intraocular injections administered at

6-week intervals. Study investigators performed an exploratory analysis of the V.I.S.I.O.N. trial and determined that early detection and treatment may result in better visual outcomes than delayed treatment in patients with early disease. These small subgroups met the following criteria for early disease: lesion size less than 2 disc areas, baseline acuity greater than or equal to 54 ETDRS letters, no prior PDT or laser in the study eye, and no scarring or atrophy within the lesion (group 1); or occult with no classic CNVM, absence of lipid, and better acuity at baseline in the fellow eye. The latest evaluation of subjects in the V.I.S.I.O.N. trial at 102 weeks suggests that the benefit of pegaptanib therapy in stabilizing vision continues into the second year, and this benefit may be greater after 2 years of treatment than after only 1 year, although just 10% of patients experienced a gain in visual acuity (three or more lines). Bevacizumab and ranibizumab are both humanized monoclonal antibodies, resulting from the engineering of genes of the murine (mouse) antibody system to express human antibodies. Both drugs bind directly to VEGF and suppress angiogenesis. Bevacizumab is a fully sized antibody, whereas ranibizumab is the antigen-binding portion of that parent molecule. Bevacizumab (Avastin, Genentech Pharmaceuticals, Inc., South San Francisco, CA, USA) has become established as a preferred therapy for advanced colorectal cancer when used in combination with fluorouracil.

Ranibizumab (Lucentis, Genentech Pharmaceuticals, Inc.) has been evaluated in monkey models of choroidal neovascularization and was noted to cause a greater reduction in angiographic leakage than PDT. A dose-ranging study in human subjects found the maximal tolerated single dose to be 500 mcg. Follow-up of patients in the phase I/II study for over 1 year revealed that ranibizumab treatment stabilized both visual acuity and lesion characteristics. The initial dosing frequency of every 4 weeks was relaxed to deferring a dose if acuity and lesion characteristics were stable on two consecutive visits, and the median rate of intravitreal injections decreased to 0.22 every 4 weeks. The most common adverse event noted in the phase I/II trial was a transient, painless, reversible inflammatory response that was most severe on the day after injection, usually resolving without treatment within 14 days.

Ranibizumab was subsequently evaluated in two large clinical trials. The MARINA trial (Minimally Classic/Occult Trial of the Anti-VEGF Antibody Ranibizumab in the Treatment of Neovascular Age-Related Macular Degeneration) evaluated monthly injections of either 0.3 or 0.5 mg in patients with minimally classic or occult CNVM. Ninety four percent of patients lost fewer than 15 letters of acuity at one year; 24.8% (0.3-mg group) and 33% (0.5-mg group) had gains of 15 or more letters. Those benefits were maintained at two years. The ANCHOR trial (Anti-VEGF Antibody for the Treatment of Predominantly Classic Choroidal Neovascularization in Age-Related

Macular Degeneration) compared monthly ranibizumab (0.3 or 0.5 mg) to PDT in patients with predominantly classic CNVM. At one year, approximately 95% of ranibizumab-treated patients had lost less than 15 letters, compared to 64% of those in the PDT group. Vision improved by 15 or more letters in 37.5% (0.3-mg group) and 40.3% (0.5-mg group) of ranibizumab-treated patients.

After observation of beneficial responses from ranibizumab in phase I/II trials, investigators proposed that bevacizumab, the parent molecule of ranibizumab, be used off-label as an anti-VEGF drug for neovascular AMD. It was initially used in a salvage trial, the Systemic Avastin for Neovascular AMD Study, administered intravenously to nine patients with CNVM over a period of 12 weeks, with infusions given at 2-week intervals. At 12 weeks the median and mean visual acuity letter scores had increased by 8 and 12 letters, respectively, and optical coherence tomography measurements detected significant improvement in retinal thickness. After two or three treatments, no retreatment was needed through 3 months of follow-up, and only one of the four patients followed to 6 months needed retreatment. Based on the results of intravenous bevacizumab therapy, investigators questioned if intravitreal administration would provide similar benefit, while avoiding the risk of adverse events with systemic therapy. Bevacizumab was administered intravitreally to a patient who was responding poorly to pegaptanib therapy, with improvement in retinal anatomy and stabilized visual acuity at 4 weeks. This initial report suggested that this agent, used off-label, may have potential for management of CNVM. Subsequent intravitreal administration of bevacizumab to a nonrandomized series of 79 patients with neovascular AMD determined that therapy was associated in the short term (1 to 8 weeks) with improved acuity, decreased retinal thickness, and reduction in angiographic leakage. Another series of 266 eyes (in 266 consecutive patients) treated with intravitreal bevacizumab reported significant decreases in macular thickness, and more than 30% of patients experienced visual acuity improvement (defined as a halving of the visual acuity angle).

Off-label use of bevacizumab has become increasingly popular for treatment of hemorrhagic AMD. The gains in vision are similar to those occurring with ranibizumab and there is a pronounced difference in cost between the two drugs: average costs are approximately \$50 for a bevacizumab injection versus \$2,000 for a ranibizumab injection. Comparison of clinical results is complicated by several factors: studies of bevacizumab injections are not randomized or placebo-controlled but are retrospective; many individuals treated with bevacizumab had failed other AMD treatments, including PDT and pegaptanib injections; and none of the bevacizumab-treated patients has been followed for two years. A head-to-head comparison trial of these drugs is sorely needed, to detect overall differences between the drugs, evaluate the potential for

reduced frequency of dosing, and to evaluate the degree of increased risk of hypertension and thromboembolic events associated with the nonspecific inhibition of VEGF. The National Eye Institute is funding a multicenter clinical trial comparing ranibizumab and bevacizumab intravitreal injections in patients with AMD.

Anecortave (Retaane, Alcon Laboratories, Inc.) is one of a class of angiostatic steroids that inhibit angiogenesis by interference with proteinases that promote vascular endothelial cell migration and proliferation. This group of steroids has minimal glucocorticoid (anti-inflammatory) or mineralocorticoid (salt-retaining) activity. Anecortave is administered through a posterior juxtasclear depot delivery system (periocular injection), which requires surgical implantation of a specially designed 56-degree blunt-tipped cannula in the superotemporal quadrant of the orbit between superior and lateral rectus muscle insertions. The cannula tip, after being fully inserted, is positioned near the macula. The drug was studied in 128 patients with subfoveal CNVM, 80% of whom presented with classic lesions at baseline. At 12 months, with administrations of anecortave at 6-month intervals, the drug was found to be effective for both stabilization of vision and for inhibition of lesion growth. Efficacy results at 2 years demonstrated that this treatment was superior to placebo for the parameters described above. Anecortave is being evaluated in a number of clinical trials, two of which warrant specific mention. A clinical study with verteporfin in over 500 patients with CNVM eligible for PDT therapy failed to demonstrate the noninferiority of anecortave to PDT, determining no statistically significant difference at 12 months between treatment groups. Clinical study C-01-99 compared anecortave to PDT with verteporfin in over 500 patients with CNVM eligible for PDT therapy; this noninferiority study found no statistically significant difference at 12 months between treatment groups. Clinical study C-02-60 will evaluate the effect of anecortave in reducing the risk of progression from dry AMD to exudative AMD in patients with multiple intermediate/large drusen in the study eye and exudative maculopathy or AMD in the nonstudy eye.

There has been a significant change in the available treatments for exudative AMD. More direct comparison trials of these different modalities are critically needed, particularly of the VEGF inhibitors, plus guidelines to establish which patients benefit most from treatment, similar to those established by the TAP and Verteporfin in Photodynamic Therapy studies. Whether these new agents are used alone, in combination with established therapies, or with newly developing modalities, they represent a new era in treatment, with patients being the beneficiaries of these treatments, which have the potential to stabilize vision loss and improve quality of life and independence for many patients.

**SELECTED BIBLIOGRAPHY****Fluorescein Angiography**

- Butner RW, McPherson AR. Adverse reactions in fluorescein angiography. *Ann Ophthalmol* 1983;15:1084.
- Halperin LS, Olk RJ, Soubrabe G, et al. Safety of fluorescein angiography during pregnancy. *Am J Ophthalmol* 1990;109:563.
- Messner LV. Fluorescein angiography. In: Onofrey BE, ed. *Clinical optometric pharmacology and therapeutics*. Philadelphia: Lippincott-Raven, 1997.
- Yannuzzi LA, Rohrer KT, Tindel LJ, et al. Fluorescein angiography complication survey. *Ophthalmology* 1986;93:611.

**Indocyanine Green Angiography**

- Hope-Ross Yannuzzi LA, Gragoudas ES, et al. Adverse reactions to indocyanine green. *Ophthalmology* 1994;101:529.
- Regillo CD. Indocyanine green angiography. In: Duane TD, ed. *Clinical ophthalmology*, vol. 3. Philadelphia: Lippincott-Raven, 1997.
- Stanga PE, Lim JI, Hamilton P. Indocyanine green angiography in chorioretinal diseases: indications and interpretation. An evidence-based update. *Ophthalmology* 2003;110:15.

**Acute Retinal Necrosis**

- Duker JS, Blumenkranz MS. Diagnosis and management of the acute retinal necrosis (ARN) syndrome. *Surv Ophthalmol* 1991;35:327.
- Fisher JP, Lewis ML, Blumenkranz M, et al. The acute retinal necrosis syndrome. Part I: clinical manifestations. *Ophthalmology* 1982;89:1309.
- Ganatra JB, Chandler D, Santos C, et al. Viral causes of the acute retinal necrosis syndrome. *Am J Ophthalmol* 2000;129:166.
- Holland GN. Standard diagnostic criteria for the acute retinal necrosis syndrome. Executive Committee of the American Uveitis Society. *Am J Ophthalmol* 1994;117:663.
- Matsuo T, Morimoto K, Matsuo N. Factors associated with poor visual outcome in acute retinal necrosis. *Br J Ophthalmol* 1991;75:450.

**CMV Retinitis**

- Bright DC. Diseases of the retina. In: Bartlett JD, Jaanus SJ, eds. *Clinical ocular pharmacology*. Boston: Butterworth Heinemann, 2001.
- Holland GN, Tufail A, Jordan MC. Cytomegalovirus diseases. In: Pepose JS, Holland GN, Wilhelmus KR, eds. *Ocular infection and immunity*. St. Louis, MO: Mosby, 1996.
- Jabs DA, Van Natta ML, Thorne JE. AIDS and ophthalmology in 2004. *Arch Ophthalmol* 2004;122:1040.
- Jabs DA, Van Natta ML, Thorne JE, et al. Course of cytomegalovirus retinitis in the era of highly active antiretroviral therapy. 1. Retinitis progression. *Ophthalmology* 2004;111:2224.
- Karavellas MP, Azen SP, MacDonald JC, et al. Immune recovery vitreitis and uveitis in AIDS. Clinical predictors, sequelae, and treatment outcomes. *Retina* 2001;21:1.

Martin DF, Sierra-Madero J, Walmsley S, et al. A controlled trial of valganciclovir as induction therapy for cytomegalovirus retinitis. *N Engl J Med* 2002;346:1119.

Martin DF, Dunn JP, Davis JL, et al. Use of the ganciclovir implant for the treatment of cytomegalovirus retinitis in the era of potent antiretroviral therapy: recommendations of the International AIDS Society-USA Panel. *Am J Ophthalmol* 1999;127:329.

**Progressive Outer Retinal Necrosis**

- Culbertson WW, Dix RD. Varicella-zoster virus diseases: posterior segment of the eye. In: Pepose JS, Holland GN, Wilhelmus KR, eds. *Ocular infection and immunity*. St. Louis, MO: Mosby, 1996.
- Engstrom RE Jr, Holland GN, Margolis TP, et al. The progressive outer retinal necrosis syndrome. A variant of necrotizing herpetic retinopathy in patients with AIDS. *Ophthalmology* 1994;101:1488.
- Ormerod LD, Larkin JA, Margo CA, et al. Rapidly progressive herpetic retinal necrosis: a blinding disease characteristic of advanced AIDS. *Clin Infect Dis* 1998;26:34.

**Toxoplasmosis**

- Bosch-Driessen LH, Verbraak FD, Suttorp-Schulten MS, et al. A prospective, randomized trial of pyrimethamine and azithromycin vs pyrimethamine and sulfadiazine for the treatment of ocular toxoplasmosis. *Am J Ophthalmol* 2002;134:34.
- Bosch-Driessen LE, Berendschot TT, Ongkosuwito JV, et al. Ocular toxoplasmosis. Clinical features and prognosis of 154 patients. *Ophthalmology* 2002;209:869.
- Bosch-Driessen LH, Plaiser MB, Stilma JS, et al. Reactivations of ocular toxoplasmosis after cataract extraction. *Ophthalmology* 2002;109:41.
- Engstrom RE Jr, Holland GN, Nussenblatt RB, et al. Current practices in the management of ocular toxoplasmosis. *Am J Ophthalmol* 1991;111:601.
- Gilbert RE, Stanford MR. Is ocular toxoplasmosis caused by prenatal or postnatal infection? *Br J Ophthalmol* 2000;84:224.
- Holland GN. Ocular toxoplasmosis: a global reassessment. Part I: epidemiology and course of disease. *Am J Ophthalmol* 2003;136:973.
- Holland GN. Ocular toxoplasmosis: a global reassessment. Part II: Disease manifestations and management. *Am J Ophthalmol* 2004;137:1.
- Holland GN, Lewis KG. An update on current practices in the management of ocular toxoplasmosis. *Am J Ophthalmol* 2002;134:102.
- Holland GN, O'Conner GR, Belfort R Jr, et al. Toxoplasmosis. In: Pepose JS, Holland GN, Wilhelmus KR, eds. *Ocular infection and immunity*. St. Louis, MO: Mosby, 1996.
- Silveira C, Belfort R Jr, Muccioli C, et al. The effect of long-term intermittent trimethoprim/sulfamethoxazole on recurrences of toxoplasmic retinochoroiditis. *Am J Ophthalmol* 2002;134:41.
- Soheilian M, Sadoughi MM, Ghajarnia M, et al. Prospective randomized trial of trimethoprim/sulfamethoxazole versus pyrimethamine and sulfadiazine in the treatment of ocular toxoplasmosis. *Ophthalmology* 2005;112:1876.
- Stanford MR, See SE, Jones LV, et al. Antibiotics for toxoplasmic retinochoroiditis. An evidence-based systematic review. *Ophthalmology* 2003;110:926.

## Toxocariasis

- Dinning WJ, Gillespie SH, Cooling RJ, et al. Toxocariasis: a practical approach to management of ocular disease. *Eye* 1988; 2(Pt 5):580.
- Messner LV. Toxocariasis. In: Onofrey BE, ed. *Clinical optometric pharmacology and therapeutics*. Philadelphia: Lippincott-Raven, 1997.
- Parke DW II, Shaver RP. Toxocariasis. In: Pepose JS, Holland GN, Wilhelmus KR, eds. *Ocular infection and immunity*. St. Louis, MO: Mosby, 1996.
- Shields JA. Ocular toxocariasis. A review. *Surv Ophthalmol* 1984;28:361.

## Sarcoidosis

- Baughman RP, Lower EE, du Bois RM. Sarcoidosis. *Lancet* 2003;361:1111.
- Crystal RG. Sarcoidosis. In: Kasper DL, Braunwald E, Fauci AS, et al., eds. *Harrison's principles of internal medicine*, ed. 16. New York: McGraw-Hill, 2005.
- Haimovici R, Foster CS. Sarcoidosis. In: Pepose JS, Holland GN, Wilhelmus KR, eds. *Ocular infection and immunity*. St. Louis, MO: Mosby, 1996.
- Khalatbari D, Stinnett S, McCallum RM, et al. Demographic-related variations in posterior segment ocular sarcoidosis. *Ophthalmology* 2004;111:357.
- Lindstedt EW, Baarsma GS, Kuijpers RW, et al. Anti-TNF- $\alpha$  therapy for sight threatening uveitis. *Br J Ophthalmol* 2005; 89:533.

## Cystoid Macular Edema

- Bresnick GF. Diabetic macular edema. A review. *Ophthalmology* 1986;93:989.
- Cardillo JA, Melo LA Jr, Costa RA, et al. Comparison of intravitreal versus posterior sub-Tenon's capsule injection of triamcinolone acetonide for diffuse diabetic macular edema. *Ophthalmology* 2005;112:1557.
- Heier JS, Topping TM, Baumann W, et al. Ketorolac versus prednisolone versus combination therapy in the treatment of acute pseudophakic cystoid macular edema. *Ophthalmology* 2000;107:2034.
- Jaffe GL, Martin D, Callanan D, et al. Fluocinolone acetonide implant (Retisert) for noninfectious posterior uveitis: thirty-four week result of a multicenter randomized clinical study. *Ophthalmology* 2006;113: 1020.
- Jager RD, Aiello LP, Patel SC, et al. Risks of intravitreal injection: a comprehensive review. *Retina* 2004;24:676.
- Jonas JB, Kreissig I, Degenring RF. Intravitreal triamcinolone acetonide for pseudophakic cystoid macular edema. *Am J Ophthalmol* 2003;136:384.
- Moshfeghi DM, Kaiser PK, Scott IU, et al. Acute endophthalmitis following intravitreal triamcinolone acetonide injection. *Am J Ophthalmol* 2003;136:791.
- Quinn CJ. Cystoid macular edema. *Optom Clin* 1996;5:111.
- Rossetti L, Chaudhuri J, Dickersin K. Medical prophylaxis and treatment of cystoid macular edema after cataract surgery. The results of a meta-analysis. *Ophthalmology* 1998; 105:397.
- Ta CN. Minimizing the risk of endophthalmitis following intravitreal injections. *Retina* 2004;24:699.

- Thompson JT. Cataract formation and other complications of intravitreal triamcinolone for macular edema. *Am J Ophthalmol* 2006;141:629.

## Age-Related Macular Degeneration

- Age-Related Eye Disease Study Research Group. A randomized, placebo-controlled, clinical trial of high-dose supplementation with vitamins C and E, beta carotene, and zinc for age-related macular degeneration and vision loss: AREDS Report No. 8. *Arch Ophthalmol* 2001;119:1417.
- Anonymous. Subfoveal neovascular lesions in age-related macular degeneration. Guidelines for evaluation and treatment in the macular photocoagulation study. Macular Photocoagulation Study Group. *Arch Ophthalmol* 1991; 109:1242.
- Avery RL, Pieramici Dj, Rabena MD, et al. Intravitreal bevacizumab (Avastin) for neovascular age-related macular degeneration. *Ophthalmology* 2006;113:363.
- Azab M, Boyer DS, Bressler NM, et al. Verteporfin therapy of subfoveal minimally classic choroidal neovascularization in age-related macular degeneration: 2-year results of a randomized clinical trial. Visudyne in Minimally Classic Choroidal Neovascularization Study Group. *Arch Ophthalmol* 2005;123:448.
- Blumenkranz MS, Bressler Nm, Bressler SB, et al. Verteporfin therapy for subfoveal choroidal neovascularization in age-related macular degeneration: three-year results of an open-label extension of 2 randomized clinical trials—TAP Report No. 5. *Arch Ophthalmol* 2002;120:1307.
- Bressler NM, Arnold J, Benchaboune M, et al. Verteporfin therapy of subfoveal choroidal neovascularization in patients with age-related macular degeneration: additional information regarding baseline lesion composition's impact on vision outcomes—TAP Report No. 3. *Arch Ophthalmol* 2002; 120:1443.
- Brown DM, Kaiser PK, Michels M, et al. Ranibizumab versus verteporfin for neovascular age-related macular degeneration. The ANCHOR Study Group. *N Engl J Med* 2006;355:1432.
- Freeman WR, Falkenstein I. Avastin and new treatments for AMD: where are we? *Retina* 2006;26:853.
- Gonzales CR, VEGF Inhibition Study in Ocular Neovascularization (V.I.S.I.O.N.) Clinical Trial Group. Enhanced efficacy associated with early treatment of neovascular age-related macular degeneration with pegaptanib sodium: an exploratory analysis. *Retina* 2005;25:815.
- Gragoudas ES, Adamis AP, Cunningham ET Jr, et al. Pegaptanib for neovascular age-related macular degeneration. VEGF Inhibition Study in Ocular Neovascularization Clinical Trial Group. *N Engl J Med* 2004;351:2805.
- Heier JS, Antoszyk AN, Pavan PR, et al. Ranibizumab for treatment of neovascular age-related macular degeneration. A phase I/II multicenter, controlled, multidose study. *Ophthalmology* 2006;113:633.
- Jampol LM. Antioxidants, zinc, and age-related macular degeneration: results and recommendations [comment]. *Arch Ophthalmol* 2001;119:1533.
- Michels S, Rosenfeld PJ, Puliafito CA, et al. Systemic bevacizumab (Avastin) therapy for neovascular age-related macular degeneration: twelve-week results of an uncontrolled open-label clinical study. *Ophthalmology* 2005;112:1035.
- Richer S, Stiles W, Statkute L, et al. Double-masked, placebo-controlled, randomized trial of lutein and antioxidant

- supplementation in the intervention of atrophic age-related macular degeneration: the Veterans LAST study (Lutein Antioxidant Supplementation Trial). *Optometry* 2004;75:216.
- Rosenfeld PJ, Moshfeghi AA, Puliafito CA. Optical coherence tomography findings after an intravitreal injection of bevacizumab (Avastin) for neovascular age-related macular degeneration. *Ophthalm Surg Lasers Imag* 2005;36:331.
- Rosenfeld PJ, Brown DM, Heier JS, et al. Ranibizumab for neovascular age-related macular degeneration. The MARINA Study Group. *N Engl J Med* 2006;355:1419.
- Schmidt-Erfurth U, Michels S, Michels R, et al. Anecortave acetate for the treatment of subfoveal choroidal neovascularization secondary to age-related macular degeneration. *Eur J Ophthalmol* 2005;15:482.
- Seddon JM, Chen CA. The epidemiology of age-related macular degeneration. *Int Ophthalmol Clin* 2004;44:17.
- Slakter JS, Bochow TW, D'Amico DJ, et al. Anecortave acetate (15 milligrams) versus photodynamic therapy for treatment of subfoveal neovascularization in age-related macular degeneration. *Ophthalmology* 2006;113:3.
- Spaide RF, Laud K, Fine HF, et al. Intravitreal bevacizumab treatment of choroidal neovascularization secondary to age-related macular degeneration. *Retina* 2006;26:383.
- Spaide RF, Sorenson J, Maranan L, et al. Photodynamic therapy with verteporfin combined with intravitreal injection of triamcinolone acetonide for choroidal neovascularization. *Ophthalmology* 2005;112:301.
- van der Hagen AM, Yolton DP, Kaminski MS, et al. Free radicals and antioxidant supplementation: a review of their roles in age-related macular degeneration. *J Am Optom Assoc* 1993;64:871.
- VEGF Inhibition Study in Ocular Neovascularization (V.I.S.I.O.N.) Clinical Trial Group. Year 2 efficacy results of 2 randomized controlled clinical trials of pegaptanib for neovascular age-related macular degeneration. *Ophthalmology* 2006;113:1508.
- Verteporfin Roundtable Participants. Guidelines for using verteporfin (Visudyne) in photodynamic therapy for choroidal neovascularization due to age-related macular degeneration and other causes: update. *Retina* 2005;25:119.
- Young RW. Pathophysiology of age-related macular degeneration. *Surv Ophthalmol* 1987;31:291.

## *Thyroid-Related Eye Disease*

*David P. Sendrowski and Robert W. Lingua*

Historically, Graves' disease has been used to describe any orbital disease related to abnormalities of the thyroid gland. Other synonymous terms are Graves' orbitopathy, dysthyroid ophthalmopathy, thyroid eye disease, thyroid-related immune orbitopathy, thyroid-related ophthalmopathy, and thyroid-related orbitopathy. Although approximately 80% of patients with Graves' disease have some degree of ocular involvement, only 15% of those patients ever develop serious functional impairment of vision. Nevertheless, the diagnosis and management of thyroid-related eye disease are often significant challenges to the eye care practitioner and endocrinologist.

### **CLINICAL PRESENTATION OF THYROID-RELATED ORBITOPATHY**

In most cases the diagnosis of Graves' disease can be made on the basis of a careful clinical history and physical examination. In one report a diagnosis of thyroid-related orbitopathy based on the clinical findings alone was made in 42 of 52 patients with laboratory-proven thyrotoxicosis. Patients often present with complaints of dry eye, such as epiphora, foreign body sensation, photophobia, and blurred vision. Family members may even have noticed proptosis or eyelid retraction (photographs can give evidence of the date of onset). More significant complaints can include orbital pain, double vision, decreased vision, and decreased color perception.

Clinically, the practitioner may observe conjunctival chemosis and erythema, abnormal eyelid position (lid retraction), lid lag, and proptosis. Conjunctival injection is most marked over the involved rectus muscles. Nervousness, palpitations, weight loss, hyperhidrosis, and heat intolerance are systemic symptoms occurring in more than 80% of hyperthyroid patients. Other signs, such as tremor, hyperreflexia, tachycardia, skin changes, stare, and eyelid lag, are observed in more than 60%. Additionally, goiter is present in more than 95% of Graves' disease patients. In most cases, however, the laboratory confirmation of thyrotoxicosis is helpful to corroborate the diagnosis.

A small percentage of patients maintain a euthyroid state with ophthalmopathy consistent with Graves' disease. The clinical diagnosis of Graves' ophthalmopathy can frequently be made on the basis of eye findings alone. Indeed, 5% of patients present with the classic signs of Graves' ophthalmopathy but are found to be chemically and clinically euthyroid. In the patient who has either a present experience or a history of hyperthyroidism, the diagnosis is usually immediate. However, in those patients without such history, evidence of eyelid retraction and eyelid lag is virtually pathognomonic. Important office-based tests include the following:

- Best corrected visual acuities
- Pupillary testing (rule out afferent papillary defect)
- Exophthalmometry (baseline readings)
- Monocular color testing (rules out optic nerve involvement)
- Motility testing (evaluates diplopia on up-gaze/possible forced duction on inferior rectus muscle)
- Lid position/assessment (rules out upper lid retraction)
- Bell's phenomenon (intact/absent)
- Retropulsion of the globe (rules out orbital tumor)
- Biomicroscopy (evaluates corneal integrity/tear film/superior limbic keratoconjunctivitis)
- Extended ophthalmoscopy (optic nerves)
- Automated perimetry (central threshold testing).

The measurement of proptosis, using an exophthalmometer to measure from the lateral orbital rim to the anterior corneal surface, is important in tracking disease progression. Vertical diplopia is common, secondary to fibrosis of the inferior rectus, and accounts for the majority of sudden-onset diplopia in middle-aged women. Therefore a thorough evaluation of the ocular motility is essential. Fibrosis of the inferior rectus muscle can also be associated with an increased intraocular pressure elevation of more than 10 mm Hg when, on attempted up-gaze, the superior rectus pulls against a tight inferior rectus, compressing the globe. Demonstrating this variation of intraocular pressure from the primary position and on attempting up-gaze strongly supports inferior rectus contracture.



The most common cause of unilateral and bilateral proptosis in an adult is thyroid-related orbitopathy. This is not true for children in whom bilateral disease is usually from tumor and unilateral disease from infection. Although Graves' disease and Hashimoto's thyroiditis account for the largest proportion of patients with bilateral proptosis, the disorder can also be produced by neoplastic, vascular, and inflammatory processes and by infections, granulomatous processes, and other endocrine (Cushing's and acromegaly) diseases. The term *dysthyroid ophthalmopathy* is used to include all forms of thyroid disease. Of course, pseudoproptosis (e.g., from a highly myopic globe), rectus paralysis, contralateral enophthalmos, asymmetric orbital size, or fissures must be excluded. Thus, the diagnosis of Graves' ophthalmopathy can be made only by carefully excluding other possible causes of proptosis.

### LABORATORY STUDIES FOR THYROID-RELATED ORBITOPATHY

The American Thyroid Association (ATA) issued updated guidelines for the use of laboratory tests in thyroid disorders. The emergence of highly sensitive thyrotropin (thyroid-stimulating hormone [TSH]) assays, capable of clearly separating normal from subnormal serum TSH levels, constitutes a practical and significant laboratory advance in clinical thyroidology. One should first measure the serum TSH level using a second- or third-generation immunometric assay with a sensitivity equal to or less than 0.01 mU/l, such as the TSH immunoradiometric assay or the sensitive TSH assay. This method of directly measuring the TSH levels permits a more rapid diagnosis of the thyroid status. Many of the older tests are less commonly used because of the advance of direct TSH evaluation. The free thyroxine ( $T_4$ ) used to measure unbound  $T_4$  in serum is not as reliable as the sensitive TSH. Likewise, the triiodothyronine ( $T_3$ ) resin uptake used to estimate  $T_4$ -binding hormone capacity is relatively insensitive and inaccurate. Finally, the free  $T_4$  index, a mathematical calculation using  $T_3$  resin uptake and total  $T_4$  ( $tT_4/T_3$ ) to estimate unbound  $T_4$  in serum, does not always correct for binding anomalies and is less sensitive than the sensitive TSH assay.

Once the TSH level is determined, the interpretation and additional testing are usually straightforward. Measurement of the TSH level is the only initial test necessary in a patient with a possible diagnosis of dysthyroid disease without evidence of pituitary disease. If patients have a normal TSH level, they are euthyroid. If their TSH level is elevated, they are hypothyroid. If the TSH level is low, implying hyperthyroidism, the  $tT_4$ , which indicates total  $T_4$  (bound and free) in serum, is measured. The results are affected by binding anomalies; the  $tT_4$  may show false elevations in pregnancy, with oral contraception, with estrogen therapy, in hepatitis, and in those patients with a congenital excess of thyroid-binding globulin.

The  $tT_4$  may be falsely reduced with congenital deficiencies of thyroid-binding globulin, with testosterone or corticosteroid therapy, with drugs that bind to thyroid-binding globulin, or in those who are severely ill. If the  $tT_4$  is normal and the TSH is low, the total  $T_3$  ( $tT_3$ ) test may be analyzed for issues of thyroid-binding globulin binding problems or patients with thyrotoxicosis. The  $tT_3$  test measures  $tT_3$  in serum and is less subject than  $tT_4$  to binding abnormalities. It is more useful after the diagnosis of hyperthyroidism.

The radioactive iodine (RAI) uptake and thyroid scan are nonroutine tests. The RAI uptake test is used to diagnose the cause of hyperthyroidism and is particularly useful in calculating the dose when iodine is used in treatment. Radionucleotide uptake and scan easily distinguish the high uptake of Graves' disease from the low uptake of thyroiditis. A thyroid scan is useful in identifying those areas of the thyroid in which thyroid function is altered from singular or multiple nodules of the gland. Malignancy should be considered in cases with active or multiple nodules. Thyroid autoantibody measurements are specialized tests used to identify immunologic forms of thyroid disease. A complete discussion of thyroid autoantibodies is beyond the scope of this text.

### EPIDEMIOLOGY OF THYROID-RELATED ORBITOPATHY

In 1960 three phases found in thyroid-related orbitopathy were described: the initial dynamic phase, a static phase, and a final quiescent phase. The dynamic phase results in eyelid retraction and proptosis. The static phase shows little improvement. The quiescent phase can show some improvement in eyelid retraction and ocular motility.

There are two basic categories of thyroid-related orbitopathy: infiltrative and noninfiltrative. Approximately 90% of patients have noninfiltrative disease. Noninfiltrative (class 1) thyroid-related eye disease is characterized by the mildest form of ocular involvement, with eyelid retraction but minimal proptosis. This occurs in up to 50% of patients with toxic diffuse goiter and can begin at any age, but patients tend to be younger, and female persons outnumber male persons in a ratio of up to 6:1.

Recent data suggest that thyroid orbitopathy is a disease most common in younger women but more severe, by most indices, in men and patients older than 50 years. These latter patients are also more likely to have asymmetric or euthyroid manifestations of the disease.

Smoking is a risk factor for Graves' hyperthyroidism and worsening orbitopathy in women. The relationship was also dose dependent. Those with the highest risk of Graves' hyperthyroidism were women with the greatest number of pack years of smoking and current smokers who smoked the most cigarettes per day. The mechanism by which smoking increases the risk of Graves' orbitopathy remains unknown.

Graves' ophthalmopathy develops in more than 80% of cases within 6 months of the diagnosis of Graves' hyperthyroidism. Graves' ophthalmopathy may occasionally develop before the diagnosis of hyperthyroidism. Thyroid-related orbitopathy is associated with Graves' hyperthyroidism in 90% of cases and with autoimmune thyroiditis (Hashimoto's disease) in some 5%. No laboratory evidence of thyroid disease is found in 5% to 10% of patients. This condition is called ophthalmic or euthyroid Graves' ophthalmopathy.

## **ETIOLOGY OF THYROID-RELATED ORBITOPATHY**

Although the precise etiology of Graves' ophthalmopathy is not well understood, a basic knowledge of the pathology associated with the disease is essential for an understanding of the mechanisms of action of the various drugs and other therapeutic modalities used in managing this disorder. The ocular involvement associated with dysthyroid state is primarily an orbital disease, and pressure-volume relations within the orbit are critical in the pathogenesis of Graves' ophthalmopathy. The most striking pathologic feature of thyroid-related orbitopathy is the marked enlargement of the extraocular muscles.

This enlargement is accompanied by mononuclear cell infiltration and proliferation of orbital fibroblasts. These cells release cytokines coincident with increased production of collagen and glycosaminoglycans into the interstitial space of extraocular muscle fibers, orbital fat, and orbital connective tissue. The activated T cells, directed against thyroid follicular cell antigens, are thought to interact with the orbital fibroblasts. The result is an increase in edema of these tissues and degenerative changes within the muscle cells. The current view is that thyroid-related orbitopathy is a T-cell-mediated autoimmune disease. Activated T cells releasing the cytokines interleukin-1 $\alpha$ , interferon- $\gamma$ , and tumor necrosis factor- $\beta$  stimulate retroorbital fibroblast glycosaminoglycan production, with attendant edema, swelling of the muscles, and an increase in retroorbital tissue. These inflammatory changes result in the clinical manifestations of ophthalmopathy; proptosis, and many of the other signs of Graves' ophthalmopathy. It was hypothesized that almost all the secondary effects of thyroid-related orbital infiltration are circulatory and that the visual field loss and color vision dysfunction are typical of optic nerve involvement either by direct compression or by interference with vascular circulation.

The role of the immune system in the pathophysiology of Graves' disease is well established. A considerable amount of information links the human major histocompatibility complex (human leukocyte antigen [HLA]) with Graves' disease. For instance, several HLA types, such as HLA-B8 and HLA-DR3, are associated with this disorder. Graves' disease in the Japanese has been found to be associated with HLA-B35, whereas in patients of Chinese

origin HLA-Bw46 confers a greater risk. Risk ratios indicating an increased probability for patients to develop Graves' hyperthyroidism range from three- to fivefold, which suggests a relatively weak association. No specific gene has been found to date.

Thyroid orbitopathy is an inflammatory disease of the orbital tissues. This inflammation is mediated through cytokine release, proliferation of fibroblasts, increased deposition of extracellular matrix, and adipocyte differentiation and proliferation. These cellular changes result in enlargement of the extraocular muscles and increased volume of orbital soft tissues, which presents clinically as exophthalmos and optic nerve compression. Edema, inflammation, and late fibrosis account for the decreased function of the extraocular muscles despite relative preservation of the muscle fibers themselves.

## **CLASSIFICATION OF GRAVES' OPTHALMOPATHY**

The clinical presentation of Graves' orbitopathy can be subdivided into predominantly "congestive" orbitopathy and "inflammatory" orbital myopathy. Predominantly congestive orbitopathy (type I) accounts for approximately 30% of all cases. It is characterized by inflammatory infiltration of the orbital connective tissues and orbital fat with relative sparing of the extraocular muscles. The infiltration, which causes inflammation, is often associated with edema and may, if severe, progress to fibrosis. These patients have less diplopia and pain with milder proptosis. The inflammatory orbital myopathy (type II) presents in about 10% of patients with inflammation, swelling, and dysfunction of the extraocular muscles complaining of painless diplopia. The inflammatory form appears to attack the extraocular muscles as the primary target. The process is characterized by white blood cell infiltration of orbital fibroadipose and skeletal muscle tissue. These patients experience diplopia, orbital pain, and proptosis and may require surgical intervention. A combination of these two subtypes is found in the remainder of the patients.

There are two main grading systems used today for Graves' orbitopathy: NOSPECS, developed and used by most endocrinologists, and the Clinical Activity Score, which places greater emphasis on inflammatory changes found in Graves' orbitopathy. For simplicity, we discuss and use the NOSPECS grading system for Graves' orbitopathy.

To achieve uniformity in terminology regarding the various ocular changes associated with thyroid disease, in 1968 the ATA adopted an initial classification of the ocular changes of Graves' disease. Various modifications to the original classification system have been proposed, and one by an endocrinologist has been approved by the ATA (Tables 32-1 and 32-2). Each class usually (but not necessarily) includes the changes indicated in the preceding class. This classification, however, suffers from

**Table 32-1**

Abridged Classification of the Eye Signs in Graves' Disease

Class	Definition (mnemonic "NOSPECS")
0	No physical signs or symptoms
1	Only signs, no symptoms (e.g., upper eyelid retraction, stare, and eyelid lag)
2	Soft tissue involvement (symptoms and signs)
3	Proptosis
4	Extraocular muscle involvement
5	Corneal involvement
6	Sight loss (optic nerve compression)

Reprinted with permission from Werner SC. Modification of the classification of the eye changes of Graves' disease. *Am J Ophthalmol* 1977;83:725-727; and ETA, LATS, Japanese-AOTA, ATA. Classification of eye changes of Graves' disease. *Thyroid* 1992;2:235-236.

several flaws. There is a lack of natural progression from one class to the next. Also, the classification fails to distinguish between the active and inactive forms of the disease. Finally, there seems to be a poor relationship between the class designation and the severity of the ophthalmopathy. The first letters of each definition form the mnemonic NOSPECS, with *NO* indicating the usually nonthreatening prognosis of classes 0 and 1 and *SPECS* indicating the relatively serious nature of classes 2 through 6.

The ATA and the European, Latin-American, and Japanese and Asia-Oceania thyroid associations reexamined the content and applications of the NOSPECS classification, reaching consensus on the following points. First, the NOSPECS classification is an ingenious memory aid for clinical examination of the orbital changes of Graves' disease, has useful educational application, and is descriptive of the ocular changes that occur in the disease process. Second, the classification and its numeric indices are less satisfactory for objective assessment of the orbital changes of Graves' disease and for reporting results of clinical studies. Regarding the evaluation of treatment response, specific and separate measurements relating to the status of eyelids, cornea, extraocular muscles, proptosis, and optic nerve function should be recorded.

An assessment of inflammatory activity of Graves' ophthalmopathy is relevant to therapy. Disease activity at any one time may be assessed by assigning one point to each of the following signs and symptoms: spontaneous retrobulbar pain, pain on eye movement, eyelid erythema, conjunctival injection, chemosis, swelling of the caruncle, and eyelid edema or fullness. The sum of these points defines the clinical activity score (range, 0 to 7). The clinician should realize that activity scores are untested and subjective. Finally, an important element in evaluating the effects of treatment of Graves' ophthalmopathy is the patient's self-assessment. Such assessments, described on

**Table 32-2**

Detailed Classification of the Eye Changes of Graves' Disease

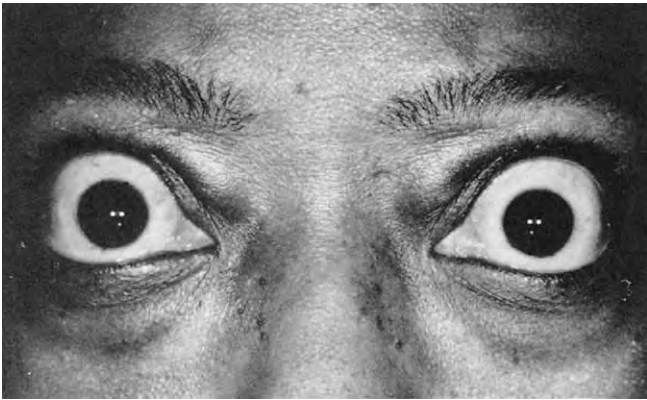Class	Grade	Suggestions for Grading
0		No physical signs or symptoms
1		Only signs
2		Soft tissue involvement with symptoms and signs
	0	Absent
	a	Minimal
	b	Moderate
	c	Marked
3		Proptosis 3 mm or more in excess of upper normal limits, with or without symptoms
	0	Absent
	a	3- to 4-mm increase over upper normal
	b	5- to 7-mm increase
	c	8-mm or greater increase
4		Extraocular muscle involvement; usually with diplopia, other symptoms, and other signs
	0	Absent
	a	Limitation of motion at extremes of gaze
	b	Evident restriction of motion
	c	Fixation of globe (unilateral or bilateral)
5		Corneal involvement primarily caused by lagophthalmos
	0	Absent
	a	Stippling of cornea
	b	Ulceration
	c	Clouding, necrosis, perforation
6		Sight loss caused by optic nerve involvement
	0	Absent
	a	Disc pallor or choking, or visual field defect; acuity 6/6 (20/20)–6/18 (20/60)
	b	Same; acuity 6/22 (20/70)–6/60 (20/200)
	c	Blindness (failure to perceive light), acuity less than 6/60 (20/200)

Reprinted with permission from Werner SC. Modification of the classification of the eye changes of Graves' disease. *Am J Ophthalmol* 1977;83:725-727.

scales of best to worst, should include appearance, visual acuity, eye discomfort, and diplopia.

### Class 1 Disease

Class 1 disease, formerly termed mild or noninfiltrative disease, is characterized by upper eyelid retraction (Figure 32-1) and occurs in more than 90% of patients with hyperthyroidism. This sign may initially occur unilaterally or bilaterally and is often asymmetric. A helpful diagnostic sign often associated with eyelid retraction is the lid tug sign, in which the retracted upper lid offers a sensation of increased resistance on attempted manual lid



**Figure 32-1** Upper eyelid retraction characteristic of class 1 Graves' ophthalmopathy.

closure (Grove's sign). The resistance to eyelid closure is noted by simply grasping the lashes of the upper lid and gently pulling down. The amount of resistance is compared with the contralateral lid in unilateral cases or with a control normal eyelid in cases of bilateral lid retraction. This test is particularly helpful in cases of questionable bilateral retraction or ambiguous unilateral retraction versus contralateral ptosis.

Eyelid retraction can produce findings in several associated tests that may correlate with the onset of the ophthalmopathy. Marginal reflex distance can be used to assess upper eyelid retraction. A light source is placed in front of a patient in primary gaze to produce a corneal reflex. This distance between the corneal reflex and the upper eyelid margin is measured. The normal measurement is 4 to 5 mm. Another possible finding is a reduction in the tear breakup time of one or both eyes. Eyelid retraction causes an increase in the ocular surface area that must be covered by the tear film, and there is an associated decrease in blink frequency in Graves' patients. An increase in tear osmolarity also affects the mechanics of tear stability in these patients. The combination of these factors affects stability of the tear film.

The most common cause of eyelid retraction is hyperthyroidism. Although eyelid retraction most frequently is associated with Graves' ophthalmopathy, other diseases may cause this sign, especially if normal thyroid function and regulation are confirmed. There are four major hypotheses for the pathogenesis of thyroid-associated lid retraction. First, in the early stages there is excessive stimulation of Müller's muscle in the upper eyelid associated with sympathetic stimulation and increased levels of thyroid hormone resulting from the marked inhibition of liver monoamine oxidase synthesis by high circulating  $T_4$  levels. Second, in long-standing Graves' disease the inferior rectus muscle becomes fibrotic. The superior rectus-levator muscle complex must overcontract on attempted up-gaze to counteract the fibrotic inferior rectus muscle. Third, there is mechanical restriction of the levator muscle, with increased orbital volume that

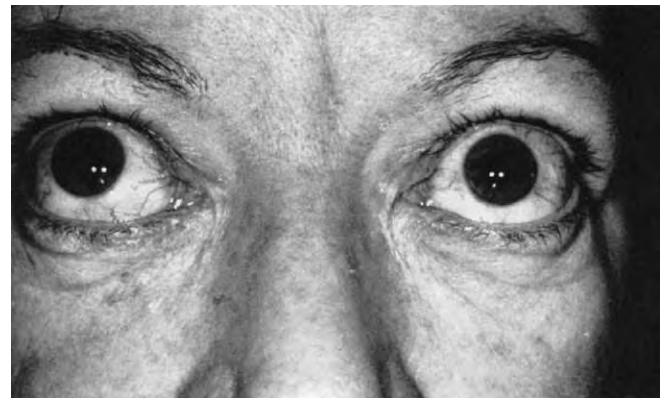causes anterior displacement of the globe, resulting in further eyelid retraction.

There is negligible lymphocytic infiltration, and the extracellular volume is not increased in the levator muscle. However, the muscle fibers become greatly enlarged, leading to hypertrophy of the levator muscle and upper eyelid retraction.

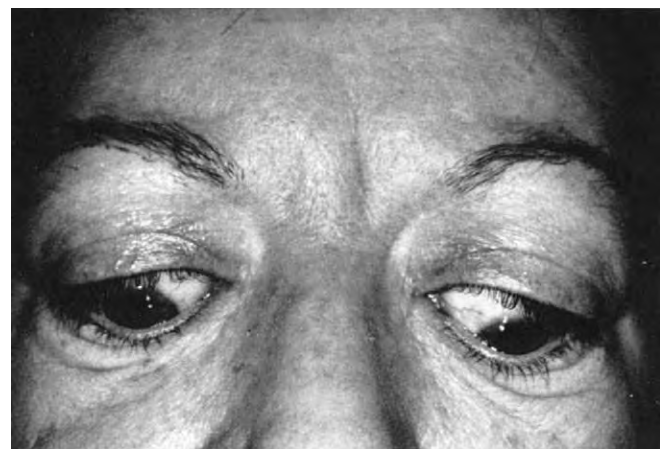Lid retraction can appear in the presence of chemical and clinical euthyroidism and is often unrelated to control of any existing thyroid dysfunction. Eyelid lag (von Graefe's sign) often accompanies lid retraction (Figure 32-2), but lid lag by itself is not pathognomonic of thyroid eye disease. Lid retraction disappears spontaneously after 15 years in approximately 60% of patients.

### **Class 2 Disease**

Classes 2 through 6 of the disease, congestive orbital disease, represent the more significant and vision-threatening changes associated with Graves' disease. Some important clinical signs of class 2 disease are swelling of the eyelids; prolapse of orbital fat, nasally in the upper lid and temporally

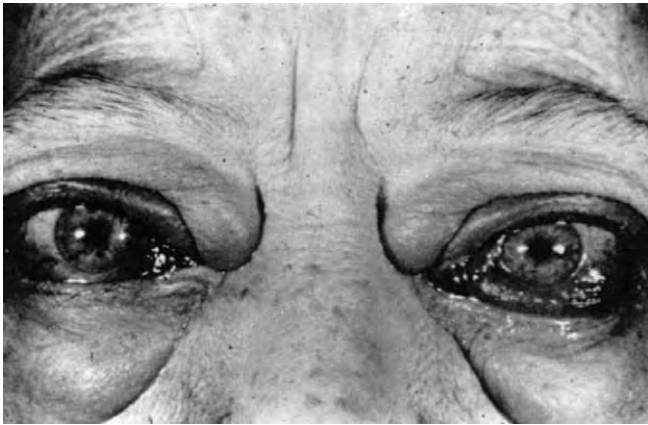

A



B

**Figure 32-2** Eyelid lag (von Graefe's sign). After extreme up-gaze (A), the upper eyelids remain retracted and fail to assume their normal depressed position on down-gaze (B).

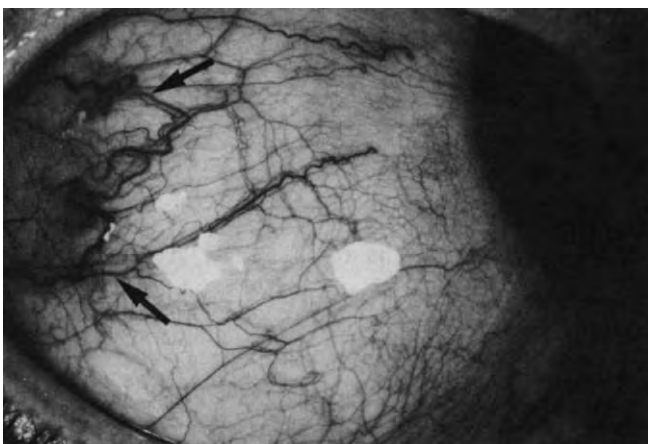


**Figure 32-3** Class 2 Graves' ophthalmopathy with upper and lower eyelid swelling, injection of conjunctival and episcleral vessels, and chemosis.

in the lower lid; a palpable lacrimal gland; injection of the conjunctival and episcleral vessels; and chemosis (Figure 32-3). These changes result in symptoms of lacrimation, light sensitivity, and gritty or sandy foreign body sensation. Orbital inflammation and edema during sleep may make these symptoms worse in the morning upon awakening. Contact lens patients may complain of sudden intolerance to lens wear. Graves' patients usually develop systemic symptomatology before or simultaneously with observable ocular signs. Inflammation and hypertrophy of the extraocular muscles (Figure 32-4) are common and are of diagnostic value in those patients even without observable proptosis.

### Class 3 Disease

The incidence of proptosis in patients with hyperthyroidism is high, with estimates ranging from 40% to 75%. Class 3 Graves' ophthalmopathy is defined as at least



**Figure 32-4** Inflammation and early hypertrophy (*arrows*) of the insertion of the lateral rectus muscle in a patient with class 2 Graves' ophthalmopathy. White spots in center are photographic artifacts.

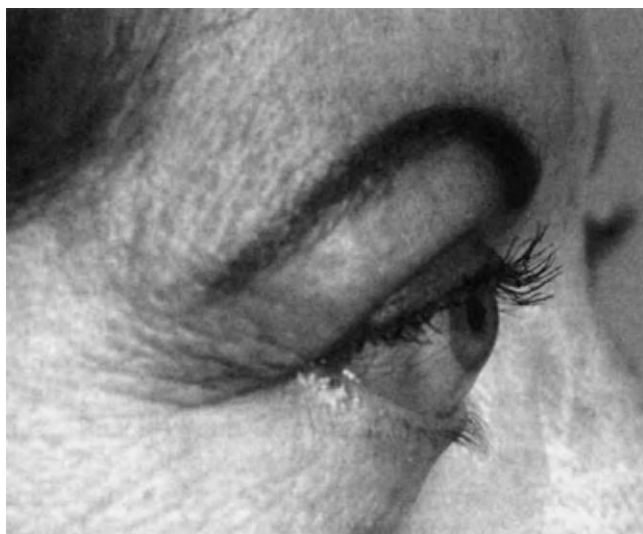23 mm of proptosis. The proptosis is almost never an isolated finding and is commonly associated with soft tissue findings and extraocular muscle involvement. If proptosis is the only presenting complaint, other etiologies of orbital disease should be investigated. Two-thirds of patients with Graves' ophthalmopathy develop exophthalmometry readings of 23 mm or more. Although computed tomography (CT) and ultrasonography (US) evaluations reveal extraocular muscle involvement, the degree of proptosis does not necessarily parallel the severity of the orbital inflammatory process. One mechanism for proptosis associated with thyroid orbitopathy has been partially clarified. Increased orbital deposition of glycosaminoglycans (mucopolysaccharides) occurs as the result of both hormonal and immunologic mediators. Approximately 50% of thyroid patients have an increase in orbital fat, and of these patients 10% show this increase as the only sign on CT or magnetic resonance imaging (MRI) examination. The proptosis may give rise to secondary lagophthalmos (Figure 32-5). Additionally, ocular hypertension in patients with Graves' ophthalmopathy is caused, in part, by increased intraorbital pressure associated with proptosis.

Like eyelid retraction, proptosis can begin unilaterally and should therefore be differentiated from the apparent proptosis simulated by unilateral lid retraction. This distinction can often be accomplished clinically by measurement using the Luedde or Hertel exophthalmometer, with which the upper limits of normal are approximately 18 mm for Asians, 20 mm for whites, and 23 mm for blacks (Table 32-3). A 2-mm or greater difference between eyes should be considered abnormal and justification for further study. Another helpful test is palpable retropulsion. With patients' eyes closed, digital palpation of the globes results in less detectable resistance in thyroid orbital disease as opposed to a greater resistance from an orbital tumor. Because hyperthyroidism is the most common cause of unilateral proptosis, the investigation of unilateral proptosis in patients without other signs of Graves' ophthalmopathy should include serum TSH levels. The degree of proptosis does not correlate well with compressive optic neuropathy. One might encounter compressive optic neuropathy with very mild proptosis in patients with shallow orbits.

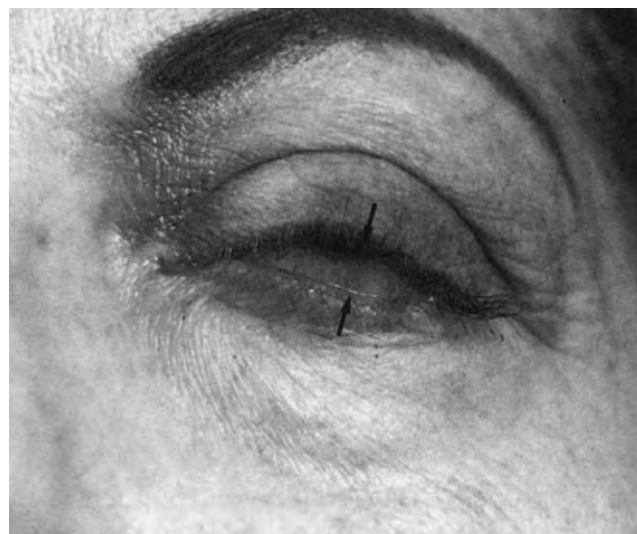### Class 4 Disease

Approximately 14% of patients with thyrotoxicosis and 33% of patients with Graves' ophthalmopathy develop class 4 involvement, in which the inflammatory changes result in loss of elasticity and fibrosis of the extraocular muscles. The usual diplopic pattern in symptomatic patients is hypertropia with or without esotropia. The esotropia is due to involvement of the medial rectus muscle. Exotropia is so uncommon in Graves' orbitopathy that one should suspect myasthenia gravis as a possible etiology in acquired exotropia. Myasthenia gravis has





A



B

**Figure 32-5** Fifty-eight-year-old woman with class 3 Graves' ophthalmopathy. (A) Proptosis of 28 mm measured with the Hertel exophthalmometer. (B) Secondary lagophthalmos (arrows).

no set pattern of extraocular muscle involvement. It can mimic any ocular motor cranial nerve palsy or central gaze disturbance. Thyroid eye disease usually starts with an “elevator palsy” due to inferior rectus involvement followed by a set pattern of recti muscle involvement with the lateral recti muscle being much less involved. More than 90% of Graves' patients have US and/or CT evidence of extraocular muscle involvement. Most commonly, patients with class 4 disease are women between the ages of 40 and 60. Characteristically, on US or CT the muscle belly is enlarged, but the disease process spares the tendinous portion near the insertion, allowing differentiation from myositis.

Electromyography and saccadic velocity studies demonstrated that the mechanical restriction of the eye is caused by interstitial edema and fibrosis of the muscles rather than by myopathy. However, in the acute phases of Graves' orbitopathy saccadic velocity testing demonstrates a neuropathic state, which resolves on fibrosis.

**Table 32-3**

Exophthalmometry Values in Healthy Adults

Race and Gender	Mean (mm)	Upper Limit of Normal (mm)
White male	16.5	21.7
White female	15.4	20.1
Black male	18.5	24.7
Black female	17.8	23.0
Asian male	14.0	18.6
Asian female	14.0	18.6

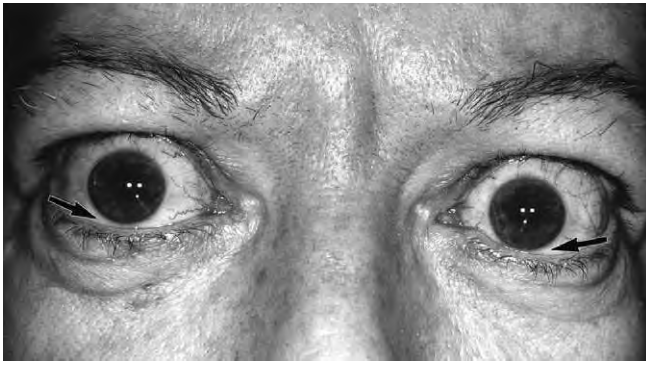Adapted from Migliori ME, Gladstone GJ. Determination of the normal range of exophthalmometric values for black and white adults. *Am J Ophthalmol* 1984;98:438-442.

The most common muscle to be involved is the inferior rectus, which is affected in 60% to 70% of cases (Figure 32-6). Twenty-five percent of patients have a fibrotic medial rectus muscle, and only 10% or fewer demonstrate a fibrotic superior rectus muscle. CT, MRI, and US demonstrate more generalized extraocular muscle enlargement than can be appreciated clinically, yet examination generally reveals greater inferior and medial recti involvement. Differentiating a fibrotic muscle from paresis of its antagonist is essential and can be achieved by performing a forced duction test, as described in Chapter 19. It is unclear why oblique muscle involvement in the disease process is rare.

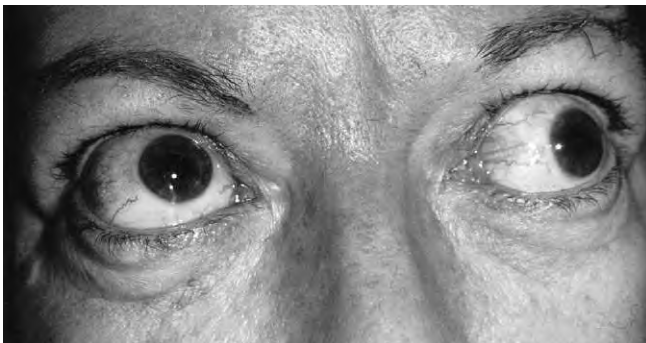Because the inferior rectus muscle usually undergoes fibrosis early, attempted up-gaze exerts traction on the globe, which elevates the intraocular pressure (Braley's sign). This phenomenon occurs in approximately 20% of patients with Graves' disease and indicates fibrosis of the inferior rectus muscle; more importantly, the absence of glaucoma can be confirmed on visual field testing, performed to rule out optic nerve compression.

### Class 5 Disease

Class 5 involvement poses a significant threat to visual function because of exposure keratopathy secondary to lagophthalmos and proptosis (Figure 32-7). Corneal exposure may be particularly severe if there is significant upper eyelid retraction, proptosis, and an abolished Bell's reflex associated with fibrosis of the inferior rectus muscle and limitation of up-gaze. Most patients with proptosis greater than 23 mm show staining of the inferior cornea on careful biomicroscopic examination. Staining of the central cornea should alert the examiner to potential exposure keratitis. Unless the disorder is



A

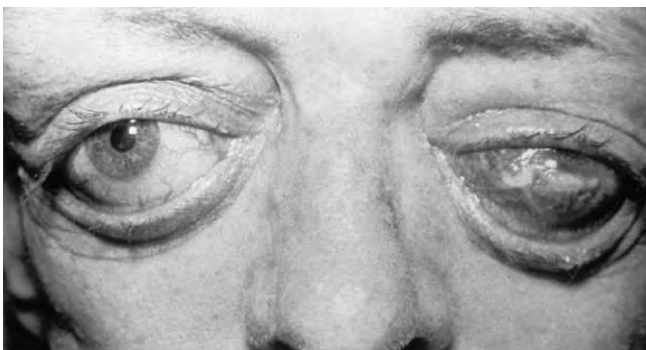

B

**Figure 32-6** (A) Note the asymmetry of visible sclera above each lower eyelid (*arrows*). By prism measurement this patient has an 8D left hypotropia in primary gaze. (B) Restriction of the left inferior rectus muscle on gazing up and left.

managed aggressively secondary corneal ulceration can ensue, with the potential risk of endophthalmitis.

Superior limbic keratoconjunctivitis is associated with thyroid dysfunction and appears to be a prognostic marker for severe Graves' ophthalmopathy. Approximately one-half of patients with superior limbic keratoconjunctivitis have eyelid retraction and one-half have eyelid lag. Whether eyelid retraction is causative or merely associated is unclear. Several patients exhibited resolution of the superior limbic keratoconjunctivitis after eyelid retraction surgery or orbital decompression.



**Figure 32-7** Severe exposure keratopathy of the left eye of a patient with class 5 Graves' ophthalmopathy.

### Class 6 Disease

The incidence of optic neuropathy in thyroid eye disease is 5% to 10%. The class 6 patient usually has mild to moderate proptosis and relatively shallow orbits. Thyroid optic neuropathy may be evidenced by papilledema, papillitis, or retrobulbar neuritis and usually is characterized by a painless and gradual loss of visual acuity. Common visual field defects include central scotomas, arcuate or altitudinal defects, paracentral scotomas, or generalized depressions. Thus visual field and optic disc examinations are the best diagnostic tools for early optic neuropathy. Occasionally, vision loss can occur precipitously over 1 or 2 weeks. Other features of optic nerve dysfunction frequently associated with the decreased visual acuity are color vision disturbances, afferent pupillary defects in the less proptotic eye in patients with asymmetric involvement, and prolongation of the pupil cycle time.

Recent CT and MRI studies showed that increased extraocular muscle volume correlates with compressive optic neuropathy as well. Although some patients show inflammation of the nerve and sheath, it has been postulated that these patients have shallow orbits or that they lack the ability to decompress anteriorly. Patients at greater risk of developing optic neuropathy are older patients with enlarged extraocular muscles and limited motility. Diabetic patients with proptosis and extraocular muscle enlargement are also more likely to develop optic neuropathy.

### DIAGNOSTIC IMAGING OF THE ORBIT

High-resolution orbital imaging using high-resolution CT, MRI, and US has significantly simplified the differential diagnosis of proptosis by eliminating such causes as orbital tumors or idiopathic myositis and often establishing the bilateral nature of the disease. High-resolution CT and MRI are now used in most centers. Both techniques work well in the critical area of the orbital apex, where US is less applicable. An advantage of MRI over CT is that MRI demonstrates tissue differentiation better than does CT. However, MRI requires a longer examination time and is somewhat more expensive.

Orbital US examination, CT, and MRI are the most helpful noninvasive techniques for the diagnosis of Graves' ophthalmopathy. Advances in US and high-resolution CT with supplemental multiplanar computer-generated reformations have significantly increased the ability to predict the location of most orbital pathology. Pulse sequences that examine  $T_2$ -weighted MR images can estimate water content of orbital tissues. When examining the extraocular muscles, normal  $T_2$  images might imply burned out fibrotic disease with low water content, whereas prolonged  $T_2$  images might suggest ongoing inflammation with tissue edema possibly amenable to immunosuppressive medications or orbital radiation. These procedures are particularly valuable when the



patient is clinically and chemically euthyroid, because they may demonstrate evidence of enlarged extraocular muscles before clinical signs and symptoms arise.

CT and MRI confirm the diagnosis of Graves' ophthalmopathy in euthyroid patients and in those with atypical or severe clinical manifestations, including compressive optic neuropathy. The extraocular muscle enlargement is seen to occupy the nontendinous (belly) portion of the muscles (Figure 32-8). Advantages of MRI over CT include higher spatial resolution, absence of bone artifacts, direct multiplanar imaging, and increased tissue contrast. However, consideration must be given to the fact that CT is often more readily available than MRI.

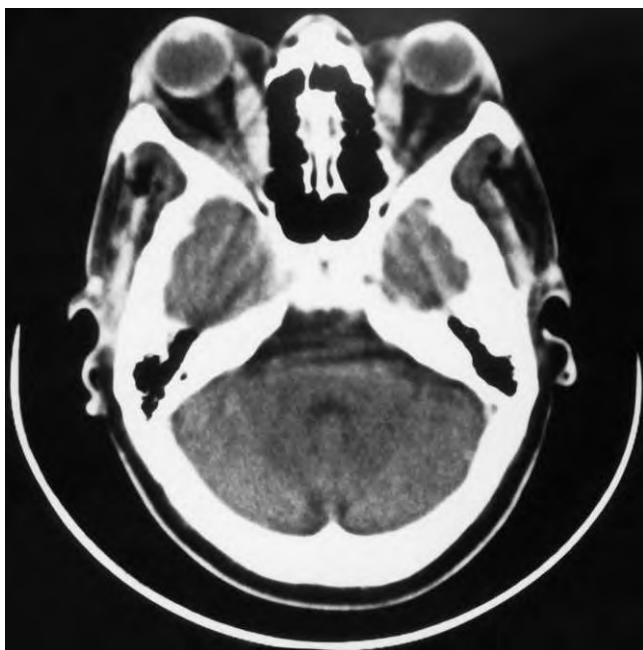
Orbital US, CT, and MRI are commonly used as imaging techniques to demonstrate pathologic changes in the orbital tissue in Graves' patients. Low cost, short time investigation, and lack of radiation characterize orbital US, a technique that should be given consideration by the health provider. When orbital disease activity or exclusion of orbital pathology is required, CT or MRI is particularly useful for these diagnostic purposes. Additionally, sudden visual acuity or field loss in a known thyroid patient requires CT or MRI to demonstrate possible optic nerve compression at the apex of the orbit.

OctreoScan has the unique ability to detect octreotide, a somatostatin analogue labeled with indium. This scan

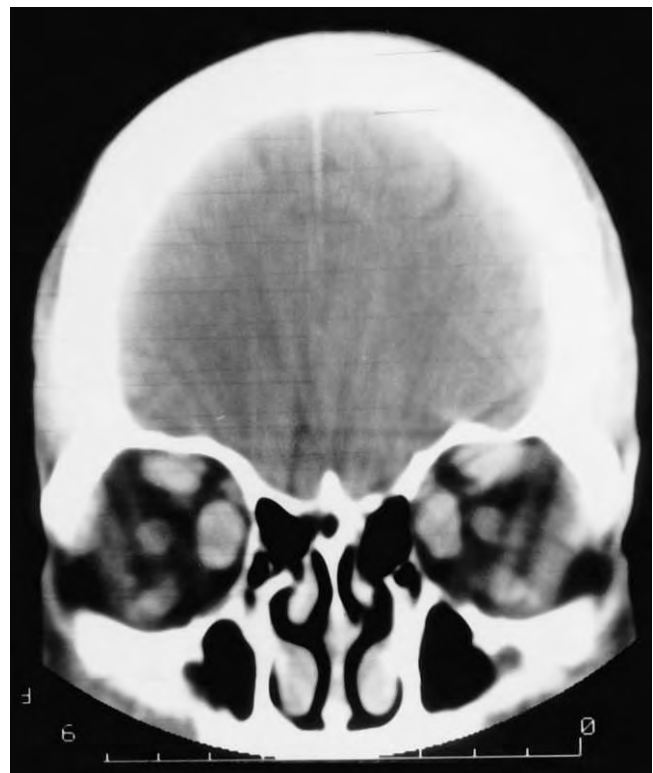technique has been used to localize tumors that possess membrane receptors for somatostatin *in vivo* and predict the inhibitory effect of octreotide on hormone secretion by these tumors. OctreoScan has been used to detect accumulation of the radionucleotide in both the thyroid gland and orbits of patients with Graves' disease.

### CLINICAL COURSE OF GRAVES' OPHTHALMOPATHY

The orbitopathy has both an active and quiescent stage. The active stage lasts between 6 and 24 months and includes a wide spectrum of orbitopathy changes and patient symptomatology. The quiescent stage may include patient improvement in both orbitopathy and symptomatology and can last for many years. The clinical manifestations of ophthalmopathy do not correlate with the thyroid disease course or activity. The ocular changes may appear before, during, or after the onset of thyrotoxicosis but usually occur within 18 months before or after the diagnosis of hyperthyroidism. It was asserted that ocular involvement, even if subclinical, is an inevitable complication of Graves' disease. All classes of ocular changes occur in euthyroid Graves' disease as well as in the euthyroid phase of hyperthyroidism. The course and duration of changes in classes 2 through 6 are extremely unpredictable,



A



B

**Figure 32-8** Computed tomography of the orbit in a patient with Graves' ophthalmopathy. (A) Proptosis and markedly enlarged extraocular muscles. (B) Coronal view showing extraocular muscle enlargement.

with progression from class 1 to class 6 often being irregular. Progression from class 1 through class 6 occurs in approximately 5% of patients, even after subtotal thyroidectomy or RAI therapy. The onset is usually subacute, with one eye frequently being affected before its fellow. The natural history of the ocular disease from onset to spontaneous remission usually covers 6 months to 3 years (mean, 2 years), after which the patient usually manifests a residual eyelid retraction, lid fullness, proptosis, and fibrotic changes of the extraocular muscles. Because of the tendency for Graves' ophthalmopathy to undergo spontaneous remission, medical or surgical treatment is intended to prevent permanent ocular damage rather than to arrest or retard progression of the disease process.

## **MANAGEMENT OF GRAVES' OPHTHALMOPATHY**

Because the natural history of Graves' ophthalmopathy is to undergo spontaneous remission, evaluating the effectiveness of various forms of treatment is sometimes difficult. Also, one must know the phase in which the patient is identified because this, too, affects the treatment. With the knowledge that some eyes are lost solely due to failure to provide treatment, appropriate therapeutic measures may serve to reduce the risk to visual function and provide the patient with symptomatic relief.

The management of noninfiltrative disease should be conservative. This approach should include patient education, reassurance, and treatment of any underlying thyroid abnormality and regular follow-up to provide treatment for dry eye. The disorder may not be truly quiescent for 2 to 3 years. After this point, if the symptoms are stable, surgical intervention for residual diplopia or other orbital changes may be considered.

The management of infiltrative disease should be appropriately aggressive. The presence of active class 2 through class 6 disease calls for prompt treatment as soon as the diagnosis is confirmed. Because the clinical manifestations of class 2 through class 6 disease are mostly caused by loss of critical orbital volume, therapy should be directed to rapidly restoring those relations toward normal. These patients are more likely to develop compressive optic neuropathy. They also tend to be older and have subsequent motility disorders. Patients with infiltrative disease and proptosis are less at risk, and they frequently do not require surgical decompression, because the proptosis is a decompressing event. However, those patients with infiltrative disease and no proptosis are most likely to need urgent irradiation and anti-inflammatory therapy. This represents a major difference between Graves' orbitopathy and other causes of proptosis.

Regardless of the stage of ocular involvement, certain general principles of management apply. Because most patients with Graves' ophthalmopathy go through a period of initial worsening followed by a plateau of variable length and, finally, spontaneous improvement,

patients should be monitored more closely if they are in the worsening phase. If spontaneous improvement is occurring, more vigorous forms of treatment, such as surgery or high-dose steroids, should be withheld.

Many patients, if relieved of the fear of losing vision, are willing to accept surprising degrees of cosmetic change and sometimes demanding treatment modalities. Several studies showed that patients with severe eye signs smoked significantly more tobacco than did those with less serious signs. Advising the patient that smoking cessation might have a positive impact on both the hyperthyroid status and the orbitopathy is very important in the treatment of the disease.

The patient should be advised of the marked variations in the course of the ocular disease and its relatively imprecise association with the status of the thyroid gland. This information may reassure the patient and maintain rapport between the practitioner and patient if the condition worsens in its later stages.

A major problem in devising effective treatment has been an inadequate understanding of the factors that cause the ocular disease. Despite this lack of knowledge, management of Graves' ophthalmopathy involves treating the thyroid dysfunction, relieving ocular pain and discomfort, restoring and protecting vision, and improving cosmetic appearance. The following recommendations are representative of the most effective treatment modalities currently available.

## **Management of Thyrotoxicosis**

As part of the treatment of Graves' ophthalmopathy, adequate control of the dysthyroid state, if it exists, is essential. The antithyroid drugs propylthiouracil (PTU) and methimazole (MMI), <sup>131</sup>I, and thyroidectomy are the three major modalities used in the treatment of hyperthyroidism. In addition,  $\beta$ -adrenergic blocking agents, such as propranolol, are useful for the rapid control of sympathetic nervous system manifestations. Nonselective beta-blockers such as propranolol are preferred because they have a more direct effect on hypermetabolism. There is general agreement that the hyperthyroid state and the ocular disease may run independent courses. Although control of hypermetabolism is necessary, this control does not ensure that the ophthalmopathy will improve concomitantly with treatment of the thyroid imbalance. However, it is essential in the treatment of the thyrotoxicosis to bring the patient gradually to euthyroidism by avoiding abrupt and exaggerated changes in the thyroid state. The ocular changes may be more likely to progress after systemic treatment that causes rapid alteration in thyroid function. Consultation with an endocrinologist is considered standard of care.

Results of survey studies among thyroid specialists who treat Graves' hyperthyroidism in Europe, Japan, or the United States showed consensus only on the relative lack of a role of thyroidectomy, except for narrow indications.

Graves' hyperthyroidism in the United States is treated in most adults (69%) with  $^{131}\text{I}$ , whereas the remaining patients receive treatment with the antithyroid drugs PTU or MMI. Conversely, antithyroid drugs are used in Europe (77%) and Japan (88%) in most Graves' disease patients, whereas the rest are treated with RAI.

Most patients with Graves' disease respond adequately to an initial dose of PTU, 300 to 450 mg, or MMI, 30 to 45 mg/day in divided doses. Doses should be adjusted subsequently by clinical response and thyroid hormone determinations. Several management options exist once the patient's hyperthyroidism has been controlled with antithyroid drugs. Some physicians reduce the dose of medication, whereas others, to maintain a euthyroid state, provide thyroid hormone replacement without modifying the amount of antithyroid drug. The use of antithyroid drugs may diminish the serum hormone level, requiring thyroid hormone replacement or discontinuation of the drug. RAI treatment is generally reserved for patients older than 30 years.

In the United States  $^{131}\text{I}$  remains the mainstay of initial therapy of thyrotoxicosis. Most patients with Graves' disease respond adequately to doses of  $^{131}\text{I}$  of between 5 and 10 mCi.

Rarely, subtotal thyroidectomy is elected in certain cases but should not be performed until the patient's disease is under adequate control. Surgery is usually preferred for pregnant women whose thyrotoxicosis is not controlled with low doses of thioureas, for patients with particularly large goiters, and whenever there is a significant chance of malignancy. Patients developing hypothyroidism should receive  $\text{L-T}_4$ , 0.1 to 0.2 mg/day (1.6 mcg/kg body weight/day). These patients should be monitored at regular intervals by serum TSH determinations.

The frequency and types of toxic reactions to PTU and MMI are similar but appear to be related to the doses used. Methimazole usually is the drug of choice in nonpregnant patients because of its lower cost, longer half-life, and lower incidence of hematologic effects. Conversely, PTU is preferred for pregnant women because MMI has been associated with rare congenital anomalies. Approximately 5% of patients experience mild side effects, ranging from gastrointestinal complaints to mild skin reactions and pruritus, which can usually be controlled adequately with antihistamines without discontinuing the antithyroid drug. The most severe and worrisome complication, however, is agranulocytosis, which occurs in approximately 0.1% to 0.5% of patients treated with these drugs. It always responds to discontinuation of the medication, but in a few instances concomitant administration of steroids may be indicated. Because this complication can be lethal if not quickly recognized, the patient should be advised to report to the physician whenever infection, sore throat, or general malaise occurs, in which case a complete blood count should be obtained.

In 15% of patients Graves' orbitopathy can develop or be worsened by the use of radioactive iodide.

The concomitant use of oral prednisone (40 to 80 mg) tapered over at least 3 months can prevent or improve severe eye disease in two-thirds of patients. Lower dose RAI sometimes is used in patients with the orbitopathy because of posttreatment hypothyroidism, which also may be associated with exacerbation of the eye disease.

### **Local Management of Ophthalmopathy**

A variety of local measures can be used to provide the patient with symptomatic relief while protecting ocular tissues and preserving visual functions. Certain measures apply to each disease classification.

#### **Class 1 Disease (Eyelid Retraction)**

The patient with class 1 disease may have lagophthalmos ranging from very mild to very severe. The eyelid retraction and lagophthalmos accelerate tear film evaporation, thus increasing tear film osmolarity and causing ocular surface damage. Any associated exposure keratopathy should be managed with ocular lubricating solutions or ointments. The clinician should try several types of nonpreserved artificial tears. This trial method allows the patient to choose the artificial tear formulation that gives the greatest symptomatic relief. Topical nonsteroidal anti-inflammatory drugs such as 0.5% ketorolac (Acular) in the preservative-free form or 0.1% diclofenac (Voltaren) may be used to reduce ocular irritation. Punctal occlusion therapy has met with limited success in these patients. Additionally, the use of topical cyclosporine (Restasis) may also provide dry eye relief, but because of the variability in severity of exposure keratopathy the use of topical cyclosporine should be considered on a case-by-case basis.

A variety of general measures may be helpful, such as the wearing of tinted lenses to shield the undesirable cosmetic appearance and to protect the eye from wind, dust, and other environmental factors. Bandage soft contact lenses may be used to reduce ocular irritation from exposure and may provide temporary relief during the day. The eyelids can be taped shut at bedtime to protect the cornea. Likewise, a plastic-wrap shield can be constructed and taped over the eye, thus creating a moisture chamber during sleep. Moreover, certain sleep positions may increase the effects of the lagophthalmos. Many clinicians have observed patients who sleep in the prone position to have more ocular symptoms than do those who sleep supine. Elevation of the head of the bed helps to reduce overnight swelling and congestion. For moderate to severe cases of corneal exposure, applying a topical broad-spectrum antibacterial ointment (e.g., bacitracin-polymyxin B) at bedtime or continuously during the day may prevent infection of the exposed corneal and conjunctival tissues. The patient should be advised to avoid environmental conditions that encourage evaporation of their tears (e.g., ceiling fans, forced air heaters, wind, etc.).

In many instances, however, the patient's primary desire is to have an improved cosmetic appearance of the eyelid retraction. Because the relationship between the clinical signs of thyrotoxicosis and the effects of increased catecholamine activity has been apparent for many decades, various attempts have been made to control or alleviate the upper lid retraction by using adrenergic blocking agents, such as guanethidine, reserpine, and thymoxamine. Because upper eyelid retraction may be mediated through sympathetic activity of Müller's muscle, drugs with  $\alpha$ -adrenergic blocking properties have been used topically and orally to manage this condition. However, these drugs do not affect the degree of proptosis, if present, because proptosis is associated with increased volume of the retrobulbar tissues and is not mediated through autonomic nervous system control. Topical bethanidine, an adrenergic blocking agent, has been used in 10% and 20% solutions to treat eyelid retraction. When used in a dosage of two or three drops daily, it effectively induces a pharmacologic Horner's syndrome with associated ptosis and miosis. Three or more weeks may be required to reach a maximum ptotic effect. No serious adverse ocular or systemic side effect has been observed. Propranolol, a  $\beta$ -adrenergic blocking agent, has been used both orally and topically to relieve lid retraction. For acute cases of eyelid retraction, propranolol, 10 mg four times daily, may be helpful. The topical use of 1% propranolol solution has produced variable results. In addition, topical timolol has been used by some practitioners for eyelid retraction, but with variable degrees of success.

Dapiprazole HCl (Rēv-Eyes) is an  $\alpha$ -adrenergic blocking agent introduced for the treatment of iatrogenically induced mydriasis. One of the side effects of this topical agent is ptosis. In theory, this effect could potentially be useful for early eyelid retraction of Graves' disease. Other side effects, however, include burning on instillation and moderate to severe conjunctival injection. There has been no published study about the efficacy of dapiprazole to relieve eyelid retraction in class 1 disease.

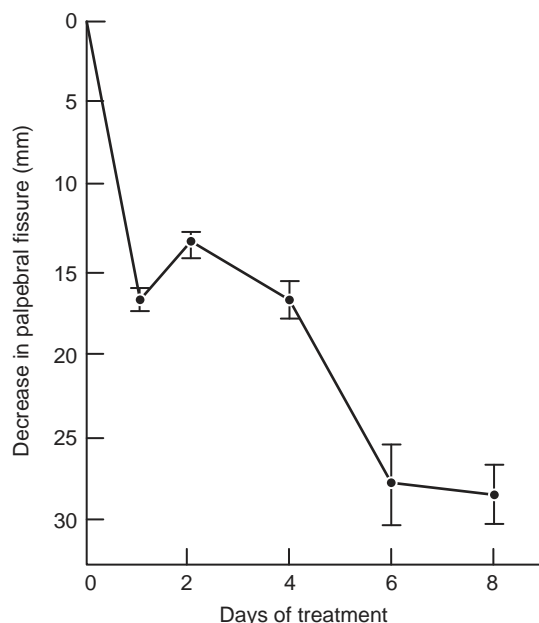
The drug used most commonly for the relief of eyelid retraction is orally or topically administered guanethidine. Guanethidine depletes sympathetic storage sites, initially causing release of norepinephrine that may lead to mydriasis and lid retraction but that eventually produces a chemical sympathectomy resembling post-ganglionic Horner's syndrome. Although guanethidine is somewhat unpredictable in the management of eyelid retraction, it seems to offer the best results with the fewest toxic effects when used in lower concentrations. Orally administered guanethidine, 15 mg/day, has been shown to lower the eyelid in some patients, but most clinicians prefer the topical route of administration. Additionally, the use of oral guanethidine may have severe systemic side effects in some patients.

When used topically in a 10% concentration, guanethidine substantially reduces lid retraction but is associated

with significant superficial punctate keratitis in approximately 50% of patients. The 5% solution is equally effective but without the attendant side effects. Unlike the effect associated with thymoxamine, the beneficial effect is usually observed in the first 72 hours after treatment is initiated (Figure 32-9). It was found that the ptosis produced by 5% topical guanethidine was approximately 1.5 mm. Systemic side effects have not been noted in most studies, but a report of two patients with severe abdominal pains and diarrhea requiring emergency hospital admission should call for caution in the use of this drug. The clinician should initiate therapy with 5% guanethidine, one drop three times daily, until maximum improvement in the eyelid position is obtained and then should reduce the frequency of administration to daily instillation if this is adequate and, if possible, further reduce the instillation to alternate days.

Several conditions may adversely affect the ability of guanethidine to lower the upper eyelid: (1) if the patient is thyrotoxic rather than euthyroid or hypothyroid; (2) if the patient is concomitantly undergoing drug therapy with adrenergic agonists, either systemically or topically; and (3) if adhesions form between the levator and the superior rectus muscles in the later stages of the disease process.

If conservative measures are insufficient to promote patient comfort or acceptance, botulinum A toxin can be injected directly into the affected levator muscle. Injection of 2.5 to 7.5 units of toxin may lower the affected



**Figure 32-9** The mean decrease in palpebral fissure of one eye as compared with pretreatment values in 14 patients receiving 10% guanethidine, two drops twice daily. Each point represents the mean ( $\pm$  SEM). Measurements were obtained by projecting the clinical photographs to eight times their original size. (Reprinted with permission from Sneddon JM, Turner P. Adrenergic blockade and the eye signs of thyrotoxicosis. *Lancet* 1966;2:525-527.)

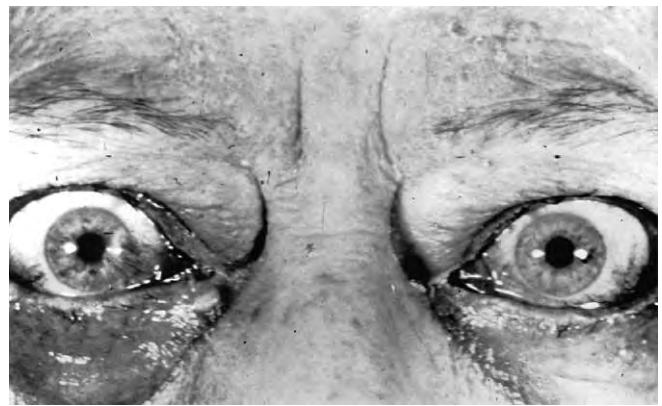
eyelid by 2 to 3 mm. The effect is short term and difficult to predict.

Surgery for class 1 disease is usually not indicated because affected patients are typically asymptomatic and because the eyelid retraction may resolve after treatment of the underlying thyrotoxicosis. Surgery, however, is a reasonable and necessary alternative for patients with severe eyelid retraction not responding to more conservative measures. The two most common reasons for surgical repair are cosmesis and relief of symptoms arising from ocular exposure. Surgical extirpation of Müller's muscle in combination with severance of the levator aponeurosis from its attachments produces successful reduction in eyelid retraction. In some patients with fibrosis of the inferior rectus muscle, recession of the tight muscle may reduce or eliminate upper eyelid retraction. Eyelid retraction procedures seem to be most effective in patients with minimum to moderate proptosis (<25 mm). In most cases surgery for eyelid retraction should not be considered until the ocular condition has been stable for at least 6 months to 1 year. If proptosis is present and is severe enough to require orbital decompression, this procedure should be performed first, because the decompression itself may reduce the eyelid retraction. The decision to lower the lids should then be postponed for several months. However, in emergencies in which corneal integrity is threatened, eyelid surgery could be contemplated together with the orbital decompression.

#### Class 2 Disease (Soft Tissue Involvement)

In many patients mild class 2 disease can be managed adequately with ocular lubricants. Elevating the head of the bed on 6-inch blocks during sleep can minimize eyelid and periocular swelling on awakening. Reduction of periorbital swelling may be measured by inserting a small straight-edged ruler into the upper eyelid fold and allowing periorbital tissue to rest on it. The number of millimeters the periorbital tissue covers is a quantitative measure of the swelling. The use of tinted lenses may provide relief from light sensitivity. Tinted lenses not only guard against irritation and light sensitivity but also have the advantage of masking the cosmetic problem. Occasionally, the use of orally administered diuretics may be of help, but it is open to debate whether diuretics, used in the past, provide relief. For patients with moderate to severe class 2 disease, the use of systemically administered corticosteroids may be of immense benefit (Figure 32-10). There is no doubt that the use of steroids in adequate dosages can decrease the severity of ocular complications, although these agents have minimal, if any, influence on the duration of the thyrotoxicosis. The use of systemic steroids seems to have the greatest benefit for patients with acute orbitopathy.

Locally administered steroids have been used with variable success. Although topically applied steroids are completely ineffective in alleviating the ocular signs or symptoms associated with class 2 disease, periocular



**Figure 32-10** Same patient as in Figure 32-3 after systemic steroid therapy. Note the marked improvement in eyelid swelling, conjunctival and episcleral injection, and chemosis.

steroids have been used with some success. Subconjunctival or retrobulbar injections of methylprednisolone are used, and sub-Tenon's capsule injection of aqueous triamcinolone (Kenalog), 40 mg/ml, can also be used. The precise dosage of methylprednisolone must be guided by the individual patient, but 10 to 20 mg per injection (40 mg/ml) has been effective when repeated at varying intervals. More concentrated preparations of methylprednisolone (Depo-Medrol), 80 mg/ml, permit the injection of higher doses with smaller volumes, which is particularly important in giving retrobulbar injections into an already tense orbit. Patients should be advised that transient proptosis may occur after the injection. In a recent randomized clinical trial peribulbar injections of 20 mg triamcinolone acetate (four injections at weekly intervals) were associated with a substantial improvement in diplopia and reduction in EOM (extraocular muscles) dysfunction. Periocular injections may be repeated at monthly or longer intervals, as required. One major advantage of retrobulbar injections of long-acting steroids is the minimized systemic effects when compared with the oral and intravenous routes.

High-dose oral glucocorticoids have been the mainstay in the management of Graves' orbitopathy. In general, favorable effects have been observed on inflammatory signs and optic nerve involvement, whereas the effects on the extraocular muscle involvement and especially proptosis have not been constantly impressive. Two recent randomized controlled clinical trials addressed the question of whether intravenous glucocorticoids are more effective than oral glucocorticoids. Although both treatments proved to be effective, the proportion of favorable responses was higher in patients treated by intravenous glucocorticoids. The intravenous treatment was also better tolerated than the oral treatment. One major concern of high-dose systemic glucocorticoid treatment is the potential risk of side effects and complications.

Orbital radiotherapy has been used to treat thyroid orbitopathy for the past 60 years. Its therapeutic use is still

studied and debated to this day. Studies using sham versus orbital radiotherapy concluded it had some beneficial effect on early and mild orbitopathy. Several other studies attempted in the United States failed to show any beneficial effect from the radiotherapy. It is a therapy option that should be agreed on by both doctor and patient after careful consideration.

### Class 3 Disease (Proptosis)

Because proptosis is not an isolated finding and is more commonly a variable finding in Graves' ophthalmopathy, it is not a useful indication of the degree of orbital infiltration or of the response to treatment. Moreover, longstanding proptosis tends to be permanent, presumably because of the permanent changes in the tissues of the orbit, and is thus not often amenable to medical therapy.

As stated, Graves' ophthalmopathy worsens in many patients despite antithyroid therapy, especially in therapies that cause rapid alteration in thyroid tissue and function. More recent studies suggested that, as compared with other forms of antithyroid therapy,  $^{131}\text{I}$  is more likely to be followed by the development or exacerbation of Graves' ophthalmopathy. This may reflect only the increase in thyrotropin-receptor antibody and other thyroid antibodies in serum after destruction of the thyroid gland by RAI. Consideration should be given to initiating oral steroid therapy before  $^{131}\text{I}$  therapy.

Proptosis, as an isolated finding, rarely requires treatment unless there is secondary exposure keratopathy or unless it represents a significant cosmetic problem. Affected patients may benefit from a trial of systemic corticosteroids. A significant decrease in the severity of proptosis may be observed in some patients. In general, if regression of the proptosis occurs after the institution of steroid therapy, it will begin soon after the onset of therapy and reach a maximum in 2 or 3 months. If no response to steroid therapy is seen after 3 to 4 weeks, the therapy should be discontinued. As mentioned previously, response to corticosteroid therapy for proptosis is variable at best.

### Class 4 Disease (Extraocular Muscle Involvement)

Some patients, perhaps up to 20%, may experience return of normal eye movements after medical control of the thyrotoxicosis. For patients who do not experience improvement, the only pharmacologic interventions shown to be effective for the specific changes associated with class 4 disease are systemic prednisone and local injections of botulinum toxin, though both modalities are rarely used, for motility signs alone, in modern therapy.

In the early stages of class 4 involvement, treatment with small doses of prednisone may be initiated when control of the hyperthyroidism or adequate therapy of hypothyroidism has not arrested the ocular activity. Improvement in motility usually occurs within 4 to 12 weeks. Many patients experience enough subsequent improvement in ocular motility so that severe class

4 disease may be considered a relative but not absolute indication for steroid therapy. However, conservative therapy is prudent in many cases and may include vision therapy to lessen the tendency for muscle fibrosis; the use of Fresnel prisms, which have a definite advantage in the management of unstable motility disorders; or simple monocular patching.

Many patients should be considered surgical candidates after the failure of steroid therapy or other more conservative therapeutic measures. Marked improvement can often be obtained in elevation of the globe and amelioration of the diplopia, after appropriate recession of the fibrotic rectus muscle. The recession of other extraocular muscles to correct existing heterotropias and associated diplopia should also be considered. Adjustable suture surgery has been used in many centers to eliminate diplopia in the primary and reading positions and has been found to provide long-term symptomatic relief in most patients. When the inferior rectus is recessed, reattachment of the lower lid retractors is critical to avoid lower lid lag, aggravating exposure. In general, surgery should be postponed for at least 6 to 12 months after stabilization of the metabolic and ocular conditions, because early surgical manipulation may acutely exacerbate the original disease process. Significant complications from eye muscle surgery are rare but include an increase of the proptosis after release of the fibrotic ocular muscles. For this reason, if the proptosis is more than 24 mm, consideration should be given to orbital decompression before muscle surgery, even if there is no significant threat to vision.

### Class 5 Disease (Corneal Involvement)

Patients with class 5 disease are at risk of serious ocular complications and loss of vision. This stage of disease occurs in patients with enough proptosis to prevent adequate eyelid closure, resulting in chronic corneal exposure. Complicating factors may include extraocular muscle involvement sufficient enough to obliterate Bell's phenomenon. In the milder forms of exposure, the administration of bland ocular lubricants at bedtime or continuously during the day may be of significant benefit in alleviating associated symptoms and preventing or delaying more serious ocular involvement. The topical application of broad-spectrum antibiotics (e.g., trimethoprim sulfate-polymyxin B) may be indicated for the prophylaxis of infection. Taping the eyelids shut at bedtime or using a plastic-wrap shield may also prove beneficial. When frank corneal ulceration is imminent, frequent use of topical broad-spectrum antibiotics (e.g., moxifloxacin) and systemic steroid therapy can prove useful. The use of systemic or intravenous steroids sometimes obviates the need for surgery (orbital decompression) but generally involves long-term therapy with the possibility of adverse effects. Steroids are also useful for patients who cannot undergo orbital decompression or lateral tarsorrhaphy because of a contraindication to general anesthesia.



Orbital decompression should be considered for patients with severe class 5 disease for whom steroids, orbital radiation, and other medical therapies have proven to be ineffective or contraindicated. This might include patients whose compliance may be poor or for whom follow-up may be difficult.

### Class 6 Disease (Optic Nerve Involvement)

The incidence of optic neuropathy in thyroid eye disease is 2% to 9%, but it is a particularly treacherous complication, because patients often do not have marked proptosis and do not have evidence of optic nerve head changes on fundus examination. Although as many as 70% of patients with optic neuropathy spontaneously experience improvement without treatment, the risk to vision is significant, and loss of vision may become permanent if the optic neuropathy is not quickly recognized and aggressively treated. The most common presentation is a patient with a complaint of visual acuity loss or a visual field defect (Figure 32-11). Patients may also manifest color defects, afferent pupillary defects, and abnormalities on visual evoked potential testing. High-resolution CT or MRI often confirms suspect cases of optic disc edema. Ideally, therapy should begin with correction of the thyroid imbalance. Replacement thyroid hormone is mandatory for hypothyroid states. Some patients with optic neuropathy have been managed by adjustment of the thyroid state, but these patients must be monitored closely.

A gratifying response to high-dose steroid therapy may be observed in many patients with optic neuropathy (see Figure 32-11). About two-thirds of patients have reduction in their symptoms and swelling in about 1 week. One study reported a 48% success rate defined as two Snellen lines of improvement in visual acuity within 2 months of steroid treatment.

Guidelines for the management of patients with optic neuropathy are as follows:

1. Patients with minimum optic nerve dysfunction (visual acuity of 20/30 [6/9] or better) may be managed by observation alone. However, the tendency for rapid progression demands serial examinations of visual acuity, visual fields, and pupillary testing.
2. Patients with progressive vision loss (with or without disc swelling) or with disc swelling and no visual defect should be treated. Oral or intravenous steroids in large doses remain the primary therapeutic modality, but if a response has not occurred within 3 or 4 weeks, continued high doses are not likely to succeed.
3. Prolonged steroid maintenance without improvement in visual function is not justified.

### Systemic Management of Ophthalmopathy

As mentioned, the hyperthyroid state must be controlled before using other therapeutic measures, including steroids and immune-modifying agents. Systemic treatment with

steroids or immunomodulators, either alone or in combination with other treatments, is based on the fact that Graves' ophthalmopathy is the consequence of an autoimmune process. These treatments attempt to relieve inflammatory or congestive signs by shrinking tissues within the orbit, resulting in decreased intraorbital pressure.

### Steroids

Systemic steroids often effectively control the optic neuropathy and other inflammatory changes of the ophthalmopathy. However, systemic steroids must be used in high dosages at the expense of their known complications and side effects, including osteoporosis, hyperglycemia, systemic hypertension, infection, gastric ulceration, cataract, cushingoid features, and psychosis. However, rapid progression of proptosis, ophthalmoplegia, and optic nerve involvement warrant such treatment. Developments of visual field defects and decreased visual acuity are absolute indications for the use of high-dose steroids. Assuming there are no life-threatening contraindications to the use of steroids, high-dose steroids as monotherapy are of use in ameliorating many of the inflammatory features of the orbitopathy. Patients who benefit do so very early in the course of treatment. Subjective improvement might occur within the first 24 hours, and extraocular muscle function and visual acuity might improve in a few days or weeks. Treatment should be initiated with large doses of prednisone (80 to 100 mg/day). When improvement is apparent, the dosage should be reduced gradually. Decreasing the dosage by 5 to 10 mg a week is a safe guideline. Whenever exacerbation occurs, the dosage should be increased to the initial treatment level. Subsequently, the steroid should be tapered more gradually.

In the last 10 years or so steroids have been used intravenously by the acute administration of high doses of methylprednisone acetate (0.5 to 1.0 g) at different intervals. The cumulative dose of steroid ranges from 1 to 21 g in different studies. In general, favorable effects have been observed on inflammatory signs and optic nerve involvement, whereas the effects on extraocular muscle involvement, and especially proptosis, have not been consistent or impressive.

In general, if optic neuropathy is responsive to steroids, exacerbations occur if the drug is withdrawn within 2 to 4 weeks. Therefore steroids must be administered until the disease process undergoes spontaneous remission. Although this increases the potential risk of serious steroid-related complications, the risk is justified in many instances. Because of the risks inherent in systemic steroid therapy, the practitioner should educate the patient regarding the potential side effects of steroids and the need for regular and long-term medical supervision.

Combining steroids with cyclosporine or orbital irradiation appears to enhance the efficacy of individual therapy. Use of steroids has also been recommended to prevent







nonrandomized study of 22 patients affected with mild to moderate Graves' orbitopathy. These drugs, given orally for 3 months, showed improvement of the orbitopathy in 9 of 11 treated patients (82%) compared with 3 of 11 placebo-treated patients (27%). Improvements were mainly related to the soft tissue complications of the orbitopathy.

The use of cytokine antagonists (monoclonal antibodies to cytokines) used in the management of rheumatoid arthritis and Crohn's disease has some beneficial effect on Graves' orbitopathy. A recent study of 10 patients with mild to moderately severe Graves' orbitopathy showed that the administration of etanercept, an antitumor necrosis factor drug (25 mg a week for 3 months) was associated with a significant improvement of the clinical activity score and ophthalmopathy index in approximately 60% of patients.

Additionally, a recent report showed that the use of the peroxisome proliferators activated receptor agonist (thiazolidinedione) drug, pioglitazone, in a man with type 2 diabetes mellitus and stable Graves' orbitopathy was associated with activation and progression of the eye disease. This report suggests that thiazolidinediones may be contraindicated in Graves' orbitopathy patients. It also opens up a potential treatment modality with antagonists to the drug class used in the management of the orbitopathy.

Finally, the orbitopathy from Graves' disease seems to be related to autoimmune reactions directed against antigens shared by the thyroid and orbit. These antigens and the mechanisms of the disease activation are still unidentified. Lacking this knowledge makes it difficult to design immunosuppressive and immunologic intervention in the near future.

## Other Forms of Management

### Orbital Irradiation

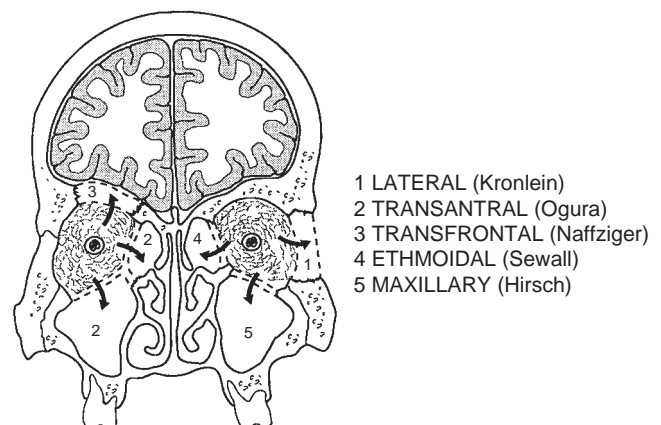
Attempts at orbital irradiation were begun more than 60 years ago but involved relatively low-dose, low-energy, or poorly collimated beams. The results were generally unsatisfactory. In the last 5 years several studies addressed the issue of effectiveness and safety of orbital radiotherapy for Graves' orbitopathy. The results have been somewhat favorable, and this approach seems to offer a reasonable alternative or additive to steroids. The irradiation has several effects on the orbital tissues, which include the biochemical effect of correcting acidosis produced by the inflammatory response and suppressing lymphocytes. The anti-inflammatory effect of irradiation is from the suppression of fibroblast production. Existing hyperthyroidism should be corrected, if possible, before irradiation. Supervoltage radiotherapy combined with corticosteroids is more effective than radiotherapy alone, blurring the true therapeutic effect of each therapy. When systemic steroids are administered simultaneously, the dose should be kept constant during the period of irradiation and for several weeks thereafter.

In general, orbital irradiation produces the most impressive results in patients with active and mild ophthalmopathy, rather than in patients with a more indolent disease course. The decision to use orbital radiation is on a case-by-case basis. Patients with diabetic retinopathy, patients presently on chemotherapy, and patients who have had prior head irradiation should not be considered for orbital irradiation.

### Orbital Decompression

Orbital decompression is used to salvage the eye and vision when extreme proptosis with corneal exposure or optic nerve compression does not respond to medical therapy. Presently, approximately one-half of the orbital decompression procedures are performed for the reduction of proptosis, as a cosmetic procedure. As many as 40% of these procedures are now performed for cosmetics. Orbital decompression for Graves' ophthalmopathy was first reported in 1911. Since then, several surgical approaches for orbital decompression have been described (Figure 32-12). In 1931 the concept of removal of the roof of the orbit by a neurosurgical transfrontal approach, the Naffziger approach, was introduced. Another approach, the Kronlein procedure, involves removing the lateral wall of the orbit with decompression into the temporal fossa. Both procedures have the disadvantage of decompressing the orbit into an area of high tissue pressure. In addition, the Naffziger approach introduces the morbidity of an intracranial operation, and the Kronlein method is a lengthy procedure involving considerable bony resection. The Walsh-Ogura (transantral resection of the medial and inferior walls of the orbit) became the mainstay for orbital decompression after its report in 1957, but chronic new diplopia was a frequent sequela.

The decompressive procedure used most commonly for Graves' orbitopathy today is the medial inferior decompression through either a transantral or translid approach. In 1992 using a transorbital three-wall decompression



**Figure 32-12** Approaches for orbital decompression. (Modified from Char DH. *Thyroid eye disease*, ed. 2. New York: Churchill Livingstone, 1990.)

through a modified blepharoplasty incision was reported. This technique allowed a single incision with wide exposure, a low incidence of permanent strabismus, lateral orbital rim and canthal tendon preservation, and a large reduction in proptosis. Many ophthalmic surgeons still use modifications of the Walsh-Ogura procedure, but regardless of the technique used, surgical experience is without question a major factor in success rate.

Recent advances include the use of a fornical incision, which is considered a technical advance in decompression surgery because it allows good views of the medial and lateral walls of the orbit. Additionally, a transcaruncular approach to the medial wall allows easy removal of the ethmoid bones.

Because of the inherent surgical risks involved, orbital decompression should be considered only after more conservative therapeutic measures have been attempted. Orbital decompression surgery does not affect the course of the inflammatory or fibrotic components of thyroid ophthalmopathy. Therefore orbital decompression should not be considered until the thyroid state is stable.

Orbital decompression is useful in nearly all patients with compressive optic neuropathy. The relief of pressure

at the orbital apex is key to surgical management. Additionally, patients with stable orbitopathy and significant exophthalmos who are willing to accept the risks of the procedure are good surgical candidates. The degree of recession of proptosis can range from 2 to 10 mm.

Postoperative diplopia is a complication of the type of surgical technique or approach used by the surgeon. As many as 70% of patients have required some form of extraocular muscle surgery after an Ogura-type decompression. Patients who require orbital decompression surgery should delay extraocular muscle surgery, because a number of patients have increased diplopia after decompression procedures. Other complications of orbital decompression include sinusitis, orbital cellulitis, late enophthalmos, globe ptosis, meningitis, epiphora, recurrent optic nerve compression, and blindness.

Graves' ophthalmopathy severe enough to warrant high-dose steroids, orbital radiotherapy, or orbital decompression is estimated to occur in not more than 20% of patients with Graves' disease. In most cases the disorder can be managed adequately with more conservative therapeutic measures. In most patients minor interventions that are required mainly include treatment of exposure keratopathy. Table 32-4 summarizes the current therapeutic approaches to the patient with Graves' ophthalmopathy.

**Table 32-4**  
Medical and Surgical Management of Graves' Ophthalmopathy

Symptom or Sign	Management
Eye discomfort (e.g., dryness, gritty sensation) and eyelid retraction	Ocular lubricants, cool compresses Eyelids closed with adhesive tape during sleep Dark spectacle lenses Adrenergic blocking agents (e.g., guanethidine) Botox injections Eyelid surgery
Periorbital edema, chemosis, injection	Sleep with head of bed elevated Beta-blockers (propranolol) Corticosteroids Radiotherapy Somatostatin analogues Orbital decompression surgery
Diplopia	Patching or lens occlusion Prism eyeglasses Extraocular muscle surgery
Disfiguring proptosis	Orbital decompression Eyelid surgery
Decreased visual acuity (i.e., optic nerve compression)	Corticosteroids Radiotherapy Orbital decompression

Adapted and modified from Garrity JA. Graves' ophthalmopathy: an ophthalmologist's perspective. *Thyroid Today* 1992;15:1-9; and Bahn RS, Garrity JA, Gorman CA. Diagnosis and management of Graves' ophthalmopathy. *J Clin Endocrinol Metab* 1990;71:559-563.

## SELECTED BIBLIOGRAPHY

- Antoszyk JH, Tucker N, Codere F. Orbital decompression for Graves' disease: exposure through a modified blepharoplasty incision. *Ophthalmic Surg* 1992;23:516-521.
- Bartalena L, Marcocci C, Pinchera A. Somatostatin analogs for Graves' ophthalmopathy: do they bounce off like a rubber bullet? *J Clin Endocrinol Metab* 2004;89:5908-5909.
- Bartalena L, Marcocci C, Tanda ML, et al. An update on medical management of Graves' ophthalmopathy. *J Endocrinol Invest* 2005;28:469-478.
- Bartalena L, Pinchera A, Marcocci C. Management of Graves' ophthalmopathy: reality and perspectives. *Endocr Rev* 2000;21:168-199.
- Bartalena L, Tanda MC, Piatanida E. The role of somatostatin analogs in the management of Graves' ophthalmopathy. *J Endocrinol Invest* 2003;(suppl 8):S109-S113.
- Cant JS, Wilson TM. The ocular and orbital circulations in dysthyroid ophthalmopathy. *Trans Ophthalmol Soc UK* 1974;94:416-429.
- Carlidge NE, Crombie A, Anderson J, et al. Critical study of 5 percent guanethidine in ocular manifestations of Graves' disease. *BMJ* 1969;4:645-647.
- Chang TC, Kao SCS, Huang KM. Octreotide and Graves' ophthalmopathy and pretibial myxoedema. *Br J Med* 1992;304:158-160.
- Dandona P, Marshall NH, Bidey SP, et al. Treatment of acute malignant exophthalmos with plasma exchange. In: Stockigt JR, Nagataki S, eds. *Thyroid research VIII*. Canberra: Australian Academy of Science, 1980: 583-586.
- Dollinger J. Die drüchenlastung der augenhöhle durch entfernung der ausseren orbitalwand bei hochgradigen exophthalmus und konsekotiver hornhauterkrantung. *Dtsch Med Wochenschr* 1911;37:1888-1890.

- Franklyn JA, Sheppard MC, Maisonneuve P. Thyroid function and mortality in patients treated for hyperthyroidism. *JAMA* 2005;294:71-80.
- Glinoeir D, Etienne-Decerf J, Schrooyen M. Beneficial effects of intensive plasma exchange followed by immunosuppressive therapy in severe Graves' ophthalmopathy. *Acta Endocrinol* 1986;111:30.
- Hale IB, Rundle FF. Ocular changes in Graves' disease. *Q J Med* 1960;29:113-126.
- Holm IA, Manson JE, Michels KB, et al. Smoking and other lifestyle factors and the risk of Graves' hyperthyroidism. *Arch Intern Med* 2005;165:1606-1611.
- Kahaly G. Imaging in thyroid-associated orbitopathy. *Eur J Endocrinol* 2001;145:107-118.
- Kloprogge S, Kowal L, Wall J, et al. The clinicopathologic basis of Graves' ophthalmopathy. A review. *Eur J Ophthalmol* 2005;14:315-323.
- Kudrmas EF, Bartley GB. Superior limbic keratoconjunctivitis: a prognostic sign for severe Graves' ophthalmopathy. *Ophthalmology* 1995;102:1472-1475.
- Lyons CJ, Rootman J. Orbital decompression for disfiguring exophthalmos in thyroid orbitopathy. *Ophthalmology* 1994;101:223.
- Prummel MF, Mourits MP, Blank L, et al. Randomized double-blind trial of prednisone versus radiotherapy in Graves' ophthalmopathy. *Lancet* 1993;342:949-950.
- Reid JR, Wheeler SF. Hyperthyroidism: diagnosis and treatment. *Am Fam Physician* 2005;72:623-629.
- Trobe JD, Glaser JS, Laflamme P. Dysthyroid optic neuropathy. Clinical profile and rationale for management. *Arch Ophthalmol* 1978;96:1199-1209.
- Walling A. An update on thyroid eye disease. *BMJ* 2004;329:385-390.

## *Pharmacologic Management of Strabismus and Amblyopia*

*Erik Weissberg*

Strabismus, defined as misalignment of the lines of sight, is a common condition affecting both children and adults with an estimated prevalence of 4% to 5%. Amblyopia, defined as a disorder in which development of the visual pathway is altered by uncorrected refractive error, strabismus, or form deprivation, is the most common cause of visual morbidity in childhood and has an estimated prevalence of 2% to 4%. The high association between the two often necessitates concurrent management of both conditions. Depending on the specific characteristics, this may involve a combination of spectacles, surgery, vision therapy, occlusion, and/or pharmacologic intervention. The pharmacologic agents used in the management of strabismus and/or amblyopia can broadly be divided into three major categories: autonomic agents, direct-acting muscle agents, and centrally acting agents (Box 33-1). Although several drugs are included in these broad categories and have been the focus of investigation, those agents currently considered to be clinically useful are a limited few and are emphasized in this chapter.

### **ANTICHOLINERGICS (CYCLOPLEGIC AGENTS)**

The most frequent and perhaps most important use of cycloplegic agents in the treatment of strabismus and amblyopia (especially accommodative esotropia and refractive amblyopia) is to determine the appropriate spectacle prescription through a cycloplegic refraction. This refraction is an essential first step before considering other aspects of care. For accommodative esotropia, maximum cycloplegia is necessary to ascertain whether refractive correction alone or additional surgical or pharmacologic intervention is required. In cases where anisometropic amblyopia is suspected, the use of cycloplegic agents helps ensure that an accurate prescription is determined that reveals the full amount of anisometropia and hyperopia. It is important that the spectacle prescription reflects the full amount of anisometropia to ensure that the amblyopic eye receives the clearest retinal image possible under binocular

viewing conditions. It has been suggested that in some cases amblyopia may improve or completely resolve with the use of optical correction alone.

Several cycloplegic agents can be used to determine a cycloplegic refraction, but all differ in duration of action and cycloplegic effect. Although tropicamide has been demonstrated to be an effective cycloplegic in myopes and low hyperopes without amblyopia and strabismus, its effectiveness has not yet been evaluated in a large group of strabismic or anisometropic hyperopes. For this reason it is not recommended for use in this population.

The two most commonly used drugs to determine a cycloplegic refraction in amblyopic and strabismic patients are cyclopentolate and atropine. Two drops of 1% cyclopentolate ophthalmic solution is routinely used in clinical practice due to its relative strong cycloplegic effect, short onset, and relatively short duration. Atropine has the strongest cycloplegic effect, but the long duration of action and long onset necessitate instillation several days before the appointment.

By paralyzing accommodation, cycloplegics may also reduce accommodative convergence. This may result in a decrease in the angle of deviation in a child with accommodative esotropia. Despite the decrease in the strabismus, the resulting blur and risk of inducing amblyopia virtually necessitate the concomitant use of optical correction. The blur at distance, and especially at near, resulting from the primary effect of anticholinergic agents may still prove important and useful as an “encouragement” for spectacle compliance. Initially, children may have difficulty in relaxing their level of habitual accommodation, leading to rejection of moderate to high-powered hyperopic spectacles. To facilitate acceptance, a cycloplegic agent may be used for a period of several weeks in both eyes. The only way to obtain clear vision under cycloplegia in moderate to high hyperopic patients is through the use of their spectacles. After acceptance of the prescription, the cycloplegic agent is discontinued. Affected children usually continue to wear the spectacles, even after the effects of the cycloplegic agent have completely worn off.

**Box 33-1** Classification of Pharmacological Agents Used in the Treatment of Strabismus and Amblyopia<sup>a</sup>

1. Autonomic agents
  - 1.1 Anticholinergics (cycloplegic agents)
    - 1.1.1 *Atropine*
    - 1.1.2 *Cyclopentolate*
  - 1.2 Anticholinesterases (miotic agents)
    - 1.2.1 Physostigmine
    - 1.2.2 *Phospholine Iodide*
    - 1.2.3 *Diisopropyl fluorophosphate*
2. Direct-acting muscle agents
  - 2.1 Paralytic agents
    - 2.1.1 *Botulinum toxin*
    - 2.1.2 Ricin-mAb35
  - 2.2 Stimulating agents
    - 2.2.1 Nerve growth factor
3. Centrally acting agents
  - 3.1 Dopaminergics
    - 3.1.1 *Levodopa/cardidopa*
    - 3.1.2 *Citicholine*

<sup>a</sup>Clinically useful drugs appear in italics.

Of the commercially available anticholinergic agents, only atropine and cyclopentolate are used clinically for this purpose. Atropine is the drug of choice because of its long-term effects, lasting up to approximately 1 week or longer. Instillation is once or twice daily, either by drop or ointment in a 0.5% or 1% concentration. Once affected children tolerate the use of spectacles, the atropine is discontinued. Because it is shorter acting and somewhat less effective than atropine, cyclopentolate may not provide as complete and consistent a level of cycloplegia and therefore may be less efficacious. The higher concentration and more frequent use of either agent should be used in patients with darker irides or higher levels of latent hyperopia.

Occlusion of the sound eye to treat amblyopia was described as early as AD 900 and continues to be the most commonly used treatment. Pharmacologic penalization, a type of “partial occlusion” that uses a cycloplegic agent to blur the dominant eye and force use of the amblyopic eye, has been described since the early 1900s. In this method, atropine is instilled into the nonamblyopic eye and prevents accommodation, which blurs the acuity of that eye to a level below the amblyopic eye, resulting in a fixation switch. Depending on the refractive error, the acuity of the amblyopic eye and the concurrent use of spectacle lenses, fixation with the amblyopic eye may occur at near only, distance only, or full time. The presence of latent hyperopia in the nonamblyopic eye increases the amount of blur once the atropine is instilled and makes a fixation switch more likely. In most cases, patients are instructed

to wear their habitual spectacle correction during treatment, which ensures that the amblyopic eye receives a clear retinal image and is used at least during near fixation. In some cases the spectacle prescription for the nonamblyopic eye is manipulated (increased or decreased) to further degrade acuity in that eye to ensure fixation with the amblyopic eye.

Atropine penalization is most useful when the level of amblyopia is relatively mild (<20/100), although success using atropine penalization with more significant degrees of amblyopia has been reported. If the amblyopia is severe, there is usually little if any benefit, because the degree of blur brought about by the drug is invariably less than that present in the amblyopic eye and a fixation switch does not occur. However, improvement has been reported even if the nonamblyopic eye with cycloplegia retains the better acuity compared with the amblyopic eye.

Historically, pharmacologic penalization was viewed as a secondary treatment for amblyopia when traditional patching failed, most commonly due to poor compliance. More recently, atropine penalization has been receiving attention as an alternative primary treatment, in part due to a recently published highly publicized report. The Amblyopia Treatment Study compared atropine penalization (one drop of 1% atropine solution instilled daily) to conventional patching (minimum of 6 hours) for the treatment of moderate amblyopia (20/40 to 20/100). Although the patching group showed an initially faster improvement, by 6 months the difference in visual acuity was clinically insignificant, with 79% of the patching group and 74% of the atropine group improving to 20/30 or three lines of visual acuity from baseline. There was no significant difference in the mean acuity or number of lines improved at the 2-year follow-up, with 51% of the patching group and 49% of the atropine group demonstrating 20/25 or better visual acuity in the amblyopic eye. However, these results must be viewed in light of study design, and it has been pointed out that although no differences existed in the treatment groups for 20/32, there were differences at acuity levels better than 20/25.

Atropine sulfate 1% solution instilled daily is a common regimen to achieve penalization. Although ointment may minimize sudden excessive systemic absorption, the prevalence of serious side effects with solution has been shown to be exceedingly rare and may be better tolerated by patients. The Amblyopia Treatment Study reported no serious side effects, with only minor side effects such as light sensitivity, facial flushing, conjunctival irritation, and/or eye pain occurring in a small number of patients. In light of the comparatively common occurrence of skin irritation resulting from adhesive patches found in this same study, the minor side effects related to topical atropine do not appear to be a reason for discontinuation of the drug. An additional concern when treating amblyopia is the rare, but real, possibility of reverse amblyopia resulting from excessive occlusion. Among other reasons, this has led to the suggestion of an intermittent instead of daily



drop schedule. In a retrospective study, clinically significant improvement was noted with drop instillation 1 to 3 days a week. Another prospective study compared daily versus weekend-only use of drops in moderate amblyopes and found no statistical difference in improvement between the two groups. Interestingly, the weekend-only group reported “light sensitivity” nearly twice as much as the daily group.

There are several advantages to using atropine penalization over traditional patching (Box 33-2), of which the most significant benefit may be improved compliance. Poor compliance is one of the major obstacles when it comes to treating amblyopia and plays a key role in determining treatment success. Whereas compliance with traditional patching depends on the caregiver and the patient (i.e., parent and child), compliance with atropine penalization is the responsibility of the parent only and has been shown to be more readily received by both parent and child compared with traditional patching. This acceptance may be due to the child’s desire to avoid the social stigma of wearing a patch. However, the true psychosocial effects of amblyopia treatment (patch or atropine) are not clear, with conflicting findings reported.

Binocularity is one of the ultimate goals of amblyopia treatment and may decrease the likelihood of posttreatment regression. Atropine penalization holds the theoretic advantage of promoting binocularity by allowing low and, in some cases, middle spatial frequency visual input during treatment; however, current research does not necessarily support this finding.

**Box 33-2** Advantages, Indications, and Contraindications for Atropine Penalization in the Management of Amblyopia

**Advantages**

Improved compliance  
 Consistency of wear; children cannot peek  
 Compliance check; dilated pupil ensures drop has been used  
 Improved cosmesis and decreased social stigma compared with traditional patching  
 Promotes binocularity  
 Material costs less than traditional patching

**Indications**

Poor compliance with traditional patching  
 Hypersensitivity or skin allergies resulting from adhesive patch  
 Latent nystagmus

**Contraindications**

Severe amblyopia (worse than 20/100)  
 Known hypersensitivity to atropine

It appears that with success rates comparable with traditional patching, high acceptance rates among patients and parents, and minimal risk of serious side effects, the use of atropine penalization is a viable alternative as a first-line treatment in select amblyopic patients. Documented noncompliance with traditional patching, moderate amblyopia (<20/100), or known skin allergies to adhesive patches are fundamental factors to consider when recommending atropine penalization. Additionally, the family dynamic and desire of the parent and patient should be considered before making the final recommendation. The pharmacology and side effects of cycloplegic agents are discussed in Chapter 9.

**ANTICHOLINESTERASES (MIOTIC AGENTS)**

For more than a century, miotics have been used for the treatment of noncompliant spectacle wearers with accommodative esotropia, but their use has neither been widespread nor routinely accepted, because of the significant risk of adverse events and the availability of valid alternative treatments options. Additional applications include diagnosis of accommodative esotropia and treatment of residual postoperative strabismus. By reducing the AC/A ratio, these agents result in a decrease in accommodative convergence, thus decreasing the esotropic deviation at near. There may also be an additional effect caused by induced miosis, increasing the depth of focus and thereby reducing the stimulus to accommodation, but this has not been confirmed.

Miotics are best used in hyperopic patients with high AC/A ratios, with the potential for binocularity. Miotics are more effective in reducing the near deviation compared with the distance deviation. These drugs are generally not indicated in patients with amblyopia or in patients who are unable to achieve some degree of binocularity. Patients should be placed on a trial of the medication for approximately 2 weeks. If there is a significant decrease in the angle of deviation at near or a restoration of binocularity, continuation of the treatment may be warranted.

Proposed advantages of using miotics rather than spectacles are the added consistency of treatment and the belief that hyperopic children experience a reduction in their refractive error due to emmetropization and perhaps no longer need their spectacles in later childhood. However, it has been reported that most patients with accommodative esotropia do not show a significant reduction in their hyperopia over time. Indeed, there is some evidence that the presence of strabismus may interfere with the process of developing emmetropia, thus perpetuating the significant hyperopia associated with accommodative esotropia.

An additional concern in the use of miotics in lieu of spectacles arises in the case of anisometropia associated with significant hyperopia and accommodative esotropia.

Uncorrected anisometropia is a significant risk factor for the development or presence of amblyopia, and allowing this type of patient to forego optical correction in lieu of miotics is inappropriate. Clearly, optical correction is an essential aspect of the treatment, and the risk incurred from the use of miotics is unacceptable if the amblyopia is not simultaneously and effectively treated.

## Pharmacology

The clinically useful anticholinesterase agents diisopropyl fluorophosphate (DFP, Floropryl) and echothiophate iodide (Phospholine Iodide [PI]) demonstrate an indirect-acting mechanism resulting in increased levels of acetylcholine at the cholinergic receptor sites. The inhibition of acetylcholinesterase produces a relatively long-lasting and irreversible effect of maintaining active levels of acetylcholine at the parasympathetic synapses.

Anticholinesterase agents create a dyskinesia between accommodation and convergence, resulting in an apparent reduction in the AC/A ratio. In addition, at least in rabbit eyes, there may be a direct stimulation of the lateral rectus, reducing the angle of deviation further. The pharmacologic action of miotic agents increases the effectiveness of acetylcholine by inactivation of acetylcholinesterase, thereby stimulating accommodation and miosis while reducing convergence. The irreversible inactivation of cholinesterase may last for days. Shorter acting miotics, such as pilocarpine or physostigmine, are no longer used in the treatment of accommodative esotropia.

DFP is currently available only as a 0.025% ophthalmic ointment. PI is available in 0.03%, 0.06%, 0.125%, and 0.25% solutions, with the 0.125% concentration most often used. The PI solution is best kept refrigerated to maximize stability. Either drug is used at bedtime for several weeks before reevaluation. If there is a reduction in the angle of deviation, it is assumed that the esotropia is at least partly accommodative in nature. If there is no reduction in the angle of deviation, it is assumed that there is no accommodative component, and the use of the miotic agent should be discontinued. If there is a positive effect, dosage is reduced to the minimum level, resulting in straighter eyes and a restoration of at least partial binocularity. Miotics may also be used diagnostically to determine an accommodative component that may be justified correcting with spectacles, before ordering the spectacles.

## Adverse Effects

Anticholinesterase agents are potent drugs with many potential adverse effects; iris cysts and anterior subcapsular lens cataracts are the most serious and well known. Other significant but less common ocular manifestations include retinal detachment, angle-closure glaucoma, and uveitis. Common but less serious adverse effects include

superficial punctate keratitis, follicular conjunctivitis, browache, and blurred distance vision.

The formation of iris cysts has been associated with the prolonged use of both DFP and PI but perhaps somewhat more often with DFP. These epithelial cysts are located at the inner margin of the pupil and can extend into the pupillary aperture, occasionally progressing to the point of occluding the pupil if miotic therapy is continued long term. Phenylephrine hydrochloride drops are frequently used concurrently with the miotic as a preventive measure. The usual dosage is one or two drops of 2.5% phenylephrine per day. Some authorities, however, recommend that the pharmacist formulate a topical solution combining both PI and phenylephrine. Patients using miotic therapy should be monitored frequently for the development of these iris cysts.

More worrisome is the effect that anticholinesterase drugs have on plasma and erythrocyte cholinesterase levels, resulting in elevated levels of cholinergic activity. Miotic agents decrease the rate of hydrolysis of succinylcholine, a drug used to facilitate general anesthesia. If a child using miotic therapy undergoes emergency surgery with the use of succinylcholine in the anesthesia, respiratory paralysis may ensue. Parents of children using these medications must be clearly informed of this potential risk. DFP may lower cholinesterase levels less than PI, possibly due to rapid hydrolysis of DFP by plasma esterases. If serious systemic toxicity is noted, intravenous atropine and pralidoxime chloride (Protopam) are effective antidotes.

The acronym "SLUDGE," which stands for salivation, lacrimation, urinary incontinence, diarrhea, gastrointestinal disorders, and emesis, is often used to describe the systemic side effects of cholinergic overdose. A "miotic upper respiratory syndrome" consisting of rhinorrhea, a sensation of chest constriction, cough, and conjunctival injection has also been reported.

## PARALYTIC AGENTS

First introduced over 30 years ago, botulinum chemodenervation has been recommended by strabismologists as the sole or supportive treatment for diverse ocular motor disorders in both children and adults (Box 33-3). However, there is disagreement among authorities regarding the effectiveness of botulinum, on both short term and long term, and about the specific indications for its use.

Chronic and acute sixth nerve palsy in adults would seem to be a prime indication for the use of botulinum. This application may be especially useful in chronic partial sixth nerve palsies in which there is secondary contracture of the medial rectus muscle with residual function of the lateral rectus muscle. Although advocated by many, the effectiveness of botulinum injected into the ipsilateral medial rectus in patients with chronic sixth nerve palsy remains ill-defined. A prospective analysis reported on 6-month success rates in chronic sixth nerve palsy.

**Box 33-3** Uses of Botulinum in Ocular Motility Disorders**Primary**

Acute and chronic sixth nerve palsies  
 Infantile and acquired esotropia of mild to moderate size  
 Consecutive strabismus (secondary to prior surgery)

**Secondary**

Intermittent exotropia  
 Restrictive strabismus (e.g., dysthyroid strabismus)  
 Third nerve palsies  
 Sensory strabismus  
 Paradoxical diplopia

A surprisingly low 10% (1 of 10 subjects) success rate was found for patients treated with botulinum alone and a 25% (2 of 8 subjects) success rate for those treated with botulinum plus surgery. In contrast, a 32% success rate was found in patients treated with botulinum alone, when similar criteria (diplopia resolution in primary gaze) for success were applied.

Acute sixth nerve palsies are often transient, with a wide range of spontaneous recovery rates reported. It has been postulated that timely use of botulinum in acute sixth nerve palsies may prevent secondary contracture of the medial rectus and allow a more complete resolution of the diplopia. A prospective analysis found similarly high recovery rates of patients with acute traumatic sixth nerve palsy who received botulinum within 3 months of onset (73%) compared with those “conservatively managed” (71%). One study compared the short-term results of botulinum versus surgical treatment of acute sixth nerve palsies and found no significant differences between treatments. Regardless of the long-term benefit from botulinum injection, the immediate advantage, in at least some patients, to reduce or eliminate diplopia, promote binocularity, and obviate the need for occlusion cannot be ignored.

The value of botulinum treatment of strabismus in children has been somewhat more uncertain compared with adults. One problem is the requirement for careful placement of the injection, which in adults or older children may be accomplished with the aid of electromyography and a local anesthetic in the office setting. Children typically require general anesthesia, which not only decreases the predictability of the electromyography but eliminates one of the major benefits of using botulinum (i.e., not requiring general anesthesia and surgery). However, injection may be performed in infants, in the office setting, without resorting to sedation or general anesthesia.

The spread of toxin from the injection site may cause ptosis of the upper eyelid, which has been demonstrated to occur more commonly in children. Additionally, the need for retreatment in children has been reported to be

almost twice as frequent as that for adults. A study found that 223 of 356 children achieved relative alignment with an average of 1.6 injections per child; although 33% developed transient ptosis, none developed amblyopia secondary to the ptosis. In a prospective study of 68 children with “acquired esotropia” and an average follow-up of 4.8 years, 88.2% motor alignment success and 70.6% of subjects with peripheral fusion were reported. A transient ptosis was observed in 35.2%, which lasted an average of 3.9 weeks, and 47.1% required more than one injection. The study concluded that when motor and sensory success are both considered, a single surgical intervention is as effective as one to three botulinum injections. Although the use of botulinum in children with sixth nerve palsy seems appropriate to restore binocularity and to prevent the development of amblyopia, additional investigation is needed to better define its usefulness.

Infantile esotropia, defined as an esotropia with an onset between birth and 6 months of age in a neurologically healthy infant, has also been a controversial topic regarding the use of botulinum. In a large but diverse series of young patients treated with botulinum, with a follow-up of at least 6 months, only 34% of patients with infantile-onset nonaccommodative esotropia had an acceptable outcome. The series noted that the need for frequent reinjection and misalignment (large-angle exotropia) after initial treatment was an impediment to an ultimately successful outcome of restoring binocularity. Conversely, a study that advocated for bilateral medial rectus injections and aimed for an initial large overcorrection made a strong case in a review of published data on large populations, showing that botulinum success rates rival that of surgical intervention.

Even among those who advocate botulinum, there continues to be debate concerning the time of intervention and method of injection. One study reported that the need for surgery was eliminated in 87.6% of 51 infantile esotropes treated with botulinum injected in an “open sky” procedure, directly into the medial rectus that was exposed by a conjunctival incision. Another study argued that a “closed sky” procedure, in which electromyogram is used to guide the injection, is very reliable and suggested that the more invasive “open sky” technique is not warranted. A report on 60 children with infantile esotropia that received botulinum injections between 5 and 8 months of age noted that 88% achieved good motor alignment with a mean injection age of 6.5 months versus 12% with poor motor alignment with a mean injection age of 7.8 months. Other investigators found a significant difference in motor alignment for those children treated at less than 12 months of age, but some reported no difference between those treated at less than 12 months of age compared with 24 months of age. One of the few studies looking at the development of sensory fusion after botulinum treatment of infantile esotropia stated that 66% of the subjects acquired stereopsis. An editorial reply explaining favorable results compared with an earlier

study emphasized the importance of early intervention, preoperative alternate patching, and bilateral medial rectus injections as possible explanations for the discrepancy in the results. Unfortunately, although comparisons with sensory fusion results of surgical intervention are warranted, the lack of methodologic standardization prevents a meaningful comparison at this time.

Not without controversy, it appears that botulinum injection offers a safe and reliable alternative to surgical intervention of infantile esotropia. Although additional long-term follow-up studies are needed, the ability to promote binocularity during the period of visual development is desirable and can be accomplished with the use of this agent.

The treatment of intermittent exotropia can often present a difficult management scenario due to the differences in the strabismus at distance compared with near. Management options include occlusion, surgery, vision therapy, over-minused spectacles, and botulinum injection. One particular challenge to successful management is the frequent recurrence of the condition and the need for continued treatment in the case of vision therapy or multiple procedures in the case of surgery. One nonrandomized case-controlled study reported a 69% success rate in achieving motor alignment with a single bilateral injection of botulinum in 32 children with intermittent exotropia. All subjects were followed for a minimum of 12 months, and with the exception of transient ptosis in nine patients and a consecutive small angle esophoria in three patients, there were no other secondary occurrences. In a review of several studies comparing the results of botulinum treatment in esotropia and exotropia, approximately 40% of patients with esotropia and 35% with exotropia attained relative alignment as defined by correction within  $\pm 10$  prism diopters, 30% of esotropes and 82% of exotropes had at least some reduction in their deviation, and 30% of esotropes and 16% of exotropes either had no improvement or became consecutive esotropes or exotropes. Botulinum injection has been suggested for use in retreatment of patients previously receiving surgical intervention for esotropia. One study found no difference in both motor and sensory outcomes for those retreated with additional surgery compared with botulinum and recommend botulinum as a less invasive alternative to additional surgeries in this population. Botulinum has also been recommended for the treatment of sensory strabismus, which results from a unilateral reduction of acuity. In a large retrospective report, 8% of the patients with sensory strabismus regained binocularity and required no treatment other than botulinum injection and only 3% of the subjects failed to obtain some reduction of the strabismus with botulinum treatment.

In summary, the mounting evidence supports the use of botulinum toxin in treating various forms of strabismus. These conditions include chronic and acute sixth nerve palsy, infantile esotropia, undercorrection or overcorrection of strabismus with some residual level of binocularity,

and sensory strabismus. The presence of some degree of fusion is an indication for the use of botulinum, and small-angle deviations are more effectively treated than are large deviations. Botulinum has the advantage over surgical intervention in that it is less invasive, quicker, and unlikely to produce scarring of the tissue. The use of botulinum has been studied more extensively in esotropia compared with exotropia, and the main advantage of not requiring anesthesia is typically lost when used in children. Botulinum appears to be a valuable adjunct to strabismus surgery, but controversy still exists regarding its role as the primary treatment. Clearly, further research on the efficacy of this therapy is required before a consensus is achieved.

## Pharmacology

Botulinum toxin is derived from the gram-negative bacterium *Clostridium botulinum*, an anaerobic rod that is commonly known as the source of an extremely harmful food-borne toxin. Although a number of different serotypes of toxin have been identified, serotype A is used in the commercially available drug Botox, or Oculinum. It is a high-molecular-weight protein that is supplied in a freeze-dried form requiring reconstitution with saline before injection.

The primary action is to bind irreversibly to the presynaptic nerve terminals of peripheral cholinergic nerve fibers. Because the drug does not penetrate the blood-brain barrier, it has no effect on the central nervous system. The binding of botulinum to the nerve terminals blocks the release of acetylcholine at the neuromuscular junction, resulting in a temporary paralysis of the muscle.

Injection of botulinum into the muscle produces maximal paralysis at approximately 5 to 7 days and lasts for up to several months. This paralysis allows the injected muscle to stretch as its antagonist contracts. More recently, the use of the immunotoxin Ricin-mAb35 has been recommended as a possible alternative to botulinum because of its longer duration of action. However, additional studies are needed before widespread use in humans.

Additionally, studies have demonstrated that botulinum may also have a more permanent therapeutic effect. Although the exact mechanism is unknown, it has been theorized that through paralysis, botulinum may alter the length-tension, force generation, and fatigability of the extraocular muscles.

## Adverse Effects

The most common adverse event associated with the use of botulinum toxin is spread of the drug beyond the intended site of action. Unintended dissemination of botulinum to the levator muscle, most often after injection into the medial rectus, may result in ptosis persisting for several weeks. In young children this event potentially increases the risk of amblyopia secondary to occlusion of

the visual axis. Less often, a vertical deviation or even diplopia may develop as well. Care must be exercised in the injection procedure to minimize the spread of toxin to unintended sites. Clinically, this is accomplished either by the use of electromyographic recording to pinpoint the location of the muscle or by direct observation during a simultaneous surgical procedure to recess or resect the muscle. Subconjunctival hemorrhage at the injection site is not uncommon. Perforation of the globe is rare.

## SELECTED BIBLIOGRAPHY

- Abrahamsson M, Fabian G, Sjostrand J. Refraction changes in children developing convergent or divergent strabismus. *Br J Ophthalmol* 1992;76:723-727.
- Biglan AW, Burnstine RA, Rogers GL, et al. Management of strabismus with botulinum toxin injection in infantile esotropia. *Ophthalmology* 1989;96:935-943.
- Caloroso EE, Rouse MW. Clinical management of strabismus. Boston: Butterworth-Heinemann, 1993: 145-146.
- Campos EC, Schiavi C, Bellusci C. Critical age of botulinum toxin treatment in essential infantile esotropia. *J Pediatr Ophthalmol Strabismus* 2000;37:328-332.
- Chatzistefanou K, Mills M. The role of drug treatment in children with strabismus and amblyopia. *Paediatr Drugs* 2000;2:91-100.
- Christiansen SP, Becker BA, Iaizzo PA, et al. Extraocular muscle force generation after Ricin-mAb35 injection: implications for strabismus treatment. *JAAPOS* 2003;7:1-6.
- Dawson ELM, Sainani A, Lee JP. Does botulinum toxin have a role in the treatment of secondary strabismus. *Strabismus* 2005;13:71-73.
- Fraunfelder FT. Ocular toxicology. In: Weisbecker CA, Fraunfelder FT, Gold AA, eds. *Physicians' desk reference for ophthalmology*. Oradell, NJ: Medical Economics Co., 1997: 17-20.
- Holmes JM, Beck RW, Kip KE, et al. Botulinum toxin treatment versus conservative management in acute traumatic sixth nerve palsy or paresis. *JAAPOS* 2000;4:145-149.
- Holmes JM, Droste PJ, Beck RW. The natural history of acute traumatic sixth nerve palsy or paresis. *JAAPOS* 1998;2:265-268.
- Holmes JM, Beck RW, Kraker RT, et al. Impact of patching and atropine treatment on the child and family in the amblyopia treatment study. *Arch Ophthalmol* 2003;121:1625-1632.
- Ing MR. Botulinum alignment for congenital esotropia. *Ophthalmology* 1993;100:318-322.
- Kushner B. Editorial comment. *Arch Ophthalmol* 1997; 116:1458.
- Lee J, Harris S, Cohen J, et al. Results of a prospective randomized trial of botulinum toxin therapy in acute unilateral sixth nerve palsy. *J Pediatr Ophthalmol Strabismus* 1994;31: 283-286.
- Lennerstrand G, Nordho OA, Tian S, et al. Treatment of strabismus and nystagmus with botulinum toxin type A. *Acta Ophthalmol Scand* 1998;76:27-37.
- Magoon EH. Chemodenervation of strabismic children: a 2 to 5 year follow-up study compared with shorter follow-up. *Ophthalmology* 1989;96:931-934.
- McNeer KW, Tucker MG, Guerry CH, et al. Incidence of stereopsis after treatment of infantile esotropia with botulinum toxin A. *J Pediatr Ophthalmol Strabismus* 2003;40:288-292.
- McNeer KW, Tucker MG. Incidence of stereopsis after treatment of infantile esotropia with botulinum toxin A [editorial]. *J Pediatr Ophthalmol Strabismus* 2004;41:70-71.
- McNeer KW, Tucker MG, Spencer RE. Management of essential infantile esotropia with botulinum toxin A: review and recommendations. *J Pediatr Ophthalmol Strabismus* 2000; 37: 63-67.
- Pediatric Eye Disease Investigator Group. A comparison of atropine and patching treatments for moderate amblyopia by patient age, cause of amblyopia, depth of amblyopia, and other factors. *Ophthalmology* 2003;110:1632-1637; discussion 1637-1638.
- Pediatric Eye Disease Investigator Group. A randomized trial of atropine vs patching for treatment of moderate amblyopia in children. *Arch Ophthalmol* 2002;120:268-278.
- Pediatric Eye Disease Investigator Group. A randomized trial of atropine regimens for treatment of moderate amblyopia in children. *Ophthalmology* 2004;111:2076-2085.
- Pediatric Eye Disease Investigator Group. Two-year follow-up of a 6-month randomized trial of atropine vs patching for treatment of moderate amblyopia in children. *Arch Ophthalmol* 2005;123:149-157.
- Repka MX, Wellish K, Wisnicki HJ, et al. Changes in the refractive error of 94 spectacle treated patients with acquired accommodative esotropia. *Binocular Vision* 1989;4:15-21.
- Repka MX, Lam GC, Morrison NA. The efficacy of botulinum neurotoxin A for the treatment of complete and partially recovered chronic sixth nerve palsy. *J Pediatr Ophthalmol Strabismus* 1994;31:79-83.
- Scott AB, Magoon E, McNeer K, et al. Botulinum toxin treatment of strabismus in children. *Trans Am Ophthalmol Soc* 1990;87:174-180.
- Scott AB, Rosenbaum A, Collins CC. Pharmacologic weakening of extraocular muscles. *Invest Ophthalmol Vis Sci* 1973;12: 924-927.
- Simons K, Stein L, Sener EC, et al. Full-time atropine, intermittent atropine, and optical penalization and binocular outcome in treatment of strabismic amblyopia. *Ophthalmology* 1997;104:2143-2155.
- Simons K. Amblyopia characterization, treatment and prophylaxis. *Surv Ophthalmol* 2005;50:123-166.
- Spencer RE, Tucker MG, Choi RY, et al. Botulinum toxin management of childhood intermittent exotropia. *Ophthalmology* 1997;104:1762-1767.
- Steele AL, Bradfield YS, Kushner BJ, et al. Successful treatment of anisometropic amblyopia with spectacles alone. *JAAPOS* 2006;10:37-43.
- Stewart CE, Fielder AR, Stephens DA, et al. Treatment of unilateral amblyopia: factors influencing visual outcome. *Invest Ophthalmol Vis Sci* 2005;46:3152-3160.
- Tejedor J, Rodriguez J. Long-term outcome and predictor variables in the treatment of acquired esotropia with botulinum toxin. *Invest Ophthalmol Vis Sci* 2001;42:2542-2546.
- Tejedor J, Rodriguez JM. Retreatment of children after surgery for acquired esotropia: reoperation versus botulinum injection. *Br J Ophthalmol* 1988;82:110-114.

## The Glaucomas

Mitchell W. Dul

### HISTORICAL PERSPECTIVE

Glaucoma was described by Hippocrates as a known affliction of the eyes. The word *glaucoma* is derived from the Greek word *glaukoma*, which means opacity of the crystalline lens and probably referred to several conditions of the eye that were not differentiated from what we now know to be glaucoma.

Treatment options for glaucoma have changed significantly in the past three decades, leading to more effective medications taken fewer times per day with, in general, fewer side effects and better tolerability. Still, patients' nonadherence to treatment and follow-up continues to be a major obstacle for many practitioners.

In addition, the advent of structural assessment instrumentation (e.g., scanning laser ophthalmoscopy) and refined functional assessment devices (e.g., automated perimetry, short wavelength perimetry, frequency doubling perimetry, multifocal electroretinogram/visually evoked potentials) has, on the one hand, made the diagnosis and management of patients more objective and efficient. On the other hand, however, these advances have been responsible for a level of intellectual curiosity, scientific scrutiny, misunderstanding, and confusion for both patients and practitioners.

Notwithstanding these innovations, perhaps the most important tool available to the glaucoma practitioner is the time spent with patients in an environment that is conducive to interpersonal interaction. Good communication skills enable the doctor and patient to work collaboratively. It is likely that this communication facilitates adherence to follow-up and treatment.

### WORLD IMPACT

In a 2002 report the World Health Organization reported that glaucoma has become the second leading cause of blindness worldwide. Overall, an estimated 12.3% of the world's 37 million blind had lost their sight because of glaucoma.

In the United States an estimated 2.2 million people aged 40 years and older have been diagnosed with primary open-angle glaucoma, and that number is expected to reach 3.3 million by the year 2020. Worldwide, primary angle-closure glaucoma (ACG) accounts for almost half of all cases of blindness due to glaucoma.

### THE GLAUCOMA EVALUATION

#### Examination

A comprehensive examination should include an analysis of risk factors including the patient's medical, surgical, and family history; measurement of intraocular pressure (IOP); assessment of the anterior chamber angle by gonioscopy; stereoscopic assessment of the optic nerve head and retinal nerve fiber layer; and assessment of the visual field typically using static automated perimetry. The structural examination of the optic nerve head is documented by any or all of the following: a detailed drawing, stereo photography, or one or more forms of scanning laser ophthalmoscopy.

#### Intraocular Pressure

IOP is not static. It is a balance between the production of aqueous from the ciliary body and the trabecular meshwork outflow facility, uveoscleral outflow, and the episcleral venous pressure. Each of these components is subject to a significant degree of variation (e.g., normal circadian rhythms, body position, sympathetic nervous system activity, anatomic variations, age-related changes), making the actual IOP a dynamic function. The measurement of IOP with our current tonometers is also laced with significant sources of error (e.g., the biomechanical properties of the cornea, the surface tension of the precorneal tear film, and calibration of the measuring device), making it a less accurate measurement than traditionally believed. These factors have led to an interest in alternative approaches to the clinical measurement of

IOP, discussed later in this chapter (see New Alternatives to Applanation Tonometry).

Notwithstanding these challenges, IOP remains a significant risk factor for the development and/or progression of glaucomatous optic neuropathy. It is the only variable known to influence the outcome of glaucoma that is subject to the influence of pharmacologic intervention (vasoprotection and neuroprotection may be offered, to varying degrees, by certain medications, but our knowledge and understanding of these mechanisms is largely confined to animal models). In addition, lowering IOP to alter the course of glaucoma is the only treatment verified by multiple clinical trials and approved by the U.S. Food and Drug Administration (FDA). Clinicians are therefore left with the task of being responsible for hitting a very important dynamic target with an imperfect instrument.

**Measurement of IOP in Clinical Practice.** Care should be taken to be as consistent as possible in the measurement of IOP. Preferably, the same tonometer (periodically calibrated) should be used by the same practitioner. The applanation prism should be placed on the central cornea (corneal thickness and curvature can vary tremendously with eccentrication). It is desirable to take measurements without forcibly holding open the eyelids. If this is necessary to access the corneal surface, then the lids should be lifted and held up against the frontal protuberance and not back toward the orbit. This technique decreases the likelihood of applying pressure to the globe while measuring. Despite these efforts, many other variables in the measurement of IOP are more challenging to control.

**Patient Variables.** Certain body types lend themselves to clinically significant increases in IOP when being positioned at the slit lamp. These patients tend to be rotund, especially in the midsection. In an upright (90-degree angle) position, the midsection and chests of these patients often contact the slit lamp and pose an obstacle to proper orientation in the chin and head rest. In an effort to avoid this, these patients are often encouraged to lean forward toward the slit lamp, causing potential compression of the thorax and breath holding that increases venous pressure, including episcleral venous pressure (a change in episcleral venous pressure of 0.8 corresponds to an increase in IOP of 1 mm Hg). As a result, although proper alignment may be attained under these circumstances, it may be at the expense of an accurate measure of IOP.

For these patients, in addition to conventional tonometric measurements at the slit lamp, IOP should be measured with a handheld tonometer in an upright sitting position, outside of the slit lamp, with their belts, ties, or other tight clothing loosened. If there is a disparity between these measurements, it is typically higher at the slit lamp. Subsequent IOP measurements can be taken in the upright position with a handheld tonometer.

In addition, it is advisable for all patients to obtain periodic measurements of IOP in a supine position. This measurement can be accomplished by laying the patient back in the exam chair for at least 3 to 5 minutes before the reading. IOP is higher in the supine position than in the sitting position in young healthy adults and untreated patients with open-angle glaucoma, and recent evidence suggests that many patients experience their maximum IOP during nighttime hours and especially in the supine position. Even during the day, IOP tends to be higher when measured in the supine versus upright position. Because most patients spend up to one-third of their day sleeping, it is important to at least have some sense as to how high the IOP is during these intervals. Absent a nighttime house visit, an in-office supine IOP may provide important information that might otherwise be overlooked.

**Effects of Contact Lenses and Diurnal Fluctuations on IOP.** Contact lenses can produce changes in corneal shape and/or corneal thickness substantive enough to cause IOP measurement error. This may be particularly true of patients who are prescribed orthokeratology for the management of refractive error. In addition, there is evidence that many soft lens wearers may develop corneal edema during the day. Low levels of contact lens-related edema (<5%) may produce a stiffening of the corneal tissue with a corresponding measured increase in IOP. When edema levels increase beyond 6% to 10% (which is less common in contact lens wear), the cornea becomes substantially softer with subsequent lower measured IOP.

Even in the absence of contact lens wear, the central corneal thickness (CCT) undergoes normal diurnal variation. CCT is thicker when awakening from sleep and decreases exponentially over approximately 2 hours.

To obtain applanation tonometry readings that are relatively unaffected by contact lens-induced or diurnal variations, contact lens wearers should remove their contacts on the day of their examination and leave them out for at least 2 hours before the tonometry measurement. For patients who are scheduled for appointments near the time of their awakening, it is advisable to obtain applanation tonometry readings after the patient has been awake for at least 2 hours.

**Variations in IOP in a 24-Hour Cycle (the IOP Circadian Rhythm).** A circadian rhythm is approximately a 24-hour cycle in the physiologic processes of living beings. Every parameter of a biologic rhythm is a statistical entity that should be viewed in light of the variabilities associated with biologic systems. The 24-hour cycle of IOP is no exception.

IOP varies significantly during the wake-sleep cycle. There are several physiologic factors that account for this variation. In addition, postural changes from upright (during the day) to supine (during sleep) create hydrostatic responses in the episcleral venous pressure and the



distribution of body fluid, which increase IOP during the nocturnal period. This phenomenon challenges popular notions that assume that, on average, IOP is at its trough during sleep. It is now well documented under controlled conditions that average IOP is significantly higher during nocturnal periods versus waking hours in patients of all ages, with or without glaucoma. Twenty-four-hour IOP troughs generally occur at the end of the day (~9:30 PM) and the peak just before daybreak (~5:30 AM). In between the trough and peak is a steady nocturnal increase in IOP of, on average, 4.0 mm Hg.

**What Is Normal?** When patients are informed of their own IOP reading, patients often ask “is my pressure normal?” It is important for the patient to understand that “normal” represents a very patient-specific range of IOP, within which the optic nerve is free from IOP-related damage. The concept of “range” in IOP is important for the patient to understand because they may recall that their IOP readings differ on different occasions.

Normal as it pertains to population studies (in patient terms: “what are most patient’s IOP’s?”) is often confused with “disease free.” In fact, normal IOP in population studies ( $15.5 \pm 2.5$ ) is a statistical average that speaks nothing of disease state. It is well known that patients can have an IOP two standard deviations above the average (Hg mm of  $>21$ ) and not have glaucoma (e.g., ocular hypertension) and, conversely, have an IOP significantly less than average and have glaucoma (normal tension glaucoma). In general, the higher the IOP, the greater the risk of conversion from ocular hypertension to glaucoma and the greater the risk of progression in established glaucoma patients.

**Influence of CCT on the Measurement of IOP.** The most widely used and most precise (lowest measurement variability) method for the measurement of IOP remains the Goldmann applanation tonometer. Hans Goldmann based his instrument calculations on an average corneal thickness of 520  $\mu\text{m}$ . He surmised that corneal resistance to deformation (applanation) resulting from this average corneal thickness would be offset by the precorneal tear layer surface tension when the area applanated had a diameter of 3.06 mm. However, the results of the Ocular Hypertension Treatment Study (OHTS) and clinical experience with pre- and post-laser in situ keratomileusis IOP readings have sensitized us to the importance of the influences of the biomechanical properties of the cornea (including, but not limited to, corneal thickness, rigidity, and radius of curvature) on IOP readings. As a general rule, the thicker the central cornea, assuming a normal healthy cornea, the more force is required to applanate the fixed area. As such, the measured reading would likely be greater in magnitude than the “true” IOP. When the normal biomechanical state of the cornea is altered, applanation IOP readings can also be misleading. For instance, in the presence of

corneal edema ( $>5\%$ ), corneal thickness is increased but overall corneal rigidity is decreased. Consequently, the force needed to applanate the corneal surface is less. This would produce a measured reading that would be lower than the true IOP.

There have been several attempts at scaling or quantifying the effects of CCT on IOP. None of these is particularly useful for individual patients. These correction nomograms should be viewed as coarse guidelines, with the understanding that the relationship between IOP and all the biomechanical properties of the cornea (of which CCT is one) is complex and not a linear function. Although, on average, a greater CCT contributes to an overestimating of IOP, it is advisable to factor the effects of CCT on IOP in broad terms, such as likely overestimated (for thick corneas  $> 580 \mu\text{m}$ ) and likely underestimated (for thin corneas  $< 500 \mu\text{m}$ ). For an individual patient the contribution of CCT on IOP measurement error has yet to be established.

**CCT as a Function of Race, Age, and Disease.** Average CCT varies with race (Box 34-1), age, and diagnosis. Whites, Chinese, Hispanics, and Filipinos tend to have comparable CCTs. Among the Asian races, Mongolians have the thinnest CCT, whereas the Japanese have thinner corneas than Chinese and Filipinos. African-Americans, patients with glaucoma, and older patients tend to have thinner corneas. Patients with ocular hypertension tend to have thicker corneas.

**Other Sources of Error in Tonometry.** There are other sources of error in the use of Goldmann-type applanation tonometers, some of which are summarized in Box 34-2.

**New Alternatives to Applanation Tonometry.** In an effort to address the biomechanical variables associated with the measurement of IOP, new IOP measuring devices have been developed and introduced. Two notable instruments are the dynamic contour (Pascal) tonometer and the ocular response analyzer (Reichert) tonometer. These technologies

**Box 34-1** Central Corneal Thickness as Function of Race

Race	Average CCT ( $\mu\text{m}$ )
Mongolian	495
Black	521–539
Japanese	532
Hispanic	548
White	550–554
Filipino	551
Chinese	556

<b>Box 34-2</b> Other Sources of Error With Use of Goldmann-Type Tonometers	
Overestimate IOP	Underestimate IOP
Thick mires	Thin mires
Valsalva maneuvers	Prior gonioscopy
Tight-fitting clothes (esp. neckties)	Multiple readings
Mechanical pressure on globe	Corneal edema
Thick corneas	Thin corneas
Steep cornea	Flat corneas
Patient holding breath	

and others will continue to mature and will likely become further integrated into routine clinical practice.

**Dynamic Contour Tonometry.** Using the principle of contour matching instead of applanation, the dynamic contour tonometer attempts to eliminate some of the variables associated with applanation tonometry. The dynamic contour tonometer uses a miniature piezoelectric pressure sensor embedded within the tonometer tip that is contour matched to the shape of the cornea. The tonometer tip rests on the cornea with a constant appositional force. When the sensor is subjected to a change in pressure, the electrical resistance is altered and the pressure change is calculated proportionate to the change in resistance. The device is able to measure multiple readings and provides a measure of quality of the pulse curve segment used for computation.

**Ocular Response Analyzer.** The ocular response analyzer applies force to the cornea in the form of a collimated air pulse, with an electrooptical system used to monitor changes in curvature during corneal deformation. The cornea moves inward with the air pulse and then returns to normal curvature. The curvature detection system records two pressure values at inward and outward applanation events. Corneal biomechanical properties create a damping effect that manifests as a difference between the two pressures. Averaging these two pressures provides a Goldmann-correlated IOP. The difference between these two pressure values is referred to as corneal hysteresis.

**Summary.** Measured IOP varies with corneal thickness, rigidity, curvature, eccentricity on the cornea, time of day, type of tonometer used, position of the patient, use of medications known to influence IOP, adherence to medication regimen, and a host of other variables. For such an important measure, it has several potential sources of error.

### Clinical Pearls

- IOP measurements are less accurate than previously supposed.
- Correction factors attempting to account for the biomechanical properties of the cornea can be very misleading and cannot quantitatively calculate the “true” IOP.
- Clinical corrections in IOP should be limited to broad categories such as likely overestimated (for thick corneas > 580  $\mu\text{m}$ ) and likely underestimated (for thin < 520  $\mu\text{m}$ ).
- In most patients IOP tends to be greatest during the night and in the supine position. Some attempt at measuring supine IOP in the clinical setting may be desirable.
- Variables capable of increasing the IOP (e.g., tight clothing, stress, Valsalva maneuvers, holding breath) should be accounted for, to the extent possible.
- Contact lens wearers should remove their contacts on the day of their examination and leave them out for at least 2 hours before the tonometry measurement.
- The applanation tonometry reading should be obtained after the patient has been awake for at least 2 hours.
- Tonometers should be periodically calibrated (once or twice a year).

### Gonioscopy

The utility of gonioscopy in the management of the glaucomas is critical for an accurate diagnostic assessment. Worldwide, primary ACG accounts for almost half of all cases of blindness due to glaucoma. Although primary open-angle glaucoma is by far the most common form of glaucoma in the United States, it is a diagnosis that should be reserved for patients who have had a thorough gonioscopic assessment to exclude glaucomas caused by angle closure or forms of secondary glaucomas.

For instance, in the absence of gonioscopic assessment, intermittent or chronic ACG could be misdiagnosed as open-angle glaucoma and could lead to inappropriate treatment and exposure to medications that may not be necessary. Although several mechanisms are responsible for ACG, most cases occur as a result of closure (acutely, intermittently, or chronically) of the anterior chamber filtration angle by the peripheral iris. This possibility makes gonioscopy an essential element in the differential diagnosis of these and other forms of glaucoma.

**Gonioscopy in Clinical Practice.** The use of gonioscopy is, unless contraindicated (e.g., in the setting of hyphema), expected in the assessment of a patient suspected of having glaucoma. Despite this fact, in studies conducted in the United States it appears that for many glaucoma patients, critical elements of the assessment are often not performed, most notably gonioscopy, optic nerve assessment, and optic nerve head documentation on a regular basis. In addition, a retrospective review of U.S. Medicare beneficiaries who underwent glaucoma surgery in 1999 showed that only 49% of them had a gonioscopic examination during the 4 to 5 years preceding their operations.

It is not clear, and it may be unreasonable to draw conclusions from these studies as to the community standard in local areas; however, gonioscopy appears to be an underperformed procedure.

**Expected Gonioscopic Findings.** From anterior to posterior, the following structures are present in the angle: Schwalbe's line (representing the posterior border of Descemet's membrane), the anterior trabecular meshwork (often less pigmented than the posterior trabecular meshwork), the canal of Schlemm within the boundaries of and deep to the trabecular meshwork (typically only visible if filled with venous blood), the posterior trabecular meshwork, the scleral spur (to which the ciliary muscle is attached), and the ciliary body band.

Care must be taken to distinguish these structures from clinical entities that can simulate normal anatomy. For instance, pigment from the structures of the anterior chamber can accumulate on and adjacent to Schwalbe's line. This pigment deposition can give the false impression of a normal trabecular meshwork and an open angle. This pigmented band is referred to as Sampaolesi's line. The appearance of the trabecular meshwork can also mislead the practitioner into believing that the nonpigmented or lightly pigmented anterior trabecular meshwork, followed posteriorly by a pigmented portion of the trabecular meshwork, is actually the scleral spur and ciliary body. This appearance is due to the fact that the meshwork extends anteriorly beyond the region that is primarily responsible for outflow of aqueous. In the region closest to the outflow, pigment tends to accumulate in greater amounts than in the region adjacent to it.

As a general rule, the width of the ciliary body band is generally equal to or less than that of the trabecular meshwork. If the width is greater, it is typically symmetric between the eyes or may represent an angle anomaly such as angle recession. In addition, the width of the ciliary body band is generally greatest in the inferior quadrant and at its thinnest in the superior quadrant.

**Gonioscopic Instruments.** Three-mirror and four-mirror lenses are the most commonly used in clinical practice. The four-mirror lens has the advantage of less mess (gonioscopic solutions such as Goniosol are not required), a more rapid procedure, and greater patient comfort. Care should be taken, at least initially, to not press too firmly on the cornea to avoid mechanically opening the angle during observation. Indenting the cornea subsequent to this initial observation (indentation gonioscopy) may be useful in determining the actual location of iris insertion if it is not otherwise visible. The three-mirror lens requires a contact solution but has the advantage of a more stable image in a blepharospastic patient (once the lens is on) and having additional mirrors, which serve other purposes (such as contact funduscopy).

**Gonioscopic Assessment.** The assessment of the angle by either technique should include the entire angle circumference and should be augmented by changing light levels to simulate the angle architecture in different environments (e.g., dimming the lights may demonstrate a crowding of the angle by the dilating iris that might have been missed under brightly lit conditions). In addition to documenting the posterior-most structure and the presence of angle pathology (e.g., angle neovascularization, neoplasm, peripheral anterior synechia, heavy pigmentation, angle recession), an assessment of the peripheral iris profile (e.g., steep, regular, concave, and plateau), including the presence of iris-trabecular meshwork contact, should be made. This profile may vary in different levels of illumination and during indentation gonioscopy, which assist in differentiating apparent angle depth from actual depth and appositional versus synechial iris-trabecular contact.

**New Anterior Chamber Technologies.** Anterior segment ocular coherence tomography allows for precise evaluation, measurement, and analysis of the anterior segment, including anterior chamber depth, anterior chamber angles, and the angle-to-angle distance (anterior chamber diameter). It can also assist in postoperative evaluation because it allows imaging and measurement of intraocular lenses and ocular implants. The procedure is relatively fast and does not contact the eye. It can be performed in complete darkness as well as in brightly lit surroundings (to assist in the dynamic assessment of the angle). The images are digitally documented, so they can be magnified, enhanced, transmitted, and measured. In addition, a technician can take the image, freeing the doctor to focus time on assessing the results.

It seems likely that manufacturers will develop archived clinical databases in future permutations of this technology. This would permit comparison of parameters such as the anterior chamber depth and configuration of the anterior chamber angle with an internal database. Probability analysis could be generated to determine the extent of deviation from a norm or the risk of angle closure.

### Clinical Pearls

- Gonioscopy is important for every patient with glaucoma (unless contraindicated).
- Gonioscopy is important for every patient who fails angle screening (e.g., van Herick technique) at the slit lamp.
- Gonioscopy should be performed statically (dim lights, no indentation) and dynamically (increased illumination and/or indentation as needed).
- Gonioscopy should include an observation of all 360 degrees of each angle.
- The clinician should be aware of anatomic masqueraders:
  - Sampaolesi's line appearing as trabecular meshwork
  - Light- and dark-banded trabecular meshwork appearing as scleral spur and ciliary body

- The peripheral iris profile should be observed and documented as steep, regular, concave, or plateau and the presence of iris-trabecular meshwork contact (either appositional or synechia).
- The clinician should observe and document secondary etiologies of glaucoma.
- This procedure should be repeated every 3 to 5 years unless otherwise indicated.

### Structural Assessment of the Optic Nerve Head and Retinal Nerve Fiber Layer

In many instances, structural changes of the optic nerve head or retinal nerve fiber layer provide the first clinical evidence of glaucoma. The assessment of these structures has improved dramatically over the past decade as scanning laser ophthalmoscopy has become more available. A consensus document by the Association of International Glaucoma Societies (which includes the Optometric Glaucoma Society and the American Glaucoma Society) suggests that the introduction of these devices has enhanced the community standard by enabling clinicians with less experience to function at a level that is closer to their experienced counterparts. The use of new technologies is becoming increasingly common. These new instruments augment but do not replace a careful clinical examination and will likely play an increasing role in management decisions in the future.

**Methods of Clinical Assessment of the Optic Nerve and Retinal Nerve Fiber Layer.** The clinical assessment of the optic nerve and retinal nerve fiber layer is typically conducted using indirect ophthalmoscopy at the slit-lamp through a dilated pupil. This affords a stereoscopic assessment of the deviations from normal optic nerve architecture that could be overlooked with the direct ophthalmoscope or retinal photography. However, these latter two techniques often provide very useful information that could be missed during indirect ophthalmoscopy. Therefore all three devices have a role in the assessment of the optic nerve and retinal nerve fiber layer. Further assessment of optic nerve and retinal nerve fiber layer parameters may be augmented using any of a variety of scanning laser ophthalmoscopes. The clinician assesses the data produced by these devices and correlates the results with the clinical gestalt acquired by assessing these structures directly. Although the scanning laser devices make comparative analyses against an internal normative database, the clinician makes a more comprehensive analysis against his or her clinical experience.

**Direct Ophthalmoscopy.** The direct ophthalmoscope is perhaps an underutilized instrument in the assessment of glaucoma. It can provide information regarding pupil function, an estimation of the anterior chamber angle depth, spherical refractive error of the patient, presence of media opacity, and a magnified view of the optic nerve

that can be enhanced with the use of filters (e.g., red-free). The size symmetry of the nerve can be assessed by using the 5-degree spot size as a reference, and the nerves can be compared with each other because the procedure allows for a relatively rapid assessment between each eye. The magnified view of the optic nerve head enables the practitioner to carefully assess the vasculature of the nerve in ways that could be overlooked by other means of assessment. Monocular cues to depth such as deflection of vessels, although not as robust as true stereoscopic view, can augment the clinical assessment. In addition, the direct ophthalmoscope is portable, the image is “right side up,” and the instrument is more accommodating to patients who have difficulty at the slit lamp.

**Indirect Ophthalmoscopy.** Indirect ophthalmoscopy of the optic nerve head and retinal nerve fiber layer affords a three-dimensional view of these structures, which provides the observer with a sense of depth that is often lacking with the direct ophthalmoscope. Most experienced practitioners acknowledge that their impression of the integrity of the neural retinal rim of the optic nerve can be tremendously different during a stereoscopic versus a monocular assessment. Too often, color cues afforded by direct ophthalmoscopy can mislead the practitioner into believing that the neural retinal rim is more intact when compared with the stereoscopic assessment. Indirect ophthalmoscopy (i.e., the stereoscopic assessment of the optic nerve, typically with condensing lenses used at the slit lamp), although generally thought of as the gold standard and an essential component of the assessment of a patient with or expected of having glaucoma, is not without its limitations. Interobserver reliability (the degree of agreement in the assessment of ophthalmoscopic findings between two or more practitioners) is not great (even between experienced practitioners). Additionally, the assessment of the retinal nerve fiber layer is, at times, very challenging, especially in the presence of a lightly pigmented retina or media opacity. The presence of optic disc (Drance) hemorrhages, arguably one of the most significant clinical findings suggestive of future compromise of the neural retinal rim and corresponding visual field, can also be overlooked. Remarkably, a significant percentage of these hemorrhages are missed by experienced practitioners but are easily observable on a retinal photograph (even in the absence of a red-free filter). This may be due, in part, to using a light source at the slit lamp that bleaches the image of the hemorrhage. In summary, although indirect ophthalmoscopy should be viewed as a highly recommended procedure for all glaucoma patients, it should, whenever possible, be augmented by other techniques.

**Retinal Photography.** Photography of the optic nerve head and retinal nerve fiber layer has the advantage of offering varying levels of magnification, filters (e.g., red-free), and a stable image even in the setting of a patient with poor

fixation or nystagmus. In addition, particularly in digital format where the image is quickly accessible, the photograph provides an excellent opportunity to educate the patient about the nuances of his or her particular optic nerve, the effects of glaucoma on the nerve, and the importance of regular monitoring of its structural integrity. These extra few minutes go a long way to demystify this symptomless chronic disease.

A photograph also reveals disc hemorrhages and retinal nerve fiber layer defects that can be overlooked by other methods (including the scanning laser ophthalmoscopes) and is an excellent way of documenting the optic nerve head, particularly if stereoscopic pairs are created. Unfortunately, commercial access to cameras that allow for simultaneous stereo photography is limited. To minimize the effects of photographic stereo artifacts associated with manually offsetting the camera, care must be taken to be as consistent as possible.

#### ***Clinical Assessment of the Optic Nerve and Retinal Nerve Fiber.***

It is important to approach the assessment of these structures in a consistent and organized manner with several key parameters noted for every optic nerve. One way to keep this assessment organized is the mnemonic CARVES, because glaucoma “carves” out the optic nerve (Courtesy of Nick Holdeman, OD, MD, and Jade Schiffman, MD):

C = Color (e.g., pink or pale)

A = Angle of the disc (e.g., deep, saucerized, tilted)

R = Rim tissue and nerve fiber layer

V = Vessels (e.g., bearing, bayoneting, disc hemorrhages)

E = Extrapapillary features (e.g., zone beta, myopic crescent)

S = Size

***Size, Shape, and Symmetry.*** The size and shape of the optic nerve influence the appearance of the neural retinal rim in significant ways. Larger discs, in general, have larger cups, and vertically elongated discs tend to have neural retinal rims that appear thinner at the long axis (superiorly and inferiorly) when compared with round rims. Round rims are more likely to follow the ISNT rule of the neural retinal rim: The thickness of the rim tends to be greatest in the inferior quadrant (I), followed by the superior (S), nasal (N), and then temporal (T) quadrants. This phenomenon is due to the convergence of the retinal ganglion cells from the superior and inferior arcades (the larger proportion of the entire population of retinal ganglion cells) onto the superior and inferior rim, in tandem with the branches of the central retinal artery and vein that also occupy this area. Although the ISNT rule is a useful guideline, it is not without its documented limitations and should be used with a degree of caution.

The disc size is also important for other reasons. Whereas a 0.7/0.8 cup-to-disc ratio might have a normal neural retinal rim in a large vertically elongated disc, this same ratio could be quite abnormal in a smaller disc. In addition, a 0.5 cup-to-disc ratio in a small disc would take

on added clinical significance if the previous assessment was significantly less. Said another way, the clinician should monitor small and large discs with equal diligence because subtle changes may easily be overlooked.

Disc symmetry is also a critical element in the assessment of the nerve. A common misinterpretation of “asymmetric cupping” is often asymmetric discs (recall large discs have large cups). Disc asymmetry is difficult to appreciate without some form of measurement from one eye to the next (the measurement need not be quantifiable; it can be a simple comparison of one eye to the next). There are several methods to assess the size of the disc. One simple way is to compare photographs taken at the same level of magnification or comparing the sizes relative to a known area (e.g., the 5-degree spot during direct ophthalmoscopy). Another is at the slit lamp when matching the length of the light beam to the long and short axis of the nerve and comparing this length from one eye to the other. Certain scanning laser ophthalmoscopes also measure the area of the disc.

***Integrity of the Retinal Nerve Fiber Layer.*** The utility of the assessment of the retinal nerve fiber layer has been known for several decades. It was not until the wide distribution of digital retinal photography and the introduction of scanning laser ophthalmoscopy that the assessment of this structure became more commonplace. Before digital photography, the nerve fiber layer assessment was conducted either with direct or indirect ophthalmoscopy (often with auxiliary filters) or by nerve fiber layer photography (also with auxiliary filters and, often, very specialized photographic film). Debates ensued over the best way to assess this structure but often with the knowledge that this level of assessment was beyond the community standard outside of academic institutions or well-known glaucoma practices. The retinal nerve fiber layer, especially in lightly pigmented fundi as a backdrop or in the presence of any significant media opacity, was a challenge to visualize.

Documentation was accomplished by drawing. Photography was equally challenging but had the added disadvantage of a delay in the processing time. With the introduction of high-quality digital photography, page proofs are “developed” in seconds, allowing the photographer to make adjustments to lighting and focus in real time. As such, the ability to photodocument the retinal nerve fiber layer has been greatly enhanced. The introduction of scanning laser ophthalmoscopes enhanced this measurement even further. These technologic advances have reawakened the clinical practitioner to the importance of the assessment of this structure. Although limitations of the assessment by ophthalmoscopy remain, the assessment and documentation of the retinal nerve fiber layer have become a community standard in the evaluation of a patient with or suspected of having glaucoma.

**Peripapillary Atrophy.** Peripapillary atrophy is not an uncommon condition and is not a sensitive means of differentiating glaucomatous from nonglaucomatous patients (especially in early glaucoma). However, the size, location, and changes in areas of peripapillary atrophy may have some significance for patients with glaucoma.

**Beta Zone and Alpha Zone.** Peripapillary atrophy is sometimes divided into two distinct zones, each with different underlying histopathologies. One zone, the alpha zone, appears as an irregular hypopigmentation and hyperpigmentation and thinning of the chorioretinal tissue layer. It is bordered anteriorly by the retina and posteriorly by either the beta zone or the scleral ring. Histopathologically, it corresponds to pigmentary irregularities in the retinal pigment epithelium. Psychophysically, this defect corresponds to a relative scotoma.

The beta zone is characterized by marked atrophy of the retinal pigment epithelium and of the choriocapillaris, good visibility of the large choroidal vessels and the sclera, and thinning of the chorioretinal tissues. It correlates histopathologically with a complete loss of retinal pigment epithelium cells and markedly diminished count of retinal photoreceptors. This defect corresponds psychophysically to an absolute scotoma.

In normal eyes both alpha and beta zones are largest and most frequently located in the temporal horizontal sector, followed by the inferior temporal area and the superior temporal region. They are smallest and most uncommonly found in the nasal peripapillary area. If both zones are present, the beta zone is always closer to the optic disc.

Alpha zones are present in almost all normal eyes and are thus more common than beta zones. Alpha and beta

zones must be differentiated from the myopic scleral crescent in eyes with high myopia.

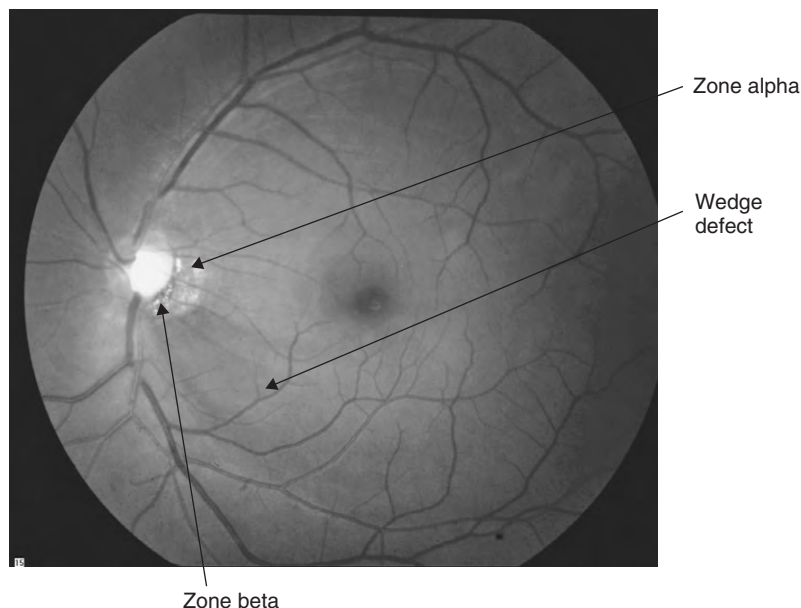
Both zones are often larger, and the beta zone occurs more often in eyes with glaucomatous optic nerve atrophy and may be correlated with thinning of the neural retinal rim and visual field loss (Figure 34-1). In unilateral glaucoma, a beta zone, if present, is found significantly more often in the affected eyes than in the contralateral nonglaucomatous eyes. Increases in the size of the beta zone may suggest progression of glaucoma in some patients.

#### Clinical Pearls

- Assessment of the optic nerve head and retinal nerve fiber layer should occur for all glaucoma patient and glaucoma suspects.
- Indirect ophthalmoscopic assessment of the optic nerve head and retinal nerve fiber layer at the slit lamp should, whenever possible, be augmented by other techniques such as direct ophthalmoscopy, retinal photography, and/or scanning laser ophthalmoscopy.
- An assessment of the optic nerve and retinal nerve fiber layer should include an assessment of the following: disc size, shape, symmetry, color, angle, vessels, and extrapapillary features such as the presence of a zone beta.

#### Glaucomatous Optic Nerve (Drance) Hemorrhages

Disc hemorrhages are an important prognostic indicator in the assessment and management of glaucoma and ocular hypertension. Glaucoma patients who develop disc hemorrhages are more likely to develop optic nerve



**Figure 34-1** Fundus photo showing wedge defect and alpha and beta zones.

head/retinal nerve fiber layer damage and visual field loss sooner than patients who do not develop these hemorrhages.

**Detection.** Most disc hemorrhages occur in the inferior temporal quadrant of the optic nerve and are of relatively short duration (~1 to 3 months). The OHTS showed that reviewing retinal photographs was considerably more sensitive at detecting disc hemorrhages when compared with clinicians viewing the nerve directly with ophthalmoscopy—even though the optic nerve heads of these patients were examined ophthalmoscopically twice per year versus retinal photographs, which were reviewed only once in the same time frame.

**Pathogenesis.** The pathogenesis of Drance hemorrhages is incompletely understood.

**Differential Diagnosis.** Differential diagnoses of disc hemorrhages include posterior vitreous detachment, diabetic retinopathy, hypertensive retinopathy, hemorrhage resulting from optic disc drusen, ischemic optic neuropathy, leukemia, and peripapillary neovascular membrane.

**Laser Imaging Devices.** Currently available imaging techniques used for examining the retinal nerve fiber layer and/or the optic disc in glaucoma include confocal scanning laser ophthalmoscopy, optical coherence tomography, and scanning laser polarimetry. Each of these techniques uses different technologies and light sources

to characterize the distribution of retinal nerve fiber layer and/or optic disc topography (Table 34-1).

There are distinct advantages to this imaging technology. Optic nerve and retinal nerve fiber layer assessment, by even very experienced clinicians, has a level of subjectivity and agreement between experienced clinicians that is not ideal. Imaging technology compares acquired data with internal databases and assesses the degree of variability from this age-matched norm. This biostatistical analysis can serve as an important adjunct to the clinical assessment of the optic nerve. This analysis also demonstrates progression over time in ways that are more sensitive than clinical observation. At this time evidence does not preferentially support any one of the above structural tests for diagnosing glaucoma. Different imaging technologies may be complementary and detect different abnormal features in the same patients. This information supplements the assessment by the clinician who compares each patient's findings with his or her clinical experience. It is ill advised to use any of these devices in the absence of sound clinical assessments and judgment.

New versions of imaging devices are available with higher resolution and more rapid acquisition time. Future improvements will include the incorporation of adaptive optics that, at present, can resolve retinal structures at the cellular level. This technology will continue to improve and play a more critical role in the management of glaucoma and eye disease in general.

**The Relationship Between Structure and Function.** The correlation between the results derived from these structural

**Table 34-1**  
Imaging Devices and Their Associated Technology

Device	Technology	Comments
Confocal scanning laser ophthalmoscopy (HRT III) (Heidelberg Engineering)	Confocal scanning diode technology to provide topographic measures of the optic disc and parapapillary retina	Most mature of these devices Several forms of analysis, including progression No pupil dilation required Race specific norms Portable Dual purpose (macular assessment)
Optical coherence tomography (StratusOCT) (Carl Zeiss Meditec, Inc.)	OCT uses interferometry and a reflection-based edge-detection algorithm to define the thickness of the circumpapillary RNFL	Higher resolution OCT introduced Pupil dilation required Cross-sectional data Dual purpose (retina)
Scanning laser polarimetry (GDx VCC) (Carl Zeiss Meditec, Inc.)	Measures the retardation of light reflected from the birefringent RNFL fibers and provides an estimated RNFL thickness	Addition of variable corneal compensator represents a significant improvement Progression analysis No pupil dilation required Race-based norms Portable

RNFL = retinal nerve fiber layer.



devices and the functional (visual field) assessment of glaucoma (particularly early glaucoma) is weak. Recent evidence suggests that this may be due, in large part, to the test-retest variability associated with our current visual fields devices and other sources of noise in the acquisition of data. Several studies have also provided evidence that the time of onset of structural and functional defects, detectable using current techniques, is different. For instance, the OHTS and European Glaucoma Prevention Study both showed that, in many eyes, structural defects develop before functional defects (perhaps in areas of high retinal redundancy), whereas in a similar number of other eyes, functional defects develop first (perhaps a result of retinal ganglion cells becoming dysfunctional before dying). The simultaneous presentation of structural and corresponding functional defect in early glaucoma is much less common. In advanced glaucoma the correlation between structure and function is quite good (a patient whose optic nerve is cupped to the inferior temporal rim will likely have a corresponding superior nasal defect), although exceptions do occur. As glaucoma progresses to end stage, the utility of the structural assessment is limited. Quite often, these optic discs are cupped to the rim in most quadrants, and most of what remains are the papillomacular bundles. At this point, imaging devices have also reached the limits of their usefulness. As such, our ability to assess changes in the structural integrity of end-stage nerves is poor. Under these circumstances, the visual field assessment is still a useful tool because most of these patients have some functional visual ability. If the condition continues to progress, alternative forms of visual fields may be indicated (e.g., 10-2 test pattern, stimulus size V, Goldmann fields).

### Clinical Pearls

- In many cases structural defects develop before functional defects.
- In many cases functional defects develop before structural defects.

- The relationship between structural and functional loss measured with our current clinical technology is weak, especially in early glaucoma.
- Both the visual field and optic disc must be monitored with equal diligence (in all but end-stage glaucoma).
- Confocal scanning laser ophthalmoscopy, ocular coherence tomography, and scanning laser polarimetry seem to be similarly able to discriminate between healthy and glaucomatous eyes.
- Retinal photography is an important adjunctive tool in the assessment of the optic nerve and retinal nerve fiber layer.
- Disc (Drance) hemorrhages and retinal nerve fiber layer defects that are visible with retinal photography can be overlooked during clinical and/or laser ophthalmoscopy.

### Functional Assessment (Visual Fields)

In many instances, functional (visual field) changes provide the first clinical evidence of glaucoma. The measurement and assessment of the visual field has seen several transformations over the past few decades. The conversion from Goldmann kinetic visual fields to static automated perimetry marked a significant milestone in the measure of retinal sensitivity in a clinic setting. No longer requiring the skilled perimetrist and having the theoretical advantage of a more objective measure of visual function, the automated visual field has become a conventional tool in most offices. Since then, these devices have increased in clinical utility with the addition of normative databases, built-in statistical analyses, and faster algorithms, aimed at assisting the practitioner in the diagnosis of glaucoma and the determination of whether a patient's condition is stable or progressing. In addition, alternative visual field stimuli aimed at specific retinal pathways have been introduced with the hope of "reducing retinal redundancy," thereby detecting functional changes in advance of conventional white-on-white (achromatic) perimetry (Table 34-2).

Achromatic (white-on-white) static automated perimetry ("standard" automated perimetry or conventional

**Table 34-2**

Visual-Function Specific Perimetric Tests

Test	Ganglion Cell Type	LGN Projection
SWAP <sup>a</sup>	Small bistratified	Koniocellular layers (interlaminar)
FDT <sup>b</sup>	Parasol cells	Magnocellular layers
HPRP <sup>c</sup>	Midget	Parvocellular layers

<sup>a</sup>SWAP (short wavelength automated perimetry): A blue size V stimulus is projected onto a bright yellow background.

<sup>b</sup>FDT (frequency doubling technology): Low spatial frequency sinusoidal gradings with wide light and dark bands undergo rapid phase reversal.

<sup>c</sup>HPRP (high-pass resolution perimetry): Rings of varying sizes are presented at 50 locations in the central 30 degrees. Because the space-averaged luminance of the entire ring is equal to the luminance of the background, when the edges of the ring cannot be resolved, the rings blend into the background. As such, the targets are either resolved (seen) or they are invisible.

LGN = lateral geniculate nucleus.

automated perimetry) presents an achromatic incremental stimulus on an achromatic background. This testing strategy has become very familiar to most practitioners. Since its introduction, much has been learned about the human retina that, we now know, is divided into several distinct retinal ganglion cell pathways that project to specific layers in the lateral geniculate nucleus en route to the visual cortex and other locations. Achromatic stimuli are not tuned to any particular cell type. In fact, any of these pathways is capable of responding to a white-on-white stimulus. The clinical effects of this overlap, or “redundancy,” theoretically means that some percentage of most of these cell types must lose their function in a given location in the retina for a white-on-white stimulus to either not be seen or to require a brighter intensity to be seen. Requiring a brighter intensity to be seen is referred to as an increase in visual threshold (or a decrease in retinal sensitivity). Although there are advantages to a redundant system, this works to our disadvantage if we are trying to detect change in sensitivity as early as possible. If perimetric stimuli could be “tuned” to the frequencies of particular cell types, then this redundancy could be reduced. Theoretically, this reduction in redundancy could produce a perimetric test that was more sensitive to early change because there would be no, or minimum, responses from alternative pathways to stimulate. In addition, if one particular cell type was believed to be affected earlier in the disease process, then tuning stimuli to this cell type may enable us to measure changes in retinal ganglion cell sensitivity in a more timely manner—assuming that early diagnosis has some impact on the long-term outcome of our patients.

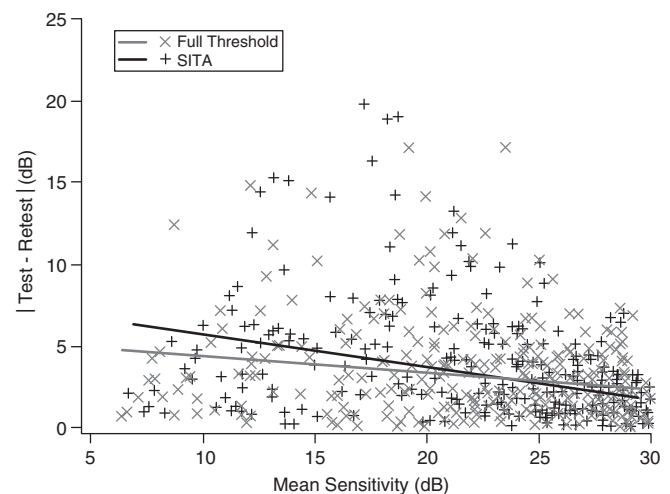
Recent evidence, however, does not support the notion that any retinal ganglion cell type is preferentially affected in early glaucoma, and perimetric stimuli tuned to specific types of ganglion cells are not necessarily more sensitive at distinguishing patients with early glaucoma or progressive glaucomatous optic neuropathy. It is often assumed that visual field stimuli tuned to specific ganglion cell pathways are more sensitive than SAP. However, when assessing the ability of these tests to identify glaucoma patients using the presence of glaucomatous optic neuropathy or progressive glaucomatous optic neuropathy as examined by expert observers, static automated perimetry performance has been shown to be equal to or slightly better than short wavelength automated perimetry and not significantly different from frequency doubling technology. Because, in general, no one test appears to be more sensitive at confirming glaucomatous optic neuropathy, perhaps a battery of functional tests that uses some or each of these test strategies may prove to be of greater benefit.

**Where We Are Now.** Static automated perimetry (white-on-white or conventional automated perimetry) has become the standard for functional testing of the visual field in the clinical setting. There are several manufacturers

of these devices. What distinguishes them from each other is the way in which the stimuli are presented and the data analyzed. There have been many attempts at striking a balance between reliable data and speed of acquisition. Contemporary algorithms are truly an improvement over the early versions, particularly when compared with full threshold data. Care should be taken in choosing appropriate algorithms for testing because some may have more variability between tests than others (e.g., Swedish Interactive Thresholding Algorithm [SITA] FAST version).

**Variability.** One serious drawback to static automated perimetry analysis is the variability of data within a given examination (short-term fluctuation) and between examinations (test–retest variability). It is well established that test–retest variability increases as a function of decreased retinal sensitivity even in the normal retina. Imagine the island of vision (Traquair’s island of vision) with its peak at the fovea and a relatively gradual slope in sensitivity until the retinal periphery where the slope decreases exponentially. Test–retest variability also increases exponentially in the periphery. This is one reason why testing beyond the central 30 degrees is seldom used in clinical practice. Simply put, it would be very difficult to distinguish any measured changes in sensitivity from the noise of the expected test–retest variability.

Decreased retinal sensitivity can also occur as a result of small pupils and media opacities (preretinal receptor factors) or from disease (e.g., glaucoma). Figure 34-2 shows test–retest variability as a function of sensitivity in the central 10 degrees in a group of patients with glaucoma. Notice that variability is less in areas of high sensitivity (e.g., ~32 dB) and very low sensitivity (~0 to 3 dB). In the former, highly sensitive areas likely remain highly

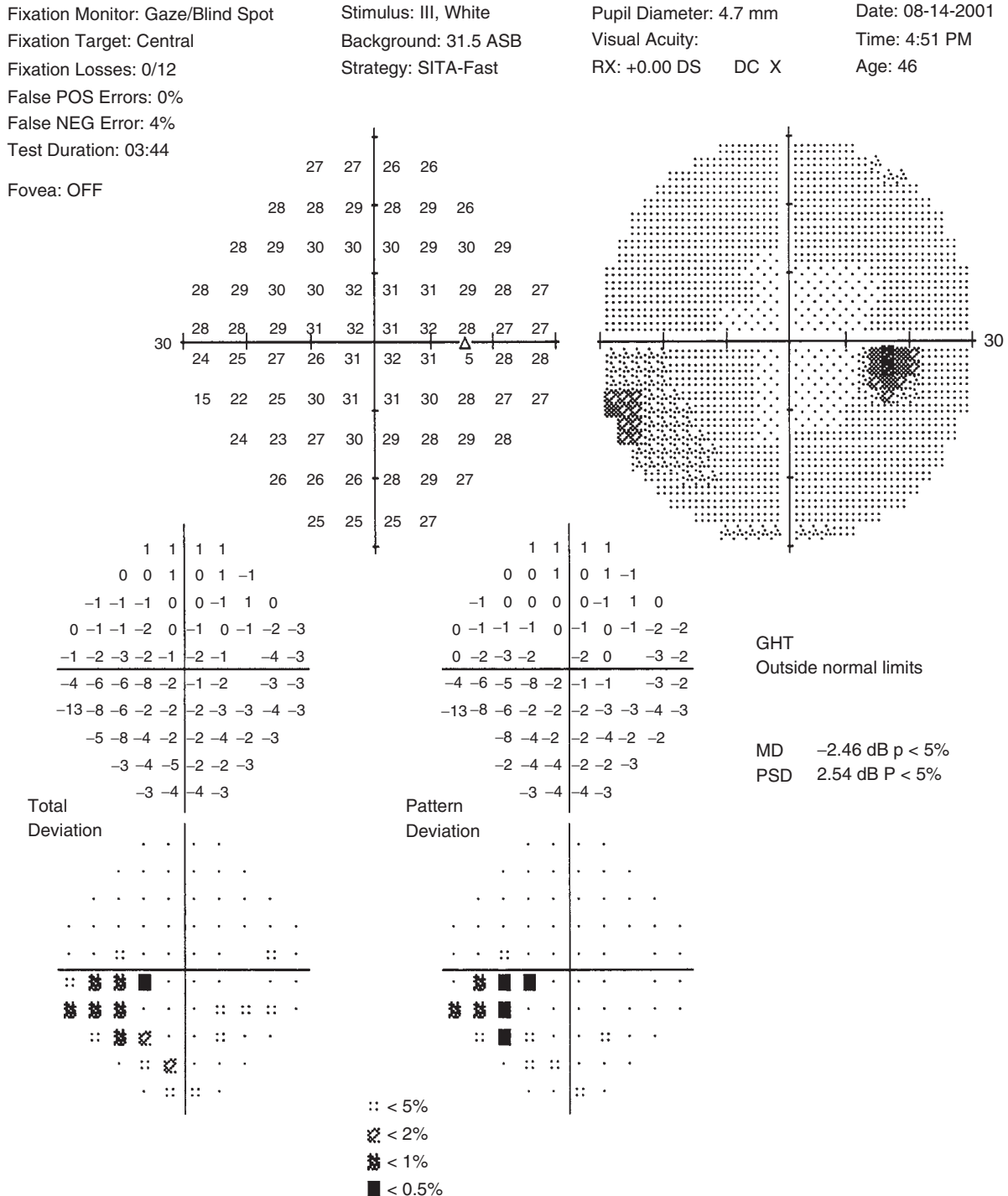


**Figure 34-2** Test–retest variability as a function of retinal sensitivity. (From Wyatt HJ, Dul MW, Swanson WH. Variability of visual field measurements is correlated with the gradient of visual sensitivity. *Vision Res* 2007;47:925–936.)

sensitive to a given stimulus from one test to the next. In the latter, areas of very low sensitivity likely do not detect a given stimulus no matter how often it is presented (the results are generally similar each time). In between these two extremes (especially between retinal sensitivities between 15 and 20 dB), test-retest variability can be quite large ( $\pm 15$  dB). Variability can also increase dramatically with small changes in fixation, particularly near the edge of a steep scotoma.

**Test-Retest Variability in the OHTS and Clinical Practice.**

Test-retest variability also proved to be a significant issue in the OHTS, where about 86% of visual fields that were consistent with glaucoma on initial testing were normal on retest. Following two consecutive glaucomatous visual field results, ~66% were subsequently read as normal on the third follow-up. These results are not uncommon in clinical practice (Figure 34-3) and speak to the need to establish a baseline before diagnosis of the disease or its severity.



**Figure 34-3** Nasal field defect not confirmed on follow-up.

Fixation Monitor: Gaze/Blind Spot  
 Fixation Target: Central  
 Fixation Losses: 2/17  
 False POS Errors: 1.0%  
 False NEG Errors: 1.0%  
 Test Duration: 07:03  
 Fovea: OFF

Stimulus: III, White  
 Background: 31.5 ASB  
 Strategy: SITA-Standard

Pupil Diameter: 4.1 mm  
 Visual Acuity:  
 RX: DS DC X

Date: 09-25-2001  
 Time: 8:21 AM  
 Age: 46

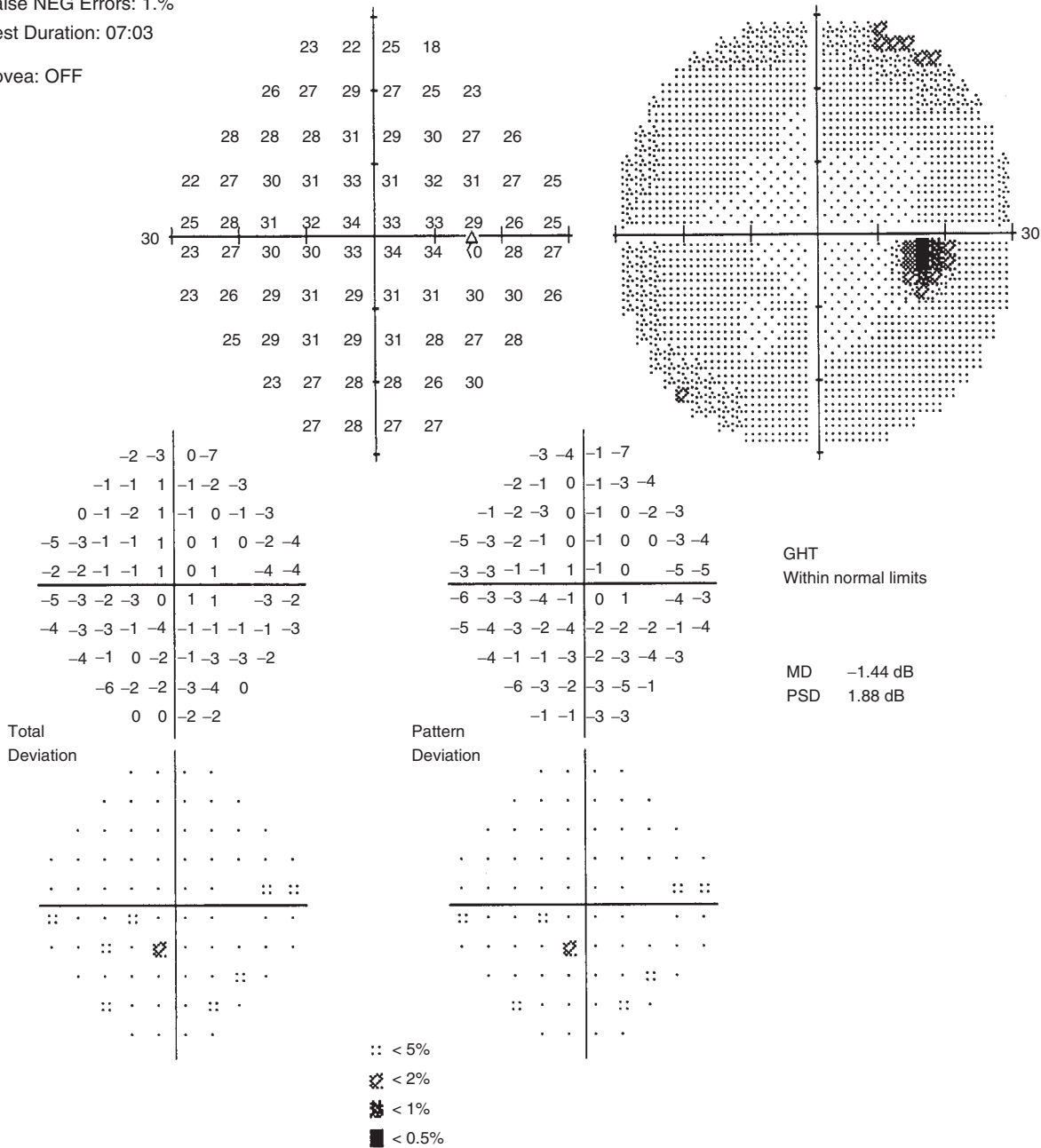


Figure 34-3, cont'd

Additionally, assessments of the stability of glaucoma rely on the quality of the baseline data.

**Management of Test-Retest Variability.** One way to manage test-retest variability is to increase the size or intensity of the stimulus presented. However, this modification would be at the expense of sensitivity to change. That is, it would take a significantly greater degree of retinal

dysfunction to produce a change in sensitivity, an untenable alternative for most clinicians who are interested in detecting change as soon as possible. This approach is used in some forms of perimetry (e.g., frequency doubling technology).

Another way to deal with variability is to gather more data. That is, repeat the visual fields on several occasions. This may also be untenable for some clinicians.


However, it is, at present, the basis for most types of serial visual field analysis (e.g., progression analysis). It may take as many as five to eight visual fields to be able to statistically differentiate true change from the noise of test-retest variability, particularly in visual fields with scotomas. Figure 34-4 shows the gray scales of 5 years of visual fields.

Note how the depth of the scotoma appears to vary considerably from one field to the next. This degree of variability is not an uncommon finding in the measurement of visual fields in glaucoma. Clinical decisions regarding the stability or progression of glaucoma based on visual fields must be tempered with an appreciation and understanding of expected variability. In fact, it is difficult to distinguish between progression of glaucomatous

visual field loss and long-term variability unless several visual field tests are obtained over time. Thus, it is necessary to confirm changes to avoid false-positive progressive visual field loss.

**The Glaucomatous Visual Field.** By the OHTS criteria, a visual field is considered abnormal if the glaucoma hemifield test is outside of normal limits and/or the corrected pattern standard deviation is  $p < 5\%$  on at least three consecutive reliable tests, with the abnormality in the same location. The patterns of glaucomatous visual fields are summarized in Box 34-3.

It may be more reasonable and consistent in clinical practice to reduce the number of confirmatory examinations



**Figure 34-4** Gray scales from right eye of one patient over a 5-year period.



**Box 34-3** Patterns of Visual Field Defects Associated With Glaucoma

Nasal step  
 Partial arcuate  
 Arcuate  
 Paracentral  
 Temporal wedge (less common)

from three to one; however, the clinician must do this with the knowledge that significantly different, even normal, results may be produced with subsequent testing. Under these circumstances the clinician must decide if, taken in its totality, the evidence supporting a diagnosis of glaucoma still exists.

**Visual Field Analysis in Advanced Glaucoma.** When visual field loss extends into the central 10 degrees of fixation, it is recommended that some form of central visual field testing be used (e.g., 10-2 test pattern). The central test strategies use a significantly greater number of test points within the central 10 degrees. In areas where retinal sensitivity is consistently measured as 0 dB or <0 dB (the patient did not respond to the brightest stimulus available for a given instrument), a larger test target may be used (e.g., stimulus size V), but this is at the expense of sensitivity to change (much more retinal structural loss or dysfunction must occur to lower sensitivities to a larger stimulus). In addition, many of the available visual field testing strategies are based on the use of stimulus size III targets. For instance, use of stimulus size V in the 10-2 Humphrey test pattern precludes the use of the Swedish Interactive Threshold Algorithm and the progression analysis software.

**Future Directions for Visual Field Analysis.** Future developments in visual field analysis will likely incorporate each of the desirable elements of existing strategies. For instance, test stimuli will be introduced that produce less test-retest variability and a more rapid test time, but not at the expense of sensitivity to change. An example of this is contrast sensitivity perimetry, which uses 0.4 cycle/deg sinusoidal patches (Gabor stimuli) to measure contrast sensitivity in glaucomatous defects showing good sensitivity to defect and low test-retest variability even in regions of reduced sensitivity. In fact, reliable and repeatable measurements are obtainable even when sensitivity to standard perimetry is at 0 dB in areas corresponding to quadrants of the optic nerve head that are cupped to the rim. This ability to measure retinal sensitivity in the presence of advanced glaucoma may make this a particularly useful strategy. In addition, these stimuli, with slow temporal modulation, have a theoretical advantage over high temporal modulation stimuli (e.g., frequency doubling technology) that are more subject to the effects

of prereceptor factors (pupil size, media opacity) and issues of adaptation. Contrast sensitivity perimetry has provided reliable measures of visual sensitivity with low variability in quadrants with dense scotomas and where clinical optic nerve assessment found little if any visible neuroretinal rim.

**Clinical Pearls**

- Variability should be expected, especially in areas of decreased sensitivity.
- A baseline should be established and all significant findings confirmed.
- Poor data (unreliable fields due to fixation or other patient factors) should be removed from the analysis.
- Periodically, a central visual field (e.g., 10-2, with 14 points per quadrant in the central 10 degrees) versus a peripheral field (e.g., 24-2, with 3 points per quadrant) should be used when field loss projects into the central 10 degrees.
- Do not expect visual field findings to correspond to the structural assessment of the optic nerve or retinal nerve fiber layer in early glaucoma.

**TREATMENT**

The goal of the management of glaucoma is to minimize, to the extent possible, the probability that a given patient, in their lifetime, will suffer a visual disability and/or diminished quality of life as a result of or due to treatment of their glaucoma. Most cases of glaucoma, given enough time, progress. As such, the focus is on managing risk as opposed to curing a disease. Unfortunately, from the onset of the condition it is not possible to predict with any meaningful degree of certainty the rate of progression or life span of an individual patient.

**The Decision to Treat**

The decision to treat a glaucoma patient is made after careful consideration of, among other things, the patient's needs, medical and surgical history, age, and abilities (e.g., to self-medicate) and the practitioner's treatment philosophy.

It might seem self-evident that if a patient has glaucoma, he or she should be treated by some means. Although all glaucoma patients should be offered therapeutic intervention, some may opt, justifiably and with concurrence of the practitioner, for careful observation. Of course, this depends, in part, on confidence that the patient will adhere to a regular follow-up schedule. An example might include a patient with a terminal medical condition and early glaucoma or a patient of very advanced age, poor medical health, and very early signs of glaucoma. In these instances, the patient should be made aware of the findings, the natural history of the type of glaucoma diagnosed, and the treatment options. Because, in general, primary open-angle glaucoma progresses slowly,

observation may be the most appropriate management for some patients.

### Risk Analysis

Because of the results of the OHTS and the familiarity with assessments of risk in other medical specialties (e.g., the Framingham study), renewed attention has been focused on the concept of risk analysis in glaucoma. The OHTS evaluated which risk factors were more common in patients with ocular hypertension who converted to glaucoma in the course of the study (Box 34-4). Because only a small percentage of patients with ocular hypertension did convert (~10%), the OHTS concluded that treatment of ocular hypertension should be reserved for patients at greatest risk of converting to glaucoma. As the number of risk factors increases for a given patient, so does the probability that the patient will convert from ocular hypertension to glaucoma. It is important to bear in mind that the results of the OHTS are best applied to patients with ocular hypertension (who, by definition, do not have glaucoma) versus the glaucoma population at large. The OHTS does not address the risk of progression of an established glaucoma patient. Therefore, caution should be exercised when applying the results of this or any other study to the general population of glaucoma patients. The concept of risk analysis in glaucoma will likely continue to mature with time, although it is not without its challenges. Unlike the studies of cardiovascular morbidity and mortality (e.g., the presence of a myocardial infarct or cardiovascular death), the “end point” in glaucoma studies is more challenging to define. There is far less disagreement over which patient has suffered from a heart attack and/or died as a consequence. In contrast, glaucoma is a relatively slow symptomless disease where only one risk factor can be controlled by intervention (i.e., IOP).

In the 2002 OHTS predictive study, diabetes appeared to be protective against the development of primary open-angle glaucoma. However, diabetes mellitus was entirely self-reported and not confirmed by chart review or blood tests. Thus, these data are probably incomplete and incorrect. Subsequent extensive statistical analyses in 2007 revealed that the association of diabetes with development of primary open-angle glaucoma could not be estimated reliably in the OHTS.

#### Box 34-4 OHTS Risk Factors

Age  
IOP > 25 mm Hg  
Vertical cupping of the optic nerve head  
Pattern standard deviation on visual fields  
Thin central corneal thickness < 555  $\mu$ m

### Target Intraocular Pressure

The target IOP is the IOP range at which the practitioner judges that the risk of progression of glaucoma is unlikely to affect a given patient's quality of life. The target pressure can be expressed as a raw number or a percentage decrease from baseline IOP. In general, target pressures are typically set lower for younger patients with more advanced disease and higher IOPs. Practitioners use many guidelines to establish a target pressure. One approach is to establish a base pressure (e.g., express the maximum IOP as a percentage, e.g., an IOP of 30 mm Hg = 30%) and, at a minimum, lower the IOP by this percentage (30 – 9 = 21). Add to the baseline percentage additional pressure lowering for disease severity (e.g., an additional 10% for each level of severity of the disease: 10% for early, 20% for moderate, and 30% for advanced) or other factors. There are many variations on this approach, and all should be viewed as estimates and a starting point for treatment.

#### Clinical Pearl

- Target IOPs require periodic reevaluation, depending on the impact of treatment on the quality of the patient's life and the stability of the patient's glaucoma and other medical conditions.

### Monocular Trials

It is generally assumed that, at least in disease-free eyes, the diurnal variation in IOP is approximately symmetric in each eye of a given individual. Following a monocular trial and a treatment period long enough to achieve a steady-state effect of the medication, the difference in IOP between the two eyes should be a result of the medication trial and not the normal diurnal fluctuation (assuming no appreciable crossover effect). In essence, the untreated eye serves as a control for the treated eye. This approach is recommended in several standard glaucoma textbooks and was used in the OHTS. The validity of this approach has been a matter of some debate because these assumptions may not apply to eyes with open-angle glaucoma. Perhaps most important, it assumes that the response to treatment of one eye accurately predicts the response to treatment of the other. In some patients it does not. However, we can increase the clinical utility of monocular trials by adding additional information to our assessment of the patient.

### Diurnal Variations in Glaucoma

The maintenance of IOP is a dynamic process with peaks and troughs in a 24-hour cycle. It stands to reason that this normal disease-free cycle would be interrupted by disease-induced changes in the outflow facility of the eye (e.g., in the presence of glaucoma). There is little reason to believe that the influence of this disease would affect both eyes identically. As such, variations in the IOP



cycle would not be unexpected. Although approximately two-thirds of eyes with primary open-angle glaucoma may have symmetric diurnal curves with synchronized peaks and troughs, diurnal variations can be large in glaucoma patients, ranging on average between 6 and 11 mm Hg. Variations greater than or equal to 3 mm Hg may occur in more than 63% of glaucoma patients on stable medication regimens. This variation comprises three dynamic processes occurring together—one, the normal diurnal cycle, two, the effects of the disease on this cycle, and, three, the effects of medication on the disease and the normal cycle. Clinically, this means that an IOP reading for a patient with glaucoma varies with the time of day (and, maybe more importantly, time of night, which is not addressed in clinical practice) and the degree to which aqueous dynamics are influenced by the disease and IOP lowering medications.

#### Predictive Value of a Monocular Trial

Like the effects of disease on IOP, the effects of medications on IOP vary as a result of several variables, including the effects of the disease on aqueous dynamics, the magnitude of the increased IOP, and the ability of the patient to properly instill the medication. The therapeutic effects of medications may not be equivalent in each eye of a patient with glaucoma. In fact, whether expressed as an absolute value (e.g., a change in IOP from 20 to 14 after treatment, or a 6-mm decrease) or as a percentage decrease from baseline (a 30% drop from baseline), there is evidence that no correlation exists between the magnitude of IOP responses of fellow eyes of patients who had a monocular trial of glaucoma medications. It is therefore possible that the monocular drug trial does not predict second-eye IOP reductions after treatment with the same medication. As a practical matter, if a monocular trial does not achieve a desired outcome, the treatment would likely be switched to another medication, independent of how the nontreated eye responds.

#### Managing Variability in Monocular Trials

Knowing that the IOP of a patient treated for open-angle glaucoma is a function of a therapeutic component (the effects of the medication) and a nontherapeutic component (the effects of diurnal variation, the influence of the disease on aqueous dynamics, and regression to the mean), some attempt should be made to account for as much of this variability as possible. The most logical approach would be to measure pretreatment serial IOP in an effort to establish a diurnal curve for each particular patient. This procedure provides information regarding variations during the day and between each eye and establishes a baseline to judge the effects of therapeutic interventions. Unfortunately, apart from 24-hour serial tonometry, which is not practical in a clinical setting, practitioners are overlooking pressure readings that may be substantially higher when compared with daytime (office time) measurements.

### Summary

In practice, it would be prudent to explain to patients that their IOP will vary during the day and night (this sets the stage for future instructions on the proper use of aqueous suppressants during times of physiologic higher aqueous production) and ensures the patient that different readings at each visit are not uncommon.

### TREATMENT MODALITIES

Once the decision has been made to proceed with treatment, the practitioner is faced with several options as the initial intervention. In broad terms surgical, laser, or medical options are available; however, medical management is the general standard of practice for the initial treatment of open-angle glaucoma. With the advent of selective laser trabeculoplasty (SLT), this procedure is being offered to some patients for initial treatment in an effort to avoid the cost, inconvenience, and adherence issues associated with topical medications. Although there may be some theoretical advantages for some patients for SLT as an initial intervention, to date, there has been no long-term, prospective, clinical trial to assess the efficacy of this approach.

### Medical Management

When medical management is deemed the most appropriate treatment option for the patient, the choice of initial treatment is based, in part, on the most appropriate means of IOP reduction (e.g., aqueous suppression, outflow facilitation, or management of inflammation or some combination thereof) and the type of glaucoma. Absent any indication for intervention via aqueous suppression (e.g., glaucoma associated with hyphema; see Special Considerations in the Treatment of Glaucoma, below) or inflammation (e.g., Posner-Schlossman syndrome), the most common initial medical intervention is the use of prostaglandins (Table 34-3). These medications work by increasing uveoscleral outflow and are often chosen as initial treatment due to their efficacy (IOP is lowered, on average, ~ 30% from baseline), their relatively good patient tolerability, low incidence of significant side effects, few contraindications, one drop a day regimen, and coverage during the nighttime hours where IOP may be the highest during the circadian cycle.

**Table 34-3**  
Prostaglandins Used in Clinical Practice

Prostaglandins	Concentration (%)
Latanoprost (Xalatan)	0.005
Bimatoprost (Lumigan)	0.03
Travoprost (Travatan)	0.004

## Prostaglandins

**Contraindications of Prostaglandins.** The use of this class of medications should be deferred in the presence of an active uveitis and should be used with caution in patients with a known history of herpes simplex keratitis or cystoid macular edema.

**Side Effects.** The most common side effect of prostaglandins is conjunctival hyperemia. In general, this is most common and most apparent with the use of bimatoprost. Fortunately, this side effect often diminishes over the course of months. Another well-known side effect is eyelash growth and increased pigmentation of the iris and periorbital tissue. This pigmentary change of the iris is particularly noticeable in hazel-colored irides and occurs over the course of months of treatment. The change in periorbital tissue pigmentation is generally difficult to discern if it occurs bilaterally but can become quite noticeable when patients are treated monocularly. Patients should therefore be informed of this possibility.

Because the concentration of the topical prostaglandins in the systemic circulation is lower than endogenous prostaglandins, it is not surprising that there have been few reports of significant systemic adverse events.

**Use in Clinical Practice.** The introduction of this class of medication significantly changed the way in which glaucoma was managed. It was not uncommon among established patients to convert from being managed on two or more medications (including oral acetazolamide) with multiple daily doses (e.g., pilocarpine four times a day) to meeting target pressures on a prostaglandin drop taken once a day. The most common complaint during the introduction of this medication class was the size, shape, transparency, and pliability of the bottle. As patients were introduced to these medications sooner in their management and as it became less common to prescribe larger volume bottles (such as pilocarpine), these initial issues became less significant.

If target pressure is not met with an initial prostaglandin, it may be useful to switch to an alternative topical prostaglandin. However, there is little scientific evidence to support this approach. In fact, in a controlled environment there is little difference in efficiency among the various prostaglandin formulations. Although there are anecdotal reports of significantly different responses to treatment within individual patients, these results are clouded by issues of compliance with the initial treatment.

Switching within this classification is useful because it keeps the patient's regimen simple (once a day dosing) with few side effects, and with the idea that additional medications may be required if this strategy fails, the patient may be more inclined to be compliant. Because bimatoprost typically causes the greatest hyperemia and

is often least tolerated, it is advisable to start a patient on either of the other two choices and switch to bimatoprost if the alternatives have been exhausted. This has the added advantage of exposing the patient to this group of medications for a period of time, which tends to reduce the hyperemic effects of bimatoprost when compared with the effect if bimatoprost had been used initially. Care should be taken when treating a patient monocularly because the increased pigmentation can become cosmetically unacceptable.

## Cholinergic Agonists

The cholinergic agonists (Table 34-4) represent another classification of glaucoma medication that functions primarily by its influence on aqueous outflow.

**Indications.** This classification of drugs is often useful in the management of acute ACG (once the pressure is reduced to ~30 mm Hg). The pupillary miosis and mechanical deformation of the scleral spur move synechia or appositional iris tissue from the angle and prepare the iris for laser peripheral iridotomy. In high concentrations, however, these drugs are capable of displacing the lens-iris diaphragm, which can exacerbate the closure.

**Contraindications.** The use of cholinergic agonists is contraindicated in the presence of acute uveitis or any condition where miosis is undesirable.

**Cholinergic Agonists in Clinical Practice.** This class of medications is not used as frequently as in the past. Pilocarpine is, however, an important medication to have available in the office in the presence of an acute ACG and is used to prepare the iris for laser peripheral iridotomy. There are instances where the use of miotics has theoretical advantages over other classifications of medications, such as the treatment of pigmentary glaucoma, where moving the iris away from the lens zonules might be desirable. However, there are also distinct disadvantages to these medications. The dosing, with the exception of pilocarpine ointment, is often three or four times a day. The resultant miosis, although appreciated by some patients as increased depth of focus and sharper visual acuity as a result of the pinhole effect, can reduce retinal illuminance to the point that it influences a

**Table 34-4**  
Cholinergic Agonists Used in Clinical Practice

Cholinergic Agonists	Concentration (%)
Pilocarpine (Isopto Carpine)	1, 2, 4
Pilocarpine (generic)	0.5, 1, 2, 3, 4, 6
Pilocarpine ointment (Pilopine HS)	4
Carbachol (Isopto Carbachol)	1.5, 3.0

patient's functional ability. This effect also had a dramatic impact on visual field testing and dilated fundus examinations. The longer the duration of treatment and the higher the concentration, the more difficult it is to obtain a satisfactory pupillary dilation. This and the loss of the suppleness of the conjunctiva with chronic use also make ophthalmic surgery (e.g., cataract, trabeculectomy) more challenging. There is some evidence that chronic miosis also may place patients at greater risk for retinal detachment. These potential complications make the use of miotics even less appealing, and with the introduction of newer classifications of medications, the use of miotics has waned.

### Aqueous Suppressants

The aqueous suppressants include the  $\beta$ -adrenergic antagonists,  $\alpha$ -agonists, carbonic anhydrase inhibitors (CAIs; topical and oral), and hyperosmotics (intravenous). The topical forms of this classification are used routinely in clinical practice. The oral and intravenous formulations are generally reserved for use under special circumstances.

**$\beta$ -Adrenergic Antagonists.** The  $\beta$ -adrenergic antagonists (Table 34-5) were considered the first-line medication for glaucoma for many years. Before the introduction of this class of medications, the most commonly used medications were pilocarpine, epinephrine, and oral acetazolamide (Diamox). The arrival of this class offered a twice-daily topical dosing regimen with generally comparable or better IOP lowering when compared with the other topical agents. There were fewer side effects, and over time clinicians became increasingly comfortable with their use.

### Side Effects and Clinical Problems Associated with Topical $\beta$ -Adrenergic Antagonists

*Ocular.* Eye irritation, burning, tearing, and foreign body sensation can occur with the use of topical  $\beta$ -adrenergic antagonists; however, these effects are usually short term. Notable long-term manifestations include dry eye and

tachyphylaxis; after years of use the IOP lowering effects of  $\beta$ -adrenergic antagonists diminish in some patients. Switching from one brand or formulation to another does not appreciably change this effect. If target pressure is not being met as a result of this loss of IOP control, it is advisable to replace the drug with an alternative class of medication.

*Systemic.* The systemic side effects of topical  $\beta$ -adrenergic antagonists are summarized in Box 34-5. These drugs are known to cause cardiovascular, respiratory, and nervous system side effects—and even death. Even with cardioselective options, this group should be used with caution in patients with known respiratory or pulmonary dysfunction. Although the safety of this class of medications periodically comes under scrutiny, the track record of these medications is now almost three decades in duration, and they continue to play an integral part in the management of glaucoma.

**Contraindications and Drug-Drug Interactions of  $\beta$ -Adrenergic Antagonists.** Contraindications to topical  $\beta$ -adrenergic antagonists include sinus bradycardia, second- or third-degree heart block, cardiogenic shock, uncompensated overt cardiac failure, severe bronchial asthma, or severe chronic obstructive pulmonary disease. Caution should be exercised when topical  $\beta$ -adrenergic antagonists are prescribed in tandem with adrenergic psychotropic, catecholamine-depleting, calcium antagonist drugs, or digitalis.

**$\beta$ -Adrenergic Antagonist Use in Clinical Practice.** Topical  $\beta$ -adrenergic antagonists remain an integral part of glaucoma management, although they are more commonly used as a second-line medication. They may work well when added to a regimen of once-at-bedtime prostaglandins because this class of medication uses a different mechanism to reduce IOP. Although the combination of these two classes (prostaglandins and beta-antagonist) is available in other parts of the world, they have not received FDA approval in the United States.

**Table 34-5**  
 $\beta$ -Adrenergic Antagonists Used in Clinical Practice

$\beta$ -Adrenergic Antagonists	Concentration (%)
Timolol maleate (Timoptic/generic)	0.25/0.50
Timolol maleate (Istalol)	0.50
Timolol maleate gel (Timoptic XE/generic)	0.25/0.50
Timolol hemihydrate (Betimol)	0.25/0.50
Betaxolol (Betoptic S)	0.25 suspension
Betaxolol (generic)	0.50
Levobunolol (Betagan/generic)	0.25/0.50
Metipranolol (OptiPranolol/generic)	0.3
Carteolol (generic)	1.0

**Box 34-5** Systemic Side Effects of  $\beta$ -Adrenergic Antagonists

Respiratory	Cardiovascular	Nervous system
Bronchospasm	Arrhythmia	Confusion
Cough	Bradycardia	Depression
Dyspnea	Cardiac arrest	Dizziness
Respiratory failure	Cardiac failure	Headache
		Insomnia
		Nightmares

Topical  $\beta$ -adrenergic antagonists may be prescribed in once-daily dosing with adequate therapeutic effect for some patients. This effectively halves the concentration of medication that the patient receives. If twice-daily dosing is indicated, it is advisable to have the patient use the medications in the early morning and then approximately 12 hours later, which, for many patients, occurs around supper-time. Nighttime administration is not ideal because, as an aqueous suppressant, the drug is not being used to its maximum potential due to the normal physiologic circadian trough in IOP, which begins in many patients in the evening. In the setting of normal tension glaucoma, nighttime administration of topical beta-blockers should be used with caution because this class of medication may negatively influence the perfusion pressure to the optic nerve head (e.g., by its influence on the heart and possibly the vessels of the optic nerve head). A prostaglandin at bedtime is a more appropriate choice to compensate for the gradual increase in IOP that occurs during the sleep cycle.

Before use of topical  $\beta$ -adrenergic antagonists and following a careful history to assess the potential risk to the patient, it is advisable to evaluate the patient's blood pressure and pulse. Patients with concurrent use of oral  $\beta$ -adrenergic antagonists should typically avoid topical agents in the same class. Patients should be informed of the potential side effects of these medications and should discontinue their use if warranted.

**$\alpha$ -Adrenergic Agonist Use in Clinical Practice.** The  $\alpha$  agonists (Table 34-6) represent a class of glaucoma medications that function, primarily, as aqueous suppressants, although they may also facilitate outflow.

Two  $\alpha$ -adrenergic agonists are available on the market. Apraclonidine 0.5% is indicated when a patient on maximum tolerated medical therapy requires short-term additional IOP lowering. Before the introduction of brimonidine, apraclonidine was the only available  $\alpha$ -adrenergic agonist and was FDA approved for short-term use. Approximately one-third of patients using apraclonidine showed little or no treatment effect. For another third the treatment effect (3 to 5 mm Hg) was short in duration (3 to 6 months); for the remainder the effect was more lasting. Consequently, this medication

**Table 34-6**

$\alpha$  Agonists Used in Clinical Practice

$\alpha_2$ Selective Agonists	Concentration %
Apraclonidine (Iopidine)	0.5, 1.0
Brimonidine (Alphagan P)	0.1, 0.15, 0.2
Brimonidine (generic)	0.2

was used as an adjunctive treatment for some patients. Today, apraclonidine is most commonly used as a pretreatment medication to prevent spikes in IOP after glaucoma laser procedures (although brimonidine is a reasonable alternative).

Brimonidine can be used either in the short term (e.g., to prevent IOP spikes after glaucoma laser procedures) or in the long term, as an adjunctive therapy or as a first-line treatment. Although it is FDA approved for three times a day dosing, it is commonly prescribed as twice daily. Introduced as a 0.2% solution, a significant percentage of patients developed a delayed hypersensitivity reaction to this preparation. Consequently, the concentration was reduced, first to 0.15% and then 0.1%, and a new preservative was used. These changes significantly reduced the incidence of adverse reactions. IOP reductions are typically 20% to 30% (approximately equivalent to timolol maleate) in all concentrations.

#### Contraindications and Drug Interactions.

Apraclonidine and brimonidine are both contraindicated with concurrent use of monoamine oxidase inhibitors (Table 34-7). Patients with hypersensitivity to clonidine should not be prescribed apraclonidine. These two compounds (apraclonidine more so than brimonidine) also have the potential to interact synergistically with central nervous system depressants and  $\beta$ -adrenergic antagonists. With brimonidine, caution should be exercised in patients susceptible to side effects of fatigue, drowsiness, somnolence, and dry mouth and should not be used in infants and young children due to increased risks of lethargy and somnolence. Long-term use of brimonidine may produce varying degrees of systemic hypotension.

**Table 34-7**

Monoamine Oxidase Inhibitors and Indications

Medication	Indication
Isocarboxazid (Marplan)	Resistant depression
Moclobemide (Aurorix, Manerix, Moclodura <sup>®</sup> )	Depression and social anxiety
Phenelzine (Nardil)	Depression
Tranylcypromine	Depression
Selegiline (Selegiline, Eldepryl)	Early-stage Parkinson's disease and senile dementia
Emsam	Depression
Nialamide	Depression
Iproniazid (Marsilid, Iprozid, Ipronid, Rivivol, Propilniazida)	Depression
Iproclozide	Depression
Toloxatone	Depression

**Table 34-8**  
Carbonic Anhydrase Inhibitors Used in Clinical Practice

Carbonic Anhydrase Inhibitors	Concentration
<b>Topical</b>	
Dorzolamide HCl (Trusopt)	2%
Brinzolamide (Azopt, suspension)	1%
<b>Oral</b>	
Acetazolamide (generic)	125-, 250-mg tablets
Acetazolamide (Diamox sequels)	500-mg capsules (sustained release)
Acetazolamide sodium (generic)	500-mg vial (IV)
Methazolamide (generic)	25-, 50-mg tablets

**Carbonic Anhydrase Inhibitors.** The CAIs (Table 34-8) are aqueous suppressants not typically used as first-line medications in the treatment of glaucoma.

**Use of Topical CAIs in Clinical Practice.** Although, as monotherapy, this class of medication can lower IOP by ~20%, topical CAIs are generally used as adjunctive therapy either as an additional separate administration or, more commonly, in a fixed combination with timolol maleate (Cosopt). It is important to explain to patients that this medication can be uncomfortable on the eye and that they may experience a bitter metallic taste associated with its use. This side effect is far more common with dorzolamide than brinzolamide.

**Serious Side Effects.** Corneal decompensation in patients with preexisting endothelial compromise (e.g., Fuchs' endothelial dystrophy) and hypotony have been reported with topical CAIs. Common adverse reactions to oral CAIs are summarized in Box 34-6.

**Use of Oral CAIs in Clinical Practice.** Use of oral CAIs is generally limited to the management of acute primary ACG or in cases where other efforts have been proven to be inadequate or contraindicated. In chronic use, methazolamide 25 or 50 mg three times a day generally carries a more favorable side effect profile than acetazolamide in any form. If acetazolamide must be used chronically, then 500 mg (at bedtime or twice daily) in a sustained-release form is preferred. This formulation may

dampen the side effects. It is noteworthy that approximately half of all patients offered oral CAIs for chronic management of glaucoma cannot tolerate these medications long term. In addition, topical and oral CAIs do not act synergistically, and therefore there is no advantage to using both formulations together.

Both acetazolamide and methazolamide are contraindicated in

- The presence of depressed sodium and/or potassium blood serum levels
- Severe kidney and/or liver disease or dysfunction
- Suprarenal gland failure
- Hyperchloremic acidosis
- Chronic congestive ACG (long-term use)

Because CAIs are sulfonamides, care should be taken to exclude a known sulfonamide allergy. Severe reactions to sulfonamides such as aplastic anemia, Stevens-Johnson syndrome, and fulminant hepatic necrosis are uncommon but have been known to occur. CAIs should be discontinued if any signs or symptoms of these conditions occur.

Topical CAIs are a considerably safer alternative. However, in theory, they carry the same potential risks due to systemic absorption.

## TREATMENT STRATEGIES

There is no “cookbook” approach to the management of glaucoma. Each case must be tailored to suit the needs of the individual patient. In all instances proper drop instillation is very important. Patients should be reminded to occlude their puncta with each drop and wait several minutes between drops in an effort to maximize the amount of medication reaching target receptors in the eye and to minimize systemic absorption.

As a general guideline, the greater the number of times a patient must take medications during the day, the greater the likelihood of nonadherence to treatment and the greater the risk of a negative impact on the quality of an individual's life. The following strategy is one of many possibilities that keeps this simplicity in mind and assumes no contraindications to any class of medications.

1. Start with a once-daily medication, for example,
  - a. Travoprost
  - b. Latanoprost
  - c. Expect ~30% reduction in IOP
2. If target pressure is not met
  - a. Reeducate the patient
  - b. Have the patient demonstrate proper drop instillation, including punctal occlusion
  - c. Reschedule for subsequent IOP check
3. If target pressure still not met
  - a. Switch within this category of medication, for example,
    - i. Latanoprost
    - ii. Travoprost, or
  - b. Switch to bimatoprost

### Box 34-6 Common Side Effects of Oral CAIs

Confusion	Diarrhea	Drowsiness
Fatigue	Malaise	Loss of appetite
Paresthesias	Polyuria	Hearing dysfunction
Kidney stones	Nausea	or tinnitus
		Taste alterations

- c. Instill a drop in the patient's eye in office and have them return later in the day for an IOP check
  - d. At this point, the patient has been instilling one drop using one bottle, once a day. Further IOP reduction requires either another medication or laser trabeculoplasty (argon laser trabeculoplasty/selective laser trabeculoplasty). Alternatively, discontinuing the prostaglandin and continuing treatment with aqueous suppressants alone (e.g.,  $\beta$ -adrenergic antagonist,  $\alpha$ -adrenergic agonist) is a reasonable alternative, although, on average, less IOP reduction is expected from aqueous suppressants as monotherapy.
  - e. Administering the drop in the office assists in ruling out poor adherence as a variable.
4. If target pressure still not met
    - a. Add morning  $\beta$ -adrenergic antagonist
    - b. Increase to every 12 hours as needed (care should be taken in the patient with normal tension glaucoma)
    - c. Expect additional ~15 % reduction of IOP
    - d. At this point the patient is taking two medications, from two bottles, two to three times per day.
  5. If some treatment effect but target pressure still not met
    - a. Discontinue  $\beta$ -adrenergic antagonist and replace with  $\beta$ -adrenergic antagonist-CAI combination every 12 hours
    - b. Expect additional ~10% reduction of IOP
    - c. Three medications, two bottles, three times per day
  6. If some treatment effect from addition of topical  $\beta$ -adrenergic antagonist-CAI combination, but target pressure not met.
    - a. Add brimonidine twice daily
  7. If target pressure still not met
    - a. Consider argon or selective laser trabeculoplasty
    - b. Consider surgical intervention (e.g., trabeculectomy)

## Drug Holidays

There are times, especially when a new patient uses several glaucoma medications, that selectively discontinuing medications is indicated to help reestablish the least amount of prescribing to achieve a target pressure. It may also help the patient reestablish good medication-taking habits. As a general rule, if the patient is on two or more medications with a similar mechanism of action (e.g., aqueous suppression), then discontinuing one medication at a time from this group is the preferred approach. This is followed by an appropriate washout period and clinical follow-up. It is not uncommon to have patients discontinue medications (under clinical guidance) and find that fewer prescriptions are possible to maintain adequate control.

## Special Considerations in the Treatment of Glaucoma

### Increased IOP in the Presence of Hyphema

Traumatic hyphema may lead to an increase in IOP. IOP reduction should be accomplished by aqueous suppressants.

The use of miotics is typically avoided in the management of this condition because their use may exacerbate ciliary spasm and inflammation and may increase the likelihood of peripheral anterior synechia. Prostaglandins are also avoided because this group of medications may exacerbate the inflammatory component. Increased IOP associated with hyphema is often of relatively short duration (2 to 3 days), and in the presence of a healthy optic nerve and moderately elevated IOPs (30 mm Hg), observation and daily follow-up may be all that is required to manage the IOP component. Surgical intervention (paracentesis and anterior chamber washout) should be considered in instances where IOP remains above 50 mm Hg for more than 24 hours or more than 35 mm Hg for more than a week. Surgical intervention may also be considered depending on the size and duration of the hyphema, presence of a second hyphema (rebleed), or the presence of corneal blood staining (erythrocyte products and hemosiderin deposition in the corneal endothelial keratocytes).

### Increased IOP in the Hyphema Patient With Sickle Cell Disease or Trait

Sustained elevated IOPs require treatment, as does any elevated IOP associated with hyphema in a patient with sickle cell disease or trait. These patients have a higher incidence of increased IOP (sickled cells do not pass through trabecular meshwork as freely as normal red blood cells), optic atrophy, and secondary hemorrhage in the setting of traumatic hyphema compared with non-sickle cell patients.

Patients with sickle cell disease are far more sensitive to increases in IOP, even of short duration (2 to 4 days) and IOPs as low as 30–35 mm Hg. These conditions are capable of occluding the central retinal artery (due, in part, from stagnation of blood in small vessels, excessive deoxygenation of erythrocytes, erythrocytosis, sickling, and increased blood viscosity). It is therefore prudent to order a sickle prep (Sickledex) or hemoglobin electrophoresis on all patients suspected of having sickle cell disease or trait (more common among African-Americans and people of Mediterranean descent) in the presence of increased IOP associated with hyphema.

### Medical Management of Increased IOP in the Hyphema Patient With Sickle Cell Disease or Trait

Treatment of IOP should concentrate on aqueous suppression, and timolol and brimonidine (or apraclonidine) should be the mainstays of IOP management. CAIs (especially oral acetazolamide and methazolamide) are capable of promoting hemoconcentration and can induce systemic acidosis, which is known to exacerbate erythrocyte sickling.

The use of dorzolamide or brinzolamide (topical CAIs) has an advantage because of their suppression of aqueous production and lack of systemic acidosis. However, there is a theoretical risk of anterior chamber acidosis, and with

no study proving safety of topical dorzolamide in sickle cell disease patients with hyphema, its use should be curtailed.

### Surgical Management of Hyphema Patient With Sickle Cell Disease or Trait

Surgical intervention (evacuation of the hyphema) should be considered if the IOP averages more than 24 mm Hg over any consecutive 24-hour period despite maximum tolerated medical therapy or if the IOP increases transiently and repeatedly above 30 mm Hg.

## NEOVASCULAR GLAUCOMA

Neovascular glaucoma is a condition marked by new blood vessel proliferation on the iris and in the anterior chamber angle usually as a result of retinal or anterior segment ischemia/hypoxia. Neovascularization of the iris usually appears first on the surface of the iris adjacent to the pupillary border. These vessels are fine in caliber and may have aneurysm-like outpouchings. Gonioscopic evaluation may reveal vessels in the anterior chamber angle even in the absence of iris vessels.

### Treatment

Prompt treatment of the underlying ischemia (e.g., panretinal photocoagulation) can prevent anterior chamber neovascularization. In the presence of neovascularization, it can often prevent neovascular glaucoma. Prompt (within 1 to 2 days) treatment of neovascularization of the iris is essential especially if accompanied by high IOP. Angle closure can occur within days to weeks. Left untreated, neovascular glaucoma can lead to no light perception, pain, and potential loss of the globe.

### Medical Management

The goal of medical management is to reduce inflammation and pain. The mainstay of medical management is topical atropine 1% (three times a day) to decrease ocular congestion and prednisolone acetate 1% (every 1 to 6 hours, depending on severity) to decrease inflammation. Concurrent use of traditional aqueous suppressant antiglaucoma medications should also be used as indicated. Miotics and prostaglandins are not recommended due to the risk of increasing inflammation, and prostaglandins may exacerbate the inflammatory component.

### Surgical Management

Surgical procedures are often aimed at pain management and include cyclocryotherapy, trabeculectomy, and tube implant. In general, outcomes are less successful compared with primary open-angle glaucoma.

## Advanced Neovascular Glaucoma

If the condition advances and the eye is left with no usable visual acuity, the focus of treatment may shift to strictly pain management with steroids and cycloplegics.

## ANGLE-CLOSURE GLAUCOMA

### Clinical Presentation of Acute Primary ACG

The classic presentation of a patient with acute ACG includes complaints of eye pain, headache, blurred vision, photophobia, the perception of halos around lights, nausea, and vomiting. Clinical signs include an edematous cornea, a fixed mid-dilated pupil, ciliary injection, high IOP, convex iris (iris bombé), and cells and flare in the anterior chamber. There may also be evidence of previous episodes such as peripheral anterior synechiae, anterior subcapsular lens opacities (glaukomflecken), sector iris atrophy, an irregular pupil, and a narrow angle in the contralateral eye.

### Medical Management of ACG

Acute ACG should be considered a true ocular urgency. Treatment should therefore be promptly initiated even if the patient is ultimately referred for further care. In general, medical management is aimed at reducing IOP to levels and reopening the angle to allow for subsequent treatment with laser (e.g., laser peripheral iridotomy, laser iridoplasty).

There is no universally accepted standard for the medical management of ACG. Treatment should be tailored to fit the needs of each patient, accounting for contraindications (e.g., use of  $\beta$ -adrenergic antagonists in the presence of asthma) and the nature of the presenting condition. The following are general guidelines for the management of acute primary ACG:

- Acetazolamide (Diamox 250 mg, 2 tablets by mouth in one dose, or 250 to 500 mg intravenously)
- Topical  $\beta$ -adrenergic antagonist (e.g., timolol maleate 0.5%), 1 drop
- Topical  $\alpha$ -adrenergic agonist every 15 minutes (e.g., apraclonidine 0.5%), 1 drop
- Topical steroid (prednisolone acetate 1%) every 15 minutes three times, then every 1 hour
  - If the eye is phakic and the angle closure is a result of pupillary block:
- Pilocarpine 1% to 2% every 15 minutes two times and pilocarpine 0.5% 1 drop to the contralateral eye
  - If the eye is aphakic or pseudophakic:
- Mydriatic and cycloplegic (e.g., cyclopentolate 2%, phenylephrine 2.5% every 15 minutes four times)
- Recheck visual acuities and IOP in 1 hour. If no improvement, repeat all topicals (with the possible exception of pilocarpine as this agent may shallow anterior



chamber) and consider intravenous hyperosmotic (e.g., mannitol 1 to 2 g/kg over 45 minutes).

## USE OF HYPEROSMOTICS

Use of hyperosmotics in the United States is limited to intravenous preparations. Hyperosmotics cause increased blood serum osmolarity, which pulls water from tissues into the bloodstream. By increasing the osmotic gradient between plasma and the eye, vitreal dehydration occurs, which results in reduced ocular volume and corresponding lowered IOP. The results are relatively rapid (15 minutes to 2 hours) and short in duration (6 to 8 hours). Hyperosmotics are indicated when there is a need for rapid temporary reduction in high IOP.

### Mannitol

Mannitol is an intravenous hyperosmotic (1.5 to 2 g/kg intravenous as 20% solution [7.5 to 10 mL/kg] or as 15% solution [10 to 13 mL/kg]) over a period as short as 30 minutes. Cardiovascular status must be carefully evaluated before rapid administration of mannitol because a sudden increase in extracellular fluid may lead to fulminating congestive heart failure.

### Urea

Urea is also an intravenous preparation (1 to 1.5 g/kg; 0.45 to 0.68 g/lb [30% solution] by slow infusion; not to exceed 4 ml/min or 120 g/d). It has a lower molecular weight than mannitol and less of a diuretic effect. Urea is contraindicated in the presence of an intracranial hemorrhage. Urea may increase risk of venous thrombosis and hemoglobinuria in patients who are hypothermic.

## Contraindications to Hyperosmotics

The following are contraindications for the use of hyperosmotics:

- Documented hypersensitivity
- Frank or impending acute pulmonary edema
- Anuria
- Severe dehydration
- Severe cardiac decompensation
- Active intracranial bleeding (especially mannitol, urea)  
Precautions should be taken in the following instances:
  - Severe dehydration
  - Confused mental states
  - Congestive heart disease
  - Other cardiac, renal, or hepatic disease
  - Hypothermia (urea may increase risk of venous thrombosis and hemoglobinuria)
  - Lithium levels decrease (mannitol and urea)

If IOP still does not decrease, consider laser peripheral iridotomy if the cornea is clear enough to accomplish

the procedure. If not, consider incisional surgical intervention.

## GLAUCOMA ASSOCIATED WITH INFLAMMATION

Scleritis, uveitis (e.g., Posner-Schlossman syndrome), keratitis, trabeculitis (e.g., herpetic), and/or episcleritis may be associated with an increase in IOP substantial enough to cause glaucomatous optic atrophy. If the patient is a “steroid responder,” the use of corticosteroids for the treatment of these conditions may also be responsible for increased IOP.

In most cases of glaucoma associated with inflammation, the anterior chamber angle is open, and the increase in IOP results from direct involvement of the trabecular meshwork as a consequence of local inflammation (e.g., secondary trabeculitis) or preexisting outflow anomalies exacerbated by perilimbal inflammation elevating episcleral venous pressure. Less commonly, local inflammation causes an increase in IOP as result of a secondary angle closure (Box 34-7).

In most cases the treatment of these conditions involves both anti-inflammatory (typically topical corticosteroids) and antiglaucoma (typically aqueous suppressants) medications. Cycloplegics are used to prevent or manage posterior synechia, secondary neovascular glaucoma, and choroidal effusion. Miotics are typically avoided in the management of these conditions because their use

### Box 34-7 Pathophysiology of Increased IOP in the Presence of Inflammation

Angle open
Local inflammation of the trabecular meshwork
Response to corticosteroid treatment
Inflammatory debris impeding aqueous outflow
Secondary closed angle
Peripheral anterior synechia resulting from inflammation and adherence of the iris to the trabecular meshwork
Posterior synechia, with pupillary block resulting from inflammation and adhesion of the iris to the lens or vitreous
Forward rotation of the ciliary body resulting from edema of the ciliary body and/or choroidal effusion, causing a forward displacement of the lens-iris diaphragm
Angle neovascularization as a result of chronic anterior chamber inflammation or retinal hypoxia
Treatment
Corticosteroids
Aqueous suppressants
Cycloplegics

may exacerbate ciliary spasm and inflammation and may increase the likelihood of synechia. Prostaglandins are also avoided because this group of medications may exacerbate the inflammatory component.

Several treatment trials have provided guidance for the management of glaucoma, which are summarized in Table 34-9. In addition, several new studies are

under way that will likely provide information on questions that regularly confront clinicians. These include studies of glaucoma in African-Americans, the effects of corneal parameters on IOP, the comparison between imaging devices and the clinical assessment of the optic nerve, novel approaches to perimetry, and evaluations of new treatment options.

**Table 34-9**

Randomized Controlled Trials That Have Provided Guidance for the Management of Glaucoma

Study	Objective	Implications and Comments
Glaucoma Laser Trial (GLT)	To determine efficacy and safety of ALT as an alternative to topical medication for controlling IOP in glaucoma	After 2 years of follow-up, more eyes were controlled by initial treatment with ALT vs. timolol. No significant differences between groups on visual acuity or visual fields. ALT may be an alternative to medication as initial treatment. Completed before prostaglandins, topical CAIs, or $\alpha$ agonists.
Collaborative Normal-Tension Glaucoma Study (CNTGS)	To determine if IOP is involved in the pathogenesis of NTG	IOP is part of pathogenic process in NTG. Lowering IOP may be beneficial for patients with NTG. A significant percentage of surgical patients developed visually significant cataracts. Because 40% of untreated eyes showed no progression, the decision to treat aggressively must be weighed against the individual likelihood of progression.
Advanced Glaucoma Intervention Study (AGIS)	To compare the outcome of ALT first vs. trabeculectomy first as intervention for advanced glaucoma refractory to medical therapy Also to determine relationship between IOP level and visual field deterioration	Most patients who met these study criteria showed visual field progression during the length of the study. Patients with IOP < 18 mm Hg for the entire duration of the study (average 12.3 mm Hg, over 6 years) had the most stable visual fields. Suggests aggressive medical management from baseline IOP values is indicated in advanced glaucoma. Vision better preserved if ALT first (vs. trabeculectomy) in African-American patients (7-year follow-up). Vision better preserved if trabeculectomy first in white patients (7-year follow-up).
Collaborative Initial Glaucoma Treatment Study (CIGTS)	To compare the efficacy of initial glaucoma treatment with medication or trabeculectomy surgery	Visual field loss was similar in both groups. Incidence of cataract removal was higher in the surgery group. Mean IOP was slightly lower with surgery (46% vs. 38%). Visual acuity loss was greater with surgery in the short term but similar after 4 years. Patients reported better comfort in medically managed group. Aggressive medical treatment provides benefits comparable with those of trabeculectomy in the initial treatment of glaucoma.

*Continued*

**Table 34-9**

Randomized Controlled Trials That Have Provided Guidance for the Management of Glaucoma—cont'd

Study	Objective	Implications and Comments
Early Manifest Glaucoma Trial (EMGT)	To compare the effect of immediate lowering of IOP vs. no treatment on the progression of newly detected open-angle glaucoma	Approximately 45% of the treated group (IOP < 25% from baseline) progressed in 6 years. Approximately 62% of the untreated group progressed. Progression in the treated group occurred significantly later. A significant percentage of patients with PXG were included in this study. More patients in the treated group developed cataracts compared with the untreated group.
The Ocular Hypertension Treatment Study (OHTS)	To determine the efficacy of topical ocular hypotensive medications in preventing or delaying the onset of primary open-angle glaucoma in patients with ocular hypertension	Approximately 10% of untreated ocular hypertension patients convert to primary open-angle glaucoma. Approximately 5% of the treated group convert to primary open-angle glaucoma. Risk factors Age IOP > 25 mm Hg Vertical cupping of the ONH Pattern standard deviation on visual fields Thin central corneal thickness < 555 $\mu$ m More disc hemorrhages detected on retinal photography vs. ophthalmoscopy by an expert clinician.

ALT = argon laser trabeculoplasty; NTG = normal tension glaucoma; ONH = optic nerve head; PXG = pseudoexfoliative glaucoma.

## PATIENT ADHERENCE TO MEDICATION AND FOLLOW-UP REGIMENS

### The Nature of the Disease

There are many barriers to adherence in the treatment of glaucoma. Some are related to the inherent nature of the disease itself. Patients with the most common form of glaucoma (primary open-angle glaucoma) are generally asymptomatic, and the condition is diagnosed incidental to the patient's chief complaint. Care should be taken to address the initial reason for the patient's visit in addition to a new diagnosis. This may prevent the situation where a patient returns to the office to determine the efficacy of the initial treatment, only to find that he or she discontinued the medication because it did not address the entering complaint. This underscores the need for good doctor-patient communication.

### Effects on Quality of Life

Assuming that the patient understands he or she has glaucoma and that, in his or her case, it requires medical management, there will be obstacles associated with treatment that must be addressed.

### Self-Medicating With Ophthalmic Medication

Unique to ophthalmic medical management, self-medicating with ophthalmic drops is a learned skill that does not come naturally. In fact, the natural defense systems of the eye (corneal reflex, blepharospasm) must be overcome to be successful. It is not uncommon, even for a patient who believes he or she is faring well, to complain that his or her 2.5-ml bottle of topical prostaglandin is lasting only 3 weeks.

### Medication Costs

Ophthalmic medications are expensive. The costs of these drugs can be prohibitive for patients who do not have prescription drug coverage. Fortunately, most ophthalmic drug companies have patient assistance programs. These programs add a layer of office administration and must be regularly renewed, but they add great value to one's glaucoma practice.

### Insurance Companies

Certain insurers have a preferred ophthalmic medication formulary. These select drugs typically represent the result of a negotiated price between a pharmaceutical company and an insurance provider. These cost-saving measures are an integral part of the health care industry and serve to keep costs manageable for the

company and for the patient. Unfortunately, they can be a source of confusion and concern. When the practitioner recommends a certain medication, the choice was typically made by taking into account the unique needs of the individual patient. When this recommendation differs from the medications available in the patient's formulary, the patient may express concern that he or she may not be receiving what is best. Although sometimes this actually is the case, it may also be a simple matter of brand preference on the part of the provider.

For patients who require a copayment for their medications, it is sometimes advantageous for them to receive a prescription written for a 90-day supply (e.g., 2.5 ml bottle  $\times$  3 vs. one 2.5-ml bottle refilled three times). A 3-month prescription may avoid the cost associated with each refill and, more importantly, reduces the chances of a patient missing doses between refills.

## SELECTED BIBLIOGRAPHY

### IOP

- Aghaian E, Choe JE, Lin S, Stamper RL. Central corneal thickness of caucasians, Chinese, Hispanics, Filipinos, African American, and Japanese in a glaucoma clinic. *Ophthalmology* 2004;111:2211-2219.
- Association of International Glaucoma Societies 4th Global Consensus Meeting, 2007. Broward County Convention Center, Fort Lauderdale, Fla., May 5, 2007.
- Doughty MJ, Zaman ML. Human corneal thickness and its impact on intraocular pressure measures: a review and meta-analysis. *Surv Ophthalmol* 2000;44:367-408.
- Kida T, Liu JH, Weinreb RN. Effect of 24-hour corneal biomechanical changes on intraocular pressure measurement. *Invest Ophthalmol Vis Sci* 2006;47:4422-4426.
- Kirstein EM. Dynamic contour tonometry. *Optometric Glaucoma Society EJournal* 2006;2(1).
- Liu JH, Kripke DE, Hoffman RE, et al. Nocturnal elevation of intraocular pressure in young adults. *Invest Ophthalmol Vis Sci* 1998;39:2707-2712.
- Liu JH, Kripke DE, Twa MD, et al. Twenty-four hour pattern of intraocular pressure in the aging population. *Invest Ophthalmol Vis Sci* 1999;40:2912-2917.
- Luce DA. Introduction to the ocular response analyzer. *Optometric Glaucoma Society EJournal* 2006;2(1).
- Whitacre MM, Stein R. Sources of error with use of Goldmann-type tonometers. *Surv Ophthalmol* 1993;39:1-30.

### GONIOSCOPY

- Coleman AL, Yu F, Evans SJ. Use of gonioscopy in Medicare beneficiaries before glaucoma surgery. *J Glaucoma* 2006;15:486-493.
- Hoskins HD. Interpretive gonioscopy in glaucoma. *Invest Ophthalmol Vis Sci* 1972;11:997-1102.
- He M, Foster PL, Ge J, et al. Gonioscopy in adult Chinese: the Liwan eye study. *Invest Ophthalmol Vis Sci* 2006;47:4772-4779.

## STRUCTURAL

- Bowd C. Structure-function relationships using confocal scanning laser ophthalmoscopy, optical coherence tomography, and scanning laser polarimetry. *Invest Ophthalmol Vis Sci* 2006;47:2889-2895.
- Budenz DL. Detection and prognostic significance of optic disc hemorrhages during the ocular hypertension treatment study. *Ophthalmology* 2006;113:2137-2143.
- Jonas JB, Martus P, Budde WM, Hayler J. Morphologic predictive factors for development of optic disc hemorrhages in glaucoma. *Invest Ophthalmol Vis Sci* 2002;43:2956-2961.
- Jonas JB, et al. Ranking of optic disc variables for detection of glaucomatous optic nerve damage. *Invest Ophthalmol Vis Sci* 2000;41:1764-1773.
- Kim SH, Park KH. The relationship between recurrent optic disc hemorrhage and glaucoma progression. *Ophthalmology* 2006;113:598-602.
- Siegner SW, Netland PA. Optic disc hemorrhages and progression of glaucoma. *Am J Ophthalmol* 2000;129:707-714.
- Zangwill LM, Medeiros FA, Bowd C, Weinreb RN. Optic nerve imaging: recent advances. In: Grehn F, Stamper R, eds. *Glaucoma*. Berlin: Springer-Verlag, 2004: 63-91.

## VISUAL FIELDS

- Anderson RS. The psychophysics of glaucoma: improving the structure/function relationship. *Prog Retin Eye Res* 2005;25:79-97.
- Artes PH, Hutchison DM, Nicoleta MT, et al. Threshold and variability properties of matrix frequency-doubling technology and standard automated perimetry in glaucoma. *Invest Ophthalmol Vis Sci* 2005;46:2451-2457.
- Budenz DL, Rhee P, Feuer WJ, et al. Comparison of glaucomatous visual field defects using standard full threshold and Swedish interactive threshold algorithms. *Arch Ophthalmol* 2002;120:1136-1141.
- Dacey DM, Lee BB. The "blue-on" opponent pathway in primate retina originates from a distinct bistratified ganglion cell type. *Nature* 1994;367:731-735.
- Dacey DM, Packer OS. Colour coding in the primate retina: diverse cell types and cone-specific circuitry. *Curr Opin Neurobiol* 2003;13:421-427.
- Frisen L. High-pass resolution perimetry: evidence for parvocellular neural channel dependence. *Neuroophthalmology* 1992;4:257-264.
- Gupta N, Ang LC, Noel de Tilly L, et al. Human glaucoma and neural degeneration in intracranial optic nerve, lateral geniculate nucleus, and visual cortex. *Br J Ophthalmol* 2006;90:674-678.
- Harwerth RS, Crawford ML, Frishman IJ, et al. Visual field defects and neural losses from experimental glaucoma. *Prog Retin Eye Res* 2002;21:91-125.
- John L, Keltner JL. Normal visual field tests following glaucomatous visual field endpoints in the Ocular Hypertension Treatment Study (OHTS). *Arch Ophthalmol* 2005;123:1201-1206.
- Keltner JL, Johnson CA, Quigg JM, et al. Confirmation of visual field abnormalities in the Ocular Hypertension Treatment Study. *Arch Ophthalmol* 2000;118:1187-1194.
- Sample PA. Identifying glaucomatous vision loss with visual-function-specific perimetry in the Diagnostic Innovations in Glaucoma Study. *Invest Ophthalmol Vis Sci* 2006;47:3381-3389.

- Sample PA, Bosworth CF, Blumenthal EZ, et al. Visual function-specific perimetry for indirect comparison of different ganglion cell populations in glaucoma. *Invest Ophthalmol Vis Sci* 2000;41:1783-1790.
- Wyatt HJ, Dul MW, Swanson WH. Variability of visual field measurements is correlated with the gradient of visual sensitivity. *Vision Res* 2007;47:925-936.
- Yucel YH, Zhang Q, Weinreb RN, et al. Effects of retinal ganglion cell loss on magno-, parvo-, koniocellular pathways in the lateral geniculate nucleus and visual cortex in glaucoma. *Prog Retin Eye Res* 2003;22:465-481.
- ## TREATMENT
- American Academy of Ophthalmology Glaucoma Panel. Preferred practice pattern. Primary open-angle glaucoma. Limited revision. San Francisco: American Academy of Ophthalmology, 2003.
- Asrani S, Zeimer R, Wilensky J, et al. Large diurnal fluctuations in intraocular pressure are an independent risk factor in patients with glaucoma. *J Glaucoma* 2000;9:134-142.
- Deutsch TA, Weinreb RN, Goldberg ME. Indications for surgical management of hyphema in patients with sickle cell trait. *Arch Ophthalmol* 1984;102:566-569.
- Drance SM. The significance of the diurnal tension variations in normal and glaucomatous eyes. *Arch Ophthalmol* 1960;64:494-501.
- Foster PJ. The epidemiology of primary angle closure and associated glaucomatous optic neuropathy. *Semin Ophthalmol* 2002;17:50-58.
- Gordon MO, Beiser JA, Brandt JD, et al. The Ocular Hypertension Treatment Study: baseline factors that predict the onset of primary open-angle glaucoma. *Arch Ophthalmol* 2002;120:714-720.
- Gordon MO and the Ocular Hypertension Treatment Study Group. European Glaucoma Prevention Study Group: validated prediction model for the development of primary open-angle glaucoma in individuals with ocular hypertension. *Ophthalmology* 2007;114:10-19.
- He M, Foster PJ, Johnson GI, Khaw PT. Angle-closure glaucoma in East Asian and European people. Different diseases? *Eye* 2006;20(1):3-12.
- Hoh ST, Aung T, Chew PT. Medical management of angle closure glaucoma. *Semin Ophthalmol* 2002;17:79-83.
- Hughes E, Spry P, Diamond J. 24-Hour monitoring of intraocular pressure in glaucoma management: a retrospective review. *J Glaucoma* 2003;12:232-236.
- Katavisto M. The diurnal variations of ocular tension in glaucoma. *Acta Ophthalmol (Copenh)* 1964;46(suppl):S1-S130.
- Liebmann JM, Ritch R. Laser surgery for angle closure glaucoma. *Semin Ophthalmol* 2002;17:84-91.
- Piltz-Seymour J, Jampel H. The one-eye drug trial revisited. *Ophthalmology* 2004;111:419-420.
- Realini T, Barber L, Burton D. Frequency of asymmetric intraocular pressure fluctuations among patients with and without glaucoma. *Ophthalmology* 2002;109:1367-1371.
- Realini T, Fechtner RD, Atreides SP, Gollance S. The unocular drug trial and second-eye response to glaucoma medications. *Ophthalmology* 2004;111:421-426.
- Ritch R, Shields MB, Krupin T. Chronic open-angle glaucoma: treatment overview. In: Ritch R, Shields MB, Krupin T, eds. *The Glaucomas*, ed. 2. St. Louis, MO: Mosby, 1996: 1512.
- Shields MB. *Textbook of glaucoma*, ed. 4. Baltimore: Williams & Wilkins, 1998: 378.
- Smith J. Diurnal intraocular pressure. Correlation to automated perimetry. *Ophthalmology* 1985;92:858-861.
- Stamper RL, Lieberman MF, Drake MV. *Becker-Shaffer's diagnosis and therapy of the glaucomas*, ed. 7. St. Louis, MO: Mosby, 1999: 424.
- Tello C, Tran HV, Liebmann J, Ritch R. Angle closure: classification, concepts, and the role of ultrasound biomicroscopy in diagnosis and treatment. *Semin Ophthalmol* 2002;17:69-78.
- Walton W, Von Hagen S, Grigorian R, Zarbin M. Management of traumatic hyphema. *Surv Ophthalmol* 2002;47:297-334.
- Wilensky JT, Gieser DK, Dietsche ML, et al. Individual variability in the diurnal intraocular pressure curve. *Ophthalmology* 1993;100:940-944.

SECTION

IV

---

# Toxicology

---

The remedy often times proves worse than the disease.

*William Penn*

## *Ocular Adverse Drug Reactions to Systemic Medications*

*C. Lisa Prokopich, Jimmy D. Bartlett, and Siret D. Jaanus*

Since the 1970s the effect of systemic drug therapies on ocular functions has received considerable attention. The dramatic increase in the number and diversity of drug therapies has necessitated the development of systematic mechanisms to identify the relative risk of adverse effects across populations. Although adverse drug reactions (ADRs) are identified in large clinical trials, often it is not until the drug is marketed and used by the public that the full picture of possible effects can be elucidated. When clinical observations are reported in significant numbers to central databases, these effects can be studied and possible causal connections between systemic drug use and ocular effects established. Because of their unique position in the health care system, primary eye care practitioners are often the first to see ADRs, in particular ocular ADRs (OADRs). The goal of early recognition and management strategies for OADRs can be complicated by numerous factors, such as multiple drug regimens, predisposing patient factors, and lack of conclusive evidence that the drug or drugs implicated are the cause of the observed reaction. Of course, an appropriate balance between the recognition, confirmation, and significance of an OADR against the physiologic need for the drug treatment in a given patient requires considerable understanding of the literature as well as collaboration with the patient and his or her team of health care professionals.

Drugs can cause direct ocular toxicity through the production of arachidonic acid derivatives, the liberation of free radicals, and the disruption of blood–aqueous and blood–retinal barriers. In addition, because of the rich blood supply and relatively small mass, the eye exhibits an unusually high susceptibility to toxic substances. Drug molecules present in systemic circulation can reach the ocular structures by way of both the uveal and retinal blood supplies. Lipophilic drugs are more able to penetrate ocular structures, including the blood–retinal barriers, at both the tight junctions of the retinal pigment epithelium (RPE) and the retinal capillary endothelium. Once in the eye, drugs and chemicals may deposit in ocular tissues. These structures, including the cornea, lens, and retina, may then act as drug reservoirs, trapping

and slowly releasing drug or enhancing the potential toxicity of the drug. Finally, the RPE is highly active metabolically and is critical in drug biotransformation via the cytochrome P-450 system, a system that is highly variable. This may further complicate the wide variation in drug effects noted between individuals, despite the attempt to control for similar dosing regimens and other clinical parameters.

Because the eye is highly accessible to clinical examination, drugs that cause a deposit or change to an ocular structure can be readily observed, often before there is any functional change noted by the patient. Thus, many systemically administered drugs can cause adverse ocular effects, nearly all structures of the eye are vulnerable, and eye care professionals must be vigilant to detect such changes.

Many reports of OADRs involve individual cases in which the administration of one or more drugs resulted in some unexpected sign or symptom. Practitioners are encouraged to report any suspected OADRs to one of a number of sources: the U.S. Food and Drug Administration's Medwatch system ([www.fda.gov/medwatch/index.html](http://www.fda.gov/medwatch/index.html)), the World Health Organization's (WHO) spontaneous reporting database ([www.who-umc.org](http://www.who-umc.org)), the National Registry of Drug-Induced Ocular Side Effects ([www.eyedrugregistry.com](http://www.eyedrugregistry.com)), the Canadian Adverse Drug Reaction Information System (<http://www.hc-sc.gc.ca/>), and the Canadian Ophthalmological Society's Canadian Ocular Drugs Reporting System ([www.eyesite.ca](http://www.eyesite.ca)). Although reports received may be imperfect, these post-marketing efforts by clinicians are considered to be critical "signals" to identify possible trends in OADRs that may not have been triggered by the initial clinical trials.

To attempt to deal with the incompleteness of data in these case-based reports, the WHO developed a classification system for these adverse events (Table 35-1). This involves identifying a temporal association with the use of the drug and the OADR, a dose–response relationship, both positive dechallenge and positive rechallenge corroboration for the effect, and a plausible scientific explanation of the effect, including similar responses being noted with other drugs in the same class. Rarely is



**Table 35-1**

World Health Organization Definitions—Causality Assessment of Suspected Adverse Drug Reactions

Assessment of Suspected Adverse Drug Reactions	Definition
“Certain”	A clinical event noted temporally to be related to the administration of a drug that cannot be explained otherwise by concurrent disease or other drugs or chemicals. Dechallenge (drug withdrawal) and rechallenge (drug reintroduction causing recurrence of the effect) should be definitive.
“Probable/likely”	A clinical event occurs within a reasonable time to drug introduction, which is unlikely to be attributed to concurrent disease or other drugs or chemicals. The drug dechallenge is clinically reasonable. Rechallenge corroboration is not available or required for this definition.
“Possible”	A clinical event occurs with a reasonable time relationship to drug initiation but that could also be explained by concurrent disease or other drugs or chemicals. Dechallenge data may be unavailable or unclear.
“Unlikely”	A clinical event not necessarily related to drug initiation, such that a causal relationship seems improbable, and in which other drugs, chemicals, or underlying disease provide plausible explanations.
“Conditional/unclassified”	A clinical event reported as an adverse reaction, about which more data are essential for a proper assessment or the additional data are being processed.
“Unable to assess/unclassifiable”	An unverifiable report suggesting an adverse reaction but with insufficient or contradictory information.

Adapted from Fraunfelder FW, Fraunfelder FT. Adverse ocular drug reactions recently identified by the National Registry of Drug-Induced Ocular Side Effects. *Ophthalmology* 2004;111:1275-1279.

the patient rechallenged with the implicated drug so that absolute causation of an adverse event is difficult to determine; however, collectively, these isolated observations may represent significant findings and warrant further study. The WHO's *Causality Assessment Guide* is useful not only to categorize ADRs with the drug but as a guide to clinicians in counseling patients and identifying problems.

This chapter considers primarily those prescription drugs that have been frequently implicated in OADR. Some of the common OADR noted in vitamin and herbal supplements are listed toward the end of the chapter. Clinically important drug effects are categorized in the ocular structure or function affected rather than in specific drug classes. A comprehensive review chart at the end of the chapter serves as a reference and study guide (Appendix 35-1). Recommendations for eye care practitioners for reporting suspected drug-induced ocular adverse effects are reviewed.

## DETERMINANTS OF ADVERSE DRUG REACTIONS

### Amount of Drug Administered

Nearly every drug, if administered in excessive amounts, may produce toxic effects. Toxic levels of drugs can result even when daily doses are in the normal therapeutic ranges if administration is prolonged or when other drugs potentiate the effects or when drug detoxification or excretion mechanisms operate more slowly than expected. The effect of excessive drug intake has been observed

with several drugs and is particularly well documented with chloroquine. When it is used as a malaria suppressant, ocular complications are rare. In control of chronic rheumatoid arthritis and systemic lupus erythematosus, however, relatively large dosages of chloroquine had been administered, and irreversible ocular complications involving the retina were determined to be a “certain” adverse effect of the drug.

### Nature of the Drug

The inherent pharmacologic properties of a drug determine its pharmacodynamic effects, and drug absorption, distribution, metabolism, and excretion are determined by the pharmacokinetic effects. The ease with which a drug passes into the systemic circulation and its ability to penetrate the blood-brain, blood-aqueous, or blood-retinal barriers determines the propensity to affect ocular tissues and functions.

The binding of drugs to melanin can lead to ocular toxicity. The free-radical nature of melanin, which is present in ocular structures such as the uveal tract and RPE, may contribute to the binding ability of certain drugs, including psychotropic agents such as chlorpromazine. Drugs can bind to ocular structures other than melanin. Digitalis accumulates in the retina and ciliary body. Other drugs may produce OADR by their systemic pharmacologic activity. For example, subconjunctival or retinal hemorrhages can be caused by use of anticoagulants such as heparin or aspirin and with the use of hormone replacement therapy or oral contraceptives.

### Route of Administration

All routes of drug administration can affect ocular structures and functions. OADR's have been associated with topical ophthalmic administrations as well as local injections. Systemically, oral drug administration has been implicated most frequently in the development of OADR's. However, parenteral as well as inhaled or nasally applied drugs have also produced OADR's. Topical application to the skin, particularly if it is abraded or burned, may result in sufficient systemic absorption to lead to ocular side effects. Dermatologic use of antibiotics has resulted in ocular hypersensitivity reactions.

### Pathophysiologic Variables

The presence of systemic disease can alter the way an individual detoxifies or excretes a drug. Liver and kidney disease, in particular, can markedly influence drug response by allowing the drug to accumulate to toxic levels. The rate of excretion of digoxin, for example, is reduced considerably in patients with renal impairment, thus causing an increased risk of alterations in color vision in these patients.

### Age and Gender

Because ADR's are more likely to occur in the very young and the elderly, lower drug dosages may be indicated at these two extremes of the human life span. The elderly are more likely to have diseases such as cancer, coronary heart disease, dementia, diabetes mellitus, hypertension, and osteoporosis and may also have adverse nutritional reactions. Deficiencies in liver and kidney function can result in marked delay of drug detoxification and elimination. Constant review of established diagnoses and treatments is important to minimize the number of drugs administered, and care must be taken to determine whether other nutritional supplements and herbal products are being incorporated into self-treatment.

In general, more adverse systemic drug reactions are reported in women than in men, although it is not clear whether this also applies to OADR's. Among the factors that may explain these gender differences are pharmacokinetic differences, including body size; the impact of hormonal changes; and the use of oral contraceptives and other medications used selectively or primarily by women.

### Multiple Drug Therapies, Recreational Drugs, Herbal Supplements, and Nutrition

In general, the incidence of ADR's increases with the number of drugs administered. Interactions can occur when a drug is added to, or withdrawn from, a therapeutic regimen. Dietary supplementation occurs in over half of

the U.S. population, whereas only half of these patients report the use of additional agents to their physicians. With the increase in the number of vitamins and herbal products being introduced to the market and being consumed by the general population, ADR's are presumed to be both increasingly numerous and more difficult to isolate to a particular agent. Social habits, including alcohol, recreational drug use, and smoking, should also be considered.

Many different sites or mechanisms can be involved. For example, an addition of an agent, be it a drug, herbal, or nutritional supplement, can alter the absorption, distribution, biotransformation, or excretion of other drugs. In addition, a drug may alter the sensitivity of certain tissues to other drugs or act at the same cellular site or on the same physiologic system. Other factors, such as drug incompatibility, can lead to inactivation and loss of pharmacologic activity.

### History of Allergy to Drugs

Adverse reactions to drugs are more likely to occur in patients with a history of previous reactions. For a drug to cause an allergic reaction, it must combine with an endogenous protein and form an antigenic complex. Subsequent exposure of the patient to the drug or an agent similar to it results in an antigen-antibody interaction that invokes the allergic response. Such reactions are not usually dose related, and relatively small quantities of drugs that act as allergens can provoke a significant reaction.

Allergic reactions are not infrequent and, more often than not, are unpredictable and sometimes difficult to manage. The skin is the most commonly involved tissue. Reactions can range from a mild rash to exfoliative dermatitis and erythema multiforme. Ocular structures most commonly affected are the eyelids and the conjunctiva.

Numerous systemic drugs have been implicated, including the penicillins and sulfonamides, which can cause swelling of the lids and conjunctiva as part of a generalized urticaria or localized angioneurotic edema. Other drugs implicated in ocular allergic reactions are antidepressants, antipsychotics, antihypertensives, antirheumatics, sedatives, and hypnotics.

### Individual Idiosyncrasy

*Idiosyncrasy* refers to an unexpected reaction that can occur in some patients after administration of a drug. These qualitatively abnormal responses have been attributed to heritable characteristics that result in altered handling of or abnormal tissue responsiveness to drugs.

Alterations in enzymatic mechanisms could be responsible for some observed toxicities. Thus, the drug itself or metabolites formed in the liver or other organs of the body could enter the eye. It is also possible for metabolites

to be formed locally in the eye, because a number of enzymes capable of metabolizing drugs have been isolated from various ocular tissues, including the corneal epithelium, iris, ciliary body, and RPE.

## DIAGNOSIS AND MANAGEMENT OF OADR<sub>s</sub> DUE TO SYSTEMIC DRUGS

An effective approach to the diagnosis of OADRs is to take a detailed drug history that includes over-the-counter drugs, nutritional and herbal medications, prescription agents, and recreational and social substances. A temporal relationship between drug use and ocular signs or symptoms is one of the first clues to diagnosis. “Dechallenge” refers to removal of the drug with concomitant elimination of the OADR. “Rechallenge” refers to the return of the effect on reintroduction of the drug. The practitioner must be familiar with the possible ocular effects of all agents that patients may be taking and be prepared to research the literature for new reports and management strategies. Detailed data should be gathered from each patient, and the practitioner should consider reporting the OADRs to an appropriate drug registry.

When used in normal therapeutic doses, most drugs have a relatively low incidence of drug-induced ocular complications. Many drugs, however, can cause adverse effects, whereas others may cause changes to ocular tissues or visual functioning when taken in excess.

The following sections consider the most important drugs that have the potential to affect the eye. Where possible, the WHO Classification for Causality is listed for each sign or symptom. Where available, a brief explanation of the etiology is provided and the management strategy for the OADR is discussed.

## DRUGS AFFECTING THE CORNEA AND CRYSTALLINE LENS

Systemic drugs and their metabolites may reach the cornea and lens via the tear film, limbal vasculature, and also the aqueous humor. Deposition may occur, as can direct toxicity to the structures of the cornea and lens. Although corneal opacities secondary to drug therapies are often irreversible with drug cessation or reduction, these opacities may signal more permanent deposits of drug in the lens and, possibly more importantly, the retina.

Many drugs have been associated with corneal and crystalline lens opacities, including phenothiazines, allopurinol, phenytoin, diuretics, and heavy alcohol consumption. Over 16 drugs are listed to be associated with epithelial vortex keratopathy alone in a recent review, whereas the stroma is affected much less frequently. A variety of ocular toxicities are well recognized, aside from isolated case reports, and the drugs responsible for these side effects are listed in Table 35-2.

**Table 35-2**  
Drugs That Can Affect the Cornea and Crystalline Lens

Drug	Adverse Effect
<b>Drugs Causing Corneal OADRs</b>	
Corticosteroids	Decreased epithelial wound healing, increased risk for infection (decreased tear lysozyme)
Chloroquine and hydroxychloroquine (also see text: Drugs Affecting the Retina)	Whorl-like epithelial opacities (also termed vortex keratopathy or corneal verticillata)
Amiodarone	Whorl-like opacities
Atovaquone	Whorl-like opacities
Tamoxifen (also see text: Drugs Affecting the Retina)	Whorl-like opacities (uncommon)
Chlorpromazine	Pigmentation of endothelium and Descemet’s membrane
Indomethacin	Stromal opacities or whorl-like epithelial opacities
Isotretinoin (also see text: Drugs Affecting the Optic Nerve)	Corneal opacities, superficial punctate keratitis, neovascularization (rare)
Gold salts	Stromal gold deposits
Crack cocaine	Ulceration, epithelial defects, loss of corneal sensitivity
<b>Drugs Causing Lenticular OADRs</b>	
Amiodarone	Anterior subcapsular opacities
Chlorpromazine	Anterior subcapsular stellate-shaped cataract
Corticosteroids	Posterior subcapsular cataract
Gold salts	Anterior capsular or subcapsular gold deposits
Psoralen (8-methoxypsoralen)	Ultraviolet-induced cataract

## Corticosteroids

Natural and synthetic steroids are used extensively to treat arthritis and other rheumatoid diseases, including rheumatic heart disease. They are also used in some cases of autoimmune diseases such as systemic lupus erythematosus, severe asthma and in some respiratory diseases, and in some ocular allergy and inflammatory conditions. Steroids can be administered orally, intravenously, or intranasally or be inhaled.

### Clinical Signs and Symptoms

The ocular side effects of corticosteroids are many and are related to the route of administration. The most common concerns are increased intraocular pressure (IOP) and cataracts, but delayed epithelial wound healing and increased risk of infection due to immune modulation and decreased tear lysozyme levels are issues for the cornea. Changes to other ocular tissues have been noted (subconjunctival hemorrhages, blue sclera, eyelid hyperemia and edema, retinal embolic events, central serous choroidopathy) and neurologic complications reported (diplopia, nerve palsies, intracranial hypertension) (see Appendix 35-1).

The association between steroid use and cataracts has been well known since the early 1960s. Visual impairment is uncommon, though patients may report light sensitivity, photophobia, reading difficulty, or glare.

The use of systemic, topical ophthalmic, topical dermatologic, and nasal aerosol or inhalation steroids has been implicated as causing posterior subcapsular (PSC) cataracts that are clinically indistinguishable from other causes, including age-related PSC cataracts. PSC cataract formation is irreversible and is likely dose dependent. The usual time of onset to cataract formation is 1 year with a dosage of 10 mg/day of prednisone, although it has been seen after as little as 5 mg/day for as short as 2 months. The range of incidence of (oral) corticosteroid-related cataract is 6.4% to 38.7%. A strong association has been found between the use of inhaled steroids and PSC cataracts, but no clear association has been noted between intranasal steroids and the development of PSC cataracts. Because of considerable variation in the numbers of patients studied, dosage and duration of treatment, criteria for diagnosis, route of drug administration, and the underlying disease process itself, attention has focused on the possibility that PSC cataract formation may be related more to factors of individual susceptibility than to drug-related factors. Hispanics appear to be more predisposed to steroid-induced PSC cataracts than are either whites or blacks. It was thought that children were more susceptible than adults, developing PSC cataracts at a lower dosage and in a shorter time; however, this may have been due to the relatively large doses of steroids used in relation to low body weight and is not seen in contemporary treatment of children, except in children in whom frequent courses of systemic steroids are used.

### Etiology

The pathogenesis of steroid-induced cataract is likely multifactorial, including bonding of certain chemicals, water accumulation, protein agglutination, and various biochemical consequences of abnormal glucose metabolism.

### Management

The short-term use of systemic steroids is not associated with a significant risk of cataract. Patients who take long-term oral or inhaled steroids, however, should have careful slit-lamp examinations performed through a dilated pupil every 6 to 12 months. Although the long-term administration of inhaled steroids is relatively safe compared with the long-term use of oral steroids, prolonged use of high dosages of inhaled steroids increases the risk of PSC and nuclear cataracts. Because it is possible for patients to develop cataracts even when taking very low dosages of steroid, every patient, regardless of dosage or route of administration, should be evaluated carefully for the presence of drug-induced cataract. When drug-induced cataracts are discovered, the prescribing practitioner should be notified. Normally, because of the ADR profile of systemic steroids, care has already been taken to taper the patient to the lowest tolerable dosage required to control his or her inflammation. However, consideration may be given to attempt to further reduce the dosage in light of the OADR. There is generally no increased risk to the patient having cataract extraction secondary to steroid-induced PSC cataracts.

## Chloroquine and Hydroxychloroquine

Chloroquine and hydroxychloroquine are quinoline drugs used for the chronic management of rheumatoid arthritis, discoid and systemic lupus erythematosus, and other collagen diseases. Because chloroquine is rapidly absorbed and becomes highly concentrated in various tissues due to melanin and protein binding, it is now used only for malaria prophylaxis. Hydroxychloroquine has replaced it primarily because of its superior safety profile.

### Clinical Signs and Symptoms

The pattern of hydroxychloroquine and chloroquine keratopathy can be divided into three stages of severity. In the early stages, fine diffuse deposits appear in the corneal epithelium. Later, the deposits aggregate into curved lines that converge and coalesce just below the central cornea. Finally, green-yellow pigment spots appear as concentric lines in a "whorl-like" opacity. Corneal deposits can be observed as early as 2 to 6 weeks after beginning therapy, and there is no relationship between the development of corneal deposits and the occurrence of retinopathy, the more significant OADR of these drugs.

Keratopathy is rare in patients taking hydroxychloroquine (1% to 28%) versus up to 95% of those who took chloroquine. Though studies have found no correlation

between the severity of keratopathy and the dosage or duration of drug therapy, doses of <400 mg/day of hydroxychloroquine generally show no keratopathy. At higher doses (800 mg/day), however, 6% developed keratopathy within 6 months of therapy, 32% during the second 6 months, and all patients had keratopathy after 4 years. A rapid rise in the incidence of keratopathy was noted when the total drug dosage exceeded 150 g. On reducing dosage or discontinuing the drug, the corneal opacities decreased or disappeared within an average of 8 months.

Less than half of patients affected with corneal changes have visual symptoms, but the most common complaints relate to halos around lights, glare, and photophobia, whereas visual acuity usually remains unchanged. On drug discontinuation, both subjective symptoms and objective corneal signs disappear.

### Etiology

Vortex keratopathies are generally associated with an intralysosomal accumulation of lipids. This mechanism is similar to that noted in Fabry's disease, a genetic disorder of sphingolipid metabolism. Once the amphiphilic drugs penetrate the lysosomes, they bind with cellular lipids, causing them to accumulate in the tissues. The changes are limited to the corneal epithelium, which the drug may reach by deposition via the tear film or by the limbal vasculature. The "whorl" appearance occurs due to a centripetal migration of limbal epithelial cells that have accumulated these lipid deposits.

### Management

Patients taking hydroxychloroquine (or chloroquine) should receive careful baseline and periodic slit-lamp examinations, with pupils dilated. Early identification of the corneal changes is facilitated by using retroillumination. The practitioner should be careful to distinguish early chloroquine keratopathy from the normal development of Hudson-Stähli lines, which it can resemble.

Keratopathy due to Fabry's disease is another important condition in the differential diagnosis. The verticillate corneal findings are quite similar to those induced by chloroquine or hydroxychloroquine, but the systemic implications in this metabolic disease warrant consultation with an internist.

Because the condition is relatively benign and only rarely results in visual symptoms, the development of chloroquine keratopathy does not contraindicate continued use of the medication. If, however, symptoms of glare, halos, or reduced vision bother the patient, consideration may be made to reduction of drug dose in consultation with the prescribing physician.

### Amiodarone

Amiodarone, a highly lipid-soluble iodine-containing drug, has been used for several decades to treat a variety of cardiac abnormalities, including atrial and ventricular arrhythmias. It is highly variable in its bioavailability after ingestion and is affected by food and other drugs. Amiodarone has been noted to cause intracytoplasmic lamellar deposits in the cornea, lens, retina, and optic nerve. The most common symptom noted in 1.4% to 40% of patients is colored rings around lights, attributed to amiodarone-related keratopathy.

### Clinical Signs and Symptoms

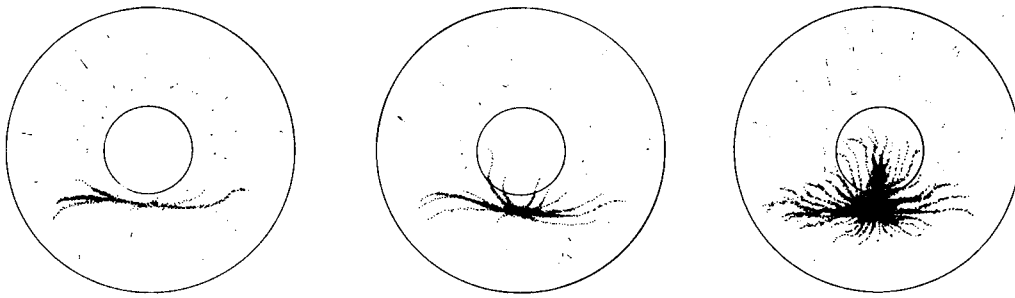
Keratopathy is the most common ocular sign found in 69% to 100% of patients. The onset of keratopathy may be as early as 6 days after initiation of therapy, although it more commonly appears after 1 to 4 months of treatment. The corneal deposits are bilateral but are often asymmetric, and they are observed easily with the slit lamp. The development of keratopathy can be divided into four grades (Table 35-3). The development of each grade of keratopathy is shown in Figure 35-1, and a clinical photograph of amiodarone keratopathy is shown in Figure 35-2.

**Table 35-3**

Grading and/or Progression of Amiodarone-Related Keratopathy

Grade	Characteristics
Grade I (usually 200–400 mg/day)	A faint horizontal line, similar to a Hudson-Stähli line, appears in the interpalpebral fissure at the junction of the middle and lower third of the cornea. It consists of fine grayish or golden-brown microdeposits in the epithelium just anterior to Bowman layer.
Grade II (usually greater dosage)	Transition to grade II occurs by 6 months, during which time the deposits become aligned in a more linear or arborizing pattern and extend toward the limbus. The grade II pattern does not necessarily proceed to grade III.
Grade III (dosages of $\geq$ 400 mg and duration > 1 year)	The deposits increase in number and density, and the lines extend superiorly to produce a whorl-like pattern into the visual axis.
Grade IV	Irregular, round clumps of deposits form.

Modified from Klingele TG, Alves LE, Rose EP. Amiodarone keratopathy. *Ann Ophthalmol* 1984;16:1172–1176.



**Figure 35-1** Stages of amiodarone keratopathy. *Left*, grade I; *center*, grade II; *right*, grade III. (Modified from Klingele TG, Alves LE, Rose EP. Amiodarone keratopathy. *Ann Ophthalmol* 1984;16:1172-1176.)

The severity of the keratopathy appears to be significantly correlated with total drug dosage and duration of treatment. In general, patients taking low dosages of drug (100 to 200 mg daily) retain clear corneas or demonstrate only mild keratopathy regardless of duration of treatment or cumulative dosage. Patients taking higher dosages (400 to 1,400 mg daily) demonstrate more advanced keratopathy depending on the duration of treatment. Once the keratopathy becomes fully developed, it remains relatively stationary until the drug dosage is reduced or the drug is discontinued. The keratopathy gradually resolves within 3 to 20 months after discontinuation of drug therapy.

Amiodarone-induced lens opacities have also been reported. Fine anterior subcapsular lens deposits occur in approximately 50% of patients taking amiodarone in moderate to high dosages (600 to 800 mg daily) after 6 to 18 months of treatment. The deposits first appear as small golden brown or white-yellow punctate opacities located just below the anterior lens capsule. Unlike the lenticular deposits associated with chlorpromazine therapy, which develop before corneal changes, the lens opacities

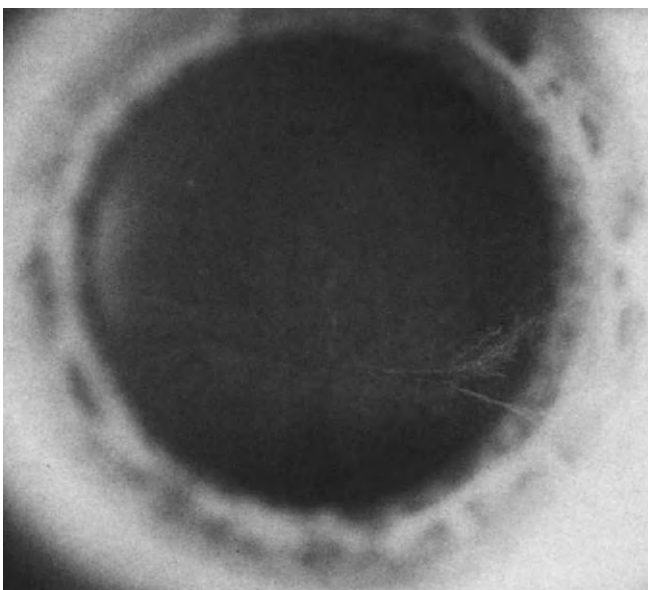
associated with amiodarone develop in the presence of marked keratopathy. Differentiation from epicapsular stars can also be made readily as these congenital darkly pigmented spots have a characteristic appearance and extend into the lens surface. Amiodarone-induced lenticular opacities generally cause no visual symptoms.

### Etiology

As an amphiphilic drug like chloroquine, amiodarone binds to polar lipids and accumulates within lysosomes. The presence of such complex lipid deposits within the corneal epithelium has led investigators to conclude that amiodarone keratopathy is probably similar to a lipid storage disease. Light exposure may be a factor in the corneal and lenticular changes, because amiodarone is a photosensitizing agent and the observed lens changes are primarily localized to the pupillary aperture. The whorl-like pattern of the keratopathy may result from an effect at the limbus on the epithelial cells that are migrating centripetally.

### Management

Because the corneal and lenticular changes associated with amiodarone therapy are benign, special follow-up of affected patients is not required unless the opacities have induced visual symptoms. If visual symptoms are annoying or incapacitating, reduction or discontinuation of drug dosage usually resolves the corneal findings, though it is unusual for ocular side effects to necessitate discontinuation of drug therapy. Occasionally, however, treatment must be discontinued because of drug intolerance or other side effects such as diarrhea, vomiting, pulmonary fibrosis, or liver damage. The use of ultraviolet (UV)-filtering lenses may be a preventive measure. Because the early stages of amiodarone keratopathy can mimic a Hudson-Stähli line, a drug history relative to amiodarone use should be elicited carefully. More advanced stages of amiodarone keratopathy may resemble the corneal changes of Fabry's disease or chloroquine toxicity. Because of the systemic implications of this disease, patients with no history of amiodarone or chloroquine use should be evaluated by an internist. Also, rare reports of optic neuropathy have occurred with amiodarone, so dilated fundus examinations and attention to patient symptoms are important (see Appendix 35-1).



**Figure 35-2** Clinical photograph of grade III amiodarone keratopathy. (Courtesy Jerry Pederson, O.D.)

**Table 35-4**

Grading and/or Progression of Chlorpromazine-Related Lenticular Opacities

Grade	Characteristics
Grade I	Fine dot-like opacities on the anterior lens surface. At this stage the pigmentary deposits are small and tend to assume a disciform distribution within the pupillary area.
Grade II	Dot-like opacities that are more opaque and denser compared with grade I. The pigmentary granules may begin to assume a stellate pattern.
Grade III	Larger granules of pigment range from white, to yellow, to tan with an anterior subcapsular stellate pattern that is easily recognized. The stellate pattern has a dense central area with radiating branches (see Figure 35-4).
Grade IV	A readily visible stellate pattern with three to nine star points. The lens changes at this stage can be recognized with a penlight, and diagnosis does not necessarily require slit-lamp examination.
Grade V	Central, lightly pigmented, pearl-like, opaque mass surrounded by smaller clumps of pigment.

### Atovaquone

Atovaquone, an antiparasitic drug used to treat pneumonia in patients intolerant of trimethoprim-sulfamethoxazole, has been reported to cause verticillate keratopathy in susceptible patients. The clinical manifestations are similar to other drug-induced vortex keratopathies. Slit-lamp examination discloses bilateral whorl-like patterns involving the inferior-central corneal epithelium, with normal stroma and endothelium. It has been proposed that the keratopathy has a pathophysiologic mechanism similar to other drug-induced verticillate conditions. The vortex pattern is probably a result of growth and repair of the corneal epithelium, with the flow of cells from peripheral to central cornea creating the whorl-like pattern. The keratopathy subsides once drug therapy is discontinued, and there is minimal risk of long-term visual impairment.

### Chlorpromazine

Chlorpromazine is a phenothiazine derivative used in the treatment of various psychiatric disorders. Often, high prolonged doses of medication are required, and these have led to well-documented phototoxic changes in the cornea and lens as well as pronounced skin discoloration. It is now generally accepted that chlorpromazine is the only phenothiazine to cause such ocular changes.

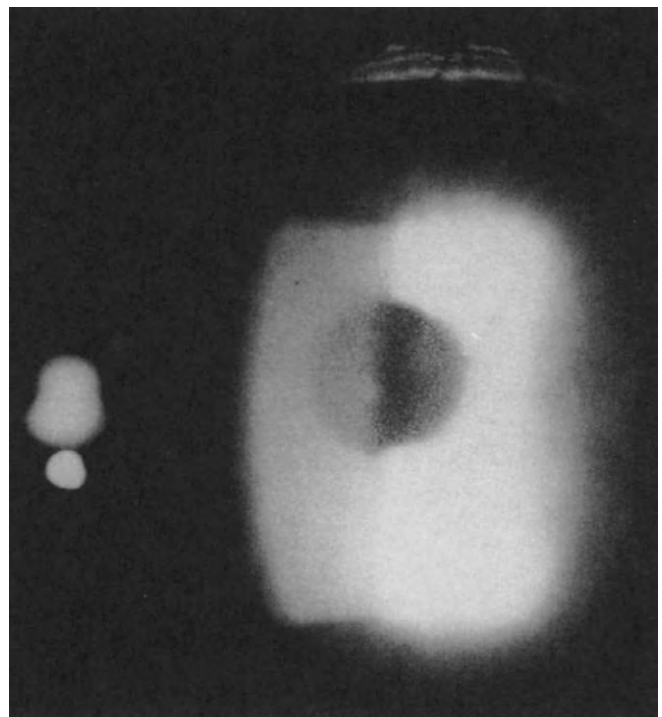
#### Clinical Signs and Symptoms

Although phenothiazine use is associated with an increased prevalence of nuclear cataract, the most widely recognized toxicities are anterior subcapsular cataract, corneal endothelial pigment deposition, and skin pigmentation changes. The ocular conditions, however, rarely reduce visual acuity, although glare, halos around lights, or hazy vision may be reported.

Corneal pigmentary changes almost invariably occur only in patients who have concomitant lens opacities in the higher grades (Table 35-4). There is often little or no corneal involvement with mild lens changes (grades I and II),

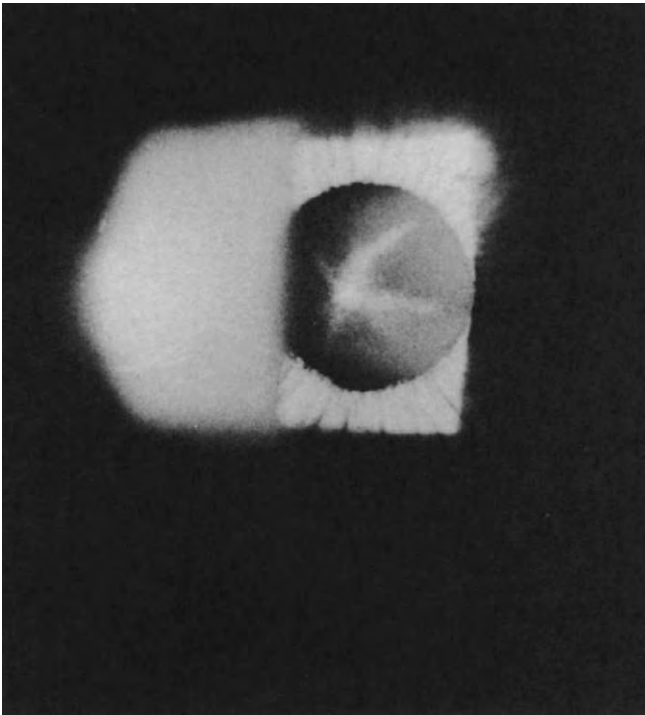
but patients with moderate to severe lens changes (grades III and higher) have detectable corneal pigmentation ranging from light to heavy. The pigmentation is white, yellow-white, brown, or black and occurs at the level of the endothelium and Descemet's membrane (rarely the stroma) and is located primarily in the interpalpebral fissure area (Figure 35-3).

The lenticular changes associated with chlorpromazine have been described to occur in five stages from fine dot-like opacities on the anterior lens surface, through a stellate pattern in the anterior subcapsular region (Figure 35-4) and finally to a central, pearl-like, opaque mass surrounded by smaller clumps of pigment (see Table 35-4).



**Figure 35-3** Heavy pigment deposits on corneal endothelium, caused by chlorpromazine administration. (Courtesy Jerome Thaler, O.D.)





**Figure 35-4** Stellate pattern of anterior subcapsular cataract associated with chlorpromazine administration. (Courtesy Jerome Thaler, O.D.)

Usually, the corneal and lenticular pigmentary changes are dose related but progress to an endpoint beyond which no further changes are observed and reduction or discontinuation of drug therapy does not reverse the effects. This is not surprising because the deposits associated with chlorpromazine therapy are located in avascular tissues. Corneal toxicity has been reported to occur within 6 months of therapy in 12% of patients receiving 2,000 mg of chlorpromazine daily but in only 1% of patients receiving 300 mg of chlorpromazine daily. Lenticular pigmentation is rarely evident when the total dosage is less than 500 g, and the prevalence of pigmentary changes increases with total dosages between 1,000 and 2,000 g, until 90% of patients demonstrate pigmentation when the total dosage exceeds 2,500 g. Because some psychiatric conditions may require daily dosages exceeding 800 mg, lenticular pigmentation can appear in as early as 14 to 20 months of therapy. Dosages consisting of 2,000 mg daily have caused lenticular changes in as little as 6 months of therapy.

### Etiology

The precise nature of the pigmentary granules in the cornea and lens is unknown. An accepted hypothesis, however, is that the pigmentary changes are a result of drug interaction with UV radiation as it passes through the cornea and lens, causing exposed proteins to denature, opacify, and accumulate in the anterior subcapsular region of the lens as well as in corneal stroma. This explains

why the keratopathy is localized to the interpalpebral fissure area.

### Management

Patients receiving high-dose or long-term low-dose chlorpromazine therapy should be monitored annually by careful slit-lamp examination. If corneal and lens changes occur but visual acuity is not affected and the patient is asymptomatic, the drug dosage can be continued without modification. If the patient becomes symptomatic, however, dosage changes should be considered, including reducing the dose or changing therapy to a nonphenothiazine drug.

### Indomethacin

Nonsteroidal anti-inflammatory drugs (NSAIDs) are commonly used for their analgesic, anti-inflammatory, and antipyretic actions in the treatment of arthritis, musculoskeletal disorders, dysmenorrhea, and acute gout. Although these drugs are widely administered and are often used for prolonged periods, ocular side effects are rare and have been poorly described. Indomethacin therapy has been associated with corneal opacities and blurred vision, optic neuritis, retinal changes, conjunctival and retinal hemorrhages, and intracranial hypertension.

### Clinical Signs and Symptoms

The prevalence of corneal toxicity associated with indomethacin therapy has been reported to be 11% to 16% and is most common with long-term therapy. The corneal lesions appear either as fine stromal speckled opacities or have a whorl-like distribution resembling chloroquine keratopathy. Corneal opacities have been noted in patients taking indomethacin for 12 to 18 months, with the daily dosage ranging from 75 to 200 mg and the total dosage ranging from 20 to 70 g. These corneal changes diminish or disappear within 6 months of discontinuing indomethacin.

Symptoms associated with the corneal opacities can range from mild light sensitivity to frank photophobia. Corneal sensitivity, however, is unaffected. In general, the only possible OADR of this drug that might warrant discontinuation are optic neuritis and intracranial hypertension (see Appendix 35-1).

### Etiology

The mechanism of these ocular changes is unknown.

### Management

Because the corneal opacities associated with indomethacin are benign and represent no significant threat to vision, patients taking this drug can be monitored annually for evidence of corneal changes. Patients who develop evidence of keratotoxicity should be reassured regarding the benign nature of these changes, and the prescribing physician should be notified. The appearance of the corneal opacities does not necessitate reduction or

discontinuation of drug therapy, except if severe corneal toxicity causes visual symptoms that are annoying or incapacitating.

## Gold Salts

Both parenteral and oral gold salts are used in the treatment of rheumatoid arthritis. After prolonged administration, gold can be deposited in various tissues of the body, a condition known as *chrysiasis*.

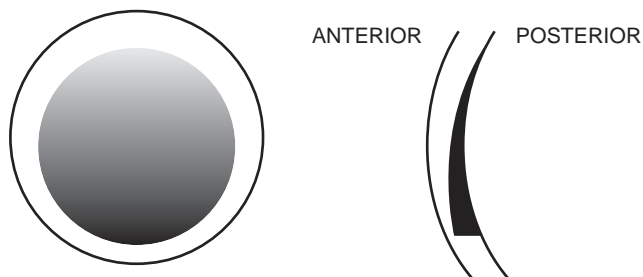### Clinical Signs and Symptoms

Ocular chrysiasis can involve generally asymptomatic deposition in the conjunctiva, cornea, and lens. Corneal chrysiasis consists of the presence of numerous minute gold particles, appearing as yellowish brown to violet or red particles distributed irregularly in the posterior one-third of the stroma. The deposition of gold generally spares the peripheral 1 to 3 mm as well as superior one-fourth to one-half of the cornea. There is typically no involvement of the epithelium, Descemet's membrane, or endothelium. Figure 35-5 shows the general distribution of gold deposits in a typical case of corneal chrysiasis. Reported corneal deposition rates have been variable, with 45% to 97% noted in patients receiving continuous long-term gold therapy for rheumatoid arthritis consisting of a cumulative dosage of 1 g. Although no correlation exists between the density of corneal deposits and the cumulative dosage, there is a positive correlation between the duration of gold therapy and the density of corneal deposits.

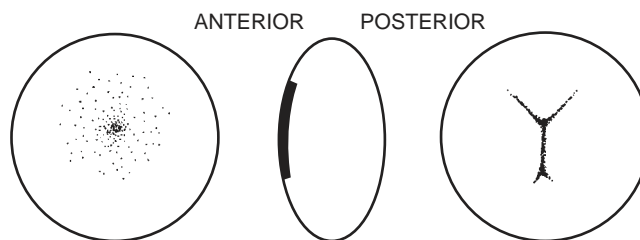
Lenticular chrysiasis appears as fine, dust-like, yellowish, glistening deposits in the anterior capsule or in the anterior suture lines (Figure 35-6). There is no significant correlation between corneal chrysiasis and lenticular chrysiasis, and deposits of gold in either tissue do not cause symptoms.

### Etiology

The available evidence suggests that gold is deposited in the cornea and lens by circulation in the aqueous fluid in the anterior chamber.



**Figure 35-5** General distribution of gold deposits in corneal chrysiasis. The deposits spare the peripheral and superior cornea and are denser inferiorly. (Modified from McCormick SA, DiBartolomeo AG, Raju VK, Schwab IR. Ocular chrysiasis. *Ophthalmology* 1985;92:1432-1435.)



**Figure 35-6** Lenticular chrysiasis. Gold deposits can diffusely involve the axial anterior capsule or can involve the anterior suture line. (Modified from McCormick SA, DiBartolomeo AG, Raju VK, Schwab IR. Ocular chrysiasis. *Ophthalmology* 1985;92:1432-1435.)

### Management

Because ocular chrysiasis does not lead to visual impairment, inflammation, or corneal endothelial changes, gold therapy does not need to be reduced or discontinued. This benign process requires only routine follow-up. The deposits often disappear within 3 to 6 months after cessation of therapy; occasionally, they are found years after therapy has been discontinued.

## Isotretinoin

An analogue of vitamin A, isotretinoin (Accutane), or 13-*cis*-retinoic acid, is used for control of severe recalcitrant cystic acne and other keratinizing dermatoses. Oral administration of 1 to 2 mg/kg body weight daily temporarily suppresses sebaceous gland activity, changes surface lipid composition of the skin, and inhibits keratinization. The therapeutic effect is resolution of lesions and, in most patients, prolonged remission of the disease.

### Clinical Signs and Symptoms

Adverse ocular effects affecting the cornea include abnormal meibomian gland secretion/gland atrophy, increased tear film osmolarity, ocular discomfort, blepharoconjunctivitis, keratitis, corneal opacities, and decreased vision. Corresponding symptoms of ocular discomfort, photophobia, and decreased tolerance to contact lens wear are related to ocular dryness. Ocular complications generally manifest within 4 weeks of drug treatment and begin to wane approximately 4 weeks after therapy cessation. Epithelial keratitis has been reported in patients treated with an average dose of 2 mg/kg. Symptoms are dose related, with 20% of patients taking 1 mg/kg/day noting blepharoconjunctivitis and 43% of patients taking 2 mg/kg/day experiencing the same. Subepithelial corneal opacities may occur in both the peripheral and central cornea, and if the visual axis is involved, vision may be impaired.

Of interest is that decreased color vision and decreased dark adaptation are also "certain" OADR, whereas corneal ulceration, diplopia, eyelid edema, and intracranial hypertension are also associated but considered "possible" OADR.

A number of other OADRs are associated with this drug but are listed as “unlikely” (corneal neovascularization, activation of herpes simplex) or “unclassifiable” (cataracts, decreased accommodation, iritis).

### Etiology

Because the meibomian glands are modified sebaceous glands, suppression of sebaceous gland activity can also cause deficiency of the normal lipid layer of the precocular tear film. This can lead to evaporation of the aqueous layer and subsequent drying of the ocular surface, followed by epithelial and subepithelial defects.

### Management

Decreasing or discontinuing the drug usually alleviates the side effects in most patients approximately 1 month after discontinuation, but several months may be required before significant clinical improvement is obtained. Topically applied artificial tears can be used as needed to improve ocular signs and symptoms of dry eye. Although most of the symptoms related to this ocular dryness resolve when treatment is discontinued, rarely the meibomian glands may show irreversible atrophy and therefore symptoms may be prolonged.

## Photosensitizing Drugs

Photosensitizing drugs are compounds that absorb optical radiation (UV and visible) and undergo a photochemical reaction, which results in chemical modifications in nearby molecules of the tissue. The psoralen compounds are photosensitizing drugs and are used by dermatologists to treat psoriasis and vitiligo. Commonly referred to as psoralen plus UV-A therapy, this treatment involves the administration of 8-methoxypsoralen or related compounds, followed by exposure to UV radiation (320 to 400 nm) for short periods. The most common photosensitizing reactions involve the skin and eye. Cataract formation is now well documented in patients having psoralen plus UV-A therapy, but visual acuity is usually unaffected.

### Etiology

The eye and the skin are susceptible to damage from nonionizing wavelengths of optical radiation (280 to 1400 nm). The crystalline lens can absorb varying amounts of UV radiation and photobind susceptible drugs present in that tissue. Because the adult crystalline lens effectively filters most UV radiation, the source for most of the ocular damage from photosensitizing drugs, there is minimal risk of photobinding susceptible drugs in the retina. UV radiation, however, can penetrate to the retina in aphakic and some pseudophakic individuals and in young persons, causing potential photosensitizing damage to the retina.

### Management

Free 8-methoxypsoralen can be found in the lens for at least 12 hours after administration. Thus, to prevent

permanent photobinding of this drug, dermatologists usually provide UV-filtering lenses to be used both indoors and outdoors for at least 12 hours. For children, patients with preexisting cataract, and those at increased risk of cataract development, such as patients with atopic dermatitis, protection for 24 hours is recommended.

## Crack Cocaine

Cocaine, particularly the alkaline smoke from the crack form, can be associated with severe ocular problems, including corneal complications. The two forms are infectious corneal ulcers that are usually painless, or sterile epithelial defects associated with vigorous eye rubbing, which are painful. The ocular signs may be associated with periocular, oral, or facial burns from homemade metal crack pipes. These may be caused by a direct toxic effect on the structural and functional integrity of the corneal epithelium, or be due to decreased corneal sensation, neurotrophic changes, mechanical causes due to eye rubbing, and subclinical alkali burn of crack cocaine. Each of these mechanisms, alone or in combination, could lead to chronic ocular surface disease and predispose to epithelial defects and subsequent corneal infection. Although intranasal cocaine has not been detected in tears using high-performance liquid chromatography, the observed decrease in corneal sensitivity can be an indication that cocaine may travel retrograde through the nasolacrimal duct to reach the ocular tissues. Therapy should be consistent with the clinical signs and symptoms present. Because patient compliance may be poor, aggressive initial therapy is recommended to prevent subsequent more serious complications.

## DRUGS AFFECTING THE CONJUNCTIVA AND EYELIDS

Drug effects on the conjunctiva and lids can be irritative or allergic or can involve pigmentary inclusions. Some of the most common OADRs of systemic medication use are listed in Table 35-5.

### Isotretinoin

An analogue of vitamin A, isotretinoin (Accutane), or 13-*cis*-retinoic acid, is used for control of severe recalcitrant cystic acne and other keratinizing dermatoses (also see Isotretinoin under Drugs Affecting the Cornea and Lens, above).

### Clinical Signs and Symptoms

The mucous membranes, including the conjunctiva, are sites associated most frequently with adverse effects of isotretinoin therapy. Therefore it is not surprising that blepharoconjunctivitis is not only considered a “certain” ocular ADR associated with oral isotretinoin use, it is also the most common, occurring in 20% to 50% of patients.

**Table 35-5**  
Drugs That Can Affect the Conjunctiva and Eyelids

Drug	Adverse Effect
Isotretinoin (also see text: Drugs Affecting the Cornea and Crystalline Lens)	Blepharoconjunctivitis, ocular surface dryness, increased tear film osmolarity, contact lens intolerance, lid edema, and hyperemia
Chlorpromazine (also see text: Drugs Affecting the Cornea and Crystalline Lens)	Slate-blue discoloration of conjunctiva and dermis of lids
Sulfonamides	Lid edema, conjunctivitis, chemosis, Stevens-Johnson syndrome
Gold salts	Gold deposits in conjunctiva
Tetracycline	Pigmented conjunctival inclusion cysts
Minocycline	Bluish discoloration of sclera
Bisphosphonates: pamidronate, alendronic acid (also see text: Drugs Affecting the Episclera, Sclera, and Uvea)	Nonspecific conjunctivitis (also uveitis, episcleritis, scleritis), eyelid and periocular/periorbital edema
Sildenafil (also see text: Drugs Affecting the Retina and Drugs Affecting the Optic Nerve)	Conjunctival hyperemia, subconjunctival hemorrhage
Corticosteroids (also see text: Drugs Affecting the Cornea and Crystalline Lens and Drugs Affecting Intraocular Pressure)	Subconjunctival hemorrhage, eyelid and conjunctiva, hyperemia/edema/angioneurotic edema, lid ptosis
Nonsteroidal anti-inflammatory agents, acetylsalicylic acid, cyclooxygenase-2 inhibitors	Subconjunctival hemorrhage
Niacin (also see text: Herbal Agents and Nutritional Supplements)	Lid discoloration, lid edema

Symptoms can vary from slight irritation associated with dry eyes to significant discomfort and discharge. Examination of the eyes may reveal scaly crusty eyelids, dilated vessels at the lid margins, and conjunctival injection along with punctate keratitis. Schirmer testing and tear break-up time results are usually decreased. As with the corneal effects, the conjunctival and lid ADRs associated with isotretinoin are dose dependent. Isotretinoin dosages of 2 mg/kg body weight daily result in blepharoconjunctivitis in 43% of patients, whereas dosages of 1 mg/kg body weight daily show a 20% incidence of blepharoconjunctivitis. Most ocular complications of isotretinoin therapy occur within 4 weeks after drug treatment is begun and disappear within 1 month after discontinuation of therapy.

### Etiology

Isotretinoin treatment alters meibomian gland function. The glands appear atrophic, and gland expressions increase in thickness and decrease in volume. The decreased meibomian gland function consequently increases tear evaporation and tear osmolarity, with subsequent ocular surface disease.

### Management

Because as many as half the patients who develop blepharoconjunctivitis have ocular symptoms before the

start of therapy, the drug may aggravate preexisting conditions. Decreasing the dosage or discontinuing the drug usually alleviates the side effects, although a few months may be required before significant relief is obtained in some individuals. Although most of the symptoms related to ocular dryness resolve when treatment is discontinued, the meibomian glands may show irreversible atrophy. Topically applied artificial tears can be used as needed to improve ocular signs and symptoms of dry eye.

### Chlorpromazine

A slate-blue discoloration of the conjunctiva, sclera, and exposed skin can occur with administration of phenothiazine derivatives. The skin of the face and lids can be equally pigmented, whereas the palpebral folds can contain an area of nonpigmented skin deep within the creases. Melanin-like granules have been observed in the superficial dermis of the skin. The oculoskin syndrome is usually associated with pigmentary deposits in the exposed interpalpebral area of the bulbar conjunctiva, especially near the limbus, but the palpebral conjunctiva is uninvolved. Patients exposed to dosages of chlorpromazine ranging from 500 to 3,000 mg daily for 1 to 6 years may develop discoloration of the exposed skin, lids, and bulbar conjunctiva.

## Sulfonamides

Ocular complications are rare with systemic use of this class of drugs. Lid edema, conjunctivitis, chemosis, anterior uveitis, and scleral reactions have been reported with high-dose administration of sulfanilamide. The observed reactions appear to be analogous to systemic hypersensitivity reactions, such as urticaria and edema, seen in some patients who are allergic to sulfonamides. Several cases of Stevens-Johnson syndrome have been reported in patients of Japanese or Korean descent who were given oral methazolamide, a sulfonamide used to decrease IOP. Stevens-Johnson syndrome tends to show acute ocular involvement in 69% of affected individuals. This is stratified into mild ocular involvement in 40%, moderate in 25%, and severe in 4%. Late complications can occur and are usually in the form of severe ocular surface disease and trichiasis.

## Gold Compounds

Chrysiasis, or gold deposition in various tissues of the body, can occur in the conjunctiva after gold injection for rheumatoid arthritis and appears as irregular brownish deposits in the cornea and superficial layers of the conjunctiva. No deposits are found in the skin of the lid. Conjunctival changes associated with gold treatment are generally benign. Discontinuation of therapy usually eliminates these effects.

## Tetracyclines

Tetracycline and its derivative, minocycline, are used for control of acne vulgaris. Conjunctival deposits similar to those seen in epinephrine-treated glaucoma patients have been observed in patients treated orally with these compounds. Dosages ranged from 250 to 1,500 mg daily of tetracycline and at least 100 mg daily of minocycline.

The deposits appear as dark brown to black granules in the palpebral conjunctiva, located nasally and temporally in the upper tarsus and temporally in the lower tarsus. The granules vary in size and are located in conjunctival cysts, surrounded by minute, gray-white, noncrystalline soft spots. Under UV radiation microscopy, the brown pigment concentrations give a yellow fluorescence characteristic of tetracycline. Along with pigment, calcium is also present in the cysts. It has been hypothesized that either tetracycline or its metabolites form an insoluble chelation complex that results in the pigmentation. Large numbers of patients have received these drugs for prolonged periods for acne, and these findings are rarely reported.

## Miscellaneous Drugs Affecting the Conjunctiva and Lids

A variety of other systemic drugs can cause irritative or allergic reactions in the conjunctiva or lids. The bisphosphonates, pamidronate, and others have been reported to

cause conjunctivitis as well as eyelid and periorbital edema. Corticosteroids have been noted to cause subconjunctival hemorrhage, eyelid edema, and ptosis. Conjunctival hyperemia and chemosis is a rare OADR of barbiturates. Dermatitis, lid swelling, and ptosis have also been related to long-term barbiturate use. The reaction can persist for months after the drug is discontinued. Patients taking niacin for hyperlipidemia have shown a higher incidence of lid edema than a similar group not taking niacin.

Salicylates may cause allergic conjunctivitis, which may be associated with urticaria of the lids. Subconjunctival hemorrhage has been reported in association with high-dose use of aspirin and oral anticoagulant therapy with warfarin. Chloroquine has been reported to cause ptosis, and phenytoin may cause chronic conjunctivitis. Drugs of abuse, such as marijuana, may lead to conjunctival injection, sometimes with eyelid edema. Although reported rarely, cocaine abuse during pregnancy has been associated with a prolonged and vision-threatening eyelid edema in newborn infants.

High-dose therapy with certain chemotherapeutic agents, including cytosine arabinoside, cyclophosphamide, methotrexate, and 5-fluorouracil, has been implicated in conjunctivitis. However, it appears that low-dose therapy with the anticancer agent tamoxifen is infrequently associated with anterior segment toxicity.

## DRUGS AFFECTING THE LACRIMAL SYSTEM

Human lacrimal fluid consists of a combination of secretions from the lacrimal gland, meibomian glands, goblet cells of the conjunctiva, and accessory lacrimal glands. Aqueous tear secretion from the lacrimal gland is controlled by the autonomic nervous system. The lacrimal gland is innervated by cholinergic fibers from the seventh cranial nerve as well as by adrenergic fibers from the pericarotid plexus. Chemically, the tears are 98.2% water and 1.8% solids. Thus, drugs that directly or indirectly affect the autonomic nervous system may cause hypersecretion or, more commonly, reduced secretions, leading to lacrimal keratoconjunctivitis, or "dry eye."

Several classes of drugs can affect aqueous tear secretion, influence tear constituents, or appear in the tears after systemic administration. Patients complaining of watery or dry eyes, eye infections, or uncomfortable contact lens wear could be exhibiting symptoms relating to actions on the tears from a variety of prescription and over-the-counter drugs.

Drugs reported to affect aqueous tear secretion are listed in Table 35-6. Among the agents that frequently reduce tear secretion are the anticholinergics and antihistamines. These classes of drugs are also present in numerous over-the-counter products such as sedatives, sleep aids, cold preparations, antidiarrheals, and nasal decongestants.

**Table 35-6**  
Drugs That Can Affect Aqueous Tear Secretion

Drug Class	Example
<b>Agents Decreasing Aqueous Tears</b>	
Antimuscarinic agents	Atropine, scopolamine
Stimulants	Methylphenidate, dextroamphetamine
Antihistaminic agents	Chlorpheniramine, brompheniramine, diphenhydramine
Vitamin A analogues	Isotretinoin, etretinate
Vitamins	Niacin
$\beta$ -Adrenoceptor blocking agents	Atenolol, practolol, propranolol, timolol,
Phenothiazines	Chlorpromazine, thioridazine
Diuretic agents	Hydrochlorothiazide
Antianxiety agents	Chlordiazepoxide, diazepam
Antidepressant drugs	Amitriptyline, nortriptyline, doxepin, imipramine Also, fluoxetine and other selective serotonin reuptake inhibitors
Hormone therapies	Oral contraceptives, hormone replacement therapy
Chemotherapeutic agents	Methotrexate, carmustine
<b>Agents Increasing Aqueous Tears</b>	
Adrenoceptor agonists	Ephedrine
Cholinergic agonists	Pilocarpine, cevimeline
Antihypertensive agents	Clonidine, reserpine, hydralazine
Antineoplastic agents	5-Fluorouracil

### Drugs That Decrease Aqueous Tears

The number of drugs known to decrease the aqueous tears and cause symptoms or signs of dry eye and/or ocular surface disease is too extensive to list. Instead, the following categories of drug effects are listed as the most common examples.

#### Antimuscarinic Agents

Dryness of mucous membranes is a common side effect of anticholinergic drug use and is due to dose-dependent inhibition of glandular secretion. In one study, oral administration of atropine caused tear secretion to fall from 15 to 3 mL/min. A similar dose of atropine given subcutaneously gave a nearly 50% reduction in lacrimal secretion. Scopolamine at a dose of 1 to 2 mg orally reduced tear secretion from 5 to 0.8 mL/min. Atropine combined with diphenoxylate (Lomotil) has been reported to cause severe keratoconjunctivitis sicca in susceptible individuals.

#### H<sub>1</sub> Antihistamines

Agents blocking H<sub>1</sub> receptor types are commonly used to treat symptoms associated with colds, hay fever, and other

allergies and to prevent motion sickness. In addition to receptor-blocking effects, H<sub>1</sub> antihistamines have varying degrees of anticholinergic actions, including the ability to alter tear film integrity. A significant reduction in tear flow was observed when 4 mg of chlorpheniramine maleate was administered daily to a group of young volunteers. Ocular dryness is less of a problem with the newer generation nonsedating antihistamines, such as loratadine and fexofenadine. Systemic use of antihistamines can aggravate existing keratitis sicca.

#### Isotretinoin

Dry eye symptoms and significant ocular surface disease frequently occur in patients taking isotretinoin. The associated symptoms may be accompanied by blepharoconjunctivitis. The presence of isotretinoin in tear fluid decreases stability (and tear break-up time) of the lipid layer of the tear film but may also cause a decrease in aqueous production, leading to ocular surface dryness. These effects could be responsible for the dry eye symptoms, contact lens intolerance, superficial punctate keratitis, and conjunctival irritation accompanying isotretinoin therapy. Use of artificial tear preparations may help to alleviate the associated discomfort.

#### $\beta$ -Adrenoceptor Blocking Agents

Drugs classified as  $\beta$ -adrenoceptor blocking agents are important in the treatment of systemic hypertension, ischemic heart disease, cardiac arrhythmias, and migraine headache. Reduced tear secretion is a reported side effect of oral beta-blocking drugs. Although most of the reported cases deal with practolol, other beta-blockers, such as propranolol and timolol, have also been implicated in dry eye syndrome. Ocular side effects of practolol have been described as an oculomucocutaneous syndrome in which patients suffer from symptomatic lesions of the outer eye. Because the ocular side effects of practolol can be so serious, this drug is no longer marketed for clinical use. Atenolol, metoprolol, oxprenolol, and pindolol have been implicated as causative agents in dry eye symptoms.

#### Oral Contraceptives and Hormone Replacement Therapy

In addition to birth control, oral contraceptives are used for many conditions (dysmenorrhea, amenorrhea, menopausal symptoms, uterine bleeding). These agents have been reported to cause reduced tear production and problems associated with contact lens wear. The literature, however, is generally devoid of well-documented studies showing a definite cause-and-effect relationship. Among patients who wear hydroxyethyl methacrylate contact lenses, symptoms of dryness and irritation are more likely to occur in those who use oral contraceptives than in nonusers of these medications. A significant decrease in goblet-cell count was also noted in subjects using oral contraceptives, suggesting a likely reproductive

hormonal influence on conjunctival goblet-cell count. A study of various sex hormones in patients with Sjögren's syndrome found an androgenic deficiency.

Estrogenic and androgenic receptors on the corneal and conjunctival cells and meibomian glands are involved in ocular surface homeostasis. Chronic inflammation in ocular surface dryness is more common in women and increases in both genders with age. An imbalance in estrogens and androgens appears to worsen the disease and symptoms in postmenopausal women, and the incidence of dry eye increases with duration of menopause and use of hormone replacement therapy. Dryness was measured by Schirmer scores in three groups of women on hormone replacement therapy, and these scores worsened in a 1-year follow-up interval in all groups. The most significant decrease among three groups on hormone replacement therapy was in the estrogen-only group compared with combinations of estrogen with progesterone alone or progesterone and androgens.

Women who are taking or considering hormone replacement therapy should be informed of the potential increased risk of dry eye syndrome with this therapy. Women on oral contraceptives who complain of dry eye or in whom ocular surface disease is noted should be advised of the potential causative aspects of their medication. In either case, therapies for dry eye are usually based on topical administration of tear substitutes, lid treatments, environmental modification, and immunomodulatory agents for inflammatory-related ocular surface disease. Hormone-based eyedrops are being studied with respect to targeting postmenopausal women with dry eye.

#### Miscellaneous Agents Causing Decreased Tears

Other drugs with possible anticholinergic actions, such as phenothiazines, anti-anxiety agents, tricyclic antidepressants, and niacin, have been associated with dry eye syndromes. Diuretics such as hydrochlorothiazide and chemotherapeutic agents such as carmustine and mitomycin can also cause both qualitative and quantitative changes in the tear film. Many drugs can have ocular surface drying effects, including stimulant drugs for attention deficit and hyperactivity disorder and most antidepressant medications.

#### Management of Aqueous Deficiencies

A good drug history is essential for every patient to determine if the drugs taken fit into the categories of agents that cause dry eye. As with many other symptomatic but not life- or vision-threatening adverse effects, the risks and benefits of the drug must be weighed against the patient's symptoms and ocular surface signs and considerations made to both ocular surface therapies as well as drug dosage reduction or discontinuation. Regardless of the cause of the deficiency, management of the symptoms and ocular surface signs is important. Guidelines for treatment are discussed in Chapters 14 and 24.

#### Drugs That Increase Aqueous Tears

Several studies indicate that systemic administration of certain cholinergic, adrenergic, and antihypertensive agents may stimulate lacrimation (see Table 35-6). Oral pilocarpine has been reported to improve radiotherapy-induced dry eye signs and symptoms and can improve symptoms in patients with Sjögren's syndrome. Neostigmine, given subcutaneously or intramuscularly, also induces lacrimation. Among the adrenoceptor agonists, ephedrine has been reported to increase tear production. Several antihypertensive agents can increase tear production, including reserpine, hydralazine, and diazoxide, and at therapeutic dosages can induce lacrimation in humans. There is some evidence that the oral immunosuppressant cyclosporine can significantly enhance tear flow in kidney transplant recipients.

A pyrimidine analogue that inhibits DNA synthesis, 5-fluorouracil is commonly used to treat carcinomas of the breast, gastrointestinal tract, and genitourinary tract. Excessive tearing associated with fluorouracil therapy can occur due to punctal and canalicular stenosis and fibrosis. Long-term excretion of the drug into tears may cause inflammation, scarring, and stenosis of the lacrimal drainage system, leading to permanent epiphora. The excessive lacrimation usually resolves spontaneously within 1 to 2 weeks after drug therapy is discontinued. Topically applied antibiotics and steroids may help prevent complete punctal or canalicular stenosis, but in patients with persisting epiphora, surgical intervention may be necessary.

Long-term use of marijuana has been reported to increase tear secretion. Tear samples have shown the presence of small amounts of  $\Delta^9$ -tetrahydrocannabinol. Some authors, however, have reported a reduction in tear secretion after marijuana use, along with a subjective feeling of dryness.

#### Management of Tearing

If the risk-to-benefit ratio for treating a concomitant systemic condition does not allow for withdrawal of the drug causing the tearing, appropriate management of tearing depends on whether there is an increase in secretion or a blockage of drainage.

#### DRUGS AFFECTING THE EPISCLERA, SCLERA, AND UVEA

Until recently, very few systemic drug therapies were implicated in ocular adverse effects in the episclera, sclera, and uvea. Topical ocular medications such as beta-blockers, latanoprost, and corticosteroids as well as other topical ocular medications have been associated with uveitis.

Some systemic therapeutic agents implicated in "probable" uveitis include cidofovir, pamidronic acid, and sulfonamides. Other medications, such as cobalt, diethyl-carbamazepine, interleukins-3 and -6, oral contraceptives,



**Table 35-7**  
Drugs That Can Affect the Episclera, Sclera, and Uvea

Drug	Adverse Effect
Bisphosphonates: pamidronate and alendronic acid	“Probable” episcleritis, scleritis, uveitis (also, conjunctivitis, blurred vision, ocular pain, photophobia)
Rifabutin	Uveitis (“certain”)
Cidofovir	Uveitis (vs. immune-recovery uveitis) (“probable”)
Tumor necrosis factor- $\alpha$ : etanercept	Uveitis (“possible”)
Sulfonamides	Uveitis (“probable”)
Corticosteroids	Blue sclera, uveitis (“possible”)
Retinoids: isotretinoin	Iritis (“unclassifiable”)
$\alpha_1$ -Adrenoceptor antagonists: tamsulosin	Intraoperative floppy iris syndrome
Tetracyclines: tetracycline, minocycline, and doxycycline	Pigmented conjunctival inclusion cysts with tetracycline; bluish discoloration of sclera with minocycline

quinidine, streptokinase, and sulfonamides, have a “possible” causal relationship to uveitis. The treatment of uveitis depends on the likelihood that the reaction is causal to the drug therapy. Drug-induced uveitis is almost always reversible within weeks of discontinuation of the drug and treatment of the inflammation. Some OADR related to the episclera, sclera, and uvea are listed in Table 35-7.

### Bisphosphonates

This class of drugs is used to treat hypercalcemia in osteolytic bone cancer and metastasis in breast cancer, multiple myeloma, and Paget disease of the bone. It is used more frequently to inhibit bone resorption in postmenopausal women and therefore has the potential for widespread effects despite a relatively low risk of ADRs.

The main drugs in this category shown to cause OADR have been pamidronate, alendronic acid, and risedronate, although etidronate and sodium clodronate have also been implicated to a lesser degree. As of 2003, 438 ocular adverse reactions had been reported to the National Registry. These OADR were considered to be “certain” by the WHO classification and included inflammation of the conjunctiva, episclera, sclera, and uvea as well as reduced vision, eye pain, and photophobia. Scleritis is the most vision-threatening ADR of this class of drugs and occurred within 48 hours in 82% of the 17 patients. “Possible” ADRs associated with these drugs included cranial nerve palsy and retrobulbar neuritis (see Appendix 35-1).

### Etiology

These drugs have been shown to stimulate the release of cytokines (interleukin-1 and -6) that may stimulate lymphocytic proliferation and enhance immune complex disease. It is not clear why these particular tissues of the eye are targeted because the degree of inflammation seems unrelated to the dose of the drug, the route of

administration, or even to the relative activity of the disease being treated.

### Management

Anterior segment inflammation may be treated without cessation of the bisphosphonate, but deeper inflammation of the uvea and sclera may require discontinuation of the systemic therapy.

### Rifabutin

Rifabutin is a semisynthetic rifamycin used to treat patients infected with human immunodeficiency virus as prophylaxis against *Mycobacterium avium* complex infections. Rifampin antibodies have been found to circulate and adhere to cells, so that when introduced to rifampin, the antigen-antibody complexes induce an inflammatory reaction. Rifabutin-associated uveitis has been reported in patients who were also taking fluconazole, which may have increased the bioavailability of rifabutin. Discontinuation of rifabutin and initiation of topical steroid therapy result in clinical improvement. The high prevalence of uveitis with rifabutin (including a large number of bilateral cases), increasing inflammation with dose increases, and improvement on dechallenge and exclusion of other possible causes strongly implicate rifabutin as having a “certain” causality with uveitis.

Prophylactic administration of rifabutin to human immunodeficiency virus-infected children has resulted in non-sight-threatening corneal endothelial deposits. The deposits are bilateral, are initially peripheral, are stellate shaped, are not associated with uveitis, and appear to increase in number with continued administration of rifabutin.

### Tamsulosin

Intraoperative floppy iris syndrome (IFIS) was first formally documented in early 2005. It is characterized by a

triad of signs noted during intraocular surgery: (1) a flaccid iris stroma that billows on ocular irrigation, (2) a tendency of the iris to prolapse toward the side-port incisions and the phacoemulsification tip, and (3) progressive intraoperative miosis despite conventional pharmacologic measures to maintain pupillary dilation (cyclopentolate, phenylephrine, and NSAIDs). Though a floppy iris is noted on occasion during cataract surgery, this full syndrome was first documented and associated with systemic administration of the  $\alpha_{1a}$ -adrenoceptor antagonist, tamsulosin (Flomax).

The  $\alpha_{1a}$ - (and  $\alpha_{1d}$ -) selective adrenoceptor antagonist, tamsulosin (Flomax), is used to relax bladder and prostatic smooth muscle to improve urinary flow, usually in the treatment of benign prostatic hypertrophy. Other  $\alpha_1$ -adrenoceptor antagonists include the following nonsubtype selective agents, which also block  $\alpha_{1b}$  receptors: alfuzosin (Uroxatral), doxazosin (Cardura), and terazosin (Hytrin). These agents show more cardiovascular adverse effects and have been used for the treatment of hypertension. Each of these agents is effective in competitive antagonism, causing sympathetically mediated iris dilator relaxation. The prevalence of IFIS has been documented to be 0.7% to 2% of the general population; however, there is a high incidence of benign prostatic hypertrophy and lower urinary tract symptoms in males over age 50 (50%) and even more so for males over age 85 (90%), which suggests that the prevalence reported may be underestimated. IFIS has been strongly associated with tamsulosin, but 45% of eyes of patients taking doxazosin (Cardura) also demonstrate the characteristics of IFIS.

### Etiology

Pupillary miosis occurs because tamsulosin blocks the iris dilator muscle, and this constant blockade is postulated to cause a form of disuse atrophy of the dilator smooth muscle. This may explain why some patients no longer taking the drug can still exhibit IFIS. Pupil dilation during cataract surgery is essential not only to visualize the full lens to enable its efficient and total removal, but also to minimize the risk of other complications such as rupture of the posterior capsule and the prevention of tears when iris retraction or stretching becomes necessary. Though poor pupillary dilation is common in other conditions, the pupillary miosis associated with tamsulosin is different in that the pupillary margin remains elastic, such that normal mechanical stretching of the iris is ineffective.

### Management

All patients should be screened before intraocular surgery for a history or current use of tamsulosin. Some sources have suggested that this and other  $\alpha_1$ -antagonists should be withdrawn before surgery, the term of which depends on monitoring of blood pressure and/or recurrence of urinary symptoms. Various interventions have been suggested for IFIS, such as alterations in surgical technique and intracameral injections of various agents (phenylephrine, atropine, and epinephrine).

### Etanercept

Etanercept and infliximab are tumor necrosis factor- $\alpha$  antagonists used on their own or in combination with other medications to reduce the pain and swelling associated with rheumatoid, juvenile rheumatoid, and psoriatic arthritis and ankylosing spondylitis. Recent evidence suggests that infliximab may have efficacy in treating ocular inflammation associated with these conditions, as well as Crohn's disease, and idiopathic scleritis, uveitis, bird-shot retinochoroiditis, and uveitic cystoid macular edema. These medications are administered as biweekly injections and are used to moderate the immune system by blocking the activity of tumor necrosis factor, a substance in the body that causes activation of immune response and plays a significant role in chronic inflammation. Risk of infection is an indication (usually temporary) for discontinuation of injections due to the reduced immune response to eliminate the infectious organism. Reactivation of tuberculosis infection is one adverse effect of its use, and one case of reactivation of tuberculosis-related chronic unilateral granulomatous panuveitis has been reported in a woman with rheumatoid arthritis. Similarly, some patients on etanercept developed scleritis, new-onset uveitis, and optic neuritis.

There is considerable discussion about whether ocular inflammation is paradoxically a potential adverse event of etanercept in either previously inflamed or previously uninfamed eyes. It is as yet unclear whether etanercept may induce new-onset uveitis or may prevent uveitis, although flares of uveitis have recently been shown to occur less than half as often in tumor necrosis factor- $\alpha$ -treated patients as placebo-treated control subjects. However, it seems clear that, because of a different mechanism of action, infliximab is more effective at treating certain types of ocular inflammation.

### Cidofovir

The use of cidofovir is a primary risk factor in the subsequent development of immune recovery uveitis, a relatively new clinical entity introduced with the widespread use of highly active antiretroviral therapy. Patients who have responded to highly active antiretroviral therapy have an increase in CD4+ counts, allowing withdrawal of cytomegalovirus maintenance therapy. Up to 40% of immune-recovered patients may have immune recovery uveitis, which may consist of signs of inflammation such as uveitis, vitritis, macular edema, or epiretinal membrane formation. Eyes with immune recovery uveitis have a high risk of additional morbidity over and above that seen with cytomegalovirus retinitis, with several-fold higher risk of cystoid macular edema and epiretinal membrane. On average, patients developed immune recovery uveitis 3 months after discontinuing anticytomegalovirus therapy. Large cytomegalovirus lesions and use of intravitreal cidofovir are risk factors for immune recovery uveitis.

Ongoing treatment of healed cytomegalovirus retinitis after immune recovery does not appear to protect against the development of immune recovery uveitis. The risk is so significant that some recommend that other antiviral treatments for cytomegalovirus retinitis be substituted for cidofovir.

### Tetracyclines

Tetracycline and its derivative, minocycline, are used for control of acne vulgaris. Minocycline therapy can cause a blue-gray discoloration of the sclera. The discoloration usually presents in a 3- to 5-mm band in the paralimbal area or in the temporal sclera within the interpalpebral fissure. Scleral pigmentation is usually associated with various degrees of pigmentary changes elsewhere, such as skin, teeth, and fingernails. Because no scleral biopsy has been performed, the precise nature of the lesions is unknown. The sooner the pigmentary changes are recognized and the drug discontinued, the greater the likelihood of resolution. The pigmentation may slowly resolve over several years, or it may be permanent.

## DRUGS AFFECTING THE PUPIL

Pupil size and function can be affected by peripheral autonomic action and by centrally initiated impulses. The iris is an excellent indicator of autonomic activity because of the delicate balance between adrenergic and cholinergic innervation to the iris dilator and iris sphincter muscles, respectively. By acting directly on these muscles, both sympathetic and parasympathetic agents can influence pupil size and activity.

### Drugs Causing Mydriasis

Anticholinergics, central nervous system stimulants and depressants, antihistamines, and phenothiazines can all cause mydriasis (Box 35-1).

#### Anticholinergics

Drugs with anticholinergic effects, such as atropine or related compounds, can cause significant mydriasis. Acute angle-closure glaucoma has been caused by administration of systemic atropine to treat bradycardia during angioplasty for an acute myocardial infarction. The anticholinergic effects of paroxetine, a selective serotonin reuptake inhibitor used as an antidepressant, have also led to angle-closure glaucoma. Nebulized ipratropium bromide, an anticholinergic agent, is often used for the emergency treatment of acute bronchospasm in both adults and children. Mydriasis and angle-closure glaucoma are believed to result from direct inoculation into the eye after leakage of drug from the face mask used for drug delivery.

Scopolamine, a semisynthetic derivative of atropine, is marketed as a transdermal delivery system (Transderm Scop) to prevent motion sickness. The device, which is

### Box 35-1 Drugs That Can Cause Mydriasis or Miosis

Mydriasis	Miosis
Anticholinergic agents	Opiates: heroin, codeine, morphine
CNS stimulants: amphetamines, methylphenidate, cocaine	Anticholinesterases: neostigmine
CNS depressants: barbiturates, antianxiety agents	
Antihistamines	
Phenothiazines	

CNS = central nervous system

placed behind the ear, consists of a 2.5-cm disk containing 1.5 mg of scopolamine in a polymeric gel. Approximately 0.5 mg of drug is released into systemic circulation over a 3-day period. Both mydriasis and reduced pupillary light response can occur when this device is used for several days. Direct contamination by rubbing the eye with the fingers after application of the patch to the skin or during wear can cause the observed pupillary dilation. Mydriasis can also occur when scopolamine is mixed with heroin. In addition to heroin-related central nervous system effects, anticholinergic manifestations include tachycardia, mild hypertension, dilated pupils, dry skin and mucous membranes, and diminished or absent bowel sounds. Similar toxicity can follow use of intranasal cocaine laced with atropine.

#### Central Nervous System Stimulants

Central nervous system stimulants include agents such as the amphetamines (Dexedrine) and methylphenidate hydrochloride (Ritalin), used to elevate mood, suppress appetite, and control hyperkinetic disorders in children. Other examples include the illegal drugs methamphetamine and cocaine. The mechanism of action of these drugs is to augment actions of the adrenergic nervous system.

High-dose long-term use of amphetamines has been observed to cause mydriasis and decreased pupillary light response. In patients with narrow anterior chamber angles, the mydriasis can precipitate an attack of acute or subacute angle-closure glaucoma. Angle-closure glaucoma can also be associated with intranasal cocaine abuse. The negative pressure generated by sniffing cocaine may allow retrograde ocular delivery via the nasolacrimal duct. Alternatively, cocaine could be absorbed across the nasal mucosa, and the systemically absorbed drug could cause mydriasis and potential angle closure due to the adrenergic agonist properties of the drug.

### Central Nervous System Depressants

Central nervous system depressants include the barbiturates, such as phenobarbital, and the antianxiety drugs, including diazepam (Valium), chlordiazepoxide (Librium), oxazepam (Serax), flurazepam hydrochloride (Dalmane), and lorazepam (Ativan). The benzodiazepines, including diazepam, occasionally cause mydriasis, presumably because of their anticholinergic side effects.

Barbiturates have little effect on the pupils. However, in acute or chronic poisoning a sluggish pupillary light reaction is common.

### Miscellaneous Drugs Causing Mydriasis

Other drugs with potential to cause mydriasis include the antihistamines and antipsychotic agents. Both classes of drugs have anticholinergic properties. Pupillary dilation has also been observed on exposure to certain plants. The dried pods of the jimson weed (*Datura stramonium*) are often used for floral arrangements during the winter. Children have been known to consume the “berries,” which contain significant concentrations of belladonna alkaloids. Systemic side effects are those typical of anticholinergic poisoning and include bilaterally dilated pupils.

### Drugs Causing Miosis

Opiates such as heroin, morphine, and codeine and anticholinesterase agents can cause miosis (see Box 35-1).

#### Opiates

Heroin, morphine, and codeine can constrict the pupil. Moreover, the pupillary light response is enhanced. This response appears to be due to action on the central nervous system, possibly on the visceral nucleus of the oculomotor nuclear complex. Note, however, that either heroin or cocaine abuse can be associated with mydriasis if the drug is mixed with scopolamine or atropine.

#### Anticholinesterase Agents

Systemic absorption of agents that inhibit the cholinesterase enzymes can result in miosis. Such substances are present in most insecticides and many toxic nerve gases. Toxic episodes involving the pupil have occurred in workers in fields being dusted with insecticides from an airplane. The miotic pupils of affected patients may not return to normal until 30 to 45 days after exposure to the toxic agent.

## DRUGS AFFECTING EXTRAOCULAR MUSCLES AND EYE MOVEMENTS

Drugs affecting the autonomic nervous system or central vestibular system or causing extrapyramidal effects have been associated with ocular manifestations such as nystagmus, diplopia, extraocular muscle palsy, and oculogyric crisis. Table 35-8 lists drugs that can affect extraocular muscles.

**Table 35-8**

Drugs That Can Affect Extraocular Muscle Movements

Drug	Adverse Effect
Salicylates	Nystagmus
Phenytoin	Nystagmus
Antihistamines	Nystagmus
Gold salts	Nystagmus
Barbiturates	Nystagmus
Lithium	Nystagmus
Carbamazepine	Nystagmus
Phenothiazines	Diplopia
Antianxiety agents	Diplopia
Antidepressants	Diplopia
Cetirizine	Oculogyric crisis
Alcohol	Impairment of version movements

Various classes of drugs have been implicated in causing nystagmus, including salicylates, phenytoin (Dilantin), antihistamines, gold, alcohol, and barbiturates. The anti-convulsant agent carbamazepine has been associated with downbeat nystagmus in a dose-related manner. Many drugs that affect central nervous system activity can result in diplopia. Included are the phenothiazines, antianxiety agents, and antidepressants.

### Lithium

The use of lithium in bipolar affective disorder has been associated with various neurologic symptoms, including nystagmus.

#### Clinical Signs and Symptoms

The patient usually presents with complaints of blurred vision, particularly in lateral gaze. Electrooculogram (EOG) recordings show a jerk nystagmus, present in both primary position and in down-gaze. The nystagmus is usually unaffected by head position, head velocity, or convergence. Saccadic eye movements are clinically normal, serum chemistry analysis is usually normal, and serum lithium levels are within the recommended therapeutic ranges. The nystagmus may not resolve with reduction of drug dosage or cessation of drug use. Prolonged drug withdrawal, up to 6 months or even years, may be necessary to produce improvement.

#### Management

Because downbeat nystagmus has neurologic significance and may be related to a variety of metabolic or drug-related causes, a careful medical history and communication with the prescribing physician are essential. Patients on long-term lithium therapy should have at least yearly ocular examinations.

### Cetirizine

Cetirizine is a potent second-generation H<sub>1</sub> receptor antagonist that is effective in the treatment of allergic

rhinitis, chronic urticaria, and pollen-induced asthma. Unlike many traditional antihistamines, it does not cause drowsiness or anticholinergic side effects. Tonic eye and lid elevation with neck hyperextension characterizes oculogyric crisis. Although oculogyric crisis is seen most commonly in association with phenothiazine toxicity, 72 drugs have been reported as possibly causing oculogyric crisis. Nine cases of oculogyric crisis due to cetirizine therapy were reported to the National Registry, with eight occurring in the pediatric age group. Two patients in this series were using other antihistamines that could have caused an additive effect. Dosage ranged from 5 to 10 mg orally, and time to onset of symptoms ranged from 3 to 184 days. Because six cases of oculogyric crisis had positive rechallenge data, the WHO category of the relationship of cetirizine as a cause of oculogyric crisis is “certain.”

### Etiology

The etiology is thought to be similar to that seen with phenothiazine toxicity such that an imbalance of dopamine and cholinergic blockade causes the dystonia.

### Management

Cessation of the drug causes rapid resolution of the crisis.

### Alcohol

Alcohol clearly affects eye movement. Both smooth pursuit movements and saccades are impaired when blood ethanol concentrations reach the range of 60 to 100 mg/dl. There is a direct linear relationship between blood alcohol concentration and a reduction in smooth-pursuit movement velocity. At a blood ethanol concentration of 80 mg/dl, the capacity of the eyes to track objects moving across the visual fields is impaired by 25%.

The fact that alcohol can affect eye movement ability has been used to devise a test known as the *alcohol gaze nystagmus test*. This procedure was developed to augment the traditional field evaluation of suspected drunk drivers by law enforcement officials. The test involves the observation of ocular version movements, end-point nystagmus, and angle of lateral deviation at which the nystagmoid movements begin. When administered and evaluated properly, the test can help to correctly identify approximately 80% of drivers with blood alcohol levels of 0.10% or higher.

## DRUGS CAUSING MYOPIA AND ACCOMMODATIVE CHANGES

Numerous reports have described patients with acute-onset of myopia after use of various oral medications or drugs applied as vaginal suppositories or creams. In most cases the amount of drug-induced myopia has been slight, but in some cases myopia exceeding 5.00D has occurred. Commonly prescribed drugs that are

### Box 35-2 Drugs That Can Cause Myopia or Cycloplegia

Myopia	Cycloplegia
Sulfonamides	Chloroquine
Diuretics	Phenothiazines
Carbonic anhydrase inhibitors	Anticholinergics
Isotretinoin	Drugs with anticholinergic side effects:
Topiramate (sulfa-containing)	Antihistamines
	Antianxiety agents
	Tricyclic antidepressants

widely recognized to cause myopia include sulfonamides, diuretics, and carbonic anhydrase inhibitors (Box 35.2). Isotretinoin use has also been associated with acute myopia. The reduction in acuity was reversed on discontinuation of the drug and recurred on subsequent rechallenge. In most instances the myopia is immediate in onset after administration of the drug and subsides within days or weeks after withdrawal of the medication.

### Sulfonamides and Diuretics

#### Clinical Signs and Symptoms

Among the drugs most commonly implicated are the sulfonamides. Two cases of transient myopia associated with oral sulfonamides were described in which there was reduced accommodation, shallow anterior chamber angles, and moderate mydriasis. Chemosis occurred in one case. A 23-year-old woman was described who had 4.00D of increased myopia in one eye and 3.00D of increase in the fellow eye after the use of oral sulfonamides. Vaginal absorption of sulfonamides can also lead to myopia. A patient was reported with 1.00 to 1.50D of myopia after use of a vaginal sulfonamide suppository and another patient with 7.00D of induced myopia after use of a sulfonamide vaginal cream.

Diuretic agents can cause myopia. Transient myopia was associated with perimacular edema apparently caused from the use of 100 mg of hydrochlorothiazide. The drug induced approximately 3.00D of myopia, which resolved within 3 days. Carbonic anhydrase inhibitors are also known to cause myopia. A case of transient myopia associated with acetazolamide was reported, in which there was also narrowing of the anterior chamber angle.

#### Etiology

In general, transient myopia results from edema of the ciliary body, lenticular edema, or accommodative spasm. Topically administered cholinergic agonists are well

known to cause myopia by stimulating accommodation, but systemically administered cholinergic agents are implicated infrequently as a cause of myopia. Most drugs that cause myopia are thought to do so by causing a forward displacement of the lens as a result of allergic ciliary body edema and rotation. Lens thickening and anterior movement with a reduction of the anterior chamber depth is the mechanism of drug-induced transient myopia, with or without choroidal detachment (Figure 35-7). The ciliary body edema, occasionally associated with retinal edema, has led to the speculation that sulfonamide-induced myopia may be related to a hypersensitivity reaction. Choroidal detachment, if present, causes forward displacement of the lens-iris diaphragm, resulting in increased myopia and anterior chamber shallowing, with potential angle-closure glaucoma.

Because carbonic anhydrase inhibitors are sulfonamide derivatives, the mechanism for carbonic anhydrase inhibitor-induced myopia is expected to be similar to that associated with sulfonamides. Indeed, it has been speculated that myopia resulting from acetazolamide use is due to a hypersensitivity reaction that leads to ciliary body edema. The instillation of cycloplegics has little influence on the refractive error, which suggests that the mechanism is unrelated to ciliary spasm.

### Management

Patients with well-documented acute myopia should be evaluated carefully to eliminate other causes of the refractive change. Intumescence of the lens associated with nuclear sclerosis is a common cause of increasing myopia and is often associated with somewhat reduced best-corrected visual acuity. After eliminating these other factors, investigate the patient's drug therapy as a cause of the myopia by reducing or discontinuing the drug under suspicion. This should be done only in consultation with the patient's primary physician. When the offending

agent is reduced or discontinued, the refractive error change should subside within several days or several weeks.

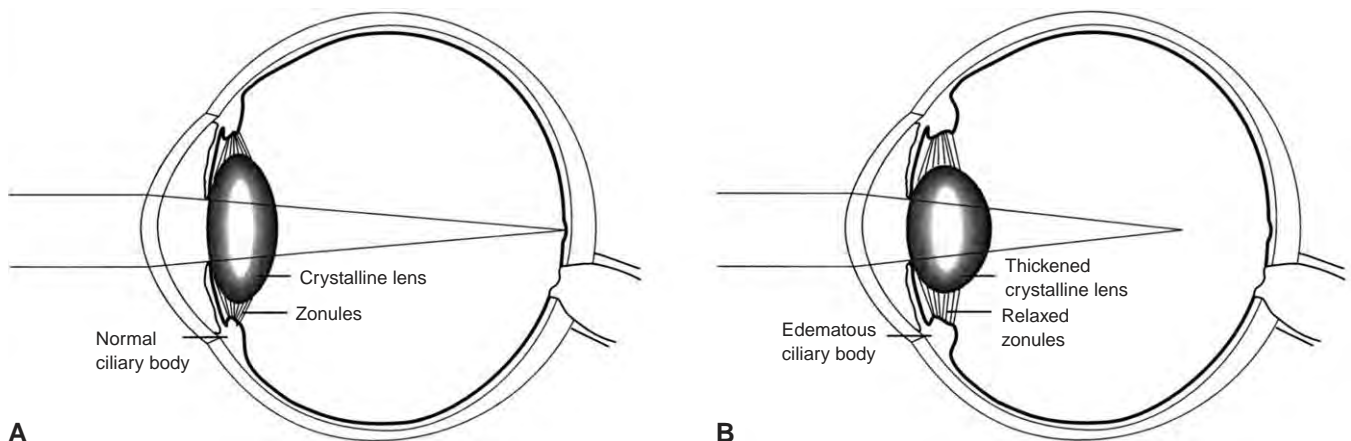
### Topiramate

Topiramate is an antiepileptic medication also used in an off-label capacity to treat migraine headaches and bipolar disorders. Acute-onset myopia with topiramate use occurs due to a different mechanism than other causes of drug-induced myopia. The lens-iris diaphragm moves forward and the anterior chamber shallows due to choroidal effusion, resulting in acute myopia (up to 8.75D) and angle-closure glaucoma. Management consists of discontinuing the drug, with aggressive use of steroids and IOP-lowering agents.

### Drugs With Anticholinergic Effects

Some drugs administered systemically are well known to have mild anticholinergic properties or side effects. These drugs include antianxiety agents, antihistamines, and tricyclic antidepressants. Agents with strong anticholinergic effects include atropine and scopolamine. Although these drugs can dilate the pupil and can cause dry eye symptoms due to the peripheral effects on the parasympathetic nervous system, the cycloplegic effects are encountered less frequently in clinical practice. Sulfadiazine and disopyramide can cause paralysis of accommodation, but the drugs whose association with clinical cycloplegia is most well documented are the phenothiazines.

Transient disturbances of accommodation often occur in patients taking chlorpromazine and other phenothiazines. These effects are most likely due to the anticholinergic properties of the medication and are most pronounced when benztropine mesylate (Cogentin) is administered along with the phenothiazine. The visual symptoms may also be ascribed to reduced tearing and drying of the cornea, which causes blurred vision. In patients with



**Figure 35-7** Mechanism of drug-induced myopia. (A) Image on retina in normal eye. (B) Drug-induced ciliary body edema causes relaxation of zonules, which in turn causes thickening of crystalline lens and myopic shift of refractive error.

narrow anterior chamber angles, acute or subacute angle-closure glaucoma secondary to pupil dilation could also contribute to symptoms of blurred vision.

### Management

Because the cycloplegic effects are usually transient and related to drug dosage, symptoms of accommodative insufficiency can be managed by prescribing appropriate reading lenses during long-term drug therapy, or in consultation with the patient's physician, drug dosages may be reduced or the drug discontinued. The cycloplegic effects often abate when the dosage is reduced, and accommodation completely returns to pretreatment levels after drug therapy is discontinued.

## DRUGS AFFECTING INTRAOCULAR PRESSURE

Several classes of drugs may alter IOP by influencing either aqueous humor production or outflow (Box 35-3). Others have the potential to affect IOP by narrowing or occluding the angle. Pupillary block occurs only in susceptible individuals (usually small eyes, with hyperopia, steep corneal and lens curvatures, narrow angles, and in certain races) so that increasing IOP associated with the anticholinergic effects of medications affects only these select individuals.

### Anticholinergics

Some systemic agents may possess sufficient anticholinergic activity to produce mydriasis and a weak cycloplegic effect. These medications include antimuscarinic drugs, antihistamines, phenothiazines, and tricyclic antidepressants (Table 35-9).

### Clinical Signs and Symptoms

Systemic antimuscarinic agents, including atropine and scopolamine, can be administered in doses that could produce mild dilation of the pupil and accommodative paresis. The degree of mydriasis and decreased pupillary reactivity to light provide a clinical measure of antimuscarinic activity. Other commonly used systemic medications with antimuscarinic activity are the H<sub>1</sub> receptor antagonists.

Of the systemic antihistamines, the ethanolamines, including diphenhydramine, have significant antimuscarinic activity. In addition, the antipsychotic agents, particularly the phenothiazines such as thioridazine (Mellaril), have well-documented anticholinergic properties. Therapeutic doses of tricyclic antidepressants, like amitriptyline hydrochloride (Elavil) and imipramine (Tofranil), produce significant anticholinergic actions and thus have the potential for ocular side effects.

### Etiology

Systemic agents with anticholinergic effects may result in sufficient mydriasis to produce pupillary block and precipitate acute or subacute angle-closure glaucoma in patients with narrow anterior chamber angles. In addition, the weak cycloplegic effect may be sufficient to increase IOP in some open-angle glaucoma patients. Relaxation of the ciliary muscle may decrease traction on the trabecular meshwork (TM) and increase resistance to aqueous outflow, especially when relatively high doses of medication are used. The risk, however, of elevating IOP is small with systemically administered anticholinergic agents in normal doses, even in patients with narrow anterior chamber angles.

### Management

If symptoms or signs suggestive of acute or subacute angle-closure glaucoma develop, patients with narrow anterior chamber angles should have a prophylactic laser iridotomy to prevent pupillary block and subsequent angle-closure glaucoma. If acute angle-closure glaucoma occurs, the patient should be managed according to the guidelines described in Chapter 34. The offending drug should be withdrawn if medically possible. Accommodative paresis (cycloplegia) can be managed with reading lenses, as necessary, depending on the expected duration of treatment with the anticholinergic medication.

## Beta-Blockers

### Clinical Signs and Symptoms

Systemic beta-blockers are used extensively for the treatment of hypertension and other cardiovascular disorders. Of the available oral beta-blockers, atenolol, metoprolol, nadolol, pindolol, propranolol, and timolol have been documented to produce a dose-dependent reduction in IOP. The ocular hypotensive effect associated with systemically administered beta-blockers can be compared with that achieved with topically applied beta-blockers such as timolol. Although specific studies have not been conducted with most of the remaining systemic beta-blockers, these agents might also be expected to reduce IOP at clinically useful doses.

### Etiology

Like topical beta-blockers (see Chapter 10), systemic beta-blockers may decrease aqueous formation via an

### Box 35-3 Drugs That Alter Intraocular Pressure

Increased IOP	Decreased IOP
Antimuscarinic agents	Beta-blockers
Antihistamines	Cannabinoids
Phenothiazines	Cardiac glycosides
Tricyclic antidepressants	Ethyl alcohol
Corticosteroids	



**Table 35-9**  
Systemic Drugs With Anticholinergic Actions

Category	Agent	Dose Associated With Antimuscarinic Side Effects (mg)
Muscarinic antagonists	Atropine	≥0.5
H <sub>1</sub> receptor antagonists: ethanolamines	Diphenhydramine	25-50
	Dimenhydrinate	50-100
Tricyclic antidepressants	Amitriptyline	10-25
	Doxepin	10-25
	Imipramine	10-25
Antipsychotic agents: phenothiazines	Chlorpromazine	200-800
	Thioridazine	150-600

action linked to receptors (predominantly  $\beta_2$  receptors) on the nonpigmented ciliary epithelium. The reduction of IOP produced by systemic beta-blockers is linked with both the  $\beta$ -receptor selectivity and the dosage of the drug. Nonselective oral beta-blockers have been particularly effective ocular hypotensive agents. The degree of  $\beta$ -receptor blockade in the ciliary body from oral nonselective beta-blocker therapy appears to be nearly complete, because topical beta-blockers often produce little additional IOP reduction with concomitant administration.

### Management

The reduction in IOP associated with systemic beta-blocker therapy may confuse the diagnosis of open-angle glaucoma. Thus, patients exhibiting glaucomatous optic neuropathy may be diagnosed incorrectly as having normal tension glaucoma. If beta-blocker therapy is subsequently discontinued, these patients may develop substantially higher IOP. In addition, glaucoma patients taking systemic nonselective beta-blockers may not show any additional ocular hypotensive effect after administration of a topical nonselective beta-blocker. Patients receiving a  $\beta_1$ -selective oral agent, however, may show a further decrease in IOP with the concurrent use of a topical nonselective beta-blocker. To minimize ineffective topical therapy in these patients, a uniocular trial with a topical beta-blocker may be useful to determine its ocular hypotensive effect. Although many patients currently use oral beta-blockers for a variety of conditions, these agents are not approved for use as ocular hypotensive agents. Nevertheless, the ocular hypotensive activity of these agents may have a beneficial effect on IOP.

### Cardiac Glycosides

#### Clinical Signs and Symptoms

When administered systemically, cardiac glycosides reduce IOP in humans. Systemic digoxin therapy has been shown to reduce IOP by 14% in the glaucomatous human eye, and aqueous humor formation can be reduced by as much as 45% after several days of digoxin therapy.

### Etiology

The effect on IOP of the cardiac glycosides, primarily digitalis derivatives and ouabain, has been of interest for many years. The physiologic effects of these agents are produced by their ability to inhibit Na<sup>+</sup>K<sup>+</sup> adenosine triphosphatase, and a ouabain-sensitive Na<sup>+</sup>K<sup>+</sup> adenosine triphosphatase has been demonstrated in the ciliary epithelium. In the ciliary nonpigmented epithelium, as in other types of secretory epithelium, Na<sup>+</sup>K<sup>+</sup> adenosine triphosphatase is thought to be responsible for the active transport of sodium, a process necessary for aqueous secretion to occur.

### Management

Systemic administration of cardiac glycosides may reduce IOP to some degree in glaucomatous and nonglaucomatous eyes, but it is unlikely to produce adequate control of IOP when maximal medical therapy has failed to achieve this goal. In addition, cardiac glycosides have a low margin of safety and are frequently associated with toxicity. Gastrointestinal disturbances, fatigue, and visual complaints are among the most common side effects encountered with cardiac glycosides. Although all types of arrhythmias have been associated with cardiac glycoside toxicity, ventricular arrhythmias are of particular concern, because they may be life threatening due to decreased cardiac output. For this reason, systemic cardiac glycosides currently have no place in the treatment of glaucoma.

### Corticosteroids

Corticosteroid administration by systemic (oral or intravenous), topical (ophthalmic and cutaneous), injected (periocular and subcutaneous), and inhalation and possibly nasal routes can elevate IOP. In patients who are steroid responders, oral steroids produce approximately 60% the increase in IOP as compared with topical agents, most likely because of differences in achieved anterior chamber concentrations of the drug. Those with primary open-angle glaucoma respond to steroids at a rate of 46% to 92% compared with 18% to 36% of

the normal population. Patients noted to be at greater risk include those with increasing age, diabetes, high myopia, connective tissue diseases such as rheumatoid arthritis, and with a first-degree relative with open-angle glaucoma.

### Clinical Signs and Symptoms

Induction of ocular hypertension after corticosteroid administration depends on the specific drug, the dose, the route and frequency of administration, and the corticosteroid responsiveness of the patient. Generally, patients with elevated IOP are asymptomatic, so examination with applanation tonometry is the key to diagnosis. If the patient shows a steroid responsiveness, the onset of IOP elevations is not immediate but occurs after approximately 2 weeks of use. However, it can occur many weeks later, and this time to onset is generally longer for systemic steroids. In responsive patients the level of IOP rise with systemic steroids averages approximately 60% of that produced by topically applied steroids.

### Etiology

The varied and complex steroid-induced morphologic and biochemical changes in the TM have been studied extensively. The result of the various known processes is an increased resistance to aqueous humor outflow resulting in ocular hypertension and, if untreated, secondary open-angle glaucoma.

Steroid responsiveness is a complex pathophysiologic process involving a large number of factors. When activated by steroids, the steroid-specific receptors in the TM (glucocorticoid receptor- $\alpha$ ) activate TM cells and cause an accumulation of amorphous material in the extracellular matrix, thickening of the trabecular beams and juxtacanalicular tissue and therefore decreasing outflow spaces in the TM. The glycosaminoglycans in the TM, a major portion of the extracellular matrix, have been shown to alter composition in the presence of steroids by increasing chondroitin, decreasing hyaluronate, and progressively increasing deposition of fibronectin. Further, steroids have been shown to cause a reduction in the essential function of the TM cells to phagocytose debris and to replace the extracellular matrix in the meshwork, which can also lead to an increase in resistance to outflow and therefore an increase in IOP. Activated TM cells lead to the induction of the *GLCIA* gene and increased expression of the myocilin protein in the TM, whereas other proteins are down-regulated. Some mutations in the *GLCIA* gene have been shown to lead to the development of dominant juvenile and a small subset of adult-onset open-angle glaucoma. Other changes to the TM have been observed in the presence of steroids, including changes to the TM cytoskeleton and cellular adhesion molecules.

### Management

The risk of developing steroid-induced glaucoma can be moderated with the judicious use of steroids and careful

monitoring and patient education to promptly identify IOP elevations when they occur. The IOP normally returns to pretreatment levels within 2 to 4 weeks of steroid taper or discontinuation. If continuation of systemic steroid therapy is necessary for the patient's systemic condition, elevated IOP can often be controlled with topical antiglaucoma medications. In terms of topical steroids, modifications of the treatment in favor of alternative steroid preparations as well as NSAIDs may be of value. Ocular hypertension or steroid-induced glaucoma should be managed according to guidelines given in Chapter 34. The use of low- to medium-dosage inhaled steroids and nasal steroids appears to have little associated risk. Because one would expect patients with established open-angle glaucoma to be particularly sensitive to the pressure-elevating effects of systemic steroids, careful monitoring is required.

### Topiramate

Topiramate is an antiepileptic medication also used in an off-label capacity to treat migraine headaches and bipolar disorders.

### Clinical Signs and Symptoms

Eighty-five percent of the 86 cases of mostly bilateral acute angle-closure glaucoma reported to the National Registry of Drug-Induced Ocular Side Effects by 2003 were noted to have occurred within the first 2 weeks of treatment initiation. Topiramate is considered to have "certain" OADR in the form of abnormal vision, acute secondary angle-closure glaucoma, acute myopia, and suprachoroidal effusions.

### Etiology

The presence of protein in the cerebrospinal fluid in one patient with bilateral conjunctivitis, areflexic mydriasis, severe anterior chamber shallowing, myopic shift, and vitritis suggests that a common inflammatory mechanism may occur due to the topiramate use.

### Management

Peripheral iridectomy is an ineffective treatment due to the secondary nature of choroidal effusions and inflammation. One case reported rapid resolution of the attack with methylprednisolone added to the intravenous mannitol.

### Ethanol

Ethanol, taken orally, may reduce IOP by increasing serum osmolarity and functioning as a short-acting hyperosmotic agent. When consumed as alcohol-containing beverages, ethanol can reduce IOP in both normal and glaucomatous eyes. The maximal ocular hypotensive effect occurs 1 to 2 hours after consumption. Therefore the practitioner must consider the actions of ethanol if consumption by the patient has occurred before measuring IOP.

## Cannabinoids

Derivatives of the marijuana plant, *Cannabis sativa*, make up a group of compounds known as *cannabinoids*. Various cannabinoids have been administered orally, topically, and by inhalation as a means of reducing IOP. Smoking and ingesting marijuana significantly reduces IOP. After smoking a single marijuana cigarette, patients with primary open-angle or secondary glaucomas can exhibit a significant reduction in IOP. The maximal ocular hypotensive response occurs 60 to 90 minutes after inhalation and lasts approximately 4 hours. These patients, however, have many systemic side effects, including postural hypotension, tachycardia, anxiety, drowsiness, euphoria, and hunger. Thus, systemic administration of presently available cannabinoids is an unacceptable route of administration for treatment of glaucoma, but the practitioner may encounter patients using marijuana and should be familiar with its ocular actions.

## DRUGS AFFECTING THE RETINA

Numerous drugs have been associated with retinal toxicity (Table 35-10). These include medications obtained by prescription or over the counter. For example, phenylpropranolamine, an adrenergic agonist formerly available over the counter and used in cold preparations and as an anorectic, has been reported to cause central retinal vein occlusion associated with systemic hypertension. This emphasizes the importance of a careful drug history. Several mechanisms can result in drugs becoming retinotoxic. Depending on the specific drug, its dosage, and the duration of treatment, these retinotoxic effects are often reversible if recognized early. Data have been reviewed

suggesting that indomethacin, tamoxifen, thioridazine, and chloroquine all produce retinopathies via a common mechanism of ocular oxidative stress.

## Chloroquine and Hydroxychloroquine

Chloroquine and hydroxychloroquine have been used to treat rheumatoid arthritis, discoid and systemic lupus erythematosus, and other collagen and dermatologic diseases since the early 1950s. Initially, retinal toxicity due to long-term use of chloroquine (Aralen) for malaria was reported, and this remains a concern in some parts of the world. Currently, hydroxychloroquine sulfate (Plaquenil) is the quinoline agent of choice for the treatment of autoimmune diseases with a far lower incidence of adverse reactions. Although chloroquine and hydroxychloroquine toxicity does occur and the results can be devastating to vision, the overall incidence is very low. Review of the published literature on these drugs suggests that well over 1,000,000 individuals have used them, whereas fewer than 20 cases of toxicity have been reported.

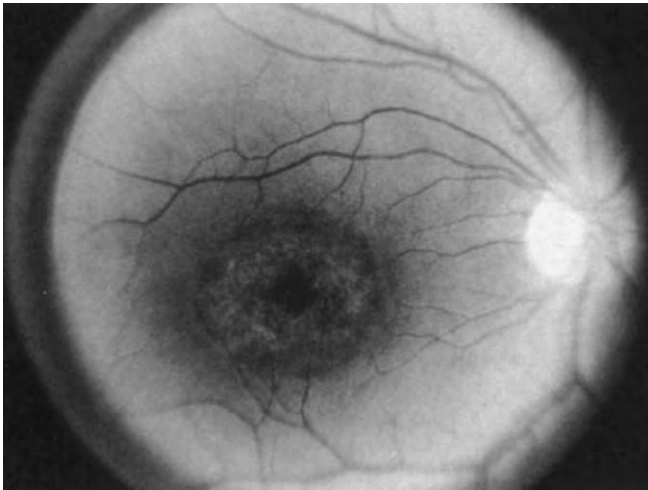
### Clinical Signs and Symptoms

Even before visible ophthalmoscopic changes are detectable, a "premaculopathy" state can exist in which the drug interferes with metabolism of the macular tissues, causing subtle relative visual field defects in patients with ophthalmoscopically normal maculae. The first visible evidence of retinopathy is a fine pigmentary mottling within the macular area, with or without loss of the foveal reflex. As the macular pigmentary changes progress, a classic pattern develops consisting of a granular hyperpigmentation surrounded by a zone of depigmentation.

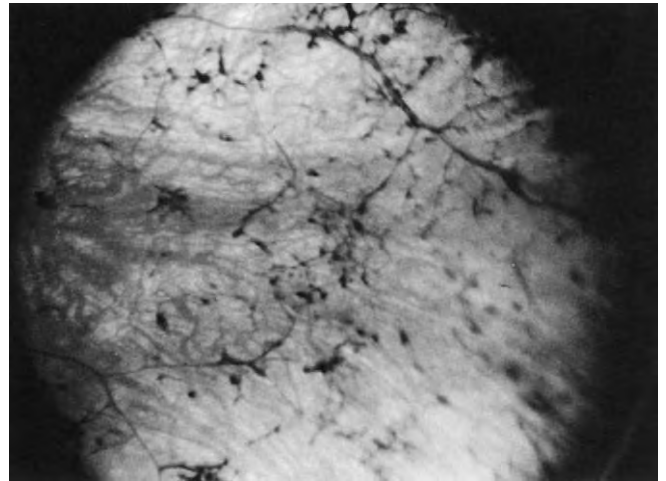
**Table 35-10**

Drugs That Can Affect the Retina

Drug	Adverse Effect
Chloroquine and hydroxychloroquine	Retinal pigmentary changes, visual field defects, color vision loss
Thioridazine	Retinal pigmentary changes, disturbances of dark adaptation, color vision loss, visual field defects
Quinine	Impairment of dark adaptation, visual field defects, vascular attenuation
Cardiac glycosides	Color vision disturbances, entoptic phenomena
Sildenafil	Color vision disturbances
Oral contraceptives, hormone replacement therapy	Retinal vascular diseases, such as vascular occlusions, hemorrhage, retinal venous thrombosis
Nonsteroidal anti-inflammatory agents: salicylates	Retinal hemorrhage
Indomethacin	Pigmentary changes, color vision loss, visual field defects
Clomiphene	Visual disturbances, entoptic phenomena
Antineoplastic agents: tamoxifen	Refractile opacities in posterior pole, macular edema
Carmustine (intravenous)	Retinal vascular disease
Vigabatrin	Visual field constriction
Isotretinoin	Impairment of dark adaptation (night blindness or nyctalopia)
Niacin	Cystoid macular edema
Talc (magnesium silicate)	Intra-arteriolar talc emboli, retinal nonperfusion, neovascularization



**Figure 35-8** Characteristic bull's eye maculopathy associated with chloroquine toxicity.

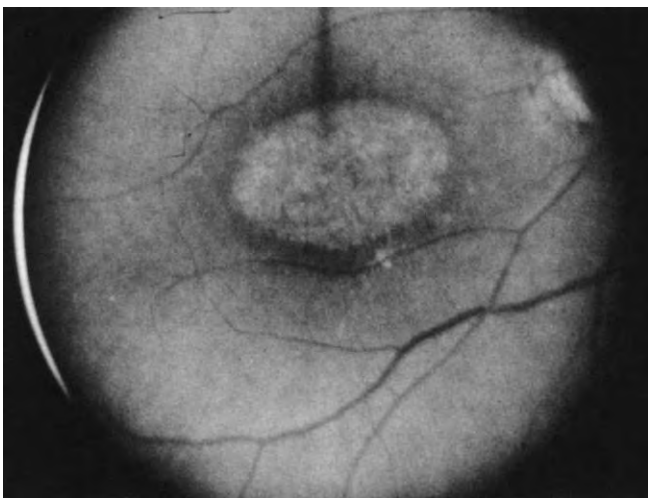

**Figure 35-10** Peripheral retinal pigment epithelial hyperplasia characteristic of pseudoretinitis pigmentosa in 42-year-old man with chloroquine toxicity.

The zone of depigmentation is, in turn, surrounded by another ring of pigment. Although this clinical picture can vary in intensity, it is pathognomonic of chloroquine retinopathy and is referred to as a “bull’s eye” maculopathy (Figure 35-8).

Variations of RPE disturbances can occur but most often appear as well-circumscribed areas of RPE atrophy in the macular area, which may resemble a macular hole (Figure 35-9). A high degree of bilateral symmetry between eyes is generally noted, but occasionally the toxicity can affect one eye more than the other.

Some patients with chloroquine retinopathy may have retinal changes resembling retinitis pigmentosa. Chloroquine retinopathy does exhibit peripheral RPE hyperplasia, but, in contrast to retinitis pigmentosa, the pigment does not tend to accumulate around the retinal veins.



**Figure 35-9** Retinal pigment epithelial atrophy in macular area as a consequence of chloroquine therapy.

The peripheral lesions can occur with or without simultaneous macular involvement (Figure 35-10). Other changes include attenuated retinal vessels, optic atrophy, peripheral visual field loss, abnormal color vision, and a subnormal electroretinogram (ERG). The fact that the dark-adaptation threshold is normal, or only minimally abnormal, further differentiates this condition from retinitis pigmentosa.

Although the visual fields may be normal even in the presence of definite macular pigmentary changes, visual field loss generally correlates well with the degree of retinal damage. The typical visual field defects in chloroquine retinopathy consist of central or paracentral scotomata, which may become confluent and form a complete ring.

In the early stages of retinopathy, electrodiagnostic studies tend to be of little value in detecting early toxicity. Both the ERG and EOG can be normal or abnormal. Advanced cases of retinopathy, however, usually exhibit markedly abnormal, or even extinguished, ERGs. This is especially true in cases involving the retinal periphery. Multifocal electroretinography may show decreased electrical responses in the macular areas of patients who have normal standardized Ganzfeld ERG results.

Although it is possible for patients with chloroquine maculopathy to be asymptomatic, extensive macular damage often leads to symptoms of decreased visual acuity, metamorphopsia, and visual field disturbances. Pericentral ring scotomas can cause reading difficulty. Although color vision is normal in the early stages of chloroquine toxicity, more extensive macular damage can lead to severe impairment of color vision. Dark adaptation is typically normal, an important feature distinguishing the peripheral retinal changes from those seen in retinitis pigmentosa.

Risk factors for the development of retinopathy are related to daily dosage, duration of treatment, serum drug levels, and patient age, size, and amount of body fat.

The incidence of retinopathy increases with patient age, and in older patients retinal toxicity appears to be correlated with total drug dosage.

The risk of retinopathy associated with hydroxychloroquine is considerably less than that associated with chloroquine. In one study retinal toxicity occurred in only 4 of 99 patients receiving hydroxychloroquine in a daily dosage of 400 mg for at least 1 year. No patient, however, sustained significant vision loss, and the abnormalities were reversible after the medication was discontinued. In some cases the macular changes may be reversible without recurrence even if the medication is reinstated. Despite early diagnosis and withdrawal of medication, permanent visual field defects can occur. The risk of retinal toxicity seems to be minimal if the daily dose of hydroxychloroquine is less than 6.5 mg/kg of body weight, the duration of treatment is less than 5 years, and renal function is normal (Table 35-11).

### Etiology

Although the precise mechanisms of chloroquine and hydroxychloroquine toxicity are not well understood, it is known that metabolic effects are noted in the retinal photoreceptors. Both agents reversibly bind to melanin in the RPE, and this binding may serve to concentrate and prolong the toxicity, even after the drug is discontinued. Although the periphery can be affected, the effects of chloroquine and hydroxychloroquine center primarily in the maculae. This suggests a relationship to cone metabolism or possibly to light absorption as a contributing factor. This can lead to degenerative changes of the RPE. The destructive process within the RPE leads to migration of pigment-laden cells from the RPE to the outer nuclear and outer plexiform layers. The foveolar cones are often spared, which explains the ophthalmoscopic appearance

seen in cases of bull's eye maculopathy. Attenuation of the retinal arterioles along with optic nerve pallor is thought to be secondary to the extensive retinal damage.

### Management

Recommendations for screening procedures for chloroquine or hydroxychloroquine toxicity have been quite variable both in frequency of examination and in types of required tests at each visit. Although examination for sight-threatening adverse effects of these medications is critical, evidence, costs, and risk-to-benefit ratios necessitate a balance of all these factors.

Patients should receive baseline examinations after starting therapy and should be examined periodically for evidence of retinal changes. Early retinopathy has been shown to be reversible if drug dosage is reduced or discontinued; however, others show a continued progression despite drug discontinuation. Baseline examination of the fundus is especially important because drug-induced maculopathy can resemble age-related macular disease. This examination should include a full ophthalmic examination, including visual acuity, Amsler grid, and Humphrey central 10-2 visual field testing. Color vision and fundus photography are useful tests. Fluorescein angiography and ERG testing are not undertaken unless another condition is to be differentiated.

Controversy has existed over the length of time to follow-up, ranging from every 3 months to infrequently. Once treatment has started, follow-up examinations should be based on risk factors (see Table 35-11). The current Preferred Practice Pattern indicates that patients at low risk of developing retinopathy can be monitored based on age; that is, at least once in the span between 20 and 29 years, at least twice between 30 and 39 years, every 2 to 4 years between 40 and 64 years of age, and

**Table 35-11**  
Recommendations for Screening for Chloroquine and Hydroxychloroquine Retinopathy

	Low Risk	High Risk
Dosage	<6.5 mg/kg Hydroxychloroquine (usually 400 mg/day or less)	>6.5 mg/kg Hydroxychloroquine (usually >400 mg/day)
Duration of use	<3 mg/kg chloroquine <5 years	>3 mg/kg chloroquine >5 years
Habitus	Lean or average body fat	High body fat level (unless dosage is lower); very low body mass
Renal/liver disease	None	Present
Concomitant retinal disease	None	Present
Age	<60 years	>60 years
Follow-up schedule in the absence of clinical symptoms or signs	20–29 years: at least once 30–39 years: at least twice 40–64 years: every 2–4 years	Yearly

Adapted from Marmor MF, Carr RE, Easterbrook M, et al. Recommendations on screening for chloroquine and hydroxychloroquine retinopathy: a report by the American Academy of Ophthalmology. *Ophthalmology* 2002;109:1377–1382.

every 1 to 2 years over the age of 65. Patients using the drug for greater than 5 years and patients determined to have other risk factors should have yearly examinations. Individual patient factors must always be considered, and the patient should be informed and the record clear regarding counseling and examination findings. Patients should be counseled that there is a small risk of toxicity within the initial 5-year period and, indeed, at all if they have a low-risk profile. Emphasis should be made, however, that they should return before their next scheduled appointment if they notice any change in visual acuity, Amsler grid appearance, color perception, or dark adaptation problems or if they develop liver or kidney problems or are given an increased dosage.

Testing of contrast sensitivity is an additional screening procedure that may detect early macular dysfunction, particularly in patients younger than 40 years of age. Color vision should be evaluated with a color vision test designed to detect both mild blue-yellow and protan red-green deficiencies. Tests that meet these criteria are the Standard Pseudoisochromatic Plates Part 2 and the American Optical Hardy-Rand-Ritter.

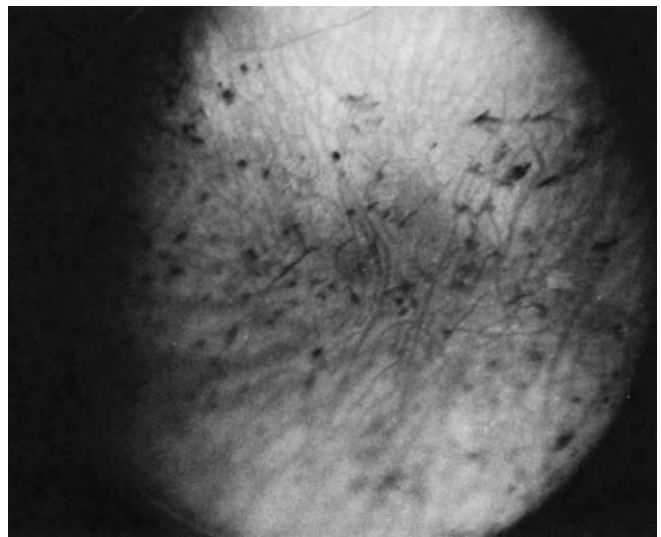
Cessation of the drug is the only management option if toxicity is suspected. Because these drugs are often critical to the management of the patient's disease, this decision should be made with the patient and his or her internist or rheumatologist. Early changes may be discussed with the patient and the caregivers and an active decision made to either continue or discontinue the drug. In the former case, close follow-up is suggested (at least every 3 months). Even after discontinuation visual loss may continue despite drug cessation, so those patients with obvious bull's eye maculopathy or vision loss should also be reexamined within 3 months and on a continual basis several years after drug cessation.

### Thioridazine

Chlorpromazine (Thorazine) and thioridazine (Mellaril), both phenothiazine derivatives, are used for their antipsychotic effects in the control of severely disturbed or agitated behavior and in schizophrenia. Thioridazine has a higher incidence of antimuscarinic effects but a lower incidence of extrapyramidal symptoms. Pigmentary changes of the retina have been reported occasionally in association with chlorpromazine therapy, although it is recognized that only thioridazine produces retinal toxicity.

#### Clinical Signs and Symptoms

Thioridazine can cause significant retinal toxicity, leading to reduced visual acuity, changes in color vision, and disturbances of dark adaptation. These symptoms typically occur 30 to 90 days after initiation of treatment. The fundus often appears normal during the early stages of symptoms, but within several weeks or months a pigmentary



**Figure 35-11** Retinal pigment epithelial hyperplasia and atrophy in 33-year-old man with thioridazine retinopathy.

retinopathy develops, characterized by fine clumps of pigment developing first in the periphery and progressing toward the posterior pole (Figure 35-11). In milder cases the pigment remains fine and peppery, but in more severe cases the pigment can form plaque-like lesions with multiple confluent areas of hypopigmentation and choroidal atrophy. Retinal edema can also occur, but the optic disc and retinal vasculature are usually normal.

It is now recognized that the primary clinical factor associated with thioridazine retinopathy is the daily dose of drug. Before becoming aware of the dose-related retinal toxicity, dosages exceeding 1,600 mg daily were commonly prescribed. Few cases of pigmentary retinopathy have been reported, however, with daily dosages of less than 800 mg.

Depending on the severity of toxicity, retinal function can return to normal with reduction or discontinuation of the drug, but the pigmentary changes are often permanent. Severe cases may result in permanent impairment of visual acuity, visual field, and dark adaptation. The pigmentary retinopathy may even progress after the drug therapy has been discontinued, and some cases of progressive retinopathy have been noted later, occurring from 4 to 10 years after discontinuation of thioridazine.

#### Etiology

Thioridazine and other phenothiazines bind to melanin in the uveal tract, especially in the choroid. Drug uptake by the choroid occurs even in patients whose serum levels of thioridazine are in the nontoxic range. Such drug binding may be retinotoxic by damaging the choriocapillaris, thus leading to changes in the overlying RPE.

### Management

Because the danger of retinal toxicity from thioridazine is significantly correlated with daily dosage, patients should be placed on dosages of less than 800 mg daily. Patients should receive careful fundus examinations during the first 2 to 4 months of therapy and every 6 months thereafter. Electrodiagnostic tests such as ERG and EOG are generally of no value in detecting early retinopathy. If symptoms or objective signs of retinal toxicity are observed, consideration should be taken with the patient's prescribing physicians for prompt discontinuation of the medication to improve the chances of resolution. Because the pigmentary retinopathy may be progressive even after thioridazine has been discontinued, patients should receive follow-up examinations on an annual basis.

### Cardiac Glycosides

Digitoxin and digoxin, both digitalis derivatives, have been widely used in the treatment of congestive heart disease and certain cardiac arrhythmias. Visual symptoms associated with digitalis may include dimming vision, flickering or flashing scotomas, and significant disturbances of color vision.

### Clinical Signs and Symptoms

The most common symptoms reported by patients are changes in color vision and impaired vision. These symptoms can take many forms and include the visual phenomena listed in Box 35-4. A common symptom is snowy vision (objects appear to be covered with frost or snow), and this observation is intensified in brightly illuminated environments. There is also evidence that digoxin may contribute to rhegmatogenous retinal detachment by decreasing the normal adhesion of the retina to the RPE.

Complaints of color vision disturbances are common with both digoxin and digitoxin, but color vision impairment can often be detected even in patients without

symptoms. Both the incidence and severity of color vision impairment tend to correlate with the plasma glycoside level. Figure 35-12 shows the results of color vision testing in patients receiving therapeutic dosages and those with toxic serum levels of digoxin. Approximately 80% of patients with digoxin intoxication demonstrate generalized color vision deficiencies, but detectable color vision impairment or other visual symptoms can occur even at normal therapeutic drug levels (Figure 35-13). In contrast, patients treated with digitoxin in therapeutic concentrations usually show no significant color vision abnormality. This difference may be related to plasma protein binding or to different distributions in the retina. Digoxin can also interact with quinidine, which raises the digoxin level approximately twofold.

The prevalence of digitalis intoxication is from 16% to 20%. Color vision disturbances are especially common and may occur before, simultaneously with, or after the onset of cardiac toxicity. Although color vision disturbances are associated with cardiac glycoside toxicity decreased visual acuity without the accompanying classic symptom of xanthopsia is also common.

Visual symptoms may occur as soon as 1 day after drug administration, but often occur within 2 weeks of initial therapy. Occasionally, ocular toxicity does not appear until after several years of treatment. Once the serum level is decreased or digitalis therapy is discontinued, however, visual symptoms quickly subside, usually within several weeks.

### Etiology

The precise mechanism whereby digoxin produces a toxic effect may involve inhibition of  $\text{Na}^+\text{K}^+$ -activated adenosine triphosphatase, an enzyme that plays a vital role in maintaining normal cone receptor function. This would explain the drug-induced interference with both dark adaptation and color vision.

### Management

Patients taking cardiac glycosides should be monitored for visual symptoms, including color vision changes, flashing or flickering lights, and other entoptic phenomena. Although the Panel D-15 test can be useful for evaluating color vision, the Farnsworth-Munsell 100-hue test has been shown to be particularly sensitive for detecting digitalis-induced color vision deficiencies. Detectable changes in color vision should warrant consultation with the prescribing physician with regard to potential digitalis intoxication.

### Sildenafil


The erectile dysfunction group of drugs, of which sildenafil is most common, are potent inhibitors of cyclic guanosine monophosphate-specific phosphodiesterase type 5 (PDE-5). The other two available drugs are tadalafil (Cialis) and

#### Box 35-4 Visual Symptoms in Digitalis Intoxication

Dyschromatopsia, including yellow or blue tinge to vision and/or colored halos  
 Colored spots surrounded by coronas  
 Snowy, hazy, or blurred vision  
 Dimming of vision  
 Flickering or flashes of light  
 Glare sensitivity

From Weleber RG, Shotts WT. Digoxin retinal toxicity. Clinical and electrophysiological evaluation of a cone dysfunction syndrome. *Arch Ophthalmol* 1981;99:1568-1572.



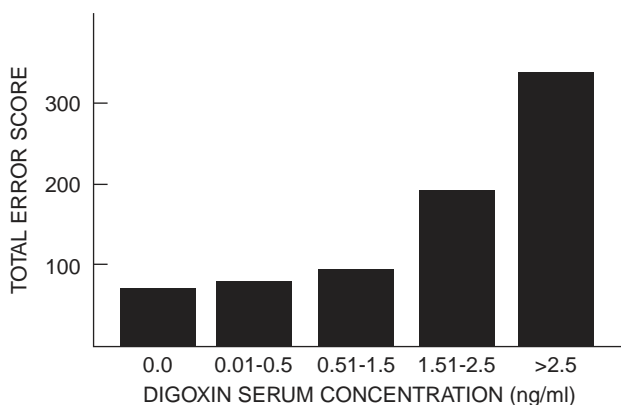


**Figure 35-12** Farnsworth-Munsell 100-hue test results in three patients with differing digoxin serum levels (0, 0.74, and 3.97 ng/ml, respectively). Total error scores were 20, 132, and 364, respectively. (Modified from Rietbrock N, Alken RG. Color vision deficiencies: a common sign of intoxication in chronically digoxin-treated patients. *J Cardiovasc Pharmacol* 1980; 2:93-99.)

ildenafil (Levitra). When orally administered, these drugs are effective and generally well-tolerated treatments for men with erectile dysfunction. The drugs enhance the effect of nitric oxide by inhibiting PDE-5, which is responsible for the degradation of cyclic guanosine monophosphate in the corpus cavernosum. Sexual stimulation causes local release of nitric oxide, and inhibition of PDE-5 causes increased levels of cyclic guanosine monophosphate in the corpus cavernosum, which results in smooth muscle relaxation and inflow of blood. Although these drugs are highly selective for PDE-5, they retain some affinity for phosphodiesterase type 6 (PDE-6), an enzyme found in the retina. Inhibition of PDE-6 may provide the basis for ocular side effects that can occur in men who use these drugs. Tadalafil is more specific to PDE-5 and therefore may produce less visual adverse effects.

### Clinical Signs and Symptoms

In a battery of vision function tests, sildenafil has been given at dosages up to twice the maximum recommended dosage. Mild, transient, dose-related impairment of color vision has been detected. The peak effect occurs near the time of peak plasma drug levels, at 30 minutes to 2 hours after ingestion. Visual side effects are reported to occur in 3% to 10% of users. OADRs considered "certain" by WHO criteria include bluish-tinged or occasionally pink- or yellowish-tinged vision and that dark colors appear darker; blurred or hazy vision; changes to light perception, including increased sensitivity to light and flashing lights; conjunctival hyperemia, ocular pain; and transient ERG changes. Most visual symptoms last several minutes to a few hours. Other OADRs for these agents listed as "possible" include nonarteritic ischemic optic neuropathy (see *Drugs Affecting the Optic Nerve*, below) and mydriasis, retinal vascular accidents, and subconjunctival hemorrhage, all of which may be related to the activities undertaken during use of the drugs.



**Figure 35-13** Mean total error scores on Farnsworth-Munsell 100-hue test according to digoxin serum concentration ranges. (Modified from Rietbrock N, Alken RG. Color vision deficiencies: a common sign of intoxication in chronically digoxin-treated patients. *J Cardiovasc Pharmacol* 1980; 2:93-99.)

### Etiology

The visual effects associated with the PDE-5 inhibitor therapies are consistent with cross-inhibition of the enzyme PDE-6, which is involved in retinal phototransduction.

### Management

Visual symptoms are mild and transient. Patients can be reassured that no permanent or clinically significant visual impairment has been associated with sildenafil use. Some patients with retinitis pigmentosa have genetic disorders of retinal PDEs. Because there is no safety information on administering sildenafil to these patients, the drug should be used with caution in patients with retinitis pigmentosa.

### Oral Contraceptives

Two large cohort studies in the United Kingdom involving 63,000 women noted no notable increase in the following

conditions, including lacrimal disease: conjunctivitis, keratitis, iritis, strabismus, cataract, glaucoma, and retinal detachment. There was consistent evidence, however, of a notable increase in risk of retinal vascular lesions in oral contraceptive users. The relative risk of retinal vascular lesions in oral contraceptive users was 2.0 to 2.4. This included all retinal vascular abnormalities, including vascular occlusion, vein thrombosis, and retinal hemorrhage. Women are counseled not to smoke when on oral contraceptives. If a retinal vascular lesion is detected on dilated fundus examination, it should be monitored in a reasonable time, depending on the nature of the abnormality, the location, and threat to vision. The patient and the prescribing practitioner should be informed of the lesion and discussions undertaken as to the risk-to-benefit ratio of continued treatment.

### **Nonsteroidal Anti-Inflammatory Agents**

NSAIDs are commonly used for their analgesic, anti-inflammatory, and antipyretic actions in the treatment of arthritis, musculoskeletal disorders, dysmenorrhea, and acute gout. Although these drugs are widely used and are often used for prolonged periods, retinal toxicity is rare.

#### **Clinical Signs and Symptoms**

Salicylates are well known to have anticoagulant properties. In high dosages or with prolonged use these drugs can cause retinal hemorrhage.

Most of the reported cases of retinopathy associated with NSAIDs have involved indomethacin therapy. Although there have been no epidemiologic studies investigating the relationship between indomethacin and retinopathy, there is evidence that the drug can induce pigmentary changes of the macula and other areas of the retina. The lesions usually consist of discrete pigment scattering of the RPE peripherally, as well as fine areas of depigmentation around the macula. In some cases the pigmentary changes are more marked in the periphery of the retina. Depending on the amount of retinal involvement, the ERG and EOG can be normal or abnormal. Likewise, the amount of retinopathy dictates whether changes occur in visual acuity, dark adaptation, and visual fields. Acquired color vision deficiencies of the blue-yellow type have been reported.

No definite relationship has been established between the dosage of indomethacin and retinal toxicity. When drug therapy is discontinued, however, most of the functional disturbances associated with the retinopathy usually improve, although the pigmentary changes of the retina are generally irreversible. Significant improvement of color vision, visual acuity, dark adaptation, and visual fields may require at least 6 to 12 months after discontinuation of drug therapy.

#### **Etiology**

Most investigators have speculated that indomethacin may have a direct or indirect effect on the RPE, but the

precise mechanism has not been clarified. The localization of the retinotoxic effect to the RPE is supported by changes observed in the ERG and EOG in patients with indomethacin retinopathy.

#### **Management**

Patients taking salicylates or indomethacin in high dosages or for prolonged periods should be monitored for evidence of retinal hemorrhage or pigmentary changes, especially in the macular area. Evaluation of color vision may be helpful in identifying patients with early retinotoxic effects associated with indomethacin. Once retinal toxicity is documented, the prognosis for improved retinal function is good, provided indomethacin therapy is decreased or discontinued. Drug therapy, however, should be changed only on the advice of the prescribing physician.

### **Clomiphene**

Clomiphene citrate (Clomid) is an orally administered nonsteroidal agent widely used for treatment of infertility. Visual side effects associated with clomiphene therapy include nonspecific blurring of vision and various entoptic phenomena, including flashes of light, scintillations, heat waves, and prolonged afterimages. The symptoms can occur as early as several days after treatment is started and usually disappear within several days to several weeks after treatment is discontinued. Cases have been reported, however, in which patients remained symptomatic from 2 to 7 years after discontinuing the medication.

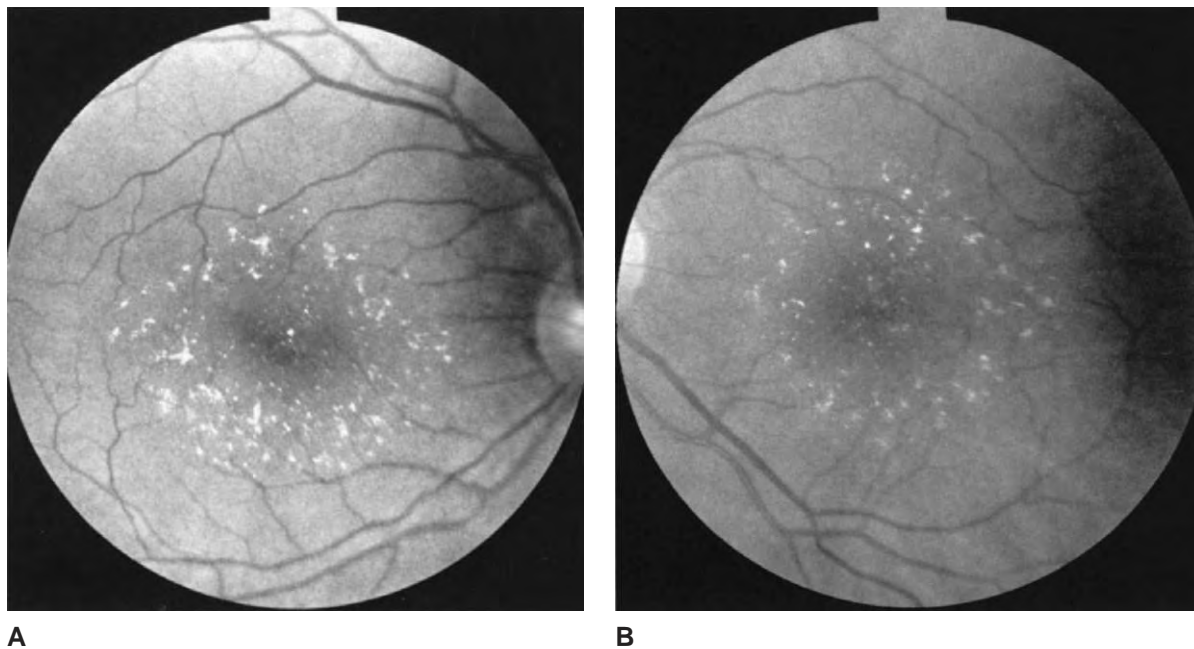
### **Antineoplastic Agents**

#### **Tamoxifen**

Tamoxifen citrate (Nolvadex), an orally administered nonsteroidal antiestrogen, is one of the most effective antitumor agents for the palliative treatment of metastatic breast carcinoma in postmenopausal women. This drug has been in clinical use since 1970 without serious side effects in most patients. It is used both alone and in combination with other agents. OADR's are reported to be as high as 6.3%; however, in low doses retinopathy is rare (0.9%).

#### **Clinical Signs and Symptoms**

Tamoxifen retinopathy has been documented in many patients, and the retinal findings include white or yellow refractile opacities in the macular and perimacular area, with or without macular edema (Figure 35-14). Although the lesions are usually more numerous in the macular area, they can also extend to the ora serrata. The lesions occur at all levels of the sensory retina, and many appear superficial to the retinal vessels. The patient may be asymptomatic or may experience reduced visual acuity associated with the macular lesions, and the visual fields can show abnormalities.



**Figure 35-14** Macular edema with yellow-white crystalline deposition in 66-year-old woman administered 120 mg of tamoxifen twice daily for 2 years. (A) Right eye, visual acuity 20/180 (6/54). (B) Left eye, visual acuity 20/60 (6/18).

Although tamoxifen is far less likely to induce ocular toxicity at the normal dosage level of 20 mg daily, retinopathy does occur, although it is usually asymptomatic. With high dosages (e.g., 90 to 120 mg twice daily), toxic effects can be observed within 17 to 27 months, as the total cumulative dose exceeds 90 g.

The most important difference between high-dose and low-dose toxicity is the extent of reversibility after discontinuing the drug. Patients taking 20 mg twice daily may demonstrate regression of retinopathy and improvement in visual symptoms.

### Etiology

It has been suggested that high-dose tamoxifen therapy causes widespread axonal degeneration, primarily in the paramacular area. The yellow-white lesions seen on fundus examination appear to represent products of the axonal degeneration and are confined to the nerve fiber and inner plexiform layers. However, others have compared this drug with other amphiphilic compounds such as chloroquine, chlorpromazine, thioridazine, and tilorone, all of which bind to polar lipids, inhibiting catabolism of the lipids and causing accumulation of drug-lipid complexes in lysosomes.

### Management

Because tamoxifen retinopathy can occur at relatively low total doses of drug, it is important to obtain a baseline examination within the first year after therapy is begun. This should include best-corrected visual acuity, visual fields and Amsler grid evaluations, and fundus examination. It is important to monitor symptomatic

patients carefully during therapy, because macular compromise can result in irreversible loss of vision. Annual examinations are sufficient if normal drug dosages are administered. However, patients receiving higher than normal dosages, ranging from 80 mg once daily to 120 mg twice daily, should be monitored every 6 months. The prevalence of ocular toxicity from low-dose tamoxifen therapy (10 mg twice daily) appears to be low, and some investigators have suggested therefore that no special ocular screening is required in these patients. If retinopathy is detected in visually asymptomatic patients, tamoxifen therapy may be continued, in consultation with the patient's oncologist.

### Carmustine

Carmustine (BCNU) is a commonly used chemotherapeutic agent for the treatment of various malignant neoplasms, including metastatic malignant melanoma, malignant gliomas of the central nervous system, metastatic breast cancer, and leukemia. It has been administered by infusion into the internal carotid artery as a method of increasing bioavailability of the drug to brain tumors within the supply of this vessel. This has led to ocular toxicity in some patients.

### Clinical Signs and Symptoms

Retinal toxicity usually begins within 2 to 14 weeks after intra-arterial infusion of BCNU. Approximately 65% of patients develop retinal complications (Box 35-5). It is common to have loss of vision from the retinopathy, and visual acuity can be reduced to 20/60, to light perception, or even to no light perception. A definite relationship

### Box 35-5 Retinal Complications of Carmustine Use

Retinal infarction  
 Retinal periarteritis  
 Retinal periphlebitis  
 Changes of retinal pigment epithelium  
 Branch retinal artery occlusion  
 Nerve fiber layer hemorrhages  
 Macular edema

between dosage of BCNU and retinopathy has not been established.

#### Etiology

The retinal toxicity resulting from intracarotid BCNU is probably related to the increased flow of drug into the ophthalmic artery. The precise mechanism whereby BCNU causes retinal toxicity is unknown, but several investigators have suggested that the drug may be toxic to the retinal and choroidal vasculature, causing segmental intraretinal vasculitis with or without vascular obstruction. This process would lead to nerve fiber layer infarcts and retinal hemorrhage.

#### Management

As previously mentioned, the retinotoxic effects of intracarotid BCNU can be largely minimized or avoided by using an infusion catheter that is advanced beyond the origin of the ophthalmic artery. If retinal complications develop, the risk-to-benefit ratio must be considered regarding the advisability of continued therapy.

#### Miscellaneous Chemotherapeutic Agents

Various other systemic chemotherapeutic agents have been associated with retinotoxic effects. Use of interferon- $\alpha$ , for example, has resulted in various retinal effects, including cotton-wool spot formation, macular edema, capillary nonperfusion, arteriolar occlusion, and intraretinal hemorrhage. Cisplatin and etoposide have induced retinal toxicity in both adults and children.

#### Vigabatrin

Vigabatrin is an effective anticonvulsant medication that selectively increases brain and retinal  $\gamma$ -aminobutyric acid.

#### Clinical Signs and Symptoms

Vigabatrin-induced visual field constriction is well documented. The visual field constriction is bilateral, usually asymptomatic, and characteristically consists of concentric peripheral field loss with temporal and macular sparing. Field loss occurs in 30% to 50% of patients and appears to be irreversible in most cases. Visual acuity and color vision can also be affected, and the best method to detect

dyschromatopsia appears to be the Farnsworth-Munsell 100-hue test. Visual symptoms can develop from several months to several years after initiation of drug therapy.

Electrodiagnostic testing may reveal normal or abnormal responses on ERG and visual evoked potential tracings, but the EOG seems to be the most sensitive electrophysiologic test. The results of electroretinography suggest reduced inner retinal cone responses and impairment of Müller and amacrine cells. The visual symptoms associated with vigabatrin therapy may represent selective vulnerability of the retina to the  $\gamma$ -aminobutyric acidergic effects of the medication.

#### Management

Patients taking this drug should have regular peripheral visual field examinations, and consideration should be given to electrodiagnostic testing, especially electrooculography.

#### Isotretinoin

Isotretinoin, or 13-*cis*-retinoic acid, is widely used for the treatment of recalcitrant cystic acne. Although this drug more commonly affects the external tissues of the eye, causing ocular surface dryness, there is sufficient evidence to designate that this agent has a "certain" retinotoxic effect, causing nyctalopia. It also has a "probably/likely" designation for reversible decreases in color vision.

#### Clinical Signs and Symptoms

Impairment of dark adaptation with or without excessive glare sensitivity has been reported with isotretinoin therapy in doses of 1 mg/kg of body weight daily. These complaints may be associated with an abnormal ERG or abnormal EOG. Once therapy is discontinued, both the abnormal dark adaptation and abnormal ERG usually resolve within several months.

#### Etiology

Although the precise mechanism explaining the effect on dark adaptation is unclear, it has been suggested that the drug could become incorporated into the rod photoreceptor elements during the process of outer disc shedding and renewal. Isotretinoin may compete for normal retinol binding sites on cell surfaces or transport molecules, which would account for the reduced retinal sensitivity. Though not proven, more recently it has been speculated that a preexisting hypovitaminosis A may predispose a patient placed on isotretinoin to nyctalopia. This may be because the isotretinoin likely binds to the sites where retinol normally would bind, but it does not subsequently biotransform to physiologically active rhodopsin, slowly affecting the photoreceptors.

#### Management

Patients taking isotretinoin should be monitored for changes in night vision. A history of night vision impairment should suggest more definitive evaluation procedures, such

as visual field testing, dark adaptometry, and electroretinography. If retinal function is documented to be abnormal, the drug should be withdrawn in consultation with the prescribing physician. Once drug therapy has been discontinued, retinal function should be monitored for improvement. These patients also must be monitored for dry eye and more unlikely events such as intracranial hypertension.

### **Inhaled Corticosteroids**

The use of inhaled steroids has been associated with the development of central serous chorioretinopathy. In susceptible patients the systemic absorption of inhaled steroids may be sufficient to induce macular detachment and reduced central visual acuity associated with central serous chorioretinopathy.

### **Quinine**

Historically, quinine has been used for the treatment of malaria, but it is now used primarily for the management of nocturnal leg cramps and myotonia congenita. Quinine toxicity has been recognized for more than 150 years, and overdosage of quinine is still encountered in patients who attempt self-induced abortion or suicide. Accidental ingestion of quinine can lead to serious side effects. Among the various features of quinine toxicity, acute vision loss is one of the most significant and dangerous.

#### **Clinical Signs and Symptoms**

Mild toxic reactions are characterized by slight reduction of visual acuity, “flickering” of vision, color vision decrease, impaired night vision, tinnitus, weakness, or confusion. In more severe cases, symptoms consist of sudden complete loss of vision, dizziness, and even deafness. Coma with circulatory collapse characterizes the most severe form of quinine toxicity. Patients may complain of impairment of night vision, but color vision is usually normal. The visual fields usually demonstrate concentric constriction. Improvement of the visual fields after the acute episode may require days or months, but the field loss may show no recovery and become permanent.

Patients presenting with acute quinine overdose frequently have no light perception in either eye, and pupils are often dilated and nonreactive to light. Ophthalmoscopic examination of the fundus soon after acute quinine overdose may reveal a normal fundus but also may reveal constriction of the arterioles, optic disc pallor, venous dilation, or retinal edema.

The visual prognosis for patients with acute quinine toxicity is guarded. Visual acuity can improve from no light perception to 20/20 within days to several weeks or months. As vision recovers there is progressive constriction of the retinal vessels, and the optic disc becomes pale. Although central vision often returns to normal levels, the visual fields can remain constricted, and night and color vision changes can be permanent.

In general, the maximum daily dosage of quinine should not exceed 2 g; quinine toxicity is common in dosages over 4 g. The lethal oral dose in adults is approximately 8 g. Toxic reactions to relatively small dosages of quinine are probably idiosyncratic in nature but can result in a clinical picture similar to that caused by higher dosages.

#### **Etiology**

Our current understanding of the pathogenesis of quinine retinal toxicity is derived primarily from various electrodiagnostic studies that have demonstrated that quinine probably has a direct toxic effect on the photoreceptors and ganglion cells. Moreover, fluorescein angiographic studies have shown no significant circulatory disturbances. Damage to the RPE is indicated by an abnormal EOG, the increased visibility of the choroid in the late stages of toxicity, and the increased background fluorescence seen on angiography. Visual evoked potential findings confirm the conduction abnormality in the nerve fiber layer associated with the secondary optic atrophy.

#### **Management**

Because central vision tends to recover spontaneously even without treatment, patients with acute quinine toxicity should generally be managed by supportive measures alone. Hyperbaric oxygen has been used in an attempt to increase oxygen delivery to the retina. The use of oral activated charcoal or any other gastric decontamination procedures does not improve clinical outcome and may, in fact, be harmful to the patient. It is important to emphasize preventive measures, such as patient education and dispensing of quinine in child-resistant containers.

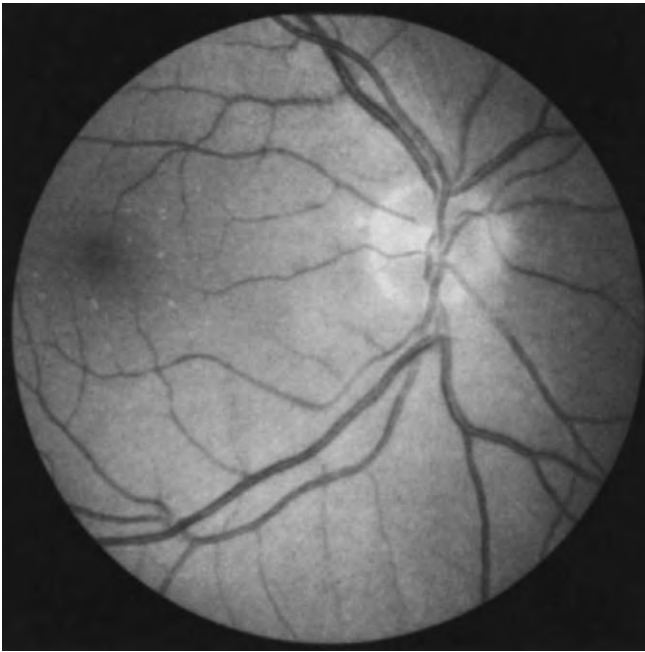After the acute episode, patients can be monitored for improvement in visual acuity, visual fields, and fundus appearance.

#### **Talc**

Tablets of medication intended for oral use contain inert filler materials such as talc (magnesium silicate), corn starch, cotton fibers, and other refractile and nonrefractile substances. Long-term drug abusers are known to prepare a suspension of medication for injection by dissolving the crushed tablet of cocaine, heroin, methylphenidate, or other narcotic in water. They then boil the solution and filter it through a crude cigarette or cotton filter before injecting the solution intravenously, subcutaneously, or intramuscularly. The talc particles eventually embolize to the retinal circulation and produce a characteristic form of retinopathy.

#### **Clinical Signs and Symptoms**

Fundus examination reveals multiple tiny, yellow-white, glistening particles scattered throughout the posterior pole but concentrated in the capillary bed and small arterioles of the perimacular area (Figure 35-15). The distribution and position of the particles remain stationary over time. In addition to these characteristic lesions, some



**Figure 35-15** Talc retinopathy characterized by numerous yellow-white intra-arteriolar particles scattered throughout perimacular area.

patients can have macular edema, venous engorgement, punctate and flame-shaped hemorrhages, and arterial occlusion. Foreign body granulomas of the retina have also been described.

Retinal neovascularization as a consequence of talc injection can occur in the retinal periphery as neovascular tufts in the shape of sea fans at the junction of the perfused and nonperfused retina. This is a potentially serious complication of talc emboli, because it can lead to retinal detachment, massive vitreal hemorrhage, and optic disc neovascularization.

Most patients have no significant visual symptoms, and visual acuity is normal. Some patients, however, report blurring of vision and blind spots in the visual fields and occasionally can have severe reduction of visual acuity associated with macular ischemia or fibrosis. Neither the extent of drug abuse nor the degree of filtration of the prepared suspension appears to be correlated with visual symptoms.

The extent of talc particles observed in the posterior pole appears to correlate with the duration of drug abuse and with the cumulative number of tablets injected. Often, the drug abuser injects from 10 to 40 tablets daily, and some abusers inject as many as 100 tablets daily for several years. Talc retinopathy is usually not found in drug abusers who have injected less than 9,000 tablets, but it is consistently found in most patients who have injected more than 12,000 tablets.

A variant of talc retinopathy has been referred to as “microtalc” retinopathy. This appears as fine refractile deposits distributed in the superficial retinal layers of the

posterior pole adjacent to the vascular arcades. These lesions were usually associated with retinal nerve fiber defects and were seen exclusively in patients with a history of free-basing crack cocaine. Visual field changes that mimic glaucoma can occur.

Other clinical signs of drug abuse may be present. These include weight loss, disheveled physical appearance, poor mental status, drug-seeking behavior, unusual infections, repetitive lost prescriptions, burns to hand and face, and “doctor shopping.”

### Etiology

As the talc, cornstarch, and other insoluble tablet fillers embolize to the lungs, they become trapped within the pulmonary tissues and eventually cause pulmonary hypertension. This leads to the development of collateral vessels that allow part of the venous return to bypass the lungs and enter the left side of the heart, where the particles are further embolized to the eye and other organs of the body. The presence of talc particles in the eye indicates that substantial foreign body damage has occurred in the lungs.

The talc particles are more numerous in the perimacular region than in other areas of the retina, probably because of the rich blood supply and greater blood flow in that area. The particles lodge in the walls of the precapillary arterioles and capillaries, producing focal occlusion of these vessels in the retina and choroid. The occlusions are caused primarily by the cellular reaction to the emboli.

The neovascular lesions of talc retinopathy are thought to be associated with peripheral arteriolar nonperfusion, which leads to retinal ischemia and secondary neovascularization. Such a pathogenesis is quite similar to that seen in sickle cell retinopathy and is confirmed by the predominantly supertemporal location of the neovascular proliferation. Macular fibrosis with significant visual loss has also been associated with talc retinopathy.

Microtalc dusting of the retina may represent minute crystalline deposits of crack cocaine’s adulterants lodged in the retinal microcirculation, the inner retinal layers, or both. It has been hypothesized that the retinal nerve fiber layer changes seen in these patients may occur from ischemia induced by focal drug-induced vasospasm of the short posterior ciliary arteries.

### Management

Because of the implications of the diagnosis, the practitioner must rule out other conditions that may have a similar clinical appearance. The differential diagnosis includes Gunn dots, multiple cholesterol emboli, drusen, and Stargardt disease.

Once the diagnosis has been established, appropriate drug abuse counseling should be given to prevent further risk of severe pulmonary or ocular complications. Consideration should also be given to pulmonary consultation, because patients with eye findings usually have

acute or chronic impairment of pulmonary function. The patient should be monitored carefully for the development of progressive ocular lesions, especially of the neovascular type. Some suggest that the static nature of this condition indicates that, in the absence of ongoing intravenous drug use, close follow-up may not be necessary. Proliferative retinopathy can be treated with the use of argon laser photocoagulation, and vitreal hemorrhage may require vitrectomy.

Patients with microvascular retinopathy should be managed with annual threshold visual field testing and fundus photography. If other risk factors for glaucoma exist, affected patients may require prophylactic topical ocular hypotensive therapy to prevent progressive visual field loss.

## DRUGS AFFECTING THE OPTIC NERVE

Drug toxicity must always be considered in the differential diagnosis of optic neuropathy. A careful history should attempt to uncover any prescribed or self-administered drugs that may have been taken in the past or present. There has been speculation that maternal drug use during pregnancy may lead to optic nerve hypoplasia. Drugs reported to cause this condition include phenytoin, quinine, alcohol, and cocaine. Other drugs known or reported to cause significant optic nerve disease are listed in Table 35-12. The most important of these drugs, ethambutol, chloramphenicol, and amiodarone, are addressed in the following sections; newer drugs such as the PDE-5 inhibitors and drugs implicated in intracranial hypertension and drug-induced systemic lupus are addressed as well.

### Ethambutol

Introduced in 1961 for the treatment of tuberculosis, ethambutol supplanted para-aminosalicylic acid for the initial treatment and retreatment of tuberculosis.

#### Clinical Signs and Symptoms

Ethambutol is well recognized to cause ocular symptoms of reduced visual acuity, changes in color vision, and visual field loss. Ocular toxicity can appear as early as several weeks after initial therapy, but the onset of ocular complications usually occurs several months after therapy has begun. Although various forms of optic neuritis have been described, the primary ocular manifestation of ethambutol toxicity is retrobulbar neuritis. This can occur in several forms (Table 35-13). The most common form involves loss of visual acuity associated with a central or paracentral scotoma and color vision disturbances and is caused by compromise of the central optic nerve fibers. Less commonly, ethambutol can affect the peripheral optic nerve fibers, causing defects in the peripheral visual field. Finally, in rare cases ethambutol can cause visible retinal manifestations, including hyperemia and swelling of the

**Table 35-12**  
Drugs That Can Affect the Optic Nerve

Drug	Adverse Effect
Ethambutol	
Chloramphenicol	
Isoniazid (rare)	Optic neuritis
Tamoxifen	(chloramphenicol and NSAIDs may show a papillitis)
Nonsteroidal anti-inflammatory drugs	
Oral contraceptives (rare)	
Amiodarone	
Methotrexate	Optic neuropathy/optic atrophy
Vigabatrin	
Corticosteroids	
Tetracyclines (including minocycline, doxycycline)	
Nitrofurantoin	Intracranial hypertension
Nalidixic acid	
Vitamin A (retinoids, including isotretinoin)	
Oral contraceptives	
PDE-5 inhibitors: sildenafil	Nonarteritic ischemic optic neuropathy
Sumatriptan	
Amiodarone	

optic disc, flame-shaped hemorrhages on the optic disc and in the retina, and macular edema. After several weeks, these signs can be followed by primary optic atrophy.

Color vision deficiencies are probably the most sensitive indicator of early ethambutol optic neuropathy and can occur even before visual acuity and visual fields are affected. Sometimes, contrast sensitivity can be affected before either visual acuity or color vision becomes impaired.

**Table 35-13**  
Characteristics of Optic Neuropathy Due to Ethambutol Use

	Central (Axial)	Peripheral
Toxic dosage	Low	High
Visual acuity	Reduced	Normal
Visual field	Central scotoma	Peripheral contraction
Color vision	Red-green deficiency	Normal

Modified from Garrett CR. Optic neuritis in a patient on ethambutol and isoniazid evaluated by visual evoked potentials: case report. *Mil Med* 1985;150:43-46.



Once changes have occurred in visual acuity, visual field, or color vision, these functional changes may continue to deteriorate even after ethambutol has been discontinued. More often, however, there is recovery of pretreatment visual acuity and visual field several months or years after discontinuation of the drug. The degree of recovery depends largely on the extent to which ethambutol has compromised optic nerve function. If the ocular toxicity is not recognized early, the drug can cause permanent loss of vision, especially in older patients.

Considerable evidence indicates that ocular toxicity associated with ethambutol therapy is dose related. It is now recognized that ethambutol rarely induces ocular changes at a dosage of 15 to 20 mg/kg of body weight daily, and this has led to the current recommendation that ethambutol dosages should not generally exceed 15 mg/kg of body weight daily. Some practitioners give the drug in dosages of 25 mg/kg daily for a period not exceeding 2 months, followed by a maintenance dosage of 15 mg/kg daily, and this has been shown to cause virtually no ocular complications. It should be noted that another antituberculosis drug, isoniazid, has also been reported to cause optic neuritis; however, the reports on this drug are far fewer, and neuropathy does not appear to occur in a dose-dependent manner.

### Etiology

Although the mechanism by which ethambutol causes retrobulbar neuritis is largely unknown, it has been suggested that ethambutol may affect the amacrine and bipolar cells of the retina, because color vision can be affected without altering visual acuity. The drug may affect mitochondrial metabolism in the optic nerve by chelating copper, or the drug-induced vision loss may be mediated through an excitotoxic pathway involving glutamate. Renal impairment can also play a role by permitting high plasma drug levels to accumulate, which may contribute to the development of optic neuropathy.

### Management

It is important for patients beginning treatment with ethambutol to have a baseline examination and frequent monitoring of visual acuity, visual fields, color vision (Farnsworth Panel D-15), and fundus appearance. Because it is rare for ocular toxicity to occur with dosages as low as 15 mg/kg daily, patients taking such dosages can be monitored every 3 to 6 months, including daily home monitoring of vision. Patients with renal insufficiency, however, should be monitored monthly because they have an impaired ability to excrete the drug and therefore may be at increased risk for developing ocular changes. Because there is some evidence that patients with lower plasma zinc levels have a higher incidence of optic neuropathy, these patients should also be examined more frequently.

Color vision and visual fields are usually more sensitive indicators of early optic neuropathy than is visual acuity

testing. The desaturated Panel D-15 test or the Farnsworth-Munsell 100-hue test can detect subtle red-green or blue-yellow color vision changes associated with early ethambutol toxicity. Visual field studies using static threshold techniques aid in detecting early visual field abnormalities. Several authors have recommended use of visual evoked potentials for the routine monitoring of patients taking ethambutol. This procedure has been effective in detecting subclinical optic nerve disease that can precede changes in visual acuity and color vision.

Ethambutol therapy must be discontinued in patients who develop reduced visual acuity, color vision deficiency, or visual field defects characteristic of optic neuropathy. Symptoms of peripheral neuropathy may indicate early ethambutol toxicity and should serve as a warning sign of impending optic neuropathy. Thus, the ethambutol dosage in patients encountering peripheral neuropathy should be reduced to prevent the development of ocular toxicity. If discontinuation of drug therapy alone does not result in improvement of visual function, consideration can be given to treatment with hydroxocobalamin, which may help with recovery of visual acuity. Although the mechanism of action of hydroxocobalamin in the treatment of ethambutol-induced optic neuropathy is elusive, this vitamin may act by neutralizing the chelating action of ethambutol on the optic nerve.

## Chloramphenicol

Chloramphenicol is used for the treatment of typhoid fever, bacterial meningitis, and certain anaerobic infections such as in the treatment of cystic fibrosis in children.

### Clinical Signs and Symptoms

Characteristics of most cases of chloramphenicol-associated optic neuritis are severe bilateral reduction of visual acuity ranging from 20/100 to 5/400 with dense central scotomata. Although there may be no fundus changes (retrobulbar neuritis), the optic discs are usually edematous and hyperemic, the retinal veins are engorged and tortuous, and hemorrhages are often seen in the peripapillary area. Optic atrophy is a late sign. Peripheral neuritis characterized by numbness and cramps of the feet often precedes the visual complaints by 1 to 2 weeks and may therefore serve as an early warning sign of impending ocular toxicity.

Visual impairment associated with chloramphenicol therapy usually recovers after the drug is discontinued, but pretreatment visual acuity is often not regained and visual field defects may persist. Some patients may tolerate further prolonged treatment with chloramphenicol without recurrent optic neuritis, and, occasionally, patients can demonstrate improvement of visual function despite continued therapy.

Most cases of optic neuritis associated with chloramphenicol therapy have occurred in children with cystic fibrosis who were treated with large daily dosages of the

drug, from 1 to 6 g daily. Although visual symptoms can occur as early as 10 days after beginning therapy, ocular toxicity commonly occurs after several months or years of treatment, with optic neuritis being considered a dose-dependent OADR.

### Etiology

The precise mechanism by which chloramphenicol produces optic neuritis is unknown. Although the view is not substantiated, several authors have proposed that chloramphenicol may induce optic neuropathy by causing a vitamin deficiency. Genetic factors may be involved, and it has also been hypothesized that chloramphenicol may be biotransformed into degradation products that are potentially toxic to the optic nerve.

Histopathologic studies have found bilateral optic atrophy with primary involvement of the papillomacular bundle, loss of the retinal ganglion cells, and gliosis of the nerve fiber layer. The presence of peripheral visual field defects in some patients is evidence that there is also involvement of the peripheral portion of the visual pathway.

### Management

Patients who are to receive long-term chloramphenicol therapy should be given a comprehensive baseline examination consisting of visual acuity testing, visual field testing, color vision testing, and fundus examination. The risk of optic neuropathy is minimized if the daily dosage of drug is limited to 25 mg/kg of body weight, or less, for a period not exceeding 3 months. Patients or their caregivers should be encouraged to be alert to the development of peripheral neuritis, which might indicate impending loss of vision. Once signs or symptoms of optic neuropathy are detected, promptly discontinue drug therapy in consultation with the prescribing physician. Because the outcome of vitamin therapy is uncertain, the case for administration of megadose vitamins is not compelling.

## Amiodarone

Not only is amiodarone well-known to cause corneal toxicity (see *Drugs Affecting the Cornea and Crystalline Lens*, above), but it also can cause optic neuropathy.

### Clinical Signs and Symptoms

Although the precise incidence of amiodarone-induced optic neuropathy is unknown, it has been estimated to occur in approximately 2% of patients. The optic nerve appearance is characterized by disc swelling with or without peripapillary disc hemorrhages. Patients who receive amiodarone may be at increased risk for developing nonarteritic anterior ischemic optic neuropathy (NAION), and the two conditions may have strikingly similar appearances and patients may have similar risk factors (>50 years of age, high blood pressure and cholesterol, diabetes, smoking, small optic disc cupping).

Optic neuropathy associated with amiodarone is characterized by an insidious onset, slow progression, bilateral vision loss, and long-standing disc swelling that tends to stabilize within months after the medication has been discontinued. In contrast, NAION is characterized by acute unilateral vision loss, and the disc edema resolves over several weeks. In amiodarone-induced optic neuropathy, the disc swelling and hemorrhages tend to persist for several months, whereas in NAION these signs usually resolve more quickly. Once drug therapy is stopped, visual acuity and visual field defects tend to stabilize or improve.

### Etiology

A primary lipidosis has been described in human optic nerves affected by amiodarone. One study has shown that intracytoplasmic inclusions may mechanically or biochemically block axoplasmic flow in large optic nerve axons, resulting in optic disc edema and hemorrhage.

### Management

Patients should receive a baseline ophthalmic examination before starting therapy with amiodarone and every 6 months thereafter. Amiodarone should be promptly discontinued in the event of optic neuropathy, as long as reasonable medical alternatives exist. These issues must be considered in consultation with the patient's cardiologist or internist. Other recommendations have suggested that if simultaneous bilateral disc edema presents and tests are negative for arteritic ischemic optic neuropathy and increased intracranial pressure, the drug should be discontinued. However, if unilateral typical NAION occurs in a crowded disc and no other sign of systemic toxicity to amiodarone is noted, then continuation of amiodarone may be considered.

## Sildenafil

Although color vision alterations, blurred vision, and light sensitivity are well-known transient OADRs that occur in less than 10% of users of the PDE-5 inhibitors, recent reports of NAION have generated considerable attention. Although NAION did not emerge in clinical trials as a possible OADR, approximately 25 published and unpublished cases have been reported to the National Registry of Drug-Induced Ocular Side Effects, most relating to sildenafil. Patients with many vascular risk factors may be at greatest risk for NAION; however, the risk in the general population may be equivocal or lower. The following factors suggest that there may not be a link between the use of these drugs and NAION:

1. The plasma half-life of sildenafil is 4 hours, and many of the reported events appeared to have occurred after this time frame.
2. The appearance of NAION does not appear to be dose dependent.
3. Dechallenge of the drug shows similar recovery to that of unrelated NAION.

4. No mechanism has been proven to date. There has been one positive rechallenge case report in the literature.

### Etiology

Currently, the etiology for NAION with PDE-5 use is controversial. The association has been made with PDE-5-related blood pressure lowering, exacerbating nocturnal hypotension, considered to be the most important feature in the development and progression of NAION. This may be exacerbated by the over-treatment of hypertension and other factors, increasing the risk of NAION in a previously predisposed patient.

### Management

The risk factors for NAION have been reported to be age >50 years, cardiovascular disease, cigarette smoking, diabetes, hyperlipidemia, hypertension, intraocular surgery, small cup-to-disc ratio, sleep apnea, factor V Leiden mutation, and history of NAION in one eye. Other potential causes include hypotension (especially nocturnal), increased IOP, migraine, and other vasospastic disorders. Therefore it is generally accepted that men with history of a previous NAION or with a number of risk factors, including diabetes, or those on aggressive antihypertensive drugs should be advised about the risk of NAION.

Given the number of prescriptions written for these medications every year, compelling evidence does not yet exist to discourage use of erectile dysfunction agents because of harmful ocular side effects. NAION is considered "possible" by WHO causality classification.

### Drug-Induced Intracranial Hypertension

Drug-induced intracranial hypertension (pseudotumor cerebri) is especially of concern because it may be asymptomatic, and therefore patients with this condition may not seek ophthalmic care. However, the general presenting signs and symptoms are the same as for the idiopathic form, including headaches, transient visual obscurations, and bilateral disc edema (papilledema). Opening pressure of cerebrospinal fluid is generally over 200 mm of water (average 320 mm of water). Computed tomography and/or magnetic resonance imaging are normal, as is the content of the cerebrospinal fluid. The only other neurologic defect is possibly diplopia associated with a fourth cranial nerve palsy. The range of measurable visual field defects is great, from no field loss to marked loss, and is likely dependent on the length of time that the optic discs have been swollen and to what degree. Treatment for the idiopathic form generally includes weight loss (where applicable), carbonic anhydrase inhibitors, and occasionally surgery to lower the intracranial pressure.

Intracranial hypertension has been linked to a number of medications (Table 35-14), including corticosteroids (withdrawal), nalidixic acid, nitrofurantoin, danazol, ciprofloxacin, and amiodarone. The main two categories

**Table 35-14**

Drugs That May Cause Intracranial Hypertension (Pseudotumor Cerebri)

Drug	Increased Intracranial Pressure
Retinoids	Vitamin A, isotretinoin, tretinoin, others
Tetracyclines	Tetracycline, minocycline, doxycycline
Antiarrhythmics	Amiodarone
Steroids	Dexamethasone, prednisone
Nonsteroidal anti-inflammatory drugs	Indomethacin, nalidixic acid
Antipsychotic	Lithium
Hormone treatments	Combination estrogen/progesterone

of drugs include the tetracyclines and their derivatives, minocycline and doxycycline, and the retinoids, from vitamin A to synthetic derivatives such as isotretinoin (Accutane), tretinoin, and retinoin.

### Tetracyclines

The onset of symptoms may be hours to days of beginning tetracycline treatment, though it is usually seen months from initiation. Minocycline, a semisynthetic tetracycline, has been associated as a cause or precipitating factor in numerous cases. Symptoms have been found to occur within 8 weeks of starting minocycline therapy in standard dosages, although others have not manifested the condition until over a year of therapy. Although most patients are symptomatic and are diagnosed promptly, others have no symptoms and may have optic disc edema long before a diagnosis is made. After drug withdrawal and resolution of the elevated intracranial pressure, some patients may be left with residual optic disc swelling or pallor and visual field abnormalities. The association between intracranial hypertension and doxycycline is the least well established, although it has been seen in patients taking this drug for malaria prophylaxis. This decreased frequency of this serious OADR may be due to a decreased propensity for doxycycline to produce increased intracranial pressure, or it may reflect less frequent prescription of this agent over minocycline.

Because patients can be asymptomatic, periodic ophthalmoscopic examination is warranted for patients on long-term therapy with tetracycline, minocycline, or doxycycline.

### Etiology

The mechanism of minocycline-induced intracranial hypertension may be similar to that postulated for the tetracyclines, which has been shown to be related to reduced cerebrospinal fluid absorption due to an effect

on cyclic adenosine monophosphate in the arachnoid villi. Because minocycline is more lipid soluble than tetracycline, it is capable of crossing the blood-brain barrier more effectively and therefore may show more of a tendency to intracranial hypertension than tetracycline.

### Management

Patients who are taking a retinoid, especially in combination with a tetracycline, should be carefully counseled to seek evaluation in the event of the development of blurred vision (static or transient), double vision, and/or headaches. These patients should have been counseled to avoid vitamin A. Discontinuation of treatment usually permits resolution of the raised intracranial pressure and disc edema, but other interventions may be undertaken if warranted.

### Retinoids

The retinoids are used to treat dermatologic conditions such as severe nodular acne and psoriasis. Although isotretinoin (Accutane) has been documented in many more case studies than the tetracyclines to cause "certain" intracranial hypertension, other retinoids have not been included in this classification until recently. This designation has been changed from "possible" to "certain" recently as a close temporal relationship has been shown (mean, 2.3 months) to development of the condition (more than 80 cases of positive dechallenge and 6 cases of positive rechallenge have been documented) and because isotretinoin belongs to a class of agents known to cause intracranial hypertension. However, the number of reported cases has decreased in recent years likely due to awareness of this potentially serious adverse effect.

The use of systemic tetracyclines in combination with the retinoid may lead to a higher risk of intracranial hypertension. Factors including obesity have been noted

in a number of the few cases of this condition and may therefore further complicate the diagnosis.

### Etiology

The mechanism of how retinoids cause intracranial hypertension is unclear; however, isotretinoin is thought to both increase the secretions from and impede the absorption by the arachnoid villi.

## DRUG-INDUCED LUPUS ERYTHEMATOSUS

Drug-induced lupus erythematosus has been recognized as a condition similar in presentation to idiopathic systemic lupus erythematosus, although the demographics of patients who develop this disease are somewhat different, including older age and equal gender distribution. Some clinical features differ, and the presentation in drug-induced lupus erythematosus tends to be milder than in systemic lupus erythematosus. Systemic lupus erythematosus is a relapsing and remitting autoimmune disorder characterized by a wide spectrum of multisystem involvement. The diagnosis is often complicated and often takes years to establish. Box 35-6 lists many of the retinal vascular, neuro-ophthalmic, and anterior segment manifestations of systemic lupus erythematosus. In terms of drug-induced lupus, the onset is variable, reported to be as soon as 1 month but as late as 12 years after drug initiation. Clinical presentation may be somewhat different from systemic lupus erythematosus, with fever, arthralgias, pleuritis, pericarditis, mild leukopenia, thrombocytopenia, anemia, and elevated erythrocyte sedimentation rate but not malar rash, alopecia, discoid lesions, and photosensitivity.

More than 80 drugs have been associated with drug-induced lupus erythematosus, including procainamide, hydralazine, isoniazid, and minocycline (Box 35-7).

### Box 35-6 Ocular Manifestations of Systemic Lupus Erythematosus

Retinal Vascular	Neuro-Ophthalmic	Anterior Segment
Hemorrhages	Cranial nerve palsies	Severe ocular dryness
Cotton-wool spots	Homonymous visual field loss	Periorbital edema
Retinal edema	Internuclear ophthalmoplegia	Discoid lesions of the lids
Microaneurysms	Nystagmus	Anterior segment neovascularization
Arteriolar narrowing	Visual hallucinations	Conjunctivitis
Venous engorgement	Intracranial hypertension with papilledema	Uveitis
Vascular tortuosity	Migraine-like headaches	Episcleritis
Arteriolar occlusion	Retrobulbar neuritis	Scleritis
Venous occlusion	Papillitis	Orbital inflammation
Perivasculitis	Optic atrophy	
Lupus choroidopathy		
Neovascularization		
Exudative retinal detachment		

**Box 35-7** Drugs Implicated in DILE

"Definite"	"Possible"	Suggested, Rare, or Recently Implicated
Hydralazine Procainamide Isoniazid Methyldopa Chlorpromazine Quinidine Minocycline	Sulfasalazine Anticonvulsants (e.g., carbamazepine, phenytoin, etc.) Antithyroid agents (e.g., propylthiouracil) Terbafine Statins Penicillamine Beta-blockers (e.g., propranolol, pindolol, atenolol, metoprolol, timolol) Hydrochlorothiazide Interferon- $\alpha$ Fluorouracil agents	Gold, penicillin, streptomycin, tetracycline, phenylbutazone, estrogens and oral contraceptives, reserpine, lithium, para-aminosalicylic acid, captopril, griseofulvin, calcium channel blockers, ciprofloxacin, rifampin, clonidine, hydroxyurea, interferons, gemfibrozil, interleukin-2, clobazam, clozapine, tocainide, lisinopril, etanercept, infliximab, zafirlukast

Modified from Sarzi-Puttini P, Atzeni F, Capsoni F, et al. Drug-induced lupus erythematosus. *Autoimmunity* 2005;38:507–518.

## HERBAL AGENTS AND NUTRITIONAL SUPPLEMENTS

Alternative therapies for human ailments and diseases are a rapidly growing segment of health care. Many are used specifically for ocular diseases (approximately 60 products), whereas others have potential ocular adverse drug effects.

Canthaxanthin, a carotenoid used as a food coloring and tanning agent, has been shown to cause a "certain" dose-related adverse effect consisting of deposition of crystals in the macular region that are slowly reversible on discontinuation.

Chamomile is considered to be a "probable" OADR, causing severe conjunctivitis when applied around the eyes. Interestingly, there are ocular "indications" for this herbal product, which include treatment of styes, inflammation, and epiphora. *Echinacea purpurea* is used to treat the common cold and other disorders but has been shown to cause "possible" conjunctivitis and eye irritation when applied topically.

Jimson weed is a form of *Datura* that can have relatively high concentrations of antimuscarinic agents and therefore is considered to be "certain" to cause pupillary dilation.

*Ginkgo biloba* is used widely for a number of disorders, including peripheral occlusive arterial disease, dementia, tinnitus, asthma, angina, and tonsillitis. Hemorrhage has been seen with this agent, both in the eye (spontaneous hyphema is considered "possible," whereas retinal hemorrhages are considered "probable") and in the brain (subarachnoid hemorrhage, subdural hematoma) and therefore should be used with caution in patients already using blood-thinning agents such as warfarin (Coumadin) and aspirin.

Licorice has been shown to have anti-inflammatory and antiplatelet effects. Large doses of this agent have

been linked to migrainous-like events considered to be a "possible" OADR. It also can cause seriously low potassium levels and digitalis toxicity if allowed to interact with diuretics and cardiac glycosides.

Niacin has been used for its triglyceride and cholesterol-lowering effects, but a "certain" association has been made to cystoid macular edema. Blurred vision is considered "probable" with this agent. Other associations include dry eyes, discoloration of the eyelids, eyelid edema, loss of brow and lash hair, and superficial punctate keratitis.

Excessive use of vitamin A can result in ocular dryness, loss of lashes, night blindness, and even intracranial hypertension, the latter of which is similar to that occurring with the other forms of vitamin A such as isotretinoin, approved for the treatment of cystic acne. With large doses, increased intracranial pressure is considered "certain."

## DETECTION AND PREVENTION OF ADVERSE REACTIONS

Ophthalmic practitioners must protect the well-being of their patients by detecting signs and symptoms of drug toxicities so that appropriate action can be taken to prevent or minimize serious ocular consequences. The detection process begins with the initial patient interview, during which a detailed drug history may reveal use of medications, herbals, nutritional supplements, and recreational agents with potential ocular side effects. A careful history is especially important in elderly patients, who typically use more medications than do younger individuals. Although most patients over age 60 years regularly take several medications, many patients are unable to identify the drugs they take. This emphasizes the importance of patient education regarding prescribed and self-administered medications.

U.S. Department of Health and Human Services

Form Approved: OMB No. 0910-0291, Expires: 10/31/08  
See OMB statement on reverse.

# MEDWATCH

For VOLUNTARY reporting of  
adverse events, product problems and  
product use errors

Page \_\_\_\_\_ of \_\_\_\_\_

FDA USE ONLY	
Triage unit sequence #	

## The FDA Safety Information and Adverse Event Reporting Program

A. PATIENT INFORMATION			
1. Patient Identifier  In confidence	2. Age at Time of Event, or Date of Birth:	3. Sex <input type="checkbox"/> Female <input type="checkbox"/> Male	4. Weight _____ lb or _____ kg
B. ADVERSE EVENT, PRODUCT PROBLEM OR ERROR			
Check all that apply:			
1. <input type="checkbox"/> Adverse Event <input type="checkbox"/> Product Problem (e.g., defects/malfunctions) <input type="checkbox"/> Product Use Error <input type="checkbox"/> Problem with Different Manufacturer of Same Medicine			
2. Outcomes Attributed to Adverse Event (Check all that apply)			
<input type="checkbox"/> Death: _____ (mm/dd/yyyy)			
<input type="checkbox"/> Life-threatening			
<input type="checkbox"/> Hospitalization - initial or prolonged			
<input type="checkbox"/> Required Intervention to Prevent Permanent Impairment/Damage (Devices)			
<input type="checkbox"/> Disability or Permanent Damage		<input type="checkbox"/> Congenital Anomaly/Birth Defect	
<input type="checkbox"/> Other Serious (Important Medical Events)			
3. Date of Event (mm/dd/yyyy)		4. Date of this Report (mm/dd/yyyy)	
5. Describe Event, Problem or Product Use Error			
6. Relevant Tests/Laboratory Data, Including Dates			
7. Other Relevant History, Including Preexisting Medical Conditions (e.g., allergies, race, pregnancy, smoking and alcohol use, liver/kidney problems, etc.)			
C. PRODUCT AVAILABILITY			
Product Available for Evaluation? (Do not send product to FDA)			
<input type="checkbox"/> Yes <input type="checkbox"/> No <input type="checkbox"/> Returned to Manufacturer on: _____ (mm/dd/yyyy)			

D. SUSPECT PRODUCT(S)		
1. Name, Strength, Manufacturer (from product label)		
#1 _____		
#2 _____		
2. Dose or Amount	Frequency	Route
#1 _____	_____	_____
#2 _____	_____	_____
3. Dates of Use (If unknown, give duration) from/to (or best estimate)		5. Event Abated After Use Stopped or Dose Reduced?
#1 _____		
#2 _____		#1 <input type="checkbox"/> Yes <input type="checkbox"/> No <input type="checkbox"/> Doesn't Apply
4. Diagnosis or Reason for Use (Indication)		#2 <input type="checkbox"/> Yes <input type="checkbox"/> No <input type="checkbox"/> Doesn't Apply
#1 _____		8. Event Reappeared After Reintroduction?
#2 _____		
#1 _____	7. Expiration Date	#1 <input type="checkbox"/> Yes <input type="checkbox"/> No <input type="checkbox"/> Doesn't Apply
#2 _____	#1 _____	#2 <input type="checkbox"/> Yes <input type="checkbox"/> No <input type="checkbox"/> Doesn't Apply
	#2 _____	9. NDC # or Unique ID
		_____
E. SUSPECT MEDICAL DEVICE		
1. Brand Name		
2. Common Device Name		
3. Manufacturer Name, City and State		
4. Model #	Lot #	5. Operator of Device <input type="checkbox"/> Health Professional <input type="checkbox"/> Lay User/Patient <input type="checkbox"/> Other: _____
Catalog #	Expiration Date (mm/dd/yyyy)	
Serial #	Other #	
6. If Implanted, Give Date (mm/dd/yyyy)		7. If Explanted, Give Date (mm/dd/yyyy)
_____		_____
8. Is this a Single-use Device that was Reprocessed and Reused on a Patient? <input type="checkbox"/> Yes <input type="checkbox"/> No		
9. If Yes to Item No. 8, Enter Name and Address of Reprocessor		
F. OTHER (CONCOMITANT) MEDICAL PRODUCTS		
Product names and therapy dates (exclude treatment of event)		
G. REPORTER (See confidentiality section on back)		
1. Name and Address		
Phone #		E-mail
_____		_____
2. Health Professional? <input type="checkbox"/> Yes <input type="checkbox"/> No	3. Occupation	4. Also Reported to:
	_____	<input type="checkbox"/> Manufacturer <input type="checkbox"/> User Facility <input type="checkbox"/> Distributor/Importer
5. If you do NOT want your identity disclosed to the manufacturer, place an "X" in this box: <input type="checkbox"/>		

PLEASE TYPE OR USE BLACK INK

FORM FDA 3500 (10/05) Submission of a report does not constitute an admission that medical personnel or the product caused or contributed to the event.

Figure 35-16 U.S. Food and Drug Administration's MEDWatch adverse drug reaction voluntary reporting form (accessed April 2007).

**ADVICE ABOUT VOLUNTARY REPORTING**

Detailed instructions available at: <http://www.fda.gov/medwatch/report/consumer/instruct.htm>

**Report adverse events, product problems or product use errors with:**

- Medications (*drugs or biologics*)
- Medical devices (*including in-vitro diagnostics*)
- Combination products (*medication & medical devices*)
- Human cells, tissues, and cellular and tissue-based products
- Special nutritional products (*dietary supplements, medical foods, infant formulas*)
- Cosmetics

**Report product problems** - quality, performance or safety concerns such as:

- Suspected counterfeit product
- Suspected contamination
- Questionable stability
- Defective components
- Poor packaging or labeling
- Therapeutic failures (product didn't work)

**Report SERIOUS adverse events. An event is serious when the patient outcome is:**

- Death
- Life-threatening
- Hospitalization - initial or prolonged
- Disability or permanent damage
- Congenital anomaly/birth defect
- Required intervention to prevent permanent impairment or damage
- Other serious (important medical events)

**Report even if:**

- You're not certain the product caused the event
- You don't have all the details

**How to report:**

- Just fill in the sections that apply to your report
- Use section D for all products except medical devices
- Attach additional pages if needed
- Use a separate form for each patient
- Report either to FDA or the manufacturer (*or both*)

**Other methods of reporting:**

- 1-800-FDA-0178 -- To FAX report
- 1-800-FDA-1088 -- To report by phone
- [www.fda.gov/medwatch/report.htm](http://www.fda.gov/medwatch/report.htm) -- To report online

**If your report involves a serious adverse event with a device** and it occurred in a facility outside a doctor's office, that facility may be legally required to report to FDA and/or the manufacturer. Please notify the person in that facility who would handle such reporting.

**If your report involves a serious adverse event with a vaccine** call 1-800-822-7967 to report.

**Confidentiality:** The patient's identity is held in strict confidence by FDA and protected to the fullest extent of the law. FDA will not disclose the reporter's identity in response to a request from the public, pursuant to the Freedom of Information Act. The reporter's identity, including the identity of a self-reporter, may be shared with the manufacturer unless requested otherwise.

*The public reporting burden for this collection of information has been estimated to average 36 minutes per response, including the time for reviewing instructions, searching existing data sources, gathering and maintaining the data needed, and completing and reviewing the collection of information. Send comments regarding this burden estimate or any other aspect of this collection of information, including suggestions for reducing this burden to:*

*Department of Health and Human Services  
Food and Drug Administration - MedWatch  
10903 New Hampshire Avenue  
Building 22, Mail Stop 4447  
Silver Spring, MD 20993-0002*

*Please DO NOT  
RETURN this form  
to this address.*

*OMB statement:  
"An agency may not conduct or sponsor, and a person is not required to respond to, a collection of information unless it displays a currently valid OMB control number."*

**U.S. DEPARTMENT OF HEALTH AND HUMAN SERVICES  
Food and Drug Administration**

FORM FDA 3500 (10/05) (Back)

Please Use Address Provided Below -- Fold in Thirds, Tape and Mail

**DEPARTMENT OF HEALTH & HUMAN SERVICES**

Public Health Service  
Food and Drug Administration  
Rockville, MD 20857

**Official Business**  
Penalty for Private Use \$300

**BUSINESS REPLY MAIL**  
FIRST CLASS MAIL PERMIT NO. 946 ROCKVILLE MD

**MEDWATCH**

The FDA Safety Information and Adverse Event Reporting Program  
Food and Drug Administration  
5600 Fishers Lane  
Rockville, MD 20852-9787



NO POSTAGE  
NECESSARY  
IF MAILED  
IN THE  
UNITED STATES  
OR APO/FPO




Figure 35-16, cont'd.





Canadian Adverse Drug Reaction Monitoring Program

Health Products and Food Branch  
Direction générale des produits de santé et des aliments

- The form should be printed and faxed toll free to: 1 866 678-6789 or mailed as per instructions provided.
- La version française de ce document est disponible à:

Report of suspected adverse reaction due to **health products\*** marketed in Canada

[http://www.hc-sc.gc.ca/dhp-mps/medeff/report-declaration/form/ar-ei\\_form\\_f.html](http://www.hc-sc.gc.ca/dhp-mps/medeff/report-declaration/form/ar-ei_form_f.html)

**PROTECTED B\*\***  
(when completed)

<b>A. Patient Information</b> (See "Confidentiality" section)				<b>C. Suspected Health Product(s)</b> (See "How to report" section)					
1. Identifier		3. Sex		4. Height		5. Weight			
2. Age at time of reaction		<input type="checkbox"/> Male  <input type="checkbox"/> Female		_____ feet or _____ cm		_____ lbs or _____ kgs			
<b>B. Adverse Reaction</b>				1. Name (give labeled strength & manufacturer, if known) # 1 _____ # 2 _____					
1. Outcome attributed to adverse reaction (check all that apply)				2. Dose, frequency & route used		3. Therapy dates (if unknown, give duration)			
<input type="checkbox"/> Death (yyyy/mm/dd) <input type="checkbox"/> Disability <input type="checkbox"/> Life-threatening <input type="checkbox"/> Congenital malformation <input type="checkbox"/> Hospitalization <input type="checkbox"/> Required intervention to prevent damage/permanent impairment <input type="checkbox"/> Hospitalization - prolonged <input type="checkbox"/> Other : _____				# 1 _____		# 1 From (yyyy/mm/dd) - To (yyyy/mm/dd)			
2. Date of reaction				# 2 _____		# 2 _____			
YYYY		MM		DD		3. Date of this report			
YYYY		MM		DD		4. Indication for use of suspected health product			
4. Describe reaction or problem				# 1 _____		5. Reaction abated after use stopped or dose reduced			
				# 2 _____		# 1 <input type="checkbox"/> Yes <input type="checkbox"/> No <input type="checkbox"/> Doesn't apply			
				# 2 _____		# 2 <input type="checkbox"/> Yes <input type="checkbox"/> No <input type="checkbox"/> Doesn't apply			
6. Lot # (if known)		7. Exp. date (if known)		8. Reaction reappeared after reintroduction					
# 1 _____		# 1 (yyyy/mm/dd)		# 1 <input type="checkbox"/> Yes <input type="checkbox"/> No <input type="checkbox"/> Doesn't apply					
# 2 _____		# 2 _____		# 2 <input type="checkbox"/> Yes <input type="checkbox"/> No <input type="checkbox"/> Doesn't apply					
5. Relevant tests / laboratory data (including dates (yyyy/mm/dd))				9. Concomitant health products (name, dose, frequency and route used), and therapy dates (yyyy/mm/dd) (exclude treatment of reaction)					
6. Other relevant history, including pre-existing medical conditions (e.g. allergies, pregnancy, smoking and alcohol use, hepatic / renal dysfunction)				10. Treatment of adverse reaction (medications and / or other therapy), include dates (yyyy/mm/dd)					
<b>D. Reporter Information</b> (See "Confidentiality" section)				1. Name, address & phone number					
				2. Health professional?		3. Occupation		4. Also reported to manufacturer?	
				<input type="checkbox"/> Yes <input type="checkbox"/> No				<input type="checkbox"/> Yes <input type="checkbox"/> No	

Submission of a report does not constitute an admission that medical personnel or the product caused or contributed to the adverse reaction.  
 \* Use this form to report suspected adverse reactions to pharmaceuticals, biologics (including fractionated blood products, as well as therapeutic and diagnostic vaccines), natural health products or radiopharmaceuticals.  
 \*\* As per the Treasury Board of Canada Secretariat Government Security Policy.

HC/SC 4016 (04/06)



Figure 35-17 Health Canada's Canadian ADR Monitoring Program form for reporting adverse drug reactions (accessed April 2007).

Return this form to the Adverse Reaction (AR) Monitoring Office listed below for your region

## **VOLUNTARY ADVERSE REACTION (AR) REPORTING GUIDELINES**

### **Confidentiality of adverse reaction information**

Any information related to the identity of the patient and/or the reporter of the AR will be protected as per the *Access to Information Act* and the *Privacy Act*. For the "identifier" box, provide some type of identifier that will allow you, the reporter, to readily locate the case if you are contacted for more information; do not use the patient's name.

**Privacy Notice Statement:** Individuals have access to and protection of any provided personal information under the provisions of the *Access to Information Act* and the *Privacy Act*. Suspected health product-related AR information is submitted on a voluntary basis, and is maintained in a computerized database. AR information is used for the monitoring of marketed health products, and may contribute to the detection of potential product-related safety issues as well as to the benefit-risk assessments of these products. For more details with regard to personal information collected under this program, visit the Personal Information Bank; Health Canada; Health Products and Food Branch; Branch Incident Reporting System; PIB# PPU 088 at: [http://infosource.gc.ca/inst/shc/fed07\\_e.asp](http://infosource.gc.ca/inst/shc/fed07_e.asp).

### **What to report?**

ARs to Canadian marketed health products, including prescription and non-prescription pharmaceuticals, biologics (including fractionated blood products, as well as therapeutic and diagnostic vaccines), natural health products and radiopharmaceuticals are collected by the Canadian Adverse Drug Reaction Monitoring Program (CADRMP). An AR is a harmful and unintended response to a health product. This includes any undesirable patient effect suspected to be associated with health product use. Unintended effect, health product abuse, overdose, interaction (including drug-drug and drug-food interactions) and unusual lack of therapeutic efficacy are all considered to be reportable ARs.

AR reports are, for the most part, only *suspected* associations. A temporal or possible association is sufficient for a report to be made. Reporting of an AR does not imply a definitive causal link.

All suspected adverse reactions should be reported, especially those that are:

- **unexpected**, regardless of their severity, i.e., not consistent with product information or labeling; or
- **serious**, whether expected or not; or
- reactions to **recently marketed health products** (on the market for less than five years), regardless of their nature or severity.

### **What is a serious adverse reaction?**

A serious AR is one that requires in-patient hospitalization or prolongation of existing hospitalization, causes congenital malformation, results in persistent or significant disability or incapacity, is life-threatening or results in death. ARs that require significant medical intervention to prevent one of these listed outcomes are also considered to be serious.

### **How to report?**

To report a suspected AR for health products marketed in Canada, health professionals or consumers (preferably in conjunction with their health professional, so that information about medical history can be included in order to make the reports more complete and scientifically valid) should complete a copy of the Report of Suspected Adverse Reaction Due to Health Products Marketed in Canada (HC/SC 4016). This form may be obtained from the Internet at [http://www.hc-sc.gc.ca/dhp-nps/medeff/report-declaration/form/ar-ei\\_form\\_e.html](http://www.hc-sc.gc.ca/dhp-nps/medeff/report-declaration/form/ar-ei_form_e.html), from your Regional AR Monitoring Office (see contact information below), and is also available in the appendices of the Compendium of Pharmaceuticals and Specialties (CPS).

All applicable sections of the AR reporting form should be filled in as completely as possible. Use a separate form for each patient. Up to two suspected health products for a particular AR may be reported on one form. Attach an additional form if there are more than two suspected health products for the AR being reported. Additional pages may be attached if more space is required. The success of the program depends on the quality and accuracy of the information provided by the reporter.

To report an Adverse Event following an Immunization (AEFI) for a vaccine used in the prevention of infectious disease, the same criteria as stated in these guidelines are used. Health professionals should complete a copy of the AEFI reporting form. This form is available on the Internet at [http://www.phac-aspc.gc.ca/im/aei-form\\_e.html](http://www.phac-aspc.gc.ca/im/aei-form_e.html), or in the appendices of the CPS. These forms also exist as customized Provincial/Territorial adverse event forms which can be obtained either from local public health departments or from the Provincial/Territorial health authorities.

For more information on CADRMP, additional copies of AR reporting forms or to report an AR, health professionals and consumers are invited to contact the Adverse Reaction Monitoring Office listed below for their region. The following toll-free numbers may be used by health professionals and consumers. Calls will be automatically routed to the appropriate Regional Adverse Reaction Monitoring Office based on the area code from which the call originates. Toll-free telephone: 1-866-234-2345 Toll-free fax: 1-866-678-6789.

**British Columbia and Yukon:** Canadian Adverse Reaction Monitoring - BC and Yukon, 400-4595 Canada Way, Burnaby, British Columbia, V5G 1J9  
British\_Columbia\_AR@hc-sc.gc.ca

**Alberta and Northwest Territories:** Canadian Adverse Reaction Monitoring - Alberta and Northwest Territories, Suite 730, 9700 Jasper Avenue, Edmonton, Alberta, T5J 4C3  
Alberta\_AR@hc-sc.gc.ca

**Saskatchewan:** Canadian Adverse Reaction Monitoring - Saskatchewan, 4<sup>th</sup> floor, Room 412, 101 - 22<sup>nd</sup> Street East, Saskatoon, Saskatchewan, S7K 0E1  
Saskatchewan\_AR@hc-sc.gc.ca

**Manitoba:** Canadian Adverse Reaction Monitoring - Manitoba, 510 Lagimodière Blvd, Winnipeg, Manitoba, R2J 3Y1  
Manitoba\_AR@hc-sc.gc.ca

**Ontario and Nunavut:** Canadian Adverse Reaction Monitoring - Ontario and Nunavut, 2301 Midland Avenue, Toronto, Ontario, M1P 4R7  
Ontario\_AR@hc-sc.gc.ca

**Québec:** Canadian Adverse Reaction Monitoring - Québec, 1001 Saint-Laurent Street West, Longueuil, Québec, J4K 1C7  
Quebec\_AR@hc-sc.gc.ca

**Atlantic:** Canadian Adverse Reaction Monitoring - Atlantic, For New Brunswick, Nova Scotia, Prince Edward Island, Newfoundland and Labrador, 1505 Barrington St., Maritime Centre, Suite 1625, 16<sup>th</sup> floor, Halifax, Nova Scotia, B3J 3Y6  
Atlantic\_AR@hc-sc.gc.ca

### **How to deal with follow-up information for an AR that has already been reported?**

Any follow-up information for an AR that has already been reported can be submitted using a new AR reporting form. It can be communicated by telephone, fax or e-mail to the appropriate Adverse Reaction Monitoring Office (see contact information above). In order that this information can be matched with the original report, indicate that it is follow-up information, and if known, the date of the original report and the case report tracking number provided in the acknowledgement letter. It is very important that follow-up reports are identified and linked to the original report.

### **What about reporting ARs to the Market Authorization Holder (manufacturer)?**

Health professionals and consumers may also report ARs to the market authorization holder (MAH). Indicate on your AR report sent to Health Canada if a case was also reported to the product's MAH.

**Figure 35-17, cont'd.**

The practitioner should record both prescribed and self-administered medications for each patient, including drug dosage, duration of therapy, and any adverse reactions noted by the patient. If ocular side effects are discovered in the examination, it is wise to advise the prescribing practitioner so that appropriate remedial action may be considered. If no side effects are uncovered but the patient is using one or more of the high-risk medications discussed in this chapter, the patient should be monitored appropriately so that any significant adverse reaction can be detected before serious consequences develop. If adverse events not previously reported are discovered in association with medication use, practitioners are encouraged to report such findings to the Food and Drug Administration. Forms are available for reporting ADRs (Figure 35-16), and electronic reporting via the Internet is also encouraged ([www.fda.gov/medwatch](http://www.fda.gov/medwatch)). Reporting may also occur to one of the other drug registries in the United States and Canada (Figure 35-17).

## SELECTED BIBLIOGRAPHY

- Apostol S, Filip M, Dagne C, Filip A. Dry eye syndrome. Etiological and therapeutic aspects. *Oftalmologia* 2003; 59:28-31.
- Arevalo JF, Lowder CY, Muci-Mendoza R. Ocular manifestations of systemic lupus erythematosus. *Curr Opin Ophthalmol* 2002; 13:404-410.
- Bartlett JD. Ophthalmic toxicity by systemic drugs. In: Chiou GC, ed. *Ophthalmic toxicology*, ed. 2. Philadelphia: Taylor & Francis, 1999.
- Brink HM, Beex LV. Punctal and canalicular stenosis associated with systemic fluorouracil therapy. Report of five cases and review of the literature. *Doc Ophthalmol* 1995;90:1-6.
- British Photodermatology Group. British photo dermatology group guidelines for PUV A. *NR J Dermatol* 1994; 130:246-255.
- Carnahan MC, Goldstein DA. Ocular complications of topical, peri-ocular, and systemic corticosteroids. *Curr Opin Ophthalmol* 2000;11:478-483.
- Chaknis MJ, Brooks SE, Mitchell KT, Marcus DM. Inflammatory opacities of the vitreous in rifabutin-associated uveitis. *Am J Ophthalmol* 1996;122:580-582.
- Chambers RB, Downie A, Foote B, Davidorf FH. Interferon alfa-associated retinopathy. *J Am Osteopath Assoc* 1997;97:43-45.
- Chiou GC. *Ophthalmic toxicology*, ed. 2. Philadelphia: Taylor & Francis, 1999.
- Chiu AM, Chuenkongkaew WL, Cornblath WT, et al. Minocycline treatment and pseudotumor cerebri syndrome. *Am J Ophthalmol* 1998;126:116-121.
- Chrousos GA, Oldfield EH, Doppman JL, Cogan DG. Prevention of ocular toxicity of carmustine (BCNU) with supraorbital intracarotid infusion. *Ophthalmology* 1986;93:1471-1475.
- Connor CG, Flockencier LL, Hall CW. The influence of gender on the ocular surface. *J Am Optom Assoc* 1999;70:182-186.
- Crandall DC, Leopold IH. The influence of systemic drugs on tear constituents. *Ophthalmology* 1979;86:115-125.
- Cumming RG, Mitchell P. Medications and cataract. The Blue Mountains Eye Study. *Ophthalmology* 1998;105:1751-1758.
- Daneshvar H, Racette L, Coupland SG, et al. Symptomatic and asymptomatic visual loss in patients taking vigabatrin. *Ophthalmology* 1999;106:1792-1798.
- de Rojas V, Dart JK, Saw V. The natural history of Stevens-Johnson syndrome: patterns of chronic ocular disease and the role of systemic immunosuppressive therapy. *Br J Ophthalmol* 2007;91:900-904.
- Drug facts and comparisons. Philadelphia: Wolters Kluwer, 2007.
- Dyson EH, Proudfoot AT, Bateman DN. Quinine amblyopia: is current management appropriate? *J Toxicol Clin Toxicol* 1985-1986;23:571-578.
- Erdem U, Ozdegirmenci O, Sobaci E, et al. Dry eye in postmenopausal women using hormone replacement therapy. *Maturitas* 2007;56:257-262.
- Fonollosa A, Segura A, Giral J, Garcia-Arumi J. Tuberculous uveitis after treatment with etanercept. *Graefes Arch Clin Exp Ophthalmol* 2007;245:950-953.
- Fraser-Bell S, Capon M. Talc retinopathy. *Clin Exp Ophthalmol* 2002;30:432-433.
- Fraunfelder FT, Fraunfelder FW, Randall JA. Drug-induced ocular side effects, ed. 5. Boston: Butterworth-Heinemann, 2001.
- Fraunfelder FW. Corneal toxicity from topical ocular and systemic medications. *Cornea* 2006;25:1133-1138.
- Fraunfelder FW. Ocular adverse drug reactions and the National Registry of Drug-Induced Ocular Side Effects. *Insight* 2004;29:7-11.
- Fraunfelder FW. Ocular side effects associated with isotretinoin. *Drugs Today (Barc)* 2004;40:23-27.
- Fraunfelder FW. Ocular side effects from herbal medicines and nutritional supplements. *Am J Ophthalmol* 2004; 138:639-647.
- Fraunfelder FW. The science and marketing of dietary supplements. *Am J Ophthalmol* 2005;140:302-304.
- Fraunfelder FW, Fraunfelder FT. Adverse ocular drug reactions recently identified by the National Registry of Drug-Induced Ocular Side Effects. *Ophthalmology* 2004;111:1275-1279.
- Fraunfelder FW, Fraunfelder FT. Drug-related adverse effects of clinical importance to the ophthalmologist. Retrieved April 10, 2007 from [www.aaof.org/am\\_handouts\\_pdfs/444FarauX129.pdf](http://www.aaof.org/am_handouts_pdfs/444FarauX129.pdf)
- Fraunfelder FW, Fraunfelder FT. Scientific challenges in postmarketing surveillance of ocular adverse drug reactions. *Am J Ophthalmol* 2007;143:145-149.
- Fraunfelder FW, Fraunfelder FT, Keates EU. Topiramate-associated acute, bilateral, secondary angle-closure glaucoma. *Ophthalmology* 2004;111:109-111.
- Friedman DI, Gordon LK, Egan RA, et al. Doxycycline and intracranial hypertension. *Neurology* 2004; Jun 22;62(12): 2297-2299.
- Garrett CR. Optic neuritis in a patient on ethambutol and isoniazid evaluated by visual evoked potentials: case report. *Mil Med* 1985;150:43-46.
- Gorin MB, Day R, Costantino JP, et al. Long-term tamoxifen citrate use and potential ocular toxicity. *Am J Ophthalmol* 1998;125:493-501.
- Graham CM, Blach RK. Indomethacin retinopathy: case report and review. *Br J Ophthalmol* 1988;72:434-438.
- Groomer AE, Terry JE, Westblom TU. Subconjunctival and external hemorrhage secondary to oral anticoagulation. *J Am Optom Assoc* 1990;61:770-775.
- Gross FJ, Schuman JS. Reduced ocular hypotensive effect of topical beta-blockers in glaucoma patients receiving oral beta-blockers. *J Glaucoma* 1992;1:174-177.

- Haimovici R, Gragoudas ES, Duker JS, et al. Central serous chorioretinopathy associated with inhaled or intranasal corticosteroids. *Ophthalmology* 1997;104:1653-1660.
- Halperin E, Yolton RL. Is the driver drunk? Oculomotor sobriety testing. *J Am Optom Assoc* 1986;57:654-657.
- Hayreh SS. Erectile dysfunction drugs and non-arteritic anterior ischemic optic neuropathy: is there a cause and effect relationship? *J Neuroophthalmol* 2005;25:295-298.
- Herd MK. Intraoperative floppy-iris syndrome with doxazosin. *J Cataract Refract Surg* 2007;33:562.
- Hiatt RL, Fuller IB, Smith L, et al. Systemically administered anticholinergic drugs and intraocular pressure. *Arch Ophthalmol* 1970;84:735-740.
- Hollander DA, Aldave AJ. Drug-induced corneal complications. *Curr Opin Ophthalmol* 2004;15:541-548.
- Imperia PS, Lazarus HM, Lass JH. Ocular complications of systemic cancer chemotherapy. *Surv Ophthalmol* 1989;34:209-230.
- Jaanus SD. Ocular side effects of selected systemic drugs. *Optom Clin* 1992;2:73-96.
- Koneru PB, Lien EJ, Koda RT. Oculotoxicities of systemically administered drugs. *J Ocul Pharmacol* 1986;2:385-404.
- Leebeck MJ. Effect of drugs on ocular muscles. *Int Ophthalmol* 1971;11:35-62.
- Marmor MF. Hydroxychloroquine at the recommended dose (< or = 6.5 mg/kg/day) is safe for the retina in patients with rheumatoid arthritis and systemic lupus erythematosus. *Clin Exp Rheumatol* 2004;22:143-144.
- Mitchell AC, Brown KW. Chlorpromazine-induced retinopathy. *Br J Psychiatry* 1995;166:822-823.
- Moorthy RS, Valluri S. Ocular toxicity associated with systemic drug therapy. *Curr Opin Ophthalmol* 1999;10:438-446.
- Moorthy RS, Valluri S, Jampol LM. Drug-induced uveitis. *Surv Ophthalmol* 1998;42:557-570.
- Oshika T, Ohashi Y, Inamura M, et al. Incidence of intraoperative floppy iris syndrome in patients on either systemic or topical alpha(1)-adrenoceptor antagonist. *Am J Ophthalmol* 2007;143:150-151.
- Pomeranz HD. Can erectile dysfunction drug use lead to ischaemic optic neuropathy? *Br J Ophthalmol* 2006;90:127-128.
- Postel EA, Assalian A, Epstein DL. Drug-induced transient myopia and angle-closure glaucoma associated with supraciliary choroidal effusion. *Am J Ophthalmol* 1996;122:110-112.
- Rhee DJ, Ramos-Esteban JC, Nipper KS. Rapid resolution of topiramate-induced angle-closure glaucoma with methylprednisolone and mannitol. *Am J Ophthalmol* 2006;141:1133-1134.
- Rofsky JE, Townsend JC, Ilsen PF, Bright DC. Retinal nerve fiber layer defects and microtalc retinopathy secondary to free-basing "crack" cocaine. *J Am Optom Assoc* 1995;66:712-720.
- Sachs R, Zigelbaum BM, Hersh PS. Corneal complications associated with the use of crack cocaine. *Ophthalmology* 1993;100:187-191.
- Santaella RM, Fraunfelder FW. Ocular adverse effects associated with systemic medications: recognition and management. *Drugs* 2007;67:75-93.
- Sarzi-Puttini P, Atzeni F, Capsoni F, et al. Drug-induced lupus erythematosus. *Autoimmunity* 2005;38:507-518.
- Schwinn DA, Afshari NA. Alpha(1)-adrenergic receptor antagonists and the iris: new mechanistic insights into floppy iris syndrome. *Surv Ophthalmol* 2006;51:501-512.
- See JA, Weller P. Ocular complications of PUVA therapy. *Australas J Dermatol* 1993;34:1-4.
- Shah GK, Auerbach DB, Augsburger JJ, Savino PJ. Acute thioridazine retinopathy. *Arch Ophthalmol* 1998;116:826-827.
- Shaikh S, Shaikh N, Chun SH, et al. Retinal evaluation of patients on chronic amiodarone therapy. *Retina* 2003;23:354-359.
- Shapiro D. The ocular manifestations of the cannabinoids. *Ophthalmologica* 1974;168:366-369.
- Song MK, Azen SP, Buley A, et al. Effect of anti-cytomegalovirus therapy on the incidence of immune recovery uveitis in AIDS patients with healed cytomegalovirus retinitis. *Am J Ophthalmol* 2003;136:696-702.
- Sullivan DA, Belanger A, Cermak JM, et al. Are women with Sjögren's syndrome androgen-deficient? *J Rheumatol* 2003;30:2413-2419.
- Taban M, Dupps WJ, Mandell B, Perez VL. Etanercept (Enbrel)-associated inflammatory eye disease: case report and review of the literature. *Ocul Immunol Inflamm* 2006;14:145-150.
- Tierney DW. Ocular chrysiasis. *J Am Optom Assoc* 1988;59(12):960-962.
- Tripathi RC, Parapuram SK, Tripathi BJ, et al. Corticosteroids and glaucoma risk. *Drugs Aging* 1999;15:439-450.
- Tsai RK, Lee YH. Reversibility of ethambutol optic neuropathy. *J Ocul Pharmacol Ther* 1997;13:473-477.
- Uncu G, Avci R, Uncu Y, et al. The effects of different hormone replacement therapy regimens on tear function, intraocular pressure and lens opacity. *Gynecol Endocrinol* 2006;22:501-505.
- Vessey MP, Hannaford P, Mant J, et al. Oral contraception and eye disease: findings in two large cohort studies. *Br J Ophthalmol* 1998;82:538-542.
- Wilcox TK, Bartlett JD. Systemic drug profiles in adult optometric outpatients. *J Am Optom Assoc* 1988;59:122-126.
- Wolin MJ. Digoxin visual toxicity with therapeutic blood levels of digoxin. *Am J Ophthalmol* 1998;406-407.
- Wooltorton E. Visual loss with erectile dysfunction medications. *CMAJ* 2006;175:355.
- Zhang X, Ognibene CM, Clark AF, Yorio T. Dexamethasone inhibition of trabecular meshwork cell phagocytosis and its modulation by glucocorticoid receptor beta. *Exp Eye Res* 2007;84:275-284.

### Appendix 35-1 Common and Critical Ocular Adverse Drug Reactions From Systemic Drugs

Drug	OADR (including WHO classification of causality, where available)	Prevention/Risks/Considerations	Management
<b>amiodarone</b> (Cordarone) (anti-arrhythmic)	<p>“<b>Certain</b>” corneal microdeposits, ocular surface dryness, blepharconjunctivitis, photosensitivity/bright lights/glare, colored halos around lights, visual sensations, hazy vision, periocular pigmentation</p> <p>“<b>Probable/likely</b>” loss of eyelashes/brows, corneal ulceration, anterior subcapsular opacities, <b>nonarteritic ischemic optic neuropathy (NAION)</b>, intracranial hypertension.</p> <p>“<b>Possible</b>” autoimmune reaction (dry mouth and eye)</p>	<p>No prevention known; baseline assessment and reevaluation every 6 months.</p> <p>As corneal opacities are dependent on dosage and duration of treatment, monitor accordingly. Keratopathy is generally present by 3 months of use. No keratopathy may be seen with 100–200 mg/day, but will be seen when dosage is 400–1,400 mg/day. Warn patients about seeking care if visual disturbances occur (rare).</p> <p>The symptoms are almost exclusively related to the keratopathy. Lens opacities have not been shown to decrease vision.</p> <p>UV-filtering lenses may decrease the keratopathy.</p>	<p>Follow-up examination periodically, perhaps every 6 months. Those with any visual disturbance should be advised to seek care promptly.</p> <p>Take a careful history. If patient is not taking or has not taken amiodarone (or chloroquine), patient should be referred for consideration of Fabry disease.</p> <p>Amiodarone-induced optic neuropathy occurs over months (vs. days to weeks with NAION), vision ranges from 20/20–20/200 (never NLP), edema of the disc may last for months (longer than NAION), and usually occurs within weeks of initiation of amiodarone. Note that diagnosis of NAION vs. amiodarone-induced optic neuropathy may be difficult given that most patients on this therapy are also at greatest risk for NAION.</p>
<b>digoxin</b> (Lanoxin and others), <b>digitoxin</b> (digitalis glycosides for certain cardiac arrhythmias, congestive heart failure)	<p>“<b>Certain</b>” decreased vision (hazy, blurred, dim); decreased CV (yellow or blue tinge, colored halos around lights); flickering or flashing lights (reversible).</p> <p>Specifically, digoxin can give visual hallucinations and mydriasis; digitoxin can give extraocular muscle paresis, photophobia.</p>	<p>Color changes are expected with toxicity related to digoxin, though are only half as common if toxicity is related to digitoxin use.</p> <p>Take a good drug history as concomitant quinidine use can double serum concentration of digitalis drugs.</p>	<p>Consultation with prescribing practitioner. Discontinue if medically acceptable risk. Symptoms may be absent or may occur as soon as 1 day after administration but usually at 2 weeks and rarely after years. Monitor CV (blue-yellow) with D-15 or Farnsworth-Munsell 100-hue test. Changes should be reported to the prescribing physician for consideration of concomitant cardiac digitalis toxicity. Surgeon may have the patient discontinue the medication for a period of time before the surgery to minimize the risk and the degree of IFIS manifestations. This might be measured by the patient's blood pressure and urinary retention. Intraoperative methods may reduce the risk of complications due to IFIS.</p>
<b>tamsulosin</b> (Flomax) and other $\alpha_1$ -adrenoceptor antagonists	<p>“<b>Certain</b>” intraoperative floppy iris syndrome (IFIS)—flaccid iris stroma billows on irrigation, iris prolapse toward incisions, intraoperative miosis; primarily with tamsulosin); amblyopia, blurred vision</p>	<p>Inquire as to whether a patient is using or has ever used tamsulosin prior to referral for ocular surgery. Advise surgeon.</p>	<p>Surgeon may have the patient discontinue the medication for a period of time before the surgery to minimize the risk and the degree of IFIS manifestations. This might be measured by the patient's blood pressure and urinary retention. Intraoperative methods may reduce the risk of complications due to IFIS.</p>
<ul style="list-style-type: none"> <li>alfuzosin (Uroxatral)</li> <li>doxazosin (Cardura)</li> <li>terazosin (Hytrin)</li> </ul> <p>(hypertension, urinary retention usually in benign prostatic hypertrophy)</p>			

<p><b>lovastatin</b> (Mevacor), <b>simvastatin</b> (Zocor), and other statins (cholesterol lowering)</p>	<p>“<b>Possible</b>” or “<b>unlikely</b>” cataracts</p>	<p>Regular comprehensive ophthalmic examinations.</p>	<p>Regular interval comprehensive examinations depending on individual patient risk factors. Cataracts have not been shown to form in normal therapeutic doses.</p>
<p><b>sildenafil</b> (Viagra), and other phosphodiesterase-5 (PDE-5) inhibitors:</p> <ul style="list-style-type: none"> <li>• tadalafil (Cialis)</li> <li>• vardenafil (Levitra) (erectile dysfunction)</li> </ul>	<p>“<b>Certain</b>” changes in color perception (blue, blue/green, pink, yellow tinges, dark colors appear darker); blurred vision (central haze, transient decreased vision); changes in light perception (flashes, increased perception of brightness); ERG changes, conjunctival hyperemia, ocular pain, photophobia (all reversible)</p> <p>“<b>Possible</b>” effects (all possibly due to the associated activity and not the drug) mydriasis, retinal vascular accidents, subconjunctival hemorrhages, <b>anterior ischemic optic neuropathy</b> (NAION), central serous chorioretinopathy (CSCR)</p>	<p>Side effects are based on the dose and are noted 15–30 minutes after ingestion (peak 60 minutes) corresponding to blood drug concentration (sildenafil). Keep doses &lt;100mg</p> <p>Dose-related incidence of ocular side effects (sildenafil):</p> <ul style="list-style-type: none"> <li>• 40–50% at 200 mg</li> <li>• 10% at 100 mg</li> <li>• 3% at 50 mg</li> </ul> <p>Those who have a history of a previous NAION or retinitis pigmentosa (PDE-6 mutations) in self or family members should be advised against using these drugs.</p> <p>Corneal deposits are generally reversible and do not affect vision. There is no mechanism of prevention of retinopathy but early detection is essential. Baseline exam within 1 year of starting medication including acuity, Amsler, CV, VF (central 10°), fundus photographs (multifocal ERG optional). Comprehensive ophthalmic examinations as follows:</p> <ul style="list-style-type: none"> <li>• age 20–29 once</li> <li>• age 30–39, seen twice</li> <li>• age 40–64, every 2–4 years</li> <li>• age &gt;65, every 1–2 years</li> </ul> <p>Any transient or unilateral defects are not considered drug-related. No evidence that the drug worsens preexisting macular degeneration.</p>	<p>CV and light perception changes are transient and related to blood concentration.</p> <p>Those who have experienced any transient losses of vision on any of these drugs should be advised against their use. Though NAION is a serious condition with permanent loss of vision, men using these drugs tend to have the risk factors associated with NAION. Twenty-five cases of NAION have been published with one rechallenge, with an additional 86 cases of visual disturbances. With over 27 million men having used sildenafil, this number is relatively small. Consider stopping the drug if CSCR persists.</p> <p>Patients should be counseled about corneal deposits; however, no change in medication is normally required. Detection is the key to limiting any damage due to irreversible retinopathy.</p> <p>Increased risk:</p> <ul style="list-style-type: none"> <li>• dose &gt;6.5 mg/kg/day (usually &gt;400 mg/day)</li> <li>• kidney or liver disease</li> <li>• &gt;5 years of use</li> <li>• Elderly (thin) patients</li> <li>• Obese patients</li> </ul> <p>Follow-up examinations (if none of the risk factors listed above):</p> <ul style="list-style-type: none"> <li>• age &lt;40, in 2–4 years</li> <li>• age 40–64, in 2 years</li> <li>• age &gt;65, in 1–2 years</li> </ul> <p>ANNUAL examinations if:</p> <ul style="list-style-type: none"> <li>• &gt;5 years of use</li> <li>• Obese, or thin</li> <li>• Progressive macular disease</li> <li>• Renal/liver disease</li> <li>• Dose &gt;6.5 mg/kg/day</li> </ul>
<p><b>hydroxychloroquine</b> (Plaquenil) (treatment of various inflammatory disorders, including rheumatoid arthritis, systemic lupus erythematosus, dermatologic conditions)</p>	<p>“<b>Certain</b>” whorl-like opacity in corneal epithelium, rarely associated with vision loss or other symptoms (reversible).</p> <p>“<b>Certain</b>” maculopathy (characteristically bilateral, reproducible Amsler grid and VF defects); early relative scotomata (paracentral) (may not advance); later retinal changes, CV loss, absolute scotomata, decreased vision (irreversible and may advance).</p>	<p>1 year of starting medication including acuity, Amsler, CV, VF (central 10°), fundus photographs (multifocal ERG optional). Comprehensive ophthalmic examinations as follows:</p> <ul style="list-style-type: none"> <li>• age 20–29 once</li> <li>• age 30–39, seen twice</li> <li>• age 40–64, every 2–4 years</li> <li>• age &gt;65, every 1–2 years</li> </ul>	<p>Increased risk:</p> <ul style="list-style-type: none"> <li>• dose &gt;6.5 mg/kg/day (usually &gt;400 mg/day)</li> <li>• kidney or liver disease</li> <li>• &gt;5 years of use</li> <li>• Elderly (thin) patients</li> <li>• Obese patients</li> </ul> <p>Follow-up examinations (if none of the risk factors listed above):</p> <ul style="list-style-type: none"> <li>• age &lt;40, in 2–4 years</li> <li>• age 40–64, in 2 years</li> <li>• age &gt;65, in 1–2 years</li> </ul> <p>ANNUAL examinations if:</p> <ul style="list-style-type: none"> <li>• &gt;5 years of use</li> <li>• Obese, or thin</li> <li>• Progressive macular disease</li> <li>• Renal/liver disease</li> <li>• Dose &gt;6.5 mg/kg/day</li> </ul>

Continued

### Appendix 35-1 Common and Critical Ocular Adverse Drug Reactions From Systemic Drugs—cont'd

Drug	OADR (including WHO classification of causality, where available)	Prevention/Risks/Considerations	Management
<b>chloroquine</b> (Aralen) (now as an anti-malarial treatment only)	(as for hydroxychloroquine)	OADRs for chronic chloroquine use are more significant and occur sooner than do hydroxychloroquine OADRs. However, this medication is not being used chronically.	Note: for chloroquine, see annually for doses <3.0 mg/kg body weight; every 3–6 months if >3.0 mg/kg body weight, or if short, obese, have renal/liver impairment, or have been on the drug for years. Central vision may recover; VFs may recover over months or remain permanent. CV and dark adaptation changes are usually permanent.
<b>quinine</b> (treatment of leg cramps, formerly for malarial treatment)	Mild toxicity: slight reduction of visual acuity, “flickering” of vision, concentric loss of VFs, impaired night vision. Severe/overdose: sudden complete loss of vision with fixed, dilated pupils.	Regular comprehensive eye examinations as toxicity is uncommon at normal doses <ul style="list-style-type: none"> <li>• normal dose is &lt;2 g/day (maximum)</li> <li>• toxicity at &gt;4 g/day</li> <li>• lethal dose is ~8 g</li> </ul>	
<b>Gold salts</b> (parenteral, oral) (rheumatoid arthritis)	“ <b>Certain</b> ” corneal stromal deposition (yellow-brown gold particles, sparing the periphery and superior cornea), anterior subcapsular cataract.	Baseline comprehensive examination. Advise if symptoms develop to seek care.	Care based on regular comprehensive care guidelines based on all individual patient risk factors.
<b>Corticosteroids</b> <ul style="list-style-type: none"> <li>• prednisone</li> <li>• others</li> </ul> (inflammatory conditions, including rheumatoid arthritis, autoimmune, respiratory) [See Carnahan, MC et al for review on steroid OADRs from other routes of administration, including inhalation]	“ <b>Possible</b> ” deposit in conjunctiva. Delayed corneal epithelial wound healing, PSC, decreased resistance to infection, decreased tear lysozyme, eyelid and conjunctiva hyperemia/edema/angioneurotic edema, subconjunctival hemorrhage, translucent blue sclera, <b>increased IOP</b> , myopia, exophthalmos, intracranial hypertension causing papilledema, diplopia, EOM paresis and eyelid ptosis, retinal hemorrhages (secondary to injection), central serous chorioidopathy, abnormal ERG/VEP, retinal embolic phenomenon (injection).	Patients should be advised of the OADRs of these medications and the need for careful monitoring as many OADRs are asymptomatic. The main OADRs of systemically administered steroids occur with oral use, with little concern with nasal administration, even long-term. (Topical ophthalmic use, which causes the most significant anterior and IOP-related effects, must be carefully monitored.)	Timing of follow-up examinations depends on doses and duration of treatment, required every 6 months for cataract formation, but sooner for IOP and retinal/nerve concerns. Those with any visual disturbance must be advised to seek care. Surgical removal of steroid-induced PSC is similar to conventional PSC. IOP elevation is asymptomatic, so must be detected with diligent and timely follow-up examinations including applanation tonometry. The timing depends on the type of steroid, route, duration and individual patient factors. If IOP is elevated, taper off of steroids if possible in conjunction with prescribing practitioner. If not advisable, determine if patient is on lowest possible dose to maintain effect for condition being treated. Use antiglaucoma agents to lower IOP and monitor according to glaucoma risk protocols (threshold VF, stereoscopic examination and photographs, optic disc and NFL imaging).



<p><b>Nonsteroidal anti-inflammatory drugs</b> (NSAIDs, general):</p> <ul style="list-style-type: none"> <li>• ibuprofen (Motrin)</li> <li>• naproxen (Naprosyn, Anaprox)</li> <li>• oxaprozin (Daypro)</li> <li>• piroxicam (Feldene)</li> </ul> <p><b>indomethacin</b> (Indocin)</p>	<p>May increase bleeding tendencies (subconjunctival hemorrhage, retinal hemorrhage).</p> <p>Blurred vision, CV changes, photophobia, Stevens-Johnson syndrome, vertigo.</p> <p>“<b>Possible</b>” or “<b>Unlikely</b>” corneal opacities (reversible), with or without photophobia (rare); diplopia. Other ADRs as other NSAIDs. Unknown classification of optic neuritis, intracranial hypertension.</p> <p>Pigmentary changes (discrete RPE pigment scattering peripherally with depigmented surround; can be in retinal periphery); accompanying CV loss, visual acuity, VF defects, decreased dark adaptation.</p>	<p>Baseline comprehensive examination including dilated fundus examination.</p> <p>Baseline comprehensive examination including dilated fundus examination with photographs.</p>	<p>Symptoms are generally rare. Consider monitoring patients on high doses. Stevens-Johnson syndrome requires immediate discontinuation of the drug and referral to primary care provider. Topical supportive therapies (e.g., steroids) will be required.</p> <p>Regular comprehensive eye examinations recommended according to protocols; include VFs, CV as needed. Consider more frequent examinations if high doses being used.</p> <p>Optic neuritis or intracranial hypertension may warrant discontinuation. Consider neuroimaging for persistent diplopia. Functional improvement on discontinuation (up to 6–12 months), although the pigmentary changes of the retina are generally irreversible.</p> <p>Avoid these agents before/after surgery, following trauma, hyphema.</p> <p>Persistence of symptoms post discontinuation of therapy is rare. Patient reassurance is the only management. Visual symptoms resolve on discontinuation with no long-term effects to vision.</p>
<p><b>acetylsalicylic acid</b> (Aspirin)</p> <p><b>clomiphene</b> (Clomid) (nonsteroidal agent for the treatment of infertility)</p> <p><b>COX-2 inhibitors</b>:</p> <ul style="list-style-type: none"> <li>• rofecoxib (Vioxx)</li> <li>• celecoxib (Celebrex)</li> <li>• valdecoxib (Bextra)</li> <li>• lumiracoxib (Prexige)</li> <li>• nimesulide (Ainex)</li> <li>• etofodac (Lodine)</li> </ul> <p>(anti-inflammatory selective for COX-2)</p> <p><b>Retinoids</b>:</p> <ul style="list-style-type: none"> <li>• <b>isotretinoin</b> (Accutane)</li> <li>• vitamin A (all-<i>trans</i>-retinoic acid)</li> <li>• tretinoin (vesanoid)</li> <li>• acitretin (Soriatane)</li> <li>• etretinate (Tegison)</li> </ul> <p>(cystic acne, psoriasis, other skin disorders)</p>	<p>Subconjunctival hemorrhage, retinal hemorrhage</p> <p>Visual symptoms (reversible) include blurred vision, flashes, scintillations, prolonged afterimages, “heat waves” in vision.</p> <p>“<b>Certain</b>” conjunctivitis, blurred vision (range from spots in vision to temporary blindness to blurred vision) (mostly with rofecoxib and celecoxib)</p>	<p>Comprehensive eye examinations.</p> <p>Onset may occur in days after initiation but usually disappear after discontinuation.</p> <p>Comprehensive eye examinations</p>	<p>Advise to return for examination if any symptoms of ocular discomfort, redness, or decreased CL wear become apparent (usually by 4 weeks). Urgent examination if decreased vision, headaches, or transient visual obscurations.</p> <p>Test/retest for ocular surface dryness, decreased CV, optic discs for edema. It is very important to recognize</p>
<p>“<b>Certain</b>” abnormal meibomian gland secretion/gland atrophy; increased tear film osmolarity, decreased tolerance to CL, ocular discomfort, blepharconjunctivitis, keratitis, corneal opacities, decreased vision, photophobia; decreased dark adaptation, myopia; <b>intracranial hypertension (IH)</b>.</p> <p>“<b>Probable/likely</b>” decreased CV (temporary), loss of dark adaptation (permanent)</p>	<p>Question or test for dark adaptation, CV, and ocular surface dryness (phenol thread, TBUT, corneal staining); delay CL fitting and/or counsel that lens wear may be limited or uncomfortable during the course of therapy and until approximately 1 month afterward.</p> <p>Explain risk/benefit in patients with retinitis pigmentosa, preexisting</p>		

Continued

### Appendix 35-1 Common and Critical Ocular Adverse Drug Reactions From Systemic Drugs—cont'd

Drug	OADR (including WHO classification of causality, where available)	Prevention/Risks/Considerations	Management
	<p>“<b>Possible</b>” corneal ulceration, eyelid edema, diplopia, optic neuritis, permanent dry eye, subconjunctival hemorrhage.</p> <p>“<b>Unlikely</b>” limbal infiltrates, corneal neovascularization, keratoconus, activation of herpes simplex, exophthalmos, pupil abnormalities, vitreous disturbance, glaucoma.</p> <p>“<b>Conditional/unclassifiable</b>” cataracts, decreased accommodation, iritis, cortical blindness, peripheral VF loss, retinal findings, scleritis.</p>	<p>night blindness, significant ocular surface dryness. Review all possible adverse effects and accompanying symptoms.</p> <p>Consider UV blocking lenses due to photosensitization.</p> <p>Note the implications of pregnancy and the use of this drug (pregnancy category X).</p>	<p>isotretinoin-induced intracranial hypertension. Onset of blurred vision and headaches is usually 2–3 months after starting therapy (range of 5 days to 2 years); however, patients may be asymptomatic.</p> <p>Discontinuation usually results in resolution of the IH, though other measures may be taken to reduce the intracranial pressure. Discontinuation should also occur if nyctalopia develops.</p>
<b>topiramate</b> (Topamax) (epilepsy, migraine headaches, weight loss)	<p>“<b>Certain</b>” acute glaucoma (bilateral) (includes anterior chamber shallowing secondary to suprachoroidal effusions with acute myopia (6–8D), increased IOP, VF defects, hyperemia, mydriasis, ocular pain, decreased vision).</p> <p>“<b>Probable/likely</b>” blepharospasm, oculogyric crisis, retinal bleeds, uveitis.</p> <p>“<b>Possible</b>” scleritis, teratogenic effects (including ocular malformations).</p> <p>“<b>Certain</b>” irreversible VF constriction (bilateral, concentric with temporal and macular sparing); cone dysfunction can cause CV loss; visual acuity can be affected.</p>	<p>Education of patient as to possible symptoms as well as to importance of follow-up. Time to onset is 3–14 days after initiation so examination should occur within and just after 2 weeks of starting the medication.</p>	<p>The medication should be stopped and the patient treated with hyperosmotics, cycloplegics, and topical IOP-lowering agents. Treatment with peripheral iridectomy is not beneficial.</p>
<b>vigabatrin</b> (Sabril) (anticonvulsant)		<p>Regular comprehensive ophthalmic assessments. Baseline screening of VF, CV (preferably Farnsworth-Munsell). If symptoms develop, do ERG and VF every 6 months.</p> <p>VF loss occurs in 10–50% and appears to be dose-related (1.4–4.5 g/day). Visual symptoms can develop from several months to several years.</p>	<p>Patients taking this drug should have regular peripheral VF examinations (every 6 months), and consideration should be given to electrodiagnostic testing (normal or abnormal responses on ERG and VEP tracings), and especially EOG (most sensitive).</p> <p>It has been suggested that, if seizures can be controlled with a lower dosage, it may not require discontinuation.</p>
<b>pamidronate disodium</b> (Aredia), and other bisphosphonates <ul style="list-style-type: none"> <li>• alendronic acid (Fosamax)</li> </ul>	<p>“<b>Certain</b>” blurred vision, pain, photophobia, ocular irritation, nonspecific conjunctivitis.</p> <p>“<b>Certain</b>” episcleritis, anterior (rarely posterior) uveitis, anterior (rarely posterior) scleritis</p>	<p>Patients should be advised of the serious OADRs of these medications. Symptoms of vision-threatening conditions such as uveitis and scleritis must be clear to the patient</p>	<p>If persistent decreased vision or ocular pain/redness occurs, ophthalmic care must be sought.</p> <p>No treatment for nonspecific conjunctivitis as will usually decrease on subsequent</p>

<ul style="list-style-type: none"> <li>• ibandronate</li> <li>• zoledronate (Zometa)</li> <li>• risendronate sodium (Actonel)</li> <li>• clodronate (Bonefos)</li> <li>• etidronate disodium (Didrocal)</li> <li>• olpadronate (inhibits calcium resorption in malignancy, Paget disease, osteolytic bone metastasis [breast cancer, multiple myeloma])</li> </ul>	<p>“<b>Probable/Likely</b>” periocular edema, lid edema, orbital edema.</p> <p>“<b>Possible</b>” retrobulbar neuritis, yellow vision, diplopia, cranial nerve palsy, ptosis, visual hallucinations.</p>	<p>with a view to seeking care if any symptoms develop.</p> <p>Onset of serious OADRs (i.e., scleritis) is usually within 6–48 hours if i.v. drug administration.</p>	<p>injections; however, nonsteroidal anti-inflammatory agents (NSAIDs) may be useful. Similarly, episcleritis may require NSAIDs but not require discontinuation. For anterior uveitis (or more uncommonly posterior or bilateral anterior uveitis), intensive topical therapies and/or systemic medications may be needed. In some cases, the drug will require discontinuation for the inflammation to resolve. Discontinuation is required for resolution of scleritis, even on full medical therapy.</p>
<ul style="list-style-type: none"> <li>• <b>ceftirizone</b> (Zyrtec)<sup>b</sup> (H<sub>1</sub> selective antagonist for seasonal/chronic allergic rhinitis, urticaria)</li> <li>• <b>tamoxifen</b> (Nolvadex) (chemotherapy for primary metastatic breast cancer)</li> </ul>	<p>“<b>Certain</b>” oculozytic crisis.</p> <p>“<b>Certain</b>” crystalline retinopathy (intraretinal crystals), posterior subcapsular cataracts; whorl keratopathy. VA is rarely affected.</p>	<p>Regular comprehensive ophthalmic assessments. Patients should be informed of this possible unusual OADR.</p> <p>Baseline exam within the first year of using tamoxifen, including slit-lamp, fundus biomicroscopy, CV, Amsler, VFs. Presence of macular degeneration, PSC. cataracts are not a contraindication to treatment.</p> <p>Keep doses &lt;6.5 mg/kg/day for 5 years or less.</p>	<p>Cessation of the drug causes rapid resolution of the episode.</p> <p>Complete eye examinations every 6 months to 2 years depending on dosage and duration of treatment, sooner if symptoms are noted. Small crystals without decrease in VA or edema, consult but usually do not discontinue drug. Significant CV loss may warrant discontinuation.</p>
<ul style="list-style-type: none"> <li>• <b>carmustine</b> (BiCNU, BCNU) (chemotherapy agent, i.v. administration)</li> <li>• <b>ethambutol</b> (Myambutol) (anti-tuberculosis)</li> </ul>	<p>“<b>Certain</b>” vision loss (up to NLP) with retinal complications (infarction, periarteritis/phlebitis, branch artery occlusions, nerve fiber layer hemorrhage, macular edema).</p> <p>Optic neuropathy is usually retrobulbar and bilateral manifesting as reduced visual acuity, CV, or central scotomata. Bitemporal VF defects may occur if the chiasm is affected.</p>	<p>Retinal vascular changes and VL may be prevented by passing the internal carotid artery catheter beyond the ophthalmic artery before releasing the drug.</p> <p>Informed consent is critical, as despite regular ophthalmic exams, optic neuropathy can occur at any stage and any dosage and the loss of vision can be irreversible and severe. Baseline examination with visual acuity, VFs, CV, dilated fundus examination including optic nerve assessment. Dose-related incidence of ocular side effects occurs, with:</p> <ul style="list-style-type: none"> <li>• 50% for 60–100 mg/kg/day</li> <li>• 5–6% for 25 mg/kg/day</li> <li>• 1% &lt;15 mg/kg/day</li> </ul>	<p>If retinal changes developed, the risk/benefit ratio must be considered with the oncologist and patient.</p> <p>Discontinue drug at any sign of decreased acuity, CV or VF defect. Consider contrast sensitivity testing. Optic atrophy not usually noted for months (2–5) after onset. Consider monthly examinations even at lower doses for patients at risk of toxicity (diabetes, renal failure, alcoholism, ethambutol-induced peripheral neuropathy, and older patients and children).</p> <p>Consider optical coherence tomography to pick up early toxicity (swelling of the nerve fiber layer) and chronic toxicity (nerve fiber layer thinning).</p>

Continued

### Appendix 35-1 Common and Critical Ocular Adverse Drug Reactions From Systemic Drugs—cont'd

Drug	OADR (including WHO classification of causality, where available)	Prevention/Risks/Considerations	Management
<b>rifabutin</b> (treatment or prophylaxis for tuberculosis)	<p>“<b>Certain</b>” uveitis.</p> <p>Others: optic neuropathy, corneal endothelial deposits, discoloration of tears (pink).</p>	<p>Ophthalmic examinations recommended monthly for doses &gt;15 mg/kg/day.</p> <p>Monitoring of fundus for signs of tuberculosis periodically. Fluconazole may increase the bioavailability of rifabutin and therefore increase the risk of ADRs.</p>	<p>Discontinuation of rifabutin and initiation of topical steroid therapy results in clinical improvement.</p>
<b>methotrexate</b> (immune modulation in rheumatoid, other inflammatory conditions)	<p>“<b>Unlikely</b>” optic neuritis.</p>	<p>Regular comprehensive ophthalmic assessments. Patients should be informed of this possible unusual OADR.</p>	<p>If appears to be related to drug, discontinue in conjunction with prescribing practitioner. Monitor for resolution of VA and VF; though expect variable results. (as above with ethambutol, methotrexate)</p>
<b>isoniazid</b> (anti-tuberculosis)	<p>“<b>Unlikely</b>” optic neuritis.</p>	<p>Optic neuritis is not dose-dependent. Ensure other drugs being taken are not implicated.</p>	
<b>Tetracyclines</b>			
• tetracycline	<p>Conjunctival deposits (black/brown) (with tetracycline); bluish discoloration of sclera (with minocycline).</p>	<p>Patients should be carefully counseled to seek evaluation in the event of the development of blurred vision (static or transient) and/or headaches, as well as double vision. Periodic examinations may be required as some cases are asymptomatic.</p>	<p>The onset of symptoms is usually ≤8 weeks from initiation, though may be hours or up to one year. Because patients can be asymptomatic, periodic examination is warranted for patients on long-term therapy.</p>
• doxycycline	<p>Intracranial hypertension (IH); although most patients are symptomatic and are diagnosed promptly, others have no symptoms and may have optic disc edema long before a diagnosis is made. (The association between IH and doxycycline is the least established.)</p>	<p>Avoid vitamin A and concomitant retinoid use.</p>	<p>Discontinuation of treatment usually shows resolution to IH and disc edema, but other interventions may be required. Some may have residual disc swelling, pallor, VF loss.</p>
• minocycline	<p>Optic neuritis (retrobulbar or papillitis) bilateral VA reduction from 20/100 to 5/400, dense central scotomata; optic disc edema/hyperemia, dilated retinal veins, peripapillary hemorrhages; late optic atrophy.</p>	<p>Patients who are to receive long-term chloramphenicol therapy should be given a comprehensive baseline examination consisting of VA, VF, CV, and dilated fundus examination.</p>	<p>Visual symptoms can occur 10 days but usually after several months/years of treatment. Peripheral neuritis may precede the visual complaints by 1–2 weeks. Once signs or symptoms of optic neuropathy are detected, promptly discontinue drug in consultation with the prescribing physician.</p>
<b>chloramphenicol</b> (antibacterial)	<p>Note: Most cases of optic neuritis have occurred in children with cystic fibrosis who were treated with large daily dosages of the drug, from 1 to 6 g daily. (Note: aplastic anemia is also a risk, but risk with topical ophthalmic agents has been grossly overplayed.)</p> <p>“Whorl-like” (verticillate) keratopathy.</p>	<p>The risk is minimized with &lt;25 mg/kg/day for &lt;3 months. Patients (or parents) should be encouraged to be alert to the development of peripheral neuritis, a possible precursor sign to VI.</p>	<p>Pretreatment VA or VF are not usually achieved despite some visual recovery.</p>
<b>atovaquone (Mepron)</b> (antiparasitic)		<p>Drug may be used in cases of resistance to usual treatments for toxoplasmosis, such as in immune deficiency.</p>	<p>Keratopathy subsides once drug therapy is discontinued.</p>

<p><b>sulfonamides</b> (antibacterial)</p>	<p>Allergic reactions (lid swelling, conjunctivitis, localized angioneurotic edema, exfoliative dermatitis); myopia.</p> <p><b>Erythema multiforme (Stevens-Johnson syndrome, or SJ)</b> is life-threatening and shows ocular involvement in 69% of cases (mild in 40%, moderate in 25%, and severe in 4%). Late complications can occur, usually in the form of severe ocular surface disease and trichiasis.</p> <p>“<b>Possible</b>” uveitis.</p>	<p>Take a careful drug history as part of the comprehensive ophthalmic examination. Inquire about previous reactions to medications. After eliminating progression of nuclear sclerosis and other causes of increased myopia, drug might be implicated.</p> <p>Patients of Japanese or Korean descent are at greater risk of Stevens-Johnson syndrome.</p>	<p>Allergy is managed by withdrawal of the drug and supportive therapies (consider steroids). Reduce or discontinue the drug in consultation with the prescribing physician. Positive dechallenge will occur if the refractive error change subsides within several days or weeks.</p> <p>SJ syndrome is life-threatening—drug must be discontinued and patients referred urgently. Immediate (steroids) and possible long-term severe dryness and ocular surface disease will require aggressive management.</p> <p>Drug withdrawal and treatment for uveitis. See SJ syndrome under sulfonamides. Blood abnormalities are noted before symptoms. Early treatment is associated with improved long-term outcomes.</p> <p>Long-term CAIs:</p> <ul style="list-style-type: none"> <li>• First 6 months of therapy: <ul style="list-style-type: none"> <li>• CBC, WBC with differential, hemoglobin, hematocrit, platelet count every 1–2 months</li> </ul> </li> </ul> <p>Thereafter, same tests every 6 months</p> <p>Symptoms include: sore throat, fever, easy bruising, petechiae, nosebleeds, fatigue, jaundice.</p>
<p><b>Carbonic anhydrase inhibitors</b>:</p> <ul style="list-style-type: none"> <li>• acetazolamide (Diamox)</li> <li>• dichlorophenamide (Daranide)</li> <li>• methazolamide (Neptazane)</li> </ul> <p>(glaucoma; acetazolamide also as anticonvulsant, to treat intracranial hypertension, to lessen air hunger in high altitudes)</p>	<p>Stevens-Johnson syndrome (see sulfonamides above); myopia, as with sulfonamides.</p> <p>Aplastic anemia (10–25× rate in CAI-treated patients), other blood dyscrasias (42%–66% of all are aplastic anemia) (no reports in topical administrations).</p> <p>Also, respiratory distress with lung disorders; osteomalacia on anti-convulsants; metabolic acidosis/coma in renal deficiency/diabetic nephropathy; ammonia poisoning with cirrhosis; hypo-potassium; enhanced trough levels of cyclosporine.</p> <p>“<b>Highly probable</b>” uveitis (related to immune-recovery uveitis, or IRU), hypotony, macular edema, preretinal macular gliosis.</p> <p>Uveitis seen especially if i.v. cidofovir has been administered previously.</p> <p>Recurrences are common and VL is more significant than that due to CMV retinitis alone.</p>	<p>Risk of SJ syndrome is greater in patients of Japanese or Korean descent and has been reported more with methazolamide.</p> <p>Short-term therapy (&lt;2 weeks) does not require screening.</p> <p>Aplastic anemia peaks at 2–3 months of use, usually occurring by 6 months of use. Onset of other dyscrasias is more variable, sometimes taking years to manifest.</p>	<p>Topical corticosteroids and cycloplegia as per usual treatment of uveitis; severe uveitis may warrant discontinuation/substitution of another therapy. Some advocate not using cidofovir due to the risk of IRU.</p>
<p><b>cidofovir</b> (Vistide) (treatment of cytomegalovirus (CMV) retinitis, i.v.)</p>	<p>Ocular surface dryness, decreased tear secretion and goblet cell density, CL intolerance.</p> <p>Symptoms and signs of dry eye increase with duration of menopause and use of HRT; Schirmer scores continue to decrease over time. Estrogen-only HRT</p>	<p>Keep vigilant in any patient on cidofovir, especially if it has previously been used to treat cytomegalovirus.</p> <p>Consider measuring serum creatinine (may be elevated indicating poor clearance of drug). CD4+ count may rise.</p>	<p>As with many other symptomatic but not life- or vision-threatening ADR, the risks/benefits of the drug must be weighed with the patient's symptoms and ocular surface signs, and considerations to both ocular surface therapies as well as drug dosage reduction or discontinuation.</p>
<p><b>Oral contraceptives (OCP); hormone replacement therapy (HRT)</b> (OCP multiple uses; including pregnancy prevention, menstrual</p>	<p>Include oral contraceptive and hormone replacement therapy in drug case history.</p> <p>Women who are taking or considering OCPs or HRT should be informed of the potential increased risk of dry eye syndrome with this therapy.</p>		

Continued

### Appendix 35-1 Common and Critical Ocular Adverse Drug Reactions From Systemic Drugs—cont'd

Drug	OADR (including WHO classification of causality, where available)	Prevention/Risks/Considerations	Management
irregularities; HRT for symptoms of menopause)	(compared to estrogen/progesterone and estrogen/progesterone with androgens) showed the greatest aqueous deficiency. (Increasingly, IOP decrease in the estrogen-only group only.)		Dry eye treatment with topical artificial tears; hot compresses/lid care routines, environment modification, immunomodulatory drugs and nutritional supplements. (Note that estrogen or androgen-based drops may be a promising new treatment.)
<b>chlorpromazine</b> (Thorazine) (phenothiazine anti-psychotic)	“ <b>Certain</b> ” corneal pigment (white, yellow, brown, or black); anterior subcapsular cataract; all rarely causing visual symptoms of haziness or halos; oculozytic crisis (NOTE: chlorpromazine is the primary phenothiazine known to cause these adverse effects.) Changes are dose-related.	UV protection is advised. <u>Grade I:</u> Fine opacities on the anterior lens surface within the pupil. <u>Grade II:</u> Dot-like, opaque pigment; stellate pattern forms. <u>Grade III:</u> Larger granules of pigment (white, yellow, tan) with an anterior subcapsular stellate pattern. <u>Grade IV:</u> A star pattern, easily recognized with a penlight. <u>Grade V:</u> Central, lightly pigmented, pearl-like, opaque mass surrounded by smaller clumps of pigment.	Lens: <ul style="list-style-type: none"> <li>No lens changes noted (0% of patients) if cumulative dose is &lt;500 g, but exceeds 90% with cumulative doses of &gt;2,500 g.</li> <li>800 mg/day may reach OADRs in 14–20 months, but if &gt;2,000 mg/day, in 6 months</li> </ul> Cornea: <ul style="list-style-type: none"> <li>1% on 300 mg/day, 12% on 2,000 mg/day</li> </ul> Monitor structures annually. If symptoms develop, consider reducing dose in conjunction with prescribing doctor, or changing to a non-phenothiazine drug. Follow-up dilated fundus examinations recommended every 2–4 months initially and every 6 months thereafter depending on dose and duration of drug administration. Symptoms may precede fundus signs, so patient and care-givers should be advised of symptoms of toxicity. Drug should be discontinued promptly at the first sign of retinopathy. Progression may occur despite discontinuation.
<b>thioridazine</b> (Mellaril) (phenothiazine anti-psychotic)	“ <b>Certain</b> ” pigmentary retinopathy (mild peppery pigment to focal confluent areas, to focal atrophy of the choriocapillaris) leading to possibility of permanent reduced visual acuity, CV, disturbances of dark adaptation.	Baseline examination with visual acuity, central VFs, CV, dilated fundus examination (with photography) is advised. Retinopathy is dose-dependent: <ul style="list-style-type: none"> <li>few reports with dose &lt;800 mg/day</li> </ul>	Monitor structures annually. If symptoms develop, consider reducing dose in conjunction with prescribing doctor, or changing to a non-phenothiazine drug. Follow-up dilated fundus examinations recommended every 2–4 months initially and every 6 months thereafter depending on dose and duration of drug administration. Symptoms may precede fundus signs, so patient and care-givers should be advised of symptoms of toxicity. Drug should be discontinued promptly at the first sign of retinopathy. Progression may occur despite discontinuation.
All <b>phenothiazines</b>	All phenothiazines may show antimuscarinic adverse effects. This can include mydriasis and cycloplegia with subsequent decreased vision.	Ensure angles are not narrow such that risk of acute or chronic angle closure is possible. Provide corrective lenses based on refractive findings, including accommodative dysfunction.	Regular comprehensive eye examinations (see chlorpromazine and thioridazine).

<p><b>quetiapine</b> (Seroquel) (schizophrenia) <b>lithium</b></p>	<p>UV-protection is suggested and tinted lenses may improve comfort with dilated pupils.</p>	<p>“<b>Unlikely</b>” cataracts.</p>	<p>Jerk nystagmus (1° position and downgaze); blurred vision (especially in lateral gaze).</p>	<p>Comprehensive ophthalmic examination as per conventional routine. Because downbeat nystagmus has neurologic significance and may be related to a variety of metabolic or drug-related causes, refer. The nystagmus may not resolve with reduction of dosage or drug cessation. Prolonged drug withdrawal, up to 6 months or even years, may be necessary to produce improvement.</p>
<p><b>8-methoxypsoralen</b> (PUV-A therapy) (treatment of vitiligo, psoriasis in combination with UV-radiation treatments) <b>talc</b> (magnesium silicate) (associated with injection of particulate matter from crushed methylphenidate, heroin, cocaine tablets in water)</p>	<p>Care should be taken to protect the eyes from UV radiation for at least 12–24 hours after therapy (including indoors as fluorescent light UV radiation is still significant; especially in children, preexisting cataract).</p>	<p>“<b>Certain</b>” cataracts; VA is usually unaffected.</p>	<p>Dose-related with retinopathy may be noted at ~9,000 tablets but consistently seen in patients who have injected &gt;12,000 tablets. Daily tablet ingestion varies but can reach 100 tablets/day. Pulmonary consultation is required as collateral vessels will be developed in the lungs to have allowed the particles to enter the left side of the heart to be transported to the organs of the body, including the eye.</p>	<p>Cataracts developed from PUV-A therapy are amenable to extraction.</p>

**General OADRs**

<b>Dryness</b>	<b>Tearing</b>
<p>Drugs that cause ADRs to the <b>Lacrimal System</b></p> <p>Antimuscarinic agents: e.g., atropine, scopolamine Stimulants: e.g., methylphenidate, dextroamphetamine Antihistamines: e.g., chlorpheniramine, brompheniramine, diphenhydramine Vitamin A analogs: e.g., isotretinoin, etretinate Vitamins: niacin β-Adrenoceptor blocking agents: e.g., atenolol, practolol, propranolol, timolol, Phenothiazines: e.g., chlorpromazine, thioridazine</p>	<p>Adrenoceptor agonists: e.g., ephedrine Cholinergic agonists: e.g., pilocarpine, neostigmine Antihypertensive agents: e.g., clonidine, reserpine, hydralazine Antineoplastic agents: e.g., 5-fluorouracil</p>

*Continued*



### Appendix 35-1 Common and Critical Ocular Adverse Drug Reactions From Systemic Drugs—cont'd

General OADRs	
Dryness	Tearing
<p>Antianxiety agents: e.g., chlordiazepoxide, diazepam            Diuretics: e.g., hydrochlorothiazide            Hormone therapies: Oral contraceptives, hormone replacement therapy            Chemotherapeutic agents: e.g., methotrexate, carmustine</p> <p><b>Mydriasis</b>            Anticholinergic agents: e.g., scopolamine            Antihistamines: e.g., diphenhydramine            CNS stimulants: e.g., amphetamines, methylphenidate, cocaine            CNS depressants: e.g., barbiturates, antianxiety agents            Phenothiazines: e.g., chlorpromazine</p> <p><b>Nystagmus</b>            e.g., salicylates, phenytoin, antihistamines,            Gold salts, lithium, carbamazepine, barbiturates</p> <p><b>Myopia</b>            e.g., sulfonamides, diuretics, carbonic anhydrase inhibitors, isotretinoin, topiramate (sulfa-containing)</p> <p><b>Increased IOP</b>            e.g., anticholinergic agents, antihistamines, phenothiazines, tricyclic antidepressants, corticosteroids</p> <p style="text-align: center;"><b>Some Common Herbal and Vitamin Therapies With OADRs</b></p>	<p><b>Miosis</b>            Opiates: e.g., heroin, codeine, morphine            Anticholinesterases: e.g., neostigmine</p> <p><b>Diplopia/Oculogyric crisis</b>            e.g., phenothiazines, antianxiety agents, antidepressants            e.g., certirizine (oculogyric crisis)</p> <p><b>Cycloplegia</b>            e.g., chloroquine, phenothiazines, anticholinergics, antihistamines, antianxiety agents, tricyclic antidepressants</p> <p><b>Decreased IOP</b>            e.g., β-blockers, cardiac glycosides, cannabinoids, ethyl alcohol</p>
Drugs that cause ADRs to the Pupil	Management
<p>Drugs that cause ADRs to</p> <p><b>Extraocular Muscle Movements</b></p> <p>Drugs that cause ADRs to</p> <p><b>Refractive</b></p> <p>Drugs that cause changes to</p> <p><b>Intraocular Pressure</b></p>	<p>Symptoms are usually reversible with recognition of the agent and discontinuing.</p>
Herbal/Vitamin	Management
<p><b>Cannabinoids</b></p> <p>Herbals:  <i>Cannabaxanthin</i></p> <p>Herbals:  <i>Chanomile</i></p> <p>Herbals:  <i>Datura</i></p> <p>Herbals:  <i>Echinacea purpurea</i></p> <p>Herbals:  <i>Ginkgo biloba</i></p>	<p><b>Prevention</b>            Inquire of all patients if they are using any nutritional supplements, vitamins.</p> <p><b>OADR</b></p> <p>“<i>Certain</i>” IOP lowering (25%), lasting 3–4 hours</p> <p>“<i>Certain</i>” crystalline retinopathy</p> <p>“<i>Certain</i>” allergic conjunctivitis</p> <p>“<i>Certain</i>” mydriasis</p> <p>“<i>Probable</i>” conjunctivitis</p> <p>“<i>Probable</i>” spontaneous hyphema, retinal hemorrhage</p>

Herbals: <b>licorice</b>	“ <b>Possible</b> ” vasospasm, VL associated with migraine-like symptoms		
Herbals: <b>niacin</b>	“ <b>Probable</b> ” cystoid macular edema “ <b>Possible</b> ” decreased vision, dry eyes, superficial punctate keratitis, discoloration of lids, lid edema, proptosis, loss of eyelashes/brows “ <b>Certain</b> ” intracranial hypertension (large doses)		
Herbals: <b>vitamin A</b>		Concomitant use of vitamin A with other retinoids can show a potentiation of effect.	Discontinue vitamin A and other possible implicating medications. Initiate treatment for intracranial pressure decrease.

*Note:* OADRs = ocular adverse drug reactions; CV = color vision; VF = visual field; VL = vision loss; NFL = nerve fiber layer; IOP = intraocular pressure; NSAIDs = nonsteroidal anti-inflammatory drugs; TBUT = tear break-up time; CL = contact lens; IH = intracranial hypertension; RD = retinal detachment; NAION = nonarteritic ischemic optic neuropathy.

Adapted from:

- Carnahan MD, Goldstein DA. Ocular complications of topical, periocular and systemic corticosteroids. *Curr Opin Ophthalmol* 2000;11:478–483.
- Fraunfelder FT, Fraunfelder FW, Randall JA. *Drug-induced Ocular Side Effects*, 5th ed. Boston: Butterworth-Heinemann; 2001.
- Fraunfelder FW, Fraunfelder FT. *Drug-related Adverse Effects of Clinical Importance to the Ophthalmologist*. From American Academy of Ophthalmology, Course 444. 13 November 2006. Retrieved 10 April 2007 from [www.aaof.org/am\\_handouts\\_pdfs/444FarauX129.pdf](http://www.aaof.org/am_handouts_pdfs/444FarauX129.pdf).
- Moorthy RS, Valluri S. Ocular toxicity associated with systemic drug therapy. *Curr Opin Ophthalmol* 1999;10:438–446.
- Also, <sup>a</sup>Fraunfelder FW, Fraunfelder FT. Drug-related Adverse Effects of Clinical Importance to the Ophthalmologist. From American Academy of Ophthalmology. October 16, 2005, <sup>b</sup>Fraunfelder FW, Fraunfelder FT. Drug-related Adverse Effects of Clinical Importance to the Ophthalmologist. From American Academy of Ophthalmology. November 17, 2003, and <sup>c</sup>Fraunfelder FW, Fraunfelder FT. Drug-related Adverse Effects of Clinical Importance to the Ophthalmologist. From American Academy of Ophthalmology, 2002. Retrieved 10 April 2007 from <http://ptodr.sterling.net/>.

# Index

Note: Page numbers followed by *f* indicates figures; numbers followed *t* indicates tables.

## A

- Abacavir, 206t
- Abbreviations used in prescriptions, 55t
- ABMD. *See* Anterior basement membrane dystrophy
- Abrasion
  - conjunctival, 479-480
  - corneal, 44, 496-498, 496f, 497f
- Abuse
  - adverse drug reactions and, 703
  - of cocaine
    - conjunctiva and, 711
    - pupil and, 718
    - of topical anesthetic, 513-514
- Acanthamoeba* keratitis, 215, 216t, 217, 536-538, 537f, 538t
- Accessory lacrimal gland, 415
- Accommodation
  - amplitude of, 6-7
  - drugs affecting, 720-722, 720b, 721f
  - residual, cycloplegics and, 346, 347
  - tropicamide and, 133-134, 135
- Accommodative esotropia
  - cycloplegic agents for, 663-665
  - mitotics for, 665
- Accommodative spasm, 169
- Accutane, 751t
- Acetaminophen
  - for child, 109t
  - clinical uses of, 103
  - contraindications to, 103
  - pharmacology of, 102-103
  - side effects of, 103
  - vitamin C and, 300
- Acetazolamide
  - adverse effects of, 755t
  - in angle-closure glaucoma, 693
  - clinical uses of, 160-161
  - complications of, 77
  - contraindications to, 162-163, 162b
  - dorzolamide and, 165
  - myopia caused by, 720
  - pharmacokinetic properties of, 161t
- Acetazolamide—cont'd
  - pharmacology of, 159-160, 161t
  - side effects of, 161-162, 162b
- Acetylcholine in myasthenia gravis, 372-373
- Acetylcholinesterase receptor, 372
- Acetylcysteine, 555t
  - in artificial tears, 271
  - for superior limbic keratoconjunctivitis, 476
  - for tear augmentation, 429
  - in vernal keratoconjunctivitis, 566
- Acetylsalicylic acid. *See* Aspirin
- Acid injury, corneal, 509
- Acidosis, metabolic, 162
- Acinetobacter*, 178t
- Acitretin, 751t
- Acne rosacea, 190
- Acquired dacryocystitis, 433-434
- Acquired immunodeficiency disease.
  - See* Human immunodeficiency virus
- Actinic keratosis, 405, 405f
- Actinomyces*, 433
- Actinomyces israelii*, 451
- Active ingredient, 28
- Active transport, 26-27
- Actonel, 753t
- Acular, 259, 554t
  - for seasonal conjunctivitis, 561
- Acular LS, 64b, 236t
- Acute hemorrhagic conjunctivitis, 459
- Acute pain, 108-109, 109f
- Acute retinal necrosis, 620-621, 620f
- Acyclovir
  - for acute retinal necrosis, 621-622
  - clinical indications for, 202t
  - for herpes simplex infection, 197, 198t-199t, 202t
  - for herpes simplex keratitis, 530
  - for herpes zoster ophthalmicus, 396, 532
  - for progressive outer retinal necrosis, 625
- Adenoviral conjunctivitis, 451-454, 452f, 453f, 453t
- Adherence to therapy, 3, 59-60, 60b
- Adie's syndrome, 357-360
  - diagnosis of, 358-360, 358b, 359f, 359t
  - etiology of, 357-358
  - management of, 360
- Administration, drug. *See* Delivery system
- Adnexa in allergic disease, 550
- Adrenal suppression, corticosteroid-induced, 233
- Adrenergic agonist
  - apraclonidine as, 154-155
  - brimonidine as, 155-158, 156f, 157f, 158f
  - decongestants as, 249
- Adrenergic innervation, 113-114
- Adrenergic mydriasis, 362, 363f
- Adult-onset asthma, aspirin and, 100
- Advanced Glaucoma Intervention Study, 695t
- Adverse drug reaction, 701-759
  - conjunctival, 711-713, 712t
  - corneal, 704-711, 704t
  - counseling about, 61
  - determinants of, 702-704
  - diagnosis of, 704
  - episcleral, 715-718, 716t
  - of extraocular muscle, 719-720, 719t
  - on intraocular pressure, 722-725, 722b, 723t
  - of lacrimal system, 713-715, 714t
  - lenticular, 704-711, 704t
  - minimizing of, 7-9
  - to mitotic agents, 666
  - myopia as, 720-722, 721f
  - optic neuropathy as, 736-741, 736t
  - prevention of, 741, 746
  - of pupil, 718-719, 718b
  - reporting of, 742f-745f
  - retinal, 725-736. *See also*, Retina, drugs adversely affecting risk disclosure about, 68-69

- Adverse drug reaction—cont'd  
of scleral, 715-718, 716t  
uveal, 715-718, 716t  
WHO definitions of, 702t
- Advil, 102t
- Affordability of drug, 3, 4t
- African-American patient  
acetazolamide and, 163  
uveitis in, 589
- Agar, 441
- Age  
adverse drug reaction and, 703  
brimonidine effects and, 158f  
in Horner's syndrome, 353  
uveitis and, 589
- Agenerase, 206t
- Age-Related Eye Disease Study, 299, 300, 636, 637
- Age-related macular degeneration, 635-639, 635f, 636f. *See also* Macular disease
- Agranulocytosis  
antithyroid drug and, 653  
methazolamide and, 164  
sulfonamides causing, 193-194
- AIDS. *See* Human immunodeficiency virus
- Ainex, 751t
- AK-Con, 248t
- AK-Homatropine, 127t
- AK-Pentolate, 127t
- Alamast, 256t, 553t
- AlbalonVasocon Regular, 248t
- Albendazole, 630
- Alcohol  
acetaminophen and, 103  
eye movement caused by, 720  
intraocular pressure and, 724
- Alcohol gaze nystagmus test, 720
- Algorithm for pain management, 109f
- Alkali injury, corneal, 509, 511f
- Alkylating agent for uveitis, 595
- All Clear AR, 248t
- Allegra, 552t  
for seasonal conjunctivitis, 561
- Allergic drug reaction, 703  
to acetazolamide, 162  
to anesthetic, 324-325  
to antihistamine, 253  
to apraclonidine, 155  
to atropine, 129  
brimonidine and, 157  
canaliculitis and, 433  
to cephalosporin, 183  
to local anesthetic, 94  
loteprednol etabonate for, 228  
to opioid, 107  
to penicillin, 182-183  
to polymyxin B, 187  
to sulfonamides, 193  
to verteporfin, 304
- Allergic eye disease  
conjunctival, 239-240, 549-574, 550, 556t-559t, 560-568  
atopic keratoconjunctivitis, 241, 466-467, 466f, 549, 557t, 559t, 567-568, 567f  
giant papillary, 561-564, 562t, 563f  
mast cell stabilizers for, 255  
medrysone for, 228  
seasonal, 550, 560-561, 560f  
vernal keratoconjunctivitis, 564-566, 565f  
cyclosporine A for, 241  
of eyelid, 568, 569t, 570-572  
atopic dermatitis as, 568, 570  
contact dermatitis as, 570-571, 570b, 571f  
urticaria as, 571-572  
immunology of, 549-550
- Allergic shiner, 560
- Alocril, 256t, 553t
- Alomide, 256t, 553t  
in seasonal conjunctivitis, 561
- Alpha-2 receptor agonist, 153-154
- Alpha zone, 678, 678f
- Alpha-adrenergic agonist, 690, 690t
- Alrex, 554t
- Alternaria*, 520
- Amb a 1-immunostimulatory oligodeoxyribonucleotide conjugate vaccine, 561
- Amblyopia, 663-669  
atropine for, 128  
cycloplegic agents for, 663-665  
cycloplegic refraction in, 344  
mitotic agents for, 664-666  
paralytic agents in, 666-669, 667b
- Amblyopia Treatment Study, 664
- American Thyroid Association, 644  
disease classification of, 645-646
- Amikacin, 190  
clinical uses of, 189  
endophthalmos and, 606
- Aminoglycoside, 187-190
- Amiodarone, adverse reaction to, 748t  
of cornea, 704t, 706-707, 706t, 707t  
of lens, 704t  
of optic nerve, 738
- Amitriptyline, antimuscarinic dosage of, 721t
- Amoxicillin  
for conjunctivitis, 447  
inclusion, 457  
for dacryoadenitis, 424  
spectrum of activity of, 180t
- Amoxicillin-clavulanate  
in preseptal cellulitis, 391  
spectrum of activity of, 181-182
- Amphetamine, 718
- Amphotericin B, 205, 208, 213t  
in fungal keratitis, 536  
indications for and side effects of, 211t
- Ampicillin, 180t
- Ampicillin/sulbactam, 181-182
- Amprenavir, 206t
- Anacin, 104t
- Analgesic, 97-111  
for child, 109-110, 109t  
mechanism of, 97-98  
narcotic, 104-108  
nonnarcotic, 98-104  
nonsteroidal anti-inflammatory drugs as, 100-102, 100b, 101t  
salicylates as, 98-100, 99t  
strategies for using, 108-109, 109f
- Anaprox, 102t
- Ancef, 184t
- ANCHOR Trial, 307, 638-639
- Anecortave, 309-310  
for age-related macular degeneration, 639  
sub-Tenon's injection of, 49
- Anemia  
aplastic  
chloramphenicol causing, 192-193  
methazolamide and, 164  
sulfonamides causing, 193-194  
hemolytic, sulfonamides causing, 193-194
- Anesthesia  
abuse of, 513-514  
for cataract surgery, 603  
for chalazion incision and drainage, 327, 327f  
complications of, 75  
for eyelid lesion removal, 326-327, 326t  
infiltrative injection technique for, 325-326, 326f  
injectable, 86-87, 87t  
local, 85-95. *See also* Local anesthetic  
mechanism of action of, 98  
presurgical evaluation and, 324-325  
regional, 323-324  
in scleritis, 581  
topical, 87-90, 88t, 89f, 319-328.  
*See also* Topical anesthesia
- Angiogenesis, 305
- Angiography, fluorescein. *See* Fluorescein angiography
- Angioscopy, fluorescein, 288
- Angiotensin-converting enzyme inhibitor  
in sarcoidosis, 632  
in uveitis, 597
- Angle-closure glaucoma, 693-694  
acetazolamide and, 160-161  
after pupil dilation, 339  
atropine and, 129  
cycloplegic refraction and, 344  
decongestants contraindicated in, 249  
pilocarpine contraindicated in, 170  
pilocarpine for, 168  
pupil dilation in, 335-337

- Angle-closure glaucoma—cont'd  
 risk of pupil dilation and, 67  
 tropicamide and, 137
- Angular blepharitis, 385, 385f
- Anhidrosis, 354
- Anidulafungin, 208, 215
- Animal model, of surface inflammation, 240
- Anisocoria, 349-351  
 differential diagnosis of, 351t  
 disorders characterized by, 350b  
 in light *versus* dark, 349-350, 351f  
 overview of, 349  
 pharmacologic evaluation of, 350-352, 352t  
 photographs of patient with, 350  
 physical findings with, 350  
 physiologic, 352  
 pupil size in, 349  
 slit-lamp examination of, 350
- Anisometropia, 665-666
- Antazoline, 254, 254t, 551t
- Antazoline-naphazoline, 255
- Anterior angle, evaluation of, 330-333  
 gonioscopy for, 332-333, 333f, 333t  
 shadow test in, 330, 331f  
 slit-lamp method for, 330, 331f, 332f
- Anterior basement membrane  
 dystrophy, 486-488, 487f  
 in recurrent corneal erosion, 504, 505, 506
- Anterior chamber in uveitis, 590
- Anterior margin of eyelid, 381-382  
 blepharitis in, 381-382  
 distribution system disorder and, 425  
 hygiene of, 384b  
 infection of, 382-384, 383f  
 seborrheic blepharitis of, 385-386, 385f, 386f
- Anterior scleritis, diffuse, 580, 580f
- Anterior segment in sarcoidosis, 632
- Anterior segment ocular coherence tomography, 675
- Anterior stroma  
 foreign body and, 502  
 puncture of, 506  
 in recurrent corneal erosion, 507
- Anterior subcapsular cataract, 708-709, 708t, 709f
- Anterior uveitis  
 complications of, 596  
 description of, 587  
 diagnosis of, 590-591, 591t  
 in interstitial keratitis, 516  
 latanoprost and, 143  
 loteprednol etabonate for, 228  
 metipranolol and, 152
- Anthralin, for psoriasis, 465
- Antiallergy drug, 245-261  
 antihistamines as, 249-250, 251t-252t, 253-255
- Antiallergy drug—cont'd  
 cell-mediated immune response and, 247  
 decongestants as, 247, 248t, 249  
 hypersensitivity response and, 245-247, 246t, 247t  
 mast cell stabilizers as, 255, 256t, 257  
 mast cell-antihistamine combinations as, 257, 258t, 259  
 nonsteroidal anti-inflammatory drugs as, 259  
 steroids as, 259
- Antiangiogenesis drug, 305-306  
 for age-related macular degeneration, 638
- Antibacterial drug, 177-196. *See also*  
 Antibiotic, prophylactic; Anti-infective drug  
 affecting cell membrane, 186-187  
 affecting cell wall synthesis, 179-186  
 bacitracin as, 185  
 cephalosporins as, 183-185  
 penicillins as, 179-183. *See also*  
 Penicillin  
 vancomycin as, 185-186  
 affecting DNA synthesis, 194-196, 194t  
 affecting folate metabolism, 193-194  
 affecting protein synthesis, 187-193  
 amikacin as, 190  
 aminoglycosides as, 187-190  
 chloramphenicol as, 192-193  
 gentamicin as, 188  
 macrolides as, 191-192  
 neomycin as, 187-188  
 tetracyclines as, 190-191, 190t  
 tobramycin as, 189  
 bacteria causing infections and, 177, 178b  
 bacterial structure and, 179  
 for blepharitis, 384  
 for conjunctivitis, 442t, 446-449  
 failure of, 177b  
 for initial treatment, 176t  
 resistance to, 177-179
- Antibiotic, prophylactic. *See also*  
 Antibacterial drug; Anti-infective agent  
 in bullous keratopathy, 494  
 for cataract surgery, 601  
 for contact lens-related complications, 540  
 for corneal abrasion, 497  
 dellen and, 512-513  
 for phlyctenular keratoconjunctivitis, 518  
 in recurrent corneal erosion, 505
- Antibiotic-associated  
 pseudomembranous colitis, 184
- Antibiotic-steroid combination, 601, 602
- Antibody  
 antinuclear, 597
- Antibody—cont'd  
 monoclonal, 306-308  
 in myasthenia gravis, 372
- Anticholinergic agent  
 adverse effects of  
 on intraocular pressure, 720, 720b, 721t  
 on pupil, 718, 718b  
 myopia caused by, 721-722  
 unilateral fixed and dilated pupil and, 361-362, 361f, 362f
- Anticholinesterase  
 for accommodative esotropia, 665  
 adverse effects on pupil, 719  
 in phthiriasis palpebrarum, 399
- Anticoagulant in acute retinal necrosis, 622
- Antidepressant for blepharospasm, 377
- Antiedema drug, 279-281, 280b, 280t, 282f
- Antifungal drug, 204, 205, 209t-213t, 213-215  
 azole, 208, 213-214  
 echinocandin, 210t-212t  
 nonnucleoside reverse transcriptase inhibitor, 206t  
 nucleoside reverse transcriptase inhibitor, 206t  
 polyene, 208, 209t-210t
- Antigen  
 in contact dermatitis, 570  
 in thyroid disease, 660
- Antiglaucoma agent  
 complications of, 77  
 conjunctiva damaged by, 8  
 drug interactions with, 6t
- Antihelminthic agent  
 for phthiriasis palpebrarum, 399  
 in toxocariasis, 630
- Antihistamine, 249-250, 251t-252t, 253-255, 558t-559t  
 adverse effects of  
 on pupil, 719  
 reduced tear production, 714  
 for blepharospasm, 377  
 contraindications to, 253-254, 255  
 examples of, 551t-553t  
 in seasonal conjunctivitis, 560  
 side effects of, 253, 255  
 for urticaria, 572
- Antihypertensive agent, lacrimation and, 715
- Anti-immune activity in epidemic keratoconjunctivitis, 527
- Anti-infective agent, 175-220  
 adenoviral conjunctivitis and, 454  
 antibacterial, 177-196. *See also*  
 Antibacterial drug  
 antifungal, 204-215. *See also*  
 Antifungal drug  
 antiprotozoan, 215, 216t, 217

- Anti-infective agent—cont'd  
 antiviral, 196-205. *See also* Antiviral agent  
 for conjunctivitis, principles of, 444  
 guidelines for using, 175-177, 176b, 177t
- Anti-inflammatory agent  
 in epidemic keratoconjunctivitis, 527  
 for toxoplasmosis, 628
- Anti-inflammatory drug, 221-244  
 corticosteroids as, 221-233. *See also* Corticosteroid  
 nonsteroidal, 97-109, 233-235. *See also* Nonsteroidal anti-inflammatory drug  
 pharmacology of, 233-235, 234f  
 for tear stimulation, 275
- Antimetabolite, for uveitis, 595
- Antimicrobial agent. *See* Anti-infective agent
- Antimuscarinic agent, reduced tear production with, 714
- Antimuscarinic effect, drugs causing, 720, 721t
- Antineoplastic agent, drugs adversely affecting, retinal, 731-733, 732f, 733b
- Antinuclear antibody, in uveitis, 597
- Antioxidant, 31b
- Antioxidant vitamin, 295. *See also* Vitamin A, Vitamin C, Vitamin E
- Antiparkinson agent, for blepharospasm, 377
- Antiprotozoan drug, 215, 216t, 217
- Antipseudomonal drug, penicillin for, 182
- Antithyroid drug, 652-653
- Antiviral agent, 196-205  
 acyclovir  
 for acute retinal necrosis, 621-622  
 clinical indications for, 202t  
 for herpes simplex infection, 197, 198t-199t, 202t  
 for herpes simplex keratitis, 530  
 for herpes zoster ophthalmicus, 396, 532  
 for progressive outer retinal necrosis, 625  
 for adenoviral conjunctivitis, 454  
 clinical indications for, 202t  
 for epidemic keratoconjunctivitis, 527  
 famciclovir  
 clinical indications for, 203t  
 guidelines for, 199t  
 for herpes zoster conjunctivitis, 456  
 for herpes zoster ophthalmicus, 532  
 pharmacology and, 204  
 for herpes simplex infection, 197, 198t-199t, 202t, 530  
 for herpes zoster conjunctivitis, 456  
 for herpes zoster ophthalmicus, 396, 532  
 intravitreal administration of, 50-51
- Antiviral agent—cont'd  
 overview of, 196-197  
 for progressive outer retinal necrosis, 625  
 valacyclovir  
 clinical indications for, 202t  
 clinical uses of, 201, 202t-203t, 204  
 guidelines for, 199t  
 pharmacology of, 201
- Aplastic anemia  
 chloramphenicol-induced, 192-193  
 methazolamide and, 164  
 sulfonamides causing, 193-194
- Applanation tonometry, 671-674, 673b.  
*See* Tonometry
- Approved Drug Products with Therapeutic Equivalency Evaluations*, 58-59
- Apraclonidine, 154-155, 690, 690t  
 in anisocoria evaluation, 352t  
 formulations of, 154t
- Aptivus, 207t
- Aqueous deficiency, 264. *See also* Dry eye
- Aqueous flow, fluorescein and, 288
- Aqueous humor  
 acetazolamide and, 160  
 betaxolol and, 151  
 dexamethasone and, 227-228  
 structure of, 23
- Aqueous layer of tear film, 17, 263-264, 264f, 416
- Aqueous suppressant, 689-691, 689b, 689t
- Aralen, 750t
- ARED study, 299, 300
- Aredia, 752t
- Arlt's line, 458, 458f
- Arthritis, 472-473
- Arthropathy, fluoroquinolones and, 195
- Artificial tears, 266-272, 426  
 autologous serum as, 272  
 buffers in, 269-270  
 characteristics of, 266  
 dellen and, 512  
 electrolytes in, 269  
 inserts for, 271-272, 272f  
 mucolytic agents in, 271  
 nutrients in, 270-271  
 polysaccharides as, 266-268  
 preservatives in, 270  
 for Thygeson's superficial punctate keratitis, 533-534
- Ascorbate in burn injury, 511
- Aspergillus*, 205, 534  
 flucytosine for, 208
- Aspirin, 99t  
 adverse effects of, 751t  
 for allergic disease, 554t  
 clinical uses of, 99  
 common formulations of, 99t  
 contraindications to, 100  
 pharmacology of, 98
- Aspirin—cont'd  
 side effects of, 99-100  
 in vernal keratoconjunctivitis, 566
- Asthma  
 aspirin and, 100  
 levobunolol and, 151  
 opioid and, 107-108  
 pilocarpine contraindicated in, 170
- Astigmatism control, suture for, 603-604
- Atazanavir, 207t
- Atopic dermatitis. *See also* Allergic eye disease  
 conjunctivitis and, 466-467, 466f  
 of eyelid, 568, 569t, 570
- Atovaquone  
 adverse effects of, 754t  
 for toxoplasmosis, 628
- Atresia of lacrimal puncta, 432
- Atrophy, peripapillary, 678, 678f
- Atropine  
 administration, 346  
 for amblyopia, 664-665, 665b  
 anticholinergic mydriasis caused by, 361-362  
 antimuscarinic dosage of, 721t  
 characteristics of, 345t  
 clinical uses of, 128  
 contraindications to, 129  
 for corneal ulcers, 524  
 in neovascular glaucoma, 693  
 pharmacology of, 126, 127t, 128  
 preparations of, 127t  
 side effects of, 129
- Atropine mydriasis, 361
- Atropine penalization, 664-665, 665b
- Autoimmune disorder  
 myasthenia gravis as, 372-376, 373f, 375f  
 scleritis in, 580  
 systemic lupus erythematosus as  
 conjunctiva in, 459, 460t, 472-474, 473f  
 drug-induced, 740, 740b, 741b  
 uveitis with, 588b
- Autologous serum  
 as artificial tears, 272  
 in recurrent corneal erosion, 506
- Auxiliary information on prescriptions, 56b
- Avastin, 307
- Avellino dystrophy, 485t
- Avitaminosis A, 478
- Azathioprine  
 in myasthenia gravis, 375, 376  
 for ocular cicatricial pemphigoid, 468  
 in systemic lupus erythematosus, 471  
 for uveitis, 595
- Azelastine, 258t, 553t  
 in seasonal conjunctivitis, 561
- Azithromycin  
 for conjunctivitis, 447  
 for internal hordeolum, 390

- Azithromycin—cont'd  
 in preseptal cellulitis, 391  
 for toxoplasmosis, 628  
 for trachoma, 458
- Azole antifungal drug, 208, 209t-210t, 213-214  
 ketoconazole as, 208, 213
- Azotemia, tetracyclines causing, 190
- B**
- Bacitracin, 185  
 for blepharitis, 384  
 for conjunctivitis, 448  
 formulations of, 186t, 187t  
 pathogens susceptible to, 442t  
 in phlyctenulosis, 475  
 steroids with, 188t
- Bacitracin-polymyxin B  
 for chronic conjunctivitis, 451  
 in thyroid disease, 653
- Baclofen, 377
- Bacteria  
 morphology of, 179f  
 structure of, 179
- Bacterial blepharitis, 382-383
- Bacterial conjunctivitis, 446-449, 449f  
 acute, 444-449, 445f, 446f  
 diagnosis of, 445-446  
 etiology of, 444-445  
 management of, 446-449, 449f  
 chronic, 451  
 hyperacute, 449-451, 450f
- Bacterial dacryoadenitis, 424
- Bacterial infection with scleritis, 577b
- Bacterial keratitis, 514-525. *See also*  
 Keratitis, bacterial  
 corneal infiltrative events versus, 519t  
 fluoroquinolones for, 195  
 infiltrative events in, 519-520, 519f, 519t  
 interstitial, 515-517, 516b, 516t  
 phlyctenular keratoconjunctivitis, 517-518, 518f  
 superficial punctate, 514-515, 514f  
 ulcers and, 520-525, 521f, 521t, 522f
- Bacteroides* in preseptal cellulitis, 391
- BAK, 269
- Band keratopathy, 596
- Bandage soft contact lens in thyroid disease, 653
- Barrier  
 compartment theory and, 25-26  
 conjunctival, 444  
 retinal, 24-25
- Basal cell carcinoma, 403-404, 403f, 404f
- Basal layer of tears, 17
- Basement membrane dystrophy,  
 anterior, 486-488, 487f
- Basic Schirmer test, 420-421
- Basophil, 550
- BC Powder, 104t
- Behçet's disease, 241
- Benadryl, 251t, 551t
- Benign essential blepharospasm, 376-379, 376f, 378t
- Benign eyelid twitching, 407-408
- Benign tumor of eyelid, 399-402  
 sebaceous cysts as, 401-402, 401f  
 sudoriferous cysts as, 401, 401f  
 verrucae as, 399-401, 400f  
 xanthoma palpebrarum as, 402, 402f
- Benoxinate, 89
- Benoxinate-sodium fluorescein, 320
- Bentropine, 721
- Benzalkonium chloride  
 effects of, 30  
 toxic conjunctivitis and, 474
- Benzodiazepine, 377
- Beta zone, 678, 678f
- Beta-blocker  
 adverse effects of  
 on intraocular pressure, 720-721  
 reduced tear production, 714  
 in angle-closure glaucoma, 693  
 betaxolol as, 151-152  
 for blepharospasm, 377  
 brimonidine and, 156  
 carteolol as, 152-153, 153f  
 choice of, 153, 153t  
 complications of, 77  
 levobunolol as, 150-151  
 metipranolol as, 152  
 systemic effects of, 9t  
 timolol as, 145-150, 146t, 148b, 149f
- Beta-carotene, 636
- Betagan, 146t
- Beta-lactamase  
 cephalosporin and, 183  
 penicillin and, 181
- Betamethasone, 231
- Betaxolol, 151-152  
 formulations of, 146t  
 for glaucoma, 689t
- Betimol, 146t
- Bevacizumab, 307, 308, 639
- Bextra, 751t
- Biguanide, 215
- Bimatoprost, 144-145, 687-688, 687t
- Binding of drug, 702
- Binocularity, testing of, 7
- Bioavailability, 27-36  
 active ingredients and, 28  
 drug release systems and, 34, 35t, 36  
 osmolarity and, 28  
 preservatives and, 28, 30-31  
 stability and, 28  
 vehicles and, 31-34, 31b, 32t, 33f
- Bioequivalency, 58-59
- Biomicroscopy  
 in anterior basement dystrophy, 486  
 in anterior uveitis, 590  
 in intermediate uveitis, 592  
 in posterior uveitis, 592-593  
 of tear film, 420
- Bion Tears, 267t, 427t
- Bird-shot retinochoroiditis, 241
- Bis-biguanide, 215
- Bisphosphonate, 716, 716t
- Blepharitis, 381-382  
 angular, 385, 385f  
 antibacterial drugs for, 176t  
 in atopic dermatitis, 568  
 in atopic keratoconjunctivitis, 567  
 cyclosporine A for, 242  
 dry eye and, 425  
 phlyctenular keratoconjunctivitis and, 518  
 in rosacea, 388-389, 388f  
 seborrheic, 385-386, 385f, 386f  
 dry eye and, 425  
 trimethoprim-polymyxin B for, 193
- Blepharoconjunctivitis  
 decongestants causing, 249  
 herpes simplex, 393, 393f
- Blepharospasm, benign essential, 376-379, 376f, 378t
- Blindness, special considerations in, 13-14, 13f-14f
- Blink, incomplete, 406
- Blinking, 417
- Block  
 nerve, 323-324, 324f  
 retrotarsal, 327f
- Blood agar, 441
- Blood count in uveitis, 597
- Blood disorder  
 chloramphenicol causing, 192-193  
 penicillin and, 182  
 sickle cell  
 acetazolamide and, 163  
 intraocular pressure and, 692-693
- Blood dyscrasias  
 acetazolamide causing, 162  
 sulfonamides causing, 193-194
- Blood pressure, phenylephrine and, 116-117
- Blood supply, drug removal by, 25
- Blood vessel, retinal, 618-619, 618f
- Blood-brain barrier, 250
- Blurred vision after pupil dilation, 339
- Bone, tetracyclines affecting, 190
- Bone marrow depression, 192
- Bonefos, 753t
- Borrelia burgdorferi*, 459
- Botulinum toxin, 666-669, 667b  
 adverse effects of, 668-669  
 for blepharospasm, 377-379, 378f, 378t  
 clinical uses of, 666-668  
 pharmacology of, 668  
 in thyroid-related orbitopathy, 654-655
- Bowman's layer  
 anatomy of, 483  
 dystrophy of, 484t  
 hydrops and, 491f
- Bowman's membrane, foreign body and, 502



- Brain injury, cycloplegic refraction in, 343  
 Branch retinal vein occlusion, 632, 634  
 Brand-name drug, 58-59  
 Breach of standard of care, 71  
 Breakup time, tear, 421-422  
 Breast feeding  
   homatropine and, 130  
   opioid and, 107  
   precautions for, 9-11  
   verteporfin and, 304  
 Brimonidine, 155-158, 156f, 157f, 158f, 690, 690t  
   clinical uses of, 157  
   contraindications to, 157-158  
   indomethacin and, 235  
   pharmacology of, 155-157  
   side effects of, 157  
   systemic effects of, 9t  
 Brinzolamide, 165-166, 166f  
 Bromfenac  
   clinical uses of, 236  
   in episcleritis, 578  
   formulations of, 236t  
 Bromhexine, 274  
 Bromocriptine, 377  
 Brompheniramine, 251t  
 Broth, thioglycolate, 441  
 Bruch's membrane, 635  
 Buffer, 31b  
   in artificial tears, 269-270  
 Bulbar conjunctiva, 437-438, 438f  
 Bulla in herpes simplex keratitis, 528  
 Bullous keratopathy, 493-494, 493f  
 Bupivacaine, injectable, 87t  
 Burn  
   chemical, 479  
   corneal, 509-511, 510f, 510t
- C**
- Calcific band keratopathy, 494-496, 495f  
 Calcineurin inhibitor, 570  
 Calcium channel, 151  
 Calcium deposit, corticosteroid-induced, 232  
 Calcium-phosphorus ratio, 494  
 Calculus, renal, 163  
 Canadian form for reporting drug reaction, 744f-745f  
 Canalicular disorder, 433  
 Cancidas, 210t  
*Candida*, 205  
   amphotericin B for, 208  
   keratitis and, 534  
 Cannabinoid, 758t  
   intraocular pressure and, 725  
 Cannula, lacrimal, 430, 431f  
 Canthaxanine, 758t  
 Canthaxanthin, 741  
 Capillary, retinal, 24  
 Capsular opacification, posterior, 611-612, 612f  
 Capsulotomy, endophthalmos and, 606
- Carbachol, 688-689, 688t  
 Carbenicillin, 180t  
 Carbonic anhydrase inhibitor, 158-167  
   acetazolamide as  
     clinical uses of, 160-161  
     contraindications to, 162-163, 162b  
     pharmacology of, 159-160, 161t  
     side effects of, 161-162, 162b  
   adverse effects of, 755t  
   brimonidine and, 156  
   complications of, 77  
   for glaucoma, 691, 691t  
   mechanism of action of, 158-159, 160f  
   methazolamide as, 163-164  
   myopia caused by, 720  
   topical, 164-167  
     brinzolamide as, 165-166, 166f  
     combination agent, 166-167  
 Carboxymethylcellulose, 32, 266-267, 267t
- Carcinoma  
   basal cell, 403-404, 403f, 404f  
   sebaceous gland, 404, 404f
- Cardiac glycoside  
   adverse effects of, 723  
   retinal effects of, 729, 729b, 730f
- Cardiovascular disease,  
   contraindications related to, 5
- Cardiovascular effect  
   of carteolol, 153  
   hydroxyamphetamine and, 119  
   phenylephrine and, 117
- Cardiovascular status, testing of, 7
- Cardiovascular system  
   apraclonidine and, 155  
   beta-blockers affecting, 148b, 149  
   betaxolol and, 151-152  
   brimonidine and, 158  
   dorzolamide and, 164
- Carmustine, 732-733, 733b, 753t  
   reduced tear production, 715
- Carteolol, 152-153, 153f  
   formulations of, 146t  
   for glaucoma, 689t
- CARVES mnemonic, 677
- Casposungin, 208, 210t, 212t, 213t, 214
- Cataract. *See also* Cataract surgery  
   anterior subcapsular, 708-709, 708t, 709f  
   in atopic dermatitis, 568  
   in atopic keratoconjunctivitis, 567  
   comanagement of, 64b  
   corticosteroid induced, 229-230, 229f  
   nutritional supplements for, 298t, 299  
   pilocarpine contraindicated in, 170  
   posterior subcapsular  
     steroid-induced, 705  
     uveitis and, 596  
 Cataract surgery, 601-615. *See also*  
   Cataract  
     complications of, 604, 606-615  
     corneal edema as, 608-609, 609f
- Cataract surgery—cont'd  
   cystoid macular edema as, 613-614, 614f  
   endophthalmos as, 604, 606-607, 606f  
   of eyelids and conjunctiva, 604  
   hyphema as, 610-611, 610f, 611f  
   intraocular lens dislocation as, 612-613, 613f  
   ocular hypertension as, 608  
   ocular hypotony as, 607, 607f  
   posterior capsular opacification as, 611-612, 612f  
   pupil distortion as, 609-610, 610f  
   retinal detachment as, 614-615, 614f  
   cystoid macular edema after, 633  
   infection prevention in, 601  
   inflammation control after, 602  
   intraocular pressure and, 603  
   latanoprost and, 143  
   optimizing vision after, 603-604, 604f  
   pain management after, 603  
   patient education about, 601  
   postoperative management of, 605t  
   pupil dilation after, 337-338, 338f  
   toxoplasmosis and, 628
- Cautery, 409
- CD4 lymphocyte, in AIDS, 204
- Ceclor, 184t
- Cefaclor  
   for conjunctivitis, 447  
   indications for, 183, 184t, 185  
   side effects of, 185
- Cefazolin  
   for corneal ulcer, 523  
   indications for, 183, 184t
- Cefepime, 184t
- Cefotan, 184t
- Cefotaxime, 447
- Cefotetan, 183, 184t
- Cefoxitin, 183, 184t
- Cefprozil, 183, 184t
- Ceftriaxone, 183, 184t
- Ceftazidime, 183, 184t
- Ceftin, 184t
- Ceftriaxone, 461
- Cefuroxime  
   for conjunctivitis, 447  
   indications for, 183, 184t
- Cefzil, 184t
- Celebrex, 102t, 751t
- Celecoxib, 751t  
   formulation of, 102t
- Cell  
   in anterior uveitis, 590, 591b  
   bacterial *versus* human, 179  
   CD4 lymphocyte, 204  
   goblet, 437-438  
   inflammatory, 439  
   Langerhans, 438  
   mast, 246f  
   xanthoma, 402, 402f

- Cell membrane, 186-187
- Cell wall synthesis, antibacterial drugs  
affecting, 179-186  
bacitracin as, 185  
cephalosporins as, 183-185  
penicillins as, 179-183. *See also*  
Penicillin  
vancomycin as, 185-186
- CellCept, 595
- Cell-mediated immunity, 247
- Cellular debris, 591
- Cellulitis  
orbital, 181  
penicillin for, 181, 182  
preseptal, 182, 391-393, 391t, 392f
- Cellulose ether, 266-268, 267t
- Central corneal thickness, 672-673, 673b
- Central crystalline dystrophy, 485t
- Central nervous system  
atropine toxicity and, 129  
beta-blockers affecting, 148b, 149  
cocaine affecting, 119  
contraindications related to, 5  
cyclopentolate and, 132-133  
nonnarcotic drugs affecting, 100  
penicillin effects on, 182  
scopolamine and, 130
- Central nervous system depressant  
adverse effects of, on pupil, 719  
in anisocoria evaluation, 352t  
as mydriatic agent, 119  
as topical anesthetic, 87-88, 88t
- Central nervous system stimulant, 718, 718b
- Central retinal vein occlusion, 632, 634
- Centrally acting agent, 98
- Cephalosporin, 183-185, 184t  
for bacterial dacryoadenitis, 424  
for internal hordeolum, 390  
in preseptal cellulitis, 391
- Ceptaz, 184t
- Certification, 63-64
- Cervicitis, 192
- Cetirizine, 250, 252t, 253, 552t, 561  
adverse effects of, 753t  
eye movement caused by, 719-720
- Chalazion, 390-391  
anesthesia for drainage of, 327, 327f
- Chamomile, 741, 758t
- Chelation, 495
- Chemical burn, 479  
corneal, 509-511, 510f, 510t
- Chemical cautery, 409
- Chemical property of tears, 17-19, 18f
- Chemosis, 440t
- Chemotherapy, conjunctival effects  
of, 713
- Chickenpox, 393
- Child  
administering topical drug to, 41  
atropine overdose in, 129  
cyclopentolate for, 132
- Child—cont'd  
cycloplegic refraction in, 343  
preseptal cellulitis in, 392f  
pupil dilation in, 334  
special considerations for, 11-12, 11f  
tropicamide and, 134, 137  
visceral larva migrans in, 629
- Chlamydia trachomatis*  
azithromycin for, 192  
doxycycline for, 190  
erythromycin for, 191  
hyperacute conjunctivitis with, 450  
inclusion conjunctivitis with, 456-457, 457f  
infections caused by, 177  
Reiter's syndrome and, 472  
trachoma with, 457-458, 458f
- Chloramphenicol, 192-193  
adverse effects of, 754t  
on optic nerve, 737-738  
for conjunctivitis, 447  
formulations of, 186t  
systemic effects of, 9t
- Chlorhexidine, 216t  
for *Acanthamoeba*, 215  
effects of, 30  
toxic conjunctivitis and, 474
- Chlorobutanol, 30
- Chloroquine  
adverse effects of, 750t  
on conjunctiva, 713  
on cornea, 704t, 705  
retinal, 725-728, 725t, 726f, 727t  
in systemic lupus erythematosus, 471
- Chlorpheniramine, 561
- Chlorpromazine  
adverse effects of, 756t  
on conjunctiva, 712, 712t  
on cornea, 704t  
on eyelid, 712, 712t  
on lens, 704t  
antimuscarinic dosage of, 721t  
lens opacity caused by, 708-709, 708t, 709f
- Chlorpropamide, 194
- Chlor-Trimeton, 251t, 551t
- Chocolate agar, 441
- Cholestatic hepatitis, erythromycin-induced, 192
- Choline-magnesium salicylate, 102t
- Cholinergic agonist  
classification of, 167b  
myopia caused by, 721  
pilocarpine as, 168-170, 168t, 171b
- Cholinergic antagonist  
atropine as, 126, 127t, 128-129  
cyclopentolate as, 130-133, 131f, 132b  
homatropine as, 129-130  
overview of, 125-126  
scopolamine as, 130  
tropicamide as, 133-137, 133f, 134f, 135t, 136f
- Cholinergic hypersensitivity in Adie's syndrome, 359-360
- Cholinergic innervation, 125, 126f
- Cholinergic overdose, 666
- Chondroitin sulfate, 268
- Chorioretinitis. *See* Posterior uveitis
- Choroidal effusion, postoperative, 607
- Choroidal neovascularization  
anecortave for, 310  
photodynamic therapy for, 303-305  
ranibizumab for, 306-307  
in retinal disease, 619-620  
rostoporfin and, 305  
verteporfin and, 304
- Choroiditis. *See* Posterior uveitis
- Chronic bacterial conjunctivitis, 451
- Chronic obstructive pulmonary disease, 163
- Chrysiasis, 713
- Chymase-containing mast cell, 549
- Cialis, 729-730
- Cicatricial pemphigoid, 467-469, 467f, 468
- Cidofovir, 623b, 623, 717-718, 755t
- Ciliary body, structure of, 23
- Ciprofloxacin, 194t  
in bullous keratopathy, 494  
in burn injury, 510  
clinical uses of, 195  
for conjunctivitis, 448  
for contact lens-related complications, 540  
for corneal ulcer, 523, 524  
for foreign body, 500  
formulations of, 186t  
for infectious conjunctivitis, 446  
for pathogens susceptible to, 442t  
in recurrent corneal erosion, 507
- Circadian rhythm of intraocular pressure, 672-673, 686-687
- Citrate, 511
- Claforan, 184t
- Clarinox, 252t, 552t  
for seasonal conjunctivitis, 561
- Clarithromycin, 447
- Claritin, 252t, 552t
- Clark's rule for pediatric dosage, 11
- Cleaning regimen for contact lens, 564
- Cleanser, eyelid, 45
- Clear Eyes, 248t
- Clemastine, 251t
- Clodronate, 753t
- Clomiphene, 751t  
retinal, 731
- Clonazepam, 377
- Clostridium*, Reiter's syndrome and, 472
- Cloxacillin, 180t
- Cluster headache, Horner's syndrome and, 353
- Cocaine  
corneal effects of, 711  
pupil and, 718
- Cocci, gram-negative, 177

- Cod liver oil, 298t
- Codeine  
for child, 109t  
formulations of, 105t  
pharmacological properties of, 104, 104t  
for severe pain, 109-110
- Cogan's syndrome, 516t
- Cogentin, 721
- Cognitive history, 4t, 6
- Colitis, antibiotic-associated  
pseudomembranous, 184
- Collaborative Initial Glaucoma Treatment Study, 695t
- Collaborative Normal-Tension Glaucoma Study, 695t
- Collagen plug, 273-274, 273f, 273t, 427
- Collagen shield, 46-47, 46f
- Collagen vascular disorder, 580
- Collarette, 383, 383f
- Colloidal system as vehicle, 34
- Collyrium Fresh, 248t
- Color vision, cardiac glycosides and, 729
- Comanagement, 64-65, 64b
- Combination agent  
for cataract surgery, 601  
for pupil dilation, 333-334  
topical carbonic anhydrase inhibitor and, 167
- Combivir, 206t
- Compartment theory, 25-27
- Complete blood count in uveitis, 597
- Compliance, 59-60, 60b  
with glaucoma treatment, 695-696
- Complications  
of cataract surgery, 604, 606-615.  
*See also* Cataract surgery, complications of  
contact lens-related  
epithelial microcysts as, 542-545, 544f  
infiltrative events as, 538-542, 540f, 544f  
of drug use  
diagnostic, 75-76  
therapeutic, 76-78  
of uveitis, 596-597
- Compress  
for atopic dermatitis of eyelid, 570  
in eyelid hygiene, 384  
for urticaria, 572
- Computed tomography  
in myasthenia gravis, 375, 375f  
in thyroid-related orbitopathy, 650-651, 651f
- Confocal scanning laser  
ophthalmoscopy, 679, 679t
- Congenital epiphora, 429-430
- Congestive orbital disease, 647-648, 648f
- Conjunctiva, 437-482, 550, 556t-559t, 560-568. *See also* Conjunctivitis  
adverse drug effects on, 711-713, 712t
- Conjunctiva—cont'd  
adverse effects on, 7t  
anatomy of, 437-438, 438f  
anesthesia for surgery on, 323  
atopic dermatitis and, 466-467, 466f  
cataract surgery complications of, 604  
in connective tissue disease, 470-474  
polyarteritis nodosa and, 471-472, 472f  
Reiter's syndrome and, 472-474, 473f  
systemic lupus erythematosus, 470-471, 471f  
immunology of, 549  
inflammation of, 439-440, 474-478  
in phlyctenulosis, 474-475, 475f  
in pinguecula, 476, 476f  
pterygium and, 477-478, 477f  
signs of, 440t  
in superior limbic keratoconjunctivitis, 475-476, 476f  
microbiologic features of, 438-439, 439b  
mucous membrane disorder of, 467-470  
cicatricial pemphigoid and, 467-469, 467f, 468f  
in erythema multiforme major, 469-470  
in Stevens-Johnson syndrome, 469-470  
in toxic epidermal necrolysis, 469-470  
in nutritional deficiency, 478  
psoriasis and, 465-466, 465f  
rosacea and, 463-465, 464f  
trauma to, 478-480, 479f
- Conjunctival compression cytology, 423
- Conjunctival hyperemia  
in atopic keratoconjunctivitis, 567  
decongestants causing, 249  
Horner's syndrome and, 354  
latanoprost and, 142
- Conjunctival injection, epithelial  
microcysts and, 543
- Conjunctival phlyctenule, 517
- Conjunctivitis, 444-463  
acute bacterial, 444-449, 445f, 446f  
diagnosis of, 445-446  
etiology of, 444-445  
management of, 446-449, 449f  
allergic, 239-240, 550, 556t-559t, 560-568  
atopic keratoconjunctivitis, 567-568, 567f  
giant papillary, 561-564, 562t, 563f  
medrysone for, 228  
seasonal, 550, 560-561, 560f  
vernal keratoconjunctivitis, 564-566, 565f  
antibacterial drugs for, 176t  
chronic bacterial, 451  
decongestants causing, 249
- Conjunctivitis—cont'd  
dorzolamide and, 165  
in epidemic keratoconjunctivitis, 525  
falsified, 480  
fluorometholone for, 228  
fluoroquinolones for, 195  
giant papillary, 558t  
contact lens-related, 542f  
loteprednol etabonate for, 228  
mast cell stabilizers for, 255  
hemorrhagic *versus* epidemic keratoconjunctivitis, 527  
hyperacute bacterial, 449-451, 450f  
inclusion, 456-457  
in Lyme disease, 459  
mechanism of infection in, 444  
*Moraxella* causing, 459  
in ophthalmia neonatorum, 460-463, 461f, 462f, 463t  
in Parinaud's oculoglandular syndrome, 459-460, 460b  
in pharyngoconjunctival fever, 452  
principles of therapy for, 444  
in Reiter's syndrome, 472-473  
toxic, 474  
trachoma, 457-458, 458f  
trimethoprim for, 193  
viral  
adenoviral, 451-454, 452f, 453f, 453t  
herpes simplex, 454-455, 455f  
molluscum contagiosum and, 458-459, 458f  
nonspecific, 459  
systemic disease associated with, 459, 460t  
varicella zoster, 455-456, 456f
- Connective tissue disease, conjunctiva  
in, 470-474  
polyarteritis nodosa and, 471-472, 472f  
Reiter's syndrome and, 472-474, 473f  
systemic lupus erythematosus, 470-471, 471f
- Conservation, tear, 426-428, 428t  
lacrimal occlusive devices for, 273-274, 273f, 274f  
ointments for, 272-273, 272t
- Constipation, opioid causing  
in child, 110  
in elderly, 111
- Consultation, documentation of, 79
- Contact dermatitis, 550  
agents causing, 570b  
of eyelid, 569t, 570-571, 571b, 571f  
ointment causing, 44  
sulfonamides and, 194
- Contact lens  
anesthesia for fitting of, 322  
complications of  
epithelial microcysts as, 542-545, 544f  
infiltrative events as, 538-542, 540f, 544f  
for corneal abrasion, 497

- Contact lens—cont'd  
 for drug delivery, 45-46  
 for exposure keratopathy, 509  
 fluorescein sodium for management of, 285-286  
 soft  
   in bullous keratopathy, 494  
   in Fuch's dystrophy, 489  
   in thyroid disease, 653
- Continuous irrigating system, 47-48, 48f
- Contraceptive, oral  
 penicillin effects on, 182  
 reduced tear production and, 714-715
- Contraindications, determination of, 4-7, 4t
- Controlled substance, 57, 57t
- Contusion, conjunctival, 479-480
- Copper, 296, 296t
- Cornea  
 adverse drug effects on, 7t, 704-711, 704t  
 anatomy of, 483  
 in anterior uveitis, 590  
 in atopic disease, 567  
 contact lens-related complications of, 538-545  
   epithelial microcysts as, 542-545, 544f  
   infiltrative events as, 538-542, 540t, 541f-544f  
 dorzolamide and, 165  
 drugs causing epithelial damage to, 29t  
 dystrophy and degeneration of, 484-496  
   anterior basement membrane, 486-488, 487f  
   bullous keratopathy and, 493-494, 493f  
   calcific band keratopathy and, 494-496, 495f  
   classification of, 484t-485t  
   Fuchs', 488-490, 489f, 490f  
   hydrops secondary to keratoconus and, 490, 491f, 492-493, 492f  
 keratitis of, 514-538. *See also* Keratitis keratoconjunctivitis and. *See* Keratoconjunctivitis  
 structure of, 19-22, 20f, 21f, 21t  
 in thyroid-related orbitopathy, 656  
 trauma to  
   abrasion as, 44, 496-498, 496f, 497f  
   burn as, 509-511, 510f, 510t  
   dellen and, 512-513, 513f  
   exposure keratopathy and, 507-509  
   foreign body causing, 498-502, 498f-502f  
   penetrating, 502-504, 502f, 503f, 504f  
   photokeratitis with, 511-512  
   recurrent erosion and, 486, 487, 504-507, 504f, 507f  
   toxic keratitis and, 513-514, 514f  
   in vernal keratoconjunctivitis, 564-565
- Corneal delamination, 507
- Corneal edema, 279-281  
 causes of, 280b  
 glucose for, 281  
 glycerin for, 280-281, 280t  
 postoperative, 608-609, 609f  
 sodium chloride for, 279-280, 280t, 281f
- Corneal epithelial debridement, 323
- Corneal epithelial healing, 232
- Corneal erosion, epithelial punctate, 143
- Corneal fleck, 485t
- Corneal laceration, 44
- Corneal scarring, 533
- Corneal toxicity, 259
- Corneal ulcer, ointment for, 44
- Corticosteroid, 221-233. *See also* Steroid  
 in acute retinal necrosis, 622  
 adverse effects of, 595, 750t  
   on conjunctiva, 713  
   on cornea, 704t, 705  
   on eyelid, 713  
   on intraocular pressure, 723-724  
   on lens, 704t  
   retinal, 734  
 alternate-day therapy with, 226  
 bioavailability of, 221-222, 222t  
 clinical uses of, 226-229, 226t  
 contraindications to, 233  
 intravitreal use of, 224-225  
 local injection of, 224  
 in myasthenia gravis, 375  
 novel delivery devices for, 225-226  
 ocular effects of, 229b  
 pharmacologic principles of, 221  
 for polyarteritis nodosa, 472  
 for postoperative inflammation, 602  
 in recurrent corneal erosion, 506  
 for retinal disease, 308-310  
   anecortave acetate and, 309-310  
   intravitreal implants and, 309  
   triamcinolone acetonide and, 308-309  
 in sarcoidosis, 632  
 in scleritis, 584  
 side effects of, 229-232, 231f  
 sub-Tenon's injection of, 49f  
 systemic effects of, 233  
 for tear stimulation, 275  
 therapeutic principles of, 222-226, 223  
 in thyroid-related orbitopathy, 655  
 topical, 223-224, 227t  
 for toxoplasmosis, 628
- Corynebacterium*, 382-383  
 in conjunctival flora, 438
- Corynebacterium diphtheriae*, 446
- Cosopt, 166-167
- Cost of care, 53-54  
 in glaucoma, 695-696
- Cotton pledget, 46, 46f
- Cox-2 inhibitor, 751t
- Coxsackievirus, 459
- Crack cocaine, 711
- Cranial nerve VII, 425
- Crixivan, 207t
- Crolom, 553t  
 in seasonal conjunctivitis, 561
- Cromolyn sodium, 255, 256t, 257, 553t  
 in seasonal conjunctivitis, 561
- Cryotherapy in scleritis, 584
- Crystalline lens. *See* Lens
- Culture  
 anesthesia for, 320  
 bacterial, 175-176  
 in conjunctival inflammation, 440-441  
 as contraindication to local  
   anesthetic, 93  
   of corneal ulcer, 521-523  
   in fungal keratitis, 535-536
- Curettage of eyelid, 411-412
- Curvularia*, 205, 534
- Cutaneous horn, 400, 400f
- Cyanoacrylate tarsorrhaphy, 408
- Cyclodextrin, 34
- Cyclogyl, 127t
- Cyclomydril, 127t
- Cyclooxygenase  
 in allergic disease, 550  
 inflammatory response and, 233
- Cyclooxygenase pathway, 233-235, 234f
- Cyclopentolate, 130-133, 131f  
 administration of, 346  
 for amblyopia, 664  
 in angle-closure glaucoma, 693  
 anticholinergic mydriasis caused by, 361-362  
 characteristics of, 345t  
 clinical uses of, 132  
 compared with other drugs, 345-346  
 contraindications to, 133  
 for infant, 335  
 pharmacology of, 130-132  
 preparations of, 127t  
 properties of, 127t  
 side effects of, 132-133  
 systemic effects of, 9t  
 tropicamide and, 134-135
- Cyclophosphamide  
 in myasthenia gravis, 376  
 for ocular cicatricial pemphigoid, 468  
 in systemic lupus erythematosus, 471
- Cycloplegic agent, 125-138  
 for amblyopia, 663-665  
 in angle-closure glaucoma, 693  
 atropine as, 126, 127t, 128-129  
 in bullous keratopathy, 494  
 characteristics of, 345t  
 cholinergic antagonists as, 125-137.  
   *See also* Cholinergic antagonist  
 cholinergic innervation and, 125, 126f  
 comparison of, 345-346, 345t  
 for corneal abrasion, 497  
 for corneal ulcers, 524  
 cyclopentolate as, 130-133, 131f, 132b  
 disclosure of risks of, 67-69, 68f, 69f

- Cycloplegic agent—cont'd  
 for herpes zoster ophthalmicus, 533  
 homatropine as, 129-130  
 overview of, 125-126  
 for pseudophakic cystoid macular edema, 614  
 in Reiter's syndrome, 473  
 scopolamine as, 130  
 selection of, 345  
 for strabismus, 663-665  
 toxic keratitis and, 514  
 tropicamide as, 133-137, 133f, 134f, 135t, 136f  
 for uveitis, 594
- Cycloplegic refraction, 343-348  
 administration of drug for, 346-347  
 agents for, 345-346, 345t  
 comparison of agents for, 345-346  
 disadvantages of, 344  
 indications for, 343-344, 344b  
 precautions for, 344  
 spectacle prescribing and, 347-348  
 techniques of, 347
- Cycloplegic spray, 43
- Cyclosporine A, 236-240, 237f, 238f, 239f, 555t  
 in allergic disease, 550  
 animal studies of, 240  
 in atopic keratoconjunctivitis, 567-568  
 clinical uses of, 240  
 contraindications to, 242  
 for dry eye, 239, 240-241  
 human studies of, 240-241  
 for immune-mediated disease, 241-242  
 in myasthenia gravis, 376  
 pharmacology of, 236-240, 237f, 238f, 239f  
 for psoriasis, 465  
 in scleritis, 584  
 side effects of, 242  
 for tear stimulation, 275-276, 429  
 for uveitis, 595  
 in vernal keratoconjunctivitis, 566
- Cyproheptadine, 377
- Cyst  
*Acanthamoeba*, 215, 537  
 of eyelid, 401-402, 401f
- Cystoid macular edema, 632-635, 633f  
 after cataract surgery, 613-614, 614f  
 ketorolac for, 236  
 latanoprost and, 142-143  
 nonsteroidal anti-inflammatory drugs and, 234-235
- Cytokine  
 cyclosporine A and, 236-237  
 dry eye and, 264-265  
 in uveitis, 588
- Cytokine antagonist, 660
- Cytology, conjunctival compression, 423
- Cytomegalovirus  
 antiviral drugs for, 204
- Cytomegalovirus—cont'd  
 intravitreal drug administration for, 50-51  
 necrotizing herpetic retinopathy and, 621-624, 621f, 622f, 622t
- D**
- Dacryoadenitis, 424, 424f
- Dacryocystitis  
 acquired, 433-434  
 antibacterial drugs for, 176t  
 penicillin for, 182
- Dandruff, 385
- Dapiprazole, 120-121, 120f, 121f, 654
- Dapsone, 468
- Daranide, 755t
- Dark in anisocoria, 349, 351f
- Darunavir, 206t
- Datura*, 361-362, 741, 758t
- Daypro, 102t  
 adverse effects of, 751t
- Deafness, vancomycin causing, 185-186
- Death, atropine causing, 129
- Debridement, anesthesia for, 323
- Decompression in thyroid-related orbitopathy, 657, 660-661, 660f
- Decongestant, 247, 248t, 249  
 in seasonal conjunctivitis, 560
- Deep lamellar endothelial keratoplasty, 490f
- Delamination, corneal, 507
- Delavirdine, 206t
- Delayed hypersensitivity reaction, 580
- Delivery system, 4, 39-52, 703  
 intracameral, 50  
 intravitreal, 35t, 50-51, 51f  
 periocular, 48-50, 49f, 50b, 50f  
 photodynamic therapy as, 51  
 topical, 39-48. *See also* Topical administration
- Dellen, corneal, 512-513, 513f
- Demodex*, 383, 383f
- Demodex brevis*, 397  
 in chalazion, 390
- Demodex folliculorum*, 397  
 rosacea and, 388  
 in seborrhic blepharitis, 385
- Demyelinating optic neuropathy, 369-370
- Dendritic lesion  
 in herpes simplex keratitis, 528  
 in herpes zoster ophthalmicus, 531f
- Dendritiform epitheliopathy, 143
- Denervation hypersensitivity in Adie's syndrome, 359
- Depigmentation, steroid-induced, 390-391
- Deposit, tetracycline, 713
- Depressant, on pupillary effects of, 719
- Depression  
 bone marrow, 192  
 respiratory, 107
- Dermatitis  
 atopic
- Dermatitis—cont'd  
 conjunctivitis and, 466-467, 466f  
 of eyelid, 568, 569t, 570  
 contact, 550, 570-571, 571b, 571f  
 ointment causing, 44  
 sulfonamides and, 194  
 varicella zoster causing, 395
- Dermatologic system. *See* Skin entries
- Dermatosis, periorbital, 568
- Descemet's membrane, 483
- Desloratadine, 250, 252t, 253, 552t  
 for seasonal conjunctivitis, 561
- Desomedine, 215
- Detachment, retinal. *See* Retinal detachment
- Dexamethasone  
 clinical uses of, 227-228  
 for corneal ulcers, 525  
 formulations of, 227t  
 ocular hypertension caused by, 231  
 for pseudophakic cystoid macular edema, 614
- Dexedrine, 718
- Diabetic macular edema, 632, 633-634
- Diamox, 755t
- Diazepam, 377
- Dichlorphenamide  
 adverse effects of, 755t  
 pharmacokinetic properties of, 161t
- Diclofenac, 235  
 clinical uses of, 235-236  
 for corneal abrasion, 496  
 in cystoid macular, 633  
 in episcleritis, 578  
 in exposure keratopathy, 509  
 for foreign body, 501  
 photorefractive keratectomy and, 236  
 for pseudophakic cystoid macular edema, 614  
 for uveitis, 595
- Dicloxacillin  
 in preseptal cellulitis, 391  
 spectrum of activity of, 180t
- Didanosine, 206t
- Didrocal, 753t
- Dietary reference intake, 295
- Dietary supplement, 295-301  
 adverse reactions and, 703
- Dietary Supplement Health and Education Act, 295
- Diethylcarbamazine, 630
- Diffuse anterior scleritis, 580, 580f
- Diffusion, 25-26
- Diflunisal, 102t, 595
- Digitoxin, 729, 748t
- Digoxin, 729, 748t
- Diisopropyl fluorophosphate, 666
- Dilation of pupil, 329-341  
 anterior angle evaluation before, 330-333  
 gonioscopy for, 332-333, 333f, 333t  
 shadow test in, 330, 331f

- Dilation of pupil—cont'd  
 slip-lamp method for, 330, 331f, 332t  
 cataract surgery and, 337-338, 338f  
 in child, 334  
 complications of, 75-76, 339-340  
 in congenital epiphora, 430-431, 430f  
 contraindications to, 329, 330b  
 disclosure of risks of, 67-69, 68f, 69f  
 examination for, 329  
 guidelines for, 333-334  
 Horner's syndrome and, 354  
 indications for, 329  
 in infant, 334-335  
 informed consent for, 68f  
 mechanics of angle closure and, 336, 336f  
 mydriatic agent for, 114-119. *See also* Mydriatic agent  
 in narrow-angle glaucoma, 335-337, 337f  
 in open-angle glaucoma, 335  
 in plateau iris, 338, 338f  
 postdilation procedures and, 338-339  
 in pregnancy, 335  
 in punctal occlusion, 433  
 routine, 334  
 in systemic disease, 335  
 unilateral, fixed, 360-362
- Dimenhydrinate, 721t
- Diphenhydramine, 250, 251t, 551t  
 antimuscarinic dosage of, 721t  
 local anesthetic and, 94  
 in seasonal conjunctivitis, 561
- Dipivalyl epinephrine, 27
- Diplopia  
 in myasthenia gravis, 373-374  
 in thyroid disease, 643
- Diquafosol, 274-275
- Direct fluorescent antibody smear, 443
- Direct ophthalmoscopy, 676
- Disc. *See* Optic nerve
- Discharge  
 in bacterial conjunctivitis, 445, 445f  
 in conjunctival inflammation, 440t
- Disciform keratitis, herpes simplex, 529
- Disclosure  
 of abnormalities, 69-70  
 of alternatives to drug therapy, 69  
 professional community standard in, 66, 66b  
 reasonable patient standard in, 66, 66b  
 of risk of treatment, 67-69, 68f, 69f
- Discoloration. *See* Pigmentation
- Disodium EDTA, 31
- Distichiasis, 405-406, 406f
- Distortion of pupil, postoperative, 609-610, 610f
- Distribution system  
 anatomy and physiology of, 417  
 disorders of, 425  
 evaluation of, 424
- Diuretic  
 myopia caused by, 720-721  
 reduced tear production with, 715
- DNA in conjunctival inflammation, 444
- DNA synthesis, 194-196, 194t
- Documentation  
 of drug use, 78-79, 78b  
 as legal issue, 78-79, 78b  
 of warnings, 70
- Dolobid, for uveitis, 595
- Dorzolamide, 156  
 timolol with, 166-167
- Dosage  
 for child, 11  
 counseling about, 61  
 in pregnancy, 9-11
- Dose-response curve for phenylephrine, 115, 115f
- Dot in anterior basement membrane dystrophy, 486
- Down syndrome, pupil dilation in, 335
- Doxepin, antimuscarinic dosage of, 721t
- Doxycycline  
 adverse effects of, 754t  
 in blepharitis in rosacea, 388-389  
 in burn injury, 511  
 clinical uses of, 190  
 drug interactions with, 191  
 dry eye and, 425  
 for inclusion conjunctivitis, 457  
 for meibomian gland infection, 387  
 for rosacea, 464
- Drainage  
 of chalazion, 327, 327f  
 lacrimal, epiphora and, 429-432, 430f, 431f, 432f  
 of lacrimal system, 417-418
- Drance, 678-679
- Drop size of drug, 18
- Drug abuse  
 adverse drug reactions and, 703  
 conjunctival effects of, 713
- Drug delivery. *See* Delivery system
- Drug development, 36
- Drug Enforcement Administration, 64
- Drug formation. *See* Formulation, drug
- Drug formulation, 17-37
- Drug holiday in glaucoma, 692
- Drug interaction. *See also* Adverse drug reaction  
 antiglaucoma causing, 6t  
 counseling about, 61  
 nonsteroidal anti-inflammatory drugs and, 235  
 with nutrient supplements, 300  
 of tetracyclines, 191
- Drug release system, 34, 36
- Drug toxicity, minimizing of, 7
- Drug-induced disorder  
 calcific band keratopathy as, 494-495  
 hearing loss as, 192
- Drug-induced disorder—cont'd  
 intracranial hypertension as, 739-740, 739t  
 myopia as, 720-722, 721f  
 Stevens-Johnson syndrome as, 469  
 systemic lupus erythematosus as, 740, 740b, 741b
- Dry eye, 263-278, 425-429  
 aqueous deficiency in, 425  
 blepharitis with, 242  
 blepharospasm and, 377  
 in burn injury, 511  
 case history for, 421b  
 classification of, 265f  
 as contraindication to local anesthetic, 93  
 cyclosporine A and, 238-239  
 drugs causing, 714-715, 714t  
 etiology of, 264-265  
 evaluation of, 424b  
 evaporative dysfunction in, 425  
 in exposure keratopathy, 508  
 LASIK-induced, cyclosporine A for, 242  
 in ocular cicatricial pemphigoid, 468  
 ocular surface disorder and, 423  
 omega-3 fatty acid and, 300  
 in Stevens-Johnson syndrome, 469-470  
 tear conservation for, 272-274, 272t, 273f, 273t, 274t  
 tear film abnormality in, 264-276  
 refractive surgery causing, 265  
 tear supplementation for, 266-272. *See also* Artificial tears  
 tear film physiology and, 263-264  
 tear stimulation for, 274-276
- Dry mouth  
 apraclonidine causing, 155  
 brimonidine and, 157
- Duct, nasolacrimal, 417-418  
 in congenital epiphora, 429-430
- Duction test, forced, 320-321, 321f
- Duricef, 184t
- Duty, negligence and, 71
- Dye, 283-294  
 fluorescein sodium as, 283-288  
 for angiography, 287-288  
 for angioscopy, 288  
 for applanation tonometry, 286, 287t  
 for contact lens management, 285-286  
 excitation and emission spectra of, 284f  
 for fluorophotometry, 288  
 intravenous applications of, 287-288  
 for lacrimal system evaluation, 286  
 preparations of, 284t  
 structure of, 283f  
 topical applications of, 284-286, 284t, 285f, 286f  
 fluorexon as, 288-289, 289f  
 indocyanine green as, 291-292, 291f

- Dye—cont'd  
 lissamine green as, 290-291, 291f  
 methylene blue as, 292  
 rose bengal as, 289-290, 289f, 290f
- Dynamic contour tonometry, 674
- Dyscrasias, blood  
 acetazolamide causing, 162  
 sulfonamides causing, 193-194
- Dysthyroid ophthalmopathy, 644. *See also*  
 Thyroid-related orbitopathy
- Dystrophy and degeneration, corneal,  
 484-496  
 anterior basement membrane, 486-488,  
 487f  
 bullous keratopathy and, 493-494, 493f  
 calcific band keratopathy and, 494-496,  
 495f  
 classification of, 484t-485t  
 Fuchs', 488-490, 489f, 490f  
 hydrops secondary to keratoconus  
 and, 490, 491f, 492-493, 492f
- E**
- Eagle punctal plugs, 273t
- Early Manifest Glaucoma Trial, 696t
- Eaton-Lambert syndrome, 375
- Echinacea purpurea*, adverse effects  
 of, 758t
- Echinocandin, 208, 214-215
- Echothiophate, 666  
 phenylephrine with, 116  
 systemic effects of, 9t
- Ectopia lentis, 335
- Ectropion, punctal, 432-433
- Eczema, 567
- Eczematous conjunctivitis, 550
- Edema  
 cystoid macular  
 after cataract surgery, 613-614, 614f  
 latanoprost and, 142-143  
 in episcleritis, 578
- Edinger-Westphal nucleus, 125
- Edrophonium in myasthenia gravis, 374
- Education, patient, 60-61  
 on antibacterial treatment, 177  
 on cataract surgery, 601  
 importance of, 3-4
- Efavirenz, 206t
- Effluent pupillary pathway, 349
- Effusion, choroidal, postoperative, 607
- Eicosapentaenoic acid synthesis  
 pathway, 235f
- Eight ball clot, 611
- Elderly patient  
 administering topical drug to, 42  
 pain management in, 110  
 special considerations for, 12-13  
 toxoplasmosis in, 628
- Electrolyte in artificial tears, 269
- Electromyography  
 in myasthenia gravis, 374  
 in thyroid disease, 649
- Electroretinography, 726
- Elestat, 258t, 553t
- Elidel, 555t  
 for atopic dermatitis of eyelid, 570
- ELISA  
 in conjunctival inflammation,  
 443-444  
 in uveitis, 597
- Emadine, 254t, 551t  
 in seasonal conjunctivitis, 560
- Emedastine, 254t, 255, 551t  
 in seasonal conjunctivitis, 560
- EMLA, 94
- Empiric therapy for conjunctivitis, 442
- Emsam, 690t
- Emtricitabine, 206t
- Emtriva, 206t
- Enbrel  
 for psoriasis, 465  
 for uveitis, 595-596
- Endophthalmitis  
 after cataract surgery, 601  
 amphotericin B for, 208  
 antibacterial drugs for, 176t  
 nematode, 629-630  
 in toxocariasis, 629
- Endophthalmos, postoperative, 604,  
 606-607, 606f
- Endothelial dystrophy, Fuchs', 488-490,  
 489f
- Endothelial growth factor, vascular,  
 310-311  
 in age-related macular degeneration,  
 635
- Endothelial keratoplasty, deep lamellar,  
 490f
- Endothelium  
 in bullous keratopathy, 493-494  
 corneal, 483  
 dorzolamide and, 165  
 structure of, 22
- Enfuvirtide, 207t
- Enlargement of lacrimal gland, 424
- Enlon test for myasthenia gravis, 374
- Enoxacin, 194t
- Enterobacter*  
 aminoglycosides for, 187  
 infections caused by, 178t  
 penicillin for, 182
- Enterovirus*, 459
- Enzyme in ciliary body, 23
- Enzyme-linked immunosorbent assay  
 in conjunctival inflammation,  
 443-444  
 in uveitis, 597
- Eosinophil  
 in allergic eye disease, 550  
 in toxocariasis, 629-630
- Epidemic keratoconjunctivitis, 452, 452f,  
 453t, 525-527, 526f
- Epidermal keratinization, 271
- Epidermal necrolysis, toxic, 469-470
- Epilation  
 in phthiriasis palpebrarum, 399  
 for trichiasis, 406, 406f
- Epinastine, 257, 258t, 553t  
 in seasonal conjunctivitis, 561
- Epinephrine, for regional anesthesia, 323
- Epiphora, 429-432, 430f, 431f, 432f
- Episclera  
 adverse drug effects on, 715-718, 716t  
 vasculature of, 575
- Episcleritis, 575-576, 578-589  
 fluorometholone for, 228  
 glaucoma with, 694  
 in polyarteritis nodosa, 472
- Epithelial, 528
- Epithelial corneal erosion, punctate, 143
- Epithelial debridement, corneal, 323
- Epithelial healing, corneal, 232
- Epithelial keratitis  
 acyclovir for, 201  
 Thygeson's superficial, 533
- Epithelial microcyst, 542-545, 544f
- Epithelial toxicity of artificial  
 tears, 270
- Epithelialization in burn injury, 510
- Epitheliopathy, dendritiform, 143
- Epithelium  
 corneal, 483  
 drugs causing epithelial damage  
 to, 29t  
 structure of, 20-21  
 in interstitial keratitis, 516  
 of palpebral conjunctiva, 480  
 in recurrent corneal erosion, 505  
 stratified squamous, of bulbar  
 conjunctiva, 437-438
- Epivir, 206t
- Epstein-Barr virus, 516t
- Epzicom, 206t
- Erosion  
 epithelial punctate corneal, 143  
 recurrent corneal, 486, 487, 504-507,  
 504f, 507f
- Erythema multiforme major, 469-470
- Erythrocyte sedimentation rate in  
 uveitis, 597
- Erythromycin  
 for blepharitis, 384  
 for chronic conjunctivitis, 451  
 for conjunctivitis, 448  
 dellen and, 513  
 formulations of, 186t  
 hearing loss and, 192  
 for internal hordeolum, 390  
 for ophthalmia neonatorum, 461  
 for pathogens susceptible to, 442t  
 phlyctenular keratoconjunctivitis and,  
 518  
 in phlyctenulosis, 475  
 for rosacea, 464  
 toxicity of, 192
- Eschar, 509



- Escherichia coli*  
aminoglycosides for, 187  
chronic conjunctivitis and, 451  
infections caused by, 177  
ophthalmia neonatorum and, 462
- Esotropia  
cycloplegics and, 343, 345, 663-665  
infantile, 667-668  
in thyroid disease, 648-649
- Essential blepharospasm, benign, 376-379, 376f, 378t
- Etanercept  
adverse effects of, 716t, 717  
for psoriasis, 465  
in thyroid disease, 660  
for uveitis, 595-596
- Ethambutol, 753t  
optic nerve and, 736-737, 736t
- Ethanol, 724. *See also* Alcohol
- Ether, cellulose, 266-268, 267t
- Ethylsuccinate syrup, 461
- Etidocaine, 87t
- Etidronate, 753t
- Etolodac, 751t
- Etretinate, 751t
- Euthyroid state, 652
- Eutectic mixture of local anesthetic, 94
- Euthyroid state, 643
- Evizon, 311
- Examination for pupil dilation, 329
- Excedrin, 104t
- Excipient, examples of, 31t
- Excision of eyelid, 412
- Excretory system, lacrimal, 417-418
- Exfoliation syndrome, 335
- Exophthalmometry in thyroid disease, 648, 649f, 649t
- Exposure keratopathy, 507-509  
in thyroid disease, 649-650, 650f
- Extracellular material, 231
- Extraocular muscle  
adverse drug effects on, 719-720, 719t  
in thyroid disease, 645, 656
- Exudate in bacterial conjunctivitis, 445f
- Eye examination, 6
- Eye movement, drugs causing, 719-720, 719t
- Eyedrop assistance device, 42, 42f
- Eyelash  
*Demodex* infestation of, 397, 398f  
phthiriasis palpebrarum and, 399
- Eyelid  
adverse drug effects on, 711-713, 712t  
allergic disease of, 550, 568, 569t, 570-572  
atopic dermatitis, 568, 570  
contact dermatitis as, 570-571, 570b, 571f  
urticaria, 571-572  
anatomy and physiology of, 381, 382f  
anterior margin of, 381-386  
angular blepharitis of, 385, 385f
- Eyelid—cont'd  
blepharitis in, 381-382  
hygiene of, 384b  
infection of, 382-384, 383f  
seborrhic blepharitis of, 385-386, 385f, 386f  
in atopic keratoconjunctivitis, 567  
basal cell carcinoma of, 403-404, 403f, 404f  
benign tumors of, 399-402  
sebaceous cysts as, 401-402, 401f  
sudoriferous cysts as, 401, 401f  
verrucae as, 399-401, 400f  
xanthoma palpebrarum as, 402, 402f  
cataract surgery complications of, 604  
hyperlaxity of, 406-408, 407f  
infestation of, 397-399, 398  
inflammatory disease of, 389-393  
chalazion as, 390-391, 390f  
external hordeolum as, 389, 389f  
internal hordeolum as, 389-390, 390f  
preseptal cellulitis as, 391-393, 391t, 392f  
lash anomaly of, 405-406, 406f  
lesions of, 326-327, 326t, 327f  
malignant tumors of, 402-405  
basal cell carcinoma as, 403-404, 403f, 404f  
sebaceous gland carcinoma as, 404, 404f  
signs of, 402b  
squamous cell carcinoma as, 404-405, 405f  
posterior margin of, 386-389  
meibomian gland dysfunction of, 386-388, 387f  
rosacea and, 388-389, 388f  
pre-malignant lesion of, 405  
retraction of  
management of, 653-655-654f  
in thyroid disease, 646-647, 647f  
in seasonal conjunctivitis, 560  
sensory nerves of, 324f  
surgery of, 408-412  
chemical cautery and, 409  
incisions for, 410-412, 411f  
neuroanatomy and, 408-409  
patient management and, 412-413  
for rhytids and, 409  
thermal cautery and, 409-410  
viral disease of, 393-397  
herpes simplex blepharoconjunctivitis as, 393, 393f  
herpes zoster ophthalmicus as, 393-397, 394f, 396f
- Eyelid scrub, 45, 46t
- Eyesine, 248t
- F**
- Factitious conjunctivitis, 480
- Famciclovir  
clinical indications for, 203t
- Famciclovir—cont'd  
guidelines for, 199t  
for herpes zoster conjunctivitis, 456  
for herpes zoster ophthalmicus, 532  
pharmacology and, 204
- Fatality, atropine causing, 129
- Fatigue, brimonidine and, 157
- Fatty acid  
omega-3, 233  
for tear stimulation, 276
- FDA "Orange Book," 58-59
- Federal regulation of drugs, 64
- Fenoprofen, formulation of, 102t
- Fever, pharyngoconjunctival, 527
- Fexofenadine, 250, 251t, 253, 552t  
in seasonal conjunctivitis, 561
- Fiber, nerve  
in Horner's syndrome, 352  
myelinated, 113  
retinal, in glaucoma, 676-678, 678f  
unmyelinated, 113
- Fibrinogen, in uveitis, 588
- Fibrosis  
in thyroid disease, 643, 649
- Fick's law, 25-26
- Filamentary keratitis, 509
- Film, tear, 17-19, 18f
- Filter paper strip as solid delivery device, 46, 46f
- Financial considerations, 53-54
- Fingerprint line, 486
- Fish-eye disease, 485t
- Fishing syndrome, mucous, 426, 426f, 480
- FK506, for uveitis, 595
- Flare in anterior uveitis, 590, 591b
- Flax seed oil for tear augmentation, 428
- Fleck, corneal, 485t
- Fleischer's ring, 491f
- Floppy eyelid syndrome, 406-408, 407f
- Flora  
of conjunctiva, 438  
gastrointestinal  
cephalosporins affecting, 184  
penicillin effects on, 182
- Flow, tear, 18-19
- Flow device, continuous, 47-48, 488
- Fluconazole, 208, 209t-210t, 211t, 213t, 214
- Flucytosine, 208, 213t
- Fluid pump, corneal, 22
- Fluocinolone acetonide, 594
- Fluorescein  
fluorexon and, 89  
for phthiriasis palpebrarum, 399
- Fluorescein angiography, 287-288  
in cystoid macular edema, 613, 632  
in retinal disease, 617-619, 618f  
in scleritis, 582  
in uveitis, 599
- Fluorescein sodium, 283-288  
adverse reactions to, 288

- Fluorescein sodium—cont'd  
 for angiography, 287-288  
 for angioscopy, 288  
 for applanation tonometry, 286, 287t  
 for contact lens management, 285-286  
 contraindications to, 288  
 excitation and emission spectra of, 284f  
 for fluorophotometry, 288  
 intravenous applications of, 287-288  
 for lacrimal system evaluation, 286  
 for ocular surface integrity testing, 284-285  
 pharmacology of, 283  
 preparations of, 284t  
 structure of, 283f  
 topical applications of, 284-286, 284t, 285f, 286f
- Fluorescent antibody smear, 443
- Fluorometholone, 555t  
 clinical uses of, 228  
 in episcleritis, 578  
 formulations of, 227t  
 ocular hypertension and, 231  
 in vernal keratoconjunctivitis, 566
- Fluorophotometry, vitreous, 288
- Fluoroquinolone, 194-196, 194t  
 in burn injury, 510-511  
 cataract surgery and, 601  
 clinical uses of, 194-195  
 for conjunctivitis, 448, 449  
 for contact lens-related complications, 540  
 contraindications to, 196  
 for corneal ulcer, 523, 524  
 for infectious conjunctivitis, 446-447  
 pharmacology of, 194  
 for pterygia, 478  
 side effects of, 195-196  
 for Stevens-Johnson syndrome, 469  
 for Thygeson's superficial punctate keratitis, 534
- 5-Fluorouracil, 715
- Flurasafe, 89
- Flurbiprofen  
 in cystoid macular, 633  
 formulations of, 236t
- Folate metabolism, 193-194
- Folic acid deficiency, 300
- Follicular conjunctivitis, 439-440, 440t  
 decongestants causing, 249  
 in pharyngoconjunctival fever, 452
- Fomivirsin, 623
- Food and Drug Administration  
 on bioequivalency, 58-59  
 drug reaction form of, 742f-743f
- Forced duction test, 320-321, 321f
- Foreign body  
 anesthesia for removal of, 322-323  
 conjunctival, 478-479, 479f  
 corneal, 498-502, 498f-502f
- Form for reporting drug reaction, 742f-745f
- Forme fruste, 565
- Form-Fit intracanalicular plug, 273t, 429t
- Formulation, drug  
 compartment theory and, 25-27, 26f  
 development of, 36  
 ocular tissue structure affecting, 17-15  
 aqueous humor, 23  
 blood supply in, 25  
 chemical properties of tears and, 17-19, 18f, 19f  
 ciliary body, 23  
 cornea and sclera, 19-22, 19f, 20f, 21f, 21t  
 iris and, 22  
 retina and optic nerve, 24-25  
 vitreous humor, 23-24
- Fornix conjunctiva, 437, 438f, 480
- Fortovase, 207t
- Foscarnet  
 for cytomegalovirus retinitis, 622-623, 622b  
 for progressive outer retinal necrosis, 625-626
- FP receptor, 139
- Friction sweat test, 354
- Fuchs' dystrophy, 485t, 488-490, 489f
- Fundus examination  
 in anterior uveitis, 591  
 in intermediate uveitis, 592  
 in posterior uveitis, 593
- Fungal infection  
 amphotericin B for, 208  
 conjunctival, 439b  
 corneal, 534-536, 535f  
 scleritis with, 577b
- Fuorexon, 89, 288-289, 289f
- Fusarium*, 205, 534
- Fusion inhibitor, 207t
- Fuzeon, 207t
- G**
- Gallium-67 citrate, 632
- Gamma linolenic acid, 233
- Ganciclovir, 204  
 for cytomegalovirus retinitis, 622-623, 622b  
 intravitreal administration of, 51  
 intravitreal implant with, 34, 36  
 for progressive outer retinal necrosis, 625-626
- Gastrointestinal disorder  
 acetaminophen and, 103  
 aspirin and, 100  
 NSAIDs and, 103  
 opioid and, 107  
 in child, 110  
 in elderly, 111
- Gastrointestinal system  
 azithromycin and, 192  
 beta-blockers affecting, 148b  
 cephalosporins affecting, 184  
 fluoroquinolones affecting, 195
- Gastrointestinal system—cont'd  
 penicillin effects on, 182  
 tetracyclines affecting, 190
- Gatifloxacin, 195  
 for conjunctivitis, 448, 449  
 for corneal ulcers, 523-524  
 formulations of, 186t  
 for pathogens susceptible to, 442t
- Gaze nystagmus test, alcohol, 720
- Gel, 45
- Gel-forming agent, 33
- Gemifloxacin, 194t, 195
- Gender  
 in adverse drug reaction, 703  
 uveitis and, 589
- General contact lens-related papillary conjunctivitis, 563
- Generic drug, 58-59
- Gentamicin  
 clinical uses of, 188  
 formulations of, 186t  
 steroids with, 188t  
 for corneal ulcer, 523  
 for infectious conjunctivitis, 446  
 for pathogens susceptible to, 442t
- Gentamicin-prednisone, 464
- GenTeal, 267t, 427t
- Giant papilla in vernal keratoconjunctivitis, 564
- Giant papillary conjunctivitis, 549  
 contact lens-related, 542f, 556t, 558t, 561-564, 562t, 563f  
 loteprednol etabonate for, 228  
 mast cell stabilizers for, 255  
 signs and symptoms of, 562t
- Giemsa stain, 535
- Ginkgo biloba*, 741, 758t
- Gland  
 lacrimal. *See* Lacrimal gland; Lacrimal system  
 meibomian. *See* Meibomian gland; Meibomianitis  
 of Moll, 263  
 sebaceous, carcinoma of, 404, 404f  
 thymus, 373  
 of Zeis, 263
- Glaucoma, 671-698  
 angle-closure, 693-694  
 atropine and, 129  
 risk of pupil dilation and, 67  
 tropicamide and, 137  
 examination of, 671-685  
 gonioscopy in, 674-676  
 of intraocular pressure, 671-674, 673b, 674b  
 of optic nerve head and retinal nerve fiber, 676-678, 678f  
 of topic nerve hemorrhages, 678-680  
 of visual fields, 680-685, 681f-684, 685b  
 historical perspective on, 671

- Glaucoma—cont'd  
   hypotensive drugs for, 139-173, 141b.  
     *See also* Hypotensive drug  
   inflammation with, 694-695, 694b  
   neovascular, 693  
   pigmentary, pupil dilation in, 335  
   pupillary block, risk of pupil dilation  
     and, 67  
   steroid-induced inflammatory, 596  
   treatment of, 685-694, 687-694,  
     695t-696t  
     alpha-adrenergic agonists in, 690,  
       690t  
     beta-adrenergic agonists in, 689-  
       690, 689b, 689t  
     carbonic anhydrase inhibitors in,  
       691, 691b, 691t  
     compliance with, 696-697  
     hyperosmotics in, 694  
     indications for, 685-686  
     monocular trials in, 686-687  
     parasympathomimetics in, 688-689,  
       688t  
     prostaglandins for, 687t, 688  
     risk analysis in, 686  
     strategies for, 691-693  
     target intraocular pressure in, 686  
     trials of, 695t-696t  
   uveitis and, 596  
   world impact of, 671  
 Glaucoma Laser Trial, 695t  
 Glaucotabs, 755t  
*GLIC1A* gene, 724  
 Globe perforation, 581  
 Glucose, 281  
 Glycerin, 280-281, 280t  
 Glycoprotein, 264  
 Glycosaminoglycan, 231  
 Goblet cell, 437-438  
 Gold salts, adverse effects of, 750t  
   on conjunctiva, 713  
   on cornea, 704t, 710, 710f  
   on lens, 704t  
 Gonioscopy, 674-767  
   for anterior angle evaluation, 332-333,  
     333f, 333t  
   in anterior uveitis, 591  
   in intermediate uveitis, 592  
   in posterior uveitis, 593  
 Gonococcal ophthalmia neonatorum, 190  
 Gonorrheal dacryoadenitis, 424  
 Good Samaritan statute, 65  
 Gram stain  
   in conjunctival inflammation, 443,  
     443t  
   in fungal keratitis, 535  
 Gramicidin, 187  
   formulations of, 187t  
   for pathogens susceptible to, 442t  
 Gram-negative bacteria  
   as conjunctival pathogen, 439b  
   infections caused by, 177  
 Gram-positive bacteria  
   as conjunctival pathogen, 439b  
   infections caused by, 177  
 Granular type I dystrophy, 484t  
 Granule, pigment, of iris, 22  
 Granuloma  
   in sarcoidosis, 630, 632  
   in toxocariasis, 629  
 Granulomatous disease, 590  
 Graves hyperthyroidism, 643-662. *See*  
   also Thyroid-related orbitopathy  
 Groenouw dystrophy, 484t  
 Growth factor, vascular endothelial,  
   310-311  
   in age-related macular degeneration,  
     635, 638  
 Guanethidine, 654  
 Guidelines  
   for antimicrobial drug, 175-176, 176b  
   for antiviral drugs, 198t-200t  
 Guttata in Fuchs' dystrophy, 488-490,  
   489f  
**H**  
 H<sub>1</sub> antihistamine, 249-250, 251t-252t,  
   253-255  
   adverse effects of, reduced tear  
     production, 714  
   for postherpetic neuralgia, 396  
   in seasonal conjunctivitis, 560  
 HAART, 204  
   for cytomegalovirus retinitis, 624  
*Haemophilus influenzae*, 741  
   azithromycin for, 192  
   in bacterial conjunctivitis, 446  
   cephalosporin and, 18  
   clarithromycin for, 192  
   in conjunctival flora, 438  
   conjunctivitis and, 447, 448  
   corneal ulcer and, 520  
   dacryocystitis and, 433  
   infections caused by, 177  
   ophthalmia neonatorum and, 462  
   penicillin for, 181-182  
   in preseptal cellulitis, 391, 392  
   trimethoprim for, 193  
 Haloperidol, 377  
 Hay fever conjunctivitis, 550. *See also*  
   Conjunctivitis, allergic  
 Healing of corneal epithelium, 232  
 Health Canada form for reporting  
   adverse reaction, 744f-745f  
 Hearing loss, erythromycin causing, 192  
 Heart, beta-blockers affecting, 149  
 Hematologic disorder  
   acetazolamide causing, 162  
   chloramphenicol causing, 192-193  
   penicillin causing, 182  
   sickle cell  
     acetazolamide and, 163  
     intraocular pressure and, 692-693  
   sulfonamides causing, 193-194  
 Hematoporphyrin, 303  
 Hemifacial spasm, 376-379, 376f, 378t  
 Hemoglobinopathy, 163  
 Hemolytic anemia, 193-194  
 Hemorrhage  
   optic nerve, 678-679  
   retinal, in sarcoidosis, 632  
 Hemorrhagic conjunctivitis, 527  
 Hepatitis, erythromycin and, 191, 192  
 Herbal medication  
   adverse reactions and, 703  
   safety of, 301  
 Hereditary optic neuropathy, Leber's, 372  
 Herpes simplex virus infection  
   blepharoconjunctivitis as, 393, 393f  
   conjunctivitis as, 454-455, 455f  
   drugs for, 197, 198t-200t, 201, 202t, 203t  
   interstitial keratitis in, 516t  
   keratitis with, 527-530, 528f, 530f  
 Herpes zoster infection, 393-397, 394f,  
   396f  
 Herpes zoster ophthalmicus, 393-397,  
   394f, 396f, 530-533, 531f, 531t, 532f  
 Herpes zoster virus infection  
   drugs for, 201, 202t-203t  
 Herpetic Eye Disease Study Group, 528,  
   529, 530  
 Herpetic infection, canalicular, 433  
 Herpetic retinopathy, necrotizing,  
   620-626  
   acute retinal necrosis as, 620-621, 620f  
   cytomegalovirus causing, 621-624,  
     621f, 622f, 622t  
   progressive outer retinal necrosis as,  
     624-626, 625f, 625t  
 Herrick lacrimal plug, 273t  
 Heterochromia iridis, 354  
 Hexamidine, 216t  
 High oxygen-permeable silicone  
   hydrogel contact lens, 497  
 Histamine, 245-247, 246f, 246t  
 Histamine blocker, 249-250, 251t-252t,  
   253-255  
   for postherpetic neuralgia, 396  
 History, patient  
   importance of, 4-6, 4t  
   of lacrimal system disorder, 418-419  
   of uveitis, 589  
 HIV. *See* Human immunodeficiency virus  
 Hivid, 206t  
 HLA-B27  
   psoriasis and, 465  
   uveitis and, 589  
 Homatropine, 129-130  
   anticholinergic mydriasis caused by,  
     361-362  
   for corneal abrasion, 497  
   for corneal ulcers, 524  
   for herpes zoster ophthalmicus, 533  
   for interstitial keratitis, 517  
   preparations of, 127t  
   properties of, 127t

- Homatropine—cont'd  
 for pseudophakic cystoid macular edema, 614  
 in recurrent corneal erosion, 505  
 in Reiter's syndrome, 473
- Homocystinuria, 335
- Hordeolum  
 antibacterial drugs for, 176t  
 external, 389, 389f  
 internal, 389-390, 390f
- Hormone replacement therapy, 755t  
 reduced tear production and, 714-715
- Hormone therapy for tear stimulation, 275
- Horn, cutaneous, 400, 400f
- Horner's syndrome, 352-357  
 diagnosis of, 353-357  
 apraclonidine test in, 355-356  
 clinical evaluation in, 353-355, 354b, 354f  
 cocaine test in, 355, 356f, 357t  
 hydroxyamphetamine test in, 355-356, 356f, 357t  
 phenylephrine test in, 356-357  
 sweat test in, 354  
 etiology of, 353b  
 management of, 357, 358f  
 overview of, 352-353
- Hospitalization for corneal ulcers, 524
- HPGuar, 269
- Human immunodeficiency virus, 204, 206t-207t  
 cytomegalovirus retinitis in, 624  
 herpes zoster ophthalmicus and, 394, 396  
 toxoplasmosis and, 628
- Human leukocyte antigen  
 in thyroid disease, 645  
 in uveitis, 598
- Human papilloma virus infection, 399-401, 400f
- Hutchinson's sign, 455, 456f
- Hydrochlorothiazide  
 myopia caused by, 720  
 reduced tear production and, 715
- Hydrocodone  
 formulations of, 105t  
 pharmacological properties of, 104t, 105
- Hydromorphone, 105t
- Hydrops, 490, 491f, 492-493, 492f
- Hydrostatic massage, 430, 430f
- Hydroxyamphetamine  
 in anisocoria evaluation, 352t  
 clinical uses of, 117-118  
 contraindications to, 119  
 dapiprazole and, 120  
 pharmacology of, 117  
 side effects of, 119
- Hydroxychloroquine, 749t  
 corneal effects of, 705
- Hydroxychloroquine—cont'd  
 retinal effects of, 725-728, 725t, 726f, 727t  
 in systemic lupus erythematosus, 471
- Hydroxyethylcellulose, 266-268, 267t
- Hydroxypropyl guar, 269
- Hydroxypropyl methylcellulose, 32, 266-267, 267t
- Hydroxyzine, 552t
- Hygiene, eyelid, 384b
- Hyoscine, 130
- Hyperacute bacterial conjunctivitis, 449-451, 450f
- Hyperemia  
 in anterior uveitis, 590  
 in atopic keratoconjunctivitis, 567  
 conjunctival  
 bacterial infection and, 445  
 Horner's syndrome and, 354  
 inflammation and, 440t  
 latanoprost and, 142  
 in episcleritis, 576
- Hyper eosinophilia in toxocariasis, 629-630
- Hyperfluorescence, 618-619, 618f
- Hyperlaxity of eyelid, 406-408, 407f
- Hypermetabolism, 652. *See also* Thyroid-related orbitopathy
- Hyperopia  
 amblyopia with, 664  
 mitotic agents and, 665
- Hyperosmolar tears, 269
- Hyperosmotic agent, 279-280, 280t, 282f  
 in glaucoma, 694  
 glucose as, 281  
 glycerin as, 280-281, 280t  
 sodium chloride as, 279-280, 280t, 281f
- Hypersensitivity  
 in Adie's syndrome, 359-360  
 to aspirin, 98-99  
 to bacitracin, 185  
 to cephalosporin, 183  
 denervation, in Adie's syndrome, 359  
 to fluoroquinolones, 196  
 to local anesthetic, 91-93, 92f, 93  
 to opioid, 107  
 to penicillin, 182  
 to tetracyclines, 191
- Hypersensitivity reaction, 245-247, 246t, 247t  
 in allergic eye disease, 549  
 in contact dermatitis of eyelid, 570
- Hypertension  
 intracranial, tetracyclines and, 190  
 ocular  
 as cataract surgery complication, 608  
 corticosteroid induced, 229-232, 241f
- Hyperthyroidism, Graves, 643-662. *See also* Thyroid-related orbitopathy
- Hypertonic agent  
 in bullous keratopathy, 493-494  
 in Fuchs' dystrophy, 489  
 in recurrent corneal erosion, 505-506
- Hypertrichosis, 142
- Hypertrophy, papillary, 439
- Hypertropia, in thyroid disease, 648-649
- Hyphema  
 acetazolamide and, 163  
 after cataract surgery, 610-611, 610f, 611f  
 intraocular pressure in, 692
- Hypoglycemic drug, 194
- Hypopyon, corneal ulcer with, 521f
- Hypotensive drug, 139-173  
 adrenergic agonist as  
 ?2 receptor agonist, 153-154  
 apraclonidine, 154-155  
 brimonidine, 155-158, 156f, 157f, 158f  
 beta-blocker as, 145-153  
 carteolol, 152-153, 153f  
 choice of, 153, 153t  
 levobunolol, 150-151  
 metipranolol, 152  
 systemic effects of, 9t  
 timolol, 145-150, 146t, 148b, 149f  
 carbonic anhydrase inhibitor as, 158-167. *See also* Carbonic anhydrase inhibitor  
 for cataract surgery, 603  
 cholinergic agonist as, 167-170  
 classification of, 167b  
 for glaucoma, 168-170, 168t, 171b  
 pilocarpine, 168-170, 168t, 171b  
 prostaglandin analogue as, 139-145  
 bimatoprost, 144-145, 145f  
 latanoprost, 139-143, 140b, 140f, 141b, 142f, 145f  
 travoprost, 143-144, 145f
- Hypotonic tears, 269
- Hypotony, after cataract surgery, 607, 607f
- ## I
- Iatrogenic disorder. *See also* Drug-induced disorder  
 dapiprazole for, 121  
 drug administration causing, 8
- Ibandronate, 753t
- Ibuprofen  
 adverse effects of, 751t  
 for child, 109t  
 formulation of, 102t
- Idiopathic episcleritis, 575
- Idiosyncrasy, drug, 703-704
- Idoxuridine, 197
- Imaging  
 anterior segment ocular coherence tomography, 675  
 computed tomography  
 in myasthenia gravis, 375, 375f  
 in thyroid-related orbitopathy, 650-651, 651f  
 magnetic resonance, 650-651, 651f  
 optical coherence tomography  
 in glaucoma, 679, 679t  
 in uveitis, 599

- Imidazole derivative, 247, 248t, 249
- Imipramine, 721t
- Immune inflammation, acute and chronic, 237f
- Immune system  
   conjunctivitis and, 444  
   in thyroid disease, 645
- Immunization, varicella zoster, 396
- Immunocompromised patient, 396
- Immunoglobulin therapy for cicatricial pemphigoid, 468
- Immunologic disease, scleritis with, 577b
- Immunology, allergic, 245-249, 549-550  
   cell-mediated response in, 247  
   treatment options and, 247  
   type I hypersensitivity in, 245-247, 246f, 246t
- Immunomodulatory agent, for tear augmentation, 429
- Immunosuppression  
   in allergic disease, 550  
   in myasthenia gravis, 375-376  
   for necrotizing scleritis, 585  
   for ocular cicatricial pemphigoid, 468  
   for polyarteritis nodosa, 472  
   in scleritis, 584, 585  
   for uveitis, 595-596
- Immunotherapy in myasthenia gravis, 376
- Impaired vision from dilation, 76
- Imuran, 595
- Incision of eyelid, 410-412, 411f
- Inclusion conjunctivitis, 456-457, 457f
- Indinavir, 207t
- Indirect ophthalmoscopy, 676
- Indocid, 236t
- Indocin  
   adverse effects of, 751t  
   for uveitis, 595
- Indocyanine green, 291-292, 291f
- Indocyanine green angiography, 619-620
- Indomethacin, 102t  
   adverse effects of  
     on cornea, 709-710  
     retinal, 730  
   brimonidine and, 235  
   formulations of, 236t  
   for uveitis, 595
- Infant  
   conjunctival flora in, 438  
   cycloplegic refraction in, 343, 344  
   epiphora in, 429-430  
   esotropia in, 667-668  
   maternal myasthenia gravis and, 373  
   pupil dilation in, 334-335
- Infection. *See also* Antibacterial drug;  
   Bacterial entries; specific infection  
   of anterior lid margin, 381-386, 383f, 385f, 386f  
   of anterior margin of eyelid, 382-384, 383f  
   bacteria causing, 177
- Infection—cont'd  
   canalicular, 433  
   of conjunctiva, 444-463. *See also*  
     Conjunctivitis  
     corticosteroid increasing, 232  
     dacryoadenitis, 424, 424f  
     fungal. *See* Fungal infection  
     meibomian gland, 386-387, 387f  
     of meibomian gland, 386-389, 387f  
     optic neuropathy in, 366-367  
     of posterior lid margin, 386-389, 387f, 388f  
   postoperative, prevention of, 601  
   in scleritis, 584  
   scleritis with, 577b  
   uveitis with, 588b  
   viral. *See* Viral infection
- Inferior rectus muscle, 649
- Infestation, eyelash, 397-399, 398
- Infiltrating basal cell carcinoma, 403
- Infiltrative event  
   in bacterial keratitis, 519-520, 519f, 519t  
   contact lens-related, 538-542, 540f, 544f
- Infiltrative injection, local, 324
- Infiltrative keratitis, 540t
- Infiltrative optic neuropathy, 366-367
- Infiltrative thyroid-related orbitopathy, 652
- Inflammation  
   acute and chronic immune, 237f  
   after cataract surgery, 602  
   canalicular, 433  
   conjunctival, 439-440, 474-478  
     in phlyctenulosis, 474-475, 475f  
     in pinguecula, 476, 476f  
     pterygium and, 477-478, 477f  
     in superior limbic  
       keratoconjunctivitis, 475-476, 476f  
   cyclosporine A as immunomodulator of, 236-242  
   dry eye and, 264-265  
   of eyelid, 568, 570  
     in chalazion, 390-391  
     in external hordeolum, 389, 389f  
     in internal hordeolum, 389-390, 390f  
   lacrimal gland and, 416  
   postoperative, 228  
   in staphylococcal blepharitis, 383f  
   in thyroid disease, 645, 648  
   in uveitis, 588
- Inflammatory cytokine, 265
- Inflammatory glaucoma, steroid-induced, 596
- Inflammatory response, 233
- Infliximab  
   adverse effects of, 716t, 717  
   for uveitis, 595
- Informed consent  
   alternatives to drug therapy and, 69  
   disclosure in, 65-66, 66b  
   documentation in, 70
- Injectable anesthetic, 86-87, 87t
- Injection  
   conjunctival, 452  
     epithelial microcysts and, 543  
   local infiltrative, 324  
   peribulbar, 49-50, 49b, 49f  
   retrobulbar, 49, 49b  
   steroid, for chalazion, 390  
   subconjunctival, 47-48, 49f  
   sub-Tenon's, 49, 49f
- Injury. *See* Trauma
- Innervation. *See also* Nerve entries  
   adrenergic, 113-114  
   cholinergic, 125, 126f
- Inorganic essential minerals, 295-301, 296t
- Insert, artificial tear, 271-272, 272f
- Instillation of solution, 40-42, 41b, 41f, 42f
- Insurance, glaucoma treatment and, 696
- Interferon, 595
- Intermediate uveitis  
   complications of, 596-597  
   description of, 587  
   diagnosis of, 591-592
- Internal limiting membrane, 306
- Interstitial keratitis, 515-517, 516b, 516t
- Intolerance to apraclonidine, 155
- Intracameral administration, 50
- Intracanalicular plug, 273t
- Intracranial hypertension, drug-induced, 739-740, 739t  
   tetracyclines and, 190
- Intracranial lesion, myasthenia gravis and, 375
- Intraocular lens dislocation, 612-613, 613f
- Intraocular pressure  
   adverse drug effects on, 7t, 722-725, 722b, 723t  
   atropine and, 129  
   cataract surgery and, 603, 608  
   corticosteroid increasing, 229-232, 241f  
   drugs for. *See* Hypotensive drug  
   hyphema and, 692  
   measurement of, 671-674, 673b  
   in retinal vein occlusion, 634  
   tropicamide and, 135-136
- Intravitreal implant, ganciclovir, 34, 36
- Intravitreal injection, 50-51, 51f  
   of corticosteroid implant, 309  
   of ranibizumab and bevacizumab, 308  
   of triamcinolone acetonide, 308-309
- Invirase, 207t
- Iontophoresis, 94
- Ipratropium bromide, 718
- Iproclozide, 690t
- Iproniazid, 690t
- Iridectomy, 336-337, 337f
- Iridocyclitis, 587. *See also* Anterior uveitis  
   rimexolone for, 229
- Iris  
   angiography of, 287-288  
   in anterior uveitis, 590

## Iris—cont'd

- injury to, 362
  - pilocarpine for, 168
  - structure of, 22
- Iritis, 587. *See also* Anterior uveitis
- Irradiation, orbital, 660
- Irrigating system, 47-48, 48f
- Irritant contact dermatitis, 570-571
- Ischemia in neovascular glaucoma, 693
- Isocarboxazid, 690, 690t
- Isoenzyme II, 164
- Isopto, 127t, 688t
- Isopto Atropine Ophthalmic, 127t
- Isotretinoin, adverse effects of, 751t
- on conjunctiva, 711-713, 712t
  - on cornea, 710-711
  - on eyelid, 711-713, 712t
  - reduced tear production, 714
  - retinal, 733-734
- Istalol, 146t
- Itraconazole, 208, 209t, 211t, 213, 213t
- of *Acanthamoeba*, 216t
- Ivermectin, 399

## J

- Jimson weed, 361-362, 741
- Jones test, 431-432
- Juvenile arthritis
- calcific band keratopathy in, 494
  - uveitis in, 599

## K

- Kaletra, 207t
- Keflex, 184t
- Kefurox, 184t
- Kefzol, 184t
- Kenalog, intravitreal, 35t
- Keratotomy, superficial
- in calcific band keratopathy, 495
  - in recurrent corneal erosion, 507
- Keratic precipitate, 587
- Keratinization, epidermal, 271
- Keratinized epithelium, 480
- Keratitis
- Acanthamoeba*, 215, 216t, 217, 536-538, 537f, 538t
  - amphotericin B for, 208
  - antibacterial drugs for, 176t
  - bacterial, 514-525
    - corneal infiltrative events versus, 519t
    - infiltrative events in, 519-520, 519f, 519t
    - interstitial, 515-517, 516b, 516t
    - phlyctenular keratoconjunctivitis, 517-518, 518f
    - superficial punctate, 514-515, 514f
    - ulcers and, 520-525, 521f, 521t, 522f
  - contact lens-related, 540t
  - epithelial, acyclovir for, 201
  - fluoroquinolones for, 195
  - fungal, 534-536, 535f

## Keratitis—cont'd

- glaucoma with, 694
  - in herpes zoster ophthalmicus, 533
  - non-*Acanthamoeba*, 217
  - Thygeson's superficial punctate, 241-242
  - toxic, 513-514, 514f
  - viral, 525-534
    - epidemic keratoconjunctivitis and, 525-527, 526f
    - herpes simplex, 527-530, 528f, 530f
    - herpes zoster, 530-533, 531f, 531t, 532f
    - Thygeson's superficial punctate, 533-534
- Keratoconjunctivitis
- atopic, 557t, 559t, 567-568, 567f
  - cyclosporine A for, 241
  - epidemic, 452, 452f, 453t
  - nontuberculous phlyctenular, 190
  - phlyctenular, 517-518, 518f
  - superior limbic, 475-476, 476f
  - vernal, 557t, 559t, 564-566, 565f
    - mast cell stabilizers for, 255

## Keratoconjunctivitis sicca

- aqueous deficiency and, 264
  - non-Sjögren's, 425-426
  - in rosacea, 389
- Keratoconus, 490, 491f, 492-493, 492f
- Keratoderma blennorrhagica, 473, 473f
- Keratolysis, diclofenac and, 235
- Keratopathy
- bullous, 493-494, 493f
  - calcific band, 494-496, 495f
  - chloroquine and, 705-706
  - exposure, 507-509
    - in thyroid disease, 649-650, 650f

## Keratoplasty

- in Fuchs' dystrophy, 490f
- penetrating
  - in fungal keratitis, 536
  - in trauma, 503-504

## Keratoconus, actinic, 405, 405f

## Ketoconazole, 208, 211t, 213t

## Ketoprofen, 102t

## Ketorolac, 102t, 235

- for allergic disease, 259, 554t
  - for corneal abrasion, 496
  - in cystoid macular, 633
  - in episcleritis, 578
  - formulations of, 236t
  - for pseudophakic cystoid macular edema, 614
  - in recurrent corneal erosion, 507
  - for seasonal conjunctivitis, 561
- Ketotifen, 257, 258t, 553t
- in seasonal conjunctivitis, 561

## Kinetics, diffusion, 26-27

*Klebsiella*

- aminoglycosides for, 187
- chronic conjunctivitis and, 451

*Klebsiella*—cont'd

- corneal ulcer and, 520
- infections caused by, 178t

## L

## Laboratory testing

- for conjunctivitis, 440-444
  - culture in, 440-442
  - indications for, 440, 441b
  - smears and scrapings in, 442-444, 443t
- for scleritis, 582, 583t
- for uveitis, 597-599, 598t, 599b

## Laceration

- conjunctival, 479-480
- corneal, ointment for, 44
- lamellar, 502-504-502f, 503f, 504f

## Lacri-Lube, 272t

Lacrimal gland. *See also* Lacrimal system

- anatomy and physiology of, 415
- blepharospasm and, 377
- disorders of, 424
- evaluation of, 423-424, 424f
- innervation to, 125
- tears and, 264

## Lacrimal occlusive device, 273-274, 273f, 274f

## Lacrimal system, 415-435

- adverse drug effects on, 713-715, 714t
  - anatomy and physiology of, 415-418, 416f
    - of distribution system, 417
    - of excretory system, 417-418
    - of secretory system, 415-417, 416f, 417f
  - disorder of
    - acquired dacryocystitis as, 433-434
    - of distribution system, 425
    - of drainage, 432-433
    - dry eye syndrome as, 425-429. *See also* Dry eye
    - of ocular surface, 424-425
  - evaluation of
    - of distribution system, 424
    - of dry eye patient, 424b
    - of lacrimal drainage system, 429-432, 430f, 431f, 432f
    - of lacrimal gland, 423-424, 424f
    - of ocular surface, 422-423, 423f
    - patient history in, 418-419
    - of secretory system, 419-420
    - of tear film, 420-422, 420f, 421b, 422f, 422t, 423f
  - fluorescein sodium for evaluation of, 286
  - overview of, 415
- Lacrisert, 271-272, 272f
- Lactation
- homatropine and, 130
  - opioid and, 107
  - precautions for, 9-11
  - verteporfin and, 304

- Lagophthalmos, 406  
nocturnal, 508
- Lamellar endothelial keratoplasty, 490f
- Lamellar laceration, 502-504-502f, 503f, 504f
- Lamivudine, 206t
- Landmark in gonioscopy, 333f
- Langerhans cell, 438
- Laser, stromal puncture with, 506
- Laser imaging in glaucoma, 679, 679t
- Laser in situ keratomileusis  
cyclosporine A for, 265  
dry eye after, 265
- Laser surgery  
iridectomy, 336-337, 337f
- Laser surgery  
acetazolamide and, 161  
apraclonidine and, 155  
brimonidine and, 157
- LASIK  
cyclosporine A for, 242  
dry eye after, 265
- Latanoprost, 139-143, 687-688, 687t  
brimonidine with, 156  
clinical uses of, 140-141  
contraindications to, 142  
pharmacology of, 139-140, 140f  
side effects of, 141-143, 141b, 142f
- Lateral tarsorrhaphy, 427-428
- Lattice type dystrophy, 485t
- Lavage for foreign body, 479f
- Law, Fick's, 25-26
- Lax eyelid syndrome, 406-408, 407f
- Legal issue, 63-81  
documentation as, 78-79, 78b  
drug use complications as, 75-78  
diagnostic, 75-76  
therapeutic, 76-78  
informed consent as, 65-70  
alternatives to drug therapy and, 69  
disclosure in, 65-70, 66b, 68f, 69f  
documentation in, 70  
misdiagnosis as, 73-75, 73t  
practice laws as, 63-70  
certification as, 63-64  
comanagement as, 64-65, 64b  
registration as, 64  
standards of care as, 72-73
- Lens  
adverse drug effects on, 7t, 704-711, 704t  
in anterior uveitis, 591  
contact. *See* Contact lens  
intraocular, postoperative dislocation of, 612-613, 613f  
spectacle, 42, 42f  
structure of, 23
- Leprosy, interstitial keratitis in, 516t
- Leukopenia, 193-194
- Leukotriene, 233
- Levitra, 730  
adverse effects of, 749t
- Levobunolol, 150-151  
formulations of, 146t  
for glaucoma, 689t
- Levocabastine, 254t, 255, 551t  
in seasonal conjunctivitis, 560
- Levodopa, for blepharospasm, 377
- Levofloxacin, 194t, 195  
for conjunctivitis, 449  
formulations of, 186t  
for infectious conjunctivitis, 446  
in preseptal cellulitis, 391
- Lexiva, 207t
- Liability, product, 78
- Licorice, 741  
adverse effects of, 759t
- Lid margin, 425
- Lid scrub, 45, 46t
- Lidocaine  
injectable, 87t  
intracameral administration of, 50  
subcutaneous injection of, 327f
- Light reaction in anisocoria, 349, 351f
- Light sensitivity after pupil dilation, 339
- Limbal conjunctival substantia propria, 438
- Limbal keratoconjunctivitis  
superior, 475-476, 476f  
vernal, 565
- Limbal phlyctenule, 474
- Limbal stem cell transplantation, 468-469
- Line  
Arlt's, 458, 458f  
fingerprint, 486  
Vogt's, 490
- Lineate incision of eyelid, 410-412, 411f
- Lipid layer of tear film, 263, 264f, 416  
evaluation of, 421
- Lipid monolayer of years, 17
- Lipitor, 749t
- Lissamine green, 290-291, 291f, 422  
in exposure keratopathy, 508f
- Lithium  
adverse effects of, 757t  
eye movement caused by, 719
- Liver  
local anesthetic precautions and, 93  
penicillin effects on, 182
- Livostin, 254t, 551t  
in seasonal conjunctivitis, 560
- Local anesthetic, 85-95, 323-324. *See also*  
Anesthesia  
classification of, 86b  
contraindications to, 92-94, 94f  
pharmacologic properties of  
mechanism of, 85-86  
physiochemical characteristics of, 85  
structure features as, 85  
self-administration of, 93-94  
side effects of, 90-92  
hypersensitivity as, 91-92, 92f  
prevention of, 92  
psychomotor, 92
- Local anesthetic—cont'd  
toxicity as, 90-91, 90f, 91f  
structure features as, 86f  
topical, 87-90, 88t, 89f
- Local infiltrative injection, 324, 325-326, 326f
- Localized contact lens-related papillary conjunctivitis, 563
- Lodine, 751t
- Lodoxamide, 255, 256t, 257, 553t  
in seasonal conjunctivitis, 561  
in vernal keratoconjunctivitis, 566
- Lomefloxacin, 194t
- Loop for foreign body removal, 499, 499f
- Lopinavir, 207t
- Loratadine, 250, 252t, 253, 552t  
for seasonal conjunctivitis, 561
- Lotemax, 555t
- Loteprednol, 554t  
as antiallergy drug, 259  
clinical uses of, 228-229  
contact lens-related papillary conjunctivitis and, 564  
for corneal ulcers, 525  
in episcleritis, 578  
formulations of, 227t  
in seasonal conjunctivitis, 561  
for Thygeson's superficial punctate keratitis, 534
- Lovastatin, 749t
- Low vision, 13-14, 13f-14f
- Lubricant  
in episcleritis, 578  
in exposure keratopathy, 508
- Lucentis, 35t, 306-307
- Lumigan, 687-688, 687t
- Lumiracoxib, 751t
- Lutein for age-related macular degeneration, 636
- Lyme disease  
conjunctivitis and, 459  
interstitial keratitis in, 516t
- Lymphatic system, in conjunctival inflammation, 440
- M**
- Macrolide  
azithromycin as, 192  
clarithromycin as, 191-192  
erythromycin as, 191  
side effects of, 192
- Macugen, 35t, 305-306
- Macular disease, 632-639  
age-related degeneration  
anecortave for, 310  
diagnosis of, 635-636  
dietary supplements for, 296, 298t, 299-300, 636-637  
etiology of, 635, 635f, 636f  
intravitreal drug administration for, 51  
management of, 636-639



- Macular disease—cont'd  
 pegaptanib for, 306  
 photodynamic therapy in, 304  
 ranibizumab for, 307  
 retinal disease and, 635-639, 635f, 636f  
 rostaporphin for, 305  
 triamcinolone acetonide for, 308  
 vascular endothelial growth factor and, 305  
 zinc and, 208  
 cystoid edema, 363f, 632-635, 633f  
 after cataract surgery, 613-614, 614f  
 ketorolac for, 236  
 latanoprost and, 142-143  
 nonsteroidal anti-inflammatory drugs and, 234-235  
 dystrophy in, 484t
- Macular Photocoagulation Study, 291, 637
- Madarosis, 383f
- Magnetic resonance imaging in thyroid disease, 650-651, 651f
- Malignant tumor of eyelid, 402t  
 basal cell carcinoma as, 403-404, 403f, 404f  
 signs of, 402b  
 squamous cell carcinoma as, 404-405, 405f
- Malnutrition, conjunctiva and, 478
- Mannitol in glaucoma, 694
- Mannitol salt agar, 441
- Map, anterior basement membrane dystrophy and, 486
- Marfan's syndrome, 335
- Marijuana, lacrimation and, 715
- MARINA trial, 307, 308, 638
- Massage in congenital epiphora, 430, 430f
- Mast cell, 549
- Mast cell activation, 246f
- Mast cell stabilizer, 255, 256t, 257, 550, 552t, 553t, 558t-559t  
 contact lens-related papillary conjunctivitis and, 564  
 in seasonal conjunctivitis, 560-561  
 in vernal keratoconjunctivitis, 566
- Mast cell-antihistamine combination, 257, 258t, 259
- Maxipime, 184t
- Maxitrol, 464
- Mebendazole, 630
- Medennium SmartPLUG polymer, 273t
- Medial canthus technique, 346
- Medical history, importance of, 4t, 5
- Medicamentosa, 513
- Medication history, importance of, 4t, 5-6
- Medrysone  
 clinical uses of, 228  
 formulations of, 227t  
 ocular hypertension and, 231
- MEDWatch form, 742f-743f
- Meesmann's dystrophy, 484t
- Mefoxin, 184t
- Meibomian gland  
 anatomy and physiology of, 415-416  
 evaluation of, 423, 423f  
 tear film and, 263
- Meibomianitis, 386-388, 387f  
 in atopic keratoconjunctivitis, 567  
 dry eye and, 425  
 tetracyclines for, 190
- Meige's syndrome, 377
- Mellaril, 756t
- Membrane  
 in adenoviral conjunctivitis, 452  
 anterior basement, 486-488, 487f  
 in bacterial conjunctivitis, 446  
 conjunctival, 439  
 Descemet's, 483
- Membrane squamous metaplasia, 271
- Mepivacaine, injectable, 87t
- Mercurial  
 in artificial tears, 270  
 effects of, 30
- Meretoja syndrome, 485t
- Metabolic acidosis, 162
- Metabolic disease, scleritis with, 577b
- Metallic corneal foreign body, 498f
- Metalloproteinase inhibitor, 190
- Metaplasia, membrane squamous, 271
- Methazolamide, 163-164  
 adverse effects of, 755t  
 pharmacokinetic properties of, 161t
- Methicillin, 180t
- Methicillin-resistant penicillin, 181
- Methicillin-resistant *Staphylococcus aureus*, 185, 449
- Methicillin-resistant *Staphylococcus epidermidis*, 185
- Methimazole, 652-653
- Methotrexate  
 adverse effects of, 754t  
 for polyarteritis nodosa, 472  
 for psoriasis, 465
- 8-Methoxypsoralen  
 adverse effect of, on lens, 704t  
 adverse effects of, 757t  
 adverse effects of, on cornea, 711
- Methylene blue, 292
- Methylphenidate, 718
- Methylprednisolone, 657
- Metipranolol, 152  
 formulations of, 146t  
 for glaucoma, 689t
- MetroGel, 464
- Metronidazole, 464
- Mezlocillin, 180t
- Micafungin, 208, 210t, 212t, 213t, 214-215
- Miconazole, 208, 211t, 213, 213t
- Microbial keratitis, 540t
- Microcyst, epithelial, 542-545, 544f
- Microflora, 184
- Microvillus, 263, 264
- Mild pain  
 in child, 109  
 in elderly, 110
- Milia, 401, 401f
- Mineral supplement, 295-301. *See also* Vitamin and mineral supplementation
- Mini-Tip culturette, 441
- Minocycline  
 adverse effects of, 754t  
 on optic nerve, 739-740  
 for meibomian gland infection, 387  
 vestibular toxicity of, 190-191
- Miosis  
 phenylephrine and, 116  
 reversal of, 120-121, 120f, 121f
- Miotic  
 for accommodative esotropia, 665  
 adverse effects of, 719  
 after pupil dilation, 339  
 complications of, 77  
 pilocarpine and, 168-170, 168t, 171b  
 side effects of, 169b
- Misdiagnosis  
 negligence and, 70  
 of open-angle glaucoma, 73-74  
 of retinal detachment, 74-75  
 therapeutic drug use related to, 77-78  
 of tumor, 74
- Mite. *See Demodex entries*
- Mitomycin  
 for pterygia, 478  
 reduced tear production and, 715  
 in vernal keratoconjunctivitis, 566
- Mnemonic  
 CARVES, 677  
 NOSPECS, 645-646, 646t
- Moclobemide, 690t
- Model of surface inflammation, 240
- Moderate pain  
 in child, 109  
 in elderly, 110
- Moisture Eyes, 267t
- Moisture Eyes PM, 272t
- Moisture Liquigel, 267t
- Moll cyst of eyelid, 401, 401f
- Molluscum contagiosum  
 conjunctivitis and, 458-459, 458f  
 of eyelid, 396-397, 396f
- Monitoring, 3-4
- Monoamine oxidase inhibitor  
 contraindications to, 690, 690t  
 phenylephrine and, 117
- Monoclonal antibody for retinal disease, 306-308
- Monocular trial glaucoma, 686-687
- Moraxella*  
 azithromycin for, 192  
 conjunctivitis and, 459  
 corneal ulcer and, 521t
- Morpheaform basal cell carcinoma, 403
- Morphine, 104

- Mortality, atropine causing, 129  
 Motion sickness, 130  
 Motrin, 102t  
   adverse effects of, 751t  
 Mouth, dry  
   apraclonidine causing, 155  
   brimonidine and, 157  
 Movement, eye, drugs causing, 719-720, 719t  
 Moxifloxacin, 194t, 195  
   in burn injury, 510  
   for conjunctivitis, 449  
   for corneal ulcers, 523-524  
   for foreign body, 500  
   pathogens susceptible to, 442t  
   in recurrent corneal erosion, 505  
   in thyroid-related orbitopathy, 656  
   for toxic keratitis, 514  
 Mucin layer of tear film, 264, 416-417  
 Mucoadhesive performance of  
   polymer, 32t  
 Mucocyst, 555t  
 Mucoïd cyst of eyelid, 401, 401f  
 Mucolytic agent, 429  
   in artificial tears, 271  
 Mucous fishing syndrome, 426, 426f, 480  
 Mucous membrane disorder of  
   conjunctiva, 467-470  
   cicatricial pemphigoid and, 467-469, 467f, 468f  
   in erythema multiforme major, 469-470  
   in Stevens-Johnson syndrome, 469-470  
   in toxic epidermal necrolysis, 469-470  
 Mucous plaque keratitis, 532f, 533  
 Mucus fishing syndrome, 480  
 Müller's muscle, 353  
 Multi-drug therapy, 703  
 Mumps, 516t  
 Munchausen syndrome  
   conjunctivitis in, 480  
   ocular, 480  
 Muscarinic receptor, 125-126  
 Muscle  
   extraocular  
     adverse drug effects on, 719-720, 719t  
     in thyroid disease, 645, 656  
     in myasthenia gravis, 373, 374  
 Myambutol, adverse effects of, 753t  
 Myasthenia gravis, 372-376  
   clinical features of, 373-374, 373f  
   diagnosis of, 373  
   epidemiology of, 373  
   etiology of, 372-373  
   management of, 375-376  
   pharmacologic evaluation of, 374  
   testing for, 374-375, 375f  
 Mycamine, 210t  
 Mycophenolate  
   in myasthenia gravis, 376  
   for uveitis, 595  
*Mycoplasma pneumoniae*, 192  
 Mydriacyl Ophthalmic, 127t  
 Mydriasis  
   atropine causing, 129  
   corticosteroid causing, 232  
   drugs causing, 22  
   jimson weed, 361-362  
   unilateral fixed and dilated pupil in, 361-362, 361f, 362, 362f  
 Mydriatic agent, 114-119  
   adrenergic innervation and, 113-114  
   adverse effects of, 718-719, 718b  
   in angle-closure glaucoma, 693  
   angle-closure glaucoma induced by, 335-336  
   cocaine as, 119  
   complications of, 75-76  
   guidelines for, 333-334  
   hydroxyamphetamine as, 117-119, 118f  
   phenylephrine as, 114-117  
     clinical uses of, 114-116  
     contraindications to, 117  
     pharmacology of, 114  
     side effects of, 116-117  
   spray as, 43, 43f  
   for uveitis, 594  
 Mydriolytic agent, 119-121, 120f, 121f  
   adrenergic innervation and, 113-114  
 Myobloc, 379  
 Myokymia, 407-408  
 Myopia  
   acetazolamide causing, 162  
   atropine for, 128  
   cycloplegic refraction in, 343  
   drugs causing, 720-722, 720b, 721f  
   sulfonamides and, 194  
 N  
 N-3 fatty acid, 276  
 NaEDTA chelation, 495  
 Nafcillin, 180t  
 Na<sup>+</sup>-K<sup>+</sup>-adenosine triphosphatase,  
   carbonic anhydrase inhibitor  
   and, 159  
 Naphazoline, 247, 248t, 249, 254t  
   in episcleritis, 578  
 Naphcon, 248t  
 Naphcon-A, 254t, 551t  
 Naprosyn, 102t  
   adverse effects of, 751t  
   for uveitis, 595  
 Naproxen  
   adverse effects of, 751t  
   for child, 109t  
   formulation of, 102t  
   for uveitis, 595  
 Narrow angle  
   after iridectomy, 336-337, 337f  
   pupil dilation in, 335-336  
 Nasal field defect, 682f-683f  
 Nasolacrimal duct, 417-418  
   in congenital epiphora, 429-430  
 Natamycin, 208, 209t, 211t, 213t  
   for *Acanthamoeba*, 216t  
   in fungal keratitis, 536  
 National Registry of Drug-Induced  
   Ocular Side Effects, 116  
 N-chlorotaurine, 526  
 Nd:YAG laser  
   for posterior capsular opacity, 612  
   stromal puncture with, 506  
 Necrolysis, toxic epidermal, 469-470  
 Necrosis, progressive outer, 624-626, 625f, 625t  
 Necrotizing herpetic retinopathy, 620-626  
   acute retinal necrosis as, 620-621, 620f  
   cytomegalovirus causing, 621-624, 621f, 622f, 622t  
   progressive outer retinal necrosis as, 624-626, 625f, 625t  
 Necrotizing interstitial keratitis, 528-529  
 Necrotizing scleritis, 580  
   immunosuppression in, 585  
   without inflammation, 579  
 Nedocromil, 255, 256t, 257, 553t  
 Needle for foreign body removal, 499, 499f  
 Negligence, 70-72  
   proof of, 71-72  
*Neisseria gonorrhoeae*  
   cephalosporin for, 183  
   conjunctival culture for, 441  
   conjunctivitis and, 447, 448  
     hyperacute, 449-451, 450f  
   infections caused by, 177, 178t  
   penicillin for, 181  
*Neisseria meningitidis*, 450  
 Nelfinavir, 207t  
 Nematode endophthalmitis, 629-630  
 Neodymium:yttrium aluminum garnet  
   laser  
   for posterior capsular opacity, 612  
   stromal puncture with, 506  
 Neomycin, 187-188  
   for conjunctivitis, 447-448  
   of *Acanthamoeba*, 216t  
   formulations of, 187t  
   for pathogens susceptible to, 442t  
   steroids with, 188t  
 Neomycin-polymyxin B-dexamethasone,  
   464  
 Neonate  
   gonococcal ophthalmia in,  
     tetracyclines for, 190  
   phenylephrine and, 117  
   pupil dilation in, 334-335  
 Neoral, 595  
 Neostigmine, 374  
 Neovascular glaucoma, 693  
 Neovascularization  
   in atopic keratoconjunctivitis, 466, 466f  
   contact lens-related, 541f  
   in retinal disease, 619-620  
   in uveitis, 588

- Nepafenac  
 clinical uses of, 236  
 in episcleritis, 578
- Nephrolithiasis, 165
- Nephropathy, diabetic, 163
- Neptazane, 755t
- Nerve  
 nociceptors and, 97  
 sensory, of eyelid, 324f
- Nerve block, regional, 323-324, 324f
- Nerve fiber  
 in Horner's syndrome, 352  
 myelinated, 113  
 retinal, in glaucoma, 676-678, 678f  
 unmyelinated, 113
- Nerve palsy  
 sixth, 666-669  
 third, 360-361, 361f
- Neuralgia, postherpetic, 395-396
- Neuron, preganglionic, 113
- Neuro-ophthalmic disorder, 349-379  
 Adie's syndrome as, 357-360, 358b, 358f, 359f, 359t  
 anisocoria as, 349-352, 350b, 351f, 351t, 352t  
 benign essential blepharospasm as, 376-379, 376f, 378t  
 hemifacial spasm as, 376-379, 378f  
 Horner's syndrome as, 352-357  
 diagnosis of, 353-357, 354b, 354f, 355t, 356f, 357t  
 etiology of, 353b  
 management of, 357  
 overview of, 352-353  
 myasthenia gravis as, 372-376, 373f, 375f  
 of optic nerve, 362-372. *See also*  
 Optic nerve disease  
 unilateral fixed and dilated pupil as, 360-362  
 in adrenergic mydriasis, 362  
 in anticholinergic mydriasis, 361-362, 362f  
 damage to iris causing, 362  
 in third nerve palsy, 360-361, 361f
- Neuropathy, toxic optic, 300
- Neurotoxicity of aminoglycosides, 189
- Nevanac, 236t
- Nevirapine, 206t
- Newborn, dacryocystitis in, 182. *See also*  
 Infant
- Niacin, 741, 759t
- Nialamide, 690t
- Nimesulide, 751t
- Nit, 398-399
- Nocturnal lagophthalmos, 508
- Nodular basal cell carcinoma, 403
- Nodular episcleritis, 575, 576, 576f, 577t, 578-579
- Nodular scleritis, 580-581, 581f
- Nolvadex, 753t
- Non-*Acanthamoeba keratitis*, 217
- Noncholinergic agent, 119-121, 120f, 121f
- Noncompliance, 59-60, 60b  
 with glaucoma treatment, 695-696
- Nonimmune defense barrier of  
 conjunctiva, 444
- Noninfiltrative thyroid-related  
 orbitopathy, 644, 646-647, 647f  
 management of, 652
- Nonnarcotic analgesic  
 combination, 103-104  
 nonsteroidal anti-inflammatory drugs  
 as, 100-102, 100b, 101t  
 salicylates as, 98-100, 99t
- Nonnucleoside reverse transcriptase  
 inhibitor, 206t
- Non-Sjögren's syndrome, 425-426
- Nonspecific viral conjunctivitis, 459
- Nonsteroidal anti-inflammatory drug,  
 233-236  
 adenoviral conjunctivitis and, 454  
 adverse effects of, 751t  
 retinal, 731  
 for allergic disease, 259, 550, 554t, 558t-559t  
 clinical uses of, 101-102  
 contact lens-related papillary  
 conjunctivitis and, 564  
 contraindications to, 102  
 for corneal abrasion, 496  
 cystoid macular and, 633  
 for elderly, 110  
 in episcleritis, 578-579  
 for exposure keratopathy, 509  
 for foreign body, 500  
 mechanism of action of, 97-98  
 in pain management, 108-109, 109f  
 pharmacology of, 100-101, 233-235, 234f  
 for postoperative inflammation, 602  
 for pseudophakic cystoid macular  
 edema, 614  
 in Reiter's syndrome, 473  
 in scleritis, 584  
 for seasonal conjunctivitis, 561  
 side effects of, 102  
 for tear augmentation, 429  
 for uveitis, 595
- Nontuberculous phlyctenular  
 keratoconjunctivitis, 190
- Norfloxacin, 194t, 195  
 formulations of, 186t
- Norvir, 207t
- NOSPECS classification, 645-646, 646t
- Nucleic acid amplification test, 444
- Nucleoside reverse transcriptase  
 inhibitor, 206t
- Nucleus, Edinger-Westphal, 125
- Nuprin, 102t
- Nursing patient. *See* Breast feeding
- NutraTear, 267t
- Nutrient of artificial tears, 270-271
- Nutritional agent, 295-301, 703. *See also*  
 Vitamin and mineral  
 supplementation; Vitamin *entries*
- Nystagmus test, alcohol gaze, 720
- O**
- Occlusion  
 for amblyopia, 664  
 of lacrimal puncta, 426-427, 432-433  
 retinal vein, 632, 634  
 vascular, 580
- Occlusive device, lacrimal, 273-274, 273f, 274f
- OctreoScan, 651
- Octreotide, 659
- Ocufen, 235, 236t
- Ocular adnexa in allergy, 550
- Ocular adverse drug reaction, 701-759.  
*See also* Adverse drug reaction
- Ocular cicatricial pemphigoid, 467-469, 467f, 468f
- Ocular coherence tomography  
 anterior segment, 675  
 in retinal disease, 307
- Ocular effect  
 of beta-blocker, 148b  
 of systemic drug, 9  
 of topical drug, 7-8
- Ocular history, importance of, 4-5, 4t
- Ocular hypertension. *See also*  
 Glaucoma; Hypotensive drug;  
 Intraocular pressure  
 as cataract surgery complication, 608  
 corticosteroid induced, 229-232, 241f
- Ocular Hypertension Treatment Study,  
 680, 682, 696t
- Ocular hypotony, 607, 607f
- Ocular immunology, 549-550
- Ocular Munchausen syndrome, 480
- Ocular pain, analgesics for, 97-111. *See also*  
 Analgesic
- Ocular response analyzer, 674
- Ocular surface  
 anatomy and physiology of, 415  
 disorders of, 263-278, 424-425. *See also*  
 Dry eye  
 evaluation of, 422-423, 423f
- Oculosympathetic paresis, 353, 354-355
- Oculosympathetic pathway, 113-114, 114f  
 in Horner's syndrome, 352
- Ocupress, 146t
- Office test for myasthenia gravis, 374
- Off-label use of bevacizumab, 308
- Ofloxacin, 194t, 195  
 for conjunctivitis, 448-449  
 for corneal ulcer, 523, 524  
 formulations of, 186t  
 for infectious conjunctivitis, 446  
 for pathogens susceptible to, 442t
- Ointment  
 administration of, 43-44, 44f  
 complications of, 44-45

- Ointment—cont'd  
  sodium chloride, in Fuchs' dystrophy, 489  
  for tear conservation, 272-273, 272t  
  tretinoin, 271  
  as vehicle, 34
- Olopatadine, 254, 257, 258t, 259, 552t, 553t  
  in seasonal conjunctivitis, 561
- Omega-3 fatty acid  
  dry eye and, 300  
  inflammatory response and, 233  
  for tear augmentation, 428-429
- Omnicef, 184t
- Onchocerciasis, 516t
- Opacification, posterior capsular,  
  postoperative, 611-612, 612f
- Opcon-A, 254t
- Open-angle glaucoma  
  acetazolamide and, 163  
  betaxolol for, 151  
  carteolol for, 152-153  
  corticosteroids and, 723-724  
  dorzolamide and, 165  
  misdiagnosis of, 74-75  
  nutritional supplements for, 297-298  
  pupil dilation in, 335  
  travoprost and, 143
- Ophthalmia  
  gonococcal, 190  
  sympathetic, Cyclosporine A for, 241
- Ophthalmia neonatorum, 460-463  
  causes of, 463t  
  chemical, 462  
  *Chlamydia trachomatis*, 461, 461f, 462f  
  herpes simplex virus, 462  
  *Neisseria gonorrhoeae*, 460-461, 461f  
  other bacterial causes of, 462  
  prevention of, 462-463
- Ophthalmoscopy  
  confocal scanning laser, 679, 679t  
  in glaucoma, 676
- Opioid, 104-108  
  clinical uses of, 106-107  
  commonly used, 105t  
  contraindications to, 107-108  
  cross-sensitivity among, 108t  
  pharmacology of, 104-106  
  pupillary effects of, 719  
  side effects of, 107, 107b
- Optic nerve  
  drugs adversely affecting, 736-741, 736t  
  amiodarone, 738  
  chloramphenicol, 737-738  
  ethambutol, 736-737, 736t  
  sildenafil, 738-739  
  tetracyclines, 739-740  
  in glaucoma, 676-678, 678f  
  hemorrhage of, 678-679  
  in sarcoidosis, 632  
  structure of, 24
- Optic neuropathy, 362-372  
  anterior ischemic, 368-369  
  demyelinating, 369-370  
  infectious, 367-368  
  infiltrative, 366-367  
  Leber's hereditary, 372  
  nutritional, 370-372  
  overview of, 362-364  
  papilledema causing, 364-366, 364t, 365f  
  pseudotumor cerebri and, 365f, 366  
  in thyroid disease, 650, 657  
  toxic, 300, 370-372, 371b
- Optical coherence tomography  
  in glaucoma, 679, 679t  
  in uveitis, 599
- Opticrom, 561
- Opticrom Crolom, 256t
- OptiPranolol, 146t
- Optivar, 258t, 553t  
  in seasonal conjunctivitis, 561
- Optometrist, certification of, 63-64
- Oral contraceptive  
  adverse effects of  
  reduced tear production, 714-715  
  retinal, 730-731  
  penicillin effects on, 182
- Oral fluorescein angiography, 288
- Oral hypoglycemic drug, 194
- Orbicularis muscle, 374
- Orbital cellulitis, 391t, 392  
  penicillin for, 181
- Orbital decompression, 657, 660-661, 660f
- Orbital radiotherapy, 655, 660
- Orbitopathy, thyroid-related, 643-662. *See also* Thyroid-related orbitopathy
- Osmolarity, bioavailability and, 28
- Ototoxicity  
  of erythromycin, 192  
  of vancomycin, 185-186
- Outer retinal necrosis, progressive,  
  624-626, 625f, 625t
- Overdose  
  of atropine, 129  
  cholinergic, 666
- Over-the-counter drug, 5
- Oxacillin, 180t
- Oxaprozin  
  adverse effects of, 751t  
  formulation of, 102t
- Oxychloro-complex in artificial  
  tears, 270
- Oxycodone  
  formulations of, 105t  
  pharmacological properties of, 104t
- Oxygen in photodynamic therapy, 303
- Oxymetazoline, 249  
  in episcleritis, 578
- Oxytetracycline  
  formulations of, 187t  
  polymyxin B with, 190
- P**
- Pachymetry, 321, 322f
- Packaging of solutions and suspensions,  
  39, 40f
- Pain  
  analgesics for, 97-111. *See also*  
  Analgesic  
  in bullous keratopathy, 494  
  in herpes zoster ophthalmicus, 395, 533  
  management of, 108-109, 109f  
  mechanism of, 97-98  
  postoperative, 603
- Palpebral conjunctiva, 437, 438f, 480
- Palpebral fissure  
  in burn injury, 509  
  in thyroid-related orbitopathy, 654, 654f
- Palpebral vernal keratoconjunctivitis, 565
- Palsy  
  sixth nerve, 666-669  
  third nerve, 360-361, 361f
- Pamidronate, 752t
- Panadol, 552t
- Panuveitis  
  description of, 587  
  diagnosis of, 593
- Papillary conjunctivitis, giant, 558t  
  contact lens-related, 542f  
  loteprednol etabonate for, 228  
  mast cell stabilizers for, 255
- Papillary hypertrophy, 439, 440t
- Papilledema, 364-366, 364t, 365f
- Papilloma  
  anesthesia for, 326-327, 327f  
  of eyelid, 399-402, 400f, 401f
- Parahydroxybenzoic acid ester, 270
- Paralytic agent, 666-669, 667b  
  adverse effects of, 668-669  
  clinical uses of, 666-668  
  pharmacology of, 668
- Parasitic infection, 626-630  
  scleritis with, 577b  
  toxocariasis as, 629-630, 629f  
  toxoplasmosis as, 626-630, 636f, 637f
- Parasympathetic nervous system, 113
- Parasympathomimetic, 688-689, 688t
- Paremyd  
  hydroxyamphetamine and, 118  
  tropicamide and, 135-136
- Parinaud's oculoglandular syndrome,  
  459-560, 460b
- Pars planitis, 632
- Pataday, 258t, 553t  
  in seasonal conjunctivitis, 561
- Patanol, 258t  
  in seasonal conjunctivitis, 561
- Patching for amblyopia, 664
- Pathogen, common conjunctival, 438
- Patient counseling, 60-61
- Patient education  
  on cataract surgery, 601  
  importance of, 3-4

- Patient history, importance of, 4-6, 4t  
 PDE-5, 730  
 PDE-6, 730  
 Peaked pupil, 609-610, 610f  
 Pediatric patient. *See* Child  
 Pediculocidal agent, 399  
*Pediculus humanus*, 397-399  
 Pegaptanib, 305-306  
   for age-related macular degeneration, 638  
 Pemirolast, 255, 256t, 257, 553t  
 Pemphigoid, cicatricial, 467-469, 467f, 468f  
 Penalization, atropine, 664-665, 665b  
 Penetrating corneal injury, 502-504-502f, 503f, 504f  
 Penetrating keratoplasty  
   for *Acanthamoeba* keratitis, 538  
   in Fuchs' dystrophy, 489f  
   in fungal keratitis, 536  
   in recurrent corneal erosion, 506-507  
   in trauma, 503-504  
 Penetration, drug, scleral, 20  
 Penicillin, 179-183  
   antipseudomonal, 180t, 182  
   clinical uses of, 181-182  
   contraindications to, 182-183  
   extended spectra of activity in, 180t, 181-182  
   for gram-positive bacteria, 180t, 181  
   for internal hordeolum, 390  
   pharmacology of, 179  
   in preseptal cellulitis, 391  
   resistant to penicillinase, 180t, 181  
   side effects of, 182  
 Penicillinase, 181  
 Penicillin-resistant *Streptococcus pneumoniae*, 185  
*Penicillium*, 534  
 Pentamidine, 215  
 Pentazocine, 104t  
 Pentolair, 127t  
*Peptostreptococcus*, 391  
 Perennial conjunctivitis, 550, 560-561, 560f  
 Perforation, globe, 581  
 Peribulbar anesthesia, 604  
 Peribulbar injection, 49-50, 49f  
 Perimetric test of visual function, 680t  
 Periocular steroid  
   for uveitis, 594, 596-597  
 Periorbital cellulitis, 391-393, 391t, 392f  
 Periorbital dermatosis, 568  
 Peripapillary atrophy, 678, 678f  
 Peripheral ulcer, 540t  
 Petrolatum ointment, 399  
 pH of tears, 17  
 Pharmacokinetics  
   of aqueous body, 23  
   blood supply and, 25  
   of ciliary body, 23  
   compartment theory and, 25-27, 26f  
   of crystalline lens, 23  
 Pharmacokinetics—cont'd  
   drug development and, 36  
   drug properties affecting, 27-36  
     active ingredients as, 28, 29t  
     bioavailability as, 27-28, 27f  
     osmolarity as, 28  
     preservatives as, 28, 30-31  
     stability as, 28  
     vehicles as, 31-34, 31b, 32t, 33f  
   drug release systems as, 34, 35t, 36  
   of iris, 22  
   of ocular structures, 17-37  
   prodrugs and, 27  
   of retina and optic nerve, 24-25, 24t  
   of sclera and cornea, 19-22, 20f, 21f, 21t  
   of tear film, 17-19, 18f, 19f  
   of vitreous humor, 23-24  
 Pharmacologic blockade, 361  
 Pharmacotherapy, 3-15  
   adverse reactions to  
     ocular, 7-8, 7t, 8f  
     systemic, 8-9, 9t  
   in child, 11-12, 11t  
   determining contraindications to  
     clinical examination in, 6-7  
     patient history in, 4-6, 4t  
   in difficulty swallowing, 14  
   in elderly patient, 12-13  
   incidence of, 5  
   initiating, 3-4  
   monitoring, 3-4  
   in pregnancy, 9-11, 10f  
   in visually handicapped patient, 13-14, 13f-14f  
 Pharyngoconjunctival fever, 452, 453t  
 epidemic keratoconjunctivitis versus, 527  
 Phenelzine, 690t  
 Phenergan, 251t  
 Pheniramine, 254t, 551t  
   side effects of, 255  
 Pheniramine-naphazoline, 254  
 Phenol red thread test, 421  
 Phenothiazine  
   accommodation disturbance and, 721  
   adverse effects of, 756t  
 Phenylephrine, 114-117, 247, 248t, 249  
   in angle-closure glaucoma, 693  
   clinical uses of, 114-116  
   contraindications to, 117  
   for corneal abrasion, 497  
   dapiprazole and, 120  
   in episcleritis, 578  
   hydroxyamphetamine and, 118  
   for infant or child, 334  
   pharmacology of, 114  
   side effects of, 116-117  
   in systemic disease, 335  
 Phlyctenular keratoconjunctivitis, 517-518, 518f  
   tetracyclines for, 190  
 Phlyctenule  
   conjunctival, 517  
   corneal, 517-518  
 Phlyctenulosis, 474-475, 475f  
 PHMB, 215, 216t  
 Photochemotherapy, 466  
 Photodynamic therapy, 51  
   for age-related macular degeneration, 637  
   for retinal disease, 303-305  
 Photography in anisocoria, 350  
 Photokeratitis, 511-512  
 Photo-oxidative stress, 635  
 Photopic condition, 157  
 Photorefractive keratectomy, 236  
 Photorefractive surgery, dry eye after, 265  
 Photosensitivity  
   pupil dilation and, 339  
   tetracyclines causing, 190  
   verteporfin and, 304  
 Photosensitizing drug, 711  
 Phototoxicity of fluoroquinolones, 195  
 Photrex, 305  
 Phthiriasis palpebrarum, 397-399, 398f  
 Physician, comanagement with, 64-65, 64b  
 Physiologic anisocoria, 352  
 Physostigmine  
   for atropine overdose, 129  
   for phthiriasis palpebrarum, 399  
 Pigmentary glaucoma, 335  
 Pigmentation  
   in anterior uveitis, 591  
   chlorpromazine causing, 712  
   of iris, 22  
   in Horner's syndrome, 354  
   latanoprost and, 141-142  
   phenylephrine and, 116  
   tetracycline causing, 713, 718  
 Pilocarpine  
   in Adie's syndrome, 359, 359f, 359t, 360  
   in angle-closure glaucoma, 693  
   in anisocoria evaluation, 352t  
   in anticholinergic mydriasis, 362, 362f  
   clinical uses of, 168  
   contraindications to, 170, 170b  
   for glaucoma, 688-689, 688t  
   lacrimation and, 715  
   pharmacology of, 168  
   side effects of, 168-169, 169b  
   systemic effects of, 9t  
   for tear stimulation, 274  
   in third nerve palsy, 360-361, 361f  
 Pilopine HS, 688t  
 Pimaricin, 208  
 Pimecrolimus, 555t  
   for atopic dermatitis of eyelid, 570  
 Pioglitazone, 660  
 Piperacillin  
   for pseudomonal infection, 182  
   spectrum of activity of, 180t  
*Pityrosporum ovale*, 385  
 Plaqueul, 749t

- Plasma protein  
acetazolamide and, 160  
aspirin and, 100
- Plasmapheresis  
in myasthenia gravis, 376  
in thyroid-related orbitopathy, 658
- Plasminogen activator, 309
- Plateau iris, 338
- Platelet, 98, 103
- Pledget, cotton, 47, 47f
- Plug  
collagen, 273-274, 273f, 273t, 427  
punctal, 426-427  
anesthesia for, 323
- Polarimetry, scanning layer, 679, 679t
- Polyacrylic acid, 33-34
- Polyarteritis nodosa, 471-472, 472f
- Polyene, 205
- Polyene antifungal drug, 208, 209t-210t
- Polyhexamethylene biguanide, 215
- Polyionic vehicle, 33
- Polymer, 32t
- Polymerase chain reaction, 444
- Polymer-based artificial tears, 266.  
*See also* Artificial tears
- Polymyxin B, 186-187, 187t  
for conjunctivitis, 447, 448  
formulations of, 187t  
for pathogens susceptible to, 442t  
in phlyctenulosis, 475  
steroids with, 188t
- Polymyxin B-bacitracin, 513
- Polysaccharide artificial tears, 266-268
- Polyvinyl alcohol, 32, 268-269
- Polyvinylpyrrolidone, 32
- Posaconazole, 208
- Posner-Schlossman syndrome, 694
- Posterior capsular opacification, 611-612, 612f
- Posterior limiting membrane, 483
- Posterior polymorphous dystrophy, 485t
- Posterior scleritis, 582-584, 583f
- Posterior segment  
in sarcoidosis, 632  
in toxoplasmosis, 627
- Posterior subcapsular cataract  
steroid-induced, 705  
uveitis and, 596
- Posterior uveitis  
complications of, 597  
description of, 587  
diagnosis of, 592-593
- Postganglionic neuron, 352-353
- Postherpetic neuralgia, 395-396
- Postoperative inflammation, 228
- Posurdex, 35t
- Posurdex implant, 309
- Povidone iodine, 454
- Practice law  
certification as, 63-64  
comanagement as, 64-65, 64b  
registration as, 64
- Precipitate, keratic, in uveitis, 587
- Pred Forte, for cataract patient, 64b
- Prednisolone  
for allergic disease, 554t  
in angle-closure glaucoma, 693  
in burn injury, 510-511  
cataract cause by, 705  
for corneal ulcers, 525  
cystoid macular and, 633  
dosages schedule for, 227t  
formulations of, 227t  
for herpes simplex keratitis, 529  
for phlyctenular keratoconjunctivitis, 518  
in Reiter's syndrome, 473  
in scleritis, 584-585  
for Stevens-Johnson syndrome, 469  
for Thygeson's superficial punctate keratitis, 534  
in toxocariasis, 630  
in vernal keratoconjunctivitis, 566
- Prednisone  
adverse effects of, 750t  
in myasthenia gravis, 375  
for ocular cicatricial pemphigoid, 468  
in sarcoidosis, 632  
in thyroid disease, 656, 657  
for toxoplasmosis, 628
- Preganglionic neuron, 113  
in Horner's syndrome, 353
- Pregnancy  
acetaminophen and, 103  
antihistamines in, 253-254  
aspirin and, 100  
clarithromycin and, 192  
cocaine and, 119  
contraindications related to, 5  
NSAIDs and, 103  
opioid and, 107  
precautions in, 9-11, 10f  
pupil dilation and, 335  
sulfonamides contraindicated in, 194  
toxoplasmosis and, 628
- Pre-instillation anesthesia, 322
- Premature infant, 334
- Prescribing spectacles, 347-348
- Prescription, 54-58  
anatomy of, 54-56, 54f, 55t, 56b  
for controlled substances, 57, 57t, 58f  
effective, 56-57  
preventing forgery of, 58  
types of, 56
- Preseptal cellulitis, 391-393, 391t, 392f  
antibacterial drugs for, 176t  
penicillin for, 182
- Preservation, tear. *See* Tear conservation
- Preservative  
in artificial tears, 270  
bioavailability and, 28, 30-31  
damage caused by, 8
- Pressure, intraocular. *See* Intraocular pressure
- Presurgical evaluation, 324-325
- Pretarsal subcutaneous block, 324
- Prevention  
of adverse drug reactions, 741, 746  
of ophthalmia neonatorum and, 462-463  
of toxocariasis, 630
- Prexige, 751t
- Prezista, 206t
- Probe, lacrimal, 430, 431f
- Probenecid, 181
- Procaine, 87t
- Prodrug, 27
- Product liability, 78
- Profenal, 236t
- Professional community standard, 66, 66b
- Prograf, 595
- Progressive outer retinal necrosis, 624-626, 625f, 625t
- Promethazine, 250, 251t
- Propamide, 216t
- Proparacaine, 89-90  
abuse of, 513-514  
for culture, 320  
for foreign body removal, 322-323  
for lacrimal drainage procedure, 322  
for punctal plug insertion, 323  
for superficial abrasion, 320
- Proparacaine-sodium fluorescein, 320
- Prophylactic antibiotic  
in bullous keratopathy, 494  
for cataract surgery, 601  
for contact lens-related complications, 540  
for corneal abrasion, 497  
dellen and, 512-513  
for phlyctenular keratoconjunctivitis, 518  
in recurrent corneal erosion, 505
- Propionibacterium acnes*, 382-383  
in conjunctival flora, 438  
endophthalms and, 606
- Propoxyphene  
formulations of, 105t  
pharmacological properties of, 104t, 105-106
- Propranolol, 377
- Proptosis in thyroid-related orbitopathy, 643-644  
characteristics of, 648, 649t  
management of, 652, 654, 656
- Propylthiouracil, 652-653
- Prostaglandin  
in glaucoma, 687-688, 687t  
inflammatory response and, 233  
nonsteroidal anti-inflammatory drugs and, 235
- Prostaglandin analogue  
brimonidine and, 156  
as hypotensive drug, 139-145  
bimatoprost, 144-145, 145f

- Prostaglandin analogue—cont'd  
 latanoprost, 139-143, 140b, 140f, 141b, 142f, 145f  
 travoprost, 143-144, 145f  
 nonsteroidal anti-inflammatory drugs and, 235
- Prostaglandin compound, 145
- Protease inhibitor, 206t-207t
- Protein  
 methazolamide and, 163  
 in uveitis, 588
- Protein kinase C, 311-312
- Protein synthesis, antibacterial drug affecting, 187-193  
 amikacin as, 190  
 aminoglycosides as, 187-190  
 chloramphenicol as, 192-193  
 gentamicin as, 188  
 macrolides as, 191-192  
 neomycin as, 187-188  
 tetracyclines as, 190-191, 190t  
 tobramycin as, 189
- Proteus*  
 conjunctivitis and, 448, 451  
 infections caused by, 177
- Protopitic, 555t, 570
- Protozoan infection, 215, 216t, 217
- Pruritus, 571
- Pseudomembrane  
 in adenoviral conjunctivitis, 452  
 in epidemic keratoconjunctivitis, 525  
 in inflammation, 439
- Pseudomembranous colitis, antibiotic-associated, 184
- Pseudomembranous conjunctivitis, 447
- Pseudomonas*, 448
- Pseudomonas aeruginosa*  
 aminoglycosides for, 187  
 cephalosporin for, 183  
 in conjunctival flora, 438  
 corneal ulcer and, 520, 521t, 522f  
 infections caused by, 177, 178t  
 ophthalmia neonatorum and, 462  
 penicillin for, 182
- Pseudophakia, 605t. *See also* Cataract surgery
- Pseudophakic cystoid macular edema, 613-614, 614f, 633
- Pseudotumor cerebri  
 drug-induced, 739  
 optic neuropathy in, 365f, 366  
 tetracyclines and, 190
- Psoralen, 704t
- Psoralen ultraviolet A irradiation, for psoriasis, 466
- Psoriasis vulgaris, 465-466
- Psychomotor reaction to local anesthetic, 92
- Pterygium, 477-478, 477f
- Ptosis—cont'd  
 in myasthenia gravis, 373, 373f
- Pulmonary function, betaxolol and, 151
- Punctal dilation, 432f
- Punctal disorder, 432-433
- Punctal plug, 428f  
 anesthesia for, 323
- Punctate bacterial keratitis, superficial, 514-515, 514f
- Punctate epithelial corneal erosion, 143
- Punctate keratitis, Thygeson's superficial, 241-242
- Punctate keratopathy, 514
- Puncture, anterior stromal, 506  
 in recurrent corneal erosion, 507
- Pupil. *See also* Mydriatic agent  
 in anisocoria, 349  
 in anterior uveitis, 590  
 cholinergic innervation and, 125, 126f  
 dilation of, 329-341. *See also* Dilation of pupil  
 complications of, 75-76  
 disclosure of risks of, 67-69, 68f, 69f  
 mydriatic agent for, 114-119. *See also* Mydriatic agent  
 examination of, 6  
 postoperative distortion of, 609-610, 610f  
 unilateral fixed and dilated, 360-362  
 adrenergic mydriasis causing, 362  
 anticholinergic mydriasis causing, 361-362, 361f, 362f  
 iris injury causing, 362  
 third nerve palsy causing, 360-361, 361f
- Pupillary block glaucoma, 67
- Purified protein derivative, in uveitis, 598
- Purite, 156, 270
- PUVA, for psoriasis, 466
- PVP, 269
- Pyrethrin, 399
- Pyridostigmine bromide, 375
- Pyrimethamine, 193-194  
 for toxoplasmosis, 627-628
- Pyrimidine, 205, 208
- Q**
- Quality of care, 53
- Quality of life in glaucoma, 695-696
- Quaternary ammonium compound, 270
- Quetiapine, 757t
- Quinine, 750t  
 retinal, 734
- R**
- Race  
 acetazolamide and, 163  
 uveitis and, 589
- Radioactive iodine uptake test, 644
- Raeder's syndrome, 355
- Ranibizumab, 306-307  
 for age-related macular degeneration, 638, 639
- Rapidly progressive herpetic retinal necrosis, 624-626, 625f, 625t
- Rash  
 penicillin causing, 182  
 sulfonamides causing, 194
- RCE. *See* Recurrent corneal erosion
- Reasonable patient standard, 66, 66b
- Rebound miosis, 116
- Recall, documentation of, 79
- Receptor  
 cholinergic, 125  
 FP, 139  
 histamine, 245-247, 246f, 246t  
 muscarinic, 125-126
- Receptor-mediated inflammatory process, 264
- Receptor-mediated inflammatory response, 264
- Record of patient care, 79
- Recreational drug, 703
- Recurrent corneal erosion, 486, 487, 504-507, 504f, 507f
- Recurrent herpes simplex keratitis, 528
- Red eye, contact lens-related, 540t
- Redness in anterior uveitis, 590
- Referral, 79
- Refraction  
 atropine and, 128  
 cycloplegic, 6, 343-348. *See also* Cycloplegic refraction
- Refractive error, 345
- Refractive surgery, 265
- Refresh, 267t
- Refresh Endura, 427t
- Refresh PM, 272t
- Refresh products, 427t
- Regional nerve block, 323-324, 324f
- Registration, 64
- Regulatory issues for prescription writing, 54-58, 54f, 55t, 58b
- Reis-Bücklers dystrophy, 484t
- Reiter's syndrome, 472-474, 473f
- Release, drug, 34, 36
- Relief decongestant, 248t
- Remicade, 595
- Renal disorder  
 contraindications related to, 5  
 dorzolamide and, 165  
 in polyarteritis nodosa, 471-472
- Renal function  
 acetazolamide and, 163  
 carbonic anhydrase inhibitor and, 162  
 cephalosporins and, 184-185  
 NSAIDs and, 103
- Rescriptor, 206t
- Residual accommodation  
 cycloplegics and, 346, 347  
 tropicamide and, 133-134

- Resistance  
 bacterial, 177-179  
 to cephalosporin, 183  
 to fluoroquinolone, 194, 448  
 corneal ulcers and, 523  
 to sulfonamides, 193
- Respiratory depression, 107
- Restasis, 241  
 for tear stimulation, 276
- Retaeane  
 for age-related macular degeneration, 639  
 intravitreal, 35t
- Retention cyst, of eyelid, 401-402, 401f
- Retina  
 drugs affecting, 725-736, 725t  
 aminoglycosides, 189  
 antineoplastic agents, 731-733, 732f, 733b  
 cardiac glycosides, 729, 729b, 730f  
 chloroquine, 725-728, 725t, 726f, 727t  
 clomiphene, 731  
 hydroxychloroquine, 725-728, 725t, 726f, 727t  
 inhaled corticosteroids, 734  
 isotretinoin, 733-734  
 nonsteroidal anti-inflammatory drugs, 731  
 oral contraceptives, 730-731  
 quinine, 734  
 sildenafil, 729-730  
 talc, 734-736, 735f  
 thioridazine, 728-729, 728f  
 vigabatrin, 733  
 structure of, 24  
 toxoplasmosis and, 217
- Retinal circulation, 164
- Retinal detachment  
 misdiagnosis of, 74-75  
 pilocarpine and, 169, 170  
 postoperative, 614-615, 614f  
 in uveitis, 588
- Retinal disease, 303-315, 617-642  
 angiogenesis and, 305-306  
 corticosteroids for, 308-310  
 cytomegalovirus causing, 621-624, 621f, 622f, 622t  
 fluorescein angiography in, 617-619, 618f  
 indocyanine green angiography in, 619-620  
 macular, 632-639  
 age-related macular degeneration as, 635-639, 635f, 636f  
 cystoid macular edema as, 632-635, 633f  
 monoclonal antibodies for, 306-308  
 necrotizing herpetic, 620-621, 620f  
 parasitic, 626-630  
 toxocariasis as, 629-630, 629f  
 toxoplasmosis as, 626-629, 626f, 627f  
 photodynamic therapy for, 303-305
- Retinal disease—cont'd  
 rostaporfin in, 305  
 verteporfin in, 303-305  
 progressive outer necrosis, 624-626, 625f, 625t  
 ruboxistaurin for, 311-312  
 sarcoidosis as, 630-632, 631f  
 squalamine for, 311  
 VEGF trap for, 310-311
- Retinal hemorrhage in sarcoidosis, 632
- Retinal nerve fiber, 676-678, 678f
- Retinal photography, 676-677
- Retinal vaso-occlusive disease, 472
- Retinal vein occlusion, 632, 634
- Retinitis, cytomegalovirus, 50-51
- Retinitis pigmentosa, vitamin A in, 300
- Retinochoroiditis, 587. *See also* Posterior uveitis  
 bird-shot, Cyclosporine A for, 241  
 toxoplasmic, 626-629, 626f, 627f  
 pyrimethamine for, 193
- Retinoid, 751t  
 optic nerve and, 740
- Retinopathy of prematurity, 334
- Retinoscopy, 345, 347
- Retisert  
 intravitreal, 35t  
 for retinal disease, 309  
 for uveitis, 594
- Retrobulbar anesthesia, 603
- Retrobulbar injection, 49, 49b
- Retrotarsal block, 324, 327f
- Retrovir, 206t
- Rev-Eyes, 121
- Reyataz, 207t
- Reye's syndrome, 100
- Rheumatoid arthritis, 580
- Rhytid, 409
- Rifabutin, 716, 716t, 754t
- Rifampin, in fungal keratitis, 536
- Rimexolone  
 clinical uses of, 229  
 in episcleritis, 578  
 formulations of, 227t
- Ring  
 Fleischer's, hydrops and, 491f  
 rust, 499, 500f
- Risedronate, 753t
- Risk, disclosure of, 67-69, 68f, 69f
- Risk analysis in glaucoma treatment, 686
- Ritalin, 718
- Ritonavir, 207t
- Rituximab, 471
- Rocephin, 184t
- Rod, gram-negative, infections caused by, 177
- Rofecoxib, 751t
- Rosacea, 463-465, 464f  
 blepharitis in, 388-389, 388f
- Rose bengal, 289-290, 289f, 290f, 422  
 in exposure keratopathy, 508f
- Rostaporfin, 305
- Roundworm, 629-630, 629f
- Route of administration, 4, 703
- Ruboxistaurin, 311-312
- Rule  
 Clark's, 11  
 professional standard, 66, 66b
- Rust ring, corneal, 499, 500f
- Rx symbol, 55
- S**
- Sabouraud's agar, 441
- Sabril, 752t
- Sac, lacrimal, 417-418
- Saccadic velocity study, in thyroid disease, 649
- Salicylate, 98-100, 99t  
 adverse effects of  
 on conjunctiva, 713  
 on eyelid, 713  
 clinical uses of, 99  
 common aspirin products, 99t  
 contraindications to, 100  
 pharmacology of, 98  
 side effects of, 99-100
- Salmonella*  
 infections caused by, 178t  
 Reiter's syndrome and, 472
- SANA study, 307
- Saquinavir, 207t
- Sarcoidosis, 630-632, 631f
- Scanning laser ophthalmoscopy, confocal, 679, 679t
- Scanning layer polarimetry, 679, 679t
- Scarring  
 of Bowman's layer, 491f, 492  
 in herpes zoster ophthalmicus, 533
- Schirmer I test, 420-421  
 anesthesia for, 322
- Schirmer II test, 421, 423-424
- Schnyder's dystrophy, 485t
- Sclera  
 adverse drug effects on, 715-718, 716t  
 structure of, 19-22, 20f, 21f, 21t  
 vasculature of, 575
- Scleritis, 579-585  
 classification of, 579f  
 diseases associated with, 577b  
 fluorometholone for, 228  
 glaucoma with, 694  
 laboratory testing in, 582, 583t  
 management of, 583-584  
 overview of, 579-581  
 posterior, 582-584, 583f
- Sclerokeratitis, 582, 582f
- Scleromalacia perforans, 581
- Sclerosing basal cell carcinoma, 403
- Scopolamine, 130  
 adverse effects of, 718  
 anticholinergic mydriasis caused by, 361-362  
 characteristics of, 345t  
 for corneal abrasion, 497



- Scopolamine—cont'd  
 preparations of, 127t  
 properties of, 127t  
 for pseudophakic cystoid macular edema, 614  
 in Reiter's syndrome, 473
- Scotoma, 157
- Scrapings, conjunctival, 442-443
- Screening for drug-induced retinopathy, 727t
- Scrub, lid, 45, 46t
- Scurf, 383, 383f, 384, 385f
- Seasonal allergy, 228, 550, 556t, 560-561, 560f
- Sebaceous cyst of eyelid, 401-402, 401f
- Sebaceous gland carcinoma, 404, 404f
- Seborrhea, meibomian, 386-387
- Seborrheic blepharitis, 385-386, 385f, 386f  
 dry eye and, 425
- Seborrheic-staphylococcal blepharitis, 385
- Sebum in seborrheic blepharitis, 385
- Secretion, meibomian gland, 386-388, 387f
- Secretory system  
 anatomy and physiology of, 415-417, 416f, 417f  
 evaluation of, 419-420
- Sector dilation, 337, 337f
- Sedation, antihistamines and, 254
- Sedative, opioid as, 107
- Seidel's sign, 607
- Seidel's test, 604, 604f
- Seizure, 133
- Selegiline, 690t
- Self-abusive behavior, 480
- Sensorineural hearing loss, 192
- Sensory nerve of eyelid, 324f
- Serratia marcescens*  
 aminoglycosides for, 187  
 chronic conjunctivitis and, 451  
 corneal ulcer and, 520  
 infections caused by, 177, 178t
- Serum test in myasthenia gravis, 374
- Seventh cranial nerve, 425
- Severe pain  
 in child, 109-110  
 in elderly, 110-111
- Sexually transmitted disease  
 azithromycin for, 192  
 erythromycin for, 191  
 tetracycline for, 190
- Shadow test  
 for anterior angle evaluation, 330, 331f, 332f  
 cycloplegic refraction and, 344
- Shield, collagen, 46-47, 46f
- Shiner, allergic, 560
- Shingles, 393-397, 394f, 396f
- Sickle cell disease  
 acetazolamide and, 163  
 intraocular pressure and, 692-693
- Sign, Hutchinson's, 455, 456f
- Sildenafil, adverse effects of, 749t  
 on optic nerve, 738-739  
 retinal, 729-730
- Silicone hydrogel contact lens, 509
- Silicone oil, 495
- Silicone plug, 273, 273t, 426-427, 428f
- Silver nitrate  
 ophthalmia neonatorum and, 462  
 for superior limbic keratoconjunctivitis, 476
- Simvastatin, 749t
- Sixth nerve palsy, 666-669
- Sjögren's syndrome, 425
- Skin  
 anesthesia of, 94  
 beta-blockers affecting, 148b  
 steroid-induced depigmentation of, 390-391
- Skin disorder  
 methazolamide and, 164  
 staphylococcal infection as, 177  
 sulfonamides causing, 194
- Skin testing, 560
- Sleep test for myasthenia gravis, 374-375
- Slit-lamp examination  
 in Adie's syndrome, 359  
 in anisocoria, 350  
 of anterior angle, 330, 331f, 332f  
 in band keratopathy, 495  
 of corneal abrasion, 497  
 of corneal ulcer, 521  
 in exposure keratopathy, 508  
 in interstitial keratitis, 516  
 phlyctenular keratoconjunctivitis and, 517  
 in phthiriasis palpebrarum, 398
- SLUDGE, 666
- SmartPlug, 429t
- Smear, conjunctival, 442-443, 443t
- Smoking and thyroid disease, 644, 652
- Social history, 4t, 6
- Sodium, 159
- Sodium ascorbate, 511
- Sodium channel, 151
- Sodium chloride  
 for corneal edema, 279-280, 280t, 281f  
 in Fuchs' dystrophy, 489
- Sodium chondroitin sulfate, 495
- Sodium ethylene diaminetetraacetic acid, 495
- Sodium fluorescein, 422
- Sodium hyaluronate, 33, 268
- Sodium perborate, 30, 270
- Soft contact lens  
 in bullous keratopathy, 494  
 for drug delivery, 45-46  
 epithelial microcysts and, 543  
 in Fuch's dystrophy, 489  
 in thyroid disease, 653
- Soft tissue in thyroid-related orbitopathy, 647-648, 648f, 655
- SofZia, 31
- Solid delivery device, 45-47, 46f, 47f  
 collagen shield as, 46-47, 46f  
 cotton pledgets as, 46, 46f  
 filter paper strips as, 46, 46f  
 soft contact lens as, 45-46
- Solution  
 instillation of, 40-42, 41b, 41f, 42f  
 packaging of, 39  
 storage of, 39-40  
 unit-dose dispensers of, 42, 43f
- SOM230, 659
- Somatostatin analogue, 658-660
- Soothe, 427t
- Soriatane, 751t
- Sparfloxacin, 194t
- Spasm, hemifacial, 376-379, 376f, 378t
- Spectacles, 347-348
- Spectrum of drug activity, 175
- Spray  
 administration of, 43-, 43f  
 cycloplegic, 346-347  
 for pupil dilation in child, 334
- Spring catarrh, 550. *See also*  
 Conjunctivitis, allergic
- Spud, 499, 499f
- Squalamine, 311
- Squamous epithelium, stratified, 437-438
- Squamous metaplasia, membrane, 271
- Stability of drug, 28
- Stabilized oxychloro-complex  
 in artificial tears, 270  
 effects of, 30-31
- Stain  
 Giemsa, 535  
 Gram  
 in conjunctival inflammation, 443, 443t  
 in fungal keratitis, 535  
 lissamine green, 508f  
 patterns of, 515b  
 rose bengal, 508f
- Standard  
 of care, 71-73  
 professional community, 66, 66b  
 reasonable patient, 66, 66b
- Staphylococcus*  
 conjunctivitis and, 448  
 corneal ulcer and, 521t  
 erythromycin for, 191  
 phlyctenulosis in, 475
- Staphylococcus aureus*  
 aminoglycosides for, 187  
 azithromycin for, 192  
 in bacterial conjunctivitis, 446  
 blepharitis and, 382-383, 384  
 canaliculal infection with, 433  
 cephalosporin for, 183  
 chronic conjunctivitis and, 451  
 clarithromycin for, 192  
 in conjunctival flora, 438  
 for conjunctivitis, 447

- Staphylococcus aureus*—cont'd  
 corneal ulcer and, 520  
 dacryocystitis and, 433  
 endophthalms and, 606  
 in external hordeolum, 389  
 infection caused by, 177, 178t  
 in internal hordeolum, 389-390  
 ophthalmia neonatorum and, 462  
 penicillin for, 181, 182  
 phlyctenular keratoconjunctivitis and, 517, 518  
 in preseptal cellulitis, 391
- Staphylococcus epidermidis*  
 blepharitis and, 382-383, 384  
 in conjunctival flora, 438  
 corneal ulcer and, 520  
 dacryocystitis and, 433  
 endophthalms and, 606  
 infection caused by, 177, 178t  
 penicillin for, 181, 182  
 tetracyclines for, 190  
 vancomycin for, 449
- Stavudine, 206t
- Stem cell transplantation, limbal, 468-469
- Stenosis of lacrimal puncta, 432
- Steroid. *See also* Corticosteroid  
 for allergic disease, 550, 554t, 558t-559t  
 in angle-closure glaucoma, 693  
 for anterior uveitis, 596  
 as anti-allergy drug, 259  
 anti-inflammatory effectiveness of, 594b  
 in burn injury, 510-511  
 for chalazion, 390  
 complications of, 77  
 for conjunctivitis, 447  
 contact lens-related papillary conjunctivitis and, 564  
 for corneal ulcers, 525  
 for epidemic keratoconjunctivitis, 454  
 in episcleritis, 578  
 for giant papillary conjunctivitis, 542f  
 for herpes zoster ophthalmicus, 533  
 for intermediate uveitis, 596-597  
 for interstitial keratitis, 517  
 for pterygia, 478  
 for rosacea, 464  
 in sarcoidosis, 631  
 in scleritis, 584-585  
 in seasonal conjunctivitis, 561  
 for Stevens-Johnson syndrome, 469  
 for tear augmentation, 429  
 for Thygeson's superficial punctate keratitis, 534  
 in thyroid-related orbitopathy, 655, 656, 657  
 for toxic keratitis, 514  
 for uveitis, 594  
 in vernal keratoconjunctivitis, 566
- Steroid-antibiotic for blepharitis, 384
- Steroid-induced inflammatory glaucoma, 596
- Steroid-induced posterior subcapsular cataract, 705
- Stevens-Johnson syndrome, 469-470
- Stimulant, pupil and, 718
- Stimulation, cocaine causing, 119
- Storage  
 counseling about, 61  
 of solutions and suspensions, 39-40
- Strabismus, 663-669  
 cycloplegic agents for, 663-665  
 cycloplegic refraction in, 343  
 mitotic agents for, 664-666  
 paralytic agents in, 666-669, 667b
- Stratified squamous epithelium, 437-438
- Streptococcus pneumoniae*  
 in bacterial conjunctivitis, 446, 446f  
 cephalosporin for, 183  
 clarithromycin for, 192  
 conjunctiva and, 438, 447, 449  
 corneal ulcer and, 520, 521t  
 infections caused by, 177, 178t  
 penicillin for, 182  
 in preseptal cellulitis, 391  
 trimethoprim for, 193  
 vancomycin for, 185
- Streptococcus pyogenes*  
 azithromycin for, 192  
 in bacterial conjunctivitis, 446  
 cephalosporin for, 183  
 erythromycin for, 191  
 infections caused by, 178t  
 penicillin for, 181  
 in preseptal cellulitis, 391
- Streptococcus viridans*, 520
- Stress, photo-oxidative, 635
- Striae, hydrops and, 491f
- Strip, filter paper, 46, 46f
- Stroma  
 corneal, 483  
 structure of, 21  
 foreign body and, 502  
 in Fuchs' dystrophy, 489f
- Stromal keratitis, herpes simplex, 528
- Stromal puncture, anterior, 506  
 in recurrent corneal erosion, 507
- Subcapsular cataract  
 chlorpromazine causing, 708-709, 708t, 709f  
 posterior  
 steroid-induced, 705  
 uveitis and, 596
- Subconjunctival injection, 47-48, 49f  
 of anesthetic, 327f  
 of medication, 323, 323f
- Subcutaneous block, pretarsal, 324
- Subscription, 55
- Substantia propria, limbal conjunctival, 438
- Substituted cellulose ether, 266-268
- Sub-Tenon's injection, 49, 49f
- Sudoriferous cyst of eyelid, 401, 401f
- Sulfacetamide, 447
- Sulfisoxazole, 447
- Sulfonamide  
 acetazolamide and, 162  
 adverse effects of, 713, 755t  
 for blepharitis, 384  
 clinical uses of, 193  
 for conjunctivitis, 447  
 contraindications to, 194  
 dorzolamide and, 165  
 myopia caused by, 720-721  
 for pathogens susceptible to, 442t  
 pharmacology of, 193  
 side effects of, 193-194
- Superficial abrasion, 320
- Superficial foreign body removal, 322-323
- Superficial punctate keratitis  
 bacterial, 514-515, 514f  
 Thygeson's, 241-242
- Superficial epithelial keratectomy, 507
- Superinfection, 385
- Superior limbic keratoconjunctivitis, 475-476, 476f  
 in thyroid disease, 650
- Supplement, dietary, 207-301
- Supplementation, tear. *See* Artificial tears
- Suprax, 184t
- Suprofen  
 clinical uses of, 235  
 formulations of, 236t
- Surface inflammation, cyclosporine A as immunomodulator of, 236-242
- Surgery  
 for atopic dermatitis, 467  
 for blepharospasm, 379  
 in bullous keratopathy, 494  
 in burn injury, 511  
 for chalazion, 391  
 of eyelid, 408-412  
 chemical cautery and, 409  
 incisions for, 410-412, 411f  
 neuroanatomy and, 408-409  
 patient management and, 412-413  
 for rhytids and, 409  
 thermal cautery and, 409-410  
 in fungal keratitis, 536  
 for pterygia, 478  
 in thyroid-related orbitopathy, 655, 656  
 for trauma, 503
- Suspension  
 instillation of, 40-42, 41b, 41f, 42f  
 packaging of, 39  
 storage of, 39-40  
 unit-dose dispensers for, 42, 43f
- Sustiva, 206t
- Suture for cataract surgery, 603-604
- Swab for conjunctival culture, 441-442
- Swallowing difficulty, 14
- Sweat test, 354
- Sympathetic nerve fiber, 352
- Sympathetic nervous system, 113-114
- Sympathetic ophthalmia, 241

- Syphilis  
 drugs for, 176t  
 interstitial keratitis in, 516t  
 penicillin for, 181  
 uveitis and, 598
- Systane, 267t, 427t
- Systemic Avastin for Neovascular AMD study, 307
- Systemic disease  
 conjunctivitis with, 459, 460t  
 episcleritis with, 576b  
 uveitis with, 588b
- Systemic drug, adverse reaction to, 701-759. *See also* Adverse reaction
- Systemic lupus erythematosus  
 conjunctiva in, 459, 460t, 472-474, 473f  
 drug-induced, 740, 740b, 741b
- T**
- T lymphocyte in thyroid disease, 645
- Tacrolimus  
 for atopic dermatitis of eyelid, 570  
 for psoriasis, 465  
 for uveitis, 595
- Tadalafil, 729-730, 749t
- Talc, 734-736, 735f
- Tamoxifen, 753t  
 cornea and, 704t  
 retina and, 731-732, 732f
- Tamsulosin, 716-717, 716t, 748t
- TAP study, 304
- Tarsorrhaphy  
 cyanoacrylate, 408  
 lateral, 427-428
- Tavist, 251t
- Tazarotene, 465
- Tazicef, 184t
- Tazidime, 184t
- Tazobactam, 180t
- Tear breakup time, 421-422
- Tear conservation, 426-428, 428t  
 lacrimal occlusive devices for, 273-274, 273f, 274f  
 ointments for, 272-273, 272t
- Tear film  
 abnormality of, 264-276  
 after refractive surgery, 265  
 artificial tears for, 266-272. *See also* Artificial tears  
 etiology of, 264-265  
 tear conservation for, 272-274, 272t, 273f, 273t, 274t  
 tear stimulation for, 274-276  
 composition of, 416-417, 417f, 419t  
 evaluation of, 420-422, 420f, 421b, 422f, 422t, 423f  
 structure of, 263-264, 264f
- Tear stimulation, 272-276
- Tear supplementation, 266-272. *See also* Artificial tears
- Tear volume test, 422, 422f, 422t
- Tearing, management of, 715
- Tears  
 adverse drug effects on, 713-715, 714t  
 artificial, 266-272. *See also* Artificial tears  
 compartment theory and, 25-26  
 epiphora and, 429-432, 430f, 431f, 432f  
 structure of, 17-19, 18f
- Tears Naturale, 267t, 427t
- Tegison, 751t
- Tendonitis, 195
- Tenofovir, 206t
- Tensilon test for myasthenia gravis, 374
- Test  
 forced duction, 320-321, 321f  
 in Horner's syndrome  
 apraclonidine, 355-356  
 cocaine test in, 355, 356f, 357t  
 hydroxyamphetamine, 355-356, 356f, 357t  
 phenylephrine, 356-357  
 sweat, 354  
 for myasthenia gravis, 344, 374  
 phenol red thread, 421
- Schirmer I, 421-422  
 anesthesia for, 322
- Schirmer II, 422, 423-424  
 shadow  
 for anterior angle evaluation, 330, 331f, 332f  
 cycloplegic refraction and, 344
- Test strip, 422f
- Tetracaine  
 abuse of, 513-514  
 as topical anesthetic, 88-89, 88t
- Tetracycline, 190-191, 190t  
 adverse effects of, 754t  
 on conjunctiva, 713  
 on optic nerve, 739-740  
 on sclera, 718
- in blepharitis, 388  
 in burn injury, 511  
 classification of, 189t  
 clinical uses of, 190  
 for conjunctivitis, 447  
 for meibomian gland infection, 387  
 for pathogens susceptible to, 442t  
 pharmacology of, 189  
 phlyctenular keratoconjunctivitis and, 518  
 in phlyctenulosis, 475  
 pigmentation caused by, 713, 718  
 in recurrent corneal erosion, 506  
 in Reiter's syndrome, 473  
 for rosacea, 464  
 for trachoma, 458
- Tetrahydrozoline, 247, 248t, 249  
 in episcleritis, 578
- TheraTears, 267t
- Thermal cautery, 409-410
- Thiabendazole, 630
- Thiazolidinedione, 660
- Thiel-Behnke dystrophy, 484t
- Thimerosal, 474
- Thioglycolate broth, conjunctival culture for, 441
- Thioridazine  
 adverse effects of, 756t  
 retinal, 728-729, 728f  
 antimuscarinic dosage of, 721t
- Third nerve palsy, 360-361, 361f
- Thorazine, 756t
- Thygeson's superficial punctate keratitis, 241-242, 533-534
- Thymectomy, 375
- Thymoxamine, 119
- Thymus gland, 373
- Thyroid disease, contraindications related to, 5
- Thyroidectomy, 652-653
- Thyroid-related orbitopathy, 643-662  
 classification of, 645-650, 646t, 647f-650f, 649t  
 clinical course of, 651-652  
 clinical presentation of, 643-644  
 epidemiology of, 644-645  
 etiology of, 645  
 imaging of, 650-651, 651f  
 laboratory studies for, 644  
 management of, 652-661, 661t  
 of corneal involvement, 656-657  
 of extraocular muscle, 656  
 of eyelid retraction, 653-655, 654f  
 of optic neuropathy, 657  
 orbital decompression in, 660-661, 660f  
 orbital irradiation in, 660  
 plasmapheresis in, 658  
 of proptosis, 656  
 of soft tissue involvement, 655-656, 655f  
 somatostatin analogues in, 658-660  
 systemic steroids in, 657-658, 659f  
 of thyrotoxicosis, 652-653
- Thyroid-stimulating hormone, 644
- Thyrotoxicosis, 648-649  
 management of, 652-653
- Thyroxine, 644
- Ticarcillin  
 for pseudomonas infection, 182  
 spectrum of activity of, 180t
- Tight junction in uveitis, 588
- Timolol  
 brimonidine and, 156f  
 clinical uses of, 148  
 contraindications to, 149-150  
 dorzolamide with, 166-167  
 formulations of, 146t  
 for glaucoma, 689t  
 pharmacology of, 145-147  
 side effects of, 148-149, 149b, 149f
- Timoptol, 146t

- Tinted contact lens in thyroid-related orbitopathy, 655
- Tipranavir, 207t
- TobraDex, 464
- Tobramycin  
in bullous keratopathy, 494  
in burn injury, 510  
clinical uses of, 189  
formulations of, 186t  
steroids with, 188t  
for corneal ulcer, 523  
for infectious conjunctivitis, 446  
for pathogens susceptible to, 442t  
in recurrent corneal erosion, 505, 507
- Tobramycin-dexamethasone, 464
- Tolbutamide, 194
- Tolerance to timolol, 145-146
- Toloxatone, 690t
- Tometin, 109t
- Tomography  
anterior segment ocular coherence, 675  
computed  
in myasthenia gravis, 375, 375f  
in thyroid-related orbitopathy, 650-651, 651f  
optical coherence  
in glaucoma, 679, 679t  
in uveitis, 599
- Tonicity agent, 31b
- Tonometry, 671-674, 673b  
alternatives to, 673-674  
anesthesia for, 320  
in anterior uveitis, 591  
dynamic contour, 674  
errors with, 674b  
fluorescein sodium for, 286, 287t  
in intermediate uveitis, 592  
in posterior uveitis, 593  
testing of, 7
- Tooth, tetracyclines affecting, 190
- Topical administration, 47-48, 48f  
gel for, 45  
lid scrubs for, 45, 46t  
ointment for, 43-45, 44f  
solid, 45-47, 46f, 47f  
solution as, 39-42  
sprays for, 43-, 43f  
suspension as, 39-42
- Topical anesthesia, 87-90, 88t, 89f, 319-328  
abuse of, 513-514  
clinical uses of, 319-320  
complications of, 75  
for diagnostic procedures, 320b  
abrasion evaluation, 320  
applanation tonometry, 320  
contact lens fitting, 322  
cultures, 320  
forced duction test, 320-321, 321f  
lacrimal drainage, 322, 322f  
pachymetry, 321, 322f  
pre-drug instillation, 322
- Topical anesthesia—cont'd  
Schirmer No. 1 test, 322  
ultrasonography, 321  
mydriatic instillation and, 333  
treatment requiring, 322-323, 323b, 323f
- Topiramate, 752t  
intraocular pressure and, 724  
myopia caused by, 721
- Topomax, 752t
- Toxic conjunctivitis, 474
- Toxic epidermal necrolysis, 469-470
- Toxic keratitis, 513-514, 514f
- Toxic optic neuropathy, 300
- Toxicity. *See also* Adverse drug reaction  
of atropine, 129  
of local anesthetic, 90-91, 90f, 91f  
minimizing of, 7  
of NSAIDs, 259  
penicillin causing, 182  
of pilocarpine, 169  
of tetracycline, 190-191
- Toxin, botulinum, 666-669, 667b  
for blepharospasm, 377-379, 378f, 378t
- Toxocariasis, 629-630, 629f
- Toxoplasma gondii*, 217
- Toxoplasmosis, 626-629, 626f, 627f  
pyrimethamine for, 193
- Trabecular meshwork  
anticholinergics and, 722  
corticosteroids and, 724
- Trabeculitis, 694
- Trachoma, 457-458, 458f
- Tramadol  
formulations of, 105t  
pharmacological properties of, 106
- Transplacental transmission of  
*Toxoplasma gondii*, 626
- Transplantation, limbal stem cell, 468-469
- Transport, active, 26-27
- Transporter, retinal, 24t
- Trantas' dots, 565-566, 565b, 565f
- Tranlycypromine, 690t
- Trauma  
conjunctival, 478-480, 479f  
corneal  
abrasion as, 44, 496-498, 496f, 497f  
burn as, 509-511, 510f, 510t  
dellen and, 512-513, 513f  
exposure keratopathy and, 507-509  
foreign body causing, 498-502, 498f-502f  
penetrating, 502-504, 502f, 503f, 504f  
photokeratitis with, 511-512  
recurrent erosion and, 486, 487, 504-507, 504f, 507f  
toxic keratitis and, 513-514, 514f  
iris, 362  
negligence causing, 71  
pain management in, 109
- Travatan, 687-688, 687t
- Travoprost, 143-144, 687-688, 687t
- Treatment of Age-related Macular Degeneration Study, 304
- Treponema pallidum*  
infections caused by, 177  
penicillin for, 181  
uveitis and, 598-599
- Tretinoin, 751t
- Tretinoin ointment, 271
- Triamcinolone acetonide  
for chalazion, 390  
in cystoid macular edema, 633  
in diabetic macular edema, 633-634  
intravitreal administration of, 50, 308-309  
for pseudophakic cystoid macular edema, 614  
in thyroid-related orbitopathy, 655  
for uveitis, 594
- Trichiasis, 405-406, 406f
- Trichophyton*, 391
- Tricyclic antidepressant, phenylephrine and, 117
- Trifluridine, 197  
guidelines for, 198t  
for herpes simplex infection, 197
- Triiodothyronine, 644
- Trimethoprim  
clinical uses of, 193  
for conjunctivitis and, 447  
contraindications to, 194  
formulations of, 187t  
for pathogens susceptible to, 442t  
pharmacology of, 193  
side effects of, 193-194
- Trimethoprim-polymyxin B  
for conjunctivitis, 447  
for infectious conjunctivitis, 446
- Trimethoprim-sulfamethoxazole  
in preseptal cellulitis, 391  
for toxoplasmosis, 628, 629
- Trizivir, 206t
- Trophozoite form of *Acanthamoeba*, 215
- Tropicacyl, 127t
- Tropicamide, 133-137  
administration, 346  
in cardiac disease, 340  
clinical uses of, 135-136  
compared with other drugs, 345-346  
contraindications for, 137  
for corneal abrasion, 497  
dapiprazole and, 120  
hydroxyamphetamine and, 118  
for infant or child, 334  
pharmacology of, 133-135, 133f, 135t  
phenylephrine with, 115-116  
preparations of, 127t  
properties of, 127t  
side effects of, 137
- Trusopt. *See* Dorzolamide
- Truvada, 206t
- Tryptase-containing mast cell, 549

- Tuberculosis  
 interstitial keratitis in, 516t  
 phlyctenular keratoconjunctivitis  
 and, 517  
 phlyctenulosis in, 475
- Tumor  
 Horner's syndrome caused by, 353  
 lacrimal gland, 424
- Tumor necrosis factor- $\alpha$  inhibitor, 716t, 717
- Twitching of eyelid, 407-408
- Tylosis ciliaris, 383f
- Tyndell effect, in anterior uveitis, 590
- U**
- Ulcer  
 bacterial, 520-525, 521f, 521t, 522f  
 contact lens-related, 539, 540t  
 corneal  
 bacterial, 520-525, 521f, 521t, 522f  
 ointment for, 44  
 in herpes simplex keratitis, 528
- Ulcerative basal cell carcinoma, 403, 403f
- Ultrasonography  
 anesthesia for, 321  
 in scleritis, 583, 583f  
 in thyroid-related orbitopathy, 650-651, 651f
- Ultraviolet light in anisocoria testing, 349-350
- Ultraviolet radiation burn, 511-512
- Unilateral fixed and dilated pupil, 360-362  
 in adrenergic mydriasis, 362  
 in anticholinergic mydriasis, 361-362, 362f  
 damage to iris causing, 362  
 in third nerve palsy, 360-361, 361f
- Unit-dose dispenser, 42, 43f
- Unmyelinated nerve fiber, 113
- Urea in glaucoma, 694
- Urethritis  
 azithromycin for, 192  
 in Reiter's syndrome, 472-473
- Urokinase-type plasminogen activator, 309
- Urticaria  
 of eyelid, 569t, 571-572  
 sulfonamides causing, 194
- Uvea, 7t, 715-718, 716t
- Uveitis, 587-599  
 anatomy in, 587  
 anterior, 590-591, 591t  
 complications of, 596  
 in interstitial keratitis, 516  
 latanoprost and, 143  
 loteprednol etabonate for, 228  
 atropine for, 128  
 classification of, 587  
 complications of, 596-597  
 corticosteroid causing, 232  
 cyclopentolate for, 132-133  
 diagnosis of, 589-593, 591t  
 diseases associated with, 588b
- Uveitis—cont'd  
 epidemiology of, 588-589  
 episcleritis and, 578  
 etiology of, 588  
 fluorescein angiography for, 599  
 glaucoma with, 694  
 imaging studies of, 599  
 intermediate, 591-592  
 complications of, 596-597  
 laboratory tests for, 597-599, 598t, 599b  
 management of, 593-596, 596f  
 corticosteroids in, 593-594, 593b, 594b  
 cycloplegic agents in, 594  
 mydriatic agents in, 594  
 nonsteroidal anti-inflammatory  
 drugs in, 595  
 periocular steroids in, 594-595  
 panuveitis, 593  
 posterior, 592-593  
 complications of, 597  
 rimexolone for, 229
- Uveitis glaucoma, 631-632
- V**
- Valacyclovir  
 clinical indications for, 202t  
 clinical uses of, 201, 202t-203t, 204  
 guidelines for, 199t  
 for herpes simplex keratitis, 530  
 for herpes zoster conjunctivitis, 456  
 for herpes zoster ophthalmicus, 532  
 pharmacology of, 201
- Valdecoxib, 751t
- Valganciclovir, 623-624
- Vancomycin, 185-186  
 endophthalmos and, 606  
 for methicillin-resistant  
*Staphylococcus aureus*, 449
- Vanquish, 104t
- Vardenafil, 730, 749t
- Varicella zoster immunization, 396
- Varicella zoster virus infection  
 conjunctival, 455-456, 456f  
 of eyelid, 393-397, 394f, 396f  
 scleral, 584
- Vasoconstrictor, 578
- Vascular closure in scleritis, 581, 581f
- Vascular disorder, collagen, 580
- Vascular endothelial growth factor, 310-311  
 in age-related macular degeneration, 635, 638  
 VEGF Inhibition Study in Ocular  
 Neovascularization and, 306  
 VEGF Trap and, 35t, 310-311
- Vascular occlusion, 580
- Vasculature of sclera and episclera, 575
- VasoClear, 248t
- Vasocon-A, 254t, 551t
- Vegetative foreign body, 497498
- VEGF Inhibition Study in Ocular  
 Neovascularization, 306
- VEGF Trap, 35t, 310-311
- Vehicle for drug administration, 31-34
- Vein occlusion, retinal, 632, 634
- Velosef, 184t
- Vernal keratoconjunctivitis, 549, 557t, 559t, 564-566, 565f  
 cyclosporine A for, 241  
 mast cell stabilizers for, 255
- Verruca, 399-400, 400f
- Verteporfin, 303-305, 639
- Verteporfin in Photodynamic Therapy  
 study, 304
- Vertical diplopia, 643
- Vesanoid, 751t
- Vesicle, 394-395
- Vestibular toxicity, tetracyclines and, 190-191
- Vfend, 210t
- Viagra, 749t
- Vidarabine, 197, 198t-199t
- Videoangiography, indocyanine green  
 for, 291-292, 291f
- Videx, 206t
- Vigabatrin, 733, 752t
- Vinyl derivative, 268-269
- Vioxx, 751t
- VIP study, 304
- Viracept, 207t
- Viral infection  
 aspirin and, 100  
 conjunctivitis  
 adenoviral, 451-454, 452f, 453f, 453t  
 herpes simplex, 454-455, 455f  
 molluscum contagiosum and, 458-459, 458f  
 nonspecific, 459  
 varicella zoster, 455-456, 456f  
 cytomegalovirus. *See also*  
 Cytomegalovirus  
 of eyelid, 393-397  
 herpes simplex blepharoconjunctivitis as, 393, 393f  
 herpes zoster ophthalmicus as, 393-397, 394f, 396f  
 scleritis with, 577b
- Viral keratitis, 525-534  
 epidemic keratoconjunctivitis and, 525-527, 526f  
 herpes simplex, 527-530, 528f, 530f  
 herpes zoster, 530-533, 531f, 531t, 532f  
 Thygeson's superficial punctate, 533-534
- Viramune, 206t
- Viread, 206t
- Virus  
 conjunctival culture for, 441  
 as conjunctival pathogen, 439b
- Visceral larva migrans, 629-630, 629f
- Viscoelastic agent, 268

- Viscous agent, 31b  
 Visine-A, 254t  
 Visine-LR, 248t  
 Vision, impaired, 76  
 Vistide, 755t  
 Visual acuity  
   in anterior uveitis, 590  
   drugs affecting, 8  
   examination of, 6  
   in intermediate uveitis, 592  
   in posterior uveitis, 592  
 Visual field  
   in glaucoma, 680-685, 680t, 681f-684f, 685b  
   in thyroid disease, 650  
 Visual impairment, 13-14, 13f-14f  
 Visudyne, 303-305  
 Vitamin, 295-301  
   food sources of, 297t  
   overdose and deficiency of, 297t  
   physiological effects of, 296t  
 Vitamin A  
   adverse effects of, 741, 751t, 759t  
   in retinitis pigmentosa, 300  
 Vitamin A deficiency, 270-271, 300  
 Vitamin and mineral supplement, 295-301  
   for age-related macular degeneration, 299-300, 636  
   for cataract, 299  
   for dry eye, 300  
   for folic acid deficiency, 300  
   ideal, 298t  
   for open-angle glaucoma, 297-299  
   for retinitis pigmentosa, 300  
   side effects of, 300-301  
 Vitamin and mineral supplement—cont'd  
   for toxic optic neuropathy, 300  
   for vitamin A deficiency, 300  
 Vitamin B<sub>12</sub>, in artificial tears, 271  
 Vitamin B deficiency, 478  
 Vitamin C  
   for age-related macular degeneration, 636  
   in burn injury, 511  
   drug interactions with, 300  
 Vitamin C deficiency, 478  
 Vitamin deficiency, 295  
   conjunctiva and, 478  
 Vitamin E, 636  
 Vitamin K, 184-185  
 Vitrase, intravitreal, 35t  
 Vitrasert  
   for cytomegalovirus retinitis, 51, 623  
   intravitreal, 35t  
 Vitravene, 623  
 Vitreous  
   in anterior uveitis, 591  
   structure of, 23-24  
 Vitreous fluorophotometry, 288  
 Viva-Drops, 267t  
 Vogt's line, 490  
 Voltaren, 236t, 595  
 Volume, tear, 17-18  
 Voriconazole, 208, 210t, 212t, 213t, 214
- W**  
 Wart, of eyelid, 399-400, 400f  
 Westergren ESR, in uveitis, 597  
 Wetting agent, 31b  
 Wood splinter foreign body, 498f
- World Health Organization, on trachoma, 458  
 Wrinkles, 409
- X**  
 Xalatan. *See* Latanoprost  
 Xalatan, 687-688, 687t  
 Xanthoma palpebrarum, 402, 402f  
 Xerostomia, 426  
 Xibrom, 236t
- Y**  
 YAG capsulotomy, endophthalmos and, 606  
*Yersinia*, Reiter's syndrome and, 472  
 Yttrium aluminum garnet capsulotomy, 606
- Z**  
 Zaditor, 258t, 553t  
   in seasonal conjunctivitis, 561  
 Zalcitabine, 206t  
 Zerit, 206t  
 Ziagen, 206t  
 Zidovudine, 206t  
 Zinacef, 184t  
 Zinc, 208  
   for age-related macular degeneration, 636  
 Zocor, adverse effects of, 749t  
 Zolendronate, 753t  
 Zometa, 753t  
 Zonula occludens, 24  
 Zymer, 64b  
 Zyrtec, 252t, 552t, 753t