

# Clinical Tests for the Musculoskeletal System

Examinations—Signs—Phenomena

Klaus Backup, M.D.

Klinikum Dortmund  
Orthopedic Hospital  
Dortmund  
Germany

521 illustrations

Thieme  
Stuttgart · New York

Backup, Clinical Tests for the Musculoskeletal System © 2004 Thieme  
All rights reserved. Usage subject to terms and conditions of license.

*Library of Congress Cataloging-in-Publication Data  
is available from the publisher*

This book is an authorized translation of the 2nd German edition published and copyrighted 2000 by Georg Thieme Verlag, Stuttgart, Germany. Title of the German edition: Klinische Tests an Knochen, Gelenken und Muskeln: Untersuchungen – Zeichen – Phänomene

Translator: John Grossman, Berlin, Germany

Illustrators: Detlev Michaelis, Friedrichsdorf, Taunus, Germany;  
Barbara Junghähnel, Dortmund, Germany

**Important note:** Medicine is an ever-changing science undergoing continual development. Research and clinical experience are continually expanding our knowledge, in particular our knowledge of proper treatment and drug therapy. Insofar as this book mentions any dosage or application, readers may rest assured that the authors, editors, and publishers have made every effort to ensure that such references are in accordance with **the state of knowledge at the time of production of the book.**

Nevertheless, this does not involve, imply, or express any guarantee or responsibility on the part of the publishers in respect to any dosage instructions and forms of applications stated in the book. **Every user is requested to examine carefully** the manufacturers' leaflets accompanying each drug and to check, if necessary in consultation with a physician or specialist, whether the dosage schedules mentioned therein or the contraindications stated by the manufacturers differ from the statements made in the present book. Such examination is particularly important with drugs that are either rarely used or have been newly released on the market. Every dosage schedule or every form of application used is entirely at the user's own risk and responsibility. The authors and publishers request every user to report to the publishers any discrepancies or inaccuracies noticed.

Some of the product names, patents, and registered designs referred to in this book are in fact registered trademarks or proprietary names even though specific reference to this fact is not always made in the text. Therefore, the appearance of a name without designation as proprietary is not to be construed as a representation by the publisher that it is in the public domain.

This book, including all parts thereof, is legally protected by copyright. Any use, exploitation, or commercialization outside the narrow limits set by copyright legislation, without the publisher's consent, is illegal and liable to prosecution. This applies in particular to photostat reproduction, copying, mimeographing, preparation of microfilms, and electronic data processing and storage.

© 2004 Georg Thieme Verlag  
Rüdigerstrasse 14, 70469 Stuttgart, Germany  
<http://www.thieme.de>  
Thieme New York, 333 Seventh Avenue,  
New York, NY 10001 USA  
<http://www.thieme.com>

Typesetting by primustype Hurler GmbH, Notzingen  
Printed in Germany by Appl, Wemding

ISBN 3-13-136791-1 (GTV)  
ISBN 1-58890-241-2 (TNY)

1 2 3 4 5

Buckup, Clinical Tests for the Musculoskeletal System © 2004 Thieme  
**All rights reserved. Usage subject to terms and conditions of license.**

# Preface to the English Edition

Advancements in orthopedics have occurred at a rapid pace in recent years. Whereas new modalities such as ultrasound, computed tomography, and magnetic resonance imaging are occasionally able to help us make precise orthopedic diagnoses more rapidly, meticulous history taking and thorough clinical examination remain crucial to any treatment.

Every medical specialty has its own particular examination methods. In orthopedics and trauma surgery, these include examination of the joints in combination with precise range of motion testing in the trunk and extremities and evaluation of the musculature. There are many standardized examination methods or tests that can aid in evaluating musculoskeletal dysfunction.

My aim was to apply my knowledge and experience to the task of compiling descriptions of these many tests and grouping them according to the various regions of the body. The book also includes chapters on the evaluation of posture deficiencies, thrombosis, and arterial ischemic disorders. Each test is described step by step, beginning with the patient's initial position. Each of these descriptions also discusses the evaluation of the test and the possible diagnosis that the test may provide. Drawings have been included with each test to illustrate the steps in the examination. Some tests for certain disorders differ only slightly from one another. I have included them nonetheless as my own experience has shown that a diagnosis can often be made only on the basis of several typical tests for a disorder.

The book is intended as a practical guide to facilitate examination of the patient and to help the physician diagnose musculoskeletal disorders and injuries more rapidly. Several editions in various languages have shown that readers are highly interested in a thorough description of standardized examination methods in the form of tests.

The individual chapters have been revised for the English edition and new tests have been included.

Dortmund, May 2004

Klaus Buckup



## **Bone and Joint Decade 2000–2010**

On January 13, 2000, the World Health Organization (WHO) at its headquarters in Geneva declared the first decade of the new millennium “Bone and Joint Decade.”

Gro Harlem Brundtland, physician and former Norwegian Prime Minister and Director-General of the WHO, stated at the opening ceremony that bone and joint disorders had already become the main cause of persistent pain and physical impairments.

Given the current demographic development, the number of people over the age of 50 suffering from such disorders will double in the next 20 years. The WHO initiative aims to increase public awareness of musculoskeletal disorders, improve their prevention and management, and promote opportunities for further education and research in this field.

This book represents my contribution in support of the WHO initiative Bone and Joint Decade 2000–2010.

Klaus Backup

---

# Contents

<b>Spine</b> .....	1
Range of Motion of the Spine (Neutral-Zero Method) .....	2
Fingertips-to-Floor Distance Test in Flexion .....	2
Table 1 Function tests: spine .....	4
Table 2 Overview of function tests of the spine .....	5
Ott Sign .....	5
Schober Sign .....	5
Skin-Rolling Test (Kibler Fold Test) .....	6
Chest Tests .....	7
Sternum Compression Test .....	7
Rib Compression Test .....	7
Chest Circumference Test .....	8
Schepelmann Test .....	9
Cervical Spine Tests .....	10
Screening of Cervical Spine Rotation .....	10
Test of Head Rotation in Maximum Extension .....	11
Test of Head Rotation in Maximum Flexion .....	12
Test of Segmental Function in the Cervical Spine .....	13
Soto-Hall test .....	14
Percussion Test .....	14
O'Donoghue Test .....	15
Valsalva Test .....	16
Spurling Test .....	16
Cervical Spine Distraction Test .....	17
Shoulder Press Test .....	18
Test of Maximum Compression of the Intervertebral Foramina .....	18
Jackson Compression Test .....	19
Intervertebral Foramina Compression Test .....	20
Flexion Compression Test .....	20
Extension Compression Test .....	21
Thoracic and Lumbar Spine Tests .....	22
Adam Forward Bend Test .....	22
Kyphosis Test on Hands and Knees .....	22
Test of Segmental Function in the Thoracic Spine in Extension .....	23
Prone Knee Flexion Test .....	23

Spinous Process Tap Test .....	24
Psoas Sign .....	25
Lasègue Straight Leg Drop Test .....	25
Springing Test .....	27
Hyperextension Test .....	27
Supported Forward Bend Test (Belt Test) .....	29
Hoover Sign .....	30
Sacroiliac Joint .....	30
Table 3 Function and provocation tests of the sacroiliac joint ..	31
Ligament Tests .....	31
Springing Test .....	33
Patrick Test (Fabere Sign) .....	34
Three-Phase Hyperextension Test .....	34
Spine Test .....	36
Standing Flexion Test .....	38
Sacroiliac Mobilization Test .....	39
Sacroiliac Joint Springing Test .....	40
Derbolowsky Sign .....	41
Gaenslen Sign .....	41
Iliac Compression Test .....	42
Mennell Sign .....	43
Yeoman Test .....	44
Laguerre Test .....	44
Sacroiliac Stress Test .....	45
Abduction Stress Test .....	46
Nerve Root Compression Syndrome .....	46
Table 4 Signs of radicular symptoms .....	48
Lasègue Sign (Straight Leg Raising Test) .....	49
Bonnet Sign (Piriformis Sign) .....	50
Lasègue Test with the Patient Seated .....	51
Contralateral Lasègue Sign (Lasègue–Moutaud–Martin Sign) ..	51
Bragard Test .....	52
Lasègue Differential Test .....	53
Duchenne Sign .....	54
Thomsen Sign .....	55
Kernig Test .....	56
Tiptoe and Heel Walking Test .....	56
Brudzinski Sign .....	57
Reverse Lasègue Test (Femoral Nerve Lasègue Test) .....	58

<b>Shoulder</b> .....	59
Range of Motion of the Shoulder (Neutral-Zero Method) .....	61
Table 5 Function tests: shoulder .....	62
Orientation Tests .....	63
Quick Test of Combined Motion .....	63
Codman Sign .....	63
Palm Sign Test and Finger Sign Test .....	65
Bursitis Tests .....	65
Bursae .....	65
Bursitis Sign .....	66
Dawbarn Test .....	66
Rotator Cuff (Impingement Symptoms) .....	67
Zero-Degree Abduction Test .....	70
Jobe Supraspinatus Test .....	70
Subscapularis Test .....	71
Lift-Off Test .....	72
Infraspinatus Test .....	73
Teres Test .....	73
Nonspecific Supraspinatus Test .....	75
Drop Arm Test .....	75
Ludington Sign .....	76
Apley's Scratch Test .....	76
Painful Arc .....	77
Neer Impingement Sign .....	78
Hawkins Impingement Sign .....	79
Neer Impingement Injection Test .....	80
Acromioclavicular Joint .....	80
Painful Arc .....	81
Forced Adduction Test .....	82
Forced Adduction Test on Hanging Arm .....	82
Test of Horizontal Mobility of the Lateral Clavicle .....	83
Dugas Test .....	83
Long Head of the Biceps Tendon .....	84
Nonspecific Biceps Tendon Test .....	84
Abbott-Saunders Test .....	84
Speed Test .....	85
Snap Test .....	86
Yergason Test .....	86
Hueter Sign .....	87
Transverse Humeral Ligament Test .....	88

Thompson and Kopell Horizontal Flexion Test (Cross-Body Action) .....	88
Ludington Test .....	89
Lippman Test .....	89
DeAnquin Test .....	89
Gilcrest Test .....	89
Beru Sign .....	90
Duga Sign .....	90
Traction Test .....	90
Compression Test .....	90
Shoulder Instability .....	91
Anterior Apprehension Test .....	92
Apprehension Test (Supine) .....	93
Rowe Test .....	94
Throwing Test .....	94
Leffert Test .....	94
Anterior and Posterior Drawer Test .....	95
Gerber-Ganz Anterior Drawer Test .....	96
Posterior Apprehension Test (Posterior Shift and Load Test) ...	97
Gerber-Ganz Posterior Drawer Test .....	98
Posterior Apprehension Test with the Patient Standing .....	99
Fukuda Test .....	100
Sulcus Sign .....	100
Inferior Apprehension Test .....	101
Relocation Test (Fulcrum Test) .....	102
<b>Elbow</b> .....	103
Range of Motion of the Elbow (Neutral-Zero Method) .....	104
Function Tests .....	104
Orientation Tests .....	104
Hyperflexion Test .....	104
Supination Stress Test .....	105
Varus Stress Test .....	105
Valgus Stress Test .....	106
Epicondylitis Tests .....	106
Chair Test .....	106
Bowden Test .....	107
Thomson Test .....	107
Mill Test .....	108
Motion Stress Test .....	109



Cozen Test .....	109
Reverse Cozen Test .....	110
Golfer's Elbow Sign .....	111
Forearm Extension Test .....	111
Compression Syndrome Tests .....	112
Tinel Test .....	112
Elbow Flexion Test .....	113
Supinator Compression Test .....	114
<b>Wrist, Hand, and Fingers</b> .....	115
Range of Motion in the Hand (Neutral-Zero Method) .....	116
Function Tests .....	118
Tests of the Flexor Tendons of the Hand .....	118
Muckard Test .....	119
Finkelstein Test .....	120
Grind Test .....	121
Linburg Test .....	121
Bunnell-Littler Test .....	122
Watson Test .....	123
Reagan Test .....	124
Scapholunate Ballotement Test .....	124
Stability Test of the Thumb .....	125
Compression Neuropathies of the Nerves of the Arm .....	126
Tests of Motor Function in the Hand .....	127
Radial Nerve Palsy Screening Test .....	129
Thumb Extension Test .....	130
Supination Test .....	131
Tinel Sign .....	132
Median Nerve Palsy Screening Test .....	132
Ochsner Test .....	133
Carpal Tunnel Sign .....	134
Phalen Test .....	134
Nail Sign .....	135
Luethy Bottle Test .....	135
Reverse Phalen Test .....	136
Pronation Test .....	137
Froment Sign .....	137
Ulnar Nerve Palsy Screening Test .....	138
Intrinsic Test .....	139
O Test .....	139
Wrist Flexion Test .....	140

<b>Hip</b> .....	141
Function Tests .....	143
Fingertip Test .....	143
Test for Rectus Femoris Contracture .....	144
Hip Extension Test .....	145
Thomas Grip .....	146
Noble Compression Test .....	148
Ober Test .....	149
Drehmann Sign .....	149
Anvil Test .....	152
Leg Pain upon Axial Compression .....	152
Trendelenburg Sign .....	153
Fabere Test (Patrick Test) for Legg–Calvé–Perthes Disease .....	154
Telescope Sign .....	156
Barlow and Ortolani Tests .....	156
Galeazzi Test .....	158
Hip and Lumbar Rigidity in Extension .....	158
Kalchschmidt Hip Dysplasia Tests .....	160
<b>Knee</b> .....	162
Range of Motion in the Knee (Neutral-Zero Method) .....	163
Table 6 Functional tests: knee .....	164
Muscle Traction Tests .....	165
Quadriceps Traction Test .....	165
Rectus Traction Test .....	165
Hamstring Traction Test .....	166
Patella .....	167
Patellar Chondropathy (Chondromalacia, Anterior Knee Pain) ..	167
Dancing Patella Test .....	167
Glide Test .....	167
Zohlen Sign .....	169
Facet Tenderness Test .....	169
Crepitation Test .....	170
Fairbank Apprehension Test .....	171
McConnell Test .....	171
Subluxation Suppression Test .....	173
Tilt Test .....	174
Dreyer Test .....	175
Meniscus .....	176
Apley Distraction and Compression Test (Grinding Test) .....	176

McMurray Test (Fouche Sign) .....	178
Bragard Test .....	179
Payr Sign .....	180
Payr Test .....	181
Steinmann I Sign .....	182
Steinmann II Sign .....	183
Böhler-Krömer Test .....	184
Merke Test .....	185
Cabot Test .....	185
Finochietto Sign .....	187
Childress Sign .....	188
Turner Sign .....	188
Anderson Medial and Lateral Compression Test .....	189
Pässler Rotational Compression Test .....	190
Tschaklin Sign .....	192
Wilson Test .....	192
Knee Ligament Stability Tests .....	193
Abduction and Adduction Test (Valgus and Varus Stress Test) .....	193
Function Tests to Assess the Anterior Cruciate Ligament .....	194
Lachman Test .....	194
Prone Lachman Test .....	196
Stable Lachman Test .....	196
No-Touch Lachman Test .....	197
Active Lachman Test .....	198
Anterior Drawer Test in 90° Flexion .....	199
Jakob Maximum Drawer Test .....	201
Pivot Shift Test .....	202
Jakob Graded Pivot Shift Test .....	204
Modified Pivot Shift Test .....	206
Medial Shift Test .....	208
Soft Pivot Shift Test .....	208
Martens Test .....	210
Losee Test .....	210
Slocum Test .....	211
Arnold Crossover Test .....	212
Noyes Test .....	212
Jakob Giving Way Test .....	213
Lemaire Test .....	214
Hughston Jerk Test .....	215
Function Tests to Assess the Posterior Cruciate Ligament .....	216
Posterior Drawer Test in 90° Flexion (Posterior Lachman Test) .....	216

Reversed Jakob Pivot Shift Test .....	217
Quadriceps Contraction Test .....	218
Posterior Droop Test .....	219
Soft Posterolateral Drawer Test .....	219
Gravity Sign and Genu Recurvatum Test .....	220
Hughston Test for Genu Recurvatum and External Rotation ...	221
Godfrey Test .....	222
Dynamic Posterior Shift Test .....	223
<b>Foot</b> .....	224
Range of Motion in the Ankle and Foot (Neutral-Zero Method) ..	225
Function Tests .....	227
Grifka Test .....	227
Strunsky Test .....	227
Toe Displacement Test .....	228
Crepitation Test .....	229
Gänsslen Maneuver .....	229
Metatarsal Tap Test .....	230
Thompson Compression Test (Calf Compression Test) .....	231
Hoffa Sign .....	232
Achilles Tendon Tap Test .....	232
Coleman Block Test .....	233
Foot Flexibility Test .....	234
Forefoot Adduction Correction Test .....	235
Test of Lateral and Medial Ankle Stability .....	235
Drawer Test .....	237
Mulder Click Test .....	238
Heel Compression Test .....	238
Tinel Sign .....	239
Tourniquet Sign .....	240
<b>Posture Deficiency</b> .....	241
Kraus-Weber Tests .....	242
Matthiass Postural Competence Tests .....	244
<b>Venous Thrombosis</b> .....	246
Lowenberg Test .....	247
Trendelenburg Test .....	248
Perthes Test .....	248
Homans Test .....	250

<b>Occlusive Arterial Disease</b> .....	251
Allen Test .....	252
George Vertebral Artery Test (De Klyn Test) .....	252
Ratschow-Boerger Test .....	253
<b>Thoracic Outlet Syndrome</b> .....	254
Costoclavicular Test .....	255
Hyperabduction Test .....	256
Intermittent Claudication Test .....	256
Allen Maneuver .....	257
<b>Hemiparesis</b> .....	258
Arm-Holding Test .....	258
Leg-Holding Test .....	258
<b>Index</b> .....	261



---

# Spine

Differential diagnosis of back pain is often a daunting task given the wide range of possible causes that must be considered. Terms such as “cervical spine syndrome” or “lumbar spine syndrome” are ambiguous as they identify neither the location nor the nature of the disorder.

Once the history has been taken, any examination of the spine should be preceded by a general physical examination. This required to properly evaluate those changes in the spine that are attributable to causes elsewhere in the body such as in the limbs and muscles. The examination begins with inspection. General body posture is noted, and the position of the shoulders and pelvis (level of the shoulders, comparison of both shoulder blades, level of the iliac crests, lateral pelvic obliquity), vertical alignment of the spine (any deviation from vertical), and the profile of the back (kyphotic or lordotic deformity, or absence of physiologic kyphosis and/or lordosis) are evaluated. Palpation can detect changes in muscle tone such as contractures or myogelosis and can identify tender areas. The active and passive mobility of the spine as a whole and the mobility of specific segments are then evaluated.

In patients presenting with a spine syndrome, the first step is to identify the location and nature of the disorder. Tissue destruction, inflammation, and severe degenerative changes usually involve a characteristic clinical picture with corresponding radiographic and laboratory findings. A number of additional diagnostic modalities can supplement plain-film radiography in cases where further diagnostic studies are indicated to confirm or exclude a tentative diagnosis. The choice of additional imaging modalities depends on the line of inquiry. For example, computed tomography with its higher contrast between bone and soft tissue is more suitable for visualizing changes in bone than is magnetic resonance imaging, whose advantage lies in its high-resolution visualization of soft tissue. Dysfunctional muscular and ligamentous structures render the clinical evaluation of spine syndromes more difficult.

Radiographic and laboratory findings alone are rarely able to provide a conclusive diagnosis in these spinal disorders. This makes manual diagnostic techniques that focus on evaluation of function particularly important. The examiner evaluates changes in the skin (hyperalgesia and characteristics of the paraspinal skin fold, also known as Kibler fold), painful muscle spasms, painfully restricted mobility with loss of

play in the joint, functional impairments with painful abnormal mobility, and radicular pain. The examination evaluates each part of the spine as a whole (cervical, thoracic, and lumbar) and each segment individually.

Because every pair of adjacent vertebrae is connected by many ligaments, only limited motion is possible in any one intervertebral joint. However, the sum of all the movements in the many vertebral articulations results in significant mobility in the spinal column and trunk as a whole. This mobility varies considerably between individuals (Fig. 1). The main motions are flexion and extension in the sagittal plane, lateral bending in the coronal plane, and rotation around the longitudinal axis. The cervical spine exhibits the greatest range of motion. It is both the most highly mobile portion of the spine and the one most susceptible to spinal disorders.

Rotation and lateral bending in the thoracic spine occur primarily in the lower thoracic spine and in the thoracolumbar junction. The lumbar spine with its sagittally aligned facet joints primarily allows flexion and extension (forward and backward bending) and lateral bending. The capacity for rotation is less well developed in this portion of the spine.

Neurologic examination can exclude sensory deficits and palsies of the lower extremities. This includes eliciting intrinsic reflexes to test for nerve stretching signs.

When examining the spine, the physician must consider the possibility that “back pain” may in fact be referred pain caused by pathology in other areas.

## ■ Range of Motion of the Spine (Neutral-Zero Method)

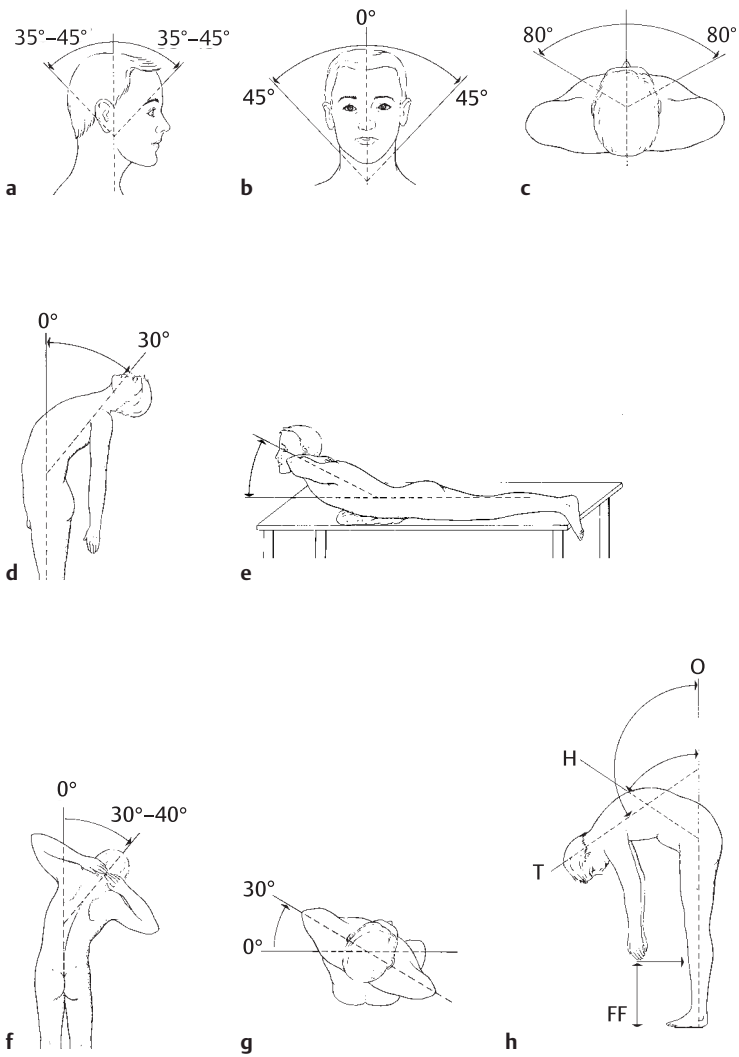
### Fingertips-to-Floor Distance Test in Flexion

Measures the mobility of the entire spine when bending forward (fingertip-to-floor distance in centimeters).

**Procedure:** The patient is standing. When the patient bends over with the knees fully extended, both hands should come to rest at approximately the same distance from the feet. The distance between the patient's fingers and the floor is measured, or how far the patient's fingers reach may be recorded (knee, mid-tibia, etc.; Fig. 1 h).

**Assessment:** This mobility test assesses a combined motion involving both the hips and the spine. Good mobility in the hips can compensate for stiffening in the spine. In addition to the distance measured, the





**Fig. 1a-h**  
**a** Forward and backward bending (flexion and extension). **b** Lateral bending.  
**c** Rotation in middle position  $80^{\circ}/0^{\circ}/80^{\circ}$ , rotation in flexion  $45^{\circ}/0^{\circ}/45^{\circ}$  ( $C_0-C_1$ ),  
rotation in extension  $60^{\circ}/0^{\circ}/60^{\circ}$ . **d-e** Backward bending (extension) of the  
spine: standing (**d**) and prone (**e**). **f** Lateral bending of the spine. **g** Rotation of  
the trunk. **h** Forward bending of entire spine: *H* flexion in hip, *T* total excursion,  
*FF* distance between fingers and floor

Table 1 Function tests: spine

General	Chest	Cervical spine	Thoracic and lumbar spine	Sacroiliac joints
Finger-tips-to-floor distance test	Sternum compression test	Screening of cervical spine rotation	Adams forward bend test	Ligament tests
Ott sign	Rib compression test	Test of head rotation in maximum extension	Kyphosis test on hands and knees	Springing test
Schober sign	Chest circumference test	Test of head rotation in maximum flexion	Tests of segmental function in flexion and extension	Patrick test (fabere test)
Skin-rolling test (Kibler fold test)	Schepelmann test	Test of segmental function	Prone knee flexion test	Three-phase hyperextension test
		Soto-Hall sign	Spinous process tap test	Spine test
		Percussion test	Psoas sign	Standing flexion test
		O'Donoghue test	Lasègue straight leg drop test	Sacroiliac mobilization test
		Valsalva test	Springing test	Sacroiliac joint springing test
		Spurling test	Hyperextension test	Derbolowsky sign
		Cervical spine distraction test	Supported forward bend test (belt test)	Gaenslen sign
		Shoulder press test	Hoover sign	Iliac compression test
		Test of maximum compression of the intervertebral foramina		Yeoman test
		Jackson compression test		Laguerre test
		Intervertebral foramina compression test		Sacroiliac stress test
		Flexion compression test		Abduction stress test
		Extension compression test		Mennell sign

Table 2 Overview of general function tests of the spine

Fingertips-to-floor distance test
Ott sign
Schober sign
Neutral-zero method

profile of the flexed spine should also be assessed (uniform kyphosis or fixed kyphosis).

A long distance between the fingertips and floor is therefore a non-specific sign that is influenced by several factors:

1. Mobility of the lumbar spine
2. Shortening of the hamstrings
3. Presence of the Lasègue sign
4. Hip function

Clinically the fingertips-to-floor distance is used to assess the effect of treatment.

### Ott Sign

Measures the range of motion of the thoracic spine.

**Procedure:** The patient is standing. The examiner marks the C7 spinous process and a point 30 cm inferior to it. This distance increases by 2–4 cm in flexion and decreases by 1–2 cm in maximum extension (leaning backward).

**Assessment:** Degenerative inflammatory processes of the spine restrict spinal mobility and hence the range of motion of the spinous processes.

### Schober Sign

Measures the range of motion of the lumbar spine.

**Procedure:** The patient is standing. The examiner marks the skin above the S1 spinous process and a point 10 cm superior to it. These skin markings move up to about 15 cm apart in flexion and converge to a distance of 8–9 cm in maximum extension (leaning backward).

**Assessment:** Degenerative inflammatory processes in the spine restrict spinal mobility and hence the range of motion of the spinous processes.

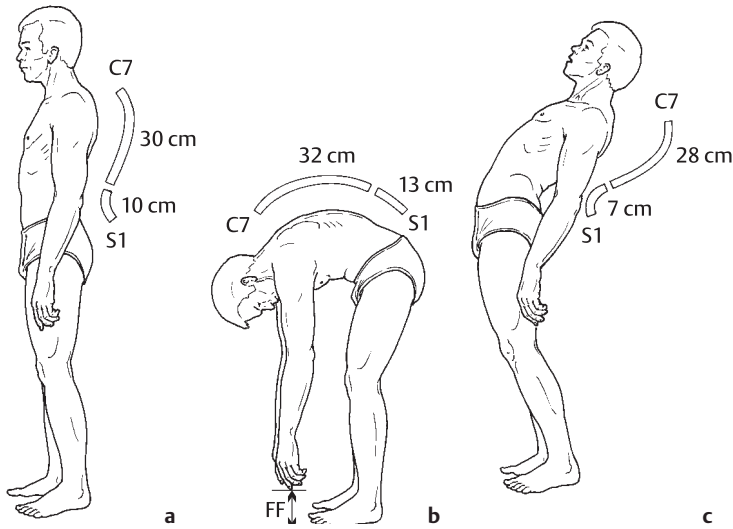


Fig. 2a–c Ott and Schober signs (fingertip-to-floor distance test): a upright position, b flexion, c extension

### Skin-Rolling Test (Kibler Fold Test)

Nonspecific back examination.

**Procedure:** The patient lies prone with arms relaxed alongside the trunk. The examiner raises a fold of skin between thumb and forefinger and “rolls” it along the trunk or, on the extremities, perpendicular to the course of the dermatomes.

**Assessment:** This test assesses regional variation in how readily the skin can be raised, the consistency of the skin fold (rubbery or edematous), and any lack of mobility in the skin. Palpation can detect regional tension in superficial and deep musculature as well as autonomic dysfunction (such as localized warming or increased sweating). In areas of hypalgesia, the skin is less pliable, more difficult to raise, and resists rolling. The patient reports pain. Areas of hypalgesia, tensed muscles, and autonomic dysfunction suggest vertebral disorders involving the facet joints or intercostal joints.

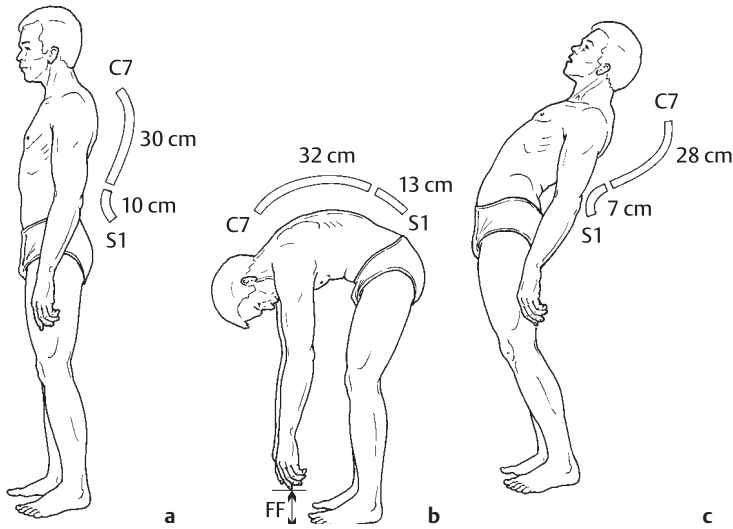


Fig. 2a–c Ott and Schober signs (fingertip-to-floor distance test): a upright position, b flexion, c extension

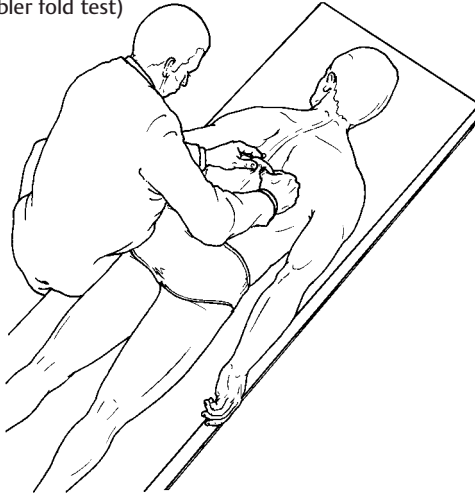### Skin-Rolling Test (Kibler Fold Test)

Nonspecific back examination.

**Procedure:** The patient lies prone with arms relaxed alongside the trunk. The examiner raises a fold of skin between thumb and forefinger and “rolls” it along the trunk or, on the extremities, perpendicular to the course of the dermatomes.

**Assessment:** This test assesses regional variation in how readily the skin can be raised, the consistency of the skin fold (rubbery or edematous), and any lack of mobility in the skin. Palpation can detect regional tension in superficial and deep musculature as well as autonomic dysfunction (such as localized warming or increased sweating). In areas of hypalgesia, the skin is less pliable, more difficult to raise, and resists rolling. The patient reports pain. Areas of hypalgesia, tensed muscles, and autonomic dysfunction suggest vertebral disorders involving the facet joints or intercostal joints.

Fig. 3 Skin-rolling test (Kibler fold test)



## ■ Chest Tests

### Sternum Compression Test

Indicates rib fracture.

**Procedure:** The patient is supine. The examiner exerts pressure on the sternum with both hands.

**Assessment:** Localized pain in the rib cage can be due to a rib fracture. Pain in the vicinity of the sternum or a vertebra suggests impaired costal or vertebral mobility.

### Rib Compression Test

Indicates impaired costovertebral or costosternal mobility or a rib fracture.

**Procedure:** The patient is seated. The examiner stands or crouches behind the patient and places his or her arms around the patient's chest, compressing it sagittally and horizontally.

**Assessment:** Compression of the rib cage increases the movement in the sternocostal and costotransverse joints and in the costovertebral

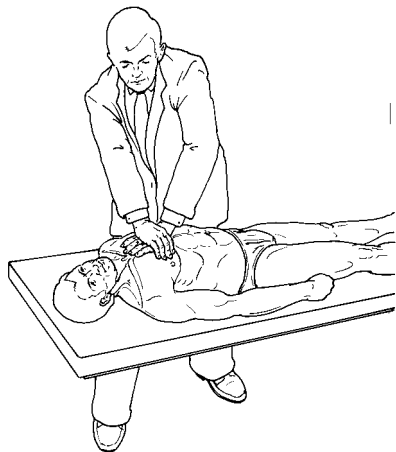


Fig. 4 Sternum compression test

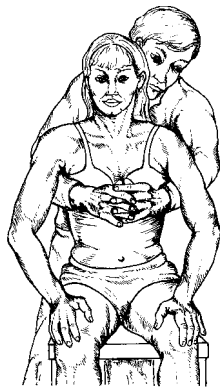

Fig. 5 Rib compression test

joints. Performing the test in the presence of a motion restriction or other irritation in one of these joints elicits typical localized pain.

Pain along the body of a rib or between two ribs suggests a rib fracture or intercostal neuralgia.

### Chest Circumference Test

Measures the circumference of the chest at maximum inspiration and expiration.

**Procedure:** The patient is standing or seated with arms hanging relaxed. The difference in chest circumference between maximum inspiration and expiration is measured. The circumference is measured immediately above the convexity of the breast in women, and immediately below the nipples in men.

The difference in chest circumference between maximum inspiration and expiration normally lies between 3.5 and 6 cm.

**Assessment:** Limited depth of breathing is encountered in ankylosing spondylitis, where the impairment of inspiration and expiration is usually painless. Impaired or painful inspiration and expiration with limited depth of breathing is observed in costal and vertebral dysfunctions (motion restricted), inflammatory or tumorous pleural processes, and pericarditis. Bronchial asthma and emphysema are associated with painless impaired expiration.

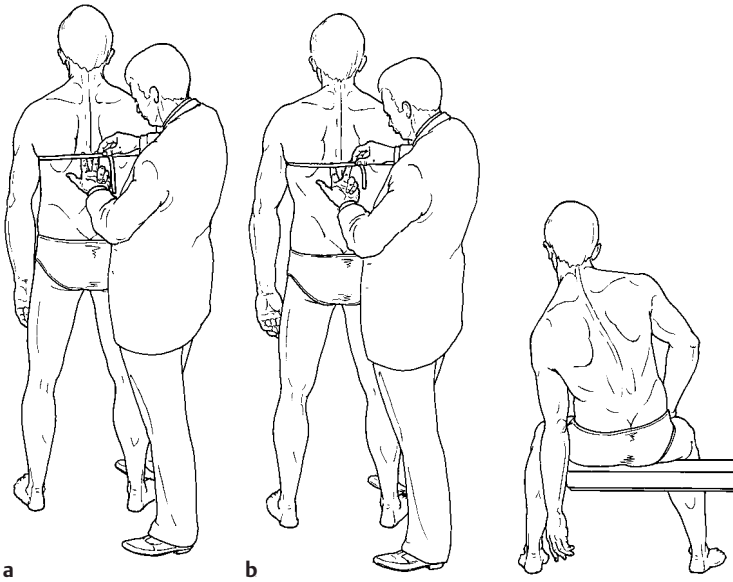


Fig. 6 Chest circumference test:  
a at maximum expiration,  
b at maximum inspiration

Fig. 7 Schepelmann test

### Schepelmann Test

For the differential diagnosis of chest pain.

**Procedure:** The patient is seated and is asked to bend first to one side, then to the other.

**Assessment:** Pain on the concave side is a sign of intercostal neuralgia; pain on the convex side is a sign of pleuritis. Rib fractures are painful on any movement of the spine.



## ■ Cervical Spine Tests

### Screening of Cervical Spine Rotation

**Procedure:** The patient is seated and upright. The examiner holds the patient's head with both hands around the parietal region and, with the patient's neck slightly extended, passively rotates the patient's head to one side and then the other from the neutral position.

**Assessment:** The range of motion is determined by comparing both sides. The examiner also notes quality of the endpoint of motion, which is resilient in normal conditions but hard when functional impairment is present.

Restricted mobility with pain is a sign of segmental dysfunction (arthritis, blockade, inflammation, or muscle shortening). Restricted rotation with a hard endpoint and pain at the end of the range of motion suggest degenerative changes, predominately in the middle cervical vertebrae (spondylosis, spondylarthritis, or uncovertebral arthritis).

A soft endpoint is more probably attributable to shortening of the long extensors of the neck or the longus colli muscle. Compromised vascular supply or irritation of the vertebral artery should be considered where vertigo and nystagmus are present.

**Note:** The active range of motion is invariably less than the passive range because the affected painful muscles are involved in active motion. Passive motion increases the muscle pain. If the active range is greater than the passive range, the reported pain is has been subjectively exaggerated.

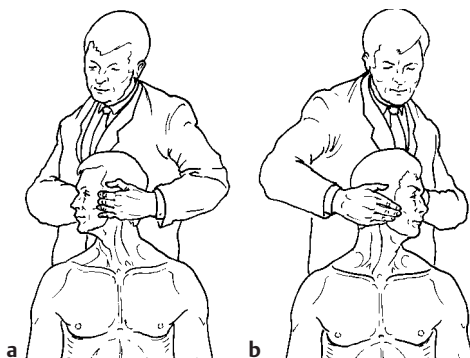


Fig. 8 Screening of cervical spine rotation:

- a at maximum right rotation,
- b at maximum left rotation

### Test of Head Rotation in Maximum Extension

Functional test of the lower cervical spine.

**Procedure:** The patient is seated. Holding the back of the patient's head with one hand and the patient's chin with the other, the examiner passively extends the patient's neck (tilts the head backwards) and rotates the head to both sides. This motion involves slight lateral bending in the cervical spine.

**Assessment:** In maximum extension, the region of the atlantooccipital joint is locked and rotation largely takes place in the lower segments of the cervical spine and in the cervicothoracic junction. Restricted mobility with pain is a sign of segmental dysfunction. The most likely causes include degenerative changes in the middle and lower cervical spine (spondylosis, spondylarthritis, or uncovertebral arthritis). Vertigo suggests compromised vascular supply from the vertebral artery.

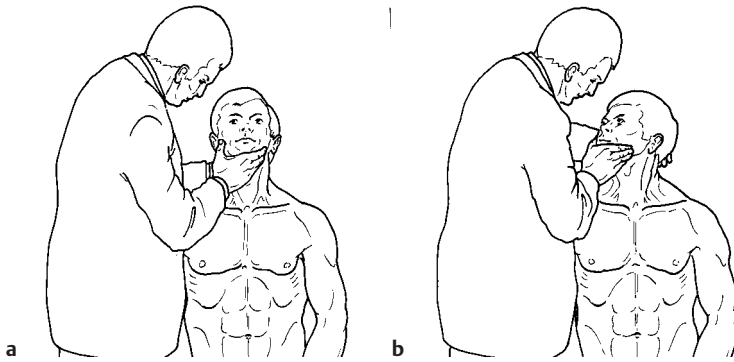
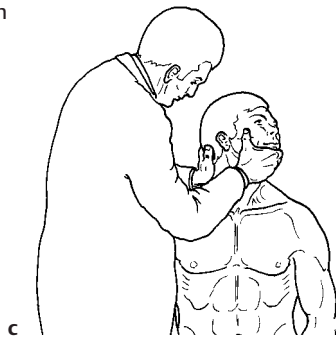


Fig. 9 Test of head rotation in maximum extension:

- a backward tilt,
- b right rotation,
- c left rotation



### Test of Head Rotation in Maximum Flexion

Functional test of the upper cervical spine.

**Procedure:** The patient is seated. Holding the back of the patient's head with one hand and the patient's chin with the other, the examiner passively flexes the patient's neck (tilts the head forward) and rotates the head to both sides. This motion involves slight lateral bending in the cervical spine.

**Assessment:** In maximum flexion, the segments below C2 are locked and rotation largely takes place in the atlantooccipital and atlantoaxial joints. Restricted mobility with pain is a sign of segmental dysfunction. The most likely causes to consider include degenerative causes, instability, and inflammatory changes. Any occurrence of autonomic symptoms such as vertigo require further diagnostic studies.

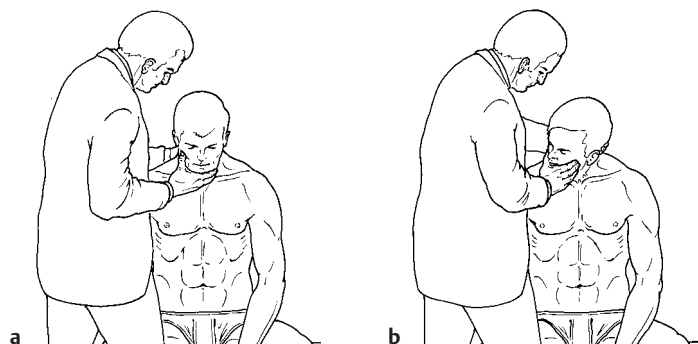
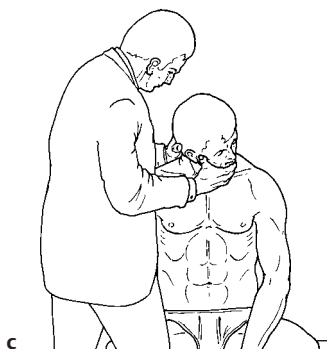


Fig. 10 Test of head rotation in maximum flexion:

- a forward tilt,
- b right rotation,
- c left rotation

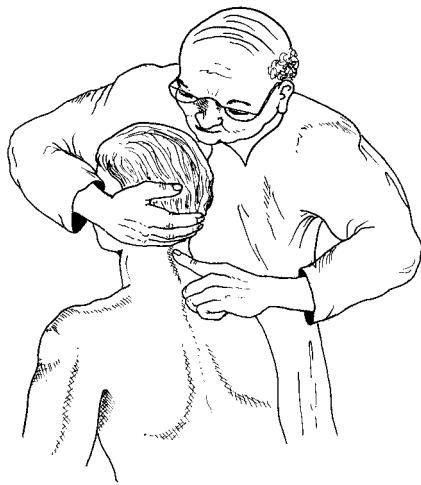

## Test of Segmental Function in the Cervical Spine

**Procedure and assessment:** For direct diagnostic testing of segmental function in the cervical spine, the examiner stands next to the patient. Placing one hand around the patient's head so that his or her elbow is front of the patient's face, the examiner then places the ulnar edge of the same hand with the little finger on the arch of the upper vertebra of the segment to be examined. Segmental mobility is evaluated with the palpating finger of the contralateral hand. Posterior and lateral mobility in the segment can be assessed by applying slight traction with the upper hand. Rotation in the segment can also be evaluated during the same examination.

For diagnostic testing of segmental function in the cervicothoracic junction in flexion and extension, the examiner immobilizes the patient's head with one hand and places the fingers of the other hand on the three adjacent spinous processes. By passively flexing and extending the patient's neck, the examiner can assess the range of motion in the individual segments by observing the excursion of the spinous processes.

Fig. 11 Test of segmental function in the cervical spine



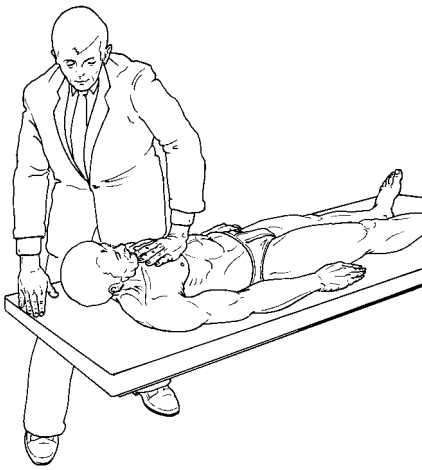


Fig. 12 Soto-Hall test

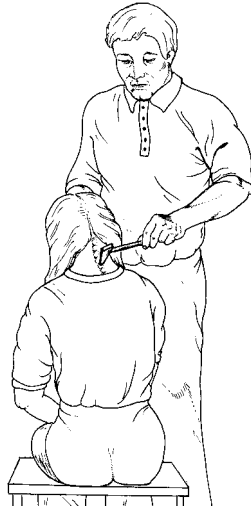

Fig. 13 Percussion test

### Soto-Hall Test

Nonspecific test of cervical spine function.

**Procedure:** The patient is supine and first actively raises his or her head slightly to bring the chin as close as possible to the sternum. The examiner then passively tilts the patient's head forward, at the same time exerting light pressure on the sternum with the other hand.

**Assessment:** Pain in the back of the neck when pressure is applied during passive raising of the head suggests a bone or ligament disorder in the cervical spine. Pulling pain occurring when the patient actively raises the neck is primarily due to shortening of the posterior neck musculature.

### Percussion Test

**Procedure:** With the patient's cervical spine slightly flexed, the examiner taps the spinous processes of all the exposed vertebrae.

**Assessment:** Localized nonradicular pain is a sign of a fracture or of muscular or ligamentous functional impairment. Radicular symptoms indicate intervertebral disk pathology with nerve root irritation.

### O'Donoghue Test

Differentiates between ligamentous pain and muscular pain in the back of the neck.

**Procedure:** The seated patient's head is passively tilted first to one side and then the other. Then the patient is asked to tilt his or her head to one side against the resistance of the examiner's hand resting on the zygomatic bone and temple.

**Assessment:** Occurrence of pain during this active head motion with isometric tensing of the ipsilateral and contralateral paravertebral musculature suggests muscular dysfunction, whereas pain during passive lateral bending of the cervical spine suggests a functional impairment involving ligaments or articular, possibly degenerative processes.

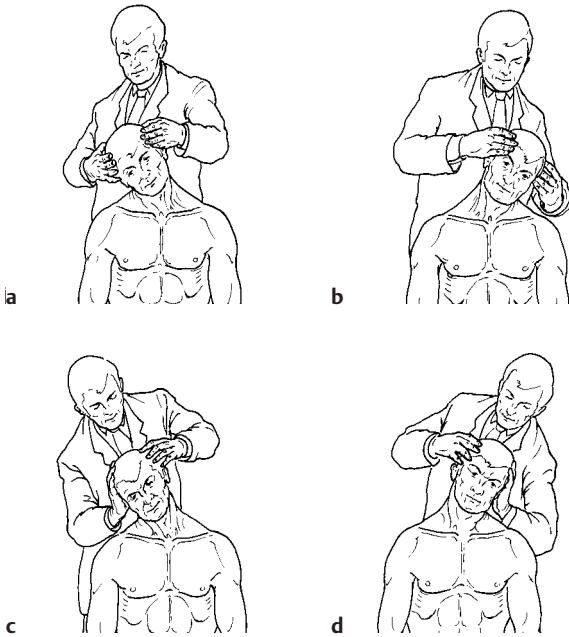


Fig. 14a–d O'Donoghue test:  
a, b passive motion,  
c, d active motion against resistance

## Valsalva Test

**Procedure:** The patient is seated with the thumb in the mouth and attempts to push the thumb out by blowing out hard.

**Assessment:** The pushing increases the intraspinal pressure, revealing the presence of space-occupying masses such as extruded intervertebral disks, tumors, narrowing due to osteophytes, and soft tissue swelling. This leads to radicular symptoms entirely confined to the respective dermatome or dermatomes.

## Spurling Test

Assesses facet joint pain and nerve root irritation.

**Procedure:** The patient is seated with the head rotated and tilted to one side. The examiner stands behind the patient with one hand placed on the patient's head. With the other hand, the examiner lightly taps (compresses) the hand resting on the patient's head. If the patient tolerates this initial step of the test, it is then repeated with the cervical spine extended as well.



Fig. 15 Valsalva test

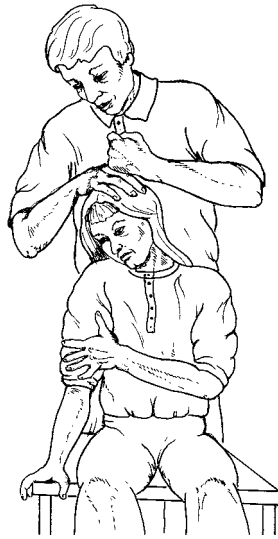


Fig. 16 Spurling test

**Assessment:** This test provides clinical evidence of both a facet syndrome and nerve root compression. Where facet joint irritation or nerve root compression is present, the examination will intensify the pain. Simultaneous extension of the cervical spine narrows the intervertebral foramina by 20–30%. Existing radicular pain will be increased by this movement.

### Cervical Spine Distraction Test

Differentiates between radicular pain in the back of the neck, shoulder, and arm and ligamentous or muscular pain in these regions.

**Procedure:** The patient is seated. The examiner grasps the patient's head about the jaw and the back of the head and applies superior axial traction.

**Assessment:** Distraction of the cervical spine reduces the load on the intervertebral disks and exiting nerve roots within the affected levels or segments while producing a gliding motion in the facet joints. Reduction of radicular symptoms, even in passive rotation, when the cervical spine is distracted is a sign of discogenic nerve root irritation. Increased pain during distraction and rotation suggests a functional impairment in the cervical spine due to muscular or ligamentous pathology or articular, possibly degenerative processes.

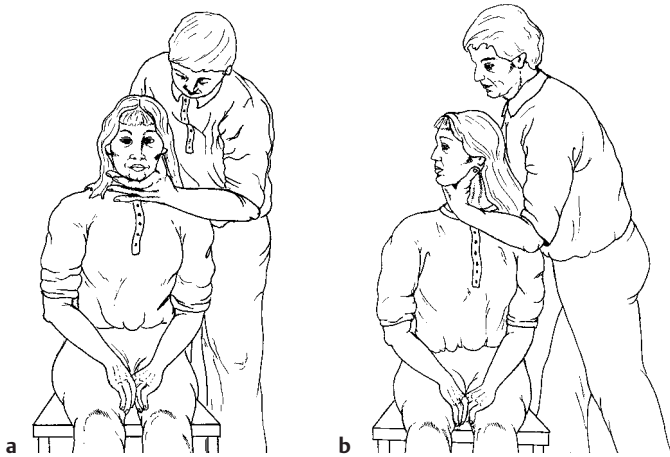


Fig. 17a, b Cervical spine distraction test:  
a middle position,  
b rotation



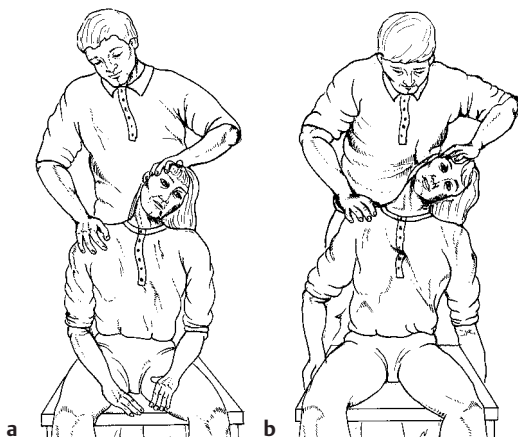


Fig. 18a, b  
Shoulder press test:  
a lateral bending,  
b forced lateral  
bending

### Shoulder Press Test

**Procedure:** The patient is seated and the examiner presses downward on one shoulder while bending the cervical spine laterally toward the contralateral side. This test is always performed on both sides.

**Assessment:** Provocation of radicular symptoms is a sign of adhesion of the dural sac and/or a nerve root. Circumscribed pain on the side of the stretched musculature indicates increased muscle tone in the sternocleidomastoid or trapezius. Decreased muscular pain in the side that is not stretched suggests a pulled muscle or a functional impairment involving shortening of the musculature.

### Test of Maximum Compression of the Intervertebral Foramina

**Procedure:** The seated patient actively rotates his or her head to one side while slightly extending the neck.

**Assessment:** This pattern of motion leads to compression of the intervertebral foramina with narrowing of the intervertebral spaces and irritation of the nerve roots with corresponding radicular pain symptoms.

Occurrence of local pain without distal radicular symptoms in the dermatome concerned will be attributable to facet joint dysfunction. Pain reported in the contralateral side will be caused by stretching of the musculature.

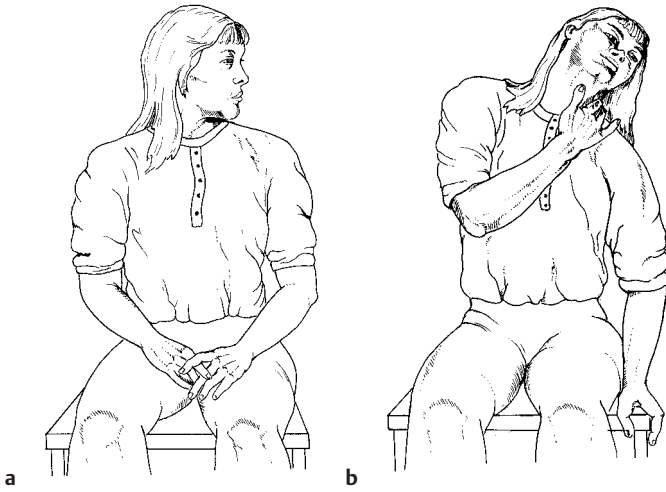


Fig. 19a, b Test of maximum compression of the intervertebral foramina:  
a rotation (start position),  
b rotation and extension

### Jackson Compression Test

**Procedure:** The patient is seated. The examiner stands behind the patient with his or her hand on the top of the patient's head and passively tilts the head to either side. In maximum lateral bending, the examiner presses down on the head to exert axial pressure on the spine.

**Assessment:** The axial loading results in increased compression of the intervertebral disks, exiting nerve roots, and facet joints. Pressure on the intervertebral foramina acts on the facet joints to elicit distal pain that does not exactly follow identifiable segmental dermatomes. Presence of nerve root irritation will cause radicular pain symptoms. Local circumscribed pain will be attributable to stretching of the contralateral musculature of the neck.

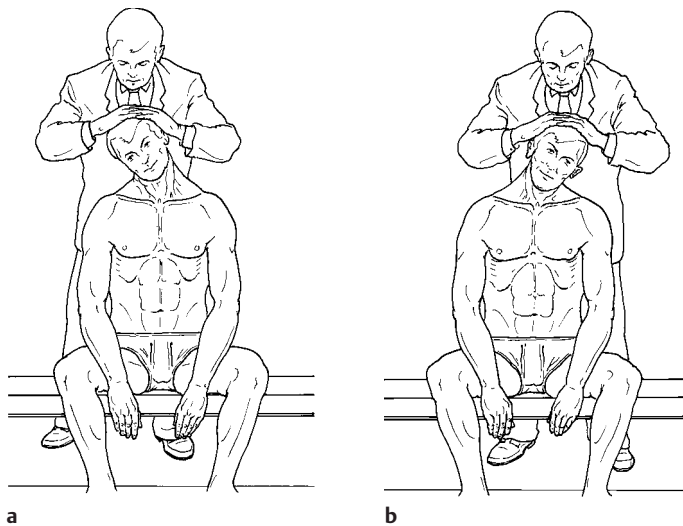


Fig. 20a, b Jackson compression test:  
a right lateral bending, b left lateral bending

### Intervertebral Foramina Compression Test

**Procedure:** Axial compression is applied to the cervical spine in the neutral ( $0^\circ$ ) position.

**Assessment:** Compression of the intervertebral disks and exiting nerve roots, the facet joints, and/or the intervertebral foramina increases a radicular, strictly segmental pattern of symptoms. The presence of diffuse symptoms that are not clearly specific to any one segment may be regarded as a sign of ligamentous or articular functional impairment (facet joint pathology).

### Flexion Compression Test

**Procedure:** The patient is seated. The examiner stands behind the patient and passively moves the cervical spine into flexion (tilts the patient's head forward). Then axial compression is applied to the top of the head.

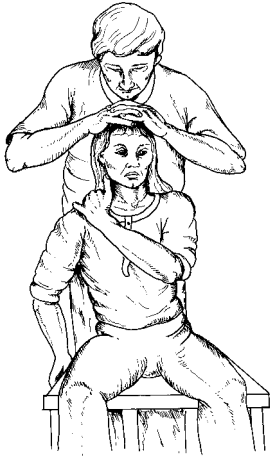

Fig. 21 Intervertebral foramina compression test

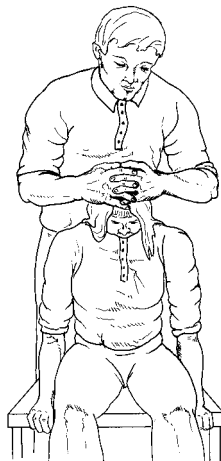


Fig. 22 Flexion compression test

**Assessment:** This is a good test of the integrity of the intervertebral disk. In the presence of a posterolateral disk extrusion, this maneuver will press the extruded portion of the disk in a posterior direction, resulting in increasing compression of the nerve root. An increase in radicular symptoms can therefore indicate the presence of a posterolateral disk extrusion.

The forward tilting of the head usually reduces the load on the facet joints and can reduce pain due to degenerative changes. Increasing pain may indicate an injury to posterior ligamentous structures.

### Extension Compression Test

**Procedure:** The patient is seated and the examiner stands behind the patient. The cervical spine is extended 30°. The examiner then applies axial compression to the top of the head.

**Assessment:** This test assesses the integrity of the intervertebral disk. Where a posterolateral extrusion with an intact annulus fibrosus is present, shifting the pressure on the disks anteriorly will reduce symptoms. Increased pain without radicular symptoms usually indicates an irritation in the facet joints as a result of decreased mobility due to degenerative changes.

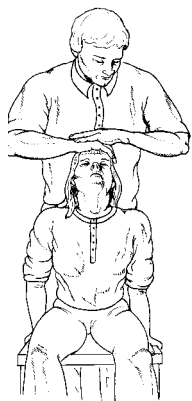


Fig. 23 Extension compression test

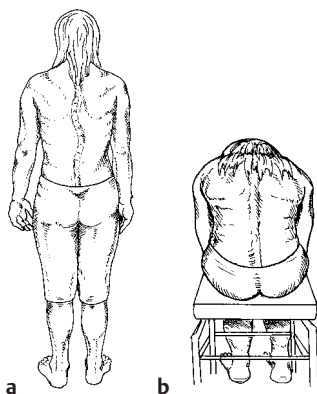


Fig. 24a, b Adams forward bend test:  
 a upright posture,  
 b forward bending

## ■ Thoracic and Lumbar Spine Tests

### Adams Forward Bend Test

Assesses structural or functional scoliosis.

**Procedure:** The patient is seated or standing. The examiner stands behind the patient and asks the patient to bend forward.

**Assessment:** This test is performed in patients with detectable scoliosis of uncertain etiology or as a screening examination in patients with a family history of scoliotic posture. If the scoliotic posture improves during forward bending, then the condition is a functional scoliosis; where the scoliotic deformity remains with the same projection of the ribs and the lumbar distortion observed in upright posture, the condition is true scoliosis with structural changes.

### Kyphosis Test on Hands and Knees

**Procedure:** The patient is asked to kneel down and stretch out his or her arms as far forward as possible on the floor.

**Assessment:** This posture will correct a flexible kyphotic deformity of the thoracic spine. A kyphotic posture that remains unchanged is a fixed deformity.

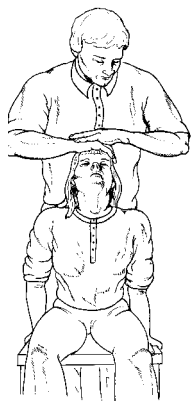


Fig. 23 Extension compression test

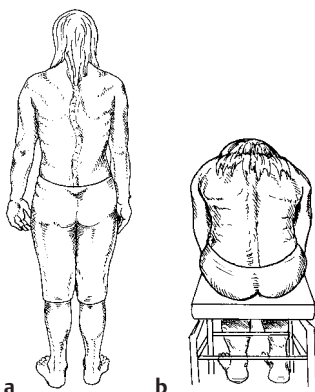


Fig. 24a, b Adams forward bend test:  
 a upright posture,  
 b forward bending

## ■ Thoracic and Lumbar Spine Tests

### Adams Forward Bend Test

Assesses structural or functional scoliosis.

**Procedure:** The patient is seated or standing. The examiner stands behind the patient and asks the patient to bend forward.

**Assessment:** This test is performed in patients with detectable scoliosis of uncertain etiology or as a screening examination in patients with a family history of scoliotic posture. If the scoliotic posture improves during forward bending, then the condition is a functional scoliosis; where the scoliotic deformity remains with the same projection of the ribs and the lumbar distortion observed in upright posture, the condition is true scoliosis with structural changes.

### Kyphosis Test on Hands and Knees

**Procedure:** The patient is asked to kneel down and stretch out his or her arms as far forward as possible on the floor.

**Assessment:** This posture will correct a flexible kyphotic deformity of the thoracic spine. A kyphotic posture that remains unchanged is a fixed deformity.

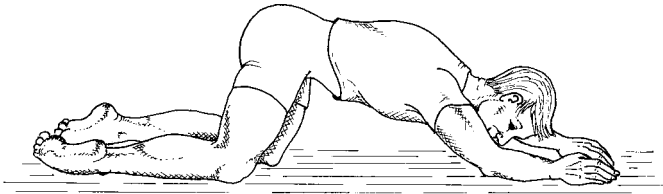


Fig. 25 Kyphosis test on hands and knees

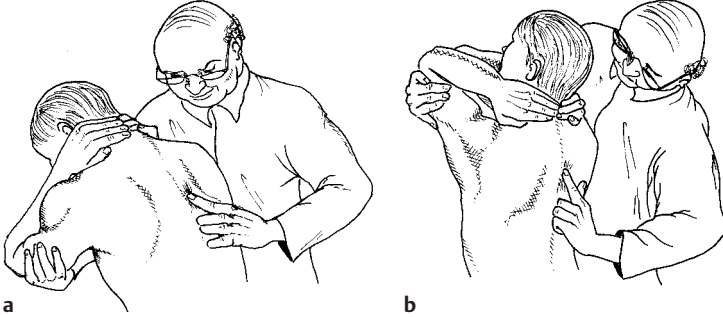


Fig. 26a, b Test of segmental function in the thoracic spine:  
a flexion,  
b extension

### Test of Segmental Function in the Thoracic Spine in Extension

**Procedure and assessment:** The seated patient clasps both hands behind his or her head with the elbows together. The examiner immobilizes the patient's arms in front of the patient with one hand while the examining hand is free to detect segmental functional impairments by palpating the individual segments while the examiner passively moves the patient's spine into flexion, extension, lateral bending, and rotation. A similar technique can also be used to evaluate segmental function in the lumbar spine.

### Prone Knee Flexion Test

Differentiates lumbar pain from iliosacral pain.

**Procedure:** With the patient prone, the examiner flexes the patient's knee and attempts to bring the heel as close to the buttocks as possible.

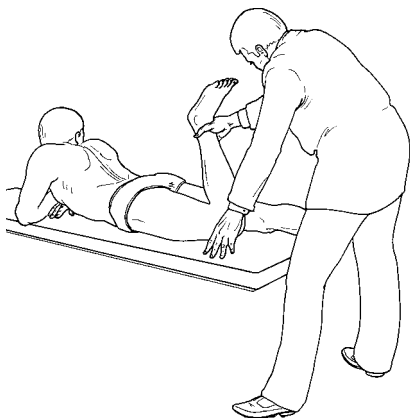


Fig. 27 Prone knee flexion test

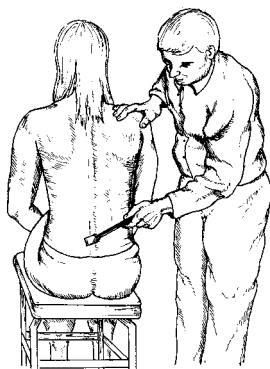


Fig. 28 Spinous process tap test

The patient should allow the passive motion at first and then attempt to extend the knee against the resistance of the examiner's hand.

**Assessment:** During the test, the patient will initially feel tension in the sacroiliac joint, then in the lumbosacral junction, and finally in the lumbar spine. This test should be performed where changes in pelvic ligaments or intervertebral disks are suspected. Pain in the sacroiliac joint, lumbosacral pain, or lumbar pain without radiating radicular pain suggests degenerative changes and/or ligamentous insufficiency. Increasing radicular pain is a sign of disk pathology.

### Spinous Process Tap Test

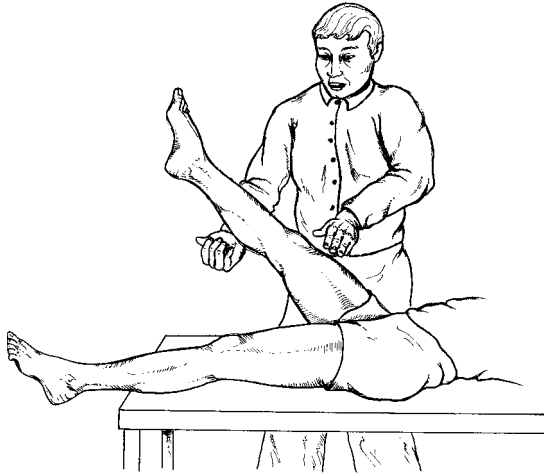
Indicates lumbar spine syndrome.

**Procedure:** The patient is seated with the spine slightly flexed. With a reflex mallet, the examiner taps on the spinous processes of the lumbar spine and on the paraspinal musculature.

**Assessment:** Localized pain can indicate irritation of the involved spinal segments as a result of degenerative inflammatory changes. Radicular pain can be a sign of disk pathology.



Fig. 29 Psoas sign



### Psoas Sign

For diagnostic assessment of lumbar pain.

**Procedure:** The patient is supine and raises one leg with the knee extended. The examiner presses suddenly on the anterior aspect of the thigh.

**Assessment:** This sudden pressure on the distal thigh causes reflexive contraction of the iliopsoas with traction on the transverse processes of the lumbar spine. Patients will report pain in the presence of changes in the lumbar spine (spondylarthritis, spondylitis, or disk herniation) or in the sacroiliac joint.

### Lasègue Straight Leg Drop Test

Differentiates lumbar pain.

**Procedure:** The patient is supine. The Lasègue straight leg raising test is performed until the patient begins to feel discomfort, then the examiner lets go of the leg from this position.

**Assessment:** Suddenly and unexpectedly letting go of the leg precipitates reflexive contraction of the muscles of the back and buttocks. It is primarily the iliopsoas that contracts, placing traction on the transverse processes of the lumbar spine. Patients will report pain in the presence

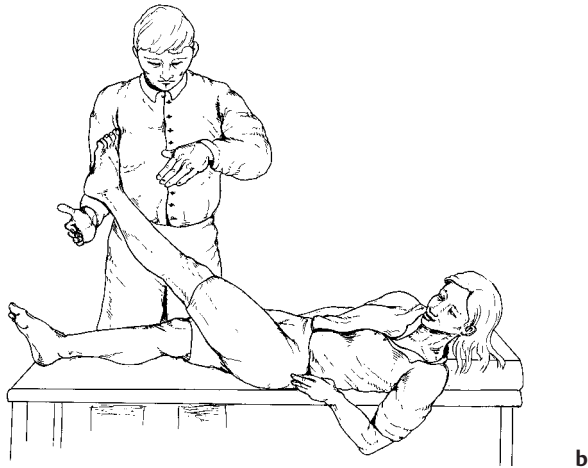
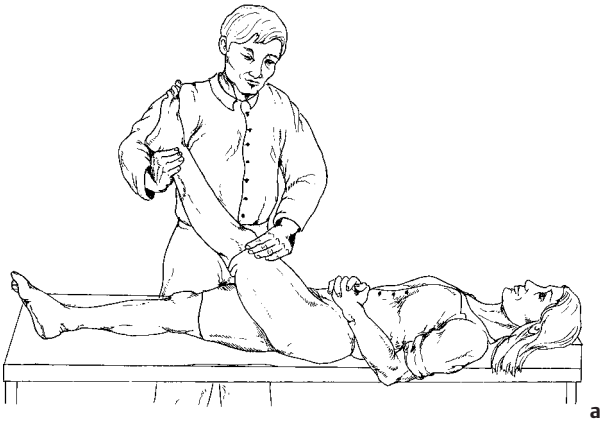


Fig. 30a, b Lasègue straight leg drop test:  
a raising the leg,  
b dropping the leg

of disorders of the lumbar spine (spondylarthritis, spondylitis, or disk herniation) or disorders of the sacroiliac joints (see psoas sign).

For a differential diagnosis it must be borne in mind that this test can also intensify visceral pain such as that caused by appendicitis.

### Springing Test

For localization of functional impairments in the lumbar spine.

**Procedure:** The patient is prone. The examiner palpates the articular processes or laminae of the vertebrae in question with his or her index and middle fingers. With the ulnar edge of the other hand, which is held perpendicularly over the palpating fingers, the examiner repeatedly presses lightly in a posteroanterior direction. The palpating fingers conduct this light springing pressure to the articular processes or laminae of the vertebrae in question.

**Assessment:** Where joint function is intact, the articular processes or laminae will be resilient.

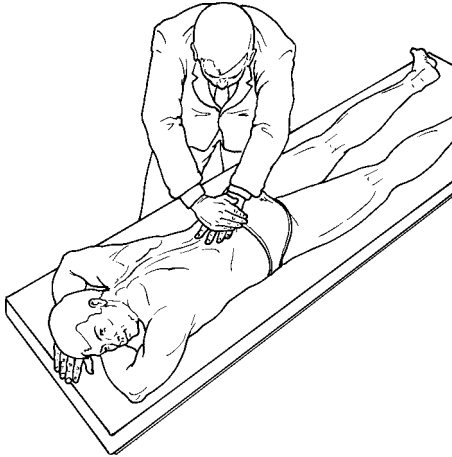
Lack of or excessive resiliency is a sign of abnormal segmental mobility, in the former case a blockade and in the latter case hypermobility. However, this test is also a provocative test for the posterior longitudinal ligament in particular and will result in an increase in the deep, dull low back pain that is typical of this structure and is difficult to localize.

### Hyperextension Test

Indicates a lumbar spine syndrome.

**Procedure:** The patient is prone. The examiner immobilizes both the patient's legs and asks the patient to raise his or her torso.

Fig. 31 Springing test



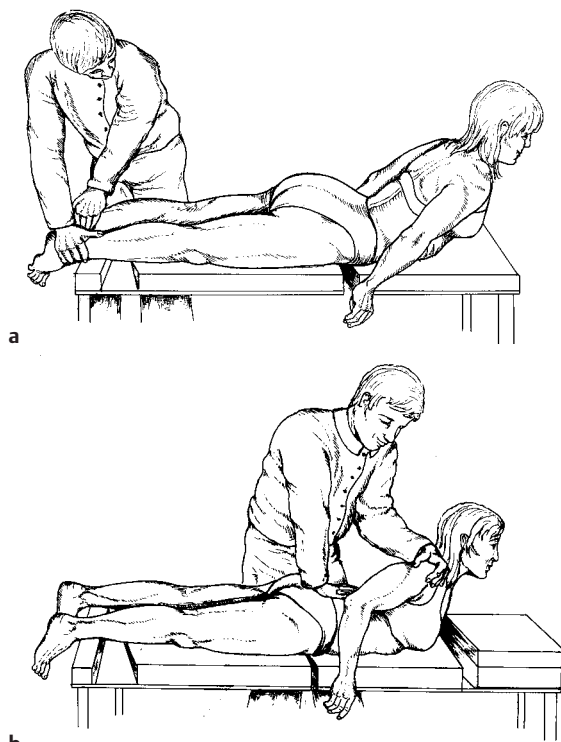


Fig. 32a, b Hyperextension test:  
a active hyperextension,  
b passive hyperextension and rotation

In the second phase of the examination, the examiner passively extends the patient's spine and adds a rotational motion. The examiner's other hand rests on the patient's lumbar spine and is used to assess both the mobility in the lumbar spine and the level of the painful site.

**Assessment:** Where segmental dysfunction in the lumbar spine is present, active extension of the lumbar spine will elicit or increase pain. The passive extension with an additional rotational motion allows the examiner to assess diminished segmental and/or regional mobility. A hard endpoint of the range of motion suggests degenerative changes, whereas a soft endpoint more probably suggests shortening of the longissimus thoracis and iliocostalis lumborum.

### Supported Forward Bend Test (Belt Test)

Differentiates lumbar pain from iliosacral pain.

**Procedure:** The patient is standing. The examiner stands behind the patient and asks the patient to bend forward until lumbosacral pain is felt. The patient then returns to the upright position. The examiner again asks the patient to bend forward. This time the examiner supports the patient's sacrum with his or her thigh and guides the motion by grasping both ilia.

**Assessment:** Forward bending requires normal function in the sacroiliac joint and the lumbosacral junction as well as mobility in the individual segments of the lumbar spine. Pain in unguided motion suggests a sacroiliac syndrome; this pain will improve or disappear in guided motion with the pelvis immobilized.

Changes in the lumbar spine will produce pain in forward bending with or without support.

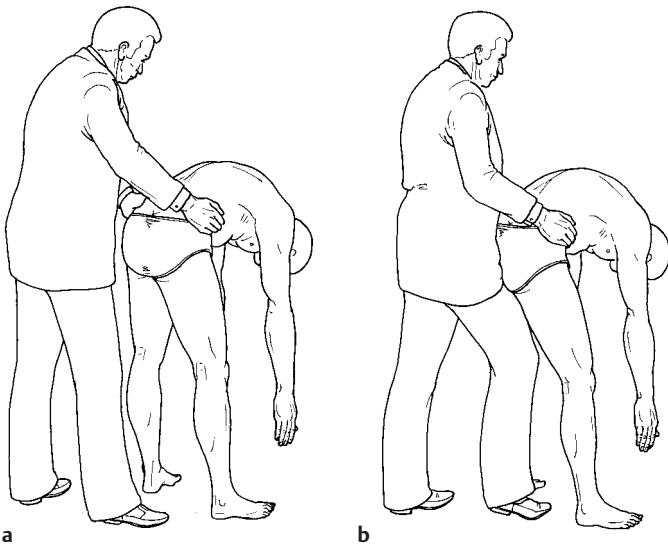
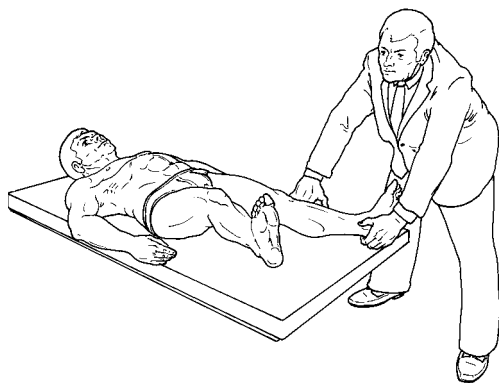


Fig. 33a, b Supported forward bend test:  
a forward bending without support,  
b supported forward bending

Fig. 34 Hoover test



### Hoover Test

Tests for simulation of lumbar spine complaints.

**Procedure:** The patient is supine. The patient is asked to raise the painful leg while the examiner holds his or her hand under the heel of the other leg.

**Assessment:** Where sciatica is actually present, the patient will be unable to raise the leg and will press the heel of the other leg against the examiner's hand. A patient simulating sciatica will not press down with the contralateral heel. Often patients will report that they cannot raise the leg at all.

## ■ Sacroiliac Joint

The sacrum forms the base of the spine and is connected to the two halves of the pelvis (the ilia) by articulations known as the sacroiliac joints. While these articulations are true joints in the anatomic sense, from a functional standpoint they may be regarded as symphyses: the tight ligaments surrounding the bone and the crescentic shape and uneven contour of the articular surfaces effectively minimize mobility in these joints. In spite of this, compensatory movements between the spine and pelvis can result in significant impairments in this joint that can eventually affect the entire spine and the joints of the lower extremities.

Motion restriction or instability of a sacroiliac joint can develop secondary to trauma, dislocation, or pelvic fractures. However, they may also develop as a result of asymmetrical loads on the pelvis or for

Table 3 Function and provocation tests of the sacroiliac joint

Mennell sign
Springing test
Mobilization test
Standing flexion test
Variable leg length
Spine test
Patrick test (fabere test)
Three-phase hyperextension test

other reasons. Pain during motion will be felt in the sacroiliac, gluteal, inguinal, and trochanteric regions. Usually it will radiate posteriorly within the S1 dermatome as far as the knee, occasionally producing symptoms resembling sciatica. Often patients will also experience pain in the lower abdomen and groin due to tension in the iliopsoas. Sacroiliac joint symptoms usually manifest themselves as tenderness to palpation and tapping in the parasacral region adjacent to the sacroiliac joints. A number of manipulative tests may be performed on the standing, supine, or prone patient to identify functional impairments in the sacroiliac joints.

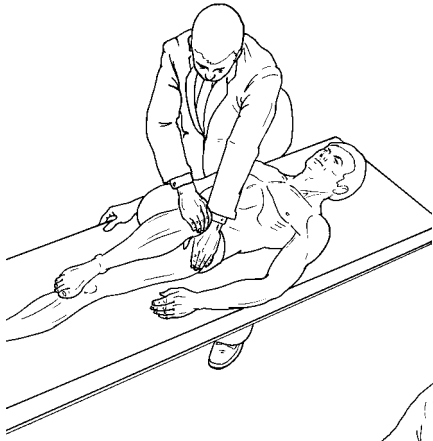
### Ligament Tests

Functional assessment of the pelvic ligaments.

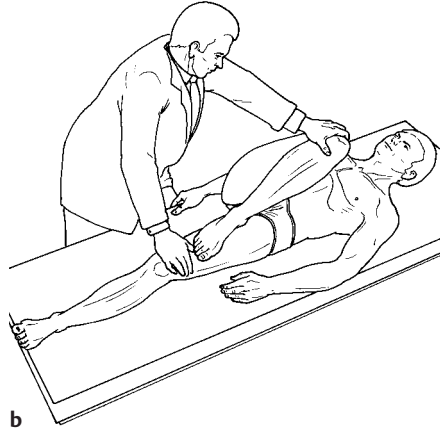
**Procedure:** The patient is prone.

- a) To evaluate the iliolumbar ligament, the patient's knee and hip are flexed and the examiner then adducts the leg to the contralateral hip. While executing this maneuver, the examiner presses on the knee to exert axial pressure on the femur.
- b) To evaluate the sacrospinous and sacroiliac ligaments, the patient's knee and hip are maximally flexed and the examiner adducts the leg toward the contralateral shoulder. While executing this maneuver, the examiner presses on the knee to exert axial pressure on the femur.
- c) To evaluate the sacrotuberal ligament, the patient's knee and hip are maximally flexed and the examiner moves the leg toward the ipsilateral shoulder.

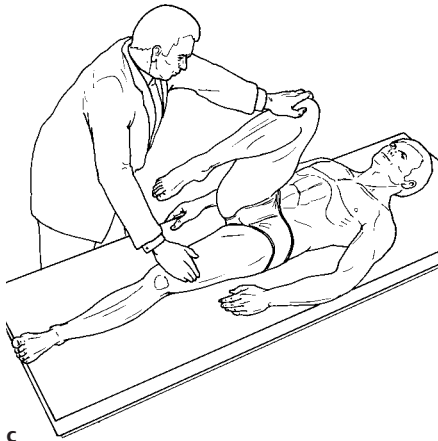
Fig. 35a-c Ligament test:  
a iliolumbar ligament,  
b sacrospinal ligament,  
c sacrotuberal ligament



a



b



c



**Assessment:** Stretching pain occurring within a few seconds suggests functional shortening and excessive stresses on the ligaments, although it can also occur in a hypermobile or motion-restricted sacroiliac joint.

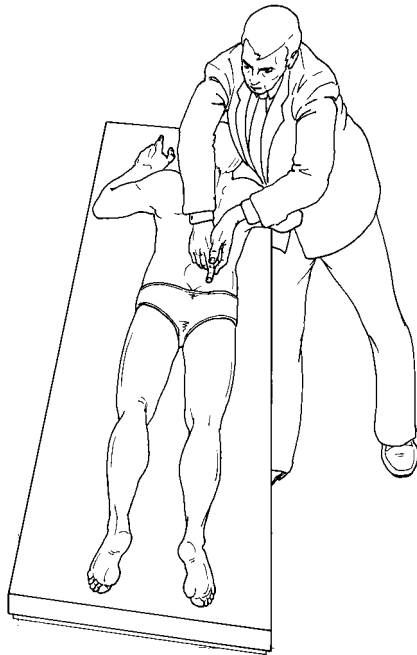
Pain caused by stretching the iliolumbar ligament is referred to the inguinal region (the differential diagnosis includes a hip disorder). Pain caused by stretching the sacrospinous and sacroiliac ligaments is felt within the S1 dermatome from a point posterolateral to the hip as far as the knee. Sacrotuberal ligament pain radiates into the posterior aspect of the thigh.

### Springing Test

Assesses facet hypermobility in the sacroiliac joint.

**Procedure:** The patient is prone. The examiner places the index finger of one hand first on the superior margin of the sacroiliac joint and then on its inferior margin (S1–S3) in such a manner that the fingertip lies on the sacrum and the volar aspect of the distal phalanx lies on the medial margin of the ilium.

Fig. 36 Springing test



The examiner's other hand grasps the index finger and exerts posteroanterior pressure which the palpating finger transmits to the sacrum.

**Assessment:** A normal sacroiliac joint will be resilient; palpating pressure will slightly increase the distance between the posterior margin of the ilium and the sacrum. This resiliency is not present in a motion-restricted sacroiliac joint. A relatively long range of motion with a hard endpoint suggests hypermobility in the sacroiliac joint. Pain during the examination can occur in both a motion-restricted and a strained hypermobile joint (painful hypermobility).

### Patrick Test (Fabere Sign)

Differentiates hip disorders from disorders of the sacroiliac joints (assessment of adductor tension).

**Procedure:** The patient is supine with one leg extended and the other flexed at the knee. The lateral malleolus of the flexed leg lies across the other leg superior to the patella.

The test may also be performed so that the foot of the flexed leg is in contact with the medial aspect of the knee of the contralateral leg. The flexed leg is then pressed or allowed to fall further into abduction. The examiner must immobilize the pelvis on the extended contralateral side to prevent it from moving during the test.

**Assessment:** Normally the knee of the abducted leg will almost touch the examining table. Comparative measurements of the distance between the knee and the table on both sides are made. On the side of the positive hyperabduction sign, motion is restricted, the adductors are tensed, and the patient feels pain when the leg is further abducted past the starting position of limited abduction.

Apart from assessing the tension in the adductors, it should also be considered whether the shortening of the adductors is attributable to hip pain (a soft endpoint) or sacroiliac motion restriction (differential diagnosis). A simple restriction of movement in the hip (hard endpoint) or a intervertebral dysfunction in the lumbar spine can also produce a positive fabere sign.

### Three-Phase Hyperextension Test

**Procedure:** The patient is prone. In the first phase of the test, the examiner grasps the patient's extended leg and raises it into hyperextension while immobilizing the pelvis with the other hand.

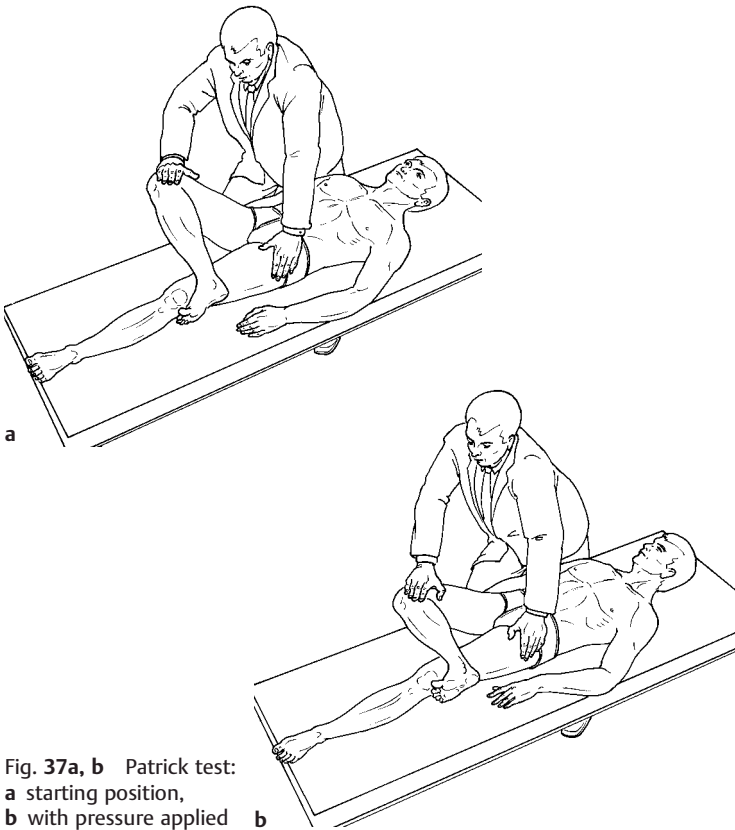


Fig. 37a, b Patrick test:  
a starting position,  
b with pressure applied

In the second phase, the examiner immobilizes the patient's sacrum parallel to the sacroiliac joint with the same hand and passively raises the patient's leg into hyperextension. In the third phase, the examiner immobilizes the fifth lumbar vertebra with the heel of one hand while passively guiding the patient's leg into hyperextension with the other hand. By moving the immobilizing hand up the spine, the examiner also evaluate higher segments of the lumbar spine.

**Assessment:** Under normal conditions no pain should occur in any phase of the test. The hip should allow about 10°–20° of hyperextension. The sacroiliac joint should exhibit slight play, and the lumbar spine should allow elastic hyperextension (lordosis) at the lumbosacral junction.

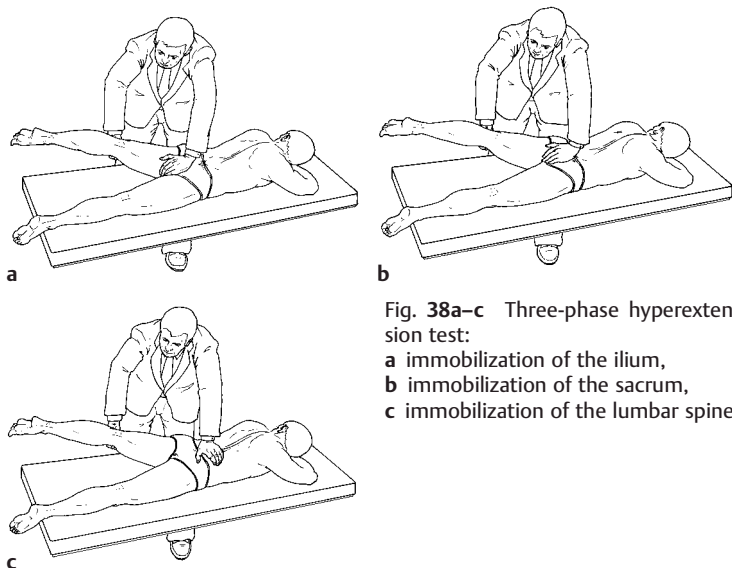


Fig. 38a–c Three-phase hyperextension test:  
**a** immobilization of the ilium,  
**b** immobilization of the sacrum,  
**c** immobilization of the lumbar spine

Pain with the ilium immobilized (phase 1) suggests a hip disorder or muscle contracture (rectus femoris and/or psoas). Pain when the sacrum is immobilized suggests motion restriction of the sacroiliac joint or other disorders of this joint, such as ankylosing spondylitis, while pain when the lumbar spine is immobilized suggests a disorder of the lumbosacral junction (vertebral motion restriction or protrusion or extrusion of an intervertebral disk).

**Note:** The test for a Mennell sign is identical to the second phase of the three-phase hyperextension test.

### Spine Test

Assesses sacroiliac joint function.

**Procedure:** The examiner stands behind the standing patient and palpates the posterior superior iliac spine and the median sacral crest (spinous processes of the fused sacral vertebrae) at the same level. The patient is asked to raise the ipsilateral leg and push his or her knee as far forward as possible.

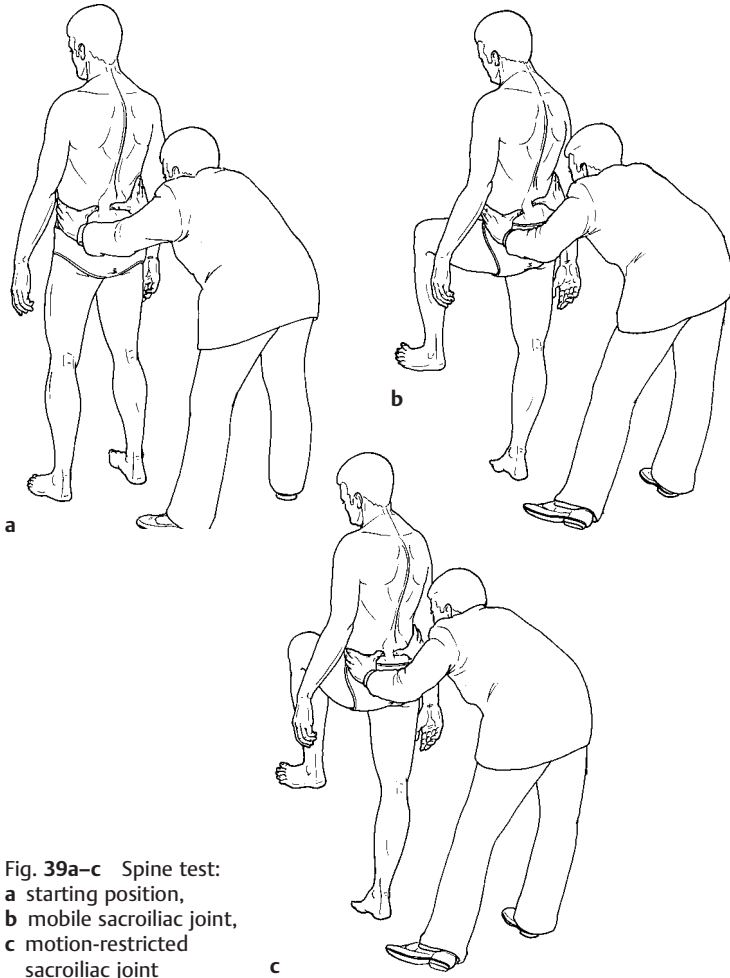


Fig. 39a-c Spine test:  
 a starting position,  
 b mobile sacroiliac joint,  
 c motion-restricted  
 sacroiliac joint

**Assessment:** If the sacroiliac joint is not motion-restricted, the ilium will move downward on the side being examined. The posterior superior iliac spine will be seen to shift inferiorly about 0.5 cm or up to at most 2 cm with the movement. This downward shift will not occur if the sacroiliac joint is motion-restricted; in fact, the motion restriction will usually cause the posterior superior iliac spine to move upwards (superiorly) as the pelvis tilts in compensation.

### Standing Flexion Test

Assesses sacroiliac joint function.

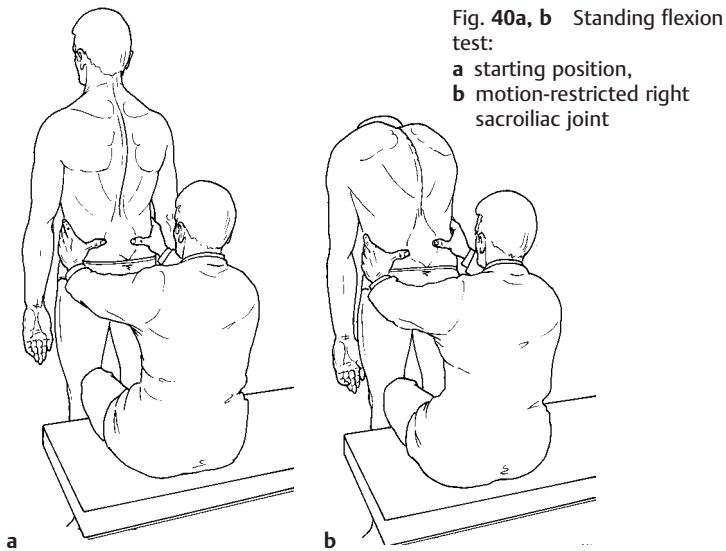
**Procedure:** The patient stands with his or her back to the examiner. The examiner's thumbs simultaneously palpate both posterior superior iliac spines. The patient is asked to slowly bend over while keeping both feet in contact with the floor and the knees extended. The examiner observes the position and/or motion of both iliac spines as the patient's torso bends forward.

**Assessment:** The sacrum rotates relative to the ilia around a horizontal axis in the sacroiliac joints. This motion is referred to as "nutation."

In normal patients with mobile sacroiliac joints, both posterior superior iliac spines will be level with each other throughout the range of motion when the patient bends over.

If nutation does not occur in the sacroiliac joint on one side, the posterior superior iliac spine on that side will come to rest farther superior with respect to the sacrum than the spine on the contralateral side.

Where nutation fails to occur or this relative superior advancement is observed, this is usually a sign of a blockade in the ipsilateral sacroiliac joint. Bilateral superior advancement can be simulated by bilateral shortening of the hamstrings.



**Note:** When evaluating this superior advancement phenomenon, the examiner must consider or exclude possible asymmetry of the pelvis and hips. Pelvic obliquity due to a difference in leg length should be compensated for by placing shims under the shorter leg.

The standing flexion test can also be performed with the patient supine. The supine patient is asked to sit up (the patient may use his or her arms for support on the edge of the examining table). The examiner places both thumbs on the tips of the medial malleoli. As the patient sits up, the right malleolus will be seen to “advance” asymmetrically compared with its position in the supine patient. This is a sign of impaired mobility in the right sacroiliac joints.

### Sacroiliac Mobilization Test

Assesses sacroiliac joint function.

**Procedure:** The patient is prone. The examiner places the fingers of the palpating hand over the sacroiliac joints, i.e., over the posterior sacral ligaments (the sacroiliac joint itself is not accessible to palpation because of its anatomic position). The examiner places the other hand around the anterior iliac wing. With this hand, the examiner performs small shaking and lifting motions in a posterior direction (moving the ilium posteriorly relative to the sacrum).

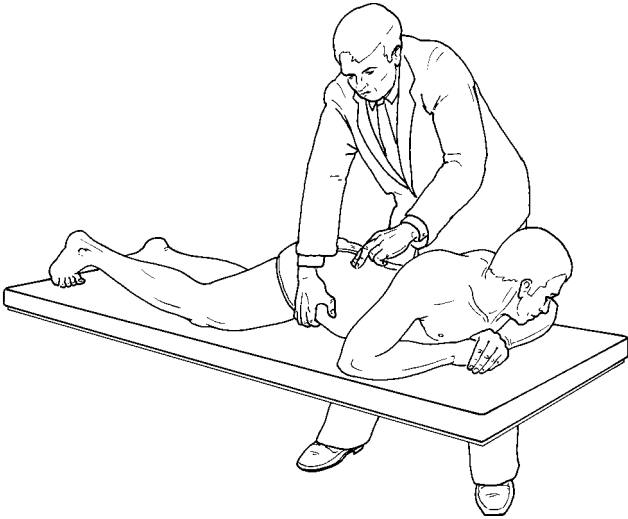


Fig. 41 Sacroiliac mobilization test

Buckup, Clinical Tests for the Musculoskeletal System © 2004 Thieme  
All rights reserved. Usage subject to terms and conditions of license.

**Assessment:** The palpating fingers over the sacroiliac joint will detect resilient motion in a normal joint, or painfully limited resiliency in the presence of a blockade.

### Sacroiliac Joint Springing Test

**Procedure:** To directly test the play in the sacroiliac joint, the patient is placed supine. The leg opposite the examiner is flexed at the knee and hip and adducted toward the examiner until the pelvis begins to follow. The other leg remains extended. Next, the examiner grasps the knee of the adducted leg and palpates the sacroiliac joint with the other hand while exerting resilient axial pressure on the knee.

**Assessment:** This maneuver normally produces a springy motion in the sacroiliac joint, which will be palpable as movement between the posterior iliac spine and the sacrum. Lack of joint play is typical of a functional impairment. This spring test is based on the knowledge that the range of motion in an intact joint can be increased by resilient pressure even with the joint at the extreme end of its range of motion. This essentially allows the diagnosis of a functional impairment in any joint by manual manipulation. However, the important thing is to perform the test with initial stress already applied to the joint. This test is recommended to supplement the prone spring tests.

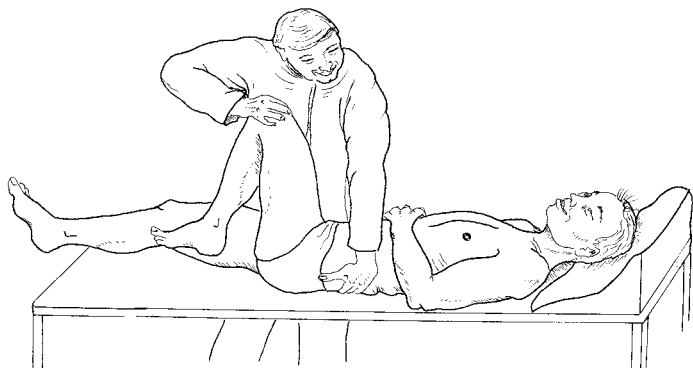
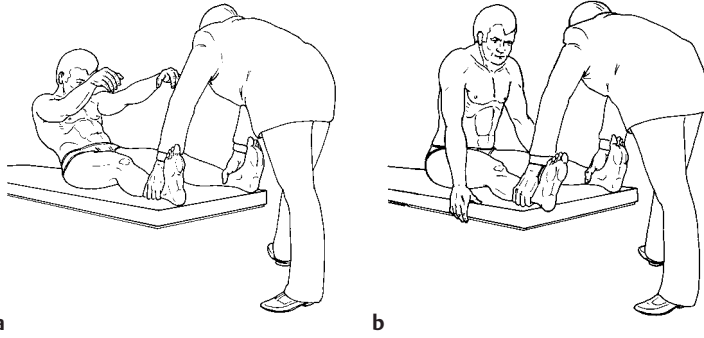


Fig. 42 Springing test of the sacroiliac joint





**Fig. 43a, b** Derbolowsky sign:  
**a** mobile sacroiliac joint,  
**b** motion-restricted right sacroiliac joint (causes leg lengthening when the patient sits up)

### Derbolowsky Sign

Assesses a leg length difference: an advancement phenomenon with the patient supine.

**Procedure:** The patient is supine. The examiner grasps both ankles, palpates the patient's medial malleoli with each thumb, and evaluates the relative level and rotation of the medial malleoli.

The patient is asked to sit up. The examiner may either help the patient do so, or the patient may use his or her hands for support.

**Assessment:** Where there is a motion restriction in the sacroiliac joint without any play between the sacrum and ilium, the ipsilateral leg will be longer when the patient sits up and apparently shorter or the same length as the other leg when the patient is supine. The examiner measures the difference in the level of the two malleoli, which previously were at the same level. A difference of less than 2 cm is not significant. The differential diagnosis should consider whether something other than a motion restriction in the sacroiliac joint may be causing the variable leg length difference. Possible such causes include shortening of the hamstrings or genuine anatomic leg lengthening or shortening.

### Gaenslen Sign

Assesses sacroiliac joint function.

**Procedure:** The patient is supine with the painful side as close as possible to the edge of the examining table or projecting beyond it.

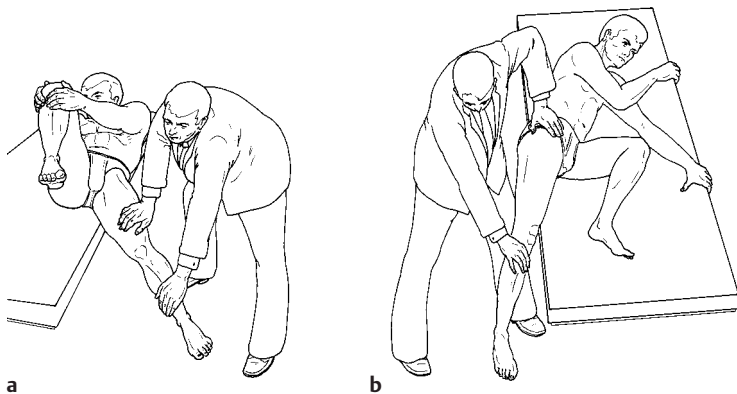


Fig. 44a, b Gaenslen sign: a supine, b lateral position

To stabilize this position and immobilize the lumbar spine, the patient flexes the knee and hip of the contralateral leg and draws the leg as close to the torso as possible. The examiner then passively hyperextends the leg next to the edge of the examining table.

The test may also be performed with the patient in a lateral position. This is done with the patient lying on his or her normal side with that leg flexed at the hip and knee. The examiner then passively hyperextends the other leg (the one not in contact with the table).

**Assessment:** If there is dysfunction in the sacroiliac joint, hyperextension of the leg will lead to motion in the sacroiliac joint, causing pain or exacerbation of existing pain.

### Iliac Compression Test

Indicates sacroiliac disease.

**Procedure:** The patient is in a lateral position. The examiner places both hands on the ilium of the affected side and exerts downward pressure on the pelvis.

**Assessment:** Occurrence of or an increase in pain in the sacroiliac joint adjacent to the examiner's hand suggests a joint disorder (such as motion restriction or inflammation).

Fig. 45 Iliac compression test

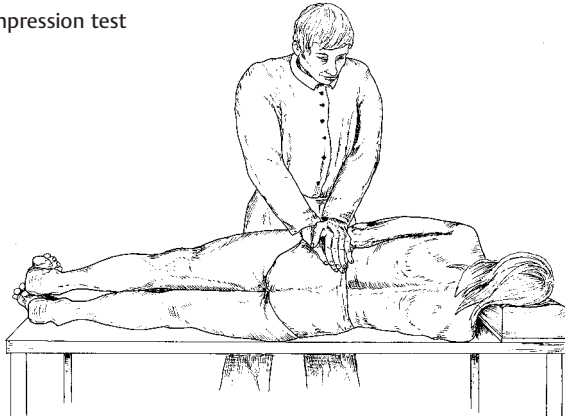
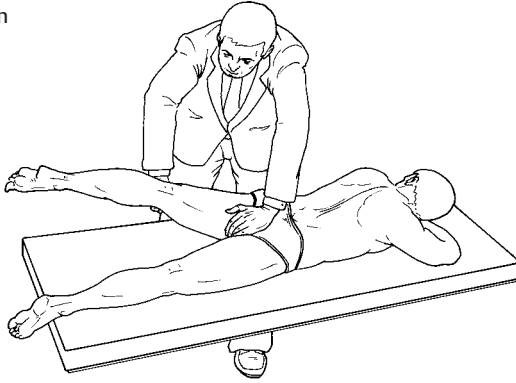


Fig. 46 Mennell sign



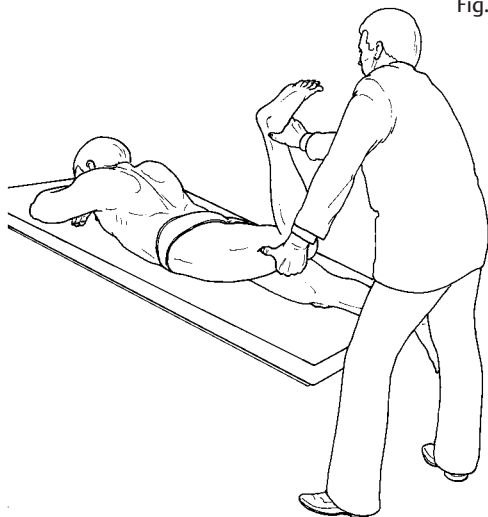
### Mennell Sign

Indicates sacroiliac disease.

**Procedure:** The patient is prone. When examining the left sacroiliac joint, the examiner immobilizes the patient's sacrum with the left hand while grasping the patient's extended left leg with the right hand and suddenly hyperextending the hip.

The examination may also be performed with the patient in a lateral position. This is done with patient lying on his or her right side and immobilizing that leg, flexed at the hip and knee, with both hands. The examiner stands behind the patient holding the patient's pelvis with his or her right hand and then suddenly hyperextends the patient's left hip with the left hand.

Fig. 47 Yeoman test



**Assessment:** Pain in the sacroiliac joint suggests a joint disorder (such as motion restriction or inflammation).

### Yeoman Test

Assesses sacroiliac pain.

**Procedure:** The patient is prone with the knee flexed 90°. The examiner raises the flexed leg off the examining table, hyperextending the hip.

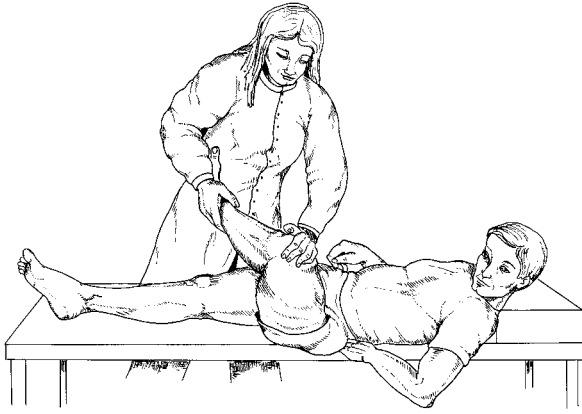
**Assessment:** The first part of this test initially places stress on the posterior structures of the sacroiliac joint; later the stress shifts to the anterior portions, primarily affecting the anterior sacroiliac ligaments. Pain in the lumbar spine suggests the presence of pathologic processes at that site.

### Laguerre Test

Differentiates hip pain from sacroiliac pain.

**Procedure:** The patient is supine. The examiner passively flexes the patient's hip and knee 90°. Then the hip is passively abducted and placed in extreme external rotation.

Fig. 48 Laguerre test



**Assessment:** This maneuver moves the femoral head into the anterior part of the joint capsule of the hip. Pain within the hip suggests degenerative joint disease, hip dysplasia, or contracture of the iliopsoas. Pain felt posteriorly in the sacroiliac joint suggests a disease process at that site.

### Sacroiliac Stress Test

Demonstrates involvement of the anterior sacroiliac ligaments in a sacroiliac joint syndrome.

**Procedure:** The patient is supine. The examiner exerts anterior pressure on the iliac wings with both hands. By crossing his or her hands, the examiner adds a lateral force vector to the compression. The antero-posterior direction of the compressive load on the pelvis places stress on the posterior portions of the sacroiliac joint, whereas the lateral component places stress on the anterior sacroiliac ligaments.

**Assessment:** Deep pain is a sign of strained anterior sacroiliac ligaments on the side of the pain (sacrospinal and sacrotuberal ligaments). Pain in the buttocks can be produced by compression from the examining table or by irritation of the posterior portions of the sacroiliac joint. Determining the precise location of the pain helps to identify its cause.

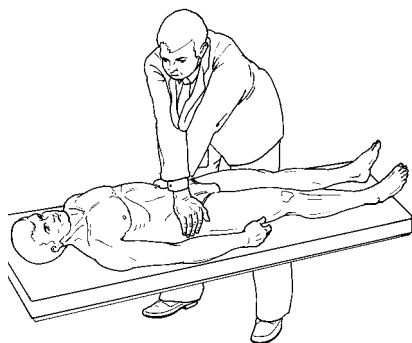


Fig. 49 Sacroiliac stress test

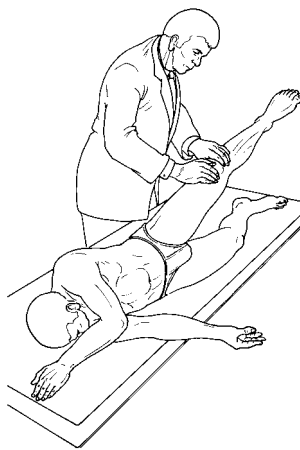


Fig. 50 Abduction stress test

### Abduction Stress Test

Indicates a sacroiliac joint syndrome.

**Procedure:** The patient is in a lateral position. With the leg in contact with the table flexed, the patient attempts to continue to abduct the upper extended leg against the examiner's resistance. This test is normally performed to evaluate insufficiency of the gluteus medius and gluteus minimus.

**Assessment:** Increasing pain in the affected sacroiliac joint is a sign of sacroiliac irritation. Patients with hip disorders may also feel increased pain when this test is performed. The location of the pain is suggestive of the type of disorder. If the patient is unable to abduct the leg or can only do so slightly, but does not report any pain, this suggests insufficiency of the gluteus medius.

## ■ Nerve Root Compression Syndrome

Disk extrusions usually lead to muscular compression syndromes with radicular pain. The pain in the sacrum and leg is often exacerbated by coughing, sneezing, pushing, or even simply walking. Mobility in the spine is severely limited, and there is significant tension in the lumbar

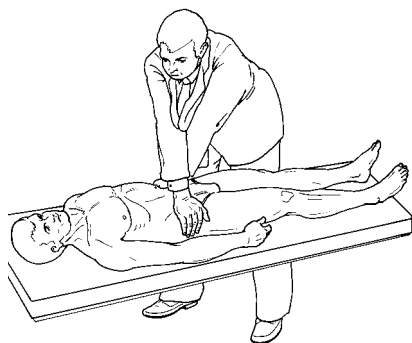


Fig. 49 Sacroiliac stress test

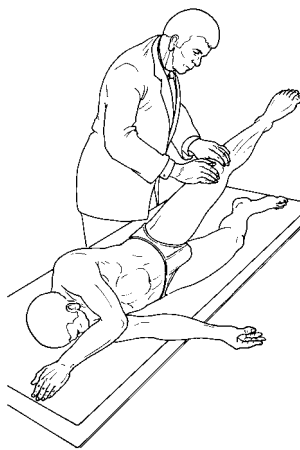


Fig. 50 Abduction stress test

### Abduction Stress Test

Indicates a sacroiliac joint syndrome.

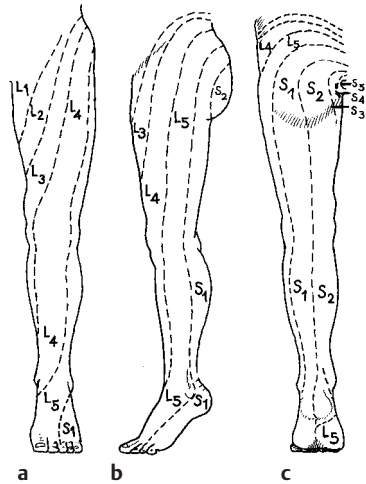
**Procedure:** The patient is in a lateral position. With the leg in contact with the table flexed, the patient attempts to continue to abduct the upper extended leg against the examiner's resistance. This test is normally performed to evaluate insufficiency of the gluteus medius and gluteus minimus.

**Assessment:** Increasing pain in the affected sacroiliac joint is a sign of sacroiliac irritation. Patients with hip disorders may also feel increased pain when this test is performed. The location of the pain is suggestive of the type of disorder. If the patient is unable to abduct the leg or can only do so slightly, but does not report any pain, this suggests insufficiency of the gluteus medius.

## ■ Nerve Root Compression Syndrome

Disk extrusions usually lead to muscular compression syndromes with radicular pain. The pain in the sacrum and leg is often exacerbated by coughing, sneezing, pushing, or even simply walking. Mobility in the spine is severely limited, and there is significant tension in the lumbar

Fig. 51 Dermatomes of the lumbar and sacral plexuses according to Herlin. The L<sub>4</sub> dermatome rarely extends as far as the foot, and the sole of the foot is rarely supplied in part by the posterior L<sub>5</sub> root



musculature. Sensory deficits and impaired reflexes are additional symptoms that occur with nerve root compression.

Often the affected nerve root can be identified by the description of the paresthesia and radiating pain in the dermatome. Extrusions of the fourth and fifth lumbar disks are especially common, extrusions of the third lumbar disk less so. Disk extrusions involving the first and second lumbar disks are rare.

The Lasègue sign is usually positive (often even at 20°–30°) in compression of the L<sub>5</sub>–S<sub>1</sub> nerve root (typical sciatica). In these cases, even passively raising the normal leg will often elicit or exacerbate pain in the lower back and the affected leg (contralateral Lasègue sign). In nerve root compression syndromes from L<sub>1</sub> through L<sub>4</sub> with involvement of the femoral nerve, the Lasègue sign is rarely positive and then only slightly and only when the L<sub>4</sub> nerve root is affected.

When the femoral nerve is irritated, the reverse Lasègue sign and/or pain from stretching of the femoral nerve can usually be triggered.

Pseudoradicular pain must be distinguished from genuine radicular pain (sciatica). Pseudoradicular pain is usually less circumscribed than radicular pain. Facet syndrome (arthritis in the facet joints), sacroiliac joint syndrome, painful spondylolisthesis, stenosis of the spinal canal, and postdiscectomy syndrome are clinical pictures that frequently cause pseudoradicular pain.



Table 4 Signs of radicular symptoms

Root	Dermatome Pain	Sensory deficit	Paralyzed muscles	Impaired reflexes
L2 L1–L2 Extraforaminal: L2–L3	Thoracolumbar junction, sacroiliac joint, groin, iliac crest, proximal medial thigh	Groin, proximal anterior and medial thigh	Paresis of the iliopsoas, quadriceps femoris, and adductors (slight)	Cremaster and patellar reflex weakened
L3 L2–L3 Extraforaminal: L3–L4	Upper lumbar spine, anterior proximal thigh	From the anterior thigh to the medial thigh and distal to the knee	Paresis of the iliopsoas, quadriceps femoris, and adductors (slight)	Absent or weakened patellar reflex
L4 L2–L3 Extraforaminal: L3–L4	Lumbar spine, anterolateral thigh, hip region	From the lateral thigh to the medial lower leg and margin of the foot	Paresis of the quadriceps femoris and tibialis anterior (difficulty walking on heels)	Weakened patellar reflex
L5 L4–L5 Extraforaminal: L5–S1	Lumbar spine, posterior thigh, lateral lower leg, medial foot, groin, hip region	From the lateral lower leg to the medial foot (great toe)	Paresis of the extensor hallucis longus and brevis, extensor digitorum longus and brevis (difficulty walking on heels)	Loss of tibialis posterior reflex (significant only when readily elicited on contralateral side)
S1 L5–S1	Lumbar spine, posterior thigh, posterolateral lower leg, lateral margin of foot, sole of foot, groin, hip region, coccyx	Posterior aspect of the thigh and lower leg, lateral margin of the foot and sole of the foot (little toe)	Paresis of the peroneus muscles and triceps surae (difficulty walking on tiptoes; foot bends laterally)	Weakening or loss of Achilles tendon reflex

### Lasègue Sign (Straight Leg Raising Test)

Indicates nerve root irritation.

**Procedure:** The examiner slowly raises the patient's leg (extended at the knee) until the patient reports pain.

**Assessment:** Intense pain in the sacrum and leg suggests nerve root irritation (disk extrusion or tumor). However, a genuine positive Lasègue sign is only present where the pain shoots into the leg explosively along a course corresponding to the motor and sensory dermatome of the affected nerve root.

The patient often attempts to avoid the pain by lifting the pelvis on the side being examined.

The angle achieved when lifting the leg is estimated in degrees. This angle gives an indication of severity of the nerve root irritation present.

Sciatica can also be provoked by adducting and internally rotating the leg with the knee flexed. This test is also described as a Bonnet or piriformis sign (adduction and internal rotation of the leg stretches the nerve as it passes through the piriformis).

Increases in sciatica pain by raising the head (Kernig sign) and/or passive dorsiflexion of the great toes (Turyn sign) are further signs of significant sciatic nerve irritation (differential diagnosis should consider meningitis, subarachnoid hemorrhage, and carcinomatous meningitis).

Sacral or lumbar pain that increases only slowly as the leg is raised or pain radiating into the posterior thigh is usually attributable to degenerative joint disease (facet syndrome), irritation of the pelvic ligaments

Fig. 52 Lasègue sign

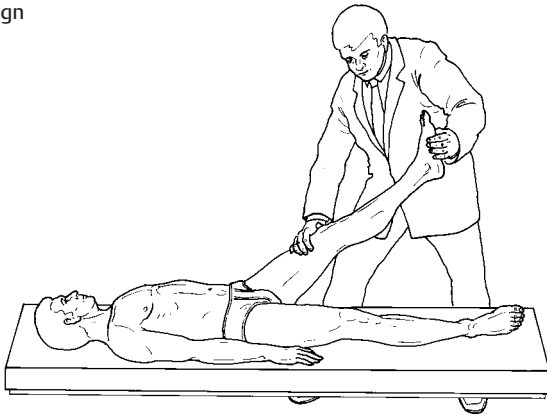
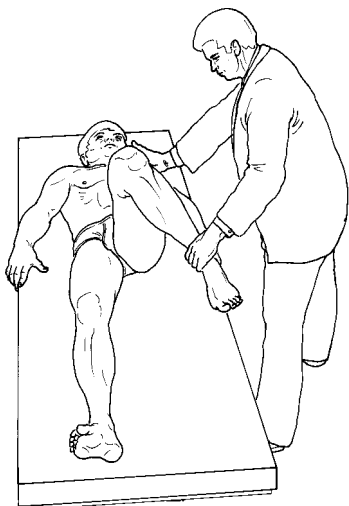


Fig. 53 Bonnet sign



(tendinitis), or increased tension in the hamstrings (indicated by a soft endpoint, usually also found on the contralateral side). It is important to distinguish this “pseudoradicular” pain (pseudo-Lasègue sign) from genuine sciatica (true Lasègue sign).

It can also be impossible to lift the leg at the hip if the patient consciously resists this and attempts to press the leg downward against the examiner’s hand. Occasionally one will encounter this behavior in experienced patients undergoing examination within the scope of an expert opinion (see Lasègue test with the patient seated).

### **Bonnet Sign (Piriformis Sign)**

**Procedure:** The patient is supine with the leg flexed at the hip and knee. The examiner adducts and internally rotates the leg.

**Assessment:** The Lasègue sign occurs earlier in this maneuver. The nerve is stretched as it passes through the piriformis, resulting in increased pain.

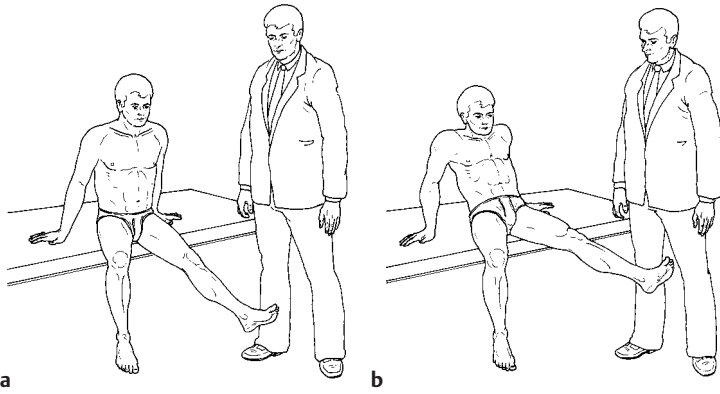


Fig. 54a, b Lasègue sign with the patient seated:  
 a beginning hip flexion,  
 b with increasing hip flexion

### Lasègue Test with the Patient Seated

Indicates nerve root irritation.

**Procedure:** The patient sits on the edge of the examining table and is asked to flex his or her hip with the leg extended at the knee.

**Assessment:** This test corresponds to the Lasègue sign. When nerve root irritation is present, the patient will avoid the pain by leaning backward and using his or her arms for support. This test can also be used to identify simulated pain. If the patient can readily flex the hip without leaning backward, then a previous positive Lasègue sign must be questioned. The examiner can also perform this test in the same manner as the test for the Lasègue sign by passively flexing the hip with the knee extended.

### Contralateral Lasègue Sign (Lasègue–Moutaud–Martin Sign)

Indicates nerve root irritation.

**Procedure:** The examiner raises the nonpainful leg, extended at the knee.

**Assessment:** In the presence of a disk extrusion with nerve root irritation, the movement of lifting the normal leg is referred to the affected segment and can cause sciatica in the other, affected leg.

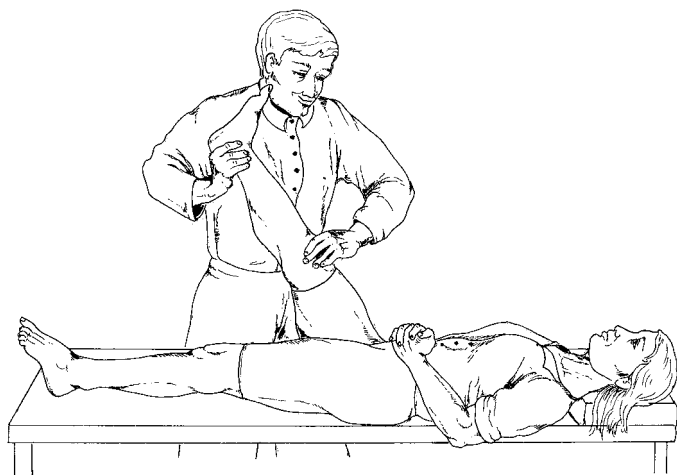


Fig. 55 Contralateral Lasègue sign

### Bragard Test

Indicates nerve root compression syndrome, differentiating a genuine Lasègue sign from a pseudo-Lasègue sign.

**Procedure:** The patient is supine. The examiner grasps the patient's heel with one hand and anterior aspect of the knee with the other. The examiner slowly raises the patient's leg, which is extended at the knee. At the onset of the Lasègue sign, the examiner lowers the patient's leg just far enough that the patient no longer feels pain. The examiner then passively moves the patient's foot into extreme dorsiflexion in this position, eliciting the typical pain caused by stretching of the sciatic nerve.

**Assessment:** A positive Bragard sign is evidence of nerve root compression, which may lie between L4 and S1.

Dull, nonspecific pain in the posterior thigh radiating into the knee is attributable to stretching of the hamstrings and should not be assessed as a Lasègue sign.

A sensation of tension in the calf may be attributable to thrombosis, thrombophlebitis, or contracture of the gastrocnemius.

The Bragard sign can be used to test whether the patient is malingering. The sign is usually negative in malingerers.

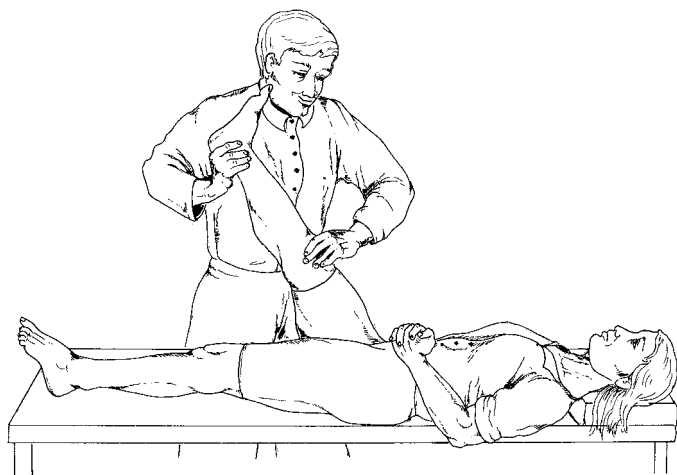


Fig. 55 Contralateral Lasègue sign

### Bragard Test

Indicates nerve root compression syndrome, differentiating a genuine Lasègue sign from a pseudo-Lasègue sign.

**Procedure:** The patient is supine. The examiner grasps the patient's heel with one hand and anterior aspect of the knee with the other. The examiner slowly raises the patient's leg, which is extended at the knee. At the onset of the Lasègue sign, the examiner lowers the patient's leg just far enough that the patient no longer feels pain. The examiner then passively moves the patient's foot into extreme dorsiflexion in this position, eliciting the typical pain caused by stretching of the sciatic nerve.

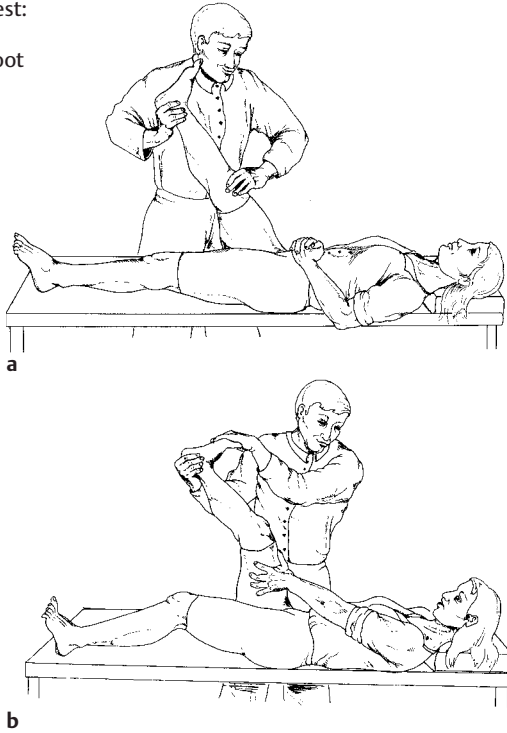
**Assessment:** A positive Bragard sign is evidence of nerve root compression, which may lie between L4 and S1.

Dull, nonspecific pain in the posterior thigh radiating into the knee is attributable to stretching of the hamstrings and should not be assessed as a Lasègue sign.

A sensation of tension in the calf may be attributable to thrombosis, thrombophlebitis, or contracture of the gastrocnemius.

The Bragard sign can be used to test whether the patient is malingering. The sign is usually negative in malingerers.

Fig. 56a, b Bragard test:  
 a starting position,  
 b dorsiflexion of the foot



### Lasègue Differential Test

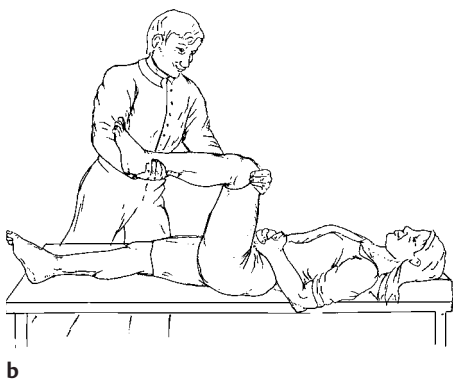
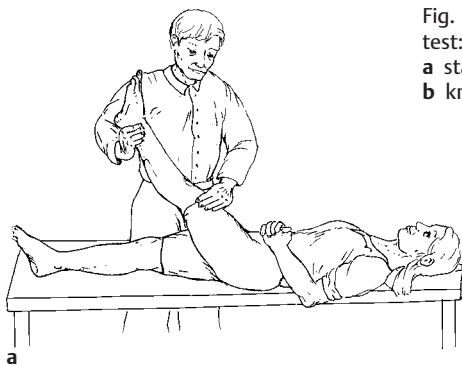
Differentiates sciatica from a hip disorder.

**Procedure:** The patient is supine. The examiner grasps the patient's heel with one hand and the anterior aspect of the knee with the other. The examiner slowly raises the patient's leg, which is extended at the knee, until the patient feels pain. The examiner then notes the location and nature of the pain and estimates in degrees the maximum pain-free angle that can be achieved when lifting the leg.

The test is repeated and the leg is then flexed once the painful angle is reached.

**Assessment:** In a patient with sciatic nerve irritation, flexing the knee will significantly reduce symptoms, even to the point that they disappear completely. Where a hip disorder is present, the pain will remain and may even be exacerbated by increasing flexion in the hip.

Fig. 57a, b Lasègue differential test:  
a starting position,  
b knee flexed



**Note:** Pain in hip disorders is usually located in the groin and only rarely in the posterolateral region of the hip. Only in the case of posterolateral pain may it be hard to differentiate between nerve root irritation and pain caused by a hip disorder.

### Duchenne Sign

Assesses a nerve root disorder.

**Procedure:** The patient is supine. The examiner grasps the patient's heel with one hand and with one finger of the other hand presses the first metatarsal head posteriorly. From this position, the patient is asked to flex the foot.

**Assessment:** In the presence of a disk disorder involving the S1 nerve root, the patient will be unable to resist the finger pressure. Paresis of



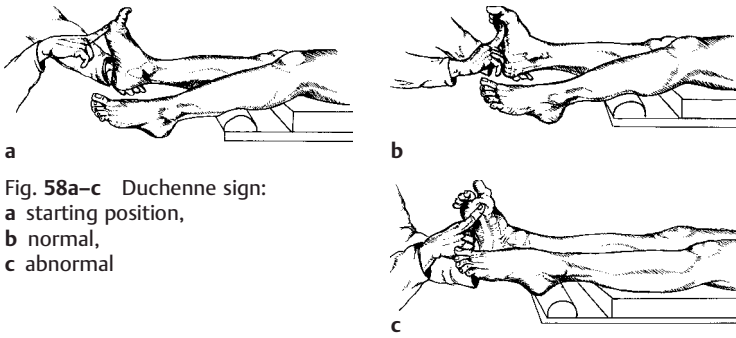
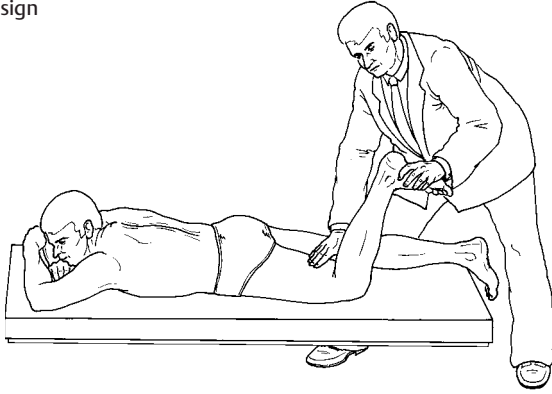


Fig. 58a–c Duchenne sign:  
 a starting position,  
 b normal,  
 c abnormal

Fig. 59 Thomsen sign



the peroneus muscles causes supination of the foot due to the action of the anterior and posterior tibial muscles.

### Thomsen Sign

Indicates nerve root irritation.

**Procedure:** The patient is prone. The examiner flexes the knee about  $90^{\circ}$ – $120^{\circ}$  with the foot dorsiflexed.

**Assessment:** Where the sciatic nerve superior to the popliteal fossa is painful to palpation, this suggests nerve root irritation. Usually, this will be attributable to a disk extrusion or tumor.

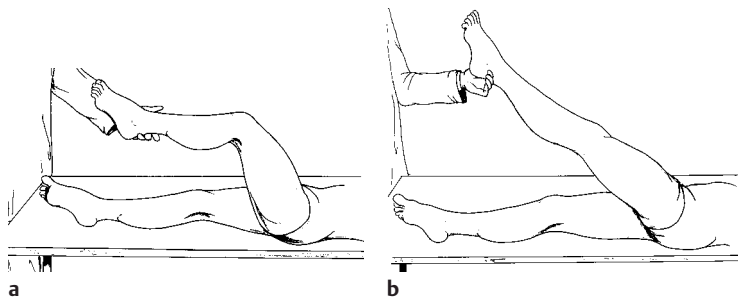


Fig. 60a, b Kernig test: a starting position, b knee flexed

### Kernig Test

Indicates nerve root irritation.

**Procedure:** The patient is supine and is asked to flex the hip and knee of one leg. In the first part of the test, the examiner attempts to passively extend the patient's knee; in the second part, the patient actively attempts to flex the knee.

**Assessment:** Pain in the spine or radicular pain in the leg occurring during active or passive knee flexion suggests nerve root irritation. Possible causes include a disk extrusion or an inflammatory or tumorous process in the spine.

### Tiptoe and Heel Walking Test

Identifies and assesses a nerve root disorder in the lumbar spine.

**Procedure:** The patient is asked to stand first on his or her heels, then on tiptoe, and then to take a few steps in each of these positions if possible.

**Assessment:** Difficulty or inability to stand or walk on tiptoe suggests a lesion of the S1 nerve root; difficulty or inability to stand or walk on the heels suggests a lesion of the L4–L5 nerve root.

**Note:** A differential diagnosis must exclude a ruptured Achilles tendon. This injury makes it impossible to stand on tiptoe, especially when standing only on the affected leg.

Fig. 61a, b Tiptoe and heel walking test:  
 a heel walking,  
 b tiptoe walking

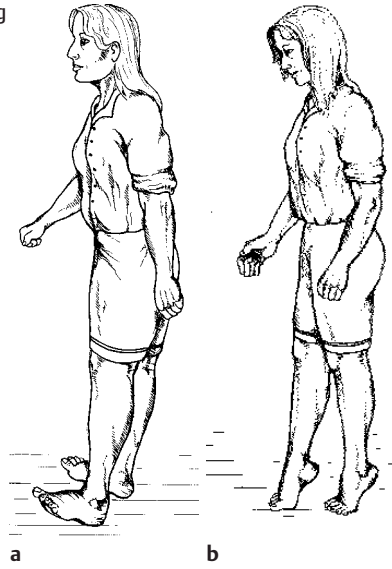
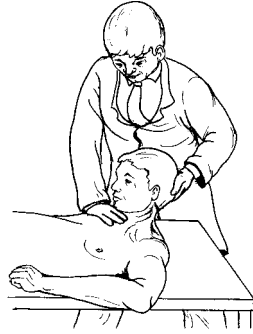

Fig. 62 Brudzinski sign



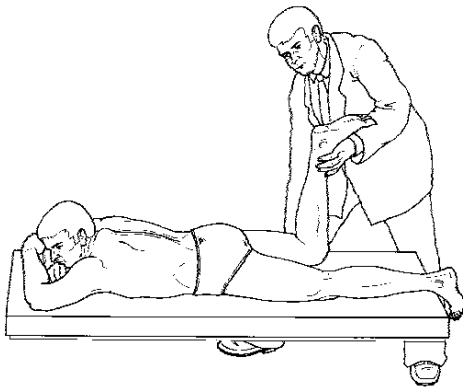
### Brudzinski Sign

Indicates meningitis.

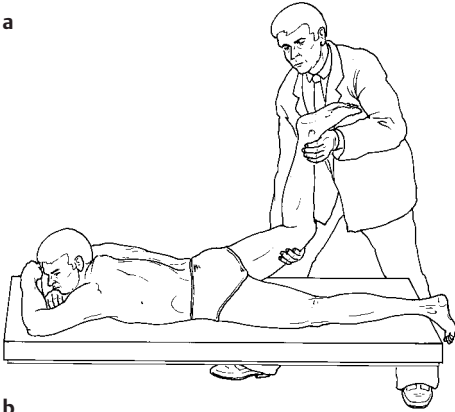
**Procedure:** The patient is supine. The examiner passively raises the patient's head and moves it into increasing flexion.

**Assessment:** If raising the patient's head causes slight flexion in the knees and hips, this is an indication of meningitis.

Fig. 63a, b Reverse Lasègue test:  
 a starting position,  
 b hip hyperextended



a



b

### Reverse Lasègue Test (Femoral Nerve Lasègue Test)

Indicates nerve root irritation.

**Procedure:** The patient is prone. The examiner passively raises the leg, which is flexed at the knee.

**Assessment:** Hyperextension of the hip with the knee flexed places traction on the femoral nerve. Occurrence of unilateral or bilateral radicular pain in the sacrum or anterior thigh, rarely in the lower leg as well, is a sign of nerve root irritation (such as a disk extrusion) in segment L3–L4. This should be distinguished from complaints caused by degenerative hip disease or by shortening of the rectus femoris or psoas.

---

# Shoulder

Disorders of the shoulder have become increasingly important in recent years. One reason for this is an aging population, with a corresponding increase in patients suffering from degenerative disorders of the shoulder or periarticular structures. Another reason is the increasing popularity of sports activities, with a corresponding increase in shoulder trauma and posttraumatic conditions.

Nowadays, technical advances in diagnostic modalities such as ultrasound, magnetic resonance imaging (MRI), computed axial tomography (CAT), CT arthrography, etc., allow more precise diagnostic evaluation of shoulder complaints than in the past. These sophisticated examination techniques should rightfully relegate the once common term “humeroscapular periarthrititis” to the annals of medical history. However, in the diagnostic assessment of shoulder complaints, history taking and physical examination should precede the use of specific examination techniques, most of which will involve use of dedicated apparatus.

Plain radiographs of the shoulder (anteroposterior and lateral or axial views) are an essential supplement to any clinical examination as they can help distinguish bony changes from soft tissue disorders right from the start.

Taking the patient’s history helps in the assessment of traumatic or degenerative and generalized inflammatory causes as well as causative factors in remote regions of the body.

In children and young adults, injuries and faulty postural habits are usually the causes of shoulder complaints. In these groups, the most common shoulder disorders are dislocation and subluxation with their various instability symptoms.

Especially in later years, shoulder complaints may also be attributable to overuse in sports or occupational activities and to wear of articular and periarticular structures as a result of developmental anomalies.

Identifying the site and type of pain, its duration, and the time of its occurrence (its circadian course) is also of great importance. Where referred pain occurs in the subacromial bursa and pain from a ruptured rotator cuff is referred to the proximal upper arm or felt diffusely in the deltoid, the acromioclavicular symptoms will be located directly over the joint. Pain at night is typical of rotator cuff injuries and of advanced impingement syndromes such as calcific tendinitis.

The location of the pain cannot always be described precisely, and pain often radiates into the arm, trunk, and head. This means that shoulder disorders must be distinguished from neurovascular disorders such as distal compression neuropathies, thoracic outlet syndrome, cervical rib syndrome, cervical spine disorders, and cardiopulmonary disease.

## ■ Range of the Motion of the Shoulder (Neutral-Zero Method)

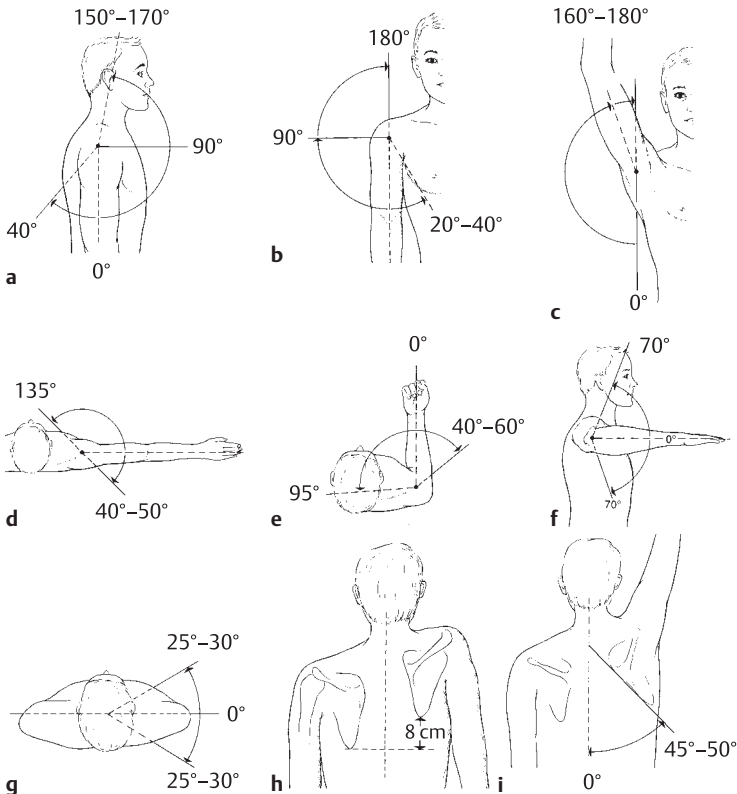


Fig. 64

- a Forward flexion and extension
- b Abduction and adduction
- c Abduction exceeding  $90^\circ$  requires external rotation of the humerus in the glenohumeral joint and rotation of scapula
- d Horizontal flexion and extension (forward and backward motion of the arm, abducted  $90^\circ$  from the body)
- e, f External and internal rotation: with the arm hanging down (e) and abducted  $90^\circ$  (f)
- g Protraction and retraction of the shoulder
- h Scapular elevation and depression
- i Scapular rotation relative to the trunk

Table 5 Function tests: shoulder

General orientation	Rotator cuff	Acromio-clavicular joint	Biceps tendon	Instability
Quick test of combined motion	Zero-degree abduction test	Painful arc	Nonspecific biceps tendon test	Anterior apprehension test
Codman sign	Jobe supraspinatus test	Forced adduction test	AbbottSaunders test	Apprehension test (supine)
Palm sign and finger sign tests	Subscapularis test	Forced adduction test on hanging arm	Speed test	Anterior and posterior drawer test
Bursitis sign	Lift-off test	Test of horizontal mobility of the lateral clavicle	Snap test	Rowe test
Dawbarn sign	Infraspinatus test	Dugas test	Yergason test	Throwing test
	Teres test		Hueter sign	Leffert test
	Nonspecific supraspinatus test		Transverse humeral ligament test	Gerber-Ganz anterior drawer test
	Drop arm test		Thompson and Kopell horizontal flexion test	Posterior apprehension test
	Ludington sign		Ludington test	Gerber-Ganz posterior drawer test
	Apley's scratch test		Lippman test	Posterior apprehension test
	Painful arc		DeAnquin test	Fukuda test
	Neer impingement sign		Gilcrest test	Sulcus sign
	Hawkins impingement sign		Beru sign	Inferior apprehension test
	Neer impingement injection test		Duga sign	Relocation test
			Traction test	
			Compression test	



## ■ Orientation Tests

### Quick Test of Combined Motion

**Procedure:** A quick test of mobility in the shoulder is to ask the patient to place hand behind his or her head and touch the contralateral scapula. In a second movement the patient places the hand behind his or her back, reaching upward from the buttocks to touch the inferior margin of the scapula.

**Assessment:** Mobility on one side that is restricted in comparison with the contralateral side is a sign that a shoulder disorder exists. Other tests may then be used to diagnose this disorder in greater detail.

### Codman Sign

Tests passive motion in the shoulder.

**Procedure:** The examiner stands behind the patient and places his or her hand on the patient's shoulder so that the thumb immobilizes the patient's scapula slightly below the scapular spine, the index rests on the anterior margin of the acromion toward the tip of the coracoid, and the remaining fingers extend anteriorly past the acromion.

Fig. 65 Quick test of combined motion:  
a touching the scapula from behind the neck,  
b touching the scapula from behind the back

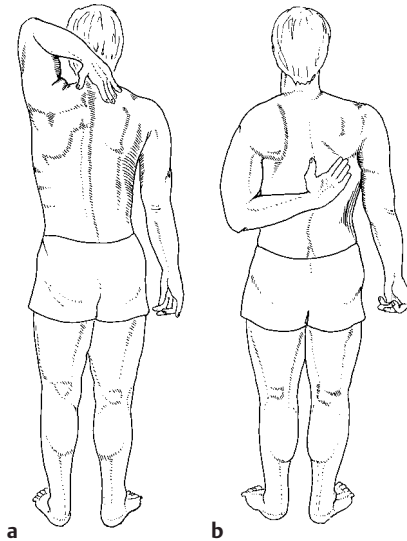
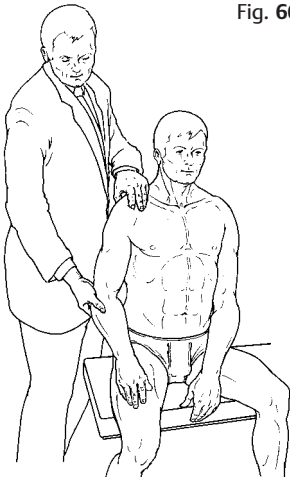


Fig. 66 Codman sign



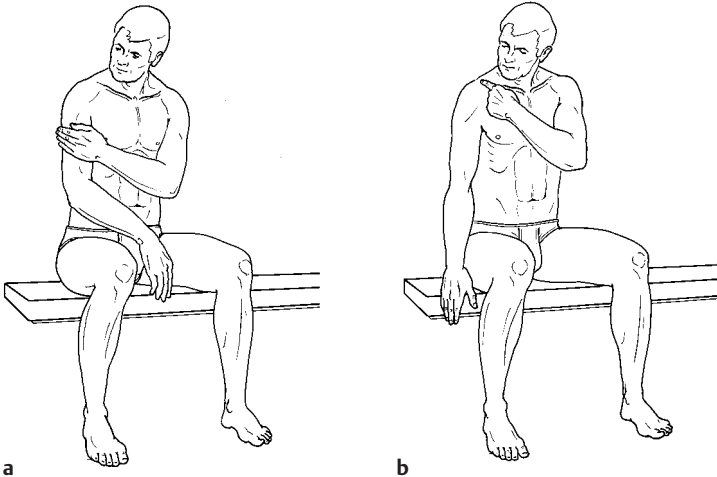
The examiner then moves the patient's arm in every direction using the other hand.

**Assessment:** The examiner notes any crepitation in the glenohumeral joint, snapping phenomena (such as dislocations of the long head of the biceps tendon), or restricted motion.

The most important bony pressure points, such as the greater and lesser tubercles of the humerus, coracoid process, and sternoclavicular and acromioclavicular joints, are assessed for tenderness to palpation. Joint stability is also assessed, and pain in the tendons of the rotator cuff is evaluated by palpation.

The range of motion is determined using the neutral-zero method. The active and passive ranges of motion are determined, as are the region of occurrence and specific localization of symptoms. Restricted motion in every direction indicates the presence of a "frozen shoulder."

In the early stages of a rotator cuff tear, only active motion is restricted; passive motion remains normal. A chronic tear or advanced impingement syndrome will exhibit the universally restricted motion of a frozen shoulder.



**a**  
**b**  
Fig. 67 Palm sign test and finger sign test:  
a palm sign,  
b finger sign

### Palm Sign Test and Finger Sign Test

Typically, shoulder pain begins in the shoulder and radiates into the upper arm. Patients usually describe this pain in two ways. The “palm sign” is typical of glenohumeral and subacromial pain; the patient places the palm of the normal contralateral hand directly under the acromion.

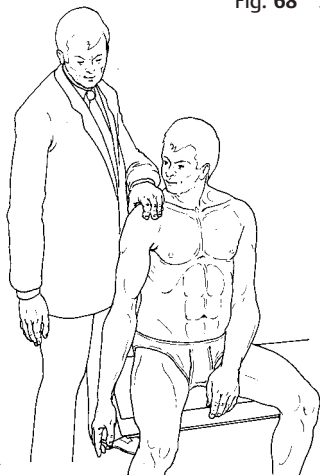
The “palm sign” is typical of pain in the acromioclavicular joint; in this case, the patient places the finger of the normal contralateral hand directly on the affected acromioclavicular joint.

## ■ Bursitis Tests

### Bursae

The shoulder contains a series of bursae. Communicating structures include the subscapular and subcoracoid bursae, and the subdeltoid bursa with its subacromial extension. Noncommunicating structures include the supraspinatus and infraspinatus bursae. The subacromial bursa is particularly important in shoulder pathology.

Fig. 68 Subacromial bursitis sign



### Bursitis Sign

Diagnosis of shoulder pains of uncertain etiology.

**Procedure:** The examiner palpates the anterolateral subacromial region with his or her index and middle fingers.

The examiner can expand the subacromial space by passively extending or hyperextending the patient's arm with the other hand and pressing the humeral head forward with the thumb. This also allows palpation of the superior portions of the rotator cuff and its insertions into the greater tubercle of the humerus.

**Assessment:** Localized tenderness to palpation in the subacromial space suggests irritation of the subacromial bursa but can also be a sign of a rotator cuff disorder.

### Dawbarn Test

Sign of subacromial bursitis.

**Procedure:** While further abducting the patient's moderately abducted arm with one hand, the examiner palpates the anterolateral subacromial space with the other hand.

The examiner exerts additional focal subacromial pressure while passively abducting the patient's arm up to 90°.

Fig. 69 Dawbarn test



**Assessment:** Subacromial pain that decreases with abduction suggests bursitis. In abduction, the deltoid glides over the margin of the subacromial bursa, reducing the pain.

### ■ Rotator Cuff (Impingement Symptoms)

Pain and varying degrees of functional impairment are typically the dominant features in the clinical picture of a rotator cuff lesion.

In the phase of acute pain, it will usually be difficult to obtain sufficient information from the examination to determine whether the shoulder is due to calcification, tendinitis, subscapularis syndrome, or a rotator cuff tear. It is even more difficult to distinguish a rotator cuff tear from disorders caused by degenerative tendon changes without rupture. Clinical classification of shoulder pain and muscle weakness only becomes easier once the pain of the acute phase has abated.

Active motion is nearly normal, but reduced overall, in supraspinatus tears involving the anterior superior portion. The loss of active motion is more pronounced in injuries to the posterior portion and most extreme

in complete tears. However, this is only an indication; the range of motion does not allow conclusions about the type of the lesion.

Pseudo-stiffening of the shoulder must be distinguished from “frozen shoulder.” Pseudo-stiffening is often caused advanced but minimally painful osteoarthritis in the sternoclavicular joint. If this change is not considered, one risks mistakenly attributing the decreased range of motion to changes in the glenohumeral joint. A good test to distinguish these two is to watch the patient shrug (elevate the shoulders); a limited range of motion may only be attributed to glenohumeral joint pathology where elevation of the shoulders is normal.

Scapular and thoracic pathology must be excluded in the same manner. A “creaking” shoulder due to a bony projection such as scapular or costal osteophytes is less serious than the scapula that becomes fixed in a posterior thoracic defect, such as can occur secondary to thoracoplasty or multiple fractures of adjacent ribs. It is equally important to exclude dysfunction of the shoulder musculature, whether the scapular and thoracic or the glenohumeral musculature. The examiner should be particularly alert to the possibility of a serratus muscle palsy, which is tested for by verifying whether the scapula lifts off when pushing away the patient with his or her arms in forward extension. Paralysis of the trapezius must also be excluded. This paralysis limits mobility in the shoulder because the scapula can no longer be immobilized. The ability to elevate the scapula rules out this paralysis, as does the ability to elevate the shoulders (in shrugging).

Even under normal circumstances, there is little space available for the structures that lie beneath the coracoacromial arch. This space is further diminished when the greater tubercle of the humerus moves beneath the acromion in elevation. The supraspinatus is particularly affected by this confinement. The space available for its motion is limited on all sides by the anterior acromion, the coracoacromial ligament, the acromioclavicular joint, and the coracoid process (the supraspinatus outlet).

Impingement syndrome is a painful functional impairment of the shoulder that occurs when the rotator tendons impinge on the anterior margin of the coracoacromial arch and/or the acromioclavicular joint. The rotator cuff and the bursa beneath it can be locally compressed on the anterior margin of the acromion in elevation, and against the coracoid process in internal rotation. A subacromial or subcoracoid impingement syndrome can occur. Impingement lesions can also involve structures other than the rotator cuff that lie in the impingement zone, such as the biceps tendon and the subacromial bursa.

According to Neer, a distinction is made between primary impingement (outlet impingement) and secondary impingement (nonoutlet

impingement). Primary impingement involves irritation of the supraspinatus as a result of mechanical constriction (in the supraspinatus outlet). Contributing factors may include congenital changes in the shape of the acromion, acquired bone spurs on the anterior margin of the acromion, inferior osteophytes on the acromioclavicular joint, and posttraumatic deformities of the coracoid process, acromion, and greater tubercle of the humerus. Secondary impingement (subacromial syndrome) involves relative constriction of the subacromial space due to the increase in volume of the structures that pass beneath the coracoacromial arch. Thickening of the rotator cuff and bursa (due to calcifications or chronic bursitis) and posttraumatic superior displacement of the greater tubercle of the humerus are the most common causes.

The failure of the depressor muscles of the humeral head that occurs in a tear of the rotator cuff or biceps tendon as the principal cause of secondary impingement. Where a defective rotator cuff is no longer able to counterbalance the superior pull of the deltoid, elevating the shoulder will cause the humeral head to shift upwards and produce impingement. The same also applies to shoulder instability, where, especially in multidirectional displacement, the humeral head is pulled against the roof of the joint capsule, producing impingement. Functional constriction can also result where muscular paralysis and weakness prevent involvement of the scapula in the overall elevation of the arm, or where separation of the acromioclavicular joint has eliminated its supporting structures. Finally, one should also remember the pathogenetic significance of a shrunken posterior capsule. If the humeral head cannot glide far enough posteriorly in flexion, it will be increasingly pressed against the anterior margin of the acromion, resulting in impingement.

The chronic stage of impingement syndrome can involve clinically conspicuous deltoid atrophy as well as supraspinatus and infraspinatus atrophy. The tendon insertions on the greater and lesser tubercles of the humerus are often tender to palpation, and mobility in the glenohumeral joint is often limited toward the end of its range of motion. Active elevation is more painful than passive elevation.

Where the patient is able to abduct his or her arm against resistance in spite of pain, this suggests degenerative tendon changes rather than a tear. The Neer impingement injection test allows one to clinically distinguish between weakness in abduction due to a rupture and that due to pain. In the presence of a tendon rupture, the weakness in abducting the arm may be expected to remain even after infiltration of the subacromial space with anesthetic has reduced or eliminated pain.

A patient with “pseudoparalysis” is unable to lift the affected arm. This global sign suggests a rotator cuff disorder. Further examinations are then required to identify the damaged tendon. Provocative tests can be very helpful in this regard. External and internal rotation against resistance is evaluated with the shoulder in various positions. Weakness is more probably due to a functional deficit (such as a rupture), whereas pain is more probably attributable to inflammation of the tendon insertions or the adjacent bursae.

### Zero-Degree Abduction Test

**Procedure:** The patient is standing with his or her arms hanging relaxed. The examiner grasps the distal third of each forearm. The patient attempts to abduct the arms against the examiner’s resistance.

**Assessment:** Abduction of the arm is initiated by the supraspinatus and deltoid. Pain and, especially, weakness in abducting and holding the arm strongly suggest a rotator cuff tear.

Eccentricity of the humeral head in the form of superior displacement of the humeral head in a rotator cuff tear causes relative insufficiency of the outer muscles of the shoulder. Small tears that can be functionally compensated for will cause minor loss of function with the same amount of pain. Larger tears are invariably characterized by weakness and loss of function.

### Jobe Supraspinatus Test

**Procedure:** This test may be performed with the patient standing or seated.

With the elbow extended, the patient’s arm is held at 90° of abduction, 30° of horizontal flexion, and in internal rotation. The examiner exerts pressure on the upper arm during the abduction and horizontal flexion motion.

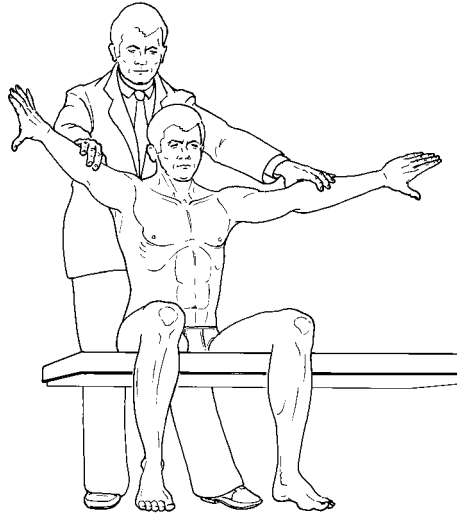
**Assessment:** When this test elicits severe pain and the patient is unable to hold his or her arm abducted 90° against gravity, this is called a positive drop arm sign.

The superior portions of the rotator cuff (supraspinatus) are particularly assessed in internal rotation (with the thumb down), and the anterior portions in external rotation.

A useful supplementary test is to have the patient hold the arm (palm up with the elbow extended, i.e., in maximum external rotation) at 90° elevation in the scapular plane. This test is the same as the Jobe test with



Fig. 70 Jobe supraspinatus test



the arm rotated in the other direction. Where pain occurs and the patient has difficulty maintaining the position, it also indicates a disorder of the subscapularis or at least its superior portion.

Since, in addition to the subscapularis, the pectoralis major and latissimus dorsi also contribute to internal rotation, this test is not always very specific, especially in the presence of pathology in these other muscles.

### Subscapularis Test

**Procedure:** This test has the opposite effect with respect to the infraspinatus. With the patient's elbow alongside but not quite touching the trunk, the examiner comparatively assesses passive external rotation in both arms and active internal rotation of the glenohumeral joint against resistance.

**Assessment:** Increased passive external rotation in comparison with the contralateral side suggests a rupture of the subscapularis (internal rotator). However, the tear may be small and may only involve the superior portion of the muscle.

Usually increased external rotation is due to inactivity of the subscapularis and not a tear.

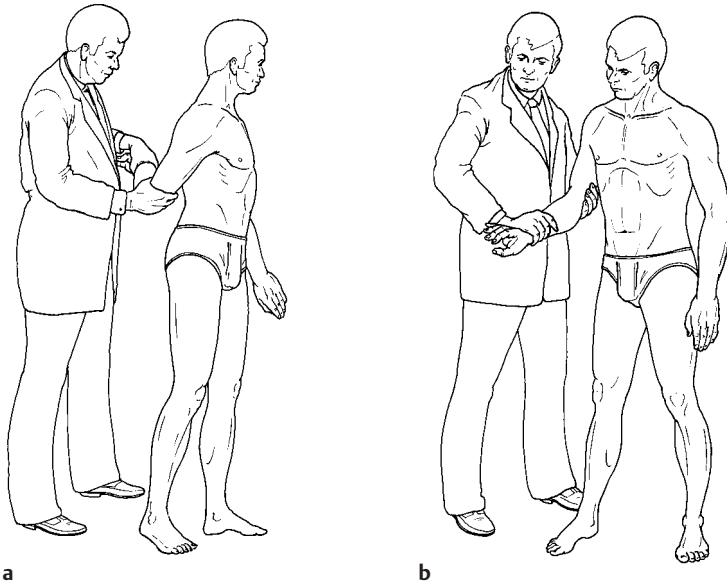


Fig. 71a, b Subscapularis test:  
**a** passive external rotation,  
**b** active internal rotation behind the back

Subscapularis pathology manifests itself as pain and weakness in internal rotation. Where pain is slight, this reduced strength suggests a tear. Where pain is more severe, it is not usually possible to distinguish between a tear and other pathology.

A more specific test for the subscapularis is active internal rotation of the arm behind the back. The arm is pressed away from the lumbar spine posteriorly (lift-off test) with the elbow flexed 90°. The passive internal rotation, a combined glenohumeral, scapular, and thoracic motion, can be measured by the spinous processes of the lumbar and thoracic spine, which the patient's thumb can just reach.

### Lift-Off Test

**Procedure:** With his or her arm internally rotated, the patient places the dorsum of the hand on the back and attempts to lift the hand off the back against the examiner's resistance.

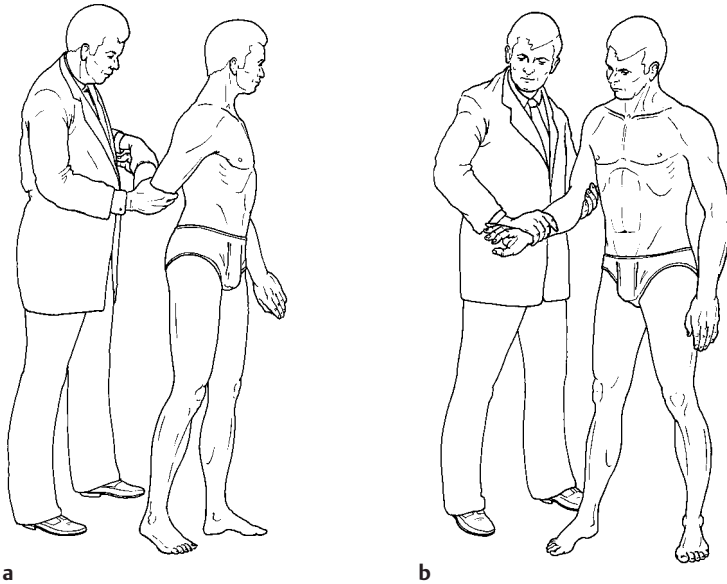


Fig. 71a, b Subscapularis test:  
**a** passive external rotation,  
**b** active internal rotation behind the back

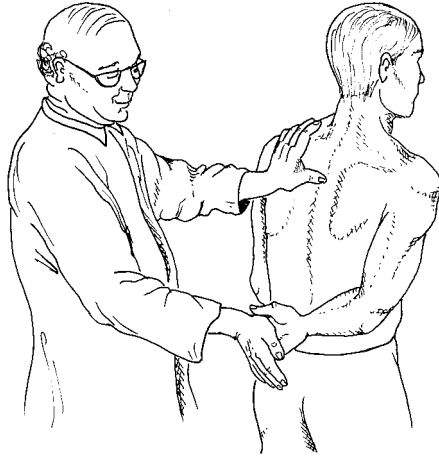
Subscapularis pathology manifests itself as pain and weakness in internal rotation. Where pain is slight, this reduced strength suggests a tear. Where pain is more severe, it is not usually possible to distinguish between a tear and other pathology.

A more specific test for the subscapularis is active internal rotation of the arm behind the back. The arm is pressed away from the lumbar spine posteriorly (lift-off test) with the elbow flexed 90°. The passive internal rotation, a combined glenohumeral, scapular, and thoracic motion, can be measured by the spinous processes of the lumbar and thoracic spine, which the patient's thumb can just reach.

### Lift-Off Test

**Procedure:** With his or her arm internally rotated, the patient places the dorsum of the hand on the back and attempts to lift the hand off the back against the examiner's resistance.

Fig. 72 Lift-off test



**Assessment:** A patient with a subscapularis tear will be unable to do this.

### Infraspinatus Test

**Procedure:** This test may be performed with the patient seated or standing.

Comparative testing of both sides is best. The patient's arms should hang relaxed with the elbows flexed 90° but not quite touching the trunk. The examiner places his or her palms on the dorsum of each of the patient's hands and then asks the patient to externally rotate both forearms against the resistance of the examiner's hands.

**Assessment:** Pain or weakness in external rotation indicates a disorder of the infraspinatus (external rotator). As infraspinatus tears are usually painless, weakness in rotation strongly suggests a tear in this muscle. This test can also be performed with the arm abducted 90° and flexed 30° to eliminate involvement of the deltoid in this motion.

### Teres Test

**Procedure:** The patient is standing and relaxed. The examiner assesses the position of the patient's hands from behind.

Fig. 73 Infraspinatus test

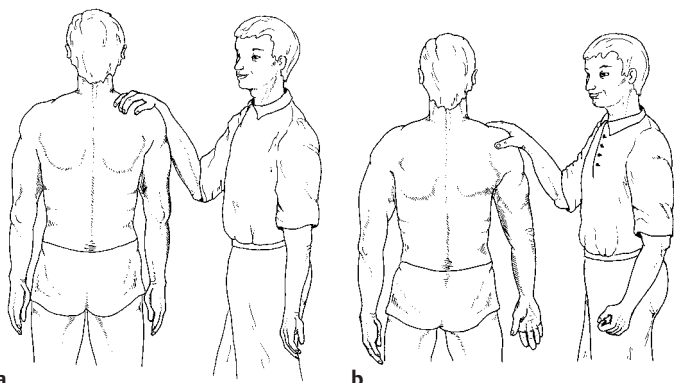
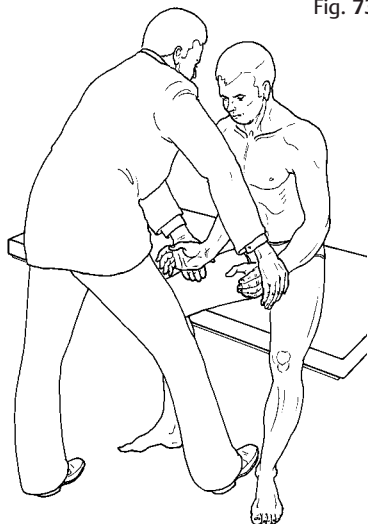


Fig. 74a, b Teres test:

a normal position,

b contracture in the right arm

**Assessment:** The teres major is an internal rotator. Where a contracture is present, the palm of the affected hand will face backward compared with the contralateral hand. With the patient standing in a relaxed position, such a finding suggests a contracture of the teres major.

Weakness of the rotator cuff or a brachial plexus lesion can also produce an asymmetrical hand position.

### Nonspecific Supraspinatus Test

**Procedure:** The patient is seated with the arm abducted 90° with the examiner's hand resting on the patient's forearm. The examiner then asks the patient to further abduct the arm against the examiner's resistance.

**Assessment:** Weakness in further abduction and/or pain indicate pathology of the supraspinatus tendon.

### Drop Arm Test

**Procedure:** The patient is seated, and the examiner passively abducts the patient's extended arm approximately 120°. The patient is asked to hold the arm in this position without support and then slowly allow it to drop.

**Assessment:** Weakness in maintaining the position of the arm, with or without pain, or sudden dropping of the arm suggests a rotator cuff lesion. Most often this is due to a defect in the supraspinatus. In pseudoparalysis, the patient will be unable to lift the affected arm. This global sign suggests a rotator cuff disorder.

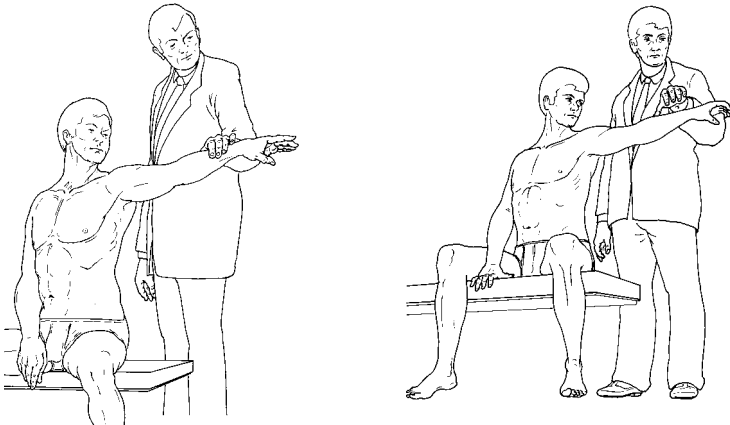


Fig. 75 Nonspecific supraspinatus test    Fig. 76 Drop arm test

## Ludington Sign

**Procedure:** The seated patient is asked to place both hands behind the neck.

**Assessment:** If the patient has to make compensatory motions or is able to place one hand behind the neck only with assistance, the limited external rotation and abduction indicate the presence of a rotator cuff tear.

## Apley's Scratch Test

**Procedure:** The seated patient is asked to touch the contralateral superior medial corner of the scapula with the index finger.

**Assessment:** Pain elicited in the rotator cuff and failure to reach the scapula because of restricted mobility in external rotation and abduction indicate rotator cuff pathology (most probably involving the supraspinatus). A differential diagnosis should consider osteoarthritis in the glenohumeral and acromioclavicular joints as well as capsular fibrosis.

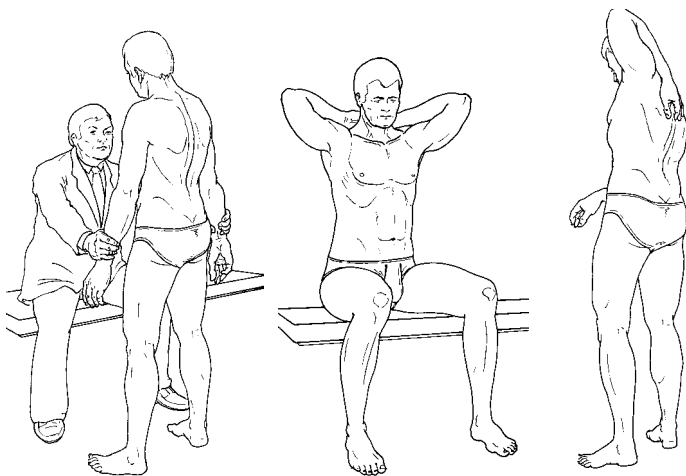
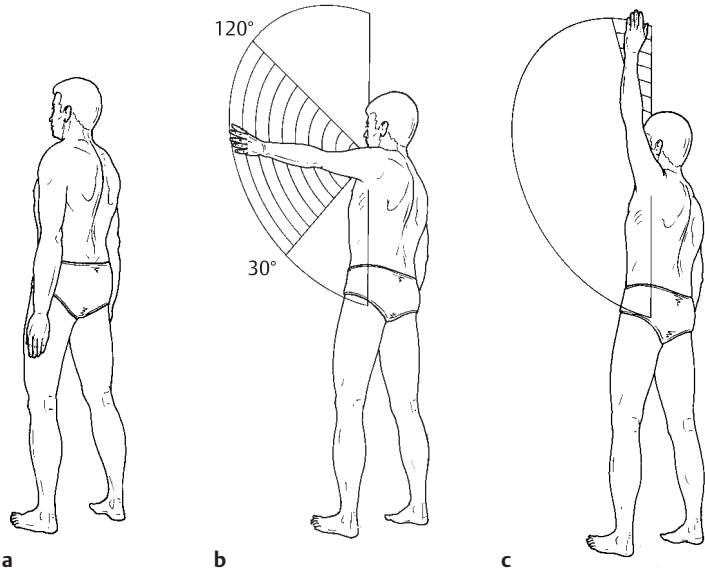


Fig. 77 0° abduction test

Fig. 78 Ludington sign

Fig. 79 Apley's scratch test



**Fig. 80a–c Painful arc:**  
**a** starting position,  
**b** painful motion between 30° and 120°,  
**c** pain at the end of the range of motion, a sign of acromioclavicular joint pathology.

### Painful Arc

**Procedure:** The arm is passively and actively abducted from the rest position alongside the trunk.

**Assessment:** Pain occurring in abduction between 70° and 120° (Fig. 80b) is a sign of a lesion of the supraspinatus tendon, which becomes impinged between the greater tubercle of the humerus and the acromion in this phase of the motion (subacromial impingement). (Contrast this with the painful arc in acromioclavicular joint disorders, where the pain only occurs only at 140°–180° of abduction, Fig. 80c; see also Fig. 84). Patients are usually free of pain above 120°.

In the evaluation of the active and passive ranges of motion, the patient can often avoid the painful arc by externally rotating the arm while abducting it. This increases the clearance between the acromion and the diseased tendinous portion of the rotator cuff, avoiding impingement in the range between 70° and 120°.



In addition to complete or incomplete rotator cuff tears, swelling and inflammation as a result of bursitis and abnormality of the margin of the acromion occasionally lead to impingement with a painful arc, as does osteoarthritis in the acromioclavicular joint.

### Neer Impingement Sign

**Procedure:** The examiner immobilizes the scapula with one hand while the other hand jerks the patient's arm forward, upward, and sideways (medially) into the scapular plane.

**Assessment:** If an impingement syndrome is present, subacromial constriction or impingement of the diseased area against the anterior inferior margin of the acromion will produce severe pain with motion.

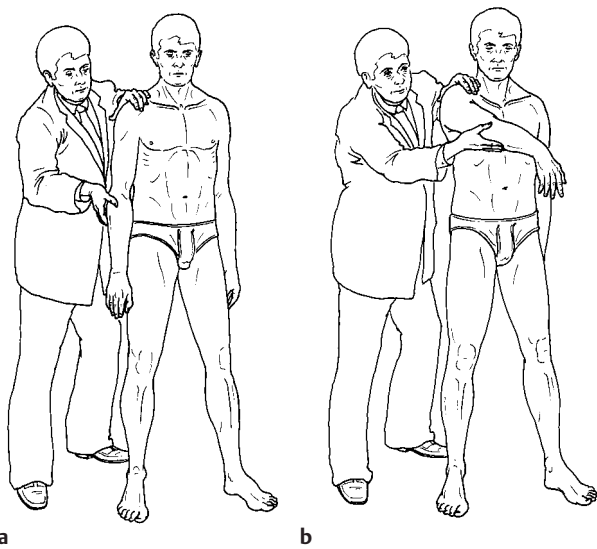


Fig. 81a, b Neer impingement sign:

a starting position,

b forcible forward flexion and adduction of the extended arm

## Hawkins Impingement Sign

**Procedure:** The examiner immobilizes the scapula with one hand while the other hand adducts the patient's 90°-forward-flexed and internally rotated arm (moving it toward the contralateral side of the body).

**Assessment:** If an impingement syndrome is present, the supraspinatus tendon will become pinched beneath or against the coracoacromial ligament, causing severe pain on motion. Coracoid impingement is revealed by the adduction motion, in which the supraspinatus tendon also impinges against the coracoid process.

In the Jobe impingement test, the forward flexed and slightly adducted arm is forcibly internally rotated. This will provoke typical impingement pain.

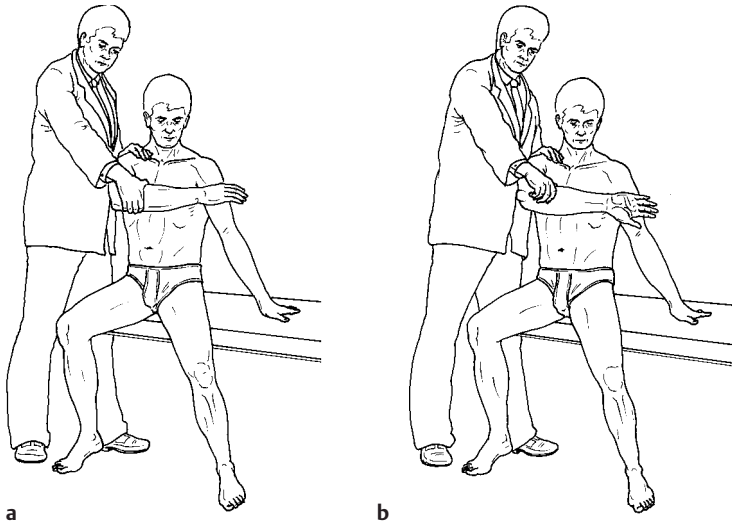
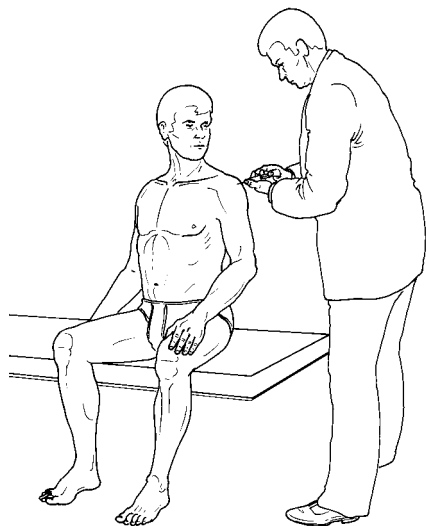


Fig. 82 Hawkins impingement sign:  
a starting position  
b forcible internal rotation (Jobe)

Fig. 83 Neer impingement injection test



### Neer Impingement Injection Test

**Procedure:** The subacromial space is infiltrated with an anesthetic.

**Assessment:** This test allows the examiner to determine whether subacromial impingement is the cause of the painful arc. A painful arc that disappears or improves after the injection is caused by changes in the subacromial space, such as bursitis or an activated rotator cuff defect.

### ■ Acromioclavicular Joint

The acromial end of the clavicle articulates with the acromion. The acromioclavicular ligament reinforces the capsule of this joint. Functionally, the articulation is a ball-and-socket joint whose range of motion is less than that of the sternoclavicular joint. Another strong ligament joins the scapula and clavicle, the coracoclavicular ligament. It arises from the coracoid process and inserts into the inferior aspect of the clavicle. Arthritic changes in the acromioclavicular joint cause pain and further constrict the subacromial space. In addition to pain with motion and tenderness to palpation over the acromioclavicular joint, findings will often include palpable bony thickening of the articular

margin. Tossy classifies acromioclavicular joint injuries into three degrees of severity:

Tossy type 1: Contusion of the acromioclavicular joint without significant injury to the capsule and ligaments.

Tossy type 2: Subluxation of the acromioclavicular joint with rupture of the acromioclavicular ligaments.

Tossy type 3: Dislocation of the acromioclavicular joint with additional rupture of the coracoclavicular ligaments.

In severe injuries to the capsule and ligaments, the pull of the cervical musculature causes the lateral end of the clavicle to displace proximally. From there it can be reduced inferiorly against elastic resistance. This procedure is sometimes referred to as the “piano key” phenomenon.

### Painful Arc

**Procedure:** The patient’s arm is passively and actively abducted from the rest position alongside the trunk.

**Assessment:** Pain in the acromioclavicular joint occurs between 140° and 180° of abduction. Increasing abduction leads to increasing com-

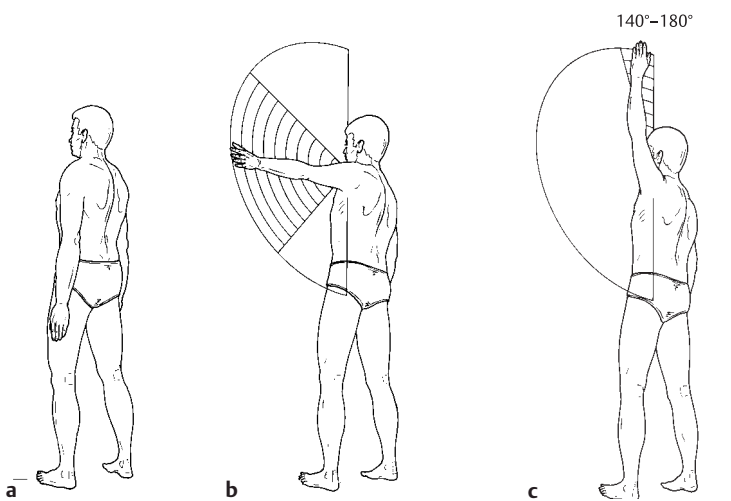


Fig. 84a–c Painful arc:

a starting position,

b pain between 30° and 120° (sign of a supraspinatus syndrome),

c pain between 140° and 180° (sign of osteoarthritis in the acromioclavicular joint)

pression and contortion in the joint. (In an impingement syndrome or a rotator cuff tear, by comparison, pain symptoms will occur between 70° and 120°; see Fig. 80).

### Forced Adduction Test

**Procedure:** The 90°-abducted arm on the affected side is forcibly adducted across the chest toward the normal side.

**Assessment:** Pain in the acromioclavicular joint suggests joint pathology or anterior impingement. (Absence of pain after injection of an anesthetic is a sign of joint disease.)

### Forced Adduction Test on Hanging Arm

**Procedure:** The examiner grasps the upper arm of the affected side with one hand while the other hand rests on the contralateral shoulder and immobilizes the shoulder girdle. Then the examiner forcibly adducts the hanging affected arm behind the patient's back against the patient's resistance.

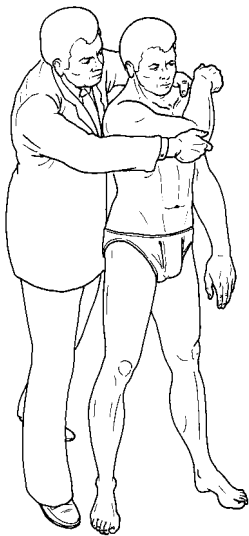

Fig. 85 Forced adduction test

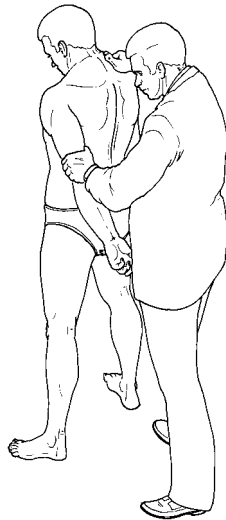

Fig. 86 Forced adduction test on hanging arm

**Assessment:** Pain across the anterior aspect of the shoulder suggests acromioclavicular joint disease or subacromial impingement. (Symptoms that disappear or improve following injection of an anesthetic indicate that the acromioclavicular joint is causing the pain.)

### Test of Horizontal Mobility of the Lateral Clavicle

**Procedure:** The examiner grasps the lateral end of the clavicle between two fingers and moves it in every direction.

**Assessment:** Increased mobility of the lateral clavicle with or without pain is a sign of instability in the acromioclavicular joint. In isolated osteoarthritis there will be circumscribed tenderness to palpation and pain with motion. Acromioclavicular joint separation with rupture of the coracoclavicular ligaments will be accompanied by a positive “piano key” sign: the subluxated lateral end of the clavicle displaces proximally with the pull of the cervical musculature and can be pressed inferiorly against elastic resistance.

### Dugas Test

**Procedure:** The patient is seated or standing and touches the contralateral shoulder with the hand of the 90°-flexed arm of the affected side.

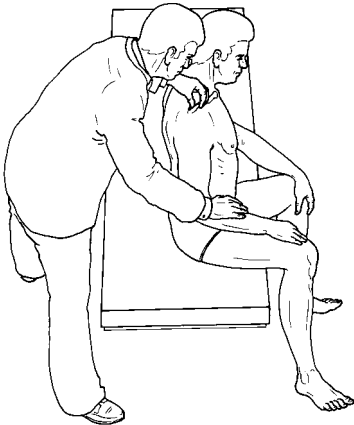

Fig. 87 Test of horizontal mobility of the lateral clavicle

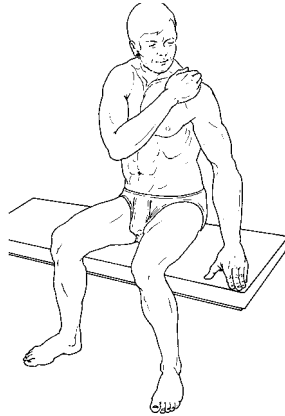


Fig. 88 Dugas test

**Assessment:** Acromioclavicular joint pain suggests joint disease (osteoarthritis, instability, disk injury, or infection). A differential diagnosis must exclude anterior subacromial impingement, due to the topographic proximity of that region.

## ■ Long Head of the Biceps Tendon

A rupture of the long head of the biceps tendon will appear as a distally displaced protrusion of the muscle belly of the biceps. The close anatomic proximity of the intraarticular portion of the tendon to the coracoacromial arch predisposes it to involvement in degenerative processes in the subacromial space. A rotator cuff tear is often accompanied by a rupture of the long head of the biceps tendon.

Isolated inflammation of the long head of the biceps tendon (bicipital tenosynovitis) is accordingly rare. In younger patients, this may occur as a tennis or throwing injury. Subluxations of the long head of the biceps tendon in the bicipital groove are usually difficult to detect. However, a series of specific tests can be used to diagnose biceps tendon injuries; the typical sign of these injuries is not the distally displaced muscle belly but incomplete contraction and/or “snapping” of the tendon.

### Nonspecific Biceps Tendon Test

**Procedure:** The patient holds the arm abducted in neutral rotation with the elbow flexed 90°. The examiner immobilizes the patient's elbow with one hand and places the heel of the other hand on the patient's distal forearm. The patient is then asked to externally rotate his or her arm against the resistance of the examiner's hand.

**Assessment:** Pain in the bicipital groove or at the insertion of the biceps suggests a tendon disorder.

Pain in the anterolateral aspect of the shoulder is often a sign of a disorder of the rotator cuff, especially the infraspinatus tendon.

### Abbott-Saunders Test

Demonstrates subluxation of the long head of the biceps tendon in the bicipital groove.

**Procedure:** The patient's arm is externally rotated and abducted about 20°. The examiner slowly lowers the arm from this position. The examiner guides this motion of the patient's arm with one hand while resting

**Assessment:** Acromioclavicular joint pain suggests joint disease (osteoarthritis, instability, disk injury, or infection). A differential diagnosis must exclude anterior subacromial impingement, due to the topographic proximity of that region.

## ■ Long Head of the Biceps Tendon

A rupture of the long head of the biceps tendon will appear as a distally displaced protrusion of the muscle belly of the biceps. The close anatomic proximity of the intraarticular portion of the tendon to the coracoacromial arch predisposes it to involvement in degenerative processes in the subacromial space. A rotator cuff tear is often accompanied by a rupture of the long head of the biceps tendon.

Isolated inflammation of the long head of the biceps tendon (bicipital tenosynovitis) is accordingly rare. In younger patients, this may occur as a tennis or throwing injury. Subluxations of the long head of the biceps tendon in the bicipital groove are usually difficult to detect. However, a series of specific tests can be used to diagnose biceps tendon injuries; the typical sign of these injuries is not the distally displaced muscle belly but incomplete contraction and/or “snapping” of the tendon.

### Nonspecific Biceps Tendon Test

**Procedure:** The patient holds the arm abducted in neutral rotation with the elbow flexed 90°. The examiner immobilizes the patient's elbow with one hand and places the heel of the other hand on the patient's distal forearm. The patient is then asked to externally rotate his or her arm against the resistance of the examiner's hand.

**Assessment:** Pain in the bicipital groove or at the insertion of the biceps suggests a tendon disorder.

Pain in the anterolateral aspect of the shoulder is often a sign of a disorder of the rotator cuff, especially the infraspinatus tendon.

### Abbott-Saunders Test

Demonstrates subluxation of the long head of the biceps tendon in the bicipital groove.

**Procedure:** The patient's arm is externally rotated and abducted about 20°. The examiner slowly lowers the arm from this position. The examiner guides this motion of the patient's arm with one hand while resting



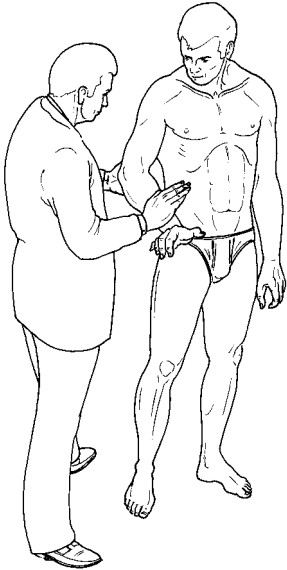


Fig. 89 Nonspecific biceps tendon test

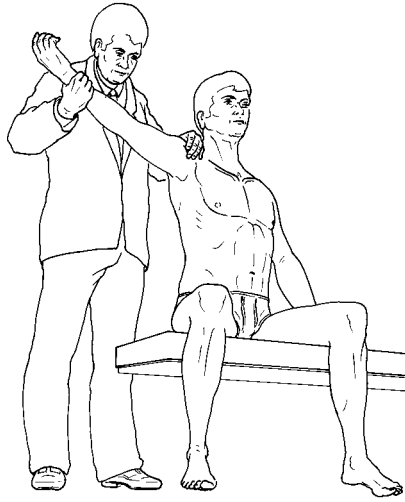


Fig. 90 Abbott-Saunders test

the other on the patient's shoulder and palpating the bicipital groove with the index and middle fingers.

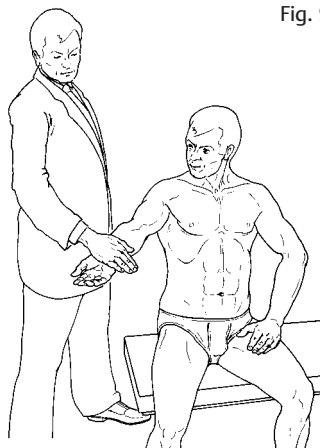
**Assessment:** Pain in the region of the bicipital groove or a palpable or audible snap suggest a disorder of the biceps tendon (subluxation sign). An inflamed bursa (subcoracoid or subscapular bursa) can also occasionally cause snapping.

### Speed Test

**Procedure:** The patient's arm is extended in supination at 90° of abduction and 30° of horizontal flexion. The patient attempts to either maintain this position or continue to abduct the arm against the downward pressure of the examiner's hand.

**Assessment:** Asymmetrical abduction strength with pain in the region of the bicipital groove suggests a disorder of the long head of the biceps tendon (tenosynovitis or a subluxation phenomenon).

Fig. 91 Speed test



### Snap Test

Tests for subluxation of the long head of the biceps tendon.

**Procedure:** The examiner palpates the bicipital groove with the index and middle finger of one hand. With the other hand, the examiner grasps the wrist of the patient's arm (abducted 80°–90° and flexed 90° at the elbow) and passively rotates it at the shoulder, first in one direction and then the other.

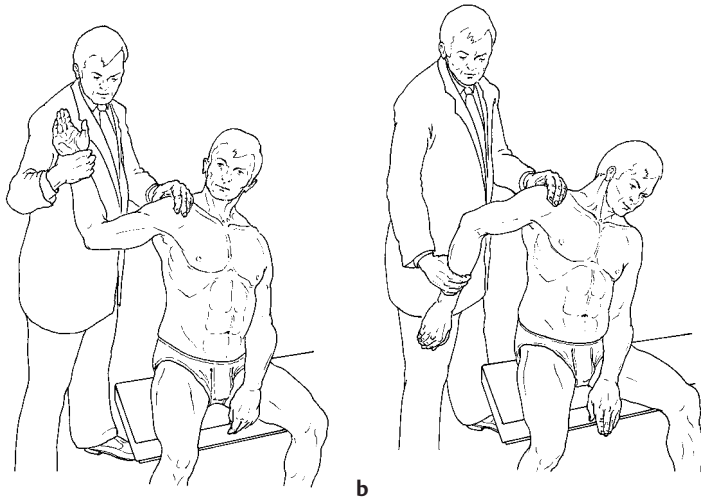
**Assessment:** Subluxation of the long head of the biceps tendon out of the bicipital groove will be detectable as a palpable snap.

### Yergason Test

Functional test of the long head of the biceps tendon.

**Procedure:** The patient's arm is alongside the trunk and flexed 90° at the elbow. One of the examiner's hands rests on the patient's shoulder and palpates the bicipital groove with the index finger while the other hand grasps the patient's forearm. The patient is asked to supinate the forearm against the examiner's resistance. This places isolated tension on the long head of the biceps tendon.

**Assessment:** Pain in the bicipital groove is a sign of a lesion of the biceps tendon, its tendon sheath, or its ligamentous connection via the transverse ligament. The typical provoked pain can be increased by pressing on the tendon in the bicipital groove.



**a** **b**  
Fig. 92a, b Snap test: **a** external rotation, **b** internal rotation

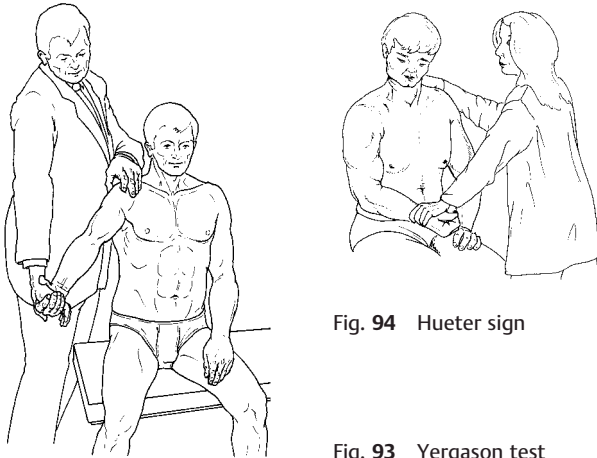


Fig. 94 Hueter sign

Fig. 93 Yergason test

### Hueter Sign

**Procedure:** The patient is seated with the arm extended at the elbow and the forearm in supination. The examiner grasps the posterior aspect of the patient's forearm. The patient is then asked to flex the elbow against the resistance of the examiner's hand.

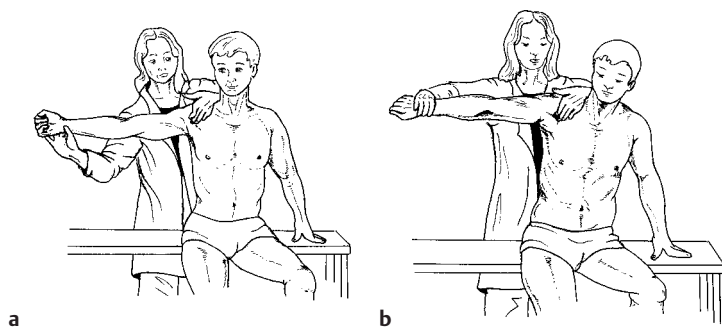


Fig. 95a, b Transverse humeral ligament test:  
**a** starting position,  
**b** palpating the biceps tendon in internal rotation

**Assessment:** In a rupture of the long head of the biceps tendon, the distally displaced muscle belly can be observed as a “ball” directly proximal to the elbow.

### Transverse Humeral Ligament Test

**Procedure:** The patient is seated with the arm abducted 90°, internally rotated, and extended at the elbow. From this position, the examiner externally rotates the arm while palpating the bicipital groove to verify whether the tendon snaps.

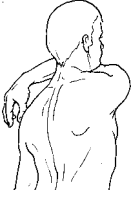**Assessment:** In the presence of ligamentous insufficiency, this motion will cause the biceps tendon to spontaneously displace out of the bicipital groove. Pain reported without displacement suggests biceps tendinitis.

### Thompson and Kopell Horizontal Flexion Test (Cross-Body Action)

**Procedure:** The patient is standing and moves the 90-° abducted arm across the body into maximum horizontal flexion.

**Assessment:** Dull, deep-seated pain above the superior margin of the scapula in the supraspinatus fossa and on the posterolateral scapula radiating into the upper arm can be caused by compression of the suprascapular nerve beneath the transverse scapular ligament as a result of distal displacement of the scapula.

Fig. 96 Thompson and Kopell horizontal flexion test



**Note:** A differential diagnosis must consider pain due to acromioclavicular joint pathology. Such pain can also be elicited by this test maneuver.

### Ludington Test

**Procedure and assessment:** Both arms are abducted and the palms placed on the head with the fingers interlaced. In a positive test, voluntary contraction of the biceps causes pain in the anterior deltoid region.

### Lippman Test

**Procedure and assessment:** With the patient's arm flexed 90° at the elbow, the examiner palpates the bicipital groove about 3 cm distal to the glenohumeral joint. Where the biceps tendon has a tendency to subluxate or dislocate, the examiner can provoke subluxation or dislocation by palpation. This will usually be accompanied by pain.

### DeAnquin Test

**Procedure and assessment:** Rotating the upper arm while palpating the biceps tendon in the bicipital groove causes pain in the presence of biceps tendon pathology.

### Gilcrest Test

**Procedure and assessment:** Reducing the biceps tendon into the bicipital groove during slow adduction after subluxation or displacement in elevation leads to increased pain in the anterior deltoid region.

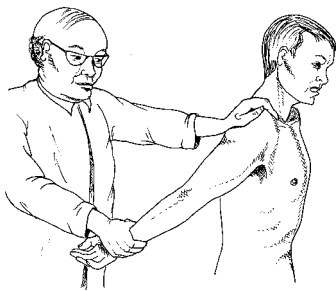


Fig. 97 Traction test

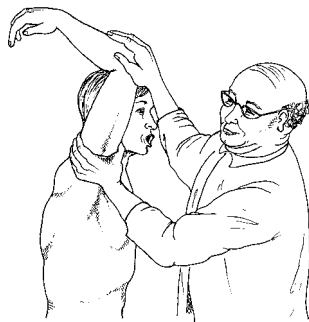


Fig. 98 Compression test

### Beru Sign

**Procedure and assessment:** Displacement of the long head of the biceps tendon can be palpated beneath the anterior deltoid when the biceps is voluntarily contracted.

### Duga Sign

**Procedure and assessment:** Where a lesion of the long head of the biceps tendon is present, the patient will be unable to touch the contralateral shoulder with the affected arm.

### Traction Test

**Procedure and assessment:** Passive retroflexion of the shoulder with the elbow extended and the forearm in pronation causes pain in the anterior deltoid region along the course of the biceps tendon. This pain also occurs if the patient attempts to actively supinate the forearm from this position, flex the elbow, or forward flex the shoulder.

### Compression Test

**Procedure and assessment:** Passive elevation of the arm to the end of its range of motion with continued application of posterior pressure

produces pain as a result of compression of the biceps tendon between the acromion and humeral head.

Evaluation of the range of motion is crucial in patients with suspected shoulder instability. Rotation should be examined both in adduction and 90°-abduction. Restricted external rotation in both adduction and abduction will often be the first sign of instability in patients with anterior instability. Flexion and abduction in the scapular plane are not normally restricted.

## ■ Shoulder Instability

Chronic shoulder pain may be attributable to an unstable shoulder. The clinical picture of subluxation in particular is often difficult to diagnose, and patients themselves can usually give only a vague description of their symptoms.

According to Neer, instability patients invariably have a history of a period of intensive shoulder use (such as competitive sports), an episode of repeated minor trauma (overhead use), or generalized ligament laxity. Both young athletes and inactive persons are affected, men and women alike.

The transition between subluxation and dislocation is continuous. Patients with voluntary instability are a separate issue. In such cases, consultation with a psychologist may be helpful in addition to repeated clinical examination.

The differential diagnosis must specifically consider an impingement syndrome, a rotator cuff tear, osteoarthritis in the acromioclavicular joint, and also a cervical spine syndrome. In cases of doubt, injection of a local anesthetic at the point of maximum pain may be required.

However, this treatment cannot permanently eliminate instability symptoms. Signs of generalized ligament laxity may include increased mobility in other joints and, especially, increased hyperextension in the elbow or retroflexion in the metacarpophalangeal joint of the thumb with the forearm extended. The use of a variety of relatively specific tests will make it easier for the examiner to arrive at a diagnosis.

Assessment of the range of motion is crucial in patients with suspected shoulder instability. Rotation should be examined in both adduction and 90°-abduction. Restricted external rotation in both adduction and abduction will often be the first sign of instability in patients with anterior instability. Flexion and abduction in the scapular plane are not normally restricted.

produces pain as a result of compression of the biceps tendon between the acromion and humeral head.

Evaluation of the range of motion is crucial in patients with suspected shoulder instability. Rotation should be examined both in adduction and 90°-abduction. Restricted external rotation in both adduction and abduction will often be the first sign of instability in patients with anterior instability. Flexion and abduction in the scapular plane are not normally restricted.

## ■ Shoulder Instability

Chronic shoulder pain may be attributable to an unstable shoulder. The clinical picture of subluxation in particular is often difficult to diagnose, and patients themselves can usually give only a vague description of their symptoms.

According to Neer, instability patients invariably have a history of a period of intensive shoulder use (such as competitive sports), an episode of repeated minor trauma (overhead use), or generalized ligament laxity. Both young athletes and inactive persons are affected, men and women alike.

The transition between subluxation and dislocation is continuous. Patients with voluntary instability are a separate issue. In such cases, consultation with a psychologist may be helpful in addition to repeated clinical examination.

The differential diagnosis must specifically consider an impingement syndrome, a rotator cuff tear, osteoarthritis in the acromioclavicular joint, and also a cervical spine syndrome. In cases of doubt, injection of a local anesthetic at the point of maximum pain may be required.

However, this treatment cannot permanently eliminate instability symptoms. Signs of generalized ligament laxity may include increased mobility in other joints and, especially, increased hyperextension in the elbow or retroflexion in the metacarpophalangeal joint of the thumb with the forearm extended. The use of a variety of relatively specific tests will make it easier for the examiner to arrive at a diagnosis.

Assessment of the range of motion is crucial in patients with suspected shoulder instability. Rotation should be examined in both adduction and 90° abduction. Restricted external rotation in both adduction and abduction will often be the first sign of instability in patients with anterior instability. Flexion and abduction in the scapular plane are not normally restricted.



## Anterior Apprehension Test

### *Tests of shoulder stability.*

**Procedure:** The examination begins with the patient seated. The examiner grasps the humeral head through the surrounding soft tissue with one hand and guides the patient's arm with the other hand. The examiner passively abducts the patient's shoulder with the elbow flexed and then brings the shoulder into maximum external rotation, keeping the arm in this position. The test is performed at 60°, 90°, and 120° of abduction to evaluate the superior, medial, and inferior glenohumeral ligaments. With the guiding hand, the examiner presses the humeral head in an anterior and inferior direction.

This test may be performed with the patient supine to better relax the shoulder musculature. The shoulder lies on the edge of the examining table, which acts as a fulcrum. In this position, the apprehension sign can be elicited in various positions of external rotation and abduction (fulcrum test). The normal contralateral shoulder is used as reference.

**Assessment:** Shoulder pain with reflexive muscle tensing is a sign of an anterior instability syndrome. This muscle tension is an attempt by the patient to prevent imminent subluxation or dislocation of the humeral head.

Even without pain, isolated muscle tensing in the anterior shoulder region (pectoralis) can be a sign of an instability syndrome.

With the patient supine, the apprehension test can often be made more specific (Fowler test; Fig. 99c, d). In the apprehension position, the humeral head is pressed posteriorly. This rapidly reduces the patient's pain and fear of dislocation.

In another stage of the apprehension test, relieving the posteriorly directed pressure on the humeral head causes a sudden increase in pain with the apprehension phenomenon.

In Jobe's modification, the apprehension phenomenon can also be classified in degrees of severity. Increasing posterior pressure on the humeral head produces increasing pain and sensation of dislocation corresponding to the increasing external rotation and abduction.

**Note:** When the patient complains of sudden stabbing pain with simultaneous or subsequent paralyzing weakness in the affected extremity, this is referred to as the "dead arm sign." It is attributable to the transient compression the subluxated humeral head exerts on the plexus.

It is important to know that at 45° of abduction, the test primarily evaluates the medial glenohumeral ligament and the subscapularis tendon. At or above 90° of abduction, the stabilizing effect of the sub-

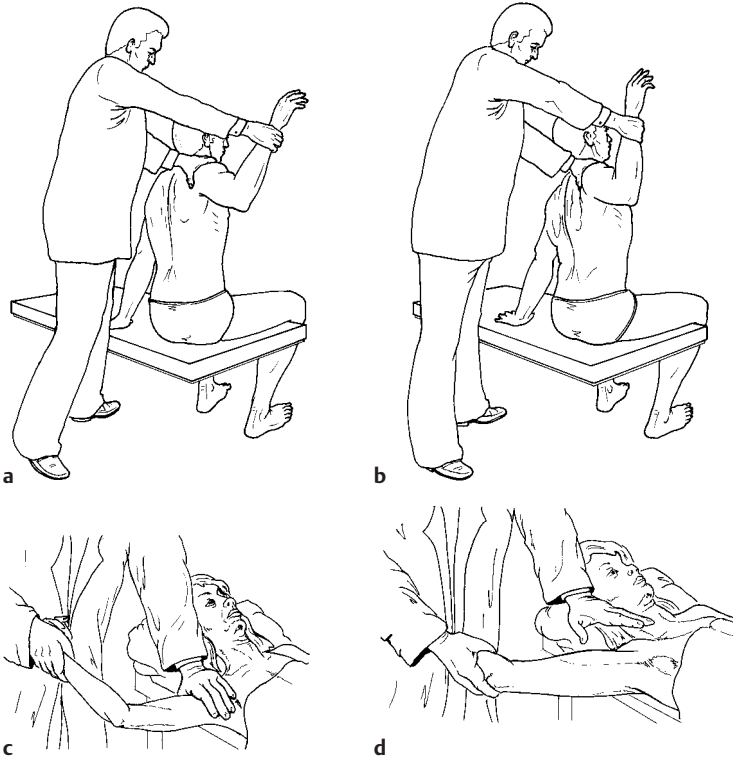


Fig. 99a–d Anterior apprehension test:  
**a** starting position,  
**b** test position,  
**c** supine with posteriorly directed pressure applied to the humeral head,  
**d** after relieving the posteriorly directed pressure

scapularis is neutralized and the test primarily evaluates the inferior glenohumeral ligament.

### Apprehension Test (Supine)

**Procedure:** The patient is supine with the arm abducted, externally rotated, and flexed at the elbow. The examiner exerts posterior pressure to displace the humeral head anteriorly.

Stability should be tested at 60°, 90°, and 120° of abduction.

**Assessment:** The patient with anterior instability expects pain the farther the humeral head moves anteriorly past the labrum in the direction of potential dislocation. The patient reacts with an avoidance movement.

### Rowe Test

**Procedure:** The patient stands and bends forward slightly with the arm relaxed. To examine the right shoulder, the examiner grasps the patient's shoulder with the left hand and with the right hand passively moves the patient's arm slightly anteriorly and inferiorly.

**Assessment:** This position allows the examiner to perform a slight anterior-inferior translation and evaluate the stability of the shoulder.

### Throwing Test

**Procedure and assessment:** In the throwing test, the patient executes a rapid throwing motion against the examiner's resistance. This test can reveal anterior subluxation that occurs during the throwing motion.

### Leffert Test

**Procedure and assessment:** The Leffert test can be used to quantify a drawer phenomenon. Looking downward at the shoulder of the seated

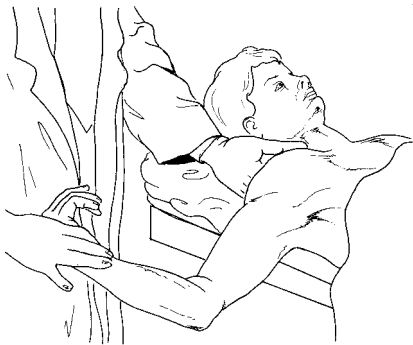

Fig. 100 Apprehension test (supine)



Fig. 101 Rowe test

patient (craniocaudal view), the examiner displaces the humeral head anteriorly. The anterior displacement of the examiner's index finger in relation to the middle finger shows the degree of anterior translation of the humeral head.

### Anterior and Posterior Drawer Test

**Procedure:** The patient is seated. The examiner stands behind the patient. To evaluate the right shoulder, the examiner grasps the patient's shoulder with the left hand to stabilize the clavicle and superior margin of the scapula while using the right hand to move the humeral head anteriorly and posteriorly.

**Assessment:** Significant anterior or posterior mobility of the humeral head suggests instability.

Fig. 102 Throwing test

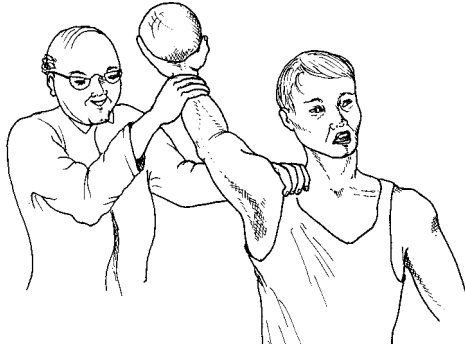


Fig. 103a, b Leffert test:  
a starting position,  
b index finger displaced  
anteriorly

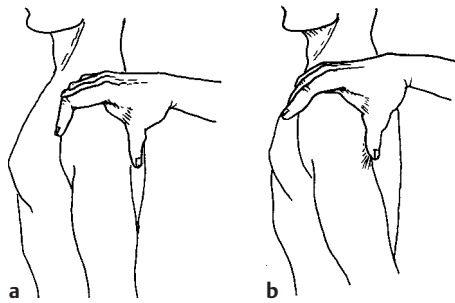


Fig. 104 Anterior and posterior drawer test

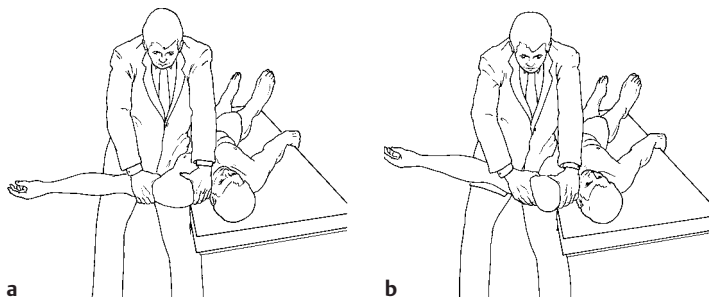
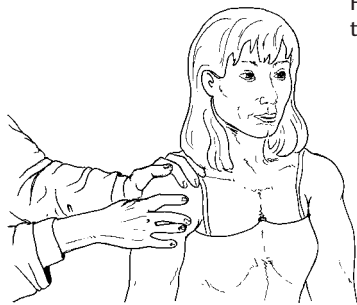

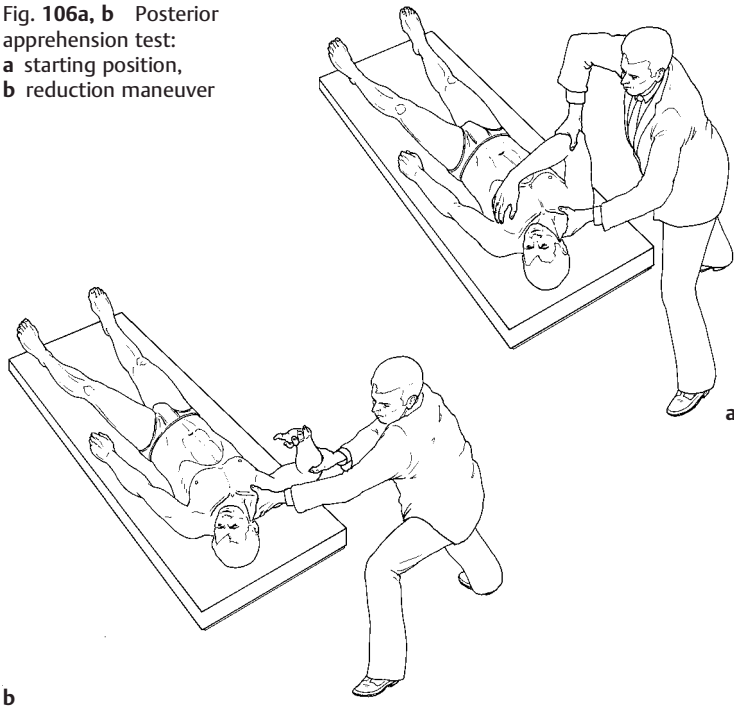
Fig. 105a, b Gerber-Ganz anterior drawer test:  
 a starting position,  
 b dislocation maneuver

### Gerber-Ganz Anterior Drawer Test

**Procedure:** The patient is supine with the affected shoulder positioned such that it projects slightly past the edge of the examining table. The affected shoulder is held in  $80^{\circ}$ – $120^{\circ}$  of abduction,  $0^{\circ}$ – $20^{\circ}$  of flexion, and  $0^{\circ}$ – $30^{\circ}$  of external rotation as loosely and without pain as possible. The examiner immobilizes the scapula with the left hand (with the index and middle fingers on the scapular spine and the thumb on the coracoid). With the right hand, the examiner tightly grasps the patient's proximal upper arm and pulls it anteriorly in a manner similar to the Lachman test for anterior instability in the knee.

**Assessment:** The relative motion between the immobilized scapula and the anteriorly displaced humerus is a measure of anterior instability and can be classified in degrees.

Fig. 106a, b Posterior apprehension test:  
 a starting position,  
 b reduction maneuver



Occasional audible clicking with or without pain can indicate an anterior labrum defect.

#### Posterior Apprehension Test (Posterior Shift and Load Test)

**Procedure:** With the patient supine, the examiner places one hand under the patient's scapula and grasps the elbow with the other. By pressing the abducted, horizontally flexed, and internally rotated arm posteriorly, the examiner attempts to provoke posterior subluxation of the humeral head.

**Assessment:** Sufficient laxity in the capsular ligaments will allow posterior subluxation or even dislocation of the humeral head with associated pain.

Maintaining the axial pressure on the humeral head increasingly abducts and retracts the arm. The previously subluxated or dislocated

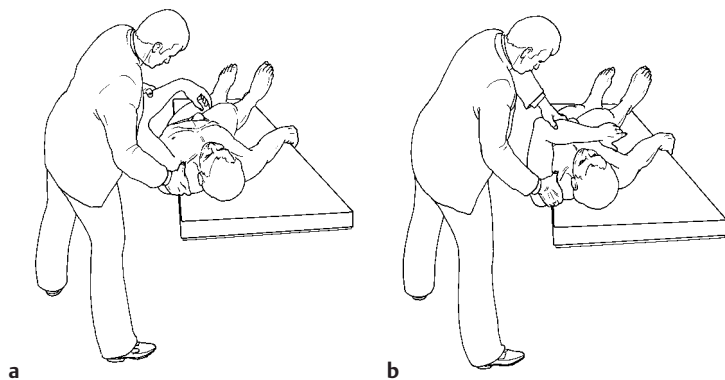


Fig. 107a, b Gerber-Ganz posterior drawer test: a starting position, b dislocation maneuver

humeral head can be reduced again with a readily palpable and audible click. (Caution: This test involves a certain risk of acute dislocation.)

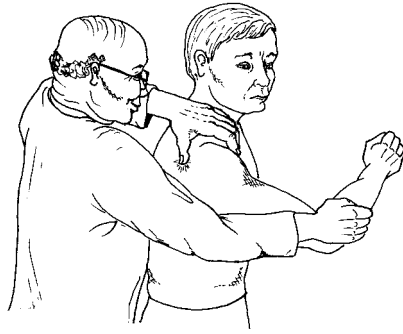
### Gerber-Ganz Posterior Drawer Test

**Procedure:** The patient is supine. Guiding the humeral head with one hand (with the thumb on the anterior humeral head and the fingers on the scapular spine, posterior humeral head, and scapular spine and posterior glenoid if necessary), with the other hand the examiner holds the patient's arm in 90° of flexion at about 20°–30° of horizontal extension.

The examiner exerts pressure on the anterior humeral head with the thumb while simultaneously holding the arm in horizontal flexion and applying axial posterior compression in slight internal rotation.

**Assessment:** Where there is sufficient laxity in the capsular ligaments, this test will provoke a posterior drawer (subluxation or dislocation of the humeral head). Horizontal extension, slight external rotation of the arm, and additional posteroanterior pressure applied by the finger to the posterior aspect of the humeral head will suffice to reduce the humeral head. The snap that accompanies reduction must be carefully distinguished from anterior subluxation. The important thing is to assess the motion of the humeral head relative to the glenoid fossa by placing the index finger posteriorly around the glenoid and pressing the humeral head in an anteroposterior direction with the thumb.

Fig. 108 Posterior apprehension test



The examination may also be performed with the patient seated. With the patient in a relaxed posture bending slightly forward with the arm hanging alongside the trunk, the examiner places his or her thumb on the patient's scapular spine or posterior glenoid and grasps the humeral head anteriorly. Applying rotation and pressure with the fingers will provoke posterior subluxation of the head where there is sufficient laxity in the capsular ligaments.

In posterior instability, the humeral head can be posteriorly displaced by one-half its diameter.

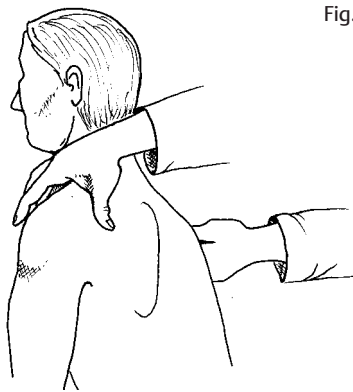
### Posterior Apprehension Test with the Patient Standing

**Procedure:** The patient is standing. The examiner abducts the affected arm between  $90^\circ$  and  $110^\circ$  at the shoulder and flexes it horizontally about  $20^\circ$ – $30^\circ$ . The examiner's other hand immobilizes the scapula from above; the examiner's fingers grasp the scapular spine and the humeral head while the thumb rests on the anterior aspect slightly lateral to the coracoid process.

**Assessment:** With slowly increasing horizontal flexion, the posterior thrust along the longitudinal axis of the humerus leads to posterior subluxation in the glenohumeral joint. Both the thumb lateral to the coracoid process and the fingers can detect the translation of the humeral head. Occasionally, the slightly prominent humeral head will be visible beneath the acromion. Extending the arm by  $20^\circ$ – $30^\circ$  in the same horizontal plane will lead to palpable reduction of the humeral head.



Fig. 109 Fukuda test



### Fukuda Test

**Procedure and assessment:** The Fukuda test elicits a passive posterior drawer sign. The patient is seated with the examiner's thumbs resting on both the patient's scapular spines. The examiner's other fingers rest anterior to the humeral head and exert posterior pressure to trigger a posterior drawer.

### Sulcus Sign

Tests for multidirectional instability.

**Procedure:** The patient is seated or standing. With one hand, the examiner stabilizes the patient's contralateral shoulder while exerting a distal pull on the patient's relaxed affected arm with the other hand. This is best done by grasping the patient's arm at the elbow with the elbow slightly flexed.

**Assessment:** Instability with distal displacement of the humeral head creates an obvious indentation (sulcus sign) inferior to the acromion. The degree of subluxation can be quantified in stress radiographs (with the patient holding weights in his or her hands).

Inferior stability is not a separate disease entity; rather, it is the same as multidirectional instability.

The test can also be performed so that the examiner supports the patient's 90°-abducted arm. Applying pressure to the proximal third of the upper arm from above can then provoke distal subluxation of the humeral head. This will create a significant step-off beneath the acromion.

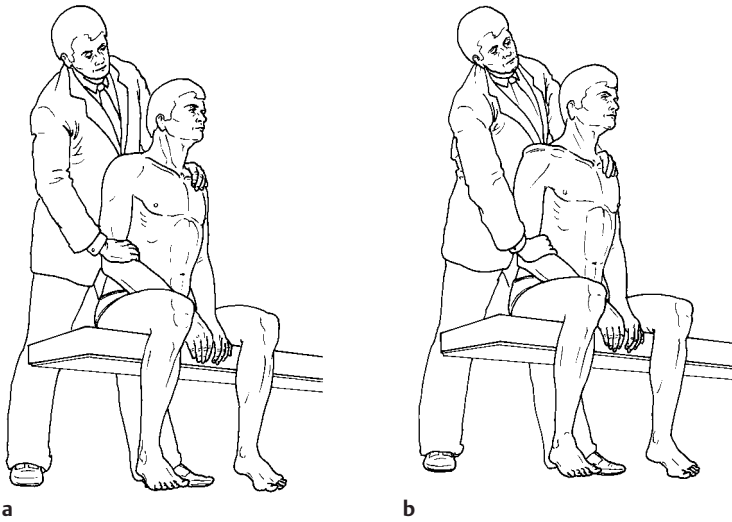
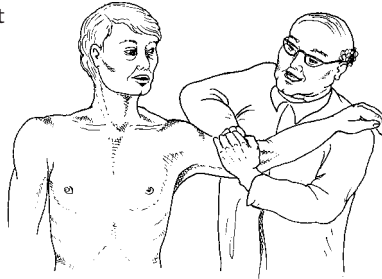


Fig. 110a, b Sulcus sign:  
a starting position,  
b sulcus sign with distal distraction of the arm

Fig. 111 Inferior apprehension test



### Inferior Apprehension Test

**Procedure and assessment:** In the inferior apprehension test, the examiner supports the patient's 90°-abducted arm with one hand. With the other hand, the examiner attempts to provoke an inferior subluxation by applying pressure from above to the patient's proximal upper arm.

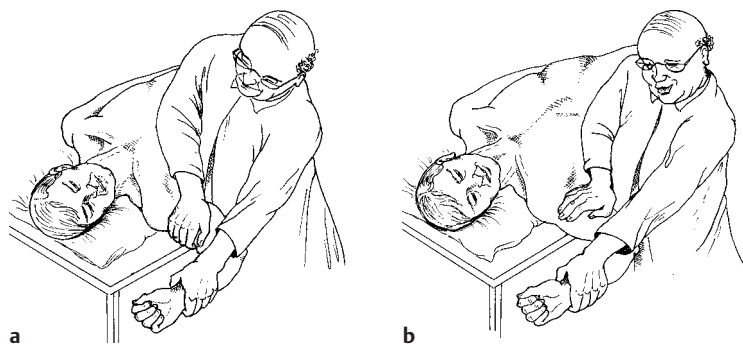


Fig. 112a, b Relocation test (fulcrum test):  
a anterior displacement of the humeral head in maximum external rotation,  
b posterior displacement of the humerus

### Relocation Test (Fulcrum Test)

**Procedure:** The patient is supine on an examining table with the affected arm externally rotated  $90^\circ$  and abducted  $90^\circ$ .

**Assessment:** Continuing to externally rotate the arm while shifting the humeral head anteriorly provokes typical muscular resistance from the patient, often combined with typical stabbing pain. The same motion (external rotation) applied while shifting the humeral head posteriorly is painless for the patient and well tolerated. This test has proven very helpful in differentiating patients with a supraspinatus syndrome from patients with rotator cuff tendinitis due to hypermobility.

---

# Elbow

Pain in the elbow may be due to a wide range of causes. Thorough clinical examination may be supplemented by a variety of functional tests to confirm the diagnosis. Particular attention should be paid to the position of the elbow. In joint effusion, synovial thickening, and degenerative joint disease, the elbow will be slightly flexed.

Synovial thickening, joint effusion, and especially olecranon bursitis are most visible and palpable posteriorly around the olecranon.

Osteoarthritis leads to palpable and audible crepitation. Where intra-articular loose bodies are present, patients complain of impingement symptoms in the joint.

The ulnar and radial collateral ligaments ensure the stability of the elbow joint. Instability can be detected using appropriate examination techniques. Swelling, contractures, and painfully restricted motion can be due to a variety of causes. Osteochondritis, inflammations such as rheumatoid arthritis and gout, chondrocalcinosis, tumors, tendinitis, and osteoarthritis are common disorders. However, constriction syndromes such as cubital tunnel syndrome can also originate in the elbow (due to osteophytic narrowing of the groove for the ulnar nerve). Under certain circumstances, a cervical spine syndrome can also cause elbow pain.

One of the most common causes of elbow complaints is lateral epicondylitis or “tennis elbow.” Less often the complaints involve the medial epicondyle, as medial epicondylitis or “golfer’s elbow.”

Aside from local tenderness to palpation, typical signs upon examination include circumscribed local pain when passive traction is applied to the extensors (tennis elbow) or flexors of the hand (golfer’s elbow) and pain from muscle tension.

Specific tests help to distinguish symptoms of epicondylar pathology from those attributable to other causes.

## Range of the Motion of the Elbow (Neutral-Zero Method)

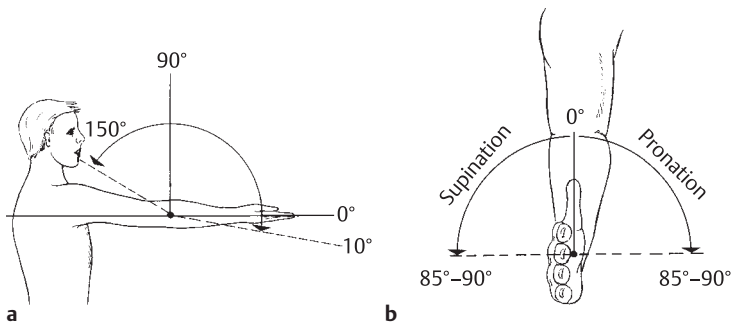


Fig. 113

a Flexion and extension

b Pronation and supination of the forearm

## Function Tests

This section describes a series of function tests that will indicate specific lesions in the region of the elbow. Those that provide the most diagnostic information are presented below. They have been divided into four groups based on the particular anatomic structure being tested.

1. General orientation tests
2. Stability tests
3. Epicondylitis tests
4. Compression syndrome tests

## Orientation Tests

### Hyperflexion Test

Indicates the presence of an elbow disorder.

**Procedure:** The patient is seated. The examiner grasps the patient's wrist and maximally flexes the elbow, carefully noting any restricted motion and the location of any pain.

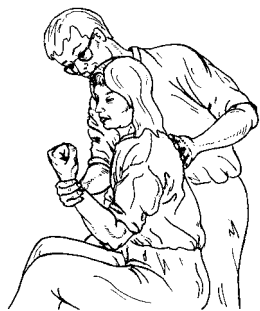

Fig. 114 Hyperflexion test

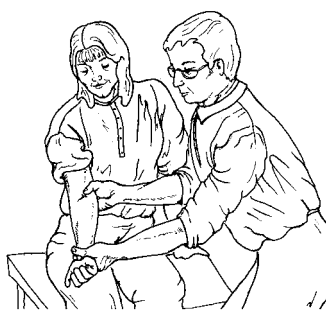

Fig. 115 Supination stress test

**Assessment:** Increased or restricted mobility in the joint coupled with pain is a sign of joint damage, muscle contracture, tendinitis, or a sprain.

### Supination Stress Test

For diagnostic assessment of an elbow disorder.

**Procedure:** The patient is seated. The examiner grasps the patient's forearm with one hand while holding the medial aspect of the elbow with the other. From this position, the examiner forcibly and abruptly supinates the forearm.

**Assessment:** This test evaluates the integrity of the elbow including the bony and ligamentous structures. Pain or restricted motion suggests joint dysfunction requiring further examination.

### Varus Stress Test

Indicates ligamentous instability.

**Procedure:** The patient is seated with the arm extended. The examiner stabilizes the medial aspect of the upper arm with one hand while with the other passively adducting the patient's forearm against the upper arm at the elbow, creating a varus stress.

**Assessment:** This test assesses the stability of the lateral collateral ligaments in the elbow. The examiner notes any pain and any unusual range of motion compared with the contralateral side.

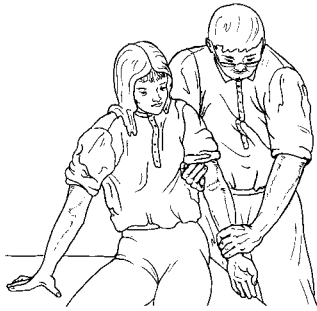

Fig. 116 Varus stress test

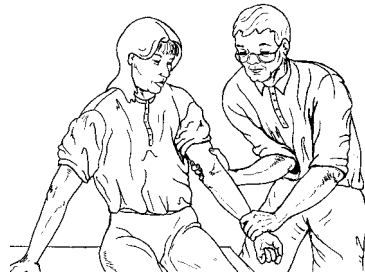

Fig. 117 Valgus stress test

### Valgus Stress Test

Indicates ligamentous instability.

**Procedure:** The patient is seated with the arm extended. The examiner stabilizes the lateral aspect of the upper arm with one hand while with the other passively abducting the patient's forearm against the upper arm at the elbow, creating a valgus stress.

**Assessment:** This test assesses the stability of the medial collateral ligaments in the elbow. The examiner notes any pain and any unusual range of motion compared with the contralateral side.

## ■ Epicondylitis Tests

### Chair Test

Indicates lateral epicondylitis.

**Procedure:** The patient is requested to lift a chair. The arm should be extended with the forearm pronated.

**Assessment:** Occurrence of or increase in pain over the lateral epicondyle and in the extensor tendon origins in the forearm indicates epicondylitis.

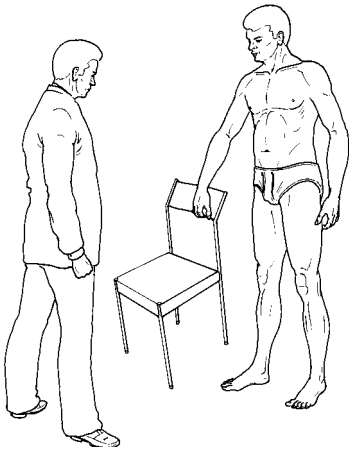


Fig. 118 Chair test

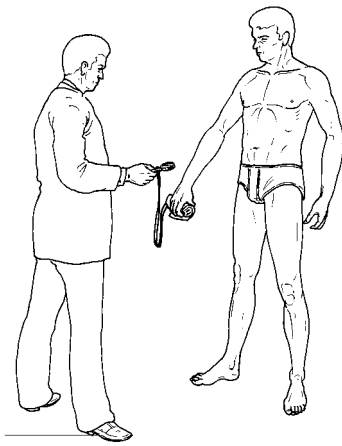


Fig. 119 Bowden test

### Bowden Test

Indicates tennis elbow (lateral epicondylitis).

**Procedure:** The patient is requested to squeeze together a blood-pressure measuring cuff inflated to about 30 mmHg (about 4.0 kPa) held in his or her hand, or, by squeezing the cuff, to maintain a pressure specified by the examiner.

**Assessment:** Occurrence of or increase in pain over the lateral epicondyle and in the extensor tendon origins in the forearm indicates epicondylitis.

### Thomson Test

Indicates lateral epicondylitis.

**Procedure:** The patient is requested to make a fist and extend the elbow with the hand in slight dorsiflexion. The examiner immobilizes the dorsal wrist with one hand and grasps the fist with the other hand. The patient is then requested to further extend the fist against the examiner's resistance, or the examiner attempts to press the dorsiflexed fist into flexion against the patient's resistance.



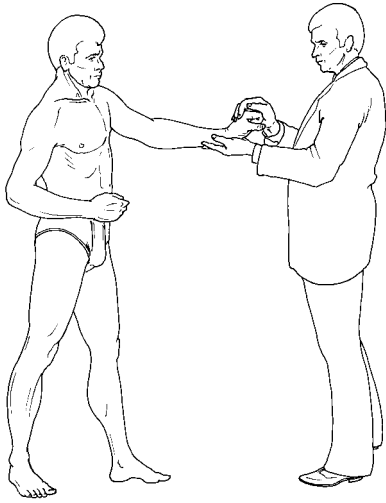


Fig. 120 Thomson test

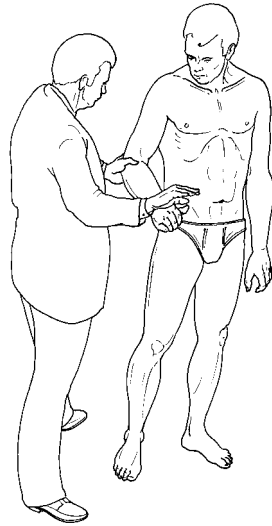

Fig. 121 Mill test

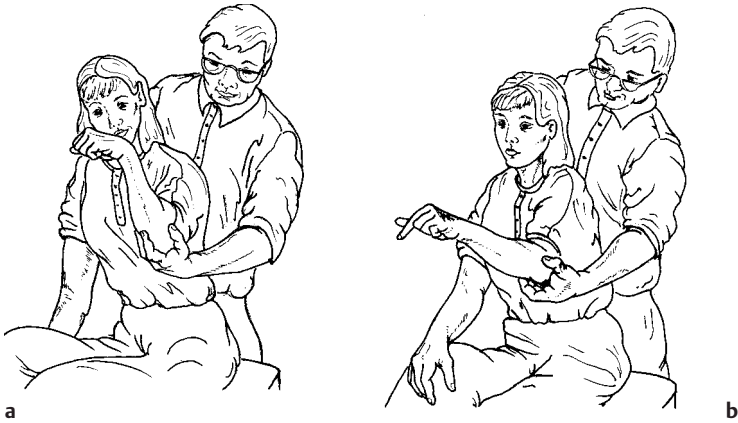**Assessment:** Severe pain over the lateral epicondyle and in the lateral extensor compartment strongly suggests lateral epicondylitis.

### Mill Test

Indicates lateral epicondylitis.

**Procedure:** The patient is standing. The arm is slightly pronated with the wrist slightly dorsiflexed and the elbow flexed. With one hand, the examiner grasps the patient's elbow while the other rests on the lateral aspect of the distal forearm or grasps the forearm. The patient is then requested to supinate the forearm against the resistance of the examiner's hand.

**Assessment:** Pain over the lateral epicondyle and/or in the lateral extensors suggests epicondylitis.



**Fig. 122** Motion stress test:  
**a** starting position,  
**b** extension and pronation

### Motion Stress Test

Indicates lateral epicondylitis.

**Procedure:** The patient is seated. The examiner palpates the lateral epicondyle while the patient flexes the elbow, pronates the forearm, and then extends the elbow again in a continuous motion.

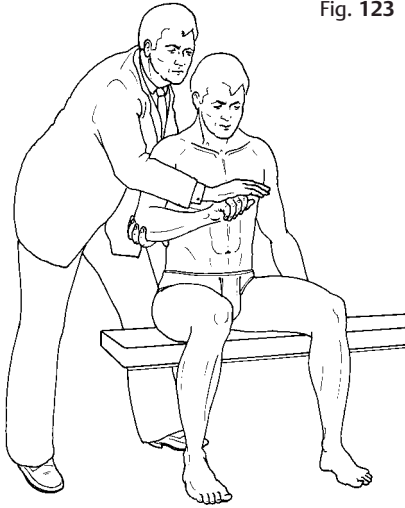**Assessment:** Pronation and wrist flexion place great stresses on the tendons of the forearm musculature that arise from the lateral epicondyle. Occurrence of pain in the lateral epicondyle and/or lateral extensor musculature with these motions suggests epicondylitis. However, pain and paresthesia can also occur as a result of compression of the median nerve because in this maneuver the action of the pronators can compress the nerve.

### Cozen Test

Indicates lateral epicondylitis.

**Procedure:** The patient is seated for the examination. The examiner immobilizes the elbow with one hand while the other hand lies flat on the dorsum of the patient's fist. The patient is then requested to dorsiflex the wrist against the resistance of the examiner's hand. Alternatively, the examiner may attempt to press the fist, which the patient

Fig. 123 Cozen test



holds with the wrist firmly extended, into flexion against the patient's resistance.

**Assessment:** Localized pain in the lateral epicondyle of the humerus or pain in the lateral extensor compartment suggests epicondylitis.

### Reverse Cozen Test

Indicates medial epicondylitis.

**Procedure:** The patient is seated. The examiner palpates the medial epicondyle with one hand while the other hand rests on the wrist of the patient's supinated forearm. The patient attempts to flex the extended hand against the resistance of the examiner's hand on the wrist.

**Assessment:** The flexors of the forearm and hand and the pronator teres have their origins on the medial epicondyle. Acute, stabbing pain over the medial epicondyle suggests medial epicondylitis.

With this test, it is particularly important to stabilize the elbow. Otherwise, a forcible avoidance movement or pronation could exacerbate a compression syndrome in the pronator musculature (pronator compartment syndrome).

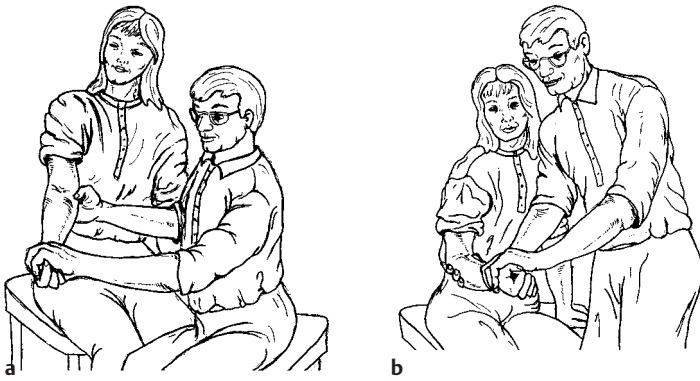


Fig. 124 Reverse Cozen test:  
 a starting position,  
 b flexion in the wrist against the resistance of the examiner's hand

### Golfer's Elbow Sign

Indicates medial epicondylitis.

**Procedure:** The patient flexes the elbow and hand. The examiner grasps the patient's hand and immobilizes the patient's upper arm with the other hand. The patient is then requested to extend the elbow against the resistance of the examiner's hand.

**Assessment:** Pain over the medial epicondyle suggests epicondylar pathology (golfer's elbow).

### Forearm Extension Test

Indicates medial epicondylitis.

**Procedure:** The seated patient flexes the elbow and holds the forearm in supination while the examiner grasps the patient's distal forearm. The patient then attempts to extend the elbow against the resistance of the examiner's hand.

**Assessment:** Pain over the medial epicondyle and over the origins of the forearm flexors suggests epicondylar pathology.

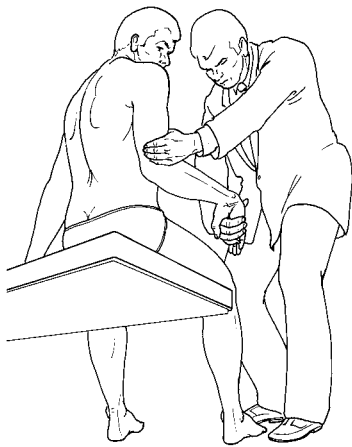


Fig. 125 Golfer's elbow sign



Fig. 126 Forearm extension test

## ■ Compression Syndrome Tests

### Tinel Test

Sign of cubital tunnel syndrome.

**Procedure:** The patient is seated. The examiner grasps the patient's arms and gently taps on the groove for the ulnar nerve with a reflex hammer.

**Assessment:** The ulnar nerve courses through a bony groove posterior to the medial epicondyle. Because of its relatively superficial position, compression injuries are common. Injury, traction, inflammation, scarring, or chronic compression are the most common causes of damage to the ulnar nerve. Pain elicited by gently tapping the groove for the ulnar nerve suggests chronic compression neuropathy.

With this test, care should be taken not to tap the nerve too hard because a forceful tap will cause pain even in a normal nerve. Note, too, that repeated tapping can injure the nerve.

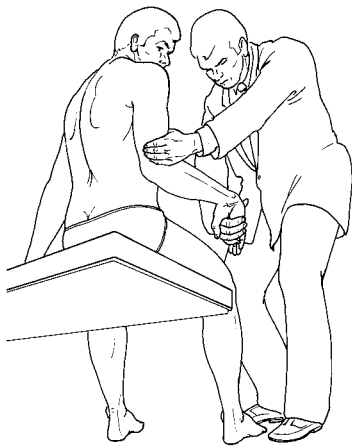


Fig. 125 Golfer's elbow sign



Fig. 126 Forearm extension test

## ■ Compression Syndrome Tests

### Tinel Test

Sign of cubital tunnel syndrome.

**Procedure:** The patient is seated. The examiner grasps the patient's arms and gently taps on the groove for the ulnar nerve with a reflex hammer.

**Assessment:** The ulnar nerve courses through a bony groove posterior to the medial epicondyle. Because of its relatively superficial position, compression injuries are common. Injury, traction, inflammation, scarring, or chronic compression are the most common causes of damage to the ulnar nerve. Pain elicited by gently tapping the groove for the ulnar nerve suggests chronic compression neuropathy.

With this test, care should be taken not to tap the nerve too hard because a forceful tap will cause pain even in a normal nerve. Note, too, that repeated tapping can injure the nerve.

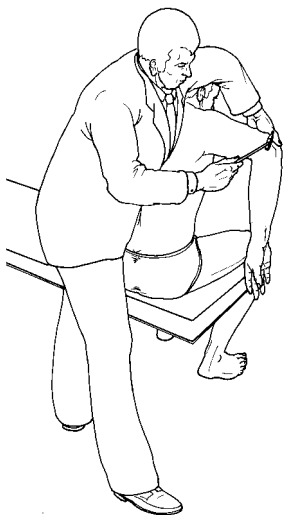


Fig. 127 Tinel test

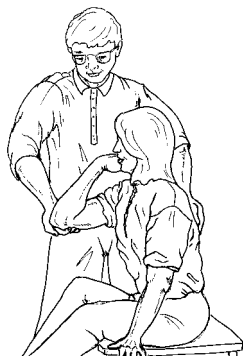

Fig. 128 Elbow flexion test

### Elbow Flexion Test

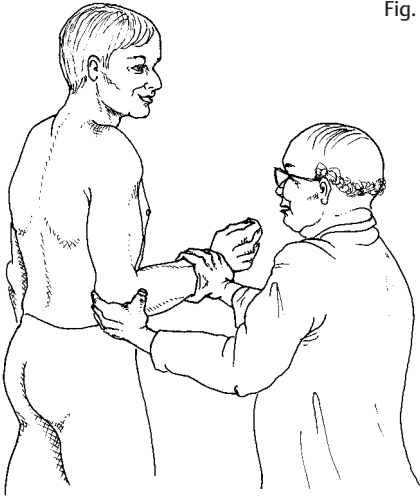
Sign of cubital tunnel syndrome.

**Procedure:** The patient is seated. The elbow is maximally flexed with the wrist flexed as well. The patient is requested to maintain this position for five minutes.

**Assessment:** The ulnar nerve passes through the cubital tunnel, which is formed by the ulnar collateral ligaments and the flexor carpi ulnaris. Maximum traction is applied to the ulnar nerve in the position described above.

Occurrence of paresthesia along the course of the nerve suggests compressive neuropathy. If the test is positive, the diagnosis should be confirmed by electromyography or nerve conduction velocity measurement.

Fig. 129 Supinator compression test



### Supinator Compression Test

Indicates damage to the deep branch of the radial nerve.

**Procedure:** The patient is seated. With one hand, the examiner palpates the groove lateral to the extensor carpi radialis distal to the lateral epicondyle. The examiner's other hand resists the patient's active pronation and supination.

**Assessment:** Constant pain in the muscle groove or pain in the proximal lateral forearm that increases with pronation and supination suggests compression of the deep branch of the radial nerve in the supinator (the deep branch of the radial nerve penetrates this muscle).

The point of tenderness lies farther anterior than the point at which pain is felt in typical lateral epicondylitis. The compression neuropathy of the nerve can be caused by proliferation of connective tissue in the muscle, a radial head fracture, or a soft tissue tumor. Weakened or absent extension in the metacarpophalangeal joints of the fingers other than the thumb indicates paralysis of the extensor digitorum supplied by the deep branch of the radial nerve.



---

## Wrist, Hand, and Fingers

Examination of the hand requires good knowledge of the anatomy and begins with inspection to detect possible defects and position anomalies. With the hand at rest in a passive position, the wrist is in a neutral position between flexion and extension and the fingers are in slight flexion (the finger flexors are about four times as strong as the finger extensors).

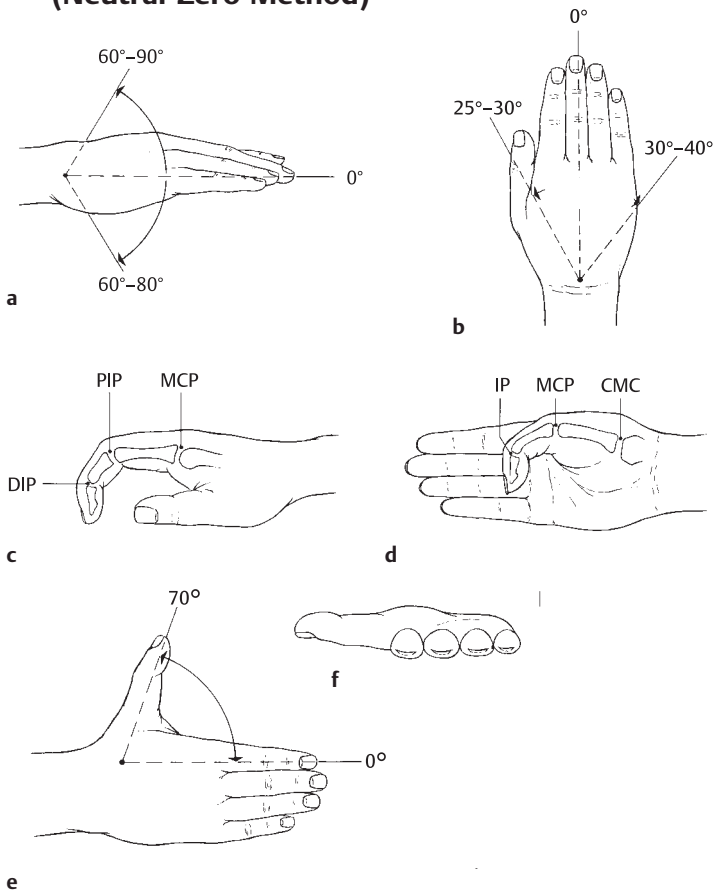
Joint inflammation causes circumscribed swelling over the respective joint, and tenosynovitis manifests itself as swelling and erythema in the skin along the course of the tendon. Nerve palsy leads to contractures. For example, radial nerve palsy leads to a limp wrist. Median nerve palsy leads to deformity resembling an ape's hand. Ulnar nerve palsy leads to a claw hand deformity in which the proximal phalanges are extended and the middle and distal phalanges are flexed.

When palpating the wrist and hand, the examiner notes the texture and quality of the skin, muscles, and tendon sheaths; evaluates swelling, inflammation, and tumors; and determines the exact localization of pain.

Passive range of motion testing can detect restricted motion (due to osteoarthritis) and instability. Painful disorders of the tendon sheaths can be associated with crepitation along the course of the tendon in both active and passive motion.

Neurologic changes, usually caused by compression neuropathies, exhibit characteristic losses of function that can be evaluated by specific functional tests.

## Range of Motion in the Hand (Neutral-Zero Method)



**Fig. 130**

**a** Flexion and extension of the wrist including the intercarpal joint,  
**b** Radial and ulnar deviation of the hand  
**c, d** Designations of the joints of the fingers (**c**) and thumb (**d**):

*DIP* = distal interphalangeal joint,

*PIP* = proximal interphalangeal joint,

*MCP* = metacarpophalangeal joint,

*IP* = interphalangeal joint (of the thumb),

*CMC* = carpometacarpal joint

**e, f** Abduction and adduction to the plane of the palm

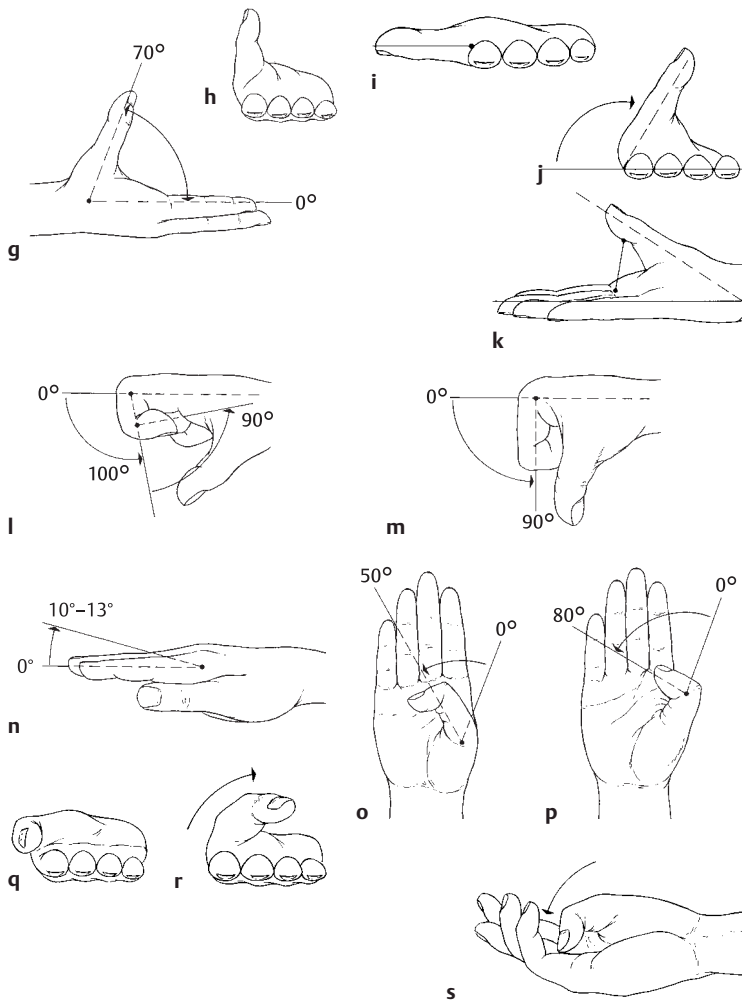


Fig. 130

- g, h** Palmar abduction and adduction of the thumb perpendicular to the plane of the palm
- i-k** Circumduction of the extended thumb
- l, m** Flexion of the finger joints: DIP and PIP joints (**l**) and MCP joint (**m**)
- n** Hyperextension of the MCP joint
- o, p** Flexion of the thumb joints: the MCP<sub>1</sub> joint (**o**) and the IP joint (**p**)
- q-s** Opposition of the thumb: starting position (**q**), during motion (**r**), and opposition position (**s**)

## ■ Function Tests

### Tests of the Flexor Tendons of the Hand

#### *Flexor Digitorum Profundus*

**Procedure:** The examiner places two fingers (index and middle fingers) on the volar aspect of the patient's affected finger so that the finger remains extended in the proximal interphalangeal joint. The patient is then asked to flex only the distal interphalangeal joint of the finger. This examination is repeated for each finger separately.

**Assessment:** The flexor digitorum profundus belongs to the deep layer of flexors in the forearm. Its tendons insert into the bases of all of the proximal phalanges of the fingers.

Inability to flex the distal interphalangeal joint is a sign of a torn tendon; painful flexion suggests tenosynovitis.

Differential diagnosis should exclude osteoarthritis of the distal interphalangeal joint (Heberden nodes) with restricted joint motion.

#### *Flexor Digitorum Superficialis*

**Procedure:** The patient is asked to flex the proximal interphalangeal joint of the affected finger while the examiner holds the other fingers in extension to neutralize the effect of the flexor digitorum profundus tendon. The flexor digitorum profundus tendons of the three ulnar fingers share a common muscle belly. Therefore, unrestricted flexion of one finger with the others immobilized in extension requires an intact flexor digitorum superficialis tendon. This examination is performed for each finger separately.

**Assessment:** The flexor digitorum superficialis is a broad strong muscle whose tendons insert into the middle phalanges of the fingers.

Wherever the patient can flex the proximal interphalangeal joint of a finger, the flexor digitorum superficialis tendon is intact. Flexion will not be possible where injuries to the tendon are present. Pain suggests tenosynovitis.

#### *Flexor Pollicis Longus and Extensor Pollicis Longus*

**Procedure:** The examiner grasps the patient's thumb and immobilizes the metacarpophalangeal joint. Then the patient is asked to flex and extend the phalanx of the thumb. The flexor pollicis longus lies in the deep layer of the flexor muscles; its tendon inserts into the base of the distal phalanx of the thumb.

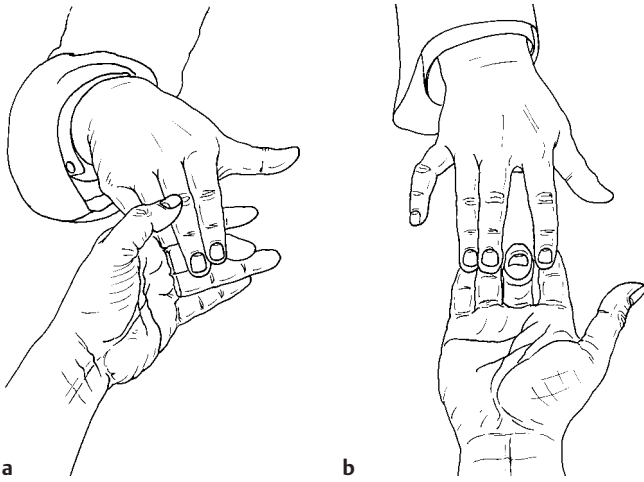
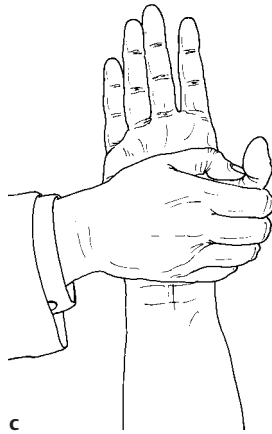


Fig. 131 Hand flexor tendon test:  
**a** flexor digitorum profundus,  
**b** flexor digitorum superficialis,  
**c** flexor pollicis longus and extensor pollicis longus



**Assessment:** Impaired flexion and extension in the interphalangeal joint of the thumb suggest injury (torn tendon) or disease (tenosynovitis) of the respective tendon.

#### **Muckard Test**

For diagnosis of acute or chronic tenosynovitis of the abductor pollicis longus and extensor pollicis brevis tendons (stenosing tenosynovitis or de Quervain's disease).

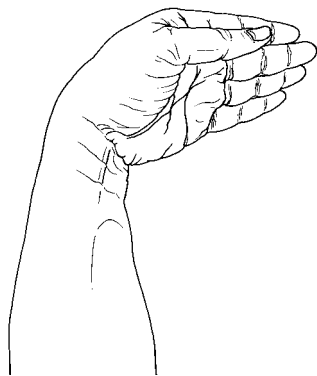


Fig. 132 Muckard test

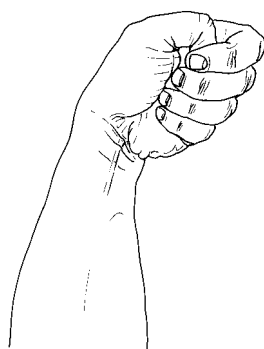


Fig. 133 Finkelstein test

**Procedure:** The patient “tilts” the hand into ulnar deviation at the wrist with the fingers extended and the thumb adducted.

**Assessment:** Severe pain in the radial styloid radiating into the thumb and forearm suggests tenosynovitis of the abductor pollicis longus and extensor pollicis brevis tendons.

Swelling and tenderness to palpation over the first dorsal compartment will usually be present as well. Abduction of the thumb against resistance is painful.

Tenosynovitis is the result of inflammation of the synovial tissue, which is often caused by overuse or inflammatory disorders. However, blunt trauma can also lead to these disorders.

A differential diagnosis should exclude osteoarthritis of the carpometacarpal joint of the thumb or radial styloiditis.

#### **Finkelstein Test**

Indicates stenosing tenosynovitis (de Quervain's disease).

**Procedure:** With the thumb flexed and the other fingers flexed around it, the wrist is moved into ulnar deviation either actively or passively by the examiner.

**Assessment:** Pain and crepitation above the radial styloid suggest nonspecific tenosynovitis of the abductor pollicis longus and the extensor pollicis brevis (see Muckard test for etiology).

It is important to differentiate stenosing tenosynovitis (de Quervain's disease) from osteoarthritis in the carpometacarpal joint of the thumb.

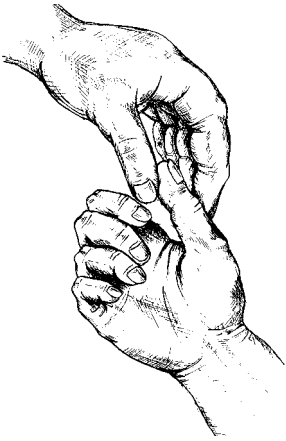

Fig. 134 Grind test

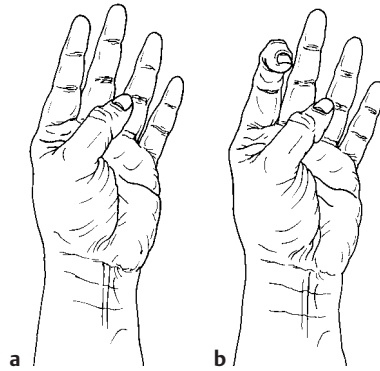


Fig. 135 Linburg test

Specific examination of the carpometacarpal joint of the thumb and a radiograph will allow a quick differential diagnosis.

The test should also be performed on both sides for comparison.

#### **Grind Test**

Assessment of osteoarthritis in the carpometacarpal joint of the thumb.

**Procedure:** The examiner grasps the painful thumb and performs grinding motions while compressing the thumb along its longitudinal axis.

**Assessment:** Pain reported in the carpometacarpal joint of the thumb is usually due to osteoarthritis in the joint. Tenderness to palpation and painful instability are additional signs of wear in the joint. The patient will typically also complain of pain in the carpometacarpal joint of the thumb when opposing the thumb against the resistance of the examiner's hand.

#### **Linburg Test**

Indicates congenital malformation of the flexor pollicis longus and flexor digitorum profundus tendons.

**Procedure:** The patient is asked to bring the thumb against the palm of the hand in a combined flexion and adduction motion with the fingers extended.

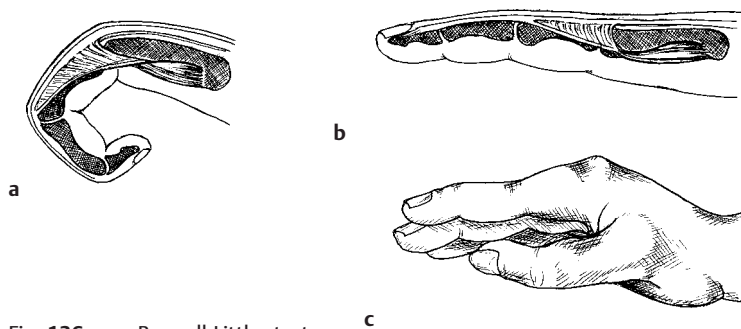


Fig. 136a–c Bunnell-Littler test:  
**a** active and passive flexion of all finger joints is possible (first part),  
**b** metacarpophalangeal joint is immobilized in extension; flexion of the middle and distal phalangeal joints is not possible (second part),  
**c** intrinsic plus deformity

**Assessment:** In the presence of a congenital ligamentous connection between the flexor pollicis longus tendon and flexor digitorum profundus tendon of the index finger, this combined thumb motion will produce flexion in the distal interphalangeal joint of the index finger.

#### **Bunnell-Littler Test**

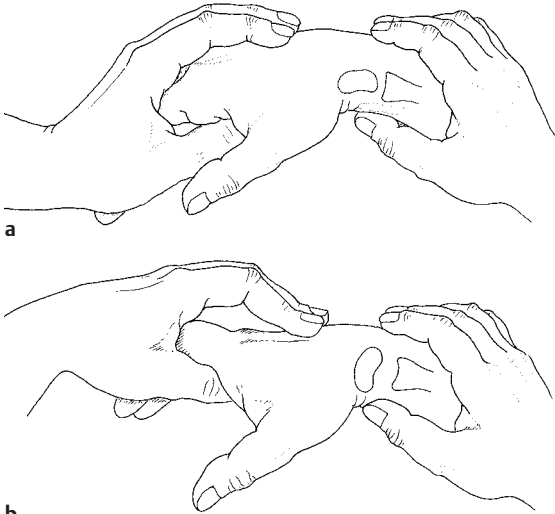
Assessment of an ischemic contracture in the intrinsic musculature of the hand.

**Procedure:** The patient's hand is extended. In the first part of the test, the examiner evaluates passive and active flexion in all three joints of a finger. In the second part of the test, the examiner immobilizes the metacarpophalangeal joint in extension and again evaluates flexion in the middle and distal interphalangeal joints of the finger.

**Assessment:** In the presence of an ischemic contracture of the intrinsic muscles of the hand, the patient will be unable to actively or passively flex or extend the middle or distal interphalangeal joint when the metacarpophalangeal joint is passively immobilized in extension. This is due to shortening of the interossei. With the wrist actively or passively flexed, active flexion of the middle and distal interphalangeal joints is possible. Usually the contracture will affect several fingers. The test allows one to distinguish an ischemic contracture from other articular changes such as joint stiffness, tendon adhesions, and tenosynovitis.

Increased pressure in the fascial compartments of the hand produces a typical deformity with flexion in the metacarpophalangeal joints,





**b**  
 Fig. 137 Watson test (scaphoid shift test):  
 a wrist in radial deviation; immobilization of the scaphoid in extension,  
 b wrist placed in ulnar deviation

extension in the middle and distal interphalangeal joints, intensification of the transverse arch of the hand, and adduction of the thumb (intrinsic plus deformity).

#### **Watson Test (Scaphoid Shift Test)**

Tests wrist stability.

**Procedure:** This test is performed with the patient seated with the elbows supported. With the patient's wrist in maximum radial deviation, the examiner immobilizes the scaphoid between his or her thumb and index finger. The examiner's thumb presses on the scaphoid tuberosity (distal pole), holding the scaphoid in extension. The wrist is then placed in ulnar deviation, which would normally be accompanied by flexion of the scaphoid but this is prevented by the pressure of the examiner's thumb.

**Assessment:** In a positive test, the proximal pole of the scaphoid displaces toward the dorsal margin of the scaphoid fossa, subluxates, and impinges against the index finger. This snapping is associated with pain and is a sign of an injury to the scapholunate ligaments. However, it provides no information on the severity of this injury.

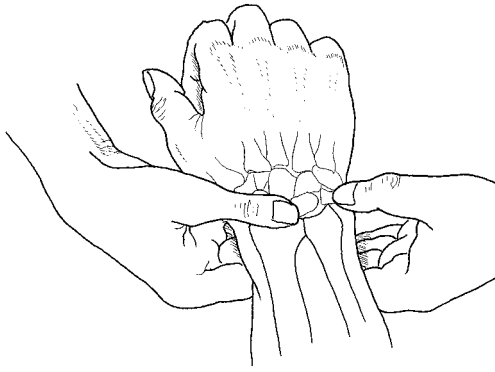


Fig. 138 Reagan test (triquetrolunate ballottement test)

#### **Reagan Test (Triquetrolunate Ballottement Test)**

Tests wrist stability.

**Procedure:** The examiner holds the lunate between the thumb and index finger of one hand and the triquetrum between the fingers of the other while attempting to move the two bones relative to each other.

**Assessment:** In a positive test, this shear motion is painful even if instability cannot always be demonstrated.

Triquetrolunate instability can result from trauma involving hyperpronation or hyperextension. Patients report pain in the proximal ulnar wrist. Tenderness to palpation over the triquetrolunate joint and pain with motion can be provoked, but pronation and supination do not cause any pain. The injury does not necessarily involve loss of strength. Patients occasionally describe the instability as a clicking that occurs during wrist motion.

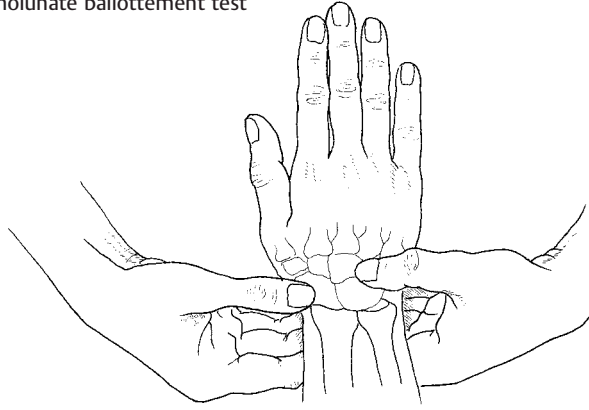
#### **Scapholunate Ballottement Test**

Tests wrist stability.

**Procedure:** The examiner holds the scaphoid and lunate tightly between the thumb and index finger of both hands while moving them relative to each other in a dorsal and volar direction, respectively.

**Assessment:** Instability is present where the resistance of the scapholunate ligament complex to these shear forces is reduced. Painful shear motion indicates a ligament injury. Scapholunate instability occurs as a result of a fall on the thumb with the forearm pronated and the wrist extended and in ulnar deviation, or as the result of an impact in ball sports. This causes a tear in the ligaments between the scaphoid and

Fig. 139 Scapholunate ballottement test



lunate. Chronic scapholunate instability can also occur without trauma, for example secondary to removal of a ganglion or in degenerative disorders. Patients complain of severe tenderness to palpation and pain with motion in the proximal radial wrist, especially when supporting the body with the hands. They also report loss of strength and occasionally describe a snapping sound when moving the wrist into ulnar deviation.

**Stability Test for a Torn Ulnar Collateral Ligament in the Metacarpophalangeal Joint of the Thumb**

**Procedure:** The patient flexes the metacarpophalangeal joint of the affected thumb  $20^{\circ}$ – $30^{\circ}$ . The examiner passively moves the thumb into radial deviation.

**Assessment:** Where the thumb can be abducted, this suggests a tear in the ulnar collateral ligament of the metacarpophalangeal joint of the thumb. Known as gamekeeper's or skier's thumb, this injury is caused by forced radial deviation of the extended thumb in a fall on the hand. Stability is tested with the thumb flexed  $20^{\circ}$ – $30^{\circ}$ . This is done to minimize the action of the accessory collateral ligament, which, if intact, could mask the tear in the collateral ligament in extension. Where the joint can be opened in extension, one may assume that a complex injury to the capsular ligaments is present.

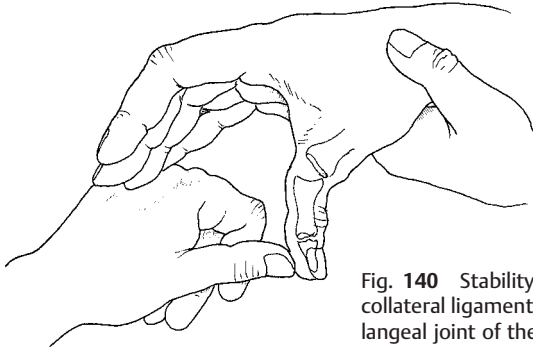


Fig. 140 Stability test for a torn ulnar collateral ligament in the metacarpophalangeal joint of the thumb

### Compression Neuropathies of the Nerves of the Arm

A number of compression neuropathies and entrapment syndromes can affect the nerves of the arm. Clinical tests can help differentiate between them.

#### *Pronator Teres Syndrome*

The median nerve can become compressed between the humeral and ulnar heads of the pronator teres.

There are a number of possible causes for a pronator teres syndrome. These include external pressure on the forearm, hypertrophy of the pronator teres (muscle tremor), and direct trauma. Pain, a burning sensation, and sensory deficits in the hand are typical symptoms, as are weakness in thumb opposition and weakness in flexion in the thumb, index finger, and middle finger. Pronation against resistance exacerbates the symptoms.

#### *Compression Neuropathy of the Ulnar Nerve in Guyon's Canal*

Guyon's canal is formed by the flexor retinaculum, pisohamate ligament, and palmar aponeurosis. The ulnar artery and nerve course through this passage.

Causes of compression of the ulnar nerve include infection, ganglion scarring, and external pressure, such as chronic compression injury in bicyclists.

Sensory impairments in the ulnar aspect of the ring and little fingers and motor impairments in the hypothenar musculature are typical symptoms of this compression neuropathy.

***Carpal Tunnel Syndrome***

Compression of the median nerve can occur in the carpal tunnel. Formed by the carpal bones and the flexor retinaculum, the carpal tunnel encloses all of the finger flexor tendons and the median nerve. Causes of carpal tunnel syndrome with stenosis of the tunnel include skeletal changes, bone tumors (ganglia), injuries, and tenosynovitis. Women between the ages of 50 and 60 are most commonly affected. Typical signs of compression include nighttime paresthesia and brachialgia, morning stiffness, and sensory and motor deficits in the region supplied by the median nerve (atrophy of the thenar musculature).

A differential diagnosis should consider cervical spinal cord and brachial plexus lesions, pronator teres syndrome, compression neuropathy in Guyon's canal, thoracic outlet syndrome, and interphalangeal osteoarthritis.

Electromyography and measurement of nerve conduction velocity by electroneurography are important studies in diagnosing carpal tunnel syndrome.

***Cubital Tunnel Syndrome***

The ulnar nerve courses through a bony groove posterior to the medial epicondyle. Because of its relatively superficial position, compression injuries are common. Injury, traction, inflammation, scarring, or chronic compression are the most common causes of damage to the ulnar nerve.

Sensory deficits (numbness in the little finger) and motor deficits in the area supplied by the ulnar nerve are typical findings in the presence of a nerve lesion.

Electromyography and sensory electroneurography can determine the location of the compression neuropathy.

**Tests of Motor Function in the Hand**

Demonstrate motor and sensory deficits in the presence of nerve lesions.

***Testing the Pinch Grip***

**Procedure:** The patient is asked to pick up a small object between the thumb and the index finger.

**Assessment:** Satisfactory performance requires intact sensation. The patient should repeat the test with his or her eyes closed. Unimpaired function of the lumbricals and interossei is essential for this maneuver.

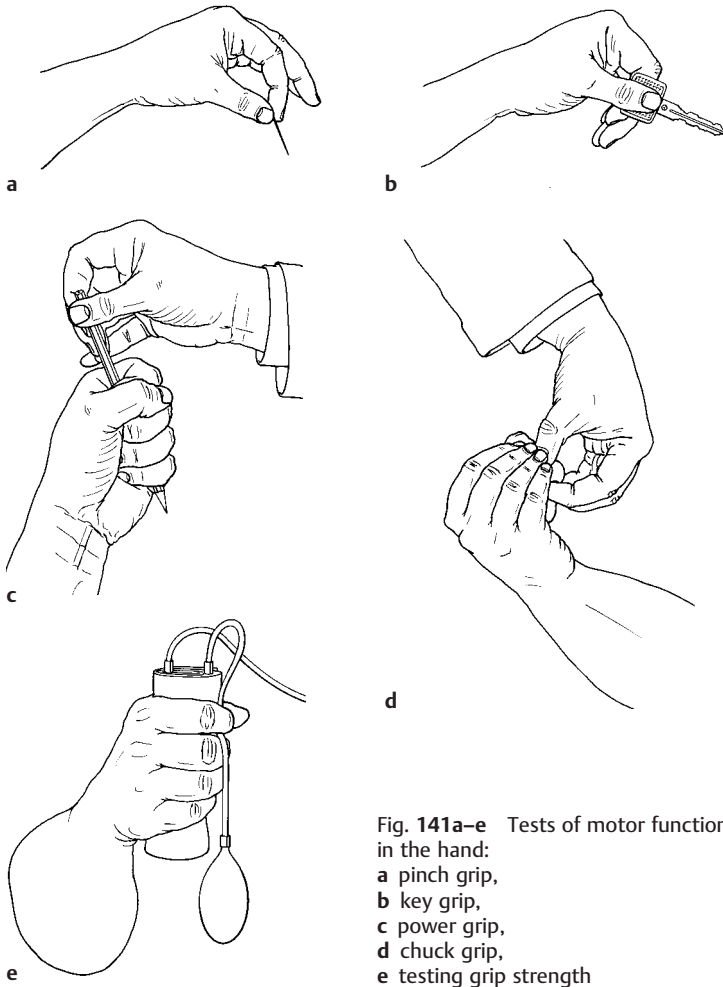


Fig. 141a–e Tests of motor function in the hand:  
**a** pinch grip,  
**b** key grip,  
**c** power grip,  
**d** chuck grip,  
**e** testing grip strength

#### Testing the Key Grip

**Procedure:** The patient is asked to hold a key between the thumb and the side of the index finger in the normal manner.

**Assessment:** A sensory deficit on the radial aspect of the index finger, such as can occur in a radial nerve lesion, renders the key grip impossible.

**Testing the Power Grip**

**Procedure:** The patient is asked to hold on to a pencil with the thumb and fingers while the examiner attempts to pull the pencil away.

Where finger flexion is restricted, the test is repeated using an object with a larger diameter.

**Assessment:** In the presence of injuries to the median or ulnar nerve, full finger flexion is not possible and strength is limited. The test will be positive in these cases.

**Testing the Chuck Grip**

**Procedure:** The precision grip maneuver is evaluated by giving the patient a small ball and having him or her hold on to it.

**Assessment:** This maneuver tests the strength of adduction in the thumb and finger flexion and thus allows evaluation of the median and ulnar nerves to be assessed.

**Testing Grip Strength**

**Procedure:** The examiner pumps a blood pressure cuff to 200 mmHg (about 26.7 kPa) and asks the patient to squeeze it together as tightly as possible.

**Assessment:** Patients with normal hand function should attain a value of 200 mmHg (about 26.7 kPa) or more. Note that the difference in strength between men and women must be taken into account, as must that between adults and children. This test should be performed with each hand for comparative evaluation.

**Radial Nerve Palsy Screening Test**

Screening method for the assessment of radial nerve palsy.

**Procedure:** The patient is asked to extend his or her wrist with the elbow flexed 90°.

**Assessment:** In radial nerve palsy affecting the wrist extensors, the patient will be unable to extend the wrist. The hand will hang down in a deformity commonly known as a limp wrist. In a second stage of the test, the patient is asked to abduct the thumb. In radial nerve palsy, the patient will be unable to abduct the thumb because of the paralysis of the abductor pollicis longus.

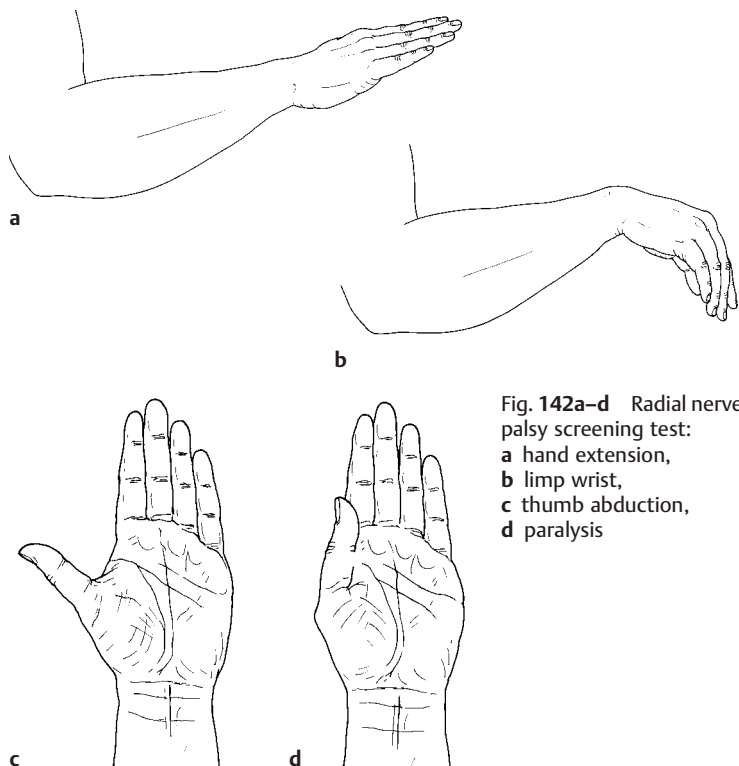


Fig. 142a–d Radial nerve palsy screening test:  
**a** hand extension,  
**b** limp wrist,  
**c** thumb abduction,  
**d** paralysis

#### **Thumb Extension Test**

Assesses a radial nerve lesion.

**Procedure:** The patient is seated. The examiner grasps the patient's wrist with one hand and presses the thumb into adduction with the other hand. Then the patient is asked to extend or abduct both the metacarpophalangeal and interphalangeal joints of the thumb.

**Assessment:** This test requires an intact radial nerve. Where this nerve is damaged, thumb extension will be weakened or will not be possible as a result of paralysis of the extensor pollicis longus and brevis. In patients with degenerative joint disease or rheumatoid arthritis in the joints of the thumb, this test generally produces pain in addition to demonstrating weakness. Simple nerve palsy without degenerative changes will not produce any joint symptoms.



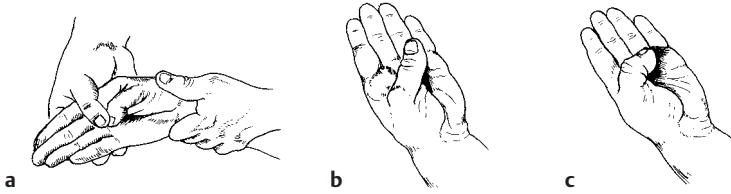


Fig. 143a–c Thumb extension test:  
 a starting position,  
 b normal function,  
 c abnormal weakness in thumb extension

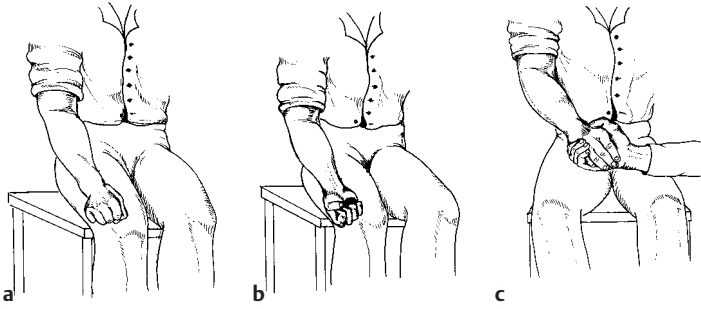


Fig. 144a–c Supination test:  
 a starting position,  
 b normal supination,  
 c supination against resistance

### **Supination Test**

Assesses supinator pathology.

**Procedure:** The patient is seated, holding the elbow slightly flexed and the forearm pronated. The elbow is held alongside the trunk to minimize motion in the shoulder. The patient is then asked to supinate his or her forearm, at first normally and then against the examiner's resistance.

**Assessment:** Weakness or loss of supination of the forearm is a sign of supinator paralysis. The muscle is supplied by the deep branch of the radial nerve.

Care should be taken not to flex the elbow too much during this test. This is because the biceps also participates in supination with increasing

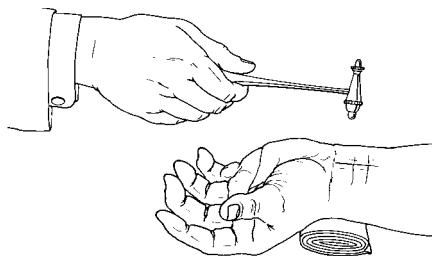


Fig. 145 Tinel sign

flexion in the elbow. Despite the fact that both muscles are naturally involved in supination, this would lead to false negative test results. This is because the biceps is involved in supination in increasing flexion, whereas the supinator has far greater influence on supination in extension.

### **Tinel Sign**

Indicates a median nerve lesion.

**Procedure:** The patient's hand is slightly dorsiflexed; the dorsum of the wrist rests on a cushion on the examining table. The examiner taps the median nerve at the level of the wrist crease with a reflex hammer or the index finger.

**Assessment:** Paresthesia and pain radiating into the hand and occasionally into the forearm as well are signs of a compression neuropathy of the median nerve (carpal tunnel syndrome). The test will produce a false negative result in a chronic compression neuropathy in which nerve conductivity has already been severely reduced.

### **Median Nerve Palsy Screening Test**

Screening method for the assessment of median nerve palsy.

**Procedure:** The patient is asked to oppose the tip of the thumb and the tip of the little finger. In the next step, the patient is asked to make a fist. Finally, the patient palmar flexes the hand slightly with the fingers extended.

**Assessment:** Paralysis of the *opponens pollicis* makes it impossible to bring the tip of the thumb and the tip of the little finger into opposition.

Because of weakness of thumb opposition and flexion in the first three digits, the patient will be unable to make a fist. This produces a typical deformity in which only the ring and little fingers are flexed while the other digits remain extended.

Fig. 146a, b Median nerve palsy screening test:  
 a normal position,  
 b "ape hand" deformity

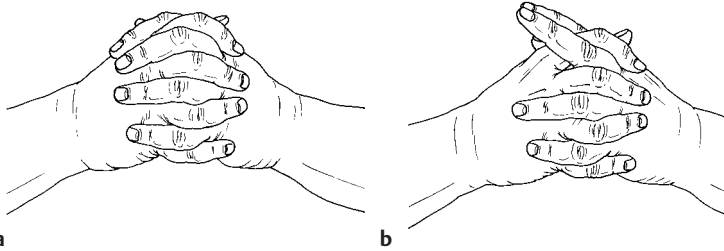
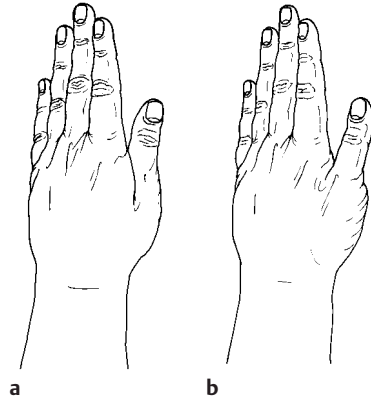


Fig. 147a, b Ochsner test:

a normal position,  
 b the index and middle fingers extended due to weakness in the flexors

Paralysis of the opponens, abductor pollicis brevis, and flexor pollicis brevis coupled with the antagonistic pull of the adductor pollicis cause the thumb to lie in the plane of the fingers. The thumbnail lies in the same plane as the fingernails, creating a deformity resembling an ape's hand, and the patient is unable to oppose the thumb.

#### **Ochsner Test**

Indicates median nerve palsy.

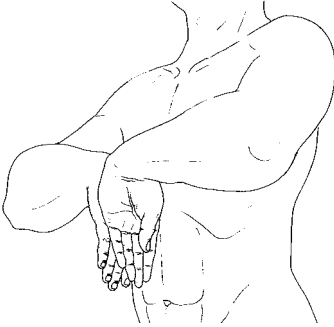
**Procedure:** The patient is asked to fold his or her hands with the fingers interlocked.

**Assessment:** If median nerve palsy is present, the patient will be unable to flex the index and middle fingers due to partial paralysis of the flexor digitorum profundus.

Fig. 148 Carpal tunnel sign

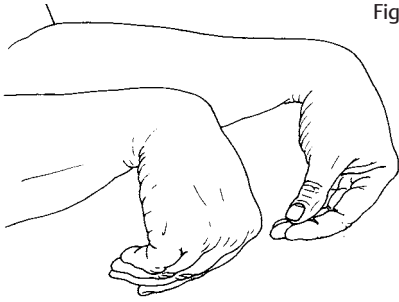

Fig. 149 Phalen test

**Carpal Tunnel Sign**

Indicates damage to the median nerve.

**Procedure:** The patient is asked to keep his or her wrists completely flexed for 1–2 minutes.

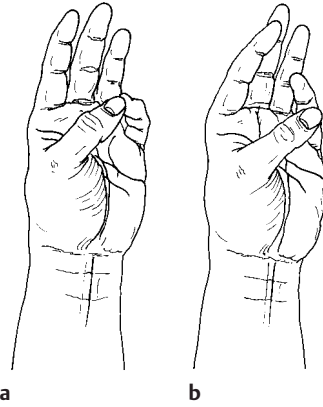
**Assessment:** Paresthesia that occurs or worsens in the region supplied by the median nerve is a sign of carpal tunnel syndrome.

**Phalen Test**

Indicates damage to the median nerve.

**Procedure:** The “wrist flexion sign” is evaluated by having the patient drop his or her hands into palmar flexion and then maintain this position for about ten minutes. Pressing the dorsa of the hands together increases pressure in the carpal tunnel.

Fig. 150a, b Nail sign:  
**a** normal,  
**b** abnormal position due to weakened  
 opposition of the thumb



**Assessment:** Pressing the dorsa of the hands together will often lead to paresthesia in the area supplied by the median nerve in normal patients as well, not just in those with carpal tunnel syndrome. Patients with carpal tunnel syndrome will experience worsening of symptoms in the Phalen test. Like the Tinel sign, this test can produce false negative results in the presence of chronic neuropathy.

#### ***Nail Sign***

Indicates damage to the median nerve.

**Procedure:** The patient is asked to touch his or her thumb to the tip of the little finger.

**Assessment:** Median nerve palsy will produce paralysis of the opponens pollicis. The thumb cannot be opposed but will only move along an arc in adduction toward the palm.

#### ***Bottle Test***

Indicates median nerve palsy.

**Procedure:** The patient is asked to grasp a bottle in each hand between the thumb and index finger.

**Assessment:** In paralysis of the abductor pollicis brevis, the web between the thumb and index finger will not be in contact with the surface of the bottle. The patient will be unable to hold the bottle between the thumb and index finger in such a way that the hand is in continuous contact with the circumference of the bottle.

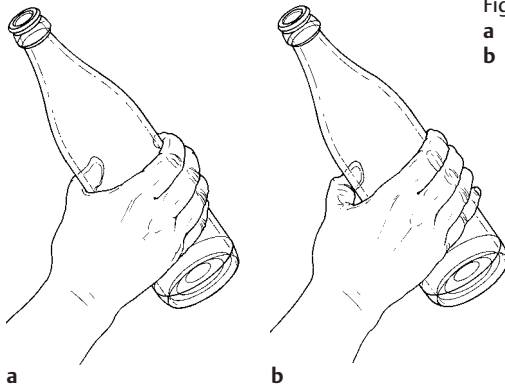


Fig. 151a, b Bottle test:  
a normal,  
b abnormal

Fig. 152 Reverse Phalen test



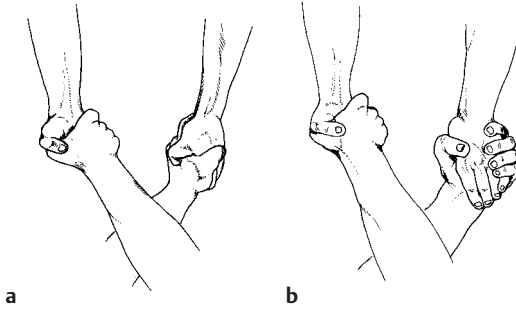
#### **Reverse Phalen Test**

Indicates carpal tunnel syndrome.

**Procedure:** The seated patient is asked to press both hands together in maximum dorsiflexion and to maintain this position for one minute.

**Assessment:** This position increases the pressure in the carpal tunnel. Paresthesia in the region supplied by the median nerve is a sign of carpal tunnel syndrome. The reverse Phalen test is less reliable than the Phalen test.

Fig. 153a, b  
Pronation test:  
a starting position,  
b weakness in  
pronation of the  
right arm



#### **Pronation Test**

Assessment of pronator teres and pronator quadratus pathology.

**Procedure:** The patient is seated with both hands and forearms in supination on the examining table. The examiner asks the patient to pronate his or her forearms, initially normally and then against the resistance of the examiner's hand.

**Assessment:** Weakness in active pronation against resistance in one arm as compared with the contralateral side indicates a median nerve lesion. The lesion normally lies at the level of the elbow. In the presence of a median nerve lesion distal to the elbow, the patient may be able to actively pronate the forearm against resistance because the pronator teres is still largely functional.

#### **Froment Sign**

Indicates a cubital tunnel syndrome.

**Procedure:** The patient is asked to hold a piece of paper between the thumb and index finger (pinch mechanism) against the pull of either the patient's contralateral hand or that of the examiner's hand. The muscle for this motion is the adductor pollicis, which is supplied by the ulnar nerve.

**Assessment:** Where there is weakness or loss of function in this muscle, the interphalangeal joint of the thumb will be flexed due to contraction of the flexor pollicis brevis supplied by the median nerve. Occasional volar hypesthesia on the ring and little fingers is also a characteristic sign.

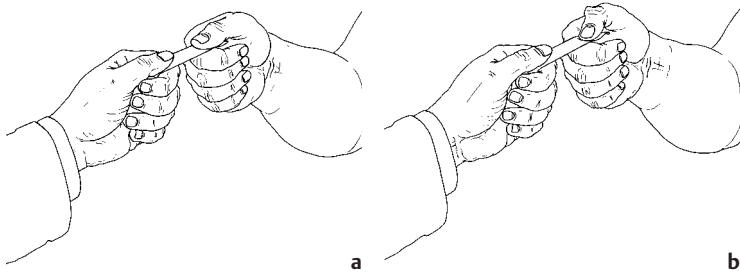
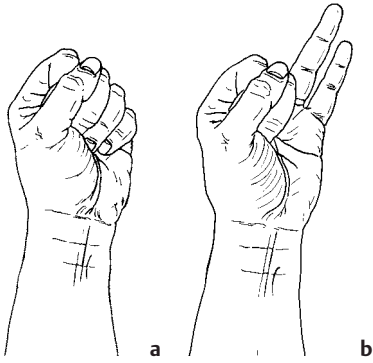


Fig. 154a, b Froment sign: **a** normal, **b** abnormal

Fig. 155a, b Ulnar nerve palsy screening test:  
**a** normal,  
**b** abnormal with loss of flexion in the ring and little fingers



#### ***Ulnar Nerve Palsy Screening Test***

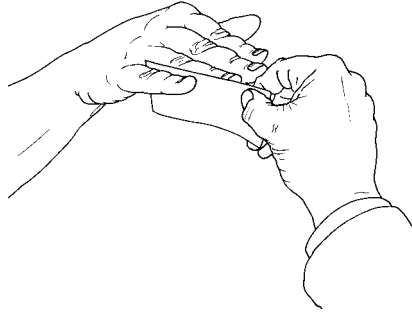Indicates ulnar nerve palsy.

**Procedure:** The patient is asked to make a fist.

**Assessment:** Where the ring and little fingers remain extended, flexion in the metacarpophalangeal and proximal interphalangeal joints of these fingers is not possible. This is a sign of paralysis of the interossei. Patients with a long history of chronic ulnar nerve palsy will exhibit significant muscle atrophy between the fourth and fifth and first and second digital rays of the hand.



Fig. 156 Intrinsic test

**Intrinsic Test**

Indicates compression neuropathy of the ulnar nerve.

**Procedure:** The patient is asked to hold a piece of paper between the ring and little fingers. The examiner attempts to pull the piece of paper away from the patient.

**Assessment:** In the presence of ulnar nerve neuropathy, adduction in the little finger will be limited and the patient will be unable to hold on to the paper. The test should be performed on both hands for comparison. Compression neuropathy of the ulnar nerve can occur in the carpal tunnel, in the elbow, and in Guyon's canal in the wrist. A positive Tinel sign and paresthesia on the ring and little fingers are additional signs of compression. Complete ulnar nerve palsy results in loss of function in the intrinsic muscles of the hand. The fingers are then hyperextended in the metacarpophalangeal joints and flexed in the proximal and distal interphalangeal joints.

**O Test**

**Procedure:** The pinch mechanism is a combined motion involving several muscles. Normally the thumb and index finger form the shape of an "O." With normal function in the muscles involved, the examiner will be unable to change the shape of the "O" by pulling on his or her own index finger inserted between the patient's thumb and index finger.

**Assessment:** In an anterior interosseous nerve syndrome with paralysis of the flexor digitorum profundus of the index finger and flexor pollicis longus, the thumb and index finger remain extended in the distal interphalangeal joints. The patient is then unable to form a proper "O" with the thumb and index finger.

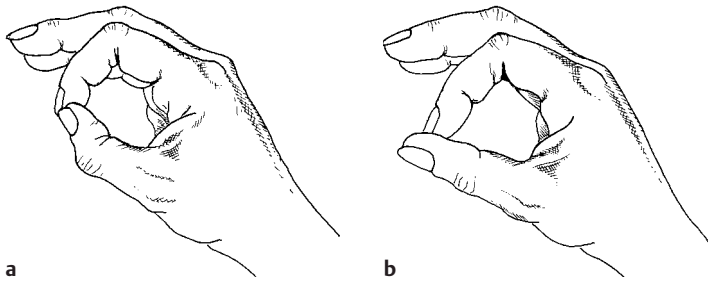


Fig. 157a, b O test: a normal, b abnormal result with paralysis of the flexor digitorum profundus of the index finger and flexor pollicis longus

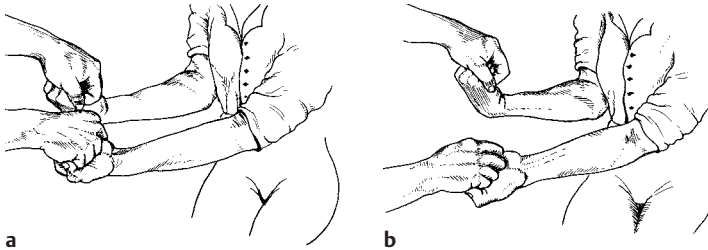


Fig. 158a, b Wrist flexion test: a normal, b abnormal with weakness in active flexion of the left forearm

### Wrist Flexion Test

Assessment of distal nerve lesion in the forearm.

**Procedure:** The patient is seated with both forearms supinated. The examiner asks the patient to flex his or her wrists, first normally and then against the resistance of the examiner's hands.

**Assessment:** Weakness in active flexion against resistance indicates paresis or paralysis of the flexors in the forearm, especially the flexor carpi radialis. Weakness in this motion without resistance is a sign of complete paralysis. Weakness in active flexion against resistance indicates a problem with the median nerve at the level of the elbow or further proximally. Complete inability to flex the wrist against resistance could indicate a lesion involving both the median and ulnar nerves.

---

# Hip

Hip pain can have any number of causes. In children and adolescents, it is usually a sign of a serious disorder and therefore always requires a thorough diagnostic workup.

Patients usually report hip pain in the groin or posterior to the greater trochanter, occasionally radiating into the medial aspect of the thigh as far as the knee. For this reason, especially in children, a hip disorder can be easily misinterpreted as a knee disorder. The differential diagnosis should include disorders of the adductor tendons, lumbar spine, and, especially, the sacroiliac joints.

Many of the hip disorders associated with pain correlate with a certain age group. Frequent causes of pain in the hip include chronic hip dislocations and Legg–Calvé–Perthes disease in children and slipped capital femoral epiphysis in adolescents. In contrast, osteoarthritis of the hip is the primary cause of hip pain in adults.

Untreated or insufficiently treated congenital hip dislocation with persisting acetabular dysplasia is one of the most frequent causes of subsequent degenerative joint disease. Pain on walking, which patients usually describe as groin pain, is often attributable to hip dysplasia.

Aseptic necrosis of the femoral head, injuries, the “normal” aging process, and rheumatic and metabolic disorders are other disorders that can lead to degenerative hip disease. The hip joint is surrounded by a strong muscular envelope. Inspection alone will provide only a modest amount of diagnostic information about the condition of the joint. Even a significant joint effusion may escape detection. The position of the legs (flexion contracture of the hip, malrotation, or leg shortening) and the position of the spine (scoliosis or lordosis) are important in evaluating the pelvis; their abnormal positions may actually be caused by a hip disorder and can allow one to draw conclusions about the condition of the hip.

The normal pelvis is tilted anteriorly, producing lordosis in the lumbar spine. Contracture of the hip results in an abnormal position of the legs, pelvis, and back. This is usually more apparent when the patient is standing upright than when lying down. Increased lumbar lordosis can be due to a flexion contracture in the hip; this contracture may be compensated for by an increased anterior tilt of the pelvis and increased lordosis. Actual and apparent leg shortening also significantly influences leg position and gait. When examining leg length, one must

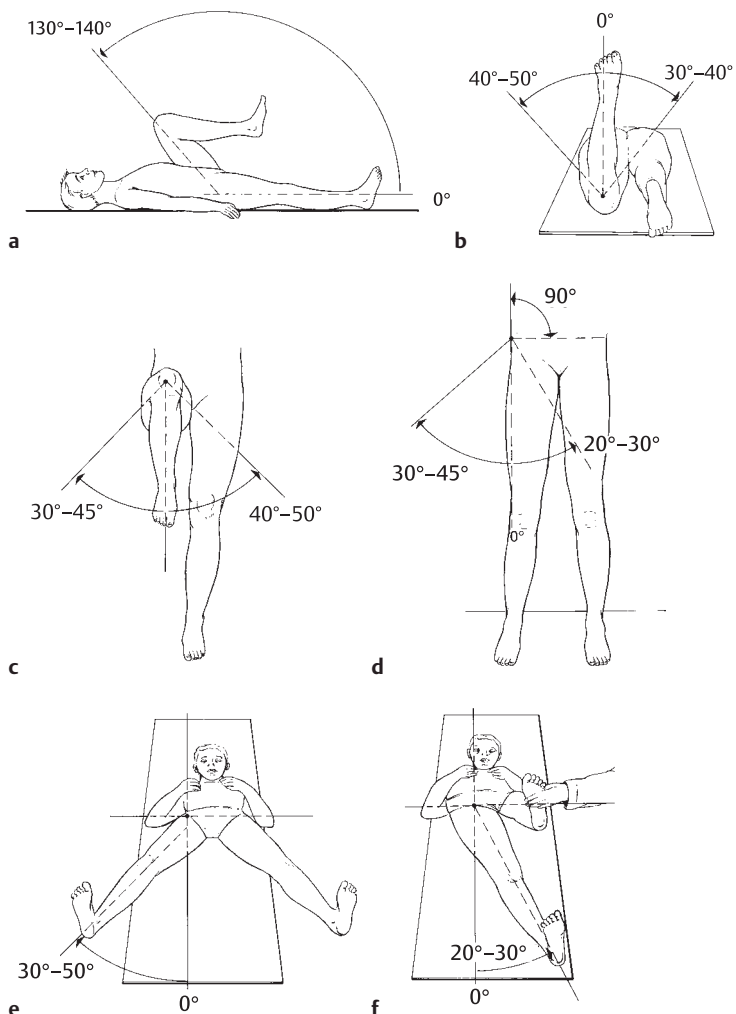


Fig. 159

- a Flexion and extension of the hip, supine
- b, c Internal and external rotation of the hip:
  - b prone, with the hip extended, c supine, with the hip flexed
- d Abduction and adduction of the hip
- e, f Abduction and adduction of the hip

consider the possibility of apparent lengthening or shortening due to an abduction or adduction contracture.

In the presence of an abduction contracture of the leg at the hip, the patient can only bring his or her legs into parallel alignment by tilting the pelvis. This pushes the normal hip upward, making that leg appear shortened. The adduction contracture has an analogous effect, although in this case the affected leg appears shortened. If the patient does not want to stand with one leg on tiptoe to compensate for the shortening, he or she will have to flex the contralateral knee. This produces an additional flexion in the hip that the patient can compensate for by increasing the anterior tilt of the pelvis.

Abnormal positioning of the pelvis due to hip anomalies usually results in changes to the spine in the form of lumbar scoliosis and spinal torsion or a compensatory curvature of the posterior lumbar section of the spine.

Assessment of the patient's gait allows the examiner to identify gait abnormalities due to articular causes (osteoarthritis or inflammation) and/or muscular causes. In Duchenne antalgic gait, the patient attempts to reduce the load on the hip that causes the pain. In a Trendelenburg gait, weakness of the hip abductors, primarily the gluteal musculature, causes the pelvis to dip toward the unaffected side in the stance phase. In a compensatory limp with leg shortening, the upper body is shifted slightly over the leg in the stance phase. Otherwise, the gait is relatively smooth. Arthrodesis of the hip does not produce a true limp in the sense that the pelvis dips in the stance phase. Rather the increased tilt of the pelvis in the sagittal plane, as it moves from hyperlordosis into lumbar kyphosis, produces femoral anteversion in the swing phase.

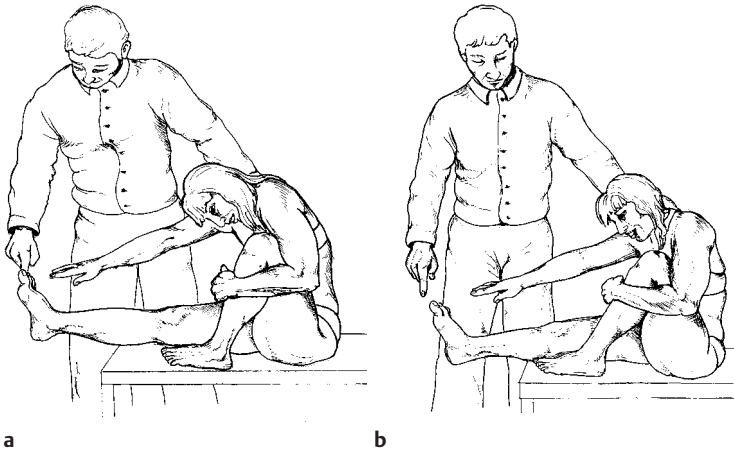
Other function tests are of help in the closer assessment of hip disorders and in clarifying their cause and confirming the diagnosis.

## ■ Function Tests

### Fingertip Test

Assesses contracture of the hamstrings.

**Procedure:** The patient is seated, holding one leg (flexed at the hip and knee) close to the trunk with the ipsilateral arm. The other leg remains extended. The patient is requested to touch the toes of the extended leg with the fingertips of the free arm. This test is then repeated on the contralateral side.



**a**  
**Fig. 160** Fingertip test:  
**a** normal,  
**b** abnormal with contracture of the hamstrings

**Assessment:** In the presence of a hamstring contracture, the patient can only bring the fingertips into the general area of the foot and complains of “pulling” pain in the posterior thigh.

The test is positive where there is a difference between both sides and symptoms are present. Uniform, painless developmental shortening of the hamstrings is common. Restricted motion can result secondary to a spinal disorder or osteoarthritis of the hip.

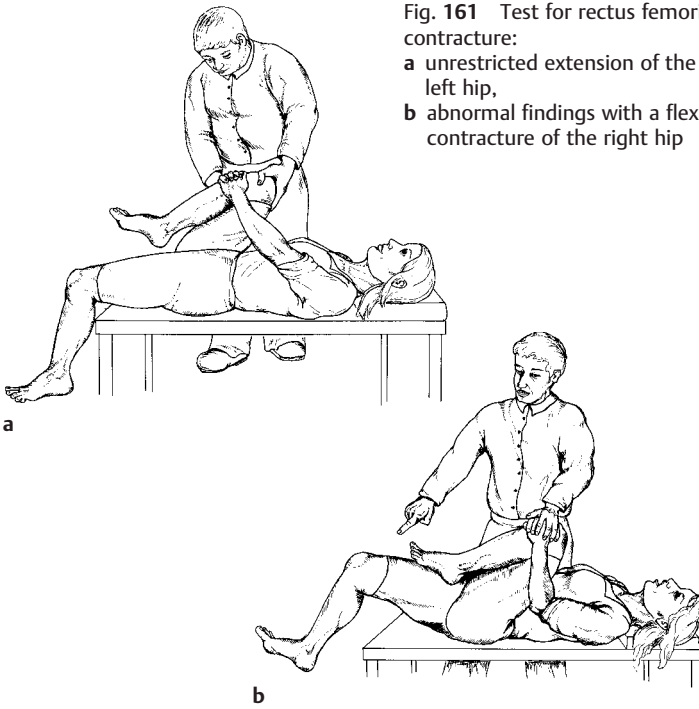
**Note:** Symptoms of nerve root irritation can be excluded by other tests. Shortened hamstrings increase retropatellar pressure and can therefore cause retropatellar symptoms.

### Test for Rectus Femoris Contracture

**Procedure:** The patient is supine with the lower legs hanging over the edge of the examining table. The patient is requested to grasp one knee and pull it up against his or her chest. The examiner notes the angle that the hanging leg assumes. The test is repeated on the contralateral side.

**Assessment:** In a contracture of the rectus femoris, drawing one knee closer to the chest will produce flexion in the other leg lying on the table; when this starts to happen will depend on the contracture. The test will also be positive in the presence of a flexion contracture of the

**Fig. 161** Test for rectus femoris contracture:  
**a** unrestricted extension of the left hip,  
**b** abnormal findings with a flexion contracture of the right hip



hip due to a hip disorder, psoas irritation (psoas abscess), lumbar spine disorder, and change in pelvic inclination.

**Note:** A contracture of the quadriceps increases the retropatellar pressure and may thus be the cause of retropatellar symptoms.

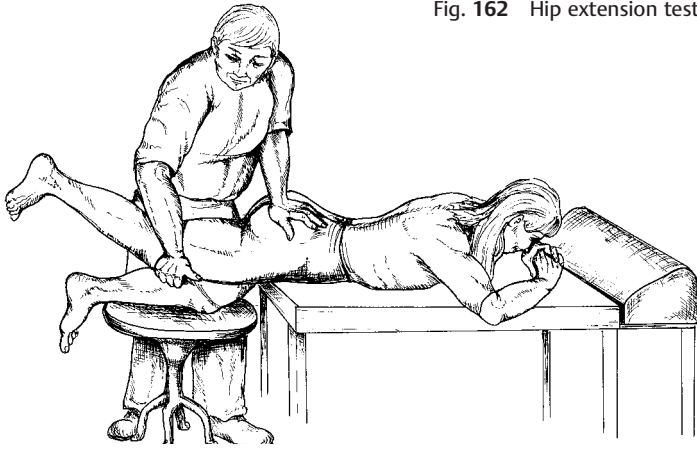
### Hip Extension Test

Assesses flexion contracture of the hip.

**Procedure:** The patient is prone with both hips flexed over the edge of the examining table. The leg that is not being examined is held between the examiner's legs, supported on a chair, or simply allowed to hang down.

With one hand, the examiner immobilizes the patient's pelvis. With the other hand, he or she slowly extends the leg to be examined. The prone position fully compensates for the lumbar lordosis.

Fig. 162 Hip extension test



**Assessment:** The point at which motion in the pelvis begins or the lumbar spine goes into lordosis indicates the endpoint of hip extension. The angle between the axis of the thigh and horizontal (the examining table) approximately indicates the flexion contracture in the hip. This test allows good assessment of a flexion contracture, especially in bilateral contractures (such as in spasticity).

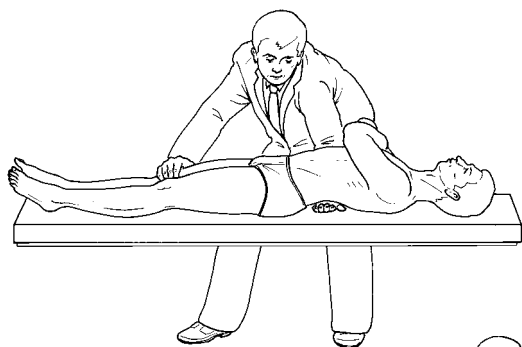
### Thomas Grip

Assesses extension in the hip.

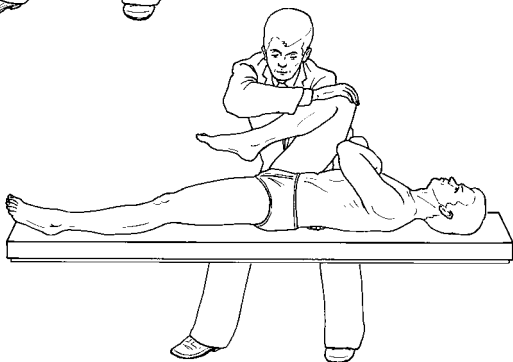
**Procedure:** The patient is supine. The unaffected, contralateral leg is flexed at the hip until the lumbar lordosis disappears. This is verified by inserting one hand between the patient's lumbar spine and the examining table. With the patient in this position, the examiner immobilizes the pelvis in its normal position. The pelvis should exhibit about  $12^\circ$  of anterior inclination. This is what creates the lumbar lordosis. An increased flexion contracture in the hip can be compensated for by an increase in lumbar lordosis, in which case the patient only appears to assume a normal position.

**Assessment:** Extension is only possible up to the neutral position ( $0^\circ$ ); the thigh lies flat on the surface of the examining table. Further flexion can tilt the pelvis further upright. So long as the leg being examined remains in contact with the examining table, the angle of pelvic tilt achieved corresponds to the maximum hyperextension of the hip.

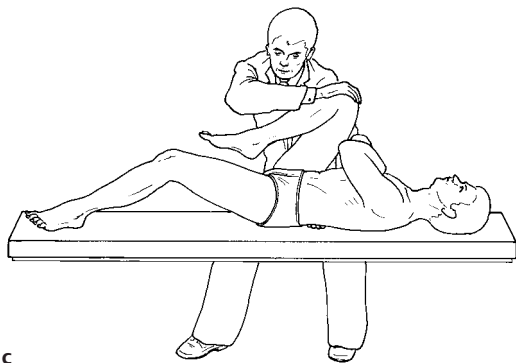




a



b



c

Fig. 163 Thomas grip: a starting position, b normal, c flexion contracture of the left hip

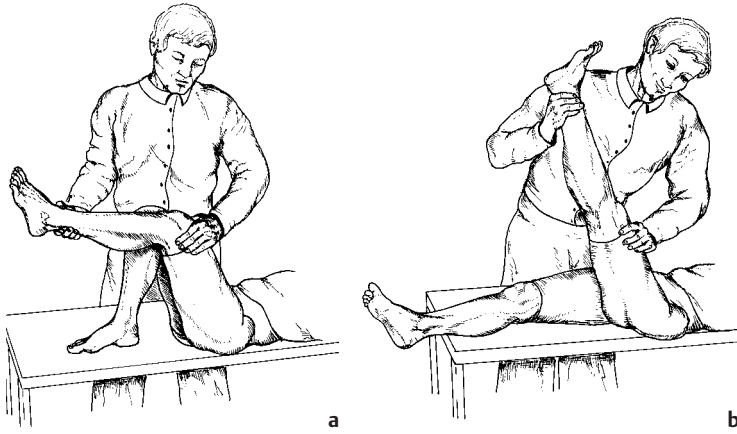


Fig. 164 Noble compression test:  
a starting position, b extension

In a flexion contracture, the hip being examined does not continue to lie extended on the examining table. Instead it moves along with the increasing hip flexion or pelvic tilt, taking on a position of increasing flexion. The flexion contracture can be quantified by measuring the angle that the flexed, affected leg forms with the examining table.

Contractures of the hip occur in osteoarthritis, inflammation, and articular deformities of the hips. They can also cause spinal disorders.

### Noble Compression Test

Evaluation of a contracture of the tensor fasciae latae.

**Procedure:** The patient is supine. The examiner passively flexes the patient's knee  $90^\circ$  and the hip approximately  $50^\circ$ . With the fingers of the left hand, the examiner gently presses on the lateral femoral condyle. Maintaining the flexion in the hip and pressure on the lateral femoral condyle, the examiner then increasingly extends the knee passively. Once the knee is in about  $40^\circ$  of flexion, the patient is requested to fully extend the knee.

**Assessment:** The tensor fasciae latae arises from the anterolateral margin of the ilium (anterior superior iliac spine). It is an anterior branch of the gluteus medius. Its tendon inserts into the anterior margin of the iliotibial tract, which reinforces the fascia lata of the thigh.

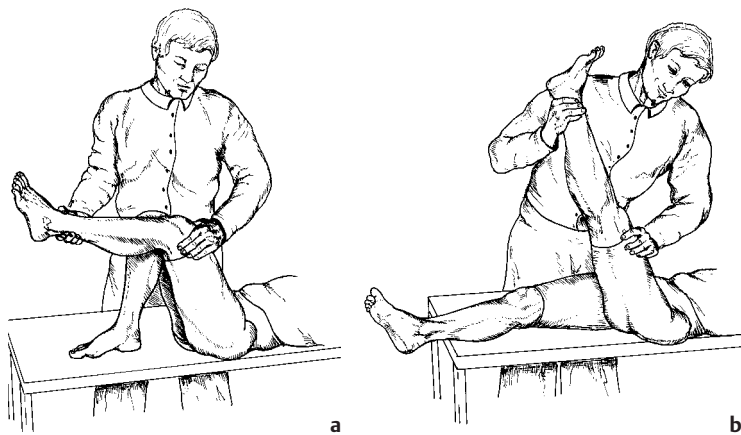


Fig. 164 Noble compression test:  
a starting position, b extension

In a flexion contracture, the hip being examined does not continue to lie extended on the examining table. Instead it moves along with the increasing hip flexion or pelvic tilt, taking on a position of increasing flexion. The flexion contracture can be quantified by measuring the angle that the flexed, affected leg forms with the examining table.

Contractures of the hip occur in osteoarthritis, inflammation, and articular deformities of the hips. They can also cause spinal disorders.

### Noble Compression Test

Evaluation of a contracture of the tensor fasciae latae.

**Procedure:** The patient is supine. The examiner passively flexes the patient's knee  $90^\circ$  and the hip approximately  $50^\circ$ . With the fingers of the left hand, the examiner gently presses on the lateral femoral condyle. Maintaining the flexion in the hip and pressure on the lateral femoral condyle, the examiner then increasingly extends the knee passively. Once the knee is in about  $40^\circ$  of flexion, the patient is requested to fully extend the knee.

**Assessment:** The tensor fasciae latae arises from the anterolateral margin of the ilium (anterior superior iliac spine). It is an anterior branch of the gluteus medius. Its tendon inserts into the anterior margin of the iliotibial tract, which reinforces the fascia lata of the thigh.

The tensor fasciae latae inserts into the iliotibial tract, which in turn inserts into the tubercle of Gerdy on the proximal tibia. Extending the knee from 30° of flexion places maximum stress on the iliotibial tract.

Pain along the proximal and distal iliotibial tract suggests a contracture of the muscle or of the iliotibial tract itself. Pain in the posterior thigh that occurs with increasing extension is most likely indicative of a contracture of the hamstrings and should not be confused with a contracture of the tensor fasciae latae.

### Ober Test

Assesses a contracture of the iliotibial tract.

**Procedure:** The patient lies on his or her unaffected side with the legs flexed at the hips and knees (to neutralize the lumbar lordosis). With one hand, the examiner grasps the patient's affected leg while stabilizing the pelvis with the other hand. The examiner then passively extends the hip, which brings the femur into line with the pelvis and thus immobilizes the iliotibial tract at the level of the greater trochanter. The leg is then adducted from this position.

**Assessment:** If the iliotibial tract is shortened, the degree of hip adduction it allows will be limited in direct proportion to the degree of shortening. The test can also be performed in such a manner that the examiner abducts the extended leg and then lets go of it from a certain degree of abduction. If the leg fails to drop back into an appropriate adduction position or if flexion or rotation suddenly occurs, then a contracture of the iliotibial tract is present. The test is usually painless although it can cause pain in some patients. Patients commonly report pain in the region of the lateral femoral condyle.

**Note:** A shortened iliotibial tract leads to chronic pain in the lateral thigh and to functional impairment in the patellofemoral joint through its attachment with the lateral patellar retinaculum.

### Drehmann Sign

Indicates a hip disorder.

**Procedure:** The patient is supine. The examiner grasps the patient's foot and knee and flexes the knee.

A hip disorder is present when flexion produces increasing external rotation in the hip. The motion may be painless or it may cause pain.

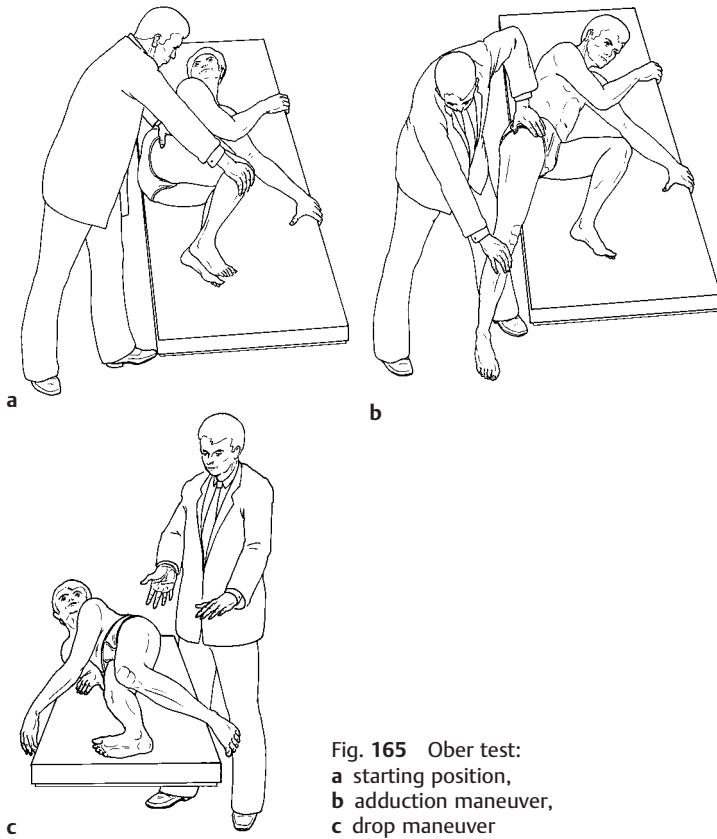
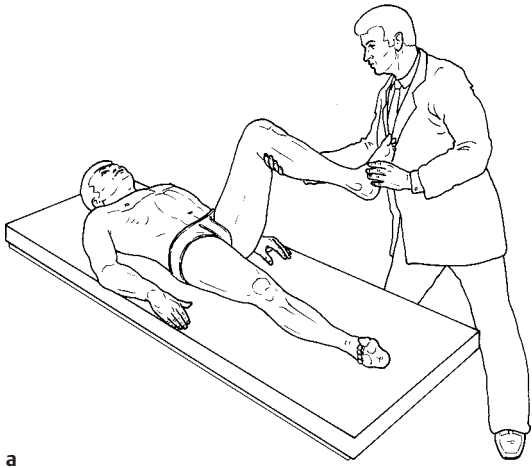


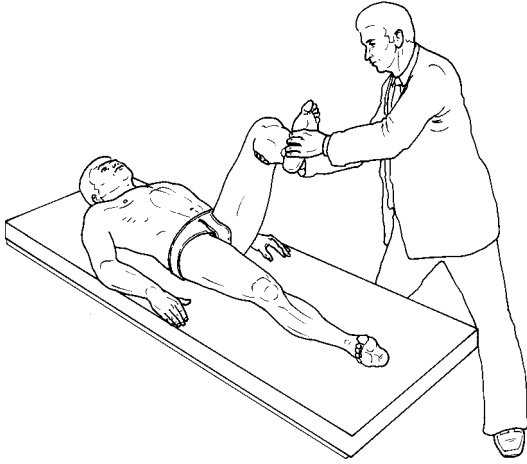
Fig. 165 Ober test:  
a starting position,  
b adduction maneuver,  
c drop maneuver

**Assessment:** In adolescents, a positive Drehmann sign occurs primarily in the presence of a slipped capital femoral epiphysis. This causes the thigh to move into increasing compensatory external rotation as the hip is flexed.

However, a hip infection, incipient osteoarthritis, or a tumor may also produce positive test results.



a



b

Fig. 166 Drehmann sign:  
a knee and hip flexion,  
b external rotation of the hip

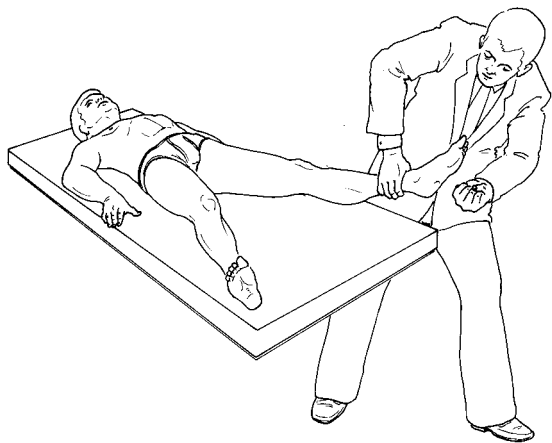


Fig. 167  
Anvil test

### Anvil Test

Indicates hip disease.

**Procedure:** The patient is supine with legs extended. The examiner raises the extended leg slightly with one hand and hits the heel axially with the fist of the other hand.

**Assessment:** The force of the blow is transmitted to the hip. Pain in the groin or in the thigh adjacent to the hip suggests hip disease (such as osteoarthritis of the hip or inflammation). In total hip arthroplasty patients, it suggests implant loosening (groin pain suggests loosening of the acetabular component, whereas pain in the lateral thigh suggests loosening of the femoral stem).

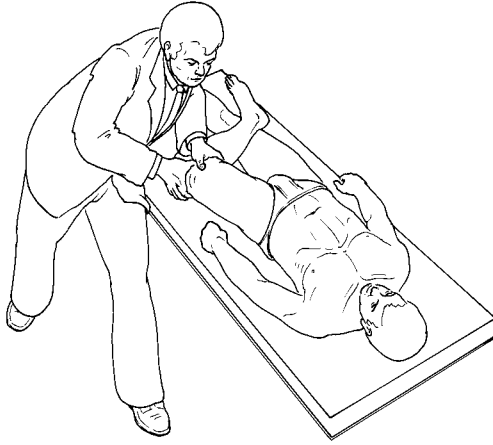
Symptoms in the lumbar spine occur in intervertebral disk disease or in rheumatoid spine disorders.

### Leg Pain upon Axial Compression

Variation of the anvil test; indicates hip disease.

**Procedure:** The patient is supine with one leg extended and the other flexed at the knee. The lateral malleolus of the flexed leg lies just superior to the patella of the contralateral leg. The examiner grasps the distal thigh of the flexed leg with both hands and compresses it axially.

Fig. 168 Leg pain upon axial compression



**Assessment:** This motion compresses the hip joint and the affected side of the pelvis.

Pain in the groin suggests hip disease such as osteoarthritis of the hip. In total hip arthroplasty patients, it suggests implant loosening.

Symptoms in the lumbar spine occur in intervertebral disk disease or in rheumatoid spine disorders.

### Trendelenburg Sign/Duchenne Sign

Tests pelvic and trochanteric muscle function.

**Procedure:** The examiner stands behind the standing patient. The patient is requested to raise one leg by flexing the knee and hip.

**Assessment:** In the single leg stance, the pelvic and trochanteric musculature (gluteus medius and gluteus minimus) on the weight-bearing side contract and elevate the pelvis on the unsupported side, holding it nearly horizontal.

This process allows uniform gait. Where the gluteal muscles are compromised (weakened as a result of a hip dislocation, due to paralysis, or following multiple hip operations) with functional deficits, they are no longer able to support the pelvis on the weight-bearing side. The pelvis then drops down on the normal, non-weight-bearing side (positive Trendelenburg sign). The patient will exhibit a typical duck-like waddling gait, especially in a bilateral condition (as in bilateral hip dislocation).



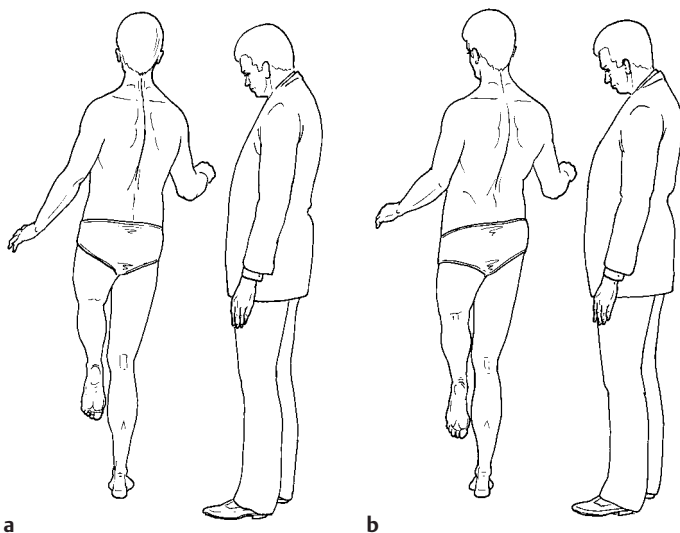


Fig. 169 Trendelenburg sign:

a normal,

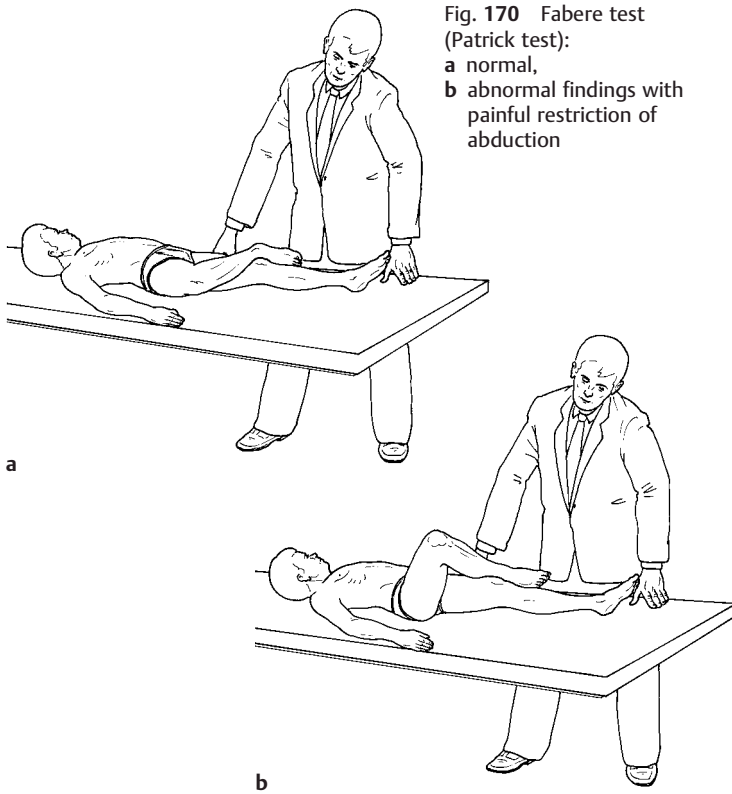
b abnormal with insufficiency of the gluteal muscles

The drop in the pelvis toward the unaffected side also shifts the body's center of gravity in that direction. Patients usually compensate by shifting the body toward the weight-bearing leg (Duchenne sign).

#### Fabere Test (Patrick Test) for Legg–Calvé–Perthes Disease

**Procedure:** The child is supine with one leg extended and the other flexed at the knee. The lateral malleolus of the flexed leg lies across the other leg superior to the patella. The test may also be performed so that the foot of the flexed leg is in contact with the medial aspect of the knee of the contralateral leg. The flexed leg is then pressed or allowed to fall further into abduction.

**Assessment:** Normally the knee of the abducted leg will almost touch the examining table. The examiner makes comparative measurements of the distance between the knee and the table on both sides. On the side of the positive Patrick sign, motion is impaired, the adductors are tensed, and the patient feels pain when the leg is further abducted past the starting position in limited abduction. Pain in the groin can be a sign of Legg–Calvé–Perthes disease.



**Fig. 170** Fabere test  
(Patrick test):  
**a** normal,  
**b** abnormal findings with  
painful restriction of  
abduction

Legg–Calvé–Perthes disease is regarded as belonging to the group of aseptic avascular necroses. The disease manifests itself in the epiphysis, metaphysis, and apophysis of the long bones and in the tarsal and carpal bones that ossify within the cartilage. Legg–Calvé–Perthes disease is the most common form of aseptic bone necrosis. It occurs primarily between the ages of 3 and 12 years, with peak occurrence between the ages of 4 and 8 years. In the early stages of the disease, children tire quickly and begin to limp slightly. They complain of slight pain in the hip; occasionally they only complain of knee pain.

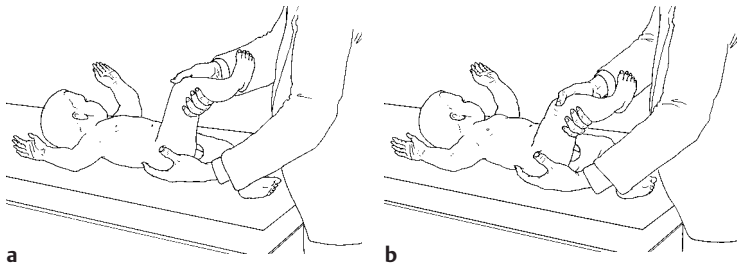


Fig. 171 Telescope sign: **a** leg “shortening” on axial compression, **b** leg “lengthening” on axial traction

### Telescope Sign

Indicates congenital hip dislocation.

**Procedure:** The examiner grasps the affected leg with one hand and passively flexes the hip and knee. The other hand rests posterolateral to the hip. The examiner palpates the greater trochanter with the thumb of this hand and the motion of the femoral head with the index finger. The hand guiding the leg alternately applies axial compression and traction to the femur.

**Assessment:** In a hip dislocation, the leg will appear to shorten or lengthen. The palpating hand follows the motion of the greater trochanter and femoral head into the dislocated position and back to reduction.

### Barlow and Ortolani Tests

Assess hip instability in infants.

**Procedure:** With the infant supine, the examiner passively flexes one leg, immobilizing the pelvis. The other hand grasps the knee and thigh of the leg to be examined in such a manner that the index finger and thumb rest inferior to the inguinal fold.

With the thigh initially in extreme adduction, the examiner carefully exerts axial pressure while simultaneously pressing the thigh into abduction from the medial side. The fingers provide controlled resilient resistance to this motion. Instability in the hip will be palpable as the direction of force changes between the fingers and thumb. This is the Barlow dislocation test.

In the second phase of the examination, the examiner slowly abducts the thigh while maintaining axial compression. If the femoral head was

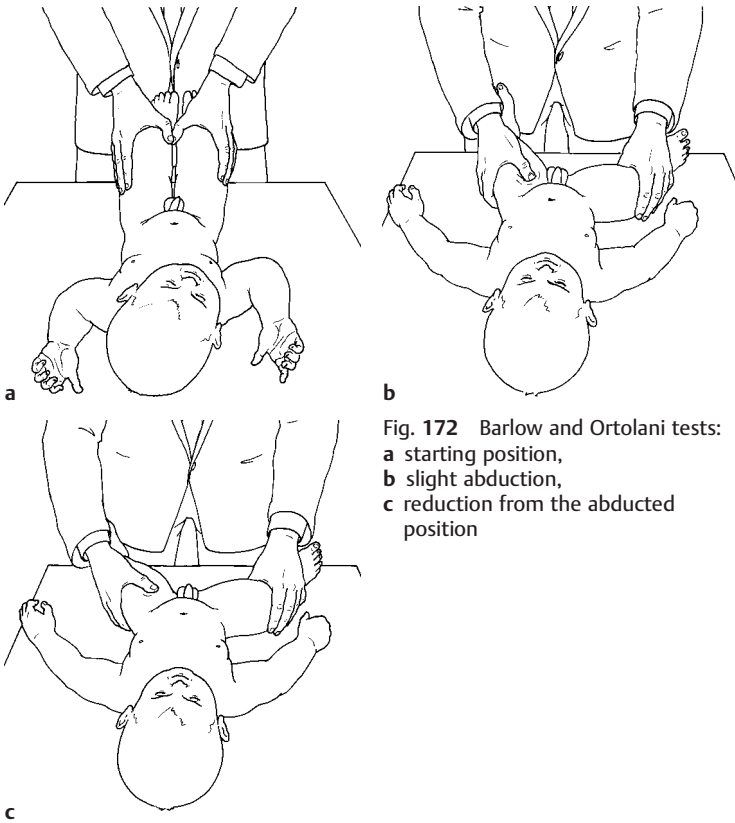


Fig. 172 Barlow and Ortolani tests:  
 a starting position,  
 b slight abduction,  
 c reduction from the abducted  
 position

pushed out of the center of the acetabulum during the first phase (Barlow test), the examiner can now reduce it into the acetabulum with a palpable snap by pressing on the greater trochanter with the fingers. This is known as the Ortolani “click.”

This test should be repeated separately for each leg.

**Assessment:** The examination detects instability of the hip and also allows one to define the degree of instability present. Toennis differentiates four grades of instability:

Grade I: Slightly unstable hip without a snap.

Grade II: Dislocatable hip. The hip can be fully or largely reduced by abduction alone (with a snap).

Grade III: Hip that can be dislocated and reduced.

Grade IV: Dislocated hip that cannot be reduced. The acetabulum is empty, and the femoral head can be palpated posteriorly; abduction is severely limited and reduction is not possible.

**Note:** A “dry click” without dislocation can often be provoked during in the first days of life, but disappears thereafter.

The Barlow and Ortolani test is particularly useful in newborns 2–3 weeks old. The Ludloff–Hohmann test is an alternative in slightly older children. With the hip flexed and abducted, spontaneous knee flexion will normally occur as a result of the physiologic tension in the hamstrings. A knee that can be fully extended with the hip flexed and abducted suggests an unstable hip.

### Galeazzi Test

Assesses leg length difference.

**Procedure:** The patient is supine with the knees flexed 90° and the soles of the feet flat on the examining table. The examiner assesses the position of both knees from the end of the table and from the side.

**Assessment:** Normally both knees are at the same level. Where one knee is higher than the other, either the tibia of that side is longer or the contralateral tibia is shorter. Where one knee projects farther forward than the other, either that femur is longer or the contralateral femur is shorter. The test for assessment of femur length is indicated as an additional test for evaluating hip dislocation. However, in such a case there is only an apparent difference in length; the femurs are the same length but one thigh appears shorter due to the hip dislocation.

Note that the Galeazzi test will yield a false-negative result in cases of bilateral hip dislocation.

### Hip and Lumbar Rigidity in Extension

Indicates spinal cord disease and intervertebral disk pathology in children.

**Procedure:** The child is supine. The examiner lifts the child's legs.

**Assessment:** Reflexive rigidity that maintains hip extension when the child's legs are lifted is a sign of a spinal cord lesion such as a tumor, compression of the spinal cord as in spondylolisthesis, or nerve root compression as in intervertebral disk extrusion.

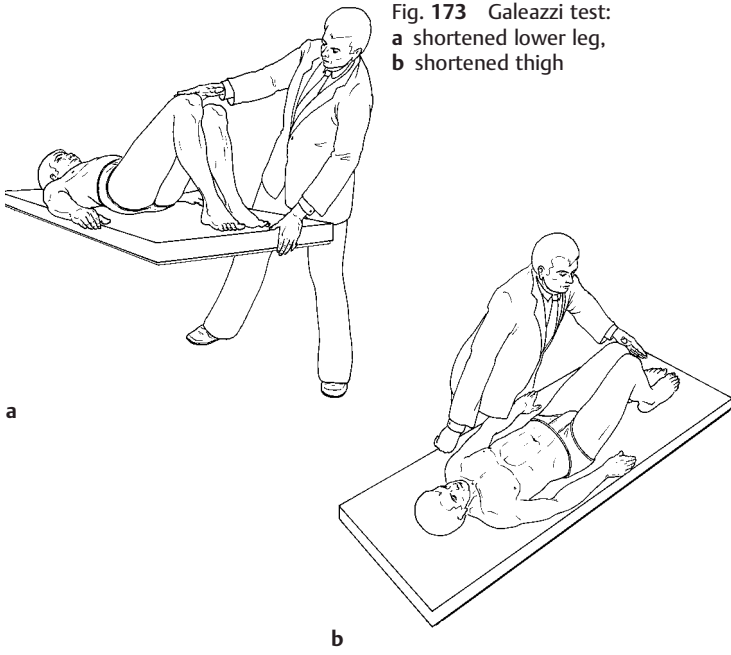


Fig. 173 Galeazzi test:  
a shortened lower leg,  
b shortened thigh

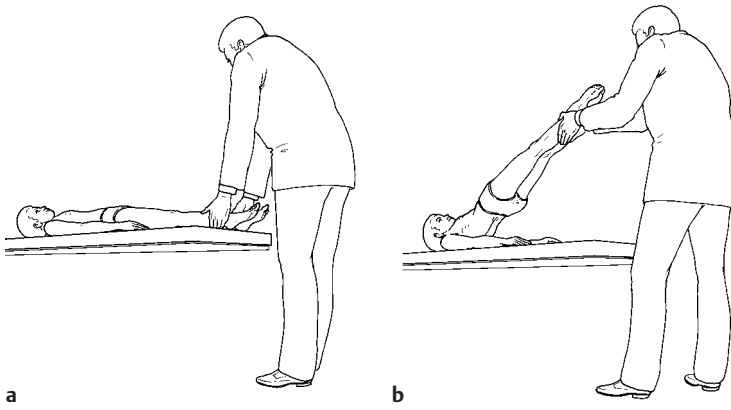


Fig. 174 Hip and lumbar rigidity in extension:  
a starting position,  
b abnormal findings

### Kalchschmidt Hip Dysplasia Tests

Assess symptoms caused by hip dysplasia.

Most patients with symptoms due to hip dysplasia report pain with weightbearing felt in the groin or the region of the greater trochanter. However, there are patients who cannot clearly identify the anatomic region of the symptoms and complain of pain in the lower back, buttock, and thigh.

The following tests are helpful where clinical and radiographic evidence suggests painful hip dysplasia:

#### **Test 1**

With the patient standing on the painful leg and the examiner guiding the patient's shoulders, the examiner turns the patient's body so that the affected hip is in maximum external rotation. Backward bending also hyperextends the hip.

Where symptoms are attributable to hip dysplasia, this posture will cause groin pain. When the patient then bends forward and the hip is brought into internal rotation by the examiner's guiding of the patient's shoulders, the pain disappears.

#### **Test 2**

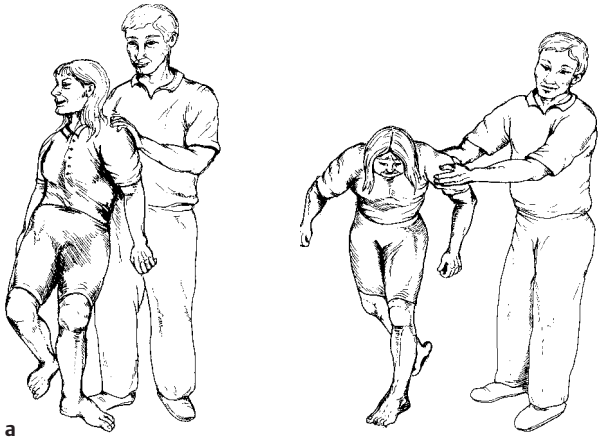
The patient is prone (a sandbag may also be placed under the knee). While pressing on the patient's buttock, the examiner passively flexes the patient's knee 90° and applies increasing resilient pressure to externally rotate the thigh.

Where symptoms are attributable to hip dysplasia, the patient will report pain in the groin region. This test provides useful diagnostic information when both sides are compared, and it is easy to perform.

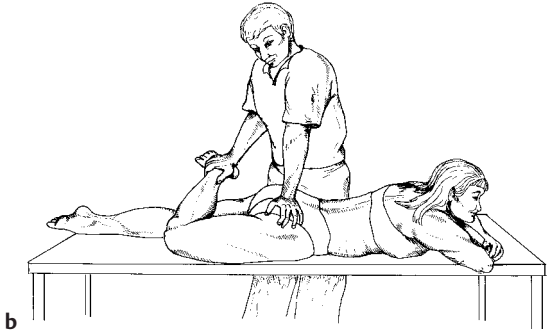
#### **Test 3**

The patient is supine. First the examiner palpates the hip beneath the anterior inferior iliac spine. The examiner then places increasing pressure on the femoral head by pressing with the hypothenar eminence of the extended arm.

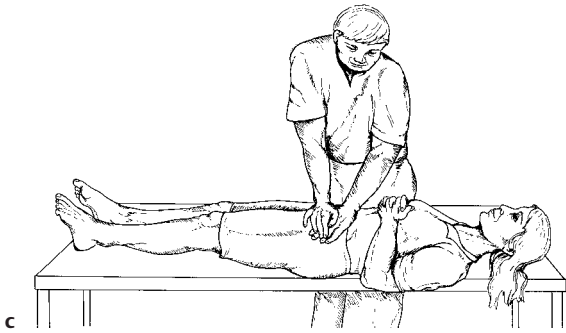
Where symptoms are attributable to hip dysplasia, the patient will report pain. This test provides useful diagnostic information, especially when both sides are compared. Often, the examiner will observe that performing the test presses an eccentric, anteriorly displaced femoral head back into the acetabulum.



a



b



c

Fig. 175 Kalchschmidt hip dysplasia tests:  
a test 1, b test 2, c test 3



---

# Knee

Our knowledge of the knee has expanded significantly over the last few decades. New information about anatomy, biomechanics, and pathophysiology has improved the detection and treatment of knee disorders. Injuries to the knee, particularly in conjunction with sports activities, have become a major focus of interest.

Noninvasive modalities such as ultrasound, computed tomography, and magnetic resonance imaging today allow precise assessment of diseased and injured structures in the knee. Diagnostic arthroscopy has evolved into a surgical method of treatment.

Diagnostic assessment of knee symptoms begins with history taking and physical examination. Anteroposterior and lateral radiographs of the knee together with an axial view of the patella and trochlear groove are required to detect changes in bony structures right at the start.

It is very important to identify the location and type of pain as well its duration or when it occurs (pain with weightbearing, joint blockade, etc.). Inspection and evaluation of axial deviations (genu valgum, genu varum, genu recurvatum, or a flexion deformity), swelling of the knee, and muscle atrophy provide information about the possible causes of joint symptoms. Palpation then allows the examiner to identify diseased joint structures with greater accuracy and assess them in greater detail. Clinical tests of passive and active motion, some of which entail complex motions, also aid in making a diagnosis. Understanding how the accident occurred is important for diagnosing knee injuries. The type and severity of the injury are dependent on the direction, duration, and intensity of the trauma and on the position of the joint at the time of the injury.

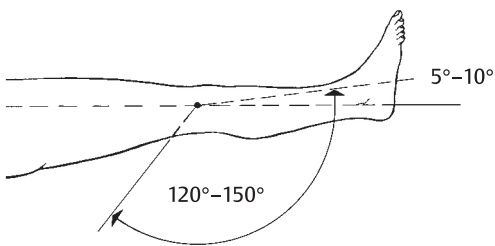
Sports injuries and developmental anomalies (axial deviations, malformation of the patella, etc.) are the most common causes of knee complaints in children and young adults. For example, Osgood–Schlatter disease should be suspected when an adolescent engaged in a jumping sport in school athletics complains of pain in the tibial tuberosity. In older adolescents, one should suspect patellar tendinitis (“jumper’s knee”). Degenerative damage to the meniscus can lead to sudden meniscus symptoms with impingement without an identifiable causative event even in early adulthood. In older patients, incipient or advanced wear in the joint due to aging processes, posttraumatic conditions, occupational stresses, and congenital or acquired deformities is

most often responsible for knee symptoms. Diffuse knee pain occurring in an older patient in the absence of trauma is almost invariably a sign of meniscus degeneration or joint wear. Swelling and a sensation of heat in the knee are normally present as well. Patients with retropatellar arthritis complain of pain on climbing stairs and walking downhill, occasionally accompanied by a feeling of instability. Patients with Baker cysts report pain in the popliteal fossa.

Aside from these characteristic descriptions of pain, any uncharacteristic pain described by the patient should be carefully assessed. The differential diagnosis must include disorders of the adjacent joints. Patients with osteoarthritis of the hip will often report pain radiating into the knee. Changes in the sacroiliac joints or lumbar spine, leg shortening, axial deviations, and ankle deformities can also cause knee symptoms.

Disorders of other organ systems should also be considered when assessing distal neurovascular dysfunction. The knee is affected in 60% of all cases in rheumatoid arthritis. Lyme disease should also be considered as a possible cause of isolated arthritis of the knee. A thorough history and extensive laboratory diagnostic studies are helpful in the differential diagnosis of such knee disorders.

### ■ Range of Motion in the Knee (Neutral-Zero Method)



**Fig. 176** Flexion and extension  
Internal and external rotation do not occur in extension. In 90° of knee flexion with the lower leg hanging freely, the knee exhibits a range of motion from 10° of internal rotation to up to 25° of external rotation

Table 6 Functional tests: Knee

Muscle traction tests	Patella	Meniscus	Medial and lateral ligaments	Anterior cruciate ligament (ACL)	Posterior cruciate ligament (PCL)		
Quadriceps traction test	Dancing patella test	Apley test	Abduction and adduction test (valgus and varus stress test) 0°–20°	Lachman test	Posterior drawer test		
Rectus traction test	Glide test	McMurray test		Prone Lachman test	Reversed pivot shift test		
	Zohlen sign	Bragard test		No-touch Lachman test	Quadriceps contraction test		
Hamstring traction test	Facet tenderness test	Payr sign		Active Lachman test	Anterior drawer test in 90° flexion	Posterior droop test	
	Crepitation test	Payr test			Jakob maximum drawer test	Soft posterolateral drawer test	
	Fairbank apprehension test	Steinmann I sign			Pivot shift test	Gravity sign	
	McConnell test	Steinmann II sign			Jakob graded pivot shift test	Genu recurvatum test	
	Subluxation suppression test	Boehler-Kroemer test		Merke test		Modified pivot shift test	Hughston test for genu recurvatum and external rotation
		Cabot test		Finochietto sign		Medial shift test	
	Tilt test	Childress sign				Soft pivot shift test	Godfrey test
	Dreyer test	Turner sign				Martens test	Dynamic posterior shift test
		Anderson medial and lateral compression test				Losee test	
		Paessler rotational compression test				Slocum test	
					Arnold crossover test		
					Noyes test		
			Jakob giving way test				
			Lemaire test				
			Hughston jerk test				

## ■ Muscle Traction Tests

The knee muscles are assessed along with testing mobility of the knee. In addition to identifying the various muscle groups, the examiner should be alert to any shortening and contractures in the musculature of the thigh and lower leg.

Often adolescent patients will complain of patellofemoral pain during sports. These complaints may be caused by reduced resilience of the quadriceps and hamstrings, which can increase compression of the patella in the trochlear groove.

### Quadriceps Traction Test

**Procedure:** The patient is prone. The examiner passively bends the knee to press the patient's heel against the buttocks.

**Assessment:** Normally both heels can be pressed against the buttocks. Shortening of the quadriceps is associated with an increased smallest distance between the heel and buttocks.

### Rectus Traction Test

**Procedure:** The rectus is evaluated with the patient supine. The patient holds the unaffected leg in maximum flexion. The examiner passively flexes the knee of the affected leg, which hangs over the edge of the examining table.

**Assessment:** Normally knee flexion will be slightly greater than 90° with the hip flexed. Shortening of the rectus femoris will result in knee flexion deficits, with total flexion less than 90°.

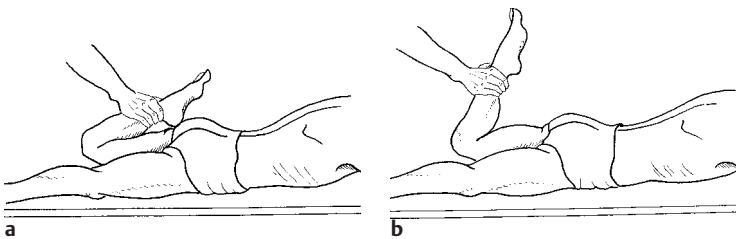


Fig. 177a, b Quadriceps traction test:  
**a** pressing the heel against the buttocks,  
**b** shortening of the quadriceps

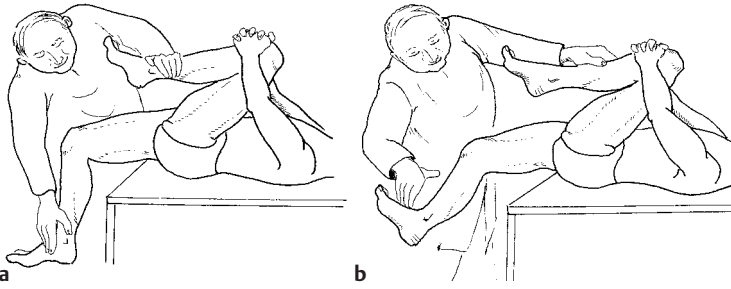


Fig. 178a, b Rectus traction test:  
**a** knee flexed 90°,  
**b** shortening of the rectus

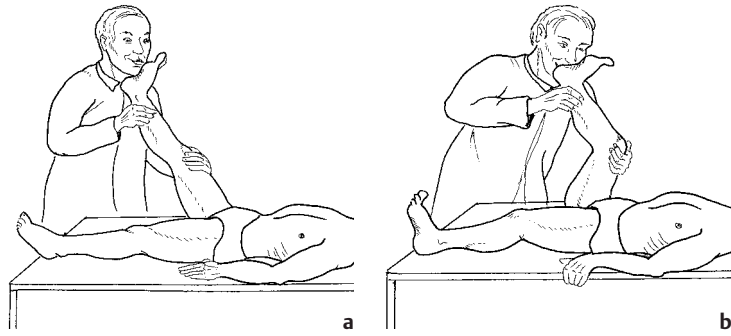


Fig. 179a, b Hamstring traction test:  
**a** flexion with knee extended,  
**b** shortened hamstrings

### Hamstring Traction Test

**Procedure:** The hamstrings are tested with the patient supine. The examiner lifts the patient's extended leg and notes the maximum hip flexion that can be achieved without involvement of lumbar lordosis.

**Assessment:** Flexion of less than 90° is regarded as abnormal. Where the hamstrings are shortened, further flexion can only be achieved by flexing the knee as well.

## ■ Patella

### Patellar Chondropathy (Chondromalacia, Anterior Knee Pain)

Malformations of the patella (patellar dysplasia) and of the trochlear groove (flattening of the lateral femoral condyle) and abnormal position of the patella (patella alta or lateral displacement) create abnormal mechanical stresses in the trochlear groove and with time can lead to arthritis. Aging processes, injuries (such as cartilage impingement or fractures), recurrent patellar dislocations, and inflammations (as in gout or rheumatism) are other factors that can lead to osteoarthritis.

Patients complain of retropatellar symptoms, pain in extreme knee flexion and when climbing stairs, and a feeling of instability.

Upon clinical examination, the patella will not be very mobile. The patient feels pain when the patella is pressed against the knee or moved, and the margins of the patella are painful. The apprehension test is usually positive.

Malformations of the patella and trochlear groove often lead to dislocation of the patella, which is then usually lateral.

Other factors promoting dislocation of the patella include patella alta (congenitally high-riding patella), axial deviation (genu valgum), malrotation of the tibia, and weak capsular ligaments.

### “Dancing Patella” Test

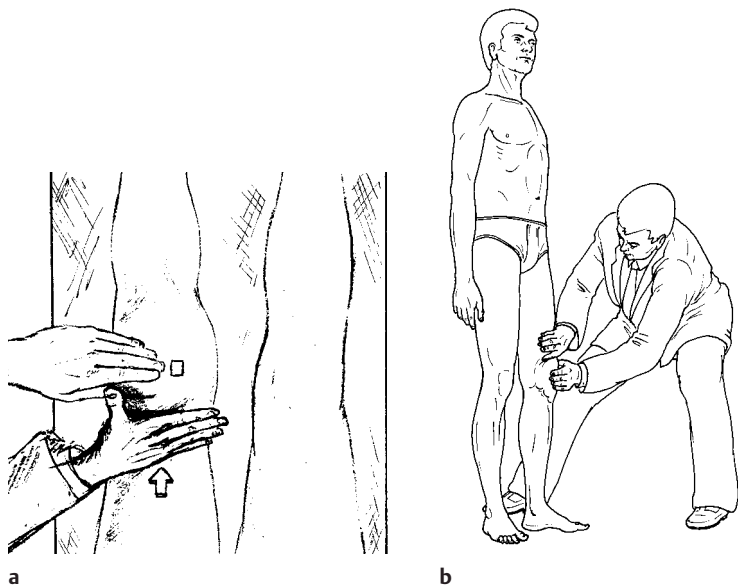
Indicates effusion in the knee.

**Procedure:** The patient is supine or standing. With one hand, the examiner smooths the suprapatellar pouch from proximal to distal while pressing the patella against the femur with the other hand or moving it medially and laterally with slight pressure.

**Assessment:** Resilient resistance (a dancing patella) is abnormal and suggests effusion in the knee.

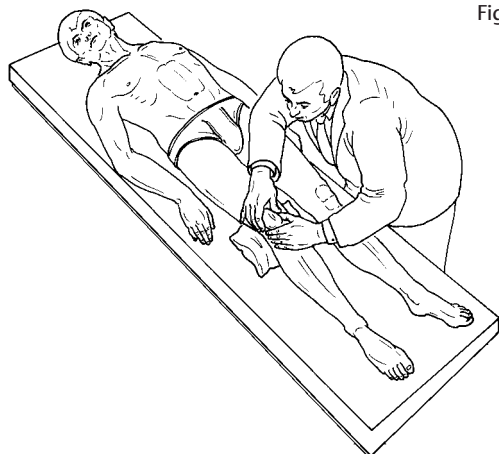
### Glide Test

**Procedure:** The patient is supine. The examiner stands at the patient's side next to the knee and grasps the proximal half of the patella with the thumb and index finger of one hand and the distal half with the thumb and index finger of the other. For the lateral glide test, the examiner's thumbs push the patella laterally over the lateral femoral condyle and the index fingers resting there. For the medial glide test, the examiner's index fingers push the patella in the opposite direction. In each case, the



**Fig. 180a, b** “Dancing patella” test:  
**a** with the patient supine,  
**b** with the patient standing

**Fig. 181** Glide test



examiner's index finger or thumb can palpate the projecting posterior surface of the patella. Where increased lateral mobility is suspected, the same test is performed to assess stability with the quadriceps tensed. The patient is asked to lift his or her foot off the examining table. The examiner then notes the resulting motion of the patella. The medial and lateral glide test provides information about the degree of tension in the medial or lateral retinaculum, respectively. The test should always be performed comparatively on both knees.

With the hands in the same position, the examiner can also place traction on the patella by lifting it off the condyles.

**Assessment:** Normal physiologic findings include symmetrical mobility of both patellae without any crepitation or tendency to dislocate. Increased lateral or medial mobility of the patella suggests laxity of the knee ligaments or habitual patellar subluxation or dislocation. Crepitation (retropatellar friction) occurring when the patella is mobilized suggests chondropathy or retropatellar osteoarthritis.

**Note:** With the hands in the same position, the examiner can expand the test by moving the patella distally. Decreased distal mobility of the patella suggests shortening of the rectus femoris or patella alta.

### Zohlen Sign

**Procedure:** The patient is supine with the leg extended. The examiner applies medial and lateral pressure to the proximal patella to press it into the trochlear groove and asks the patient to extend the leg further or tense the quadriceps.

**Assessment:** The quadriceps exerts a proximal pull on the patella, pressing it tightly against the trochlear groove. This will cause retro-patellar and/or peripatellar pain in the presence of retropatellar cartilage damage.

**Note:** Test results will be positive even in many normal patients. A negative Zohlen sign means that severe cartilage damage is unlikely.

### Facet Tenderness Test

**Procedure:** The patient is supine with the knee extended. The examiner first elevates the medial margin of the patella with his or her thumbs and palpates the medial facet with a thumb, then elevates the lateral margin with the index fingers and palpates the lateral facet with an index finger.



Fig. 182 Zohlen sign

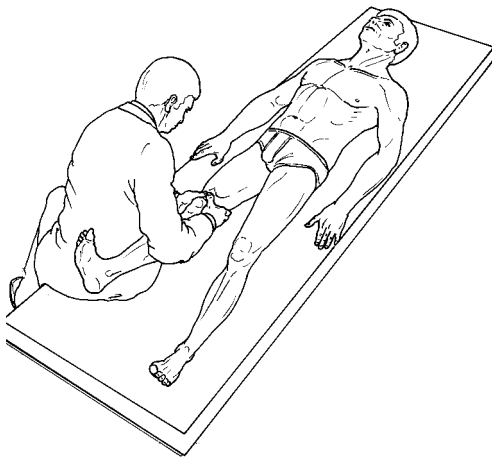
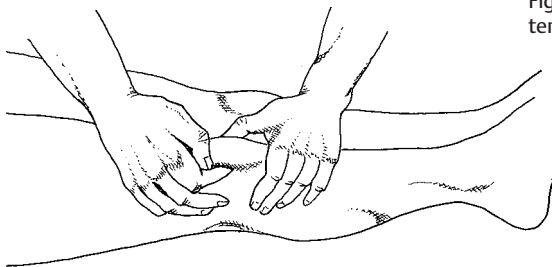


Fig. 183 Facet tenderness test



**Assessment:** Patients with retropatellar osteoarthritis, tendinitis, or synovitis will report pain, especially when the examiner palpates the medial facet.

### Creptitation Test

**Procedure:** The examiner kneels in front of the patient and asks the patient to crouch down or do a deep knee bend. The examiner listens for sounds posterior to the patella.

**Assessment:** Creptitation (“snowball crunch” sound) suggests severe chondromalacia (grades II and III). Cracking sounds like those that occur in almost everyone during the first or second deep knee bend have no significance. For this reason, the patient is asked to do several deep knee

Fig. 184 Crepitation test



bends. Usually the insignificant cracking sounds will decrease in intensity. In the absence of any audible retropatellar crepitation, the examiner may safely conclude that no severe retropatellar cartilage damage is present. However, the test results should not be used as a basis for far-reaching therapeutic decisions. They only provide information about the condition of the retropatellar cartilage. The crepitation test will be positive in many patients with normal knees.

### Fairbank Apprehension Test

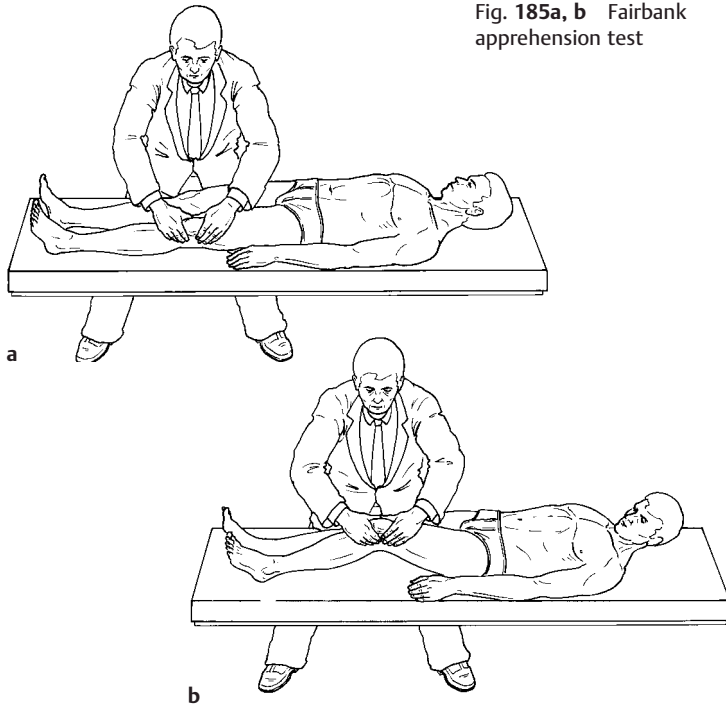
**Procedure:** The patient is supine with the knee extended and the thigh muscles relaxed. The examiner attempts to simulate a dislocation by placing both thumbs on the medial aspect of the knee and pressing the patella laterally. The patient is asked to flex the knee.

**Assessment:** Where a patella dislocation has occurred, the patient will report severe pain and will be apprehensive of another dislocation in extension or, at the latest, in flexion.

### McConnell Test

**Procedure:** The patient is seated with the legs relaxed and hanging over the edge of the table. This test attempts to provoke patellofemoral pain with isometric tensing of the quadriceps. This is done with the knee in various degrees of flexion ( $0^\circ$ ,  $30^\circ$ ,  $60^\circ$ , and  $120^\circ$ ). In each position, the examiner immobilizes the patient's lower leg and asks the patient to

Fig. 185a, b Fairbank apprehension test

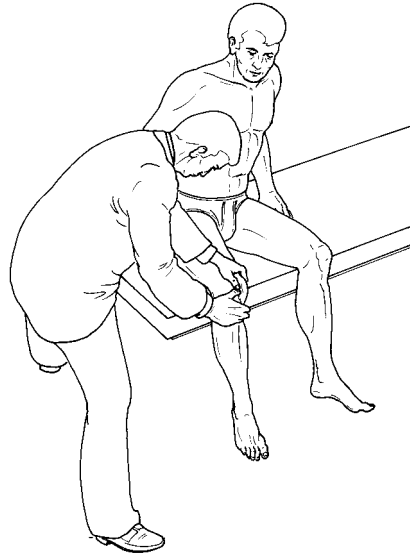


extend the leg against the examiner's resistance (this requires contraction of the quadriceps).

**Assessment:** Where the patient reports pain or a subjective sensation of constriction, the examiner medially displaces the patella with his or her thumb. In a positive test, this maneuver reduces pain. The examination should always be performed comparatively on both knees. Alleviation of pain by medial displacement of the patella is a diagnostic criterion for the presence of retropatellar pain.

**Note:** In a positive McConnell test, pain can often be reduced by taping the knee so as to pull the patella medially. This "McConnell tape" bandage includes a lateral-to-medial slip that pulls the patella medially. A small plaster slip running medially from the middle of the patella is applied where a lateral patellar tilt requires correction. If required, a rotational slip extending from the medial knee to the tip of the patella and then to the lateral aspect can be applied to bring the patella into a neutral position. Physical therapy should concentrate on

Fig. 186 McConnell test



strengthening the vastus medialis and stretching the rectus femoris and iliotibial tract.

### **Subluxation Suppression Test**

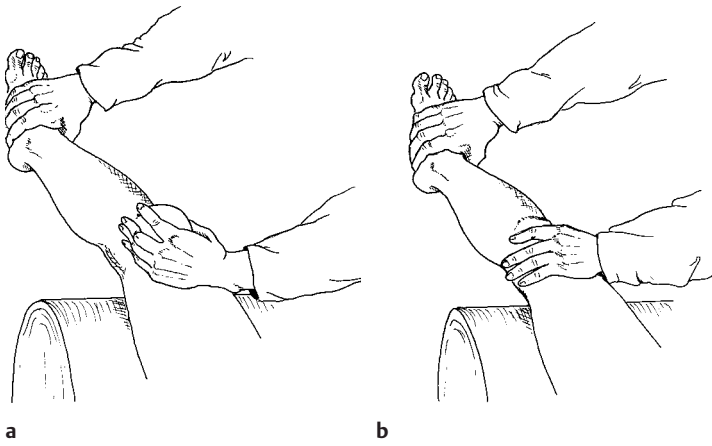
Demonstrates lateral or medial patellar subluxation.

#### ***Lateral Subluxation Suppression Test***

**Procedure and assessment:** To demonstrate lateral subluxation, the examiner places his or her thumbs on the proximal half of the lateral patellar facet. The patient is then asked to flex the knee. Either the thumb will be seen to prevent lateral subluxation or the examiner will feel the lateral motion of the patella. Flexing the knee without any attempt to prevent subluxation will lead to lateral patellar subluxation.

#### ***Medial Subluxation Suppression Test***

**Procedure and assessment:** To demonstrate medial subluxation, the examiner places his or her index fingers on the proximal half of the medial patellar facet. The patient is then asked to flex the knee. The examiner's finger will be seen to prevent medial subluxation. In con-



**Fig. 187a, b** Subluxation suppression test:  
**a** lateral subluxation test,  
**b** medial subluxation test

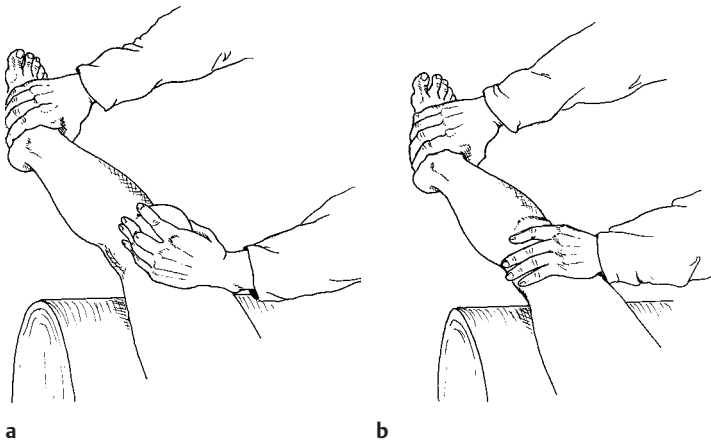
trast, flexing the knee without any attempt to prevent subluxation will lead to medial patellar subluxation (this is extremely rare).

### Tilt Test

**Procedure:** The patient is supine. The examiner passively displaces the patella laterally, noting how it behaves during lateral displacement.

**Assessment:** Where the lateral retinaculum is very tight due to contracture, the lateral facet will dip toward the femur (negative “abnormal” tilt test). Where there is normal tone in the retinaculum, the patella will remain at roughly the same height with respect to the femur (neutral tilt test). With laxity of the lateral retinaculum and with generalized ligament laxity, the lateral margin of the patella will rise up out of the trochlear groove (positive tilt test).

**Note:** The primary purpose of the tilt test is to evaluate tension in the lateral retinaculum. Where the tilt test is neutral or positive, a lateral release to decompress the patellofemoral joint will hardly improve symptoms at all. However, it may be expected to improve symptoms in cases where the tilt test is negative. Patients with a positive tilt test greater than 5° and medial and lateral gliding of the patella exhibit poor results after an isolated lateral release. Dysplasia of the trochlear groove



**Fig. 187a, b** Subluxation suppression test:  
**a** lateral subluxation test,  
**b** medial subluxation test

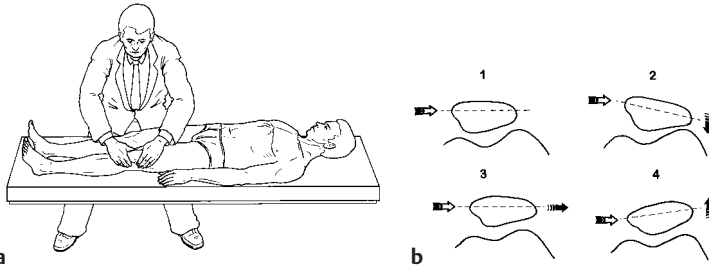
trast, flexing the knee without any attempt to prevent subluxation will lead to medial patellar subluxation (this is extremely rare).

### Tilt Test

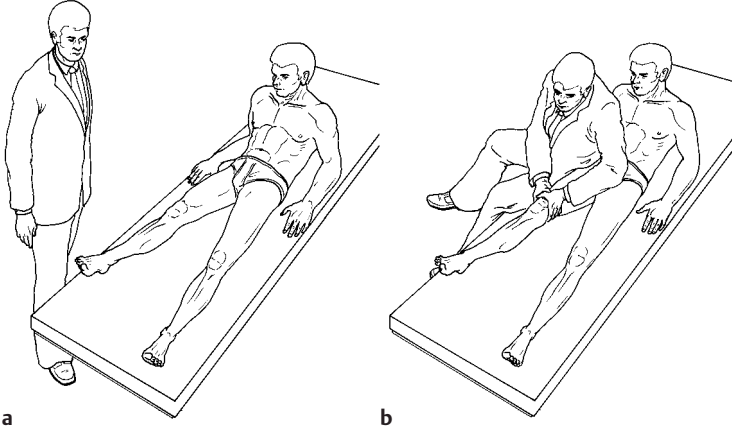
**Procedure:** The patient is supine. The examiner passively displaces the patella laterally, noting how it behaves during lateral displacement.

**Assessment:** Where the lateral retinaculum is very tight due to contracture, the lateral facet will dip toward the femur (negative “abnormal” tilt test). Where there is normal tone in the retinaculum, the patella will remain at roughly the same height with respect to the femur (neutral tilt test). With laxity of the lateral retinaculum and with generalized ligament laxity, the lateral margin of the patella will rise up out of the trochlear groove (positive tilt test).

**Note:** The primary purpose of the tilt test is to evaluate tension in the lateral retinaculum. Where the tilt test is neutral or positive, a lateral release to decompress the patellofemoral joint will hardly improve symptoms at all. However, it may be expected to improve symptoms in cases where the tilt test is negative. Patients with a positive tilt test greater than 5° and medial and lateral gliding of the patella exhibit poor results after an isolated lateral release. Dysplasia of the trochlear groove



**a**  
**Fig. 188a, b** Tilt test:  
**a** passive lateralization of the patella;  
**b** starting position (1), negative "abnormal" tilt test (2), neutral test (3), positive test (4)



**a** **b**  
**Fig. 189a, b** Dreyer test:  
**a** abnormal: patient is unable to lift the leg;  
**b** with the examiner stabilizing the patella

can lead to atypical test results. The tilt test should always be performed comparatively on both knees.

### Dreyer Test

Assesses a quadriceps tendon tear at the superior pole of the patella.

**Procedure:** The supine patient is asked to raise the extended leg. If the patient is unable to do so, the examiner stabilizes the quadriceps tendon proximal to the patella and has the patient lift the leg again.

**Assessment:** When stabilizing the tendon allows the patient to lift the leg, the examiner should suspect an avulsion of the quadriceps tendon from the patella or a chronic patellar fracture in applicable cases.

## ■ Meniscus

The menisci are important in guiding motion and ensuring stability in the knee. They also transmit and distribute compressive stresses between the femur and tibia. Meniscus injuries include tears or avulsions of the cartilage disks. Anatomic factors predispose the medial meniscus to a far higher incidence of injury than the lateral meniscus.

Meniscus lesions be degenerative or traumatic in origin. Degenerative tissue changes in the menisci, which may begin in adolescence, can lead to damage as a result of everyday activities in patients without a history of trauma or knee disease. In diagnosing knee injuries, one must always be alert to the possibility of a combined injury involving the collateral and cruciate ligaments in addition to the meniscus injury. Any insufficiently treated ligament injury with instability of the knee can also lead to meniscus damage. The primary symptoms of late sequelae of meniscus injuries include pain with exercise accompanied by occasional impingement symptoms and joint effusions with irritation.

There are a number of diagnostic signs of meniscus damage. The function tests are based on pain provocation as a result of compression, traction, or shear forces acting on the meniscus.

An isolated function test will rarely be sufficient to evaluate a meniscus lesion. Usually a combination of various maneuvers is required to confirm the diagnosis.

### Apley Distraction and Compression Test (Grinding Test)

**Procedure:** The patient is prone with the affected knee flexed 90°. The examiner immobilizes the patient's thigh with his or her knee. In this position, the examiner rotates the patient's knee while alternately applying axial traction and compression to the lower leg.

**Assessment:** Pain in the flexed knee occurring during rotation of the lower leg with traction applied suggests injury to the capsular ligaments (positive distraction test). Pain with compression applied suggests a meniscus lesion (positive grinding test).

Snapping phenomena can occur with discoid menisci or meniscal cysts. Pain in internal rotation suggests injury to the lateral meniscus or



**Assessment:** When stabilizing the tendon allows the patient to lift the leg, the examiner should suspect an avulsion of the quadriceps tendon from the patella or a chronic patellar fracture in applicable cases.

## ■ Meniscus

The menisci are important in guiding motion and ensuring stability in the knee. They also transmit and distribute compressive stresses between the femur and tibia. Meniscus injuries include tears or avulsions of the cartilage disks. Anatomic factors predispose the medial meniscus to a far higher incidence of injury than the lateral meniscus.

Meniscus lesions be degenerative or traumatic in origin. Degenerative tissue changes in the menisci, which may begin in adolescence, can lead to damage as a result of everyday activities in patients without a history of trauma or knee disease. In diagnosing knee injuries, one must always be alert to the possibility of a combined injury involving the collateral and cruciate ligaments in addition to the meniscus injury. Any insufficiently treated ligament injury with instability of the knee can also lead to meniscus damage. The primary symptoms of late sequelae of meniscus injuries include pain with exercise accompanied by occasional impingement symptoms and joint effusions with irritation.

There are a number of diagnostic signs of meniscus damage. The function tests are based on pain provocation as a result of compression, traction, or shear forces acting on the meniscus.

An isolated function test will rarely be sufficient to evaluate a meniscus lesion. Usually a combination of various maneuvers is required to confirm the diagnosis.

### Apley Distraction and Compression Test (Grinding Test)

**Procedure:** The patient is prone with the affected knee flexed 90°. The examiner immobilizes the patient's thigh with his or her knee. In this position, the examiner rotates the patient's knee while alternately applying axial traction and compression to the lower leg.

**Assessment:** Pain in the flexed knee occurring during rotation of the lower leg with traction applied suggests injury to the capsular ligaments (positive distraction test). Pain with compression applied suggests a meniscus lesion (positive grinding test).

Snapping phenomena can occur with discoid menisci or meniscal cysts. Pain in internal rotation suggests injury to the lateral meniscus or

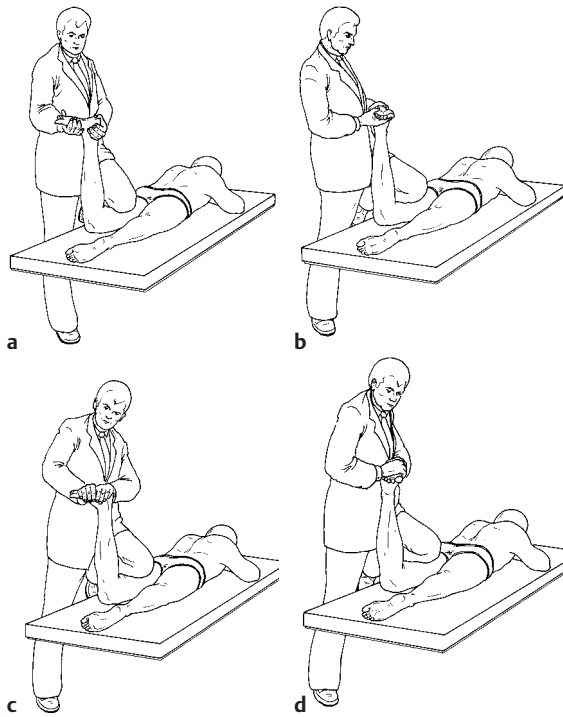
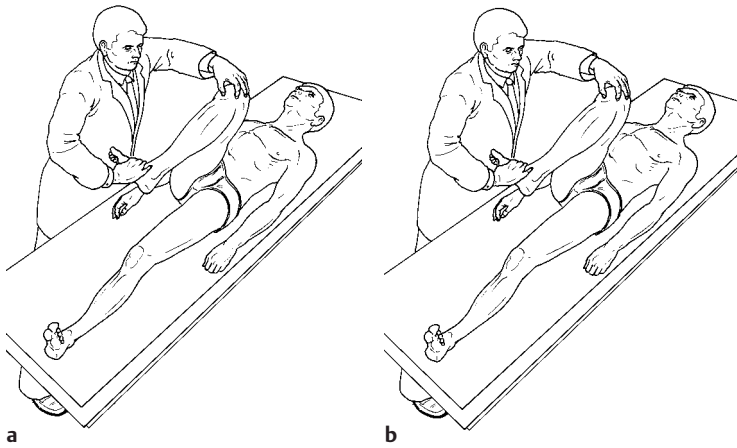


Fig. 190a–d Apley distraction and compression test:  
**a** distraction and external rotation,  
**b** distraction and internal rotation,  
**c** compression and external rotation,  
**d** compression and internal rotation

lateral capsule and/or ligaments; pain in external rotation suggests injury to the medial meniscus or medial capsule and/or ligaments.

The sign cannot be elicited where the capsular ligaments are tight, nor is this possible in an injury to the posterior horn of the lateral meniscus.

Wirth describes a modification of the grinding test (compression test), in which the knee is extended with the lower leg in fixed rotation. Wirth was able to confirm the presence of a meniscus lesion in over 85% of all cases with this modified Apley test.



**Fig. 191a, b** McMurray test:  
**a** in maximum flexion,  
**b** in 90° of flexion

### McMurray Test (Fouche Sign)

**Procedure:** The patient is supine with the knee and hip of the affected leg in maximum flexion. The examiner grasps the patient's knee with one hand and the patient's foot with the other. Holding the patient's lower leg in maximum external or internal rotation, the examiner then passively extends the knee into 90° of flexion.

**Assessment:** Pain while extending the knee with the lower leg externally rotated and abducted suggests a medial meniscus lesion; pain in internal rotation suggests an injury to the lateral meniscus. A snapping sound in extreme flexion occurs when a projecting meniscal flap becomes impinged on the posterior horn. Snapping in 90° of flexion suggests an injury in the middle section of the meniscus.

The snapping symptoms can be increased by moving the entire lower leg in a circle (modified McMurray test).

**Note:** Continuing the extension as far as the neutral (0°) position corresponds to the Bragard test. This test, when performed by slowly extending the knee with the lower leg in internal rotation, is also described as the Fouche sign. The McMurray test is positive in 30% of all children with normal knees. Approximately 1% of the normal population should test positive.

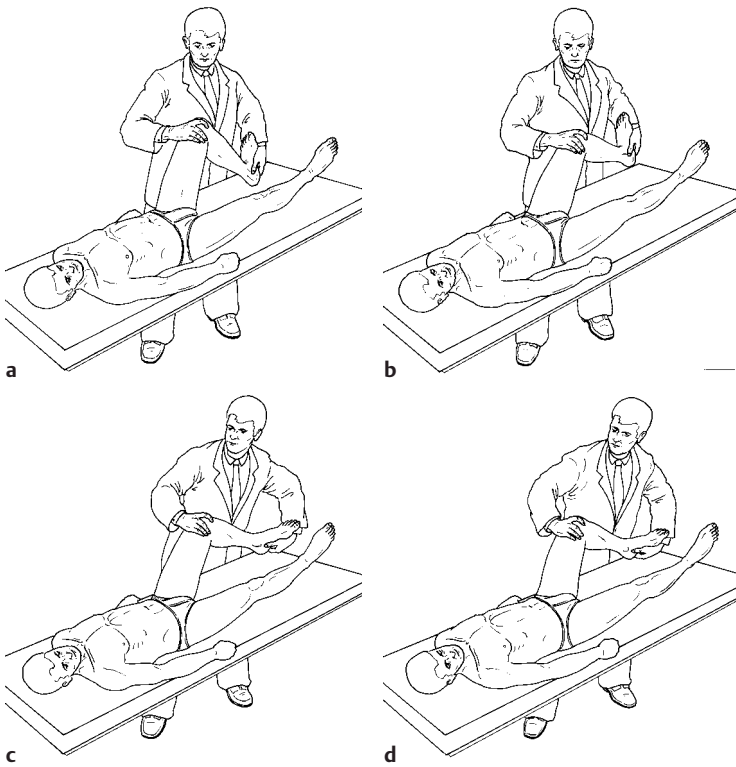


Fig. 192a–d Bragard test:  
 a flexion,  
 b extension with increasing pain,  
 c knee extension is increased with the lower leg internally rotated,  
 d migrating tenderness to palpation

### Bragard Test

**Procedure:** The patient is supine. With one hand, the examiner grasps the patient's 90°-flexed knee and palpates the lateral and medial joint cavity with the thumb and index finger. With the other hand, the examiner grasps the patient's foot and rotates the patient's lower leg.

**Assessment:** Pain felt over the joint cavity indicates a meniscus lesion. In an injury to the medial meniscus, external rotation and extension from a flexed position increases the pain in the medial joint cavity.

With internal rotation and increasing flexion in the knee, the meniscus migrates back into the interior of the joint and is no longer accessible to the examiner's palpating finger. This reduces pain.

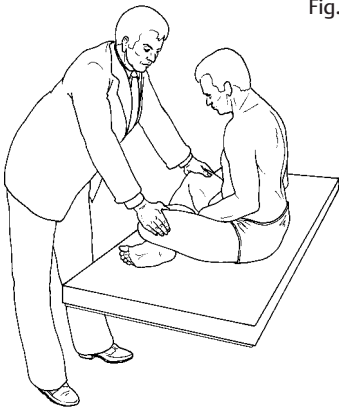
Where a lateral meniscus lesion is suspected, the examiner palpates the lateral meniscus. This is done while first extending and internally rotating the knee from a position of maximum flexion and then internally rotating it. This maneuver reduces pain. The diagnosis is more certain if the tenderness to palpation migrates with joint motions. The lateral meniscus, and with it the tenderness to palpation, migrates posteriorly as the knee is internally rotated.

### Payr Sign

**Procedure:** The patient is seated cross-legged. The examiner exerts intermittent pressure on the affected leg, which is flexed and externally rotated.

**Assessment:** Pain in the medial joint cavity suggests meniscus damage (usually a lesion of the posterior horn). Occasionally, patients themselves will be able to provoke snapping. Moving the knee back and forth causes the injured portion of the meniscus to be drawn into the joint and then spring back out with a snap when the joint cavity is distended.

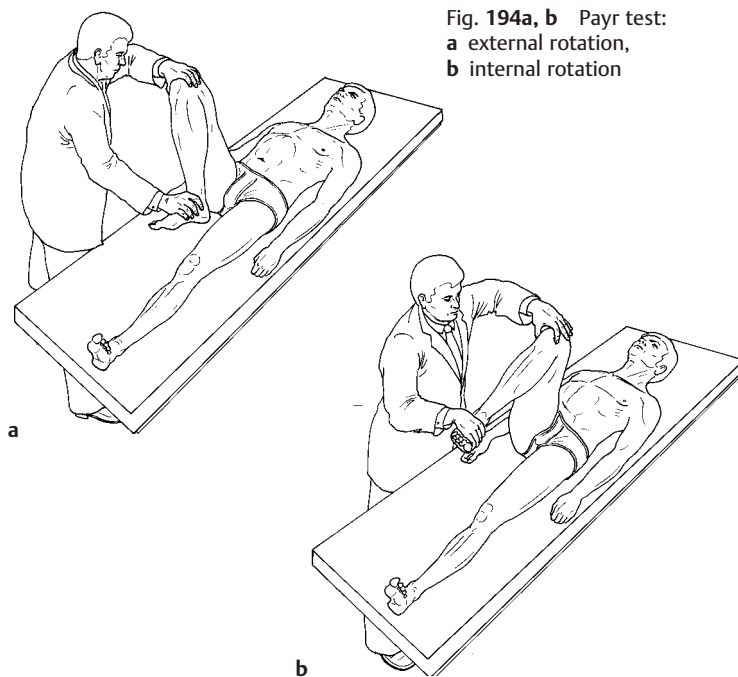
Fig. 193 Payr sign



## Payr Test

**Procedure:** The patient is supine. The examiner immobilizes the patient's knee with his or her left hand and palpates the lateral and medial joint cavity with the thumb and index finger, respectively. With the other hand, the examiner grasps the patient's ankle. With the knee maximally flexed, the lower leg is externally rotated as far as possible. Then with the knee in slight adduction (varus stress), the leg is flexed further in the direction of the contralateral hip.

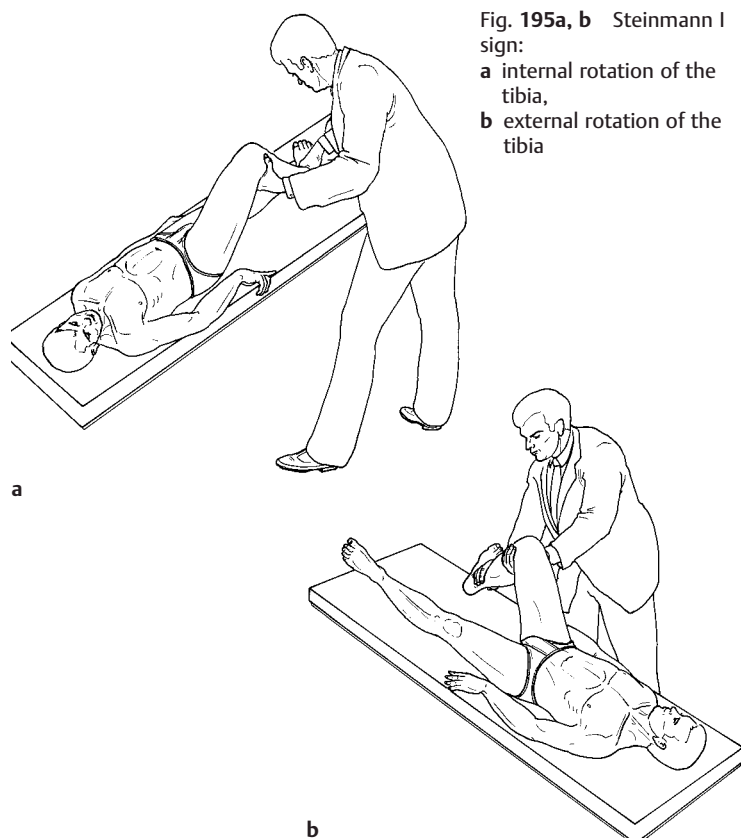
**Assessment:** Pain in the posterior medial joint cavity suggests damage to the medial meniscus (most often the posterior horn is involved, which is compressed by this maneuver). The posterior horn of the lateral meniscus can be similarly examined with the knee internally rotated and abducted (valgus stress).



## Steinmann I Sign

**Procedure:** The patient is supine. The examiner immobilizes the patient's flexed knee with the left hand and grasps the lower leg with the other hand. The examiner then forcefully rotates the lower leg in various degrees of knee flexion.

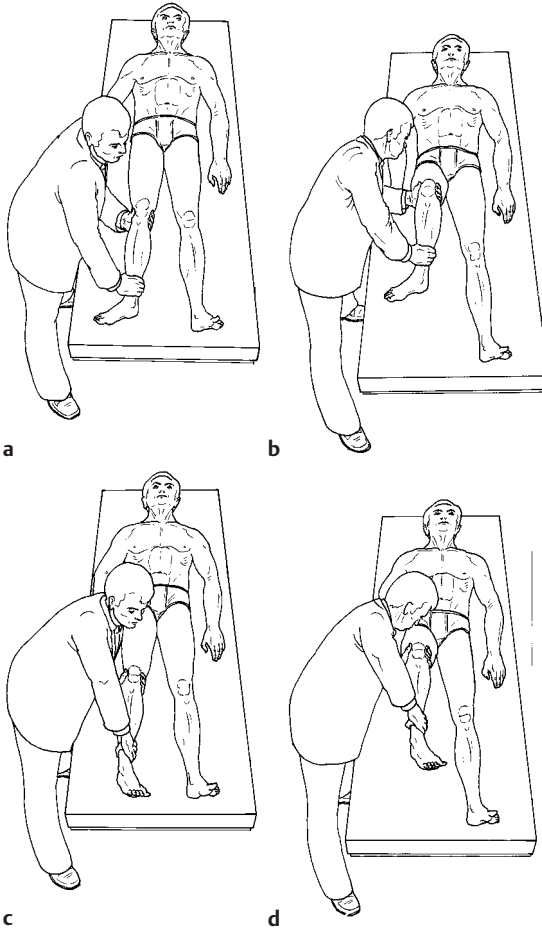
**Assessment:** Pain in the medial joint cavity in forced external rotation suggests damage to the medial meniscus; pain in the lateral joint cavity in internal rotation suggests damage to the lateral meniscus. Because the localization of the tear can vary, the test for the Steinmann I sign should be performed with the knee in varying degrees of flexion.



## Steinmann II Sign

**Procedure:** The patient is supine. The examiner grasps the knee with the left hand and palpates the joint cavity. With the right hand, the examiner grasps the patient's lower leg slightly proximal to the mortise of the ankle. With the patient's thigh immobilized, the examiner places the lower leg first in external rotation, then in internal rotation, in each case alternately flexing and extending the lower leg while applying slight axial compression.

Fig. 196a–d  
Steinmann II sign:  
a starting position  
with the lower  
leg externally  
rotated,  
b flexion,  
c starting position  
with the lower  
leg internally  
rotated,  
d flexion





**Assessment:** Pain in the medial or lateral joint cavity suggests a meniscus injury. The tenderness to palpation in the joint cavity migrates medially and posteriorly during flexion and slight external rotation of the knee; it then migrates back anteriorly as the knee is extended. Where a meniscus injury is suspected and the lower leg is placed in internal rotation, the tenderness to palpation will migrate anteriorly as the knee is extended and posteriorly as it is flexed.

**Note:** Although this test can also be used for an injury to the lateral meniscus, its primary purpose is to help evaluate medial meniscus lesions. A differential diagnosis must consider osteoarthritis and lesions of the medial collateral and capsular ligaments.

### Boehler-Kroemer Test

**Procedure:** The patient is supine. The examiner stabilizes the lateral femur with one hand and grasps the medial malleolus with the other. With the lower leg abducted (valgus stress applied), the examiner then passively flexes and extends the knee.

With his or her hands on the patient's lateral malleolus and medial thigh, the examiner grasps the leg and flexes and extends the knee with the lower leg adducted (varus stress applied).

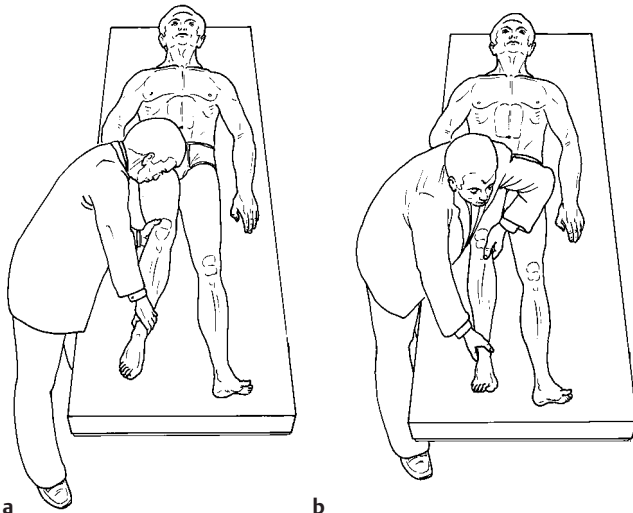


Fig. 197a, b Boehler-Kroemer test:  
a lower leg abducted (valgus), b lower leg adducted (varus)

**Assessment:** Flexing and extending the knee with the lower leg alternately adducted and abducted (the Kroemer test) alternately increases compression of the medial meniscus and lateral meniscus. Opening the joint cavity compresses the opposite meniscus. Opening the medial cavity creates a valgus stress for testing the lateral meniscus; opening the lateral cavity creates a varus stress for testing the medial meniscus.

**Note:** The Boehler meniscus tests in the coronal plane (with the knee extended) allow simultaneous assessment of the ligaments of the knee in the side opposite the motion.

### Merke Test

**Procedure:** The patient bears weight on the affected leg with the knee slightly flexed. The examiner immobilizes the foot of the affected leg.

The examiner lifts the patient's contralateral leg slightly and asks the patient to internally and externally rotate the thigh of the affected leg.

The lower leg is rotated as in the Steinmann I test.

**Assessment:** Because of the increased axial compression due to the weight of the body, the Merke test usually elicits more severe pain. Pain occurring in the medial joint cavity in internal rotation of the thigh (corresponding to external rotation of the lower leg) suggests a medial meniscus lesion.

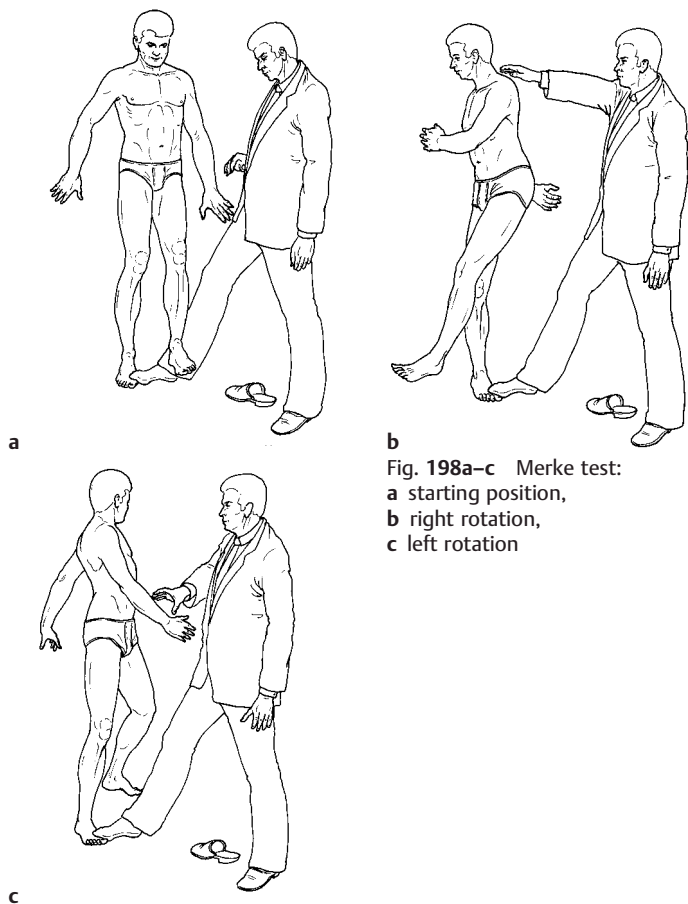
Pain occurring in external rotation of the thigh (corresponding to internal rotation of the lower leg) suggests a lateral meniscus lesion.

The Merke test is occasionally positive in the presence of collateral ligament lesions.

### Cabot Test

**Procedure:** The patient is supine with the affected leg flexed at the knee and placed over the proximal portion of the contralateral lower leg. With his or her left hand, the examiner grasps the patient's knee and palpates the lateral joint cavity with the thumb. With the other hand, the examiner grasps the patient's lower leg slightly proximal to the subtalar joint. The patient is then asked to extend the knee against the resistance of the examiner's hand.

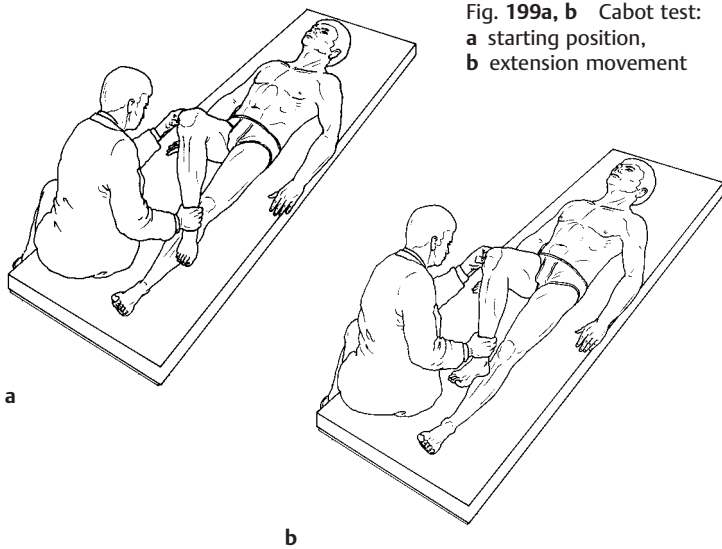
**Assessment:** Pain will occur where there is a lesion of the posterior horn of the lateral meniscus. Depending on the severity of the pain, the patient will often be unable to extend the knee farther. The painful point, which palpable with the thumb, lies primarily in the lateral



**Fig. 198a–c** Merle test:  
**a** starting position,  
**b** right rotation,  
**c** left rotation

posterior joint cavity. Occasionally patients will report pain radiating into the popliteal fossa and calf.

**Note:** The Cabot test is also described in the literature as the popliteus sign.



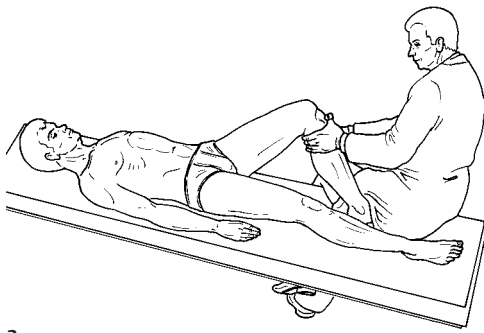
### Finochietto Sign

Simultaneously tests cruciate ligament and meniscus injuries.

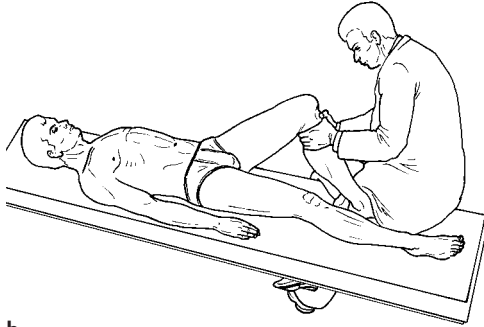
**Procedure:** The patient is supine. The anterior drawer test is performed with the knee flexed 90°.

**Assessment:** Where the injury also involves an anterior cruciate ligament tear, the anterior drawer test with the knee flexed 90° will cause anterior displacement of the tibia. The laxity of the knee ligaments causes the femoral condyle to ride up over the posterior horn of the medial meniscus under the stress of the anterior drawer. A positive Finochietto test produces an audible snap and/or a palpable skip. If the tibia is then pressed posteriorly, the femoral condyle will glide back down from the posterior horn of the medial meniscus. Occasionally, reduction of the displaced meniscus will be necessary following a positive Finochietto test. In this case, there is reason to suspect a full posterior separation of the medial meniscus and/or a longitudinal or bucket handle tear.

**Note:** In the setting of anterior cruciate ligament insufficiency, damage to the posterior horn of the medial meniscus or its capsular attachments results from derangement of the rolling and sliding mechanism secondary to a cruciate ligament tear. This produces a shear injury to the posterior horn of the medial meniscus.



a



b

Fig. 200a, b  
Finochietto sign:  
a anterior drawer,  
b reduction

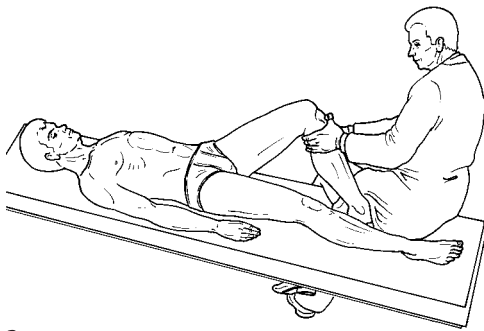
### Childress Sign

**Procedure:** The patient assumes a squatting position, preferably with the buttocks in contact with the heels. The patient is then asked to waddle in this position.

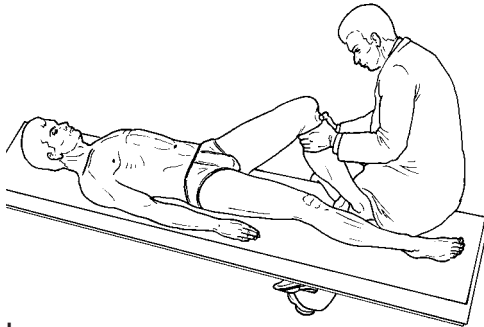
**Assessment:** In the presence of an injury to the posterior horn, the patient will notice a painful snapping shortly before maximum flexion or in the early phase of extension. This is caused by impingement of the injured meniscus. Patients in severe pain will usually be unable to assume the squatting position.

### Turner Sign

In 1931, Turner described a meniscus sign caused by chronic irritation of the infrapatellar branch of the saphenous nerve. A meniscus lesion will often be accompanied by an irregular hyperesthetic area measuring



a



b

Fig. 200a, b  
Finochietto sign:  
a anterior drawer,  
b reduction

### Childress Sign

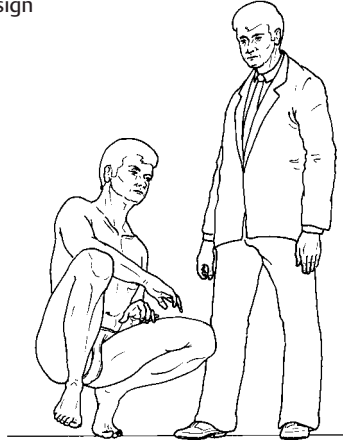
**Procedure:** The patient assumes a squatting position, preferably with the buttocks in contact with the heels. The patient is then asked to waddle in this position.

**Assessment:** In the presence of an injury to the posterior horn, the patient will notice a painful snapping shortly before maximum flexion or in the early phase of extension. This is caused by impingement of the injured meniscus. Patients in severe pain will usually be unable to assume the squatting position.

### Turner Sign

In 1931, Turner described a meniscus sign caused by chronic irritation of the infrapatellar branch of the saphenous nerve. A meniscus lesion will often be accompanied by an irregular hyperesthetic area measuring

Fig. 201 Childress sign



approximately 4–5 cm. This area will be located at the level of and slightly proximal to the medial joint cavity on the medial aspect of the knee or along the course of the infrapatellar branch of the saphenous nerve. Thermal and mechanical stimuli (tapping) are used to test the area for local hypersensitivity. According to Zippel, careful examination technique will demonstrate this symptom more often than one would expect. No similar sign is known for injuries to the lateral meniscus.

### Anderson Medial and Lateral Compression Test

**Procedure:** The patient is supine. The examiner grasps the patient's lower leg and immobilizes the foot between his or her own forearm and waist. With the free hand, the examiner palpates the anterior joint cavity. The examiner flexes the knee to 45° while applying a valgus stress and extends it while applying a varus stress. This produces a circular movement in the knee.

**Assessment:** A longitudinal or flap tear in the meniscus causes pain and/or friction rub at the level of the joint cavity. Complex tears lead to chronic friction rub. However, the same symptoms can occur with osteoarthritis or secondary to resection of a meniscus. This test involves placing stresses on the knee as it approaches extension and in moderate flexion. Therefore, one can occasionally provoke subluxation as the knee approaches extension as in a positive pivot shift test with insufficiency of the anterior cruciate ligament.

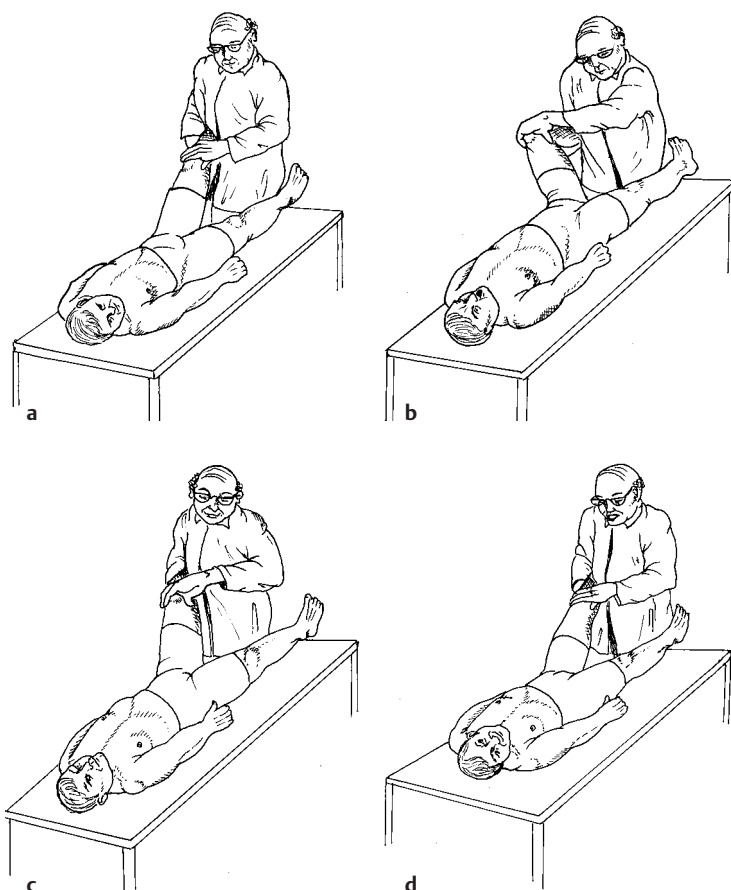


Fig. 202a–d Anderson medial and lateral compression test:

a starting position,

b valgus stress during flexion of the knee to 45°,

c extension of the 45° flexed knee,

d varus stress during extension of the knee

### Paessler Rotational Compression Test

**Procedure:** The patient is seated. The examiner immobilizes the foot of the leg to be examined, holding it between his or her own legs slightly proximal to the knees. To evaluate the medial meniscus, the examiner



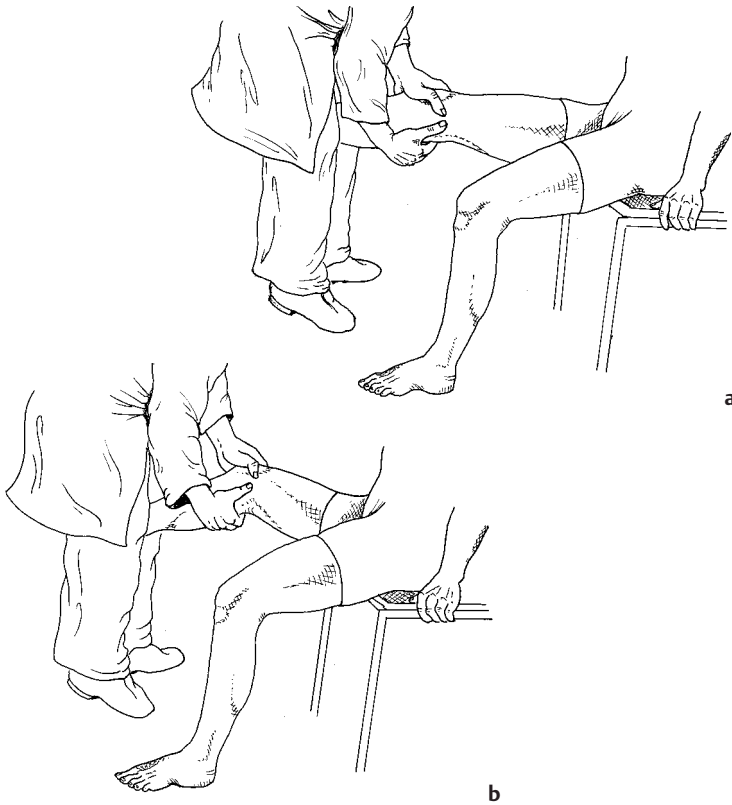

Fig. 203a, b Paessler rotational compression test:  
a starting position with examiner's thumb on medial joint cavity,  
b circular motion of the knee

rests both thumbs on the medial joint cavity and moves the patient's knee in a circle in the form of external and internal rotational movements. This causes the knee to move through various degrees of flexion. At the same time, the examiner applies a varus or valgus stress, respectively.

**Assessment:** The test is positive when the patient reports pain with the circular motion. It is considered strongly positive when pain can be elicited by the circular motion alone in either the medial joint cavity (suspected lateral meniscus lesion) or the lateral joint cavity (suspected medial meniscus lesion).

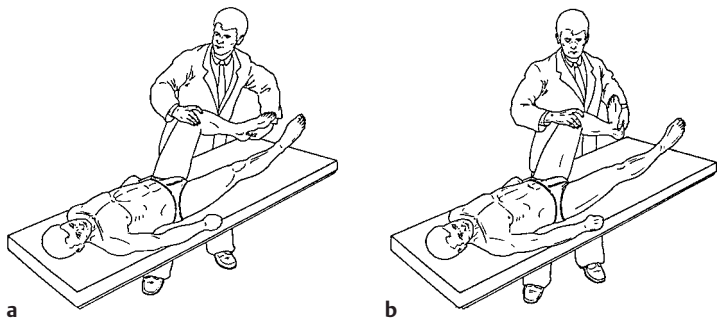


Fig. 204a, b Wilson test:  
 a extension in internal rotation,  
 b external rotation

### Tschaklin Sign

Quadriceps atrophy is often encountered in chronic meniscus lesions. Atrophy of the vastus medialis in medial meniscus lesions is often associated with compensatory increase in muscle tone in the sartorius, which is known as the Tschaklin sign.

### Wilson Test

Demonstrates osteochondritis dissecans on the medial femoral condyle.

**Procedure:** The examiner grasps the patient's knee proximal to the patella with one hand, palpating the medial joint cavity.

**Assessment:** In osteochondritis dissecans, compression due to joint motion and the palpating finger will produce symptoms between 20° and 30° of flexion. These symptoms can then typically be reduced by externally rotating the lower leg.

**Note:** Osteochondritis dissecans is an aseptic necrosis that arises in the subchondral bone of the articular surfaces and disrupts the overlying cartilage. In its advanced stages, separation of part of the articular cartilage and underlying bone can occur, creating an intraarticular loose body. Osteochondritis dissecans should always be considered in adolescents presenting with joint effusion and knee pain.

## ■ Knee Ligament Stability Tests

The knee is stabilized by the ligaments, menisci, the shape and congruency of the articular surfaces, and the musculature. The ligaments ensure functional congruency by guiding the femur and tibia and limiting the space between them. Ligament injuries lead to functional impairment of the knee with instability. Knee ligament stability tests can help to identify and differentiate these instabilities.

Abnormal directions of motion can be divided into three categories:

1. Direct instability in a single plane
2. Rotational instability
3. Combined rotational instability

Clinical instability is divided into three degrees. Estimated joint opening or drawer of up to 5 mm is defined as 1+ (or +), 5–10 mm as 2+ (or ++), and over 10 mm as 3+ (or +++).

### Abduction and Adduction Test (Valgus and Varus Stress Test)

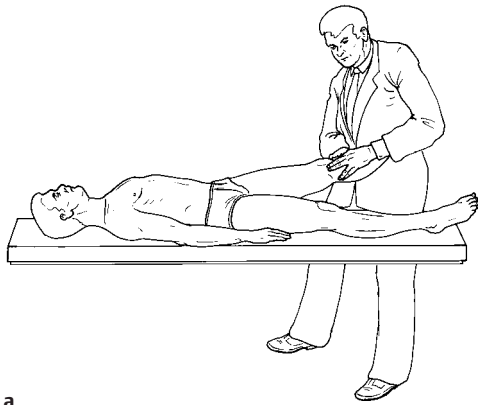
Assesses medial and lateral knee stability.

**Procedure:** The patient is supine. The examiner grasps the patient's knee at the tibial head with both hands while palpating the joint cavity. The examiner immobilizes the patient's distal lower leg between his or her own forearm and waist while applying a valgus and varus stress to the knee. The fingers resting on the joint cavity can palpate any opening of the joint.

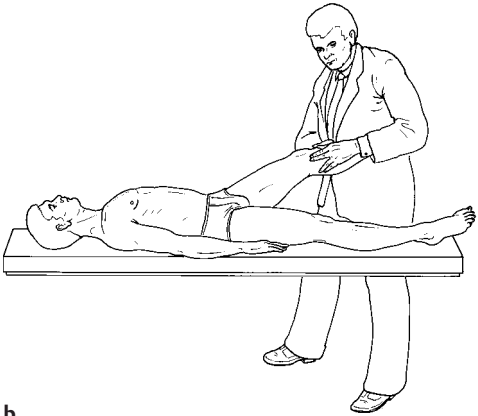
**Assessment:** Lateral stability is assessed in 20° of flexion and in full extension. Full extension prevents lateral opening as long as the posterior capsule and posterior cruciate ligament are intact, even if the medial collateral ligament is torn. In 20° of flexion, the posterior capsule is relaxed. Applying a valgus stress in this position evaluates the medial collateral ligament alone as the primary stabilizer. This allows the examiner to identify the nature of damage to the posteromedial capsular ligaments.

The opposite applies to adduction (varus) stress. In 20° of flexion, the primary lateral stabilizer is the lateral collateral ligament. The anterior cruciate ligament and popliteus tendon act as secondary stabilizers.

When testing lateral stability, the examiner assessed the degree of joint opening and the quality of the endpoint.



a



b

Fig. 205a, b Abduction and adduction test:  
**a** valgus and varus stress as the knee approaches extension,  
**b** valgus and varus stress in flexion

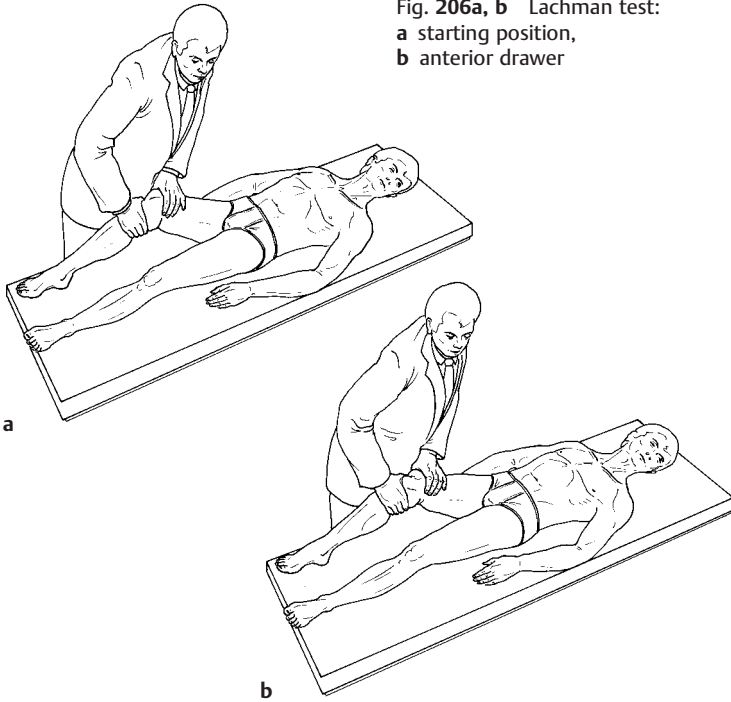
## ■ Function Tests to Assess the Anterior Cruciate Ligament

### Lachman Test

**Procedure:** The patient is supine with the knee flexed  $15^{\circ}$ – $30^{\circ}$ . The examiner holds the femur with one hand while pulling the tibia anteriorly with the other. The quadriceps and knee flexors must be completely relaxed.

**Assessment:** The anterior cruciate ligament is damaged when mobility of the tibia with respect to the femur can be demonstrated. The end-

Fig. 206a, b Lachman test:  
a starting position,  
b anterior drawer



point of motion must be soft and gradual without a hard stop; any hard stop suggests a certain stability of the anterior cruciate ligament. A hard endpoint within 3 mm suggests complete stability of the anterior cruciate, whereas one after 5 mm or more suggests relative stability of the anterior cruciate ligament, such as may be present following an earlier sprain.

Cruciate ligament injury should be suspected where the endpoint is soft or absent. In the presence of a drawer exceeding 5 mm, comparison with the contralateral knee is helpful in excluding congenital laxity of the articular ligaments.

A positive Lachman test is certain proof of anterior cruciate ligament insufficiency.

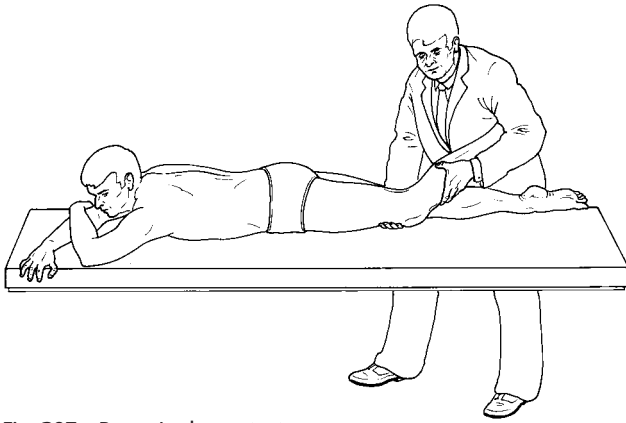


Fig. 207 Prone Lachman test

### Prone Lachman Test

**Procedure:** The patient is prone. The examiner grasps the lateral aspect of the proximal tibia and immobilizes the patient's leg in his or her own axilla. With the other hand, the examiner grasps the distal femur immediately proximal to the patella to immobilize the thigh. Then the examiner pushes the tibia anteriorly with respect to the femur.

**Assessment:** Identical to the Lachman test (see p. 194).

**Note:** Although the patient is relaxed in the prone position, it is not always easy to assess the quality of the endpoint. A hard endpoint and hemarthrosis suggest an acute partial tear; a hard endpoint without hemarthrosis suggests a suspected chronic partial tear, elongation, or excessive laxity.

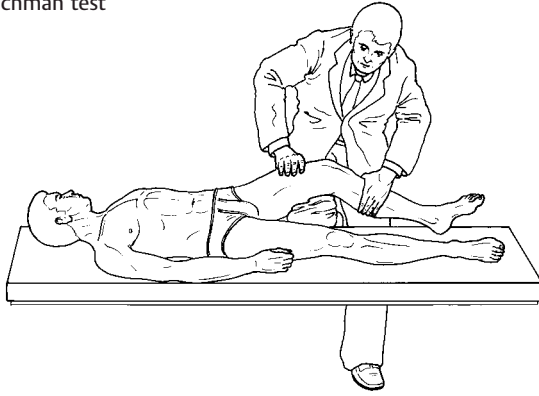
A soft endpoint and hemarthrosis suggest a complete tear; a soft endpoint without hemarthrosis suggests a chronic complete tear. Where the endpoint is hard, a posterior cruciate lesion must be excluded by testing the spontaneous posterior drawer and applying the active tests.

### Stable Lachman Test

A variation of the classic Lachman test.

**Procedure:** The patient is supine. The examiner places the patient's thigh over his or her own thigh. This holds the patient's leg in constant

Fig. 208 Stable Lachman test



flexion that the patient cannot change. With the distal hand, the examiner pulls the tibia anteriorly while the other hand immobilizes the patient's thigh on the examiner's own thigh.

**Assessment:** Identical to the classic Lachman test.

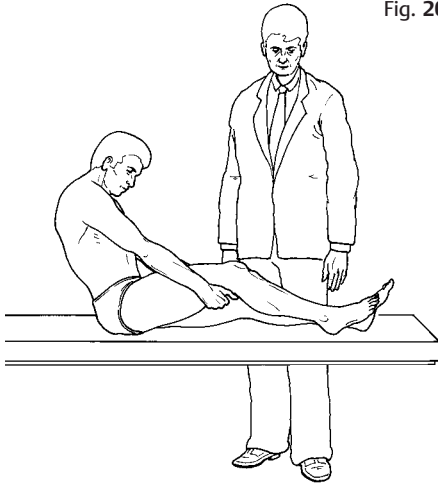
**Note:** The classic Lachman test not only presents problems for examiners with small hands; simultaneously immobilizing the thigh and lower leg can be also difficult for any examiner with an obese or muscular patient. Using one's own thigh as a "workbench" for examining the patient's knee is an easy solution in such cases and one that allows examination even of obese or muscular patients. The character of the endpoint (hard or soft) is easier to evaluate in this test.

#### No-Touch Lachman Test

**Procedure:** The patient is supine and grasps the thigh of the affected leg near the knee with both hands and slightly flexes the knee. The patient is then asked to raise the lower leg off the examining table while maintaining flexion in the knee. The examiner observes the position of the tibial tuberosity during this maneuver.

**Assessment:** If the ligaments are intact, there will be no change in contour, or only a slight one as the tibial tuberosity moves slightly anteriorly. In an acute injury to the capsular ligaments involving the anterior cruciate and medial collateral ligaments, the examiner will observe a significant anterior displacement of the tibial tuberosity (subluxation of the joint).

Fig. 209 No-touch Lachman test



**Note:** This test often allows one to exclude complex injuries without having to touch the patient.

### Active Lachman Test

**Procedure:** The examiner asks the supine patient to extend the leg in such a way as to lift the foot off the examining table. During this maneuver, the examiner keeps his or her eyes on the knee the better to discern the contours of the tibial tuberosity and patellar ligament. The examiner achieves slight passive flexion in the knee by passing one hand beneath the thigh of the patient's affected leg and resting it on the contralateral knee. The effect of the quadriceps is increased by immobilizing the foot on the examining table.

**Assessment:** Slight migration of the tibial head will be observed where the anterior cruciate ligament is intact. In a cruciate tear, there will be a significant anterior migration compared with the contralateral side. This is because the anterior cruciate ligament no longer limits the displacement caused by contraction of the quadriceps.

**Note:** The physiologic drawer in active motion as the knee approaches extension usually measures 2–3 mm. In contrast, tibial displacement of 3–6 mm will be observed with an anterior cruciate ligament tear. This test should only be performed after excluding a posterior cruciate ligament injury, in which the tibia would spontaneously displace pos-



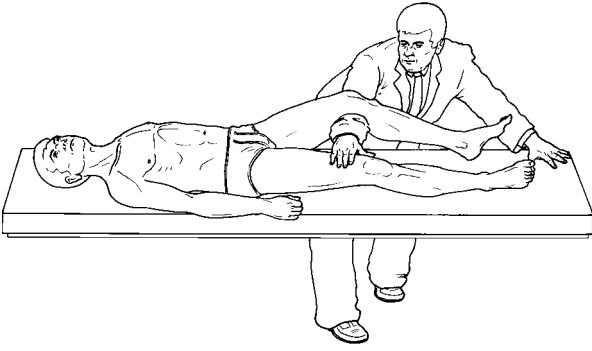


Fig. 210 Active Lachman test

teriorly. There, too, contraction of the quadriceps will produce significant anterior displacement of the tibia and with it a false-positive active anterior drawer test.

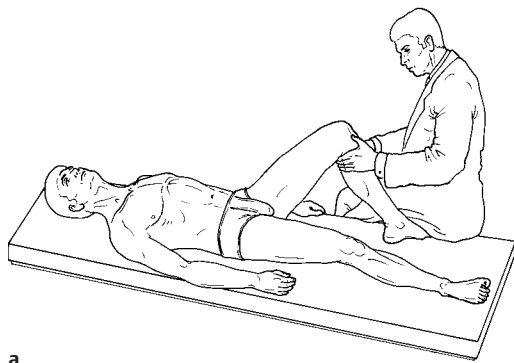
Contraction of the quadriceps can also cause meniscal impingement where loosening of the posterior attachment of the medial meniscus accompanies the insufficiency of the medial ligaments and anterior cruciate.

The active Lachman test differs from the traditional Lachman test in that the lower leg can easily be immobilized in various degrees of rotation and the stabilizing effect of the medial and lateral capsular ligaments can be assessed. Generalized anterior instability (involving the anterior cruciate ligament and the medial, posteromedial, lateral, and posterolateral capsular ligaments) will produce significant active anterior tibial displacement in internal and neutral rotation and, especially, in external rotation.

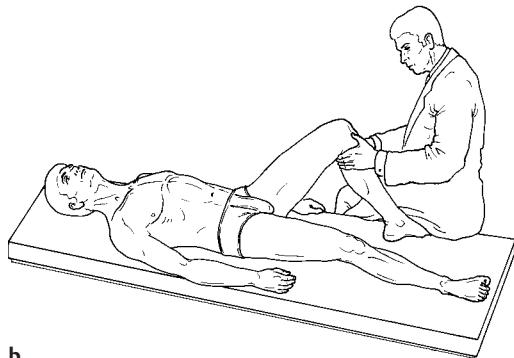
#### Anterior Drawer Test in 90° Flexion

Passive anterior drawer test to assess the stability of the anterior cruciate ligament.

**Procedure:** The patient is supine with the hip flexed 45° and the knee flexed 90°. The examiner sits on the edge of the examining table and uses his or her buttocks to immobilize the patient's foot in the desired rotational position. The examiner then grasps the tibial head with both hands and pulls it anteriorly with the patient's knee flexors relaxed. The test is performed in a neutral position, with the foot in 15° of external rotation to assess anterior and medial instability, and with the foot in 30° of internal rotation to assess anterior and lateral instability.



a



b

Fig. 211a, b Anterior drawer test in 90° flexion:  
a starting position in external rotation,  
b anterior traction on the tibia

**Assessment:** A visible and palpable anterior drawer (that is, anterior displacement of the tibia with a soft endpoint) is present in chronic insufficiency of the anterior cruciate ligament.

The anterior drawer test in 90° of flexion is often negative in acute injuries because pain often prevents the patient from achieving this degree of flexion and causes reflexive muscle contraction. Additionally, these are usually combined injuries involving complete or partial ligament tears so that the stress of the drawer test stretches the partially torn medial and lateral structures. The resulting pain produces false-negative test results, giving the appearance of a stable joint.

In acute injuries in particular, the test should preferably be performed with the knee in slight flexion (Lachman test). The situation is

different in chronic ligament injuries, where the primary symptom is the sensation of instability. In these cases, the test can usually be performed painlessly in 90° of flexion and still provide useful diagnostic information.

**Note:** As a rule, the anterior drawer is best assessed in neutral rotation. This allows one to demonstrate the greatest degree of displacement. Rotation forces the tibia into a position where the twisting of the peripheral ligaments and capsular structures increases tension in the joint, impairing the mobility of the drawer. Assessment of rotational stability together with assessment of lateral stability in flexion and extension provides information about the complexity of the ligament injury and the stability of the secondary stabilizers.

An anterior drawer should not automatically be interpreted as an anterior cruciate ligament tear. On the other hand, a negative drawer test does not necessarily confirm that the anterior cruciate is intact. The proximal portion of the tibia is pulled anteriorly or pushed posteriorly. It can be difficult to determine the exact starting position (the neutral position) from which an anteriorly directed force will produce an anterior drawer. For example, where the examiner exerts an anterior drawer stress in the presence of a posterior cruciate ligament injury in which the tibial head is posteriorly depressed (a spontaneous posterior drawer), it will seem as if an isolated anterior drawer were present. What has actually happened in this case is that the tibia has merely been drawn anteriorly out of its posterior displacement (due to the posterior cruciate tear) and into a neutral position. The anterior cruciate then tenses and limits further anterior displacement of the tibia.

**Caution:** An apparent anterior drawer may only be interpreted as a true anterior drawer once the absence of a posterior drawer has been demonstrated.

### Jakob Maximum Drawer Test

**Procedure:** The patient is supine with the knee flexed 50°–60°. The examiner pushes the tibial head into maximum anterior subluxation with his or her forearm while grasping the patient's contralateral knee with the hand of the same arm. With the other hand, the examiner grasps the tibial head and palpates how far anteriorly the medial or lateral joint cavity is displaced. The patient's lower leg is not immobilized in this test so that rotation is not restricted. This allows maximum tibial displacement.

**Assessment:** See anterior drawer test in 90° flexion.

different in chronic ligament injuries, where the primary symptom is the sensation of instability. In these cases, the test can usually be performed painlessly in 90° of flexion and still provide useful diagnostic information.

**Note:** As a rule, the anterior drawer is best assessed in neutral rotation. This allows one to demonstrate the greatest degree of displacement. Rotation forces the tibia into a position where the twisting of the peripheral ligaments and capsular structures increases tension in the joint, impairing the mobility of the drawer. Assessment of rotational stability together with assessment of lateral stability in flexion and extension provides information about the complexity of the ligament injury and the stability of the secondary stabilizers.

An anterior drawer should not automatically be interpreted as an anterior cruciate ligament tear. On the other hand, a negative drawer test does not necessarily confirm that the anterior cruciate is intact. The proximal portion of the tibia is pulled anteriorly or pushed posteriorly. It can be difficult to determine the exact starting position (the neutral position) from which an anteriorly directed force will produce an anterior drawer. For example, where the examiner exerts an anterior drawer stress in the presence of a posterior cruciate ligament injury in which the tibial head is posteriorly depressed (a spontaneous posterior drawer), it will seem as if an isolated anterior drawer were present. What has actually happened in this case is that the tibia has merely been drawn anteriorly out of its posterior displacement (due to the posterior cruciate tear) and into a neutral position. The anterior cruciate then tenses and limits further anterior displacement of the tibia.

**Caution:** An apparent anterior drawer may only be interpreted as a true anterior drawer once the absence of a posterior drawer has been demonstrated.

### Jakob Maximum Drawer Test

**Procedure:** The patient is supine with the knee flexed 50°–60°. The examiner pushes the tibial head into maximum anterior subluxation with his or her forearm while grasping the patient's contralateral knee with the hand of the same arm. With the other hand, the examiner grasps the tibial head and palpates how far anteriorly the medial or lateral joint cavity is displaced. The patient's lower leg is not immobilized in this test so that rotation is not restricted. This allows maximum tibial displacement.

**Assessment:** See anterior drawer test in 90° flexion.

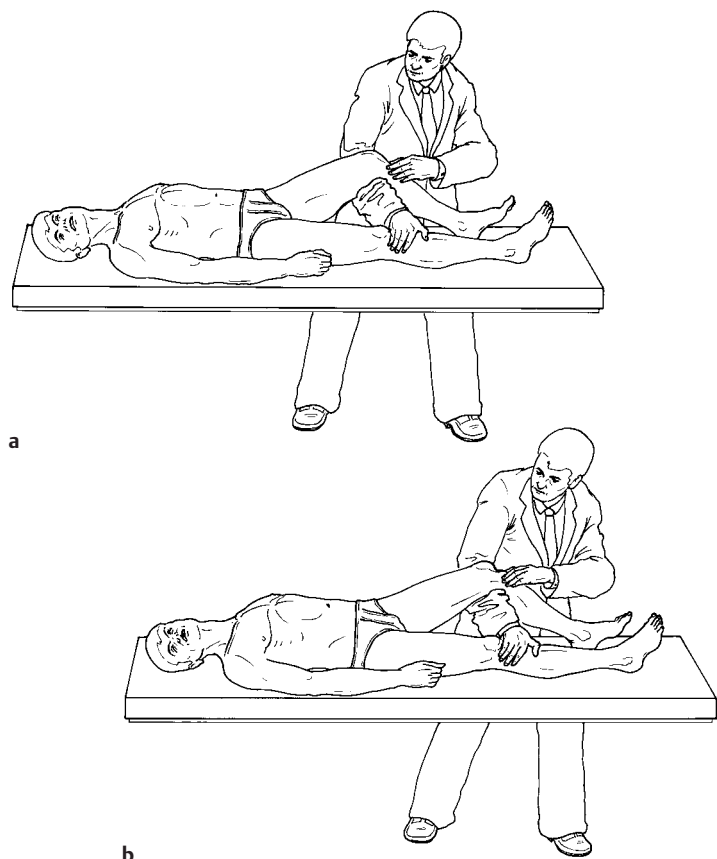


Fig. 212a, b Jakob maximum drawer test:  
a starting position,  
b maximum anterior traction on the tibia

### Pivot Shift Test

**Procedure:** The patient is supine. The examiner grasps and immobilizes the lateral femoral condyle with one hand and palpates the proximal tibia or fibula with the thumb. With the other hand, the examiner holds the patient's lower leg in internal rotation and abduction (valgus stress). From this starting position the knee is then moved from extension into flexion.

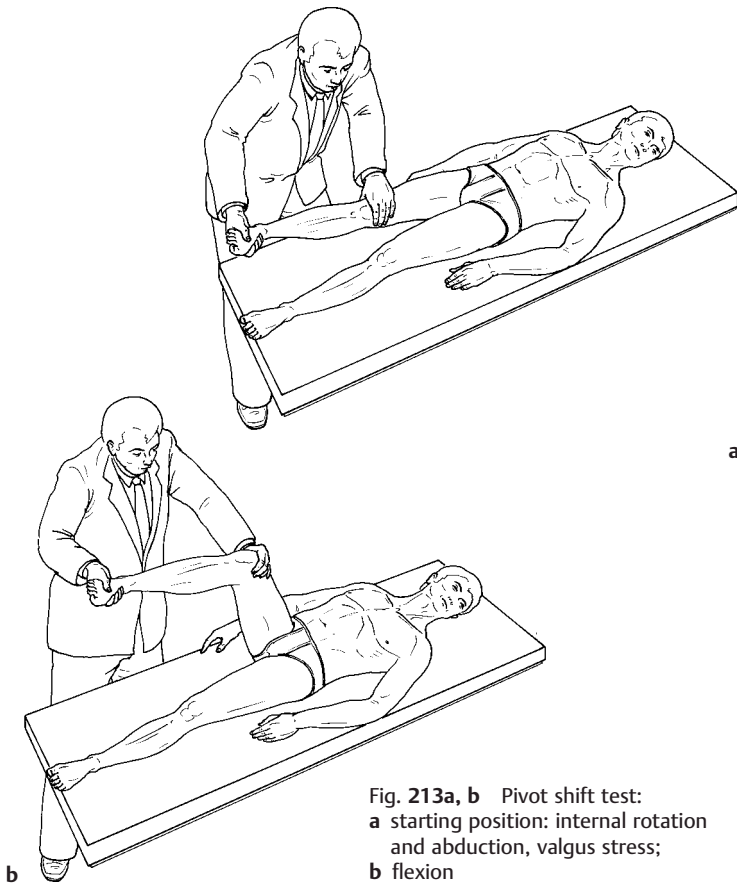


Fig. 213a, b Pivot shift test:  
a starting position: internal rotation  
and abduction, valgus stress;  
b flexion

**Assessment:** In the presence of a torn anterior cruciate ligament, the valgus stress will cause the tibia to subluxate anteriorly while the knee is still in extension. The blockade of the knee in anterior subluxation depends on the degree of valgus stress applied; occasionally the sign can be elicited more easily when the examiner immobilizes the patient's leg between his or her own forearm and waist while applying slight axial compression. The knee is then flexed while the same internal rotation and abduction of the lower leg is maintained; this then causes the subluxated tibial head to reduce posteriorly at 20°–40° of flexion. The iliotibial tract, which with increasing flexion glides from a position

anterior to the lateral epicondyle in extension to a position posterior to the axis of flexion, draws the tibial head posteriorly again. The degree of reduction and flexion depends on the severity of the anterior subluxation. Reduction occurs earlier when there is only slight anterior translation. The patient usually confirms the diagnosis by reporting that the typical sensation of the knee giving way felt in sports activities can be reproduced in this test.

According to Jakob, a genuine pivot shift phenomenon can partially disappear, despite anterior cruciate ligament insufficiency, under the following conditions:

1. When a complete tear of the medial collateral ligament is present, the valgus opening prevents force concentration in the lateral compartment. Subluxation cannot occur under these circumstances.
2. When the iliotibial tract is traumatically divided, only the subluxation will be observed, not the abrupt reduction.
3. A bucket handle tear of the medial or lateral meniscus can prevent anterior translation or reduction of the tibia.
4. Increasing osteoarthritis in the lateral compartment with osteophytes can create a concave contour along the once convex lateral tibial plateau.

### Jakob Graded Pivot Shift Test

Gradation of the pivot shift test allowing for translation and rotation of the tibia.

**Procedure:** The procedure is identical to the pivot shift test except that here instability of the knee is assessed with the lower leg in not only internal rotation, but in neutral and external rotation as well.

**Assessment:** Pivot shift grade I: The pivot shift test is positive only in maximum internal rotation; it is negative in neutral and internal rotation. The subluxation as the knee approaches extension is more palpable than visible to the examiner (slight translation may be apparent).

Pivot shift grade II: The pivot shift test is positive in internal and neutral rotation; however, it is negative in external rotation. There is visible and palpable translation on the lateral aspect of the joint.

Pivot shift grade III: The pivot shift test is clearly positive in neutral rotation and particularly conspicuous in external rotation. The sign is less distinct in internal rotation.

Pivot shift grade IV can only be demonstrated in acute knee injuries where the posteromedial and lateral structures are damaged in addition to the anterior cruciate. In chronic instability, a grade III pivot shift will

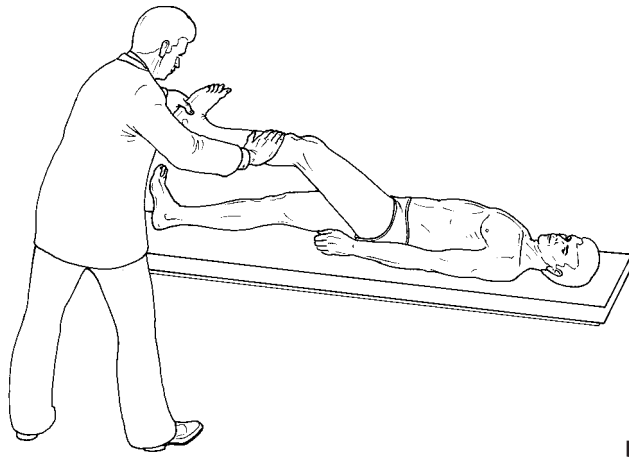
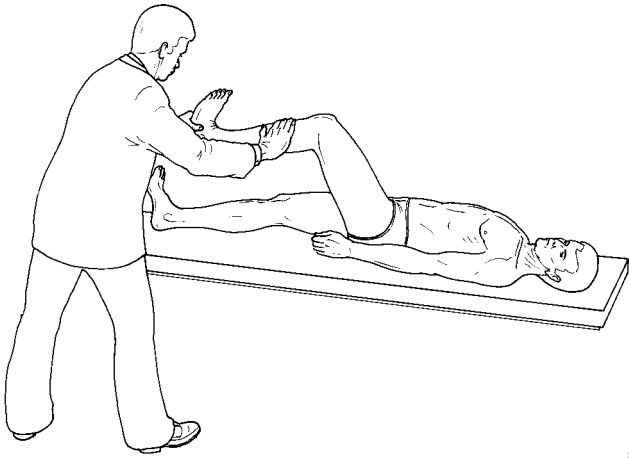


Fig. 214a, b Jakob graded pivot shift test:

**a** starting position: flexion and internal rotation of lower leg, valgus stress on the knee;

**b** anterior subluxation of the lateral tibial head as the knee approaches extension with lower leg internally rotated and valgus stress on the knee



be detectable in cases where the secondary stabilizers have loosened over time.

**Note:** In an anterior cruciate tear, both the medial and lateral portions of the tibia migrate anteriorly under the stress of the anterior drawer.

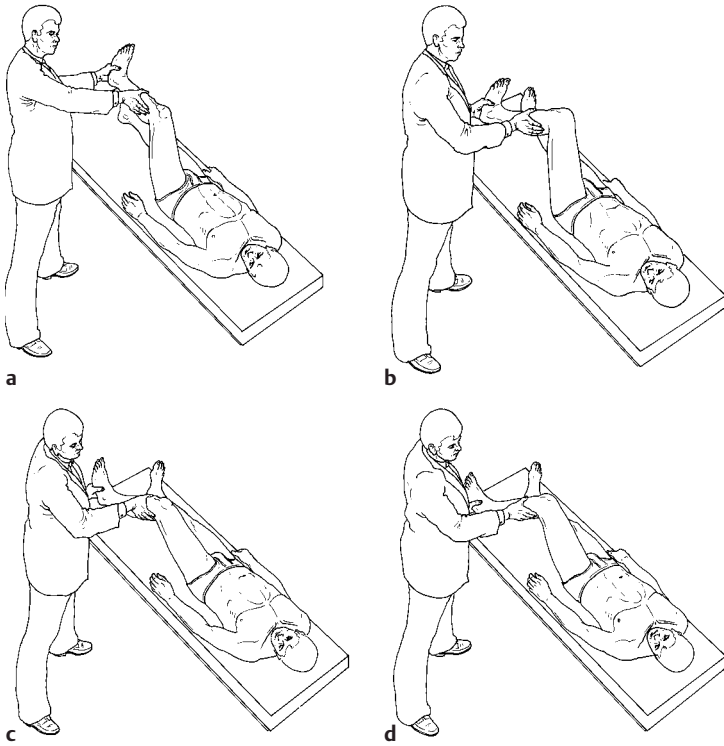
In an isolated tear of the anterior cruciate ligament, the anterior motion of the lateral portion of the tibia will be more pronounced than that of the medial portion. The anterior motion of the medial portion of the tibial plateau increases relative to that of the lateral portion as the number of injured medial structures increases. Increasing anterior motion of the medial tibial plateau in turn increases the severity of the subluxation and subsequent reduction phenomenon observed by the examiner. This reduction will also be observed to occur at an increasingly high degree of flexion.

### Modified Pivot Shift Test

**Procedure:** The patient is supine. With one hand, the examiner holds the patient's lower leg in internal rotation while the other hand grasps the tibial head laterally and holds it in a valgus position. In a positive test, this alone will produce anterior subluxation of the lateral tibial head. The rest of the procedure is identical to the pivot shift test. Subsequently flexing the knee while maintaining internal rotation and valgus stress on the lower leg causes posterior reduction of the subluxated tibial head at about 30° of flexion. The test is performed with the femoral head in abduction and adduction and in each case with the lower leg in external and internal rotation.

**Assessment:** The iliotibial tract plays an important role in subluxation as the knee approaches extension and in subsequent reduction as flexion increases in the pivot shift test. The initial stress present in the iliotibial tract greatly influences the severity of subluxation. The iliotibial tract is relaxed in hip abduction, whereas it is under tension in hip adduction.

The iliotibial tract contributes directly and indirectly (passively) to stabilizing the lateral knee. The portion of the iliotibial tract between the fibers of Kaplan and Gerdy's tubercle can be regarded as a passive ligament-like structure that is placed under tension by the proximal portion of the tract that courses through the thigh. The tension in this passive femorotibial portion of the tract determines the degree of subluxation of the tibial head. Internally rotating the lower leg and adducting the hip tenses the entire iliotibial tract, which increases tension in the ligament-like portion that spans the knee. This tension will prevent



**Fig. 215a–d** Modified pivot shift test:  
**a** subluxation during extension of the adducted leg with valgus stress and lower leg internally rotated,  
**b** reduction during flexion of the leg from the same position,  
**c** subluxation during extension of the abducted leg with valgus stress on the knee and lower leg externally rotated,  
**d** reduction during flexion of the leg from the same position

anterior subluxation of the tibial head during the pivot shift test in the presence of a torn anterior cruciate ligament. However, externally rotating the lower leg reduces the tension in the portion of the iliotibial tract that spans the knee, allowing greater anterior subluxation of the tibial head. The degree of subluxation is even greater when the leg is abducted.

### Medial Shift Test

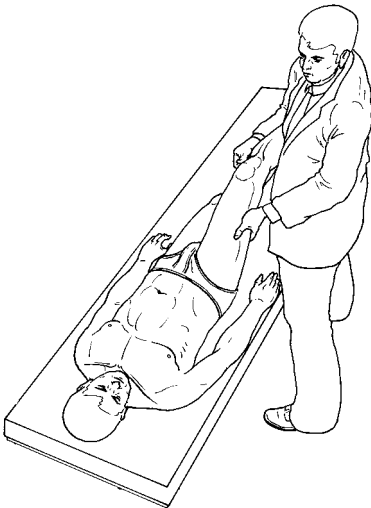
**Procedure:** The examiner immobilizes the patient's lower leg between his or her forearm and waist to evaluate the medial or lateral translation (tibial displacement) as the knee approaches extension. To assess medial translation, the examiner places one hand on the lower leg slightly distal to the medial joint cavity while the other hand rests on the lateral thigh. While applying a valgus stress to the knee via the lower leg, the examiner presses medially with the hand resting on the patient's thigh.

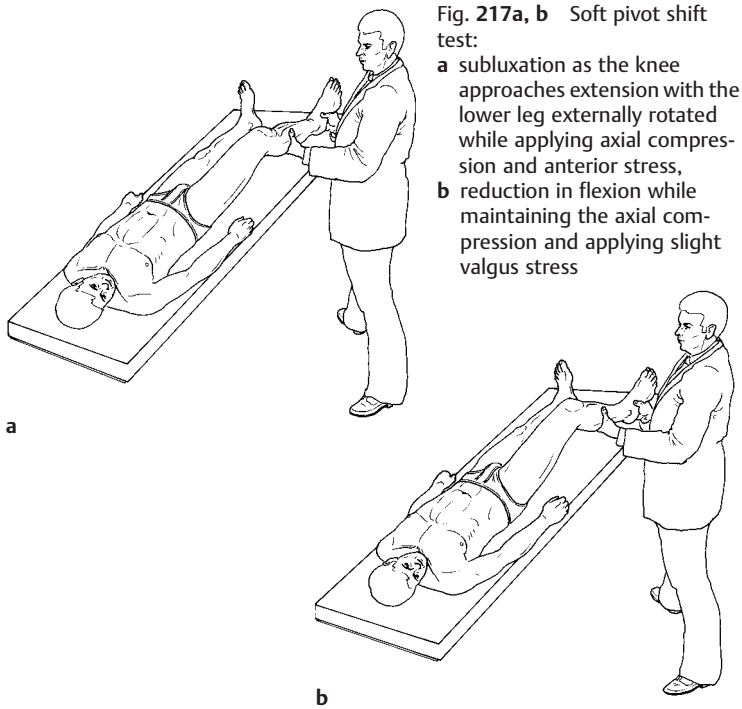
**Assessment:** In an anterior cruciate tear, the tibia can be displaced medially until the intercondylar eminence comes in contact with the medial femoral condyle. Because the posterior cruciate ligament courses from medial to lateral, lateral translation of the tibial head will be detectable in the presence of a posterior cruciate tear (positive lateral shift test).

### Soft Pivot Shift Test

**Procedure:** The patient is supine. The examiner grasps the patient's foot with one hand and the calf with the other. First, the examiner alternately flexes and extends the knee carefully, using these normal everyday motion sequences to alleviate the patient's anxiety and reduce

Fig. 216 Medial shift test





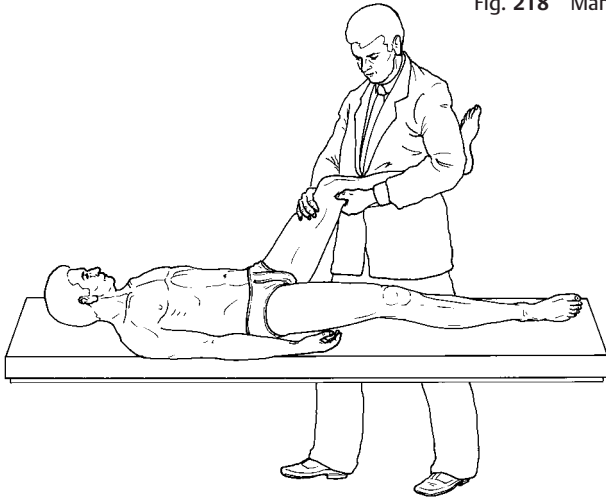
reflexive muscle tension. The patient's hip is abducted, and the foot is held in neutral or external rotation.

Next, the examiner gently applies axial compression after about 3–5 flexion and extension cycles. With the hand resting on the calf, the examiner applies a mild anterior stress.

**Assessment:** Under axial compression and mild anterior stress, slight subluxation will occur as the knee approaches extension, with reduction occurring as flexion increases. By varying the speed of the flexion and extension cycle, the axial compression, and anteriorly directed pressure, the examiner can precisely control the intensity of the subluxation and subsequent reduction. In this test, the examiner literally feels his or her way toward the subluxation and reduction.

**Note:** The soft pivot shift test ensures reduction with minimal pain or even with no pain at all. Carefully performed, this test can be repeated several times without the patient's complaining of pain.

Fig. 218 Martens test



### Martens Test

**Procedure:** The patient is supine. The examiner stands lateral to the injured leg and immobilizes the patient's calf distal to the knee with one hand, resting the index finger on the fibula. The patient's lower leg is immobilized between the examiner's forearm and waist while a valgus stress is applied. While pulling the lower leg anteriorly with one hand, the examiner pushes the distal thigh posteriorly with the other.

**Assessment:** The maneuver begins with the knee in a position approaching extension. As flexion is increased from this starting position, the subluxated lateral portion of the tibia will reduce at about 30° of flexion if an anterior cruciate ligament injury is present.

### Losee Test

**Procedure:** The patient is supine. The examiner grasps the knee laterally with the thumb posterior to the fibular head and the fingers resting on the patella. The other hand grasps the lower leg medially proximal to the ankle. In contrast to the other dynamic subluxation tests, the examiner does not internally rotate the lower leg but instead moves it into slight external rotation.

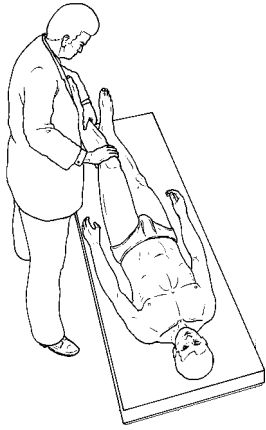


Fig. 219 Losee test

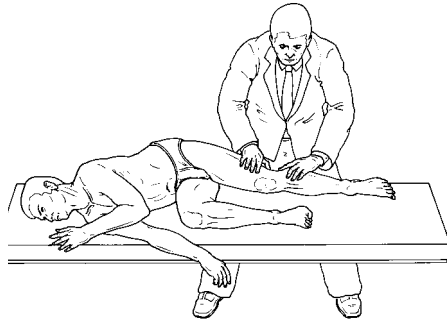


Fig. 220 Slocum test

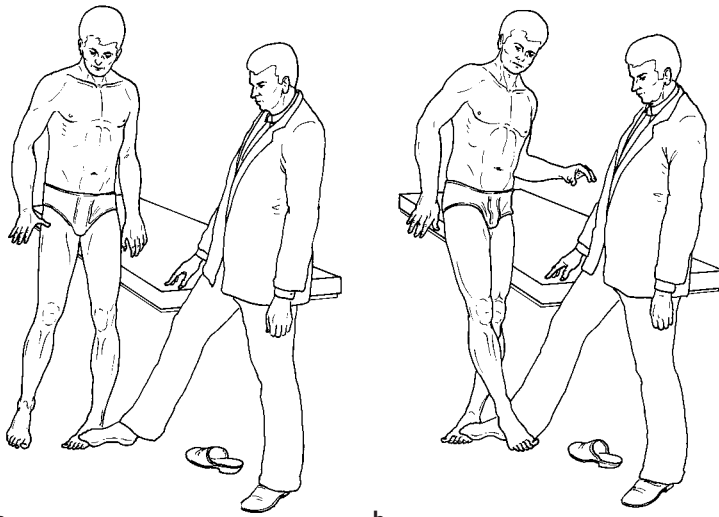
**Assessment:** When the knee is extended from  $40^{\circ}$ – $50^{\circ}$  of flexion, an anterior cruciate ligament injury will lead to visible and palpable anterior subluxation of the lateral portion of the tibial head.

**Note:** Traditionally, the external rotation of the lower leg has marked out the Losee test among the dynamic subluxation tests. However, it is important for the examiner not to force this external rotation, but to hold the lower leg in a relaxed way in external rotation with the knee flexed. Extending the knee causes the lateral portion of the tibia to subluxate anteriorly, meaning that the entire lower leg moves into internal rotation. The examiner must not interfere with this relative internal rotation.

### Slocum Test

**Procedure:** The patient lies on the unaffected side with the hip and knee flexed, holding the injured upper leg in slight internal rotation with the foot extended where possible. In this position, the weight of the leg exerts a slight valgus stress. The examiner stands behind the patient and grasps the patient's thigh with one hand, palpating the fibular head with the thumb or index finger.

**Assessment:** In an injury to the anterior cruciate ligament, the lateral tibial head will subluxate anteriorly with the knee in a position approaching extension. Subsequent flexion will then lead to posterior reduction of the tibial head at about  $30^{\circ}$  of flexion.



**a**  
**Fig. 221a, b** Arnold crossover test:  
**a** starting position,  
**b** crossover

### Arnold Crossover Test

**Procedure:** The examiner immobilizes the foot of the patient's injured leg. The patient then crosses the normal leg over the injured leg, rotating the pelvis and trunk toward the injured side.

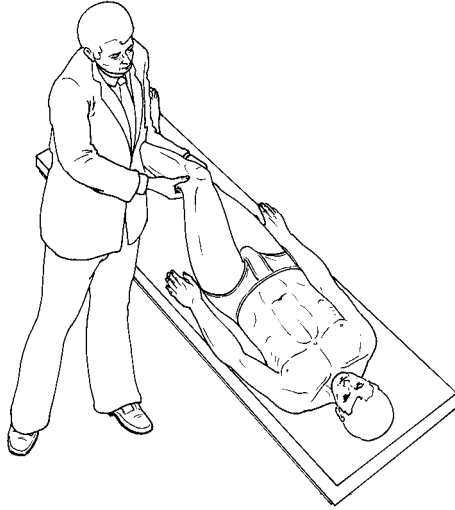
**Assessment:** The contraction of the quadriceps causes the immobilized leg to reproduce the lateral pivot shift phenomenon. The patient will experience an unpleasant sensation and report that the knee is about to dislocate.

**Note:** In muscular patients, this test usually provides more useful diagnostic information than the other dynamic anterior cruciate ligament tests.

### Noyes Test

**Procedure:** The patient is supine. The examiner grasps the tibial head with both hands and immobilizes the patient's distal lower leg between his or her forearm and waist. With the knee in about 20° of flexion, the

Fig. 222 Noyes test



examiner elicits a slight anterior drawer motion while simultaneously using the index fingers to evaluate whether the hamstrings are relaxed. The distal femur will drop into external rotation and slightly recede posteriorly (subluxation). The knee is then flexed from this position.

**Assessment:** In contrast to other dynamic anterior subluxation tests, it is not the lateral portion of the tibia but the distal femur that is tested for reduction and subluxation relative to the tibial head, which the examiner immobilizes and guides posteriorly. The test is positive when knee flexion results in palpable internal rotation of the distal femur (reduction). This indicates cruciate ligament insufficiency.

**Note:** The Noyes test is suitable for assessing cruciate ligament insufficiency in an apprehensive patient who has difficulty relaxing the hamstrings.

### Jakob Giving Way Test

**Procedure:** The patient leans against the wall on the normal side and distributes his or her body weight over both legs. The examiner places one hand each proximal and distal to the injured knee and applies a valgus stress while the patient flexes the knee.



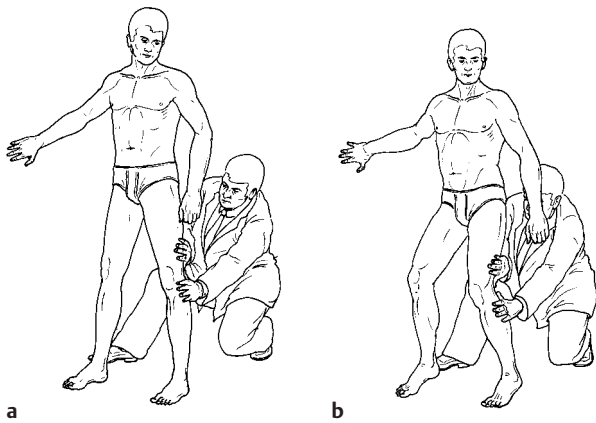


Fig. 223a, b Jakob giving way test:  
**a** starting position with valgus stress,  
**b** reduction in flexion while maintaining valgus stress

**Assessment:** The test is positive when anterior subluxation of the tibial head occurs and the patient reports a subjective sensation of the knee “giving way.”

### Lemaire Test

**Procedure:** The patient is supine. The examiner internally rotates the patient’s foot with one hand while pressing against the lateral thigh with the other hand, which rests proximal to the lateral femoral condyle. The examiner then carefully extends and flexes the knee.

**Assessment:** In an anterior cruciate ligament tear, the examiner will observe anterior subluxation of the lateral tibial head as the knee approaches extension. Spontaneous reduction will then occur at 30°–50° of flexion.

**Note:** This test method was described first by Lemaire and subsequently by Galway and McIntosh; it is often referred to by the latter names.

Fig. 224 Lemaire test

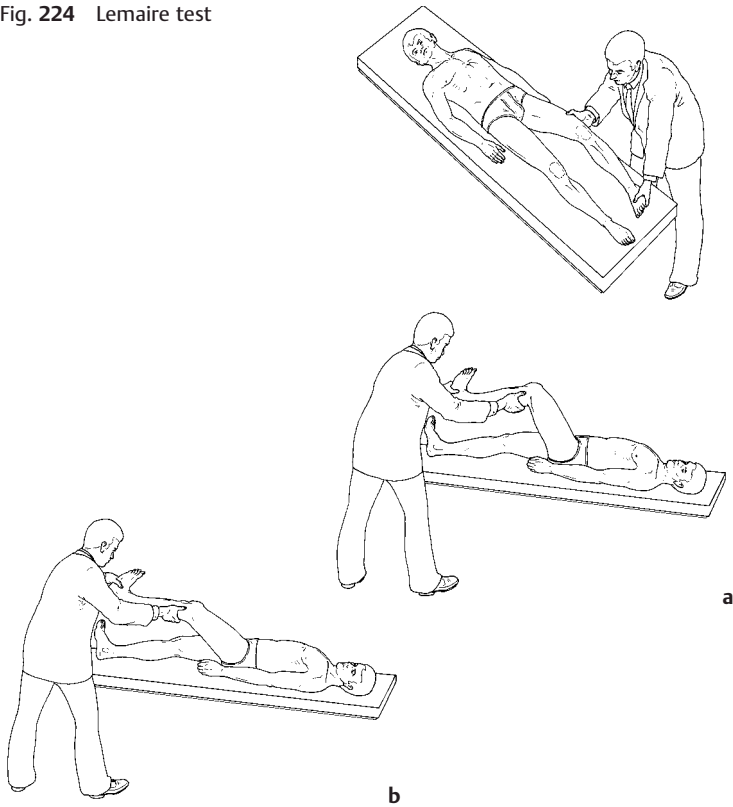


Fig. 225a, b Hughston jerk test:  
**a** starting position with knee flexed 70°, lower leg internally rotated, and valgus stress applied;  
**b** anterior subluxation of the lateral tibial head at 20° of flexion with the lower leg internally rotated and valgus stress applied

### Hughston Jerk Test

**Procedure:** The patient is supine with the knee flexed 60°–70°. The examiner grasps the patient's foot with one hand and internally rotates the lower leg while applying a valgus stress with the other hand.

**Assessment:** The flexed knee is extended with the tibia in slight internal rotation. In an anterior cruciate ligament tear, the lateral portion of the tibial head will abruptly subluxate anteriorly at about 20° of flexion.

**Note:** The jerk test can also be performed in external rotation. It begins with the knee in a position approaching extension. A positive test in external rotation indicates generalized anterior instability, which will not necessarily be present in every patient with an anterior cruciate tear.

## ■ Function Tests to Assess the Posterior Cruciate Ligament

### Posterior Drawer Test in 90° Flexion (Posterior Lachman Test)

**Procedure:** The posterior drawer test is performed with the knee in flexion and in a position approaching extension. It is similar to the anterior drawer test except that it is used to evaluate posterior translation in neutral, internal, and external rotation.

**Assessment:** Isolated posterolateral instability exhibits maximum posterior translation with the knee in a position approaching extension. Maximum posterolateral rotation and minimum posterior drawer are

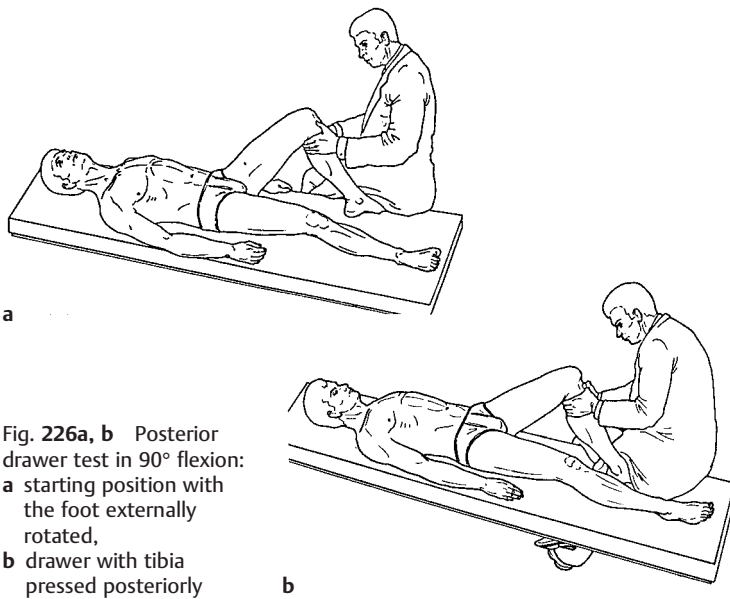


Fig. 226a, b Posterior drawer test in 90° flexion:  
a starting position with the foot externally rotated,  
b drawer with tibia pressed posteriorly

**Note:** The jerk test can also be performed in external rotation. It begins with the knee in a position approaching extension. A positive test in external rotation indicates generalized anterior instability, which will not necessarily be present in every patient with an anterior cruciate tear.

## ■ Function Tests to Assess the Posterior Cruciate Ligament

### Posterior Drawer Test in 90° Flexion (Posterior Lachman Test)

**Procedure:** The posterior drawer test is performed with the knee in flexion and in a position approaching extension. It is similar to the anterior drawer test except that it is used to evaluate posterior translation in neutral, internal, and external rotation.

**Assessment:** Isolated posterolateral instability exhibits maximum posterior translation with the knee in a position approaching extension. Maximum posterolateral rotation and minimum posterior drawer are

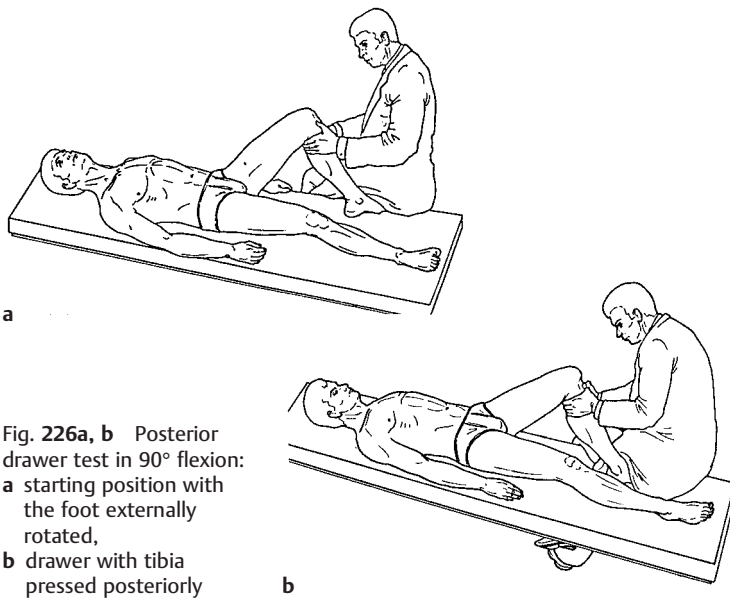


Fig. 226a, b Posterior drawer test in 90° flexion:  
a starting position with the foot externally rotated,  
b drawer with tibia pressed posteriorly

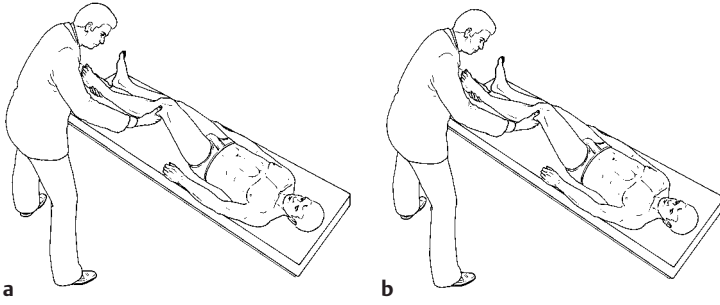


Fig. 227a, b Reversed Jakob pivot shift test:  
**a** posterior subluxation of the tibia with knee flexed more than 60°,  
**b** reduction as the knee approaches extension

observed with the knee in 90° of flexion. In an isolated posterior cruciate ligament injury, maximum posterior translation occurs in flexion, and posterolateral translation will be observed neither in flexion nor with the knee in a position approaching extension.

Where there is combined insufficiency of the posterior cruciate ligament and the posterolateral structures, an increased posterior drawer, external rotation, and lateral opening will be observed in all degrees of flexion.

### Reversed Jakob Pivot Shift Test

Assesses posterolateral rotational instability.

**Procedure:** The patient is supine. The examiner stands on the side of injured leg. With one hand, the examiner grasps the patient's foot while the other hand supports the lateral aspect of the lower leg at the level of the knee. The thumb of this hand palpates the fibular head and applies valgus pressure. The examiner now flexes the patient's knee 70°–80°. Externally rotating the foot in this position causes posterior subluxation of the lateral tibial plateau. The examiner then slowly extends the knee while maintaining slight valgus stress.

**Assessment:** In the presence of a posterolateral injury with the knee flexed, the tibia follows gravity and drops into posterolateral subluxation. Externally rotating the tibia increases this subluxation. As the knee is then extended and passes through 30°–20° of flexion, the iliotibial tract begins to act as an extensor and reduces the joint. The posterolateral capsule, the posterior soft tissue envelope of the knee, and the quadriceps also contribute to the reduction.

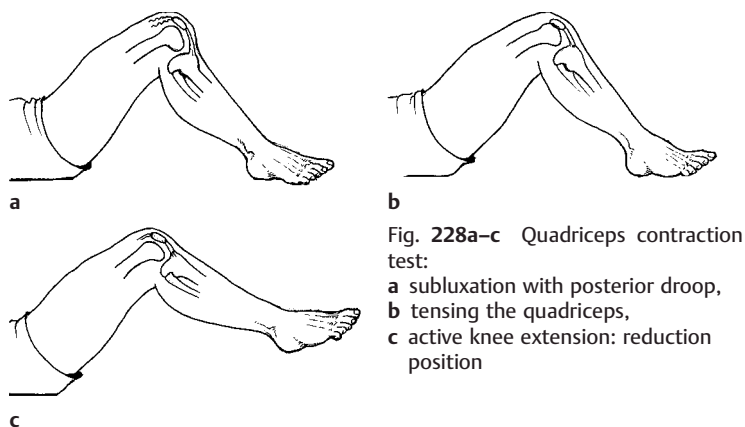
**Note:** This test is the functional counterpart of the dynamic anterior subluxation test. However, it can be positive in patients with increased generalized laxity of the ligaments. This test is only clinically significant when a positive result can be elicited unilaterally and faithfully reproduces the painful subluxation symptoms described by the patient. A positive test primarily suggests a posterolateral capsular ligament injury. Injury to the posterior cruciate ligament is likely in patients with a history of trauma and simultaneous posterolateral instability in the form of a positive posterior drawer when the lower leg is in external rotation.

### Quadriceps Contraction Test

Assesses a posterior cruciate ligament injury.

**Procedure:** The patient is supine. The injured leg is flexed 90° at the knee and placed in external rotation. The patient is asked to tense the quadriceps and lift the leg off the examining table.

**Assessment:** In the presence of posterolateral instability, the external rotation of the foot causes posterior subluxation of the lateral tibia relative to the lateral femoral condyle. The examiner observes this as a posterior droop of the lateral tibial plateau. The active quadriceps contraction and increasing knee extension cause the lateral tibial plateau to move anteriorly out of posterior subluxation and into reduction with a sort of reverse pivot shift. The joint reduces at about 30°–20° of flexion. This test is also called an active reduction test and can usually be demonstrated only in the presence of chronic ligament injuries.



### Posterior Droop Test

**Procedure:** Both knees are held parallel in 90° of flexion.

**Assessment:** Inspecting the silhouettes of both tibial heads from the side reveals that the tibial head in the affected knee appears to “droop.” The rest position of the posterior drawer is influenced by gravity and is a sensitive sign of a posterior cruciate ligament injury.

### Soft Posterolateral Drawer Test

**Procedure:** The patient is seated with the legs relaxed and hanging over the edge of the table. The foot of the affected leg rests lightly on the thigh of the examiner, who crouches in front of the patient. The examiner grasps the tibial head with both hands and presses it posteriorly with the balls of the thumbs.

**Assessment:** Posterior translation (drawer motion) of the lateral tibial plateau is a sign of posterolateral instability.

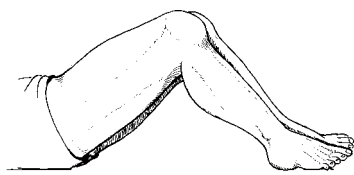


Fig. 229 Posterior droop test

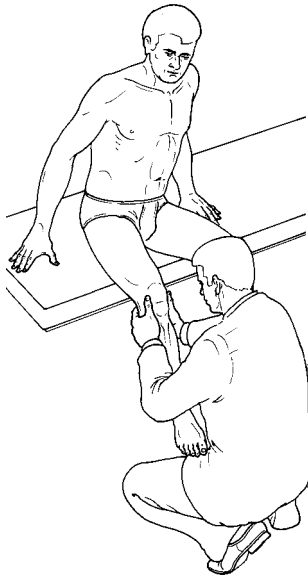


Fig. 230 Soft posterolateral drawer test

### Gravity Sign and Genu Recurvatum Test

**Procedure:** The patient is supine with the hip and knee of the affected leg flexed 90°. With one hand, the examiner grasps the patient's lower leg while stabilizing the knee proximal to the patella with the other hand. The examiner then abruptly pulls away the stabilizing hand from the knee.

**Assessment:** If the posterior cruciate ligament is torn, the tibia will recede posteriorly (posterior droop).

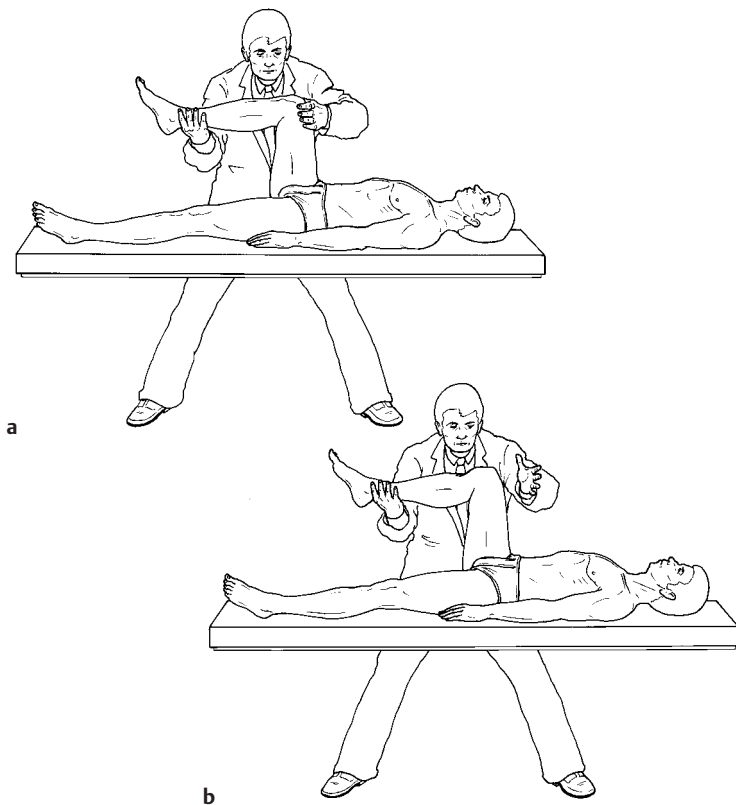


Fig. 231a, b Gravity sign and genu recurvatum test:  
a stabilizing the joint,  
b posterior droop of the tibia after removal of stabilization



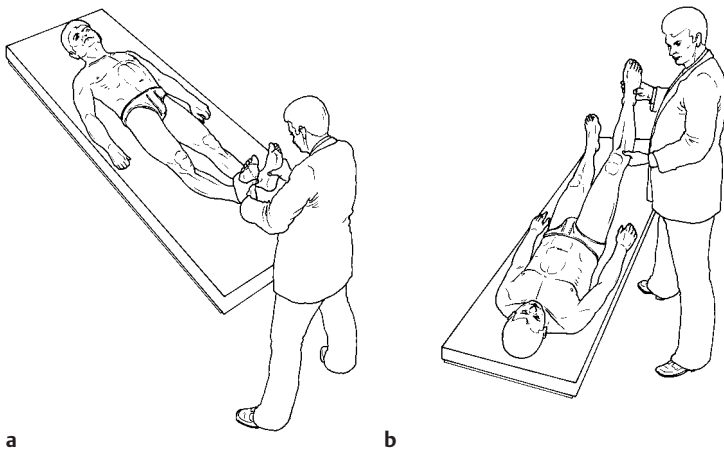
**Note:** In the genu recurvatum test, the extended leg is lifted. A torn posterior cruciate ligament will result in a posterior droop of the tibia.

### Hughston Test for Genu Recurvatum and External Rotation

**Procedure:** The patient is supine with both quadriceps completely relaxed. The examiner then lifts each forefoot.

**Assessment:** In posterolateral instability, this maneuver will produce a hyperextended varus position in the knee with simultaneous external rotation of the tibia.

**Note:** To demonstrate the external rotation and genu recurvatum deformity (hyperextension) more clearly, the test may be performed on one leg at a time. This is done by moving the knee from slight flexion into extension. The examiner places one hand on the posterior aspect of the knee to palpate the posterior droop and the slight external rotation of the proximal tibia.



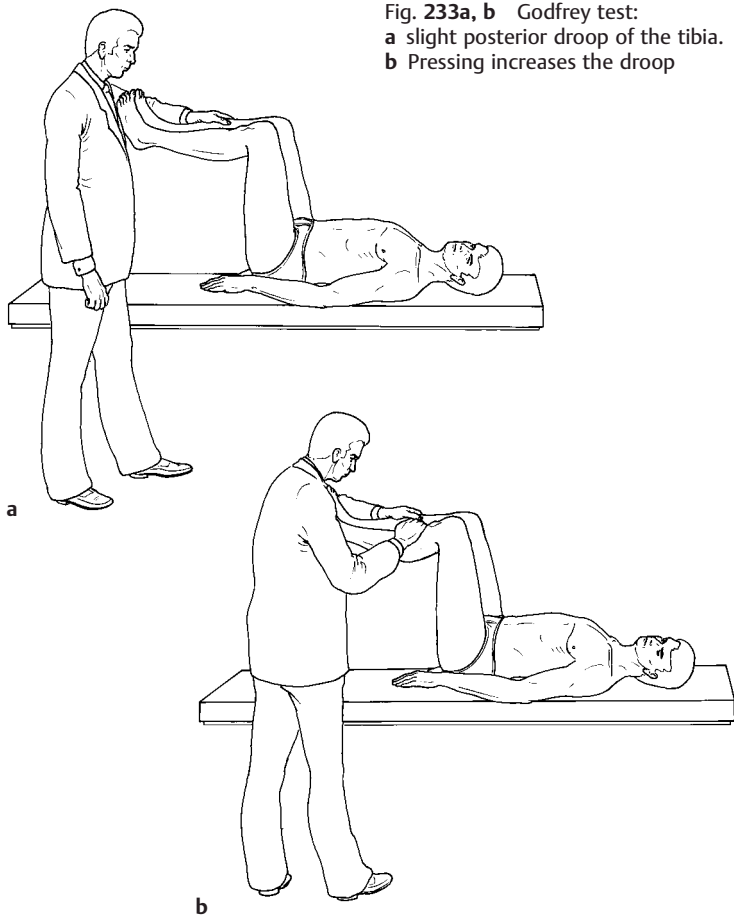
**a** **b**  
Fig. 232a, b Hughston test for genu recurvatum and external rotation:  
**a** hyperextended varus position,  
**b** flexion into extension movement

## Godfrey Test

**Procedure:** The patient is supine with both knees and hips flexed 90°. The examiner holds the patient's lower legs while pressing the tibial tuberosity of the injured knee posteriorly.

**Assessment:** Even in the starting position, the examiner will readily notice the slight posterior droop in the proximal tibia indicative of posterior cruciate ligament insufficiency. Applying pressure to the anterior tibia increases the posterior droop of the lateral tibial plateau.

Fig. 233a, b Godfrey test:  
a slight posterior droop of the tibia.  
b Pressing increases the droop



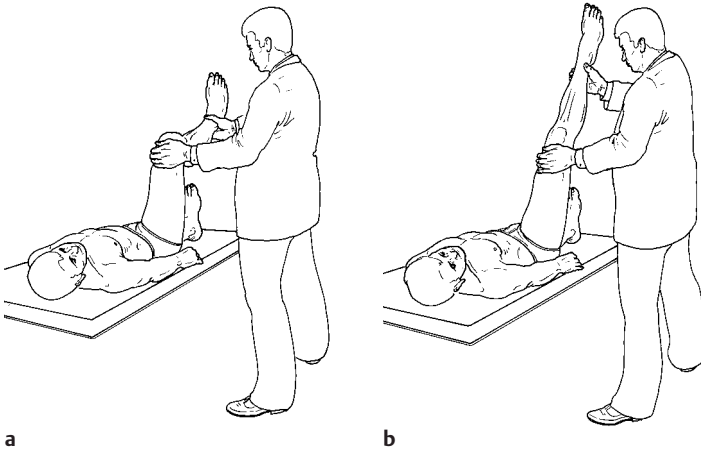


Fig. 234a, b Dynamic posterior shift test:  
a subluxation with hip and knee flexed 90°,  
b reduction as the knee approaches extension

### Dynamic Posterior Shift Test

**Procedure:** The patient is supine. The examiner passively flexes the hip and knee of the affected leg 90°, holding the knee in neutral rotation. One of the examiner's hands rests on the thigh and acts as a buttress while the examiner slowly extends the knee with the other hand.

**Assessment:** Once the knee reaches about 20° of flexion, the examiner will be able to observe and palpate an abrupt movement of the tibial plateau out of posterior subluxation into reduction and external rotation.

---

## Foot

Almost all patients presenting with foot problems have pain. For this reason, a precise history is very important in diagnosing the disorder.

Age, gender, occupation, and leisure activities are important factors to consider in every patient. It is important to enquire about the character of the onset of pain, its location and radiation, its nature, and about factors that can cause pain. Both feet and the adjacent joints such as the knee should be examined and assessed comparatively. Axial deviations in the legs should also be given consideration. Inspection of the shape and soles of the patient's shoes is important as asymmetric wear on the soles may provide an initial indication of the cause of the patient's complaints.

In addition to a palpatory examination with assessment of mobility and tenderness to palpation in the specific region, it is important to observe the foot during weight bearing and walking. Metatarsalgia is a general term for pain in the forefoot. Splay foot is the most common deformity of the foot and the most common cause of metatarsalgia. The collapse of the transverse metatarsal arch as a result of weakness of the muscles and ligaments leads to secondary changes in the foot with claw toe and hammer toe deformities and hallux valgus. Plantar calluses from the increased stresses on the metatarsal heads in turn lead to additional problems.

Other causes of forefoot pain include osteoarthritis (hallux rigidus), neuromas (Morton neuroma), stress fractures, avascular necrosis (Koehler disease), disorders of the sesamoids, plantar warts, and compression neuropathies (tarsal tunnel syndrome).

Certain systemic diseases tend to involve the foot. Often the first clinical symptoms of these disorders will appear in the foot. Such disorders include diabetes mellitus, peripheral arterial disease, gout, psoriasis, collagen disorders, and rheumatoid arthritis.

## ■ Range of Motion in the Ankle and Foot (Neutral-Zero Method)

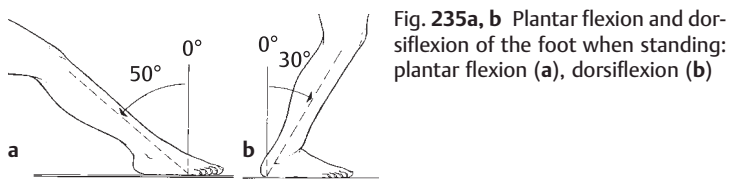
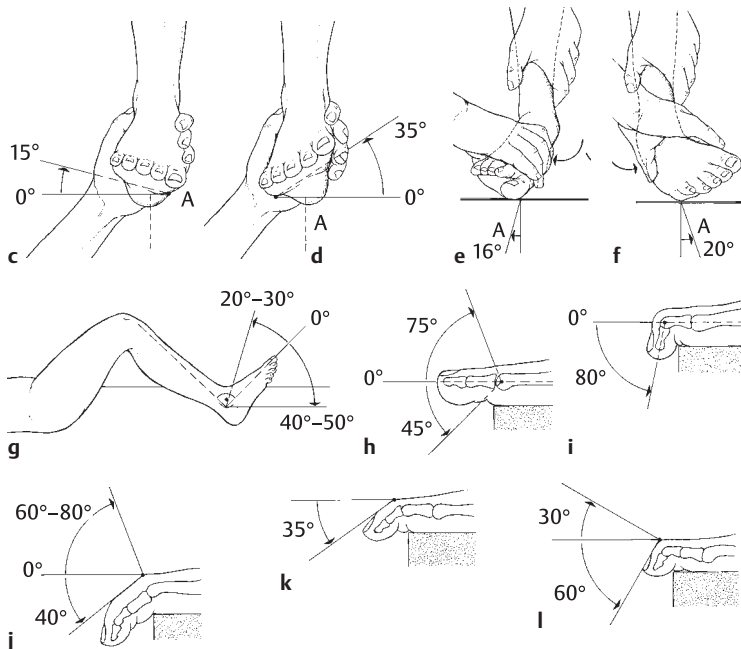


Fig. 235a, b Plantar flexion and dorsiflexion of the foot when standing: plantar flexion (a), dorsiflexion (b)



**c, d** Pronation (c) and supination (d) of the forefoot.

One hand grasps the heel and the other turns the forefoot. Only the angle of the forefoot relative to the hindfoot is measured as pronation and supination

**e, f** Eversion (e) and inversion (f) of the hindfoot.

One hand grasps the lower leg and the other grasps the posterior aspect of the forefoot, holding the calcaneus between thumb and forefinger (not shown).

The inversion and eversion is evaluated on the calcaneus (axis of the calcaneus, A). Care should be taken to avoid pronation or supination of the foot

**g** Plantar flexion and dorsiflexion of the ankle (talocrural joint) with the foot hanging relaxed

**h-l** Motion in the metatarsophalangeal joints: great toe (h, i), other toes (j-l)

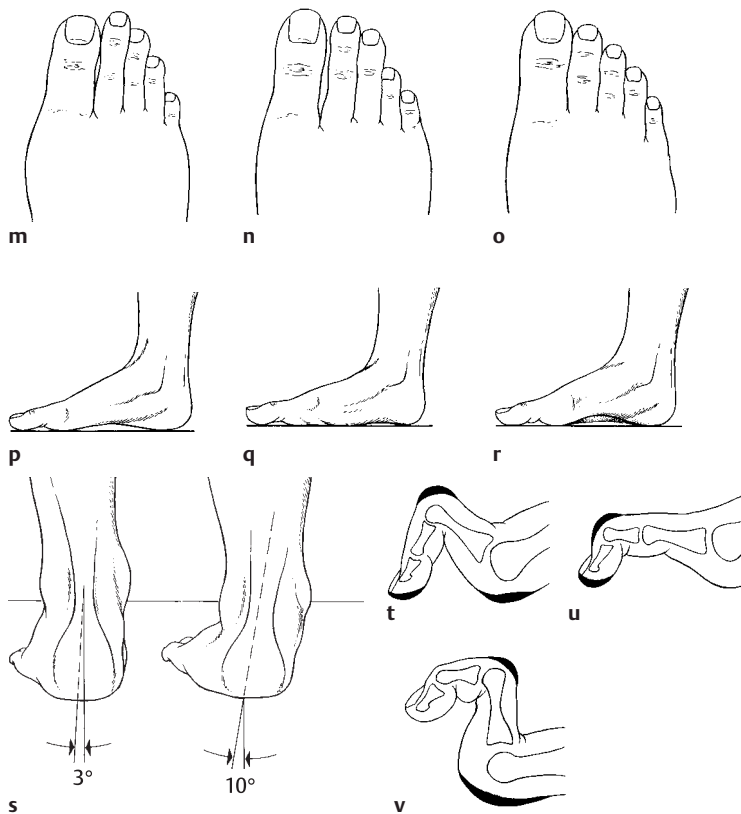


Fig. 235

**m-o** The most common variations in forefoot and toe length:

Greek (**m**), square (**n**), and Egyptian as described by Lelièvre (**o**)

**p-r** Assessment of the medial longitudinal arch of the foot: normal arch rising slightly above the floor (**p**), absent arch or flatfoot (**q**), abnormally high arch or pes cavus (**r**)

**s** Assessment of the position of the hindfoot. Normal position is a valgus angle of  $0^{\circ}$ – $6^{\circ}$ . A valgus angle exceeding  $6^{\circ}$  is pes valgus; any varus angle is pes varus

**t-v** The most important toe deformities: hammer toe in the proximal interphalangeal joint (**t**), hammer toe in the distal interphalangeal joint (**u**), claw toe as described by Lelièvre (**v**)

## ■ Function Tests

### Grifka Test

Assesses splay foot.

**Procedure:** After passively dorsiflexing the toes of one foot, the examiner applies distal and plantar finger pressure to longitudinally compress the metatarsal heads in the metatarsophalangeal joints.

**Assessment:** This compression corresponds to the transfer of compressive forces to the metatarsal heads in the painful toe-off phase of walking. With a splay foot, this is often painful while plantar compression alone is painless.

### Strunsky Test

Provocation test to assess metatarsalgia.

**Procedure:** The patient is supine with the feet hanging over the edge of the examining table. With each great toe between the thumb and index finger, the examiner grasps the patient's other toes in a pincer grip and forcefully plantar flexes the metatarsophalangeal joints.

**Assessment:** Where there is chronic irritation of the metatarsophalangeal joints with metatarsalgia, this test significantly increases symptoms as a result of the increased pressure on the metatarsophalangeal joints. Subsequent palpation of the metatarsophalangeal joints can then identify the painful joint.

Fig. 236 Grifka test

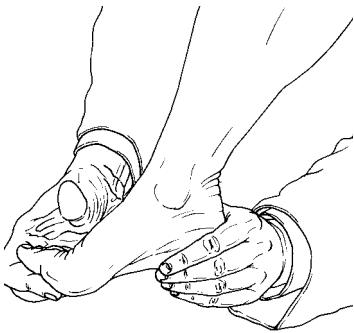

Fig. 237a, b Strunsky test:  
 a plantar flexion,  
 b joint palpation

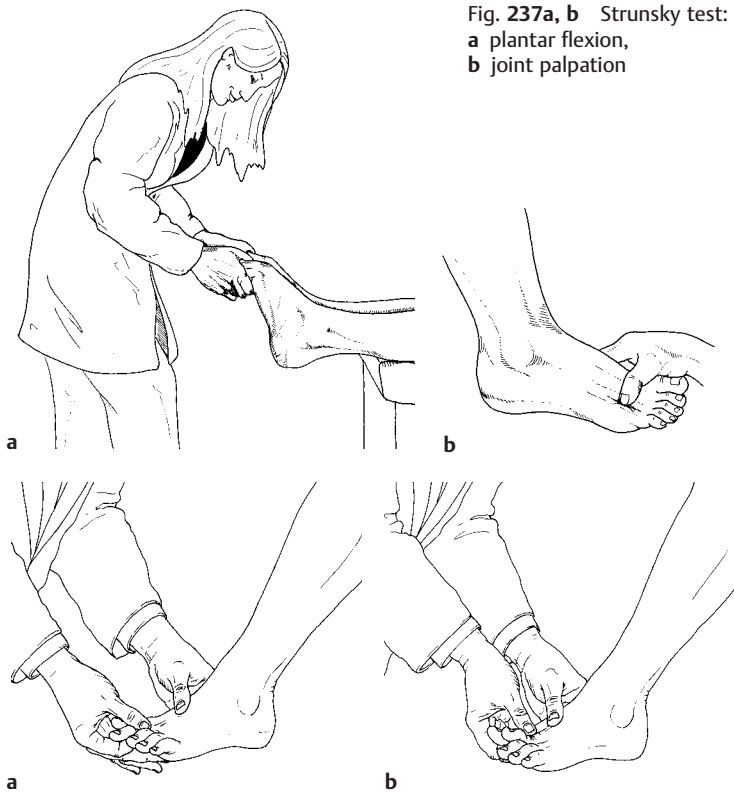


Fig. 238 Toe displacement test:  
 a posterior displacement, b plantar displacement

### Toe Displacement Test

Tests instability of the metatarsophalangeal joints.

**Procedure:** While immobilizing the medial forefoot with one hand, the examiner grasps the distal portion of one proximal phalanx with the other hand and moves it posteriorly and plantarward relative to the metatarsal head.

**Assessment:** Motion pain in the metatarsophalangeal joint accompanied by signs of instability suggests an increasing deformity of the toe leading to a functional claw toe deformity during weight bearing. Pro-



gression of this instability leads to a permanent claw toe deformity with the metatarsophalangeal joint fixed in dorsiflexion.

In a dislocation of the metatarsophalangeal joint, it will be impossible to reduce the joint in the toe displacement test. The result is metatarsalgia with development of plantar calluses.

### Crepitation Test

Indicates hallux rigidus.

**Procedure:** With the patient's foot relaxed and hanging, the examiner approaches from distally and grasps the proximal phalanx of the great toe, with his or her thumb on its posterior aspect and fingers on its plantar aspect. The examiner immobilizes the lateral forefoot with the other hand, placing the thumb on its plantar aspect and the fingers on its posterior aspect. The examiner passively plantar flexes, dorsiflexes, and rotates the metatarsophalangeal joint.

**Assessment:** In hallux rigidus, joint motion in every direction will be painful and, primarily in dorsiflexion, restricted. This will be accompanied by palpable or audible crepitation as a result of osteoarthritic changes in the joint.

### Gaensslen Maneuver

Assessment of forefoot pain.

**Procedure:** The examiner immobilizes the metatarsal heads in one plane between the fingers of one hand on the plantar aspect of the foot and the thumb on the posterior aspect. The other hand grasps the toes in a pincer grip, applying medial and lateral compression to the forefoot via the metatarsal heads of the great toe and little toe.

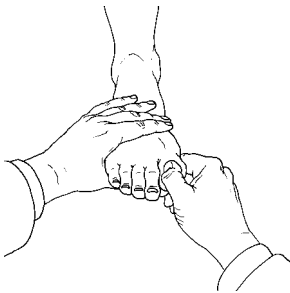


Fig. 239 Crepitation test

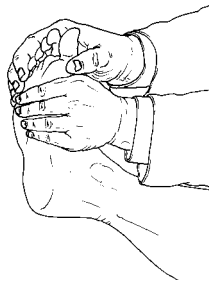
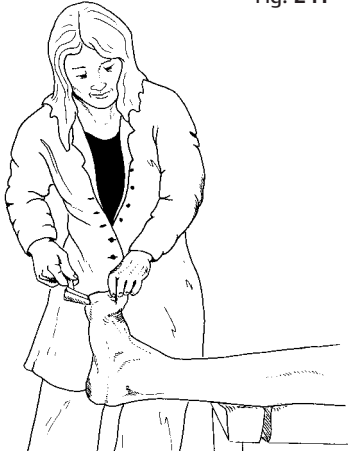

Fig. 240 Gaensslen maneuver

Fig. 241 Metatarsal tap test



**Assessment:** This forefoot “pincer grip” will elicit pain between the metatarsal heads, often with acute episodic pain radiating into the adjacent toes, in the presence of a Morton neuroma (a painful interdigital neuroma). It will also often cause pain in a significant splay foot deformity where there is irritation of the joint capsule.

### Metatarsal Tap Test

Provocation test for assessment of metatarsalgia.

**Procedure:** The patient is supine with the feet hanging over the edge of the examining table. The examiner slightly hyperextends the toes with one hand and taps the metatarsal heads or metatarsophalangeal joints with a reflex hammer held in the other hand.

**Assessment:** In a patient with metatarsalgia due to chronic irritation of the metatarsophalangeal joints, tapping the ball of the foot will exacerbate the metatarsalgia symptoms. Pain upon tapping that occurs between the metatarsal heads—primarily the third and fourth metatarsals—with acute episodic pain radiating into the adjacent toes suggests a Morton neuroma (see Mulder click test).

**Thompson Compression Test (Calf Compression Test)**

Indicates an Achilles tendon tear.

**Procedure:** The patient is prone with the feet projecting past the edge of the examining table. The examiner grasps the calf of the affected leg with one hand and forcefully compresses the musculature.

**Assessment:** Compressing the calf muscles should normally provoke rapid passive plantar flexion of the foot. Absence of this plantar flexion suggests a torn Achilles tendon. The response to the compression test is not always unambiguous in patients with partial tears and will depend on the degree of disruption. In an Achilles tendon tear, the patient will be unable to stand on tiptoe, especially when standing only on the injured leg, and the Achilles tendon reflex will be absent.

**Note:** The test can also be performed with the patient prone and the knee flexed 90°. In this position, the examiner grasps the patient's calf with both hands and forcefully compresses the musculature. Loss of plantar flexion is a sign of an Achilles tendon tear (Simmond test).

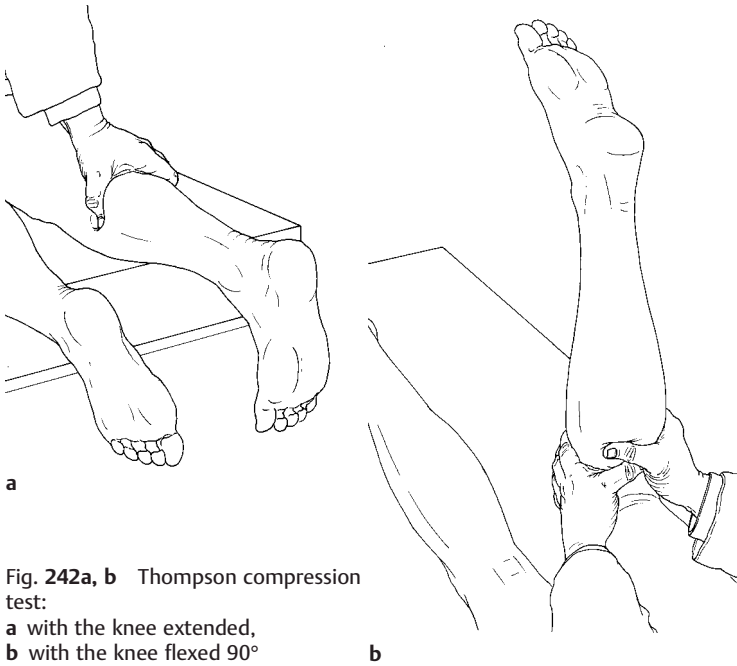


Fig. 242a, b Thompson compression test:

a with the knee extended,  
b with the knee flexed 90°

### Hoffa Sign

Indicates a chronic Achilles tendon tear.

**Procedure:** The patient is prone with the feet projecting over the edge of the examining table. The examiner passively dorsiflexes both feet.

**Assessment:** In a chronic Achilles tendon tear, tension in the Achilles tendon will be reduced and the affected foot can be dorsiflexed farther than the contralateral foot. The patient is then requested to stand on tiptoe on each leg. This will be impossible with an Achilles tendon tear in the injured leg.

### Achilles Tendon Tap Test

Indicates an Achilles tendon tear.

**Procedure:** The patient is prone with the knee flexed 90°. The examiner taps the distal third of the Achilles tendon with a reflex hammer.

**Assessment:** Increased pain and loss of plantar flexion (Achilles tendon reflex) are signs of a tear in the Achilles tendon. In the absence of an Achilles tendon reflex, a differential diagnosis should exclude neurologic changes.

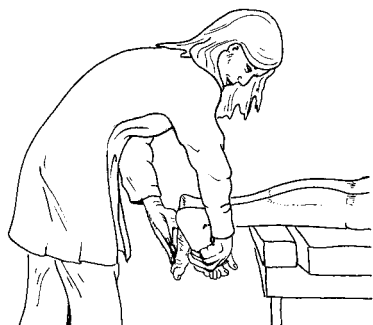

Fig. 243 Hoffa sign

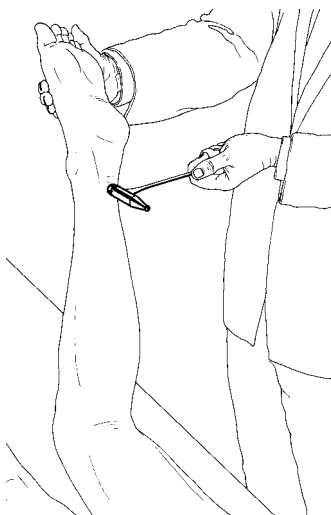


Fig. 244 Achilles tendon tap test

### Coleman Block Test

Flexibility test for assessment of hindfoot deformities.

**Procedure:** The patient is standing. The lateral block test involves placing wooden blocks of varying height beneath the heel and the lateral margin of the foot. The blocks are placed according to the severity and shape of the foot deformity so as to allow the first metatarsal to reach the floor. In the medial block test, the wooden block must be placed beneath the first metatarsal head.

**Assessment:** The block test is a good method for determining the flexibility of compensatory hindfoot deformities in the presence of simultaneous fixed forefoot contractures. The lateral block test is used

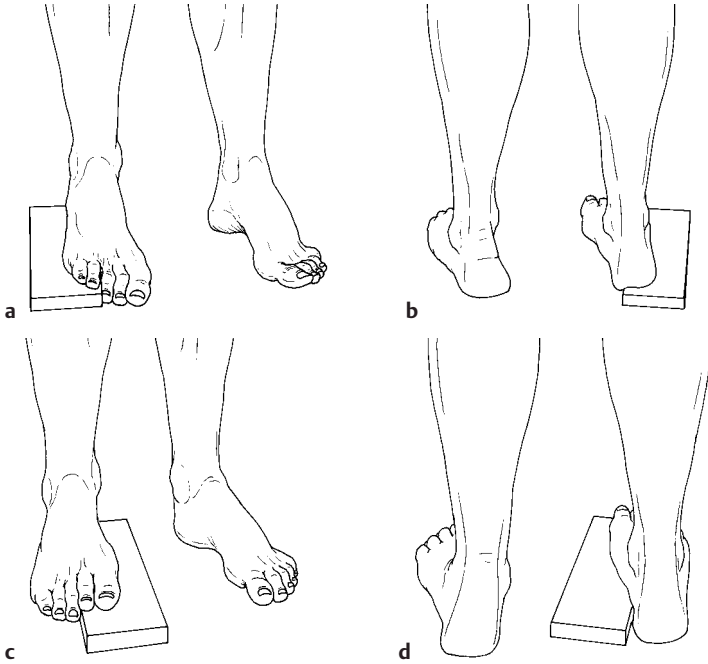


Fig. 245a–d Coleman block test:  
**a** hindfoot varus and forefoot valgus viewed from the front,  
**b** hindfoot varus and forefoot valgus viewed from the rear,  
**c** hindfoot valgus and forefoot varus viewed from the front,  
**d** hindfoot valgus and forefoot varus viewed from the rear

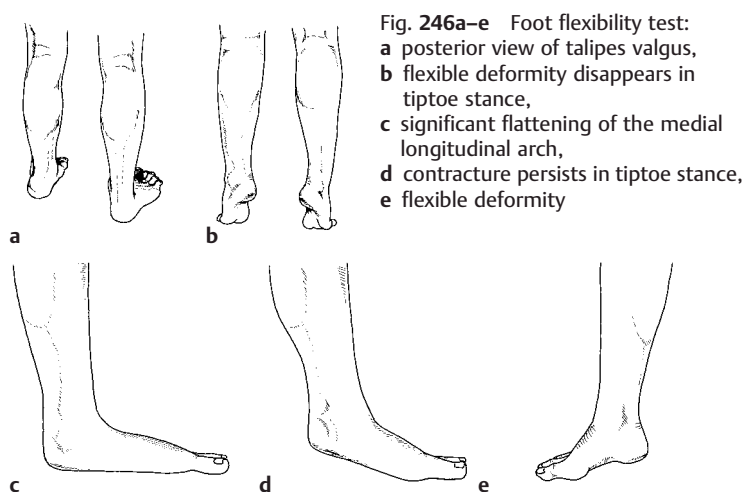
to determine the flexibility of a varus hindfoot deformity in the presence of a simultaneous valgus forefoot contracture. A flexible compensatory varus hindfoot deformity will be corrected by the lateral block. Where a varus forefoot contracture is present, the medial block test will allow evaluation of the flexibility and/or severity of the contracture in the hindfoot deformity.

### Foot Flexibility Test

Assesses rigid or flexible talipes planovalgus deformity.

**Procedure:** Talipes planovalgus is a foot deformity in which the medial longitudinal arch of the foot is flattened (flatfoot, talipes planus, or pes planus) and the valgus position of the heel is increased (talipes valgus). The feet are examined from the side and from behind with the patient standing in the normal position and on tiptoe.

**Assessment:** Persistent flattening of the medial longitudinal arch and persistent valgus position of the heel when the patient stands on tiptoe indicate a rigid talipes planovalgus deformity. In a flexible talipes planovalgus deformity, the tiptoe stance will bring about a varus shift in the heel to compensate for the valgus deformity, and the medial longitudinal arch will reappear.



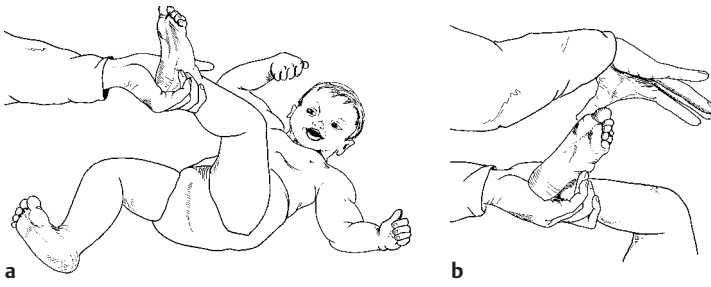


Fig. 247a, b Forefoot adduction correction test:  
**a** deformity,  
**b** passively correctable

### Forefoot Adduction Correction Test

For assessment and differential diagnosis of rigid and flexible pes adductus.

**Procedure:** The child is supine. The examiner grasps the foot of the affected leg with one hand and attempts to correct the pes adductus deformity by pressing on the medial aspect of the forefoot with thumb of the other hand.

**Assessment:** Where this maneuver readily moves the forefoot across the midline and eliminates the pes adductus, the deformity is usually flexible and will be spontaneously corrected. A deformity that cannot be passively corrected is a rigid pes adductus.

Congenital pes adductus deformities that resist manual correction will require rigorous timely treatment in corrective plaster casts.

### Test of Lateral and Medial Ankle Stability

Assesses a lateral ligament injury in the ankle.

**Procedure:** The patient is supine. The examiner grasps the posterior lower leg adjacent to the malleoli with one hand. With the other hand, the examiner grasps the lateral metatarsus and attempts to open the ankle by means of passive supination. To test the medial ligaments, the examiner grasps the medial metatarsus and attempts to open the ankle medially by means of pronation.

The tibiototalcalcaneal joint complex is comprised of the ankle and subtalar joint. These are complex articulations that combine to form a functional unit; the subtalar joint also acts in concert with the trans-

Fig. 248 Test of lateral and medial ankle stability



verse tarsal joint (joint of Chopart). Some of the medial and lateral collateral ligaments span both joints; others span only the ankle.

The ankle is stabilized by tight collateral ligaments. The lateral (fibular) structures include the anterior talofibular, calcaneofibular, and posterior talofibular ligaments; the medial (tibial) structures include the deltoid ligament.

Upward motion of the forefoot is referred to as dorsiflexion, downward motion as plantar flexion. There is wide individual variation in the physiologic range of this motion. The subtalar joint allows pronation and supination as in the hand. Lifting of the medial margin of the foot is referred to as supination; lifting of the lateral margin, pronation.

**Assessment:** Injury to one of these ligaments leads to instability and increased opening of the lateral or medial joint cavity. Increased supination suggests an injury to the anterior talofibular and calcaneofibular ligaments. Increased pronation may be due to injury to the deltoid ligament. Rotational trauma in supination is the most common mechanism of ankle injury and almost invariably involves the anterior talofibular ligament. Children normally have greater mobility in the ankle, which must not be misinterpreted as a ligament injury. This means that a comparative examination of both feet should be performed as matter of course. Stress radiographs are necessary to document capsular ligament injuries particularly in the ankle. Depending on specific requirements, they may be obtained with a supination or pronation stress applied, with the foot in a middle position, and in an anterior or posterior drawer position. Comparative stress radiographs of both legs should be obtained.



## Drawer Test

Examines ankle stability.

**Procedure:** The patient is supine. The examiner immobilizes the posterior tibia with one hand and grasps the metatarsus with the other. The examiner then pushes the foot posteriorly in the ankle against the hand immobilizing the tibia. In a second step, the examiner grasps the anterior tibia and grasps the heel posteriorly. Then the foot is pulled anteriorly against the hand immobilizing the tibia.

**Assessment:** A comparative examination of both legs is performed. A torn lateral collateral ligament in the ankle will result in increased mobility of the foot in the ankle; there will be increased anterior mobility where the anterior ligaments are involved and increased posterior mobility with involvement of the posterior ligaments.

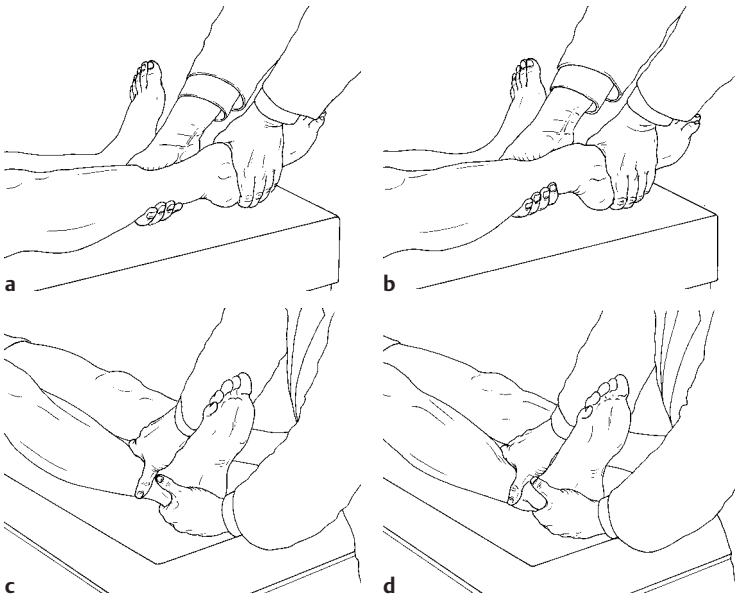


Fig. 249a–d Drawer test:  
a starting position,  
b foot is pushed,  
c starting position,  
d foot is pulled anteriorly

### Mulder Click Test

Indicates an interdigital neuroma (Morton neuroma).

**Procedure:** The examiner grasps the patient's forefoot in a pincer grip and presses it together. This pushes the adjacent metatarsal heads against each other.

**Assessment:** Where an interdigital neuroma is present, pushing the metatarsal heads against one another will cause pain with occasional paresthesia radiating into the adjacent toes. Small fibroma-like hardened areas between the toes will also be palpable and will displace, sometimes with a clicking sound, as the forefoot is compressed. Morton neuroma is a spindle-shaped bulb that develops in a plantar nerve. Painful interdigital neuromas usually develop in the second or third interdigital fold; neuromas in the first or fourth interdigital fold are rare.

### Heel Compression Test

Assesses a stress fracture of the calcaneus.

**Procedure:** The examiner symmetrically compresses the patient's heel between the balls of both thumbs.

**Assessment:** In a stress fracture of the calcaneus, the patient will feel intense pain in the heel. Stress fractures of the calcaneus primarily occur in patients with significant osteoporosis. Patients with these fractures exhibit a conspicuous antalgic gait, often without any weight bearing on

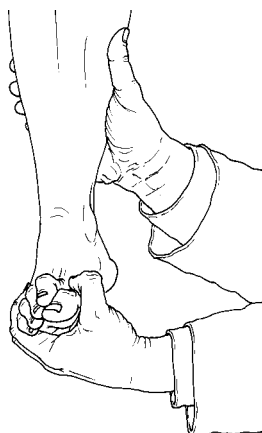


Fig. 250 Mulder click test

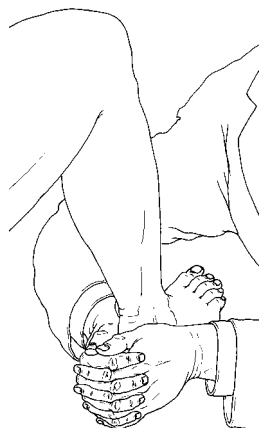


Fig. 251 Heel compression test

the heel at all. The heel itself may exhibit diffuse swelling and tenderness to palpation. The heel compression test rarely causes serious pain in patients with heel pain from other causes such as retrocalcaneal bursitis.

### Tinel Sign

Indicates a tarsal tunnel syndrome.

**Procedure:** The patient is prone with the knee flexed 90°. The examiner taps the tibial nerve posterior to the medial malleolus with a reflex hammer.

**Assessment:** Pain and discomfort in the sole of the foot suggest a tarsal tunnel syndrome. This disorder involves chronic neuropathy at the medial malleolus beneath the flexor retinaculum. The nerve can be palpated posterior to the medial malleolus, which will elicit pain. Advanced neuropathy is associated with sensory deficits in the regions supplied by the plantar nerves and paresthesia and atrophy in the plantar muscles.

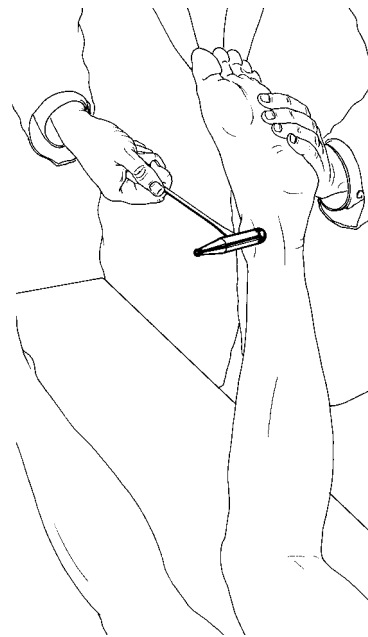


Fig. 252 Tinel sign

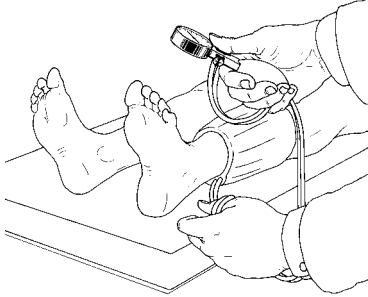
**Tourniquet Sign**

Indicates a tarsal tunnel syndrome.

**Procedure:** The patient is supine. A blood pressure cuff is applied superior to the malleoli and pumped up above the systolic pressure.

**Assessment:** Pain and discomfort in the sole of the foot occurring after the pressure has been maintained for a minute indicate compression neuropathy of the tibial nerve at the medial malleolus.

Fig. 253 Tourniquet sign



---

## Posture Deficiency

Rigid erect posture is not only defined by the position of the spine—or trunk—but is primarily the result of muscular activity. We differentiate between rigid erect posture and relaxed erect posture. By rigid erect posture we mean a tense attitude of readiness characterized by a balance in the forces within the musculature, whereas relaxed posture is a lax attitude. This relaxed posture is usually a habitual posture or is characteristic of the individual and depends largely on the individual's particular spinal and pelvic anatomy.

Postural weakness may be defined as extreme difficulty in achieving and maintaining rigid erect posture. The patient is either unable to shift from a relaxed posture to a rigid erect posture or only able to maintain the rigid erect posture temporarily. Chronic postural weakness can lead to degeneration of posture and eventually to a chronic deformity. Postural weakness and degeneration of posture define a continuum, and it is important to promptly identify children and adolescents who are at risk in order to prevent the development of a postural deformity. Posture depends on the quality of the musculature and the existing anatomy. Various functional deviations from the physiologic curvatures have been described. According to Wagenhaeuser, they represent deficient variations of normal posture. These include unsteady posture, round back, sway back, flat back, and lateral deformities.

A differential diagnosis must consider functional postural deficiencies due to spinal disorders such as Scheuermann disease and spondylolisthesis. A variety of posture tests can be used to assess postural deficiencies.

The Matthiass postural competence test allows assessment of the competence of the postural muscles. The Kraus-Weber test allows assessment of the competence of the trunk and pelvic muscles. The strength and endurance of the muscles of the abdomen and back are measured. This test aids in determining the quantitative and qualitative effect of muscular action in neutralizing the effect of the body's weight.

### Kraus-Weber Tests

Test the competence of the trunk and pelvic muscles.

**Procedure: A:** The patient is supine with the legs and feet extended and the hands clasped behind the head. The patient is then asked to raise his or her extended legs 25 cm and to hold them at this height for 10 seconds. This tests the lower abdominal muscles. It counts 10 points.

**B:** The patient is supine with the hands clasped behind the head. The examiner immobilizes the patient's feet. The patient is asked to sit up. This tests the upper abdominal muscles. Sitting up 90° counts 10 points; sitting up 45° counts 5 points.

**C:** The patient is supine with the hands clasped behind the head but with the legs flexed. The examiner immobilizes the patient's feet. The patient is asked to sit up. This tests all of the abdominal muscles with the effect of the psoas neutralized.

**D:** The patient is prone with a cushion beneath the abdomen and hands clasped behind the head. The examiner immobilizes the patient's hips and feet against the examining table. The patient is asked to raise his or her body off the examining table and to maintain that position for 10 seconds. This tests the upper back muscles. It counts 10 points.

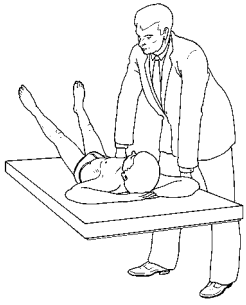
**E:** The patient is prone with a cushion beneath the pelvis. The examiner immobilizes the patient's trunk and hips against the examining table. The patient is asked to raise his or her legs off the examining table with the feet extended and to maintain that position for 10 seconds. This tests the lower back muscles. It counts 10 points.

**F:** The patient stands barefoot with hands at his or her sides. The patient is then asked to bend over with the knees extended. The examiner measures the distance to the floor.

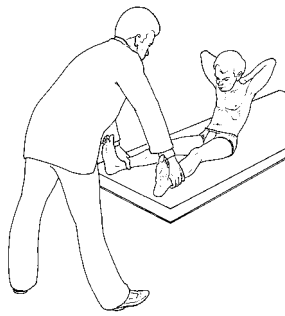
**Assessment:** Normal results for the Kraus-Weber test are indicated by this index:

$$A \frac{10}{10} \quad B \frac{10}{10} \quad \text{FBA} = 0$$

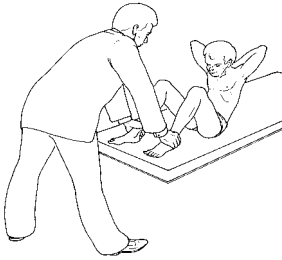
where A represents the strength of the abdominal muscles and B the strength of the back muscles. The numerators are the values for the upper abdominal muscles and upper back muscles, respectively; the denominators are the values for the lower abdominal muscles and lower back muscles including the psoas, respectively.



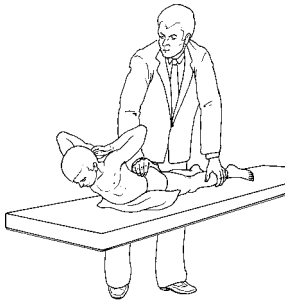
Test A



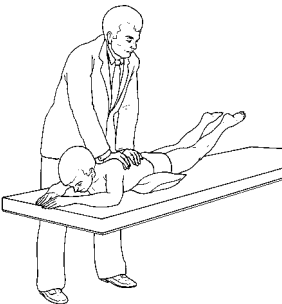
Test B



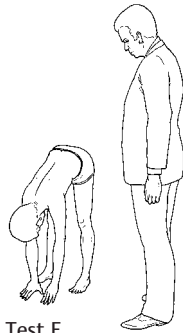
Test C



Test D



Test E



Test F

Fig. 254 Kraus-Weber tests

### Matthiass Postural Competence Tests

Assess the competence of the back and trunk muscles in children and adolescents.

**Procedure:** The examination is performed with the patient standing. The child is asked to lift the arms and keep them in that position.

**Assessment:** Raising the arms shifts the body's center of gravity forward.

The child with normal posture compensates for the shift in the center of gravity by leaning the entire body slightly backward. A child with postural weakness will exhibit increased thoracic kyphosis and lumbar lordosis.

Matthiass identifies two degrees of postural weakness.

Patients with full muscular function will usually be able to achieve and maintain full erect posture with minimal backward bending in the arm-raising test. In first-degree postural weakness, the child can actively achieve full erect posture but within 30 seconds slumps into a backward bending posture with increased thoracic kyphosis and lumbar lordosis.

Second-degree postural weakness is where the child is unable to actively achieve full erect posture and slumps backward right at the start of the arm-raising test. The child will push the pelvis forward and greatly increase the lumbar lordosis. This is referred to as postural degeneration.

The differential diagnosis must include functional postural deficits due to organic spinal disorders. A thorough clinical examination with function tests will allow postural weakness to be distinguished from deformities and idiopathic disorders at an early stage. In particular, examination must exclude scoliosis and kyphosis, as well as deformities such as flat back, round back, or sway back.



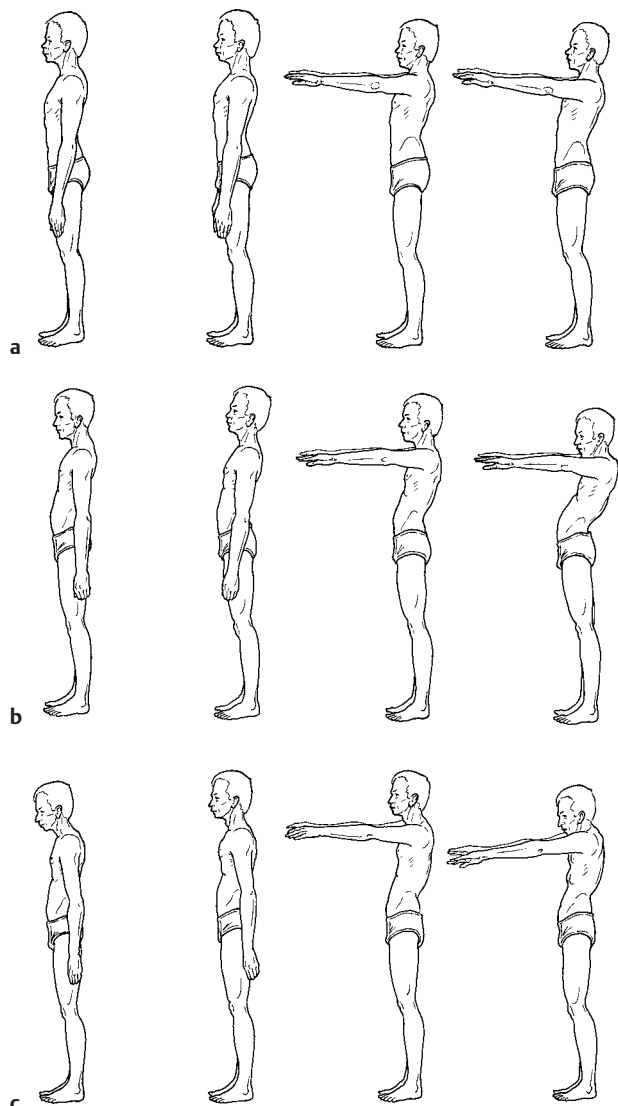


Fig. 255a–c Matthiass postural competence tests:  
 a normal posture,  
 b postural weakness,  
 c postural degeneration

---

## Venous Thrombosis

Acute deep venous thrombosis ranks with acute arterial occlusion as one of the most serious and dramatic vascular emergencies. Factors contributing to thrombosis include vessel wall, blood flow, and coagulation characteristics. Thromboses most commonly develop in the lower extremities. They are a feared postoperative complication as they involve the risk of acute massive or recurrent pulmonary embolism. Thrombosis in the deep veins of the leg is less symptomatic yet involves a far greater risk of embolism than thrombosis in the superficial veins. Swelling in the extremity (primarily in the left leg at the vascular spur in the pelvic veins), often associated with spontaneous pain in the groin, and pain radiating into the leg upon coughing or straining, local blue discoloration of the skin, and in some cases elevated temperature and pulse are important signs. However, a pulmonary infarction will often be the first clinical symptom. Yet typical early signs of deep venous thrombosis may also occur. These include spots that are painful to palpation, extending from the sole of the foot (Payr) to, in certain cases, the groin (Rielander), and pain upon compression of the calf (Lowenberg) when a blood pressure cuff is applied and pumped up to 100 mmHg (13.3 kPa). However, these thrombosis signs are nonspecific and should by no means be regarded as conclusive. The unilateral edema that usually occurs develops gradually and begins in the malleolar region. Additional characteristic findings include distended congested peripheral veins in the affected extremity (Pratt "warning" veins), evidence of superficial collateral veins, and an expanding edema.

In patients with chronic venous disease, a number of test methods are helpful in evaluating the function of the deep veins and perforating veins.

**Lowenberg Test**

Early sign of venous thrombosis.

**Procedure:** The examiner applies a blood pressure cuff to each lower leg and pumps them up.

**Assessment:** Normally, discomfort will occur only beyond 180 mmHg (24 kPa). Where thrombosis is present, the normal leg will be observed to tolerate compression of the calf musculature with far higher pressure than the affected leg.

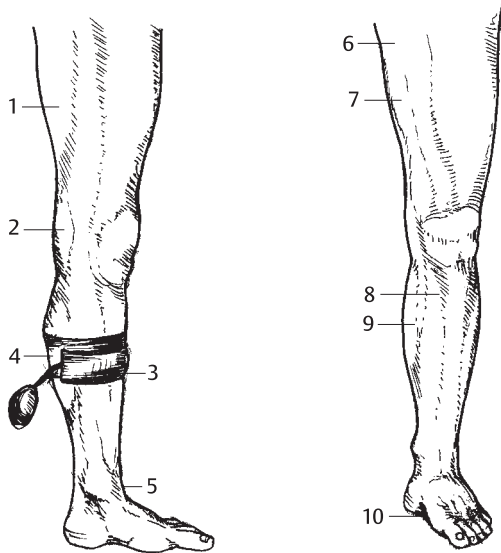


Fig. 256a, b Early signs of deep venous thrombosis:

- 1 tenderness to palpation on the medial aspect of the thigh (sartorius, gracilis),
- 2 tenderness to palpation in the knee (muscular insertions and medial joint cavity),
- 3 pain on compression of the calf (Lowenberg),
- 4 pain in the calf on dorsiflexion of the foot (Homans sign),
- 5 tenderness to palpation,
- 6 groin pain,
- 7 tenderness to palpation along the adductors,
- 8 Pratt warning sign,
- 9 Meyer pressure points along the great saphenous vein,
- 10 pain in the sole of the foot, Payr sign upon pressing or tapping the sole of the foot with the edge of the hand

### Trendelenburg Test

Assesses varicose veins in the thigh. Tests the function of the lesser saphenous vein and perforating veins.

**Procedure:** With the patient supine and the leg raised, the examiner smooths the distended veins. The examiner then compresses the greater saphenous vein with a tourniquet distal to its junction with the femoral vein at the inguinal ligament and asks the patient to stand up.

**Evaluation:** If the varices only fill up slowly or not at all within 30 seconds of the patient standing up but then fill rapidly from proximal once the tourniquet is loosened, this indicates valvular insufficiency of the saphenous vein with normal function of perforating veins. Relatively rapid filling from distal can occur as a result of insufficient perforating veins or anastomoses with an insufficient lesser saphenous vein. Rapid filling of the varices from both distal and proximal once the tourniquet is released indicates insufficiency of both the greater saphenous vein and the communication with the deeper venous system.

### Perthes Test

Assesses the function of deep veins and perforating veins.

**Procedure:** With the patient standing, the examiner applies a tourniquet to the thigh or lower leg proximal to the filled varices. The patient is then asked to walk around with the tourniquet in place.

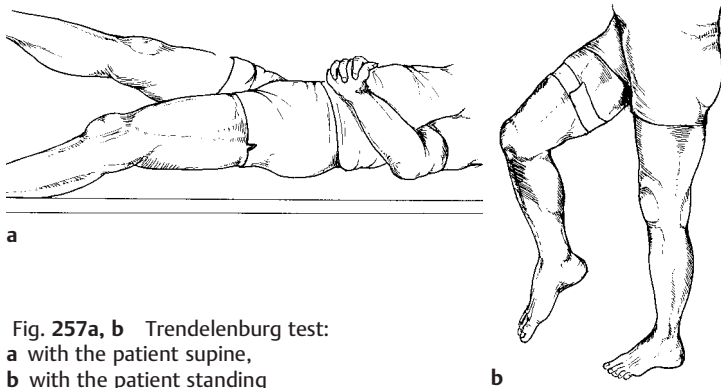
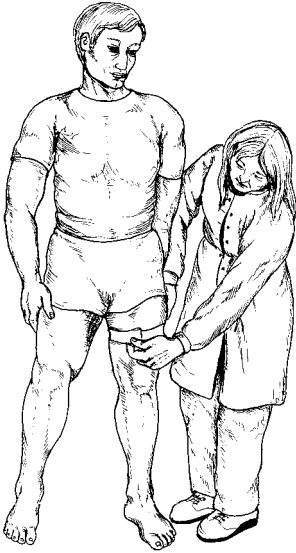


Fig. 257a, b Trendelenburg test:  
a with the patient supine,  
b with the patient standing

Fig. 258 Perthes test



**Assessment:** Complete emptying of the varices as a result of muscular activity indicates proper function of the perforating veins and intact deep venous drainage. The congestion is attributable to valvular insufficiency in the saphenous vein. Incomplete emptying is observed where there is moderate valvular insufficiency of the communicating veins. Unchanged filling in the varices occurs with significant insufficiency of the perforating veins and impaired blood flow in the deep veins. An increase in filling suggests a severe post-thrombotic syndrome with reversed blood flow in the perforating veins.

**Note:** The Schwartz test or the percussion method of Schwartz and Hackenbruch is used to assess valvular insufficiency in the region of the greater saphenous vein. With the patient standing, the examiner places one finger on the distended vein being examined and taps on the junction of the greater saphenous and femoral veins with one finger of the other hand. If this tapping is transmitted back to the first finger, the blood flow is continuous, indicating that the valves in the portion of the vein being examined are not intact. The test is not necessarily definitive, but it is good method for determining whether a superficial venous branch communicates with the greater or lesser saphenous vein.

**Homans Test**

Assesses deep venous thrombosis.

**Procedure:** The patient is supine. The examiner lifts the affected leg and rapidly dorsiflexes the patient's foot with the knee extended. This maneuver is repeated with the patient's knee flexed while the examiner simultaneously palpates the calf.

**Assessment:** Pain occurring upon dorsiflexion of the foot with the knee extended and flexed indicates thrombosis.

Calf pain with the knee extended can also be caused by intervertebral disk disease (radicular symptoms) or muscle contractures.

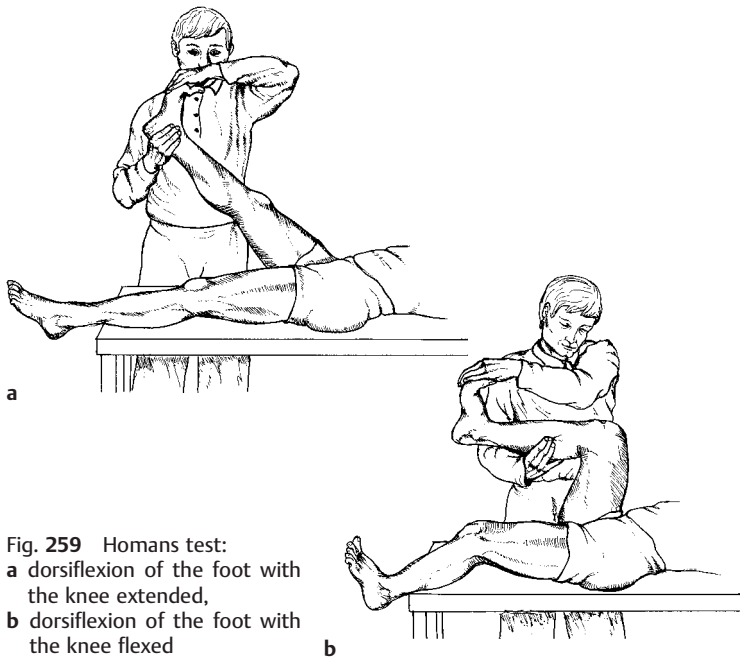


Fig. 259 Homans test:  
a dorsiflexion of the foot with  
the knee extended,  
b dorsiflexion of the foot with  
the knee flexed

---

## Occlusive Arterial Disease

Occlusive arterial disease is often associated with orthopedic disorders. Notably, nearly 90% of all cases of obliterative arteriosclerosis involve exclusively the lower extremities. Prior to treating the actual orthopedic disorder, the physician must take care to exclude or identify any possible arterial ischemic disorders. After obtaining a detailed history, a diagnosis can usually be made on the basis of inspection, palpation, and specific function tests, and usually will not require the use of any diagnostic technology.

Weakened or absent arterial pulse, cool and pale skin (or cyanotic skin), patches of erythema, and trophic disturbances are signs of occlusive arterial disease. Ulceration and gangrene are signs of advanced disease. Where typical symptoms of intermittent claudication (calf pain after walking short distances) are present, determining the maximum distance the patient can walk without experiencing these symptoms can help in estimating the severity of the disorder (Fontaine classification of the severity of occlusive arterial disease). The differential diagnosis of intermittent claudication must include spinal claudication from compression of the cauda equina, the cardinal symptom of lumbar spinal stenosis. The intermittent claudication in cauda equina pathology is not a sharply defined clinical syndrome. Radicular symptoms such as paresthesia, pain, sensory deficits, and weakness can occur in one or both legs when the patient stands or walks. These symptoms may improve or disappear when the patient stops moving, as in the vascular form, but more often will do so only on certain body movements.

**Note:** The walking test allows assessment of peripheral circulatory disruption. The patient is asked to walk up and down a long corridor for up to three minutes at about 120 paces per minute. The time of occurrence of symptoms and the site of pain are clinically assessed, as are gait and any pauses. If the patient pauses after only 60 seconds, this suggests disruption of vascular supply to the muscles. Symptoms of moderately severe circulatory disruption will manifest themselves after 1–3 minutes of walking. Symptoms that occur only after three minutes or more of walking indicate only slight circulatory disruption.

Note that exercise tolerance may be limited by cardiac and pulmonary disorders as well as orthopedic disorders such as osteoarthritis of the hip or degenerative knee disorders.

### Allen Test

Assesses an arterial ischemic disorder in the upper extremities.

**Procedure:** The patient is seated and raises his or her arm above the horizontal plane. The examiner grasps the patient's wrist and applies finger pressure to block the vascular supply from the radial and ulnar arteries. The patient then makes a fist so as to force the venous blood out of the hand via the posterior veins. After one minute, the patient lets the arm hang down and opens the now pale hand. The examiner simultaneously releases compression, first from one artery then from the other.

**Evaluation:** Rapid, uniform reddening of the hand in the areas supplied by the respective arteries indicates normal arterial supply. If vascular supply to the hand and fingers is compromised, the ischemic changes in the hand will only slowly recede.

### George Vertebral Artery Test (De Klyn Test)

Tests for insufficiency of the vertebral artery.

**Procedure:** This test requires certain preliminary findings as it is not entirely without risk. Parameters requiring prior assessment include blood pressure, arm pulse, and pulses in the common carotid and subclavian arteries with auscultation to detect any murmurs or bruits. This test should not be performed if any of these prior examinations produces significantly abnormal findings. In the absence of any significant abnormalities, the seated patient is asked to maximally rotate his or her head to one side while extending the neck. The test can also be performed with the patient supine, in which case the patient's head projects over the edge of the examining table and rests in the examiner's hands. Then with the head hanging down (in the De Klyn position), the head is maximally rotated and the neck extended. The head

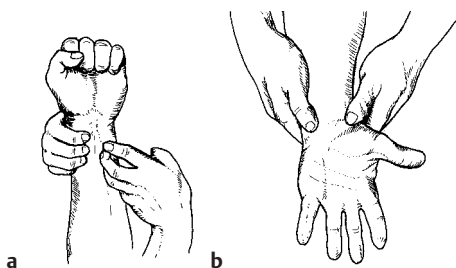


Fig. 260a, b Allen test:  
a palpation of vessels with the arm raised,  
b palpation of vessels with the arm hanging and evaluation of skin perfusion



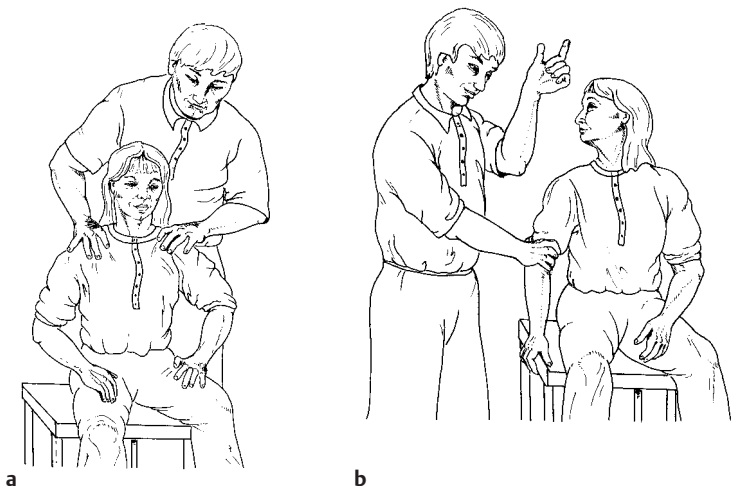


Fig. 261a, b George vertebral artery test:  
**a** starting position,  
**b** rotation of the head and extension of the cervical spine

should remain or be held in maximum rotation and extension for about 20–30 seconds. The patient is then requested to count out loud.

**Assessment:** Abnormal auscultatory findings in the common carotid artery, vertigo, visual symptoms, nausea, fatigue, or nystagmus occurring during this maximum rotation and extension indicate stenosis of the vertebral artery or common carotid artery. The test is especially important in candidates for treatment (such as traction or manipulative therapy) of cervical spine symptoms associated with vertigo. The vertebral artery provocation test aids in the differential diagnosis because nausea, vertigo, and nystagmus initially increase but then rapidly decrease in intensity where a vertebral blockade is present. In the presence of vertebral artery insufficiency, the intensity of nausea and vertigo symptoms will rapidly increase within a few seconds.

### Ratschow-Boerger Test

Assessment of vascular disease in the pelvis and legs.

**Procedure:** The supine patient is asked to raise the legs as high as possible and continuously rotate or plantar flex and dorsiflex the feet.

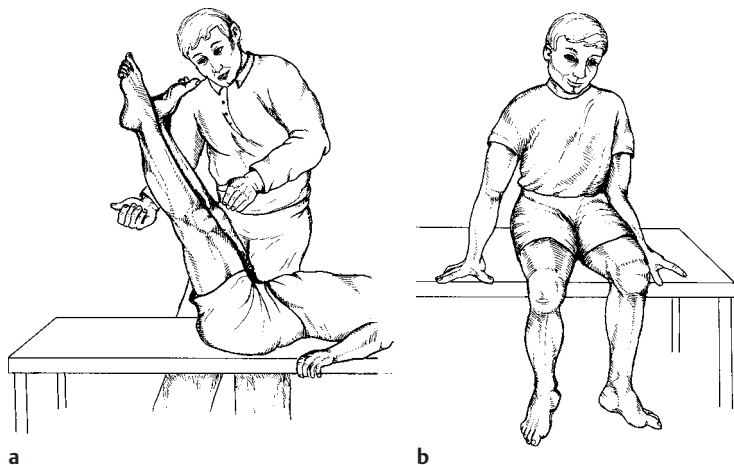


Fig. 262a, b Ratschow-Boerger test:

a patient supine with the legs raised

b patient sitting with the legs hanging down over the edge of the examining table

**Assessment:** Patients with normal vascular function will be able to perform this maneuver without any pain and without the soles of the feet becoming pale. Patients with compromised vascular function will experience varying degrees of pain and significant ischemia in the sole of the foot on the affected side. After about two minutes, the patient is requested to sit up quickly and let the legs hang over the edge of the examining table. Reactive hyperemia and refilling of the veins will occur within 5–7 seconds in patients with normal vascular function. In patients with compromised vascular function, this reaction will be delayed in proportion to the severity of vascular stenosis.

## ■ Thoracic Outlet Syndrome

Thoracic outlet syndrome is a compression syndrome at the base of the neck with compromised neurovascular function. Thoracic outlet syndrome can be a congenital disorder resulting from factors such as a cervical rib, a superiorly displaced first rib, atypical ligaments, and the presence of an atypical small scalene muscle. It may also be acquired as a result of callus formation, osteophytes on the clavicle and first rib, and changes in the scalene muscles such as fibrosis or hypertrophy.

This syndrome may be further differentiated according to the compression site as a cervical rib syndrome, first-rib syndrome, or scalene muscle syndrome.

### Costoclavicular Test

Assesses a neurovascular compression syndrome in the costoclavicular region.

**Procedure:** The patient is seated with the arms hanging relaxed. The examiner palpates the wrists to take the pulse in both radial arteries, noting amplitude and pulse rate. Then the patient abducts and externally rotates both arms and retracts the shoulders. With the patient in this position, the examiner again palpates the wrists and evaluates the pulse in both radial arteries.

**Assessment:** Unilateral weakness or absence of the pulse in the radial artery, ischemic skin changes, and paresthesia are clear signs of compression of the neurovascular bundle in the costoclavicular region (between the first rib and clavicle).

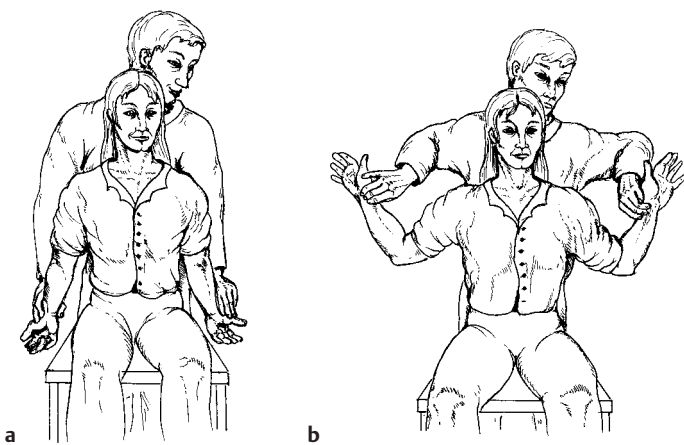
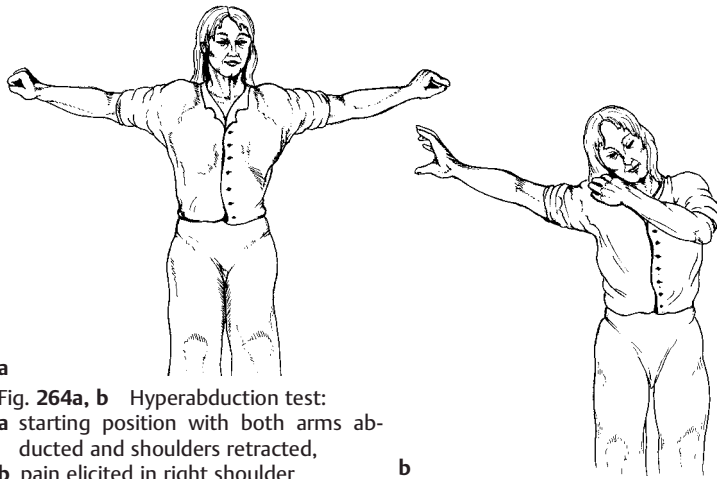


Fig. 263a, b Costoclavicular test:  
a starting position with the examiner palpating the pulse in the radial arteries,  
b palpation of the pulse in the radial arteries in abduction, with arms externally rotated and shoulders retracted



**Fig. 264a, b** Hyperabduction test:  
**a** starting position with both arms ab-  
 ducted and shoulders retracted,  
**b** pain elicited in right shoulder

### Hyperabduction Test

Indicates a scalene muscle syndrome.

**Procedure:** The standing patient abducts both arms past 90° while retracting the shoulders. Then the patient opens each hand and makes a fist with each hand for two minutes.

**Assessment:** Pain in the shoulder and arm, ischemic skin changes, and paresthesia are clear signs of compression of the neurovascular bundle, which is primarily attributable to changes in the scalene muscles (fibrosis, hypertrophy, or presence of a small scalene muscle).

### Intermittent Claudication Test

Sign of a costoclavicular compression syndrome.

**Procedure:** The standing patient abducts and externally rotates both arms. Then the patient is instructed to rapidly flex and extend the fingers of each hand for one minute.

**Assessment:** If one arm begins to droop after a few cycles of finger motion and ischemic skin changes, paresthesia, and pain in the shoulder and arm occur, this suggests a costoclavicular compression syndrome affecting neurovascular structures.

Causes include osteophytes, rib changes, and anatomic variations in the scalene muscles.

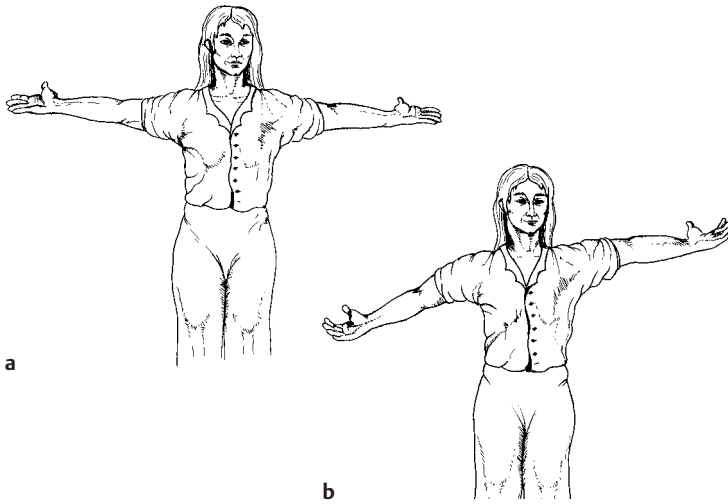


Fig. 265a, b Intermittent claudication test:  
a starting position with both arms abducted and externally rotated,  
b pain on the right side with drooping right arm

### Allen Maneuver

Indicates a thoracic outlet syndrome.

**Procedure:** The patient is seated. The affected arm is held in a middle position alongside the trunk with the elbow flexed 90°. The examiner stands behind the patient and grasps the patient's wrist with one hand, palpating the pulse in the radial artery. With the other hand, the examiner supports the patient's upper thoracic spine. The examiner then draws the patient's arm backward into hyperextension and internal rotation at the shoulder. The patient is asked to rotate his or her head toward the contralateral side (away from the side being examined).

**Assessment:** Weakening or loss of the pulse in the radial artery, pain in the shoulder and arm, ischemic changes, and paresthesia are signs of a costoclavicular syndrome (compression of the subclavian artery between the first rib and the clavicle) or of a scalene muscle syndrome (compression of the neurovascular bundle between the middle and anterior scalene muscles due to fibrosis or hypertrophy).

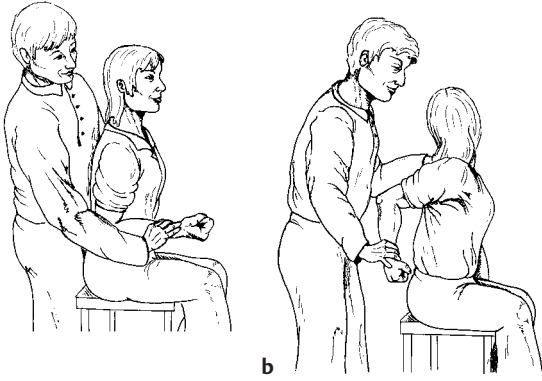


Fig. 266a, b Allen maneuver:

**a** starting position with the examiner palpating the pulse in the radial arteries,  
**b** adduction with the arm hyperextended and internally rotated at the shoulder  
 and the head rotated toward the contralateral side

## ■ Hemiparesis

### Arm-Holding Test

Assessment of latent hemiparesis.

**Procedure:** The patient is asked to supinate both arms and raise them to 90° while keeping his or her eyes closed.

**Assessment:** Pronation and a drop in one arm suggest latent central hemiparesis. Where the arm first drops and then pronates with the patient's eyes closed, one should consider psychogenic influence.

### Leg-Holding Test

Assessment of latent central hemiparesis.

**Procedure:** The patient is supine and is asked to close his or her eyes and flex both hips and both knees. The examiner watches the lower legs to see if they drop down.

**Assessment:** The neurologic examination of the lower extremities in a patient capable of standing and walking begins with inspection of gait. The patient is asked to stand and walk on tiptoe and then on his or her heels. This will usually exclude any gross motor deficits. With the

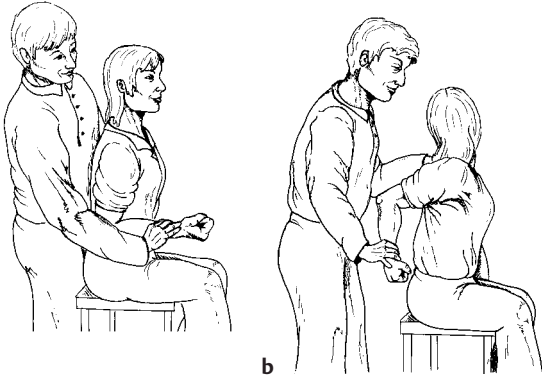


Fig. 266a, b Allen maneuver:

**a** starting position with the examiner palpating the pulse in the radial arteries,  
**b** adduction with the arm hyperextended and internally rotated at the shoulder  
 and the head rotated toward the contralateral side

## ■ Hemiparesis

### Arm-Holding Test

Assessment of latent hemiparesis.

**Procedure:** The patient is asked to supinate both arms and raise them to 90° while keeping his or her eyes closed.

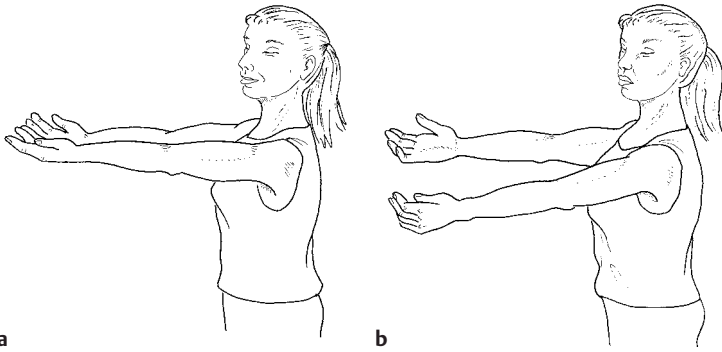
**Assessment:** Pronation and a drop in one arm suggest latent central hemiparesis. Where the arm first drops and then pronates with the patient's eyes closed, one should consider psychogenic influence.

### Leg-Holding Test

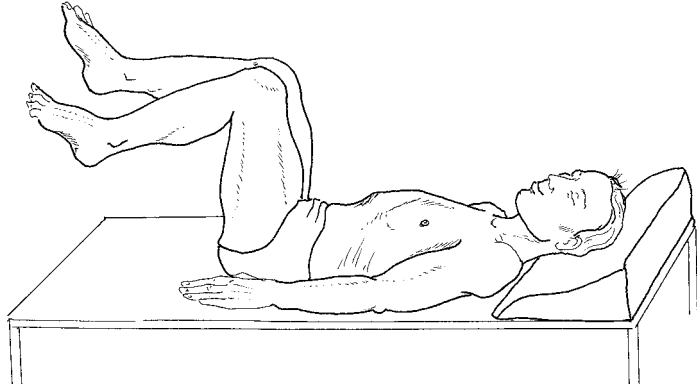
Assessment of latent central hemiparesis.

**Procedure:** The patient is supine and is asked to close his or her eyes and flex both hips and both knees. The examiner watches the lower legs to see if they drop down.

**Assessment:** The neurologic examination of the lower extremities in a patient capable of standing and walking begins with inspection of gait. The patient is asked to stand and walk on tiptoe and then on his or her heels. This will usually exclude any gross motor deficits. With the



**a**  
**Fig. 267a, b** Arm holding test:  
**a** Both arms supinated and raised up to 90° with closed eyes,  
**b** Pronation and drop in one arm



**Fig. 268** Leg holding test

patient supine, the strength of the quadriceps is then tested by having the patient extend the knee against the examiner's resistance (L3–L4). Strength in the extensor digitorum and hallucis longus is tested by dorsiflexion of the toes (L5) against resistance, and strength in the triceps surae is tested by plantar flexion of the foot (S1) against resistance. One or both lower legs dropping down during the leg holding test can be a sign of latent central hemiparesis.





---

# Index

Numbers in *italics* indicate figures.

## A

- Abbott-Saunders test 84–5, *85*
- abduction
  - hip 142–3
    - stress test 46, *46*
    - test 193, *194*
  - hyperabduction 256, *256*
    - valgus stress test 106, *106*
- abductor pollicis brevis muscle 133, 135
- abductor pollicis longus muscle 129
- abductor pollicis longus tendon 119–20
- Achilles tendon 56, 231–2
- acromioclavicular joint 65, 68–9, 81–84, 89
  - arthritis 76, 78, 80–1
- acromion 78
- Adam forward bend test 22, *22*
- adduction
  - correction test 235, *235*
  - hip 142–3
    - test 193, *194*
      - forced 82–3, *82*
    - varus stress test 105, *106*
- adductor pollicis muscle 137
- Allen
  - maneuver 257, *257*
  - test 252, *252*
- anastomoses 248
- Anderson compression test 189, *190*
- ankle
  - joints 225, 235–7
  - ligaments 199, 204
- anvil test 152, *152*
- ape's hand deformity 133
- Apley
  - scratch test 76, *76*
  - tests 176–7, *177*
- apprehension test
  - anterior 92–3, *93*
  - inferior 101, *101*
  - posterior 97–9, *97, 99*
  - supine 93–4, *94*
- arm 75, 131–2, 137, 258–9
  - adduction 82–3
  - compression 126–7
  - forearm 111–12
- Arnold crossover test 212, *212*
- arteries
  - carotid 253
  - disease 224, 251
  - ischemia 252
  - radial 252, 257–8
  - sclerosis 251
  - thrombosis 251–9
  - ulnar 252
  - vertebral 252–3
- arthritis 167
  - acromioclavicular joint 76, 78, 80–1
  - carpometacarpal joint 120–1
  - glenohumeral joint 76
    - see also* osteoarthritis, rheumatoid arthritis, spondylarthritis
- arthrodesis 143
- arthroplasty 152–3
- asthma 8–9
- avascular necrosis 224

**B**

Baker cysts 163  
 Barlow  
   and Ortolani test 158  
   test 156–8, 157  
 belt test 29, 29  
 Beru sign 90  
 biceps muscle 89  
 biceps tendon 68, 84–90  
 bicyclists, compression injury 126  
 Böhler meniscus test 185  
 Böhler-Krömer test 184–5, 184  
 bones *see* individual types of bones  
 Bonnet sign 50, 50  
 Bowden test 107, 107  
 brachialgia 127  
 Bragard  
   sign 52  
   test  
     meniscus 178–80, 179  
     spine 52, 53  
 Brudzinski sign 57, 57  
 Brunnell-Littler test 122–3, 122  
 bucket handle tear 204  
 bursae 65  
 bursitis 65–7, 78, 80, 85

**C**

Cabot test 185–6, 187  
 calcaneofibular ligament 236  
 calcaneus 238  
 calf compression test 231, 231  
 capsular ligaments 125, 176–7, 197, 236  
   laxity 97–9  
   lesions 184  
   posterior 193  
 capsule, joint 76  
 carotid artery 253  
 carpal tunnel  
   sign 134, 134  
   syndrome 127, 134–6  
 carpometacarpal joint 116, 120–1  
 cartilage 167, 169–71  
 cauda equina 251

cervical spine 12–13, 20–21  
   arthritis 10–11  
   disks 14  
   ligaments 14–15, 17  
   muscles 14–15, 17–19  
   spondylosis 10–11  
 chair test 106, 107  
 chest 7–9  
 children 154–8  
 Childress sign 188, 189  
 chondrocalcinosis 103  
 Chopart, joint of 236  
 claudication test 256, 257  
 clavicle 83, 83  
 claw hand 115  
 claw toe 224, 226  
 Codman sign 63–4, 64  
 Coleman block test 233–4, 233  
 collagen 224  
 collateral ligaments 93, 176, 236  
   accessory 125  
   lesions 184  
   stability 105–6  
 compression 42–3, 90–1, 189–91  
   axial 152–3  
   intervertebral foramina 18–20  
   nerve root 46–7, 52–3, 158  
   rib 7–8  
   spinal cord 158  
   supinator muscle 114  
   suprascapular nerve 88–9  
   syndrome 46–7, 52–3, 112–14  
     costoclavicular 255–7  
     median nerve 134–6  
     thoracic outlet syndrome 254–5, 257–8  
 compression neuropathies 115, 224  
   tibial nerve 240  
   ulnar nerve 126–7, 139  
 condyle  
   femoral 202, 208  
   osteochondritis dissecans 192  
 contracture 144–5, 250  
   gastrocnemius muscle 52  
   hamstring 143–4, 166  
   hip 141, 144–6, 148  
   iliotibial tract 148–9, 206  
   quadriceps muscle 165, 199  
   test 218, 218

- contracture  
 rectus femoris muscle 144, 165–6  
 sacroiliac joint 35–6  
 teno fasciae latae muscle 148–9  
 teres major muscle 73–4
- coracoclavicular ligament 83
- costoclavicular compression 255–7
- Cozen test 109–10, 110  
 reverse 110, 111
- crepitation  
 foot 229  
 patella 170–1  
 tendons 115
- cross-body action 88–9
- cruciate ligaments  
 anterior 95–6, 176, 194–216  
 posterior 95–6, 187, 193, 208,  
 216–23
- cubital tunnel syndrome 103, 112–13,  
 127, 137–8
- cysts  
 Baker 163  
 meniscus 176–7
- D**
- dancing patella test 167, 168
- Dawbarn test 66–7, 67
- De Klyn position 252
- de Quervain's disease 120–1
- dead arm sign 92
- DeAnquin test 89
- deformities  
 back 22, 244–5  
 foot 224, 233–4  
 hand 115, 133  
 hip 141–3, 148  
 knee 221
- deltoid ligament 236
- Derbolowsky sign 41, 41
- dermatome 47
- diabetes mellitus 224
- disks 24–6, 54–6, 158, 250  
 extrusion 49–50  
 intervertebral 35–6, 152–3
- dislocation  
 biceps tendon 89  
 hip 141, 153, 158  
 humerus 97–9  
 patella 167, 169, 171
- distraction test 17, 17
- drawer  
 signs 100  
 tests 237, 237  
 anterior 199–201, 200  
 anterior and posterior 94–5, 96  
 posterior 216–17, 216  
 soft posterolateral 219, 219
- Drehmann sign 149–50, 151
- Dreyer test 175–6, 175
- droop test 219, 219
- drop arm test 75, 75
- Duchenne  
 antalgic gait 143  
 sign 54–5, 55, 154
- Dugas sign 90
- Dugas test 83–4, 83
- dysplasia 160–1
- E**
- elbow 103–106  
 compression 112–14  
 cubital tunnel syndrome 103,  
 112–13  
 epicondylitis 106–11  
 flexion 104–5, 113
- emphysema 8–9
- epicondylitis 106–11
- extension  
 compression test 21, 22  
 hyperextension test 27–8, 28
- extensor digitorum muscle 259
- extensor pollicis brevis muscle 130
- extensor pollicis brevis tendon  
 119–20
- extensor pollicis longus muscle  
 118–19, 130
- F**
- fabere test (Patrick test) 34, 35, 154–5,  
 155

facet joint 47, 49, 169–70  
 femoral nerve 58  
 femur 141, 143, 150  
 fibrosis 76  
 fingers 65, 129, 133, 139–40  
 Finkelstein test 120–1, *120*  
 Finochietto sign 187, *188*  
 flexion 38–9  
   compression 20–1  
   dorsiflexion 225  
   elbow 104–5, 113  
   foot 225, 234  
   hip 141–2, 144–6, 148  
   hyperflexion 104–5  
   knee 23–4  
   sacroiliac joint 38–9  
   wrist 140  
 flexor carpi radialis muscle 140  
 flexor digitorum profundus muscle 118, 133, 139  
 flexor digitorum profundus tendon 121–2  
 flexor digitorum superficialis muscle 118  
 flexor pollicis brevis muscle 133, 137  
 flexor pollicis longus muscle 118–19, 139  
 flexor pollicis longus tendon 121–2  
 flexor tendons, tests 118–25  
 Fontaine classification 251  
 foot  
   calluses 224  
   deformities 224, 233–4  
   flexion 225, 234  
   hallux rigidus 229  
   Köhler disease 224  
   metatarsalgia 224  
   Morton neuroma 224  
   pes adductus 235  
   pes cavus 226  
   splay 224, 227, 230  
   stress fractures 224  
   tarsal tunnel syndrome 239–40  
   warts 224  
 forward bend test 29, *29*  
 Fouche sign 178, *178*  
 Fowler test 92  
 fractures

cervical spine 14  
 rib 7–9  
 stress 224, 238  
 Froment sign 137, *138*  
 Fukuda test 100, *100*  
 fulcrum test 102, *102*

## G

Gaenslen sign 41–2, *42*  
 Galeazzi test 158, *159*  
 Galway and McIntosh 214  
 gamekeeper's thumb 125  
 gangrene 251  
 Gänsslen maneuver 229–30, *229*  
 gastrocnemius muscle 52  
 genu recurvatum 221  
 genu valgum 167  
 George vertebral artery test 252–3, *253*  
 Gerber-Ganz drawer tests 96–9, *96, 98*  
 Gerdy, tubercle of 149, 206  
 Gilcrest test 89  
 glenohumeral joint 64, 76, 99  
 glide test 167–9, *168*  
 gluteus medius muscle 153–4  
 gluteus minimus muscle 153–4  
 Godfrey test 222, *222*  
 golfer's elbow 103, 110–12  
 gout 224  
 gravity sign 220–1, *220*  
 Grifka test 227, *227*  
 grind test 121, *121*  
 grip tests 127–9, *128*  
   Thomas 146–8, *147*  
 Guyon's canal 127

## H

hallucis longus muscle 259  
 hallus rigidus 224  
 hammer toe 224, 226  
 hamstring 50, 143–4, 166  
 hand  
   ape's hand 133  
   claw hand 115

- hand  
 flexor tendon 118–25  
 grip 127–9  
 ischemic contracture 122  
 motor function 127–40  
 pronator quadratus muscle 137  
 pronator teres muscle 126–7, 137  
 tenosynovitis 118
- Hawkins impingement test 79, 79
- head, rotation test 11–12, 11–12
- Heberden nodes 118
- heel 231–2, 238–9
- hemarthrosis 196
- hip 142–6, 153–4  
 arthrodesis 143  
 arthroplasty 152–3  
 deformities 141–3, 148  
 degenerative joint disease 141  
 dislocation 141, 153, 158  
 congenital 156  
 disorder 53–4, 149–51  
 Duchenne, antalgic gait 143  
 dysplasia 160–1  
 acetabular 141  
 flexion 141, 144–6, 148  
 grip 146–8  
 inflammation 148, 152–3  
 instability 156–8  
 and lumbar rigidity 158–9  
 osteoarthritis 144, 148, 150, 152–3  
 tumors 150
- Hoffa sign 232, 232
- Homans  
 sign 247  
 test 250, 250
- Hoover  
 sign 30  
 test 30
- Hueter sign 87–8, 87
- Hughston  
 genu recurvatum test 221, 221  
 jerk test 215–16, 215
- humeral ligament test 88, 88
- humerus  
 dislocation 97–9  
 epicondylitis 106–11  
 subluxation 92, 97–9
- I**
- iliac compression test 42, 43
- iliocostalis lumborum muscle 28
- iliotibial tract 148–9, 206
- inflammation  
 arthritis *see* arthritis  
 bursitis 65–7, 78, 80, 85  
 epicondylitis 106–11  
 erythema 115  
 hip 148, 152–3  
 osteochondritis 103  
 pericarditis 8–9  
 pleuritis 8–9  
 psoriasis 224  
 spine 5, 10–12, 56  
 spondylitis 8–9, 25–6, 35–6  
 tenosynovitis 118
- infraspinatus muscle 73–4
- instability  
 elbow 103  
 hip 156–8  
 knee 193–216  
 metatarsophalangeal joint  
 228–9  
 posterolateral ligament 216–19,  
 221  
 shoulder 91–102  
 relocation test 102, 102  
 Rowe test 94, 94  
 triquetrolunate joint 124
- intercarpal joint 116
- interosseous nerve 138–9
- interphalangeal joint 119, 122–3, 137,  
 139, 226  
 distal 116–18  
 proximal 116–18, 138
- intervertebral foramina 18–20
- intrinsic test 139, 139
- ischemia 252
- J**
- Jackson compression test 19, 20
- Jakob  
 giving way test 213–14, 214  
 maximum drawer test 201, 202

- Jakob  
 pivot shift test  
   graded 204–6, 205  
   reverse 217–18, 217
- Jobe  
 modification 92  
 supraspinatus test 70–1, 71
- joints  
 arthrodesis 143  
 arthroplasty 152–3  
 capsule 76  
 hemarthrosis 196  
 inflammation *see* arthritis;  
   inflammation  
*see also* individual types of joints
- K**
- Kalchschmidt hip dysplasia test  
 160–1, 161
- Kaplan, fibers of 206
- Kernig  
 sign 49  
 test 56, 56
- Keyle 69
- Kibler fold 1  
 test 6, 7
- knee 162–3, 171–7  
 effusion 167  
 flexion 23–4  
 genu recurvatum 221  
 glide 167–9  
 instability 193–216  
 ligaments 169, 193–223  
 motion 163  
 patella 167–74  
 reticulum 174  
 subluxation 104, 204
- knock knees *see* genu valgum
- Köhler disease 224
- Kraus–Weber test 241–2, 243
- Krömer test 185
- kyphosis 244  
 lumbar 143  
 test 22, 23
- L**
- Lachman test 194–5, 195, 200  
 active 198–9, 199  
 no-touch 197–8, 198  
 posterior 216–17, 216  
 prone 196, 196  
 stable 196–7, 197
- Laguerre test 44–5, 45
- Lasègue  
 differential test 54  
 sign 47, 49–50, 49, 51, 52  
   contralateral 51, 52  
 straight leg drop test 25–6, 26  
 test  
   differential 53–4  
   reverse 58, 58  
   seated 51
- Lasègue-Moutaud-Martin sign 51, 52
- Leffert test 94–5, 95
- leg 47, 49–52, 258–9  
 compression 152–3  
 length 41, 158–9  
 vascular disease 253–4
- Legg-Calvé-Perthes disease 141,  
 154–5
- Lelièvre 226
- Lemaire test 214–15
- lesions  
 biceps tendon 86–7, 90  
 brachial plexus 75, 127  
 capsular ligament 184  
 collateral ligament 184  
 distal nerve 140  
 median nerve 132, 137, 140  
 meniscus 176–80, 185–6, 190–1  
 radial nerve 128, 130  
 rotator cuff 75  
 spinal cord 127, 158  
 ulnar nerve 140
- lift-off test 72–3, 73
- ligaments 31–3  
 capsular 125, 176–7, 197, 236  
 laxity 97–9  
 lesions 184  
 posterolateral 199, 217–19,  
   221  
 posteromedial 193, 199, 204

- ligaments  
 lateral 199, 204  
 ankle 25  
 collateral 193, 237  
 medial 199  
 collateral 197, 204  
 patella 167  
 pelvic 31–2, 49–50  
 talofibular 236  
*see also* individual types of ligaments
- Linburg test 121–2, 121
- Lippman test 89
- longissimus thoracis muscle 28
- lordosis 141, 145–6  
 hyperlordosis 143  
 lumbar 244
- Losee test 210–11, 211
- Lowenberg 246–7, 247  
 test 247, 247
- Ludington  
 sign 76, 76  
 test 89
- Ludloff-Hohmann test 158
- lumbar spine 22–24, 27  
 disks 152–3  
 muscles 27–8  
 nerve root disorder 56  
 sciatica 30  
 spondylarthritis 25–6  
 spondylitis 25–6  
 stenosis 251  
 syndrome 27–9
- lungs 8–9
- Luethy bottle test 135, 136
- M**
- McConnell test 171–3, 173
- McMurray test 178, 178
- Martens test 210, 210
- Matthiass postural competence test  
 241, 244, 245
- median nerve  
 compression 127, 134–6  
 palsy 132–3
- meningitis 57
- meniscus  
 compression 189–91  
 cysts 176–7  
 discoid 176–7  
 lesions 177–89, 204  
 Mennell sign 36, 43–4, 43  
 Merke test 185, 186
- metacarpophalangeal joint 116–18,  
 122, 125, 138
- metatarsi 235  
 hallus rigidus 229  
 metatarsalgia 227, 230
- metatarsophalangeal joint 225, 227–9
- Meyer pressure points 247
- Mill test 108, 108
- Morton neuromas 24–6, 224, 230, 238
- Muckard test 119–20, 120
- Mulder click test 230, 238, 238
- muscles 239, 241–4  
 cervical 83  
 contractures 165–6, 250  
*see also* individual types of muscles
- N**
- nail sign 135, 135
- necrosis  
 aseptic 154–5, 192  
 avascular 224  
 femur 141
- Neer 68–9  
 impingement injection test 80, 80  
 impingement sign 78, 78
- nerve root  
 compression 46–7, 52–3, 158  
 disorder 54–5  
 irritation 49–52, 55–6, 58
- nerves  
 brachial plexus 75  
 cauda equina 251  
 distal 140  
 interossei 138–9  
 median 127–9  
 lesion 132, 137, 140  
 palsy 115, 132–3, 135  
 paresthesia 134, 136  
 plantar 238–9



- nerves
- radial 114, 131
    - lesion 128, 130
    - palsy 115, 129
  - sciatic 49, 53–4
  - suprascapular 88–9
  - tibial 240
  - ulnar 112–13, 129
    - compression 126, 139
    - lesion 140
    - palsy 115, 138–9
- neuralgia 9
- neuromas
- interdigital 238
  - Morton 23, 224, 230
- neuropathies
- compression 115, 126–7, 224, 240
    - arm 126–7
    - cauda equina 251
    - Guyon's canal 127
    - median nerve 127, 132
    - tarsal tunnel syndrome 224
    - tibial nerve 240
    - ulnar nerve 126, 139
  - entrapment, metatarsalgia 224
  - medial malleolus 239
- neutral–zero method 61, 104, 116–17, 163, 225–6
- noble compression test 148–9, 148
- Noyes test 212–13, 213
- O**
- O test 139, 140
- Ober test 149, 150
- Ochsner test 133, 133
- O'Donoghue test 15
- opponens pollicis muscle 132–3, 135
- orientation tests 104–6
- Ortolani test 156–8, 157
- Osgood–Schlatter disease 162
- osteoarthritis 84, 115, 189, 204
- carpometacarpal joint 120–1
  - elbow 103
  - hallus rigidus 224, 229
  - hip 144, 148, 150, 152–3
  - interphalangeal joint 118, 127
  - metatarsophalangeal joint 229
  - patella 169–70
  - sternoclavicular joint 68
- osteophytes 16, 68, 204, 256
- osteoporosis 238
- Ott sign 5, 6
- P**
- painful arc
- acromioclavicular joint 81–2, 81
  - rotator cuff 77–8, 77
- palm, adduction 65, 117
- palsy 134–6
- median nerve 115, 132–3, 135
  - radial nerve 115, 129–30
  - serratus muscle 68
  - ulnar nerve 115, 138–9
- paralysis
- abductor pollicis brevis muscle
    - 133–5
  - abductor pollicis longus muscle
    - 129
  - extensor pollicis brevis muscle
    - 130
  - extensor pollicis longus muscle
    - 118–19
  - flexor carpi radialis muscle 140
  - flexor digitorum profundus muscle
    - 118, 133, 139
  - flexor pollicis brevis muscle 133
  - flexor pollicis longus muscle
    - 118–19, 139
  - hemiparesis 258–9
  - hip 153
  - interossei nerve 138
  - opponens pollicis muscle 132–3, 135
  - supinator muscles 131–2
- paresthesia 134–6, 139, 239, 256
- nighttime 127
- Paessler rotational compression test 190–1, 191
- patella 167–74
- patellofemoral joint 167
- Patrick test (fabere test) 34, 35, 154–5, 155

Payr 246  
   sign  
     meniscus 180, 180  
     venous thrombosis 247  
   test 181, 181  
 pelvis  
   ligaments 31–2, 49–50  
   muscles 242  
   tendinitis 49–50  
 percussion test 14  
 pericarditis 8–9  
 Perthes test 248–9, 249  
 pes cavus 226  
 Phalen test 134–5, 134  
   reverse 136, 136  
 piriformis sign 50, 50  
 pivot shift test 202–4, 203  
   modified 206–7, 207  
   soft 208–9, 209  
 plantar muscles 239  
 pleuritis 9  
 plexi 75, 127  
 popliteus sign 185–6, 187  
 popliteus tendon 193  
 postdiscectomy syndrome 47  
 posture 241–5  
   Matthiass competence test 241, 244, 245  
 Pratt warning 246  
 pronation test 137, 137  
 pronator quadratus muscles 137  
 pronator teres muscle 137  
   syndrome 126–7  
 pseudoradicular sign  
   (pseudo–Lasègue sign) 50  
 psoas muscle 24–5, 145  
 psoas sign 25, 25  
 psoriasis 224, 224

## Q

quadriceps muscle 259  
   atrophy 192  
   contraction 165, 199, 218  
 quadriceps tendon 175–6

## R

radius 47–8, 116, 120  
   nerve 129–30  
 Ratschow-Boerger test 253–4, 254  
 Reagan test 124, 124  
 rectus femoris muscle 144–5, 165–6  
 relocation test 102, 102  
 rheumatoid arthritis 103, 130, 224  
 ribs 7–9  
 Rielander 246  
 rotator cuff  
   defect 80  
   impingement 67–70, 79  
   infraspinatus tendon 73–4, 84  
   lesions 75  
   painful arc 77–8  
   pathology 76  
   subscapularis tendon 71–2  
   supraspinatus tendon 70–1, 75, 77–8  
   tears 67, 70, 76, 78, 82  
   tendinitis 102  
   weakness 75  
 Rowe test 94, 94

## S

sacroiliac joint 34–41  
   abduction 46  
   disease 42–4  
   disks 35–6  
   flexion 38–9  
   ligaments 31–3, 45  
   mobility 33–4, 38–41  
   spondylitis 35–6  
   syndrome 46–7  
 saphenous vein 248–9  
 scalene muscle 256–7  
 scaphoid shift test 123, 123  
 scapholunate ligament 124–5  
 scapula, displacement 88–9  
 Schepelmann test 9  
 Scheuermann disease 241  
 Schober sign 5, 6

- Schwartz  
 and Hackenbruch percussion  
 method 249  
 test 249
- sciatic nerve 49, 53–4
- sciatica 30, 49–51  
 Bonnet sign (piriformis sign) 50, 50  
 Kernig sign 49  
 Lasègue sign 49–50, 49  
 Turyn sign 49
- scoliosis 141–2, 244
- serratus muscle 68
- sesamoids 224
- shift and load test 97–9, 97, 99
- shift test  
 medial 208, 208  
 posterior, dynamic 223, 223  
 scaphoid 123, 123
- shoulder 18  
 bursa 65–7  
 bursitis 65–7, 78, 80, 85  
 disorders 59–60  
 drawer 94–5  
 frozen 64  
 impingement 68–9, 78–9, 82–3  
 instability 92–102  
 labrum 97  
 motion 61–5  
 osteophytes 68  
 pseudo–stiffening 68  
 subluxation 94, 101  
 tears 69
- Simmond test 231
- skier's thumb 125
- skin  
 dermatome 47  
 skin–rolling test 7
- slocum test 211, 211
- snap test 86, 87
- Soto–Hall test 14
- speed test 85, 86
- spinal canal 47
- spinal cord 158
- spine 5–7, 23–4, 36–7  
 disks 20–1, 24–6  
 facet joint 6, 18–21  
 syndrome 16  
 inflammation 56  
 intercostal joints 6  
 kyphosis 22–3  
 ligaments 20  
 mobility 2–6  
 muscles 18  
 nerve root 16, 19  
 osteophytes 16  
 rheumatoid 152–3  
 sacroiliac joint *see* sacroiliac joint  
 Scheuermann disease 241  
 spondylolisthesis 241  
 tumors 16, 55  
*see also* cervical spine, lumbar  
 spine, thoracic spine
- spinous process tap test 24
- spondylarthritis 10–11, 25–6
- spondylitis 25–6  
 ankylosing 8–9, 35–6
- spondylolisthesis 47
- spondylosis 10–11
- sports injuries  
 bicyclist compression 126  
 gamekeeper's thumb 125  
 golfer's elbow 103, 110–11, 112  
 skier's thumb 125  
 tennis elbow 103, 106–10
- springing test 27, 40, 40  
 sacroiliac joints 33–4, 33, 40, 40
- Spurling test 16–17, 16
- Steinmann  
 I sign 182, 182  
 I test 185  
 II sign 183–4, 183
- stenosis 253
- sternoclavicular joint 68
- sternum compression test 7, 8
- stress fractures 224
- stress test  
 motion 109, 109  
 sacroiliac joint 46, 46
- Strunsky test 227, 228
- subacromial bursitis test 66
- subluxation  
 biceps tendon 84–6, 89  
 glenohumeral joint 99  
 humerus 92, 97–9  
 knee 104, 204  
 patella 169, 173–4

- subluxation  
   shoulder 94, 101  
   suppression test 173–4, 174  
   tibia 201–7, 210, 214–15, 218, 223  
 subscapularis muscle 67, 70–3, 72  
 subtalar joint 235–6  
 sulcus sign 100, 101  
 supination  
   stress test 105, 105  
   test 131, 131–2  
 supinator muscle 114, 131–2  
 suppression test 173–4  
 suprascapular nerve 88–9  
 supraspinatus muscle 75–6, 81, 102  
 supraspinatus tendon 70–1, 75
- T**
- talocrural joint 225  
 talofibular ligaments 236  
 tarsal tunnel syndrome 224  
   Tinel sign 239, 239  
   tourniquet sign 240, 240  
 tarsi, transverse joint 235–6  
 tears  
   Achilles tendon 231–2  
   bucket handle 204  
   collateral ligament 125  
   cruciate ligament 187  
   meniscus 187, 189, 203  
   rotator cuff 67, 70, 76, 78, 82  
   subscapularis muscle 71–3  
 telescope sign 156, 156  
 tendinitis 67, 86, 103  
   biceps tendon 86  
   patella 170  
   pelvis 49–50  
   pseudoradicular sign 50  
   rotator cuff 102  
 tendons 115  
   *see also* individual types of tendon  
 tennis elbow 103, 106–10  
 tenosynovitis 115, 127  
   abductor pollicis longus muscle  
     119–20  
   biceps tendon 85  
   de Quervain's disease 119–21  
   extensor pollicis brevis muscle  
     119–20  
   proximal interphalangeal joint 118  
   thumb 119  
   tensor fasciae latae muscle 148–9  
   teres major muscle 73–5, 74  
   Thomas grip 146–8  
   Thompson  
     compression test 231, 231  
     and Kopell horizontal flexion test  
       88–9, 89  
   Thomsen sign 55, 55  
   Thomson test 107–8, 108  
 thoracic outlet syndrome 127, 254–7  
   Allen maneuver 257, 257  
   costoclavicular test 255, 255  
 thoracic spine 22–30  
   inflammation 5  
   kyphosis 22  
   mobility 5  
   scoliosis 22  
 three-phase hyperextension test  
   34–6, 36  
 thrombophlebitis 52  
 thrombosis 52  
   arterial 251–9  
   venous 246–50  
 throwing test 94, 95  
 thumb 121–2  
   circumduction 117  
   degenerative joint disease 130  
   rheumatoid arthritis 130  
   tendons 119  
   tenosynovitis 119  
 tibia  
   malrotation 167  
   Osgood-Schlatter disease 162  
   rotation 204  
   subluxation 201–7, 210, 214–15,  
     218, 223  
 tibiotalar joint 235  
 tilt test 174–5, 175  
 tinel sign 132, 132, 139, 239, 239  
 Tinel test 112, 113  
 tiptoe and heel walking test 56, 57  
 toes  
   claw toe 224, 226  
   displacement test 228–9, 228

toes  
  Strunsky test 227, 228  
Toennis gradings 157–8  
tourniquet sign 240, 240  
traction test 90, 90  
trapezius muscle 68  
Trendelenburg  
  gait 143  
  sign 153–4, 154  
  test 248, 248  
triceps surae muscle 259  
triquetrolunate joint 124, 124  
trochlear groove 167  
trunk muscles 242  
Tschaklin sign 192  
tumors 55  
  elbow 103  
  hip 150  
  nerve root 49–50  
  neuromas  
    interdigital 238  
    Morton 23, 224, 230  
  pleural processes 8–9  
  spinal cord 158  
  spine 16, 55  
Turner sign 188–9  
Turyn sign 49

**U**

ulcers 251  
ulna 116  
ulnar ligament 125  
ulnar nerve 126–7, 138–9

**V**

valgus stress test 106, 106  
Valsalva test 16, 16  
varicose veins 248, 248  
varus stress test 105, 106  
vastus medialis muscle 192  
veins  
  anastomoses 248  
  dorsal 252  
  saphenous 248–9  
  thrombophlebitis 52  
  thrombosis 50, 237, 246–50  
  varicose 248, 248  
vertebrae, blockade 8–9  
vertebral artery 252–3  
vertigo 10–12  
volar hypesthesia 137

**W**

Wagenhaeuser 241  
Watson test 123, 123  
Wilson test 192, 192  
wrist 123–4, 134–5, 137–8, 140

**Y**

Yeoman test 47, 47  
Yergason test 86, 87

**Z**

zero-degree abduction test 70, 76  
Zippel 189  
Zohlen sign 169, 170