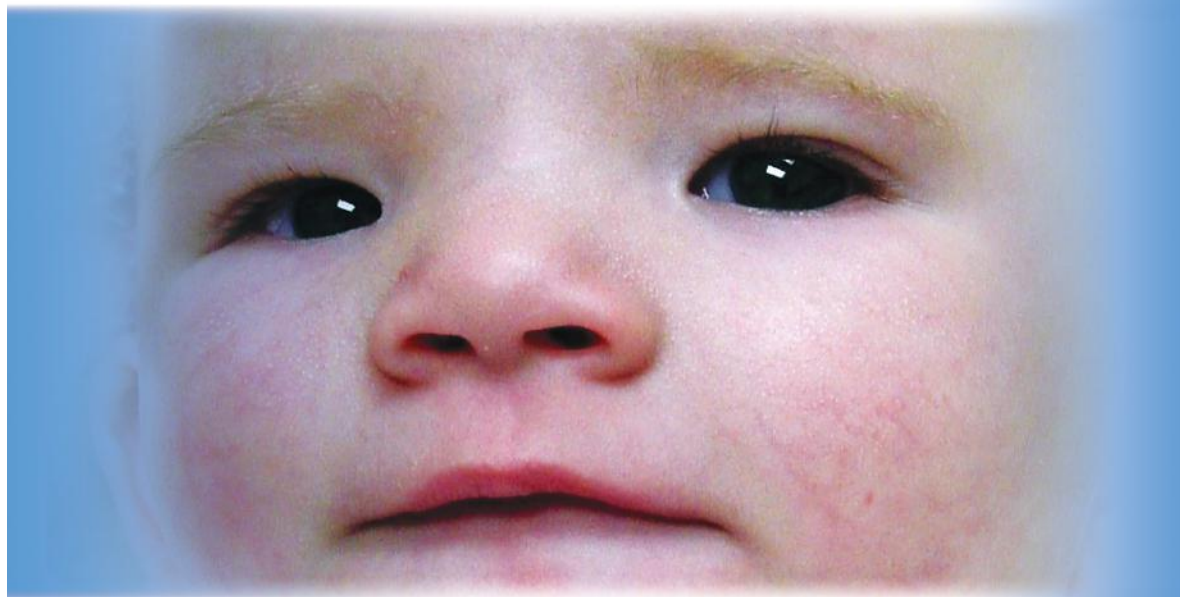

A COLOR HANDBOOK

# PEDIATRIC NEUROLOGY

JAMES F. BALE JR.  
JOSHUA L. BONKOWSKY  
FRANCIS M. FILLOUX  
GARY L. HEDLUND  
DENISE M. NIELSEN  
PAUL D. LARSEN



 MANSON  
PUBLISHING



**A Color Handbook**

# **Pediatric Neurology**

**James F. Bale, Jr, MD**

**Joshua L. Bonkowsky, MD, PhD**

**Francis M. Filloux, MD**

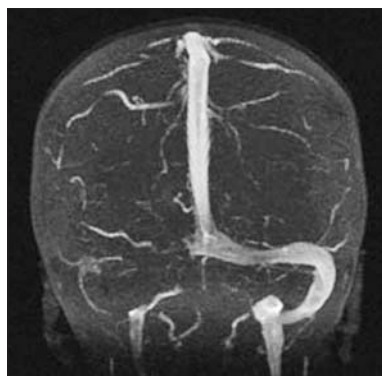
**Gary L. Hedlund, DO**

**Denise M. Nielsen, MD**

**All at the University of Utah School of Medicine, Salt Lake City, UT, USA**

**Paul D. Larsen, MD**

**University of Nebraska College of Medicine, Omaha, NE, USA**



---

 **MANSON  
PUBLISHING**

---

CRC Press  
Taylor & Francis Group  
6000 Broken Sound Parkway NW, Suite 300  
Boca Raton, FL 33487-2742

© 2012 by Taylor & Francis Group, LLC  
CRC Press is an imprint of Taylor & Francis Group, an Informa business

No claim to original U.S. Government works  
Version Date: 20150224

International Standard Book Number-13: 978-1-84076-602-8 (eBook - PDF)

This book contains information obtained from authentic and highly regarded sources. While all reasonable efforts have been made to publish reliable data and information, neither the author[s] nor the publisher can accept any legal responsibility or liability for any errors or omissions that may be made. The publishers wish to make clear that any views or opinions expressed in this book by individual editors, authors or contributors are personal to them and do not necessarily reflect the views/opinions of the publishers. The information or guidance contained in this book is intended for use by medical, scientific or health-care professionals and is provided strictly as a supplement to the medical or other professional's own judgement, their knowledge of the patient's medical history, relevant manufacturer's instructions and the appropriate best practice guidelines. Because of the rapid advances in medical science, any information or advice on dosages, procedures or diagnoses should be independently verified. The reader is strongly urged to consult the relevant national drug formulary and the drug companies' and device or material manufacturers' printed instructions, and their websites, before administering or utilizing any of the drugs, devices or materials mentioned in this book. This book does not indicate whether a particular treatment is appropriate or suitable for a particular individual. Ultimately it is the sole responsibility of the medical professional to make his or her own professional judgements, so as to advise and treat patients appropriately. The authors and publishers have also attempted to trace the copyright holders of all material reproduced in this publication and apologize to copyright holders if permission to publish in this form has not been obtained. If any copyright material has not been acknowledged please write and let us know so we may rectify in any future reprint.

Except as permitted under U.S. Copyright Law, no part of this book may be reprinted, reproduced, transmitted, or utilized in any form by any electronic, mechanical, or other means, now known or hereafter invented, including photocopying, microfilming, and recording, or in any information storage or retrieval system, without written permission from the publishers.

For permission to photocopy or use material electronically from this work, please access [www.copyright.com](http://www.copyright.com) (<http://www.copyright.com/>) or contact the Copyright Clearance Center, Inc. (CCC), 222 Rosewood Drive, Danvers, MA 01923, 978-750-8400. CCC is a not-for-profit organization that provides licenses and registration for a variety of users. For organizations that have been granted a photocopy license by the CCC, a separate system of payment has been arranged.

**Trademark Notice:** Product or corporate names may be trademarks or registered trademarks, and are used only for identification and explanation without intent to infringe.

Visit the Taylor & Francis Web site at  
<http://www.taylorandfrancis.com>

and the CRC Press Web site at  
<http://www.crcpress.com>



# Contents

Preface . . . . .	5	Electroretinography . . . . .	58	Learning disability . . . . .	96
<b>SECTION 1: CORE CONCEPTS</b>		<b>CHAPTER 4</b>		Autism spectrum disorders (ASD) and related conditions . . . . .	97
<b>CHAPTER 1</b>		<b>Cerebrospinal fluid</b> . . . . .	59	Organic brain disorders of childhood . . . . .	98
<b>The pediatric neurological examination</b> . . . . .	9	Introduction . . . . .	59	Conversion disorders . . . . .	99
Introduction . . . . .	9	CSF production . . . . .	60	<b>CHAPTER 9</b>	
What is the lesion? . . . . .	10	CSF pressure . . . . .	60	<b>Disorders of language and hearing</b> . . . . .	101
Where is the lesion? . . . . .	11	Lumbar puncture (spinal tap) . . . . .	60	Introduction . . . . .	102
Adaptation of the neurological examination to the child . . . . .	12	CSF content . . . . .	63	Language disorders . . . . .	102
Mental status: examining the cortex . . . . .	13	Specialized diagnostic testing of CSF samples . . . . .	64	Epileptic causes . . . . .	105
Cranial nerves . . . . .	16	<b>CHAPTER 5</b>		Other causes . . . . .	105
Coordination . . . . .	24	<b>Genetic evaluation</b> . . . . .	67	Hearing disorders . . . . .	110
Sensory examination . . . . .	26	Introduction . . . . .	68	Conditions associated with hearing loss . . . . .	112
Motor examination . . . . .	26	Human genetics: a primer . . . . .	69	<b>CHAPTER 10</b>	
Conclusions . . . . .	32	Diagnostic tools . . . . .	72	<b>Disorders of head size and shape</b> . . . . .	115
<b>CHAPTER 2</b>		Future directions . . . . .	74	Introduction . . . . .	116
<b>Neuroimaging</b> . . . . .	33	<b>CHAPTER 6</b>		Macrocephaly . . . . .	118
Introduction . . . . .	33	<b>Newborn screening and metabolic testing</b> . . . . .	75	Microcephaly . . . . .	122
Patient safety and preparation for imaging . . . . .	34	Newborn screening . . . . .	76	Misshapen heads . . . . .	126
Magnetic resonance imaging (MRI) . . . . .	34	Abnormal results on a newborn screen . . . . .	76	<b>CHAPTER 11</b>	
Computed tomography (CT) . . . . .	39	Inborn errors of metabolism . . . . .	76	<b>Disorders of cranial nerves</b> . . . . .	131
Cranial ultrasound imaging . . . . .	40	Inborn errors in newborns . . . . .	77	Introduction . . . . .	132
Magnetoencephalography (MEG) . . . . .	40	Laboratory screening . . . . .	77	Cranial nerve 1 (olfactory nerve) . . . . .	132
Nuclear medicine brain imaging . . . . .	41	Imaging . . . . .	78	Cranial nerve 2 (optic nerve) . . . . .	133
Catheter angiography . . . . .	42	Later clinical presentations . . . . .	80	Cranial nerve 3 (oculomotor nerve) . . . . .	140
<b>CHAPTER 3</b>		<b>SECTION 2: A PROBLEM-BASED APPROACH TO PEDIATRIC NEUROLOGICAL DISORDERS</b>		Cranial nerve 4 (trochlear nerve) . . . . .	143
<b>Electrophysiological evaluation of Infants, children, and adolescents</b> . . . . .	43	<b>CHAPTER 7</b>		Cranial nerve 5 (trigeminal nerve) . . . . .	143
Introduction . . . . .	44	<b>Disorders of development</b> . . . . .	83	Cranial nerve 6 (abducens nerve) . . . . .	144
Electroencephalography . . . . .	44	Introduction . . . . .	84	Cranial nerve 7 (facial nerve) . . . . .	145
Recognizable EEG abnormalities in children . . . . .	50	Motor delay . . . . .	84	Cranial nerve 8 (acoustic nerve) . . . . .	147
Video-EEG monitoring . . . . .	55	Global developmental delay . . . . .	88	Cranial nerves 9 and 10 (glossopharyngeal and vagus nerves) . . . . .	148
Brainstem auditory evoked potentials . . . . .	55	Developmental regression . . . . .	88	Cranial nerve 11 (spinal accessory nerve) . . . . .	149
Visual evoked potentials . . . . .	55	Management of developmental delay . . . . .	88	Cranial nerve 12 (hypoglossal nerve) . . . . .	149
Electromyography and nerve conduction studies . . . . .	56	<b>CHAPTER 8</b>			
Polysomnography . . . . .	57	<b>Disorders of behavior and cognition</b> . . . . .	91		
Electronystagmography and balance testing . . . . .	58	Introduction . . . . .	92		
		Disorders of attention . . . . .	92		
		Neurobehavioral toxicity of antiepileptic drugs . . . . .	92		
		Disorders of cognition . . . . .	94		

CHAPTER 12	CHAPTER 16	Congenital infection . . . . . 280
<b>Disorders of peripheral nerves</b> . . . . . 151	<b>Acute focal deficits</b> . . . 199	Lyme disease . . . . . 284
Introduction . . . . . 152	Introduction . . . . . 200	Cat-scratch disease . . . . . 285
Neonatal brachial plexopathy 152	Acute arm or leg weakness . 200	Neurocysticercosis . . . . . 285
Brachial plexopathy of children or adolescents . . 154	Acute facial weakness . . . . 204	Cerebral malaria . . . . . 286
Lumbosacral plexopathy . . . 154	Acute visual loss . . . . . 205	HIV/AIDS . . . . . 288
Sacral neuropathy . . . . . 155	Acute double vision (diplopia) . . . . . 206	CHAPTER 21
Hereditary neuropathy with liability to pressure palsy 156	CHAPTER 17	<b>Movement disorders</b> . . 291
Guillain-Barré syndrome . . 158	<b>The dysmorphic child</b> . 209	Introduction . . . . . 291
Complex regional pain syndrome . . . . . 159	Introduction . . . . . 210	Stereotypy . . . . . 292
Inherited peripheral neuropathy . . . . . 160	The hypotonic infant . . . . 212	Tremor . . . . . 293
Critical illness polyneuropathy/myopathy . . . . . 160	The neonate with encephalopathy or seizures . . . . . 215	Tic disorders and Tourette syndrome . . . . . 294
Miscellaneous causes of peripheral neuropathy . . 160	The child with seizures . . . 219	Chorea . . . . . 296
CHAPTER 13	The child with language impairment . . . . . 222	Dystonia . . . . . 298
<b>Disorders of gait and balance</b> . . . . . 161	The child with global developmental delay . . . 223	Myoclonus . . . . . 299
Introduction . . . . . 162	The child with deafness . . . 227	Hypokinetic movement disorders in childhood . . 299
Evaluation . . . . . 162	The child with a stroke . . . 227	CHAPTER 22
Patterns of presentation . . . 166	The child with neurological signs or symptoms and birth marks . . . . . 228	<b>Seizures and other paroxysmal disorders</b> . 301
CHAPTER 14	The infant with a neural tube defect . . . . . 238	Introduction . . . . . 302
<b>Disorders of sleep</b> . . . 173	CHAPTER 18	Cardiac arrhythmia . . . . . 302
Introduction . . . . . 174	<b>Headaches</b> . . . . . 241	Nonepileptic events . . . . . 304
Normal sleep of infants, children, and adolescents 174	Introduction . . . . . 241	Seizures and epilepsy . . . . 306
Common sleep disorders . . 177	Migraine . . . . . 242	Specific seizure types and pediatric epilepsy syndromes . . . . . 306
Parasomnias . . . . . 178	Migraine variants . . . . . 245	Management of seizures . . 310
Neonatal sleep myoclonus . 179	Chronic daily headaches . . 245	Management of children with epilepsy . . . . . 312
Narcolepsy . . . . . 180	Other headache syndromes . 246	CHAPTER 23
Delayed sleep-phase syndrome . . . . . 180	CHAPTER 19	<b>Pediatric neurological emergencies</b> . . . . . 313
Advanced sleep-phase syndrome . . . . . 180	<b>Hypotonia and weakness</b> . . . . . 253	Introduction . . . . . 314
CHAPTER 15	Introduction . . . . . 253	Seizures . . . . . 314
<b>Disorders of the newborn</b> . . . . . 181	The hypotonic infant . . . . 254	Status epilepticus . . . . . 314
Introduction . . . . . 182	Selected disorders in infants 256	Alterations of consciousness 317
Assessing the neonate . . . . 182	Weakness in children and adolescents . . . . . 261	Acute CNS injury . . . . . 322
Neuroimaging of the newborn . . . . . 184	Selected disorders in children and adolescents . . . . . 262	Acute neuromuscular weakness . . . . . 329
EEG in the newborn . . . . . 186	CHAPTER 20	Acute poisonings . . . . . 330
EMG in the newborn . . . . . 186	<b>Infections of the nervous system</b> . . . . . 269	Hypertensive encephalopathy . . . . . 332
Specific conditions . . . . . 187	Introduction . . . . . 270	<b>Abbreviations</b> . . . . . 333
	Bacterial meningitis . . . . . 270	<b>Further reading and bibliography</b> . . . . . 335
	Viral meningitis . . . . . 275	

Forty years ago Dr. Patrick Bray published the text *Neurology in Pediatrics*. Among Dr. Bray's goals were to make his book practical and comprehensive and to demystify the nervous system to trainees and practitioners. He realized that virtually all children with neurological diseases are seen first by a primary care provider, whether pediatrician or family physician. Had hospitalists, physician assistants, nurse practitioners, and pediatric emergency medicine physicians existed then, Dr. Bray's insights would have applied equally well to them. This book, *A Color Handbook of Pediatric Neurology*, has been prepared by the trainees of Dr. Bray and the trainees of his trainees. We have not forgotten the many lessons we learned from him, and these lessons inspired us as we prepared this text. The past 40 years have seen remarkable advances in pediatric neurology and in many interfacing disciplines, especially medical imaging, genetics, and infectious diseases. Yet, the fundamentals of the neurological examination and history remain essential in the accurate diagnosis of conditions affecting the child's nervous system.

The text is divided into two sections. The first, Core Concepts, covers material basic to the formulation of differential diagnoses and the management of neurological conditions of infancy, childhood, and adolescence. Cognizant of the importance of accurate localization, we begin the book with a detailed discussion of the neurological examination. The material is abundantly illustrated, given our goal of providing more than simple narrative descriptions of these important techniques. The first section continues with succinct overviews of neuroradiology, electrophysiology, and genetic and metabolic testing. During our practice careers, amazing advances have occurred in genetic diagnosis; more are yet to come. We have included a section on the cerebrospinal fluid, emphasizing that sampling this important body fluid still has an essential role in the diagnosis and management of infectious conditions, demyelinating disease, and arcane, but potentially treatable, disorders of central nervous system neurotransmitters.

The second section, A Problem-Based Approach to Pediatric Neurological Disorders, describes neurological disease as it is encountered by practitioners. With very few exceptions parents do not arrive at their practitioner's office carrying a card that states 'my child has vanishing white matter disease', unless, of course, they have already been to their consultant or researched their child's condition on the Internet. Rather, children come to care providers because their parents are concerned about certain signs or symptoms. Recognizing how disease presents in the real world, the longer second section employs practical symptom- and sign-based strategies for virtually all conditions that will be encountered by the practitioner. In this section, we cover a wide variety of topics including 'Disorders of Head Shape and Size', 'Seizures and other Paroxysmal Disorders', 'Disorders of Language and Hearing'. Again, numerous illustrations, a unique attribute of this text, accompany the narrative. We have used textboxes to draw readers to key points that will enable them to diagnose and manage their patients more effectively. We conclude with a detailed discussion of neurological emergencies, again cognizant that children with such conditions will present first to someone other than a pediatric neurologist. Throughout the text, we emphasize how recognizing patterns of disease, whether based on historical or physical signs, comprises the first step in successfully managing the child with a neurological problem.

Such texts are not written without the contributions of many. The parents and children of those with neurological disorders featured in this book were unsparing in their patience and willingness to provide clinical examples and photographs. The parents provided permission to show their children's faces unmasked, thus enhancing the utility of this text. We thank Dr. Alan Rope of the Division of Medical Genetics, The University of Utah, for generously providing many photographs of children with genetic and syndromic disorders. Our colleagues, Drs. David Dries and Robert Hoffman, the Division of Pediatric Ophthalmology, Primary Children's

## 6 PREFACE

Medical Center, Dr. Bruce Herman, the Division of Emergency Medicine, the Department of Pediatrics, Dr. Steven Chin, the Department of Pathology, Dr. Richard Sontheimer, Department of Dermatology, and Dr. Mark Bromberg, the Department of Neurology, all at the University of Utah, each provided photographs and illustrations that contribute greatly to the information contained in this text. We thank several pediatricians, Drs. David Folland, Chuck Norlin, Tom Metcalf, and Wendy Hobson-

Rohrer, for their suggestions, advice, and reading of the manuscript. Finally, we appreciate the keen perspective of our trainees, Drs. Russell Butterfield, Matthew Sweney, and Wendy Osterling who read and critiqued this work. A fundamental goal of our effort is to provide comprehensive information about the child's nervous system that is as highly relevant to those embarking on careers in pediatric neurology as it will be to the experienced practitioner.

# **CORE CONCEPTS**

**Chapter 1**  
**The pediatric neurological examination**

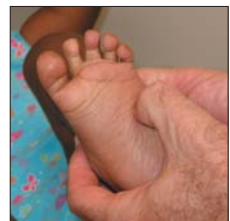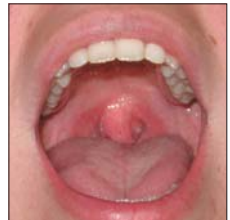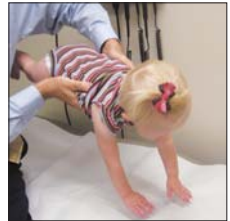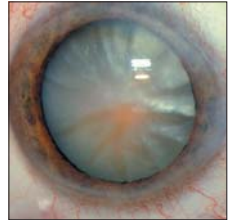
**Chapter 2**  
**Neuroimaging**

**Chapter 3**  
**Electrophysiological evaluation of infants,  
children, and adolescents**

**Chapter 4**  
**Cerebrospinal fluid**

**Chapter 5**  
**Genetic evaluation**

**Chapter 6**  
**Newborn screening and metabolic testing**



*This page intentionally left blank*

# The pediatric neurological examination

## Main Points

- The clinician uses the history and diagnostic studies to answer ‘what is the lesion?’ and the neurological examination to answer ‘where is the lesion?’.
- The clinician hears and sees the effects of disease and uses powers of reasoning to identify the biologic cause.
- The temporal profile or chronology of disease enables clinicians to hypothesize the nature of the lesion.
- The elements of the adult neurological examination are the foundation for the pediatric examination and the verbal child can be taught the examination.
- The pediatric neurological examination must be conducted and interpreted in the context of expected neurodevelopmental milestones.
- For the preverbal child, the examination must be tailored to the age-specific expectations of the developing nervous system.
- Many neurological deficits can be detected by watching the child walk, talk, and play.

## Introduction

A clinician hears and sees the effects of disease in patients and uses this information and deductive powers to identify the cause of the signs and symptoms. This Sherlock Holmesian process is common to many areas of medicine, and neurology is no exception. Essential in this diagnostic process is the clinician’s ability to answer two basic questions: ‘Where in the nervous system is the lesion?’ and ‘What is

the lesion?’. The first question can be answered by combining historical information and the neurological examination. The second question, ‘What is the lesion?’, is often suggested by the patient’s history or examination and confirmed by the appropriate laboratory or neurodiagnostic tests. Consequently, this chapter addresses first the key elements of the neurological history and then focuses on the neurological examination.

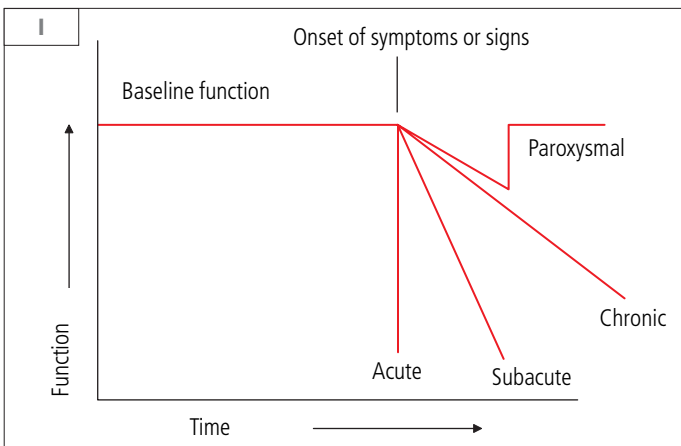
## What is the lesion?

The pediatric patient presents with a chief complaint and a history of the present illness. This complaint and present illness must be viewed in the context of the past medical history, family history, and social history. With this information, the clinician constructs a temporal profile of the child's illness. This profile can be conceptualized as a graph with 'function' on the vertical axis, and 'time' on the horizontal axis (1). The patient's baseline function is determined by his past history, family history, and social history. The chief complaint and the present illness represent a departure from this baseline level of function. The chronology or the period of time over which the present illness evolves is critical in determining the most likely disease process that has caused the symptoms.

The common pathologies of the nervous system have relatively stereotyped patterns in which they appear. The time line can be acute (seconds, minutes, hours), subacute (hours, days), chronic (days, months), or paroxysmal (episodes of illness with returns to baseline). An adolescent, for example, can present with a left hemiparesis. If the hemiparesis developed over a matter of seconds, it is most likely the result of

a stroke. If it developed over a period of several months, a brain tumor must be considered. Stroke is now unlikely. Not only do these pathologies have typical temporal profiles, they can be considered in terms of whether they produce focal or diffuse brain dysfunction and whether the disease process is static or progressive. The typical temporal profile, localization, and course of the most common pathologies that affect the brain are summarized in *Table 1*.

Two additional aspects of the history deserve special emphasis in pediatric neurology: the developmental history and the family history. The child's nervous system is a dynamic and maturing organ system. Whether the child reaches appropriate developmental milestones and the rate at which they are achieved are important indicators of brain function. The clinician must obtain a concise and reasonably precise history regarding when developmental milestones were achieved. Because many conditions of the child's nervous system have a genetic basis, it is also essential that a complete family history be obtained. A useful question to ask is: 'Does anyone else in the family have anything similar to the patient's problem?'. Creating a family pedigree helps the family and the clinician construct a thorough family history.



1 The temporal profile of neurological disease, depicting acute, subacute, chronic, or paroxysmal changes from baseline.



## Where is the lesion?

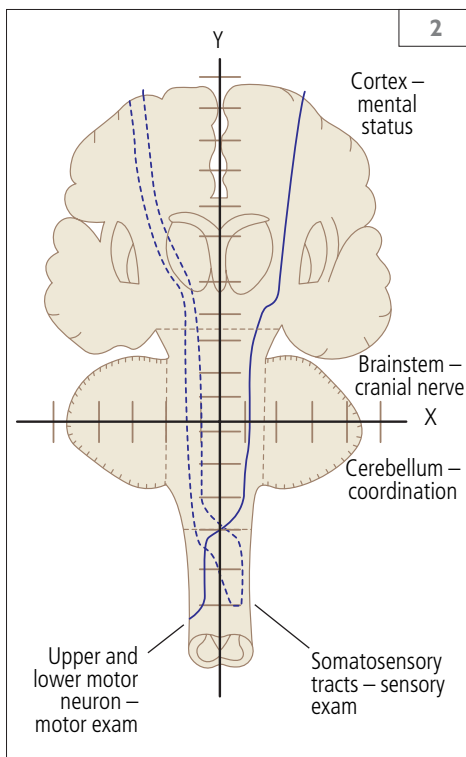
The history provides important etiologic clues, but the neurological examination and neuroimaging studies confirm the anatomical location of the child's chief complaint. The neurological examination is the window through which the clinician views the nervous system. When the examination is approached in a systematic and logical fashion organized by anatomical levels and systems, the clinician can use clinical findings to determine the location of the lesion causing the child's symptoms. To facilitate anatomical localization, the clinician can think of a coronal view of the brain, spinal cord, and peripheral nerves superimposed on an 'x, y' graph (2), with brain function on the vertical axis and location (left, right, and midline) on the horizontal axis. Ascending and descending systems exist at multiple levels and cross the midline during their course, enabling localization on both vertical and horizontal axes.

Elements of the neurological examination allow the physician to obtain x and y values so that an anatomical location can be determined. On the vertical axis are the cerebral cortex, brainstem, cerebellum, spinal cord, muscle, and peripheral nerves; each structure has a left and right side. The corresponding elements of the neurological examination for each of these levels are: cortex: mental status examination; brainstem: cranial nerves; cerebellum: coordination; spinal cord, muscle, and peripheral nerves: sensory and motor. The motor system involves all levels, including peripheral nerve and muscle. The sensory and motor systems are not only located in the spinal cord and peripheral nerves, but also ascend or descend through the brainstem and the cerebral hemispheres. Because they decussate at the level of the spinal cord or lower brainstem, findings on motor and sensory examinations have powerful localizing value when combined with cranial nerve, cerebellar, or cortical findings.

A few examples help to illustrate the power of this paradigm in anatomical localization. A child presents with a right hemiparesis and left hemifacial weakness. The only place that the lesion can be located in the neuraxis is at the level of the pons on the left side where the 7<sup>th</sup> cranial nerve nucleus and corticospinal tract are located. When the disorder begins insidiously, magnetic resonance imaging (MRI) may confirm the

**Table 1 Temporal profile and localization of important pathologies affecting the brain**

<b>Acute</b>	Vascular/infarct – focal
	Hypoxic – diffuse
	Trauma – focal or diffuse
<b>Subacute</b>	Inflammatory/infectious – focal or diffuse
	Immune – focal or multifocal
	Toxic/metabolic – diffuse
<b>Chronic</b>	Congenital – focal or diffuse
	Degenerative – diffuse or system related
	Neoplastic – focal
<b>Paroxysmal</b>	Seizure – focal or diffuse
	Vascular/syncope – diffuse
	Pain/headache – focal or diffuse



**2** The neuraxis of neurological localization.

presence of a brainstem glioma. If the child has acute aphasia and a right hemiparesis, the lesion must be at the level of the cerebral hemispheres on the left side where corticospinal tracts or motor cortex is located near the speech centers of the brain. MRI, using diffusion-weighted images, may demonstrate acute ischemia affecting the distribution of the left middle cerebral artery. Similarly, if the child has weakness of the legs, loss of sensation below the nipple line, and preserved arm function, the lesion must be at or near the T4 level of the spinal cord. MRI may show demyelination compatible with multiple sclerosis or acute disseminated encephalomyelitis, an immune-mediated inflammatory disorder of the central nervous system (CNS).

This approach to anatomical localization is necessary for evaluating children, but it is not sufficient alone. The interpretation of the neurological examination must be couched in the context of neurodevelopmental milestones. What one expects from a newborn is vastly different from what one expects from a child or adolescent. Expression of motor and cognitive function is influenced immensely by the maturation of the nervous system. Patterns of development are important indicators of childhood brain dysfunction and must be considered when establishing anatomical localization.

In many instances the neurological examination will be normal or nonspecific, leading some to question the value of the examination in modern practice. What does the examination contribute to the evaluation and management of the patient? First, the neurological examination provides essential data regarding anatomical localization, as outlined above. Second, the absence of an abnormality is often equal in importance to the presence of an abnormality. The examination must be normal, for example, to conclude that headaches in a young child are not the result of a brain tumor. Third, a complete neurological examination reassures the family and child that their concerns have been taken seriously. This is particularly important when parents are worried that their child's headaches are the result of a brain tumor. Finally, documenting the examination over time is essential in evaluating neurological disorders that evolve over time. Rett syndrome, for example, becomes the likely cause of devel-

opmental delay in a young girl when head growth velocity slows and hand stereotypies appear.

## **Adaptation of the neurological examination to the child**

The neurological examination of the adult is the foundation for the neurological examination of the child. Many of the same techniques and maneuvers can be used in the verbal child who can be taught what is needed in the examination. On the other hand, forcing the infant or the toddler to comply with the routine adult-based neurological examination leads to an unpleasant and unrewarding experience for both child and examiner. The examination must be adapted to the child, his/her temperament, and developmental level. More can be learned by watching spontaneous movement and interactions than by having an uncooperative, crying child resist the examination.

With this in mind, the first thing to consider when examining the child is to resist touching them. Step back and observe. Divide what you see into its parts. Is the child socially interacting and displaying a symmetric smile? Does an infant have good head control, posture, and symmetric movements? Does the infant reach for items and explore the environment? What sounds or words does he or she make? These observations can then be registered into the mental matrix of the information that the clinician carries forward in building the differential diagnosis of the child's condition.

After these spontaneous observations are made, the second part of the examination starts. This is when the physician approaches the child for the 'hands-on' part of the examination. Touching and examining the infant or toddler can be very threatening, therefore the examination is best performed with the infant in the parent's lap for security. The tools of the examination can also be alarming. For example, the child sees the reflex hammer as something that may be harmful. Distraction and imaginative suggestion are important skills that can reduce the child's anxiety and facilitate cooperation. The reflex hammer, for example, can be turned into a stick horse with a puppet rider (3). Add sound effects and eliciting muscle

stretch reflexes becomes a nonthreatening game. Finger puppets or brightly colored toys engage the child in play which maximizes the information for the clinician and makes the process pleasant for all.

The third and final part of the examination is all those things that are potentially unpleasant and unsettling for the child. This would include undressing the child, looking at the fundus with the ophthalmoscope, using the otoscope, testing for the gag reflex, and measuring the head circumference.

After all the elements of the examination have been completed, the clinician should reflect on the findings to organize them for analytical diagnostic reasoning. In keeping with the concept of analyzing the neurological examination in terms of levels and systems, information should be recorded in the following sequence: mental status (the cortex); cranial nerves (the brainstem level); coordination (the cerebellar system); sensory (ascending system); motor (descending system); and gait (putting it all together). The following sections focus on each of the elements of the examination in this order.

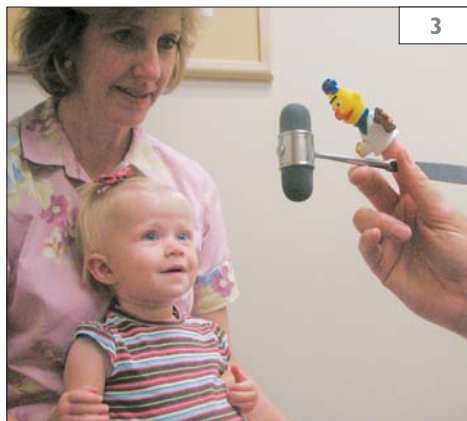### Mental status: examining the cortex

The purpose of the mental status examination is to interrogate the function of the cerebral cortex. The cortex, the highest level of the

neuraxis, integrates perception, cognition, and emotion and results in thought, feelings, and behavior. For the child, the cortex is the site of the most dynamic and age-dependent brain development and growth. At birth, an infant's behavior is predominantly reflex driven, but as maturation and development progress, the cortex determines and shapes all areas of behavior. The examination of mental status should be tailored to the expected developmental age of the child.

The first element of the mental status examination is to assess the child's level of alertness. Is the child alert, sleepy, lethargic, or unresponsive? Without appropriate arousal, the content of consciousness cannot be assessed. Does the child establish eye contact and attend to the environment? Is the child able to understand personal boundaries and are social skills appropriate for the child's age? Is the child curious and interested in exploring the environment? Does the child laugh, appreciate humor, and is he/she willing to engage in play? Does the child have odd or peculiar behaviors? Are there repetitive or self stimulation behaviors such as hand flapping or twirling and stereotypic behavior such as hand clapping, patting, or wringing? Does the child use language and gestures in a meaningful way to communicate and connect with parents and the examiner? The answers to these questions create a gestalt of the patient's mental status and cortical function.

**3** Using a reflex hammer as a horse and a puppet as a rider to keep the child's attention and increase cooperation.



**Table 2 Standardized pediatric neurodevelopmental tests**

<b>Newborn</b>	Neonatal Behavioral Assessment Scale (Brazelton)
<b>Infant</b>	Bayley Scales of Infant Development Cattell Infant Intelligence Scale
<b>Young child</b>	McCarthy Scales of Children's Abilities Stanford–Binet Intelligence Scale
<b>Older child</b>	Wechsler Preschool and Primary Scale of Intelligence NEPSY: A Developmental Neuropsychological Assessment

**Table 3 Cortical function tested by the mental status examination**

<b>Frontal lobes</b>	Attention – working memory Executive function Motivation Social behavior
<b>Frontotemporal lobes: language</b>	Dominant hemisphere Receptive and expressive language Nondominant hemisphere Prosody (affective and emotion quality of language) Receptive and expressive
<b>Temporal lobes</b>	Episodic and semantic memory
<b>Parietal lobes</b>	Visuospatial processing

The order and the content of the examination are determined by the developmental age of the child; many elements of the mental status examination can be assessed while taking the history. Detailed assessment of cortical function from infancy to adolescence is facilitated by utilizing standardized tests administered by trained individuals. *Table 2* lists age-appropriate instruments available for assessing cortical function.

Because of the complexity and integration of cortical function, any clinical method used to examine the cortex will be over-simplified and artificially compartmentalized. It is useful, nonetheless, to organize the mental status examination in terms of anatomical localization. The cortical areas examined include functions of the frontal lobes, frontotemporal (language), temporal and parietal lobes; their general functions are listed in *Table 3*.

In newborns the mental status examination consists mainly of observations of the infant's alertness, response to environmental stimuli such as light and sound, sleep–wake cycles, and temperament. By 2–3 months of age, a social smile develops, and the infant becomes more attentive to the examiner and the environment. At 6 months, the infant laughs,

coos, jabbbers, and works to reach for a toy or interesting object, such as the reflex hammer. By 12 months, the infant imitates simple motor tasks, indicates wants, plays simple games, and has one or two meaningful words. As the child matures, the ability to perform self-care skills such as eating and dressing, increases. Language skills increase as well, corresponding to dramatic growth in vocabulary at 18–22 months of age and the use of two word 'sentences' by 24 months. As children reach preschool and school levels, components of a standard, adult-type mental status examination can be utilized (*Table 4*).

### Frontal lobe function

The frontal lobes are important for attention, working memory, executive function, and social judgment. For the older child testing frontal lobe function includes repeating 3–4 numbers, spelling a word backwards, or naming the months of the year backwards. The frontal lobes are important for directing attention and ignoring competing or distracting stimuli, organizing daily activities, regulating emotion, and establishing appropriate interpersonal boundaries, features that are considered execu-

**Table 4 Mental status examination for the older child or adolescent**

Appearance
Mood and affect
Orientation to place, person, time
Attention/working memory – digit span
Memory:
List of three words, recall in 5 minutes
Questions about recent and remote events
Language – appropriate for age:
Naming objects
Meaning of words
Following commands
Show a picture and ask questions about the picture
Reading
Writing
Visuospatial – appropriate for age:
Copy a design
Draw a person
Draw clock
Name fingers
Left–right and examiner’s left and right

tive functions. Certain screening tests can test selected aspects of frontal lobe function. The patient is instructed to tap twice when the examiner taps once and tap once when the examiner taps twice. A variation is the Go–No Go test in which the patient is asked to tap when the examiner taps once and not to tap when the examiner taps twice. The patient with frontal lobe dysfunction will repeat the motor pattern demonstrated by the examiner rather than following the directions given for the test. Another test is to tell the patient not to grasp the examiner’s hand and then to place your hand in the patient’s outstretched hand. The patient should be able to inhibit the impulse to grasp the examiner’s hand.

### Frontotemporal function: language

Receptive language ability precedes and is more developmentally advanced than expressive language ability. At 12 months the child waves ‘bye-bye’, plays simple games like pat-a-cake or

peek-a-boo, and is able to follow simple directions when a task is demonstrated such as placing a small object in cup or bottle. At this age the child should have two meaningful words, such as mama and dada. By 18 months the child’s vocabulary should include at least 10 words and the child should be able to point to at least one or two pictures such as a cat or dog or other common or well-known animals or objects. The child should also be able to point to two body parts when asked. By 24 months of age the child should have a 50 word vocabulary and speak in two word phrases. By 3–4 years of age the child should speak in 3–4 word sentences, using prepositions and pronouns.

The older child can be tested for age-appropriate reading and writing skills. Language assessment is most often thought of as assessing dominant cerebral hemisphere function, but the affective and emotional aspect or prosody of language is a nondominant cerebral hemisphere function. The child should be able to comprehend and express these important prosodic elements of language. Does the child understand and express emotions in language such as anger, joy, and sadness as well as the inflections used in questions and exclamations?

### Temporal lobe: memory

The hippocampi of the temporal lobes participate in the formation and consolidation of new memories. Recent memory can be tested by asking the older child or adolescent to remember three unrelated items, such as banana, twelve, and paper cup, and 3 minutes later asking the child or adolescent to recall those items. Younger children can be shown three pictures to remember and then later asked to identify the pictures from a larger selection of pictures. Episodic memory can be tested by asking the child to recall recent personal events, such as the most recent meal. Semantic knowledge can be tested by asking the patient age-appropriate questions, such as the names of important historical figures, nonpersonal historical events, or recent news items.

## Parietal lobe: visual spatial processing

The parietal lobe function is assessed in three domains, discriminatory somatosensory function, visual spatial processing, and symbol/spatial sequencing. Discriminatory somatosensory processing is assessed by having the child close his/her eyes and name numbers that are drawn on the child's hand (graphesthesia) or identify familiar objects placed in their hand (stereognosis).

The nondominant parietal lobe subserves visual spatial processing. Patients with lesions in this part of the brain will often neglect the side opposite to the involved hemisphere and have trouble drawing figures. Subtle neglect can be detected by double simultaneous stimulation. With eyes closed, the patient is asked to identify if they are being touched on the right, left, or both sides. The patient may correctly identify single right and left touch but neglect the touch contralateral to the involved parietal lobe with simultaneous touch. The complexity of drawn objects is age dependent (textbox).

### Drawing tasks for screening parietal lobe function

Age	Object
3 years	circle
4 years	cross
5 years	triangle
6 years	diamond
9 years	cylinder
11 years	box

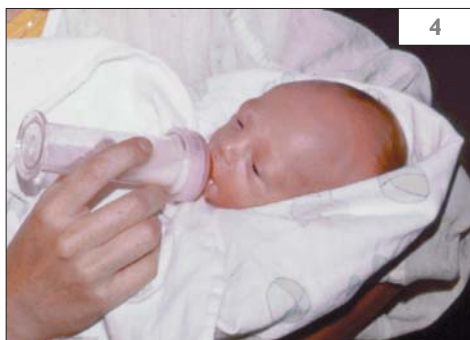The dominant parietal lobe is important for symbol and spatial sequencing tasks such as right-left identification, finger naming, math, and writing. Testing for these abilities is age dependent.

## Cranial nerves

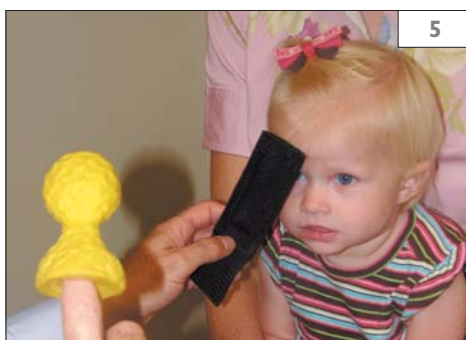The cranial nerve examination provides a view of the neuraxis from the level of the olfactory tracts and optic nerves in the telencephalon to the level of the hypoglossal nerve nucleus in the medulla. Cranial nerve findings combined with long tract signs (such as corticospinal or somatosensory tracts) have powerful localizing value. Clinicians can become frustrated because of the lack of cooperation when examining the cranial nerves of the infant and young child. Even in the totally uncooperative newborn, however, most cranial nerves can be assessed by watching the infant's spontaneous activity and response to stimuli (*Table 5*). This section focuses on the cranial nerve examination and the adaptation of the examination to the developmental level of the child.

**Table 5 Cranial nerve examination in infants**

Cranial nerve (CN)	Testing
CN2	Observe the response to bright light (blink) Elicit the red reflex (present and symmetric)
CN3, 4, 6	Inspect for the eyes aligned in conjugate gaze Perform the Doll's eye maneuver (rotate head in horizontal and vertical planes and observe conjugate eye rotation in the opposite direction) Elicit the pupillary response (CN2 and 3)
CN5	Observe suck (4) Test the corneal reflex; watch for a grimace with a nasal tickle
CN7	Observe the face during grimacing and crying
CN8	Observe the behavioral response to loud noise
CN9, 10	Assess suck and swallow with feeding; suck on pacifier, the quality of cry; elicit the gag reflex
CN11	Observe the symmetry of neck movements, head control
CN12	Observe tongue movement during sucking



**4** Watching a newborn feed assesses alertness and cranial nerve function.



**5** Cover test using a finger puppet to keep the child's attention.

### Olfactory nerve (CN1)

Examining the olfactory nerve is unfeasible until the child has the cognitive and language capacity to identify odors. For the older child, a small container of a substance, such as lemon, orange, or vanilla flavoring, that emits a non-noxious odor can be used. With eyes closed the child is asked if they smell something and can identify the smell. Scratch and sniff cards can be used effectively in younger children. Documenting the perception of the smell is more important than actually naming the smell.

### Optic nerve (CN2)

Optic nerve function is assessed in four domains:

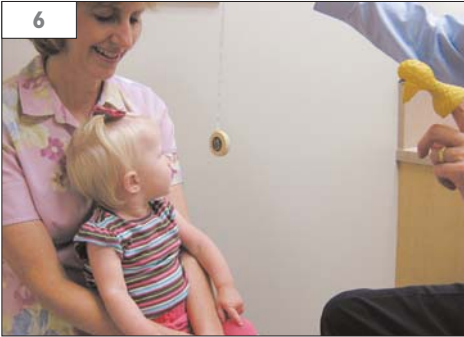- Visual acuity.
- Visual fields.
- Pupillary responses.
- Funduscopy.

Visual acuity for the child 4 years and older can be assessed by using the tumbling E or animal picture Snellen chart. For the younger child who is verbal, the examiner can ask the child to identify small objects. For the preverbal

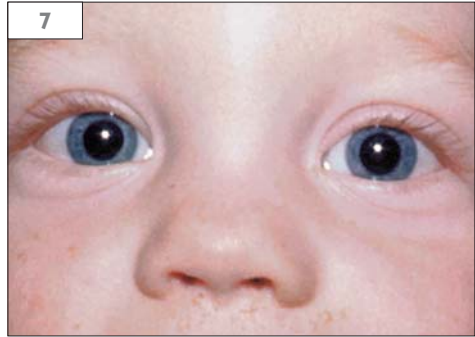infant, the examiner can present the infant with small objects and observe visual fixation and eye tracking movements. The clinician can cover one eye, then the other, while the infant looks at an object (5). If there is decreased visual acuity in one eye, the infant will resist having the eye with normal vision covered. If the child is visually inattentive, then assessment by an ophthalmologist is required.

Visual fields are assessed by confrontation. Each eye is ideally tested separately, but for screening purposes both eyes can be tested together. The simplest way to test the verbal child is to ask the child to focus on the examiner's nose while facing the child. Holding up both hands to the side, superiorly and inferiorly, he asks if the child can see normal hands on both sides out of the corner of their eye. Another technique is to have the child look at the examiner's nose and ask him to say 'now' as soon as he sees the tip of a cotton applicator move into his side vision. For the infant who can't cooperate, attract the infant's attention to a colorful object held in front of him and then use a dangling measuring tape and slowly move the tape from outside of his peripheral vision towards the midline. When the infant notices the tape he

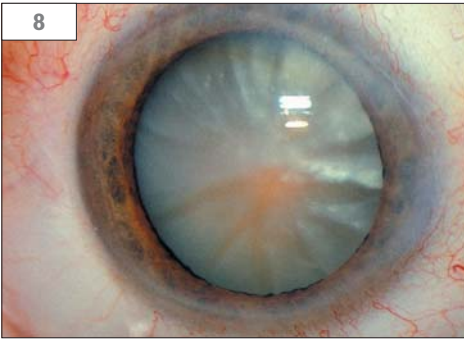




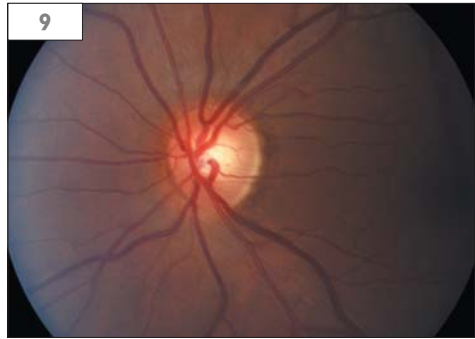6 Using a dangling tape and a finger puppet to assess visual fields.



7 Assessing for pupillary symmetry in a young child.



8 A congenital cataract obscures the red reflex.



9 A normal-appearing fundus. Note the color and shape of the optic nerve.


will turn his head and look at it (6). This technique is most valuable when there is asymmetry in the response. Formal perimetry may be required for accurate detailed visual field testing.

Pupillary light response tests two cranial nerves. The afferent limb of the reflex depends on the perception of light by the optic nerve (CN2) while the efferent limb is mediated by the parasympathetic nerves that are associated with the oculomotor nerve (CN3). Use a flashlight in a dimly lit room to test the child's direct and consensual pupillary constriction. If the pupils are unequal and direct pupillary constriction is absent, an oculomotor lesion is most likely. If both pupils are equal, but one pupil constricts less to light, an optic nerve lesion is present causing less light perception. This phenomenon,

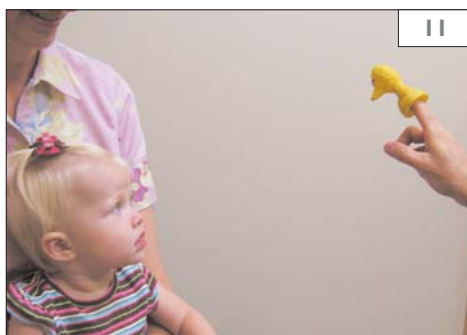
known as an afferent pupillary defect, can be detected best by the swinging flashlight test. The flashlight is swung slowly back and forth from eye to eye. The pupil of the eye with the afferent defect will dilate when the flashlight strikes the affected eye, indicating impaired transmission of light by the optic nerve.

The last element of examining CN2 is using the ophthalmoscope to view the optic disk and the fundus. The first step is to elicit the red reflex. In uncooperative infants or children this may be the only thing that is accomplished by the clinician. When viewed through an ophthalmoscope held approximately 24 inches (61 cm) in front of the child, the pupils should appear uniformly round and red (7). Color asymmetry can be caused by any opacity between the surface of the eye and the retina,





10 Inspecting for symmetry of the pupils and palpebral fissures.



11 Testing extraocular movements using a finger puppet.

such as a cataract (8) or retinoblastoma, or by near or far sightedness. Asymmetry of the red reflex must be further evaluated by an ophthalmologist.

After the red reflex is assessed, the examiner focuses on the retina and notes the appearance of the optic disk, the cup, the vessels, and the retinal background (9). The optic disk will appear pale yellow or nearly white if there is atrophy. A small optic disk with a double ring sign indicates optic nerve hypoplasia. Every child who presents with headaches or signs or symptoms suggesting increased intracranial pressure must have an adequate fundoscopic examination to determine if papilledema is present (textbox).

#### Key findings in papilledema

- Loss of venous pulsations.
- Venous engorgement.
- Disk hyperemia.
- Blurring of disk margins.
- Flame hemorrhages.
- Loss of physiological cup.

All infants with suspected nonaccidental trauma must have a fundoscopic examination to look for retinal hemorrhages. Examination of the retina can detect chorioretinitis, indicating congenital infections, peripheral pigmentation, suggesting retinitis pigmentosa, or lacunar retinopathy, suggesting Aicardi syndrome. If an adequate view of the fundus cannot be obtained, referral to an ophthalmologist should be considered.

### Oculomotor, trochlear, and abducens nerves (CN3, 4, and 6)

These three cranial nerves control eye movements and are considered together because they are assessed together. The oculomotor nerve innervates the eye muscles for adduction (medial rectus), elevation (superior rectus and inferior oblique), depression (inferior rectus), and elevation of the eyelid (levator palpebrae superioris). Parasympathetic nerves for the pupil also accompany CN3. The abducens nerve innervates the lateral rectus for abduction of the eye, and the trochlear nerve innervates the superior oblique muscle which is essential for looking down and inward toward the midline.

The first step in assessing these cranial nerves is to observe the child with the eyes looking straight ahead. The eyes should be aligned and the light reflex should be on the same location of each cornea. The pupils should be equal and the width of the palpebral fissures should also be equal (10). The eye movements are then tested by having the child follow an object that is moved through the six cardinal positions of gaze (textbox [overleaf] and 11).

**Cardinal positions of gaze and the eye muscles tested**

- Right up: right superior rectus and left inferior oblique.
- Right: right lateral rectus and left medial rectus.
- Right down: right inferior rectus and left superior oblique.
- Left up: left superior rectus and right inferior oblique.
- Left: left lateral rectus and right medial rectus.
- Left down: left inferior rectus and right superior oblique.

If the corneal light reflex is not symmetric, the clinician should suspect strabismus. Strabismus can be paralytic or nonparalytic. Paralytic strabismus is caused by a cranial nerve palsy, while nonparalytic strabismus is caused by misalignment of the eyes but with intact and full action of the eye muscles. The difference can be sorted out by using versions (testing the six cardinal positions with both eyes together) and ductions (testing each eye individually with the other eye covered). With paralytic strabismus the abnormal eye movement will be present on both version and duction testing. With nonparalytic strabismus misalignment is seen on versions, but full range of motion is observed for each eye with ductions. Nonparalytic strabismus in children is rarely caused by neurological conditions, but can cause amblyopia; such children should be evaluated and managed by an ophthalmologist.

With an oculomotor palsy the affected eye will deviate down and out; adduction, elevation, and depression of the eye will be limited. If there is compression of CN3, ptosis and pupillary dilation occur ipsilaterally. A CN3 palsy from ischemia often spares the pupil and causes minimal ptosis. When a CN4 palsy is present the affected eye deviates up and sometimes out. The resulting diplopia is maximum when the child looks down and toward the midline. The head is tilted to the opposite shoulder in order to minimize the double vision. For a CN6 palsy, the affected eye usually has some degree of medial deviation and cannot be fully abducted. The child will turn his head to the side of the affected CN6 to reduce diplopia. Diplopia is usually the result of an acquired lesion of CN3,

4, or 6 (textbox), and occurs because the viewed image no longer falls on the corresponding areas of both retinas; therefore, the brain interprets this as two images instead of one.

**Rules for determining the cause of diplopia**

- Diplopia is greatest when gazing in the direction of the paretic muscle.
- The ghost image is always the most peripheral image.
- Weakness of the medial or lateral rectus muscles causes horizontal diplopia.
- Weakness of the depressor or elevator muscles (inferior or superior oblique and/or inferior or superior rectus) causes vertical diplopia.

When presented with a child with unequal pupils and ptosis, the clinician must decide if the abnormality is a pupil that is too small or a pupil that is too large (textbox).

**Distinguishing between Horner syndrome and oculomotor palsy**

- Horner syndrome: mild ptosis; small, reactive pupil; normal eye movements.
- Oculomotor palsy: prominent ptosis; large, unreactive pupil; restricted eye movements.

**Trigeminal nerve (CN5)**

The trigeminal nerve has both sensory and motor components. The sensory component consists of three divisions (ophthalmic, maxillary, and mandibular); somatosensory function of each is tested with light touch and sharp/dull discrimination. The ophthalmic division (V1) is sensory for the forehead as well as for the cornea and the mucosa of the nose. The corneal reflex tests both the sensory afferent limb (V1 of CN5) and the motor efferent limb (branches of CN7). The edge of the cornea is lightly touched using a small thread of cotton formed from a cotton tip applicator (12). A cotton tip applicator can also be used to irritate the nasal mucosa which tests the integrity of V1 and causes grimacing and eversion from the stimulus. The maxillary (V2) and

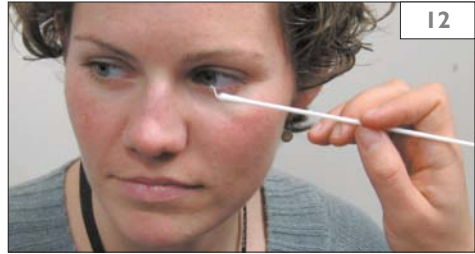mandibular (V3) divisions are tested for sharp/dull sensation over the cheek and jaw, respectively.

The major muscles supplied by the motor division of CN5 include the temporalis, masseter, and pterygoid muscles. The temporalis and masseter muscles can be palpated as the child clenches the teeth or bites down. They are also tested as the child opens and closes the mouth or when the child keeps the mouth open as the examiner attempts to close it by pushing up on the chin. When unilateral weakness is present, the jaw deviates to the side of the weakness. In young children who won't cooperate, motor assessment of this cranial nerve consists only of palpating the muscles and observing spontaneous jaw movement or movement with chewing and eating.

The examination of CN5 should also include assessment of the jaw jerk. The examiner places his finger on the jaw and taps it with a reflex hammer (13). Usually there is very little reflex movement of the jaw. If there is prominent palpable and observable movement, the jaw jerk is considered hyperactive; this may indicate an upper motor neuron lesion or corticobulbar dysfunction as in pseudobulbar palsy (see discussion of pseudobulbar palsy under CN9 and 10).

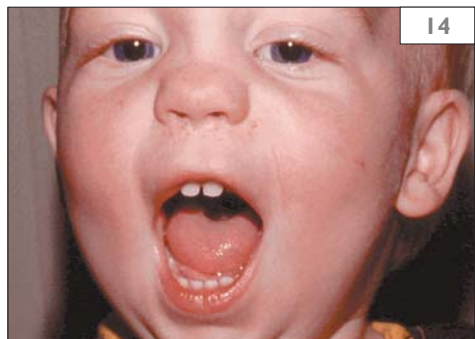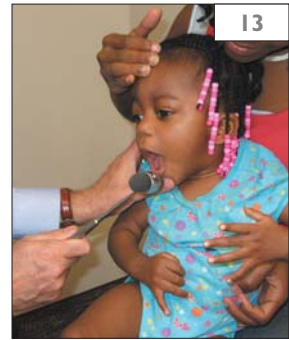
### Facial nerve (CN7)

The facial nerve is examined by watching the child's facial expression particularly when smiling, laughing, or crying (14). If the child is old enough to follow commands and is cooperative, the examiner asks the child to smile, show his teeth, close his eyes tightly, and wrinkle his forehead. Another way to test labial muscle action is to have the child say 'pah-pah-pah'. With lesions at the level of the facial nucleus or nerve (so called, peripheral 7<sup>th</sup>), the child has weakness of all muscles of facial expression ipsilateral to the lesion. With a central 7<sup>th</sup> or corticobulbar lesion affecting the muscles of facial expression, the weakness involves the orbicularis oculi, buccinator, and orbicularis oris muscles but spares the frontalis muscle. The child can still wrinkle the forehead. This finding separates facial weakness due to an upper motor neuron lesion (as might occur in a stroke) from a lower motor neuron lesion (as might occur in Bell's palsy). CN7 also subserves taste to the anterior two-thirds of the tongue.



12 Assessing the corneal reflex using a cotton-tipped applicator.

13 Performing the jaw jerk reflex.



14 Inspecting for facial symmetry in a laughing child.

This sensory function is tested when there is a weakness from lesions of the facial nerve, as in Bell's palsy.

## Vestibulocochlear nerve (CN8)

Unless the child complains of vertigo or unsteadiness, the auditory portion of this cranial nerve is the main focus for a screening neurological examination. Having the child identify whispered words, a ticking watch, or the rubbing of the examiner's fingers are the typical ways for hearing screening. Hearing is compared in the right and left ears. If asymmetry is present, a tuning fork is used to perform the Weber and Rinne tests.

For the Weber test, the tuning fork is struck and placed at the midline of the forehead (15). The vibrations lateralize to the normal ear if there is a unilateral sensorineural hearing loss, and to the involved ear if there is a conductive hearing loss. For the Rinne test, the tuning fork is then struck again and placed on the mastoid bone and held there until the child can no longer perceive any vibrations (16). The examiner then moves the tuning fork over the external ear and asks the child if he or she can hear the vibrations. Because air conduction is more effective than bone, the child should still be able to hear the sound of the vibrating tuning fork. The Rinne test helps to confirm a conductive hearing loss because bone conduction will be better than air conduction. By contrast, the air conduction will still be greater than bone conduction in sensorineural hearing loss. The above screening tests are inadequate, however, to assess accurately auditory nerve function. Any child with suspected hearing loss or language or speech delay must have a formal audiometric evaluation.

With vestibular dysfunction, the child complains of vertigo. The examination reveals nystagmus with the slow component toward the involved nerve and the fast corrective component away from the nerve. Formal testing can be done with a rotational chair and ice water caloric testing. With the latter testing, the slow component of the nystagmus will be toward the irrigated ear, while the fast corrective component is away from the irrigated ear. Ice water calorics are most often done in assessing brainstem function in the comatose child. The comatose child with intact brainstem function will have the eyes deviate toward the irrigated ear, but lacks corrective nystagmus away from the irrigated ear. The corrective or fast component of the

nystagmus is only seen in the conscious patient with intact vestibular function. Lack of the response to ice water caloric testing is one of the criteria used in establishing brain death.

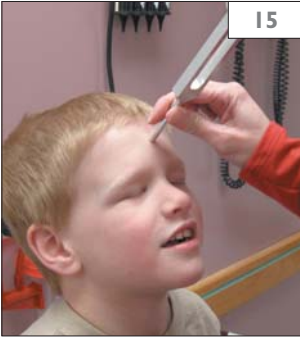## Glossopharyngeal and vagus nerves (CN9 and 10)

These two cranial nerves are considered together because they are tested together. They are tested by asking the child to say 'ah' or 'cah' and observing the palate rise and occlude the nasopharynx (17). If there is unilateral weakness the uvula will deviate away from the side of the lesion and the arch of the palate will be lower on the affected side. With upper motor neuron lesions that affect bilateral CN9 and 10 function, both sides of the palate fail to elevate when saying 'ah' or 'cah', and there is excessive nasalization of the produced sound because of lack of occlusion of the nasopharynx. If the palate fails to rise with volitional activation, then the gag reflex is tested. The gag reflex assesses the sensory afferent limb and the motor efferent limb for CN9 and 10.

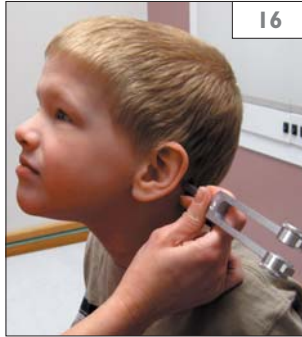With an upper motor neuron lesion, known as pseudobulbar palsy, the gag reflex will be hyperactive similar to the hyper-reflexia of the deep tendon reflexes observed with upper motor neuron lesions. Pseudobulbar palsy is most commonly observed in conditions that cause diffuse upper motor neuron disease, such as spastic quadriparetic cerebral palsy or traumatic brain injury, or in frontal lobe dysfunction. Lower motor neuron lesions causing bilateral CN9 and 10 palsy are unusual because of the bilateral upper motor neuron input to these cranial nerve nuclei. Bilateral lower motor neuron CN9 and 10 palsy can be a complication of Guillain-Barré syndrome (GBS) or Möbius syndrome.

## Accessory nerve (CN11)

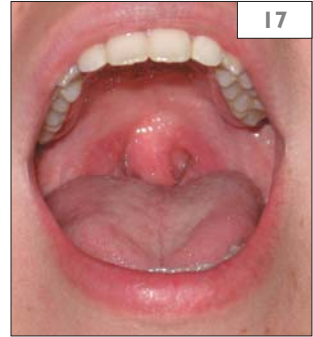The accessory nerve is tested by asking the child to shrug his shoulders and watching the action of the trapezius muscles bilaterally. The sternocleidomastoid muscles are then tested individually by having the child turn his or her head to one side and then the other side against the resistance of the examiner's hand upon the cheek (18). The strength of resistance can be felt and the activated sternocleidomastoid muscle in the neck can be palpated.



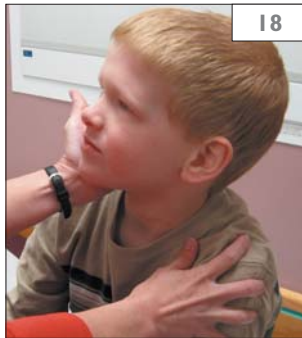**15** Performing the Weber test of hearing. The sound should be heard equally in both ears.



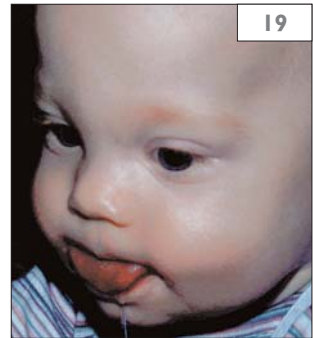**16** Performing the Rinne test of hearing. When the child no longer hears the sound of the tuning fork held against the mastoid (bone conduction), the ability to hear the vibration when the tuning fork is held beside the ear (air conduction) should be preserved.



**17** Assessing palate symmetry and uvula position. Note the midline uvula.



**18** Testing the strength of the sternocleidomastoid muscle by assessing the child's lateral head movement against resistance.



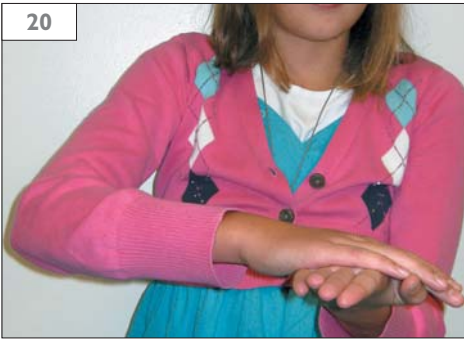**19** Assessing tongue protrusion by watching the child spontaneously extend his tongue.

## Hypoglossal nerve (CN12)

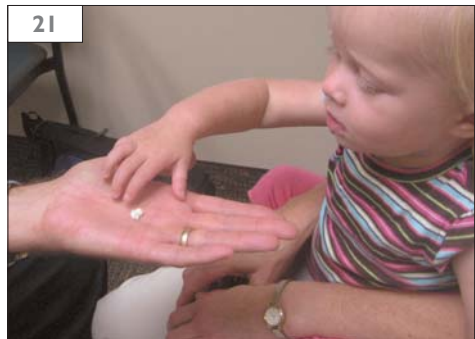The hypoglossal nerve is assessed by inspecting the tongue for any evidence of atrophy and fasciculations; both occur with lower motor neuron lesions. The patient is then asked to stick out the tongue (19). With a lesion of CN12, the tongue will deviate to the side of the lesion. With bilateral upper motor neuron lesions (pseudobulbar palsy) the patient will slowly and incompletely protrude the tongue; side-to-side

tongue movements will be slow and accompanied by jaw movement. A rapid screening test for CN7, 9, 10, and 12 function is to ask the child to repeat several times 'lah-pah-cah'. These sounds require intact tongue, lip, and palate muscles innervated by these CNs.





**20** Having the child perform rapid alternating movements to assess coordination.



**21** Assessing a child's coordination by having her pick up small objects.

## Coordination

The principal area of the brain examined by assessing coordination is the cerebellum and its connections. Incoordination is primarily caused by cerebellar disorders, but there are other causes, including vestibular dysfunction and weakness. Although the cerebellum is increasingly recognized as important in nonmotor brain function, including cognition, coordination is the main cerebellar function assessed during the formal neurological examination.

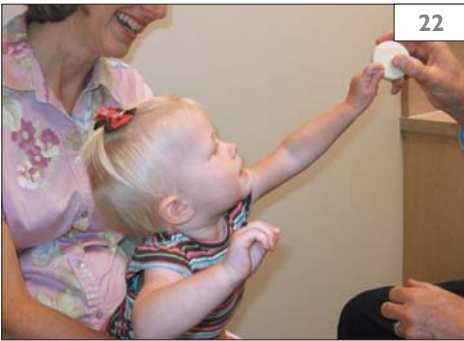The cerebellum controls the timing of agonist and antagonist muscle contraction across multiple joints to ensure smooth, flowing goal-directed movements. When cerebellar dysfunction occurs, goal-directed movements become uncoordinated, and missed timing of muscle contraction results in overshooting and undershooting of the intended movement. Terms used to describe these uncoordinated movements include dysmetria and ataxia.

The cerebellum supports the integration of sensory input to correct and modulate motor output. The ability to experience cerebellar dysfunction depends upon the maturity of the motor systems supported by the cerebellum. Testing coordination, for example, is not even part of the newborn neurological examination. Cerebellar assessment awaits the acquisition of fine motor skills. As the baby acquires a pincer grasp and begins to manipulate small objects, fine motor testing assumes the characteristics of coordination testing. Maturing of the cerebellar system can be seen as the infant progresses from sitting without support to cruising (taking steps

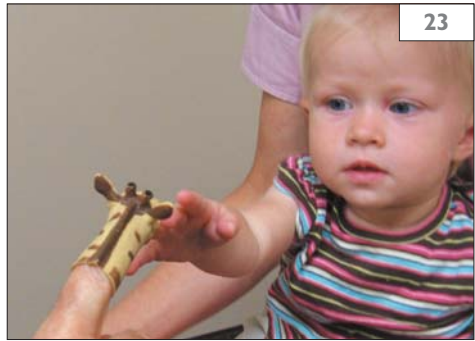with support) and then walking independently with a wide-based or toddler's gait. At 3 years of age, the child is able to balance on one foot, and at 4 years the child can hop on one foot. By 6 years of age most children can narrow their station (stance) to the point of being able to tandem walk and maintain sufficient balance to ride a bicycle. Thus, cerebellar testing must take into account the developmental level of the child and the acquisition of normal milestones.

Ataxia can be thought of in terms of two main categories: gait and truncal ataxia or appendicular (extremity) ataxia. Stability of the trunk and coordination in walking is predominantly a function of the midline structures of the cerebellum (the vestibulocerebellum and spinocerebellum). By contrast, fine motor coordination of the extremities is the function of the cerebellar hemispheres (neocerebellum). Testing of cerebellar function is usually directed toward assessment of the extremities and then assessment of trunk stability and gait coordination. The standard tests for appendicular coordination include repetitive finger and foot tapping, front-to-back hand patting (20) (diadochokinesia), finger-to-nose and heel-to-shin testing. Trunk and gait assessment is accomplished by observing the child get in and out of a sitting position, noting stability in the sitting and standing positions, and watching the child walk and performing age-appropriate skills such as hopping, walking tandem, or balancing on one foot.

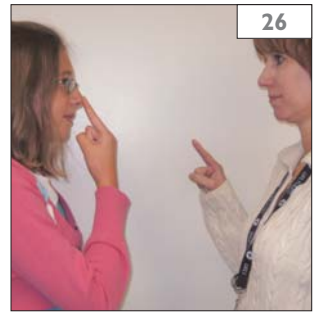For the older child, the standard coordination examination can be used, but adaptation is needed for the infant and toddler. The key is to



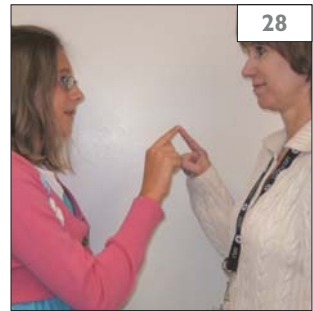**22** Assessing for coordination by having the child reach for an object.



**23** Using a finger puppet to assess cerebellar function akin to the finger-to-nose test.



**24–28** Assessing the finger-to-nose maneuver in an adolescent. The movements should be performed smoothly and accurately.



engage the child in playful activities that will interrogate coordination. For example, picking up a small object such as a small wad of paper can be used for testing extremity fine motor coordination (21). The child can reach for and grasp the examiner's reflex hammer or the end of the measuring tape (22). For finger-to-nose testing, ask the child to touch the nose or eyes of a finger puppet and then to touch their own

nose (23). Older children and adolescents can perform standard finger-to-nose testing (24–28). Using blocks or other stacking toys is another useful assessment strategy. Because the under- and over-shooting movement of ataxia resembles a tremor, this type of ataxia is often called an intention or ataxic tremor. This tremor is greatest at the end point or the most demanding part of the movement.

## Sensory examination

Two somatosensory pathways are examined during the sensory examination: the spinothalamic and the dorsal column–medial lemniscus system. The spinothalamic system is tested by assessing responses to painful stimuli (such as a pin prick) and temperature. The dorsal column–medial lemniscus system is tested by assessing vibratory, position sense, and discriminatory sensation. In order for these tests to be useful, the child must be old enough to cooperate and to report what they are subjectively experiencing. Because of this, sensory examination is difficult to perform and often neglected in young children.

For children, the sensory examination is most important in suspected spinal cord or peripheral nerve conditions. Much of the time, the sensory examination of the young child assesses only whether the child localizes touch or pin prick and if there is an appropriate affective response. Demonstrating a lack of appropriate response in a peripheral nerve, dermatome, or sensory level pattern can be very helpful in making an anatomical diagnosis.

For the infant or young child, useful sensory dependent reflexes are the anal wink and the cremasteric reflex. The anal wink consists of sphincter contraction when the skin adjacent to the rectal sphincter is pricked with a pin. The cremasteric reflex is seen when the skin of the inner thigh is stroked with a cotton tip applicator and the ipsilateral testicle retracts upward. The afferent sensory limb of these reflexes must be present in order to obtain them. The Romberg, a test of dorsal column function, becomes important when a child has gait ataxia. The child must be old enough to cooperate and be able to stand still with his eyes open and closed (29). If he or she can stand still with the eyes open, but becomes unstable or falls when the eyes are closed, this indicates abnormal proprioception, and is considered a positive Romberg sign.

## Motor examination

The elements of the motor examination include assessment of tone, strength, and reflexes (textbox).

- Inspection and palpation of muscles.
- Assessment of tone:
  - Postural tone/range of motion.
  - Phasic tone/muscle stretch (deep tendon) reflexes.
- Muscle strength testing.
- Observation of muscle stretch (deep tendon) reflexes.
- Assessment of developmental reflexes, including:
  - Primitive reflexes.
  - Postural reflexes.
- Assessment of motor milestones.
- Detection of pathological reflexes.

## Inspection and palpation

The motor examination begins with inspection of muscle mass. The examiner must look for growth disparity of the extremities as well as evidence of atrophy of individual muscles or groups of muscles. Prominent atrophy plus fasciculations indicate a lower motor neuron lesion. The pattern of the atrophy can indicate a peripheral nerve, nerve root, or an upper motor neuron lesion. Although atrophy and contractures are most prominent with anterior horn cell, nerve, and muscle disease, they can be seen with upper motor neuron disease as well. With an upper motor neuron lesion that occurs early in life there is often decreased muscle mass and impaired growth of the involved extremity with the distal growth more affected than the proximal growth. If there is weakness, it is important to palpate the muscle. Muscle tenderness can accompany inflammatory myopathies such as dermatomyositis. Calf muscles may have pseudohypertrophy and a woody or rubbery consistency in Duchenne–Becker muscular dystrophy (DMD).

## Assessment of tone

Tone indicates the resistance of the resting muscle to stretch. Clinically there are two types of tone: postural tone and phasic tone. Postural tone, the bias or tension maintained by the muscle to resist gravity, is assessed by putting the relaxed muscle through a passive range of motion (30). When there is too much resistance, hypertonia is present. Hypertonia



usually results from upper motor neuron or basal ganglia disease. Spasticity, hypertonia from upper motor neuron disease, is rate and force dependant, while rigidity, hypertonia from basal ganglia disease, is constant throughout the range of motion and not dependent on the rate or the force of the range of motion.

When the child has too little resistance to passive movement, hypotonia is present. Hypotonia is usually seen with disease of the motor unit (anterior horn cell, nerve, and muscle). Common exceptions are the hypotonias from upper motor neuron disease in young infants and children or immediately after acute lesions at any age. When hypotonia results from upper motor neuron lesions, it is called cerebral or central hypotonia. This type of hypotonia occurs acutely in infants with hypoxic–ischemic encephalopathy and chronically in those with congenital brain malformations, chromosomal disorders, metabolic disease, or cerebral palsy. Hypotonia from a central etiology can be distinguished from a neuromuscular cause by assessing tone variability and phasic tone.

Phasic tone is assessed by delivering a quick, brisk stretch to the muscle which results in a fast, brief contraction of the corresponding muscle. By striking a muscle tendon with a reflex hammer, the deep tendon reflex (DTR) (also known as a muscle stretch reflex [MSR]) is elicited. With upper motor neuron diseases resulting in spasticity or central hypotonia, the DTRs are present and typically hyperactive. With hypotonia of neuromuscular disease, the DTRs are absent or decreased. Variability of tone also allows the clinician to distinguish central from neuromuscular hypotonia. With neuromuscular hypotonia the low tone is invariable, while tone in central hypotonia can be variable. When a child with central hypotonia becomes upset or irritated, the tone increases and the child often stiffens. Pathological reflexes, such as the Babinski signs, are often observed in children with central hypotonia.

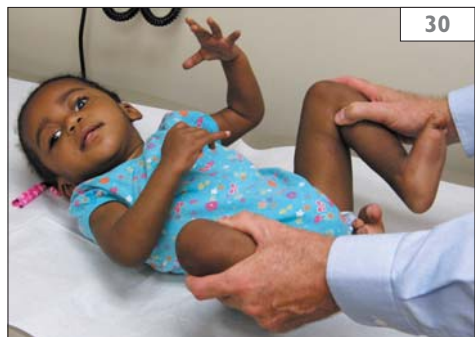Obtaining accurate DTRs in infants and children is an art. The muscle being tested should be positioned so that it is midway in its usual range of motion. This provides some background tension in the muscle. The child must be relaxed and not tensing the muscle or fighting the examiner who is trying to obtain the reflex. This can be difficult if the child is

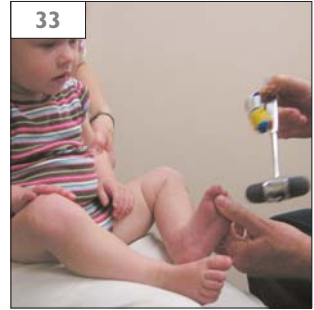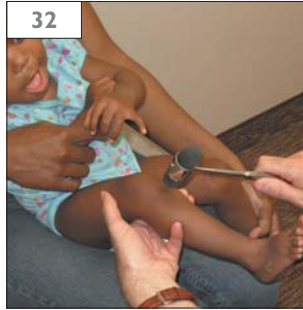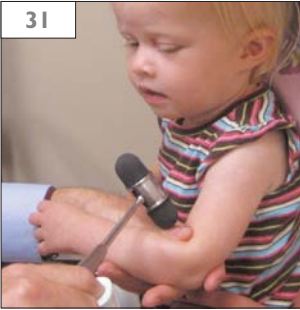apprehensive about being struck with the reflex hammer. The child's fears can be calmed by converting the process into a game. The reflex hammer can be an imaginary toy or a means to elicit the child's 'jumpers'. The examiner can first do the biceps jerk, in which the hammer

**29** The Romberg is tested by having the child stand with his/her eyes closed and hold the hands and arms at the side.



**30** Assessing the tone and range of motion of a young child by alternately abducting and adducting the hips.





31–33 Eliciting the biceps jerk (31), knee jerk (32), and ankle jerk (33).

strikes his or her own thumb as it is held on the biceps tendon (31). Reflexes can be elicited with the child in either the supine or the sitting position, but they are best obtained in the sitting position. When the child is supine, the examiner must place the knee in a semi-flexed position (32). In infants the Achilles tendon response can be obtained easily by placing the examiner's fingers on the ball of the foot and striking them with the foot semi-dorsiflexed (33). The

brachioradialis response, often the most painful, should be saved until last. The reflexes are graded 0–4 according to the briskness of the response (textbox).

**Grading reflexes**

- 0 = absent.
- 1 = decreased but present.
- 2 = normal.
- 3 = brisk but without clonus.
- 4 = clonus.

**Table 6 Testing and root innervation of major muscles**

Upper extremity		
<i>Muscle</i>	<i>Testing</i>	<i>Major nerve root level</i>
Deltoid	Abduction of upper arm	C5
Biceps	Supinated arm flexion	C6
Triceps	Extending forearm	C7
Extensor carpi muscles	Extend wrist	C6, C7
Hand intrinsic muscles	Hand grasp	C8, T1
<i>Lower extremity</i>		
<i>Muscle</i>	<i>Testing</i>	<i>Major nerve root level</i>
Iliopsoas	Hip flexion	L2
Quadriceps femoris	Leg extension	L3, L4
Hamstring muscles	Leg flexion	S1
Gastrocnemius	Foot extension	S1
Tibialis anterior and toe extensors	Foot and toe dorsiflexion	L5, S1

## Muscle strength testing

For the child who can cooperate and follow directions, muscle strength testing is performed as it is in the adult examination. Muscle strength is graded at all ages using the 0–5 scale (textbox). A rapid screen for upper extremity muscle strength is to have the child grasp the examiner's fingers with both hands. The examiner then instructs the child, 'Squeeze my fingers as hard as you can and don't let me move your arms'. The examiner then tests the muscle

strength by moving in directions that force the child to use the various muscles of the upper extremity. The strength of the lower extremity muscles can be assessed well by watching the child lift the weight of his/her own body against gravity and during squat/rise and heel/toe walk. Important muscles to test, their major nerve root innervation, and the method of testing are summarized in *Table 6*.

**Table 7** Maneuvers and positions for infant strength and tone assessment

### Head and trunk control

*Newborn* – in sitting position, the head should come to the upright position at least for a few seconds

*3 months* – some head wobbling but the head is held upright with good control most of the time

*6 months* – sits with a straight back and good head control

### Traction

*Newborn* – while pulling to sitting position, arms should be slightly flexed, mild head lag

*3 months* – no or only slight head lag

*6 months* – when pulled to the sitting position the arms are well flexed, trunk and head are forward

### Ventral suspension

*Newborn* – in the prone position with the examiner's hand under the chest, the head should stay in the same plane, back has some resistance to gravity, and the extremities are semi-flexed

*3 months* – back should be straight, the head extended and looking forward

### Vertical suspension

*Newborn* – holding the baby around the chest, the examiner suspends the baby in the upright position. The baby's shoulder girdle should be strong enough to prevent slipping through the examiner's hands

*3 months* – supports its weight on the feet

### Prone position

*Newborn* – turns the head side-to-side, the extremities should be in flexion

*3 months* – lifts the head 45–90° off the mat, supports weight on the forearms (34)

*6 months* – the chest is off the mat and the weight is on the hands.

### Grading muscle strength

0 = no observable contraction.

1 = slight contraction, but no movement.

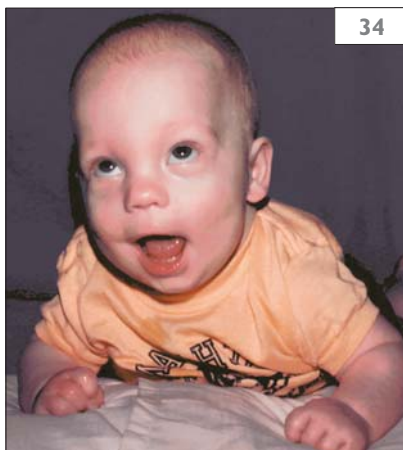2 = full range of motion, but not against gravity.

3 = full range of motion against gravity.

4 = full range of motion against some resistance.

5 = full range of motion against full resistance.

For the child who is too young to cooperate or follow directions, strength testing can be a challenge. Watching the child's spontaneous activity or movements during rolling, sitting, or pulling to stand provide the clinician with useful information regarding strength. Most of the motor assessment of the newborn and the infant is carried out this way. *Table 7* lists maneuvers and positions for strength and tone assessment of these infants. For the older, uncooperative child, strength testing is accomplished by observing the child rise from the floor, climb, walk, run, and play.



**34** Head elevation in a 3-month-old baby.

## Developmental reflex assessment

The newborn infant operates predominantly at a reflex level (textbox). Primitive reflexes should be present, and their absence can indicate significant neurological dysfunction. As the infant's nervous system matures, these primitive reflexes should diminish. By 4–6 months most of the primitive reflexes are gone. As the primitive reflexes are diminishing, postural reflexes are emerging; the earliest postural reflex appears at 3–4 months and the last one appears at 8 months. The postural reflexes are essential for the child to oppose gravity successfully and acquire the ability to walk (*Table 8*). Persistence of primitive reflexes and absence of postural reflexes are important indicators of upper motor neuron lesions in this age group.

### Neonatal primitive reflexes

- Moro: hold baby's head and shoulders off the mat. With a sudden drop towards the mat, the arms will extend, abduct, hands form a C-shape and then arms return to midline.
- Suck, root: strong suck with coordinated stripping action of the tongue. Gently stroking the cheek towards the lips, the baby opens the mouth and turns towards the stimulus.
- Galant (trunk incurvation): hold the baby in ventral suspension and stroke the skin on one side of the lower back. The trunk and hips swing towards the side of the stimulus.
- Grasp: strong grasp with the fingers or toes when pressure is applied to the palm of the hand or ball of the foot.

## Assessment of motor developmental milestones

The development of motor control proceeds in a head-to-toe fashion and reflects the progressive myelination of the corticospinal tracts. The tracts with the shortest length, those controlling head movement and cranial nerve function, are myelinated first. Tracts of intermediate length, affecting the arms and

trunk, are myelinated next. The longest and last tracts to become fully myelinated are those of the lower extremities. Myelination for these tracts typically occurs during the second year of life. Thus, the child's gross motor developmental sequence is head control first, trunk stability and upper extremity control next, and walking and further maturing of the gait last. The latter allows running, hopping, and more demanding motor skills. Acquisition of these milestones occurs at predictable times for the child (textbox), and delay in obtaining motor milestones provides the clinician with important indicators of neurological disease.

### Major motor milestones of childhood

- 2–4 months: rolling over.
- 5–7 months: sitting without support.
- 8–9 months: moving from lying to sitting.
- 9–11 months: cruising.
- 12–16 months: walking.
- 14–18 months: running.
- 3–4 years: hopping on one foot.
- 3–4 years: can ride a tricycle.
- 6–7 years: can ride a bicycle.

## Detection of pathological reflexes

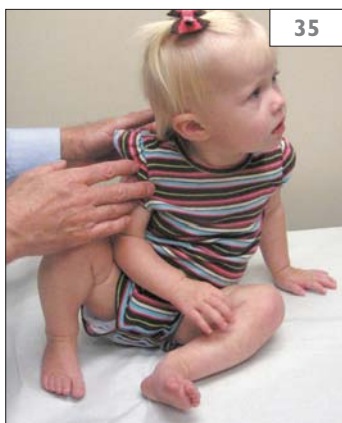The main pathological reflex sought in children is the Babinski sign, the response of the great toe elicited by stroking the plantar surface of the foot. Because of the lack of myelination of the corticospinal tracts for the lower extremities, a Babinski or an up going toe (also called the extensor plantar response) is the normal finding during the first year of life. After the first year of life the great toe should go down on plantar stimulation. The Babinski sign becomes pathological after the first year of life and has greatest utility when the responses are asymmetrical. Proper testing for the Babinski sign consists of firmly stroking the lateral aspect of the foot starting at the heel and moving toward the fifth toe (37). If the medial aspect of the foot is stimulated then a plantar grasp reflex rather than Babinski response is elicited. Confident elicitation of the Babinski response can be extremely challenging in the young child who withdraws the foot during the maneuver.

If the child is old enough to follow directions, the examiner should test for the presence of pronator drift. This sign is sometimes called the pronator Babinski because it has the clinical significance similar to the Babinski sign. The child is asked to extend his or her arms in front with palms up. The child is then asked to close their eyes and to hold the arms still (38). Pronation and downward drift of either arm is abnormal. Pronator drift occurs in corticospinal tract disease because the supinators of the forearm are weak and pronator tone exceeds supinator tone.

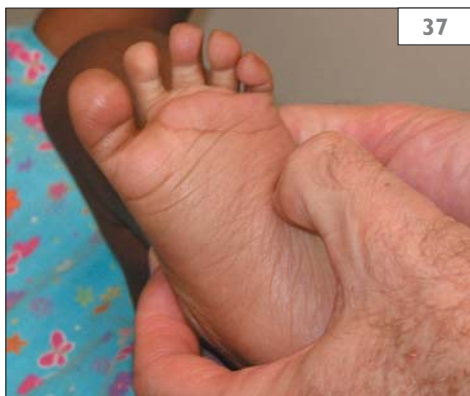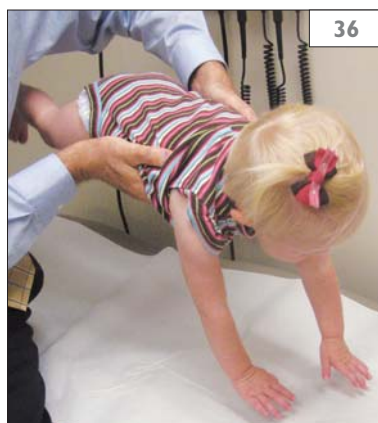**Table 8 Postural reflexes**

Reflex	Age of appearance	Description
Positive support	3–4 months	Infant extends legs and supports his weight when held in the vertical position with feet touching a surface
Landau	4–5 months	In ventral suspension, the infant extends head and legs
Lateral propping	5–7 months	Infant prevents falling to one side by extending the appropriate arm and hand to catch himself (35)
Parachute	8–9 months	When the infant is turned face down and suspended in the air, the arms and hands extend forward toward the mat (36)

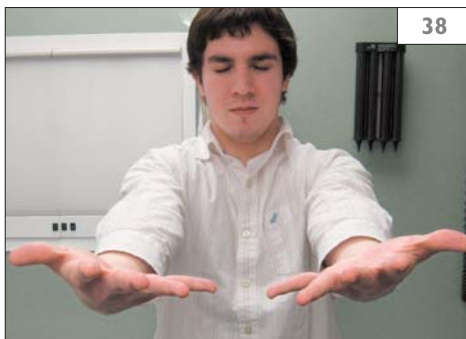
**35** Lateral propping response in a healthy young child.



**36** Using the parachute response to assess the symmetry of upper extremity function.



**37** Eliciting the Babinski sign.



**38** Watching for pronator drift, an upper motor neuron sign, by having the patient stand with their eyes closed and arms extended.

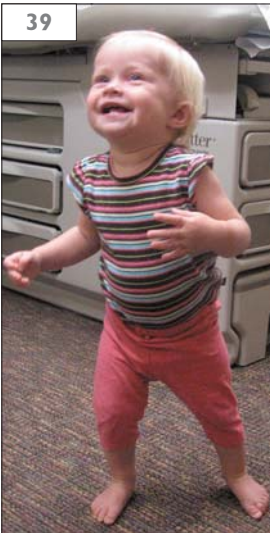

## Gait

Gait must be assessed in the context of development. The infant first develops postural reflexes and then gets in and out of the sitting position and pulls to stand. After cruising, the child begins to take steps on their own at 12–15 months of age. In this early, toddler gait, the station is wide based and arms are held in front in the high guard position (39). During the next few months the station gradually narrows, the gait stabilizes, and arms drop into the mid and low guard positions. By 18 months the arms are held to the side and associated arm swing appears. As the child matures, other gait-related testing can be preformed, such as toe, heel, hop, and tandem walking (40). In conditions such as Angelman syndrome, the gait remains toddler-like (41).

## Conclusions

The neurological examination provides clinicians with a window to the brain. Although the process is an indirect view, the neurological examination, when conducted with anatomical localization in mind, becomes a powerful diagnostic tool. The neurological examination of the child must be couched in the context of age-appropriate neurodevelopmental expectations. Although it can be frustrating to examine an uncooperative child, patience and imagination can transform the examination into a rewarding experience for examiner, child, and parent. Exploiting the child's natural inclination toward play facilitates the successful examination. Many significant neurological findings can be elicited by the simplest of strategies, watching the child walk, talk, and play.



39 A normal toddler's gait.



40 Performing the tandem gait by having the adolescent walk heel-to-toe.



41 A wide-based gait in a young child with Angelman syndrome.

# Neuroimaging

## Main Points

- Several modalities, including magnetic resonance imaging (MRI), computed tomography (CT), and ultrasonography can be used to image the developing and mature brain.
- MRI provides sensitive and accurate information regarding infection, neoplasms, hemorrhage, stroke, developmental malformations, and spinal cord lesions. Infants and young children or uncooperative older children require sedation to achieve optimal MRI studies.
- CT accurately detects hemorrhage, hydrocephalus and intracranial calcifications and can be performed urgently, usually without sedation.
- Ultrasonography provides useful information regarding intracranial hemorrhage and hydrocephalus in neonates and tethered cord or other spinal anomalies in infants <6 months of age. Ultrasonography can be performed at the bedside in unstable infants.
- Pediatric radiologists should be consulted when ordering neuroimaging studies in young children, especially those who require sedation.

## Introduction

Many resources are currently available to image the developing and mature central nervous system. The modalities include: magnetic resonance imaging (MRI) and MRI adjuncts (magnetic resonance angiography [MRA], magnetic resonance venography [MRV], diffusion-weighted magnetic resonance imaging [dMRI], diffusion tensor imaging [DTI] and fiber tracking, perfusion-weighted magnetic resonance imaging [pMRI], magnetic resonance spectroscopy [MRS], and functional MRI [fMRI]); computed tomography (CT), including CT angiography and positron emis-

sion tomography (PET)-CT; nuclear medicine brain imaging (single photon emission computed tomography (SPECT) and PET); magnetoencephalography (MEG); sonography (cranium and spine); and conventional catheter angiography. This chapter describes the modalities and their utility, including their risks and benefits.

Although remarkable advances in imaging technology have been realized among all modalities, MRI and advanced MRI adjunctive techniques have had the greatest impact upon the diagnosis of pediatric neurological disorders. MRI provides an *in vivo* method to evaluate CNS structure, development, and

disease. In addition to allowing exquisite depiction of neuroanatomy, MRI and its adjuncts provide physiological information regarding vascular morphology, flow, tissue perfusion (MRA, MRV, and pMRI), cellular viability (dMRI), cellular biochemistry (MRS), and functional brain activation (fMRI). Additionally, advances in computer hardware and software enable the fusion of large imaging data sets from several imaging modalities, enabling clinicians to superimpose functional information upon high-resolution structural anatomy.

## Patient safety and preparation for imaging

In an age of medical subspecialization and with legitimate concerns over quality, cost, and utilization of imaging technology, the pediatric practitioner must rely heavily on the pediatric neuroimaging consultant to navigate through the maze of diagnostic neuroimaging tests. When questions arise, consultation with a pediatric neuroradiologist is invaluable. Once the decision has been made to proceed with a neuroimaging examination, the successful and safe completion of the diagnostic neuroimaging study rests in thoughtful patient preparation.

The majority of cranial and spinal ultrasound (US) and CT studies last seconds to minutes and can be successfully accomplished without sedation or with distraction techniques (e.g. involvement of play therapists or movie presentations using television monitors or video goggles). MRI and nuclear medicine brain imaging examinations tend to be of longer duration, often requiring 30–60 minutes. In many children between the ages of 4 years and 8 years, motion can be limited by using distraction techniques. Children less than 4–6 years of age commonly require sedation (textbox).

The initial step in obtaining high quality diagnostic neuroimaging studies is for the clinician to determine the necessity for sedation or anesthesia support. When in doubt, consult your medical imaging colleague.

Models for sedating pediatric patients can include the utilization of pediatricians, emergency medicine physicians, hospitalists, intensivists, radiologists, or pediatric nurse practitioners supervised by pediatric anesthesiologists. Pediatric patients with complex medical problems, such as severe developmental delay, obstructive airway symptoms, congenital heart disease, and chronic pulmonary insufficiency, are best served by having their MRI examination conducted under the direct supervision of a pediatric anesthesiologist. Conventional angiography procedures are typically performed using general anesthesia or conscious sedation with agents such as intravenous midazolam or ketamine.

## Magnetic resonance imaging (MRI)

MRI has become an integral component of the evaluation, diagnosis, and treatment surveillance of many pediatric neurological disorders. Prior to entering the MRI scanning environment, the patient and parent will be assessed for any contraindications to performing the MRI, such as the presence of a variety of implantable devices and any history of penetrating trauma with foreign bodies (e.g. BB shot). The neuroradiologist must confirm that a patient with an implantable device or retained foreign body can safely enter the MRI environment (textbox).

MRI can be safely performed on patients with many types of implantable devices including some types of cardiac pacemakers. Certain devices are safe at 1.5 Tesla (T) but not at 3.0 T. See: [www.MRIsafety.com](http://www.MRIsafety.com).

## Conventional MRI

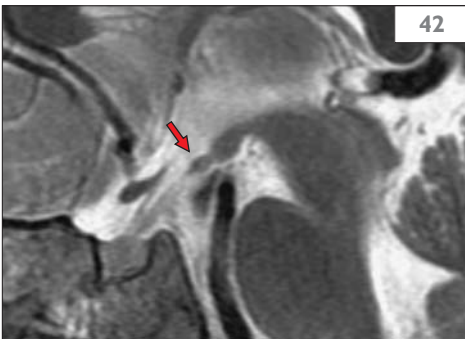
Conventional MRI accurately characterizes brain organization and maturity, demonstrates malformations of the brain and spine, comprehensively assesses traumatic injury to the brain, and characterizes neoplastic, inflammatory, infectious, metabolic, and neurodegenerative disorders. Contrast enhanced MRI contributes additional information in the evaluation of vascular malformations, neoplasms, leukoencephalopathies, complications of



meningoencephalitis, neuroendocrine disorders, and the characterization of CNS vascular morphology and patency (42). However, the modality has some drawbacks (textbox).

Magnetic resonance imaging data are corrupted by the presence of dental braces, intracranial hemorrhage, and patient motion. All create susceptibility artifacts. MRI may miss or underestimate calcification and subarachnoid hemorrhage. Noncontrast CT offers greater sensitivity for calcium.

The common nomenclature are described in *Table 9*.



**42** T2-weighted sagittal MRI showing a small sessile hamartoma of the tuber cinereum (arrow). The child has gelastic seizures.

## Advanced MRI adjuncts

The improvements in MRI hardware and software have made it clinically feasible and practical to complete a comprehensive conventional MRI examination and include MRI adjuncts such as MRS, MRA, MRV, dMRI, DTI, pMRI, and fMRI. Communication between the pediatric practitioner and the pediatric neuroradiologist facilitates a tailored MRI strategy that best answers clinical questions. All advanced MRI adjuncts are more robust at higher MRI field strengths, such as 3.0 T.

## Diffusion-weighted imaging

The rapid acquisition of diffusion-weighted imaging information during the MRI examination (dMRI) adds significantly to the sensitivity and specificity of MRI findings (textbox).

### Diffusion-weighted imaging

- Diffusion-weighted imaging usually requires less than 30 seconds of scanning time and should be included in all brain MRI protocols.
- Diffusion-weighted imaging is a sensitive means to detect hypoxic or ischemic injuries.
- Diffusion-weighted imaging can be corrupted by scalp IV sites, dental braces, and intracranial hemorrhage.

**Table 9 MRI imaging nomenclature**

Notation	Description	Use
T1WI	T1-weighted imaging	Defines anatomy
T2WI	T2-weighted imaging	Detects edema and pathology
GRE	Gradient recall imaging	Detects blood
SPGR	Spoiled gradient recall imaging	3D techniques are particularly helpful to detect cortical malformations
FLAIR	Fluid attenuated inversion recovery	Sensitive to parenchymal lesions close to CSF spaces, good for depicting demyelinating lesions
SWI	Susceptibility-weighted imaging	Detects blood, shear, and slow flow
DWI	Diffusion-weighted imaging	Detects cytotoxic edema, shear strain, abscess characterization
ADC	Apparent diffusion coefficient	Reflects 'true diffusion' restriction
DTI	Diffusion tensor imaging/tractography	Characterizes white matter tracts; used for surgical planning, malformation characterization, assessment of trauma, ischemia

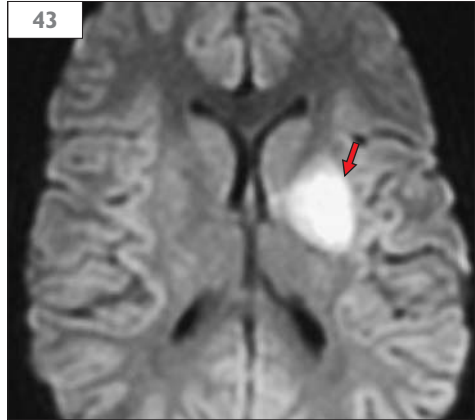
Signal alteration in a diffusion-weighted image relates to diminished random translational movement of water molecules in tissue. Diffusion-weighted signal abnormality and the decrease in apparent diffusion coefficient (ADC) of water in ischemic tissue reflects dysfunction in cell membrane depolarization and resultant intracellular (cytotoxic) edema. Tissue ischemia and infarction are common causes of cytotoxic edema (43, 44). Vasogenic edema (extracellular) is associated with increased ADC values. Other causes of restricted diffusion and low ADC values include: shear strain axonal injury; necrotizing infections (e.g. herpes simplex encephalitis); mitochondrial cytopathies; toxic substances, such as intermediary metabolites and organic acids; highly cellular anaplastic tumors; abscess; empyema; acute demyelination; and congenital tumors such as epidermoid cysts.

### Diffusion tensor imaging (DTI)

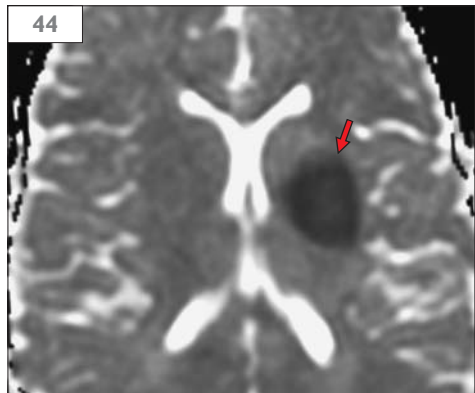
Diffusion tensor imaging (DTI) and fiber tractography provide unique information regarding white matter microstructure and connectivity within the human brain, thus improving the clinician's understanding of developmental anomalies, neurological disorders, and psychiatric conditions. DTI and tractography can be used for mapping eloquent white matter tracts prior to the resection of intracranial masses. DTI and fiber tractography can also characterize developmental malformations such as agenesis of the corpus callosum, holoprosencephaly, and Joubert syndrome. DTI can quantify axonal loss after CNS injury of many causes (45).

### Perfusion-weighted MRI (pMRI)

Current clinical MRI systems operating at 1.5 and 3.0 T field strengths enable perfusion MRI techniques. These techniques can use endogenous (arterial spin labeling) or exogenous contrast (susceptibility-weighted contrast enhanced) techniques to investigate capillary density and angiogenesis. Characterization of relative cerebral blood volume and mean transit time of contrast through tissue reflects tissue capillary density. Perfusion MRI facilitates the evaluation of stroke patients with



43 Diffusion-weighted image showing hyperintense signal in an acute thromboembolic stroke of the left putamen (arrow).



44 Corresponding ADC map to 43 showing hypointense signal reflecting cytotoxic edema (arrow).

diffusion-perfusion mismatch. Here, pMRI can identify the ischemic penumbra of salvageable tissue surrounding the infarct core. Other applications of pMRI include characterization and grading of intracranial neoplasms, discrimination between neoplasm and post-treatment effects such as radiation therapy, distinction of tumefactive multiple sclerosis (MS) from neoplasm, and evaluation of revascularization of the brain following pial synangiosis.

## MRI vascular imaging

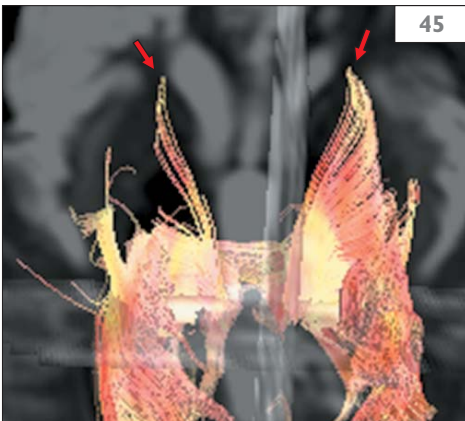
Magnetic resonance angiography (MRA) and magnetic resonance venography (MRV) are useful supplements to MRI and often substitute for catheter angiography in the evaluation of pediatric intracranial vascular disease. MRA reflects the signal generated from protons within flowing blood. Flow direction, blood volume, and velocity of flow affect the quality of signal and the apparent size of the vessel. The MRA techniques most commonly utilized in the evaluation of pediatric neurological disorders are time-of-flight (TOF) MRA, phase contrast angiography (PCA) and, more recently, dynamic time-resolved contrast enhanced MRA. TOF techniques take advantage of differences in signal amplitude between stationary tissue from flowing blood, whereas PCA exploits the difference in signal phase between flowing and stationary spins or protons. Factors that influence the appearance of flow within blood vessels include the direction of flow relative to the plane of imaging, the geometry of vessels, velocity of flow, and the complexity of flow patterns.

At MRI field strengths of 1.5 and 3.0 T, intravenous contrast is usually not necessary to image cerebral arterial vasculature (textbox). However, contrast administration in MRA of the cervical vasculature can be useful. Dynamic

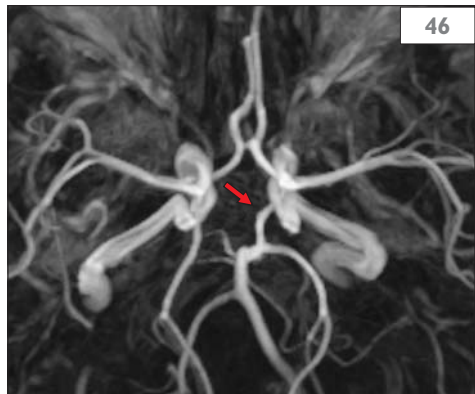
contrast enhanced MRA techniques can visualize the dynamic process of contrast passing through the vascular system. T1 relaxation (T1 shortening) with intracranial hemorrhages may create the false illusion of flow during routine MRA. Therefore, contrast enhanced MRA is preferred in a setting of suspected or known intracranial hemorrhage or dural venous sinus thrombosis. However, gadolinium should be avoided in patients with severe renal failure, given the risk of nephrogenic systemic fibrosis.

The clinical applications of MRA include investigation and evaluation of: developmental vascular anomalies, such as embryonic basilar to carotid artery connections; unusual vessel turns that may mimic an aneurysm or varix; the relationship of tumors to vessels (displacement versus encasement); vessel occlusion; arterial dissection; vasculitis; and suspected arteriovenous malformations (AVMs) (46).

Intracranial MRA can be accomplished without or with contrast. However, evaluation of cervical arterial anatomy and intracranial venous anatomy is best performed using intravenous MRI contrast.

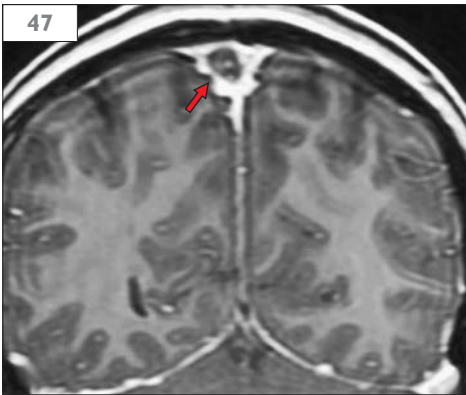


**45** Diffusion tensor tractography showing loss of bifrontal white matter tracts (arrows).



**46** MRA reveals a persistent trigeminal artery (arrow), a remnant of the embryonic carotid to basilar artery connection.

MRV is commonly used to evaluate children or adolescents with suspected dural sinovenous thrombosis. In this setting, contrast enhanced 3D spoiled gradient recall (SPGR) imaging with multiplanar reformations has the greatest sensitivity in detecting venous sinus clots. Contrast enhanced, fluoro-triggered MRV elegantly depicts cortical veins as well as venous sinuses, thus aiding the neurosurgeon in tumor resection and repair of congenital lesions, such as an encephalocele, that may be juxtaposed to venous sinuses (47).



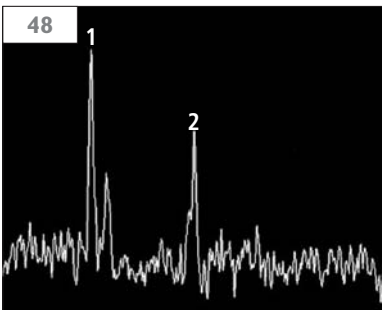
47 Coronal enhanced MRV showing a clot in the sagittal venous sinus (arrow).

## Magnetic resonance spectroscopy (MRS)

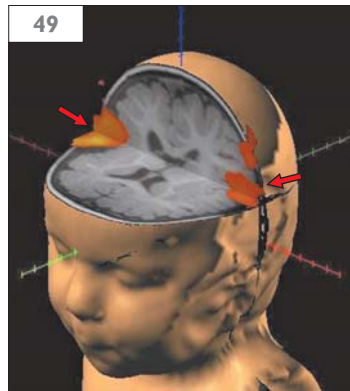
MRS provides an additional window into brain imaging and evaluates brain metabolism *in vivo*. The broad and growing applications of MRS include the evaluation and characterization of brain tumors, metabolic and genetic disorders, epilepsy, chronic infection (especially HIV and subacute sclerosing panencephalitis [SSPE] [48]), demyelinating disorders, hypoxic ischemic encephalopathy, head trauma, developmental delay, and creatine deficiency states. Technical limitations for performing MRS include the presence of dental braces, intracranial hemorrhage, and patient motion.

## Functional MRI (fMRI)

Functional MRI exploits the blood oxygen level dependent (BOLD) technique to detect alterations in the oxy/deoxyhemoglobin ratio following activities (paradigms) that are designed to stimulate areas of the brain. Functional MRI can be used noninvasively to map eloquent regions of brain function prior to resection of tumors or epileptogenic foci. Paradigms can exploit motor function, visual cortical activity, language, memory, and auditory pathways (49). In many pediatric medical centers fMRI has replaced invasive Wada testing (textbox). Some fMRI paradigms can be accomplished in sedated pediatric patients.



48 MRS showing elevated choline (1) and reduced N-acetylaspartate (2) peaks in a child with SSPE.



49 3D functional MRI shows activation of the auditory cortex bilaterally (arrows). (Courtesy of Brandon Zielinski M.D., Ph.D.)

Wada testing, named after the neurologist Juhn Wada, MD, is used to determine which side of the brain subserves language and memory. A short-acting barbiturate is given directly into the right or left carotid arteries during cerebral angiography to anesthetize each side of the brain independently while the child or adolescent is shown objects, pictures, or words. The responses enable the neurologist, neurosurgeon, and neuropsychologist to determine which side is the dominant hemisphere.

## Fetal MRI

Improved MRI software and hardware and clinical scanning at higher field strengths allowing fast scanning sequences enable high-resolution evaluation of the fetus. In many cases, MRI provides considerable information that supplements the commonly performed fetal sonography examination. Before therapeutic decisions are made on the basis of sonographic ‘abnormalities’, fetal MRI should be strongly considered.

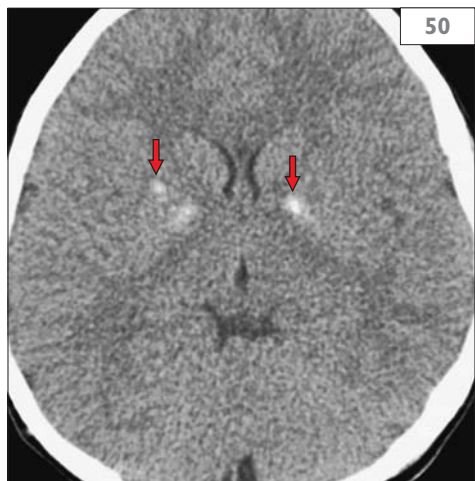
## Computed tomography (CT)

CT remains a highly useful test for evaluating disorders of the brain, orbits, face, neck, and spine. Common nomenclature is shown in *Table 10*. Common pediatric neurological applications of CT technology include trauma to the cranial spinal axis, detection and localization of intracranial hemorrhage and calcium, interrogation of complex anomalies in bony development of the skull, craniovertebral junction and spine, identification of cerebral calcifications (50), investigation of macrocrania, and assessment of ventricular and extraventricular fluid spaces in patients with shunted hydrocephalus.

The utility and benefits of CT in diagnostic imaging are counterbalanced by the knowledge that CT contributes to a patient’s lifetime ionizing radiation exposure. The risk of adverse health effects, including cancer, is proportional to the amount of absorbed radiation (textbox). Concerns regarding the long-term effects of radiation have fostered initiatives to reduce the absorbed dose from medical imaging procedures, especially CT. Current CT equipment allows flexibility for dose modulation and dose reduction while preserving useful diagnostic information.

**Table 10** CT imaging nomenclature

Notation	Description	Use
NCCT	Noncontrast CT	Detects blood, calcium, fractures, and skull base and calvarial malformations
CECT	Contrast enhanced CT	Shows tissue enhancement, venous sinuses, neck and intracranial vessels
CTV	CT venography	Detects venous sinus maldevelopment, clot, or injury
CTA	CT angiography	Identifies arterial dissection, aneurysm, AVM



**50** Noncontrast CT showing focal globus pallidus calcifications (arrows) in a child with hypoparathyroidism.

**Radiation exposure to children**

- Children are considerably more sensitive to radiation than adults.
- Children have a longer expected life than adults, resulting in a larger window of opportunity for radiation damage and tumor development.
- Children often receive a higher dose than necessary when 'adult CT settings' are used. See: [www.imagegently.org](http://www.imagegently.org).

**CT for vascular imaging**

Current multislice CT scanning equipment allows for sub-millimeter slice thicknesses and isotropic reconstructions in multiple planes. This robust, high spatial resolution technology is particularly valuable in the trauma setting for immediate evaluation of vascular injury (dissection, venous sinus disruption, or post-traumatic venous thrombosis) (51). CT angiography (CTA) and venography (CTV) may be used when MR vascular imaging yields equivocal results. Another useful application of CTA is in the preoperative evaluation of complex congenital anomalies of the craniovertebral junction and cervical spine. Here, characterizing arterial to vertebral foraminal relationships may avert an operative mishap.

**Cranial ultrasound imaging**

Cranial US is particularly helpful in newborns and infants up to 6 months of age. The anterior fontanelle, posterior fontanelle, and transmastoid suture are acoustic windows that allow imaging of the developing brain. The major US applications include: investigation for neonatal intracranial hemorrhage and periventricular white matter injury (textbox); evaluation of cerebral edema; screening for cerebral malformations, especially midline malformations, such as agenesis of the corpus callosum; and the investigation of macrocephaly (52). In addition to standard real time imaging, transcranial Doppler sonography can noninvasively measure velocity and pulsatility of blood flow within the intracranial arteries and veins that are more centrally located. The

indications for transcranial Doppler in children include the evaluation of sickle cell disease, moyamoya syndrome and disease, and arteriovenous malformations. In some centers, transcranial Doppler plays a role in the evaluation of suspected brain death. Other indications include the evaluation of intracranial vasospasm following subarachnoid hemorrhage and the characterization of resistive indices in neonates with hydrocephalus.

Cranial sonography provides useful information about the ventricles and periventricular white matter, but limited information about the peripheral brain and adjacent extra-axial spaces.

**Ultrasound imaging of the spine**

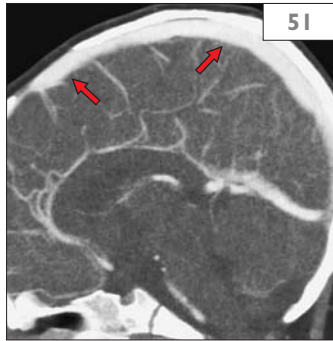US of the pediatric brain and spine is most useful in the newborn and infants in the first 6 months of life. A common clinical indication for spinal US is the evaluation of the newborn or infant up to 6 months of age with suspected occult spinal dysraphism. US of the lumbosacral spine can detect tethered cord and intraspinal lipoma or neural tube defects (53). However, MRI remains the preferred imaging modality for complex lumbosacral skin abnormalities, such as verrucous hemangioma, combination of dermal sinus and hemangioma, or dermal sinus alone.

**Magnetoencephalography (MEG)**

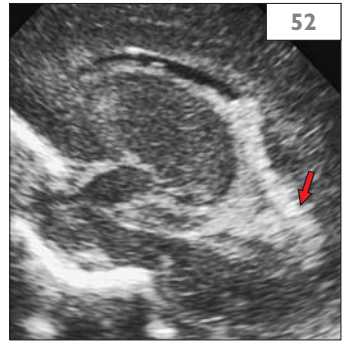
This noninvasive imaging technique measures the magnetic fields produced by electrical activity in the brain. An instrument known as a biomagnetometer detects small magnetic fields within the periphery of the brain. Mathematical algorithms applied to the data allow for relatively accurate estimation or mapping of the source of the field in three dimensional space. MEG thus provides information that is entirely different from that of CT or MRI. The latter modalities provide structural and/or anatomical information, whereas MEG provides functional mapping information regarding potential



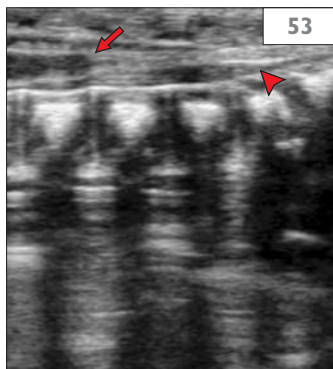
**51** CT venography shows homogeneous enhancement of the sagittal venous sinus (arrows).



**52** Cranial sonography in a 7-day-old baby with an intraventricular hemorrhage (arrow).

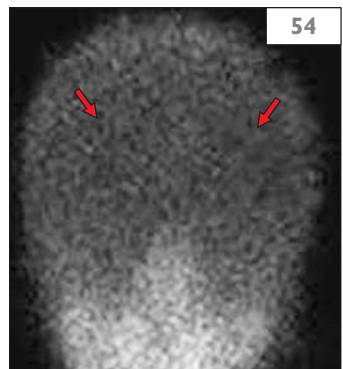


**53** Prone spinal sonography of an infant of a diabetic mother shows a truncated termination of the conus medullaris at L3 (arrow) and thickening of the filum terminale (arrowhead). At surgery a thickened fibrolipomatous filum was found.



**54** Nuclear medicine brain death assessment.

Anteroposterior early flow image from a TC-HMPAO scan shows no intracerebral blood flow (arrows).



epileptiform discharges. When superimposed upon 3D SPGR high-resolution brain MRI, the MEG information provides accurate anatomical localization of the electrical fields emanating from the brain. MEG applications include: localizing the origin or pathological substrate for seizures; assisting researchers in determining the functions of the various parts of the brain; and providing neurofeedback.

## Nuclear medicine brain imaging

Select nuclear medicine brain imaging techniques detect brain perfusion and metabolism and neurochemistry (54). The most highly developed techniques are single photon emission computed tomography (SPECT)

and positron emission tomography (PET). Currently, SPECT offers spatial resolution similar to PET imaging. Many of the SPECT and PET tracers take advantage of the tight coupling between cerebral perfusion and metabolism. SPECT tracers, such as technetium-99-m-hexamethylpropylene amine oxime (Tc-HMPAO), are extracted by brain tissue on the first arterial pass after intravenous injection and remain within the brain for several hours. This allows the patient to be imaged within hours of the administration of the radioisotope. SPECT imaging has been most useful in identifying a seizure focus. During or immediately after a seizure (the ictal period), the epileptogenic focus demonstrates *increased* nuclear medicine tracer uptake. Between seizures (the interictal period) the seizure focus shows *reduced* tracer uptake, indicating reduced

perfusion or metabolism. PET displays similar features, although clinically useful information is usually derived from areas of reduced cerebral metabolism. Current PET radiopharmaceuticals include fluorine-18 (F-18) fluorodeoxyglucose (FDG) (18-FFDG PET), 11-carbon (C)-flumazenil PET (useful in temporal lobe epilepsy) and  $\alpha$ [11-C] methyl-L-tryptophan PET (used to identify epileptogenic tubers in tuberous sclerosis). Finally, SPECT and PET images can be coregistered with either CT or MRI to create multimodal images of function and anatomy.

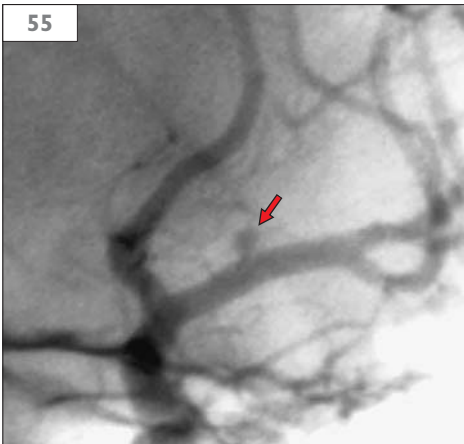
tumors; petrosal venous sampling in patients with Cushing syndrome; and venous sinus manometry for the evaluation of pseudotumor cerebri. In addition, catheter angiography has important therapeutic applications, including embolization of tumors and vascular malformations, clot removal in the setting of venous thrombosis, and coil occlusion of congenital vascular abnormalities, such as vein of Galen malformations. The development of spiral 3D angiographic techniques have shortened examination time and diminished radiation dose and contrast requirements.

## Catheter angiography

In many clinical situations, MRA, MRV, and CTA have supplanted catheter angiography. However, there remain several important indications for catheter angiography (textbox). These include: the initial characterization and follow-up evaluation of vascular malformations (55); the demonstration and stenting treatment of suspected arterial injuries (dissection and pseudoaneurysm); the preoperative evaluation and transcatheter treatment of highly vascular

### Catheter angiography

- Risk of femoral artery occlusion after catheter angiography rises in children less than 10 kg.
- General anesthesia is commonly necessary in pediatric patients who require cerebral angiography.
- AVM flow characteristics and associated abnormalities (aneurysm, varix, and stenosis) are best evaluated with catheter angiography.



**55** Catheter cerebral angiogram, oblique anteroposterior; midarterial image shows a small saccular aneurysm off the left middle cerebral artery.



# Electrophysiological evaluation of infants, children, and adolescents

## Main Points

- Clinicians should understand common electrophysiological procedures including: brainstem auditory evoked potentials, polysomnography, electroencephalography, and electromyography.
- Electroencephalography is useful in the evaluation of the following:
  - Suspected seizures.
  - Unexplained alterations of consciousness.
  - Unexplained encephalopathy.
  - Evaluation for neurosurgical procedures.
  - Suspected brain death.
- An electroencephalogram, 'a sample in time', may demonstrate:
  - Seizure-like (epileptiform) patterns.
  - Asymmetries of amplitude or frequency.
  - Slowing of EEG frequencies.
  - Wave forms of potential clinical utility (e.g. triphasic waves, periodic lateralized epileptiform discharges).
- Electromyography and nerve conduction studies are difficult to perform well in young children; clinicians should be aware of the implications of certain abnormal patterns.
- Other electrophysiological studies of value in pediatric patients include: polysomnography, visual and somatosensory evoked potentials, electroretinography, and electronystagmography.

## Introduction

Electrophysiological tests, especially electroencephalography (EEG), can assist the clinician's evaluation of pediatric patients with suspected or proven neurological disorders. Given the dynamic development of young children and the difficulty posed by the uncooperative child, however, obtaining high quality, valid results can be challenging. This chapter describes common electrophysiological tests and focuses on the EEG, electromyography, and nerve conduction testing.

## Electroencephalography

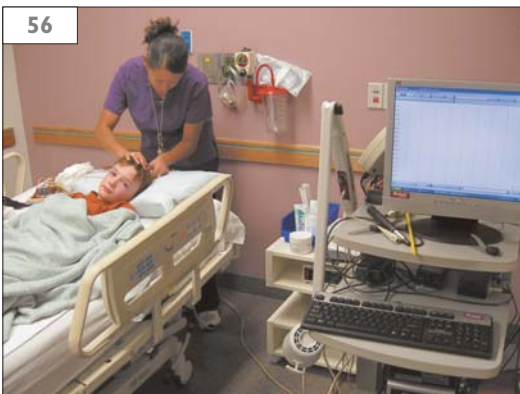Aside from brain imaging, the EEG is the most widely used tool for the investigation of children with neurological disorders (56). The tool provides extraordinarily useful information in children with possible seizures, but interpretation of the results depends on a thorough knowledge of the specificity and sensitivity of EEG.

## Basics of EEG

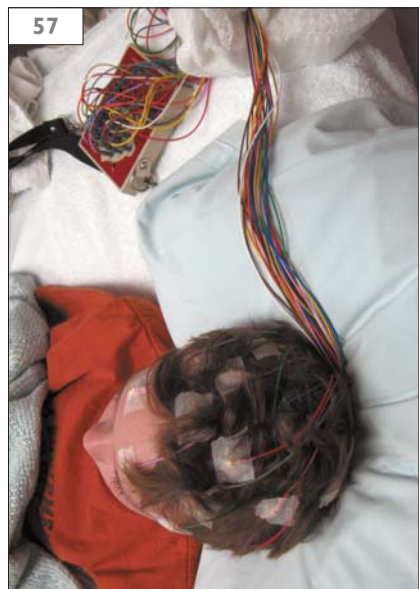EEG is essentially an electrocardiogram (ECG) of the brain. Electrodes applied to the child's

scalp (57) collect electrical signals from the underlying brain and muscle, and the signals are amplified and compared through a series of 'differential amplifiers' in a manner comparable to ECG. In contrast to ECG, however, the source signals are of much lower strength (amplitude); hence the 'signal to noise ratio' is much lower. The typical ECG source signals are in the millivolt (mV) range, while those from the brain are usually recorded in microvolts ( $\mu\text{V}$ ). This causes considerably more artifacts in EEG, a situation not aided by the fact that young children and those with neurological problems are often less than enthusiastic about having their heads covered with electrodes!

Likewise, the time scale of an EEG differs from that of an ECG. In ECG the typical time scale is 25 mm/sec, while in EEG one usually views 10 sec of recorded time across a page or computer screen. An ECG represents 10 or fewer seconds of heart electrical activity, while a routine EEG consists of 30–45 minutes or more of brain wave activity. While ambulatory monitoring is very common with ECG ('event recorders' or 'Holter monitors'), ambulatory EEG recordings are obtained infrequently in pediatrics, given that they are difficult to interpret and limited to 3 days of data acquisition. In contrast to ECG, in which video record-



56 Obtaining an EEG in a cooperative child.



57 EEG electrodes affixed to a child's scalp.

ings have no role currently, video-EEG can be immensely useful, as discussed further below.

The EEG recording reflects the summed activity of numerous postsynaptic brain currents. The EEG signal (voltage) measured at each electrode is compared with one or more other electrodes in a pair-wise fashion. The difference in voltage between each pair is determined by a differential amplifier, and the output produces a recording that fluctuates up and down depending on this difference. By convention, an upward deflection of the recording indicates that the voltage at ‘input 1’ is negative relative to that at ‘input 2’ (58A).

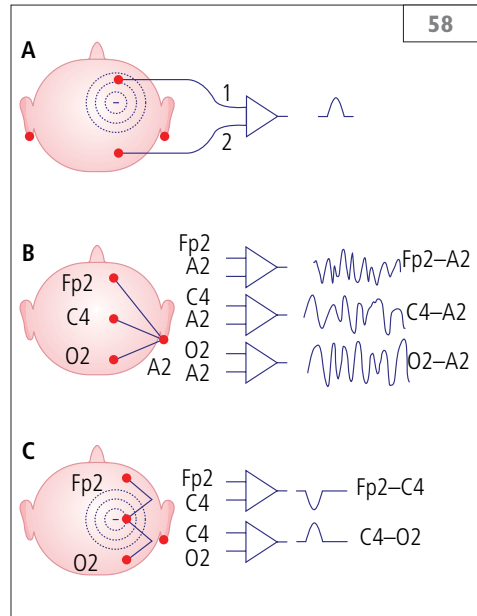
Multiple pair-wise comparisons are laid out in a presentation known as a ‘montage’ (from the French for ‘lay-out’). The locations of electrodes are noted by letters (F = frontal; Fp = frontal polar; T = temporal; C = central; P = parietal; and O = occipital) and numbers (even = right; odd = left). The montages are described as either *referential* or *bipolar* (58B, C). In the referential montage each scalp electrode is compared with a more distant, relatively silent or ‘reference’ electrode, such as an electrode applied to the ear lobe (58B). For bipolar montages each scalp electrode is compared to a neighboring and active scalp electrode (58C). Since most epileptic foci represent strong negative voltages, bipolar arrays around a (negative) epileptic focus will ‘point’ to the source of the discharge (58C). This pattern, known as a ‘phase reversal’, is a very useful feature of EEG facilitating pattern recognition of epileptiform discharges. EEG waves are subdivided by convention into frequency and amplitude ranges (textbox).

**Categories of EEG activity**

- **Delta:** slow waves, <4 Hz; amplitude <5 to >200  $\mu\text{V}$ ; can be diffuse or localized.
- **Theta:** slow to medium frequency waves, 4–7 Hz; amplitude 5–100  $\mu\text{V}$  or greater; diffuse or central location.
- **Alpha:** medium frequency waves, 8–13 Hz; amplitude 20–100  $\mu\text{V}$ ; typically posterior in location, attenuates with eye opening.
- **Beta:** high frequency waves, 14–25 Hz or higher; amplitude 5–20  $\mu\text{V}$ ; usually frontocentral in location.

**Normal EEG patterns in children**

Pediatric EEG is made challenging by the fact that EEG patterns evolve dramatically over the course of brain development. Neonatal electroencephalographers recognize useful patterns in premature infants as young as 28 weeks gestation or less, but features resembling some adult patterns are not seen until well after 6 months of age. Amplitudes, frequencies, and wake–sleep patterns continue to evolve until reaching adult-like appearances at approximately 8 years of age (textbox).



58A EEG signal as measured at scalp electrodes; B EEG signal referenced to the ipsilateral ear; C Bipolar EEG signal.

The evolution of normal EEG patterns from infancy to childhood is depicted in Figures 59–64. Amplitudes tend to be higher in young infants, presumably due to the relatively thin

skull, and frequencies tend to be slower in younger children, especially in wakefulness and deeper stages of non-REM (rapid eye movement) sleep.

**Characteristic EEG features at various ages**

**Preterm infants**

- Different patterns for quiet and active sleep emerge; discontinuous patterns (tracé discontinue) can be normal in extremely premature infants.

**Term infants**

- Wake: low to medium amplitude activity in mixed frequencies (activité moyenne).
- Active sleep: similar to wakefulness.
- Quiet sleep: discontinuous pattern with delta brushes (tracé alternant).

**First year of life**

- Wake: appearance of 4–5 Hz dominant posterior frequency.

- Sleep: sleep spindles; become bisynchronous by end of first year.

**Second year of life**

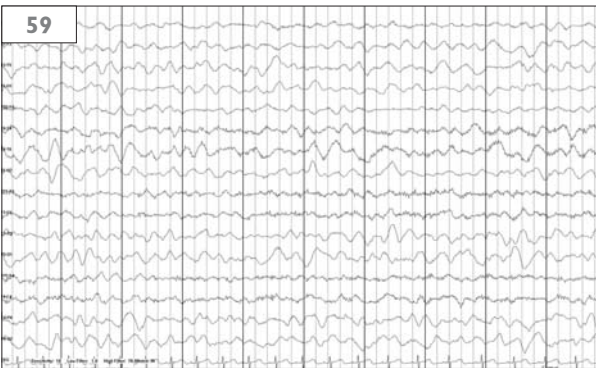- Wake: 4–8 Hz dominant posterior frequency.
- Sleep: vertex waves, sleep spindles.

**By 4 years of age**

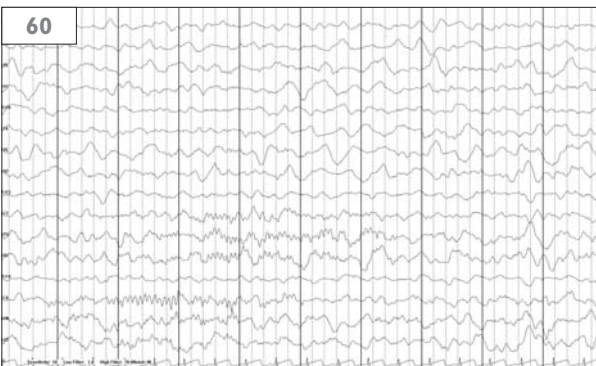- Wake:  $\geq 8$  Hz dominant posterior frequency.
- Sleep: Near-adult patterns.

**By 8 years of age**

- Generally similar to adult patterns.

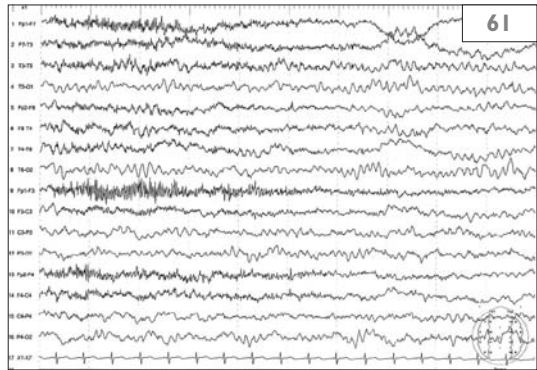


**59** Awake EEG in a healthy term newborn infant.

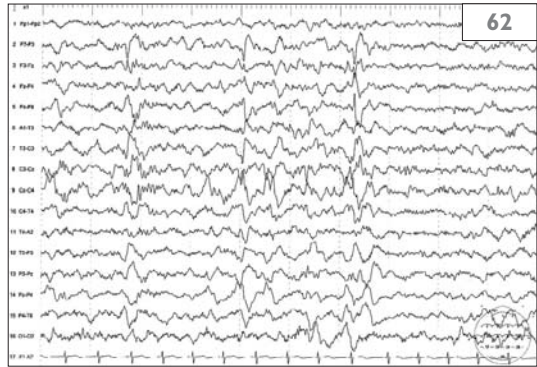

**60** Sleep EEG in a healthy term newborn infant.

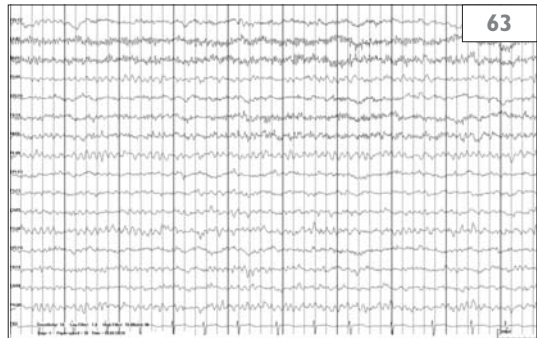**61** Awake EEG in a healthy 3-month-old infant.



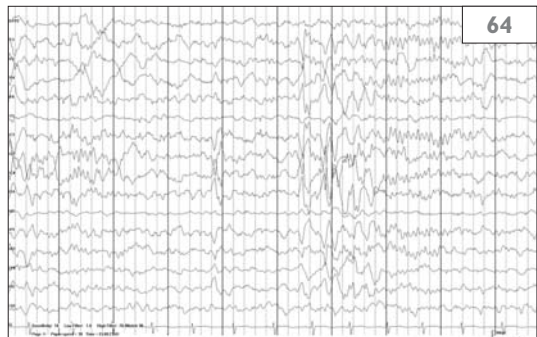**62** Sleep EEG in a healthy 3-month-old infant.



**63** Awake EEG in a healthy 6-year-old.



**64** Sleep EEG in a healthy 6-year-old.



## Abnormal EEG patterns in children: general considerations

### AMPLITUDE

In general, any tissue/material (e.g. accumulation of cerebrospinal fluid (CSF), subdural blood, or scalp edema) that occupies space between the brain and the collecting electrodes will *reduce* amplitude causing attenuation of the EEG activity (65, 66). In addition, various diseases that cause encephalopathy are often associated with EEG attenuation (67).

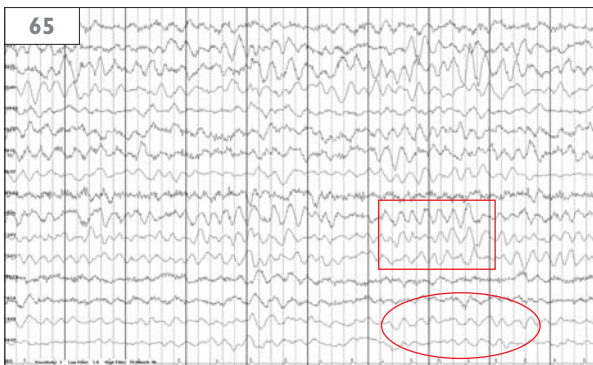### FREQUENCY

The frequencies of EEG wave forms are *reduced* in most forms of brain dysfunction which produce acute or static encephalopathies (e.g. encephalitis, tumor, or ischemic injury). The resultant abnormalities are described as slowing of the EEG (the presence of excessive slow waves for age). The background frequency may be uniformly slow (e.g. in a child with developmental delay) or focal slowing may be seen over a diseased area of brain (e.g. in a child with a cortical malformation, stroke, or brain tumor). The main exceptions to this rule are epileptic encephalopathies (in which continuous epileptiform activity may occur) and intoxication with sedative medications (barbiturates and benzodiazepines) in which excess fast (beta) activity is seen with therapeutic levels of these medications (68). Very high levels of these medications cause EEG flattening (attenuation) or a burst suppression pattern.

### EPILEPTIFORM ACTIVITY

Epilepsy, a clinical condition, is defined simply as a history of two or more unprovoked seizures. The EEG hallmark of epileptic conditions is 'epileptiform activity' which refers to particular patterns that abruptly deviate from normal background patterns. Epileptiform activity is characterized as interictal or ictal depending on whether the abnormal feature occurs in between or during an epileptic event, respectively. Sometimes, the distinction between these two may be very difficult, especially in children with markedly abnormal EEGs. Interictal abnormalities are usually isolated or brief, although they may recur very frequently, while ictal events are usually sustained for at least several seconds.

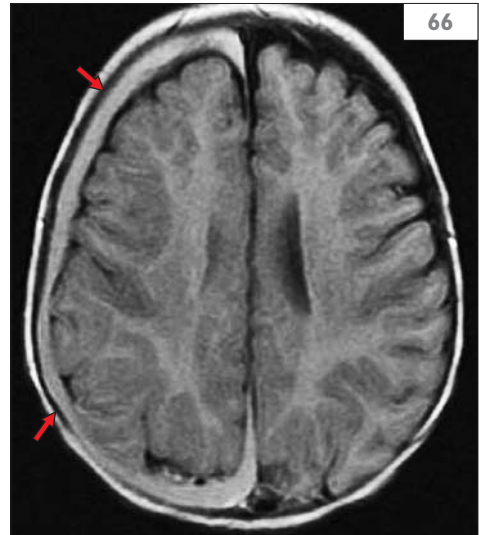
Approximately 5% of normally developing children without known seizure disorders have epileptiform EEGs. Likewise, 4–6% of children with attention deficit hyperactivity disorder (ADHD) and higher percentages of children with language impairments have epileptiform EEGs; up to 30–50% of children with autism have an abnormal EEG. A potential clinical pitfall is the presence of frequent epileptiform activity in neurologically impaired children who do not have clinical seizures. Children with cortical blindness due to remote occipital lobe injury, for example, have occipital spikes (epileptiform discharges), but do not necessarily have ongoing epileptic seizures. A child with hemiplegic cerebral palsy (CP) may have an epileptiform EEG while not clinically suffering from seizures. Thus, the routine use



**65** EEG attenuation over the right hemisphere secondary to a subdural hematoma. Lower amplitudes are apparent from the right hemisphere (oval) than from corresponding areas of the left hemisphere (box).

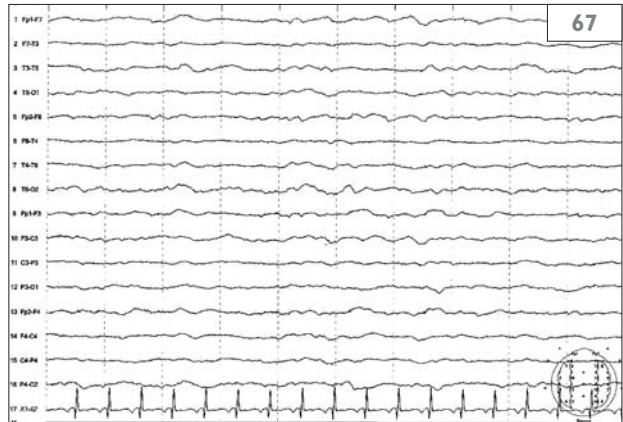


of EEG in children with these conditions can be seriously misleading. An abnormal EEG is insufficient to make a diagnosis of a seizure disorder or epilepsy, unless electrographic and clinical seizures are captured.

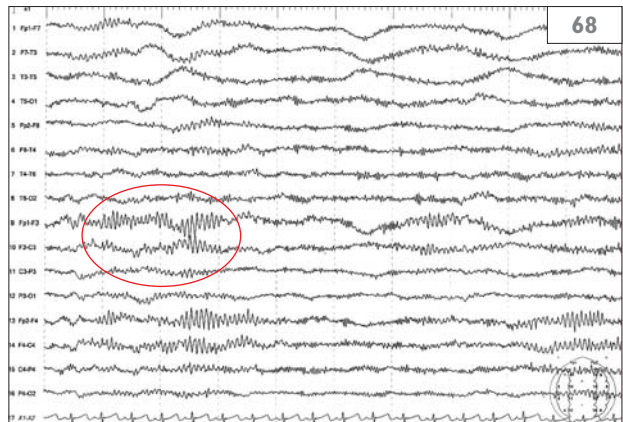


**66** FLAIR MRI showing the subdural hematoma (arrows) in **65**.

**67** Low amplitude EEG in an infant with hypoxic ischemic encephalopathy.



**68** Medium amplitude frontal, fast activity (oval), as a medication effect.





## Recognizable EEG abnormalities in children

### Patterns of background abnormalities

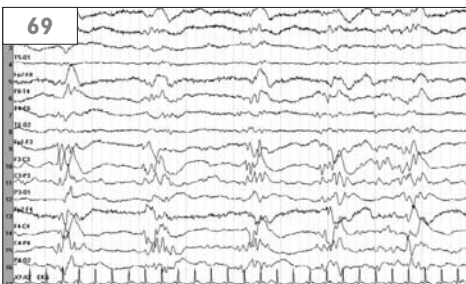
Background slowing of the EEG is usually nonspecific. Irregular, unpatterned, localized or generalized slowing (often referred to as polymorphic slowing) may result from virtually any pathological process. Background slowing, referred to as postictal slowing, is often seen in childhood following seizures (febrile or otherwise). Other processes that result in localized or diffuse brain dysfunction, such as hypoxic or ischemic injury, global developmental impairments, encephalitis, metabolic encephalopathies, and so forth, will also often be associated with focal or diffuse EEG slowing. The most severe encephalopathies typically follow a continuum of diffuse slowing and attenuation, to episodic suppression (attenuation) of EEG activity interrupted by bursts of activity (burst-suppression pattern; **69**), to marked generalized attenuation, and ultimately to an isoelectric (or flat) pattern with absence of all cerebrocortical activity (**70**).

Rarely, certain recognizable patterns of EEG slowing may suggest particular neurological impairments. Regular, somewhat sharply contoured frontally dominant periodic slow waves (often known as triphasic waves) are typical of hepatic and other metabolic encephalopathies, while periodic clusters of frontal intermittent rhythmic delta activity (referred to as frontal intermittent rhythmic delta activity, FIRDA; **71**) may suggest structural disease, such as brain tumor, or encephalopathy.

### Patterns of epileptiform activity

In neonates, a common pattern of epileptiform activity consists of frequent electrographic seizures often seen in the setting of hypoxic ischemic injury. Such protracted trains of epileptiform activity are not always associated with clinical seizure activity, but are still considered ictal events (subclinical seizures or electrographic seizures). They will often occur independently from both hemispheres at different times. Typically, such findings suggest a poor prognosis. Likewise in the neonatal period and early infancy, a pattern of alternating bursts of chaotic high amplitude spikes and slow waves interrupted by periods of marked EEG attenuation (so-called suppression-burst patterns) can be seen in several epileptic encephalopathies associated with metabolic or structural disease, such as nonketotic hyperglycinemia, also known as glycine encephalopathy.

Later, the classic pattern of hypsarrhythmia is seen in infants with infantile spasms and closely related clustered tonic spasms. This pattern, with a peak incidence in midinfancy, consists of high amplitude, chaotic generalized and multifocal spike and spike-wave discharges with loss of normal background patterns (**72**, **73**). Often, brief periods (lasting seconds or less) of EEG attenuation (electrodecremental responses) can occur in association with the actual tonic spasms. A milder version of this abnormality, variably defined by different experts, is known as modified hypsarrhythmia.



**69** A burst-suppression EEG, an ominous finding at any age.



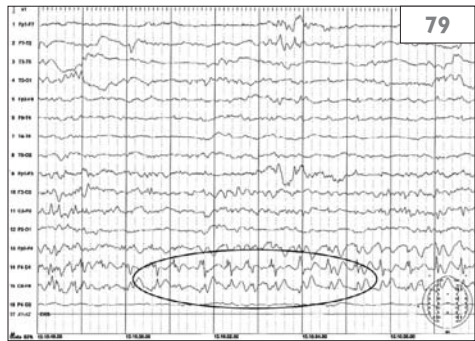
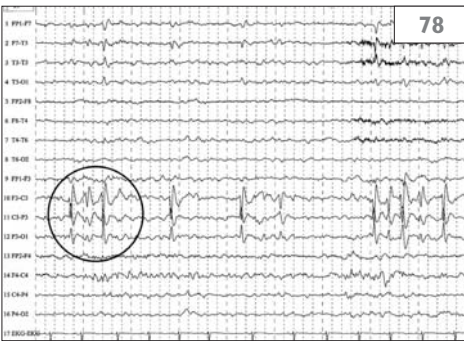
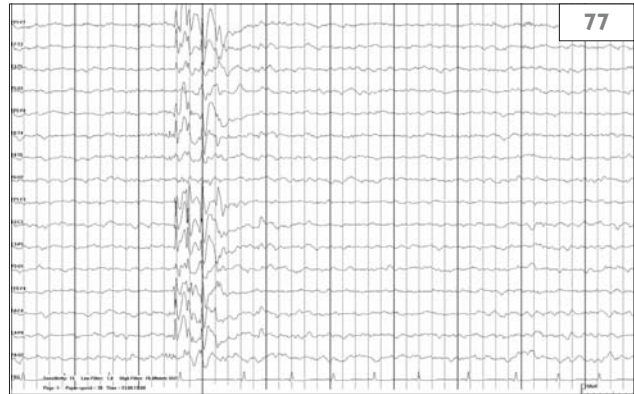
intractable epilepsies such as Lennox–Gastaut syndrome (75) or myoclonic–astatic epilepsy of Doose. Irregular generalized spike-wave discharges occurring at faster frequencies (4–5 Hz) and photoparoxysmal responses, provoked by photic stimulation, are seen in children or

adolescents with juvenile myoclonic epilepsy (JME) (76, 77).

Benign partial epilepsies of childhood produce characteristic focal discharges that often occur in clusters or brief trains and increase markedly in frequency during drowsiness and sleep (78–80).

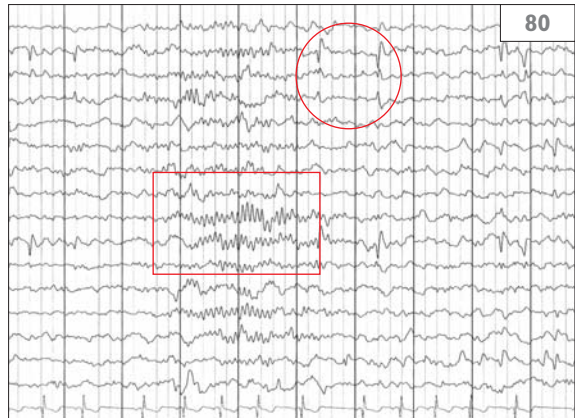**77** A brief burst of irregular spike-wave activity in JME.



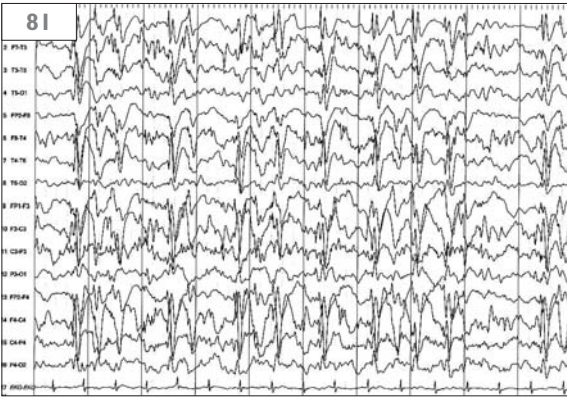**78** Rhythmic sharp and slow wave activity (circle) in a child with rolandic epilepsy.

**79** A train or run of sharp/slow discharges in a child with rolandic epilepsy (oval).

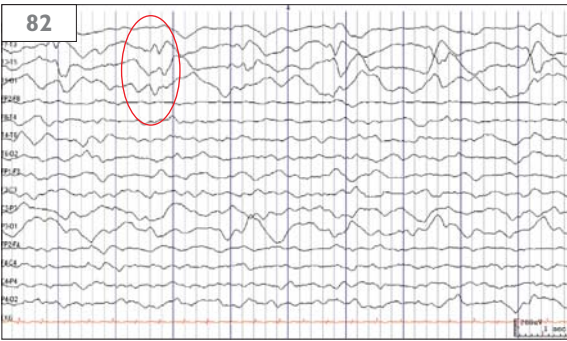**80** Sleep EEG in a child with rolandic epilepsy shows sleep spindles (box) and centro-temporal sharp and slow wave discharges (oval). Sleep typically activates epileptiform discharges in children with Rolandic epilepsies.







**81** Electrical status epilepticus of sleep.



**82** PLEDs in a young child with herpes simplex virus encephalitis (circled).



**83** An EEG control room for a contemporary epilepsy monitoring unit.

Sometimes the discharges occur bilaterally in an independent fashion (i.e not simultaneously from both hemispheres). Benign rolandic epilepsy (benign epilepsy with centrotemporal spikes, BECTS) is the most common of these so-called benign partial epilepsies. Benign occipital epilepsy of childhood is another example.

An unusual pattern referred to as continuous spike-wave of slow wave sleep (CSWS) or electrical status epilepticus of sleep (ESES) is seen in a variety of children with mixed neurodevelopmental and neurobehavioral problems. A subset of these may have acquired epileptic aphasia (Landau–Kleffner syndrome), a disorder

in which a child with relatively normal early language acquisition appears to acutely or subacutely lose language skills to the point of appearing deaf (auditory agnosia). Such children may have a few clinical seizures, but their EEG may demonstrate nearly continuous epileptiform activity during slow wave sleep (81).

In acute CNS injuries, an unusual pattern of periodic, epileptiform-like discharges, consisting of sharply contoured, localized slow waves or sharp waves recurring at a slow frequency, can be seen. These are known as periodic lateralized epileptiform discharges (PLEDs). This pattern usually reflects acute localized structural injury, such as ischemic damage from profound hypotension or focal infection/inflammation from herpes simplex virus encephalitis and other causes (82).

### Video-EEG monitoring

Well-designed EEG laboratories can record EEG with video for extended periods (83). In some cases, portable systems allow for longer term recording of EEG in the ambulatory setting without video. The former is used primarily in three settings: 1) evaluation of children with ‘seizure-like’ spells of uncertain nature; 2) evaluation of children to characterize better the type of epilepsy/seizures; and 3) presurgical evaluation of children with intractable localization-related epilepsy who may be candidates for epilepsy surgery. In practical terms, 24-hour video-EEG, which is relatively commonly available, is usually appropriate only if a child’s episodes of concern occur more than once a day. Otherwise, for less frequent episodes, longer periods of monitoring may be required. Most ambulatory systems, subject to greater degrees of artifact, are limited to 48 or 72 hours of continuous recording. Higher quality data usually result from inpatient monitoring, but capturing spells sometimes requires that the child be in their own environment and necessitates ambulatory monitoring.

### Brainstem auditory evoked potentials

Evoked potentials are less commonly used in pediatric neurology than in adult neurology. Brainstem auditory evoked potential (BAEP), also known as a brainstem auditory evoked response (BAER), is utilized commonly to evaluate hearing when other methods are equivocal or cannot be performed due to poor cooperation. This method assesses hearing thresholds at different frequencies and, when successful, provides information regarding the functional and structural integrity of brainstem auditory pathways. Cerebral responses (essentially, a limited EEG) to repetitive auditory stimuli are summed such that responses, fixed in time relative to the stimulus, are amplified while random noise tends to cancel out. The result, a tracing of activity *vs.* time, depicts waves attributed to the activation of several structures along brainstem auditory pathways. Abnormalities such as absence of waves, delayed conduction between waves, or asymmetries between ears may be clinically important. Because the procedure is technically challenging, absence of wave I, generated by nerve fibers as they exit the cochlea, can be due to technical failure or can suggest profound sensorineural hearing loss.

### Visual evoked potentials

Similar to a BAEPs, a visual evoked potential (VEP) measures the cortical response to visual stimuli. VEP sums the EEG responses time-linked to a repeating visual stimulus. The method can assess visual function in infants and young children, and may detect delays in conduction from retina to occipital cortex, as might occur in optic neuritis, multiple sclerosis, or acute disseminated encephalomyelitis.

## Electromyography and nerve conduction studies

Electromyography (EMG) and nerve conduction studies (nerve conduction velocity, NCV) are performed less frequently in children than in adults. These technically difficult studies should be performed by a pediatric or adult neurologist with considerable subspecialty training and experience. Since the procedure produces modest pain and apprehension, EMG and NCV studies frequently require conscious sedation. The pediatrician and child neurologist should remember that interpretation of the EMG and NCV can be subjective and limited by the difficulties noted above. Thus, findings must always be considered within the context of the child's clinical presentation. Often, muscle biopsy or specific genetic testing (e.g. testing for survival motor neuron [SMN1] mutations in suspected spinal muscular atrophy) provides more useful diagnostic information.

When assessing the function of motor nerves, the electromyographer delivers an electrical shock at a specific point over a peripheral nerve (84, 85) and identifies the resultant contraction of muscle (the compound muscle action potential or CMAP). The NCV is then calculated by dividing the distance in meters separating stimulating and recording electrodes by the time interval in seconds between the stimulus and the appearance of the CMAP response. In similar fashion, the conduction velocities of sensory nerves can be determined by stimulating a sensory nerve and recording the time it takes for the stimulus to reach a distal recording site. Generalized slowing of motor NCVs occurs in Guillain-Barré syndrome (GBS), whereas localized slowing may suggest compression neuropathy, as in carpal tunnel syndrome.

The pattern of the CMAP can also be useful. Decreased amplitude occurs with diminished muscle activation or with marked muscle atrophy, while a broader, temporally dispersed CMAP can be seen when the various axons within a nerve bundle conduct electrical impulses at different velocities. The latter can be observed with peripheral demyelination in children or adolescents with GBS.

The electromyographer performs an EMG by inserting a very fine needle electrode into a muscle and measuring the muscle's spontaneous

activity and response to activation. The muscle activity is viewed on an oscilloscope, and the pattern of activity can be heard via a speaker. The electromyographer recognizes specific conditions not only by the appearances of wave forms (86), but also by their characteristic sounds.

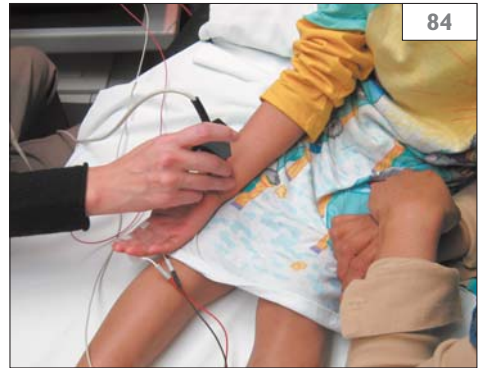When muscle innervation is diminished (i.e. the muscle is denervated) or muscles are inflamed, muscle fibers fire spontaneously creating fibrillations and positive waves. In addition, denervation is often accompanied by reinnervation of denervated muscle cells by fibers from healthy alpha motor neurons. This results in the formation of large motor units because a given anterior horn cell now innervates more than the usual number of muscle fibers. Activation of these large motor units is recognized as large polyphasic motor unit potentials (MUPs). Thus, denervation produces fibrillations, positive waves, fasciculations and large polyphasic MUPs. In addition, purposeful activation of the muscle by the patient is less effective since motor nerves are not properly innervating their target muscle cells. This results in decreased recruitment (fewer motor units are activated for a given effort), also known as an incomplete interference pattern. The amount of electrical activity with voluntary muscle contraction appears incomplete on the oscilloscope screen.

By contrast, myopathy or dystrophy produces small, polyphasic MUPs because the motor unit consists of many, weaker muscle fibers that generate frequent and smaller amplitude responses. There is relatively normal recruitment of motor units, but because each of these motor units produces small MUPs, the resulting interference pattern is irregular and of low amplitude. Thus, the hallmarks of myopathic disorders are normal NCVs, small polyphasic MUPs, and a low amplitude interference pattern.



## Polysomnography

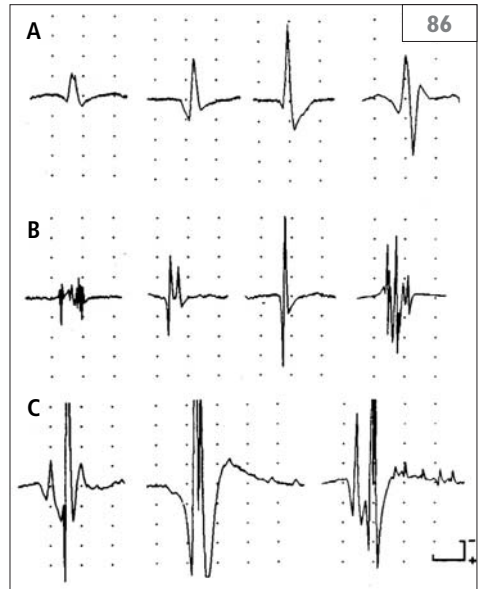
Polysomnography is being used more frequently in children to evaluate sleep disorders, nocturnal events, apnea, breathing disorder in sleep, and narcolepsy. Continuous recording of various physiological variables occurs overnight and sometimes during daytime sleep the next day (87). A typical polysomnogram includes recordings of air flow, oxygen saturation, muscle movement (usually chin and leg), eye movement, abdominal and chest wall movement, and an ECG. Although some EEG data are collected



84 Obtaining median nerve conduction velocity.

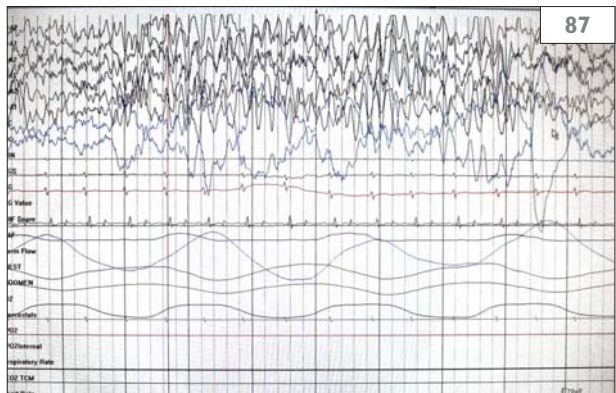


85 Recording nerve conduction velocities in a young child.



86 Electromyogram showing: **A** Normal; **B** Myopathic responses (small polyphasic potentials); **C** Neurogenic responses (large polyphasic potentials).

87 Polysomnography showing simultaneous recordings of EEG and several physiological parameters.



(usually via only two EEG leads), the typical polysomnogram provides limited information regarding nocturnal epileptiform activity. If seizures are strongly considered as a potential cause of a sleep disturbance, a full coverage EEG may be collected simultaneously with the polysomnogram.

## Electronystagmography and balance testing

Formal evaluation of the vestibular system may be useful when evaluating children and adolescents with vertigo or unexplained balance disorders. Hearing and balance centers provide comprehensive data regarding hearing (using BAEPs), and vestibular function, using electronystagmography, posturography, and the rotary chair test. Clinicians often receive a complex interpretation from such centers and must rely on the conclusions provided by the individuals performing these specialized studies. The procedure may be useful in the evaluation of children with unexplained dizziness, vertigo, or balance difficulties, as might occur in multiple sclerosis, a disorder that can be seen in children as young as 4 years of age. Absence of objective abnormalities in children or adolescents with episodic dizziness or vertigo often supports a diagnosis of migraine or migraine variants. High-resolution MRI of the temporal bones can be a useful procedure in children with sensorineural hearing loss or balance dysfunction.

## Electroretinography

The electroretinogram (ERG) consists of an evoked potential of the retina. A contact lens placed on the eye records the response of rods and cones to flash stimuli with white, red, and blue light. This response, the ERG, reflects retinal function. The response can be altered in a useful manner by light or dark adaptation and by the nature or intensity of the flash stimulus. The ERG obtained in clinical retinal physiology laboratories generally consists of an 'a-wave' followed by a 'b-wave' that together reflect the functioning of various components of the retinal system.

Rod responses are enhanced under *scotopic* (dark adapted, red light stimulus) circumstances, while cone responses are enhanced under *photopic* conditions (bright ambient light, high flash intensity). In addition, repetitive flashing of an intense light at 30 Hz normally elicits a following response of the b-wave of the ERG. This pattern is known as the flicker response. The flicker response is believed to be generated by retinal cones specifically.

The ERG, combined with VEP, can be useful in identifying neurological disorders associated with retinal involvement. These include disorders associated with retinitis pigmentosa, such the mitochondrial disorder NARP (neuropathy, ataxia, and retinitis pigmentosa), rare neurodegenerative disorders, such as neuronal ceroid lipofuscinosis (e.g. Batten disease), and disorders of the optic nerve or retina, such as Leber congenital amaurosis or Leber hereditary optic neuropathy, another mitochondrial disorder. By contrast, the ERG remains normal in children with Tay-Sachs disease, an infantile disorder associated with seizures, exaggerated startle responses, and a cherry-red spot at the macula. The ERG offers a reliable means of monitoring retinal toxicity in very young children treated with vigabatrin.

# Cerebrospinal fluid

## Main Points

- CSF examination (lumbar puncture or spinal tap) provides diagnostic information when clinicians suspect meningitis, encephalitis, idiopathic intracranial hypertension (pseudotumor cerebri), and rare metabolic conditions, such as glucose transporter (GLUT1) deficiency, cerebral folate deficiency, and disorders of neurotransmitters.
- The polymerase chain reaction performed on CSF samples is the gold standard for diagnosing many viral infections of the CNS, especially encephalitis due to herpes simplex virus type 1.
- CSF examination can provide supportive diagnostic information in MS, GBS, and CNS leukemia.
- CSF examination infrequently provides useful information in afebrile children or adolescents with seizures or headaches.
- CSF examination is contraindicated in patients with cerebral edema and intracranial or intraspinal mass lesions, including tumors, brain abscess, and hemorrhage.

## Introduction

This chapter describes the physiology of cerebrospinal fluid (CSF) production and the utility of CSF examination. The latter examination, usually consisting of a lumbar puncture or ‘spinal tap’, provides supportive or definitive diagnostic information in several central nervous

system (CNS) conditions, including infections, demyelinating disorders, metabolic disorders, malignancies, and disorders of intracranial pressure. By contrast, lumbar puncture infrequently provides useful information in afebrile, otherwise healthy children with headache (including migraine) or seizures.

## CSF production

Humans produce approximately 0.3 ml of CSF per minute, corresponding to 400–500 ml per day for the average adult. CSF arises from modified ependymal cells of the choroid plexus, a highly vascular structure within the lateral, third, and fourth ventricles. Modest amounts of CSF are also produced by ependymal cells that line the ventricular system within the brain. CSF largely represents an ultrafiltrate of blood; each cardiac systole facilitates production of CSF, whereas each diastole allows resorption of CSF into the systemic circulation. Certain components of CSF, such as glucose and protein, enter the CSF via facilitated or active transport, as discussed further below. The intracranial volume of CSF in adults averages approximately 75 ml; the volume in all CSF spaces is approximately 150 ml in adults. By contrast, the total CSF volume in young infants is only 30–50 ml.

Most of the CSF originates from the choroid plexus of the lateral ventricles. CSF flows caudally from each lateral ventricle into the third ventricle through the paired foramina of Monro (88), small channels that connect the two lateral ventricles with the single, midline third ventricle. CSF continues its caudal journey by flowing from the third ventricle through the tiny aqueduct of Sylvius within the midbrain into the small fourth ventricle at the level of the midpons and cerebellum (89). CSF then exits the brain through the medial foramen of Magendie and the lateral foramina of Luschka into the cisterna magna at the base of the cerebellum. From this point CSF flows caudally around the spinal cord and eventually turns rostrally into the subarachnoid space over the cerebral hemispheres, where the majority of CSF is absorbed into systemic circulation via the connections between arachnoid (Pacchionian) granulations and dural sinuses. Minor amounts of CSF are absorbed into the venous circulation via the CSF-containing perivascular (Virchow–Robin) spaces.

## CSF pressure

CSF pressure varies according to the age of the child, the location within the CNS, and the state of the patient at the time of the measurement. CSF pressure is lowest within the lateral ventricles and highest in the lumbar region when a person stands or lies in a lateral recumbent position, the typical position for performing a spinal tap. As measured by a lumbar puncture, normal CSF pressure ranges between 100–250 mmH<sub>2</sub>O. CSF pressures above 180 mmH<sub>2</sub>O in young children are generally considered elevated (intracranial hypertension) whereas pressures below 60 mmH<sub>2</sub>O are considered low (intracranial hypotension). However, pressures up to 250 mmH<sub>2</sub>O may be normal in children over 8 years of age and adolescents, provided that papilledema is not present.

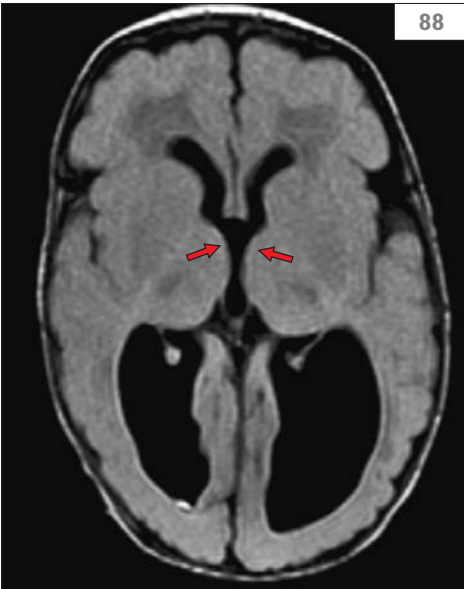## Lumbar puncture (spinal tap)

Sampling the CSF by lumbar puncture provides useful diagnostic information regarding many conditions affecting the central and peripheral nervous systems. Before performing the lumbar puncture, the clinician should reconfirm the goal(s) of the CSF examination and assess the patient for contraindications (textbox).

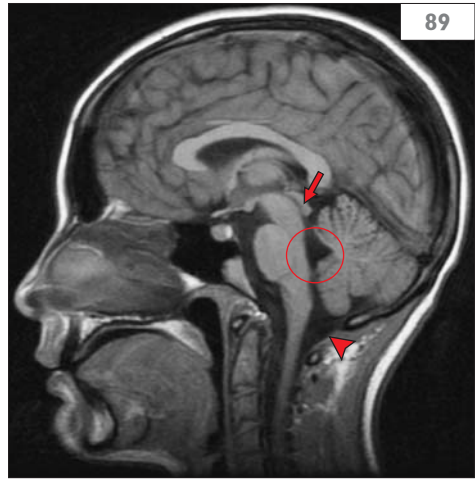
### Contraindications to lumbar puncture

- Papilledema: *must* have imaging performed to exclude intracranial mass lesion.
- Known or suspected intracranial mass lesion, especially of the posterior fossa.
- Cerebral edema with or without CT or MRI features of central or uncal herniation.
- Transtentorial herniation.
- Spinal subarachnoid block by mass or hemorrhage.
- Chiari malformation (90).
- Infection of the skin overlying the L3–L5 interspaces.
- Platelet count <50,000/mm<sup>3</sup> (a relative contraindication).
- INR >1.5.

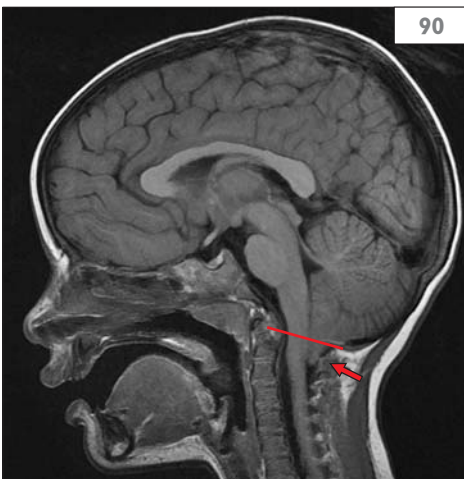
A serum sample should be obtained prior to the tap to measure the serum glucose content. The lumbar puncture is typically performed at the L3–L4 or L4–L5 interspace (91).



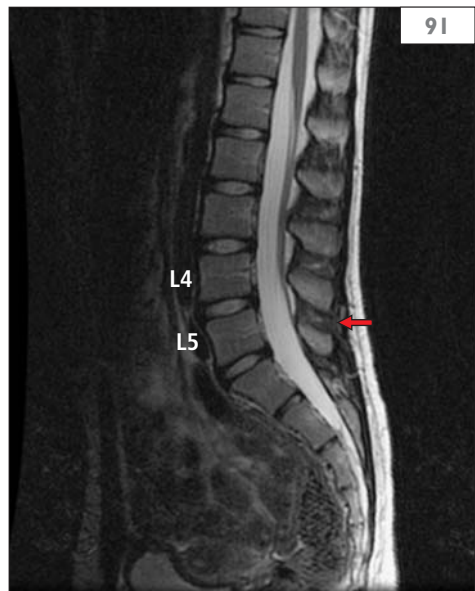
**88** Axial FLAIR MRI showing normal appearing foramina of Monro (arrows).



**89** Normal, sagittal T1-weighted MRI showing the cerebral aqueduct (arrow), fourth ventricle (circle), and cisterna magna (arrowhead).



**90** Sagittal, T1-weighted MRI showing a Chiari type I malformation (arrow). The cerebellar tonsil extends below the foramen magnum (line).



**91** A normal sagittal spine MRI showing L4–L5 interspace, a potential location of a lumbar puncture (arrow).

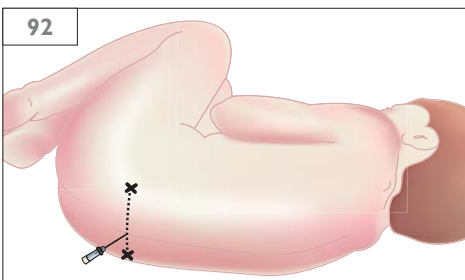
The infant, child, or adolescent is placed in the lateral recumbent position (92); careful positioning greatly enhances the success rates of lumbar puncture. Young or anxious children may require sedation, and all will benefit from placement of a topical anesthetic, such as EMLA<sup>®</sup> cream (a mixture of lidocaine and prilocaine), at least 30 minutes before the lumbar puncture is performed.

Sterile procedures are used to minimize the risks to the patient and the person performing the procedure. The skin of the lower back is exposed, cleansed with an iodinated substance and alcohol, and covered with a sterile, disposable drape. The landmarks of the iliac crest and spinous processes are identified to reconfirm the proper site for the lumbar puncture (92). The skin and subcutaneous tissues overlying the L3–L4 or L4–L5 interspace are anesthetized using an injectable, local anesthetic, such as lidocaine. After sufficient time has passed for the anesthetic to be effective, a sterile spinal needle, oriented bevel up and with stylet in place, is introduced, angled toward the umbilicus and slowly advanced a few millimeters. After each advance, the stylet is withdrawn to determine if the subarachnoid space has been reached. Often, a subtle but distinct ‘pop’ is felt when the spinal dural membrane is punctured. Needles without stylets should not be used, since using such needles can induce dermoid tumors of the lumbar space.

When CSF begins to flow, the opening pressure can be measured by attaching a three way stopcock and manometer. The child or adolescent should be encouraged to extend his/her legs and to relax as much as possible. When the patient fights, ‘bears down’, or

performs the Valsalva maneuver, the CSF pressure rises. Samples of CSF are collected into sterile tubes; a minimum of three tubes, each containing at least 1 ml should be collected (tube 1: Gram stain and bacterial or viral studies; tube 2: chemistries [protein and glucose]; tube 3: cell count [leukocytes and erythrocytes]). Some authorities suggest that tube 1 be sent for chemistries and tube 2 for microbiological studies. Additional tubes will be necessary for CSF cytology or specialized studies, such as assays of CSF neurotransmitters, amino acids, or organic acids or studies for multiple sclerosis (MS). When in doubt, consult the reference laboratory for the appropriate tubes and required volumes. In general, 3–6 ml of CSF is obtained routinely from infants and children. Up to 15 ml can be obtained safely from adolescents.

After removing the spinal needle, gentle pressure should be placed over the insertion site to minimize local hemorrhage. Potential complications of lumbar puncture include headache, local pain, infection, hemorrhage, nerve root irritation, tonsillar herniation, and spinal coning (clinical deterioration after lumbar puncture in patients with spinal cord neoplasm and CSF block). Postlumbar puncture headache, the most common complication, usually occurs in adolescent girls or young adults and consists of a throbbing headache that begins within 72 hours of the lumbar puncture and is exacerbated by sitting, standing, coughing, or sneezing. Migraine-like features, including nausea, vomiting, and photophobia, can be present. The headache often remits spontaneously, but when severe, may require a blood patch performed by an anesthesiologist.



**92A** A diagram showing the ideal position of the child for performing a lumbar puncture.



## CSF content

Normal CSF is a watery liquid with a specific gravity of approximately 1.005. CSF differs from pure water by the presence of minute amounts of protein, glucose, and minerals. Substances that can be identified in the CSF also include lactate, neurotransmitters, steroids, amino acids, organic acids, albumin/immunoglobulins, and complement factors. During certain conditions, bacteria, viral nucleic acids, leukocytes, erythrocytes, and tumor cells can also be detected.

## Color

Normally, CSF is clear and colorless. Xanthochromia (literally, yellow color) reflects the presence of heme pigment in the CSF and may indicate subacute subarachnoid hemorrhage and red cell lysis. Xanthochromia appears within 2–4 hours of subarachnoid hemorrhage and can persist for as long as 2 weeks after the hemorrhage. Xanthochromia can also be observed when the serum bilirubin exceeds 15 mg/dl (256.5  $\mu\text{mol/l}$ ) and in infants or children with hypercarotenemia.

## Protein

CSF protein content arises in large part from serum albumin; however, some CSF proteins result from intrinsic synthesis within the CNS. The lumbar CSF protein content varies somewhat with age. The content tends to be highest in neonates, when the amount can be as high as 150 mg/dl (1500 mg/l) in healthy infants, and lowest in young children and adolescents, when values of 15–45 mg/dl (150–450 mg/l) are considered normal. The CSF protein content rises in many disorders of the CNS, including infections, leukodystrophies, neoplasms, and demyelinating disorders, both central (leukodystrophies) and peripheral (e.g. Guillain–Barré syndrome, GBS). Values of >500 mg/dl (>5000 mg/l) can be observed during bacterial meningitis, spinal tumors, or spinal subarachnoid space obstruction. When blood contaminates the CSF, the protein rises 1 mg/dl (10 mg/l) for every 750–1000 red blood cells/ $\text{mm}^3$ .

## Glucose

Glucose enters the CSF from the blood via facilitated transport. The CSF glucose level typically averages two-thirds of the blood glucose; equilibration from blood to CSF requires 1–3 hours. The CSF glucose content is generally considered low when the value is <40% of the serum glucose or the absolute value falls below 40 mg/dl (2.22 mmol/l) in children and adolescents and 20 mg/dl (1.11 mmol/l) in neonates. Low CSF glucose levels (hypoglycorrachia) can be observed in bacterial or fungal meningitis, CNS neoplasms, inflammatory disorders, occasional cases of viral encephalitis, and glucose transport deficiency (a disorder due primarily to mutations in the gene encoding the facilitated glucose transporter protein GLUT1). A CSF/serum glucose ratio <0.4 supports the latter condition. Hypoglycorrachia in bacterial meningitis reflects impaired glucose transport into the CSF and, to a lesser degree, utilization of CSF glucose by bacterial and leukocytes. Elevated CSF glucose levels have no diagnostic importance other than to suggest a previously elevated serum glucose level.

## Cells

Normal CSF contains no erythrocytes and very few leukocytes. Modest numbers of erythrocytes can be seen during mildly traumatic lumbar punctures, the consequence of nicking capillaries or venules during the introduction of the spinal needle; occasionally the CSF is grossly bloody due to the lumbar puncture alone. Waiting for the CSF to clear and collecting an extra tube of clearer CSF can improve the sensitivity and specificity of cell counts after a traumatic lumbar puncture. Clarifying a sample of bloody CSF by centrifugation can help distinguish a bloody tap from a subarachnoid hemorrhage; xanthochromia will be observed in the latter. Detecting bloody CSF can indicate subarachnoid hemorrhage secondary to nonaccidental trauma, rupture of a CNS aneurysm, hemorrhagic neoplasm of the spine or brain, or certain infections, such as herpes simplex virus (HSV) encephalitis.



The normal CSF leukocyte count varies somewhat with age. Neonates up to 4 weeks of age commonly have increased numbers of CSF leukocytes, as many as 20 white blood cells (WBCs)/mm<sup>3</sup>. By contrast, CSF leukocyte counts should be below 5/mm<sup>3</sup> in children or adolescents; however, leukocyte counts of 5–10/mm<sup>3</sup> may be normal and must be viewed with caution. When the lumbar puncture has been traumatic, approximately 1 leukocyte is present for every 700–1000 erythrocytes/mm<sup>3</sup>. The number and type of leukocytes in a CSF sample can provide useful information regarding bacterial, viral, or fungal infections of the CNS (textbox). Cytological examination of the CSF is useful in many malignancies affecting children and adolescents.

#### CSF in CNS infections

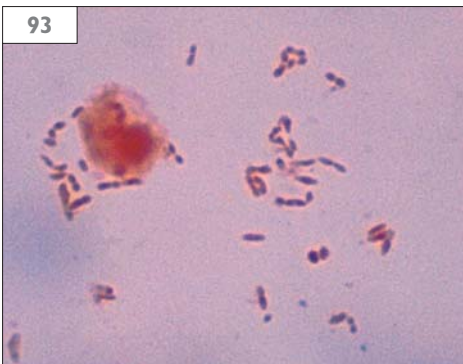- Viral infections are suggested by normal glucose, normal or modestly elevated protein, and lymphocytic pleocytosis. A mixed pleocytosis can be detected in the early stages of viral disease.
- Bacterial infections are suggested by low glucose, elevated protein, and neutrophilic pleocytosis.
- Tuberculous meningitis is suggested by low glucose, elevated protein, and lymphocytic pleocytosis.

## Specialized diagnostic testing of CSF samples

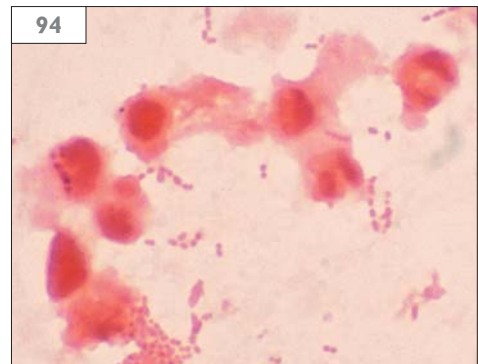
### Infectious diseases

The diagnosis of meningitis or encephalitis requires examination of the CSF. When increased intracranial pressure accompanies these infections in older children or adolescents, the lumbar puncture is sometimes deferred initially and the patient treated empirically with antibiotics based on historical or laboratory clues. Some experts suggest that mannitol (0.25 g/kg) be given to obtunded subjects with suspected bacterial meningitis approximately 30 minutes before attempting the lumbar puncture. Head CT should be obtained in obtunded patients, but antibiotic therapy must not be delayed while awaiting the scan. In patients with brain abscess, CSF examination by lumbar puncture is avoided, given that adverse outcomes in such patients commonly correlate with performance of the lumbar puncture; the microbiological diagnosis is best made by neurosurgical aspiration or biopsy of the abscess.

When bacterial CNS infection is suspected, the clinician should obtain routine studies of the CSF (protein, glucose, and cell count) as well as a Gram stain and bacterial culture. The sensitivity of the Gram stain in bacterial infections is approximately 70%; either Gram-negative or Gram-positive bacteria can be detected (93, 94). Culture is considered the



93 CSF sample showing leukocytes and gram-positive bacteria (*Streptococcus* species).



94 CSF sample showing leukocytes and gram-negative bacteria (*Haemophilus influenzae*).

‘gold standard’; however, the polymerase chain reaction (PCR) has promise as a rapid, sensitive, and specific means to detect bacterial pathogens within the CSF. When viral infection is suspected, the above studies should also be obtained, given the overlap in clinical features between bacterial and viral diseases. Studies specific for viral CNS infections include PCR, culture and assays of serum, and/or CSF antibodies (*Table 11*).

## Multiple sclerosis

Although brain MRI has generally supplanted the need for CSF examination in typical cases of MS, lumbar puncture can be useful in atypical cases or suspected cases with normal or equivocal radiographic studies (textbook).

### Clinical features of pediatric MS

- Optic neuritis.
- Unexplained fatigue.
- Vertigo, gait disturbance.
- Bladder dysfunction.
- Weakness or sensory changes.

**Table 11** Diagnosis of selected CNS viral infections

Virus	Microbiological diagnosis
<i>Herpes viruses</i>	
Herpes simplex virus types 1 and 2	CSF PCR; serum or lesion fluid PCR in neonates
Epstein–Barr virus	Serology; CSF PCR
Varicella zoster virus	CSF antibody; CSF PCR
Cytomegalovirus	Urine PCR; CSF PCR; urine culture
Human herpesvirus-6	Serology; CSF PCR
Human herpesvirus-7	Serology; CSF PCR
<i>Enteroviruses</i>	
Nonpolio enteroviruses	CSF RT-PCR; serum RT-PCR; stool culture
Polioviruses	CSF RT-PCR; stool, CSF, saliva culture
<i>Arthropod-borne viruses</i>	
West Nile virus	CSF IgM antibody; serology
LaCrosse virus	CSF IgM antibody; serology
Japanese encephalitis virus	CSF IgM antibody; serology
St. Louis encephalitis	CSF IgM antibody; serology
Tick borne encephalitis viruses	CSF IgM antibody; serology
<i>Human immunodeficiency virus</i>	Saliva or serum antibody; serum DNA/RNA PCR
<i>Rabies</i>	CSF RT-PCR; saliva or serum antibodies

PCR: polymerase chain reaction

RT-PCR: reverse transcription polymerase chain reaction

Most reference laboratories offer a CSF MS panel consisting of CSF immunoglobulin G (IgG) synthesis rate, CSF IgG/albumin ratio, and assays for oligoclonal IgG bands and myelin basic protein. These assays typically require 3–5 ml of CSF. To enable these calculations, the patient's serum is assayed concurrently. MS can be suggested by detection of oligoclonal bands, elevated CSF IgG synthesis rate, or elevated CSF IgG/albumin ratio.

## Metabolic disorders

Analysis of the CSF can provide useful diagnostic information regarding several metabolic disorders, including disorders of neurotransmitters, amino acids, organic acid synthesis, or mitochondrial function. Children or adolescents with mitochondrial disorders may have elevated CSF lactate; lactate elevations can also be observed in bacterial meningitis but such patients also have leukocytosis and, usually, hypoglycorachia, features not observed in patients with mitochondrial disorders.

Cerebral folate deficiency, a rare disorder associated with irritability, slow head growth, psychomotor retardation, ataxia, dyskinesias, and seizures, is supported by low CSF levels of 5-methyltetrahydrofolate. Neurological symptoms and signs in infants or children with this disorder can resolve with folinic acid supplementation. CSF amino acid analysis provides the definitive diagnosis in infants with nonketotic hyperglycinemia (glycine encephalopathy), a life-threatening, autosomal recessive disorder associated with apnea, neonatal myoclonus, neonatal seizures, hypotonia, and hiccups. Infants with this disorder have elevated CSF to plasma glycine ratios.

Assay of CSF neurotransmitters provides diagnostic clues regarding several rare disorders, including GTP cyclohydrolase deficiency (dopa-responsive dystonia; Segawa disease), tyrosine hydroxylase deficiency, aromatic L-amino acid dehydrogenase deficiency, and succinate semialdehyde dehydrogenase deficiency (textbox).

### Clinical features of selected pediatric neurotransmitter disorders

- GTP cyclohydrolase deficiency (Segawa disease): fluctuating dystonia, tremor, postural dystonia, and oculogyric crisis; onset in childhood.
- Tyrosine hydroxylase deficiency: oculogyric crisis, parkinsonism, tremor, and alterations of tone; onset in infancy or early childhood.
- Aromatic L-amino acid dehydrogenase deficiency: hypotonia, torticollis, dystonia, tremor, and dyshydrosis; onset in infancy.
- Succinate semialdehyde dehydrogenase deficiency: hypotonia, seizures, ataxia, developmental delay, mental retardation, autism, aggression, and anxiety; onset in infancy or early childhood.

Seizures, developmental delay, chorea, dystonia, autism, ptosis, oculogyric crisis and tremor are among the potential manifestations of these rare but likely under-recognized disorders. Patients with Segawa disease can improve dramatically with L-dopa therapy.

## Miscellaneous conditions

Examining the CSF has an important role in establishing the diagnosis of several other conditions, including GBS, pseudotumor cerebri, and CNS leukemia. Within approximately 2 weeks of onset of their symptoms, the majority of children or adolescents with GBS have elevated CSF protein levels, sometimes as high as 1000 mg/dl (10 g/l). The CSF in GBS typically has no cells, a finding known as the albuminocytologic dissociation. Persons with pseudotumor cerebri, also known as idiopathic intracranial hypertension, have normal CSF parameters, but elevated CSF opening pressures. Finally, performing a cytopathological examination of the CSF can be diagnostic in children with CNS leukemia or carcinomatous meningitis.

---

# Genetic evaluation

**Main Points**

- Genetic and syndromic disorders represent major causes of neurological disorders of infants, children, and adolescents.
- Web-based clinical and laboratory resources, especially [www.genetests.org](http://www.genetests.org), provide essential information for clinicians.
- Clinicians should understand the implications of autosomal dominant, autosomal recessive, X-linked, and mitochondrial modes of inheritance.
- Genetic studies available to clinicians include karyotype, FISH, DNA methylation, comparative genomic hybridization, and gene sequencing.

## Introduction

Understanding the genetic cause of a neurological disease provides both families and clinicians with powerful information. First, families find considerable comfort in knowing the name of the condition that affects their child. Second, certain disorders have specific treatments that can be used only if the disease is diagnosed. The number of unique therapies, such as enzyme replacement therapy in lysosomal storage diseases, grows daily. Third, when the diagnosis is known, clinicians can provide accurate anticipatory guidance and avoid unnecessary testing. Making the diagnosis of Rett syndrome, for example, enables clinicians to give families specific, detailed information regarding the natural history of the disorder. Fourth, many conditions affecting the nervous system are inherited, and knowing whether a condition is recessive or dominant enables families to plan for their and their children's futures. Finally, knowing the outcome of a disease, whether it is death within a few years or a life with minimal handicaps, provides immense comfort to many families and children.

Several web-based, user-friendly resources provide useful and accurate information for generalists, subspecialists, families, and patients. The most convenient site is *GeneTests* ([www.genetests.org](http://www.genetests.org)). Information at *GeneTests*, searchable by disease name, includes current information regarding clinical manifestations, treatment, outcome, the genetic etiology (when known), and a list of laboratories that perform the diagnostic testing. Another powerful search engine, PubMed, links users to the entire database of the USA National Library of Medicine. Families and patients access considerable information on the web, and clinicians can assist in their search. Disease-specific foundations, such as the Tuberous Sclerosis Alliance and many others, represent essential resources for families (textbox).

### Resources for genetic disorders and genetic testing

GeneTests: <http://www.genetests.org/>  
 National Human Genome Research Institute: <http://www.genome.gov/>  
 MedLine Plus: <http://www.nlm.nih.gov/medlineplus/genetictesting.html>  
 National Office of Public Health Genomics: <http://www.cdc.gov/genomics/>  
 UK Genetic Testing Network: <http://www.ukgtn.nhs.uk/gtn/Home>  
 OMIM: <http://www.ncbi.nlm.nih.gov/sites/entrez?db=omim>

The entire field of genetic testing is advancing rapidly; for example, whole genome comparative hybridization has only been used clinically for the past 5 years. As gene sequencing techniques improve in efficiency and the costs decrease, screening for the causes of diseases, either at the level of entire genes or of whole genomes, will become a reality. Advances in the technology not only offer tremendous advantages for early and accurate diagnosis, but also create new challenges for counseling and ethics.

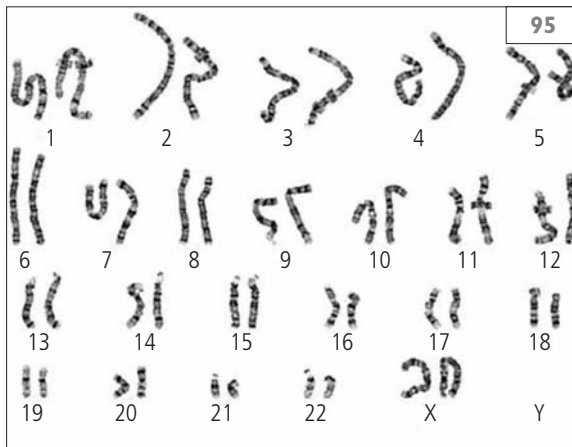
To treat neurological diseases of the developing nervous system effectively, clinicians must possess a basic understanding of human genetics. Because families will ask probing questions about their child's disease, clinicians must be prepared. This chapter provides an overview of human genetics and the methods used to detect genetic disorders.

## Human genetics: a primer

Humans have 23 pairs of chromosomes (22 autosomal pairs and 2 sex chromosomes for 46 total chromosomes); each parent contributes one set of chromosomes (95). Each chromosome is comprised of deoxyribonucleic acid (DNA). The information, written in a specific nucleotide code on the sense (5' to 3') DNA strand, provides instructions how to build and operate the body. There are three basic types of DNA sequences: *coding* DNA, which contains the coded sequence for amino acids enabling cells to make proteins; *regulatory* DNA, which contains essential information for cells to recognize when to make proteins, how much to make, and in which cells to make it; and *other* DNA. The other DNA used to be considered dismissively as 'junk' DNA, but we now understand that much of the so-called

junk DNA is necessary for subtle cellular functions, including gene regulation.

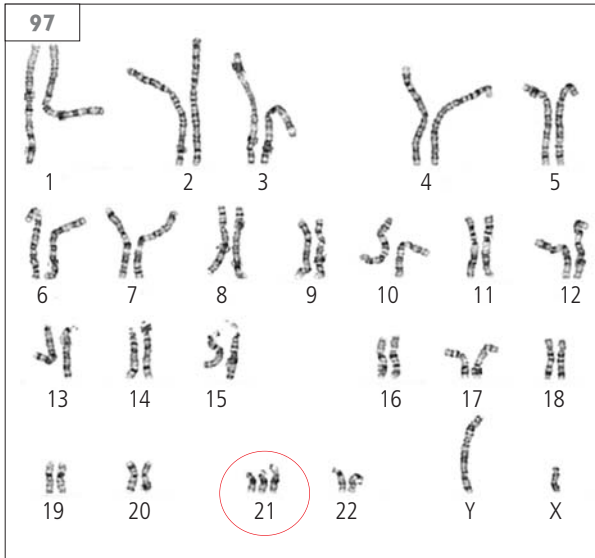
Human DNA is not neatly laid out like vegetable displays in a grocery store, but is mixed together like a tossed salad. A single gene, responsible for making one protein, may be chopped up and spread out over a large segment of DNA. Regulatory and other DNA, or even other genes, may lie in between. To organize this information, each chromosome possesses a number (1 through 22, X and Y), and each gene has a name. Each segment of the chromosome also receives a number based on a pattern of bands that has historically been identified using special dyes. The location of a gene can be on the short (p: for petite) or long (q: follows p in the alphabet) arm of the chromosome. Finally, sequencing of the entire human genome allowed scientists to assign a number to each individual base pair of the DNA.



95 A normal female karyogram.

96	
<b>Wild type</b>	GTT GCA CCA AGC GAA CAA CGT GGT TCG CTT Amino Acids Glu Arg Gly Ser Leu
<b>Nonsense</b>	GTT GCA CCA ATC GAA CAA CGT GGT TAG CTT Amino Acids Glu Arg Gly Stop
<b>Missense</b>	GTT GCA GCA AGC GAA CAA CGT CGT TCG CTT Amino Acids Glu Arg GLU Ser Leu
<b>Deletion</b>	GTT GCA AGC GAA GAA CGT TCG CTT Amino Acids Glu Arg Ser Leu
	<div style="border: 1px solid black; padding: 2px; display: inline-block;">CCA</div> ↑
<b>Insertion</b>	GTT GCA GCC AAG CGA A CAA CGT CGG TTC GCT T Amino Acids Glu Arg Arg Phen Ala T

96 Summary of the types of common DNA mutations.



97 A karyogram showing trisomy 21 (circle).



In genetics anything that can go wrong does go wrong, at least on occasion (96). Trisomy 21 (Down syndrome) occurs, for example, because a child inherits an entire extra chromosome 21 (97) or at least extra portions of critical gene regions of chromosome 21. Velocardiofacial syndrome (deletion 22q11), also known as Shprintzen/DiGeorge syndrome (98), arises when an essential piece of chromosome 22 is deleted. Pelizaeus–Merzbacher disease, a rare disorder of white matter (leukodystrophy) can be caused by a mutation (base substitution) in the sequence of the DNA that makes the proteolipid protein (PLP22).

A few surprises make genetics and genetic diagnosis more complicated. Potential sources of confusion are genetic polymorphisms, changes in DNA that may or may not be causally related to a child's condition. For example, a girl may have autistic features that seem like Rett syndrome, but sequencing of her MECP2 gene may show only a single base pair change that may not change the encoded protein or does so only a little. So, is the mutation meaningful? Only by comparing the girl's DNA sequence to her family members, other girls with Rett syndrome, or a large normal population can it be determined whether the genetic polymorphism is significant.

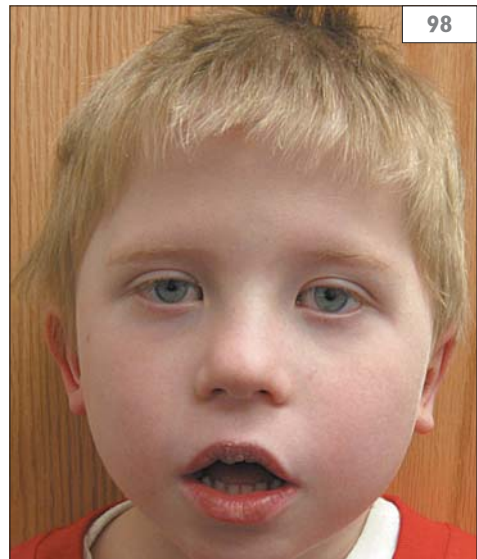Another confusing problem is mitochondrial genetics. Mitochondria, the power plants of

human cells, have their own DNA inherited only from the mother. Some proteins of the mitochondria are encoded by the mitochondrial DNA, but additional mitochondrial proteins are encoded by the nuclear or regular DNA. Mitochondrial disorders can result from mutations in either nuclear or mitochondrial DNA or from mutations in both. Nuclear DNA mutations account for most mitochondrial disorders in childhood.

Consequently, a child may have clinical features compatible with Leigh disease, a progressive neurodegenerative disorder associated with mitochondrial dysfunction, but determining the responsible mitochondrial or nuclear gene can be very challenging.

A final twist to genetics is the observation that one disease can have different genes that cause it (genetic heterogeneity) or mutations in a single gene can cause different diseases (phenotypic heterogeneity). Vanishing white matter disease, for example, a leukodystrophy with progressive neurological decline, can be caused by a mutation in any one of at least five different genes encoding a eukaryotic initiation factor. Mutations in the PLP gene can cause Pelizaeus–Merzbacher disease, a disabling leukodystrophy that causes severe developmental delay with onset in infancy, or X-linked spastic paraparesis, a slowly progressive disorder of adolescence or adulthood

**98** The typical facial appearance of DiGeorge syndrome (22q11 deletion) showing a long nose, epicanthal folds, posteriorly rotated ears, and underdeveloped philtrum.



associated with stiffness and weakness of the legs.

Understanding inheritance enables clinicians to provide basic genetic counseling to families including a discussion of recurrence risk. A recessive disorder means that both copies of a mutated gene (one copy from each parent) are necessary for a child to have the disease. Many lysosomal storage diseases, such as Tay Sachs disease or metachromatic leukodystrophy, are inherited in this fashion. Because the condition is recessive, both parents are well, even though they each carry one mutated copy of the gene. Each offspring of parents carrying a recessively-inherited disorder has a 25% chance of being affected; 50% of the offspring are carriers. The remaining 25% inherit both copies of the normal gene and are neither affected nor carriers.

Dominant conditions require a single mutated gene for the disorder to be apparent. In this instance, an affected parent passes the condition to an affected child. For a disorder with dominant inheritance, such as Huntington's disease, the risk of the disease in a child is 50%. There are no carriers in dominantly inherited conditions, only affected or unaffected individuals. However, some dominant conditions can be modified by other genes or environmental factors, leading to variations in how the disorder becomes expressed in an individual (called variable penetrance).

Finally, X-linked disorders are inherited by mutations in genes on the X chromosome. Because males have only one X chromosome, 50% of the male offspring of a woman carrying an X-linked mutation are affected, and 50% are unaffected. Examples of X-linked disorders are Duchenne muscular dystrophy (DMD) and fragile X syndrome. The situation for the female offspring of carriers of X-linked disorders can be complex. In general, 50% of the daughters are carriers and 50% lack any risk of passing the disorder to their offspring, either female or male. Girls or women who carry X-linked disorders, however, sometimes manifest a milder phenotype. Female carriers of dystrophin mutations, for example, can have cardiomyopathy, a serious complication of DMD in affected boys and men.

## Diagnostic tools

### Chromosome studies

#### KARYOTYPE

A karyotype (95, 96), the most basic chromosome study, reveals large chromosomal deletions, duplications, or rearrangements as well as disorders of chromosome number (e.g. Down syndrome [trisomy 21] or Turner syndrome [XO]). In this test the cytogenetic laboratory harvests mononuclear leukocytes from the patient's blood. The leukocytes (monocytes and lymphocytes) are stimulated to proliferate for 3–4 days to enrich the sample with actively dividing cells. The laboratory then treats the cells with a chemical to arrest the cells at metaphase. The cells are stained with a Giemsa stain to enable microscopic visualization of chromosomal banding patterns. The chromosomes are paired, photographed, and analyzed. When ordering a karyotype, the clinician should request a high-resolution chromosome karyotype. The higher resolution means that the staining can detect smaller areas of abnormality than the standard karyotype resolution.

#### FLUORESCENT *IN SITU* HYBRIDIZATION (FISH)

FISH can detect chromosomal deletions or duplications that are too small to visualize using standard or high-resolution karyotype (99). Each FISH is designed to probe a single region of the chromosome and therefore detects only a single genetic disorder or mutation. A fluorescently-labeled FISH probe (composed of DNA) hybridizes (anneals) to its complementary sequence on the chromosome. Since humans possess two pairs of genes and chromosomes, FISH shows two fluorescent signals when both are present; samples from a child with a deletion syndrome show only a single fluorescent signal. In cri du chat syndrome, for example, FISH detects a single fluorescent signal (100), indicating deletion of a region of chromosome 5p.

#### COMPARATIVE GENOMIC HYBRIDIZATION (CGH)

CGH enables genetic laboratories to screen samples for large numbers of mutations

simultaneously. Developed initially to measure DNA copy number in cancer cells, the method allows mass screening for many different gene deletions, insertions, or duplications. The method employs slide-based microarrays that contain DNA regions of interest. The laboratory extracts DNA from a patient's leukocytes, mixes it with control DNA, and hybridizes minute quantities of this mixture to the slide. Fluorescent probes are added to the slide, and the results are computer-generated and analyzed. This method can simultaneously determine, for example, if a child has Angelman syndrome or a different gene deletion disorder.

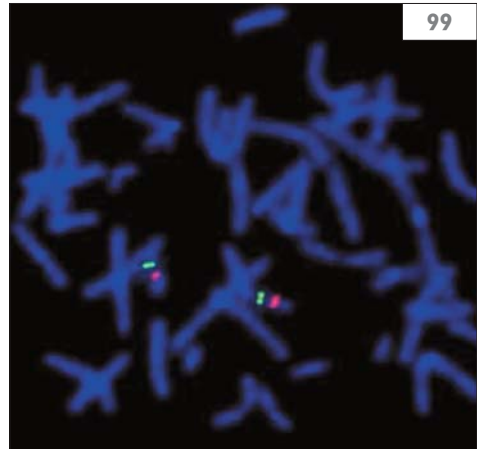
## Gene studies

### POLYMERASE CHAIN REACTION (PCR)

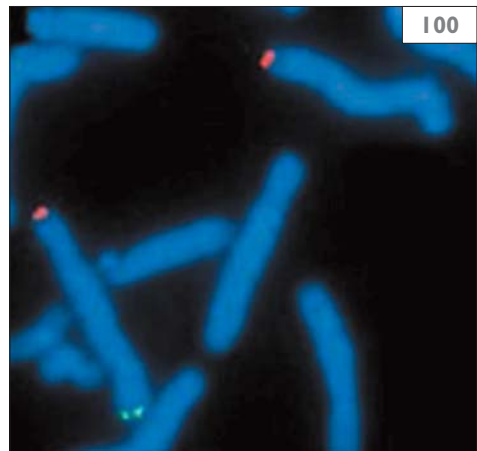
PCR is a rapid, sensitive method that targets an individual gene or chromosome region. PCR exploits the fundamental principle of DNA replication. In this test the laboratory uses specific primers (short pieces of DNA) that specifically anneal to DNA sequences that flank the region or gene of interest. The laboratory then amplifies the region between primers by heating and cooling the sample repeatedly in the presence of a DNA polymerase. The segment of DNA of interest is amplified exponentially. The PCR product can be analyzed qualitatively (the presence or absence of a PCR product) or quantitatively (the base pair size of the product). For example, PCR in fragile X syndrome, the result of an expansion of CGG triplet repeats, detects a product that is larger than normal. In this instance, >200 repeats indicate fragile X syndrome; <50 are considered normal, whereas 55–200 are considered a 'premutation'.

### SEQUENCING

Sequencing analyzes the actual base pair (nucleotide) sequence of a specific gene or region of the genome. Sequencing is necessary to detect the different single nucleotide mutations that can render a protein nonfunctional and therefore cause the disease. In this method, the laboratory extracts a patient's DNA and then recreates a nucleotide sequence map of the entire gene. For example, most cases of Rett syndrome result from one of eight mutations (four *missense* mutations –



99 Normal FISH showing two signals (green) for the short arm of chromosome 5.



100 Abnormal FISH showing one green signal, indicating cri du chat syndrome (5p-).

a single or point mutation that codes for the wrong amino acid, and four *nonsense* mutations – a point mutation that results in a premature stop in protein synthesis), but >200 individual mutations in the methyl CpG binding protein 2 (MECP2) gene have been associated with the disorder. Limitations of sequencing include the length of time necessary to produce results and the presence of polymorphisms that may not be specific for the genetic condition in question. Sequencing can miss gene duplications.

## Mitochondrial studies

Testing for mitochondrial DNA mutation can be done by any of the methods discussed above. Mitochondrial testing is rendered complex by *heteroplasmy*, the mixture of mitochondria, and mitochondrial DNA, inherited from the child's mother. Mutations in mitochondrial genes may be present, but may not lead to disease. Testing for mitochondrial disorders therefore relies heavily on functional assays that measure the aggregate activity of mitochondrial enzyme complexes in human tissues, usually muscle or skin fibroblasts. Mitochondrial disorders can be inherited as the result of mutations in the nuclear DNA, mitochondrial DNA, or the interplay of both mitochondrial and nuclear DNA.

## Obtaining testing

Testing can be hospital or institution specific, and depends upon the relationships or contracting that exists between hospitals and reference laboratories. Many universities and large clinics support laboratories that perform basic cytogenetic analysis and specialized testing, such as FISH, on site. Highly specialized testing, such as gene analysis by sequencing or CGH array, is typically performed by a regional or national reference laboratory. Tests for rare disorders may be performed only at one or two locations in the world (e.g. the gene test for vanishing white matter disease is currently available only at a laboratory in the Netherlands). Finally, certain tests are not available on a clinical basis; unless you find a researcher interested in your patient's disease, you will be unable to obtain testing. If a child possesses the clinical criteria for a disease, but the testing has been negative, don't hesitate to consult with a pediatric neurologist or medical geneticist.

## Future directions

Three major issues in the future of genetic testing in pediatric neurology loom on the horizon. One is the rapid advance in medical knowledge. Biomedical science has uncovered many the genetic causes of neurological disease (e.g. Rett syndrome, hereditary spastic paraplegia), but cost currently limits diagnostic testing. This phenomenon can limit our ability to provide families with specific genetic diagnoses, despite the scientific potential to do so. Within the next 20 years affordable, rapid sequencing of entire genomes may be available, but in the meantime, clinicians may be restricted in what can be offered to patients and their families.

A second challenge to the clinician is the wealth of information in the medical literature and lay press. Motivated patients and families read material about medical conditions on the internet and ask clinicians questions about specific disorders. While one of the authors was discussing the differential diagnosis of a newly diagnosed leukodystrophy, the grandmother of the child politely interrupted him and asked "Doctor, why isn't this vanishing white matter disease?" As you might guess, the grandmother was correct; the child had vanishing white matter disease. Clinicians must be prepared and accept the fact that parents and grandparents may possess more current information than the clinician. Viewing the care of children with neurological conditions as a partnership between clinicians and families can greatly enhance the experience for all.

A final area of uncertainty surrounds complex neurological traits such as autism, epilepsy, ADHD, tics, Tourette syndrome, and many more. Although some may depend largely on genetic contributions, the relationships between environmental factors and the genes causing these disorders have not been fully defined. Moreover, these disorders may result from complex multigenic effects or gene-environment interactions. At present, genetic linkage studies reported in the lay and scientific literature may impart a false sense that specific, meaningful testing is already available.

# Newborn screening and metabolic testing

**Main Points**

- Newborn screening allows detection of treatable metabolic disorders prior to the onset of neurologic damage.
- Abnormal newborn screening results require prompt consultation with knowledgeable consultants.
- Inborn errors of metabolism can cause encephalopathy, seizures, and failure to thrive in infants and young children.
- Older children with encephalopathy, seizures, or cognitive declines may have a metabolic disorder.

## Newborn screening

The goal of newborn screening is to identify infants with potentially morbid, but treatable metabolic disorders prior to the onset of symptoms. Newborn screening is mandatory or recommended in many regions of the world; however, parents may opt out for religious or other reasons, depending on the locale. In the USA the majority of states require expanded newborn screening for galactosemia, amino acidopathies, organic acidemias, biotinidase deficiency, congenital hypothyroidism, congenital adrenal hypoplasia, disorders of fatty acid oxidation, cystic fibrosis, and hemoglobinopathies.

The first newborn screening test is obtained in the first 2 days of life, before the infant leaves the hospital, by performing a lateral heel stick. The drops of blood are collected onto a special filter paper card (the PKU or Guthrie card), allowed to dry, and mailed to the health department or reference laboratory for processing. Some regions require a second screen at the 2-week well-child check or within the first 4 weeks of life. Abnormal results are referred to the primary care provider or, occasionally, the hospital, and recommendations for further testing are provided. The primary care provider assumes responsibility for contacting the patient's family, evaluating the infant, discussing the results, prescribing initial management, and determining if the child requires immediate hospitalization.

There are pitfalls in newborn screening. For instance, the collection paper cannot be contaminated with food, lotion, hand cleansers and so on, and must be transported to the testing facility within 24 hours. Excessive heat can also interfere with the test, especially when screening for galactosemia; prior blood transfusion can alter results for disorders such as hemoglobinopathies, and hyperalimentation can alter results as well. Some disorders, such as galactosemia, only appear when the child has been exposed to the substance that cannot be metabolized (e.g. galactose); thus, the child may be asymptomatic as well as lack metabolic derangement early in life. Like most screening evaluations, a normal newborn screen does not eliminate the possibility of disease. Some conditions, such as urea cycle abnormalities, are not detected by current newborn screening methods. Similarly, an abnormal result on newborn screen may not

indicate disease, since frequent false positives occur. Whenever there is clinical suspicion for an inborn error, regardless of whether newborn screening has been obtained, additional diagnostic testing is indicated.

## Abnormal results on a newborn screen

An abnormal newborn screen result often requires immediate or emergent action by the practitioner, including evaluation of the patient and initiation of potentially life-saving treatment as described on the ACTion (ACT) algorithms (textbox). Prompt consultation with a metabolic geneticist is always indicated. Pediatricians and family physicians should prospectively identify a metabolic expert (e.g. a metabolic geneticist) and keep updated contact information readily available for current and future reference. (An excellent review is: Newborn screening expands: recommendations for pediatricians and medical homes—implications for the system. *Pediatrics* 2007;**121**:192–218.)

In most regions of the USA, an abnormal result is referred to the primary care provider identified on the newborn screening paperwork.

The ACT algorithms can be obtained through the American Academy of Pediatrics ([www.medicalhomeinfo.org/screening/newborn.html](http://www.medicalhomeinfo.org/screening/newborn.html)) and the American College of Medical Genetics ([http://www.acmg.net/AM/Template.cfm?Section=ACT\\_Sheets\\_and\\_Confirmatory\\_Algorithms&Template=/CM/HTMLDisplay.cfm&ContentID=5661](http://www.acmg.net/AM/Template.cfm?Section=ACT_Sheets_and_Confirmatory_Algorithms&Template=/CM/HTMLDisplay.cfm&ContentID=5661)).

## Inborn errors of metabolism

This section describes the clinical aspects of inborn errors of metabolism as they present in infants and children. Clinicians must be able to recognize the initial signs and symptoms of these disorders, initiate therapy, and refer such children promptly to a pediatric neurologist or metabolic geneticist to establish a diagnosis and continue treatment. Early treatment can prevent permanent neurological damage from many of these disorders.



## Inborn errors in newborns

Metabolic disorders affecting the term or preterm newborn commonly present with seizures and encephalopathy. Infants with these symptoms and signs require urgent evaluation for infection, electrolyte derangement, hypoglycemia, and other common causes of seizures. If such a cause is not readily apparent, clinicians should consider an inborn error of metabolism and begin an evaluation for this. Historical clues suggesting the possibility of a metabolic disorder include the onset of encephalopathy or seizures 2–7 days after birth, as toxic metabolites accumulate. Clinical clues suggestive of an inborn error of metabolism are characteristic odors of the infant’s sweat, urine, or other body fluids (such as ‘musty feet’, ‘maple

syrup’ or ‘cat urine’). If the newborn is clinically ill and an inborn error is considered a possibility, a metabolic geneticist should be contacted immediately. The clinician should anticipate shock and hypoglycemia, features common in metabolic conditions; infants should receive intravenous fluids containing glucose. Some inborn errors of metabolism are exacerbated by dietary intake of amino acids or proteins, and these nutrients should be avoided until the underlying disorder is identified.

## Laboratory screening

Inborn errors cause abnormalities in multiple metabolic tests (*Table 12*); urea cycle disorders, for example, cause elevated plasma ammonia levels but also cause characteristic patterns of the

**Table 12 Initial laboratory studies to evaluate inborn errors of metabolism**

Test	Class of disorder	Example	Abnormal results	Additional testing
Plasma amino acids, urine organic acids	Amino acidopathies; organic acidopathies	Maple syrup urine disease	Elevated branched chain amino acids: leucine, isoleucine, valine; low alanine	Varies, depending upon disorder
Ammonia	Urea cycle disorder	Ornithine transcarbamylase (OTC) deficiency	Elevated ammonia	Check for elevated urine orotic acid to confirm the diagnosis
Lactate	Mitochondrial disorder	MELAS	Elevated lactate	Recheck lactate and pyruvate to determine the ratio (normal lactate: pyruvate is 20:1)
Very long chain fatty acids	Peroxisomal disorder; leukodystrophy	Zellweger spectrum disorder; neonatal adrenal leukodystrophy	Abnormal plasma very long chain fatty acid analysis	Check piperolic acid, phytanic acid, and plasmalogen synthesis to differentiate between peroxisomal disorders
Acylcarnitine profile; carnitine levels	Disorders of fatty acid oxidation; metabolic myopathy; mitochondrial disorders	Medium chain acyl CoA dehydrogenase deficiency	Abnormal profile of plasma acylcarnitines; abnormal pattern of serum or plasma carnitine	Genetic mutation analysis of chromosome; region 1p31

MELAS: mitochondrial myopathy, encephalopathy, lactic acidosis, and stroke syndrome.

serum or plasma amino acids. For this reason, the initial evaluation should include several metabolic tests, even if only one subtype of an inborn error is clinically suggested. These tests can include plasma amino acids, urine organic acids, serum acylcarnitine profile, serum carnitine levels, plasma very long chain fatty acids, serum lactate, and serum ammonia. Routine urinalysis prior to administration of glucose may also aid in diagnosis, but intravenous glucose should not be withheld from ill infants or children simply to obtain testing.

Additional testing may be necessary based on the infant or child's presentation (*Table 13*). If clinical suspicion is high, it is not necessary to wait for the results of initial testing to send further testing or to initiate therapy. This is especially important when managing and diagnosing disorders that require urgent medical intervention, such as ornithine transcarbamylase deficiency, a urea cycle disorder.

## Imaging

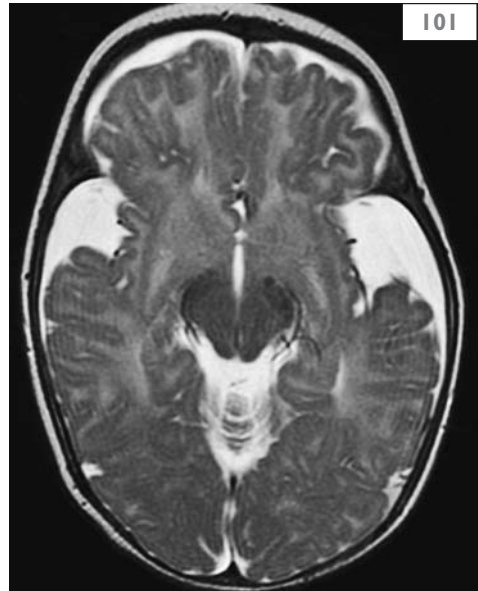
Brain MRI should be considered in the evaluation of infants or children with suspected inborn errors of metabolism. Glutaric acidemia or Zellweger spectrum disorder, for example, has characteristic imaging features (**101**). Consultation with a pediatric radiologist or neuroradiologist prior to imaging the child can assist with the identifying the necessary imaging sequences or whether contrast should be administered. MRS can also be helpful for diagnosis of certain inborn errors of metabolism, such as nonketotic hyperglycinemia or creatine deficiency (**102**), a disorder that can mimic cerebral palsy.

**Table 13 Additional testing for metabolic disorders based on clinical features**

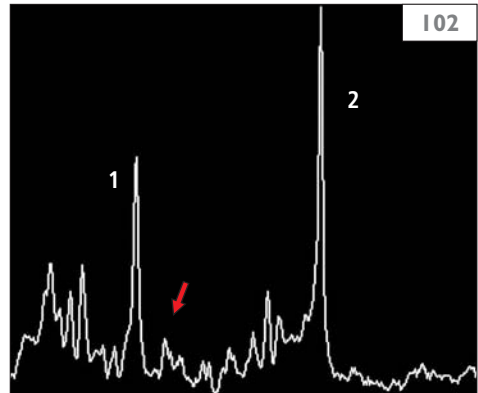
Clinical feature	Disorder(s) to consider	Additional testing
Intractable seizures	Sulfite oxidase deficiency; molybdenum cofactor deficiency	Urine sulfocysteine level
Intractable seizures	Pyridoxine deficiency; pyridoxine dependency	Trial of pyridoxine 50–100 mg per day; mutation analysis of the antitiquin gene
Intractable seizures	Cerebral folate deficiency	CSF level of 5-methyltetrahydrofolate
Cerebellar hypoplasia	Congenital disorder of glycosylation	Carbohydrate deficient transferrin levels
Alopecia, eczema, seizures	Biotinidase deficiency	Serum biotinidase level
'Hiccups' or seizures <i>in utero</i>	Nonketotic hyperglycinemia	CSF glycine level
Excessive startle	Tay–Sachs disease, Sandhoff disease; Krabbe disease ( <b>103</b> ); pyridoxine dependency	Leukocyte lysosomal enzyme analysis

CSF: cerebrospinal fluid

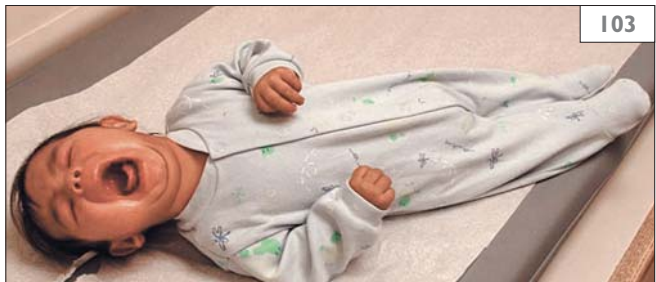**I01** A T2-weighted MRI showing middle fossa fluid collections characteristic of glutaric acidemia type 1.



**I02** MRS showing markedly diminished creatine peak (arrow) in creatine deficiency due to guanidinoacetate methyltransferase deficiency. 1, choline; 2, NAA.



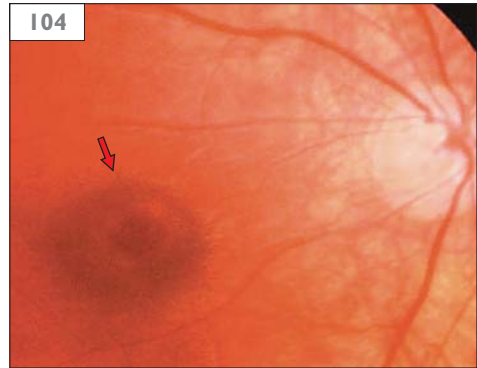**I03** A young infant with Krabbe disease demonstrating irritability and spastic quadriplegia.



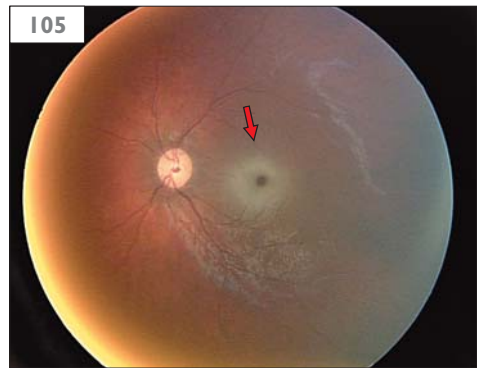
## Later clinical presentations

After the newborn period, inborn errors of metabolism may vary in their presentation. A previously healthy infant who develops periodic encephalopathy, new seizures, or failure to thrive may have an inborn error. Key elements to review when taking the history are whether the symptoms began after changing from breastfeeding to formula or after the introduction of new foods, or if symptoms occur after fasting or with fever. For example, medium chain acyl-coA dehydrogenase (MCAD) deficiency, an autosomal recessive disorder of fatty acid oxidation, causes hypoglycemia and hyperammonemia after fasting; these symptoms can appear as the infant begins to sleep through the night and does not receive frequent feedings. Some cases of sudden infant death syndrome (SIDS) may be due to previously undiagnosed metabolic disorders, including MCAD. A family history of SIDS or other unexplained childhood death should heighten suspicion for an underlying inborn error of metabolism.

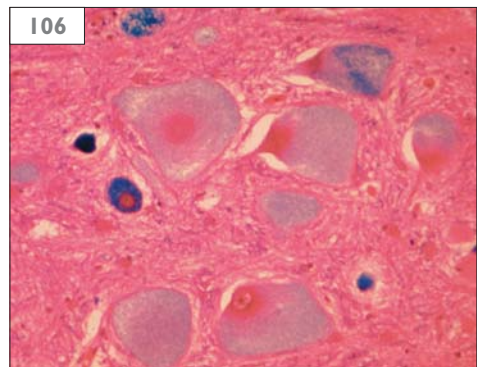
Older children or adolescents with inborn errors may present with progressive cognitive decline, seizures, myoclonus, or visual deterioration. Clinicians should recognize visual deterioration and cognitive decline, sometimes manifesting as declining school performance, as the initial symptoms of rare disorders such as neuronal ceroid lipofuscinosis (NCL) (104), juvenile onset Tay–Sachs disease, or Niemann–Pick Type C. Ophthalmological features, such as impaired vertical gaze in Niemann–Pick Type C or a cherry red spot in Tay–Sachs disease (105), may be the initial clue to a specific diagnosis. Referral to an experienced pediatric ophthalmologist should be considered in all cases of suspected neurodegenerative or metabolic disorders. Figure 106 shows characteristic neuropathological abnormalities of Tay–Sachs disease.



**104** 'Bullseye' maculopathy (arrow) in a child with late infantile neuronal ceroid lipofuscinosis.



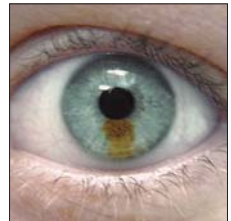**105** Macular cherry red spot (arrow) in Tay–Sachs disease.



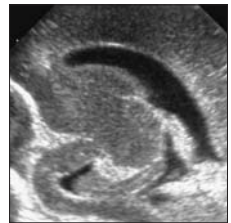
**106** Autopsy specimen showing pale, ballooned neurons in Tay–Sachs disease (H&E).

# **A PROBLEM-BASED APPROACH TO PEDIATRIC NEUROLOGICAL DISORDERS**

**Chapter 7**  
**Disorders of development**



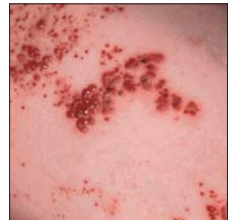**Chapter 8**  
**Disorders of behavior and cognition**



**Chapter 9**  
**Disorders of language and hearing**

**Chapter 10**  
**Disorders of head size and shape**

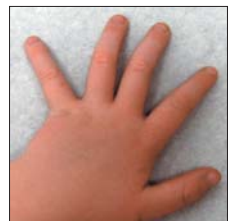**Chapter 11**  
**Disorders of cranial nerves**



**Chapter 12**  
**Disorders of peripheral nerves**

**Chapter 13**  
**Disorders of gait and balance**

**Chapter 14**  
**Disorders of sleep**



**Chapter 15**  
**Disorders of the newborn**

**Chapter 16**  
**Acute focal deficits**

**Chapter 17**  
**The dysmorphic child**

**Chapter 18**  
**Headaches**

**Chapter 19**  
**Hypotonia and weakness**

**Chapter 20**  
**Infections of the nervous system**

**Chapter 21**  
**Movement disorders**

**Chapter 22**  
**Seizures and paroxysmal disorders**

**Chapter 23**  
**Pediatric neurological emergencies**



# Disorders of development

**Main Points**

- Clinicians should determine whether one or more developmental categories are involved.
- When the delay is global, MRI and genetic studies are indicated.
- Clinicians must define whether the clinical course is static or regressive.
- Cases of developmental regression should be referred for evaluation promptly.
- Supportive therapies should be initiated as soon as developmental delay is suspected.

## Introduction

As many as 15–20% of infants and children have delays in one or more areas of development. The clinician's role in evaluating children with suspected developmental delay is to recognize significant delays, assess for associated neurological and non-neurological comorbidities, and refer children appropriately for further evaluation, as needed. The initial clinical evaluation should determine if the child has delays in single or multiple developmental categories and establish if the child's development is static, progressing, or regressing. Developmental regression not due to intercurrent illness or other comorbidity merits a prompt referral to a developmental specialist or child neurologist. This chapter reviews the presentation and common causes of isolated categories of delay and global developmental delay and closes with a discussion of developmental regression. Treatment of the child with developmental delay will eventually be tailored to fit the underlying diagnosis. In all cases, however, the clinician should refer the child promptly to appropriate therapists, including speech, occupational, and physical even before the diagnosis is established.

## Motor delay

### DIAGNOSIS AND CLINICAL FEATURES

Infants and young children achieve gross motor milestones at predictable rates (textbox).

#### Timing of major motor milestones (World Health Organization)

Milestone	Age
Sitting without support	4–9 months
Standing with assistance	5–11 months
Walking with assistance	6–14 months
Standing alone	7–16 months
Walking alone	8–18 months

Delay in attaining motor milestones can be diagnosed when the skill level is less than two standard deviations below the level expected for age. There are many causes of isolated gross

motor delay, some benign and others due to underlying structural, genetic, or metabolic disorders affecting the brain, spinal cord, nerves, or muscles. A specific, etiologic diagnosis is made in <50% of the children with gross motor delays. Nonetheless, establishing a diagnosis helps the clinician, child, and family understand the implications for the child and family.

Based on the history and physical exam, the clinician should categorize the patient's gross motor delay according to the following domains:

- Temporal profile: static *vs.* regressive.
- Muscle tone: hypotonic *vs.* hypertonic.
- Distribution: hemiplegic, diplegic, or quadriplegic.

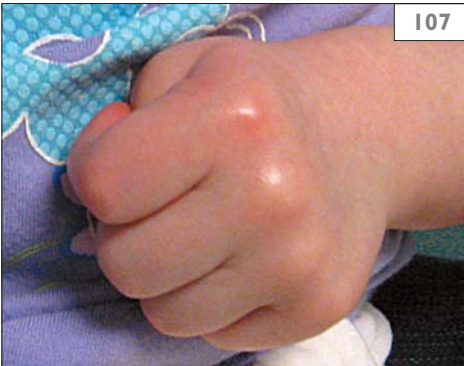These domains help determine the urgency of referral, the probability of establishing a diagnosis, and the initial steps of evaluation. Motor regression, discussed at the end of this chapter, requires prompt referral. Intercurrent medical illness, such as failure to thrive, substantial weight loss, symptomatic cardiac disease, or psychological stress, can cause transient regression and may require distinct interventions.

A common scenario encountered by the clinician is the child with a static motor delay. The motor deficit is rarely evident at birth, but as the infant matures, the deficit becomes apparent. An example of this is hemiparesis due to perinatal stroke. At birth the infant moves all four extremities smoothly and equally, but by 6 months of age hemiparesis and abnormal tone, often manifesting as a fisted (cortical) thumb (107), become apparent. Such an infant may acquire hand dominance long before this skill is developmentally appropriate. Acquiring handedness before the age of 12 months is considered potentially abnormal, but some normal children do not display hand preference until the age of 18 months. Although the infant's motor deficit is static, the deficit may become more noticeable as the child grows and attempts to acquire new skills. Evaluation of the child with a static motor delay is not urgent. Of greater importance is the early referral for physical or occupational therapy to enhance use of the affected limb.

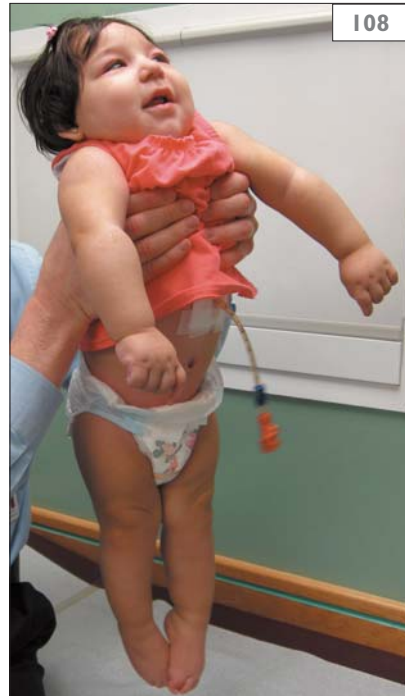The clinician should characterize the distribution of motor deficit (*Table 14*). Hemiparesis

**Table 14 Selected causes of gross motor delay and associated clinical findings**

<i>Condition</i>	<i>Associated features</i>
<b>Perinatal</b>	
Hypoxic–ischemic encephalopathy	Complicated delivery; quadriplegia (108)
PVL/IVH	Prematurity; spastic diplegia
Arterial ischemic stroke	Neonatal seizures; hemiparesis
Kernicterus	Neonatal hyperbilirubinemia
<b>Congenital/genetic</b>	
Prader–Willi syndrome	High forehead; narrow bitemporal diameter; retrognathia; hypotonia; neonatal failure to thrive
Cerebral malformations	Microcephaly; macrocephaly; abnormal MRI
Myelodysplasia	Spastic/hypotonic paraparesis/paraplegia
Spinal muscular atrophy	Frog-leg posture; areflexia; tongue fasciculations
Congenital myotonic dystrophy	Mother with myotonic dystrophy; neonatal bulbar dysfunction and/or respiratory failure
Duchenne muscular dystrophy	Progressive weakness in childhood; male sex; Gower sign
IVH: intraventricular hemorrhage	
MRI: magnetic resonance imaging	
PVL: periventricular leukomalacia	



**107** Cortical thumb indicating upper motor neuron dysfunction.



**108** Scissoring (crossing) of the legs in a child with cerebral palsy and spastic quadriplegia.

refers to weakness of one side of the body, i.e. right hemiparesis refers to weakness of the arm and leg on the right side. Weakness tends to be greatest in the arm, followed by the leg, and sometimes the face (109). The presence of hemiparesis implies a contralateral cerebral lesion, such as a cortical dysplasia or perinatal stroke (110). Diplegia refers to weakness or paralysis of both lower extremities; this typically occurs as a consequence of periventricular leukomalacia (PVL) in which the descending motor fibers to the legs are disrupted by demyelination and axonal damage (111). Similar findings can also be found after bilateral intraventricular hemorrhage (IVH) with periventricular infarction. In the absence of an appropriate history or brain MRI findings of PVL, a lesion of the spinal cord should be considered.

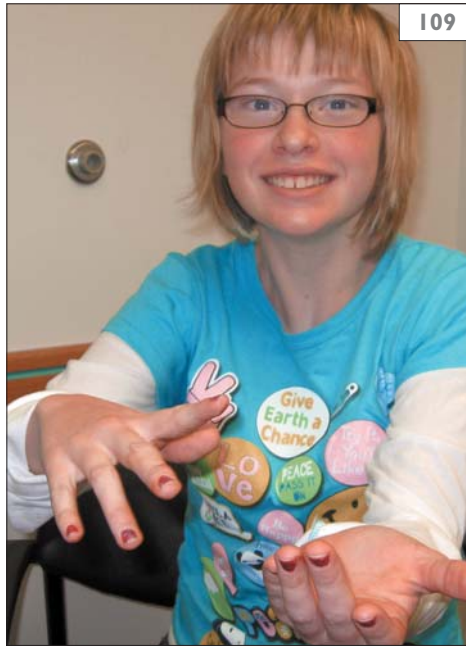Quadriparesis, or weakness of all four limbs, should be categorized according to the underlying tone abnormality. Quadriparesis with increased tone or spasticity is often the result of brain injury due to perinatal or prenatal factors, such as hypoxic–ischemic injury (108). Some congenital muscular dystrophies may cause weakness with rigidity or contractures that can mimic spastic quadriparesis. By contrast, quadriparesis with hypotonia, as in ‘floppy baby’ syndrome, suggests a neuromuscular cause, such as spinal muscular atrophy.

The diagnosis of cerebral palsy (CP) can be made when an infant or young child has hemiparesis, quadriparesis, or diplegic paraparesis of prenatal or perinatal origin. CP affects approximately 1 of every 500 newborns, resulting from hypoxic–ischemic injury, intrauterine infection, or perinatal stroke. CP is a descriptive diagnosis, and every child with this diagnosis should be evaluated for an underlying cause. Most are the result of prenatal events. Children with CP generally face life-long disability, although this can range from mild to severe. Although CP denotes motor impairment, children with CP often have comorbidities, such as epilepsy, cognitive impairment, poor growth, gastrointestinal ailments, and orthopedic abnormalities, including progressive scoliosis. Despite advances in obstetric and neonatal care, rates of CP have not changed substantially over the past several decades. CP

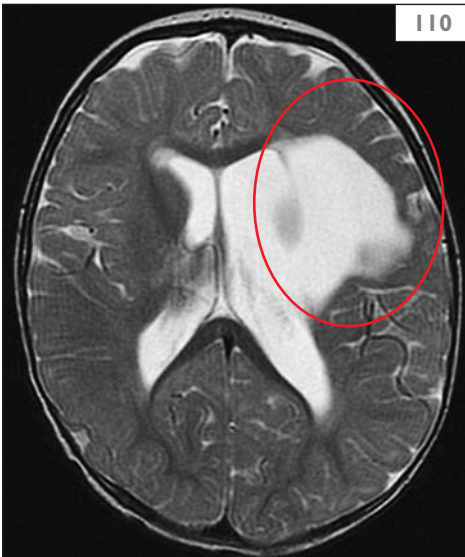can develop in both term and preterm infants, although rates are much higher in premature infants.

The brain injury causing CP does not progress, but the clinical manifestations, especially muscle tone and orthopedic complications, may change as the child grows and develops. Early on, the infant with incipient CP may appear weak and hypotonic, but over time spasticity appears in most instances. Infants with suspected CP should be referred early for services, including physical and developmental therapies. Children with CP are best managed by a multidisciplinary team that includes pediatricians, child neurologists, neurodevelopmental pediatricians, orthopedists, and therapists. Depending upon the severity of the CP, children with this condition may require orthotics, walkers, wheelchairs, and assisted communication devices.

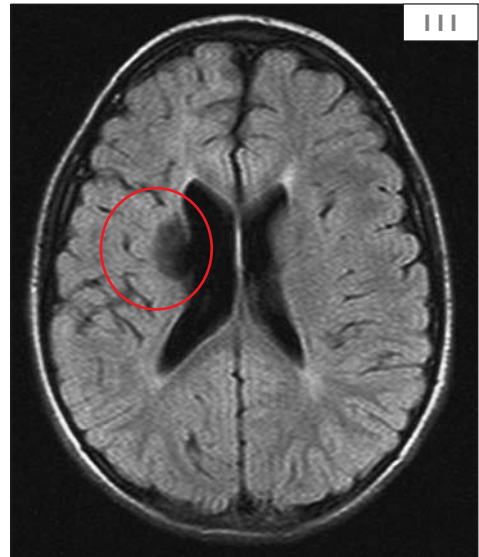Isolated gross motor delay often simply represents the extreme end of the normal, bell-shaped curve of development. Dissociation of motor maturation, characterized by delays in sitting or walking but with otherwise normal development, is most often a benign condition. Affected children may walk as late as 2 years of age without any long-term motor impairments. As infants, they may appear to ‘sit on air’ when held in vertical suspension; the family history may suggest other late walkers. Congenital hypotonia without cause is another benign condition presenting with hypotonia and delayed motor milestones. Such children may roll, sit, and walk late, but appear completely normal by late childhood. Both conditions require close monitoring to confirm their benign clinical course.



109 The asymmetrically outstretched hand in a child with a right hemiparesis.



110 T2-weighted MRI showing a large area of porencephaly (circle) in a child with hemiparetic cerebral palsy due to an *in utero* stroke.



111 FLAIR MRI showing cystic PVL (circle) in a child with hemiparetic cerebral palsy.

## Global developmental delay

The term global developmental delay describes an infant or child with significant delays in two or more developmental categories; most often, these are in the motor and language domains. Unlike isolated motor delay, global developmental delay does not typically have a benign etiology or complete resolution of symptoms or signs. Thus, clinicians must recognize this situation early and initiate evaluation and supportive treatment to maximize the child's motor, social, and cognitive outcomes. A cause can be found in up to 50–60% of such cases. Common causes of global developmental delay are listed in *Table 15*. Again, the clinician's role is to determine the temporal profile of the child's condition and the distribution of the child's deficits; in this instance, however, the clinician should determine whether the deficits are in the gross motor, language, social, and/or fine motor areas. The clinician must again initiate appropriate supportive treatment and refer the child, as needed, for further evaluation. Standardized developmental assessment tools, such as the PEDS: Developmental Milestones, allow rapid and reasonably accurate screening of development in the primary care setting.

**Table 15 Selected causes of global developmental delay**

Condition	Associated features
Hypoxic–ischemic encephalopathy	Complicated delivery, quadriparesis
Congenital infection	Microcephaly, intracranial calcifications
Fetal alcohol syndrome	Microcephaly, dysmorphic features
Chromosomal anomalies	Dysmorphic features, brain anomalies
Syndromic disorders	Dysmorphic features, brain anomalies
Autism spectrum disorders	Impaired language skills, poor social reciprocity, stereotypic behaviors

## Developmental regression

Developmental regression usually suggests serious underlying neurological disease (*Table 16*). The clinician's role is to recognize regression promptly in any of the developmental domains, differentiate this from transient regression due to intercurrent disease or psychosocial stress, and initiate appropriate referral for services as well as diagnostic evaluation. Gross motor regression can be noted as early as the first few months of life; language regression is usually identified much later, once language has been acquired. Language regression is discussed extensively in Chapter 9 Disorders of Language and Hearing.

## Management of developmental delay

Developmental assessment is a cornerstone of well-child evaluations. Isolated gross motor delay and isolated language delay can be referred on a nonurgent basis while supportive therapies (physical, occupational, language, or developmental) are being initiated. When an infant or child has global developmental delay without an

**Table 16 Selected causes of developmental regression**

Age	Condition	Features
3–6 months	Tay Sachs disease	Seizures, excessive startles, cherry-red spot
1–3 years	Rett syndrome	Loss of language and purposeful hand skills ( <b>113</b> )
1–3 years	Autism	Loss of language and social skills
3–8 years	Landau–Kleffner syndrome	Loss of expressive and receptive language (acquired epileptic aphasia); abnormal behavior



apparent, underlying systemic cause, clinicians should utilize algorithms, such as the American Academy of Neurology Practice Guidelines for Evaluation of the Child with Global Developmental Delay, to guide their initial evaluation (112). According to this approach, brain MRI and genetic testing have the highest diagnostic yield. MRS, a useful adjunct to standard brain MRI, provides essential diagnostic information for certain conditions, such as mitochondrial disorders or creatine deficiency. When these studies are unrevealing, the patient can be referred for subspecialty evaluation coincident with starting physical, occupational, or speech therapy, as needed. Loss of previously acquired motor or language skills, i.e. developmental regression, always merits prompt evaluation.

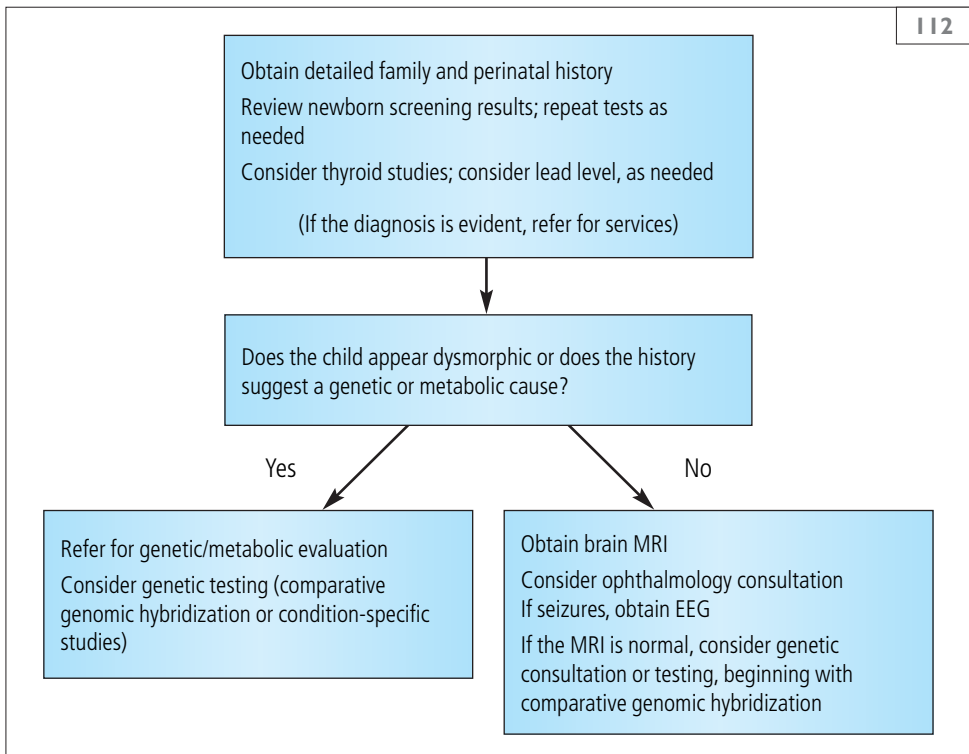
## Representative clinical scenarios

### CASE 1

An otherwise healthy 16-month-old boy has gross motor delay. He rolled at 7 months, and sat without support at 10 months. He has just begun to pull to stand and will now ‘walk’ supported along furniture. He has five individual words and interacts appropriately with the examiner. He has no dysmorphic features; his neurological examination shows normal muscle strength and mild diffuse hypotonia. He is an only child; no family members have neurological or neuromuscular disorders.

This child likely has the syndrome of dissociated motor maturation. A normal serum creatine kinase (CK) level, free T<sub>4</sub>, and thyroid stimulating hormone (TSH) will eliminate

112



112 Diagnostic algorithm for children with global developmental delay.

Duchenne muscular dystrophy (DMD) and hypothyroidism. Management consists of continued observation, although referral for developmental services could be considered.

### CASE 2

An 18-month-old girl has no words and does not understand simple instructions; she can pull to stand, but does not take steps independently. Examination shows a social child with an occipital frontal circumference (OFC) <3<sup>rd</sup> percentile; she has wide-spaced teeth, brachycephaly, angular jaw, and diffuse hypotonia.

This child likely has Angelman syndrome. This can be confirmed by DNA methylation studies for 15q11.2-13 deletion/uniparental disomy/imprinting and in some, analysis for UBE3A gene mutation. As many as 10% of children with Angelman phenotypes have normal genetic studies. The child requires referral for genetic counseling and developmental services.

### CASE 3

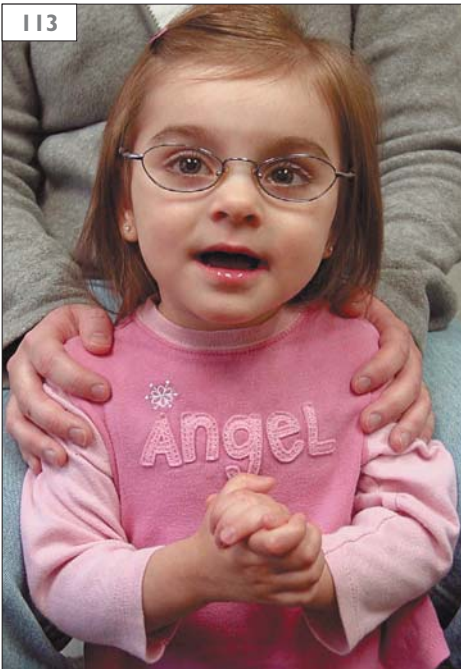A previously healthy 3-year-old boy is referred for evaluation of frequent falls and inability to keep up with his peers. He walked at 1 year of age and seemed normal until approximately 6 months ago. Examination shows a waddling gait and a Gower sign.

This child likely has DMD. A serum CK value of several thousand units/L supports this diagnosis; DMD can be confirmed by mutation analysis of the dystrophin gene. He should be referred to a center with expertise in the management of neuromuscular disorders.

### CASE 4

The development of a previously healthy 11-month-old girl plateaus. During the subsequent 3 months, she stops saying “mama” or “dada” and shows less interest in playing with her toys. Examination shows a nondysmorphic child who does not reach for objects. She has mild diffuse hypotonia and diminished muscle stretch reflexes. Her head circumference, once at the 25<sup>th</sup> percentile, now plots at the 10<sup>th</sup> percentile.

This child likely has Rett syndrome, the most frequently identified cause of developmental regression in young girls. Common features include developmental regression, acquired microcephaly, and a characteristic movement disorder consisting of repetitive hand-to-mouth or hand-wringing movements (113). The disorder can be confirmed in >90% of cases by identifying mutations in the methyl CpG binding protein-2 (MeCP2) gene.



113 The hand wringing movements characteristic of Rett syndrome.

# Disorders of behavior and cognition

## Main Points

- Disorders of attention occur commonly in children with:
  - Epilepsy, especially when intractable.
  - Learning disabilities or cognitive impairments.
  - Acute or chronic encephalopathies.
  - Sleep disorders.
- Several anticonvulsant medications affect behavior and cognition:
  - Phenobarbital causes hyperactivity and impairs short-term memory.
  - Topiramate commonly causes reversible cognitive impairment.
  - Divalproex sodium or valproic acid can cause reversible dementia.
  - Levetiracetam may cause oppositional disorders, especially in adolescents.
- Children with disorders of cognition may require:
  - MRI with or without MRS.
  - Genetic evaluation including directed FISH for specific conditions or comparative genomic hybridization.
- In autism spectrum disorders (ASD):
  - Children commonly have disorders of language and behavior.
  - The diagnostic yield of MRI is low.
  - Specific neurological conditions, such as epileptic aphasia (Landau–Kleffner syndrome), can present similarly to ASD.
- Organic brain syndromes can present with acute, subacute, or chronic disorders of behavior and cognition.

## Introduction

Disorders of behavior and cognition, often called neurobehavioral disorders, occur commonly in children. Moreover, many neurological disorders, such as epilepsy, developmental delay, tic disorders, acute or chronic encephalopathies, and traumatic brain injury (TBI), can be accompanied by neurobehavioral dysfunction that can exceed the morbidity of the neurological disorder *per se*. Not surprisingly, these situations produce considerable parental distress and family discord. This chapter describes selected disorders and emphasizes that children and parents benefit from a multidisciplinary approach to managing these conditions.

## Disorders of attention

Approximately 5–10% of boys and a nearly equal number of girls living in the USA and other countries may fit criteria for attention deficit hyperactivity disorder (ADHD). The majority of these children do not have other identifiable functional or structural neurological impairments. The principal features of ADHD are hyperactivity and difficulties with attention and impulse control. The disorder can be categorized into subtypes (hyperactive–impulsive, inattentive, or combined), depending upon the predominant symptoms or signs. The diagnosis of ADHD relies upon the observations of parents and teachers and the utilization of questionnaires, such as the Vanderbilt ADHD Diagnostic Parent and Teacher Rating Scales, that score key behaviors present in children with ADHD.

Management of ADHD requires a combination of behavioral approaches and medications, such as the stimulants methylphenidate, amphetamine, and dextroamphetamine, and a norepinephrine reuptake inhibitor, atomoxetine. Side-effects of stimulants include decreased appetite, poor growth, insomnia, and tics. Children or adolescents with ADHD may have coexisting disorders, including learning disability, oppositional defiant disorder, anxiety and depression, emphasizing that individuals with ADHD often need a multidisciplinary

therapeutic team consisting of primary care clinicians, psychologists, and child or adolescent psychiatrists.

Children with neurological disorders affecting the function of the cerebrum and associated with so-called ‘static encephalopathies’ or ‘organic brain syndromes’ have high rates of impairments of attention (*Table 17*). Some studies suggest that the latter children are less likely to respond to stimulant medication than children with ADHD alone, although this conclusion is controversial.

Management of the underlying neurological disorder must often be accompanied by thorough evaluation and management by a child psychologist, behavioral therapist, and/or child psychiatrist. Clinicians must understand the child’s cognitive abilities and neuropsychological profile to manage a child’s condition well. Such information guides an optimal educational plan, allows families and educators to set appropriate expectations and, as the child approaches adult age, allows for identification and recruitment of available community resources and transition services. Preparation for the transition to adulthood is too often overlooked; the child and family are best served by providing anticipatory guidance several years in advance of the young adult’s needs.

## Neurobehavioral toxicity of antiepileptic drugs

The majority of the antiepileptic drugs (AEDs) have ‘neurotoxic’ side-effects. In general, drugs that enhance GABAergic tone (e.g. barbiturates, benzodiazepines, tiagabine) are more likely to produce unacceptable cognitive and behavioral side-effects than others (*Table 18*). Most of these effects are dose dependent and increased by polypharmacy. The practitioner must query the patient and family regarding medication side-effects at every visit. It is also useful to warn the family regarding these potential side-effects and to engage in a pact with parents ahead of time that AED treatment will be altered or adjusted in the event of such toxicity. This approach will foster a greater degree of trust between the family and the physician.

**Table 17 Selected conditions causing acute and subacute onset of organic brain syndrome in children and adolescents**

Condition	Typical age of onset	Cardinal feature(s)
Opsoclonus–myoclonus syndrome (OMS)	Infancy to 5 years of age	Neuroblastoma; acute cerebellar ataxia; opsoclonus
Lennox–Gastaut syndrome (LGS)	2 years to early childhood	Astatic, atypical absence and generalized convulsive seizures; generalized spike-wave discharges on EEG $\leq 2.5$ cps)
Myoclonic–astatic epilepsy of Doose (MAE)	2 years to early childhood	Astatic and atypical absence seizures; generalized spike-wave discharges on EEG $\leq 2.5$ cps)
Systemic lupus erythematosus (and/or anticardiolipin antibody syndrome)	Older than 5 years	Rash; splinter hemorrhages; acute encephalopathy +/- stroke-like symptoms or chorea
Accidental or purposeful intoxication (drugs, products, natural substances)	Any age	Variable degrees of obtundation, disorientation, agitation
Medication side-effects (corticosteroids, chemotherapeutic agents, OTC agents, etc.)	Any age	Variable degrees of obtundation, disorientation, agitation
Meningeal malignancy (leukemia, lymphoma, primitive neuroectodermal tumor [PNET])	Any age	Headache; agitation; confusion; seizures
Acute disseminated encephalomyelitis (ADEM)	Any age	Acute/subacute encephalopathy; optic neuritis; seizures; long tract signs
Posterior reversible encephalopathy syndrome (PRES)	Any age	Evidence of hypertension; visual impairment; headache; agitation; confusion; seizures
Gliomatosis cerebri	Second decade	Behavioral decline; disinhibition; confusion; agitation; seizures

**Table 18 Neurobehavioral effects of commonly used anticonvulsant medications**

AED	Effect*
Carbamazepine/oxcarbazepine	Aggressiveness (uncommon)
Clobazam	Somnolence
Ethosuximide	Somnolence, sleep disturbances, psychosis
Felbamate	Insomnia, anxiety
Lamotrigine	Sedation
Levetiracetam	Oppositional/defiant behavior (especially in adolescents)
Phenobarbital	Hyperactivity, impaired short-term memory, sedation
Tiagabine	Somnolence
Topiramate	Cognitive/memory and language impairment, sedation, hyperactivity (especially in younger children)
Valproic acid/divalproex sodium	Asthenia, sedation, dementia (rare)
Vigabatrin	Somnolence

\*Some anticonvulsants may increase the risk of suicidal thoughts or behaviours.

## Disorders of cognition

Disorders of cognitive processing, relatively common in childhood, cause considerable sadness and frustration for parents. This difficult situation is compounded by the absence of a specific etiologic diagnosis for the majority of children with mild intellectual retardation (intellectual quotient [IQ] 50–70) or learning disabilities (LDs); parents may be distraught that ‘nobody can tell them what is going on’. Included in this category are disorders of global cognitive impairment (mental or intellectual retardation) and more restricted disorders of cognition, known as LDs, in which academic achievement in one or more selective areas is impaired more than expected relative to the child’s overall intellectual potential. Children with severe LDs and language impairment may function less well than children with mild intellectual retardation. Individuals with cognitive disorders often have associated difficulties with social judgment, problem solving, impulse control, self-esteem, and emotional stability.

### DEFINITIONS

Mental retardation (intellectual impairment or intellectual retardation), a neurological condition associated with global intellectual difficulty, is defined by the combination of two features: 1) IQ less than 70 (normal = 100 with a standard deviation of 15) (textbox), and 2) associated functional impairments in age-appropriate activities and expectations. The latter, a vague concept, is difficult to measure.

IQ	Mental retardation
70–79	Borderline
50–69	Mild
35–49	Moderate
20–34	Severe
<20	Profound

LDs are more difficult to define because there is no established consensus. Operationally, these are defined as cognitive impairments in which a significant discrepancy exists between academic achievement and overall intellectual potential. In the UK and

other European countries, the term ‘learning disability’ has been used nearly synonymously with the USA term ‘mental retardation’.

### DIAGNOSIS AND CLINICAL FEATURES

Evaluation of suspected intellectual retardation relies on standardized tests of cognitive ability (IQ tests) administered by a qualified psychologist (textbox).

#### Standardized tests of intellectual function

##### Standard

Stanford Binet (2.5 yr to young adult)  
 Weschler Preschool and Primary Scale of Intelligence (WPPSI) (2.5–7 yr of age)  
 Weschler Intelligence Scale for Children (WISC) (6–16 yr of age)  
 Weschler Adult Intelligence Scale (WAIS) (16–89 yr of age)

##### Nonverbal

Leiter (2–20 yr of age)  
 Universal Nonverbal Intelligence Test (UNIT) (5–17 yr of age)  
 Test of Nonverbal Intelligence (TONI) (6–89 yr of age)

This evaluation can be affected by socioeconomic, cultural, or linguistic backgrounds and complicated in children with autism, deafness, language disorders, and emotional or psychiatric conditions. The diagnosis of mental retardation cannot be made confidently in children under 2 years of age. However, a developmental quotient (DQ) generated by standardized instruments, such as the Gesell Developmental Schedules, does correlate well with future measures of IQ.

Based on standardized IQ measurements and associated population based studies, approximately 2% of the population has an IQ <70 and is considered intellectually impaired. The majority of persons with an IQ of 50–70 lack identifiable syndromic or structural brain abnormalities that explain their cognitive impairment. Nevertheless, some individuals within this group do possess brain malformations, congenital syndromes, or identifiable, familial condi-



tions. Thus, evaluation for such entities should be considered. Among individuals with IQ <50, the majority are associated with other medical or neurological disorders, including congenital syndromes and cerebral palsy. Medical history, e.g. history of perinatal encephalopathy or encephalitis, and examination, e.g. physical features suggesting a specific syndromic disorder, guide the diagnostic assessment.

All children with cognitive disorders require careful physical and neurological evaluation and thorough psychoeducational testing. The diagnostic evaluation beyond IQ testing is warranted when a child has a history of global developmental delay before the age of 2 years, evidence of dysmorphism, or a family history consistent with an identifiable condition such as fragile X syndrome, X-linked hydrocephalus, myotonic dystrophy, and others. Published practice parameters regarding children with global developmental delay suggest that brain imaging (MRI) followed by genetic testing offers the highest yield. In some cases, MRS may add to the diagnostic yield, especially in children with suspected mitochondrial disorders or creatine deficiency (guanidinoacetate methyltransferase deficiency). Studies for inborn errors of metabolism (metabolic disorders) have very low yields in the absence of suggestive features (e.g. children with homocystinuria display neurological deterioration, arachnodactyly, myopia, and ectopia lentis).

Given the rapid technical advances in the field of genetics, the 'best' approach to genetic testing constantly changes. Current options include: a) early referral to a medical geneticist; b) targeted genetic testing using FISH for a suspected genetic defect (e.g. 7q11.23 deletion in Williams syndrome); or c) comparative genomic hybridization (CGH) which may have higher yield if no specific entity is suspected. The latter study, however, can miss larger chromosomal anomalies such as balanced translocations, indicating that routine high resolution karyotyping is still useful. Many experts recommend molecular studies for fragile X mutation in any boy with unexplained mental retardation; restricting such testing to boys with typical clinical features or with a suggestive family history may be more cost effective.

## MANAGEMENT

The inability to provide effective medical therapies for the vast majority of children with intellectual retardation causes considerable pessimism among pediatricians and child neurologists. Families often resort to alternative or complementary medical interventions found on the internet or in the lay literature. Nootropic agents, such as piracetam, are not widely used in the USA.

By contrast, thoughtful anticipatory guidance, as well as early recruitment of optimal multidisciplinary resources, is invaluable. The pediatrician or child neurologist can help families identify proper professional, educational, and community resources. Associated disorders of mood and attention may require specific pharmacotherapy with stimulants or antidepressants. Behavioral and family therapy may provide considerable benefits to the child and family. Attention to future transition services and to community programs and services available once the child is older than 18 is essential. These vary across communities; practitioners should create a comprehensive list of such resources that can be provided to parents.

## Learning disability

### DIAGNOSIS AND CLINICAL FEATURES

LDs consist of heterogeneous disorders of cognitive processing in which academic achievement in one or more cognitive domains is worse than expected based on the individual's overall intellectual potential. Approximately 5% of children in the USA receive special education, but an even higher percentage is likely to have LDs (textbox).

#### Common subtypes of learning disability

- **Dyslexia:** impairment of reading despite normal intellect.
- **Nonverbal LD:** difficulties with visuospatial processing, spatial organization, nonverbal problem solving and nonverbal social skills.
- **Mathematical disability:** impairment of arithmetical and mathematical ability.
- **Writing disability:** impairment of written language.
- **Disorders of executive function:** impairment of organization and regulation of behavior and abilities.

The prototype and most prevalent of these is dyslexia. Dyslexia refers to significant impairment in reading ability despite normal intelligence; however, the term is often used to encompass various deficits of language processing and learning in which difficulties in reading are prominent.

LD should be considered in children with school difficulties and strongly suspected when formal psychometric testing identifies a discrepancy between academic achievement and IQ. The definition and implications of LD vary widely among authorities and educational systems. Identification of children with LD is further complicated by that fact that such discrepancies may also result from numerous, noncognitive confounders such as sociocultural and linguistic background, emotional and psychiatric disorders, stress and anxiety, educational neglect, and sleep disorders. Especially challenging are the children with borderline IQs and deficits in specific cognitive areas. Such children do not qualify as mentally or intellectually retarded and may not demonstrate

discrepancies of sufficient magnitude to be labeled LD, yet may have academic abilities substantially more disabling than those of children with mild mental retardation.

Most children with LD do not have identifiable neurological or medical conditions that explain their disorders. However, studies suggest a strong genetic influence on LD, emphasizing the importance of a thorough review of the family history. The simple question “who in the family is your child most like?” often provides important insights for both clinicians and parents. Recent studies using fMRI and diffusion tensor imaging suggest a neuroanatomical basis for certain conditions. Subtle cortical dysgenesis in the sylvian and posterior temporoparietal regions of the left hemisphere has been identified in persons with LD. The usual asymmetry of the planum temporal (the posterior–superior portion of the temporal lobe that encompasses language and is normally larger on the left side of the brain) may be absent or reversed in persons with dyslexia. LDs can also be associated with numerous medical, syndromic, and neurological disorders (textbox).

#### Selected conditions associated with learning disability

- Diabetes mellitus.
- Epilepsy.
- HIV/AIDS.
- Low birth weight/prematurity.
- Neurofibromatosis type 1.
- Velo-cardio-facial (Shprintzen–DiGeorge) syndrome.
- Turner syndrome.
- Fragile X carrier state.
- Tourette syndrome.

### MANAGEMENT

The management of children with LD must involve parents, educators, and clinicians. No specific pharmacotherapy exists, although psychostimulants have roles in children with disorders of attention. Certain nations, such as the USA, mandate services for children with LD. Generalists and specialists, e.g. child neurologists, should function as advocates for children with LD and assist families in identifying and implementing the appropriate resources for their

children. Children with LD place an enormous emotional burden on many families, often necessitating psychological and psychiatric services for the child and family. Although these disorders affect children lifelong, many children will improve or adapt, particularly when the appropriate psychoeducational interventions have been identified.

## Autism spectrum disorders (ASD) and related conditions

### DIAGNOSIS AND CLINICAL FEATURES

Impaired social interaction represents the core feature of childhood conditions subsumed under the rubric of the 'pervasive developmental disorders' or ASD. At their extreme, these relatively common conditions cause some of the most disabling impairments of neurological functioning among children, adolescents, and adults. The pathogenesis and optimum management of these disorders remain poorly defined. We focus here on neurological issues specifically related to the pervasive developmental disorders.

The DSM-IV defines autism according to a checklist of criteria in three domains: a) reciprocal social interactions; b) communication; and c) restricted and repetitive patterns of behavior or interests, with an onset in the first 3 years of life. If a child meets an adequate number of criteria, the diagnosis of childhood autism is made; if fewer criteria are applicable, the child is identified as having pervasive developmental disorder not otherwise specified, PDD-NOS. Established standardized instruments have been utilized for the more formal diagnosis of autism (textbox).

#### Autism spectrum disorder diagnostic checklists

- DISCO (Diagnostic Interview for Social and Communication Disorders).
- ADI (Autism Diagnostic Interview).
- ADOS (Autism Diagnostic Observational Schedule).
- CHAT (Checklist of Autism in Toddlers).
- STAT (Screening Tool for Autism in Two-year-olds).
- SCQ (Social Communication Questionnaire).

Frequently, the cardinal clinical features are evident from a careful history and observational clinical examination. In milder or atypical cases, formal evaluation may be necessary to confirm one's diagnostic impression. Depending on the community, the services desired, and the educational program, definitive diagnosis by one of the instruments listed may be required.

Consensus documents regarding the medical and neurological evaluation and management of children with autism indicate that neurodiagnostic studies are of limited value. In ASD without associated neurological or dysmorphic features, the yield of brain imaging (MRI) is very low; most abnormal findings are incidental. EEG to identify continuous spike-wave of slow wave sleep should be considered in children with language regression. Genetic testing is indicated if the child has dysmorphic features or a family history suggesting a genetic etiology. Only 2–5% of children with autism have a recognizable disorder, such as tuberous sclerosis or fragile X syndrome; CGH may detect unsuspected genetic mutations in a small number of children with ASD.

### Childhood disintegrative disorder

This enigmatic condition is often thought of as ‘late-onset autism’. These are children who acquire core features of autism after the age of 3 years. Fortunately, this tragic condition is rare. Children presenting in this fashion deserve thorough and complete neurological evaluation; the differential diagnosis overlaps considerably with that of childhood onset organic brain disorders discussed below. Landau–Kleffner syndrome (also known as acquired epileptic aphasia) deserves consideration in young children with language regression (textbox; see Chapter 9 Disorders of Language and Hearing).

#### Features of Landau–Kleffner syndrome

- Onset between 3 and 7 years of age.
- Loss of the ability to understand spoken language (so-called auditory agnosia).
- Loss of spoken language.
- Abnormal EEG showing epileptiform features, often lateralizing.
- Behavioral abnormalities, such as hyperactivity, aggression, or depression.

### Organic brain disorders of childhood

The term ‘organic brain disorder’ or ‘organic brain syndrome’ refers to a heterogeneous group of conditions in which changes in behavior and higher cortical function represent the core manifestations of a medical rather than a psychiatric disorder. Although rare, these conditions present considerable challenges for physicians and families. In general, conditions presenting acutely (less than 1–2 days) or in a subacute fashion (days to weeks) are caused by unrecognized or established systemic diseases or their treatment (*Table 17*). Those presenting with slow deterioration in function may be due to such conditions as well, but may also represent uncommon familial or hereditary metabolic or neurodegenerative diseases (*Table 19*). Separation from psychiatric disorders remains extremely challenging and relies on recognition of historical or examination clues and on targeted diagnostic testing.

## Conversion disorders

Previously referred to as hysteria, conversion disorders encompass a group of conditions in which demonstrable or putative psychogenic factors lead to clinical signs and symptoms that mimic ‘organic’ neurological disease. According to this formulation, suppressed or unconscious psychological conflict is converted into outward physical manifestations. Distinguishing conversion from malingering (conscious, wilful mimicking of organic disease with intent to deceive) can be challenging, so the two are considered together here.

Many parents and some physicians are unaware that conversion disorder occurs commonly in children; the condition is a common source of diagnostic challenges and treatment failures. The adage that conversion disorder is a diagnosis of exclusion is probably overstated as there can be specific clinical features that can allow for confident diagnosis and management. When conversion is

suspected, clinicians should consult an experienced child or adolescent psychiatrist (textbox).

### Clinical features suggesting conversion in children or adolescents

- Nonepileptic paroxysmal events.
- Gait disorders (astasia-abasia).
- Paralysis of one or more limbs.
- Blindness.
- Amnesia.

## Psychogenic nonepileptic paroxysmal events

Children 8 years of age or older may present with paroxysmal events resembling seizures. The events are often frequent or recurrent and typically occur in the presence of others. They do not occur in sleep (although parents and caretakers may mistakenly come to this

**Table 19** Conditions causing chronic or slowly progressive organic brain syndrome in children or adolescents

Condition	Typical age of onset	Inheritance	Cardinal features
Subacute sclerosing panencephalitis (SSPE)	Childhood	Acquired (nonfamilial)	History of measles; behavior change; myoclonus; dysarthria; dysphagia; blindness
Adrenoleukodystrophy	2–10 years or later	X-linked	ADHD-like disorder; behavioral decline; long track signs; skin hyperpigmentation
Metachromatic leukodystrophy	Adolescent or older	Recessive	Psychosis; later long track signs
GM2 gangliosidosis	Older child or adolescent	Recessive	Psychosis; mania; cognitive decline
Wilson disease	After first decade	Recessive	Behavioral disturbance; dementia; dystonia; trismus; Kayser–Fleischer (K-F) rings
Neuronal ceroid lipofuscinoses (NCL)	Various types	Recessive	Cognitive decline; seizures; visual decline; ataxia and myoclonus
Pantothenate kinase-associated neurodegeneration	Late first decade	Recessive	Cognitive decline; dystonia; dysarthria; iron deposition

conclusion) and rarely occur when the child or adolescent is alone. Up to 10% or more of children with psychogenic nonepileptic events also have epileptic seizures, a feature that compounds diagnosis and management. These may resemble nearly any seizure type, including absence, generalized convulsion, and complex-partial. Sometimes, the child has seen individuals with seizures, enabling the child to mimic the event. Certain clinical features are characteristic of psychogenic nonepileptic seizures allowing for a high index of suspicion and guided diagnostic evaluation (textbox).

As soon as the disorder is suspected, parents should be informed of the differential diagnosis and video-EEG monitoring should be obtained. Prompt diagnosis will reduce hospital stay and morbidity and enable more effective and appropriate intervention; medication-related deaths or severe allergic reactions have occurred in children with psychogenic nonepileptic events! Despite accurate diagnosis, the therapy of psychogenic nonepileptic events remains challenging.

**Features suggesting psychogenic nonepileptic events**

- Occurrence primarily when caretakers/medical personnel are nearby.
- Cognitive response to intervention during apparent generalized convulsion.
- Ability of medical personnel to influence event by coaxing or cajoling.
- Crying or screaming during an event.
- Eye closure during the event and resistance to eye opening.
- Lateral, to-and-fro neck or head movements.
- Pelvic thrusting.
- Asynchronous limb movements.
- Absence of a postictal state after >1 minute convulsion.
- Duration >5 minutes without systemic compromise.



# Disorders of language and hearing

## Main Points

- Disorders of language affect as many as 3% of all children.
- Permanent hearing loss affects 1 of every 750 children.
- Clinicians should screen for language and hearing deficits at every opportunity.
- Stuttering appears between the ages of 2 and 5 years and typically resolves. Persistent stuttering affects 1% of the population.
- Autism spectrum disorders, a common cause of impaired language, are associated with varying impairment of communication and social reciprocity.
- Angelman syndrome should be suspected in a boy or girl with global developmental delay and little or no language.
- Genetic disorders account for 50% or more of permanent deafness.
- Connexin 26 mutation, GJB2/DFNB1, is the most common gene disorder associated with sensorineural hearing loss.
- Congenital cytomegalovirus infection is the most common nongenetic cause of permanent deafness.

## Introduction

The human capacity for language, a unique and precious ability, causes distress when absent or impaired. When a child does not learn to communicate, many concerns and diagnoses must be considered. Language, the most sensitive marker of early cognitive development, enables social and emotional development to proceed normally. Language delay and/or impairment affect approximately 2–5% of 3-year-old children. Closely linked to the development of language is the facility of hearing. In the absence of normal hearing, language development is impaired. Bilateral, permanent hearing impairment of moderate or greater severity occurs in 1 of 750 children; 80% of permanent hearing loss is present at birth.

## Language disorders

Broadly speaking, impairments in language can be acquired or congenital. An acquired language disorder implies that a child had a normal period of language development and then experienced a decline in ability. By contrast, congenital language impairment indicates deficits in language ability that have been persistent since birth and often preclude normal language development.

## Normal language development

The development of language, a fascinating, shared human trait demonstrated across cultures, follows relatively stereotyped patterns. Even deaf children who acquire sign language and not spoken language display a similar sequence of language development; deaf infants ‘babble’ using their hands. Importantly, a delay in language ability not only implies language impairment, but raises concerns regarding other potential medical, neurological, or genetic disorders.

Several instruments allow clinical assessment of language milestones. For example, the Denver II (Denver Developmental Screening Tool II), a widely used screening tool for developmental disorders, screens over 30 different language milestones. Of these, four or five key milestones can alert the clinician to the possibility of a problem in language acquisition (*Table 20*). Although most children achieve given milestones by a certain age, a range exists. Since referral and evaluation of children by language specialists often takes several weeks or months, the clinician should refer early, rather than late, when concern about language delay appears. The milestones listed in *Table 20* are ‘late’ milestones, i.e. most children will have achieved the milestone several months before, so that any child who has not achieved the milestone falls well outside two standard deviations from the norm (textbox).

**Table 20 ‘Late’ language milestones**

Age	Milestone
Before age 12 months	Infants should respond to sounds and voice, and should be making vocalizations
By age 15 months	Child should be using one word to specifically indicate something; it is acceptable that the one word is not entirely correct (1 word at 1 year; easy to remember)
By age 2 years	Child should be combining words, and should have a vocabulary of over 200 words (2 word phrases by 2 years)
By age 3 years	Child should be able to name a body part and a color, and be constructing phrases longer than three words (3 word phrases by 3 years)

**Concern exists regarding language development when the child cannot:**

- Use one word specifically by age 15 months.
- Combine two words by age 2 years.
- Use a three word phrase by age 3 years.

Certain conditions, such as prematurity, a bilingual home, serious chronic medical conditions (for example, congenital heart disease requiring multiple hospitalizations), can delay the early achievement of language development. However, between 2 and 3 years of age the majority of children with such factors should be catching up with their peers. Receptive language, the ability to understand, is usually more advanced than expressive language. Parents can be reassured, in most cases, if a child has mildly delayed expressive language, but normal receptive language.

A confusing aspect of understanding language disorders are the many terms used in the literature and by language specialists. Definitions are listed below for some of the more commonly used terms and phrases.

*Language:* language refers to the ability to communicate. Language is broader than the ability of speech, as it includes sign and spoken language, as well as the subtler aspects of communication such as *prosody* (the flow of speech) or accompanying facial expressions.

*Speech:* speech is the vocal output of language. Speech impairments or difficulty can reflect an underlying language impairment. However, speech impairment can also result from a biomechanical problem; for example, the child with a tracheostomy tube which impairs vocal cord movement.

*Aphasia:* aphasia, a disorder of language, can be expressive or receptive and complete or partial, but may not be related to overall intelligence.

*Expressive language:* expressive language is the output of language. It can be in any form (speech or sign).

*Receptive language:* receptive language is the ability of a person to understand language. This can be tested by asking parents if their child comprehends commands (for example, “Go get your teddy bear”). The clinician should use questions to assess receptive ability but must

avoid nonverbal clues (for example, clinicians shouldn’t ask “Where is your nose?” while they point to their own nose).

*Mixed impairment:* a mixed language impairment refers to the presence of both expressive and receptive language impairments. The expressive and receptive impairments may be equal in their severity or mismatched.

*Specific language impairment:* specific language impairment is a deficit in language ability in the absence of other developmental delays. This contrasts with global developmental delay in which the child exhibits delays in two or more developmental areas (e.g. both language and gross motor skills). A child who cannot say a word by age 2 years has specific language impairment, whereas a 2-year-old child who does not speak nor walk has global developmental delay.

*Apraxia:* apraxia describes the inability to perform a skilled action, despite having the motor, cognitive, and sensory abilities to perform the action. Apraxia of speech refers to a child who appears to have normal cognition and understanding of expressive language, but has difficulty constructing or programming their speech (i.e. the child has trouble saying what they want to say).

*Dysarthria:* dysarthria refers to an articulation disorder producing speech that is slurred or difficult to understand.

## Neuroanatomy of language

Language depends on a complex, interconnected set of brain structures. Three critical regions are especially important: Broca's area, Wernicke's area, and the arcuate fasciculus (114). The concept of three regions responsible for language is, however, a gross oversimplification of the neural circuitry that generates language; several other brain areas (including the basal ganglia and cerebellum) have important roles. The major language areas are located in the left cerebral hemisphere in the majority of right-handed individuals (about 90–95%) and left-handed individuals (about 75%).

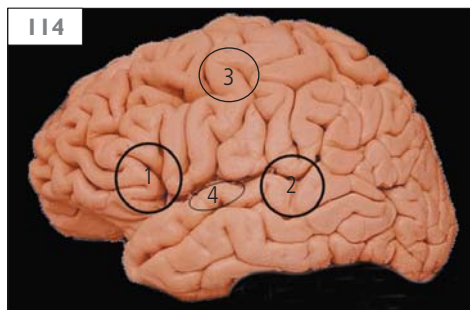
Broca's area, located in the inferior lateral frontal lobe, controls the production or motor aspects of language. By contrast, Wernicke's area, located in the superior posterior temporal lobe adjacent to the auditory cortex (Heschl's gyrus), controls the understanding or sensory aspects of language. Broca's and Wernicke's areas are connected by the arcuate fasciculus.

## Testing

The assessment of a child's language abilities begins with the parental report of a child's progress. In addition, clinicians can include a few simple questions to ensure that a child is meeting broadly defined developmental milestones for language. Early screening for language delay and prompt treatment may reduce the requirements for later special education (textbox).

### Key steps in recognizing and treating children with language delays

- Assess developmental milestones during well-child visits and heed parental concerns regarding their child's language ability.
- In the child with language delay, perform a hearing screen and determine if a neurological or genetic cause is apparent.
- Refer the child for speech and language therapy.
- Refer to a child neurologist when the child has global developmental delay.



114 The lateral surface of the brain showing areas (Broca [1] and Wernicke [2]) and pathways (arcuate fasciculus [3]) involved in language. 4, Heschl's gyrus.

## Epileptic causes

### Landau-Kleffner syndrome (LKS)

LKS, a rare disorder, is marked by a relatively abrupt regression or loss of language skills, usually in young school-aged children between 5 and 8 years of age. Clinicians should consider LKS when a school age child begins to show auditory agnosia, the inability to understand spoken words.

The child with LKS begins to have trouble understanding or responding to words spoken to them (a verbal agnosia). In approximately 70% of cases the loss of language is associated with seizures, but in the remaining cases no clinically apparent seizures herald the onset of LKS. EEG recordings reveal epileptiform discharges during sleep; eventually >70–80% of the EEG during sleep is filled with spike and wave discharges (electrical status epilepticus of sleep [ESES]).

Some authorities suspect that LKS is part of a continuum of disorders that includes autism spectrum disorders (ASDs). Children with LKS have impaired language and often exhibit behavioral abnormalities that include impaired socialization skills. Unlike autism, children with LKS may respond to treatment with corticosteroids or intravenous immunoglobulin. This condition should be considered in a child over 2 years of age with language regression. Despite temporary responses to treatment, the prognosis is poor; only 18% recover fully, and 63% have persistent developmental delay/intellectual impairment.

### Electrical status epilepticus of sleep (ESES)/continuous spike-wave of slow wave sleep (CSWS)

ESES, a poorly understood disorder of language and behavior known also as continuous spike-wave of slow wave sleep (CSWS), is defined by a specific electrographic pattern during sleep. A sleep EEG shows spike and wave discharges occupying >75–80% of sleep (81). This condition differs from LKS in the younger age of onset (typically less than 5 years of age) and the failure of language to progress. ESES should be considered in the child with a pre-existing history of seizures who fails to achieve normal language milestones. Obtaining an EEG is key for

diagnosis. Treatment and long-term prognosis for ESES are not well understood, although there appear to be permanent effects on learning for children who have had ESES.

## Other causes

### Stroke

Stroke, the prototype of neurological conditions that lead to loss of language, can affect children, as well as adults. Broca's aphasia results from a stroke in the frontal cortex, leading to an inability to speak; comprehension generally remains intact. By contrast, a Wernicke's aphasia affects the temporal lobe and causes impaired comprehension (114). However, a stroke's effects on language may not conform precisely into a pure Broca's or Wernicke's aphasia.

The effect of stroke on language varies widely in children depending upon the age at which the stroke occurs. In general, the later a child has a stroke, the more likely the effects on language will mimic those of adult stroke. Conversely, the earlier a child has a stroke, the less likely language will be affected, at least to as great an extent. Stroke after the age of 10 years of age generally affects language in a child as it would in an adult. Prenatally and in early childhood, language areas are less fixed, and hence the degree of recovery of language ability is considerably greater. However, large strokes can cause language impairment and cognitive disability even in young infants. Because of the disruptions in the normal circuitry of the brain, strokes of any size can impair normal language development. A child who had a perinatal stroke affecting Broca's area may learn to talk normally, but may display permanent deficits that are evident during psychoeducational testing.

### Autism/autism spectrum disorders/pervasive developmental delay

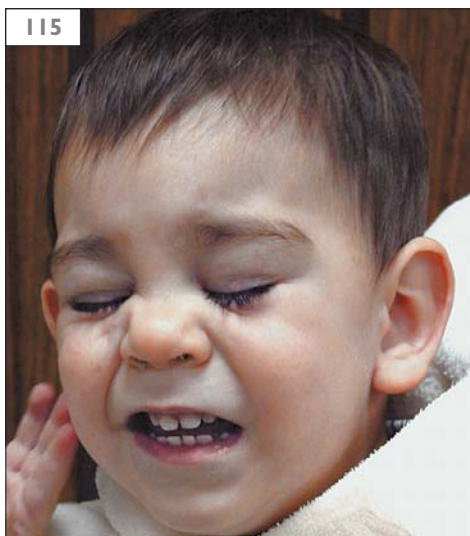
Language impairment is a *sine qua non* for the pervasive developmental disorders, including autism. Although these disorders overlap substantially in their clinical characteristics, their underlying pathophysiology is poorly understood. Autism is defined as the triad of impaired communication, impaired social interactions, and restricted and/or repetitive behaviors. Language deficits range from a complete lack of language to near normal ability. Autism is a clinical diagnosis, but is not an etiologic diagnosis. For example, children with fragile X syndrome (115) or tuberous sclerosis may be autistic. Recent studies have revealed that autism can arise from very subtle genetic changes, such as deletion or duplication of a particular region on chromosome 16q.

### Neoplasms

The effects of cancer on language fall into two categories. First, there can be direct effects from the cancer itself. A brain tumor can compress or invade the normal language areas of the brain, causing delay or loss of language development. Brain tumors as a group are the second most common childhood malignancy, comprising 2.2% of all childhood malignancies. The symptoms or signs of brain tumors can be subtle initially, consisting of changes in personality or language ability, but more ominous features, such as headache, lethargy, ataxia, or cranial nerve abnormalities, eventually appear.

The other main effect of cancer is the delayed effects on language from the surgeries, chemotherapy, and radiation therapy that encompass treatment. First, language impairment can result directly from surgery necessary to remove tumors growing in areas involved in language production. Second, chemotherapy and radiation therapy can have long-term effects on neurocognitive development. For chemotherapy alone, processing speed and verbal memory are affected. Cranial radiation therapy is avoided, whenever possible, before the age of 3–4 years given the potentially severe effects on language and cognitive development.

A unique entity, cerebellar mutism syndrome, occurs within 1–2 days postoperatively in as many as 25% of children who undergo resection of tumors in the posterior fossa, especially medulloblastoma. The children have markedly diminished speech, often progressing to mutism, emotional lability, hypotonia, and ataxia. The mutism resolves in a majority of cases, often over a prolonged time period of months, but most children have a degree of permanent neurological impairment, including speech impairment.



115 A young boy with fragile X syndrome shows large, prominent ears, a cardinal feature of the disorder.



## Genetic causes

Language impairments commonly affect families, and monozygotic twins are more often affected than dizygotic twins. Despite these observations, the progress on identifying genetic causes of language impairment has been remarkably slow. To date, there are no commercial tests available to examine for causes of isolated language delay (termed specific language impairment, SLI), and only one gene controlling language has been identified.

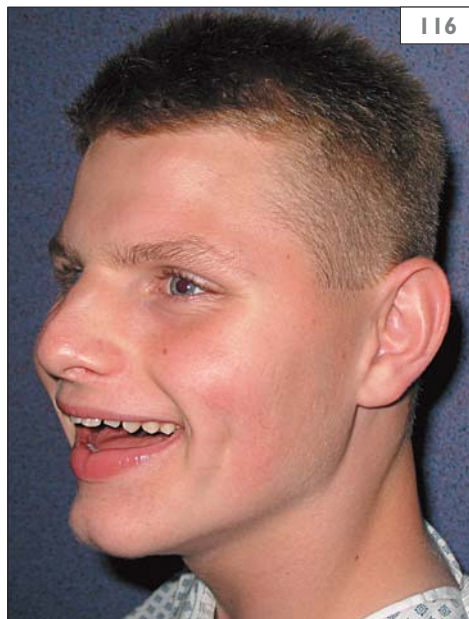The identification of *FOXP2*, a gene that causes a failure of language development when mutated, marked a new era in the understanding language development. Children with mutations in *FOXP2* have fairly severe difficulties in talking, moderately impaired grammatical and comprehension abilities, and some degree of oromotor apraxia. Thus far, *FOXP2* is believed to be responsible for only a small minority (probably <1%) of all children with impaired language development. However, genes downstream of *FOXP2*, such as *CNTNAP2*, may participate in a greater proportion of pediatric language disorders.

Several other genetic causes of language impairment should be considered in the appropriate clinical context. Children with Angelman syndrome have near complete absence of language; the ability to speak more than five single words or combine words into sentences nearly always makes a diagnosis of Angelman syndrome unlikely. Children with Angelman syndrome also have marked developmental delay, gait and/or limb ataxia, seizures, and a happy demeanor (sometimes termed ‘happy puppet’) (116). Angelman syndrome, a contiguous gene deletion syndrome, is caused by loss of the maternal chromosome 15q11.2-q13 region. Loss of the paternally-inherited copy of this same region causes Prader–Willi syndrome.

Girls with Rett syndrome, caused by a mutation in the *MeCP2* gene on the X chromosome, have normal early development, but between the ages of 6 and 18 months, development plateaus, and developmental skills, including language, regress. Characteristics of girls with Rett syndrome include midline hand-wringing movements (113), autistic behaviors, seizures, breathing abnormalities, unsteady gait, tremors, and deceleration of head growth leading in some to microcephaly. Boys can be

severely affected and usually die in infancy or young childhood.

Fragile X syndrome, a disorder of boys and men, presents with developmental delay, seizures, and difficulty with behavior and language; IQ is often <70 and approximately one-fifth have autism. The gene causing fragile X syndrome is a triplet, CGG repeat expansion of the *FMRI* gene on the X chromosome. Normal individuals possess <50 CGG repeats in this region; individuals with fragile X syndrome have 200 or more (the full mutation). Persons with 55–200 are considered premutation carriers. Classic physical exam findings include a large head, long face, protruding ears (115), and large testes (after the onset of puberty). Girls or women with the full mutation can also be affected, occasionally, but have a less severe phenotype. Adult premutation carriers, more often men, can display intention tremor, ataxia, dementia, parkinsonism and autonomic dysfunction, a condition that has been named fragile X-associated tremor and ataxia syndrome (FXTAS). Women premutation carriers experience fragile X-related ovarian failure.

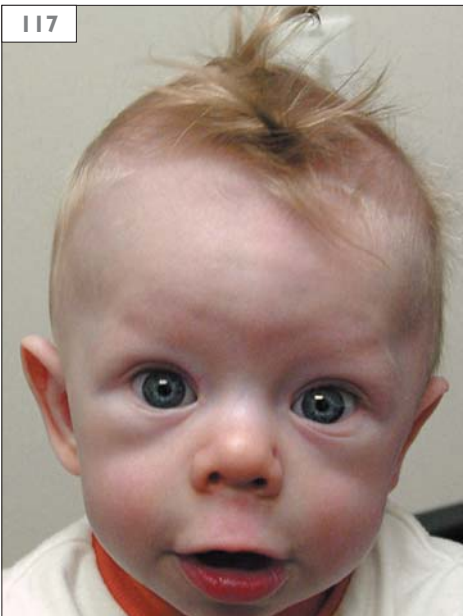

**116** An adolescent with Angelman syndrome showing typical features of microbrachycephaly and happy disposition.

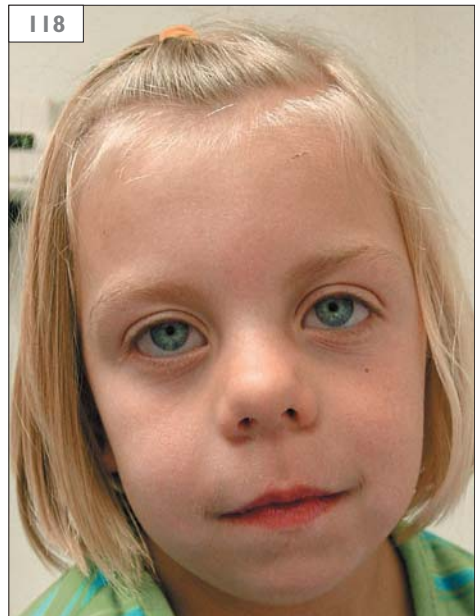Children with Williams syndrome have relatively preserved language skills in the face of relatively low IQ. Children with Williams syndrome are very gregarious and often maintain a chatter of conversation ('cocktail party' personality). The mutation causing Williams syndrome is a contiguous gene deletion at the 7q11.23 region of chromosome 7. Other important clinical features of children with Williams syndrome include hypercalcemia, cardiovascular disease (especially aortic or pulmonary stenosis), hypotonia and feeding difficulties in infancy, endocrine and growth abnormalities in later childhood, and a

distinctive 'elfin' facial appearance, consisting of a small upturned nose, long philtrum, wide mouth, and full lips (117, 118).

In the absence of an identifiable syndrome only modest advice can be offered currently to the parents of a child with an inherited deficit in language without obvious cause. The risk of recurrence may be as low as 6% (for a sporadic trait) to as high as 25% (assuming a recessive mode of inheritance). Because the same genetic defect may display phenotypic heterogeneity, one child might have a very profound difficulty in learning to speak, while another child might be only mildly affected.



**117** A child with Williams syndrome demonstrating characteristic 'elfin' features, including a wide mouth with full lips and a broad forehead.



**118** An older child with Williams syndrome.

## Stuttering

Stuttering, a disorder of speech, not language, consists of disruptions in the normal flow of speech with prolongations and/or repetitions of words or parts of words. It can be a life-long disorder, although symptoms are usually at their worst during the peak age of onset between 2 and 5 years of age. Stuttering has been linked to mutations in GNPTAB, a gene on chromosome 12 that participates in cell recycling.

Persistent developmental stuttering affects approximately 1% of the population, but affects up to 5% of children. Boys and girls are equally affected, but more girls recover than boys, so over a lifetime, boys and men have a higher prevalence rate. The spontaneous recovery rate is approximately 80%. The likelihood of spontaneous recovery is lowest in boys with onset in primary school or later, and less likely if they have concurrent language impairment.

## Meningitis and encephalitis

Meningitis or encephalitis can damage areas of the brain necessary for language; meningitis can also produce hearing loss. Thus, assessments of hearing and language should be performed in all children who experience encephalitis or bacterial meningitis. Approximately 15% of children who survive bacterial meningitis have persistent language difficulties through childhood. As many as 50% of children who survive herpes simplex virus (HSV) encephalitis have permanent deficits of language and memory. In general, meningitis or encephalitis in the neonatal period tends to be associated with more severe neurodevelopmental sequelae.

## Head trauma

Children who experience traumatic brain injury (TBI) commonly experience post-traumatic disorders of language. Many children recover slowly; cognitive recovery occurs over 1–3 years, but after this time period there is little additional improvement. The number of intracranial lesions and the initial Glasgow Coma Score are the clinical factors most predictive of final language outcomes. Age at which the injury occurred does not correlate with eventual outcome. For children with inflicted TBI (child abuse, nonaccidental trauma) approximately two-thirds have permanent speech and language difficulties. MRI, especially T2-weighted FLAIR images, can establish the extent and severity of brain injury.

## Management

Treatment for language impairment can be effective, depending on the severity of impairment and the cause. Because early treatment is associated with improved outcome, and because referral and evaluation can take several months, clinicians should refer children promptly. Meta-reviews of treatment show that children with expressive language difficulty respond well to treatment. By contrast, children with receptive language impairment respond less well. Therapy often consists of a mixture of didactic (direct teaching) and less structured (responsive) modes. Therapy longer than >8 weeks is associated with an improved outcome. The clinician should identify a team of therapists who can work with language impaired children. In the USA, early intervention referrals can be made for children <3 years of age; school-based programs are available for older children.

Stuttering ceases within 1 year of the onset in approximately 40% of children who stutter. For children with persistent stuttering, a variety of speech therapist and/or parent-directed approaches are available. Medications have no proven benefit for stuttering. Because of the potential emotional and social effects of persistent stuttering, counseling is indicated for older children.

## Hearing disorders

Permanent hearing loss, especially sensorineural hearing loss (SNHL), has been linked to long-term deficits in cognitive outcome. The severity of the disability is correlated with the degree of hearing loss and the age at which hearing loss occurs. In addition, the presence of other medical conditions (either causative, associated, or in addition to the hearing loss) such as learning difficulties or cerebral palsy, also affect the long-term prognosis. Historically, the typical student with SNHL graduated from secondary school with the language and academic achievement level of a 10-year-old child.

Congenital bilateral permanent hearing loss affects 112 of every 100,000 live born children (about 0.1%). Because of the adverse outcomes associated with congenital hearing loss, universal newborn hearing screening has been instituted in the USA during the past 15 years. Prior to universal newborn screening, hearing loss was detected at an average age of 2–3 years. Multiple studies have shown that early treatment of those with hearing impairments leads to improved language skills and better IQ test results. Besides the treatment, the other major factor associated with improved outcomes was the degree of family involvement.

## Neuroanatomy of hearing

Sound enters the human ear as vibrations. The vibrations are converted by the cochlea to nerve impulses that are carried by the cochlear (auditory) nerve (CN8) to the hearing centers of the cerebral cortex. Unilateral hearing loss can occur from damage to the middle ear, cochlea, or CN8. After arriving in the brainstem, signals are sent ipsilaterally and contralaterally through the medial geniculate ganglia of the thalamus and eventually reach the primary auditory cortex (Heschl's gyrus; **114**). Bilateral hearing loss indicates damage to both cochlea or implies a more widespread problem, since the nerves that carry information about sound transmit their information to both sides of the nervous system immediately after entering the brainstem. The auditory cortex, where sound is 'heard', is responsible for decoding sound into meaningful pieces of information. People with very small lesions of the auditory cortex can have pure word deafness, being unable to understand spoken language, despite having normal hearing, reading, and writing ability.

SNHL is diagnosed based on reduced hearing acuity by auditory testing. Hearing is measured in decibels (dB), where 0 dB is defined as a tone burst at a given frequency in which young adults can perceive the sound 50% of the time. Hearing loss can be categorized as mild, moderate, severe, or profound. Mild hearing loss (25–40 dB threshold) leads to loss of some consonant sounds; moderate (40–70 dB), the inability to hear much of conversational speech; severe (70–90 dB), the inability to hear even one's own vocalizations; and profound (>95 dB), absence of all hearing.

## Testing

Hearing screening of infants employs testing of otoacoustic emissions (OAE) or the automated auditory brainstem response (AABR or ABR). OAE measures the response of cochlear hair cells to an acoustic stimulus using a probe and microphone placed in the ear canal. AABR measures the brain's response to a 35 dB stimulus delivered to the infant using small earphones. Infants can fail OAE because of hearing loss or disorders of the middle ear; both screening tests identify infants who should undergo more sensitive and specific evaluation using the AABR (ABR).

ABR records the brain's electrophysiological response to sound stimuli delivered at several intensities and frequencies. The response to

sounds delivered via headphones is recorded via electrodes placed on the infant's forehead and over the mastoid bones. The test can identify sensorineural or conductive hearing loss. After the age of 3 years, the hearing of most children can be assessed using behavioral audiometry. The latter can consist of play audiometry, in which correct identification of sounds is rewarded by engaging activities, or observational audiometry, in which the audiologist assesses hearing by observing the child's response to sounds. Neuroimaging, especially temporal bone MRI, should be considered in all children with sensorineural hearing loss (SNHL). MRI accurately detects many of the acquired or congenital disorders of the cochlea associated with deafness (*Table 21*).

**Table 21 Disorders of cochlear anatomy associated with deafness in childhood**

Condition	Definition
Mondini dysplasia	Congenital defect of the cochlea associated with a reduced number of cochlear turns, hearing loss, and endolymphatic-perilymphatic fistula
Enlarged vestibular aqueducts	Congenital or acquired enlargement of fluid-filled canals within the temporal bone; can be a feature of Pendred and Waardenburg syndromes ( <b>119</b> )
Cochlear hypoplasia	Various forms of hypoplasia can be observed in children with brachio-otorenal syndrome



**119** A child with Waardenburg syndrome demonstrating hypertelorism and a characteristic eye appearance.

## Conditions associated with hearing loss

### Genetic disorders

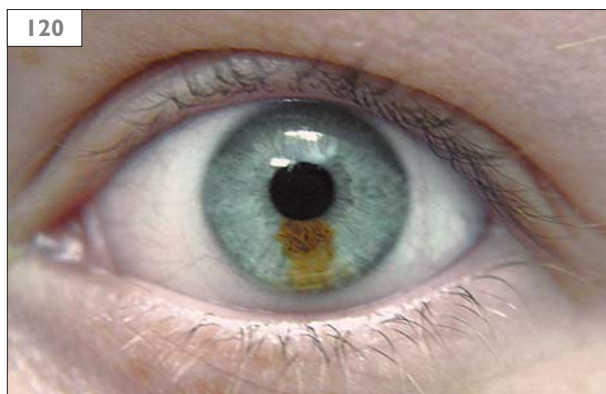Approximately 50% of deafness is genetic. Genetic disorders can be divided into nonsyndromic causes, largely due to mutations in the genes encoding the gap junction protein connexin 26 (GJB2/DFNB1), and those associated with syndromic disorders. Approximately 50% of genetic hearing loss results from mutations in GJB2/DFNB1. More than 400 syndromes are associated with deafness (Table 22).

### Infectious disorders

Congenital infections and bacterial meningitis remain major causes of congenital and acquired hearing loss, respectively, in infants and young children. Congenital cytomegalovirus (CMV) infection accounts for up to 20% of SNHL in children; 50% of the infants with symptomatic congenital CMV infections (CMV disease) and 7% of those with asymptomatic infections have hearing loss. Ganciclovir therapy of infants with CMV disease appears to reduce the frequency and severity of hearing loss. Sensorineural deafness can also complicate congenital infections with rubella, *Toxoplasma gondii*, and *Treponema pallidum*.

**Table 22 Selected syndromes associated with deafness**

Syndrome	Features
<b>Autosomal dominant</b>	
Waardenburg (119)	Sensorineural deafness; white forelock; heterochromia iridis (120)
Branchio-otorenal	Sensorineural, conductive, or mixed hearing loss; renal anomalies; preauricular pits
Stickler	Sensorineural deafness; cleft palate; osteoarthritis
<b>Autosomal recessive</b>	
Usher	Sensorineural deafness; retinitis pigmentosa
Pendred	Sensorineural deafness; euthyroid goiter
<b>X-linked recessive</b>	
Alport	Sensorineural deafness; progressive glomerulonephritis



**120** Heterochromia iridis in Waardenburg syndrome.



SNHL develops in 3–30% of infants, children, and adolescents with bacterial meningitis. The likelihood of deafness correlates with the severity of meningitis and the length of illness prior to antibiotic therapy. Although some controversy persists regarding the role of corticosteroids, most authorities recommend early dexamethasone treatment in children with bacterial meningitis, especially *H. influenzae* meningitis.

## Otitis media

Children with otitis media commonly have transient conductive hearing loss. Approximately 50% of children with persistent otitis media with effusion (OME) have mild hearing loss, while 5–10% have moderate hearing loss. This can lead to a transient impairment of speech and language; however, there are limited data linking OME to permanent impairments in language ability.

## Auditory processing disorder

Not strictly a disorder of hearing, auditory processing disorder, also known as central auditory processing disorder, reflects the brain's ability to discriminate words or sounds; formal hearing testing and intelligence are normal. The clinician should suspect a disorder of auditory processing in children who have poor listening skills, difficulty with multistep problems, or cannot acquire vocabulary. Disorders of auditory processing may coexist with dyslexia, ADHD, ASD, or developmental delay. Management includes the use of auditory trainers, training in auditory memory enhancement, and modifications of the educational environment.

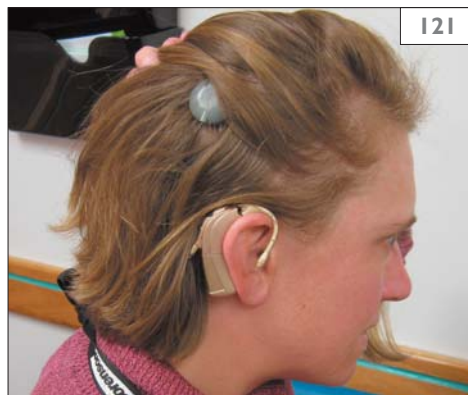## Management

### HEARING AIDS

A hearing aid, consisting of a tiny microphone, amplifier, and speaker, can assist the child with SNHL. An aid amplifies vibrations by converting sound to electrical pulses (analog technology) or to binary signals (digital technology). 'Behind the ear' hearing aids contain an ear mold that transmits sounds and an electronic case that is worn behind the ear. 'In the ear' aids place all elements of the aid within the ear. Clinicians should consult audiologists to ensure that the child receives the proper hearing aid.

### COCHLEAR IMPLANTS

A cochlear implant is an electronic device that can improve the recognition of sounds by children or adults with sensorineural deafness. It consists currently of external (microphone, sound processor, and transmitter) and internal (receiver and electrodes) components (121). The device 'hears' environmental sounds and sends electrical currents to the auditory nerve. Thus, a cochlear implant can bypass the defective portions of the middle or inner ear. Approximately 4 weeks after implantation, the cochlear implant is turned on, and over the next several months the amplitude is gradually adjusted so that the recipient adapts to the new sounds. Currently, the USA Food and Drug Administration has approved implantation in children as young as 12 months.



121 The external appearance of a cochlear implant in a young woman with profound deafness.



*This page intentionally left blank*

# Disorders of head size and shape

## Main Points

- Occipital-frontal circumference (OFC) provides essential information regarding intracranial volume, brain size, and growth.
- The majority (80%) of postnatal brain growth occurs in the first 2 years of life.
- Macrocrania (large head) can be caused by megalencephaly, hydrocephalus, extra-axial fluid collections, or a thickened calvarium.
- Microcephaly (small head) can be the result of congenital, acquired, genetic, hereditary, syndromic, or environmental disorders.
- Megalencephaly (large brain) is the result of familial, syndromic, or storage disorders.
- Skull growth occurs in the plane perpendicular to the suture.
- A misshapen head often reflects positional plagiocephaly.
- Craniosynostosis can be acquired, syndromic, or genetic. Sagittal synostosis, causing dolichocephaly (scaphocephaly or long head), is the most common form of craniosynostosis.

## Introduction

Just as periodic assessments of height and weight represent important parameters of somatic growth in childhood, measuring the head circumference enables clinicians to assess the growth of the brain. The human brain grows from 400 g at birth to approximately 1400 g at adulthood (brain size is smaller in women and larger in men). Early childhood is a dynamic time as 80% of the postnatal brain growth occurs during the first 2 years of life. Whereas fetal brain growth is determined primarily by neuronal proliferation, postnatal growth occurs principally because of myelination and increased neuronal cell and neuropil volume. Genetic programming and disorders affecting brain growth have dramatic effects on the brain during this period of rapid growth. This chapter focuses on the diagnostic evaluation of children with macrocephaly, microcephaly, and misshapen heads caused by positional deformation or craniosynostosis.

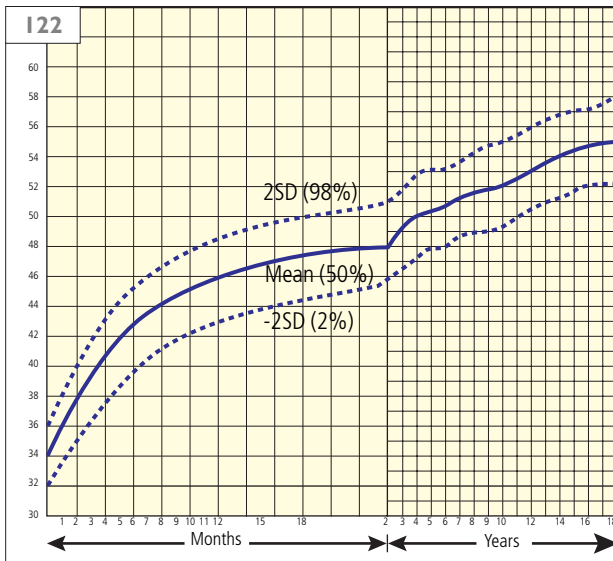
## Testing

Measuring the head circumference during childhood provides an indirect clinical assess-

ment of brain growth. The occipital-frontal circumference (OFC) is proportional to the intracranial volume: 80% brain; 10% blood; and 10% CSF. Since the brain contributes the majority of the volume, the OFC largely reflects the growth of the brain. Head circumference growth charts, standardized for the normal population from birth to 18 years of age (122), define normal as within 2 standard deviations (SD) of the mean (textbox).

### Estimating OFC in normal infants and children

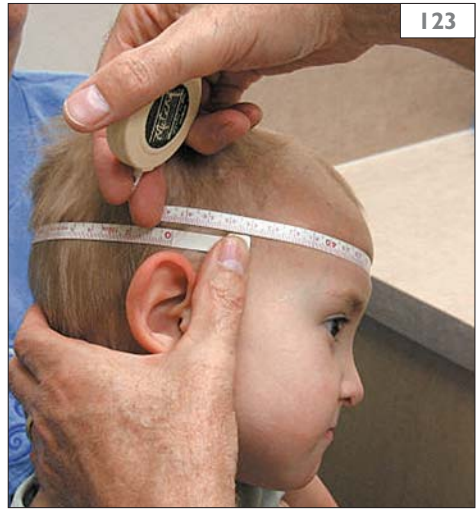- The rule of '3s and 9s': after an average OFC of 35 cm at birth, 5 cm increments occur at 3 months (40 cm), 9 months (45 cm), 3 years (50 cm), and 9 years (55 cm).
- The expected OFC  $\pm$  1 cm for a given infant <12 months of age can be estimated by the formula:  $[\text{length (cm)}] / 2 + 10 \text{ cm}$ . For example, a newborn infant who is 50 cm long (20 inches) should have an OFC of 35 cm.



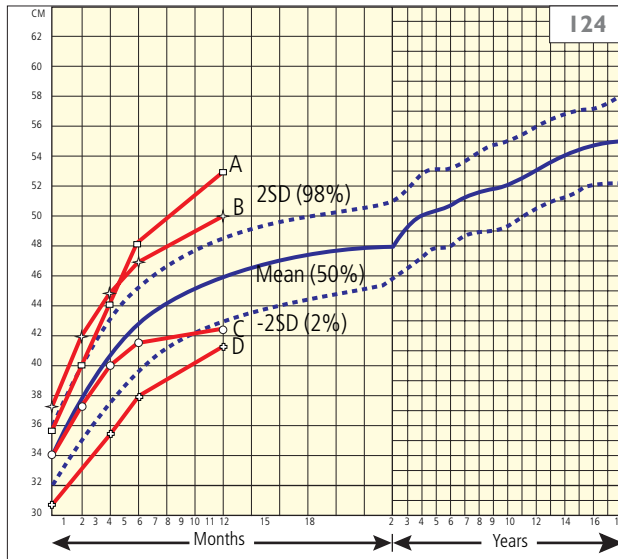
122A head size chart for young girls.

An OFC greater than 2 SD is macrocrania (also called macrocephaly), while an OFC less than 2 SD is microcrania (also called microcephaly). In using 2 SD for such definitions, 2% of the normal population will be either macrocephalic or microcephalic. If one uses 3 SD as the cut-off, nearly all individuals in these groups have pathological disorders of the brain.

To obtain an accurate OFC the clinician should use a flexible but nonstretching measuring tape. The head should be measured at its greatest circumference, typically at the level of the frontal and occipital prominences (123), and verified by the reproducibility of the measurement (obtaining the same value for 2 of 3 measurements). Serial OFC measurements are more valuable than a single measurement as they indicate growth velocity (124). Head growth that follows percentile lines has different implications than acceleration or deceleration of



123 How to measure the occipital-frontal circumference (OFC).



124A head size chart showing patterns in (A) hydrocephalus, (B) familial macrocrania, (C) acquired microcephaly, as in Rett or Angelman syndrome, and (D) congenital microcephaly.

head growth. Acceleration across percentile lines indicates an excessive increase in the intracranial volume, as seen in hydrocephalus, subdural hematomas, metabolic megalencephaly, and familial macrocephaly, whereas deceleration indicates a disease process that has destroyed brain tissue or severely affected neuronal growth or myelination. Patterns that show consistently small or large OFCs since birth usually indicate that the process is congenital, having occurred during fetal brain development.

The clinical assessment of the head also includes inspection of the skull for shape and palpation of the fontanels and the sutures (textbox).

#### Fontanels

- A large posterior fontanel may suggest hypothyroidism or a syndromic disorder affecting bone growth.
- The anterior fontanel closes between 10 and 20 months of age; the fontanel is closed in approximately 40% of normal 12-month-old infants.

The posterior fontanel is open at birth, but by 6 weeks it is usually nonpalpable. The anterior fontanel, approximately  $3 \times 3$  cm at birth, progressively closes as the infant grows. By 6 months the anterior fontanel can be quite small ( $1 \times 1$  cm) in normal infants, but the fontanel does not close completely until 10–20 months of age. The anterior fontanel should be flat or slightly concave with the quiet infant in the sitting position. A tense, bulging fontanel can indicate increased intracranial volume; increased volume can also lead to ‘splitting’ or widening of the cranial sutures to accommodate an increase in volume that has occurred too rapidly for bone growth. When there is deficient brain growth, the sutures may be overriding. This can be confused with suture synostosis, but the head shape remains normal, albeit small, reflecting impaired brain growth rather than craniosynostosis. If the head is normal in size, but misshapen, a positional deformation or craniosynostosis should be suspected.

## Macrocephaly

By definition, macrocephaly means that the head circumference is greater than 2 SD above the mean. Causes of macrocephaly include a large brain (megalencephaly), obstruction of CSF pathways and absorption (hydrocephalus), compartmentalization of blood or CSF (e.g. subdural collections), or a thickened skull or scalp (*Table 23*).

The evaluation of the child with macrocephaly begins with measuring the head circumference and documenting whether the large head is congenital or acquired. Family history and measurements of parental and sibling head sizes are essential. A thorough developmental history can identify associated brain dysfunction. The examination should include: comparison of head size to height and noting somatic overgrowth or dwarfism; identification of dysmorphic features; careful skin inspection for signs of neurocutaneous disorders; palpation for visceromegaly; and a complete neurological examination to detect neurological deficits. Most children with macrocephaly require neuroimaging, particularly MRI. MRI provides the most sensitive imaging of the brain parenchyma and detects most malformations. Genetic and/or metabolic evaluation may be necessary, depending upon the history, physical, and imaging results.

## Megalencephaly

The causes of megalencephaly (large brain) have traditionally been divided into anatomical versus storage. The anatomical enlargement of the brain, the most common type of megalencephaly, can be caused by excessive proliferation of neurons, increased size of the neurons, or combination of both with no known metabolic etiology. Included in this category are familial causes, with or without neurological deficits. Because familial megalencephaly (124, line B) without neurological deficits is most commonly an autosomal dominant feature, the clinician must obtain the head measurements of parents and siblings. Megalencephaly can also be seen in somatic overgrowth syndromes and some types of dwarfism.

Megalencephaly, part of a constellation of findings that may indicate a particular disorder, occurs in >100 syndromes. All children with megalencephaly should be examined closely for cutaneous stigmata of neurocutaneous disorders, especially neurofibromatosis type 1 (Table 23). Making a syndromic diagnosis requires identifying the child's abnormal findings and matching the features with known syndromes. Thickened skull or scalp, perhaps the least common cause of macrocephaly, occurs in certain bone diseases and syndromes. Classic examples of storage megalencephaly are Tay Sachs disease (105, 106) and the mucopolysaccharidoses (258).

**Table 23 Selected causes of macrocephaly**

### Megalencephaly

#### Anatomic

- Benign familial
- Symptomatic familial
- With somatic overgrowth:
  - Sotos
  - Simpson–Golabi–Behmel
  - Weaver
- With dwarfism:
  - Achondroplasia

#### Neurocutaneous syndromes:

- Neurofibromatosis
- Bannayan

#### Metabolic

- Leukodystrophy:
  - Canavan
  - Alexander
- Lysosomal storage disease:
  - Tay Sachs
  - Mucopolysaccharidoses (Hurler, Hunter, Sanfilippo syndromes)

### Hydrocephalus

- Aqueductal stenosis
- Dandy–Walker cyst
- Chairi II malformation
- Obstruction from tumor, cysts, infection, hemorrhage

### Subdural fluid

- Hematoma
- Hygroma
- Benign extra-axial fluid collection of infancy

### Thickened skull or scalp

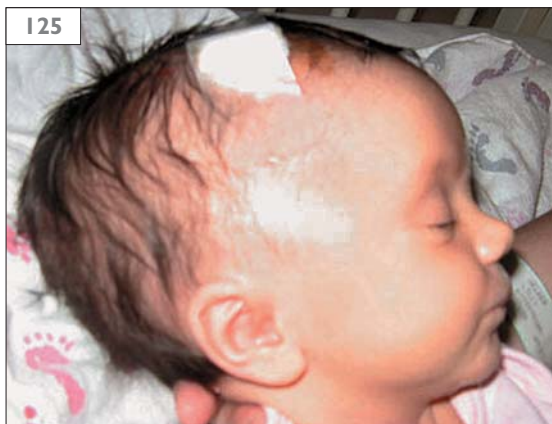- Severe anemia
- Craniometaphyseal dysplasia
- Cranioskeletal dysplasia
- Proteus syndrome
- Osteogenesis imperfecta

## Hydrocephalus

Children with hydrocephalus, an important, treatable cause of macrocephaly, have OFC patterns that show acceleration of head growth velocity (124, line A). The infant with hydrocephalus typically has suture separation (diastasis) and a bulging fontanel. The child typically has signs and symptoms of increased intracranial pressure and a cranial vault that is large in proportion to the face (125). Common causes of congenital hydrocephalus include aqueductal stenosis (CSF obstruction at the cerebral aqueduct), Dandy–Walker malformation (obstruction of the outlet of the 4<sup>th</sup> ventricle with cerebellar hypoplasia; 126), and Chiari II (small posterior fossa with cerebellar tonsils and medulla well below the foramen magnum and associated with myelomeningocele). Chiari III is associated with occipital encephalocele (127). Acquired hydrocephalus can result from any disease process that obstructs the CSF pathways including tumor, meningitis, and subarachnoid hemorrhage.

## Subdural collection

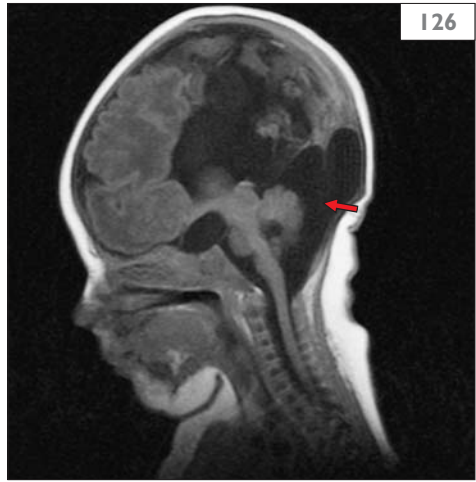
Macrocephaly due to subdural collection of blood or CSF is potentially treatable and therefore important to identify. Subdural hematomas (66) with head enlargement and signs of increased intracranial pressure can be one of the presentations of nonaccidental trauma. Benign extra-axial fluid collections of infancy (128), a common condition associated with macrocrania, can sometimes be confused with chronic subdural hematomas or hygromas. This condition should be suspected in infants with accelerated head growth that crosses percentiles but eventually stabilizes above the 98<sup>th</sup> percentile. This condition is thought to reflect disproportional skull growth relative to brain growth, causing increased subarachnoid space between the two structures. During the second year of life the brain growth catches up and the CSF space diminishes. Benign extra-axial CSF collections can be distinguished from subdural collections by identifying cortical veins traversing the space, normal sized or slightly enlarged lateral ventricles, absence of mass effect, and CSF density of the extra-axial fluid. Such infants can be managed conservatively, although some may have mild developmental delays.



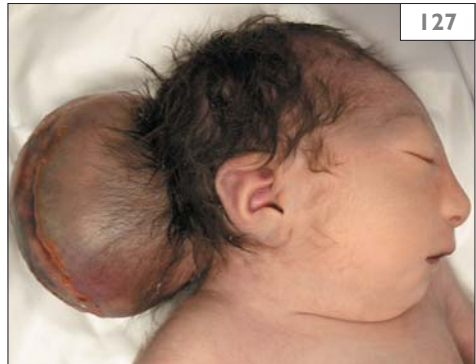125 The large cranium of a child with hydrocephalus.



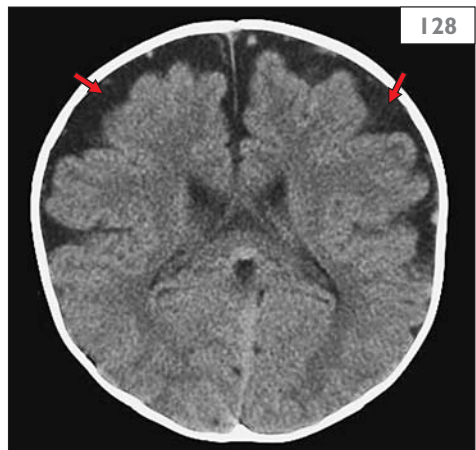
**126** Sagittal T1-weighted MRI showing the characteristic features of Dandy–Walker malformation. The arrow denotes the large, retrocerebellar CSF collection (cyst). This child also has agenesis of the corpus callosum.



**127** An infant with a large occipital encephalocele.



**128** Noncontrast CT showing benign extra-axial fluid collections of infancy (arrows).

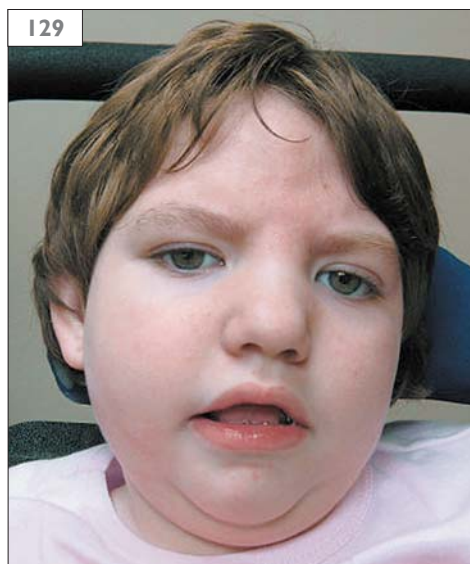


## Microcephaly

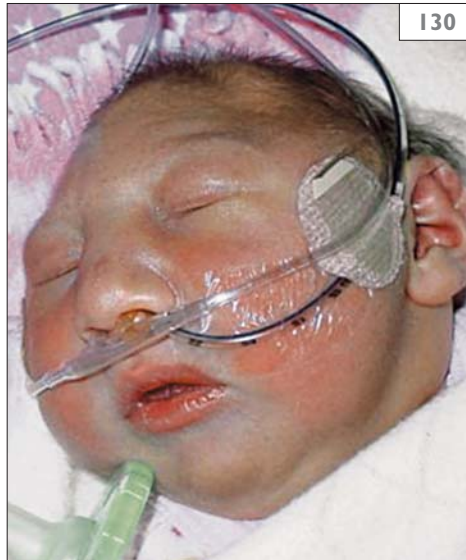Microcephaly indicates that the brain is small, more than 2 SD below the mean for age. Although mildly microcephalic individuals can have normal intelligence, mental retardation and neurological deficits are usually proportional to the degree of microcephaly. The child with microcephaly has craniofacial disproportion with the cranial vault small relative to the face (129). For normal infants, the midline of the oval formed by the face and the cranial vault should be at the eyebrow level. In microcephalic infants the forehead slopes backward and the face below the eyebrows comprises more of the oval volume than normal (130). A useful method for estimating microcephaly for infants less than 6 months of age is to compare the head circumference with the chest circumference. In microcephalic infants, the OFC will be smaller than the chest circumference, whereas the OFC should equal the chest circumference in normal infants.

Microcephaly can result from a lack of normal neuronal proliferation, diminished neuronal growth and myelination, or encephaloclastic processes with loss of brain tissue. An approach to classifying microcephaly is to consider the onset as congenital (prenatal) or acquired (postnatal). Within these categories are both genetic and environmental causes (Table 24). The genetic etiologies involve abnormal brain growth or proliferation with or without associated malformations. The environmental etiologies usually limit brain growth or involve loss of brain parenchyma.

Congenital microcephaly (124, line D) without any other associated malformations can be autosomal dominant, recessive, or X-linked. Other genetic causes of microcephaly include trisomy, ring, and deletion chromosome syndromes. Microcephaly with other brain and somatic malformations is associated with >450 syndromes listed in McKusick's Catalog of Mendelian Inheritance in Man (<http://www.ncbi.nlm.nih.gov/sites/entrez?db=omim>).



**129** A child with microcephaly showing a relatively small forehead and cranium in proportion to the face.



**130** An infant with microcephaly showing a small, backward sloping forehead and cranium.

**Table 24 Selected causes of microcephaly**

Congenital	Acquired
Genetic	Environmental
Familial: AD, AR, XLR	Hypoxia/ischemia
Syndromic: Smith–Lemli–Opitz, Cornelia de Lange, Rubinstein–Taybi, Dubowitz, Williams	Infection: meningitis, encephalitis
Associated with other brain malformations	Trauma: nonaccidental
Chromosome abnormalities: trisomy, deletions	Endocrine:
Environmental	Hypothyroid
Congenital infection:	Hypopituitarism
Cytomegalovirus	Metabolic:
Rubella virus	Hypoglycemia
Lymphocytic choriomeningitis virus	Aminoacidurias
Drugs or toxins:	Organic acidurias
Alcohol	Malnutrition
Antiepileptics	Genetic
Cocaine	Rett syndrome
Heroin	Angelman syndrome
Maternal PKU	
Radiation exposure	
Ischemic vascular events	

AD: autosomal dominant; AR: autosomal recessive; PKU: phenylketonuria; XLR: X-linked recessive

A syndromic diagnosis can be established by identifying the complete constellation of brain and somatic malformations and matching the findings with known syndromes using search tools such as OMIM, Genetests (<http://www.genetests.org/>) or *Smith's Recognizable Patterns of Human Malformation* (2006, Elsevier Saunders, Philadelphia) (Table 25).

Congenital infections, important, potential causes of microcephaly, often produce intracranial calcification, as well as chorioretinitis, cataracts, or SNHL. Rubella virus (German measles) and CMV are congenital infections associated with microcephaly. Lymphocytic choriomeningitis (LCM) virus, a rodent-borne arenavirus, should be considered in infants who have negative studies for CMV or *Toxoplasma gondii*. *In utero* drug and alcohol exposure can affect the developing brain as can maternal radiation exposure, diabetes mellitus, or uncontrolled maternal phenylketonuria (PKU). Ischemic vascular events and placental insufficiency can also affect the developing brain and cause microcephaly.

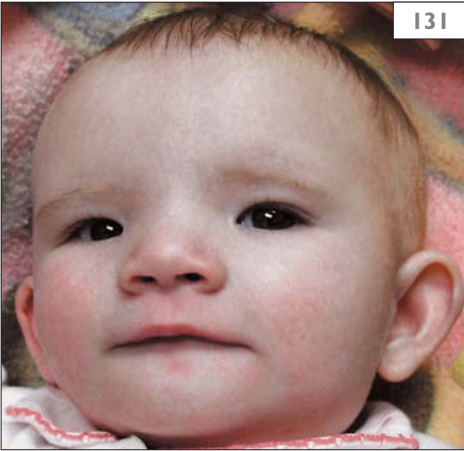Perinatal asphyxia is a potential cause of acquired microcephaly. In order for microcephaly to be ascribed to asphyxia, however, infants must have neonatal histories compatible with hypoxic ischemia encephalopathy. Postnatal meningitis and encephalitis as well as nonaccidental trauma can also cause microcephaly. Inborn errors of metabolism commonly affect the growth of the brain and are a consideration in the diagnostic evaluation. Untreated congenital hypothyroidism can cause microcephaly as can hypoglycemia and hypopituitarism. Although not common in developed countries, extreme malnutrition can also affect brain growth. Finally, Rett and Angelman syndromes are among the disorders that should be considered in children with acquired microcephaly. Rett syndrome is a major cause of acquired microcephaly in girls (124, line C). However, not all girls with Rett syndrome will be microcephalic despite the postnatal deceleration in head growth.

The diagnostic evaluation of infants or children with microcephaly begins with an accurate measurement of the head circumference and a careful search for dysmorphic features and other organ involvement that might suggest a specific syndrome. A complete history should be obtained with attention to pregnancy-associated

**Table 25 Selected syndromes associated with microcephaly**

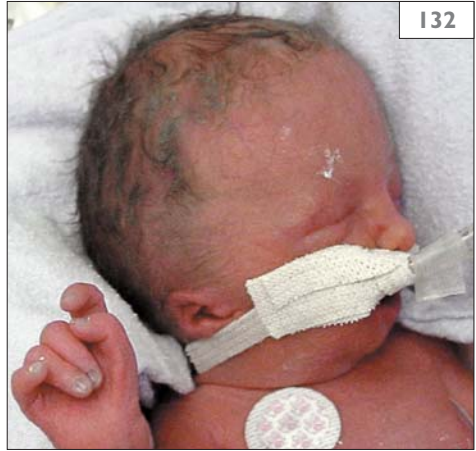Syndrome	Features
Angelman syndrome	Microcephaly and brachycephaly, fewer than 5 single words, wide mouth, prognathism, widely-spaced teeth, jerky/ataxic gait; pleasant personality
Rett syndrome	Postnatal microcephaly in many, developmental regression, loss of language and purposeful hand movements, characteristic movement disorder
Cri du chat syndrome	Microcephaly, low birth weight, short stature; meowing cry as infants (131)
Trisomy 18	Microcephaly, rocker-bottom feet, congenital heart defects, cleft lip and palate (132)
Trisomy 13	Microcephaly, midface hypoplasia fingers over-lapping the thumbs, polydactyly, holoprosencephaly (133)
Wolf-Hirschhorn syndrome	Microcephaly, seizures, cleft lip, 'fish-like' mouth, hypotonia
Miller Dieker syndrome	Microcephaly, lissencephaly, seizures, characteristic facies
Smith-Lemli-Opitz syndrome	Microcephaly, hypotonia, polydactyly, syndactyly, characteristic facies, hypospadias in boys

risk factors, including prenatal infections or drug and alcohol use, and to the infant's perinatal period. Infants with microcephaly require neuroimaging. Brain MRI accurately identifies most brain malformations, but head CT is more likely to identify calcifications that may suggest congenital infections (134). Genetic evaluation involves the identification of possible syndromes. High resolution chromosomes, fluorescent *in situ* hybridization (FISH), methylation studies, and comparative genomic hybridization should be considered, depending upon the child's features. Metabolic studies to consider include free T4, TSH, serum lactate, serum amino acids, and urine organic acids.



I31

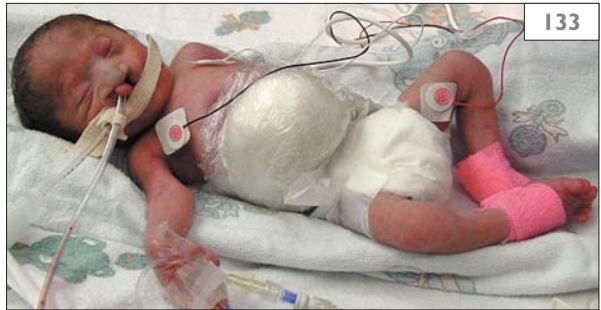**I31** A child with cri du chat (5p-) syndrome demonstrating microcephaly and a characteristic facial appearance.



I32

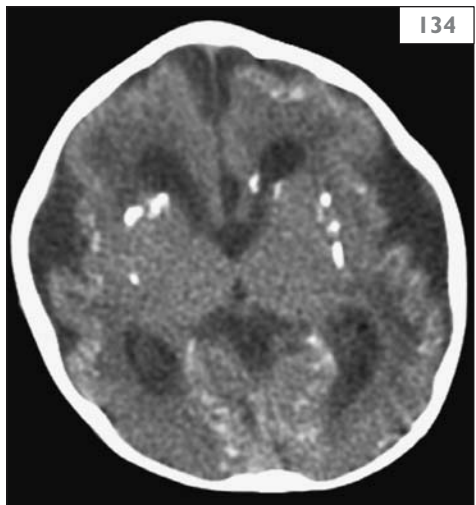
**I32** A child with trisomy 18 showing characteristic hand position.

**I33** A child with trisomy 13 showing cleft lip, midface hypoplasia, omphalocele, and abnormal toes.



I33

**I34** A noncontrast CT showing intracranial calcifications in congenital CMV disease.



I34

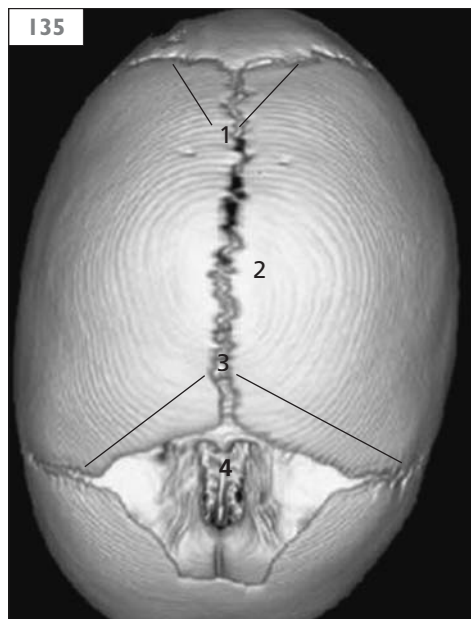## Misshapen heads

Abnormal head shape is described as:

- Dolichocephaly (scaphocephaly): long head, front-to-back.
- Brachycephaly: short head, front-to-back.
- Plagiocephaly: parallelogram or trapezoidal head.
- Trigonocephaly: triangular head (pointed forehead).
- Turricephaly: tall head, shaped like a tower.
- Oxycephaly: cone-shaped head.

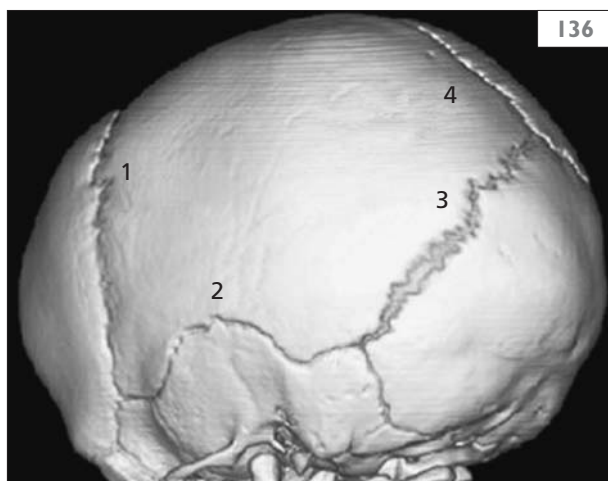
The skull (calvarium) grows to accommodate the growth of the brain, leading to a calvarium that is oval or round in shape and symmetrical. The skull can grow because of the sutures (**135**, **136**), open spaces between each of the skull's eight bones. The sutures function as growth plates for the skull bones, and growth occurs perpendicular to the suture. If a suture prematurely closes (synostosis), compensatory growth

occurs from the remaining open sutures. The net effect of compensatory growth is that the skull now grows maximally in the direction parallel to the closed suture. If sagittal suture synostosis occurs, compensatory growth perpendicular to the coronal and lambdoid sutures produces elongation of the head or dolichocephaly/scaphocephaly. In synostosis of the coronal sutures, compensatory growth perpendicular to the sagittal suture leads to brachycephaly, a short head front-to-back, with a broad forehead. Similarly, metopic suture synostosis causes trigonocephaly (**137**), a triangle-shaped head from compensatory growth perpendicular to the coronal sutures. With synostosis of one of the two lambdoid sutures, compensatory growth perpendicular to the open lambdoid suture results in posterior plagiocephaly. Finally, synostosis of multiple sutures at the skull base leads to turricephaly, a tall head shaped similar to a castle tower, or oxycephaly, a cone-shaped skull.

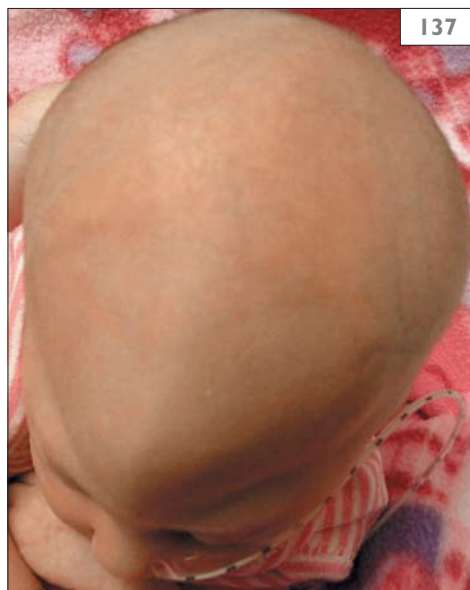

**135** A helical CT showing the locations of the cranial sutures in superior view. 1: Lambdoid sutures; 2: sagittal suture; 3: coronal sutures; 4: anterior fontanel.





**136** A helical CT showing the locations of the cranial sutures in lateral view. 1: Coronal; 2: squamosal; 3: lambdoid; 4: sagittal.



**137** A child with trigonocephaly showing pointed forehead and suture ridging due to metopic suture craniosynostosis.



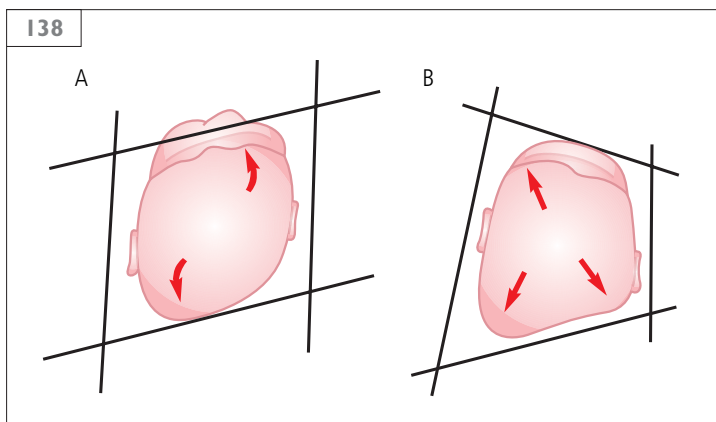
## Positional or deformational plagiocephaly

The most common cause of a misshapen head is not craniosynostosis but positional or deformational plagiocephaly. Because of the ‘back to sleep’ recommendation for the infants’ sleep position, 5–48% of otherwise healthy newborns exhibit some degree of positional plagiocephaly. Torticollis can also contribute to plagiocephaly. The characteristic shape of the head in positional plagiocephaly is a ‘parallelogram’ with flattening of one side of the occiput and forward advancement of the ipsilateral forehead and ear. The parallelogram deformation can best be appreciated by looking down at the top of the baby’s head so that comparison can be made of the position of the ears and the prominence of the forehead and face on the ipsilateral face.

Positional plagiocephaly can often be distinguished from the much rarer lambdoid synostosis by the head shape (138). Whereas positional plagiocephaly will have the parallelogram appearance, the head in plagiocephaly due to craniosynostosis has a trapezoidal

shape with compensatory bossing of the contralateral occipital–parietal area and posterior displacement of the ipsilateral ear. Helical CT of the skull may be needed to detect lambdoid suture synostosis.

Treatment of positional plagiocephaly consists of positioning the head of the supine infant toward the side opposite to the flattening. This can include arranging the crib so the infant turns toward the nonflattened side and increasing supervised ‘tummy time’ when the infant is awake. If these maneuvers fail and the skull deformity remains disfiguring, the infant may benefit from a skull molding helmet. If torticollis is present, there should be regular stretching of the involved sternocleidomastoid muscle. This can be accomplished by turning the infant’s head and neck so that the chin touches one shoulder, holding this position for 10 seconds, and then repeating the process to the other shoulder. The parent should perform three repetitions at each diaper/nappy change. In addition, the trapezius muscles should be stretched by tilting the head so the ear touches each ipsilateral shoulder, held for 10 seconds, and then repeated three times for each shoulder.



**138** Diagrams showing head shape in (A) positional plagiocephaly, and (B) lambdoid craniosynostosis.

## Cranial synostosis

Sagittal suture synostosis, the most common type of craniosynostosis, causes an elongated head, dolichocephaly or scaphocephaly, the latter named for the keel-like ridge of the fused sagittal suture. Sagittal fusion accounts for about 50% of all cases of craniosynostosis. Bicoronal synostosis, causing 25% of cases, results in brachycephaly. Approximately 33% of children with brachycephaly have a single gene mutation as the cause of their disorder. Metopic synostosis, accounting for 10% of cases of craniosynostosis, results in trigonocephaly. Because metopic craniosynostosis can be associated with deletion syndromes, genetic testing, including karyotype and microarray, should be considered. Finally, lambdoid synostosis, the least common form of craniosynostosis, accounting for only 2–4% of cases, may be associated with intrauterine constraint.

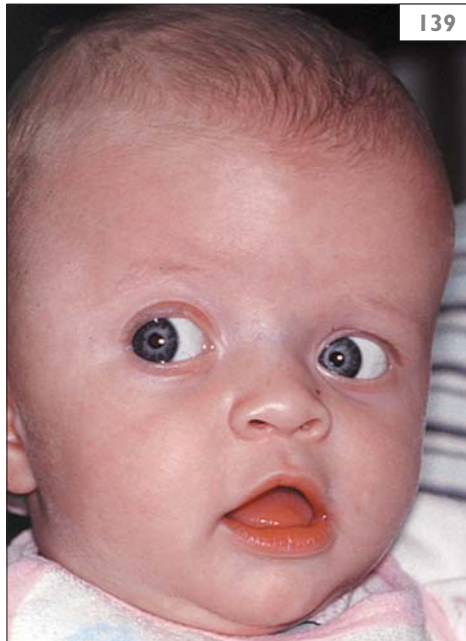In order of frequency, the patterns of craniosynostosis are: sagittal (50–60%); coronal (20–30%); metopic (5–10%); lambdoid (2–4%); and multiple (uncommon).

More than 180 syndromes are associated with craniosynostosis (textbox).

### Selected syndromes associated with craniosynostosis

- Crouzon (139).
- Antley–Bixler.
- Apert.
- Pfeiffer.
- Saethre–Chotzen.

Many of the more common syndromic forms of craniosynostosis are autosomal dominant with variable expressivity and involve mutations of the fibroblast growth factor receptors (FGFRs) or related genes. FGFRs are important signaling molecules that regulate cell proliferation, differentiation, and migration through complex pathways.



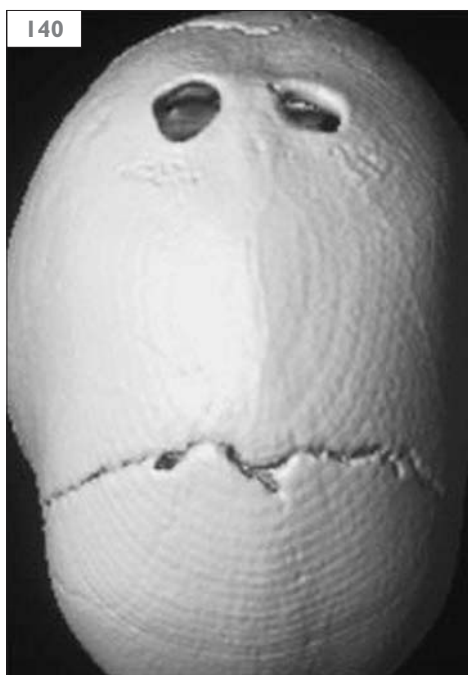**139** A child with Crouzon syndrome, showing the shallow orbits and tall forehead.

**DIAGNOSIS**

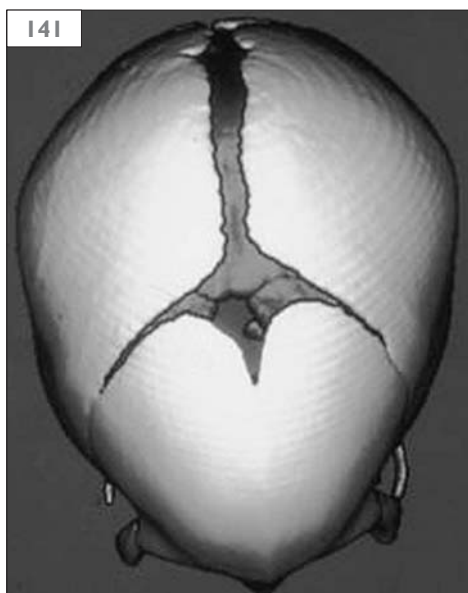
Evaluation of patients with craniosynostosis first involves documenting the involved suture(s) and identifying associated craniofacial and brain malformations. Brain malformations are best detected by MRI, while 3D (helical) CT allows for 3-dimensional reconstruction of the bony anatomy of the skull and face (140, 141). The child should be examined for dysmorphic features and any associated skeletal or other organ involvement. Because disorders of hearing and vision can accompany coronal synostosis, such children should have thorough ophthalmological and audiological evaluations. Clinicians should be aware that increased intracranial pressure can complicate multiple suture synostoses and search for worrying signs or symptoms, such as headaches, diplopia, or papilledema. Developmental screening, psychoeducational testing, and genetic screens for single gene mutations may be appropriate for children with syndromic causes of craniosynostosis.

**MANAGEMENT**

Management and comprehensive evaluation of children with craniosynostosis are best accomplished at a craniofacial center which has a multidisciplinary team of specialists for the surgical and medical management for these children. Because growth of the skull allows maximum benefit from corrective surgery, clinicians should refer children with suspected craniosynostosis as early as possible.



**140** A helical CT showing dolichocephaly and absence of the sagittal suture indicative of sagittal synostosis.



**141** A helical CT showing trigonocephaly and metopic suture craniosynostosis.

# Disorders of cranial nerves

## Main Points

- Isolated disorders of the cranial nerves, i.e. cranial neuropathies, are uncommon in childhood.
- With the exception of cranial nerves 1 and 2 which originate from cerebral neurons, the cranial nerves arise from neurons located in the brainstem, extending from the midbrain rostrally to the medulla caudally.
- Bell's palsy, the most common cranial neuropathy, causes weakness of the upper and lower portions of the face.
- Papilledema, an abnormality of the optic nerve (CN2), usually signifies increased intracranial pressure.
- Horizontal diplopia suggests disorders of CNs 3 and 6, whereas vertical diplopia indicates a disorder of CNs 3 or 4.
- Möbius syndrome, a rare disorder, consists of agenesis of the motor nuclei for CNs 6 and 7.
- Crossed signs, consisting of paralysis of a cranial nerve on one side and paralysis of the arm and/or leg on the opposite side, indicate a brainstem lesion at the level of the cranial neuropathy.
- Inflammatory conditions (i.e. neuritis) can affect CNs 2, 3, 4, 6, 7, 8, and 12. Some of these improve with corticosteroid treatment.

## Introduction

With the possible exception of Bell's palsy, the acute paralysis of the 7<sup>th</sup> or facial cranial nerve, disorders of cranial nerves (CNs) 1–12 are infrequently encountered by the typical pediatric practitioner. This chapter, organized sequentially by cranial nerve, describes the clinical manifestations of several disorders of the cranial nerves and provides clinicians with information for their effective management. Please refer to Chapter 1 The Pediatric Neurological Examination for additional details regarding the clinical examination of each cranial nerve.

## Cranial nerve 1 (olfactory nerve)

Congenital or acquired disorders affecting smell are extremely uncommon; consequently, few pediatric or adult neurologists assess smell during the routine neurological examination. Anosmia, the loss of smell, can be difficult to detect in young children who lack the developmental ability to describe smells or respond to neurological testing of smell; older children can provide reliable information regarding smell. Congenital anosmia is a feature of Kallman syndrome, a disorder characterized principally by hypothalamic hypogonadism. Kallmann syndrome affects 1 in 10,000–86,000 persons. Additional features of Kallman syndrome include brachydactyly, cleft lip or palate, color blindness, and SNHL. The disorder exists in several forms: 1) an X-linked condition (KAL1) due to mutations in KAL; and 2) autosomal dominant conditions (KAL2, KAL3, and KAL4) due to mutations in FGFR1, PROKR2, and PROK2, respectively. These gene abnormalities account for approximately 25% of cases of Kallman syndrome; the remainder are of uncertain genetic origin.

Kallman syndrome can be suspected by detecting incomplete sexual maturation or arrested puberty and low or normal levels of leuteinizing and follicle stimulating hormones in the presence of low levels of sex hormones. The function of hypothalamic–pituitary hormones is otherwise normal. Testing by FISH or gene sequence analysis can confirm the genetic etiology of Kallman syndrome, but gene testing will be unrevealing in approximately

75%. Brain MRI in persons with Kallman syndrome may show absence or hypoplasia of the olfactory bulb and tracts or absence of the olfactory sulci and may be associated with agenesis of the corpus callosum. Management consists of replacement of sex steroids and treatment with human chorionic gonadotropin and gonadotropin releasing hormone.

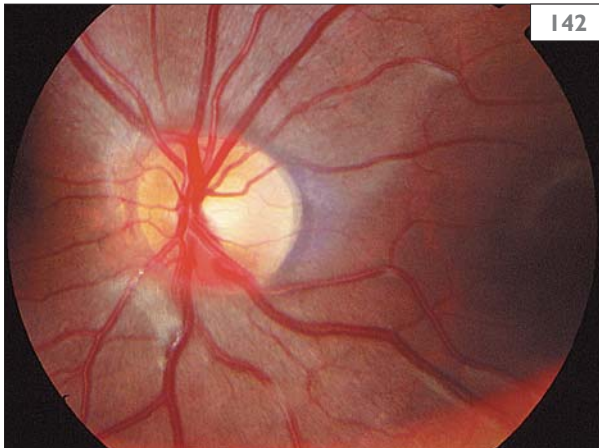Anosmia affects 10% or fewer individuals with mild TBI, but 50% or more of persons with severe TBI. In general, the likelihood of post-traumatic anosmia varies inversely with the patient's lowest Glasgow Coma Scale score. Anosmia after head injury can result from cerebral contusion to the olfactory centers, injury of the olfactory nerve, usually at the level of the cribriform plate, and trauma to the nose and sinuses. Unfortunately, the majority of persons with post-traumatic anosmia have permanent loss of smell; only a small percentage recovers normal smell completely. Olfactory nerve dysfunction can also be the consequence of acute rhinitis, medication use, smoking, holoprosencephaly, cystic fibrosis, and CHARGE (coloboma of the eye, heart anomaly, choanal atresia, retardation, and ear anomalies) syndrome.

## Cranial nerve 2 (optic nerve)

Because disorders of CN2 affect vision, such conditions are often recognized readily by children or their parents. Potential causes of optic nerve or visual dysfunction include toxic neuropathies (textbox), optic neuritis, migraine, neoplasms, trauma, metabolic disorders, vascular disorders, vitamin deficiencies, leukemia, infections of the CNS, and congenital

disorders, such as septo-optic dysplasia. Clinicians should examine the fundus routinely and become comfortable with the appearance of the optic nerve (142).

Drugs or toxins associated with optic neuropathy include: methanol, carbon monoxide, ethylene glycol, vincristine, lead, isoniazid, ethambutol, and quinine.



142 An enlarged, but otherwise normal appearing optic nerve.

## Optic neuritis

Optic neuritis, inflammation of the optic nerve, occurs most frequently in young adults between the ages of 20 and 45 years, thus overlapping with the age of greatest risk for MS. Only 5% or so of cases of optic neuritis involve children or adolescents, but, like adults, there is a female predominance. In contrast to adults, children frequently have bilateral optic neuritis and infrequently have MS. Symptoms associated with optic neuritis, consisting of vision loss or blurring, headache, and pain during eye movement, can begin abruptly within 24 hours or insidiously over 1–2 weeks. Neuro-ophthalmological findings include decreased visual acuity, especially for red–green colors, optic disk swelling (‘papillitis’, either unilateral or bilateral) (143), retinal hemorrhages and, when optic neuritis is unilateral, an afferent pupillary defect. The latter can be detected using the swinging flashlight test.

Children with suspected optic neuritis should be studied by MRI with and without gadolinium using fat-suppressed STIR (short T1-inversion recovery) sequences (144). Optic nerves, as well as brain and spinal cord, should be studied, given the potential associations of optic neuritis with MS, Devic’s disease, or acute disseminated encephalomyelitis (ADEM) (145). The majority of cases of optic neuritis in children can be linked to recent infectious illnesses, including Epstein–Barr virus (146) or immunization; MS deserves consideration when optic neuritis occurs in adolescents or when the brain MRI shows features suggestive of MS.

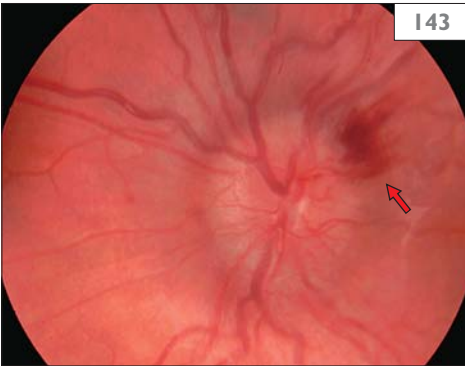Children with optic neuritis should be treated with corticosteroids, using modifications of the adult optic neuritis treatment protocol (textbox).

### Optic neuritis treatment protocol

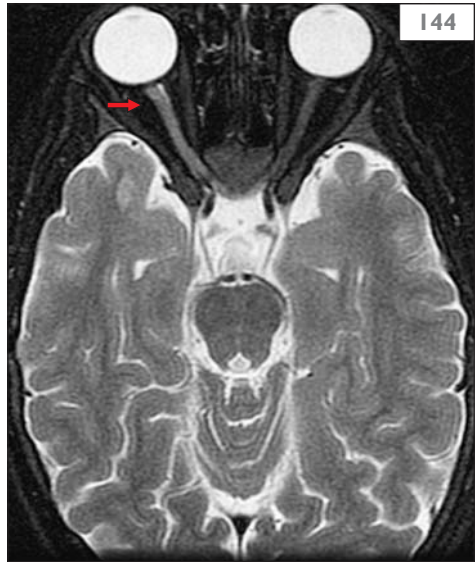- Methylprednisolone 15 mg/kg/day (maximum 1000 mg/day) IV in equally divided doses every 6 hr for 3 days, followed by
- Prednisone 1 mg/kg/day (maximum 60 mg/day) PO for 11 days, followed by
- Prednisone 0.5 mg/kg/day (maximum 60 mg/day) PO QOD for 3 days.

Most children recover completely, although some will later have neurological features suggesting MS or spinal cord disease compatible with neuromyelitis optica (Devic’s disease). The latter can be associated with circulating IgG (neuromyelitis optica [NMO] antibodies) to aquaporin-4, the brain’s most abundant water channel.

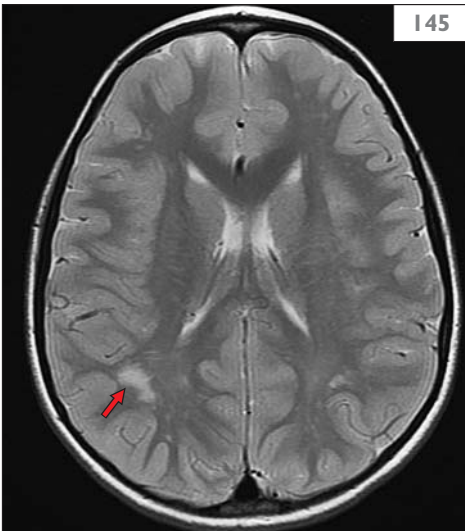




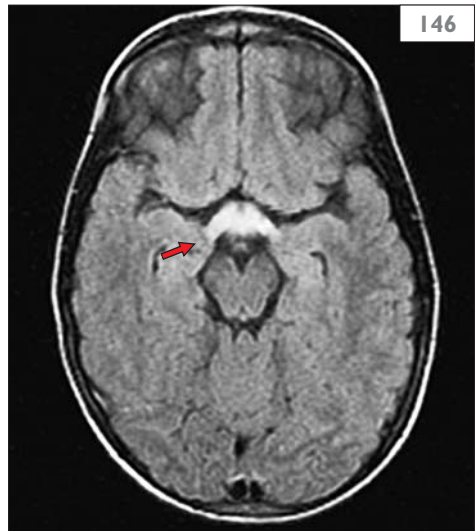
**I 43** Papillitis (optic neuritis) with optic nerve swelling and hemorrhage (arrow).



**I 44** AT2-weighted, fat suppressed MRI showing an enlarged nerve (arrow) with signal hyperintensity compatible with optic neuritis.



**I 45** AT2-weighted MRI showing characteristic multifocal hyperintensities (arrow) consistent with ADEM.



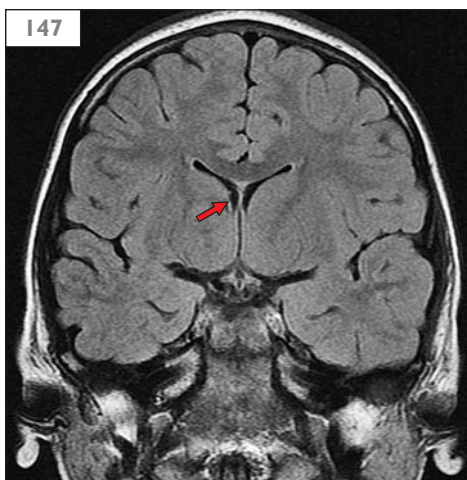
**I 46** A FLAIR MRI in EBV-induced optic neuritis showing signal hyperintensity in the optic chiasm (arrow) compatible with inflammation.

## Optic nerve hypoplasia

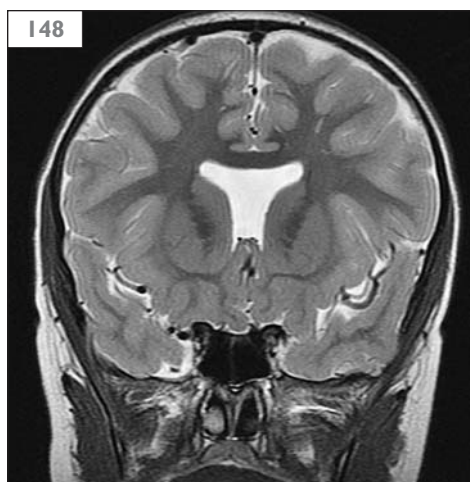
When clinicians encounter optic nerve hypoplasia, they should consider congenital disorders of the CNS, including septo-optic dysplasia, lissencephaly, schizencephaly, hydranencephaly, hydrocephalus, fetal alcohol syndrome, anencephaly, and intrauterine infections (cytomegalovirus, *Toxoplasma gondii*, lymphocytic choriomeningitis virus, rubella, syphilis).

Septo-optic dysplasia (DeMossier syndrome) is a heterogeneous condition associated with optic nerve hypoplasia, absence of the septum pellucidum, brain anomalies, and endocrinologic dysfunction. Ophthalmological features may consist of nystagmus and impairments of visual fixation and pursuit. The imaging hallmark of this condition is an absent septum pellucidum, detectable either by CT or MRI (147–149). Sagittal T1 MRI can reveal pituitary ectopia, a finding that has a strong association with hypothalamic–pituitary axis dysfunction and disorders of TSH, growth hormone, and/or adrenocorticotrophic hormone (ACTH). Septo-optic dysplasia has been linked to mutations in several genes involved in neural development, including HESX1, a homeobox gene, and SOX2 and SOX3, genes encoding transcription factors. Management of septo-optic dysplasia consists of hormone replacement, vision therapy, and treatment of associated features, such as seizures. Long-term prognosis for children with septo-

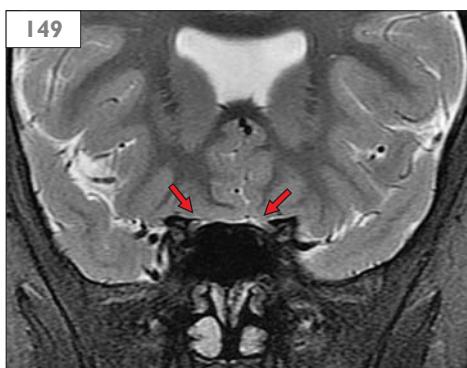
optic dysplasia varies according to the severity of associated brain anomalies; many have permanent neurodevelopmental disabilities.



**147** A normal coronal FLAIR MRI showing an intact septum pellucidum (arrow).



**148** A coronal T2-weighted MRI in septo-optic dysplasia showing absence of the septum pellucidum.

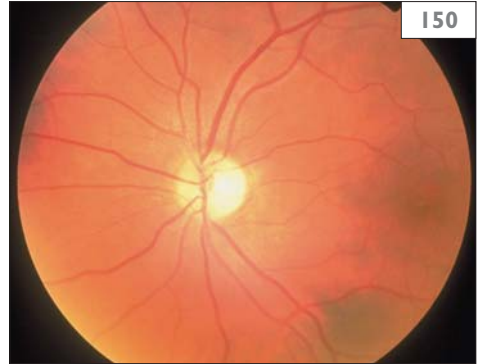

**149** AT2-weighted coronal MRI showing absent septum pellucidum and small optic nerves (arrows) in a child with septo-optic dysplasia.

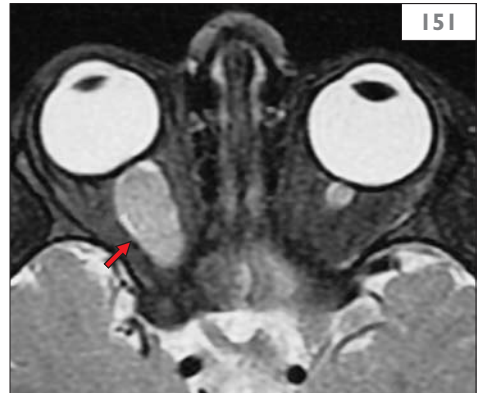
## Optic nerve atrophy

Acquired optic nerve atrophy (150) results from hydrocephalus, CNS tumors, metabolic disorders, demyelinating disorders, or genetic conditions. Optic atrophy commonly accompanies chiasmal or optic nerve gliomas in patients with neurofibromatosis type 1 (NF-1) (151), a neurocutaneous disorder that should be suspected when children have axillary freckling (152) and multiple café au lait spots. Optic nerve gliomas appear in approximately 10–20% of patients with NF-1; conversely, one-third or more of children with optic gliomas have NF-1. Most optic nerve gliomas in children with NF-1 can be followed clinically without intervention; treatment can be required when tumors grow aggressively and cause vision loss or hydrocephalus.

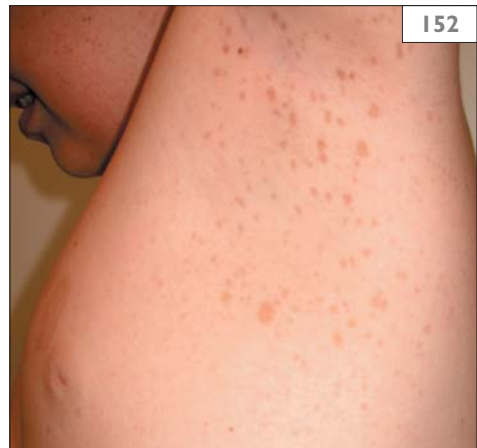Acquired optic nerve atrophy can be a manifestation of Leber's hereditary optic neuropathy (LHON), a mitochondrial disorder that results from mutations in the genes encoding nicotinamide adenine dinucleotide hydride (NADH) dehydrogenase in complex I of the electron transport chain. Persons with this disorder experience the fairly abrupt onset of painless visual loss that can progress to complete blindness within several months; most affected patients are adults, but onset during childhood is reported. Rarely, patients with LHON can have ataxia, tremor, or prolonged QT syndrome. The diagnosis of LHON can be supported by electrophysiological studies (showing abnormal VEPs) or ophthalmological examination (showing microangiopathy or disk edema) and confirmed by detecting the characteristic point mutations in mitochondrial DNA. No effective therapy exists.



150 A fundus photograph showing a pale optic nerve consistent with optic nerve atrophy.



151 AT2-weighted, fat-suppressed axial MRI showing a markedly enlarged optic nerve (arrow) in a patient with NF-1 and optic glioma.



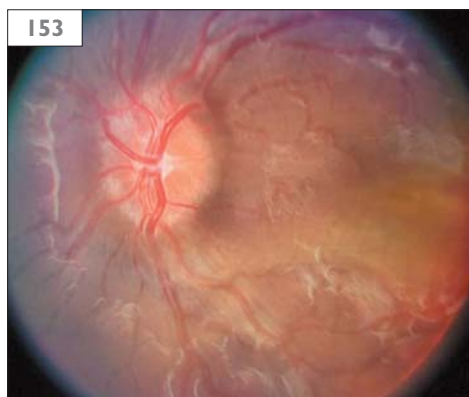152 Axillary freckling consistent with NF-1.

## Papilledema

Papilledema, swelling of the optic nerve, often indicates increased intracranial pressure due to intracranial mass lesions or idiopathic intracranial hypertension (pseudotumor cerebri) (153–155). Features include edema of the optic nerve, blurring of the disk margins, retinal hemorrhages, loss of venous pulsations, and enlargement of the physiological blind spot. However, papilledema can also be seen in children with hydrocephalus, encephalitis, venous sinus thrombosis, and lead intoxication. Optic nerve swelling, considered papillitis, is a common feature of optic neuritis. Papilledema should be differentiated from pseudopapilledema (Drusen), a condition that results from progressive calcification of proteins and polysaccharides that accumulate within the optic nerve and elevate the nerve (156). Drusen infrequently appears before the age of 12 years and rarely produces visual symptoms.

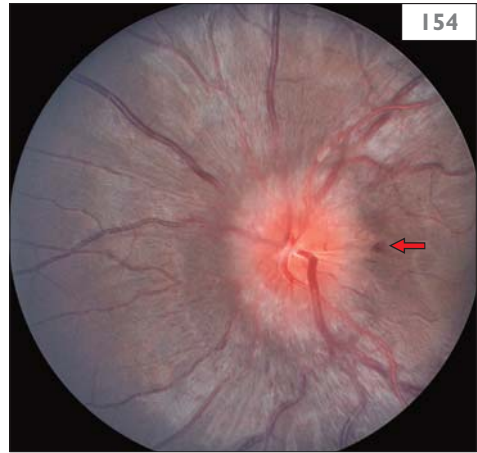
## Post-traumatic blindness

Post-concussive blindness, although not due to optic nerve dysfunction, is a disorder that clinicians will encounter. Post-concussive blindness can occur after relatively minor head injury in young children. The disorder does not result from direct trauma to the optic nerves, but reflects cortical visual impairment. Blindness begins immediately after head trauma and persists for minutes to hours. When the disorder occurs as a migraine variant, transient blindness can be accompanied by headache, nausea, vomiting, confusion, or agitation. The neurological examination reveals intact pupillary responses to light and normal appearing optic nerves. EEG may reveal medium to high amplitude posterior slowing, whereas imaging studies, either CT or MRI, are usually normal. Less commonly, acute cortical blindness can be a manifestation of posterior reversible encephalopathy syndrome (PRES) or mitochondrial disorders, such as MELAS.

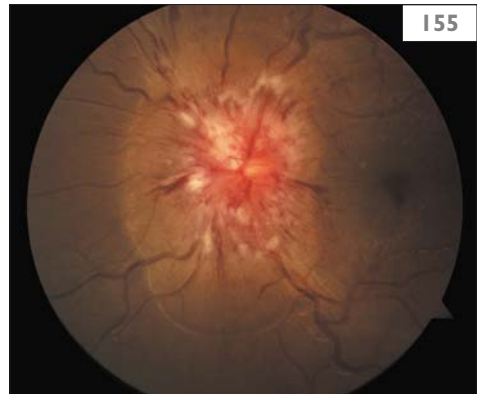

**153** Papilledema in a child with increased intracranial pressure.

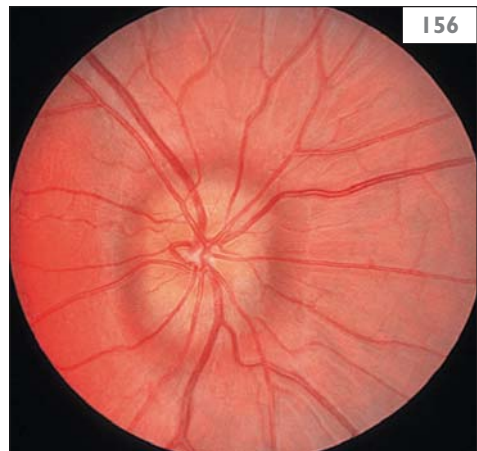
**154** Papilledema and retinal hemorrhage (arrow) in a child with increased intracranial pressure.



**155** High-grade papilledema with retinal hemorrhage.



**156** Optic nerve drusen. Note enlargement of the optic nerve and blurring of the disk margins.

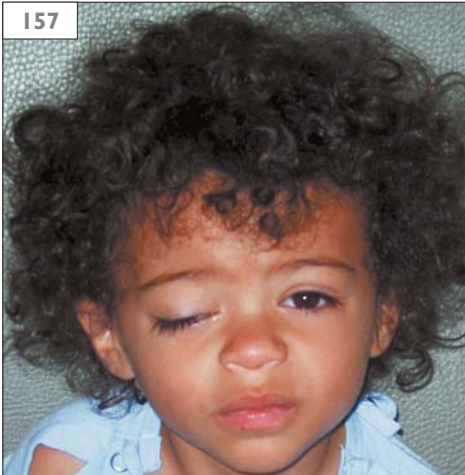



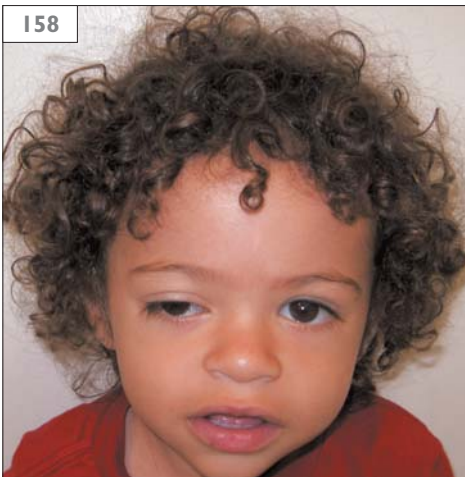### Cranial nerve 3 (oculomotor nerve)

The oculomotor nerve innervates the medial, superior, and inferior rectus muscles, the levator muscle of the upper eye lid, the constrictor of the pupil, and the ciliary body.

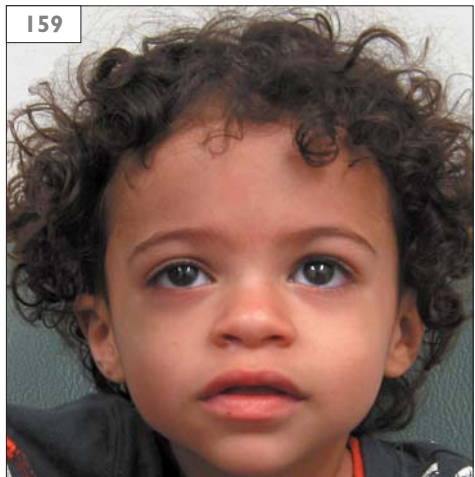Consequently, lesions of the oculomotor nerve cause varying combinations of ptosis, pupillary abnormalities, and abnormal extraocular movements. Complete paralysis results in ptosis, mydriasis, absent pupillary responses, and downward/outward deviation of the eye (157–159).



**157**A-3-year old child with an acute right oculomotor nerve (CN3) palsy with ptosis and ophthalmoplegia.



**158**The child shown in 157 2 weeks later with milder ptosis and residual strabismus. Note the lateral deviation of the right eye.



**159**The child shown in 157, 158 with recurrence of mild right ptosis without strabismus or pupillary involvement 3 months later.

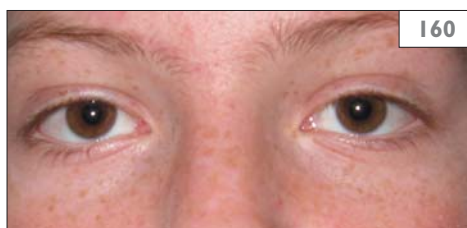## Abnormalities of pupil size

Pupillary size reflects the relative balance of parasympathetic and sympathetic pupillary tone as well as the intensity of the ambient light and the integrity of the optic nerve or retina (160–162). Parasympathetic stimulation of the circular muscle of the pupil causes pupillary constriction, whereas sympathetic stimulation of the radial muscle causes pupillary dilation (also called dilatation). Pupillary dilation (mydriasis) can result from increased sympathetic tone or decreased parasympathetic tone; conversely, pupillary constriction (miosis) results increased parasympathetic tone or from lesions that affect sympathetic innervation of the pupil (textbox).

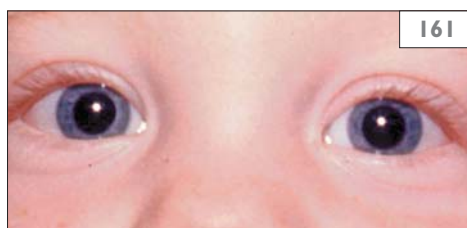### Pupillary abnormalities

- Adie pupil: a dilated pupil, usually unilateral, that does not react to light or convergence.
- Argyll Robertson pupils: small pupils that constrict during accommodation but do not constrict in response to bright light.
- Marcus Gunn pupil: another name for a relative afferent pupillary defect; a pupil that dilates paradoxically to bright light (the 'swinging flashlight test').

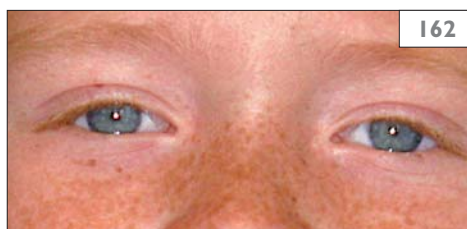Mydriasis can be observed in angry or excited persons or in children or adolescents experiencing absence seizures. Unilateral mydriasis can indicate an oculomotor nerve palsy, and because the parasympathetic fibers travel in the outer bands of the nerve, unilateral pupillary dilatation in an obtunded or comatose child or adolescent suggests herniation of the uncus of the temporal lobe. Horner syndrome (163), a condition associated with unilateral miosis, ptosis, and ipsilateral reduction of facial sweating, can be congenital or acquired. The pupils may appear equal in the light and pupillary asymmetry (anisocoria) becomes apparent in a darkened or dimly-lit room. Acquired Horner syndrome can be the result of birth trauma to the brachial plexus, tumor, carotid artery dissection, migraine or, in a toddler-aged child, a neuroblastoma affecting the sympathetic fibers from the spinal roots of C8, T1, T2, or T3 or sympathetic neurons in the superior cervical ganglion. MRI, including intravenous contrast



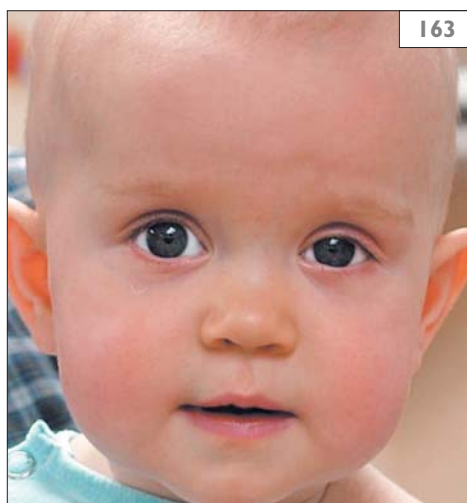160 Normal sized pupils.



161 Mydriatic pupils in a healthy child.



162 Miotic pupils in a healthy child.



163 A child with Horner syndrome. Note the ptosis and miosis of the left eye.



and fat-suppressed techniques, should encompass anatomy from the hypothalamus superiorly through T3 inferiorly in children with Horner syndrome.

### **Congenital third nerve palsy**

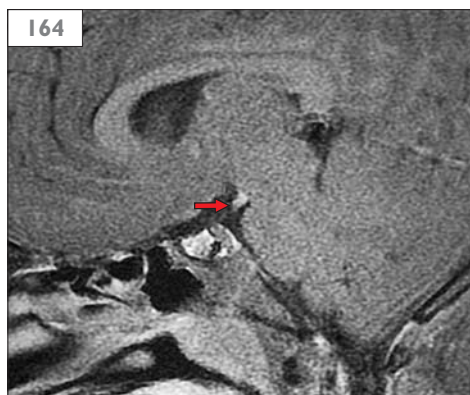
Paralysis of the oculomotor nerve, nearly always unilateral, can be present at birth, occasionally as the consequence of birth trauma, but more commonly as a cryptogenic process. Congenital oculomotor paralysis, often unrecognized in the newborn period, can also be associated with septo-optic dysplasia or congenital brainstem hypoplasia. Consequently, infants with features suggesting congenital oculomotor palsy should undergo MRI. Uncommon causes of oculomotor paralysis in childhood include aneurysms of the posterior cerebral artery, stroke, tumor, carotid artery–cavernous sinus fistula, and cavernous sinus thrombosis. Amblyopia is a common complication of congenital oculomotor paralysis. Cyclic oculomotor palsy, a rare congenital disorder of the oculomotor nerve known also as oculomotor palsy with cyclic spasms, produces rhythmic or cyclic mydriasis and ptosis.

### **Ophthalmoplegic migraine**

Ophthalmoplegic migraine, an uncommon migraine variant, typically affects the oculomotor nerve, causing ptosis, exotropia, diplopia, and mydriasis. Headache and vomiting, other potential signs and symptoms compatible with migraine, may or may not accompany the oculomotor paralysis; headache can precede the onset of paralysis by several days. The paralysis can last from hours to several days or more. MRI may show inflammation or gadolinium enhancement of the oculomotor nerve, suggesting that the pathogenesis of transient ophthalmoplegia of childhood represents acute inflammation and reversible demyelination (164). Occasional children have recurrent attacks of oculomotor paralysis. Because the majority of affected children recover completely, the treatment consists primarily of managing pain.

### **Myasthenia gravis**

Ptosis and diplopia, features suggesting partial CN3 palsy, can be relatively common manifestations of juvenile myasthenia gravis. In contrast to true lesions of CN3, including ophthalmoplegic ‘migraine’, myasthenia gravis spares the pupils and rarely causes pain. The diagnosis of myasthenia gravis is supported by resolution of ptosis and diplopia after administration of edrophonium chloride (the ‘tensilon test’) or neostigmine.



**164** Gadolinium enhanced sagittal T1-weighted MRI showing an enhancing CN3 (arrow) in a child with ophthalmoplegic ‘migraine’.

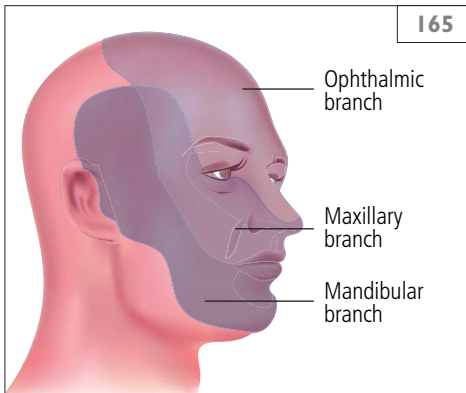
## Cranial nerve 4 (trochlear nerve)

Isolated lesions of CN4 or trochlear nerve are extremely uncommon. Children with CN4 palsies, whether congenital or acquired, exhibit head tilt or diplopia in the vertical plane. Difficulty descending stairs in the presence of normal balance and muscle strength can be an important clue that a child or adolescent has trochlear nerve dysfunction. Like congenital oculomotor palsy, congenital CN4 palsy may not be identified until early childhood. Acquired CN4 palsies can be the result of head trauma, demyelination (as might occur in MS) or increased intracranial pressure. Children with acquired trochlear palsies usually improve spontaneously. Persistent deficits and congenital trochlear palsies may require strabismus surgery or prism therapy.

## Cranial nerve 5 (trigeminal nerve)

The trigeminal nerve (CN5) innervates the muscles of mastication and subserves sensation to the face via the ophthalmic, maxillary, and mandibular branches (165). Isolated lesions of the trigeminal nerve are exceedingly uncommon. Rarely, tumors of the trigeminal nerve, such as schwannomas or meningiomas, can produce motor or sensory dysfunction of the trigeminal nerve and, if large or infiltrating, the tumors may also affect the function of the cerebellum or other CNs. Wallenberg or lateral medullary syndrome, an important stroke syndrome in adults, causes 'crossed' sensory signs consisting of impaired facial sensation on the side ipsilateral to the stroke and loss of pain and temperature in the extremities on the side opposite the stroke. Trigeminal nerve dysfunction can also accompany cavernous sinus thrombosis.

Trigeminal neuralgia or tic douloureux, an uncommon disorder in childhood, causes intense, lancinating pain in the distribution of the trigeminal nerve. The disorder has been described in children as young as 13 months. Children with trigeminal neuralgia should undergo MRI studies of the brainstem to exclude tumors or other lesions of the trigeminal nerve or brainstem; the disorder has been associated with lipoma, schwannoma, and an infiltrating rhabdomyosarcoma. Management should begin with medications, such as gabapentin, carbamazepine, or oxcarbazepine, which ameliorate neurogenic pain. Microvascular decompression has been used successfully to treat children who did not respond to medication management.



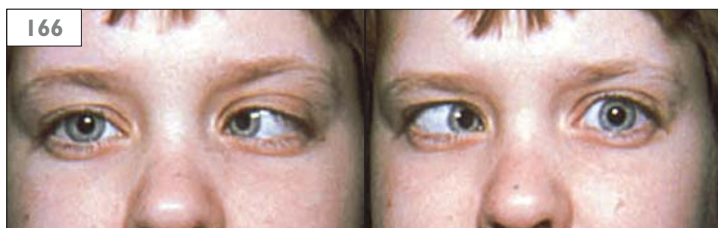**165** Schematic showing the distribution of the sensory branches of the 5<sup>th</sup> cranial nerve.

## Cranial nerve 6 (abducens nerve)

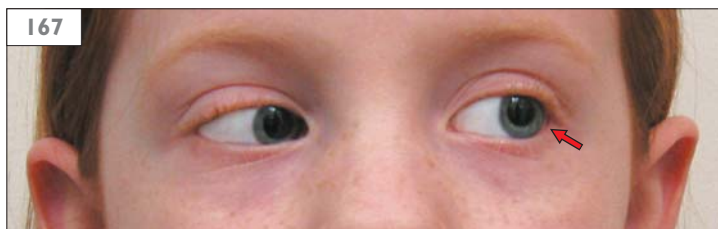Because of the long intracranial course of the abducens nerve, paralysis of this nerve, characterized by deviation of the eye medially, weakness of abduction and diplopia (166, 167), occurs frequently in children or adolescents with increased intracranial pressure. This paralysis, considered a ‘false localizing sign’, can be the result of intracranial tumors, infections, or idiopathic intracranial hypertension (pseudotumor cerebri). Gradenigo syndrome, caused by inflammation of the abducens nerve, can complicate otitis media or mastoiditis and produces pain as a result of concomitant inflammation of the trigeminal nerve. Möbius syndrome, a rare, congenital disorder associated with aplasia of the motor neurons of CNs 6 and 7, causes facial diplegia and absent ocular abduction.

## Duane syndrome

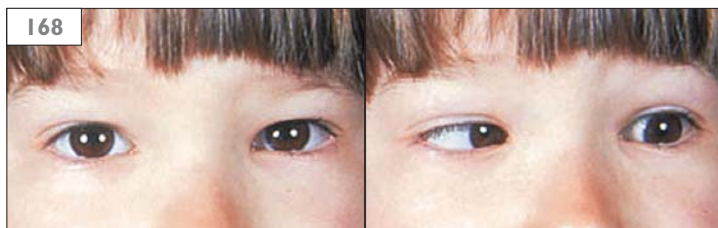Duane syndrome or Duane’s retraction syndrome, a disorder that can mimic abducens palsy, results from aberrant innervations of the lateral and medial recti muscles that control abduction and adduction, respectively. The lateral rectus muscle is commonly fibrosed, usually unilaterally, producing restriction of abduction (168). The disorder has been linked to a mutation in the gene encoding alpha2-chimaerin, a signaling protein involved in the pathfinding of corticospinal axons. Children or adolescents with this disorder do not experience diplopia and can be managed conservatively with prism therapy.



**166** Left abducens (CN6) palsy. In the left panel, the child is looking forward; in the right panel the child is attempting to look left. The left eye fails to abduct.



**167** Mild left abducens palsy showing that the child cannot fully abduct the left eye (arrow).




**168** Duane syndrome. In the left panel the child is looking straight ahead; there is mild strabismus with the left eye adducted. In the right panel, the child is attempting to look to the left, but cannot fully abduct the left eye.

## Cranial nerve 7 (facial nerve)

### Bell's palsy

Bell's palsy, by far the most common cranial neuropathy, affects 1 in 7,500 children or adults annually in the USA. The disorder often begins with pain behind the ear; paralysis of the face appears shortly thereafter. In contrast to upper

motor neuron lesions, such as stroke, that produce weakness of the lower portion of the face, Bell's palsy causes weakness of both the upper and lower portions of the face. Thus, a child or adolescent with Bell's palsy displays an asymmetric smile (169) and weakness of eye closure (170). Because CN7 subserves taste and innervates the stapedius muscle, persons with Bell's palsy may experience altered taste, tinnitus, or hypersensitivity to sounds (hyperacusis).



**169** Left Bell's palsy, at rest. The smile is asymmetric.



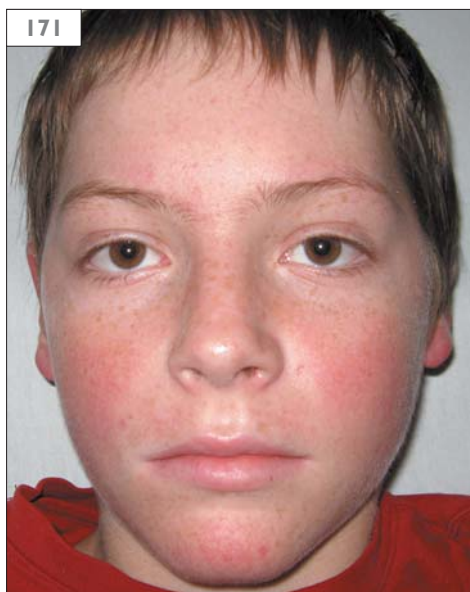**170** Left Bell's palsy, when attempting to close the eyes tightly. The entire left side of the face is weak.

The disorder, usually unilateral, can be bilateral (171, 172) when it accompanies conditions such as GBS or Lyme disease. Acute facial paralysis in children and adolescents can be seen in children with hypertension, otitis media, leukemia, varicella-zoster infection (Ramsay Hunt syndrome), cat scratch disease, or tumors involving the facial nerve.

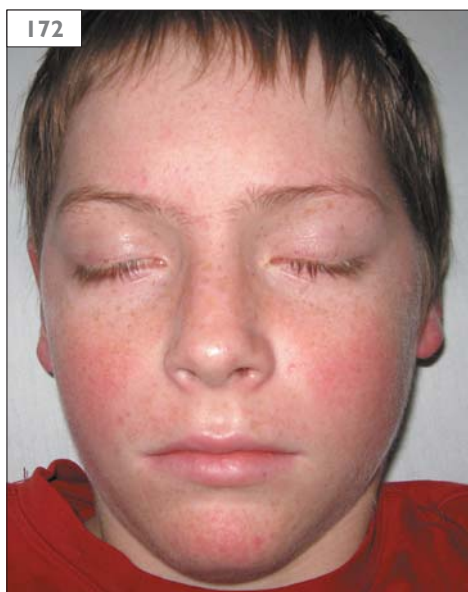The weakness associated with idiopathic Bell's palsy usually reaches its peak within 2 days, but recovery can take weeks or months. Because virus-induced inflammation, possibly due to herpes simplex virus (HSV) type 1, is believed to be an inciting factor in Bell's palsy, many authorities recommend treatment with aciclovir (or valaciclovir) and prednisone orally. Children or adolescents with Lyme disease-induced Bell's palsy require antibiotic therapy, usually with amoxicillin. The authors suggest prednisone 1–2 mg/kg/day orally (maximum of 60 mg/day) for 7–10 days in children or adolescents with Bell's palsy and an absence of signs suggesting Lyme disease, hypertension, leukemia, or varicella-zoster virus infection. A complete blood cell count should be considered to exclude acute leukemia. Pain can be managed

with simple nonsteroidal anti-inflammatory agents, such as ibuprofen or acetaminophen. Surgical decompression of the nerve, once considered an important therapeutic adjunct, is rarely considered currently. The majority of pediatric patients with Bell's palsy recover completely, although occasional individuals have residual disorders of taste, hearing, or facial movement. Bell's palsy recurs in 5–10% of children; contrast-enhanced MRI of the temporal bones should be considered in recurrent or persistent Bell's palsy to exclude lesions of CN7 or skull base.

Progressive facial hemiatrophy, also known as Parry–Romberg syndrome, is associated with slowly progressive atrophy of fat and subcutaneous tissues on one side of the face, more often the left. The disorder of unknown cause typically begins in children or adolescents between the ages of 5 and 15 years. Children or adolescents with Parry–Romberg syndrome can experience seizures or trigeminal neuralgia. The disorder cannot be cured, although surgical procedures, including fat implantation, can minimize the disfigurement associated with the disorder.



171 A child with facial diplegia at rest.



172 The child in 171 when attempting to close his eyes tightly. He cannot bury his eye lashes.

## Cranial nerve 8 (acoustic nerve)

Disorders of hearing, sometimes the result of lesions of the cochlear division of the acoustic nerve are discussed in Chapter 9 Disorders of Language and Hearing. Disorders of the vestibular division, the portion of the nerve that receives efferent impulses from the three semicircular canals, produce vertigo, often interpreted by children or adolescents as ‘dizziness’. Inflammation of the vestibular nerve (vestibular neuritis) can accompany several infections, especially those of the upper respiratory tract. Children or adolescents with vestibular neuritis experience the relatively abrupt onset of intense vertigo, nausea and vomiting, and nystagmus, the cardinal sign of vestibular dysfunction. Symptoms are exacerbated by movement, so most individuals with vestibular neuritis prefer sedentary activities until the acute phase subsides. Signs or symptoms of cochlear nerve dysfunction, such as tinnitus or hearing loss, are absent.

Children with acute vestibular neuritis should undergo brain MRI to exclude other causes of vestibular dysfunction, such as intracranial tumors, MS, or ADEM, and may require neurophysiological studies, such as electronystagmography. Evaluation in a hearing and balance center can provide useful information. Although the acute symptoms associated with viral neuritis begin to resolve in several days, movement-induced vertigo can persist for several months. Some authorities suggest a brief course of oral corticosteroids, similar to that used in Bell’s palsy, in persons with vestibular neuritis. Other disorders can cause acute or episodic vestibular dysfunction in children and adolescents (textbox).

### Miscellaneous disorders of childhood associated with acute or episodic vestibular dysfunction

- Waardenburg syndrome.
- Migraine, especially variants such as benign paroxysmal vertigo.
- Multiple sclerosis.
- Benign paroxysmal positional vertigo.
- Complex partial epilepsy.
- Ménière disease (rare in childhood).
- Postconcussion syndrome.

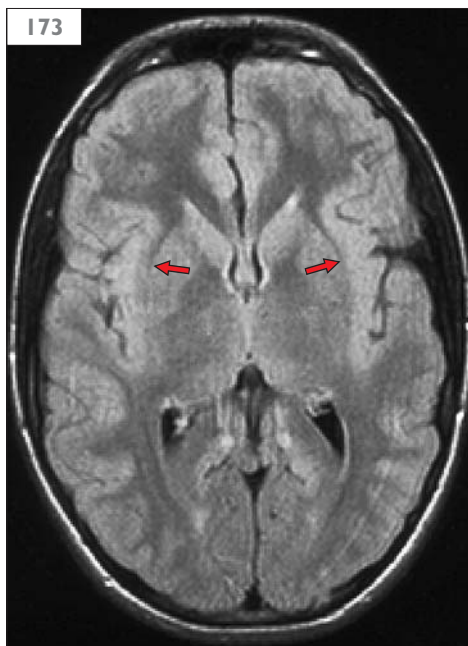
Labyrinthitis, acquired infection or inflammation of the bony labyrinth, produces vestibular and cochlear dysfunction. Thus, persons with this disorder have tinnitus and hearing loss, in addition to vertigo. Labyrinthitis can be viral or bacterial and associated with mastoiditis and purulent or aseptic meningitis. Bacterial disease requires aggressive antibiotic therapy. Mondini dysplasia, a congenital anomaly of the cochlea and semicircular canals, can be associated with deafness, vestibular dysfunction, and a risk of recurrent bacterial meningitis due to the presence of an endolymphatic–perilymphatic fistula. Temporal bone MRI is useful in the evaluation of the membranous labyrinth.



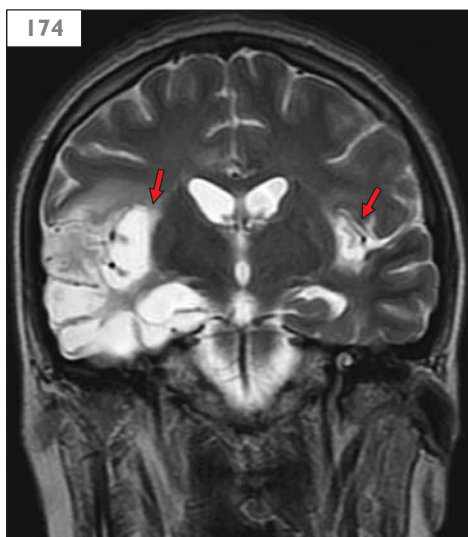
## Cranial nerves 9 and 10 (glossopharyngeal and vagus nerves)

CN9 and CN10 are often considered together because isolated disorders of the glossopharyngeal nerve, such as a schwannoma or aplasia of the motor nuclei, are rarely encountered. By contrast, bilateral dysfunction of CN9 and 10 can be a prominent feature of cerebral palsy or CNS trauma. Cerebral palsy can be associated with pseudobulbar palsy, an upper motor neuron disorder associated with abnormalities of swallowing and speech. Bilateral bulbar dysfunction can also be the result of bilateral perisylvian polymicrogyria, a congenital disorder also known as the syndrome of Foix–Chavany–Marie (173), or after HSV encephalitis-associated damage to the insular cortices bilaterally (174).

Because the muscles of the larynx are innervated by branches of the vagus nerve, lesions of the vagus nerve produce vocal cord dysfunction manifesting as hoarseness of voice. Unilateral vocal cord dysfunction can be the result of TBI, surgical damage to the recurrent laryngeal nerve, or congenital aplasia. Bilateral vocal cord dysfunction, incompatible with life unless managed by tracheostomy, can be associated with Chiari II malformation and dysplasia of the brainstem nuclei.



**173** Axial FLAIR MRI showing a thickened insular cortex (arrows) compatible with polymicrogyria in Foix–Chavany–Marie syndrome.



**174** Coronal T2-weighted MRI showing atrophy of the insular cortices bilaterally (arrows) in a child who survived HSV encephalitis but could not move his face normally or swallow.

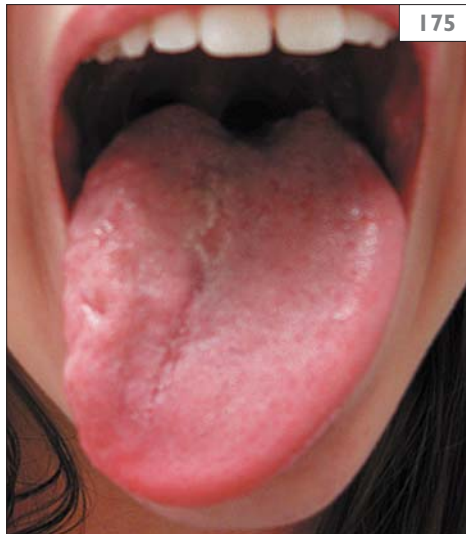


## Cranial nerve 11 (spinal accessory nerve)

Isolated lesions of the spinal accessory nerve, extremely uncommon in children, can be post-traumatic or iatrogenic after neck surgery. Tumors of the nerve, although described, are exceptionally rare. The signs and symptoms of spinal accessory nerve dysfunction consist of trapezius atrophy, limitation of shoulder elevation (shrugging), shoulder pain, and shoulder weakness. The majority of persons with spinal accessory nerve palsies recover with physical therapy and conservative management.

## Cranial nerve 12 (hypoglossal nerve)

Lesions of the hypoglossal nerve, usually unilateral, produce ipsilateral weakness, atrophy, and fasciculations of the tongue (175). Hypoglossal neuropathy can be idiopathic, postinfectious (e.g. after infectious mononucleosis), post-traumatic, postsurgical, or associated with tumors of the nerve or vascular anomalies that impinge upon the nerve as it exits the medulla. Children or adolescents with idiopathic hypoglossal neuropathy may have a favorable outcome with recovery of tongue function. Children or adolescents with neck-tongue syndrome, an uncommon disorder, experience transient, intense neck pain and altered sensation of half of the tongue following sudden neck rotation. The disorder has been attributed to compression of the C2 nerve root containing afferent nerve fibers from the tongue. Finally, tongue fasciculations are a common feature in infants with spinal muscular atrophy.



**175** Atrophy of the right side of the tongue and deviation of the tongue to the right in a right hypoglossal nerve (CN12) palsy of uncertain origin.

*This page intentionally left blank*

# Disorders of peripheral nerves

## Main Points

- Disorders of the peripheral nervous system are much less common in children than disorders of the central nervous system.
- Brachial plexus injuries often occur with prolonged second stage of labor and in infants with birth weight >4500 g or shoulder dystocia.
- Guillain–Barré syndrome, acute inflammatory demyelinating polyneuropathy, can manifest with autonomic dysfunction and weakness of facial, bulbar, respiratory, and extremity muscles.
- Complex regional pain syndrome should be suspected when children or adolescents display pain and weakness that seems disproportional to the extent and severity of the inciting injury.
- Ankle or lower leg weakness, frequent ankle sprains, and pes cavus should suggest the possibility of Charcot–Marie–Tooth disease, a heterogeneous neuromuscular disorder linked to several gene mutations.

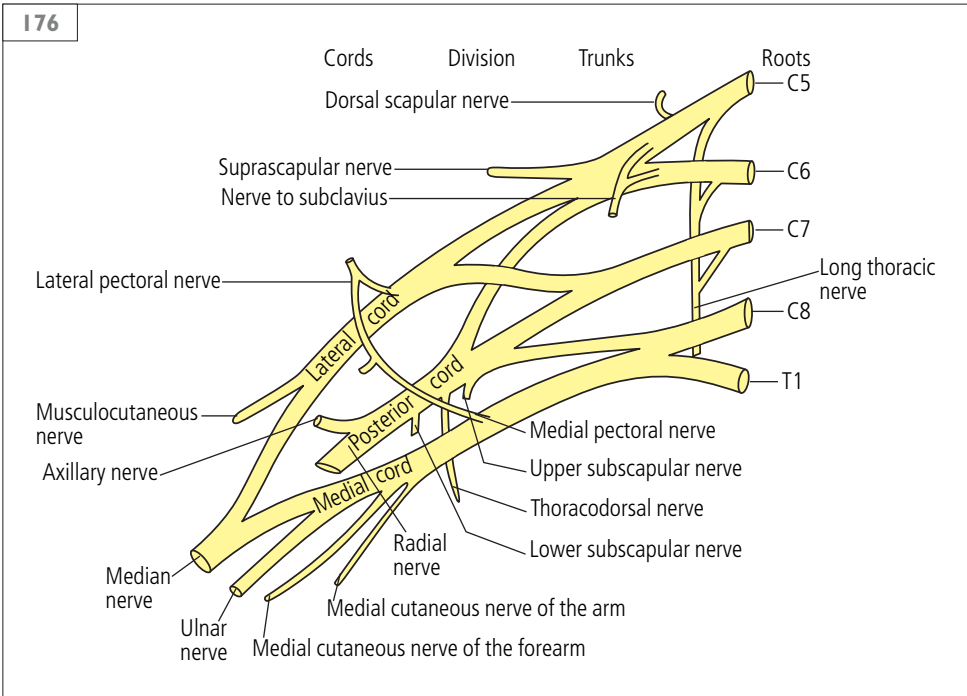
## Introduction

In contrast to disorders of the CNS, which are very common, disorders of the peripheral nervous system are relatively uncommon in infants, children, and adolescents. Despite this, most generalists will encounter at least two conditions, neonatal brachial plexopathy and Guillain-Barré syndrome (GBS), more than once during their practice careers. Other pediatric disorders of peripheral nerves, such as sacral neuropathy, porphyria, complex regional pain syndrome, and others, will likely be encountered only by child or adult neurologists. This chapter describes selected disorders, focusing on the clinical manifestations and management of these conditions.

## Neonatal brachial plexopathy

### DIAGNOSIS AND CLINICAL FEATURES

Neonatal brachial plexopathy, a condition that affects approximately 2 of every 1000 live-born (0.2%) infants, usually results from stretch injuries to the plexus during an infant's delivery. Risk factors for brachial plexus injuries include large size, especially birth weight >4.5 kg, prolonged second stage of labor, and shoulder dystocia. The brachial plexus, formed by nerve roots C5–T1 (176), innervates the muscles of the arm and also contains sympathetic fibers travelling in T1. Consequently, the newborn with brachial plexopathy displays varying



176 Brachial plexus.

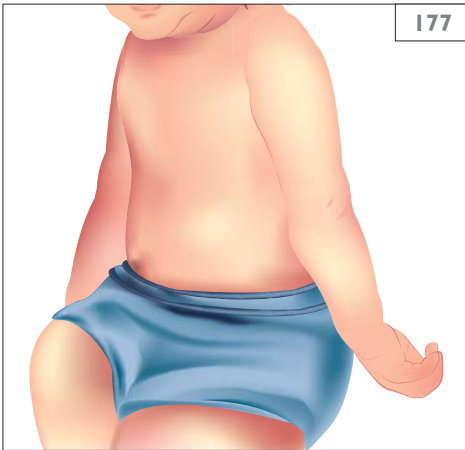degrees of arm weakness, and when T1 is involved due to injuries to the entire plexus or the lower trunk, the infant has a Horner syndrome (163).

Neonatal brachial plexus injuries have been traditionally categorized as Erb's palsy, the most common manifestation, reflecting injury to C5–C7, and Klumpke palsy, denoting injury to C8–T1. Erb's palsy produces weakness of the shoulder muscles and flexion/supination of the forearm. Hand function is preserved. By contrast, Klumpke palsy produces weakness of the flexors of the wrist and intrinsic muscles of the hand but preservation of the upper arm. Consequently, the infant with an Erb's palsy maintains the arm extended, internally rotated

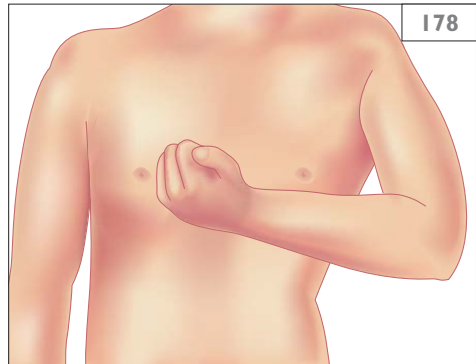
at the shoulder, and flexed at the wrist (177), whereas the infant with a Klumpke palsy has a claw-like hand with preserved upper arm function (178). Muscle stretch reflexes are absent in both forms. Neonatal brachial plexopathy can be associated with clavicular fracture, facial paralysis, or diaphragmatic paralysis due to involvement of the phrenic nerve which arises from the C3–C5 roots.

### MANAGEMENT

The infant with neonatal brachial plexopathy should be managed conservatively for the first week, unless avulsion of the nerve roots, an uncommon situation, is suggested by the presence of Horner syndrome and complete,



177 Erb's palsy.



178 Klumpke palsy.

severe paralysis of all muscles subserved by the plexus. In this instance, the infant should undergo MRI of the cervical spine and plexus, and neurosurgical consultation should be obtained. If available, EMG and nerve conduction studies can define the extent of the injury and the potential for recovery, especially when obtained at 2–3 weeks of age. In infants with less severe plexus injuries, physical therapy should begin after 7 days. Many infants with brachial plexus injuries improve during the first few weeks, and approximately two-thirds have recovered satisfactory use of the arm by 2 years of age.

The surgical management of infants with brachial plexus injuries remains controversial. Surgical procedures include nerve grafting, usually with a segment of the sural nerve, and neurolysis, a process in which the nerve sheath is cut and adhesions removed to diminish tension on the nerve. Some authorities suggest that neurosurgical consultation be obtained if the infant has no signs of biceps function at 3 months. Others suggest that surgical intervention can be delayed until after 6 months without substantially affecting the long-term outcome. Intense physical therapy remains a major component of rehabilitation regardless of decisions regarding surgical management. Orthopedic procedures, including osteotomies and tendon transfers, may become necessary in older children who have limited recovery of motor function.

## Brachial plexopathy of children or adolescents

Brachial plexopathy can occasionally occur in children or adolescents as the result of trauma (especially sports injuries), infection, tumors, and reactions to immunizations. In some instances, no cause can be identified. Brachial plexus neuritis, a postinfectious or immunization-related disorder, produces intense shoulder pain, and weakness of the muscles innervated by the upper roots of the plexus appears after 5–7 days. With the exception of the pain, the clinical features mimic those of Erb's palsy. EMG 2 or more weeks after an injury or the onset of pain in neuritis shows features of denervation including positive waves and fibrillations. MRI of the spine or plexus should be normal in brachial plexus neuritis or reveal nonspecific bony changes. Management consists of physical therapy and pain management.

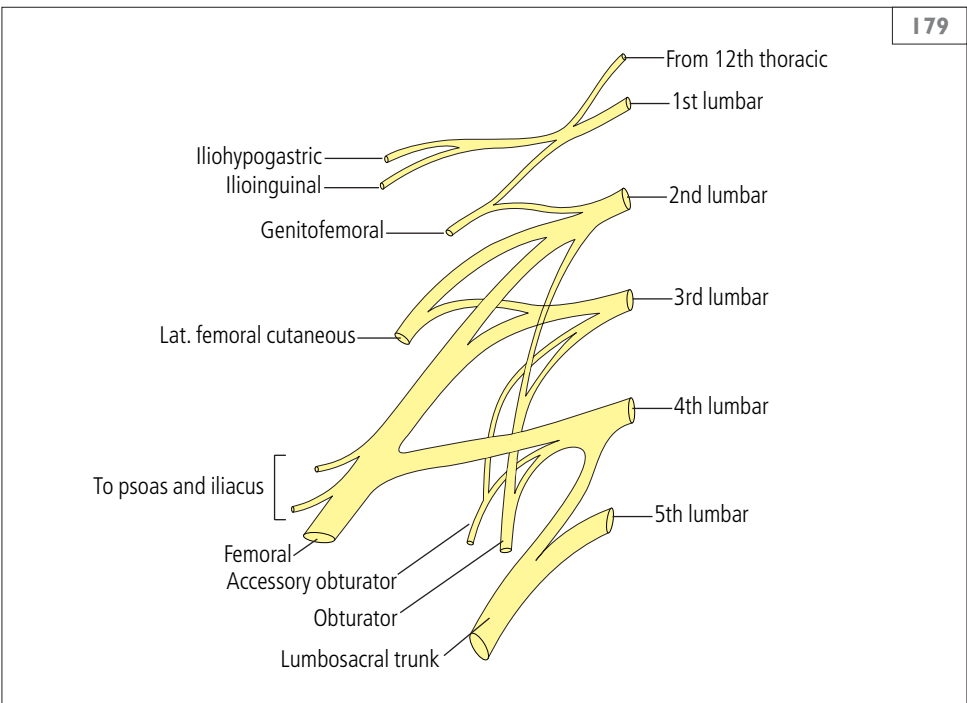
## Lumbosacral plexopathy

The lumbosacral plexus, consisting of nerve roots L1–S4 (179), innervates the muscles of the lower extremities and subserves sensation to the buttocks, perineum, thighs, and legs. Conditions that affect the function of the lumbosacral plexus are much less frequent than those affecting the brachial plexus, and include trauma, radiation, neoplasia, vascular lesions, and infection. Children or adolescents with lumbar plexopathies display varying degrees of motor and sensory dysfunction in the buttocks and leg. Iatrogenic lumbosacral plexopathy has been reported after pelvic surgery or child birth; a certain number of cases are idiopathic. Definitive management and prognosis of lumbosacral plexopathies depend upon the etiology; most conditions require physical therapy.

## Sacral neuropathy

Sacral neuropathy, an uncommon neurological condition in childhood, can be secondary to trauma, inflammation, hemorrhage, or tumor and can occur in children or adolescents after prolonged surgical procedures, such as liver transplantation, as a consequence of reversible nerve compression. The sciatic nerve provides

both motor and sensory function to the leg. Persons with sciatic neuropathy display weakness of knee flexion and weakness of dorsiflexion, plantar flexion, eversion, and inversion of the foot. Sensory loss occurs in the posterior portion of the leg from the buttocks to the foot, the medial surface of the leg below the knee, and the dorsal as well as plantar surfaces of the foot.



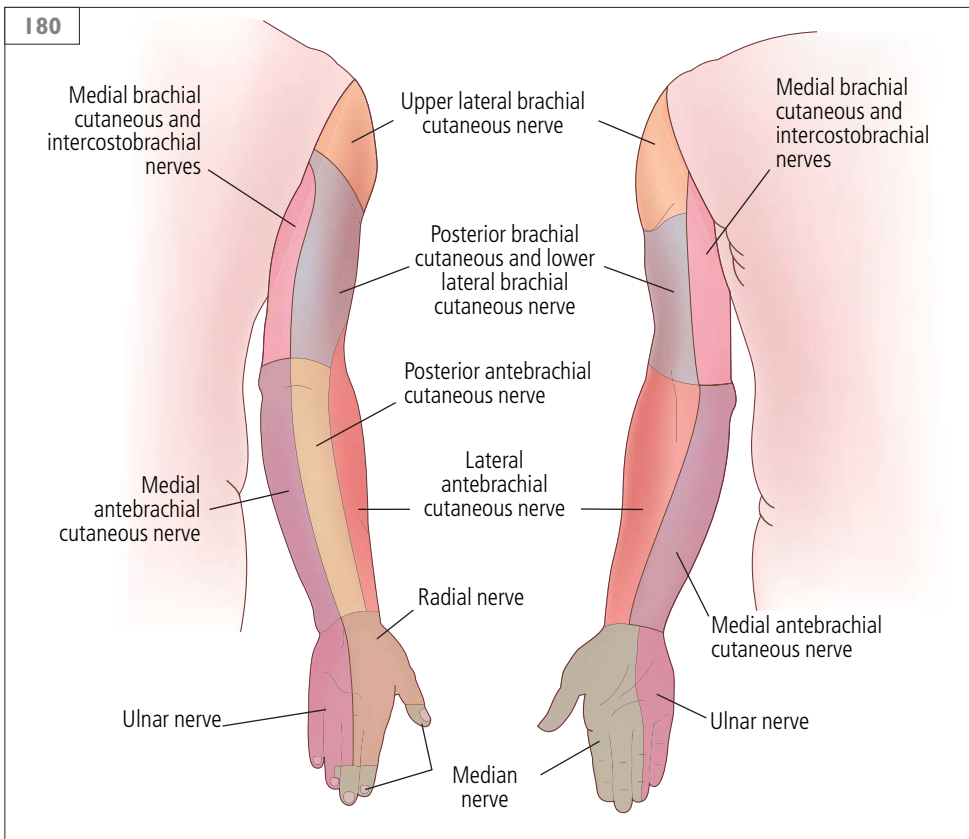
**179** The lumbar plexus.



## Hereditary neuropathy with liability to pressure palsy

Hereditary neuropathy with liability to pressure palsy (HNPP), an autosomal dominant disorder secondary to mutations in the gene encoding peripheral myelin protein 22 (PMP22 located at 17q11.2), usually presents in adults who experience sensory loss or weakness as the result of mild trauma, repetitive motion, or nerve compression. The

disorder affects approximately 3 per 100,000 persons, and reflects damage to, and slow repair of, peripheral myelin. Persons with HNPP often have carpal tunnel syndrome, a disorder causing weakness, sensory loss, and paresthesias in the distribution of the distal median nerve (180). Carpal tunnel syndrome, an uncommon disorder in childhood or adolescents, can be seen in persons with hypothyroidism or diabetes mellitus, pregnant women, men or women with work-related repetitive motion injuries, and persons with



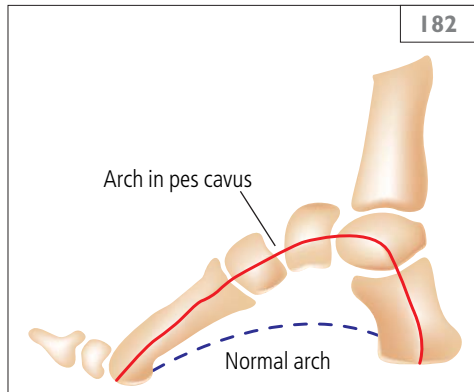
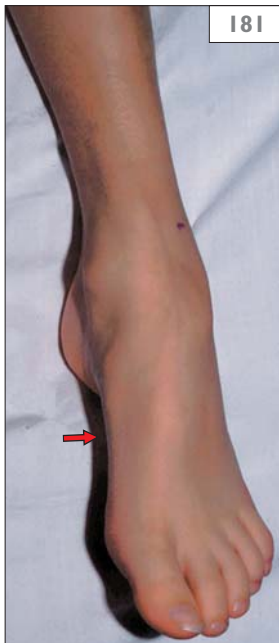**180** The sensory nerves of the arm and their distribution.

mucopolysaccharidoses due to accumulation of glycosaminoglycans.

HNPP should be suspected in adolescents who have carpal tunnel syndrome or recurrent and prolonged paresthesias or weakness associated with trivial nerve compression (such as after crossing the legs for extended periods or falling asleep with an arm resting on a chair, so-called ‘Saturday Night Palsy’). Onset in early childhood has been described. The sensory and motor abnormalities are usually transient, but in adulthood, mild

disability can occur as the result of prolonged or permanent motor dysfunction. The neurological examination may show reduced muscle stretch reflexes, especially at the ankles and, occasionally, pes cavus (181, 182). The diagnosis can be supported by finding prolonged distal latencies on electrodiagnostic studies and confirmed by identifying deletions in PMP22 using FISH or gene sequencing. Management consists currently of providing education and anticipatory guidance regarding provocative factors.

**181** An adolescent with pes cavus (arrow) due to Friedreich ataxia.



**182** Diagram of the arch in pes cavus.

## Guillain–Barré syndrome

### DIAGNOSIS AND CLINICAL FEATURES

GBS, also known as acute inflammatory demyelinating polyneuropathy (AIDP), affects approximately one in 100,000 persons annually. The disorder can affect children or adolescents, and is an immune-mediated condition associated with macrophage-induced damage of myelin and blockage of nerve transmission. Infection, immunization, and surgery can act as triggers for the disorder. Infectious agents are the most commonly identified triggers associated with GBS, including Epstein–Barr virus, CMV, *Campylobacter jejuni*, rubella virus, dengue virus, influenza viruses, *Mycoplasma pneumoniae*, and several other agents, both viruses and bacteria, that produce respiratory or gastrointestinal illnesses.

GBS can begin insidiously over 1–3 weeks or abruptly in 24 hours or less. Painful paresthesias or distal weakness are the usual initial symptoms in children or adolescents. Weakness, the more serious aspect of GBS, often begins in the legs and ascends to involve the arms, the face, and the muscles of respiration. Less frequently, the motor cranial nerves controlling swallowing or eye movement can be involved. Papilledema can be observed occasionally. Variations in the pattern and severity of weakness occur; some children or adolescents have severe weakness that progresses rapidly to complete quadriplegia and ventilator dependence. Autonomic nervous system dysfunction, consisting of hypertension, tachycardia, or bradycardia, can be a prominent feature and, along with respiratory muscle involvement, be life-threatening.

GBS should be suspected in previously-healthy children or adolescents who experience rapidly evolving lower extremity weakness associated with subjective sensory complaints or autonomic instability. Painful paresthesias can be a prominent and, occasionally, the first symptom. The presence of facial diplegia (171, 172), as well as absence of a sensory level, distinguishes GBS from transverse myelopathy, another postinfectious disorder that causes extremity weakness. The diagnosis can be confirmed by electrophysiological studies that demonstrate slowed nerve conduction velocities, motor conduction block, or absence or prolongation of F waves or H responses, measures of the integrity and function of the

spinal efferent and afferent loop. Spinal MRI may show nerve root enhancement (219). Examination of the CSF characteristically shows an albuminocytologic dissociation (elevated protein in the absence of cells), especially 1–2 weeks after the onset of symptoms.

### MANAGEMENT

Treatment consists of meticulous monitoring of pulmonary function and institution of either plasmapheresis or intravenous immunoglobulin (IVIG). Most pediatric neurologists favor the latter, given the ease of administration and the apparent therapeutic equivalency of IVIG and plasmapheresis in adults. There are, as yet, no randomized controlled trials comparing these modalities in children or adolescents, however. The standard regimen of IVIG is 2 g/kg given in equally divided doses over 2–5 days; there are no data to favor shorter or longer courses. Corticosteroids, either orally or intravenously, have no role in the acute management of GBS. The respiratory effort (via bedside measurement of the negative inspiratory force [NIF] and the forced vital capacity [FVC]) and swallowing (gag reflex) of nonventilated children or adolescents must be monitored at least every 6 hours during the initial phases of the disorder. The treating physician must also attend carefully to the vital signs for evidence of autonomic instability, especially hypertension or cardiac dysrhythmias, which may require medication management. Rehabilitation services should be instituted early. Although as many as 30% of adults with GBS have motor sequelae despite treatment, approximately 90% of children or adolescents with GBS recover completely; rarely, relapses can occur.

### RELATED DISORDERS

The Miller Fisher variant of GBS, a not uncommon condition in children, produces ataxia, ophthalmoplegia, and areflexia. Like conventional GBS, triggers include infection and immunization. This variant of GBS has been associated with antibodies against GQ1b, a ganglioside present in peripheral myelin, in as many as 90% of cases. Management consists of administering IVIG in doses using a regimen identical to that of GBS.

Chronic inflammatory demyelinating polyneuropathy (CIDP), considered a related disorder distinct from AIDP (GBS), consists of

neurogenic pain and prolonged or relapsing bouts of weakness, especially of the legs. Children or adolescents with this disorder have electrodiagnostic results similar to those with GBS and, like those with GBS, respond to IVIG. In contrast to those with GBS, however, children or adolescents with CIDP improve with modest doses of corticosteroids (e.g. prednisone) given orally for days to weeks after IVIG. Some persons with CIDP occasionally require therapy with other immunomodulating drugs.

In the USA and Europe the 'axonal variant' of GBS (referred to as acute axonal polyneuropathy) is rare, but this variant is much more common in Asia, particularly in Japan. In this form, weakness and atrophy are more profound, and EMG and nerve conduction studies demonstrate axonopathy and denervation. The rate of recovery is much slower than in GBS, and the likelihood of full recovery is less. No preferred treatment exists.

## **Complex regional pain syndrome**

Complex regional pain syndrome (CPS), known previously as reflex neurovascular dystrophy or reflex sympathetic dystrophy, is an important but relatively infrequent cause of extremity pain and weakness in children and adolescents. The disorder has been divided into two categories, CPS I, a disorder triggered by tissue injury, and CPS II, a condition associated with nerve injury. Both cause chronic, often disabling pain in children or adults. The disorder begins after relatively minor injury to an extremity and progresses over the ensuing days or weeks to a chronic pain syndrome that eventually leads to disuse, weakness, trophic skin changes, joint stiffness, and muscle atrophy. Children or adolescents with this disorder exhibit changes in skin temperature of the affected extremity and burning, dysesthetic pain that is disproportional to the inciting injury. Although the pathogenesis of CPS remains poorly defined, current theories invoke the role of neurotransmitters and immunologic responses. The diagnosis remains largely clinical.

Management consists of physical therapy and treatment with medications effective against neurogenic pain, such as gabapentin, pregabalin, carbamazepine, or amitriptyline. Because emotional stress seems to participate in the pathogenesis or persistence of pain, psychological therapies appear to have a role in the management of children or adolescents with CPS.

## Inherited peripheral neuropathy

Several inherited disorders of peripheral nerves can appear in children or adolescents. The most common of these, Charcot–Marie–Tooth disease (CMT), affects approximately 1 in 2500 persons. CMT represents a clinically and genetically heterogeneous autosomal dominant or recessive disorder caused by mutations at more than 20 different gene loci. Type 1A, for example, results from duplication of the PMP22 gene, which causes protein overproduction, Schwann cell dysfunction, and demyelination. The disorder begins in late childhood or adolescence with difficulty walking, especially on rough surfaces, being an early symptom. Affected persons commonly experience recurrent ankle sprains and often come to diagnosis through the astute observations of experienced orthopedists or pediatricians. Persons with CMT exhibit pes cavus (181, 182), loss of muscle stretch reflexes, and weakness of ankle dorsiflexion and eversion, causing foot drop and a steppage gait, and muscle wasting, causing a stork leg appearance. Over time, weakness of hand and forearm muscles appears, and many persons with CMT have neurogenic pain of the hands and feet. The disorder cannot be cured, but the disorder progresses slowly and does not affect life span. Management consists of physical therapy, pain management, orthotic use, and careful orthopedic intervention.

## Critical illness polyneuropathy/myopathy

Critical illness polyneuropathy/myopathy, an uncommon disorder, produces diffuse weakness or flaccid quadriplegia in children (and adults) who experience sepsis and/or multiorgan system dysfunction and require extended mechanical ventilation. Factors associated with this disorder include administration of corticosteroids and prolonged hospitalization in intensive care units. Electrodiagnostic studies may show axonal neuropathy; serum CK levels may be markedly elevated. Children with critical illness neuropathy/myopathy recover spontaneously, although recovery can be gradual and incomplete. Affected individuals may require extensive neurorehabilitation.

## Miscellaneous causes of peripheral neuropathy

Other causes of peripheral neuropathy in children and adolescents include:

- Acute intermittent porphyria.
- Mitochondrial disorders.
- Fabry disease.
- Familial dysautonomia.
- Neurofibromatosis type 1.
- Nerve tumors (schwannoma, neurofibroma, sarcoma).
- Systemic lupus erythematosus.
- Chemotherapy-related peripheral neuropathy (especially vincristine).
- Heavy metal intoxication.

# Disorders of gait and balance

## Main Points

- Many childhood neurological problems present as impairment of gait or balance.
- The clinician should assess disorders of gait along three axes:
  - Temporal profile: acute, subacute, chronic.
  - Distribution: symmetric vs. asymmetric; ascending vs. descending; proximal vs. distal.
  - Diagnostic category: orthopedic, inflammatory/rheumatologic, neurological, psychogenic.
- The more acute the onset the greater the need for prompt evaluation; optimal outcome may depend on expeditious diagnosis and treatment.
  - Bowel and bladder dysfunction implies spinal cord involvement and the need for timely MRI.
- Common neurological disorders resulting in *acute* symmetric impairment of gait and balance include: Guillain–Barré syndrome; syndromes of spinal cord compression; transverse myelitis; acute cerebellar ataxia; intoxications; multiple sclerosis.
- Common neurological disorders resulting in *subacute* symmetric impairment of gait and balance include: Guillain–Barré syndrome; polymyositis/dermatomyositis; midline tumors of the posterior fossa; other inflammatory and neoplastic conditions.
- Neurological disorders resulting in chronic slowly progressive gait and balance impairments usually result from neoplastic or hereditary degenerative conditions.

## Introduction

Numerous pediatric neurological disorders present as impairments of gait or balance and comprise a very broad and diverse group of neurological conditions. Often, these disorders represent serious neurological conditions in which prompt evaluation and management may dramatically alter outcome. In other circumstances, accurate diagnosis avoids unnecessary diagnostic testing and provides early peace of mind for families; alternatively, correct disease identification may at least allow for proper counseling and prognostication. Most of these disorders require evaluation by a specialist, but the clinician should recognize when urgent evaluation is critical.

## Evaluation

In evaluating disorders of gait the clinician must consider a broad differential diagnostic categorization early on, since many gait disorders represent specific orthopedic or rheumatologic disorders (*Table 26*). Specific neurological disorders often display a specific temporal profile (*Table 27*). The rate of onset and distribution of impairment provide useful clues to the differential diagnosis (*Tables 28 and 29*, pages 164, 165).

As a rule of thumb, orthopedic and rheumatologic causes of gait impairment present in a subacute fashion (aside obviously from traumatic disorders) and display a substantial degree of asymmetry.

**Table 26 Orthopedic and rheumatologic conditions presenting as gait disorders**

	Age of onset	Location	Symmetry	Clinical features	Temporal profile/ other features	Laboratory/ imaging findings
Diskitis	2–7 yr	Spine: lower thoracic–lumbar intervertebral disk	Yes	Refusal to walk/stand; increased lumbar lordosis	Acute onset; mild fever	Abnormal uptake intervertebral disk (BS); narrowed intervertebral space and end-plate edema (MRI)
Toxic synovitis	3–6 yr	Hip	No	Antalgic gait; hip, thigh, or knee pain	Subacute; mild fever	Increased acetabulum–femoral head distance (PF); joint effusion (US)
Septic arthritis	Any age	Variable	Rarely	Antalgic gait; monoarticular signs 'pseudoparalysis'/ diminished range of motion	Acute/subacute; fever/systemic signs	Elevated ESR, CRP, WBC; tissue and joint space effusion, swelling (PF)
Legg–Calvé–Perthes disease	4–8 yr; M>>F	Hip	Rarely	Antalgic gait; mild groin, hip, thigh or knee pain; stiffness; thigh atrophy	Subacute/chronic	Varies with stage of disease (PF)
Slipped capital femoral epiphysis	F: 11–13 yr; M: 13–15 yr	Hip	Rarely	Antalgic gait; pain (hip, thigh, or knee); tenderness; decreased range of motion; spasm; leg shortening	Acute/subacute; no fever	Medial displacement of epiphysis (PF)

BS: bone scan; MRI: magnetic resonance imaging; PF: plain radiograph; US: ultrasound; ESR: erythrocyte sedimentation rate; CRP: C-reactive protein; WBC: white blood cell count



**Table 27** Localization of gait disorders along the neuraxis

Neuraxis level	Clinical features	Specific examples
Neocortical	Impaired higher cortical functions; encephalopathy	Cerebral infarction; lysosomal storage diseases; peroxisomal disorders
Basal ganglia	Dystonia; rigidity/bradykinesia; other movement disorders	Idiopathic torsion dystonia; extrapyramidal syndromes
Brainstem	Cranial nerve deficits; crossed sensory deficit <sup>1</sup> ; crossed motor signs <sup>2</sup>	Infarction; tumor/abscess; hemorrhage
Cerebellum	Ataxia/coordination impairment/tremor; hypotonia; pendular reflexes <sup>3</sup> ; rebound phenomenon <sup>4</sup>	Acute cerebellar ataxia; pilocytic astrocytoma; medulloblastoma ( <b>183</b> ); opsoclonus–myoclonus syndrome; ataxia-telangiectasia; Friedreich ataxia; congenital disorders of glycosylation ( <b>184</b> )
Spinal cord	Sensory level; mixed UMN + LMN signs; bowel + bladder dysfunction	Transverse myelitis; mass lesion; infarct/hemorrhage; Friedreich ataxia
Alpha motor neuron	Weakness; atrophy (early); hypotonia; areflexia; fasciculations	Spinal muscular atrophy; poliomyelitis syndromes; anterior spinal artery syndrome
Peripheral nerve	Weakness; atrophy (varies); hypotonia; hypo- or areflexia; +/- sensory loss	AIDP; CIDP; other peripheral neuropathies; compression/traumatic
Muscle	Muscle pain/tenderness; weakness (proximal > distal); normo- or hypoactive reflexes; pseudohypertrophy (DMD); atrophy (late)	Poly/dermatomyositis; muscular dystrophies

AIDP: acute inflammatory demyelinating polyneuropathy; CIDP: chronic inflammatory demyelinating polyneuropathy; DMD: Duchenne/Becker muscular dystrophy; LMN: lower motor neuron; UMN: upper motor neuron

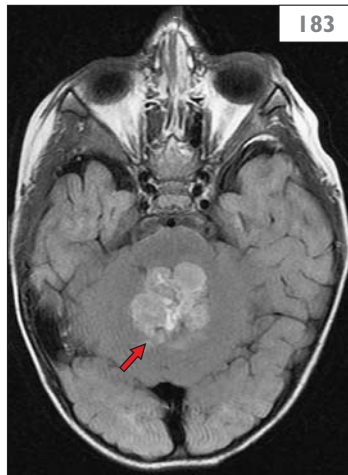
<sup>1</sup>Facial sensory loss opposite to body sensory loss.

<sup>2</sup>Unilateral lesion in brainstem above the level of pyramidal decussation (lower medulla) may cause facial, tongue, or bulbar weakness on one side and extremity weakness on the other.

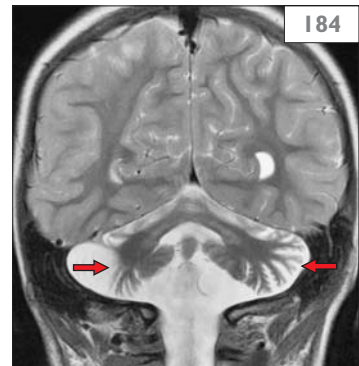
<sup>3</sup>Response to 'knee-jerk' reflex results in several to-and-fro oscillations of the distal lower extremity.

<sup>4</sup>Failure to check and adjust spontaneously to sudden, unexpected imposed movements of the limbs or trunk.

**183** Axial FLAIR MRI showing characteristic appearance of a medulloblastoma filling the 4<sup>th</sup> ventricle (arrow).



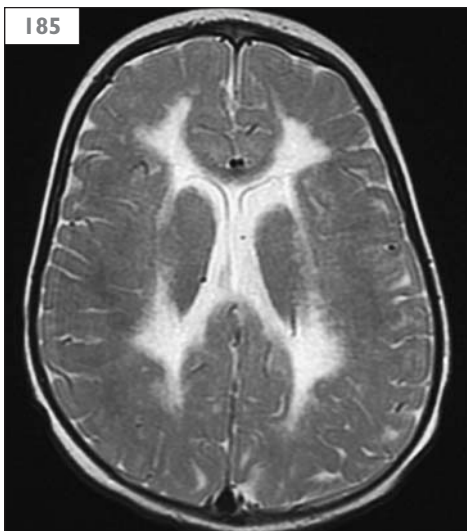**184** Coronal, T2-weighted MRI showing pancerebellar atrophy (arrows) in a child with a congenital disorder of glycosylation (CDG1a).



**Table 28** Specific causes of gait/balance disorders classified by rate of onset

Acute	Chronic
Cerebral/cerebellar/brainstem infarction	Lysosomal storage diseases:
Drug intoxication:	Krabbe disease, metachromatic leukodystrophy,
Phenytoin, ethanol, sedative hypnotics	Fabry disease
Anterior spinal artery syndrome	Peroxisomal diseases:
Spinal epidural hemorrhage	Adrenoleukodystrophy, adrenomyeloneuropathy
Transverse myelitis	Other metabolic disorders:
Trauma (usually obvious)	Congenital disorders of glycosylation
Guillain–Barré syndrome (AIDP)	(especially CDG1a; <b>184</b> )
Psychogenic (astasia/abasia)	Mevalonic aciduria
	Some disorders of fatty acid oxidation
<b>Subacute</b>	Other leukodystrophies:
ADEM	Vanishing white matter disease ( <b>185, 186</b> )
Idiopathic torsion dystonia	Neoplastic disorders:
Acute cerebellar ataxia	Mass lesion, lymphoma, leukemia
OMS (idiopathic or paraneoplastic)	Spinal muscular atrophy (type III particularly)
Vitamin B12 deficiency	Genetic disorders:
Vitamin E deficiency	Ataxia telangiectasia
AIDP	Friedreich ataxia
Polymyositis/dermatomyositis	Other spinocerebellar degenerative disorders
	Muscular dystrophy
	Myotonic dystrophy
	Duchenne/Becker muscular dystrophy

ADEM: acute disseminated encephalomyelitis; AIDP: acute inflammatory demyelinating polyneuropathy; OMS: opsoclonus–myoclonus syndrome



**185** Axial T2-weighted MRI showing increased signal intensity diffusely throughout the white matter in a child with vanishing white matter disease.

**Table 29** Specific disorders classified by distribution of impairment**Symmetric**

ADEM  
 Neurodegenerative  
 Midline tumors (posterior fossa)  
 Acute cerebellar ataxia  
 Transverse myelitis  
 AIDP  
 Polymyositis/dermatomyositis  
 Muscular dystrophy

**Asymmetric**

ADEM  
 Infarction  
 Some spinal cord masses  
 Compression neuropathies

**Ascending**

AIDP  
 Peripheral neuropathies  
 Myotonic dystrophy

**Descending**

Cervical cord tumors  
 Syring

**Proximal**

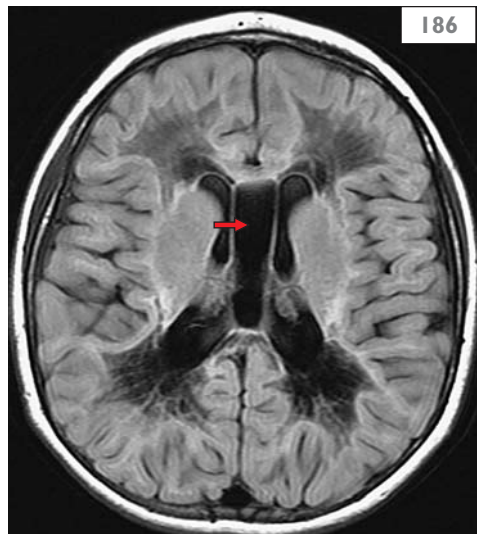
Polymyositis/dermatomyositis  
 Muscular dystrophies (most)

**Distal**

Cerebral infarction  
 Anterior horn cell disease  
 (spinal muscular atrophy)  
 Peripheral neuropathies  
 AIDP  
 Myotonic dystrophy

ADEM: acute disseminated encephalomyelitis; AIDP: acute inflammatory demyelinating polyneuropathy

**186** Axial T1-weighted MRI showing diffuse loss and cystic changes of white matter in a child with vanishing white matter disease. The child also has a cavum vergae (arrow).



Pain, swelling, and deformity of limbs or joints are often present. The child, reluctant to bear weight, manifests an antalgic or painful gait. Muscle bulk, strength, tone, and reflex patterns usually remain intact. In some fulminant cases of idiopathic juvenile arthritis, however, striking muscle atrophy and weakness may be present and be accompanied by signs and symptoms of arthritis, including swelling, tenderness, rubor/calor, and early morning joint stiffness that may improve as the day progresses. Likewise, thigh muscle atrophy may be present with chronic Legg–Calve–Perthes disease (aseptic necrosis of the femoral head). The rheumatologic exception to the above rules is polymyositis/dermatomyositis, but here we include this as a neurological disorder given involvement of muscle as the cause of gait impairment.

### DISTRIBUTION WITHIN THE NERVOUS SYSTEM

Once the above analysis has been carried out, one should consider what level of the nervous system is affected (textbox).

Upper motor neuron lesions are typically associated with increased tone (spasticity), hyper-reflexia, preservation of muscle bulk, and Babinski signs.

Lower motor neuron lesions are typically associated with decreased tone (hypotonia), hyporeflexia, and early loss of muscle bulk.

This enables clinicians to establish the correct diagnosis and direct evaluation and management. Key points regarding level of involvement along the neuraxis are noted in *Table 27*. Clinicians must recognize that in acute disorders of the CNS (cerebral hemisphere, brainstem, and spinal cord) the “typical” upper motor neuron (UMN) findings of hypertonicity (spasticity) and hyper-reflexia may be replaced temporarily by profound hypotonia (or flaccidity) and hypo- or areflexia. Babinski responses to plantar stimulation may also be absent (silent plantar response) making identification of an early UMN process challenging.

## Patterns of presentation

### Acute/subacute ‘ascending’ paraparesis

The prototypic disorder causing an ascending paraparesis is Guillain–Barré syndrome (GBS). The typical patient with GBS presents with relatively symmetric lower extremity weakness, sometimes accompanied by hyperpathia and hyperalgesia, that progresses rapidly in hours to a few days. Weakness progresses in a distal to proximal, lower extremity to upper extremity fashion. A substantial proportion of children and adolescents also have various degrees of facial nerve weakness (165, 171, 172), especially bilateral paralysis, and some have abducens palsies and/or papilledema. Motor involvement is usually far more prominent than sensory symptomatology, although the latter may appear as severe neuropathic pain. Autonomic dysfunction in the form of tachycardia or hypertension may be prominent features, and bladder dysfunction can also occur. Prominent bowel or bladder dysfunction, however, should suggest spinal cord pathology. The differential diagnosis includes transverse myelitis, other spinal cord syndromes, poliomyelitis syndromes, meningeal leukemia, or lymphoma. GBS should be considered in children or adolescents with acute or subacute paraparesis, especially when accompanied by prominent paresthesias.

### Acute paraparesis with sensory level and bowel and bladder dysfunction

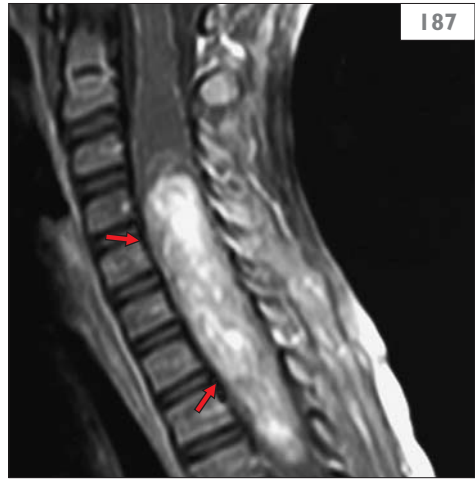
This pattern, the classic spinal cord syndrome, of abrupt onset of paraparesis, sensory level, and bladder or bowel dysfunction is a neurological emergency and requires urgent MRI imaging of the spinal cord. Children usually present with the abrupt onset of lower extremity paralysis evolving over a period of several hours. This is associated with back pain, anesthesia, and/or hypalgesia below a certain spinal level and impairments of bowel or bladder function presenting as urinary retention and diminished defecation often associated with stool leakage. This constellation of features and its potentially grave implications must be considered a neurosurgical emergency. Hence, MRI with and

without contrast of the entire spinal cord must be performed as soon as feasible even in the absence of trauma or suspected infection. Urgent neurosurgical consultation should follow if a mass lesion (187) or traumatic spinal cord injury is identified. Lumbar puncture must not be performed before the MRI.

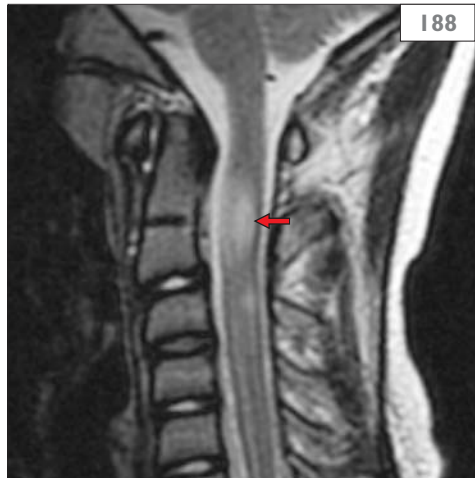
In the absence of a mass lesion, the diagnosis is usually acute transverse myelitis (also called idiopathic or acute myelitis; 188). When associated with optic neuritis, the condition is known as neuromyelitis optica (NMO or Devic's disease, potentially associated with aquaporin antibodies). In either case, the condition is generally considered to be a postinfectious or parainfectious, immune-mediated disorder; a history of a prodromal infectious illness is often elicited. The CSF may be normal or show a mild to moderate lymphocytic pleocytosis with mild to moderate protein elevation. Nerve conduction studies should be normal initially, but if anterior horn cells are affected directly, signs of denervation emerge later.

### MANAGEMENT

Treatment of acute paraparesis in pediatric patients involves supportive care, attention to airway protection (especially in rapidly progressive GBS), physical therapy, and administration of IVIG or corticosteroids. Children with GBS improve with administration of IVIG, given as a total dose of 2 g/kg over 2–5 days. Plasmapheresis also provides benefit in GBS, but ease of IVIG administration, especially in young children, and the more favorable side-effect profile of IVIG favor this therapy over plasmapheresis in pediatric patients. Most authorities recommend administration of high-dose corticosteroids, using methylprednisolone or equivalent intravenously, in acute myelitis, and some advocate IVIG, but the relative efficacy of these therapies is currently unknown. The prognosis for GBS is quite favorable in children, with 80% or more recovering completely. By contrast, the prognosis for acute transverse myelitis is not as favorable. Approximately one-third of pediatric patients with myelitis have an excellent outcome with full or nearly full recovery, one-third improve sufficiently to walk independently but have neurological sequelae, and the final third have limited recovery and remain nonambulatory with severe para- or quadriplegia.



**187** T1-weighted, gadolinium-enhanced spine MRI showing an intramedullary tumor that was found at surgery to be an ependymoma (arrows).



**188** T2-weighted spine MRI showing areas of signal hyperintensity in the cervical region compatible with transverse myelitis (arrow).

## Acute/subacute asymmetric impairment of gait

This pattern of gait abnormality has a much broader differential diagnosis with many cases being due to non-neurological disorders (*Table 26*). Other causes include cerebral, brainstem, or spinal cord infarction or hemorrhage, traumatic or compressive neuropathies or neuropraxias, vasculitis and other putative immune-mediated neurological disorders, and idiopathic torsion dystonia presenting with unilateral lower extremity dystonia. Careful attention to the

presence of pain, swelling, local signs of inflammation, local trauma or pressure, or of an antalgic gait assists in establishing the correct diagnosis. In absence of clues, directed neuroimaging is necessary to clarify the underlying disorder.

## Subacute symmetric muscle weakness

This is the classic pattern of polymyositis/dermatomyositis. These conditions are described in Chapter 19 Hypotonia and Weakness.

**Table 30 Selected causes of acute ataxia in childhood**

- Intoxication:
  - Sedatives, anticonvulsants, alcohol, antihistamines
- Infection:
  - Meningitis, encephalitis, especially of the brainstem
  - Labyrinthitis, vestibular neuronitis
- Mass lesions:
  - Cerebellar astrocytoma
  - Medulloblastoma, ependymoma
  - Hydrocephalus
- Immunologic:
  - Postinfectious cerebellitis (varicella, nonpolio enteroviruses)
  - ADEM
  - OMS:
    - paraneoplastic (occult neuroblastoma),
    - postinfectious, idiopathic
  - Miller Fisher variant of GBS
- Seizure
- Vascular:
  - Brainstem or cerebellar infarction: vertebral artery dissection
  - Cerebellar hemorrhage
  - Vascular malformation or ruptured aneurysm
- Traumatic brain injury, including concussion
- Familial ataxias (e.g. acetazolamide responsive)
- Psychogenic disorders (e.g. conversion)
- Metabolic disorders:
  - Urea cycle abnormalities
  - Hartnup disease
  - Mitochondrial disorders

ADEM: acute disseminated encephalomyelitis; GBS: Guillain-Barré syndrome; OMS: opsoclonus–myoclonus syndrome

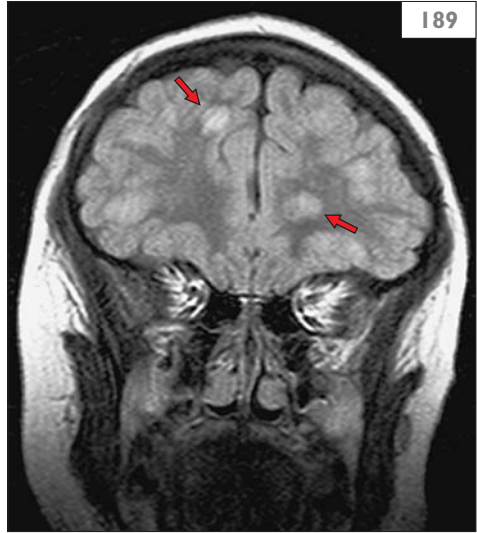
## Acute/subacute ataxia

Most cases of acute cerebellar ataxia represent postinfectious or parainfectious disorders preceded by a mild infection (*Table 30*). In the past, varicella was recognized as a common prodromal illness; cases have occasionally been observed after varicella vaccination. Children with acute ataxia, often of toddler age, refuse to walk or display truncal and gait instability that appears over hours to a few days. The child often otherwise appears well, although some have headache and persistent vomiting.

Given the broad differential diagnosis, urgent neuroimaging is required in all cases. This can consist of an unenhanced head CT initially to exclude a posterior fossa tumor, hemorrhage, or infarction. If these are absent, and there is no evidence of intoxication, then a presumptive diagnosis of acute postinfectious cerebellar ataxia is usually made. MRI should be obtained to exclude subtle infarction, encephalitis, or ADEM (**189**). CSF analysis may be considered (particularly if meningitis is a realistic consideration), but the results rarely help clarify the diagnosis. Therapy consists of supportive care, and resolution is anticipated in a period of weeks or less. Corticosteroids can be indicated if MRI demonstrates features of ADEM.

Careful follow-up is needed to recognize other disorders associated with acute ataxia, particularly OMS. This condition may initially present in a fashion identical to acute cerebellar ataxia with later appearance of opsoclonus ('dancing eyes') and myoclonus ('dancing hands and feet') as well as of an encephalopathy characterized by intense irritability, disinhibition, sleep disruption, and randomly aggressive behavior. Opsoclonus can be recognized as abrupt, random, rapid, or shimmering bursts of conjugate eye movements occurring in all directions of gaze. These are often gaze-evoked and may be associated with synchronous eyelid twitching movements (myoclonus). This neuro-ophthalmologic manifestation can be extremely subtle, and sustained observation of the child's eye movements is often necessary to detect it. Abrupt, rapid, 'random' twitching of limbs, face, or trunk (myoclonus) may also be evident, but this also can be very subtle.

At least fifty percent of the time OMS is a paraneoplastic neurological disorder associated with occult neuroblastoma, usually low-grade,



**189** White matter lesions compatible with ADEM (arrows) on a coronal FLAIR MRI.

in the abdomen, chest, pelvis, or neck. The evaluation of such children requires a careful abdominal and rectal examination, urine for homovanillic (HVA) and vanillylmandelic (VMA) acids, as well as imaging of the neck, chest, abdomen, and pelvis. Imaging may include combinations of CT, MRI, and iodine-131-meta-iodobenzylguanidine (MIBG) scintiscan. Children with opsoclonus/myoclonus and negative initial studies for occult neuroblastoma should undergo periodic rescreening, as above, for at least 6–12 months. Resection of the neuroblastoma, if found, may not result in clinical improvement. Treatment consists of high-dose ACTH plus monthly IVIG for months; various other immunomodulatory therapies have been used, including rituximab, cyclophosphamide, and 6-mercaptopurine. The course is usually protracted and the outcome poor, with most children sustaining long-term neurobehavioral sequelae.



### **Chronic, slowly progressive gait impairment with spasticity**

Disorders resulting in this pattern of gait impairment are generally heredo-familial genetic disorders of various types, although rare cases in children of neoplastic, paraneoplastic, and infectious disorders may present in this fashion (e.g. acquired immunodeficiency syndrome [AIDS]-related myelopathy or chronic myelopathy secondary to radiation and high-dose methotrexate). MRI of brain and spinal cord may be helpful in guiding the diagnostic evaluation. Based on the clinical pattern and neuroimaging results, specific genetic testing or CSF analysis may be helpful.

### **Slowly progressive gait impairment with lower extremity atrophy and areflexia**

These conditions represent the spectrum of hereditary motor and sensory neuropathies of which CMT is the prototype. However, CMT has now been subdivided into a large number of unique, specific genetic conditions. These too are heredo-familial genetic disorders of various types and some represent variant forms of the conditions above.

### **Slowly progressive gait impairment with proximal muscle weakness**

This pattern generally indicates an underlying muscular dystrophy of which Duchenne/Becker muscular dystrophy (DMD) is the prototype. This is discussed in detail in Chapter 19 Hypotonia and Weakness.

### **Chronic or slowly progressive ataxias**

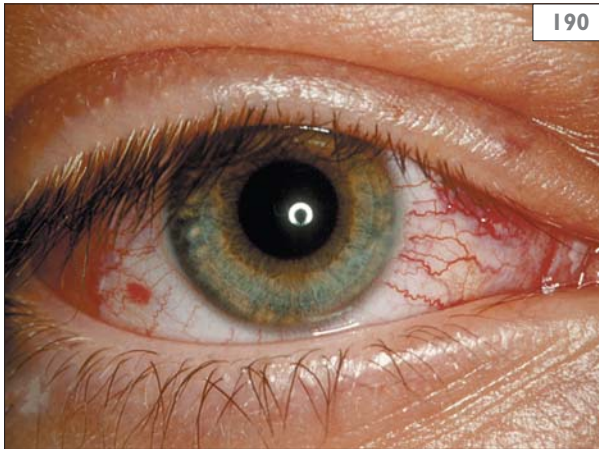
Numerous rare heredo-familial genetic disorders present with slowly progressive ataxia. These heterogeneous genetic disorders share only the commonality of truncal +/- appendicular ataxia. Inheritance is often autosomal dominant with variable penetrance and anticipation. Ataxia telangiectasia (AT), a rare,

autosomal recessive neurodegenerative disorder affecting approximately 1 in 50,000 persons worldwide, results from mutations in the ATM gene, a gene encoding a protein that promotes DNA repair. Young children with this disorder display oculomotor apraxia, dysarthria, chorea, myoclonus, and progressive ataxia that usually begins after the child starts to walk but before age 5 years. Ocular telangiectasias (190), considered a hallmark feature of AT, are usually present by 5–7 years of age. Children with AT typically live into middle adulthood, but have a 40% risk of malignancy, especially leukemia and lymphoma. MRI shows progressive cerebellar atrophy.

Friedreich ataxia, an autosomal recessive disorder affecting approximately 1 in 50,000 persons, usually begins in late childhood or early adolescence. The disorder results from excessive triple nucleotide repeats (GAA) in the gene (*FXN*) encoding frataxin, a protein that participates in protecting cells, especially the cell's mitochondria, from oxidative stress. Persons with this disorder have progressive ataxia, foot deformities, including pes cavus (181, 182), optic atrophy, deafness, scoliosis, heart disease (hypertrophic cardiomyopathy and conduction defects), progressive loss of vibratory and position sense, and an increased risk of diabetes mellitus. The diagnosis of Friedreich ataxia, supported by detecting abnormal ECG, EMG, and nerve conduction studies, is confirmed by genetic testing. The disorder has a variable prognosis, with cardiomyopathy or cardiac conduction abnormalities being a cause of premature death in many patients with Friedreich ataxia. Therapy with idebenone, an antioxidant similar to coenzyme Q10, may be beneficial.

### **Psychogenic gait disorders, including astasia/abasia**

Inability to walk and severe unsteadiness in walking can be manifestations of conversion disorder. Many children of age 8–18 will present to the emergency department or less commonly to their primary care physician with severe gait impairment. Recognizing children with a conversion (non-neurological) or factitious disorder often requires consultation with a child neurologist.



**190** Sclera in a child with ataxia telangiectasia showing telangiectatic blood vessels.

*This page intentionally left blank*

# Disorders of sleep

## Main Points

- Benign sleep myoclonus occurs in as many as two-thirds of healthy children. When the disorder affects infants, the clinical features must be distinguished from neonatal seizures.
- Night terrors, a common parasomnia, usually begin between the ages of 2 and 4 years.
- Nightmares, frightening dreams, usually appear between the ages of 3 and 5 years.
- Sleep walking begins between the ages of 4 and 8 years and affects as many as 15% of children.
- Restless leg syndrome causes night time leg discomfort in 1% of children and adolescents.
- Delayed sleep-phase syndrome represents a common sleep disorder of adolescents.
- Enuresis, which behaves as an autosomal dominant trait, occurs in 10% of 6-year-olds and in 1% of 15-year-olds.
- Narcolepsy, an uncommon disorder with onset in adolescence, consists of cataplexy (abrupt loss of muscle tone), hypnagogic hallucinations, sleep paralysis, and excessive day time somnolence.

## Introduction

Disorders of sleep represent some of the most common neurological conditions affecting children and adolescents. Although most are benign and many remit over time, childhood disorders of sleep account for many lost hours of sleep for parents and numerous referrals to primary care physicians and specialists. The general absence of randomized controlled trials in pediatric sleep disorders greatly limits the clinician's ability to manage these conditions scientifically. This chapter describes the ontogeny of sleep in children and focuses on common childhood disorders of sleep, including the restless leg syndrome and the parasomnias.

## Normal sleep of infants, children and adolescents

Much like the motor and cognitive development of infants and young children, sleep undergoes orderly stages of maturation that begin *in utero* and continue into adulthood. Fetuses, as expectant mothers can readily confirm, have cyclic patterns compatible with sleep and wakefulness as early as 28–30 weeks of gestation. At birth infants spend approximately 66% of each 24 hour period asleep, characteristically in blocks of 3–4 hours after which the healthy infant awakens for feedings. Much of the infant's sleep time is spent in rapid eye movement (REM) or active sleep (textbox).

**REM:** rapid eye movement or 'active' sleep, the first stage of sleep in infants. During this stage, muscle twitches, smiles, grimaces, and nystagmoid eye movements can be observed, especially in young infants.

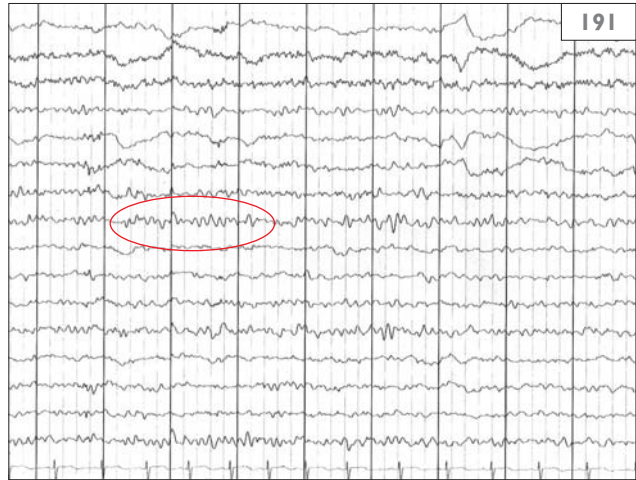**Non-REM:** nonrapid eye movement or 'quiet' sleep, the first stage of sleep in children, adolescents, and adults. During this stage, little eye or muscle activity is observed.

By 1 year of age, children spend approximately 12 hours each day in sleep, and most of this time is spent in quiet sleep. The amount of time devoted to sleep and also to REM sleep continues to decline gradually throughout childhood and adolescence, achieving adult patterns by mid- to late-adolescence. In adolescents, delayed sleep-phase patterns, characterized by late bed times and difficult morning arousals, often appear. By age 20 the sleep pattern is characterized by 8–9 hours of sleep per night with approximately 25% of this time spent in REM sleep.

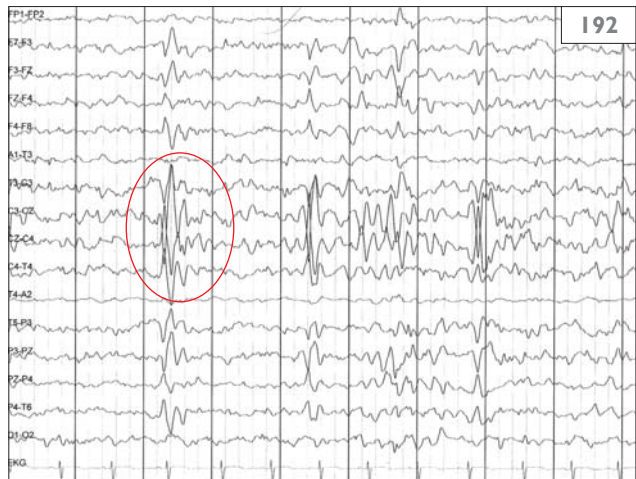Non-REM sleep stages are graded 1–4. Stage 1 sleep follows drowsiness and the EEG at this time shows sharp waves ('transients') in the midline at the top of the head ('vertex') without sleep spindles (191, 192).

Stage 2 sleep, a state of deeper sleep, follows stage 1; the EEG at this stage shows sleep spindles (rapid [12–14 Hz], crescendo-decrescendo, low to medium amplitude waves that appear over the vertex [193]) and K complexes (spontaneous or stimulated sharp waves and high amplitude slow waves that are also observed best over the vertex).

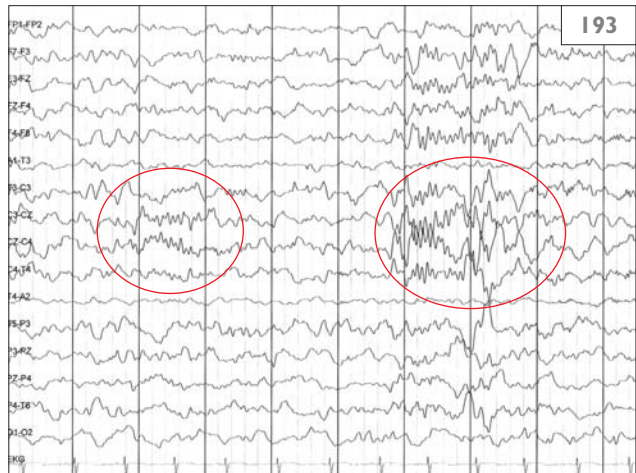
**191** Normal awake EEG in a 6-year-old child showing rhythmic posterior dominant activity (alpha waves; circled) in a longitudinal bipolar ('double banana') montage.

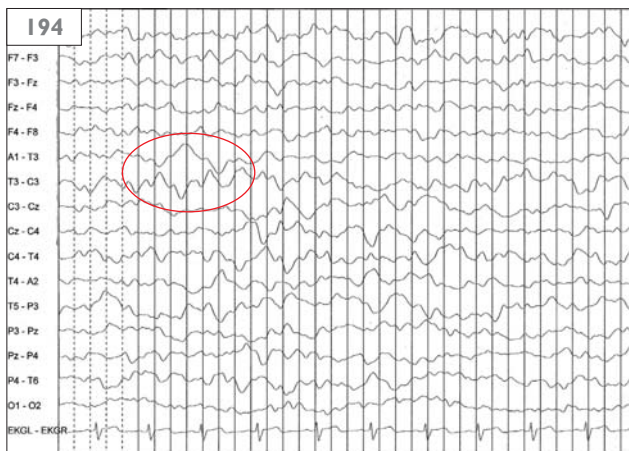


**192** EEG showing vertex transients (circled) in stage 1 sleep (coronal montage).

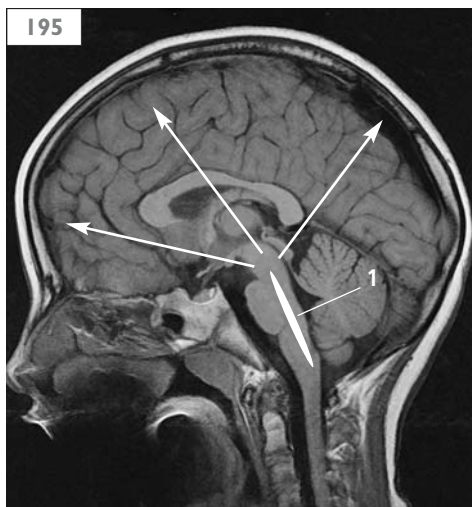


**193** EEG showing sleep spindles (circled) in stage 2 sleep (coronal montage).





**194** EEG showing slow waves (circled) of stage 3–4 sleep (coronal montage).



**195** Sagittal T1-weighted MRI annotated to show the pathways of the reticular activating system (1).

Stages 3 and 4, the deepest stages of sleep, are considered slow wave sleep (194); the EEG at this time shows medium to high amplitude slow waves of approximately 2–3 Hz. Overall, stages 1–4 occupy approximately 5%, 50%, 5%, and 15% of sleep, respectively, in adolescents and adults; the remainder consists of REM sleep.

Sleep reflects complex interactions between the cerebral cortex and brainstem. The reticular activating system, a vague neural network that involves numerous cells of the pons, medulla, thalamus, and hypothalamus (195), plays the major role in determining sleep–wake cycles. Several neurotransmitters, including serotonin, norepinephrine, and acetylcholine, participate

in this process. REM sleep appears to arise from the locus caeruleus, whereas the median raphe nucleus and thalamus contribute to non-REM sleep.

A sleep study or polysomnogram consists of simultaneous monitoring of several physiological components (87). These include recordings of muscle activity (EMG) of the chin and extremities (usually the tibialis anterior muscle), heart rate (ECG), breathing (including nasal/oral airflow and oxygen saturation), limited leads of the EEG, eye movements, and both video and audio recordings of the child's activity in sleep. Depending upon the child's symptoms, the sleep study may also include a multiple sleep latency test (MSLT), a test that assesses the child's ability to fall asleep. The typical MSLT consists of five opportunities to nap, beginning 1–3 hours after usual awakening, and records sleep onset and REM latency. Short sleep latencies may suggest conditions, such as narcolepsy, that produce excessive somnolence.



## Common sleep disorders

### Snoring and obstructive sleep apnea

Approximately 2–10% of children snore. Snoring, the sound of the oropharyngeal structures vibrating during sleep, occurs in children with adenotonsillar hypertrophy, asthma, and second-hand exposure to tobacco smoke. Some children who snore also have obstructive sleep apnea, a relatively common disorder that can produce hypoxemia, hypercapnia, and frequent night time arousals. Snorers, and those with obstructive sleep apnea, can exhibit excessive day time somnolence, hyperactivity, or impaired school performance. Management begins with a polysomnogram; children with obstructive sleep apnea may benefit from adenectomy or weight loss if obese. If severe, night-time continuous positive airway pressure (CPAP) or bilevel positive airway pressure (BIPAP) may be necessary.

### Nocturnal enuresis

Enuresis remains one of the most troubling problems encountered by primary care physicians. The condition is common because it reflects the continuum of the normal evolution of gaining nocturnal urinary continence. At the age of 3 years, as many as one-third of otherwise healthy children are enuretic, and by 6 years of age, the proportion has declined to 10% or less. The condition continues to disappear, but as many as 1% of 15-year-olds still have enuresis. Enuresis behaves as an autosomal dominant trait with variable expressivity. Before the age of 10 years, boys are affected by enuresis more than girls; after this age, boy and girls are affected equally.

Enuresis can occur throughout the night, independent of sleep stage or depth of sleep. Children with enuresis are more likely to have parasomnias, such as sleep walking, sleep starts, or night terrors, but otherwise appear normal. Although genetic factors are the major determinants of the risk of enuresis, certain other conditions, such as chronic urinary tract infection, anatomical or neurological abnormalities, account for as many as 10% of cases of childhood enuresis. Secondary enuresis, night time wetting that appears after continence has

been achieved, can suggest urinary tract infection, abuse, or other psychological issues.

### MANAGEMENT

Management should begin with a thorough history regarding onset, associated features, and family history. Most children with enuresis have family members or second degree relatives who had enuresis, and this information can be used to reassure parents that enuresis is nearly always 'outgrown'. Behavioral strategies, such as day time bladder training, limiting fluids after the evening meal, and routine bladder emptying before bedtime, can be effective initial approaches. For those children who do not respond to such therapies, desmopressin (DDAVP) can be used at bedtime. Imipramine, a tricyclic antidepressant, has been used, as well, but this drug has many side-effects including constipation, sedation, and the potential for fatal overdoses.

## Restless leg syndrome

Restless leg syndrome, affecting as many as 10% of adults, also occurs commonly in children, affecting as many as 2% of children and adolescents. Features that suggest restless leg syndrome include the urge to move the legs, usually associated with painful sensations, during periods of inactivity or sleep, and painful sensations in the legs that are relieved by walking or standing. Children with restless leg syndrome commonly have a parent or close relative with the disorder. Although some children with restless leg syndrome also have ‘growing pains’, not all children with growing pains meet criteria for restless leg syndrome (textbox).

### Criteria for restless leg syndrome in children

- An urge to move the legs, usually accompanied by uncomfortable sensations.
- Movement relieves the uncomfortable sensations or the urge to move the legs.
- A description from the child of leg discomfort.
- A family history of the disorder is supportive.

Adopted from an USA National Institutes of Health Workshop on Restless Leg Syndrome.

Management strategies for children are not yet well defined; however, studies for iron deficiency (ferritin, serum iron, iron binding capacity) should be considered, and any iron deficiency should be treated with oral iron supplementation. Serum hemoglobin levels alone have low sensitivity for detecting iron deficiency.

## Parasomnias

As a group, parasomnias in one form or another, are remarkably common in children, affecting nearly all children at some point during the maturation of their sleep patterns (textbox). Some, such as sleep starts, teeth grinding (bruxism), or nocturnal myoclonus, are minor phenomena that require reassurance only, whereas others, such as sleep walking (somnambulism) or nocturnal head banging (jactatio capitis nocturna), may require intensive behavioral and medication therapy.

### Selected parasomnias affecting children and adolescents

- Sleep walking: affects as many 15% of children and adolescents.
- Bruxism (teeth grinding): affects as many as 30% of children and often remits by age 5 years.
- Nocturnal myoclonus (‘sleep starts’): a sleep–wake transition phenomenon, begins in infancy and affects up to two-thirds of all children.
- Sleep talking: a very benign parasomnia, affects the majority of children.
- Head banging and body rocking: can be common in young children; serious injury, such as subdural hematoma, has been reported.
- Night terrors: a disorder of slow wave sleep, start abruptly and have dramatic behavioral and autonomic features (mydriasis, tachycardia, diaphoresis).

## Nightmares and night terrors

Nightmares and night (or sleep) terrors affect as many as 40–50% of children, usually between the ages of 3 and 5 years. Distinguished from night terrors by their milder nature and occurrence in late sleep, nightmares typically occur during REM sleep. The child awakens, frightened but oriented, and describes a terrifying dream. By contrast, the child with night terrors, often slightly younger than one with nightmares, awakens abruptly, often during the first few hours after sleep onset, screaming, disorientated with amnesia, and has dramatic

autonomic features with papillary dilation, tachycardia, and diaphoresis. Night terrors arise from stage 3 or 4 sleep. The child with nightmares can be consoled by parents, whereas the child with night terrors is often inconsolable and may run from the parents in fear.

### MANAGEMENT

Management of both nightmares and night terrors begins with comprehensive parental education and behavioral approaches. Potential triggering factors, such as late night television, computer games just before bed, or liquids in the evening, should be eliminated; parents should be reassured that their children are otherwise normal. Modest amounts of diazepam (1–2 mg depending upon the child's age or weight), or melatonin (1–3 mg) at bedtime may be necessary in severe cases of night terrors.

EEG should be considered in severe cases to exclude nocturnal epilepsies, such as nocturnal frontal lobe epilepsy, a disorder that can produce screaming, stiffening, thrashing, kicking, and other dramatic motor phenomena. Occasionally, rolandic epilepsy (benign childhood epilepsy with centrotemporal spikes) produces motor or behavioral phenomena that can be confused with a sleep disorder.

### Sleep walking

Sleep walking, a dramatic parasomnia that affects up to 10% of the pediatric population, usually begins between the ages of 4–8 years. Clinical manifestations vary from sitting up in bed with or without motor automatisms to walking about performing complex tasks, such as urinating, eating, or exiting the house. Polysomnography in the child with somnambulism shows an arousal from deep sleep, stages 3 or 4. Management includes behavioral strategies, such as door alarms or locks that are child proof, and avoidance of factors that influence arousal or sleep stage, such as medications or fluids before bed time.

### Neonatal sleep myoclonus

Neonatal sleep myoclonus, an almost universal phenomenon in young infants, begins as early as the first few days of life and peaks in the first 2 months of life. The infant with myoclonus has jerking or twitching of the arms and legs that characteristically occurs in sleep. A variation of this condition consists of side-to-side head movements that occur as the nursing child becomes drowsy and drifts into light sleep. The myoclonic movements, especially those of the legs, can be quite dramatic, at times, and raise concern to parents and providers regarding the possibility of seizures. Neonatal sleep myoclonus can usually be distinguished from seizures by its consistent occurrence only in sleep. Reviewing videos obtained by the parents can be very useful, but in some instances an overnight video-EEG is necessary to exclude the diagnosis of epileptic seizures. Older children with sleep myoclonus, a benign disorder, experience the sensation of abruptly falling, followed by myoclonus and arousal.

## Narcolepsy

Narcolepsy, an uncommon disorder characterized principally by excessive somnolence, can begin during puberty. The prevalence of narcolepsy in the adult population is estimated to be approximately 1 per 2000 persons; the prevalence in adolescence is likely lower, on the order of 1 per 6000. Narcolepsy consists of several elements: abrupt loss of muscle tone and movement (cataplexy); excessive day time somnolence (narcolepsy); vivid auditory or visual hallucinations at the end or beginning of sleep (hypnagogic hallucinations); and sleep paralysis (a sense of immobility, usually at sleep onset). The pathogenesis of narcolepsy seems linked to abnormalities in hypocretin in the lateral hypothalamus.

The diagnosis of narcolepsy is established by history, polysomnography, and MSLT. MSLT shows a shortened sleep latency, often less than 5 minutes, and early onset REM sleep. These findings, coupled with the presence of other features, such as cataplexy, usually establish the diagnosis of narcolepsy. Management consists of behavioral and environmental modifications and medications, such as modafinil, sodium oxybate, and methylphenidate.

## Delayed sleep-phase syndrome

Many adolescents have sleep patterns compatible with delayed sleep-phase syndrome. This disorder, characterized by the late onset of sleep and late arousals the next morning, often begins when adolescents reach junior or senior high school. Affected adolescents stay up late, reading, doing homework, playing video games, or watching television, and have difficulty arising for school the next morning. Weekends pose fewer issues since adolescents can usually sleep later. These changes reflect environmental factors, such as the demands of homework and school attendance, but may also indicate physiological differences unique to adolescence. Management consists of restoration of more normal sleep/wake cycles through improved 'sleep hygiene'. Encouraging physical activity (walking or jogging) in the afternoon sun (light therapy) and limiting the amount of time spent watching television after 9 pm can be useful

therapeutic strategies. Melatonin in doses of 3–5 mg 1 hour before the desired sleep time has also been beneficial. Parental reassurance is warranted when the adolescent is making appropriate academic and social progress.

## Advanced sleep-phase syndrome

Advanced sleep-phase syndrome, much less common than delayed sleep-phase syndrome, is associated with early morning arousals and the inability to stay awake in the evening (textbox). The disorder does not usually cause academic difficulties, given that affected children or adolescents do not have excessive day time somnolence, but advanced sleep-phase syndrome can affect social function. Management consists of light therapy in the evening, to sustain wakefulness, and melatonin in the early morning, to restore sleep.

**Delayed sleep-phase syndrome** is associated with late sleep onset and late arousals.

**Advanced sleep-phase syndrome** is associated with early sleep onset and early arousals.

# Disorders of the newborn

## Main Points

- Extremely premature infants have high risks of permanent neurodevelopmental disorders including cerebral palsy, developmental delay, and epilepsy.
- Refinements in MRI technology make this the preferred imaging modality for infants with neurological disorders.
- Neonatal encephalopathy due to hypoxia and ischemia remains a common condition with considerable long-term consequences.
- Stroke largely affects term infants, causing seizures and disability.
- Diagnosing brain death in newborn infants remains challenging. However, clinicians can gain valuable information by assessing cortical and brainstem responses.
- Premature infants with grade 3 and 4 intraventricular hemorrhages have high rates of disability.

## Introduction

The intrauterine and neonatal periods are associated with dramatic changes in CNS development. Certain disease entities, affecting term or preterm infants, present only during this time. With technological advances in neonatal medicine in the developed world, more than 85% of the infants weighing less than 1500 g at birth currently survive. Extremely premature and low birth weight infants who survive the neonatal period have substantial risks of permanent neurological disabilities, and 20% or more of the surviving infants have cerebral palsy (CP), defined as a nonprogressive or static disorder affecting motor function. Many more are at risk for learning disabilities, ADHD, autism, developmental delay, and mental retardation. This chapter provides a brief overview of conditions unique to this critical period of life.

## Assessing the neonate

When evaluating newborn infants, clinicians must consider several factors. First, the clinician must seek historical information that helps clarify the clinical situation. Historical information relevant to the care of newborns arises from the prenatal, perinatal, or immediately postnatal periods (*Table 31*). Second, clinicians must use powers of observation to identify clinical features in the neonate that provide important diagnostic clues. Such information can include intrauterine growth retardation, hepatosplenomegaly, orthopedic anomalies, abnormalities of head size such as microcephaly (**129, 130**) or macrocephaly (**125**) and dysmorphic or cutaneous features that suggest specific disorders. Clinicians must also recognize that medication therapy with benzodiazepines, opiates, or barbiturates, even in modest doses, can adversely affect an infant's alertness, tone, respiratory effort, and motor activity.

Often, however, the history and examination yield few specific clues, and an infant may appear much worse neurologically than can readily be explained. In these cases, a step-wise approach should be utilized. Some form of CNS imaging should be considered strongly. Although the available imaging modalities have different advantages and disadvantages, a brain MRI should be obtained if an infant has an abnormal neurological examination. An EEG should be obtained if a child is encephalopathic or has abnormal movements that might suggest seizures. Hypotonic infants may require EMG and nerve conduction studies, although these studies are challenging to perform and interpret in young infants.

**Table 31 Historical factors to consider in the evaluation of neonates****Prenatal**

- Familial conditions
- History of late fetal miscarriage
- Maternal health and prenatal care:
  - folate intake/stores; diabetes; other maternal conditions
- Maternal substance use or abuse (ethanol, other drugs)
- Maternal age
- Intrauterine growth restriction (IUGR)
- Trauma (physical/psychological)
- Premature labor
- Oligo- or polyhydramnios
- Fetal movement pattern (decrease or increase [e.g. hiccups or seizures *in utero*])
- Fetal ultrasound
- Amniocentesis

**Perinatal**

- Prematurity
- Placental issues (previa, abruption, insufficiency)
- Prolonged rupture of membranes (PROM)
- Maternal fever
- Maternal infection status (HIV, HSV, group B streptococci)
- Loss of fetal movement

**Postnatal**

- Gestational age
- Body size (large for gestational age [LGA], small for gestational age [SGA])
- Birth asphyxia
- Neonatal seizures
- Infection/meningitis
- Systemic disease



## Neuroimaging of the newborn

Several modalities can be used to image the brain of a newborn infant (textbox).

### Comparison of modalities for imaging the newborn brain

- Head ultrasound:
  - Rapid, portable.
  - Low resolution and user dependent.
- Computed tomography:
  - Rapid.
  - Exposure to ionizing radiation; usually requires transport of the infant.
- Magnetic resonance imaging:
  - Sensitive, high resolution.
  - Longer scan times and requires transport of the infant.

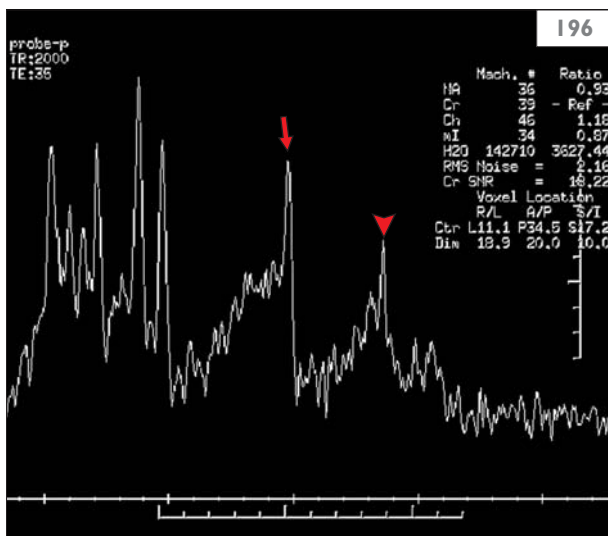
Cranial or head ultrasound (US) has been used clinically for more than 30 years. Head US can be performed relatively quickly at the bedside, a useful characteristic when evaluating critically ill infants. However, US studies of the brain are limited by overall resolution, the skill of the technician acquiring the images, and the ability of the physician who interprets the images. Sensitivity is highest for midline or supratentorial processes and those producing striking changes in tissue density, and is lowest for processes involving the cortex of the brain and posterior fossa. Overall, the detection of abnormalities and prediction of outcomes by head US is frequently constrained by modest sensitivity and lower specificity.

Computed tomography (CT), an X-ray based technology, exposes young infants to ionizing radiation. In most hospitals infants must be moved from the newborn intensive care unit (NICU) to the radiology department; however, scan time is short (typically 5–10 minutes, or less), so unstable infants can be returned quickly to the NICU. CT reliably detects acute intracranial bleeding, intracranial calcifications, and major developmental brain defects, and accurately assesses ventricular size. When combined with contrast administration, CT visualizes major cerebral veins and sinuses well. Enhanced CT or CT angiography can be

useful in infants with stroke or suspected sinovenous thrombosis.

Magnetic resonance imaging (MRI) of the brain, the preferred modality for assessing most CNS conditions affecting the neonate, accurately and sensitively detects subtle abnormalities of brain tissue integrity including congenital malformations, cortical migration defects, tissue ischemia, inflammation or hemorrhage, infection, trauma, and others. The major drawbacks of MRI include the length of time required to acquire a complete scan, typically 30 minutes, and the reality that infants must be transported to the scanner. Specific sequences permit the prompt identification of acute neuronal damage as in stroke (diffusion-weighted imaging [DWI] along with calculation and mapping of the apparent diffusion coefficient [ADC]), visualization of major axon tracts (diffusion tensor imaging, DTI) and visualization of venous and arterial structures (magnetic resonance venography [MRV] and angiography [MRA], respectively).

MR spectroscopy (MRS) provides additional information regarding tissue metabolism and well-being, offering the ability to identify elevations in lactate (as in acute ischemia; **196**), decrements in N-acetylaspartate (NAA; as in neuronal loss from prior injury) or absence of the creatine peak (the principle clue to guanidinoacetate methyltransferase (GAMT) deficiency) (**102**). As the application of these techniques becomes more widespread in the neonatal period, MRI combined with MRS may offer additional prognostic information which would otherwise be inaccessible.



**196** MRS showing reduced N-acetylaspartate (NAA) peak (arrow) and a prominent lactate peak (arrowhead) in hypoxic-ischemic injury.

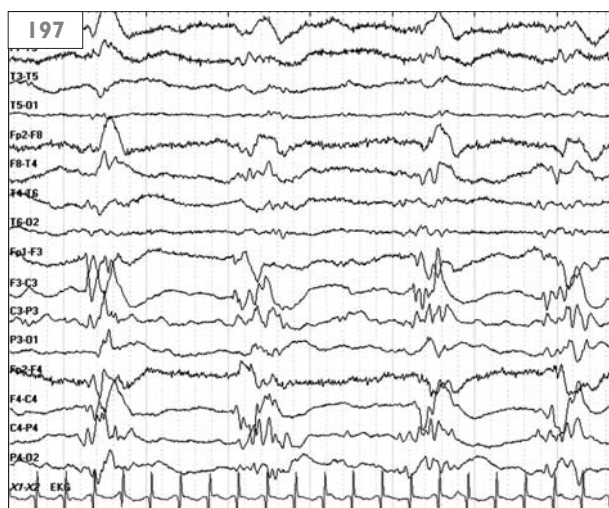## EEG in the newborn

The patterns of the neonatal EEG depend greatly on the gestational age of the infant. The EEG patterns of 28 weeks gestation infants, for example, differ dramatically from those of 37 weeks gestation or near-term infants. EEG patterns in the newborn can occasionally be diagnostic, but are often frustratingly vague. Nonetheless, EEG can provide important prognostic information when obtained serially in infants with neonatal encephalopathy due to hypoxic-ischemic encephalopathy (HIE). EEG patterns are discussed in greater detail in Chapter 3 (Electrophysiological Evaluation of Infants, Children, and Adolescents).

Burst suppression (197), a severely abnormal EEG finding, often portends a serious, sometimes grim, prognosis, especially in full-term infants. The pattern, indicating global brain dysfunction, can be observed in infants with severe congenital brain malformations, severe HIE, or specific inborn errors of metabolism (e.g. nonketotic hyperglycinemia), but can also be encountered in neonates who are unexplicably encephalopathic. When the neonatal burst suppression pattern is encountered, clinicians should consider several conditions, including HIE.

## EMG in the newborn

Electromyography (EMG) and nerve conduction velocity (NCV) testing of newborns poses several problems, including variable sensitivity and specificity and the frequent need to sedate fragile infants. Despite these limitations, EMG and NCV often enable clinicians to distinguish neuromuscular disorders (e.g. spinal muscular atrophy or congenital hypomyelinating neuropathy, a genetic condition due to mutations in several genes involved in myelin formation) from other conditions producing neonatal hypotonia, such as Prader-Willi syndrome and other genetic disorders.



197A burst suppression EEG compatible with severe, diffuse brain injury.

## Specific conditions

### Neonatal encephalopathy and HIE

The major cause of neonatal encephalopathy (abnormal brain function in the newborn) is hypoxic–ischemic injury, a consequence of ‘birth asphyxia’. Birth asphyxia is often defined as an Apgar score below 7 at 5 minutes (*Table 32*).

Although birth asphyxia and HIE are often used interchangeably with neonatal encephalopathy, many infants with the latter condition lack obvious evidence for asphyxia or hypoxia–ischemia. Severe HIE affects approximately 3 of every 1000 live-born infants. Infants with HIE often have nonepileptic myoclonus or seizures in the first 12–24 hours of life.

The Sarnat staging system, used to grade the severity of an infant’s HIE, combines clinical findings, as summarized in *Table 33*, and EEG patterns to help predict the outcomes of infants who survive HIE. Several studies suggest that EEG patterns, especially when combined with MRI features, have reasonable predictive value. Asphyxiated infants with normal or non-epileptiform EEGs, for example, have better outcomes than infants whose EEGs show abnormally slow background activity. Infants with neonatal MRIs showing diffuse white or gray matter abnormalities also are more likely to have adverse neurodevelopmental outcomes after HIE. Therapy currently consists of supportive care. Head cooling (hypothermia), the standard approach to management at many centers, appears to reduce long-term neurological morbidity.

**Table 32 Components of the Apgar score (worst score = 0; best score = 10)**

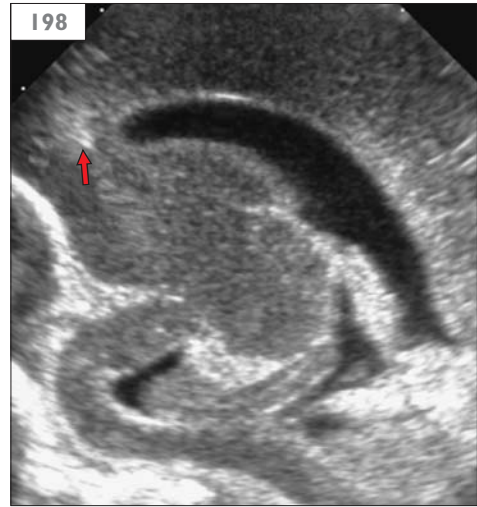Element	Score		
	0	1	2
Skin color	Completely cyanotic	Acrocyanosis	No cyanosis
Heart rate	Asystolic	<100 bpm	>100 bpm
Reflex irritability	No response to stimuli	Grimace/weak cry	Strong cry/withdrawal
Muscle tone	Flaccid	Some tone	Active movements
Respiratory activity	None	Irregular/weak	Robust effort

**Table 33 Sarnat staging system of HIE**

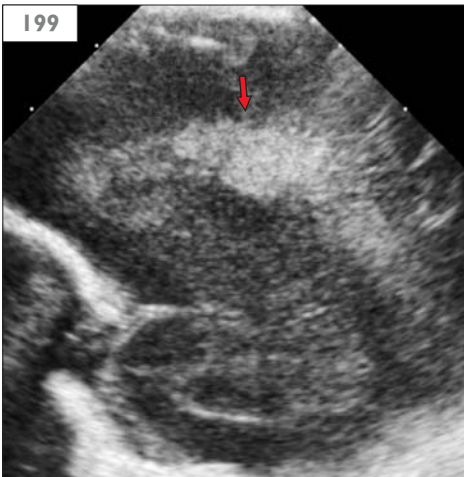
Sarnat stage	Mental status	Ventilator	Feeding difficulty	Tone	Seizures	Probability of severe handicap or death
1 (mild)	Hyperalert	No	Mild	Jittery	No	<1%
2 (moderate)	Lethargy	No	Moderate	High	Yes	25%
3 (severe)	Coma	Yes	Severe	Flaccid	Yes	up to 75%

## Periventricular leukomalacia

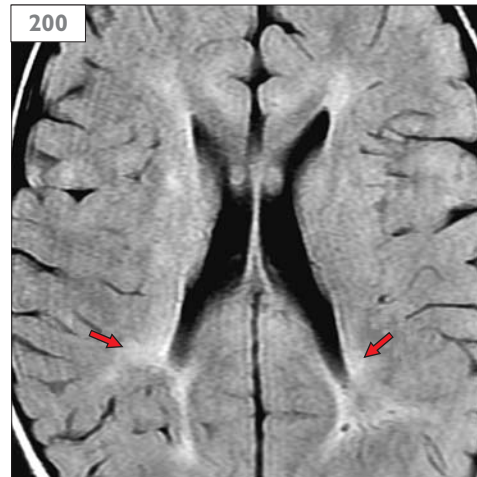
Periventricular leukomalacia (PVL), one of the most common injuries to the CNS of premature infants, is technically a neuropathological diagnosis determined at autopsy. However, MRI and head US findings can accurately predict the presence of PVL in many instances. PVL, caused by ischemia in the periventricular region at the border zone between different arterial supplies, consists of damage to the white matter tracts that lie adjacent to the lateral edges of the ventricles (198–201). Because of the location of the injury, PVL affects the corticospinal tracts, axons projecting from the neurons that control body movement (109, 202). PVL leads to CP, especially spastic diplegia, but all four limbs can be affected, a condition known as spastic quadriplegia, especially when PVL leads to extensive axonal loss (203). Besides having spasticity (108, 204), infants with PVL have increased rates of epilepsy, suggesting neuronal as well as axonal injury.



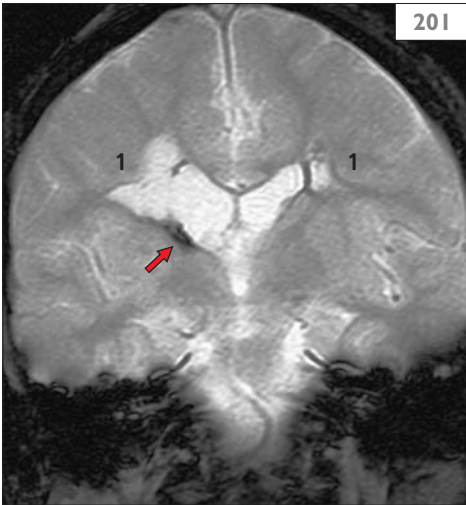
**198** Cranial sonography showing periventricular hyperechogenicity compatible with edema and tissue infarction (arrow).



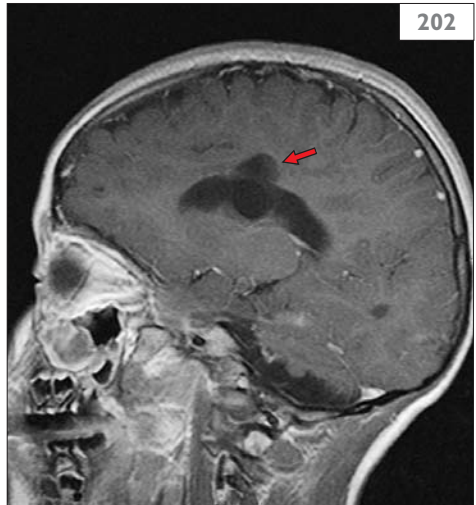**199** Sagittal cranial sonography showing periventricular hyperechogenicity (arrow) compatible with PVL.



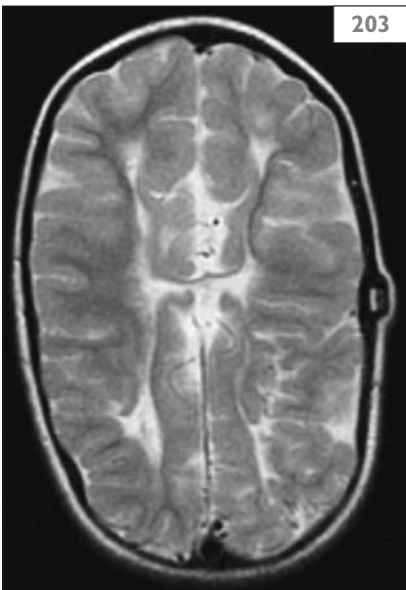
**200** Axial FLAIR MRI showing PVL and gliosis (arrows).



**201** Coronal gradient recall echo (GRE) MRI showing PVL (1) and hemosiderin indicating germinal matrix hemorrhage (arrow).



**202** A gadolinium-enhanced sagittal T1-weighted MRI showing cystic PVL (arrow) in a child with hemiparetic cerebral palsy.



**203** An axial T2-weighted MRI showing marked white matter volume loss as a consequence of severe PVL.



**204** Bilateral cortical thumbs and flexion posture of the arms in spastic quadriplegia.

## Kernicterus

Kernicterus, bilirubin encephalopathy, can occur in premature or full-term infants with elevated serum levels of unconjugated bilirubin. Risk factors in full-term infants include early onset jaundice (first 24 hours of life), unrecognized disorders (e.g. ABO incompatibility) that predispose to hemolysis, glucose-6-phosphate dehydrogenase deficiency, cephalohematoma, infection (sepsis), and dehydration. Early clinical features of kernicterus consist of lethargy, alterations of muscle tone (hypo- or hypertonia), high-pitched cry, and opisthotonus. Subsequent neurological abnormalities include deafness, ophthalmoplegia (especially limitation of vertical gaze), staining of the deciduous teeth, and athetoid CP. Kernicterus and the permanent neurological disability associated with this disorder can be prevented by strict adherence to published algorithms for managing hyperbilirubinemia in neonates.

## Stroke

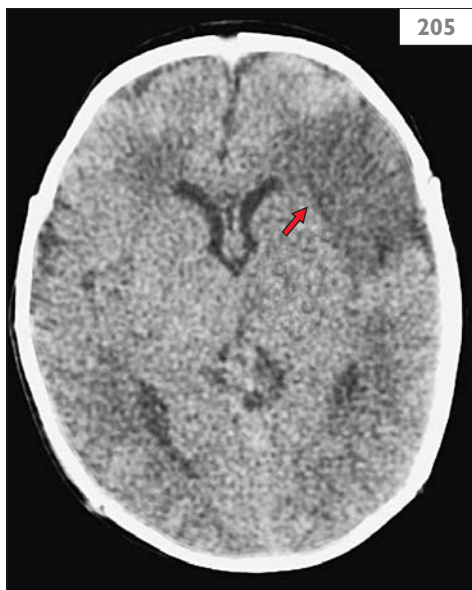Neonatal stroke, defined as a stroke occurring in the first 28 days of postnatal life, has a prevalence of 1 in every 4000 births. Stroke more often affects term infants and accounts for approximately 10% of the seizures that occur among such infants during the first week of life. However, many infants with strokes that occurred perinatally or prenatally do not present with neurological signs until 4–6 months of age when they exhibit asymmetric leg or arm movement. Neonatal strokes can be arterial (205–207) or venous, and associated with congenital heart disease, infection, or thrombophilic disorders. Many infants lack a readily identifiable cause. Although the risk for stroke recurrence is quite low (<5%), infants with stroke should undergo a comprehensive evaluation for thrombophilic disorders (textbox), especially when venous thrombosis is detected.

### Thrombophilic or hemorrhagic disorders associated with neonatal stroke

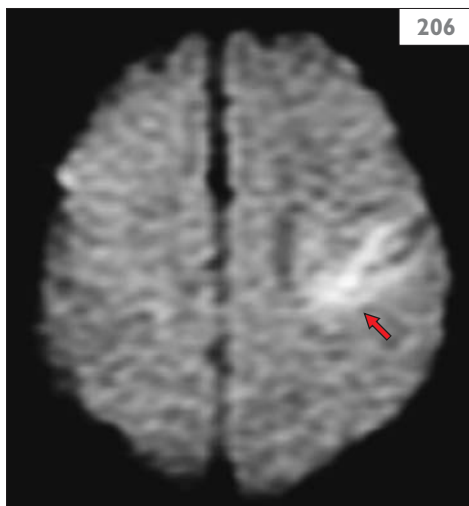
- Factor V Leiden mutation.
- Prothrombin G20210A mutation.
- Deficiencies of protein C, protein S, or antithrombin.
- von Willebrand disease.

Treatment consists of supportive care and anticonvulsant medications, as needed. Infants with stroke are at risk for epilepsy and permanent disabilities affecting motor and cognitive function.

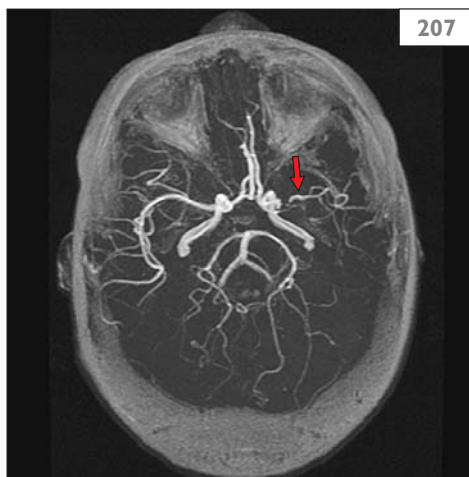




**205** Noncontrast head CT in neonate showing a hypodense area in the left frontal region (arrow) compatible with a cerebral infarction.



**206** A diffusion-weighted MRI in a newborn showing cytotoxic edema in the left hemisphere compatible with cerebral infarction (arrow).



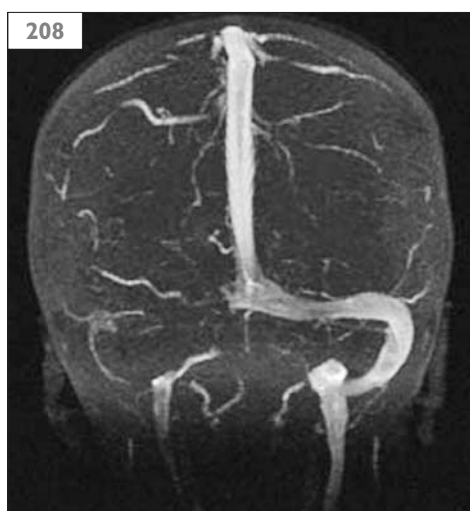**207** MRA showing decreased flow in the left middle cerebral artery (arrow).

## Intracranial sinovenous thrombosis

Thrombosis of intracranial venous sinuses and veins can be precipitated by several factors, including dehydration, meningitis, or hypercoagulable states such as factor V Leiden and prothrombin G20210A mutations and disseminated intravascular coagulation. Clinicians must maintain a high index of suspicion because infants with sinovenous thrombosis often have nonspecific signs or symptoms, including lethargy, poor feeding, seizures, or autonomic instability. When severe, sinovenous thrombosis can lead to infarction and intracranial hemorrhage. Sinovenous thrombosis is best detected and monitored by MRI and MRV (208), although Doppler US or CT venograms can also be used. Management consists of intravenous hydration and treatment of seizures. Anticoagulation with unfractionated heparin should be considered for infants with extensive clots and little or no intracranial hemorrhage. Head CT should be obtained 24–48 hours after the initiation of heparin to confirm the absence of intracranial hemorrhage.

## Brain death in the neonate

Because of the factors that impair our ability to assess the mental status of term or premature infants, the neonatal brain death examination must be approached with considerable caution. Metabolic disturbances and drug effects must be excluded to ensure that the clinical examination is not affected by these confounding factors. The brain death examination begins by excluding reversible conditions. The infant should have normal temperature and blood pressure and be unresponsive to all stimuli. The clinician must document the absence of cortical and brainstem functions (textbox), including flaccid tone, absent spontaneous or induced movements (other than spinal reflex movement), unreactive midposition or dilated pupils, absent oculocephalic (doll's eyes) and oculo-vestibular (caloric) responses, absent gag, absent primitive reflexes (suck, root, gag), and absence of respiratory effort in response to a rising  $\text{CO}_2$ .



**208** An MRV with absent flow in the right transverse sinus compatible with an intracranial venous sinus thrombosis.

### Features of the brain death examination

- Cortical: coma, absence of response to all stimuli, absent muscle stretch reflexes, flaccid paralysis.
- Brainstem: absence of pupillary responses, gag, respiratory effort, primitive reflexes, oculocephalic, and caloric responses.

Determining cerebral blood flow by radionuclide imaging can be used to confirm brain death, but cerebral blood flow can be preserved in some infants in the acute stage of clinical brain death. The absence of cerebral blood flow in brain death appears to be due to a combination of low cerebral perfusion pressure coupled with the presence of vasoconstrictors released in the brain parenchyma. Other imaging studies, including MRI, have limited utility in the assessment of brain death in neonates.

The current criteria to establish brain death in term infants more than 7 days of age are a minimum of two detailed neurological examinations, separated by 48 hours, confirming absent cortical and brainstem activity as above, and two EEGs showing isoelectric tracings (70), also separated by a minimum of 48 hours. The EEGs must be performed in a precise fashion, as specified by the American Electroencephalographic Society. Criteria for brain death in preterm infants or infants less than 7 days of age do not exist. The absence of criteria in preterm infants reflects the immaturity of the CNS; for example, the pupillary light responses do not appear until 29 or 30 weeks gestation, and the oculocephalic reflex is not present until about 32 weeks gestation.

## Seizures

Seizures are reliable but nonspecific indicators of neurological dysfunction in infants, and affect approximately 1 in every 200–1000 live-born neonates. Causes of neonatal seizures include infection, stroke, HIE, metabolic or genetic disorders, structural brain abnormalities, drug withdrawal, and intracranial hemorrhage. Neonatal seizures usually do not consist of generalized tonic–clonic seizures, even when the underlying abnormal electrical activity is generalized. Rather, neonatal seizures tend to be focal or multifocal, often with repetitive movements that can be mistaken for normal baby activity. Complicating the evaluation of neonates with suspected seizures are the facts that electrographic seizures can be observed on an EEG without clinical correlates and that abnormal movements similar to seizures can occur without EEG abnormalities.

Phenobarbital remains the most commonly used medication to treat neonates with seizures (*Table 34*). The drug can be given as an intravenous loading dose of 10–20 mg/kg; an oral or intravenous maintenance dose of 3–5 mg/kg/day divided into two equal doses can be initiated 12 hours after the load. Useful adjuncts include lorazepam, 0.05–0.1 mg/kg intravenously, and phenytoin, given as a fosphenytoin loading dose of 15–20 mg/kg intravenously and an intravenous or oral maintenance dose of 3–7 mg/kg/day divided into two equal doses starting 12 hours after the load. However, therapeutic phenytoin levels are difficult to maintain with oral dosing. Levetiracetam appears to have some promise as a safe, effective anticonvulsant for neonatal seizures.

**Table 34 Anticonvulsants for neonatal seizures**

Medication	Loading dose	Maintenance dose	Levels
Phenobarbital	10–20 mg/kg IV	3–5 mg/kg/day	15–40 µg/ml
Lorazepam	0.05–0.1 mg/kg IV	N/A	N/A
Phenytoin	10–20 mg/kg IV	3–7 mg/kg/day	10–20 µg/ml
Levetiracetam	20 mg/kg IV	10–60 mg/kg/day	N/A

N/A = not applicable

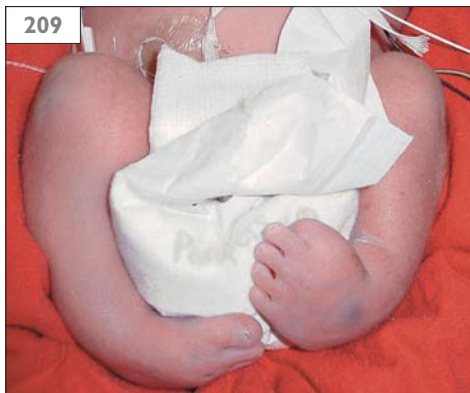Infants with pyridoxine-dependent seizures, a unique and extremely rare entity, often present in the first days of life with intractable seizures that are resistant to multidrug therapy. Treatment consists of intravenous pyridoxine (50–100 mg) as a bolus, given while the infant undergoes an EEG and close monitoring for apnea, a potential complication of intravenous pyridoxine administration. In classic cases the EEG normalizes and the seizures stop within minutes of pyridoxine administration. However, administration of pyridoxine (vitamin B6) orally for 2 weeks thereafter may be necessary to exclude this condition reliably, especially in older infants or atypical cases. The disorder results, in most classic cases, from mutations in the *ALDH7A1* gene which encodes antiquitin, a member of the aldehyde dehydrogenase superfamily. Elevated urinary levels of alpha-amino adipic semi-aldehyde ( $\alpha$ -AASA) can be identified in infants with pyridoxine-dependent seizures. Folinic acid-responsive seizures, another cause of neonatal seizures, also appears to result from mutations in the *ALDH7A1* gene.

## Neuromuscular disorders

The newborn infant with low tone, feeding difficulties, contractures, or respiratory insufficiency may have a neuromuscular disorder. The approach to neonatal hypotonia is discussed in detail in the chapter regarding hypotonia and weakness. The clinician should inspect hypotonic or weak infants for contractures and should assess the position of the legs and arms at rest, the spontaneous movements of the limbs and face, including eye opening, the tone, and the character of muscle stretch reflexes. While the absence of reflexes can be indicative of lower motor neuron conditions in children or adults, the character of the muscle stretch reflexes in infants is a less reliable sign. Arthrogryposis (209), consisting of congenital contractions and immobility of one or more limbs, can be due to several disorders affecting the CNS or peripheral nervous system (textbox).

### Causes of arthrogryposis

- Congenital muscular dystrophy.
- Intrauterine viral infection.
- Spinal muscular atrophy.
- Maternal myasthenia gravis.
- CNS anomalies.
- Spinal cord defects.
- ARC (arthrogryposis, renal dysfunction, cholestasis) syndrome.
- 22q11 (velocardiofacial) syndrome.
- Nemaline myopathy.
- Oligohydramnios.

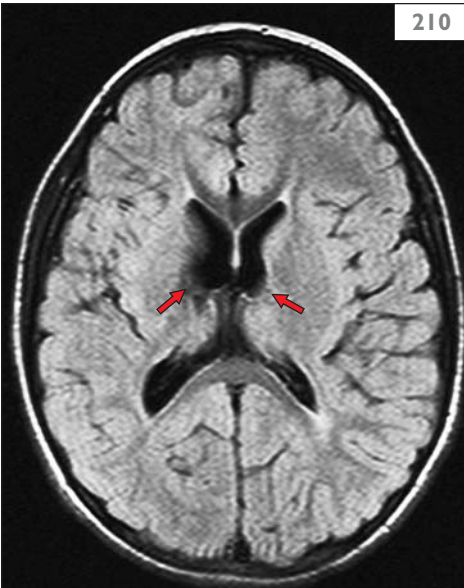


**209** An infant with arthrogryposis, fixed abnormal posture of the feet.

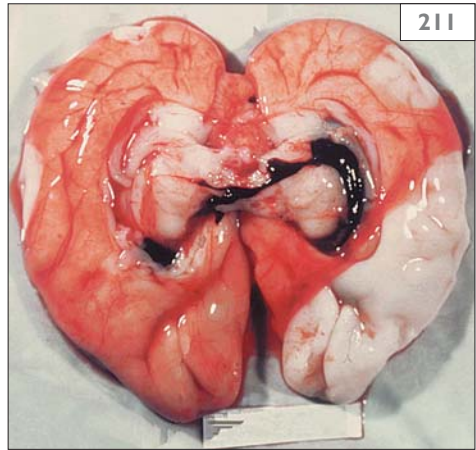
## Intraventricular hemorrhage (IVH)

Neonatal IVH usually results from hemorrhage in the periventricular germinal matrix (210–213), a highly vascular zone of cell proliferation from which neurons and glia arise in the developing brain (*Table 35*, overleaf). The germinal matrix is especially vulnerable to the

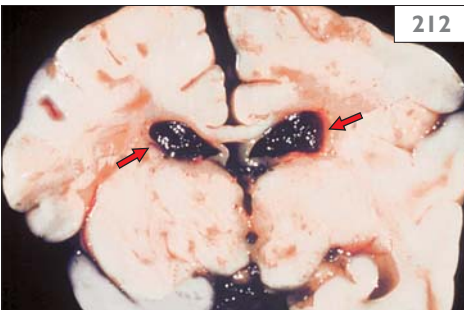
effects of perinatal hypoxia and birth asphyxia. The risk for IVH correlates inversely with gestational age: IVH affects 20–40% of infants <28 weeks gestation but almost no infants after 34 weeks gestation. Because of the improved survival of extremely premature, small infants, the rates of IVH and its complications have increased. The occurrence of IVH after birth



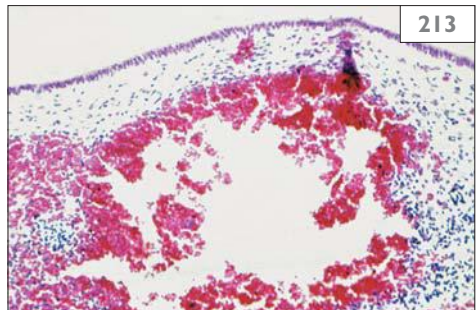
**210** An axial FLAIR MRI showing bilateral germinal matrix infarctions (arrows).



**211** Postmortem gross specimen in fatal neonatal intraventricular hemorrhage in a premature infant.



**212** Coronal section of another infant with intraventricular hemorrhage shows clots filling both lateral ventricles (arrows).



**213** Histological specimen showing germinal matrix hemorrhage (H&E).

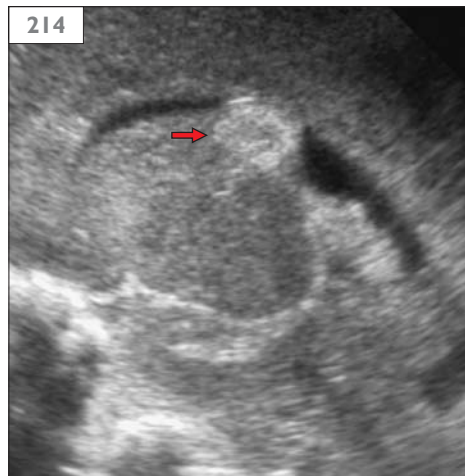
**Table 35 Grading of neonatal intraventricular hemorrhage**

Grade	Features
Grade 1	Germinal matrix hemorrhage only
Grade 2	Germinal matrix hemorrhage and some intraventricular blood
Grade 3	Germinal matrix hemorrhage and intraventricular blood that distends one or both ventricles
Grade 4	Germinal matrix hemorrhage, intraventricular hemorrhage with ventricular distention (hydrocephalus) and intraparenchymal hemorrhage

can be marked by severe or subtle clinical signs including seizures, autonomic disturbances, or a full fontanel; more often, it is clinically silent. The major complications of IVH include death, CP, cognitive delay, and posthemorrhagic hydrocephalus that sometimes necessitates neurosurgical intervention and/or the placement of a shunt. IVH can be graded reliably by the head US findings (214–217).

Hydrocephalus following IVH, a complication of grade 3 or 4 IVH, results from obstruction to CSF flow at the aqueduct of Sylvius, posterior fossa, or pacchionian granulations from the blood clots and inflammatory responses. Posthemorrhagic hydrocephalus

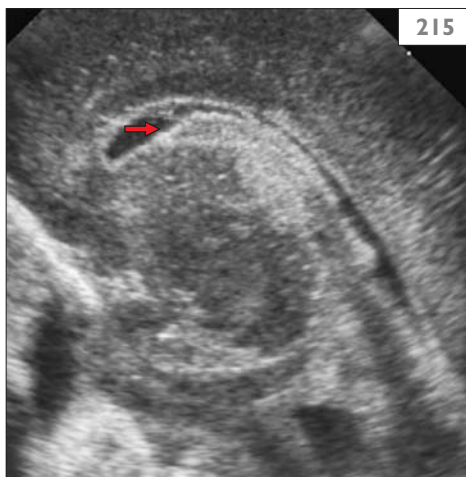
must be managed in concert with the NICU team and neurosurgeon. A combination of lumbar punctures and external ventricular drain can be used for initial management; infants or young children requiring chronic treatment require placement of a permanent ventriculo-peritoneal shunt. Unfortunately, severe IVH can be an ominous complication of prematurity. As many as 20–30% of infants with grade 3 or 4 IVH die, and 50% of the survivors require ventricular drainage. Many have CP as a consequence of concomitant PVL. By contrast, the outcomes of premature infants with grade 1 or 2 IVH do not differ from premature infants without IVH.



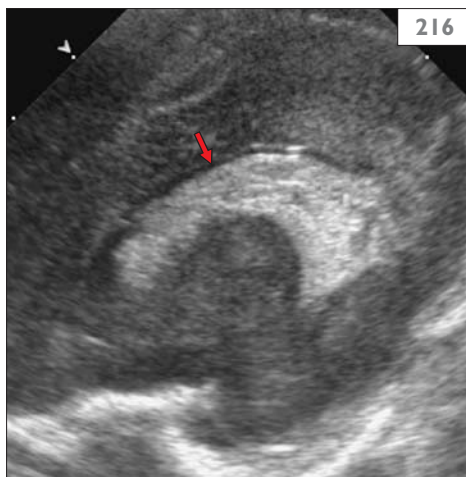
**214** Sagittal cranial sonography showing neonatal grade 1 IVH (arrow indicates blood).



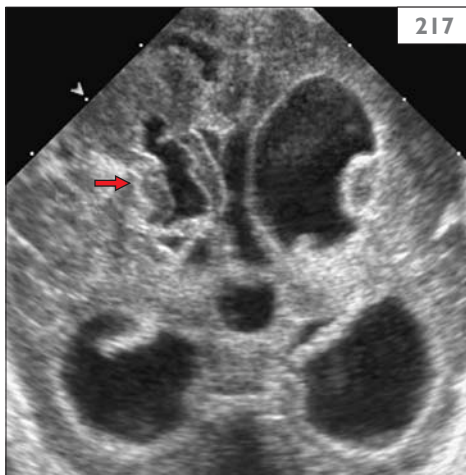
**215** Sagittal cranial sonography showing neonatal grade 2 IVH (arrow indicates blood).



**216** Sagittal cranial sonography showing neonatal grade 3 IVH (arrow shows blood filling and distending the lateral ventricle).



**217** Axial cranial sonography in neonatal grade 4 IVH showing ventriculomegaly and periventricular infarction (arrow).





*This page intentionally left blank*

# Acute focal deficits

**Main Points**

- Acute focal neurological deficits require urgent evaluation, often in an emergency department.
- Acute visual loss or double vision requires urgent evaluation in an emergency department or by an ophthalmologist.

## Introduction

This chapter focuses on the evaluation and neurological causes of an acute focal deficit in infants, children, and adolescents. Non-neurological causes of acute deficits, such as orthopedic, rheumatologic, or infectious disorders are not discussed. This material emphasizes the key historical and examination findings, as well as the differential diagnosis for focal deficits due to neurological disorders.

## Acute arm or leg weakness

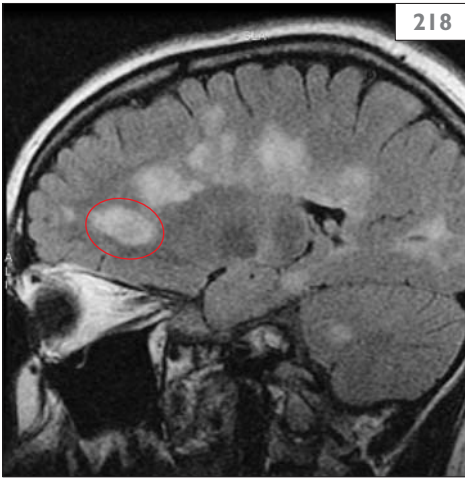
When assessing acute limb weakness, the clinician must obtain a detailed history and perform a focused neurological examination. The history should focus on the events immediately preceding the onset of the weakness, and clinical progression which can be ‘maximal at onset and then static’, ‘worsening’, ‘improving’ or ‘fluctuating’. The goal of the neurological examination is to localize the lesion and to deduce whether the problem is in the brain, the spinal cord, the peripheral nerves, the neuromuscular junction, or muscle. Defining the temporal profile and localizing the process enable the clinician to generate a comprehensive differential diagnosis. For example, acute ascending weakness of both legs implies a process involving the spinal cord or peripheral nerves, whereas acute weakness of a leg, arm, and one side of the face implies a lesion of the brain or brainstem.

## Acute bilateral leg weakness

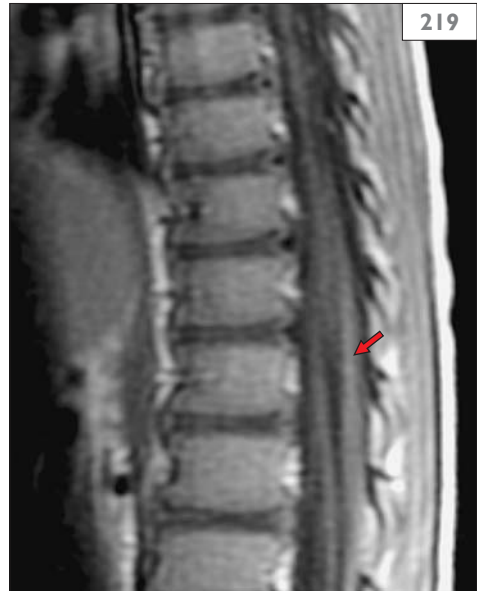
The most common neurological processes causing acute weakness in both legs involve the spinal cord or the peripheral nerves. The differential diagnosis of acute spinal cord lesions in children includes trauma, spinal tumors, transverse myelitis, acute disseminated encephalomyelitis (ADEM) or multiple sclerosis (MS) (218), and vascular events such as rupture of an arteriovenous malformation (AVM) or spinal cord ischemia. Acute bilateral leg weakness, usually the result of trauma or inflammation, requires urgent neuroimaging of the spine to exclude lesions, such as tumors or hemorrhages, compressing the spinal cord and requiring emergent neurosurgical intervention.

The history should focus on symptoms potentially associated with these conditions, including preceding illnesses, fever, neck or back pain, recent trauma, urinary retention or incontinence, constipation, and family history. The most common acute process involving the peripheral nerves in children is Guillain–Barré syndrome (GBS); other, much less common causes of acute or subacute peripheral neuropathy include heavy metal poisoning, nutritional deficiencies, metabolic disorders, and chemotherapeutic agents (*Table 36*). The history should focus on the common symptoms associated with GBS, such as preceding illness, surgery or immunization, numbness or tingling in the feet or legs, (common early features in children or adolescents with GBS), as well as symptoms or signs that suggest vasculitis or toxin exposure.

The first priority in examining the child with acute bilateral leg weakness is to determine if the child has upper motor neuron (UMN) or lower motor neuron (LMN) signs. UMN signs include hyper-reflexia and Babinski signs; spinal cord lesions usually induce a sensory level or decreased rectal tone. LMN signs include hyporeflexia/areflexia and absent Babinski signs; peripheral neuropathies affecting both motor and sensory nerves have sensory loss in radicular or peripheral nerve distributions. After determining whether the process involves the UMN (brain and spinal cord) or LMNs (peripheral nerve, neuromuscular junction, or muscle), the clinician can formulate a differential diagnosis and create a diagnostic or therapeutic plan.



**218** A sagittal FLAIR MRI in an adolescent showing areas of signal hyperintensity compatible with MS (circle = Dawson finger).



**219** A gadolinium-enhanced, T1-weighted spine MRI showing nerve root enhancement in GBS (arrow).

## MANAGEMENT

Initial management of acute bilateral leg weakness should include immobilization of the entire spine if there is a history of trauma. In every case, recent injury or not, the patient requires urgent evaluation in an emergency department. MRI of the cervical, thoracic, and lumbar spine, with and without contrast, is the best imaging modality to evaluate an acute spinal cord process. Even if the neurological examination localizes the lesion to one segment of the spinal cord, the entire cord should be imaged to detect subclinical involvement at other levels of the spinal cord. When GBS is being considered, L-spine MRI with and without intravenous gadolinium supports the diagnosis of GBS when enhancing nerve roots are found (219). A CSF profile showing an elevated protein with normal white blood cell count is another supportive finding. However, lumbar puncture should not be performed until an intraspinal mass lesion is excluded by a spine MRI.

**Table 36** Peripheral causes of bilateral leg weakness

### Predominantly motor nerves

- Guillain-Barré syndrome
- Hexane inhalation or 'huffing'
- Lead toxicity

### Motor and sensory nerves

- Vasculitis (systemic lupus erythematosus, Sjögren's syndrome, HIV)
- Arsenic and other heavy metal toxicity

## Unilateral leg weakness

Unilateral leg weakness is often due a non-neurological process such as a joint or other orthopedic problem, often secondary to trauma. However, the same neurological processes that cause acute bilateral leg weakness can cause acute unilateral leg weakness, including spinal cord tumor, transverse myelitis, or early GBS. Poliomyelitis and polio-like conditions caused by the nonpolio enteroviruses (e.g. EV71) occasionally deserve consideration. A frontal lobe brain lesion, such as a tumor or abscess, can also cause unilateral leg weakness. If a rheumatologic or orthopedic cause is not evident, the history and examination should focus on the spinal cord and peripheral nerve causes of weakness. Brain and spine MRIs with and without intravenous contrast should be considered.

## Bilateral arm weakness

Bilateral arm weakness, a rare presentation of acute weakness in children, indicates a process involving the cervical spinal cord, such as spinal cord syringohydromyelia (syrinx) (220) or transverse myelitis (221), or an acute vascular event such as hemorrhage or infarction. The classic presentation of a cervical syrinx is the gradual onset of sensory loss in a cape-like distribution. Later, as the syrinx expands, the motor fibers exiting the anterior horns are affected, and weakness appears, often first in the intrinsic muscles of the hands. Thenar atrophy can be detected by having the child produce a tight fist or palpating the belly of the first dorsal interosseus muscle (222). Transverse myelitis, usually preceded by a viral illness, may present with neck or back pain. Acute spinal cord infarction or spinal cord vascular malformation with an acute hemorrhage could cause acute painless weakness of both arms. A rare cause of bilateral arm weakness in children is bilateral brachial plexitis. This can be due to viral infection such as cytomegalovirus (CMV) or varicella-zoster virus (VZV) and presents with deep, boring shoulder pain in addition to arm weakness and hyporeflexia.

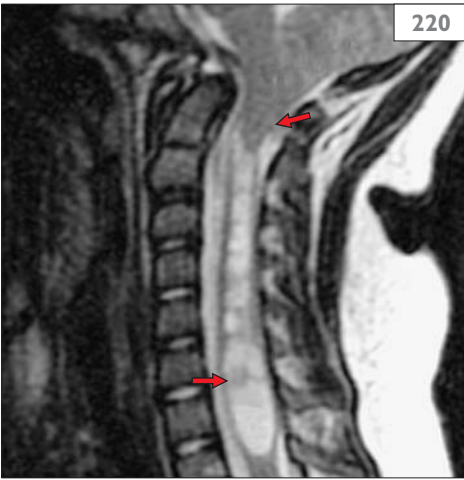
## Unilateral arm weakness

As with unilateral leg weakness, isolated arm weakness is an unusual neurological presentation. However if the initial evaluation does not identify a rheumatologic or orthopedic cause, the neurological entities causing bilateral arm weakness should be considered. Stroke can cause acute unilateral arm weakness, sometimes accompanied by subtle weakness of the leg or face that is not noticed by the patient. Brachial plexus neuritis, an uncommon condition, can also cause acute, unilateral arm weakness.

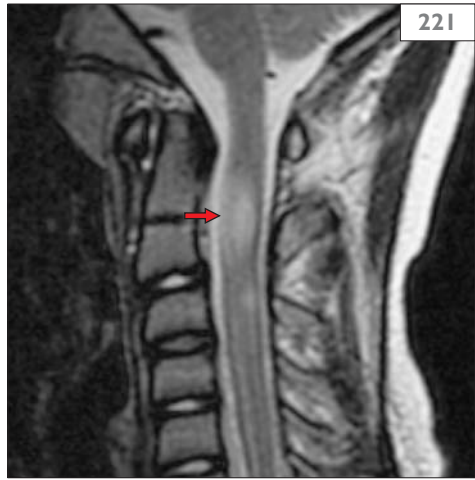
## Hemiparesis/hemiplegia

Hemiparesis refers to weakness (paresis) involving one side of the body (right or left), whereas hemiplegia refers to complete paralysis of one side. In most cases the correct description for a deficit is hemiparesis, but the words are often used interchangeably. Acute hemiparesis, the most common presentation of stroke in children, requires urgent evaluation in the nearest emergency department. Other disorders causing acute hemiparesis include migraine, brain tumor, abscess, intracranial hemorrhage, and metabolic disorders such as mitochondrial disorders or hypoglycemia. Complicated migraine is discussed in Chapter 18 Headaches, and post-ictal (Todd's) paralysis is discussed in Chapter 22 Seizures and Other Paroxysmal Disorders.

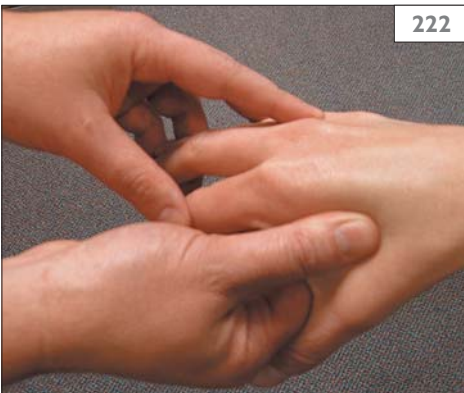Noncontrast brain CT, the fastest initial brain imaging, accurately detects intracranial hemorrhage and most mass lesions. The typical temporal profile for most causes of acute hemiparesis is maximal deficit at onset and static course (e.g. ischemic stroke) or improvement over hours (e.g. complicated migraine or post-ictal Todd's paresis). However, some ischemic strokes can have a fluctuating course; thus, episodes of acute hemiparesis need complete evaluation for underlying cause, even if they have resolved. The most sensitive imaging modality for detecting acute ischemia, infarction, or tumor (223) is MRI of the brain.



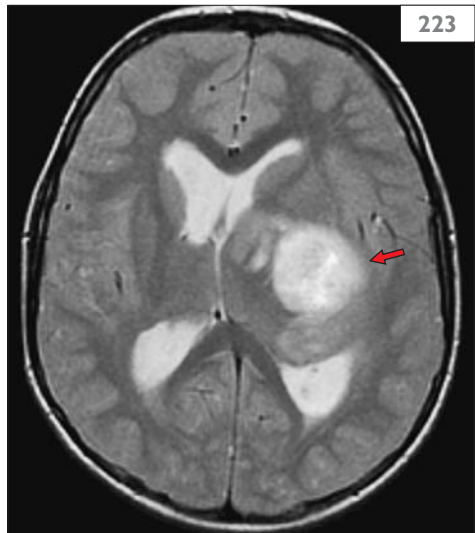**220** A T2-weighted spine MRI showing Chiari malformation (upper arrow) and a cervical syrinx (lower arrow).



**221** A T2-weighted spine MRI showing an area of signal hyperintensity compatible with transverse myelitis.



**222** Palpating for atrophy of the first dorsal interosseus muscle.



**223** Axial T2-weighted MRI showing a large tumor (arrow) causing shift of the midline and ventricular enlargement.

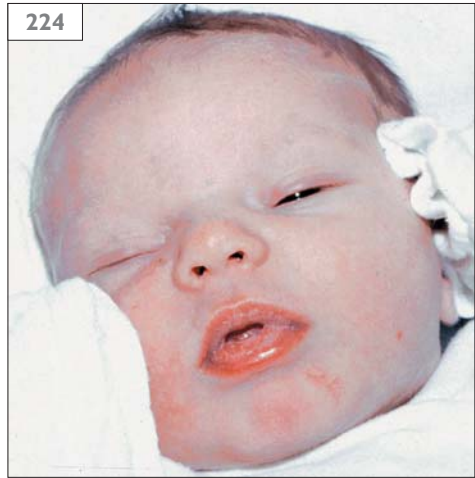## Acute facial weakness

Acute unilateral facial (hemifacial) weakness in a child is usually due to Bell's palsy, a condition that can occur from the neonatal period through old age. The examination (textbox) reveals facial asymmetry that may be inapparent at rest and only evident upon facial movement, such as smiling or eye closure (169, 170). Prominent signs include asymmetric forehead wrinkling, elicited by encouraging a child to look upwards while holding their head still, unilateral weakness of eye closure, and drooping of the corner of the mouth. The affected side often appears 'fuller', due to asymmetric flattening of the nasolabial fold. By definition, Bell's palsy is an idiopathic process affecting CN7. If other CNs are affected, the child needs evaluation for an evolving brainstem process. Bell's palsy improves dramatically and often resolves in the first 4 weeks after onset, with further recovery possibly occurring over the next 6 months. Recurrence occurs in up to 10% of cases and may prompt evaluation, such as a contrast-enhanced MRI of the brainstem and temporal bone, for other causes of CN7 palsy.

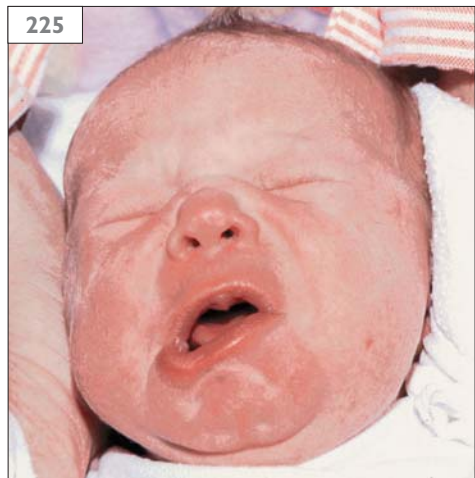### Key elements of the neurological examination in facial weakness

- Bell's palsy or lesions of the CN7 or its pontine nucleus
  - Forehead and lower face are weak.
  - Facial sensation is normal.
  - Associated symptoms can include heightened sensitivity to sound (hyperacusis) and altered taste.
- Cerebral stroke
  - Forehead movement is normal; eye and mouth closures are weak.
  - Facial sensation may be affected.
  - Associated symptoms can include arm or leg weakness.

Acute hemifacial weakness that spares the forehead is the result of stroke until proven otherwise. The child with this finding should be evaluated immediately in an emergency department with special attention towards underlying, treatable causes of stroke such as arterial dissection or unsuspected congenital



**224** An infant with asymmetric crying face syndrome at rest.



**225** An infant with asymmetric crying face syndrome when crying. Note that eye closure is normal.

heart defects. Other CNS causes of acute hemifacial weakness include brain tumor, brain abscess, and demyelinating diseases, such as ADEM or MS.

Congenital hemifacial weakness is occasionally noticed suddenly rather than having a truly acute onset. Inspecting old photographs



can help differentiate congenital from acute causes. Congenital causes of facial asymmetry include asymmetric crying face syndrome (224, 225), due to hypoplasia of the depressor anguli oris muscle that causes asymmetry of the lower portion of the face when crying, and Möbius syndrome, congenital aplasia of brainstem nuclei for CN6 and 7 and, occasionally, other motor CNs.

Acute bilateral facial weakness is uncommon in children, but may be due to GBS, bilateral Bell's palsy and botulism in infants. Infantile botulism presents with poor feeding, constipation, weakness of the eyelids and face and later, weakness of the extremities and muscles of respiration. The acute onset of bilateral ptosis and facial diplegia can be mistaken for lethargy, suggesting infection or encephalopathy, but infants remain alert, often with robust arm and leg movements, at least initially. Pupils can be large or midposition and sluggishly reactive to bright light. The diagnosis can be confirmed by identifying toxin in the infant's stool or by detecting an incremental response during repetitive nerve stimulation during EMG.

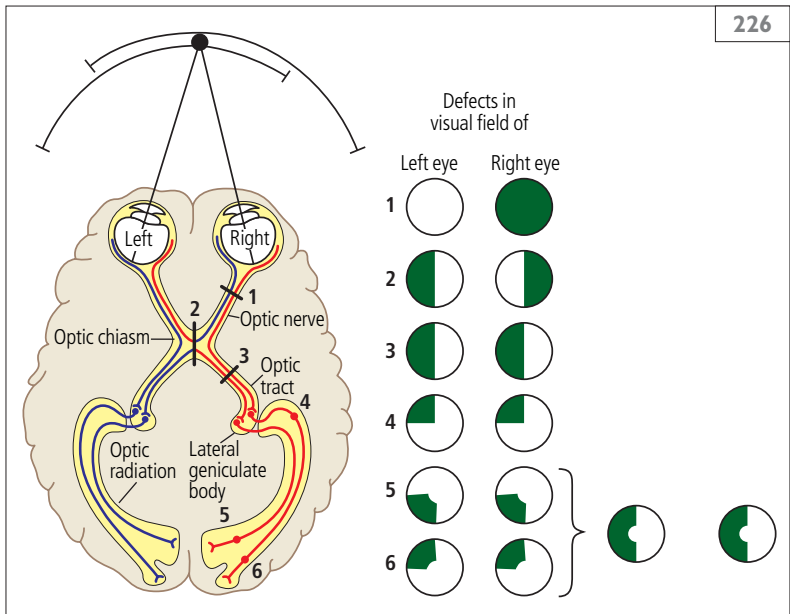
## Acute visual loss

Acute visual loss can be separated into two categories: monocular and binocular (textbox). The following material discusses the key elements of the history and neurological examination and the differential diagnosis for both conditions. Acute visual loss requires urgent evaluation in an emergency department or by an ophthalmologist, even if the symptoms are resolving. Lesion location and the corresponding visual field deficit are depicted in Figure 226.

### Key elements of the eye examination in acute visual loss

- Determine if the loss is monocular or binocular.
- If binocular, determine if there is a homonymous hemianopsia.
- If monocular, determine if there is optic disk swelling suggesting optic neuritis.
- Document visual acuity.
- Determine if this is primarily an ophthalmological disorder and if so, refer urgently to an ophthalmologist, otherwise refer to the emergency department.

**226** Diagram to show visual fields and lesions of the visual pathway.



226

## Acute monocular visual loss

Monocular visual loss, a visual deficit confined to one eye only, is typically due to a process anterior to the optic chiasm affecting the optic nerve, the retina, or the globe. Neurological causes of monocular visual loss include optic neuritis or optic neuropathy; less commonly, embolic stroke or vasospasm due to vasculitis (both rare in children) can cause occlusion of the retinal arteries with transient or permanent retinal ischemia. The initial examination should document visual acuity, pupillary response, visual fields, the appearance of the optic nerve, and a neurological examination to localize the lesion. Vision in the unaffected eye is normal in all respects, including preservation of fields of gaze. The child should be evaluated with urgent imaging and referral to an emergency department. If a primary ophthalmological process such as acute glaucoma is suspected, the patient should be examined by an ophthalmologist.

## Acute binocular visual loss

Binocular visual loss presents with loss of vision that persists when either eye is closed. This is typically due to a lesion posterior to the optic chiasm, i.e. a process involving the fibers of the visual pathway, but can also occur in acute, bilateral, optic neuritis. Sudden hypotension, as in syncope, can cause symmetrically decreased perfusion of the occipital lobe and bilateral visual loss, but this is a rare cause of bilateral vision loss in childhood. Migraine can cause transient visual scotomata (blind spots in the visual field) that may be perceived with one or both eyes open.

Referral to an emergency department for comprehensive evaluation is appropriate for this presentation, especially if there are unexplained syncopal symptoms. If there is a quadrantanopsia or hemianopsia, the most sensitive imaging modality is MRI of the brain, including the orbits, optic nerve, and optic pathways; gadolinium enhancement should be considered when there is concern for demyelinating disease, tumor, or abscess.

## Acute double vision (diplopia)

As in acute visual loss, the initial evaluation must determine whether the problem is in the eye or the brain (textbox). The examiner should ask the patient to cover one eye. If double vision persists, then the disorder may involve the cornea or the globe or be nonphysiological. If the double vision resolves with covering one eye, however, double vision is due to eye misalignment. This is most often due to a disorder of CN3, 4, or 6 or an intraocular or retrobulbar process preventing full movement of the globe. The latter can occur with ocular muscle hypertrophy, as in thyroid eye disease, or with an intraorbital mass, such as a lymphoma.

### Key elements of the eye examination in acute double vision

- Determine if the double vision is monocular or binocular.
- If monocular, inspect for cataract, corneal scarring, or dryness, or an intraorbital mass. Most cases require urgent referral to an ophthalmologist.
- If binocular, examine the eye movements, looking for ocular misalignment. Consider urgent referral to an ophthalmologist.
- Determine if the double images are side-by-side or up-and-down.
- Side-by-side images suggest CN3 or CN6 palsy.
- Up-and-down images suggest CN3 or CN4 palsy.

**Table 37 Typical abnormalities in eye position and eye movement in CN palsies affecting the right eye**

GAZE	CN3 (R)	CN4 (R)	CN6 (R)
Forward	Right eye down and out	Right eye is higher	Slight adduction of the right eye
Left	Impaired adduction of the right eye	Impaired adduction of the right eye	Full adduction
Right	Full abduction	Full abduction	Impaired abduction of the right eye
Up	Impaired right eye	Impaired right eye	Normal
Down	Impaired right eye	Impaired right eye	Normal
Other features	Ptosis and dilated pupil right eye	Right head tilt	Slight head turn to right

## Eye misalignment

First, inspect the eye for proptosis; if present, this suggests a mass preventing full eye movement. If there is no proptosis, determine whether a CN is involved by assessing the position of the eyes when looking forward and when attempting to look up, down, left, and right. A child with a new palsy requires urgent imaging, especially

palsies of CN6. Such palsies can be seen with any cause of increased intracranial pressure, even if the nerve itself is not directly involved. *Table 37* shows typical abnormalities in eye position and eye movement in CN palsies of the right eye; findings in left-sided palsies will be the opposite. See Chapter 11 for additional information regarding cranial nerve palsies.

*This page intentionally left blank*

# The dysmorphic child

## Main Points

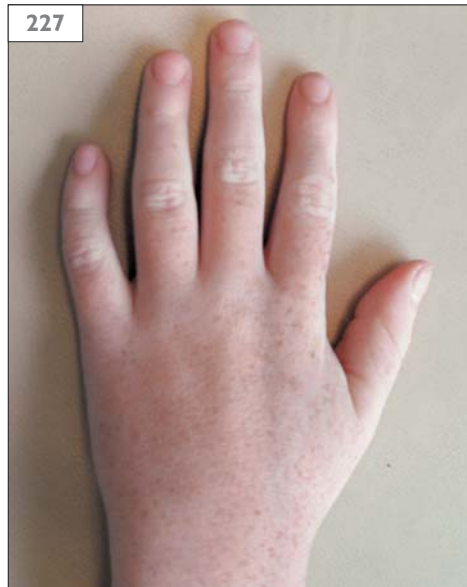- Isolated dysmorphic features are common and generally insignificant.
- In hypotonic infants, consider Prader–Willi, Down, or Smith–Lemli–Opitz syndrome and congenital myotonic dystrophy or spinal muscular atrophy.
- In the child with seizures and dysmorphic features, consider Aicardi (girls only), Angelman, Wolf–Hirschhorn, or velocardiofacial (22q11) syndrome.
- Homocystinuria, Down syndrome, neurofibromatosis type 1 (NF-1), Fabry disease, mitochondrial encephalopathy lactic acid stroke syndrome (MELAS), and cerebral autosomal dominant arteriopathy with subcortical infarcts and leukoencephalopathy (CADASIL) can cause strokes in pediatric patients.
- Mucopolysaccharidoses, fragile X syndrome and fetal alcohol syndrome should be considered in children with global developmental delays.
- NF-1 should be considered when the child has multiple café au lait spots, and tuberous sclerosis complex should be considered in infants or children with multiple hypopigmented macules.

## Introduction

Dysmorphic means an abnormal shape, and when applied to humans, refers to a body feature that differs from the normal appearance. Certain isolated, minor dysmorphic features, such as clinodactyly (incurving of the little (fifth) finger; 227) or syndactyly (fusion or webbing) of the second and third toes (228, 229), are very common and usually have little diagnostic significance. In a child with neurological issues such as developmental delay, seizures, or stroke, however, a dysmorphic feature (230) or a pattern of dysmorphic features can be a major clue to a specific diagnosis. Dysmorphic features (birth defects), such as microbrachycephaly or prognathism in Angelman syndrome (116), as an example, may be the herald signs of the underlying disorder. Moreover, children with three or more minor birth defects have a high probability of having a major birth defect and, often, an identifiable syndromic or genetic disorder.

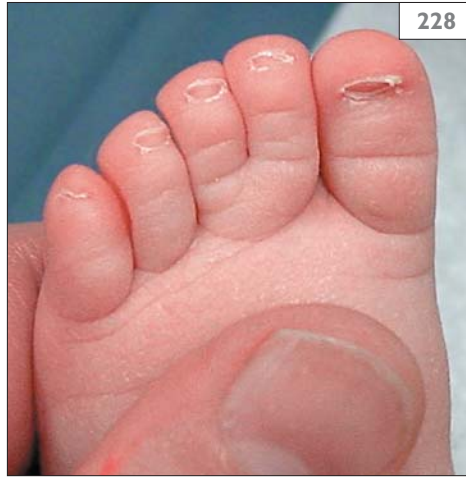There are many different ways to categorize dysmorphic features, and consultation with a clinical geneticist or dysmorphologist should be considered strongly for the child with subtle or unusual physical features. Several excellent resources exist for evaluating children with a single or multiple dysmorphic features, including *Smith's Recognizable Patterns of Human Malformation* (2006, Elsevier Saunders, Philadelphia) or *Medical Genetics*, and on-line resources, such as OMIM (On-line Mendelian Inheritance in Man) ([www.ncbi.nlm.nih.gov/sites/entrez?db=omim](http://www.ncbi.nlm.nih.gov/sites/entrez?db=omim)) and GeneTests ([www.genetests.org](http://www.genetests.org)).

Here, we have grouped dysmorphic features according to their clinically-associated features as a clinician might encounter them in practice. This chapter is not intended to be an encyclopedic review of genetic syndromes and dysmorphology, but focuses on neurologically-relevant disorders with physical features that provide critical diagnostic clues.

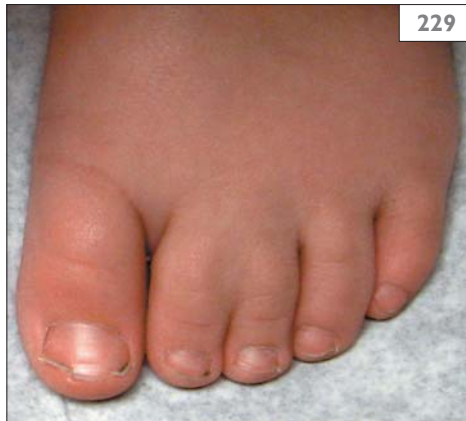

227 Mild clinodactyly.

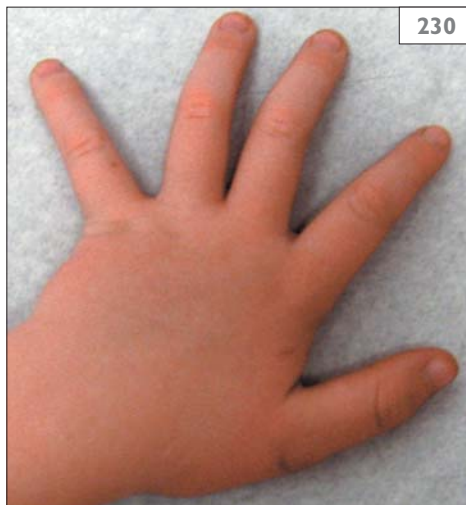**228** Syndactyly of the second and third toes in an infant.



**229** Syndactyly of the second and third toes of a young child.



**230** Long tapering fingers characteristic of 22q11 deletion syndrome.





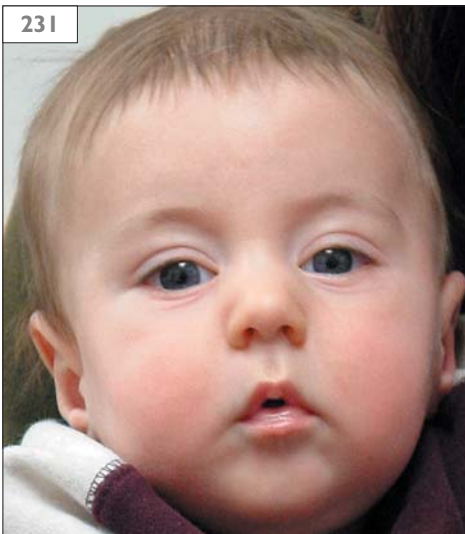## The hypotonic infant

### Prader-Willi syndrome

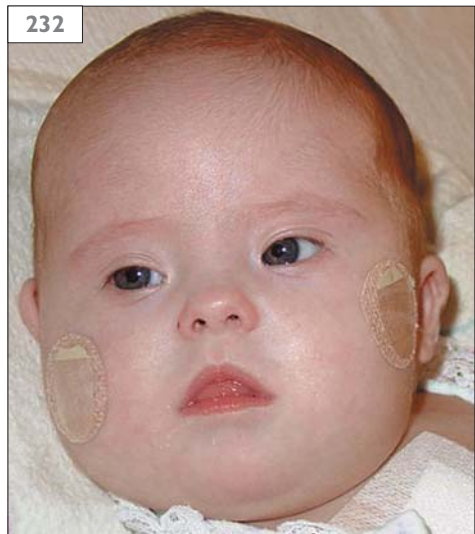Infants with Prader-Willi syndrome, the result of uniparental disomy at 15.q11.2, have striking hypotonia, weak cry, feeding difficulties, hypoplastic genitalia, and modest intrauterine growth retardation. Their facial appearance can be characteristic showing high forehead, narrow bifrontal diameter, micrognathia, and abnormal external ears. Children and adults with Prader-Willi syndrome have prominent hyperphagia, obesity, almond-shaped eyes, fine hair, small hands or feet, emotional lability, and developmental delay (231).

### Down syndrome

Down syndrome, caused by trisomy of all or critical regions of chromosome 21 (97), remains the most commonly recognized dysmorphic syndrome, affecting approximately 1 in 1000 newborns. Infants with Down syndrome have hypotonia and characteristic dysmorphic features including epicanthal folds, flat nasal bridge, midface hypoplasia (232, 233), short hands and fingers, a single, transverse palmar crease (234), and Brushfield spots (235). A substantial number of infants have congenital heart lesions, especially of the atrioventricular canal, and disorders of the gastrointestinal tract, including duodenal stenosis and Hirschsprung disease. Older children and adults with Down syndrome have developmental delay/intellectual retardation and high rates of hypothyroidism and leukemia.

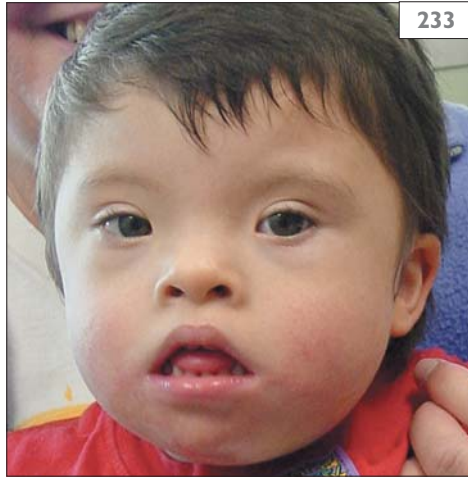

231 The characteristic facial appearance of Prader-Willi syndrome.

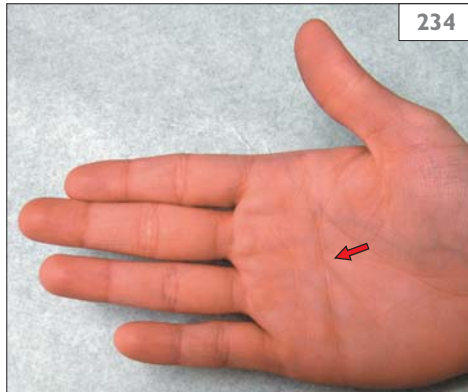


232 The face of an infant with trisomy 21 (Down syndrome) showing midface hypoplasia, epicanthal folds, and posteriorly rotated ears.

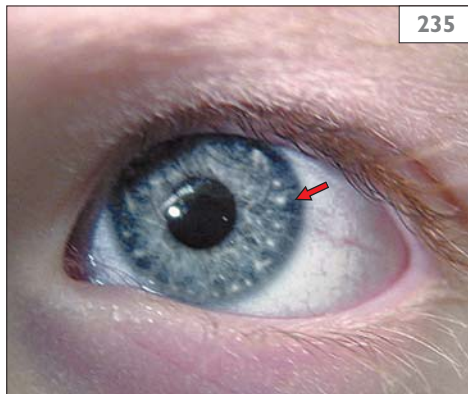
**233** A child with trisomy 21 (Down syndrome) showing facial features characteristic of the disorder.



**234** A transverse palmar crease (arrow).



**235** Brushfield spots (arrow).



### Myotonic dystrophy

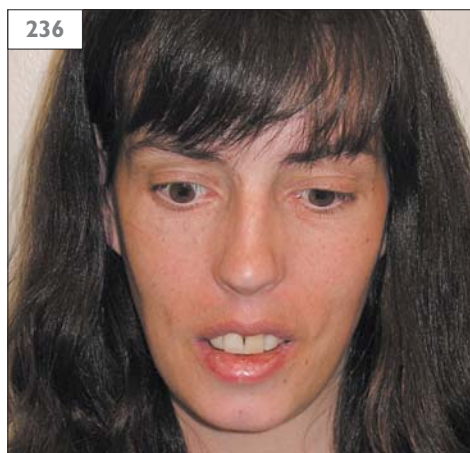Myotonic dystrophy, an autosomal dominant disorder due to an expanded CTG triplet repeat in the gene encoding dystrophia myotonica protein kinase (DMPK), can present in the neonatal period, particularly when the infant's mother is the affected parent. Neonates with myotonic dystrophy, in addition to being markedly hypotonic, have marked weakness of facial and bulbar muscles, leading to respiratory failure and poor feeding. The infants may have foot deformities (talipes) but lack the dysmorphic features typical of adults (cataracts, thin face, male pattern baldness). The mother must be examined for signs of myotonic dystrophy (236) when considering this disorder.

### Congenital spinal muscular atrophy (Werdnig Hoffman disease)

Infants with the congenital form of spinal muscular atrophy, Werdnig Hoffman disease, can present in the neonatal period with profound hypotonia. Such infants can have areflexia and arthrogryposis (multiple contractures; 209) because of intrauterine inactivity. The disorder can be confirmed by analysis of the survival motor neuron-1 gene, present on chromosome 5.

### Smith–Lemli–Opitz syndrome

Infants with Smith–Lemli–Opitz syndrome, an autosomal recessive disorder mapping to 11q12-q13, have hypotonia, microcephaly, ambiguous genitalia in males, and characteristic facial appearance consisting of micrognathia, V-shaped upper lip, microglossia, short nose, and anteverted nostrils. The disorder results from deficiency of 7-dehydrocholesterol reductase; infants with Smith–Lemli–Opitz syndrome can be diagnosed by detecting elevated serum levels of 7-dehydrocholesterol.



**236** Myotonic dystrophy in an adult woman with a myopathic face (slight tenting of the upper lip, ptosis, and flat nasolabial folds).

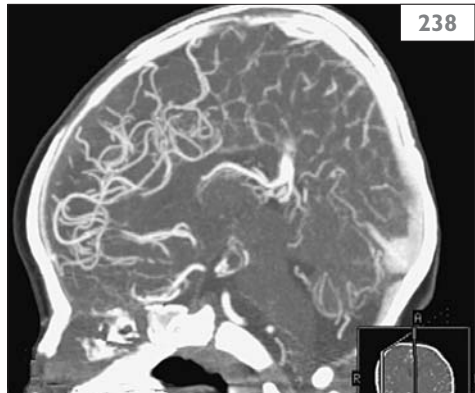
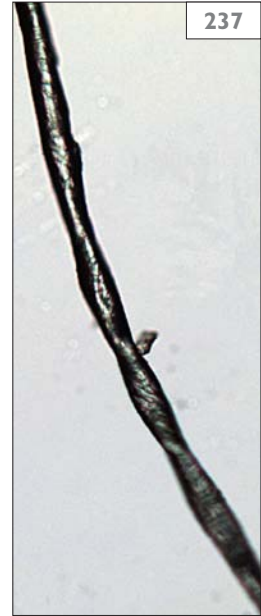## The neonate with encephalopathy or seizures

### Menkes disease

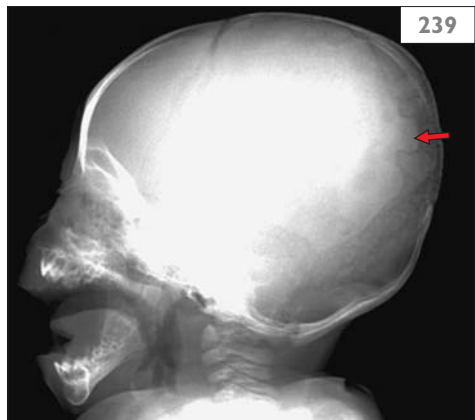
Menkes disease, an X-linked disorder due to a mutation in the copper transporting ATPase gene (*ATP7A*) causes neonatal hypothermia, failure to thrive, developmental delay, hypotonia, and seizures. Infants have sparse, brittle, and twisted (kinky) hair, although this phenotype may not be recognizable until the infants are a few months old. The diagnosis can be suspected by detecting pili torti (twisted hair; **237**) or low levels of serum copper and ceruloplasmin (the copper carrying protein), and confirmed by sequence analysis of *ATP7A*, the gene responsible for the disorder. MRI shows abnormalities of white matter and progressive cortical atrophy, MRA shows tortuous blood vessels (**238**), and skull radiographs show wormian bones (**239**). Treatment with subcutaneous injections of copper histidine or copper chloride beginning before 10 days of age may improve the outcome of infants with classic Menkes disease.

**238** Sagittal reconstruction of a CT angiogram showing tortuous blood vessels in Menkes disease.

**237** Pili torti in Menkes disease.



**239** Wormian bones in Menkes disease.



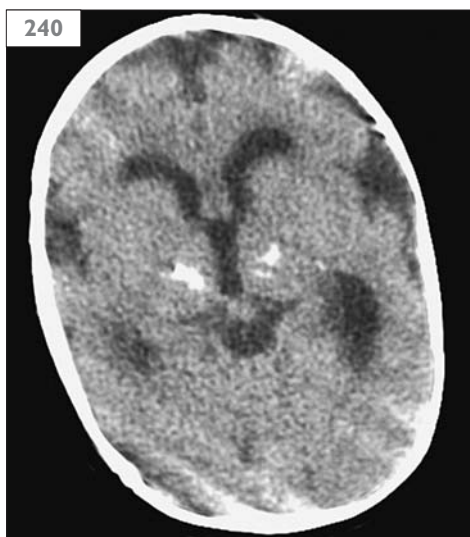### Aicardi–Goutières syndrome

Aicardi–Goutières syndrome (pseudoTORCH syndrome) is the result of a mutation in the TREX1 gene at chromosome 3p21. Infants present in the first days or months of life with encephalopathy, seizures, impaired head growth, sterile pyrexias, and abnormalities of tone, spasticity, and/or dystonic posturing. These infants resemble those with congenital infection by the presence of microcephaly, intracranial calcifications (240), leukodystrophy and CSF pleocytosis. Infants with Aicardi–Goutières syndrome have elevated CSF levels of alpha-interferon. Up to 40% have puffy swelling of the fingers and toes.

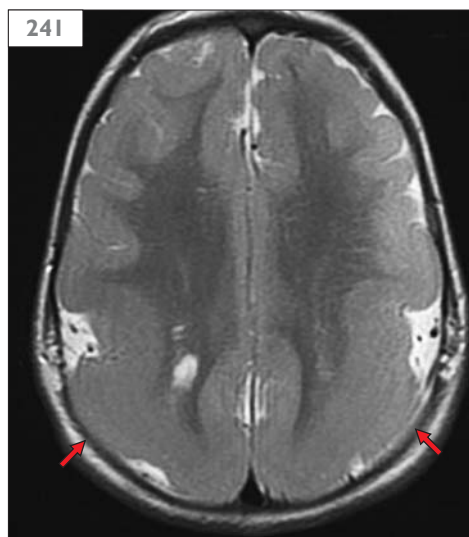### Lissencephaly and holoprosencephaly syndromes

Major malformations of the brain, such as holoprosencephaly or lissencephaly, are often associated with abnormal facial features. Infants with Miller–Dieker syndrome, a lissencephaly (‘smooth brain’) syndrome (241) caused by a contiguous deletion of the *LIS1* gene on chromosome 17, have seizures and characteristic facial features (prominent forehead, brow furrowing, bitemporal hollowing, flat midface, thick upper lip). The spectrum of features depends on the size of the contiguous gene deletion and involvement of other genes in the same region.

Holoprosencephaly, a spectrum of disorders in which the cerebrum fails to cleave, consists of alobar (the most severe with no separation and single ventricle), semilobar, and lobar (the least severe with fusion in the frontal lobes only) (243–245). Dr. William DeMyer observed in the 1960s that the appearance of the face of the

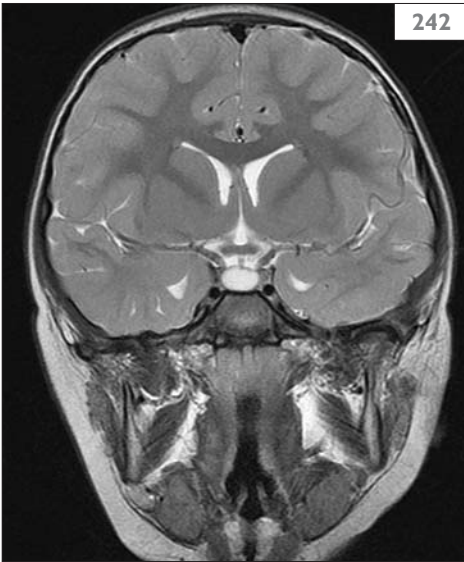


240 Thalamic calcifications in pseudoTORCH syndrome.

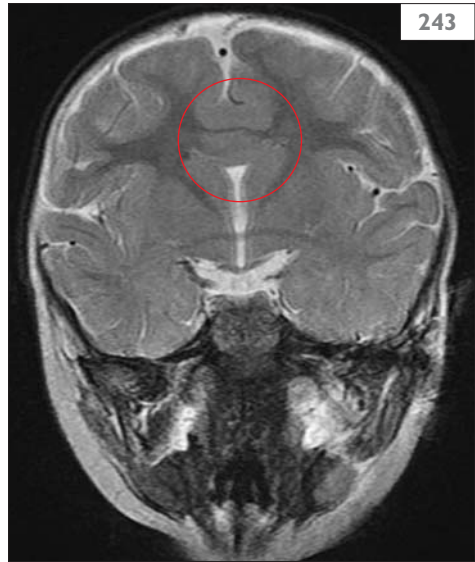

241 Posterior lissencephaly in a child with *LIS1* gene mutation.

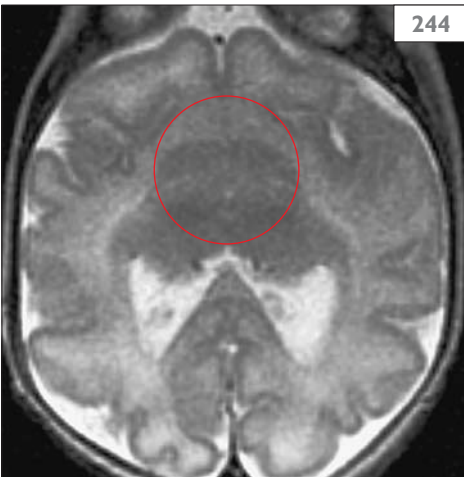



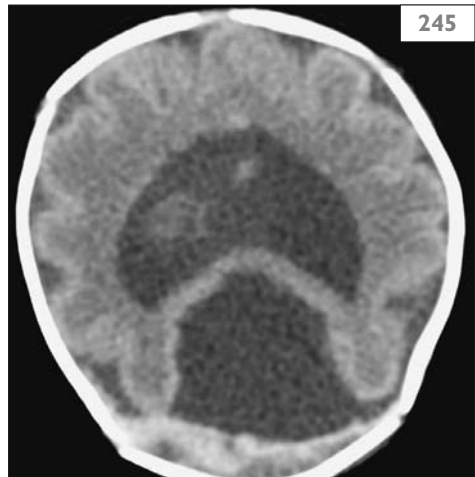**242** Normal coronal T2-weighted MRI of the brain.



**243** A coronal T2-weighted MRI showing fusion of the frontal lobes (circle) consistent with lobar holoprosencephaly.



**244** An axial T2-weighted MRI showing thalamic fusion (circle) and a single ventricle compatible with semilobar holoprosencephaly.

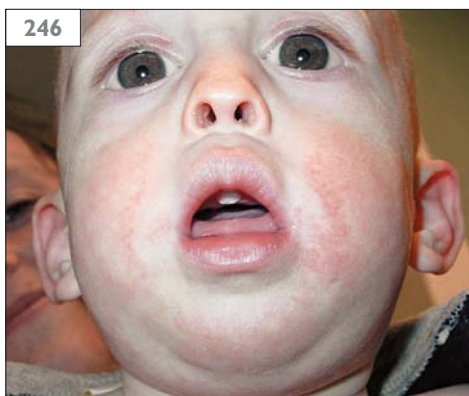

**245** A head CT scan showing a fusion of the hemispheres and a large single ventricle in alobar holoprosencephaly.

child with holoprosencephaly often predicts the brain malformation. Infants or children with holoprosencephaly display facial anomalies ranging from cyclopia and proboscis (single eye and rudimentary nose) or cleft lip and palate to subtle features such as single or widely spaced central incisors and normal facial appearance (246, 247). Microcephaly is an additional, common feature. Infants of diabetic mothers are at risk of holoprosencephaly; up to 50% result from gene abnormalities, such as trisomy 13 or 18, or deletions and duplications including 13q, del(18p), del(7)(q36), dup(3)(p24-pter), del(2)(p21), and del(21)(q22.3). Others appear to follow an autosomal dominant pattern with variable penetrance. Neurodevelopmental outcome varies; those with severe defects (alobar holoprosencephaly) have poor outcomes.

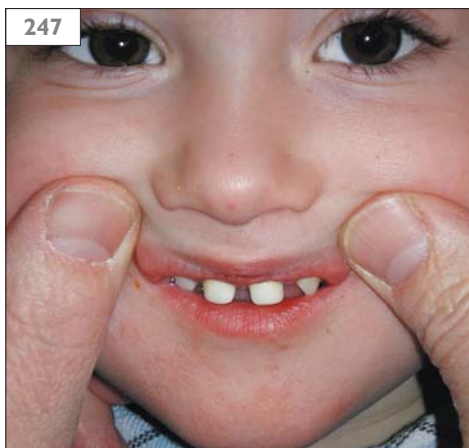### Zellweger spectrum disorder

Zellweger spectrum disorder (also known as cerebrohepatorenal syndrome) is a group of disorders due to mutations in any of several genes encoding peroxisomal biogenesis. It can present in the neonatal period with seizures, encephalopathy, and hypotonia. Infants may appear normal, or they may have a flattened midface, large anterior fontanel, high forehead (248), hepatomegaly, hypotonia, and bony stippling apparent on long bone radiographs. Infantile Refsum disease and neonatal adrenoleukodystrophy are additional disorders in the Zellweger spectrum. The diagnosis can be established by measuring plasma very long chain fatty acids or performing sequence analysis of peroxisomal (PEX) genes.



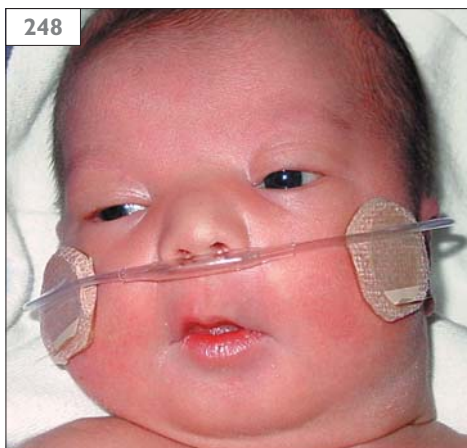246

**246** Single, central megaincisor in a child with holoprosencephaly.



247

**247** Wide spaced teeth in a child with lobar holoprosencephaly.



248

**248** An infant with Zellweger syndrome showing characteristic facial appearance.



## The child with seizures

### Aicardi syndrome

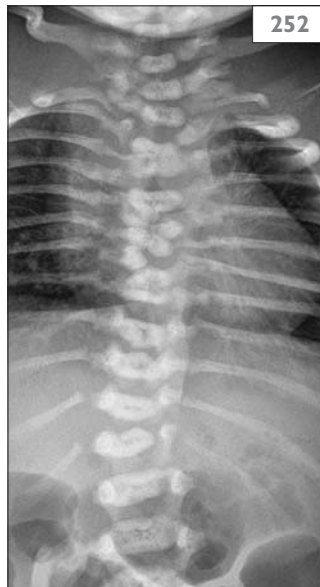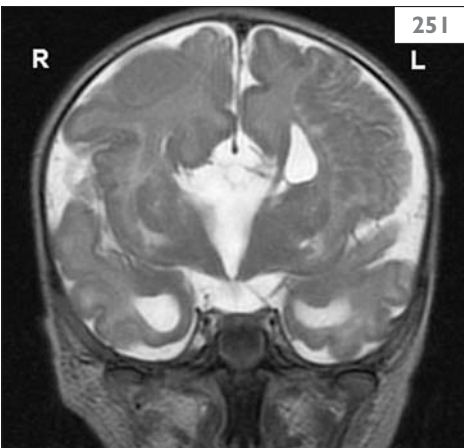
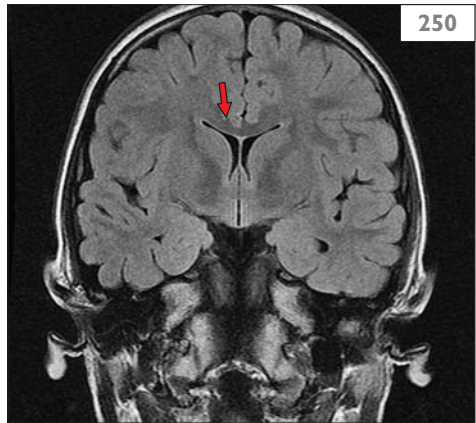
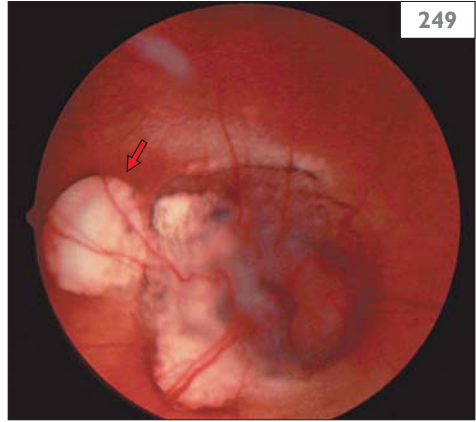
Aicardi syndrome, an X-linked disorder distinct from Aicardi–Goutières syndrome, should be considered in infant girls with infantile spasms, chorioretinal lacunae (249), detected by ophthalmological exam, agenesis of the corpus callosum (250, 251), confirmed by CT or MRI, and vertebral anomalies that can be detected on chest radiographs (252). Girls with Aicardi syndrome have a characteristic facial appearance consisting of a prominent premaxilla, upturned nasal tip, decreased angle of the nasal bridge, and sparse lateral eyebrows. The disorder maps to Xp22, although a specific gene has not, as yet, been linked to the disorder.

**249** Lacunar retinopathy (arrow) of Aicardi syndrome.

**250** Normal coronal T1-weighted MRI with intact corpus callosum (arrow).

**251** Coronal T2-weighted MRI in Aicardi syndrome showing absent corpus callosum and cortical dysplasia of the left hemisphere.

**252** Anomalous vertebral bodies in a child with Aicardi syndrome.

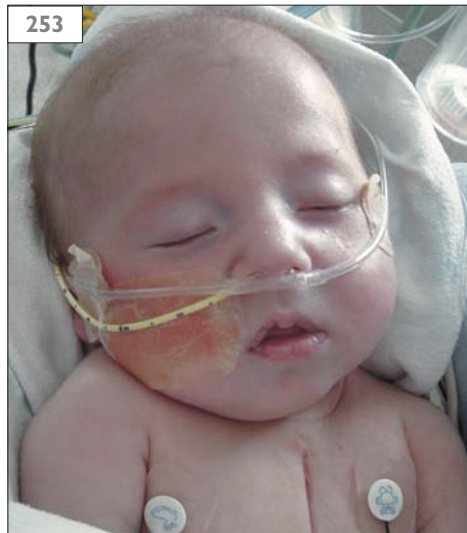

## 22q11 (velocardiofacial) syndrome

Children with DiGeorge/Shprintzen (velocardiofacial) syndrome, caused by a contiguous gene deletion in the 22q11.2 region, can have seizures and developmental delay. Depending upon the extent of the deletion they may have hypocalcemia as an infant, congenital heart disease (tetralogy of Fallot, atrial septal defect, ventricular septal defect, truncus arteriosus, or pulmonic stenosis), immunodeficiency, and dysmorphic features (98, 253), including cleft lip or palate, elongated face (254), almond-shaped eyes, small ears, polydactyly, and asymmetric crying facies (224, 225). Less frequent features include microcephaly, mental retardation, short stature, slender hands and digits (255), and inguinal hernia. Children or adults with velocardiofacial syndrome may display nasal speech, related to palatine insufficiency or clefting, learning disabilities, or behavioral disorders. Some have called this CATCH 22 syndrome, an acronym derived from cardiac anomalies, abnormal facies, thymic hypoplasia, cleft palate, and hypocalcemia due to abnormalities of chromosome 22.

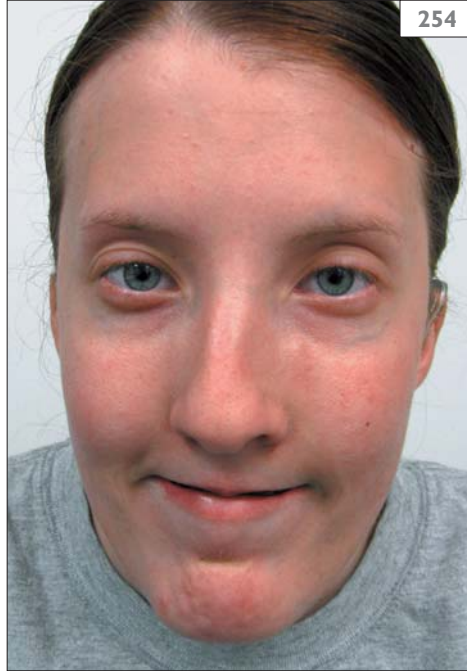## Wolf–Hirschhorn syndrome

Wolf–Hirschhorn syndrome, caused by partial deletion of the short arm of chromosome 4, presents in infancy with seizures (affecting more than half of the patients), hypotonia, developmental delay, and congenital heart disease. Infants have a ‘Greek warrior helmet appearance’ of the head, microcephaly, and malformed ears with pits/tags, as well as fish-like mouth, small chin, short philtrum, cleft lip or palate, coloboma of the eye, and cardiac septal defects.

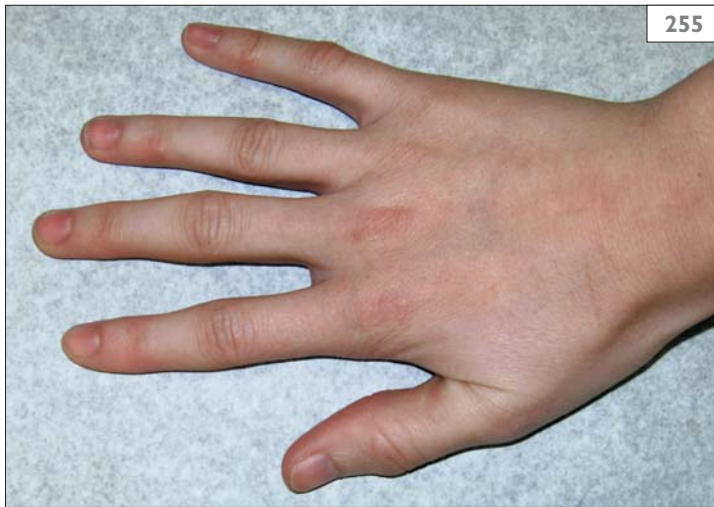


**253** An infant with velocardiofacial (Shprintzen–DiGeorge) syndrome due to 22q11 deletion. The child has midface hypoplasia and characteristic appearance to the nose.

**254** An adolescent with hearing loss and characteristic facial features (long nose) in 22q11 deletion syndrome.



**255** Long, tapering fingers in 22q11 deletion syndrome.



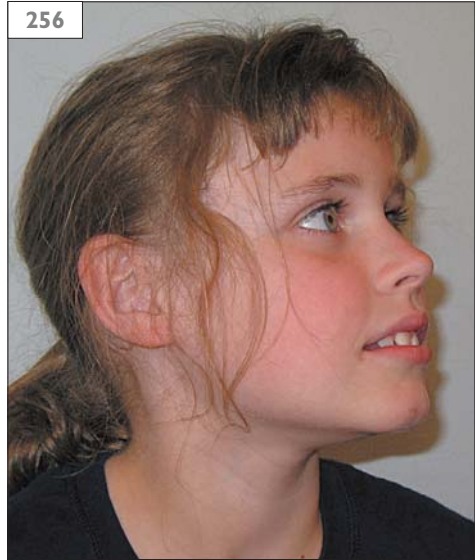## The child with language impairment

### Angelman syndrome

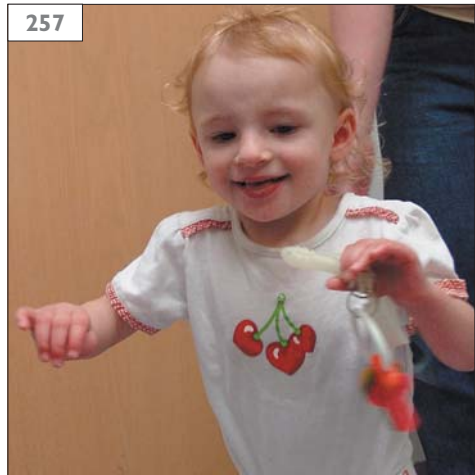
Children with Angelman syndrome have a distinct phenotype that consists of developmental delay, microbrachycephaly, widely-spaced teeth, and prominent mandible (116, 256). Children with Angelman syndrome have profound language delays with minimal or no speech; more than five individual words or use of two word phrases makes Angelman syndrome unlikely. Receptive language and nonverbal skills are better than expressive skills. The child with Angelman syndrome has jerky, ataxic gait with raised arms (40) and a distinctive behavioral phenotype consisting of hyperactivity and a happy, smiling demeanor (257). Seizures can be difficult to control in some children. Angelman syndrome results from loss or mutations of the maternally-derived *UBE3A* gene on chromosome 15. Approximately 70% of cases result from deletion of the region (15q12) containing this gene; 10% result from mutations in *UBE3A*.

### Williams syndrome

Children with Williams syndrome, the result of contiguous gene deletions in the 7q11.23 region, exhibit a gregarious, loquacious personality despite having mental retardation. Children with this disorder have a distinctive, elfin facial appearance including a long brow, low nasal bridge, broad philtrum, and small widely spaced teeth (117, 118). Supravalvular aortic stenosis and infantile hypercalcemia are additional, important features of Williams syndrome.



256 Prognathism in a girl with Angelman syndrome.



257 Stereotypic hand and arm posture in a child with Angelman syndrome.

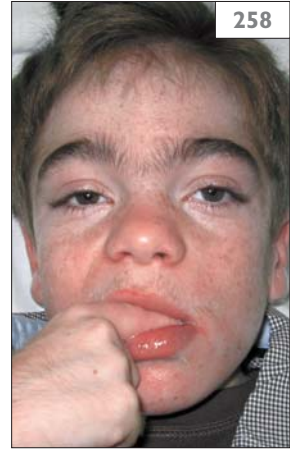## The child with global developmental delay

### Mucopolysaccharidoses

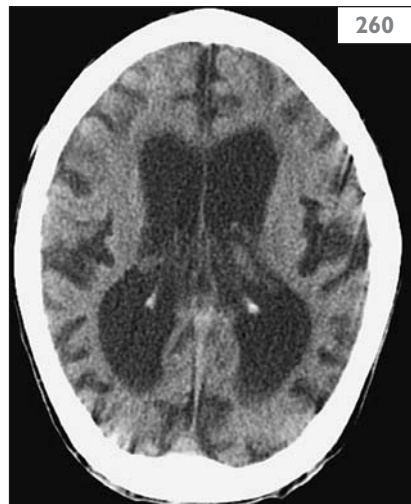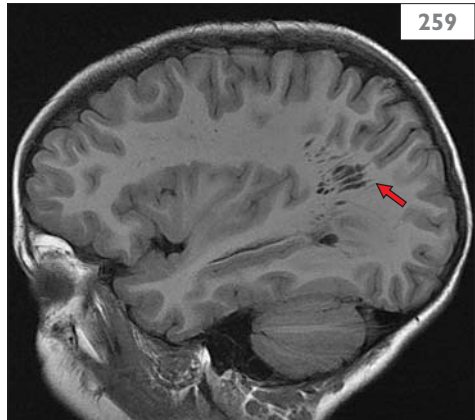
Three mucopolysaccharide (MPS) disorders, Hurler, Hunter, and Sanfilippo syndromes, affect the CNS and cause global developmental delay, hepatosplenomegaly, and dysmorphic features (258). Hurler syndrome or MPSI results from deficiency of alpha-L iduronidase, and Hunter syndrome or MPSII results from deficiency of iduronate-2-sulfatase. Sanfilippo syndrome, MPSIII, has four subtypes (A–D) resulting from enzymes involved in the metabolism of the glycosaminoglycan, heparan sulfate. Hurler and Sanfilippo syndromes are autosomal recessive, whereas Hunter syndrome is X-linked recessive.

Each of these disorders can produce progressive neurological deterioration, although persons with the Hurler–Scheie and the attenuated form of Hunter disease can have normal intelligence. Seizures can be a complication of Sanfilippo syndrome. Common to all mucopolysaccharidoses is the tissue accumulation of glycosaminoglycans that can lead to hepatosplenomegaly, short stature, macrocephaly, macroglossia, conductive hearing loss, spinal stenosis, cardiac valvular disease, and coarse facial features. The latter can be striking in Hurler syndrome, the most severe of the mucopolysaccharidoses, and mild to absent in children with Sanfilippo syndrome. MRI may show enlarged perivascular (Virchow–Robin) spaces (259) and dramatic cortical atrophy during the advanced stages of the condition (260). Cardiorespiratory complications shorten the life span of persons with mucopolysaccharidoses. Enzyme replacement therapy, often coupled with bone marrow transplantation, is emerging as a promising means to address the systemic complications of some of these disorders.

**258** The coarse facial appearance and synophrys of Sanfilippo syndrome.



**259** Prominent Virchow–Robin (perivascular) spaces (arrow) as in mucopolysaccharidosis.



**260** Marked cerebrocortical atrophy in the later stages of Sanfilippo syndrome.



## **Congenital disorders of glycosylation**

The congenital disorders of glycosylation (CDG) are a heterogeneous group of disorders with multiorgan involvement; symptoms can include developmental delay, ataxia, neuropathy, and cardiac, liver, and gastrointestinal involvement. CDG1a, the most common with more than 400 cases worldwide, causes inverted nipples, abnormal accumulations of subcutaneous fat, retinitis pigmentosa, and dysmorphic facial appearance with almond-shaped eyes. MRI shows pancerebellar atrophy (184). The diagnosis is suggested by finding elevated serum carbohydrate deficient transferrins and confirmed by enzyme analysis of fibroblasts. Specific treatment is currently available only for CDG1b.

## **Fragile X syndrome**

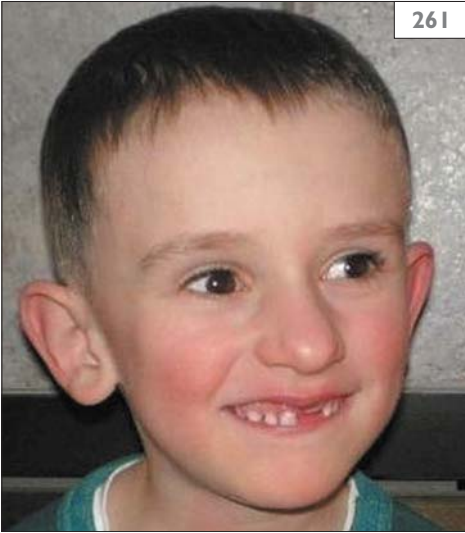Boys and men with fragile X syndrome, due to a trinucleotide (CGG) repeat expansion in the FMR1 gene, have a distinctive facial appearance with large ears, long, narrow face, midface hypoplasia, large lips, and prominent jaw (261). Affected individuals exhibit moderate to severe developmental delay/mental retardation, macro-orchidism, and behavioral abnormalities with aggressiveness, hyperactivity, and autism. Fragile X syndrome accounts for 1–2% of boys with autism. The diagnosis can be confirmed by molecular analysis of the FMR1 gene. Affected males have >200 CGG repeats; persons with 55–200 repeats have a ‘premutation’ and are at risk for fragile X-associated tremor, ataxia syndrome (FXTAS), a neurodegenerative disorder that causes intention tremor, ataxia, and cognitive decline after the age of 50 years.

## **Noonan syndrome**

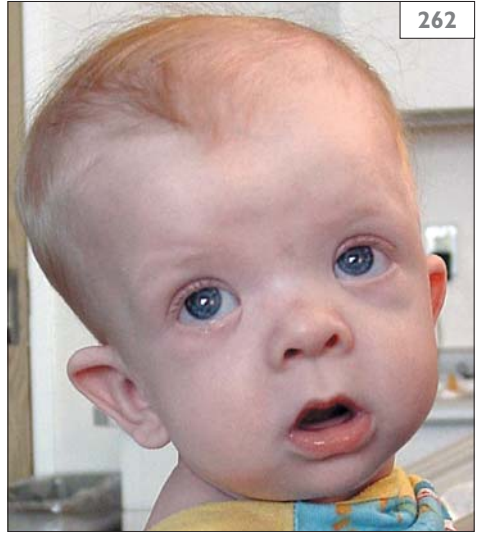Noonan syndrome should be considered in a child with motor developmental delay, short stature, congenital heart disease (especially pulmonary valve stenosis or hypertrophic cardiomyopathy), and facial characteristics (262) including hypertelorism, low set and/or abnormally shaped ears, and vivid blue or blue-green irises.

## **Cornelia de Lange syndrome**

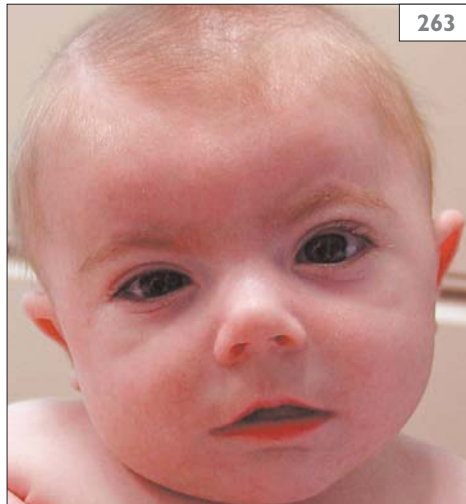
Children with Cornelia de Lange syndrome have moderate to severe mental retardation, with distinctive facial features including synophrys (confluent eyebrows), arched eyebrows, long eyelashes, and microcephaly (263). Other clinical feature can include hearing loss, autism, cardiac septal defects, and hypoplastic genitalia. Inheritance is X-linked or autosomal dominant with two known genes.



**261** A child with fragile X syndrome and prominent ears.



**262** The characteristic facial appearance of Noonan syndrome.

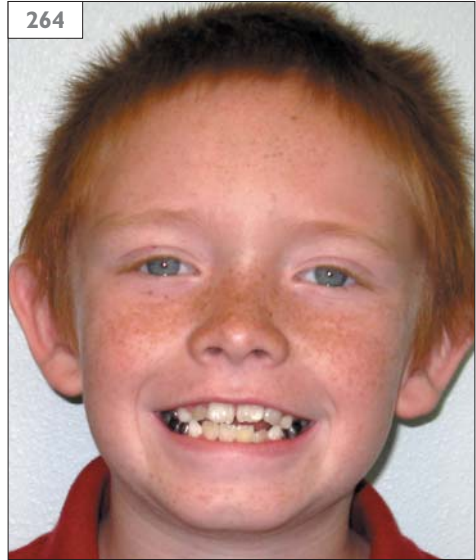

**263** The facial appearance of Cornelia de Lange syndrome.

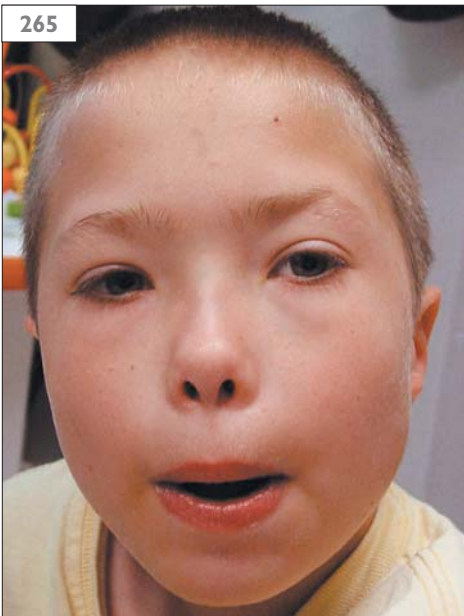

### Fetal alcohol syndrome


Children with fetal alcohol syndrome, also called fetal alcohol spectrum disorder (FASD), can have mild to severe symptoms and signs consisting of developmental delay/intellectual retardation, hyperactivity, failure to thrive, microcephaly, and cardiac defects. Dysmorphic features of FASD include short palpebral fissures, short upturned nose, smooth, long philtrum, thin vermillion border of the upper lip, and small fingers and finger nails (264–266).



**264** Facial appearance (thin vermillion border of the upper lip) suggestive of fetal alcohol exposure.



**265** A child with fetal alcohol syndrome with a poorly developed philtrum, microcephaly, and thin vermillion border of the upper lip.



**266** Abnormal hand creases (arrow) in fetal alcohol syndrome.

## The child with deafness

### Pendred syndrome

Pendred syndrome, caused by a mutation in the *SLC26A4* gene, represents the most common syndromic cause of hearing loss. Children with this disorder have sensorineural hearing loss (SNHL) and goiter. Mutation in the *SLC26A4* gene has also been associated with the large vestibular aqueduct syndrome and hearing loss.

### Alport syndrome

Alport syndrome, another syndromic cause of deafness, results in SNHL and progressive glomerulonephritis that can lead to end-stage renal failure.

### Usher syndrome

Usher syndrome, the result of a mutation in the gene encoding myosin VIIA, causes retinitis pigmentosa before puberty and severe congenital SNHL. Ataxia can also occur.

### Congenital cytomegalovirus infection

Congenital cytomegalovirus (CMV) infection represents the most common nongenetic cause of deafness in childhood. Infants with congenital CMV infection can be symptomatic at birth (congenital CMV disease), exhibiting microcephaly, jaundice, hepatosplenomegaly, and petechial rash, or be silently affected and appear normal at birth. Hearing loss affects approximately 50% of the infants with CMV disease and 8% of the infants who are silently infected.

## The child with a stroke

Several genetic disorders are associated with an increased risk of stroke during childhood or adolescence. These include homocystinuria, Down syndrome, neurofibromatosis type 1 (NF-1), Fabry disease, mitochondrial encephalopathy with lactic acidosis and stroke (MELAS), and cerebral autosomal dominant arteriopathy with subcortical infarcts and leukoencephalopathy (CADASIL). The latter disorder, which rarely presents in childhood, is the result of mutations in *NOTCH3*, a gene encoding a transmembrane protein that promotes smooth muscle cell survival. Arterial or venous thrombosis can be observed in infants, children, or adolescents with factor V Leiden or prothrombin 20210 gene mutations.

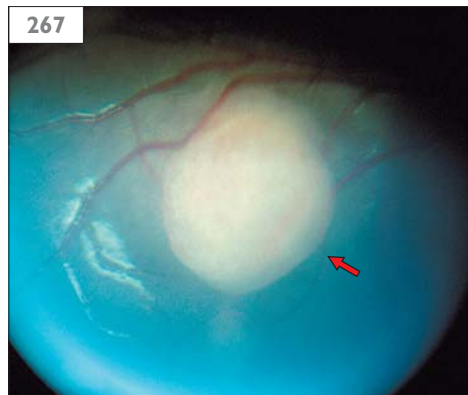
## The child with neurological signs or symptoms and birth marks

Common neurocutaneous disorders include:

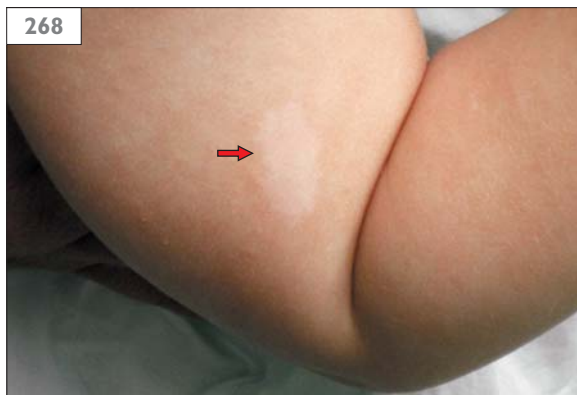
- NF-1: affects 1 in 3000–4000 children.
- Tuberous sclerosis (TS): affects 1 in 6000 children; 50% are new mutations.
- Sturge–Weber syndrome: 3 per 1000 children have facial hemangiomas; 10% or less of these have Sturge–Weber syndrome.

## Tuberous sclerosis

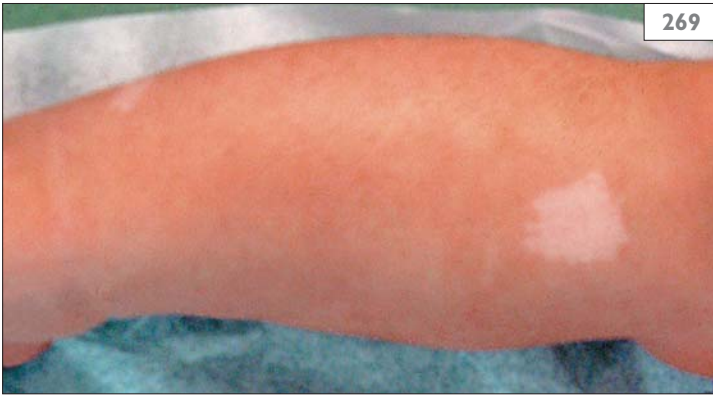TS or tuberous sclerosis complex (TSC), an autosomal dominant disorder due to mutations at 9q34 (TSC1) or 16p13.3 (TSC2), is a multisystem condition producing epilepsy, learning difficulties, behavioral disorders (including autism), skin lesions, retinal lesions (267), renal angiomyolipomas, and cardiac rhabdomyomas. The skin lesions consist of hypopigmented macules (268–271), raised fleshy areas, shagreen patches (thickened areas of skin, consisting of orange peel-like



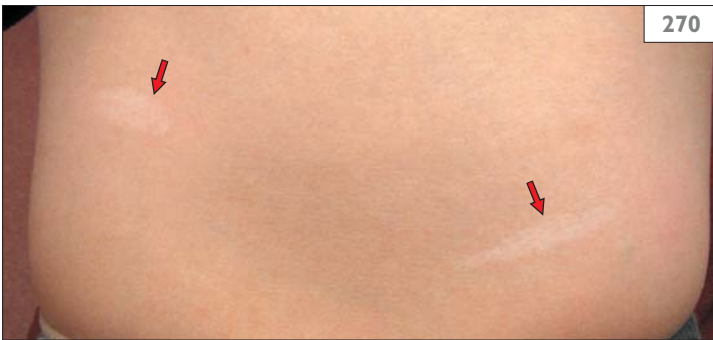267 Retinal angioma in tuberous sclerosis (arrow).



268 Hypopigmented skin lesion in a child with tuberous sclerosis (arrow).



269 Hypopigmented skin lesion in another child with tuberous sclerosis.



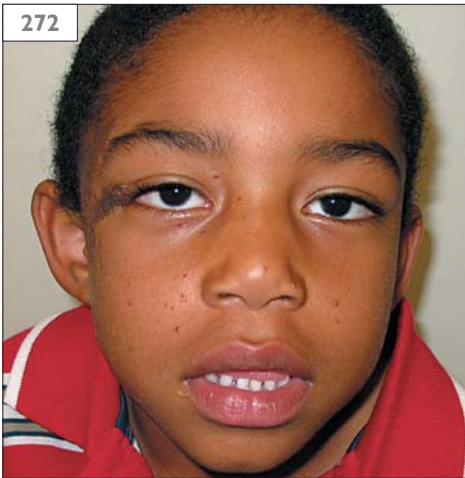270 Truncal ash leaf spots characteristic of tuberous sclerosis (arrows).



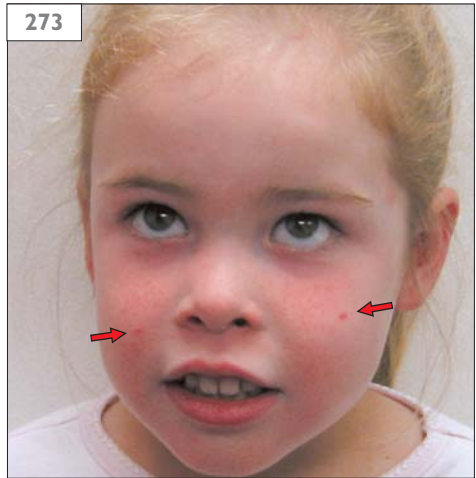
271 The same truncal ash leaf spots in 270 viewed with a Woods lamp (arrows).

hamartomas, usually found in the low back), facial angiofibromas (272, 273) and subungual fibromas. The diagnosis can be suspected in children with epilepsy or developmental delay and >3 hypopigmented macules; neuroimaging features, consisting of calcified periventricular

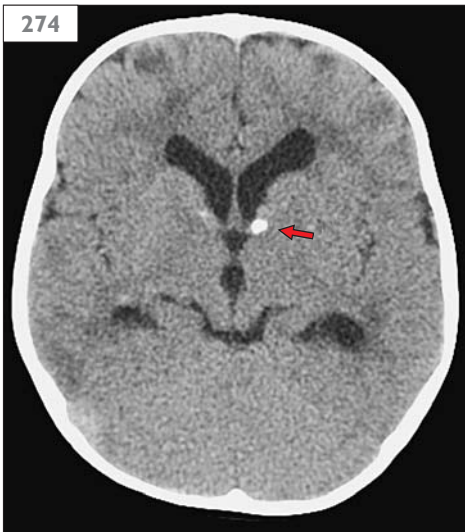glial nodules, subependymal giant cell tumors, and subcortical tubers (274–278), are sufficiently characteristic to confirm the diagnosis. Pathological findings consist of firm subcortical tubers and hard periventricular gliotic nodules (279, 280).



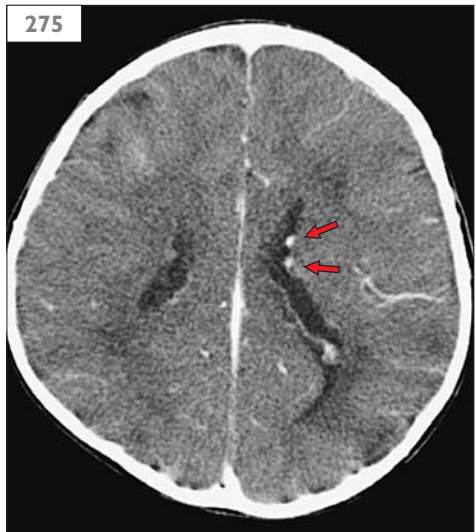272 Facial angiofibromas in tuberous sclerosis.



273 Facial angiofibromas in tuberous sclerosis (arrows).

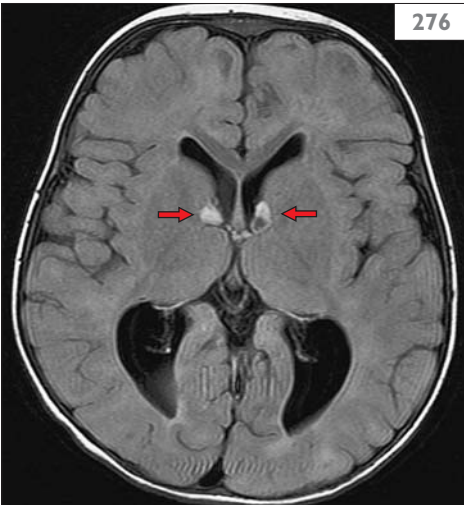


274 Characteristic CT scan appearance in tuberous sclerosis showing a calcified lesion near the foramen of Monro (arrow).

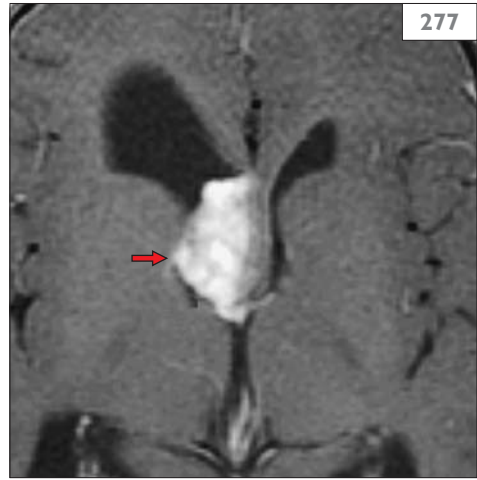

275 Enhancing periventricular nodules in tuberous sclerosis (arrows).

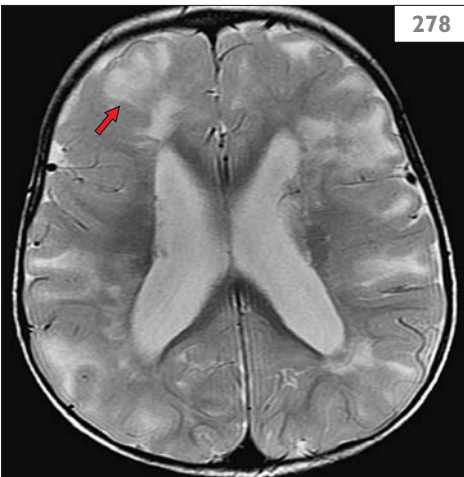




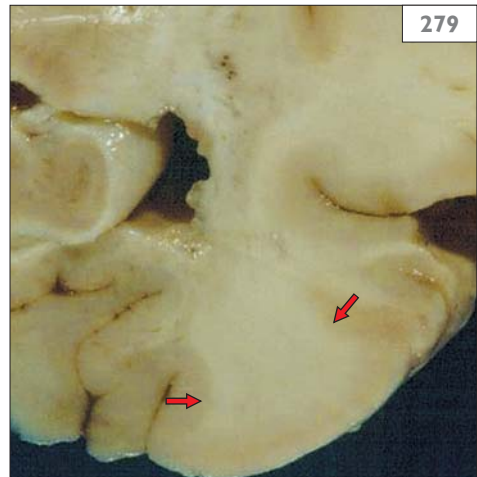
**276** Gadolinium-enhanced axial FLAIR MRI in tuberous sclerosis showing enhancing giant cell tumors near the foramen of Monro (arrows).



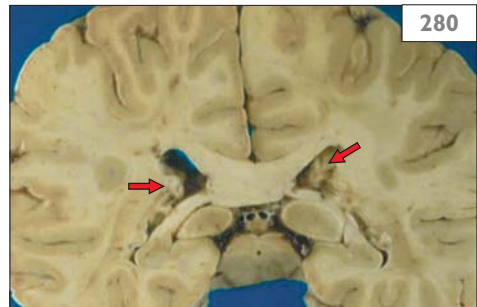
**277** Gadolinium-enhanced axial T1-weighted MRI showing a giant cell tumor (arrow) extending into the anterior horn of the lateral ventricle and obstructing the foramen of Monro.



**278** Axial T2-weighted MRI showing numerous cortical tubers (arrow) in tuberous sclerosis.



**279** Pathological specimen showing the appearance of a cortical tuber (arrows) in tuberous sclerosis.



**280** Pathological specimen showing intraventricular gliotic nodules (arrows) in tuberous sclerosis.

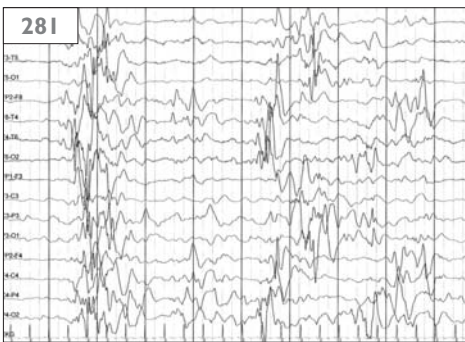
Infants with TSC have increased rates of infantile spasms (281), an ominous epilepsy syndrome associated with developmental delay and intractable seizures. Most authorities in the USA suggest adrenocorticotropic hormone (ACTH) initially; such therapy should be guided by a child neurologist. In many regions of the world, as well as in the USA, vigabatrin is considered, but especially in infants who do not respond to ACTH. Children with TSC require periodic ultrasound evaluation of the heart and kidneys. Cardiac rhabdomyomas typically regress with age, whereas renal lesions, including angiomyolipomas and cysts, usually appear and grow over time. Children with TSC, especially TSC2, are at risk of hypertension and renal failure. Subependymal giant cell tumors can obstruct the foramina of Monro (277) and cause hydrocephalus. Some authorities suggest annual or every other year MRIs in children with TSC until 21 years of age and early resection when subependymal giant cell tumors show contrast enhancement or rapid interval growth.

## Neurofibromatosis type 1

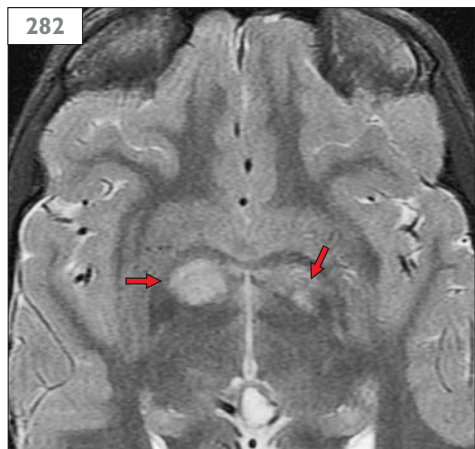Children with NF-1, caused by mutations in the neurofibromin gene 1 at chromosome 17q11.2, may present to clinicians because of macrocephaly, hypertension, learning disability, vision loss, seizures, or developmental delay. MRI commonly shows areas of T2 prolongation in the basal ganglia, pons, and cerebellum (282, 283). The diagnosis is suggested by the presence of café au lait spots: >6 spots >5mm in size for a prepubertal child and >6 spots >15 mm in size for a postpubertal child (284).

The diagnosis of NF-1 can be confirmed by the presence of café au lait spots *and* one or more of the following clinical criteria:

- 2 or more neurofibromas of any type or 1 plexiform neurofibroma (285).
- Freckling in the axillary or inguinal regions (286).
- Optic glioma (287).
- 2 or more Lisch nodules (iris hamartomas; 288).
- A distinctive osseous lesion such as sphenoid dysplasia or thinning of the long bone cortex with or without pseudarthrosis.
- A first degree relative (parent, sibling, or offspring) with NF-1 by the above criteria.

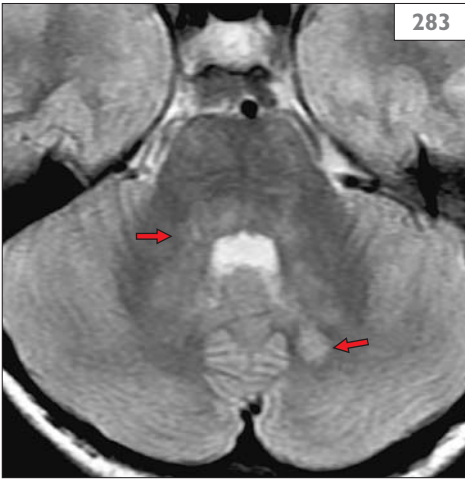


**281** An EEG showing hypsarrhythmia characteristic of infantile spasms, a common feature of tuberous sclerosis.

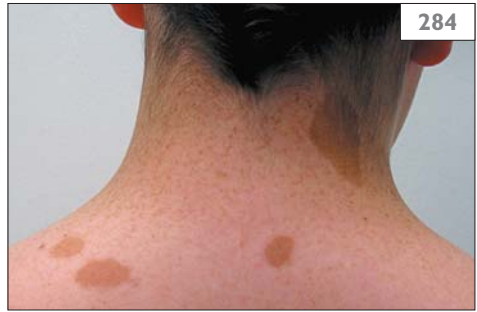

**282** Areas of T2 MRI signal hyperintensity (arrows) in the basal ganglia of a child with NF-1.



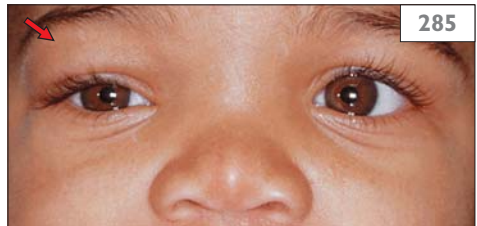

**283** Axial T2-weighted MRI showing signal hyperintensities in the pons and cerebellum (arrows) in NF-1.



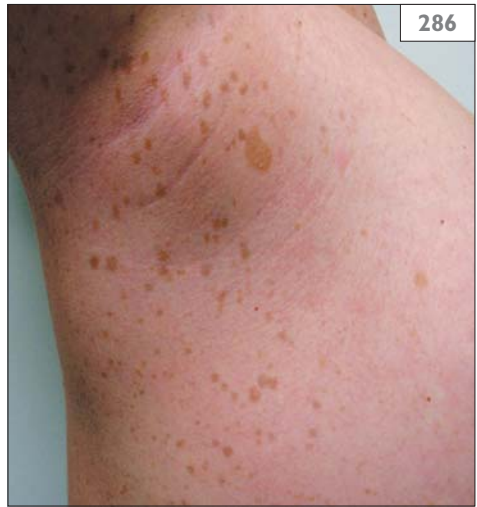**284**

**284** Café au lait spots in NF-1.



**285**

**285** Orbital plexiform neurofibroma (arrow) in NF-1.

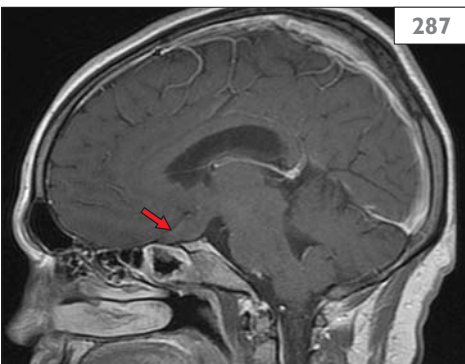

**286**

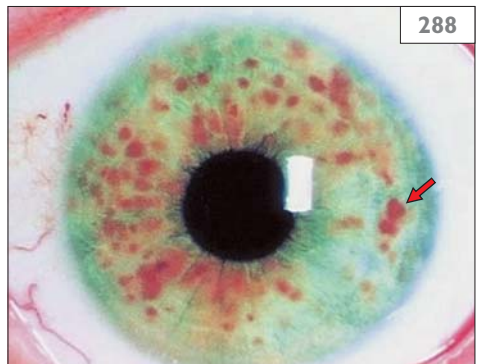
**286** Axillary freckling in NF-1.

**287** Gadolinium-enhanced sagittal T1-weighted MRI showing a fusiform glioma (arrow) of the right optic nerve in NF-1.

**288** Lisch nodules (arrow) of the iris in a person with NF-1.



**287**



**288**

Children with NF-1 have high rates of optic nerve gliomas, as well as other intracranial neoplasms, and require annual ophthalmological examinations. Optic atrophy can be the first sign of an optic glioma. Some authorities suggest an MRI at the time of the diagnosis of NF-1 to establish the extent of brain involvement. MRIs can be obtained thereafter based on the appearance of new neurological signs or symptoms, such as headaches, seizures, vision loss, or changes in personality or behavior. Neurocognitive testing can facilitate school placement in children with academic difficulties and suspected learning disabilities. Rarely, children with NF-1 can have hydrocephalus as the result of aqueductal stenosis.

### Neurofibromatosis type 2

NF-2, a distinct disorder caused by mutation in the gene encoding neurofibromin-2, also called merlin, located on chromosome 22q12.2, causes tumors of CN8 (usually bilateral acoustic neuromas or schwannomas; 289), cerebral meningiomas, and schwannomas of the dorsal spinal roots. Virtually all patients with NF-2 lack cutaneous or peripheral manifestations of NF-1, as described above. NF-2 rarely presents before 14 years of age, but should be suspected in children or adolescents with deafness, especially bilateral, or unexplained vestibular dysfunction.

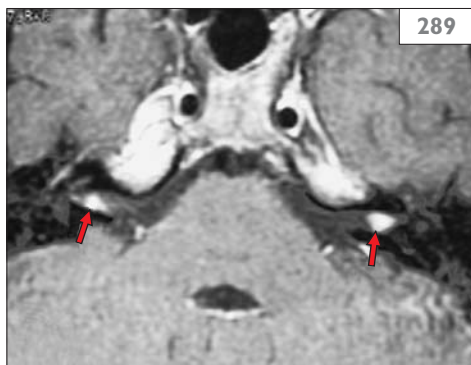### Sturge–Weber syndrome

Children with Sturge–Weber syndrome (SWS) have facial port-wine hemangiomas (nevus flammeus; 290), seizures, leptomeningeal angiomas, hemiparesis, and glaucoma. Hemangiomas can occur in other body areas in children with SWS; the syndrome can overlap with Kippel–Trenaunay–Weber syndrome, a disorder associated with extremity or truncal hemangiomas and extremity hypertrophy. The probability of intracranial leptomeningeal angiomas in infants with facial hemangiomas depends upon the extent of facial involvement; hemangiomas in the V1 (ophthalmic) division of the trigeminal nerve have the strongest association with intracranial angiomas. Rarely, SWS can occur without facial hemangioma.

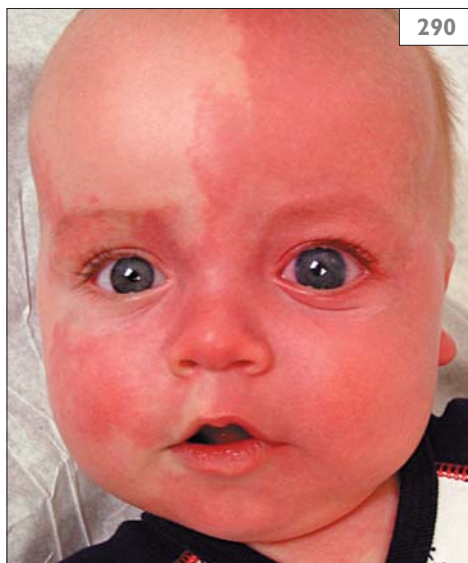Infants and children with SWS are at high risk for glaucoma (291) and should be referred promptly to an ophthalmologist when this is suspected. Buphthalmos (enlargement of the globe) and glaucoma occur commonly. MRI in SWS shows progressive cerebral hemiatrophy related to the meningeal angioma; early on, infants with SWS show accelerated myelination ipsilateral to the intracranial angioma (292). CT shows leptomeningeal calcification over time (293). Epilepsy in patients with SWS requires aggressive management with anti-convulsants and early consideration of epilepsy surgery in children with SWS and intractable seizures. Laser treatments can reduce the appearance of the port-wine stain.

### Von Hippel Lindau syndrome

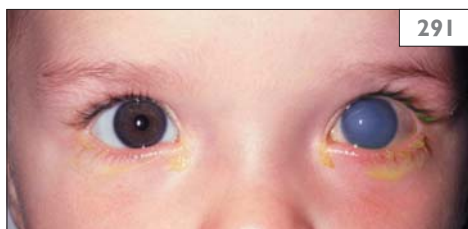Von Hippel Lindau syndrome, a disorder due to mutations in the tumor suppressor gene *VHL* on chromosome 3, causes angiomas of the retina, hemangioblastomas of the cerebellum or spinal cord, and increased rates of carcinoma of the kidney and pancreas. Headache can be a common presenting feature in an otherwise healthy-appearing child; headaches or unexplained posterior fossa or spinal hemorrhage should suggest the diagnosis. Pheochromocytomas frequently occur and produce hypertension. The diagnosis is confirmed by ophthalmological examination and neuroimaging, especially with MRI.



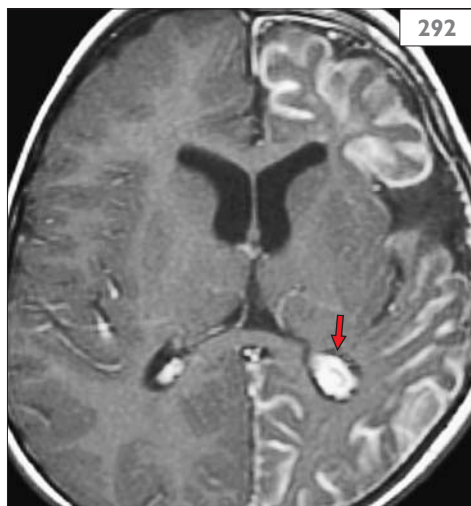**289** Gadolinium-enhanced axial T1-weighted MRI showing enhancing auditory canal schwannomas in NF-2 (arrows).



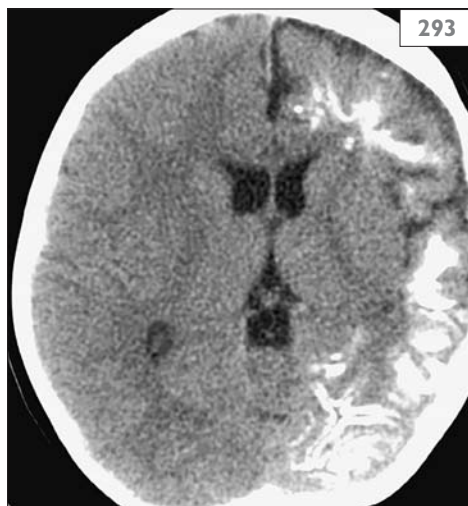**290** The facial appearance of a child with Sturge-Weber syndrome showing a port-wine stain (facial hemangioma).



**291** Congenital glaucoma of the left eye, as seen in Sturge-Weber syndrome.



**292** Axial T1-weighted, gadolinium-enhanced MRI showing hemispheric atrophy and leptomeningeal enhancement in Sturge-Weber syndrome. Arrow indicates an angioma in the trigone of the left lateral ventricle.



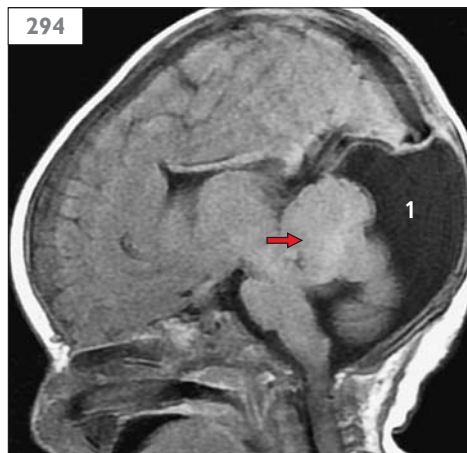
**293** CT showing cortical calcifications in Sturge-Weber syndrome.

## PHACES syndrome

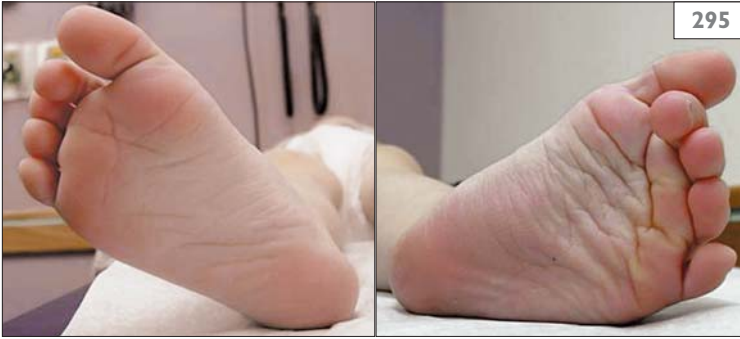PHACES syndrome, a disorder that can be confused with SWS because of facial port-wine staining, is an acronym for: posterior fossa abnormalities; hemangioma of the face; arterial cerebrovascular anomalies; cardiac defects, especially coarctation of the aorta; eye anomalies; and sternal defects. The majority of infants with PHACES syndrome are female. Several ophthalmological abnormalities have been observed in these infants, including choroidal hemangiomas, coloboma, microphthalmos, strabismus, and optic nerve hypoplasia or atrophy. MRI facilitates the diagnosis because posterior fossa abnormalities are exceptionally rare in SWS but fairly characteristic of PHACES syndrome (294).

## Miscellaneous neurocutaneous syndromes

Proteus syndrome and Cowden syndrome are overgrowth syndromes (295) that can present with macrocrania in childhood. They are associated with mutations in the phosphatase and tensin homolog (*PTEN*) gene, a tumor suppressor gene. Persons with these disorders are at increased risk for tumors of the breast, prostate, uterus, and brain. A related disorder, Bannayan–Riley–Ruvalcaba syndrome, also associated with *PTEN* mutations, causes macrocephaly, motor developmental delay, and subcutaneous lipomas. Incontinentia pigmenti, a rare neurocutaneous disorder caused by mutations in the gene *NEMO* (NF-kappaB essential modulator), can be associated with waxy lesions of the skin (296), developmental delay, seizures, and microcephaly. Cataracts and anomalies of the teeth, e.g. peg-shaped teeth, can be additional features of incontinentia pigmenti. Epidermal nevi can be observed in several pediatric syndromes, including epidermal nevus syndrome, hemimegalencephaly (297) and Proteus syndrome.

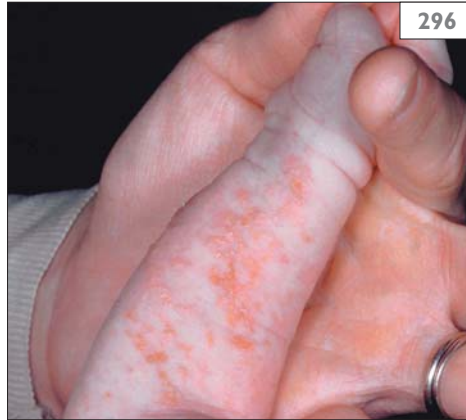

294 Sagittal T1-weighted MRI showing an anomalous posterior fossa in an infant with PHACES syndrome (arrow = dysplastic cerebellum; 1 = retrocerebellar cyst).

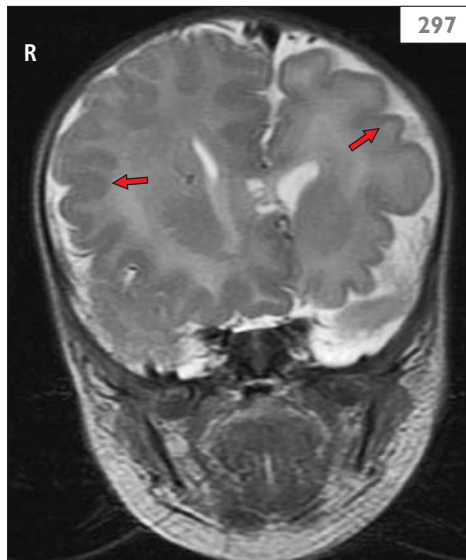


295 Hemihypertrophy in Proteus syndrome.

296 The waxy, hyperpigmented lesions of incontinentia pigmenti.



297 Hemimegalencephaly, as seen in the epidermal nevus syndrome. Arrows indicate the cerebral cortical gray matter. Note the thickened cortex on the right, indicative of cortical dysplasia.





## The infant with a neural tube defect

The human CNS begins as a flat plate, the neural plate, on the dorsal surface of the developing embryo. This plate then folds, becoming the neural groove, and the groove closes dorsally to form the neural tube. The neural tube briefly has openings at each end, rostrally, the anterior neuropore, and caudally, the posterior neuropore. These events evolve rapidly during the first 4 weeks of gestation, typically before a woman recognizes that she is pregnant; the anterior neuropore closes by 26 days and the posterior neuropore closes by 28 days. When the neural tube fails to close or closes aberrantly, neural tube defects are the result. Neural tube defects, consisting of open defects such as anencephaly and myelomeningocele (MMC), and closed defects such as spina bifida occulta and tethered cord, affect approximately 1 in 1000 live-born infants in the USA. Although the precise etiology of most neural tube defects remains uncertain, folic acid supplementation (0.4–4.0 mg daily) reduces the incidence of MMC, suggesting that folate deficiency or folate-associated factors have important roles in the embryogenesis of these disorders.

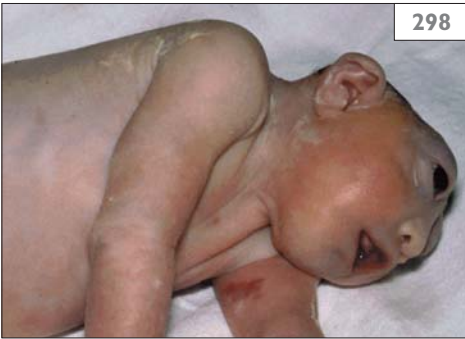### Anencephaly

Anencephaly, failure of anterior neuropore closure, represents the most dramatic and severe of the neural tube defects and is incompatible with life. Infants with this disorder, more often female, lack much of the scalp, skull, and cerebrum (298, 299), but may have residual portions of the brainstem. Consequently, newborn infants with anencephaly may temporarily display rudimentary brainstem functions, such as breathing, sucking, and swallowing.

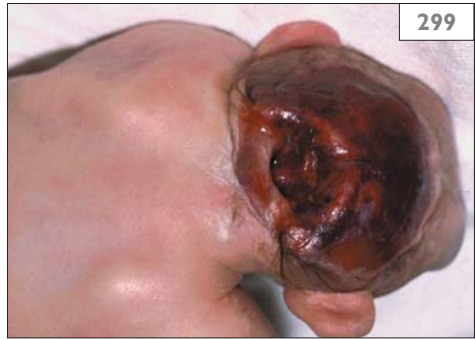
### Myelomeningocele

MMC (a bony defect of the spine containing both meninges and neural elements) and meningocele (a bony defect of the spine containing meninges only) reflect failure of posterior neuropore closure. These disorders, along with related conditions lipomeningocele, lipomyelomeningocele, anterior meningocele, are considered manifestations of spinal bifida or ‘open spine’. Myelomeningocele and meningocele usually occur at the lumbar or lumbosacral levels (300, 301); however, these disorders can also affect the cervical or thoracic regions.

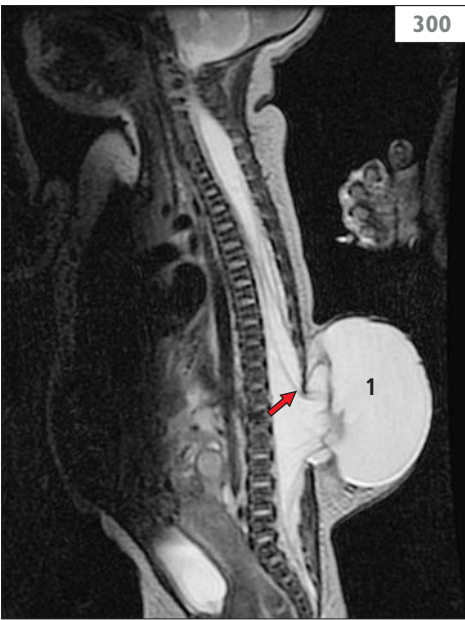
The manifestations and neurological outcomes of these disorders depend upon the level and severity of the defect and the presence of complications, such as hydrocephalus and infection. A MMC at the L4 level or below or a meningocele at any level is usually associated with independent ambulation, whereas a MMC above this level usually does not provide sufficient motor control to allow independent ambulation. Hydrocephalus, a common associated feature of MMC, results from a Chiari II malformation (302) and requires placement of a ventriculoperitoneal shunt. Urological and orthopedic issues are also common, indicating that infants, children, or adults with MMCs should be managed by an experienced multidisciplinary team consisting of neurosurgeons, urologists, orthopedists, and rehabilitation specialists. Seizures can occur, necessitating neurological consultation, and varying degrees of cognitive dysfunction may be present, especially in children with hydrocephalus.



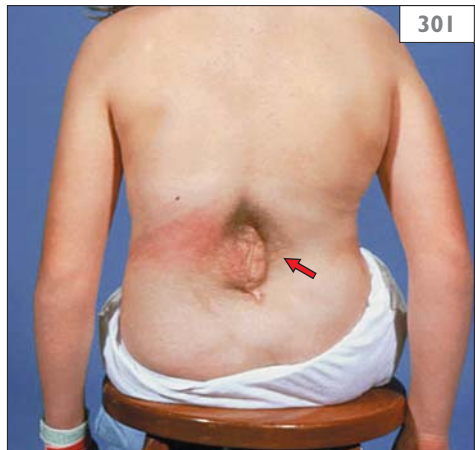298 An infant with anencephaly (side view).



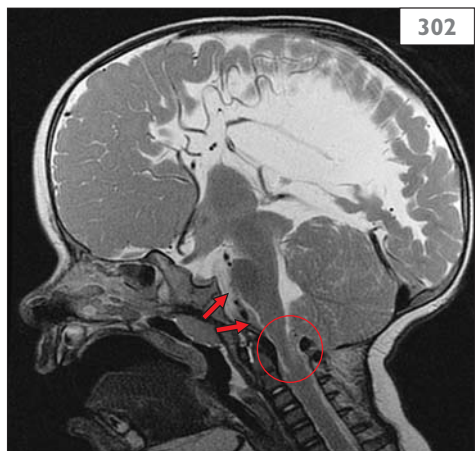
299 The infant in 298 shown posteriorly. Note the absence of scalp, skull, and cerebral cortex.



300 Sagittal T2-weighted spine MRI showing a myelomeningocele. Neural elements (arrow) extend into the CSF-containing myelomeningocele (1).



301 A child with a repaired lumbar MMC (arrow). Note the hair patch adjacent to the defect.



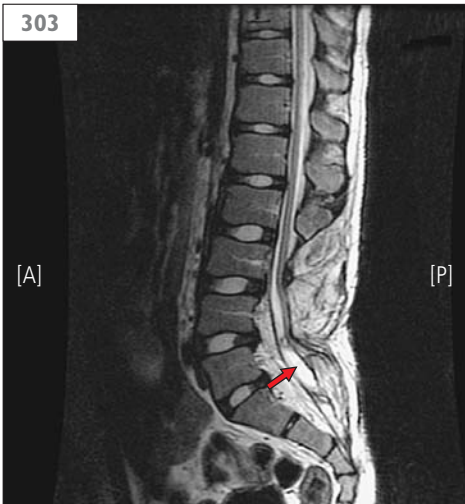302 Chiari type II showing a dysplastic, elongated brainstem (arrows) and the cerebellum extending below the level of the foramen magnum (circle).



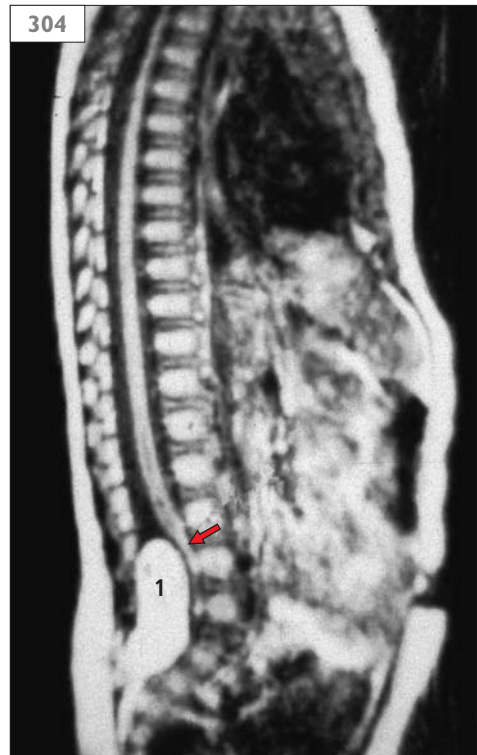## Tethered cord

Tethered cord, a less severe manifestation of neural tube defects, should be considered in young children with low back pain, scoliosis, accentuated lumbar lordosis, and unexplained delays in achieving urinary continence. Such children often have cutaneous signs, such as lipomas, hemangiomas, or hairy patches in the lumbosacral region, or unilateral foot deformities. Tethered cord can be detected in the first

6 months of life by spinal ultrasound (53) or later in life by spinal MRI (303). Tethered cord can be associated with intraspinal lipoma (304), hydrosyringomyelia (220) or Chiari I malformation (220, 264), indicating that children with suspected tethered cord usually require imaging of the entire spine and brain. Management consists of neurosurgical release of the tethered spinal cord.



**303** T2-weighted sagittal spine MRI showing a tethered spinal cord (arrow).



**304** T1-weighted sagittal spine MRI showing a tethered spinal cord (arrow) and an intraspinal lipoma (1).

# Headaches

## Main Points

- Migraine affects 3% to 15% of children and adolescents.
- Rescue medications for pediatric migraine include nonsteroidal anti-inflammatory drugs and the triptans.
- Pediatric migraine can be prevented using cyproheptadine, topiramate, divalproex sodium, amitriptyline,  $\beta$ -blockers, and calcium channel blockers.
- Major migraine variants include paroxysmal vertigo, paroxysmal torticollis, cyclic vomiting, basilar migraine, hemiplegic migraine, the Alice-in-Wonderland syndrome, and acute confusional migraine.
- As many as 5% of the adolescent population, mostly female, have chronic daily headaches, a multifactorial disorder in which migraine and psychological factors have important roles.
- Headaches associated with intracranial tumors are chronic, mild, often occipital in location and associated with other signs or symptoms, including unexplained emesis, diplopia, ataxia, or seizures.
- Pseudotumor cerebri (idiopathic intracranial hypertension) produces daily headaches and visual changes, including diplopia and transient obscurations.
- Postconcussion syndrome, a common complication of mild traumatic brain injury, causes daily headaches, memory loss, somnolence, and dizziness or vertigo.

## Introduction

Headaches represent some of the most common problems encountered by primary care physicians and child neurologists. As many as 50% of adolescents report occasional headaches, and 8–15% of adolescents, or more, have migraine. Moreover, 1 of every 100 children (1%) under 5 years of age also has headaches, usually migraines. Headaches cause considerable concern for parents and physicians. Although brain tumors certainly cause headaches, the vast majority of

headaches in childhood or adolescence are not the result of tumors or other life-threatening conditions. However, tumors do occur, and the challenge posed to clinicians is to differentiate headaches due to tumors from headaches due to less serious conditions. This section focuses on two types of headaches, migraine, a common disorder producing intermittent or occasional headaches, and chronic daily, a disorder that causes persistent headaches, and also describes other headache syndromes that can affect children and adolescents.

## Migraine

### DIAGNOSIS AND CLINICAL FEATURES

Migraine reflects the complex interaction of genetic predilections to headaches and environmental factors that trigger migraines. Most neurologists and neuroscientists currently favor the neurovascular pathogenesis which states that cortical spreading depression and neurochemically-induced vascular dilatation lead to the aura and headache, respectively. Several environmental factors, including certain foods and activities, can initiate the cascade of events that lead to migraine headaches and their associated features.

The International Headache Society defines migraine without aura, formerly known as common migraine, as intermittent headaches, unilateral or bilateral, that last 1–72 hours and produce nausea or vomiting (textbox).

#### Migraine without aura (~70% of pediatric migraine)

- At least five attacks.
- Headache lasting 1–72 hours.
- Unilateral or bilateral, pulsatile, intense, or aggravated by activity (at least two features).
- Nausea or vomiting, photophobia or phonophobia (at least one feature).
- No other cause (positive family history).

Migraines are often made worse by bright lights (photophobia) and loud sounds (phonophobia). Migraine headaches can be constant, pulsatile, and worsen with movement or activity. Many children with migraine also have motion- or car-sickness, recurrent epistaxis, or allodynia (cutaneous pain, usually of the scalp).

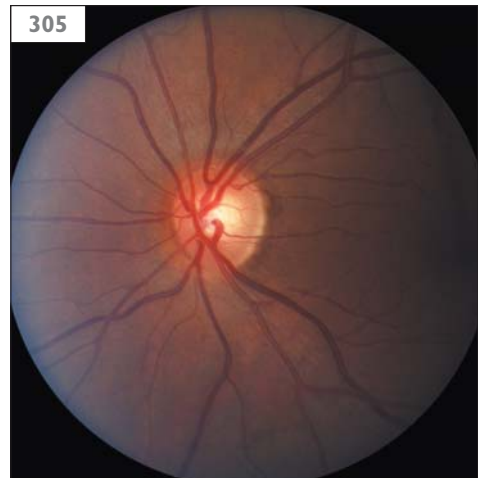
Migraine with aura, formerly known as classic migraine, includes these features, but is preceded or accompanied by a fully reversible aura that can consist of vertigo, ‘dizziness’, dysarthria, paresthesias, and visual phenomena, including flashes, sparkles, or a scintillating scotoma with zig-zag margins (known as a fortification spectrum) that can progress to complete hemianopsia (textbox).

#### Migraine with aura (~30% of pediatric headache)

At least two attacks of headache with at least three of the following features:

- Fully reversible aura.
- Aura develops gradually over 4 minutes.
- Aura lasts no more than 60 minutes.
- Headache that follows the aura within 60 minutes or may begin before or simultaneously with the aura.

The evaluation of children with suspected migraine should begin with a comprehensive medical history and physical examination. Physicians should pay particular attention to the child’s head circumference, blood pressure, and funduscopic examination (305). A child with migraine should have a normal neurological examination and a positive family history of the disorder before a clinician can assume that the child’s headaches represent migraines.



305 Normal optic nerve.

## MANAGEMENT

Treating childhood migraine begins with a thorough search for migraine triggers. Many foods or chemicals, including prepared meats, monosodium glutamate, cheeses, aspartame, caffeine and chocolate, provoke migraine. Dehydration, stress (both good and bad), altitude, lack of adequate sleep, and irregular routines can also trigger migraines in many children. Thus, a peaceful night's rest and adequately spaced meals of the appropriate foods are the foundations of optimum management of migraine for all children.

Unfortunately, many children or their parents cannot identify specific triggering factors that can be avoided. Thus, migraine management in most children relies heavily upon pharmacological and nonpharmacological therapies. Specific strategies depend upon the frequency of the migraines and the effects that the migraines have on school attendance and job or athletic performance. Infrequent migraines (less than four per month) that last less than 24 hours and do not interfere with school attendance or other activities can be treated with rescue or abortive medications (*Table 38*, overleaf). Low cost, well-tolerated, over-the-counter preparations, such as acetaminophen, ibuprofen, and naproxen sodium, work effectively for many children and adolescents, especially when coupled with rest and brief cessation of activity.

The available data suggest that certain triptans (sumatriptan nasal spray and zolmitriptan nasal spray) have benefit in pediatric migraine and produce few side-effects. Some children will benefit with administration of anti-nausea medications, such as metoclopramide or hydroxyzine, concurrently. We currently reserve triptans for the adolescent or the occasional older child who does not respond to appropriate doses of the nonsteroidal anti-inflammatory drugs (NSAIDs). A rescue plan based on the child's age and their response to abortive medications should be provided for all children with migraine (textbox).

### Rescue plan for migraine in children <12 years of age or adolescents who do not respond to triptans:

- Ibuprofen or naproxen sodium (10 mg/kg) at migraine onset. If nausea and vomiting accompany the headaches, consider metoclopramide or hydroxyzine orally or promethazine suppositories (the latter should not be used in children <2 yr). Be alert for extrapyramidal side-effects.
- If the headache persists for 4 hours and there is no vomiting, give naproxen sodium 10 mg/kg.
- If the headache persists for 6 hours and the child cannot sleep, consider diphenhydramine, 12.5–25 mg, depending upon weight and age, for sedation.
- If the headache persists for >12 hours and the child cannot sleep, consider evaluation by a physician.

### Rescue plan for migraine in adolescents (>12 years of age):

- Ibuprofen or naproxen sodium orally at migraine onset. Some adolescents respond favorably to aspirin-containing preparations. (Because of the risk of Reye syndrome, aspirin-containing medications must be avoided in adolescents with chicken pox or influenza). If the adolescent does not usually respond to NSAIDs, provide sumatriptan nasal spray (5–20 mg) or zolmitriptan nasal spray (5 mg). If nausea or vomiting occur consider metoclopramide orally or promethazine rectally.
- If the headache persists for 2 hours, repeat the triptan.
- If the headache persists for 4 hours, give naproxen sodium, 10 mg/kg orally.
- If the headache persists for 6 hours and promethazine has not been used, give diphenhydramine, 25 mg.
- If the headache persists for >12 hours and the adolescent cannot sleep, consider evaluation by a physician.
- Ergotamine preparations (e.g. dihydroergotamine) cannot be given if the adolescent has received a triptan in the preceding 24 hours.

**Table 38 Medications for the acute treatment of pediatric migraine (rescue medications)**

<i>Drug</i>	<i>Dose</i>	<i>Side-effects</i>
<b>Nonsteroidal Analgesics</b>		
Acetaminophen	10 mg/kg PO	GI upset
Naproxen sodium	10 mg/kg PO	GI upset
Ibuprofen	10 mg/kg PO	GI upset
<b>Combination medications</b>		
Aspirin–caffeine–acetaminophen <sup>1</sup>	1 or 2 tablets PO	GI upset
Isometheptene–dichloralphenazone–acetaminophen	1 or 2 capsules PO	Sedation, dizziness
Acetaminophen, butalbital, and caffeine <sup>2</sup>	1 tablet PO	Sedation
<b>Triptans</b>		
Zolmitriptan	5 mg nasal spray	Jaw tightness, weakness, anxiety
Sumatriptan	5–20 mg nasal spray	Bad taste, tingling, flushing, nausea

<sup>1</sup>Aspirin-containing preparations should be avoided when children or adolescents have chicken pox and influenza.

<sup>2</sup>Given the potential for addiction, this should be used sparingly.

When migraines exceed four per month and interfere with school attendance and performance or participation in activities, prevention should be considered (*Table 39*). The choice of medication depends on the child's age and weight, the side-effect profile of the medication, and the presence of comorbid factors. Many commonly used medications, including cyproheptadine, divalproex sodium, imipramine, gabapentin, and amitriptyline, have not been studied adequately in pediatric populations. Sedation and weight gain can limit the satisfactory use of the above medications, especially in adolescents. After age 10 years the risk of valproate hepatotoxicity is negligible when this drug is used as monotherapy. There is a 1–2% risk of spina bifida and fetal valproate syndrome in the offspring of mothers who take valproate during their pregnancies.

Currently, we suggest cyproheptadine in children of normal weight under age 10 years; topiramate in adolescents and overweight children, and amitriptyline in adolescents who report insomnia or depression. Topiramate therapy can be associated with cognitive dysfunction, such as memory loss and word-finding problems, especially at higher doses, whereas amitriptyline and cyproheptadine therapy can be associated with appetite stimulation, weight gain, and sedation. Alternative and complementary therapies, including massage therapy, biofeedback, megavitamin therapy (especially riboflavin), relaxation–distraction methods, craniosacral therapy, and chiropractic manipulation, have been used with variable success, especially in adolescents who experience frequent, prolonged migraines.

**Table 39 Medications for prevention of pediatric migraine**

<i>Drug</i>	<i>Dose</i>	<i>Side-effects</i>
Cyproheptadine	2–8 mg/day PO	Sedation, weight gain
Amitriptyline	10–50 mg/day PO	Sedation, weight gain
Divalproex sodium	10–15 mg/kg/day PO	Weight gain, sedation, hair loss
Topiramate	0.25–2 mg/kg/day PO	Weight loss, sedation, cognitive dysfunction, dyshidrosis causing over-heating, nephrolithiasis

## Migraine variants

Several transient neurological phenomena of children and adolescents are considered migraine variants. Some, but not all, are associated with headache, indicating that a family history of migraine has an important role in establishing these diagnoses. These variants include:

- **Paroxysmal vertigo:** a disorder of young children associated with recurrent episodes of abrupt and transient vertigo and often, emesis.
- **Paroxysmal torticollis:** a disorder of infants and young children associated with recurrent episodes of abrupt torticollis lasting hours to a few days.
- **Cyclic vomiting:** a childhood disorder with recurrent bouts of unexplained emesis that often begins in the early morning and lasts several hours.
- **Ophthalmoplegic migraine:** recurrent bouts of ophthalmoplegia, usually affecting the oculomotor (CN3) nerve, often without headache. Many authorities believe that this condition is due to inflammation of the oculomotor nerve rather than a migraine variant. MRI with intravenous contrast may show inflammation of the nerve near its exit from the midbrain (164).
- **Hemiplegic migraine:** a disorder of children and adolescents associated with episodes of acute and transient hemiparesis.
- **Basilar migraine:** a disorder of adolescents characterized by intermittent episodes of vertigo, dysarthria, and ataxia, followed or accompanied by headache; can be associated with syncope.
- **Acute confusional migraine:** a disorder, usually occurring in adolescents, producing abrupt confusion, often associated with anxiety, fear, or combativeness.

## Chronic daily headaches

### DIAGNOSIS AND CLINICAL FEATURES

After the age of 13 years chronic daily headache becomes an extremely common headache syndrome, accounting for as many as 40% of headaches and affecting as many as 5% of adolescents (textbox).

#### Chronic daily headache

- Occur at least 15 days per month.
- Present for at least 3 months.
- Last more than 4 hours per day.
- No identifiable intracranial pathology.

Approximately 75% of adolescents with chronic daily headache are female. Chronic daily headache appears to be a multifactorial disorder, with a migraine predilection and female sex being major predisposing factors.

The components of chronic daily headaches can sometimes be organized according to vulnerabilities (e.g. female sex and a family history of migraine); precipitants (e.g. acute or chronic illness, family discord); and maintenance factors (e.g. depression, perfectionist personality type). Medication overuse (rebound headaches) of NSAIDs, opiates, or triptans, can be an additional maintenance factor that is often under-recognized in children. The headaches of chronic daily headache tend to be daily, holocranial, and moderate in severity. Many adolescents with such headaches have also frequent, intercurrent migraine-like phenomena with nausea, phonophobia, and photophobia that impart an undulating or fluctuating course to this headache syndrome. Neurological examination is typically normal, as are neuroimaging results, routine laboratory studies, and, if performed, CSF analysis.

**MANAGEMENT**

Adolescents with chronic daily headaches require a comprehensive neurological examination, including funduscopy; most should undergo brain MRI to exclude intracranial abnormalities (e.g. Chiari malformation; **306**). Thyroid studies, complete blood cell count, erythrocyte sedimentation rate, urinalysis, and comprehensive metabolic panel should be considered, depending upon the associated symptoms. CSF examination is usually not indicated unless there are signs or symptoms suggestive of idiopathic intracranial hypertension (IIH; pseudotumor cerebri).

Because chronic daily headaches often represent transformed migraines, we suggest that therapy begins with migraine preventive medications such as topiramate or amitriptyline (textbox).

**Treatment of chronic daily headaches**

- Eliminate medication (especially NSAIDs and opiates) or caffeine overuse.
- Consider amitriptyline or topiramate.
- Manage comorbid conditions such as depression and sleep disorders.
- Consider complementary therapies, including distraction–relaxation, biofeedback, chiropractic, riboflavin, and craniosacral therapy.

Clinicians should search for comorbid factors, including depression, family stressors, and sleep disorders, including restless legs syndrome. Headaches may not improve unless these comorbid factors are managed satisfactorily. Therapies that may benefit selected adolescents with chronic daily headaches include megavitamin therapy (especially riboflavin), craniosacral therapy, and chiropractic. With the passage of time, headaches usually improve in adolescents who have chronic daily headaches precipitated by minor head trauma or infections, such as infectious mononucleosis or *Mycoplasma pneumoniae*.

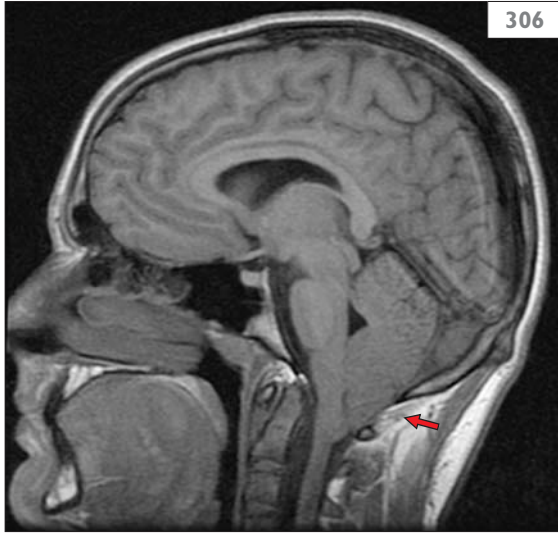
**Other headache syndromes****Tension-type headaches**

Tension-type, nonmigrainous headaches affect as many as 15–20% of adolescents. The clinical features consist of bilateral, nonpulsatile headaches of mild to moderate intensity that last 30 minutes to several days. Children or adolescents with tension-type headaches, often described as a tightening sensation, do not have nausea, vomiting, or exacerbations with activity and may respond to amitriptyline, biofeedback, or relaxation–distraction strategies.

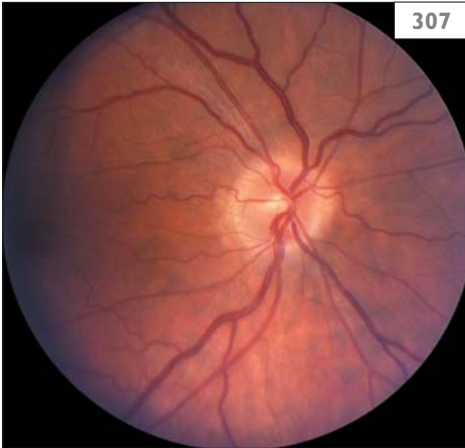**Idiopathic intracranial hypertension (pseudotumor cerebri)**

Also known as pseudotumor cerebri, IIH represents an infrequent, but important cause of headaches in childhood and adolescence. Factors associated with IIH include medication use, especially minocycline, endocrinological disorders, such as hypothyroidism, and obesity. The headache can be holocranial, intermittent or constant, and exacerbated by activity. Affected patients may complain of diplopia or transient visual obscurations (episodes of blurred vision lasting less than 30 seconds); neurological examination usually reveals papilledema (**307, 308**) and sixth cranial nerve palsy (**166, 167**). Brain MRI and MRV should be obtained to exclude intracranial mass lesions and cerebral sinovenous thrombosis, potential causes of increased intracranial pressure. The diagnosis is confirmed by lumbar puncture that detects an elevated CSF opening pressure, usually >250 mm H<sub>2</sub>O. Therapy consists of repeated lumbar punctures or administration of acetazolamide; rarely, optic nerve sheath fenestration is necessary to preserve optic nerve function.

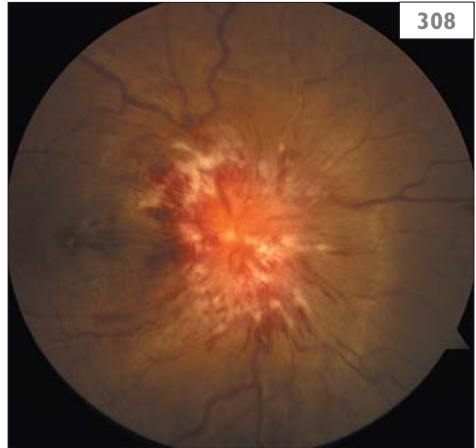



**306** Sagittal T1-weighted MRI showing a Chiari type I malformation (arrow).



**307** Mild papilledema showing indistinct optic nerve margins and elevation of the nerve in idiopathic intracranial hypertension (pseudotumor cerebri).

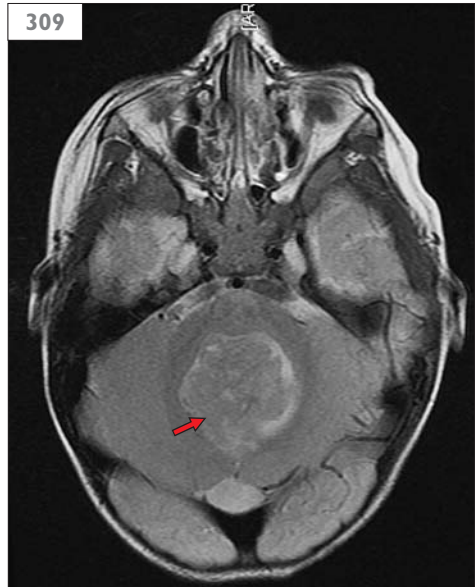


**308** High-grade papilledema showing obliteration of the disk margin, disk elevation, and hemorrhages.

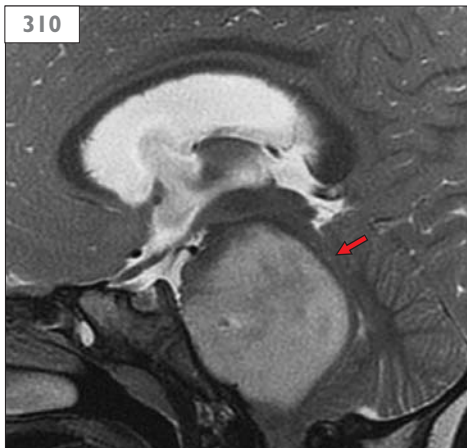
## Intracranial neoplasms

Headaches associated with intracranial mass lesions result from increased intracranial pressure and traction on intracranial vascular structures. Such headaches tend to be more noticeable during the early morning hours or upon awakening and may remit as the day progresses. With time, other neurological signs and symptoms appear, such as ataxia, diplopia, personality change, seizures, or focal deficits.

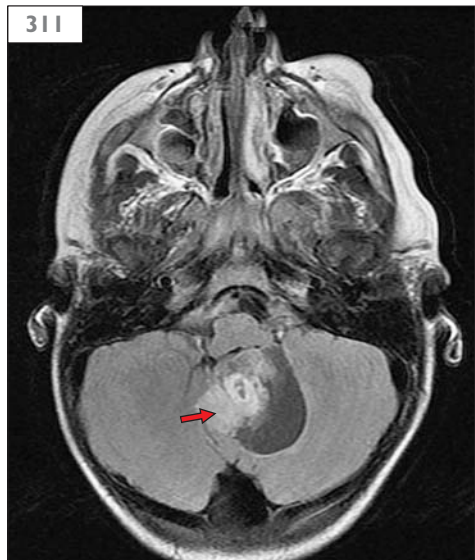Approximately two-thirds of pediatric brain tumors involve structures of the posterior fossa (309–311), causing early cerebellar dysfunction and signs or symptoms of increased intracranial pressure (312), including ataxia, diplopia, headache, vomiting, and papilledema (313). Signs and symptoms of supratentorial tumors include headaches, seizures, and changes in personality or vision (314, 315) (Table 40, page 250). The diagnosis of intracranial tumors is established best by brain MRI, typically with intravenous administration of gadolinium.



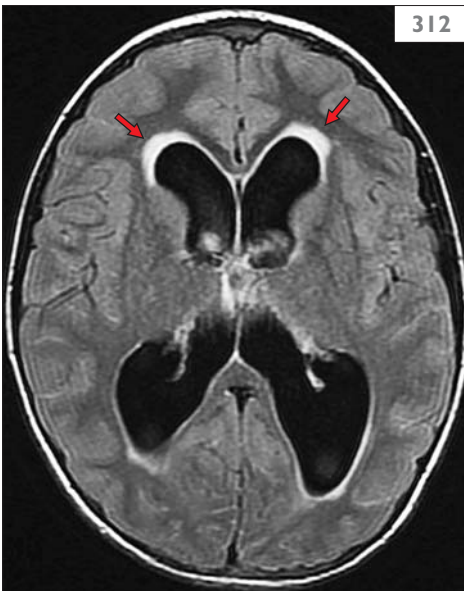
**309** Unenhanced axial T2-weighted MRI showing a tumor (arrow), compatible with a medulloblastoma, filling the 4<sup>th</sup> ventricle.



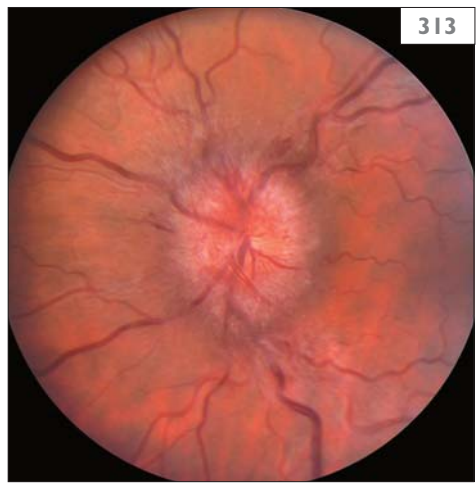**310** Sagittal T2-weighted MRI showing hydrocephalus and posterior displacement of the 4<sup>th</sup> ventricle by a brainstem glioma (arrow).



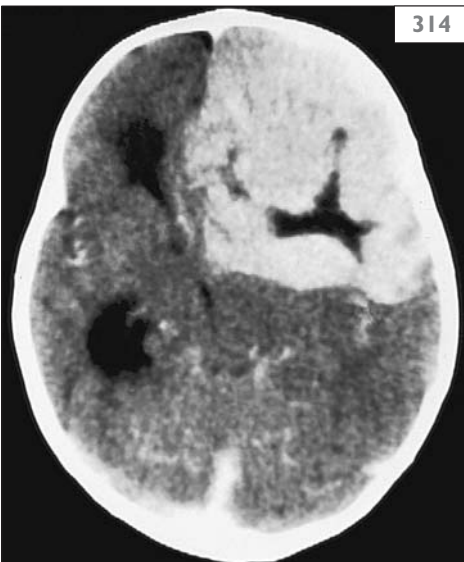
**311** Axial FLAIR MRI showing a medulloblastoma (arrow) within the 4<sup>th</sup> ventricle.



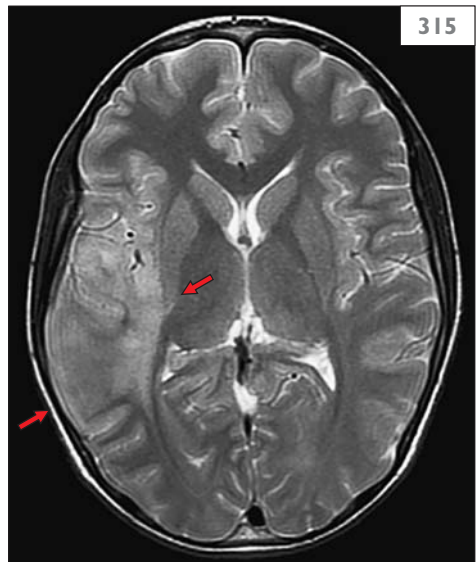
**312** Axial FLAIR MRI with transependymal flow (arrows) indicating increased intracranial pressure in a child with a neoplasm obstructing the 4<sup>th</sup> ventricle.



**313** Fundus photograph showing papilledema.



**314** Contrast CT showing a large enhancing mass that was shown by biopsy to be a supratentorial primitive neuroectodermal tumor.



**315** Axial FLAIR MRI showing a diffuse, hemispheric lesion (arrows) that was shown by biopsy to be a glioblastoma multiforme.

**Table 40 Childhood intracranial neoplasms and associated symptoms or signs**

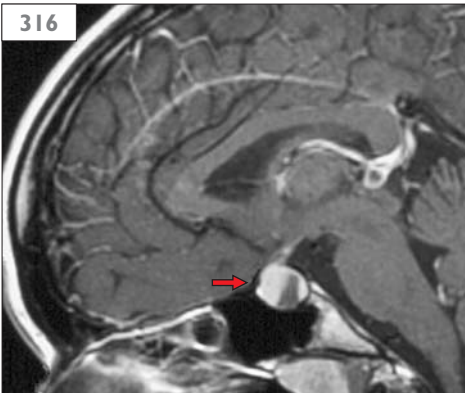
*Neoplasm Features*

**Supratentorial**

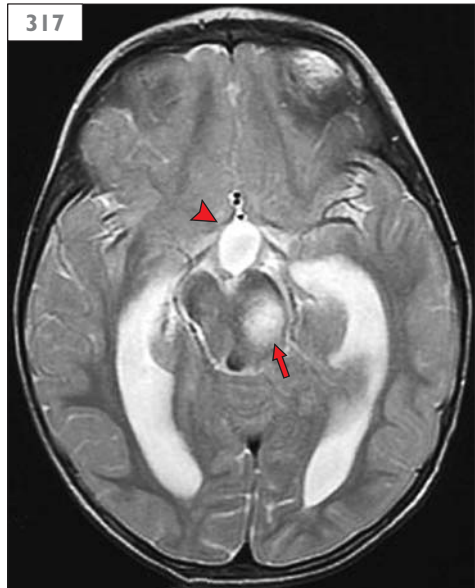- Glioblastoma multiforme  
Seizures, headaches, personality change (315)
- Oligodendroglioma  
Seizures, headaches
- Optic pathway glioma  
Vision changes, headaches
- Primitive neuroectodermal tumor (PNET)  
Seizures, macrocephaly (314)
- Hypothalamic tumors (gliomas, hamartoma)  
Seizures, vision changes, endocrinopathies, diencephalic syndrome (elfin faces, growth failure)
- Choroid plexus papilloma  
Hydrocephalus, headaches
- Teratoma  
Seizures, headaches
- Pituitary adenoma (uncommon in childhood) (316)  
Headaches, bitemporal hemianopsia

**Infratentorial**

- Medulloblastoma  
Headaches, vomiting, ataxia (309)
- Pilocytic astrocytoma  
Headaches, vomiting, ataxia
- Ependymoma  
Headaches, vomiting, ataxia
- Brainstem glioma (310, 317)  
Focal deficits (e.g. diplopia, facial weakness), 'crossed signs' (focal cranial neuropathy associated with contralateral hemiparesis)



**316** A gadolinium-enhanced sagittal T1-weighted MRI shows a pituitary adenoma (arrow).



**317** Axial T2-weighted MRI in a child with headache shows a brainstem tumor (arrow) and enlarged 3<sup>rd</sup> ventricle (arrowhead) indicating aqueductal obstruction.

## Vasculitis

Headache is the presenting complaint in as many as 40% of adolescents with systemic lupus erythematosus. The headaches can be intermittent, resembling migraine, or chronic, resembling chronic daily headaches of childhood and adolescence. Patients with vasculitic disorders typically have elevated serum inflammatory markers, CSF pleocytosis and protein elevations, and abnormal MRIs showing inflammation, stroke, or vascular abnormalities, such as stenosis, beading, or occlusion. CNS vasculitis and stroke can be a complication of varicella zoster virus infection in young children and resemble the adult disorder of herpes zoster ophthalmicus and stroke.

## Postconcussion syndrome

Headache frequently accompanies the postconcussion syndrome, a condition that follows 50% or more of cases of traumatic brain injury. The headaches consist of daily, dull, often disabling pain that disrupts concentration, school performance, and other activities of daily living. The pathogenesis of the postconcussion syndrome remains controversial, and some believe that psychological factors, such as depression or anxiety, may contribute to postconcussion syndrome. The diagnosis is established clinically, based upon the presence of symptoms, including headache, dizziness, fatigue, irritability, and sleep problems. Concentration and memory can also be affected. The majority of children or adolescents with the postconcussion syndrome recover spontaneously, usually within 3–6 months. Amitriptyline, topiramate, and nonpharmacological strategies can be used when headaches interfere with daily activities.

## Miscellaneous headache syndromes

- Exertional headaches: headaches provoked by running, swimming, weight lifting, and other activities. May remit with indomethacin therapy.
- Ice cream headaches: brief headaches (<5 minute duration) provoked by ingestion of cold food or drink. Common in persons with migraine.
- Altitude headaches: holocranial, throbbing headaches associated with travel to altitude above 2,348 metres (8,000 feet). Can be treated or prevented with acetazolamide or dexamethasone.
- Hypertensive encephalopathy: produces severe, throbbing, or constant headaches that are present upon awakening. MRIs show T2 prolongation affecting the occipital and parietal cortices; also known as posterior reversible encephalopathy syndrome (PRES).
- Intracranial hypotension: produces migraine-like headaches that are typically positional in nature. The child or adolescent may be asymptomatic when supine; headaches appear and intensify when the child is standing. Intracranial hypotension occurs iatrogenically after lumbar puncture or neurosurgical procedures or spontaneously with dural leaks. Persons with Marfan or Ehlers–Danlos syndromes are at increased risk for spontaneous dural leaks and intracranial hypotension. MRI may identify the site of the leak; isotope cisternography can be used to confirm CSF leakage.
- Paroxysmal hemicrania: produces frequent unilateral orbital or supraorbital pain that can occur several times per day and last 2–30 minutes. Autonomic symptoms can be prominent features. The headaches may respond to indomethacin.
- Jolts and jabs: considered by some to be a variation of migraine, this type of headache lasts seconds and can occur many times per day. Pain can be quite severe and may respond to indomethacin.

*This page intentionally left blank*

# Hypotonia and weakness

## Main Points

- Neonatal hypotonia ('the floppy infant') can result from disorders of the brain, spinal cord, nerve, and muscle, as well as from genetic, hereditary, or systemic conditions.
- Spinal muscular atrophy, a degenerative disorder of anterior horn cells, usually presents in the first year of life and causes progressive weakness.
- Duchenne muscular dystrophy, the most common muscular dystrophy, causes chronic, progressive, fatal weakness in boys.
- Myasthenia gravis, uncommon in young children, is suggested by bulbar dysfunction and fluctuating systemic weakness.
- Dermatomyositis, an uncommon cause of weakness in children or adolescents, is suggested by skin rash, especially over the knuckles, and diffuse muscle weakness and tenderness.

## Introduction

Hypotonia and muscle weakness, relatively common symptoms and signs in young children, result from many different conditions, including disorders of muscle, neuromuscular junction, peripheral nerve, and the CNS. Specific diagnoses are influenced by age, sex, the rate of progression, and the presence of other

signs and symptoms, features that may enable the clinician to recognize specific disease patterns. This chapter describes important causes of hypotonia and weakness in infants, children, and adolescents, focusing on neonatal hypotonia, spinal muscular atrophy, Duchenne muscular dystrophy, congenital myopathies, dermatomyositis, and myasthenia gravis.



## The hypotonic infant

### DIAGNOSIS AND CLINICAL FEATURES

An infant's muscle tone reflects the complex interactions of the brain, spinal cord, peripheral nerve, neuromuscular junction, and muscle. Lesions at any of these levels can produce abnormally low muscle tone (hypotonia), with or without weakness (textbox).

#### Potential causes of hypotonia in infants

- CNS: intracranial hemorrhage, neonatal brain tumor, hydrocephalus, developmental brain abnormalities such as lissencephaly or the Dandy–Walker malformation.
- Neuromuscular: spinal muscular atrophy, congenital myopathy, congenital hypomyelinating polyneuropathy, neonatal myasthenia gravis
- Syndromic: trisomy 21 (**232–235**), Prader–Willi syndrome (**231**), Turner syndrome (**318, 319**), Zellweger spectrum disorders (**248**), Angelman syndrome (**257**), Rett syndrome (**113**), Williams syndrome (**118**), and others.
- Infectious: congenital (TORCH) infections, neonatal meningitis, herpes simplex virus encephalitis, sepsis, infant botulism.
- Metabolic: hypoglycemia, hypocalcemia, hyponatremia, hyperbilirubinemia, hypothyroidism, disorders of organic acid or amino acid metabolism, mitochondrial disorders, glycogen storage disorders.
- Miscellaneous: benign congenital hypotonia.

In addition, systemic conditions, such as congenital or perinatal infections, metabolic derangements, such as hypoglycemia or hypocalcemia, and genetic or hereditary disorders, such as Prader–Willi syndrome (**231**), represent important, potential causes of hypotonia. Thus, the clinician must evaluate the hypotonic or ‘floppy infant’ comprehensively and thoughtfully, paying close attention to all physical and laboratory clues.

Assessing tone requires considerable patience and clinical practice. The clinician must create internal norms through repeated examinations of infants of various gestational ages and must

utilize a consistent battery of examination techniques that distinguish normal variations in tone from the clearly abnormal. In addition, the clinician must take into account the infant's state; a satiated infant who has just finishing nursing may seem weak and hypotonic when compared to the crying, hungry infant. Components of the Dubowitz Maturity Examination provide a useful foundation for examining tone in newborn infants (textbox).

#### Components of the Dubowitz Examination for assessing an infant's tone

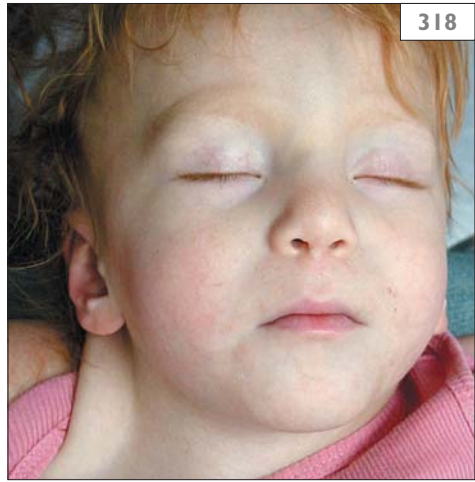- Square window: flexion of the infant's wrist.
- Scarf sign: adduction and flexion of the infant's arm across the chest.
- Popliteal angle: flexion/extension of the infant's knee.
- Heel to ear: flexion of the infant's leg and hip.

Assessment of tone should include moving the extremities through their entire ranges of motion; especially important in young infants are: flexion/extension at the elbow; flexion/extension at the wrist; flexion/adduction/abduction at the hips; flexion/extension at the knees; and flexion/extension at the ankles. The resting posture of a full-term infant with normal tone consists of flexion/adduction of the shoulders and hips and flexion of the elbows and knees. By contrast, a hypotonic term infant assumes a ‘frog leg’ posture (**320**) consisting of abduction and extension of the legs as well as the arms. Healthy preterm infants assume varying degrees of ‘frog leg’ postures, depending upon the degree of prematurity.

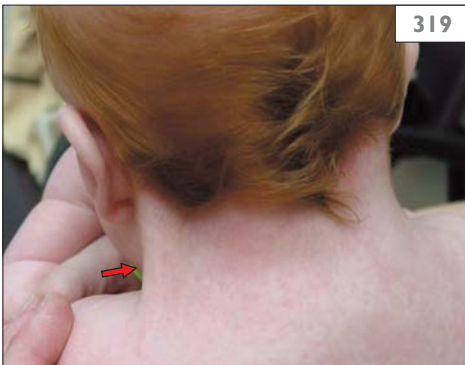The two remaining components of the motor examination, strength and reflexes, can provide important insights to the etiology of hypotonia in infants. Although difficult to test in a young infant, strength can be assessed by gauging the infant's arm or leg withdrawal in response to a noxious stimulus applied distally, e.g. pressure to the finger or toe nail bed. An infant with normal strength withdraws vigorously, whereas the response in a weak infant will be feeble. The infant's response to noxious stimuli depends not only on the infant's

strength, but also on his or her alertness. A somnolent, obtunded, or comatose infant may appear hypotonic and weak despite having normal neuromuscular function. Again, repeated practice is essential in creating internal norms for examining an infant's strength.

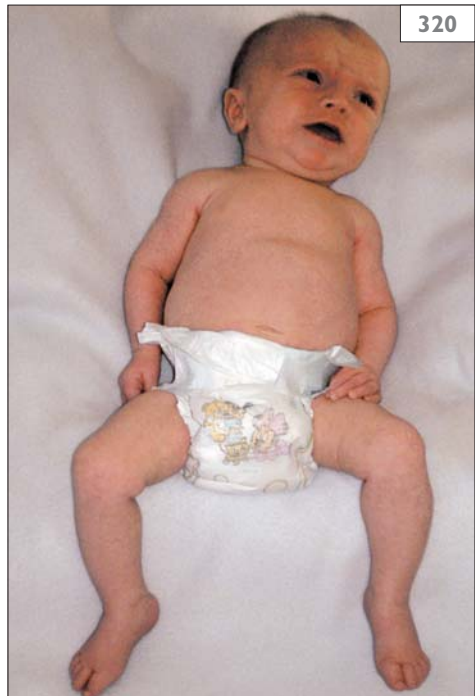Muscle stretch reflexes, also known as deep tendon reflexes, are more easily assessed than strength, especially at the infant's biceps, knees, and ankles. The examiner can apply the same scale used to grade the reflexes of older children or adults: 0: absent; 1: minimally present; 2: normally active; 3: hyperactive; and 4: clonus. In general terms, a hypotonic, weak infant with absent or markedly diminished muscle stretch reflexes likely has a disorder of the anterior horn cells or peripheral nerves, whereas a hypotonic infant with easily obtainable reflexes, whether weak or not, may have a systemic or CNS cause of hypotonia.



**318** The facial appearance of a child with Turner syndrome. Note the webbing on the right side of the child's neck.



**319** Neck webbing (arrow) in Turner syndrome.



**320** Frog leg posture in an infant with Werdnig-Hoffman disease (spinal muscular atrophy).

## Selected disorders in infants

### Spinal muscular atrophy

Spinal muscular atrophy (SMA), a progressive, autosomal recessive condition, has an incidence of 1 in 10,000 live births.

#### DIAGNOSIS AND CLINICAL FEATURES

SMA has three distinct phenotypes with onset in childhood (textbox).

##### Phenotypes of SMA

- Type 1 (Werdnig–Hoffman disease): onset in the first 6 months; infants never sit and usually die within 2 years.
- Type 2: onset between 7 and 18 months; infants sit but never walk; they may die in childhood or live to adulthood.
- Type 3 (Kugelberg–Welander disease): onset after 18 months; children will walk and live to adulthood.

Infants with Werdnig–Hoffman disease, the most severe form, usually appear normal at birth and present with hypotonia in the first few weeks of life. Occasionally, the disorder begins *in utero*, causing an arthrogryposis syndrome with diminished fetal movements, weakness, and multiple contractures (209). Infants with Werdnig–Hoffman disease have symmetric weakness, proximal more than distal, tongue fasciculations and absent or markedly diminished muscle stretch reflexes. The infant with this disorder typically exhibits a frog leg posture (320). Because facial movements are normal, these infants appear bright and alert (321), but head control and cry are noticeably weak. These infants never sit and have progressive bulbar and respiratory weakness. Without respiratory and nutritional support, such infants typically die within the first 2 years of life.

Type 2 and type 3 SMA affect toddlers and young children. Children with either type may be seen because of motor developmental delay and slowly progressive weakness. Examination shows hypotonia, symmetric, proximal > distal weakness and markedly diminished or absent muscle stretch reflexes. Bulbar and respiratory dysfunction may be prominent in type 2 SMA,

but these complications are only a late or minor feature in type 3 SMA. A fine tremor, most noticeable when the child reaches for objects, can be seen in both types 2 and 3. Intellect is preserved in all types of SMA.

SMA results from mutations in the survival motor neuron (SMN) gene, located on chromosome 5q13. This mutation causes progressive loss of anterior horn cells, denervation, and muscle cell death. The diagnosis of SMA currently relies upon demonstrating a homozygous deletion affecting exon 7 of SMN1. SMN1, the gene mutated in SMA, has a nearly identical copy, known as SMN2, on the same chromosome. The SMA phenotype reflects the interactions of the SMN1 mutation(s) and the number of copies of SMN2 possessed by the child. Children with type 1 SMA have one or two copies of SMN2, whereas those with type 2 or 3 tend to have three or more.

#### MANAGEMENT

Management of SMA requires a team approach, involving neuromuscular specialists, primary care physicians, respiratory therapists, physical therapists, dietitians, and parents. The management must begin by providing parents with accurate and candid information regarding the cause, therapy, and prognosis of SMA. Pulmonary disease remains the most common cause of death in both types 1 and 2 SMA. Current guidelines favor noninvasive approaches to respiratory care, consisting of frequent suctioning, chest physiotherapy, and noninvasive ventilation such as bilevel positive airway pressure (BiPAP). Gastrostomy can provide a safe, effective means for providing adequate fluids and calories.

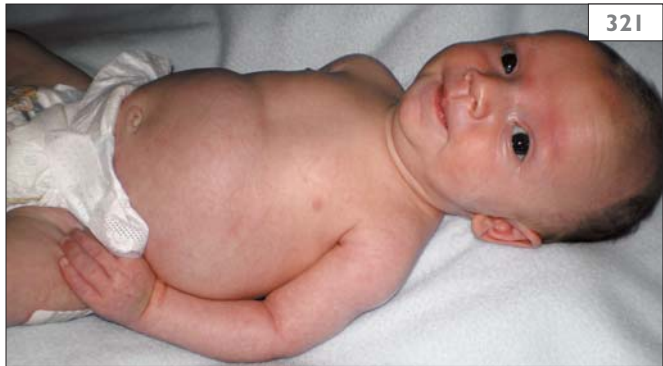### Prader–Willi syndrome

Hypotonia in the neonatal period is the most common early feature of Prader–Willi syndrome, a genetic disorder due to an abnormality on chromosome 15. In approximately 70% of cases Prader–Willi results from a deletion on the paternal chromosome 15; in 25% the condition is the result of maternal uniparental disomy, a situation in which the infant inherits two maternal copies of chromosome 15, but no copies from the father. Infants with Prader–Willi syndrome display hypotonia, small hands and feet, almond-shaped eyes (322), and poor suck that leads to early failure to thrive. In contrast to infants with neuromuscular causes of hypotonia, infants with Prader–Willi syndrome have normal strength. Children with Prader–Willi syndrome usually have short stature, behavioral

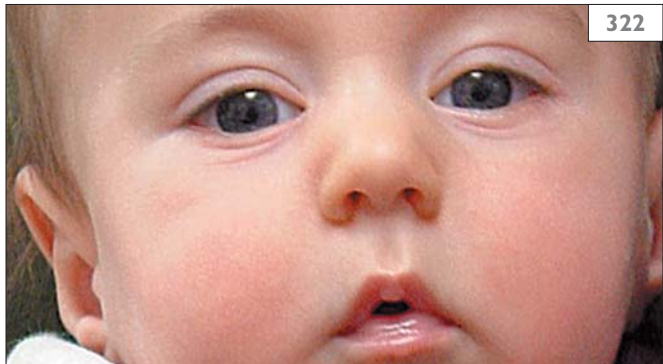problems (especially compulsions), cognitive/developmental delays, and hyperphagia that leads to morbid obesity and obstructive sleep apnea. Growth hormone deficiency commonly occurs in children with Prader–Willi syndrome and may warrant replacement therapy. The diagnosis can be established by DNA methylation studies, the most sensitive test, or FISH analysis.

Absence or deletions of the maternal chromosome 15 causes Angelman syndrome, a disorder that also causes hypotonia in the neonatal period. The childhood phenotype of Angelman syndrome, distinctly different from that of Prader–Willi syndrome, consists of microbrachycephaly (116), severe developmental delay/mental retardation, and seizures.

**321** Paradoxical respirations and alert appearance in a child with Werdnig–Hoffman disease.



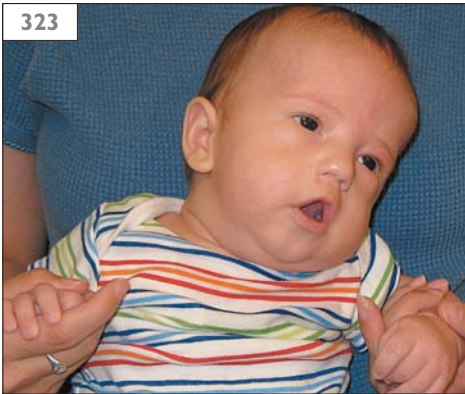**322** Almond-shaped eyes in Prader–Willi syndrome.



## Neonatal myotonic dystrophy

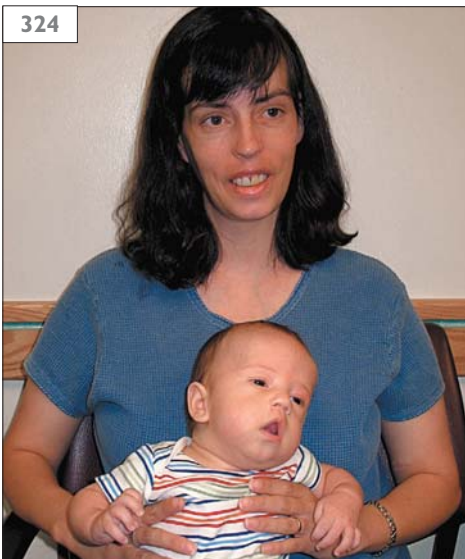Myotonic dystrophy, an autosomal dominant disorder affecting approximately 1 in 10,000 persons, occasionally presents in the neonatal period. Such infants have diffuse hypotonia, symmetric weakness of the extremities, bulbar dysfunction, facial diplegia, respiratory distress and, often, club feet. Infants display a characteristic ‘tenting’ appearance of the upper lip (323). In nearly all instances of severe neonatal myotonic dystrophy, the mother is the affected

parent (324). The diagnosis can be established by molecular genetic studies that demonstrate markedly high numbers of trinucleotide (CTG) repeats (typically >2000 with normal <34) in the dystrophia myotonica protein kinase (DMPK) gene. A substantial number of infants with severe congenital myotonic dystrophy die in the neonatal period. Survivors improve, but are usually developmentally delayed and subsequently display the slowly progressive myopathy typical of childhood- or adult-onset forms.



323

**323** Characteristic facial appearance (hypotonia, ptosis, tenting of the upper lip) in an infant with myotonic dystrophy.



324

**324** Myotonic dystrophy in the mother and infant.



## Congenital myopathies

Congenital myopathies, a heterogeneous group of conditions, have been divided historically into disorders with an identified metabolic defect, such as the glycogen storage disorders, and genetic or structural disorders of muscle, such as nemaline myopathy (textbox).

### Selected congenital myopathies

#### 'Metabolic'

- Glycogen storage disease type II (Pompe disease): see text.
- Carnitine deficiency: variable presentation with myopathy, hepatomegaly, metabolic/encephalopathic crisis, or a SIDS-like presentation. It can be primary, due to a defect in the carnitine transporter protein, or secondary, due to disorders of fatty acid oxidation or organic acids.
- Mitochondrial disorders: many, varied presentations.

#### 'Structural'

- Nemaline myopathy: congenital, childhood, and adult forms; variable clinical features; autosomal recessive and autosomal dominant inheritance; may respond to L-tyrosine.
- Central core disease: static weakness with onset in infancy or early childhood; autosomal dominant or sporadic inheritance.
- Myotubular myopathy: severe weakness, often with death in early childhood; X-linked recessive inheritance.

elevations of serum CK. In the case of Pompe disease the diagnosis can be established by measuring acid alpha-glucosidase (GAA) enzyme activity in cultured skin fibroblasts. Enzyme replacement therapy with alglucosidase alfa (synthetic GAA) beginning before 6 months of age improves motor function and increases survival rates in infants with Pompe disease; enzyme replacement therapy may improve strength and respiratory function in late-onset forms.

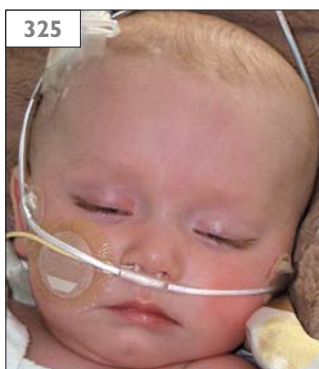Infants with nemaline myopathy, inherited as an autosomal dominant or recessive disorder, resemble those with SMA1 and manifest with neonatal hypotonia, weak suck, and respiratory dysfunction. In contrast to infants with SMA1, however, infants with nemaline myopathy slowly improve, although they continue to show motor delays. The diagnosis is established by demonstrating red nemaline rods on Gomori trichome stained muscle tissue. Mutations in the muscle proteins,  $\alpha$ -actin or nebulin, can be identified in some children with nemaline myopathy. Therapy with L-tyrosine appears to improve bulbar function in infants or children with this disorder.

Most congenital myopathies have been linked to specific gene regions or genetic mutations. Infants with these conditions, as a group, display hypotonia and systemic and/or bulbar weakness at birth or in the first few weeks of life, as well as certain systemic features, depending upon the disorder. Infants with glycogen storage disease type II, Pompe disease, for example, have hepatomegaly, failure to thrive, macroglossia, hearing loss, cardiomegaly, and characteristic ECG patterns consisting of a shortened PR interval with a broad, wide QRS complex. Infants with Pompe disease and other congenital myopathies may have nonspecific

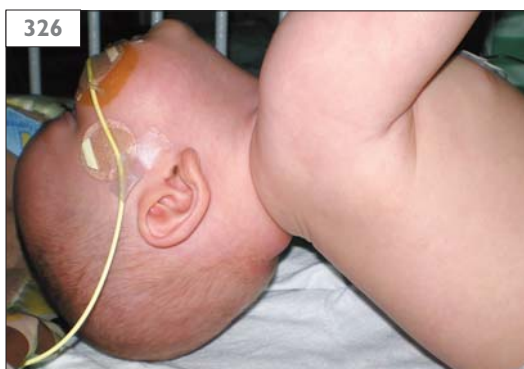## Infant botulism

Infant botulism appears in previously healthy infants between the ages of 3 and 8 months. However, cases have been described with onset as early as the first week of life or as late as 12 months of age. Symptoms and signs of infant botulism usually develop over several days, although infant botulism occasionally begins abruptly and causes a sudden infant death syndrome (SIDS)-like disorder. The earliest symptoms are poor suck, poor feeding, weak cry and a 'lethargic' appearance. The latter is the result of prominent ptosis (325). As the disorder progresses, respiratory distress, diffuse hypotonia, and weakness of the arms and legs appear, leading to a floppy, 'frog leg' posture. Constipation is a prominent early feature in nearly all cases. Examination of infants with botulism shows ptosis, head lag (326), absent or weak gag, diffuse hypotonia and weakness, mydriasis, weak suck, and cry. Muscle stretch reflexes may be normal, hypoactive, or absent, depending upon the stage and severity of the disorder.

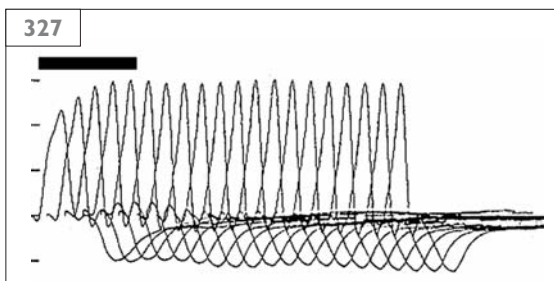
In contrast to adult-type botulism, which results from ingestion of preformed toxin, infant botulism results from ingestion of *Clostridium botulinum* spores. *C. botulinum* spores can be found in soils and in certain foods, such as raw honey. Because infants lack sufficient gastric acidity to kill *C. botulinum*, the spores multiply and produce toxin. The toxin, the most potent neurotoxin, enters the systemic circulation and binds to cholinergic synapses, causing weakness and constipation. The diagnosis of infant botulism is established by detecting toxin in stool samples; EMG facilitation of >15% on repetitive stimulation at 20 or 50 Hz supports the diagnosis (327). Management currently consists of providing botulism immune globulin (BabyBIG) which shortens the duration of the disorder. Infants recover from infant botulism completely, although a small number of infants (~5%) experience relapses that are generally shorter and less severe than the initial episode of infant botulism.



325



326



327

**325** Ptosis in a young infant with botulism.

**326** Marked head lag in a 5-month-old with infant botulism.

**327** Facilitation (bar) during repetitive EMG stimulation in infant botulism.



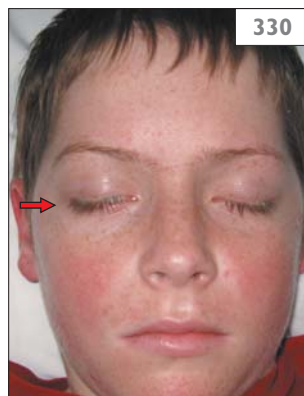## Weakness in children and adolescents

Performing the motor examination on toddlers requires patience, skill, and creativity, but with sufficient time even the most fearful 2-year-old can cooperate. The motor exam can begin with the child sitting on a parent's lap. Washable toys, such as finger puppets or plastic animals, can be used to examine the child's upper extremity strength and dexterity. Most will reach for a rubber duck or other toy eagerly, and the experienced examiner can gauge the strength of the child's grasp and resistance to pulling the toy away. Toys can also facilitate the examination of gait and lower extremity strength. The toy can be tossed a short distance down a hallway, and most young children (2 years of age and older) can be enticed to chase and recover the toy. Having the child arise from the floor (328, 329) provides a reasonable assessment of pelvic girdle strength. The uncooperative child who kicks, hits, or cries unwittingly provides comprehensive information regarding the strength and symmetry of face, arm, and leg movements!

Assessing the strength of older children and adolescents can be a friendly competition between the examiner and examinee. Each practitioner should devise a routine, so that no component of the motor examination is overlooked. Given the relevance of facial weakness to many neuromuscular conditions, the exam should begin with the face by inspecting for ptosis,

having the child smile, show their teeth, and close his or her eyes tightly, 'as if they have soap in them' and then having the child look surprised. The child with normal facial strength should be able to smile fully and 'bury' the eye lashes with tight eye closure, whereas a child with facial weakness cannot (330). The examiner can then move caudally down the body, first examining the muscles of the shoulder girdle and arms and ending with an examination of leg strength. Finally, watching the child walk (39) not only provides essential information regarding distal leg strength, but also useful information regarding the symmetry of movements and muscle tone.

Tone should be assessed formally by moving each joint through a full range of motion. Proximal tone in the lower extremities of infants and young children can be assessed by alternately adducting and abducting the hips, and distal tone can be assessed by gentle dorsiflexion of the ankles. The ankles should dorsiflex above 90° without resistance. Muscle stretch reflexes ('jumpers' for the toddler) can be assessed using regular techniques and graded 0–4, as outlined above. The symmetry and intensity of the biceps, brachioradialis, patellar, and Achilles tendon reflexes (31–33) provide sufficiently comprehensive information. Hyporeflexia suggests disorders of the lower motor neuron, whereas hyper-reflexia suggests disorders of the upper motor neuron.



**328, 329** Arising from the floor as a test of pelvic girdle muscle strength.

**330** Inability to 'bury' the eye lashes in facial weakness (arrow).

## Selected disorders in children and adolescents

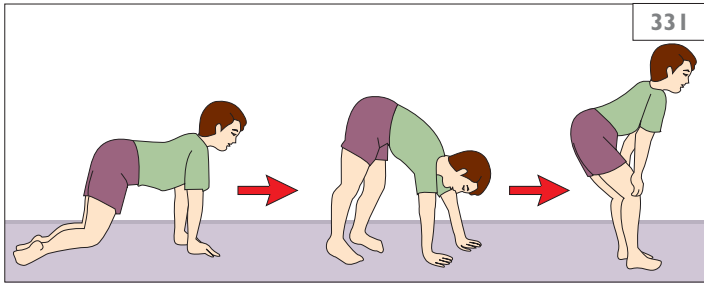
### Duchenne muscular dystrophy

Duchenne muscular dystrophy (DMD), a progressive, X-linked disorder due to mutations in the dystrophin gene, affects 1 of every 3300 live-born males. The disorder typically begins between the ages of 2 and 5 years. Parents note that their young boys cannot keep up with their peers and do not walk or run normally. Examination at this time demonstrates symmetric, proximal muscle weakness manifesting as a waddling gait and a Gower sign or maneuver in which the boy uses arm support to achieve the standing position (331). The latter sign, although not specific for DMD, indicates pelvic girdle weakness. Lumbar lordosis and pseudohypertrophy of the gastrocnemius muscles (332), secondary to replacement of muscle tissue with fat and connective tissue, are also usually noted over time.

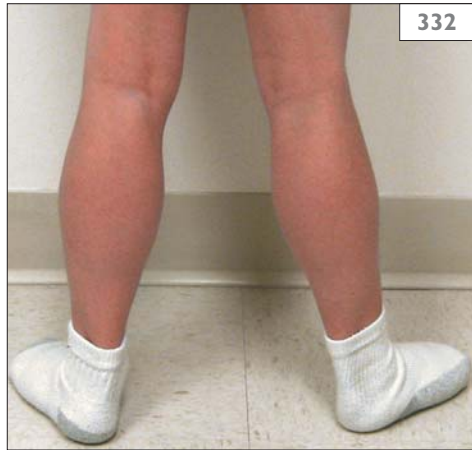All voluntary muscles, as well as the heart and muscles of respiration, are eventually affected in boys with DMD. This leads to progressive weakness, contractures, scoliosis, cardiomyopathy, and respiratory insufficiency. Boys with DMD usually lose the ability to walk by the time they are 12 or 13 years of age. Because dystrophin is also expressed in brain, boys with DMD often have neurocognitive abnormalities affecting verbal memory. Girls and women, carriers of the condition, are rarely mildly symptomatic.

Boys with DMD have markedly elevated (several thousand times normal) serum levels of CK and characteristic findings on muscle biopsy including variation in fiber size, proliferation of collagen, and replacement of muscle by adipose tissue (333, 334). Dystrophin gene analysis reveals mutations that lead to premature stop codons in the vast majority of boys with DMD and complete absence of the dystrophin protein. Dystrophin connects the intracellular cytoskeleton and the extracellular matrix, assisting with load bearing and cell signaling. Dystrophin gene mutation testing by PCR will detect a deletion or other mutation in about 70% of cases; in the remainder, muscle biopsy with immunostaining for dystrophin is necessary.

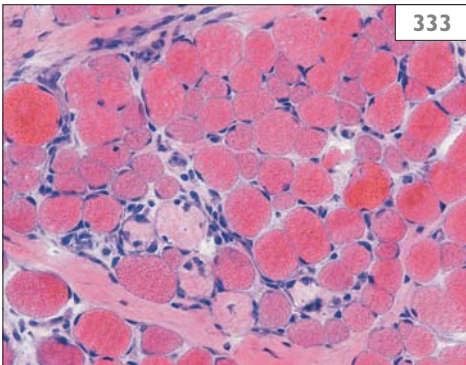
Although there remains no cure, boys with DMD benefit from daily corticosteroid therapy, using prednisone 0.75 mg/kg/day. Prednisone therapy prolongs the ability to ambulate which, in turn, delays the appearance and progression of contractures, scoliosis, and respiratory insufficiency. Weight gain is a potential side-effect that can adversely affect muscle function. Survival into the mid-20s is not uncommon. Physical therapy, supportive care, and periodic assessment of cardiac function should be done. Novel genetic therapies that aim to increase dystrophin protein expression may hold promise for some patients with certain frame shift or other dystrophin mutations.



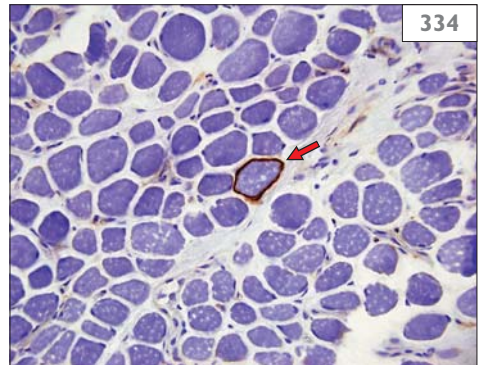
**331** The Gower sign indicating pelvic girdle muscle weakness. This is a common early feature in boys with Duchenne muscular dystrophy.



**332** Pseudohypertrophy of the calves in Duchenne muscular dystrophy.



**333** Muscle biopsy in a 3-year-old boy with Duchenne muscular dystrophy shows marked variation in the size of muscle fibers, necrotic fibers, and mild endomysial fibrosis (H&E).



**334** Muscle biopsy in the same child showing only a single muscle fiber (arrow) staining for dystrophin. Normally, all muscle fibers should show dystrophin staining.

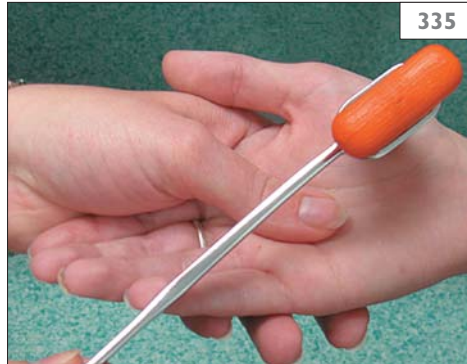## Other muscular dystrophies

Other forms of muscular dystrophy are much less common than DMD (textbox). Becker dystrophy, a dystrophinopathy with onset in adolescence or early adulthood, progresses more slowly than DMD and can be associated with a near-normal life span. Pelvic girdle weakness and striking calf hypertrophy are typical findings, and cardiomyopathy can be a prominent feature. The latter complication necessitates annual cardiac evaluation and echocardiography. Fascioscapulohumeral dystrophy, an autosomal dominant disorder caused by a deletion on chromosome 4, produces weakness of the face, shoulder, and pelvic girdle musculature. Symptoms usually appear by the age of 20 years, although a severe congenital form can present in infancy with hypotonia, diffuse weakness, and sensorineural hearing loss. Myotonic dystrophy can present as severe disease in the neonatal period, as discussed elsewhere, or in adolescence as a slowly progressive condition associated with muscle weakness of the face ('myopathic facies'), hands, and legs. After the age of 5 years, children or adolescents with this disorder have grip or percussion myotonia (335, 336); asking the patient to squeeze your fingers and 'let go fast' is a useful screening test for a myotonic grip. Children with myotonic dystrophy will release your fingers very slowly. Adolescents and adults with myotonic dystrophy have a multisystem disorder with frontal balding, cataracts, learning disability/mental retardation, cardiac conduction abnormalities, diabetes mellitus, and abnormalities of gastrointestinal motility. 'Tenting' or a 'fish-mouth' appearance of the upper lip is an important sign (337).

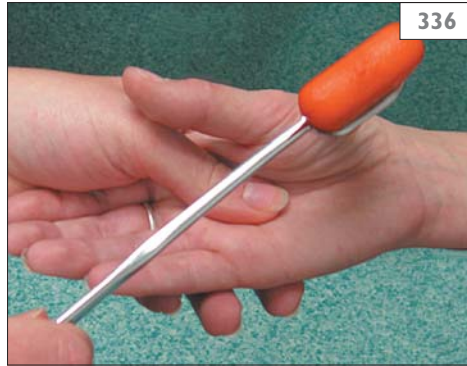### Muscular dystrophies with onset in infancy, childhood, or adolescence

- Myotonic dystrophy: neonatal form with bulbar dysfunction; childhood or adolescent form with facial diplegia, grip myotonia, learning disability, and progressive systemic weakness.
- Duchenne muscular dystrophy: dystrophinopathy with onset in early childhood, causing severe, progressive systemic weakness.
- Becker muscular dystrophy: dystrophinopathy with onset in adolescence, causing calf hypertrophy, pelvic girdle weakness, and cardiomyopathy.
- Fascioscapulohumeral dystrophy: onset by age 20 years, causing facial and shoulder girdle muscle weakness; severe neonatal form with diffuse weakness and hearing loss.
- Limb girdle dystrophy: a heterogeneous genetic disorder with variable onset and progression causing lower extremity weakness.
- Congenital muscular dystrophy: a heterogeneous disorder with variable patterns of inheritance; some involve muscle, eye, and brain disorders such as polymicrogyria or lissencephaly (e.g. Fukuyama muscular dystrophy due to a mutation in the gene encoding the protein, fukutin).

**335** Eliciting myotonia by percussion in myotonic dystrophy.



**336** Involuntary adduction of the thumb, indicating myotonia, in response to percussion of the thenar muscle in myotonic dystrophy.



**337** An older child with myotonic dystrophy showing myopathic ('expression-less') facies with tenting of the upper lip.

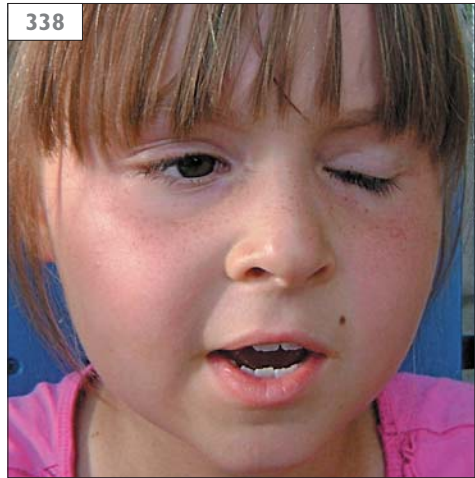



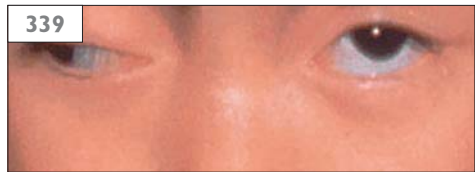## Myasthenia gravis

Myasthenia gravis (MG), an uncommon pediatric neuromuscular disorder, has several forms in childhood: a transient neonatal form that usually occurs in the offspring of women with MG; a neonatal form in infants whose mothers do not have MG; an ocular form with ophthalmoparesis; and a juvenile form that begins in late childhood or adolescence and resembles the adult disorder. With the exception of congenital MG which has a genetic basis, other forms of MG result from circulating antibodies that interfere with acetylcholine transmission at the neuromuscular junction. Infants with neonatal MG display hypotonia, diffuse weakness, facial paresis, ptosis, and bulbar and respiratory dysfunction. Resolution of ptosis, facial paresis, and hypotonia after the administration of neostigmine, a longer-acting acetylcholinesterase inhibitor, confirms the diagnosis.

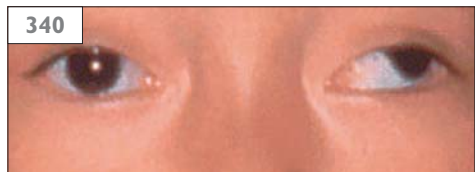
Children with the ocular form of MG have recurrent or persistent ptosis (338) and ophthalmoparesis that may respond poorly to acetylcholinesterase inhibitors. The juvenile form begins in late childhood or adolescence with fluctuating systemic weakness, ptosis, diplopia, dysarthria, and dysphagia. The diagnosis can be suspected by electrodiagnostic findings of a decremental response to repetitive stimulation and confirmed by detection of MG-specific antibodies or resolution of weakness (e.g. ptosis) following administration of the acetylcholinesterase inhibitors, edrophonium chloride (the Tensilon Test) (339, 340) or neostigmine. As many as 80% of children with generalized MG have detectable serum antibodies to acetylcholine receptors, and a substantial proportion of those without acetylcholine receptor antibodies have circulating antibodies to the muscle-specific tyrosine kinase (anti-MuSK antibodies). Management of juvenile forms involves administration of the acetylcholinesterase inhibitor pyridostigmine, immunomodulation using prednisone, azathioprine, or intravenous immunoglobulin, and thymectomy. Because children or adolescents with MG occasionally have thymomas, a common feature in adult MG, chest CT should be obtained in all children and adolescents with MG.



**338** Unilateral ptosis compatible with myasthenia gravis.



**339** Ptosis and ophthalmoplegia in a child with myasthenia gravis.



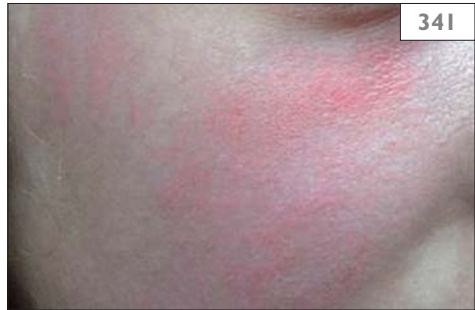**340** Improvement in ptosis but persistence of ophthalmoplegia after administration of edrophonium chloride (Tensilon Test).

## Dermatomyositis/ polymyositis

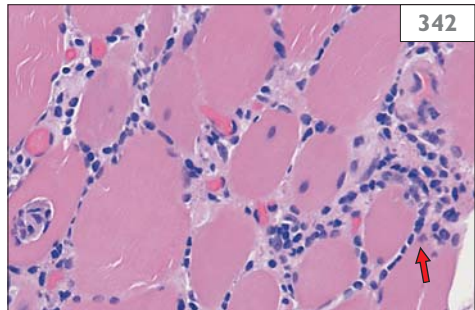
Dermatomyositis, an uncommon inflammatory myopathy of childhood, begins insidiously with symmetric, proximal weakness affecting arm and leg muscles. Affected children fatigue easily when climbing stairs and may have bulbar dysfunction that can resemble MG. The disorder can be distinguished from MG by the lack of response to acetylcholinesterase inhibitors and the presence of a skin rash that can appear before, during, or after the onset of muscle weakness. Muscle bulk is usually normal unless the disease has been present for months, but muscle tenderness and diffuse discomfort may be evident. Skin findings that suggest dermatomyositis include periorbital heliotrope, a ‘butterfly’ rash reminiscent of systemic lupus erythematosus (341), or a scaly, erythematous, eczematoid rash over the knuckles of the fingers or toes (Gottron sign).

Markers of muscle inflammation, including erythrocyte sedimentation rate or serum CK can be normal or elevated; biopsy of affected muscles shows perifascicular muscle cell atrophy and inflammation (342). Other measures of muscle involvement (aldolase or serum creatinine) can be elevated in the absence of an elevated CK. Treatment consists of physical therapy and long-term administration of immunomodulating agents including prednisone, intravenous immunoglobulin, and cyclophosphamide. High-dose oral corticosteroids, prednisone 1–2 mg/kg day initially with change to alternate day steroids and gradual taper over weeks to months, remain the mainstay of therapy. Various ‘steroid-sparing’ strategies are also advocated including concurrent use of cyclophosphamide, methotrexate, azathioprine, or cyclosporin, as well as ‘pulse’ steroid strategies. The disease is protracted, but most children ultimately go into remission and long-term prognosis is generally favorable. Unlike adults, pediatric patients with dermatomyositis rarely have underlying or occult malignancies.

In children with polymyositis progressive proximal muscle weakness develops over a period of weeks. There may be associated muscle pain and tenderness but sensory disturbances, as seen in acute inflammatory demyelinating polyneuropathy (AIDP), or dermatologic features, as seen in dermato-



341 Facial rash in dermatomyositis.



342 Muscle biopsy in dermatomyositis shows variation in fiber size and perifascicular inflammation (arrow) ( $\times 200$ ).

myositis, are absent. Pelvic girdle muscles are typically affected leading to a waddling gait, increased lumbar lordosis, difficulty climbing stairs or walking uphill, and fatigability. Reaching for objects on shelves, combing one's hair, and similar actions become difficult due to proximal upper extremity weakness. Treatment also relies on immunomodulators, but the course of disease is generally shorter and more favorable than in dermatomyositis.



*This page intentionally left blank*

# Infections of the nervous system

## Main Points

- Fever, behavior change, headache, and meningeal signs suggest meningitis or encephalitis. Children with encephalitis have seizures, altered mental status, and/or focal deficits.
- Infants with suspected herpes simplex virus encephalitis require urgent therapy with aciclovir, using 60 mg/kg/day.
- Acute disseminated encephalomyelitis (ADEM), a postinfectious disorder, accounts for approximately 10–15% of childhood encephalitis.
- Congenital infection is suggested by hepatosplenomegaly, jaundice, rash, intrauterine growth retardation, microcephaly, hydrocephalus, and intracranial calcifications.
- Lyme disease, due to the spirochete, *Borrelia burgdorferi*, is a major cause of Bell's palsy among children living in endemic areas.
- Cat-scratch disease, due to *Bartonella henselae*, causes fever of unknown origin and rarely, an encephalitis-like disorder.
- Neurocysticercosis, caused by the larvae of *Taenia solium*, is a major cause of seizures and hydrocephalus among children in many regions of the world.

## Introduction

Several infectious disorders have become uncommon as a consequence of compulsory immunization programs. Such disorders include poliomyelitis, *Haemophilus influenzae* type b meningitis, mumps meningoencephalitis, measles encephalomyelitis, Japanese encephalitis, congenital rubella embryopathy, and subacute sclerosing panencephalitis. By contrast, many other infectious disorders, including congenital and postnatal disorders, cannot be prevented by immunization. These remain potential causes of death and neurodevelopmental disorders among children worldwide. This chapter describes selected infectious disorders of the CNS that may be encountered by primary care physicians and neurologists (textbox).

### Infections of the CNS

- Bacterial meningitis.
- Viral (aseptic) meningitis.
- Virus encephalitis.
- Congenital infections.
- Lyme disease.
- Cat-scratch disease
- Neurocysticercosis.
- Cerebral malaria,
- HIV/AIDS.

## Bacterial meningitis

### DIAGNOSIS AND CLINICAL FEATURES

Many different bacteria, acquired through maternal transmission or environmental contact, cause meningitis in newborn infants (textbox).

#### Bacteria causing meningitis in infants:

- *Streptococcus agalactiae* (group B streptococcus).
- *Escherichia coli*.
- *Staphylococcus* species.
- *Listeria monocytogenes*.
- *Pseudomonas aeruginosa*.
- *Citrobacter* species.

#### Bacteria causing meningitis in children and adolescents:

- *Haemophilus influenzae* type b.
- *Streptococcus pneumoniae*.
- *Neisseria meningitidis*.
- *Mycobacterium tuberculosis*.

After the age of 6 months, three organisms cause the majority of cases of bacterial meningitis in developed nations (textbox). However, meningitis due to *H. influenzae* type b has nearly disappeared in populations with compulsory *H. influenzae* type b (HIB) vaccination programs. In many regions of the world *Mycobacterium tuberculosis* constitutes a potential cause of bacterial meningitis.

Risk factors for *S. pneumoniae* meningitis include sickle cell anemia, asplenia, human immunodeficiency virus/acquired immune deficiency syndrome (HIV/AIDS), nephrotic syndrome, cochlear implantation, and cranio-cerebral trauma causing CSF leaks. College students or persons with inherited deficiencies of the complement system are at increased risk for *N. meningitidis* infections. Risk factors for *H. influenzae* meningitis include sickle cell anemia, asplenia, and HIV/AIDS.

Chronic conditions, such as leukemia, lymphoma, or immunodeficiency states, may predispose to infection with *Pseudomonas aeruginosa* or other gram-negative organisms. Recent ventriculoperitoneal shunt procedures increase the risk of meningitis or ventriculitis

due to *Staphylococcus* species or gram-negative organisms, including *Escherichia coli*. Shunt-related CNS infections are most likely during the first 3 months after the operative procedure. Risk factors for tuberculous meningitis include contact with persons at high-risk (drug addicts, prisoners) or residence in an endemic area.

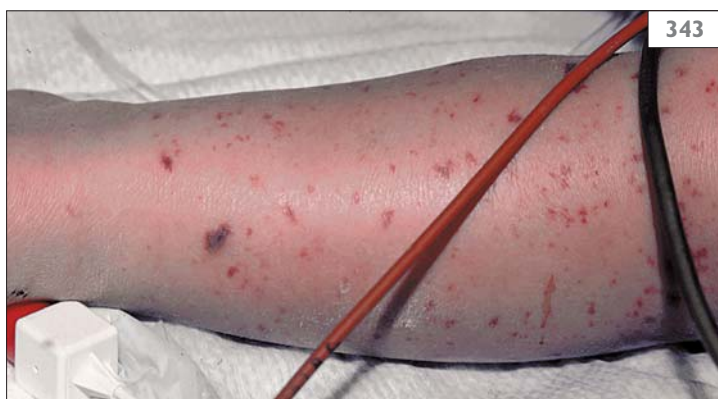In the newborn the early signs of bacterial meningitis consist of poor feeding, vomiting, low-grade fever, or change in behavior. Seizures and lethargy occur often. The physical signs of meningitis may be subtle in infancy, consisting only of somnolence or irritability and a full or bulging fontanel. In the older child, symptoms and signs include somnolence, headache, stiff neck, vomiting, and fever. After 1 year of age,

signs of meningeal irritation can usually be elicited (textbox).

#### Signs of meningeal irritation in the supine child or adolescent

- Brudzinski sign: flexion of the legs evoked by neck flexion.
- Kernig sign: spasms of the hamstring muscles evoked by knee extension.

Pneumonia can be present in children or adolescents with *S. pneumoniae* or *H. influenzae* meningitis. Petechiae or purpura (343) should prompt physicians to suspect *N. meningitidis*.



343 Petechial and purpuric rash in a child with meningococemia.

**Table 41 Cerebrospinal fluid findings in neurological infections**

Infection	Cell Count <sup>1</sup>	Protein <sup>2</sup>	Glucose	Gram stain
Bacterial meningitis	↑↑ to ↑↑↑ (N)	↑↑↑	Low <sup>3</sup>	Bacteria
Aseptic meningitis	↑ to ↑↑↑ (M/L)	↑↑	Normal	No organisms
TB meningitis	↑ to ↑↑↑ (L)	↑↑↑	Low	No organisms
Virus encephalitis	N to ↑↑↑ (M/L)	↑↑	Normal	No organisms

<sup>1</sup>Cell count

↑	10–100 leukocytes/μl
↑↑	100–1000 leukocytes/μl
↑↑↑	>1000 leukocytes/μl

<sup>2</sup>Protein

↑↑	50–200 mg/dl (500–2000 mg/l)
↑↑↑	>200 mg/dl (>2000 mg/l)

N = Neutrophilic; L = Lymphocytic; M = Mixed

The pleocytosis associated with virus infections is often mixed (neutrophilic and lymphocytic) during the early phase of infection but typically becomes lymphocytic during the subsequent stages of infection.

<sup>3</sup>Low = less than two-thirds of serum; can be as low as 0.

The diagnosis of bacterial meningitis is confirmed by performing a lumbar puncture and examining the spinal fluid (*Table 41*). Most bacteria can be detected by culture methods and identified by automated techniques. The polymerase chain reaction (PCR) can be used to detect *Mycobacterium tuberculosis* or bacteria in cases of pre- or partial antibiotic treatment. Imaging studies, such as CT or MRI, may show hydrocephalus (**344**) or meningeal enhancement (**345**). When hydrocephalus is present early in meningitis of children or adolescents, tuberculous meningitis deserves consideration. Infants with *Citrobacter* species meningitis commonly have brain abscesses (**346**).

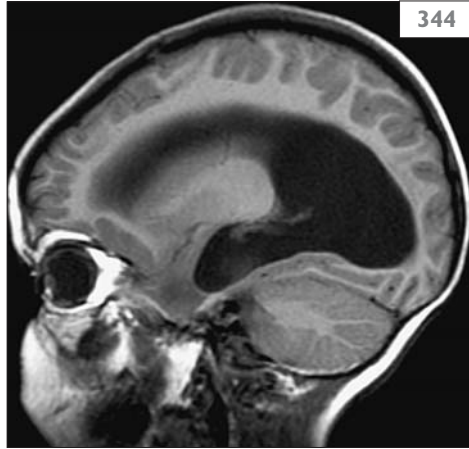
## MANAGEMENT

Prompt treatment of bacterial meningitis, using empiric strategies, can diminish the potential for death or severe neurodevelopmental sequelae (*Table 42*).

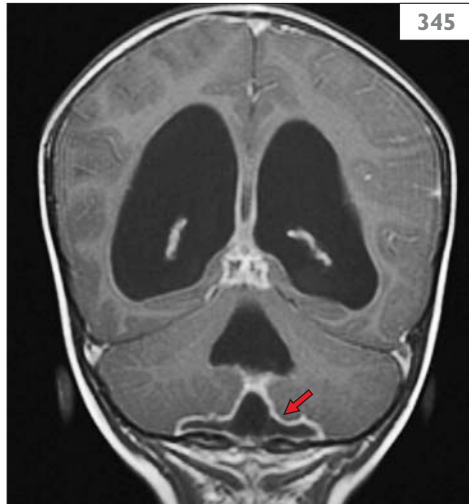
**Table 42 Empiric treatment of bacterial meningitis in the pediatric age group**

Drug	Dose
<b>Neonates (infants up to 90 days of age)</b>	
Ampicillin	150–300 mg/kg/d, divided q 6–8 hours, AND
Gentamicin	2.5–7.5 mg/kg/d, daily or divided q 8 hours, AND
Cefotaxime	150–300 mg/kg/d, divided q 6–8 hours
<b>Children and adolescents</b>	
Vancomycin	60 mg/kg/d, divided q 6 hours, AND
Cefotaxime	300 mg/kg/d, divided q 6–8 hours
	OR
Vancomycin	60 mg/kg/d, divided q 6 hours, AND
Ceftriaxone	100 mg/kg/d, divided q 12 hours

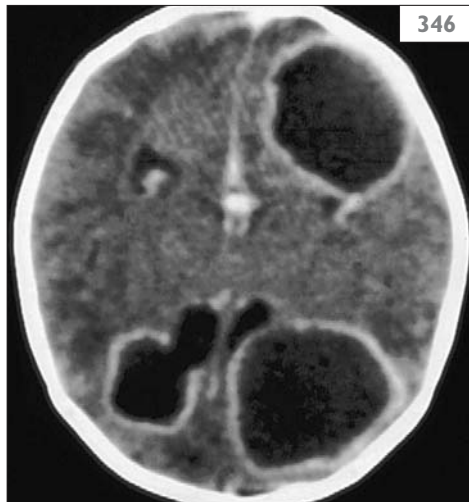
**344** Hydrocephalus in *Haemophilus influenzae* meningitis.



**345** Enhancement of leptomeninges of the cisterna magna (arrow) in *H. influenzae* meningitis, compatible with basilar inflammation.



**346** Multiple brain abscesses in neonatal *Citrobacter koseri* (*diversus*) meningitis.



Upon confirmation of the bacterial species and antibiotic susceptibility profile, the antimicrobial regimen can be modified (Table 43). Many authorities suggest that dexamethasone should be given empirically in children or adolescents with suspected meningitis, using 0.6 mg/kg/day in four divided doses for 2–4 days, with the first dose given before the first dose of antibiotics. Dexamethasone therapy is associated with improved outcomes, including lower rates of hearing loss, especially in children with *H. influenzae* meningitis.

Mortality rates for infants with bacterial meningitis range from less than 10% for term infants to more than 30% for infants weighing less than 1000 g. Approximately 40% of infants who survive neonatal bacterial meningitis have neurodevelopmental sequelae, such as cerebral palsy, neurodevelopmental disorders, hydrocephalus, or seizures. As many as 40% of children or adolescents with pneumococcal meningitis die. Up to 10% of the children or adolescents who survive bacterial meningitis have sensorineural hearing loss (SNHL); some survivors have hydrocephalus, cognitive impairment, or motor disabilities.

**Table 43 Antimicrobial therapy in bacterial meningitis**

Pathogen	Antibiotic(s)	Dose <sup>1</sup>
<i>Streptococcus agalactiae</i>	Penicillin G	250,000–400,000 U/kg/d
<i>Escherichia coli</i> and other gram-negative organisms	Cefotaxime AND Gentamicin	150–300 mg/kg/d 2.5–7.5 mg/kg/d
<i>Listeria monocytogenes</i>	Ampicillin AND Gentamicin	150–300 mg/kg/d 2.5–7.5 mg/kg/d
<i>Staphylococcus aureus</i> or <i>Staphylococcus epidermidis</i>	Vancomycin OR Nafcillin	60 mg/kg/d 100–200 mg/kg/d
<i>Streptococcus pneumoniae</i> (penicillin sensitive)	Penicillin G	250,000–400,000 U/kg/d
(penicillin resistant)	Vancomycin AND Cefotaxime OR Ceftriaxone	60 mg/kg/d 300 mg/kg/d 100 mg/kg/d
<i>Neisseria meningitidis</i>	Penicillin G	250,000–400,000 U/kg/d
<i>Haemophilus influenzae</i> type b β-lactamase-negative	Ampicillin	300–400 mg/kg/d
β-lactamase-positive	Cefotaxime OR Ceftriaxone	300 mg/kg/d 100 mg/kg/d

Antibiotics are given intravenously in equally divided doses every 4–12 hours, depending upon the drug. The duration of therapy ranges from 7–28 days, depending upon the organism, the age of the child, and response to therapy. Gentamicin doses must be adjusted for gestational and postnatal ages.

<sup>1</sup>From various sources.



## Viral meningitis

### DIAGNOSIS AND CLINICAL FEATURES

Unlike bacterial meningitis which is a life-threatening condition, viral (aseptic) meningitis is usually a benign, self-limited disorder. The principal reason to identify viral meningitis is to exclude bacterial meningitis.

Many different viruses produce aseptic meningitis. Common causes include the nonpolio enteroviruses and West Nile virus. The signs and symptoms of viral meningitis mimic those of bacterial disease, although they are usually less intense. Infants may have fever, vomiting, irritability, or somnolence, whereas children or adolescents frequently have headache, neck stiffness, photophobia, vomiting, and fever. Depending upon the etiology additional clinical features may include malaise, diarrhea, rash, myalgia, cough, or chest pain. Hepatomegaly, congestive heart failure, or disseminated intravascular coagulopathy can occur in neonates with severe nonpolio enterovirus infections.

The diagnosis is made by examining the CSF and performing microbiologic studies. Mixed or neutrophilic pleocytosis can be common during the early stages of viral infections, but normal glucose content usually distinguishes viral from bacterial meningitis. PCR can detect several viral pathogens, including the nonpolio enteroviruses and members of the herpesvirus family, and serologic studies have utility in several viral infections, including those due to Epstein–Barr virus and several arthropod-borne viruses.

### MANAGEMENT

Management of aseptic meningitis consists of supportive care and anticipation of complications such as liver failure, myocarditis, or disseminated intravascular coagulation (DIC), especially in neonates. Aciclovir, using 60 mg/kg/day divided every 8 hours, should be given empirically to neonates with suspected viral meningitis, given the possibility of herpes simplex virus infection.

## Encephalitis

### DIAGNOSIS AND CLINICAL FEATURES

Virus encephalitis occurs worldwide (textbox).

#### Major causes of encephalitis in the pediatric age group

Viruses:

- Herpes simplex viruses types 1 and 2.
- Epstein–Barr virus.
- West Nile virus.
- Rabies virus.
- Tick-borne encephalitis viruses.
- LaCrosse virus.
- Japanese encephalitis virus.
- Nonpolio enteroviruses.

Nonviral pathogens:

- *Mycoplasma pneumoniae*.
- Rickettsia.
- *Bartonella henselae*.

In the USA the nonpolio enteroviruses, herpes simplex viruses type 1 (HSV-1) and type 2 (HSV-2), Epstein–Barr virus, West Nile virus, and LaCrosse virus are major causes. Japanese encephalitis, the most common cause of virus encephalitis worldwide, can affect persons in Asia and India. Rabies, although rare in the developed world, causes many deaths annually in Africa, India, Asia, and certain areas of Latin America. Several nonviral conditions, including systemic lupus erythematosus, lymphoma, leukemia, stroke, and fungal, rickettsial, or parasitic infections, produce clinical features that can mimic virus encephalitis. Acute disseminated encephalomyelitis (ADEM), a postinfectious disorder induced by many different infectious agents, accounts for approximately 15% of cases of viral encephalitis.

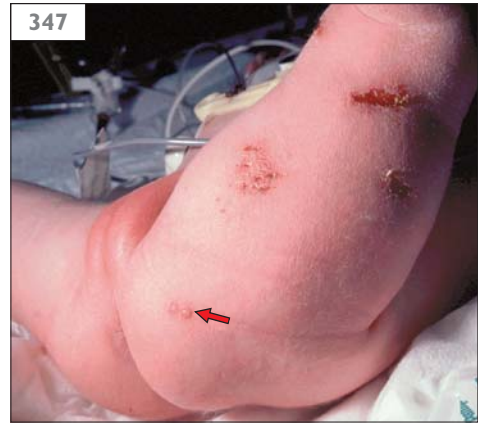The clinical features of virus encephalitis in infants are nonspecific, consisting of poor feeding, vomiting, fever, and change in behavior, especially somnolence or irritability. Seizures may be an early sign of neonatal HSV

encephalitis; some, but not all infants with HSV encephalitis, have skin vesicles, especially with HSV-2 (347). Children or adolescents often experience headache, somnolence, seizures, vomiting, and fever. However, fever can be absent or low-grade, especially in young infants. The examination of older children and adolescents may show hyper-reflexia, ataxia, cognitive impairment, and focal deficits (e.g. hemiparesis), especially in cases of HSV-1 or LaCrosse virus encephalitis.

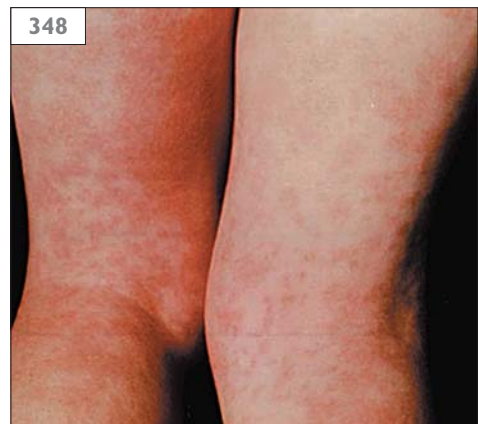Infections with Epstein–Barr virus, a relatively frequent cause of encephalitis, may have a lacey, erythematous rash, especially if treated with ampicillin (348). Zoster suggests varicella-zoster virus infection (349). Children with rabies may show agitation, irritability, or diffuse weakness and areflexia mimicking Guillian–Barré syndrome (GBS). Subacute sclerosing panencephalitis (SSPE), a condition that has become uncommon in countries with compulsory immunization against measles, produces a relatively stereotyped, progressive disorder that begins with myoclonus and personality or cognitive regression and culminates in debility and death.

Infants, children or adolescents with suspected encephalitis require an expedited evaluation that should consist of a brain imaging study (preferably MRI), EEG, microbiological studies and examination of the CSF by lumbar puncture. The CSF may be normal or reveal a ‘viral’ pattern. EEG often shows diffuse or focal slowing or epileptiform discharges. Periodic lateralizing epileptiform discharges (PLEDs) can be seen in HSV-1 encephalitis (82), although this is not a consistent finding. MRI findings may suggest a specific etiologic agent. Children or adolescents with HSV-1 encephalitis frequently have focal areas of T2 prolongation or gadolinium enhancement in the insular cortex, mesial temporal lobe, inferior frontal lobe, and/or cingulate gyrus (350, 351).

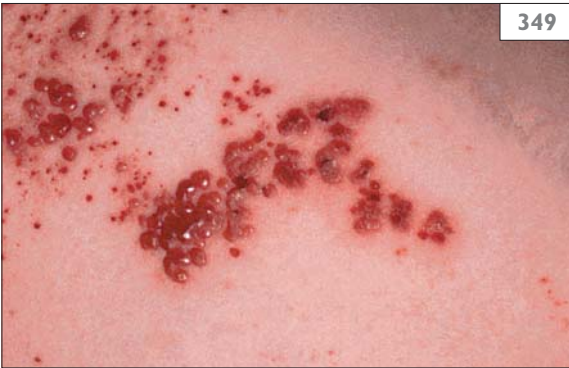On the other hand, infants with neonatal HSV encephalitis usually have diffuse cerebral infections, due to the hematogenous dissemination of the virus, usually HSV-2, to the brain (352). Multifocal areas of T2 prolongation suggest ADEM (145). Children with SSPE have leukoencephalopathy and progressive cortical atrophy (353, 354).



**347** HSV skin vesicles in a neonate infected with HSV-2, including intact vesicles (arrow).

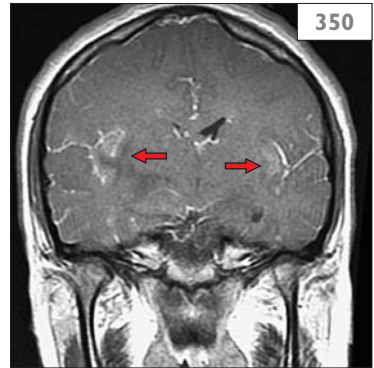


**348** Erythematous rash affecting the legs in a child with Epstein–Barr virus infection.



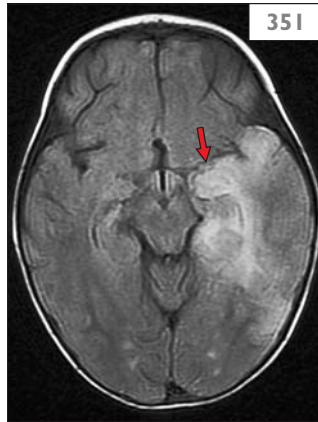
349

**349** Herpes zoster vesicular rash.



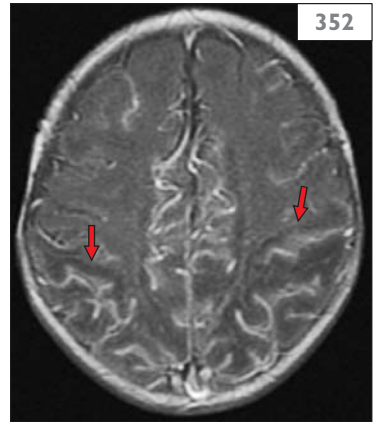350

**350** Coronal T1-weighted MRI showing gadolinium enhancement of the insular cortices bilaterally in HSV-1 encephalitis (arrows).



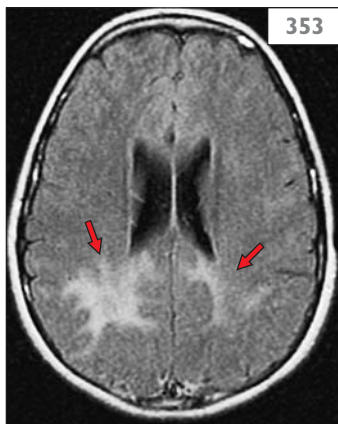
351

**351** Axial FLAIR MRI showing signal hyperintensity in the temporal lobe (arrow) in a child with HSV-1 encephalitis.



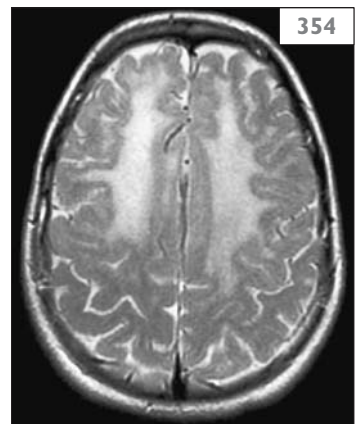352

**352** Gadolinium-enhanced, axial T1-weighted MRI showing diffuse gyriform enhancement (arrows) in an infant with neonatal HSV encephalitis.



353

**353** Axial FLAIR MRI showing leukoencephalopathy in early SSPE (arrows).



354

**354** T2-weighted MRI showing mild, diffuse cortical atrophy and progressive leukoencephalopathy in the later stages of SSPE.

Children with suspected viral encephalitis should undergo a comprehensive microbiological evaluation that includes CSF PCR studies and serum assays for viral pathogens (Table 44). Often, tests should be obtained for other infectious pathogens that produce disorders that may mimic viral encephalitis. These may include serologic studies for *Mycoplasma pneumoniae*, *Bartonella henselae* (the cause of cat-scratch disease), *Borrelia burgdorferi* (the cause of Lyme disease), and various Rickettsiae, depending upon the geographic region. Rarely, brain biopsy is needed in children with progressive encephalitis of uncertain origin (355, 356). The evaluation of children with suspected encephalitis should be tailored to the season, geographic region, travel history, or presence of immunocompromising disorders.

## MANAGEMENT

The treatment of virus encephalitis consists of supportive care and provision of specific antiviral agents, when available. Infants, children, or adolescents with suspected virus encephalitis should receive aciclovir empirically pending the identification of the specific pathogen. If HSV type 1 or 2 infection is confirmed or strongly suspected, aciclovir should be continued for a total of at least 21 days (textbox).

### Aciclovir therapy for HSV types 1 and 2 encephalitis

- Infants and children up to 30 kg:
  - 60 mg/kg/d divided equally every 8 hours for at least 21 days.
- Children over 30 kg and adolescents:
  - 1500 mg/m<sup>2</sup>/d divided equally every 8 hours for at least 21 days.

Most authorities recommend that a CSF HSV PCR be obtained after 21 days of aciclovir therapy. If the PCR is negative, aciclovir can be discontinued, but if the PCR remains positive for HSV DNA, at least 1 additional week of aciclovir should be provided. The role of suppressive therapy in infants after completion of 21–28 days of intravenous aciclovir with HSV continues to be investigated.

Children with varicella zoster virus encephalitis should also receive aciclovir,

using 30 mg/kg/d in children <1 year of age and 1500 mg/m<sup>2</sup>/d in older children or adolescents. Ganciclovir, using 12 mg/kg/d for 14 or more days, should be used in immunocompromised patients with cytomegalovirus (CMV) encephalitis.

Virus encephalitis has a variable prognosis that depends upon the child's age, the etiologic agent, and the presence of immunocompromising conditions. Mortality of HSV encephalitis averages 20% or less, but as many as 50% of survivors have sequelae despite appropriate treatment with aciclovir (357). Survivors of many forms of virus encephalitis have permanent sequelae consisting of cognitive or behavioral impairment, epilepsy, or motor disability. The majority of children with LaCrosse encephalitis survive without sequelae, whereas virtually all children with rabies or SSPE die.

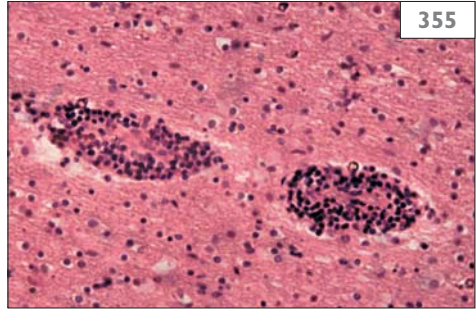
**Table 44 Diagnostic methods for detecting viruses that cause central nervous system infections**

Virus	Microbiological test
Nonpolio enteroviruses	CSF and serum PCR
Human herpesviruses:	
Herpes simplex virus type 1	CSF PCR
Herpes simplex virus type 2	CSF and serum PCR
Varicella zoster virus	CSF PCR; antibody studies
Cytomegalovirus	Urine or CSF PCR
Epstein–Barr virus	Serology <sup>1</sup> ; CSF PCR
Human herpesvirus type 6	CSF PCR
Human herpesvirus type 7	CSF PCR
Human immunodeficiency virus type 1	Serology; culture; serum PCR
West Nile virus	Serum and CSF IgM
Japanese encephalitis virus	Serology
LaCrosse virus	CSF IgM; serology
Tick-borne encephalitis viruses	CSF IgM; serology
Rabies virus	Serology; CSF RT-PCR; IFA <sup>2</sup>

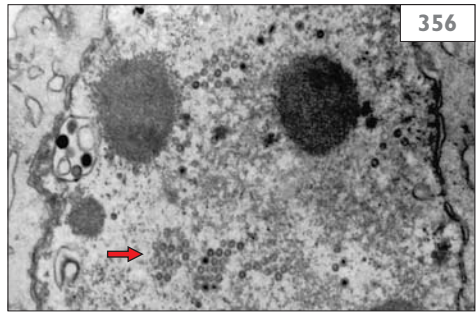
CSF: cerebrospinal fluid; IFA: immunofluorescence assay; Ig: immunoglobulin; PCR: polymerase chain reaction; RT-PCR: reverse transcription polymerase chain reaction

<sup>1</sup>Acute Epstein–Barr virus (EBV) infection is confirmed by the presence of IgM and/or IgG antibodies to EBV viral capsid antigen (VCA) and the absence of IgG antibodies to Epstein–Barr nuclear antigen (EBNA).

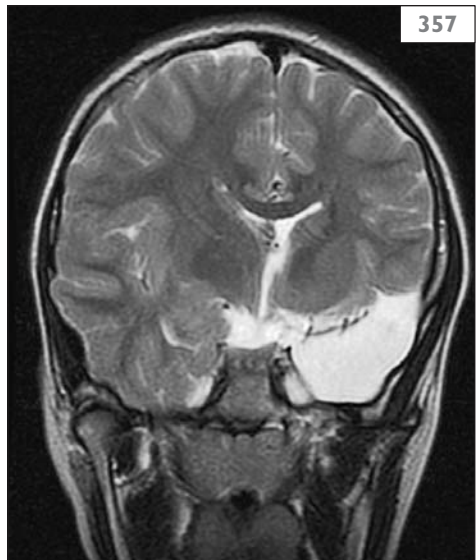
<sup>2</sup>Rabies can be diagnosed by performing immunofluorescence antibody staining of skin obtained by biopsy at the nape of the neck.



**355** Brain biopsy in HSV encephalitis showing perivascular lymphocytic infiltration (H&E).



**356** Electron microscopy showing an intranuclear cluster of herpesviruses (arrow).



**357** Coronal T2-weighted MRI showing cystic encephalomalacia of the left temporal lobe in a child who survived HSV-1 encephalitis.



## Congenital infection

### DIAGNOSIS AND CLINICAL FEATURES

Congenital (intrauterine) infection is caused by a wide variety of organisms (textbox).

#### Causes of congenital (intrauterine) infection

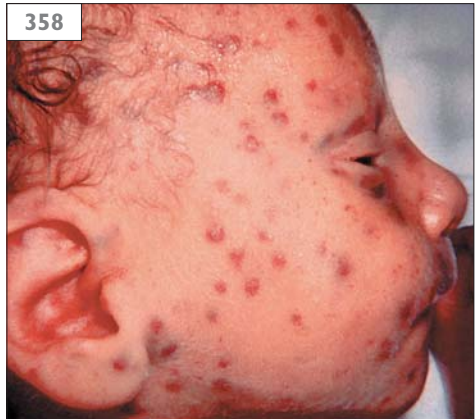- *Toxoplasma gondii*.
- Rubella virus.
- CMV.
- HSV.
- Varicella zoster virus (VZV).
- *Treponema pallidum*.
- Lymphocytic choriomeningitis virus.
- *Trypanosoma cruzi*.
- Venezuelan equine encephalitis virus.
- HIV.

In many regions of the world CMV infects approximately 1% of all newborns and causes congenital disease in as many as 1 in every 1000–2000 newborns. *Toxoplasma gondii* infects 0.1–2% of the population annually and causes congenital infection in as many as 40% of the women who acquire the parasite during their pregnancies. HSV-1 and HSV-2, varicella zoster virus, lymphocytic choriomeningitis virus, *Trypanosoma cruzi*, and *Treponema pallidum* are infrequent but potentially severe causes of congenital infection. Congenital rubella syndrome (CRS), once the most common congenital infection, has disappeared in many regions of the world because of compulsory childhood immunization.

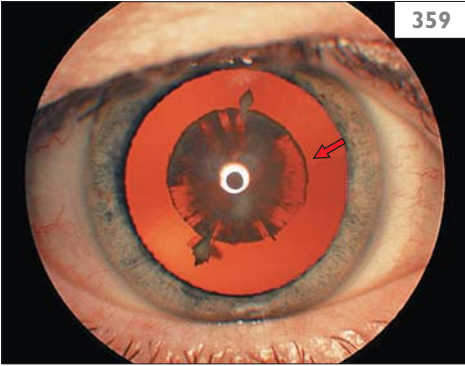
TORCH infection, a term introduced in the 1970s to denote *Toxoplasma gondii*, Rubella, Cytomegalovirus, and Herpes simplex virus, remains a unifying concept that reminds clinicians that congenital infections can produce similar clinical manifestations independent of the specific organism. Features common in several infections, including toxoplasmosis, CMV, HSV, VZV, and rubella, are jaundice, hepatomegaly, splenomegaly, rash (358), cataracts (359), or chorioretinitis (360, 361), SNHL, microcephaly, or hydrocephalus. Certain congenital disorders have distinctive features. Rubella often produces cardiac lesions, consisting of patent ductus arteriosus, valvular stenoses, and ventricular or atrial septal defects, whereas varicella commonly

causes Horner syndrome (163), limb hypoplasia, and a cicatrix, skin scarring in a dermatomal pattern. Lymphocytic choriomeningitis virus can cause postnatal hydrocephalus via aqueductal obstruction. Syphilis produces early signs, including pseudoparalysis or osteochondritis, and late signs, consisting of dental abnormalities, saddle nose, and saber shins.

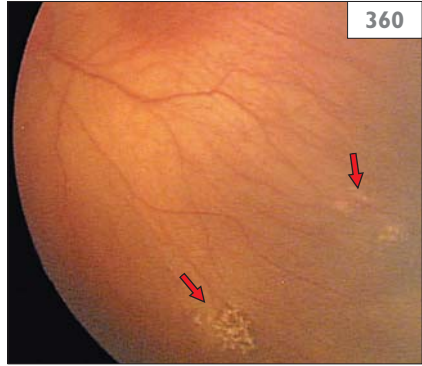
Infants with suspected congenital infections require a thorough evaluation that includes neuroimaging, ophthalmological examination, audiometry, and microbiological studies (362–364).



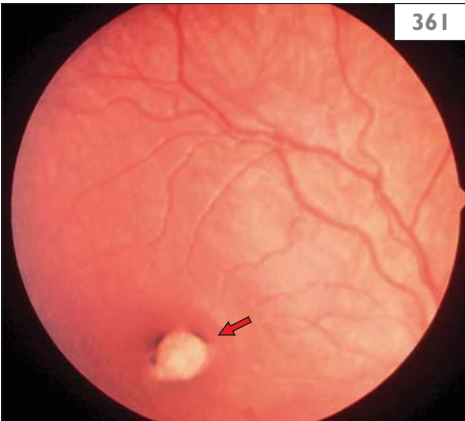
**358** Blueberry muffin' rash compatible with congenital infection with CMV or rubella.




359 Congenital cataract (arrow).



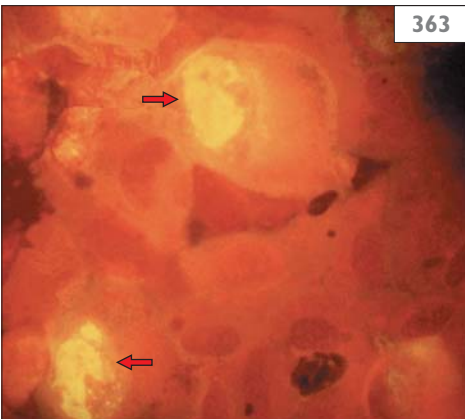
360 Chorioretinitis (arrows) in an infant with congenital CMV infection.



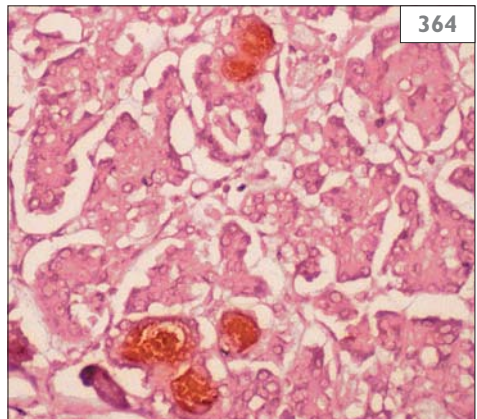
361 Focal chorioretinal scar (arrow) in a child with congenital CMV infection.



362 Uninfected human foreskin fibroblast monolayer.

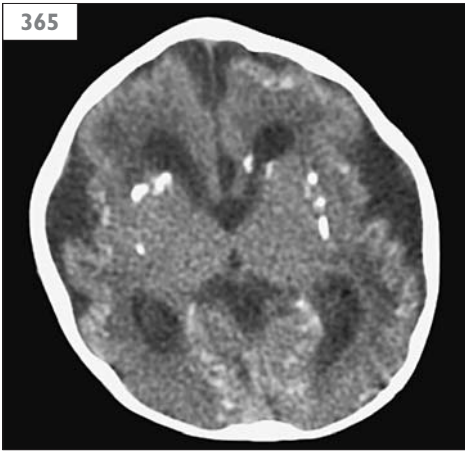


363 CMV-infected cells (arrows) stained with a monoclonal antibody specific for human CMV.

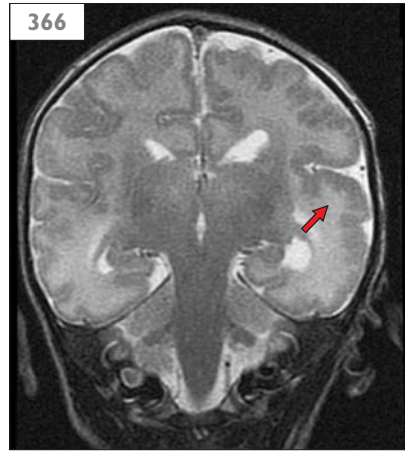


364 Human pancreatic tissue showing brown stained cells infected with CMV.





**365** Noncontrast cranial CT showing multiple cerebral calcifications in a child with congenital CMV infection.



**366** Coronal T2-weighted MRI showing cortical dysplasia/polymicrogyria (arrow) in a child with congenital CMV infection.

When CRS is suspected, cardiology consultation is required. Nonspecific laboratory features in the neonatal period can include thrombocytopenia, leukopenia, anemia, direct hyperbilirubinemia, and elevations of serum transaminases. Skeletal radiographs may show osteochondritis in infants with infections due to *T. cruzi*, *T. pallidum*, or rubella virus. Neuroimaging studies can reveal a variety of abnormalities including intracranial calcification(s), hydrocephalus, cortical dysplasia, lissencephaly, hydranencephaly, or schizencephaly (365–371).

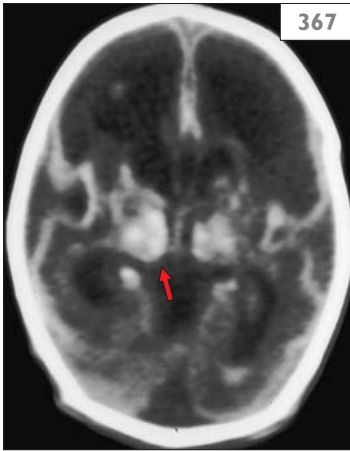
### MANAGEMENT

Specific antimicrobial therapy is available for HSV, CMV, *T. gondii*, and *T. pallidum*. Therapy with ganciclovir, using 12 mg/kg/d, divided in equal doses every 12 hours for up to 6 weeks, may improve long-term hearing outcomes for children with congenital CMV disease, but the drug's effect on neurodevelopment has not been determined. Infants with asymptomatic congenital CMV infections are at risk of late-onset or progressive SNHL, but the role of ganciclovir in such infants is unknown. Infants with congenital HSV infections should be treated with aciclovir, using 60 mg/kg/d, divided in equal doses every 8 hours for 21 days. However, the drug has minimal effect on the

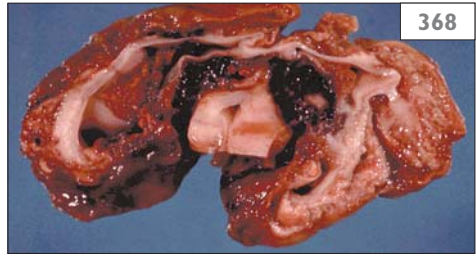outcome of infants with congenital HSV infections.

Aggressive antitoxoplasma therapy can substantially improve the outcome of congenital infections with *T. gondii*. This should consist of 1 year of therapy with pyrimethamine 1 mg/kg/d orally, 2–3 times per week, and sulfadiazine 100–200 mg/kg/d orally every day. Folinic acid, 5–10 mg orally 3 times per week should be given concurrently. Prenatal diagnosis can allow maternal antitoxoplasma therapy, although the effect on fetal outcomes is uncertain. Infants with symptomatic congenital syphilis require treatment with aqueous crystalline penicillin G 50,000 U/kg intravenously every 12 hours during the first week of life and every 8 hours thereafter for a total of 10 days.

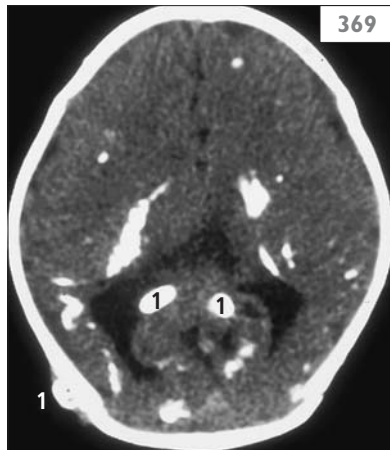The prognosis of congenital infections depends upon the agent and the timing of the intrauterine infection. In general, infections earlier in gestation are associated with fetal loss or more severe neurodevelopmental sequelae. Infants with intracranial calcifications or other neuroimaging features, such as polymicrogyria or lissencephaly, are likely to have permanent neurodevelopmental disabilities. Permanent SNHL is common to several congenital infections.



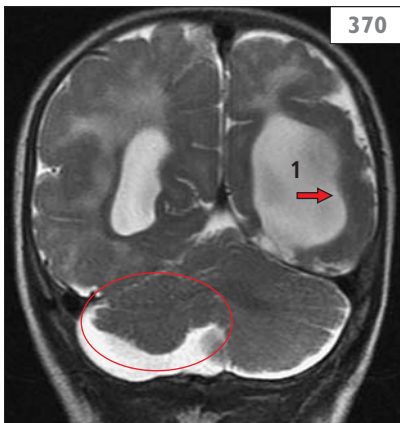
**367** Noncontrast cranial CT showing dense thalamic calcifications (arrow) in an infant with congenital HSV infection.



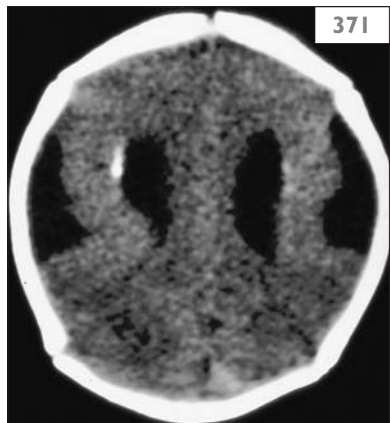**368** Postmortem brain specimen showing extensive gliosis, cystic change, and periventricular calcification in congenital HSV infection.



**369** Noncontrast cranial CT in an infant with congenital toxoplasmosis shows numerous parenchymal calcifications (1 = shunt tubing).



**370** Coronal, T2-weighted MRI in an infant with congenital CMV infection shows ventricular (1) enlargement, cortical dysplasia (arrow), and unilateral cerebellar hypoplasia (circle).



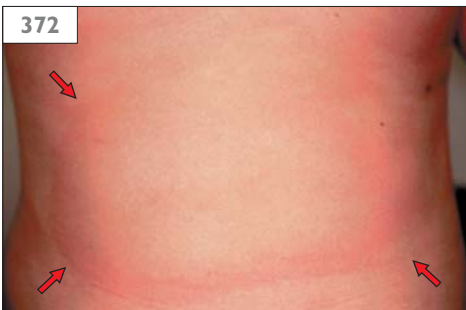**371** Noncontrast head CT showing periventricular calcification and cortical dysplasia in an infant with congenital lymphocytic choriomeningitis virus infection.

## Lyme disease

### DIAGNOSIS AND CLINICAL FEATURES

Lyme disease, caused by the spirochete *Borrelia burgdorferi*, emerged as the cause of many different neurological syndromes in the 1980s. Linked originally to an arthritis outbreak near Lyme, Connecticut and with polyradiculopathy in Scandinavia, *B. burgdorferi* is now recognized as a cause of Bell's palsy, lymphocytic meningitis, chronic encephalopathy, polyradiculopathy (known as Bannwarth's syndrome in Europe), chronic daily headache, SNHL and a pseudo-tumor cerebri-like disorder. *Ixodes scapularis* (deer tick) serves as the principal vector in most regions of the USA, but several additional ticks, including *Ixodes pacificus* (Western black legged tick), *Ixodes ricinus* (castor bean tick), and *Amblyomma americanum* (lone star tick) can transmit the spirochete to humans. *I. ricinus* and *I. persulcatus* serve as vectors for *B. burgdorferi* in Europe and parts of Asia.

*Borrelia*-induced Bell's palsy, the most common neurological condition associated with Lyme disease, typically occurs from March to November. Approximately one-third of affected children have a history of the typical Lyme disease rash, erythema migrans (372). As many as one-third have bilateral facial nerve palsy, and many children have mild to moderate lymphocytic pleocytosis. Meningitis, the next most frequent neurological condition associated with Lyme disease, causes headache, malaise, and behavioral changes.



372 Erythema migrans rash in a child with Lyme disease (arrows).

Lyme-associated neurological conditions are best diagnosed by serological studies and examination of the CSF. The CSF typically shows a lymphocytic pleocytosis, elevated protein content, and evidence for intrathecal synthesis of *Borrelia*-specific IgG. *Borrelia*-specific DNA can be detected by PCR; rarely, the organism can be isolated from the CSF. Serodiagnosis of Lyme disease relies upon a two step process to detect *Borrelia*-specific IgM and IgG using enzyme immunoassay and western immunoblot analysis (textbox).

### Serological diagnosis of Lyme disease

- IgM: must show reactivity against  $\geq 2$  of the following polypeptides:
  - 23/24 kDa; 39 kDa; and 41 kDa.
- IgG: must show reactivity against  $\geq 5$  of the following bands:
  - 18 kDa; 23/24 kDa; 28 kDa; 30 kDa; 39 kDa; 41 kDa; 45 kDa, 60 kDa; 66 kDa; and 93 kDa.

### MANAGEMENT

Treatment of Lyme disease depends upon the stage of infection and the extent of neurological condition (textbox).

### Antibiotic therapy for Lyme disease

- Isolated facial (Bell's) palsy:
  - Doxycycline orally, 100 mg BID for 21–28 days (8 years of age or older).
  - Amoxicillin orally, 50 mg/kg/day (max. 1.5 g) divided TID for 21–28 days **OR**
  - Cefuroxime 30 mg/kg/day IV (max. 1 g) divided BID for 21–28 days.
- Meningitis or encephalitis:
  - Ceftriaxone 75–100 mg/kg/day IV or IM once daily for 14–28 days **OR**
  - Penicillin 300,000 U/kg/day IV in six divided doses for 14–28 days.

Antibiotic therapy is recommended in cases of Bell's palsy to eradicate the organism, but therapy does not shorten the course of facial weakness. The vast majority of persons with Lyme-associated Bell's palsy recover completely.

Children or adolescents with Lyme-associated meningitis or encephalitis require extended courses of parenteral antibiotics. In general, treated children recover completely.

## Cat-scratch disease

Cat-scratch disease, a common condition in many regions of the USA, results from infection with the gram-negative bacterium, *Bartonella henselae*. As many as 50% of domestic and wild cats in the USA possess antibodies to *B. henselae*; human infections are more likely in the more humid areas of the USA, including the coastal regions, South, and Midwest. The disease has many different clinical presentations, including fever of unknown origin, regional lymphadenopathy, disseminated infection resembling infectious mononucleosis, Parinaud's oculoglandular syndrome, and neurological disease. Less than 1% of children with cat-scratch disease have neurological complications.

The most frequent neurological complication of cat-scratch disease, an encephalitis/encephalopathy syndrome, mimics viral encephalitis and ADEM. Features include somnolence, fever, weakness or malaise, and seizures, including status epilepticus. MRI may show multifocal areas of T2 prolongation within white matter; the CSF shows a lymphocytic pleocytosis and protein elevation. In cases of suspected or proven cat-scratch disease and neurological complications, especially encephalitis, treatment with any of several effective antibiotics (azithromycin, erythromycin, ciprofloxacin, trimethoprim-sulfamethoxazole, or rifampin) should be considered. With very few exceptions patients recover completely.

## Neurocysticercosis

Cysticercosis, infection of human tissues by the larvae of *Taenia solium*, the pork tapeworm, begins when humans ingest viable eggs. The eggs hatch in the human stomach, and the larvae penetrate the intestinal mucosa and enter the circulation. The larvae travel hematogenously to many tissues, including muscles, the eye, and brain, where they reside and form cysts. When the larvae die, inflammatory responses lead to clinical signs and symptoms; neurocysticercosis reflects the death of larvae within the brain and spinal cord, adjacent edema, and local cerebral hypoperfusion.

In endemic regions, including Mexico, Central and South America, India, Africa, and China, neurocysticercosis causes new-onset seizures and obstructive hydrocephalus. Clinical manifestations of neurocysticercosis, headache, seizures, focal deficits, visual dysfunction, behavioral changes, and papilledema or other signs of increased intracranial pressure, reflect, in part, the number and distribution of dying larvae. Occasionally, larval penetration of the eye or spinal cord leads to blindness or cord dysfunction.

The diagnosis of neurocysticercosis is usually suggested by the appearance of neuroimaging studies. During the acute and subacute stages of neurocysticercosis brain MRI and CT may show circular or ring-enhancing lesions (373–375), typically with adjacent cerebral edema. The lesions eventually calcify, so CT shows intracranial calcifications (376), often multiple, during the quiescent, chronic phase of the condition. During the acute stages, examination of the CSF reveals a lymphocytic or eosinophilic lymphocytosis and protein elevation. Serological diagnosis is possible; the sensitivity of detecting *Taenia*-specific IgG or IgM increases with increasing numbers of active intracranial cysts. Although opinions regarding the value of therapy vary, most authorities suggest that a course of albendazole be considered, especially when there are multiple, acute CNS lesions (textbox).

#### Antiparasitic therapy in suspected or proven neurocysticercosis

- Albendazole:
  - 15 mg/kg/day PO BID with meals (maximum of 800 mg/day) for 7 days.
  - For persons >60 kg, 400 mg PO BID with meals for 7 days.
  - Many authorities recommend that corticosteroids (dexamethasone or prednisone) be given before or concurrently with albendazole to minimize symptoms associated with parasite death.

## Cerebral malaria

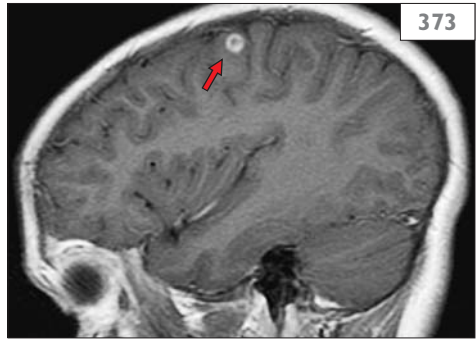Malaria, the consequence of infection with *Plasmodium* parasites (*P. falciparum*, *P. ovale*, *P. vivax*, and *P. malariae*), remains endemic throughout most of the southern hemisphere, especially India, Southeast Asia, and sub-Saharan Africa. As many as 500 million persons worldwide experience malaria annually, and more than one million of these infected persons die. Children living in the tropical regions of Africa are particularly vulnerable to severe malaria with *P. falciparum*; children in these regions comprise approximately 75% of deaths due to severe malaria.

Transmitted to humans by the bite of infected female *Anopheles* species mosquitoes, malaria has an incubation period of 1–4 weeks. Infected persons experience chills, fever, headache, nausea, vomiting, and malaise, often in cycles every 1–4 days. Fever and anemia have a high positive predictive value for malaria among persons living in endemic regions. Persons with severe malaria have a multiorgan system, sepsis-like disorder with renal, hepatic, and hematological disease, and cerebral signs and symptoms. The latter can include seizures, coma, focal deficits, and features of cerebral edema and increased intracranial pressure. Laboratory findings can consist of acidosis, severe hemolytic anemia, azotemia, and hypoglycemia. Although serological and molecular studies can be used to diagnose malaria, detecting parasites in a patient's Giemsa-stained blood smear is the gold standard for the diagnosis of malaria.

Treatment of severe, cerebral malaria remains challenging, especially in late cases when the mortality rates are as high as 75% and because of the emergence of drug resistance in most endemic regions. The therapy consists of supportive care and administration of a rapidly effective, artemisinin compound (artesunate, artemether, artemotil, dihydroartemisinin) in combination with longer-acting drugs, such as doxycycline, clindamycin, lumefantrine, sulfadoxine–pyrimethamine, atovaquone–proguanil, or mefloquine. Quinine remains a World Health Organization-recommended option for children living in high-transmission regions. Seizures require therapy with benzodiazepines, phenobarbital, or phenytoin; fluids should be provided to treat shock. Children who survive



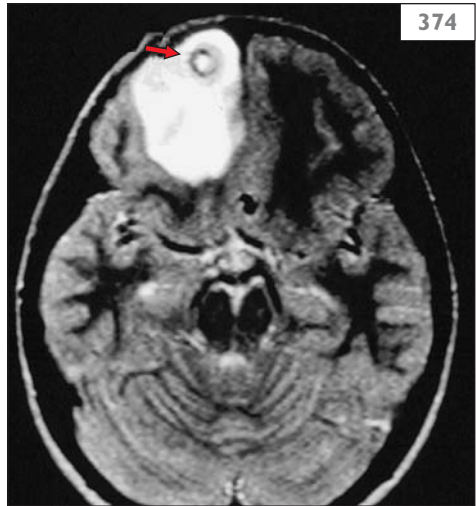
cerebral malaria are a risk for epilepsy and motor and cognitive deficits. Brain MRI can show hyperintensities in the white matter, thalami, and corpus callosum. Malaria can be prevented through the use of antimalarial medications, mosquito abatement, and the use of insecticide-treated bed nets.



373

**373** Gadolinium-enhanced sagittal T1-weighted MRI showing solitary lesion of neurocysticercosis (arrow).

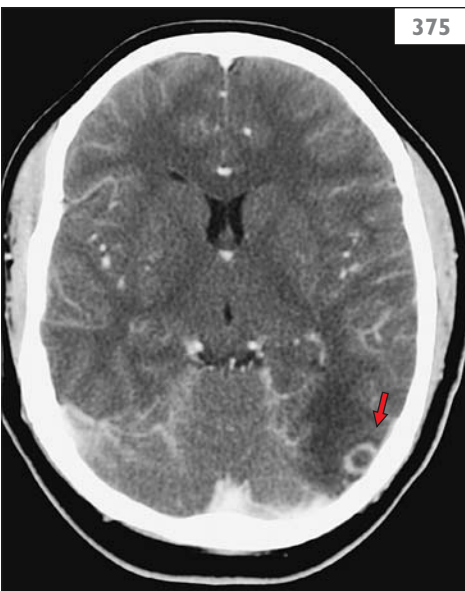**374** Axial T2-weighted MRI showing extensive edema adjacent to a solitary neurocysticercosis lesion (arrow).



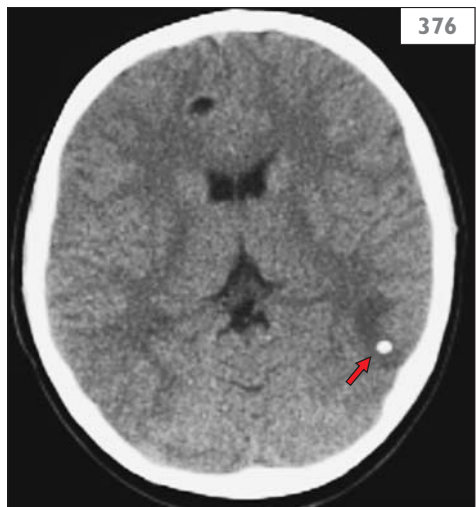
374

**375** Contrast-enhanced cranial CT showing a round lesion (arrow) and adjacent cerebral edema consistent with neurocysticercosis.

**376** Unenhanced CT showing a solitary calcification (arrow) consistent with neurocysticercosis.



375

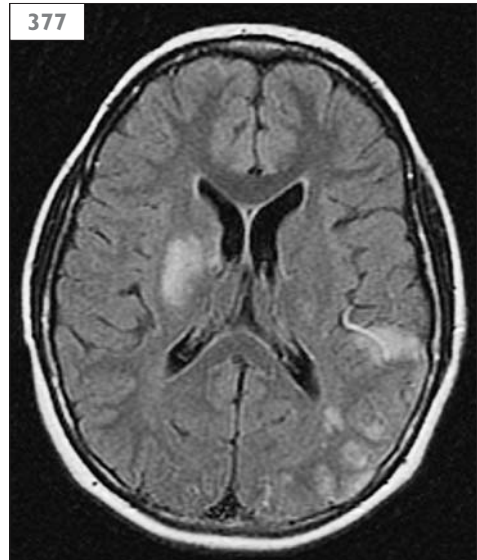


376

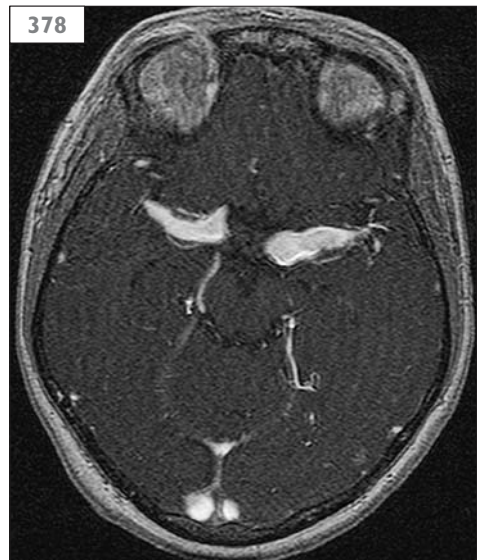## HIV/AIDS

Pediatric cases of the acquired immune deficiency syndrome (AIDS) appeared in the USA in the early 1980s, and the causative agent, the human immunodeficiency virus type 1 (HIV), a novel retrovirus, was identified by investigators in France in the mid-1980s. Early cases of HIV/AIDS were attributed to blood transfusions or factor replacement in hemophilia; the majority of current pediatric HIV/AIDS cases result from perinatal transmission from HIV-infected women. The number of people living with HIV/AIDS was 33 million in 2007 (two-thirds reside in sub-Saharan Africa); 2 million of these were children (Table 45). More than 25 million infants, children, and adults have died since the first cases of HIV/AIDS were identified in 1981.

Without antiretroviral therapies, infants and children with HIV/AIDS encephalopathy exhibit progressive motor dysfunction, cognitive abnormalities, developmental delay, and acquired microcephaly. Typical findings consist of apathy, dementia, ataxia, hyperreflexia, weakness, seizures, or myoclonus. Infants with vertical HIV infections can become symptomatic after the third month of life, manifesting hepatomegaly, lymphadenopathy, failure to thrive, interstitial pneumonitis, opportunistic infections (especially with *Pneumocystis jiroveci* or CMV), or neurological disease. HIV infection can cause aseptic meningitis, meningoencephalitis, myopathy, and GBS-like conditions; HIV/AIDS has many secondary CNS complications, including stroke (377, 378), primary CNS lymphoma, and opportunistic infections with *T. gondii*, CMV, VZV, *Mycobacterium tuberculosis*, fungi, and JC virus, the cause of progressive multifocal leukoencephalopathy (PML).



377 Axial FLAIR MRI showing patchy hyperintensities in an HIV-infected adolescent.



378 MRA showing fusiform aneurysms of the middle cerebral arteries in HIV arteriopathy.



**Table 45 Revised Pediatric HIV Classification System (US Centers for Disease Control and Prevention; Updated 2008)****Category A: Mildly symptomatic**

Children with 2 or more of the following conditions but none of the conditions listed in categories B and C: Lymphadenopathy ( $\geq 0.5$  cm at more than two sites; bilateral = one site); hepatomegaly; splenomegaly; dermatitis; parotitis; recurrent or persistent upper respiratory infection, sinusitis, or otitis media

**Category B: Moderately symptomatic**

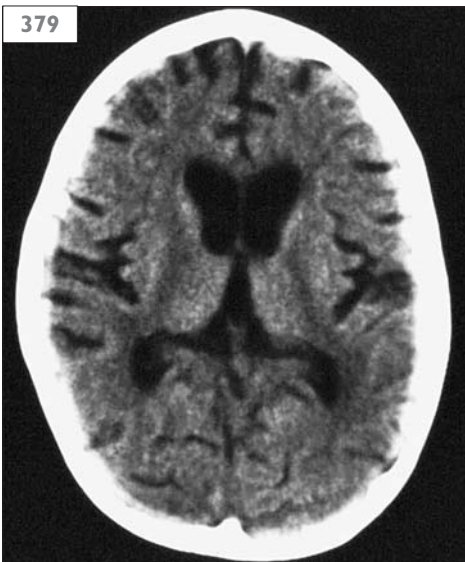Children who have symptomatic conditions, other than those listed for category A or category C, that are attributed to HIV infection. Examples of conditions in clinical category B include, but are not limited to, the following: Anemia ( $< 8$  g/dl), neutropenia ( $< 1,000$  cells/mm<sup>3</sup>), or thrombocytopenia ( $< 100,000$  cells/mm<sup>3</sup>) persisting  $\geq 30$  days; bacterial meningitis, pneumonia, or sepsis (single episode); candidiasis, oropharyngeal (i.e. thrush) persisting for  $> 2$  months in children aged  $> 6$  months; cardiomyopathy; cytomegalovirus infection with onset before age 1 month; diarrhea, recurrent or chronic; hepatitis; herpes simplex virus (HSV) stomatitis, recurrent (i.e. more than two episodes within 1 year); HSV bronchitis, pneumonitis, or esophagitis with onset before age 1 month; herpes zoster (i.e. shingles) involving at least two distinct episodes or more than one dermatome; leiomyosarcoma; lymphoid interstitial pneumonia (LIP) or pulmonary lymphoid hyperplasia complex; nephropathy; nocardiosis; fever lasting  $> 1$  month; toxoplasmosis with onset before age 1 month; varicella, disseminated (i.e. complicated chickenpox)

**Category C: Severely symptomatic**

Children who have any condition listed in the 1987 surveillance case definition for acquired immunodeficiency syndrome (below), with the exception of LIP (which is a category B condition); serious bacterial infections, multiple or recurrent (i.e. any combination of at least two culture-confirmed infections within a 2-year period), of the following types: septicemia, pneumonia, meningitis, bone or joint infection, or abscess of an internal organ or body cavity (excluding otitis media, superficial skin or mucosal abscesses, and indwelling catheter-related infections); candidiasis, esophageal or pulmonary (bronchi, trachea, lungs); coccidioidomycosis, disseminated (at site other than or in addition to lungs or cervical or hilar lymph nodes); cryptococcosis, extrapulmonary; cryptosporidiosis or isosporiasis with diarrhea persisting  $> 1$  month; cytomegalovirus disease with onset of symptoms at age  $> 1$  month (at a site other than liver, spleen, or lymph nodes); encephalopathy (at least one of the following progressive findings present for at least 2 months in the absence of a concurrent illness other than HIV infection that could explain the findings): a) failure to attain or loss of developmental milestones or loss of intellectual ability, verified by standard developmental scale or neuropsychological tests; b) impaired brain growth or acquired microcephaly demonstrated by head circumference measurements or brain atrophy demonstrated by computerized tomography or magnetic resonance imaging (serial imaging is required for children  $< 2$  years of age); c) acquired symmetric motor deficit manifested by two or more of the following: paresis, pathological reflexes, ataxia, or gait disturbance; HSV infection causing a mucocutaneous ulcer that persists for  $> 1$  month; or bronchitis, pneumonitis, or esophagitis for any duration affecting a child  $> 1$  month of age; histoplasmosis, disseminated (at a site other than or in addition to lungs or cervical or hilar lymph nodes); Kaposi's sarcoma; lymphoma, primary, in brain; lymphoma, small, noncleaved cell (Burkitt's), or immunoblastic or large cell lymphoma of B-cell or unknown immunologic phenotype; *Mycobacterium tuberculosis*, disseminated or extrapulmonary; *Mycobacterium*, other species or unidentified species, disseminated (at a site other than or in addition to lungs, skin, or cervical or hilar lymph nodes); *Mycobacterium avium* complex or *Mycobacterium kansasii*, disseminated (at site other than or in addition to lungs, skin, or cervical or hilar lymph nodes); *Pneumocystis jirovecii* pneumonia; progressive multifocal leukoencephalopathy; *Salmonella* (nontyphoid) septicemia, recurrent; toxoplasmosis of the brain with onset at  $> 1$  month of age; wasting syndrome in the absence of a concurrent illness other than HIV infection that could explain the following findings: a) persistent weight loss  $> 10\%$  of baseline; OR b) downward crossing of at least two of the following percentile lines on the weight-for-age chart (e.g. 95th, 75th, 50th, 25th, 5th) in a child  $\geq 1$  year of age; OR c)  $< 5$ th percentile on weight-for-height chart on two consecutive measurements,  $\geq 30$  days apart PLUS 1) chronic diarrhea (i.e.  $\geq 2$  loose stools per day for  $> 30$  days), OR 2) documented fever (for  $\geq 30$  days, intermittent or constant)

Passive transfer of maternal antibody complicates the diagnosis of HIV infection during the first 18 months of life. HIV infection in infants can be confirmed by serial serum PCR assays with the first test in the immediate newborn period, a second test during the first or second month of age, and a third test after 4 months of age. If two samples are positive for HIV, the infant is considered infected; two successive negative tests make infection unlikely. In children and adolescents, serological studies using ELISA and western blotting can identify HIV infection. RT-PCR monitoring of virus loads guides the treatment of HIV/AIDS. The CSF is usually normal in HIV-associated encephalopathy, whereas the EEG may demonstrate diffuse slowing. Neuroimaging studies in HIV/AIDS can reveal cortical atrophy (379) and calcifications of the basal ganglia or frontal white matter in perinatally-acquired infections.

Current drug antiretroviral therapy and refined treatments for the infectious or neoplastic complications greatly improve the survival and the quality of life of pediatric patients with HIV/AIDS (textbox).



**379** Unenhanced CT showing diffuse cortical atrophy in a child with hemophilia and HIV infection.

#### Current antiretroviral drugs for pediatric HIV/AIDS

- Nucleoside/nucleotide analogue reverse transcriptase inhibitors: abacavir, didanosine, emtricitabine, lamivudine, stavudine, tenofovir, and zidovudine.
- Non-nucleoside analogue reverse transcriptase inhibitors: efavirenz, etravirine, and nevirapine.
- Protease inhibitors: atazanavir, darunavir, fosamprenavir, indinavir, lopinavir/ritonavir, nelfinavir, ritonavir, saquinavir, and tipranavir.

Combined, highly-active antiretroviral therapy (HAART) relies upon combinations of nucleoside/nucleotide analogue reverse transcriptase inhibitors, protease inhibitors, and non-nucleoside analogue reverse transcriptase inhibitors. The goal of therapeutic strategies is to reduce the HIV viral load to undetectable levels and restore immunological function. All HIV-infected infants <12 months of age require treatment; decisions regarding treatment in older infants, children, and adolescents depend upon severity of symptoms, the degree of immunosuppression, and the viral RNA load. Current combined drug regimens, using antepartum and intrapartum therapy of the HIV-infected woman and postpartum therapy of exposed infants, can prevent HIV transmission.

Given the complexities of treatment and the potential for drug interactions or side-effects, infectious disease experts experienced in HIV treatment of children should be consulted (for information regarding the available antiretroviral therapies and current treatment guidelines, see: [www.aidsinfo.nih.gov](http://www.aidsinfo.nih.gov)). Despite the remarkable success of antiretroviral treatment, current therapies do not eradicate HIV from infected persons. Persons who reach end-stage AIDS despite therapy frequently experience AIDS-defining conditions, such as HIV dementia/encephalopathy, PML, lymphoma, or invasive CMV infections, during the 12 months prior to death. Vaccines to prevent HIV/AIDS are not yet available.

# Movement disorders

## Main Points

- Most movement disorders, common and often benign, can usually be managed by the generalist. Common disorders include stereotypies, tics, and tremor.
- Stereotypies can be mistaken for seizures in young children.
- Tremor is most commonly familial and benign.
- Most tics are transient and require no therapy.
- Chorea, irregular jerky movements, usually indicates rheumatic fever.
- Observation and home videos provide invaluable information regarding movement disorders of infancy, childhood, and adolescence.

## Introduction

Neurologists consider ‘movement disorders’ as a heterogeneous group of conditions in which impaired or excessive and involuntary movement occurs independent of a corticospinal tract or spinal cord disorder such as cerebral palsy (CP) or spinal muscular atrophy (SMA). Traditionally, movement disorders are classified as hypokinetic (the prototype being Parkinson disease) or hyperkinetic (the prototype being Huntington disease); in the former there is a preponderance of impaired or restricted mobility, while in the latter involuntary movements occur in excess.

Most hyperkinetic movement disorders subside in sleep. Tics may persist in early stages of sleep and sleep-onset myoclonus occurs only with sleep onset. A unique form of myoclonus, known as palatal myoclonus, persists in sleep. Chorea, athetosis, primary and secondary dystonias, most tremors, and all stereotypies generally disappear in sleep. Movement disorders, extremely common in children, are mostly due to relatively benign or self-limited hyperkinetic conditions including stereotypies and tic disorders. Movement disorders causing disability or severe impairment are fortunately infrequent.

## Stereotypy

This extremely common movement disorder causes an extraordinary degree of anxiety for parents and physicians considering its benign nature. Stereotypies consist of ‘stereotyped’ (meaning always the same) complex patterns of movement that are usually fairly symmetric and stimulus-dependent. They often take the form of ‘tensing’, ‘flapping’, flipping of the fingers, dancing, or stepping up and down on toes, and so forth, sometimes associated with grimacing (380). These may begin in infancy, but peak in toddlers. The patterned movement is nearly always triggered when the child is anticipating excitement (seeing a toy or a movie) or engaging in satisfying play activities (the child colors, looks at his drawing then has his stereotypy). Stereotypies are invariably interruptible.

A subset of stereotypies, described as ‘stimming’ or ‘self-stimulatory behavior’, can be seen in normal children or in autistic spectrum disorders (ASDs). These complex, patterned, stereotyped motor behaviors usually occur in situations when the child is over-stimulated, trying to withdraw or escape a stressful circumstance, or tired and relaxing. A common pattern is described as ‘masturbation’ when the child crosses his or her legs and rocks the pelvis rhythmically. Children may sit or lie prone on the floor when they engage in this behavior.

Most pediatric neurologists can make the diagnosis of stereotypies by observing the behavior a few times or having the parents bring a short video of the movements. In rare instances, a video-EEG may be necessary to distinguish the episodes from seizures. The majority of stereotypies decline in frequency and eventually disappear by school age or earlier, although they can persist or be intrusive in children with neurodevelopmental disabilities. Stereotypies may also persist into middle childhood or beyond in occasional children with normal intelligence and social skills. Gentle redirection of the child followed by engaging the child in another activity is the most effective intervention. Punitive or humiliating tactics are counterproductive.



**380** The jerky gait of Angelman syndrome and the child's stereotypic hand movements.

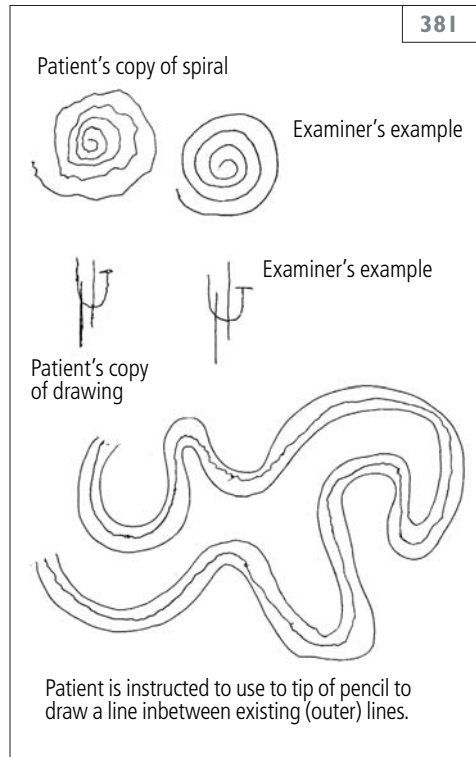
## Tremor

### DIAGNOSIS AND CLINICAL FEATURES

Tremor is traditionally divided into three types: postural (typical of essential tremor), resting (i.e. as in Parkinson's disease), and intention (usually associated with cerebellar disease and ataxia). Only the first is common in children. Resting tremor in children is usually limited to cases due to neuroleptic toxicity and/or to the adverse effects of these medications. Intention tremor is discussed in Chapter 13 Disorders of Gait and Balance.

Mild to moderate postural tremor, common in children, typically affects only the upper extremities. Rarely does one encounter truncal or head titubation, tremor of the chin, or involvement of the legs. A postural tremor is typically relatively fast (8–10 Hz), small amplitude (excursions of a few mm), and exaggerated by sustained antigravity posture. Maneuvers such as holding the arms outstretched with fingers splayed out or holding the arms in abduction at the shoulders, with flexion at the elbows with instruction to maintain the index fingers 'nearly touching' will often enhance tremor. The intensity of a postural tremor can vary greatly; any increase in adrenergic tone can aggravate tremor. Thus, tremor increases with or after exercise and with anxiety, fear, stress, anger, strong emotion, caffeinated beverages, sympathomimetic drugs, and hypoglycemia. Finally, there is often a modest 'intention' component to the typical postural tremor, such that the tremor intensifies when performing fine motor tasks such as putting a key in a lock, writing, or drinking from a cup. Unlike pathological cerebellar tremors, however, the intensification is very modest, and the target is still correctly approached.

In a healthy child with normal heart rate, blood pressure, and general examination, and with mild to moderate tremor, laboratory evaluation is usually unnecessary. If there is concern, evaluation for hyperthyroidism, hypoglycemia, abnormality of serum calcium, or Wilson disease may be considered. MRI should be considered in severe tremor, asymmetric tremor, when other neurological impairments are present, or if there is concern for acute or progressive disease. Having the child write and draw (spiral or 'racetrack' [381]) assists follow-up and monitoring of response to treatment.



381 Delineation of tremor.

### MANAGEMENT

Treatment of postural tremor in childhood is rarely needed. The clinician should educate families regarding aggravating factors (such as use of caffeinated beverages or sympathomimetic medications). Occupational therapy for optimal hand and arm positioning to improve writing may be helpful. Keyboarding should be encouraged for completion of written assignments at school. Pharmacologic treatment with propranolol or primidone may be attempted for more disabling cases. The use of other medications (levetiracetam, topiramate) is less well supported by medical evidence.

## Tic disorders and Tourette syndrome

### DIAGNOSIS AND CLINICAL FEATURES

Tics, too, are ‘stereotyped’ motor behaviors. Unlike stereotypies, however, tics are less predictable and often last only a few seconds or less (although they can occur repeatedly, in clusters or in longer patterns). They tend to ‘wax and wane’ and change over time. While more common under circumstances of stress, anger, excitement, or anxiety, they are not evoked in the same manner as stereotypies. Tics, classified as simple or complex, motor or vocal, commonly present as simple motor movements of grimacing or sudden shaking of the head.

As many as 15% of children experience a transient tic, whereas chronic tic disorders affect 1–2% of people. Tics typically begin between 5 and 8 years of age, although many parents acknowledge that previously unrecognized tics occurred before age 5. Tic disorders tend to spontaneously abate in late adolescence or early adulthood, such that many adults will perceive that they ‘used to’ have problems with tics.

Tourette syndrome consists of at least one vocal tic and one motor tic that occur over at least 1 year and cause subjective distress. The latter requirement suggests that psychological and cultural factors unrelated to the physical nature of the tics themselves determine whether or not a pattern of tics can be considered Tourette syndrome. Associations with attention deficit hyperactivity disorder (ADHD) (50%), obsessive compulsive disorder (OCD) (50%), anxiety, mood disorders, low frustration tolerance, and behavioral difficulties including impulsive aggressiveness (‘short-fuse’ behavior) are well recognized, but very variable from child to child.

Genetic factors likely play a role in Tourette syndrome, but single or multiple genes responsible for the majority of cases have yet to be identified. Evidence supports an autosomal dominant inheritance with extremely variable penetrance, although autosomal recessive inheritance of a recessive trait with a very high gene frequency has also been suggested. Early studies suggested that males tend to manifest tics while females may be more prone to the OCD features.

A controversial area relates to the association of tics/OCD with prior group A beta-hemolytic streptococcal infection, a putative immunologic condition referred to by the acronym PANDAS (pediatric autoimmune neuropsychiatric disorders associated with streptococcal infection). At this time, this construct remains controversial and might best be considered as a promising hypothesis. Therapies used in children with rheumatic fever do not benefit children with presumed PANDAS.

The diagnosis of tic disorders and Tourette syndrome remains a clinical one based on a history of waxing and waning stereotypic movements and sounds. The historical information provided by parents is often supplemented with home videos enabling the clinician to see and hear the child’s tics. Subtle obsessive–compulsive traits are common, such as ‘making it even’ and counting (arithmomania). In the former, children must repeat on one side what was done on the other (such as touching the arms of a chair), and in the latter there is an urge to carry out a given behavior a certain number of times or in even or odd numbers. Brain imaging in Tourette syndrome is normal, and thus is performed only when evaluating children with confusing or complex cases, such as instances in which tics resemble dystonia, a more serious movement disorder. EEG is occasionally needed when it is difficult to distinguish the stereotyped movement from a focal or absence seizure (such as upward eye deviation with fluttering of the eyelids). In some cases of abrupt onset or with dystonic-like tics, Wilson disease deserves consideration. Analysis of serum copper and ceruloplasmin and ophthalmologic slit lamp examination for Kayser–Fleischer rings (382) may be necessary. Evaluation for prior streptococcal infection with antistreptolysin O (ASO) and antiDNAse B titers is optional; the results are of limited practical value in most cases.

### MANAGEMENT

The treatment of tic disorders and Tourette syndrome must be tailored to the individual based on the presence or absence and relative severity of comorbid conditions. It is often sufficient for the clinician to reassure the family and to provide information concerning natural



history and prognosis. Medications should be reserved for instances in which the child desires it and not to assuage the parent's concern about self-image, teasing, and so on. It can be helpful for the child and parent to disclose the condition to others, even to the child's classmates and teachers, to improve understanding and reduce stigmatization. Parents must be understanding and avoid belittling or teasing the child; punitive measures to reduce tics are most often counterproductive.

### Tics are the main problem

In these cases, tic suppressant medication may be helpful. However, none is 100% effective, and all have potential adverse effects. Most child neurologists use clonidine initially; somnolence may be a limiting side-effect, particularly in younger children (<10 years of age). Dosage is started at 0.025 mg (one-quarter of a 0.1 mg tablet) TID in young children and up to 0.05 mg (one-half of a 0.1 mg tablet) TID in older children. An alternative is to use the transdermal clonidine patch (Catapres). Here, treatment is usually initiated with the lowest dose (the TTS-1 patch, changed weekly) and titrated upward every 1–2 weeks as needed and tolerated. Skin inflammation is the major side-effect. When clonidine is ineffective or not well tolerated, haloperidol and pimozide can be used. If only one or a few disabling tics are present, a behavioral therapy known as habit reversal may be effective. This requires a skilled psychologist.

### ADHD is the main problem but tics are present

Clinicians and parents may be concerned that treatment of ADHD with stimulant medication may cause permanent aggravation of tics. This is, in fact, uncommon. Up to 50% of children with tics and ADHD may experience transient worsening of tics when stimulants are administered, but the change is rarely permanent. Furthermore, 40% of treated children have no worsening, and in the remainder, tics may improve. Thus, if ADHD is debilitating for the child, clinicians should treat with the optimal agent for the attention difficulties while carefully monitoring for tic worsening. If tics are significantly aggravated, then treatment with atomoxetine (Strattera), clonidine, or guanfacine may

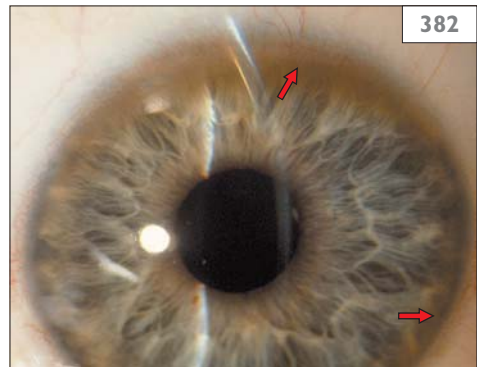
be helpful. Behavioral management of ADHD is preferable in any case.

### OCD is the major problem

In this circumstance, behavioral management, psychotherapy and treatment with a selective serotonin-reuptake inhibitor (SSRI) are indicated. Occasionally, tics with a highly compulsive component (usually complex motor or vocal tics, or patterned tic sequences) may also be ameliorated considerably by these therapies. Combining an SSRI with other medications is possible, but caution is advised in circumstances where drug interactions and QT prolongation are possible (e.g. SSRI plus pimozide, for instance). Clinicians and parents must be alert for the emergence of suicidal ideation and/or bipolar psychosis.

### Behavioral problems are the major issue

Separate from ADHD, some children, particularly boys, with Tourette syndrome suffer from severe behavioral dyscontrol. This can be the most disabling phenotype of this condition and requires multimodal treatment usually directed by an experienced child psychiatrist. No particular medication is predictably helpful in this setting, although many are used! Behavioral and cognitive therapies are the most effective measures.



**382** Kayser–Fleischer ring of Wilson disease (arrows).



## Chorea

### DIAGNOSIS AND CLINICAL FEATURES

Chorea consists of involuntary, nonsuppressible, nonstereotyped, irregular jerking or dancing movements of the face, trunk, and limbs, distally more than proximally. The hyperkinesia is usually symmetric, but striking asymmetry occurs in a substantial proportion of children with Sydenham chorea. Facial movements can be tic-like, but are typically less stereotyped than tics or stereotypies. Movements can be aggravated by strategies used to evaluate children with tremor as well as by asking the child to protrude the tongue for as long as possible, to hold the arms and hands up toward the ceiling, to maintain a sustained, consistent handgrip on the examiner's fingers, to stand on one foot, and to perform a tandem walk.

The above maneuvers demonstrate an inability to maintain the sustained position (so called motor impersistence) without extraneous twitches, jerks, and various twisting and darting movements. Having the patient hold your fingers tightly can elicit the milkmaid sign (rhythmic grasping and releasing of the patient's fingers) and having the patient keep his/her tongue protruded assesses for the chameleon sign (a darting tongue). The child with chorea will often attempt to suppress the movements by crossing the arms or legs, holding the limb down, or sitting on the hands. In chronic chorea, the movements will be unconsciously melded into a semi-purposeful action such as scratching the head or patting the thighs. The voice and speech may be affected, resulting in dysarthria, and swallowing may be impaired. Chorea is typically accompanied by hypotonia and pendular reflexes, and in more severe cases the affected muscle groups may actually be weak (paralytic chorea). Spooning of an extended hand can be an additional sign of subtle weakness (383). Muscle stretch reflexes, however, are preserved but not exaggerated, and plantar responses are flexor.

Since its resurgence in the mid 1980s, rheumatic fever again appears to be the most common cause of chorea (Sydenham chorea) in children in the USA. The anticardiolipin antibody syndrome with or without systemic lupus erythematosus (SLE) is probably second in importance. Sydenham chorea is often accompanied and sometimes preceded by subtle

personality, mood, or behavioral changes. The child is described as emotionally labile, inattentive and 'touchy'; depression or obsessive-compulsive traits may appear.

The differential diagnosis includes, in addition to the conditions mentioned above, focal cerebral lesions, hyperthyroidism, disorders of calcium regulation with calcification of the basal ganglia, mitochondrial diseases, other neurodegenerative disorders, and various obscure conditions. The clinician should carefully inquire and examine the child for any evidence of the major and minor criteria of rheumatic fever (the modified Jones criteria, textbox).

#### The revised Jones criteria for the clinical diagnosis of rheumatic fever

- Major: polyarthritis, carditis, chorea, erythema marginatum, and subcutaneous nodules.
- Minor: fever, arthralgia, previous rheumatic fever, acute phase reactants, and prolonged PR interval.

The diagnosis requires two major criteria or one major and two minor criteria and evidence for a recent streptococcal infection. Chorea alone, however, is sufficient to diagnose rheumatic fever in children or adolescents with serologic evidence for recent streptococcal infections.

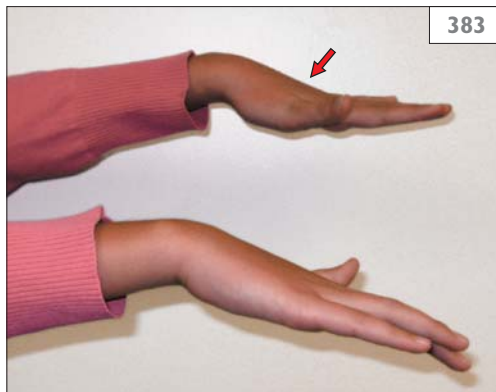
Given the two most common diagnostic conditions (rheumatic fever and anticardiolipin antibody syndrome/SLE), initial evaluation should begin with antistreptolysin O (ASO) and AntiDNase B titers, anticardiolipin antibodies (IgM and IgG), antinuclear antibody (ANA), ECG, and thyroid function tests. If the chorea is strikingly asymmetric, an MRI of the brain may be appropriate. If there is any evidence of rheumatic fever and/or if antistreptococcal antibodies are present, echocardiography is indicated to detect mitral valve regurgitation. If the latter is identified, further evaluation is unnecessary, and the child is treated for rheumatic fever. If the diagnosis of rheumatic fever cannot be firmly established, imaging and additional laboratory testing are strongly recommended. Clinicians should obtain MRI of

the brain with and without contrast, MRS (for lactate), serum copper and ceruloplasmin, liver enzymes, ophthalmologic consultation, serum and possible CSF lactate, blood smear for acanthocytes, careful review of the family history (for any suggestion of Huntington disease; textbox), possible genetic testing for the Huntington disease gene trinucleotide repeat, and further evaluation for autoimmune disease. Consultation with a rheumatologist may be warranted.

Huntington chorea, an autosomal dominant disorder, may present in childhood and exhibit a hypokinetic movement disorder with Parkinsonian features (the so-called Westphal variant), rather than the slowly progressive chorea of face and limb chorea of adults. When a child has Huntington chorea, the father is almost always the affected parent.

## MANAGEMENT

Penicillin prophylaxis (or alternative in case of penicillin allergy) is critical in patients with rheumatic chorea. When Sydenham chorea interferes with the ability to walk or eat independently, many authors suggest treatment with corticosteroids (prednisone 1–2 mg/kg/day orally for 1–2 weeks with subsequent taper over 1–2 weeks), although a small study suggested that plasmapheresis may be preferable to oral prednisone. Others favor symptomatic treatment. The latter is fraught with difficulty, as many reportedly effective options are either ineffective or result in unacceptable side-effects. Options include: benzodiazepines, valproic acid/divalproex sodium, baclofen, levetiracetam, and typical and atypical neuroleptics. Treatment of chorea associated with SLE requires immunomodulation, and the anti-cardiolipin antibody syndrome relies on immunomodulation plus anticoagulation, given the risk of stroke. Treatment of most other forms of chorea is symptomatic with the strategies suggested above. In severe, refractory cases, neurosurgical procedures have been employed.



**383** Spooning of the left hand (arrow) as seen in children with chorea.

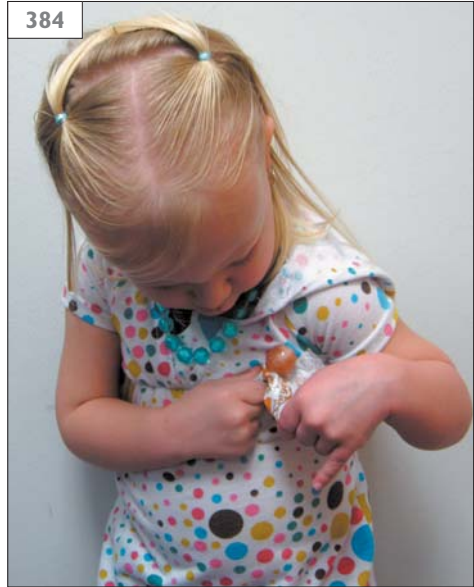## Dystonia

### DIAGNOSIS AND CLINICAL FEATURES

Dystonia, rare in childhood, consists of variably sustained twisting deformation of a limb (384), contiguous parts of the body, or of the trunk. Dystonia may be focal (torticollis, writer's cramp, dysphonia), segmental (limb and contiguous neck musculature), or generalized. Dystonic movements are often intermittent (spasmodic dystonia) or triggered by willful movement (action-induced dystonia). Given the complexity of evaluating children with dystonia, clinicians should initiate early referral to a pediatric neurologist. Dystonias can be considered primary, usually the result of a genetic disorder, or secondary, due to medications or a CNS injury, often CP.

The prototype of primary dystonias is progressive dystonia with diurnal variation, also known as dopa-responsive dystonia or Segawa disease. Recognition facilitates proper treatment and dramatic improvement in the quality of life. This autosomal dominant condition is due to a mutation in the guanosine triphosphate (GTP) cyclohydrolase-1 gene, resulting in impaired biosynthesis of tetrahydrobiopterin, the essential cofactor for tyrosine hydroxylase which in turn is the rate-limiting enzyme in catecholamine biosynthesis. The disorder usually presents in mid-childhood (5–15 years of age) with transient and fluctuating dystonia affecting gait and posture. The condition is often mistaken for stroke, CP, localized limb trauma, malingering, or conversion disorder.

The diagnosis of Segawa disease used to depend on demonstration of a dramatic response to low-dose L-dopa, but now analysis of CSF neurotransmitters demonstrates low concentrations of biopterin and neopterin, while sequencing demonstrates a pathogenic mutation of the GTP cyclohydrolase-1 gene in up to 80% of cases. The condition is exquisitely sensitive to treatment with L-dopa (and to a lesser degree with anticholinergics such as trihexyphenidyl). Treated patients usually remain asymptomatic throughout their life and do not generally have the time-emergent side-effects of L-dopa seen in patients with Parkinson disease.



**384** Dystonic posturing of the hands, especially the left, in a young child attempting to unwrap a lollipop.

A patient treated by one of the authors provided the following reflections several years after the diagnosis of Segawa disease and the initiation of L-dopa therapy:

“I am nearly 28 now, and not a day goes by that I don’t think about how wonderful it is to be healthy and mobile. I am so grateful for your help. I was able to attend college and law school. I am able to live alone and go out to explore the world without assistance. I am able to go work every morning, to exercise every evening . . . You gave me the ability to achieve my dreams.”

Another primary dystonia with onset in childhood is dystonia with DYT-1 mutation. This disorder represents the prototypic autosomal dominant familial dystonia in which variable penetrance may lead to lack of recognition of subtle manifestations of dystonia in affected relatives (e.g. writer's cramp, torticollis, spasmodic dysphonia, and mild limb dystonia). Unlike Segawa disease where mutations have been identified throughout the GTP cyclohydrolase-1 gene, this familial disorder is associated with the same mutation in families from virtually all ethnic groups (a 3 basepair GAG deletion in the *TOR1A* gene). Unfortunately, this condition is not as responsive to pharmacotherapy. High-dose anticholinergic medication (doses of trihexyphenidyl [Artane] of up to 60–150 mg/day) may be partly effective. Botulinum toxin injection can provide considerable relief. Neurosurgical procedures may prove necessary in severe, refractory cases.

An unusual but unique familial form of dystonia with myoclonus, the 'myoclonus-dystonia' syndrome, (also known as familial dystonia, DYT) often presents in childhood with myoclonus and spasmodic dystonia of muscles of the neck and shoulder girdle. Mutations in the epsilon-sarcoglycan gene (*SGCE*) have been identified in many but not all kindreds. Maternal inheritance is associated with reduced penetrance (imprinting). The movements in this condition respond to ingested ethanol and treatment with benzodiazepines, valproic acid, or topiramate.

Secondary dystonias can be drug-induced or associated with CP. The pediatrician should be attentive to drug-induced dystonias. Commonly used dopamine antagonists such as metoclopramide (Reglan), promethazine (Phenergan), and prochlorperazine (Compazine) are common offenders. The former can result in dramatic cases of oculogyric crisis and torticollis in infants treated for gastroesophageal reflux, which will bring terrified parents to the emergency department. Such episodes are often mistaken for seizures. Prompt treatment with diphenhydramine is both diagnostic and therapeutic. Dystonia in children with CP represents a chronic, often disabling condition that may respond to medications, such as baclofen, or botulinum toxin injections.

## Myoclonus

Myoclonic movements can be difficult to distinguish from tics, but myoclonic movements are much more rapid ('lightening-like'), irregular, and less stereotyped. The child with myoclonus usually lacks the subjective 'premonitory urge'. Massive myoclonus (whole body jerks) occur in certain epilepsies, in mitochondrial disorders, and in hyperekplexia (a condition originally described in French Canadian families with a specific glycine receptor mutation, hence the term 'jumping Frenchmen of Maine'). Most cases result from inflammatory, toxic, or metabolic conditions. In numerous severe cases no definitive explanation can be discovered. Treatment depends upon the etiology.

## Hypokinetic movement disorders in childhood

Hypokinetic movement disorders are extremely rare in children. The most common are iatrogenic, due to treatment with neuroleptic medications. The Westphal variant of Huntington disease presents with bradykinesia and rigidity and only minimal chorea. Familial and sporadic cases of juvenile-onset Parkinson disease are very uncommon. Various hypokinetic movement disorders with or without dystonia or choreoathetosis may follow CNS injury from global hypoxic-ischemic injury or encephalitis. L-dopa is rarely as effective in these disorders as it is in typical adult-onset Parkinson disease.

*This page intentionally left blank*

# Seizures and other paroxysmal disorders

## Main Points

- Seizures and paroxysmal events can occur at all ages.
- The child with the first seizure, whether provoked or unprovoked, can be appropriately evaluated by the generalist.
- Benign rolandic epilepsy with centrotemporal spikes causes approximately 10% of childhood epilepsy.
- Infants with suspected infantile spasms should be referred promptly to a pediatric neurologist.
- Most anticonvulsants and their dose adjustments can be managed safely by the generalist.
- Viewing videoed events is very helpful in evaluating paroxysmal disorders.

## Introduction

The clinician's role in the diagnosis of paroxysmal events is to recognize the typical clinical presentation of epileptic seizures and to differentiate these from the typical presentations of other paroxysmal disorders of infancy and childhood. This chapter begins by discussing the clinical features of common nonepileptic paroxysmal disorders and then focuses on the evaluation and management of epileptic seizures.

Infants and children can experience many types of episodic or paroxysmal events. To differentiate and diagnose these events, the clinician should start with three questions:

1. What was the child doing just prior to the event?
2. What happened during the event?
3. What was the child's condition just after the event?

Events starting during sleep are more likely to be seizures, whereas breathholding spells, movement disorders, self-stimulatory behaviors, migraine variants, shuddering attacks, stereotypies, daydreaming, and conversion disorder typically occur during wakefulness. An event during exercise could suggest a cardiac cause, such as prolonged QT syndrome or Wolff–Parkinson–White syndrome. The description of the event itself can be diagnostic, such as a breathholding spell or self-stimulatory behavior. The child's state just after the event is often altered after an epileptic seizure, but not after movement disorders, for example. It is often helpful for parents or caregivers to videotape events. In addition to the description of the event, the age of the child is often an important clue. Whereas epileptic seizures and cardiac arrhythmias can present at any age, many other paroxysmal disorders have a typical age of onset (*Table 46*).

## Cardiac arrhythmia

Cardiac arrhythmias can present at any age. Often, but not always, the seizure-like event is provoked by exercise or excitement. A screening ECG can detect features suggesting long QT syndrome, but a normal ECG does not exclude paroxysmal cardiac arrhythmias. The corrected QT interval ( $QT_c$ ) can be calculated using the equation:

$$QT_c = QT/\sqrt{RR}$$

in which  $\sqrt{RR}$  = the square root of the R-R interval.

Referral to a pediatric cardiologist should always be considered when evaluating children with paroxysmal events provoked by exercise or characterized primarily by syncope.



**Table 46** Age of onset of seizures and other paroxysmal events

Disorder	Age				
	0–3 mo	3–12 mo	1–4 yr	5–10 yr	11–18 yr
Epileptic seizure	✓	✓	✓	✓	✓
Cardiac arrhythmia	✓	✓	✓	✓	✓
Gastroesophageal reflux	✓	✓	+/-	×	×
Breath-holding spell	+/-	✓	✓	+/-	×
Self-stimulation	×	✓	+/-	×	×
Migraine variant	✓	✓	✓	✓	✓
Shuddering attacks	×	+/-	✓	+/-	×
Stereotypies	×	+/-	✓	✓	✓
Daydreaming	×	×	✓	✓	✓
Psychogenic nonepileptic seizure	×	×	+/-	✓	✓

✓: can occur

+/-: rare

×: usually absent

## Nonepileptic events

### Gastroesophageal reflux (Sandifer syndrome)

Gastroesophageal reflux (GER) can produce a paroxysmal movement disorder with sustained back arching, head turning, and fussiness that typically occur after feeding. The neurological features of GER are known as Sandifer syndrome, a condition that can be associated with a hiatal hernia. The episodes can last for several minutes, suggesting seizures, and afterwards the child can appear quiet, tired, or fussy. Unlike epileptic seizures, limb jerking is not a common clinical feature. Neurological symptoms associated with GER can occur from birth onward, but usually resolve by 2–3 years of age.

### Breath-holding spells

Breath-holding spells typically occur from 6 months to 4 years, but can appear as early as the first week of life and persist into middle childhood. They always occur in an awake child and are always provoked by minor injury, discipline, or a strong emotion such as startle, fright, anger, or frustration. There are two classic presentations: pallid or cyanotic. In pallid breath-holding, the spell is provoked by fright or pain (such as bumping the head on furniture) and the child turns pale, becomes unresponsive, rigid, and apneic. In cyanotic breath-holding spell, the child is upset or crying and then becomes nonresponsive, stops breathing, and turns very dusky. In either case, the child can stiffen or have transient jerking of the extremities; this can be considered severe breath-holding or convulsive syncope. Seizures can complicate any episode of syncope, especially when the child is held upright, and status epilepticus in young children can occasionally be provoked by breath-holding spells.

Breath-holding spells are very alarming to parents and other observers, and typically last for 1–2 minutes. The child may be subdued afterwards or even sleep. The child may be given rescue breaths and brought to medical attention. Evaluation of an initial event should be comprehensive, with special attention to potential cardiac causes of syncope. Breath-

holding spells can be a manifestation of systemic iron deficiency. Thus, if breath-holding spells are suspected, iron studies (serum iron and iron binding capacity, serum ferritin or serum transferrin receptor level) should be obtained, even when the hematocrit or hemoglobin is normal. Breath-holding spells can improve dramatically with oral iron therapy.

### Self-stimulatory behavior

Self-stimulatory behavior, masturbation or ‘gratification behavior’ can appear as early as the first month of life and can last to 5 years of age or beyond. The event is characterized by lower extremity posturing, rhythmic movements, quiet vocalizations or grunting, and facial flushing. The event can last for many minutes and is always interruptible. This kind of self-stimulatory behavior represents a normal element of growth and development in infants and children; redirection, rather than punishment, is the best management.

### Migraine variants

Migraine variants can present from infancy onward and consist of a characteristic movement, a family history of migraine, and a strong likelihood for subsequent migraine headaches as the child ages. Migraine variants, diagnoses of exclusion, usually require neuroimaging and electrophysiological studies. Benign paroxysmal torticollis of infancy occurs from 1–12 months of age. The episodes are sometimes accompanied by vomiting, and can last from 10 minutes to 48 hours. The child is normal between the episodes. Benign paroxysmal vertigo (BPV) typically presents in toddlers, but can also occur in younger children. The episodes are characterized by abrupt vertigo with nystagmus and vomiting. BPV should be differentiated from benign paroxysmal positional vertigo, a disorder of adolescents and adults, characterized by vertigo and nystagmus provoked by simple movements such as rolling over in bed.

## Shuddering attacks

Shuddering attacks occur from 4 months of age through middle childhood. They happen only during wakefulness and can be provoked by excitement. The child exhibits momentary, seconds long quivering or shivering movements of the head, shoulders, and trunk. There is no alteration of consciousness, eye deviation, or postictal state. As soon as the shuddering ends, the child returns to his/her normal state. Shuddering attacks are benign; propranolol can be effective, but therapy is rarely necessary.

## Stereotypies

Stereotypies are purposeful movements, that are often provoked by excitement, especially in anticipation of something enjoyable. They can begin as early as 1 year of age and last through adolescence. The stereotypic movements have a broad range of manifestations including hand flapping, vocalizations, or dystonic arm extension. As the name implies, one event is like another. The child with stereotypies has no loss of consciousness during the event or postictal state afterward. Stereotypies require no treatment. They can occur in children with autism or developmental delay, and in normal, healthy children.

## Daydreaming

Daydreaming or episodic nonresponsiveness affects nearly all children, and can be more noticeable in children with developmental delay or attention deficit hyperactivity disorder (ADHD). Daydreaming can be differentiated from absence seizures by an EEG that lacks epileptiform features during a typical event (see discussion of absence epilepsy). Daydreaming spells are typically less frequent and longer lasting than absence seizures; they differ from complex partial seizures by the lack of automatisms such as eye blinking, lip smacking or hand movements. Daydreaming is typically not provoked by hyperventilation, whereas absence seizures can be.

## Psychogenic nonepileptic seizures

Psychiatric and behavioral disorders, such as conversion disorder, can manifest with a wide range of symptoms, including paroxysmal events such as nonepileptic seizures. Nonepileptic seizures can start as early as 5 years of age and extend through adolescence and adulthood. Some children or adults with psychogenic nonepileptic seizures, 8–25% in some studies, also have epileptic seizures, making the diagnosis and treatment of these disorders challenging. Conversion disorder is a treatable medical condition. Compared with adults who have psychogenic nonepileptic seizures, pediatric patients have a higher likelihood (80% *vs.* 40%) of becoming seizure-free with early and appropriate intervention.

## Other disorders

Paroxysmal dyskinesias are rare, underdiagnosed movement disorders that present in childhood. These uncontrollable movements can be provoked by certain actions, such as playing with toys, or becoming excited. Immediately after the provoking action, the child experiences choreoathetoid movements or dystonic posturing of the extremities, most commonly the arms. There is no alteration of consciousness during the event or postictal state. In some cases, the seemingly bizarre posturing occurs spontaneously and can be misdiagnosed as a psychiatric condition. The diagnosis of these disorders is often made by a pediatric neurologist or movement disorder specialist, but generalists should be aware of these disorders to avoid misdiagnosis.

## Seizures and epilepsy

Pediatricians and family physicians are typically the first providers to evaluate infants or children with new-onset seizures. The generalist's role is to use the history and physical exam to establish the differential diagnosis, and if seizures or epilepsy remains a consideration, the generalist should initiate the appropriate evaluation. Comprehensive practice parameters published by the American Academy of Neurology and the Child Neurology Society guide generalists in the initial management of children with febrile or nonfebrile seizures. Resources can be found at [www.epilepsyfoundation.org](http://www.epilepsyfoundation.org).

## Evaluation of children with suspected seizures

The acute evaluation of an infant or child with a seizure should always start with the ABCs: airway, breathing, and circulation. Once the patient is medically stable, the clinician should determine whether the seizure was provoked or unprovoked. Examples of provoked seizures include seizures in the setting of head trauma, hypernatremia, hyponatremia, hypoglycemia, hypocalcemia, meningitis, encephalitis, and fever, as well as severe breath-holding, as noted earlier in this chapter. Simple febrile seizures will be discussed separately. For infants and children with their first unprovoked seizure, current practice parameters in the USA recommend obtaining laboratory studies and neuroimaging on a case-by-case basis, depending on the history.

EEG assists the evaluation of the child with a first seizure, especially if an epileptic syndrome can be identified. However, a normal EEG does not rule out a seizure. Although an EEG within 24 hours of the event is more likely to display abnormalities, these abnormalities can be transiently related to the postictal state. Typically, EEG is performed on an outpatient basis in the first week or two after the first seizure. Anticonvulsant therapy, if necessary when the events are recurrent, should not be delayed while waiting to obtain an EEG. With the exception of valproic acid/divalproex sodium and the benzodiazepines, anticonvulsants do not alter the EEG. The majority of children with unprovoked seizures should undergo neuroimaging; MRI has the highest diagnostic yield of neuroimaging studies in the child with his/her first seizure.

## Specific seizure types and pediatric epilepsy syndromes

### Infantile spasms

Infantile spasms typically present between 3 and 6 months of age, but can begin as early as 1 month of age and as late as 24 months (textbox).

#### Causes of symptomatic infantile spasms

- Genetic: tuberous sclerosis; Down syndrome; Miller–Dieker syndrome; Aicardi syndrome.
- Structural: schizencephaly; holoprosencephaly; cortical dysplasia (385); polymicrogyria; hydranencephaly.
- Metabolic: maple syrup urine disease; PKU; biotinidase deficiency; nonketotic hyperglycinemia; pyridoxine dependency.
- Perinatal: hypoxic–ischemic (neonatal) encephalopathy.
- Infectious: congenital infections (CMV, *T. gondii*, rubella virus, lymphocytic choriomeningitis virus); neonatal encephalitis (herpes simplex virus); neonatal bacterial meningitis.

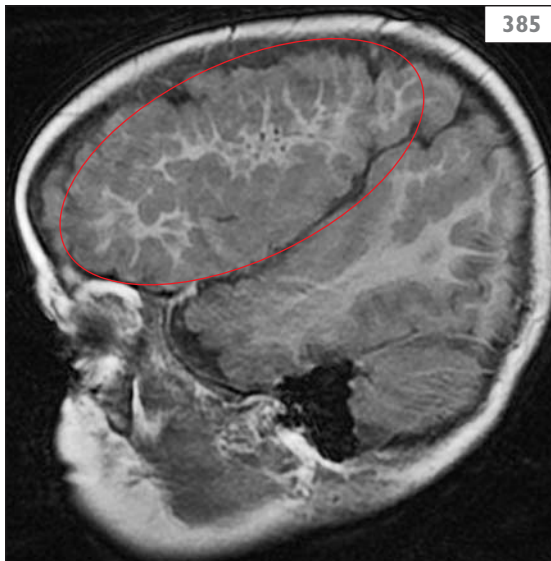
The majority of infants with infantile spasms have flexor spasms. In these, the infant abruptly flexes the head and trunk and may extend the arms and flex at the hips ('salaam' or jackknife attacks). Less commonly, infants have extensor spasms with abrupt arching of the head and back and extension of the arms similar to the Moro response. Each spasm lasts a few seconds, but the spasms recur in clusters of 20 or more over a 10–30 minute interval, especially when the infant becomes sleepy or awakens from sleep. The infant may cry, as if in discomfort, and have nystagmoid movements or upward eye deviation during the spasm.

Infantile spasms can be classified as symptomatic, when a cause can be identified, or cryptogenic, when no cause can be found after a comprehensive evaluation. Approximately 20% of patients presenting with infantile spasms have tuberous sclerosis (TS), so a thorough skin exam can be diagnostic (268–273). West syndrome, a term sometimes used

synonymously with infantile spasms, describes the triad of infantile spasms, developmental delay, and the EEG finding of hypsarrhythmia.

Infants with infantile spasms require a comprehensive evaluation that includes brain MRI, EEG, ophthalmological examination, and, depending upon coexisting historical or examination features, genetic or metabolic testing. The latter may include assays of serum amino acids and urine organic acids. The EEG often shows hypsarrhythmia (281), a chaotic EEG pattern with poorly organized background and abundant, multifocal epileptiform discharges, but its absence does not exclude the

diagnosis of infantile spasms. Some infants have normal EEGs at the onset of their spasms, but hypsarrhythmia or modified hypsarrhythmia eventually appears in nearly all cases of infantile spasms. The prognosis for infants with spasms depends, in large part, on the etiology. Virtually all infants with symptomatic spasms have recurring seizures and long-term neurodevelopmental delays. Many evolve to Lennox-Gastaut syndrome, a disorder associated with intractable epilepsy and developmental delay/mental retardation. By contrast, as many as 50% of the infants with cryptogenic spasms respond well to treatment and have favorable neurodevelopmental outcomes.



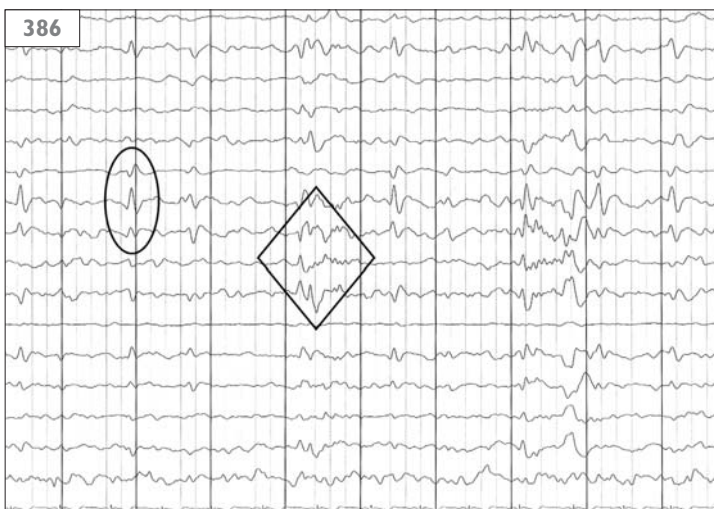
**385** Diffuse cortical dysplasia (circle) in a child with macrocephaly, polymicrogyria, polydactyly, and hydrocephalus syndrome.

## Febrile seizures

A simple febrile seizure consists of a generalized, tonic-clonic seizure lasting less than 15 minutes in a child between the ages of 6 months to 6 years of age with fever  $>102^{\circ}\text{F}$  ( $38.9^{\circ}\text{C}$ ). If these criteria are met and the child lacks neurological abnormalities or developmental deficits at baseline, no further evaluation is routinely recommended. Children with complex febrile seizures have long ( $>15$  minutes), focal or repetitive seizures during the acute phase. Children with complex febrile seizures or those with simple febrile seizures and a family history of epilepsy may require further diagnostic evaluation with EEG and neuroimaging studies. Febrile seizures can also be features of more serious conditions, including meningitis and encephalitis.

## Benign rolandic epilepsy

Benign rolandic epilepsy or centrotemporal epilepsy typically begins between 3 and 12 years of age and spontaneously remits by mid-adolescence in nearly all cases. Rolandic epilepsy, the most common childhood epilepsy, accounts for approximately 10% of all pediatric epilepsy. The characteristic seizure presents as a partial motor or sensory seizure of the face and arm occurring within the first hour after falling asleep. Children often experience secondary generalization into brief tonic-clonic seizures. The diagnosis rests on obtaining a normal developmental history and examination and finding characteristic EEG abnormalities of centrotemporal spikes that are accentuated by drowsiness and light sleep (78–80, 386). Most child neurologists consider treatment of rolandic epilepsy optional; when seizures are atypical (occur during wakefulness or are repetitive) or cause considerable parental angst, oxcarbazepine or carbamazepine can be considered. Rolandic seizures remit completely by age 14 years in 95% or more of affected children.



**386** The EEG in rolandic epilepsy. Diamond box: vertex transients and sleep spindles (normal findings of stage 2 sleep); circle: centrotemporal sharp and slow wave discharges characteristic of rolandic epilepsy.

## Childhood absence epilepsy

Childhood absence epilepsy presents in boys or girls between 3 and 10 years old. Absence seizures, often called petit mal seizures, are characterized by brief disturbances of consciousness ('spacing out') lasting 15 seconds or so, with abrupt onset and termination and no postictal state. They can be accompanied by slow head nodding or arm elevation or by automatic movements, such as walking. They can occur in clusters and are provoked by hyperventilation. Absence seizures are always associated with generalized 3 Hz spike-wave discharges during the seizure (74). If the EEG does not show this abnormality during an episode of unresponsiveness, the child does not have absence seizures.

## Juvenile myoclonic epilepsy

Juvenile myoclonic epilepsy (JME) presents in boys or girls 12–18 years of age. They often come to medical attention because of a generalized tonic–clonic seizure, but some patients with JME had absence epilepsy prior to the onset of myoclonic or generalized tonic–clonic seizures. A thorough history often elicits clumsiness or limb jerking (myoclonus), typically upon awakening in the morning, or provocation of seizures by playing video games or watching television. Myoclonus can consist of spontaneously dropping or throwing objects because of the abrupt, involuntary jerks of the upper extremities. Adolescents with JME are developmentally and neurologically normal, but have abnormal EEGs with brief spike-wave bursts or photoparoxysmal discharges (76, 77). The clinical seizures in JME are often controlled with a single anticonvulsant, such as divalproex sodium, levetiracetam, or lamotrigine; however, seizures often recur if anticonvulsants are discontinued.

## Additional epilepsy syndromes of childhood

- Benign familial neonatal seizures: a dominantly inherited condition with usual onset between 2 and 5 days of age. The disorder, caused by mutations in voltage-gated potassium channels, remits spontaneously in most cases within 6–12 months.
- Ohtahara syndrome: a rare, early-onset epileptic encephalopathy syndrome with intractable seizures, including infantile spasms and later, Lennox–Gastaut syndrome. EEG shows a burst-suppression pattern.
- Dravet syndrome: a rare, sporadic disorder with seizure onset in the first year of life, often starting with febrile seizures. Seizure types include myoclonic, atypical absences, or atonic seizures. Many children with this disorder have mutations in SCN1A, a voltage-gated sodium channel.
- Doose syndrome (myoclonic–astatic epilepsy of childhood): an uncommon disorder associated with generalized seizures usually beginning in the first 2 years of life. All children with this disorder have myoclonic or myoclonic/astatic (drop) seizures. It can be refractory to medication therapy and may improve with the ketogenic diet. The ketogenic diet, an additional treatment strategy for children with intractable epilepsy, consists of a diet high in fat and low in protein and carbohydrate. The ketogenic diet can cause a dramatic reduction in seizure frequency in some children.



## Management of seizures

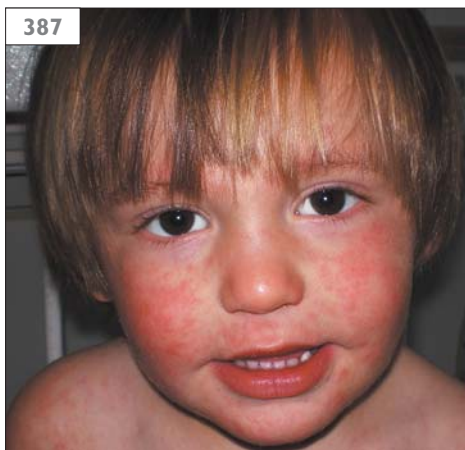The decision to initiate an anticonvulsant for a child with seizures depends on the likelihood of further seizures and the potential morbidity associated with seizures in that particular patient. Side-effects, drug interactions, and drug availability influence the decision to start anticonvulsant therapy. Parents should be advised that mucocutaneous drug eruptions, including DRESS (drug rash with eosinophilia and systemic symptoms) syndrome are common with many anticonvulsants, especially phenobarbital, phenytoin, carbamazepine, oxcarbazepine, and lamotrigine (387, 388). These reactions commonly appear 1–6 weeks after drug initiation.

Parents should be advised that antiepileptic medications have potential cognitive or behavioral side-effects and may increase the risk of suicidal thoughts or behaviors.

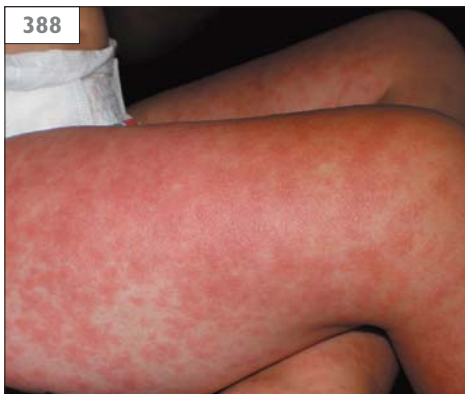## Recurrence risk

After having a single unprovoked seizure, approximately 50% of children will have another seizure. The risk of recurrence is increased in children with prior brain injury, developmental delay, or an abnormal EEG. Children with a single seizure and a normal EEG have a 25% risk of seizure recurrence, whereas children with a single seizure and an abnormal EEG with epileptiform features have a 75% recurrence risk. If the first unprovoked seizure was prolonged, the next seizure is likely to be prolonged, although the recurrence risk is the same as if the first seizure were brief.

In simple febrile seizures, the recurrence risk is about 30%. Children with younger age, lower temperature at the time of the febrile seizure, and family history of febrile seizures have the highest risk of recurrent febrile seizures. The risk of epilepsy in children with simple febrile seizures is very low. By contrast, children with complex febrile seizures or children with simple febrile seizures and a family history of epilepsy have increased rates of epilepsy during childhood or adolescence.



**387** The face of a young child with drug rash with eosinophilia and systemic symptoms (DRESS) syndrome secondary to phenobarbital therapy.



**388** Characteristic rash of DRESS syndrome involving the legs of the same child as in 387.

## Choosing an anti-convulsant

Age and seizure type are two important factors to consider when choosing an anticonvulsant (*Tables 47, 48*). Formulation (liquid suspension, tablet, or sprinkle capsules) and time to therapeutic effect also influence medication selection. For infants and children up to 2 or 3 years of age, phenobarbital is often chosen first, given its ease of use and substantial clinical experience with this medication. For infants or children with focal onset seizures,

**Table 47 Guide to anticonvulsant use**

Seizure type	Medication
Infantile spasms	ACTH, prednisolone, vigabatrin (especially in tuberous sclerosis)
Generalized tonic-clonic	
<3 yr	Phenobarbital, levetiracetam
3 to 16 yr	Divalproex sodium, levetiracetam, phenytoin
>16 yr	Lamotrigine, levetiracetam, divalproex sodium (avoid in girls)
Absence	Ethosuximide, divalproex sodium, lamotrigine
Partial	Carbamazepine, oxcarbazepine, levetiracetam, topiramate, lacosamide, zonisamide
Myoclonic	Levetiracetam, divalproex sodium (avoid divalproex sodium or valproic acid in patients with mitochondrial disorders), lamotrigine
Lennox–Gastaut syndrome	Divalproex sodium, benzodiazepines, zonisamide, felbamate, topiramate, lamotrigine

**Table 48 Anticonvulsant dosing**

Drug	Loading dose	Maintenance dose	Tablet/capsule	Suspension	Serum level
Carbamazepine	NA	10–30 mg/kg/day	100, 200 mg 100, 200 mg XR	100 mg/5 ml	4–12 µg/ml
Divalproex sodium	10 mg/kg	15–60 mg/kg/day	125, 250, 500 mg 250, 500 mg XR	–	50–125 µg/ml
Ethosuximide	NA	15–40 mg/kg/day	250 mg	250 mg/5 ml	40–100 µg/ml
Felbamate*	NA	15–45 mg/kg/day	400, 600 mg	600 mg/5 ml	NA
Gabapentin	NA	10–30 mg/kg/day	100, 300, 400, 600, 800 mg	250 mg/5 ml	A <sup>1</sup>
Lacosamide	NA	2–12 mg/kg/day	50, 100, 200 mg	10 mg/ml	NA
Lamotrigine**	NA	2–5 mg/kg/day (with VPA) 5–15 mg/kg/day (without VPA)	2, 5, 25, 50, 100 mg	–	A <sup>1</sup>
Levetiracetam	10–20 mg/kg	10–60 mg/kg/day	250, 500, 750 mg 1000 mg	100 mg/ml	A <sup>1</sup>
Oxcarbazepine	NA	10–60 mg/kg/day	150, 300, 600 mg	300 mg/5 ml	15–35 µg/ml
Phenobarbital	10–20 mg/kg	3–7 mg/kg/day	15, 16.2, 30, 32.4, 60, 64.8 mg	20 mg/5 ml	15–40 µg/ml
Phenytoin	15–20 mg/kg	3–5 mg/kg/day	30, 50, 100 mg	125 mg/5 ml	10–20 µg/ml
Topiramate	NA	2–12 mg/kg/day	15, 25, 30, 50, 100 mg	–	A <sup>1</sup>
Valproic acid	NA	15–60 mg/kg/day	250, 500 mg	250 mg/5 ml	50–125 µg/ml
Vigabatrin	NA	40–100 mg/kg/day	500 mg	500 mg powder	A <sup>1</sup>
Zonisamide	NA	2–12 mg/kg/day	25, 50, 100 mg	–	A <sup>1</sup>

\*Note warnings regarding aplastic anemia and hepatic failure

\*\*To avoid allergic reactions with lamotrigine, dose adjustments must be made at 2 week intervals initially, especially in children receiving valproic acid or divalproex sodium

A<sup>1</sup>: available, not routinely used; NA: not applicable; VPA: valproic acid or divalproex sodium; XR: extended release

oxcarbazepine or carbamazepine is often the first consideration. Levetiracetam, one of the newest anticonvulsants, appears beneficial, and has very few side-effects.

Divalproex sodium is very effective for all types of generalized epilepsy, including absence, generalized tonic-clonic and myoclonic, but the risk of hepatotoxicity in children under 3 years of age often precludes its use in this age group. Certain metabolic disorders, especially mitochondrial disorders, may predispose young children to divalproex sodium's hepatic complications, including fatal liver failure. Given the risk of teratogenicity (developmental delay, facial dysmorphism, and spinal bifida), divalproex sodium (or valproic acid) must be avoided in young women of child-bearing age. Administration of folic acid does not prevent fetal valproate syndrome and spina bifida. Absence seizures are treated with ethosuximide, but when generalized tonic-clonic seizures appear, divalproex sodium or lamotrigine is used, since ethosuximide does not adequately protect patients from seizure types other than absence.

Phenytoin, one of the oldest anticonvulsants, can be used for generalized tonic-clonic or partial seizures in children, but rapid metabolism makes its use challenging in young patients. Topiramate and lamotrigine are also used with good success in children, although lamotrigine carries a US Food and Drug Administration (FDA) 'black box' warning regarding serious allergic reactions, including Stevens-Johnson syndrome, in pediatric patients <16 years of age.

Infantile spasm is the only seizure type routinely treated by a course of intramuscular adrenocorticotrophic hormone (ACTH). Other treatment options in infants with spasms include topiramate, prednisolone, the ketogenic diet, and in the case of infantile spasms due to TS, vigabatrin.

## Management of children with epilepsy

The generalist's role is to monitor the efficacy and side-effects of anticonvulsant therapy, to assist titration of anticonvulsants in patients (especially those receiving single anticonvulsants) and to encourage healthy living by reviewing activity and seizure precautions at every opportunity. In general, pediatric patients should be managed with the lowest therapeutic dose of a single anticonvulsant, whenever possible. Seizure precautions for persons with seizures include avoiding unsupervised baths or swimming and activities, such as climbing or motor vehicle operation, in which a sudden loss of consciousness could cause severe injury to the person or others. Participation in sports depends on the sport, the child's seizure frequency, and the risk of injury. 'Above the ground' gymnastics and competitive swimming should be avoided, but persons with well-controlled epilepsy can participate in virtually all other sports. Each country has specific laws regarding epilepsy and operating a motor vehicle; clinicians should familiarize themselves with the laws in their region. Finally, clinicians and parents should be aware that children and adolescents with epilepsy have a slightly-increased risk of sudden death, a condition known as 'sudden unexplained death in epilepsy' (SUDEP).

# Pediatric neurological emergencies

## Main Points

- Seizures lasting longer than 5–10 minutes require intervention.
- Treatment of status epilepticus, seizures lasting longer than 15 minutes, requires a systematic approach beginning with the ABCs and continuing with administration of rapidly acting and maintenance anticonvulsants.
- The neurological examination is used to identify the neuroanatomical localization of unconsciousness (coma).
- Evaluation of the comatose child should include screening for systemic causes and evaluation by CNS imaging.
- Concussion causes confusion and amnesia with or without loss of consciousness.
- Nonaccidental trauma should be suspected in infants with acute changes in mental status, especially when accompanied by apnea. Funduscopic examination should be performed to detect retinal hemorrhages, a hallmark of nonaccidental trauma.
- Hypertensive encephalopathy (posterior reversible encephalopathy syndrome) should be considered in children with hypertension and seizures, headaches, and focal neurological signs, especially involving vision.
- Spinal cord injury can occur without radiographic evidence of bony injury.
- Respiratory function must be monitored closely in infants or children with neuromuscular disorders causing weakness.
- Many acute poisonings display toxidromes with specific CNS manifestations.

## Introduction

Neurological emergencies, although not common, require that clinicians respond rapidly and efficiently to minimize injury to the nervous system. Most clinicians will encounter patients with seizures and concussion, and many will be called upon to manage infants or children affected by ingestions, coma, or nonaccidental trauma. This chapter describes several pediatric neurological emergencies and management strategies that will enable clinicians to treat their patients effectively.

## Seizures

Seizures represent paroxysmal, usually self-limited events that typically cease after 2 minutes or less, allowing the infant, child, or adolescent to return quickly or gradually to the baseline state. Seizures end because of  $\gamma$ -aminobutyric acid-mediated recurrent CNS inhibition that occurs in response to the seizure. When seizures recur in rapid succession or become prolonged, they may not cease spontaneously, and emergency treatment becomes necessary. This concept of an 'enduring epileptic condition' is the basis for defining status epilepticus. Every clinician who cares for children should be able to provide emergency management for status epilepticus.

## Status epilepticus

### DIAGNOSIS AND CLINICAL FEATURES

Historically, status epilepticus was defined as continuous seizure activity for 30 minutes or repetitive seizures with incomplete recovery that lasts for 30 minutes. This definition was based on animal data that indicated that after this time the animal started to experience deleterious systemic effects from the ongoing seizure activity. We recognize now that this definition does not adequately direct appropriate responses to the convulsing child. Current strategies categorize status epilepticus according to progressive stages of severity based on the duration and the response to appropriate anticonvulsant therapy (textbox).

#### Categories of status epilepticus

- Early or impending status epilepticus: 5 minutes of continuous generalized convulsive seizure or 15 minutes of nonconvulsive or focal seizure, or two seizures without full recovery between the seizures.
- Late or established status epilepticus: continuous seizure activity or repetitive seizure activity with incomplete recovery between seizures that last for 30 minutes or longer.
- Refractory or persistent status epilepticus: persistent or continuous seizure activity despite appropriate doses of two or three anticonvulsants.

Assessment of the child with status epilepticus must address potential causes and must consider the context of the event. If the child has had an acute febrile illness, for example, the clinician must determine if derangements of electrolytes, calcium, or glucose require immediate therapy or if an infection of the CNS must be treated expeditiously. In the appropriate setting clinicians must consider whether status epilepticus results from an acute or chronic intracranial structural process or ingestion of a toxic substance. One of the most common causes of status is the child with a refractory epilepsy and the tendency for prolonged breakthrough seizures (textbox).

**Causes of status epilepticus**

- Metabolic: hypoglycemia, hypo- & hypernatremia, hypocalcemia, anoxia/hypoxia.
- Infectious: meningitis, encephalitis.
- Structural: congenital malformations, trauma, tumor, vascular malformations, vascular events.
- Toxic: substance abuse, drugs, poisoning, withdrawal.
- Febrile: in the age-appropriate child.
- Loss of seizure control or medication noncompliance.

When children experience status epilepticus, the probability is at least 30% that the next seizure event will also consist of status epilepticus.

**MANAGEMENT**

Managing status epilepticus begins with the ABCs (airway, breathing, circulation) of patient care. An adequate airway must be established, and the child should be given supplemental oxygen. A peripheral intravenous (IV) line should be started so that drugs can be administered. As the line is being placed, blood can be drawn for appropriate laboratory tests to determine if metabolic or toxic factors are causing the seizure. Blood glucose level by Dextrostix or equivalent should be obtained, and 25% glucose (2–4 ml/kg) should be given IV if the child has hypoglycemia. After the line has been secured, a rapidly acting anticonvulsant should be given (textbox).

The most frequently administered initial medication is a benzodiazepine, either diazepam or lorazepam. Both are equally effective, but lorazepam has become the drug of choice because of a longer duration of action and lower rate of respiratory depression requiring intubation. Lorazepam is given in a dose of 0.1 mg/kg IV, up to 8 mg total, over 1 minute. The dose of diazepam is 0.3 mg/kg IV, up to 20 mg total, over 1 minute. If the seizure does not stop after one dose, a second dose should be given. After two doses of either diazepam or lorazepam, it is unlikely that additional doses of these medications will be beneficial. When these drugs are given IV, especially in larger doses, the

clinician should be prepared to ventilate the child, either by bag/mask or intubation.

If the child continues to have seizures, the next drug to give is fosphenytoin. Fosphenytoin, a prodrug rapidly metabolized to phenytoin, has several advantages over phenytoin, including neutral pH, absence of the vehicle propyleneglycol, and ability to be mixed with dextrose-containing solutions. Thus, fosphenytoin can be given at a faster infusion rate with less tissue toxicity and fewer cardiovascular side-effects. The dosing of fosphenytoin is measured in phenytoin equivalent (PE), with 1 PE equal to 1 mg of phenytoin. The dose of fosphenytoin is 20 PE/kg IV given at a rate not exceeding 150 PE/min. This dose usually achieves a serum level of 20–25 µg/ml; levels of phenytoin peak in the serum 2 hours after the IV load. If the seizure persists, another 5 mg/kg of fosphenytoin can be given IV.

If seizures continue, phenobarbital is given IV at a dose of 20 mg/kg and a rate of 100 mg/min. For every 1 mg/kg of phenobarbital given the serum level rises by 1 µg/ml; thus, 20 mg/kg achieves a serum level of 20 µg/ml. The therapeutic range for phenobarbital is 15–40 µg/ml. If seizures continue, additional doses of phenobarbital can be given in increments of 5–10 mg/kg up a total of 40 mg/kg. When phenobarbital is given, especially in combination with one of the benzodiazepines, one must be prepared to intubate and ventilate the child, given the potential respiratory depression associated with the medications and the continued seizures.

**Drug management of status epilepticus**

- Lorazepam: 0.1 mg/kg IV (up to 8 mg) over 1 minute (x2 if needed).
- Diazepam: 0.3 mg/kg IV (up to 20 mg) over 1 minute (use if lorazepam is not available).
- Fosphenytoin: 20 PE/kg IV at 150 PE/min (may give additional 5 PE/kg).
- Phenobarbital: 20 mg/kg IV at 100 mg/min (can give additional doses of 5–10 mg/kg).

*Continued overleaf*

**Drug management of status epilepticus***(continued)*

Valproate and levetiracetam are adjuncts for treating status epilepticus:

- Levetiracetam (Keppra): 30 mg/kg IV at 5 mg/kg/min (maximum of 3 g).
- Valproate (Depacon): 20–30 mg/kg IV at 5 mg/kg/min.

If seizure activity persists after the above medications have been given, the child is considered to be in refractory status epilepticus. There are several options for treating refractory status epilepticus, including IV propofol, midazolam (textbox), or pentobarbital. All require intubation and close cardiovascular monitoring of the patient in an intensive care setting.

Midazolam: IV bolus 0.2 mg/kg (maximum 10 mg), may repeat  $\times 1$  then continuous infusion starting at 0.1 mg/kg/hr and increase as needed to a maximum of 2 mg/kg/hr.

Some clinicians prefer pentobarbital over midazolam. The following is a protocol of inducing pentobarbital coma as a means to stop status epilepticus:

- Establish continuous EEG monitoring.
- Pentobarbital IV 5 mg/kg boluses until EEG is in a burst suppression pattern. (69)
- Monitor for hypotension; use vasopressors as necessary.
- Once burst-suppression is obtained, start maintenance pentobarbital at 1–3 mg/kg/hr and adjust dose to maintain burst-suppression on the EEG.
- After 24 hours slow or stop the infusion and monitor the EEG to see if electrographic seizures return.

Before concluding the discussion of status epilepticus, it is worthwhile to mention the use of rectal diazepam (Diastat) (textbox).

**Dosing for rectal diazepam**

- <1 yr: not used.
- 1–5 yr: 0.5 mg/kg.
- 6–11 yr: 0.3 mg/kg.
- $\geq 12$ yr: 0.2 mg/kg (maximum dose at any age: 20 mg).

When an IV cannot be established or when prolonged seizures or clusters of seizures occur at home, rectal diazepam can be of value. Within 5 minutes of rectal diazepam, serum levels are equal to the levels achieved by intravenous administration. Intranasal midazolam, 0.2 mg/kg via a nasal atomizer to a maximum dose of 10 mg, is also widely used.



## Alterations of consciousness

### DIAGNOSIS AND CLINICAL FEATURES

Consciousness represents the awareness of self and the environment. Loss of or altered consciousness is the inability to perceive what is occurring in the environment and to respond to environmental events in a manner that reflects perception and a purposeful response. Alterations of consciousness can be rated ranging from mild to profound (textbox).

#### Terms that describe altered states of consciousness

- Confusion: misperception of sensory phenomena often associated with periods of hyperexcitability and irritability alternating with drowsiness.
- Delirium: marked confusion with visual hallucinations and agitation.
- Somnolence: mild decrease in alertness, arousal to voice or light tactile stimulation.
- Lethargy: moderate decrease in alertness, decreased attention span, arousal to voice stimulation with some verbal response.
- Stupor: patient requires vigorous and repeated stimuli to arouse then returns to unresponsiveness; there may be some purposeful motor response to noxious stimuli.
- Coma: unarousable, no vocalization, no purposeful movements.

In order for a person to be aware of self and the environment, there must be arousal and the ability to process the content of the awareness. These two basic concepts have neuroanatomical correlates: arousal = brainstem reticular formation (195); content = cerebral hemispheres. The brainstem reticular formation extends from the midbrain to the medulla, receives rich inputs from all sensory modalities, and showers the cerebral cortex through output via the thalamus and direct connections. The activating system maintains arousal and the awake state of the cerebral hemispheres. Once aroused, the cerebral hemispheres provide the processing and the content of awareness. Loss of consciousness occurs with lesions of the brainstem affecting the reticular formation,

thalamus bilaterally, or cerebral cortex diffusely.

Lesions affecting the reticular formation in the brainstem usually affect nearby neuro-anatomical structures that control breathing, pupillary response, eye movements, and brainstem motor control systems. Cortical dysfunction can result from large lesions that affect most of one cerebral hemisphere or from disease processes that affect neuronal function diffusely, such as hypoxia or hypoglycemia. Clinicians examining unconscious infants, children, or adolescents must determine if the disease is located in the brainstem or diffusely in the cerebral cortex or both (textbox).

#### Causes of loss of or altered consciousness

- Trauma: transient brainstem and cortical dysfunction – concussion; mass lesion – contusion, hemorrhage.
- Electrical: seizure or the postictal state.
- Vascular: decreased perfusion (shock, cardiac arrest); infarction (small brainstem or large cerebral hemisphere).
- Increased intracranial pressure: mass effect (tumor, blood, infection); edema (diffuse or focal).
- Metabolic: hypoxia; hypoglycemia; electrolyte or acid–base abnormalities renal; or hepatic dysfunction.
- Toxic: ingestion, accidental or deliberate.
- Infection: encephalitis, post-infectious encephalopathy

Altered consciousness associated with confusion and delirium is most often seen in metabolic, toxic, or infectious etiologies. When altered consciousness is from increased intracranial pressure, patients exhibit a constellation of findings that can include papilledema, pupillary abnormalities, ophthalmoplegia, and flexor or extensor posturing.

The evaluation of an unconscious child begins with the rapid assessment of vital signs and the ABCs of patient care. During this initial assessment, clinicians should obtain a history from witnesses or knowledgeable individuals. The history should include the temporal profile of the patient's alteration of consciousness. The syndromes of increased intracranial pressure and meningeal irritation are important to

recognize as they are often associated with altered consciousness and require urgent intervention (textbox).

- Syndrome of increased intracranial pressure: vomiting, lethargy, papilledema, dilated pupils, abducens (CN6) palsy, hypertension, bradycardia, central or uncus herniation.
- Syndrome of meningeal irritation: headache, vomiting, nuchal rigidity, alteration in consciousness.

Risk factors for alteration of consciousness should be sought for and pertinent past medical history taken into account. After assessing vital signs, the Glasgow coma scale (GCS) provides a quick assessment of arousal, content, and cortical and brainstem function. Scoring enables monitoring of the child's neurological status over time. Three areas are assessed for the GCS: eye opening to assess arousal, best motor response to assess motor function, and best verbal response to assess cortical content. The GCS has been modified for children with age-appropriate expectations and norms (textbox).

### Pediatric Glasgow coma scale

Eye opening:

Spontaneous = 4; to speech = 3; to pain = 2; none = 1.

Best verbal response:

Oriented = 5; words = 4; vocal sounds = 3; cries = 2; none = 1.

Best motor response:

Obeys commands = 5; localizes pain = 4; flexion to pain = 3; extension to pain = 2; none = 1.

Maximum aggregate score

Birth–6 mo	9
6–12 mo	11
1–2 yr	12
2–5 yr	13
5 yr and older	14

After assessing the level of consciousness, clinicians should perform a physical examination and attend closely to respiratory pattern,

pupil size and responsiveness, ocular movement, and motor response. When these elements of the neurological examination are analyzed in combination, they provide valuable insights as to the level or the anatomical localization of the brain dysfunction that has caused the coma. Abnormal respiratory pattern can indicate levels of abnormal brain function:

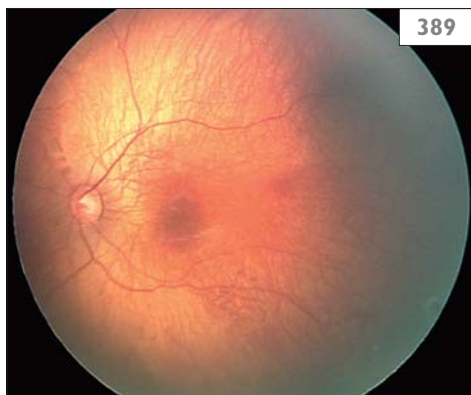
- Cheynes–Stokes: breathing that crescendos and decrescendos interspersed with brief periods of apnea. This pattern is seen in diffuse cortical dysfunction.
- Central neurogenic hyperventilation: sustained rapid breathing, indicates midbrain dysfunction.
- Ataxic or gasping respirations: irregular unsustained breathing, indicates lower brainstem dysfunction.

Eye findings provide important information about the comatose patient. The pupillary response indicates intact balance between parasympathetic and sympathetic inputs to the pupillary eye muscles. The pupillary findings have localizing value because of this (textbox).

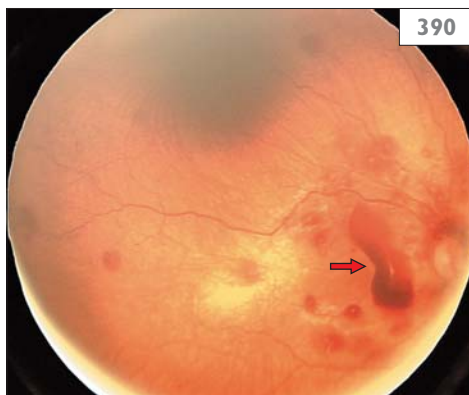
### Pupillary findings of importance in comatose patients

- Small but reactive: diffuse cortical dysfunction, most likely metabolic or toxic.
- Large fixed pupils: severe diffuse hypoxic–ischemic injury.
- Unilateral fixed, dilated pupil: uncus herniation.
- Midposition (3–4 mm) fixed: midbrain injury.

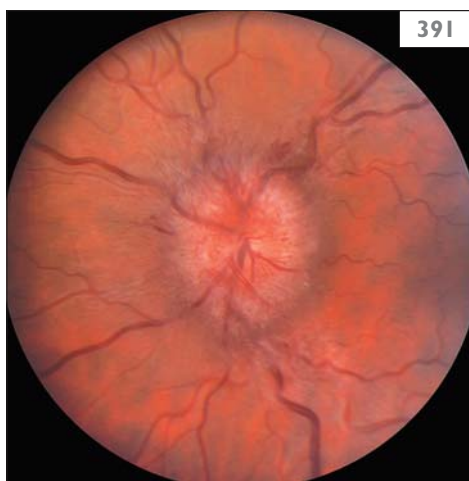Along with the supranuclear oculomotor pathways, the pathways that control pupillary response have close anatomical proximity to the brainstem reticular formation. Consequently, assessment of pupil size and responsiveness provides important insights regarding brainstem function and herniation syndromes. After the pupillary light responses are examined, extraocular movements are tested. In the comatose patient this is initially done by using the doll's eye maneuver to assess the oculocephalic reflex; if that is absent, the clinician should use ice water caloric stimulation to test the oculo-vestibular reflex (textbox).



**389** Normal fundus.



**390** Retinal hemorrhages (arrow) in nonaccidental trauma (child abuse).



**391** Papilledema.

#### Ocular movement reflexes of importance in comatose patients

- Oculocephalic (Doll's eyes reflex): turn head one way and the eyes conjugately turn in the opposite direction. Reflex is present in comatose patient with normal brainstem function. If there is brainstem dysfunction, such as in central herniation, this reflex is lost.
- Oculovestibular (ice water caloric): the unobstructed ear canal is irrigated with ice water. If the patient is unconscious but the brainstem is intact, the eyes will deviate to the side of the irrigated ear. Absence of eye movement is seen with brainstem dysfunction. (The mnemonic COWS applies only to the caloric responses of the conscious patient.)

The last key element of the eye examination is to visualize the fundi (**389**). If retinal hemorrhages (**390**) are present in an infant or toddler, coma may be the result of nonaccidental trauma. If papilledema is present (**391**), the child likely has increased intracranial pressure (ICP). Papilledema usually requires up to 24–48 hours of increased ICP before its appearance.

The motor examination provides additional insights regarding the neuroanatomical level of neurological dysfunction. The clinician should assess the spontaneous motor activity, reactive or induced purposeful movements, withdrawal to noxious stimuli, and posturing. There are basically two types of posturing, decorticate or flexor, and decerebrate or extensor; both have anatomical localizing value. In decorticate (flexor) posturing, the upper extremity is in flexion and the lower extremity is in extension.

Table 49 Rostral–caudal neurological deterioration of central herniation

	Diencephalic	Midbrain	Medullary
Respiratory	Cheyne–Stokes	Hyperventilation	Gasping, irregular
Pupils	Small, reactive	Fixed, midposition	Fixed, midposition or dilated
Ocular	(+) Doll's	Impaired Doll's	(–) Doll's
Motor	Decorticate	Decerebrate	Flaccid

This occurs with lesions that occur above the level of the midbrain. In decerebrate (extensor) posturing, both upper and lower extremities are in extension. This occurs with lesions that are at the level of the midbrain or below.

The clinician must be alert for signs that suggest cerebral herniation. Central herniation syndrome reflects mass effect involving both cerebral hemispheres with herniation of supratentorial brain structures through the tentorial notch. Unless central herniation is recognized early and reversed, irreversible damage to the brainstem and cerebral cortex occurs. Once the medullary phase is reached the process is irreversible, and the brain dies (*Table 49*).

## MANAGEMENT

After the airway is secure and oxygen is given, IV access should be established. A bedside blood glucose level is obtained immediately, and an IV bolus of 25% glucose 2–4 ml/kg is given for hypoglycemia. Patients with suspected malnutrition or alcohol abuse should receive thiamine 100 mg IV before receiving glucose. At the time of establishing an IV, blood should be drawn for diagnostic laboratory tests (textbox) and urine is obtained as well (usually a Foley catheter is inserted not only to obtain a urine sample but also to monitor urine output). These tests are screening in nature; their purpose is not only diagnostic but to direct therapeutic intervention.

### Recommended screening laboratory studies in comatose children

Electrolytes, glucose, calcium, liver function tests, renal function tests, arterial blood gas, serum ammonia, serum lactate, complete blood count, toxicology screen, urinalysis. Blood and urine cultures if febrile.

If laboratory screening fails to establish a diagnosis, the patient should undergo a neuroimaging study. An unenhanced head CT scan is usually obtained first, because the study is more readily available on an emergent basis, the scanning time is short, and CT identifies most conditions that require immediate intervention, such as space occupying lesions, cerebral edema, and intracranial hemorrhages. If the etiology of the coma is still unknown after the screening labs and the CT scan, an enhanced head MRI scan should be obtained. MRI provides more sensitive information regarding stroke and inflammation as well as superior visualization of the posterior fossa. If the child is febrile, lumbar puncture should be considered urgently. When there are signs of increased ICP and focal neurological deficits, a head CT scan should be obtained first to identify features that may contraindicate an LP. If there is a high index of suspicion for meningitis, antibiotics should be given empirically while awaiting the head CT scan. Whenever a lumbar puncture is

performed, the opening pressure should be recorded. An EEG can be useful at this time in patients with suspected seizures or encephalitis or if the child must be paralyzed and sedated for ventilation.

### ADDITIONAL MANAGEMENT STRATEGIES

- Focal mass and intracranial hemorrhages: if there is a tumor, neurosurgical consultation should be obtained. Acutely, dexamethasone 5–10 mg (approximately 0.25 mg/kg) can be given to reduce the edema associated with the tumor. Surgical intervention is needed for epidural hematomas and subdural hematomas of significant size.
- Seizures: subclinical seizures can contribute to altered consciousness. EEG monitoring has value in this situation.
- Infection: neuroimaging, lumbar puncture, and EEG are helpful in this setting. Therapy is outlined in Chapter 20 Infections of the Nervous System.
- Drug ingestion: consult a poison control center for management and therapeutic intervention. Use specific antidotes, when available, such as naloxone for opiate overdose.
- Fever: hyperthermia should be treated as it will increase cerebral blood flow and brain metabolism. The patient should be kept at normal body temperature. Mild systemic hypothermia (33–36°C) for 24 hours postcardiopulmonary arrest may be beneficial.
- Increased intracranial pressure: IV fluids should be limited to one-half to three-quarters of maintenance to avoid over-hydration. Patients should be monitored for signs of the syndrome of inappropriate antidiuretic hormone (SIADH). The head should be elevated to facilitate venous outflow. A quiet environment is important; sedation may be necessary. Hyperventilation may have some benefit to lower the ICP acutely by reducing cerebral blood flow, but it has limited long term benefit; pCO<sub>2</sub> levels less than 30 mmHg should be avoided. Osmotic agents, such as mannitol (0.25–1 g/kg over 10–20 minutes) or hypertonic saline, can reduce cerebral

edema. Serum osmolality should be maintained in the 310–320 mOsm range. The ICP should be kept below 20 mmHg and the cerebral perfusion pressure above 50 mmHg. Monitoring ICP has not been shown to be beneficial in anoxic brain injury.

## Acute CNS injury

Head trauma remains a leading cause of hospitalization, death, and disability at all ages. The type of head injury varies with age. Inflicted or nonaccidental head trauma is the major cause of craniocerebral injury in infants. Among toddlers and young children the leading causes are falls and motor vehicles crashes. Motor vehicle crashes, assault, and sports-related injury are the major causes of head injury in adolescents.

Traumatic brain injury results from linear and rotational forces. The linear forces result in site of impact fracture, hemorrhage, and contusion, as well as countercoup brain injury. The rotational forces generate shearing injury to white matter tracts which results in diffuse axonal injury and microhemorrhages. In addition to the primary biomechanical forces that cause brain injury, secondary injury can result from anoxia, ischemia, and edema. Medical intervention is directed at treating the results of the primary brain injury and preventing further injury from the secondary mechanisms.

## Inflicted or nonaccidental trauma

Inflicted or nonaccidental trauma is caused by shaking, throwing, hitting, strangulation, or smothering. The perpetrator is usually an adult. The young infant, the most vulnerable victim, has a relatively large head to body ratio, poor neck strength, and considerable skull compliance. The infant's brain is not only susceptible to the biomechanical factors that result in traumatic injury, but is also likely to suffer secondary hypoxic-ischemic injury.

The typical clinical scenario is a previously healthy infant, 2 weeks to 6 months of age, who presents with sudden loss of consciousness, apnea, and hypotonia. The acute traumatic injury has occurred immediately or very shortly prior to presentation, and the perpetrator of the trauma is usually the caregiver at the time of the event. Apnea results from the head trauma; hypotension is frequently present, and seizures often occur within 24 hours of the injury. Infants with less severe inflicted head trauma may present with depressed level of consciousness, irritability, vomiting, poor feeding, and seizures.

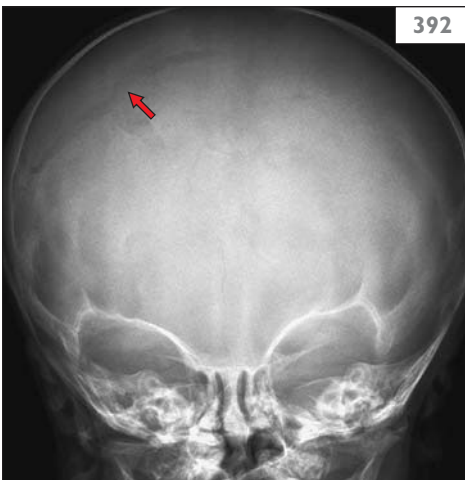
The clinician must examine the infant carefully for signs of cutaneous and soft tissue injury (textbox).

### Evaluation of infants with suspected nonaccidental trauma

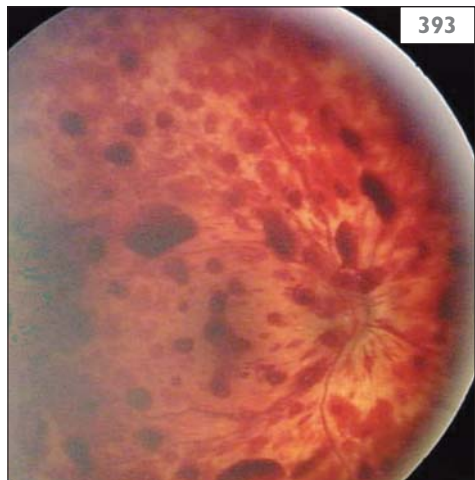
- Noncontrast head CT scan emergently (with bone algorithm).
- Head MRI delineates ischemia/infarction and injury to vessels and parenchyma.
- Assessment for spinal cord injury.
- Complete skeletal survey including skull films (392).
- Complete blood count.
- Comprehensive metabolic panel to include electrolytes, glucose, renal and liver function tests.
- Coagulation studies: prothrombin time (PT), partial thromboplastin time (PTT).
- Notification of child protective services.

The head, neck, trunk, buttocks, and extremities should be inspected for unusual patterns of bruises, marks, or swelling, and the skull, ribs, and long bones should be examined. Abnormal findings should be documented and photographed. The head circumference should be measured and plotted, and the sutures palpated for evidence of separation (diastasis).

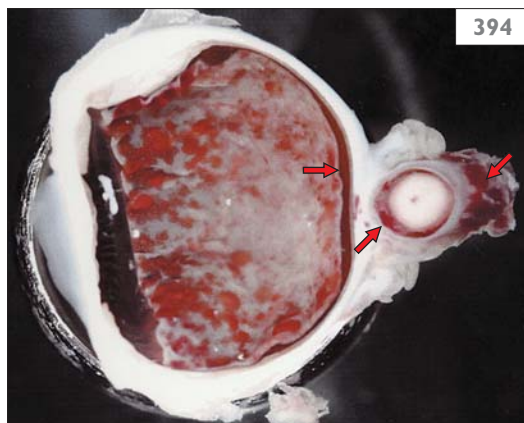
Infants with suspected nonaccidental trauma must have a detailed fundoscopic examination for retinal hemorrhages (393). An ophthalmologist should be consulted for a dilated fundus examination. Retinal and optic nerve sheath hemorrhages (394), uncommon in accidental trauma or cardiopulmonary resuscitation, usually suggest nonaccidental



**392** A plain skull radiography showing a linear skull fracture (arrow).

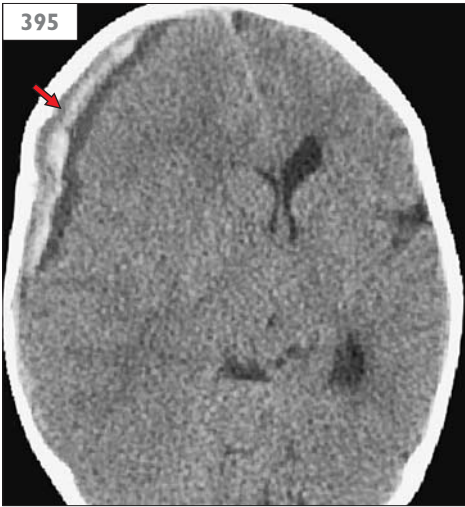

**393** Diffuse, severe retinal hemorrhages in an infant who sustained an inflicted injury (nonaccidental trauma).

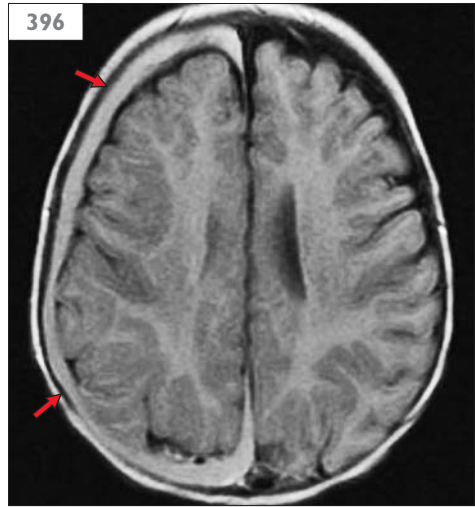


**394** Pathological specimen of the eye showing subretinal and optic nerve hemorrhages (arrows) consistent with nonaccidental trauma.

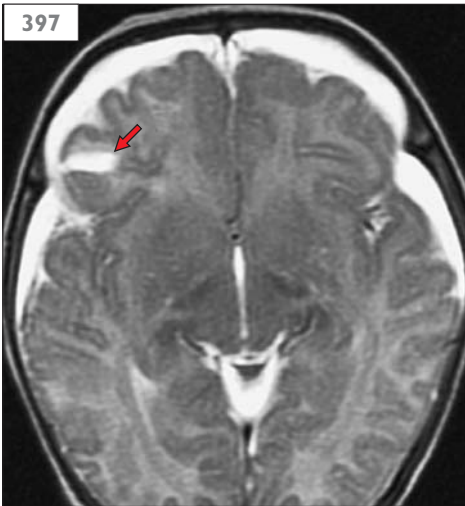




**395** Noncontrast cranial CT showing a subdural hematoma (arrow) in a child with nonaccidental trauma.



**396** Axial FLAIR MRI showing an extensive subdural hematoma (arrows) in nonaccidental trauma.



**397** An axial T2-weighted MRI showing a laceration in the right frontal lobe (arrow) in an abused child.

trauma. The most common intracranial injuries are subdural hematomas, subarachnoid hemorrhages, intraparenchymal hemorrhages, infarctions, and anoxic injury (395–397).

Short falls (<4 ft [1 m] vertically), falls down stairs, walker falls, and collisions with another child or adult do not generate sufficient mechanical force to cause the type of injuries seen in nonaccidental trauma. There are rare reports that infants with glutaric aciduria type 1, Menkes disease, and type I osteogenesis imperfecta can present with subdural hematomas, but the clinical setting and associated findings are rarely confused with inflicted head trauma.

## Concussion

Concussion remains the most common form of mild traumatic brain injury in children and adolescents. Children usually recover uneventfully unless there is recurrent head injury or associated intracranial hemorrhage. The management of children with concussion therefore consists of an evaluation for serious intracranial pathology and anticipatory guidance to prevent additional head trauma (textbox).

### Management of the child with a concussion

- Identify impairments of neurological status: memory, attention, cognition, coordination, headache, or nausea. If present, the child or adolescent should rest, be observed until the symptoms resolve, and not return to play or activity until he or she is totally asymptomatic. If symptoms persist, then transport to emergency department for further medical evaluation. Any loss of consciousness requires emergency department evaluation.
- Obtain neuroimaging: emergent head CT scan for persistent symptoms or loss of consciousness to detect intracranial hemorrhage or edema that requires further intervention. Head CT scan should include bone algorithm to detect skull fractures. Not all skull fractures will be detected by CT scan so skull X-rays may be needed.
- If the patient's neurological status improves to the point that there is no neurological impairment and if there has been brief loss of consciousness and normal CT scan, the patient can be sent home as long as there are reliable caretakers.

Concussion represents trauma-induced neurological dysfunction with or without loss of consciousness. The most common acute symptoms of concussion are transient confusion, amnesia, headache, nausea, vomiting, and unsteadiness. Although less common, temporary cortical blindness and an immediate impact seizure can occur. The last two symptoms can occur without demonstrable intracranial hemorrhage, but their occurrence mandates neuroimaging. Loss of consciousness is considered the most severe form of concussion. Common postconcussive symptoms include persistent headache, nausea and vomiting, irritability, listlessness, poor concentration, and behavioral changes. These symptoms are usually self-limited, although postconcussion syndrome can persist for several months after head injury.

The child or adolescent should not return to activities that pose a risk of further concussion until totally asymptomatic. Although the potentially lethal second impact syndrome occurs rarely, a person who sustains a concussion has a high risk of recurrent concussions. Some guidelines suggest that an adolescent who has had brief symptoms without amnesia or loss of consciousness that resolve within 20 minutes may return to sports activities that day. A more conservative approach is to prevent such individuals from engaging in sports play until cleared by a medical evaluation. If the concussion is associated with amnesia, the player should not return to play for a least 1 week. He or she should be asymptomatic at rest and upon exertion. If there has been loss of consciousness, the player should be out of play for 1 month and be free of symptoms (e.g. headache, dizziness, changes in behavior) at rest or exertion for at least 2 weeks prior to return to play. The return should be gradual and less strenuous activities should be attempted first before returning to full sports activities.

## Severe intracranial injury

### DIAGNOSIS AND CLINICAL FEATURES

Concussion, considered at the mild end of the spectrum of traumatic brain injury, can also be associated with more severe forms of brain injury. These include intracranial hemorrhages (398) (textbox) which can be associated with herniation syndromes, diffuse cerebral swelling, and axonal injury. Contusion indicates demonstrable radiographic (399, 400) injury to brain parenchyma analogous to a bruise.

#### Intracranial hemorrhage

- Epidural hematoma (398): can be arterial or venous; causes acute or subacute neurological symptoms and signs. Commonly supratentorial due to tearing of the middle meningeal artery; can also be in the posterior fossa. Lens-shaped on CT or MRI. Requires immediate neurosurgical consultation.
- Subdural hematoma (395, 396): caused by tearing of the bridging veins crossing the subdural space; crescent-shaped on neuroimaging. Produces progressive depression of mental status with focal neurological deficits or excessive head growth in infants. Requires neurosurgical evaluation and treatment of increased intracranial pressure.
- Subarachnoid hemorrhage (401): common with head trauma. Produces altered mental status, meningeal irritation with headache and nuchal rigidity, and seizures. CT or MRI show blood in the subarachnoid space over the convexity of the brain or in the sulci, fissures, and cisterns.
- Intraparenchymal hemorrhage, contusions, and lacerations (397): usually occur at the site of direct impact. Often located in the frontal and temporal lobes at the surface of the brain.

Infants and children with head trauma often sustain skull fractures, most commonly linear. Fractures usually heal within 1–2 months, but follow-up is necessary to ensure that the fracture heals and a leptomeningeal cyst does not develop. Leptomeningeal cysts occur most often

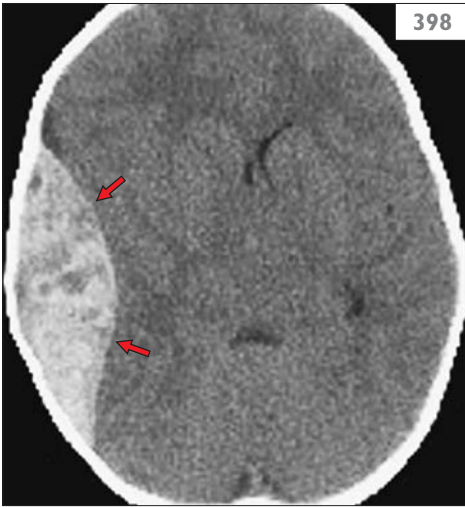
in the parietal area in children under 3 years of age with initial fracture separation  $>3$  mm.

Basilar skull fractures can be associated with periorbital ecchymosis (raccoon eyes), retroauricular ecchymosis (Battle's sign), hemotympanum, CSF or bloody otorrhea or rhinorrhea. Surgery may be necessary to repair CSF leaks. Evaluation of a skull fracture is best accomplished with a head CT scan with a bone algorithm. Skull films can be necessary if the clinical index of suspicion for fracture remains high, and the CT is negative. Depressed skull fractures require CT and neurosurgical consultation.

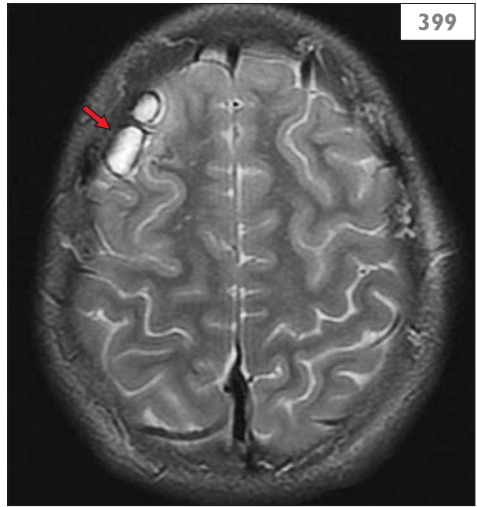### MANAGEMENT

The management of the child with severe head injury begins with the ABCs of patient care. An intravenous line should be established and fluids given to treat shock. Stabilization of the neck is important to prevent worsening of a possible spinal cord injury until cervical spine stability can be confirmed by neurosurgical consultation. A GCS score should be assigned, and the neurological examination should focus on cranial nerve and motor function and sensory responses. The patient is closely examined to determine the extent of both CNS and systemic injuries. Imaging should include CT of the head with bone algorithms, as well as cervical spine evaluation by CT or plain radiographs. Neurosurgery should be consulted. Medical management should treat hypoxia, cerebral hypoperfusion, hyperthermia, and increased intracranial pressure, potential secondary mechanisms for worsening brain injury.

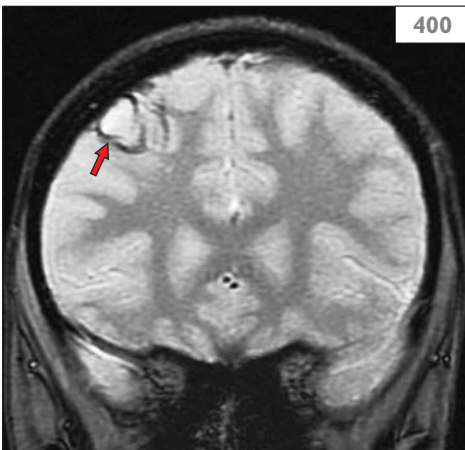
Because of the potential for early post-traumatic seizures, an anticonvulsant should be considered. Fosphenytoin, 20 mg/kg IV as a loading dose and 5 mg/kg/day in two divided doses for maintenance, is often used. Levetiracetam, 30 mg/kg IV loading dose and 30 mg/kg/day in two divided doses for maintenance, can be used as an alternative. Use of anticonvulsants acutely does not alter the risk of later seizures, but does decrease the contribution of early seizures to secondary brain injury.



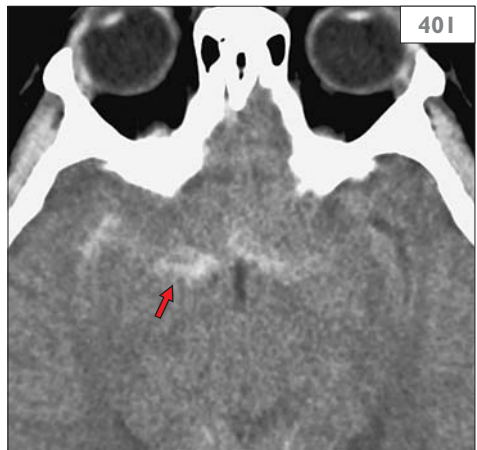
**398** A noncontrast cranial CT showing the characteristic appearance of an epidural hematoma (arrows).



**399** Axial T2-weighted MRI showing a cerebral contusion (arrow) secondary to a motor vehicle crash.



**400** Coronal gradient recall echo MRI of the brain in the same child as in 399 shows hemosiderin staining (arrow) adjacent to the contusion.



**401** A noncontrast cranial CT showing acute subarachnoid hemorrhage (arrow).

## Spinal cord injury

### DIAGNOSIS AND CLINICAL FEATURES

Three to five percent of spinal cord injuries affect persons less than 15 years of age. Motor vehicle accidents, falls, and sport-related accidents cause most spinal cord injuries, most often involving the cervical region. Multiple anatomical and developmental factors influence the vulnerability of infants, children, and adolescents to spinal cord injury (textbox).

#### Factors influencing the risk of spinal cord injuries in childhood

- Relatively large head of the infant.
- Underdevelopment of the neck musculature.
- Ligamentous laxity.
- Wedge-shaped vertebral bodies.
- Incomplete ossification and shallow angulation of the facet joints.
- Dens synchondrosis until 4 years of age.
- Fulcrum of neck motion is at the C2–3 level versus C5–6 level in adults.

The mechanisms of spinal cord injury include forward and lateral flexion, rotation, hyperextension, and axial compression. These forces result in vertebral distraction, dislocation, fracture, and disk herniation that cause direct injury to the cord by concussion, contusion, laceration, hemorrhage, and ischemia. Because of the ligamentous laxity of the pediatric spinal cord, spinal cord injury can occur without radiographic abnormality (SCIWORA) (textbox).

#### Spinal cord injury syndromes

- Complete cord syndrome: complete loss of sensory and motor below the level of the lesion; flaccid tone, autonomic dysfunction, and spinal cord shock.
- Central cord syndrome: end artery injury, upper extremities with lower motor neuron findings and dysesthesia; lower extremities with upper motor neuron findings.
- Anterior spinal artery syndrome: lower motor neuron findings at level of the

lesion; upper motor neuron findings below the lesion and sensory level at the level of the spinal cord lesion; sparing of posterior column sensory modalities.

- Brown–Sequard, hemicord syndrome: ipsilateral motor and dorsal column sensory deficit and contralateral pain and temperature deficit below the level of the spinal cord lesion; usually incomplete; seen with penetrating spinal cord injury and inflammatory or demyelinating lesions.

### MANAGEMENT

The acute management of childhood spinal cord injury must include immediate stabilization of the neck and the spinal column. This includes placing the child on a firm backboard and preventing head movement with sandbags or rolled towels and tape across the forehead. In the hospital, a hard cervical collar should be used. An airway and adequate ventilation and oxygenation must be established; circulation should be supported with IV fluids. A nasogastric tube should be placed to empty gastric contents, and a Foley catheter should be placed to establish and monitor urine output. The neurological examination should attend to the cranial nerves (especially facial sensation which can be abnormal in high cervical cord injury) and sensory and motor function below the neck. Serial exams can define the evolution of spinal cord deficits.

Radiographic evaluation should include the complete pediatric spine as there can be multiple levels of injury. If there are subtle findings or findings that are inconclusive, CT scan of the area in question may be needed. MRI is used to image the injured spinal cord. Neurosurgery should be involved early in the management of the child with spinal cord injury. Controversy persists regarding the role of corticosteroids in spinal cord injury. Some evidence suggests that IV methylprednisolone 30 mg/kg infused within 8 hours after the injury followed by 5.4 mg/kg/hr for the next 23 hours may improve outcome of the spinal cord injury.

## Acute neuromuscular weakness

### DIAGNOSIS AND CLINICAL FEATURES

Acute progressive bilateral weakness without mental status changes is usually due to disease of the spinal cord or one of the components of the motor unit (textbox). Spinal cord disease will usually have a combination of sensory and motor findings, with lower motor neuron findings at the level of the lesion and upper motor neuron findings below the level of the lesion. Diseases acutely affecting the motor unit include those that affect the anterior horn cell, the nerve root and peripheral nerve, the neuromuscular junction, and the muscle. Infections or postinfectious conditions account for the majority of these disorders in the pediatric population.

#### Considerations for acute weakness in pediatric patients

##### Spinal cord

- Transverse myelitis: weakness progressing over hours to few days, usually thoracic level, sensory level, acute flaccid weakness in the lower extremities, bladder dysfunction (**188**).

##### Anterior horn cell

- Acute flaccid paralysis syndrome: asymmetric ascending paralysis due to poliovirus, nonpolio enteroviruses, and West Nile virus.

##### Nerve root and peripheral nerve

- Guillain-Barré syndrome: symmetric ascending paralysis, distal painful dysesthesia, progression over days to 3 weeks, bladder and autonomic dysfunction. CSF albuminocytologic dissociation, lumbar-sacral nerve root enhancement on MRI (**219**).

##### Neuromuscular junction

- Infant botulism: acute descending paralysis, pupillary dilation, ophthalmoplegia, constipation, respiratory distress (**325–327, 402**).
- Myasthenia gravis: weakness involving ocular muscles, bulbar cranial nerves, proximal muscles; weakness is fatigue-related (**338–340**).

##### Muscle

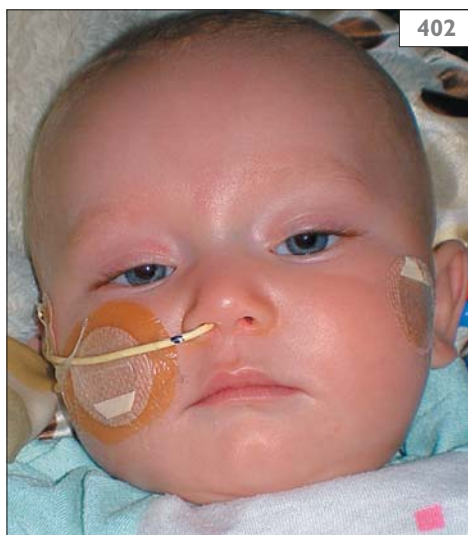- Myositis: progressive muscle weakness, muscle tenderness, often associated with rhabdomyolysis. When due to influenza virus characteristically produces intense gastrocnemius muscle pain and toe-walking.

### MANAGEMENT

Respiratory failure must be anticipated in any infant, child, or adolescent with acute weakness. For the ascending paralysis syndromes, the likelihood of respiratory failure increases considerably once the weakness has reached the upper extremities. Vital capacity must be assessed and monitored serially in all cooperative patients with weakness. Tachypnea, inability to talk in full sentences, soft muffled voice or cry, and agitation may be signs of impending respiratory failure in young children. These children should be observed in a setting where there can be a quick skilled response to possible respiratory failure. Early intubation and mechanical ventilation must be considered prior to overt respiratory failure.

#### Transverse myelitis

These patients should have a spinal cord MRI to exclude a compressive lesion, an eye exam to



**402** An infant with bilateral ptosis and dilated pupils due to infant botulism.



exclude optic neuritis (143), monitoring for cardiovascular instability, Foley catheter for bladder autonomic dysfunction, and a bowel program for constipation. High dose IV methylprednisolone 20 mg/kg/day for 5 days has been suggested for treatment. Physical therapy is started immediately. Approximately 50% of children or adolescents with transverse myelitis recover completely. Unfortunately, some children have permanent paralysis.

### Guillain-Barré syndrome (GBS)

If the weakness progresses to the point that the patient cannot walk, IVIG or plasma exchange can be used. Both are equally efficacious. We recommend that children or adolescents receive IVIG 2 g/kg in divided doses over 2 days. Patients with GBS must be observed for respiratory failure and cardiovascular instability. Urinary retention and dysesthetic pain must be managed, as well. The vast majority of children with GBS recover completely.

### Myasthenia gravis (MG)

MG should be treated initially with an acetylcholinesterase inhibitor. Pyridostigmine, the most commonly used medication, is begun at 7 mg/kg/day in three or more divided doses. Muscarinic side-effects are frequent. If the patient cannot take oral medication, pyridostigmine can be given IV at one-thirtieth the oral dose (1 mg of the IV form equals 30 mg of the oral preparation). If the patient experiences myasthenic crisis and cannot swallow, handle oral secretions, or breathe normally, the patient should be intubated and supported and the dose of acetylcholinesterase inhibitor temporarily suspended. Other therapeutic modalities include IVIG, corticosteroids, or plasma exchange transfusion. Long-term management of patients with MG usually includes thymectomy and immunosuppression with oral prednisone.

## Acute poisonings

### DIAGNOSIS AND CLINICAL FEATURES

Poisonings, one of the most common childhood medical emergencies, often present with alterations of neurological function. Most poisonings in childhood involve substances found at home. Different methods of poisonings should be considered for different age groups. For the infant, poisonings results from medication errors or nonaccidental abuse, whereas poisoning in the toddler-aged child is usually an accidental ingestion. Substance abuse, recreational experimentation, and suicide attempts occur in older children or adolescents. Acute poisonings may mimic other pathological processes such as metabolic derangements, infections, trauma, neoplasm, or psychiatric illnesses. Neurological presentations of poisonings include altered mental status ranging from coma to delirium, seizures, generalized weakness, ataxia, extrapyramidal findings (parkinsonism or dystonia), and autonomic dysfunction. Toxidromes, defined by a constellation of systemic and neurological findings, can provide important clues to the offending poison (*Table 50*). The neurological symptoms and signs usually reflect the effect of the drug(s) on CNS neurotransmitters and the autonomic system.

Caretakers and witnesses should be questioned carefully about possible exposures. Drugs and substances that are found in the house or that the child could have been exposed to should be sought. Any medication, dose, and duration of treatment that the child may be receiving should be noted. The child's respiratory and cardiovascular status should be assessed immediately and adequate airway, breathing, and perfusion established. Examination should focus on the toxidromes, as well as specific organ system assessments. Laboratory studies should be obtained, including complete blood count, electrolytes, anion gap (textbox), renal and liver function tests, arterial blood gas, and ECG. Blood alcohol or serum drug levels are ordered when there is appropriate clinical suspicion. A toxicology screen of blood and/or urine is typically ordered, but screens vary across laboratories.



**Anion gap** =  $[\text{Na}] - ([\text{Cl}] + [\text{HCO}_3])$   
(normal = 8 to 16 mEq/l)

**Increased anion gap:**

- Diabetes mellitus.
- Renal disease.
- Nutritional deficiencies.
- Dehydration.
- Toxins (salicylates, ethylene glycol, methanol, alcohol).

**Decreased anion gap:**

- Hyponatremia.
- Hyperchloremia.
- Lithium intoxication.
- Hypothyroidism.
- Renal disease.

**MANAGEMENT**

Inducing emesis with syrup of ipecac is no longer recommended. Orogastric lavage can be indicated for certain types of ingestions, but should not be done in persons with altered mental status or vulnerable airways. Other interventions, such as use of activated charcoal, antidotes (e.g. naloxone), acidification of the urine, or active removal with hemodialysis, are based on the type and severity of the ingestion. A poison control center should be contacted to provide specific diagnostic and management recommendations.

**Table 50 Toxidromes in acute poisoning**

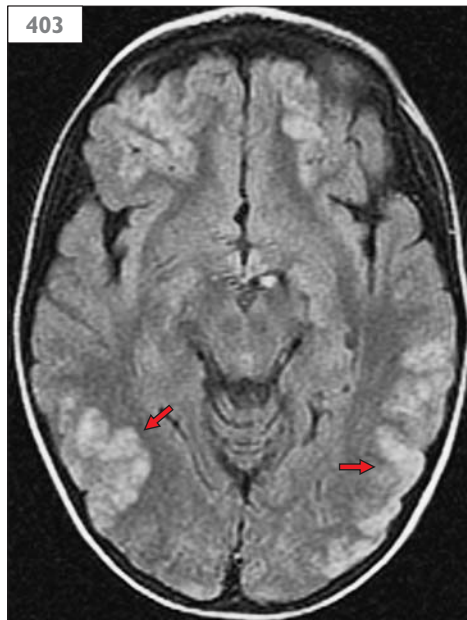
Mechanism	Signs/symptoms	Causes
Cholinergic	Depressed mental status, seizures, muscle fasciculations, and weakness (DUMBELS: diarrhea, urination, miosis, bronchospasm, emesis, lacrimation, salivation)	Some types of mushrooms, organophosphate pesticides and nerve agents, anticholinesterases
Anticholinergic	Depressed mental status, delirium, seizure, mydriasis, dry skin, flushing, fever, urinary retention, hypoactive bowels	Atropine, belladonna alkaloids, jimsonweed, some mushrooms, phenothiazines, some antihistamines, tricyclic antidepressants
Adrenergic	Agitation, delirium, seizures, mydriasis, tremulous, diaphoresis, tachycardia, hypertension	Amphetamines, cocaine, ephedrine, xanthines
Serotonergic	Confusion, tremor, myoclonus, ataxia, fever, flushing, sweating, diarrhea	SSRIs (especially with MAO inhibitors), isoniazid, tranylcypromine
Narcotic	Altered mental status, seizures, ataxia, miosis, respiratory suppression, bradycardia, hypotension, gastric hypomotility	Opioids, meperidine, propoxyphene
Sedative-hypnotic	Mental status depression, respiratory suppression, miosis, ataxia, hypotonia	Barbiturates, benzodiazepines
Withdrawal	Agitation, hallucinations, anxiety, mydriasis, lacrimation, diarrhea, yawning	Alcohol, narcotics, barbiturates, benzodiazepines

MAO: monoamine oxidase; SSRI: selective serotonin-reuptake inhibitor

## Hypertensive encephalopathy

Hypertensive encephalopathy can occur during the course of any systemic condition producing abrupt elevations in blood pressure. Common inciting conditions among children and adolescents include poststreptococcal glomerulonephritis and acute nephrotic syndrome. Children or adolescents with this disorder have mental status changes, headaches, seizures, and visual dysfunction, including blurring, obscuration, transient blindness, or diplopia. Neurological examination may show papilledema or focal neurological deficits. Hypertension is a

major factor in the posterior reversible encephalopathy syndrome (PRES); both PRES and hypertensive encephalopathy reflect loss of cerebrovascular autoregulation. PRES has also been observed in children with sickle cell crisis and systemic lupus erythematosus and during therapy with L-asparaginase, ciclosporin, or tacrolimus. Clinical features of this disorder overlap with those of hypertensive encephalopathy. Imaging studies, particularly MRI, show T2 hyperintensities, especially posteriorly (403). Management consists of antihypertensive medication therapy, as needed, and removal of inciting factors, when possible.



**403** Axial FLAIR MRI in a child with hypertension shows increased signal intensity posteriorly (arrows) compatible with posterior reversible encephalopathy syndrome (PRES).

# Abbreviations

- 18-FFDG fluorine-18-fluorodeoxyglucose  
 AABR (ABR) automated auditory brainstem response  
 AASA alpha-amino adipic semialdehyde  
 ACTH adrenocorticotrophic hormone  
 AD autosomal dominant  
 ADC apparent diffusion coefficient  
 ADEM acute disseminated encephalomyelitis  
 ADHD attention deficit hyperactivity disorder  
 AED antiepileptic drug  
 AIDP acute inflammatory demyelinating polyneuropathy  
 AIDS acquired immunodeficiency syndrome  
 ANA antinuclear antibody  
 AR autosomal recessive  
 ARC arthrogryposis, renal dysfunction, cholestasis syndrome  
 ASD autism spectrum disorder  
 ASO antistreptolysin O  
 AT ataxia telangiectasia  
 AVM arteriovenous malformation  
 BAEP brainstem auditory evoked potential  
 BAER brainstem auditory evoked response  
 BECTS benign epilepsy with centrottemporal spikes  
 BiPAP bilevel positive airway pressure  
 BOLD blood oxygen level dependent  
 BPV benign paroxysmal vertigo  
 BS bone scan  
 CADASIL cerebral autosomal dominant arteriopathy with subcortical infarcts and leukoencephalopathy  
 CDG congenital disorders of glycosylation  
 CGH comparative genomic hybridization  
 CHARGE coloboma of the eye, heart anomaly, choanal atresia, retarded growth, genital abnormality, and ear abnormality  
 CIDP chronic inflammatory demyelinating polyneuropathy  
 CK creatine kinase  
 CMAP compound muscle action potential  
 CMT Charcot–Marie–Tooth disease  
 CMV cytomegalovirus  
 CN cranial nerve  
 CNS central nervous system  
 CP cerebral palsy  
 CPAP continuous positive airway pressure  
 CPS complex regional pain syndrome  
 CRP C-reactive protein  
 CRS congenital rubella syndrome  
 CSF cerebrospinal fluid  
 CSWS continuous spike-wave of slow wave sleep  
 CT computed tomography  
 CTA computed tomography angiography  
 DDAVP desmopressin  
 DIC disseminated intravascular coagulation  
 DMD Duchenne/Becker muscular dystrophy  
 DMPK dystrophin myotonic protein kinase  
 dMRI diffusion-weighted magnetic resonance imaging  
 DNA deoxyribonucleic acid  
 DQ developmental quotient  
 DRESS drug rash with eosinophilia and systemic symptoms  
 DTI diffusion tensor imaging  
 DTR deep tendon reflex  
 DWI diffusion-weighted imaging  
 ECG electrocardiography/electrocardiogram  
 EEG electroencephalography/electroencephalogram  
 ELISA enzyme linked immunosorbent assay  
 EMG electromyography/electromyogram  
 ERG electroretinogram  
 ESES electrical status epilepticus of sleep  
 ESR erythrocyte sedimentation rate  
 FASD fetal alcohol spectrum disorder  
 FGFR fibroblast growth factor receptor  
 FIRDA frontal intermittent rhythmic delta activity  
 FISH fluorescent *in situ* hybridization  
 FLAIR fluid-attenuated inversion recovery  
 fMRI functional magnetic resonance imaging  
 FVC forced vital capacity  
 FXTAS fragile X-associated tremor and ataxia syndrome  
 GAA acid alpha-glucosidase  
 GAMT guanidinoacetate methyltransferase  
 GBS Guillain–Barré syndrome  
 GCS Glasgow coma scale  
 GER gastroesophageal reflux  
 GRE gradient recall echo

- GTP guanosine triphosphate  
 H&E hematoxylin and eosin  
 HAART highly-active antiretroviral therapy  
 HIE hypoxic-ischemic encephalopathy  
 HIV human immunodeficiency virus  
 HNPP hereditary neuropathy with liability to pressure palsy  
 HSV herpes simplex virus  
 HVA homovanillic acid  
 ICP intracranial pressure  
 IFA immunofluorescent assay  
 IgG immunoglobulin G  
 IIH idiopathic intracranial hypertension  
 IQ intelligence quotient  
 IUGR intrauterine growth retardation  
 IVH intraventricular hemorrhage  
 IVIG intravenous immune globulin  
 JME juvenile myoclonic epilepsy  
 KF Kayser-Fleischer  
 LCM lymphocytic choriomeningitis  
 LD learning disability  
 LGA large for gestational age  
 LGS Lennox-Gastaut syndrome  
 LHON Leber's hereditary optic neuropathy  
 LKS Landau-Kleffner syndrome  
 LMN lower motor neuron  
 MAE myoclonic-astatic epilepsy of Doose  
 MAO monoamine oxidase  
 MCAD medium chain acyl-coA dehydrogenase  
 MeCP2 methyl CpG binding protein 2  
 MEG magnetoencephalography  
 MELAS mitochondrial myopathy, encephalopathy, lactic acidosis, and stroke syndrome  
 MG myasthenia gravis  
 MIBG meta-iodobenzylguanidine  
 MMC myelomeningocele  
 MPS mucopolysaccharide  
 MRA magnetic resonance angiography  
 MRI magnetic resonance imaging  
 MRS magnetic resonance spectroscopy  
 MRV magnetic resonance venography  
 MS multiple sclerosis  
 MSLT multiple sleep latency test  
 MSR muscle stretch reflex  
 MUP motor unit potential  
 NAA N-acetylaspartate  
 NADH nicotinamide adenine dinucleotide hydride  
 NARP neuropathy, ataxia, and retinitis pigmentosa  
 NCL neuronal ceroid lipofuscinosis  
 NCV nerve conduction velocity  
 NF-1 neurofibromatosis type 1  
 NICU newborn intensive care unit  
 NIF negative inspiratory force  
 NMO neuromyelitis optica  
 NSAID nonsteroidal anti-inflammatory drug  
 OAE otoacoustic emissions  
 OCD obsessive compulsive disorder  
 OFC occipital-frontal circumference  
 OME otitis media with effusion  
 OMS opsoclonus-myoclonus syndrome  
 OTC ornithine transcarbamylase  
 PANDAS pediatric autoimmune neuropsychiatric disorders associated with streptococcal infection  
 PCA phase contrast angiography  
 PCR polymerase chain reaction  
 PDD-NOS pervasive developmental disorder not otherwise specified  
 PE phenytoin equivalent  
 PET positron emission tomography  
 PEX peroxisomal (gene)  
 PF plain radiograph  
 PKU phenylketonuria  
 PLED periodic lateralized epileptiform discharge  
 PLP proteolipid protein  
 PML progressive multifocal leukoencephalopathy  
 PMP22 peripheral myelin protein 22  
 pMRI perfusion-weighted magnetic resonance imaging  
 PNET primitive neuroectodermal tumor  
 PRES posterior reversible encephalopathy syndrome  
 PROM premature rupture of membranes  
 PT prothrombin time  
 PTT partial thromboplastin time  
 PVL periventricular leukomalacia  
 RAS reticular activating system  
 REM rapid eye movement  
 RNA ribonucleic acid  
 RT-PCR reverse transcription polymerase chain reaction  
 SD standard deviation  
 SGA small for gestational age  
 SIADH syndrome of inappropriate antidiuretic hormone  
 SIDS sudden infant death syndrome  
 SLE systemic lupus erythematosus  
 SLI specific language impairment  
 SMA spinal muscular atrophy  
 SMN1 survival motor neuron-1

SNHL sensorineural hearing loss	TOF time-of-flight
SPECT single photon emission computed tomography	TS tuberous sclerosis
SPGR spoiled gradient recall	TSC tuberous sclerosis complex
SSPE subacute sclerosing panencephalitis	TSH thyroid stimulating hormone
SSRI selective serotonin-reuptake inhibitor	UMN upper motor neuron
SUDEP sudden unexplained death in epilepsy	US ultrasound
SWS Sturge–Weber syndrome	VEP visual evoked potential
TBI traumatic brain injury	VMA vanillylmandelic acid
Tc-HMPAO technetium-99-m-hexamethylpropylene amine oxime	VZV varicella-zoster virus
	WBC white blood cell
	XLR X-linked recessive

# Further reading and bibliography

## Chapter 1: THE PEDIATRIC NEUROLOGICAL EXAMINATION

- Haere AF (1992). *DeJong's The Neurologic Examination*, 5th edn. Lippincott Williams & Wilkins, Philadelphia.
- Larsen PD, Stensas SS. NeuroLogic Examination: a neuroanatomical approach. (Accessed 11/10/2010.) [http://library.med.utah.edu/neurologic\\_exam/html/home\\_exam.html](http://library.med.utah.edu/neurologic_exam/html/home_exam.html)
- Mayo Clinic (1997). *Examinations in Neurology*, 7th edn. Elsevier, Amsterdam.
- Swaiman KF (2006). General aspects of the patient's neurologic history. In: Swaiman KF, Ashwal S, Ferriero DM (eds). *Pediatric Neurology. Principles and Practice*, 4th edn. Mosby/Elsevier, Philadelphia, pp. 3–16.

## Chapter 2: NEUROIMAGING

- Atlas SW (ed) (2008). *Magnetic Resonance Imaging of the Brain and Spine*, 4th edn. Lippincott-Williams & Wilkins, Philadelphia.

- Barkovich AJ (ed) (2005). *Pediatric Neuroimaging*, 4th edn. Lippincott-Williams & Wilkins, Philadelphia.
- Barkovich AJ (ed) (2007). *Diagnostic Imaging Pediatric Neuroradiology*, Amirsys Inc., Salt Lake City.
- Brandao LA, Domingues RC (eds) (2004). *MR Spectroscopy of the Brain*. Lippincott-William & Wilkins, Philadelphia.
- Mukherjee P (ed) (2006). Advanced pediatric imaging. *Neuroimaging Clin N Am* 16:1–216.

## Chapter 3: ELECTROPHYSIOLOGICAL EVALUATION OF INFANTS, CHILDREN, AND ADOLESCENTS

- Blum AS, Rutkove SB (2007). *The Clinical Neurophysiology Primer*. Humana Press, Springer, New York.
- Edebol Eeg-Olofson K (ed) (2006). *Pediatric Clinical Neurophysiology*. International Review of Child Neurology Series, MacKeith Press, London.

Kimura J (2001). *Electrodiagnosis in Diseases of Nerve and Muscle. Principles and Practice*, 3rd edn. Oxford University Press, New York.

#### Chapter 4: CEREBROSPINAL FLUID

Fishman RA (1980). *Cerebrospinal Fluid in Diseases of the Nervous System*. WB Saunders, Philadelphia.

Johansen C (2003). Choroid plexus, cerebrospinal fluid circulatory dynamics: impact on brain growth, metabolism and repair. In: Conn PM (ed). *Neuroscience in Medicine*, 2nd edn. Humana Press, Totowa, pp. 173–200.

Pearl PL, Taylor JL, Trzcinski S, Skohl A (2007). The pediatric neurotransmitter disorders. *J Child Neurol* **22**:606–16.

Roos K (2005). Cerebrospinal fluid. In: Roos K (ed). *Principles of Neurological Infectious Disease*. McGraw Hill, New York.

Wiegand C, Richards P (2007). Measurement of intracranial pressure in children: a critical review of current methods. *Dev Med Child Neurol* **49**:935–41.

Zheng W, Chodowski A (2005). *The Blood–Cerebrospinal Fluid Barrier*. Chapman and Hall/CRC, Boca Raton.

#### Chapter 5: GENETIC EVALUATION

Gene Tests. <http://www.genetests.org>. (Accessed 11/10/2010.)

Jorde L, Carey JC, Bamshad M, White R (2007). *Medical Genetics*. Mosby, St. Louis.

OMIM. On-Line Mendelian Inheritance in Man. (Accessed 11/10/2010.) <http://www.ncbi.nlm.nih.gov/sites/entrez?db=omim>

#### Chapter 6: NEWBORN SCREENING AND METABOLIC TESTING

Botkin JR, Clayton EW, Fost N, *et al.* (2006). Newborn screening technology: proceed with caution. *Pediatrics* **117**:1793–9.

Kayser MA (2008). Inherited metabolic diseases in neurodevelopmental and neurobehavioral disorders. *Pediatr Clin North Am* **15**:27–31.

Kemper AR, Boyle CA, Aceves J, *et al.* (2008). Long-term follow-up after diagnosis resulting from newborn screening: statement of the US Secretary of Health and Human Services' Advisory Committee on Heritable Disorders and Genetics Disease in Newborns and Children. *Genet Med* **10**:259–61.

Therrell BL, Hannon WH (2006). National evaluation of US newborn screening system components. *Ment Retard Dev Disabil Res Rev* **12**:236–45.

#### Chapter 7: DISORDERS OF DEVELOPMENT

Chahrouh M, Zoghbi HY (2007). The story of Rett syndrome: from clinic to neurobiology. *Neuron* **56**:422–37.

Moeschler JB (2008). Genetic evaluation of intellectual disabilities. *Semin Pediatr Neurol* **21**:117–22.

Shevell M (2006). Office evaluation of the child with developmental delay. *Semin Pediatr Neurol* **13**:256–61.

Shevell M, Ashwal S, Donley D, *et al.* (2003). Practice parameter: evaluation of the child with developmental delay. Report of the Quality Standards Subcommittee of the American Academy of Neurology and the Practice Committee of the Child Neurology Society. *Neurology* **60**:367–80.

Srouf M, Mazer B, Shevell M (2006). Analysis of clinical features predicting etiologic yield in developmental delay. *Pediatrics* **118**:139–45.

#### Chapter 8: DISORDERS OF BEHAVIOR AND COGNITION

Bishop DV (2009). Genes, cognition and communication: insights from neurodevelopmental disorders. *Ann N Y Acad Sci* **1156**:1–18.

Calles JL Jr (2008). Use of psychotropic medications in children with developmental disabilities. *Pediatr Clin North Am* **55**:1227–40.

Deokar AM, Huff MB, Omar HA (2008). Clinical management of adolescents with autism. *Pediatr Clin North Am* **55**:1147–57.

- Deutsch CK, Dube WV, McIlvane WJ (2008). Attention deficits, attention-deficit hyperactivity disorder, and intellectual disabilities. *Dev Disabil Res Rev* **14**:285–92.
- Ekinci O, Titus JB, Rodopman AA, Berkem M, Trevathan E (2009). Depression and anxiety in children with epilepsy. Prevalence, risk factors and treatment. *Epilepsy Behav* **14**:8–18.
- Kelly DP (2008). Learning disorders in adolescence: the role of the primary care physician. *Adolesc Med State Art Rev* **19**:229–41, viii.
- Myers SM, Johnson CP (2007). Management of children with autism spectrum disorders. American Academy of Pediatrics Council on Children with Disabilities. *Pediatrics* **120**:1162–82.
- Rapin I, Tuchman RF (2008). Autism: definition neurobiology, screening, diagnosis. *Pediatr Clin North Am* **55**:1129–46.
- Salpekar JA, Dunn DW (2007). Psychiatric and psychosocial consequences of pediatric epilepsy. *Semin Pediatr Neurol* **14**:181–8.
- Shipman K, Taussig H (2009). Mental health treatment of child abuse and neglect. The promise of evidence-based medicine. *Pediatr Clin North Am* **56**:417–28.
- Chapter 9: DISORDERS OF LANGUAGE AND HEARING**
- Bertoglio K, Hendren RL (2009). New developments in autism. *Psychiatr Clin North Am* **32**:1–14.
- Hone SW, Smith RJ (2002). Medical evaluation of pediatric hearing loss: laboratory, radiographic and genetic testing. *Otolaryngol Clin North Am* **35**:751–64.
- Peterson RL, McGrath LM, Smith SD, Pennington BF (2007). Neuropsychology and genetics of speech, language and literacy disorders. *Pediatr Clin North Am* **54**:543–61, vii.
- Prasse JE, Kikano GE (2008). Stuttering: an overview. *Am Fam Phys* **77**:1271–6.
- Shaywitz SE, Shaywitz BA (2008). Paying attention to reading: the neurobiology of reading and dyslexia. *Dev Psychopathol* **20**:1329–49.
- Smith RJ, Bale JF Jr, White KR (2005). Sensorineural hearing loss in children. *Lancet* **365**:879–90.
- Wells EM, Walsh KS, Khademian ZP, Keating RF, Packer RJ (2008). The cerebellar mutism syndrome and its relationship to cerebellar cognitive function and cerebellar affective disorder. *Dev Disabil Res Rev* **14**:221–8.
- Chapter 10: DISORDERS OF HEAD SIZE AND SHAPE**
- Cunningham ML, Heike CL (2007). Evaluation of the infant with an abnormal skull shape. *Curr Opin Pediatr* **19**:645–5.
- Dover MS (2008). Abnormal skull shape: clinical management. *Pediatr Radiol* **38** (Suppl 3):S484–7.
- Glass RB, Fernbach SK, Norton KI, Choi PS, Naidich TP (2004). The infant skull: a vault of information. *Radiographics* **24**:507–22.
- Lekovic GP, Bristol RE, ReKate HL (2004). Cognitive impact of craniosynostosis. *Semin Pediatr Neurol* **11**:305–10.
- Lian G, Sheen V (2006). Cerebral development disorders. *Curr Opin Pediatr* **18**:614–20.
- Losee JE, Mason AC (2005). Deformational plagiocephaly: diagnosis, prevention and treatment. *Clin Plast Surg* **32**:53–64.
- Vertinsky AT, Barnes PD (2007). Macrocephaly, increased intracranial pressure and hydrocephalus in the infant and young child. *Top Magn Reson Imaging* **18**:31–51.
- Wilkie AO, Bochukova EG, Hansen RM, et al. (2007). Clinical dividends from the molecular genetic diagnosis of craniosynostosis. *Am J Med Genet A* **143A**:1941–9.
- Williams CA (2005). Neurological aspects of Angelman syndrome. *Brain Dev* **27**:88–94.
- Chapter 11: DISORDERS OF CRANIAL NERVES**
- Borchert M, Garcia-Fillon P (2008). The syndrome of optic nerve hypoplasia. *Curr Neurol Neurosci Rep* **8**:395–403.



- Cassidy L, Taylor D (1999). Congenital cataract and multisystem disorders. *Eye* **13**:464–73.
- Hertle RW (2008). Nystagmus in infancy and childhood. *Semin Ophthalmol* **23**:307–17.
- Lam BL, Morais CG Jr, Pasol J (2008). Drusen of the optic nerve. *Curr Neurol Neurosci Rep* **8**:404–8.
- Liam SA, Siatkowski RM (2004). Pediatric neuro-ophthalmology. *Curr Opin Ophthalmol* **15**:437–43.
- McMillan HJ, Keene DL, Jacob P, Humphreys P (2007). Ophthalmoplegic migraine: inflammatory neuropathy with secondary migraine? *Can J Neurol Sci* **34**:349–5.
- Pohl D (2008). Epidemiology, immunopathogenesis and management of pediatric central nervous system demyelinating disorders. *Curr Opin Neurol* **21**:366–72.
- Singhi P, Jain V (2003). Bell's palsy in children. *Semin Pediatr Neurol* **10**:289–97.
- Thompson EO, Smoker WRK (1994). Hypoglossal nerve palsy: a segmental approach. *RadioGraphics* **14**:939–58.

## Chapter 12: DISORDERS OF PERIPHERAL NERVES

- Connolly AM (2001). Chronic inflammatory demyelinating polyneuropathy in childhood. *Pediatr Neurol* **24**:177–82.
- Hughes RA, Raphaël JC, Swan AV, van Doorn PA (2006). Intravenous immunoglobulin for Guillain-Barré syndrome. *Cochrane Database Syst Rev* Jan 25;(1):CD002063.
- Malessy MJ, Pondaag W (2009). Obstetric brachial plexus injuries. *Neurosurg Clin N Am* **20**:1–14.
- McDonald CM (2001). Peripheral neuropathies of childhood. *Phys Med Rehabil Clin N Am* **12**:473–90.
- Wilder RT (2006). Management of pediatric patients with complex regional pain syndrome. *Clin J Pain* **22**:443–8.
- Williams S, Horrocks IA, Ouvier RA, Gillis J, Ryan MM (2007). Critical illness polyneuropathy and myopathy in pediatric intensive care: a review. *Pediatr Crit Care Med* **8**:18–22.

## Chapter 13: DISORDERS OF GAIT AND BALANCE

- Haas RH, Parikh S, Falk MJ, Saneto RP, Wolf NI, Darin N, Cohen BH (2007). Mitochondrial disease. A practical approach for primary care physicians. *Pediatrics* **120**:1326–33.
- Bernard G, Shevell M (2008). The wobbly child: an approach to inherited ataxias. *Semin Pediatr Neurol* **15**:194–208.
- Pandolfo M (2003). Friedreich ataxia. *Semin Pediatr Neurol* **10**:163–72.
- Ryan MM, Engle CC (2003). Acute ataxia in childhood. *J Child Neurol* **18**:309–16.
- van der Knaap MS, Pronk JC, Scheper GC (2006). Vanishing white matter disease. *Lancet Neurol* **5**:413–23.
- Waldman A, O'Connor E, Tennekoon G (2006). Childhood multiple sclerosis: a review. *Ment Retard Dev Disabil Res Rev* **12**:147–56.

## Chapter 14: DISORDERS OF SLEEP

- Kotagal S (2008). Parasomnias in childhood. *Curr Opin Pediatr* **20**:659–65.
- Peterson PC, Husain AM (2008). Pediatric narcolepsy. *Brain Dev* **30**:609–23.
- Szuhay G, Rotenberg J (2009). Sleep apnea in pediatric neurological conditions. *Curr Neurol Neurosci Rep* **9**:145–52.
- Trenkwalder C, Paulus W, Walters AS (2005). Restless legs syndrome. *Lancet Neurol* **4**:465–75.

## Chapter 15: DISORDERS OF THE NEWBORN

- Allen MC (2008). Neurodevelopmental outcomes of premature infants. *Curr Opin Neurol* **21**:123–8.
- Chau V, Poskitt KJ, Miller SP (2009). Advanced neuroimaging techniques for the term newborn with encephalopathy. *Pediatr Neurol* **40**:181–8.
- du Plessis AJ (2008). Cerebrovascular injury in premature infants: current understanding and challenges for future prevention. *Clin Perinatol* **35**:609–41.
- Kirton A, deVeber G (2009). Advances in perinatal ischemic stroke. *Pediatr Neurol* **40**:205–14.

- Laptook AR (2009). Use of therapeutic hypothermia in the term infant with hypoxic-ischemic encephalopathy. *Pediatr Clin North Am* **56**:601–16.
- Silverstein FS, Jensen FE (2007). Neonatal seizures. *Ann Neurol* **62**:112–20.

### Chapter 16: ACUTE FOCAL DEFICITS

- Banwell B, Ghezzi A, Bar-Or A, Mikaeloff Y, Tardieu M (2007). Multiple sclerosis in children: clinical diagnosis, therapeutic strategies, and future directions. *Lancet Neurol* **6**:887–902.
- Bernard TJ, Goldenberg NA, Armstrong-Wells J, *et al.* (2008). Treatment of childhood arterial stroke. *Ann Neurol* **63**:679–96.
- Chabas D, Strober J, Waubant E (2008). Pediatric multiple sclerosis. *Curr Neurol Neurosci Rep* **8**:434–4.
- Chan AK, deVeber G, Monagle P, *et al.* (2003). Venous thrombosis in children. *J Thromb Haemost* **1**:1443–55.
- Kirton A, Westmacott R, deVeber G (2007). Pediatric stroke: rehabilitation of the developing brain. *NeuroRehabilitation* **22**:371–82.
- Menge T, Kieseier BC, Nessler S, *et al.* (2007). Acute disseminated encephalomyelitis: an acute hit against the brain. *Curr Opin Neurol* **20**:247–54.
- Pittock SJ, Lucchinetti CF (2006). Inflammatory transverse myelitis: evolving concepts. *Curr Opin Neurol* **16**:362–8.
- Roach ES, Golomb MR, Adams R, *et al.* (2008). Management of stroke in infants and children: a scientific statement from a Special Writing Group of the American Heart Association Stroke Council and the Council on Cardiovascular Disease in the Young. American Heart Association Stroke Council; Council on Cardiovascular Disease in the Young. *Stroke* **39**:2644–91.

### Chapter 17: THE DYSMORPHIC CHILD

- Au KS, Ward CH, Northrup H (2008). Tuberous sclerosis complex: disease modifiers and treatment. *Curr Opin Pediatr* **20**:628–33.

- Comi AM (2007). Update on Sturge–Weber syndrome: diagnosis, treatment, quantitative measures and controversies. *Lymphat Res Biol* **5**:257–74.
- Cornish K, Turk J, Hagerman R (2008). The Fragile X continuum: new advances and perspectives. *J Intellect Disabil Res* **52**:469–82.
- Davidson MA (2008). Primary care for children and adolescents with Down syndrome. *Pediatr Clin North Am* **55**:1099–111.
- GeneTests. <http://www.genetests.org>. (Accessed 11/10/2010.)
- Gerber PA, Antal AS, Neumann NJ, *et al.* (2009). Neurofibromatosis. *Eur J Med Res* **14**:102–5.
- Jones K (2005). *Smith's Recognizable Patterns of Human Malformation*, 6th edn. Elsevier Saunders, Philadelphia.
- Lew SM, Kothbauer KF (2007). Tethered cord syndrome: an updated review. *Pediatr Neurosurg* **43**:236–48.

### Chapter 18: HEADACHES

- Lewis DW, Ashwal S, Dahl G, *et al.* (2002). Practice parameter: evaluation of children and adolescents with recurrent headaches: Report of the Quality Standards Subcommittee of the American Academy of Neurology and the Practice Committee of the Child Neurology Society. *Neurology* **50**:490–8.
- Lewis DW, Ashwal SA, Hershey A, *et al.* (2004). Practice parameter: pharmacological treatment of migraine headache in children and adolescents: Report of the Quality Standards Subcommittee of the American Academy of Neurology and the Practice Committee of the Child Neurology Society. *Neurology* **63**:2215–24.
- Lewis D, Gozzo YF, Avner MT (2005). The ‘other’ primary headaches in children and adolescents. *Pediatr Neurol* **33**:303–13.
- Mack KJ, Gladstein J (2008). Management of chronic daily headaches in children and adolescents. *Paediatr Drugs* **10**:23–9.
- NINDS. Headaches: Hope through Research. [http://www.ninds.nih.gov/disorders/headache/detail\\_headache.htm](http://www.ninds.nih.gov/disorders/headache/detail_headache.htm) (Accessed 11/10/2010.)

- Walker DM, Teach SJ (2008). Emergency department treatment of primary headaches in children and adolescents. *Curr Opin Pediatr* **20**:248–54.
- Winner P (2008). Pediatric headache. *Curr Opin Neurol* **21**:316–22.
- Wolf A, Hutcheson KA (2008). Advances in evaluation and management of pediatric idiopathic intracranial hypertension. *Curr Opin Ophthalmol* **19**:391–7.

### Chapter 19: HYPOTONIA AND WEAKNESS

- Arnon SS, Schechter R, Maslanka SE, Jewell NP, Hatheway CL (2006). Human botulism immune globulin for the treatment of infant botulism. *N Engl J Med* **354**:462–71.
- Chiang LM, Darras BT, Kang PB (2009). Juvenile myasthenia gravis. *Muscle Nerve* **39**:423–43.
- Hall JG (1997). Arthrogyrposis multiplex congenita: etiology, genetics, classification, diagnostic approach, and general aspects. *J Pediatr Orthop B* **6**:159–66.
- Harris SR (2008). Congenital hypotonia: clinical and developmental assessment. *Dev Med Child Neurol* **50**:889–92.
- Thompson JA, Filloux FM, Van Orman CB, *et al.* (2005). Infant botulism in the age of botulism immune globulin. *Neurology* **64**:2029–32.
- Tidball JG, Wehling-Henricks M (2004). Evolving therapies for Duchenne muscular dystrophy: targeting downstream events. *Pediatr Res* **56**:831–41.
- Tsao CY, Mendell JR (1999). The childhood muscular dystrophies: making order out of chaos. *Semin Neurol* **19**:9–23.
- Wang CH, Finkel RS, Bertini ES, *et al.* (2007). Consensus statement for the standard of care in spinal muscular atrophy. *J Child Neurol* **22**:1027–49.
- Cruz AT, Starke JR (2008). Treatment of tuberculosis in children. *Expert Rev Anti Infect Ther* **6**:939–57.
- Hayes EB, O’Leary DR (2004). West Nile virus infection: a pediatric perspective. *Pediatrics* **113**:1375–81.
- Kimberlin D (2007). Herpes simplex virus infections of the newborn. *Semin Perinatol* **21**:19–25.
- Mushahwar IS (ed) (2007). Congenital and other related infectious diseases of the newborn. *Perspect Med Virol* **13**, Elsevier.
- Peltola H, Roine I (2009). Improving the outcomes in children with bacterial meningitis. *Curr Opin Infect Dis* **22**:250–5.
- Riordan A, Bugembe T (2009). Update on antiretroviral therapy. *Arch Dis Child* **94**:70–4.
- Whitley RJ (2008). Therapy of herpes virus infections in children. *Adv Exp Med Biol* **609**:216–32.

### Chapter 21: MOVEMENT DISORDERS

- Dale RC (2005). Post-streptococcal autoimmune disorders of the central nervous system. *Dev Med Child Neurol* **47**:785–91.
- Dooley JM (2006). Tic disorders in childhood. *Semin Pediatr Neurol* **13**:231–42.
- Dressler D, Benecke R (2005). Diagnosis and management of acute movement disorders. *J Neurol* **252**:1299–306.
- Gilbert D (2006). Treatment of children and adolescents with tics and Tourette syndrome. *J Child Neurol* **21**:690–700.
- Paolicchi JM (2002). The spectrum of nonepileptic events in children. *Epilepsia* **43** (Suppl 3):60–4.
- Sanger TD (2003). Pathophysiology of pediatric movement disorders. *J Child Neurol* **18** (Suppl):S9–24.
- Stern JS, Bruza S, Robertson MM (2005). Gilles de la Tourette’s syndrome and its impact in the UK. *Postgrad Med J* **81**:12–19.
- Walker AR, Tani LY, Thompson JA, *et al.* (2007). Rheumatic chorea: relationship to systemic manifestations and response to corticosteroids. *J Pediatr* **151**:679–83.
- Wolf DS, Singer HS (2008). Pediatric movement disorders: an update. *Curr Opin Neurol* **21**:491–6.

### Chapter 20: INFECTIONS OF THE CENTRAL NERVOUS SYSTEM

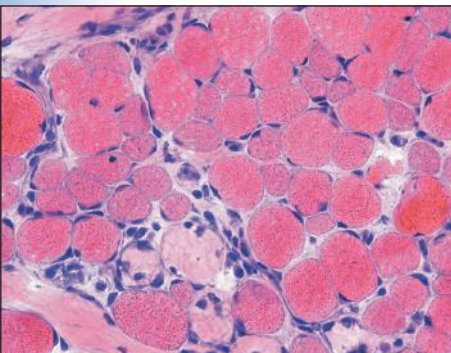
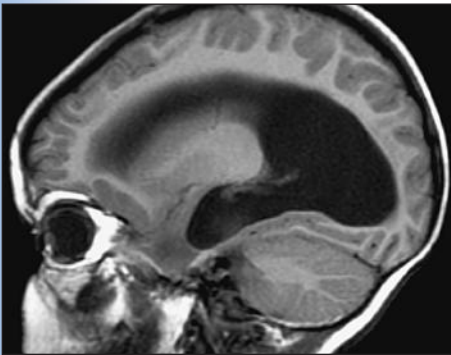
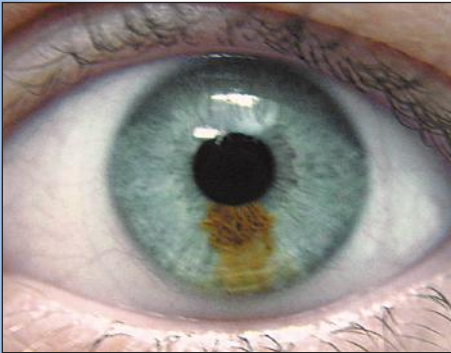
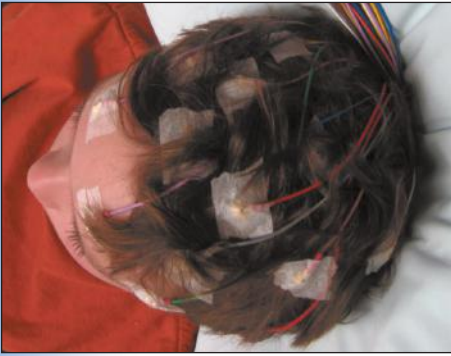- Bale JF (2006). Viral infections of the nervous system. In: Swaiman KF, Ashwal S, Ferriero DM (eds). *Pediatric Neurology: Principles and Practice*, Mosby/Elsevier, Philadelphia, pp. 1598–1629.

## Chapter 22: SEIZURES AND PAROXYSMAL DISORDERS

- Arzimanoglou A, Guerrine R, Aicardi J (2004). *Aicardi's Epilepsy in Children*, 3rd edn. Lippincott Williams & Wilkins, Philadelphia.
- Epilepsy Foundation. <http://www.epilepsyfoundation.org> (Accessed 11/10/2010.)
- Hirtz D, Ashwal SA, Berg A, *et al.* (2000). Practice parameter: evaluating a first nonfebrile seizure in children: Report of the Quality Standards Subcommittee of the American Academy of Neurology and the Practice Committee of the Child Neurology Society. *Neurology* **55**:616–23.
- Hirtz D, Berg A, Bettis D, *et al.* (2003). Practice parameter: treatment of the child with a first unprovoked seizure: Report of the Quality Standards Subcommittee of the American Academy of Neurology and the Practice Committee of the Child Neurology Society. *Neurology* **60**:166–75.
- Kossoff EH, Zupec-Kania BA, Amark PE, *et al.* (2009). Optimal clinical management of children receiving the ketogenic diet: recommendations of the International Ketogenic Diet Study Group. *Epilepsia* **50**:304–17.
- Mackay MT, Weiss SK, Adams-Webber T, *et al.* (2004). Practice parameter: medical treatment of infantile spasms: Report of the Quality Standards Subcommittee of the American Academy of Neurology and the Practice Committee of the Child Neurology Society. *Neurology* **62**:1668–81.
- Nickels K, Wirrell E (2008). Electrical status in sleep. *Semin Pediatr Neurol* **15**:50–60.
- Panayiotopoulos CP, Michael M, Sanders S, Valeta T, Koutroumanidis M (2008). Benign childhood focal epilepsies. Assessment of established and newly recognized syndromes. *Brain* **131**:2264–86.
- Parisi P, Bombardieri R, Curatolo P (2007). Current role of vigabatrin in infantile spasms. *Eur J Paediatr Neurol* **11**:331.
- Pellock JM, Bourgeois BFB, Dodson EW, Nordli DR, Sankar R (2008). *Pediatric Epilepsy and Therapy*, 3rd edn. Demos Medical Publishing, New York.

## Chapter 23: PEDIATRIC NEUROLOGICAL EMERGENCIES

- Chiesa A, Duhaime AC (2009). Abusive head trauma. *Pediatr Clin North Am* **56**:317–31.
- Gorelick MH, Blackwell CD (2005). Neurologic emergencies. In: Fleisher GR, Ludwig S, Henretig FM, *et al.* (eds). *Textbook of Pediatric Emergency Medicine*, 5th edn. Lippincott-Williams and Wilkins, Philadelphia, pp. 759–82.
- Mami AG, Nance ML (2008). Management of the mild head injury in the pediatric patient. *Adv Pediatr* **55**:385–94.
- Mungan NK (2007). Update on shaken baby syndrome. *Curr Opin Ophthalmol* **18**:392–7.
- Pellock JM (2007). Overview: definitions and classifications of seizure emergencies. *J Child Neurol* **22**:9s–13s.
- Shemie SD, Pollack MM, Morioka M, Bonner S (2007). Diagnosis of brain death in children. *Lancet Neurol* **6**:87–92.



This *Color Handbook* begins with the fundamentals of neurological examination and differential diagnosis, followed by a problem-based approach that recognizes how diseases present in the real world. It employs practical, symptom, and sign-based strategies for virtually all conditions encountered by the practitioner.

Throughout, the authors emphasize patterns of disease and how distinguishing them can be the first step to successful management of the child with a neurological problem. They conclude with a detailed discussion of neurological emergencies and recognize that such conditions present first to someone other than to a pediatric neurologist.

Of interest to pediatric neurologists, pediatricians, primary care physicians, and emergency physicians in training and practice.

#### COLOR HANDBOOK SERIES

- Acute Adult Dermatology*: Creamer  
*Dermatology, 2nd edition*: Rycroft  
*Endocrinology and Metabolism*: Camacho  
*Gastroenterology, 2nd edition*: Boulton  
*Human Anatomy*: McMinn  
*Oral Medicine*: Lewis  
*Pediatrics and Child Health*: Strobel  
*Pediatric Neurology*: Bale  
*Pediatric Clinical Ophthalmology*: Nelson  
*Pediatric Rheumatology*: Reed  
*Renal Medicine*: Pattison  
*Skin Diseases in the Elderly*: Evans

ISBN 978-1-84076-134-4



9 781840 761344